

Demystifying Idiopathic Interstitial Pneumonia

Harold R. Collard, MD; Talmadge E. King, Jr, MD

Careful histopathological evaluation has shown the traditionally clinical diagnosis of idiopathic interstitial pneumonia to be more heterogeneous than once thought. Its subclassification, based on clinicopathological criteria, has important therapeutic and prognostic implications. The most important distinction is the presence of usual interstitial pneumonia, the histopathological pattern seen in idiopathic pulmonary fibrosis. Idiopathic pulmonary fibrosis has a worse response to therapy and prognosis. New insight into the pathophysiology of idiopathic pulmonary fibrosis suggests a distinctly fibroproliferative process, and antifibrotic therapies show promise. Although the clinical and radiographic diagnosis of idiopathic pulmonary fibrosis can be made confidently in some cases, many patients require surgical lung biopsy to determine their underlying histopathological pattern. A structured, clinicopathological approach to the diagnosis of idiopathic interstitial pneumonia, with particular attention to the identification of idiopathic pulmonary fibrosis, ensures proper therapy, enhances prognosis, and allows for further investigation of therapies aimed at the distinct pathophysiology.

Arch Intern Med. 2003;163:17-29

The diagnosis and management of idiopathic interstitial pneumonia have challenged physicians since its initial description more than a century ago. Much has changed in our understanding of idiopathic interstitial pneumonia during the past decade, most important being our appreciation of the clinical relevance of histopathology. When faced with a patient suspected of having idiopathic interstitial pneumonia, physicians must have a rigorous and organized approach to its diagnosis, as therapy and prognosis depend on the patient's underlying histopathological pattern. This fact remains unappreciated by many physicians, and as a result, patients often undergo incomplete evaluation and empirical treatment.

From the Departments of Medicine, Division of Pulmonary Sciences and Critical Care Medicine, University of Colorado Health Sciences Center, Denver (Dr Collard), and San Francisco General Hospital, University of California–San Francisco (Dr King). Dr King was the chairman of the advisory committee of a multicenter study of the efficacy of interferon beta-1a (Avonex) in the treatment of idiopathic pulmonary fibrosis, sponsored by Biogen Inc, Cambridge, Mass, and is a member of the Scientific Advisory Committee for InterMune Protocol GIPF-001 sponsored by InterMune Pharmaceuticals Inc, Burlington, Calif, for which he receives consulting fees.

This review aims to describe idiopathic interstitial pneumonia and its different histopathological subgroups, explain the therapeutic and prognostic importance of careful histopathological distinction, and provide an understanding of the utility of clinical, radiographic, and surgical approaches to the diagnosis.

METHODS

We reviewed the epidemiology, clinical presentation, pathogenesis, diagnosis, and treatment of idiopathic interstitial pneumonia. After a search of MEDLINE, we identified articles published from 1966 to 2001 using the exploded Medical Subject Heading terms *lung diseases* and *interstitial and pulmonary fibrosis* and the keyword terms *idiopathic pulmonary fibrosis*, *idiopathic interstitial pneumonia*, *usual interstitial pneumonia*, *desquamative interstitial pneumonia*, *respiratory bronchiolitis/interstitial lung disease*, *nonspecific interstitial pneumonia*, *acute interstitial pneumonia*, *fibrosis*, and *inflammation*. Identified articles and additional sources such as textbook chapters and meeting abstracts were reviewed for relevant publications. All included reports underwent peer review.

DEFINING IDIOPATHIC INTERSTITIAL PNEUMONIA

Initial Description

Interstitial pneumonia has been recognized as a chronic progressive lung disease for more than a century. In 1892, Osler¹ described chronic interstitial pneumonia, also called *cirrhosis of the lung*, as “a fibrinoid change, which may have its starting point in the tissue about the bronchi and blood-vessels, the interlobular septa, the alveolar walls or in the pleura. So diverse are the different forms and so varied the conditions under which this change occurs that a proper classification is extremely difficult.” An association with inorganic dust inhalation was by this time well established, but little attention was paid to clinical or pathological subcategorization.

In 1944, Hamman and Rich² described 4 cases of acute diffuse interstitial fibrosis in which “the lungs were the seats of a widespread connective tissue hyperplasia throughout the interstitial structures. The alveolar walls were tremendously thickened; in the early stages of the process crowded with fibroblasts.” Although all 4 of these cases were acute in onset and rapidly progressive, the term *Hamman-Rich syndrome* was used for some time to describe any diffuse idiopathic fibrotic lung disease.

By the mid-1960s, significant progress in the subcategorization of interstitial lung disease had been made, with inherited conditions, collagen-vascular diseases, drugs, and occupational exposures being recognized as potential causes. Those conditions that remained idiopathic were collectively called by various names, including *chronic idiopathic interstitial fibrosis*, *diffuse interstitial fibrosis*, *diffuse fibrosing alveolitis*, *Hamman-Rich syndrome*, *diffuse pulmonary alveolar fibrosis*, *idiopathic pulmonary fibrosis*, and *idiopathic interstitial pneumonia*. The preferred term at present is *idiopathic interstitial pneumonia*, and we will use this term for the remainder of the discussion.

Liebow and Carrington Classification

In 1969, Liebow and Carrington³ described the following 5 histopathological subgroups of chronic idiopathic interstitial pneumonia: usual interstitial pneumonia (UIP); diffuse lesions similar to UIP with superimposed bronchiolitis obliterans termed *bronchiolitis interstitial pneumonia*; desquamative interstitial pneumonia; lymphoid interstitial pneumonia; and giant cell interstitial pneumonia. Hamman-Rich disease was considered an acute form of UIP. Liebow and Carrington suggested that lung biopsy and histopathological classification might help distinguish clinically distinct conditions, as “there are correlations [of histopathological findings] with radiographic appearance, clinical course and prognosis. Clues to etiology and pathogenesis, which currently are scanty, will in time be forthcoming.”³

Katzenstein and Meyers Classification

The subgroups identified by Liebow and Carrington³ have evolved into the classification schema used at present for idiopathic interstitial pneumonia as described in 1998 by Katzenstein and Myers.⁴ Their classification schema includes 4 histopathologically distinct subgroups: UIP, desquamative interstitial pneumonia and a closely related pattern termed *respiratory bronchiolitis-associated interstitial lung disease* (RBILD), acute interstitial pneumonia (formerly Hamman-Rich syndrome), and nonspecific interstitial pneumonia (NSIP). The lymphoid interstitial pneumonia and giant cell interstitial pneumonia subgroups identified by Liebow and Carrington³ are excluded because their causes, a lymphoproliferative condition and a hard-metal pneumoconiosis, respectively, are no longer idiopathic. Bronchiolitis interstitial pneumonia, now known as bronchiolitis obliterans with organizing pneumonia, is also excluded because it is a predominantly intraluminal process. The Katzenstein and Myers⁴ method of histopathological categorization incorporates the temporal heteroge-

neity of inflammation and fibrosis, the extent of inflammation, the extent of accumulation of intra-alveolar macrophages, and the presence of honeycombing or hyaline membranes.

American Thoracic Society and European Respiratory Society Classification

The American Thoracic Society and the European Respiratory Society have recently revised the classification schema of Katzenstein and Myers⁴ to emphasize the importance of an integrated clinical and pathological approach to the diagnosis of idiopathic interstitial pneumonia.⁵ The classification of the American Thoracic Society and the European Respiratory Society combines the histopathological pattern seen on lung biopsy findings (as described by Katzenstein and Myers) with clinical information to arrive at a final clinicopathological diagnosis. This approach allows for the preservation of existing histopathological and clinical terms while precisely defining the relationship between them. When the terms are the same for the histopathological pattern and the clinical diagnosis (eg, desquamative interstitial pneumonia), it was recommended that the pathologist use the addendum *pattern* when referring to the appearance on lung biopsy findings (eg, desquamative interstitial pneumonia pattern) and reserve the initial term for the final clinicopathological diagnosis.

CLINICAL PRESENTATION

The various histopathological subgroups are often clinically indistinguishable (with the exception of acute interstitial pneumonia). Although patients with UIP are generally older (two thirds are older than 60 years at diagnosis) than those with other forms of idiopathic interstitial pneumonia, age is not a reliable predictor of histopathology. Symptoms are identical for all subgroups, with the typical patient reporting progressive dyspnea for months to years and a chronic, nonproductive cough. Physical examination will often reveal digital clubbing and the presence of bibasilar fine inspiratory crackles (“Velcro” crackles). Results of pul-

monary function testing reveal restrictive lung disease (decreased forced vital capacity and total lung capacity [TLC]) and abnormal gas exchange (decreased diffusion capacity of carbon dioxide and resting or exercise PaO₂). The most useful clinical tool for distinguishing between subclasses is high-resolution computed tomography (HRCT) of the chest. The diagnostic utility of HRCT is discussed later in this review.

Acute interstitial pneumonia presents much differently, with the acute onset of dyspnea and cough and the rapid development of respiratory failure. The clinical picture is usually indistinguishable from that of acute respiratory distress syndrome, with hypoxemia, diffuse crackles, and bilateral alveolar opacities present on a chest x-ray film. The age of onset is typically younger than for the other subgroups of idiopathic interstitial pneumonia. A few cases of chronic relapsing acute interstitial pneumonia have been described, usually leading to progressive deterioration in lung function.⁶

HISTOPATHOLOGICAL SUBGROUPS

Relative Frequency of Diagnosis

The relative distribution of the 4 histopathological subgroups can be estimated from several case series of patients with idiopathic interstitial

pneumonia (**Table 1**).⁷⁻¹⁰ These studies suggest that UIP is the most common (50%-60%), with NSIP (14%-36%) and desquamative interstitial pneumonia/RBILD (10%-17%) less common, and acute interstitial pneumonia quite rare (0-2%). The histopathological patterns described herein can be seen in conditions other than idiopathic interstitial pneumonia.⁴ This is especially true of NSIP, which has been described in a variety of conditions, including collagen-vascular disease, hypersensitivity pneumonitis, recent acute lung injury, and drug reactions.¹² Therefore, before the diagnosis of idiopathic interstitial pneumonia is made, a careful clinical evaluation to rule out such associated conditions is paramount.

Usual Interstitial Pneumonia

Usual interstitial pneumonia is characterized by a heterogeneous, predominantly subpleural distribution of involvement, a pattern quite distinguishable even on low-power magnification (**Figure 1A**). Temporal heterogeneity is seen, with areas of end-stage fibrosis and honeycombing (thickened collagenous septa surrounding airspaces lined by bronchial epithelium) abutting areas of active proliferation of fibroblasts and myofibroblasts. These discrete areas of acute fibroblastic proliferation have been termed *fibroblastic foci* and are essential to the histo-

pathological diagnosis of UIP (**Figure 1B**). Generally, minimal interstitial inflammation is seen, and if present in significant amounts, the histopathological diagnosis should be reconsidered.

Nonspecific Interstitial Pneumonia

Nonspecific interstitial pneumonia evolved as a categorization reserved for idiopathic interstitial pneumonia that did not meet the criteria for UIP, desquamative interstitial pneumonia/RBILD, or acute interstitial pneumonia. It is characterized by varying degrees of inflammation and fibrosis, with some forms primarily inflammatory (cellular NSIP) and others primarily fibrotic (fibrotic NSIP).¹² Although NSIP may have significant fibrosis, it is usually of temporal uniformity, and fibroblastic foci and honeycombing, if present, are rare (**Figure 1C**). The temporal uniformity is distinctly different from that seen in UIP. Nonetheless, fibrotic NSIP can be difficult to distinguish reliably from UIP, and significant interobserver variability exists even among expert histopathologists.⁹

Desquamative Interstitial Pneumonia/RBILD

Desquamative interstitial pneumonia and RBILD, once considered distinct entities, are arguably different

Table 1. Histopathological Diagnosis in Case Series of Idiopathic Interstitial Pneumonia*

Reference (Year)	Design	No. of Patients	% of Patients				
			UIP	NSIP	DIP/RBILD	AIP	Other
Bjoraker et al ⁷ (1998)	Included all patients with a previous diagnosis of IIP who had undergone open-lung biopsy from 1976 to 1985	104	62	14	10	2	12†
Nagai et al ⁸ (1998)	Included all patients from a larger IIP cohort with the histopathological diagnosis of UIP, NSIP, or BOOP (time for enrollment not stated)	129	50	24	NA	NA	26‡
Travis et al ¹⁰ (2000)	Included all patients from a larger IIP cohort with the histopathological diagnosis of UIP, NSIP, or DIP from 1970 to 1992	101	55	29	16	NA	NA
Nicholson et al ⁹ (2000)	Included all patients with a previous diagnosis of IIP who had undergone open-lung biopsy from 1978 to 1989	78	47	36	17	NA	NA

Abbreviations: AIP, acute interstitial pneumonia; BOOP, bronchiolitis obliterans with organizing pneumonia; DIP/RBILD, desquamative interstitial pneumonia/respiratory bronchiolitis-associated interstitial lung disease; IIP, idiopathic interstitial pneumonia; NA, not applicable; NSIP, nonspecific interstitial pneumonia; UIP, usual or undifferentiated interstitial pneumonia.

*Data from Collard and King.¹¹

†Includes bronchiolitis (n = 4), BOOP (n = 4), chronic eosinophilic pneumonia (n = 1), hypersensitivity pneumonitis (n = 1), honeycomb changes only (n = 1), hemorrhage (n = 1), and scarring and pneumonia (n = 1).

‡Includes BOOP.

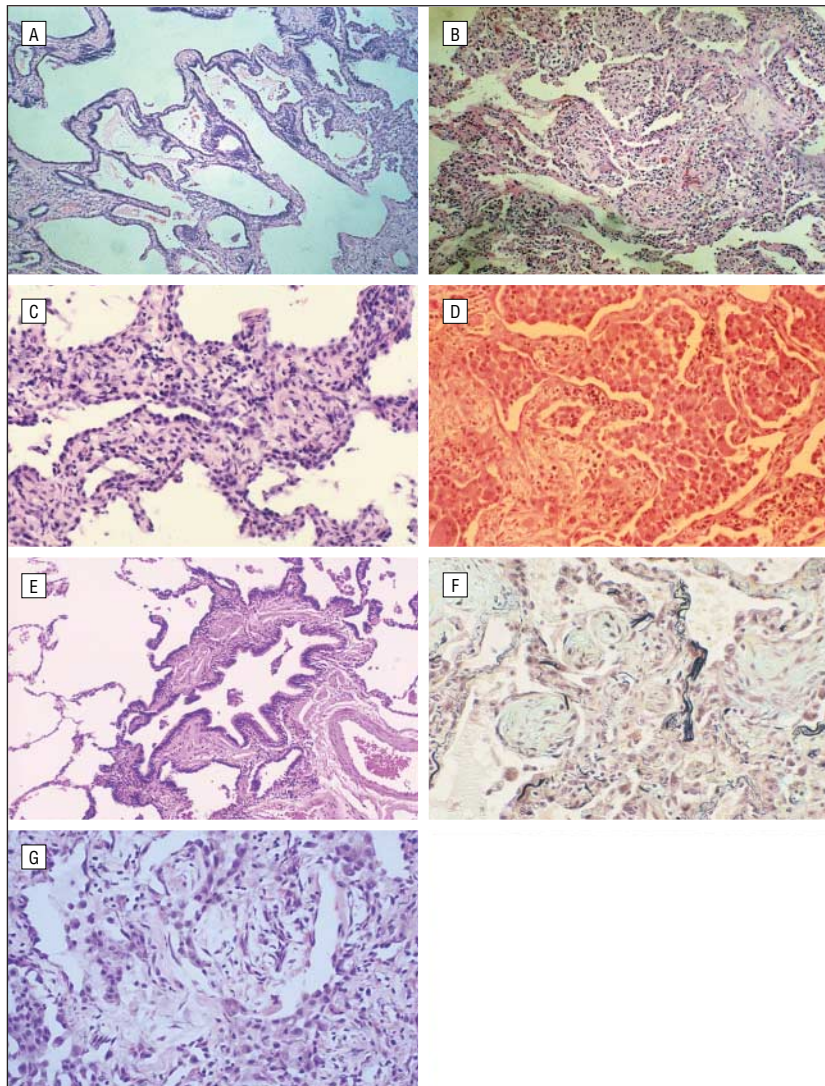


Figure 1. Histopathological subgroups of idiopathic interstitial pneumonia. A, The pattern of usual interstitial pneumonia (UIP) often shows a striking subpleural distribution. This photomicrograph is from an area with severe remodeling of the lung architecture with cystic (honeycomb) changes present (hematoxylin-eosin, original magnification $\times 10$). B, Pattern of UIP with mild interstitial changes. In the upper right side of the slide, a fibroblastic focus of loose organizing connective tissue is seen (hematoxylin-eosin, original magnification $\times 20$). C, Nonspecific interstitial pneumonia, cellular pattern. The interstitium is infiltrated by a moderate chronic inflammatory infiltrate. The infiltrate consists of lymphocytes and plasma cells. Fibrosis is absent (hematoxylin-eosin, original magnification $\times 40$). D, Desquamative interstitial pneumonia pattern. The alveolar spaces are diffusely involved with marked alveolar macrophage accumulation, and mild interstitial thickening is seen (hematoxylin-eosin, original magnification $\times 100$). E, Respiratory bronchiolitis-associated interstitial lung disease. Mild thickening of the wall of the respiratory bronchiole and adjacent alveolar walls is seen. Faintly pigmented alveolar macrophages often fill the lumen of respiratory bronchioles and the surrounding airspaces (hematoxylin-eosin, original magnification $\times 10$). F, Organizing pneumonia pattern. Patchy lung involvement with loose plugs of connective tissue within the alveolar ducts and alveolar spaces is seen. The architecture of the lung is preserved, and the connective tissue is all the same age (pentachrome, original magnification $\times 20$). G, Diffuse alveolar damage in a patient with acute interstitial pneumonia. The lung shows diffuse alveolar wall thickening with proliferating connective tissue, type II pneumocytes, and hyaline membranes (hematoxylin-eosin, original magnification $\times 60$).

manifestations of the same condition.^{13,14} Desquamative interstitial pneumonia/RBILD is quite distinct in histopathological appearance from UIP, with a much more homogeneous geographical distribution. Significantly less septal thickening is seen, and fibroblastic foci and honeycombing are absent. The most

striking feature of these two conditions is the filling of alveoli by pigment-laden macrophages (Figure 1D). These macrophages were originally and incorrectly thought to be desquamated alveolar epithelial cells; thus the name *desquamative interstitial pneumonia*. If the macrophage infiltrate is predominantly peribron-

chiolar, the term *RBILD* is used. If widespread alveolar involvement is found, the process is called *desquamative interstitial pneumonia*.

Acute Interstitial Pneumonia

Acute interstitial pneumonia is a diffuse, fibroproliferative process that is indistinguishable from the organizing stage of diffuse alveolar damage, the histopathological corollary of acute respiratory distress syndrome. Widespread proliferation of fibroblasts and myofibroblasts is seen, with minimal inflammatory infiltrate (Figure 1E). The fibrotic changes are temporally homogeneous and may be accompanied by the presence of hyaline membranes. With time, end-stage fibrosis develops, and large cystic airspaces resembling honeycomb form. These cystic spaces, however, are lined with alveolar epithelium, not bronchial epithelium as seen in UIP.

RESPONSE TO THERAPY

Corticosteroids

Many studies have addressed the therapeutic responsiveness of idiopathic interstitial pneumonia. Corticosteroids have been the mainstay of therapy since their initial release for clinical use in 1948.¹⁵ Unfortunately, no prospective randomized placebo-controlled trial has examined the role of corticosteroids for idiopathic interstitial pneumonia. Retrospective reviews have suggested a clinical response to corticosteroids in 16% to 57% of patients (**Table 2**).¹⁶⁻¹⁸ These studies did not distinguish between histopathological subgroups and relied on the clinical diagnosis (not confirmed by biopsy findings) of idiopathic interstitial pneumonia in most patients. They also used a variety of subjective (eg, dyspnea scale) and objective (eg, forced vital capacity and radiographic improvement) outcome measures to document response, many of which are of questionable use as meaningful end points. Two recent studies of 38 and 41 patients with idiopathic interstitial pneumonia confirmed by surgical lung biopsy findings reported a 26% and 27% improvement, respectively, in clinical, radiographic, and

Table 2. Response to Therapy in Idiopathic Interstitial Pneumonia*

Reference (Year)	Disease	Therapy	Study Design	Outcome
No Histopathological Distinction				
Corticosteroids				
Flaherty et al ²⁰ (2001)	IIP	Prednisone (1 mg/kg for 3 months or taper to 40 mg after 1 month)	Prospective case series of 41 patients	27% Responded
Gay et al ¹⁹ (1998)	IIP	Prednisone (1 mg/kg for 18 months)	Prospective case series of 38 patients	26% Responded
Tukiainen et al ¹⁶ (1983)	IIP	Prednisone (40 mg for 3 months)	100 Patients	30% Responded
Turner-Warwick et al ¹⁷ (1980)	IIP	Prednisone (variable regimens)	Retrospective 220 patients; 143 treated	57% Subjectively responded; 17% objectively responded
Stack et al ¹⁸ (1972)	IIP	Prednisone (20-40 mg for 2-8 weeks)	96 Patients; 69 treated	16% Significantly responded; 41% responded somewhat
Immunomodulators with corticosteroids				
Kolb et al ³⁰ (1998)	IIP	Prednisone plus cyclophosphamide (1-13 g/mo)	Prospective case series of 18 patients	28% Improved
Raghu et al ²⁵ (1991)	IIP	Prednisone with or without azathioprine sodium, 3 mg/kg	27 Patients; 13 received prednisone; 14 prednisone and azathioprine	Prednisone, 15%-23% improved; prednisone plus azathioprine, 2%-50% improved; not statistically significant
Johnson et al ²⁶ (1989)	IIP	Prednisone with or without cyclophosphamide, 100-120 mg	Randomized controlled trial of 43 patients	Prednisone, 32% improved; prednisone plus cyclophosphamide, 24% improved; not statistically significant
Histopathological Distinction				
Olson et al ²⁴ (1990)	AIP	Prednisone (variable regimens)	Retrospective case series of 29 patients (20 treated)	Treated, 45% survival; untreated, 33% survival; not statistically significant
Yousem et al ¹⁴ (1989)	DIP/RBILD	Prednisone (variable regimens) in most DIP, few RBILD cases	Retrospective case series of 54 patients (36 with DIP, 18 with RBILD)	DIP, 56% improved; RBILD, 81% improved
Myers et al ¹³ (1987)	RBILD	Prednisone (variable regimens)	Retrospective case series of 6 patients (3 treated)	100% Stabilization or improved (no difference between treated and untreated)
Carrington et al ²¹ (1978)	UIP, DIP	Prednisone, 30-60 mg/d, tapered and maintained for 1 year	Prospective case series of 93 patients (40 with DIP, 53 with UIP)	UIP treated, 11.5% response; UIP untreated, 0% response; DIP treated, 61.5% response; DIP untreated, 21.9% response
Immunomodulators with or without corticosteroids				
Nicholson et al ⁹ (2000)	UIP, NSIP, DIP/RBILD	Prednisone (60 mg tapered) or prednisone (20 mg/d) plus cyclophosphamide (100-120 mg/d)	Retrospective case series of 78 patients (37 with UIP, 28 with NSIP, 13 with DIP/RBILD)	UIP, 11% response; NSIP, 29% response; DIP/RBILD, 80% response
Zisman et al ²⁷ (2000)	UIP	Cyclophosphamide (2 mg/kg per day)	Prospective case series of 19 patients	5% Improved
Daniil et al ²³ (1999)	UIP, NSIP	Prednisone with or without azathioprine sodium or cyclophosphamide (variable regimens)	Retrospective case series of 30 patients (25 treated)	UIP, 8% improved; NSIP, 23% improved
Antifibrotic agents with or without corticosteroids				
Douglas et al ²⁸ (2000)	UIP	Prednisone (variable regimens), colchicine (variable regimens), or no treatment	Retrospective review of 487 patients	No difference in survival among treated and untreated groups
Ziesche et al ²⁹ (1999)	UIP	Prednisolone sodium phosphate with or without interferon gamma-1b (200 µg 3 times a week)	Randomized, controlled trial of 18 patients	Prednisolone, no improvement; prednisolone plus interferon gamma-1b, significant improvement
Douglas et al ²² (1998)	UIP	Prednisone (60 mg/d tapered over 1 year); colchicine (0.6-1.2 mg/d)	Randomized trial of 26 patients	Prednisone, 83% failure; colchicine, 64% failure; not statistically significant†

Abbreviations are explained in the first footnote to Table 1.

*Data from Collard and King.¹¹

†Failure indicates decreased forced vital capacity, drug intolerance, or removal from the study.

physiological variables with corticosteroids.^{19,20} These data have been used to justify the use of corticosteroids in patients with idiopathic interstitial pneumonia, and most patients receive them.^{31,32}

Attempts to predict who will respond to treatment have been largely disappointing. The results of several large studies have been reviewed by Mapel et al.¹⁵ Clinical factors possibly associated with responsiveness to corticosteroid therapy include younger age, lesser degree of dyspnea, and female sex. A stronger association has been suggested with the degree of inflammation on open lung biopsy findings. Of more than 100 biopsy samples reviewed, 64% of patients with primarily inflammatory biopsy specimens responded to corticosteroids, compared with 23% of patients with primarily fibrotic patterns. Unfortunately, most patients in these early studies did not undergo biopsy, and when biopsy specimens were obtained, they were not classified by histopathological subgroup. Nonetheless, this association suggested an important role for the histopathological subclassification of idiopathic interstitial pneumonia in predicting responsiveness to therapy.

Relatively few studies address the treatment of specific histopathological subgroups of idiopathic interstitial pneumonia (Table 2). The best data on corticosteroid responsiveness in UIP and desquamative interstitial pneumonia were published in 1978 by Carrington et al.²¹ They retrospectively reviewed patients with UIP and desquamative interstitial pneumonia and found that when treated with corticosteroids, 11% and 62%, respectively, improved as measured by a combination of clinical, physiological, and radiographic indices. The same patients, when untreated during a different period, had 0% and 22% improvement, respectively.²¹ The criteria used for histopathological classification at that time did not distinguish UIP from NSIP, likely augmenting the response rate for UIP. More recent studies have found similarly poor response rates to corticosteroids for patients with UIP (8%-17%).^{9,22,23} No prospective treatment studies exist for NSIP or RBILD. However, retrospective reviews of observational studies in

which most patients received corticosteroids have suggested excellent responsiveness for these diseases.^{9,12,14,23} Respiratory bronchiolitis-associated interstitial lung disease appears to resolve in most patients with smoking cessation alone.^{13,14} No good data exist on corticosteroid therapy for acute interstitial pneumonia, with one study of 29 patients showing no significant difference in survival with or without treatment.²⁴ Taken together, these studies demonstrate a distinct difference in corticosteroid responsiveness on the basis of histopathological subgroup.

Immunomodulatory Agents

Because of the often poor responsiveness of idiopathic interstitial pneumonia to corticosteroids, immunomodulatory agents have been tried with mixed results (Table 2). A prospective, double-blind, randomized placebo-controlled trial of 27 patients with idiopathic interstitial pneumonia compared azathioprine sodium plus prednisone with prednisone alone and showed no statistically significant difference in lung function at 1 year or in survival, although a trend favored the azathioprine group.²⁵ A randomized controlled trial of 43 patients with idiopathic interstitial pneumonia compared cyclophosphamide (anhydrous) plus low-dose prednisolone with standard-dose prednisolone alone and also showed no statistically significant difference in improvement or survival between the 2 groups, although a combined end point of time to change of treatment and survival was better for the cyclophosphamide group.²⁶ A trial of single-agent therapy with cyclophosphamide in 19 patients with UIP in whom corticosteroid therapy had failed showed no significant response to therapy and significant toxic effects.²⁷

Antifibrotic Agents

Recently, antifibrotic agents have been tried alone or in combination with corticosteroids in patients with UIP (Table 2). Colchicine was compared with prednisone in 26 patients with biopsy-proved UIP who

were followed up for 1 year.^{22,28} Although improvement was not directly reported, a trend was found toward a lower failure rate (eg, clinical decline, drug intolerance) and a lower incidence of serious adverse effects with colchicine. A recent study of another agent, interferon gamma-1b, showed significantly better lung function (total lung capacity and PaO₂ at rest and with exercise) at 12 months in patients treated with interferon gamma-1b and prednisolone compared with prednisolone alone.²⁹ Interest is increasing in these and other antifibrotic agents for reasons we will discuss (see "Abnormal Wound Healing" subsection of the "UIP: Pathophysiological Paradigm Shift" section).

Lung Transplantation

Lung transplantation should be considered in all patients with progressive disease who are unresponsive to medical treatment. A consensus guideline outlining general indications and contraindications for lung transplantation recommends referral for transplantation when patients have progressive symptoms, a vital capacity below 60% to 70% of that predicted, and a diffusing capacity corrected for alveolar volume below 50% to 60%.³³ Unfortunately, patients with idiopathic interstitial pneumonia are often referred for transplantation too late, with 30% or more of such patients dying while on the waiting list.³⁴ A recent review suggests that survival may be optimized when patients are referred on the basis of a combination of diffusion capacity and HRCT fibrosis score.³⁵ Single-lung transplantation is equal to bilateral lung transplantation³⁶ and leads to improvement in exercise capacity, pulmonary function, and gas exchange.³⁷ Most important, lung transplantation has been shown to improve survival in patients with pulmonary fibrosis.³⁸

SURVIVAL

Several excellent retrospective studies have compared survival between histopathological subgroups of idiopathic interstitial pneumonia (Table 3). Excluding acute in-

Table 3. Survival in Idiopathic Interstitial Pneumonia by Histopathological Subclass

Reference (Year)	Subclass	Design	Treatment	Survival		
				UIP	DIP/RBILD	NSIP
Douglas et al ²⁸ (2000)	UIP	Retrospective case series of 487 patients	Some received corticosteroids, some colchicins, and some no therapy	4 Years, 35%*	NA	NA
Douglas et al ²² (1998)	UIP	Randomized trial of 26 patients	All received prednisone or colchicins	2 Years, 42%	NA	NA
Wells et al ³⁹ (1994)	UIP	Prospective case series of 205 patients	78% Received high-dose corticosteroids	30% (Median follow-up, 50.6 months)	NA	NA
Nicholson et al ⁹ (2000)	UIP, NSIP (cellular and fibrotic), DIP/RBILD	Retrospective case series of 78 patients	Most received corticosteroids with or without immunomodulators	5 Years, 12%*	5 Years, 100%*	5 Years*: cellular, 100%; fibrotic, 45%
Travis et al ¹⁰ (2000)	UIP, NSIP (cellular and fibrotic), DIP/RBILD	Retrospective case series of 101 patients	Not reported	5 Years, 43%; 10 years, 15%	5 Years, 100%; 10 years, 100%	5 Years; cellular, 100%; fibrotic, 90%; 10 years; cellular, 100%; fibrotic, 35%
Bjoraker et al ⁷ (1998)	UIP, NSIP, other†	Retrospective case series of 97 patients	>90% Received corticosteroids	5 Years, 20%*	NA	5 Years; NSIP, 70%*; other, 80%*
Daniil et al ²³ (1999)	UIP, NSIP	Retrospective case series of 30 patients	25 Received corticosteroids with or without immunomodulators	7% (Follow-up, 1.5 to 72 months)	NA	71% (Follow-up, 1.5 to 72 months)
Katzenstein and Fiorelli ¹² (1994)	NSIP	Retrospective case series of 64 patients	Most patients received corticosteroids	NA	NA	82% (Follow-up, 10 days to 10 years)
Carrington et al ²¹ (1978)	DIP, UIP	Retrospective case series of 93 patients (40 with DIP, 53 with UIP)	Most patients received corticosteroids	5 Years, 55%; 10 years, 29%	5 Years, 95%; 10 years, 70%	NA
Yousem et al ¹⁴ (1989)	DIP/RBILD	Retrospective case series of 54 patients (36 with DIP, 18 with RBILD)	Most patients received corticosteroids	NA	DIP, 100%; RBILD, 68% (mean follow-up, 108 months for DIP and 67 months for RBILD)	NA
Myers et al ¹³ (1987)	RBILD	Retrospective and prospective case series of 6 patients	3 Patients received corticosteroids	NA	100% (Average follow-up, >3 years)	NA

Abbreviations are explained in the first footnote to Table 1.

*Survival was approximated from the graph in the article.

†Includes bronchiolitis (n = 4), BOOP (n = 4), chronic eosinophilic pneumonia (n = 1), hypersensitivity pneumonitis (n = 1), honeycomb changes only (n = 1), hemorrhage (n = 1), and scarring and pneumonia (n = 1).

terstitial pneumonia, which is usually clinically distinct and has a poor prognosis (less than half of patients survive),²⁴ the most important prognostic information is the presence or absence of UIP. In 1978, Carrington et al²¹ compared survival in 93 patients with UIP and desquamative interstitial pneumonia and found a dramatically better 5-year survival for patients with desquamative interstitial pneumonia (95%) than for those with UIP

(55%). More recently, Bjoraker et al⁷ reviewed 97 cases of idiopathic interstitial pneumonia and found an even worse 5-year survival for patients with UIP (20%) compared with those with NSIP (70%) and desquamative interstitial pneumonia/RBILD (80%). The patients with UIP in the study by Carrington et al²¹ likely included many who would have been classified as having NSIP by Bjoraker et al,⁷ which may explain the higher UIP survival rate re-

ported by Carrington et al. The dramatic difference in survival between UIP and the histopathological subgroups desquamative interstitial pneumonia, RBILD, and NSIP has been substantiated by several other studies.^{8,9,12-14,23,39} The further classification of NSIP into cellular and fibrotic subgroups appears to be important prognostically, with cellular NSIP having a significantly better prognosis than fibrotic NSIP.^{9,10} A recent study of patients with UIP

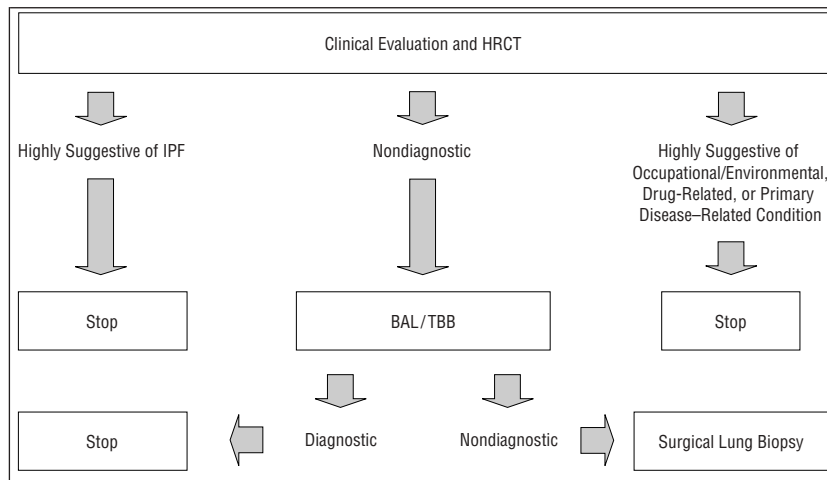


Figure 2. Approach to the diagnosis of idiopathic pulmonary fibrosis (IPF). The initial evaluation of suspected IPF should include a careful history and physical examination, pulmonary function testing, and high-resolution chest tomography (HRCT). In approximately half (48%-62%) of patients, this will lead to a highly specific diagnosis of IPF. Less commonly, it will lead to a highly specific diagnosis of occupational/environmental, drug-related, or primary disease-related (eg, sarcoid, collagen-vascular disease) interstitial lung disease. For patients in whom the initial evaluation is nondiagnostic, bronchoscopic techniques such as bronchoalveolar lavage (BAL) and transbronchial biopsy (TBB) may aid in the diagnosis of occult infections, malignancy, or primary pulmonary diseases. For the remaining patients, surgical lung biopsy is recommended.

showed that, unlike in NSIP, the extent and severity of interstitial cellularity or fibrosis are not predictive of survival.⁴⁰ Instead, the specific histopathological features that predicted survival are the degree of granulation tissue deposition in the alveolar space and the extent of young connective tissue present within the fibroblastic foci.⁴⁰

UIP: PATHOPHYSIOLOGICAL PARADIGM SHIFT

Abnormal Wound Healing

It is now clear that distinguishing UIP from the other histopathological subgroups of idiopathic interstitial pneumonia has important therapeutic and prognostic implications. For years, the prevailing pathophysiological theory in interstitial lung disease has held that generalized inflammation eventually leads to widespread parenchymal fibrosis and progressive decline in pulmonary function. This model seems to hold true for many of the corticosteroid-responsive interstitial lung diseases (eg, desquamative interstitial pneumonia/RBILD, cellular NSIP, hypersensitivity pneumonitis, eosinophilic pneumonia, sarcoidosis, and organizing pneumonia), but only for a few, if any, patients with UIP. The historical belief that UIP

represents the final common pathway for all forms of idiopathic interstitial pneumonia is likely incorrect. Instead, UIP appears to be a distinct pathophysiological entity characterized by minimal inflammation and chronic fibroproliferation due to abnormal parenchymal wound healing.⁴¹

The histopathological observations of temporal heterogeneity and focal proliferation of fibroblasts and myofibroblasts (fibroblastic foci) have led to the hypothesis that UIP is a result of ongoing diffuse microscopic alveolar epithelial injury and abnormal wound healing.⁴¹ Usual interstitial pneumonia is characterized by fibroblast/myofibroblast migration and proliferation to sites of injury, decreased myofibroblast apoptosis, and increased activity of and response to fibrogenic cytokines such as transforming growth factor β_1 , tumor necrosis factor α , platelet-derived growth factor, and insulin-like growth factor. In addition, inappropriate reepithelialization of the alveolar epithelium and impaired remodeling of the extracellular matrix appear to be characteristic. The lack of any significant inflammatory stimulus in this fibroproliferative model may explain the poor response of UIP to anti-inflammatory therapies such as corticosteroids.

New Definition of Idiopathic Pulmonary Fibrosis/UIP

To emphasize the distinct pathophysiology and clinical course of UIP, the American Thoracic Society and the European Respiratory Society have recommended reserving the term *idiopathic pulmonary fibrosis* (IPF) for the clinical condition characterized by progressive dyspnea, cough, restrictive lung disease, and the histopathological pattern of UIP.⁴² This is an important semantic change that emphasizes the clinical relevance of histopathology. Idiopathic pulmonary fibrosis has been used historically to refer to a wide variety of interstitial pulmonary conditions, and it is still commonly used to refer to idiopathic interstitial pneumonia irrespective of the histopathological subgroup. It is important that the profession attempts to clarify and define the nomenclature used for idiopathic interstitial pneumonia so that clinicians and researchers will communicate clearly and effectively. The American Thoracic Society/European Respiratory Society definition of IPF will be used throughout the remainder of this article.

APPROACH TO DIAGNOSIS

The patient with suspected idiopathic interstitial pneumonia presents a formidable diagnostic challenge to physicians, and an organized approach is critical. Our approach to the overall diagnosis of IPF is presented in **Figure 2**. The clinically important distinction to be made when diagnosing idiopathic interstitial pneumonia is whether the patient has IPF (as defined by the presence of UIP). A full description of the diagnosis of IPF requires a general discussion of the approach to interstitial lung disease, which is beyond the scope of this review. Several excellent reviews of the general approach to the diagnosis of interstitial lung disease have been published in the past several years.⁴³⁻⁴⁷ Our discussion will focus specifically on the ability of different clinical modalities to distinguish IPF from the other histopathological subgroups of idiopathic interstitial pneumonia.

Clinical Characteristics

The history and results of physical and laboratory evaluations have little diagnostic accuracy for IPF.⁴⁸ In all chronic forms of idiopathic interstitial pneumonia, patients usually present with progressive dyspnea on exertion and dry cough. Fine inspiratory crackles are common on the physical examination, with digital clubbing less frequent but often present. Pulmonary function testing commonly demonstrates restrictive lung disease (decreased forced vital capacity and total lung capacity) and abnormal gas exchange (decreased diffusion capacity of carbon dioxide and resting or exercise PaO₂).

Bronchoscopic Techniques

Unfortunately, no bronchoalveolar lavage findings are specific to IPF. Using the cellular constituency of the bronchoalveolar lavage fluid from patients with idiopathic interstitial pneumonia to predict the underlying histopathological features has been of little clinical utility.⁴⁹⁻⁵¹ Patients with IPF demonstrate a non-specific increase in bronchoalveolar lavage levels of neutrophils, eosinophils, and, less commonly, lymphocytes.⁵² Several studies have suggested that a predominance of bronchoalveolar lavage lymphocytes predicts corticosteroid responsiveness and improved survival.^{51,53} This finding has led to the recommendation that isolated bronchoalveolar lavage lymphocytosis should suggest alternative, corticosteroid-responsive diagnoses such as NSIP, sarcoidosis, hypersensitivity pneumonitis, and bronchiolitis obliterans with organizing pneumonia.⁴² Transbronchial biopsy is limited by the small size of the specimen obtained and the lack of histological preservation due to mechanical crushing of the tissue. Because of these factors, transbronchial biopsy specimens have poor diagnostic accuracy for IPF.⁵⁴⁻⁵⁶

Conventional Chest Radiograph

The chest radiograph lacks diagnostic specificity in interstitial lung disease, with a correct diagnosis made

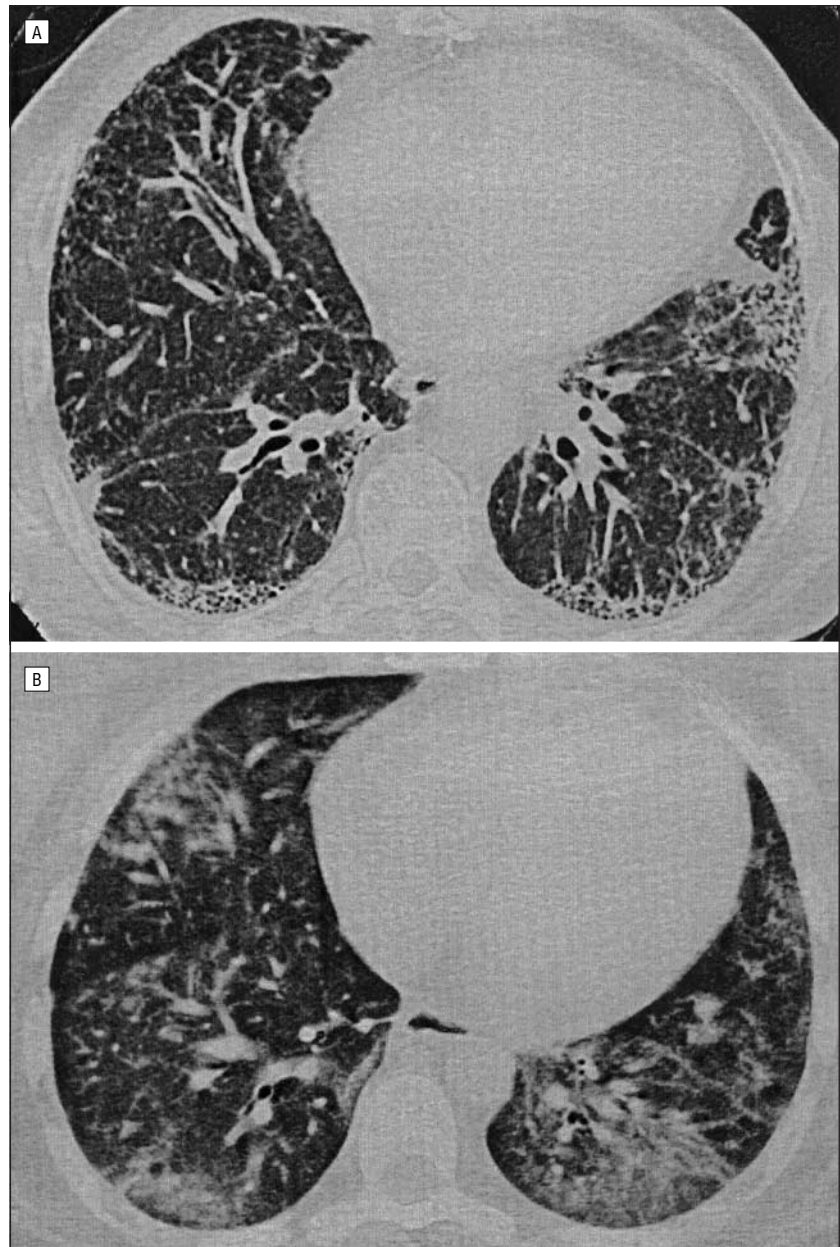


Figure 3. High-resolution computed tomography (HRCT) findings in idiopathic interstitial pneumonia. A, HRCT of the chest in a patient with idiopathic pulmonary fibrosis. A representative HRCT chest image shows bilateral, patchy, subpleural reticular opacities with evidence of subpleural honeycombing. B, HRCT of the chest in a patient with nonspecific interstitial pneumonia. A representative HRCT chest image shows bilateral, patchy, subpleural ground-glass opacities without evidence of subpleural honeycombing.

in less than 50% of cases and only a 70% interobserver agreement.^{57,58} Sensitivity is better, but up to 10% of patients with histopathologically confirmed interstitial fibrosis have normal findings on chest radiographs.⁵⁷⁻⁶⁰ In addition, the chest radiograph correlates poorly with the histological pattern (eg, UIP or NSIP), the anatomic distribution, and the severity of the disease, with the exception of honeycombing, which is quite specific.⁶¹⁻⁶⁴ High-resolution computed tomography (HRCT) is significantly

more sensitive and specific for the diagnosis of IPF and has replaced conventional chest radiography as the preferred imaging method.⁵⁸

High-Resolution CT

The characteristic radiographic features of IPF on HRCT have been well described (**Figure 3**).⁶⁵⁻⁶⁷ These include patchy, predominantly basilar, subpleural reticular opacities; absent or limited ground-glass opacities; traction bronchiectasis and

Table 4. Accuracy of the CT Diagnosis of Idiopathic Pulmonary Fibrosis/Usual Interstitial Pneumonia

Article	No. of Patients	Study Design	Results*
Hunninghake et al ⁷³ (2001)	Patients with suspected IPF (N = 91); 54 with UIP diagnosed by means of surgical lung biopsy	HRCT scans were compared with histopathological findings; observers were provided no clinical information	Likely diagnosis of IPF; sensitivity of 76% and specificity of 72%; certain diagnosis of IPF; sensitivity of 48% and specificity of 97%
Raghu et al ⁷⁵ (1999)	Patients with new-onset interstitial lung disease (N = 59); 29 with UIP defined as between 6 and 24 months of symptoms and/or radiographic evidence, diagnosed by means of transbronchial or surgical lung biopsy	HRCT scans were compared with histopathological findings; observers knew only that the patients were referred for possible interstitial lung disease	Diagnosis of UIP; sensitivity of 78.5% and specificity of 90%
Johkoh et al ⁷⁴ (1999)	Patients with idiopathic interstitial pneumonia (N = 129); 35 with UIP diagnosed by means of surgical lung biopsy	Thin-section CT scans were compared with histopathological findings; observers knew that the diagnosis was 1 of the 5 idiopathic interstitial pneumonias	Likely diagnosis of UIP; sensitivity of 71% and specificity of 88%; certain diagnosis of UIP; sensitivity of 43% and specificity of 95%
Swensen et al ⁷⁶ (1997)	Patients with diffuse lung disease (N = 85); 18 with UIP diagnosed by means of surgical lung biopsy	Regular or thin-section CT scans were compared with histopathological findings; observers were masked to all but age and sex	Likely diagnosis of UIP; sensitivity of 89% and specificity not reported; highly confident diagnosis of UIP; sensitivity of 67% and specificity of 97%
Tung et al ⁷¹ (1993)	Patients with diffuse lung disease (N = 86); 41 with UIP diagnosed clinically (n = 9) or by means of lung biopsy (n = 32)	HRCT scans were compared with clinical or histological diagnosis; observers were blinded to all information	Likely diagnosis of UIP; sensitivity of 89% and specificity of 87%; definite diagnosis of UIP; sensitivity of 60% and specificity of 98%
Nishimura et al ⁶⁹ (1993)	Patients with diffuse infiltrative lung disease (N = 134); 28 with UIP diagnosed by means of surgical lung biopsy, autopsy, or microbiology	HRCT scans were compared with histopathologic findings; observers were masked to all but age and sex	Diagnosis of UIP; sensitivity of 77% and specificity of 93%
Padley et al ⁷⁰ (1991)	Total patients (N = 100), 86 with diffuse lung disease; 24 with UIP diagnosed clinically or by means of surgical lung biopsy	HRCT scans were compared with clinical or histological diagnosis; observers were masked to all but age and sex	Diagnosis of UIP; sensitivity of 70% and specificity data not reported
Mathieson et al ⁵⁸ (1989)	Patients with diffuse infiltrative lung disease (N = 118); 34 with UIP diagnosed by means of lung or lymph node biopsy	Regular and HR CT scans were compared with histopathologic findings; unclear degree of masking	Likely diagnosis of UIP; sensitivity of 88% and specificity data not reported; highly confident diagnosis of UIP; sensitivity of 71% and specificity data not reported

Abbreviations: CT, computed tomography; HRCT, high-resolution CT; IPF, idiopathic pulmonary fibrosis. Other abbreviations are explained in the first footnote to Table 1.

*Sensitivity and specificity were calculated for this review based on data reported in each article.

bronchiolectasis; and honeycombing. Atypical findings include extensive ground-glass opacities, nodules, upper-lobe or midzone predominance of findings, and significant hilar or mediastinal lymphadenopathy. The presence of more ground-glass opacities than reticular changes is particularly confounding, as its histopathological correlation is quite variable.⁶⁸ Thus, the presence of significant ground-glass opacities on HRCT should bring in to question the radiographic diagnosis of IPF.

The use of HRCT chest findings to diagnose IPF has been widely

investigated (**Table 4**).^{58,69-72} Most published studies have used surgical lung biopsy as the comparative gold standard. The radiographic and histopathological criteria used for the diagnosis of IPF in these studies have varied by institution and over time. The most recent studies of HRCT have reported sensitivities of 43% to 78% and specificities of 90% to 97% for the confident radiographic diagnosis of IPF.⁷³⁻⁷⁶ Inclusion of less confident radiographic diagnoses improves sensitivity, but leads to significant numbers of false-positive findings (ie, lower specificity.) On the basis of these data, HRCT can be

used to make a confident, highly specific diagnosis of IPF in half to two thirds of patients with idiopathic interstitial pneumonia.

Accuracy of Combined Clinical and Radiographic Diagnosis

Two recent studies have addressed the accuracy of the combined clinical and radiographic diagnosis of IPF. In both studies, clinicians were masked to the results of the surgical lung biopsies, which were used as the gold standard for diagnosis. Raghu et al⁷⁵ prospectively studied 59 patients who were referred for

evaluation of new-onset interstitial lung disease, all of whom underwent diagnostic transbronchial or surgical lung biopsies. A clinical diagnosis of IPF was made if a patient met all of the following criteria: (1) absence of clinical features suggestive of infectious, neoplastic, collagen-vascular, occupational, environmental, or drug-related conditions or hereditary diseases known to be associated with IPF; (2) age greater than 50 years; (3) insidious onset of exertional dyspnea of greater than 6 months' duration; (4) bibasilar end-expiratory crackles; (5) restrictive lung defect without coexisting airflow obstruction, decreased diffusing capacity, and increased alveolar-arterial oxygen gradient at rest or with exercise; (6) chest radiograph or HRCT with characteristic findings of IPF; and (7) transbronchial biopsy findings or bronchoalveolar lavage cellular profile lacking features to support a specific alternative diagnosis. When compared with the histopathological diagnosis, the clinical diagnosis of IPF had a sensitivity of 62% and a specificity of 97%. Hunninghake et al⁷³ performed a similar study of 91 patients suspected of having IPF. No predetermined criteria for clinical diagnosis were described. The confident clinical diagnosis of IPF had a sensitivity of 48% and a specificity of 89%. These 2 studies argue that, when the clinical and radiographic diagnoses are consistent, IPF can be confidently diagnosed. They also demonstrate that this consistency is present in only about half of patients with biopsy-confirmed UIP.

ROLE OF SURGICAL LUNG BIOPSY

Diagnosing IPF Without Surgical Lung Biopsy

The American Thoracic Society and the European Respiratory Society recently published a consensus statement describing major and minor criteria for the clinical diagnosis of IPF, given in **Table 5**.⁴² The presence of all 4 major criteria and at least 3 of 4 minor criteria increases the likelihood of a correct clinical diagnosis. The panel noted that in the absence

Table 5. Major and Minor Criteria Supporting the Clinical Diagnosis of Idiopathic Pulmonary Fibrosis*

Major criteria

1. Exclusion of other known causes of ILD, such as certain drug toxicities, environmental exposures, and connective tissue diseases.
2. Abnormal findings of pulmonary function studies that include evidence of restriction (reduced VC often with an increased FEV₁/FVC ratio) and impaired gas exchange (increased alveolar-arterial oxygen gradient with rest or exercise, or decreased DLCO).
3. Bibasilar reticular abnormalities with minimal ground-glass opacities on HRCT.
4. Transbronchial lung biopsy or bronchoalveolar lavage showing no features to support an alternative diagnosis.

Minor criteria

1. Age >50 years.
2. Insidious onset of otherwise unexplained dyspnea on exertion.
3. Duration of illness of 3 or more months.
4. Bibasilar, inspiratory dry crackles (Velcro type).

Abbreviations: DLCO, diffusion capacity for carbon monoxide; FEV₁, forced expiratory volume in 1 second; FVC, forced vital capacity; HRCT, high-resolution computed tomography; ILD, interstitial lung disease; VC, vital capacity.

*Adapted from American Thoracic Society.⁴² For major criteria, all 4 must be present; for minor, at least 3 of 4 must be present.

of surgical lung biopsy findings, the diagnosis of IPF remains unproved. Ultimately, individual clinicians and patients must decide the degree of diagnostic specificity with which they are comfortable. If patients do not meet these major and minor criteria, we believe that surgical lung biopsy should be pursued in all patients except those too frail or ill to tolerate it.¹¹

Surgical Lung Biopsy

In 1980, the largest retrospective review of open-lung biopsy in patients with infiltrative lung disease reported a diagnostic yield of 92% and overall morbidity and mortality of 2.5% and 0.3%, respectively.⁷⁷ Recent studies have confirmed this diagnostic yield.^{78,79} Thoracoscopy was introduced in the early 1980s as a potential alternative to thoracotomy.⁸⁰ Many articles have since evaluated the role of video-assisted thoracoscopic surgery in the diagnosis of interstitial lung disease⁸¹⁻⁸³ and compared the thoracoscopic and open approaches with lung biopsy.^{78,79,84-87} Video-assisted thoracoscopic surgery appears to have an equivalent diagnostic yield, equal or lower morbidity, and equal or decreased length of stay compared with the open surgical approach. In addition, thoracoscopy often allows the surgeon to view and sample more distant areas of the lung.

The choice between video-assisted thoracoscopic surgery and open-lung biopsy should generally

be made by the thoracic surgeon on the basis of individual patient characteristics, but most patients today undergo video-assisted thoracoscopic surgery. However, video-assisted thoracoscopic surgery is contraindicated in the following 3 important situations: inability to tolerate single-lung ventilation (eg, severe hypoxemia or high airway pressures), coagulopathy, and pleural adhesions or scarring from previous thoracic surgery or pleurodesis. If a histopathological diagnosis is essential in these patients, a limited thoracotomy is usually the surgical approach of choice.

CONCLUSIONS

The past few years have seen extensive redefinition of idiopathic interstitial pneumonia, with an increased understanding of the clinical importance of histopathological subclassification. In addition, we have begun to understand the underlying pathophysiology to a much greater extent, and in so doing realized that the old paradigm of inflammation leading to fibrosis might not apply to all conditions. How does this relate to the care of patients with idiopathic interstitial pneumonia in the year 2003?

First, all patients with suspected idiopathic interstitial pneumonia should undergo careful evaluation, with an in-depth history and physical examination, pulmonary

function testing, bronchoscopy, and HRCT by physicians experienced in the care of patients with idiopathic interstitial pneumonia. Many patients can be classified as having IPF with a high degree of specificity without the need for surgical lung biopsy.

Second, patients whose diagnosis is unclear after a thorough clinical and radiographic evaluation should undergo surgical lung biopsy to establish the underlying histopathological pattern. It is quite clear that IPF (as defined by the presence of UIP) does not respond to corticosteroids in most patients. Given the significant adverse effects of corticosteroids, the diagnosis of IPF should lead to careful consideration of the decision to use corticosteroids and prompt the addition of a second agent. The American Thoracic Society and the European Respiratory Society have recommended that initial therapy for IPF involve corticosteroids and immunomodulatory agents (cyclophosphamide or azathioprine) for 6 months, with progressive clinical decline or substantial adverse effects of treatment prompting cessation or modification of therapy.⁴²

Third, physicians need to counsel their patients with IPF early with regard to prognosis, as it is distinct from the other forms of idiopathic interstitial pneumonia. Referral for lung transplantation should be pursued early in those patients with progressive disease that is unresponsive to therapy who are candidates.

Last, clear establishment of the diagnosis of IPF allows patients who are refractory to standard therapy to be enrolled in clinical trials of antifibrotic agents and other new therapies. As our understanding of the pathophysiology of IPF grows, we will surely develop promising new agents that may significantly affect the morbidity and mortality of patients with this devastating disease.

Accepted for publication June 12, 2002.

Corresponding author and reprints: Talmadge E. King, Jr, MD, San Francisco General Hospital, Room 5H22, 1001 Potrero Ave, San Francisco, CA 94110 (e-mail: tking@medsfgh.ucsf.edu).

REFERENCES

- Osler W. *The Principles and Practice of Medicine*. New York, NY: D Appleton & Co; 1892.
- Hamman L, Rich A. Acute diffuse interstitial fibrosis of the lung. *Bull Johns Hopkins Hosp*. 1944; 74:177-212.
- Liebow AA, Carrington CB. The interstitial pneumonias. In: Simon M, Potchen EJ, LeMay M, eds. *Frontiers of Pulmonary Radiology*. New York, NY: Grune & Stratton Inc; 1969:102-141.
- Katzenstein AL, Myers JL. Idiopathic pulmonary fibrosis: clinical relevance of pathologic classification. *Am J Respir Crit Care Med*. 1998;157(pt 1):1301-1315.
- American Thoracic Society/European Respiratory Society international multidisciplinary consensus classification of idiopathic interstitial pneumonias: general principles and recommendations. *Am J Respir Crit Care Med*. 2002;165:277-304.
- Vourlekis JS, Brown KK, Cool CD, et al. Acute interstitial pneumonitis: case series and review of the literature. *Medicine (Baltimore)*. 2000;79:369-378.
- Bjoraker JA, Ryu JH, Edwin MK, et al. Prognostic significance of histopathologic subsets in idiopathic pulmonary fibrosis. *Am J Respir Crit Care Med*. 1998;157:199-203.
- Nagai S, Kitaichi M, Itoh H, Nishimura K, Izumi T, Colby TV. Idiopathic nonspecific interstitial pneumonia/fibrosis: comparison with idiopathic pulmonary fibrosis and BOOP. *Eur Respir J*. 1998; 12:1010-1019.
- Nicholson A, Colby TV, du Bois RM, Hansell DM, Wells AU. The prognostic significance of the histologic pattern of interstitial pneumonia in patients with the clinical entity of cryptogenic fibrosing alveolitis. *Am J Respir Crit Care Med*. 2000; 162:2213-2217.
- Travis WD, Matsui K, Moss J, Ferrans VJ. Idiopathic nonspecific interstitial pneumonia: prognostic significance of cellular and fibrosing patterns: survival comparison with usual interstitial pneumonia and desquamative interstitial pneumonia. *Am J Surg Pathol*. 2000;24:19-33.
- Collard H, King T Jr. The clinical significance of histopathologic subgroups in idiopathic interstitial pneumonia: is surgical lung biopsy essential? *Semin Respir Crit Care Med*. 2001;22:347-356.
- Katzenstein AL, Fiorelli RF. Nonspecific interstitial pneumonia/fibrosis: histologic patterns and clinical significance. *Am J Surg Pathol*. 1994;18: 136-147.
- Myers JL, Veal CF Jr, Shin MS, Katzenstein AL. Respiratory bronchiolitis causing interstitial lung disease: a clinicopathologic study of six cases. *Am Rev Respir Dis*. 1987;135:880-884.
- Yousem SA, Colby TV, Gaensler EA. Respiratory bronchiolitis-associated interstitial lung disease and its relationship to desquamative interstitial pneumonia. *Mayo Clin Proc*. 1989;64:1373-1380.
- Mapel DW, Samet JM, Coultas DB. Corticosteroids and the treatment of idiopathic pulmonary fibrosis: past, present, and future. *Chest*. 1996; 110:1058-1067.
- Tukiainen P, Taskinen E, Holsti P, Korhola O, Valle M. Prognosis of cryptogenic fibrosing alveolitis. *Thorax*. 1983;38:349-355.
- Turner-Warwick M, Burrows B, Johnson A. Cryptogenic fibrosing alveolitis: response to corticosteroid treatment and its effect on survival. *Thorax*. 1980;35:593-599.
- Stack BHR, Choo-Kang YFJ, Heard BH. The prognosis of cryptogenic fibrosing alveolitis. *Thorax*. 1972;27:535-542.
- Gay SE, Kazerooni EA, Toews GB, et al. Idiopathic pulmonary fibrosis: predicting response to therapy and survival. *Am J Respir Crit Care Med*. 1998;157:1063-1072.
- Flaherty KR, Toews GB, Lynch DA, et al. Steroids in idiopathic pulmonary fibrosis: a prospective assessment of adverse reactions, response to therapy, and survival. *Am J Med*. 2001;110:278-282.
- Carrington CB, Gaensler EA, Coutu RE, Fitzgerald MX, Gupta RG. Natural history and treated course of usual and desquamative interstitial pneumonia. *N Engl J Med*. 1978;298:801-809.
- Douglas WW, Ryu JH, Swensen SJ, et al, and Members of the Lung Study Group. Colchicine versus prednisone in the treatment of idiopathic pulmonary fibrosis: a randomized prospective study. *Am J Respir Crit Care Med*. 1998;158:220-225.
- Daniil ZD, Gilchrist FC, Nicholson AG, et al. A histologic pattern of nonspecific interstitial pneumonia is associated with a better prognosis than usual interstitial pneumonia in patients with cryptogenic fibrosing alveolitis. *Am J Respir Crit Care Med*. 1999;160:899-905.
- Olson J, Colby TV, Elliott CG. Hamman-Rich syndrome revisited. *Mayo Clin Proc*. 1990;65:1538-1548.
- Raghu G, Depaso WJ, Cain K, et al. Azathioprine combined with prednisone in the treatment of idiopathic pulmonary fibrosis: a prospective double-blind, randomized, placebo-controlled trial. *Am Rev Respir Dis*. 1991;144:291-296.
- Johnson MA, Snell NJC, Nunn AJ, Darbyshire JH, Turner-Warwick M. Randomized controlled trial comparing prednisolone alone with cyclophosphamide and low dose prednisolone in combination in cryptogenic fibrosing alveolitis. *Thorax*. 1989;44:280-288.
- Zisman DA, Lynch JP III, Toews GB, Kazerooni EA, Flint A, Martinez FJ. Cyclophosphamide in the treatment of idiopathic pulmonary fibrosis: a prospective study in patients who failed to respond to corticosteroids. *Chest*. 2000;117:1619-1626.
- Douglas WW, Ryu JH, Schroeder DR. Idiopathic pulmonary fibrosis: impact of oxygen and colchicine, prednisone, or no therapy on survival. *Am J Respir Crit Care Med*. 2000;161:1172-1178.
- Ziesche R, Hofbauer E, Wittmann K, Petkov V, Block LH. A preliminary study of long-term treatment with interferon gamma-1b and low-dose prednisolone in patients with idiopathic pulmonary fibrosis. *N Engl J Med*. 1999;341:1264-1269.
- Kolb M, Kirschner J, Riedel W, Wirtz H, Schmidt M. Cyclophosphamide pulse therapy in idiopathic pulmonary fibrosis. *Eur Respir J*. 1998;12: 1409-1414.
- Smith CM, Holbrook T. Utilization of the transbronchial biopsy (TBB) and open lung biopsy for tissue to establish the diagnosis of idiopathic pulmonary fibrosis: survey of the California Thoracic Society membership [abstract]. *Am Rev Respir Dis*. 1990;141:A62.
- Johnston IDA, Gomm SA, Kalra S, Woodcock AA, Evans CC, Hind CRK. The management of cryptogenic fibrosing alveolitis in three regions of the United Kingdom. *Eur Respir J*. 1993;6:891-893.
- The American Society for Transplant Physicians (ASTP)/American Thoracic Society (ATS)/European Respiratory Society (ERS)/International Society for Heart and Lung Transplantation (ISHLT). International guidelines for the selection of lung transplant candidates. *Am J Respir Crit Care Med*. 1998;158:335-339.

34. Meester JD, Smits JM, Persijn GG, Haverich A. Lung transplant waiting list: differential outcome of type of end-stage lung disease, one year after registration. *J Heart Lung Transplant*. 1999;18:563-571.
35. Mogulkoc N, Brutsche MH, Bishop PW, Greaves SM, Horrocks AW, Egan JJ. Pulmonary function in idiopathic pulmonary fibrosis and referral for lung transplantation. *Am J Respir Crit Care Med*. 2001;164:103-108.
36. Meyers BF, Lynch JP, Trulock EP, Guthrie T, Cooper JD, Patterson GA. Single versus bilateral lung transplantation for idiopathic pulmonary fibrosis: a ten-year institutional experience. *J Thorac Cardiovasc Surg*. 2000;120:99-107.
37. Grossman RF, Frost A, Zamel N, et al. Results of single-lung transplantation for bilateral pulmonary fibrosis. *N Engl J Med*. 1990;322:727-733.
38. Hosenpud JD, Bennett LE, Keck BM, et al. Effect of diagnosis on survival benefit of lung transplantation for end-stage lung disease. *Lancet*. 1998;351:24-27.
39. Wells AU, Cullinan P, Hansell DM, et al. Fibrosing alveolitis associated with systemic sclerosis has a better prognosis than lone cryptogenic fibrosing alveolitis. *Am J Respir Crit Care Med*. 1994;149:1583-1590.
40. King TE Jr, Schwarz MI, Brown K, et al. Idiopathic pulmonary fibrosis: relationship between histopathologic features and mortality. *Am J Respir Crit Care Med*. 2001;164:1025-1032.
41. Selman M, King TE Jr, Pardo A. Idiopathic pulmonary fibrosis: prevailing and evolving hypotheses about its pathogenesis and implications for therapy. *Ann Intern Med*. 2001;134:136-151.
42. American Thoracic Society. Idiopathic pulmonary fibrosis: diagnosis and treatment: joint statement of the American Thoracic Society (ATS) and the European Respiratory Society (ERS). *Am J Respir Crit Care Med*. 2000;161:646-664.
43. Michaelson JE, Aguayo SM, Roman J. Idiopathic pulmonary fibrosis: a practical approach for diagnosis and management. *Chest*. 2000;118:788-794.
44. British Thoracic Society. The diagnosis, assessment and treatment of diffuse parenchymal lung disease in adults. *Thorax*. 1999;54(suppl 1):S1-S28.
45. Raghu G. Interstitial lung disease: a diagnostic approach: are CT scan and lung biopsy indicated in every patient? *Am J Respir Crit Care Med*. 1995;151:909-914.
46. du Bois RM. Diffuse lung disease: an approach to management. *BMJ*. 1994;309:175-179.
47. Schwarz MI. Approach to the understanding, diagnosis, and management of interstitial lung disease. In: Schwarz MI, King TE Jr, eds. *Interstitial Lung Disease*. 3rd ed. Burlington, Ontario: BC Decker Inc; 1998:3-30.
48. Grenier P, Chevret S, Beigelman C, Brauner M, Chastang C, Valeyre D. Chronic diffuse infiltrative lung disease: determination of the diagnostic value of clinical data, chest radiography, and CT with Bayesian analysis. *Radiology*. 1994;191:383-390.
49. Drent M, Van Nierdop AMF, Gerritsen FA, Wouters EFM, Mulder PGH. A computer program using BALF-analysis results as a diagnostic tool in interstitial lung diseases. *Am J Respir Crit Care Med*. 1996;153:736-741.
50. Robinson PC, Watters LC, King TE Jr, Mason RJ. Idiopathic pulmonary fibrosis: abnormalities in bronchoalveolar lavage fluid phospholipids. *Am Rev Respir Dis*. 1988;137:585-591.
51. Watters LC, Schwarz MI, Cherniack RM, et al. Idiopathic pulmonary fibrosis: pretreatment bronchoalveolar lavage cellular constituents and their relationships with lung histopathology and clinical response to therapy. *Am Rev Respir Dis*. 1987;135:696-704.
52. Bronchoalveolar lavage constituents in healthy individuals, idiopathic pulmonary fibrosis and selected comparison groups. *Am Rev Respir Dis*. 1990;141(suppl):S169-S196.
53. Haslam PL, Turton CWG, Heard B, Lukoszek JV, Salsbury AJ, Turner-Warwick M. Bronchoalveolar lavage in pulmonary fibrosis: comparison of cells obtained with lung biopsy and clinical features. *Thorax*. 1980;35:9-18.
54. Burt ME, Fiyeh MW, Webber BL, Wesley RA. Prospective evaluation of aspiration needle, cutting needle, transbronchial, and open lung biopsy in patients with pulmonary infiltrates. *Ann Thorac Surg*. 1981;32:146-153.
55. Gilman MJ, Wang KP. Transbronchial lung biopsy in sarcoidosis. *Am Rev Respir Dis*. 1980;122:721-724.
56. Wall CP, Gaensler EA, Carrington CB, Hayes JA. Comparison of transbronchial and open biopsies in chronic infiltrative lung disease. *Am Rev Respir Dis*. 1981;123:280-285.
57. McLoud TC, Carrington CB, Gaensler EA. Diffuse infiltrative lung disease: a new scheme for description. *Radiology*. 1983;149:353-363.
58. Mathieson JR, Mayo JR, Staples CA, Muller N. Chronic diffuse infiltrative lung disease: comparison of diagnostic accuracy of CT and chest radiography. *Radiology*. 1989;171:111-116.
59. Epler GR, McLoud TC, Gaensler EA, Mikus JP, Carrington CB. Normal chest roentgenograms in chronic diffuse infiltrative lung disease. *N Engl J Med*. 1978;298:934-939.
60. Liebow AA, Steer A, Billingsley JG. Desquamate interstitial pneumonia. *Am J Med*. 1965;39:369-404.
61. Winterbauer RH, Hammar SP, Hallman KO, et al. Diffuse interstitial pneumonitis clinicopathologic correlations in 20 patients treated with prednisone/azathioprine. *Am J Med*. 1978;65:661-672.
62. Watters LC, King TE Jr, Schwarz MI, Waldron J, Stanford RE, Cherniack RM. A clinical, radiographic and physiologic scoring system for the longitudinal assessment of patients with idiopathic pulmonary fibrosis. *Am Rev Respir Dis*. 1986;133:97-103.
63. Swensen SJ, Aughenbaugh GL, Brown LR. High-resolution computed tomography of the lung. *Mayo Clin Proc*. 1989;64:1284-1294.
64. Felson B. A new look at pattern recognition of diffuse pulmonary disease. *AJR Am J Roentgenol*. 1979;133:183-189.
65. Muller N, Miller RR, Webb RW, Evans KG, Ostrow DN. Fibrosing alveolitis: CT-pathologic correlation. *Radiology*. 1986;160:585-588.
66. Nishimura K, Kitaichi M, Izumi T, Nagai S, Kanaoka M, Itoh H. Usual interstitial pneumonia: histologic correlation with high-resolution CT. *Radiology*. 1992;182:337-342.
67. Orens JB, Kazerooni EA, Martinez FJ, et al. The sensitivity of high-resolution CT in detecting idiopathic pulmonary fibrosis proved by open lung biopsy: a prospective study. *Chest*. 1995;108:109-115.
68. Remy-Jardin M, Giraud F, Remy J, Copin MC, Goselin B, Duhamel A. Importance of ground glass attenuation in chronic diffuse infiltrative lung disease: pathologic-CT correlation. *Radiology*. 1993;189:693-698.
69. Nishimura K, Izumi T, Kitaichi M, Nagai S, Itoh H. The diagnostic accuracy of high-resolution computed tomography in diffuse infiltrative lung disease. *Chest*. 1993;104:1149-1155.
70. Padley SPG, Hansell DM, Flower CDR, Jennings P. Comparative accuracy of high-resolution computed tomography and chest radiography in the diagnosis of chronic diffuse infiltrative lung disease. *Clin Radiol*. 1991;44:222-226.
71. Tung KT, Wells AU, Rubens MB, Kirk JME, du Bois RM, Hansell DM. Accuracy of the typical computed tomographic appearances of fibrosing alveolitis. *Thorax*. 1993;48:334-338.
72. Lynch DA, Newell JD, King TE Jr, Muller N. Can CT distinguish hypersensitivity pneumonitis from idiopathic pulmonary fibrosis? *AJR Am J Roentgenol*. 1995;165:807-811.
73. Hunninghake GW, Zimmerman MB, Schwartz DA, et al. Utility of a lung biopsy for the diagnosis of idiopathic pulmonary fibrosis. *Am J Respir Crit Care Med*. 2001;164:193-196.
74. Johkoh T, Müller NL, Cartier Y, et al. Idiopathic interstitial pneumonias: diagnostic accuracy of thin-section CT in 129 patients. *Radiology*. 1999;211:555-560.
75. Raghu G, Mageto YN, Lockhart D, Schmidt RA, Wood DE, Godwin JD. The accuracy of the clinical diagnosis of new-onset idiopathic pulmonary fibrosis and other interstitial lung disease: a prospective study. *Chest*. 1999;116:1168-1174.
76. Swensen SJ, Aughenbaugh GL, Myers JL. Diffuse lung disease: diagnostic accuracy of CT in patients undergoing surgical biopsy of the lung. *Radiology*. 1997;205:229-234.
77. Gaensler EA, Carrington CB. Open biopsy for chronic diffuse infiltrative lung disease: clinical, roentgenographic, and physiological correlations in 502 patients. *Ann Thorac Surg*. 1980;30:411-426.
78. Bensard DD, McIntyre RC Jr, Waring BJ, Simon JS. Comparison of video thoracoscopic lung biopsy to open lung biopsy in the diagnosis of interstitial lung disease. *Chest*. 1993;103:765-770.
79. Ayed AK, Raghunathan R. Thoracoscopy versus open lung biopsy in the diagnosis of interstitial lung disease: a randomised controlled trial. *J R Coll Surg Edinb*. 2000;45:159-163.
80. Boutin C, Viallat JR, Cargnino P, Rey F. Thoracoscopic lung biopsy: experimental and clinical preliminary study. *Chest*. 1982;82:44-48.
81. Rena O, Casadio C, Leo F, et al. Videothoracoscopic lung biopsy in the diagnosis of interstitial lung disease. *Eur J Cardiothorac Surg*. 1999;16:624-627.
82. Zegdi R, Azorin J, Tremblay B, Destable MD, Lajos PS, Valeyre D. Videothoracoscopic lung biopsy in diffuse infiltrative lung diseases: a 5-year surgical experience. *Ann Thorac Surg*. 1998;66:1170-1173.
83. Krasna MJ, White CS, Aisner SC, Templeton PA, McLaughlin JS. The role of thoracoscopy in the diagnosis of interstitial lung disease. *Ann Thorac Surg*. 1995;59:348-351.
84. Hartman DZ, Mylet D, Gaither JG, et al. Comparison of thoracoscopic lung biopsy with open lung biopsy in diffuse interstitial lung disorders [abstract]. *Am Rev Respir Dis*. 1992;145:A750.
85. Carnochan FM, Walker WS, Cameron EW. Efficacy of video assisted thoracoscopic lung biopsy: an historical comparison with open lung biopsy. *Thorax*. 1994;49:361-363.
86. Ferson PF, Landreneau RJ, Dowling RD, et al. Comparison of open versus thoracoscopic lung biopsy for diffuse infiltrative pulmonary disease. *J Thorac Cardiovasc Surg*. 1993;106:194-199.
87. Miller JD, Urschel JD, Cox G, et al. A randomized, controlled trial comparing thoracoscopy and limited thoracotomy for lung biopsy in interstitial lung disease. *Ann Thorac Surg*. 2000;70:1647-1650.