

IRB00051415

NCT01574287

Protocol

Amino Acid Transport Imaging of Parathyroid Adenomas with anti-3-[18F] FACBC

Principal Investigator: David M Schuster, M.D.

Date: 11/22/2013

Amino Acid Transport Imaging of Parathyroid Adenomas with *anti-3-[¹⁸F]FACBC*

David M Schuster, M.D.

Emory University

Department of Radiology and Imaging Sciences

Emory University School of Medicine, Atlanta, GA

Phone: (404) 712-4859

email: dschust@emory.edu

Rianot Amzat, MD

Pooneh Taleghani, MD

Mark M Goodman, MD

Raghu Halkar, MD

Collin Weber, MD

Jyotirmay Sharma, MD

Dr. Susan Safley

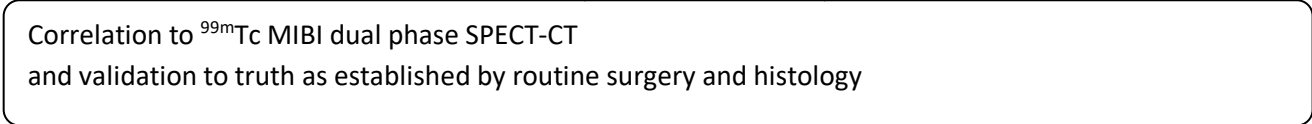
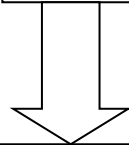
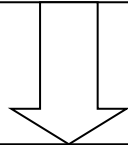
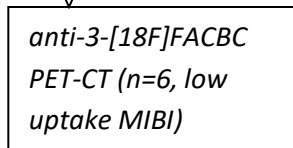
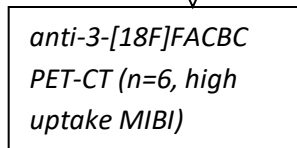
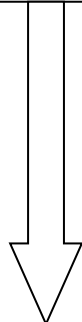
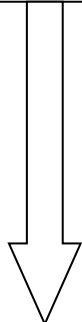
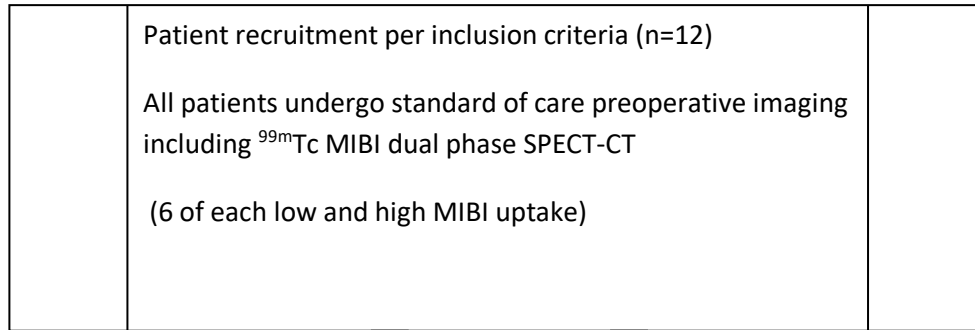
Francois Villinger, DVM, PhD

Weiping Yu, PhD

Carlos Moreno, PhD

Cynthia Cohen, MD

Schema:



Precis/Abstract:

Hyperparathyroidism is an increasingly significant medical and public health condition. The most common technique for preoperative localization is a SPECT/CT, utilizing Tc-99m-sestamibi as a radiotracer. However, the reported sensitivity and specificity is only 80%. Thus there is a need for more accurate preoperative localization of parathyroid adenomas. *Anti*-1-amino-3-^[18F]fluorocyclobutane-1-carboxylic acid (*anti*-3-^[18F]FACBC) is a synthetic amino acid analog for positron emission tomography (PET) which has demonstrated promise for the staging and restaging of carcinoma. There is some preliminary evidence that amino acid transport may be upregulated in parathyroid adenomas and hyperplasia. We plan to perform a pilot study in 12 patients who are scheduled for surgery after standard preoperative evaluation for biochemically confirmed hyperparathyroidism. Patients will undergo *anti*-3-^[18F]FACBC PET-CT. 6 each in high group will have had low or high uptake of MIBI. Uptake within proven disease will be measured for the amino acid PET radiotracer, compared against current imaging standard exams such as dual phase sestamibi SPECT-CT, and validated to truth by surgery and histologic proof. Results of this pilot study will be used to possibly design larger and more comprehensive studies examining clinical utility.

A. Introduction and Background:

Hyperparathyroidism is an increasingly significant medical and public health condition. In the past two decades, the incidence of hyperparathyroidism has increased 300%, and currently the disease affects at least 30,000 new patients each year in the United States. Parathyroid adenomas, parathyroid hyperplasia in primary and secondary hyperparathyroidism, and parathyroid carcinomas all are increasing in frequency. Primary hyperparathyroidism is seen in one out of 500-1000 people and is caused by a single adenoma in 85% of cases (1). The mechanisms responsible for the increased incidence of hyperparathyroidism are not known. Environmental factors such as ionizing radiation exposure have been suggested by some authorities. Multiple organs are affected in patients with hyperparathyroidism; notably, a worsening of the severity of osteoporosis and accelerated arteriosclerotic disease and hypertension. Parathyroid carcinoma no longer is a rare illness. There is no effective oncologic therapy for parathyroid carcinoma, and it is often fatal.

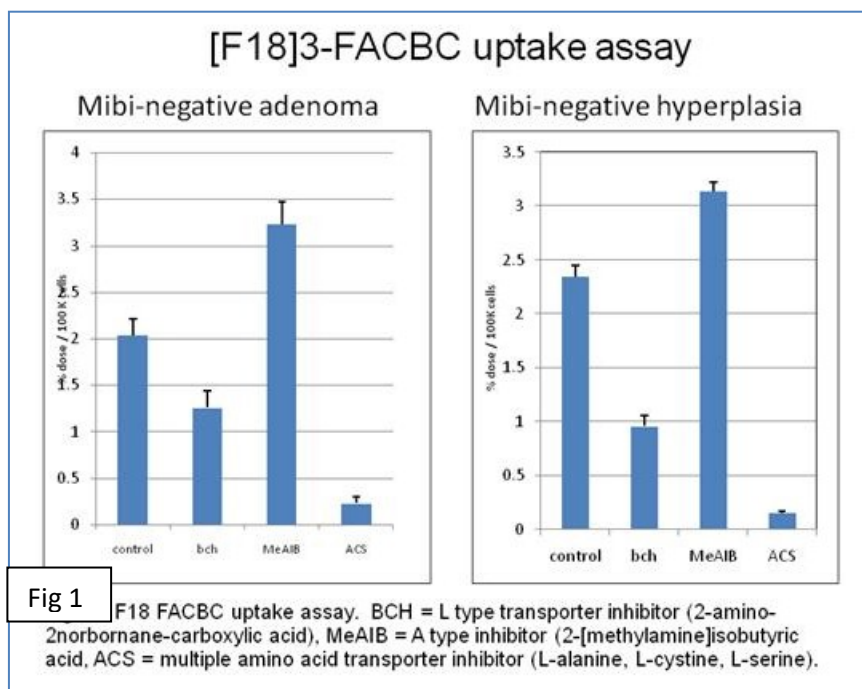
Surgery is the only effective management for primary hyperparathyroidism. Preoperative localization of the adenoma allows unilateral neck exploration for removal of the tumor (2, 3). Since this approach decreases duration of surgery and morbidity, preoperative localization is gaining more importance. However, pre-operative and intra-operative parathyroid tumor localization can be challenging, in part because current imaging methodologies are sub-optimal, failing to identify the parathyroid tumor in as many as 30% of patients (4). In reoperative parathyroidectomy for persistent or recurrent hyperparathyroidism, localization plays an even greater role (5). Unfortunately current multiple imaging modalities fail to localize 10-15% these of tumors.

The most common technique for preoperative localization is a SPECT/CT, utilizing Tc-99m-sestamibi (MIBI) as a radiotracer. ^{99m}Tc MIBI early and delayed (dual phase) imaging with Single Photon Emission Computerized Tomography (SPECT) or SPECT/CT has become the standard of care (4). ^{99m}Tc MIBI is an isonitrile compound which tends to accumulate in mitochondria and has a short half life of 6 hours, physical characteristics ideally suited for imaging with a Gamma camera. ^{99m}Tc MIBI concentrates both in thyroid and parathyroid tissues but washes out faster from thyroid tissue than parathyroid tumors, allowing dual phase imaging to localize the parathyroid tumors (6). SPECT imaging improves the contrast and facilitates location of the parathyroid tumors, while SPECT/CT provides three-dimensional localization (7). However, the reported sensitivity and specificity is only 80% (4, 8). Parathyroid glands usually are located close to the thyroid and ^{99m}Tc MIBI concentrates both in thyroid and parathyroid tissue. Hence there is a need for a tracer/imaging tool that concentrates in the parathyroid but not in the thyroid.

A more sensitive and specific radiotracer/tracking agent would markedly improve our ability to identify parathyroid tumors preoperatively, and thus offer more patients a minimally invasive parathyroidectomy.

Amino acids are involved in many aspects of human nutrition including the synthesis of proteins. Amino acid metabolism has been demonstrated to be upregulated in many tumors including prostate carcinoma (9). A number of amino acid radiotracers have been utilized to study carcinoma and other tumors including naturally occurring L-[11C]methionine, L-3-[123I]iodo-alpha-methyl tyrosine (IMT), and L-[1-11C]5-hydroxytryptophan (5-HTP). *Anti-1-amino-3-[18F]fluorocyclobutane-1-carboxylic acid* (*anti-3-[18F]FACBC*) is a non-natural amino acid analog with low renal excretion and high pancreatic concentration. In some manner it may be transported similar to the amino acid leucine. *anti-3-[18F]FACBC* has demonstrated promise for the staging and restaging of prostate carcinoma (10) and has demonstrated utility for cerebral neoplasia (11). *anti-3-[18F]FACBC* biodistribution studies demonstrate that radiotracer concentration in the thyroid is less than that in the muscle (12).

Parathormone is a peptide hormone, and the bioactive conformation includes a long helical dimer containing 10 Leucine residues. Our initial work with *anti-3-[18F]FACBC* in primary cultures of human parathyroid cells (Figure 1) have shown significant specific uptake of *anti-3-[18F]FACBC* by these parathyroid cells. *anti-3-[18F]FACBC* incorporation in



parathyroid tumor cells in vitro was assayed by gamma counting. Specific uptake of *anti-3-[18F]FACBC*, an L-leucine analog, was shown by blocking with an L-type transporter inhibitor (BCH) and a multiple amino acid inhibitor (ACS), while an A-type inhibitor (MeAIB) did not block uptake. Hence we hypothesize that parathyroid cells will concentrate *anti-3-[18F]FACBC*, and thus *anti-3-[18F]FACBC* can be used as a tracer for positron emission imaging.

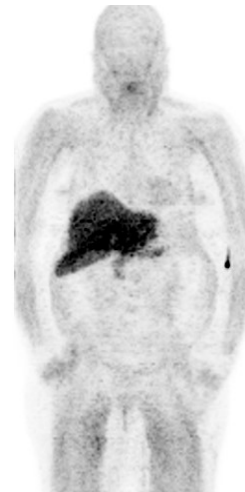
Figure 2 is an example of the biodistribution patterns of *anti-3-[18F]FACBC*, but with no significant normal uptake within thyroid. We will perform a pilot study of this amino acid analogue radiotracer to determine if there is sufficient uptake within parathyroid adenomas to necessitate a larger study of clinical utility.

In addition, we have constructed a microarray examining genetic expression of amino acid transporters (AAT) via RT-PCR analysis, to determine which amino acid transporters may be responsible for *anti-3-[18F]FACBC* uptake within parathyroid adenomas, if any. If imaging results

are promising, we will utilize this microarray on the adenoma tissue obtained from surgical excision. This will be followed by IHC analysis using antibodies to prime AAT candidates to confirm phenotypic expression.

Figure 2:

anti-3-[¹⁸F]FACBC PET at approximately 30 minutes demonstrating the normal biodistribution pattern but with no significant normal thyroid uptake.



B. Objectives

Accurate preoperative identification of parathyroid adenomas is critical in enabling appropriate minimally invasive surgery and in identifying ectopic adenomas that would necessitate a change in surgical approach.

Our overarching goal is to establish if amino acid analogue imaging with the positron emission tomographic radiotracer *anti*-3-[¹⁸F]FACBC demonstrates sufficient uptake within parathyroid adenomas to make a more comprehensive study worthwhile. Future studies may be directed at a larger clinical trial. In addition, we will examine the proteomics of amino acid transport mechanism via gene array, RT-PCR, as well as immunohistochemistry of resected adenoma tissue to help determine the mechanism of uptake of *anti*-3-[¹⁸F]FACBC PET-CT, and to correlate with Sestamibi positive or negative status.

The primary aim of this study is to determine if *anti*-3-[¹⁸F]FACBC PET-CT demonstrates uptake within parathyroid adenomas and to understand time-activity studies in a dynamic manner to record preliminary data of uptake kinetics if present.

Specific Aims

Specific Aim 1. To evaluate the presence or absence of uptake of *anti*-3-[¹⁸F]FACBC in parathyroid adenomas and uptake kinetics if present, and if this uptake varies with sestamibi avidity of the adenomas.

Specific Aim 2. To evaluate uptake mechanisms and specific amino acid transporter regulation of *anti*-3-[¹⁸F]FACBC in parathyroid adenomas.

Rationale. As has been outlined in Section A of the proposal, current imaging techniques in the preoperative identification and localization are good, but not ideal. More accurate techniques are required to better select patients for minimally invasive surgery. Parathormone is a peptide hormone containing 10 Leucine residues. We have developed an amino acid analogue PET radiotracer at Emory which may exploit amino acid transport mechanisms in parathormone receptor activation or via upregulation of amino acid transport in parathyroid adenomas and hyperplasia compared to normal parathyroid tissue. Our initial work with *anti*-3-[¹⁸F]FACBC in primary cultures of human parathyroid cells (Figure 1) has shown significant specific uptake of *anti*-3-[¹⁸F]FACBC by these parathyroid cells.

The specific hypothesis in this proposal is that amino acid transport in parathyroid adenoma and hyperplasia is upregulated compared with normal parathyroid tissue and that this elevated uptake can be exploited for lesion identification by use of PET amino acid radiotracer imaging. The most comprehensive manner to assess our hypothesis is to undertake a prospective pilot study in patients with biochemical evidence of primary hyperparathyroidism and who are scheduled for standard of care surgery and typical preoperative clinical imaging including ^{99m}Tc MIBI SPECT-CT.

We propose assembling a dedicated multidisciplinary team of experts in amino acid radiotracer synthesis and imaging as well as surgical therapy of hyperparathyroidism. Outcomes will be validated by direct comparison to truth as established by histology and surgical findings. We will also in Specific Aim 2, examine potential mechanisms of uptake via gene array, RT-PCR analysis and immunohistochemical techniques.

C. Study design and methods

Experimental design. We will undertake a study with 12 patients who have biochemical and clinical evidence of primary hyperparathyroidism and who are scheduled for routine surgery and preoperative imaging. The patients will serve as their own control. This study will not interfere with standard patient evaluation or delay therapy. Patients will receive one additional study using the amino acid analogue with *anti*-3-[¹⁸F]FACBC. Within the group of 12, we will choose 6 patients with low MIBI uptake and 6 with high uptake since amino acid uptake could also vary in each sub-population. Dynamic imaging will be performed for 60 minutes.

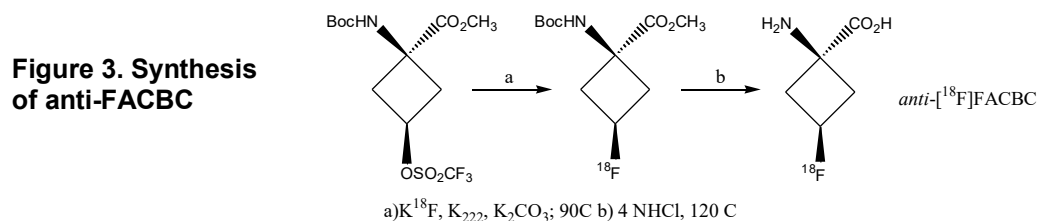
All patients will undergo routine preoperative imaging including dual phase ^{99m}Tc sestamibi scanning and other imaging as appropriate such as ultrasound, MRI, and/or contrast enhanced CT scanning.

We will investigate amino acid transport kinetics and conspicuity within parathyroid adenomas utilizing *anti*-3-[¹⁸F]FACBC PET-CT (Specific Aim #1). We will compare various uptake parameters to that of standard of care imaging with dual phase ^{99m}Tc sestamibi SPECT-CT and validate to truth via surgery and histologic analysis. Resected tissue will also undergo gene

array, RT-PCR analysis and immunohistochemistry as appropriate to investigate amino acid transport mechanism and other factors in uptake (Specific Aim #2).

C.1 *anti*-3-[¹⁸F]FACBC Radiolabeling

Methods. We will prepare *anti*-3-[¹⁸F]FACBC by the automated synthesis developed by J. McConathy and M.M. Goodman (13) as outlined in Figure 3. The automated radiosynthesis of *anti*-3-[¹⁸F]FACBC will be carried out in a chemical process control unit (CPCU) with a computer interface. The two-step reaction sequence will involve incorporation of no-carrier-added potassium [¹⁸F]fluoride into a protected triflate precursor and deprotection using aqueous hydrochloric acid. The crude reaction mix will be passed in series through ion-retardation resin, an alumina-N SepPak®, an HLB cartridge and a 0.22 µm sterile filter, and the resulting aqueous solution will be collected in a dose vial. The radiochemical purity of the product will be determined by TLC. Additional chemical solvent purity will be measured by Gas Chromatography (GC). The total time for synthesis of *anti*-3-[¹⁸F]FACBC after delivery of ¹⁸[F]fluoride will be ~70 minutes, and the average decay-corrected yield of *anti*-3-[¹⁸F]FACBC will be 24 ± 4 % (n = 40 runs, average ± standard error) in over 99% radiochemical purity. This procedure will provide 140-200 mCi of *anti*-[¹⁸F]FACBC at the end of synthesis. We have prepared greater than 30 batch productions for tumor imaging in volunteer subjects.



C.2 PET-CT imaging protocol

PET-CT images will be acquired on a GE Discovery DLS (8 slice), DST (16 slice), MV600 (16 slice), MV690 (16 Slice) or similar PET-CT scanner as described in the literature (14). Quality control scans are performed every morning and the scanner is calibrated by scanning uniform phantoms with the same activity concentration and protocols as used in the various experiments. All studies will use measured attenuation correction (routinely acquired through the initial CT portion of the scan). Dead time, detector efficiency and scatter corrections will be applied using the routines supplied by the manufacturer. The resulting images will be quantitatively calibrated and have 6 mm isotropic resolution.

All subjects will initially be required to fast for four hours to normalize their neutral amino acid levels. The study will typically take place in the afternoon. Oral or IV contrast will not be used for this study. Prior to placement in the tomographic gantry, an intravenous catheter will be placed for injection of tracer. The subject will be placed in the tomographic gantry for completion of the CT scan utilizing standard acquisition parameters of approximately 80-120 mA to be utilized for anatomic imaging and correction of emission data (approximately 1 minute). *anti*-3-[¹⁸F]FACBC (10 mCi) will be injected into an antecubital vein in a slow bolus infusion over 1-2 minutes. Subsequently, 2-3 consecutive 2-4 minute per bed position (depending on scanner

type and patient body habitus) will be obtained of the neck then chest to the anterior border of the heart for one hour.

Summary of PET-CT Scanning Procedure

- 1) The patient will be placed in the tomographic gantry for a CT scan of the chest (80-120 mA) to be utilized for anatomic imaging and correction of emission data (approximately 1 minute).
- 2) The patient will then receive a bolus of *anti-3-[¹⁸F]FACBC* injected IV over 1-2 minutes
- 3) The dosage will be approximately 10.0 mCi (370 MBq).
- 4) A 2-4 minute per bed position PET acquisition will start at the neck with the inferior aspect of the acquisition to include the anterior border of the heart.
- 5) 2-3 bed positions will be obtained which should cover the neck through the anterior border of the heart.
- 6) This sequence will be repeated for 60 minutes of dynamic imaging.
- 7) The entire study including injection of radiotracer should take approximately 60 minutes.

C.4 Image Analysis of anti-[¹⁸F]FACBC PET-CT

Methods. The methods of image analysis to be used for the *anti-3-[¹⁸F]FACBC* PET-CT are as follows:

- 1) Images will be reconstructed with iterative technique and hardware fused (PET to CT) on a GE AW or MimVista workstation which enables SUV (mean, maximum) as well as standard size measurements of lesions. Whenever possible we will use 3 dimensional PET-Edge conformational regions of interest (ROI) to encompass the entire structure under question such as a lymph node or prostate bed.
- 2) Visual inspection of the PET-CT images in separate sessions by a board certified nuclear medicine physicians/nuclear radiologist will take place with calculation of SUVmax, SUVmean, total lesion activity of target lesions within parathyroid lesions (either at typical location posterior to the thyroid or in well described ectopic locations including the mediastinum). In addition, we will derive similar measurements of background structures from key organs including thyroid, muscle (pectoralis muscle), bone marrow (T5), and blood pool (aorta at arch). Tumor to background values will also be calculated. All measurements will take place over multiple time periods, including but not limited to 15min, 30 min, 45 min and 60 min in order to also calculate retention indices of tracer. More formal time-activity curves will also be constructed on separate specialized platforms.
- 3) Subsequent to analysis of the FACBC PET images, results of dual phase sestamibi study will be unblinded to the original reader and results correlated to sestamibi imaging as well as other imaging that may have been acquired such as ultrasound, MR, and/or contrast CT of the neck.

C.5 Comparison to "Truth"

Results of the amino acid PET imaging will be measured against surgical findings and histologic proof. Both size of adenoma, cellular density, as well as other pathologic criteria will be correlated to various uptake parameters described above.

C.6 Followup

Success of surgery (and thus confirmation that all adenomas or hyperplasia have been resected) will be by usual clinical means resulting in normalization of intraoperative and/or post-operative PTH levels. But this will be done as part of routine standard of care without special visits required of the patient.

C.7 Tissue analysis

Resected tissue will be analyzed in reference to amino acid transporter characteristics with well-established RT-PCR techniques and immunohistochemistry in current use by this group on related projects. Briefly, we have constructed a genotypic microarray for amino acid transporters. These include but are not limited to: LAT1, LAT2, LAT3, ASCT1, ASCT2, BAT1, PAT1, xCT, yLAT1, and yLAT2. Tissue will be microdissected from the adenoma and normal parathyroid tissue and sent for analysis. If we determine overexpression of candidate AAT, the samples will then undergo IHC analysis utilizing commercially available antibodies to candidate transporters. In addition, depending on imaging and preliminary analysis, resected samples may undergo more generic gene array (DASL) and other IHC analyses to better understand biologic mechanisms involved with and correlating to varying degrees of *anti-3-[¹⁸F]FACBC* and Sestamibi uptake.

D. Participant Selection:

Methods.

All patients will be recruited from Emory Healthcare Parathyroid Surgery clinics per the inclusion and exclusion criteria below.

Written informed consent will be obtained before subject participation in the study. No procedures will be performed before written informed consent is obtained. Participants will be assigned an identification number for screening purposes; data collected during the screening process will be recorded using that number.

PET Scan Day: The following procedures will be performed:

- Obtain written informed consent
- Inclusion/exclusion criteria review
- Vital signs measurements
- Medication history review
- Clinical laboratory tests (serum chemistries, CBC and urinalysis)
 - To be repeated within one week after scan

Pregnancy based on serum or urine pregnancy test obtained within 24 hours prior to injection of radiotracer imaging prior to injection of radiotracer (for women of childbearing potential per Radiology Department clinical guidelines)

•

Inclusion Criteria:

1. Patients must be 18 years of age or older.
2. Patients will have biochemical and/or clinical evidence of primary hyperparathyroidism and be a surgical candidate for definitive parathyroid surgery .
3. Ability to lie still for PET scanning
4. Patients must be able to provide written informed consent

Exclusion Criteria:

1. Age less than 18.
2. Inability to lie still for PET scanning.
3. Cannot provide written informed consent.
4. History of secondary hyperparathyroidism.
5. Positive serum or urine pregnancy test within 24 hours of imaging prior to injection of radiotracer (for women of childbearing potential per Radiology Department clinical guidelines)

E. Statistical Analysis.

Since this is a pilot study only descriptive statistics will be possible.

F. Adverse Event Reporting

Any patient death that may be due to the study procedure (i.e. severe radiotracer reaction), unanticipated problem, or protocol deviation/non-compliance would be promptly reported to the Emory IRB office. Additionally any patient death not associated with the study procedure or serious anticipated event (i.e. radiotracer allergy) will be reported to the Emory IRB and FDA upon continuing review. This radiotracer is studied under IND 72437 and monitoring will be performed per already agreed upon FDA guidance. Over 100 patients have been studied without adverse events.

G. Data and Safety Monitoring Plan (DSMP):

Patients will be monitored by the technologists and study nurse before and after the studies for any adverse events/reactions. They will be given contact phone numbers to call if they experience any problems (i.e. problems with the IV site, any allergic reaction symptoms). They will be followed routinely by their referring surgeon with clinical exams, and the PI will work with

the co-investigators and referring physicians to ensure that the patients continue to follow up as scheduled.

In addition, a DSMB who will consist of Drs. Weber, Galt, Schuster, Halkar, and Sharma will meet formally if an adverse event has been reported. Any serious adverse events (see above) will be communicated by the PI to the Emory IRB using standard adverse event reporting forms.

H: Pharmaceutical, biologic, and device information

Radiation Dosimetry. The study will be approved by not only the Emory IRB but also the Radiation Safety Committee. The maximum number of PET studies a patient will receive in this protocol is 1 FACBC study.

Depending on the distribution of the radionuclide in the body, the whole body dose may not be the critical factor in single or longitudinal studies. It is also of interest to know which organ receives the highest absorbed dose. This organ is referred to as the critical organ. Often the limit for an individual organ dose is reached before the limit established for the whole-body. The United States Food and Drug Administration in Title 21 CFR Part 361 limits the whole body radiation dose to adult research subjects to less than 3 rem (30 mSv) for a single injection and 5 rem (50 mSv) effective dose equivalent (EDE) annually. A single organ cannot receive more than 5 rem (50mSv) in a single injection and 15 rem (150 mSv) effective dose equivalent annually. These constraints on dose will limit the maximum number of injections for research subjects. The studies proposed in this application fall within these guidelines.

Whole-body human biodistribution studies of FACBC show that it is retained in liver and pancreas. A 10 mCi (370 MBq) injection of FACBC results in a whole-body effective dose equivalent of 0.52 rem (5.2 mSv) and a critical organ absorbed dose of 1.9 rad (19.3 mGy) to liver (12).

The level of radiation for the PET scan is the same as received in widely used diagnostic studies such as the currently used ¹⁸F-FDG and is equal to or less than 20 percent of the amount allowed a radiation worker in a year (5 rem). The calculated whole body exposure to the individual will be less than 0.5 rem for each PET scan. Radiation exposure for the transmission images on the PET-CT is comparable to a routine CT scan, which is .5 rem at 80-120 mA for the limited body area covered (chest only).

The radiotracer used in this study is governed by FDA IND 72437 and is subject to agreed upon safety monitoring by the FDA, a copy of which is on file with the IND holder, Dr. David Schuster.

I. References and appendices

1. Sharma J, Mazzaglia P, Milas M, et al. Radionuclide imaging for hyperparathyroidism (HPT): which is the best technetium-99m sestamibi modality? *Surgery*. 2006;140(6):856-63; discussion 63-5.
2. Schachter PP, Issa N, Shimonov M, Czerniak A, Lorberboym M. Early, postinjection MIBI-SPECT as the only preoperative localizing study for minimally invasive parathyroidectomy. *Arch Surg*. 2004;139(4):433-7.
3. Coakley AJ, Kettle AG, Wells CP, O'Doherty MJ, Collins RE. 99Tcm sestamibi--a new agent for parathyroid imaging. *Nucl Med Commun*. 1989;10(11):791-4.
4. Ishibashi M, Nishida H, Hiromatsu Y, Kojima K, Uchida M, Hayabuchi N. Localization of ectopic parathyroid glands using technetium-99m sestamibi imaging: comparison with magnetic resonance and computed tomographic imaging. *Eur J Nucl Med*. 1997;24(2):197-201.
5. Ishibashi M, Nishida H, Hiromatsu Y, Kojima K, Tabuchi E, Hayabuchi N. Comparison of technetium-99m-MIBI, technetium-99m-tetrofosmin, ultrasound and MRI for localization of abnormal parathyroid glands. *J Nucl Med*. 1998;39(2):320-4.
6. Esteves FP, Khan A, Correia LC, et al. Absent coronary artery calcium excludes inducible myocardial ischemia on computed tomography/positron emission tomography. *Int J Cardiol*. 2011;147(3):424-7.
7. Zeng W, Sepulveda JN, Nye J, et al. Posterior bladder layering of excreted 18F-FDG on PET/CT. *Nucl Med Commun*. 2010;31(10):859-63.
8. Schreibmann E, Nye JA, Schuster DM, Martin DR, Votaw J, Fox T. MR-based attenuation correction for hybrid PET-MR brain imaging systems using deformable image registration. *Med Phys*. 2010;37(5):2101-9.
9. Sakata T, Ferdous G, Tsuruta T, et al. L-type amino-acid transporter 1 as a novel biomarker for high-grade malignancy in prostate cancer. *Pathol Int*. 2009;59(1):7-18.
10. Schuster DM, Votaw JR, Nieh PT, et al. Initial Experience with the Radiotracer Anti-1-Amino-3-18F-Fluorocyclobutane-1-Carboxylic Acid with PET/CT in Prostate Carcinoma. *J Nucl Med*. 2007;48(1):56-63.
11. Schuster DM, Votaw JR, Halkar RK, et al. Uptake of the Synthetic PET Amino Acid Radiotracer 1-Amino-3-[18F]Fluorocyclobutane-1-Carboxylic Acid (18F-FACBC) Within Primary and Metastatic Brain Cancer Compared with 18F-Fluorodeoxyglucose (18F-FDG). *J Nucl Med*. 2003;5:167p.
12. Nye JA, Schuster DM, Yu W, Camp VM, Goodman MM, Votaw JR. Biodistribution and Radiation Dosimetry of the Synthetic Nonmetabolized Amino Acid Analogue Anti-18F-FACBC in Humans. *J Nucl Med*. 2007.
13. McConathy J, Voll RJ, Yu W, Crowe RJ, Goodman MM. Improved synthesis of anti-[18F]FACBC: improved preparation of labeling precursor and automated radiosynthesis. *Appl Radiat Isot*. 2003;58(6):657-66.
14. Schuster DM, Savir-Baruch B, Nieh PT, et al. Report of a clinical trial of anti 1 amino 3 [18F]fluorocyclobutane-1-carboxylic acid (anti-[18F]FACBC) PET-CT in recurrent prostate carcinoma. *J Nucl Med*. 2010;51 (Suppl. 2):127P.