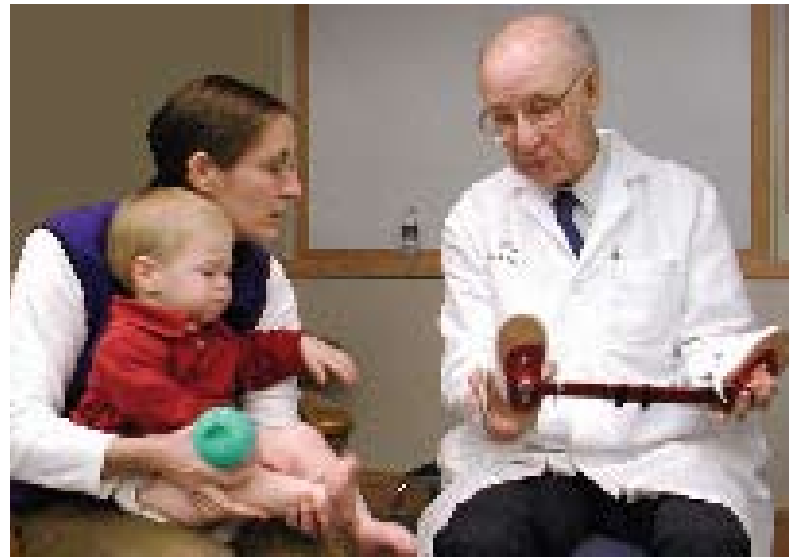

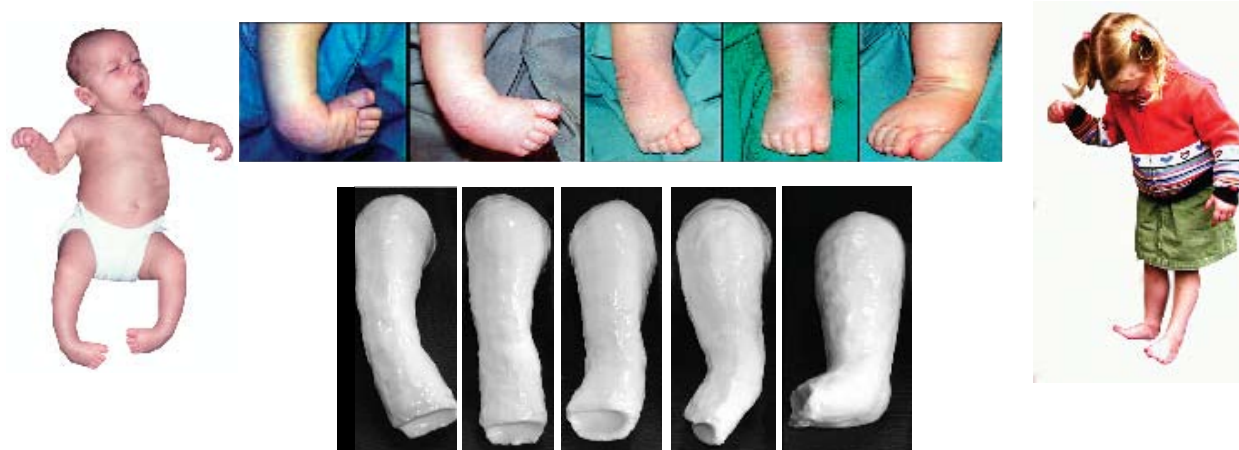
# Clubfoot: Ponseti Management

## Dr. Ignacio Ponseti



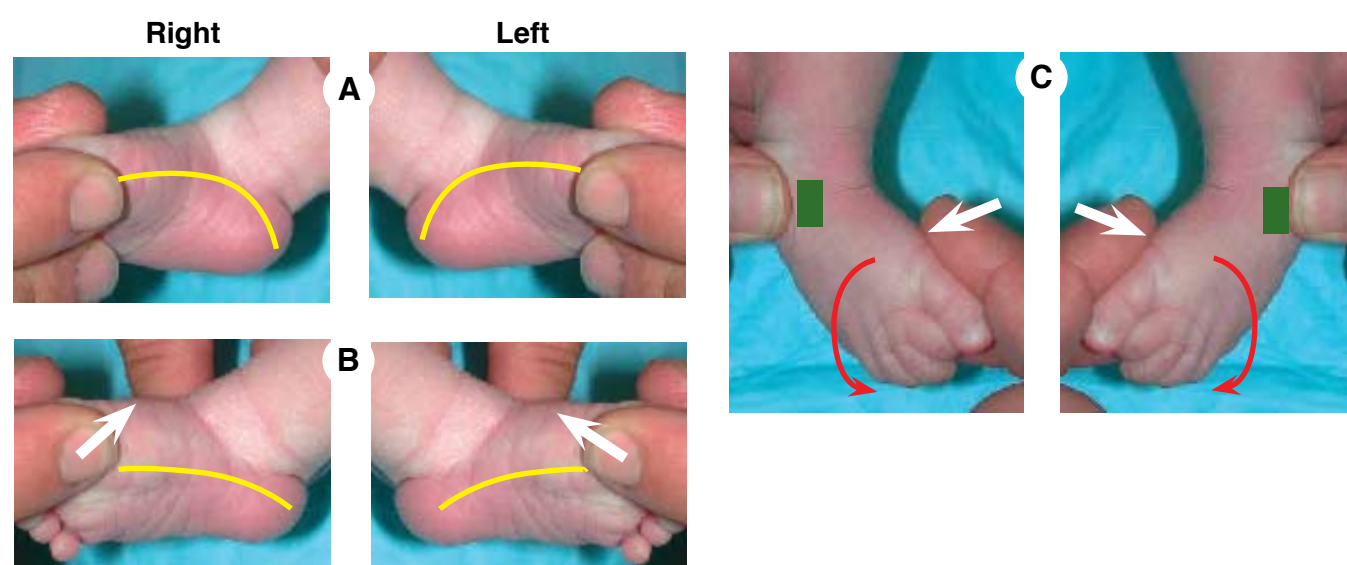
Ponseti management is best for all countries and cultures because the feet are strong, flexible, and pain-free for a lifetime. In addition, the treatment is inexpensive and non-invasive.

## Principles of Correction



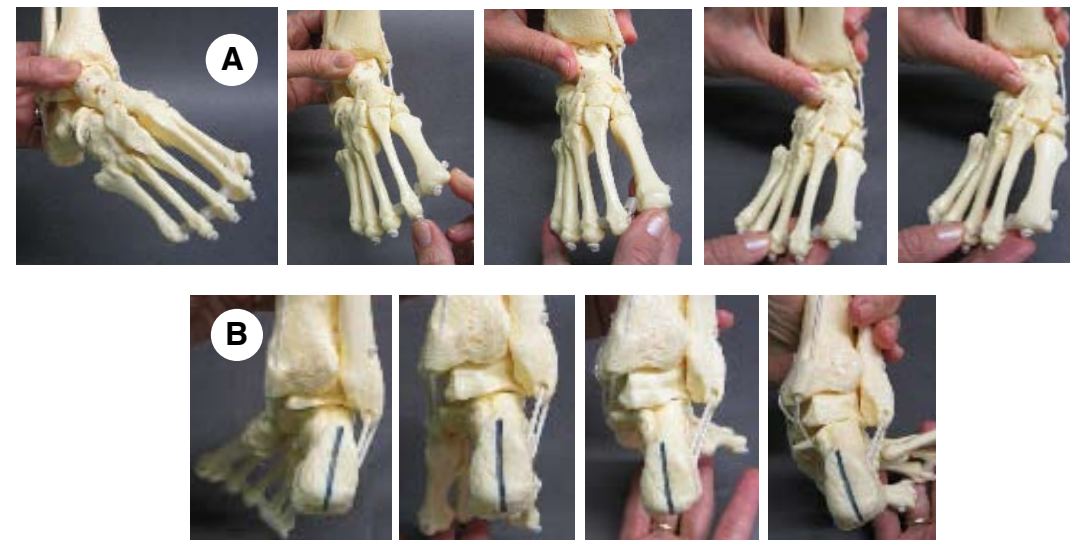
In the vast majority of infants, the clubfoot deformity can be corrected over a period of several weeks by manipulation and casting. This correction is done in several steps.

## Cavus Correction



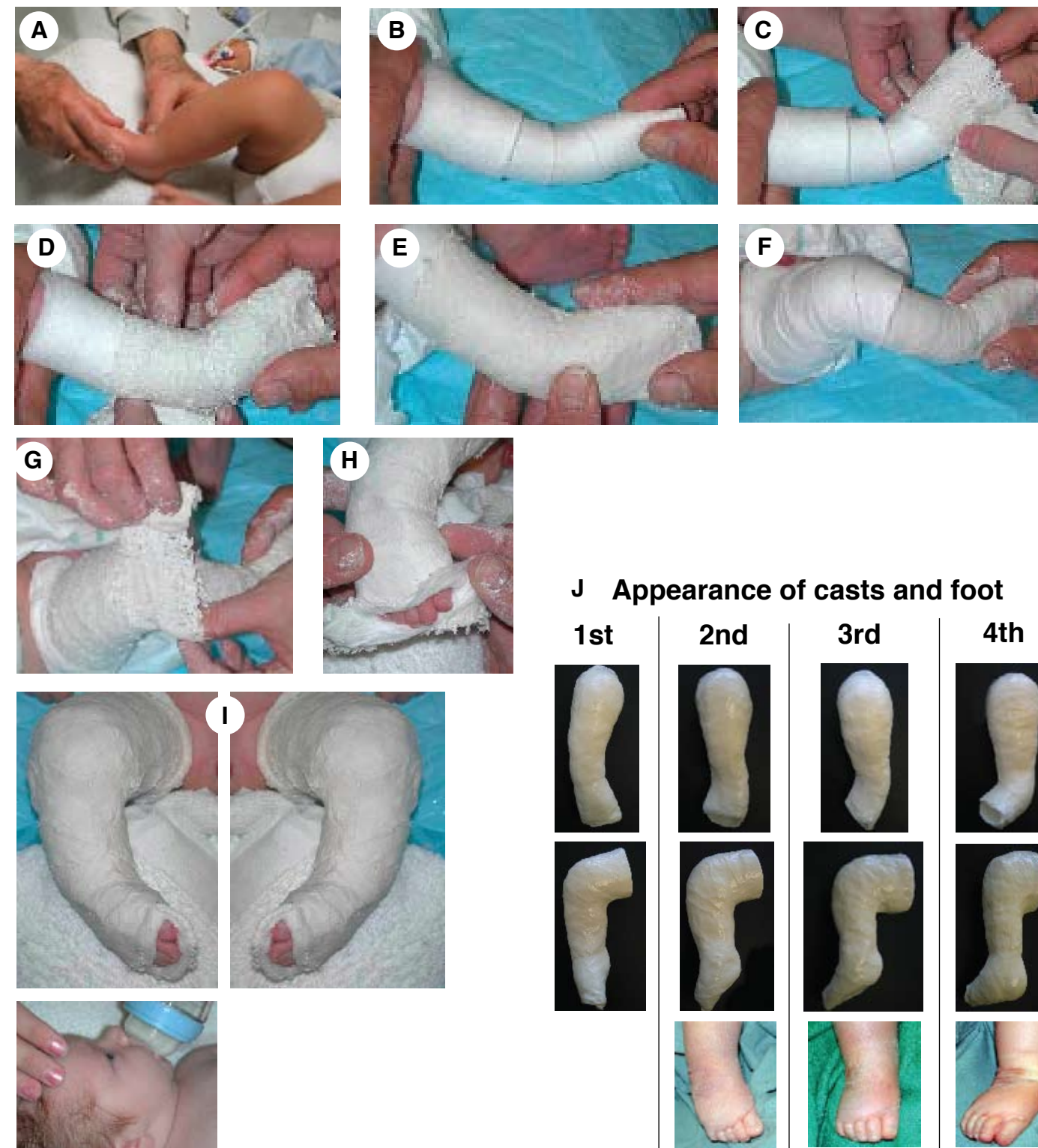
Note the cavus deformity in the untreated foot [A]. Correction is achieved by supination of the forefoot [white arrows in B and C].

## Correction of Adductus & Varus

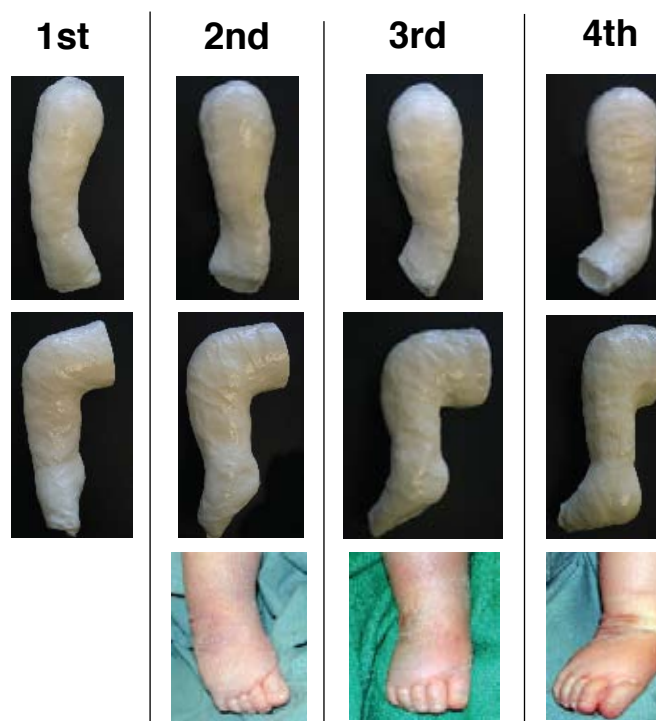


Note the correction of the adductus [A] and heel varus [B] occurs when the foot is everted and abducted around the head of the talus

## Cast Application

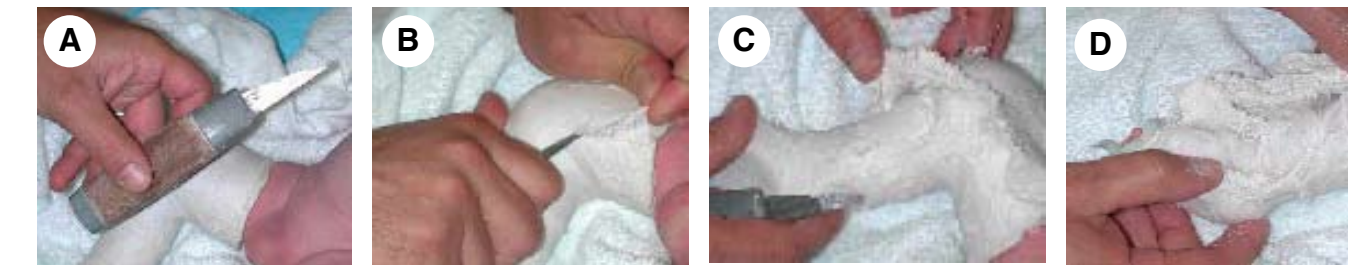


### J Appearance of casts and foot



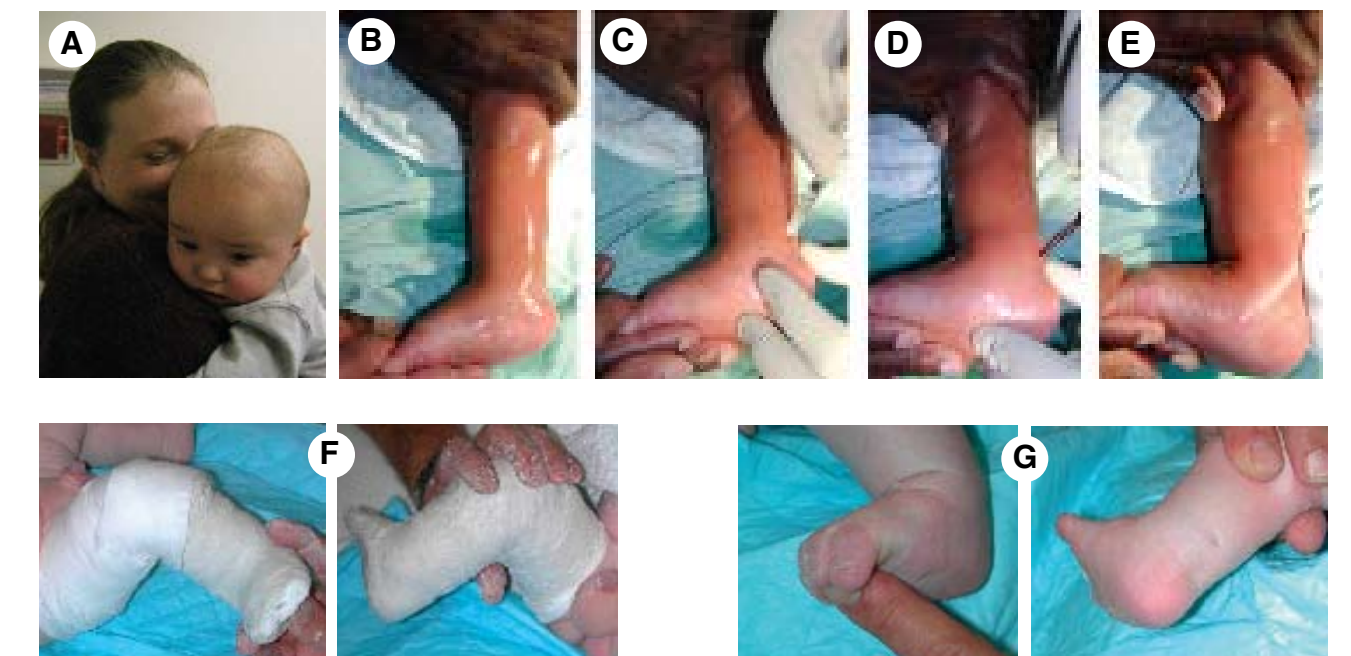Note the a plaster long leg cast is applied in stages to hold the correction achieved by manipulation [A – I]. The appearance of the casts and foot show the correction [J].

## Cast Removal



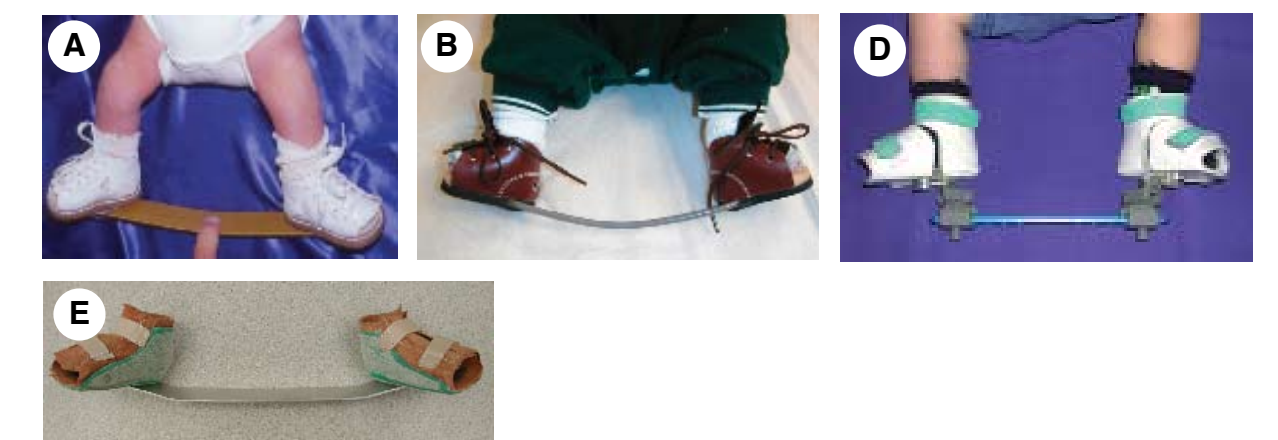
Remove the cast just before the remanipulation. After soaking the cast in water, use a cast knife to avoid frightening the infant.

## Heel-Cord Lengthening



Nearly all of the infants will require a percutaneous heel-cord lengthening. Perform this in clinic with local anesthesia [A–E]. Cast in dorsiflexion [F]. Note the final correction [G].

## Bracing



Post-correction bracing is essential to prevent recurrences. Effective types of braces include: Denis Browne [A], Steenbeek [B], Lyon [C], and Gottenberg [D] designs.