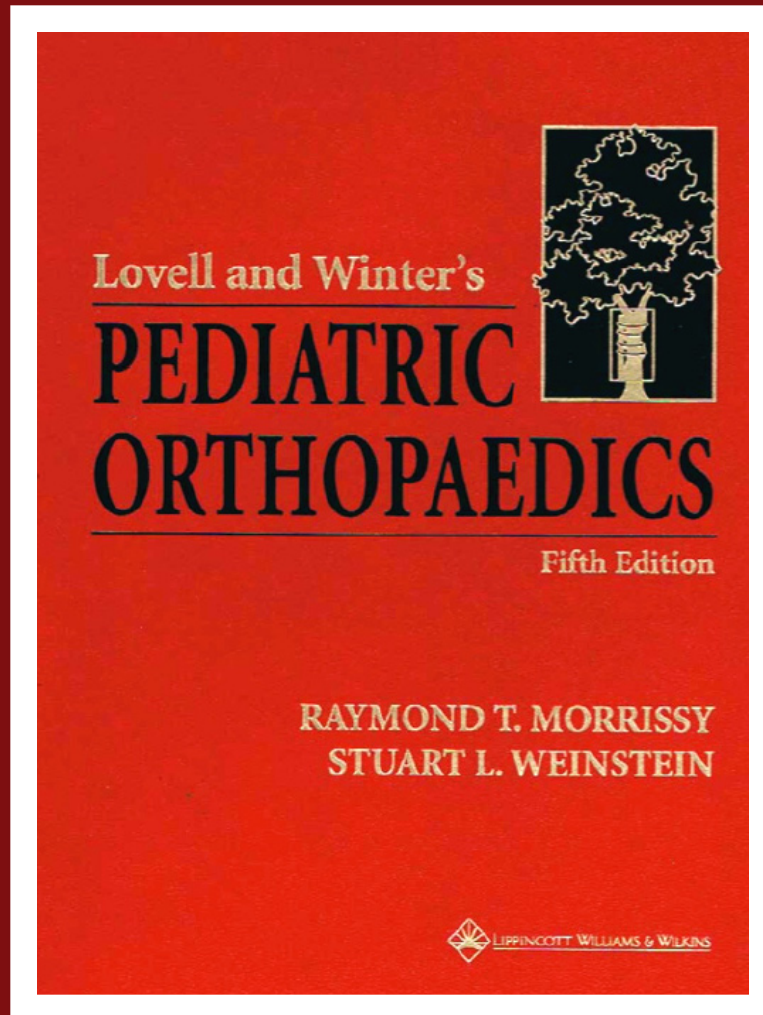


Lovell & Winter's Pediatric Orthopaedics

[5th Edition]




**Raymond T. Morrissy
Stuart L. Weinstein**

[CLICK HERE FOR TABLE OF CONTENTS](#)



GLOBAL HELP

This CD is a publication of Global HELP



Lovell & Winter's Pediatric Orthopaedics [5th Edition]

Editors:

Raymond T. Morrissy
Stuart L. Weinstein

Contributors:

Behrooz A. Akbarnia, M.D.
Benjamin A. Alman, M.D., F.R.C.S.C.
David D. Aronsson, M.D.
Frank R. Berenson, M.D.
Michael T. Busch, M.D.
Robert M. Campbell, Jr., M.D.
William G. Cole, M.D.
Leonard P. Connolly, M.D.
Colleen Coulter-O'Berry, M.S.,
P.T., P.C.S.
Jon R. Davids, M.D.

Dennis P. Devito, M.D.
Frederick R. Dietz, M.D.
Alain Diméglio
Peter G. Gabos, M.D.
Mark C. Gebhardt, M.D.
Brian J. Giavedoni, B.Sc., C.P. (C)
Michael J. Goldberg, M.D.
Walter B. Greene, M.D.
Diego Jaramillo, M.D.
Douglas K. Kehl, M.D.
Richard E. Lindseth, M.D.
Randall T. Loder, M.D.
John E. Lonstein, M.D.
William G. Mackenzie, M.D.
José A. Morcuende, M.D.
Raymond T. Morrissy, M.D.

Vincent S. Mosca, M.D.
Colin F. Moseley, M.D., C.M.
Peter O. Newton, M.D.
Jonathan H. Phillips, M.D.
Charles T. Price, M.D.
Thomas S. Renshaw, M.D.
Margaret M. Rich, M.D., Ph.D.
Perry L. Schoenecker, M.D.
Paul D. Sponseller, M.D.
Dempsey S. Springfield, M.D.
George H. Thompson, M.D.
William C. Warner, Jr., M.D.
Peter M. Water, M.D.
Stuart L. Weinstein, M.D.
Dennis R. Wenger, M.D.
Dowain A. Wright, M.D., Ph.D.

[CLICK HERE FOR
TABLE OF CONTENTS](#)

Navigating the PDFs*:

Blue lines running underneath certain sections of text are clickable (as seen below) and will link you to the content. Logos are also linked to each organization's web-site.

[07. Metabolic and Endocrine Abnormalities](#)

*PDF files work more effectively
copied to your computer's hard- drive.

Links:

Global HELP

www.global-help.org

Lippincott Williams & Wilkins

www.lww.com

Seattle Children's Hospital

www.seattlechildrens.com

Support for this project provided by:




LIPPINCOTT
WILLIAMS & WILKINS

Large and considerable
thanks to Lippincott Williams
& Wilkins for permission to
reprint the original book.

Children's
Hospital & Regional Medical Center

Thanks to Seattle Children's
Hospital & Regional Medical
Center for their generous
support and funding of this
project.

Click www.lww.com For The Publisher's Most Current Edition



LOVELL AND WINTER'S

**PEDIATRIC
ORTHOPAEDICS**

FIFTH EDITION

VOLUME 1

Edited by

RAYMOND T. MORRISSY, M.D.

*Chief
Department of Orthopaedics
Children's Healthcare of Atlanta
at Scottish Rite
Clinical Professor of Orthopaedics
Emory University
Atlanta, Georgia*

STUART L. WEINSTEIN, M.D.

*Ignacio V. Ponseti Chair of Orthopaedic Surgery
Department of Orthopaedic Surgery
University of Iowa Hospital
Iowa City, Iowa*

With 43 Contributors



LIPPINCOTT WILLIAMS & WILKINS

A **Wolters Kluwer** Company

Philadelphia • Baltimore • New York • London
Buenos Aires • Hong Kong • Sydney • Tokyo

Acquisitions Editor: Robert Hurley
Developmental Editor: Brian Brown and Sonya L. Seigafuse
Production Editor: Deirdre Marino
Manufacturing Manager: Tim Reynolds
Cover Designer: Co. Laborative Design
Compositor: Maryland Composition Company, Inc.
Printer: Maple Press

© 2001 by LIPPINCOTT WILLIAMS & WILKINS
530 Walnut Street
Philadelphia, PA 19106 USA
LWW.com

All rights reserved. This book is protected by copyright. No part of this book may be reproduced in any form or by any means, including photocopying, or utilized by any information storage and retrieval system without written permission from the copyright owner, except for brief quotations embodied in critical articles and reviews. Materials appearing in this book prepared by individuals as part of their official duties as U.S. government employees are not covered by the above-mentioned copyright.

Printed in the USA

Library of Congress Cataloging-in-Publication Data

Lovell and Winter's pediatric orthopaedics.—5th ed. / editors, Raymond T. Morrissy, Stuart L. Weinstein.

p. ; cm.

Includes bibliographical references and index.

ISBN 0-7817-2582-8

1. Pediatric orthopedics. I. Title: Pediatric orthopaedics. II. Lovell, Wood W., 1915–
III. Winter, Robert B., 1932– IV. Morrissy, Raymond T. V. Weinstein, Stuart L.
[DNLML: 1. Orthopedics—Adolescence. 2. Orthopedics—Child. 3. Orthopedics—Infant.
WS 270 L911 2000]
RD732.3.C48 P43 2000
618.92'7—dc21

00-042433

Care has been taken to confirm the accuracy of the information presented and to describe generally accepted practices. However, the authors, editors, and publisher are not responsible for errors or omissions or for any consequences from application of the information in this book and make no warranty, expressed or implied, with respect to the currency, completeness, or accuracy of the contents of the publication. Application of this information in a particular situation remains the professional responsibility of the practitioner.

The authors, editors, and publisher have exerted every effort to ensure that drug selection and dosage set forth in this text are in accordance with current recommendations and practice at the time of publication. However, in view of ongoing research, changes in government regulations, and the constant flow of information relating to drug therapy and drug reactions, the reader is urged to check the package insert for each drug for any change in indications and dosage and for added warnings and precautions. This is particularly important when the recommended agent is a new or infrequently employed drug.

Some drugs and medical devices presented in this publication have Food and Drug Administration (FDA) clearance for limited use in restricted research settings. It is the responsibility of the health care provider to ascertain the FDA status of each drug or device planned for use in their clinical practice.

10 9 8 7 6 5 4 3 2 1


*To Orthopaedic Residents and Fellows
that through continued inquiry and learning
they may find medicine to be fun for a lifetime*

➡ Cross-references to the *Atlas of Pediatric Orthopaedic Surgery*,
Third Edition

In this edition of *Lovell and Winter's Pediatric Orthopaedics*, we have taken some time and inserted cross-references to surgical procedures in the *Atlas of Pediatric Orthopaedic Surgery*. In order to make these references visible but not intrusive, we have used a simple back-arrow symbol followed by the procedure number in the third edition of the atlas. Thus, "➡ 2.9" refers the reader to the ninth procedure in Chapter 2 of the atlas, which illustrates placement of segmental hook and pedicle screw instrumentation for scoliosis.

We feel that this intermeshing of the content of the atlas and the textbook greatly enhances the value of both to the reader by making the pair more user-friendly and more comprehensive. These references are also used as hot-links on the CD-ROM, which contains both the textbook and the atlas. We hope that you find this new feature useful.

RTM
SLW



CONTRIBUTING AUTHORS

Behrooz A. Akbarnia, M.D.

Clinical Professor
Department of Orthopaedics
University of California—San Diego
9500 Gilman Drive
La Jolla, California 92093
Medical Director
San Diego Center for Spinal Disorders
8010 Frost Street
San Diego, California 92123

Benjamin A. Alman, M.D., F.R.C.S.C.

Assistant Professor
Department of Surgery
University of Toronto
Orthopaedic Surgeon and Scientist
Department of Orthopaedic Surgery/Developmental
Biology
The Hospital for Sick Children
555 University Avenue
Toronto, Ontario M5G 1X8
Canada

David D. Aronsson, M.D.

Professor
Department of Orthopaedics and Rehabilitation and
Pediatrics
University of Vermont College of Medicine
Robert T. Stafford Hall
Burlington, Vermont 05405
Chief, Pediatric Orthopaedics
Department of Orthopaedics and Rehabilitation and
Pediatrics
Fletcher Allen Health Care
111 Colchester Avenue
Burlington, Vermont 05401

Frank R. Berenson, M.D.

Clinical Assistant Professor
Department of Pediatrics
Mercer University
1550 College Street
Macon, Georgia 31207
Child Neurologist
Department of Pediatrics
Children's Healthcare of Atlanta at Scottish Rite
1001 Johnson Ferry Road Northeast
Atlanta, Georgia 30342

Michael T. Busch, M.D.

Vice-Chief of Orthopaedics
Director of Sports Medicine
Department of Orthopaedics
Children's Healthcare of Atlanta at Scottish Rite
5455 Meridian Mark Road
Atlanta, Georgia 30342

Robert M. Campbell, Jr., M.D.

Associate Professor
Department of Orthopaedics
University of Texas Health Science Center at San
Antonio
7703 Floyd Curl Drive
San Antonio, Texas 78229
Staff Physician
Principal Investigator for Titanium Rib Project
Department of Pediatric Orthopaedics
Christus Santa Rosa Children's Hospital
519 West Houston Street
San Antonio, Texas 78207

William G. Cole, M.D.

Professor of Surgery and Genetics
University of Toronto
Head, Division of Orthopaedics
The Hospital for Sick Children
555 University Avenue
Toronto, Ontario M5G 1X8
Canada

Leonard P. Connolly, M.D.

Assistant Professor
Department of Radiology
Harvard Medical School
25 Shattuck Street
Staff Radiologist
Department of Radiology
Children's Hospital
300 Longwood Avenue
Boston, Massachusetts 02115

Colleen Coulter-O'Berry, M.S., P.T., P.C.S.

Team Leader, Limb Deficiency
Physical Therapist IV
Department of Orthotics and Prosthetics
Children's Healthcare of Atlanta at Scottish Rite
5445 Meridian Mark Road
Atlanta, Georgia 30342

Jon R. Davids, M.D.

Assistant Consulting Professor
Department of Orthopaedic Surgery
Duke University Medical Center
Durham, North Carolina 27710
Director, Motion Analysis Laboratory
Shriners Hospital
950 West Faris Road
Greenville, South Carolina 29605

Dennis P. Devito, M.D.

Department of Orthopaedics
Children's Healthcare of Atlanta at Scottish Rite
5455 Meridian Mark Road
Atlanta, Georgia 30342

Frederick R. Dietz, M.D.

Professor
Department of Orthopaedic Surgery
University of Iowa
Division of Pediatric Orthopaedics
University of Iowa Hospitals and Clinics
200 Hawkins Drive
Iowa City, Iowa 52242

Alain Diméglio

Service d'Orthopédie Pédiatrique
Hôpital Lapeyronie
371 Avenue du Doyen Gaston Giraud
34295 Montpellier
Cedex 5, France

Peter G. Gabos, M.D.

Assistant Clinical Professor
Department of Orthopaedic Surgery
Jefferson Medical College
Thomas Jefferson University Hospital
Philadelphia, Pennsylvania 19107
Pediatric Orthopaedic Surgeon
Department of Orthopaedic Surgery
Alfred I. duPont Hospital for Children
1600 Rockland Road
Wilmington, Delaware 19899

Mark C. Gebhardt, M.D.

Frederick W. and Jane M. Ilfield Professor of
Orthopaedic Surgery
Department of Orthopaedic Surgery
Harvard Medical School
Boston, Massachusetts 02115
Associate Orthopaedic Surgeon
Orthopaedic Service
Massachusetts General Hospital
55 Fruit Street
Boston, Massachusetts 02114

Brian J. Giavedoni, B.Sc., C.P.(C)

Clinical Supervisor for Prosthetics
Department of Orthotics and Prosthetics
Children's Healthcare of Atlanta at Scottish Rite
5445 Meridian Mark Road
Atlanta, Georgia 30342

Michael J. Goldberg, M.D.

Henry H. Banks Professor and Chairman
Department of Orthopaedics
Tufts University School of Medicine
Orthopaedist-in-Chief
Department of Orthopaedics
New England Medical Center
750 Washington Street
Boston, Massachusetts 02111

Walter B. Greene, M.D.

Chairman
Department of Orthopaedic Surgery
University of Missouri Health Science Center
One Hospital Drive
Columbia, Missouri 65212

Diego Jaramillo, M.D.

Associate Professor
Department of Radiology
Harvard Medical School
25 Shattuck Street
Boston, Massachusetts 02115
Chief, Division of Pediatric Radiology
Department of Radiology
Massachusetts General Hospital
55 Fruit Street
Boston, Massachusetts 02114

Douglas K. Kehl, M.D.

Associate Clinical Professor
Department of Orthopaedic Surgery
Emory University School of Medicine
69 Butler Street Southeast
Atlanta, Georgia 30303
Department of Orthopaedic Surgery
Children's Healthcare of Atlanta at Scottish Rite
1001 Johnson Ferry Road Northeast
Atlanta, Georgia 30342

Richard E. Lindseth, M.D.

Professor and Chairman
Department of Orthopaedic Surgery
Indiana University School of Medicine
541 Clinical Drive
Indianapolis, Indiana 46202

Randall T. Loder, M.D.

Clinical Professor
Department of Orthopaedics
University of Minnesota
420 Delaware Street Southeast
Minneapolis, Minnesota 55455
Chief of Staff
Shriners Hospital
2025 East River Parkway
Minneapolis, Minnesota 55414

John E. Lonstein, M.D.

Clinical Professor
Department of Orthopaedic Surgery
University of Minnesota
Minneapolis, Minnesota 55455
Staff Physician
Twin Cities Spine Center
913 East 26th Street
Minneapolis, Minnesota 55404

William G. Mackenzie, M.D.

Clinical Assistant Professor
Orthopaedic Department
Thomas Jefferson Medical College
1015 Walnut Street
Philadelphia, Pennsylvania 19107
Pediatric Orthopaedic Surgeon
Department of Orthopaedics
Alfred I. duPont Hospital for Children
1600 Rockland Road
Wilmington, Delaware 19803

José A. Morcuende, M.D., Ph.D.

Department of Orthopaedic Surgery
University of Iowa
Iowa City, Iowa 52242

Raymond T. Morrissy, M.D.

Chief
Department of Orthopaedics
Children's Healthcare of Atlanta at Scottish Rite
5445 Meridian Mark Road
Clinical Professor of Orthopaedics
Emory University
Atlanta, Georgia 30342

Vincent S. Mosca, M.D.

Associate Professor and Chief
Pediatric Orthopaedics
Department of Orthopaedics
University of Washington School of Medicine
Seattle, Washington 98195
Director, Department of Orthopaedics
Children's Hospital and Regional Medical Center
4800 Sand Point Way Northeast
Seattle, Washington 98105

Colin F. Moseley, M.D., C.M.

Clinical Professor
Department of Orthopaedics
University of California—Los Angeles
1010 Westwood Boulevard
Chief of Staff
Shriners Hospital for Children
3160 Geneva Street
Los Angeles, California 90020

Peter O. Newton, M.D.

Assistant Clinical Professor
Department of Orthopaedic Surgery
University of California—San Diego
Director, Scoliosis Service
Department of Orthopaedic Surgery
Children's Hospital and Health Center
3030 Children's Way
San Diego, California 92123

Jonathan H. Phillips, M.D.

Department of Orthopaedics
Nemours Children's Clinic
83 West Columbia Street
Orlando, Florida 32806

Charles T. Price, M.D.

Surgeon in Chief and Chief of Orthopaedics
Nemours Children's Clinic
83 West Columbia Street
Orlando, Florida 32806

Thomas S. Renshaw, M.D.

Professor
Department of Orthopaedic Surgery
Yale University
800 Howard Avenue
New Haven, Connecticut 06520
Attending Physician
Department of Orthopaedic Surgery
Yale–New Haven Hospital
20 York Street
New Haven, Connecticut 06510

Margaret M. Rich, M.D., Ph.D.

Assistant Chief of Staff
Shriners Hospital for Children
2001 South Lindbergh Boulevard
St. Louis, Missouri 63131

Perry L. Schoenecker, M.D.

Professor
Department of Orthopaedic Surgery
Washington University School of Medicine
#1 Barnes-Jewish Plaza
St. Louis, Missouri 63110
Chief of Staff
Shriners Hospital for Children
2001 South Lindbergh Boulevard
St. Louis, Missouri 63131

Paul D. Sponseller, M.D.

Associate Professor
Orthopaedic Surgery
Johns Hopkins Medical Institutions
Head, Division of Pediatric Orthopaedics
Department of Orthopaedic Surgery
Johns Hopkins Hospital
601 North Caroline Street
Baltimore, Maryland 21287

Dempsey S. Springfield, M.D.

Professor and Chairman
Leni and Peter W. May Department of Orthopaedics
Mount Sinai School of Medicine
Chief of Service
Department of Orthopaedics
Mount Sinai Hospital
1 Gustave L. Levy Place
New York, New York 10029

George H. Thompson, M.D.

Professor
Department of Orthopaedic Surgery and Pediatrics
Case Western Reserve University
Director, Pediatric Orthopaedics
Rainbow Babies and Children's Hospital
11100 Euclid Avenue
Cleveland, Ohio 44106

William C. Warner, Jr., M.D.

Associate Professor
Department of Orthopaedics
University of Tennessee
956 Court Avenue
Memphis, Tennessee 38163
Staff Physician
Campbell Clinic
1400 South Germantown Road
Germantown, Tennessee 38138

Peter M. Waters, M.D.

Associate Professor
Orthopaedic Surgery Department
Harvard Medical School
Clinical Director
Hand and Upper Extremity Surgery
Children's Hospital
300 Longwood Avenue
Boston, Massachusetts 02115

Stuart L. Weinstein, M.D.

Ignacio V. Ponseti Chair of Orthopaedic Surgery
Department of Orthopaedic Surgery
University of Iowa Hospital
Iowa City, Iowa 52245

Dennis R. Wenger, M.D.


Clinical Professor
Department of Orthopaedic Surgery
University of California–San Diego
Director, Pediatric Orthopaedics
Children's Hospital and Health Center
3030 Children's Way
San Diego, California 92123

Dowain A. Wright, M.D., Ph.D.

Clinical Assistant Professor
Department of Pediatrics
University of California–San Francisco School of
Medicine at Fresno
Department of Rheumatology and Immunology
Valley Children's Hospital
9300 Valley Children's Place
Madera, California 93638

David J. Zaleske, M.D.

Associate Professor
Department of Orthopaedics
Harvard Medical School
Boston, Massachusetts 02115
Chief, Pediatric Orthopaedics Unit
Massachusetts General Hospital
15 Parkman Street
Boston, Massachusetts 02114



PREFACE TO THE FIRST EDITION

The field of pediatric orthopaedics has changed significantly in recent years. In the main, textbooks have kept abreast of change, to the extent that there is now a broad and useful literature addressed to the techniques of treatment of the orthopaedic disorders of children. The editors believe, however, that their fellow surgeons will have increasingly shared the desire for a work focused especially upon the decision-making process that precedes and governs the selection of surgical technique. Basic research and clinical specialization have had a dual effect upon clinical decision making. They have broadened the field of choice, and at the same time have made judicious choice more difficult.

Chapters that will aid the reader at the critical junctures at which decisions must be made have been contributed by authorities of eminence, persons who have long and successful experience dealing with the conditions about which they

have written. The reader will notice that each topic is covered in depth, and that the emphasis on decision making will facilitate his assessment of the indications and contraindications for a particular treatment approach.

Although we have attempted to match depth with breadth, children's fractures have not been included because the subject is well covered in other textbooks that have recently appeared.

We would like to state that our task has been made not only worthwhile but pleasurable by the continued thoughtful and kind cooperation of the contributors whose names appear in the pages of this book. They have our deepest thanks.

*Wood W. Lovell, M.D.
Robert B. Winter, M.D.*



PREFACE

The fifth edition of *Lovell and Winter's Pediatric Orthopaedics* is appearing at the beginning of a new millenium and in the same year that the World Health Organization is launching the Bone and Joint Decade, aimed at improving the quality of life for people with musculoskeletal conditions, and at advancing understanding and treatment of these conditions through research, prevention, and education.

In looking through the first edition of the book—published 25 years ago—the tremendous changes in the orthopaedic care of infants, children, and adolescents is striking. However, as we read through the chapters of the fifth edition we are also struck by how much remains unknown. There are significant gaps in our knowledge of the natural history of many of the common orthopaedic conditions of childhood, the biologic basis of many of these conditions, and the long-term effectiveness of our current treatments. This fifth edition, with all of its new knowledge, is still testimony to the purpose of the Bone and Joint Decade—to improve the quality of life for those affected with musculoskeletal conditions through research, prevention, and education.

As the fifth edition is published we are in the midst of a scientific revolution that will have a profound effect on pediatric orthopaedics. While surgical techniques continue to advance, they are far outpaced by the advances in molecular genetics, where key discoveries are made weekly. As we edited the final proofs, authors were making changes to incorporate new genetic discoveries relevant to the diagnosis and mechanism of diseases for which there was no such information when they submitted their manuscripts a few short months before, let alone when the fourth edition was published five years ago. As these discoveries are applied to the clinical setting, our practice will change at an ever-increasing pace.

In this fifth edition of *Pediatric Orthopaedics*, we have tried to keep pace with the rapid advances in basic research as applied to clinical medicine by presenting discussions of the knowledge about each condition as it currently exists. Twelve chapters are written by new authors, and five previous contributors have added coauthors for this edition. Each author was carefully chosen for his expertise in a designated area. An important new chapter on the growth of the child, long overdue, has been added. All chapters summarize the current information on the natural history of a condition when known and the outcomes of standard treatments.

The contributors have indicated their evidence-based preferences for treatment when such evidence exists, and have clearly pointed out the lack thereof with other treatment alternatives. The editors have entered into a give-and-take dialogue with each contributor to identify controversial areas and to present a balanced view of them. New with this edition are cross-references to the third edition of the *Atlas of Pediatric Orthopaedic Surgery*, which link the detailed surgical techniques with the indications in the textbook.

The editors realize that some readers of this edition will be among the leaders of the new generation of orthopaedic surgeons who will fill in the gaps in our knowledge and improve the orthopaedic care of children. Patients and parents both expect and deserve their physicians to provide them with the latest evidence regarding their condition and its treatment so they can make informed choices. This is a significant burden for a parent who is deciding on the course of treatment for their child; the treatment may have significant consequences for their child in the decades ahead. We hope that this edition will provide the latest and best information for the pediatric orthopaedic surgeon practicing in the new millenium.

Raymond T. Morrissy
Stuart L. Weinstein



ACKNOWLEDGMENTS

The editors would like to acknowledge the great fortune that we have had to practice our profession in the finest medical system in the world during a period of unprecedented advances in research and innovation combined with extraordinary cross-fertilization provided by our scientific societies and publishers. This text stands as testimony to these advances and provides an information base for our colleagues that physicians of past generations would certainly envy.

We would like to give special thanks to those who have contributed to this book. These individuals were selected

because they have worked hard to attain their knowledge and expertise and have the special talent of being able to relate the knowledge and expertise to others. In addition, we readily acknowledge the work of all of our colleagues in orthopaedics and other fields of medicine who have contributed to our knowledge.

Finally, we acknowledge the opportunity to be involved in teaching residents and fellows. Their stimulating inquiries have been a large part of what has made orthopaedic surgery fun and exciting for us over the past two decades.

TABLE OF CONTENTS

Contributing Authors: page xi
 Preface to the First Edition: page xv
 Preface: page xvii
 Acknowledgments: page xix

VOLUME 1

01. Embryology and Development of the Musculoskeletal System	001
02. Growth in Pediatric Orthopaedics	033
03. Imaging Techniques and Applications	063
04. The Pediatric Orthopaedic Examination	099
05. Normal Gait and Assessment of Gait Disorders	031
06. Genetic Aspects of Orthopaedic Conditions	157
07. Metabolic and Endocrine Abnormalities	177
08. The Skeletal Dysplasias	243
09. Syndromes of Orthopaedic Importance	287
10. Localized Disorders of Bone and Soft Tissue	339
11. Diseases Related to the Hematopoietic System	379
12. Juvenile Idiopathic Arthritis	427
13. Bone and Joint Sepsis	459
14. Bone and Soft Tissue Tumors	507
15. Cerebral Palsy	563
16. Myelomeningocele	601
17. Other Neuromuscular Disorders	633
18. Idiopathic and Congenital Scoliosis	677

VOLUME 2

19. Kyphosis	741
20. Spondylolysis and Spondylolisthesis	777
21. The Cervical Spine	799
22. The Upper Limb	841
23. Developmental Hip Dysplasia and Dislocation	905
24. Legg-Calve-Perthes Syndrome	957
25. Slipped Capital Femoral Epiphysis	999
26. Developmental Coxa Vara, Transient Synovitis, and Idiopathic Chondrolysis of the Hip	1035
27. The Lower Extremity	1059
28. Leg Length Discrepancy	1105
29. The Foot	1151
30. The Limb-Deficient Child	1217
31. Sports Medicine in Children and Adolescents	1273
32. Management of Fractures	1319
33. The Role of the Orthopaedic Surgeon in Child Abuse	1423



EMBRYOLOGY AND DEVELOPMENT OF THE MUSCULOSKELETAL SYSTEM

**FREDERICK R. DIETZ
JOSÉ A. MORCUENDE**

DEVELOPMENTAL ANATOMY OF EARLY EMBRYOGENESIS AND ORGANOGENESIS 2

Cleavage: Creating Multicellularity 2
Implantation and Gastrulation: Organizing the Embryonic
Cells to Form Tissues and Organs 3
Early Organogenesis in Vertebrate Development:
Neurulation and Mesoderm Segmentation 5
Conceptual Insights of Embryogenesis and Early
Organogenesis 7
Clinical Significance 9

DEVELOPMENTAL ANATOMY OF THE LIMB 9

Molecular Insights of Limb Development 13
Clinical Significance 16

DEVELOPMENTAL ANATOMY OF THE VERTEBRAL COLUMN 18

Molecular Insights of Vertebral Column Development 21
Clinical Significance 21

DEVELOPMENTAL ANATOMY OF THE NERVOUS SYSTEM 22

Molecular Insights of Nervous System Development 23
Clinical Significance 23

BONE FORMATION AND GROWTH 23

Intramembranous Ossification 24
Endochondral Ossification 24
Growth Plate Structure and Development 24
Vascular Anatomy of the Growth Plate 27

The development of an adult organism from a single cell is an unparalleled example of integrated cell behavior. The single cell divides many times to produce the trillions of cells of the organism, which form structures as complex and varied as the eyes, limbs, heart, or the brain. This amazing achievement raises a multitude of questions: How are the

body's tissues and organs are formed? How do the different patterns form in the embryo that tell different parts what to become? How do individual cells become committed to particular development fates? Increased knowledge in developmental biology comes from the understanding of how genes direct those developmental processes. In fact, developmental biology is one of the most exciting and fast-growing fields of biology, and has become essential for understanding many other areas of biology and medicine.

Embryology at the level of gross anatomy and microscopic anatomy is fairly well described. Manipulation of experimental animals, mainly the chick and mouse, have provided insights into the relationship of tissues involved in

F. R. Dietz: Department of Orthopaedic Surgery, University of Iowa; Division of Pediatric Orthopaedics, University of Iowa Hospitals and Clinics, Iowa City, Iowa 52242.

J. A. Morcuende: Department of Orthopaedic Surgery, University of Iowa, Iowa City, Iowa 52242.

normal growth and differentiation. Molecular mechanisms underlying developmental events are being discovered. An integration of the approaches of genetics, molecular biology, developmental biology, and evolutionary biology is taking place, resulting in an explosion in understanding of the importance of individual genes and interactions of cells and tissues in specifying development of complex organisms from single cells. One of the major reasons for the synthesis and complementarity of these varying disciplines is the existence of homology, both within organisms and between species. Genes and their gene products are often very similar in structure and function in fruit flies, chickens, mice, and men. For example, *HOX* genes, which convey body/plan positional information, are conserved among species, and are similar in structure and function, i.e., homologous. In complex organisms, the same gene is often used at different times in development, and in different areas of the body, to perform similar functions.

The picture is as yet fragmented. Genes and gene products are being identified as important for development through the timing and location of their activation, the effects of their ectopic expression, and the consequences of their inactivation. However, “upstream” and “downstream” causes and effects of gene activity are often complex and may be key to manipulating biology in the service of disease and disorder prevention and correction. The mechanisms of gene actions and tissue interactions, which truly regulate and direct development, will be clearer in the coming several decades.

This chapter describes the early stages of embryonic development, followed by the descriptive anatomy of limb development and the formation of the vertebral column. It also examines bone formation and growth, and emphasizes progress in the understanding of the cellular and molecular mechanisms involved in these aspects of development. Concluding each section are observations that relate developmental anatomy to the clinical problems faced by orthopaedic surgeons.

DEVELOPMENTAL ANATOMY OF EARLY EMBRYOGENESIS AND ORGANOGENESIS

Embryogenesis has been traditionally divided into the embryonic period and the fetal period. The embryonic period is considered the time from fertilization to the end of the eighth week. During this period, the body plan is completed and all major organs are established. The stages of the embryonic period include fecundation, cleavage, gastrulation, neurulation, and organogenesis. By the eighth week of gestation, the organism's shape is fully formed, and the remaining of the gestation will involve the growth and the maturation of the organ functions.

Cleavage: Creating Multicellularity

The first stage of development after fertilization is a series of cleavage divisions in which the zygote divides in an ordered

pattern to produce a ball of much smaller cells, called a blastula. This starts the production of a multicellular organism. Cleavage is a very well-coordinated process under genetic regulation. The specific type of cleavage depends upon the evolutionary history of the species and on the mechanism used to support the nutritional requirements to the embryo. The pattern and symmetry of cell cleavage particular to a species is determined by the amount and distribution of the cytoplasm (yolk), and by those factors in the cytoplasm influencing the angle of the mitotic spindle and the timing of its formation. In most species (mammals being the exception), the rate of cell division and the placement of the blastomeres with respect to one another is completely under the control of proteins and mRNA stored in the mother oocyte. The zygote DNA is not used in early cleavage embryos. In addition, the differential cellular cleavage provides the embryo with axis information, dividing the cell into an animal pole (where the nucleus is frequently found) and a vegetal pole.

In mammals, the protected uterine environment permits an unusual style of early development. It does not have the same need as the embryos of most other species to complete the early stages rapidly. Moreover, the development of the placenta provides for nutrition from the mother, so that the zygote does not have to contain large stores of material such as yolk. Thus, cleavage has several specific characteristics. First, it is a relatively slow process. Each division is approximately 12 to 24 hours apart. A frog egg, for example, can divide into 37,000 cells in just 43 hours. Second, there is a unique orientation of the cells with relation to one another. The first cleavage is a meridional division, but in the second division, one pair of cells divides meridionally and the other equatorially (Fig. 1-1). This type of cleavage is called rotational cleavage (1). Third, there is an asynchrony in the early divisions. Cells do not divide at the same time. Therefore, embryos do not increase evenly from 2- to 4- to 8-cell stages, but frequently contain an odd number of cells. Fourth, the zygotic genome is activated early during cleav-

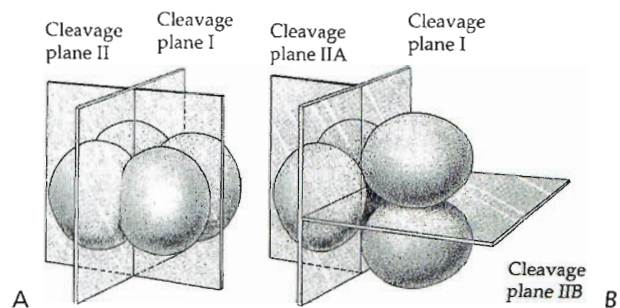


FIGURE 1-1. Comparison of early cleavage divisions in the sea urchin and in mammals. **A:** The plane of cell division in the sea urchin is perpendicular to cells. In mammals (**B**, rabbit) in the second division, one of the two blastomeres divides meridionally and the other divides equatorially. Early cell division in mammals is asynchronous—not all cells divide at the same time. (From ref. 2, with permission.)

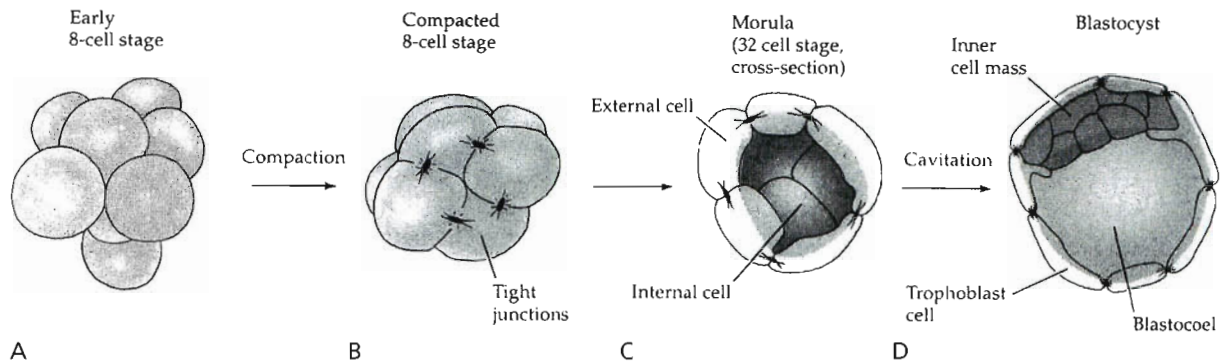


FIGURE 1-2. The cleavage of a mouse embryo, up to blastocyst. **A:** Early 8-cell stage with loose cell arrangement. **B:** Compacted 8-cell stage. During the process of compaction, cells suddenly huddle together, maximizing their contacts. Tight junctions, sealing off the inside of the sphere, stabilize outside cells. The inner cells develop gap junctions, which enables the passing of small molecules and ions. **C:** Morula with differentiation between the external cells and the inner cell mass. **D:** Blastocyst before implantation. (From ref. 2, with permission.)

age divisions to produce the proteins needed for the process to occur (3). Finally, the most crucial difference from other species is the phenomenon of compaction. At the 8-cell stage, blastomeres form a loose arrangement of cells, but after the third division, the cells cluster together and form a compact ball, with the outside cells stabilized by tight junctions and the inner cells developing gap junctions that enable the passing of small molecules and ions (Fig. 1-2).

Up to the 8-cell stage, the embryo is remarkably adaptable, and each of its cells can form any part of the later embryo or adult. One example is seen in the development of a pair of identical twins from a single fertilized egg. Similarly, this embryonic cell potential can be demonstrated experimentally by using chimeras. These are animals made by combining individual cells from early embryos of genetically different strains of animals, then the reaggregated cells are implanted in foster mothers. Analysis of the genetic composition of the tissues of the developed animal shows that the single cells from the 4-cell stage can participate in forming many different parts of the animal; they are said to be totipotent (4,5).

In mammals, the next stage in development is the generation of the cells that will form the placenta and the membranes that surround the developing embryo. The cells of the compacted embryo divide to produce a 16-cell morula. This morula consists of a small group (1 or 2) of internal cells surrounded by a larger group of external cells (Fig. 1-2C) (6). The position of a cell at this stage determines whether it will form extraembryonic structures or contribute to the embryo proper. Inner cells will form the embryo and most of the external cells will form the trophoblast. This structure will enable the embryo to get oxygen and nourishment from the mother, and will secrete hormones and regulators of the immune response so that the mother will not reject the embryo. Experimentally, this separation of cell activities also has been shown with chimeras. Cells from different strains of mouse can be arranged so that the cells of one strain surround the cells of the other strain. The

development of such cell-aggregates shows that only the cells on the inside contribute to mouse development (7). By the 64-cell stage, the inner cell mass and the trophoblast have become separate cell layers, neither of which contributes cells to the other group. Thus, the distinction between these two cell types represents the first differentiation event in mammalian development.

Implantation and Gastrulation: Organizing the Embryonic Cells to Form Tissues and Organs

In human beings, implantation begins 1 or 2 days after the blastocyst enters the uterus, approximately on day 7 (Fig. 1-3A). At the time of implantation, the exposed surface of the uterine lining, the endometrium, is a single-layered epithelial sheet, which forms numerous tubular glands. Having adhered to the epithelium, the trophoblastic cells penetrate it and erode it (Fig. 1-3B). The endometrium responds by a dramatic increase in vascularity and capillary permeability, the so-called “decidual reaction” (Fig. 1-4). These processes are apparently mediated by estrogens produced by the blastocyst and estrogen receptors in the wall of the uterus. In addition, the trophoblast initiates the secretion of human chorionic gonadotropin, which will maintain the production of progesterone by the ovaries, essential for the maintenance of the pregnancy. Human chorionic gonadotropin is detectable in the blood and urine, and serves as the basis of pregnancy tests.

The next phase of development—gastrulation—involves a remarkable process in which the ball of cells of the blastula turns itself into a multilayered structure and rearranges to form the three embryonic tissue layers known as endoderm, ectoderm, and mesoderm. In addition, during gastrulation, the body plan of the organism is also established. Gastrulation thus involves dramatic changes in the overall structure of the embryo, converting it into a complex three-dimensional structure.

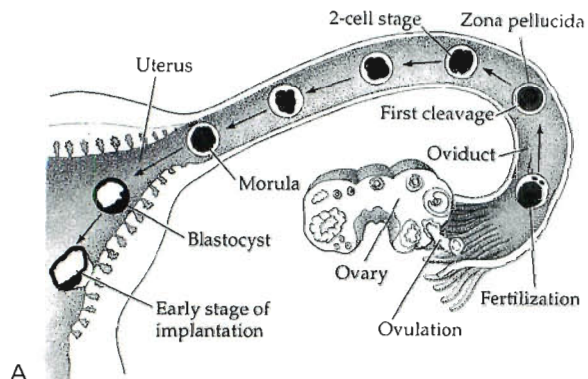


FIGURE 1-3. A: Development of human embryo from fecundation to implantation (blastocyst at 7 days). **B:** Tissue formation of human embryo between days 7 and 8. The inner cell mass will give rise to the embryo proper, and the trophoblast to the placenta. The distinction between those two groups of cells represents the first differentiation event in embryonic development. (From ref. 2, with permission.)

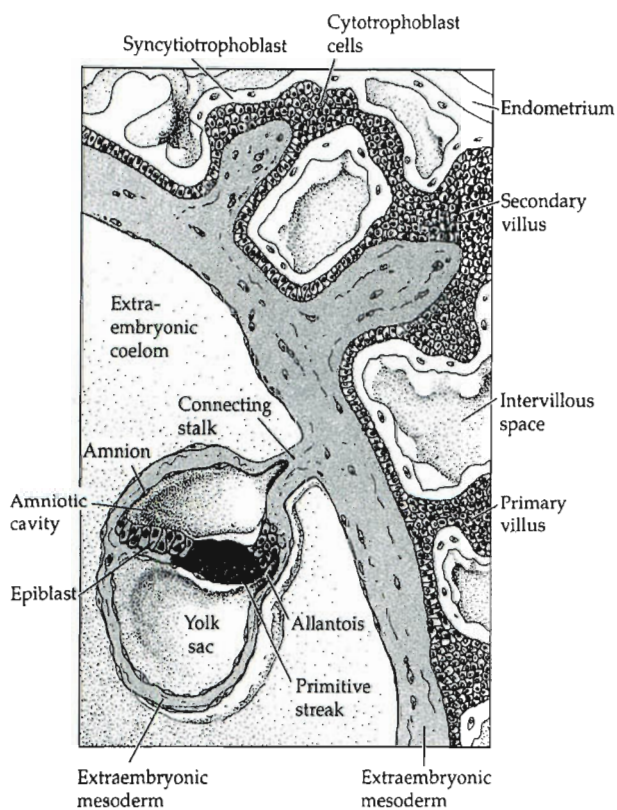
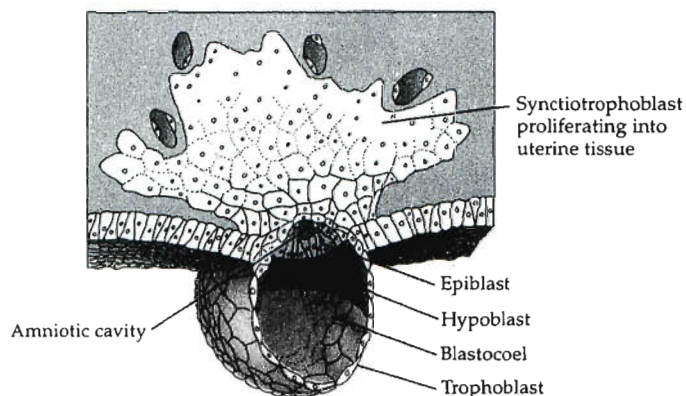
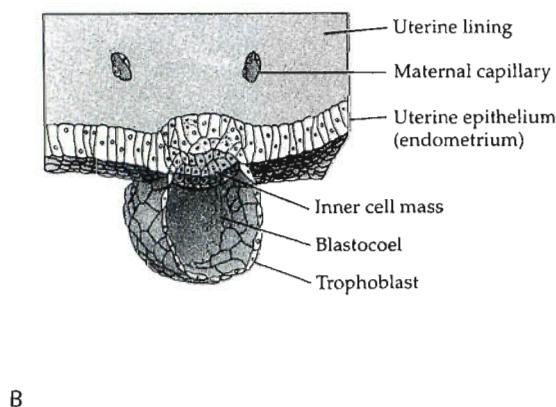


FIGURE 1-4. Placenta development in the human embryo at the end of the third week of gestation. The trophoblast cells forming the placenta are coming into contact with the blood vessels of the uterus. The endometrium responds by a dramatic increase in vascularity and capillary permeability, the so-called decidual reaction. The trophoblast divides into the cytotrophoblast, which will form the villi, and the syncytiotrophoblast, which will ingress into the uterine cavity. The actual embryo forms from the cells of the epiblast. (From ref. 11, with permission.)

The mechanics of gastrulation in mammals are not well understood. In sea urchins and insects, the phenomenon of gastrulation can be compared to what happens if a ball is punctured, then kicked: the ball collapses and the inner surface on one side makes contact with the other side, making a large dimple. In the embryo, a large area of cells on the outside of the embryo is brought to lie inside it by a complicated invagination. Subsequent development depends on the interactions of the outer ectoderm, middle mesoderm, and inner endoderm layers of cells. The ectoderm will give rise to the epidermis of the skin and to the nervous system; the mesoderm will give rise to connective tissues, including the bones, muscle, and blood; and the endoderm will give rise to the lung and the lining of the gut and associated organs.

In addition, during gastrulation, the cells are positioned according to the body plan appropriate to the species, and there is a process of differentiation of the functional characteristics required of each part of the body plan. Specification of the axes in mammals does not involve any maternal component. The dorsoventral axis is established by the interaction between the inner cell mass and the trophoblast, whereas the anteroposterior axis may be set only at implantation. The generation of the left–right asymmetry is under genetic control. This vertebrate body plan will be maintained thereafter as the embryo grows.

The movements of gastrulation involve the entire embryo. Cell migration in one part of the embryo must be intimately coordinated with other cell movements occurring simultaneously elsewhere. However, gastrulation depends on a relatively simple repetition of basic cell activities. Cells can change their shape by extending or contracting. They can group or separate by forming or breaking their adhesions to neighboring cells or to the extracellular matrix.

They can secrete extracellular matrix that constrains or guides their location or movement. These activities, together with cell proliferation, underlie almost all morphogenetic activities during gastrulation. The special problem posed in early embryonic development is to understand how these and other elementary cell activities are coordinated in space and time.

Recent experiments have suggested that the maternal and paternal genomes (imprinting) have different roles during mammalian gastrulation. Mouse zygotes can be created that have only sperm-derived or oocyte-derived chromosomes. The male-derived embryos die without embryo proper structures, but with well-formed chorionic structures. Conversely, the female-derived embryos develop normally, but without chorionic structures (8,9). This observation also has been confirmed using mouse chimeras (10). Therefore, the maternal and paternal genomic information may have distinct functions during early development.

Early Organogenesis in Vertebrate Development: Neurulation and Mesoderm Segmentation

During gastrulation, the germ layers (ectoderm, mesoderm, and endoderm) move to the positions in which they develop into the structures of the adult organism. The anteroposterior body axis of the vertebrate embryo emerges, with the head at one end and the future tail at the other. During the next stage of development, the main organs of the body begin to emerge gradually (11). A major set of interactions takes place between the mesodermal cells and the ectoderm in the dorsal midline (Hensen's node) so that the ectoderm cell layer will form the nervous system (Fig. 1-5). At the

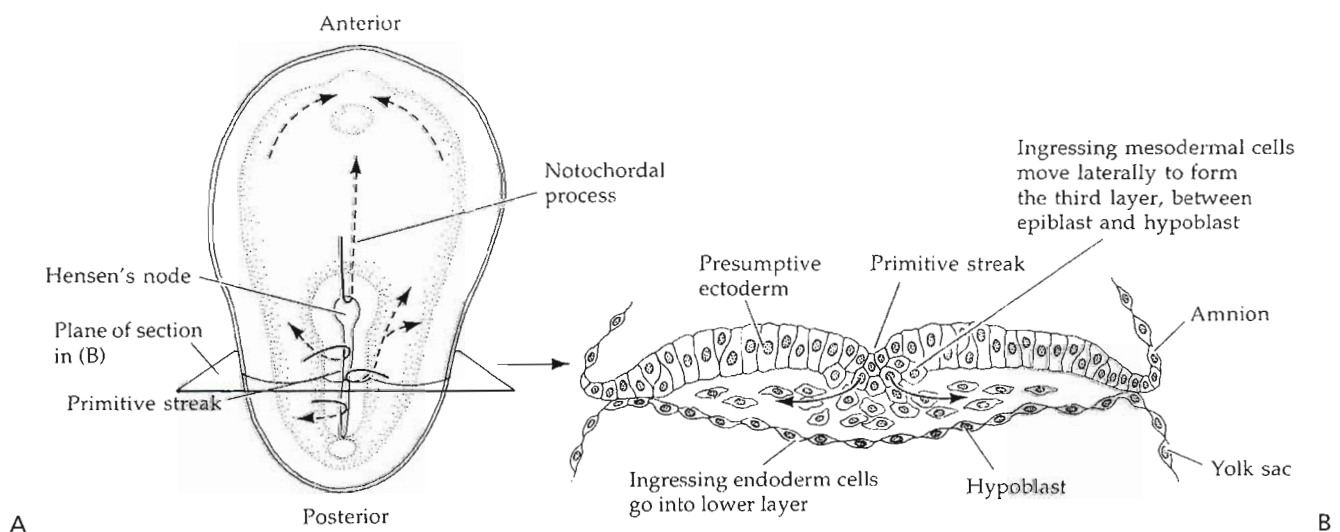


FIGURE 1-5. Cell movements during the gastrulation stage. **A:** Surface view of cells migrating through Hensen's node which travel anteriorly to form the notochord. Cells traveling through the primitive streak will become the precursors of mesoderm and endoderm. **B:** Transverse section of the embryo. (From ref. 11, with permission.)

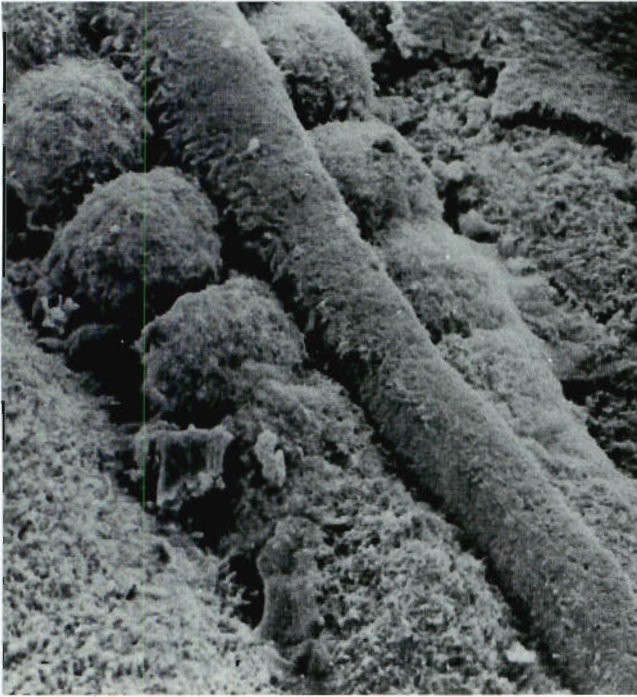


FIGURE 1-6. Scanning electron microscopy showing the neural tube and the well-formed somites with paraxial mesoderm that has not yet separated into distinct somites. (Courtesy of K. W. Tosney.)

same time, the mesoderm on either side of the middle breaks up into blocks of cells to form the somites, a series of repeated segments along the axis of the embryo (Fig. 1-6) (12). The interactions between the dorsal mesoderm and its overlying ectoderm are one of the most important of all development. The action by which the flat layer of ectodermal cells is transformed into a hollow tube is called neurulation (Fig. 1-7). The first indication of neurulation is a change in cell shape in the ectoderm. Midline ectodermal cells become elongated, whereas cells destined to form the epidermis become flattened. The elongation of the cells causes this region to rise above the surrounding ectoderm, thus creating the neural plate. Shortly thereafter, the edges of the neural plate thicken and move upward to form the neural folds, which subsequently will fuse to form the neural tube beneath the overlying ectoderm. The formation of the neural tube does not occur all at once. It starts near the anterior end of the embryo and proceeds anteriorly and posteriorly. The two open ends are called anterior and posterior neuropores (Fig. 1-8). In mammals, failure to close the anterior neuropore results in anencephalia, and the posterior neuropore in spina bifida. Neural tube defects can be detected during pregnancy by ultrasonography and chemical analysis of the amniotic fluid.

The process of neurulation is intimately linked to changes in cell shape generated by the cytoskeleton (microtubules and microfilaments). Differential cell division seen in different regions of the neural plate would also contribute

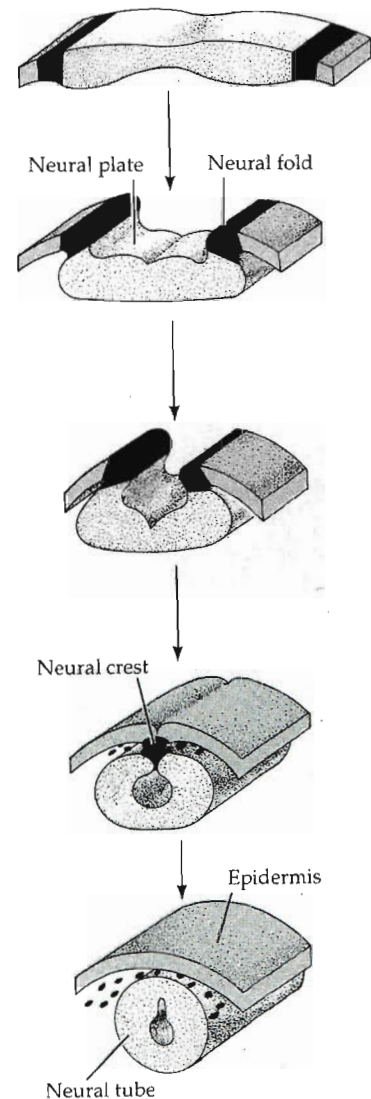


FIGURE 1-7. Diagrammatic representation of neural tube formation. The ectoderm folds in at the most dorsal point, forming a neural tube that is connected by neural crest cells, and an outer epidermis. (From ref. 11, with permission.)

to the size and shape of this region. In addition, those cells directly adjacent to the notochord and those cells at the hinges of the neural groove will also help to mold the neural tube. Separation of the neural tube from the ectoderm that will form the skin requires changes in cell adhesiveness. Although molecules that can induce neural tissue, such as noggin protein, have been identified, induction of neurulation is due to inhibition of bone morphogenetic protein (BMP) activity. Positional identity of cells along the antero-posterior axis is encoded by the combinatorial expression of genes of the four *HOX* complexes.

The cells at the dorsalmost portion of the neural tube become the neural crest. These cells will migrate through the embryo, and will give rise to several cell populations.

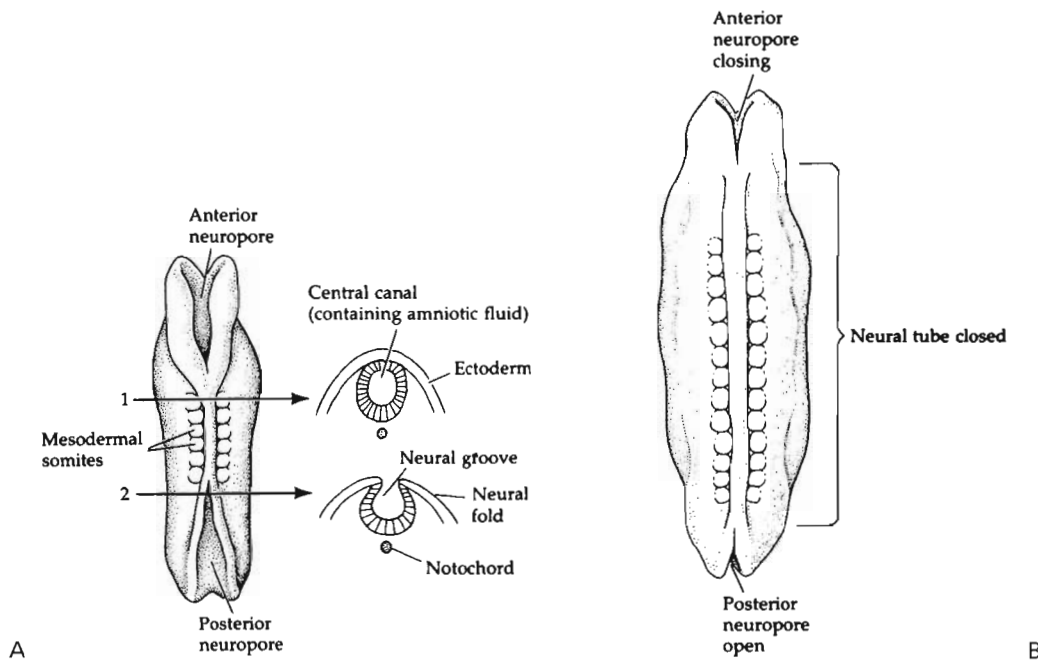


FIGURE 1-8. Neural tube formation in human embryos does not occur simultaneously throughout the ectoderm. **A:** At the initial stages, both anterior and posterior neuropores are open. **B:** Closing of the neural tube proceeds both cranially and caudally. Failure to close the posterior neuropore at day 27 results in spina bifida, the severity of which depends upon how much of the spinal cord remains open. Failure to close the anterior neuropore results in lethal anencephaly. (From ref. 11, with permission.)

Although derived from the ectoderm, the neural crest has sometimes been called the fourth germ layer because of its importance. It gives rise to the neurons and supporting glial cells of the sensory, sympathetic, and parasympathetic nervous systems; the melanocytes of the epidermis; and the cartilage and connective tissue components of the head. Although not well understood, the mechanisms of neural crest migration are not random but rather follow precise pathways specified by the extracellular matrix. Differences in adhesiveness between the anterior and posterior halves of the somites result in the neural crest being prevented from migrating over the posterior halves. Thus, presumptive dorsal ganglia cells collect adjacent to anterior halves, giving them a segmental arrangement.

The formation of mesodermal structures does not occur subsequent to that of the neural tube, but simultaneously. The brain and spinal cord must develop in the correct relationship with other body structures, particularly the mesoderm. Five regions of mesoderm can be identified at the neurula-stage embryo (Fig. 1-9): the chordamesoderm, which will generate the notochord, a transient organ whose functions include inducing neural tube formation and establishing the body axis; the dorsal (somitic) mesoderm, which will produce many of the connective tissues of the body; the intermediate mesoderm, which will form the urinary system and genital ducts; the lateral plate mesoderm, which will give rise to the heart, blood vessels and blood

cells, and the body lining cavities; and lastly, the head mesoderm, which will contribute to the connective tissues and muscles of the face.

At the neural stage, the body plan has been established and the regions of the embryo that will form limbs, eyes, heart, and the other organs have been determined. But although the positions of various organs are fixed, there is no overt sign yet of differentiation. The potential to form a given organ is now confined to specific regions. Each region has, however, considerable capacity for regulation, so that, if a part of the region is removed, a normal structure can still form. In later sections, limb and axial skeleton formation will be discussed in more detail.

Conceptual Insights of Embryogenesis and Early Organogenesis

Development is essentially the emergence of organized and specialized structures from an initially very simple group of cells. Thus, the cells of the body, as a rule, are genetically alike (they all have the same DNA content) but phenotypically different—some are specialized as muscle, others as neurons, and so on. During development, differences are generated between cells in the embryo that lead to spatial organization, changes in form, and the generation of different cell types. All these features are ultimately determined

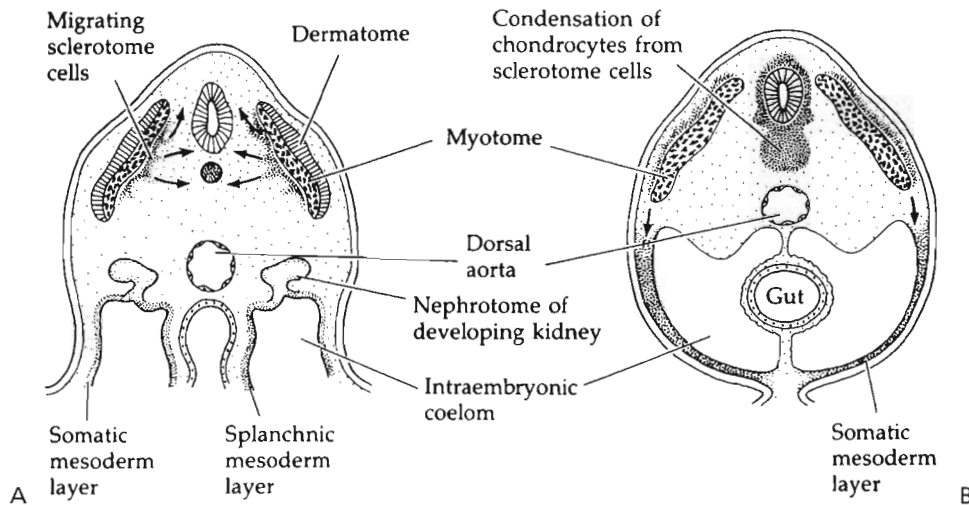


FIGURE 1-9. Mesoderm formation in human embryo. Diagram of a transverse section through the trunk of an early 4-week (A) and late 4-week embryo (B). Sclerotome cells migrate from the somite, and these cells ultimately become chondrocytes. The remaining dermatome cells will form the dermis. The myotome will give rise to the striated muscle of both the back and limbs. (From ref. 11, with permission.)

by the DNA sequence of the genome. Each cell must act according to the same genetic instructions, but it must interpret them with regard to time and space.

Multicellular organisms are very complex, but they are generated by a limited repertoire of cell activities. In the same way that an artist moves from one part of a sculpture to another to achieve first the overall figure's shape, then the specific anatomic features, using a selected number of instruments over and over again, nature also displays a comparable economy in choosing processes and molecular tools. The key to understanding development lies in cell biology, in the processes of signal transduction, and in the control of gene expression that results in changes of cell state, movement, and growth. The single most important fact in development is based on the surprising finding that the developmental control genes are maintained through evolution. Thus, for many genes discovered in the invertebrate systems, homologue genes have been identified in vertebrates. These have similar developmental roles in species ranging from the fruit fly to fish to mouse to human.

It is convenient to distinguish three main developmental processes, even though they considerably overlap with, and influence, one another. These are the emergence of pattern, cell differentiation, and change in form or morphogenesis.

Pattern Formation

Pattern formation is the process by which spatial and temporal arrangements of cell activities are organized within the embryo, so that a well-defined structure develops. Pattern

formation is critical for the proper development of every part of the organism. In the developing limb, for example, pattern formation enables the cells to know whether to make the upper arm or the fingers, and where the muscles should form.

Pattern formation in many animals is based on a mechanism in which the cells first acquire a positional identity, which determines their future behavior. The ability of cells to sense their relative positions within a limited population of cells, and to differentiate according to this position, has been the subject of intense research. Pattern formation in many systems has similar principles, and, more striking, similar genes. Many of the so-called homeotic genes that determine segment identity in *Drosophila* have turned up in vertebrates, and appear to play similar roles in segmentation of structures such as the brain or the vertebral column.

Homeotic genes are like embryonic switches, analogous to switches of railroad yards that direct trains into one path rather than another. Homeotic genes are involved in specifying regional identity along the anteroposterior axis. The name comes from the fact that mutations in some of these genes result in what is called a homeotic transformation, in which one body structure replaces another. For example, in mice in whom *HOXD11* is mutated, anterior sacral vertebrae are transformed into lumbar vertebrae. Homeotic genes in all systems work similarly: They code for proteins called transcription factors, which control gene expression. In vertebrates and *Drosophila*, the order of homeotic genes on the chromosome corresponds to their temporal and spatial expression on the anteroposterior axis of the embryo.

Cell Differentiation

Cell differentiation is the process in which cells become structurally and functionally different from each other, ending up as distinct types, such as muscle, bone, or cartilage. Because each cell of the organism has the same genetic material, the achievement and persistence of the differentiation state depends on a series of signals that ultimately control the transcription of specific genes. In humans, the zygote gives rise to about 250 clearly distinguishable types of cells. One of the major goals of developmental biology is to discover how these differences emerge from the fertilized oocyte.

In any organism, differentiation leads to the production of a finite number of discrete kinds of cells, each with its peculiar repertory of biochemical activities and possible morphological configurations. When cells achieve a distinctive state of differentiation, they do not transform into cells of another type. Differentiation leads to a stable, irreversible set of cellular activities. At the organ level, once an embryonic part is capable of realizing its prospective fate in the absence of the conditions that established that capability, it is said to be determined. Determination is thus a step that limits the subsequent development of the part to a specific tissue and cellular differentiation.

Pattern formation and cell differentiation are very closely interrelated, as can be seen by considering the difference between the upper and lower extremities. Both contain the same tissues—muscle, cartilage, bone, and so on—yet the patterns in which they are arranged are different. It is essentially pattern formation that makes human beings different from rabbits or chimpanzees.

Morphogenesis

Although vertebrate morphogenesis—change in form—is far from completely understood, developmental biology supports the findings that the same family of molecules and pathways that guide the earliest stages of embryogenesis, setting up such basic elements of body pattern as the head-to-tail and dorsoventral axis, also help out in morphogenesis. What is more, these molecules and pathways have been conserved over the course of evolution. Morphogenesis relies on a rather restricted number of cellular activities and encompasses the formation of all tissues and organs from the first embryonic tissue layers to the finished limb, spine, or brain. However, before any tissue or organ can form, earlier steps must occur, steps that tell cells who they are and what tissues they should form. Those early steps take place in the “control room” for development, and morphogenesis is then what happens on the “factory floor”—the actual assembly of the tissues and organs that make up the organism. In addition, spatial patterns of cell proliferation, folding of cell groups, rearrangement of cells, and cell migration make important contributions to morphogenesis, the

process that shapes the embryo. Finally, as the embryo develops, cells become different, and this process culminates in the specialization of cells for particular functions. Therefore, during development, morphogenesis gives rise to structures appropriate to their position within the embryo, and, within these structures, the differentiation of individual cells and their interactions are spatially ordered.

Clinical Significance

Broadly defined, birth defects or congenital abnormalities occur in 6% of all live births. Twenty percent of infant deaths are due to congenital anomalies. Approximately 3% of newborns have significant structural abnormalities. At present, the cause of approximately 50 to 60% of birth defects is unknown: chromosomal abnormalities cause 6 to 7%, specific gene mutations cause 7 to 8%, environmental teratogens are responsible for 7 to 10% of defects, and combined genetic predisposition with environmental factors cause the remaining 20 to 25% of congenital abnormalities.

Starting from a single cell, the embryo can spawn all the new cells and tissues needed to provide an organism with its correct complement of organs. Many of the molecules and pathways known to control cell differentiation and growth during organ formation in the embryo do not become obsolete in the adult. They do help maintain and repair tissues and regulate their response to external environment signals. Some of these proteins are or will soon be in clinical use, such as erythropoietin, which triggers red blood cell production; platelet-derived growth factor (PDGF) for diabetic skin ulcers; and BMP for bone and cartilage regeneration. Finally, in malignant disease, the control of cell activities, such as proliferation, differentiation, and migration, appears to break down. An understanding of the way in which cell behavior is coordinated in embryos could therefore give insights into bone and cartilage regeneration and cancer biology.

DEVELOPMENTAL ANATOMY OF THE LIMB

At 26 days after fertilization, the upper limb is evident as a slight elevation on the ventrolateral body wall at the level of the pericardial swelling. The lower limb elevation appears 2 days later, just caudal to the level of the umbilical cord, and develops similarly, but slightly later than the upper limb (Fig. 1-10). At this time, the neural tube is closed, all somites are present, and the anlage of the vertebrae and intervertebral discs is present. The limb bud initially consists of loose mesenchymal tissue enclosed in an epithelial ectodermal sheath. The limb bud is formed from mesenchymal cells of the lateral plate, then augmented by cells from the adjacent somites. The skeletal elements and tendons develop from the lateral plate mesenchyme, whereas limb muscle arises from somitic mesenchymal cells that migrate into the limb bud.

	mm	4	5	6	8	10	15	20	25	30				
	Weeks	5				6				7		8		
Feature	Stage	11	12	13	14	15	16	17	18	19	20	21	22	23
Ectodermal ring		■	■	■										
Upper limb bud			■											
Lower limb bud				■										
Brachial plexus					■									
Apical ectodermal ridge for upper limb					■	■	■	■	■	■				
Hand plate						■	■	■	■	■				
Apical ectodermal ridge for lower limb						■	■	■	■	■				
Mesenchymal humerus, radius & ulna							■	■	■	■				
Lumbosacral plexus; foot plate							■	■	■	■				
Chondrifying humerus; nerves enter hand plate							■	■	■	■				
Chondrifying radius; finger rays								■	■	■				
Chondrifying femur, tibia, & fibula									■	■				
Chondrifying ulna & metacarpus										■	■			
Mesenchymal clavicle; chondrifying scapula											■	■		
Many muscles; toe rays in some												■	■	
Chondrifying carpus, tarsus, & metatarsus													■	■
Ossifying clavicle														■
Chondrifying phalanges														■
Major joints, e.g., hip & knee														■
Various ligaments														■
Ossifying humerus														■
Ossifying radius														■
Ossifying ulna, femur, & tibia														■
Cavitation in major joints, e.g., hip & knee														■

FIGURE 1-10. Timing of the appearance of limb features. (From ref. 83, with permission.)

This mesenchymal swelling is covered by ectoderm, the tip of which thickens and becomes the apical ectodermal ridge (AER) (Fig. 1-11). Underlying the AER are rapidly proliferating, undifferentiated mesenchymal cells that are called the progress zone (PZ). Proliferation of these cells causes limb outgrowth. Cells begin to differentiate only after leaving the PZ. The interaction between the AER and the undifferentiated mesenchymal cells underlying it is crucial for limb development. Experimental procedures on chick embryos reveal the following about the limb bud mesenchyme: (i) if removed, no limb develops; (ii) when grafted under the ectoderm at a location other than the normal limb area, an AER is induced and a limb will develop; (iii) lower limb mesoderm will induce leg formation when placed under an upper limb AER. Grafting experiments with the AER reveal that: (i) AER removal aborts further limb development. The later in limb development the AER is removed, the less severe is the resulting limb truncation (limb elements develop from proximal to distal); (ii) an extra AER will induce a limb bud to form supernumerary limb structures; (iii) nonlimb mesenchymal cells placed beneath the AER will not result in limb development, and the AER withers (13).

The implications of these experiments are that the AER is necessary for the growth and development of the limb, whereas the limb bud mesenchyme induces, sustains, and instructs the AER. In addition to biochemical influence on the PZ, the tightly packed columnar cells of the AER perform a mechanical function, directing limb shape by containing these undifferentiated cells in a dorsoventrally flattened shape. The length of the AER controls the width of the limb, as well. When all limb elements have differentiated, the AER disappears.

The three axes of limbs—anteroposterior (AP: thumb to small finger), dorsoventral (DV: back of hand to palm), and proximal-distal (PD)—are specified very early in limb development. The AP and DV axes are fixed before morphological differentiation of limb components occurs. The PD axis is determined as the limb grows out. The AP axis is set first, followed by the DV axis, then the PD axis. This has been shown by rotation of transplanted limb buds from their normal position and finding, at different stages, whether the limb bud retained the axis orientation of its original limb position or developed the orientation of the host bud (10,14,15).

AP axis determination is under the control of an area of

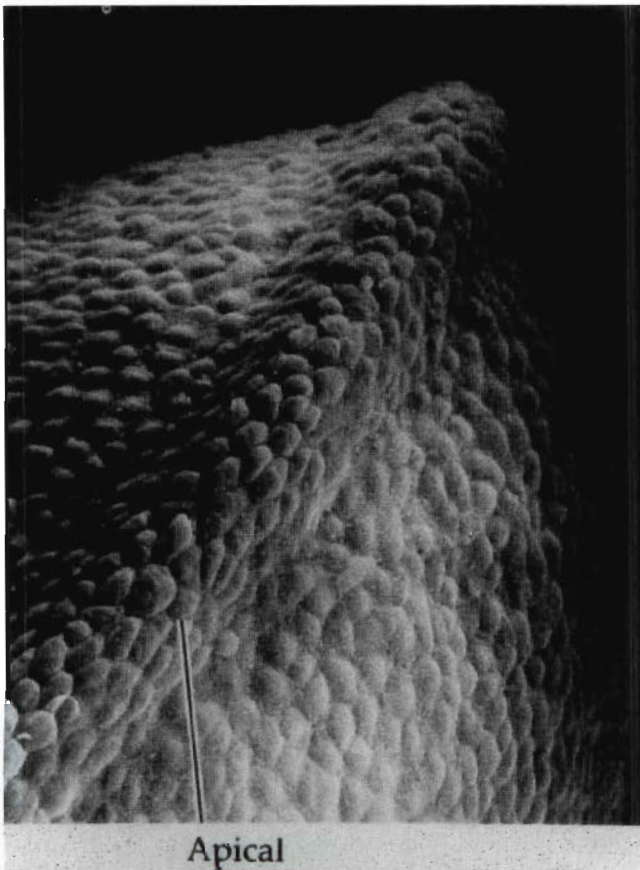


FIGURE 1-11. Scanning electron photomicrograph of an early chick forelimb bud, with the apical ectodermal ridge at the tip of the limb bud. (Courtesy of K. W. Tosney.)

tissue in the posterior aspect of the limb bud called the zone of polarizing activity (ZPA), or polarizing region. If this tissue is grafted onto the anterior aspect of a limb bud, a duplication of digits in a mirror image to the normally present digits occurs (16). Cells for the new digits are recruited from the underlying mesoderm, and the distal part of the limb widens, as does the AER. If less tissue from the polarizing region is grafted, fewer new digits develop (17). This and other experiments suggest that a morphogenic gradient of a diffusible signal originating from the ZPA determines AP axis. This is discussed in the section on the molecular biology of limb development.

The DV axis is under the control of both the mesoderm and ectoderm of the limb bud at different stages of development. The mesoderm specifies the axis initially, but, very early after limb bud formation, the ectodermal orientation becomes preeminent. If the ectoderm of a right limb bud is transplanted onto the mesenchyme of a left limb bud, the distal limb that develops will be that of a right limb, with respect to muscle pattern and joint orientation (14,15).

The PD axis seems to be determined by the length of time a mesodermal cell remains at the tip of the limb bud

in the progress zone under the influence of the AER. Once a cell leaves the tip, its position in the limb is fixed. Young tips grafted onto older limb buds will duplicate existing limb elements, whereas older tips grafted on young buds will only form distal elements. The best hypothesis as to how this information is passed is that the number of rounds of cell division that occur while under the influence of the AER determines the PD fate of a cell. Support for this hypothesis comes from experiments in which the limb bud is irradiated. The surviving cells of the irradiated tip have to undergo several extra rounds of mitosis before they can escape the influence of the AER and thereby gain positional determination. In these experiments, intermediate limb elements are not formed, only the preexisting proximal elements and newly formed distal elements (18).

Cellular differentiation of the homogenous, undifferentiated-appearing mesenchymal cells in the limb bud results from signals different than those conveying the axis/positional information as described above. The center of the limb bud develops a condensation of cells that prefigures the skeletal elements—the chondrogenic core, which begins at the body wall and progresses distally with limb elongation. A rich vascular bed surrounds the chondrogenic core. Immediately adjacent to the vascular bed is a thick avascular zone that extends to the ectodermal sheath of the limb bud. Although the signaling mechanism has not been discovered, the ectoderm appears to control initial mesodermal differentiation by maintaining the adjacent mesenchymal cells in a flattened configuration, which prevents differentiation into chondrogenic cells. The central mesenchymal cells assume a rounded shape and form the chondrogenic core (17,19). This process of differentiation occurs from proximal to distal. Early in the 7th week, cartilage anlage of the entire upper limb skeletal elements, with the exception of the distal phalanges, is present. Paddle-shaped hand plates have formed by the end of the 6th week, and condensations of cells have formed identifiable digital rays in the hand. The same is true of the foot 1 week later. The cells between the digital rays are a loose mesenchyme that undergoes programmed cell death (apoptosis) to create the separated fingers and toes.

After the chondrogenic anlagen of the future skeletal structures and the vascular bed develop, the ingrowth of nerves develops, followed immediately by the development of muscle tissue. All bones are prefigured in mesenchyme, followed by cartilage, then bone. Actual bone appears toward the end of the embryonic period, first in the clavicle, mandible, and maxilla, between the 6th and 7th weeks. Ossific centers appear soon after in the humerus, radius, femur, tibia, and ulna, in that order. Just prior to birth, ossific centers appear in the calcaneus, talus, cuboid, distal femoral epiphysis, and proximal tibial epiphysis.

The mechanisms controlling the development and patterning of the vasculature are not well worked out. Vascular cells are believed to have an intrinsic capacity to form vessels

and to branch, which is controlled by inhibitory signals extrinsic to the angiogenic tissues. Well-developed veins develop on the postaxial border of the limb buds and persist as the fibular and saphenous veins, permitting identification of the embryonic postaxial border, even in mature organisms. The early preaxial veins, the cephalic and great saphenous veins, develop secondarily. The initial arterial supply to the limb bud organizes into a single axial artery. In the arm, this artery becomes the subclavian, axillary, brachial, and anterior interosseous arteries. In the leg, the axial artery comes from the umbilical artery and becomes the inferior gluteal, sciatic, proximal popliteal, and distal peroneal arteries. The femoral and tibial arteries develop secondarily.

The brachial and lumbosacral plexuses and the major peripheral nerves are present by the 5th week. They progressively invade their target tissues, and by the 7th week have innervated the muscles and cutaneous tissues in the adult pattern. Each dermatome represents a single dorsal root's sensory fibers. From cranial to caudal, the dermatomes of the limbs descend along the preaxial border and ascend along the postaxial border of the limb. Overlapping and variability among individuals make assessment of dermatomal sensation nonspecific for single nerves (Fig. 1-12).

Mesenchymal cells that are to become limb muscles migrate from the somatic layer of the lateral mesoderm during the 5th week, and surround the chondrogenic core of the limb bud. They develop into dorsal and ventral groups from an undifferentiated mass and individual muscles gradually become distinct, again in a proximal/distal sequence. Most anatomically distinct adult muscles are identifiable in the

eighth week. Mesenchymal cells develop into myoblasts (activation of a single gene, *MyoD1*, is sufficient to turn a fibroblast into a myoblast phenotype in tissue culture), which then elongate, form parallel bundles, and fuse into myotubes. Muscle-specific contractile proteins, actin and myosin, are synthesized, and the myotubes form sarcomeres. By the 8th week, both myotube development and innervation are sufficiently advanced for movement to begin. By 12 weeks the cross-striations of the myofibrils are apparent in myotube cytoplasm. Most muscle cells are formed prior to birth, with the remaining cells developing in the first year of life. Enlargement of muscles results from an increase in diameter with the creation of more myofilaments and elongation with the growth of the skeleton. Ultimate muscle size results from genetic programming, exercise, and the hormonal milieu.

Development of the synovial joints commences in the 6th week of development. A condensation of cells in which the joint develops is called the interzone. The interzone cells differentiate into chondrogenic cells, synovial cells, and central cells. The chondrogenic cells are adjacent to the mesenchymal cells, and form the articular cartilage. The central cells form the intraarticular structures. The synovial cells differentiate into both the tough fibrous capsule and the loose, vascular synovium. Programmed cell death (apoptosis) results in cavitation that produces the joint *per se*. Motion is necessary for normal joint development, as the host of conditions causing arthrogryposis demonstrate, as well as animal experiments that create joint anomalies by paralyzing the developing fetus.

During the embryonic period, all four limbs are similar,

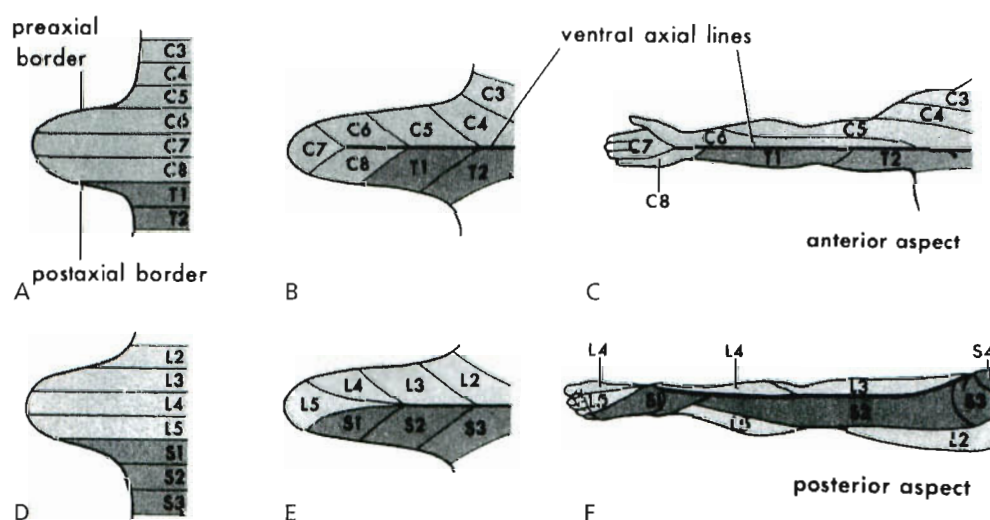


FIGURE 1-12. Development of the dermatome pattern in the limb. **A** and **D**: Diagram of the segmental arrangement of dermatomes in the 5th embryonic week. **B** and **E**: The pattern is shown one week later as the limb bud grows. **C** and **F**: The mature dermatome pattern is shown. The original ventral surface becomes posterior in the mature leg and anterior in the mature arm, due to the normal rotation of the limbs. (From ref. 20, with permission.)

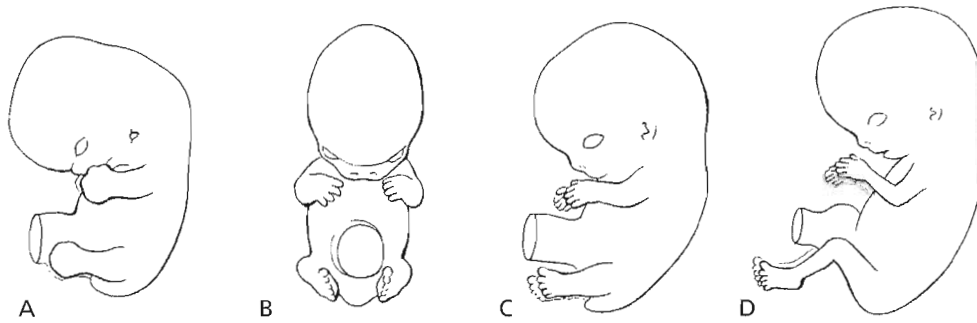


FIGURE 1-13. Normal limb rotation is depicted. **A:** 48 days, the hand and foot plates face each other. **B:** 51 days, elbows are bent laterally. **C:** 54 days, the soles of the feet face each other. **D:** lateral rotation of the arms and medial rotation of the legs result in caudally facing elbows and cranially facing knees. (From ref. 20, with permission.)

with parallel axes. The preaxial borders are cephalad and the postaxial borders are caudad. The thumb and hallux are preaxial; the radius/tibia and ulna/fibula are homologous bones occupying the same positions in the limb bud. The longitudinal axis at this stage passes through the long finger and the second toe. During the fetal period, the upper limb rotates 90 degrees externally (laterally), and the lower limb rotates 90 degrees internally (medially). The forearm flexors come to lie medially and the forearm extensors, laterally. The leg extensors lie ventrally, and the leg flexors lie dorsally (Fig. 1-13).

Thus, by the 8th week, the task of tissue differentiation is largely completed and growth is the major task ahead.

Molecular Insights of Limb Development

The explosion in molecular biology and molecular genetic techniques has revealed much about how an individual gene's activation at specific moments in development can cause the events that create complex organisms from single cells. The story is incomplete, and this section highlights presently known or suspected molecular mechanisms that underlie development. The development of organs employs mechanisms of cell growth, differentiation, and patterning similar to those that occur in earlier development of the basic body plan. The mechanisms for differentiation and patterning are remarkably conserved from fruit flies to chicks to mice and to humans.

The limb is one of the best-studied body structures and much information is available from the study of nonhuman animals, especially chicks, mice, and fruit flies. Much knowledge is inferred from the observations that certain genes and gene products are present at crucial moments in development. Often, many different genes and molecules are expressed simultaneously or in a closely overlapping sequence, and the complex interactions that control development are not fully worked out. The information presented in this section is based on study of limb development in the chick, except where noted. Most other information

comes from gene “knock out” experiments in mice, wherein a specific gene is rendered nonfunctional and the effects on development are noted.

Limb Bud Outgrowth and Proximal-distal Patterning (Fig. 1-14)

As discussed previously, the AER is required for limb bud outgrowth. The AER is a band of cells at the limb bud tip, lying between the dorsal and ventral limb ectoderm. Although the stimulus for AER formation, which resides in the mesoderm, is unknown, some of the molecular signals that are important in specifying the location of the AER have been identified. *Engrailed-1* (*En-1*) is a homeobox-containing transcription factor whose expression is limited to the ventral limb ectoderm (21). *Radical fringe* (*r-Fng*) is a secreted factor that modulates signaling that is expressed only in the dorsal ectoderm (22). *Radical fringe* is a homolog of the *Drosophila* gene *fringe*, which helps specify dorsal–ventral boundaries in the fruit fly (23,24).

Excision of the AER results in truncation of the limb. The earlier the excision, the more proximal is the truncation. Limb bud outgrowth can be sustained after excision of the AER, by insertion of beads carrying fibroblast growth factors (FGF). Fibroblast growth factors are a group of similar proteins that affect cell proliferation, differentiation, and motility. During development, they have in common a role in mediating mesenchymal–epithelial tissue interaction. To obtain the most normal limb development, two FGF-soaked beads must be placed so that the polarizing region is mimicked, as well as the AER (25). The absence of the mechanical flattening of the limb bud by the AER results in a bulbous limb bud and bunching of the digits. Nevertheless, fully differentiated limb skeletal structures can be produced.

FGF2, -4, and -8 are expressed in the AER, and each is able by itself to sustain limb bud outgrowth (probably because of the ability of different FGFs to activate the same

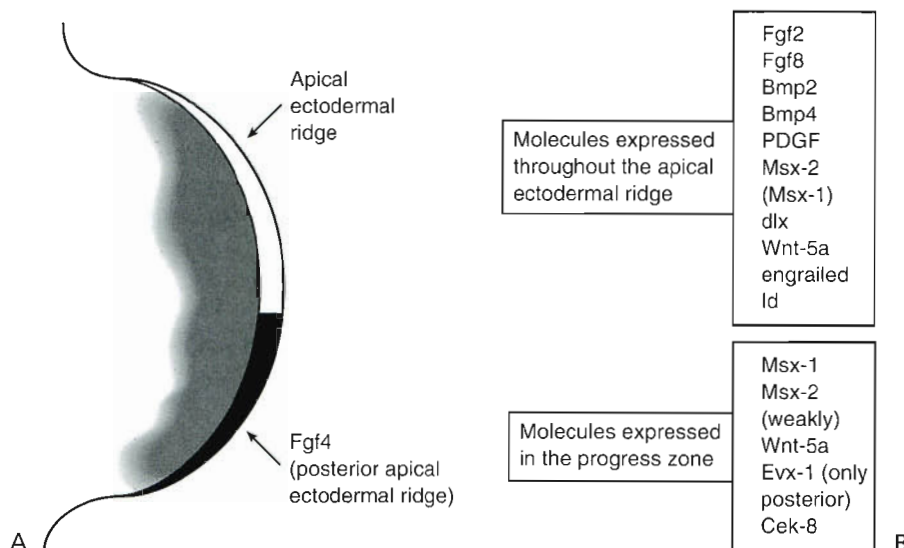


FIGURE 1-14. A diagram of the tip of the limb bud showing the apical ectodermal ridge and progress zone (A) and some of the molecules that are expressed in these tissues (B). (Adapted from ref. 83, with permission.)

receptors) (26–28). *In vivo* FGF-8 is found in the entire AER, whereas FGF-4 expression is limited to the posterior portion of the AER. FGF-10 and 8 are the critical FGFs expressed during the initiation of limb bud outgrowth. FGF-10 is expressed first in the lateral plate mesoderm at the site of the future limb bud. FGF-10 induces FGF-8 expression in ectodermal cells that will become the AER. Some experiments suggest that FGF-8 and FGF-10 act in a positive feedback loop; that is, the expression of each supports and promotes the expression of the other. Mice in whom FGF-10 function is eliminated develop normally, except for the complete absence of limbs and failure of normal pulmonary development (29).

Proximal-distal positional information is engraved upon individual cells in the progress zone based on the length of time (number of mitoses?) the cell spends in the progress zone as discussed in the section Developmental Anatomy of the Limb in this chapter (30,31). Some experimental work suggests that transforming growth factor β (TGF- β) acts in a gradient from the AER to increase cell adhesion by activating integrins, which are mediators of cell adhesion. Perhaps the longer a cell is in the progress zone, the more TGF- β it sees, and the more integrins are activated, the greater the cell adhesion, and ultimately, the more distal is the limb positional information programmed into the cell.

Anterior-Posterior Axis Determination/Zone of Polarizing Activity (Fig. 1-15)

The ability of a small piece of tissue excised from the posterior and proximal limb bud to induce duplication of digits, when grafted to an anterior position on another limb bud,

suggested that this region of polarizing activity synthesized a morphogen, acting by a gradient to specify anterior-posterior limb elements (16). If acting through a morphogenic gradient, the zone of polarizing activity should give different digit patterns when transplanted to different areas of the limb bud, which it does (32). Furthermore, if a physical barrier is placed between the anterior and posterior parts of the limb bud, a normal number and order of digits is formed in the posterior portion of the limb bud, and no digits are formed anteriorly (33).

By serendipity, retinoic acid was found to cause reduplication of limbs in amputated salamanders (34). Subsequently, retinoic acid was identified in the limb bud, with a high concentration posteriorly and a low concentration anteriorly. Retinoic acid on filter paper, placed anteriorly, induces mirror-image digits to those formed from the natural posterior gradient (35). Nevertheless, retinoic acid is not a simple morphogen acting through a gradient. Bathing an entire limb bud in retinoic acid should eliminate the gradient, but instead mirror-image reduplication occurs. Also, when retinoic acid concentration is at a minimum, the zone of polarizing activity is at a maximum. The action of retinoic acid is complex and includes several classes of nuclear retinoic acid receptors and retinoic-binding proteins in the cytoplasm. These different receptors and binding proteins are present in different amounts in various parts of the developing limb, suggesting a very complex role for retinoic acid. If retinoic acid synthesis is blocked, limb bud outgrowth does not occur or is severely stunted. At present, it appears that retinoic acid acts by regulating the cells that can express a protein called sonic hedgehog (shh) (36). It is likely that

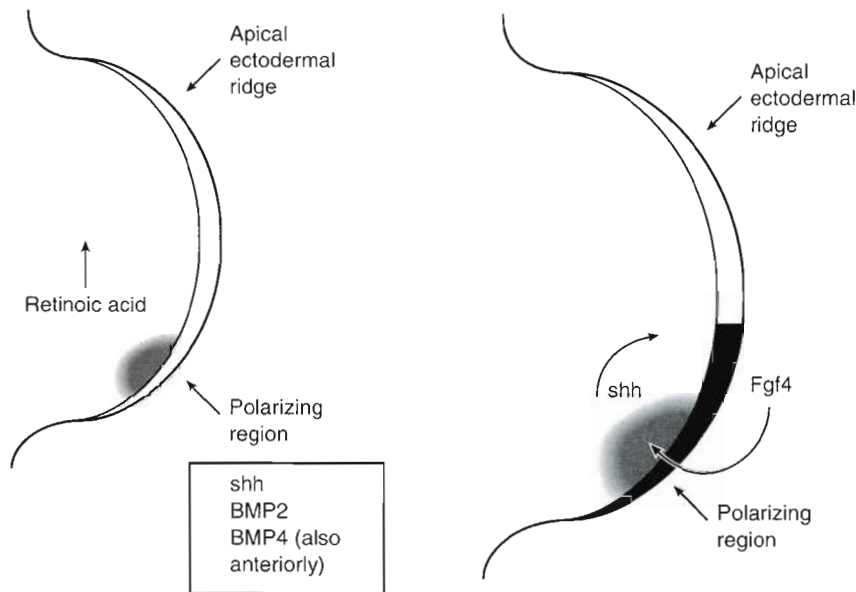


FIGURE 1-15. The two diagrams of the tip of the limb bud illustrate some of the molecules involved in the interaction between the polarizing region and mesenchyme of the progress zone that specify the anteroposterior axis of the limb. On the left, the arrow shows the direction of the decreasing concentration of retinoic acid. Retinoic acid acts by regulating cell production of sonic hedgehog (*shh*). *shh*, in turn, stimulates bone morphogenetic protein2 (*BMP2*) which is a homologue of a *Drosophila* segment polarity-specifying gene. *BMP4* expression overlaps that of *BMP2*, and is, therefore, probably involved in anteroposterior axis determination, as well. The diagram on the right shows the feedback loop between *shh* and fibroblast growth factor-4 (*FGF4*), an ectodermally expressed protein, that appears to maintain the apical ectodermal ridge. (Adapted from ref. 83, with permission.)

an *HOX* gene is an intermediate that is stimulated by retinoic acid and the *HOX* gene expression specifies the *shh*-expressing cells. If retinoic acid receptors are blocked after *shh* expression has been established, limb malformations still occur, suggesting some additional role in limb patterning, perhaps through its effect on *HOX* genes (36). Retinoic acid is interesting and important, not only for its role in normal development, but because it is a powerful teratogen. Various retinoids, which are derivatives of vitamin A, have been used in pharmacological doses, mainly to treat dermatologic conditions, such as types of acne, psoriasis, exfoliative dermatitis, and disorders of keratinization. The retinoids have been associated in animals and humans with multiple different birth defects. Because of the prolonged elimination half-life of systemic retinoids, pregnancy is not recommended for 2 years after discontinuing their usage (37).

Liver and central nervous system toxicity, as well as anemia and hyperlipidemia, may occur with systemic retinoid use. These problems usually resolve with discontinuation of retinoid therapy. Rheumatologic complications of retinoid use include hyperostosis, arthritis, myopathy, vasculitis, and a condition mimicking seronegative spondyloarthropathy (38).

The *shh* gene is expressed in the zone of polarizing activ-

ity. Activation of this gene through cell transfection in anomalous locations in the limb bud, will cause digit duplication in the same manner as transplantation of the zone of polarizing activity tissue (39). It appears that *shh* stimulates the gene for bone morphogenetic protein 2 (*BMP2*) (40). The gene activation of both occurs in the same cells, with *shh* preceding that of *BMP2*. The bone morphogenetic proteins are members of the TGF- β superfamily, and *BMP2* is, specifically, a homolog of a fruit fly gene that specifies segment polarity, making it a good candidate for an axis-determining gene. *BMP2* is secreted from cells, and, therefore, its action extends over a larger area than just the cells in which it is produced. *BMP4* expression overlaps that of *BMP2*, and it is probably involved in anteroposterior axis specification as well. *shh* in the mesenchyme also appears to participate in a positive feedback loop with FGF-4 in the ectoderm, which may be important in maintaining the AER and supporting continued limb outgrowth and patterning (41). *BMP2* and *BMP4* also function in regulating the size and shape of long bones. Overexpression of these genes appears to cause an increase in the quantity of mesenchymal cells that differentiate into the chondrogenic precursors of the skeleton.

It appears that *BMP2* and *BMP4* are involved as well in the molecular mechanisms of joint formation. If noggin, a

BMP inhibitor, is not present, joints do not form. Present evidence suggests that members of the HOXA and HOXD families are regulators of BMP and growth and differentiation factor 5 (GDF-5). GDF-5 (a BMP-related protein) is expressed specifically in the prospective joint region. If noggin is not present, GDF-5 is not expressed and BMP2 and BMP4 are not inhibited, resulting in a continuous, jointless skeleton. A balance of activating and inhibiting signals seems to be necessary for normal joint cavitation (42,43).

Some experimental work suggests that cell–extracellular matrix interactions are involved in the mechanism of joint cavitation. Specifically, CD44s, an isoform of a cell surface receptor that interacts with hyaluronan, is found in a single layer of cells outlying the presumptive joint cavity in rats (44). One hypothesis is that the creation of a hyaluronan-rich, but proteoglycan- and collagen II-poor extracellular matrix results in a loss of cell adhesion and allows joint cavity formation (44).

Dorsal-ventral Axis Patterning/Ectodermally Controlled Patterning

Experiments in which limb bud ectoderm is transplanted onto mesoderm, with reversal of its dorsal-ventral axis, reveal that digits, muscles, and tendons conform to the axis of the overlying ectoderm (14). Several genes involved in dorsal-ventral specification have been identified. Evidence suggests that Wnt-7A, a secreted signaling protein, confers the dorsal character to the ectoderm and stimulates Lmx-1 (45). Lmx-1 is a homeobox-gene that encodes a transcription factor that dorsalizes mesoderm. The ventral limb expresses the homeobox-containing transcription factor engrailed (En-1). En-1 appears to suppress Wnt-7A expression, thereby limiting the activity of Lmx-1 to the dorsal mesenchyme (46).

The actions of several genes are important in determining more than a single axis. For example, Wnt-7A expression is necessary for normal anteroposterior digit formation and shh is necessary for limb outgrowth, proximal-distal, in addition to anteroposterior patterning. The coordinated development of all three axes is believed to be regulated by interactions of several signaling genes. Wnt-7A, shh, and FGF-4 are promising candidates for this role (47,48).

Both the AER and the ZPA activate *HOXA* and *HOXD* genes. *HOX* genes are the vertebrate homologs of the fruit fly homeogenes, which specify body segment identity. *HOXD* genes are expressed in an overlapping, nested fashion in the anteroposterior axis of the developing limb (49) (Fig. 1-16). *HOXD* genes can also be activated by shh alone. *HOXA* genes have an overlapping expression along the dorsal axis, suggesting a role in specifying limb components. *HOX* genes have specifically been shown to affect the growth of cartilage and precartilaginous condensations (50,51). They may be important in determining the length, segmentation, and branching of limb elements. *HOX* genes are not

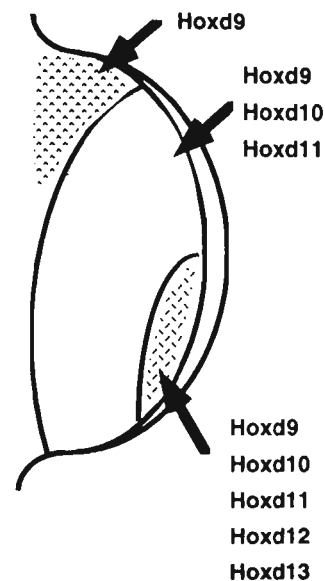


FIGURE 1-16. The pattern of expression of the HOXD genes is shown. The overall HOXD expression is sequential from the anterior to posterior aspect of the limb buds; however several individual HOXD genes have clustered expression patterns. The pattern of HOXD gene expression can be altered by polarizing signals, implicating the Hoxd genes in limb pattern determination. (From ref. 83, with permission.)

expressed strictly along AP or DV axes, and their position of expression differs in various areas of the limb. Human limb malformations caused by mutations in *HOX* genes have been identified, and will be discussed in the section on clinical significance. The activity of *HOX* genes overlaps, and is sufficiently redundant that a mutation of a single *HOX* gene generally results in a minor limb anomaly.

The specific signals and mechanisms that control muscle, ligament, and tendon development have not been identified. Exploration of these mechanisms may ultimately be of great clinical utility.

Clinical Significance

Limbs are extremely susceptible to anomalies, probably because of their complex developmental biology and their exposed position outside of the body wall. Nearly all teratogens and chromosomal anomalies have ill effects on limb development. A large number of single gene mutations disturb the normal development of limbs, as well. Rapid advances in molecular genetics are resulting in the identification of the gene(s) responsible for many Mendelian disorders. Developmental molecular biologists are identifying genes that create limb deformities in animals, whose homologous human genes may be responsible for other specific limb defects.

Limb deficiencies occur in 3 to 8 of 1,000 live births (52). One-half of limb deficiencies occur as isolated defects

and the other half occur with associated malformations (52). Associated malformations may be life-threatening. The most common associated malformations are musculoskeletal, head and neck, cardiovascular, gastrointestinal, and genitourinary.

As discussed previously, destruction of the AER or the progress zone, or failure of expression of critical signaling molecules, can result in truncation or absence of limb development. Although specific defects have not been identified in humans, there are several inherited disorders with limb deficiencies that may well have a mutation in a specific signaling molecule. These include Roberts syndrome with phocomelia, acheiropodia (Brazil type) with absent hands and feet, Buttiens distal limb deficiencies syndrome, and CHILD syndrome with variable transverse and longitudinal deficiencies. A mouse mutant with a single digit has been found to have a mutation in the *HOXA-13* gene (53). Human split-hand/split-foot deformity (lobster claw deformity) is characterized by a failure of central ray formation, and at least one causative gene has been localized, but not yet identified (54).

Vascular anomalies or accidents probably cause some limb deficiencies by prohibiting limb outgrowth or by causing necrosis of already differentiated limbs (55,56). Amniotic bands result in amputation by interfering with vascular supply (52).

Intercalary limb deficiencies, with absence of proximal structures, may result from a temporary injury to the progress zone as discussed in the section Developmental Anatomy of the Limb.

Synostoses are failures of joint formation or separation of adjacent bone, such as the radius and ulna, with a single exception. That exception is distal syndactyly, which is caused by amniotic bands (57). The vast majority of synostoses are inherited, but only a few of the mutated genes have been identified. Identification of the causative genes is likely in the near future, and will shed much light on the mechanisms of normal joint formation and of normal bone modeling from the mass of undifferentiated mesenchymal cells that prefigure the skeletal elements. Nearly 100 disorders have synostosis as a feature (see ref. 52, pp. 721–724). The mouse mutant-limb deformity gives a flavor for the kind of causation of these deformities. Limb-deformity mice are characterized by fusion of adjacent bones, such as the radius and ulna. The limb bud is narrow and the AER is patchy (58). A decrease in *shh* expression and an absence of *Fgf-4* expression have been found (59).

Teratogens, such as thalidomide and alcohol, can cause synostoses in humans. Retinoic acid creates synostoses in animals when applied during chondrogenesis of developing limbs (60).

Failure of programmed cell death may be an important factor in causing some disorders with synostosis as a feature. A failure of apoptotic cell death in the interdigital mesenchyme is presumed to be the cause of some syndactyly.

Excessive partitioning of skeletal elements are usually inherited conditions. Triphalangeal thumb is the most common of these disorders. The abnormality has been linked to a region on chromosome 7 in several affected families, but the gene has not been identified (61,62). Other families do not link to this locus, implying that more than one gene mutation causes triphalangeal thumb.

Polydactyly, whether isolated or associated with other anomalies, is usually an inherited condition. Given the complex interactions that occur in limb pattern specification, it is not surprising that a number of causes of this condition are being found.

Grieg cephalopolysyndactyly is an autosomal dominant disorder characterized by postaxial polysyndactyly of the hands and preaxial polysyndactyly of the feet and dysmorphic facies. A DNA-binding transcription factor, named *GLI 3*, is the cause of this disorder (63). The expression of *GLI 3* is restricted to the interdigital mesenchyme and joint-forming regions of the digits. A mouse mutant with a defect in the homologous gene has ectopic expression of both *shh* and *FGF-4* in the anterior limb bud (64). Another mutation causing human polydactyly is in the *HOXD* cluster of homeobox genes that has been implicated in digit specification. Synpolydactyly is caused by a mutation of *HOXD-13* (65). Smith-Lemli-Opitz syndrome is characterized by a variety of birth defects, including postaxial polydactyly and brachydactyly. Cholesterol synthesis is defective in children with this syndrome and *shh* utilizes cholesterol as a transport molecule. It is possible that the limb anomalies in this syndrome result from a distortion of the normal *shh* gradient due to cholesterol insufficiency.

Skeletal dysplasias are a heterogeneous group of disorders whose genetic causes are rapidly being discovered, giving insight into the mechanisms of normal and disordered skeletal development (see Chapter 8).

Many single and group congenital anomalies that occur sporadically are believed to result from vascular disturbances in the embryo or fetus. The best-developed of the vascular causation hypotheses is the subclavian artery disruption sequence, which seeks to explain Klippel-Feil syndrome, Poland anomaly, Mobius syndrome, absence of the pectoralis major, terminal transverse limb deficiencies, and Sprengel deformity. A disruption occurs when a normal embryo suffers a destructive process with cascading consequences. Because all the tissues affected in these various disorders receive their major blood supply from the subclavian artery, it is hypothesized that a defect of arterial formation or an injury to existing arteries causes these defects. The location and extent of tissue abnormality is determined by the extent, location, and timing of the interruption of normal blood supply. The observation underlying this hypothesis is that the disorders listed above often occur together in various combinations.

Possible mechanisms resulting in arterial ischemia include vessel occlusion from edema, thrombus, or embolus; extrinsic vessel compression caused by surrounding tissue

edema, hemorrhage, cervical ribs, aberrant muscles, amniotic bands, or uterine compression; abnormal embryologic events, including delayed or abnormal vessel formation and disruption of newly formed vessels; and environmental factors such as infection, hyperthermia, hypoxia, vasculitis, or drug effects. It is possible that some fetuses suffer ischemia due to normal embryologic events that are idiosyncratically not well tolerated, such as the rapid descent of the heart and great vessels.

The vascular accident hypothesis is attractive in explaining combinations of congenital anomalies and their usually sporadic occurrence. However, there are often combinations of anomalies that are difficult to relate to a single vascular event, and the question of whether the anomalies resulted in, rather than being caused by, vascular abnormalities is not easily resolved.

Amniotic bands or constriction rings cause a large portion of nonhereditary congenital limb anomalies. Constriction rings are diagnosed by the occurrence of a soft tissue depression encircling a limb or by injury from amputations or disruptions. Constriction rings are commonly multiple and may be broad or narrow. The depth of the ring determines whether the limb distal to the ring is normal, hypoplastic, engorged (from venous or lymphatic obstruction), or amputated (from vascular insufficiency). Syndactyly, clubfoot, and clubhand have also been associated with constriction rings.

The origin of constriction rings is uncertain. The mechanisms by which amniotic strands might form are disputed (66–69). One hypothesis holds that amnion adheres to areas of preoccurring hemorrhage and by themselves are not pathogenic (70). Nonetheless, the syndrome is common, affecting one in 5,000 to 15,000 births. Recurrence risks of this syndrome are low (52).

DEVELOPMENTAL ANATOMY OF THE VERTEBRAL COLUMN

The vertebral column, be it cartilage or bone, defines the species of the subphylum of vertebrates. Evolution of a vertebral column to replace the notochord allows a strength, flexibility, and protection to the neural tube that conferred many advantages to vertebrate species. Minor and even major anomalies of the vertebral column are compatible with life and good function. Vertebral column development depends on the appropriate prior development of the notochord and somites.

While the mesoderm is forming during gastrulation, a mass of ectodermal cells proliferates and forms the archenteron, a tube that migrates cranially in the midline between the ectoderm and the endoderm. The floor of the archenteron forms the notochordal plate. For a short time, there is a direct connection between the primitive gut and the amniotic cavity, since the endodermal floor is not continu-

ous and the blastopore (the opening of the archenteron) communicates with the amniotic cavity. This connection is obliterated by the end of the 3rd week and remnants of this connection are presumed to be responsible for diastematomyelia.

The notochord arises from cells in the primitive streak, which come from the ingress of cells from the epiblast during gastrulation and, later, from the caudal eminence. This ingress of cells forms the endoderm as well as the notochord and the paraxial mesoderm (segmental plate). The notochord develops from cranial to caudal by adding cells as it develops. It is initially a solid rod in which a small central canal develops. The notochord induces the formation of the neural groove, which gradually closes to form a tube with a central canal. By the 23rd day, the neural groove is closed, except at its most cranial and caudal ends. These openings are termed the neuropores, which close by the end of the 4th week. Closure of the neural tube progresses cranially to caudally. Failure to close properly is hypothesized to be the cause of neural tube defects such as myelomeningocele.

The somites also develop from cells that are internalized through the primitive streak. These cells form the paraxial mesoderm that will become the somites, and ultimately become the vertebrae. Presomitic cells cluster by increased adhesion into distinct balls of epithelial cells surrounding mesenchymal cells, giving the embryo its first segmental organization. Positional information is programmed into the somites by the time they are morphologically distinct. For example, a thoracic somite will still form a rib when transplanted into the cervical region. The positional information is imparted during gastrulation (69,70). Somites do not depend on interaction with the neural tube or notochord for development and fated cells will develop into somites *in vitro*.

Four occipital, 8 cervical, 12 thoracic, 5 lumbar, 5 sacral, and 4 or 5 coccygeal pairs of somites will develop. The first somites are evident at 3½ weeks and 30 pairs are present at 4½ weeks. Not all of the somites are visible simultaneously. Somites develop a complex internal organization. The somite begins as a ball of pseudostratified epithelium surrounding a central cavity, the somitocoel. The central cavity becomes filled with mesenchymal cells. Some of these cells, along with cells in the medioventral portion of the somite, become the sclerotome. Cells from the sclerotome will form the vertebral bodies and vertebral arches and emerge without the epithelial portion of the sclerotome to surround the neural tube. In addition to contributing to the sclerotome, cells from the central cavity migrate to become the intervertebral discs and contribute to rib formation. The dorsolateral wall of the somite is called the dermatomyotome. It separates into the dermatome laterally and the myotome lying between the dermatome and the sclerotome. The dermatome gives rise to the dermis of the skin, and the myotome supplies cells for muscle, tendons, and fascia (Fig. 1-17).

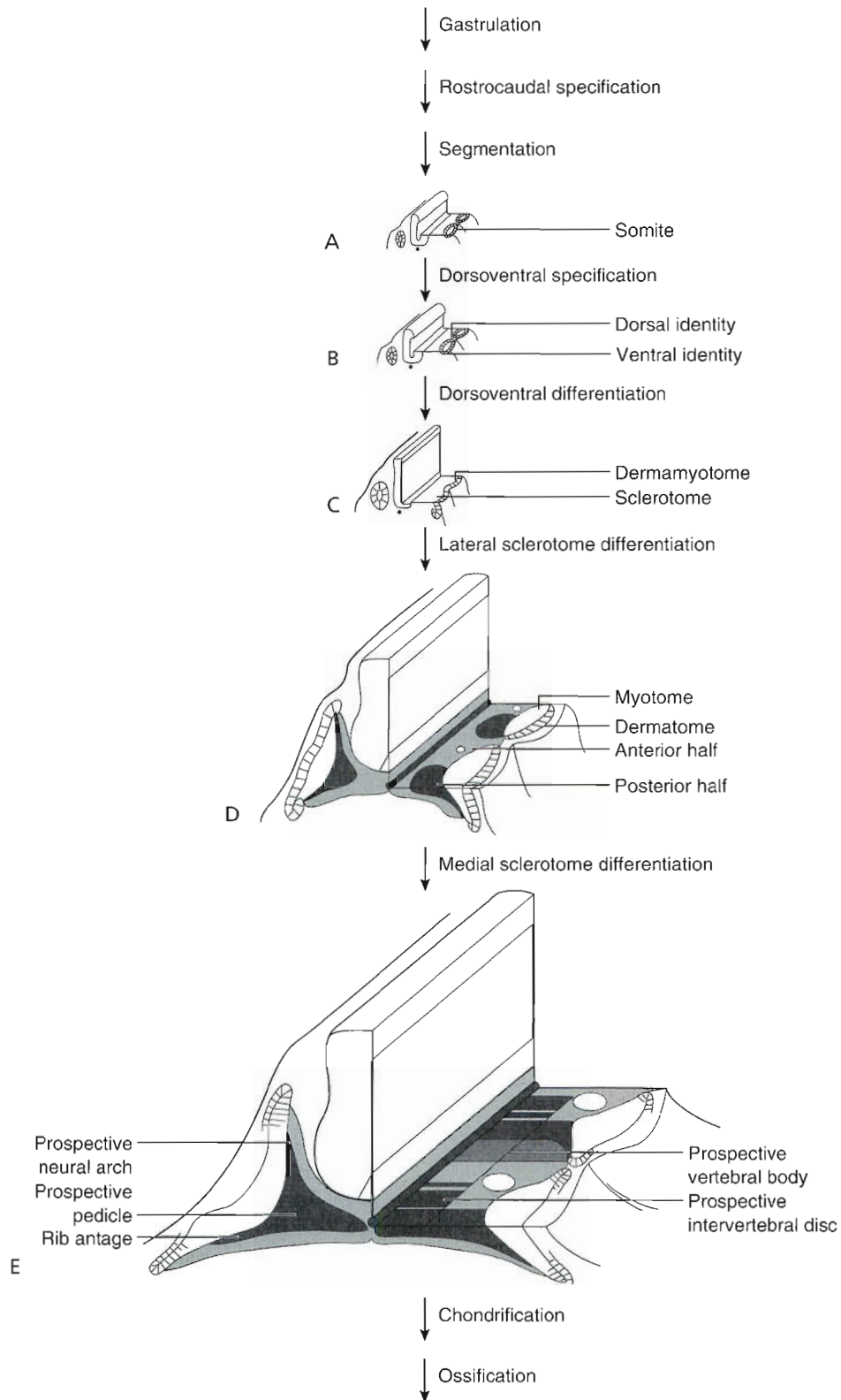


FIGURE 1-17. The progressive differentiation of the vertebral column is illustrated in A–E. The dark areas in D and E demonstrate the portion of the sclerotome that develops into the neural arch, the vertebral body, rib anlage, and the intervertebral disc. (Adapted from ref. 83, with permission.)

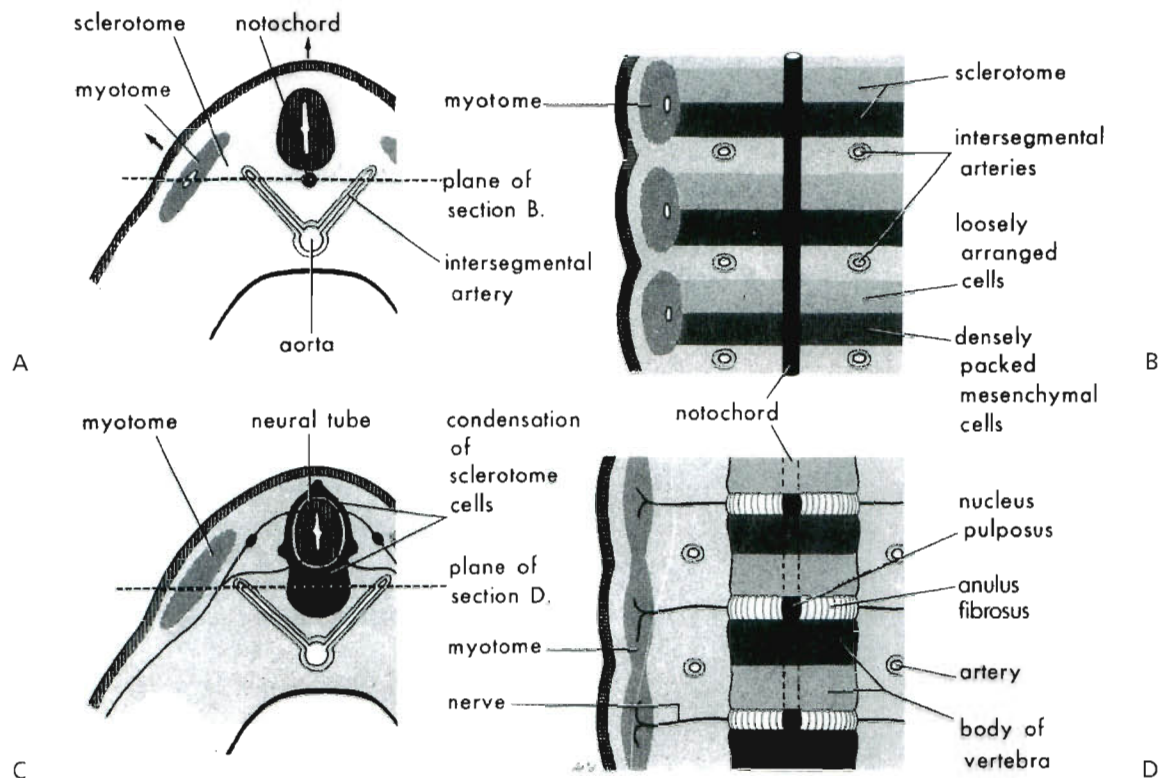


FIGURE 1-18. A: Transverse section through a 4-week embryo. The top arrow shows the direction of the growth of the neural tube, and the side arrow shows the dorsolateral growth of the somite remnant. B: Coronal section of the same-stage embryo, showing the condensation of sclerotomal cells around the notochord, with loosely packed cells cranially and densely packed cells caudally. C: A transverse section through a 5-week embryo, depicting the condensation of sclerotome cells around the notochord and neural tube. D: Coronal section illustrating the formation of the vertebral body from cranial and caudal halves of adjacent sclerotomes, resulting in the segmental arteries crossing the bodies of the vertebrae and the spinal nerves lying between the vertebrae. (From ref. 20, with permission.)

The sclerotomal cells from the paired somites migrate medially, meeting around the notochord and separating it from the dorsal neural tube and the ventral gut. The continuous perichordal sheath is distinct from the more lateral, segmented sclerotomes. Between the adjacent somites lies the transverse intersegmental arteries. The segmental spinal nerves originally exit at the midportion of the somitic sclerotomal mass. Resegmentation of the sclerotomic tissues occurs at 4½ weeks (Fig. 1-18). This process of resegmentation occurs by variable-rate mitosis, which results in each somitic sclerotome's thinning cranially and condensing caudally. The transverse intersegmental arteries and spinal nerves traverse the cellularly loose cranial portion of the sclerotome. The dense caudal portion of each sclerotome unites with the cranial, less-condensed part of the next sclerotome, to form the primordium of the vertebrae. Thus, the skeletal portions of the somites no longer correspond to the original segmentation. The segmental spinal nerves that originally were in midsomite now lie at the level of the disc. The intersegmental arteries located between somites come to lie

at the midportion of the vertebral bodies, and the myotomes bridge the vertebrae. The densely cellular, caudal portion of the sclerotome gives rise to the vertebral arch. The initially continuous notochordal sheath segments into loosely cellular cranial, and densely cellular caudal, portions. The cranial portion becomes the vertebral centrum, and the dense, caudal portion becomes the intervertebral disc. The vertebral centrum surrounds the notochord and forms the vertebral body. Notochordal cells in the vertebral centrum degenerate, although some remnants of the notochord may remain. Rests of notochordal cells persisting in the sacral or cervical areas may give rise to chordomas in later life. The neural arches develop from ventral to dorsal, enclosing the neural tube, and unite in the fetal period. The spinal nerves and the dorsal root ganglia arise at the level of the somite and enter the myotome at the beginning of the 6th week. The presence of ganglia are necessary for normal neural arch segmentation. Although somites form from cranial to caudal, resegmentation progresses from midspine cranially and caudally.

Neural crest cells (a specialized region of neuroectoderm) accumulate just before closure of the neural tube cranially, and are situated between the neural tube and somites. These cells become the peripheral nervous system sensory cells and nerve fibers, as well as the Schwann cells and melanocytes. Peripheral nerve afferents and preganglionic fibers of the autonomic nervous system develop from the neural tube, as do the brain and spinal cord. At each cervical, thoracic, and lumbar somite, a corresponding ganglion develops.

Molecular Insights of Vertebral Column Development

HOX genes are expressed in an overlapping fashion in the developing spinal column, and evidence suggests that they specify individual vertebrae's morphology (73). Transgenic mice, with out-of-sequence activation of certain *HOX* genes, can be created that transform the atlas into a cervical vertebra with a body, and lumbar vertebrae can become like thoracic vertebrae with rib formation (74,75). Conversely, *HOX* gene inactivation can transform the axis into an atlas-appearing vertebra (76). Overlapping, redundant expression of *HOX* genes occurs and inactivation of more than one adjacent *HOX* gene has been found necessary to alter vertebral morphology in some regions of the vertebral column (77). Retinoic acid application can alter the normal expression patterns of *HOX* genes, and it can create varying morphologic abnormalities, depending on the timing and location of its application. A particular retinoic acid receptor (the gamma receptor) is expressed only in prebone tissue, and its inactivation causes transformation of the axis to an atlas and C7 to C6 (78).

PAX genes are a family of genes containing a DNA-binding domain, and are expressed in the sclerotome at high levels during sclerotome condensation. Some evidence suggests that a defect in specific *PAX* genes, or genes they modify, may result in failure of formation of vertebral elements (79). The homeobox gene *MSX2* is necessary for spinous process development in mice (80). Clearly, the interactions of genes and tissues involved in vertebral column formation are complex.

Clinical Significance

The vertebral column represents the central characteristic skeletal structure of vertebrates, and it is remarkable how even severe vertebral abnormalities are so well tolerated by the organisms. Because vertebral column development has been highly conserved during evolution, most if not all the vertebral abnormalities seen in vertebrates can also be found in humans. In fact, mouse genetics had led to the identification of probably all types of vertebral abnormalities (81,82).

Defects at different stages of embryo development will result in different vertebral malformations. In general, the earlier the disruption in the developmental process, the

more severe will be the phenotype. The developmental processes that can be affected include mesoderm formation during gastrulation, axial patterning, notochordal mesoderm induction, somite formation, sclerotome condensation, neural tube closure, and axial identity specification. Although disorders in pattern formation result in specific pre-vertebral phenotypes, general disorders of mesenchyme condensation, cartilage, or bone formation affect composition, and therefore morphology, of the skeleton. Misspecifications of vertebral identity, called homeotic transformations, are characterized by the presence of all vertebral components, but with shapes characteristic of usually the adjacent vertebra.

Disruption of the allocation of the mesodermal cells during gastrulation leads to a block in the whole vertebral column formation. Because gastrulation also generates the other two germ layers, the embryo will have multiple congenital abnormalities and will not survive (83). Defects during sclerotome formation are compatible with life and typically result in segmental vertebral agenesis. Because sclerotome formation depends on the inductive activity of the notochord, it is mainly notochord mutants that are found within this category. In the affected region, somite ventralization is hindered, and the corresponding vertebrae appear to be deleted.

Although disruptions of gastrulation and sclerotome formation lead to absence, truncation, or interruption of vertebral column formation, disorders of somatogenesis are compatible with vertebral development. However, multiple vertebral components can be lacking or fused. Variations on number, shape, and position of vertebrae are common developmental anomalies. Most columns have 24 segments, including 7 cervical, 12 thoracic, and 5 lumbar vertebrae. However, columns with 23 or 25 elements are commonly seen, and they are most likely related to differences in the number of elements of the lumbar spine. This number difference may be due to the last lumbar vertebra being incorporated into the sacrum (sacralization) or the first sacral vertebra being freed (lumbarization).

Developmental anomalies that affect vertebral shape are varied. The most common conditions are spina bifida, hemi-vertebra and wedge vertebrae, and vertebral bars. Spina bifida occulta is a failure in the completion of the neural arch, but without neurological compromise. Failure of the neural arch to fuse in the cervical spine, and sometimes in the upper thoracic spine, is seen shortly after birth, but spina bifida is most commonly seen at the level of the lumbosacral spine. This is a normal finding in children at 2 years of age, in 50% at 10 years, and in approximately 20% of adults. Neural tube defects (NTDs) can be subdivided into four subgroups. The first, a meningocele, is a cyst that involves only the meninges but not the neural elements. The second, a myelomeningocele, includes the neural elements as part of the sac. The third, a lipomeningocele, is a deformity in which there is a sac containing a lipoma that is intimately involved with the sacral nerves. The fourth, rachischisis, is

a complete absence of skin and sac, with exposure of the muscle and dysplastic spinal cord.

Closure of the neural tube progresses cranially to caudally. Failure to close properly is widely believed to be the cause of most cases of myelomeningocele (84). This hypothesis is supported by observations of early fetuses with myelomeningocele and is consistent with animal models of neural tube defects (85). The competing hypothesis, championed by Gardner, suggests that overdistension and rupture of a closed neural tube causes NTDs (86,87). Myelomeningocele has multiple causes, resulting in a common phenotype. An inherited predisposition to NTDs appears to be present in some cases, based on an increased incidence of NTDs in some families and a variation in prevalence in different ethnic groups (86). Furthermore, a mouse model of NTD has been shown to result from a mutation in the gene *Pax-3*. *Pax-3* is a homeobox gene that has been shown to be involved in the fusion of the dorsal neural tube, as well as in neural crest cell migration and dermomyotome development (85). Environmental factors are responsible for some proportion of NTDs, and multiple teratogens have been identified that interfere with neurulation. Examples include vinblastine, which disrupts actin microfilaments, and calcium channel blockers, which interfere with microfilament contraction (88,90). Retinoic acid, hydroxyurea, and mitomycin C interfere with the timing of neuroepithelial development and cause NTDs in animal models (91). Folate supplements taken during pregnancy decrease the risk of NTD in subsequent children when a prior child has been affected, as well as decreasing the incidence of NTDs in pregnancies without a prior history of NTD (84). The mechanism of the effect of folate on NTDs is unknown. The interaction of genes and environment that act to cause myelomeningoceles, as well as the molecular pathology, is under active investigation (85).

Defects of vertebrae formation or segmentation include hemivertebra and vertebral bars. Hemivertebra appears as a wedge, usually situated laterally between two other vertebrae. As a consequence, a lateral curvature of the spine develops. Vertebral bars are due to localized defects in segmentation and are observed most frequently in the posterolateral side of the column, resulting in absence of growth in that side. The outcome is a progressive lordosis and scoliosis. When located anteriorly, vertebral bars lead to progressive kyphosis. Klippel-Feil sequence is regarded as a defect in cervical segmentation. Clinically, there is a short, broad neck, low hairline, limited range of motion of the head and neck, and multiple vertebral abnormalities.

Finally, other congenital abnormalities may be observed. Diastematomyelia is a longitudinal splitting of the spinal cord associated with a bony or fibrocartilaginous spicule or septum arising from the vertebral body, which is believed to result from remnants of the early connection between the primitive gut or the amniotic cavity. It is commonly associated with skin changes and abnormalities of the lower extremities. A chordoma is a neoplasm that arises from noto-

chordal rests, and is found especially in the sacrococcygeal region. Sacrococcygeal teratoma is a neoplasm composed of multiple embryonic tissues that can undergo malignant transformation.

DEVELOPMENTAL ANATOMY OF THE NERVOUS SYSTEM

The neural tube is pivotal in development, and has been discussed in the section Developmental Anatomy of the Vertebral Column. The neural tube becomes the central nervous system (the brain and spinal cord), and the neural crest develops into most of the peripheral nervous system. The spinal cord develops from the portion of the neural tube that is caudal to the four occipital somites. The neural tube forms from the folding of the neural groove and begins at the brain/spinal cord junction. As the neural groove fuses, so does the neural fold. Neural crest cells begin their migration from neural-fold tissue, just after neural tube closure occurs in the spinal regions. Neural crest cells migrate either beneath the surface ectoderm or between the neural tube and the somite. Migration occurs through extracellular matrix along relatively cell-free paths. Neural crest cells form the pia mater, the spinal ganglia, and the sympathetic trunks and ganglia.

As the neural tube closes, the dorsal region, called the alar laminae, is separated from the ventral basal laminae by a shallow groove—the sulcus limitans. A thin bridge of tissue persists to connect the two halves of the alar and basal laminae, named the roof and floor plates. The alar plate develops into the sensory pathways (dorsal columns), and the basal plate develops into the motor pathways (ventral horns). The notochord is necessary for floor plate induction, and the floor plate appears to specify the dorsoventral organization of cell types in the developing spinal cord.

The ventral horn neurons develop axons that form the ventral roots. The dorsal root ganglia develop from neural crest cells. The axons of the ganglion cells form central processes, which become the dorsal roots and peripheral processes that end in sensory organelles.

Spinal cord development proceeds in a rostral-caudal direction, and motor neurons develop neural capabilities before sensory nerves. Autonomic nerve function is established last (44). Movement is visible by ultrasound 5½ weeks post-fertilization. The spinal cord extends the entire length of the vertebral column during the embryonic period. During fetal development, the vertebral column grows more rapidly than the spinal cord. Coupled with some loss of caudal spinal cord tissue, the caudal tip of the spinal cord ends at the 2nd or 3rd lumbar vertebra in newborns. In the adult, the spinal cord terminates at the inferior portion of the first lumbar vertebra. Thus, the lumbar and sacral nerve roots have an oblique course below the conus medullaris, before their exit from their intervertebral foraminae, resulting in the formation of the cauda equina (Fig. 1-19).

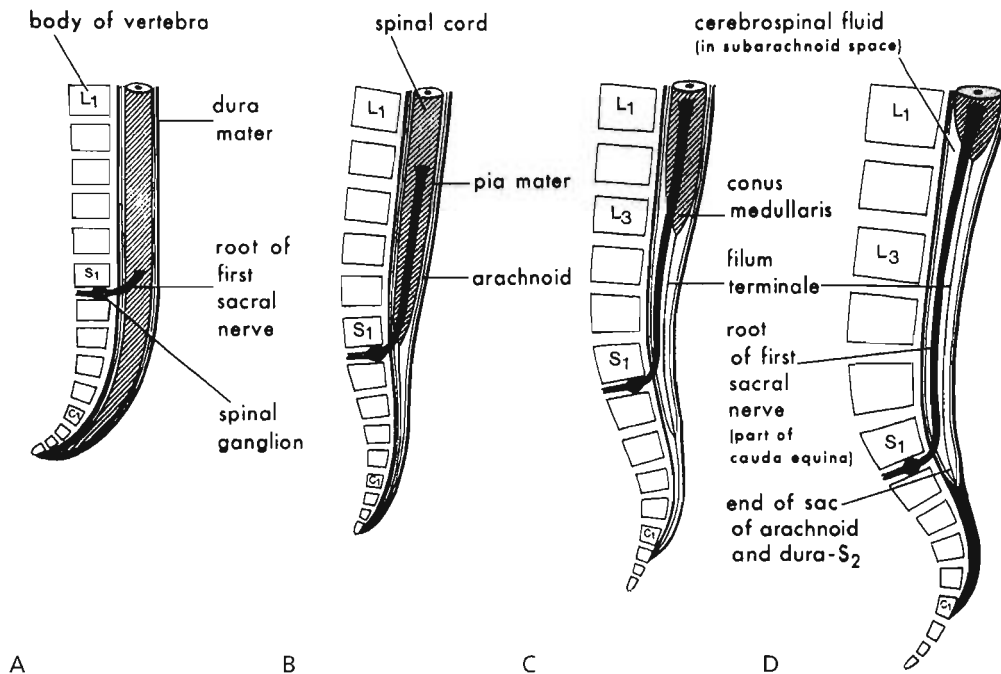


FIGURE 1-19. Illustration of the position of the spinal cord and meninges in relation to the vertebral column at 8 weeks (A), 24 weeks (B), birth (C), and adult (D). (From ref. 20, with permission.)

Myelination of peripheral nerve axons begins in the fetal period and continues during the first year after birth. Schwann cells myelinate peripheral nerves, whereas oligodendrocytes myelinate the axons within the spinal cord.

Molecular Insights of Nervous System Development

The molecular basis of nervous system formation is not well understood, but probably will be in the next decade. There is an intimate relationship between the notochord and the neural plate and tube, which is necessary for differentiation of the floor plate or the spinal cord, and for specification of ventral structures in the developing spinal cord. Hepatocyte nuclear factor-3 appears to regulate *shh* (an important axis-specifying gene in the limb as well), which can induce ventral structures (92). *PAX* genes have dorsoventrally restricted expression in the developing spinal cord. Dorsal structures can develop without the notochord, but specific molecules may be necessary for complete dorsal specification. For example, dorsalin-1, a TGF- β family member, can induce neural crest cell differentiation (93). The transcription factor genes, *Pax-3* and *Gli-3*, are necessary for neural tube closure (94). The large number of NTDs suggests that neural tube closure does not have a large redundancy in its developmental regulation.

Clinical Significance

Multiple anomalies of the brain occur and have orthopaedic implications because of disordered control of limbs, but will not be discussed here. Failure of closure of the caudal neuropore may result in myelomeningocele. Other evidence suggests that increased cerebrospinal fluid pressure causes rupture of an already closed neural tube at its weakest point—where it closed last. At least ten genes have been identified in mutant animals that result in NTD. Multiple teratogens, such as valproic acid and vitamin A, or exposure to hypothermia, can cause NTD. Although the mechanism is unknown, periconception folic acid decreases the incidence of NTD in humans.

Myeloschisis is a rare condition in which the neural groove fails to form a neural tube. Myelomeningocele has uncovered neural tissue that has herniated into the dysraphic area of the spine. Meningocele, in which the neural elements remain in their normal location, is probably a primary defect of the vertebral column development, rather than a primary neural defect. Ten percent of people have spina bifida occulta in which the vertebral neural arch fails to fully develop and fuse, usually at L5 or S1.

BONE FORMATION AND GROWTH

An examination of the human skeleton reveals the numerous sizes and shapes of bones, which have precise functions

of locomotion and protection of vital organs, are major sites for hematopoiesis, and participate in calcium hemostasis and storage of phosphate, magnesium, potassium, and bicarbonate. The molecular composition of the bone is remarkably constant. Regardless of the animal species or the bone considered, bone is always a two-phase composite substance made up of two very different materials. The two major components of bone are the organic matrix, or osteoid, and the inorganic matrix. Various calcium salts, primarily hydroxyapatite, are deposited in crystals within and between the matrix. These inorganic crystals give bone its rigidity, hardness, and strength to compression.

Connective tissue, cartilage, and bone all differentiate from that type of diffuse mesoderm known as mesenchyme. Mesenchyme arises primarily from the primitive streak and secondarily from mesodermal segments and the lateral somatic and splanchnic mesodermal layers (see Fig. 1-9). In early embryos, the mesenchyme acts as an unspecialized “packing” material, but soon differentiates into various tissues and organs.

There are two mechanisms of bone formation (osteogenesis), and both involve the transformation of a preexisting connective tissue into bone tissue. The transformation of fibrous primitive connective tissue into bone is called intramembranous ossification. The replacement of cartilage by bone is called “endochondral ossification.” Except for the clavicle and the flat bones of the skull, all bones of the appendicular and axial skeleton form by endochondral ossification.

Intramembranous Ossification

Intramembranous ossification occurs by mesenchymal cells derived from the neural crest that interact with the extracellular matrix secreted by the epithelia cells arising from the head. If the mesenchymal cells do not contact this matrix, no bone will be developed (95,96). The mechanism responsible for the conversion of mesenchymal cells to bone is still unknown. However, bone morphogenetic proteins may play a significant role in this process.

During intramembranous ossification, the mesenchymal cells proliferate and condense into packed nodules. Some of these cells differentiate into capillaries and others change their shape to become osteoblasts. These cells are capable of secreting osteoid, the organic extracellular matrix that subsequently will become mineralized. High levels of alkaline phosphatase and the appearance of matrix vesicles mark the commencement of ossification. The cells will eventually be surrounded by calcified matrix and become osteocytes.

Endochondral Ossification

By far the most common mechanism of ossification is cartilaginous (or endochondral). The process begins with the formation of a cartilage precursor or template. Mesenchyme cells condense and proliferate, but, instead of turning into

osteoblasts, as in intramembranous ossification, they become chondroblasts. These cells will then secrete the cartilage extracellular matrix. Soon after the cartilaginous model is formed, the cells in the center become hypertrophic and secrete a matrix that will subsequently be invaded by capillaries. As this matrix is degraded and the chondrocytes die, osteoblasts carried by the blood vessels begin to secrete bone matrix. Eventually, all cartilage is replaced by bone (Fig. 1-20). This process appears to be dependent on the mineralization of the extracellular matrix. A special, condensed mesenchymal tissue, the perichondrium, surrounds the cartilage model. This tissue is essentially the same as that surrounding the intramembranous centers of ossification, but in the perichondrium, the osteoprogenitor cells remain dormant for a time, while the cartilage model is enlarged by the chondrocytes.

Ossification begins at the primary center, within the shaft, and proceeds outward from the medullary cavity and inward from the periosteum, in a repetitive sequence. As the cartilage model is replaced by bone, extensive remodeling occurs. First, the medullary cavity is created and enlarged by resorption of the bony struts and spicules. Second, the developing bone continues to enlarge by both interstitial and appositional growth. The same repetitive sequence of events occurs in the epiphyseal centers of ossification. Once the shaft and epiphyses are ossified, leaving the cartilage physeal plates between them, each skeletal segment increases in size until maturity. The initiation of the endochondral ossification process, as well as the highly ordered progression of the chondrocytes through the growth plate, must be under strict spatial and temporal control. In view of the complexity of the process, it is remarkable that the human bones in the limbs can grow for some 15 years independently of each other, and yet eventually match to an accuracy of 0.2 percent.

Growth Plate Structure and Development

Growth of the different parts of the body is not uniform, and different bones grow at different rates. Patterning of the embryo occurs while the organs are still very small. For example, the limb has its basic structure established when its size is approximately 1 cm long. Yet, it will grow to be hundreds of times longer. How is this growth controlled? Most of the evidence suggests that the cartilaginous elements in the limb have their own individual growth programs. These growth programs are specified when the elements are initially patterned and involve both cell proliferation and extracellular matrix secretion. An understanding of the processes of bone formation, growth, and remodeling is fundamental in pediatric orthopaedics.

The process of endochondral ossification, which occurs in all growth plates, is unique to the immature skeleton. Once the growth plates have been formed, longitudinal growth of the bones occurs by appositional growth of cells

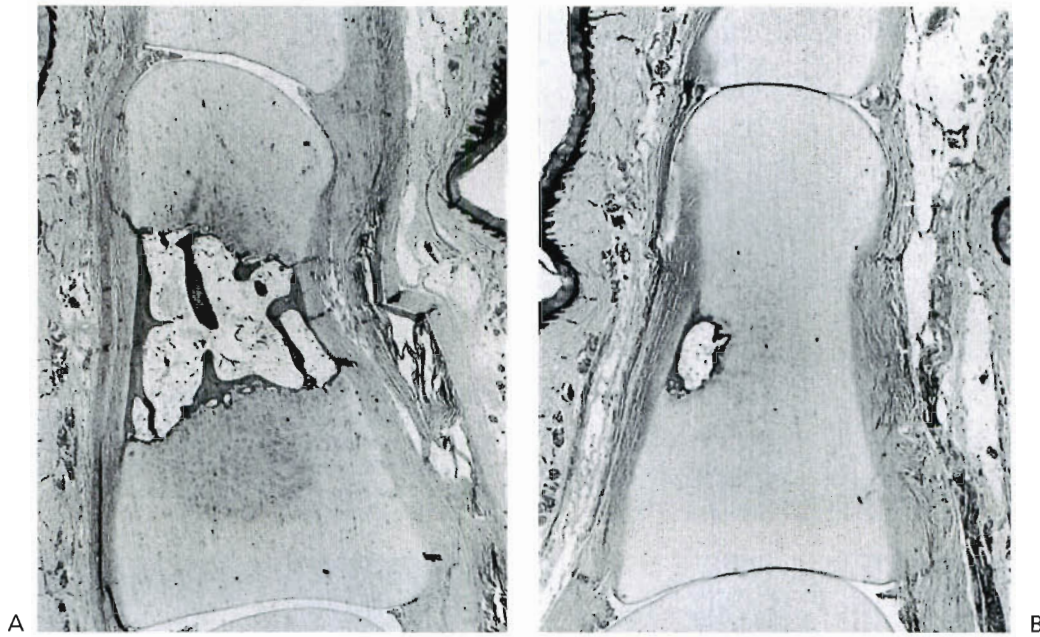


FIGURE 1-20. A: Formation of the primary ossification center of a phalanx. Note the central location with bone and bone marrow formation. B: Delayed ossification center formation in a case of digital duplication. (From ref. 97, with permission.)

and extracellular matrix from within the growth plate, and new bone formation on the metaphyseal side. The rate of increase in the length of a long bone is equal to the rate of new cell production per column multiplied by the mean height of the enlarged cell. The rate of proliferation depends on the time the cells take to complete a cell cycle in the proliferative zone, and the size of this zone. Generally, the greater the number of chondrocytes and the higher the plate, the faster the growth rate of the bone (Fig. 1-21). In addition, total longitudinal growth for the life span of the growth plate depends on the total number of progenitor cell divisions and the number of divisions of each daughter cell. The number of cell divisions is genetically determined, but the rate is influenced by hormonal and metabolic factors.

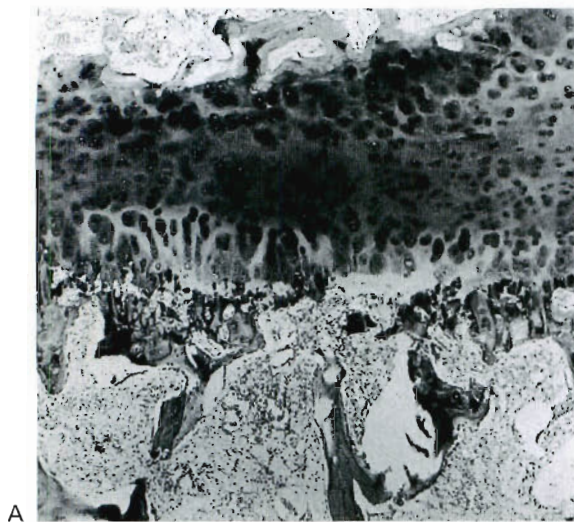
The function of the growth plate is related to its structure as an organ, which depends on the integrated function of three distinct components. The first component is the physal cartilage, which is divided into three histologically recognizable zones: resting, proliferative, and hypertrophic. The second component is the metaphysis, which is the region in which calcified cartilage is replaced by bone. The third component is the circumferential structures known as the perichondrial ring of LaCroix and the groove of Ranvier. Each of these components has its unique cellular architecture and extracellular matrix biochemistry; their integrated functioning results in longitudinal and latitudinal bone growth. Interestingly, although cartilage lacks blood vessels, to a large extent the metabolic activity of each zone depends on the blood supply system around the physis.

Physal Cartilage

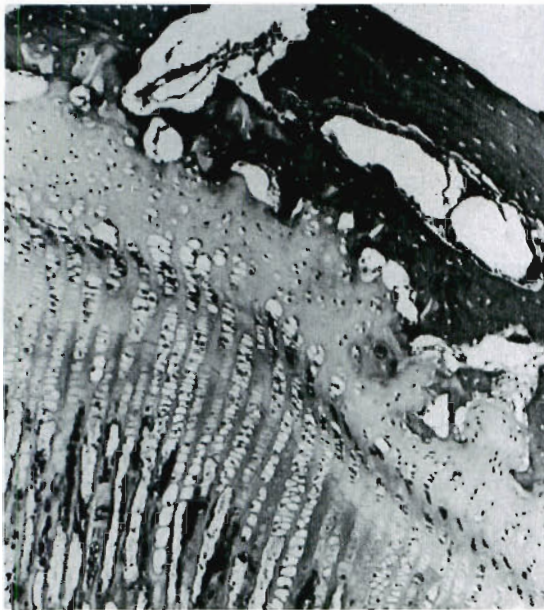
Resting Zone. The resting zone, located just below the secondary center of ossification, contains chondrocytes that are widely dispersed in an abundant matrix. The cells contain abundant endoplasmic reticulum characteristic of protein synthesis, but low intracellular and ionized calcium content. The function of these cells is not well understood, but data indicate that the resting zone is relatively inactive in cell or matrix turnover, although it may be a source for the continuous supply of chondrocytes to the proliferative zone.

Proliferative Zone. The proliferative zone is characterized histologically by longitudinal columns of flattened cells parallel to the long axis of the bone. The cells contain glycogen stores and significant amounts of endoplasmic reticulum. The total calcium is similar to the resting zone, but the ionized calcium is significantly greater. The oxygen tension is high in this zone (57 mm Hg), and, together with the presence of glycogen, suggests an aerobic metabolism. Of the three zones, it has the highest rate of extracellular matrix synthesis and turnover.

Hypertrophic Zone. The hypertrophic zone is characterized by enlargement of the cells to five to seven times their original size in the proliferative zone. Electron microscopy studies suggest that these cells maintain cellular morphology compatible with active metabolic activity. Biochemical studies have demonstrated that mitochondria of the hypertrophic chondrocyte are used primarily to accumulate and

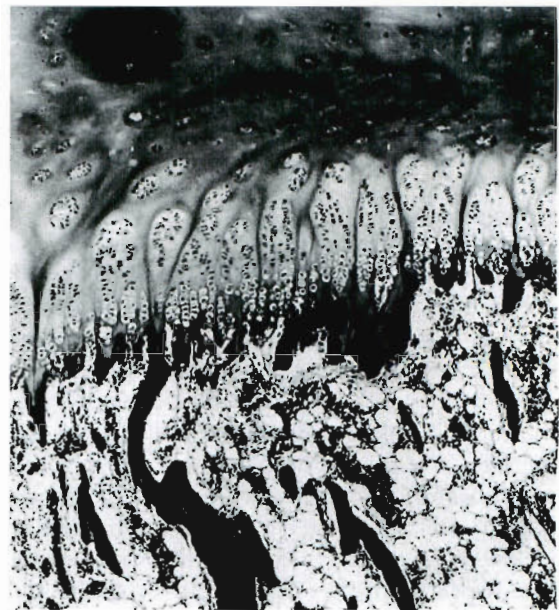


A



B

FIGURE 1-21. Variations on growth plate morphology. **A:** Limited column formation in a slow-growing physis. **B:** Elongated cell columns in a fast-growing physis (distal femur). **C:** Some physis form clusterlike groups divided by longitudinal cartilaginous columns. (From ref. 97, with permission.)



C

release calcium, rather than for ATP production. In addition, the cells have the highest concentration of glycolytic enzymes and synthesize alkaline phosphatase, neutral proteases, and type X collagen, thereby participating in mineralization. Because the growth plate is radially constrained by the ring of LaCroix, its volume changes are expressed primarily in the longitudinal direction. In the last part of this zone there is a provisional calcification of the cartilage.

Metaphysis

The metaphysis functions in the removal of the mineralized cartilage of the hypertrophic zone, and in the formation of the primary spongiosa. Bone formation begins with the invasion of the hypertrophic lacunae by vascular loops,

bringing with them osteoblasts that begin the synthesis of bone. The osteoblasts progressively lay down bone on the cartilage template. Subsequently, the initial woven bone and cartilage of the primary trabeculae are resorbed by osteoblasts and replaced by lamellar bone to produce the secondary spongiosa.

Perichondral Ring of Lacroix and Groove of Ranvier

Surrounding the periphery of the physis there is a wedge-shape structure, the groove of Ranvier, and a ring of fibrous tissue, the ring of LaCroix. The groove of Ranvier has active proliferative cells that contribute to the increase in diameter, or latitudinal increase, of the growth plate. The ring of

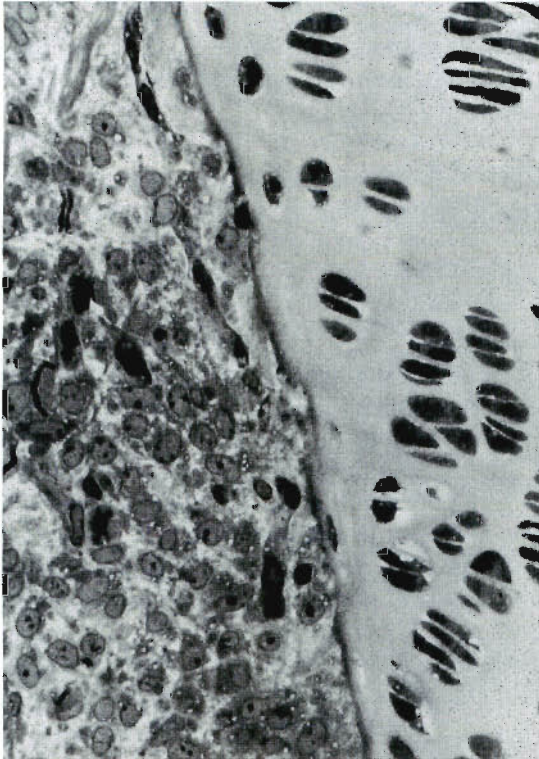


FIGURE 1-22. Photomicrograph of the zone of Ranvier, demonstrating the demarcation between the cells of the growth plate and the mesenchymal cells of the zone of Ranvier. (From ref. 97, with permission.)

LaCroix contains a thin extension of the metaphyseal cortex and fibrous portion of the groove of Ranvier, and periosteum that provides it with a peripheral supporting girdle around the growth plate (Fig. 1-22).

Vascular Anatomy of the Growth Plate

There are three major vascular systems that supply the growth plate. The epiphyseal arteries enter the secondary ossification center, and the terminal branches pass through the resting zone and terminate at the uppermost cell of the proliferative cells. The nutrient artery of the diaphysis supplies the extensive capillary loop network at the junction of the metaphysis and growth plate. Finally, the perichondral arteries supply the ring of LaCroix and the groove of Ranvier. Capillaries from this system communicate with the epiphyseal and metaphyseal systems, in addition to the vessels of the joint capsule.

Bone grows in thickness in addition to length. Because the metaphysis is larger than the diaphysis, some of it must be trimmed during the process of remodeling. This process is called funnelization. In the area termed the cut-back zone, osteoclasts resorb the peripheral bone of the metaphysis. In this way, the metaphysis gradually narrows to the width of

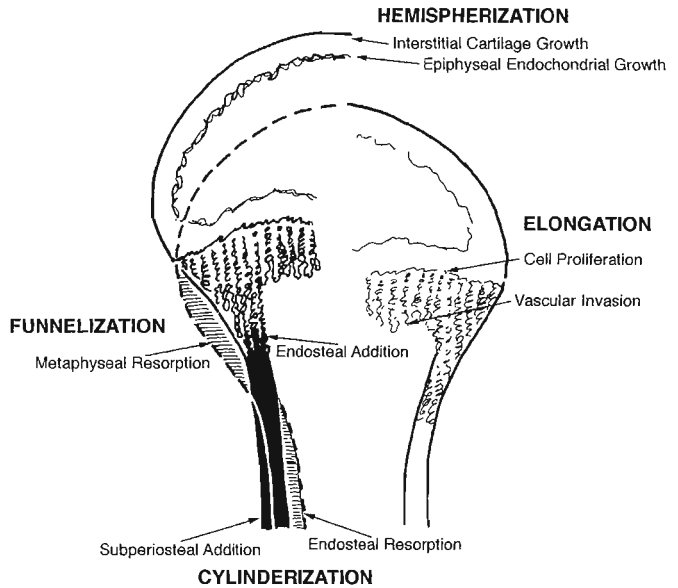


FIGURE 1-23. Diagrammatic representation of the remodeling process of bone during growth. Bone resorption and deposition result in longitudinal growth and shape changes of the epiphysis, metaphysis, and diaphysis. (From ref. 98, with permission.)

the diaphysis. The epiphysis also grows in circumference by a process called hemispherization, which is a process similar to that occurring in the growth plate. Thus, the bone acquires its final shape by a combination of intramembranous ossification, at the diaphyseal level, and endochondral ossification, at the epiphysis and growth plate, with process of elongation, funnelization, hemispherization, and cylinderization (Fig. 1-23).

Glossary

Allele A particular form of a gene. One allele is inherited from each parent in diploid organisms (thus, two alleles of each gene are present), which may or may not be the same.

Apical ectodermal ridge A ridgelike thickening of the ectoderm at the tip of the developing limb bud in chicks and mammals. This structure interacts with the underlying mesoderm of the progress zone in the development of the limb bud.

Apoptosis Programmed cell death. This type of cell death is unlike necrotic cell death in that no damage to surrounding tissue occurs. It is characterized by fragmentation of the DNA and shrinkage of the cell, and occurs widely during development.

Blastocyst Stage of mammalian development that corresponds to the blastula stage of other animal embryos. It is the stage at which the embryo implants in the uterine wall.

Blastula Hollow ball of cells, composed of an epithelial layer of small cells enclosing a fluid-filled cavity—the blastocoel.

Body plan Describes the overall organization of an organism, and, in most animals, is organized around two main axes, the anteroposterior axis and the dorsoventral axis, with a plane of bilateral symmetry, where it exists.

Cell differentiation Process by which cells become structurally and functionally different from one another and become distinct cell types, e.g., muscle, bone, cartilage cells.

Cell motility The ability of cells to change shape and move.

Chimera An organism made up of cells from two or more different species.

Cleavage Stage in development that occurs after fertilization, and consists of a series of rapid cell divisions without growth, which divides the embryo into a ball of much smaller cells called a blastula. This stage is the beginning of a multicellular organism.

Compaction Process in which the blastomeres undergo a change in behavior and maximize their contact to form a compact ball of cells. Perhaps the most crucial difference between mammalian cleavage and all other types of animal cleavage.

Dermatome The region of the somite that gives rise to the dermis.

Dermomyotome The region of the somite that gives rise to both muscle and dermis.

Determination A stable change in the internal state of a cell, such that its eventual cell type (or group of cell types) is fixed. A determined cell will not alter its eventual cell type, even when grafted into other regions of the embryo.

Embryonic stem cells (ES cells) Cells derived from the inner cell mass of a mammalian embryo that can be indefinitely maintained in culture.

Epiblast Group of cells within the blastocyst (mouse) or blastoderm (chicken), which gives rise to the embryo proper. In the mouse, it develops from cells of the inner cell mass.

Gastrulation Process in which the blastula turns itself into a multilayered structure and rearranges to form the three embryonic germ layers. In addition, during gastrulation, the body plan of the organism is also established.

Gene knock-out The inactivation of a specific gene in a transgenic organism.

Genotype The exact genetic make-up of a cell or organism in terms of the alleles it possesses for any given gene(s).

Germ layers Regions of the early animal embryo that will give rise to distinct types of tissue. Most animals have three germ layers—ectoderm, mesoderm, and endoderm.

Haploid Cells containing only one set of chromosomes (half the diploid number of chromosomes), and thus containing only one copy of each gene. In most animals, the only haploid cells are the gametes—the sperm or egg.

Hensen node Condensation of cells at the anterior end of the primitive streak that will give rise to the notochord. It corresponds to the Spemann organizer in amphibians.

Homeobox A region of DNA in a homeotic gene, encoding a DNA-binding domain called the homeodomain. The homeodomain is present in a large number of transcription factors that are important in development, and are conserved—present with relatively minor variations—in a large number of species of animals from fruit flies to mice to humans.

Homeotic gene A type of gene that was originally identified in *Drosophila* (fruit fly), which is important in specifying body-segment identity during development, for example, specifying thorax vs. abdomen.

Homologous genes Genes in different animals that share a significant similarity in their nucleotide sequence and are derived from a common ancestral gene, often, but not always, with similarity in function.

HOX genes A group or “family” of homeobox-containing genes that are present in all animals, and are involved in patterning the anteroposterior axis.

Induction A process whereby one group of cells signals (or induces) another group of cells to develop in a particular way.

Inner cell mass Group of cells in the early mammalian embryo, derived from the inner cells of the morula, which form a discrete mass of cells in the blastocyst. Some of the cells of the inner cell mass give rise to the embryo proper.

Invagination Local inward movement of a sheet of embryonic epithelial cells to form a bulgelike structure, as in early gastrulation.

Lateral plate mesoderm In vertebrate development, a group of cells that lies lateral and ventral to the somites, and gives rise to the tissues of the heart, kidney, gonads, and blood.

Mesenchyme Term describing loose connective tissue, usually of mesodermal origin, whose cells are capable of migration. Some epithelia of ectodermal origin, such as the neural crest, undergo an epithelial to mesenchymal transition.

Mesoderm Germ layer that gives rise to the skeletomuscular system, connective tissues, the blood, and internal organs, such as the kidney and heart.

Morphogen A substance that effects pattern formation based on its local concentration—often a gradient or threshold effect.

Morula Solid ball of cells in the very early stage in mammalian development, resulting from the process of cleavage.

Myotome The part of the somite that gives rise to muscle.

Neural crest cells Cells derived from the edge of the neural plate that migrate to different regions of the body and give rise to the autonomic nervous system, the sensory nervous system, melanocytes, and some cartilage of the head.

Neurulation The process in which the neural plate develops folds and forms the neural tube, which becomes the brain and spinal cord.

Notochord A rodlike structure of mesodermal origin that runs from head to tail, and lies beneath the future central nervous system.

Ontogeny Development of an individual organism.

Organizer or organizing region Signaling center that directs the development of part of the embryo or the whole embryo. In amphibians, the organizer usually refers to the Spemann organizer.

Organogenesis Stage of development when the main organs of the body begin to emerge gradually.

Pattern formation The process by which cells in a developing embryo acquire identities that lead to a well-ordered spatial pattern of cell activities.

PAX genes Genes encoding proteins that regulate DNA transcription and contain both a homeodomain and another protein motif, the “paired” motif. *PAX* genes are related to the pair-rule genes in *Drosophila*, which are expressed in transverse stripes in the blastoderm, each pair-rule gene being expressed in alternate parasegments.

Phenotype The observable characteristics of a cell or an organism, as distinguished from the genotype, which includes alleles that are not expressed in the phenotype of the cell or organism.

Phylogeny Evolutionary history of a species or group.

Progress zone Undifferentiated mesenchymal cells at the tip of the bud, which result in limb outgrowth and are under regulatory control of the apical ectodermal ridge.

Segmentation Division of the body of an organism into a series of morphologically similar units or **segments**.

Somites Segmented balls of mesoderm that lie on both sides of the notochord. They give rise to muscles, the vertebral column, and the dermis.

Stem cell Cell type found in certain adult tissues that is both self-renewing and also gives rise to differentiated cell types.

Transcription factor A protein that initiates or otherwise regulates transcription of a gene into RNA by binding to specific regions of the DNA.

Transgenic An organism that has been genetically altered by the artificial introduction or removal of a gene or genes.

Zone of polarizing activity An area at the posterior margin of the limb bud that has been identified in mice and chicks, and is critical in specifying the anteroposterior axis in the developing limb.

References

Developmental Anatomy of Early Embryogenesis and Organogenesis

1. Gulyas BJ. A reexamination of the cleavage pattern in eutherian mammalian eggs: rotation of the blastomere pairs during second cleavage in the rabbit. *J Exp Zool* 1975;193:235.
2. Gilbert SF. *Developmental biology*, 4th ed. Sunderland, MA: Sinauer Associates, 1994:178.
3. Piko L, Clegg KB. Quantitative changes in total RNA, total poly(A), and ribosomes in early mouse embryos. *Dev Biol* 1982; 89:362.
4. McLaren A. *Mammalian chimeras*. Cambridge: Cambridge University Press, 1976.
5. Kelly SJ. Studies of the developmental potential of 4- and 8-cell stage mouse blastomeres. *J Exp Zool* 1977;200:365.
6. Barlow P, Owen DA, Graham C. DNA synthesis in the preimplantation mouse embryo. *J Embr Exp Morphol* 1972;27:432.
7. Hillman N, Sherman MI, Graham CF. The effect of spatial arrangement of cell determination during mouse development. *J Embryol Exp Morphol* 1972;28:263.
8. McGrath J, Solter D. Completion of mouse embryogenesis requires both maternal and paternal genomes. *Cell* 1984;37:179.
9. Surani MAH, Barton SC, Norris ML. Development of reconstituted mouse eggs suggests imprinting of the genome during gametogenesis. *Nature* 1984;308:548.
10. Saunders JF, Errick J. Inductive activity and enduring cellular constitution of a supernumerary apical ectodermal ridge grafted to the limb bud of the chick embryo. *Dev Biol* 1976;50:16.
11. Gilbert SF. *Developmental biology*, 3rd ed. Sunderland, MA: Sinauer Associates, 1991.
12. Keynes RJ, Stern CD. Mechanisms of vertebrate segmentation. *Development* 1988;103:413.

Developmental Anatomy of the Limb

13. Saunders JF. The experimental analysis of chick limb bud development. In: Ede DA, Hinchliffe JR, Balls M, eds. *Vertebrate limb and somite morphogenesis*. Cambridge: Cambridge University Press, 1977:1.
14. MacCabe JA, Errick J, Saunders JW. Ectodermal control of the dorsoventral axis in the leg bud of the chick embryo. *Dev Biol* 1974;39:69.
15. Akita, K. The effect of the ectoderm on the dorsoventral pattern of epidermis, muscles and joints in the developing chick leg: a new model. *Anat Embryol* 1996;193:377.

16. Saunders JW, Gasseling MT. Ectoderm-mesenchymal interactions in the origin of the wing symmetry. In: Fleischmajer R, Billingham RE, eds. *Epithelial-mesenchymal interactions*. Baltimore, MD: Williams and Wilkins, 1968:78.
17. Solursh M, Singley CT, Reiter RS. The influence of epithelia on cartilage and loose connective tissue formation by limb mesenchyme cultures. *Dev Biol* 1981;86:471.
18. Wolpert L, Tickle C, Sampford M. The effect of cell killing by X-irradiation on pattern formation in the chick limb. *J Embryol Exp Morphol* 1979;50:175.
19. Zanetti N, Solursh M. Control of chondrogenic differentiation by the cytoskeleton. *J. Cell Biol* 1984;99:115.
20. Moore KI, Persaus TVN. *Before we are born. Essentials of embryology and birth defects*, 4th ed. Philadelphia: WB Saunders, 1993:266.
21. Davis CA, Holmyard DP, Millen KJ, et al. Examining pattern formation in mouse, chicken and frog embryos with an En-specific antiserum. *Development* 1991;111:287.
22. Johnston SH, Rauskolb C, Wilson R, et al. A family of mammalian Fringe genes implicated in boundary determination and the Notch pathway. *Development* 1997;124:2245.
23. Wu JY, Wen L, Zhang WJ, et al. The secreted product of *Xenopus* gene lunatic Fringe, a vertebrate signaling molecule. *Science* 1976;273:355.
24. Cohen B, Bashirullah A, Dagnino L, et al. Fringe boundaries coincide with Notch-dependent patterning centers in mammals and alter Notch-dependent development in *Drosophila*. *Nature Genet* 1997;16:283.
25. Niswander L, Tickle C, Vogel A, et al. FGF-4 replaces the apical ectodermal ridge and directs outgrowth and patterning of the limb. *Cell* 1993;75:579.
26. Ohuchi H, Nakagawa T, Yamamoto A, et al. The mesenchymal factor, FGF10, initiates and maintains the outgrowth of the chick limb bud through interaction with FGF8, an apical ectodermal factor. *Development* 1997;124:2235.
27. Ohuchi HTN, Yamauchi T, Ohata T, et al. An additional limb can be induced from the flank of the chick embryo by FGF-4. *Biochem Biophys Res Commun* 1995;209:809.
28. Cohn MJ, Izpisua-Belmonte JC, Abud H, et al. Fibroblast growth factors induce additional limb development from the flank of chick embryos. *Cell* 1995;80:739.
29. Min H, Danilenko DM, Scully SA, et al. *Fgf-10* is required for both limb and lung development and exhibits striking functional similarity to *Drosophila branchless*. *Genes Dev* 1998;12:3156.
30. Summerbell D, Lewis JH, Wolpert L. Positional information in chick limb morphogenesis. *Nature Lond* 1973;244:492.
31. Summerbell D, Lewis JH. Time, place, and positional value in the chick limb-bud. *J Embryol Exp Morphol* 1975;33:621.
32. Tickle C, Summerbell D, Wolpert L. Positional signalling and specification of digits in chick limb morphogenesis. *Nature Lond* 1975;254:199.
33. Summerbell D. The zone of polarizing activity: Evidence for a role in normal chick limb morphogenesis. *J Embryol Exp Morphol* 1979;50:217.
34. Maden M. Vitamin A and pattern formation in the regenerating limb. *Nature Lond* 1982;295:672.
35. Summerbell D. The effect of local application of retinoic acid to the anterior margin of the developing chick limb. *J Embryol Exp Morphol* 1983;78:269.
36. Thaller C, Eichele G. Retinoid signaling in vertebrate limb development. In: Crombrughe B, Horton WA, Olsen BR, et al., eds. *Molecular and developmental biology*. New York: Ann NY Acad Sci 1996;785:1.
37. Monga M. Vitamin A and its congeners. *Semin Perinatol* 1997;21:135.
38. Nester G, Zuckner J. Rheumatologic complications of vitamin A and retinoids. *Semin Arthritis Rheum* 1995;24:291.
39. Riddle R, Johnson R, Laufer E, et al. Sonic hedgehog mediates the polarizing activity of the ZPA. *Cell* 1993;75:1401.
40. Francis P, Richardson M, Brickell P, et al. Bone morphogenetic proteins and a signalling pathway that controls patterning in the chick limb. *Development* 1994;120:209.
41. Niswander L, Jeffrey S, Martin GR, et al. A positive feedback loop coordinates growth and patterning in the vertebrate limb. *Nature* 1994;371:609.
42. Brunet LJ, McMahon JA, McMahon AP, et al. Noggin, cartilage morphogenesis, and joint formation in the mammalian skeleton. *Science* 1998;280:1455.
43. Dickman S. Growing joints use their noggins. *Science* 1998;280:1350.
44. Noonan KJ, Reiter RS, Kurriger GL, et al. Spatial and temporal expression of CD44 isoforms in the developing and growing joints of the rat limb. *J Orthop Res* 1998;16:100.
45. Dealy CN, Roth A, Ferrari D, et al. *Wnt-5a* and *Wnt-7a* are expressed in the developing chick limb bud in a manner suggesting roles in pattern formation along the proximodistal and dorsoventral axes. *Mech Dev* 1993;43:175.
46. Riddle RD, Ensini M, Nelson C, et al. Induction of the LIM homeobox gene *Lmx1* by *Wnt7a* establishes dorsoventral pattern in the vertebrate limb. *Cell* 1995;83:631.
47. Parr, BA, McMahon AP. Dorsalizing signal *Wnt-7a* required for normal polarity of D-V and A-P axes of mouse limb. *Nature* 1995;374:350.
48. Yang Y, Niswander L. Interaction between the signaling molecules *Wnt7a* and *SHH* during vertebrate limb development: dorsal signals regulate anteroposterior patterning. *Cell* 1995;80:939.
49. Izpisua-Belmonte JC, Ede DA, Tickle C, et al. Mis-expression of posterior *Hox-4* genes in *Talpid* (*ta³*) mutant wings correlates with the absence of anteroposterior polarity. *Development* 1992b;114:959.
50. Duboule D. Vertebrate Hox genes and proliferation: an alternative pathway to homeosis? *Curr Opin Genet Dev* 1995;5:525.
51. Goff DJ, Tabin CJ. Analysis of *HoxD-13* and *HoxD-11* mis-expression in chick limb buds reveals that Hox genes affect both bone condensation and growth. *Development* 1997;124(3):627.
52. Stevenson RE, Hall JG, Godoman RM. Human malformations and related anomalies: vol II. In: *Oxford monographs on medical genetics*, no. 27. New York: Oxford University Press, 1993.
53. Mortlock DP, Post LC, Innis JW. The molecular basis of hypodactyly (Hd): a deletion in *Hoxal 3* leads to arrest of digital arch formation. *Nature Genet* 1996;13:284.
54. Raas-Rothschild A, Manouvrier S, Gonzales M, et al. Refined mapping of a gene for split hand-split foot malformation (SHFM3) on chromosome 10q25. *J Med Genet* 1996;33:996.
55. Hoyme HE, van Allen MI, Benirschke K. Vascular pathogenesis of transverse limb reduction defects. *Pediatrics* 1982;101:839.
56. Van Allen MI, Hoyme HE, Jones KL. Vascular pathogenesis of limb defects. I. Radial artery anatomy in radial aplasia. *J Pediatr* 1982;101:832.
57. Torpin R. Fetal malformation caused by amnion rupture during gestation. Springfield, IL: Charles C Thomas, 1968.
58. Zeller R, Jackson-Grusby L, Leder P. The limb deformity gene is required for apical ectodermal ridge differentiation and anteroposterior limb pattern formation. *Genes Dev* 1989;3:1481.
59. Chan DC, Wynshaw-Boris A, Leder P. Formin isoforms are differentially expressed in the mouse embryo and are required for normal expression of *fgf-4* and *shh* in the limb bud. *Development* 1995;121:3151.
60. Kochhar DM. Cellular basis of congenital limb deformity induced in mice by vitamin A. In: Bergsma D and Lenz W, eds.

Morphogenesis and malformation of the limb, vol. 13. Birth Defects Original Article Series. New York: Liss, 1977:111.

61. Heutink P, Zguricas J, van Oosterhout L, et al. The gene for triphalangeal thumb maps to the subtelomeric region of chromosome 7q. *Nature Genet* 1994;6:287.
62. Radhakrishna U, Blouin J-L, Solanki JV, et al. An autosomal dominant triphalangeal thumb: polysyndactyly syndrome with variable expression in a large Indian family maps to 7q36. *Am J Med Genet* 1996;66:209.
63. Hui CC, Joyner AL. A mouse model of Greig cephalopolysyndactyly syndrome: the *extra-toes* mutation contains an intragenic deletion of the *Gli3* gene. *Nature Genet* 1993;3:241.
64. Masuya H, Sagai T, Wakana S, et al. A duplicated zone of polarizing activity in polydactylous mouse mutants. *Genes Dev* 1995;9:1645.
65. Muragaki Y, Mondlos S, Upton J, et al. Altered growth and branching patterns in synpolydactyly caused by mutations in *HOXD 13*. *Science* 1996;272:548.
66. Lockwood C, Ghidini A, Romero R, et al. Amniotic band syndrome: reevaluation of its pathogenesis. *Am J Obstet Gynecol* 1989;160:1030.
67. Patterson TS. Congenital ring constriction. *Br J Plast Surg* 1961;14:1.
68. Streeter GL. Focal deficiencies in fetal tissues and the relation to intra-uterine amputation. *Contrib Embryol* 1930;22:41.
69. Van Allen MI, Curry C, Gallagher L. Limb body wall complex: I. Pathogenesis. *Am J Med Genet* 1987;28:529.
70. Houben JJ. Immediate and delayed effects of oligohydramnios on limb development in the rat: chronology and specificity. *Teratology* 1984;30:403.
71. Chevallier A. Role due mesoderme somitique dans le developpement de la cage thoracique de l'embryon d'oiseau. *J Embryol Exp Morphol* 1975;33:291.
72. Chevallier A, Kieny M, Mauger A, et al. Developmental fate of the somitic mesoderm in the chick embryo. In: Ede DA, Hinchliffe JR, Balls M, eds. *Vertebrate limb and somite morphogenesis*. Cambridge: Cambridge University Press, 1977:421.
73. Kessel M, Gruss P. Homeotic transformations of murine vertebrae and concomitant alteration of Hox codes induced by retinoic acid. *Cell* 1991;67:89.
74. Kessel M, Balling R, Gruss P. Variations of cervical vertebrae after expression of a *Hox-1.1* transgene in mice. *Cell* 1990;61:301.
75. Pollock RA. Altering the boundaries of *Hox-3.1* expression: evidence for anipodal gene regulation. *Cell* 1992;71:911.
76. Ramirez SR. Hoxb-4 (Hox-2.6) Mutant mice show homeotic transformation of a cervical vertebra and defects in the closure of the sternal rudiments. *Cell* 1993;73:279.
77. Chisaka O, Capecchi MR. Regionally restricted developmental defects resulting from targeted disruption of the mouse homeobox gene *hox-1.5*. *Nature* 1991;350:473.
78. Kessel M. Reversal of axonal pathways from rhombomere 3 correlates with extra Hox expression domains. *Neuron* 1993;10:379.
79. Dietrich S, Gruss P. Undulated phenotypes suggest a role of *Pax-1* for the development of vertebral and extravertebral structures. *Dev Biol* 1995;167:529.
80. Takahashi Y, Monsoro-Burq A-H, Bontoux M, et al. A role for *Qbox-8* in the establishment of the dorsoventral pattern during vertebrate development. *Proc Natl Acad Sci USA* 1992;89:10,237.
81. Gruneberg H. *The pathology of development*. Oxford: Blackwell Scientific, 1963.
82. Lyon MF, Seale AG. *Genetic variations and strains of the laboratory mouse*. Oxford: Oxford University Press, 1989.
83. Dietrich S, Kessel M. The vertebral column. In: Thorogood P, ed. *Embryos, genes and birth defects*. New York: John Wiley and Sons, 1997.
84. Dias MS. Myelomeningocele. In: Choux M, DiRocco C, Hockley AD, et al., eds. *Pediatric neurosurgery*. London: Churchill Livingstone, 1997:32.
85. George TM, McLone DG. Mechanisms of mutant genes in spina bifida: a review of implications from animal models. *Pediatr Neurosurg* 1995;23:236.
86. Gardner WJ. Diastematomyelia and the Klippel-Feil syndrome. Relationship to hydrocephalus, syringomyelia, meningocele, meningomyelocele, and iniencephalus. *Clev Clin Q* 1964;31:19.
87. Gardner WJ. The dysraphic states from syringomyelia to anencephaly. Amsterdam: *Excerpta Medica*, 1973.
88. Partington MD, McLone DG. Hereditary factors in the etiology of neural tube defects. *Pediatr Neurosurg* 1995;23:311.
89. Papalopula N, Kintner CR. Molecular genetics of neurulation. In: Bock G, Marsh J, eds. *Neural tube defects*. Ciba Foundation Symposium No. 181. Chichester, UK: John Wiley, 1994:299.
90. Schoenwolf GC, Smith JL. Mechanisms of neurulation: traditional viewpoint and recent advances. *Development* 1990;109:243.
91. Copp AJ, Brook FA, Estibeiro P, et al. The embryonic development of mammalian neural tube defects. *Prog Neurobiol* 1990;35:363.

Developmental Anatomy of the Vertebral Column

Developmental Anatomy of the Nervous System

Bone Formation and Growth



2

GROWTH IN PEDIATRIC ORTHOPAEDICS

ALAIN DIMÉGLIO

BASIC CONCEPTS 33

BIOMETRIC MEASUREMENTS 34

Standing Height 35
Sitting Height 36
Subischial Limb Length 38
Arm Span 38
Weight 38

CHRONOLOGY 39

Intrauterine Development 39
From Birth to 5 Years 39
From 5 to 10 Years of Age 40
Puberty 41
Secondary Sexual Characteristics 41
Pubertal Diagram 41

RADIOLOGICAL STUDY 43

GROWTH OF TRUNK AND THORAX 50

Growth in the Spinal Column 50
Cervical Spine 50
T1-S1 Segment 51
Thoracic Spine (T1-12) 51
Lumbar Spine (L1-5) 52
Thoracic Perimeter 53
Scoliosis and Puberty 53

LOWER LIMB GROWTH 54

Femoral Growth 55
Tibial Growth 55
Knee Growth 55
Foot Growth 56
Growth and Limb-length Discrepancy 56

UPPER LIMB GROWTH 58

Growth in the Paralytic Child 58

LESSONS LEARNED FROM GROWTH 59

BASIC CONCEPTS

It is growth that distinguishes adult from pediatric orthopaedics. It is this ongoing 17-year adventure, punctuated by upheavals and accidents along the way, and jolted by seismic shocks, that gives this discipline its originality and

makes it so interesting. Growth analysis is the evaluation of the effects of time in the growing child. Growth is a complex and well-synchronized phenomenon with a hierarchical pattern that organizes the different types and rates of growth in various tissues, in various organs, and in various individuals through time (1).

Growth can be considered as "microgrowth," which is mainly growth at the cellular level, e.g., in the growth plate. Even though the histological structure is the same, each growth plate has its own characteristics and dynamics (1). The study of height, weight, and body proportions may

be considered as the study of "macrogrowth." This is the culmination of all of the effects of microgrowth on the individual: the meeting point of growth of the lower limbs, growth of the trunk, growth of the upper limbs, increase in weight, etc. (2–5). It is this latter form of growth that this chapter deals with.

The scope of this process called growth, and the changes it brings, are made more palpable by some facts. From birth onward, height will increase by 350% and weight will increase 20-fold; the femur and tibia will triple in length and the spine will double in length (2,6,7). This requires an enormous amount of energy.

The energy requirements in the first 3 years of life are much greater than those of the adult: calories, 110 versus 40 calories per kilogram per day; protein, 2 versus 1 grams per kilogram per day; water, 150 versus 5 milliliters per kilogram per day. Skeletal mineralization alone requires storage of 1 kg of calcium between birth and adulthood (8).

In pediatric orthopaedics, the effects of various diseases, disorders, and injuries are best analyzed on the basis of past growth, whereas treatments often are planned mostly based on assumptions about future or remaining growth of various parts of the body. Growth is an essential element in the natural history of any orthopaedic disorder in the growing child (9). It would be a mistake to assume that only growth in height is important. It is equally important to consider the manner in which the skeletal system develops, i.e., the timing of growth in various parts of the body and the changing proportions of various body segments (5,8,10). In addition, the orthopaedist must not lose sight of other aspects of growth, such as growth of the nervous system.

The orthopaedist will need to know the normal values for many parameters and how to measure them (11–15). He or she will need to know the significance of these values, e.g., the significance of bone age on the growth of the lower limb in a girl with a bone age of 13 years, or the effect of a ten-level spinal fusion in a boy with a bone age of 10 years. Bone age, Tanner classification of the stages of puberty, and measurement of the upper and lower portions of the body are all parameters that may need to be considered in the analysis of any particular case (2,16).

Knowledge of the synchronization of the various events in growth will also allow the orthopaedist to anticipate certain events, e.g., the onset of the increase in growth velocity in a girl with early breast development. However, these values vary with the individual, and average values may not apply to a particular individual. What is most important is the pattern and rate of growth for the particular individual. It is the rate of growth that will influence orthopaedic decisions, more than the final height. Likewise, a change in direction, of one of the parameters, which alters its synchronization with other parameters, may signal an abnormality, a return to normal, or the onset of a normal phase of growth. For this reason, a sequence of measurements of the important parameters is far superior to a single measurement.

The problem often raised about growth data is that such

data are ethnically specific, and that it is difficult to transfer parameters from one population to another. For example, bone age atlases are not transferable between populations, nor are growth curves transferable from one country to another. Comparing data from children in England (13–15), Switzerland (17), France (18), and the United States (12,16,19) reveals no significant differences in final heights, bone ages, or other parameters of growth. Looking beyond racial diversity, there are growth constants, i.e., stages through which every child must pass, regardless of age, that are the same in all ethnic groups.

A few simple tools are required at the time of the consultation: a height gauge, scales, a metric tape, and a bone age atlas. With these tools, the specialist will be able to perform rapid mental arithmetic and reach a reasonable decision. A few simple questions will guide the orthopaedist to the information that is required (2).

How tall is the child?

What is the child's sitting height?

How long is the subischial leg length?

What is the child's chronological age? What is the bone age?

How much has the child grown in a single year?

How much growth does the child have left in the trunk and in the lower limbs?

Exactly what point has the child reached on his or her developmental path?

Where is the child in relation to puberty?

Are the child's proportions within normal limits?

How much does the child weigh?

BIOMETRIC MEASUREMENTS

There is not much useful data that can be obtained from a single measurement. A single measurement can be an error, two measurements constitute an indication, and three measurements define a tendency.

In any child with a disturbance of growth, whether generalized or localized to a particular part of the body, measurements of growth should be taken at regular intervals (3,11–15,20,21). Examples would be children with skeletal dysplasia (22), spinal deformity (23), limb-length discrepancy (24), or paralytic conditions (25–27). Birthdays are a convenient reminder for annual evaluations such as measurements of growth. At every clinic, the first response must be to measure the different anthropometric parameters. Checking the child every 6 months, preferably once around his or her birthday, allows an easy assessment of the growth velocity of the child and the different body segments (2). These measurements provide a real-time image of growth, and, carefully recorded in a continually updated "growth notebook," they provide charts that make decisions easier (2,7). Growth velocity is an excellent example, because it provides the best indicator of the beginning of puberty, on

which so many decisions rest. The first sign of puberty is the increase in growth to more than 0.5 cm per month or 6 cm per year.

The orthopaedic surgeon must be familiar with the measurement of these parameters. He or she should be able to perform these measurements and teach the correct method to others. It is often useful and possible to instruct the family or the primary physician how to obtain necessary data.

Standing Height

The height gauge is to the orthopaedic specialist what the stethoscope is to the cardiologist (2). In children younger than 5 years of age, standing height is measured with the child lying down, because in this age group it is both easier and more reliable (15).

Between birth and maturity, the body will grow approximately 1.20, or even 1.30, meters. Growth is brisk before the age of 5 years. After that, it slows considerably until the onset of puberty, which is around 11 years in girls and 13 years in boys. At 5 years of age, standing height is 60% of the adult height; it reaches 80% of the final height by the age of 9 years. At puberty, standing height increases more rapidly.

Standing height is a global marker, and it is composed of two more specific measurements known as subischial height (the growth of the lower limbs) and sitting height (the growth of the trunk) (7,15). These two different regions often grow at different rates at different times, which is valuable information for decisions in orthopaedics. Values for the standing heights of girls and boys at various ages are given in Tables 2-1 and 2-2. The percentages of standing

TABLE 2-1. STANDING HEIGHTS OF GIRLS AT VARIOUS AGES

Age (yr)	Height (cm)							SD	50th Centile as Percentage of Adult Height
	3rd	10th	25th	50th	75th	90th	97th		
0.08	49.2	50.4	51.6	53.0	54.4	55.6	56.8	2.00	32.7
0.25	54.9	56.2	57.5	59.0	60.5	61.8	63.1	2.16	36.4
0.50	61.1	62.5	63.9	65.5	67.1	68.5	69.9	2.34	40.4
0.75	65.5	67.0	68.6	70.2	72.0	73.5	74.9	2.52	43.3
1.00	69.1	70.8	72.4	74.2	76.0	77.7	79.3	2.69	45.7
1.25	72.2	73.9	75.7	77.6	79.5	81.2	82.9	2.85	47.8
1.50	74.9	76.7	78.5	80.5	82.6	84.4	86.2	3.01	49.7
1.75	77.2	79.1	81.1	83.2	85.3	87.2	89.1	3.15	51.3
2.00	79.4	81.3	83.4	85.6	87.8	89.8	91.8	3.30	52.8
2.0	78.4	80.3	82.4	84.6	86.8	88.8	90.8	3.30	52.1
2.5	82.2	84.3	86.5	88.9	91.3	93.5	95.6	3.57	54.8
3.0	85.7	88.1	90.4	93.0	95.6	97.9	100.2	3.83	57.3
3.5	89.2	91.6	94.1	96.8	99.6	102.0	104.5	4.07	59.7
4.0	92.3	94.9	97.5	100.4	103.3	105.9	108.5	4.30	61.9
4.5	95.4	98.1	100.8	103.8	106.9	109.7	112.4	4.52	64.0
5.0	98.2	101.1	104.0	107.2	110.3	113.2	116.1	4.74	66.1
5.5	101.0	104.0	107.0	110.3	113.7	116.7	119.6	4.94	68.0
6.0	103.8	106.8	110.0	113.4	116.9	120.0	123.1	5.14	69.9
6.5	106.4	109.6	112.8	116.4	120.0	123.2	126.4	5.31	71.8
7.0	109.1	112.4	115.7	119.3	123.0	126.3	129.6	5.46	73.6
7.5	111.7	115.0	118.4	122.2	126.0	129.4	132.8	5.60	75.3
8.0	114.2	117.6	121.1	125.0	128.9	132.4	135.8	5.75	77.1
8.5	116.7	120.3	123.8	127.8	131.8	135.3	138.8	5.87	78.8
9.0	119.3	122.9	126.6	130.6	134.6	138.3	141.9	6.00	80.5
9.5	121.9	125.6	129.3	133.5	137.6	141.3	145.0	6.14	82.3
10.0	124.5	128.3	132.1	136.4	140.6	144.5	148.3	6.31	84.2
10.5	127.1	131.1	135.0	139.5	143.9	147.9	151.8	6.56	86.1
11.0	129.5	133.7	138.0	142.7	147.4	151.6	155.8	6.97	88.1
11.5	132.0	136.5	141.0	146.1	151.1	155.6	160.1	7.47	90.1
12.0	135.0	139.6	144.2	149.3	154.4	159.1	163.6	7.61	92.0
12.5	139.0	143.3	147.7	152.5	157.4	161.8	166.1	7.21	94.0
13.0	142.6	146.7	150.9	155.5	160.2	164.4	168.5	6.90	95.9
13.5	145.4	149.4	153.4	157.9	162.3	166.3	170.3	6.61	97.3
14.0	147.6	151.4	155.3	159.6	163.9	167.8	171.6	6.38	98.4
14.5	149.4	153.1	156.9	161.1	165.3	169.0	172.7	6.20	99.3
15.0	150.3	153.9	157.6	161.7	165.8	169.5	173.2	6.09	99.8
15.5	150.6	154.2	157.9	162.0	166.1	169.7	173.4	6.04	99.9
16.0	150.9	154.5	158.2	162.2	166.2	169.9	173.5	6.00	100.0

(From ref. 15, with permission.)

TABLE 2-2. STANDING HEIGHTS OF BOYS AT VARIOUS AGES

Age (yr)	Height (cm)								50th Centile as Percentage of Adult Height
	3rd	10th	25th	50th	75th	90th	97th	SD	
0.08	50.2	51.4	52.7	54.0	55.4	56.6	57.8	2.00	30.9
0.25	56.6	57.9	59.2	60.7	62.1	63.4	64.7	2.16	34.7
0.50	63.8	65.2	66.6	68.2	69.7	71.2	72.6	2.34	39.0
0.75	67.9	69.4	71.0	72.7	74.4	75.9	77.4	2.52	41.6
1.00	71.2	72.8	74.5	76.3	78.1	79.7	81.4	2.69	43.7
1.25	74.0	75.7	77.4	79.4	81.3	83.0	84.7	2.85	45.4
1.50	76.5	78.3	80.1	82.1	84.2	86.0	87.8	3.01	47.0
1.75	78.7	80.6	82.5	84.6	86.7	88.7	90.5	3.15	48.4
2.00	80.7	82.7	84.7	86.9	89.1	91.1	93.1	3.30	49.8
2.0	79.7	81.7	83.7	85.9	88.1	90.1	92.1	3.30	49.2
2.5	83.5	85.6	87.8	90.2	92.6	94.8	96.9	3.57	51.6
3.0	87.0	89.3	91.6	94.2	96.8	99.1	101.4	3.83	53.9
3.5	90.4	92.8	95.3	98.0	100.8	103.2	105.7	4.07	56.1
4.0	93.5	96.1	98.7	101.6	104.5	107.1	109.7	4.30	58.2
4.5	96.5	99.2	102.0	105.0	108.1	110.8	113.5	4.52	60.1
5.0	99.4	102.2	105.1	108.3	111.5	114.4	117.2	4.74	62.0
5.5	102.2	105.2	108.2	111.5	114.8	117.8	120.8	4.94	63.8
6.0	104.9	108.0	111.1	114.6	118.1	121.2	124.3	5.14	65.6
6.5	107.6	110.8	114.0	117.6	121.2	124.4	127.6	5.31	67.3
7.0	110.3	113.5	116.8	120.5	124.2	127.5	130.8	5.46	69.0
7.5	112.9	116.2	119.6	123.4	127.2	130.6	133.9	5.60	70.6
8.0	115.4	118.8	122.3	126.2	130.0	133.5	137.0	5.73	72.2
8.5	117.9	121.4	125.0	128.9	132.9	136.4	139.9	5.85	73.8
9.0	120.4	124.0	127.6	131.6	135.7	139.3	142.9	5.98	75.4
9.5	122.8	126.5	130.2	134.3	138.4	142.1	145.8	6.10	76.9
10.0	125.1	128.8	132.6	136.8	141.0	144.8	148.5	6.24	78.3
10.5	127.2	131.0	135.0	139.3	143.6	147.6	151.4	6.44	79.8
11.0	129.4	133.3	137.4	141.9	146.4	150.4	154.4	6.67	81.3
11.5	131.7	135.8	140.0	144.7	149.4	153.6	157.8	6.95	82.7
12.0	133.7	138.0	142.4	147.3	152.2	156.6	160.9	7.24	84.1
12.5	136.3	140.7	145.3	150.3	155.4	159.9	164.4	7.48	85.5
13.0	138.7	143.4	148.2	153.4	158.7	163.5	168.2	7.82	87.1
13.5	141.5	146.4	151.3	156.8	162.3	167.2	172.0	8.11	89.1
14.0	145.0	150.0	155.0	160.7	166.3	171.3	176.2	8.31	92.0
14.5	148.4	153.4	158.4	164.0	169.6	174.6	179.6	8.30	94.6
15.0	152.3	157.1	161.9	167.3	172.7	177.6	182.4	8.00	96.6
15.5	155.9	160.4	165.0	170.1	175.2	179.8	184.3	7.55	97.9
16.0	158.9	163.1	167.4	172.2	177.0	181.3	185.5	7.08	98.8
16.5	160.7	164.8	168.9	173.5	178.0	182.1	186.2	6.77	99.4
17.0	161.7	165.7	169.8	174.3	178.8	182.8	186.8	6.67	99.8
17.5	162.0	166.0	170.0	174.5	179.0	183.0	187.0	6.66	99.9
18.0	162.2	166.2	170.2	174.7	179.2	183.2	187.2	6.65	100.0

(From ref. 15, with permission.)

and sitting heights attained for various ages are given in Table 2-3. Values for sitting heights and subischial lengths for girls and boys are given in Figures 2-1 and 2-2.

Sitting Height

In children younger than 2 years of age, sitting height is measured with the child lying down, for the same reasons that standing height is measured supine in this age group (7,15) (Fig. 2-3). After age 2 years, the child should be placed on a stool or table at a convenient height. The most

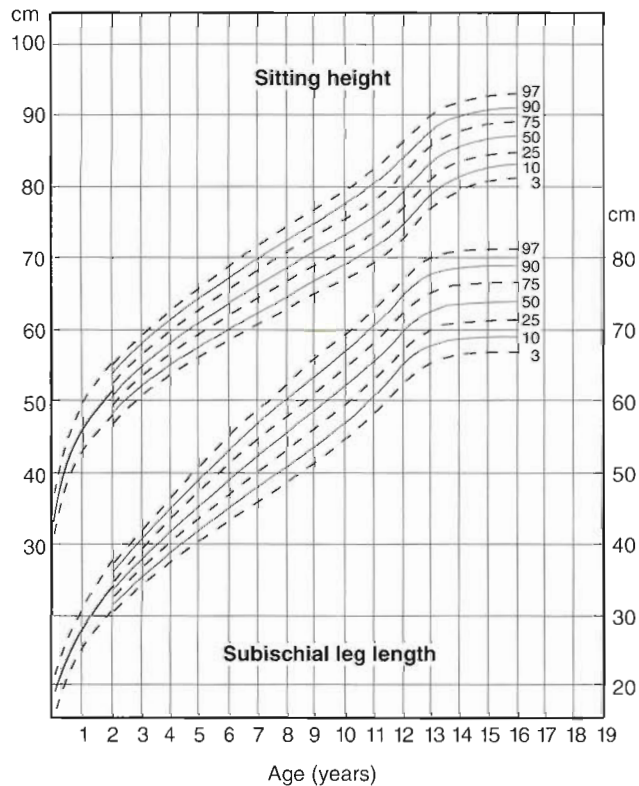
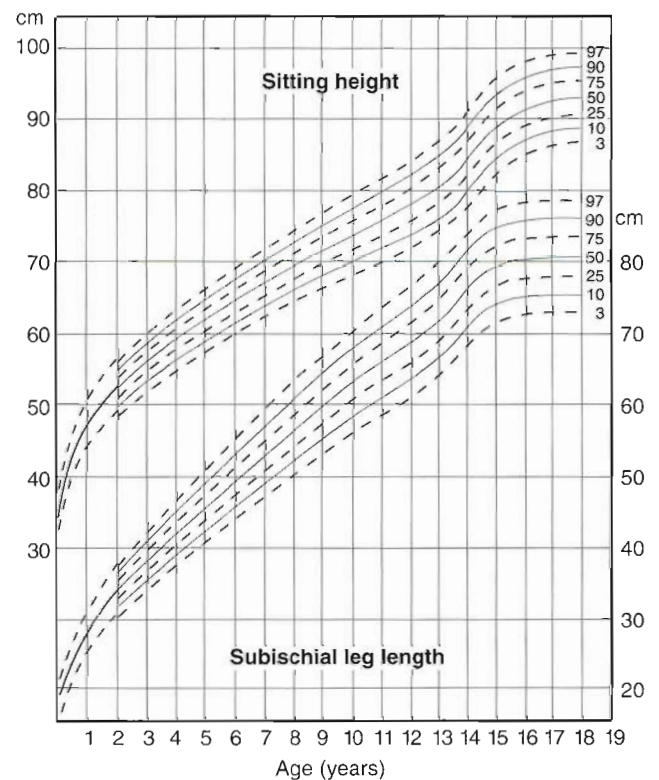
important consideration of all is that the child should always be measured under the same conditions using the same measuring instruments. The sitting height averages 34 cm at birth and averages 88 cm for girls and 92 cm for boys at the end of growth.

In patients with scoliosis, it can be instructive to follow the sitting height rather than the standing height (7,28). If one is treating a girl at age 6 years with juvenile scoliosis, her sitting height will be approximately 64 cm, and will grow to about 88 cm. Thus, one will have to control the curve while her trunk grows 24 cm. The measurement of

TABLE 2-3. PERCENT OF STANDING AND SITTING HEIGHT ATTAINED EACH YEAR

Age (yr)	Girls' Standing Height (%)	Girls' Sitting Height (%)	Girls' Subischial Leg Length (%)	Boys' Standing Height (%)	Boys' Sitting Height (%)	Boys' Subischial Leg Length (%)
0	31	37	25	29	35	23
1	46	53	37	43	50	35
2	52	58	44	50	55	41
3	57	63	50	54	59	47
4	62	67	56	58	63	52
5	66	70	61	64	66	57
6	70	73	66	65	69	61
7	73	76	70	69	67	65
8	77	78	75	72	74	69
9	80	81	79	75	76	73
10	84	84	83	78	78	77
11	88	87	89	81	81	81
12	92	90	94	84	83	84
13	96	95	98	87	86	89
14	98	98	100	92	90	93
15	100	99	100	96	95	98
16	100	100	100	98	98	100
17	100	100	100	99	99	100
18	100	100	100	100	100	100

(From ref. 15, with permission.)

**FIGURE 2-1.** Normal values for sitting height and subischial leg length (stature minus sitting height) in girls. (Adapted from ref. 15, with permission.)**FIGURE 2-2.** Normal values for sitting height and subischial leg length (stature minus sitting height) in boys. (Adapted from ref. 15, with permission.)

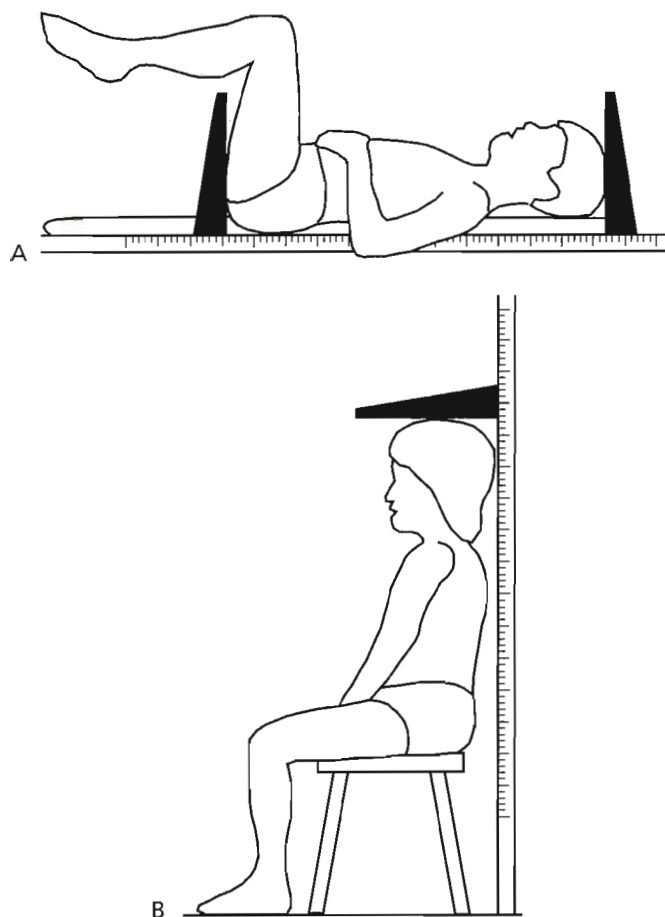


FIGURE 2-3. A: Measurement of sitting height. B: Once the child is able to sit reliably, measurement with a sitting height gauge can be accurately accomplished by sitting the patient on a firm table or stool at a convenient height.

sitting height can also be useful in anticipating the onset of puberty (7). In an average population, puberty starts at about 75 cm sitting height in girls and 78 cm in boys. At 84 cm sitting height, 80% of girls have menarche (2,7,29).

Subischial Limb Length

The segment of the body made up of the legs is measured to determine the subischial leg length. As implied by the name, it is measured by subtracting the sitting height from the standing height (15).

At birth, the subischial leg length averages 18 cm. At the completion of growth, it will average 81 cm in boys and 74.5 cm in girls. This 63 cm of growth in boys and 56.5 cm of growth in girls contributes a far greater percentage of growth in height than does the trunk (15). This accounts for the changing proportions of the body during growth (Fig. 2-4).

Arm Span

The arm span provides an indirect way to control the standing height. Combining these two measurements avoids virtually all errors. To measure the arm span, the patient simply raises the arms to a horizontal position, and the distance between the tips of the middle fingers is measured with a tape measure (30,31). There is an excellent correlation between the arm span and the standing height. The standing height is about 97% of the arm span (30). In 77% of normal children, the arm span will be 0 to 5 cm greater than the standing height; in 22%, it will be 5 to 10 cm greater; and in 1%, it will be 10 cm or more greater. This relationship remains throughout puberty, with the arm span tending to be slightly greater in proportion to standing height in boys than in girls. If the trunk is normal, i.e., without deformity, its length will equal about 52% of the arm span, and the lower limbs will be equal to about 48%, or the same as their proportions in the standing height (2).

The relationship of arm span to standing height is useful in determining what would be the normal height of a child who is in a wheelchair; this allows calculation of the normal height and weight (25–27,30). It is routinely used for any child who has a spine deformity, e.g., scoliosis, to calculate the normal values for pulmonary function. This relationship also is useful in diagnosing certain disorders characterized by a disproportion between the limbs and the trunk, e.g., Marfan syndrome, in which the arm span is usually 5 cm greater than the standing height. In children with spinal deformity, the arm span is a good estimate of what the standing height would be if there were no scoliosis.

Weight

Weight must always be brought into the equation when making a surgical decision, whether one is dealing with a case of idiopathic scoliosis, paralytic scoliosis, or lower limb osteotomy. Children should always be weighed at consultations (2,12,13). There may be striking morphological changes from one year to the next. If weight evaluation becomes an integral part of each consultation, changes will become obvious, and can be incorporated into the orthopaedic specialist's deliberations. A simple rule for a boy's weight is: 18 to 20 kg at age 5 years; 30 kg at age 10 years; and 60 kg at age 17 years (2). Note that weight doubles between 10 and 17 years of age. At age 5 years, the weight has reached 32% of the final normal weight (2,15).

Weight that is greater than 10% of normal for the patient may be part of the reason that a scoliosis brace is no longer correcting the curve as it did before or may account for the fact that a hip deformed by Perthes disease is now symptomatic, or that the child cannot walk or run as far. Weight can explain delayed menarche, because girls generally need to reach 40 kg for menarche to occur. If the patient's weight (obesity) becomes a problem that aggravates the orthopaedic

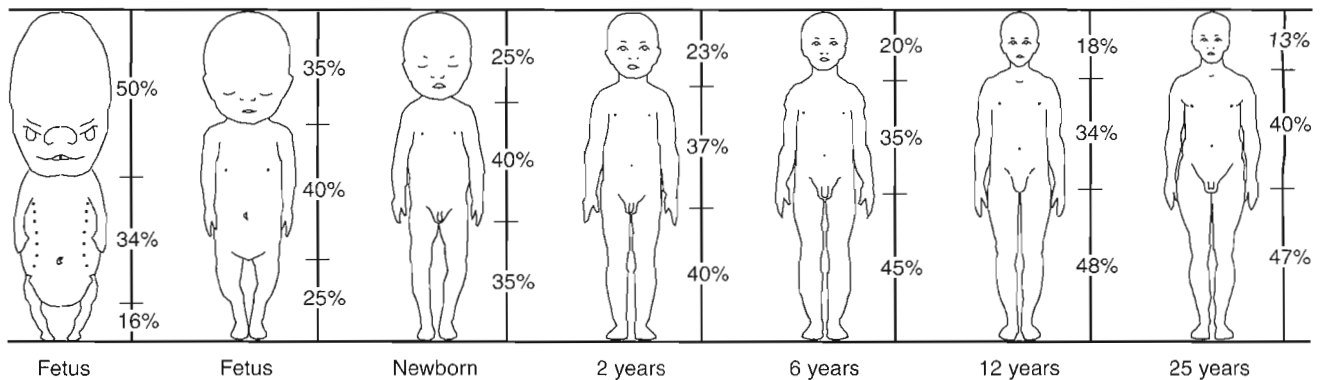


FIGURE 2-4. The proportions of the body as they change during growth. The head and trunk together constitute the sitting height. The segment below is the subischial leg length. (Adapted from ref. 8, with permission.)

condition, it is useful to have objective measurements to document the problem for the patient and his or her parents. A generally accepted estimate of body fat is expressed in Quetelet's body mass index: weight (kg)/height (m^2) (31). In this index, 20 to 25 kg/m^2 is normal; 25 to 30 kg/m^2 is moderate obesity; 30 to 40 kg/m^2 is major obesity; and more than 40 kg/m^2 is morbid obesity.

CHRONOLOGY

Intrauterine Development

Growth does not start at birth. During the first trimester of gestation, the systems are busy organizing themselves, and are developing at a brisk pace (32–35). During this period, the fetus makes daily progress, reaching a weight six million times greater than that of the egg by the time the infant is born. By the second month of life, sitting height is increasing at a rate of 1 mm daily, which subsequently increases to 1.5 mm per day. Were this rate of growth to continue until the age of 10 years, the child would stand 6 m tall (2).

From the third month onward, the embryo becomes a fetus, and turns into a miniature adult. At the end of the second trimester of gestation, the fetus has reached 70% of its size, measuring 30 cm, but has achieved no more than 20% of birth weight (approximately 800 g). It is during the third trimester that the fetus gains weight at the highest rate (700 g per month). This means that various stages of growth do not occur simultaneously during intrauterine life. Length increases steadily and rapidly during the first 6 months *in utero*, whereas weight gain is most rapid during the final 3 months of gestation.

Today, with high-resolution ultrasonography, it is possible to follow the growth of the fetus and to detect the slight-

est abnormality. Several good references are available regarding these measurements (36,37). It can be anticipated that many orthopaedic conditions characterized by disproportionate or abnormal growth will be diagnosed prenatally.

After birth, not only does the overall rate of growth vary at different ages, but the rates at which various segments of the body grow differ, as well. For example, during the first 5 years of life, sitting height and subischial leg length increase at about the same rate; from age 5 years to puberty, the sitting height accounts for one-third of the gain and the subischial leg length accounts for two-thirds; from puberty to maturity, the ratio is reversed, with the sitting height accounting for two-thirds of the gain in height and the subischial leg length accounting for one-third (2; Fig. 2-4). The amounts of increase in sitting height and subischial leg length for various ages are shown for girls and boys in Figures 2-5 and 2-6.

From Birth to 5 Years

Birth marks a very obvious transition in the growth of the child. At birth, standing height for the neonate is 30% of the final height (50 to 54 cm). By the age of 5 years, the standing height has increased to 108 cm, which is double the birth height and 62% of the final height. The first year of life sees particularly vigorous growth rates, with the infant's height increasing by 25 cm (2). This means that the height gain during a single year is as great as it is during the entire surge of puberty. At the age of 1 year, the growth rate starts to slow down, but remains strong, with the infant growing another 10 cm between 1 and 2 years of age and 7 cm between 3 and 4 years of age (2).

At birth, the sitting height of the neonate is approximately 34 cm, which is roughly two-thirds of the standing height and 37% of the final sitting height. By the age of 5 years, the sitting height will have increased to 62 cm,

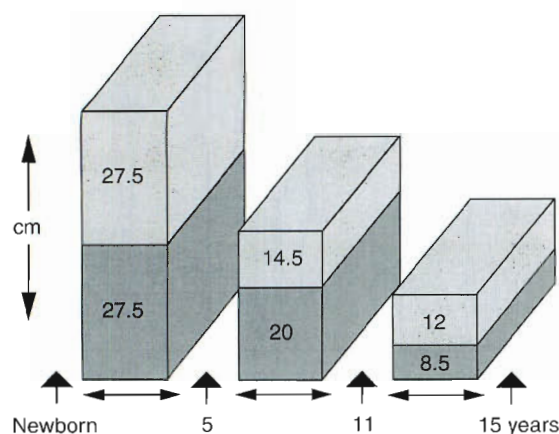


FIGURE 2-5. The growth in sitting height (top bars) and subischial leg length (bottom bars) at various ages in girls. These data are from our studies, and are in agreement with the figures of Tanner (15).

approximately 66% of the final sitting height, with only about 30 additional centimeters to grow (7,38). This information is useful in anticipating the effects of the deformity and the consequences of arthrodesis in spinal deformity in young patients.

Increase in the subischial leg length follows a pattern almost identical to that for sitting height. At birth, the lower limbs are relatively small, compared with the trunk (only 18 cm). By the age of 5 years, the subischial leg length will have increased by an average of 28 cm, to about 46 cm, representing more than 50% of the final length. At age 5 years, the subischial leg length will increase by about another 35 cm in boys and 28.5 cm in girls, before growth ceases; this is a considerable amount of growth, but less than occurred in the first 5 years (2).

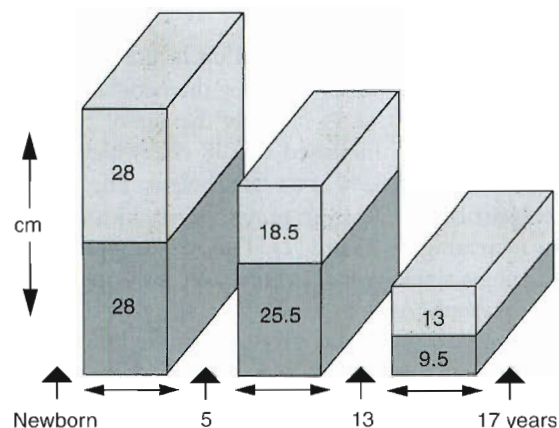


FIGURE 2-6. The growth in sitting height (top bars) and subischial leg length (bottom bars) at various ages in boys. These data are from our studies, and are in agreement with the figures of Tanner (15).

At birth, the weight is between 3,000 and 3,500 g, 5% of the final figure. At 5 years, the weight averages 18 to 20 kg, 32% of the final adult weight. In 5 years, the weight gain is 15 to 17 kg.

During the first 5 years of growth after birth, the proportions change. The cephalic end of the body becomes relatively smaller, whereas the subischial leg length increases (Fig. 2-4). It is now readily appreciated why any congenital limb deformity or chondrodystrophy has such a dramatic onset during this period of rapid growth. Similarly, any limb paralysis occurring during the first years of life will usually result in severe shortening, not only because so much growth remains, but also because its effects are felt when growth is extremely rapid.

During this period, growth is not only a vertical, but also a volumetric phenomenon. Birth weight triples in a single year, and quadruples by the age of 3 years. The circumference of the chest is 32 cm at birth, but increases 25 cm, to reach 57 cm by the age of 5 years (2,7,38). Chest morphology has undergone dramatic changes. There has been neurological growth: the head circumference is 35 cm at birth and increases by 12 cm in the first year, reflecting the growth of the nervous system. Any neurological assault on the infant during this period can have serious effects on neurological development. By the time the child has reached 5 years of age, sitting height has approximately 26 to 30 cm of growth left (38). This figure demonstrates how difficult the decisions about the management of scoliosis can be during childhood (7). The lower limbs have approximately 35 cm of growth left. This indicates a need for great caution whenever predictions are being made concerning inequality of length.

From 5 to 10 Years of Age

Between 5 and 10 years of age, there is a marked deceleration in growth, with standing height increasing at approximately 5.5 cm per year. Two-thirds of this growth (3.5 cm) occurs in the lower limb, and one-third (2 cm) occurs in the sitting height (7). The trunk is now growing at a slower rate, whereas the lower limbs are growing faster than the trunk, thus changing the proportions of the body (Fig. 2-4). During this 5-year period, standing height will increase by 26% (almost 28 cm), sitting height by 13% (10 cm), and subischial leg length by 20% (18 cm) (Figs. 2-5 and 2-6).

At the age of 10 years, approximately 38 cm of growth remains in standing height for boys and 24 cm for girls, made up of 20 cm in sitting height and 18 cm in the lower limb for boys and 16 cm in sitting height and 10 cm in the lower limb for girls. At the age of 10 years, the average weight is 30 kg, which represents an increase of 12 kg from 5 to 10 years of age, or approximately 2.5 kg per year. The weight at age 10 years represents only 48% of the final average weight at maturity. At this age, in contrast, the

standing height is 78% of the final standing height for boys and 83% for girls. Thus, at age 10 years, the child has attained more than 75% of his or her height, but less than 50% of his or her weight (2,12–14).

Puberty

Although age is a poor indicator of puberty, we may start anticipating puberty at age 10 years in girls and age 12 years in boys. It is the acceleration in the velocity of growth that best characterizes the beginning of puberty. From a clinical viewpoint, puberty will be recognized by a combination of factors other than growth: sexual development, chronological age, and bone age. After the age of 10 years, the growth of boys and girls proceeds differently. On average, girls will experience the onset of puberty at 11 years, boys at 13 years. Puberty and its accompanying rapid growth is a period of great importance to the orthopaedic surgeon. Thus, it is important to recognize the period just before puberty (2,9,10,12–15,17,28,39–43).

There are four main characteristics that dominate the phase of growth called puberty:

- a dramatic increase in stature (2);
- changing of the proportions of the upper and lower body segments (8,10,31);
- change in overall morphology: biacromial diameter, pelvic diameter, fat distribution, etc. (30); and
- development of sexual characteristics (15,39,40).

The picture during puberty (from 11 to 13 years in girls and from 13 to 15 years in boys) is dominated by a return to a dramatic increase in the growth rate. However, this time the growth is far more noticeable in the trunk than in the lower limbs. During puberty, annual growth rates for the different parts of the body reverse: two-thirds for sitting height, one-third for subischial leg length.

It is during this period that boys surpass girls in height. On average, boys are 13 cm taller than girls. This is accounted for by two factors. First, boys have approximately 2 more years of growth than girls. Second, boys have a slightly greater increase in the rate of growth during puberty than girls, accounting for approximately 2 cm of additional height.

During puberty, the standing height increases by approximately 1 cm per month. At the onset of puberty, boys have 14% ($\pm 1\%$) of their remaining standing height to grow. This is approximately 22.5 cm (± 1 cm), made up of 13 cm in sitting height and 9.5 cm in subischial leg length. Girls have 12% ($\pm 1\%$) of their standing height to grow. This is approximately 20.5 cm (± 1 cm), made up of 12 cm in sitting height and 8.5 cm in subischial leg length.

The peak in the growth rate during puberty occurs between 13 and 15 years of bone age in boys and between 11 and 13 years of bone age in girls (2,5,15,31,39,40,42). By the time girls and boys have passed bone ages of 13 and 15

years, respectively, lower limb growth virtually ceases, with all remaining growth (4.5 cm) taking place in sitting height. This is an extremely important factor to consider in the treatment of many disorders, especially scoliosis and limb-length discrepancy.

These figures, ratios, and rates provide only a partial reflection of the growth phenomenon. Precise evaluation of the characteristics of puberty, using the Tanner classification, the onset of menstruation, and the Risser sign, is something that needs to be undertaken with a great deal of care. One of the major problems with using only the onset of menarche and the Risser sign is that they occur after the growth of puberty has begun to slow.

Secondary Sexual Characteristics

Secondary sexual characteristics develop throughout the course of puberty; the first appearance of pubic hair, the budding of the nipples, and the swelling of the testes are the first physical signs to signal the onset of puberty (2,15,39,40). The first physical sign of puberty in boys, testicular growth in 77% (31), occurs on average 1.7 years before the peak height velocity and 3.5 years before attaining adult height. The bone age will be approximately 13 years at the onset of puberty; the Risser sign is 0, and the triradiate cartilage is open. At this age, girls have well-developed secondary sexual characteristics, and their rate of growth is decelerating.

In 93% of girls, the first physical sign of puberty is breast budding, which occurs about 1 year before peak height velocity (31). This averages 11 years in bone age. The Risser sign is still 0, and the triradiate cartilage is still open at the onset of puberty. Menarche occurs about 2 years after breast budding, and final height is usually achieved 2.5 to 3 years after menarche. After menarche, girls will gain the final 5% of their standing height, about 3 to 5 cm (7,29,43). The appearance of axillary hair, although variable, often signals the peak of the pubertal growth curve.

The secondary sexual characteristics generally develop in harmony with bone age, but there are discrepancies in 10% of cases (2,5,7,15,31). In these circumstances, it is best to believe the bone age. Puberty may be accelerated and growth can end more quickly than usual, catching the unaware physician off guard. In fact, it has been demonstrated that it is not uncommon to see an acceleration of the bone age during puberty (31).

Pubertal Diagram

Using all of these landmarks, it is possible to draw a diagram relating the events occurring during puberty (Figs. 2-7 and 2-8). Even if one indicator is missing or does not match the other, it is still possible to have a good idea of where the child is on his or her own way through puberty (2,7). By plotting the gains in standing height and sitting height

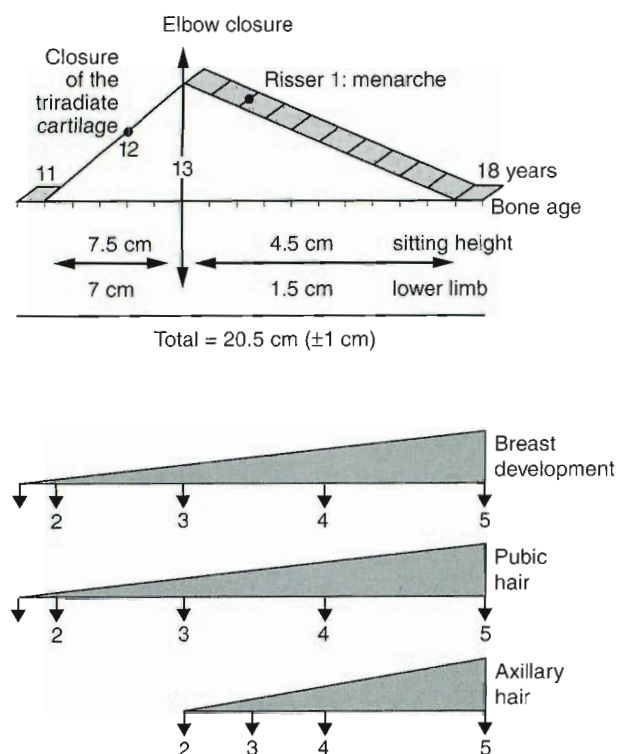


FIGURE 2-7. Top: The pubertal growth curve in girls, illustrating the relationship between the various landmarks. Bottom: The corresponding clinical Tanner stages. (Adapted from ref. 7, with permission.)

every 6 months, a picture of the period of puberty is developed. It is also easy to divide this into two parts. The first phase, i.e., the ascending limb of the growth curve, is characterized by an increase in the velocity of growth, and is the major portion of the pubertal growth spurt. The second phase, i.e., the descending limb of the growth curve, is characterized by a slowing of the rate of growth (2,7).

Although the peak of this curve is fleeting, it can be roughly identified by accurate assessment of certain skeletal markers at 6-month intervals. Triradiate cartilage closure occurs about halfway up the ascending limb of the pubertal curve. This closure corresponds to an approximate bone age of 12 years for girls and 14 years for boys. After closure of the triradiate cartilage, there is still a significant amount of growth remaining: greater than 12 cm of standing height for girls and more than 14 cm for boys.

The closure of the olecranon apophysis in the elbow is a very good skeletal marker for the peak of the growth spurt (7). The closing of the growth centers of the elbow (discussed below) divides the ascending and descending phases of puberty, and, as such, is useful in assessing further growth. It is especially useful, because this is a period when there are few changes occurring in the bones of the hand and wrist, as used in the Greulich and Pyle atlas (G&P) (16).

Menarche usually occurs after closure of the olecranon

apophysis, on the descending limb of the growth curve, when the rate of growth is slowing. This is usually between bone ages of 13 and 13.5 years, and corresponds to Risser I on the iliac apophysis (28,29,44–46). At this stage, the average girl will gain an additional 4 cm of sitting height and 0.6 cm of subischial leg length. The menarche is not as precise as many other indicators during puberty. Forty-two percent of girls experience menarche before Risser I, 31% at Risser I, 13% at Risser II, 8% at Risser III, and 5% at Risser IV (7).

The first phase of the pubertal growth spurt is the ascending phase, which corresponds to the acceleration in the velocity of growth. This phase lasts 2 years, from approximately 11 to 13 years of bone age in girls and from 13 to 15 years of bone age in boys. The gain in standing height for girls during this phase is about 14.5 cm, made up of 7.5 cm in sitting height and 7 cm in subischial leg length. The gain in standing height for boys during this phase is about 16.5 cm, made up of 8.5 cm in sitting height and 8 cm in subischial leg length. During this first phase of the pubertal growth spurt, the sitting height contributes 53% and the subischial leg length contributes 47%. Thus, more

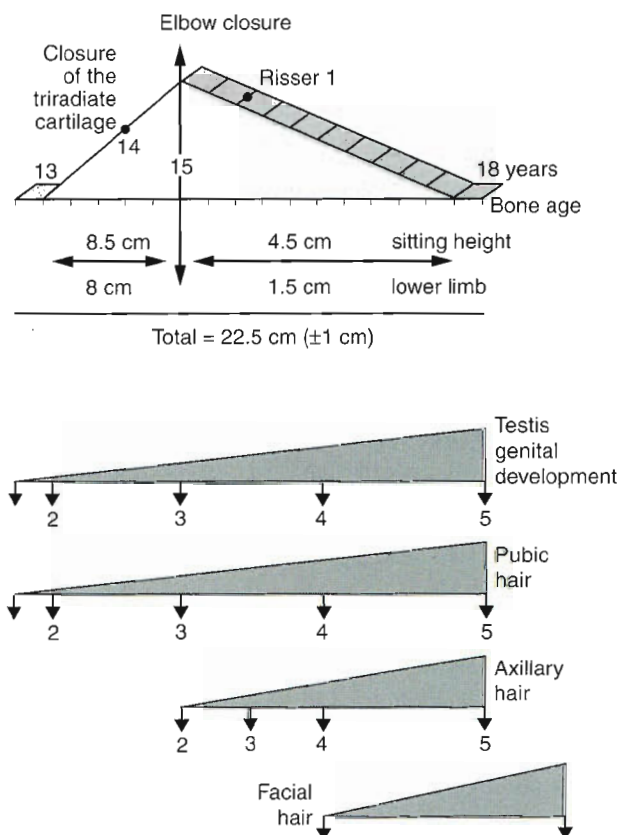


FIGURE 2-8. Top: The pubertal growth curve in boys, illustrating the relationship between the various landmarks. Bottom: The corresponding clinical Tanner stages. (Adapted from ref. 7, with permission.)

growth comes from the trunk than from the legs during this phase of growth (7).

The second phase of the pubertal growth spurt is a period of deceleration in the rate of growth. This phase lasts 2.5 years, from 13 to 15.5 years of bone age in girls and from 15 to 17.5 years of bone age in boys. During this phase, boys and girls will gain about 6 cm in standing height, with 4.5 cm coming from an increase in sitting height and 1.5 cm coming from an increase in subischial leg length. During this phase, the increase in sitting height contributes 80% of the gain in the standing height (7).

At skeletal maturity, the average weight for boys is 63 kg, with a standing height of 174 cm (± 1 cm), and the average weight for girls is 56 kg, with a standing height of 166 cm (± 1 cm). From 10 to 20 years of age, the gain in weight averages 33 kg in boys and 26 kg in girls. During the growth spurt of puberty, the average gain in weight each year is 5 kg (2).

RADIOLOGICAL STUDY

In pediatric orthopaedics, chronological age is of no significance. Everything turns on bone age. Personal data indicate that about 50% of children have a bone age that is significantly different from their chronological age. In some disorders, this is characteristic: delayed bone age in Perthes disease (47,48), slipped capital femoral epiphysis (49–51), severe cerebral palsy, and rickets with nephropathy. Whether it is a case of Legg-Calvé-Perthes disease, limb-length discrepancy, or chondrodystrophy, all reasoning, analysis, forecasting, and decision-making must be based on bone age.

Accurate assessment of bone age is not easy (7,52–56). The younger the child, especially before puberty, the more difficult it is to determine future growth, making errors more likely. In addition, children are often bone age mosaics. Bone age determinations for the hands, elbows, pelvis, and knees will not always agree with one another (2,7).

Often, the bone age determination is made too quickly and with too little information. The standard deviations for determining bone age must be understood, as well as the nuances of what to look for in the interpretation of the radiograph. When using a particular method, e.g., the Greulich and Pyle atlas (16), it is important to read the entire book to understand what to look for and to know the standard error, and not simply to compare radiographs. If there is a major decision to be made, it is better to have two interpretations of the child's bone age, and to enlist the support of pediatric radiologists with experience in bone age determination (55,56).

Cundy and colleagues (56) demonstrated that four radiologists' interpretations of skeletal age differed by more than 2 years in 10% of patients. Carpenter and Lester (54) evaluated bone age in children younger than 10 years of

age. It was shown that separate readings of the distal radius and ulna, the carpal bones, the metacarpals, and the phalanges could magnify these errors, and that the age of the carpal bones and the distal radius and ulna often lagged behind the age of the metacarpals and phalanges. In Legg-Calvé-Perthes disease, discrepancy in maturation between carpal bone and metacarpal bone is frequent (48). This means that excessive haste in reading the bone age can result in fatal strategic errors.

There are several different methods to evaluate bone age. Knowledge of these methods and their limitations is important to the orthopaedist, especially in difficult cases (16,57–59). Like the goniometer, the Greulich and Pyle atlas (16) forms an essential part of the tool kit for the orthopaedic specialist. Our use of this atlas enabled us to compare it with its French counterpart, the Sempé and Pavia atlas (18). We learned that there is no major significant difference between these two atlases. The Tanner and Whitehouse method, although accurate, is very time-consuming and difficult, making it impractical for daily use (58). Therefore, the Greulich and Pyle atlas is sufficient for clinical decision-making in orthopaedic practice, when used by physicians knowledgeable in the method.

One of the weaknesses of the Greulich and Pyle atlas is that there are few changes in the hand during the critical time of puberty. For this reason, the author has found the Sauvegrain method (59) to be of enormous value during puberty (Fig. 2-9). This method evaluates the anteroposterior and lateral views of the elbow, assigning a value to the epiphyses, which is then plotted on a chart to give the bone age. It is reliable and based on the skeletal maturation of the elbow, which occurs during a 2-year period corresponding with the ascending limb of the growth velocity curve. Thus, it is extremely helpful in boys aged 13 to 15 years and in girls aged 11 to 13 years, a period in which many of the clinical decisions involving future growth are made. In addition, it shows good correlation with the Greulich and Pyle atlas but is much easier to use.

At the beginning of puberty, the growth centers of the elbow are wide open, but 2 years later, when the peak velocity of the pubertal growth spurt is reached and growth begins to slow, they are all completely closed. This complete closure occurs 6 months before Risser I. There is great value in analysis of olecranon ossification (7). At the start of puberty, at bone age 11 years for girls and 13 years for boys, two ossification centers appear (Fig. 2-10). Six months later (bone age 11.5 years for girls and 13.5 years for boys), they merge to form a half-moon shape. By bone age 12 years for girls and 14 years for boys, the olecranon apophysis has a rectangular appearance. Six months later (bone age 12.5 years for girls and 14.5 years for boys), the olecranon apophysis begins to fuse with the ulna, a process that takes another 6 months, being completed by the bone age of 13 years in girls and 15 years in boys. The radiographic appearance of

a	Condyle and Epicondyle	1	2	3	4	5	6	7	8	9
b	Trochlea	1	2	3	4	5				
c	Olecranon	1	2	3	4	5	6	7		
d	Radial Epiphysis	1	2	3	4	5	6			

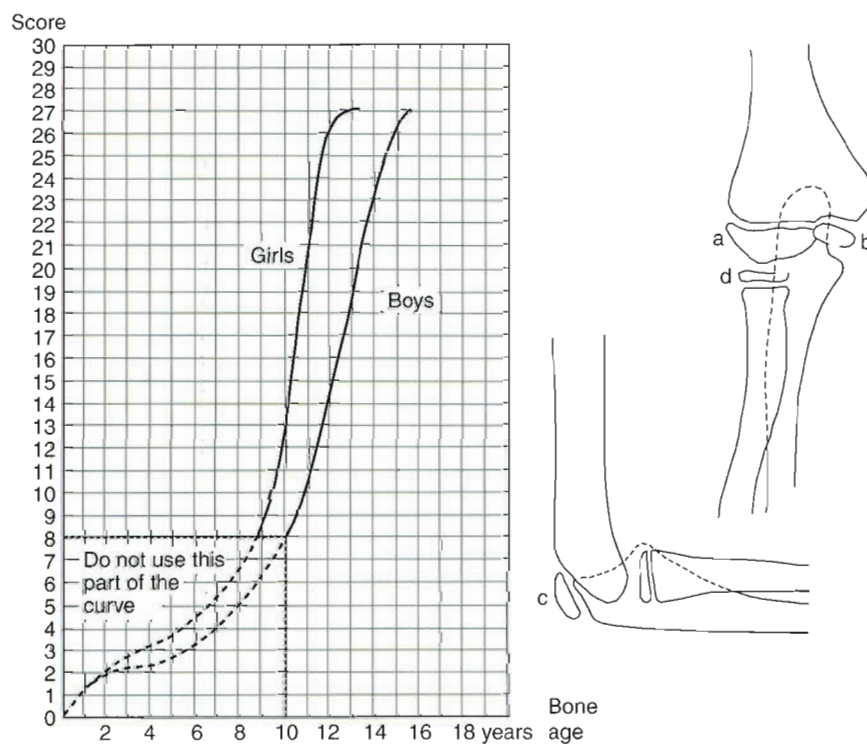


FIGURE 2-9. The Sauvegrain method of assessing skeletal age uses anteroposterior and lateral radiographs of the elbow. It is useful only in boys at ages 11 to 15 years and in girls at ages 9 to 13 years. The condyle and epicondyle, the trochlea, the olecranon, and the head of the radius are compared with the drawings, and each part is assigned the corresponding coefficient marked on the drawing, which represents the radiograph. Next, the overall summed value is plotted on the y axis of the chart. A horizontal line through this point intersects the line of the curve for either boys or girls, thus giving the corresponding bone age. (Adapted from ref. 59, with permission.)

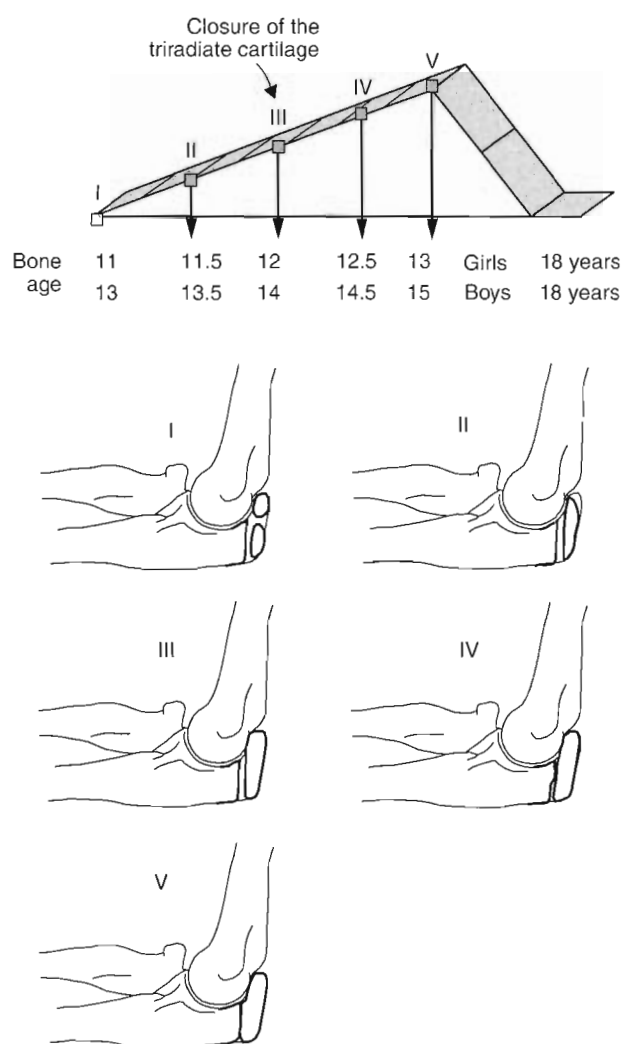


FIGURE 2-10. A simplification of the Sauvegrain method using only the stages of closure of the olecranon apophysis and its relationship to the pubertal growth curve and the Risser sign. *I*: 11 years in girls; 13 years in boys; double ossific nucleus. *II*: 11 years, 6 months in girls; 13 years, 6 months in boys; semi-moon shape. *III*: 12 years in girls; 14 years in boys; quadrangular shape. *IV*: 12 years, 6 months in girls; 14 years, 6 months in boys; beginning of fusion. *V*: 13 years in girls; 15 years in boys; complete fusion.

the hand and elbow at the peak of the pubertal growth curve is shown in Figure 2-11.

The Risser sign is one of the most commonly used markers of skeletal maturation, especially in the treatment of scoliosis (7,28,60–62). It appears on the radiograph of the pelvis, which is often seen in the assessment of this disorder, thus obviating the need for an additional radiograph. The duration of excursion of the Risser sign is also variable, and may range from 1 to 3 years (44,45). However, the value of this sign for accurate decision making has been questioned. Little and Sussman (63) concluded that, all things considered, it is better to rely on chronological age. Al-

though this author does not agree with their conclusions, when important decisions are made the Risser sign should be augmented with the bone age, as determined by the method of Greulich and Pyle (16). Figures 2-12 and 2-13 show these correlations.

There are several useful relationships between the events of puberty and the Risser sign. What is important to understand, first, is that the Risser sign is 0 for the first two-thirds of the pubertal growth spurt. This period of Risser 0 is important in the decision-making for many conditions; thus, it is necessary to have more precise markers of the stage of puberty (growth) during this period. Ideally, Risser 0 would be a sign of the period corresponding to the ascending limb of the growth-acceleration curve, but the child is Risser 0 for years before the onset of puberty. Therefore, Risser 0 gives little information other than to indicate that the peak of the growth velocity curve has not been reached. The author has recommended dividing this period of the ascending limb of the pubertal growth curve, characterized by Risser 0, into three periods, based on the triradiate cartilage and the closure of the olecranon apophysis: triradiate cartilage open, triradiate cartilage closed but olecranon open, and olecranon closed (7) (Fig. 2-12).

Risser I heralds the beginning of the descending slope of the pubertal growth peak. It generally appears after the olecranon apophysis is united to the ulna (Fig. 2-12), and when the epiphyses of the distal phalanges (II, III, IV, V) of the hand fuse (Fig. 2-13). The rate of growth in sitting height and standing height decreases abruptly. Axillary hair generally appears during this period (Figs. 2-7 and 2-8).

At Risser II, the greater trochanteric apophysis unites to the femur. This corresponds to a bone age of 14 years in girls and 16 years in boys (Fig. 2-12). There is approximately 3 cm left to grow in sitting height. The proximal phalangeal epiphyses fuse in the hand (Fig. 2-13). At Risser II, there is still a 30% risk of progression (5 degrees or more) for a 30-degree curve and a 2% risk for a 20-degree curve (64).

At Risser III, there is 1 year of growth remaining. This corresponds to bone ages of 14.5 years for girls and 16.5 years for boys. Sitting height will increase about 2 cm. The phalangeal epiphyses of P1-2 fuse during this period (Figs. 2-12 and 2-13). At this point, there is a 12% risk of a curve of 20 degrees or greater progressing 5 degrees or more (7).

Risser IV corresponds to a bone age of 15 years for girls and 17 years for boys. The distal epiphysis of the ulna is united to the shaft. The trunk still has to grow 1 cm, and the risk of the progression of scoliosis is markedly decreased, although, for boys, a slight risk remains (65).

Risser V is very much like Risser 0: it is a long period that does not provide much information to the clinician. The distal radial epiphysis generally unites around the time of Risser V. The iliac apophysis may fuse at age 22 or 23 years, but in some cases it never fuses. Thus, it would be futile, if not naive, to wait until the iliac crest is completely ossified, before discontinuing the treatment of scoliosis (53).

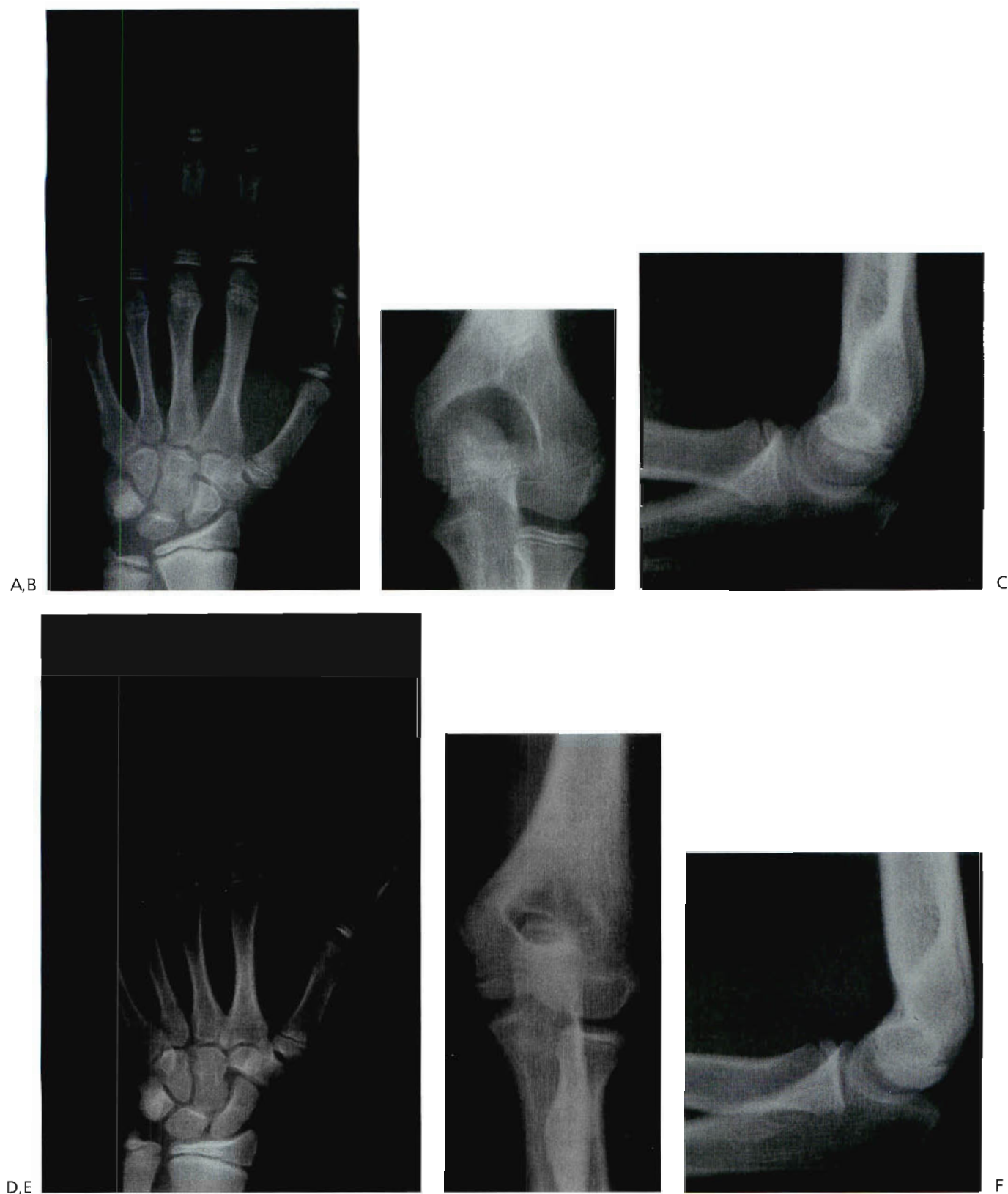

FIGURE 2-11. Radiographs of the elbow and hand in children, around the time of puberty, illustrate the appearance at various bone ages. These figures can be used to compare the method of Sauvegrain (Fig. 2-9), the simpler method of Diméglio, using only the olecranon apophysis (Fig. 2-10), and the Greulich and Pyle atlas (16). **A–C:** Girls 10 years, 9 months; boys 12 years, 9 months (3 months before puberty). **D–F:** Girls 11 years; boys 13 years (beginning of puberty).

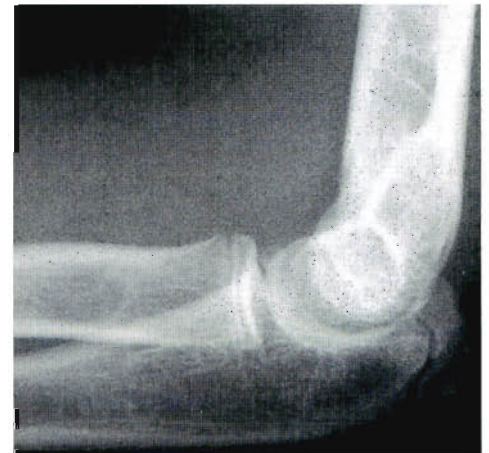
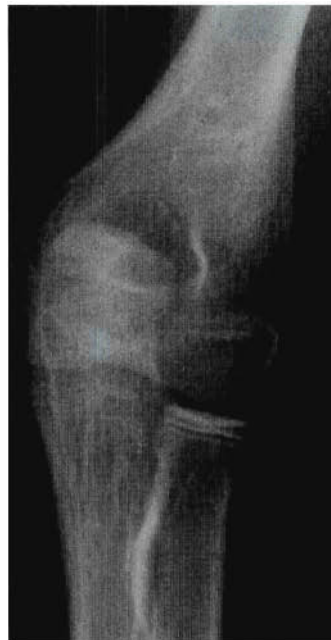
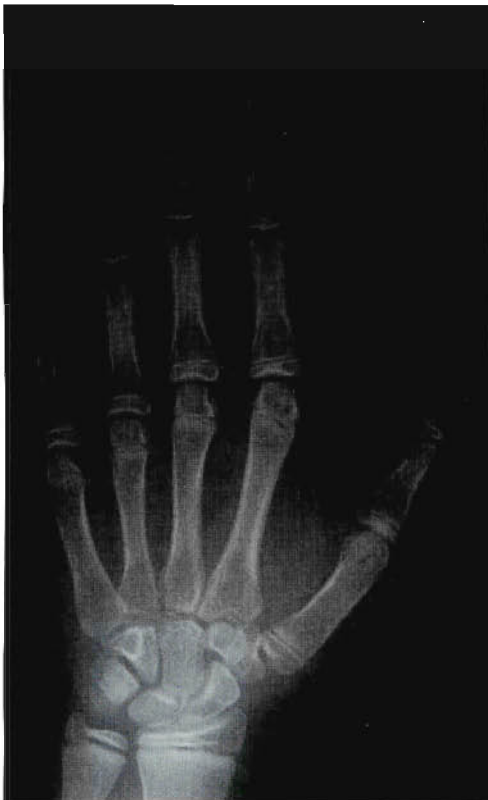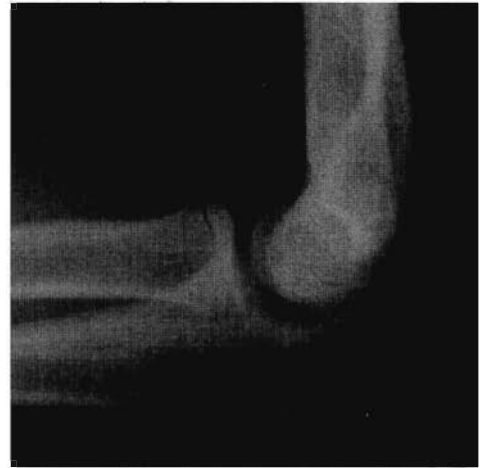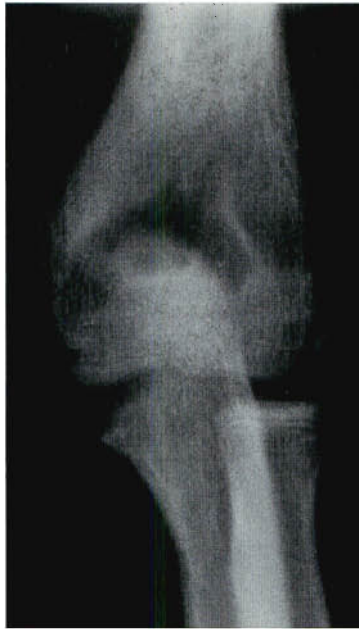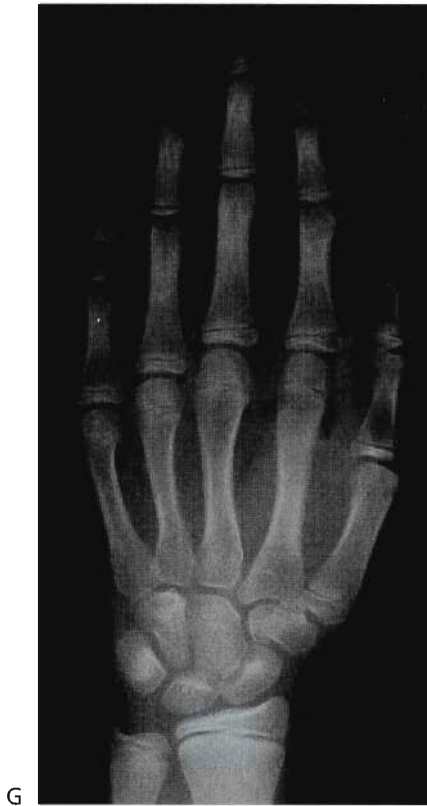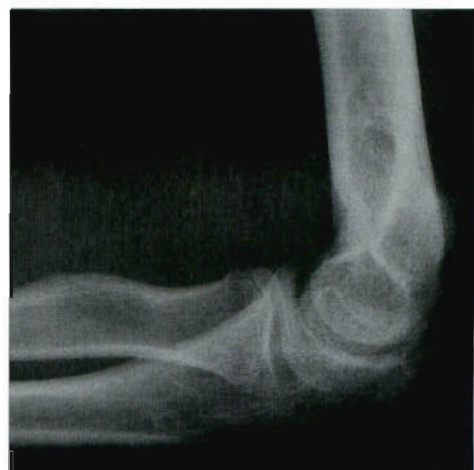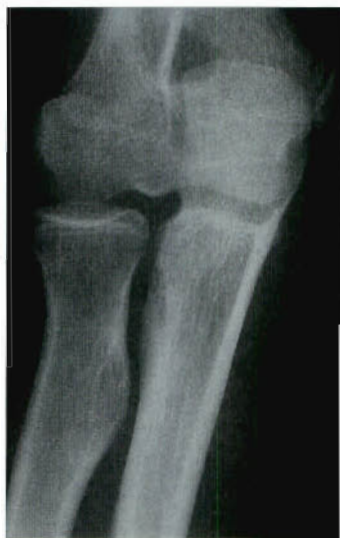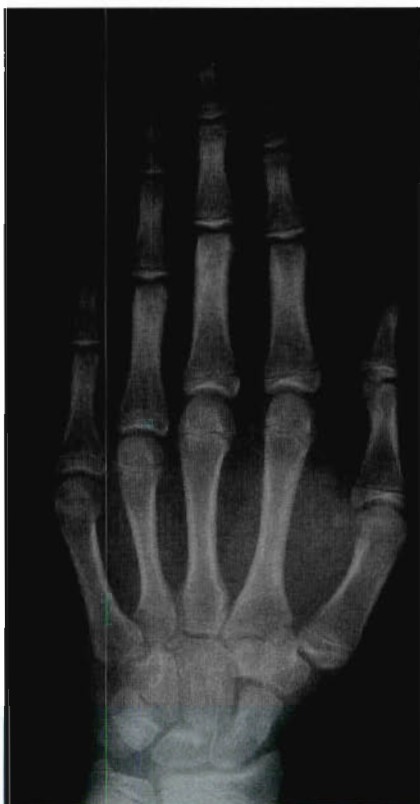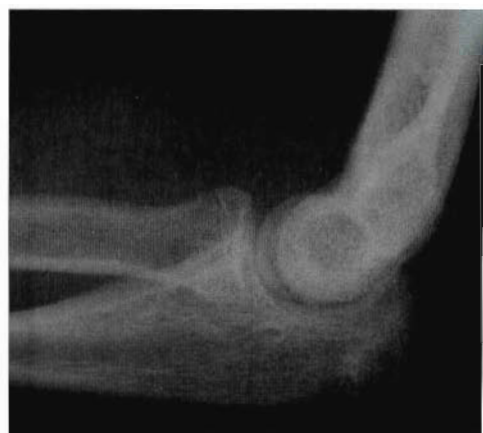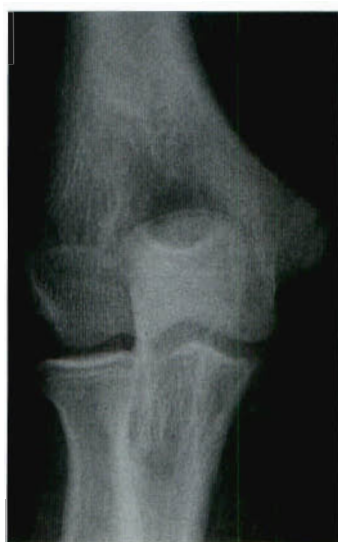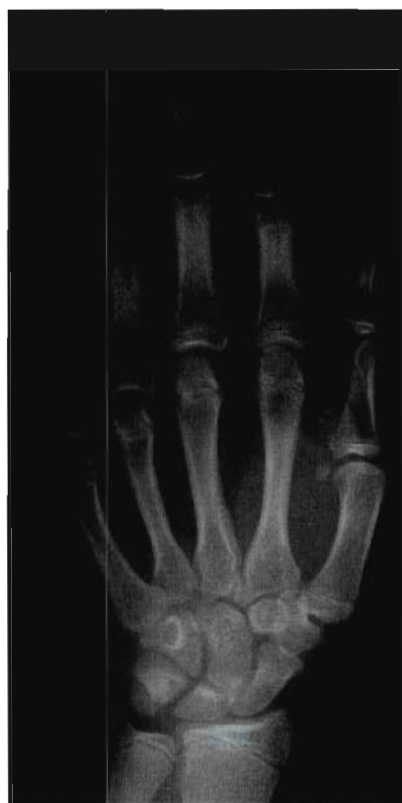FIGURE 2-11. (continued) G-I: Girls 11 years, 6 months; boys 13 years, 6 months. J-L: Girls 12 years; boys 14 years.

M,N



O

P,Q



R

FIGURE 2-11. (continued) M–O: Girls 12 years, 6 months; boys 14 years, 6 months. P–R: Girls 12 years, 9 months; boys 14 years, 9 months.

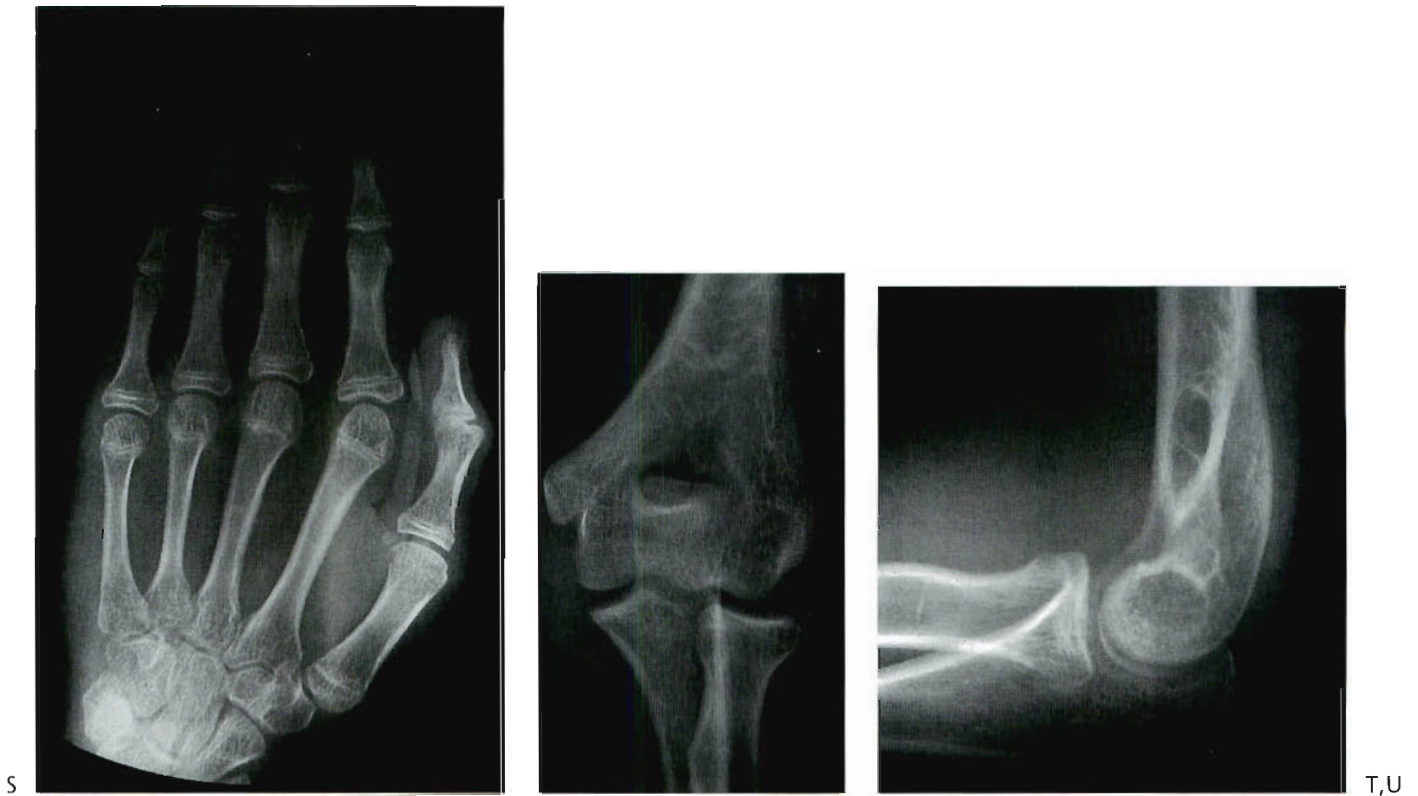

FIGURE 2-11. (continued) S–U: Girls 13 years, 6 months; boys 15 years, 6 months (elbow closure and fusion of the distal phalanx of the thumb).

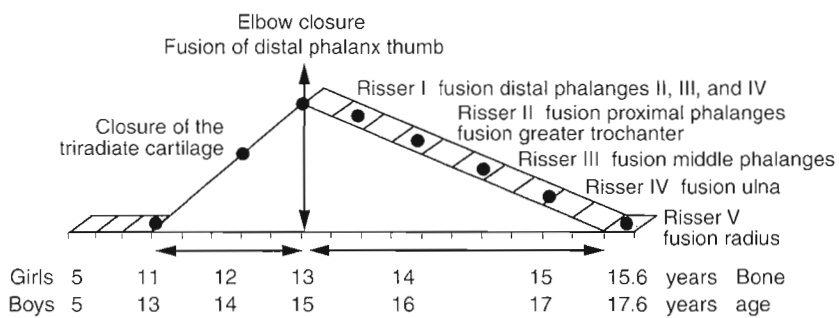


FIGURE 2-12. The relationship between the closure of the olecranon apophysis, the Risser sign, and the bone age, from the Greulich and Pyle atlas (16). The closure of the olecranon apophysis occurs before Risser I at the peak of the pubertal growth curve, and, at the same time, there is fusion of the distal phalanx of the thumb.

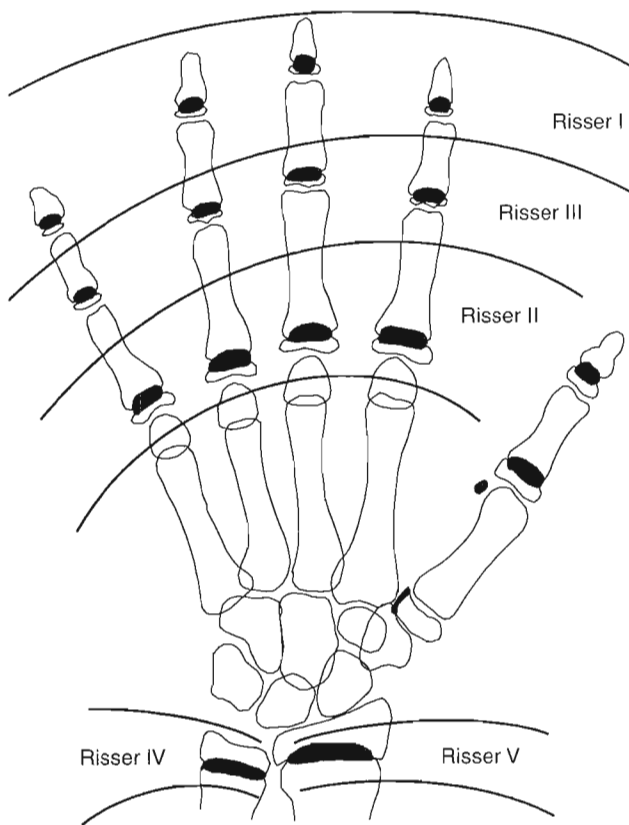


FIGURE 2-13. The correlation between the closure of the physes in the hand and the Risser sign that occurs in 80% of adolescents. The thumb is a special zone. The distal phalanx of the thumb fuses just as the olecranon apophysis closes, or at a Sauvegrain score of 27. This is bone age 13 years in girls and 15 years in boys. The Risser sign will still be 0. The sesamoid ossifies at the beginning of puberty.

GROWTH OF TRUNK AND THORAX

Growth in the Spinal Column

Measurement of sitting height provides an indirect reflection of spinal growth. The spine makes up 60% of the sitting height, whereas the head represents 20%, and the pelvis represents 20% (6,7,66). If we accept the fact that there are at least three growth zones per vertebra (sometimes four), the resulting morphology of the spinal column is the product of 100 growth plates. The pattern of growth in the posterior arch, where closure is linked in particular to the presence of the neural stem, differs from that seen in the body of the vertebrae, which behaves like a long bone (6,7,23).

If you held any of the vertebrae of a newborn in your hand, you would find very little morphological variation between them. The process by which cervical, thoracic, and lumbar vertebrae acquire their individual identities is gradual. In the vertebral body, ossification first appears in the

dorsal region, which forms a hub from which it radiates to the cranial and caudal parts of the spine. The process of ossification is extremely slow, and does not finish until the 25th year of life.

The lumbosacral vertebrae are relatively smaller at birth than the thoracic and cervical vertebrae. However, during the first years of growth, they grow more rapidly. Between 3 and 15 years of age, the lumbar vertebrae and their disks increase about 2 mm per year, whereas the thoracic vertebrae and their disks increase 1 mm. The disks account for approximately 30% of the height of the spinal segment at birth. At maturity, this figure will decrease to 25%, with the disks constituting 22% of the cervical spine, 18% of the thoracic spine, and 35% of the lumbar spine (6,7).

The anterior and posterior portions of the vertebrae do not grow at the same rate. In the thoracic region, the posterior components grow at a faster pace than their anterior counterparts. The reverse occurs in the lumbar region. Growth potential thus varies from one level to the next, differing from anterior to posterior. Also, as the vertebrae develop, there is a constant remodeling of the anatomic organization of the spine, e.g., the articular apophyses change in both morphology and direction (7,23,24).

The height of the spine will nearly triple from birth to adulthood. The average adult spine is approximately 70 cm long in men, with the cervical spine measuring 12 cm, the thoracic spine 28 cm, the lumbar spine 18 cm, and the sacrum 12 cm. The average female spine is approximately 65 cm long at maturity. At birth, the vertebral column is approximately 24 cm long. In the newborn, only 30% of the spine is ossified, and, as mentioned above, there is little significant difference in morphology from one vertebra to another. The height of a thoracic vertebra is about 7.6 mm, and a lumbar vertebra is about 8 mm in height (6,7).

Cervical Spine

At birth, the cervical spine measures 3.7 cm; it will grow about 9 cm, to reach the adult length of 12 to 13 cm. The length of the cervical spine will nearly double by 6 years of age, and will gain an additional 3.5 cm during the pubertal growth spurt. The cervical spine represents 22% of the C1-S1 segment and 15 to 16% of the sitting height (6,7).

The diameter of the cervical spinal canal varies with location, typically decreasing in width from C1 to C7 or from C1 to C3, then widening slightly. These differences are important in the clinical setting, because the room available for the spinal cord can be very consequential. It should be remembered that, regardless of the size of the child, e.g., in dwarfing conditions, the spinal cord will attain the usual adult diameter. The average width of the cervical cord is 13.2 mm, and the average anteroposterior depth is 7.7 mm (6,7). Therefore, the transverse and sagittal diameters of the cervical canal are important. In the adult, at C-3, the normal

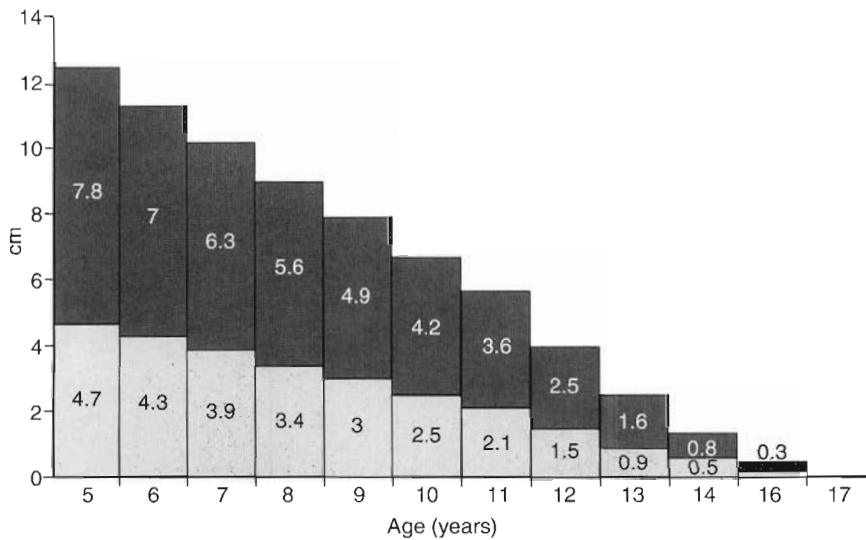


FIGURE 2-14. Growth remaining in the spine for both thoracic spine (*top bars*) and lumbar spine (*bottom bars*) segments in girls at various ages. (Adapted from ref. 7, with permission.)

transverse diameter is 27 mm and the average sagittal diameter is approximately 19 mm (6,7).

T1-S1 Segment

The T1-S1 segment is very important, because the most frequent disorders of the spine during growth will originate in this segment. The T1-S1 segment measures about 19 cm at birth and 45 cm at the end of growth in the average man and 42 to 43 cm in the average woman (6,7,66). This segment makes up 49% of the sitting height at maturity. Knowledge of the effects of arthrodesis on this segment of the spine require precise knowledge of the growth remaining at various ages (7) (Figs. 2-14 and 2-15).

Thoracic Spine (T1-12)

The thoracic spine is about 11 cm long at birth, and will reach a length of about 28 cm in boys and 26 cm in girls at the end of growth. Its length more than doubles from birth to the end of the growth period. The growth of the thoracic segment has a rapid phase from birth to 5 years of age (7 cm), a slower phase from 5 to 10 years of age (4 cm), and rapid growth through puberty (7 cm) (6,7).

The T1-12 segment represents 30% of the sitting height, so a single thoracic vertebra and its disc represents 2.5% of the sitting height. By knowing the amount of growth that each vertebra contributes to the final height, the effect of a circumferential arthrodesis, which stops all growth in the vertebrae and discs, can be calculated (Figs. 2-14 to 2-17).

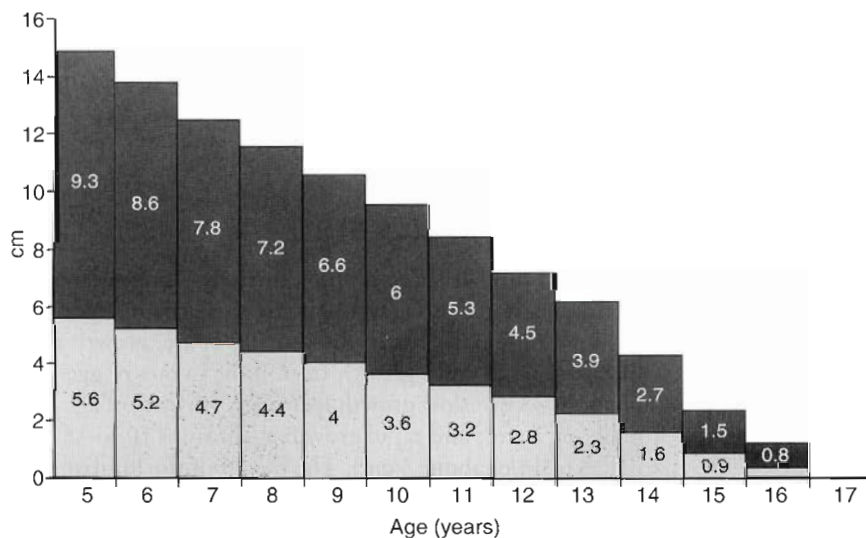


FIGURE 2-15. Growth remaining in the spine for both thoracic spine (*top bars*) and lumbar spine (*bottom bars*) segments in boys at various ages. (Adapted from ref. 7, with permission.)

If you perform a circumferential arthrodesis of six thoracic vertebrae in a 10-year-old boy, you will lose about 3 cm of sitting height:

the remaining growth in sitting height is about 20 cm

the remaining growth from T1 to S1 is about 10 cm

the remaining growth of T1-12 is 30% of the sitting height: $(20 \text{ cm} \times 30)/100 = 6 \text{ cm}$

for six thoracic vertebrae, $6 \times 2.5\% = 15\%$: $(20 \text{ cm} \times 15)/100 = 3 \text{ cm}$

On the other hand, posterior arthrodesis results in only one-third of this deficit (2.5% of sitting height for each thoracic vertebra), about 0.8% of final sitting height.

The thoracic spinal canal is narrower than either the lumbar or the cervical canal. The fifth finger may be intro-

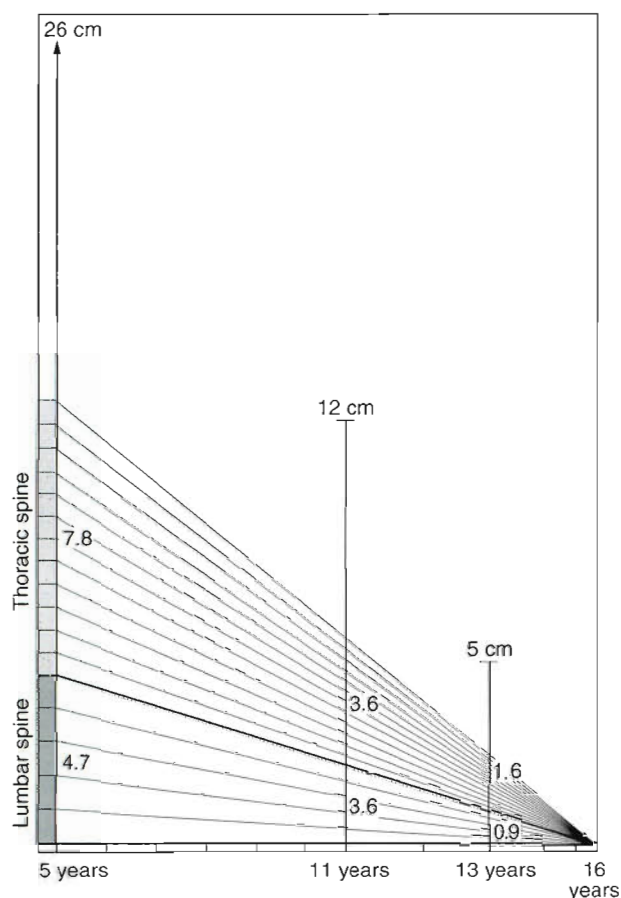


FIGURE 2-16. From this table, the effect of a circumferential fusion of the spine in girls can be calculated. The numbers at the top of the vertical lines represent the remaining sitting heights at various ages. The numbers on the horizontal lines represent the amount of growth remaining in each spinal segment during various periods of growth. To determine the effect of circumferential arthrodesis on five thoracic vertebrae at age 7 years, divide 7.8 cm by 12 thoracic vertebrae, and multiply the answer by 5. For a posterior arthrodesis, divide values by 3. (Adapted from ref. 7, with permission.)

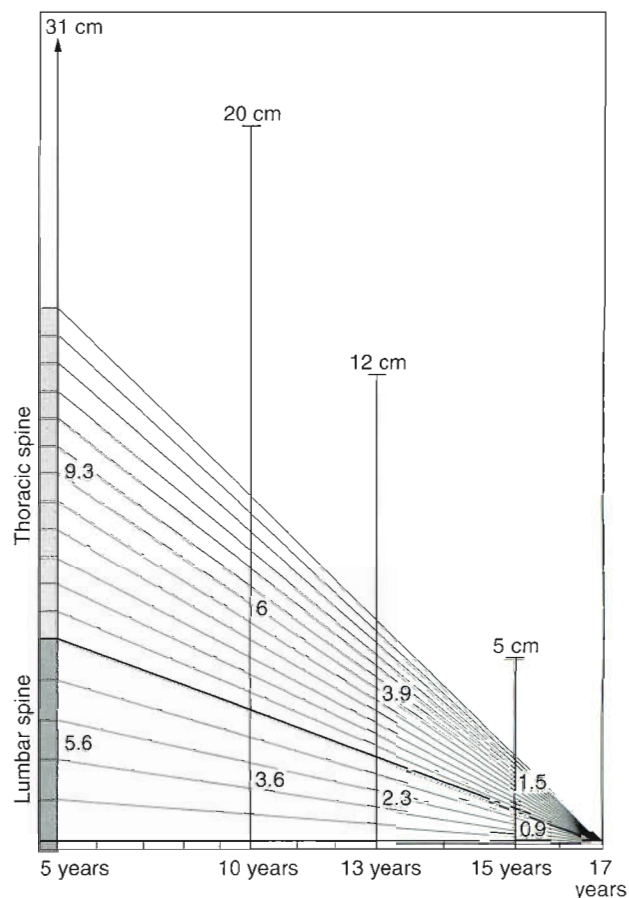


FIGURE 2-17. From this table, the effect of a circumferential fusion of the spine in boys can be calculated. The numbers at the top of the vertical lines represent the remaining sitting heights at various ages. The numbers on the horizontal lines represent the amount of growth remaining in each spinal segment during various periods of growth. To determine the effect of circumferential arthrodesis on five thoracic vertebrae at age 7 years, divide 9.3 cm by 12 thoracic vertebrae, and multiply the answer by 5. For a posterior arthrodesis, divide values by 3. (Adapted from ref. 7, with permission.)

duced into this canal at age 5 years, when it has attained its maximum volume. The average transverse and antero-posterior diameter at T7 is about 15 mm.

Lumbar Spine (L1-5)

The L1-5 lumbar spine is approximately 7 cm in length at birth, and it grows to approximately 16 cm in males and 15.5 cm in females. As in the thoracic spine, growth is not linear: there is rapid growth from 0 to 5 years of age (gain of about 3 cm); slow growth from 5 to 10 years of age (gain of about 2 cm); and rapid growth again from 10 to 18 years of age (gain of about 3 cm). The height of the lumbar spine doubles from birth to maturity (6,7).

The lumbar spine represents 18% of the sitting height,

and a single lumbar vertebra and its disc account for 3.5% of the sitting height. Values for the remaining growth of the lumbar segment at various ages are given in Figures 2-14 and 2-15. A circumferential arthrodesis, stopping all the growth of one lumbar vertebra at 10 years of age, results in a 3.5% deficit in the final sitting height. On the other hand, a posterior vertebral arthrodesis results in a deficit only one-third this great, a bit more than 1% of the final sitting height (6,7).

At the skeletal age of 10 years, the lumbar spine has reached 90% of its final height, but only 60% of its final volume. The medullar canal in the lumbar spine is wider than that in the thoracic spine. The forefinger can be introduced. At birth, the spinal cord ends at L3, and at maturity, it ends between L1 and L2.

Thoracic Perimeter

The growth of the thorax represents the fourth dimension of the spine (7). The thoracic circumference is a rough but valuable indicator of this fourth dimension of spinal growth. The thorax has a circumference of 32 cm at birth, and it will grow 56 cm in boys and 53 cm in girls, to almost three times its size at birth. The thoracic circumference is approximately 96% of the sitting height (7).

In boys, the thoracic circumference is 36% of its final size at birth, 63% at age 5 years, 73% at 10 years, 91% at 15 years, and 100% at 18 years. From birth to 5 years, the thoracic circumference grows exponentially and increases by 24 cm. From age 5 to 10 years, the increase is slower, and the thoracic perimeter is 66 cm at 10 years, which means that it grew only 10 cm in 5 years. It then is at 73% of its final value. Another acceleration occurs from age 10 to 18 years, particularly during puberty. The thoracic circumference then increases by 23 cm, i.e., as much as from birth to 5 years.

The thoracic circumference equals 96% of sitting height. These do not grow simultaneously, especially during puberty. At age 10 years, the thoracic circumference is at 74% of its final size, whereas sitting height is almost at 80% of its value at the end of growth. The transverse and anteroposterior diameters, which can be measured with obstetrical calipers, are two more parameters to assess the growth of the thorax. At the end of growth, the thorax has an anteroposterior diameter of about 21 cm and a transverse diameter of 28 cm in boys. In girls, the respective values are 17 cm and 24 cm. Thus, the transverse diameter has increased by 14 cm and the anteroposterior diameter has increased by 9 cm since birth. The addition of the values for the transverse and anteroposterior diameters of the thorax should equal 50% or more of the sitting height (7).

It is easy to note in all of these growth data the nonparallel but well-synchronized growth of the various parts of the body.

Scoliosis and Puberty

The sitting height plays an essential part in the treatment of scoliosis (7); unfortunately, it is not recorded often enough. Gain in sitting height always needs to be compared with angular development (7,9). This relationship is all that is needed for the proper assessment of treatment efficacy. If the increase in sitting height is accompanied by stable angulation, the treatment is definitely working well (7,9,67). If, on the other hand, it is accompanied by deterioration of angulation, the treatment needs to be reconsidered.

When we treat scoliosis, we must also think of growth. In congenital scoliosis, the intrauterine growth, and that occurring in the first few years of life, can reveal a great deal about the future behavior of the curve. In idiopathic infantile and juvenile scoliosis, the growth during the first 10 years of life can be very important, and may give clues to the behavior of the curve during the pubertal growth spurt (7,67). However, in adolescent idiopathic scoliosis, the most common form of scoliosis, there is no information before the curve begins in puberty. The ultimate outcome of the curve will be determined during the pubertal growth spurt. Thus, monitoring the behavior of a curve during this short and decisive period gives the only clues to the natural history of the curve. To detect these clues, it is necessary to know the onset of puberty (7).

The natural history of the curve can be judged during the first 7-cm increase of sitting height in girls and during the first 8-cm increase in boys, just after the start of the increased velocity of growth that marks the onset of puberty. Any curve increasing by 1 degree each month (12 degrees per year) during the ascending phase of the pubertal peak is likely to be a progressive curve that will require treatment. Any curve increasing by 0.5 degree each month during this phase must be monitored closely. Any curve gaining less than 0.5 degree each month during this phase can be considered mild (7). This observation of the natural history of the curve during the early part of puberty gives information about the behavior of the curve during the last phase of puberty, as growth is slowing, and thus can give guidance regarding the frequency of follow-up visits and the duration of bracing.

However imprecise and approximate the Risser sign may be, it is widely used as a deciding factor in many reports of brace treatment or surgery, and can be very useful if its limitations are understood. The data of Lonstein and Carlson (64), relating Risser sign and curve magnitude, have been discussed. As was pointed out above, because two-thirds of the pubertal growth spurt occurs before the appearance of Risser I, and because of its often ambiguous relationship to bone age, its value in both clinical decision-making and research should be questioned. Bone age, the growth rate, and secondary sexual characteristics are the most reliable parameters. Risser stages must not be regarded as a first-choice indicator; they must always be compared with bone

age, especially when making decisions that will have major consequences, such as ordering or removing a brace or scheduling vertebral fusion (7).

Evaluation of the vertebral ring apophyses has been recommended by Blount (68) and G. Duval-Beaupère (personal communication), as another way to judge the remaining growth of the spine and thus the risk of progression of the curve. Although there may be some value in this radiological sign, it is important to know that in some patients these apophyses may not close until after 20 years of age (53).

A frequent question asked by parents, and considered by physicians, is how much will a spinal fusion for scoliosis decrease the final height of the child. To determine the answer to this question, the surgeon needs to know the remaining growth in sitting height and the contribution to that height made by the vertebrae that will be fused (7,69). After a bone age of 13 years in girls, when there is only 4 cm of future growth in sitting height, and a bone age of 15 years in boys, when there is only 5 cm of remaining growth in sitting height, there is little need for concern about final height. Figures 2-14 and 2-15 show the growth remaining in the spine at various ages, and Figures 2-16 and 2-17 show the effects of arthrodesis at various ages.

However, arthrodesis for deformity is often required before these ages. Faced with deformity in a developing spine, the specialist may be best advised to carry out a vertebral arthrodesis to prevent progression of a severe deformity (70). It may be better to have a short spine that is straight than to have a longer but crooked spine with the same sitting height (69). In addition, the vertebrae in many cases of congenital scoliosis will not grow normally, and thus arthrodesis of these vertebrae does not alter the height as much as it would in a normal spine. Arthrodesis of five vertebral bodies, at the age of 3 years, will result in an approximately 12-cm deficit in sitting height. Other examples are discussed above.

The crankshaft effect on the spine, after arthrodesis for scoliosis, was described by Dubousset and colleagues in 1989 (71). The crankshaft phenomenon occurs when there is a solid posterior arthrodesis with sufficient anterior growth remaining to produce a rotation of the spine and trunk with progression of the curve. Thus, it is very important for the surgeon to consider the state of skeletal maturity and the amount of growth remaining in the portion of the spine that is to be fused (72,73).

Roberto et al. (74) reviewed 86 immature patients who underwent posterior arthrodesis at Risser 0 or I. They found that 72% of the patients progressed less than 10 degrees, 21% progressed 11 to 15 degrees, and seven patients progressed more than 16 degrees. Patients in Tanner stage I, with open triradiate cartilage, had the greatest increase in the curve, and the crankshaft phenomenon decreased with greater maturity. There was no correlation between the amount of curve progression and subjective patient satisfaction.

Sanders and colleagues (75) performed a retrospective study of posterior spinal instrumentation with fusion in 43 patients with idiopathic scoliosis, who were at Risser 0 at the time of surgery. The triradiate cartilage was open in 23 patients and closed in 20 patients. The crankshaft effect was observed in 10 of the 23 patients with open triradiate cartilage, and in 1 patient with a closed triradiate cartilage.

These studies emphasize the problem with using only one factor in determining the remaining growth of the spine, which is difficult at best. They also emphasize the fact that, for much of the decision-making required in the treatment of scoliosis, the Risser sign is not useful, because so much of the spinal growth occurs before Risser I. The last spurt of puberty predominantly involves the growth of the thorax, which may completely change the evolution of idiopathic scoliosis (7,72). The growth of the thorax, a largely ignored factor, can explain some surgical results. In addition, the greater the residual curve, the greater the chance of significant crankshaft development (7,72).

In paralytic scoliosis, in which the curve is severe or rapidly progressive, circumferential fusion with segmental instrumentation is the best strategy to avoid the crankshaft phenomenon. The greater the magnitude of the curve, the more complex and hazardous is the surgery, and the more unlikely it is to correct the curve to 0 degrees. In such cases, there is no reason to wait for the pubertal spurt (7). Puberty can only worsen the situation. The deficit in sitting height caused by such early fusion is largely compensated by the correction of the curve. A loss of sitting height by early arthrodesis at 10 years of age is not significant for the patient who will live, at least most of the time, in a wheelchair. At age 5 years, the spinal canal has grown to 95% of its definitive size; therefore, circumferential arthrodesis will have no influence on the size of the spinal canal (7).

In congenital scoliosis, the first 5 years of life are the golden period to perform hemiepiphysiodesis (38,76,77). A gain in angulation of 10 to 15 degrees for each vertebral segment can be obtained.

LOWER LIMB GROWTH

The lower limb grows more than the trunk. The femur and tibia combined grow about 55 cm in girls and 63 cm in boys from birth to the end of growth. The cycle of growth in the lower limb is very regular: a strong increase in growth during the first 5 years of life, a steady and slower growth from 5 years of age to the beginning of puberty, a slight growth spurt during the accelerated velocity of growth at the beginning of puberty, and early cessation after the velocity peak (78–81). The femur grows more than the tibia.

The relation between the femur and the tibia is constant throughout growth. The proportions are set as early as age 5 years. The difference in length between the two bones is 2 cm at birth and 10 cm at the end of growth. The length

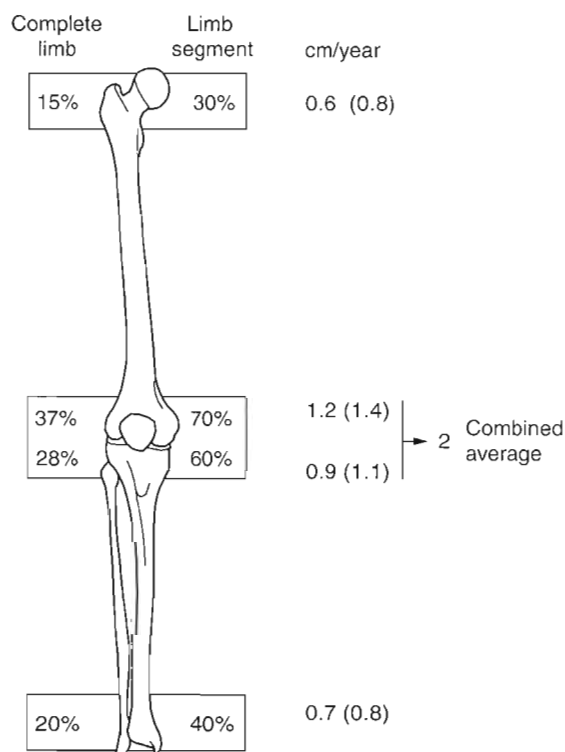


FIGURE 2-18. A diagrammatic illustration of the contributions of the various growth plates to the length of the lower limb and its individual bones as a percentage, and in centimeters, of growth per year. The numbers in parentheses represent the increased growth seen during the first year of puberty in the growth plates. All other numbers are averages for the remaining period of growth.

of the tibia is 80% that of the femur. This is a useful ratio to remember when balancing lower limb lengthening. The relation between the tibia and the fibula is also constant. The length of the fibula is 98% that of the tibia, i.e., there is no significant difference. The contributions of the various growth plates to the length of the lower limb and its individual bones are shown in Figure 2-18.

Femoral Growth

The femur is approximately 9 cm long at birth and will undergo a fivefold increase in length, to 45 cm by the time growth has finished. Growth is particularly vigorous during the first 5 years of life, with the femur doubling in length by 4 years of age, and reaching 60% of the final length by 5 years of age (79).

Between birth and 5 years of age, the femur grows 15 cm (± 1 cm). From 5 years of age until puberty, femoral growth slows to a steady rate of less than 2 cm per year, increasing to more than 2.5 cm during puberty. The proximal femoral physis of the femur accounts for 30% of the femoral growth, or approximately 10 cm. The distal and

proximal femoral growth plates grow roughly 1 cm and 0.7 cm, respectively, each year. At puberty, this rate of growth increases to approximately 1.2 cm for the distal femur and 0.8 cm for the proximal femur.

Tibial Growth

The tibia is 7 cm long at birth, and grows at a slower rate than the femur. By the time it has stopped growing, it will be 35 cm long, having also increased practically fivefold in length. By the age of 4 years, the tibia will have nearly doubled its length, and it will have attained 50% of its final length by age 5 years. The tibial and femoral growth profiles are almost identical, with vigorous growth during the first 5 years of life, which then slows to about 1.3 cm each year until puberty, when growth increases to 1.6 cm per year.

The proximal tibial physis accounts for about 60% of the length of the tibia, or about 15 cm. This occurs at a rate of roughly 0.9 cm per year. The distal tibial physis grows slower, and accounts for about 40% of growth potential, equivalent to 10 cm. The proximal physis grows about 0.7 cm each year from age 5 years until puberty, when it increases to 0.9 cm per year. The distal physis grows about 0.5 cm from age 5 years until puberty, when it increases to 0.7 cm per year (78–81).

The growth of the tibia and the fibula is interdependent, and perfect harmony is necessary. Excessive growth in the fibula, which happens in cases of achondroplasia, may lead to genu varum. Similarly, resection of the fibula during growth may result in ankle valgus. These clinical examples demonstrate how important it is to restore continuity, length, and growth to either bone if deformity is to be avoided.

Knee Growth

Consideration of the growth of the distal femur and the proximal tibia together illustrates the importance of injury to both of these growth centers. Any serious injury to the growth centers around the knee during the early years of life is likely to result in severe shortening of the lower limb. The knee undergoes the greatest growth of all. From birth to maturity, the knee grows about 40 cm in boys (25 cm for the femur and 15 cm for the tibia) and 35 cm in girls (22 cm for the femur and 13 cm for the tibia). The knee accounts for two-thirds of growth (65%) in the lower limb (37% for the femur and 28% for the tibia) (78–81).

Stated another way, the knee grows about 2 cm per year from age 5 years onward, with slightly more than 1 cm (1.2 cm) of growth in the femur and slightly less than 1 cm (0.8 cm) in the tibia. The ratio between the length of the femur and the length of tibia is 1.04, and this remains constant after 5 years of age. When the growth of the femur and the tibia are combined, total growth in the lower limb averages

around 3.5 cm per year, with the femur accounting for 54% of growth and the tibia accounting for 46%.

Foot Growth

When the sizes of the fetal foot and the lower limb are compared, the ratio is 1.41 at 8 weeks, 0.9 at birth, and 0.6 in adults. This means that the length of the foot is relatively great during intrauterine life and decreases throughout growth. At birth, the foot is about 7.5 cm long, i.e., 40% of its final size. At age 10 years, a girl's foot will grow about 3.5 cm and a boy's foot will grow about 5.5 cm. At that age, a girl's foot has attained about 91% of its final length and a boy's foot has attained about 85% of its final length (5,82).

The foot is the first organ of the musculoskeletal system that begins to grow at puberty (5). The growth spurt of the foot occurs a few months before the start of puberty, i.e., at the time of the increase in size of the testes and the appearance of the sesamoid bone in the thumb. Although it is the first to start growing during puberty, the foot is also the first musculoskeletal structure that stops growing. Growth of the foot stops at bone age 12 years in girls, i.e., 3 years before the end of growth, and at bone age 14 years in boys (82).

This makes the foot unique among the musculoskeletal structures in that its rate of growth mostly declines during puberty. When puberty begins, at approximately bone age 11 years in girls, the foot is already 22 cm long, and has only 1.6 cm or 2% of its growth left. When puberty starts in boys, around age 13 years, the foot is about 24 cm long, and has 2 cm or 2.5% of its growth remaining. Thus, arthrodesis at the beginning of puberty will have no significant impact on the length of the foot.

The foot represents 15% of the standing height in both girls and boys at skeletal maturity. This illustrates the importance of using clinical measures of limb-length discrepancy, along with the scanogram data, in decision-making. Conditions that affect the size of the foot can affect the total limb length, and this additional amount will not be reflected on the scanogram.

Growth and Limb-length Discrepancy

Although there are many methods for prediction, an understanding of the growth of the limbs gives the physician important information, both in predicting limb-length discrepancy and in more accurately applying the information from the various methods, e.g., the Moseley straight-line graft (80).

Contrary to widespread belief, there is more growth in the trunk or in sitting height during puberty than there is in the subischial length or growth of the limbs (2). The growth spurt in the lower limbs occurs during the first year of puberty, and, after bone age of 12.6 years in girls and

14.6 years in boys, the growth of the limbs decreases rapidly (43,83). The following examples give some idea of the timing of epiphysiodesis for different amounts of correction.

5 to 6 cm. Both tibia and femur at the beginning of puberty. Bone age 11 years in girls and 13 years in boys.

4 cm. Both tibia and femur 6 months after the onset of puberty. The elbow is useful for this determination.

3 cm. Only femur at the beginning of puberty or both tibia and femur at bone age 12 years in girls and 14 years in boys.

2 cm. Only femur at bone age 12 years in girls and 14 years in boys.

When performing an epiphysiodesis at the beginning of puberty or later, the risk of overcorrection is relatively small. The risk of undercorrection is greater, but, because the discrepancy is decreased if not totally corrected, the patient is often happy with the result. The growth of the limbs is complete at Risser I, or at bone age 13.6 years in girls and 15.6 years in boys (43,83). In the Greulich and Pyle atlas (16), this corresponds to fusion of the distal phalangeal physis of the index and middle fingers. The amounts of growth remaining at the various growth plates in the lower extremity are given in Figures 2-19 and 2-20.

With knowledge of the growth of the lower limbs (expressed as a percentage), it is easy to make a quick prediction of limb inequality at skeletal maturity (79). It can be assumed that the leg discrepancy at age 3 years will double for girls and at age 4 years for boys, if the inhibition of growth remains constant. Thus, a boy with a 4-cm discrepancy at age 4 years will have an 8-cm difference at the end of growth. At 9 years, the lower limb still has an average of 20% of its growth to attain in girls, and 27% of its growth to attain in boys. So a 4-cm discrepancy at that age will increase to 4.8 cm in girls and 5.08 cm in boys. At the onset of puberty, 10% average of the growth of the lower limb remains, so the final length discrepancy will be around 4.4 cm (2,79). A general rule for a quick prediction of limb-length discrepancy, for a problem such as congenital short femur, is to multiply the discrepancy at certain ages by a factor, e.g., multiply the discrepancy by 3 at age 1 year, by 2 at 4 years, by 1.8 at 5 years, by 1.4 at 9 years for boys and by 1.2 at 9 years for girls, and by 1.1 at the beginning of puberty for both boys and girls.

Such predictions are general, and should be used with caution. For the final decision in complex cases, it is best to use all of the information possible—standing height, sitting height, Hechard-Carlioz chart (84), Moseley chart (80), and Lefort residual coefficient (85)—while considering the bone age to lessen the margin of error. The younger the patient, the higher the risk of inaccurate prediction (86).

Thanks to the Green and Anderson tables (78) and to the Moseley, Hechard-Carlioz, and Lefort charts, limb-length discrepancy can be predicted. These forecasts do not need to be interpreted with mathematical strictness, because there

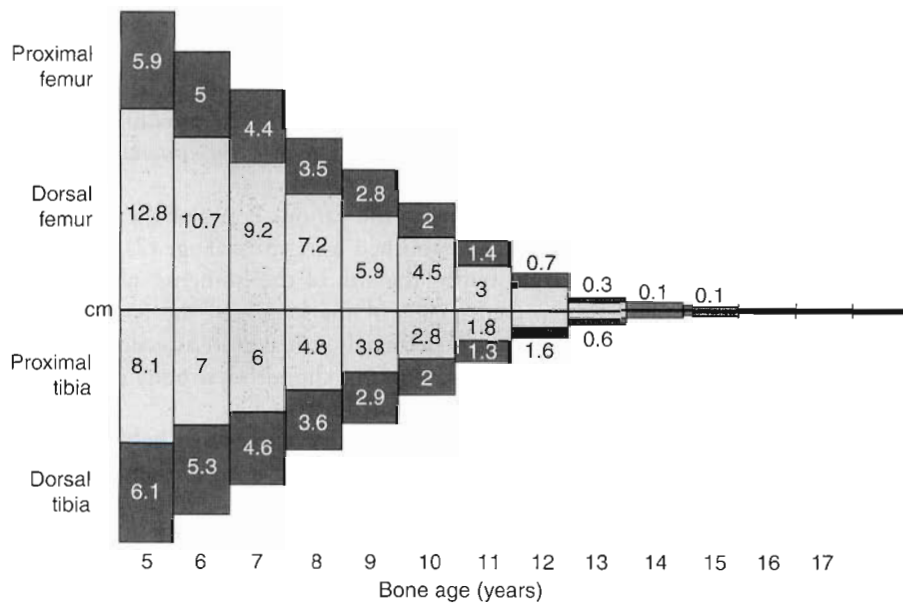


FIGURE 2-19. The remaining growth in the lower limbs of girls at the four growth plates, between the ages of 5 and 17 years. (Adapted from ref. 79, with permission.)

is a reasonable margin for error (2,86). Furthermore, these forecasts are best suited to cases of malformation and injury in which the difference in the rate of growth between the two limbs remains constant. Other causes of limb-length discrepancy, such as poliomyelitis, vascular malformation, and chronic arthritis, may not follow a constant curve and are more difficult to evaluate (87).

A decision for lengthening versus epiphysiodesis often depends on the final height of the child. Predicting the final height before puberty is inexact (20). Approximately 80% of children will remain in the same percentile for height after age 5 years. Tables to make these predictions from bone age are found in the Greulich and Pyle atlas (16). The timing of epiphysiodesis remains a controversial subject.

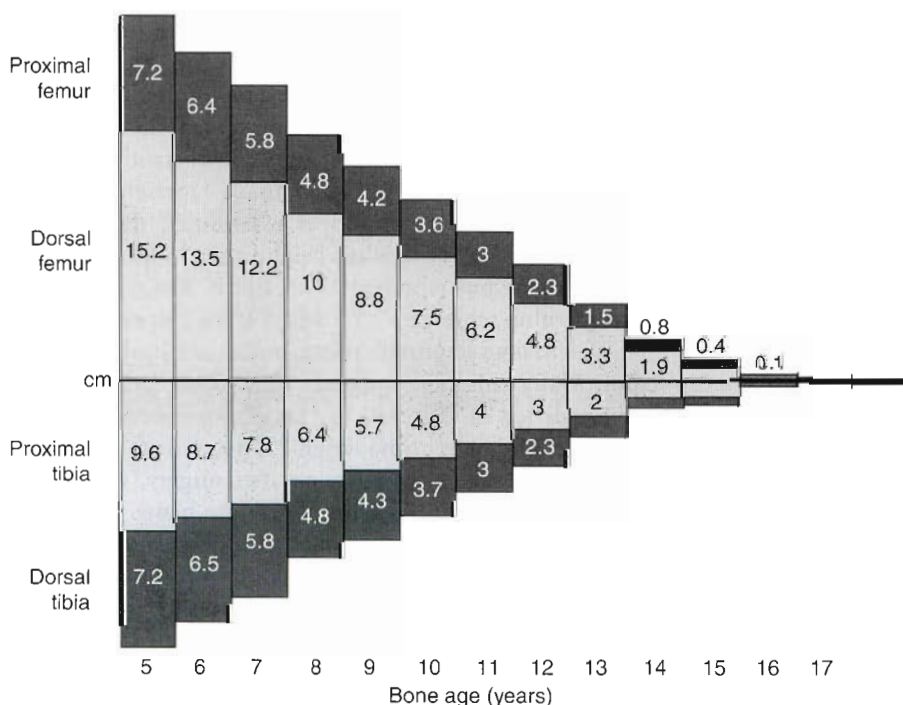


FIGURE 2-20. The remaining growth in the lower limbs of boys at the four growth plates, between the ages of 5 and 17 years. (Adapted from ref. 79, with permission.)

The main problem with this procedure is to reduce the margin of error (79,88,89).

UPPER LIMB GROWTH

Upper limb growth follows the same pattern as lower limb growth (2). The first 5 years of life are characterized by an acceleration of growth velocity, between 5 years and the beginning of puberty there is a plateau, and at the very beginning of puberty there is a slight spurt in growth (2,90–92). At birth, the length of the upper limb is 20 cm: the humerus makes up 7.5 cm, the ulna 6.5 cm, and the hand 6 cm. The upper limb grows 10 cm during the first year, 6 cm during the second year, approximately 5 cm during the third year, and 3.5 cm in the fourth year. After the age of 5 years, the rate of growth decreases. The contributions of the various growth plates to the length of the upper limb and its individual bones are shown in Figure 2-21 (2,3,93).

The upper limb grows about 3 cm annually from age 5 years to puberty, when it grows about 3.5 cm each year until the end of growth. This growth is made up of approximately 1.3 cm in the humerus, 1.1 cm in the ulna, 1 cm in the radius, and 0.7 cm in the hand. The length of the upper limb bones nearly doubles by 3 years of age. By 5 years of age, the bones of the upper extremity have reached half their final length (2,92).

The maturity gradient in the upper limbs is similar to

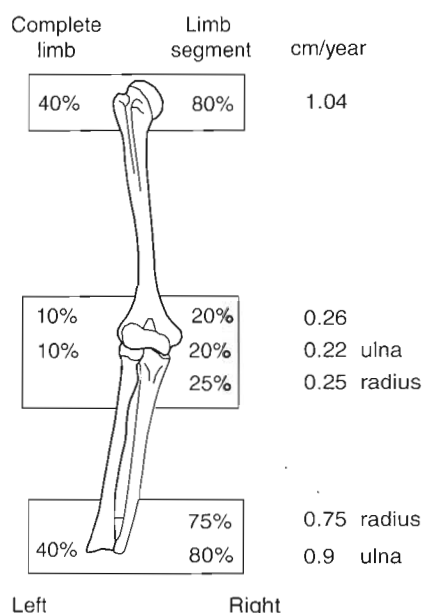


FIGURE 2-21. A diagrammatic illustration of the contributions of the various growth plates to the length of the upper limb and its individual bones as a percentage and in centimeters of growth per year.

that in the lower limbs. The hand shows its relatively slight acceleration of growth about 6 months before the forearm, and the forearm reaches its peak growth velocity about 6 months before the upper arm (94). The proximal humerus reaches its maximal growth rate at approximately the same time as the trunk.

Proportions among the various bones of the upper and lower limbs are established by 5 years of age (2). Thus, the ulna is eight-tenths the size of the humerus, and the humerus represents 70% of the length of the femur. Study of these indices is extremely valuable in assessing retarded growth during the course of chondrodystrophy (rhizomelic and mesomelic dwarfism) (2,95).

There are growth charts and curves that help to predict inequality (2,3,92). Surgical lengthening of the upper limbs may be rare, but it is feasible.

Growth in the Paralytic Child

The growth pattern is abnormal in many children with paralytic disorders, e.g., cerebral palsy, spina bifida, and poliomyelitis. In these children, therefore, it is essential to record and follow the parameters of growth closely to establish a surgical indication with as much accuracy and safety as possible (25–27,96,97). There are two problems that make it difficult to measure and evaluate the parameters of growth in such children. First, contractures and deformities make morphometric measurements difficult to impossible. Second, reference values that pertain to normal children are not applicable to these children.

Nevertheless, it is still possible to gain valuable information about growth if the child is scrutinized carefully from head to foot. The length of only one bone more or less spared by the deficit could be sufficient to determine the standing height of the child. For example, after age 8 years, the proportions of the body segments remain the same; thus, the length of the femur represents 28% of standing height, and the length of the tibia and fibula represents 24% of standing height. For the upper extremities, the humerus represents 19% of standing height and 36.5% of sitting height, the radius represents 14.5 and 27.8%, respectively, and the ulna represents 15.5 and 29.5%, respectively (2).

Weight is an important parameter to take into consideration. Many children, especially those with cerebral palsy, have a deficit of 20 to 30 kg. Surgical procedures are not the same for children who weigh 20, 40, and 60 kg. Underweight creates a risk of infection after surgery, when it reflects malnutrition (98–100). There are many parameters that are used to assess nutritional status, e.g., measuring the triceps and the subscapular skinfold, or measuring the total lymphocyte count. Whichever tests the surgeon relies on should be used before surgery on underweight children, especially those with chronic conditions.

On the other hand, obesity can also be a problem in

surgery. The obesity of children with muscular dystrophy or spina bifida may restrict the choice of surgical approaches and instrumentation. The gain in weight during puberty is the major enemy of the diplegic or ambulatory quadriplegic child (2,101).

The assessment of bone age is more difficult with paralyzed children. Bone age retardation can be very severe in cerebral palsy. These patients sometimes display a wide range of bone ages, with the bone age of the hand not matching that of the elbow or the pelvis (personal experience). The real bone age, therefore, must be approximated. This information must be correlated with the results of anthropometric measurements (25–27). These measurements are based on radiographs that measure the bone length, but they can also be obtained during a clinical examination. For the tibia, a simple measurement is possible from the medial joint line of the knee to the inferior rim of the medial malleolus (102).

LESSONS LEARNED FROM GROWTH

Charts and diagrams are only models or templates (2). They do not by themselves define a true age. They define trends and outline the evolution of growth. They should be taken as just what they are: a convenient means to map the route through puberty. They record ephemeral points in the processes of growth and anticipate the events that lie in the future. Their use helps the surgeon to avoid uncertain or unnecessary treatments, and aids in successful strategies. Nothing can produce worse results than decisions leading into uncharted territory (2,9).

Percentages provide an extremely valuable and objective tool for evaluating residual growth, particularly with respect to the proportions between the lengths of various segments of the limbs and the limbs and the trunk (2,7). However diverse their ethnic origins, and even though stature has been increasing in succeeding generations over the centuries, boys of all generations and ethnic backgrounds will always have approximately 14% of outstanding growth in sitting height and 10% of length of the femur or tibia remaining at the beginning of puberty. Neither the percentage nor the proportions change, and even the ratios are stable. The humerus makes up, and will always make up, about 20% of sitting height and 38% of standing height (2,4,95,103,104).

A figure in isolation is meaningless; a ratio is more reliable. For instance, the length of the femur in relation to standing height, or the length of the thoracic segment in relation to sitting height, provides more objective values. To gain this information, the examiner should try to obtain a general overview of the child's growth, and to plot the child's anthropometric chart.

The ratios of the various body segments are important in many conditions, especially the various types of dwarfism. The ratio of sitting height to subischial leg length is essential

when analyzing chondrodystrophy. Special curves can be used to follow these patients (105,106). Dwarfism can be divided into two families: short-trunk dwarfism, the prime example of which is represented by Morquio syndrome, and normal-trunk dwarfism, in which mainly the limbs are shorter than normal. The prime example here is achondroplasia (2). In this disease, the weight is an important parameter to consider, and obesity is a frequent cause of complications (107).

The various processes that make up growth are well synchronized, organized, and interdependent, but they vary widely in the time during growth when they occur. For instance, the growth of the trunk accounts for the majority of increase in standing height during the last part of puberty. Also, weight gain lags behind growth in length until puberty, when the percentage gain in weight far exceeds the percentage gain in height. All changes are gradual. Growth itself is a succession of phases, periods of deceleration or acceleration, spurts, and alternating processes. However intellectually comfortable it may be to believe that the limbs grow linearly, checking growth curves every 6 months reveals that there are breaks and phases during which growth alternates between the proximal and distal parts of a limb.

Treatment of children often requires a consideration of remaining growth. Puberty is the time when most of these decisions will be made. Treatment is easiest when it is done in anticipation of future growth. Puberty is a short period of about 2 years with rapid changes in growth. The milestones that mark the path during this short period must be noted and understood by the orthopaedic surgeon. Measurements at one period of time, e.g., the Risser sign or the length of the femur, are of limited value. Thus, in children in whom growth disturbance is anticipated, it is best to record several parameters over time to have an accurate picture of growth.

References

Basic Concepts

1. Buckwalter JA, Ehrlich MG, Sandell LJ, et al. *Skeletal growth and development: clinical issues and basic science advances*. Rosemont, IL: American Academy of Orthopaedic Surgeons, 1997.
2. Diméglio A. *La croissance en orthopédie*. Montpellier, France: Sauramps Médical, 1987.
3. Exner GU. *Normalwerte in der kinderorthopädie: wachstum und entwicklung*. Stuttgart, Germany: Georg Thieme Verlag, 1990.
4. Godin P. *Recherches anthropologiques sur la croissance des diverses parties du corps de 13 à 18 ans*. Maloine A, ed. Paris: 1903.
5. Marshall WA. *Human growth and its disorders*. London: Academic, 1977.
6. Diméglio A, Bonnel F. Growth of the spine. In: Raimondi AJ, Choux M, Di Rocco C, eds. *Principles of pediatric neuro-surgery: the pediatric spine, development and the dysraphic state*. New York: Springer-Verlag, 1989;9:39.
7. Diméglio A, Bonnel F. *Le rachis en croissance*. Paris: Springer-Verlag, 1990.

8. Lowrey GH. *Growth and development of children*, 6th ed. Chicago: Mosby-Year Book, 1973.
9. Duthie R. The significance of growth in orthopaedic surgery. *Clin Orthop* 1959;14:7.
10. Sinclair D. *Human growth after birth*, 2nd ed. London: Oxford University Press, 1969.
11. Hensinger RN. *Standards in pediatric orthopedics: charts, tables and graphs illustrating growth*. New York: Raven, 1986.
12. Tanner JM, Davies PSW. Clinical longitudinal standards for height and height velocity for North American children. *J Pediatr* 1985;107:317.
13. Tanner JM, Whitehouse RH, Takaishi M. Standards from birth to maturity for height, weight, height velocity and weight velocity: British children 1965, parts I and II. *Arch Dis Child* 1966; 41:454.
14. Tanner JM, Whitehouse RH. Clinical longitudinal standards for height, weight, height velocity and weight velocity and the stages of puberty. *Arch Dis Child* 1976;51:170.
15. Tanner JM. Physical growth and development. In: Forfar JO, Arneil GC, eds. *Textbook of paediatrics*, 2nd ed. New York: Churchill Livingstone, 1978;7:249.
16. Greulich WW, Pyle SI. *Radiographic atlas of skeletal development of the hand and wrist*, 2nd ed. Stanford, CA: Stanford University Press, 1959:50.
17. Prader A, Largo RH, Molinari L, et al. Physical growth of Swiss children from birth to 20 years of age: first longitudinal study of growth and development. *Helv Paediatr Acta* 1989;52 [Suppl].
18. Sempé M, Pavia C. *Atlas de la maturation squelettique*. Paris: SIMEP, 1979.
19. Hamill PVV, Drizd TA, Johnson CL, et al. National Center for Health Statistics percentiles. *Am J Clin Nutr* 1979;32: 607.

Biometric Measurements

20. Bailey DK, Pinneau S. Tables for predicting adult height from skeletal age. *J Pediatr* 1952;40:421.
21. Cheng JCY, Leung SSF, Chiu BSK, et al. Can we predict body height from segmental bone length measurements? A study of 3,647 children. *J Pediatr Orthop* 1998;18:387.
22. Goldberg MJ. *The dysmorphic child: an orthopedic perspective*. New York: Raven, 1983.
23. Lonstein JE. Embryology and spine growth. In: Lonstein JL, Bradford DS, Winter RB, et al., eds. *Moes' textbook of scoliosis and other spinal deformities*, 3rd ed. Philadelphia: WB Saunders, 1995:23.
24. Moseley CF. Growth. In: Lovell WW, Winter RB, eds. *Pediatric orthopaedics*, 2nd ed. Philadelphia: Lippincott-Raven, 1986:25.
25. Miller F, Koreska J. Height measurement of patients with neuromuscular disease and contractures. *Dev Med Child Neurol* 1992;34:55.
26. Stevenson RD. Measurement of growth in children with developmental disabilities. *Dev Med Child Neurol* 1996;38: 855.
27. Stevenson RD. Use of segmental measures to estimate stature in children with cerebral palsy. *Arch Pediatr Adolesc Med* 1995; 149:658.
28. Duval-Beaupère G. Les repères de maturation dans la surveillance des scolioses. *Rev Chir Orthop* 1970;56:59.
29. Duval-Beaupère G. Croissance résiduelle de la taille et des segments après la première menstruation chez la fille. *Rev Chir Orthop* 1976;62:501.
30. Jarzem PF, Gledhill RB. Predicting height from arm measurement. *J Pediatr Orthop* 1993;13:761.
31. Buckler J. *A longitudinal study of adolescent growth*. New York: Springer-Verlag, 1990.

Chronology

32. O'Rahilly R, Meyer DB. The timing and sequence of events in the development of the human vertebral column during the embryonic period proper. *Anat Embryol* 1979;157:167.
33. Ounsted M, Ounsted C. On fetal growth rate: its variations and their consequences. *Clin Dev Med* 1973;46:1.
34. Uhthoff HK. *The embryology of the human locomotor system*. New York: Springer-Verlag, 1990.
35. Gruenwald P. Growth of the human foetus. *Am J Obstet Gynecol* 1966;94:1112.
36. Jeanty P, Kirkpatrick C, Dramaix-Wilmet M, et al. Ultrasonic evaluation of fetal limb growth. *Radiology* 1981;140:165.
37. Mahony BS. Ultrasound evaluation of the fetal musculoskeletal system. In: Callen PW, ed. *The ultrasonography in obstetrics and gynecology*. Philadelphia: WB Saunders, 1994:254.
38. Diméglio A. Growth of the spine before age 5 years. *J Pediatr Orthop Br* 1993;1:102.
39. Marshall WA, Tanner JM. Variation in the pattern of pubertal changes in girls. *Arch Dis Child* 1969;44:291.
40. Marshall WA, Tanner JM. Variations in the pattern of pubertal changes in boys. *Arch Dis Child* 1970;45:13.
41. Staheli LT. *Fundamentals of pediatric orthopedics*. New York: Raven, 1992:1.1.
42. Terver S, Kleinman R, Bleck EE. Growth landmarks and the evolution of scoliosis: a review of pertinent studies on their usefulness. *Dev Med Child Neurol* 1980;22:675.
43. Duval-Beaupère G, Combes J. Segments supérieur et inférieur au cours de la croissance physiologique des filles: étude longitudinale de la croissance de 54 filles. *Arch Fr Pediatr* 1971;28: 1057.
44. Caffey J. *Pediatric x-ray diagnosis*, 7th ed. Chicago: Mosby-Year Book, 1978.
45. Ozonoff MB. *Pediatric orthopedic radiology*, 2nd ed. Philadelphia: WB Saunders, 1992.
46. Buric M, Moncilovic MD. Growth pattern and skeletal age in school girls with idiopathic scoliosis. *Clin Orthop* 1982;10: 238.

Radiological Study

47. Harrison MHM, Turner MH, Jacobs P. Skeletal immaturity in Perthes disease. *J Pediatr Orthop Br* 1976;58:37.
48. Krismundsdottir F, Burwell RG, Hall DJ. A longitudinal study of carpal bone development in Perthes' disease: its significance for both radiologic standstill and bilateral disease. *Clin Orthop* 1986;209:115.
49. Loder RT, Farley FA, Herzenberg JE, et al. Narrow window of bone age in children with slipped capital femoral epiphyses. *J Pediatr Orthop* 1993;13:290.
50. Exner GU. Growth and pubertal development in slipped capital femoral epiphysis: a longitudinal study. *J Pediatr Orthop* 1986; 6:403.
51. Exner GU. Slipped capital femoral epiphysis and puberty. *Mapfre Medicina* 1999;10[Suppl 1]:22.
52. Anderson M. Use of the Greulich-Pyle "Atlas of Skeletal Development of the Hand and Wrist" in clinical context. *Am J Phys Anthropol* 1971;35:347.
53. Bunch W, Dvorch V. Pitfalls in the assessment of skeletal immaturity: an anthropologic case study. *J Pediatr Orthop* 1983; 3:220.
54. Carpenter CT, Lester EL. Skeletal age determination in young

children: analysis of three regions of the hand/wrist film. *J Pediatr Orthop* 1993;13:76.

55. Graham CB. Assessment of bone evaluation: methods and pitfalls. *Radiol Clin North Am* 1972;10:185.
56. Cundy P, Paterson D, Morris L, et al. Skeletal age estimation in leg length discrepancy. *J Pediatr Orthop* 1988;8:513.
57. Acheson RM. The Oxford method of assessing skeletal maturity. *Clin Orthop* 1957;10:19.
58. Frisch H, Riedl S, Waldhört T. Computer-aided estimation of skeletal age and comparison with bone age evaluations by the method of Greulich-Pyle and Tanner-Whitehouse. *Pediatr Radiol* 1996;26:226.
59. Sauvegrain J, Nahm H, Bronstein N. Etude de la maturation osseuse du coude. *Ann Radiol* 1962;5:542.
60. Biondi J, Weiner DS, Bethem D, et al. Correlation of Risser's sign and bone age determination in adolescent idiopathic scoliosis. *J Pediatr Orthop* 1985;5:697.
61. Dhar S, Dangerfield PH, Dorgan JC, et al. Correlation between age and Risser's sign in adolescent idiopathic scoliosis. *Spine* 1993;18:14.
62. Risser JC. The iliac apophysis: an invaluable sign in the management of scoliosis. *Clin Orthop* 1958;11:111.
63. Little DG, Sussman MD. The Risser sign: a critical analysis. *J Pediatr Orthop* 1994;14:569.
64. Lonstein JE, Carlson JM. The prediction of curve progression in untreated idiopathic scoliosis during growth. *J Bone Joint Surg Am* 1984;106:1.
65. Karol LA, Johnston CE, Browne RH, et al. Progression of the curve in boys who have idiopathic scoliosis. *J Bone Joint Surg Am* 1993;75:1804.

Growth of Trunk and Thorax

66. Nehme AEE, Riseborough EJ, Reed RB. Normal spine growth. In: Zorab PA, Siegler S, eds. *Scoliosis*. London: Academic, 1980: 103.
67. Duval-Beaupère G, Dubouset J, Queneau P. Pour une théorie unique de l'évolution des scolioses. *Presse Med* 1970;78: 1141.
68. Blount WP. Use of the Milwaukee brace. *Orthop Clin North Am* 1972;3:1.
69. Winter RW. Scoliosis and spinal growth. *Orthop Rev* 1977;6: 17.
70. Risser J, Agostini S, Sampaio J, et al. The sitting-standing height ratio as a method of evaluating early spine fusion in the growing child. *Clin Orthop* 1973;24:7.
71. Dubouset J, Herring JA, Shufflebarger HL. The crankshaft phenomenon. *J Pediatr Orthop* 1989;9:541.
72. Shufflebarger HL, Clark CE. Prevention of crankshaft phenomenon. *Spine* 1991;16[Suppl 8]:S409.
73. Richards BS. The effects of growth on the scoliotic spine following posterior spinal fusion. In: Buckwalter JA, Ehrlich MG, Sandell LJ, et al., eds. *Skeletal growth and development: clinical issues and basic science advances*. Rosemont, IL: American Academy of Orthopaedic Surgeons, 1997;3:577.
74. Roberto RF, Lonstein JE, Winter RB, et al. Curve progression in Risser stage 0 on patients after posterior spinal fusion for idiopathic scoliosis. *J Pediatr Orthop* 1997;17:718.
75. Sanders JO, Herring JA, Browne RH. Posterior arthrodesis and instrumentation in the immature (Risser-grade-0) spine in idiopathic scoliosis. *J Bone Joint Surg Am* 1995;77:39.
76. Roaf R. The treatment of progressive scoliosis by unilateral arrest. *J Bone Joint Surg Br* 1963;45:637.
77. Winter RB. Convex anterior and posterior hemiarthrodesis and

hemiepiphyodesis in young children with progressive congenital scoliosis. *J Pediatr Orthop* 1989;1:361.

Lower Limb Growth

78. Anderson M, Green WT, Messner MB. Growth and predictions of growth in the lower extremities. *J Bone Joint Surg Am* 1963; 45:1.
79. Diméglio A, Bonnel F. Growth and development of the knee. In: De Pablos J, ed. *The immature knee*. Barcelona: Biblio Stm, 1998:3.
80. Moseley CF. A straight-line graph for leg length discrepancies. *J Bone Joint Surg Am* 1977;59:174.
81. Tupman GS. A study of bone growth in normal children and its relationship to skeletal maturation. *J Bone Joint Surg Br* 1962; 44:42.
82. Blais MM, Green WT, Anderson M. Lengths of the growing foot. *J Bone Joint Surg Am* 1956;38:998.
83. Duval-Beaupère G, Sayet A. Contribution respective des segments supérieur et inférieur à la croissance des garçons. *Arch Fr Pediatr* 1979;36:369.
84. Hechard P, Carlizot H. Méthode pratique de prévision des inégalités de longueur des membres inférieurs. *Rev Chir Orthop* 1978;64:81.
85. Lefort J. Utilisation du coefficient de croissance résiduelle dans le calcul prévisionnel des inégalités de longueur des membres inférieurs. *Rev Chir Pediatr Orthop* 1981;67:753.
86. Kasser JR, Jenkins R. Accuracy of leg length prediction in children younger than 10 years of age. *Clin Orthop* 1997; 338:9.
87. Shapiro F. Developmental patterns in lower extremity length discrepancies. *J Bone Joint Surg Am* 1982;64:95.
88. Little DG, Nigo L, Aiona MD. Deficiencies of current methods for the timing of epiphysiodesis. *J Pediatr Orthop* 1996;16:173.
89. Menelaus MB. Correction of leg length discrepancy by epiphysial arrest. *J Bone Joint Surg Br* 1966;48:336.

Upper Limb Growth

90. Maresh MM. Growth of major long bones on healthy children: a preliminary report on successive roentgenograms of the extremities from early infancy to twelve years of age. *Arch Dis Child* 1943;66:227.
91. Maresh MM. Linear growth of long bones of extremities from infancy through adolescence: continuing studies. *Am J Dis Child* 1955;89:725.
92. Pritchett JW. Growth and prediction of growth in the upper extremity. *J Bone Joint Surg Am* 1988;70:520.
93. Pritchett JW. Growth-plate activity in the upper extremity. *Clin Orthop* 1991;268:235.
94. Flatt A. Growth, size, function of the hand. In: *The care of congenital hand anomalies*. St. Louis: Mosby, 1977:16.
95. Aldegheri R, Agostini S. A chart of anthropometric values. *J Bone Joint Surg Br* 1983;75:86.
96. Spender QW, Cronk CE, Charney EB, et al. Assessment of linear growth of children with cerebral palsy: use of alternative measures to height or length. *Dev Med Child Neurol* 1989;31: 206.
97. Belt-Niedballa BJ, Ekval SW, Cook CM, et al. Linear growth measurement: a comparison of single-arm lengths and arm-span. *Dev Med Child Neurol* 1986;28:319.
98. Jensen JE, Jensen TG, Smith TK, et al. Nutrition in orthopaedic surgery. *J Bone Joint Surg Am* 1982;64:1263.
99. Klein JD, Garfin SR. Nutritional status in the patient with spinal infection. *Orthop Clin North Am* 1996;27:33.
100. Szoke GM, Lipton G, Miller F, et al. Wound infection after

- spinal fusion in children with cerebral palsy. *J Pediatr Orthop* 1998;18:727.
101. Samilson RL, Green WT, Jones M, et al. Orthopaedic aspects of cerebral palsy. *Clin Dev Med* 1975;52/53:71.
 102. Zorab PA, Prime FJ, Harrison A. Estimation of height from tibial length. *Lancet* 1963;1:195.
 104. Mahmoud Y, El-Najjar. Reconstruction of the individual from the skeleton. In: *Forensic anthropology*. Springfield, IL: Charles C Thomas, 1978:55.
 105. Horton WA, Hall JG, Scott CI Jr, et al. Growth curves for height for diastrophic dysplasia, spondyloepiphyseal dysplasia congenita, and pseudoachondroplasia. *Am J Dis Child* 1982;136:316.
 106. Horton WA, Rotter JI, Rimoin DL, et al. Standard growth curves for achondroplasia. *J Pediatr* 1978;93:435.
 107. Hecht JT, Hood OJ, Schwartz RJ, et al. Obesity in achondroplasia. *Am J Med Genet* 1988;31:597.

Lessons Learned from Growth

103. Godin P. Lois de la croissance basées sur 2 000 observations d'enfants. *Comptes Rendus Acad Sci* 1914;(July):99.



3

IMAGING TECHNIQUES AND APPLICATIONS

**DIEGO JARAMILLO
LEONARD P. CONNOLLY**

RADIOGRAPHIC TECHNIQUES: PLAIN RADIOGRAPHS, ARTHROGRAPHY, CONVENTIONAL TOMOGRAPHY, COMPUTED TOMOGRAPHY 64

Basis of Radiographic Contrast 64
Intravenous and Arthrographic Contrast Materials 64
Normal Age-related Changes and Variants 65
Main Applications and Specific Technical Considerations 67

ULTRASONOGRAPHY 74

Mechanisms of Contrast 74
Normal Sonographic Anatomy of the Hip 74
Main Applications 77
Utilization Trends 77

MAGNETIC RESONANCE IMAGING 78

Mechanisms of Contrast 78
Clinical Use of Pulse Sequences 80
Contrast Materials 80
Normal Age-related Changes and Variants 80
Main Applications 82

Risks and Limitations 83
Utilization Trends 85

NUCLEAR MEDICINE 85

Mechanism of Contrast 85
Skeletal Scintigraphy 85
Main Applications 88
Risks 89
Utilization Trends 89

BONE DENSITOMETRY 89

Techniques 90
Main Applications of Bone Densitometry 90
Risks, Limitations, and Utilization Trends 90

RADIATION EXPOSURE: PRACTICAL ISSUES 90

Radiation Effects 91
Dosimetry 91
Relationship between Radiation Dose and Effect 91
Radiation Exposure and Diagnostic Examinations 91
Practical Steps to Reduce Radiation Exposure 92

SEDATION FOR IMAGING 92

Imaging of the pediatric skeleton has changed dramatically over the last decade. Although plain films remain the main-

stay of orthopaedic practice, magnetic resonance (MR) imaging and ultrasonography now allow visualization of cartilaginous structures and, more recently, their blood supply. Various techniques to investigate the biochemical and metabolic composition of the cartilage are being developed, and may soon be clinically useful. The revolution in image processing allows reconstruction of an imaging data set in multiple projections. It is now possible to generate curved

D. Jaramillo: Department of Radiology, Harvard Medical School, Boston, Massachusetts 02115; Division of Pediatric Radiology, Massachusetts General Hospital, Boston, Massachusetts 02114

L. P. Connolly: Department of Radiology, Harvard Medical School; Department of Radiology, Children's Hospital, Boston, Massachusetts 02115.

reformations, maximal intensity projections, computer-simulated disarticulations, and even computer-simulated surgery. Most images, with the exception of conventional radiographs, are now in digital format, and it is possible to transmit, store, and manipulate data with increasing ease. The information is not only more readily available and less often lost, but results can become standardized and quantified. Some techniques are being replaced by less-invasive or easier approaches. Conventional tomography, diagnostic angiography, myelography, and, to a lesser extent, arthrography, are used much less. Unfortunately, the newer imaging modalities remain costly, and access to them is still limited. The expertise of orthopaedic surgeons in the use and interpretation of these modalities has increased remarkably. This chapter provides an overview of the imaging modalities, their mechanisms of contrast, some information about normal appearances and variations, a discussion of risks and limitations, and an overview of costs and trends in utilization. Radiation exposure and sedation for the more complex examinations is discussed at the end of the chapter.

RADIOGRAPHIC TECHNIQUES: PLAIN RADIOGRAPHS, ARTHROGRAPHY, CONVENTIONAL TOMOGRAPHY, COMPUTED TOMOGRAPHY

Basis of Radiographic Contrast

Radiographic density depends on the relative absorption of an x-ray beam by the structures being imaged. There are five main radiographic densities: heavy metal, calcium, water and water-density tissues, fat, and air. In the bones, radiographic density primarily reflects calcium content. The relative content of water and fat in the marrow has much less influence on the radiographic density. In the soft tissues, the relative concentrations of fat and water are the main determinants of density. The fat around the joints, in between the muscles, and underneath the skin is detectable on routine radiographs. Analysis of soft tissue abnormalities, such as displacement or effacement of fat planes or fat pads, is crucial in the radiographic detection of subtle injury or infection.

In the newborn, the skeleton is made up of woven bone, which is very radiopaque (Fig. 3-1). The newly formed bone of the metaphysis is particularly sclerotic. There is little differentiation between cortex and medulla. With age, the marrow cavity becomes larger, and the woven bone becomes lamellar bone (1); this transformation and the fatty conversion of the marrow (2) result in a skeleton with clear differentiation between cortical bone and the much less dense medullary cavity.

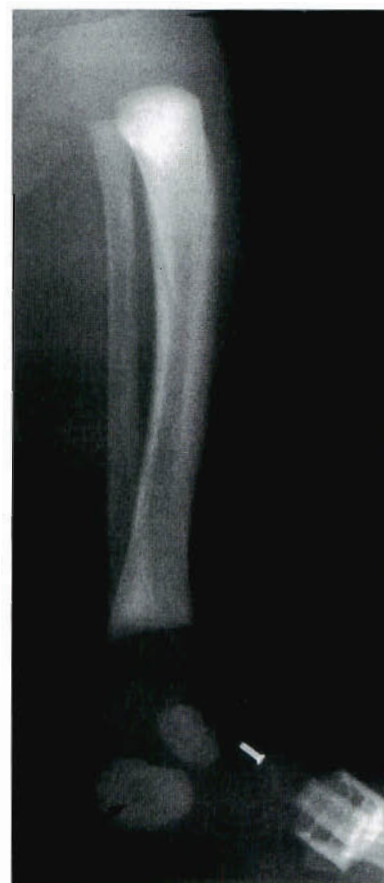

FIGURE 3-1. Normal radiographic appearance of bones in the newborn. The bones are sclerotic and the perichondral regions are prominent. The calcaneal nutrient foramen is normally prominent (arrow).

Intravenous and Arthrographic Contrast Materials

Iodinated contrast material is used intravenously for computed tomography (CT) examinations and for arthrography and myelography. Radiographic contrast materials are iodine-based compounds, and can be ionic or nonionic. Non-ionic agents are several times as expensive, but deliver a smaller osmolar load, and are associated with less morbidity and mortality (3). When administered intravenously, ionic agents have a 5 to 12% incidence of side effects (vomiting, pain, and allergic reactions), compared with 1 to 3% for nonionic agents. The rate of fatal outcomes for all contrast media studies is approximately 0.9 per 100,000 (4), but less than 5% of these occur in children (5).

When administered arthrographically, reactions to contrast agents are infrequent, but nonionic contrast materials are associated with less pain and a greater persistence in the joint (6). Epinephrine, particularly in the knee, slows loss

of contrast from the joint and prevents dilution due to influx of fluid. Air, which allows double contrast, is a safe adjunct, but is infrequently used in pediatric hip arthrography.

Normal Age-related Changes and Variants

Although ossification normally occurs in a very predictable pattern, the variation in some areas can resemble disease. Normal variants are often bilateral, but reassuring symmetry is not always present. It is, therefore, important to become familiar with the most common normal variants of the growing skeleton.

Epiphyseal and Apophyseal Variants

Distal Femoral Epiphyseal Irregularity. The secondary center of ossification of the distal femur can be very irregular throughout childhood. Irregularity is found in approximately two-thirds of boys and 40% of girls (Fig. 3-2). The irregularity, when present, involves both condyles in 44% of cases, only the lateral condyle in 44%, and only the medial condyle in 12% (7). Accessory centers of ossification are

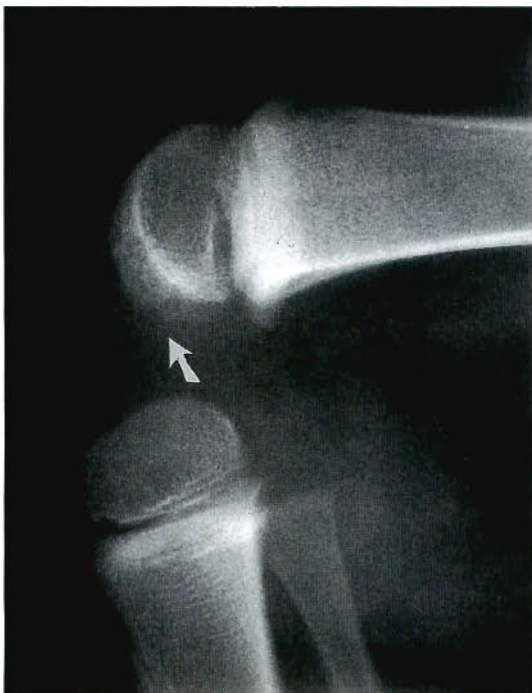

FIGURE 3-2. Femoral epiphyseal irregularity. Lateral radiograph of a 17-month-old boy shows abnormality of the contour of the posterior aspect of the epiphysis (*arrow*), a normal variant. Incidentally noted is the normal sclerosis of the metaphysis of the distal femur and proximal tibia.

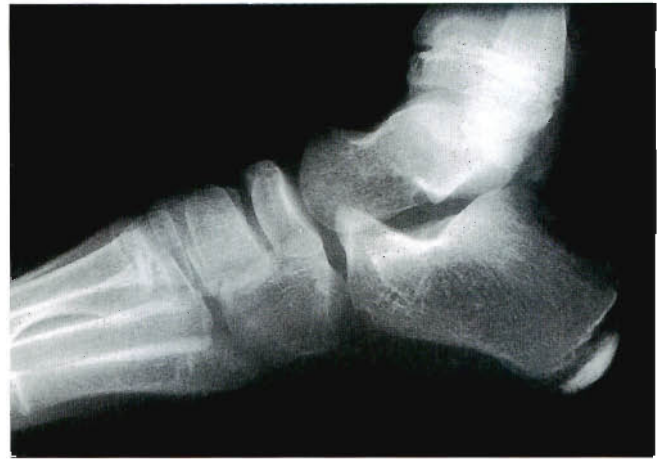

FIGURE 3-3. Normal calcaneal sclerosis in a 9-year-old girl. The density of the calcaneal apophysis is much greater than that of the rest of the calcaneus.

more conspicuous in the posterior femoral condyles, and are almost always later incorporated into the parent bone.

Irregularity of the Tibial Tubercle. The tibial tubercle ossifies between 8 and 12 years of age in girls and 9 and 14 years of age in boys (8). During this time, normal irregularity of ossification must be differentiated from Osgood-Schlatter disease. In the latter, the child has local pain and inflammation. Edema anterior to the tubercle and patellar tendon thickening are readily detectable by soft tissue radiography, sonography, and magnetic resonance (MR) imaging. Osgood-Schlatter disease, however, is diagnosed clinically, rather than by imaging.

Calcaneal Sclerosis. The calcaneal apophyseal center ossifies in girls at 4 to 6 years of age, and in boys at 4 to 9 years of age. Ossification is uneven and asymmetric, and neither fragmentation nor sclerosis indicates disease (Fig. 3-3). Normal calcaneal sclerosis decreases with disuse of the foot or after a month of not bearing weight (9). The diagnosis of Sever's disease (calcaneal apophysitis) is primarily clinical. Soft tissue swelling on radiographs or cross-sectional images, and increased scintigraphic activity, may provide supportive evidence; imaging evaluation, however, is not necessary (10).

Physeal Variants

Pseudofracture Due to Physeal Obliquity. When the radiographic beam penetrates the physis obliquely, one end of the physeal disc is projected above the other, which suggests a fracture. This pseudofracture is easily recognized in

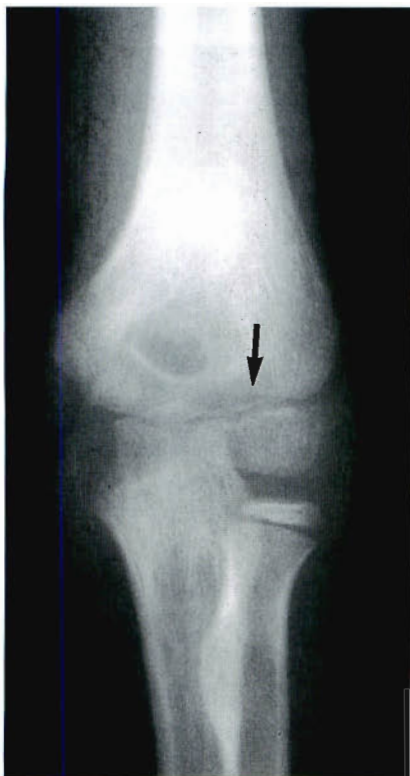

FIGURE 3-4. Physeal obliquity resembling a fracture in an 8-year-old boy. The physis of the capitellum is projected over the metaphysis of the distal humerus (arrow), creating the false impression of a lateral condylar fracture.

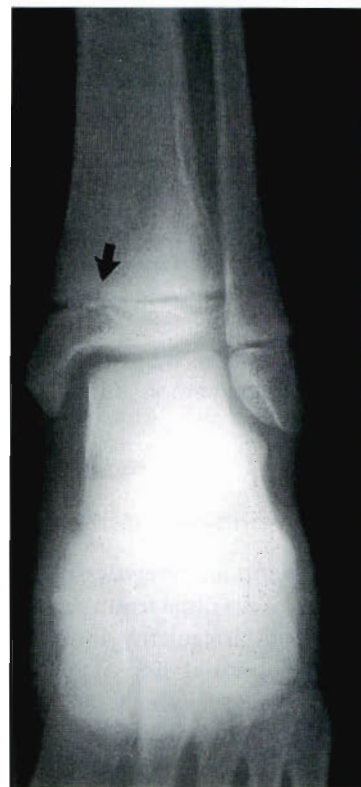

FIGURE 3-5. Normal physeal closure of the distal tibial physis in an 11-year-old girl who sprained her ankle. Cephalad to the medial talar hump is a physeal "hump" (arrow), which corresponds to the area of normal physeal closure.

the proximal humerus. In the distal humerus, however, it can be confused with a lateral condylar fracture (Fig. 3-4).

Poland's Hump of Distal Tibia. The distal tibial physis closes asymmetrically. An undulation, known as Poland's hump (or Kump's bump), is located just above the medial talar hump. The physis becomes thinner and closes first here (Fig. 3-5). The obliquity of this area may give the false impression of early physeal closure.

Metaphyseal Variants

Transverse Metaphyseal Bands. The juxtaphyseal metaphysis of weight-bearing bones can be sclerotic during childhood (11) (Fig. 3-6). Metaphyseal sclerosis is normal between 2 and 6 years of age. Unlike this normal density, the metaphyseal band of lead intoxication affects both weight-bearing and nonweight-bearing bones (such as the fibula). Increased density in chronic lead poisoning is not due to metal deposition, but to osteoclastic dysfunction, which results in failure of resorption of the trabecula of the metaphyseal spongiosa.

Following a fracture or a period of slower growth due

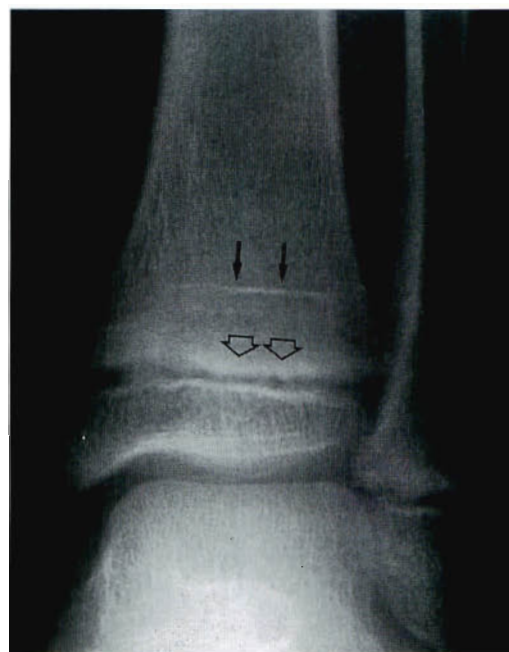

FIGURE 3-6. Metaphyseal sclerosis and multiple growth recovery (Harris) lines in a 7-year-old girl. The most prominent Harris line is outlined by the two closed arrows. This parallels the growth plate, which has migrated away from the line since the time of the growth slowdown. The open arrows denote a normal metaphyseal sclerosis of the distal tibia.

to disease, a disc of sclerotic bone forms in the metaphysis next to the physis. A growth recovery line, or Harris line, is formed when the physis migrates away from this disc (Fig. 3-6). Before it becomes separated from the metaphysis, however, the growth recovery line and the metaphyseal spongiosa overlap and create a spurious metaphyseal density.

Apparent metaphyseal sclerosis can result from resorption of the metaphyseal trabecula, with preservation of the zone of provisional calcification. This can be seen in neonates under stress, and in children with leukemia or methotrexate osteopathy (12).

Avulsive Cortical Irregularity. Sites of tendinous insertions at metadiaphyseal junctions have thin cortices. Because these areas are prone to repeated minor avulsive injury, the cortex can become irregular, and new bone formation can be mistaken for a neoplasm (13). This is most prominent in the posterior aspect of the distal femur, at the insertion of the medial head of the gastrocnemius muscle (Fig. 3-7). The cortex is thin or absent in this region, such that, on a frontal radiograph, a cortical defect appears as a rounded lucency. Tangential radiographs show irregularity or discontinuity of the cortex.

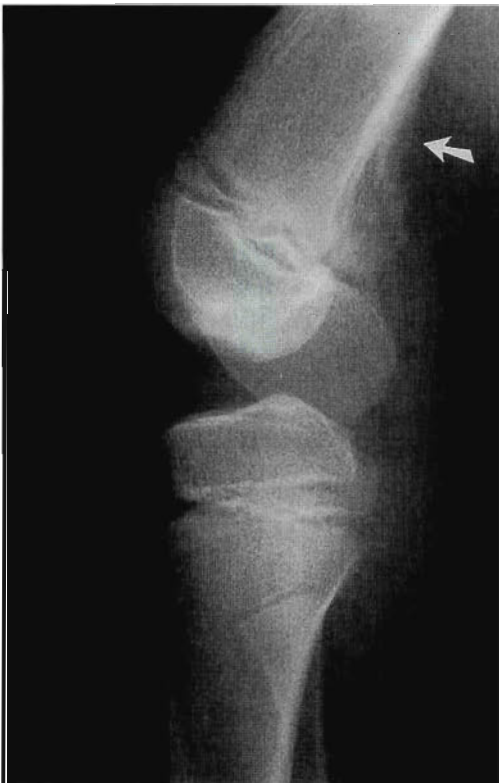

FIGURE 3-7. Normal distal femoral metaphyseal cortical irregularity (arrow) at the insertion of the medial head of the gastrocnemius muscle. In this radiograph, a slight obliquity accentuates the normal variant.

If a cortical irregularity has a characteristic radiographic appearance, no further imaging is needed. When there is uncertainty about the nature of the lesion, a limited CT can be used to confirm the diagnosis, by showing a typical defect in the posterior cortex and no soft tissue mass. MR imaging is not indicated unless there is a strong suspicion for a tumor. A large cortical defect encountered incidentally during an MR study of the knee may be confused with a marrow lesion on coronal images, but analysis of the entire data set clarifies the potential pitfall (14).

Round Bone Variant

Tarsal Navicular Fragmentation. The navicular is the last tarsal bone to ossify (see scintigraphic normal variants in the section Skeletal Scintigraphy below). There are normally two ossification centers, but multiple irregular, dense centers can develop, fusing close to age 20. Normal navicular fragmentation and sclerosis differs from aseptic necrosis of the navicular, or Kohler's disease, which affects older children, and is associated with pain (15).

Main Applications and Specific Technical Considerations

Plain Radiographs

General Principles. Coning (decreasing the area exposed to x-rays) reduces scatter radiation, improves image quality, and reduces radiation exposure. Coning is easy and always beneficial. When multiple anatomic areas need to be imaged, it is better to obtain multiple coned-down radiographs, rather than a single large radiograph. Whenever possible, gonads and breasts should be shielded. When examining the hips, however, one of the radiographs must be obtained without gonadal shielding, because the shield can hide abnormalities of the sacrum in girls and the pubis in boys. Radiation dose considerations are discussed at length at the end of this chapter and in Tables 3-1 and 3-2. Good positioning is crucial, particularly when obtaining lateral projections of the elbow, wrist, and ankle.

The soft tissues should be well-depicted on properly exposed radiographs. The subcutaneous fat is more lucent than the deeper muscles and ligaments. The deep soft tissues have fat planes between the muscles that are also discernible radiographically. The analysis of soft tissue abnormalities is crucial in the evaluation of early osteomyelitis, because deep soft tissue swelling is present as early as 3 days after the beginning of the infection. In effusions in the elbow and ankle, displacement of periarticular fat pads is often the first indicator of occult fractures. Effacement or displacement of the fat planes around the bones is important in the evaluation of fractures of the navicular (navicular fat pad sign),

TABLE 3-1. RADIATION DOSES FOR COMMON RADIOGRAPHIC PROCEDURES

Patient Age	Estimated Midline Doses (mrad)
Posteroanterior Chest (400-speed)	
10–15 yr	2.3
6–10 yr	2.2
3–6 yr	2.1
1–3 yr	1.8
3-Foot Spine Posteroanterior (1,100-speed)	
25–30 cm	17
20–25 cm	15
17–20 cm	15
13–17 cm	12
3-Foot Spine Lateral (1,100-speed)	
35–40 cm	35
30–35 cm	29
27–30 cm	26
23–27 cm	22
Anteroposterior Pelvis and Hips (400-speed)	
10–15 yr	11
6–10 yr	6.4
3–6 yr	4.7
1–3 yr	4.5
Anteroposterior Hand (100-speed)	
10–15 yr	3.0
6–10 yr	2.6
3–6 yr	2.6
1–3 yr	2.6

(Adapted from ref. 16, with permission.)

and fractures of the distal radius (pronator quadratus sign). Evaluation of superficial soft tissues is useful in evaluation of cellulitis and in the detection of foreign bodies. Specific radiographic exposures for the evaluation of soft tissues can be obtained, if necessary; with digital imaging it is possible to modify the window and level of the image to depict primarily the soft tissues.

Evaluation of Skeletal Maturity. Determination of skeletal maturity, or bone age, is of great importance, and consti-

tutes nearly 1% of pediatric imaging examinations (17). Skeletal age is usually determined during the evaluation of metabolic disorders, skeletal dysplasias, and short stature. Bone age is also estimated during assessment of residual growth, which is crucial to time spine fusion for scoliosis and epiphysiodesis for limb-length discrepancy.

The most widely used technique is to compare the radiographic appearance of the physes and secondary centers of ossification of the left hand to radiographic standards, usually those of Greulich and Pyle (18). The book of Greulich and Pyle provides standard deviations for each chronological age obtained by the Brush foundation study. A bone age that differs more than two standard deviations from the chronological age is considered abnormal.

In young children, the bone age determination is based on whether the ossification centers have appeared. In older children, as the ossification centers become elongated, the width of the epiphyseal ossification center approaches that of the metaphysis. In late childhood and puberty, the physes become progressively undulated, and the epiphyses begin to cap the metaphyses. In adolescence, physal closure becomes the most important feature. Carpal bones should not be analyzed during routine evaluation of patients who are relatively normal, because including the carpal bones makes the evaluation less consistent. Carpal bones, however, are more sensitive indicators of dysfunctional maturation such as occurs in endocrinopathies and skeletal dysplasias.

In the first year of life, when the hand epiphyses and carpal bones are solely cartilaginous, other techniques can be applied. The best is to radiograph the knee and ankle, and use the standards of Pyle and Hoerr (19,20), in a fashion similar to those described for the hand. Alternatively, skeletal maturity can be determined by the Sontag method (21), based on counting the number of ossification centers in the hemiskeleton.

There has been growing concern about the generalizability of the standards of Greulich and Pyle (G&P). These standards were derived from white children of upper socioeconomic status in the 1930s, and may not be exactly applicable to children of other ethnic groups or socioeconomic conditions. Recently, preadolescent and adolescent black

TABLE 3-2. ESTIMATED RADIATION DOSES FROM BONE SCINTIGRAPHY BY AGE [rad/mCi (mGy/MBq)]

Target Organ	Newborn	1 Year	5 Years	10 Years
Kidneys	0.340 (0.092)	0.137 (0.037)	0.077 (0.021)	0.052 (0.014)
Ovaries	0.115 (0.031)	0.055 (0.015)	0.033 (0.009)	0.022 (0.006)
Bone surfaces	5.92 (1.6)	1.813 (0.49)	0.777 (0.21)	0.444 (0.12)
Red marrow	0.592 (0.16)	0.208 (0.056)	0.104 (0.028)	0.059 (0.016)
Testes	0.010 (0.027)	0.048 (0.013)	0.027 (0.007)	0.169 (0.047)
Urinary bladder wall	1.48 (0.40)	0.629 (0.17)	0.34 (0.091)	0.225 (0.061)
Effective dose equivalent*	0.407 (0.11)	0.154 (0.042)	0.077 (0.021)	0.052 (0.014)

* rem/mCi (mSv/MBq).

and Hispanic girls and Asian and Hispanic boys have been found to have a skeletal age (determined by G&P standards) that exceeds the chronological age by approximately 9 months (22,23). The skeletal age of Pakistani children (as determined by G&P standards), on the other hand, is estimated to be 6 months to a year lower than the chronological age (24), whereas that of central European children can be evaluated accurately by those standards (25). Interobserver variability studies show an average spread of 1 year for the G&P method (26). A recent study depicts the G&P method as very inaccurate, with 95% confidence intervals of -2.5 to 2.2 years (27). All these reservations notwithstanding, the method continues to be the standard against which all other techniques are measured, and the most disseminated way of determining skeletal maturity. The Tanner-Whitehouse method (28), based on assigning a maturity score to each bone of the hand and wrist, is more comprehensive and reproducible, but its determination takes four times longer (26). There are computer programs that can be used to aid in the evaluation, but these are not widely available (29).

Also included in the book by Greulich and Pyle are the standards of Bayley and Pinneau. These allow the estimation of the final height of the patient, based on the current height and the chronological age. A recent evaluation of the technique showed that it remained reliable, although height is underestimated early in life and overestimated when predicted closer to maturity (30).

Investigation of Child Abuse. Plain film radiography is the most important tool for evaluating child abuse. Most fractures of child abuse, particularly the characteristic metaphyseal fractures, are subtle, and are often undetected unless great attention is paid to the technical details of imaging (31). In a small infant, including most of the skeleton in a single large film is tempting, but is likely to lead to missed diagnoses. Most subtle injuries are found only when there is appropriate collimation (which reduces unwanted scatter radiation), and when the x-ray beam is centered on the area evaluated. Only high-detail film screen combinations should be used (32). A complete skeletal survey needs to be obtained in every case. This includes anteroposterior (AP) and lateral views of the skull and thorax, a lateral view of the spine, AP views of the abdomen and pelvis, oblique views of the hands, and AP views of each of the other segments of the extremities (32).

Digital Radiography. Digital radiography is becoming the most widely used technique to obtain x-ray images of the skeleton (33). Digital radiographs can be manipulated electronically, archived digitally, and transmitted with great ease. In children, the use of an air gap between the extremity and the detector further improves musculoskeletal computed imaging by reducing scatter (34).

Most large radiology departments in the United States are implementing picture archiving and communication systems (PACS), of which digital radiography is an integral part. Many departments record images only digitally. Such "filmless" departments are likely to become the norm over the next decade (35,36). Integration of multiple modalities has become possible because there is now a standard for network interfaces, the Digital Imaging and Communications in Medicine (DICOM) (1). Most modern imaging equipment is DICOM-compatible.

Computed radiography results in dose reduction, because exposure is decreased (less milliamperere seconds), and because there are less repeat radiographs related to exposure errors. Other advantages of computed musculoskeletal radiography include improved contrast resolution, ability to enhance images after acquisition, and elimination of film screen contact problems (33). Disadvantages of digital radiography include higher initial costs and lower resolution than conventional radiography, which is particularly noticed in the detection of subtle fractures.

Arthrography

Despite advances in cross-sectional imaging of the hip, arthrography remains a valuable diagnostic technique for children with developmental dysplasia of the hip (DDH) and Legg-Calvé-Perthes (LCP) disease (37). In both, arthrography depicts the femoroacetabular relationship in different anatomic positions. This information is not currently provided by conventional MR imaging, in which the hips are studied in a neutral position, or with CT or sonography (38). In children, arthrography is usually performed intraoperatively, prior to immobilization or corrective surgery.

Technique. Arthrography is performed by introducing a needle under fluoroscopic or sonographic guidance. If done fluoroscopically, the needle can be introduced 1 cm distal to the proximal femoral physis, and 1 cm medial to the lateral aspect of the femoral head (39,40), avoiding the femoral artery. Alternatively, the needle can be placed inferior to the adductor muscle, and directed superiorly into the joint space, under fluoroscopic control. This medial adductor approach minimizes degradation of the image by extraarticular contrast, when the initial injection fails, because contrast material in the soft tissues does not overlap with the femoral head.

Once the needle hits the bone, it is withdrawn 1 mm so that it rests in the joint space. A small trial injection is important to confirm the intraarticular location of the needle, and to minimize extraarticular contrast material. Nonionic contrast material is infused into the joint until mild capsular distention is attained. In general, it is best to dilute the contrast material (e.g., 5 mL of contrast material

in 5 mL of normal saline solution). The contrast material should be just enough to coat the anatomic structures adequately. Too much contrast leads to overdistention, which distorts the normal articular relationships and obscures the anatomic landmarks. In the infant hip, 1 to 2 mL of this mixture is adequate for joint depiction (41), but the volume varies significantly with age and with the laxity of the joint. Once the joint space is opacified, images are obtained with the hip held in various positions, such as neutral, abduction, mild adduction, abduction with flexion and external rotation (frog lateral or Lauenstein projection), and abduction with internal rotation (Von Rosen projection) (38, 42,43).

Normal Anatomy. In infants and children, there is usually a large discrepancy between the contour of the bones and the cartilaginous structures outlined arthrographically. The structures depicted on arthrography include the cartilaginous and ossified femoral head, the acetabulum, and the labrum. The acetabulum should be concave inferiorly; its lateral extent is defined by the fibrocartilaginous acetabular labrum, which is also radiolucent. The capsule extends just cephalad to the labral tip, creating a recess between the superior surface of the labrum and the capsule. This recess resembles a rose thorn, when filled with contrast material, surrounding the tip of the labrum (40) (Fig. 3-8). The acetabular cartilage has a smooth surface, and has a radius of curvature appropriate to the size of the child. The width of

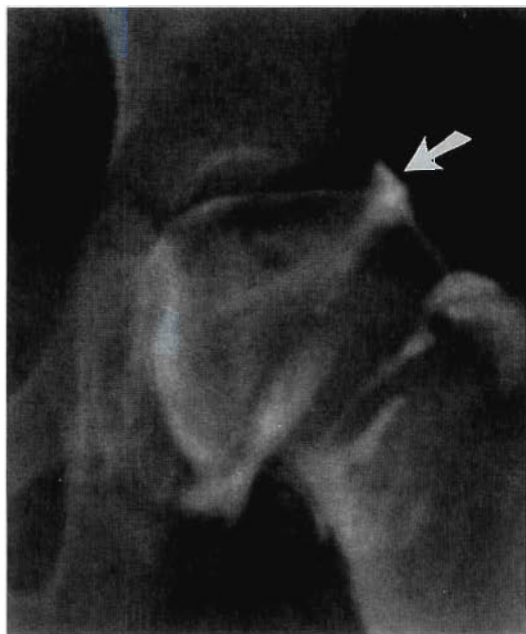

FIGURE 3-8. Arthrography of the hip in a 7-year-old boy with Legg-Calvé-Perthes disease. Anteroposterior arthrogram in the neutral position shows that the deformed femoral head is flattened and incompletely contained by the acetabulum. The arrow points to the "rose thorn," the capsular recess surrounding the lateral aspect of the acetabular labrum.

the acetabular cartilage is increased in DDH. The normal femoral cartilaginous head is smooth, and fits tightly within the acetabulum. Any pooling of contrast between the femoral head and the acetabulum is abnormal. The contrast agent collects around the femoral head and metaphysis, but is contained by the orbicular ligament, forming a waist known as the "zona orbicularis."

Developmental Dysplasia of the Hip. Arthrography is indicated during reduction of dislocation of the hip, to indicate the position of the femoral head during the reduction maneuvers, and to identify any obstacles to reduction (2). Arthrography ensures that the reduction has been adequate, and that it is maintained after the placement of a spica cast. It shows the medial joint space after reduction, showing whether the femoral head is properly seated.

Obstacles to reduction (43) include structures that may get interposed between the articular surfaces, such as a pulvinar (Latin for "cushion"), a hypertrophied ligamentum teres, a redundant capsule with areas of infolding, a hypertrophied transverse acetabular ligament, and a psoas tendon indenting the capsule between the acetabulum and the femoral head. The pulvinar is seen as a radiolucent structure with irregular borders, located in the depth of the acetabulum. This fibrofatty tissue usually recedes after the hip is located. A redundant, large ligamentum teres is outlined by contrast, and is usually easy to identify. Psoas interposition is not reliably detected by arthrography, and capsular and transverse ligament interpositions may be difficult to detect. There is some controversy about the relative importance of these obstacles to reduction.

Another important factor interfering with reduction is an abnormal configuration of the acetabulum (44) and the acetabular labrum ("inverted labrum" or "limbus") (45). Histologic studies suggest that, rather than being a mere labral inversion, this abnormality consists of a true cartilaginous ridge within the acetabular concavity, creating two separate acetabular chambers (4). Imaging in the abduction and internal rotation (Von Rosen) position differentiates between a subluxated hip with intervening soft tissues and a dysplastic hip with increased femoral anteversion. With increased anteversion, medial pooling of contrast resolves in the Von Rosen position (2).

Legg-Calvé-Perthes Disease. Arthrography is often performed in severe LCP disease to decide whether the hips require bracing or surgery (osteotomies), and to assess the best position for immobilization (5-8). It helps assess *containment* of the femoral head by the acetabulum, *congruency* of the femoral head and the acetabulum, and *deformity* of the cartilaginous femoral head. It helps to determine the optimal position of the femoral head for immobilization

during the process of epiphyseal healing (46). In order to maximize containment (9), it is important to document which positions lead to the greatest percentage of the femoral head being covered by the acetabulum (Fig. 3-8). On the other hand, it is desirable to place the head in a position in which the acetabulum and femoral head are congruent. When the contours of the acetabulum and the femoral head are parallel, only minimal contrast should come between the articular surfaces. Lack of congruity is seen as pooling of contrast between the flattened portions of the femoral head and the acetabulum. Unfortunately, the maneuvers that increase containment, such as abduction, also increase the pool of contrast material between the femoral head and the acetabulum. In summary, arthrography is performed to detect causes of decreased containment, and to show positional changes in the joint (47,48).

In LCP disease, lateral displacement of the femoral head is usually multifactorial. The epiphyseal cartilage is abnormally thick, and there is hypertrophy of the synovium and of the ligamentum teres. Occasionally, increased joint fluid may contribute to the subluxation. With severe flattening of the femoral head, the abducted femur can hinge on the lateral acetabular margin. This "hinge abduction" (49) separates the femoral head from the acetabulum, simultaneously reducing containment and congruity (5). Arthrography can also be used to detect irregularity of the articular cartilage, which is important prognostically (50).

Conventional Tomography

Conventional tomography is a radiographic technique to show fine detail of structures within a specific anatomic plane. This is accomplished by blurring the structures below and above a certain plane by moving the radiographic tube (10). The more complex the motion (hypocycloidal, tri-spiral), the better the detail; the wider the arc of motion, the thinner the slice. The widespread use of CT and MR imaging has almost eliminated the need for tomography, and most major hospitals no longer have complex motion units. Linear tomography is the only technique still widely available, but its resolution is less than that of complex motion tomography, because the blurring is less optimal. The most important use of conventional tomography in pediatric orthopaedic imaging is in the evaluation of pseudoarthrosis after spinal fusion, when orthopaedic hardware may produce severe artifacts on CT or MR imaging.

Computed Tomography

CT is an extension of plain radiography, but its contrast resolution is 100 times greater. CT can detect changes in radiologic attenuation as small as 0.1% (51). CT displays

various musculoskeletal structures; pixel brightness represents x-ray attenuation. The attenuation of muscle and cartilage is very similar, so that the main contribution of orthopaedic CT is to outline the contour of the bony structures. CT also provides tomographic display and allows digital manipulation and storage of the data. Multiplanar and three-dimensional (3D) reconstructions can be performed with great ease, if the images are acquired appropriately. There are many image reconstruction packages that can be used on a conventional workstation; alternatively, the vendors of CT units also market workstations with proprietary software. Most can generate a 3D image with surface or volume rendering in one or two minutes. In complex cases, it is advisable for the orthopaedic surgeon and the radiologist to review the images jointly on the workstation, because significant information can be gained from options, such as simulated disarticulation, color display, and cine-loop, to display the objects in motion.

The image is acquired by rotating an x-ray beam around the patient and detecting the attenuated beam after it traverses the patient. The data from the detectors is sent to a computer, which reconstructs it into an axial (transaxial) image. With conventional CT, the motion of the x-ray beam is circular, and single slices are obtained at predetermined increments. With helical (spiral) CT, the source-detector system rotates continuously as the patient is advanced through the gantry, so that the scanning motion is spiral. This helical method of scanning is faster and acquires a continuous set of data. The interval between slices, and the location of the center of the slice, can be modified after imaging, if the raw data is still available (52). Although helical CT can deliver a lower radiation dose in examinations of the chest and abdomen, for the high spatial resolution required for most musculoskeletal studies, the radiation doses for helical and conventional CT are essentially equal (52). Most orthopaedic studies are performed with a slice thickness of 1 to 3 mm. Coronal and sagittal reconstructions can be obtained routinely, and are very helpful.

The main disadvantage of spiral CT is that it produces blurring and stair-step artifacts. Helical CT is also slightly less sensitive than conventional CT for detecting subtle fractures (53). In children, however, the loss of sensitivity is more than offset by the reduction of artifacts caused by motion. Spiral CT is faster, and provides better images and reconstructions than conventional CT in almost every pediatric application.

Indications. Trauma is one of the main indications for CT. CT scanning is used extensively to evaluate fragment separation in triplane and Tillaux fractures, clearly demonstrated by multiplanar reconstructions. In patients with scaphoid fractures, CT can demonstrate subtle fractures and subsequent nonunion. In slipped capital femoral epiphysis, CT demonstrates the physeal irregularity, the degree of infe-

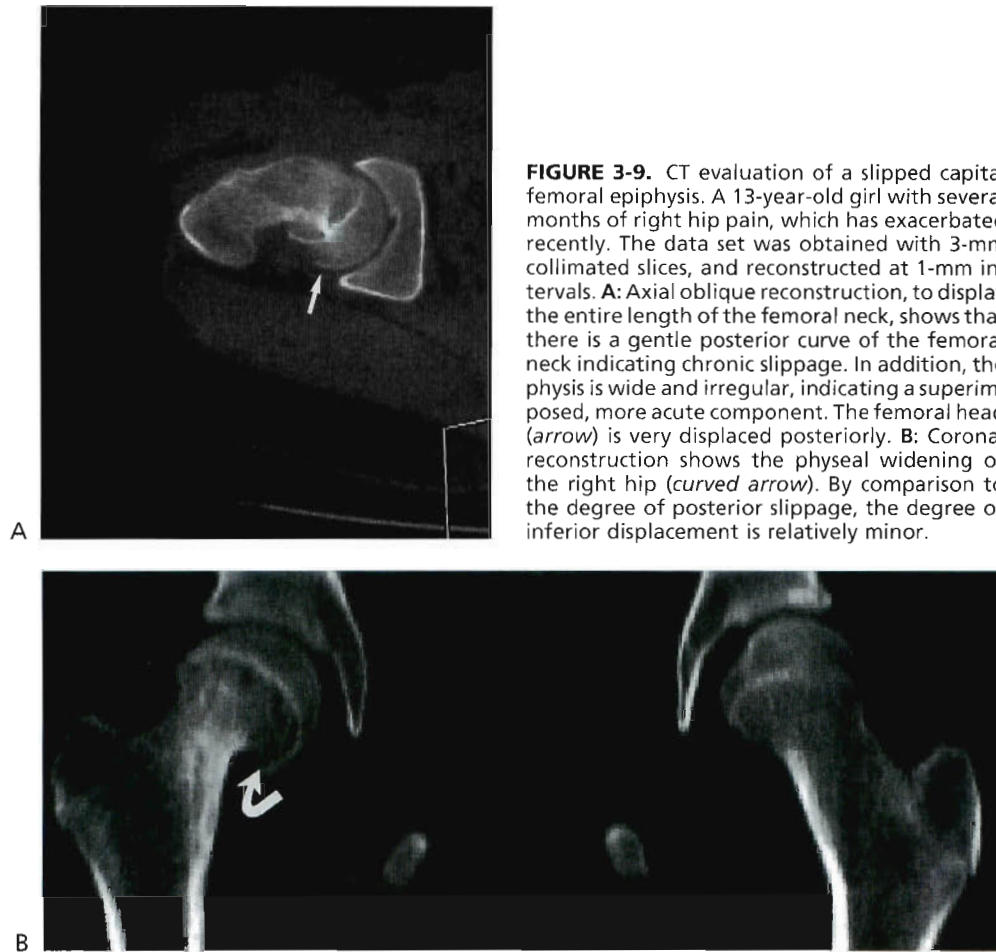


FIGURE 3-9. CT evaluation of a slipped capital femoral epiphysis. A 13-year-old girl with several months of right hip pain, which has exacerbated recently. The data set was obtained with 3-mm collimated slices, and reconstructed at 1-mm intervals. **A:** Axial oblique reconstruction, to display the entire length of the femoral neck, shows that there is a gentle posterior curve of the femoral neck indicating chronic slippage. In addition, the physis is wide and irregular, indicating a superimposed, more acute component. The femoral head (arrow) is very displaced posteriorly. **B:** Coronal reconstruction shows the physeal widening of the right hip (curved arrow). By comparison to the degree of posterior slippage, the degree of inferior displacement is relatively minor.

rior and posterior displacement of the femoral head (Fig. 3-9), and the retroversion of the contralateral femur. In acetabular fractures, 3D reconstructions better demonstrate the relationships between fragments.

In infants with hip dislocation who have undergone reduction and placement of the hips in an abduction spica cast, CT can be used to assess the position of the femoral heads (54). A cross-sectional technique is very useful in this setting, because frontal radiographs fail to show posterior redislocation. The assessment of the position of the femoral head can be done with less than five CT sections (Fig. 3-10). If a low mAs technique is used, the total ovarian dose can be as low as 112 mrad (1.12 mGy) (53). In adolescents and young adults with undetected hip dysplasia, CT with 3D reconstructions demonstrates the configuration and containment of the femoral head, the acetabular architecture, and the narrowing of the joint space (Fig. 3-11). In the spine, vertebral abnormalities and intervertebral fusions are easily demonstrated with CT.

CT can be used for measurements of the orientation of various skeletal structures. *Glenoid version* is the angle be-

tween the main axis of the scapula and the glenoid (55). *Femoral anteversion* is determined by obtaining slices from the femoral head to the lesser trochanter, and slices through the distal femoral condyles. A line through the main axis of the femoral neck and another along the posterior surfaces of the distal femoral condyles form the angle of femoral anteversion. The angle of anteversion is 32 degrees at birth and 16 degrees by age 16 years (56). A more recent study found a mean angle for children of 34 degrees and 22.2 degrees for adults, using CT, and angles of 23.2 degrees and 15.7 degrees, respectively, using MR imaging (57). *Tibial torsion* is determined by obtaining a single slice through the widest portion of the proximal tibial epiphysis and another one through the malleoli. The angle of tibial torsion is formed by a line through the center of the epiphysis (representing the main axis of the proximal tibia), and a line connecting the distal tibial malleolus. External tibial torsion determined by physical examination is normally 4 degrees at birth, and 14 degrees at 10 years of age (58,59). Using CT, a study of 50 adults revealed an external tibial torsion of 37.5 degrees in females and 40.5 degrees in males (60).

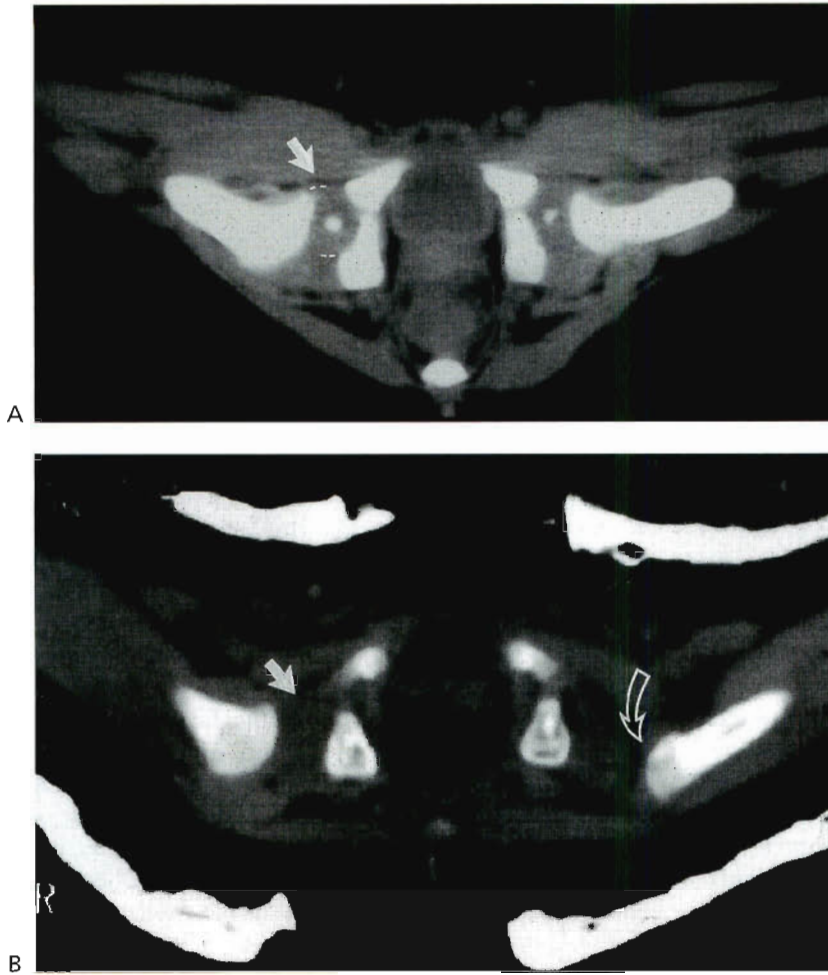


FIGURE 3-10. CT scanning to verify the position of a hip after dislocation of reduction and spica cast placement in two different infant girls. **A:** Normal anatomy. Both hips are located concentrically. The ossification centers are present. *Dotted lines* partially outline the contour of the right cartilaginous epiphysis. **B:** Redislocation of the left hip. The right hip is located concentrically (*closed arrow*). The left hip has redislocated posteriorly. The *open curved arrow* points to the left metaphysis, because the unossified epiphysis is not visible on this slice.

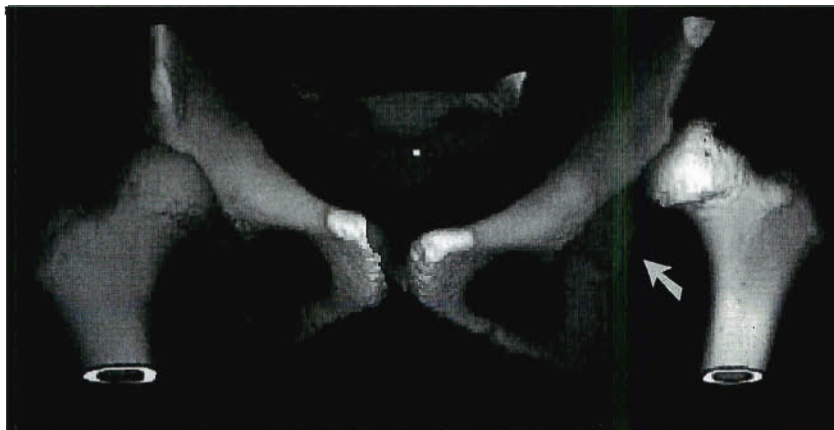


FIGURE 3-11. 3D-CT evaluation of developmental dysplasia of the hip. Surface transparent rendering of a 3D reconstruction of a helical CT in a 10-year-old girl with developmental dysplasia of the left hip shows a poorly developed acetabulum, which is empty (*arrow*). There is also superior subluxation of the femoral head and irregularity of the contour of the capital femoral epiphysis. The data set was obtained with 3-mm collimated slices, and reconstructed at 1-mm intervals.

We were unable to find a systematic large study of tibial torsion in children using CT, which may reflect the decreasing use of these measurements.

Tarsal coalition is evaluated by obtaining thin sections through the hindfoot. The subtalar joint, usually difficult to depict on radiographs, is imaged in the coronal plane. The patient lies horizontally, with the hips and knees in flexion and the ankles in plantar flexion, so that the feet are flat on the CT table. Coronal imaging optimizes the evaluation of talocalcaneal coalitions. Both feet should be studied, because bilateral abnormalities can be seen in up to 81% of patients (61). CT images demonstrate a complete osseous fusion if the coalition is bony, or irregularity of the articular surfaces of the anterior and middle facets if it is fibrous. The subtalar joint is reoriented in an inferomedial direction (62). Calcaneonavicular coalitions, which are usually evident on oblique radiographs, are best seen on sagittal reconstructions (63).

If a calcaneonavicular coalition is found on radiographs, we routinely do not obtain a CT. A recent large series, however, showed that multiple tarsal coalitions may be more frequent than previously thought, with an incidence of 20% (64) and not 5 to 10%, as previously believed. This would argue for obtaining CT studies more often. The accuracy for detecting tarsal coalitions is comparable for CT and MR imaging (65). CT allows easier evaluation of both feet, and it is less expensive and more readily available; we prefer to use CT for the initial evaluation of talocalcaneal coalitions.

Risks and Limitations. The main limitation of CT is that it delivers a high radiation dose (see section on Radiation). Most body parts can only be imaged axially, but with high detail reconstructions, this is a less important limitation.

Utilization Trends. CT has replaced conventional tomography for most applications. In musculoskeletal imaging, CT is the modality of choice whenever evaluation of bony contours is the most important goal.

ULTRASONOGRAPHY

Mechanisms of Contrast

Sonography is based on the application of high-frequency sound pulses and the detection of the reflected echoes. The intensity of the echoes depends on the differences in speed of sound transmission at tissue interfaces. A structure that reflects most of the ultrasound beam is termed highly echogenic, and is bright on ultrasonographic display. Sound-transmitting structures, such as water, allow the passage of the ultrasound beam, and are darker (free of echoes) on the display screen. Higher-frequency sound beams have greater resolution, but less penetration. In musculoskeletal imaging, it is very useful to image the contralateral side, because sub-

tle increases in echogenicity or thickening of soft tissues may be detectable only by comparison. Superficial lesions are sometimes difficult to detect because the ultrasound transducers themselves deform the contour of the structures, but they can be imaged successfully through a soft standoff pad.

Ultrasonography is safe (11), easy to perform, and relatively inexpensive. Images are displayed in real time, and joint motion can be analyzed. Most units are unable to display large fields of view, which limits the depiction of large lesions. The sound beam is wholly reflected by bone, and the cortex is seen as a bright interface with complete shadowing beyond it. Fat, ligaments, and tendons have high echogenicity, but less than that of bone. Cartilage and muscle are of low echogenicity. Articular cartilage is uniformly hypoechoic, whereas epiphyseal cartilage has many internal echoes, which represent the epiphyseal vascular canals. These canals form a parallel array of echogenic lines at birth, but later they tend to converge toward the ossification center. The muscle fibers have a striated appearance, separated by the echogenic epimysium and perimysium (66). Fluid-filled collections, whether filled with watery contents (cysts) or blood (aneurysms), are hypoechoic. Gas is highly echogenic, and is suggested by the "comet tail artifact," a series of echoes that trail a bright echo. The distinctive parallel lines of tendons represent individual echogenic fibers (66). Tissue calcification can produce significant increases in echogenicity. Edema also increases echogenicity because of an increased number of interfaces in the swollen tissues.

Doppler Sonography

When a sound beam hits moving objects, such as blood cells, the frequency of the reflected beam increases when the object is moving toward the transducer, and decreases when the object moves away from the transducer. This is the Doppler effect. Its frequency shifts can be used to assess flow (67). Flow-related Doppler shifts can be displayed as a spectral time-frequency graph, or by superimposing the Doppler information on the gray scale imaging, as occurs with color Doppler and power Doppler sonography. With color Doppler sonography, flow toward the transducer is typically encoded red, whereas flow away from it is encoded blue (12). With power Doppler sonography, only the amplitude of the Doppler signal is shown. Power Doppler sonography has a greater sensitivity to slow flow, but it lacks directional information (13).

Normal Sonographic Anatomy of the Hip

Sonography is a fundamental modality for evaluation of the hip in infants younger than 6 months, because it allows dynamic assessment of articular relationships and depicts the nonosseous structures without radiation exposure (68). Five major structures are displayed: the hypoechoic carti-

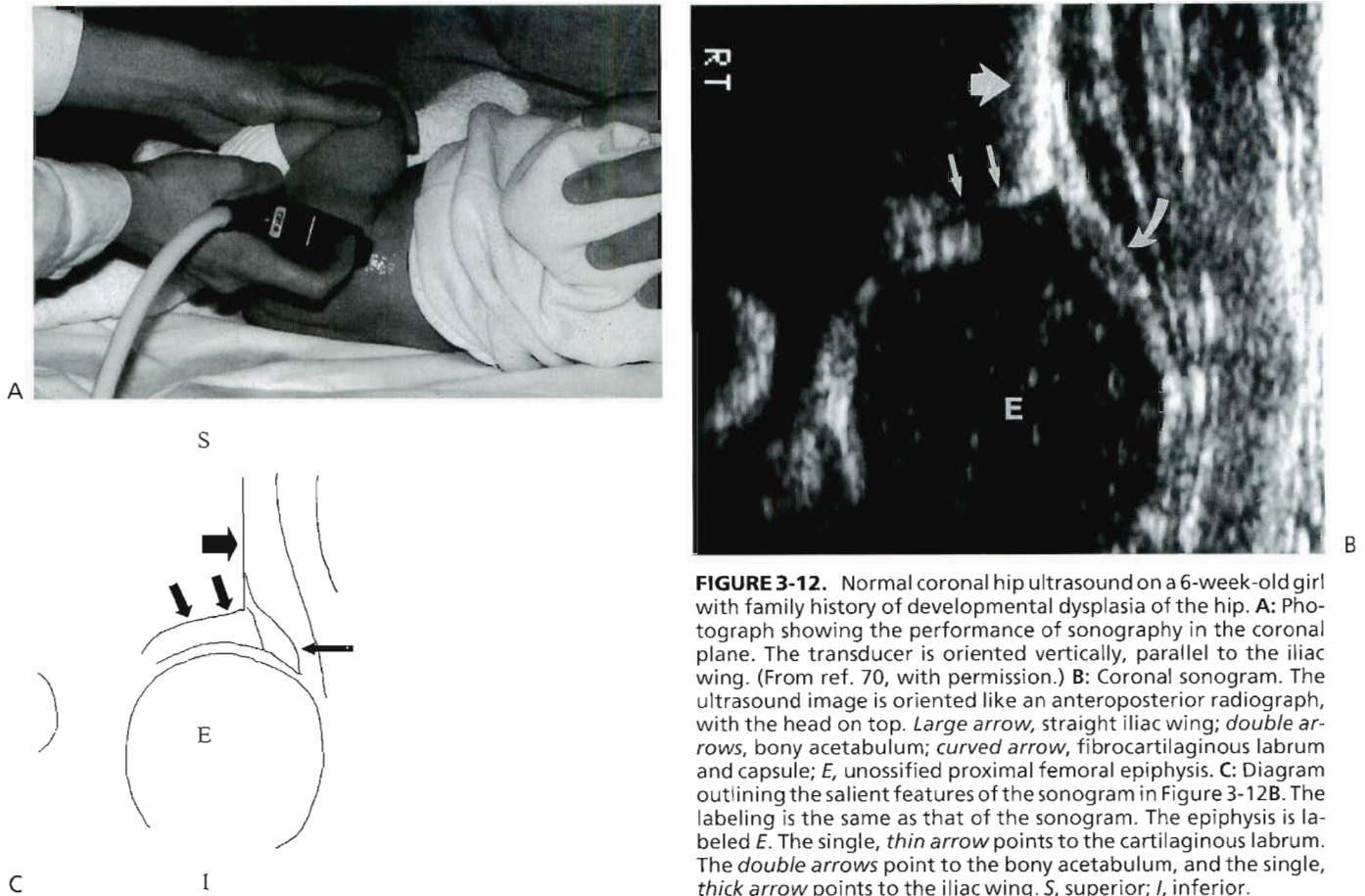


FIGURE 3-12. Normal coronal hip ultrasound on a 6-week-old girl with family history of developmental dysplasia of the hip. **A:** Photograph showing the performance of sonography in the coronal plane. The transducer is oriented vertically, parallel to the iliac wing. (From ref. 70, with permission.) **B:** Coronal sonogram. The ultrasound image is oriented like an anteroposterior radiograph, with the head on top. *Large arrow*, straight iliac wing; *double arrows*, bony acetabulum; *curved arrow*, fibrocartilaginous labrum and capsule; *E*, unossified proximal femoral epiphysis. **C:** Diagram outlining the salient features of the sonogram in Figure 3-12B. The labeling is the same as that of the sonogram. The epiphysis is labeled *E*. The single, *thin arrow* points to the cartilaginous labrum. The *double arrows* point to the bony acetabulum, and the single, *thick arrow* points to the iliac wing. *S*, superior; *I*, inferior.

lages of the proximal femoral epiphysis and acetabulum; the very echogenic bones of the proximal femoral metaphysis and acetabulum; and the echogenic fibrocartilaginous labrum (Fig. 3-12).

Sonography of hip dysplasia is based primarily on coronal and transverse views (69). Both are obtained with the transducer placed lateral to the joint (Figs. 3-12 to 3-14). Graf and Schuler described the coronal view, comparable to a frontal radiograph, to show the morphology of acetabular structures (71). With proper positioning of the transducer, the lateral edge of the iliac bone is depicted as a straight line. The bony acetabular roof is an oblique, slightly concave, much shorter line. Sonograms in which the iliac bone is curved are either too anterior or too posterior, are technically inadequate, and may spuriously enlarge or reduce the size of the acetabular roof. The angle between the iliac wing and the bony acetabulum (the alpha angle) is approximately 60 degrees in normal newborns (72).

The sonolucent cartilaginous acetabulum is more concave than the bony roof, and it is in direct contact with the cartilaginous epiphysis. It blends laterally with the fibrocartilaginous labrum. Cephalad and lateral to the labrum is

the thin echogenic capsule. Superomedially, the capsule is continuous with the fibrous perichondrium, which is attached to the ilium (73). The femoral epiphysis is sonographically homogeneous at birth. The ossification center is seen with sonography several weeks earlier than with radiographs (74). The junction between the cartilage and bone of the proximal femoral metaphysis is an interrupted line. When imaged in internal rotation, the cartilages of the greater trochanter and femoral head are continuous.

Harcke and Grissom have developed the transverse view to examine hip motion and detect subluxation dynamically (75). It is usually obtained with the hip in mild flexion, when the femoral metaphysis obscures the anterior acetabulum. The ischial portion of the acetabulum is a short echogenic line just posterior to the femoral epiphysis. The femoroacetabular relationships can be assessed during abduction and adduction, and during the Barlow maneuver. Alternatively, the transverse view can be obtained with the hip extended, allowing visualization of the pubic component of the acetabulum. The anterior axial view is used to detect adequacy of reduction. The two hips are easily compared. Other views have been useful in specific situations.

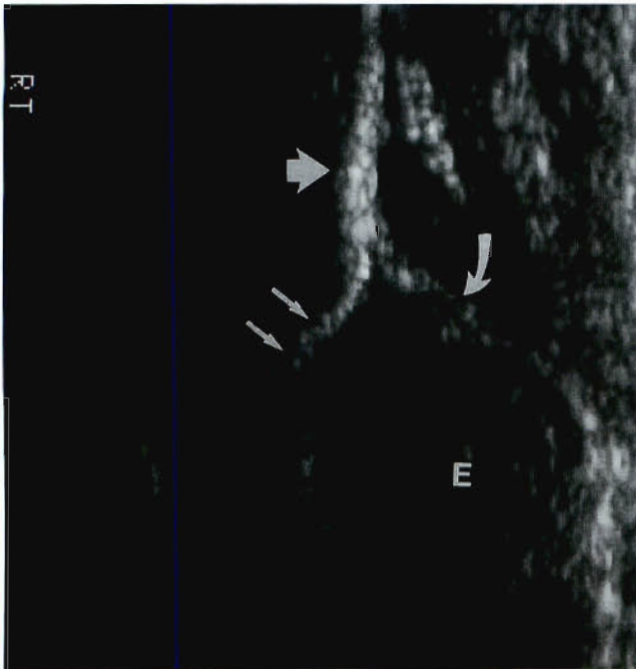
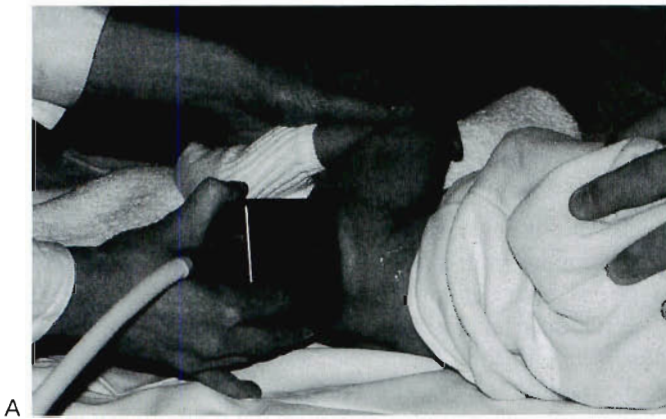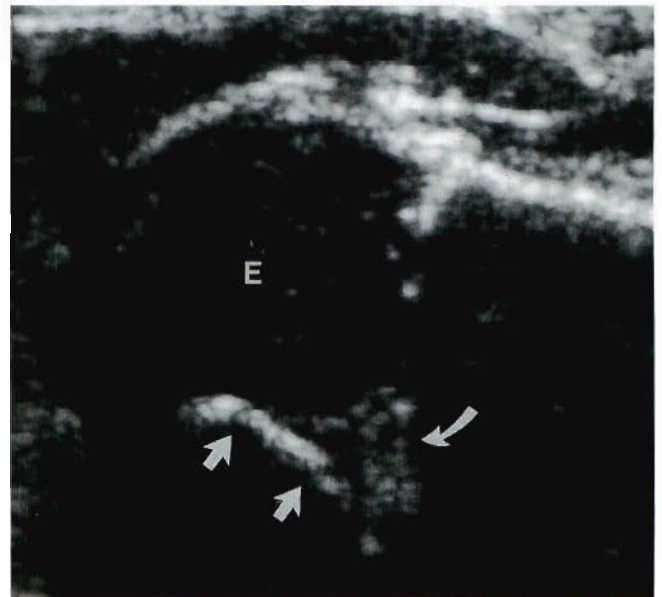


FIGURE 3-13. Coronal sonogram in a 1-month-old girl with bilateral hip dysplasia; only one side is displayed. The femoral head is incompletely covered by the acetabulum. The acetabulum is shallow and has a vertical orientation. There is an echogenic pulvinar deep to the femoral head. *Large arrow*, straight iliac wing; *double arrows*, bony acetabulum; *curved arrow*, fibrocartilaginous labrum and capsule; *E*, unossified proximal femoral epiphysis.

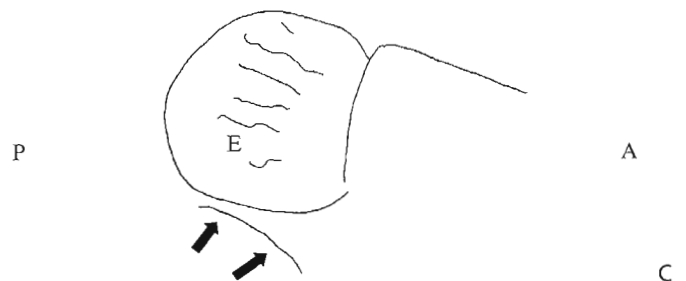


A



B

FIGURE 3-14. Transverse sonogram in a 1-month-old girl with hip dysplasia. **A:** Photograph showing the performance of sonography in the transverse plane. The transducer is oriented horizontally, perpendicular to the iliac wing. In this case, the examination is being done with the hip in flexion, but it can also be done in the neutral position. (From ref. 70, with permission.) **B:** Axial sonogram shows the unossified proximal femoral epiphysis (*E*) being displaced posteriorly with respect to the ischium (*double arrows*). An echogenic pulvinar (*curved arrow*) displaces the femoral head laterally. **C:** Line diagram outlining the salient features of Fig. 3-14B. The labeling is the same as that of the sonogram. The unossified epiphysis is marked *E*. It is continuous with the metaphysis. The two *arrows* point to the ischium. *A*, anterior; *P*, posterior.



C

Main Applications

Developmental Dysplasia of the Hip

In infants less than 6 months of age, we use ultrasonography as the first imaging study performed to detect hip dysplasia. The value of hip sonography is dependent on the experience and skill of the individual performing the study; when an expert operator is not available, a radiograph of the hip is preferred as the initial study. In some parts of Europe, sonography is used to screen the entire newborn population. In Coventry, England, screening of more than 14,000 newborns detected a 6% incidence of sonographic abnormalities. Of these, nearly 80% were normal by 4 weeks and 90% by 8 weeks (76); uncritical acceptance of sonographic abnormalities in the first weeks of life can lead to overtreatment. In the United States, however, hip sonography is usually performed when the physical examination is abnormal or when there are risk factors (77). These include a positive family history, breech delivery, oligohydramnios, and conditions sometimes caused by uterine crowding, such as torticollis, clubfoot, or metatarsus adductus.

Graf has divided hips into various types according to (a) the angle between the acetabulum and the iliac wing (alpha), (b) the angle between the fibrocartilaginous labrum and the iliac wing (beta), (c) the characteristics of the bony roof (good, deficient, or poor), and (d) the appearance of the acetabular rim (angular, round, or flat) (72). Under 3 months of age the hip can appear slightly dysplastic due to immaturity, but any infant hip with an alpha angle under 50 degrees, a beta angle over 70 degrees, or subluxability on the dynamic examination is clearly abnormal. Before 2 weeks of age, hormonally induced ligamentous laxity can confound the evaluation of hip stability; up to 6 mm of posterior displacement of the femoral head with the Barlow maneuver is normal (75). Hip sonography for evaluation of dysplasia should only be performed after this period, when any displacement during the dynamic study is considered abnormal. Graf and Harcke have recommended a unified study in which evaluation of acetabular morphology, primarily done coronally, is done in tandem with the dynamic assessment of joint stability (77). Sonography is of little value when hip dislocation is clinically obvious. When the femoral head is dislocated, the acetabular concavity cannot be adequately depicted, and it is very difficult to align the femoral head with the midplane of the acetabulum. Infants with successfully treated dysplasia should be evaluated with a radiograph at 6 months of age to ensure that the acetabular abnormality has indeed been resolved.

Other Applications

Sonography can also detect femoral head ischemia and hip effusion. Doppler sonography in any plane has been used to show the vascularity of the femoral head of infants and

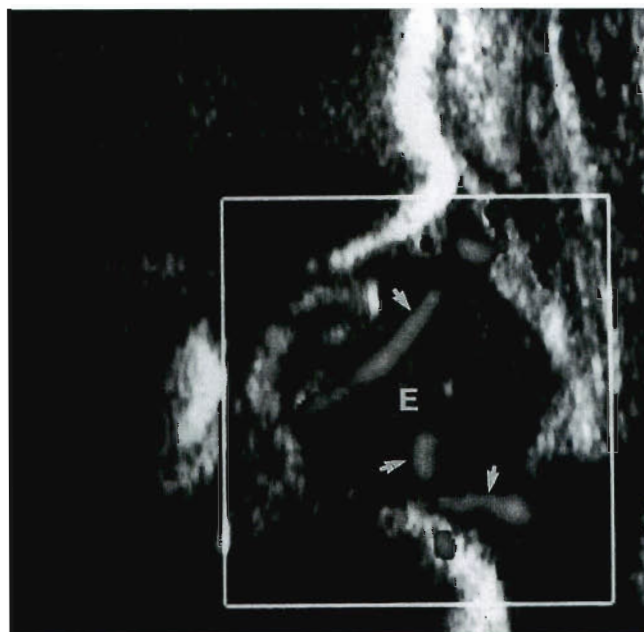


FIGURE 3-15. Power Doppler sonography of the normal hip. In this coronal view, there is clear depiction of flow in the vascular canals (arrows) of the proximal femoral epiphysis (E).

newborns (78) (Fig. 3-15). There are, unfortunately, many pitfalls. Blood flow may be difficult to detect when the infant is moving significantly. Usually, only a few vessels are detected; it is difficult to differentiate normal perfusion from ischemia limited to a portion of the head. The main limitation, however, is that ultrasound cannot be performed through a cast; infants in spica casts, who would be the ideal candidates, cannot be readily examined sonographically.

The evaluation of joint fluid is performed using an anterior approach with the transducer placed in the groin along the femoral neck (Fig. 3-16). The metaphysis, physis, and epiphysis are well seen. An effusion makes the capsule and the joint fluid between the capsule and the femoral neck clearly visible (79). This technique detects as little as 1 cc of joint fluid. There is no relationship between the amount of echogenicity of the joint fluid and its likelihood of being infected. Absence of fluid on sonography speaks strongly against septic arthritis. On Doppler sonography, increased flow in the capsule is sensitive, but not specific for infection (80). Ultimately, if septic arthritis is suspected and fluid is detected, the hip should be tapped and the fluid analyzed. This should be done expeditiously; some prefer to use sonography for confirmation and guidance, whereas others elect to go directly to aspiration and obtain imaging guidance when osteomyelitis is suspected.

Utilization Trends

The use of sonography is increasing rapidly. Sonography is one of the main modalities for evaluation of hip dysplasia.

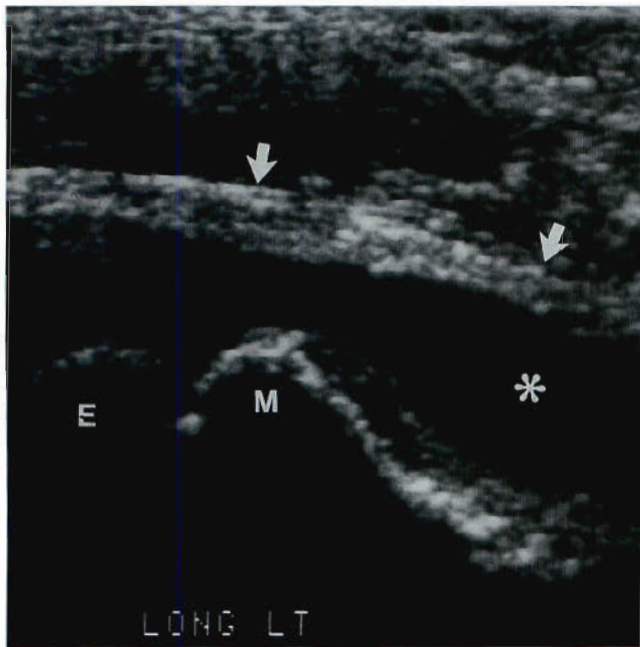


FIGURE 3-16. Large hip effusion in a 3-year-old boy with juvenile rheumatoid arthritis. Ultrasound evaluation reveals a large effusion (asterisk) contained by a thick capsule (arrows). E, epiphyseal ossification center; M, metaphysis.

It is also the most important imaging study in the evaluation of a septic hip. Sonography has become increasingly important in the evaluation of other joints, particularly to show relationships in various positions. The role of sonography in the evaluation of superficial masses in the extremities is expanding; it is commonly used to determine whether masses are cystic, and to evaluate the vascularity of malignant bone tumors. There is also increasing interest in its use for evaluation of complications of osteomyelitis, such as subperiosteal or soft tissue abscess (81). Sonography is particularly useful in patients with metallic hardware suspected of osteomyelitis, in whom MR imaging, CT, and even scintigraphy would have limitations (82). It should be used with caution in osteomyelitis, however, because pus can be isoechoic with normal soft tissues and difficult to detect, and because sonography cannot depict the intramedullary extension of the infection. There has been significant progress in imaging tendinous and ligamentous abnormalities in adults, but little has been done in children.

MAGNETIC RESONANCE IMAGING

Mechanisms of Contrast

MR imaging relies on the application of a radiofrequency pulse to induce resonance in certain nuclei, usually hydro-

gen (83). In order to resonate, the protons need to be aligned in a magnetic field. Following the application of the radiofrequency pulse, the protons relax and emit a radio signal, which is processed to generate an image.

The radiofrequency pulse causes protons, which are aligned longitudinally in the direction of the magnet, to flip 90 degrees into the transverse plane. Once the pulse is discontinued, the protons return to their original state of longitudinal alignment with the main magnetic field. There are two mechanisms of relaxation: T1 relaxation, related to recovery of magnetization in the longitudinal plane; and T2 relaxation, related to decay of magnetization in the transverse plane.

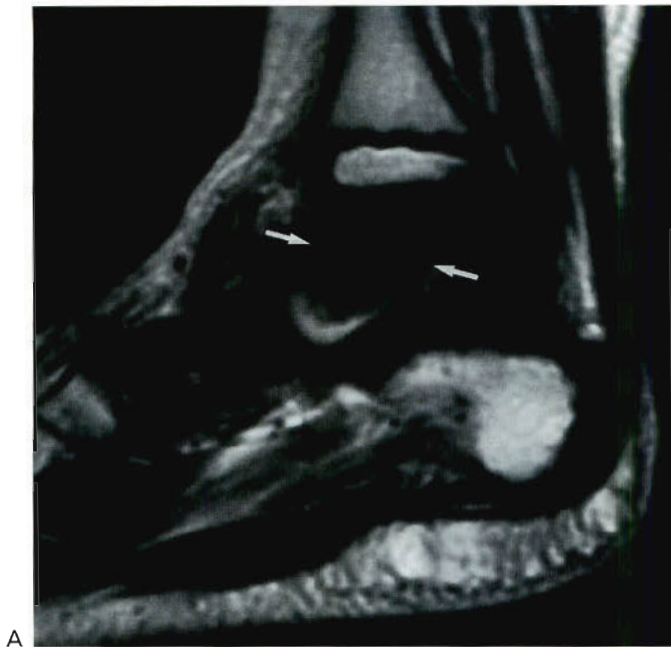
During T1 relaxation, the magnitude of the longitudinal magnetization increases exponentially. The rate of relaxation differs among tissues. The hydrogen protons in fat relax faster than those in water, for example. Contrast on T1-weighted images reflects these differences in relaxation. Because protons in fat relax rapidly, their longitudinal magnetization, and thus their signal intensity, will increase at a faster rate than those in water. On a T1-weighted image, therefore, fat has a high signal intensity, and appears bright. Protons in water, on the other hand, will not have relaxed to the same degree. Thus, on T1-weighted images, water is of low signal intensity, and appears dark (Fig. 3-17).

When the radiofrequency pulse is applied, all the protons are aligned in the transverse plane, and emit signal together. Transverse magnetization is greatest at this time. Subsequently, the protons lose their alignment (dephase) along the transverse plane, losing transverse magnetization and therefore signal intensity. T2 relaxation is the decay in transverse magnetization due to dephasing of the protons. Protons in water relax more slowly than those in fat, so their signal decays at a slower rate. Thus, on an image that reflects differences in T2 relaxation time, the signal intensity of water is greater than that of fat.

Intermediate images (often called proton-density images) are obtained at a time when the signal increase due to T1 relaxation is greatest and the signal decay due to T2 relaxation is smallest. These images have maximal signal, but less contrast.

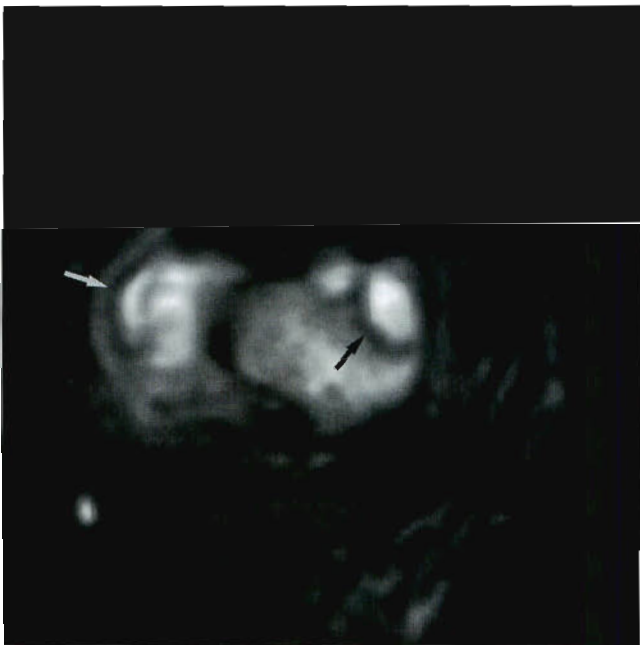
Other factors affecting contrast include magnetic susceptibility and flow. *Magnetic susceptibility* reflects distortion of the magnetic field due to tissue inhomogeneity. In the skeleton, for example, multiple interfaces between marrow fat and bony trabeculae decrease the signal from bones. Magnetic susceptibility accounts for much of the image degradation due to metallic artifacts.

Flow results in decrease in signal, intensity in slower sequences. On most MR images of the skeleton, therefore, vessels appear dark. Paradoxically, in faster sequences, the flow of unsaturated protons into the imaged slice of tissue produces flow-related enhancement.

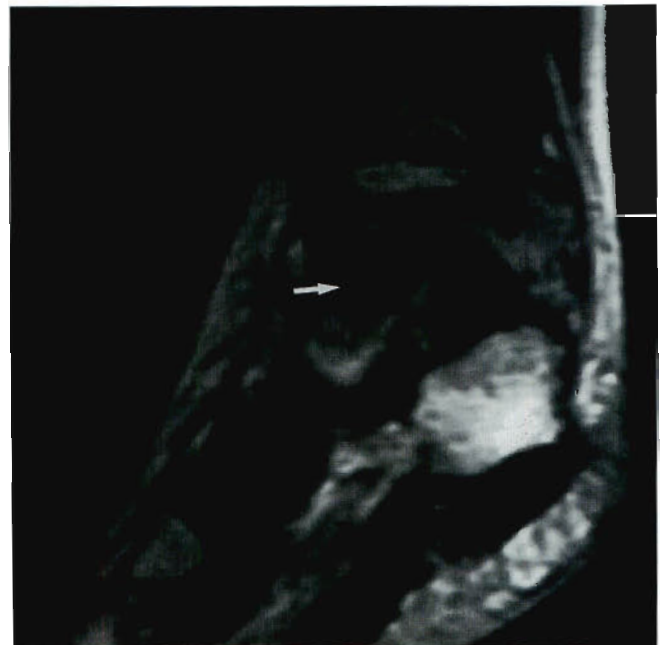


A

FIGURE 3-17. Osteomyelitis of the talus in a 2-year-old boy presenting with foot pain and fever. **A:** Sagittal T1-weighted image of the foot shows decreased signal intensity in the talus (*arrows*). This reflects marrow edema, and suggests osteomyelitis. **B:** Coronal fat-suppressed, T2-weighted image of the same ankle shows that there are two discrete areas of higher signal intensity within the talar dome (*black arrow*). The signal of the marrow of the entire talus is abnormal. There is a joint effusion (*white arrow*). **C:** Sagittal T1-weighted image following the administration of gadolinium shows that most of the talus enhances. The center of the talus, however, does not enhance, indicating a small abscess (*arrow*).



B



C

Clinical Use of Pulse Sequences

Many pulse sequences have been devised over the past several years. Because they are so numerous, and because many have peculiarities that are vendor-specific, it is impossible to review pulse sequences adequately in this setting (84). T1-weighted images are the best to determine the intramedullary extent of a tumor. They are anatomically informative, and can depict marrow edema. T2-weighted images are more sensitive than T1-weighted images for detection of increased water content, as is seen in infection, trauma, or tumor (Fig. 3-17). Obtaining T2-weighted images takes longer, and therefore they are almost exclusively acquired using fast spin-echo techniques. Intermediate (proton density)-weighted images are the best for depiction of anatomy, but provide little contrast resolution. Gradient-recalled echo images are good for evaluating ligaments and cartilage. Spoiled gradient-recalled echo images allow excellent differentiation between cartilage and bone, and show cartilaginous abnormalities well (Fig. 3-18). Short tau inversion recovery (STIR) images are very sensitive to marrow lesions (Fig. 3-19). Fat suppression can be used with any of the sequences mentioned above to maximize optical visual contrast between the lesion and the adjacent tissues.

Contrast Materials

Gadolinium (Gd) is the most widely used contrast agent for musculoskeletal MR imaging. The element with the most unpaired electrons in its outer shell, Gd distorts the local magnetic field. This distortion hastens T1 and T2 relaxation. As mentioned previously, a faster T1 relaxation increases signal intensity on T1-weighted images. After Gd administration, signal intensity on T1-weighted images will be increased in hyperemic areas and decreased in ischemic regions.

Gd is used in ionic and nonionic forms. There is little difference in safety between them, and the images obtained are almost indistinguishable. There is, however, one important difference: nonionic Gd diffuses freely into cartilage, whereas ionic Gd does not. Negatively charged ionic Gd is bound to diethylenetriamine pentaacetic acid (DTPA) to form $\text{Gd}(\text{DTPA})^{2-}$. $\text{Gd}(\text{DTPA})^{2-}$ penetrates cartilage only when the similarly charged glycosaminoglycan molecules break down. This suggests that ionic Gd can map glycosaminoglycan content in cartilage (85).

Gd compounds are not nephrotoxic. Serious adverse events have been reported at a rate of 1/20,000 (86) in adults, but are probably much less frequent in children. The only absolute contraindication for use of $\text{Gd}(\text{DTPA})^{2-}$ is pregnancy. There is some *in vitro* evidence suggesting that Gd may predispose to erythrocyte sickling. Contrast, however, has been used to evaluate patients with sickle cell disease, without complications (87).

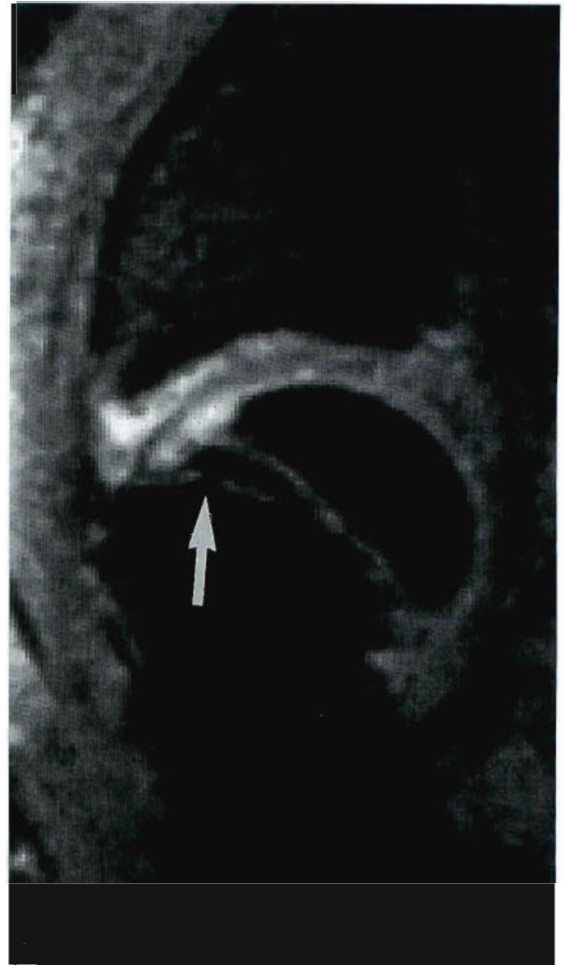


FIGURE 3-18. MR evaluation of a Salter-Harris type 1 fracture of the proximal femur. This 14-year-old boy had a severe trauma to the hip. Sagittal reconstruction of a 3D, fat-suppressed, spoiled gradient-recalled echo acquisition reveals a posterior displacement of the femoral head. The separation of the femoral physis from the metaphysis is seen as a dark cleft (arrow).

Intravascular Gd diffuses rapidly into the intracellular space. It shows increased vascularity in inflamed synovium, infected marrow, traumatized bone, and active tumor. It is perhaps most useful in showing areas devoid of blood flow, such as an abscess in bone or soft tissues, necrotic tumor, or an ischemic femoral head. When injected intravenously, Gd can also be used to obtain MR angiographic images of the arterial and venous systems (Fig. 3-19).

Injected intraarticularly, Gd leads to MR arthrographic images (Fig. 3-20). MR arthrography has revolutionized imaging of the shoulder and hip, and is the most reliable way to diagnose labral tears in these joints.

Normal Age-related Changes and Variants

Age-related transformations of cartilage to bone, and of hematopoietic to fatty marrow, strongly influence the MR

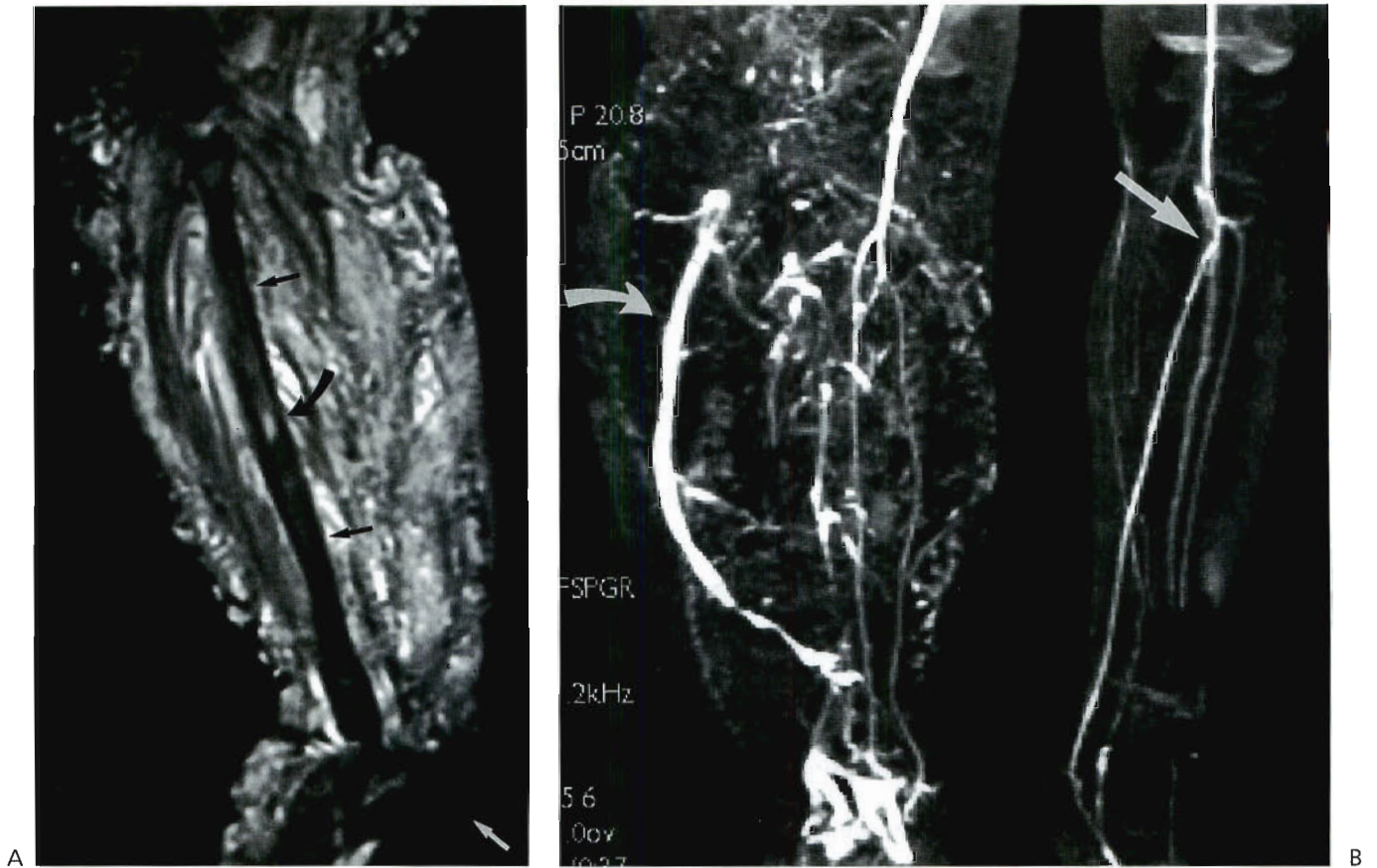


FIGURE 3-19. Marked deformity of the right limb of a 3-year-old boy with Klippel-Trenaunay syndrome. **A:** Sagittal fast short tau inversion recovery (STIR) image at the level of the fibula (*straight black arrows*) shows that there is extensive involvement of the subcutaneous tissues, sparing the heel (*white arrow*). The marrow of the midfibula is abnormal (*curved black arrow*). **B:** 3D contrast-enhanced magnetic resonance angiography shows that the major arteries are intact, but that there is a large superficial draining vein (*curved arrow*). The normal trifurcation of the contralateral side is clearly shown (*straight arrow*).

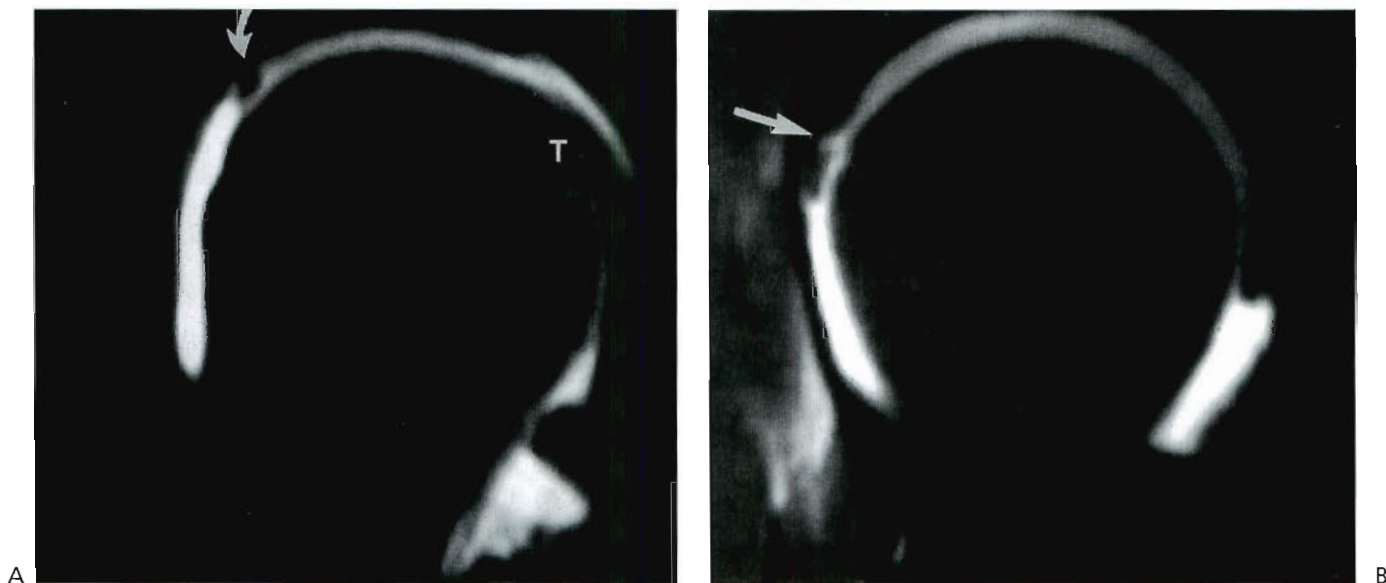


FIGURE 3-20. MR arthrography in a 25-year-old woman with hip dysplasia and hip pain. **A:** Coronal fat-suppressed, T1-weighted image after the intraarticular administration of gadolinium shows the ligamentum teres (T) and the transverse ligament. There is irregularity of the superior labrum (*arrow*). **B:** Oblique sagittal image of the same patient shows that the irregularity extends to the anterior labrum (*arrow*).

appearance of the growing skeleton. Epiphyseal cartilage is of homogeneous signal intensity at birth; it has intermediate signal intensity on T1-weighted images and low signal intensity on T2-weighted images and STIR images. During the first years of life, epiphyseal cartilage becomes hypointense in weight-bearing regions. Later, signal intensity increases in areas of active ossification (88). The secondary ossification center is initially spherical, but becomes hemispherical as the ossification center abuts the physis.

Epiphyseal vascular canals are visible after the intravenous administration of gadolinium (89). Enhancement of these vascular canals excludes epiphyseal ischemia. The physis is of high signal intensity on most pulse sequences. It is a few millimeters thick, and becomes progressively undulated as the child matures. With physeal closure, the cartilage loses signal intensity and ultimately disappears (90).

Because of its high water content, normal hematopoietic marrow is of low signal intensity on T1-weighted images, intermediate signal intensity on conventional T2-weighted and STIR images, and high signal intensity on fast spin-echo T2-weighted images and STIR images (91). These imaging characteristics closely resemble those of diseased fatty marrow. It is therefore important to know the normal distribution of hematopoietic marrow, which changes greatly with age. Conversion of hematopoietic to fatty marrow begins in the epiphyses and diaphysis, then advances from the diaphysis into the metaphyses. In the extremities, conversion begins in the fingers and toes, and ends in the proximal humeral and femoral metaphyses. In the axial skeleton, hematopoietic marrow persists throughout life (2).

Main Applications

Spinal Disorders

MR imaging depicts the vertebral bodies, disc spaces, spinal cord, epidural space, and nerve roots, in excellent detail. In infants, it evaluates abnormalities of segmentation very well. The normal conus medullaris is at the L2 level. If the conus is caudal to it, the cord may be tethered. Infections and tumors involving the epidural and subarachnoid spaces are best demonstrated with Gd-enhanced imaging. MR imaging is the best modality for evaluating protrusion or herniation of the discs, spinal stenosis, and nerve root compression, all of which are uncommon in the first decade.

Joint Disorders

MR imaging demonstrates the contour of the cartilaginous structures and the marrow, and can detect synovial abnormalities. In complicated cases of DDH, MR imaging depicts the position of the femoral head before and after reduction,

and detects obstacles to reduction (pulvinar, interposed psoas tendon, deformed labrum, or capsular infolding) (92–95). This can be done less invasively than with arthrography, although arthrography remains the best technique for guidance during the operative procedure. After placement of the hip in a cast, the reduction of the hip can be verified without the radiation required for a CT. Gd-enhanced MR imaging may detect ischemia related to abduction during treatment for DDH (96,97). If it becomes cheaper and more available, MR imaging may become the procedure of choice for evaluating many of the complex problems in hip dysplasia.

MR imaging can also be useful in the early diagnosis of LCP disease. Although radiographs are often diagnostic at presentation, MR imaging can be helpful when the clinical presentation is unclear. Marrow edema is seen early on MR images; suspected avascular necrosis can be confirmed by lack of Gd enhancement of the femoral epiphysis (98). At a later stage of the disease, MR imaging can be useful prognostically by showing physeal and metaphyseal abnormalities (99) and the extent of marrow involvement (100–102). In advanced disease, MR imaging shows the containment of the femoral head and the congruity of the articular surfaces (38). These factors can be best assessed when imaging in multiple positions, similar to those studied during arthrography (103).

Osteomyelitis

MR imaging has been shown to have sensitivity and specificity greater than 90% for detecting bone infection in children (104). It is useful for detection of marrow abnormality by showing edema and increased blood flow in the infected bone (Fig. 3-17). Any MR imaging of osteomyelitis should include Gd enhancement to ascertain whether the infected volume contains drainable pus. An abscess is seen as a non-enhancing (dark) center (the collection of pus) surrounded by a ring of enhancing tissue in the abscess wall (105). In spinal osteomyelitis, MR imaging is crucial for detecting epidural abscess and extension of the infection into the paraspinal soft tissues. MR imaging is preferable to scintigraphy (106,107) in pelvic osteomyelitis, where bony geometry is complex and soft tissue involvement is often the most important component of the infection. MR imaging is also recommended in patients who do not begin to respond after 48 hours of antibiotic therapy to exclude a subperiosteal or soft tissue abscess. It is useful in osteomyelitis involving the physis, in which adequate mapping of the infection is important to minimize physeal damage during surgical drainage.

The question of when to use MR imaging for osteomyelitis is not resolved (108). MR imaging is superior to scintigraphy in that it shows whether there are drainable collections in the bone, subperiosteal space, and soft tissues. The main

advantage of scintigraphy over MR imaging is that it can show the entire skeleton. We recommend MR imaging whenever the disease is localized, and scintigraphy when the affected area cannot be defined (as in a difficult-to-examine infant or young child), or when the disease has a high likelihood of being multifocal (as in a newborn).

Disorders of the Epiphysis, Physis, Articular Cartilage, and Meniscus

MR imaging helps in the evaluation of epiphyseal separation related to birth trauma or child abuse (109,110). MR imaging also detects extension of a lateral or medial condylar fracture into the unossified epiphysis of the elbow (111–115). A patellar sleeve fracture is shown by MR imaging as a separation between the cartilage and bone of the lower pole of the patella (116). MR imaging can show occult fractures in children and adolescents; just like with infections, it is better to use MR imaging, a more specific test, whenever the symptoms are localized. On the other hand, scintigraphy is preferable when the clinical picture is less well-defined, as in the limping young child.

Repeated trauma to the physis of young gymnasts may produce focal areas of physeal widening, and sometimes transphyseal bridging. These are demonstrated well on MR images (117). Distal radial physeal dysfunction results in positive ulnar variance. In these patients, MR imaging can show associated tears of the triangular fibrocartilage complex. Other sports-related injuries can affect other physes in the same manner. Similar chronic physeal injury can be seen in ambulatory meningomyelocele patients in whom impaired sensation and continued motion result in repeated physeal damage.

In patients with a suspected posttraumatic bony bridge, MR imaging can define the size and location of the bridge, as well as the percentage of the physis affected by the abnormality (111,118,119). A 3D, fat-suppressed, spoiled gradient-recalled echo sequence provides most, if not all, of the information required to assess growth arrest (120,121). The ratio between the area of the bridge and the area of the physis can be calculated on an axial map (122), to ascertain the resectability of the bridge.

In osteochondritis dissecans, MR imaging can show whether the articular cartilage overlying the osteochondral injury is ruptured, the size of the osteochondral fragment, the stability of the fragment, and the presence of loose bodies. High-signal-intensity fluid, on T2-weighted images between the parent bone and the fragment, indicates that the fragment is unstable, even if the overlying cartilage appears to be intact (123).

Meniscal and ligamentous injuries have a similar MR imaging appearance in children and adults (124). Meniscal tears, which are usually vertical in children (125), should not be confused with the intrameniscal nutrient vessel. Meniscal

vessels are horizontal, central, originate from the capsular attachment, and do not extend to the articular surface (126).

Tumors

The length of an intramedullary tumor is best depicted on T1-weighted images with a large field of view (Fig. 3-21). T1-weighted images also depict skip lesions and metastases or multifocal disease in the contralateral extremity (127). Higher-resolution postcontrast images show involvement of the epiphysis and joint space. Extension into the joint, although uncommon, is generally extrasynovial. In the knee, it is shown by MR images along the cruciate ligaments (128). Axial images show whether the lesion arises in the medullary cavity, in the surface of the bone (cortex or periosteum), or in the soft tissues. They also help detect involvement of the vessels (particularly the popliteal vessels) and of adjacent muscles (Fig. 3-21).

The dimensions of the tumor should be measured in orthogonal planes. For planning of surgery or radiation therapy, it is important to measure the distances between the tumor and the nearest articular surface, and between the tumor and the adjacent physis (129).

Risks and Limitations

There are no known harmful physiologic effects on human beings of magnetic fields as high as 10 T (most clinical magnets have field strengths ranging from 0.5 to 1.5 T (130). Switched gradient fields can produce peripheral nerve stimulation, but this is not seen in routine clinical practice, and is not considered harmful (131). The real dangers in MR imaging come from metallic devices and pieces of metal in the body (132). Pacemakers are an absolute contraindication to MR imaging. MR imaging is also contraindicated in patients with shrapnel, bullets, or other metallic objects. Most orthopaedic hardware can be imaged safely, because these devices are not ferromagnetic, and they are well-secured in the body. External fixators, however, are usually contra-indicated. Detailed information about the safety of devices and objects in the MR environment is available in the excellent publications (periodically updated) by Schellack and Kanal (133) and at their web site (<http://Kanal.arad.upmc.edu/mrsafety.html>). Orthopaedic hardware can cause significant artifact that limits the evaluation of adjacent tissues. The artifact is less with titanium hardware, with hollow objects, or if the orthopaedic devices are aligned with the magnetic field. Some pulse sequences minimize metallic artifacts (134).

Perhaps the greatest limitation of MR imaging is its cost (Table 3-3). The greater the field, the stronger the signal resonating from the protons, but the more expensive the equipment.

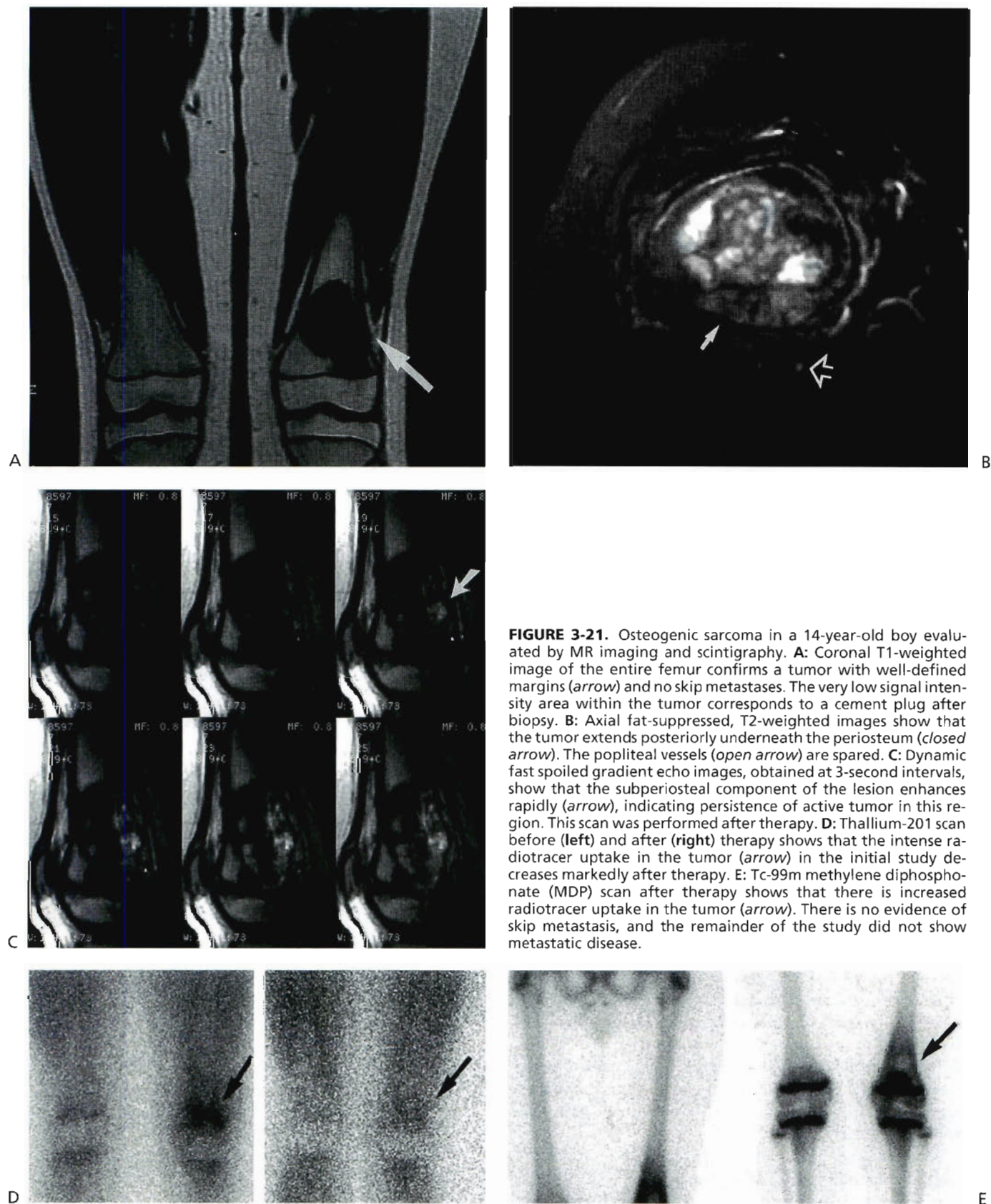


TABLE 3-3. RELATIVE COSTS OF RADIOGRAPHIC PROCEDURES (NORMALIZED TO CONVENTIONAL RADIOGRAPHS)

MR	
Enhanced	8
Unenhanced	6
CT	
Enhanced	5
Unenhanced	4
Bone scintigraphy	
3-Phase with magnification	6.5
SPECT	3.5
Hip ultrasound	1.3
Radiography: 2 views of hip	1

SPECT, single-photon emission computed tomography.

Utilization Trends

MR imaging is the main cross-sectional imaging modality for evaluating the pediatric skeleton. Joint pathology, particularly in the knee, shoulder, elbow, and ankle, is almost exclusively evaluated with MR imaging. Its use in the hip is increasing. MR imaging is the most important modality for detecting tumor extent, and is increasingly used in musculoskeletal infection and trauma. In a child with complex trauma or suspected osteomyelitis needing imaging beyond radiographs, we recommend the following. If the symptoms and signs are poorly defined, or if the disease has a high likelihood of being multifocal (e.g., child abuse or multifocal osteomyelitis), scintigraphy is preferred. If the disease can be localized MR imaging is usually the best modality because of its superior resolution and its capability to show cartilage and soft tissues in addition to bone.

NUCLEAR MEDICINE

Mechanism of Contrast

Radiation emitted by a radiopharmaceutical within a patient is imaged in nuclear medicine studies. Most radiopharmaceuticals consist of a radionuclide bound to a ligand whose distribution reflects a physiologic function. The vast majority of clinical applications rely on detection of gamma rays emitted during decay of technetium-99m (Tc-99m), iodine-123 (I-123), iodine-131 (I-131), gallium-67 (Ga-67), and indium-111 (In-111) or x-rays emitted during decay of thallium-201 (Tl-201). Radionuclides that emit positrons, which then interact with free electrons in matter to produce gamma rays, are also used. Positron emission tomography (PET) uses radionuclides, such as fluorine-18 (most often bound to glucose), and isotopes of oxygen, nitrogen, and carbon to assess regional tissue physiology. The use of positron-emitting radionuclides has mostly been limited to cen-

ters with immediate access to a cyclotron. Recent improvements in regional distribution methods for these unstable short-lived radionuclides, along with advances in imaging technology, promise to greatly change the practice of nuclear medicine over the next decade.

The primary imaging instrument used in nuclear medicine is the gamma camera. In a gamma camera, scintigraphic images are produced by gamma rays or x-rays as they strike a detector. The field of view of a typical gamma camera is 40 cm × 50 cm. Dynamic images may be obtained by continuous image acquisition, before a radiopharmaceutical becomes fixed to its target tissue, or while a radiopharmaceutical is being excreted. Static images show the distribution of a radiopharmaceutical at a particular point in time. These are usually obtained after tissue fixation. Scintigraphic imaging is most often displayed two-dimensionally (planar imaging), but can also be performed in a way that enables 3D tomographic display.

Skeletal Scintigraphy

Skeletal scintigraphy is performed with Tc-99m-labeled diphosphonates. Diphosphonates are analogs of pyrophosphate, a normal constituent of bone. Within 4 hours of intravenous administration, 40% to 60% of administered radiopharmaceutical localizes in the skeleton, concentrating in amorphous calcium phosphate and crystalline hydroxyapatite. The remainder is excreted by the kidneys.

In determining the radiopharmaceutical dose to be administered for pediatric skeletal scintigraphy, the goal is to keep the child's absorbed radiation dose at a minimum, while retaining the ability to obtain a study of diagnostic quality. Pediatric doses of radiopharmaceuticals are generally calculated by adjusting recommended adult doses according to body weight or body surface area. For neonates and infants, the minimal total dose, below which a study will be inadequate, is given. The minimal total dose is determined by the type of examination, the time over which the examination is to be performed, and the characteristics of the imaging system being used (135). The units of administered doses are the curie (radioactivity of a sample decaying at a rate of 3.7×10^{10} disintegrations per second), or its newer *Système Internationale* (SI) equivalent, the becquerel (radioactivity of a sample decaying at a rate of 1 disintegration per second). For scintigraphy with Tc-99m methylene diphosphonate (MDP), we administer a dose of 0.2 millicuries (mCi) per kg, or 7.4 megabecquerels (MBq), per kg. The minimum dose administered is 1.0 mCi (37 MBq) when only skeletal-phase images are obtained, and 2.0 mCi (74 MBq), when multiphase imaging is indicated. The maximum administered dose is 20 mCi (740 MBq).

At our institution, simple immobilization techniques have proven sufficient, and sedation is rarely required for skeletal scintigraphy in children. This is true even in young

children, provided that the imaging team takes time to gain the trust and allay the anxieties of the child and the parents.

Skeletal scintigraphy may include angiographic-phase, tissue-phase, and skeletal-phase imaging. When all three phases are obtained, the study is referred to as a three-phase bone scan. Skeletal-phase imaging is performed for all indications. The need to include radionuclide angiography- and tissue-phase imaging depends on the clinical question. A three-phase bone scan is routinely performed when musculoskeletal infection is suspected, and may help evaluate benign and malignant bone tumors and some traumatic injuries.

For radionuclide angiography, the patient is positioned so that the region of highest clinical concern is within the field of view. Recording begins immediately after the administration of a radiopharmaceutical as a rapid bolus and continues for 60 seconds. During the angiographic phase, radiopharmaceutical distribution reflects regional perfusion. Immediately following the radionuclide angiogram, static tissue-phase imaging may be performed of the regions of interest. Tissue-phase images, sometimes referred to as "blood pool images," depict tracer in the blood vessels and soft tissue. Early tracer localization in bone, particularly at sites of active bone formation, is also shown. Static skeletal-

phase imaging is performed between 2 and 4 hours after radiopharmaceutical administration, depending on the specific Tc-99m-labeled diphosphonate used. By this time the tracer has almost completely cleared from the blood and soft tissues, and is seen principally in the skeleton and, in variable amounts, in the kidneys and bladder. More delayed skeletal-phase images may be useful when clearance from the blood and soft tissues is slow. This is rare in children. The highest skeletal-phase localization of Tc-99m-labeled diphosphonates occurs in areas of high blood flow, active bone growth, and high osteoblastic activity.

Optimal performance of skeletal scintigraphy in children requires the ability to depict normal and abnormal Tc-99m-labeled diphosphonate distribution in anatomically small structures, in anatomically small regions within larger structures, and in metaphyseal bone adjacent to the highly diphosphonate-avid physis. The choice of collimator, which is the component of the gamma camera that projects the emitted gamma rays or x-rays onto the detector, is therefore extremely important. Skeletal scintigraphy of children should be performed with high-resolution or ultrahigh-resolution collimators. "All-purpose" collimators, which are appropriately used for imaging adult patients, do not provide the resolution needed for pediatric studies.

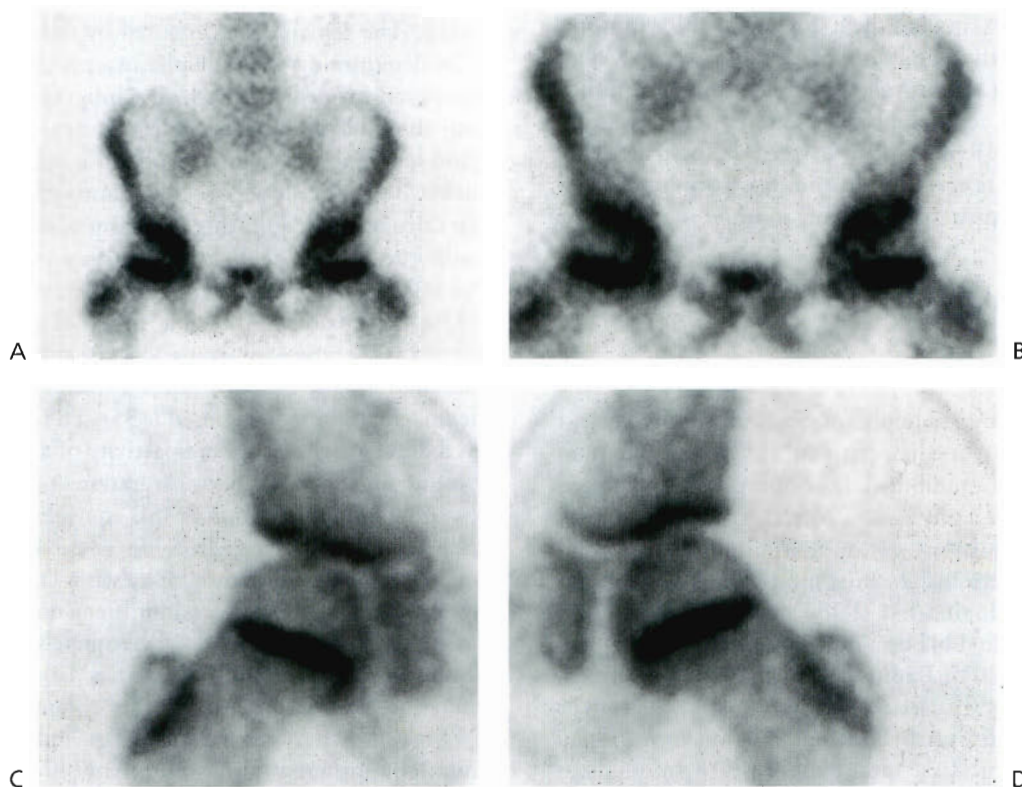


FIGURE 3-22. Comparison of high-resolution planar imaging of the pelvis without (A) and with (B) postprocess zoom, and pinhole imaging of the hips (C,D). Anatomic detail is best demonstrated with pinhole images, but the field of view is restricted.

Magnification is useful when resolution superior to that provided by high-resolution or ultrahigh-resolution collimators is required for skeletal-phase imaging. Two general magnification methods are available to nuclear medicine practitioners. *Electronic magnification* includes acquisition and postprocess zoom. Acquisition zoom limits an acquired image to a portion of a gamma camera's field of view, thereby concentrating more pixels on an object of interest. Postprocess zoom is performed on display systems by increasing the size, but not the number, of pixels in the central portion of a gamma camera's field of view. *Collimator magnification* involves the use of a pinhole or converging collimator. Collimator magnification, unlike electronic magnification, improves system resolution. A pinhole collimator is capable of providing substantial improvements in system resolution, whereas relatively modest gains are provided by a converging collimator (Fig. 3-22). Pinhole collimation provides the highest spatial resolution (1.5–2.0 mm) attainable in clinical nuclear medicine (136). This level of resolution is often crucial in assessing small structures, such as the femoral capital epiphyses (Figs. 3-23 and 3-24), and in evaluating metaphyseal bone abutting the physes. A pinhole

collimator is an essential component of nuclear medicine imaging systems that are used in children.

The pinhole collimator must be close to the object of interest, at or just above the skin surface, for most clinical studies. This limits the field of view and increases imaging time. Imaging a single hip using a pinhole collimator will typically require 10 to 20 minutes. In contrast, the acquisition time for an image of both hips and the entire pelvis obtained using a high-resolution parallel hole collimator is typically approximately 5 minutes. Despite this limitation, pinhole images should be obtained when high-resolution or ultrahigh-resolution planar imaging is equivocal for indicating or excluding abnormalities in small structures or metaphyseal bone. Pinhole imaging should also be strongly considered when the clinical suspicion of pathology at one of these sites is high, and high-resolution or ultrahigh-resolution planar imaging appears normal.

Using similar principles to those employed in MR imaging and CT, the gamma camera system can be rotated around the patient to obtain tomographic images. This technique, single-photon emission computed tomography (SPECT), provides better 3D lesion localization and greater

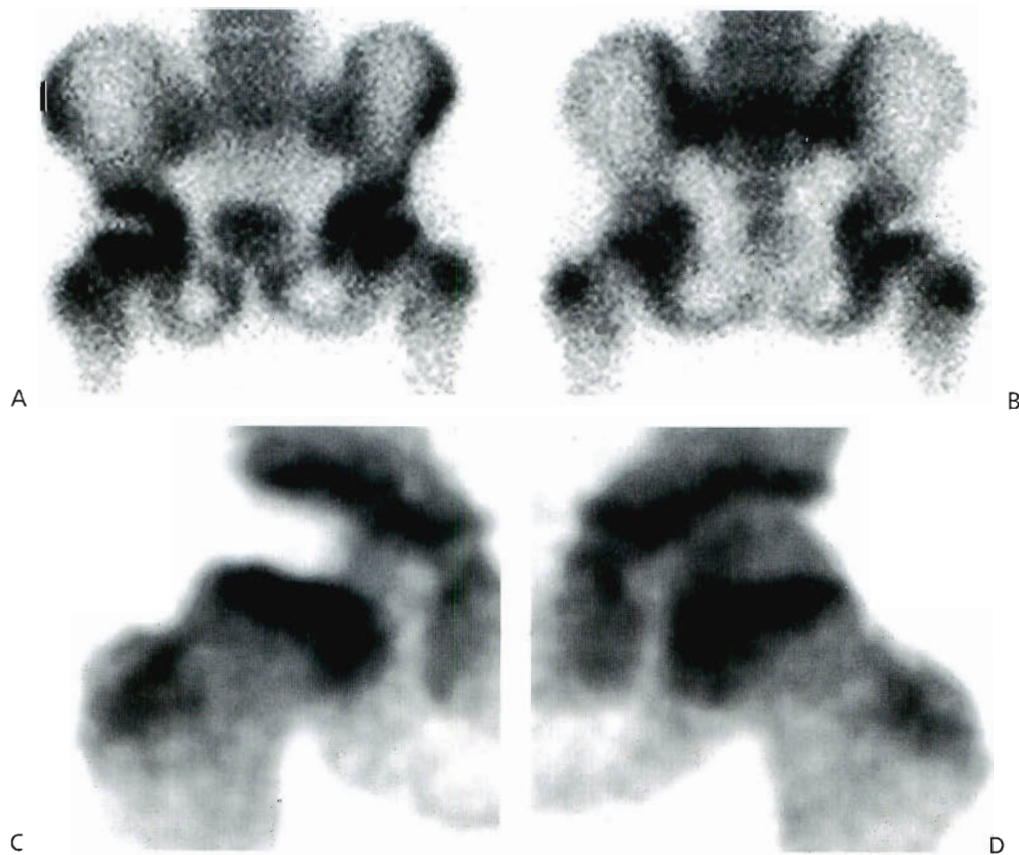


FIGURE 3-23. Legg-Calvé-Perthes disease. Absence of Tc-99m methylene diphosphonate (MDP) uptake in the right femoral capital epiphysis is identifiable on high-resolution images (A, anterior; B, posterior projection). This is shown unequivocally by anterior projection pinhole imaging (C, right hip; D, normal left hip). (From ref. 136, with permission.)

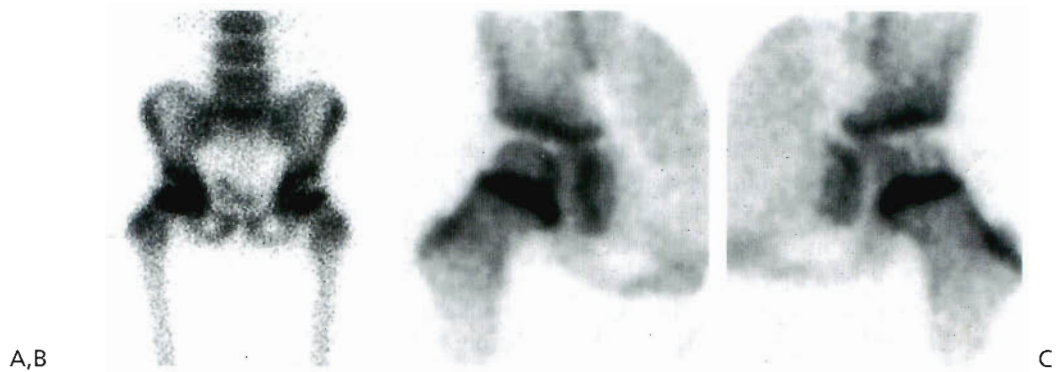


FIGURE 3-24. Transient synovitis with vascular tamponade. Preserved, but decreased Tc-99m methylene diphosphonate (MDP) uptake in the left femoral capital epiphysis is shown less convincingly on the high-resolution image (A) than with pinhole magnification imaging: normal right hip (B), left hip (C). (From ref. 136, with permission.)

contrast than does planar imaging. For evaluating complex structures, such as the spine and pelvis, the 3D properties of SPECT more than compensate for a spatial resolution slightly lower than that of planar imaging.

Familiarity with the normal distribution of Tc-99m-labeled diphosphonates, within the skeleton at different ages, is essential to differentiate normal variations from pathologic conditions (137,138). Uptake of Tc-99m diphosphonate is high in long-bone physes and in physal equivalents of the flat bones. This high, but physiologic, uptake decreases gradually with age, but may persist even after the growth centers appear closed radiographically. A structure that has not begun ossification has no Tc-99m diphosphonate uptake. For example, absent uptake is normal (if symmetrical) in the femoral capital epiphyses during the first 6 months of life. Similarly, the tarsal navicular, which ossifies between the ages of 1 and 3.5 years in girls and between 3 and 5.5 years in boys, is also not visualized when cartilaginous; absence of uptake should not be misinterpreted for Köhler disease (130,139). Comparison of side-to-side symmetry of Tc-99m-labeled diphosphonate localization is valuable, but will not always prevent mistaking the normal for the abnormal. In the ischiopubic synchondroses, which typically ossify between the ages of 4 and 12 years, asymmetric ossification and Tc-99m-labeled diphosphonate localization common (140,141).

Main Applications

There are numerous indications for skeletal scintigraphy in children. Skeletal scintigraphy derives its value from a high sensitivity for detecting osseous pathology and an ability to evaluate the entire skeleton with relative ease.

Skeletal scintigraphy can show abnormalities within diseased or injured bone, well before radiographic changes become apparent. This is particularly important with osteomyelitis, which typically produces abnormal Tc-99m-

labeled diphosphonate uptake within 24 to 48 hours (Fig. 3-25), whereas radiographic osseous manifestations are seen after 7 to 10 days. The high sensitivity of skeletal scintigraphy enables diagnosis of avascular necrosis, detection of skeletal metastases, and identification of traumatic injuries, before radiographic manifestations develop. Among traumatic injuries, skeletal scintigraphy is most important for identifying lower-extremity injuries of toddlers and stress injuries of young athletes. A higher sensitivity of skeletal scintigraphy, compared to radiography, for rib fractures and diaphyseal injuries in abused infants and children, makes skeletal scintigraphy useful when child abuse is suspected. For this indication, it must be emphasized, however, that the radiographic skeletal survey is the imaging study of choice, because scintigraphy often fails to detect linear skull fractures and certain metaphyseal injuries. In child abuse, skeletal scintigraphy complements the radiographic skeletal

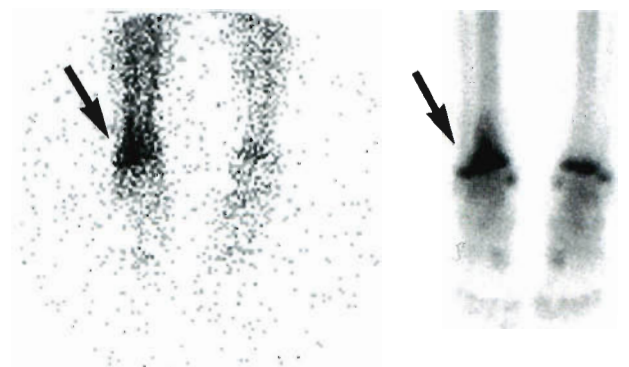


FIGURE 3-25. Twelve-year-old boy with osteomyelitis of the distal right tibia seen on a Tc-99m methylene diphosphonate (MDP) scan. A: Radionuclide angiogram shows increased perfusion of the entire tibia, most noticeable in the distal tibial metaphysis (arrow). B: Static image demonstrates the increased radiotracer uptake in the distal tibia compatible with osteomyelitis (arrow).

A,B

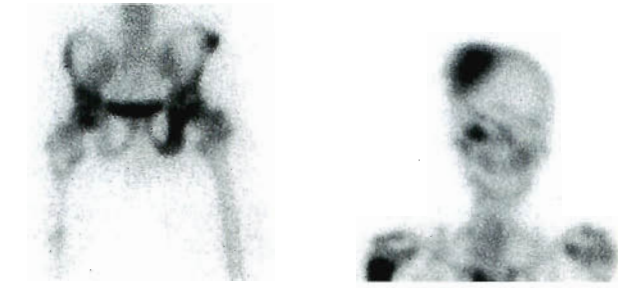


FIGURE 3-26. Metastatic osteosarcoma in a 17-year-old adolescent male. Tc-99m methylene diphosphonate (MDP) scan shows areas of increased uptake in the left ileum, left ischium, skull, face, and proximal humerus, compatible with bony metastases.

survey (142,143), being most valuable when radiographs are negative, or when the demonstration of additional injuries to those shown radiographically would significantly increase diagnostic certainty.

Skeletal scintigraphy allows evaluation of the entire body without increasing radiation exposure relative to that delivered by a limited examination. This is not the case when a radiographic examination is extended from a limited to a wide area. The ability to provide a whole-body evaluation is also an advantage of scintigraphy over MR imaging because sensitive, practical methods of evaluating the entire skeleton with a single MR imaging examination have not been established. Coupled with the high sensitivity described above, the ability to provide a whole-body evaluation has resulted in skeletal scintigraphy playing an essential role in staging and surveillance of a number of pediatric malignancies, most notably osteosarcoma, Ewing's sarcoma, and neuroblastoma (Fig 3-26). Imaging of the entire skeleton is useful when acute osteomyelitis may be multifocal, as in newborns (144,145), and in assessing some other benign conditions, such as chronic recurrent multifocal osteomyelitis. The ability to extend the examination beyond a limited area is invaluable in evaluating children with poorly localized skeletal pain or limping, and in identifying sites of pathology that present with referred pain.

The main limitation of skeletal scintigraphy is a lack of specificity. Many different bone diseases lead to increased Tc-99m-labeled diphosphonate uptake. This limitation requires that scintigraphy be interpreted with close consideration of clinical and other imaging findings. The anatomic resolution of skeletal scintigraphy is poorer than that provided by other imaging modalities. Information regarding the soft tissues is very limited with skeletal scintigraphy.

Risks

Radiopharmaceuticals administered for clinical use, including the Tc-99m-labeled diphosphonates, deliver radiation doses that are considered safe and acceptable (146). Ab-

sorbed doses vary with a patient's age and weight, physiologic status, and pathologic condition. They also vary slightly with the specific diphosphonate used.

Pediatric radiation dosimetry per unit of administered radioactivity of Tc-99m diphosphonate, as estimated by Stabin (147), is summarized in Table 3-2. The highest dose is delivered to the bone surfaces, with the actual dose varying with the abovementioned factors. For example, the bone surfaces of an infant administered our minimal dose of 1.0 mCi (37 MBq), would absorb 5.92 rads (59.2 mGy), whereas the bone surfaces of a 15-year-old weighing 50 kg would absorb 2.81 rads (28.1 mGy), following an administered dose of 10 mCi. The effective dose equivalent for the body would be 0.407 rem (4.07 mSv) for the infant and 0.33 rem (3.33 mSv) for the 15-year-old.

Utilization Trends

Skeletal scintigraphy is likely to remain a mainstay of orthopaedic diagnosis, despite advances in other imaging modalities. The complementary roles of skeletal scintigraphy and other modalities are increasingly apparent. Scintigraphy is preferable when more than a limited area must be imaged, when metallic artifacts interfere with CT or MR imaging, or when specific physiologic information is desired.

Other scintigraphic techniques may assume increasing importance. Nuclear medicine researchers have placed particular emphasis on developing radiopharmaceuticals and techniques that assess tumoral viability and chemotherapeutic response. Available methods relevant to pediatric orthopaedics include the use of Tl-201, Tc-99m-hexakis-2-methoxyisobutylisonitrile (MIBI), and [fluorine-18] fluorodeoxyglucose (FDG) in assessing skeletal malignancies, as well as I-131 or I-123 metaiodobenzylguanidine (MIBG) and In-111 octreotide for evaluating neuroblastoma. In regards to FDG, it is worth noting that increased access to FDG, and the commercial availability of gamma cameras capable of imaging both positron-emitting and conventional radiopharmaceuticals, will make PET widely available to clinical practitioners. An additional area in which considerable efforts have been applied in nuclear medicine is infection. Diagnosis of infection in bone already affected by another condition that causes abnormal uptake of Tc-99m-labeled diphosphonates can be assisted by studies performed with radiolabeled (In-111 or Tc-99m) leukocytes or Ga-67 citrate.

BONE DENSITOMETRY

Modern techniques for measuring bone density are based on measuring the attenuation of a beam of energy as it passes through bone. They include dual energy x-ray absorptiometry (DEXA), and quantitative CT (QCT). Techniques measuring radiographic attenuation mostly reflect the inor-

ganic component (hydroxyapatite crystals) of the bone (148). Other modalities that do not use radiation are being developed. Quantitative ultrasound measures the change in velocity and energy of sound waves as they are attenuated by bone. Measurement of bone density by MR imaging, based on the magnetic susceptibility induced, is still an experimental technique (149). Bone density is frequently evaluated in adults. In children, bone densitometry is difficult because of lack of dedicated pediatric equipment and a paucity of normal data. Whether the evaluation should be of trabecular or cortical bone is not clear. Turnover is faster in trabecular than in cortical bone, but cortical bone density does not change with age.

Techniques

Dual-energy X-ray Absorptiometry

DEXA is the most common technique for measuring bone density. An x-ray tube produces a photon beam, and a computer determines the attenuation of the beam and converts the result into a value for bone mineral content or bone mineral density (150,151). The result is expressed as gm/cm³ of ashed bone or equivalent hydroxyapatite. The study takes 2 to 15 minutes, depending on whether the whole body, the lumbar spine, or the proximal femur are examined. Sedation is often necessary in the youngest patients, because motion can increase the projected bone area by nearly 10% (41,152).

DEXA is limited because density measurements are based on a two-dimensional projection of the body, and thus depend on both the mass and the size of the bone being examined (152). Size varies considerably in children, and DEXA does not allow for bone size, which leads to significant error. Other problems include the marked variation in normal values reported in children and the variation in results due to the changing composition of bone marrow and overlying soft tissues.

Despite its limitations, the use of DEXA in children continues to grow because of its availability, low radiation dose (see below), and low cost. DEXA can measure total body fat, as well as density of bone. This is important for certain metabolic studies.

Quantitative Computerized Tomography

QCT is the most accurate technique for evaluating bone density, because it can assess both the size of a bone and its density (153). Radiographic attenuation values of the bone determined by CT scanning are compared to those of a reference phantom. QCT allows cortical and trabecular density to be measured separately, and can provide a measurement of the cross-sectional area of a vertebral body (152). QCT is generally performed in a conventional CT unit, and, therefore, unlike DEXA, does not require addi-

tional equipment purchases or siting costs. The capability of QCT to measure cortical and cancellous bone separately is important, because cortical bone density in the appendicular skeleton varies little with age, size, gender, race, or the passage of puberty. There is also abundant data about normals (154–156). QCT, however, is used less than DEXA, because of its higher cost and greater radiation dose.

Main Applications of Bone Densitometry

There is increasing interest in the clinical evaluation of bone density (150). Assessment of bone density is justified to evaluate loss or lack of bone mineral content (osteopenia). In children, this can be due to osteoporosis (lack of both collagen matrix and mineral content); rickets (osteomalacia, lack of mineral content only); or abnormal bone formation in conditions such as osteogenesis imperfecta and several chondrodysplasias (152).

It is sometimes useful to know the bone density of a patient being evaluated for scoliosis, or who has had surgery for this disease. Children often receive therapy that decreases bone mineral content, such as steroids for rheumatoid arthritis or inflammatory bowel disease. Children with eating disorders are sometimes evaluated with bone densitometry. There is great interest in identifying children who are likely to develop osteoporosis as adults; intervention may be more fruitful at a young age.

Risks, Limitations, and Utilization Trends

Radiation exposure is less with DEXA than with CT. One DEXA study results in an effective dose of 0.1 mrem (1 microSv) for lumbar spine measurements and 0.4 mrem for measurements of the entire body. QCT exposes the body to a total equivalent dose of 4–9 mrems. Although this is 10 to 20 times the DEXA dose, it is still much lower than the exposure for conventional CT or for ordinary radiographs. For reference, it is useful to consider that a child on a round-trip transcontinental flight in North America is exposed to 6 to 8 mrems of ionizing radiation (152). DEXA has become the dominant modality, because of convenience and lower radiation exposure.

RADIATION EXPOSURE: PRACTICAL ISSUES

Patients and parents frequently ask about the risks of examinations that utilize ionizing radiation (radiography, CT, nuclear medicine). It is important for orthopaedic surgeons to understand these risks, and to communicate them clearly. In order to do this, the physician must be familiar with the radiation effects, the way in which radiation dose is measured, and the way in which radiation risks are estimated and prevented.

Radiation Effects

The effects of radiation are classified as stochastic or nonstochastic (or deterministic). Stochastic effects include carcinogenesis and mutagenesis; their *probability of occurrence* is a function of dose, and any radiation exposure increases risk. For nonstochastic effects, *severity* of the effect varies with dose; examples include cataract formation, bone marrow cellular depletion, and nonmalignant skin damage. The threshold for nonstochastic effects is higher than would be expected to be delivered with diagnostic examinations.

When a patient or parent asks whether an examination is safe, they are primarily asking about risk of cancer, which is the main late somatic effect of radiation, and the risk of genetic mutations. The most common radiation-induced malignancies are leukemia, thyroid, and lung in both sexes, and the breast in women. The minimum latent period following radiation exposure is 2 to 10 years. The data from radiation carcinogenesis comes from exposure to large doses such as nuclear accidents; how this data can be extrapolated to clinical data is unclear.

Dosimetry

Radiation dosimetry is described in either traditional units or SI units. The traditional unit, by which radiation absorbed by tissue is quantified, is the rad. The SI unit for absorbed dose is the gray (Gy), which is equivalent to 100 rads. Because the biological effectiveness of the various types of ionizing radiation differs, the concept of dose equivalent has been introduced to quantify radiation dose. The traditional unit for dose equivalent is the rem, and SI unit is the sievert (Sv). For diagnostic imaging, the dose equivalent in rems or sieverts is numerically equal to the absorbed dose in rads or grays (157).

Radiation effect varies according to the tissues exposed. Some tissues, such as the breasts and gonads, are much more susceptible to radiation damage than the tissues of the extremities (157). Children are more susceptible to the deleterious effects of radiation than are adults. Additionally, the potential for damage from a radiation dose distributed uniformly over the entire body, as resulted from atomic bomb detonations, is greater than that of the same dose received by only a part of the body, as occurs with diagnostic radiographs. Finally, a given dose has less potential for damage when absorbed over months or years, than when absorbed over seconds, minutes, or hours.

Relationship between Radiation Dose and Effect

Based on epidemiological studies of groups such as survivors of the atomic bombs dropped during World War II, the risk of developing a fatal malignancy secondary to low doses of radiation has been estimated as 5% per Sv (0.05% per

rem) and the risk for developing a nonfatal malignancy has been estimated as 1% per Sv (0.01% per rem) (158,159). For children, the risk of developing a fatal malignancy may be 10% per Sv (160). The mutagenic potential of radiation is difficult to assess because of a fairly high rate of spontaneously occurring mutations in man; the estimated risk of a severe genetic effect in all succeeding generations has been estimated as 1% per Sv (0.01% per rem) (158,159). Because the general population includes individuals who are past their reproductive years, this risk is higher in children. It is important to emphasize that although the above numbers sound precise, they are rough approximations of risk that have been derived from methods in which the level of uncertainty is high.

Radiation Exposure and Diagnostic Examinations

Table 3-1 provides entrance doses at our institution for some commonly performed studies. It can be readily seen that the risk of these studies is small. This is made more apparent when it is noted that the risk estimations discussed above are based on uniform radiation of the entire body. The exposure to structures outside the x-ray beam (e.g., the lungs of a child whose foot is being imaged), and of internal structures within the x-ray beam, are less than the reported skin entry dose. Exposure from nuclear medicine studies is expressed in terms of the radiation to specific structures, and in terms of the equivalent dose.

When communicating risks of radiation to patients or their parents, it is essential that they understand the rationale for performing an examination, and how the results of the examination are to be used in guiding management. They need to be aware of the risk implied by not obtaining the examination, so that this risk can be weighed against that of radiation. The patient and/or parent should also be made aware that, although many epidemiological and animal studies have assessed the risk of low-level radiation, none is conclusive, and that whatever risk assessment is provided is an opinion. Sometimes, it is useful to put the risk assessment in the context of easily comprehended numbers or daily risks. Using the risk estimations described previously, each 0.00001 Sv (10 μ Sv or 1 mrem) dose equivalent delivered to a child could be considered to impart a one in one million risk of death from fatal malignancy. This is roughly equivalent to the risk of death from driving 47 miles by car (160). It also is useful to compare radiation related to diagnostic imaging with that of natural background radiation resulting from cosmic radiation, radioactive deposits within the earth surface, radon gas, and other sources. Yearly average background radiation exposure in the United States is approximately 0.003 Sv (3 mSv or 300 mrem). This is about equivalent to what an adult might receive from 15 to 20 chest radiographs for which the dose equivalent range is 0.15 to 0.20 mSv (15 to 20 mrem) (161). The risk of

developing cancer, and dying as a result of irradiation received from a chest radiograph, is equivalent to the risk of death by cancer from flying 1000 miles by jet or living two months in Denver (because of the increased exposure to solar irradiation at higher altitudes) (162,163). The risk from diagnostic studies involving the appendicular skeleton is likewise low.

The effects of examinations that result in irradiation of the pelvis or breasts may be more significant; these studies should be requested with more caution. According to the National Radiological Protection Board of the United Kingdom, one x-ray of the hip, for example, is equivalent to 7 weeks of natural background radiation. An x-ray of the pelvis is equivalent to 4 months, and an x-ray of the lumbar spine is equivalent to 7 months. A CT of the abdomen and pelvis approximates 4.5 years of natural background radiation [<http://www.nrp.org.uk/Qmedical.htm>].

One study of scoliosis patients indicated that each patient received a mean of 14.1 single x-ray exposures over a mean of 44 months. The ovaries received a mean total cumulative dose of 183 uSv over the time period study, indicating that an improvement in ovarian protection needs to be made (164). In a study of dose distribution to the spine in children, lumbar spine examinations caused the highest mean entrance surface doses (2.6 mGy, anteroposterior projection; 6.7 mGy, lateral projection), with the female gonads receiving the highest dose. The mean entrance surface doses were lower for thoracic spine examinations (2.1 mGy, frontal view; 6.1 mGy, lateral view), with the breasts, thyroid, lungs, and esophagus receiving the highest dose (165). In a study of adolescents with idiopathic scoliosis, it was found that a three- to sevenfold reduction in cumulative doses to the thyroid gland and female breast could be achieved by replacing anteroposterior views with posteroanterior views. This leads to a three- to fourfold reduction in the lifetime risk of breast cancer, and halves the lifetime risk of thyroid cancer (166).

Practical Steps to Reduce Radiation Exposure

The presence of some risk, and an inability to precisely quantify that risk, requires that every effort be made to limit the potential for radiation effects. There are many concrete steps that physicians can take in order to reduce radiation risks and damage to their patients. The best way to reduce radiation exposure from diagnostic studies is to avoid unnecessary examinations. If the study is indicated, however, the main goal should be to maximize the diagnostic information. Obtaining a suboptimal study to reduce exposure may require a repeat examination and defeat the effort to minimize radiation dose. Imaging teams that deal with children need to be adept at immobilization techniques to prevent unnecessary exam repetition. X-ray beams should be restricted to the area of interest. Gonadal shielding should

be carefully positioned for radiographic studies in which the gonads are within the radiated field (unless this would obscure the area of clinical concern), or outside, but within 5 cm of the radiated field.

Proper use of fluoroscopy reduces dosage to patients and operators. Use of the smallest field possible reduces overexposure to adjacent areas of the patient's body, and reduces scattered radiation, producing higher-quality images. The greater the distance between the patient and the fluoroscopic x-ray source, the greater the decrease in radiation dosage to the patient. Radiation dosage can also be reduced by decreasing the distance between the patient's body and the image receptor/intensifier. Unfortunately, this creates a greater amount of scattered radiation, which results in poorer image quality. Reduction of beam-on time also reduces dosage to the patient. Short and intermittent, rather than continuous and extended, exposures should be used. This is facilitated by systems that can display the last image of the patient, even after the beam has been disengaged. Finally, magnification can be both useful and necessary, but does contribute to a higher dosage. Electronic magnification causes less radiation dosage than geometric magnification (167).

Occupational radiation exposure is of great concern to orthopaedic surgeons who may have to use lengthy fluoroscopic guidance during complex surgical cases. The dose to an individual standing 1 meter from the patient is approximately 0.02% of the entrance dose to the patient, or 0.3 to 0.9 mrad (0.003 to 0.009 mGy) per minute (168). Aprons reduce radiation levels by a factor of 20 to 100. Because radiation intensity falls off with the square of the distance, any surgeon not involved in directly holding the patient can reduce the exposure by a factor of 4, simply by stepping back 2 m from the fluoroscopic unit. Direct exposure to the hands can result in exposures of 40 to 100 rads (0.4 to 1 Gy). In order to reduce exposure, the surgeon's hands should not be in the field when the beam is on, and, when possible, should be kept on the exit side of the patient. Fluoroscopy is not contraindicated during pregnancy, but every possible precaution to minimize radiation to the conceptus should be taken, including the use of double aprons, and strict monitoring of exposure.

CT examinations deliver high doses of radiation. Because a higher beam energy increases the dose, the peak kilovoltage should be kept at appropriate and limited levels. The type of filter used in the x-ray beam, collimation of the x-ray beam, reducing the number and spacing of adjacent sections, and allowing more statistical noise can also reduce the patient dose, but often at the expense of image quality (167).

SEDATION FOR IMAGING

Most imaging procedures require patients to remain still. MR imaging, for example, requires the child to remain still

for 45 minutes to an hour. In most institutions, sedation is performed routinely for all MR imaging, for most CT studies, and for some nuclear medicine examinations and bone density studies of children under the age of 5 years. General radiography and ultrasonography seldom require sedation.

Close monitoring of the sedated child during the procedure is essential. This requires pulse oximetry, electrocardiographic monitoring, and, sometimes, capnometry. When performing MR imaging, it is important to verify that all monitoring devices are MR-compatible, in order to avoid burns (from heating of the wires) or accidents. Fiberoptic systems are being increasingly used, in order to avoid the risk of these complications.

Sedation is performed under strict compliance with the guidelines of the American Academy of Pediatrics (169–172). A limited sedation formulary facilitates reproducibility, familiarity with the medications and their complications, and quality control. Chloral hydrate is commonly used for children less than 1 year of age; intravenous sodium pentobarbital is used for older children. The sedation protocol of the Department of Radiology at Children's Hospital in Boston includes the following recommendations: For children under 1 year of age, oral chloral hydrate is given in a dose of 50 mg/kg, repeated after 30 minutes, if needed. In other institutions, doses in the 80 to 100 mg/kg range (maximum, 2.5 g) have given a 96% success rate for pediatric MR imaging (173–175). For children 1 to 5 years old, intravenous sedation is recommended, because it is reliable, fast, and easily controlled. Our protocol includes diluted sodium pentobarbital at a dose of 3 to 6 mg/kg (maximum, 200 mg). In general, intravenous sedatives are administered in small increments, in order to avoid oversedation. If the patient is not adequately sedated after receiving the total of 6 mg/kg of sodium pentobarbital, an additional 2 mcg/kg of fentanyl may be administered intravenously.

References

Radiographic Techniques: Plain Radiographs, Arthrography, Conventional Tomography, Computed Tomography

1. Ogden J. Anatomy and physiology of skeletal development. In: Ogden J, ed. *Skeletal injury in the child*. Philadelphia: WB Saunders, 1990:23.
2. Kricun M. Red-yellow marrow conversion: its effect on the location of some solitary bone lesions. *Skeletal Radiol* 1985;14:10.
3. Cohen MD. A review of the toxicity of nonionic contrast agents in children. *Investigative Radiology* 1993;28[Suppl 5]:S87.
4. American College of Radiology. *Manual on iodinated contrast material*. Reston, VA: American College of Radiology, 1991.
5. Shehadi WH. Death following intravascular administration of contrast media. *Acta Radiol [Diagn] (Stockh)* 1985;26:457.
6. Obermann WR, Bloem JL, Hermans J. Knee arthrography:

- comparison of iotrolan and ioxaglate sodium meglumine. *Radiology* 1989;173:197.
7. Caffey J, Madell SH, Royer C, et al. Ossification of the distal femoral epiphysis. *J Bone Joint Surg Am* 1958;40:647.
 8. Ogden J. Radiology of postnatal skeletal development: X. Patella and tibial tuberosity. *Skeletal Radiol* 1984;11:246.
 9. Shopfner C, Coin C. Effect of weight-bearing on the appearance and development of the secondary calcaneal epiphysis. *Radiology* 1966;86:201.
 10. Lawson JP. Symptomatic radiographic variants in extremities. *Radiology* 1985;157:625.
 11. Laor T, Jaramillo D. Metaphyseal abnormalities in children: pathophysiology and radiologic appearance. *AJR Am J Roentgenol* 1993;151:1029.
 12. Ecklund K, Laor T, Goorin AM, et al. Methotrexate osteopathy in patients with osteosarcoma. *Radiology* 1997;202:543.
 13. Keats T, Joyce J. Metaphyseal cortical irregularities in children. *Skeletal Radiol* 1984;12:112.
 14. Yamazaki T, Maruoka S, Takahashi S, et al. MR findings of avulsive cortical irregularities of the distal femur. *Skel Radiol* 1995;24:43.
 15. Schmidt H, Freyschmidt J. *Köhlerl/Zimmer Borderlands of normal and early pathologic findings in skeletal radiography*, 4th ed. Stuttgart: Thieme, 1993.
 16. Godderidge C. *Pediatric imaging*. Philadelphia: WB Saunders, 1995.
 17. Laor T, Jaramillo D, Oestreich AE. Musculoskeletal system. In: Kirks DR, Griscom NT, eds. *Practical pediatric imaging: diagnostic radiology of infants and children*. 3rd ed. Philadelphia: Lippincott-Raven, 1998:327.
 18. Greulich W, Pyle S. *Radiographic atlas of skeletal development of the hand and wrist*, 2nd ed. Stanford: Stanford University Press, 1959.
 19. Hoerr N, Pyle S, Francis C. *Radiographic atlas of skeletal development of the foot and ankle*. Springfield, IL: Charles C Thomas, 1962.
 20. Pyle S, Hoerr N. *A radiographic standard of reference for the growing knee*. Springfield, IL: Charles C Thomas, 1969.
 21. Sontag L, Snell D, Anderson M. Rate of appearance of ossification centers from birth to the age of five years. *Am J Dis Child* 1939;58:949.
 22. Ontell FK, Ivanovic M, Ablin DS, et al. Bone age in children of diverse ethnicity [see comments]. *Am J Roentgenol* 1996;167:1395.
 23. Loder R, Estle D, Morrison K, et al. Applicability of the Greulich and Pyle skeletal age standards to black and white children of today. *AJDC* 1993;147:1329.
 24. Shaikh AH, Rikhasor RM, Qureshi AM. Determination of skeletal age in children aged 8–18 years. *J Pak Med Assoc* 1998;48:104.
 25. Groell R, Lindbichler F, Riepl T, et al. The reliability of bone age determination in central European children using the Greulich and Pyle method. *Br J Radiol* 1999;72:461.
 26. King DG, Steventon DM, O'Sullivan MP, et al. Reproducibility of bone ages when performed by radiology registrars: an audit of Tanner and Whitehouse II versus Greulich and Pyle methods. *Br J Radiol* 1994;67:848.
 27. Bull RK, Edwards PD, Kemp PM, et al. Bone age assessment: a large scale comparison of the Greulich and Pyle, and Tanner and Whitehouse (TW2) methods. *Arch Dis Child* 1999;81:172.
 28. Tanner JM, Whitehouse RH, Cameron N, et al. *Assessment of skeletal maturity and prediction of adult height (TW2 method)*, 2nd ed. London: Academic Press, 1983.
 29. Tanner JM, Gibbons RD. A computerized image analysis system for estimating Tanner-Whitehouse 2 bone age. *Hormone Res* 1994;42:282.

30. Kahlyss S, Hoepffner W, Keller E, Willgerodt H. [The determination of bone age by the Greulich-Pyle and Tanner-Whitehouse methods as a basis for the growth prognosis of tall-stature girls]. *Pediatr Grenzgeb* 1990;29:137.
31. Kleinman PK. Skeletal imaging strategies. In: Kleinman PK, ed. *Diagnostic imaging of child abuse*. St. Louis: Mosby, 1998:237.
32. Belanger PL. Quality assurance and skeletal survey standards. In: Kleinman PK, ed. *Diagnostic imaging of child abuse*. St. Louis: Mosby, 1998:418.
33. Kortamasu SR, Kuhns LR, Stringer DA. Pediatric musculoskeletal computed radiography. *Pediatr Radiol* 1997;27:563.
34. Kortamasu SR, Kuhns LR. Musculoskeletal computed radiography in children: scatter reduction and improvement in bony trabecular sharpness using air gap placement of the imaging plate. *Pediatr Radiol* 1997;27:119.
35. Huang HK. Display, picture archiving and communicating systems, and teleradiology. *Acad Radiol* 1995;2[Suppl 2]:S103.
36. Huang HK, Wong ST, Pietka E. Medical image informatics infrastructure design and applications. *Med Inform Lond* 1997;22:279.
37. Aliabadi P, Baker ND, Jaramillo D. Hip arthrography, aspiration, block, and bursography. *Radiol Clin North Am* 1998;36:673.
38. Kaniklides C. *Diagnostic radiology in Legg-Calvé-Perthes disease*. Uppsala: Uppsala University, 1996.
39. Wilkinson R. Hip arthrography in children. In: Dalinka M, ed. *Arthrography*. New York: Springer-Verlag, 1980:119.
40. Ozonoff M. *The hip*. *Pediatric orthopedic radiology*, 2nd ed. Philadelphia: W.B. Saunders, 1992:164.
41. Harcke HT. Imaging techniques and applications. In: Morrissy RT, Weinstein SL, eds. *Lovell & Winter's Pediatric Orthopaedics*, 4th ed, vol. 1. Philadelphia: Lippincott-Raven, 1996:25.
42. Lonnerholm T. Arthrography of the hip in children; technique, normal anatomy and findings in unstable hip joints. *Acta Radiol* 1980;21:279.
43. Drummond D, O'Donnell J, Breed A, et al. Arthrography in the evaluation of congenital dislocation of the hip. *Clin Orthop* 1989;243:148.
44. MacEwen GD, Mason B. Evaluation and treatment of congenital dislocation of the hip in infants. *Orthop Clin North Am* 1988;19:815.
45. Ponseti IV. Morphology of the acetabulum in congenital dislocation of the hip. *J Bone Joint Surg Am* 1978;60:586.
46. Herring JA. The treatment of Legg-Calvé-Perthes disease. *J Bone Joint Surg Am* 1994;76:448.
47. Gershuni DH, Axer A, Hendel D. Arthrographic findings in Legg-Calvé-Perthes disease and transient synovitis of the hip. *J Bone Joint Surg Am* 1978;60:457.
48. Kamegaya M, Moriya H, Tsuchiya K, et al. Arthrography of early Perthes' disease; swelling of the ligamentum teres as a cause of subluxation. *J Bone Joint Surg Br* 1989;71:413.
49. Reinker KA. Early diagnosis and treatment of hinge abduction in Legg-Perthes disease. *J Ped Orthop* 1996;16:3.
50. Gallagher J, Weiner D, Cook A. When is arthrography indicated in Legg-Calvé-Perthes disease? *J Bone Joint Surg Am* 1983;65:900.
51. Chung T, Kirks DR. Techniques. In: Kirks DR, Griscom NT, eds. *Practical pediatric imaging: diagnostic radiology of infants and children*, 3rd ed. Philadelphia: Lippincott-Raven, 1998:1.
52. White K. Helical/spiral CT scanning: a pediatric radiology perspective. *Pediatr Radiol* 1996;26:5.
53. Link TM, Meier N, Rummeny EJ, et al. Artificial spine fractures: detection with helical and conventional CT. *Radiology* 1996;198:515.
54. Eggl KD, King SH, Boal DKB, et al. Low-dose CT of developmental dysplasia of the hip after reduction: diagnostic accuracy and dosimetry. *Am J Roentgenol* 1994;163:1441.
55. Waters PM, Smith GR, Jaramillo D. Glenohumeral deformity secondary to brachial plexus birth palsy. *J Bone Joint Surg Am* 1998;80:668.
56. Ruby L, Mital MA, O'Connor J, et al. Anteversion of the femoral neck: comparison of methods of measurements in patients. *J Bone Joint Surg Am* 1979;61:46.
57. Tomczak RJ, Guenther KP, Rieber A, et al. MR imaging measurement of the femoral anteroposterior angle as a new technique: comparison with CT in children and adults. *Am J Roentgenol* 1997;168:791.
58. Ritter MA, DeRosa GP, Babcock JL. Tibial torsion? *Clin Orthop* 1976;120:159.
59. Staheli LT, Lingel GM. Tibial torsion: a method of assessment and a survey of normal children. *Clin Orthop* 1972;86:183.
60. Reikeras O, Hoiseth A. Torsion of the leg determined by computed tomography. *Acta Orthop Scand* 1989;60:330.
61. Leonard MA. The inheritance of tarsal coalition and its relationship to spastic flat foot. *J Bone Joint Surg Br* 1974;56:520.
62. Laor T. Helical CT applications in musculoskeletal disorders. In: Marilyn J, Siegel MD, eds. *Special course in pediatric radiology: current concepts in body imaging at the millennium*. Chicago, 1999:247.
63. Wechsler RJ, Schweitzer ME, Deely DM, et al. Tarsal coalition: depiction and characterization with CT and MR imaging. *Radiology* 1994;193:447.
64. Clarke DM. Multiple tarsal coalitions in the same foot. *J Pediatr Orthop* 1997;17:777.
65. Emery KH, Bissler GS, Johnson ND, et al. Tarsal coalition: a blinded comparison of MRI and CT. *Pediatr Radiol* 1998;28:612.

Ultrasonography

66. Erickson SJ. High-resolution imaging of the musculoskeletal system. *Radiology* 1997;205:593.
67. Merritt C. Physics of ultrasound. In: Rumack C, Wilson S, Charboneau J, eds. *Diagnostic ultrasound*, vol. 1. St. Louis: Mosby-Year Book, 1998:3.
68. Grissom L, Harcke HT. The pediatric hip. In: Rumack C, Wilson S, Charboneau J, eds. *Diagnostic ultrasound*, vol. 2. St. Louis: Mosby-Year Book, 1998:1799.
69. Graf R. Advantages and disadvantages of various access routes in sonographic diagnosis of dysplasia and luxation in the infant hip. *J Pediatr Orthop B* 1997;6:248.
70. Share JC, Teele RL. Ultrasonography of the infant hip: a practical approach. *Appl Radiol* 1992:27.
71. Graf R, Schuler P. *Sonography of the infant hip: an atlas*. Weinheim: VCH Verlagsgesellschaft, 1986.
72. Graf R. *Guide to sonography of the infant hip*. New York: Thieme, 1987.
73. Graf R, Fronhofer G. [Redefinition of the proximal perichondrium and perichondrial gap in hip ultrasound imaging.] *Orthopade* 1997;26:1057.
74. Harcke HT, Lee MS, Sinning L, et al. Ossification center of the infant hip: sonographic and radiographic correlation. *Am J Roentgenol* 1986;147:317.
75. Harcke HT, Grissom LE. Performing dynamic sonography of the infant hip. *Am J Roentgenol* 1990;155:837.
76. Marks DS, Clegg J, al-Chalabi AN. Routine ultrasound screening for neonatal hip instability. Can it abolish late-presenting congenital dislocation of the hip? *J Bone Joint Surg Br* 1994;76:534.
77. Harcke HT. Screening newborns for developmental dysplasia of the hip: role of sonography. *Am J Roentgenol* 1994;162:395.

78. Bearcroft P, Berman L, Robinson A, Butler G. Vascularity of the neonatal femoral head: in vivo demonstration with Power Doppler US. *Radiology* 1996;200:209.
 79. Miralles M, Gonzalez G, Pulpeiro JR, et al. Sonography of the painful hip in children: 500 consecutive cases. *Am J Roentgenol* 1989;152:579.
 80. Strouse PJ, DiPietro MA, Adler RS. Pediatric hip effusions: evaluation with power Doppler sonography. *Radiology* 1998;206:731.
 81. Mah ET, LeQuesne GW, Gent RJ, Paterson DC. Ultrasonic features of acute osteomyelitis in children [see comments]. *J Bone Joint Surg Br* 1994;76:969.
 82. Bureau NJ, Chhem RK, Cardinal E. Musculoskeletal infections: US manifestations [In Process Citation]. *Radiographics* 1999;19:1585.
- ### Magnetic Resonance Imaging
83. Balter S. An introduction to the physics of magnetic resonance imaging. *Radiographics* 1987;7:371.
 84. Nitz WR. MR imaging: acronyms and clinical applications. *Eur Radiol* 1999;9:979.
 85. Bashir A, Gray ML, Boutin RD, et al. Glycosaminoglycan in articular cartilage: in vivo assessment with delayed Gd(DTPA)2-enhanced MR imaging. *Radiology* 1997;205:551.
 86. Prince MR. Contrast-enhanced MR angiography: theory and optimization. *Magn Reson Imaging Clin North Am* 1998;6:257.
 87. Bonnerot V, Sebag G, Monralember MD, et al. Gadolinium-DOTA enhanced MRI of painful osseous crises in children with sickle cell anemia. *Pediatr Radiol* 1994;24:92.
 88. Jaramillo D, Shapiro F. Growth cartilage: normal appearance, variants and abnormalities. *Magn Reson Imaging Clin North Am* 1998;6:455.
 89. Barnewolt CE, Shapiro F, Jaramillo D. Normal gadolinium-enhanced MR images of the developing appendicular skeleton: Part I. Cartilaginous epiphysis and physis. *Am J Roentgenol* 1997;169:183.
 90. Chung T, Jaramillo D. Normal maturing distal tibia and fibula: changes with age at MR Imaging. *Radiology* 1995;194:227.
 91. Babyn PS, Ranson M, McCarville ME. Normal bone marrow: signal characteristics and fatty conversion. *Magn Reson Imaging Clin North Am* 1998;6:473.
 92. Suzuki S, Kashiwagi N, Seto Y, et al. Location of the femoral head in developmental dysplasia of the hip: three-dimensional evaluation by means of magnetic resonance image. *J Pediatr Orthop* 1999;19:88.
 93. McNally EG, Tasker A, Benson MK. MRI after operative reduction for developmental dysplasia of the hip [see comments]. *J Bone Joint Surg Br* 1997;79:724.
 94. Kashiwagi N, Suzuki S, Kasahara Y, et al. Prediction of reduction in developmental dysplasia of the hip by magnetic resonance imaging. *J Pediatr Orthop* 1996;16:254.
 95. Suzuki S. Deformity of the pelvis in developmental dysplasia of the hip: three-dimensional evaluation by means of magnetic resonance image. *J Pediatr Orthop* 1995;15:812.
 96. Jaramillo D, Villegas-Medina OL, Doty DK, et al. Gadolinium-enhanced MR imaging demonstrates abduction-caused hip ischemia and its reversal in piglets. *Am J Roentgenol* 1996;166:879.
 97. Jaramillo D, Villegas-Medina O, Laor T, et al. Gadolinium-enhanced MR imaging of pediatric patients after reduction of dysplastic hips: assessment of femoral head position, factors impeding reduction, and femoral head ischemia. *Am J Roentgenol* 1998;170:1633.
 98. Bos CFA, Bloem JL, Bloem RM. Sequential magnetic resonance imaging in Perthes disease. *J Bone Joint Surg Br* 1991;73:219.
 99. Jaramillo D, Kasser JR, Villegas-Medina OL, et al. Cartilaginous abnormalities and growth disturbances in Legg-Calvé-Perthes disease: evaluation with MR imaging. *Radiology* 1995;197:767.
 100. Ducou le Pointe H, Haddad S, Silberman B, et al. Legg-Perthes-Calvé disease: staging by MRI using gadolinium. *Pediatr Radiol* 1994;24:88.
 101. Sebag G, Pointe HDL, Klein I, et al. Dynamic gadolinium-enhanced subtraction MR imaging—a simple technique for the early diagnosis of Legg-Calvé-Perthes disease: preliminary results. *Pediatr Radiol* 1997;27:216.
 102. Sebag GH. Disorders of the hip. *Magn Reson Imaging Clin North Am* 1998;6:627.
 103. Jaramillo D, Galen TA, Winalski CS, et al. Legg-Calvé-Perthes disease: MR imaging evaluation during manual positioning of the hip—comparison with conventional arthrography. *Radiology* 1999;212:519.
 104. Mazur J, Ross G, Cummings R, et al. Usefulness of magnetic resonance imaging for the diagnosis of acute musculoskeletal infections in children. *J Pediatr Orthop* 1995;15:144.
 105. Dangman B, Hoffer F, Rand F, et al. Osteomyelitis in children: gadolinium enhanced MR imaging. *Radiology* 1992;182:743.
 106. Glyls-Morin VM. MR imaging of pediatric musculoskeletal inflammatory and infectious disorders. *Magn Reson Imaging Clin North Am* 1998;6:537.
 107. Jaramillo D, Treves ST, Kasser JR, et al. Osteomyelitis and septic arthritis in children: appropriate use of imaging to guide therapy. *Am J Roentgenol* 1995;165:399.
 108. Harcke HT. Role of imaging in musculoskeletal infections in children [Editorial]. *J Pediatr Orthop* 1995;15:141.
 109. Lazar RD, Waters PM, Jaramillo D. The use of ultrasonography in the diagnosis of occult fracture of the radial neck. A case report. *J Bone Joint Surg Am* 1998;80:1361.
 110. Nimkin K, Kleinman PK, Teeger S, et al. Distal humeral physeal injuries in child abuse: MR imaging and ultrasound findings. *Pediatr Radiol* 1995;25:562.
 111. Jaramillo D, Hoffer F, Shapiro F, et al. MR imaging of fractures of the growth plate. *Am J Roentgenol* 1990;155:1261.
 112. Jaramillo D, Hoffer FA. Cartilaginous epiphysis and growth plate: normal and abnormal MR imaging findings. *Am J Roentgenol* 1992;158:1105.
 113. Beltran J, Rosenberg ZS, Kawelblum M, et al. Pediatric elbow fractures: MR evaluation. *Skeletal Radiol* 1994;23:277.
 114. Beltran J, Rosenberg ZS. MR imaging of pediatric elbow fractures. *MRI Clin North Am* 1997;5:567.
 115. Gordon I, Peters A, Gutman A, et al. Tc-99m bone scans are more sensitive than I-123 MIBG scans for bone imaging in neuroblastoma. *J Nucl Med* 1990;31:129.
 116. Bates GD, Hresko MT, Jaramillo D. Patellar sleeve fracture: demonstration with MR imaging. *Radiology* 1994;193:825.
 117. Shih C, Chang C, Penn I, et al. Chronically stressed wrists in adolescent gymnasts: MR imaging appearance. *Radiology* 1995;195:855.
 118. Rogers L, Poznanski A. Imaging of epiphyseal injuries. *Radiology* 1994;191:297.
 119. Havranek P, Lizler J. Magnetic resonance imaging in the evaluation of partial growth arrest after physeal injuries in children. *J Bone Joint Surg Am* 1991;73:1234.
 120. Disler DG. Fat-suppressed three-dimensional spoiled gradient-recalled MR imaging: assessment of articular and physeal hyaline cartilage. *Am J Roentgenol* 1997;169:1117.
 121. Borsa JJ, Peterson HA, Ehman RL. MR imaging of physeal bars. *Radiology* 1996;199:683.

122. Craig JG, Cramer KE, Cody DD, et al. Premature partial closure and other deformities of the growth plate: MR imaging and three-dimensional modeling. *Radiology* 1999;210:835.
123. De Smet A, Fisher DA, Graf BK, et al. Osteochondritis dissecans of the knee: value of MR imaging in determining lesion stability and the presence of articular cartilage defects. *Am J Roentgenol* 1990;155:549.
124. Zobel MS, Borrello JA, Siegel MJ, et al. Pediatric knee MR imaging: patterns of injuries in the immature skeleton. *Radiology* 1994;190:397.
125. Busch MT. Meniscal injuries in children and adolescents. *Clin Sports Med* 1990;9:661.
126. Al-Otaibi L, Siegel MJ. The pediatric knee. *Magn Reson Imaging Clin North Am* 1998;6:643.
127. Laor T, Chung T, Hoffer F, et al. Musculoskeletal magnetic resonance imaging: how we do it. *Ped Radiol* 1996;26:695.
128. Schima W, Amann G, Stiglbauer R, et al. Preoperative staging of osteosarcoma: efficacy of MR imaging in detecting joint involvement. *Am J Roentgenol* 1994;163:1171.
129. Jaramillo D, Laor T, Gebhardt MC. Pediatric musculoskeletal neoplasms. Evaluation with MR imaging. *Magn Reson Imaging Clin North Am* 1996;4:749.
130. Budinger TF. MR safety: past, present, and future from a historical perspective. *Magn Reson Imaging Clin North Am* 1998;6:701.
131. Schaefer DJ. Safety aspects of switched gradient fields. *Magn Reson Imaging Clin North Am* 1998;6:731.
132. Price RR. The AAPM/RSNA physics tutorial for residents. MR imaging safety considerations. Radiological Society of North America. *Radiographics* 1999;19:1641.
133. Shellock FG, Kanal E. *Magnetic resonance, bioeffects, safety, and patient management*. Philadelphia: Lippincott-Raven, 1994.
134. Eustace S, Shah B, Mason M. Imaging orthopedic hardware with an emphasis on hip prostheses. *Orthop Clin North Am* 1998;29:67.

Nuclear Medicine

135. Treves ST. *Pediatric nuclear medicine*, 2nd ed. New York: Springer-Verlag, 1995.
136. Connolly LP, Treves ST, Connolly SA, et al. Pediatric skeletal scintigraphy: applications of pinhole magnification. *Radiographics* 1998;18:341.
137. Connolly L, Treves ST. *Pediatric skeletal scintigraphy with multimodality imaging correlations*. New York: Springer-Verlag, 1997.
138. Hahn K, Fischer S, Gordon I. *Atlas of bone scintigraphy in the developing paediatric skeleton*. Berlin: Springer-Verlag, 1993.
139. Connolly L, Treves ST. *Pediatric skeletal scintigraphy*. New York: Springer-Verlag, 1998.
140. Cawley KA, Dvorak AD, Wilmot MD. Normal anatomic variant scintigraphy for the ischiopubic synchondrosis. *J Nucl Med* 1983;24:14.
141. Kloiber R, Pavlosky W, Portner O, et al. Bone scintigraphy of hip joint effusions in children. *Am J Roentgenol* 1983;140:995.
142. Nimkin K, Kleinman PK. Imaging of child abuse. *Pediatr Clin North Am* 1997;44:615.
143. Conway JJ, Collins M, Tanz RR, et al. The role of bone scintigraphy in detecting child abuse. *Semin Nucl Med* 1993;23:321.
144. Aigner RM, Fueger GF, Ritter G. Results of three-phase bone scintigraphy and radiography in 20 cases of neonatal osteomyelitis. *Nucl Med Commun* 1996;17:20.
145. Bressler E, Conway J, Weiss S. Neonatal osteomyelitis examined by bone scintigraphy. *Radiology* 1984;152:685.
146. Adelsreйн S. Radiation risk. In: Treves ST, ed. *Pediatric nuclear medicine*, 2nd ed. New York: Springer-Verlag, 1995:17.
147. Stabin MG. *Internal dosimetry in pediatric nuclear medicine*. In:

Treves ST, ed. *Pediatric nuclear medicine*, 2nd ed. New York: Springer-Verlag, 1995:556.

Bone Densitometry

148. Weiner S, Traub W. Bone structure: from angstroms to microns. *FASEB J* 1992;6:879.
149. Majumdar S, Kothari M, Augat P, et al. High-resolution magnetic resonance imaging: three-dimensional trabecular bone architecture and biomechanical properties. *Bone* 1998;22:445.
150. Genant HK. Current state of bone densitometry for osteoporosis. *Radiographics* 1998;18:913.
151. Jergas M, Genant HK. Spinal and femoral DXA for the assessment of spinal osteoporosis. *Calcif Tissue Int* 1997;61:351.
152. Gilsanz V. Bone density in children: a review of the available techniques and indications. *Eur J Radiol* 1998;26:177.
153. Kovanlikaya A, Loro ML, Hangartner TN, et al. Osteopenia in children: CT assessment. *Radiology* 1996;198:781.
154. Gilsanz V, Skaggs DL, Kovanlikaya A, et al. Differential effect of race on the axial and appendicular skeletons of children [see comments]. *J Clin Endocrinol Metab* 1998;83:1420.
155. Gilsanz V, Boechat MI, Gilsanz R, et al. Gender differences in vertebral sizes in adults: biomechanical implications [see comments]. *Radiology* 1994;190:678.
156. Gilsanz V, Roe TF, Mora S, et al. Changes in vertebral bone density in black girls and white girls during childhood and puberty [see comments]. *N Engl J Med* 1991;325:1597.

Radiation Exposure: Practical Issues

157. Sorenson J, Phelps M. Radiation safety and health physics. In: Sorenson J, Phelps M, eds. *Physics in nuclear medicine*. Philadelphia: WB Saunders, 1987:519.
158. International Commission on Radiation Protection. 1990 recommendations of the International Commission on Radiation Protection. ICRP Publication 60. *Ann ICRP* 1991;21:1.
159. Gibbs S. Basic mechanism of radiation injury—somatic and genetic. In: American College of Radiology Commission on Physics and Radiation Safety Committee on Radiologic Units S, and Protection. *Radiation risk: a primer*. Reston: American College of Radiology, 1996.
160. Poznanski A. Approaches to minimizing risk in pediatric radiology. In: American College of Radiology Commission on Physics and Radiation Safety Committee on Radiologic Units S, and Protection. *Radiation risk: a primer*. Reston: American College of Radiology, 1996:19.
161. Tolbert D. Sources of radiation exposure. In: American College of Radiology Commission on Physics and Radiation Safety Committee on Radiologic Units S, and Protection. *Radiation risk: a primer*. Reston: American College of Radiology, 1996:3.
162. Kelsey CA, Mettler FA Jr, Sorenson JA, et al. Health care workers' perceptions of risks. *Health Phys* 1987;53:541.
163. Sorenson JA. Perception of radiation hazards. *Semin Nucl Med* 1986;16:158.
164. Palmer SH, Starritt HC, Paterson M. Radiation protection of the ovaries in young scoliosis patients. *Eur Spine J* 1998;7:278.
165. Almen AJ, Mattsson S. Dose distribution at radiographic examination of the spine in pediatric radiology. *Spine* 1996;21:750.
166. Levy AR, Goldberg MS, Mayo NE, et al. Reducing the lifetime

risk of cancer from spinal radiographs among people with adolescent idiopathic scoliosis. *Spine* 1996;21:1540, 1548.

167. Parry RA, Glaze SA, Archer BR. The AAPM/RSNA physics tutorial for residents. Typical patient radiation doses in diagnostic radiology. *Radiographics* 1999;19:1289.

Sedation for Imaging

168. Wagner LK. *Radiation bioeffects and management test and syllabus*, vol. 32. Reston: The American College of Radiology, 1991.
169. American Academy of Pediatrics. Guidelines for monitoring and management of pediatric patients during and after sedation for diagnostic and therapeutic procedures. *Pediatrics* 1992;89:1110.
170. Thompson JR, Schneider S, Ashwal S, et al. The choice of sedation for computed tomography in children: a prospective evaluation. *Radiology* 1982;143:475.
171. Strain JD, Harvey LA, Foley LC, et al. Intravenously administered pentobarbital sodium for sedation in pediatric CT. *Radiology* 1986;161:105.
172. Strain JD, Campbell JB, Harvey LA, et al. IV Nembutal: safe sedation for children undergoing CT. *Am J Roentgenol* 1988;151:975.
173. Greenberg SB, Faerber EN, Aspinall CL. High dose chloral hydrate sedation for children undergoing CT. *J Comput Assist Tomogr* 1991;15:467.
174. Greenberg SB, Faerber EN, Aspinall CL, et al. High-dose chloral hydrate sedation for children undergoing MR imaging: safety and efficacy in relation to age. *Am J Roentgenol* 1993;161:639.
175. Greenberg SB, Faerber EN, Radke JL, et al. Sedation of difficult-to-sedate children undergoing MR imaging: value of thioridazine as an adjunct to chloral hydrate. *Am J Roentgenol* 1994;163:165.
176. Stabin MG. Internal dosimetry in pediatric nuclear medicine. In: Treves ST, ed. *Pediatric nuclear medicine*, 2nd ed. New York: Springer-Verlag, 1995:556.



4

THE PEDIATRIC ORTHOPAEDIC EXAMINATION

DAVID D. ARONSSON

THE ORTHOPAEDIC EXAMINATION FROM BIRTH TO 4 YEARS OF AGE 102

- A 1-month-old Girl Is Referred for Evaluation of a Hip Click 102
- A 2-year-old Boy Is Referred for Evaluation of Intoeing and Tripping over His Feet 104
- An 18-month-old Boy Is Referred for Developmental Delay and Inability to Walk 106
- A 2-month-old Girl Is Referred for Evaluation Because She Is Not Moving Her Left Arm Like She Moves the Right Arm 109
- A 3-year-old Girl Is Referred for Evaluation of Bowed Legs (Genu Varum) 110
- A 2-year-old Boy Is Referred for a Limp of the Right Lower Extremity That Developed after He Fell Down the Basement Stairs Earlier That Day 110
- A 3-year-old Boy Is Referred Because He Was Limping on the Right Side for 2 Days, Then Awoke That Morning and Refused to Walk 111
- A 4-month-old Girl Is Referred for Evaluation Because She Has an Extra Finger on the Right Hand 113

THE ORTHOPAEDIC EXAMINATION FROM 4 TO 10 YEARS OF AGE 113

- A 4-year-old Boy Is Referred Because He Is Walking on His Toes 113

- A 7-year-old Boy Is Referred for Evaluation of Right-sided Thigh Pain with a Limp That Has Persisted for 4 Months Despite Decreasing His Activities 116
- A 5-year-old Boy Is Referred for Evaluation of a Flatfoot Deformity (Pes Planus) That the Parents First Noted When He Began Walking at 13 Months of Age 117
- A 6-year-old Boy Is Referred for Evaluation of Acute Pain and Swelling Involving the Left Elbow after Falling from the Monkey Bars at School 118
- A 9-year-old Boy Is Referred for Evaluation Because He Is Having Pain in His Left Heel That Is Aggravated by Playing Soccer 119

THE ORTHOPAEDIC EXAMINATION FROM 10 TO 18 YEARS OF AGE 120

- A 13-year-old Girl Is Referred for Evaluation of Scoliosis 120
- A 14-year-old Boy Is Referred for Evaluation of Persistent Right Knee Pain That Causes Him to Limp 121
- A 14-year-old Girl Is Referred for Evaluation of Right Knee Pain and Giving Way That Is Aggravated by Playing Soccer and Basketball 122
- A 13-year-old Girl Is Referred for Evaluation of Right Shoulder Pain That Is Aggravated by Swimming 125
- A 15-year-old Boy Is Referred for Evaluation of Pain and Swelling of the Right Ankle That Developed after He Twisted His Foot while Playing Basketball 128

The pediatric orthopaedic examination may vary depending on the age of the child, the chief complaint, and the magnitude of the problem. In all cases, it is important for the clinician to respect the dignity of the child, the parents or legal guardian, and any other health care professionals that accompany the patient. The clinician begins by washing his or her hands and introducing himself or herself to the child, parents or legal guardian, and other health care professionals, and shaking their hands. If a resident physician accompanies the clinician into the examination room, it is important to introduce the resident and explain why he or she is present. The clinician then sits down and slowly takes an accurate history from the child and parents or legal guardian, while simultaneously making eye contact with them. These basic principles of respect for the child, parents or legal guardian, and other health care professionals are followed in all situations.

Although a short, focused history and limited physical examination may be appropriate for a 5-year-old boy sustaining a torus fracture, a thorough history and physical examination are required to evaluate a 2-year-old boy with developmental delay and inability to walk. The history begins with the chief complaint in the words of the child, or, if the child is not yet talking, in the words of the parents or legal guardian. The history of present illness includes details concerning when and how the problem developed, how it has evolved, whether it has been treated, and any situations that aggravate or relieve the symptoms. The developmental history includes the birth history, with details concerning the pregnancy, delivery, and perinatal course. The developmental history also includes developmental milestones, such as when the child first sat independently, pulled to standing, cruised, walked independently, and developed handedness. The past medical history includes any allergies, hospitalizations, operations, major illnesses, and if the patient is taking any medication. The family history includes the siblings, parents, grandparents, and any other relatives who had a similar problem or any major illness. The review of systems includes general questions about each system, such as the gastrointestinal system or the musculoskeletal system, to detect any problems that may or may not be associated with the history of present illness. The personal and social history reviews the living situation of the patient and any habits that he or she may have, such as smoking.

The physical examination includes the height and weight of the patient, and a thorough examination of the skin, spine, and upper and lower extremities, as well as a neurologic examination. The pediatric orthopaedic examination does not typically include the vital signs or a detailed examination of the head, eyes, ears, nose, throat, chest, heart, or abdomen. These aspects of the physical examination are usually performed by the child's pediatrician, but if con-

cerns about these areas arise during the examination, they are examined in detail.

The history and physical examination also vary with the age of the patient, because infants and young children are unable to give a history, whereas older children will often give a more accurate history than their parents or legal guardian. The teenage boy with a postural round back deformity may have a benign history with no concerns, but the parents or legal guardian may be concerned that he will develop a kyphotic deformity with osteoporosis, like his grandmother. Many pediatric orthopaedic disorders develop only in certain age groups, such as Legg-Calvé-Perthes disease, which typically develops in 4- to 10-year-old boys. As a result, discussion of the pediatric orthopaedic examination in this chapter is divided into three sections, according to the age of the patient.

The first section includes newborns, infants, and young children from birth to 4 years of age. These patients are usually unable to give an accurate history, so the majority of the history is obtained from the parents or legal guardian. Such young patients are often apprehensive about going to the doctor, and are not interested in being examined; so some type of user-friendly materials, such as toys or stickers, may be necessary to earn their trust, so that they will allow the examiner to perform an accurate and thorough physical examination. The majority of the physical examination of an infant often can be done in the mother's lap. For pertinent parts of the examination, the infant can be placed on the examining table; if he or she is upset or uncooperative, bottle-feeding during this part of the examination can calm the infant. The 2-year-old child, in the "terrible twos," is often very apprehensive about going to the doctor and being placed in an examination room. The clinician should not burst into the room, conduct a brief history, and then perform a physical examination on an upset and combative child. At first, the parents will often try to help the clinician if the child is uncooperative, but if the clinician perseveres with the examination in the face of an uncooperative child, the parents will usually side with their child. In this situation, the parents may themselves become uncooperative and not volunteer any new information, just to get out of the examination room as quickly as possible. As a result, rather than leaving the office with the knowledge and confidence that the clinician has solved the problem, they leave with the impression that the problem is not resolved, and that the clinician was hurried, uncaring, and not interested in helping their child. Some clinicians believe that the problem is "the white coat," whereas others believe that it involves the entire situation of taking an apprehensive 2-year-old child to the doctor, being placed in an examination room, then having a stranger come in who expects to conduct a physical examination. These issues can be avoided if the clinician can gain the respect and trust of the child before embarking on the physical examination. This can be

achieved by sitting down with the child while conducting the history with the parents or legal guardian, and by simultaneously engaging the child in the conversation and taking short interruptions to entertain or play with the child. Once the history is completed, the physical examination can then be initiated in a nonthreatening manner.

The second section includes children from 4 to 10 years of age. These patients are usually interested in participating in the examination, and will often correct their parents if the information given is incorrect. They like receiving stickers, playing with toys in the examination room, and playing with the water at the sink. As a result, they are usually calm and not threatened by the clinician, and will typically cooperate during the physical examination. Many children between 4 and 10 years of age do not like removing their clothes and putting on a johnny or hospital gown. This situation can be avoided if they wear a pair of shorts and a T-shirt for the examination. In this age group, some children with special health needs will be particularly resistant to anyone attempting to conduct a physical examination on them. In this situation, it is often helpful to tell the parents or legal guardian what you would like to accomplish. For example, if you would like to examine the child for possible scoliosis, and to perform an Adams

forward-bending test, this can easily be explained to the parents or legal guardian. Once explained, they will often be able to get the child into the correct position, so that you can perform the test.

The third section includes children and adolescents from 10 to 18 years of age. These patients are usually very motivated to get better, and will give an accurate history, believing that the doctor can indeed help them to get better. Teenagers are often very concerned about removing their clothes, so it is reassuring to them to know that they do not need to remove their shorts or underwear. If conducted appropriately and in a manner that respects their privacy, teenagers will typically allow the clinician to perform a complete physical examination.

In all age groups, it is often beneficial to begin with a patient profile, which is filled out by the parents or legal guardian (ages birth to 4 years old), the parents or legal guardian with help from the patient (ages 4 to 10 years old), or the patient with help from the parents or legal guardian (ages 10 to 18 years old) before the actual examination (Fig. 4-1). The patient profile includes the chief complaint and history of present illness, with details concerning the birth and developmental history. It also lists any allergies, medications that the patient is taking, previous hospitalizations, or

Name of patient _____		Birthdate _____	
Age: Years _____ Months _____		Grade in school _____	
Brothers _____		Sisters _____	
_____		_____	
_____		_____	
Height of mother _____		Height of father _____	
Referring physician _____		Family physician _____	
What is the reason for today's visit? _____			
When did the problem first start? _____			
Is it better or worse than when you first noticed it? _____			
Is there a family history of this problem? _____			
Have you had any treatment? _____			
If yes, please list treating physician(s) and treatment _____			

Past history:			
Major illnesses?	Yes _____	No _____	If yes, please list _____
Operations?	Yes _____	No _____	If yes, please list _____

FIGURE 4-1. Patient profile.

FIGURE 4-1. (continued)

THE ORTHOPAEDIC EXAMINATION FROM BIRTH TO 4 YEARS OF AGE

A hip click may be a benign click that reflects a popping sensation as the iliopsoas tendon slides over the anterior hip capsule with internal and external rotation of the hip, or it may indicate a subluxation or dislocation reflecting developmental dysplasia of the hip (DDH). To distinguish between these two very different entities, the clinician focuses on certain aspects of the history and physical examination that are associated with DDH. The history begins with a review of the pertinent findings from the patient profile with the parents or legal guardian. The most important information, the hip click, is documented in the chief complaint and history of present illness. For an infant with a hip click, it is important to document when and how it was first de-

rected. If the infant has DDH, the type of treatment and the prognosis will vary, depending on the age of the patient and the magnitude of the DDH. The birth history is important in this case, because DDH is associated with primigravida mothers, oligohydramnios, breech presentations, congenital muscular torticollis, and certain types of foot deformities, such as metatarsus adductus. The breech presentation is the most important of these findings because even if born by cesarean section, if the infant was in the frank (single) breech presentation, the frequency of DDH is 20 to 30%. The developmental history is also important; if the child has a neuromuscular disorder, such as arthrogryposis multiplex congenita, the infant may have a teratologic, rather than a typical, DDH. A patient with a teratologic DDH usually requires a completely different treatment approach than a patient with a typical DDH. The family history may reveal DDH in the parents, siblings, cousins, or aunts and uncles. This information may be crucial in evaluating the patient, because the incidence of DDH is higher when other family members have the disorder. It is also important to ask about any previous treatment that has been rendered by clinicians or paramedical personnel, because this may influence patient management.

The examination of a 1-month-old infant with a hip click can be started with the infant in the mother's lap. In this position, the infant is comfortable and not threatened, and the clinician can examine the range of motion of the hands, wrists, elbows, and shoulders. The neck can be examined to look for a congenital muscular torticollis with a contracture of the sternocleidomastoid muscle, a condition that is seen in association with DDH. With the infant in the same position, the knees, ankles, and feet can be examined to look for a metatarsus adductus deformity, another condition that is seen in association with DDH. The infant can then be placed prone over the mother's shoulder, similar to the position for burping the infant, while the clinician examines the spine and looks for a sacral dimple, hairy patch, or anal problems. A sacral dimple or hairy patch may be a sign of an underlying tethered spinal cord or lipomeningocele. These disorders can cause varying degrees of paralysis of the lower extremities that may result in a paralytic dislocation of the hip with a positive hip click. Finally, after the majority of the physical examination has been completed and the infant and parents or legal guardian are comfortable with the clinician, the infant can be placed on a firm surface to thoroughly examine the hips.

The key to the early diagnosis of DDH is the physical examination. The examination should be performed on a firm surface with the infant relaxed. If the infant is crying or upset, the DDH may not be detected. In this situation, allow the parent or legal guardian to feed or calm the infant and begin the examination as soon as the infant is happy and comfortable. The examination begins with the hips and knees flexed to 90 degrees. The examiner places the thumb along the medial thigh and the long finger laterally along the axis of the femur. Gentle pressure is applied to the knee in a posterior direction, while the examiner palpates a "clunk" as the hip dislocates out of the acetabulum. If the hip subluxates rather than dislocates, the examiner may note only a sensation of sliding as the femoral head slides over the posterior lip of the acetabulum. This telescoping maneuver is often termed the "Barlow provocative test," which represents a "sign of exit" as the hip dislocates from the acetabulum (Fig. 4-2A). With the hip in the dislocated or subluxated position, the examiner then gently abducts the hip, while pushing anteriorly with the long finger over the greater trochanter, and palpates another clunk as the hip slides over the posterior lip and into the acetabulum. This is a positive Ortolani maneuver, which represents a "sign of entry" as the hip reduces into the acetabulum (Fig. 4-2B). The original Barlow test was actually a two-part test: the first part included an Ortolani maneuver to determine if the hip was dislocated. The second part, or the Barlow provocative test, was performed to determine if the hip could be dislocated or subluxated. The Barlow and Ortolani tests detect ligamentous laxity and instability, and although they are valuable during the neonatal period, they usually become negative by 3 months of age (1).

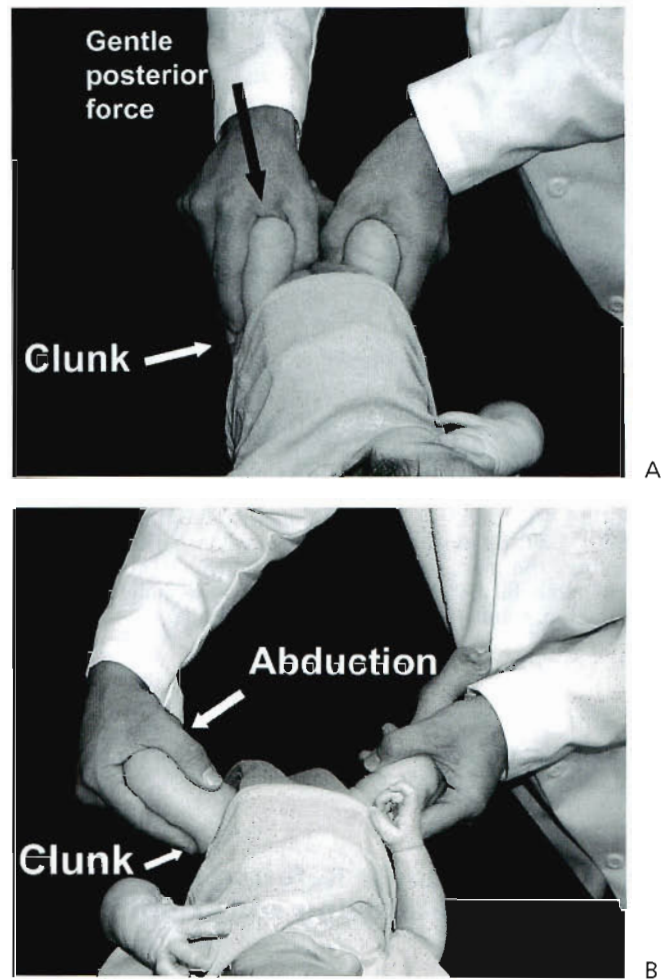


FIGURE 4-2. A: The Barlow test is performed in two parts to determine if the hip is located and stable, located and able to be subluxated or dislocated, dislocated and able to be located, or dislocated and not able to be located. The first part of the test is an Ortolani maneuver to determine if the hip is dislocated. The second part, or the Barlow provocative test, is performed with the hips flexed to 90 degrees; the clinician places the thumb along the medial thigh and the long finger along the lateral axis of the femur. Gentle pressure in a posterior direction is applied to the knee, while the clinician palpates a "clunk" as the hip dislocates or subluxates out of the acetabulum. B: The Ortolani maneuver is performed by gently abducting the hip, while pushing anteriorly with the long finger over the greater trochanter; the clinician palpates another clunk as the hip slides over the posterior lip and into the acetabulum.

Once the infant is 3 months old, the ligamentous laxity has usually resolved, and if the hip is subluxated or dislocated superolaterally, the adductor and flexor muscles become tight, causing an adduction contracture. At this age, the most common physical finding is limited abduction of the hip (Fig. 4-3). The superolateral subluxation of the hip causes a limb-length discrepancy that may be detected by examining the overall limb lengths. The shortening of the thigh causes an increased number of thigh folds compared with the other thigh, and if the hips are flexed to 90 degrees,

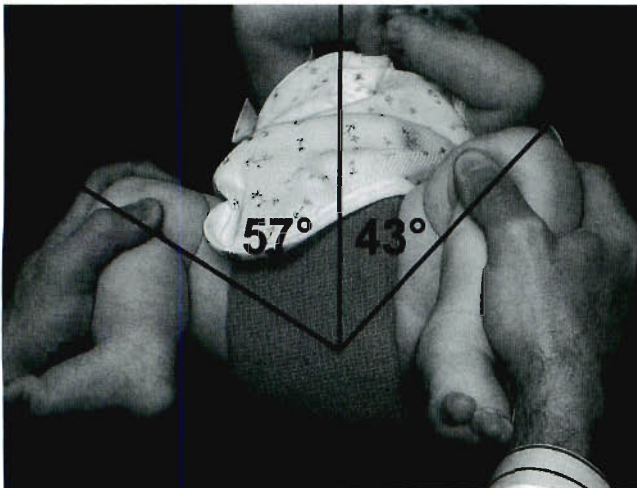


FIGURE 4-3. Once the infant is 3 months old, the ligamentous laxity usually disappears and the hip develops an adduction contracture. The most common physical finding in a patient with developmental dysplasia of the hip at this age is limited abduction of the hip, compared with the uninvolved side.

the knee of the involved hip will be lower than the opposite side (Galeazzi sign) (Fig. 4-4).

A 2-year-old Boy Is Referred for Evaluation of Intoeing and Tripping over His Feet

In this case, the clinician focuses on certain aspects of the history and physical examination to determine if the child

is developing satisfactorily and tripping like most 2-year-old children, or if there is evidence of developmental delay. If there is a delay in development, there may be associated problems with coordination or retention of primitive reflexes. The clinician begins by reviewing the chief complaint and history of present illness. If the intoeing is physiologic and represents a normal developmental variation, it will often first be noted by the grandparents, parents, or legal guardian when the child begins walking, and it will usually be symmetric. The clinician asks if the parents believe that the intoeing is originating from the hips, thighs, legs, or feet. A unilateral problem, involving a foot with intoeing and tripping over the foot, may indicate a mild clubfoot or a neurologic problem such as a tethered spinal cord. The clinician also reviews the pertinent findings in the birth history and developmental history in the patient profile with the parents or legal guardian. Most children who are developing satisfactorily will sit independently (without hand support) by 6 to 9 months of age, cruise (walk with assistance) by 10 to 14 months of age, and walk independently by 8 to 18 months of age (Table 4-1).

If there is concern about possible developmental delay, it is important to verify the details concerning the birth history to determine if the infant was premature, or if there were any perinatal complications. Premature infants born after 25 to 30 weeks of gestation, with a birth weight of 750 to 1500 g, have an increased incidence of cerebral palsy, particularly spastic diplegia. The first sign of this disorder may be noted by the parents when they discover that their child is delayed in walking or having trouble with intoeing and tripping over his or her feet. While verifying the developmental history with the parents or legal guardian, it is valuable to ask if the infant is ambidextrous, right-handed,

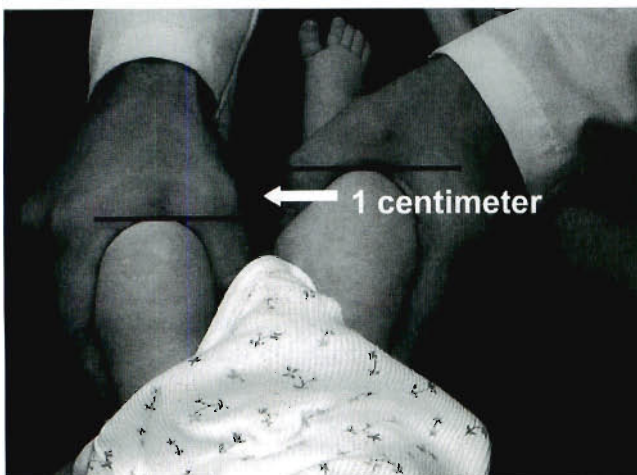


FIGURE 4-4. The Galeazzi sign is elicited by flexing the hips and knees to 90 degrees, with the patient supine. If there is superolateral subluxation of the femoral head with shortening of the thigh segment, the knee of the involved hip will be lower than the opposite side.

TABLE 4-1. AVERAGE DEVELOPMENTAL ACHIEVEMENT BY AGE

Age	Achievement
1 month	Partial head control in prone position
2 months	Good head control in prone position; partial head control in supine position
4 months	Good head control in supine position; rolls over prone to supine
5 months	Rolls over supine to prone
6 months	When prone, lifts head and chest with weight on hands; sits with support
8 months	Sits independently; reaches for toys
10 months	Crawls; stands holding onto furniture
12 months	Walks independently or with hand support
18 months	Developing handedness
2 years	Jumps; knows full name
3 years	Goes upstairs alternating feet; stands momentarily on one foot; knows age and gender
4 years	Hops on one foot; throws ball overhand
5 years	Skips; dresses independently

or left-handed. Children who are developing satisfactorily will usually remain ambidextrous until 18 months to 2 years of age (Table 4-1). If the child is 2 years old and strongly right-handed or left-handed, the birth and developmental history may reveal a previous intrauterine cerebral vascular accident, and the handedness may be one of the early signs of cerebral palsy with spastic hemiplegia.

For a 2-year-old boy with intoeing and frequent falling, the examination will usually proceed in a different fashion than it would for a 1-month-old girl with a hip click. Before beginning the physical examination, the clinician needs to remember that infants and young children enjoy being with their parents, and are often not particularly interested in being examined. They do not understand why they are trapped in an examination room with the door closed and why a stranger in a white coat wants to “wiggle” their legs. This awkward situation can be overcome if the clinician can gain the respect and trust of the child and the child’s parents or legal guardian before embarking on anything that the child may perceive as threatening, such as a physical examination. The clinician can sit down with the child and parents or legal guardian and review the chief complaint, history of present illness, and the exact details about the birth and developmental history, while taking frequent breaks to talk and play with the child. Once the history is completed and everyone is more at ease, particularly the child, the physical examination can be initiated in a non-threatening manner.

It is often beneficial with a 2-year-old child to begin the physical examination by opening the door and asking the child and parents or legal guardian if they would like to take a walk down the hall. This is a very nonthreatening way to begin the examination, and there is nothing that the child wants to do more than get out of the room. The clinician will find that most toddlers are more comfortable walking away from than walking toward the clinician. The clinician can stay in the room for a moment, then look out the door as the family is walking down the hall to observe the child’s gait pattern and the foot-progression angle (2). The foot-progression angle compares the axis of the foot, a line connecting a bisector of the heel with the center of the second metatarsal head, with an imaginary straight line drawn on the floor (Fig. 4-5). The normal foot-progression angle in children 1 to 4 years of age can vary from 40 degrees of inward rotation to 40 degrees of outward rotation. The gait pattern can also vary considerably in this age group, but usually it will be relatively symmetric, with a similar amount of time being spent in the stance phase (60% of the gait cycle) and the swing phase (40% of the gait cycle) between the two extremities. The degree and location of any rotational variations or torsional deformities can be documented by creating a rotational profile (Fig. 4-6). The rotational profile includes the foot-progression angle, internal rotation of the hips, external rotation of the hips, the thigh-foot angle, and any foot deformities. The

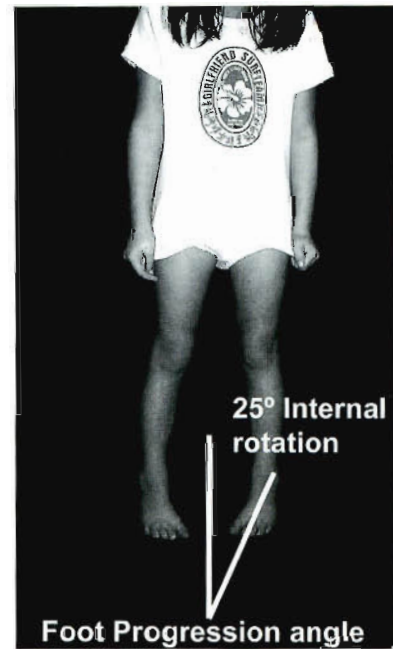


FIGURE 4-5. While the patient is walking, the foot-progression angle compares the axis of the feet with an imaginary straight line drawn on the floor.

foot-progression angle measures the degree of intoeing or outtoeing compared with an imaginary straight line drawn on the floor. The internal and external rotation of the hip measures the femoral version or torsional deformity of the femur (Fig. 4-7). The thigh-foot angle is the angle between the axis of the thigh and the axis of the foot, with the knee bent to 90 degrees (Fig. 4-8). This angle measures the tibial version or torsional deformity of the tibia (3). The foot examination records the amount of metatarsus adductus or any other foot deformity that may be contributing to the intoeing or outtoeing. Once the profile is filled out, it gives an objective view of the location and magnitude of any rotational variations or torsional deformities of the lower

	Right	Left
FPA		
MR		
LR		
TFA		
Foot		

FIGURE 4-6. Rotational profile.

FPA, foot-progression angle; MR, hip medial rotation; LR, hip lateral rotation; TFA, thigh-foot angle. Record angles in degrees, and describe foot deformity.

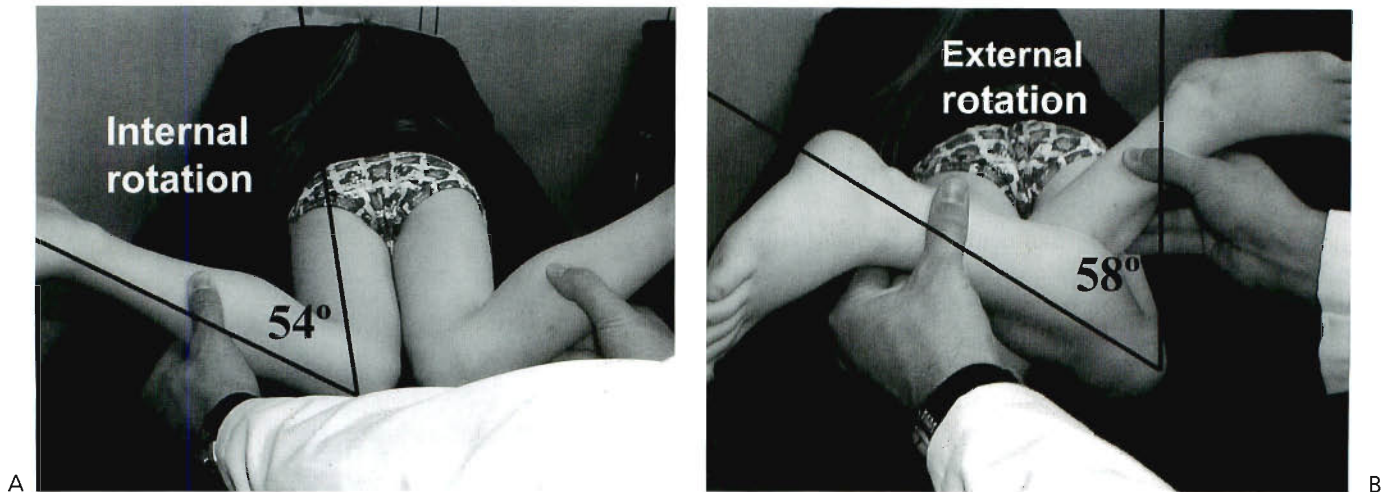


FIGURE 4-7. The internal and external rotation of the hips can be measured in the supine or the prone position. **A:** Standing at the foot of the bed, with the patient prone, the clinician uses gravity to allow the hips to fall into internal rotation. The angle between the leg and a line perpendicular to the tabletop measures the internal rotation. **B:** With the patient in the same position, the clinician uses gravity to allow the hips to fall into external rotation. The angle between the leg and a line perpendicular to the tabletop measures the external rotation.

extremities. The rotational profile can then be used as a baseline while following the child to document that the deformity does indeed improve with growth. Two-year-old boys often have persistent internal femoral or internal tibial torsional deformities that cause them to walk with the feet turned in, or pigeon-toed.

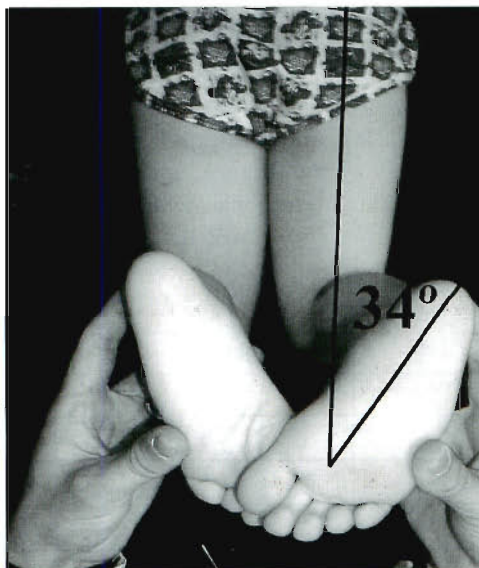


FIGURE 4-8. Standing at the foot of the bed, with the patient prone, the clinician measures the angle between the axis of the thigh and the axis of the foot, with the foot held in a neutral position. This angle, termed the "thigh-foot angle," measures the amount of tibial torsion.

An 18-month-old Boy Is Referred for Developmental Delay and Inability to Walk

The chief complaint and history of present illness reveals that the parents are concerned that their son is unable to walk. On further questioning, it is revealed that the parents first suspected that their son might be delayed when he was 4 months old and was still having difficulty with head control. They became more concerned when he was still unable to sit independently at 10 months of age. He just recently began pulling to standing, and he is unable to walk. The birth history reveals that he was born after a 28-week gestation, with a birth weight of 1100 g. He had perinatal respiratory difficulties, and was hospitalized in the neonatal intensive care unit for 2 months. He developed a seizure disorder at 1 year of age, and his seizures are now under good control with medication.

In this case, the boy is developmentally delayed, so the physical examination will focus on the neurologic examination and developmental progress. It is often convenient to begin the physical examination with the boy in the supine position; the clinician grasps his hands and gradually pulls him into the sitting position, while looking for head and trunk control. An infant will usually have head control by 3 to 4 months of age and trunk control by 6 to 8 months of age (Table 4-1). Delayed head and trunk control may indicate overall developmental delay, which, if associated with prematurity and a low birth weight, may indicate cerebral palsy. In infants there are a series of primitive reflexes, including the Moro, grasp, neck-righting, symmetric tonic neck, and asymmetric tonic neck reflexes, which are often

TABLE 4-2. PRIMITIVE AND POSTURAL REFLEXES

Primitive Reflex	Age When It Disappears
Grasp	3 months
Moro	6 months
Asymmetric tonic neck	6 months
Symmetric tonic neck	6 months
Neck-righting	10 months
Postural Reflex	Age When It Appears
Foot-placement	Early infancy
Parachute	12 months

present at birth, then gradually disappear with normal growth and development by 4 to 10 months of age (Table 4-2). If these reflexes persist beyond 6 to 10 months of age, it may be an early sign of a neuromuscular disorder.

The Moro reflex is present at birth, and is elicited by introducing a sudden extension of the neck. The shoulders abduct and the upper limbs extend, with spreading of the fingers, followed by an embrace (Fig. 4-9). The Moro reflex usually disappears by 6 months of age (4). The grasp reflex is elicited by placing a finger in the infant's palm from the ulnar side. The infant's fingers will firmly grasp the examiner's finger. If traction is applied to the hand, the grasp reflex is so strong that the examiner can lift the infant's shoulder from the table (Fig. 4-10). The grasp reflex usually disappears by 3 months of age. The neck-righting reflex is elicited by turning the head to one side, and is positive if the trunk and limbs turn toward the same side. This reflex usually disappears by 10 months of age (4). The symmetric

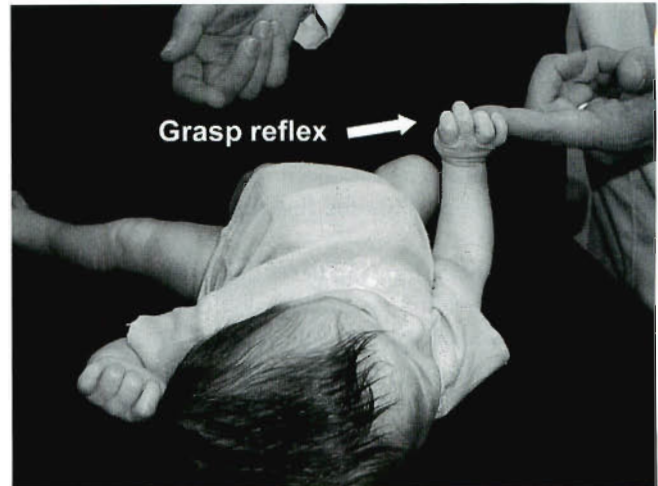


FIGURE 4-10. The grasp reflex is elicited by introducing the clinician's finger into the infant's palm from the ulnar side. The infant's fingers will flex and firmly grasp the clinician's finger. If traction is applied, the muscles of the arm and shoulder girdle contract, allowing the clinician to temporarily suspend the infant by grasp reflex.

tonic neck reflex is elicited by flexion of the neck, which causes flexion of the upper limbs and extension of the lower limbs. Similarly, extension of the neck causes extension of the upper limbs and flexion of the lower limbs. The asymmetric tonic neck reflex is elicited by turning the head to the side, which results in extension of the upper and lower extremities on the side toward which the head is turned, and flexion of the upper and lower extremities on the opposite side (the "fencing" position) (Fig. 4-11). The symmetric and asymmetric tonic neck reflexes usually disappear by 6 months of age. The extensor thrust, an abnormal reflex, is

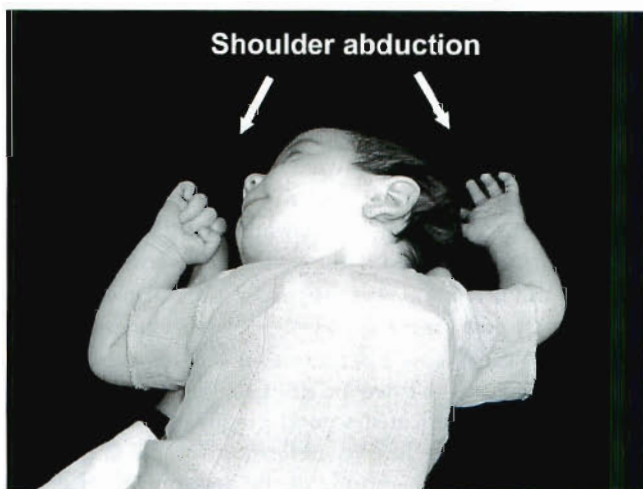


FIGURE 4-9. The Moro reflex is elicited by gently lifting the infant with the clinician's right hand under the upper thoracic spine and the left hand under the head. The clinician then drops the left hand to allow sudden neck extension; the infant abducts the upper limbs, with spreading of the fingers, followed by an embrace.

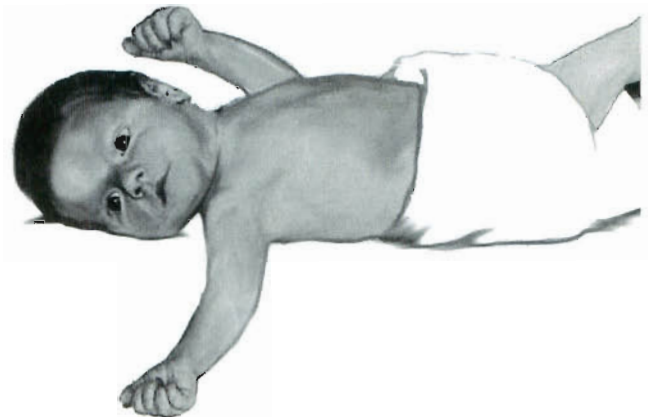

FIGURE 4-11. In the supine position, the asymmetric tonic neck reflex is elicited by turning the head to one side, then the other. A positive response is extension of the upper and lower limbs on the facial side and extension on the occipital side (the "fencing" position). (From ref. 5, with permission.)

elicited by holding the infant under the arms and touching the feet to the floor, which causes a rapid extension of the joints of the lower limb, progressing from the feet to the trunk (Fig. 4-12). A normal infant will flex rather than extend the lower extremities when placed in this position. All of these primitive reflexes need to resolve with development before it is possible for the child to walk independently.

There is another group of reflexes that disappear at different stages of development, including the rooting, startle, gallant, and Landau reflexes. The rooting reflex is elicited by touching the corner of the mouth, which results in the mouth and tongue turning toward the side that was stimulated. The startle reflex is elicited by making a loud noise, which results in a mass myoclonic response resembling a Moro reflex, except that the elbows remain flexed in the startle. The startle reflex may persist until late childhood. The gallant reflex is elicited by stroking the side of the trunk, which results in the infant bending the spine toward the side that was stimulated. The Landau reflex is elicited by supporting the infant by the trunk in the horizontal prone position; the typical response is extension of the neck and spine. If the infant collapses into an upside-down U, it may indicate hypotonia.

There is another group of postural reflexes that gradually

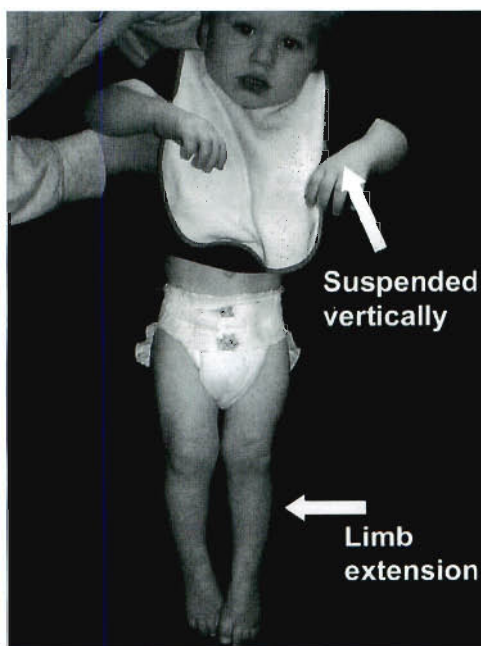


FIGURE 4-12. The extensor thrust is elicited by holding the infant under the arms and gradually lowering the infant until the feet touch the floor. An extensor thrust is an abnormal reflex in which there is progressive extension of the lower limbs, progressing superiorly from the feet to the trunk. The typical response in a normal infant is flexion of the lower extremities.

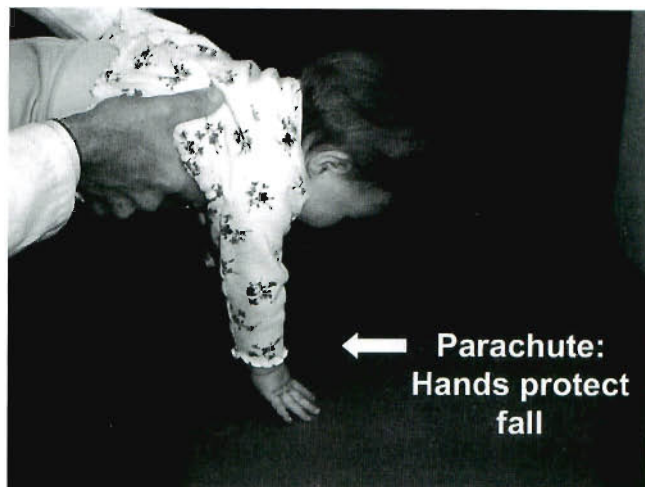


FIGURE 4-13. The parachute reflex is elicited by holding the infant in the air in the prone position, then suddenly lowering or tipping the infant headfirst toward the table. The reflex is positive if the infant extends the upper extremities and places the hands on the tabletop.

appear as a result of development of the nervous system, including the parachute reflex and the foot-placement reaction (Table 4-2). The parachute reflex is elicited by holding the infant in the air in the prone position, then suddenly lowering the infant headfirst toward the table, simulating a fall. The reflex is positive if the infant extends the upper extremities as if to break the fall (Fig. 4-13). This reflex usually appears by 12 months of age, and remains until late adulthood. The foot-placement reaction is elicited by holding the infant under the arms, then gently lifting the infant, so that the dorsum of the foot comes up against the underside of the table. It is positive if the infant picks up the extremity as if to step up onto the table (Fig. 4-14). The foot-placement reaction usually develops early in infancy, and may persist until the age of 3 or 4 years.

Bleck (4) studied 73 infants and children who were 12 months of age or older and were still not yet walking independently. He used seven tests to develop a prognosis for walking to predict if an infant would subsequently walk. One point was assigned if the primitive reflexes were still present, and one point was assigned if the normal postural reflexes were still absent (Table 4-3). A score of two points or more indicated a poor prognosis for walking, a one-point score indicated a guarded prognosis (might walk), and a zero-point score indicated a good prognosis.

Analysis of these different reflexes gives the clinician a general idea of the magnitude of the developmental delay. The examination can then proceed by evaluating the spine for any scoliosis or kyphosis. An examination of the upper and lower extremities is performed to assess range of motion of the joints and to document any contractures. If any con-

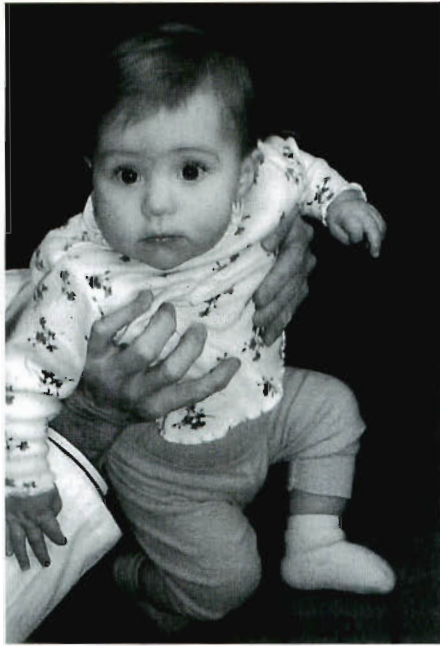


FIGURE 4-14. The foot-placement reaction is elicited by holding the infant under the arms, then gently lifting the infant so that the dorsum of the foot or the anterior surface of the tibia comes up against the underside of the table. It is positive if the infant picks up the extremity as if to step up onto the table.

fractures or deformities are identified the clinician attempts to passively correct the contracture or deformity to determine if it is flexible or rigid. The reflexes are tested, including the Babinski reflex, because children with spastic cerebral palsy and developmental delay may have hyperreflexia with a positive Babinski reflex. If the child is spastic with adduction and flexion contractures of the hips, an antero-posterior pelvis radiograph is beneficial, because many of these children with increased tone may have subluxated hips.

TABLE 4-3. PROGNOSIS FOR WALKING

Reflex	Points
Primitive reflex	
Asymmetric tonic neck	1
Neck-righting	1
Moro	1
Symmetric tonic neck	1
Extensor thrust	1
Postural reflex	
Parachute	1 if absent
Foot-placement	1 if absent

Prognosis for walking: 2 points, poor; 1 point, guarded (might walk); 0 points, good.

(From ref. 2, with permission.)

A 2-month-old Girl Is Referred for Evaluation Because She Is Not Moving Her Left Arm Like She Moves the Right Arm

In this case, the examination will focus on the upper extremities, comparing the paralyzed left side with the right side, and looking for any asymmetry. It is important to distinguish traumatic brachial plexus neuropathy, a true paralysis of the upper extremity, from osteomyelitis, septic arthritis, or birth fractures, which can cause a pseudoparalysis of the extremity. The treatment for each of these conditions is different, and delay in diagnosis in infants with osteomyelitis and septic arthritis can be devastating. An infant with osteomyelitis, septic arthritis, or a birth fracture will usually have swelling at the site, whereas an infant with traumatic brachial plexus palsy will usually have no swelling or swelling may be detected in the neck. In an infant with traumatic brachial plexus palsy or birth fracture of the humerus, the paralysis is usually noted at birth, whereas an infant with osteomyelitis or septic arthritis will often use the arm normally, then suddenly develop the pseudoparalysis. It is important to ask the parents or legal guardian the exact time that the paralysis was noted, whether it has changed with time, and if there was any associated swelling. Traumatic brachial plexus palsy is one of the most common birth injuries, often seen in cases of primigravida mothers with large babies after difficult deliveries. It occurs because of traction and lateral tilting of the head to deliver the shoulder, or, if in the breech presentation, by traction and lateral tilting of the trunk and shoulders to deliver the head. There are three types of brachial plexus palsies, depending on which part of the brachial plexus is affected.

The Erb type affects the upper roots, typically C5 and C6; the Klumpke type affects the lower roots, typically C8 and T1; and the total plexus involvement type affects all of the roots in the brachial plexus. The prognosis for recovery depends on the magnitude of the injury and the time of recovery of certain key muscles (e.g., biceps). In an infant with upper brachial plexus palsy (Erb type), the clinical picture is easily recognized by the absence of active motion of the involved extremity in the Moro reflex. Paralysis of C5 and C6 causes the shoulder to be held in adduction and internal rotation, with the elbow and wrist in extension and the fingers flexed, a position not seen in an infant with a birth fracture involving the humerus. In an infant with lower brachial plexus palsy (Klumpke type), the clinical picture is recognized by an absence of the grasp reflex in the involved extremity. The hand is flaccid, with little or no voluntary control. When there is total plexus involvement, the entire extremity is flaccid, and the Moro and grasp reflexes are both absent. In all types of brachial plexus palsies, after the birth there may be swelling in the supraclavicular area and an associated fracture of the clavicle or humerus,

particularly if it was a difficult delivery. The supraclavicular swelling usually disappears by the time the infant is referred to the orthopaedist.

A 3-year-old Girl Is Referred for Evaluation of Bowed Legs (Genu Varum)

In developing the history of present illness, the clinician asks who first noted the deformity and exactly when it was first noted. It is also valuable to ask if the problem has changed since it was first detected, because a developmental variation will usually improve with growth, but a deformity may get worse over time. In a girl with bowed legs, the birth history and developmental history are typically unremarkable, so the history and physical examination will focus on the lower extremities, in a search for asymmetry between the limbs. The terms “varus” and “valgus” refer to the orientation of the distal fragment compared with the midline of the body. For example, in a child with a bowleg deformity, the distal fragment (the tibia) is angulated toward the midline, so it is termed “genu varum” (Fig. 4-15). In a child with a knock-knee deformity, the distal fragment (the tibia) is angulated away from the midline, so it is termed “genu valgum.” Genu varum (bowed legs) and genu valgum (knock-knees) can be developmental variations that correct spontaneously with growth, or they can be actual deformities that are associated with other medical problems (6).

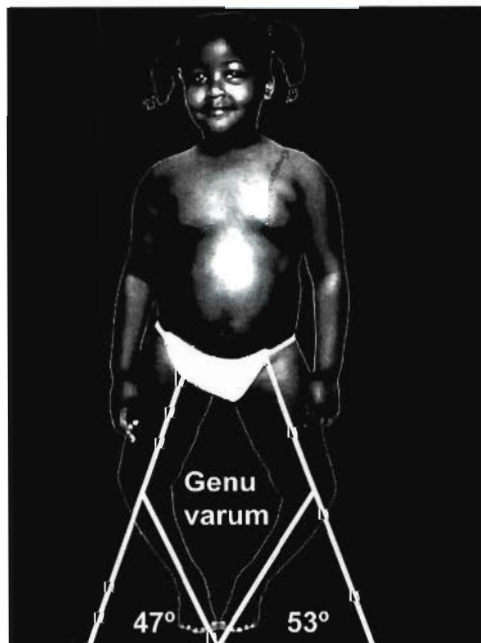


FIGURE 4-15. Varus and valgus deformities are named by how the distal segment is positioned, compared with the proximal segment. In a child with a bowleg deformity, the distal segment (the tibia) is positioned toward the midline, compared with the proximal segment (the femur), so it is termed “genu varum.”

The family history may be relevant in this situation, because there may be several family members with short stature and genu varum. The review of systems may also be relevant in this situation, if the clinician discovers that there have been kidney problems in the past, and the girl has renal rickets with genu varum. It is important to remember that most infants have genu varum, and that it gradually corrects to neutral alignment by 18 to 24 months of age. The lower extremities then gradually develop a genu valgum, which reaches a maximum between 3 and 5 years of age. After the age of 5 years, the genu valgum gradually improves to reach the normal adult tibiofemoral alignment of 7 degrees of genu valgum by the end of growth.

On physical examination, it is important to record the height and weight of the child, and whether either one is more than two standard deviations from the mean. Short stature may be associated with nutritional rickets or another metabolic disorder that is associated with the genu varum. The limbs are closely inspected to determine exactly where the deformity is located. If the genu varum deformity is located in the proximal tibia, it may indicate tibia vara or Blount’s disease. If the genu varum deformity appears to involve the entire limb in a symmetric fashion, it may indicate physiologic bowing, a developmental variation (6). The spine and upper extremities are examined for any findings that may be associated with a metabolic disorder or a particular syndrome, such as spondyloepiphyseal dysplasia. If the boy was referred for genu varum, the deformity or developmental variation is documented by measuring the intercondylar distance. To measure the intercondylar distance, the child is placed in the supine position, with the lower extremities in extension. The feet are brought together until the medial malleoli are just touching, and the magnitude of the genu varum deformity is recorded in centimeters as the distance between the femoral condyles (Fig. 4-16). Similarly, if the girl was referred for genu valgum, the deformity or developmental variation is documented by measuring the intermalleolar distance. The child is again placed in the supine position, with the lower extremities in extension. The feet are brought together until the femoral condyles are just touching, and the magnitude of the genu valgum deformity is recorded, in centimeters, as the distance between the medial malleoli (Fig. 4-17).

A 2-year-old Boy Is Referred for a Limp of the Right Lower Extremity That Developed after He Fell Down the Basement Stairs Earlier That Day

In this case, the history and physical examination will proceed in a different manner. This problem may be the result of a contusion or fracture, so a careful history is obtained from the parents or legal guardian. Details concerning the mechanism of injury and the child’s method of coping with the injury are solicited from the parents or legal guardian.

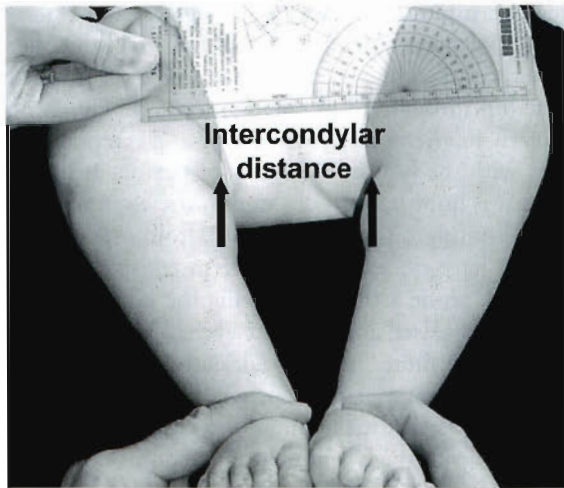


FIGURE 4-16. To measure the intercondylar distance, the child is placed supine, with the lower extremities in extension. The feet are brought together until the medial malleoli are just touching, and the intercondylar distance is the distance between the femoral condyles.

The clinician asks if there are any other injuries, such as a head contusion or laceration. The past medical history may reveal that the boy has had multiple previous fractures, causing the clinician to consider the diagnosis of osteogenesis imperfecta. If the history is not consistent with the magnitude of the physical findings, it is important to remember the possibility of a battered child syndrome. Each year, more than 2.5 million children in the United States sustain injuries that are inflicted by their parents, legal guardians, or caregivers. Although possible, it is unusual for a child

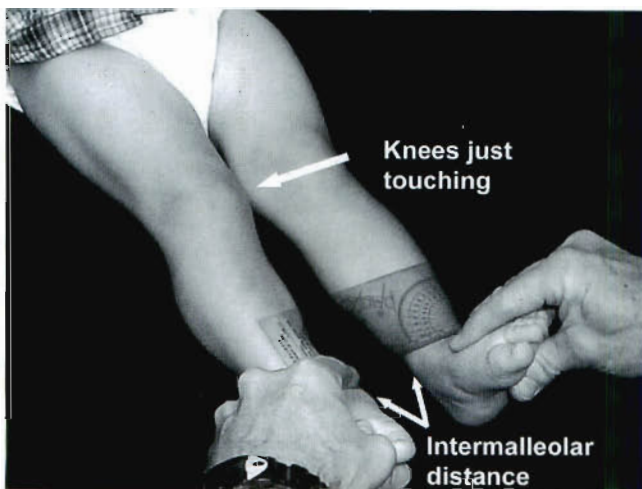


FIGURE 4-17. To measure the intermalleolar distance, the child is placed supine, with the lower extremities in extension. The feet are brought together until the femoral condyles are just touching, and the intermalleolar distance is the distance between the medial malleoli.

younger than 2 years of age to sustain a fracture of the femur or humerus in a normal fall. The examining clinician must keep this in mind when examining infants and children with these injuries. If the child has a fracture or contusion, there will be focal pain and swelling at the site. This can often be demonstrated by squeezing the noninjured side and observing the reaction of the child, then squeezing the injured side at the site of the fracture or contusion and observing the reaction of the child. If there is a fracture or contusion, the child will usually grimace or react to the painful stimulus. If there is focal tenderness and swelling indicating a possible fracture, anteroposterior and lateral radiographs of the involved bone will usually document the fracture.

A 3-year-old Boy Is Referred Because He Was Limping on the Right Side for 2 Days, Then Awoke That Morning and Refused to Walk

This is a typical history for a patient with toxic synovitis involving the hip, but it is also typical for a patient with septic arthritis of the hip, or osteomyelitis involving the proximal femur. Although less common, the history is also consistent with an acute attack of juvenile rheumatoid arthritis, or an early sign of acute lymphoblastic leukemia. A 3-year-old boy will often be interested in showing the clinician exactly where it hurts. If steered in the appropriate direction, the child may point to the groin area, the distal femur, or the knee when describing the pain. It is important to remember that pain can be referred, and hip disorders presenting as knee pain are a classic example of referred pain. The parents or legal guardian can expand on the history to include the exact time of onset and whether the pain is constant or intermittent. A patient with acute septic arthritis involving the hip would typically have a history of 1 to 2 days of severe and constant pain, whereas a patient with juvenile rheumatoid arthritis may have had intermittent low-grade pain for months, then recently developed severe pain. The pain associated with juvenile rheumatoid arthritis is often worse in the morning, which is not usually seen with the other disorders. If the patient has toxic synovitis involving the hip joint, a detailed history from the parents or legal guardian will often reveal that the child had an upper respiratory infection or sore throat 1 to 2 weeks before developing the limp and inability to walk. The history may reveal that the patient had chicken pox 2 weeks before developing the limp and inability to walk. In this case, the clinician may question the possibility of a *Streptococcus* infection. If the patient has been ill with decreased appetite and weight loss, the clinician may want to order blood tests to evaluate for leukemia.

In beginning the physical examination, the clinician remembers that, although the history revealed that the patient refused to walk, that does not necessarily mean that he will

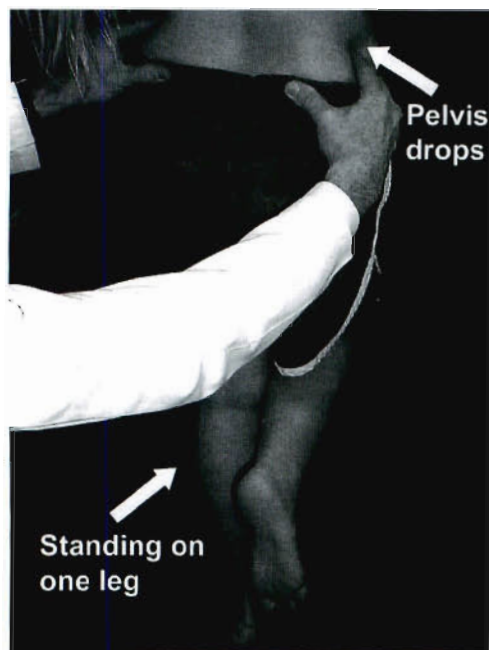


FIGURE 4-18. The clinician palpates the iliac crests while the patient stands on the left lower extremity. When a child stands on the left lower extremity the right iliac crest normally rises because the left hip abductor muscles contract to support the pelvis. The Trendelenburg test is positive if the right iliac crest drops, indicating weakness of the left hip abductor muscles. A trunk shift toward the weightbearing limb also indicates abductor weakness.

not want to walk now. The door can be opened and the parents asked if they would like to go for a walk with the child. The child is observed to see if he will stand and walk, and if successful, the gait is observed to determine if it is symmetric. If the child has an antalgic (painful) gait on one side, with a shortened stance phase, the clinician observes to determine the location of the pain. If the child will not walk, but will stand, he can be asked to stand on one leg, then on the opposite leg. When standing on one leg, the hip abductor muscles (gluteus medius) flex to hold the pelvis up on the opposite side, increasing the hip joint reactive forces. If the hip is irritable, the increased joint reactive forces are so painful that the patient will not contract the hip abductor muscles, causing the pelvis to drop on the opposite side—a positive Trendelenburg test (Fig. 4-18).

It is important to palpate the spine, pelvis, and lower extremities, beginning with the uninvolved side. If the patient has osteomyelitis involving the spine, sacroiliac joint, or distal femur, the clinician will appreciate focal increased pain and swelling to palpation. The hips are examined with the child relaxed in the supine position, and the clinician looks for any asymmetry as the hips are taken through a range of motion. A 3-year-old boy will typically remain relaxed as the hips are taken through a full range of motion. In a 3-year-old boy, the hips should easily flex to 130 degrees, extend to 0 degrees, abduct to 80 degrees, adduct to

30 degrees, internally rotate to 75 degrees, and externally rotate to 75 degrees. If the patient has an irritable hip, he will guard and contract his muscles, not allowing the clinician to take the hip through a full range of motion. This is noted particularly in attempting to internally and externally rotate the hip, with the hip in 90 degrees of flexion. If the hip is irritable, it is important to distinguish toxic synovitis, a benign self-limiting disorder of the hip, from septic arthritis, which can have devastating long-term consequences. The patient with septic arthritis involving the hip will typically be ill, with decreased appetite and a fever. The clinical findings are usually more pronounced, with severe pain occurring with any range of motion, whereas the patient with toxic synovitis will usually allow the clinician to flex and extend the hip through a limited range of motion. If there is any question about the diagnosis, hip aspiration under fluoroscopic control is recommended.

After examining the hip, the limb can then be placed in the figure-4 position, with the hip in flexion, abduction, and external rotation (FABER test) (Fig. 4-19). In this position, if the knee is pushed toward the examination table, it transmits a tensile force to the sacroiliac joint. If there is septic arthritis or inflammation involving the sacroiliac joint, it will be painful during the FABER test.

The knees are also examined in the supine position by palpating for any focal areas of tenderness. The clinician evaluates for an effusion or fluid in the knee by gently milking the suprapatellar pouch and lateral aspect of the knee, and observing a fluid wave on the medial aspect (Fig. 4-20). If there is a large effusion, the patella can be balloted against the femoral condyles when the knee is in extension.

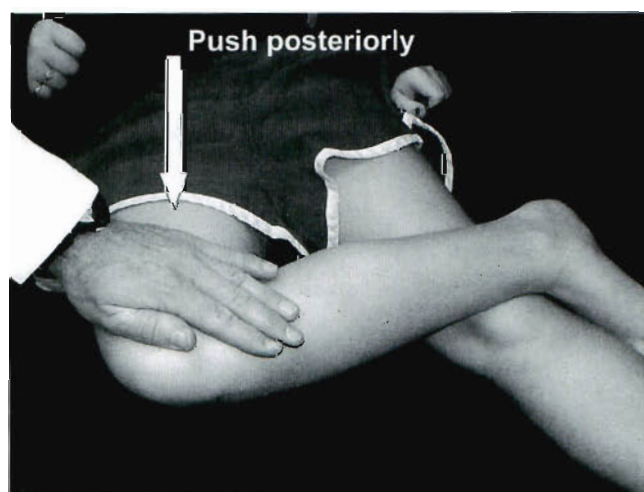


FIGURE 4-19. With the patient supine, the right lower extremity is placed in the figure-4 position with the hip in flexion, abduction, and external rotation (FABER test). In this position, if the knee is pushed toward the examination table, it transmits a tensile force to the sacroiliac joint that can cause pain if the sacroiliac joint is inflamed.

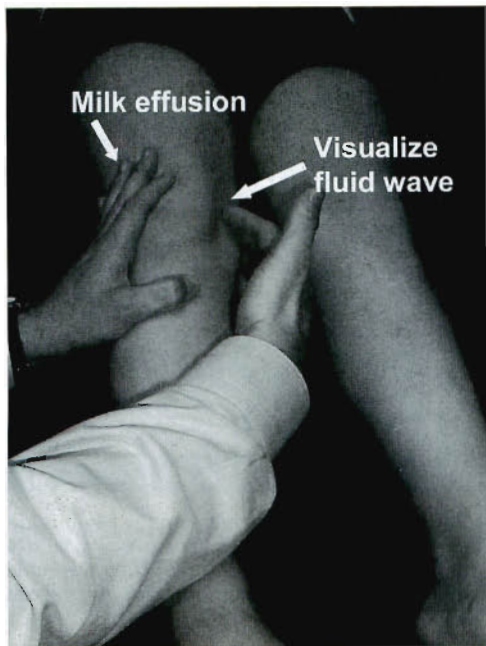


FIGURE 4-20. To palpate for an effusion of the right knee, the clinician's left hand milks the suprapatellar pouch and the lateral aspect of the knee. An effusion is easily visualized as a fluid wave on the medial aspect of the knee.

If the patient has septic arthritis or juvenile rheumatoid arthritis involving the knee, there will typically be an effusion that is easily detectable on clinical examination.

A 4-month-old Girl Is Referred for Evaluation Because She Has an Extra Finger on the Right Hand

Polydactyly occurs when there are more than five digits on the hand or foot; it is one of the more common congenital deformities in newborns. It is common to have polydactyly involving both the hands and feet in the same infant, and polydactyly is often seen in association with syndactyly, in which case it is termed polysyndactyly. The history begins by verifying the pertinent data from the patient profile. The clinician asks when the extra digit was first noted and whether the parents or legal guardian believe that it is functioning properly. This helps the clinician understand whether the parents or legal guardian are mainly concerned about functional limitations, cosmesis, or both. The birth and developmental history are typically unremarkable in a patient with polydactyly. The family history is important, because polydactyly is typically inherited as an autosomal dominant trait. If other members of the family had polydactyly, the clinician asks if any of them had treatment for the disorder. In polydactyly, if the extra digit is located on the radial side of the hand or the tibial side of the foot, it is termed preaxial polydactyly. If the extra digit involves the

index, long, and ring fingers, or the second, third, and fourth toes, it is termed central polydactyly. If the extra digit is located on the ulnar side of the hand or the fibular side of the foot, it is termed postaxial polydactyly. In the review of systems, it is important to ask about other medical problems, because postaxial polydactyly is associated with a number of syndromes, such as trisomy 13 (7).

On physical examination, the polydactyly is not always obvious, but if the clinician looks specifically at the hands or feet, the extra digit is noted. The extra digit should be closely observed while the child plays with a toy, and it should be taken through a full range of motion to determine if there are any functional limitations of the digit. Watching the child play is probably the best way to detect functional limitations. When the infant is 4 to 6 months of age, an occupational therapy evaluation is often valuable for the parents or legal guardian to obtain more information about the function of the hand.

THE ORTHOPAEDIC EXAMINATION FROM 4 TO 10 YEARS OF AGE

A 4-year-old Boy Is Referred Because He Is Walking on His Toes

The history reveals that the parents first noted that the child walked on his toes when he began walking independently at 2 years of age. If asked, he is able to walk with his feet flat on the floor, but, if he is not thinking about it, he returns to walking on his toes. He has continued to walk on his toes about 95% of the time since he was 2 years old. The birth history reveals that he was born after a 28-week gestation, when his mother spontaneously went into labor. The birth was by emergency cesarean section, and the birth weight was 1400 g. The perinatal course was complicated, and the patient was hospitalized in the neonatal intensive care unit for 6 weeks because of pulmonary problems. The developmental history reveals that he first sat at 11 months of age and first walked independently at 2 years of age. The family first noted that he was right-handed at 12 months of age when he preferred to play with toys using the right hand. The past history and family history are unremarkable, and the child is being evaluated to determine if he should begin kindergarten this fall or wait until next year.

The child wore his own shorts and T-shirt for the physical examination to avoid having to wear a johnny or hospital gown. The clinician begins by asking the patient to walk in the hallway, and notes that he is walking on his toes. There is no heel strike, foot flat, or toe-off, but he remains on his toes. This type of gait pattern is termed a toe-toe gait pattern, in contrast to the typical heel-toe gait pattern. In the typical gait pattern, the stance phase begins with heel strike, followed by foot flat (the first rocker), then, in mid-stance, there is forward rotation of the tibia over the foot

(the second rocker), and, at terminal stance, there is plantar flexion of the foot and ankle at push-off (the third rocker), beginning the swing phase of the gait cycle. In this patient, because he ambulates with a toe-toe gait pattern, there is a loss of the first rocker and a decrease of the second and third rockers. The clinician also notes that the gait pattern is asymmetric, because he spends more time in the stance phase on his right side, compared with the left (8). This is an important observation, because patients with myopathy or idiopathic toe-walking will typically have a symmetric gait pattern. During gait, it is also noted that, at the end of the swing phase, the knees do not extend completely, and, at the end of the stance phase, the hips do not extend completely. When he is asked to walk at a faster pace, the child tends to posture both upper extremities, left more than right, with the elbows in flexion, the forearms in pronation, and the wrists in flexion. This is also an important observation, because posturing of the upper extremities during gait is commonly seen in patients with cerebral palsy. While he is walking, he is noted to have a foot-progression angle of 10 degrees of inward rotation on the left and 5 degrees of inward rotation on the right.

After observation of the patient's gait pattern the physical examination begins with the spine and continues with the upper and lower extremities. The spine is examined from the back with the patient standing while the clinician looks for any asymmetry. The clinician's hands are placed on the patient's iliac crests, and the right iliac crest is 5 mm higher than the left, indicating a slight limb-length discrepancy, with the right longer than the left. The patient is then asked to bend forward at the waist, as if he is touching his toes, and the examiner observes for a rib or lumbar prominence, indicating a rotational deformity of the spine, as is often seen in patients with scoliosis (the Adams forward-bending test). In this case, there is a left lumbar prominence that measures 6 degrees by scoliometer at L3 (3). This prominence may reflect a structural scoliosis or a postural scoliosis secondary to the limb-length inequality. The spinous processes are palpated to determine if there is any tenderness in the spine.

The patient is then asked to sit on the examination table for examination of the upper extremities. The patient is asked to pick up an object, to determine if there is hand preference, and to determine if he can do it with both hands. Grasp strength of both hands is tested simultaneously by having the patient squeeze the clinician's index and long fingers of both hands at the same time. Pinch strength is tested by having the patient pick up a pen or small object between the index finger and the thumb. Stereognosis is tested by placing a known object, such as a coin, into the hand, and asking the patient to identify the object without looking at it. The shoulders, elbows, forearms, and wrists are taken through a full range of motion, to determine if there are any contractures. In this patient, no weakness or contractures were noted. Patients with spastic cerebral palsy will often have adduction contractures of the shoulders, flex-

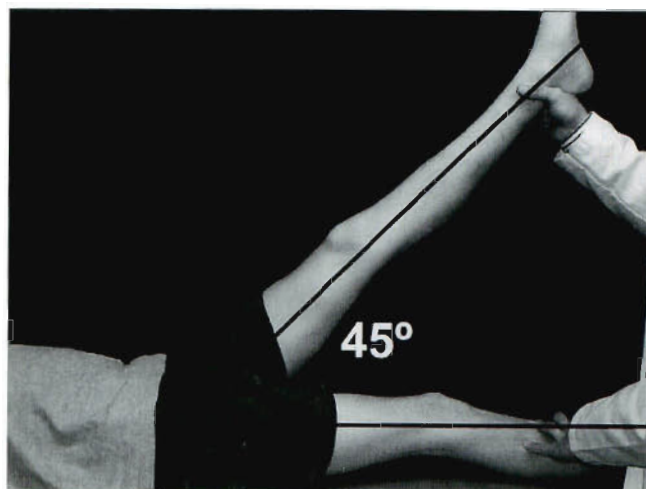


FIGURE 4-21. With the patient supine on the examination table, the clinician gradually raises one lower extremity by flexing the hip with the knee in extension. The straight-leg-raising test measures the angle between the lower limb and the tabletop.

ion contractures of the elbows, pronation contractures of the forearms, flexion contractures of the wrists, and a thumb-in-palm contracture of the hand.

The patient is then placed supine on the examination table, and a straight-leg-raising test is performed, demonstrating 45 degrees of straight-leg raising on the left and 50 degrees on the right (Fig. 4-21). If limited straight-leg raising is noted, it often indicates contracture of the hamstring muscles, but it may indicate radiculopathy with nerve root compression. This can be differentiated by observing the popliteal angle, which may cause some discomfort if there is contracture of the hamstring muscles, but may cause shooting pains down the leg if there is radiculopathy (Fig. 4-22). In this case, the popliteal angles are 64 degrees on the left and 45 degrees on the right. In the supine position, the hips are taken through a full range of motion. Patients with spastic cerebral palsy will often have flexion and adduction contractures of the hips. A flexion contracture is demonstrated by flexing one hip completely so that the knee is against the chest, and observing the amount of flexion of the other hip. Placing the knee against the chest flattens the lumbar spine and levels the pelvis, so that gravity will allow the other hip to extend. Any residual flexion of the other hip is recorded in degrees; this patient has a flexion contracture of 64 degrees on the left and 20 degrees on the right (Thomas test) (Fig. 4-23). A hip flexion contracture can also be demonstrated by placing the patient in the prone position with the lower extremities flexed over the end of the table. This position flattens the lumbar spine and levels the pelvis. One hip remains flexed while the clinician gradually extends the other hip; as soon as the pelvis moves, the amount of residual hip flexion is the flexion contracture (prone Staheli test) (9) (Fig. 4-24). With the patient in the




FIGURE 4-22. With the patient supine on the examination table, the clinician gradually raises one lower extremity by flexing the hip and knee to 90 degrees. The hip is kept at 90 degrees of flexion, and the knee is gradually extended as far as is comfortable. The popliteal angle is the angle between a line drawn along the leg and a line drawn along the axis of the thigh.

supine position and the hips flexed to 90 degrees, the hips should abduct to 75 degrees. In this patient, there is abduction to only 40 degrees on the left and 60 degrees on the right. The decrease in the amount of hip abduction with

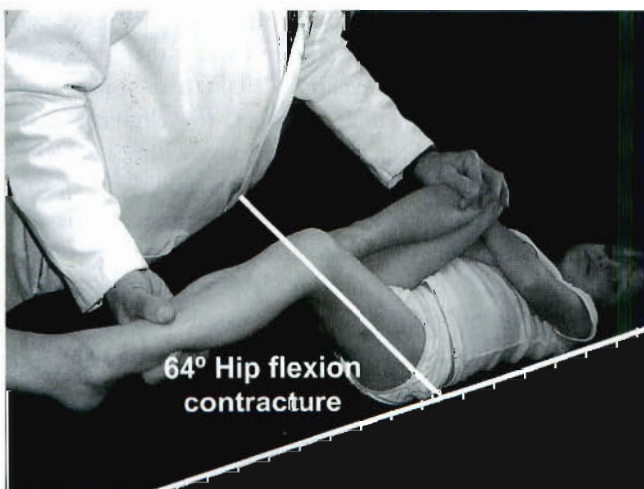


FIGURE 4-23. The Thomas test is performed by flexing the opposite hip and knee into the knee-chest position. This flattens the lumbar spine, correcting the anterior pelvic tilt; the other lower extremity should remain on the table with the hip extended. If the other hip remains flexed, the angle between the thigh and the tabletop measures the flexion contracture of the hip.

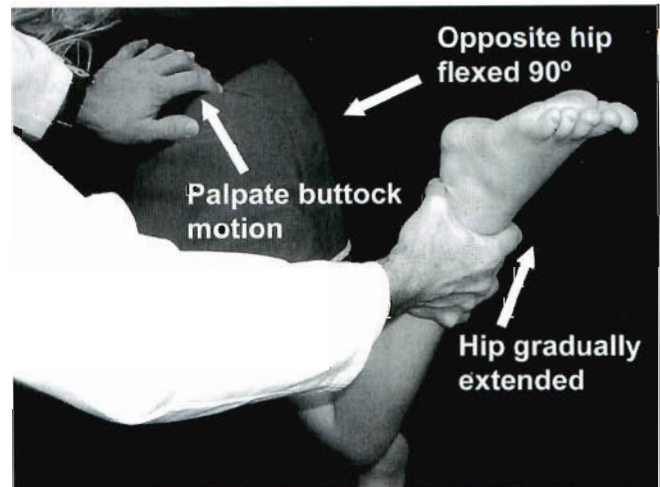


FIGURE 4-24. The prone Staheli test is another technique to measure a hip flexion contracture. The patient is placed prone, with the lower extremities flexed at the hips over the end of the table. This position flattens the lumbar spine and corrects the anterior pelvic tilt. One hip remains flexed, while the clinician gradually extends the other hip until motion is detected in the pelvis. The amount of hip flexion that is present when the pelvis first moves is the flexion contracture.

the knees extended compared to that with the knees flexed, represents the contribution of the medial hamstrings to the adduction contracture (Phelps-Baker test). Limited abduction, particularly if asymmetric and associated with flexion contracture, may indicate hip subluxation or dislocation. The patient is then placed in the lateral decubitus position, with the lower hip flexed against the chest, flattening the lumbar spine and leveling the pelvis. The higher hip is then adducted with the knee flexed and with the knee extended. The hip will typically adduct to 30 degrees, and any loss of adduction represents an abduction contracture (Ober test) (10). The increase in the abduction contracture with the knee in extension, compared to that with the knee in flexion, demonstrates the contribution of the tensor fasciae latae. A patient with spastic cerebral palsy will typically develop an adduction contracture of the hip, whereas a patient with poliomyelitis will often develop an abduction contracture secondary to a tight tensor fasciae latae.

The patient is then placed in the prone position, and is noted to have symmetric hip internal rotation to 90 degrees and external rotation to 70 degrees. Patients with spastic cerebral palsy often have increased anteversion of the proximal femur, which causes an increase in internal rotation and a decrease in external rotation of the hips. In contrast, patients with developmental coxa vara, or slipped capital femoral epiphysis, typically have a retroversion deformity of the femoral neck, which causes an increase in external rotation and a decrease in internal rotation of the hips. With the patient in the prone position, the knee is flexed to 130

degrees, and the clinician notes that the hip spontaneously flexes, causing the buttocks to rise off the table, indicating a contracture of the rectus femoris component of the quadriceps muscle (Ely test) (Fig. 4-25).

The patient is again placed in the supine position, the knees are taken through a full range of motion, and any flexion contractures are recorded. The feet are then examined to determine if there is an equinus or equinovarus contracture. It is important to supinate the hindfoot to lock the subtalar joint when examining for equinus contracture of the ankle, because one can get a false impression that there is adequate ankle dorsiflexion as a result of hypermobility in the subtalar and tarsal joints. In this patient, when the ankle is dorsiflexed, there is a 20-degree plantar flexion contracture, but, when gradual pressure is applied to the foot and ankle, 20 degrees of dorsiflexion is eventually achieved. Performing the test slowly helps to distinguish between the dynamic component of the contracture and the actual static contracture of the Achilles tendon. The decrease in the amount of dorsiflexion achieved with the knee extended, compared to that with the knee flexed, represents the contribution of the gastrocnemius muscle to the equinus contracture (Silverskiöld test) (11).

When the patient is standing, the clinician notes that there is a varus deformity of the hindfoot. In this case, it is beneficial to determine if the hindfoot varus deformity represents a primary deformity of the hindfoot, or if it is caused by a pronated first metatarsal. The patient is asked to stand with his back facing the clinician, and the amount of hindfoot varus is noted. The patient is then asked to stand with the foot on a 1- to 2-cm block, and the first and second metatarsal heads are allowed to fall off the block onto the floor. The amount of correction of the hindfoot

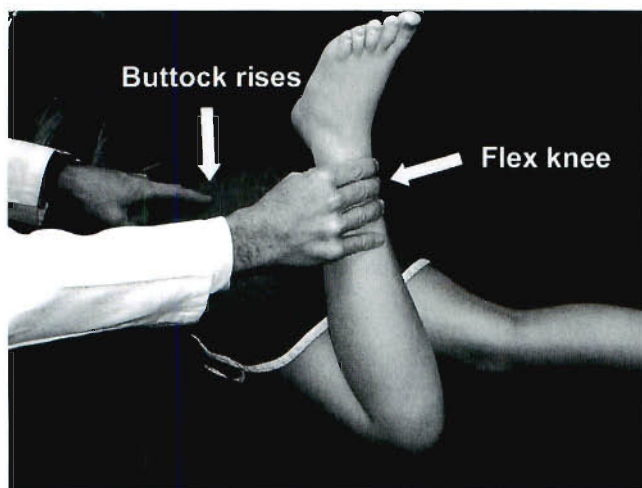


FIGURE 4-25. The Ely test is designed to detect a contracture of the rectus femoris component of the quadriceps muscle. With the patient prone, the clinician gently flexes the knee to 130 degrees. If there is simultaneous flexion of the hip, causing the buttocks to rise off the table, there is a rectus femoris contracture.

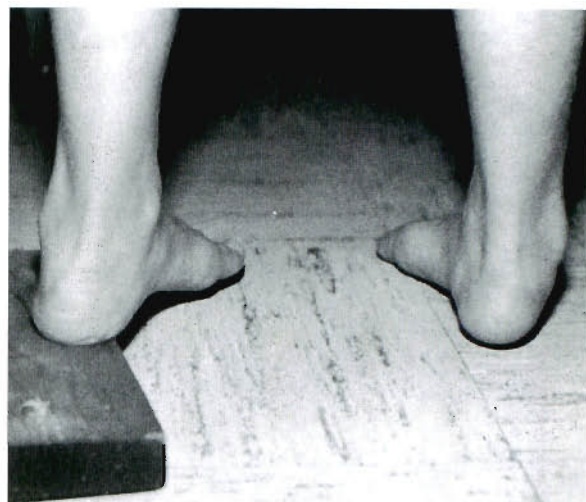

FIGURE 4-26. The patient has bilateral pes cavus deformities, and the clinician observes the amount of hindfoot varus with the patient standing. The patient then stands on a 1- to 2-cm block, and the first and second metatarsal heads are allowed to pronate and fall off the block onto the floor. The amount of correction of the hindfoot varus deformity on the Coleman block test represents the forefoot contribution to the hindfoot varus deformity. (From ref. 13, with permission.)

deformity, when the patient stands on the block, represents the forefoot contribution to the hindfoot varus deformity (Coleman block test) (12) (Fig. 4-26). The peripheral pulses and reflexes in the upper and lower extremities are tested, including the Babinski reflex. Patients with spastic cerebral palsy will typically have an increased stretch reflex of the “clasp-knife type.” They will usually have hyperreflexia, clonus, and a positive Babinski reflex. Patients with athetosis will typically have purposeless-type movement patterns, particularly involving the upper extremities. If the athetosis is of the tension type, tension can be “shaken out” of the limb by the clinician. If there is dystonia, the clinician notes distorted posturing of the limbs and trunk without evidence of any contractures. If the patient has rigidity, it can be the “lead-pipe type,” with continuous resistance to passive motion, or it can be the “cog-wheel type,” with discontinuous resistance to passive motion. If the patient has ataxia, there is a loss of balance, with decreased coordination of the limbs causing a wide-based gait pattern (4).

A 7-year-old Boy Is Referred for Evaluation of Right-sided Thigh Pain with a Limp That Has Persisted for 4 Months Despite Decreasing His Activities

The patient profile is reviewed with the patient and parents or legal guardian to verify exactly when the symptoms began. Four months earlier, he played baseball all day with

his friends, and the next morning, he complained of right thigh pain. Later that afternoon he was playing in the yard, and his parents noted that he was limping on the right side. It is unusual to sustain a groin muscle injury at this age, and symptoms from a groin muscle injury will typically improve in 2 to 4 weeks. The patient is asked about activities that aggravate the symptoms and activities that improve the symptoms. The pain and limp are directly related to activities, and are worse when he plays hard with his friends, and are relieved when he rests. The birth and developmental history are discussed with the parents or legal guardian, although in this case one would expect an unremarkable birth and developmental history, with independent walking by the appropriate time. If the patient is black, he may have sickle cell disease, with a bone infarct involving the femoral head or another bone in the lower extremity. A patient with Legg-Calvé-Perthes disease may be of short stature, and a patient with osteochondrodysplasia will often be of short stature, and may have a family history of the disorder. The insidious onset of pain and a limp is a common presentation for a patient with a bone cyst or tumor involving the femur or tibia. Patients with an osteoid osteoma involving the proximal femur, although typically older, will often complain of night pain that is relieved by aspirin or antiinflammatory medication.

The physical examination of a patient complaining of thigh pain and a limp can begin by asking the patient to walk in the hallway. A patient with Legg-Calvé-Perthes disease, or a bone cyst involving the femur, will often have an antalgic or painful type of limp during gait. This is characterized by a decreased time in the stance phase of the gait cycle, with swaying of the trunk over the painful hip, to decrease the joint reactive forces (Trendelenburg gait). The Trendelenburg gait pattern is an important clinical observation, because it leads the clinician to suspect a problem with the hip, rather than in the knee, leg, or foot. After observation of the patient's gait pattern, an examination of the back and upper extremities is followed by an examination of the lower limbs. During the examination, the clinician compares the symptomatic side with the uninvolved side, looking for any asymmetry. A patient with synovitis involving the hip will typically have a loss of internal rotation, abduction, and extension of the involved hip. This patient has a loss of 40 degrees of internal rotation, 20 degrees of abduction, and 15 degrees of extension, compared with the uninvolved side. The loss of internal rotation is usually the most pronounced, and this is best demonstrated by examining the patient in the prone position with the hips in extension. In this position, with the knees flexed to 90 degrees, the hips are simultaneously internally rotated, and any asymmetry is noted (Fig. 4-7).

The patient is then examined in the supine position, and each hip is flexed to 90 degrees, and gently internally and externally rotated through a range of motion. The clinician notes the range of internal and external rotation of each hip, and observes for any involuntary muscle guarding on the

right side. Guarding indicates that the hip is irritable or inflamed; if present, it is a very important observation, because it indicates that the problem most likely involves the hip. The guarding is typically more pronounced as the clinician takes the hips toward the maximum of internal and external rotation. If there is a limited range of motion without any guarding it may indicate a bony deformity, such as a femoral neck retroversion deformity, which is seen in patients with developmental coxa vara. Because the history and physical examination have isolated the problem to the hip, anteroposterior and frog pelvis radiographs are recommended.

A 5-year-old Boy Is Referred for Evaluation of a Flatfoot Deformity (Pes Planus) That the Parents First Noted When He Began Walking at 13 Months of Age

The patient profile is reviewed with the patient and parents or legal guardian to verify that the pes planus deformity was in fact first noted at 13 months of age. The time that the deformity was first noted might be important, because a rigid pes planus deformity, such as that seen in patients with congenital vertical talus, is typically noted at birth. A rigid pes planus deformity that is seen in patients with tarsal coalition is often not noted until the child is 10 to 12 years of age, when the cartilaginous bar begins to ossify and limits the range of motion of the foot. A flexible pes planus deformity collapses with weightbearing, so it is not unusual that it was first noted by the parents or grandparents when the child first began to walk. A 5-year-old boy with a flexible flatfoot deformity will not usually have any pain associated with the deformity. In fact, a 5-year-old boy usually will not even notice that he has a deformity. This is verified by asking the child if he notices anything different about his feet, compared with his friends, and if he has any pain or limitation of activities because of his feet. It is also valuable to ask the parents or legal guardian if their concern is mainly cosmetic or if they believe that the child is having difficulty with pain, function, or keeping up with his friends. The family history may be relevant, because flexible flatfeet can be familial, and, if the deformity is present in other family members, it is helpful to know if they had or have any functional limitations. Patients who have a tarsal coalition (peroneal spastic flatfoot) are older, and will typically have pain aggravated by activities, and limited subtalar motion that may predispose them to frequent ankle sprains.

The physical examination of a 5-year-old boy with a pes planus deformity begins by asking him to walk in the hallway. He walks with a symmetric heel-toe gait pattern, with a foot-progression angle of 25 degrees of external rotation (Fig. 4-5). This is not surprising, because a patient with a pes planus deformity also has a tendency to toe-out, whereas a patient with a pes cavus deformity has a tendency to toe-in. Before focusing on the feet, a general physical examination of the back, upper extremities, and lower extremities

is performed. A flexible pes planus deformity is the most common type of flatfoot deformity in childhood. It is most likely caused by excessive laxity of the ligaments and joint capsules, allowing the tarsal arch to collapse with weightbearing. The key is to differentiate this benign condition from the more serious types of flatfoot deformities, such as congenital vertical talus or tarsal coalition. When standing, patients with a flexible pes planus deformity have a collapsed medial longitudinal arch with a pronated foot and a valgus heel. The arch returns when the patient is sitting, because the weightbearing force that caused the collapse of the arch is relieved. The arch is also recreated by dorsiflexing the great toe, or by asking the child to stand on his tiptoes (Fig. 4-27). The clinician uses these simple tests to document that the patient has a flexible pes planus deformity, a benign condition that does not require any treatment, rather than rigid deformity, which often benefits from treatment.

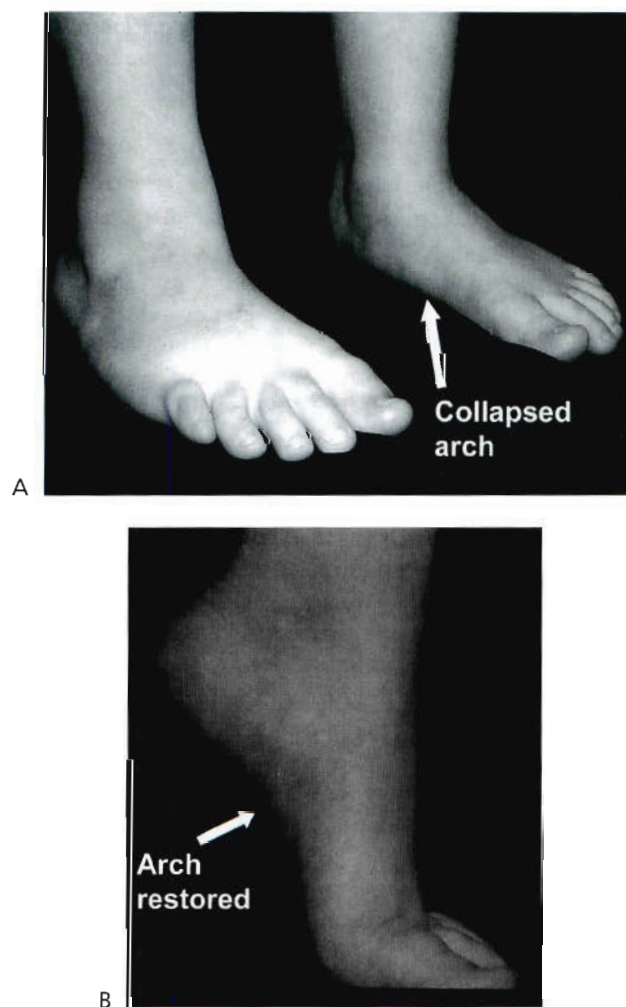


FIGURE 4-27. A: This patient has bilateral flexible pes planus deformities with a collapsed medial longitudinal arch, pronated feet, and valgus heels. B: The arch returns when the patient stands on his tiptoes, demonstrating that the pes planus is flexible.

A 6-year-old Boy Is Referred for Evaluation of Acute Pain and Swelling Involving the Left Elbow after Falling from the Monkey Bars at School

This child was apparently in excellent health until earlier in the day, when he fell from the monkey bars and immediately developed pain and swelling about the elbow. The parents called their pediatrician, who recommended that they go directly to the emergency room (ER) at the hospital, and the ER physician is requesting an orthopaedic consultation. In this situation, the patient and family are anxious about the injury, apprehensive about going to the ER, and frightened that the examination or treatment may be painful. The patient is typically found lying on a gurney in the ER, with the elbow in a temporary splint. Knowledge of the mechanism of injury is important for the clinician to assess the magnitude of the trauma that caused the injury and the likelihood of associated complications. The patient remembers that the monkey bars were about 4 ft off the ground, and that he was playing with his friends when he fell, landing on the outstretched arm. A fall on an outstretched arm is the same mechanism of injury that can cause a fracture of the distal humerus, an elbow dislocation, a forearm fracture, a fracture of the distal radius, or any combination of these injuries. If the fall was from a height of 2 ft, the clinician might suspect a contusion or minimally displaced fracture, whereas if the fall was from 20 ft, it could cause a displaced fracture with an associated neurovascular injury. The past history may be helpful, because if the patient has had multiple fractures associated with a disorder such as osteogenesis imperfecta, he may have a pathologic fracture, which is usually minimally displaced and not associated with other injuries. The past history may reveal a kidney problem with renal osteodystrophy, which would increase the likelihood of a pathologic fracture. He has been in excellent health, and does not complain of any numbness or tingling in the hand, and there is no reason to believe that the injury could have been nonaccidental.

The clinician asks if the boy would like to remove the splint himself or if he would prefer to have someone else do it for him. He is asked if he would prefer to be checked while lying down or if he would prefer to be seated. He is also reassured that his parents or legal guardian can stay with him during the examination. Once the patient and family realize that they have the power to make these simple yet important decisions, they become less apprehensive about the entire setting in the ER. When the splint has been removed and the patient is comfortable, the physical examination begins by examination of the uninjured upper extremity, so the patient learns what is involved with the examination. This also allows the clinician to understand what the normal side looks like, and to assess the child's level of apprehension. The injured arm is then observed,

and marked swelling and ecchymosis are noted over the distal humerus. These findings are more consistent with a fracture of the distal humerus, or a fracture-dislocation of the elbow, than with a simple contusion. When examining the injured side, the clinician gently palpates the elbow and the distal humerus, and, with the help of the patient, locates the point of maximum tenderness. In most cases, the point of maximum tenderness will be the location of the fracture or contusion.

If the patient has a fracture of the distal humerus, the immediate concern is not the fracture, but whether there is an associated injury to the soft tissues, particularly the arteries and nerves. As a result, a neurocirculatory examination of the hands is performed to compare pulses, capillary fill, pain, light touch, strength, and range of motion of the fingers, between the injured and the uninjured sides. A distal humeral fracture or an elbow dislocation can interfere with the circulation to the hand, either by directly injuring the brachial artery at the elbow or by causing swelling in the compartments of the forearm, which can interfere with capillary blood flow. If the artery is lacerated or trapped in the fracture site, there may be no pulses and the hand may be cool and white. If there is swelling within a compartment that is interfering with capillary blood flow, it may lead to muscle ischemia, and although the pulses and circulation to the hand may appear normal, an early compartment syndrome may be developing. In this case, a high index of suspicion and the finding of pain out of proportion to the mechanism of injury, or pain with passive motion of the fingers, may be the only signs of an impending compartment syndrome.

The results of the neurocirculatory examination may be within normal limits initially, but may change during the next few hours. A compartment syndrome occurs when there is swelling within a closed space, and after an elbow injury; the compartment that most often develops excessive swelling is the volar compartment of the forearm. Swelling in a compartment causes increased pressure that interferes with capillary flow, resulting in muscle ischemia. An early compartment syndrome may be first detected by noticing that the patient is experiencing pain that seems to be out of proportion to the physical findings. Another early sign of a compartment syndrome is pain to passive stretching of the ischemic muscles. If the flexor muscles in the forearm are ischemic, the patient may complain of pain when the fingers are passively extended. As soon as the swelling in the compartment reaches the level of the systolic blood pressure, it will obliterate the pulse at the wrist. However, once a compartment syndrome has reached this stage, the muscles in the forearm may already be necrotic. When the necrotic muscles scar and develop fibrosis, a contracture develops, causing a flexion deformity of the wrist and fingers, termed a "Volkmann ischemic contracture." A Volkmann con-

tracture can markedly interfere with hand function, so it is important to diagnose a compartment syndrome early and avoid this devastating complication.

A distal humeral fracture or an elbow dislocation may injure a nerve, either by direct contusion or by stretching from traction and angulation at the injury site. A complete neurologic examination of the hand is important to document any nerve injuries before embarking on treatment. It is always less stressful for an apprehensive child to begin by examining the uninjured extremity. To evaluate the sensory component of any nerve, it is accurate and nonthreatening to test two-point discrimination using a paper clip to compare the injured side with the noninjured side. The radial nerve is tested by asking the patient to extend his fingers (motor), and checking the sensation in the dorsal web space between the thumb and the index finger (sensory). The median nerve is tested by asking the patient to flex the long and ring fingers (motor), and checking the sensation on the volar aspect of the index finger (sensory). The ulnar nerve is tested by asking the patient to spread his fingers apart (motor), and checking the sensation on the volar aspect of the little finger (sensory). The anterior interosseous nerve is tested by holding the index finger in extension at the metacarpophalangeal and proximal interphalangeal joints, and asking the patient to flex the tip of the finger (motor). The anterior interosseous nerve does not have a sensory component, so an injury to this nerve may not be detected, unless the clinician tests the motor component of the nerve. If the patient and family or legal guardian are extremely anxious, it is possible for the physical examination to be compromised. If that occurs, it is important to document the problem with the examination in the medical record. After the examination is completed, anteroposterior and lateral radiographs centered at the point of maximum tenderness, including a joint above and below, will usually show the fracture or dislocation.

A 9-year-old Boy Is Referred for Evaluation Because He Is Having Pain in His Left Heel That Is Aggravated by Playing Soccer

The history reveals that the patient has been in good health until 1 month earlier, when he began to experience left heel pain. The pain is worse in the evenings after he has played soccer during the day. The patient is a healthy, active boy who is very involved in sports, including soccer, basketball, and baseball. The pain is relieved by rest, and seems to improve when he is not participating in soccer. When asked whether it hurts while he is playing soccer or after he has played, he acknowledges that the pain usually does not bother him while playing, but begins afterwards. The parents have noted swelling in the past, but there is no swelling at the present time. The history is consistent with a calcaneal apophysitis, also termed "Sever disease," but the differential

diagnosis also includes tumor, bone cyst, or juvenile rheumatoid arthritis. On further questioning, he denies any morning pain or stiffness, such as one might see in patients with juvenile rheumatoid arthritis. Some children with calcaneal apophysitis will have heel pain in the morning when they first get out of bed.

On physical examination, the feet appear symmetric and no swelling is detected. The pain is located in the heel, right over the calcaneal apophysis, and is aggravated by squeezing the posterior aspect of the calcaneus. There is no pain at the insertion of the Achilles tendon, as would be seen in a patient with Achilles tendonitis, and there is no pain at the origin of the plantar fascia, as would be seen in a patient with plantar fasciitis. Achilles tendonitis and plantar fasciitis, although common in adults, are not frequently seen in children. Calcaneal apophysitis (Sever disease) is an overuse syndrome, and the symptoms should subside with activity modification. If the pain is unilateral or persists despite activity modification, anteroposterior and lateral radiographs may help with the differential diagnosis.

THE ORTHOPAEDIC EXAMINATION FROM 10 TO 18 YEARS OF AGE

A 13-year-old Girl Is Referred for Evaluation of Scoliosis

The pertinent findings in the patient profile are reviewed with the patient and parents or legal guardian. The scoliosis was first detected 4 months earlier, on a routine annual checkup by the family pediatrician. The patient states that she occasionally gets pain in the lower back after sitting for long periods of time, and that otherwise she is in excellent health. She denies any problems with bowel or bladder function, and states that she is active in sports, including soccer and tennis. The family history reveals that she has two maternal cousins with scoliosis, one of whom required operative correction of the deformity. She has a 16-year-old brother and a 9-year-old sister who are in good health, without evidence of scoliosis. There is no family history of anyone with muscular dystrophy or a neuromuscular disorder, and no one in the family died prematurely. She has not yet begun the menses, and her mother states that she has grown 2 in. in the last 6 months. She is 5 ft 2 in. tall, and her mother is 5 ft 6 in. tall.

The physical examination begins with the patient standing; the spine is observed from the back. The clinician looks for any asymmetry in the height of the shoulders, the prominence of the scapular spines, the surface shape of the rib cage, or the contour of the waist. The skin is observed for any café-au-lait marks or freckling in the axilla that may indicate neurofibromatosis. If the patient is tall and has long, prominent fingers (arachnodactyly), it may indicate Marfan syndrome. A plumb bob is suspended from the spi-

nous process of the seventh cervical vertebra, and the clinician notes if it falls over the gluteal cleft. If the spine is compensated and the patient is standing erect, the head should be centered directly over the pelvis and the plumb bob should fall over the gluteal cleft. If the spine is decompensated to the right or left, the distance from the plumb bob to the gluteal cleft is recorded in centimeters. The clinician observes the posterior iliac dimples in stance to determine if they are symmetric and level, indicating equal limb lengths. The clinician's hands are placed on the iliac crests to determine if the pelvis is level, or if there is a limb-length discrepancy. If the patient has a limb-length discrepancy, a compensatory postural scoliosis deformity may develop that is convex toward the shorter limb. If there is a limb-length discrepancy with a compensatory lumbar scoliosis, the waist may be more accentuated on the concave side, which the patient often interprets as the "hip sticking out." Scoliosis that occurs because of a limb-length discrepancy is a postural scoliosis that should correct when the limb-length discrepancy is corrected. This can be accomplished by placing an appropriately sized wooden block under the foot of the short leg to equalize the limb lengths. The spinous processes are palpated to determine if there is any focal tenderness, and the patient is asked to arch her back, to determine if it causes any discomfort. Patients who have spondylolysis or spondylolisthesis will often have discomfort when they hyperextend the lumbar spine.

The patient is then asked to place the hands together in front of her, as if she were diving into a pool, and to bend forward at the waist, as if she were touching her toes. This is termed the "Adams forward-bending test," and is one of the most sensitive clinical tests for detecting a scoliosis deformity (Fig. 4-28). As the patient bends forward, the

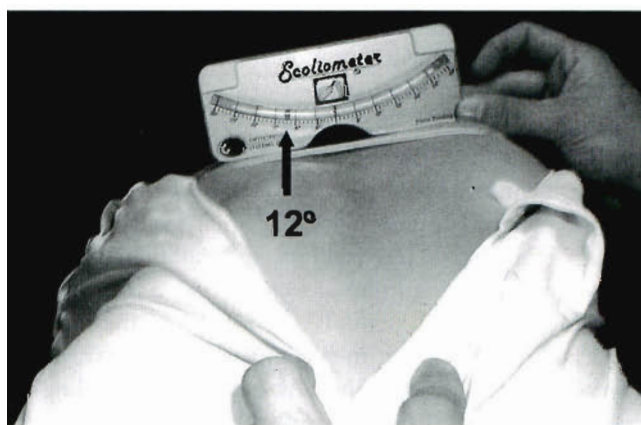


FIGURE 4-28. The Adams forward-bending test is conducted by asking the patient to place the hands together in front of her, as if she were diving into a pool, and to bend forward at the waist, as if she were touching her toes. As the patient bends forward, the clinician observes the spine to determine if it is supple, and if it flexes symmetrically. Once the patient has bent forward so that the spine is parallel to the floor, the clinician measures the rib prominence in degrees using a scoliometer.

clinician observes the spine to determine if it is supple and flexes symmetrically. If the patient bends to one side rather than straight ahead, the clinician should take note, because this may indicate tight hamstring muscles that may be associated with spondylolisthesis, disk herniation, or tumor. As the patient bends forward, if the spine flexes excessively in the thoracic area (thoracic kyphosis), but not in the lumbar area, it may indicate Scheuermann disease. Once the patient has bent forward, the clinician looks for any asymmetry of the trunk, notes any rib or lumbar prominence, and measures the prominence using a scoliometer (14) (Fig. 4-28). The rib prominence reflects the rotational component of the scoliosis deformity that occurs in the axial plane. The most common type of scoliosis deformity is a convex right thoracic curve, in which the vertebrae rotate into the convexity of the curve, twisting the rib cage, so that the ribs are more prominent posteriorly on the patient's right side. The ribs are also more prominent anteriorly on the patient's left side, which may cause some breast asymmetry. While the patient is in the forward-bending position, the clinician asks her to bend from side to side to assess the flexibility of the scoliosis deformity.

Scoliosis is seen in association with neuromuscular disorders, such as muscular dystrophy or cerebral palsy, and is also seen in association with spinal cord anomalies, such as syringomyelia or tethered spinal cord. As a result, a neurologic examination of the patient is essential to rule out an occult neuromuscular or neurologic cause of the scoliosis deformity. With the patient standing, the Romberg sign is tested for by asking the patient to stand with the feet placed closely together. The patient is then asked to close her eyes, and the clinician looks for any sway or instability. The patient with balance problems or cerebellar ataxia will sway or move her feet to maintain balance. This test may be important because scoliosis is commonly seen in patients with Friedreich ataxia. Lower extremity strength and reflexes, including the Babinski reflex, are tested to rule out any occult neurologic problems. With the patient in the supine position, a straight-leg-raising test is performed to look for hamstring tightness or radiculopathy. If the previous examination suggested a limb-length discrepancy, the lower extremity lengths can be measured from the anterior superior iliac spine to the medial malleolus using a tape measure. While measuring the lower extremity lengths, it is important that the hips are in a neutral position, because abduction of one hip and adduction of the other hip will affect the measurements. The abdominal reflexes are tested by gently stroking the side of the abdomen; the umbilicus should deviate toward the stimulus. Any asymmetry of the abdominal reflexes is documented, because this may reflect an underlying spinal cord problem. In patients with adolescent idiopathic scoliosis, it is important to assess their maturity, because the risk of progression of the scoliosis deformity is higher in younger patients and in patients with larger

curves. If a scoliosis deformity is suspected on the physical examination, appropriate radiographs are indicated.

A 14-year-old Boy Is Referred for Evaluation of Persistent Right Knee Pain That Causes Him to Limp

The history reveals that the pain and limp developed spontaneously 4 months earlier, and that the patient has otherwise been in good health. There is no history of injury, and he does not recall any swelling in the knee. In describing the pain, he points to the anterior aspect of the right knee and to the inner thigh. He states that the pain is worse with activity, and the parents state that the limp is usually worse toward the end of the day. The birth and developmental history are unremarkable, and there is no family history of any leg problems or arthritis. The personal and social history reveals that he has always been overweight, but in the last year, his weight has increased markedly.

On physical examination, the patient is obese (greater than the 95th percentile for weight), and, on observation of his gait pattern, he is seen to ambulate with a limp (antalgic or painful gait) on the right. When he walks, he leans his head and trunk over his right lower extremity during the stance phase. This shifting of his weight over the right lower extremity in stance is done to decrease the pain in the extremity, and is termed a Trendelenburg gait pattern. He has a shortened stance phase on the right, and his foot-progression angle is 10 degrees of external rotation on the left and 30 degrees of external rotation on the right (Fig. 4-5). With the patient standing, the spine is observed from the back, and any asymmetry is noted. The clinician's hands are placed on the iliac crests, and the right iliac crest is noted to be 1 cm lower than the left, indicating a limb-length discrepancy, with the right shorter than the left. With the examiner's hands still on the iliac crests, the patient is asked to stand on the left lower extremity and lift the right foot off the floor. When the patient stands on the left leg, the right iliac crest rises up 1 cm, indicating that the abductor muscles of the left hip are functioning satisfactorily. In contrast, when the patient stands on the right leg, the left iliac crest drops 1 cm, indicating insufficiency of the abductor muscles on the right (positive Trendelenburg test) (Fig. 4-18). In single-limb support, contraction of the abductor muscles markedly increases the compressive forces between the femoral head and the acetabulum, so patients with hip pain will often limp, rather than experience increased discomfort from contracting the abductor muscles.

In the supine position, the knee has a full range of motion from 0 to 135 degrees. To look for an effusion the suprapatellar pouch and lateral aspect of the knee are milked, while observing for a fluid wave on the medial aspect. If there was a large effusion, the patella would float above its articulation with the femoral trochlea, and when the clinician pushed the patella toward the femur a ballottable patella

would be appreciated. The patient points to the anterior aspect of the knee and the inner thigh when describing the pain, yet the knee is nontender to palpation and stable to stress, and the remainder of the knee examination is unremarkable. Because the same nerves that supply the knee (obturator, sciatic, and femoral) also supply the hip, it is not unusual for a patient with hip pathology to perceive that the pain is coming from the knee. As a result, it is important to examine both the knees and the hips in a patient complaining of knee pain.

Examination of the patient's hips reveals flexion to 130 degrees on the left and 120 degrees on the right. Abduction is to 70 degrees on the left and 50 degrees on the right. Internal rotation is to 30 degrees on the left and 0 degrees on the right. External rotation is to 70 degrees on the left and 85 degrees on the right. When the left hip is flexed it remains in neutral rotation, but when the right hip is flexed it simultaneously also goes into abduction and external rotation. These physical findings indicate a retroversion deformity of the right femoral neck, with an increase in external rotation and a decrease in internal rotation of the right hip. An overweight adolescent boy with this type of deformity involving the hip has a high probability of having a slipped capital femoral epiphysis, so rather than obtaining radiographs of the knee, anteroposterior and frog-lateral pelvis radiographs are recommended.

A 14-year-old Girl Is Referred for Evaluation of Right Knee Pain and Giving Way That Is Aggravated by Playing Soccer and Basketball

The history reveals that the patient was in good health until 6 months earlier, when she began noting right knee pain after soccer practice. She states that the knee felt better between the soccer and basketball seasons, but that the pain recurred when she began playing basketball. The pain is also aggravated by sitting with the knee flexed for prolonged periods of time, such as while riding in the back seat of a car or at the movie theater. Patients with anterior knee pain or patellofemoral pain syndrome will often have pain when they have to sit still with the knee flexed for a prolonged period of time. This finding has been termed a positive "movie sign." Two months earlier, while playing basketball, the knee gave out, causing the patient to fall to the floor. She developed swelling after the injury, and the swelling resolved over the next few days.

On physical examination, the patient is asked to point to the area of maximum tenderness. An adolescent can usually point exactly to the spot that is bothering her, and she points to both the medial and lateral sides of the patella in describing her pain. She has tenderness to palpation on the under-surface of the patella, which can be elicited by gently pushing the patella laterally with the knee in extension to palpate the lateral facet, and pushing it medially to palpate the me-

dial facet. If the anterior knee pain is caused by a problem with the patellofemoral joint, it can be identified by performing a patellar inhibition test. This test is performed with the patient relaxed in the supine position with the knee in extension. The patient is asked to do a straight-leg raise while the clinician holds the patella, preventing it from ascending along the femoral sulcus. This maneuver increases the pressure between the patella and the femoral sulcus, causing discomfort in patients who have a disorder involving the patellofemoral joint (Fig. 4-29).

A patient with anterior knee pain may have the miserable malalignment syndrome, with internal femoral torsion in conjunction with external tibial torsion. The internal femoral torsion is associated with squinting patellae, in which the kneecaps are pointing inward when the patient is standing, despite the fact that the feet are pointing straight ahead. The internal femoral and external tibial torsional deformities cause an increase in the Q-angle. The Q-angle is the angle formed between a line connecting the anterior superior iliac spine with the center of the patella and a line connecting the tibial tubercle with the center of the patella, and this patient's Q-angle is 12 degrees (Fig. 4-30). The Q-angle should be measured with the knee in 30 degrees of flexion so that the patella is in contact with the femoral sulcus. Patients with an increased Q-angle may develop anterior knee pain as a result of abnormal tracking of the patella in the femoral sulcus. This maltracking can be detected by observing the patella as the patient extends the knee. With the patient sitting and the knees flexed to 90 degrees over the front of the table, the patient is asked to gradually extend the knee. The patella is observed to remain in the femoral sulcus as it ascends along the axis of the

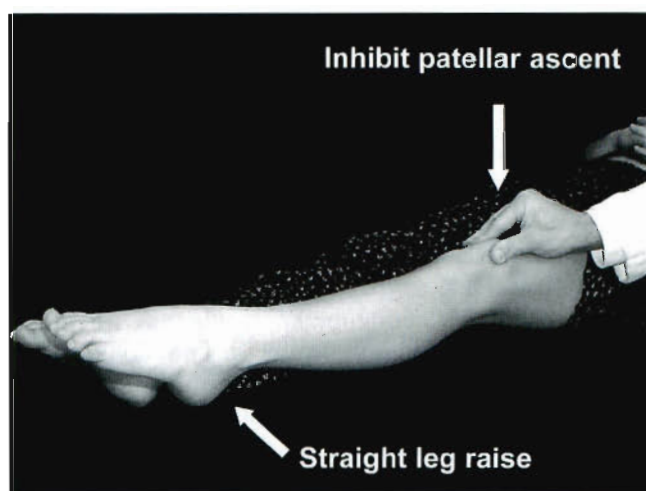


FIGURE 4-29. The patellar inhibition test is performed with the patient supine and the knee in extension. The clinician holds the patella, inhibiting it from ascending, while the patient performs a straight-leg raise. This maneuver increases the forces in the patellofemoral joint. If the patient experiences discomfort, it often indicates a patellofemoral joint disorder.

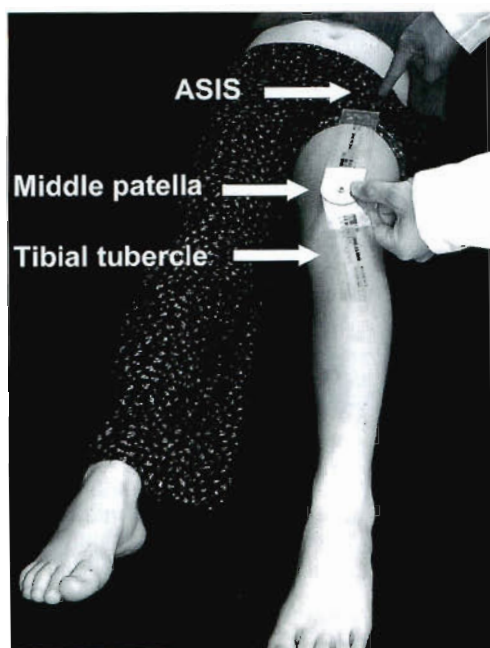


FIGURE 4-30. The Q-angle is the angle formed between a line connecting the anterior superior iliac spine (ASIS) with the center of the patella and a line connecting the tibial tubercle with the center of the patella. The Q-angle is measured with the knee in 30 degrees of flexion, so that the patella is in contact with the femoral sulcus.

femur with knee extension, but as the knee reaches full extension, the patella deviates laterally like an upside-down J (positive J-sign). Patients with patellofemoral joint instability may be identified by performing a “patellar apprehension test.” This test is performed with the patient in the supine position and the knee flexed to 30 degrees. The clinician gently pushes the patella laterally, subluxating it from the patellofemoral joint, and observes if the patient experiences any discomfort. Patients with patellofemoral joint instability often have discomfort with this maneuver, and some are so apprehensive that they contract their quadriceps, preventing the clinician from performing the test (Fig. 4-31). Another problem often seen in patients with anterior knee pain is a pes planus deformity of the foot. The pes planus deformity causes the tibia to rotate inward, decreasing the Q-angle. A decreased Q-angle is also associated with an increased incidence of patellofemoral pain.

Patients with anterior knee pain do not typically have any pain in the back of the knee. If the patient complains of pain in the back of the knee, particularly if it is associated with swelling, it may indicate a Baker cyst. A Baker cyst is a ganglion that develops between the semimembranosus tendon and the medial head of the gastrocnemius muscle. The cyst usually communicates with the knee joint, and will often develop swelling that is aggravated by activities and relieved by rest.

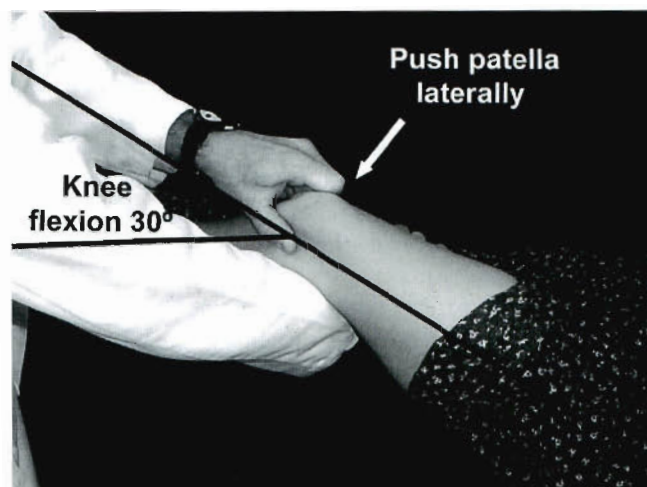


FIGURE 4-31. The patellar apprehension test is performed with the patient supine and the knee flexed to 30 degrees. The clinician gently pushes the patella laterally, and, if the patient experiences discomfort or apprehension, it is a positive test, often indicating patellofemoral instability.

Patients with anterior knee pain will typically have a full range of motion from 0 to 135 degrees. The straight-leg-raising test is often limited to 60 degrees because of decreased flexibility of the hamstring muscles. There is usually no evidence of an effusion or any swelling about the knee. The knee is palpated to determine if there are specific areas of tenderness. Pain located over the tibial tubercle, at the insertion of the patellar tendon, is seen in patients with Osgood-Schlatter disease. Pain located at the inferior pole of the patella is typical for patients with Sinding-Larsen-Johansson disease (15). Pain elicited by direct palpation over the articular surface of the femoral condyle, with the knee flexed, may be seen in patients with osteochondritis dissecans. The pain can be reproduced by flexing the knee to 90 degrees, internally rotating the tibia, then gradually extending the knee. As the knee approaches 30 degrees of flexion, the patient with an osteochondritis dissecans lesion, located on the medial femoral condyle, will experience pain that is relieved by externally rotating the tibia (positive Wilson test [16]).

Pain that is located directly over the joint line is often seen in a patient with a torn meniscus. A torn meniscus can be evaluated by flexing the knee to 135 degrees, and, while applying a valgus stress, gradually extending the knee and externally rotating the tibia. Pain elicited with this maneuver (often associated with a palpable clunk) is often secondary to a torn meniscus (positive McMurray test). With the patient in the prone position, pressure can be applied to the heel, loading the knee in compression, while the tibia is internally and externally rotated on the femur. Patients with a torn meniscus will often experience pain with this maneuver when the torn meniscus is trapped between the tibia and the femur (positive Apley test). To further evaluate

the status of the meniscus, the patient is then asked to relax the knee while the leg is held in full extension. The examiner rapidly pulls up on the foot, then drops it several inches, causing the knee to hyperextend, flex, then hyperextend again. Most patients will tolerate this test without any difficulty, but if the patient has a torn meniscus, this test may be uncomfortable, causing a reflex contraction of the hamstring muscles that prevents the knee from hyperextending (positive bounce test).

Although the patient with anterior knee pain will not typically have any ligamentous instability, these important knee stabilizers are examined. With the patient in the supine position and the knees flexed to 90 degrees, the clinician looks for a posterior sag of the tibia, which is often seen in patients with a posterior cruciate ligament-deficient knee. A torn posterior cruciate ligament can be elicited by the quadriceps active test (17). This test is performed with the patient in the supine position and the knee flexed to 90 degrees. The patient is asked to slide her foot down the table, while the examiner prevents the foot from moving. The force of the quadriceps muscle will pull the tibia anteriorly, reducing the posterior subluxation that is seen in a patient with a posterior cruciate ligament-deficient knee (Fig. 4-32). The anterior drawer test, to evaluate the anterior cruciate ligament, is also performed with the patient supine and the knee flexed to 90 degrees. As the tibia is pulled forward at the knee, the examiner feels a solid stop after 3 to 4 mm of translation of the tibia on the femur, indicating an intact anterior cruciate ligament. A more sensitive test to detect an anterior cruciate ligament-deficient knee is the Lachman test. This test is performed with the patient in

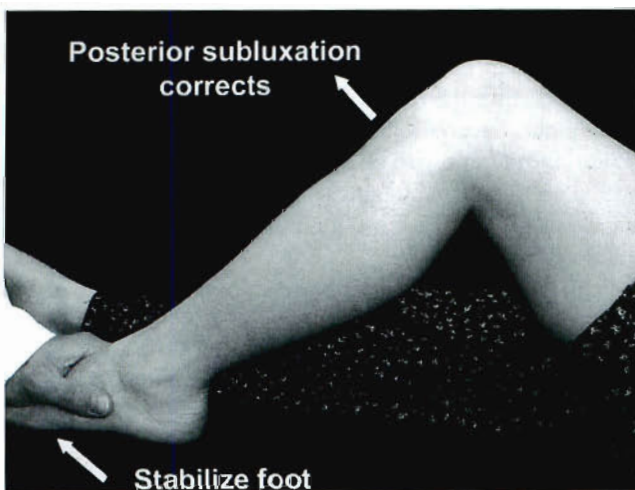


FIGURE 4-32. The quadriceps active test is performed with the patient supine and the knee flexed to 90 degrees. In a patient with a posterior cruciate ligament-deficient knee, the tibia is subluxated posteriorly in this position. The patient is asked to slide her foot down the table while the examiner prevents the foot from moving. The force of the quadriceps muscle pulls the tibia anteriorly, reducing the posterior subluxation of the tibia.

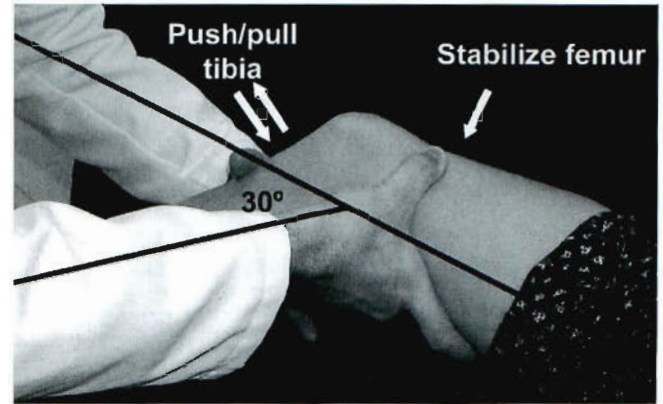


FIGURE 4-33. The Lachman test is performed with the patient supine and the knee flexed to 30 degrees. To test the left knee, the femoral condyles are held with the clinician's right hand, while the tibia is pulled anteriorly with the clinician's left hand. Anterior subluxation greater than 5 mm, without a solid end point, indicates anterior cruciate ligament insufficiency.

the supine position and the knee flexed to 30 degrees. The femoral condyles are held in one hand, while the tibia is pulled anteriorly and pushed posteriorly with the other hand. Subluxation greater than 5 mm, without a solid end point, indicates anterior cruciate ligament insufficiency (Fig. 4-33). The anterior cruciate ligament-deficient knee can also be detected using the pivot-shift test. This test is performed with the patient in the supine position and the knee in extension. A valgus and internal rotation force is applied to the leg, causing the tibia to subluxate anteriorly in an anterior cruciate ligament-deficient knee. As the knee is flexed, when the iliotibial band crosses the axis of the knee joint, the tibia rapidly shifts or reduces to its normal position, and a clunk is seen and felt by the clinician. This pivot shift of the tibia indicates an anterior cruciate ligament-deficient knee.

The medial and lateral collateral ligaments are located just under the skin, so an injury to one of these structures is usually associated with pain to palpation over the ligament. By gently palpating the uninjured side and comparing it with the injured side, the clinician can often pinpoint the location of the injury. The medial and lateral collateral ligaments are tested with the knee in 30 degrees of flexion, because varus or valgus laxity can be masked by the intact cruciate ligaments with the knee in extension. The medial joint line is palpated with a finger while the examiner applies a valgus stress to the knee, and the lateral joint line is similarly palpated while the examiner applies a varus stress to the knee. The amount of joint line widening is recorded in millimeters, and 0 to 5 mm of widening with a solid end point is considered a normal amount of ligamentous laxity. Medial and lateral collateral ligament sprains are classified according to the amount of widening or opening of the joint space on the clinical examination. A grade I sprain

opens 0 to 5 mm, a grade II sprain opens 5 to 10 mm, and a grade III sprain opens more than 10 mm.

A 13-year-old Girl Is Referred for Evaluation of Right Shoulder Pain That Is Aggravated by Swimming

The history reveals that the patient has been a competitive swimmer since she was 6 years old, and that she was in good health until 3 months earlier. She was swimming lengths in practice when she began noting pain in the front of the right shoulder. The pain is relieved by rest, and is particularly aggravated by swimming freestyle. The remainder of the history reveals that she has always been athletic, and has no other medical problems. A swimmer or gymnast who is having difficulty with shoulder pain will usually have an overuse syndrome caused by extensive or improper training. In this situation, it is important to discuss the type of training or workouts that the patient is doing, in view of the fact that they are causing shoulder pain. Often, a training error is discovered that, when corrected, will relieve the symptoms.

On physical examination, inspection of the shoulder reveals that there is no muscle wasting, swelling, or deformity. She is tender to deep palpation over the supraspinatus tendon and the anterior aspect of the acromion. A patient who has an imbalance of the rotator cuff muscles will often have impingement with tendonitis involving the supraspinatus tendon. Range of motion of the shoulder reveals elevation to 180 degrees, external rotation with the arm at the side to 70 degrees, and internal rotation to the point where the thumbs will touch the spinous process of the fifth thoracic vertebra. In this patient, internal rotation is to the spinous process of T4 on the left and T9 on the right. This limited internal rotation indicates tight posterior structures, a common finding in patients who do a great deal of overhead athletics. The tight posterior structures can also be identified by evaluating passive crossed-arm adduction. The arm is positioned in 90 degrees of forward elevation and decreased adduction of the right shoulder, compared with the left, is secondary to tight posterior structures. Muscle strength of the shoulder in flexion, abduction, and internal and external rotation are tested, and the muscles are graded from 0 to 5, according to the scale of the Medical Research Council (18) (Table 4-4). An imbalance of the rotator cuff is often seen in patients with weakness of the periscapular muscles, including the rhomboids, serratus anterior, subscapularis, and trapezius muscles. As a result, it is important to also examine these muscles to determine if there is any associated weakness that may be contributing to the rotator cuff imbalance.

A swimmer or gymnast with shoulder pain may have ligamentous laxity with multidirectional instability and rotator cuff tendonitis with impingement. There are several tests that the clinician can use to detect instability and im-

TABLE 4-4. GRADING OF MUSCLE STRENGTH USING THE MEDICAL RESEARCH COUNCIL RATING SYSTEM

Grade	Rating	Muscle Strength	Assessment
0	Zero	No palpable contraction	Nothing
1	Trace	Muscle contracts, but no movement of the bone	Trace
2	Poor	Muscle moves the bone, but not against gravity	With gravity eliminated
3	Fair	Muscle moves the bone through a full range of motion against gravity	Against gravity
4	Good	Muscle moves the bone against resistance	Near normal
5	Excellent	Normal strength against full resistance	Normal

(From ref. 18, with permission.)

pingement. Ligamentous laxity and instability can be evaluated by palpating the amount of glenohumeral translation. With the patient seated, the clinician evaluates the amount of glenohumeral translation by stabilizing the scapula and clavicle with one hand while pushing and pulling the proximal humerus in an anterior and posterior direction with the other hand. The amount of glenohumeral translation is measured in millimeters, and compared with the uninjured shoulder (Fig. 4-34). This test is essentially a shoulder “drawer sign.” Another maneuver that the clinician can use to evaluate for ligamentous laxity is the “sulcus sign.” With

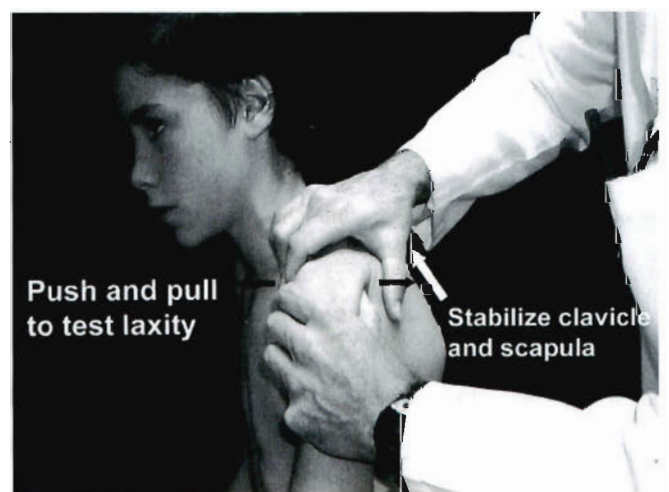


FIGURE 4-34. Ligamentous laxity of the left shoulder is evaluated with the patient seated, by holding the scapula and clavicle with the right hand while pushing the humeral head anteriorly and pulling it posteriorly with the left hand. The amount of glenohumeral translation is measured in millimeters, and compared with the uninjured shoulder. This test is a shoulder “drawer sign.”

the patient standing and relaxed, the clinician applies a longitudinal inferior traction force on the upper extremity while palpating the distance between the humeral head and the acromion. Excessive laxity of the superior glenohumeral ligament will allow the humeral head to subluxate inferiorly (Fig. 4-35).

The apprehension tests to evaluate for anterior instability can be performed with the patient sitting and the clinician standing behind the patient. If the left shoulder is being examined, the clinician abducts the shoulder to 90 degrees, then gradually increases the amount of external rotation using the left hand. The right hand of the clinician is placed over the humeral head, and the clinician gently pushes the humeral head forward with the right thumb, but has the fingers strategically placed anteriorly to control any sudden instability. Patients with anterior instability of the shoulder will experience discomfort or apprehension with this test (Fig. 4-36). Combining the external rotation with controlled anterior translation creates an impending feeling of anterior instability, termed an “apprehension sign.” This test has also been referred to as the “crank test.” This apprehension is relieved when the clinician pushes posteriorly on the humeral head, reducing it in the glenoid. If the apprehension is relieved with this maneuver, it is termed a positive “relocation test.” The apprehension test and the relocation test can also be performed in the supine position, with the shoulder placed in 90 degrees of abduction and external rotation. The apprehension test, when performed in the supine position, is termed the “fulcrum test,” because the table is used as a fulcrum to support the scapula. The

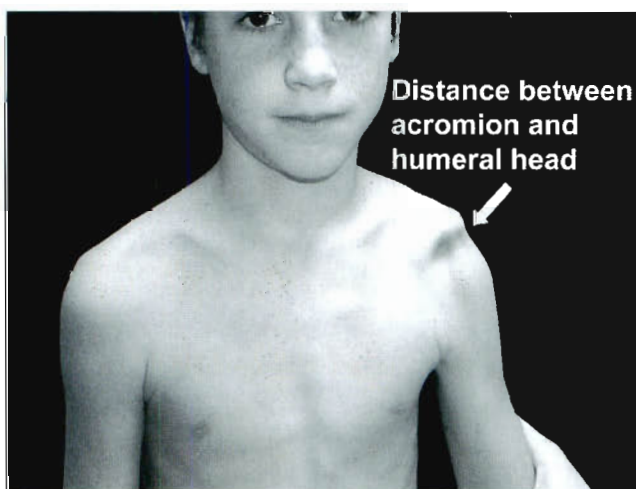


FIGURE 4-35. Ligamentous laxity of the shoulder can also be evaluated with the patient standing with his arms at his sides. The clinician applies a longitudinal inferior traction force to both upper extremities while palpating the distance between the humeral head and the acromion. Excessive laxity of the superior glenohumeral ligament will allow the left humeral head to subluxate inferiorly, compared with the right side. This increased laxity is termed a positive “sulcus sign.”

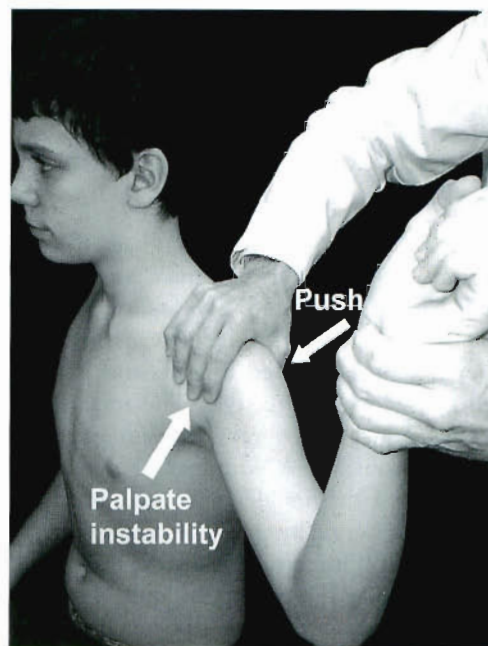


FIGURE 4-36. The apprehension test of the left shoulder is performed with the shoulder abducted to 90 degrees and externally rotated by the clinician’s left hand. The clinician gently pushes the humeral head forward with the right thumb, while the fingers are strategically placed anteriorly in front of the humeral head, to prevent any sudden instability. Discomfort or apprehension with this maneuver indicates anterior instability of the shoulder.

supine relocation test is performed by abducting the shoulder to 90 degrees and externally rotating the arm up to the point where the patient experiences apprehension. The amount of external rotation is noted; the clinician then pushes the humeral head posteriorly, and the patient immediately experiences a loss of apprehension with increased external rotation of the shoulder (19) (Fig. 4-37). Posterior instability of the shoulder is typically a subluxation, rather than a dislocation, and can often be demonstrated by the patient. Because the posterior subluxation is usually asymptomatic, a posterior apprehension sign is typically absent. Posterior instability can be evaluated with the Jahnke test. This test is performed by flexing the arm forward to 90 degrees of elevation in neutral rotation, and posteriorly stressing the arm to subluxate the humeral head posteriorly. The arm is then gradually brought toward the coronal plane, while the clinician gently pushes the humeral head anteriorly, and a palpable clunk is felt as the humeral head reduces from its subluxated position (Fig. 4-38).

A swimmer with shoulder pain may have tendonitis involving the rotator cuff muscles, particularly the supraspinatus tendon. To determine if the patient has tendonitis, the clinician can perform several impingement tests. If the patient has tendonitis involving the supraspinatus tendon, forcible elevation of the arm to 180 degrees will cause the inflamed tendon to impinge against the anterior inferior

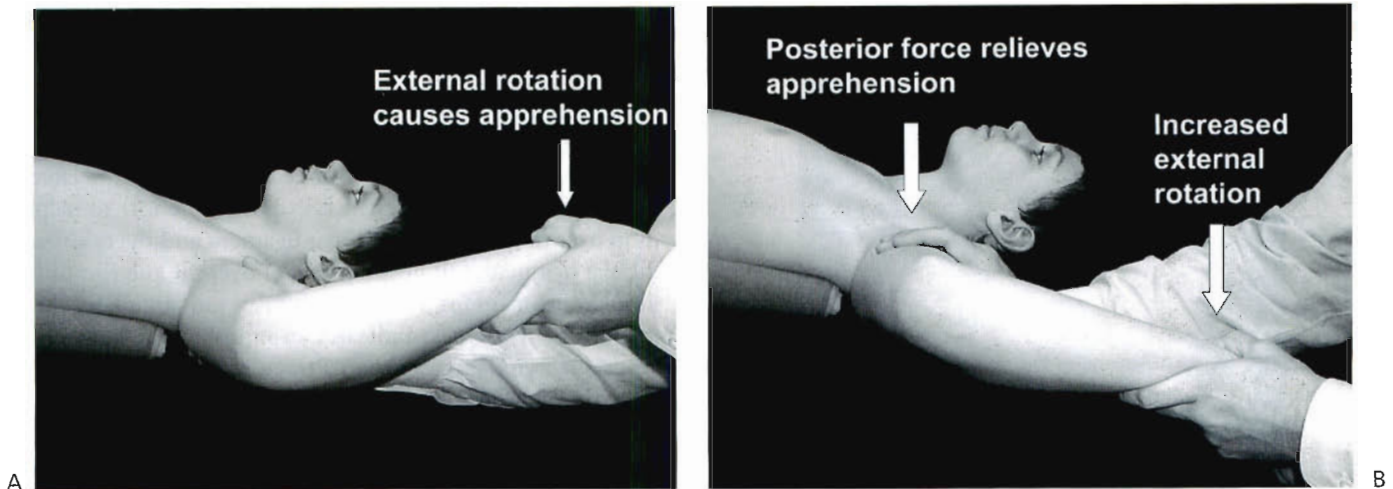


FIGURE 4-37. A: The apprehension test of the shoulder can also be performed in the supine position with the shoulder elevated to 90 degrees, then externally rotated up to the point where the patient experiences discomfort or apprehension. B: In the supine relocation test, after the shoulder is placed in this position, the clinician stabilizes the humeral head by pushing it posteriorly with the right hand. If the patient has increased external rotation, with a loss of apprehension as the shoulder relocates, it reflects a positive relocation test.

acromion and coracoacromial ligament, causing discomfort for the patient. This discomfort or grimacing facial expression is termed a positive Neer impingement sign (Fig. 4-39). Another method to detect shoulder impingement is to flex the shoulder forward to 90 degrees of elevation in neutral rotation, with the elbow flexed to 90 degrees. In this position, forcible internal rotation will cause discomfort or grimacing facial expression, as the supraspinatus tendon im-

pings against the coracoacromial ligament. This maneuver is termed a positive Hawkins sign (Fig. 4-40). This test is also a good method to evaluate for tightness of the posterior capsule.

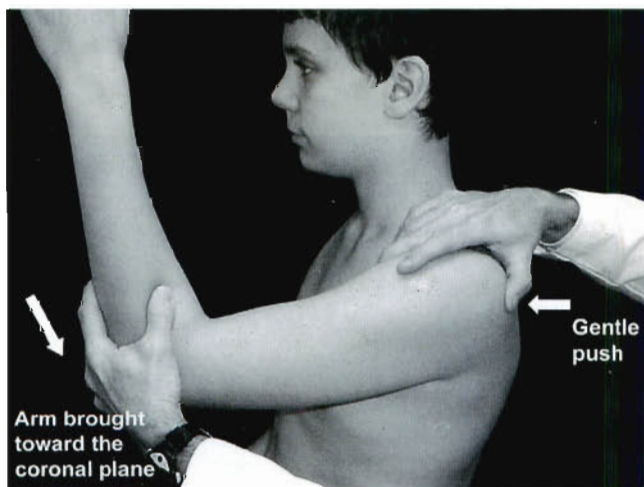


FIGURE 4-38. The Jahnke test, developed to evaluate posterior instability, is performed by flexing the patient's arm forward to 90 degrees of elevation in neutral rotation, and applying a posteriorly directed force to the arm to sublaxate the humeral head posteriorly. The elevated arm is then gradually brought toward the coronal plane, while the clinician's thumb gently pushes the humeral head anteriorly. A palpable "clunk" is felt as the humeral head reduces from its sublaxated position.

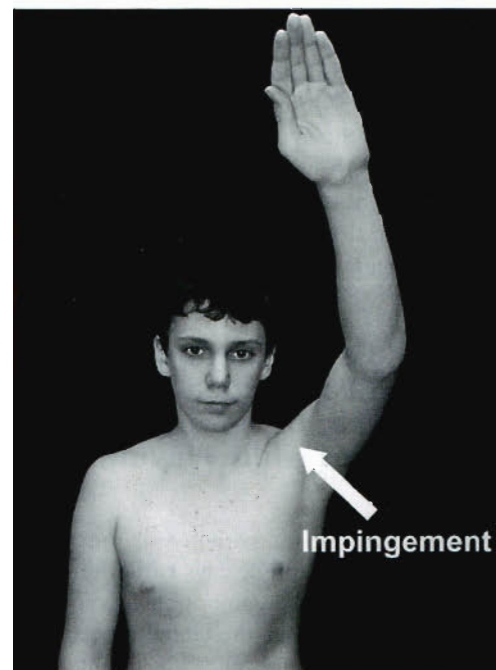

FIGURE 4-39. If the patient has tendonitis involving the supraspinatus tendon, forcible elevation of the arm to 180 degrees will cause discomfort when the inflamed tendon impinges against the anterior inferior acromion and coracoacromial ligament. This discomfort or grimacing facial expression is termed a positive Neer impingement sign.

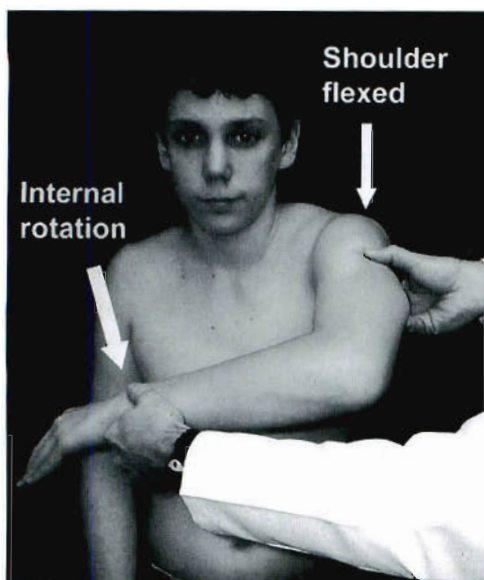


FIGURE 4-40. The Hawkins test is another maneuver that was developed to detect shoulder impingement. This test is performed with the shoulder flexed forward to 90 degrees. If internal rotation in this position causes discomfort, it indicates impingement between the inflamed supraspinatus tendon and the anterior inferior acromion and the coracoacromial ligament.

A patient with shoulder pain that is aggravated by swimming or gymnastics may have multidirectional instability, with an associated tear of the glenoid labrum. The labrum surrounds the glenoid cavity, deepening the glenohumeral joint, and the humeral head rests against the labrum. If there is a tear of the superior labrum, it is termed a “SLAP lesion,” for superior labrum anterior and posterior. If the labral tear involves the anteroinferior labrum, it is termed a “Bankart lesion.” If the attachment of the labrum to the glenoid is torn, it causes increased shoulder instability because the capsular attachment to the glenoid has been disrupted, further aggravating the symptoms.

A 15-year-old Boy Is Referred for Evaluation of Pain and Swelling of the Right Ankle That Developed after He Twisted His Foot while Playing Basketball

The history reveals that the patient was jumping for a rebound in a basketball game 2 days earlier and twisted his right foot when he landed on an opponent’s foot. He developed pain and swelling over the lateral aspect of the ankle immediately after the injury, and was unable to continue playing. The trainer immediately applied ice to the ankle, but he continues to have pain and swelling that are aggravated by walking. He has always been athletic and in good health, but he has had two similar injuries of the right ankle

in the past. One occurred the previous year while playing basketball, and the other occurred 18 months earlier while playing tennis. There is no family history of frequent ankle sprains, and the remainder of the history is unremarkable.

On physical examination, there is marked swelling noted over the lateral malleolus, with ecchymosis over the lateral side of the foot. The patient is exquisitely tender to palpation over the anterior talofibular ligament and the calcaneofibular ligament, but he is not tender over the anterior tibiofibular ligament or the distal fibular growth plate. This pattern of tenderness indicates an injury to the ligaments, a sprained ankle, rather than a fracture of the distal fibular growth plate. In a younger patient, the ligaments are stronger than the growth plate, so the clinician would expect the area of maximum tenderness to be located over the distal fibular growth plate. Laxity of the anterior talofibular ligament can be detected by performing an anterior drawer test. This test is performed by applying anterior traction to the calcaneus with one hand, while holding the tibia in a fixed position with the other hand, and comparing the amount of anterior subluxation of the talus in the ankle joint between the injured and uninjured sides (Fig. 4-41). Laxity of the calcaneofibular ligament can be detected by performing a talar-tilt test, and comparing the injured side with the uninjured side. The talar-tilt test is performed by stabilizing the tibia with one hand while applying a varus stress to the calcaneus with the other hand, and feeling for asymmetry between the injured and uninjured sides.

In a patient with a sprained ankle, it is important to evaluate the range of motion of the ankle, subtalar, tarsal, and tarsometatarsal joints, because limited subtalar or tarsal motion may predispose the patient to frequent ankle sprains. A tarsal coalition between the talus and calcaneus, or between the calcaneus and navicular, may markedly restrict subtalar or tarsal motion. This loss of motion in the

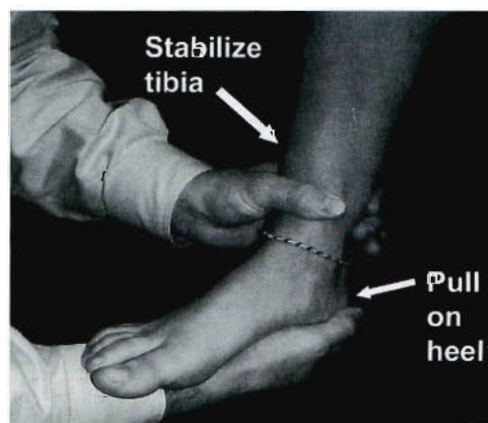


FIGURE 4-41. The anterior drawer test is performed by pulling the calcaneus forward with one hand, while stabilizing the tibia with the other hand. The amount of anterior subluxation is measured in millimeters, and compared with the other side.

subtalar or tarsal joints transmits forces to the ankle during athletic activities, increasing the risk that the patient may sustain an ankle sprain.

A sprained ankle typically occurs after a supination- or inversion-type injury to the ankle. As a result, the injury involves the ligaments on the lateral side of the ankle, and the medial side is not injured. If there is associated pain and swelling over the medial malleolus or the deltoid ligament, it may indicate a rotational type of injury pattern, which is often seen in fractures involving the ankle. This question can be answered by obtaining appropriate radiographs of the ankle.

References

The Orthopaedic Examination from Birth to 4 Years of Age

1. Aronsson DD, Goldberg MJ, Kling TF, et al. Developmental dysplasia of the hip. *Pediatrics* 1994;94:201.
2. Yngve D. Foot-progression angle in clubfeet. *J Pediatr Orthop* 1990;10:467.
3. Staheli LT, Corbett M, Wyss C, et al. Lower-extremity rotational problems in children: normal values to guide management. *J Bone Joint Surg Am* 1985;67:39.
4. Bleck EE. *Orthopaedic management in cerebral palsy*. Philadelphia: JB Lippincott, 1987.
5. Illingworth RS. *The development of the infant and young child: normal and abnormal*, 9th ed. New York: Churchill Livingstone, 1987.
6. Salenius P, Vankka E. The development of the tibiofemoral angle in children. *J Bone Joint Surg Am* 1975;57:259.
7. Nathan PA, Kenniston RC. Crossed polydactyly. *J Bone Joint Surg Am* 1975;57:847.

The Orthopaedic Examination from 4 to 10 Years of Age

8. Sutherland DH, Olshen R, Cooper L, et al. The development of mature gait. *J Bone Joint Surg Am* 1980;62:336.
9. Staheli LT. The prone hip extension test. *Clin Orthop* 1977;123:12.
10. Ober FR. The role of the iliotibial band and fascia: a factor in the causation of low back disorders and sciatica. *J Bone Joint Surg Am* 1936;18:105.
11. Silverskiöld N. Reduction of the uncrossed two joint muscles of the one-to-one muscle in spastic conditions. *Acta Chirurg Scand* 1923;56:315.
12. Coleman SS, Chesnut WJ. A simple test for hindfoot flexibility in the cavovarus foot. *Clin Orthop* 1977;123:60.
13. Sullivan JA. The child's foot. In: Morrissy RT, Weinstein SL, eds. *Lovell and Winter's pediatric orthopaedics*, 4th ed. Philadelphia: Lippincott-Raven, 1996;2:1077.

The Orthopaedic Examination from 10 to 18 Years of Age

14. Bunnell WP. An objective criterion for scoliosis screening. *J Bone Joint Surg Am* 1984;66:1381.
15. Medlar RC, Lyne ED. Sinding-Larsen-Johansson disease: its etiology and natural history. *J Bone Joint Surg Am* 1978;60:1113.
16. Wilson JN. A new diagnostic sign in osteochondritis dissecans of the knee. *J Bone Joint Surg Am* 1967;49:477.
17. Diduch D, Scuderi G, Scott WN. Knee injuries. In: Scuderi GR, McCann PD, Bruno PJ, eds. *Sports medicine: principles of primary care*. St. Louis: Mosby, 1997:336.
18. Medical Research Council. *Aids to the examination of the peripheral nervous system*. Memorandum 45. London: Her Majesty's Stationery Office, 1943.
19. Hawkins RJ, Bokor DJ. Clinical evaluation of shoulder problems. In: Rockwood CA, Matsen FA, eds. *The shoulder*. Philadelphia: WB Saunders, 1998:164.



5

NORMAL GAIT AND ASSESSMENT OF GAIT DISORDERS

JON R. DAVIDS

NORMAL GAIT 133

THE GAIT CYCLE 135

Ankle 139

Knee 140

Hip 143

Pelvis/Trunk/Upper Extremities 143

THE RUNNING CYCLE 143

MATURATION OF GAIT 145

COMMON GAIT DEVIATIONS 145

Ankle 146

Knee 146

Hip 147

GAIT ANALYSIS 148

Observational Gait Analysis 148

Quantitative Gait Analysis 148

Kinematic Analysis 149

Kinetic Analysis 150

Dynamic Electromyography 151

Energetics 151

Clinical and Research Applications 152

The evolutionary forces that engendered life's emergence from the primordial slime, and subsequent domination of the local environment, greatly favored organisms with the ability to move from one spot to another. Locomotion evolved from reptilian slithering to advanced quadrupedal and bipedal gait. Quadrupedal locomotion is greatly favored in the animal kingdom, because it promotes stability and speed (1). The center of mass of a quadruped is located between the front and hindlimbs, which form a stable base of support. Speed is enhanced by the use of the trunk musculature to augment stride length and power. Ventral flexion of the trunk allows the animal to bring the flexed hind-

limbs forward beyond the planted forelimbs. After weight has been transferred to the hindlimbs, the hips, shoulders, and trunk extend in synchrony to advance the forelimbs forward to complete a single cycle (1).

Bipedal gait sacrifices stability and speed to free the upper extremities for prehensile functions, imparting a tremendous evolutionary advantage. An upright position requires the center of mass to be balanced above the base of support, which is an inherently less stable and energy-efficient alignment (2–6). The diminished ability to use the trunk musculature to advance the swing limb limits stride length and power, compromising the speed of ambulation.

The early human fascination with normal gait and its deviations is revealed in the primitive cave paintings that illustrate hunters pursuing their prey. The modern era of motion analysis began with artists and mathematicians who were primarily interested in anatomy, aesthetics, and body segment motion (2,7,8). Eadward Muybridge, a British

J. R. Davids: Department of Orthopaedic Surgery, Duke University Medical Center, Durham, North Carolina 27710; Motion Analysis Laboratory, Shriners Hospital, Greenville, South Carolina 29605.

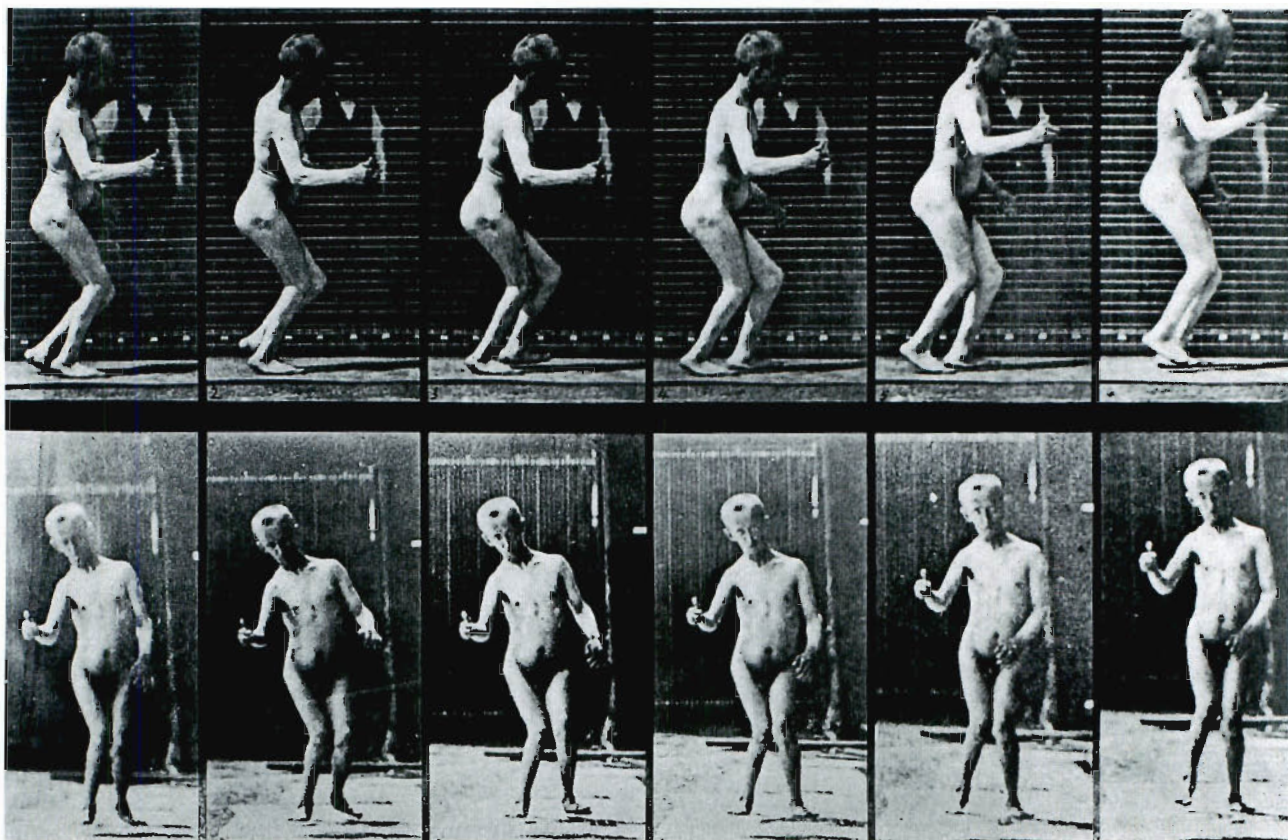


FIGURE 5-1. Muybridge's study of a young man with Little's disease, published in 1887. The subject exhibits many of the common gait deviations seen in children with cerebral palsy. (From ref. 9, with permission.)

photographer working in California, was the first to photograph fast motion (9). In 1872, his technique, which was the forerunner of modern motion pictures, was initially financed by Leland Stanford, who sought to win a wager by proving that a trotting horse, at some point in its stride, had all four feet off the ground at the same time. Muybridge's work was later supported by the University of Pennsylvania, where he created elegant studies of animal and human locomotion (Fig. 5-1). This extensive body of work has been collected into three volumes, and can still be found in the art section of large bookstores (9).

Etienne-Jules Marey was the first to develop a method of graphic notation derived from recording devices attached to the animal or person being studied (2,7,9,10). His "experimental shoe," described in 1873, is the direct forerunner of the electrical foot switch developed in the 1950s. In 1894, Braune and Fischer performed the first systematic study of human gait (10). Their subjects were Prussian soldiers who were placed into rubberized suits with electrical tubes attached to define the body segments (Fig. 5-2). It took 8 h to dress each volunteer, primarily because of concerns about potential electrocution. The mathematical analysis of the data was performed by hand and took several months to

complete. Their analysis, however, was as mechanically sophisticated as that currently performed by computer-driven quantitative motion analysis systems (10). Shortly after World War II, Dr. Verne T. Inman, an orthopaedist and functional anatomist, and defense industry-based colleagues in engineering and physiology became involved in lower limb prosthetics research (3,6). This collaboration led to the development of the first modern motion analysis laboratory. Inman's work was advanced, and the value of motion analysis was disseminated by two of his students and orthopaedic residents, Jacqueline Perry and David H. Sutherland. There are now approximately 70 clinical motion analysis laboratories in North America.

Quantitative motion analysis has had a significant impact on virtually all fields within orthopaedics, primarily by facilitating the objective analysis of an individual's functional deficits of movement. Quantitative motion analysis before and after an intervention allows assessment of the outcome in technical and functional domains not previously possible in clinical orthopaedics. Although some investigators may be discouraged by the cost and labor intensity of performing quantitative motion analysis, the central role of outcome studies in the ongoing reform of health care services in

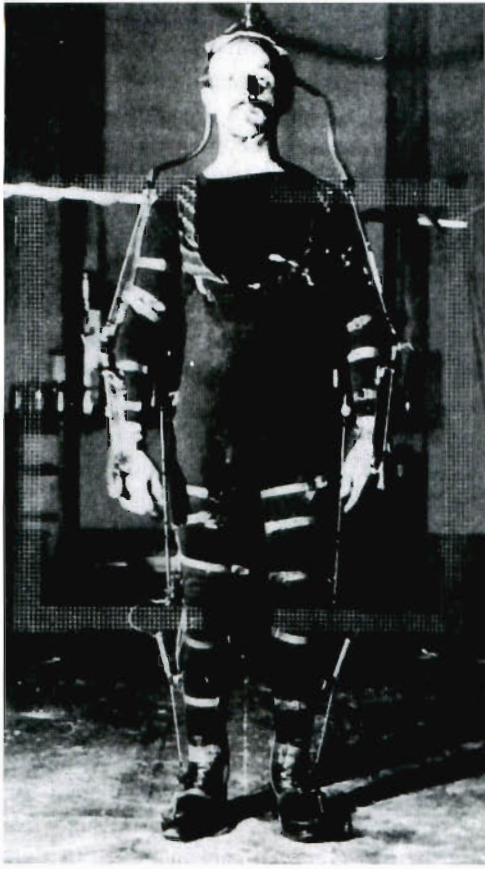


FIGURE 5-2. Rubberized suit with electrical tubes attached to various body segments, used by Braune and Fisher to study human gait in 1894. (From ref. 10, with permission.)

North America suggests that the application of this technique will play a crucial part in the redefinition of the clinical practice of orthopaedics in the future.

In pediatric orthopaedics, quantitative motion analysis has advanced treatment concepts in cerebral palsy, myelodysplasia, muscle disease, and limb deficiency. The study of patients with cerebral palsy has revealed several principles: the separation of primary gait abnormalities due to the underlying neurologic lesion from secondary or compensatory gait deviations; the value of reducing the energy expenditure associated with pathologic gait by interventions aimed at reestablishing normal mechanical parameters; recognition of the significance of muscles that cross two joints; and the significance of skeletal malalignment, particularly in the transverse plane, in compromising the biomechanical ability of muscles to generate the forces required to stabilize motor limb segments (1,11,12). Quantitative motion analysis has identified common gait deviations at the hip, knee, and ankle (1,12–33). The efficacy of orthoses, tendon releases, tendon transfers, dorsal rhizotomy, and botox injections have been studied with motion analysis (34–58).

In cases of myelodysplasia, quantitative motion analysis

has been used to evaluate the impact of orthotic design on gait and joint loading in three planes, as well as to assess the surgical treatment of calcaneus gait by anterior tibial tendon transfer to the os calcis and Achilles tenodesis (59–65). For children with Duchenne muscular dystrophy, the pathomechanics of the deterioration of their gait have been elucidated, with implications for the timing and nature of surgical intervention (66,67). Children with congenital and acquired limb deficiencies have been studied to evaluate various reconstructive procedures, such as posteromedial release and Van Nes rotationplasty, and to assess prosthesis design (68–77).

Adult orthopaedics has also proven to be fertile ground for the application of quantitative motion analysis. The issues of adult joint disease examined include the energy costs of various arthrodeses, prediction of the efficacy of high tibial osteotomy, and functional recovery after knee and hip arthroplasty (78–84). In sports medicine, the various adaptations and their significance in gait of anterior cruciate ligament deficiency, and the biomechanics of throwing, swimming, running, and cycling have been assessed by motion analysis (85–92). Quantitative motion analysis has also been applied to adults with stroke, closed head injury, acquired limb deficiency, and spinal cord injury (26,93–100).

Using the results of quantitative motion analysis, this chapter defines and describes normal gait, running gait, and the maturation of gait. The most common gait deviations seen in the practice of pediatric orthopaedics are delineated. A technique of observational gait analysis is described, and the technology and technique of quantitative motion analysis are considered, primarily to facilitate a critical review of clinical studies that employ quantitative motion analysis.

NORMAL GAIT

The primary goal of gait is to provide a smooth, energy-efficient transfer of the body through space (2,3,5,8,11, 101,102). Normal gait is an extremely complex process that is built on the manipulation of selective synergistic motor patterns (i.e., “hard wired” spinal cord reflexes) and incorporation of learned sequential motor patterns (1,103,104). The remarkable similarity of gait between individuals is thought to be a consequence of the underlying demand for energy-efficient locomotion (3,6). Mechanically, this phenomenon is observed by considering the excursion of the body’s center of gravity, located anterior to the second sacral vertebra, during gait. Although the body grossly appears to be walking a straight path, the center of gravity actually follows a sinusoidal course in the coronal and sagittal planes (Fig. 5-3). The maximum vertical displacement of the body’s center of gravity occurs at the point of minimal horizontal displacement, which is a relatively energy-efficient pattern (1,3). In the sagittal plane, the body’s center of gravity is at its highest point (i.e., minimum

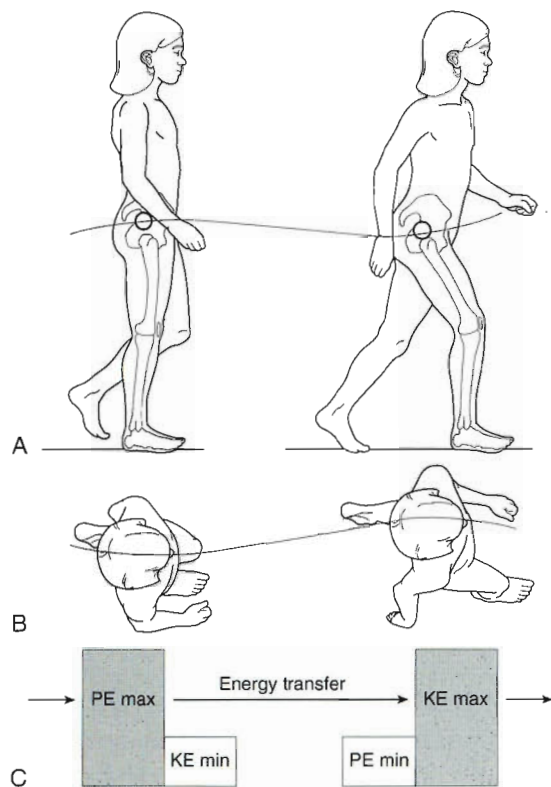


FIGURE 5-3. The excursion of the body's center of gravity follows a sinusoidal path in the sagittal (A) and coronal planes (B). Notice that the maximal excursion in one plane occurs in synchrony with minimal excursion in the other plane. C: Kinetic energy is maximal in double support periods (left), and potential energy is maximal in single-limb support periods (right). (Adapted from refs. 1 and 3, with permission.)

velocity, maximum potential energy) in midstance, and at its lowest point (i.e., maximum velocity, maximum kinetic energy) in terminal stance, when the two limbs are farthest apart (105,106). The transformation of potential to kinetic energy, and the use of the kinetic energy to accelerate the body and create potential energy, is a cyclic process occurring throughout gait. This form of energy transfer is effective but costly, with only 30 to 50% of the potential energy recovered as kinetic energy (1,101). Gait is therefore most efficient when the magnitude of the energy transferred is minimized. This is accomplished by minimizing the excursion of the center of gravity, one of three significant mechanisms of energy conservation (discussed below), which are best appreciated by applying basic mechanical principles to the analysis of normal gait.

Dynamic mechanical modeling of gait considers the motions that occur at joints and body segments (i.e., kinematics) and the forces that produce the motion (i.e., kinetics). Kinematic data describe gait and its deviations, including sagittal, coronal, and transverse joint angles, velocities, and

accelerations (107,108). Kinetic data address the causes of motion and movement abnormalities, including the ground reaction forces, joint moments, and joint powers (107,108). A joint moment is the product of the force generated by a muscle and the distance of the muscle from the joint's estimated center of rotation (11,106,109,110). The ground reaction forces, in conjunction with gravitational and inertial forces, produce an external moment about the joints, and the moments generated by the muscles, ligaments, and joint capsules that cross the joint are called internal moments. Joint power is the product of a net joint moment and the joint's angular velocity (11,106,109,110). Power generation occurs when a muscle contracts concentrically (i.e., shortens), to produce a joint motion in the same direction that the muscle pulls (107). Power absorption occurs when the joint motion is opposite to the direction of the muscle pull, and the muscle exhibits an eccentric (i.e., lengthening) contraction (107).

This mechanical model recognizes three major mechanisms by which the body conserves energy during gait (1,12). The first mechanism involves minimizing the excursion of the center of gravity (2,3,5,6,29,101). This is accomplished by synchronized pelvic, hip, knee, and ankle motions. Multilevel lower extremity joint and segment motions are so well coordinated with and across planes, that pelvis and trunk deviations during normal gait usually cannot be appreciated by observational gait analysis. For this reason, it is helpful to consider the lower extremities as the body's locomotor segment, and the pelvis and trunk as the passenger segment (101). The efficacy of this mechanism is illustrated by the analysis of above-knee amputee gait, in which the energy cost is approximately double that for nonamputee gait (97,111). The second mechanism uses internal moments generated by passive structures (such as ligaments and joint capsules), instead of active internal moments (generated by muscle contractions), to counterbalance applied external moments and achieve joint stability during the gait cycle (1,8,11,12,105–107,112–115).

Because of proper positioning of the ankle in midstance, which is controlled by eccentric contraction of the soleus, the ground reaction force falls in front of the knee, generating an external extension moment in which stability at the knee is achieved by the internal flexion moment generated by the knee ligaments and joint capsules. In children with cerebral palsy, incompetence of the ankle plantar flexors after overlengthening of the heel cord leads to poor control of ankle position in midstance, posterior displacement of the ground reaction force at the knee, and creation of an external flexion moment. With time, this overwhelms the stabilizing internal knee extension moment generated by the quadriceps, resulting in a progressive crouch gait pattern, which is extremely energy inefficient (28,29). A similar coupling occurs at the hip, where the ground reaction force falls behind the joint center to generate an external extension

moment, which is stabilized by the internal flexion moment generated by the anterior hip ligaments (101). The final mechanism involves the efficient transfer of energy between body segments (1,12). Early work suggests that two-joint muscles, such as the rectus femoris, which can generate power when serving as a hip flexor, while simultaneously absorbing power in its role as a knee extensor during rapid walking, serve a central role in the efficient transfer of energy between nonadjacent segments (77,116). The physiologic confirmation of this mechanism is under investigation (117). Current investigations of normal and pathologic gait mechanisms include dynamic mechanical modeling of muscle length and calculation of joint stiffness (17,118).

THE GAIT CYCLE

A single gait cycle, also called “stride,” functionally defines the events occurring between two sequential floor contacts by the same limb. The gait cycle is logically divided into two phases, stance and swing, respectively defined by the presence or absence of floor contact for the limb being considered. Normal walking allows each limb to accomplish three tasks during each gait cycle: weight acceptance, single-limb support, and limb advancement (101) (Fig. 5-4). Pathologic deviations of gait compromise the achievement of these tasks and increase the energy cost of ambulation. The events of gait are temporally described as occurring at specific percentages of the gait cycle. Stance phase constitutes the first 60% of the gait cycle, and contains two periods of “double support,” when both limbs are in contact with the floor. The first period occurs immediately after the

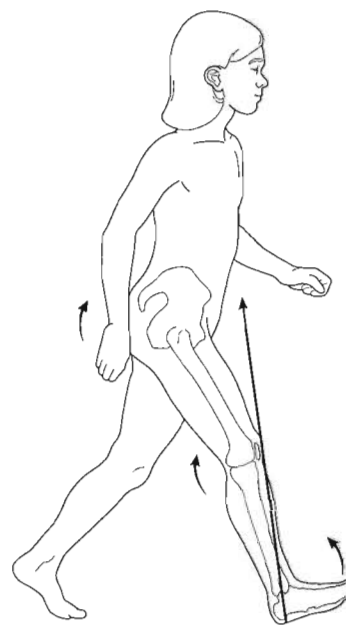


FIGURE 5-5. Initial contact. The *long arrow* represents the ground reaction force. Its position relative to each joint determines the external moment. The *smaller arrows* represent the net internal moments that are generated by the muscles and other soft tissue structures crossing each joint.

initiation of stance phase, and the second just before the end of stance. Clinically, stance phase is further divided into five subphases, each of which has a functional objective: initial contact, loading response, midstance, terminal stance, and preswing (Figs. 5-5 through 5-9; Table 5-1).

GAIT CYCLE							
PHASE	STANCE					SWING	
TASK	Weight Acceptance		Single Limb Support			Limb Advancement	
SUB-PHASE	Initial Contact (IC)	Loading Response (LR)	Mid Stance (MSt)	Terminal Stance (TSt)	Pre Swing (PSw)	Initial Swing (ISw)	Terminal Swing (TMSw)

FIGURE 5-4. The division of the gait cycle into phases, tasks, and subphases facilitates the analysis of normal and pathologic gaits.

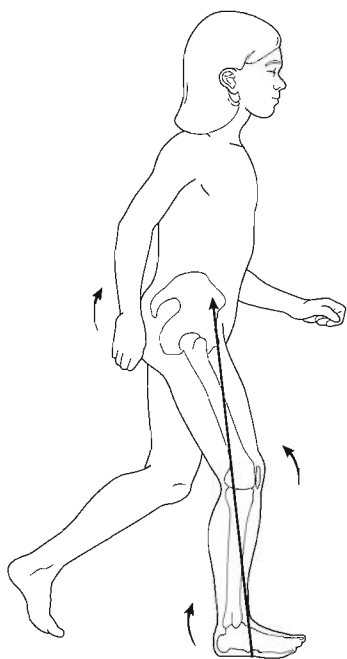


FIGURE 5-6. Loading response. Shock absorption by the quadriceps and controlled ankle plantar flexion are the central events. The ankle plantar flexion sets up the first, or heel, rocker. *Long arrow*, ground reaction force; *curved arrows*, net internal moments generated by muscles crossing each joint.

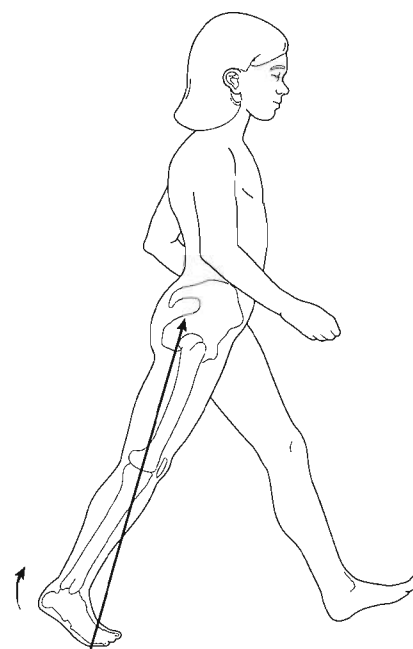


FIGURE 5-8. Terminal stance. Heel rise occurs as the body advances and the ankle plantar flexors resist the large external dorsiflexor moment. (This constitutes the third, or forefoot, rocker.) *Long arrow*, ground reaction force; *curved arrow*, internal plantar flexion moment.

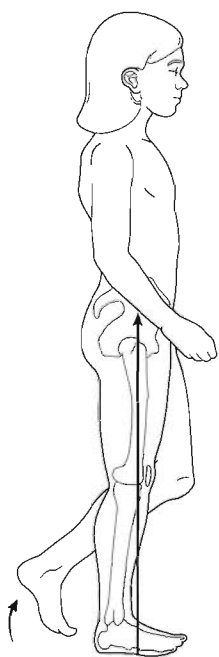


FIGURE 5-7. Midstance. After the ground reaction force (*long arrow*) falls in front of the knee, generating an external extension moment, and behind the hip, generating an external extension moment, internal muscle-generated moments are no longer necessary for joint stability. This is one of the energy-efficient mechanisms often lost in pathologic gait deviations. Tibial advancement over the foot constitutes the second, or ankle, rocker, and is controlled by an internal ankle plantar flexion moment (*small arrow*).

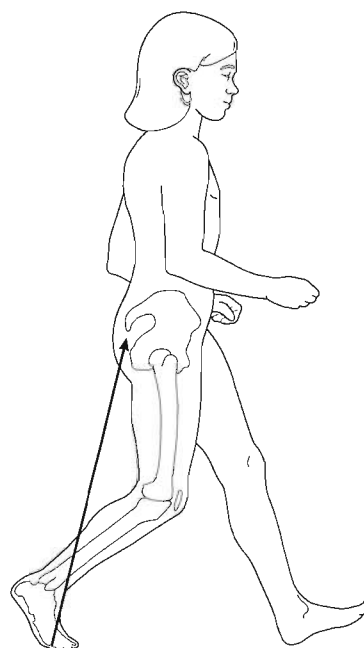


FIGURE 5-9. Preswing. "Passive" ankle plantar flexion, knee flexion (i.e., no internal muscle moments), and active hip flexion occur as the limb is unloaded. *Long arrow*, ground reaction force.

TABLE 5-1. STANCE PHASE OF THE GAIT CYCLE

<p>Initial Contact (see Fig. 5-5)</p> <p>Interval: 0% of the gait cycle</p> <p>Task: weight acceptance</p> <p>Critical events: the ankle is positioned so the heel strikes first as the foot comes in contact with the floor</p> <p>Kinematics</p> <p>Ankle: 0 degrees</p> <p>Knee: 0 degrees</p> <p>Hip: 25 degrees flexion</p> <p>Kinetics</p> <p>Ankle: external plantar flexion moment, which is balanced by internal dorsiflexion moment by tibialis anterior</p> <p>Knee: external extension moment; hamstring activity decelerates the advancing limb</p> <p>Hip: external flexion moment, controlled by hamstring extension moment, which also contributes to deceleration</p>	<p>flexion moment by the soleus decelerates ankle dorsiflexion, stabilizes the tibia, and controls the position of the ground reaction force vector at the knee and hip</p> <p>Knee: external moment changes from flexion to extension as the ground reaction force vector moves anteriorly; internal muscle moments are no longer necessary for joint stability after the vector passes in front of the knee</p> <p>Hip: external moment changes from flexion to extension as the ground reaction force vector moves posteriorly; internal extension moment generated by the gluteus maximus is no longer required; the pelvis is stabilized in the coronal plane by action of the gluteus medius (i.e., internal abduction moment)</p>
<p>Loading Response (see Fig. 5-6)</p> <p>Interval: 0–10% of the gait cycle</p> <p>Task: weight acceptance; shock is adsorbed, primarily by the quadriceps, as forward momentum is preserved</p> <p>Critical events: controlled ankle plantar flexion and knee flexion; hip stability</p> <p>Kinematics</p> <p>Ankle: 10 degrees plantar flexion</p> <p>Knee: 15 degrees flexion</p> <p>Hip: 25 degrees flexion</p> <p>Kinetics</p> <p>Ankle: external plantar flexion moment; internal dorsiflexion moment by tibialis anterior decelerates and stabilizes the foot and advances the tibia anterior to the ground reaction force vector</p> <p>Knee: external flexion moment; internal extension moment by quadriceps stabilizes the knee in flexion and absorbs the shock of floor contact</p> <p>Hip: diminishing external flexion moment as the body advances; activity of the hip extensors and abductors stabilizes the hip and pelvis</p>	<p>Terminal Stance (see Fig. 5-8)</p> <p>Interval: 30–50% of the gait cycle</p> <p>Task: single-limb support; the body passes in front of the foot, and forward progression is accelerated by kinetic energy generated primarily by the ankle plantar flexors</p> <p>Critical events: heel rise</p> <p>Kinematics</p> <p>Ankle: 10 degrees dorsiflexion</p> <p>Knee: 0 degrees</p> <p>Hip: 20 degrees extension</p> <p>Kinetics</p> <p>Ankle: maximum external dorsiflexion moment is opposed by internal plantar flexion moment from the gastrocnemius, leading to heel rise as the body advances forward; this muscle is the principal source of power, accelerating the limb as it enters the swing phase</p> <p>Knee: external extension moment is diminishing, but no internal muscle moments are required to maintain stability</p> <p>Hip: maximal external extension moment is attained as the body advances</p>
<p>Midstance (see Fig. 5-7)</p> <p>Interval: 10–30% of the gait cycle</p> <p>Task: single-limb support; the body progresses over the foot in a controlled manner; forward momentum is generated by the contralateral swing limb</p> <p>Critical events: controlled tibial advancement</p> <p>Kinematics</p> <p>Ankle: 5 degrees dorsiflexion</p> <p>Knee: 0 degrees</p> <p>Hip: 0 degrees</p> <p>Kinetics</p> <p>Ankle external dorsiflexion moment; internal plantar</p>	<p>Preswing (see Fig. 5-9)</p> <p>Interval: 50–60% of the gait cycle</p> <p>Task: swing-limb advancement; the principal objective is preparation and positioning of the limb for swing</p> <p>Critical events: passive knee flexion</p> <p>Kinematics</p> <p>Ankle: 20 degrees plantar flexion</p> <p>Knee: 40 degrees flexion</p> <p>Hip: 0 degrees</p> <p>Kinetics</p> <p>Ankle: passive plantar flexion as the limb is unloaded</p> <p>Knee: passive flexion as the limb is unloaded; the rectus femoris, a biarticular muscle, may assist in energy transfer between the knee and hip in this subphase</p> <p>Hip: passive flexion as the limb is unloaded</p>

The swing phase constitutes the remaining 40% of the gait cycle, and begins at the point where the limb is unloaded and the foot comes off the ground. The limb is advanced from behind the body to in front of the body, reaching out to take the next step. Foot clearance and correct positioning for the initiation of the subsequent stance phase are critical components of swing-limb advancement (101). The velocity of gait can be altered by changing the stride length (i.e., distance covered by a single gait cycle) or the cadence (i.e., number of gait cycles per unit time) (109,116,119). Changes in cadence are primarily accomplished by altering the duration of swing phase (1). A period of variable acceleration (i.e., initial swing), a transitional period (i.e., mid-swing), and a final period of deceleration and limb positioning (i.e., terminal swing) are the recognized subphases of swing. Kinetic analysis of the joints in swing phase is much simpler, because there is no external moment generated by the ground reaction force. External moments may be generated by gravitational and inertial forces, and are usually dominated by the internal muscle-generated moments (107) (Figs. 5-10 through 5-12; Table 5-2).

In addition to analysis by phase, task, and subphase, the functional assessment of gait is facilitated by considering the kinematics and kinetics of anatomic areas, such as joints and body segments, throughout the gait cycle.

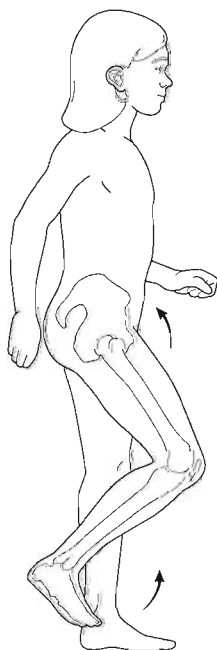


FIGURE 5-10. Initial swing. Hip flexion, knee flexion, and ankle dorsiflexion contribute to limb clearance. *Curved arrows*, internal hip flexion and ankle dorsiflexion moments.

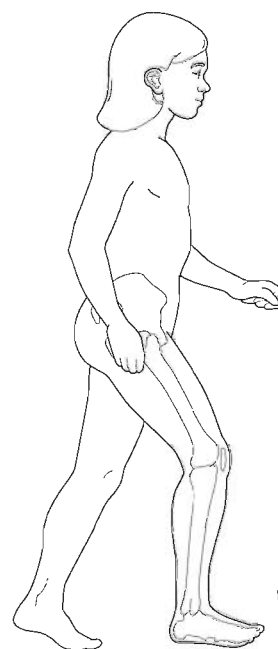

FIGURE 5-11. Midswing. Gravitational and inertial external moments dominate at the hip and knee. The ankle position for clearance is determined by an internal dorsiflexion moment (*curved arrow*).

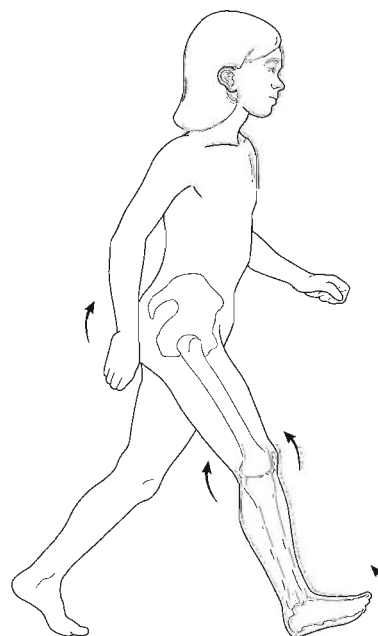


FIGURE 5-12. Terminal swing. Internal muscle moments at the hip, knee (i.e., simultaneous flexion and extension moments), and ankle decelerate the limb, and position it correctly for the initiation of the subsequent stance phase. *Curved arrows*, internal moments generated by the muscles crossing each joint.

TABLE 5-2. SWING PHASE OF THE GAIT CYCLE

<p>Initial Swing (see Fig. 5-10)</p> <p>Interval: 60–75% of the gait cycle</p> <p>Task: swing-limb advancement; variable acceleration is possible</p> <p>Critical events: foot clearance</p> <p>Kinematics</p> <p>Ankle: 10 degrees plantar flexion</p> <p>Knee: 60 degrees flexion</p> <p>Hip: 15 degrees flexion</p> <p>Kinetics</p> <p>Ankle: the pretibial musculature generates a dorsiflexion moment; diminished plantar flexion alignment contributes to foot clearance</p> <p>Knee: at a normal cadence, increased knee flexion is determined by external flexion moments generated by inertial and gravitational forces; at a slower cadence, an internal flexion moment, generated by the lateral hamstrings, may be present (63,100); at a faster cadence, the rectus femoris contributes to limb acceleration by generating an extension moment at the knee (21,110)</p> <p>Hip: the flexors and adductors generate an internal flexion moment, which contributes to limb advancement and acceleration</p> <p>Midswing (see Fig. 5-11)</p> <p>Interval: 75–90% of the gait cycle</p> <p>Task: swing-limb advancement</p> <p>Critical events: vertical alignment of the tibia; foot clearance</p> <p>Kinematics</p> <p>Ankle: 0 degrees</p> <p>Knee: 25 degrees flexion</p> <p>Hip: 25 degrees flexion</p>	<p>Kinetics</p> <p>Ankle: internal dorsiflexion moment from the tibialis anterior supports the ankle and prevents footdrop</p> <p>Knee: external moment from inertial forces begin to extend the knee</p> <p>Hip: external moment from inertial forces causes further hip flexion</p> <p>Terminal Swing (see Fig. 5-12)</p> <p>Interval: 90–100% of the gait cycle</p> <p>Task: swing-limb advancement, achievement of maximal step length, position the foot for initial contact, and deceleration of swing limb</p> <p>Critical events: knee extension to neutral</p> <p>Kinematics</p> <p>Ankle: 0 degrees</p> <p>Knee: 0 degrees</p> <p>Hip: 25 degrees flexion</p> <p>Kinetics</p> <p>Ankle: internal dorsiflexion moment maintains the foot in the proper position for initial contact</p> <p>Knee: internal extension moment by the quadriceps extends the knee for stance; internal flexion moment by the hamstrings decelerates and stabilizes the advancing swing limb</p> <p>Hip: internal extension moment by the hamstrings contributes to deceleration</p>
---	--

Ankle

Stance Phase

Ankle function during stance phase is best considered in terms of three rockers (120,121) (Fig. 5-13). The first, or heel, rocker begins at initial contact, and extends through the loading response. Correct ankle position at initial contact ensures that the heel strikes the floor first, creating an external plantar flexion moment. The 10 degrees of plantar flexion seen in the loading response lowers the foot to the floor, and is resisted by the internal moment generated by the ankle dorsiflexor muscles. The second, or ankle, rocker occurs during midstance, and the external moment favors dorsiflexion. The 5 degrees of dorsiflexion is resisted by the internal moment generated by the ankle plantar flexor muscles. This deceleration of ankle dorsiflexion controls tibial advancement, and contributes to stance stability by ensuring that the ground reaction force is anterior to the knee and posterior to the hip, creating an external extension moment at each joint. This promotes joint stability through ligaments (and other soft tissue structures), and without muscle action, which is energy-efficient. The third, or forefoot, rocker occurs during terminal stance, as the body advances over the stance limb. The greatest external moment of the

gait cycle, favoring ankle dorsiflexion, occurs at this point (101,107,112, 115,122). The ankle plantar flexors meet the challenge, generating the greatest internal muscle moment occurring at any joint at any time in the gait cycle. The net joint moment favors ankle plantar flexion, and accelerates the advancing limb. Minimal ankle movement at this point causes the heel to rise as the forefoot dorsiflexes through the metatarsophalangeal joints, maintaining momentum and efficiently transferring energy between body segments (11,101,115). Heel rise should occur just before the opposite limb enters weight acceptance at initial contact.

Before quantitative analysis and mechanical modeling, heel rise was imprecisely perceived as active ankle plantar flexion and referred to as “push-off,” which implies propulsion, but is misleading. Although the ankle plantar flexors are active, they are resisting the external dorsiflexion moment, effectively stabilizing the ankle joint and promoting controlled tibial advancement over the forefoot. A child with a calcaneal gait pattern (e.g., low lumbar-level myelodysplasia) loses heel rise and has uncontrolled tibial advancement over the foot, which leads to instability and poor energy transfer proximally during terminal stance. Twenty degrees of ankle plantar flexion does occur during preswing, as the body weight is transferred to the other limb. This

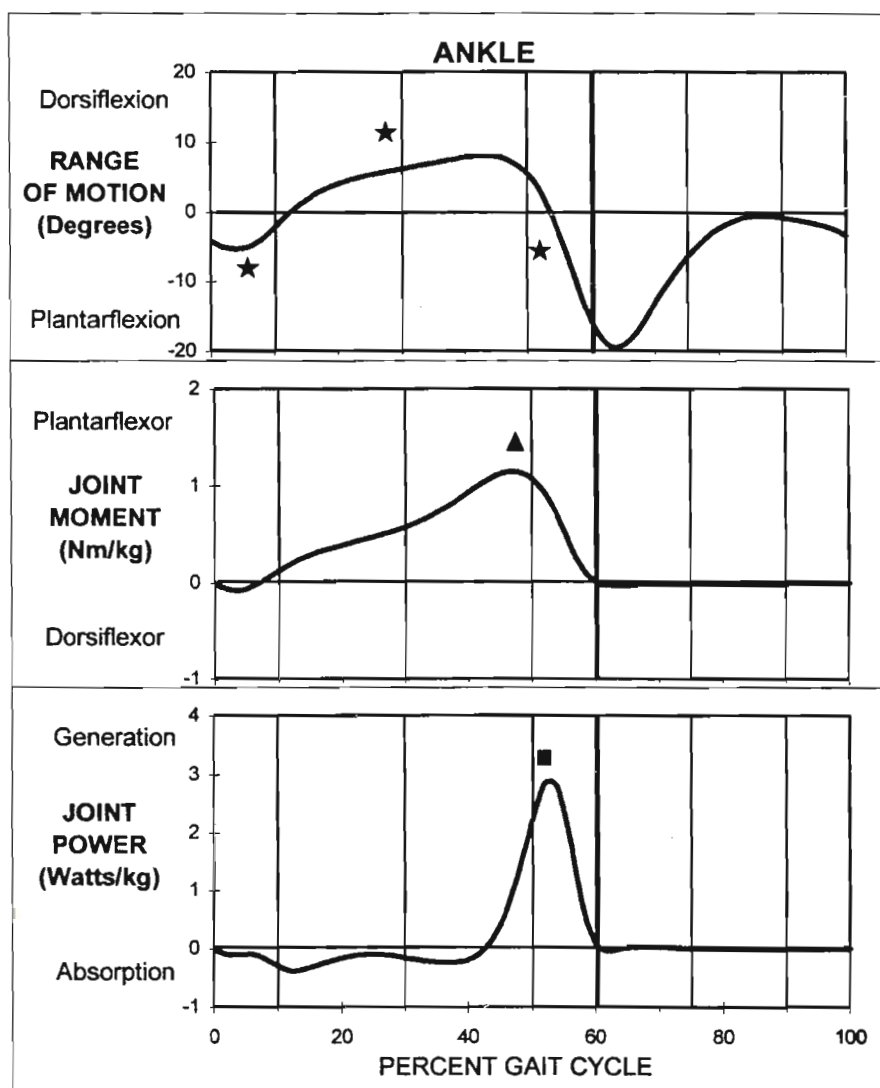


FIGURE 5-13. Normal motion, moments, and powers of the ankle. Motion is in the sagittal plane. Notice the three rockers (★) that occur during stance phase. The joint moment curve describes the net internal muscle moment, generated in response to the external moments from the ground reaction force, gravity, and inertia. The internal plantar flexion moment generated at the end of the terminal stance (TSt) subphase (▲) is the greatest muscle moment occurring at any joint at any time in the gait cycle. The TSt power generation (■) reflects the crucial role of the ankle plantar flexors in accelerating the limb as it enters the swing phase (i.e., energy transfer). (From refs. 8, 101, 107, and 122, with permission.)

plantar flexion takes place during a period of unloading, in response to external moments generated by inertia and gravity forces, not as a result of active internal muscle moments.

Swing Phase

Active ankle dorsiflexion begins during initial swing to assist in early swing-limb clearance. The internal dorsiflexion moment in midswing resists inertia and gravity forces to pro-

vide clearance. In terminal swing, the internal muscle moments position the ankle for initial contact, so the heel strikes the floor first, generating the first, or heel, rocker.

Knee

Stance Phase

The knee exhibits a single flexion wave during stance phase (Fig. 5-14). Full extension at initial contact provides stabil-

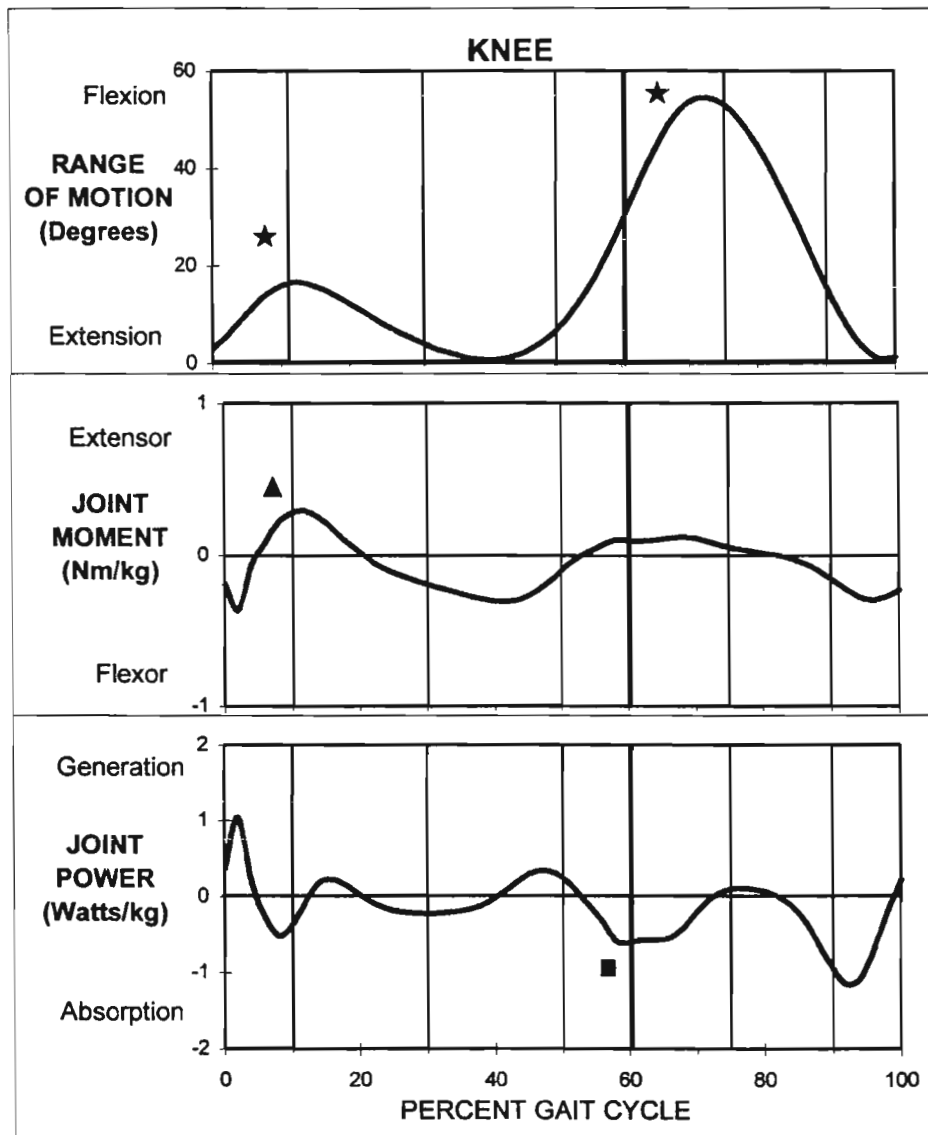


FIGURE 5-14. Normal motion, moments, and powers of the knee. Sagittal plane motion of the knee is characterized by two flexion waves (★). Stance-phase knee flexion (during loading response [LR] subphase) reflects shock absorption, and the swing-phase flexion wave promotes limb clearance. Note that 40 degrees of knee flexion occurs before the extremity enters swing phase. The quadriceps are the primary shock absorbers at the knee, generating the internal muscle extension moment seen during the LR subphase (▲). Power absorption occurs during LR and terminal stance (■). The relatively low level of power generation and absorption reflects the transfer of energy across the knee (between body segments above and below) by two joint muscles, such as the rectus femoris, biceps femoris, and gastrocnemius. (From refs. 8, 101, 107, and 122, with permission.)

ity for weight acceptance and contributes to optimal foot position. Flexion at the knee in the loading response is the principal means of shock absorption, and is a consequence of the external flexion moment generated by the ground reaction force (123). The alignment of this applied force behind the knee is controlled by the heel rocker. Although knee flexion promotes shock absorption, it must not compromise knee stability. Competent quadriceps function to generate an internal knee extension moment to prevent ex-

cessive knee flexion and instability (25). The knee extends in midstance to promote stability and advancement. The ankle rocker correctly aligns the ground reaction force, so that an external knee extension moment is generated, promoting energy-efficient knee stability. The phenomena whereby the position of the foot and ankle in stance phase determines the relative position of the ground reaction force to the knee joint center is known as the ankle plantar flexion–knee extension couple. As implied by the name, in-

creasing ankle plantar flexion is associated with a greater external knee extension moment. Conversely, increasing ankle dorsiflexion is associated with a greater external flexion moment at the knee. Maximum knee extension is attained in terminal stance, maintaining stability during forward progression. As the stance limb is unloaded in preswing, the knee flexes, driven primarily by the external flexion moment from the ground reaction force, which falls behind the knee as the body advances forward (11). Approximately two-thirds of the knee flexion necessary for swing-limb clearance

occurs in the preswing subphase before the foot leaves the floor.

Swing Phase

A second flexion wave of greater peak magnitude occurs during swing phase. The principal function of this flexion wave is limb clearance (101). Further knee flexion occurs during initial swing, which is crucial for foot clearance because the ankle is in equinus at this point (124). After the

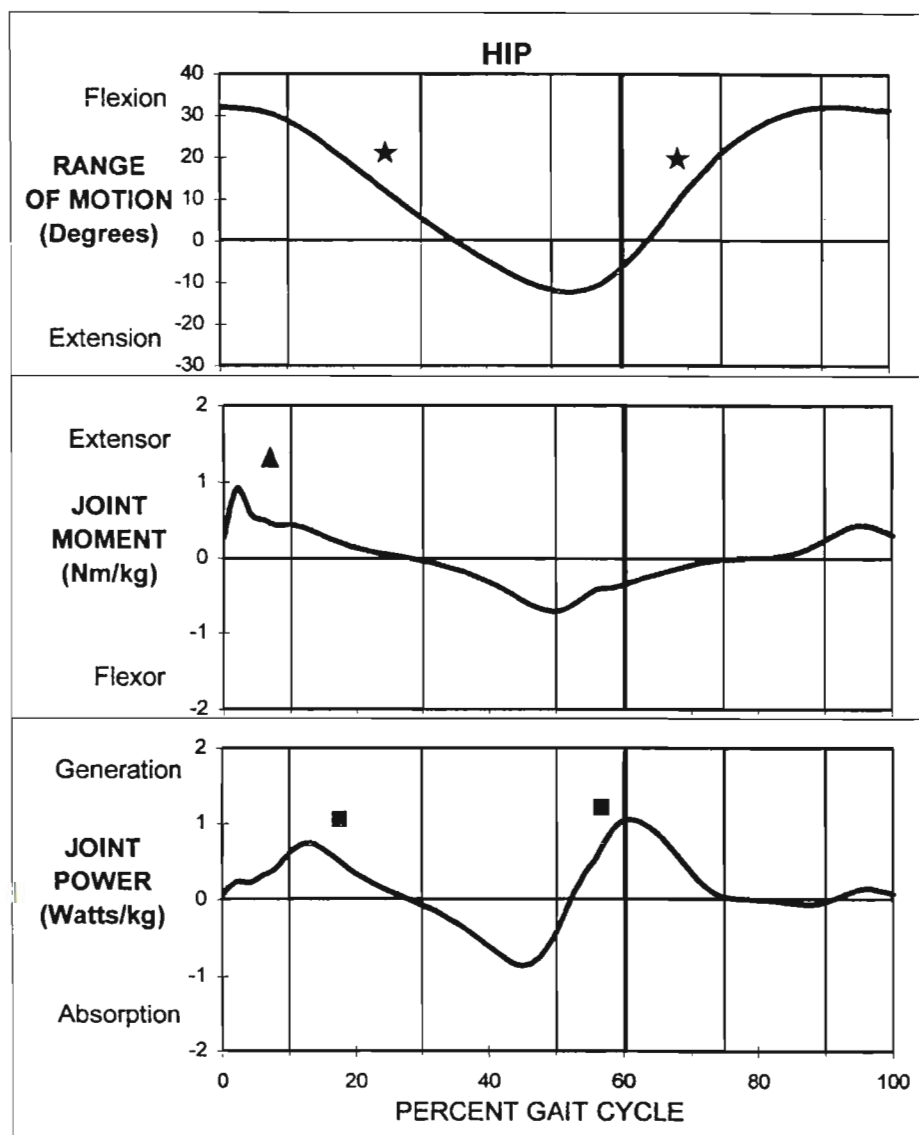


FIGURE 5-15. Normal motion, moments, and powers of the hip. Sagittal plane motion of the hip is characterized by an extension wave in stance phase and a flexion wave in swing phase (★). The extensor moment generated by the hamstrings in the loading response subphase (▲) is the second-greatest internal muscle moment in the gait cycle. The two periods of power generation (■) serve to accelerate the limb in the stance and swing phases. (From refs. 8, 101, 107, and 122, with permission.)

tibia has attained a vertical alignment, clearance has been achieved, and the primary function at the knee becomes limb advancement and stride length (101). The knee therefore extends, primarily because of an external moment derived from the forces of inertia and gravity. Optimal stride length is achieved by further knee extension in terminal stance. Internal (i.e., muscle) and external (i.e., gravitational and inertial) moments contribute to knee extension and limb positioning for the initial contact subphase. An internal flexion moment, generated by the hamstrings, decelerates the advancing limb before beginning the stance phase.

Hip

Stance Phase

The hip exhibits a single extension wave during stance phase (Fig. 5-15). At initial contact, the hip is flexed to promote limb position. During the loading response subphase, the ground reaction force falls in front of the hip joint, generating the second-highest external moment of the entire gait cycle (101,107). The internal muscle extension moment, generated by the hamstrings, stabilizes the hip. In the coronal plane, the weight of the contralateral swing limb causes the ground reaction force to fall medial to the stance-limb hip, creating an adduction moment that is resisted by the internal muscle moment of the gluteus medius (125,126). In midstance, the hip is extending as the body advances. After the ground reaction force falls at or behind the hip joint, an external extension moment is generated, and hip stability is provided by the anterior ligaments—an energy-efficient mechanism. In the coronal plane, the hip adduction moment persists. As the limb is unloaded in the pre-swing subphase, the hip begins to flex. In the coronal plane, the external adduction moment diminishes as the contralateral limb begins weight acceptance.

Swing Phase

The hip exhibits a single flexion wave in swing phase. During the initial swing subphase, internal muscle flexion moments may contribute to hip flexion. The remaining flexion in swing phase is a consequence of inertial and gravitational external moments (106,107). The hip flexion contributes to limb clearance early in swing and limb positioning, for weight acceptance after the terminal swing subphase.

Pelvis/Trunk/Upper Extremities

As noted earlier, it is helpful to consider the pelvis and trunk as the passenger segment during gait. This is most appropriate given the limitations of observational gait analysis. However, appreciation of pelvic and trunk motion during normal gait is possible with qualitative gait analysis. Motion of these segments is clearly coupled to the lower

extremities, and is characterized by minimal (i.e., between 0 and 5 degrees) excursion or dynamic range.

In the “sagittal plane,” the pelvis and trunk are both tilted slightly anterior throughout the gait cycle. In the “coronal plane,” trunk obliquity is inversely coupled to pelvic obliquity, which is directly coupled to hip ab/adduction. When the right hemipelvis is up, the right hip is adducted and the trunk is shifted down to the right. In the “transverse plane,” trunk rotation is directly coupled to pelvic rotation, which is inversely coupled to hip rotation. The most significant “cross plane” coupling occurs between the pelvis and the hip. Pelvic external rotation is coupled with hip flexion and adduction (contributing to apparent hip hyperextension in terminal stance), while pelvic internal rotation is coupled to hip extension and abduction.

In the sagittal plane, the upper extremities flex and extend in a reciprocal fashion, relative to each other. The motion of the upper extremity is inversely coupled to the ipsilateral lower extremity, with flexion of the arm occurring as the leg extends during stance phase.

THE RUNNING CYCLE

As the velocity of gait increases, bipedal ambulators progress from walking to running to sprinting. The transitional velocity at which an individual switches from one form of ambulation to the other is not constant; it is a function of multiple factors, including leg length (109). For this reason, children begin to run at lower velocities than adults. Walking is differentiated from running and sprinting by the pattern of ground contact (91,109,119,127). In walking, there is always ground contact with one or both feet, but running and sprinting are characterized by “double float” periods when neither foot is on the ground (Fig. 5-16).

In terms of the gait cycle, walking can be differentiated from running by the duration of the stance phase. In walking, the two periods of double support (i.e., both feet in contact with the floor) ensure that the duration of the stance phase is greater than 50% of the gait cycle (1,109,119). In running, both periods of double support are lost. The toe-off motion occurs before the opposite heel strike, creating two periods of double float (i.e., neither foot in contact with the floor), which constitute portions of the swing phase. In running, the duration of the stance phase constitutes less than 50% of the gait cycle (1,109,119). As the velocity of walking increases, the duration of double support decreases. As the velocity of running/sprinting increases, the duration of double float increases (127).

Running and sprinting are most easily differentiated by the position of the foot at initial contact (109,119,127). In running, the initial contact is made with the heel, as in walking. In sprinting, the initial contact is made with the forefoot, which is advantageous at higher velocities.

Biomechanical analysis of running divides the stance

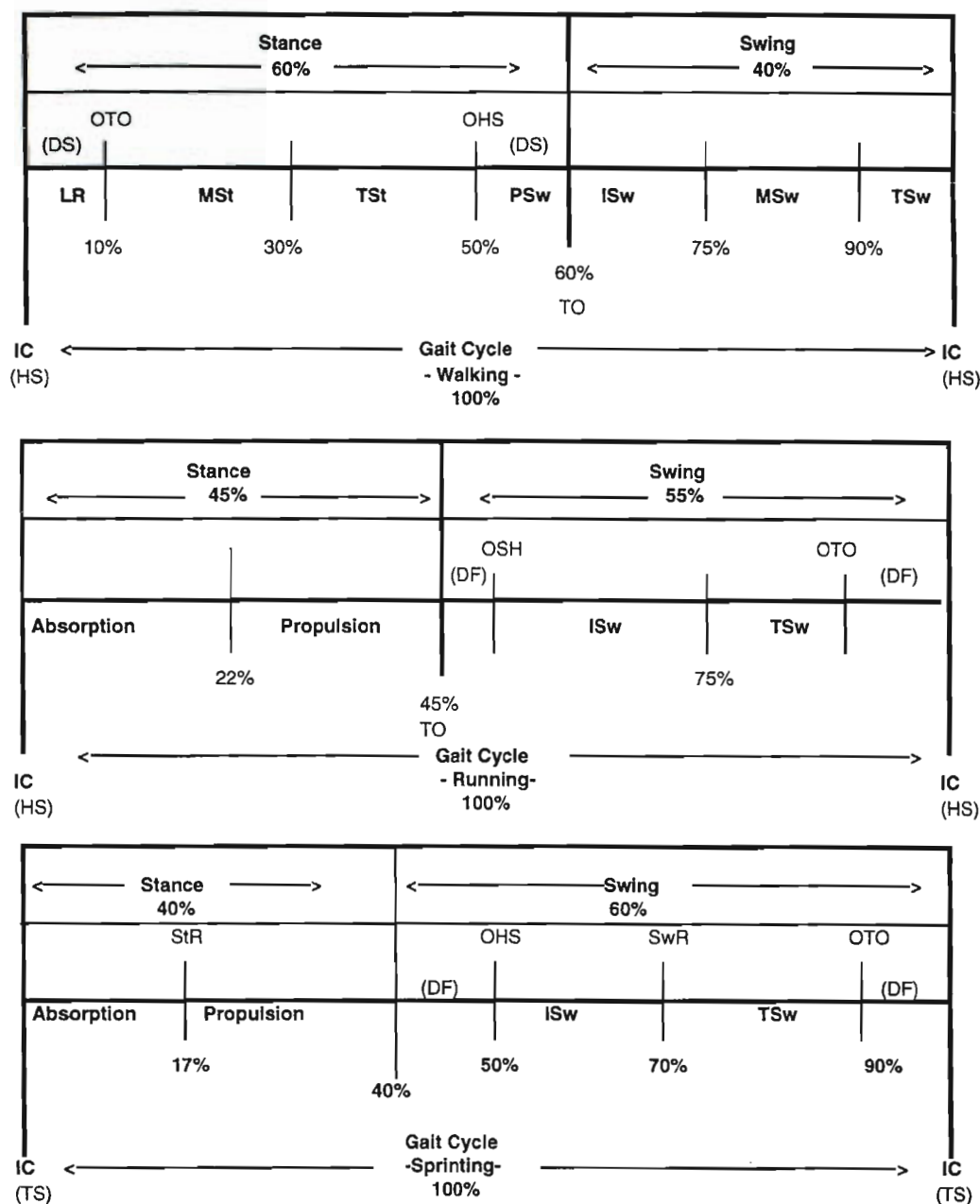


FIGURE 5-16. Comparison of the walking, running, and sprinting gait cycles. In walking, the stance phase constitutes more of the gait cycle than the swing phase. In running, this relation is reversed. In walking, heel strike (HS) and opposite heel strike (OHS) occur before opposite toe-off (OTO) and toe-off (TO), respectively, creating two periods of double support (DS), when both feet are touching the ground. In running, HS and OHS occur after OTO and TO, respectively; both periods of DS are lost, and two additional periods of double float (DF) are created. IC, initial contact; LR, loading response; MSt, midstance; TSt, terminal stance; PSw, preswing; ISw, initial swing; MSw, midswing; TSw, terminal swing; StR, stance phase reversal; SwR, swing phase reversal. (From refs. 1, 109, 119, and 127, with permission.)

phase into two subphases. During the absorption subphase, the hip and knee flex, and the ankle dorsiflexes. Kinetic studies of children running suggest that the knee and ankle are primary and secondary energy absorbers, respectively, during this subphase (109,127). The propulsion subphase

is characterized by active hip and knee extension and ankle plantar flexion. Kinetic analysis reveals that the ankle is the primary power generator in running, while the hip is the primary power generator during sprinting (109,127). This period of active ankle plantar flexion occurs during the pro-

pulsion subphase of running, and can correctly be called the “push-off period.”

MATURATION OF GAIT

The widely recognized developmental milestones of infants, such as rolling over, sitting, crawling, and standing, occur sequentially in conjunction with the physiologic maturation of the neuromuscular system (128). Animal models of spinal cord injury, and the presence of mass flexion and extension reflexes in neonates, suggests the existence of “hard-wired” motor synergies emanating from the spinal cord (103,104). With maturation, these spinal cord reflexes are manipulated to produce and control a reciprocating gait pattern. With further development, complex learned motor activities can be incorporated into the neuronal circuitry (1). With appropriate training, such learned activities can be performed with increasing ease. In all likelihood, the development of a mature gait pattern represents a combination of physiologic maturation of the neuromuscular system and incorporation of complex, learned motor activities (129–133).

Landmark studies by Sutherland et al., employing quantitative gait analysis, have characterized the different stages in the maturation of gait (8,29,131,132). In toddler gait, the upper extremities are held in abduction with elbow extension. Reciprocal arm movement does not occur. The foot and ankle exhibit a toe-strike pattern at initial contact, increased stance-phase dorsiflexion, and increased swing-phase plantar flexion. The knee shows diminished flexion throughout the gait cycle. The hip is externally rotated during the stance and swing phases. The stance phase is characterized by diminished single-limb stance time and a widened base of support in double stance. In the swing phase, circumduction (i.e., hip abduction) is used to clear the externally rotated, extended, and plantar-flexed extremity.

By 2 years of age, significant maturation is exhibited. Reciprocal arm swing is achieved by most children. Heel strike occurs at initial contact, and ankle dorsiflexion facilitates limb clearance during the swing phase. The knee flexion wave also occurs during the stance phase. Rotation at the hip has normalized. The stance phase is characterized by increased single-limb stance time, and the movement during swing phase shows normalized clearance mechanisms.

By 3 years of age, most adult kinematic patterns are present. Subsequent changes in time–distance parameters, such as cadence, velocity, and step length, continue to occur until 7 years of age, when an adult gait pattern is achieved.

Sutherland and coworker’s analysis of more than 300 children identified five statistically significant parameters of gait maturity (132):

1. Single-limb stance duration increases with age and maturation.

2. Walking velocity increases with age and limb length.
3. Cadence decreases with age and limb length.
4. Step length increases with age and limb length.
5. The ratio of the interankle distance to the pelvic width decreases with age and maturation.

COMMON GAIT DEVIATIONS

Mechanical modeling of gait assumes mobile body segments powered by internal muscle activity and external applied forces. The pathologic processes that affect gait usually compromise joint mobility and muscle activity by three general mechanisms: deformity, muscle dysfunction, and pain (78,101,134).

In deformity, soft tissue contractures limit joint motion. Fixed contractures create rigid deformity, and elastic contractures lead to dynamic deformity. Ligament laxity causes instability that can contribute to joint deformity. Osseous tissues may be altered by trauma, infection, and vascular compromise. Abnormally applied mechanical forces may affect growth mechanisms, leading to the development of bony deformities that limit joint mobility.

Disorders of the neuromuscular system can cause dynamic muscle weakness that alters gait. Children with lower motor neuron lesions or primary muscle diseases can often compensate for the function deficit. This capacity to substitute depends on the preservation of proprioception and selective control (101,134). Primary compensatory mechanisms include changing the timing of other muscle actions during gait, and use of postural adjustments to substitute for deficient muscle forces. Children with upper motor neuron lesions have the most challenging functional deficits. Their gait deviations are a consequence of spasticity, persistent primitive locomotor patterns (i.e., mass flexion or extension reflexes), poor selective control, and impaired proprioception (1,101).

Pain can contribute to joint deformity and muscle dysfunction. After an injury, the body assumes a natural resting joint position that minimizes intraarticular pressure (101). This mechanism contributes to soft tissue and osseous tissue changes over time. Neurologic control mechanisms exist that protect joint structures from destructive pressures (101). These protective reflexes limit the ability to activate certain muscles after an injury, which over time, cause disuse atrophy, and contributes to a vicious cycle of progressive functional deficits. An antalgic gait reflects the body’s efforts to compensate for pain or instability in the stance-phase limb by minimizing the duration and magnitude of loading. It is a gait pattern characterized by diminished single-limb stance time.

Within this framework, gait abnormalities may be seen as primary, if they are the direct result of a mechanical change related to the injury or disease process; secondary, when a primary deviation at another joint causes a patho-

logic deviation at the reference joint; or compensatory, reflecting an adaptation to an applied pathologic condition. Treatment should be directed toward primary gait deviations that cause functional deficits. Interventions that address secondary or compensatory gait deviations are generally ineffective and should be avoided. It is an error to intervene when a compensatory gait deviation successfully substitutes for a functional deficit. Treatment is appropriate when the compensations are inadequate or when they require excessive energy cost, joint strain, or muscle overuse (12,78,134). This concept may be illustrated by considering the child with Duchenne muscular dystrophy who is ambulatory. The primary functional deficit is weakness, particularly of the muscles about the trunk, hip, and knee. These children favor a toe-toe gait pattern (which, in this case, is a secondary, compensatory deviation), in order to utilize the plantar flexion–knee extension couple to maintain the ground reaction force in front of the knee, effectively substituting for the weak quadriceps during stance phase. Over time, the child will develop diminished ankle range of motion, with myostatic deformity of the gastrocnemius muscle group. Surgical treatment of the tight heel cord, while the child remains an independent ambulator, will restrict the child's ability to utilize this compensation and greatly limit the child's ability to ambulate independently. In this situation, the secondary deviation (i.e., the toe-toe gait pattern) should be accepted, until the underlying muscle weakness becomes so great that independent ambulation is no longer possible. At this point, correction of the equinus deformity, to facilitate bracing for possible orthotics- and assistive-device-augmented ambulation is appropriate.

Ankle

Excessive Ankle Plantar Flexion

The primary causes of excessive ankle plantar flexion in the stance phase include plantar flexor muscle spasticity, contracture, and impaired proprioception. Compensatory ankle plantar flexion is seen as a substitution pattern for weak quadriceps or for ankle or forefoot pain. Increased ankle plantar flexion in midstance and terminal stance, called "vaulting," may occur as a compensatory mechanism to facilitate swing clearance of a relatively long contralateral limb. The consequences of excessive plantar flexion in stance phase include diminished shock absorption by limiting knee flexion in the loading response subphase, and decreased forward progression of the tibia over the foot and ankle, which interferes with the heel and ankle rockers. The primary causes of excessive ankle plantar flexion in the swing phase include weakness or impaired selective control of the ankle dorsiflexors and plantar flexor spasticity or contracture. Excessive ankle plantar flexion during the swing phase interferes with foot clearance and foot positioning for initial contact.

Excessive ankle plantar flexion is clinically described as an "equinus gait," and is commonly seen in patients with cerebral palsy; muscle diseases, such as Duchenne muscular dystrophy; and posttraumatic conditions, such as anterior compartment nerve injury or compartment syndrome.

Excessive Ankle Dorsiflexion

The most common primary cause of excessive ankle dorsiflexion during the stance phase is weakness of the ankle plantar flexors. This is seen in conditions such as low lumbar-level myelodysplasia, and after overlengthening of the heel cord in children with cerebral palsy. This circumstance is clinically described as a "calcaneous gait." A common secondary cause of excessive ankle dorsiflexion in the stance phase is excessive knee flexion due to hamstring contracture or spasticity, as seen in cerebral palsy. Excessive ankle dorsiflexion may serve as a compensation for forefoot pain, and as a mechanism to shorten the step length of the opposite limb (101,122).

The consequences of excessive ankle dorsiflexion are significant in all of the subphases of stance. In the loading response and midstance subphases, exaggeration of the heel and ankle rockers increases the demand on the quadriceps (i.e., knee extensors) and diminishes limb stability. The crouch gait in cerebral palsy is a consequence of this deviation. In the terminal stance and preswing subphases, heel rise is compromised, which places the ankle plantarflexor muscles at a mechanical disadvantage with respect to power generation, and diminishes the step length of the opposite limb. This decreases the subsequent shock absorption demands of the loading response. Excessive ankle dorsiflexion during the swing phase is unusual, and interferes with the foot position for initial contact.

Knee

Inadequate Flexion/Excessive Extension

Primary inadequate flexion or excessive extension of the knee in the stance phase is usually caused by quadriceps spasticity or contracture. Hyperextension of the knee in stance phase, called "recurvatum gait," may be a primary consequence of overly aggressive medial and lateral distal hamstring lengthening in children with cerebral palsy. The most common secondary cause of these deviations is increased stance-phase ankle plantar flexion, which in the extreme, also causes knee hyperextension or recurvatum deformity by the plantar flexion–knee extension couple. Inadequate flexion or excessive extension of the knee in the stance phase may also reflect a compensatory deviation for knee or patellofemoral pain, or indicate a weakness of the quadriceps, classically seen in children with polio. The consequences of the deviation in the stance phase are decreased shock absorption ability, decreased forward progression of

the tibia, and potential injury to the posterior knee joint structures.

A common primary cause of inadequate flexion or excessive extension of the knee in the swing phase is quadriceps spasticity or contracture, as seen in the stiff knee gait pattern in children with cerebral palsy. Hip flexor weakness is a secondary cause of this deviation in swing phase (30). During the terminal-swing subphase, inadequate flexion or excessive extension of the knee may occur as a compensatory mechanism for knee pain or quadriceps weakness. The principal consequence of this deviation in initial and midswing subphases is impaired foot clearance. Suboptimal positioning of the limb for initial contact and loading response is the principal consequence of this deviation in terminal swing.

Excessive Flexion/Inadequate Extension

The primary causes of excessive flexion or inadequate extension of the knee in the stance phase include hamstring spasticity or contracture, as seen in cerebral palsy patients, and quadriceps weakness, as seen in patients with polio. The jump gait and crouch gait deviations seen in children with cerebral palsy are characterized by increased knee flexion in stance phase (30). Secondary causes are related to increased ankle dorsiflexion in the stance phase, usually a consequence of ankle plantar flexor weakness, as seen in low lumbar-level myelodysplasia, or after excessive lengthening of the heel cord in cerebral palsy patients. This deviation is rarely used as a compensatory mechanism, because it is energy-inefficient. The consequences of excessive flexion or inadequate extension of the knee in the stance phase are increased demands on the quadriceps, increased joint reaction forces at the knee and patellofemoral joint, diminished limb stability, and decreased step length of the contralateral limb.

The primary causes of excessive flexion or inadequate extension of the knee in the swing phase are hamstring spasticity or contracture and persistence of primitive locomotor reflex patterns (i.e., inability to extend the knee while flexing the hip), as seen in patients with cerebral palsy (101). Increased knee flexion in the initial and midswing subphases may be a compensatory mechanism to facilitate limb clearance in the face of ankle plantar flexion or diminished hip flexion, which, clinically, is termed a “steppage gait” pattern. Similarly, this deviation during terminal swing allows forefoot strike at initial contact, which would be a compensatory mechanism for a child with heel pain. The consequences of excessive flexion or inadequate extension of the knee in swing phase are diminished step length and impaired positioning of the foot for heel strike at initial contact.

Excessive Varus/Valgus

Primary (or true) excessive varus or valgus dynamic gait deviations are generally related to underlying coronal plane

skeletal malalignment. Common examples in pediatric orthopaedics include the stance-phase varus thrust seen in children with rickets and infantile tibia vara. A stance-phase valgus thrust may be seen with other metabolic bone disease (like renal osteodystrophy), longitudinal deficiency of the fibula (with associated lateral femoral condylar hypoplasia), and congenital or obligatory dislocation of the patella.

Secondary (or apparent) excessive varus or valgus dynamic gait deviations at the knee are a consequence of the combination of sagittal plane deviations and transverse plane malalignment or deviations. Increased knee flexion associated with external rotation (e.g., in compensation for internal tibial torsion, or dynamic at the pelvis or hip) will appear as varus on observational gait analysis. Increased knee flexion associated with internal rotation (e.g., as seen with femoral anteversion, or dynamic at the pelvis or hip) will appear as valgus. Quantitative gait analysis is often necessary to accurately characterize these deviations.

Hip

Inadequate Extension/Excessive Flexion

The primary causes of inadequate extension or excessive flexion of the hip in the stance phase include hip flexor spasticity or contracture, as seen in cerebral palsy patients; hamstring or hip extensor weakness, as seen in those with myelodysplasia; iliotibial band contracture, as seen in children with Duchenne muscular dystrophy; and hip joint pain. The most common secondary cause of this deviation in the stance phase is excessive ankle dorsiflexion, as seen in low lumbar-level myelodysplasia patients, and in the crouch gait pattern of patients with cerebral palsy.

The consequences of inadequate extension or excessive flexion of the hip in stance phase are related to the associated anterior pelvic tilt and the result of forward trunk lean. Children have the flexibility to compensate for this hip deformity by increasing their lumbar lordosis (101,122). This places increased strain across the lumbar spine over time. Incomplete compensation for forward trunk lean moves the ground reaction force anteriorly, increasing the external extension moment at the knee and dorsiflexion moment at the ankle.

The most common primary cause of this deviation in the swing phase is hip flexor spasticity or contracture. Compensatory increased hip flexion during the swing phase is used to facilitate limb clearance in the face of inappropriate ankle plantar flexion or knee extension. The main consequence of this deviation in swing phase is increased energy cost.

Excessive Adduction

The primary causes of excessive adduction of the hip during the stance phase are adductor muscle spasticity or

contracture and ipsilateral abductor muscle weakness. Secondary causes include contralateral hip abductor muscle contracture and scoliosis with pelvic obliquity. The consequences of this deviation in the stance phase are a decreased base of support in the coronal plane and diminished limb stability.

Excessive adduction of the hip is seen as a primary deviation in the swing phase caused by adductor muscle spasticity or contracture. A common secondary cause is limb-length inequality. A significantly short contralateral limb causes pelvic obliquity in the stance phase, effectively adducting the reference limb in swing phase. Compensatory hip adduction in the swing phase occurs when the hip adductors substitute for weak hip flexors to assist with limb clearance (101,122). The principal consequence of excessive hip adduction in swing phase is a relative increase in the limb length, which can cause problems with clearance. The scissor gait deviation, seen in children with cerebral palsy, may appear to be due to excessive hip adduction during swing phase. However, quantitative gait analysis has shown this deviation to most commonly be a consequence of increased hip flexion and internal rotation (because of increased femoral anteversion or dynamic rotational deviation).

A child who exhibits contralateral pelvic drop when asked to stand on one leg (a sign of ipsilateral hip abductor muscle weakness), is said to have a positive Trendelenburg sign. Contralateral pelvic drop during the stance phase of the reference limb is called a “Trendelenburg gait” or “uncompensated gluteus medius gait” pattern. A common compensation for this inefficient gait deviation is lateral trunk lean over the stance limb, which effectively moves the body’s center of mass closer to the stance-phase hip joint, and diminishes the demand on the gluteus medius muscle, the principal hip abductor. This deviation is called the “abductor lurch” or “compensated gluteus medius gait” pattern.

Excessive Abduction

The primary cause of excessive abduction of the hip during the stance phase is abductor muscle contracture. Secondary causes are limb-length inequality, in which the ipsilateral limb is significantly short, and scoliosis with pelvic obliquity. Excessive abduction of the hip in the stance phase may also be a compensatory mechanism for a relatively long limb. The consequences in the stance phase are to increase the base of support in the coronal plane, and to decrease the relative length of the stance limb.

The primary cause of excessive abduction of the hip in the swing phase is ipsilateral abductor muscle contracture. Compensatory excessive hip abduction in swing is seen as a substitution pattern for weak hip flexors (5,101,122). This deviation is also used, in combination with increased pelvic rotation and upward pelvic obliquity, as a means to clear a long limb (i.e., absolute length, or relatively long, due to inadequate knee flexion or ankle dorsiflexion). This complex deviation is called “circumduction.” The principal con-

sequence of excessive hip abduction in the swing phase is to decrease the functional length of the ipsilateral limb.

GAIT ANALYSIS

Observational Gait Analysis

A systematic method of observational gait analysis promotes a comprehensive assessment of gait deviations and functional deficits and avoids the common pitfall of focusing exclusively on the most striking component of a complex multilevel problem. The technique described has three phases: preparation, observation, and interpretation.

The preparation begins with determination or confirmation of the underlying diagnosis by taking a clinical history. It is essential to determine the principal gait problems as perceived by the child, the parents, and the referring physician or therapist. A physical examination should assess the active and passive range of motion of the hips, knees, ankles, and subtalar joints. A thorough neurologic evaluation should include muscle strength, selective control, spasticity (i.e., response to fast stretch), contracture (dynamic versus fixed or myostatic), presence or persistence of primitive mass reflexes, sensation, and proprioception.

The observation phase begins with a global assessment of the child’s gait, focusing on velocity, cadence, step length, stability, and effort. This is followed by serial horizontal analyses, beginning at the ankle and proceeding to the hip, of each anatomic area relative to the eight subphases of the gait cycle: initial contact, loading response, midstance, terminal stance, preswing, initial swing, midswing, and terminal swing. Analysis of one limb is completed at each joint before analysis of the opposite limb. Sagittal-plane analysis is performed from the right and left sides as the child walks by the observer. Coronal-plane analysis is performed with the child walking toward and away from the observer. The observations are entered, as they are made, on a standardized form (Fig. 5-17).

Interpretation begins with horizontal summation, by anatomic area, of the data collected. This approach can identify the gait deviations at each joint. Vertical summation of the data can identify the functional deficits with respect to gait tasks and the subphases of the gait cycle. A review of the gait deviations and functional deficits helps to determine the primary deviations, secondary deviations, and compensatory deviations. Appropriate interventions can be determined and implemented at this point.

Quantitative Gait Analysis

Technologic advances, many of which have occurred as spin-offs from the defense industry between the 1960s and 1990s, have greatly enhanced the ability to objectively quantify the movements associated with normal gait, and to catalogue common deviations associated with pathologic gait.

NAME _____ Side: Right / Left		Weight Acceptance		Single Limb Support			Swing Limb Advancement			Gait Deviations (By Anatomic Area)
Anatomic Area	Deviation	IC	LR	MSt	Tst	PSw	ISw	MSw	TSw	
ANKLE	↑ Dorsiflexion									
	Neutral									
	↑ Plantar Flexion									
	Varus									
	Valgus									
KNEE	↑ Flexion									
	Neutral									
	↑ Extension									
	Varus									
	Valgus									
HIP	↑ Flexion									
	Neutral									
	↑ Extension									
	Adduction									
	Abduction									
FUNCTIONAL DEFICITS (By Gait Tasks)										

FIGURE 5-17. Standardized form used when performing observational gait analysis. IC, initial contact; LR, loading response; MSt, midstance; Tst, terminal stance; PSw, preswing; ISw, initial swing; MSw, midswing; TSw, terminal swing. (From ref. 122, with permission.)

Quantitative gait analysis, as applied to pediatric orthopaedics, is performed in a motion analysis laboratory equipped to study children of all sizes. These laboratories perform analyses in several domains, depending on the nature of the child's gait deviations and the clinical questions being asked.

Kinematic analysis describes gait deviations by determining the magnitude and timing of limb segment motion with joint angles, velocities, and accelerations. Stride analysis may be considered as a subset of kinematic analysis, documenting parameters, such as velocity, cadence, step and stride lengths, and duration of the subphases of the gait cycle. Kinematic data are presented graphically as a waveform for a particular joint or limb segment in a particular plane or dimension.

Kinetic analysis explains gait deviations by determining the magnitude and location of the mechanical forces acting around the joints. Kinetic data are also presented graphi-

cally, and include both moment analysis, which describes the net internal or external forces acting around the joint, and power analysis, which in most situations correlates with the type of muscle activity (i.e., eccentric versus concentric) occurring about the joint.

Dynamic electromyography (EMG) assesses the timing and magnitude of skeletal muscle activity occurring during the gait cycle. Energetics evaluates the energy expenditure associated with walking, and determines the physiologic efficiency of gait.

Kinematic Analysis

Biomechanical analysis of limb movement in gait reduces the skeletal segments to rigid bodies moving through space, which are interconnected by frictionless joints. There are

two main types of automated video systems used to generate kinematic data (101,110). The first and most widely used technique consists of video cameras that generate digital data by tracking passive, retroreflective markers fixed to body landmarks based on surface anatomy. A central computer analyzes these data to determine the three-dimensional coordinates of each marker throughout the gait cycle. To generate accurate, reproducible data, all cameras must record data simultaneously, and the image space must be calibrated frequently. Each marker must be traced throughout the duration of the gait cycle by at least two cameras to enable three-dimensional calculations. When attempting to study both limbs simultaneously, five or six cameras are required.

This first technique has several limitations. First, it assumes that surface anatomy, which determines marker placement, is consistently related to the underlying osseous anatomy. It also considers the marker position to be stable throughout the gait cycle. The margin of error is acceptable when calculating limb-segment movement. However, more sophisticated kinetic analysis requires determination of the joint centers from the surface anatomy, which remains a controversial and less widely accepted practice. Current research is directed at validation and improvement of this technique. Second, the cameras require a minimum distance of 5 to 7 cm between markers for recognition (101,110). This can make it difficult to analyze small anatomic areas, such as the foot and ankle of a child. Third, any event that blocks the marker from the camera, such as a swinging hand, an assistive device, or the overlap of two markers in the camera field, causes the computer to lose track of the marker. This is called "marker dropout," and can only be corrected by manual sorting of the marker trajectories, which can be labor intensive. Sampling rates are generally limited to 50 to 60 images per second (2,8). This precludes the study of most athletic activities beyond running, like throwing, batting, and swinging a golf club.

The second type of automated video system uses active markers to designate anatomic sites. Each marker is a light-emitting diode that is activated sequentially by a central computer. A computer-controlled optical detector tracks the markers in a similar sequence. This technique facilitates data differentiation, and has fewer problems with marker spacing and dropout (101,110). Problems with this system include background reflections of the markers from the floor and walls, and electronic interference when simultaneously recording EMG during the gait cycle. As a result, this second technique is less widely used in clinical motion analysis laboratories.

Gait can be characterized by temporal and distance parameters. Velocity is the distance per unit time; cadence is the steps per unit time; stride length is the distance between two sequential initial contacts by the same limb; step length is the distance between the initial contact by each foot;

and single-limb stance time is the period during which the opposite limb is in the swing phase with no floor contact. Compensations for diminished velocity include increased cadence and, when possible, increased stride length (108,135). In children, changes in temporal and distance parameters with age are primarily a function of increasing limb length (101,131–133). Adults have a wide range of safe and comfortable walking velocities, influenced primarily by voluntary variability (136). Age has no significant effect until the person is older than 60 years of age (101).

Stride analysis can be performed by several techniques. The indirect method uses kinematic data. A single foot or ankle marker is tracked with respect to time and distance over a predetermined gait cycle sequence.

Direct techniques measure the foot contact with the floor. This is accomplished with a foot switch system, which consists of individual pressure sensors that are placed beneath the heel and the metatarsal heads (29,32,101, 110,137). Time and distance parameters can be determined directly from the activation patterns of the different sensors. Insertable insole pressure sensors enable analysis of more complex patterns of foot pressure distribution.

Kinetic Analysis

As the body advances forward over the stance-phase limb, a three-dimensional ground reaction force, which is equal in magnitude and opposite in direction to the force being experienced by the stance-phase limb, is generated (i.e., Newton's third law). The magnitude of the vertical, horizontal, and axial components of the ground reaction force can be determined by a force platform (101,107,110,123, 138,139). This device is a rigid plate mounted on four piezoelectric or strain gauge transducers. With each corner having a transducer sensitive to applied loads in three dimensions, the vertical force and horizontal shear forces (i.e., mediolateral and progression) can be measured directly. Summation of this data allows the examiner to calculate the center of pressure, which is the point on the foot about which the ground reaction force has zero moment, and to calculate its progression (101,110,139).

By combining the position of the ground reaction force with the position of the joint centers, which are derived from the kinematic data, the external joint moments can be calculated (107). These moments reflect the demands applied to the joints by body-segment position, gravity, and inertia. The external moments determine the requirements for the internal moments generated by the muscles and other soft tissue structures. Further kinetic analysis combines the position of the ground reaction force with the joint angular velocity, which is derived from the kinematic data, to determine joint powers (107).

To obtain accurate data, the child must walk across the force platform in a spontaneous, natural fashion. Deliber-

ately stepping onto the platform, an action called “targeting,” compromises the data collected, and is avoided by mounting the platform flush with the floor and camouflaging it with a thin “skin” that matches the rest of the floor. The foot of the reference limb must strike the platform completely, while the opposite foot remains clear. Children who use assistive devices, such as walkers or crutches, cannot be studied with a standard force platform, because only a portion of their body weight is supported by the stance-phase limb.

Dynamic Electromyography

EMG documents the electrical activity associated with skeletal muscle contraction on a visual record (29,101, 140–142). Dynamic EMG uses surface or internal electrodes to record these myoelectric potentials. Surface electrodes are pairs of metal pads that are placed directly on the skin overlying the muscle to be studied. They are easy to apply and cause no pain or discomfort. Unfortunately, they pick up signals from other muscles in the same area, which can interfere with the signal from the muscle being studied. This phenomenon is called “muscle cross talk” and limits the use of surface electrodes to superficial muscles, such as the gluteus maximus, or muscle groups, such as the medial or lateral hamstrings (110,143). Internal electrodes are 50-mm-diameter wires, which are introduced through the skin with a 27-gauge needle and embedded in the muscle belly. The principal advantage of the internal electrode is its ability to record the activity of a specific muscle without interference from surrounding muscles (137). It is ideal for studying deeper or smaller muscles, such as the iliopsoas or posterior tibialis (26,110). The disadvantages associated with the use of fine-wire electrodes include pain on insertion, difficulty of accurate placement, and wire movement with muscle contraction (110,142,144). Moreover, the temporal parameters of gait in children with cerebral palsy can change after insertion of fine-wire electrodes (145).

Controversies encumber the interpretation of EMG data, particularly with respect to the determination of muscle force. The raw EMG signal is quantified by computer-based digital sampling, rectification (i.e., transposition of the negative signals to the positive side of the graphic display to avoid the positive and negative signals cancelling each other out in subsequent data processing), and integration (i.e., summing of the digitized, rectified EMG signals over time) (101,110). The signal is then normalized to a selected reference value, usually that generated by a maximal-effort manual muscle test (106,144). Other investigators have noticed improved reproducibility when the selected reference value is the peak EMG activity generated by the muscle during a representative gait cycle (101,106). The former technique is difficult to apply in children with cerebral palsy who have

poor selective control. The latter technique fails to differentiate between weak and strong muscular activity (101).

The use of dynamic EMG to determine the timing of muscle activity is widely accepted, even though the determination of actual on and off is subjective, with the minimum significant signal arbitrarily defined as being greater than or equal to 5% of the maximal manual muscle test (137, 141–143). There is poor consensus concerning the relation of muscle force to the EMG signal, with linear and nonlinear correlations having been reported (34,106,101, 110). Potentially significant confounders include the type of muscle contraction (i.e., concentric versus eccentric versus isometric), the speed of the contraction, the joint position (i.e., affecting the resting muscle length and the muscle’s moment arm), and electromechanical delay (101). It is most accurate to consider dynamic EMG to be a measure of the timing of muscle activation, and not a direct measure of muscle force generation when attempting to relate the activity of a particular muscle to a particular gait deviation.

Energetics

Measurement of the energy required for walking provides a comprehensive parameter of gait performance and a means of quantifying the physiologic cost of various gait deviations (1,110,111,146–148). Total body calorimetry, which is a measurement of the body’s heat and work production, is the most accurate technique of energy use assessment, but is not clinically practical.

Indirect calorimetry assumes that anaerobic metabolism contributes little to energy production during steady-state ambulation at a self-determined walking velocity (111,136, 148). In this model, the energy needs of gait are completely met by the aerobic metabolism of inspired oxygen (O_2). The magnitude of O_2 consumed reflects the energy requirements for walking. Indirect calorimetry uses open spirometry to measure O_2 consumption (148).

While ambulating, the child inspires ambient air and expires air into a closed capture system. Analysis and comparison of the O_2 content of the ambient and expired air determines the child’s O_2 consumption over time. The O_2 consumption is reported as the O_2 rate, expressed in milliliters per kilogram minute, and is a reflection of the intensity of the effort required to ambulate (111,148).

When comparing gait patterns, the most valuable parameter is the O_2 cost, which is a measure of the physiologic efficiency of gait. In general, children are studied at their self-determined walking speed, which represents the most energy-efficient compromise between progression and stability. The O_2 cost is defined as the O_2 rate divided by the walking velocity, and is expressed as milliliters per kilogram meter. The O_2 cost describes the amount of energy needed to walk a standard distance (111,148). Children with cere-

bral palsy tend to have O_2 rates similar to healthy normal children, indicating a common range of energy used for walking (102,146,147). However, the self-selected walking velocity is significantly less for the children with cerebral palsy. As a result, their relatively energy-inefficient gait is best described by the O_2 cost, which is greater than the controls (146,147). Energetics analysis has traditionally been performed with a metabolic cart. The facemask worn by the child is directly connected to the cart, which is wheeled alongside the child as he or she walks. More recently, technologic advances have supported the development of a lightweight, telemetric device, which is easily carried by the child in a neoprene fanny pack (149). Such devices should have a less disruptive effect on the subject's gait. In addition, they should facilitate the collection of energetics data outside of the hospital setting, during more relevant community-based activities.

Given the cost and inconvenience of performing quantitative energetics analysis in children with disabilities, some investigators have attempted to utilize the heart rate as a substitute for O_2 rate. Based on a linear relationship between heart rate and O_2 rate, these investigators developed the physiologic cost index (PCI, walking minus resting heart rates, divided by walking velocity) as a measure of gait efficiency (146,147,150). Subsequent investigators have found increased intrasubject variability and poor correlation when comparing the PCI to O_2 cost (151).

Clinical and Research Applications

Although quantitative motion analysis has been practiced in pediatric orthopaedics for over 20 years, its role remains controversial (152). Improved technology has made data collection faster and more accurate. Improved processing has allowed clinical data to be available almost immediately after a study has been performed. Improved graphics have made data output formats more user-friendly. Clinical experience, with the application of quantitative motion analysis for children with cerebral palsy, has improved understanding of pathologic gait (e.g., the functional significance of skeletal malalignment) (1,12,19), resulted in the abandonment of certain procedures (e.g., aggressive adductor muscle release and anterior branch obturator neurectomy for apparent scissoring gait) (31,49,57,153), led to the development of other procedures to address previously poorly understood gait deviations (e.g., rectus femoris transfer and intrapelvic fractional lengthening of the psoas) (38, 45–47,55,56), and provided a rationale for the selection of certain procedures over others (e.g., performing muscle lengthenings at the myotendinous junction, instead of at the level of the tendon, in order to preserve power generation) (17,20,51,58,154).

The role of quantitative motion analysis in biomechanical and clinical research has been widely accepted. Teaching gait analysis techniques to a variety of health care profession-

als utilizing quantitative motion analysis data and principles, although not widely appreciated, has also proven to be very effective. Despite these benefits, widespread acceptance and use of quantitative motion analysis in preoperative decision-making by pediatric orthopaedists have not occurred. Critics argue that the application of quantitative motion analysis is too expensive, and that the testing circumstances (i.e., in the artificial setting of the motion laboratory) have little to do with day to day functional activities. Resistance to the application of this technology is due, in part, to the fact that the data are complex and requires significant experience to interpret. In addition, there are misconceptions about what the data can, and cannot, do. Quantitative motion analysis is a diagnostic tool that complements, but does not replace, clinical judgment. In the same way that technologic advances in dynamic functional assessment have changed the way clinical medicine is practiced in fields such as cardiology, so too should quantitative motion analysis improve the pediatric orthopaedist's ability to diagnose complex gait disorders, and to critically analyze the outcomes of various treatment options. Continued refinement of this technology in the research arena, and earlier exposure to the data in the literature and in residency training programs, should facilitate its ultimate acceptance by clinicians.

ACKNOWLEDGMENTS

The author wishes to recognize the contributions of David H. Sutherland, M.D., Jacqueline Perry, M.D., and James R. Gage, M.D., to the field of motion analysis, and to refer interested readers to ref. 1, 29, 101, and 132.

References

1. Gage JR. *Clinics in developmental medicine*, no. 121. Oxford: MacKeith, 1991.

Normal Gait

2. Hoffinger SA. Gait analysis in pediatric rehabilitation. *Phys Med Rehabil Clin North Am* 1991;2:817.
3. Inman VT, Ralston H, Todd F. *Human walking*. Baltimore: Williams & Wilkins, 1981.
4. Mann RA, Hagy JL, White V, et al. The initiation of gait. *J Bone Joint Surg Am* 1979;61:232.
5. Perry J. Mechanics of walking. *Phys Ther* 1967;47:778.
6. Saunders JBdeCM, Inman VT, Eberhart HD. The major determinants in normal and pathologic gait. *J Bone Joint Surg Am* 1953;35:543.
7. Steindler A. A historical review of the studies and investigations made in relation to human gait. *J Bone Joint Surg Am* 1953; 35:540.
8. Sutherland DH, Valencia FG. Pediatric gait. In: Drennan JC, ed. *The child's foot and ankle*. New York: Raven, 1992:19.
9. Muybridge E. *Complete human and animal locomotion*. New York: Dover, 1980.

10. Braune W, Fischer D. *The human gait*. Berlin: Springer-Verlag, 1987.
11. Gage JR. An overview of normal walking. *Instr Course Lect* 1990;39:291.
12. Gage JR. Gait analysis: an essential tool in the treatment of cerebral palsy. *Clin Orthop* 1993;288:126.
13. Abel MF, Damiano DL. Strategies for increasing walking speed in diplegic cerebral palsy. *J Pediatr Orthop* 1996;16:753.
14. Barto PS, Supinski RS, Skinner SR. Dynamic EMG findings in varus hindfoot deformity and spastic cerebral palsy. *Dev Med Child Neurol* 1984;26:88.
15. Damiano DL, Abel MF. Functional outcomes of strength training in spastic cerebral palsy. *Arch Phys Med Rehabil* 1998;79:119.
16. Davids JR, Bagley AM, Bryan M. Kinematic and kinetic analysis of running in children with cerebral palsy. *Dev Med Child Neurol* 1998;40:528.
17. Delp SL, Arnold AS, Speers RA, et al. Hamstrings and psoas lengths during normal and crouch gait: implications for muscle-tendon surgery. *J Orthop Res* 1996;14:144.
18. DeLuca PA. Gait analysis in the treatment of the ambulatory child with cerebral palsy. *Clin Orthop* 1991;264:65.
19. Gage JR, DeLuca PA, Renshaw TS. Gait analysis: principles and applications. Emphasis on its use in cerebral palsy. *J Bone Joint Surg Am* 1995;77:1607.
20. Gage JR. The clinical use of kinetics for evaluation of pathologic gait in cerebral palsy. *Instr Course Lect* 1995;44:507.
21. Hicks R, Durinick N, Gage JR. Differentiation of idiopathic toe-walking and cerebral palsy. *J Pediatr Orthop* 1988;8:160.
22. Kalen V, Adler N, Bleck EE. Electromyography of idiopathic toe walking. *J Pediatr Orthop* 1986;6:31.
23. Norlin R, Odenrick P. Development of gait in spastic children with cerebral palsy. *J Pediatr Orthop* 1986;6:674.
24. Perry J, Hoffer MM, Giovan P, et al. Gait analysis of the triceps surae in cerebral palsy. *J Bone Joint Surg Am* 1974;56:511.
25. Perry J, Antonelli D, Ford W. Analysis of knee-joint forces during flexed-knee stance. *J Bone Joint Surg Am* 1975;57: 961.
26. Perry J. Determinants of muscle function in the spastic lower extremity. *Clin Orthop* 1993;288:10.
27. Skinner SR, Lester DK. Gait electromyographic evaluation of the long-toe flexors in children with spastic cerebral palsy. *Clin Orthop* 1986;207:70.
28. Sutherland DH, Cooper L. The pathomechanics of progressive crouch gait in spastic diplegia. *Orthop Clin North Am* 1978;9:143.
29. Sutherland DH. *Gait disorders in childhood and adolescence*. Baltimore: Williams & Wilkins, 1984.
30. Sutherland DH, Davids JR. Common gait abnormalities of the knee in cerebral palsy. *Clin Orthop* 1993;288:139.
31. Tylkowski CM, Simon SR, Mansour JM. Internal rotation gait in spastic cerebral palsy. In: Nelson JP, ed. *The hip*. St. Louis: CV Mosby, 1982:89.
32. Wills CA, Hoffer MM, Perry J. A comparison of foot-switch and EMG analysis of varus deformities of the feet of children with cerebral palsy. *Dev Med Child Neurol* 1988;30:227.
33. Winters TF, Gage JR, Hicks R. Gait patterns in spastic hemiplegia. *J Bone Joint Surg Am* 1987;69:437.
34. Boscarino LE, Ounpuu S, Davis RB, et al. Effects of selective dorsal rhizotomy on gait in children with cerebral palsy. *J Pediatr Orthop* 1993;13:174.
35. Bowen TR, Miller F, Castagno P, et al. A method of dynamic foot-pressure measurement for the evaluation of pediatric orthopaedic foot deformities. *J Pediatr Orthop* 1998;18:789.
36. Brodke DS, Skinner SR, Lamoreux LW, et al. Effects of ankle-foot orthoses on the gait of children. *J Pediatr Orthop* 1989;9:702.
37. Cahan LD, Adams JM, Perry J, et al. Instrumented gait analysis after selective dorsal rhizotomy. *Dev Med Child Neurol* 1990;32:1037.
38. Chambers H, Laver A, Kaufman K, et al. Prediction of outcome after rectus femoris surgery in cerebral palsy: the role of cocontraction of the rectus femoris and vastus lateralis. *J Pediatr Orthop* 1998;18:703.
39. Corry IS, Cosgrove AP, Duffy CM, et al. Botulinum toxin A compared with stretching casts in the treatment of spastic equinus: a randomized prospective trial. *J Pediatr Orthop* 1998;18:304.
40. Cosgrove HP, Corry IS, Graham HK. Botulinum toxin in the management of the lower limb in cerebral palsy. *Dev Med Child Neurol* 1994;36:386.
41. DeLuca PA, Davis RB III, Ounpuu S, et al. Alterations in surgical decision making in patients with cerebral palsy based on three-dimensional gait analysis. *J Pediatr Orthop* 1997;17:608.
42. DeLuca PA, Ounpuu S, Davis RB, et al. Effect of hamstring and psoas lengthening on pelvic tilt in patients with spastic diplegic cerebral palsy. *J Pediatr Orthop* 1998;18:712.
43. Etnyre B, Chambers CS, Scarborough NH, et al. Preoperative and postoperative assessment of surgical intervention for equinus gait in children with cerebral palsy. *J Pediatr Orthop* 1993;13:24.
44. Hoffer MM. Ten year follow-up of split anterior tibial tendon transfer in cerebral palsied patients with spastic equinovarus deformity. *J Pediatr Orthop* 1985;5:432.
45. Miller F, Cardoso Dias R, Lipton GE, et al. The effect of rectus EMG patterns on the outcome of rectus femoris transfers. *J Pediatr Orthop* 1997;17:603.
46. Ounpuu S, Muik E, Davis RB, et al. Rectus femoris surgery in children with cerebral palsy. Part I: the effect of rectus femoris transfer location on knee motion. *J Pediatr Orthop* 1993;13:325.
47. Ounpuu S, Muik E, Davis RB, et al. Rectus femoris surgery in children with cerebral palsy. Part II: a comparison between the effect of transfer and release of the distal rectus femoris on knee motion. *J Pediatr Orthop* 1993;13:331.
48. Ounpuu S, Bell KJ, Davis RB III, et al. An evaluation of the posterior leaf spring orthosis using joint kinematics and kinetics. *J Pediatr Orthop* 1996;16:378.
49. Perry J, Hoffer MM, Antonelli D, et al. Electromyography before and after surgery for hip deformity in children with cerebral palsy. *J Bone Joint Surg Am* 1976;58:201.
50. Perry J, Hoffer MM. Preoperative and postoperative dynamic electromyography as an aid in planning tendon transfers in children with cerebral palsy. *J Bone Joint Surg Am* 1977;59:531.
51. Segal LS, Sienko TSE, Mazur JM, et al. Calcaneal gait in spastic diplegia after heelcord lengthening: a study with gait analysis. *J Pediatr Orthop* 1989;9:697.
52. Sienko TS, Aiona MD, Buckon CE, et al. Does gait continue to improve 2 years after selective dorsal rhizotomy? *J Pediatr Orthop* 1997;17:387.
53. Steffen RM, deSwart RJ, Dodgin DA, et al. Kinematic and kinetic analysis of distal derotational osteotomy of the leg in children with cerebral palsy. *J Pediatr Orthop* 1998;18:81.
54. Subramanian N, Vaughn CL, Peter JC, et al. Gait before and after rhizotomy in children with cerebral palsy spasticity. *J Neurosurg* 1998;88:1014.
55. Sutherland DH, Santi M, Abel MF. Treatment of stiff-knee gait in cerebral palsy: a comparison by gait analysis of distal rectus femoris transfer versus proximal rectus release. *J Pediatr Orthop* 1990;10:433.
56. Sutherland DH, Zilberfarb JL, Kaufman KR, et al. Psoas release

- at the pelvic brim in ambulatory patients with cerebral palsy: operative technique and functional outcome. *J Pediatr Orthop* 1997;17:563.
57. Thometz J, Simons S, Rosenthal R. The effect on gait of lengthening of the medial hamstrings in cerebral palsy. *J Bone Joint Surg Am* 1989;71:345.
 58. Yngve DA, Chambers C. Vulpius and Z-lengthening. *J Pediatr Orthop* 1996;16:759.
 59. Banta JV, Sutherland DH, Wyatt MP. Anterior tibial transfer to the os calcis with Achilles tenodesis for the calcaneal deformity in myelomeningocele. *J Pediatr Orthop* 1981;1:125.
 60. Cuddeford TJ, Freeling RP, Thomas SS, et al. Energy consumption in children with myelomeningocele: a comparison between reciprocating gait orthosis and hip-knee-ankle-foot orthosis ambulators. *Dev Med Child Neurol* 1997;39:239.
 61. Duffy CM, Hill AE, Cosgrove AP, et al. Three-dimensional gait analysis in spina bifida. *J Pediatr Orthop* 1996;16:786.
 62. Hullin MG, Robb JE, Loudon IR. Ankle-foot orthosis function in low-level myelomeningocele. *J Pediatr Orthop* 1992;12:518.
 63. Lim R, Dias L, Vankoski S, et al. Valgus knee stress in lumbosacral myelomeningocele: a gait-analysis evaluation. *J Pediatr Orthop* 1998;428.
 64. Thomson JD, Ounpuu S, Davis RB III, et al. The effects of ankle-foot orthoses on the ankle and knee in persons with myelomeningocele: an evaluation using three-dimensional gait analysis. *J Pediatr Orthop* 1998;18:27.
 65. Vankoski C, Moore C, Statler KD, et al. The influence of forearm crutches on pelvic and hip kinematics in children with myelomeningocele: don't throw away the crutches. *Dev Med Child Neurol* 1997;39:614.
 66. Hsu JD, Furumasa J. Gait and posture changes in the Duchenne muscular dystrophy child. *Clin Orthop* 1993;288:122.
 67. Sutherland DH, Olsen R, Cooper LB, et al. The pathomechanics of gait in Duchenne muscular dystrophy. *Dev Med Child Neurol* 1981;23:3.
 68. Asperheim MS, Moore C, Carroll NC, et al. Evaluation of residual clubfoot deformities using gait analysis. *J Pediatr Orthop* 1995;43:49.
 69. Davids JR, Meyer LC. Proximal tibiofibular bifurcation synostosis for the management of longitudinal deficiency of the tibia. *J Pediatr Orthop* 1998;18:110.
 70. Engsberg JR, Lee AG, Tedford KG, et al. Normative ground reaction force data for able-bodied and below-knee-amputee children during walking. *J Pediatr Orthop* 1993;13:169.
 71. Fowler E, Zernicke R, Setoguchi Y, et al. Energy expenditure during walking by children who have proximal femoral focal deficiency. *J Bone Joint Surg Am* 1996;78A:1857.
 72. Karol LA, Concha MC, Johnston CE II. Gait analysis and muscle strength in children with surgically treated clubfeet. *J Pediatr Orthop* 1997;17:790.
 73. Karol LA, Haideri NF, Halliday SE, et al. Gait analysis and muscle strength in children with congenital pseudarthrosis of the tibia: the effect of treatment. *J Pediatr Orthop* 1998;18:381.
 74. Kaufman KR, Miller LS, Sutherland DH. Gait asymmetry in patients with limb-length inequality. *J Pediatr Orthop* 1996;16:144.
 75. Lewallen R, Kyck G, Quanbury A, et al. Gait kinematics in below-knee child amputees: a force plate analysis. *J Pediatr Orthop* 1986;6:291.
 76. Liu XC, Fabry G, Molenaers G, et al. Kinematic and kinetic asymmetry in patients with leg-length discrepancy. *J Pediatr Orthop* 1998;18:187.
 77. Steenhoff JRM, Daanen HAM, Taminiav AHM. Functional analysis of patients who have had a modified Van Nes rotationplasty. *J Bone Joint Surg Am* 1993;75:1451.
 78. Andriacchi TP. Evaluation of surgical procedures and/or joint implants with gait analysis. *Instr Course Lect* 1990;39:343.
 79. Berman AT, Zarro VJ, Bosacco SJ, et al. Quantitative gait analysis after unilateral or bilateral total knee replacement. *J Bone Joint Surg Am* 1987;69:1340.
 80. Kroll MA, Otis JC, Sculco TP, et al. The relationship of stride characteristics to pain before and after total knee arthroplasty. *Clin Orthop* 1989;239:191.
 81. Long WT, Dorr LD, Healy B, et al. Functional recovery of noncemented total hip arthroplasty. *Clin Orthop* 1993;288:73.
 82. Prodromos C, Andriacchi T, Galante J. A relationship between gait and clinical changes following high tibial osteotomy. *J Bone Joint Surg Am* 1985;67:1188.
 83. Skinner HB. Pathokinesiology and total joint arthroplasty. *Clin Orthop* 1993;288:78.
 84. Waters RL, Barnes G, Huserl T, et al. Comparable energy expenditure following arthrodesis of the hip and ankle. *J Bone Joint Surg Am* 1988;70:1032.
 85. Andriacchi TP, Birac D. Functional testing in the anterior cruciate ligament-deficient knee. *Clin Orthop* 1993;288:40.
 86. Berchuck M, Andriacchi TP, Bach BR, et al. Gait adaptations by patients who have a deficient anterior cruciate ligament. *J Bone Joint Surg Am* 1990;72:871.
 87. Glousman R. Electromyographic analysis and its role in the athletic shoulder. *Clin Orthop* 1993;288:27.
 88. Limbird TJ, Shiavi R, Frazer M, et al. EMG profiles of knee joint musculature during walking: changes induced by anterior cruciate ligament deficiency. *J Orthop Res* 1988;6:630.
 89. Pink M, Jobe FW, Perry J, et al. The normal shoulder during the butterfly swim stroke: an electromyographic and cinematographic analysis of twelve muscles. *Clin Orthop* 1993;288:48.
 90. Pink M, Jobe FW, Perry J, et al. The painful shoulder during the butterfly stroke: an electromyographic and cinematographic analysis of twelve muscles. *Clin Orthop* 1993;288:60.
 91. Schwab GH, Moynes DR, Jobe FW, et al. Lower extremity electromyographic analysis of running gait. *Clin Orthop* 1983;176:166.
 92. Tibone JE, Antich TJ. Electromyographic analysis of the anterior cruciate ligament-deficient knee. *Clin Orthop* 1993;288:35.
 93. Kozin SH, Keenan MAE. Using dynamic electromyography to guide surgical treatment of the spastic upper extremity in the brain-injured patient. *Clin Orthop* 1993;288:109.
 94. Perry J, Waters RL, Perrin T. Electromyographic analysis of equinovarus following stroke. *Clin Orthop* 1978;131:47.
 95. Pinzur MS. Dynamic electromyography in functional surgery for upper limb spasticity. *Clin Orthop* 1993;288:118.
 96. Water RL, Yakura JS, Adkins RH. Gait performance after spinal cord injury. *Clin Orthop* 1993;288:87.
 97. Waters RL, Perry J, Antonelli D, et al. The energy cost of walking of amputees—influence of level of amputation. *J Bone Joint Surg Am* 1976;58:42.
 98. Waters RL, Garland DE, Perry J, et al. Stiff-legged gait in hemiplegia: surgical correction. *J Bone Joint Surg Am* 1979;61:927.
 99. Waters RL, Lunsford BR. Energy cost of paraplegic ambulation. *J Bone Joint Surg Am* 1985;67:1245.
 100. Waters RL, Campbell J, Perry J. Energy cost of three-point crutch ambulation in fracture patients. *J Orthop Trauma* 1987;1:170.
 101. Perry J. *Gait analysis: normal and pathologic function*. Thorofare, NJ: Slack, 1992.
 102. Waters RL, Hislop HJ, Thomas L, et al. Energy cost of walking in normal children and teenagers. *Dev Med Child Neurol* 1983;25:184.
 103. Grillner S. Neurobiological bases of rhythmic motor acts in vertebrates. *Science* 1985;228:143.

104. Joseph J. Neurological control of locomotion. *Dev Med Child Neurol* 1985;27:822.
105. Winter DA. Biomechanical motor patterns in normal walking. *J Motor Behav* 1983;15:302.
106. Winter DA. *The biomechanics and control of human gait*. Waterloo: University of Waterloo Press, 1987.
107. Ounpuu MS, Gage JR, Davis RB. Three-dimensional lower extremity joint kinetics in normal pediatric gait. *J Pediatr Orthop* 1991;11:341.
108. Winter DA. Kinematic and kinetic patterns in human gait: variability and compensating effects. *Human Movement Sci* 1984;3:51.
109. Ounpuu S. The biomechanics of running: a kinematic and kinetic analysis. *Instr Course Lect* 1990;39:305.
110. Sutherland DH, Kaufman KR. Motion analysis: lower extremity. In: Nickel VL, Borte MJ, eds. *Orthopaedic rehabilitation*. 2nd ed. New York: Churchill Livingstone, 1992:223.
111. Waters RL, Lunsford BR. Energy expenditure of normal and pathologic gait: application to orthotic prescription. In: Bunch WH, ed. *Atlas of orthotics*. St. Louis: CV Mosby, 1985:151.
112. Simon SR, Mann R, Hagy JL, et al. Role of the posterior of calf muscles in normal gait. *J Bone Joint Surg Am* 1978;60:465.
113. Skinner SR, Antonelli D, Perry J, Lester DK. Functional demands on the stance limb in walking. *Orthopaedics* 1985;8:355.
114. Sutherland DH. An electromyographic study of the plantar flexors of the ankle in normal walking on the level. *J Bone Joint Surg Am* 1966;48:66.
115. Sutherland DH, Cooper L, Daniel D. The role of ankle plantar flexors in normal walking. *J Bone Joint Surg Am* 1980;62:354.
116. Winter DA. Energy generation and absorption at the ankle and knee during fast, natural, and slow cadence. *Clin Orthop* 1983;175:147.
117. Lieber RL. *Skeletal muscle structure and function*. Baltimore: Williams & Wilkins, 1992.
118. Davis RB, DeLuca PA. Gait characterization via dynamic joint stiffness. *Gait Posture* 1996;4:224.

The Gait Cycle

119. Mann RA, Hagy J. Biomechanics of walking, running, and sprinting. *Am J Sports Med* 1980;8:345.
120. Katoh Y, Chao EYS, Laughman RK, et al. Biomechanical analysis of foot function during gait and clinical applications. *Clin Orthop* 1983;177:23.
121. Perry J. Anatomy and biomechanics of the hindfoot. *Clin Orthop* 1983;177:9.
122. Pathokinesiology Department, Physical Therapy Department. *Observational gait analysis handbook*. Downey: The Professional Staff Association of Rancho Los Amigos Medical Center, 1989.
123. Chao EY, Laughman RK, Schneider E, et al. Normative data of knee joint motion and ground reaction forces in adult level walking. *J Biomechanics* 1983;16:219.
124. Mansour JM, Audu ML. Passive elastic moment at the knee and its influence on human gait. *J Biomech* 1986;19:369.
125. Lyons K, Perry J, Gronley JK, et al. Timing and relative intensity of hip extensor and abductor muscle action during level and stair ambulation: an EMG study. *Phys Ther* 1983;63:1597.
126. Pare EB, Stern JT, Schwartz JM. Functional differentiation within the tensor fasciae latae. *J Bone Joint Surg Am* 1981;63:1457.
127. Novacheck TF. Walking, running, and sprinting: a three-dimensional analysis of kinematics and kinetics. *Instr Course Lect* 1995;44:497.

Maturation of Gait

128. Devivo DC. A clinical approach to neurologic disease. In: Rudolph A, Hoffman J, Rudolph C, eds. *Rudolph's pediatrics*. 20th ed. Norwalk: Appleton & Lange, 1996:1853.
129. Beck RJ, Andriacchi TP, Kuo KN, et al. Changes in the gait patterns of growing children. *J Bone Joint Surg* 1981;63:1452.
130. Statham L, Murray MP. Early walking patterns of normal children. *Clin Orthop* 1971;79:8.
131. Sutherland DH, Olsen R, Cooper L, et al. The development of mature gait. *J Bone Joint Surg Am* 1980;62:336.
132. Sutherland DH, Olsen RA, Biden EN, Wyatt MP. *The development of mature walking*. London: MacKeith, 1988.
133. Todd FN, Lamoreux LW, Skinner SR, et al. Variations in the gait of normal children. *J Bone Joint Surg Am* 1989;71:196.

Common Gait Deviations

134. Perry J. Pathologic gait. *Instr Course Lect* 1990;39:325.

Gait Analysis

135. Andriacchi TP, Ogle JA, Galante JO. Walking speed as a basis for normal and abnormal gait measurements. *J Biomech* 1977;10:261.
136. Waters RL, Lunsford BR, Perry J, et al. Energy-speed relation of walking: standard tables. *J Orthop Res* 1988;6:215.
137. Kadaba MP, Wooten ME, Gainey J. Repeatability of phasic muscle activity: performance of surface and intramuscular wire electrodes in gait analysis. *J Orthop Res* 1985;3:350.
138. Soames RW. Foot pressure patterns during gait. *J Biomed Eng* 1985;7:120.
139. Takegami Y. Wave pattern of ground reaction force of growing children. *J Pediatr Orthop* 1992;12:522.
140. Basmajian JV, DeLuca CJ. *Muscles alive: their functions revealed by electromyography*. 5th ed. Baltimore: Williams & Wilkins, 1985.
141. Shiavi R, Green N, McFadyen B, et al. Normative childhood EMG gait patterns. *J Orthop Res* 1987;5:283.
142. Wooten ME, Kadaba MP, Cochran GV. Dynamic electromyography. II. Normal patterns during gait. *J Orthop Res* 1990;8:259.
143. Perry J, Easterdays CS, Antonelli D. Surface versus intramuscular electrodes for electromyography of superficial and deep muscles. *Phys Ther* 1981;61:7.
144. Perry J, Ireland ML, Gronley J, et al. Predictive value of manual muscle testing and gait analysis in normal ankles by dynamic electromyography. *Foot Ankle* 1986;6:254.
145. Young CC, Rose SE, Biden EN, et al. The effect of surface and internal electrodes on the gait of children with cerebral palsy, spastic diplegic type. *J Orthop Res* 1989;7:732.
146. Butler P, Engelbrecht M, Major RE, et al. Physiological cost index of walking for normal children and its use as an indicator of physical handicap. *Dev Med Child Neurol* 1984;26:607.
147. Rose J, Gamble JG, Medeiros J, et al. Energy cost of walking in normal children and in those with cerebral palsy: comparison of heart rate and oxygen uptake. *J Pediatr Orthop* 1989;9:276.
148. Waters RL. Energy expenditure. In: Perry J, ed. *Gait analysis: normal and pathologic function*. Thorofare, NJ: Slack, 1992:443.
149. Corry IS, Duffy CM, Cosgrove AP, et al. Measurement of oxygen consumption in disabled children by the Cosmed K2 portable telemetry system. *Dev Med Child Neurol* 1996;38:585.
150. Rose J, Gamble JG, Lee J, et al. The energy expenditure index: a method to quantitate and compare walking energy expenditure for children and adolescents. *J Pediatr Orthop* 1991;11:571.
151. Bowen TR, Lennon N, Castagno P, et al. Variability of energy-

- consumption measures in children with cerebral palsy. *J Pediatr Orthop* 1998;18:738.
152. Morton R. New surgical interventions for cerebral palsy and the place of gait analysis. *Dev Med Child Neurol* 1999;41:424.
153. Scott AC, Chambers C, Cain TE. Adductor transfers in cerebral palsy: Long-term results studied by gait analysis. *J Pediatr Orthop* 1996;16:741.
154. Rose SA, DeLuca PA, Davis RB III, et al. Kinematic and kinetic evaluation of the ankle after lengthening of the gastrocnemius fascia in children with cerebral palsy. *J Pediatr Orthop* 1993;13:727.



6

GENETIC ASPECTS OF ORTHOPAEDIC CONDITIONS

WILLIAM G. COLE

MOLECULAR BASIS OF INHERITANCE 158

Chromosomes 158
Gene Structure 158
Transcription and RNA Processing 159
Translation 159
Posttranslational Modification and Protein Assembly 160

MOLECULAR BASIS OF MUTATIONS 160

Point Mutations 160
Deletions and Insertions 161
Detection of Mutations 161

CHROMOSOME DISORDERS 162

Abnormalities of Autosomal Chromosome Number 162
Abnormalities of Autosomal Chromosome Structure 162
Abnormalities of Sex Chromosomes 163

SINGLE-GENE DISORDERS 163

Autosomal Dominant Disorders 164
Autosomal Recessive Disorders 167

X-linked Disorders 168
Other Patterns of Single-gene Inheritance 169

MULTIFACTORIAL DISORDERS 171

TERATOLOGIC DISORDERS 171

Principles of Teratology 171
Teratogenic Agents 172

GENETIC COUNSELING AND PRENATAL DIAGNOSIS 173

Indications for Genetic Counseling 173
Diagnostic Precision 173
Estimation of Recurrence Risk 173
Burden of Genetic Diseases 173
Neonatal and Prenatal Diagnosis 174

TREATMENT OF GENETIC DISEASES 174

Many orthopaedic conditions are associated with genetic anomalies that produce congenital, developmental, metabolic, immunologic, and neoplastic disorders. Identification of the genes responsible for many of these conditions has resulted in more precise diagnoses and yielded insights into

the pathogenesis, classification, prognosis, and treatment of the disorders. Further advances are likely to influence the orthopaedic care of families with genetic disorders of the musculoskeletal system. This chapter summarizes the principles of genetics as they apply to orthopaedic conditions, and highlights the advances in knowledge in this field. The information provided, however, will need to be updated periodically, because genetic knowledge is rapidly advancing. The World Wide Web site <http://www3.ncbi.nlm.nih.gov:80/Omim/> provides easy access to chronological ac-

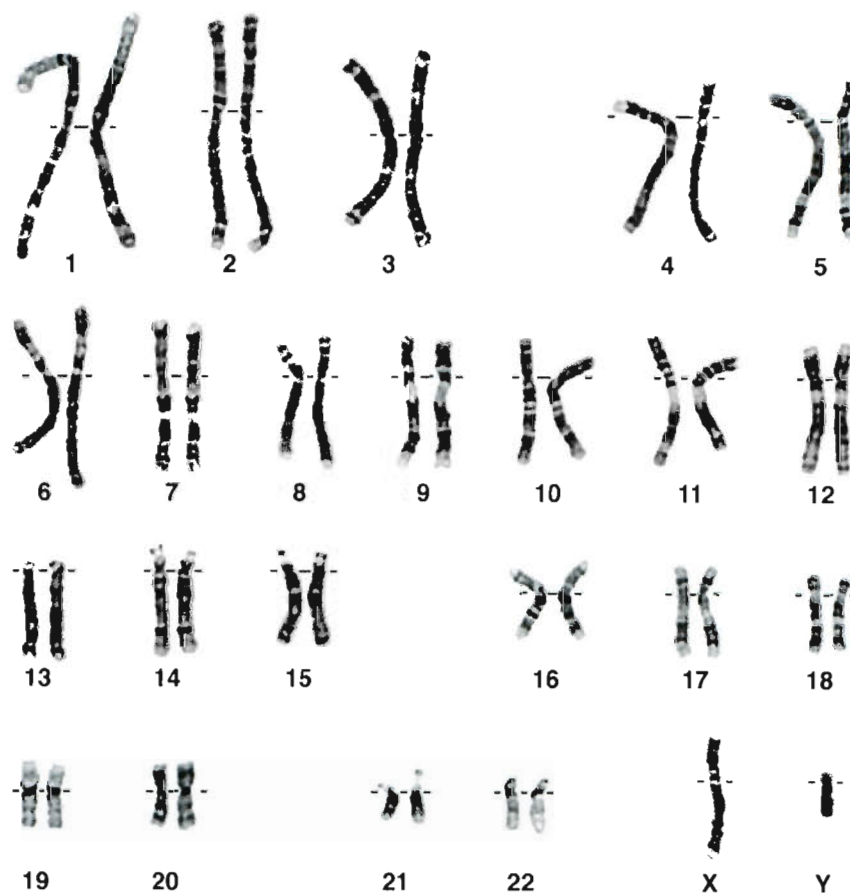


FIGURE 6-1. Normal 46,XY karyotype.

counts of advances in each genetic disorder, as well as access to specialized disease-related databases and other genetic information.

MOLECULAR BASIS OF INHERITANCE

Chromosomes

Chromosomes are rod-shaped organelles in the nucleus. The chromosomes contain genes, which are the DNA units of genetic information. They are linearly arranged along the chromosomes, and each gene occupies a particular position or locus.

The karyotype of a cell refers to its complement of chromosomes (1). Human somatic cells contain 23 pairs of chromosomes, referred to as euploidy (Fig. 6-1). Twenty-two of them are autosomes that occur in males and females. The remaining pair, the sex chromosomes, are designated XX in females and XY in males. The members of a pair of autosomes and a pair of X chromosomes contain matching genetic information.

During the metaphase of mitosis, the chromosomes consist of two chromatids joined at the centromere, which is the

primary constriction of the chromosome. The centromere divides the chromosome into the short p arm and the long q arm. Cytogenetic techniques divide the arms into banded regions that are used to indicate the sites of chromosomal rearrangements and the loci of genes. For example, the *COL1A1* gene for one of the type I collagen protein chains is located on chromosome 17 at locus q21.3-22. The latter notation indicates that the gene is located on the q arm of chromosome 17 at the band 21.3-22 (Fig. 6-2).

Somatic cells divide during growth, development, and repair by the process of mitosis. The daughter cells contain the identical genetic profiles of the parent cells. Germline cells undergo meiosis during gametogenesis. In this process, the diploid number of 46 chromosomes is reduced to the haploid number of 23, including one of each of the autosomes and either an X or a Y chromosome. The random assortment of each of the chromosome pairs during meiosis is central to the mendelian inheritance pattern of single-gene disorders and some forms of chromosomal rearrangements.

Gene Structure

About 100,000 genes are present in the human genome of about 7 billion base pairs of DNA. Genes are made up of

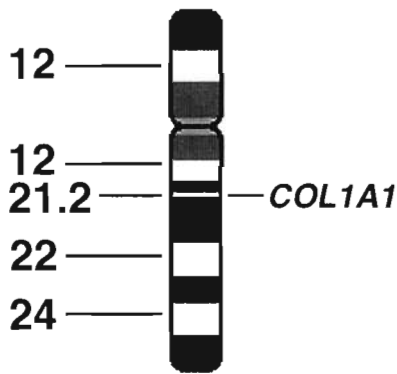


FIGURE 6-2. Diagram of chromosome 17 showing its banded structure and the location of the *COL1A1* gene encoding the pro- $\alpha 1(I)$ chain of type I collagen.

linearly aligned nucleotides. Each unit or nucleotide of DNA consists of a deoxyribose sugar, a purine or pyrimidine base, and a phosphate group. There are two purine bases, adenine (A) and guanine (G), and two pyrimidines, thymine (T) and cytosine (C). The nucleotides form long polynucleotide chains.

DNA forms a double-stranded structure, called the double helix, in which the component polynucleotide chains run in opposite directions and contain complementary sequences. Central to the Watson and Crick model of the DNA double helix are the complementary sequences of the chains, which are held together by hydrogen bonding between complementary pairs of nucleotide bases. An A of one chain pairs with a T of the other, and a G of one chain pairs with a C of the other.

A typical gene is illustrated in Figure 6-3. The coding sequence is divided into exons that are separated by noncoding introns or intervening sequences. The exons contain codons that encode specific amino acids. Each codon contains three nucleotides. Exons often delimit functional domains within the protein. The 5', or upstream, end of the gene contains promoter sequences that regulate the expres-

sion of the gene. The promoter immediately precedes the start site of transcription of messenger RNA (mRNA).

Transcription and RNA Processing

During transcription, an exact RNA copy of the gene, called pre-mRNA, is synthesized from the start site of transcription to the 3' untranslated region. The pre-mRNA undergoes several modifications to form mRNA, which is transported from the nucleus to the cytoplasm and ribosomes. After the introns are spliced out, the remaining exons form a continuous coding sequence. The coding region is flanked by a 5' untranslated region that contains sequences essential for ribosomal binding and translation. The 3' untranslated region contains sequences that are important for mRNA stability. The polyadenylation signal contains sequences that result in the addition of a polyA nucleotide tail, a polyadenosine sequence that characterizes most mRNAs.

Translation

Translation of the DNA code, copied by the mRNA to the amino acid code of the corresponding protein, is achieved on the ribosomes. The key to the genetic code is the codon, which is a group of three bases. Because each codon contains three of the four nucleotide bases, there are 64 possible triplet combinations. In humans, there are only 20 relevant amino acids, and most of them are encoded by more than one codon. Three of the codons are called stop or nonsense codons, because they designate the site of termination of translation.

The first codon of the coding sequence of mRNA encodes the amino acid methionine. This codon establishes the translational reading frame, ensuring that the correct amino acids are added sequentially to the growing polypeptide chain. Addition of the appropriate amino acids is achieved by specific transfer RNAs (tRNAs) for each amino acid. They contain the anticodon sequences that recognize the complementary codon sequences of the mRNA. As an amino acid is added to the carboxyl end of the polypeptide

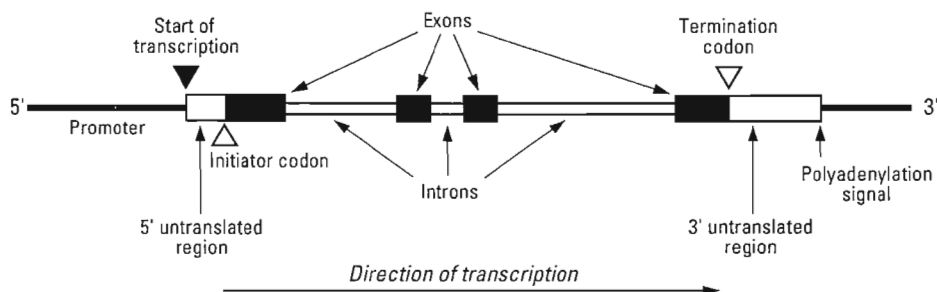


FIGURE 6-3. General structure of a typical human gene, showing the main functional domains. (From ref. 1, with permission.)

chain, the mRNA slides exactly one codon length along the ribosome, and brings the next codon into line for interaction with its specific tRNA. The proteins are synthesized from the amino terminus to the carboxyl terminus, which corresponds to translation of the mRNA from 5' to 3'. Translation ceases at the first stop codon. The completed polypeptide is released from the ribosome.

Posttranslational Modification and Protein Assembly

Many proteins undergo numerous posttranslational modifications in the rough endoplasmic reticulum, Golgi apparatus, and outside the cell. For example, the core proteins of collagen and glycosaminoglycans undergo extensive enzymatic modification. Many proteins are produced with terminal extensions that are removed to convert the preproproteins into functional proteins. The functional proteins are assembled into complex polymers.

MOLECULAR BASIS OF MUTATIONS

A mutation is any permanent change in the sequence or arrangement of DNA. It can occur in somatic cells, as observed in many cancers, but, when it occurs in germline cells, the mutation can be transmitted to subsequent generations. Permanent changes in DNA sequences are rarely deleterious, but add to the genetic diversity among individuals. Loci that have many alternative forms, called alleles, are polymorphic.

Mutations occur on various scales, from genome mutations that involve misaggregation of chromosomes, to chromosome mutations that involve chromosome rearrangements and specific gene mutations.

Point Mutations

Point mutations are the most common mutations. These nucleotide substitutions can result in several molecular outcomes (1):

- missense mutations that alter the amino acid sequence
- nonsense mutations that introduce a premature termination codon
- alteration of promotor sequences
- mRNA splicing mutations that result in exon loss

Although point mutations are often considered to occur randomly, there are mutational hot spots in the genome, commonly at CG dinucleotides, and mutations tend to recur at such sites. Transitions, which exchange one pyrimidine for the other or one purine for the other, are more common than transversions, which exchange a purine for a pyrimidine, or vice versa. Transitions and transversions are responsible for most of the mutations of the type I collagen genes in osteogenesis imperfecta and of the type II collagen gene in the spondyloepiphyseal dysplasias.

Advanced paternal age is a frequent factor in cases of sporadic point mutations, and is referred to as the paternal age effect on new mutations (2,3). It is common in achondroplasia. Germline mosaicism for the new mutation also occurs in achondroplasia and other skeletal dysplasias. It accounts for the birth of affected siblings from clinically normal parents (4). The paternal age effect and germline mosaicism are explained by differences in gametogenesis in males and females. Spermatogonia go through a few mitotic divisions before embarking on the meiotic divisions that lead to mature sperm (5). Some of the products of the mitotic divisions are returned to the "cell bank" to replenish the supply of spermatogonia. Mutations that occur during DNA replication can accumulate, providing a basis for the paternal age effect and for germline mosaicism.

Missense Mutations

A missense mutation occurs when a single nucleotide substitution alters the sense of a codon and a different amino acid is added to the elongating polypeptide. Mutations of this kind are common in many structural proteins, such as the collagens in osteogenesis imperfecta and in some of the chondrodysplasias.

Nonsense Mutations

Nonsense mutations occur when a single nucleotide substitution converts a codon for an amino acid to a termination codon. The introduction of a termination codon into the sequence results in the premature termination of translation and a truncated protein. Such proteins are rarely functional, because they lack the carboxyl-terminal domains that are usually required for the formation of the secondary and higher orders of protein structure. The mRNAs containing a premature translational termination codon are often retained within the nucleus. Because the mutant allele is essentially functionless, it produces a state of haploid insufficiency. This type of mutation produces the common mild form of osteogenesis imperfecta.

Promotor Mutations

Point mutations within the promotor may alter the transcription of the gene. They have been identified in the β -globin gene and in the factor IX gene in hemophilia B. Few other mutations of this type have been identified in humans.

Mutations of the 3' untranslated region may result in altered transcription or instability of mRNA, reducing the production of the relevant protein. Such mutations have been identified in the β -globin gene, but not in the genes that produce musculoskeletal diseases.

mRNA Splicing Mutations

Mutations of mRNA splicing are common in large genes that contain numerous exons and introns. Commonly, the

point mutations occur in the consensus sequences at the exon–intron boundaries. The adjoining exon is usually spliced out, resulting in a shortened protein chain. If the exon normally starts and finishes with complete codons, the normal translational reading frame is retained, and the amino acid sequence is normal beyond the spliced-out exon. The resulting protein functions abnormally, because it is shorter than normal, and because it lacks the functional domain encoded by the lost exon. If the exon contains split codons at its ends, the translational reading frame beyond the spliced-out exon is abnormal and the amino acid sequence is incorrect. A frequently encountered premature translational termination codon results in the synthesis of a truncated protein.

Abnormal splicing can also occur because of point mutations that create a new or cryptic splice site. The consequences of such mutations are often complex, because splicing may remove part of an exon and include intron sequences. Lethal forms of osteogenesis imperfecta and spondyloepiphyseal dysplasia frequently result from such mutations of the type I and type II collagen genes, respectively.

Deletions and Insertions

Small and large deletions and insertions produce major changes in gene structure and in the transcript. These genetic variations result from several types of molecular alterations:

- frameshift mutations caused by incomplete codon gain or loss
- complete codon deletions or insertions
- gene deletions and duplications
- insertion of duplicated elements

A protein of abnormal length and sequence may be produced. The protein may be partially functional, as observed with the shortened forms of dystrophin produced by deletions in the *DMD* gene in patients with the Becker form of muscular dystrophy (6).

Detection of Mutations

Genetic mutations are identified by specifying the locus that is the cause of the disease, and defining the range of mutations in the disease.

Identification of the disease locus involves several approaches. In some diseases, candidate genes are selected and tested for their association with the disease. For example, the type I collagen genes were the candidate genes in osteogenesis imperfecta, because the type I collagen is found in all of the major tissues affected by the disease, and because protein anomalies were directly identified in these tissues. The candidate gene can be directly studied for mutations in affected individuals. Alternatively, linkage analysis is used

to determine whether genetic markers or polymorphisms in, or flanking, the candidate gene are coinherited with the disease phenotype in families.

Knowledge concerning the disease locus is often lacking, and a list of candidate genes cannot be prepared. The chromosome, and region of the chromosome containing the disease gene, may be revealed by cytogenetic analysis. Translocations may disrupt a gene, producing the disease, and a microdeletion may indicate loss of contiguous genes. Linkage and gene-mapping studies can then focus on these regions. Similar conditions in the mouse or other species in which the disease locus has been determined can be used as a guide for analysis of the corresponding part of the human genome. However, no leads may be forthcoming, necessitating a general genome search to identify the disease gene.

The general genome studies rely on access to families, preferably of at least three generations, in which the members have been carefully evaluated for the disease. Blood is collected from each member. DNA is extracted for analysis of polymorphic DNA markers, which are distributed throughout the genome, particularly in regions containing the highest concentrations of genes. Linkage of a DNA marker to a disease locus is a statistical exercise. After a linked gene marker has been identified, additional studies are required to identify the disease locus. Candidate genes are sought in the region. Such an approach was used successfully to identify the Marfan locus, which was at the same site as the fibrillin-1 gene (7). A similar approach successfully identified the fibroblast growth factor receptor 3 (*FGFR3*) gene as the achondroplasia locus (8). However, there may not be any candidate genes known in the region of the genome linked to the disease phenotype. This problem is rapidly being overcome by the identification of known and unknown genes in the DNA sequences being generated from the Human Genome Project. Consequently, the most important aspect of mutational analysis is to identify the region of the genome containing the disease gene of interest.

Mutations can be identified in the disease gene or in its products. Protein analysis may be used to verify that an individual is affected, but it is infrequently used to define the abnormal amino acid sequence, because that is more easily deduced from the abnormal DNA sequence. A popular method of identifying mutations is to prepare mRNA from cells that express the gene. The mRNA, with its compact protein-coding sequence, is converted to complementary DNA (cDNA). The cDNA is amplified millions of times by the polymerase chain reaction (PCR), which is one of the most widely used techniques in molecular biology. The amplified PCR products are screened for mutations, such that only a portion of the cDNA needs to be sequenced.

If mRNA and cDNA are not available, genomic DNA is used for mutational analysis. It is much more difficult to localize the mutation with genomic DNA, because genes contain more noncoding than coding sequences. However,

PCR is used to amplify all exons and exon–intron boundaries for mutational screening, and for DNA sequencing of abnormal fragments.

Coinheritance of the putative gene mutation and the disease phenotype provides indirect evidence that the mutation gives rise to the disease. Direct evidence of disease causation is sought using cells that express the disease gene, such as skin fibroblasts in patients with Marfan syndrome or osteogenesis imperfecta. If the cells that normally express the disease gene, e.g., chondrocytes or osteoblasts, are not available, then the disease genes can be transfected into other types of cells. An alternative means of establishing the importance of the disease gene is to produce mice bearing a mutant disease gene (transgenic mice) or mice lacking the disease gene (knock-out mice).

CHROMOSOME DISORDERS

Chromosome disorders are more frequent than all of the single-gene disorders together (9). They occur in about 0.7% of live births, in 2% of all pregnancies of women older than 35 years of age, and in 50% of all spontaneous first-trimester abortions. They are being recognized with increasing frequency because of improvements in cytogenetic techniques. Chromosome abnormalities of number or structure can involve autosomes or sex chromosomes.

Abnormalities of Autosomal Chromosome Number

Incidence

An abnormal chromosome number, called aneuploidy, occurs in about 4% of pregnancies. Most aneuploid patients are trisomic; they have three, instead of the normal pair, of a particular chromosome. Monosomy, which is the loss of one member of a pair, occurs less commonly. The most common trisomies of an entire autosome compatible with postnatal survival are trisomy 21 (i.e., Down syndrome), trisomy 18, and trisomy 13. They all produce growth retardation, mental retardation, and multiple congenital anomalies. It is likely that the additional dosage of the specific genes on the extra chromosome is responsible for the abnormal phenotype (10).

Down Syndrome

About 1 child in 800 is born with Down syndrome, and the frequency is higher among pregnancies of mothers older than 35 years.

The specific karyotype has little effect on the phenotype, but is important for counseling. In 95% of patients, trisomy 21 results from meiotic nondisjunction of the chromosome

21 pair (Fig. 6-4). The recurrence risk increases with maternal age, particularly in women older than 30 years of age. Nondisjunction usually occurs during maternal meiosis I, and occasionally during paternal meiosis I. The cause of nondisjunction is uncertain.

About 4% of patients have 46 chromosomes, one of which is a translocation between chromosome 21q and the long arm of chromosome 14 or 22. The resulting karyotype for a robertsonian translocation between chromosome 14 and 21 is 46,XX or XY, –14, +t(14q21q), with a loss of chromosome 14, designated –14, and a new hybrid 14q21q chromosome, designated +t(14q21q). This karyotype produces a trisomy 21 state. The translocation forms of Down syndrome are not related to maternal age, but there is a high recurrence risk, particularly when the mother is a carrier of the translocation. A carrier involving chromosomes 14 and 21 has only 45 chromosomes, because one of each of these chromosomes is missing, and is replaced by the translocation chromosome t(14q21q). Down syndrome is produced when the fetus inherits a normal chromosome 21 from one parent and an unbalanced complement of chromosomes, including a normal chromosome 21 and the translocation chromosome, from the other parent. The unbalanced chromosome complement appears in 15% of the progeny of carrier mothers, which is less than the expected proportion, and it rarely appears in the progeny of carrier fathers.

Rarely, Down syndrome is produced by the inheritance of a translocation chromosome t(21q21q), made up of two chromosome 21 long arms from one parent and a normal chromosome 21 from the other parent. Carriers of this translocation chromosome usually only have children with Down syndrome.

About 1% of cases of Down syndrome are mosaic for the trisomy state. There is wide variability in the severity of the phenotype, probably because of the variable proportion of trisomic and euploid cells. Germline mosaicism may account for the higher-than-expected recurrence risk in young mothers.

Abnormalities of Autosomal Chromosome Structure

Structural anomalies occur less frequently than anomalies of chromosome number. They are balanced if the chromosome set has the normal complement of DNA, or unbalanced if there is additional or missing DNA.

Unbalanced rearrangements alter the amount of genetic information, and commonly produce abnormal phenotypes. Duplication of part of a chromosome produces a partial trisomy, and deletion leads to a partial monosomy. Increasingly, small deletions and insertions are detected by cytogenetic techniques. The phenotypes of some of the deletion syndromes can be readily explained by the loss of contiguous genes. For example, in the Langer-Giedion syn-

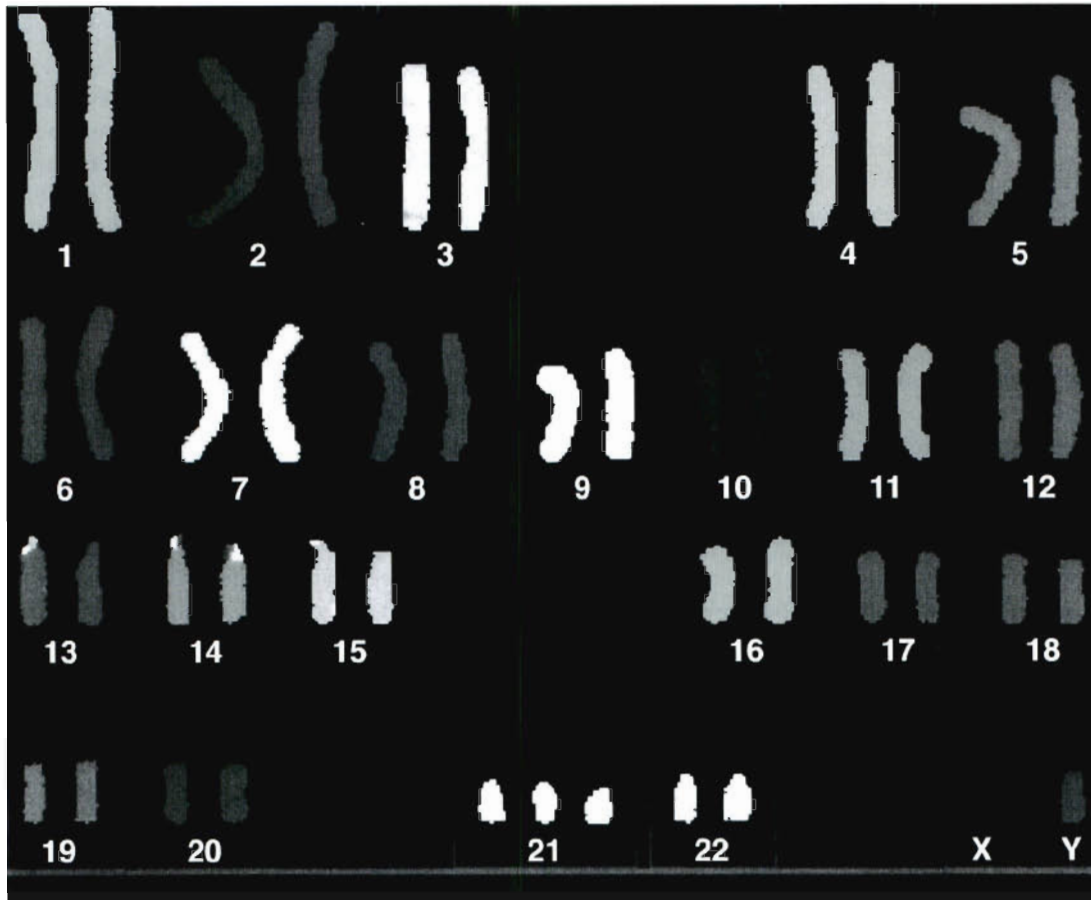


FIGURE 6-4. Karyotype in Down syndrome attributable to meiotic nondisjunction of the chromosome 21 pair. There are three copies of chromosome 21.

drome, deletion of chromosome 8q24.11–q24.13 produces mental retardation, dysmorphism, and osteochondromas. The osteochondromas occur because the deletion includes the *EXT1* locus, which is abnormal in some patients with autosomal dominant multiple exostoses.

Balanced rearrangements do not usually have a phenotypic effect, because all of the genetic information is present, although it is arranged differently. Occasionally, such rearrangements do disrupt a gene at the site of chromosome break. Balanced rearrangements increase the risk of unbalanced rearrangements in progeny.

Abnormalities of Sex Chromosomes

Sex chromosome aneuploidy produces syndromes that are associated with abnormally tall and short statures. The 47,XXY chromosome constitution, called Klinefelter syndrome, and the 47,XYY constitution produce abnormally tall stature in males. Trisomy X (47,XXX) is the female counterpart of Klinefelter syndrome, producing tall stature, and 45,X and its variants (e.g., Turner syndrome) are associated with short stature.

SINGLE-GENE DISORDERS

In contrast to the chromosomal disorders, single-gene defects are not detectable by current cytogenetic methods. Single-gene defects alter one or both copies of a gene. Alternative forms of a gene are called alleles. Many genes have only one allele, and others have many alleles that contain nonpathologic changes of DNA sequence. These loci are polymorphic. Mutant alleles contain changes in DNA sequence that can produce single-gene disorders.

The genetic constitution at one or more loci is the genotype. The detectable expression of the genotype is called the phenotype. Single-gene disorders are produced by a specific allele at a single locus of one or both members of a chromosome pair. If the alleles are identical, the individual is homozygous for that trait; if they are dissimilar, the individual is heterozygous; and if they have two different mutant alleles, the individual is a compound heterozygote. Males are hemizygous for X-linked genes, because they only have one X chromosome.

Patterns of transmission of single-gene defects are determined by pedigree analysis. They may involve genes on

autosomes (i.e., autosomal inheritance) or genes on the X chromosome (i.e., X-linked inheritance) (11). The phenotypes are dominant if the disease is expressed when only one chromosome carries a mutant allele, and recessive if both chromosomes need to carry the mutant allele. For many genetic diseases, there is little detailed knowledge of the critical factors that link the genotype and the phenotype. Many other genetic and environmental factors modify the expression of the genotype; some affected individuals show minimal or no clinical anomalies, but others show severe changes.

“Penetrance” is the probability that a gene defect will have any phenotypic expression at all. In pedigrees, particularly autosomal dominant pedigrees, some affected individuals fail to express the genotype. The penetrance of a gene can be defined as the proportion of individuals with the appropriate genotype who express it.

Variable expressivity refers to different severities of the phenotype among individuals who have the same genotype. Many autosomal dominant disorders show variable expressivity. For example, patients with Marfan syndrome may have few or all of the classic features of the condition.

Another form of variable expressivity is called anticipation, which refers to the apparent worsening of the disease in successive generations. This is a feature of pedigrees of myotonic dystrophy, Huntington disease, and fragile X mental retardation, and it is caused by variable and unstable expansions of DNA. Myotonic dystrophy, for example, is caused by the unstable expansion of a CTG trinucleotide repeat located in the 3′ untranslated region of a gene on chromosome 19 that encodes a protein kinase (12).

Variable expressivity can also be a function of the age of onset of the phenotype. Some single-gene disorders, such as achondroplasia, are evident at birth, and are therefore congenital. Others, such as pseudoachondroplasia, are not apparent at birth, but become so after the patient is 2 to 3 years of age, when growth retardation and dysmorphism appear.

Many single-gene defects give rise to the diverse phenotypic effects referred to as pleiotropy. For many diseases, there is no obvious causative link between their diverse manifestations. It is likely, however, that links will be established as more knowledge is obtained about the molecular pathology of the single-gene disorders. For example, the pleiotropic musculoskeletal, ocular, and cardiovascular manifestations of Marfan syndrome are causally linked by fibrillin-1, the microfibrillar protein at fault in this syndrome, which is distributed throughout all of the affected tissues (7).

In contrast to the considerable heterogeneity that exists in the phenotypic expression within and between the single-gene disorders, the underlying molecular changes in their mutant loci are similar, reflecting the limited number of ways in which a single gene can be altered.

Autosomal Dominant Disorders

About half of the known single-gene defects are autosomal dominant traits. Affected individuals are heterozygous for the mutation; they have one normal and one mutant allele of the gene. However, the product of the normal allele is unable to compensate for the abnormality produced by the mutant allele. Matings of two heterozygous individuals can produce homozygous autosomal dominant traits. The homozygotes are usually much more severely affected, often with perinatal death, than heterozygotes.

Many autosomal dominant disorders have major musculoskeletal anomalies. They include many of the chondrodysplasias, osteogenesis imperfecta, Marfan syndrome, Ehlers-Danlos syndrome, acrocephalosyndactyly syndromes, absent tibial syndromes, Charcot-Marie-Tooth disease types IA and IB, and neurofibromatosis 1.

In typical families, the autosomal dominant trait is transmitted from generation to generation by affected individuals who transmit the mutant gene to about half of their offspring (Fig. 6-5). Males and females are equally affected, and unaffected individuals do not carry or transmit the mutant gene. Typical multigeneration autosomal dominant pedigrees (Fig. 6-5) are common in families with neurofibromatosis, osteogenesis imperfecta type I, and Marfan syndrome. However, there is wide variability of penetrance and expression of the genotype in such families. For example, in families with the common type I form of osteogenesis imperfecta, some members have gray-blue scleras and severe osteoporosis with multiple fractures, whereas others have gray-blue scleras, a characteristic feature of the disease, without clinical evidence of bone fragility. Similar variability is observed in families with neurofibromatosis 1 and Marfan syndrome, when the clinical manifestations are correlated with the inheritance of the mutant allele. Many of the individuals shown to carry the mutant allele lack the major

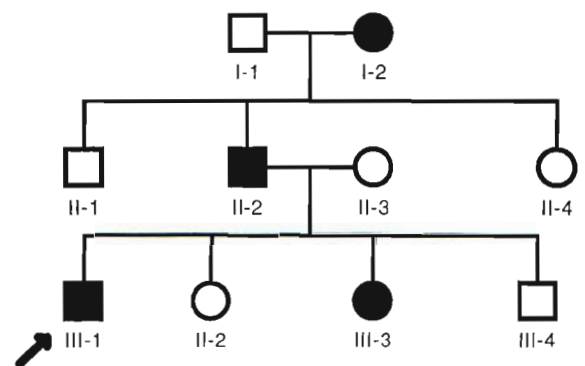


FIGURE 6-5. Typical autosomal dominant pedigree. Each individual is identified by a generation number and the position within each generation. Males are indicated by squares and females by circles. Filled symbols indicate clinically affected individuals. The proband (arrow) is the family member through whom the family history was ascertained.

clinical features required for a firm clinical diagnosis, and are unaware that they have the disease. The latter observation applies particularly to young people, who are likely to develop more obvious features with age.

Atypical autosomal dominant pedigrees occur with new dominant mutations. About half of the individuals with osteogenesis imperfecta or Marfan syndrome, and most individuals with achondroplasia, have new autosomal dominant mutations. The mutation occurs in the ovum, or in the sperm involved in the formation of the fertilized ovum, for the first affected individual in the family. New dominant mutations are often associated with increased paternal age, presumably as a result of an increased level of mutagenesis during spermatogenesis in older men. The affected individuals transmit the trait to half of their offspring, which is typical of an autosomal dominant inheritance pattern.

Some families with osteogenesis imperfecta and Marfan syndrome show an apparently autosomal recessive form of inheritance, with clinically normal parents and multiple affected offspring. In most instances, genetic testing has shown that one parent is mosaic for the dominant mutation, and transmits the trait to multiple children. Presumably, a spontaneous mutation occurs early in the embryogenesis of the mosaic parent, and some of the somatic cells and gametes carry the mutation. Mosaic parents may show some minor clinical features of the disease. Genetic testing of dermal fibroblasts, hair follicles, and leukocytes reveals the proportion of cells carrying the mutant allele. The sperm can be similarly tested. Rapid progress is being made in identifying mutant genes in autosomal dominant disorders that produce musculoskeletal anomalies. Several disorders illustrate important principles, and are discussed in the following sections.

Osteogenesis Imperfecta

Many of the principal features of autosomal dominant diseases are illustrated by recent findings in osteogenesis imperfecta. The majority of cases are inherited as autosomal dominant traits, or occur from new autosomal dominant mutations. The mutations usually involve one of the two genes that encode the chains of type I collagen, the principal collagen of the tissues affected by the disease. The *COL1A1* gene on chromosome 17 encodes the pro- $\alpha 1(I)$ chain, and the *COL1A2* gene on chromosome 7 encodes the pro- $\alpha 2(I)$ chain. Each type I collagen molecule contains two $\alpha 1(I)$ chains and one $\alpha 2(I)$ chain.

Although osteogenesis imperfecta is clinically and genetically heterogeneous, the genetic patterns are relatively simple (13,14). The common type IA form, with gray-blue scleras, osteoporosis, mild bone fragility, normal teeth, ligament laxity, and premature deafness, is caused by mutations of the *COL1A1* gene, in which the mutant allele is functionless. The mutant allele usually produces an mRNA containing a premature stop codon that would be expected to pro-

duce a truncated and functionless $\alpha 1(I)$ collagen chain. However, the nucleus retains most of the mutant mRNA, and the cytoplasm contains predominantly normal $\alpha 1(I)$ mRNA, although in half of the normal amounts. The type I collagen produced by the osteogenesis imperfecta type IA cells is normal, but the amount produced is about half of the normal amount. Each family has been shown to have its own private mutation, leading to premature stop codons at different sites of the mRNA. Despite this genetic heterogeneity, there is a final common pathway of type I collagen deficiency that accounts for this type of osteogenesis imperfecta. Nonetheless, because the severity of the disease varies between and within families, it is likely that modifying genes and epigenetic factors also play a role in the pathogenesis of the disease.

The more severe forms of osteogenesis imperfecta are usually caused by autosomal dominant mutations of the *COL1A1* or *COL1A2* gene, which result in the production of a mixture of normal and mutant collagen chains and type I collagen molecules. A registry of type I collagen mutations is available at <http://www.le.ac.uk/genetics/collagen/>. The most common mutation involves the substitution of a glycine residue in one of the 338 glycine-X-Y triplets, the mandatory repetitive triplet sequence required for triple helix formation. Proline is often in the X position and hydroxyproline in the Y position of the triplets. Abnormal helix formation occurs after substitution of glycine, the smallest amino acid, with the larger amino acids, alanine, valine, cysteine, arginine, aspartic acid, and glutamic acid. Collagen α chains carrying these substitutions are able to combine with normal chains to produce type I collagen molecules. In cases of *COL1A1* mutations, half of the $\alpha 1(I)$ chains are expected to be mutant and half are expected to be normal. Because type I collagen molecules contain two $\alpha 1(I)$ chains, it is expected that about 25% of the molecules will be normal and 75% will contain one or two mutant $\alpha 1(I)$ chains. The particular $\alpha 1(I)$ chain composition of the type I collagen molecules enhances the impact of the heterozygous *COL1A1* mutation.

Similarly, with *COL1A2* mutations, about half of the $\alpha 2(I)$ chains will be normal and half will be mutant. Because type I collagen molecules contain only one $\alpha 2(I)$ chain, about half of the molecules will be normal and half will contain the mutant $\alpha 2(I)$ chain. The mutant molecules, whether containing the mutant $\alpha 1(I)$ or $\alpha 2(I)$ chain, are more susceptible to degradation and are poorly secreted. Once secreted, they interfere with the formation of the extracellular matrix of bone and other type I collagen-containing tissues. These mutations act in a dominant-negative fashion, because the mutant collagen chains impair the function of the normal α chains.

Most affected families also have their own private mutations, as shown for the perinatal lethal forms of osteogenesis. There are a few examples of unrelated families with the same mutation. Variability in the severity of the disease has

also been observed in such families, indicating that modifying genes and epigenetic factors contribute to the pathogenesis of the dominant negative forms of osteogenesis imperfecta.

Little is known about the factors that are important in determining the clinical severity of the disease resulting from dominant negative mutations of the type I collagen genes. However, most of the perinatal lethal cases result from mutations that involve the carboxyl-terminal half of the collagen chains. Substitutions of glycine by cysteine yield a gradient of severity, with lethal cases at the carboxyl terminus, moderately severe cases in the middle, and milder cases at the amino terminus of the α chains.

Mosaic cases giving rise to an apparently autosomal recessive form of inheritance are common. As a result, the empiric risk of recurrence in a family with a sporadic form of osteogenesis imperfecta is about 6%. The risk can be better assessed by genetic testing of the parents, but it is still only a rough estimate, because the proportion of affected gametes is usually unknown. Intrauterine DNA testing for osteogenesis imperfecta is available at specialized centers.

Spondyloepiphyseal Dysplasia

The chondrodysplasias are a diverse group of genetically determined diseases that affect the structure and function of cartilage. Spranger grouped the disorders with similar features into families (15). One family consists of a heterogeneous group of spondyloepiphyseal dysplasias. The severity of these disorders varies markedly among the lethal forms of achondrogenesis type II and hypochondrogenesis, the severely dwarfing forms of spondyloepiphyseal dysplasia congenita and Kniest syndrome, the marfanoid form of Stickler syndrome or hereditary arthroophthalmopathy, and mild forms with premature osteoarthritis. Heterozygous mutations of type II collagen, the principal collagen of cartilage, or type XI collagen, a minor collagen of cartilage, are found in this family of spondyloepiphyseal dysplasias. The general categories of mutations found in osteogenesis imperfecta are also found in this family of dysplasias.

Some patients with Stickler syndrome have null mutations of the *COL2A1* gene on chromosome 12 that encode the pro- α 1(II) chains of type II procollagen (16). The types of *COL2A1* mutations observed in these patients are similar to those found in the *COL1A1* gene in patients with osteogenesis imperfecta type IA. In both of these diseases, the mutant alleles of the respective genes are functionless and lead to the production of normal collagen, although in about half of the normal amounts. Other individuals with Stickler syndrome have mutations of the *COL11A1* gene on chromosome 1p21, which encodes the α 1(XI) chain, or of the *COL11A2* gene on chromosome 6p21.3, which encodes the α 2(XI) chain of type XI collagen.

The other members of this family of spondyloepiphyseal dysplasias are caused by heterozygous mutations that alter

the structure of the triple helical domain of type II collagen (14,16). Unlike the marfanoid habitus of individuals with Stickler syndrome, these individuals are often severely dwarfed. The dominant negative effects of the mutations are severe, because type II collagen molecules contain three α 1(II) chains. About 12.5% of the molecules contain three normal chains, and 87.5% of them contain one, two, or three mutant chains. As in osteogenesis imperfecta, the mutant molecules are poorly secreted, are more susceptible to degradation, and impair normal formation of the extracellular matrix.

Achondroplasia

Achondroplasia is the most common form of short-limb dwarfism. It is inherited as an autosomal dominant trait with complete penetrance. About 87% of cases are caused by new mutations. There is a considerable reduction in the effective reproductive fitness of patients with achondroplasia.

Patients with achondroplasia have less phenotypic heterogeneity than occurs in other skeletal dysplasias, such as osteogenesis imperfecta and the type II collagen family of spondyloepiphyseal dysplasias. The clinical and radiographic features are remarkably constant, and the growth plates are histologically normal, despite the severe retardation of longitudinal growth. The similarity of phenotype between unrelated patients can be explained by the molecular defects in achondroplasia.

The gene for achondroplasia was assigned to chromosome 4 at locus p16.3 by linkage analysis, and mutations were identified in the gene for fibroblast growth factor receptor 3 (*FGFR3*) (7,17–19). Transcripts of this gene are most abundant in the nervous system, and may account for the megalencephaly of some patients. Outside the nervous system, the highest levels are found in the cartilage anlage of all bones and in the resting chondrocytes of the growth plates (20). All patients have missense mutations that change glycine residue 380 to arginine, or, less often, that change a nearby amino acid residue (17,21). The codon for amino acid residue 380 includes a CG dinucleotide, which is a “hot spot” for mutations. These mutations are expected to alter the structure of the transmembrane domain of the receptor, and to produce similar functional abnormalities, accounting for the relatively invariant phenotype of achondroplasia.

Hypochondroplasia, which has a milder phenotype than achondroplasia, is caused by mutations of other regions of the *FGFR3* gene. Thanatophoric dwarfism, a lethal chondrodysplasia that shares some phenotypic features with achondroplasia, is also caused by mutations of *FGFR3* (22).

Homozygous achondroplasia, which arises from achondroplasia matings, is extremely severe and often lethal. The same mutations as those observed in heterozygous cases of

achondroplasia have been detected in homozygous achondroplasia.

Neurofibromatosis 1

Also known as von Recklinghausen disease, neurofibromatosis 1 shows complete penetrance in that all individuals who carry the mutation express the mutation. However, expression is highly variable, and some individuals within affected families have extremely severe disease and others may have café-au-lait spots as their only manifestation of neurofibromatosis 1.

The gene responsible for this disease, *NF1*, is located on chromosome 17 at locus q11.2 (23). It is a very large gene that encodes a protein called neurofibromin. It is a guanine triphosphatase-activating protein that acts as a tumor-suppressor gene (24,25). The protein is most abundant in the nervous system.

The mutations of *NF1* include deletions, insertions, missense mutations, and nonsense mutations (26). About 80% of these mutations potentially encode a truncated protein because of premature termination of translation. The disease expression is probably the result of haploid insufficiency, because the truncated proteins are likely to be functionless. The normal allele produces a reduced amount of normal neurofibromin that is insufficient for normal development and function of the tissues that express the *NF1* gene.

Patients with affected mothers often have more severe disease than patients with affected fathers (27). This phenomenon probably reflects genomic imprinting, which is a poorly understood process that alters the relative expression of the paternally and maternally derived genes.

In a few cases, the mutation is transmitted from a clinically unaffected father in whom some of the sperm contains a mutant *NF1* allele. This process is an example of gonadal or germline mosaicism.

In about 50% of patients, the disease arises from a new mutation that is not inherited from either parent. The spontaneous mutation rate is about 1 in 10,000 gametes, which is one of the highest levels in humans. This high rate presumably reflects the large size of the gene and its resulting susceptibility to deletions, insertions, point mutations, and major rearrangements. In most cases, the new mutation occurs in the paternally derived gene. This finding suggests that the mutation may occur during mitotic division, which takes place in male gametogenesis but not in female gametogenesis. Because there is little or no evidence of the accumulation of mutations, reflected by the absence of a paternal age effect, the mutations may accumulate in cells that are not involved in the process of replenishment of the germ cell bank.

In neurofibromatosis 1, malignant tumors are homozygous for *NF1* gene anomalies, and benign tumors are still heterozygous for *NF1* anomalies. The malignant process arises by somatic mutation of the normal *NF1* allele, and

results in homozygous loss of the tumor-suppressor activity of the gene (24,28).

Autosomal Recessive Disorders

Autosomal recessive disorders account for about one-third of the single-gene defects (1). Affected individuals are homozygous, having inherited a mutant allele from each parent (Fig. 6-6). The clinically normal parents are heterozygotes, also called carriers. Carrier frequency varies considerably, but, for common autosomal recessive disorders such as cystic fibrosis, it affects about 1 in 45 individuals. The mutant alleles in a population occur much more frequently in carriers than in affected individuals. For example, about 98% of the cystic fibrosis alleles are present in asymptomatic carriers, and only 2% are present in homozygous patients.

Males and females are equally likely to be affected. Autosomal recessive traits are more frequent in consanguineous marriages, particularly if the mutant gene is rare.

Many autosomal recessive diseases produce inborn errors of metabolism, a term introduced by Garrod (29). They result from deficiencies of specific enzymes that lead to a block in a normal metabolic pathway, with accumulation of the substrate and a deficiency of the product. Because most enzymes are normally present in vast excess, a major reduction in their activity is required before a metabolic pathway is blocked. As a result, carriers rarely express inborn errors of metabolism, because the activity of the enzyme produced by the normal allele is sufficient to ensure normal metabolic activity. In the homozygous state, the activity of the specific enzyme is often reduced to about 5% or less of normal values. Reductions of this magnitude are usually required before a metabolic pathway is blocked.

The consequences of an enzyme deficiency result from the accumulation of its substrate, the deficiency of its product, or both. Substrates may be readily diffusible, and are found in excessive amounts in all body fluids and in all

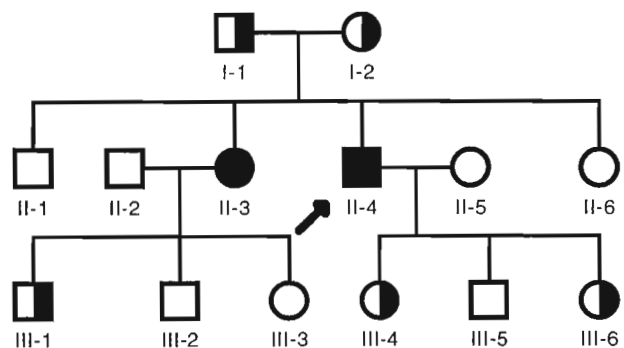


FIGURE 6-6. Typical autosomal recessive pedigree. Homozygous affected individuals are indicated by filled symbols. Asymptomatic carriers, who are heterozygotes, are indicated by half-filled symbols. The proband is indicated by the arrow.

tissues. An example is phenylalanine, which accumulates in phenylketonuria, the classic example of an autosomal recessive disease. In diseases of this kind, the widespread accumulation of the substrate may result in pathologic changes in tissues that are not normally involved in the particular metabolic pathway. Damage to the developing nervous system in phenylketonuria results from this mechanism. Most of the inborn errors of amino acid metabolism produce types of changes similar to those observed in phenylketonuria. Homocystinuria is one of the few inborn errors of amino acid metabolism that produces musculoskeletal anomalies. Affected individuals have a marfanoid appearance.

Nondiffusible substrates accumulate within the cells that are normally involved in the metabolic process. Cell function deteriorates, eventually producing cell death, as the substrate progressively accumulates intracellularly. Diseases caused by this abnormality are often referred to as storage diseases, because the affected tissues progressively enlarge. Typical examples include lysosomal storage diseases, such as Gaucher disease, and the mucopolysaccharidoses. The lysosomal enzymes are responsible for the degradation of macromolecules, such as the mucopolysaccharides of the extracellular matrix. Deficiencies of the lysosomal enzymes involved in the degradative cascade of the mucopolysaccharides produce a heterogeneous group of diseases, some of which manifest severe skeletal anomalies. This group includes Hurler, Scheie, Sanfilippo A to D, Morquio A and B, Maroteaux-Lamy, and Sly syndromes.

Similar clinical phenotypes, such as Sanfilippo A to D syndromes, can occur with different enzyme deficiencies, a phenomenon referred to as "locus heterogeneity." Partial and complete deficiencies of the enzymes can also alter the severity of the phenotype, which is referred to as "clinical heterogeneity." These syndromes may also show wide variation in clinical severity as a result of allelic heterogeneity, in which different defects occur in the same gene.

The clinical manifestations of some enzyme deficiencies are caused by a deficiency of the normal product, rather than an accumulation of the substrate. For example, some forms of congenital hypothyroidism result from enzyme defects in the synthesis of thyroxine.

Autosomal recessive diseases are also produced by other mechanisms, including defects in receptor proteins, membrane transport, and cell organelles. Cystic fibrosis is caused by mutations of a protein called cystic fibrosis transmembrane conductance regulator. Disorders of peroxisomes, which are subcellular organelles, produce a variety of diseases, including rhizomelic chondrodysplasia punctata.

X-linked Disorders

X-linked disorders are readily identified by their characteristic patterns of inheritance (Fig. 6-7). Males are unaffected or affected, because they have only one X chromosome, and

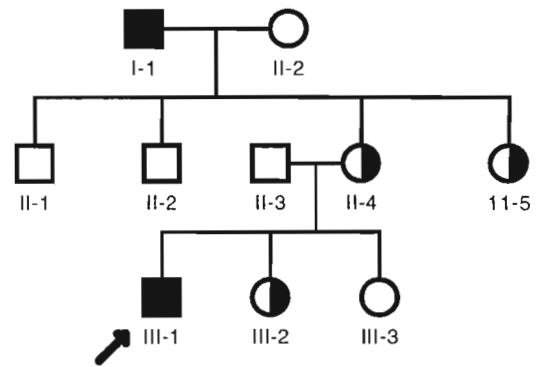


FIGURE 6-7. Typical X-linked recessive pedigree. Affected hemizygous males are indicated by filled squares. Asymptomatic carrier females are indicated by half-filled circles.

are therefore hemizygous for X-linked genes. Females are homozygous unaffected, homozygous affected, or heterozygous, because they have a pair of X chromosomes.

Heterozygous females show variable expression of X-linked disorders, because of the normal random inactivation of one of the X chromosomes in their somatic cells. The random inactivation of the X chromosome is called the Lyon hypothesis, which accounts for the similar levels of expression of one allele in males and a pair of alleles in females. This process is also referred to as "dosage compensation"; the level of expression of one dose of an X-linked gene in a male is equivalent to that of two doses of an X-linked gene in a female.

At the 16- to 64-cell stage of embryogenesis, random inactivation of the paternal or maternal X chromosome occurs in each somatic cell. The descendants of each cell have the same inactive X chromosome. As a result, the somatic cells of females are mosaic, with some cells expressing one X chromosome and the remainder expressing the other. The inactive X chromosome is condensed, and, with the exception of the pseudoautosomal region, its genes are not expressed. Because heterozygous females have various proportions of cells expressing either X-linked allele, there is marked variability in the expression and clinical phenotypes. Some females appear normal, whereas others, referred to as manifesting heterozygotes, have the typical phenotype displayed by hemizygous males.

X-linked disorders are classified as dominant, recessive, and atypical forms of inheritance.

X-linked Dominant Disorders

Classification and Incidence. An X-linked phenotype is classified as dominant if it is expressed in heterozygous females. A characteristic feature of such pedigrees is that all of the daughters and none of the sons of affected males are affected. The affected females transmit the mutation in a

manner similar to an autosomal dominant trait, because they have a pair of X chromosomes. As a result, affected females transmit the mutation to half of their children, regardless of gender. Affected females are usually less severely affected than affected males, because of random inactivation of one of the X chromosomes. The expression depends on the proportion of cells that express the normal or mutant allele.

Typical X-linked dominant disorders with musculoskeletal manifestations include X-linked hypophosphatemic rickets and Rett's syndrome. Rett's syndrome is lethal in males at birth, but heterozygous affected females are severely mentally retarded.

Hypophosphatemic Rickets. This disorder is also called vitamin D-resistant rickets. It resembles metaphyseal chondrodysplasia-type Schmid, which results from mutations of type X collagen. This collagen is specific to the hypertrophic zone of the growth plate. These disorders are differentiated by the low serum inorganic phosphorus levels in children with hypophosphatemic rickets.

The males always express the disease, because they are hemizygous, with only one X chromosome. Variable expression occurs in heterozygous females, because of random inactivation of the paternal and maternal X chromosomes (30). Mutations of the *PHEX* gene (phosphate-regulating gene with homologies to endopeptidases on the X chromosome) cause the disease.

X-linked Recessive Disorders

Classification and Incidence. An X-linked phenotype is classified as recessive if it is expressed in all males, but only in homozygous females. The latter situation is rare, because expression in females is usually limited to the manifesting heterozygotes in whom the normal X chromosome has by chance been inactivated in most somatic cells.

The X-linked gene causing the disorder is transmitted from an affected male through all his daughters. Consequently, a daughter's sons have a 50% chance of inheriting the gene. Males do not transmit the gene directly to their sons.

Typical X-linked recessive disorders include hemophilia A, which produces a deficiency of factor VIII, and Duchenne muscular dystrophy, which produces a deficiency of dystrophin.

Duchenne Muscular Dystrophy. In males, this X-linked recessive disorder is lethal in the late teenage years. It is caused by mutations of the large *DMD* gene that encodes the protein dystrophin, a normal component of the muscle membrane. About one-third of cases are new mutations, and the remainder are inherited from carrier females. Most of the mutations are deletions (6). Affected males infrequently reproduce, and the disease is transmitted by carrier females who are usually clinically unaffected. Some muta-

tions produce Becker muscular dystrophy, which has a milder phenotype.

Atypical X-linked Disorders

Classification. The inheritance pattern of an X-linked disorder may not fall into the typical dominant or recessive pattern. Fragile X syndrome is an example of a disorder with an atypical X-linked inheritance pattern.

Fragile X Syndrome. After Down syndrome, fragile X syndrome is the most common cause of mental retardation in males. Females can be affected, although the phenotype is usually milder, and is characterized by learning disabilities or mild mental retardation. Postpubertal males have a marfanoid appearance, macroorchidism, and mental retardation. They also have lax joints, resembling milder forms of Ehlers-Danlos syndrome.

The name for fragile X syndrome came from a characteristic cytogenetic anomaly. The chromatin in the fragile site at position Xq27.3 fails to condense during mitosis. The molecular defect is attributable to an amplification of a region containing a variable CGG trinucleotide repeat in the 5' untranslated region of the *FMR1* gene (31). Expression of the *FMR1* gene is deficient in affected males, although normal individuals, carrier females, and males with the premutation all show normal expression (32). Allele sizes vary from 6 to 54 repeats in normal individuals, from 52 to 200 repeats in individuals with premutations, and from 200 to more than 1000 repeats in affected individuals (31). Expansion of premutations to full mutations occurs only after passage through the female germline. Males can pass on the premutation for this condition to their daughters, but it is only after female gametogenesis that sufficient trinucleotide expansion occurs to silence the *FMR1* gene, and give rise to the clinical manifestations found in grandsons of the premutation males (33).

Huntington disease and myotonic dystrophy are caused by unstable expansion of trinucleotide repeats in other genes. They, like fragile X syndrome, also have a parental sex bias in the transmission of the mutation, with respect to the age of onset or clinical expression (34).

Other Patterns of Single-gene Inheritance

Most single-gene disorders are inherited in accordance with mendelian principles. However, alternative modes of inheritance have been identified in humans. For example, some neuromuscular and ocular diseases are caused by mutations of mitochondrial, rather than nuclear, DNA. They are inherited from the mother, because mitochondria are transmitted in the ovum, but not in sperm. As a result, women transmit their mitochondrial DNA to all of their

children, but men do not transmit their mitochondrial DNA to any of their children.

Other patterns include mosaicism, genomic imprinting, and uniparental disomy.

Mosaicism

All somatic cells are usually considered to contain identical nuclear DNA derived from a single zygote. However, mutations can produce cell clones that are genetically different from the original zygote (34). Such individuals are said to be mosaic. Mosaicism can be somatic, gonadal, or both.

Somatic Mosaicism. Mutations that occur early in embryogenesis may produce somatic and gonadal mosaicism; later in embryogenesis or in postnatal life, mutations are limited to producing somatic mosaicism. Some unusual clinical manifestations and inheritance patterns have been observed. Asymmetrical Marfan syndrome affects one side of the body, and segmental neurofibromatosis 1 affects one segment of the body. These mutations appear to arise early in embryogenesis, and produce somatic and gonadal mosaicism, with transmission of the typical disease to offspring. Many mutations, however, occur later in embryogenesis and are limited to somatic cells.

McCune-Albright Syndrome. This syndrome is a sporadic disease that produces polyostotic fibrous dysplasia, café-au-lait spots, sexual precocity, and other dysfunctional endocrinopathies. Activating missense mutations in the gene for the α -subunit of Gs, the G protein that stimulates cyclic adenosine monophosphate formation, have been identified in these patients (35). The mutations are found in variable abundance in different affected endocrine and nonendocrine cells, including osteoblast precursors, consistent with the mosaic distribution of abnormal cells generated by somatic cell mutation early in embryogenesis. However, because the mutations are not transmitted to offspring, presumably they occur after cells are committed to form gametes.

Other examples of sporadic segmental and symmetrical disorders that probably arise by a similar mechanism of somatic mosaicism include Proteus syndrome, other hemihypertrophy and local gigantism syndromes, and Ollier disease.

Malignant Tumors. Somatic mosaicism also plays a major role in the cascade of genetic events leading to the development of malignant neoplasms (36,37). Using retinoblastoma, which can be associated with osteosarcomas, as a model, the inherited types can be explained by a germline mutation of the *RB1* gene, followed by a somatic mutation of the remaining normal allele in a given cell. In the sporadic form, the two mutations are somatic in origin, affecting both copies of the normal allele of the *RB1* gene in the same cells. A similar mechanism applies to the development of

malignant tumors in individuals with neurofibromatosis 1. However, more complex arrangements occur, with combinations of somatic mutations and chromosomal rearrangements. The chromosomal rearrangements in tumors, such as the t(11;12)(q24;q12) translocation in Ewing sarcoma, alter the structure or regulation of cellular oncogenes or tumor-suppressor genes (37). Mutations involving the tumor-suppressor gene *P53* are common in many malignant tumors.

Germline Mosaicism. Germline mosaicism has been observed in autosomal dominant diseases, such as osteogenesis imperfecta and Marfan syndrome, and in X-linked disorders. In affected families, multiple affected children can be shown by genetic testing to be heterozygous for the mutation, although the parents are clinically normal. Such pedigrees were previously considered to show autosomal recessive inheritance of the trait, with the resulting prediction that 25% of offspring would be homozygous for the mutation, and clinically affected. The predicted recurrence risk may be greater, depending on the proportion of germline cells that contain the mutant gene. If there is only one affected child, the prediction of recurrence risk is difficult. If neither parent is mosaic for the mutation, the recurrence risk is equal to the spontaneous occurrence rate of the disease in that ethnic group, which is usually low. However, the recurrence rate is significantly higher if either parent has germline mosaicism. In the absence of genetic testing of germline cells, the empiric recurrence risk of autosomal dominant or X-linked disorders for phenotypically normal parents, is about 6%. The affected heterozygous children will transmit the mutation to half of their offspring.

Genomic Imprinting

Genomic imprinting refers to the concept that certain genes are marked, or imprinted, in such a way that they are expressed differently when they are inherited from the mother than when they are inherited from the father (34). The process of imprinting often involves differences in DNA methylation that alter the transcriptional regulation of the paternally derived and the maternally derived genes.

Genomic imprinting is an important process in many human diseases, including familial cancers, chromosomal deletion syndromes, and single-gene disorders such as retinoblastoma, neurofibromatosis 1, Beckwith-Wiedemann syndrome, Huntington disease, and myotonic dystrophy. More severe forms of myotonic dystrophy and neurofibromatosis 1 occur when the mutant gene is inherited from the mother. More severe forms of Huntington disease and autosomal dominant spinocerebellar ataxia occur when the mutant gene is inherited from the father.

Beckwith-Wiedemann syndrome is a generalized overgrowth syndrome. Hemihypertrophy, Wilms tumors, and other tumors are common in affected individuals. Cytogenetic duplication of band p15 of chromosome 11 occurs in

these patients, and it is paternal in origin (38). There is increased expression of the insulin-like growth factor type 2 gene (*IGF2*), which maps to this band. The maternal *IGF2* allele is normally repressed, but is activated in some maternally inherited forms of the syndrome. These women carry chromosomal rearrangements involving chromosome 11 at locus p15, which appear to activate the *IGF2* gene. The syndrome results from increased expression of *IGF2* by paternal duplication or maternal activation of the gene.

The chromosome deletion disorders, Prader-Willi and Angelman syndromes, highlight further the importance of genomic imprinting and the parental origin of genetic material (34,36). Prader-Willi syndrome produces hypotonia, obesity with hyperphagia, hypogonadism, mental retardation, short stature, and small hands and feet. Angelman syndrome is clinically distinct. Affected individuals have a happy disposition, mental retardation, repetitive ataxic movements, abnormal facies with a large mouth and protruding tongue, and an unusual type of seizure. Despite their clinical dissimilarity, these syndromes share the same cytogenetic deletion of chromosome 15 (15q11q13). In Prader-Willi syndrome, the deletion is inherited from the father, and in Angelman syndrome, it is inherited from the mother.

Uniparental Disomy

Individuals with uniparental disomy have cells that contain two chromosomes of a particular type that have been inherited from only one parent (34,36). Isodisomy exists when one chromosome is duplicated, and heterodisomy exists when both homologs have been inherited from one parent. Examples include patients with Prader-Willi syndrome lacking cytogenetic anomalies, in whom both copies of chromosome 15 had been inherited from the mother. Conversely, some cases of Angelman syndrome lacking cytogenetic anomalies result from the inheritance of both copies of chromosome 15 from the father. Some of these individuals carry two identical copies of the same chromosome 15, and have uniparental isodisomy, and others carry two different copies of chromosome 15 from one parent and have uniparental heterodisomy. These findings suggest that the lack of the q11-13 region of the paternal chromosome 15 leads to Prader-Willi syndrome, and that the lack of the equivalent region of the maternal chromosome 15 produces Angelman syndrome. These observations also indicate that both parental chromosome contributions serve necessary and complementary functions in normal growth and development.

Uniparental disomy has been observed in a few patients with cystic fibrosis who had unexplained short stature at birth. It is unclear whether there is a higher frequency of uniparental disomy in patients with intrauterine growth retardation syndromes, such as Russell-Silver syndrome, which is also associated with limb-length discrepancy.

Uniparental disomy can involve the X and Y chromo-

somes. For example, a boy with hemophilia A inherited both sex chromosomes from his father, with no contribution of sex chromosomes from his mother. Although such events occur rarely, they add to the difficulties of predicting recurrence risks.

MULTIFACTORIAL DISORDERS

Many diseases of orthopaedic importance show multifactorial inheritance (39). Neural tube defects, congenital talipes equinovarus, and developmental dislocation of the hip are examples of multifactorial disorders that involve a combination of multiple genetic and environmental factors. Little is known about the genetic or environmental factors involved in the pathogenesis of clubfoot or developmental dislocation of the hip. However, folic acid intake during pregnancy appears to be an important nutritional factor in the pathogenesis of neural tube defects.

Many of the multifactorial disorders behave as multifactorial threshold traits (39). There appears to be an underlying continuous variation in liability to each multifactorial disease that has to exceed a threshold before the abnormal phenotype appears.

Several additional principles have emerged from studies of the multifactorial inheritance of diseases (1). The disorders are familial, but do not show the inheritance patterns typical of single-gene defect disorders. The risk to first-degree relatives is about the square root of the population risk, but the risk is much lower for second-degree relatives. For example, the risk of congenital talipes equinovarus in the general population is about 0.001, but it is 25 times higher in first-degree relatives, only 5 times higher in second-degree relatives, and only twice as common in third-degree relatives. If the disorder is more common in one sex, the recurrence risk is higher for relatives of the less susceptible sex. The recurrence risk is higher when there is more than one affected family member, and when the malformation is more severe. The recurrence risk is also increased when the parents are consanguineous.

Genetic counseling about multifactorial disorders involves the provision of empiric risk, which is the recurrence risk observed in similar families. It may not be accurate for a given family. Progress in defining the genes at fault can be expected to improve the risk estimates. Preventative measures, such as taking folic acid during the periconception period, may diminish the risk of neural tube defects. The pregnancy can also be monitored using α -fetoprotein levels in maternal serum and amniotic fluid, and by ultrasonography of the fetus.

TERATOLOGIC DISORDERS

Principles of Teratology

The effects of known teratogens on the fetus are determined by the timing of exposure and dosage (40,41). During

blastocyst formation, teratogens usually result in fetal death and spontaneous abortion. During the period of organogenesis, 18 to 60 days after conception, the fetus is most vulnerable to the effects of teratogens. Easily recognizable structural defects are the usual result. Later in pregnancy, teratogens may produce no anomaly or subtle changes.

Most teratogens act by interfering with metabolic processes. They may act on cell membranes or the metabolic machinery of cells. The final common pathway of these various levels of action is cell death or a failure of replication, migration, or fusion of cells. These changes often involve specific organs, but can produce more general changes in the fetus.

Exposure of the father to teratogens does not appear to play a significant role in the development of birth defects. Most agents that interfere with the DNA of sperm produce sterility, rather than teratogenic effects in the fetus.

Current methods for detecting potential teratogens are inadequate. Interspecies differences in sensitivity are common. For example, thalidomide is teratogenic in rabbits, but not in rats and mice. Many agents known to be teratogenic in animals, such as glucocorticoids in rats, do not produce any detectable anomalies in humans.

Most known teratogenic agents in humans have been identified from clinical observations of unexpected outbreaks of malformations. In most instances, however, unexpected clusters of cases result from natural fluctuations in the frequency of specific birth defects, as shown by birth defect registers. Epidemiologists associated with birth defects registers play an important role in assessing whether apparent outbreaks are potentially important.

Teratogenic Agents

The selected items in the following list are teratogenic agents in humans (41):

- drugs and environmental chemicals
- androgens
- aminopterin
- chlorobiphenyls
- Warfarin (Coumadin)
- cyclophosphamide
- diethylstilbestrol
- D-penicillamine
- goitrogens and antithyroid drugs
- isoretinoin
- methyl mercury
- phenytoin
- tetracyclines
- thalidomide
- valproic acid
- infections
- cytomegalovirus
- rubella

- syphilis
- toxoplasmosis
- maternal metabolic imbalance
- alcoholism
- diabetes mellitus
- phenylketonuria
- virilizing tumors
- ionizing radiation

There is continuing concern about the possible adverse effects of drugs and other environmental factors on the developing fetus. However, relatively few agents have proven to be teratogenic.

Thalidomide

Lenz (42) in Germany and McBride (43) in Australia reported an increased frequency of limb-deficient babies born to mothers who used thalidomide as a sedative during pregnancy. The agent was shown from clinical studies to produce its major effects during the period of limb formation.

Warfarin

Teratogenic effects occur from exposure of the fetus to warfarin from 6 to 9 weeks of gestation. Stippling of the epiphyses is one of the characteristic changes. Exposure during the second and third trimesters produces severe neural anomalies.

Retinoic Acid

Retinoic acid has been used in the treatment of severe cystic acne. Recipient females are often of childbearing age and are at risk from the potent teratogenic effects of this agent. It produces craniofacial, cardiac, thymic, and central nervous system defects. Megadoses of vitamin A are also teratogenic. Vitamin A, retinoic acid, and its analogs should be avoided during pregnancy. If women of childbearing age use these agents, unplanned pregnancies should be avoided by contraception.

Alcohol

Alcohol is the most common teratogen to which a pregnancy is likely to be exposed (11,35). Regular intake of two alcoholic drinks each day during pregnancy results in a slightly reduced birth weight. Chronic intake of eight to ten drinks each day is likely to produce babies with low birth weights, craniofacial anomalies, mental retardation, incoordination, short stature, and increased frequency of congenital heart disease. A gradient of severity of these effects is seen with intermediate levels of alcohol intake. Alcohol should be avoided during pregnancy.

Radiation

Pregnant women should avoid unnecessary exposure to radiographs and isotopes. Doses in excess of 1 Gy should be avoided, and doses in excess of 10 Gy produce microcephaly, growth retardation, and mental retardation. Women of childbearing age should not be exposed to unnecessary radiation, if they may be, or are known to be, pregnant.

Infections

Syphilis was the first known infectious teratogen. Its deleterious effects on the fetus can be prevented by routine testing of pregnant women, and treatment when necessary. The virus that causes acquired immunodeficiency syndrome has emerged as a major teratogen. Rubella embryopathy is preventable by vaccination of young girls. When the fetus is exposed to the virus in the first trimester, blindness, deafness, cataracts, microphthalmos, congenital heart disease, limb deficiencies, and mental retardation occur. Cytomegalovirus infection and toxoplasmosis also produce birth defects.

Diabetes Mellitus

Abnormal embryogenesis occurs more often in babies of diabetic mothers, particularly if their diabetes is poorly controlled in the first trimester of the pregnancy. For example, cardiac malformations occur three to four times more often in babies of diabetic mothers than of normal mothers, and anencephaly and myelomeningocele occur in 1 to 10% of babies born to diabetic mothers. Caudal regression syndrome, with sacral hypoplasia and fusion of the legs, is a rare disorder, but it is more common in babies of diabetic mothers.

GENETIC COUNSELING AND PRENATAL DIAGNOSIS

Genetic counseling aims to provide sufficient information for an individual or couple to make an informed decision about future pregnancies, and to assist them in coming to terms with the issues they face (44).

Indications for Genetic Counseling

Anyone who suspects that there may be an increased risk of producing a child with a birth defect should receive formal genetic counseling. Appropriate genetic counseling requires diagnostic precision and knowledge of the recurrence risk, the burden of the disorder, and the reproductive options. There are several indications for genetic counseling (28,44):

- couples who have a stillbirth or multiple miscarriages
- a child with a birth defect

- mental retardation
- a family history of any of the above problems
- relatives with known genetic diseases, such as muscular dystrophy
- exposure to radiation, drugs, or infections during pregnancy
- advanced maternal age
- consanguinity
- chromosomal translocations

Diagnostic Precision

The most important element in counseling is establishing the correct diagnosis. A precise diagnosis cannot be made for about half of the children who present with mental retardation or dysmorphic features. However, there is a large amount of empiric data that can be used for counseling in this group.

Estimation of Recurrence Risk

After diagnostic evaluation, an estimate of the recurrence risk is made. This is a numeric estimate of the likelihood of a particular disorder occurring in subsequent children, such as a 1 in 4 risk of an autosomal recessive disorder and a 1 in 2 risk of an autosomal dominant disorder. The recurrence risk for multifactorial disorders, after a single affected child, is about 3 to 5%.

Many families do not have a grasp of probabilities and need a careful discussion to give meaning to any risk estimate. For example, a 1 in 4 risk applies to each pregnancy, but many families believe that they can have three more children without worry, if they already have one abnormal child.

Another aspect of risk is the background level of risk for major birth defects. About 1 in 25 children are born with a major defect. In this setting, risks of 1 in 2 and 1 in 4 are high, and risks of 1 in 100 are low.

Burden of Genetic Diseases

The burden of genetic diseases is important in genetic counseling. Clinodactyly is a common autosomal dominant condition with a high recurrence risk of 1 in 2, although it has minimal or no burden to those who have it. Clubfeet and congenital dislocation of the hip are multifactorial diseases with lower risks of recurrence. The potential burden of these conditions is minimized by early diagnosis and treatment. In contrast, the burden of additional children with Duchenne muscular dystrophy, severe osteogenesis imperfecta, or severe chondrodysplasia is considerable, because there are no curative treatments available.

There may be disparities between the doctor's concept of burden and the family's concept. Some families are prepared to accept a 1 in 4 risk of a perinatally lethal disorder,

knowing that the child will die at, or soon after birth, or be normal. Other families may not be willing to accept the burden of recurrent deformities such as clubfeet, despite the lower risk and the availability of treatment.

Neonatal and Prenatal Diagnosis

General neonatal screening programs for inborn errors of metabolism, such as phenylketonuria and hypothyroidism, have been highly successful. The severe consequences of these diseases have been prevented by early diagnosis and treatment.

Prenatal diagnosis is used more selectively, but is being offered to an increasing number of families, as the number of diseases that can be detected in early pregnancy increases. The most common indication is a maternal age of 35 years or older. The indications for prenatal diagnosis are shown in the following list:

- advanced maternal age (older than 35 years)
- known chromosomal anomaly in one parent or in a previous pregnancy
- previous neural tube defect, high serum level of α -fetoprotein, or neural tube defect suspected from ultrasound results
- family history of disorders detectable by biochemical or DNA technology, including Duchenne and Becker muscular dystrophy, myotonic dystrophy, hemoglobinopathies, hemophilia A or B, Huntington disease, cystic fibrosis, and other rare detectable genetic diseases

In most instances, prenatal diagnosis does not reveal an abnormality, providing reassurance to the parents. The availability of prenatal diagnosis increases the number of families willing to have children, instead of refraining from having them, because of a fear of birth defects.

Serum α -Fetoprotein Screening

α -Fetoprotein is a fetal protein produced by the yolk sac and liver. It reaches a peak in fetal serum at about 13 weeks of gestation and decreases thereafter. Amniotic levels are high in the fetus with a lesion that is not covered by skin, such as open spina bifida, anencephaly, and exomphalos. The protein leaks into the amniotic fluid and into the maternal circulation. An increased maternal serum level of α -fetoprotein is not diagnostic of open spina bifida, but is an indication for further investigation. Abnormally high levels also occur in cases of fetal death, cystic hygroma, polycystic kidneys, and Turner syndrome.

Ultrasound Screening

Real-time ultrasonography is used to visualize the fetus and fetal movements. Ultrasonography is commonly undertaken to determine gestational age. However, more extensive stud-

ies by experienced ultrasonographers are required when examining for fetal abnormalities in at-risk pregnancies. Such examinations are increasingly undertaken as screening investigations in all pregnancies.

Amniocentesis and Chorionic Villus Sampling

Ultrasound-guided amniocentesis is a relatively safe procedure when undertaken at 16 weeks of gestation. The risk of fetal loss is about 0.5 to 1%. The amniotic fluid is most often used for determination of α -fetoprotein levels. The amniotic cells are used for karyotype analysis for the determination of enzyme levels in cases of inborn errors of metabolism, and for DNA diagnosis using direct detection of a previously defined mutation, or indirect detection using polymorphisms. Chorionic villus sampling can be undertaken between 9 and 11 weeks of gestation, and allows earlier diagnosis of many genetic diseases, and first-trimester termination. The risk of fetal loss is about 4%.

Prenatal Counseling

Families at risk for genetic diseases and birth defects should seek counseling before the mother becomes pregnant. This approach ensures that there is sufficient time to establish the diagnosis, recurrence risk, burden of the disorder, reproductive alternatives, and suitability for prenatal diagnosis. These options may be limited when counseling is sought during the pregnancy. Parents must be fully informed about the risks of investigational procedures and anticipated delays in receiving test results. They must be given all test results and appropriate explanations of their significance. Parents require much support at this difficult time, and are responsible for the decision to terminate a pregnancy.

TREATMENT OF GENETIC DISEASES

Early treatment of phenylketonuria and hypothyroidism has effectively prevented mental retardation and other consequences of these diseases. However, they are the exceptions, because treatment is not available for most genetic diseases, and, when available, it is relatively ineffective. Table 6-1 lists the various levels at which intervention is possible.

Most methods of treatment, such as metabolic manipulations and protein replacement, occur beyond the level of the gene. However, bone marrow transplantation has been used successfully to cure or ameliorate diseases such as congenital immune deficiencies, infantile malignant osteopetrosis, thalassemia, lysosomal storage diseases, infantile agranulocytosis, and chronic granulomatous disease. The normal genes of the transplanted cells produce the protein, usually an enzyme, which corrects the metabolic defect. The stem cells within the donor marrow continue to replicate, providing a continuing source of the normal protein. As

TABLE 6-1. LEVELS OF TREATMENT OF GENETIC DISEASES

Level of Intervention	Treatment Strategy
Mutant gene	Modification of somatic genotype Modulation of gene expression
Mutant messenger RNA	Modulation of mutant messenger RNA expression
Mutant protein	Protein replacement or stimulation of residual function
Metabolic or biochemical dysfunction	Specific metabolic manipulation
Clinical phenotype	Nonspecific medical or surgical intervention
The family	Genetic counseling, carrier detection, and pre-symptomatic diagnosis

(From ref. 45, with permission.)

transplantation technology improves, it is likely that specific subsets of stem cells within the bone marrow, peripheral blood, or other tissues will be used to target specific organs. For example, stem cells that can develop into osteoblasts, fibroblasts, or chondrocytes may be used as a form of cell therapy to correct genetic defects of the appropriate connective tissues. Growth factors will be needed to direct the cell differentiation pathways. An alternative approach to cell therapy is to use embryonic stem cells, which are pluripotent. Despite the great potential of this treatment, many ethical and practical issues need to be resolved before embryonic stem cells can be used in clinical practice.

Somatic gene therapy is in its infancy, but is likely to become available for many genetic diseases. Gene transfer is used to replace a gene that is nonfunctional, such as the *DMD* gene in boys with Duchenne muscular dystrophy. For other diseases, the adverse effects of the mutant allele are blocked by specific gene therapy directed to the mutant sequence. Therapy of the latter kind is most applicable to diseases in which many affected individuals share the same mutation. Designing gene therapy is more difficult for diseases in which most individuals have their own mutations, as occurs in osteogenesis imperfecta.

There are many challenges to achieving safe and effective somatic gene therapy. One of the challenges is to target the therapy to specific cells. Transplantation of modified autologous bone marrow cells is likely to be suitable for hematologic diseases and for some bone diseases. Specific cell surface receptor-mediated gene transfer is likely to be more suitable for other diseases, as in transferring a replacement gene into the skeletal and cardiac muscle cells of young children with Duchenne muscular dystrophy.

Less-dramatic solutions are likely to be applicable in patients with autosomal dominant disorders that give rise to haploid insufficiency. In such patients, the protein produced is qualitatively normal, but is reduced in amount because only the normal allele is functional. In this situation, the amount of normal protein produced from the normal allele can be increased by specific pharmacologic modulation of gene expression. Therapy of this kind is potentially

curative for half of all patients with osteogenesis imperfecta and Marfan syndrome.

References

Molecular Basis of Inheritance

1. Thompson MW, McInnes RR, Willard HF. *Genetics in medicine*, 5th ed. Toronto: WB Saunders, 1991.
2. Penrose LS. Parental age in achondroplasia and mongolism. *Am J Hum Genet* 1957;9:167.
3. Stoll C, Roth M-P, Bigel P. A reexamination of parental age effect on the occurrence of new mutations for achondroplasia. In: Papadatos CJ, Bartsocas CS, eds. *Skeletal dysplasias*. New York: Alan R. Liss, 1982:419.
4. Bowen P. Achondroplasia in two sisters with normal parents. *Birth Defects* 1974;10:31.
5. Clermont Y. Renewal of spermatogonia in man. *Am J Anat* 1966; 118:509.
6. Gillard EF, Chamberlain JS, Murphy EG, et al. Molecular and phenotypic analysis of patients with deletions within the deletion-rich region of the Duchenne muscular dystrophy (DMD) gene. *Am J Hum Genet* 1989;45:507.
7. Dietz HC, Cutting GR, Pyeritz RE, et al. Marfan syndrome caused by a recurrent de novo missense mutation in the fibrillin-1 gene. *Nature* 1991;352:337.
8. Shiang R, Thompson LM, Zhu Y-Z, et al. Mutations in the transmembrane domain of FGFR3 cause the most common genetic form of dwarfism, achondroplasia. *Cell* 1994;78:335.

Chromosome Disorders

9. Bargaonkar DS. *Chromosomal variation in man: a catalog of chromosomal variants and anomalies*, 5th ed. New York: Alan R. Liss, 1989.
10. Epstein CJ. *The consequences of chromosome imbalance: principles, mechanisms and models*. New York: Cambridge University Press, 1986.

Single-gene Disorders

11. McKusick VA. *Mendelian inheritance in man: catalogs of autosomal dominant, autosomal recessive, and X-linked phenotypes*, 9th ed. Baltimore: The Johns Hopkins University Press, 1990.
12. Redman JB, Fenwick SK, Fu TH, et al. Relationship between parental trinucleotide GCT repeat length and severity of myotonic dystrophy in offspring. *JAMA* 1993;269:1960.

13. Byers PH, Wallis GA, Willing MC. Osteogenesis imperfecta: translation of mutation to phenotype. *J Med Genet* 1991;28:433.
14. Cole WG. Collagen genes: mutations affecting collagen structure and expression. *Prog Nucleic Acid Res Mol Biol* 1994;47:29.
15. Spranger J. Bone dysplasia "families." *Pathol Immunopathol Res* 1988;7:76.
16. Spranger J, Winterpacht A, Zabel B. The type II collagenopathies: a spectrum of chondrodysplasias. *Eur J Pediatr* 1994;153:56.
17. Francomano CA, Ortiz de Luna RI, Hefferon TW, et al. Localization of the achondroplasia gene to the distal 2.5 Mb of human chromosome 4p. *Hum Mol Genet* 1994;3:787.
18. Le Merrer M, Rousseau F, Legeai-Mallet L, et al. A gene for achondroplasia: hypochondroplasia maps to chromosome 4p. *Nat Genet* 1994;6:314.23.
19. Velinov M, Slaughterhaupt SA, Stoilov I, et al. The gene for achondroplasia maps to the telomeric region of chromosome 4p. *Nat Genet* 1994;6:318.
20. Peters K, Ornitz D, Werner SM, et al. Unique expression pattern of the FGF receptor 3 gene during mouse organogenesis. *Dev Biol* 1993;155:423.
21. Superti-Furga A, Eich G, Bucher HU, et al. A glycine 375-to-cysteine substitution in the transmembrane domain of the fibroblast growth factor receptor-3 in a newborn with achondroplasia. *Eur J Pediatr* 1995;154:215.
22. Aterman K, Welch JP, Taylor PG. Presumed homozygous achondroplasia: a review and report of a further case. *Pathol Res Pract* 1983;178:27.
23. Goldgar DE, Green P, Parry DM, et al. Multipoint linkage analysis in neurofibromatosis type 1: an international collaboration. *Am J Hum Genet* 1989;44:6.
24. Legius E, Marchuk DA, Collins FS, et al. Somatic deletion of the neurofibromatosis type 1 gene in a neurofibrosarcoma supports a tumour suppressor gene hypothesis. *Nat Genet* 1993;3:122.
25. Nakafuku M, Nagamine M, Ohtoshi A, et al. Suppression of oncogenic Ras by mutant neurofibromatosis type 1 genes with single amino acid substitutions. *Proc Natl Acad Sci USA* 1993;90:6706.
26. Weiming X, Yu Q, Lizhi L, et al. Molecular analysis of neurofibromatosis type 1 mutations. *Hum Mutat* 1992;1:474.
27. Miller M, Hall JG. Possible maternal effect of severity of neurofibromatosis. *Lancet* 1978;11:1071.
28. Shannon KM, O'Connell P, Martin GA, et al. Loss of the normal NF1 allele from the bone marrow of children with type 1 neurofibromatosis and malignant myeloid disorders. *N Engl J Med* 1994;330:597.
29. Harper PS. *Practical genetic counselling*, 2nd ed. Bristol, England: Wright, 1984.
30. Glorieux F, Scriver CR. Loss of a PTH sensitive component of phosphate transport in X-linked hypophosphatemia. *Science* 1972;175:997.
31. Fu Y, Kuhl DP, Pizzuti A, et al. Variation of the CGG repeat at the fragile X site results in genetic instability: resolution of the Sherman paradox. *Cell* 1991;67:1047.
32. Picretti M, Zhang F, Fu Y, et al. Absence of expression of the FMR-1 gene in fragile X syndrome. *Cell* 1991;66:817.
33. Driscoll DJ. Genomic imprinting in humans. *Mol Genet Med* 1994;4:37.
34. Austin KD, Hall JG. Nontraditional inheritance. *Pediatr Clin North Am* 1992;39:335.
35. Shenker A, Weinstein LS, Sweet DE, et al. An activating Gs α mutation is present in fibrous dysplasia of bone in the McCune-Albright syndrome. *J Clin Endocrinol Metab* 1994;79:750.
36. Cohen MM, Rosenblum-Vos LS, Prabhakar G. Human cytogenetics: a current overview. *Am J Dis Child* 1993;147:1159.
37. Delattre O, Zucman J, Melot T, et al. The Ewing family of tumors: a subgroup of small round-cell tumors defined by specific chimeric transcripts. *N Engl J Med* 1994;331:294.
38. Weksberg R, Shen DR, Fei YL, et al. Disruption of insulin-like growth factor 2 imprinting in Beckwith-Wiedemann syndrome. *Nat. Genet* 1993;5:143.

Multifactorial Disorders

39. Carter CO. Genetics of common single malformations. *Br Med Bull* 1976;32:21.

Teratologic Disorders

40. Danks DM, Rogers JG. Birth defects. In: Robinson MJ, ed. *Practical paediatrics*, 2nd ed. London: Churchill Livingstone, 1990:19.
41. Shepard TH. *Catalog of teratologic agents*, 6th ed. Baltimore: The Johns Hopkins University Press, 1989.
42. Lenz W. Thalidomide embryopathy in Germany, 1959–1961. *Prog Clin Biol Res* 1985;163C:77.
43. McBride WG. Thalidomide embryopathy. *Teratology* 1977;16:79.

Genetic Counseling and Prenatal Diagnosis

44. Rogers JG. Genetic counselling. In: Robinson MJ, ed. *Practical paediatrics*, 2nd ed. London: Churchill Livingstone, 1990:55.

Treatment of Genetic Diseases

45. Valle D. Genetic disease: an overview of current therapy. *Hosp Pract* 1987;22:167.



7

METABOLIC AND ENDOCRINE ABNORMALITIES

DAVID J. ZALESKE

REVIEW OF FACTORS IN SKELETAL DEVELOPMENT 177

MINERAL PHASE 181

Calcium and Phosphorus Homeostasis 181
Rickets and Osteomalacia 186

ORGANIC PHASE 204

Bone Physiology 204
Osteogenesis Imperfecta 205
Idiopathic Juvenile Osteoporosis 210

Osteopetrosis 212
Periosteal Reaction and Soft Tissue Calcification and Ossification 214
Connective Tissue Syndromes 218

ENDOCRINOPATHIES 221

Normal Variant Short Stature 224
Growth Hormone Deficiency and Hypopituitarism 225
Hypothyroidism 226
Gonadal Abnormalities and Sex Steroids 226
Glucocorticoid-related Abnormalities 228
Fibrous Dysplasia 228

Metabolic bone disease includes systemic disorders of calcium and phosphorus that affect osseous tissue. The immature skeleton forms bone through turnover, which is affected by all the disorders considered to be metabolic bone disease, and bone is formed at the interface between vascular tissue and proliferating cartilage, which can be affected by genetic and endocrine disturbances that interfere with growth (1–3).

The advances in molecular biology tend to blur traditional disciplines (4,5). Pediatric patients with metabolic and endocrine abnormalities are usually under the care of pediatric endocrinologists, nephrologists, or gastroenterologists, in addition to a primary pediatrician. The pediatric

orthopaedic surgeon is presented with children with alterations in morphology. He or she may have to participate in the diagnosis and needs to understand the basic science for an intelligent approach to treatment. This chapter describes the physiology and pathophysiology of the formation of bone and cartilage in the immature skeleton as the basis for pediatric orthopaedic care. Certain aspects of the clinical entities described are most completely understood when the reader also refers to information in Chapter 1, “Embryology and Development of the Musculoskeletal System”; Chapter 6, “Genetic Aspects of Orthopaedic Conditions”; Chapter 8, “The Skeletal Dysplasias”; and Chapter 9, “Syndromes of Orthopaedic Importance.”

REVIEW OF FACTORS IN SKELETAL DEVELOPMENT

Genetic, metabolic, endocrine, and physical factors interact to produce the shape of the immature skeleton (4,5). Em-

TABLE 7-1. GROWTH FACTORS

Factors	Effects
TGF- β superfamily	
TGF- β 1 (C1F-A)	Upregulate bone and cartilage components of types I, II, III, V, VI, and X collagen, fibronectin, osteopontin, osteonectin, thrombospondin, proteoglycans, alkaline phosphatase
TGF- β 2 (C1F-B)	
BMP-2 through BMP-7	Downregulate metalloproteinases, osteoclasts
BMP-3 (osteogenin)	Indefinite effect on chondrocytes
BMP-1 (OP-1)	Osteoclasts lead to or promote up regulation of TGF- β
FGF	
Acidic (aFGF) and basic (bFGF)	Upregulate endothelial cell and chondrocyte replication and neovascularization
Insulin-like growth factors	
Somatomedins	In skeletal growth, mediate many growth-promoting effects of growth hormone Upregulate the incorporation of sulfate into proteoglycan
PDGF	
A and B chains	Potent mitogen for cells of connective origin TGF- β leads to or promotes up regulation of PDGF-B, which leads to or promotes up-regulation of protooncogenes MYC and FOS

BMP, bone morphogenetic protein; C1F, cartilage-inducing factor; FGF, fibroblast growth factor; OP, osteogenic protein; PDGF, platelet-derived growth factor; TGF, transforming growth factor.

bryology has been discussed extensively in Chapter 1. A brief review here of this topic is intended to add the perspective that factors active in morphogenesis are important in postnatal skeletal growth, homeostasis, and repair (6). During the embryonic period (i.e., from 1 week after conception to the end of the second month of gestation), morphogenesis occurs (7). An interactive cascade of events (i.e., epigenesis) produces shape. The molecular basis of this complex process is being elucidated (8,9). Activation of genes involved in specifying shape may in turn control the synthesis and release of morphogens, such as the growth factors (Table 7-1), the spatial distribution of which defines body plan (4,9–11). At 8 weeks of gestation, vascular invasion occurs at the midshaft of the humerus, in association with endochondral bone formation; this marks the end of the embryonic period and the beginning of the fetal period.

Primary centers of ossification appear rapidly at other sites. In long bones, chondrocyte hypertrophy and death, followed by osseous replacement, advance toward both ends, leaving the cartilaginous growth plates or physes, which continue to function as endochondral bone generators until adolescence. Bone formation in the cartilaginous epiphyses occurs in the secondary centers of ossification, many of which do not appear until after birth. The timing of endochondral bone formation in various anatomic sites can be useful in establishing biologic or bone age (12).

The fine structures of bone and cartilage have certain similarities. Both have well-defined cell populations and a characteristic extracellular matrix, and collagen is an important constituent of the matrices of both of these tissues (13–15) (Table 7-2). Class 1 collagens (i.e., types I, II, III, V, and XI) are the banded, fiber-forming collagens. The fibrillar collagens consist of three parallel protein chains, called α -chains, organized into triple helices. The α -chains

differ in their primary amino acid sequences, total amino acid compositions, and degrees of glycosylation (13,14). In bone, the matrix is mostly type I collagen, organized to allow nucleation and growth of hydroxyapatite crystals at a finite number of sites (16). The type I collagen consists of two α 1(I)-chains and one α 2(I)-chain. Type II collagen is the major collagen of cartilage matrix. It consists of three identical α 1(II)-chains.

Class 2 collagens (i.e., types IX and XII) do not form aggregates alone, but rather bind to the other collagens in forming fibrils. Class 3 collagens (i.e., types IV, VI, VII, and X) form fibrous structures separate from the banded collagen fibers. Class 4 includes types VIII and XIII, the function of which is still being investigated.

Several noncollagenous proteins are not so abundant as collagen, but they may be important in the regulation of mineralization (17–19). These proteins are proteoglycans, phosphoproteins, and osteocalcin, which binds calcium through an α -carboxyglutamic acid moiety.

The cell types of osseous tissue are osteoblasts, osteocytes, and osteoclasts. It appears that osteoblasts are derived from mesenchymal osteoprogenitor cells. Osteoblasts are large, active cells that elaborate the matrix for bone formation. Osteoblasts that become surrounded by matrix, and eventually become ossified bone, persist in the form of osteocytes. Osteoclasts are multinucleated cells, originating from hematopoietic tissues, which are responsible for bone resorption (20). Bone is a dynamic tissue, and its turnover results from a fairly close coupling of resorption and formation. The net effect of these processes in the normal immature skeleton is an increase in mass throughout growth. Bone tissue remodeling or turnover is a complex phenomenon mediated by the variety of metabolic and endocrine factors that are being presented in this chapter. Turnover is important, not

TABLE 7-2. COLLAGEN TYPES

Types of Collagen	Tissues
Class 1: fiber-forming collagens	
Type 1 $\alpha 1(I)_2\alpha 2(I)$	Skin, tendon, ligament, bone, cornea
Gene for $\alpha 1(I)$ = COL1A1 on chromosome 17	
Gene for $\alpha 2(I)$ = COL1A2 on chromosome 7	
Type II $\alpha 1(II)_3$	Cartilage, nucleus pulposus
Gene for $\alpha 1(II)$ = COL2A1 on chromosome 12	
Type III $\alpha 1(III)_3$	Skin and a variety of connective tissues with type 1
Type V $\alpha 1(V)\alpha 2(V)\alpha 3(V)$	Fetal and vascular tissues
Type XI	Cartilage
Class 2: fibril-associated collagens	
Type IX	Cartilage
Type XII	Ligament, tendon, perichondrium, periosteum
Class 3: independent fiber systems	
Type IV	Basement membranes
Type VI	In cartilaginous and noncartilaginous connective tissues
Type VII	Anchoring fibrils
Type X	Hypertrophic chondrocytes during endochondral ossification
Class 4: unknown fiber forms and functions	
Type VIII	
Type XIII	

only in skeletal homeostasis but in fracture healing and bone graft incorporation (6,10,21,22).

There are three types of cartilage in the body: hyaline (e.g., articular cartilage, growth plates), fibrocartilage (i.e., menisci), and elastic cartilage (i.e., ear cartilage). All cartilages have an extracellular matrix consisting of collagen and proteoglycan; the matrix is particularly well defined in hyaline cartilage. Proteoglycan occurs in several macromolecular forms consisting of long-chain sugar polymers (i.e., chondroitin sulfates and keratin sulfate) attached to a core protein. Large numbers of proteoglycans form hydrophilic, highly electronegative aggregates along a filament of hyaluronic acid, and are crucial to the structure of the cartilaginous mass. Collagen and proteoglycan are synthesized by chondrocytes.

Different types of cartilage have different compositions. Articular cartilage is aneural, alymphatic, and avascular. The property of resisting vascular invasion is important to the function of physal cartilage. Growth plates or physes are specialized hyaline cartilaginous structures responsible for bone growth (23). In long bones, a physis becomes radiographically distinct at either end with the appearance of the secondary center of ossification. In round and flat bones, the growth plate is a roughly spherical structure and therefore is never visualized as a distinct radiolucency. The growth characteristics of physal regions are endowed during the embryonic period, but are subject to a variety of postnatal modifications, including metabolic factors and physical force (7).

A longitudinal section of a growth plate reveals several zones (23). On the epiphyseal side of the growth plate is

the resting zone, which appears to participate in storing lipids and other materials. The proliferative zone contains the dividing cells of the growth plate. In the hypertrophic zone, the flattened cells of the proliferative zone enlarge and become spherical to ellipsoid. On the metaphyseal side is the zone of provisional calcification and formation of the primary spongiosa. The blood supply to the growth plate is dual, with epiphyseal vessels supporting the zone of growth and metaphyseal vessels supporting ossification. In the lower hypertrophic zone, matrix vesicles, membrane-bound particles that contain calcific materials, are formed by the chondrocytes and are deposited in the longitudinal septa, presumably as a prerequisite for bone formation (24,25). Neutral protease and pyrophosphatase activity located in this region decrease the concentration of inhibitors of calcification and allow ossification to proceed (26). A mini-growth plate beneath the articular cartilage serves to enlarge the epiphysis during growth, but rather than ossifying at maturity, it remains cartilaginous and may be subject to stimulation even after maturity.

Cartilage proliferation and growth plate function throughout the body are subject to control by several humoral and local factors (11,27,28). Most notable are growth hormone and the somatomedins (Table 7-1). Early experimental studies showed that growth was at least partially regulated by growth hormone by demonstrating that administration of pituitary extracts to hypophysectomized rats caused a significant proliferative response in growth plates (29). Subsequent experiments demonstrated that the relation between administration of growth hormone and the phenomenon of epiphyseal growth was indirect and that it

was mediated by somatomedins, materials synthesized in the liver in response to the administration of the pituitary preparation (2).

Somatomedins are a group of short-chain polypeptides that affect DNA synthesis in the growth plate chondrocytes and enhance amino acid transport, RNA synthesis, and synthesis of proteoglycan and collagen (11). Sensitivity to somatomedins is reduced in cartilage from older persons and in cartilage from early embryonic tissues, so that it is postulated that these materials are less important for growth in early development. The growth plate chondrocytes also demonstrate sensitivity to basic fibroblast growth factor (30,31).

Numerous other factors are important in growth plate regulation. Nutrition and insulin regulate growth plate function. Protein in the diet exerts a positive control over the somatomedins. Excess glucocorticoids appear to inhibit growth, partly by an inhibitory effect on protein synthesis in cartilage, but also by interference with somatomedin production and action. Estrogens decrease somatomedin production; androgens increase growth, but not through the somatomedin system. Similarly, increased thyroxine causes increased growth, but it is not clear whether this effect is mediated through growth hormone and somatomedins (32,33).

The regulation of bone formation is equal in complexity to that of cartilage proliferation. In the immature skeleton, under conditions of normal physiology, the two are linked at the physis, and many of the humoral factors discussed have an effect on osseous, as well as cartilaginous, tissue (17,22,34–38). Bone formation is also controlled by the serum concentration of ions, such as calcium and phosphate, which contribute to the mineral phase; by the hormones (e.g., parathyroid hormone, calcitonin) that regulate these ions; and by a variety of other factors, such as prostaglandin E_2 , osteoclast-activating factor, and forms of transforming growth factor- β (19,39–41).

Excess glucocorticoids inhibit bone formation in a complex manner. Glucocorticoid excess is associated with a decrease in calcium and phosphate levels and an inhibition of matrix synthesis (42). Insulin is associated with an increase in bone formation (18). Although *in vitro*, direct, anabolic effects on bone have been demonstrated, *in vivo* effects may be mediated by interaction with somatomedins and nutrition. Conversely, defects in early fracture healing have been documented in experimental diabetes (43). Thyroid hormones are necessary for normal turnover of bone. Thyroid hormone increases osteoclastic bone resorption, but, as indicated previously, it is also associated with increased growth, possibly mediated through the somatomedins.

Androgens and estrogens affect skeletal growth and net bone formation. Testosterone has been shown to cause an increase in growth plate activity, but estrogens appear to be inhibitory in their action. Estrogen is important in growth plate closure in both genders (44,45). The action on bone

is far less clear. In the growing skeleton, testosterone seems to increase skeletal mass (possibly on the basis of androgen-induced increase in muscle mass), whereas estrogen appears to stabilize the skeleton (or at least has an antiosteoporotic effect in postmenopausal women).

Prostaglandin E_2 is a potent stimulator of bone resorption (39). Perhaps because of the combination of bone resorption and formation, bone synthesis may also be stimulated in the immature skeleton. Cyanotic infants treated with prostaglandin E_2 to maintain patency of the ductus arteriosus have been observed to have increased periosteal bone formation (43,46). Osteoclast-activating factor is elaborated by lymphocytes and may have a role in the formation of hematopoietic marrow (19).

The physiology of parathyroid hormone (PTH), vitamin D, and calcitonin are fully discussed later in this chapter. At this point, it is sufficient to indicate that calcium levels are normally maintained constant by the body; phosphate levels vary more with intake, but are also defended. Vitamin D exists in a variety of forms. It stimulates the transport of calcium and phosphate across the intestine and can also stimulate bone resorption. PTH, in response to low serum calcium, stimulates osteoclastic resorption of bone, mediated through osteoblasts (20). PTH increases the renal tubular reabsorption of calcium and decreases that of phosphate. Calcitonin has the reverse effect, promoting the movement of calcium and phosphate into bone. However, at least in humans, its importance does not seem to be as great as that of PTH.

Physical factors are important in regulating bone formation (47,48). Two laws define the effect of load on proliferating cartilage and bone (49). The Hueter-Volkmann principle states that growth plates exhibit increased growth in response to tension and decreased growth in response to compression (50). Wolff's law states that osseous tissue remodels in response to the stress placed across it (51). An example of compressive inhibition of growth, according to the Hueter-Volkmann principle, is the decreased growth anticipated from the concavity of the kyphotic spine in untreated Scheuermann disease. An example of bone remodeling, according to Wolff's law, is the arrangement of the trabeculae in the femoral neck. The basis of these laws at the level of the cell is gradually being elucidated (52,53). Experimental data link mechanical force to a class of cell receptors, called integrins, which transduce the force to changes in the cytoskeleton and, presumably, ultimately to the genome (54).

Although all the factors described previously play a role in the development and function of the skeletal system, genetic determinants expressed through the biology of the cell, even in postnatal life, may be the critical unifying factor. The concentrations of the enzymes necessary for normal differentiation of the skeleton, the number and availability of hormone receptors on chondrocytes and bone cells, the production of hormones, the transport systems for calcium

and phosphate, and the synthetic systems for vitamin D may be genetically determined, and, in normal populations, may ultimately dictate such variations in the size, thickness, and shape of bones. In people whose skeletal morphology falls outside the normal range and who are regarded as displaying metabolic bone disease, genetic errors may be significant factors in the development of the often stereotypical syndrome, either as a primary cause or as an accessory cause. In the pediatric population, in whom acquired disorders are less common, genetic causes should not be overlooked.

The following sections contain discussions of pathologic states and specific disorders often grouped as metabolic bone diseases. They are classified according to whether the primary abnormality is mainly in the mineral phase, in the organic phase, in the endocrine system, or in an indeterminate site.

MINERAL PHASE

Excluding the rachitic syndromes, the bone diseases of children in which disorders of calcium and phosphorus metabolism play a significant role are for the most part either genetic (e.g., pseudohypoparathyroidism, hypophosphatasia, hyperphosphatasia) or iatrogenic (e.g., corticosteroid-induced osteopenia, anticonvulsant rickets, and others). True metabolic bone diseases as seen in adults are rare in children, and disorders such as hyperparathyroidism and milk alkali syndrome are so infrequently seen in the pediatric population that they are rarely mentioned. A discussion of metabolic bone disease in children is mostly confined to the subjects of rickets and renal osteodystrophy (1). To appreciate the aberrations seen in these two still-prevalent disorders, a brief review of calcium and phosphorus balance and homeostasis is essential.

Calcium and Phosphorus Homeostasis

With the exception of the small but important amount of protein-bound and ionic calcium in the serum and extracellular space, most of the body's calcium is stored in the bones and is held in the form of hydroxyapatite, a salt with the generic formula $\text{Ca}_{10}(\text{PO}_4)_6(\text{OH})_2$, which is composed of very tiny crystals embedded in the collagen fibers of the cortical and cancellous bone (55–58). The small size of the crystals ($5 \times 10 \times 20$ nm) provides an enormous surface area, and this factor, combined with the reactivity of the crystal surface and the hydration shell that surrounds it, allows a vast and rapid exchange process with the extracellular fluid. This process converts the mechanically solid structure of bone to a highly interactive reservoir for calcium, phosphorus, and a number of other ions (57,59). In disorders such as rickets and renal osteodystrophy, the depleted extracellular compartment of calcium can be replenished

from the bone compartment, although at the expense of the strength and integrity of the skeleton.

In analyzing the homeostatic mechanisms that control the metabolism of calcium and phosphorus, three truths become evident. These principles underlie all internal shifts, and it is necessary to understand them fully to comprehend the causes and mechanisms of the rachitic syndromes.

First, a principle of inorganic chemistry states that the salt, CaHPO_4 , is not freely soluble in water. At the pH of body fluids, calcium and phosphate concentrations in the serum exceed the critical solubility product, and are presumed to be held in solution by an elaborate inhibitor system. This metastable state allows the deposition of hydroxyapatite during bone formation, with minimal expenditure of energy, and simultaneously makes the body potentially susceptible to ectopic calcification and ossification as a result of increments in either or both of these materials.

Second, a principle of physiology states that the irritability, conductivity, and contractility of smooth and skeletal muscle, and the irritability and conductivity of nervous tissue, are inversely proportional to the calcium ion concentration. The equation for cardiac muscle is the reverse: a direct proportionality. Calcium is also an intracellular messenger, and it may be fundamental to biologic function in differential cellular organelle function (24,60,61). The concentration of calcium in each of these compartments is a fine balance, and, under certain circumstances, an exquisite one, and minimal decreases in ionic calcium concentration can lead to tetany, convulsions, or diastolic death. Conversely, increases in the concentration of calcium can lead to muscle weakness, somnolence, and ventricular fibrillation. It is obviously important for the body to guard the concentration of ionized calcium, and many of the mechanisms to be described are designed to protect against such disasters (62,63).

Third, a principle of biochemistry states that diffusion of calcium across a cellular barrier cannot take place without a transport system. The discoveries of the components of this transport system have constituted some of the major scientific accomplishments of the twentieth century, and have greatly altered our approaches to the treatment of the rachitic syndromes.

The transport of calcium across a gut cell occurs during absorption of calcium from the lumen of the gastrointestinal tract, across the renal tubular cell to the peritubular space in the process of tubular reabsorption of calcium, or across a bone cell in the process of crystal lysis, which occurs during bone resorption (57,59,62,64,65). Although some evidence suggests that the mechanisms for these three processes differ somewhat, they all involve the action of the active form of vitamin D and PTH, and are inhibited by an increase in the concentration of cytosol phosphate (59,66–68). The principal and best-defined model is transport across the gut cell.

The gut cell at the site of absorption of calcium (i.e., distal duodenum and proximal jejunum) has a surface recep-

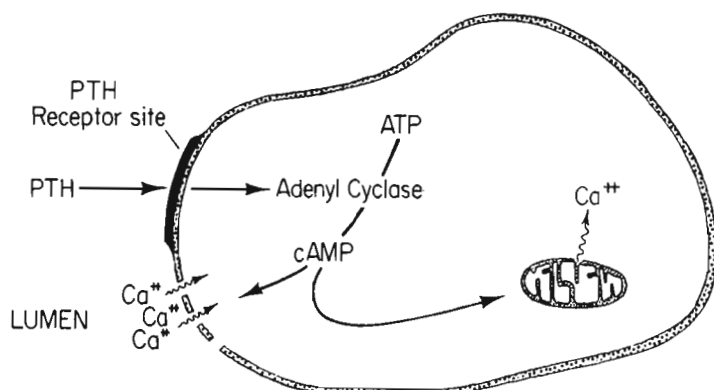


FIGURE 7-1. Action of parathyroid hormone (PTH) in calcium transport in the gut cell. Circulating PTH binds to the receptor site on the cell membrane and activates an adenyl cyclase system that induces the synthesis of cyclic adenosine monophosphate (cAMP) from adenosine triphosphate (ATP). cAMP acts to render the cell membrane more permeable to calcium ions and to induce the mitochondria to release calcium. Both of these actions fill the cytosol with ionized calcium (Ca^{++}). ECF, extracellular fluid.

tor for PTH. The circulating level of PTH is increased in response to a decrease in the serum ionized calcium. The circulating hormone binds to the receptor and activates an intracellular mechanism in which adenosine triphosphate is converted to cyclic adenosine monophosphate (cAMP) by the action of adenyl cyclase (Fig. 7-1). cAMP has two effects. It renders the cell membrane more permeable to ionic calcium, presumably by altering the charge on the membrane, and it induces the mitochondria, which are intracellular storehouses for calcium, to release their calcium. Both actions markedly increase the intracellular concentration of calcium, but do not promote transport to the extracellular space.

At this point, the active form of vitamin D, 1,25-dihydroxyvitamin D₃, or calcitriol, acts intranuclearly to enhance the transcription from DNA of a messenger RNA that codes for the synthesis of calcium transport factor or binding protein (69). This low-molecular-weight protein is capable of binding and transporting calcium across the cell into the pericellular space and the extracellular fluid (70–74) (Fig. 7-2). PTH and vitamin D work independently, but not completely so. Increased concentrations of

PTH are partly responsible for the increased rate of synthesis of 1,25-dihydroxyvitamin D from 25-hydroxyvitamin D. The active form of vitamin D is essential to the system, but the role of PTH is less important (48,66,75,76). This explains why the vitamin D-deficient state is more serious than hypoparathyroidism.

Phosphate does play a role in the calcium transport system. Increases in the cytosol concentration of phosphate, such as those that occur with chronic renal failure, turn off the system and act at the level of the renal tubule to decrease the synthesis of the potent vitamin D (77). Presumably as a protective action against exceeding the critical solubility product for calcium acid phosphate (first principle), high levels of phosphate prevent absorption of phosphate from the gastrointestinal tract, prevent reabsorption of calcium from the renal tubules, and probably prevent lysis of bone crystal. High levels of phosphate do not protect against the osteoclastic resorption of the skeleton associated with excessive concentrations of PTH.

A review of the process by which the ingested or synthesized provitamins D are converted into the active material necessary for transport of calcium can aid in the understand-

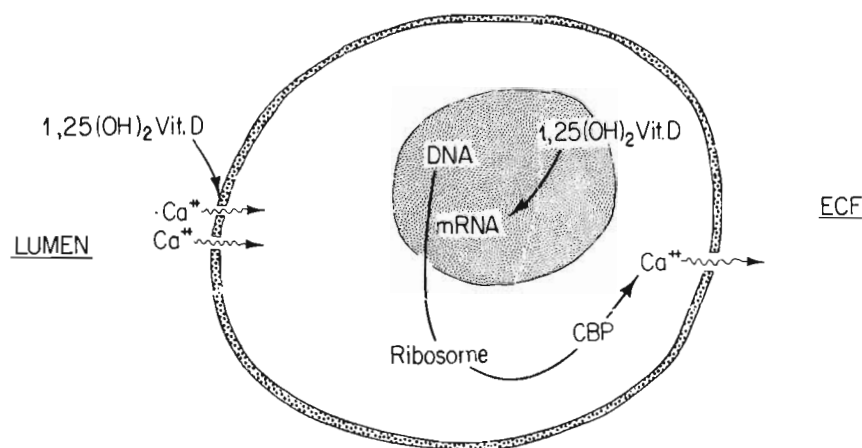


FIGURE 7-2. Actions of vitamin D on intracellular transport of calcium by the gut cell. The active hormone derived from ingested or synthesized vitamin D, 1,25-dihydroxyvitamin D [$1,25(\text{OH})_2\text{Vit.D}$], acts intranuclearly to enhance transcription of messenger RNA (mRNA) for the synthesis of a calcium-binding protein (CBP), a low-molecular-weight protein that is material in the transport of calcium ion across the cell membrane. As for most sterols, 1,25-dihydroxyvitamin D exerts a nonspecific effect on the cell membrane to render it more permeable for the transport of the ionized calcium (Ca^{++}). ECF, extracellular fluid.

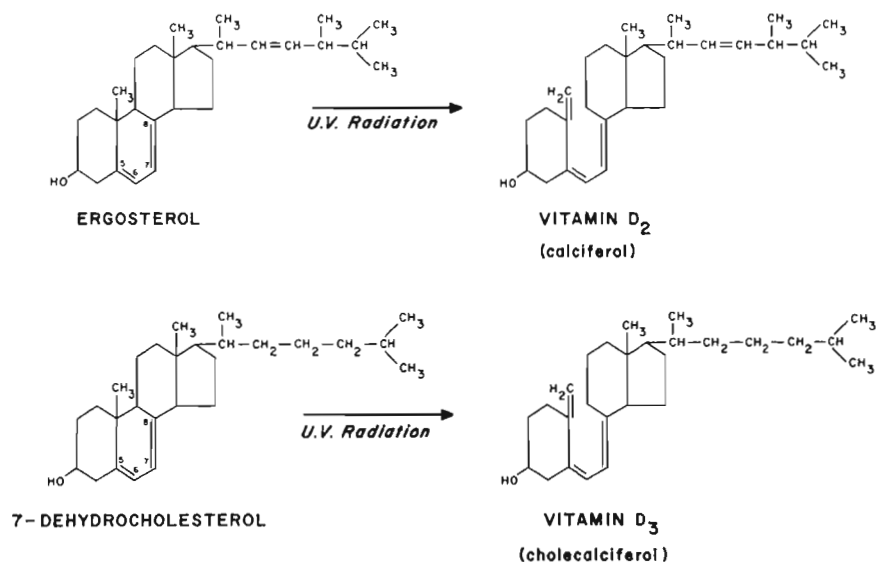


FIGURE 7-3. Provitamins ergosterol and 7-dehydrocholesterol are stored in the skin and activated by ultraviolet (U.V.) radiation to vitamins D₂ and D₃, respectively, by opening a bond in the first ring.

ing of calcium homeostasis and the development of the rachitic syndromes (69). The provitamins D consist of ergosterol ingested in the form of animal fats and 7-dehydrocholesterol synthesized in the liver (55,65) (Fig. 7-3). Both sterols are metabolically inactive, are transported in the serum by a special transport protein, and are stored in the skin (75). In the presence of ultraviolet light at a wavelength of about 315 nm, a chemical conversion occurs with the opening of a bond on the first ring. The structures are activated to form calciferol (i.e., vitamin D₂) and cholecalciferol (i.e., vitamin D₃) (55,78) (Fig. 7-3). The compounds are then transported to the liver, in which, in the presence of an appropriate hydrolase, they are converted to the first polar metabolite, 25-hydroxyvitamin D (Fig. 7-4). In experimental circumstances, the latter material has been found to be more active than the parent compounds, and acts considerably more rapidly (79–83).

The final and most critical conversion occurs in the kidney. In the presence of specific hydrolases and a number of biochemical cofactors, the 25-hydroxyvitamin D is converted to either 24,25-dihydroxyvitamin D or 1,25-dihydroxyvitamin D. The former acts as a balance hormone, probably with only limited action on gut, kidney, and bone. The latter serves as the potent transport promoter for the three cellular sites (48,84,85) (Fig. 7-5). The generic name of 1,25-dihydroxyvitamin D₃ is calcitriol. The conditions that seem to dictate which of the two polar metabolites is synthesized have been established. The data suggest that a low serum calcium level and a high PTH level favor conversion to the 1,25 analog, and a high serum calcium level, a higher serum phosphate level, and a low PTH level favor formation of the less-potent 24,25-dihydroxyvitamin D (47,48,86–88) (Fig 7-5). The protective action of the level of serum phosphate on the calcium-absorptive mechanisms

is essential. A high concentration of phosphate appears to shunt the 25-hydroxyvitamin D into the less active 24,25-dihydroxy form and away from the more active 1,25-dihydroxy form.

In understanding calcium homeostasis, it is important to review some aspects of PTH metabolism and action. PTH is elaborated by the normal glands, almost entirely in response to the serum concentration of ionized calcium (59,62). Magnesium plays a role in release of the hormone, but the synthetic response is directed by a negative feedback system with calcium only (59,89,90). The lower the serum level,

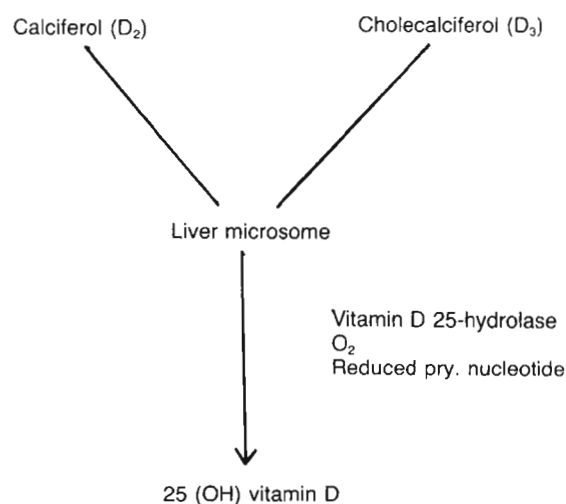


FIGURE 7-4. The first conversion of vitamin D takes place in the liver, where a specific enzyme, vitamin D 25-hydrolase, acts on the molecules to form 25-hydroxyvitamin D, a more active form of the sterol.

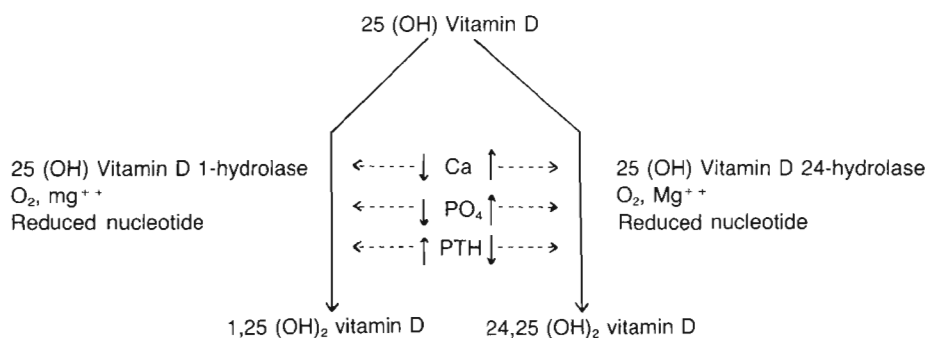


FIGURE 7-5. The second conversion of vitamin D takes place in the kidney, where at least two pathways have been described. The *maintenance* pathway (when the need is minimal, as defined by a normal calcium and phosphorus and a low parathyroid hormone [*PTH*]) occurs in the presence of a specific enzyme (25-hydroxyvitamin D 24-hydroxylase) and results in the less-active 24,25-dihydroxyvitamin D. If calcium transport is required, as signaled by the presence of low serum calcium and phosphorus levels and a high *PTH* level, the body converts the 25-hydroxyvitamin D to the much more active form, 1,25-dihydroxyvitamin D.

the more *PTH* is synthesized and elaborated. *PTH* acts with 1,25-dihydroxyvitamin D to facilitate cellular calcium transport in absorption from the gut, reabsorption from the renal tubule, and lysis of hydroxyapatite crystal (59,66,90). *PTH* acts independently of vitamin D to activate the osteoclast population to resorb bone; this action, and the three others mentioned, tend to flood the extracellular space and serum with ionized calcium, correcting the deficit that initiated the demand (68,90). Such activity puts the patient at risk of exceeding the critical solubility product for calcium and phosphorus. Another action of *PTH* (also probably independent of vitamin D) is to diminish markedly the tubular reabsorption of phosphorus. This causes a phosphorus diabetes and eliminates, at least partially, the threat posed by the increased concentration of ionized calcium (63,77,90).

In considering the actual handling of calcium and phosphorus by the intact mammalian system, it should be apparent that there are three sites of cell-mediated transport, particularly for calcium—the gut cell, the renal tubule, and bone—and that the transport taking place at these sites is

mediated by the synergistic action of at least two hormones exogenous to the cell: *PTH* and 1,25-dihydroxyvitamin D. Both hormones are at least partially controlled by negative feedback to the concentrations of calcium. Both also appear to be inhibited at the level of the cell by hyperphosphatemia. Two other actions of *PTH*, which are independent of vitamin D and uninhibited by hyperphosphatemia, are osteoclastic resorption of bone and decreased tubular reabsorption of phosphorus.

Because of the tight control exerted by the calcium transport system on calcium absorption from the gastrointestinal tract, it is difficult to define a minimum daily requirement for balance (62,78,91). Most people on a well-balanced diet ingest approximately 1.0 g of calcium per day, but, if a person does not eat or drink dairy products regularly, this value may decrease considerably (Fig. 7-6). If a person is in neutral balance for calcium, less than 200 mg of the ingested 1.0 g is absorbed; the remainder passes out in the feces.

In addition to vitamin D and *PTH*, additional factors

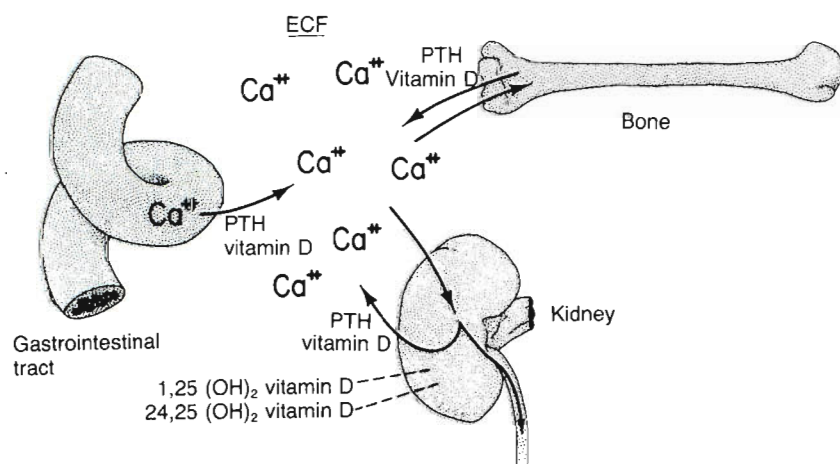


FIGURE 7-6. Calcium kinetics in the normocalcemic state. The synergistic actions of vitamin D and parathyroid hormone (*PTH*) appear to be necessary for the transport of calcium ions across the gut wall. Depending on the need for increased transport, 25-hydroxyvitamin D is converted to 24,25- or 1,25-dihydroxyvitamin D. *ECF*, extracellular fluid.

operating in the gastrointestinal tract significantly affect the absorption of calcium. The first factor is pH (92). All calcium salts are more soluble in acid media, and the ingested ionized calcium is no exception. Loss of the normal contribution of acid from the stomach reduces the solubility of the calcium salts and decreases the absorption of the ionized cation. The second factor is also a function of solubility; CaHPO_4 is not freely soluble at the pH of body solutions, even in the acidic medium of the upper gastrointestinal tract. A diet rich in phosphate may decrease the absorption of calcium by binding the cation to HPO_4^{2-} and precipitating most of the ingested calcium as insoluble material (57,93).

Ionic calcium can be chelated by some organic materials with a high affinity for the element. Although these materials may remain soluble, they cannot be absorbed (93). The materials that bind calcium in this manner include phytate, oxalate, and citrate, and excesses of these substances in the diet may markedly reduce the absorption of calcium (57,93–95). Calcium, in the presence of a free fatty acid, forms an insoluble soap that cannot be absorbed (93,96). Disorders of the biliary or enteric tracts, associated with steatorrhea, are likely to reduce the absorption of calcium, because it forms an insoluble compound, and because ingested fat-soluble vitamin D is less likely to be absorbed under these circumstances (97).

Absorption of phosphorus occurs somewhat lower in the gastrointestinal tract than that of calcium, and probably requires some cellular action (57,62,98) (Fig. 7-7). The action, however, is not selective, and there is not much control exerted by the endogenous or exogenous systems, because most of the phosphorus presenting to the cell in the ionized form (mostly as H_2PO_4^- or HPO_4^{2-}) is absorbed. Approximately 2 g of phosphorus is ingested daily by people on a normal diet; more than three-fourths of this amount is absorbed and eventually excreted in the urine. The only additional conditions in the gastrointestinal tract that exert

any influence on the absorption of phosphate are high concentrations of calcium and the presence of beryllium, an unusual enteric constituent, or aluminum, which is much more common because of the use of $\text{Al}(\text{OH})_3$ in many anti-acid preparations (57,62,98). Aluminum phosphate is a relatively insoluble material, and its formation markedly reduces the rate of absorption of phosphate.

A balance diagram for calcium is shown in Fig. 7-6. The absorption of calcium from the gastrointestinal tract, reabsorption of calcium from the renal tubule, and bone–blood exchange are the three major components of the calcium control system. All are under control of the potent 1,25-dihydroxyvitamin D and PTH synergistic transport system. If calcium concentrations diminish (e.g., in a deficiency state for calcium or vitamin D), the response in the intact normal person is brisk and highly effective (Fig. 7-8). The decreased serum calcium level stimulates the production of PTH, which activates the synthesis of 1,25-dihydroxyvitamin D. Together, the two agents act to increase calcium absorption from the gut, tubular reabsorption of filtered calcium in the kidney, and resorption of bone. (Bone resorption occurs by lysis of the crystalline apatite and by osteoclastic resorption.) Any excess phosphate that appears as a result of the breakdown of bone is, under the influence of excess PTH, rapidly excreted by the kidney by means of a marked decrease in tubular reabsorption of phosphate. In this manner, short-term calcium deficits, even if profound, may be rapidly corrected by a highly effective balance system.

The system in humans that counteracts hypercalcemia is not nearly as efficient as the system that responds to hypocalcemia (Fig. 7-9). The principal mechanism of control is to turn off PTH action and vitamin D metabolism, but there is also a mechanism for decreasing serum calcium, which, at least in humans, is not very effective. The hormone calcitonin mediates this direct mechanism. In avian species, calcitonin is very potent in this role. In mammals,

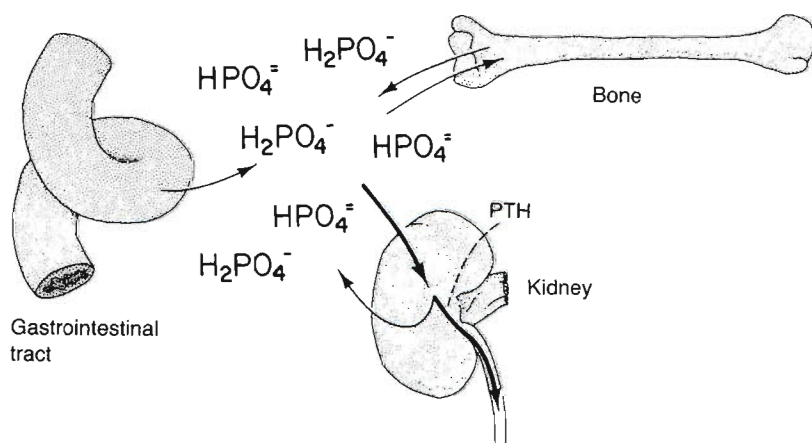


FIGURE 7-7. Diagrammatic representation of phosphate kinetics. Phosphate (PO_4) is absorbed lower in the gastrointestinal tract than calcium, and is freely transported across the gut cell to enter the extracellular space, in which it represents a major buffer system. Transport into and out of the bone is passive and related to the kinetics of the formation and breakdown of hydroxyapatite crystals. Tubular reabsorption of phosphate, however, is highly variable, with reabsorption ranging from almost 100% to less than 50%. The principal factor in decreasing tubular reabsorption of phosphate is parathyroid hormone (PTH).

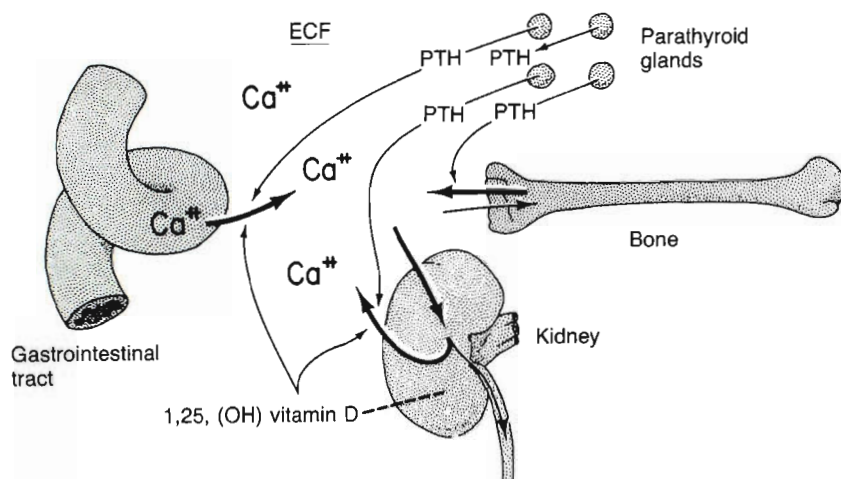


FIGURE 7-8. Calcium kinetics in the hypocalcemic state. A reduced concentration of calcium ion in the extracellular fluid (ECF) signals the parathyroid glands to release more of the potent hormone, which then acts at the level of the gut cell, renal tubule, and bone to increase transport of calcium and rapidly replenish the body fluids with calcium. An increase in parathyroid hormone (PTH) favors the synthesis of 1,25-dihydroxyvitamin D in the kidney and acts to promote phosphate diuresis by markedly diminishing the tubular reabsorption of phosphate.

calcitonin elicits only a limited response. Moreover, the autogenous calcitonin secreted by the C-cells of the thyroid gland is not adequate to counteract a significant calcium overload, acutely or chronically (59,63,99). If exogenous calcitonin is added (even from a different species), it may be effective in reducing hypercalcemia. This effect suggests that the calcitonin receptors, particularly on the bone cell, are operative, but that the autogenous supply or release under control of the response feedback loop is inadequate. The major action of either endogenous or exogenous calcitonin is at the level of bone. Numerous studies have demonstrated that calcitonin decreases the number of osteoclasts and the activity of the remaining osteoclasts (67,99,100). This action reduces the rate of bone breakdown. Such a reduction in bone breakdown seems to be precisely what is desired in Paget disease, and calcitonin has been used

extensively in the treatment of this disease. The actions of calcitonin on the enteric tract and the renal cell remain far less well defined.

Rickets and Osteomalacia

The earliest reports describing the syndrome of rickets appeared in the English literature around 1650, suggesting that the disease is an ancient one (101,102). The history of discovery of the causes of the disorder is a fascinating saga of medical detective work and should be reviewed by the interested reader (1,57,62).

Although there are numerous etiologic pathways, all the disease states grouped under the term "rickets" have as their pathogenic mechanism a relative decrease in calcium, phosphorus, or both, which is of such magnitude that it interferes

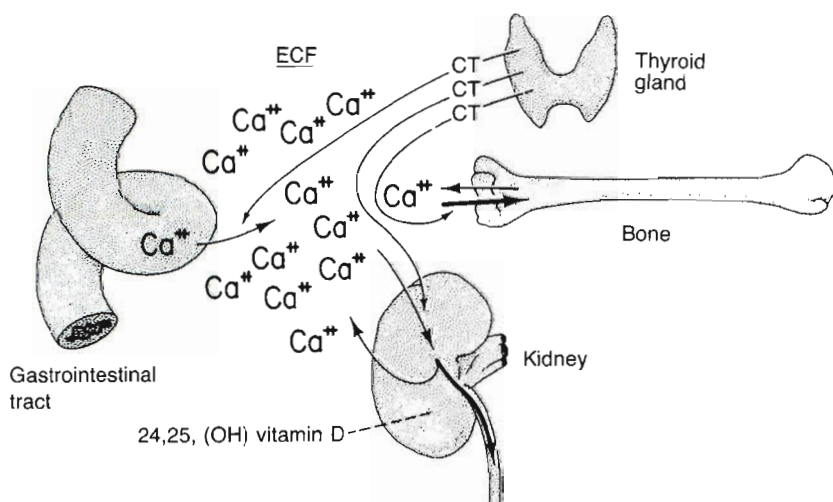


FIGURE 7-9. Calcium kinetics in the hypercalcemic state. Increased concentrations of calcium in the extracellular fluid (ECF) can cause release of calcitonin (CT) from the C-cells of the thyroid gland (the ultimobranchial body in avian species), which acts to diminish calcium concentration principally by stabilizing the osteoclast and decreasing its action on the bone. Hypercalcemia and a low concentration of parathyroid hormone act independently to diminish the synthesis of 1,25-dihydroxyvitamin D and decrease transport of calcium in the gut cell, tubule, and bone. The mechanism is not effective in humans.

with the processes of epiphyseal growth and normal mineralization of the skeleton of the growing child. The counterpart of these disorders in the adult, osteomalacia, lacks the factor of growth abnormality, but the effects on the bones are identical. When rickets or osteomalacia occurs in patients with chronic renal failure, it has additional features that affect the skeleton; it is then known as renal osteodystrophy.

Despite the rather extensive list of possible causes of rickets and osteomalacia, the clinical presentation, histologic abnormality, radiographic changes, and at least some of the chemical abnormalities are virtually identical. All patients with rickets show a striking similarity to one another, and the disease, regardless of cause, is stereotypical in presentation.

Clinical Manifestations of Rickets

Children with rickets are described as apathetic and irritable, often with a short attention span and seeming indifference. They are content to sit for long periods of time, and, as has been noted frequently in earlier texts, often assume a Buddha posture (103,104). The height of children with rickets is often under the third percentile, although their weight may be normal or higher than that of age-matched normal cohorts (105,106).

In younger children with florid disease, a rather remarkable constellation of characteristic signs may be demonstrated. Children with rickets show flattening of the skull, prominence of the frontal bones (i.e., frontal bossing), enlargement of the cartilaginous components of the suture lines (i.e., caput quadratum or hot-cross-bun skull), delayed dentition, enamel defects, and frequent and severe carious lesions in the teeth (107). Examination of the chest is likely to show enlargement of the costal cartilages (i.e., rachitic rosary), indentation of the lower ribs where the diaphragm inserts (i.e., Harrison's groove), and occasionally a pectus carinatum (103,107,108). Children often have respiratory infections, and, in earlier days, pneumonia was a common cause of morbidity and mortality.

The spine is commonly affected in the rachitic child, most characteristically with a long, smooth dorsal kyphosis, known as the rachitic cat back; occasionally, slight to moderate scoliosis of limited progression is seen. Abdominal distension is common (i.e., rachitic pot belly), and diarrhea and constipation have been described.

Children with florid rickets may have weak musculature of the abdomen (contributing to the pot-belly appearance) and of the extremities, which sometimes appear flaccid (109–111). Abductor weakness and a lurching gait are prominent features in some children who are walkers, and the onset of walking is often delayed.

The extremities are most profoundly affected in rickets, and cause the child to be brought to the orthopaedist. Ligamentous laxity is common. The long bones are often some-

what shortened and deformed, usually with bowing abnormalities in the lower extremities and varus deformities of the humeri and forearms. Because of the cupping and flaring of the epiphyseometaphyseal regions, the elbows, wrists, knees, and ankles appear enlarged on physical examination. Fractures are frequent. Slipped capital femoral epiphyses are rarely seen in vitamin D-deficient or vitamin D-resistant rickets, but are commonly seen in renal osteodystrophy (112–115). Mehls and colleagues believe that epiphyseal slippage in renal osteodystrophy results more from the associated hyperparathyroidism and metaphyseal resorption and failure than from the widening of the growth plate (115). This, together with the increasing availability of chronic dialysis while awaiting renal transplantation, increases the population at risk for epiphyseal slippage at the proximal femur and at other anatomic locations (116).

These changes are characteristic of children with severe and florid disease, usually caused by vitamin D deficiency. The changes are rarely seen in the United States today, but may be prevalent in other areas of the world (117–121). The findings usually are subtle and vague (122). The child with rickets is irritable and inattentive. He or she is short, has slightly thickened wrists or ankles, and possibly has bowing of one or both tibias. The diagnostic challenge is much greater with these limited findings.

Histologic Changes in Rickets

The osseous and epiphyseal changes in the rachitic skeleton are striking (107,123–126). The cortices are thinned and often show areas of increased resorption (107,127). The quantity of medullary bone is decreased, and the trabeculae are thin and irregularly shaped. The feature that most significantly helps to establish the diagnosis is the presence of a layer of unmineralized bone (osteoid seam) surrounding a mineralized segment (127–131) (Fig. 7-10). This failure to mineralize newly formed bone appears most prominently in the spicules of the medulla and can be highlighted by appropriate staining techniques (130). Although the finding is not pathognomonic (i.e., it also occurs in hyperparathyroidism, fibrous dysplasia, and some bone tumors), wide osteoid seams are characteristic of rickets and osteomalacia. Bone morphometricians can often establish the diagnosis with certainty on the basis of a properly studied iliac crest biopsy (114,127,128,132). Extensive focal collections of osteoid may be seen in specific locations of the skeleton that correspond to the Looser lines; this finding is pathognomonic of the disease (57,107).

Histologic alterations in the epiphyseal plate seen in rickets are equally striking and are diagnostic. With the exception of hypophosphatasia and, to a lesser extent, the milder forms of metaphyseal dysostosis (Schmid type), no other syndrome produces changes remotely resembling rickets. The resting and proliferative zones of the rachitic physal plate are relatively normal in appearance, although some

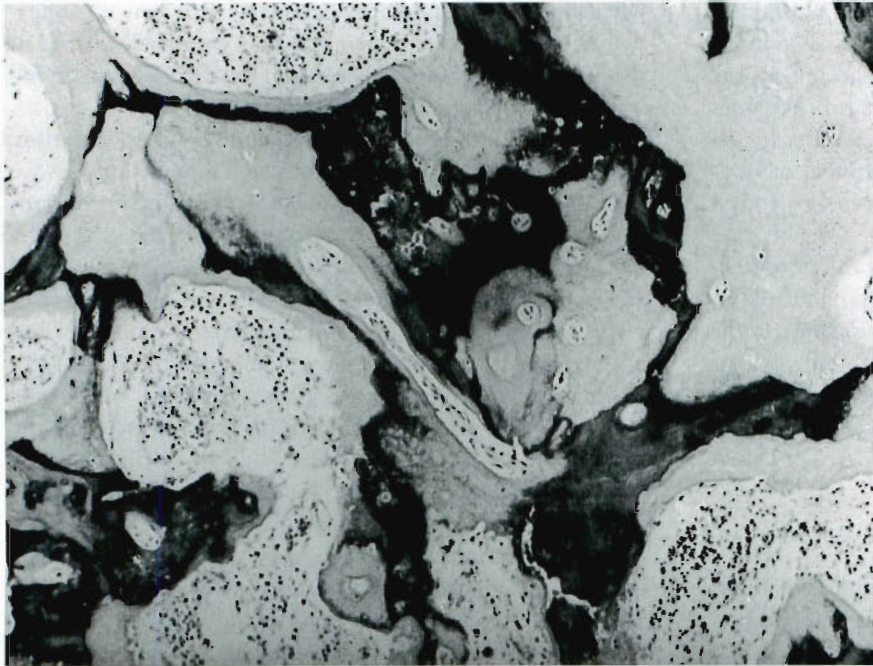


FIGURE 7-10. Histologic appearance of trabecular bone in a patient with rickets. The trabeculae are smaller than normal, but the striking feature is the presence of large masses of unmineralized osteoid surrounding central portions of irregularly mineralized bone. These osteoid seams are not pathognomonic, but when they are as wide as shown in this figure, they are diagnostic of rickets and osteomalacia. The darker-staining central portions of the bone are mineralized, and the lighter outer portions are osteoid. (von Kossa stain; 350 \times original magnification.)

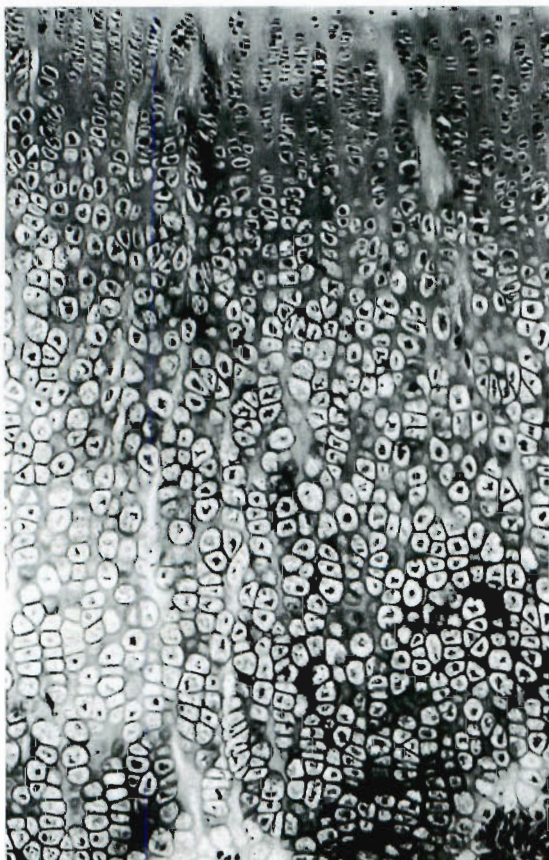


FIGURE 7-11. Histologic appearance of the epiphyseal plate in rickets. The resting and proliferative zones are relatively normal, but there is an extensive and pathognomonic alteration in the maturation zone, which shows a loss of columnization, a marked increase in the axial height of the zone, and a profuse proliferation of the cells. The zone of provisional calcification is poorly calcified and irregular. (Safranin-O, fast green, iron hematoxylin stain; 100 \times original magnification.)

researchers have described a shortening of the columns in the region of the proliferative zone. The maturation zone, however, shows a gross distortion (Fig. 7-11). The normally orderly columnation is usurped by a disorderly increase in the hypertrophic zone, with only a small amount of intervening matrix (107,123,124). The plate is enlarged in its width, presumably because of the softening of the structure, with limited resistance to the mechanical forces acting on it, and, more characteristically, in its axial height, by as much as 5 to 15 times normal (107,123,133).

The zone of provisional calcification seen in patients with rickets is poorly defined, with only a few of the defective bars between the almost nonexistent columns of chondrocytes showing the deposition of mineral (125). Tongues of viable cartilage, without evidence of active endochondral replacement, descend far into the metaphyseal regions (134,135). The blood supply of the physes is altered. The zone of primary spongiosa shows only limited bone formation. The few spicules of bone that form are poorly mineralized or nonmineralized and have wide osteoid seams (107).

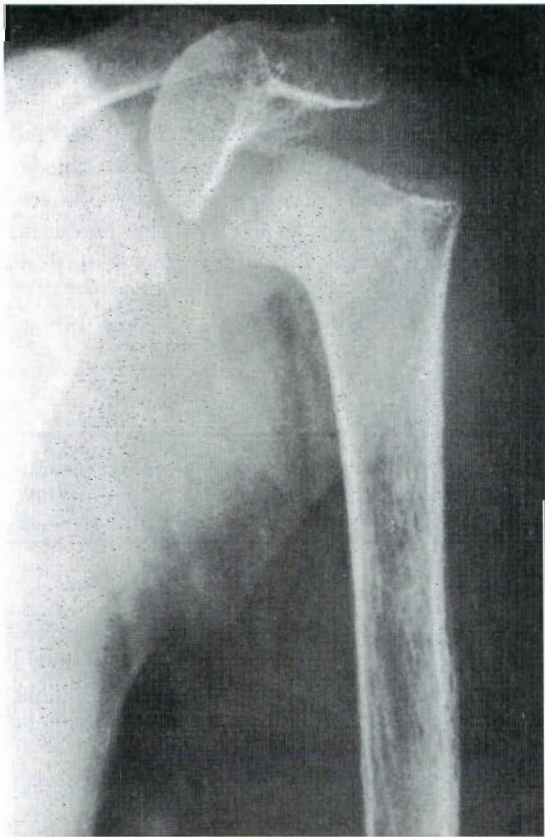


FIGURE 7-12. Radiographic appearance of rachitic changes in the humerus of an 11-year-old girl with florid vitamin D-resistant rickets. Notice the thin and indistinct cortices and the fuzzy, poorly defined trabeculae. The axial height of the epiphyseal plate is markedly increased, and the zone of provisional calcification is almost completely absent.

Radiographic Changes in Rickets

When the clinician has knowledge of the altered histology, it is simple to define the radiographic changes observed in children with rickets (136,137). The decreased bone mass of the skeletal system can be translated into osteopenia, with thin cortices and smaller trabeculae (62,138–140). However, the irregular mineralization of bone, which causes the histologic finding of osteoid seams, creates an indistinct image on radiographs, and the cortical and trabecular markings are often described as fuzzy or coarse and irregular (140–142). The appearance of the physis or growth plate, however, is the most remarkable feature and is virtually pathognomonic (138) (Figs. 7-12 and 7-13). The normally curvilinear, or almost transverse, well-defined line on radiography often shows irregular cupping and widening. In-

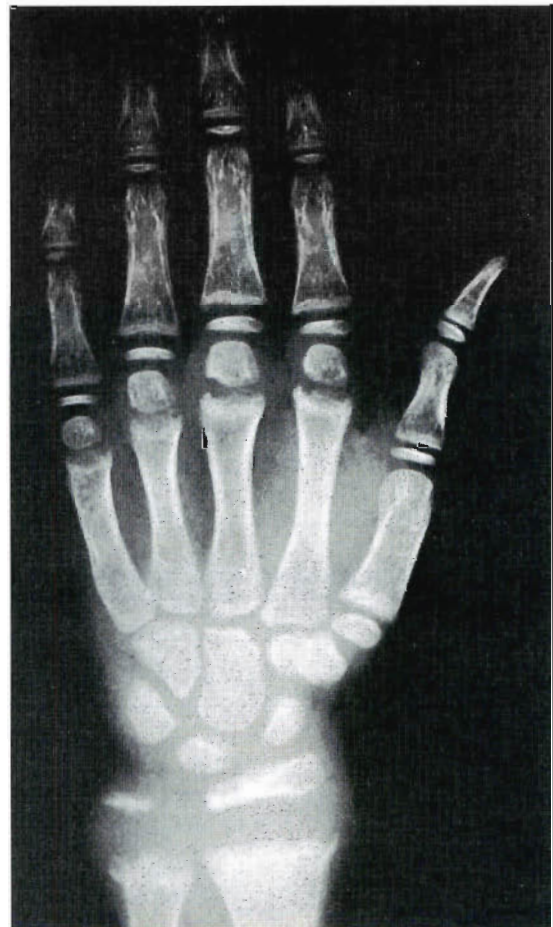

FIGURE 7-13. Changes in the epiphyseal plates of the wrist and hand are seen in this radiograph of an 8-year-old child with florid rickets. The distal radial and ulnar epiphyseal lines are markedly increased in axial height and show cupping; the zone of provisional calcification is absent. The changes in the slower-growing physes of the more distally placed bones are less marked, emphasizing the fact that rickets is a disease of the growing skeleton (in contrast to osteomalacia), and if the physal regions grow slowly, the findings are much less prominent.

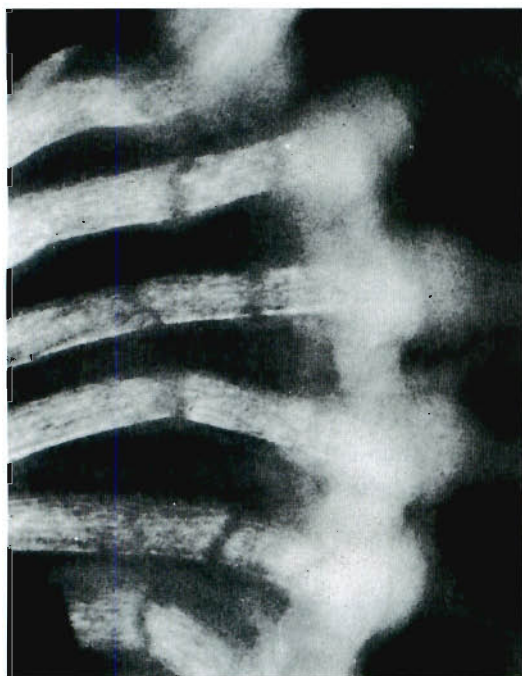

FIGURE 7-14. Looser lines seen in the rib cage of a child with florid rickets. These transverse radiolucent lines, which resemble incomplete fractures, are localized accumulations of osteoid of unknown cause. They are pathognomonic for rickets and osteomalacia.

variably, the axial height of the line is markedly increased (1,62,138). The zone of provisional calcification, which is ordinarily a thin, dense, white line on the radiograph, appears indistinct or is absent (136,140). The primary spongiosa of the metaphysis is often even more osteopenic than

the remainder of the bones, giving a washed-out appearance to the juxtaepiphyseal region (107,139,140,143).

In children with rickets, the most significant finding among the bone changes is the Looser lines, also known as umbauzonen or Milkman pseudofractures (Fig. 7-14). These localized collections of osteoid appear as ribbon-like linear radiolucent lines, transverse to the long axis of the bone, often not extending completely across the bone and preferring the concave sides of the long bones, medial femoral neck, ischial and pubic rami, ribs, clavicles, and axillary borders of the scapulas. Although not true fractures, the Looser lines represent areas of weakening of the bone and may become complete transverse fractures, sometimes with only minor trauma (144). Looser lines occur in 20% of patients with rickets of all types, but are more common in the vitamin D-resistant and renal osteodystrophic groups (143).

Radiographic changes in patients with florid rickets are extensive and virtually unmistakable. However, in mild cases, there may be minimal or no changes, which makes the diagnosis more difficult. Bone scanning is sometimes helpful, because there may be patchy increased activity over the shafts of the long bones, ribs, and skull, especially at the sites of Looser lines (145,146). It is appropriate first to order laboratory tests for calcium, phosphorus, and alkaline phosphatase in suspected metabolic bone disease. After obtaining the history and performing a physical examination, the physician customarily orders radiographs and analysis of the serum calcium, phosphorus, and alkaline phosphatase levels. Although changes may be subtle, this approach usually detects an abnormality (Table 7-3) that establishes the diagnosis or merits proceeding with further testing and obtaining appropriate consultation.

TABLE 7-3. CHEMICAL FINDINGS IN VARIOUS FORMS OF RICKETS

Type of Rickets	Serum						Urine		Miscellaneous Serum and Urine Values
	Ca ²⁺	P	Alk Phos	PTH	25(OH) Vit D	1,25(OH) ₂ Vit D	% TRP	Ca ²⁺	
Vitamin D-deficient rickets	↓ or →	↓	↑	↑	↓	↓	↑	↓	
Dietary phosphate deficiency	→	↓	↑	→	→	→	→	→	
Gastrointestinal rickets	↓	↓	↑	↑	↓	↓ or →	↓	↓	↓ Absorption from gastrointestinal tract
Vitamin D-resistant rickets									Amino acids, sugar, water, base in urine
Phosphate diabetes	→	↓↓	↑	→	→	→	↓↓	→	
Reduced 1,25-dihydroxyvitamin D production	↓	↓	↑	↑	→	↓↓	↓	↓	
End-organ insensitivity	↓	↓	↑	↑	↑ or →	↑ or →	↓	↓	
Renal tubular acidosis	↓	↓	↑	↑	↑ or →	↑ or →	↓	↑	Na ↓, K ↓, Cl ↑; acidosis alkaline urine
Renal osteodystrophy	↓	↑	↑	↑↑	↓↓	↓↓	?	↓↓	BUN ↑

↑, increased; ↓, decreased; →, unchanged or normal; *Alk Phos*, alkaline phosphatase; *BUN*, blood urea nitrogen; *Ca*, calcium; *Cl*, chloride; *K*, potassium; *Na*, sodium; *P*, phosphate; *PTH*, parathyroid hormone; *TRP*, tubular reabsorption of phosphate; *Vit D*, vitamin D forms.

TABLE 7-4. CAUSES OF RICKETS AND OSTEOMALACIA

Deficiency diseases
Vitamin D deficiency
Chelators in the diet
Phosphorus deficiency
Gastrointestinal disorders
Gastric rickets
Hepatobiliary disease
Enteric disorders
Vitamin D-resistant rickets (acquired or genetic)
Phosphate diabetes
Decrease in 1,25-dihydroxyvitamin D production
End-organ insensitivity
Renal tubular acidosis
Unusual forms of rickets
Rickets with fibrous dysplasia
Rickets with neurofibromatosis
Rickets with soft tissue and bone tumors
Rickets with anticonvulsant medication
Renal osteodystrophy

Causes of Rickets

Numerous factors are involved in the pathogenesis of rickets (Table 7-4). The symptoms, physical findings, and radiographic alterations rarely provide clues to the cause of the disease, with the exception of renal osteodystrophy. Most

patients present for evaluation with a remarkably stereotypical pattern.

In general, changes associated with nutritional rickets appear earlier and are milder than those seen with vitamin D-resistant disease (122). Changes occurring with gastrointestinal disease often are consistent with the stigmata of those disorders. Patients with chronic renal disease have findings consistent with severe secondary hyperparathyroidism and may radiographically display ectopic calcification, ossification, and occasionally osteosclerosis. To understand the manifestations of the different types of rickets and how to differentiate them and how to plan treatment, it is essential to consider their pathogenesis.

Deficiency rickets primarily include vitamin D-deficient rickets, possibly chronic calcium deficiency (147), phosphate deficiency (107) (a rare cause), and the presence of chelators in the diet (57,62,128,148,149). All forms are rare in the United States, except in children subjected to highly atypical diets (150–152) or in infants born prematurely (48,131,153–156). The model for the pathogenesis of deficiency rickets (except rickets resulting from primary hypophosphatemia) is shown in Fig. 7-15 (62). The patient's intake of vitamin D is inadequate, and an insufficient quantity of 1,25-dihydroxyvitamin D is synthesized by the kidney. The result is diminished absorption of calcium from the gastrointestinal tract and resultant hypocalcemia, which promotes the release of PTH. Release of PTH partially restores the serum calcium to normal, but causes a marked

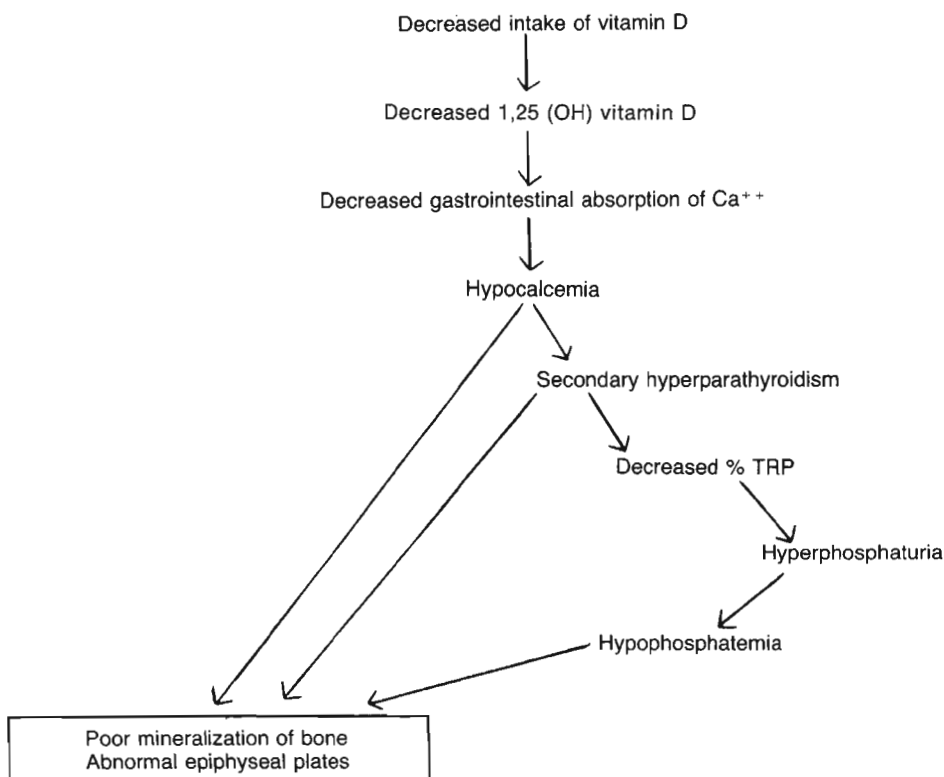


FIGURE 7-15. Mechanism of development of vitamin D-deficient rickets. A diminished intake of vitamin D causes a decreased synthesis of the potent 1,25-dihydroxyvitamin D, which causes a reduction in the absorption of calcium from the gastrointestinal tract. This progression leads to hypocalcemia, which causes a secondary hyperparathyroidism, and a reduced tubular reabsorption of phosphate (TRP), which decreases the serum phosphate. The reduced concentrations of calcium and phosphorus and the secondary hyperparathyroidism cause the clinical, histologic, and radiographic manifestations of rickets and osteomalacia.

decrease in phosphate reabsorption in the kidney. The combination of low serum calcium, mild secondary hyperparathyroidism, and hypophosphatemia produces the syndrome of classic or vitamin D-deficient rickets. Children with this disorder usually show low to low-normal serum calcium levels, low serum levels of phosphorus, elevated levels of serum alkaline phosphatase, elevated PTH levels, low concentrations of 25-hydroxyvitamin D and 1,25-dihydroxyvitamin D, diminished levels of urinary calcium, and markedly diminished tubular reabsorption of phosphate (Table 7-3) (1,57,62,157–159).

Gastrointestinal Rickets. Gastrointestinal causes of rickets are more common in most settings in the United States today than those associated with deficiency states. Gastric rickets, an unusual sequel to ulcer surgery and the dumping syndrome, is rare in children, but hepatic and small bowel problems are considerably more common, and probably account for most of the acquired forms of the disease seen in pediatric practice (160–162). The hepatic causes are principally disorders in which there is an obstructive jaundice or a significant interference with the production of bile salts (163,164). Without the emulsification action of these salts, fat accumulates in the feces and causes a significant interference with the absorption of fat-soluble vitamin D and, if free fatty acids are present, with the precipitation of the ingested calcium ions as insoluble soaps (165,166). In addition, if sufficient hepatic damage is present, synthesis of 25-hydroxyvitamin D is reduced (55,167,168).

In the enteric forms of rickets, injury to the gut wall, caused by such disorders as the malabsorption syndrome (164,169), gluten-sensitive enteropathy (170,171), Crohn's disease, chronic ulcerative colitis, sarcoidosis, and tuberculosis, and by surgical bypass procedures (62,98,164, 172,173), decreases the rate of absorption of both vitamin D and calcium. If the factors of steatorrhea and rapid transit are added, there may be a profound decrease in the extracellular compartment of calcium and the development of mild to moderately severe rickets (157,174). The mechanism by which these disorders produce rickets is not unlike that shown in Fig. 7-15 for classic vitamin D-deficiency disease, except that the causes of the decrease in gastrointestinal absorption of calcium are those just cited. Beyond that level, the disorder progresses in a manner similar to that shown in the illustration. Chemically, the patients are found to be hypocalcemic, hypophosphatemic, hyperphosphatasic, and hypocalciuric, and they demonstrate elevated levels of PTH and variable concentrations of 25-hydroxyvitamin D and 1,25-dihydroxyvitamin D (depending on the amount of interference with the absorption of the vitamin) (175). These patients commonly have test results that show altered hepatic function and diminished absorptive capacity by the gut wall, and abnormalities are discovered on endoscopic and imaging studies designed to elucidate the nature of the disease process in the small bowel (Table 7-4).

Vitamin D-resistant Rickets. Vitamin D-resistant rickets may be acquired or genetic in origin, and have a rather wide distribution of patterns, many of which are eponymically and, less commonly, biochemically distinct (1,57, 62,96,108,152,176–188). Historically, patients with these diseases were first differentiated on the basis of their resistance to the ordinary treatment doses of vitamin D, and were found to have abnormal urinary excretory patterns for phosphate, sugar, amino acids, water, fixed base, bicarbonate, and some unusual materials, such as ketone bodies (i.e., Lowe syndrome) and glycine (i.e., superglycine syndrome) (186,189,190). Others were found to have deposition of crystals of cystine in the liver, bone marrow, and anterior chamber of the eye (i.e., Lignac-Fanconi syndrome) (177,191), or the presence of pure renal tubular acidosis (Butler-Albright syndrome) (192–195). Although it is historically correct and sometimes valuable to categorize vitamin D-resistant rickets in this way, there are only four basic pathogenic mechanisms operative, and all the syndromes result from one (or sometimes two) of these mechanisms (196,197). Grouping the syndromes according to pathogenic mechanisms is a much sounder system, because it better directs the plan of treatment.

There are four types of vitamin D-resistant rickets: phosphate diabetes (i.e., failure of the reabsorptive mechanism for phosphate); failure of production of 1,25-dihydroxyvitamin D (i.e., vitamin D-dependent rickets); end-organ insensitivity to 1,25-dihydroxyvitamin D; and renal tubular acidosis.

In patients with phosphate diabetes, the defect principally lies in the renal tubule and is characterized by a failure to resorb phosphate filtered by the glomerulus (108, 128,197). Although there may be other resorptive defects for glucose (1,183,185,190), amino acids (182, 183,198), or even water and fixed base (1,199) and an impairment of vitamin D synthesis in some cases (197), the main cause of rachitic disease is probably hyperphosphaturia and profound hypophosphatemia (197,200). After examining the mechanism for vitamin D-deficient rickets (Fig. 7-15), it should be apparent that children with phosphate diabetes rickets absorb vitamin D normally, make an adequate amount of 1,25-dihydroxyvitamin D, absorb calcium normally from the gastrointestinal tract, and have no mild secondary hyperparathyroidism. However, they become rachitic because of a vast decrease in phosphate available for mineralization of the skeleton (201). The same mechanism is operative in the rare patient who develops a dietary hypophosphatemia. The chemical findings in this group of patients are unique in that the calcium, PTH, 25-hydroxyvitamin D, and 1,25-dihydroxyvitamin D levels are often normal or only slightly decreased, but the serum level of inorganic phosphate is markedly reduced and the rate of tubular reabsorption of phosphate is often less than 50% (1,108,202) (Table 7-3). Treatment of this group of patients with excessive amounts of vitamin D is of little value, and, to achieve even a partial cure, fairly large doses of

neutral phosphate must be added to the diet often (203–207).

Patients who synthesize inadequate amounts of the potent 1,25-dihydroxyvitamin D are similarly resistant to standard doses of the vitamin, because they are less able to convert 25-hydroxyvitamin D to 1,25-dihydroxyvitamin D (208,209) (Fig. 7-15). Biochemically, they show all the manifestations of the vitamin D-deficient group, except that their 25-hydroxyvitamin D levels may be normal, but their concentrations of 1,25-dihydroxyvitamin D are remarkably diminished (208) (Table 7-3). Treatment of this group is best achieved by the addition of exogenous 1,25-dihydroxyvitamin D, which, if the syndrome has been diagnosed correctly, should be curative (209–212).

Patients who have end-organ insensitivity are similar to patients in the second group, because they ingest adequate amounts of vitamin D, but, instead of a block to synthesis, they produce both polar metabolites, 25-hydroxyvitamin D and 1,25-dihydroxyvitamin D, in ample quantities. The problem appears to lie with the gut cell, which displays a relative insensitivity to autogenous 1,25-dihydroxyvitamin D (142,213). Despite adequate amounts of the active D vitamins, the gut cell is unable to synthesize the transport system, and the movement of calcium is sharply reduced. These patients develop hypocalcemia, secondary hyperparathyroidism, hypophosphatemia, reduced urinary calcium, and reduced tubular reabsorption of phosphate, but the values for 25-hydroxyvitamin D and 1,25-dihydroxyvitamin D are normal or, in many cases, elevated (213) (Table 7-3). Management of patients with end-organ insensitivity is difficult. In some patients, the insensitivity is relatively mild, and can be overcome by increased amounts of exogenous 1,25-dihydroxyvitamin D (still less than the level of toxicity) (213). In other patients, calcium infusions may present a temporary solution, but obviously have limited application in long-term management (214).

The fourth form of vitamin D-resistant rickets, renal tubular acidosis, is a misnomer, because it is not directly related to vitamin D, but is due to an acquired or genetic error in renal handling of fixed base and bicarbonate (192,195,215–217). In one form, the kidney is unable to establish a hydrogen ion gradient, and therefore must excrete fixed base, including sodium and calcium (193). In another form, the failure of the tubule to resorb bicarbonate causes a loss of fixed base as a cation (193). Regardless of cause, the patient develops renal tubular acidosis, characterized chemically by a hyperchloremic, hyponatremic, and hypokalemic acidosis with an alkaline urine (193–195, 218–220) (Table 7-3). In many patients with a broader lesion, resorption of phosphate is also impaired, heightening the degree of metabolic bone disease. In some patients, because of the increased movement of calcium through the collecting system at an alkaline pH (and failure of citrate production), renal calcinosis can be severe and can lead to renal failure (1,62,92,218,221).

Because of the pathogenesis of these syndromes, the use of vitamin D in other than low doses is usually contraindicated. The treatment of choice is correction of the metabolic abnormality by alkalinization. For most patients, this rectifies the metabolic disturbance (219,222).

Unusual Forms of Rickets. Several unusual forms of rickets deserve attention. Three are certain types of vitamin D-resistant rickets and are defined in terms of the disease state and the associated syndrome. For example, severe rickets may be a concomitant finding in patients with neurofibromatosis (1,223,224) or fibrous dysplasia (225–229). Rickets may also occur in certain patients with benign or even low-grade malignant soft tissue tumors or, less frequently, with bone tumors of the fibrous series (230–233). Production of an antivitamin D factor or a phosphaturic agent by the lesion has been postulated, primarily on the basis of the almost immediate reversal of the metabolic and radiographic alteration with resection of the tumor (234) (and the prompt return of the metabolic problem with recurrence of the lesion). A report partially characterizing such a factor has been made (235). The occurrence of hypercalcemia in association with malignancy is discussed in a later section. Its cause has been linked in some cases to the systemic release of an agent related to PTH, parathyroid-related protein. A section describing parathyroid-related protein and its role in metabolic bone disease is included at the end of this section on the entities with pathophysiology primarily in the mineral phase.

Another unusual form is rickets associated with anticonvulsant medication. Patients who receive almost any anticonvulsant medication may develop mild chemical (and occasionally osseous) rickets (111,138,236–242). Although the disorder is reversible with administration of vitamin D, it represents a major problem, partly because it is difficult to diagnose by standard means and, more important, because the irritability of the central nervous system is inversely proportional to calcium ion concentration (i.e., second principle) (243,244). As the concentration of calcium decreases in relation to the use of anticonvulsant medication, the patient may not respond to medication, and may experience more convulsions. The biochemical defect in these patients appears to result from a mild injury to the hepatic cell, which alters the microsomal enzyme system sufficiently to decrease the concentration of 25-hydroxyvitamin D (201,240,242,245). Diagnosis is based on the findings of classic vitamin D deficiency in a child who is receiving anticonvulsant medication. The concentrations of 25-hydroxyvitamin D are usually sharply reduced. The goal of treatment is to increase vitamin D and, if possible, to reduce the levels of the anticonvulsant drugs (246). The relation between the administration of anticonvulsant medication and the occurrence of rickets, in an otherwise healthy population, may not be a simple one (247).

Renal Osteodystrophy

The constellation of clinical problems associated with chronic renal failure affect most of the organ systems and produce moderate to severe impairment of these systems. The skeletal system shares in these disabilities to an extraordinary degree. It is affected by the problems associated with the chronic debilitating illness itself (e.g., osteoporosis, osteomyelitis, gout, and disturbances in calcium and phosphorus homeostasis) and the problems associated with attempts at management (e.g., corticosteroid-induced osteoporosis, osteonecrosis, dialysis osteomalacia, arthropathy). This constellation of problems is subsumed under the term "renal osteodystrophy" (248,249).

In the years that preceded the period of aggressive therapy of chronic renal disease, the prognosis for survival of patients with renal failure was so poor that the osseous manifestations were considered a medical curiosity, worthy only of emergency treatment for fractures and other acute changes,

but of little importance to the overall picture. This pattern has changed radically. With dialysis systems and renal transplantation, patients with chronic renal disease can live considerably longer, and can be expected to participate in activities that require a competent skeleton. Management of the whole patient now demands careful attention to the problems of the skeletal system and a thorough understanding of their pathogenesis (250,251).

Pathophysiology. The pathophysiologic events that lead to the syndrome of renal osteodystrophy are illustrated in Fig. 7-16. Damage to the glomerulus causes retention of phosphate, producing hyperphosphatemia (57,252). Concomitant tubular injury leads to a reduction in the production of 1,25-dihydroxyvitamin D (1,55,253–256). Hyperphosphatemic suppression of 1,25-dihydroxyvitamin D synthesis and reduced tubular mass conspire to offer only a small fraction of the potent principle to the gut cell (257). The

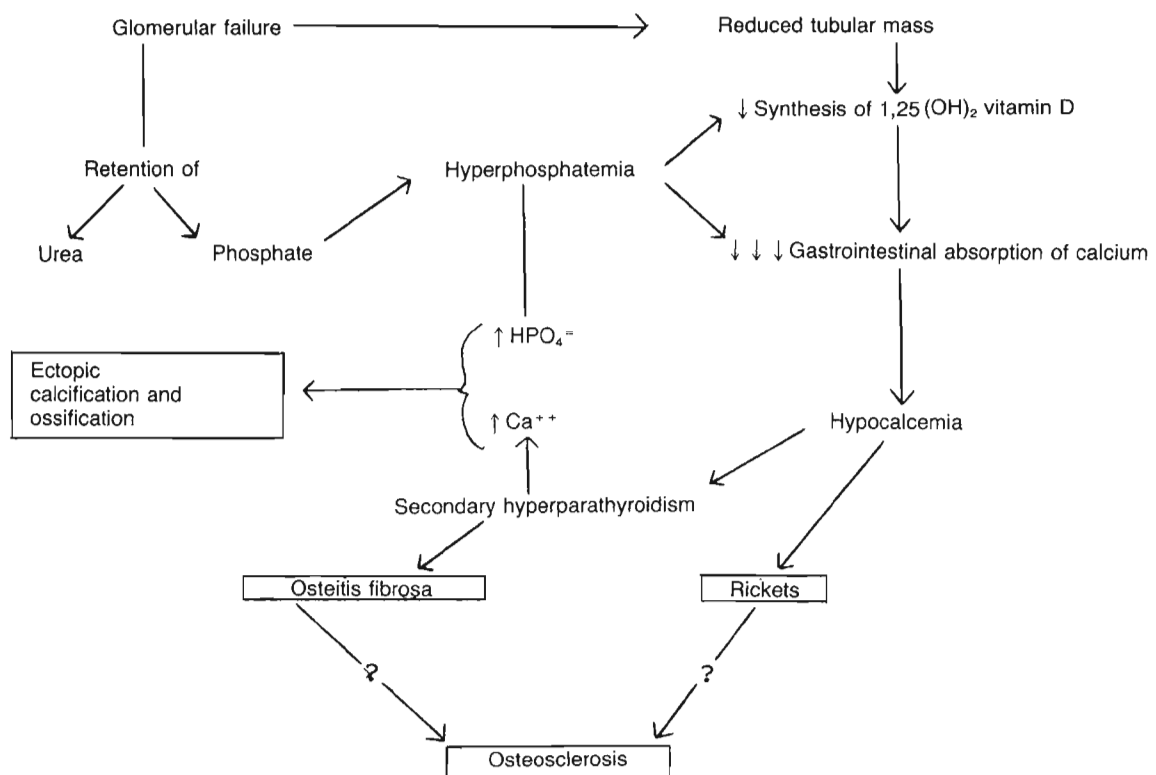


FIGURE 7-16. Mechanism of development of the chemical and bony changes in renal osteodystrophy. Reduced renal function and glomerular failure cause retention of urea and phosphate, leading to hyperphosphatemia, which, along with a reduction in tubular mass, causes a profound reduction in the synthesis of 1,25-dihydroxyvitamin D. This condition, plus the direct effect of increased concentrations of phosphate in the serum, reduces the gastrointestinal absorption of calcium and causes a profound hypocalcemia and severe secondary hyperparathyroidism. These changes produce the clinical syndromes of rickets and osteitis fibrosa. For unknown reasons, 20% of patients with this combination of chemical abnormalities also have an osteosclerosis. Because the phosphate concentration is chronically increased, an occasional increment in the serum calcium level can lead to rapid ectopic calcification and ossification in the conjunctivae, skin, blood vessels, and periarticular regions.

increased concentration of phosphate in the cytosol reduces the absorption of calcium to virtually zero. Balance studies have shown that more calcium is excreted in the feces than is ingested in the diet, suggesting intestinal secretion of the mineral. All these factors conspire to produce a profound hypocalcemia (253,258–264).

If it were not for the acidosis characteristic of chronic renal disease, which makes more soluble the small quantity of available calcium salts, the level of calcium in the serum would lead to severe neural, motor, and cardiac disorders in many patients. The negative feedback system that causes elaboration of PTH in response to decreases in serum calcium is unimpaired by chronic renal failure, and, within a short period of time, marked secondary hyperparathyroidism occurs, usually in the form of a clear-cell hyperplasia of all four glands (1,198,256,265,266). The increased elaboration of PTH is ineffective in increasing gastrointestinal absorption or renal tubular reabsorption, because of the absence of vitamin D and the presence of increased phosphate. The principal action of the increased PTH is on the skeleton (107). The syndrome that occurs includes rickets (associated with the reduced concentration of calcium in the body fluids) and osteitis fibrosa, a severe lysis of the skeleton from overproduction of PTH (107,256,267).

For reasons not fully understood, 20% of patients with renal osteodystrophy also show osteosclerosis, most frequently in the spine, but sometimes affecting the long bones as well, which is characterized histologically by an increase in the numbers of trabeculae, rather than an increased mineral accretion in the osteoid of the rachitic bone or repair of the destructive lesions associated with chronic hyperparathyroidism (268–272).

Patients with chronic renal disease are hyperphosphatemic, and even when there is reduced pH, which shifts the solubility product, they depend on a decreased serum calcium to avoid precipitation of the relatively insoluble CaHPO_4 . If for any reason, such as spontaneous improvement, dietary indiscretions, or dialysis factors, calcium increases to near-normal levels, then calcium salts may be precipitated in a variety of ectopic sites. The principal findings in this unfortunate group of patients depend on the sites of deposition of the salts, but calcification or ossification of the corneas and conjunctivae (red eyes of renal failure) (273–277), skin, muscular coats of the major arteries and arterioles (249,278–281), and periarticular soft tissues is the typical pattern encountered (276,280).

The four pathophysiologic entities—rickets-osteomalacia, osteitis fibrosa (secondary hyperparathyroidism), osteosclerosis, and ectopic calcification/ossification—constitute the syndrome of renal osteodystrophy (282). Frequently associated with this syndrome are the side effects of treatment (e.g., dialysis, steroid treatment), infections, and pathologic fractures.

The pediatric patient with renal osteodystrophy is almost

always shorter than his or her peers, and is slow in reaching milestones and exhibiting age-related phenomena, such as appearance of secondary centers of ossification or signs of sexual maturation (283). Older terms for the disorder, such as renal infantilism or renal nanism, are reflections of this retardation, which is considerably more marked in these patients than in patients with rickets of other causes.

Clinical Manifestations. The patient with chronic renal failure may show all the features of rickets and exhibit bone tenderness and skeletal fragility (107,256,263,283,284). Fractures occur frequently with minor trauma and are very disabling. The presence of calcification in the conjunctivae and skin can produce significant irritation and itching. The periarticular calcification and ossification can cause severe limitation and pain in one or several joints (Fig. 7-17). The gait is disturbed, sometimes because of rickets-associated ligamentous laxity and muscular weakness, and because of slipped femoral epiphyses that can occur from alterations in the mechanics and physiology of the proximal femurs (112,113,115,130) (Fig. 7-18). Slippage of epiphyses at other anatomic sites has been described (115,116). The profound hyperparathyroidism seen in renal osteodystrophy and the consequent resorption of metaphyseal regions, combined with the chronicity of this entity because of modern medical management, provide the basis for the common occurrence of slipped epiphyses (115). Although hyperparathyroidism does exist with vitamin D-deficient or vitamin D-resistant rickets, it is less profound in patients with these entities than in patients with renal osteodystrophy. Moreover, the time for medical correction of these conditions is

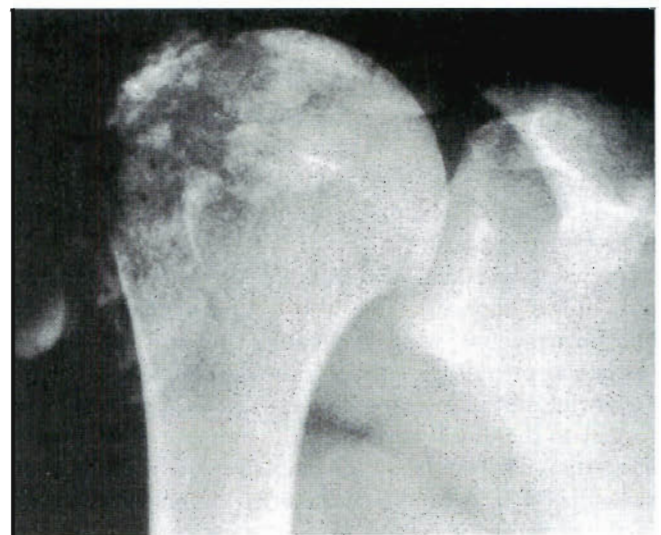

FIGURE 7-17. Radiograph of the shoulder of a young patient with renal osteodystrophy shows extensive calcification in the deltoid muscle, which has caused severe limitation of movement. Because of the radiographic projection, most of the calcification projects over the humeral head.

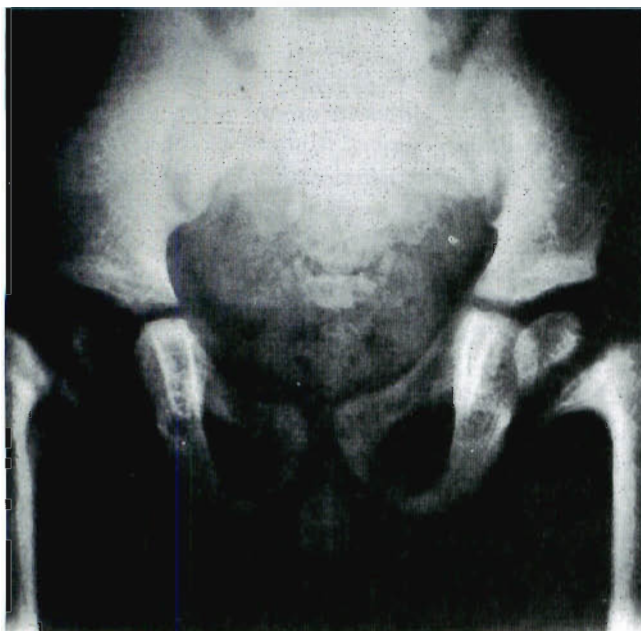


FIGURE 7-18. Renal osteodystrophic changes on a radiograph of the pelvis of a 12-year-old child. Notice the bony changes, suggestive of osteomalacia, and the marked abnormalities of the epiphyseal line, with increased axial height, cupping, and loss of sharp definition of the zone of provisional calcification. Epiphysiolysis also is present. This finding is not commonly seen with vitamin D-deficient or vitamin D-resistant rickets, but occurs frequently with renal osteodystrophy.

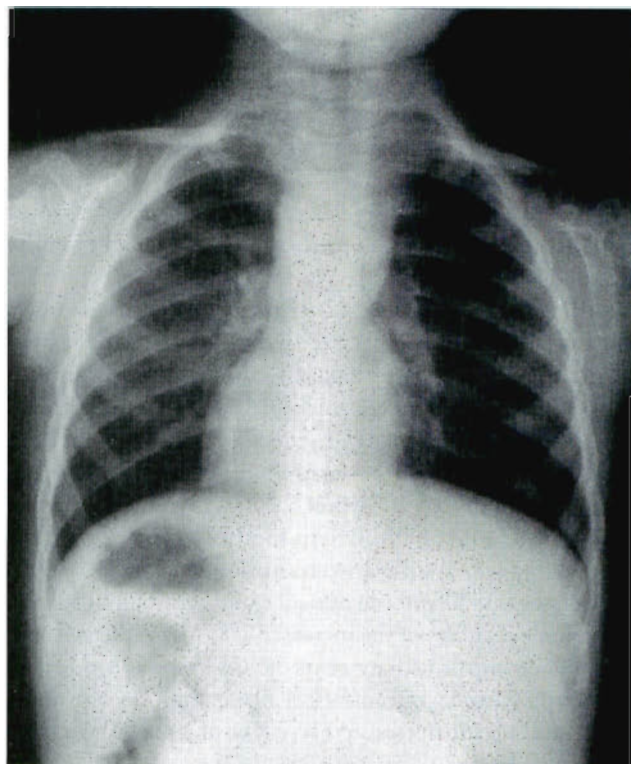


FIGURE 7-19. The radiographic changes of hyperparathyroidism are seen in this patient with renal osteodystrophy. Notice the resorption at the distal ends of the clavicles.

relatively short, and slipped epiphyses are rarely seen in vitamin D-deficient or vitamin D-resistant rickets.

The radiographic changes seen in renal dystrophy are also unique in that the findings of rickets (indistinguishable from those associated with other causes) may be overshadowed by the changes of osteitis fibrosa (268,269,272, 283–287). “Salt-and-pepper” skull, absence of the lamina dura on dental films, loss of the cortical outline of the outer centimeter of the clavicles (288,289), subperiosteal resorption of the ulnas (290) and terminal tufts of the distal phalanges (291–293), and rarefaction and subperiosteal resorption of the medial proximal tibias may dominate the picture (293,294) (Fig. 7-19).

In severe and long-standing cases of renal osteodystrophy, brown tumors, large oval or round rarefactions with indistinct margins, which sometimes thin and expand the cortex and provide the sites of pathologic fractures, may be present in the pelvis or long bones (Fig. 7-20). These may suggest to the unwary examiner the presence of a primary bone tumor or metastatic disease, such as lymphoma or leukemia (107). Areas of sclerosis are occasionally seen next to the areas of rarefaction. This is most common in the spine, in which the alternating areas look like the stripes of a rugby jersey, but a similar pattern is seen occasionally in the long bones. Ectopic calcification and ossification are frequently noted on routine radiographs and, particularly

in the pediatric age group, are helpful in establishing the diagnosis.

The biochemical alterations in patients with chronic renal disease and osteodystrophy clearly reflect the general state of the disturbances in both renal and osseous physiology. Blood urea nitrogen (BUN), creatinine, and uric acid levels are elevated, and acidosis and hypoalbuminemia usually are detected. The calcium concentration is almost invariably low (usually less than 8.0 mg per dL), and the serum inorganic phosphate level is elevated (greater than 5 mg per dL). The alkaline phosphatase and PTH levels are increased commensurate with the extent of the disease. Concentrations of 25-hydroxyvitamin D and 1,25-dihydroxyvitamin D are always diminished, and urinary calcium is low, although fecal calcium is increased (Table 7-3).

Management

The orthopaedist's role in the diagnosis and treatment of the many disorders associated with rickets and renal osteodystrophy has shifted considerably with the understanding of the basic science of these entities. Pediatric orthopaedic surgeons and pediatricians continue to be the principal diagnosticians dealing with children who have findings suggestive of rachitic disease. The various forms of rickets should

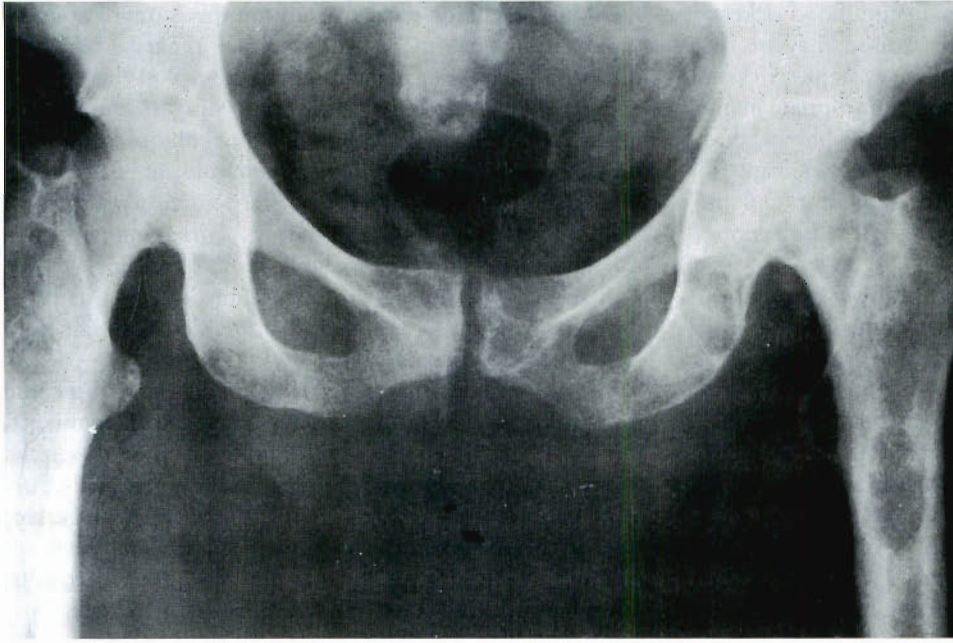


FIGURE 7-20. Radiograph of the pelvis of a patient with renal osteodystrophy shows the marked changes of secondary hyperparathyroidism. Several brown tumors are seen in the femoral shafts and ischial rami. These appear as expanded destructive lesions, resembling primary or metastatic bone tumors.

continue to be important elements of the differential diagnosis in children who present for evaluation with a bowed extremity, repeated fractures, abnormalities of the spine, gait disturbances, diminished height, and failure to thrive. Radiography, radionuclide imaging, and measurements of BUN, creatinine, calcium, phosphorus, alkaline phosphatase, 25-hydroxyvitamin D, 1,25-dihydroxyvitamin D, PTH, and a variety of urinary measurements, also including calcium, are invaluable aids in establishing the diagnosis of rickets and in categorizing according to precise cause. The physician begins with a history and physical examination. Radiographs of the knee, including the most active growth plates in the body, the distal femoral and proximal tibial physes, are useful as a screen. Serum calcium, phosphorus, and alkaline phosphatase levels are customarily measured as part of this initial evaluation. Additional radiographic studies, and the chemical studies suggested in Table 7-3, may then be pursued to a diagnosis. If the pediatric orthopaedist is making the diagnosis, communication with the primary pediatrician is then appropriate, after which further consultation may be obtained with specialists in pediatric nephrology or gastroenterology.

Determination of the change in skeletal morphology associated with metabolic bone disease is guided by general principles, and is designed specifically to address the pathophysiology of the subcategory of illness and the needs of the individual patient. Management of the underlying metabolic disturbance is always the necessary first step, because it alone may be curative, the general health status of the individual depends on it, and orthopaedic intervention without it will prove disappointing. However, will manage-

ment of the metabolic disturbance alone be sufficient to address the skeletal abnormality? Generally, the extent of remodeling that is likely to occur depends on the growth remaining after correction of the abnormal physiology. There are no definitive data about the change in morphology with bracing. Because of the wider experience with children's fractures, remodeling in this setting tends to be appreciated under the heading of clinical judgment. The problem in metabolic bone disease in childhood is more complicated. The underlying pathophysiology may be improved, but not actually rendered normal; growth, the basis for remodeling, may itself be abnormal; and the biomechanical properties of the bone may be particularly adversely affected when the child is most ill, making fixation difficult if operative intervention is undertaken. Every clinical situation requires individual analysis.

In its various forms, rickets tends to manifest in infancy or early childhood. The pediatrician, pediatric endocrinologist, nephrologist, or gastroenterologist addresses the altered physiology with the use of agents such as vitamin D, 1,25-dihydroxyvitamin D, calcium infusions, neutral phosphate solutions, and other dietary and pharmacologic interventions. It is usually possible to achieve a cure in many rickets patients, with expectations of normal growth and lifestyle (250). In fractures and rickets in very low birth weight infants, improved enteral intake is the major intervention, with orthopaedic intervention largely a matter of occasional splinting and observation (295). Similarly, deficiency rickets, gastrointestinal rickets, and vitamin D-resistant rickets in infancy or early childhood usually respond to the correction of the metabolic abnormality. However,

remodeling of skeletal deformity, even in childhood rickets, is not necessarily universal, and intervention may be required, particularly in vitamin D-resistant rickets (206,296). Fractures in childhood require appropriate management. Vigilance for uncommon subsequent physal disturbances is still appropriate. In the multiple-handicapped patient during adolescence, the existence of vitamin D deficiency as the basis of underlying fractures needs to be considered (297).

Angular and rotatory deformities of the lower extremities in metabolic bone disease need to be interpreted from a perspective of natural history. Salenius and Vankka (298) described the physiologic development of the tibiofemoral angle, starting at 15 degrees of varus at birth, becoming neutral at 18 months of age, then proceeding to valgus of approximately 10 degrees, and achieving physiologic valgus at 7 years of age. This general progression is associated with an internal tibial torsion that also tends to change to an external torsion during early childhood (299). The extant alignment at the time of occurrence of the metabolic bone disease is usually accentuated (300). Rickets occurring within the first year of life usually leads to a pronounced genu varum and internal tibial torsion. With correction of the metabolic abnormality, return to the pattern described by Salenius and Vankka is anticipated. If this is not the case, coordination of care between the pediatric orthopaedic surgeon and the physician making the metabolic adjustments is important to ensure that metabolic response is appropriate. After that is ascertained, the issue of bracing arises.

The use of bracing, presumably using the Hueter-Volkman principle intelligently, to change the morphology of the skeleton usually generates some controversy. For physiologic alignment changes, there is little need to brace, and what in the past had been interpreted as a response to brace treatment is generally regarded as the progress of normal development (298,299). For metabolic problems, the pediatric orthopaedist can observe for some relatively arbitrary period. If the malalignment fails to improve in the face of metabolic correction, bracing to counteract the deformity should be considered. Although uncommon in rickets, refractory cases may require surgery (301). Full-length standing radiographs in anteroposterior and lateral planes are essential to establish the deviations in the mechanical axis (302). The sites of the deviations can be established, and the plan for osteotomy or osteotomies can be devised with tracings. In early childhood rickets, fixation that does not affect the growth plates is particularly important [➡6.1–6.6]. Plates have been advocated (301). Before using plates, the osseous tissue quality must be corrected by metabolic intervention, or there is a tendency for the screws to lose purchase. Intramedullary fixation is generally easier to use when there are multiple deviations in the mechanical axis necessitating multiple osteotomies and/or the quality of the osseous tissue cannot be rendered normal, such as in osteogenesis imperfecta and some types of rickets [➡4.11,6.7] (303).

Management of renal osteodystrophy is more complicated and involves management of the primary disorder by dialysis or renal transplantation and control of the calcium and phosphate levels by appropriate drug treatment and infusions (155,304). Occasionally, parathyroidectomy is necessary to control the hyperparathyroidism, particularly in patients with tertiary hyperparathyroidism (304,305). Administration of vitamin D must be carried out with considerable care to avoid the complications of ectopic ossification and calcification (256). Intravenous infusion of 1,25-dihydroxyvitamin D has been advocated in some refractory cases of osteitis fibrosa (306).

As with rickets, the orthopaedic manifestations include fractures, growth disturbances, and angular malalignments. Only some of these resolve with improvement in metabolic status (251). Site-specific fracture management is important. The incidence of fractures should decrease with correction of the metabolic disturbances. Slipped epiphyses are common in renal osteodystrophy at the proximal femur, distal femur, distal tibia, and forearm (115,116,251). Correction of the metabolic status is always the first step to restore the overall physiologic status of the patient and improve the quality of the bone. At sites other than the proximal femur, some period of observation is logical for the remodeling considerations discussed previously, and subsequent corrective osteotomy is performed if remodeling is not occurring. Slipped capital femoral epiphysis in renal osteodystrophy is perhaps more controversial. Although some of the general principles governing idiopathic slipped capital femoral epiphyses also apply, the questions of fixation and bilaterality have led to different approaches (307). Because these slips in renal osteodystrophy can occur in patients younger than 10 years of age, methods of fixation that might allow growth, rather than promoting growth plate closure, at least merit consideration (308). In adolescence, after correction of metabolism, fixation to promote growth plate closure can be performed [➡3.14] (251,309). Concerns have been noted that with metabolic bone problems fixation to achieve growth plate closure may be difficult. Presumably, the purchase of a screw on the weakened bone of the secondary center of ossification and the metaphysis can be overcome by the distractive force of the growth plate. The use of a bone peg to transgress the growth plate and promote ossification has been advocated in such situations, but it is not the only approach (310).

The mechanism of growth disturbance is not completely defined. In addition to the overall physiologic status of the patient, disturbance in the growth factor control of physes has been implicated. Somatomedin disturbance and disturbance in the bone morphogenetic proteins and osteogenic proteins may also occur (311). Because the major production site of one of the osteogenic proteins is the kidneys, renal failure could interfere with its production. The problem of growth disturbance in renal osteodystrophy, even after treatment with transplantation, has yet to be solved.

Because renal osteodystrophy tends to occur in later

childhood, and because there is a physiologic valgus at that point in development, genu valgum is frequently encountered and may persist even after metabolic abnormalities are corrected (251). The principles applied in genu varum can be applied in this condition. Observation during the period of medical management is prudent. Failure to improve over months, in the face of medical improvement, should prompt consideration of bracing. Persistence is appropriately treated surgically. The deviations in the mechanical axis are established with full-length radiographs (302). Valgus occurring through the distal femur is common in renal osteodystrophy and may be treated with stapling toward the end of growth. The amount of overgrowth from the lateral aspect of the growth plate required for correction may be determined from the Green-Anderson growth charts (300). Stapling of the medial aspect of the growth plate may then be performed at the time indicated. If this option cannot be enacted because of insufficient growth remaining, metaphyseal osteotomies may be required using either staple or blade plate fixation (303). An alternative approach is to perform a gradual angular correction with an external fixator (312).

Hypophosphatasia

In some classification systems, hypophosphatasia is included with deficiency states of calcium and vitamin D, renal tubular disorders, and renal glomerular disorders (renal osteodystrophy) as a cause of rickets. Although there are some clinical and roentgenographic similarities, hypophosphatasia has a different pathophysiology from that of rickets. The link should be noted, but the distinction of hypophosphatasia from rickets and osteomalacia must also be made.

Hypophosphatasia was described as early as 1929, but it was subsequently differentiated from the rachitic syndromes by Rathbun in 1948 (313,314). It has since been documented as resulting from a genetic error in the synthesis of alkaline phosphatase by bone, leukocytes, intestinal mucosa, and kidney (314,315). Hypophosphatasia is transmitted as an autosomal recessive trait (316,317). Asymptomatic heterozygotes may also be readily identified by a decrease in serum and leukocyte alkaline phosphatase and, as in patients with clinical disease, by the presence of large concentrations of phosphoethanolamine in the urine.

Patients affected with hypophosphatasia usually show changes early in life (314,316,318). The principal findings in individuals with the fully developed syndrome are growth retardation, failure to thrive, irritability, fever, vomiting, constipation, and signs of increased intracranial pressure (316). Craniosynostosis is a common finding in infants, and the cranial bones may be poorly ossified. Suture lines may be enlarged and bear a close resemblance to craniotabes. As in rickets, dentition may be markedly delayed, and the teeth show extensive caries (319). Examination of the extremities and thorax is likely to show enlargement of the metaphyseal areas adjacent to the joints, bowing, and knock-knee de-

formities, prominent costochondral junctions, and kyphosis. Milder forms of the disorder, in which the onset of symptoms is delayed, have been described and may not be present until adolescent or adult life (317,320,321). Manifestations include fractures after minor trauma, poor fracture healing with laboratory study abnormalities, and the radiographic appearance of osteomalacia (322).

Radiographic studies of the patient affected with hypophosphatasia show generalized osteopenia, most marked in the calvarium and metaphyseal regions of the long bones (323). The bones may be bowed, and the epiphyseometaphyseal areas may show a peculiar cupped or wedge-shaped deformity, principally affecting the center of the physis and irregular notches at the margins (323) (Fig. 7-21). This is similar to the radiographic appearance of rickets. The epiphyseal centers are somewhat delayed in appearance, but normal in outline. Histologic studies show large quantities of unmineralized osteoid in the bones, particularly in regions of active growth and in the region of the synostotic sutures (316). As in rickets, the epiphyseal cartilages are irregular, with lengthening of the columns and diminished vascular invasion and mineralization (314,320).

The cause of hypophosphatasia is believed to be a decreased production of alkaline phosphatase, presumably because of an error in DNA coding by the cells that ordinarily produce the enzyme (316,324). Because the enzyme is necessary for the maturation of the primary spongiosa of the developing epiphyseal plate, the deformities that develop in affected patients are mostly evident in the skeleton, in which they mimic the change of rickets. Synthesis of bone is probably unimpaired, but, because of the relative absence of alkaline phosphatase, the mineralization process is inadequate, and large quantities of osteoid are produced. Diagnosis is based on the finding of a uniformly low concentration of serum alkaline phosphatase, with usually normal values for calcium, 25-hydroxyvitamin D, 1,25-dihydroxyvitamin D, and PTH (313,316,320,321,325). Some severely affected children may have marked hypercalcemia of unknown cause, which is thought to be caused by hypersensitivity to vitamin D (325). An unusual feature of the disease is the increased serum concentration and excessive urinary excretion of phosphoethanolamine (314,325–327). The significance of this finding, which is not specific to hypophosphatasia, is still unexplained (328).

Children or adults with mild forms of hypophosphatasia are often shorter in stature than their peers, but have limited symptoms or signs (317,322). Those with florid disease at birth present major problems in management. Increased intracranial pressure, hypercalcemia, renal failure, and overwhelming infections may cause considerable threat to life. The mortality for the infantile form of hypophosphatasia is high, ranging from 50 to 70% (318). If the child survives, considerable skeletal deformity and disability occur. Fractures are common in these patients and have been shown to heal very slowly (322,329).

There is no definitive therapy. In theory, diseases with

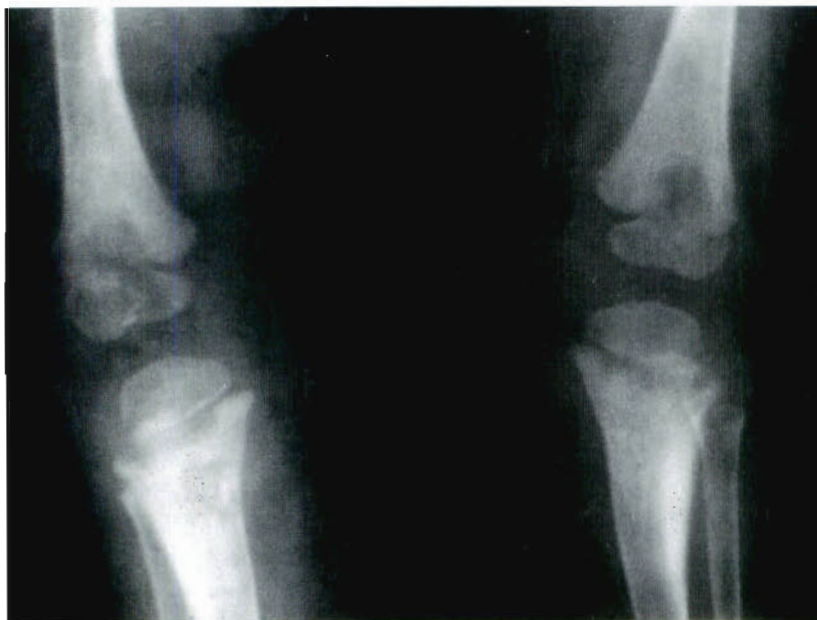

FIGURE 7-21. The central cup- or wedge-shaped ossification defects of the physes are particularly prominent at the distal femurs in a patient with hypophosphatasia.

an enzyme deficiency as the underlying cause may ultimately be treated by introduction of the appropriate gene into a stem cell population, but practical application is still in the future. Vitamin D in large doses has provided some benefit that was reversed with withdrawal of the medication (325). Pathologic fracture in hypophosphatasia (as in metabolic and endocrine entities with bone of poor mechanical quality) may be a difficult problem for the orthopaedist. In the pediatric patient with the severe form of hypophosphatasia, the dilemmas bear a resemblance to those encountered in osteogenesis imperfecta. Intramedullary fixation can be undertaken in an attempt to avoid growth plate injury. In the adult patient, intramedullary fixation and bone grafting may be indicated (322,330).

Parathyroid Disorders

Primary disorders of calcium homeostasis, except for rickets and renal osteodystrophy, are not common in children. Although it is unlikely that the pediatric orthopaedist will be the first practitioner to see patients with parathyroid disorders, it is worthwhile for him or her to be aware of several such entities.

Hyperparathyroidism. An increased level of PTH in renal failure has been discussed previously. In chronic renal failure, the hyperparathyroidism is secondary or tertiary. Secondary hyperparathyroidism is compensatory for the hypocalcemia, and remains reversible with correction of the underlying renal failure. Tertiary hyperparathyroidism is also compensatory originally, but because of the long-standing stimulation of the parathyroid glands, becomes autono-

mous, even with correction of the renal failure. In primary hyperparathyroidism, autonomous hyperfunction of the glands occurs not as a compensation for any antecedent stimulus, and hypercalcemia itself is the basis for the presenting symptoms (331–333). In the clinical situation, because of the diffuse effects of the disturbance in calcium homeostasis, the symptoms at first are bewildering. If the mnemonic device, “stones, bones, and abdominal groans,” is remembered, the bewildering complaints become explicable on the basis of hypercalcemia. The critical solubility product of calcium and phosphorus is exceeded; precipitation in the urinary tract leads to renal calculi and colic. The induced osteoclastic resorption of bone causes skeletal pain. Smooth muscle action in the gut is inhibited by hypercalcemia. Abdominal pain, constipation, and weight loss follow. The irritability and conductivity of nervous tissue are decreased by hypercalcemia. Aberrations of mental status and, ultimately, lethargy and obtundation ensue. Hypertension is frequently present.

The radiographic features of primary hyperparathyroidism are similar to those of secondary hyperparathyroidism. There is generalized osteopenia and cortical thinning. Resorption is particularly severe at the terminal tufts of the distal phalanges and the distal clavicles (Fig. 7-19).

The classic laboratory findings in patients with hyperparathyroidism are elevated serum calcium, decreased serum phosphorus, and elevated alkaline phosphatase (333). Unfortunately, these values can be normal, despite an elevated PTH. Further testing may be required in difficult situations to establish the diagnosis. These tests include a urinary clearance study to clarify a decreased percentage of tubular reabsorption of phosphate, measurement of urinary cAMP, and assaying directly for serum PTH.

Treatment is directed toward correcting the underlying cause of hyperparathyroidism. For adenomas and hyperplasia, treatment is usually surgical (334). Preliminary metabolic management may be required. Although fractures can occur and need to be managed by customary principles, there should be pediatric endocrinologic management of the hypercalcemia (335,336).

Hypoparathyroidism. The manifestations of hypoparathyroidism are recognized more easily by the disturbance of calcium homeostasis than by the skeletal changes (337). The principles of calcium homeostasis discussed previously logically explain the symptoms and signs that are seen. Irritability of nervous and muscle tissue is high because the serum calcium is low (338). Tetany, paresthesias, and alteration in mental status may be seen. If hypocalcemia occurs early in development, mental retardation may result. If it occurs later, mood changes may be seen. The Chvostek and Trousseau signs are used to elicit the tetany and spasm.

Radiographic findings in patients with hypoparathyroidism include increased density of the long bones and skull. Soft tissue calcifications, including the basal ganglia, may also be seen.

Laboratory changes include a decrease in total and serum ionized calcium and elevated serum phosphorus. As with all calcium measurements, hypocalcemia must be interpreted with the serum albumin, because decreased albumin necessarily leads to decreased bound serum calcium and total serum calcium.

Treatment for hypoparathyroidism is endocrine-related, rather than orthopaedic (339). The principal treatment agent is vitamin D. Vitamin D and PTH work synergistically to facilitate the transport of calcium across the gut, by the renal tubule, and from the bone. Vitamin D is capable of exerting its effect at each of these sites. Considerably higher than physiologic (i.e., pharmacologic) doses of vitamin D are required. Management must be carried out very carefully to avoid vitamin D toxicity.

Albright Hereditary Osteodystrophy. In 1942, Albright et al. described a syndrome of short stature, short metacarpals, and rounded facies, and termed it "pseudohypoparathyroidism" (PHP) because of the associated hypocalcemia and hyperphosphatemia that were unresponsive to parathormone (340). A similar syndrome was subsequently described in which affected patients demonstrated all the clinical stigmata of PHP but showed no chemical alterations. This disorder, also genetic and presumably a variant, was termed "pseudopseudohypoparathyroidism" (PPHP). The hypocalcemia was demonstrated to be a variable expression in the same entity, so both PHP and PPHP are now included under Albright hereditary osteodystrophy (AHO).

AHO is more an endocrine than an orthopaedic entity (341). Skeletal changes are present, however, and the disorder represents an unusual but important form of metabolic bone disease that is associated with end-organ insensitivity.

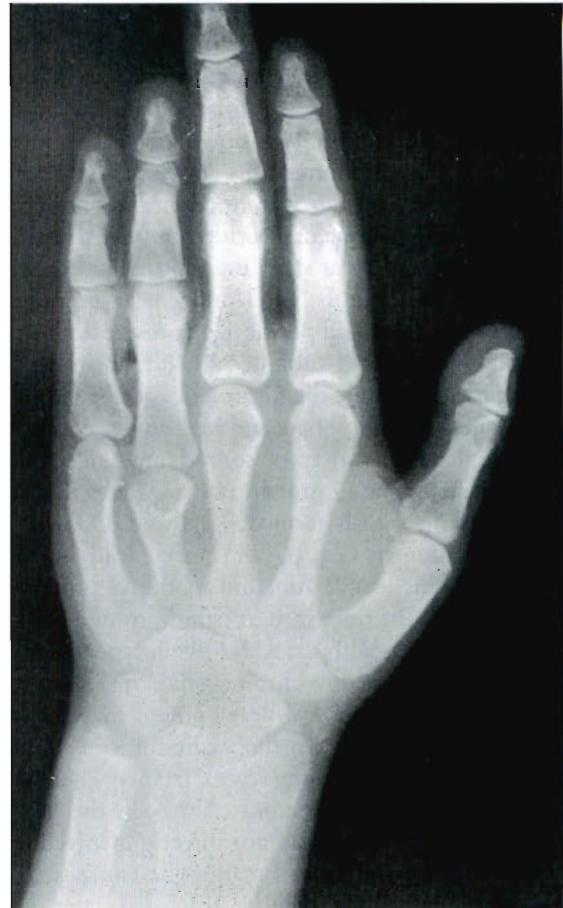

FIGURE 7-22. Radiograph of the hand of a patient with pseudohypoparathyroidism. Notice the shortened fourth and fifth metacarpals.

In addition to the characteristics of AHO already mentioned, mental retardation and central nervous system irritability and tetany are also present. Radiographs may reveal soft tissue calcifications that are especially common in the basal ganglia. Hand films demonstrate shortening of the fourth and fifth metacarpals (Fig. 7-22). Brachydactyly can be seen as part of many syndromes (342). In AHO, workup is usually pursued by genetics and pediatric endocrine services. Biochemical findings include a low serum calcium and a high serum inorganic phosphorus concentration in PHP, and these may require metabolic management.

The phenotype of AHO with PHP became regarded as a genetic disorder in which production of PTH was normal, but the cells that serve as the target for the hormone were unresponsive (341,343–346). Several different types of defects were felt to cause the lack of response. A sex-linked dominant mode of transmission with variable penetrance was one type. Heterogeneity existed even beyond the PHP/PPHP presentations, and other modes of transmission were suggested.

Because of advances in the molecular biology of develop-

ment, mechanisms are gradually being established linking developmental genes (Chapters 1 and 6), growth factors, and autocrine, paracrine, and endocrine factors (347–349). Perhaps the most important issue for a pediatric orthopaedic surgeon to appreciate in AHO is how these factors interact; it is also important to contrast this entity with fibrous dysplasia. This necessitates an introduction and short review of G proteins. G (guanine nucleotide-binding) proteins are on–off switches in cellular signaling (350). They consist of three polypeptide subunits (α , β , and γ) that are noncovalently associated. In the off position, guanosine diphosphate is tightly bound to the α -subunit. When a hormone binds with its cellular receptor, the G protein is activated by displacing guanosine diphosphate and replacing it with guanosine triphosphate. A variety of second messengers can in turn be activated. The G protein that mediates the activation of adenylyl cyclase is termed G_s . In AHO, there is a germline mutation in G_{α_s} (*GNAS1*) that leads to loss of function. It is this loss of function of the G protein that causes the end-organ resistance to parathormone (351). At least in some patients with the AHO phenotype, the genetic defect has been localized to chromosome 2q37. Genes important in skeletal and neural development may lie in this region (352). The pediatric orthopaedic surgeon should be aware of this correlation among several factors, which is now being linked back to the genome. Although the pediatric orthopaedic surgeon is usually not directly involved in patients with AHO, this entity can now be contrasted with fibrous dysplasia, which will be discussed later in the chapter.

Hypercalcemia

In addition to the hypercalcemia associated with hyperparathyroid states, there are several other causes of hypercalcemia in childhood (353,354). These causes are relatively rare and are more frequently based on endocrine disorders than on metabolic bone disease. These entities are often of considerable importance; therefore, despite their rarity in orthopaedic practice, a brief review is necessary.

Hypervitaminosis D can cause a profound and occasionally life-threatening hypercalcemia. Vitamin D and the potent 1-hydroxyvitamin D and 1,25-dihydroxyvitamin D are used in the treatment of rickets, osteomalacia, and hypoparathyroidism. Despite the clear need of the patient, it is possible to overdose with these drugs, especially with potent analogs, and the resultant hypercalcemia causes a situation similar to that described in the section on primary hyperparathyroidism. Treatment consists of decreasing the serum calcium. Vitamin D administration should be stopped, and the patient should be promptly treated by diuresis, which is usually accomplished by administration of large volumes of saline and furosemide. Replacement of urinary losses of water, sodium, and potassium is often necessary, and these should be carefully monitored. Although sodium phosphate

infusions were advocated at one time, they are now contraindicated, because a reconsideration of the calcium homeostasis mechanism clearly indicates that such an infusion is likely to cause precipitation of calcium acid phosphate. Administration of oral phosphate in a nonabsorbable preparation binds calcium in the intestinal lumen and decreases absorption. Glucocorticoids can diminish calcium absorption and decrease tubular reabsorption.

Hypercalcemia can be seen in association with some neoplasms, although more frequently in adults than in children (355,356). The mechanisms postulated are multiple. Direct invasion of bone by massive metastases can produce hypercalcemia. Some tumors tend to produce agents that act in a manner similar to PTH or prostaglandins and cause significant increases in the resorption of bone, and sometimes profound hypercalcemia (39). The discovery of parathyroid-related protein occurred because of its role in the hypercalcemia of malignancy. Its role in the physiology of cartilage regulation has been demonstrated to be essential, and this will be described in detail in the following section.

Treatment of the hypercalcemia of malignancy begins as just described for hypervitaminosis D. In some cases of malignant disease, treatment with mithramycin, a chemotherapeutic agent that interferes with osteoclastic resorption, may be justified.

Hypercalcemia arising during periods of immobilization has been reported, more often in adults than in children (357–361). Disuse osteoporosis is not an unusual consequence of immobilization, but it is almost never associated with hypercalcemia. Children placed on prolonged bed rest, in traction or casts, can rarely develop a florid hypercalcemia, with lethargy, obtundation, abdominal symptoms, and urinary calculi (361). However, hypercalcemia must be considered in the differential diagnosis in immobilization situations. Treatment is as described for hypervitaminosis D.

Idiopathic hypercalcemia of childhood is a rare condition, seen more often in Great Britain than in the United States. The disorder is not clearly a single entity, and most recently it has been considered to be a series of heterogeneous syndromes. One of the more common syndromes, Williams syndrome, is characterized by a peculiar elfin facies with a small mandible and upturned nose (362). Cardiovascular anomalies, such as supravalvular aortic stenosis, have been reported, in addition to mental retardation. The multiple anomalies suggest an *in utero* mesenchymal defect, but the relationship of the abnormality in calcium handling to the other defects is not clear. Williams syndrome should be distinguished from the idiopathic hypercalcemia that was first described in Great Britain and thought to be due to hypervitaminosis D secondary to overzealous supplementation.

Parathyroid-related Protein

The hypercalcemia of malignancy has been studied. A circulating peptide was detected that seemed to be mediating

this phenomenon. PTH was a logical candidate. However, this peptide shared homology with PTH, yet was distinct from it. It was named "parathyroid-related protein" (PTHrP). Subsequently, it was shown that PTH and PTHrP, although distinct, shared the same cellular receptor. Under physiologic conditions, PTH is a circulating hormone and PTHrP exerts its effect locally in autocrine or paracrine fashion. In the growth plate, PTHrP is part of a negative feedback loop that slows the conversion of chondrocytes from the small cell to the hypertrophic phenotype. In certain malignancies, PTHrP may be released into the circulation. The shared PTH/PTHrP receptors are activated. The result is hypercalcemia through the mechanism described for hyperparathyroidism, yet the PTH levels are not elevated.

Further work then demonstrated that the Jansen-type chondrodysplasia results from a continually active PTH/PTHrP receptor. This abnormal receptor mediates a too-rapid conversion from small to hypertrophic chondrocyte in the growth plates, with resultant short stature. Because the receptor is continually on, a hypercalcemia results from the systemic effects on bone and kidney, as in hyperparathyroidism (363,364).

The Schmid-type chondrodysplasia has the radiographic appearance of rickets. This dysplasia results from an abnormality in type X collagen, the collagen associated with endochondral ossification at the lower hypertrophic zone of the growth plate (365).

The molecular bases of these two types of metaphyseal chondrodysplasias are included here to illustrate the correlations that may now be drawn among embryology (Chapter 1), molecular genetics (Chapter 6), metabolic and endocrine abnormalities (Chapter 7), and clinical genetics (Chapters 8 and 9). The signals that regulate embryonic cartilage and bone formation are recapitulated during growth and in fracture repair (6).

Heavy Metal Intoxication

Heavy metal poisoning is usually not considered among the metabolic bone diseases of children. Indeed, the manifestations of lead intoxication, which is the most common variety of metal poisoning, are more frequently neurologic and gastrointestinal than osseous (366). However, the pediatric orthopaedist may be presented with certain radiographic findings that should be recognized (367).

Lead can be stored in the metaphyses, where bone is being rapidly laid down by growth plates. The radiographic appearance is characteristically broad bands of markedly increased radiodensity located in the metaphyseal area, adjacent to the epiphyseal plates (Fig. 7-23). Normally, the metaphyseal region in growing children may appear slightly more dense than in adults, because the zone of provisional calcification and the primary spongiosa on the metaphyseal side of the growth plate contain calcified cartilage. Calcified cartilage has more mineral than bone, and is more radio-

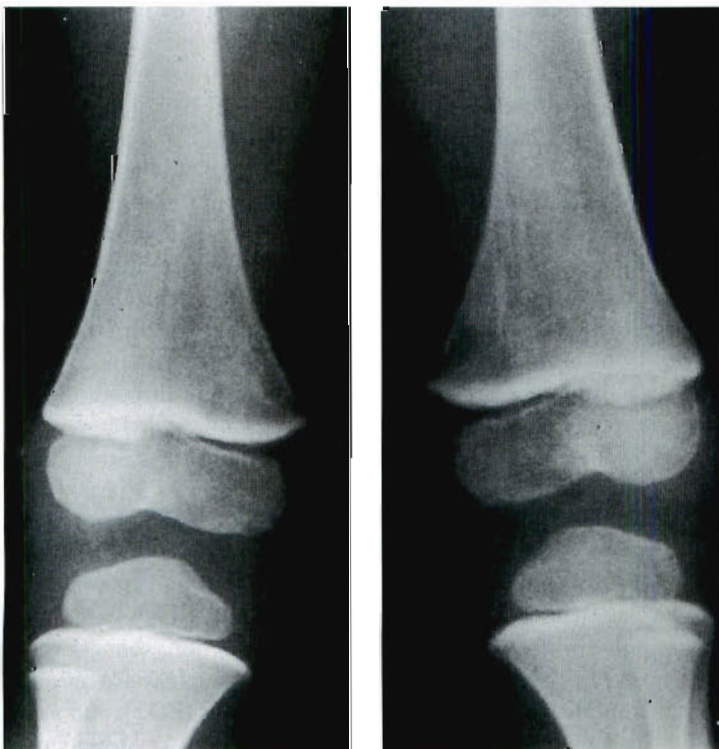


FIGURE 7-23. Radiograph of the knee of a patient with lead poisoning. Notice the broad, radiodense metaphyseal lines. Lead has accumulated at the site of bone formation.

dense. The radiodensity in most cases of lead intoxication is far beyond the normal range. In a few cases, the radiographs are negative or equivocal. Lead lines in the gums and hematologic and chemical findings establish the diagnosis (343).

ORGANIC PHASE

Although differentiation of the mineral phase from the organic phase of bone metabolism is simplistic and neglects interactions between the two phases, the classification is useful for discussing physiology and differentiating clinical syndromes. Mineral homeostasis was discussed earlier in this chapter. The diseases of the organic phase are introduced by a brief review of the cellular and organic aspects of bone physiology.

Bone Physiology

Bone is a specialized form of connective tissue with several important roles. It is rigid, provides form, and contributes to structural stability. Bone is the primary body store for calcium and phosphorus and also serves as an envelope for the blood-forming marrow elements. When injured, bone normally heals with its native tissue rather than scar. In the child, the modeling process accounts for growth and continued reshaping of the bones (368). In the adult, although the shape of the bones in **general remains** unchanged, the tissue undergoes continued internal remodeling, in which bone cells are responsible for continued resorption and formation, resulting in the replacement of old bone by new bone (369,370).

Bone is a composite material. Based on dry weight, 77% is inorganic, primarily hydroxyapatite. The remaining 23% is organic, and almost 90% of this is in the form of collagen. The remaining noncollagenous organic material consists of phospholipids, other glycoproteins, and proteoglycans. The collagen molecules within the fibers are highly ordered, with the fibrillar arrangement consisting of a three-fourths stagger (16). There is an 8% overlap that produces hole zones essential to the deposition of hydroxyapatite crystals and the linkage to the noncollagenous proteins within and in juxtaposition to the collagen fibers. The biomechanical properties of bone in part result from the organic and inorganic components. Bone is anisotropic; the collagen molecules and fibrils, haversian systems, and trabeculae are not randomly oriented. Their orientation ensures that the biomechanical properties of the materials composing the tissue are maximized.

The collagen molecule is a macromolecule made up of three polypeptide chains, each of about 1,000 amino acids, arranged in a triple helix (371–373). One-third of the amino acids are glycine, and 20 to 30% are proline or hydroxyproline. Many different types of collagen have been

described (13,371,372,374) (Table 7-2; refer also to Chapter 6). Type I collagen, the most common, is found in bone, tendon, and skin. Type II collagen is the predominant form in cartilage.

The individual chains of collagen are synthesized in the rough endoplasmic reticulum, and assembled into a triple helix intracellularly before extrusion. Several posttranslational changes occur, including hydroxylation of some of the proline and lysine residues and glycosylation of some of the hydroxylysine residues. The hydroxyproline residues make the triple helix more heat-stable, and the hydroxylysine residues are important in the development of cross-links. After translocation to the extracellular space, portions of the amino- and carboxy-terminal nonhelical portions of the procollagen molecule are cleaved, and the collagen molecules aggregate to form fibrils in which additional reactions occur to produce stable intramolecular and intermolecular cross-links. Interspersed around the collagen molecules are the other noncollagenous proteins.

After collagen production, additional events occur that render the bone matrix (osteoid) mineralizable. Under appropriate conditions, including the presence of adequate amounts of calcium and phosphorus and the production of alkaline phosphatase by the cells, the hydroxyapatite crystals are deposited within the collagen fiber. Many aspects of the mineralization process are still being investigated (13,25, 375–377). Some investigators have suggested that the process is due primarily to physicochemical phenomena that occur as a result of the specific nature of collagen and noncollagenous organic structure. Others have suggested that mineralization begins as an energy-dependent intracellular process that requires the presence of one or more vitamin D metabolites. Proteoglycans also may play a significant role in the process (378).

The process is not completed with the end of mineralization. Because of incompletely understood signals, bone as an organ responds to stress, according to Wolff's law. After mineralization, bone may undergo partial resorption with subsequent new formation, possibly in a different location, for the purpose of producing bone that is more appropriately oriented to resist stress. This action depends on combined osteoclastic and osteoblastic activity (20). Its mediation at the cellular level may occur by mechanical transduction across the cell membrane and through the cytoskeleton, with an effect on the genome (54).

Advances in knowledge of collagen biochemistry, physiology of mineralization, and cellular processes responsible for bone cell differentiation and function have led to a better understanding of many metabolic bone diseases. Defects in the mineralization process are numerous and may lead to the rachitic diseases discussed previously. There are many sites for disturbances in collagen production; some of these defects have been identified in diseases such as osteogenesis imperfecta, the Ehlers-Danlos syndromes (EDS), and some skeletal dysplasias (14). Problems with bone cell differentia-

tion, function, or both have been found in osteopetrosis and idiopathic juvenile osteoporosis. As additional metabolic and biochemical abnormalities are identified in these diseases, greater insight will be gained regarding pathogenesis, and more effective forms of treatment will evolve.

Osteogenesis Imperfecta

The molecular genetics of osteogenesis imperfecta is covered in Chapter 6. The discussion here focuses on the clinical aspects of this condition.

Osteogenesis imperfecta has traditionally been categorized as a heritable disorder of connective tissue, affecting both the bone and the soft tissue; studies have also revealed a number of metabolic abnormalities (379). The disease was probably first described by Malebranche (380) in 1674, and since then it has been discussed under at least 40 different names or eponyms, some of the more common of which are Lobstein disease (381), Vrolik disease (382), van der Hoeve disease, fragilitas ossium, osteomalacia congenita, and osteoporosis fetalis (383–386). Advances in collagen biochemistry and electron microscopy, and recent genetic, epidemiologic, and dental studies, support the concept that osteogenesis imperfecta is a series of syndromes representing classes of molecular defects, each with a reasonably well-defined clinical pattern (385,387,388). Most types of osteogenesis imperfecta have been linked to mutations in type I collagen (14).

Clinical Manifestations

The nature and severity of the clinical features depend on the type of osteogenesis imperfecta (14,385,389,390). General features include the characteristic fragility of bone, short stature, scoliosis, defective dentinogenesis of deciduous or permanent teeth or both, middle ear deafness, laxity of ligaments, and blue sclerae and tympanic membranes. Many patients have misshapen skulls with wide intertemporal measurements and small, triangular faces. The bones are gracile and diffusely osteopenic, with thin cortices and an attenuated trabecular pattern. The long bones have narrow diaphyses, and bowing and fractures are common. The fracture-healing process is undisturbed in terms of sequence of events, but the new bone has the same deficient biomechanical characteristics. Fractures may occur at any age, and the age of occurrence is one basis for classification. In the milder forms of osteogenesis imperfecta, the incidence of fractures decreases with age.

The pelvis in osteogenesis imperfecta may have a trefoil shape, and protrusio acetabuli is common, presumably because of repeated fractures. A softened base of the skull may lead to platybasia and potential neurologic sequelae. Dentinogenesis imperfecta results in soft, translucent, and brownish teeth. The teeth are affected in a nonuniform manner; the primary and secondary teeth may be involved

to a greater or lesser degree. The osteopenic vertebrae may fracture easily, resulting in a flattened or biconcave shape. The laxity of the ligaments results in hypermobile joints and an increased incidence of joint dislocation. Inguinal, umbilical, and diaphragmatic hernias are common. The skin is thin, translucent, and easily distensible. Although increased vascular fragility is common, major arterial or aortic aneurysms are rarely encountered. The differential diagnosis includes juvenile osteoporosis, nonaccidental injury (391), and, rarely, a malignancy such as leukemia. The severity of involvement ranges from a crushed stillborn fetus, in the most severe cases, to an infant with multiple or unusual fractures (392) or severe postnatal deformities, to an almost symptom-free adult (393). The adult, on careful clinical evaluation, reveals a history of occasional fracture and mild osteopenia, and family history may be contributory.

The issue of discerning nonaccidental injury from osteogenesis imperfecta can arise. Because a given, single fracture may occur in nonaccidental injury or osteogenesis imperfecta, it is inadvisable to exclude osteogenesis imperfecta by the radiographic pattern alone (391). Conversely, multiple fractures at different stages of healing, posterior rib fractures, and metaphyseal corner fractures are highly specific for nonaccidental injury (394,395). The history is extremely helpful. Fractures from child abuse occur most frequently in children younger than 3 years of age (394). If the physician is caring for a patient who is not yet ambulatory and has multiple fractures, interpreting the data as osteogenesis imperfecta would imply a severe type, which is usually diagnosed with fractures at birth. It is possible for a child with a mild form of osteogenesis imperfecta to become ambulatory and sustain a fracture with relatively mild trauma. A positive family history, signs such as abnormal dentition or blue sclerae, or a systemic osteopenia revealed by radiography might be helpful in this situation.

Culture of dermal fibroblasts for characterization of the type I collagen may be part of the workup, but the molecular basis for the entire spectrum of osteogenesis imperfecta has not been established (14). The matching of a child's type I collagen with a previously described molecular abnormality may establish the diagnosis of osteogenesis imperfecta, but not matching does not necessarily exclude osteogenesis imperfecta in problem situations. The combination of history, physical examination, and radiographic pattern still remains of paramount significance. Fractures and rickets can occur in very low birth weight infants, but the setting of a birth weight less than 1,500 g, hospitalization, biochemical abnormalities, and subsequent resolution with development are key features of this syndrome (295). Fractures can occur as noted in primary hyperparathyroidism, but there are biochemical abnormalities in this setting (335,336). A patient with Menkes kinky-hair syndrome can present with metaphyseal corner fractures, but the presentation is more likely in the setting of a newborn boy (X-linked recessive trait) with failure to thrive and the sparse, kinky hair that

gives the syndrome its name (396). "Overdiagnosis of child abuse is a tragedy, but an incorrect diagnosis of osteogenesis imperfecta may put a child's life at risk" (394).

The inheritance of osteogenesis imperfecta was thought to be autosomal dominant. The fact that there was considerable variability of phenotypic expression in different members of a kindred led to the concept of variable penetrance and expressivity (386). Investigations of multiple kindreds led some authors to conclude that there was a high rate of spontaneous mutation, but others emphasize the need for a careful history, physical examination, and metabolic studies and collagen typing to detect subclinical involvement in some patients in a pedigree.

Classification

It is not surprising that numerous classifications have been proposed for osteogenesis imperfecta. Looser used the terms *congenita* and *tarda* to differentiate what he believed were different forms of the disease, based on when the first fractures occurred, applying *congenita* only to intrauterine fractures (384). Sedorff used this definition of *congenita*, but divided *tarda* into *gravis* (i.e., fractures occurring at birth or within the first year of life) and *levis* (fractures occurring after 1 year) (397). Bauze et al. used deformity of the femurs as a guide to distinguish clinical types (389).

The classification most widely accepted is the Silience classification. The Silience classification of osteogenesis imperfecta takes into account multiple features of this entity to provide some order to the wide heterogeneity (385,388). This classification provides the framework to which much of the molecular biology is being added (14). Silience proposed a numeric classification, types I to IV, with several modifiers. Types I and IV were felt to be transmitted by an autosomal dominant mode and types II and III by an autosomal recessive mode. Dental findings were used to further subtype (i.e., A indicates without and B indicates with dentinogenesis imperfecta). Silience also recognized several pedigrees that seemed to have an X-linked inheritance pattern, although these are not included in the classification that he proposed (Table 7-5).

Type I osteogenesis imperfecta is the common mild form. The molecular basis for this is a 50% reduction in the production of type I collagen (14). Overall morphology may be normal or nearly so, with fractures occurring in later childhood and decreasing toward adolescence. Type II is lethal in the perinatal period, with many of the mutations being mutations in glycine residues of type I collagen. Type III osteogenesis imperfecta is the severe form, with fractures present at birth. The molecular basis for this type of osteogenesis imperfecta has not been as fully characterized as it has been for the other types. Types II and III are not difficult to diagnose clinically, but correlation of these clinical entities with molecular defects expands our knowledge of bone physiology, and ultimately may provide more effective

TABLE 7-5. OSTEOGENESIS IMPERFECTA CLASSIFICATION

Type	Inheritance	Clinical Features
I	Autosomal dominant	Bone fragility, blue sclerae, onset of fractures after birth (most preschool age). Type A, without dentinogenesis imperfecta; type B, with dentinogenesis imperfecta
II	Autosomal recessive	Lethal in perinatal period, dark blue sclerae, concertina femurs, beaded ribs
III	Autosomal recessive	Fractures at birth, progressive deformity, normal sclerae and hearing
IV	Autosomal dominant	Bone fragility, normal sclerae, normal hearing. Type A, without dentinogenesis imperfecta; type B, with dentinogenesis imperfecta

(From refs. 385 and 388, with permission.)

forms of treatment. Type IV is a moderately severe form of osteogenesis imperfecta, with glycine point mutations in type I collagen. Clinically, this type has great variation, overlapping types I and III, and it may represent a heterogeneous group of patients who do not readily fit into the other categories. A molecular characterization of this group aids in establishing the diagnosis of osteogenesis imperfecta and typing it in problematic situations.

Orthopaedic management for type I osteogenesis imperfecta is customary fracture management. Management for types III and IV includes adaptive equipment, rehabilitation, intramedullary rodding, and scoliosis management. This approach also points to another problem. The Silience classification, which has been and remains the most helpful classification for the geneticist in ordering the many features of this entity, may be less helpful for the pediatric orthopaedist consulted in the perinatal period and confronted by concerned parents with questions about musculoskeletal prognosis.

Shapiro has advanced a *congenita/tarda* classification to try to address this issue (398). In this classification scheme, *congenita* implies fractures occurring *in utero* or at birth. The *congenita* group is further subdivided into A (i.e., crumpled femurs and ribs) and B (i.e., normal bone contours, but with fractures). The *tarda* group is also divided into A (i.e., fractures before walking) and B (i.e., fractures after walking). At follow-up, the *congenita* A group had a high mortality rate (94%). The *congenita* B mortality rate was only 8%; 59% were in wheelchairs and 33% were ambulatory. In the *tarda* A group, 33% were in wheelchairs and 67% were ambulatory. In the *tarda* B group, 100% were ambulatory. Most intramedullary rodding was performed in the *congenita* B and *tarda* A groups.

The problems of the Sillence classification for the pediatric orthopaedist do not obviate its usefulness and general acceptance, and it will be the classification used for the remainder of the discussion.

The radiographic features of osteogenesis imperfecta patients are variable, depending on the disease type, but they must be interpreted with history and physical examination to establish the type (385,388,399) (Figs. 7-24 through 7-27). Findings may or may not be obvious at birth, depending on the type. In almost every case, some degree of generalized osteopenia can be detected. In type II and, to a certain extent, in type III, the femurs have a crumpled "concertina" appearance. A similar deformity, presumably caused by previous fractures, may or may not be seen early in type I. Later in childhood in type I, the long bones appear slender and gracile, with thin cortices and deformities resulting from multiple fractures. In type III in later childhood, the bones are often short, and children may have disproportionate short stature. The head is misshapen, and the skull exhibits wormian bones. The vertebrae may show evidence of multiple fractures, with resultant platyspondylia and sometimes severe scoliosis. In severe cases, the metaphyses may appear cystic, a finding occasionally present at birth but more often developing during infancy or childhood.

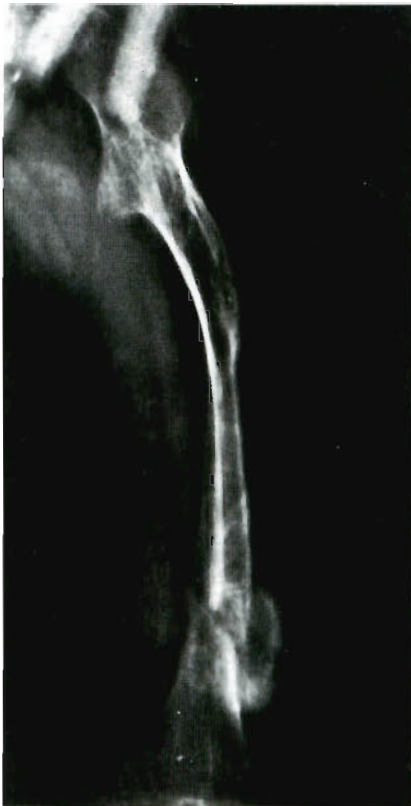

FIGURE 7-24. Radiograph of a patient with osteogenesis imperfecta, type I. The patient had blue sclerae. Fractures began soon after birth, with resulting deformity.

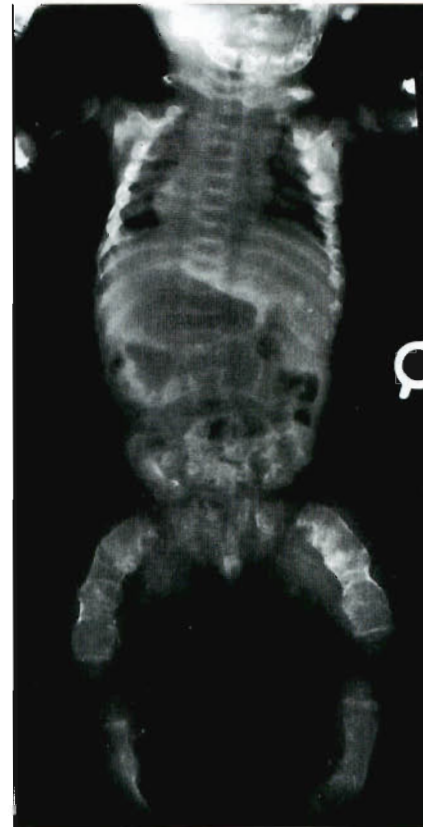

FIGURE 7-25. Child with osteogenesis imperfecta, type II. Notice the concertina-like appearance of the femurs and the beading of the ribs.

The histologic changes in the bones of patients with osteogenesis imperfecta have been the subject of considerable investigation, and researchers vary in their description of them, in part reflecting the heterogeneity of the entity. Toward the more severe end of the spectrum of osteogenesis imperfecta, fairly uniform agreement exists with regard to the nature of the bone, which often appears woven and only occasionally exhibits a lamellar pattern. The cortices are thin, with poorly developed haversian systems, and the trabeculae in the metaphyses are markedly attenuated. Several investigators have observed a hypercellularity, with increased numbers of osteocytes per unit area or volume of bone (400). No change has been noted in the osteoclast population. The collagen fibers of the cornea and skin share in the disturbance and have a looser arrangement and thinner fibers. Histologic study of the epiphyseal and articular cartilages have failed to show an abnormality. Ultrastructural studies confirm the more random arrangement of the collagen fibers of the bone (and other sites) and the thinner fiber diameters. The osteoblasts contain excessive concentrations of glycogen. In type II osteogenesis imperfecta, chondrogenesis at the growth plates is normal, with the skeletal dysmorphology arising from abnormal endochondral ossifi-

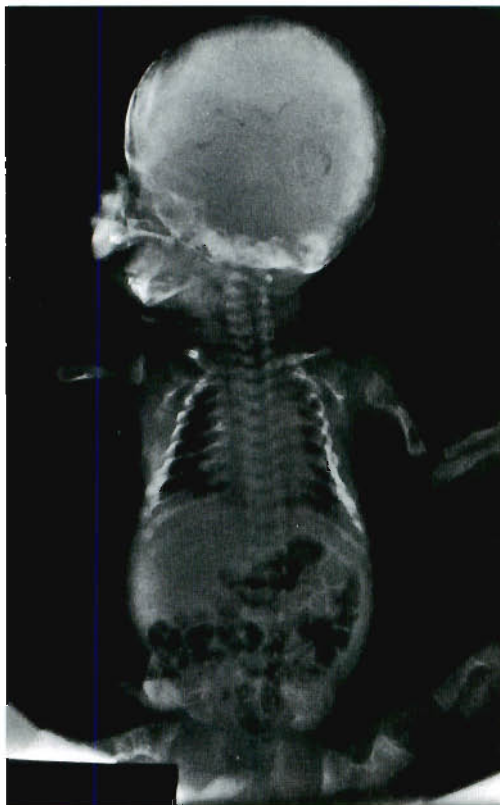

FIGURE 7-26. Child with osteogenesis imperfecta, type III. Fractures were present at birth; progressive deformity occurred with further development.

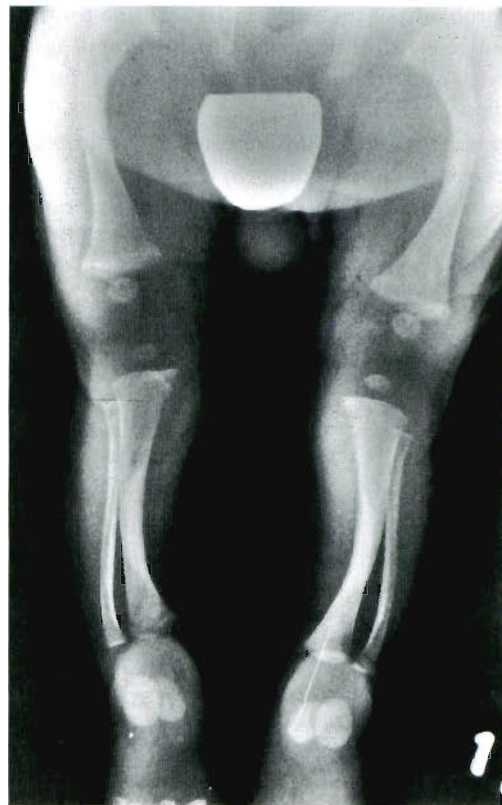

FIGURE 7-27. Patient with osteogenesis imperfecta, type IV. The patient had normal sclerae. The femurs and tibias are bowed. The type IV phenotype, when severe, can overlap with that of type III.

cation on the metaphyseal side of the physis, failure of the ring of LaCroix, and multiple fractures with axial and angular distortion (401).

The techniques of molecular biology demonstrated abnormalities in type I collagen as the basis for at least some types of osteogenesis imperfecta (14). Elucidation of this cause required much classic investigative work to provide the pertinent information on which to build the molecular search. Biochemical studies of osteogenesis imperfecta patients have shown the calcium, phosphorus, magnesium, vitamin D, and PTH levels to be within normal limits. Subsequent research began to reveal abnormalities in collagen (402,403). In normal bones, the collagen is almost entirely type I, although, in fetal tissues and in very young infants, some of the collagen is in the form of type III or V. This finding diminishes with age; in most older children, only type I collagen can be recognized. In lethal osteogenesis imperfecta, a considerable increase in the concentration of types III and V and a marked variation in cross-linking were found (404). Changes in the various types of osteogenesis imperfecta were documented, including an increase in collagen hydroxylysine residues in bone, a decrease in hydroxylysinonorleucine in skin collagen, and abnormalities of $\alpha 1$ -

and $\alpha 2$ -polypeptides of type I collagen in cultured skin fibroblasts (387,405–407). With an improved classification system of the heterogeneity in osteogenesis and expanding techniques in molecular biology, increasingly precise abnormalities in type I collagen are being correlated with the clinical syndromes and with entities such as the Ehlers-Danlos syndromes and skeletal dysplasias (14,408).

Not all the clinical manifestations nor all the subtypes of osteogenesis imperfecta may be linked directly to collagen abnormalities, and other metabolic disturbances may at least be contributory (400,409,410). Increased sweating, heat intolerance, increased body temperature, and resting tachycardia and tachypnea have been described. Although this finding suggested the possibility of hyperthyroidism, increased serum thyroxine levels have been an inconsistent finding. Hyperthermia during anesthesia has been reported, and occasionally a patient manifests true malignant hyperthermia. The serum inorganic pyrophosphate concentrations can be increased, and studies of leukocyte metabolism suggest an uncoupling of oxidative phosphorylation. Platelet function studies have demonstrated defects in adhesion and clot retraction.

Management

Treatment depends on the type of osteogenesis imperfecta. Type I osteogenesis, at least in its milder forms, may have little impact on the patient, and the role of the pediatric orthopaedic surgeon may be limited to conventional fracture care. Type II, lethal perinatal osteogenesis imperfecta, has some degree of variability. In the most severe cases, the very early death occurs before pediatric orthopaedic intervention. Types III and IV represent the greatest challenges.

Several systemic treatment modalities have been attempted. Investigators have used calcium, vitamin C, vitamin D, fluoride, calcitonin, diphosphonates, and magnesium without benefit (411). An early report on the efficacy of (3-amino-1-hydroxypropylidene)-1,1-bisphosphonate (pamidronate) was made (412). Subsequent reports in the basic science and clinical literature further support the use of this bisphosphonate in severe cases of osteogenesis imperfecta (413,414). Pamidronate does not cure osteogenesis imperfecta. It inhibits osteoclastic resorption, but the abnormality in the type I collagen remains.

The theoretical possibilities of molecular treatments for specific types of osteogenesis imperfecta loom on the horizon (14). Stimulating production of type I collagen in type I osteogenesis imperfecta or correcting the point mutations in certain cases of types II or IV should, in theory, cure the disease, but achieving this outcome in practice remains a goal for the future. Other strategies include bone marrow transplantation to replace abnormal stem cells with normal stem cells and suppression of mutant collagen gene expression (415).

Orthopaedic management of even the severe types III and IV osteogenesis imperfecta can be important in fracture prevention, fracture management, and function (416–421). As with any heterogeneous condition, controversies about the efficacy of any specific treatment abound. It does seem worthwhile to proceed with an aggressive program of exercises, standing with bracing, working to develop ambulatory potential, and proceeding with appropriate seating, including wheelchair locomotion, if required (422).

The treatment for fractures in osteogenesis imperfecta is sometimes difficult, because of the patient's ligamentous laxity, structural abnormalities of the bones, and frequency of multiple fractures with even minor or no trauma. Fractures heal readily, often with exuberant callus, but the callus formed in response to the fracture is identical in structure to the rest of the skeleton; it is plastic and easily deformed by forces associated with weight-bearing or simply the action of muscles across the fracture site. As a result, uncontrollable deformities or shortening often occur during or after the treatment phase, which contribute to the crippling and disability experienced by patients with severe forms of the disease.

Closed treatment methods are often used. Use of light-

weight polypropylene splints or braces may prove helpful in getting the child to bear weight quickly to avoid the compounding problems of immobilization. Devices such as a parapodium may help a child to acquire an upright posture. Vacuum pants have been described for use in this situation (423). If management by closed means proves difficult, treatment with internal fixation may be enacted. Intramedullary fixation is superior to plates and screws, which tend to dislodge from the weakened bones.

The issue of the optimal age for operation has attracted different opinions. Ryoppy et al. advocated proceeding as early as 6 weeks of age (424). Their criteria for this decision were recurrent fractures with appropriate care, progressive deformation, a cycle of immobilization leading to further weakening, and humanitarian reasons. Solid devices were used to anticipate a change to elongating devices. It was thought that this approach decreased the incidence of refracture and aided function. The insertion of solid rods percutaneously after closed osteoclasis has been reported (424–426).

The alternative, which has been elected more frequently, has been to accept deformity or to treat deformity with closed methods as soon as possible in the course of early fracture management, get the child to the approximate age of 5 years, and proceed with corrective osteotomies of larger bones. The method of multiple corrective osteotomies with intramedullary fixation for the lower and upper extremities has been accepted for managing recurrent fractures with deformity and maintaining function (427–429). Such procedures have been done with solid rods, using exchanges as the child grew [►4.11]. The introduction of the elongating Bailey-Dubow rod seemed to provide a solution, but also generated problems, such as disconnection of the T-piece from the rods. Crimping the T-piece seems to provide an effective, although incomplete, solution. Nevertheless, use of the Bailey-Dubow rods seems to be a method of intramedullary fixation that diminishes the rate of reoperation and has a complication rate similar to that of use of non-elongating rods (430–432) (Fig. 7-28). Other alternatives include closed osteoclasis with subsequent management using pneumatic splints or casting (433).

Fractures in the more mild types of osteogenesis imperfecta may present some problems with different options for solution. In the very mild forms, customary fracture management may apply. In more severe forms, recurrent fracture and subsequent bowing may be seen, especially at the femurs or tibias. There is no absolute rule on which to base intervention with intramedullary rodding in these situations. The risk-benefit analysis should consider recurrent fracture (i.e., two to three fractures being an arbitrary but practical limit before surgery) and deformity versus possible injury to the blood supply and physal regions of the growing ends of long bones.

One of the most difficult disorders to treat in osteogenesis imperfecta, and in other disorders with osteopenia,

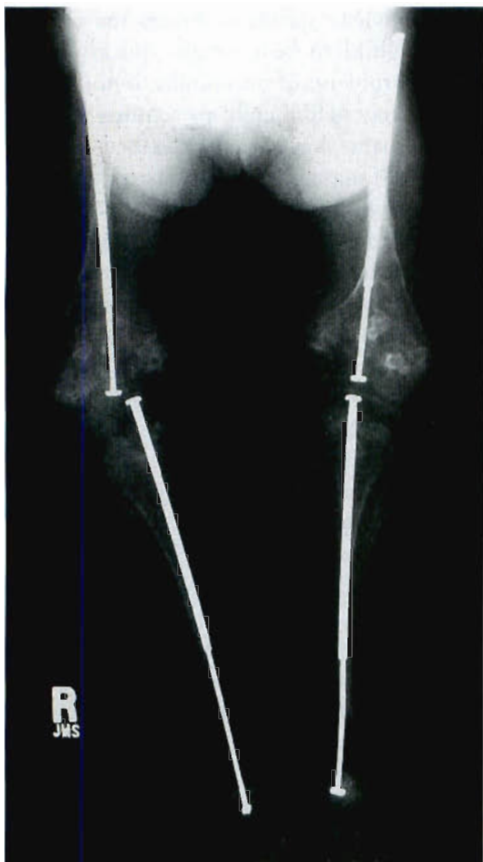


FIGURE 7-28. Radiograph of a patient with osteogenesis imperfecta, type III, after insertion of Bailey-Dubow rods.

is scoliosis. The curves tend to advance relentlessly, and bracing is ineffective in controlling the progression of the deformity. Internal fixation is considerably hampered by the poor quality of the bone. Newer methods of segmental instrumentation are changing the approach to scoliosis in

osteogenesis imperfecta and other diseases with osteopenia (434) [→2.5, 2.9]. Curves may be fused early (at 40 degrees) to halt the relentless progression (434,435). This should help to maintain function and prevent respiratory complications.

Idiopathic Juvenile Osteoporosis

It is important to clarify any confusion regarding the terminology of metabolic bone disease. Osteopenia is a nonspecific term, indicating only a reduction in bone mass as determined by radiographic study or by special techniques, such as computed tomographic analysis or absorption photometry. Within this category, there are four diagnostic groups, based on the pathology and special studies of tissue, such as histology and bone morphometric analysis. These groups are osteoporosis, in which the bone is normal in appearance and structure but reduced in amount; osteomalacia, in which the bone matrix is laid down normally but is not properly mineralized; osteitis fibrosa, in which the bone is resorbed rapidly as a result of excessive PTH; and malignant disease, in which the bone is replaced and at times actively resorbed by local deposits of malignant cells. When radiographic examination reveals decreased bone mass, it is essential to view the process initially as osteopenia, rather than to make a more specific diagnosis such as osteoporosis, and to seek to define its cause among the various syndromes within the four broad categories defined.

Idiopathic juvenile osteoporosis is a rare, self-limited disorder of unknown cause, which affects previously healthy children (436,437). Since it was first described, at least 45 patients have been reported, but much remains to be learned about its cause and pathophysiology (438–442). Although one series has been reported in which several patients had symptoms before 5 years of age, the age of onset of symp-

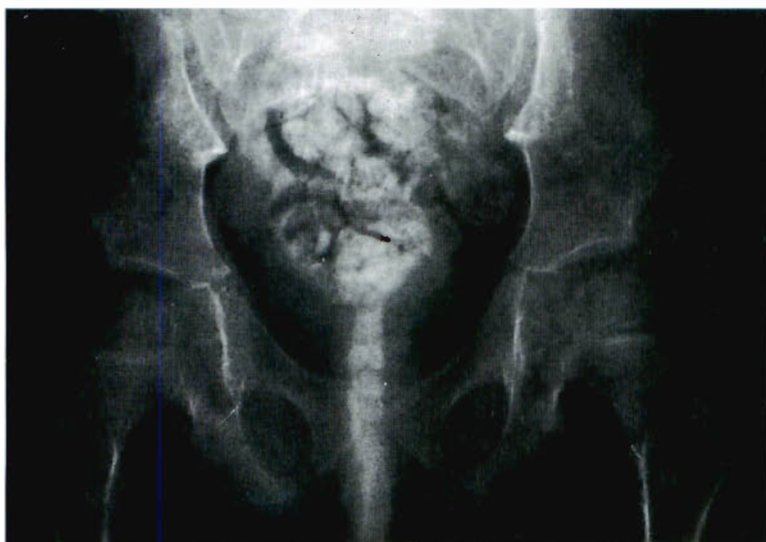

FIGURE 7-29. Child with juvenile osteoporosis. The osteoporosis affects the pelvis and the femurs.

toms is usually between 8 and 14 years, and resolution usually occurs spontaneously within 2 to 4 years after onset or after puberty. Idiopathic juvenile osteoporosis must be differentiated from other osteopenic conditions affecting children, especially from osteogenesis imperfecta, hematologic malignancies, thyrotoxicosis, and Cushing disease. The diagnosis of idiopathic juvenile osteoporosis is made by the positive identification of features of this disease, and by ruling out other diseases with similar manifestations.

Idiopathic juvenile osteoporosis is initially characterized by bone and joint pain, followed by an arrest of growth, varying degrees of osteopenia, vertebral body collapse, and metaphyseal fractures (Figs. 7-29 and 7-30). The disease may be limited to the spine. When long bones are involved, bone loss is generalized, but usually more marked at the metaphyses. The diaphyses, affected to a lesser degree, are not as thin and narrow as in osteogenesis imperfecta. Prolonged disuse may exaggerate and enhance this situation.

The pathophysiology of idiopathic juvenile osteoporosis is obscure (443–445). Symptoms usually resolve after puberty, which suggests that the disease is endocrine in origin. Biochemical measurements of these patients are difficult to interpret, because of the extraordinarily rapid alterations in metabolism that occur just before puberty. Serum calcium

and phosphorus levels are normal. Alkaline phosphatase and urinary hydroxyproline levels are normal or slightly above normal. Metabolic studies have shown these patients to be in a negative calcium balance initially and in a positive calcium balance during recovery. Intestinal calcium absorption is abnormally low, and hypercalciuria may exist. Normal 25-hydroxyvitamin D levels with very low 1,25-dihydroxyvitamin D levels have been reported (446). Few data regarding PTH levels are available.

Microradiographic and histomorphometric studies of bone biopsies of patients with idiopathic juvenile osteoporosis have been confusing (437). Increased resorbing surfaces have been demonstrated with microradiographic techniques, but the rates of formation were not evaluated. A normal osteoclast population with a decrease in the number of osteoblasts has been reported, suggesting a defect in bone formation. Other evidence suggests increased resorption and increased formation or a combined high turnover state. One serious problem with these studies is that of sampling error. The osteopenic changes are most marked in the metaphyseal regions, but the biopsies are obtained from the iliac crests.

Because the cause and pathophysiology of idiopathic juvenile osteoporosis are poorly understood, it is not surprising that effective treatment remains ill defined. It is not clear whether any of these regimens can favorably alter the natural history. A greater awareness of idiopathic juvenile osteoporosis, using careful metabolic studies before and after treatment, should help to elucidate the pathophysiology of this rare but interesting disease.

The pediatric orthopaedic surgeon sees patients with idiopathic juvenile osteoporosis for the spinal deformity (i.e., kyphosis) and pain, which may be present, especially at the outset of the disease (447). He or she must be aware of the stage of workup for the patient, so that the differential diagnosis has been excluded and idiopathic juvenile osteoporosis has been established. In this setting, antikyphotic bracing has been recommended (448). It is initiated at 23 hours per day for approximately 1 year, then weaned down, consistent with maintaining a normal kyphosis with relief of symptoms. Because this is a relatively small group of patients with a tendency to improve, the efficacy of bracing might be questioned, but residual deformity without bracing has been noted (448).

Although osteoporosis secondary to disuse is not idiopathic, it is mentioned for two reasons. First, the lack of stress across osseous tissue can affect the balance between absorption and formation, causing a net decrease in bone mass (Fig. 7-31). Although the precise link between mechanical force and cell physiology is unknown, such a link may play a role in the development of osteoporoses of unknown cause (52,54). Second, disuse atrophy has practical consequences in pediatric orthopaedics. After prolonged cast immobilization, children often show some degree of osteoporosis with resultant weakening of the skeleton. This

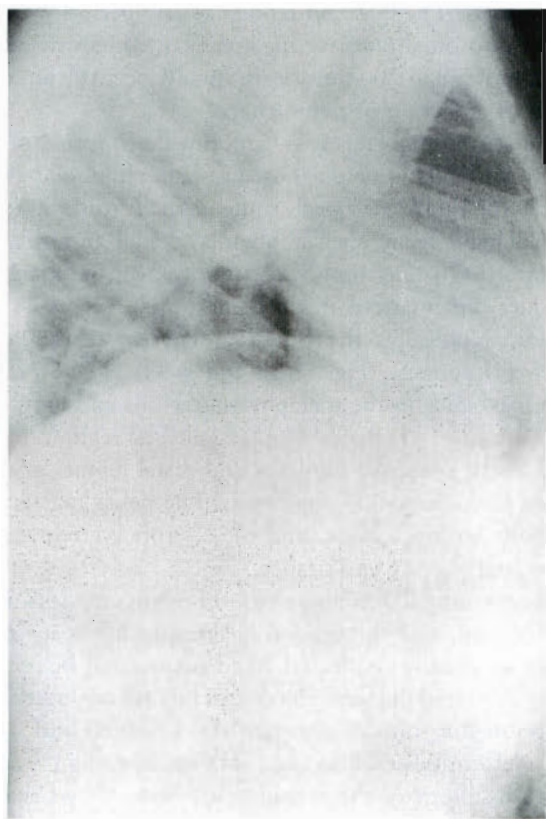


FIGURE 7-30. Juvenile osteoporosis. This lateral radiograph of the spine shows the typical biconcave appearance of the vertebrae.

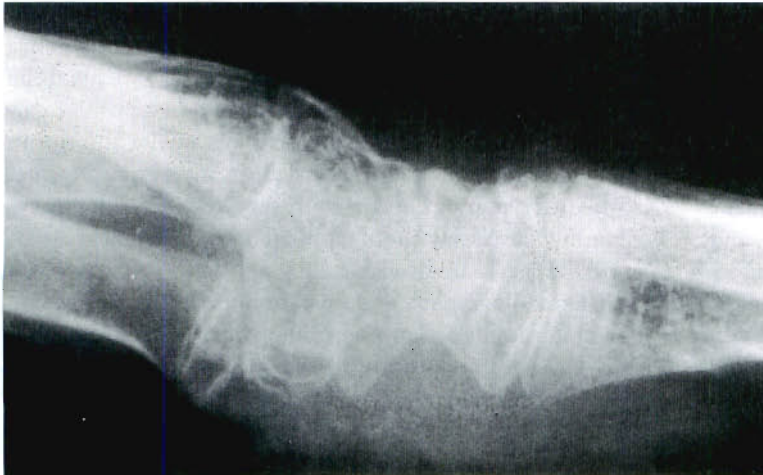

FIGURE 7-31. Disuse atrophy of the wrist and distal forearm after cast immobilization.

phenomenon is accentuated in children with neuromuscular diseases. A gradual return to activity is important in fracture rehabilitation in patients with neuromuscular diseases, including functional polypropylene bracing, to avoid vicious cycles of increased fragility followed by recurrent fracture after removal of the immobilizing devices.

Osteopetrosis

Osteopetrosis is an unusual disorder of the skeletal system in which, because of a failure of osteoclastic and chondroclastic resorption, the bones become exceedingly dense. The marrow spaces and foraminal openings are encroached on by the unresorbed masses of dense bone, and these features, plus the fragility of the pathologic bone, dominate the clinical picture (449,450). Three clinically distinct forms of osteopetrosis are now recognized (451). The infantile-malignant form is transmitted as an autosomal recessive type and is fatal within the first several years of life without treatment. An intermediate form, also transmitted as an autosomal recessive type, appears within the first decade of life and does not follow a malignant course. The patient with the autosomal dominant type has a normal life expectancy but many orthopaedic problems. The autosomal dominant form was first described by Albers-Schonberg (i.e., Albers-Schonberg disease) (452). Other names applied to both forms of the disease are marble bone disease and osteosclerosis fragilis generalisata (453–455). Although generally considered a primary disorder of bone metabolism, with diminished bone resorption due to an osteoclast defect, studies indicate that osteopetrosis may more appropriately be considered an immune disorder resulting from a thymic defect that leads to the osteoclast abnormality (456).

The autosomal recessive malignant form of osteopetrosis is manifested in infancy with thick, poorly remodeled dense

bones and poor development of the medullary canal (457). The child generally shows a failure to thrive, myelophthisic anemia and thrombocytopenia, hepatosplenomegaly, lymphadenopathy, spontaneous bruising, abnormal bleeding, and multiple fractures. Because of the abnormal bone modeling process, the neural foramina in the skull become small, causing neural encroachment and optic, oculomotor, and facial palsies. There are no reports of any person with untreated autosomal recessive malignant osteopetrosis surviving for more than 20 years; death usually occurs from overwhelming infection or hemorrhage.

The autosomal recessive intermediate form of osteopetrosis tends to be diagnosed in later childhood after a fracture (451). In retrospect, some of the features noted in the malignant form, such as anemia, dental anomalies, or disproportion (short limb/short stature), can be identified in milder presentations in this condition.

Radiographically, the bones are overly dense in osteopetrosis patients (Figs. 7-32 and 7-33). There may be transverse bands in the metaphyseal regions and longitudinal striations in the shafts. The metaphyseal regions, particularly in the proximal humerus and distal femur, may develop a flask-shaped configuration. The pelvis may appear as a bone within a bone, and the sclerotic vertebrae may have a rugby jersey appearance.

The autosomal dominant form of osteopetrosis is much more benign, and the general health and life span of the patient are usually unaffected. Mild anemia may be present; facial palsies and deafness can occur, but are not necessarily features of this form of osteopetrosis. Fractures and subsequent deformities such as coxa vara are common.

The histology of the osteopetrotic bone shows that, in addition to thickened trabeculae and cortices, tongues of cartilage bars persist at the sites of endochondral bone formation, and may project far into the metaphysis and even

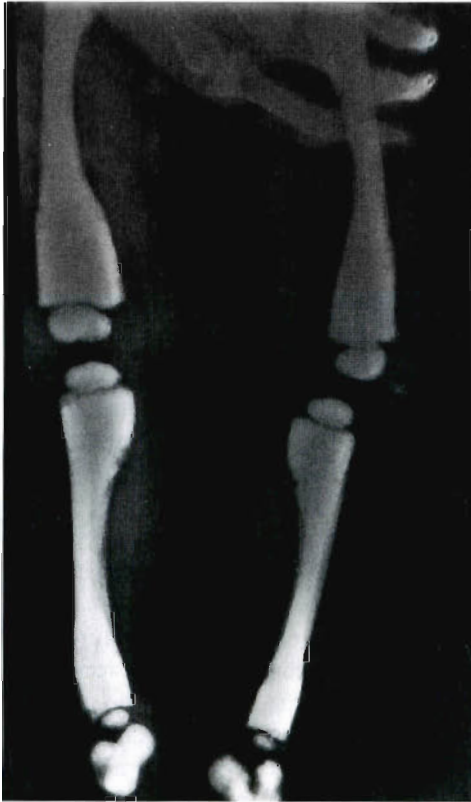

FIGURE 7-32. Patient with osteopetrosis and generalized increased density of the bones.

into the diaphysis (457,458). The persistence of cartilage bars, normally resorbed by osteoclastic action in the zone of primary spongiosa, is a characteristic of both rickets and osteopetrosis, but, in osteopetrosis, the cartilage bars are

calcified, and their central portions undergo osseous metaplasia. The bone is relatively hypocellular, with a paucity of osteoblasts and an almost complete absence of osteoclasts. The subperiosteal new bone is in part nonlamellar, suggesting that intramembranous bone formation is also abnormal, but it is less well defined than the abnormality in endochondral bone formation. Kinetic data for calcium in osteopetrotic rats and humans have shown a low accretion rate and a dramatically reduced resorption rate (459–463). These observations suggest a defect in bone cell differentiation and function, the most obvious of which involves the osteoclast (464).

The classic experiments of Walker demonstrated that osteopetrosis in mice was reversible with parabiosis or marrow transplantation (463,465,466). Several studies in osteopetrotic rodents and humans have revealed the role of a thymic defect in this disease. Osteopetrotic mice of the *op* strain have been found to have precocious thymic atrophy. Milhaud and co-workers have found that the cell mitogens concanavalin A and phytohemagglutinin have little effect on tritiated thymidine incorporation in thymic cells from osteopetrotic rats, and several other immune defects have been demonstrated in these rodent models (467,468). In some strains, parenteral administration of bone marrow or transplantation of thymic tissue from normal littermates appears to correct the bone abnormalities, but in other strains, splenic or thymic lymphocytes alone may cure the disease (465,469).

Systemic treatment is an issue in the autosomal recessive malignant form. High-dose 1,25-dihydroxyvitamin D₃ coupled with a low-calcium diet has been used because of its ability to simulate osteoclasts and bone resorption (451). The autosomal recessive malignant form of osteopetrosis

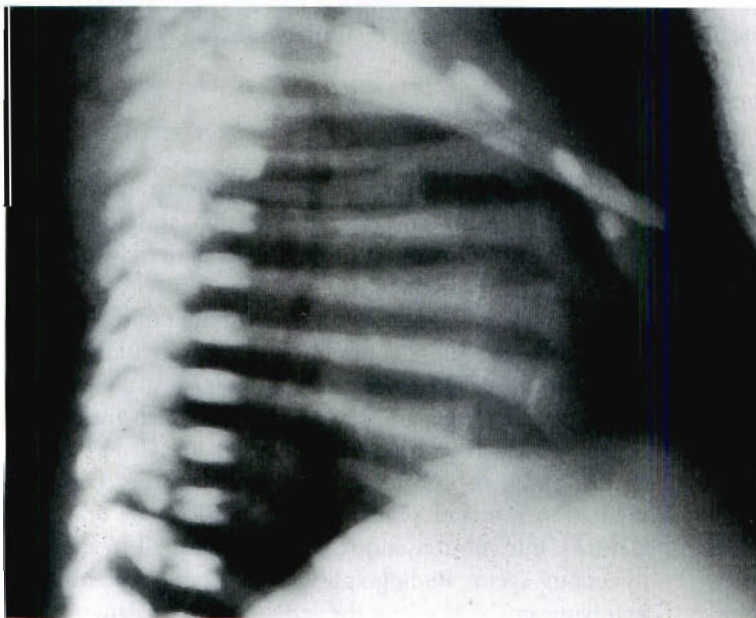


FIGURE 7-33. Patient with osteopetrosis. The increased bone density is also present in the vertebrae. In some patients, an alternating pattern of density is seen, producing a rugby jersey spine.

has been treated successfully by allogeneic bone marrow transplantation from human leukocyte antigen–identical siblings, or by marrow ablation with cyclophosphamide and total body irradiation, or busulfan followed by marrow transplantation from a human leukocyte antigen–mismatched donor (470–475). Treatment of osteopetrosis with recombinant human interferon- γ was reported more recently (476). These studies represent significant progress in the treatment of this disease and also provide further insight into the origin of the osteoclast (477).

The pediatric orthopaedic concerns about osteopetrosis are numerous (451). Transverse fractures with minimal displacement occur in the infantile malignant form and may be difficult to recognize. Without immobilization, abundant callus can occur in the healing phase. Fractures in the intermediate recessive and dominant forms are common and require conventional treatment. Although healing does occur, time to healing can be prolonged (450). Coxa vara and long-bone deformity can result during the course of treatment of multiple fractures. Both are amenable to corrective osteotomy (450,451). Intramedullary fixation is desirable, but can be difficult because of the hardness of the bone and compromise of the marrow space. Osteomyelitis is common because of the diminished vascularity and immune response. This problem is most common in the mandible, but it also can be seen in the long bones. Back pain is frequently encountered in the benign dominant form of osteopetrosis and responds to rest, bracing, and antiinflammatory medication.

Periosteal Reaction and Soft Tissue Calcification and Ossification

Numerous metabolic, inflammatory, traumatic, neoplastic, and idiopathic disorders of the infant's or child's skeleton may produce symptoms of localized or diffuse periosteal new bone formation on radiographic study (478,479). Unlike that of adults, the child's periosteum is easily stimulated to form new bone, and depending on the nature of the process, new bone formation may be diffuse and may cause considerable disability. Three of these disorders—hypervitaminosis A, Caffey disease, and scurvy—are discussed in this chapter in detail, but a brief history and a chronologic differential for the various syndromes are first provided.

The salient features of periosteal reaction, or cortical thickening in infancy or early childhood, are listed in Table 7-6. Physiologic periosteal reaction of the newborn is most prominent from 1 to 6 months of life. This is usually an incidental finding on radiographs obtained for other reasons. The periosteal reaction is thin, even, and symmetric, occurring along the femur, tibia, and humerus on both sides. Periosteal reaction can be seen in Menkes kinky-hair syndrome, an X-linked recessive disorder producing defective copper absorption (396). Although the radiographic

pattern with metaphyseal spurs and adjacent periosteal reaction may suggest abuse or healing rickets, the typical child is a male neonate with profound failure to thrive and progressive central nervous system degeneration, in addition to the characteristic kinky hair for which the entity is named.

In Engelmann-Camurati disease, which is autosomal dominant in transmission, the progressive cortical thickening of long bones is customarily seen at 4 to 6 years of age, in association with a waddling gait resulting from progressive neuromuscular degeneration (480).

Infection can occur at any age; in bacterial osteomyelitis, the periosteal reaction is usually associated with lytic and blastic metaphyseal changes. Congenital syphilis rarely is manifested in children younger than 3 months of age. Severe spirochetal infection may lead to fetal loss; survivors may develop early or late childhood lesions in rather protean manifestations. However, during infancy, a periosteal reaction resulting from syphilis usually occurs with metaphyseal lesions (481).

A periosteal reaction resulting from trauma can occur at any age; the features that differentiate accidental trauma from nonaccidental trauma were discussed previously. Periosteal new bone can be associated with burns (482). Metabolic conditions can cause periosteal reaction in a variety of settings. Hypervitaminosis A and scurvy usually appear no earlier than 9 months of age.

The neoplastic conditions that can result in the periosteal reaction in early childhood are leukemia, neuroblastoma, and retinoblastoma. Diffuse periosteal reaction associated with leukemia most often appears in children older than 2 years of age. Neuroblastoma and retinoblastoma can have similar radiographic appearances and may be seen earlier.

Although the peak occurrence of Caffey disease is at 6 weeks to 6 months of age, it can occur before 6 weeks. Periosteal new bone formation before 6 weeks is consistent with infection, trauma, or Caffey disease (391,394,395).

Caffey Disease

Infantile cortical hyperostosis, or Caffey disease, is a disorder of unknown cause affecting the skeleton and contiguous myofascial tissues (483–486). It is characterized by a febrile illness with hyperirritability, swelling of soft tissues, and cortical thickening of bone (487). The bones of the jaw and forearm are the most common sites, but occasionally the lesion is diffuse. The average age of onset is usually younger than 9 weeks of age, and several cases in which the disease began *in utero* have been described.

The child with Caffey disease may be febrile. The sedimentation rate and serum alkaline phosphatase are often elevated, but cultures and serologic studies fail to show an infectious agent. Radiographs reveal a periosteal reaction involving any bone except the vertebrae and phalanges. Caf-

TABLE 7-6. CAUSES OF PERIOSTEAL REACTION AND CORTICAL THICKENING IN INFANCY AND EARLY CHILDHOOD

Entity	Peak Age at Detection	Characteristics
Physiologic periosteal reaction of newborn	1–6 mo	Thin, even periosteal reaction symmetric along femora, tibiae, humeri
Congenital or genetic		
Menkes kinky-hair syndrome	Newborn	Failure to thrive; X-linked defective copper absorption; boys; sparse; kinky hair; central nervous system degeneration, metaphyseal fractures, and periosteal reaction confused with abuse and rickets
Engelmann-Camurati disease	4–6 yr	Autosomal dominant; progressive midshaft thickening of long bones; waddling gait; normal laboratory findings, except slight elevation of alkaline phosphatase
Infective		
Osteomyelitis	Any age	Classic bacterial osteomyelitis with lytic or blastic changes at metaphysis and periosteal reaction as disease progresses; elevated erythrocyte sedimentation rate (ESR); viral and fungal types exist; <i>Salmonella</i> osteomyelitis in sickle cell disease may begin at diaphysis; ESR not elevated
Congenital syphilis	>3 mo (severe spirochetal infection can cause fetal loss)	Many manifestations possible; osteochondritis with metaphyseal lytic lesions; diaphyseal osteitis; periostitis; positive serology for syphilis
Inflammatory		
Juvenile chronic arthritis	5–10 yr	Periarticular reaction at phalanges, metacarpals, and metatarsals
Traumatic		
Accidental or nonaccidental injury	Any age	Accidental injury should result in local reaction consistent with age-appropriate activities (i.e., single tibial reaction 7–10 d after injury in a child who is walking); nonaccidental injury can result in multiple areas of periosteal reaction inconsistent with age-appropriate activities
Burns	Weeks to months after burn	Usually a local response, but can have elements of hypertrophic osteoarthropathy
Metabolic		
Hypertrophic osteoarthropathy	Any age	Usually associated with physiologic abnormality in pulmonary, cardiac, or gastrointestinal system; tibial, fibular, radial, ulnar diaphyseal and metaphyseal involvement; clubbing
Hypervitaminosis A	>9 mo	Periosteal reaction in long bones, typically ulnas and metatarsals; epiphyseal and metaphyseal ossification abnormalities and physeal lesions possible; elevation of serum vitamin A level
	>9 mo	Epiphyseal and metaphyseal changes most prominent around knees, with associated subperiosteal hemorrhages; abnormal vitamin C levels in serum or blood
Hyperphosphatemia	Associated with tumoral calcinosis; second and third decades of life, but reported in childhood and infancy	Periostitis in tubular bones; calcified soft tissue masses; elevated serum phosphorus level
Healing phase of rickets	After treatment of rickets	Periosteal reaction adjacent to healing growth plates
In prostaglandin-induced hyperostosis	After weeks of prostaglandin E ₁ administration to maintain ductus patency in congenital heart disease	Symmetric, diffuse periosteal reaction in long bones and ribs; elevated alkaline phosphatase level
Neoplastic		
Acute leukemia	2–5 yr	Diffuse osteopenia, metaphyseal rarefactions; commonly, symmetric periosteal reaction in long bones
Metastatic neuroblastoma, retinoblastoma	Similar to leukemia, with presentations <2 yr	Similar to leukemia
Idiopathic		
Caffey disease	6 wk–6 mo	Mandibular involvement, asymmetric involvement of clavicle, scapula, ribs, or tubular bones without associated lytic lesions; elevated alkaline phosphatase level and ESR

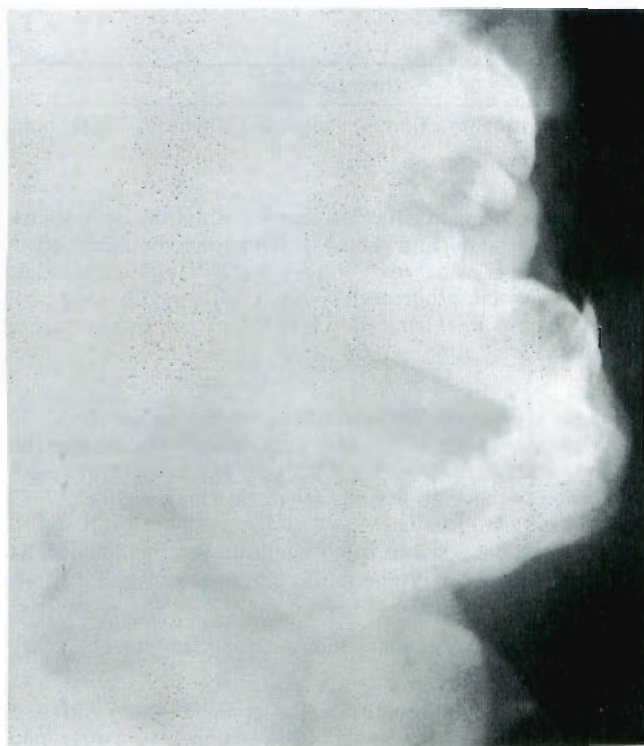

FIGURE 7-34. This oblique view of the mandible of a patient with Caffey disease demonstrates the characteristic periosteal reaction.

fey makes the point that involvement of a single bone, with the exception of the mandible, suggests trauma (484). Mandibular involvement is characteristic (Fig. 7-34). In the extremities, the ulna is most frequently involved (Fig. 7-35).

Pathologic study of the involved tissue in patients with Caffey disease has failed to define a specific alteration, although hyperplasia of collagen fibers and fibrinoid degeneration have been seen. A case report described the absence

of cortical bone at the diaphyses, which were entirely cancellous (487). Most patients recover spontaneously, but, for some, the disease becomes sufficiently severe to require short periods of corticosteroids to reduce the morbidity. Occasionally, a patient develops a chronic syndrome that persists into late childhood. The possibility of coexistent infection needs to be considered (488).

Hypervitaminosis A

Overdosage with vitamin A can be acute or chronic (489–491). Vitamin A is a necessary constituent in the synthesis of visual pigments, but it is also required in appropriate amounts for membrane stability. Excess or deficiency may lead to rupture of lysosomal membranes. Vitamin A participates in the biology of the epithelium, and, in excess, it causes a proliferation of basal cells and hyperkeratinization. Acute hypervitamin A intoxication causes intracranial pressure, vomiting, and lethargy. Several weeks or months of chronic overingestion (if the child survives) leads to a syndrome characterized by pruritus, skin lesions, failure to thrive, and muscle and bone tenderness. Radiographs in this later phase show the periosteal reaction in many of the long bones. Epiphyseal and metaphyseal ossification abnormalities occur with central physal arrests. Hypercalcemia may be present, and serum vitamin A levels are elevated. Histologic study of the bones shows an increase in resorptive surfaces, suggesting that the combination of resorption and formation has been accelerated to a hypermetabolic state.

Scurvy

Scurvy, the pathologic state associated with a deficiency of vitamin C, is perhaps the best-understood metabolic disease, and is certainly the most preventable (492). All the clinical and pathologic manifestations of scurvy are based on the now well-defined role of ascorbic acid in the synthesis of

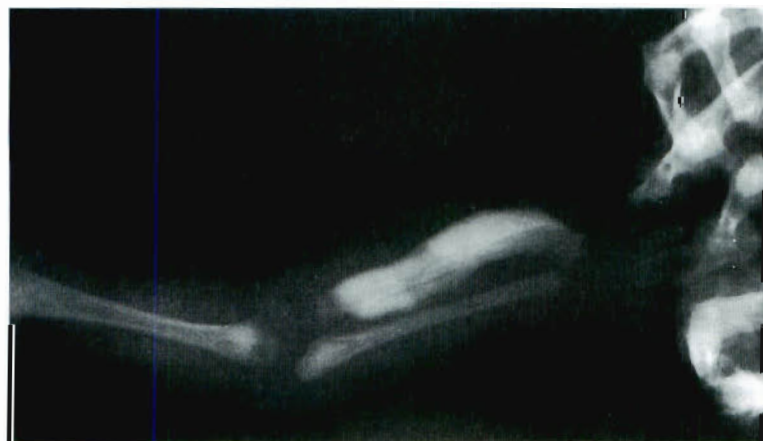


FIGURE 7-35. The ulna is the most frequently involved bone in the extremities of patients with Caffey disease.

collagen. In the course of collagen synthesis, a necessary step is the hydroxylation of the amino acids proline and lysine to hydroxyproline and hydroxylysine, both active participants in the intramolecular and intermolecular cross-links that stabilize collagen. The hydroxylation step takes place early in the synthetic process and requires ferrous iron, oxygen, α -ketoglutarate, and ascorbic acid. In the absence of ascorbate (neither humans nor guinea pigs can synthesize vitamin C), this step cannot occur, and the collagen that is synthesized is defective. If the mother's intake of vitamin C is adequate during pregnancy, the infant usually does not manifest the disease for several months (i.e., late onset), even if there is dietary insufficiency. Breast-feeding by a mother who has an adequate supply of vitamin C is usually sufficient to prevent scurvy.

The pathologic process that results from inadequate intake of vitamin C is characterized by production of collagen fibers of poor quality; all the body's systems are affected. Blood vessels become excessively permeable and rupture readily, normal bone formation is reduced, and bone that forms is lacking in tensile strength and is defective in structural arrangement.

Clinically, children with scurvy appear undernourished, apathetic, and irritable. They show generalized weakness, poor wound healing, petechial hemorrhages, ecchymoses, and bone pain that often leads to pseudoparalysis.

Radiographic findings in the skeleton of patients with scurvy may be seen in any of the long bones, but are most prominent around the knees (Fig. 7-36). Bone density is diminished, and the cortices are markedly thinned. An area of marked radiolucency, which causes the zone of provisional calcification at the physeometaphyseal junction to stand out in bold relief (i.e., white line of Fraenkel), is observed in the metaphysis. Brittleness of the zone of provisional calcification may lead to fractures and marginal spurs (i.e., Pelken sign). A zone of radiolucency forms beneath this zone, and separation may occur. The epiphyseal nucleus is also markedly radiolucent, but the calcification front of the cartilage is unaffected, producing an appearance of ringed epiphyses (i.e., Wimberger sign). Subperiosteal hemorrhages occur, lifting the periosteum and causing pain and pseudoparalysis. These areas calcify with treatment and have the appearance of periosteal new bone.

Laboratory studies may help to differentiate scurvy from other possible entities, most notably sepsis. A fasting serum vitamin C level can be determined if scurvy is being considered. This can be difficult to interpret. Ascorbic acid concentration in the buffy coat of blood is believed to be a better measure. A nonspecific aminoaciduria also exists in scurvy. Treatment is replacement of the deficient ascorbic acid. Minimal daily requirements are 30 mg for infants and 50 mg for adults. Therapeutic dosages may be 200 mg or higher.

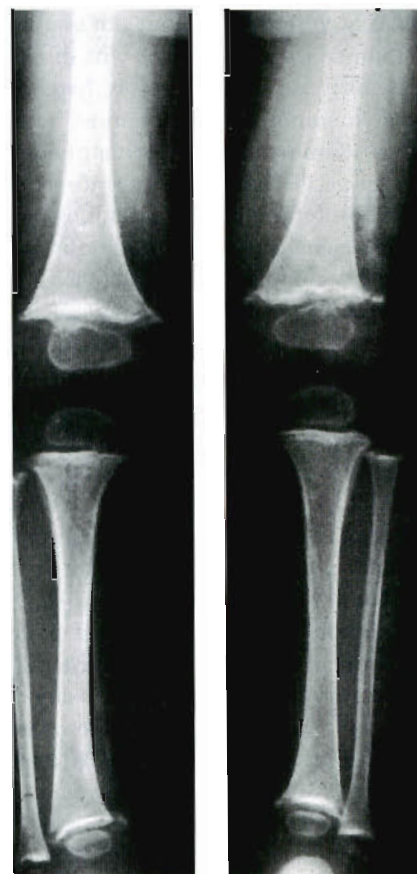


FIGURE 7-36. Patient with scurvy, early in treatment. The subperiosteal hemorrhage, especially on the left femur, has begun to ossify. The white lines of Fraenkel can still be seen at the distal femurs.

Calcification of Soft Tissues

Calcification or ossification in the soft tissues can represent diagnostic and therapeutic problems. Cutaneous calcification may be secondary to injury, to disturbance in calcium and phosphorus metabolism, as described previously, or to unknown factors. Depending on distribution, cutaneous calcification may be termed "calcinosis universalis" or "calcinosis cutis circumscripta" (493). True ossification or cutaneous osteomatosis has been reported, although rarely in the pediatric age group (491). If these entities are caused by a metabolic disturbance, treatment is directed toward rectifying the underlying problem. For idiopathic types of soft tissue calcification, such as that associated with collagen vascular diseases, no specific treatment exists, and removal of symptomatic deposits may be indicated.

Tumoral calcinosis consists of lobulated, calcified soft tissue masses adjacent to joints (494–496). Although it usually is seen in the second and third decades of life, it can be seen in infants and children. The serum phosphorus level is sometimes elevated. A defect in phosphorus transport or

metabolism has been implicated, but not established as the cause of the tumoral calcinosis (497). The differential diagnosis includes collagen vascular diseases, hyperparathyroidism, and hypervitaminosis D, which must be excluded by history, physical examination, and laboratory data. Excision of the lesions surgically has not been entirely satisfactory, because of the possibilities of skin ulceration or recurrence (495,498). Treatment of tumoral calcinosis in adults has been successfully accomplished medically with phosphorus deprivation (496,499). Reports of tumoral calcinosis in children (495,498) and infants (494,500) have been made. The best treatment in this age group remains open to some judgment. Use of phosphorus deprivation in the immature skeleton, at least in theory, would be rachitogenic; hence, excision of symptomatic lesions may be the logical course (494,498,500). However, successful medical treatment with aluminum hydroxide antacid administration to bind phosphate and dietary phosphate restriction for 6 months has been reported for a 6-year-old child (495). An initial medical approach appears justified, even for a patient who is skeletally immature. A pediatric orthopaedist and a pediatric nephrologist or gastroenterologist make a logical team to balance the ongoing calcium and phosphorus needs of the skeleton with a restriction sufficient to affect the lesions favorably. If these somewhat conflicting goals cannot be met, excision may be indicated (494,498,500).

Ossification in the deeper soft tissues may represent fibrodysplasia ossificans progressiva (i.e., myositis ossificans progressiva) or myositis ossificans circumscripta or traumatica. Fibrodysplasia ossificans is a genetic condition (501,502). Digital abnormalities are present at birth, the most common being underdevelopment of the great toes and short, abnormal first metatarsals. Hearing loss, premature baldness, and mental retardation also can be clinical features of this entity. There is an abnormal modulation of pluripotential fibroblasts into osteoblasts. A bone morphogenetic protein (BMP) may mediate this process (503). Because of the knowledge of limb development at the molecular level, abnormal expression of BMP would be an attractive candidate to explain heterotopic ossification and brachydactyly (504). At present, there is no satisfactory treatment. Excision alone does not halt progressive ossification and limitation of the range of motion of joints. The effect of adjunctive metabolic treatments is difficult to assess. Respiratory failure with chest wall constriction may be terminal. The characterization of a BMP antagonist may provide a more effective treatment for this difficult entity (504).

In myositis ossificans circumscripta, there is usually either a clear history of trauma or an associated condition, such as neurologic or thermal injury, in which case the entity is usually termed "myositis ossificans traumatica" (482, 505,506). In spontaneous myositis ossificans circumscripta without a clear history of trauma or an associated condition, the entity may be called "pseudomalignant myositis" (507). Spontaneous myositis ossificans circumscripta is uncom-

mon, but has been reported in early childhood (508). The history of the patient with myositis ossificans traumatica usually facilitates the radiographic distinction from malignant processes. The ossification is more mature at the surface peripheral to the underlying bone, with an intervening space without osseous tissue. Although the periosteum as a source of the ossification has been considered, pluripotential fibroblasts modulating into osteoblasts may also be the source of myositis ossificans traumatica.

In myositis ossificans traumatica, spontaneous resolution can occur with only observation. When there is limitation of joint range of motion (particularly in association with conditions such as burns and head injuries), resection of a traumatically induced myositis may be undertaken during the quiescent phase when it is clear that it is no longer growing or resolving spontaneously (482,505). Adjunctive regimens such as radiation (509) are not indicated in children, but antiinflammatory programs have been used (506). Occasionally, the distinction of pseudomalignant myositis from malignant conditions may prove difficult, necessitating biopsy, and this is best coordinated with the pathologist to review all features of the case in interpreting the histologic findings.

Connective Tissue Syndromes

Marfan Syndrome

Marfan syndrome is a genetic disorder of connective tissue, and, like osteogenesis imperfecta and EDS, it has some degree of heterogeneity. The mode of inheritance is thought to be autosomal dominant transmission (379,510). Common findings are in the skeletal, ocular, and cardiovascular systems. The skeleton shows arachnodactyly (i.e., abnormally long and slender digits), dolichostenomelia (i.e., long, narrow limbs), pectus deformities, and scoliosis. In the cardiovascular system, aortic regurgitation, aortic dilatation, aneurysms, and mitral valve prolapse can occur. Ocular findings are myopia and superior displacement of the lens (compare with homocystinuria, in which the lens displacement is inferior).

Marfan syndrome has been classified into four more or less distinct types: asthenic, nonasthenic, contractural, and hypermobile. Cardiac manifestations are particularly pronounced in the asthenic type. In contractural Marfan syndrome, the joints have a decreased range of motion. In the hypermobile type, joint motion is increased (compare with EDS, type III).

Marfan syndrome has been linked to a fibrillin gene on chromosome 15, as has ectopia lentis; congenital contractural arachnodactyly has been linked to a fibrillin gene on chromosome 5 (511). These findings make possible the diagnosis of Marfan syndrome on the basis of genetic linkage and analysis. However, the diagnosis is still established by a combination of findings in two of the three affected systems (i.e., ocular, cardiac, and musculoskeletal) and a

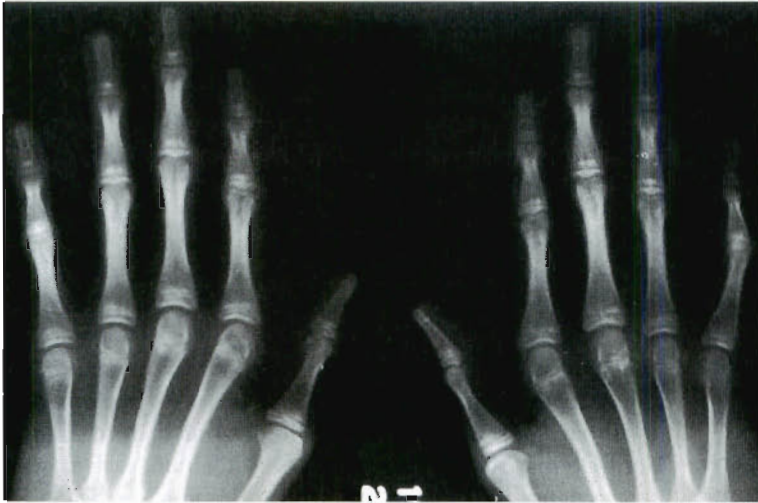

FIGURE 7-37. Hands showing arachnodactyly. Notice the long, thin metacarpals and phalanges.

positive family history (510). Although genetic analysis usually establishes the diagnosis, the pediatric orthopaedist frequently participates in this process at some point relative to the musculoskeletal findings. The ratio of upper segment (i.e., head to pubic symphysis) to lower segment (i.e., pubic symphysis to plantar surface) is calculated. In the normal mature skeleton, this ratio is 0.93. (Tables are required to calculate the normal ratio at various points during growth.) Because of the dolichostenomelia, in Marfan syndrome this ratio is decreased to approximately 0.85 or less (512). Steinberg (513) described the thumb sign. The thumb is grasped in a clenched fist. In Marfan syndrome, because of the arachnodactyly, the thumb protrudes past the ulnar border of the hand. Similarly, when the thumb and index finger are wrapped around the opposite wrist, there is overlap. Arachnodactyly alone does not make a diagnosis of Marfan syndrome.

Although the radiographic findings in patients with Marfan syndrome are fairly typical for this disorder, no single sign is pathognomonic, because of variable expressivity in this syndrome and considerable overlap with the normal population. Arachnodactyly can easily be defined by radiographic examination because of the long, slender phalanges, metatarsals, and metacarpals, and the increased ratio of length to width of the second to fifth metacarpals (Fig. 7-37). The lengths of the second to fifth metacarpals are divided by the widths of the respective diaphyses. The ratios are averaged. Positive arachnodactyly is defined as a ratio greater than 8.8 in males and greater than 9.4 in females (514). These findings may also be seen in minimally affected individuals who have no other manifestations of the disease.

Scoliosis may be present and is relatively indistinguishable from that in other patients, but in some patients, the vertebral height is notably increased (Fig. 7-38). Bone density is normal compared with the osteopenia seen in homo-

cystinuria. The curve pattern frequently is either single right thoracic or double right thoracic and left lumbar (515). The thoracic curve is most commonly lordoscoliotic. The thoracolumbar junction is prone to kyphosis, probably related to the underlying ligamentous laxity (516).

It is important for the orthopaedist who sees undiag-

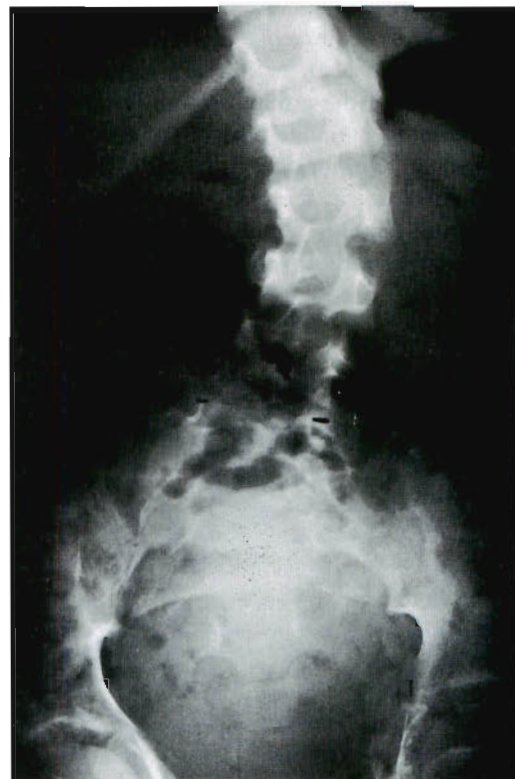

FIGURE 7-38. Patient with Marfan syndrome. Scoliosis is obvious. The bone quality is normal, unlike the osteopenia seen in homocystinuria.

nosed patients with the Marfan phenotype to consider it when treating sprains and other injuries associated with the altered ligamentous structure or scoliosis. The potential for serious ocular abnormalities and life-threatening cardiac abnormalities exists in association with the musculoskeletal problems. The potential cardiac problems are aortic and mitral valvular disease, aortic aneurysm, and conduction defects that can cause sudden death. After the diagnosis of Marfan syndrome has been considered and workup pursued, an electrocardiogram and an echocardiogram are customarily obtained. If the echocardiogram reveals positive findings, the cardiology service should participate in the patient's care. Scoliosis should be treated aggressively [➔2.9]. The treatment guidelines follow those for idiopathic scoliosis. Curves greater than 50 degrees require surgery (517). The cardiac status is important at this juncture. Valvular disease requires antibiotic prophylaxis, with specific recommendations varying among cardiology services.

Ehlers-Danlos Syndrome

Ehlers-Danlos syndrome (EDS) once was considered to be a single genetically induced entity characterized by hyperextensibility of the skin, joint hypermobility, easy bruisability, soft tissue and bony fragility, calcification of soft tissues, and various degrees of osteopenia. The syndrome was thought to result from a single error, but to have variable expressivity. It has now been clearly established, however, that EDS is a family of disorders embracing a large variety of defects in collagen metabolism (13). At least 13 types of EDS have been identified, and the groups are now considered to be the most common heritable disorder of connective tissue (14). The genetic basis for types I, II, and III does not seem to reflect a difference in the type I or III collagens, which are in skin and ligaments. Presumably, the mechanism underlying these types must involve other collagens or noncol-

lagenous proteins in the matrix. Type VII EDS has abnormalities in type I collagen similar to the abnormality found in type IV osteogenesis imperfecta, but the two syndromes are distinct (14). Type VII EDS has multiple joint dislocations but no clinical bone fragility, whereas type IV osteogenesis imperfecta has joint hypermobility, but no instability, and the bone fragility characteristic of osteogenesis imperfecta.

The orthopaedic manifestations of EDS vary with the type, but may also be considered collectively (518,519). This has practical significance for the pediatric orthopaedic surgeon because, like individuals with Marfan syndrome, these patients may present to the pediatric orthopaedist without a previous diagnosis. Consideration of the diagnosis of EDS may then prompt further consultation, such as with the genetics and dermatology services, leading to a diagnosis, subtyping, and a clearer definition of the associated conditions. The general orthopaedic conditions include joint hypermobility, joint instability (520,521), arthralgias, and scoliosis. Scoliosis is particularly common in types III and VI EDS. As in Marfan syndrome, treatment generally proceeds according to guidelines for idiopathic scoliosis, with an awareness of associated conditions and a particularly cautious monitoring of the response to bracing.

In EDS type I, the gravis variety, joint hypermobility, and skin hyperextensibility dominate the picture. The skin, although hyperextensible, is not lax and returns to its original configuration. Areas of recurrent bruising can be recognized by the accumulation of pigment (Fig. 7-39). Subcutaneous calcified nodules may be present in these regions and may be seen on radiographs. EDS type I is transmitted as an autosomal dominant trait.

In EDS type II, or the mitis variety, the manifestations are similar to those in EDS type I, but milder. Transmission is also as an autosomal dominant trait.

In EDS type III, also known as benign familial hypermo-

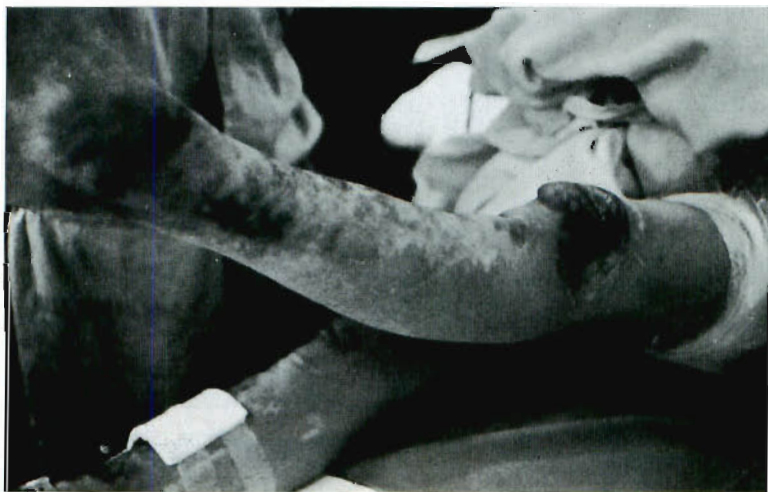

FIGURE 7-39. Patient with Ehlers-Danlos syndrome, type I. The knees and pretibial regions have been subjected to recurrent injury and have accumulated heme pigmentation. (Courtesy of Michael G. Ehrlich, M.D., Providence, RI.)

bility, joint hypermobility is present, but scar formation is normal, unlike the situation in EDS types I and II. The inheritance pattern is autosomal dominant. There is not a clinical laboratory test to establish a diagnosis of EDS type III, which is made on the basis of history (including family history) and physical examination. It is worthwhile for the orthopaedist to consider this diagnosis in a patient with instability of multiple joints. In such a setting, successful surgical reconstruction may be difficult, and ultimately, fusion may be required (519). Cardiac evaluation for the possibility of a floppy mitral valve may be desirable.

EDS type IV is the vascular or ecchymotic type and can be further subtyped. It results from abnormalities in type III collagen, the type required for vascular integrity. Autosomal dominant and recessive modes of transmission have been described. The clinical findings are thin skin, usually normal joint mobility, and visceral rupture.

In EDS type V, the skin hyperextensibility is similar to that in EDS type II, but with less marked joint mobility and skin fragility. Its transmission is considered to be X-linked.

EDS type VI is the most clearly biochemically characterized syndrome. Patients with this ocular-scoliotic type show a relative decrease in concentrations of lysine hydroxylase and therefore deficient concentrations of hydroxylysine in the collagen (522). Because lysine hydroxylation is a post-translational modification of the collagen necessary for normal cross-links, the collagen fibers are loosely organized and more soluble. As with most enzymatically based genetic diseases, transmission occurs as an autosomal recessive trait. Ocular fragility and scoliosis are present.

EDS type VII, arthrochalasia multiplex congenita, is notable for extreme joint laxity. Three subtypes with abnormalities in type I collagen metabolism have been identified (14). Developmental dysplasia of the hip is common (521). Autosomal dominant and recessive modes of transmission exist.

In EDS type VIII, the usual stigmata are present, but progressive periodontal disease is a distinguishing feature. The biochemical defect is unknown. Inheritance is as an autosomal dominant trait.

Homocystinuria

Cysteine ($\text{SH-CH}_2\text{-CH}[\text{NH}_2]\text{-COOH}$) is not an essential amino acid; it is synthesized from methionine and serine. Cystine or dicysteine is the disulfide resulting from the oxidation of two cysteine moieties. The homolog homocysteine ($\text{SH-CH}_2\text{-CH}_2\text{-CH}[\text{NH}_2]\text{-COOH}$) contains an additional methyl group compared with cysteine. Homocystine is the disulfide from two homocysteine groups. Homocysteine is an intermediary metabolite in the production of cysteine from methionine. There are three enzymatic steps in this pathway for which defects have been described that lead to

the accumulation of homocysteine and homocystine in the blood and homocystine in the urine (523,524).

Type I homocystinuria has a phenotype similar to that of Marfan syndrome (525). Patients with homocystinuria are tall with long limbs and may have arachnodactyly and scoliosis. Dislocation of the lens is common, but, unlike that seen in Marfan syndrome, the displacement is inferior. Osteoporosis is a marked feature of type I homocystinuria, but in Marfan syndrome, bone quality is normal. Vertebral osteoporosis may be present in homocystinuria, producing biconcavity and flattening of vertebral bodies. Florid arachnodactyly and scoliosis are more common in Marfan syndrome, in which the vertebral bodies are normal or excessively tall. Widening of the epiphyses and metaphyses of long bones is more typically seen in homocystinuria. Mental retardation is not a feature of Marfan syndrome. Mental retardation does occur in approximately half of all patients with homocystinuria (526). Another notable feature of type I homocystinuria is an abnormality in clotting, which leads to venous and arterial thromboembolic episodes (527).

The biochemical defect in type I homocystinuria is thought to be a deficiency of cystathionine synthetase, which normally catalyzes the chemical union of homocysteine and serine to form cystathionine. The enzyme uses pyridoxine (vitamin B_6) as a cofactor. Blood levels of methionine are increased in patients with this metabolic error. Screening of marfanoid patients for homocystine in the urine with the cyanide nitroprusside test can differentiate type I homocystinuria from the phenotypically similar Marfan syndrome.

Types II and III homocystinuria are biochemically distinct, because the errors cause blocks at other points. Blood levels of methionine are normal. The other stigmata, such as skeletal changes and thromboses, are absent.

Treatment for homocystinuria depends on the type. In type I, the typical course is methionine restriction and pyridoxine supplementation. This may also have the beneficial effect of preventing thromboses (527). For types II and III, methionine restriction is harmful. Treatment with cofactors also varies for the other types. Vitamin B_{12} is suggested in the management of type II, and folic acid for type III.

As with all inborn errors of metabolism, homocystinuria may reveal other physiologic aspects. Hyperhomocysteinemia has been determined to be an independent risk factor for vascular disease (528). It may have a role in the generation of neural tube defects (529). The role of folate, B_6 , and B_{12} in treating hyperhomocysteinemia and its sequelae is evolving.

ENDOCRINOPATHIES

Although the spectrum of disorders of the endocrine glands can manifest symptoms in several ways, alterations in rate of growth and skeletal morphology are common in children.

The pediatrician usually detects the problem, then consults the orthopaedist; it is essential that he or she be aware of the nature and significance of these disorders. Although skeletal growth has been discussed extensively in Chapters 1 and 2, some salient features of the growth process are particularly germane to endocrine physiology and are reviewed briefly here.

Several parameters are useful in assessing growth: height, sitting height, arm span, head circumference, and body weight (530,531). These factors must be interpreted in relation to chronologic and biologic age. Because of difficulties

in interpretation, investigators have advocated increasingly sophisticated means of assessment (532,533). Nevertheless, these factors are appropriate in the primary study of the patient. All parameters must be interpreted according to cross-sectional distributions in the general population, or, if possible, longitudinally in the individual over time. The latter approach is especially useful in determining whether a borderline value is actually pathologic for a given patient.

Examples of different growth patterns are shown in Figs. 7-40 through 7-43. The child whose curve continues to fall below the normal percentiles is much more likely to have

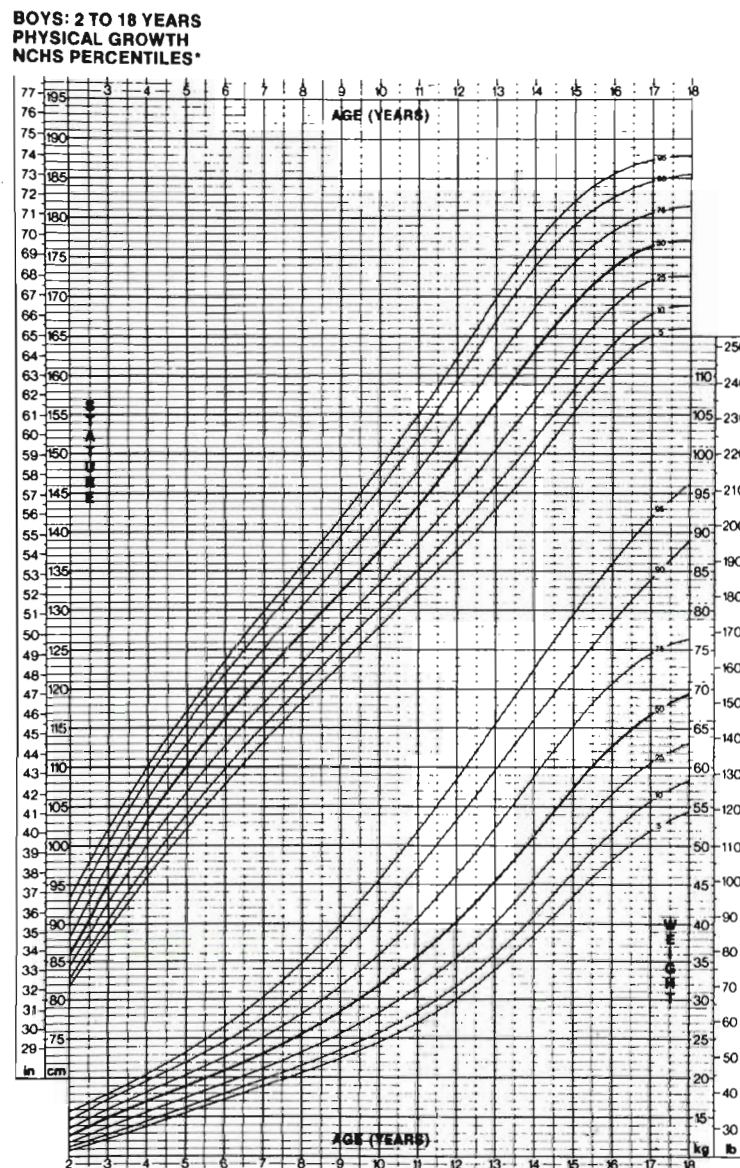


FIGURE 7-40. Normal growth chart for boys, 2 to 18 years of age. (Adapted from ref. 534, with permission.)

a hormonal problem than the child whose curve stays constantly in a low percentile. Placement in the third percentile and below in absolute height raises suspicion, and, when combined with a commensurate decrease in growth velocity, such an abnormality warrants further investigation.

Several features of morphometry and growth can be assessed in a crude manner without consulting the available standard charts. The first of these is the ratio or percentage of sitting height relative to total height. At birth, the ratio should approximate 70%. (This value also can be expressed as a ratio of upper segment [i.e., head to pubic symphysis]

to lower segment [i.e., pubic symphysis to plantar surface] and should equal 1.69.) By 3 years of age, the sitting height should constitute 57% of total height, and, in adolescence, the value should be 52%. As a rough approximation, 25 cm of growth can be expected in the first year of life, 10 cm in the second year, 6 cm in the third and fourth years, and 5 cm annually thereafter, with a spurt at the beginning of adolescence. The velocity of growth throughout childhood has been the subject of extensive analytic study and is a far more sensitive indicator than absolute stature in the detection of a problem (Fig. 7-43).

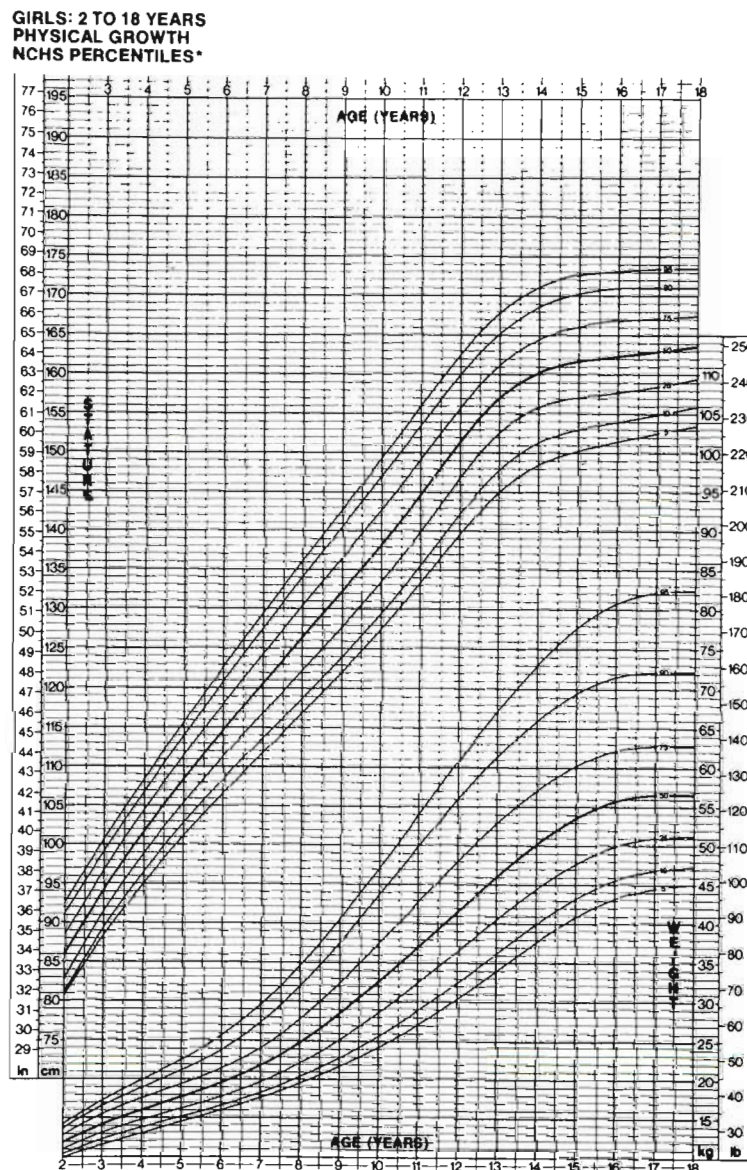


FIGURE 7-41. Normal growth chart for girls, 2 to 18 years of age. (Adapted from ref. 534, with permission.)

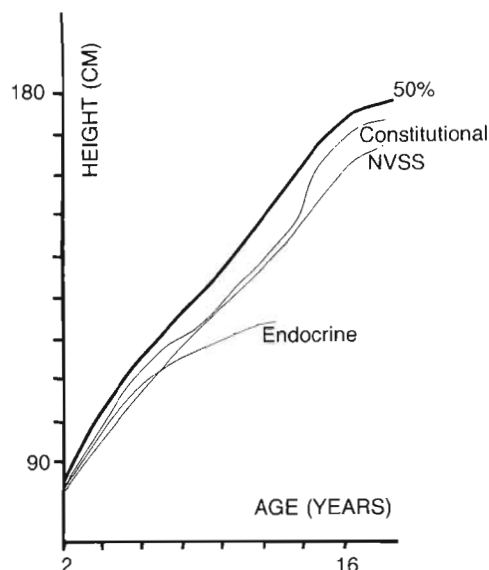


FIGURE 7-42. Different patterns of growth disturbance. The normal fiftieth percentile serves as a reference. In the endocrine disturbance, a progressive deceleration in growth occurs. In constitutional growth delay, growth starts normally, decreases during the first few years of life, and finally regains its earlier percentile level. In normal variant short stature (NVSS), growth remains at a constant but low (third or less) percentile.

Correlating these parameters relative to some index of maturity is obviously an important issue, and Tanner and associates have devoted a great deal of thought to this (530,531). Because any stage of development is a combination of anatomic and physiologic changes, and this combi-

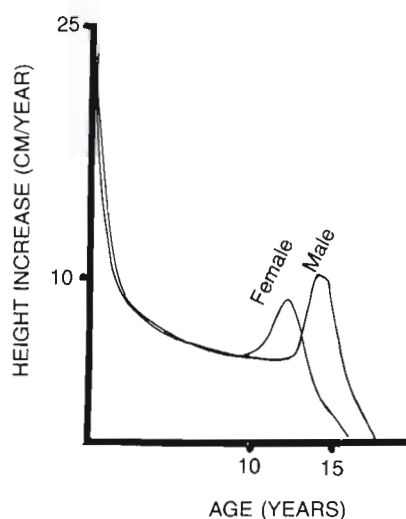


FIGURE 7-43. Growth velocity curves. Plotted in this manner, changes in growth rates frequently can be detected early. (Adapted from ref. 531, with permission.)

nation may be different for each person, any single parameter for a person compared with standard parameters may not accurately reflect that person's maturity. A combination of physical and radiographic criteria may have to be invoked. For most orthopaedic applications, radiographs of the left wrist and hand are the customary index of bone age in children 2 years of age and older, but the orthopaedist must be aware that there are limitations to this method (12,533). These include interobserver variability in determining the bone age, variation in the correlation of growth with bone age among different genetic populations, and a relatively large standard deviation in the correlation within a population during the growth spurt.

The initial diagnostic approach for patients suspected of having an endocrine-related growth problem should include a careful history of the pattern of growth, a family history, and a history of associated gastrointestinal, renal, and neurologic signs or symptoms. Endocrine disturbances should be evaluated. Menarchial history is important in girls. In addition to a general physical examination, the growth patterns described previously must be measured accurately. Breast development and the age of appearance and the extent of development of axillary and pubic hair and gonads should be assessed. Routine laboratory studies should include complete blood count, urinalysis, and glucose, BUN, creatinine, electrolytes, calcium, phosphorus, and alkaline phosphatase levels, and left wrist and hand radiographs should be obtained for the determination of bone age. Additional laboratory studies may be necessary in the pursuit of specific entities.

Normal Variant Short Stature

By definition, normal variant short stature (NVSS) involves a current and predicted height below the third percentile, a birth weight greater than 2.5 kg, no apparent organic cause for growth retardation, and a normal serum growth hormone level (when tested with pharmacologic provocation) (535). NVSS has tentatively been further classified, but the significance of this has yet to be established. Practically speaking, the majority of short-statured persons (85%) fall into this category, for which no specific cause can be established. A slightly different category of short stature is described by the term "constitutional growth delay." In this situation, there is normal early growth, then a deceleration during the first 2 years, and subsequent reestablishment of a normal pattern. As with NVSS, no metabolic or endocrine abnormality can be established. This growth pattern is clear in retrospect, but causes concern at the time of presentation; workup is recommended to rule out other problems. The differential diagnosis includes conditions (discussed in subsequent sections) that cause short stature.

Treatment is usually a matter of explanation and reassurance. One report suggested a role for growth hormone as

therapy for a subgroup of this population; the use of growth hormone is still evolving (535,536). The role of nutrition as a cause of NVSS has yet to be evaluated fully, and improving dietary intake of proteins and other important constituents remains part of the management (537).

Growth Hormone Deficiency and Hypopituitarism

Deficiency of growth hormone leads to progressive inhibition of linear growth and maturation (538,539). Birth weight and height are usually normal in children with this disorder. Typically, the deviations begin to become evident after the first year of life. Deficiency of growth hormone may or may not be associated with other deficiencies of hypothalamic-releasing factors or other pituitary hormones, including, from the anterior portion, human growth hormone, adrenocorticotropin (ACTH), thyroid-stimulating hormone (TSH), follicle-stimulating hormone, prolactin or lactogenic hormone, luteinizing hormone, or testicular interstitial cell-stimulating hormone; from the middle portion, melanocyte-stimulating hormone; and from the posterior portion, antidiuretic hormone and oxytocin (540,541). The clinical manifestations of growth hormone deficiency can be narrow, affecting only growth, or diffuse, with a broad range of additional abnormalities. Deficiencies of ACTH and TSH can be recognized by appropriate biochemical tests, but deficiencies of gonadotropins usually cannot be diagnosed until the age at which puberty would otherwise be expected. The basic clinical manifestation is progressive retardation in growth and maturation (Fig. 7-44).

When growth hormone deficiency is suspected on clinical grounds, laboratory testing is essential (542). The studies available are one-time assay tests, with results varying according to stress and alterations in response to chemical and pharmacologic manipulation. The first major investigative effort is an exercise test in which growth hormone levels are measured by radioimmunoassay during walking. Resting values are usually less than 5 ng per mL; minimum peak values are in the 7 to 12 ng per mL range. If the exercise test result is normal, the production of growth hormone is considered adequate. If it is abnormal, a pharmacologic stress test can be performed. Several protocols have been advanced, including insulin-induced hypoglycemia, arginine infusion, and an L-dopa-propranolol test (543). If the increase in growth hormone is still inadequate and thyroid function is normal, growth hormone deficiency has been confirmed.

The underlying cause of growth hormone deficiency may be idiopathic, previous head injury, psychosocial problems, including malnutrition and neglect, and intracranial tumor (544,545). It is particularly important to rule out the presence of a craniopharyngioma by thorough neurologic examination, visual field studies and funduscopic examination,

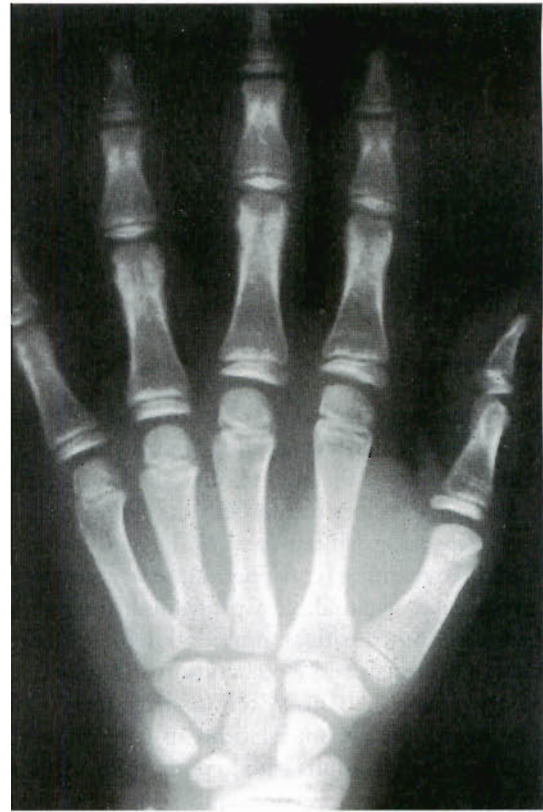

FIGURE 7-44. Patient with panhypopituitarism. The patient had retarded height and maturation. The bone age was 11 years; the chronologic age was 20 years.

skull radiography, and computed tomography or magnetic resonance imaging.

The differential diagnosis of growth hormone-deficient short stature includes several entities. In NVSS, the patient continues to grow at a constant but low level, but, in constitutional growth delay, there is a return to a higher growth curve without intervention. Although delayed puberty may be difficult to distinguish from growth hormone deficiency, maturity milestones, once established, continue to appear at a normal rate. A growth hormone assay may be helpful in making these differential diagnoses. At times, children with one of the gastrointestinal or renal diseases mentioned in previous sections may present for evaluation because of growth retardation, but the general initial workup will reveal the presence of such disease. Disorders associated with chromosomal abnormalities should be considered. Turner syndrome usually has many other stigmata, but an XO/XX mosaic may be more difficult to differentiate. Hypothyroidism and gonadal dysfunction also must be included in the differential diagnosis.

Treatment for growth hormone deficiency must start with the exclusion and correction of the psychosocial causes of the deficiency, because in these cases, response to admin-

istration of growth hormone will be suboptimal. In other cases, human growth hormone administration is the treatment of choice (536,546). If growth hormone deficiency is associated with other hormonal deficiencies, replacement treatment for these factors must be included in the therapeutic regimen. The response to growth hormone in these selected cases is usually dramatic. Unfortunately, a few patients develop antibodies to the hormone, and its value is markedly diminished.

Hypothyroidism

The manifestations of a deficiency in thyroid hormone depend on age. In the newborn period, hypothyroidism manifests itself as cretinism; the infant is described as sluggish and shows increasingly short stature and developmental delay, immature facies, a broad flat nasal bridge, and coarse hair. The child often manifests constipation, severe feeding problems, persistence of jaundice, a protruding tongue, and a protuberant abdomen with an umbilical hernia. Mental development is retarded, and if recognition and treatment are delayed, irreparable nervous system damage may occur.

In the older child, manifestations usually more closely resemble those seen in adults with hypothyroidism. Changes in facial appearance are less commonly seen. Retardation of growth is characteristic, and radiographically, the secondary centers of ossification appear late and show a peculiar fragmentation that may be misinterpreted as evidence of osteonecrosis (547). Lethargy, changes in personality, and poor school performance may be the presenting features. Slipped capital femoral epiphyses may be seen (548) [→3.14]. In untreated cases, slippage may not be seen until the child is older; because it can also occur during the treatment for hypothyroidism as the bone age advances, vigilance is important at this time (549) (Fig. 7-45). In some children

with mild hypothyroidism, retarded linear growth and delayed skeletal maturation may be the only manifestations.

Specific laboratory studies for hypothyroidism include measurement of thyroid hormones and TSH. Additional thyroid studies may be necessary to define the precise locus of the hypothyroidism. Normal values must be interpreted in terms of age. In the case of growth retardation, a growth hormone assay must also be performed. However, the serum growth hormone level usually does not increase, even in response to the provocative tests, until the hypothyroidism has been corrected. Bone age is typically delayed to a more severe degree than in other endocrinopathies affecting maturation. Delay in the appearance of secondary centers involves all epiphyses. For congenital hypothyroidism, a knee film is more useful than a wrist film (Fig. 7-46). The distal femoral secondary center of ossification, which should be present at term, is absent. Occasionally, irregularities in ossification give a stippled appearance to the secondary centers. In the proximal femur, this may impart a Perthes-like radiographic appearance, but both proximal femurs are symmetrically involved (Fig. 7-47). One study found a group of Perthes patients to be generally euthyroid but to have a moderate elevation of free thyroxine, suggesting a disturbance in chondrocyte maturation in this disease (550).

Treatment for hypothyroidism is replacement with an appropriate dosage of thyroid hormone, a therapy that requires careful fine-tuning to avoid acceleration in bone maturation and premature closure of epiphyseal plates. Even with appropriate treatment, evidence indicates that juvenile acquired hypothyroidism results in a permanent height deficit relative to the duration of hypothyroidism before treatment (547).

Gonadal Abnormalities and Sex Steroids

Some of the effects of sex steroids on growth and turnover were discussed in the early part of this chapter. The manner

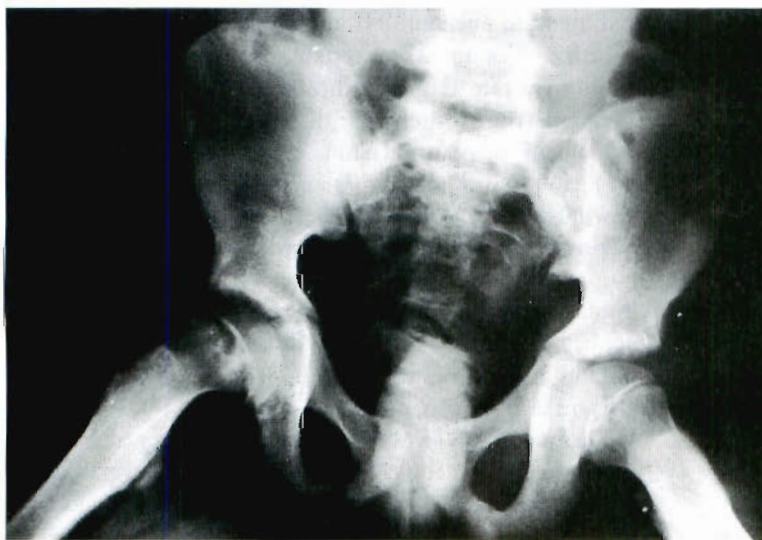


FIGURE 7-45. Slipped capital femoral epiphysis in a boy being treated for hypothyroidism. The patient's chronologic age was 13 years, 11 months, and his bone age was 12 years, 6 months.

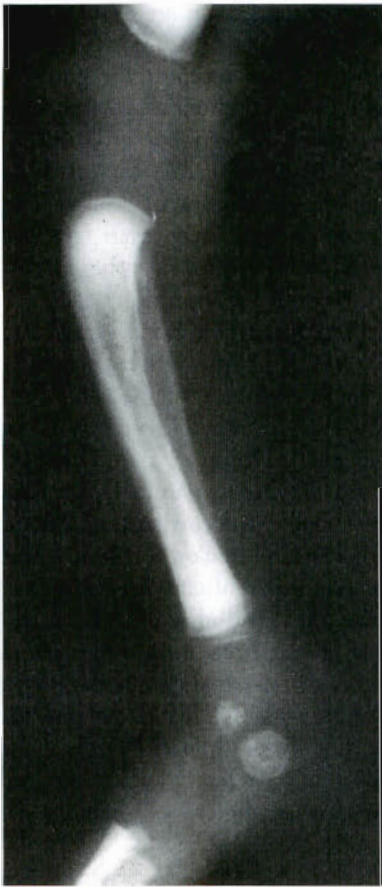

FIGURE 7-46. Child with congenital hypothyroidism at term. The distal femoral secondary center should be ossified, but is absent.

by which these hormones act is still not completely clear, but according to theory, specific receptors for these steroids are on the membrane or in the cytoplasm of the target cells (551,552). No receptors for androgens or estrogens have been identified in chondrocytes from the epiphyseal plate, in contrast to specific receptors for somatomedins (30).

Despite the absence of specific binding sites, two major effects of sex steroids on the skeleton have been identified: promotion of maturation and an increase in the rate of growth. The typical early finding in syndromes associated with sexual precocity is accelerated growth. At first, the child is taller than his or her peer population, according to chronologic age. Later, the acceleration of maturation predominates, and if untreated, the patient ultimately suffers a growth impairment compared with his or her peer group. As an example, an increased concentration of testosterone in childhood results in virilization and initially increased epiphyseal growth. With advancing time, the plate closes prematurely, and ultimately, the child is shorter in stature than his peers. Conversely, in humans and animals, early castration initially slows the rate of growth, but materially increases the length of time until epiphyseal closure; the eunuch is often taller than the average child. Estrogens also promote maturational changes in the epiphysis, but cell proliferation and matrix production are often retarded, so that the person with an abundance of estrogen may be considerably shorter.

Sex steroids are also produced by the adrenal cortex. They may be especially important for girls, because they are converted to testosterone activity and may initiate the adolescent growth spurt.

It is evident from the foregoing facts that the syndromes associated with precocious puberty and adrenal hyperplasia

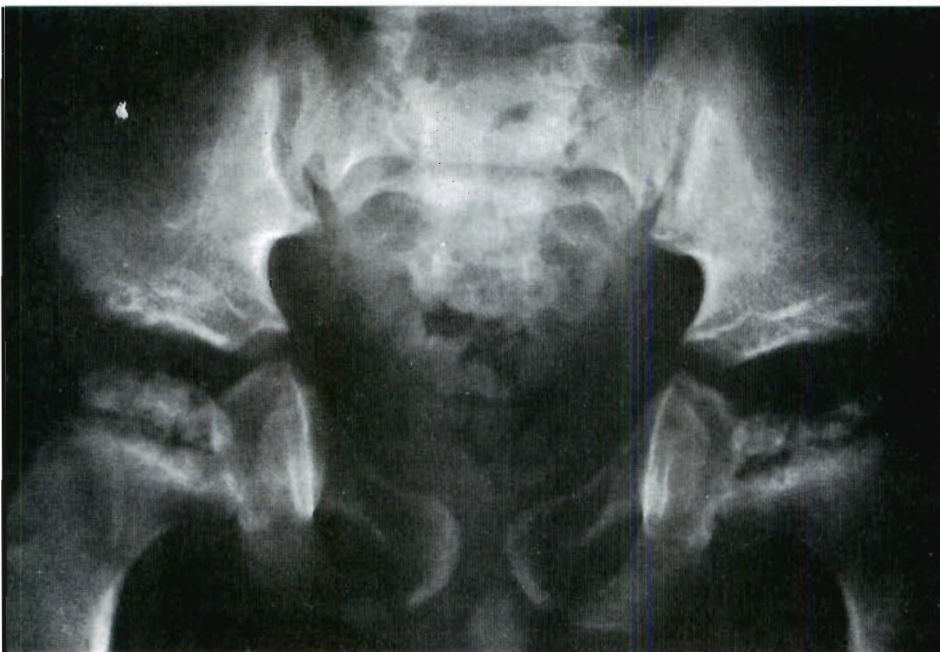

FIGURE 7-47. Patient with later-onset hypothyroidism. A Perthes-like pattern can be seen in the femoral epiphyses, but both are at a similar stage of fragmentation.

must be considered in the differential diagnosis of disturbances of growth or premature skeletal maturation, and the abnormalities associated with decreased gonadal function, such as Turner syndrome or Prader-Willi syndrome, must be considered in the differential diagnosis of delayed skeletal maturation.

Glucocorticoid-related Abnormalities

The abnormalities in the skeleton associated with alterations in adrenal glucocorticoid production are encountered considerably less frequently in children than in adults. However, Cushing syndrome occurs (Fig. 7-48), and the musculoskeletal abnormalities of Addison disease have also been reported (540,553). Iatrogenic problems secondary to the administration of steroids for asthma, neoplasms, immuno-

suppression, and other diseases are more common in childhood.

Although no definite receptor for glucocorticoids has been found in epiphyseal chondrocytes, the effects of these agents on the growing skeleton are profound. Proteoglycan and collagen synthesis are sharply decreased, and chondrocyte differentiation in the zone of growth is impaired. An excess of glucocorticoids may exert an effect through suppression of growth hormone synthesis or somatomedin production. Corticoids also inhibit calcium absorption; however, based on this factor alone, rickets must be rare.

Of greatest concern is the action of glucocorticoids on the skeleton itself, because sustained high doses produce profound and usually irreversible osteopenia, even after the drug is discontinued. However, a study in adults demonstrated that 1,25-dihydroxyvitamin D₃ and calcium, used prophylactically, prevented corticosteroid bone loss in the lumbar spine (554). Children on corticosteroids may exhibit fairly severe osteoporosis, often with compression fractures of the vertebrae. The possibility of osteonecrosis occurring in 6 to 25% of children receiving prolonged therapy with high doses of corticosteroids is significant; it is a major cause of disability. Unfortunately, there is no absolutely safe dosage of glucocorticoids for children. These agents should be used when absolutely necessary and at the lowest possible dosage consistent with clinical well-being.

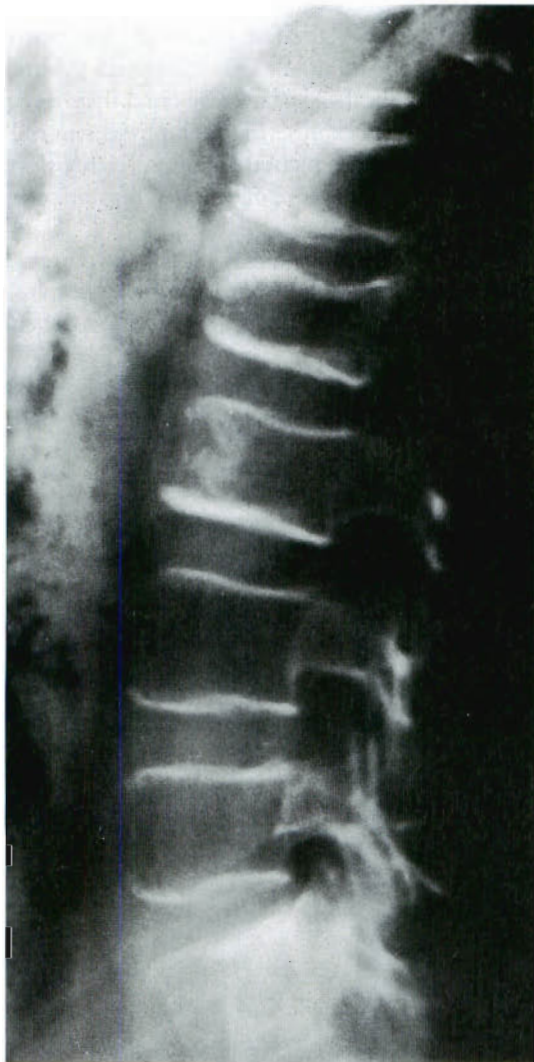

FIGURE 7-48. Cushing syndrome in an adolescent. There is marked steroid-induced osteoporosis.

Fibrous Dysplasia

Fibrous dysplasia (i.e., osteitis fibrosa cystica disseminata) results from a somatic mutation that produces sites in one, several, or occasionally many bones in which the normal medullary mix of osseous and marrow elements is replaced by what appears to be benign neoplastic fibrous tissue (555–557).

Traditionally, fibrous dysplasia has been a difficult entity to classify. It can be classified under neoplasms and is discussed partially in that Chapter 14 of this text. The intriguing, but previously unexplained, association with multiple endocrine problems has always earned a place for this entity in a metabolic chapter. In affected areas of the skeleton, there is both decreased formation and increased absorption of bone. The fibrous tissue undergoes ossification by a form of intramembranous bone formation, without apparent conversion of the fibroblasts to osteoblasts; the bone produced consists of small, irregular, purposeless, and often poorly mineralized trabeculae. The disease process is most active during growth, showing considerable activity on bone scan and causing internal scalloping of the cortices, weakening of the bone, and pathologic fracture. It often persists into adult life. Fibrous dysplasia may be associated with significant endocrine disturbances, which can dominate the picture (558).

The clinical manifestations of fibrous dysplasia may vary greatly (555). The lesions may be isolated (i.e., monostotic),

or found in several bones on one side of the skeleton, or scattered throughout the skeleton (i.e., polyostotic). Solitary lesions are rarely accompanied by endocrine problems and usually are of no concern to the patient unless fracture occurs. At the opposite end of the spectrum are the cases in which the lesions are polyostotic and widely disseminated. The patient may display multiple sites of skeletal involvement, with severe distortion of the normal bony configuration and facial appearance as a result of asymmetric enlargement of the facial bones (i.e., hemihypertrophy cranii). Patients with florid disease suffer frequent fractures, particularly at such sites as the pelvic rami and necks of femurs. Lesions in the necks of femurs may cause progressive coxa vara, leading to the shepherd's crook deformity.

Radiologic findings in patients with fibrous dysplasia vary somewhat, depending on the bone involved and the site, but the bone usually is expanded at the site. The cortices are thinned but intact and scalloped from within. The area of the lesion shows few trabecular markings; instead, the fibrous tissue and small bony spicules (below the resolution of the x-ray beam) project a ground-glass consistency. In florid cases of fibrous dysplasia, deformities and other sequelae of old fractures are evident. Skin abnormalities are frequently seen in the more florid types of polyostotic fibrous dysplasia. These lesions are macular and light brown (cafe au lait spots). They often have an irregular border ("coast of Maine"), unlike similar lesions with a smooth border ("coast of California") seen in neurofibromatosis.

The McCune-Albright syndrome (MAS) includes polyostotic fibrous dysplasia, cafe au lait spots, precocious puberty, and hyperfunction of multiple endocrine glands. This entity, like Albright hereditary osteodystrophy (AHO), has been linked to an abnormality in G protein function. As discussed in the section on AHO, G proteins are trimers

of three different protein subunits (α , β , and γ) that link many different cell membrane receptors, such as hormone receptors, to their effector molecules, such as enzymes or ion channels (350,559,560). The G protein that couples receptors to adenylyl cyclase activity is designated G_s . Mutations in the α -subunit of G_s (*GNAS1*) have been shown to cause both AHO and MAS. However, the mutation in AHO is a germline loss of function, whereas the mutation in MAS is a somatic gain of function with sporadic distribution. Activating mutations of G_s protein have also been demonstrated in monostotic fibrous lesions of bone (561). Furthermore, in an animal model, the activating mutation of the G_s protein also induced higher expression of interleukin-6, which may be responsible for the increased bone resorption in this disease (562). Therefore, there is an evolving molecular explanation for the various manifestations of fibrous dysplasia.

The natural history of fibrous dysplasia is variable (556). If multiple lesions become obvious during early childhood, the skeletal deformity may become severe. Localized lesions that manifest in adolescence are less likely to cause problems.

Treatment for fibrous dysplasia has been surgical intervention at the site at which the lesion has caused, or is likely to cause, pathologic fracture. Deformity at the proximal femur may be particularly difficult to treat (Fig. 7-49). Generous osteotomies may be required in this location to move the femoral neck out of the considerable varus. As in other diseases with bone of poor quality, intramedullary fixation is preferable to plates and screws alone, which tend to dislodge from such bone (563,564). The issue of the best graft or bone-inducing agent or synthetic in this condition has been debated. Bone grafting in fibrous dysplasia is challenging. Autografts tend to be replaced with fibrous tissue, reflecting the increased resorption seen in this condition. One study

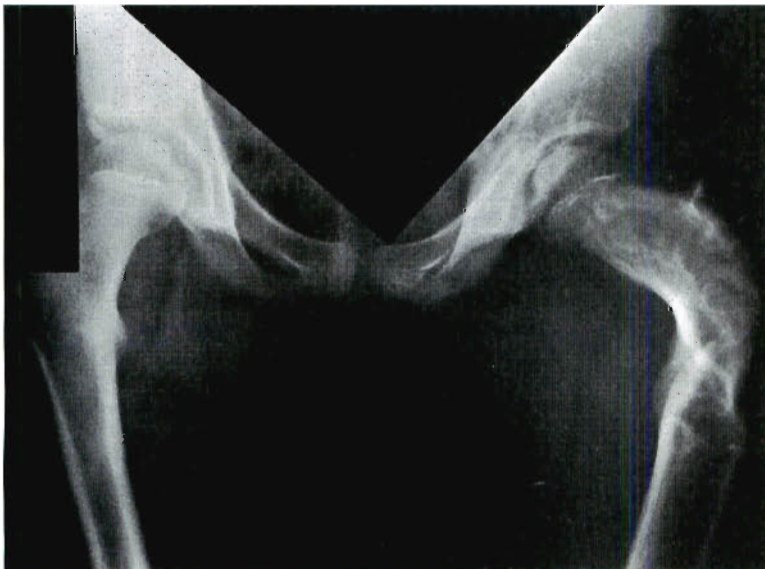

FIGURE 7-49. A patient with fibrous dysplasia has a shepherd's crook deformity of the left hip.

has indicated that valgus osteotomy alone is as effective as osteotomy and autogenous bone grafting (565) [►4.5]. In general, allografted bone is more slowly revascularized than autografted bone (566–569). The persistence of an allograft on a clinical radiograph may not correlate with increased biomechanical strength. Nevertheless, the use of allografts applied to fibrous dysplasia raises interesting possibilities (570). Fibular strut allografts have been used successfully in combination with sliding compression screws (571).

The advent of agents that are effective in inhibiting absorption, particularly the bisphosphonates, has opened the possibility of medical management of several conditions with diminished bone strength seen in pediatric orthopaedics. Studies in the literature for osteogenesis imperfecta were cited in that section. These agents may have wider application, including use in fibrous dysplasia. The safety and efficacy of the various agents will need to be established by protocols. Pediatric orthopaedic surgeons will need to interact with pediatric endocrinologists at their institutions as these treatments bring basic science to clinical application and increase optimism for favorably affecting an extremely difficult condition.

References

- Mankin HJ. Metabolic bone disease. *J Bone Joint Surg Am* 1994; 76:760.
- Phillips LS, Vassilopoulos-Sellin R. Somatomedins. *N Engl J Med* 1980;302:371, 438.
- Zaleske DJ. Cartilage and bone development. In: Cannon WD Jr, ed. *Instructional course lectures*. Rosemont, IL: American Academy of Orthopaedic Surgeons, 1998:461.
- Erlebacher A, Filvaroff EH, Gitelman SE, et al. Toward a molecular understanding of skeletal development. *Cell* 1995;80:371.
- Zaleske DJ. Overview of musculoskeletal development. In: Buckwalter JA, Ehrlich MG, Sandell LJ, et al, eds. *Skeletal growth and development*. Rosemont, IL: American Academy of Orthopaedic Surgeons, 1998:5.
- Vortkamp A, Pathi S, Peretti GM, et al. Recapitulation of signals regulating embryonic bone formation during postnatal growth and in fracture repair. *Mech Dev* 1998;71:65.
- Sledge CB, Zaleske DJ. Developmental anatomy of joints. In: Resnick D, Niwayama G, eds. *Diagnosis of bone and joint disorders*, 2nd ed. Philadelphia: WB Saunders, 1988:604.
- Tabin CJ. Retinoids, homeoboxes, and growth factors: toward molecular models for limb development. *Cell* 1991;66:199.
- Johnson RL, Tabin CJ. Molecular models for vertebrate limb development. *Cell* 1997;90:979.
- Sandberg MM, Aro HT, Vuorio EI. Gene expression during bone repair. *Clin Orthop* 1993;289:292.
- Trippel SB. Basic science of the growth plate. *Curr Opin Orthop* 1990;1:279.
- Greulich WW, Pyle SI. *Radiographic atlas of skeletal development of the hand and wrist*, 2nd ed. Stanford: Stanford University Press, 1959.
- Burgeson RE, Nimni ME. Collagen types: molecular structure and tissue distribution. *Clin Orthop* 1992;282:250.
- Cole WG. Etiology and pathogenesis of heritable connective tissue diseases. *J Pediatr Orthop* 1993;13:392.
- Hiltunen A, Aro HT, Vuorio E. Regulation of extracellular matrix genes during fracture healing in mice. *Clin Orthop* 1993; 297:23.
- Glimcher MJ, Krane SM. The organization and structure of bone and the mechanism of calcification. In: Ramachandran GN, Gould BS, eds. *Treatise on collagen*. New York: Academic, 1968:67.
- Canalis E. Effect of growth factors on bone cell replication and differentiation. *Clin Orthop* 1985;193:246.
- Canalis EM, Dietrich JW, Maina DM, et al. Hormonal control of bone collagen synthesis in vitro: effects of insulin and glucagon. *Endocrinology* 1977;100:668.
- Raisz LG, Kream BL. Regulation of bone formation. *N Engl J Med* 1983;309:29, 83.
- Vas G. Cellular biology and biochemical mechanism of bone resorption: a review of recent developments on the formation, activation, and mode of action of osteoclasts. *Clin Orthop* 1988; 231:239.
- Friedlaender GE. Current concepts review. Bone grafts. *J Bone Joint Surg Am* 1987;69:786.
- Einhorn TA. The cell and molecular biology of fracture healing. *Clin Orthop* 1998;355:7.
- Brighton CT. Longitudinal bone growth: the growth plate and its dysfunctions. In: Griffin PP, ed. *Instructional Course Lectures XXXVI*. Park Ridge, IL: American Academy of Orthopaedic Surgeons, 1987:3.
- Wuthier RE. A review of the primary mechanism of endochondral calcification with special emphasis on the role of cells, mitochondria and matrix vesicles. *Clin Orthop* 1982;169:219.
- Reinholt FP, Hjerpe A, Jansson K, et al. Stereological studies on the epiphyseal growth plate in low phosphate, vitamin D-deficiency rickets with special reference to the distribution of matrix vesicles. *Calcif Tissue Int* 1984;36:95.
- Ehrlich MG, Armstrong AL, Neuman RG, et al. Patterns of proteoglycan degradation by a neutral protease from human growth-plate epiphyseal cartilage. *J Bone Joint Surg Am* 1982; 64:1350.
- Goddard AD, Covello R, Luoh S-M, et al. Mutations of the growth hormone receptor in children with idiopathic short stature. *N Engl J Med* 1995;333:1093.
- Wilsman NJ, Farnum CE, Leiferman EM, et al. Differential growth by growth plates as a function of multiple parameters of chondrocytic kinetics. *J Orthop Res* 1996;14:927.
- Daughaday WH, Reeder C. Synchronous activation of DNA synthesis in hypophysectomized rat cartilage by growth hormone. *J Lab Clin Med* 1968;68:357.
- Trippel SB, Van Wyk JJ, Mankin HJ. Localization of somatomedin-C binding to bovine growth-plate chondrocytes in situ. *J Bone Joint Surg Am* 1986;68:897.
- Trippel SB, Chernauek SD, Van Wyk JJ, et al. Demonstration of type I and type II somatomedin receptors on bovine growth plate chondrocytes. *J Orthop Res* 1988;6:817.
- Froesch LR, Zapf J, Audhya TK, et al. Non-suppressible insulin-like activity and thyroid hormones: major pituitary-dependent sulfation factors for chick embryo cartilage. *Proc Natl Acad Sci USA* 1976;73:2904.
- Burch WM, Van Wyk JJ. Triiodothyronine stimulates cartilage growth and maturation by different mechanisms. *Am J Physiol* 1987;252:E176.
- Ibbotson KJ, Twardzik DR, D'Souza SM, et al. Stimulation of bone resorption *in vitro* by synthetic transforming growth factor- α . *Science* 1985;228:1007.
- Rosier RN. Orthopaedic basic science: update. *Orthopedics* 1987;10:1793.

Review of Factors in Skeletal Development

36. Sporn M, Roberts AB, Wakefield LM, et al. Transforming growth factor-beta: biological function and chemical structure. *Science* 1986;233:532.
37. Urist MR, DeLange RJ, Finerman GAM. Bone cell differentiation and growth factors. *Science* 1983;220:680.
38. Sadowski H, Shuai K, Darnell JE Jr, et al. A common nuclear signal transduction pathway activated by growth factor and cytokine receptors. *Science* 1993;261:1739.
39. Bennett A, Harvey W. Prostaglandins in orthopaedics. *J Bone Joint Surg Br* 1981;63:152.
40. Centrella M, McCarthy TL, Canalis E. Transforming growth factor-beta and remodeling of bone. *J Bone Joint Surg Am* 1991;73:1418.
41. Glowacki J. Angiogenesis in fracture repair. *Clin Orthop* 1998;355S:82.
42. Tam CS, Wilson DR, Hirschman AJ, et al. Protective effect of vitamin D₂ on bone apposition from the inhibitory action of hydrocortisone in rats. *Calcif Tissue Int* 1981;33:167.
43. Drvaric DM, Parks WJ, Wyly JB, et al. Prostaglandin-induced hyperostosis. *Clin Orthop* 1989;246:300.
44. Smith EP, Boyd J, Frank GR, et al. Estrogen resistance by a mutation in the estrogen-receptor gene in a man. *N Engl J Med* 1994;331:1056.
45. Federman DD. Life without estrogen. *N Engl J Med* 1994;331:1088.
46. Ueda K, Saito A, Nakano H, et al. Cortical hyperostosis following long-term administration of prostaglandin E in infants with cyanotic congenital heart disease. *J Pediatr* 1980;97:834.
47. DeLuca HF. Parathyroid hormone as a trophic hormone for 1,25-dihydroxy vitamin D₃, the metabolically active form of vitamin D. *N Engl J Med* 1972;287:250.
48. Cheeney RW. Current clinical applications of vitamin D metabolite research. *Clin Orthop* 1981;161:285.
49. Moss ML. The design of bones. In: Owen R, Goodfellow J, Bullough P, eds. *Scientific foundations of orthopaedics and traumatology*. Philadelphia: WB Saunders, 1980:59.
50. Huerter C. Anatomische Studien an den Extremitatengelenken Neugeborener und Erwachsener. *Virchows Arch* 1862;25:572.
51. Wolff J. *Das Gesetz der Transformation de Knochen*. Berlin: Hirschwald, 1892.
52. Brighton CT, Strafford B, Gross SB, et al. The proliferative and synthetic response of isolated calvarial bone cells of rats to cyclic biaxial mechanical strain. *J Bone Joint Surg Am* 1991;73:320.
53. Greco F, DePalma L, Speddia N, et al. Growth plate cartilage metabolic response to mechanical stress. *J Pediatr Orthop* 1989;9:520.
54. Wang N, Butler JP, Ingber DE. Mechanotransduction across the cell surface and through the cytoskeleton. *Science* 1993;260:1124.
55. Avioli LV, Haddad JG. Progress in endocrinology and metabolism. Vitamin D: current concepts. *Metab Clin Exp* 1973;22:507.
56. Hoffman WS. *The biochemistry of clinical medicine*, 4th ed. Chicago: Year Book, 1970.
57. Morgan B. *Osteomalacia, renal osteodystrophy, and osteoporosis*. Springfield, IL: Charles C Thomas, 1973.
58. Widdowson EM, McCance RA. The metabolism of calcium, phosphorus, magnesium and strontium. *Pediatr Clin North Am* 1965;12:595.
59. Raisz LG. Bone metabolism and calcium regulation. In: Avioli LV, Krane SM, eds. *Metabolic bone disease*. New York: Academic, 1978.
60. Iannotti JP, Brighton CT, Stambough JL, et al. Calcium flux and endogenous calcium content in isolated mammalian growth-plate chondrocytes, hyaline-cartilage chondrocytes, and hepatocytes. *J Bone Joint Surg Am* 1985;67:113.
61. Rasmussen H. The calcium messenger system. *N Engl J Med* 1986;314:1094.
62. Fourman P, Royer P. *Calcium metabolism and bone*, 2nd ed. Philadelphia: FA Davis, 1968.
63. Rasmussen H. Ionic and hormonal control of calcium homeostasis. *Am J Med* 1971;50:567.
64. Borle AB. Membrane transfer of calcium. *Clin Orthop* 1967;52:267.
65. DeLuca HF. Vitamin D: new horizons. *Clin Orthop* 1971;78:423.
66. Arnaud C, Fischer J, Rasmussen H. The role of the parathyroids in the phosphaturia of vitamin D deficiency. *J Clin Invest* 1964;43:1256.
67. Arnaud C, Tsao HS, Littledike T. Calcium homeostasis, parathyroid hormone and calcitonin: preliminary report. *Mayo Clin Proc* 1970;45:125.
68. Harrison HE, Harrison HC. The interaction of vitamin D and parathyroid hormone on calcium, phosphorus and magnesium homeostasis in the rat. *Metab Clin Exp* 1964;13:952.
69. Kanis JA. Vitamin D metabolism and its clinical application. *J Bone Joint Surg Br* 1982;64:542.
70. Drescher D, DeLuca HF. Vitamin D stimulated calcium binding protein from rat intestinal mucosa: purification and some properties. *Biochemistry* 1971;10:2302.
71. Fullmer CS, Wasserman RH. Bovine intestinal calcium-binding proteins (CaBP): purification and some properties. *Fed Proc* 1972;31:693.
72. MacGregor RR, Hamilton JW, Cohn DV. The induction of calcium-binding protein biosynthesis in intestine by vitamin D₃. *Biochim Biophys Acta* 1970;222:482.
73. Taylor AM. Intestinal vitamin D-induced calcium-binding protein: time course of immunocytochemical localization following 1,25-dihydroxyvitamin D₃. *J Histochem Cytochem* 1983;31:426.
74. Taylor AM, Wasserman RH. Vitamin D-induced calcium binding protein: comparative aspects in kidney and intestine. *Am J Physiol* 1972;223:110.
75. Harmeyer J, DeLuca HF. Calcium-binding protein and calcium absorption after vitamin D administration. *Arch Biochem Biophys* 1969;133:247.
76. Norman AW. Evidence for a new kidney-produced hormone 1,25-dihydroxy-cholecalciferol, the proposed biologically active form of vitamin D. *Am J Clin Nutr* 1971;24:1346.
77. Bijvoet OLM. Kidney function in calcium and phosphate metabolism. In: Avioli LV, Krane SM, eds. *Metabolic bone disease*. New York: Academic, 1977:49.
78. Beal VA. Calcium and phosphorus in infancy. *J Am Diet Assoc* 1968;53:450.
79. Blunt JW, DeLuca HF. The synthesis of 25-hydroxycholecalciferol: a biologically active metabolite of vitamin D₃. *Biochemistry* 1969;8:671.
80. Blunt JW, DeLuca HF, Schnoes HK. 25-Hydroxycholecalciferol: a biologically active metabolite of vitamin D₃. *Biochemistry* 1968;7:3317.
81. Blunt JW, Tanaka Y, DeLuca HF. The biological activity of 25-hydroxycholecalciferol: a metabolite of vitamin D₃. *Proc Natl Acad Sci USA* 1968;61:1503.
82. Jones G, Schnoes HK, DeLuca HF. Isolation and identification of 1,25 dihydroxy vitamin D₂. *Biochemistry* 1975;14:1250.
83. Lund J, DeLuca HF. Biologically active metabolite of vitamin D from bone, liver and blood serum. *J Lipid Res* 1966;7:739.
84. Holick MF, Schnoes HK, DeLuca HF, et al. Isolation and iden-

Mineral Phase

- rification of 24,25-hydroxycholecalciferol, a metabolite of D₃ made in the kidney. *Biochemistry* 1972;11:4251.
85. Holick MF, Schnoes HK, DeLuca HF, et al. Isolation and identification of 1,24-dihydroxycholecalciferol: a metabolite of vitamin D active in intestine. *Biochemistry* 1971;10:2799.
 86. Boyle IT, Gray RW, DeLuca HF. Regulation by calcium of *in vivo* synthesis of 1,25-dihydroxycholecalciferol and 21,25-dihydroxycholecalciferol. *Proc Natl Acad Sci USA* 1971;68:2131.
 87. Fraser DR, Kodicek E. Regulation of 25-hydroxycholecalciferol-1-hydrolase activity in kidney by parathyroid hormone. *Nature* 1973;241:163.
 88. Rasmussen H, Wong M, Bikle D, et al. Hormonal control of 25-hydroxycholecalciferol to 1,25-dihydroxycholecalciferol. *J Clin Invest* 1972;51:2502.
 89. Albright F, Reifenstein EC. *The parathyroid glands and metabolic bone disease*. Baltimore: Williams & Wilkins, 1948.
 90. Arnaud CD, Tenenhouse AM, Rasmussen H. Parathyroid hormone. *Annu Rev Physiol* 1967;29:349.
 91. *Food and Nutrition Board recommended dietary allowances*, 7th ed. Washington: National Academy of Sciences, National Research Council, 1968; publication no 1694.
 92. Huth EJ, Webster GD Jr, Elkinton JR. Renal excretion of hydrogen ion in renal tubular acidosis. III. An attempt to detect latent cases in a family: comments on nosology, genetics, and etiology of primary disease. *Am J Med* 1960;29:586.
 93. Avioli LV. Intestinal absorption of calcium. *Arch Intern Med* 1972;129:345.
 94. Bruce HM, Callow RK. Cereals and rickets: the role of inositol-hexaphosphoric acid. *Biochem J* 1934;28:517.
 95. Wills MR, Phillips JB, Day RC, et al. Phytic acid and nutritional rickets in immigrants. *Lancet* 1972;1:771.
 96. DeToni G. Renal rickets with phospho-gluco-amino renal diabetes. *Ann Paediatr* 1956;187:42.
 97. Tryfus H. Hepatic rickets. *Ann Paediatr* 1959;192:81.
 98. Moore JH, Tyler C. Studies on the intestinal absorption and excretion of calcium and phosphorus in the pig. 2. The intestinal absorption and excretion of radioactive calcium and phosphorus. *Br J Nutr* 1955;9:81.
 99. Minkin C, Talmage RV. A study in secretion and function of thyrocalcitonin in normal rats. In: Talmage RV, Balanger LF, eds. *Parathyroid hormone and thyrocalcitonin (calcitonin)*. Amsterdam: Excerpta Medica, 1968:339.
 100. Austen LA, Heath H. Calcitonin: physiology and pathophysiology. *N Engl J Med* 1981;304:269.
 101. Glisson R. *De rachitide sive morbo puerili qui vulgo The Rickets Dicitur Tractatus. Adscitis in operis societatem Georgio Bate et Ahasuero Regemortero*. London: G Du-Gardi, 1650.
 102. Whistler D. *Disputatio Medica Inauguralis de Morbo puerili Anglorum quem patrio idiomate indigenae vocant the rickets*. London: Wilhemii, Christiani, Boxii, 1645.
 103. Smith R. The pathophysiology and management of rickets. *Orthop Clin North Am* 1972;3:601.
 104. Smith R, Stern G. Muscular weakness in osteomalacia and hyperparathyroidism. *J Neurol Sci* 1969;8:511.
 105. Streeter GL. Developmental horizons in human embryos. IV. A review of the histogenesis of cartilage and bone. *Contrib Embryol* 1949;33:149.
 106. Olin A, Creasman C, Shapiro F. Free physal transplantation in the rabbit: an experimental approach to focal lesions. *J Bone Joint Surg Am* 1984;66:7.
 107. Jaffe HL. *Metabolic, degenerative, and inflammatory diseases of bones and joints*. Philadelphia: Lea & Febiger, 1972:381.
 108. Parfitt AM. Hypophosphatemic vitamin D-refractory rickets and osteomalacia. *Orthop Clin North Am* 1972;3:653.
 109. Schott GD, Wills MR. Muscle weakness in osteomalacia. *Lancet* 1976;1:626.
 110. Skaria J, Katiyar BC, Srivastava TP, et al. Myopathy and neuropathy associated with osteomalacia. *Acta Neurol Scand* 1975;51:37.
 111. Villareale ME, Chiroff RT, Bergstrom WH, et al. Bone changes induced by diphenylhydantoin in chicks on a controlled vitamin D intake. *J Bone Joint Surg Am* 1978;60:911.
 112. Floman Y, Yosipovitch Z, Licht A, et al. Bilateral slipped upper femoral epiphysis: a rare manifestation of renal osteodystrophy. Case report with discussion of its pathogenesis. *Isr J Med Sci* 1975;11:15.
 113. Goldman AB, Lane JM, Salvati E. Slipped capital femoral epiphyses complicating renal osteodystrophy: a report of three cases. *Radiology* 1978;126:33.
 114. Martin W, Riddervold HO. Epiphyseolysis in rickets. *Va Med Mon* 1980;107:566.
 115. Mehls O, Ritz E, Krempien B, et al. Slipped epiphyses in renal osteodystrophy. *Arch Dis Child* 1975;50:545.
 116. Tebor GB, Ehrlich MG, Herrin J. Slippage of the distal tibial epiphysis. *J Pediatr Orthop* 1983;3:211.
 117. Goel KM, Sweet EM, Logan RW, et al. Florid and subclinical rickets among immigrant children in Glasgow. *Lancet* 1976;1:1141.
 118. Laditan AA, Adeniyi A. Rickets in Nigerian children: response to vitamin D. *J Trop Med Hyg* 1975;78:206.
 119. Miller CG, Chutkan W. Vitamin D-deficiency rickets in Jamaican children. *Arch Dis Child* 1976;51:214.
 120. Ohara-May J, Widdowson EM. Diets and living conditions of Asian boys in Coventry with and without signs of rickets. *Br J Nutr* 1976;36:23.
 121. Salimpour R. Rickets in Tehran: study of 200 cases. *Arch Dis Child* 1975;50:63.
 122. Rudolf M, Arulanatham K, Greenstein RM. Unsuspected nutritional rickets. *Pediatrics* 1980;66:72.
 123. Dodds GS, Cameron HC. Studies on experimental rickets in rats. IV. The relation of rickets to growth, with special reference to the bones. *Am J Pathol* 1943;19:169.
 124. Dodds GS, Cameron HC. Studies on experimental rickets in rats. III. The behavior and rate of cartilage remnants in the rachitic metaphysis. *Am J Pathol* 1939;15:723.
 125. Dodds GS, Cameron HC. Studies on experimental rickets in rats. II. The healing process in the head of the tibia and other bones. *Am J Pathol* 1938;14:273.
 126. Dodds GS, Cameron HC. Studies on experimental rickets in rats. I. Structural modifications of the epiphyseal cartilages in the tibia and other bones. *Am J Anat* 1934;55:135.
 127. Frost HM. *Bone dynamics in osteoporosis and osteomalacia*. Springfield, IL: Charles C Thomas, 1966.
 128. Arnstein AR, Frame B, Frost HM. Recent progress in osteomalacia and rickets. *Ann Intern Med* 1967;67:1296.
 129. Jaworski ZFG. Pathophysiology, diagnosis, and treatment of osteomalacia. *Orthop Clin North Am* 1972;3:623.
 130. Marie PJ, Pettifor JM, Ross FP, et al. Histological osteomalacia due to dietary deficiency in children. *N Engl J Med* 1982;307:584.
 131. Oppenheimer SJ, Snodgrass GJ. Neonatal rickets: histopathology and quantitative bone changes. *Arch Dis Child* 1980;55:945.
 132. Ramser JR, Villaneuva AR, Frost HM. Cortical bone dynamics in osteomalacia, measured by tetracycline bone labeling. *Clin Orthop* 1966;49:89.
 133. Park EA. Observations on the pathology of rickets with particu-

- lar reference to the changes at the cartilage shaft junctions of the growing bones. *Bull NY Acad Med* 1939;14:495.
134. Huffer WE, Lacey DL. Studies on the pathogenesis of avian rickets. II. Necrosis of perforating epiphyseal vessels during recovery from rickets caused by vitamin D₃ deficiency. *Am J Pathol* 1982;109:302.
 135. Lacey DL, Huffer WE. Studies on the pathogenesis of avian rickets. I. Changes in epiphyseal and metaphyseal vessels in hypocalcemic and hypophosphatemic rickets. *Am J Pathol* 1982; 109:288.
 136. Pitt MJ. Rachitic and osteomalacia syndromes. *Radiol Clin North Am* 1981;19:581.
 137. Swischuk LE, Hayden CK. Rickets: a roentgenographic scheme for diagnosis. *Pediatr Radiol* 1979;8:203.
 138. Caffey J. *Pediatric x-ray diagnosis*, 5th ed. Chicago: Year Book, 1967.
 139. Reynolds WA, Karo JJ. Radiologic diagnosis of metabolic bone disease. *Orthop Clin North Am* 1972;3:521.
 140. Steinbach HG, Noetzi M. Roentgen appearance of the skeleton in osteomalacia and rickets. *AJR* 1964;91:955.
 141. Feist JH. The biologic basis of radiologic findings in bone disease: recognition and interpretation of abnormal bone architecture. *Radiol Clin North Am* 1970;8:183.
 142. Stamp TCB, Baker LR. Recessive hypophosphatemic rickets and possible etiology of the vitamin D-resistant syndrome. *Arch Dis Child* 1976;51:360.
 143. Steinbach HL, Kolb FO, Gilfillan R. Mechanism of production of pseudofractures in osteomalacia (Milkman's syndrome). *Radiology* 1954;62:388.
 144. Hodgkinson HM. Fracture of the femur as a presentation of osteomalacia. *Gerontol Clin* 1971;13:189.
 145. Paul PD, Lloyd DJ, Smith FW. The role of bone scanning in neonatal rickets. *Pediatr Radiol* 1983;13:89.
 146. Singh BN, Spies SM, Mehra SP, et al. Unusual bone scan presentation in osteomalacia: symmetrical uptake. A suggestive sign. *Clin Nucl Med* 1978;3:292.
 147. Pettifor JM, Ross P, Wang J, et al. Rickets in children of rural origin in South Africa: is low dietary calcium a factor? *J Pediatr* 1978;92:320.
 148. Soggen E. Calcium-binding substances and intestinal absorption. *Acta Pharmacol Toxicol* 1964;21[Suppl 1]:1.
 149. Winnacker JL, Yeager H, Saunders RB, et al. Rickets in children receiving anticonvulsant drugs: biochemical and hormonal markers. *Am J Dis Child* 1977;131:286.
 150. Backrach S, Fisher J, Parks JS. An outbreak of vitamin D-deficiency rickets in a susceptible population. *Pediatrics* 1979;64: 871.
 151. Dwyer JT, Dietz WH, Hass G, et al. Risk of nutritional rickets among vegetarian children. *Am J Dis Child* 1979;133:134.
 152. Harrison HE, Harrison HC. Rickets then and now. *J Pediatr* 1975;87:1144.
 153. Callenback JC, Sheehan MB, Abramson SJ, et al. Etiologic factors in rickets of very low birthweight infants. *J Pediatr* 1981; 98:800.
 154. Bosley AR, Verrier-Jones ER, Campbell MJ. Aetiological factors in rickets of prematurity. *Arch Dis Child* 1980;55:683.
 155. Crutchlow WP, David DS, Whitsell J. Multiple skeletal complications in a case of chronic renal failure treated by kidney homotransplantation. *Am J Med* 1971;50:390.
 156. Glass EJ, Hume R, Hendry GMA, et al. Plasma alkaline phosphatase activity in rickets of prematurity. *Arch Dis Child* 1982; 57:373.
 157. Garabedian M, Vainsel M, Mallet E, et al. Circulating vitamin D-metabolite concentrations in children with nutritional rickets. *J Pediatr* 1983;103:381.
 158. Arnaud SB, Stickler GB, Haworth JC. Serum 25-hydroxy-vitamin D in infantile rickets. *Pediatrics* 1976;57:221.
 159. Raghuramulu N, Reddy V. Serum 25-hydroxy vitamin D levels in malnourished children with rickets. *Arch Dis Child* 1980;55: 285.
 160. Clark CG, Crooks J, Dawson AA. Disordered calcium metabolism after Polya partial gastrectomy. *Lancet* 1964;1:734.
 161. Deller DJ, Begley MD. Calcium metabolism and the bones after partial gastrectomy. I. Clinical features and radiology of the bones. *Aust Ann Med* 1963;12:282.
 162. Eddy RL. Metabolic bone disease after gastrectomy. *Am J Med* 1971;50:442.
 163. Atkinson M, Nordin BEC, Sherlock S. Malabsorption and bone disease in prolonged obstructive jaundice. *Q J Med* 1956;25: 299.
 164. Nordin BEC. Effect of malabsorption syndrome on calcium metabolism. *Proc R Soc Lond* 1961;54:497.
 165. Kooh SW, Jones G, Reilly BJ, et al. Pathogenesis of rickets in chronic hepatobiliary disease in children. *J Pediatr* 1979;94: 870.
 166. Long RG, Wills MR. Hepatic dystrophy. *Br J Hosp Med* 1978; 20:312.
 167. Daum F, Rosen JF, Roginsky M, et al. 25-Hydroxycholecalciferol in the management of rickets associated with extrahepatic biliary atresia. *J Pediatr* 1976;88:1041.
 168. Heubi JE, Tsang RC, Steichen JJ, et al. 1,25-Dihydroxy-vitamin D₃ in childhood hepatic osteodystrophy. *J Pediatr* 1979;94:977.
 169. Thompson GR, Lewis B, Booth CC. Absorption of vitamin D₃-³H in control subjects and patients with intestinal malabsorption. *J Clin Invest* 1966;45:94.
 170. Mann JG, Brown WR, Kern F. The subtle and variable expressions of gluten-induced enteropathy (adult celiac disease, non-tropical sprue). *Am J Med* 1970;48:357.
 171. Moss AJ, Waterhouse C, Terry R. Gluten-sensitive enteropathy with osteomalacia without steatorrhea. *N Engl J Med* 1965;272: 825.
 172. Clayton BE, Cotton DA. A study of malabsorption after resection of the entire jejunum and the proximal half of the ileum. *Gut* 1961;2:18.
 173. Zerwekh JE, Glass K, Jowsey J, et al. A unique form of osteomalacia associated with end-organ refractoriness to 1,25-dihydroxyvitamin D and apparent defective synthesis of 25-hydroxyvitamin D. *J Clin Endocrinol Metab* 1979;49:171.
 174. Franck WA, Hoffman GS, Davis JS, et al. Osteomalacia and weakness complicating jejunoileal bypass. *J Rheumatol* 1979;6: 51.
 175. Hepner GW, Jowsey J, Arnaud C, et al. Osteomalacia and celiac disease: response to 25-hydroxyvitamin D. *Am J Med* 1965;65: 1015.
 176. Albright F, Butler AM, Bloomberg E. Rickets resistant to vitamin D therapy. *Am J Dis Child* 1937;54:529.
 177. Baar HS, Bickel H. Cystine storage disease with aminoaciduria and dwarfism. Part 8. Morbid anatomy, histology, and pathogenesis of Lignac-Fanconi disease. *Acta Paediatr Scand Suppl* 1952;90:171.
 178. Burnett CH, Dent CE, Harper C, et al. Vitamin D-resistant rickets: analysis of twenty-four pedigrees with hereditary and sporadic cases. *Am J Med* 1964;36:222.
 179. Butler AM, Wilson JL, Farber S. Dehydration and acidosis with calcification at renal tubules. *J Pediatr* 1936;8:489.
 180. Dent CE. Rickets and osteomalacia from renal tubule defects. *J Bone Joint Surg Br* 1952;34:266.
 181. DeToni G. Remarks on the relations between renal rickets (renal dwarfism) and renal diabetes. *Acta Paediatr Scand* 1933;16:479.
 182. Fanconi G. Der fruhinfantile nephrotisch-glykosurische Zwerg-

- wuchs mit hypophosphatämischer Rachitis. *Jahrb Kinderheilkd* 1936;147:299.
183. Fraser DR, Salter RB. The diagnosis and management of the various types of rickets. *Pediatr Clin North Am* 1958;26:417.
 184. Harrison HE, Harrison HC. The effect of acidosis upon the renal tubular absorption of phosphate. *Am J Physiol* 1941;134:781.
 185. Lightwood R, Payne WW, Black JA. Infantile renal acidosis. *Pediatrics* 1953;12:628.
 186. Lowe CU, Terrey M, MacLachlan EA. Organic aciduria, decreased from renal ammonia production, hydrophthalmos, and mental retardation. *Am J Dis Child* 1952;83:164.
 187. Perry W, Stamp TC. Hereditary hypophosphatemic rickets with autosomal recessive inheritance and severe osteosclerosis. *J Bone Joint Surg Br* 1978;60:430.
 188. Yong JM. Cause of raised serum alkaline phosphatase after partial gastrectomy and in other malabsorption states. *Lancet* 1966;1:1132.
 189. Chutorian A, Rowland LP. Lowe's syndrome. *Neurology* 1966;16:115.
 190. Dent CE, Harris H. Hereditary forms of rickets and osteomalacia. *J Bone Joint Surg Br* 1956;38:204.
 191. Bickel H, Baar HS, Astley R, et al. Cystine storage disease with aminoaciduria and dwarfism. *Acta Paediatr Scand Suppl* 1952;90:1.
 192. Morris RC. Renal tubular acidosis: mechanisms, classification, and implication. *N Engl J Med* 1969;281:1405.
 193. Morris RC, Sebastian A, McSherry E. Renal acidosis. *Kidney Int* 1972;1:322.
 194. Relman AS, Levinsky NG. Kidney disease: acquired tubular disorders with special reference to disturbances of concentration and dilution and of acid-base regulation. *Annu Rev Med* 1961;12:932.
 195. Seldin DW, Wilson JD. Renal tubular acidosis. In: Stanbury JB, Wyngaarden JB, Fredrickson DS, eds. *The metabolic basis of inherited disease*, 2nd ed. New York: McGraw-Hill, 1966:1230.
 196. Habener JF, Mahaffey JE. Osteomalacia and disorders of vitamin D metabolism. *Annu Rev Med* 1978;29:327.
 197. Isogna KL, Broadus AD, Gertner JM. Impaired phosphorus conservation and 1,25-dihydroxyvitamin D generation during phosphorus deprivation in familial hypophosphatemic rickets. *J Clin Invest* 1983;71:1562.
 198. Harrison HE. The varieties of rickets and osteomalacia associated with hypophosphatemia. *Clin Orthop* 1957;9:61.
 199. Morris RC, Sebastian A. Renal tubular acidosis and Fanconi syndrome. In: Stanbury JB, Wyngaarden JB, Fredrickson DS, et al., eds. *The metabolic basis of inherited disease*, 5th ed. New York: McGraw-Hill, 1983:1808.
 200. Walton J. Familial hypophosphatemic rickets: a delineation of its subdivisions and pathogenesis. *Clin Pediatr* 1976;15:1007.
 201. Hahn TJ, Scharp CR, Halstead LR, et al. Parathyroid hormone status and renal responsiveness in familial hypophosphatemic rickets. *J Clin Endocrinol Metab* 1975;41:926.
 202. Dancaster CP, Jackson WPU. Familial vitamin D-resistant rickets. *Arch Dis Child* 1957;34:383.
 203. Chan JC, Barrant FC. Hypophosphatemic rickets: effect of 1,α,25-dihydroxyvitamin D₃ on growth and mineral metabolism. *Pediatrics* 1979;64:448.
 204. Evans GA, Arulanantham K, Gage J. Primary hypophosphatemic rickets: effect of phosphate and vitamin D on growth and surgical treatment. *J Bone Joint Surg Am* 1980;62:1130.
 205. Frame B, Smith RW Jr, Fleming JL, et al. Oral phosphates in vitamin D-refractory rickets and osteomalacia. *Am J Dis Child* 1963;106:147.
 206. Loeffler RD, Sherman FC. The effect of treatment on growth and deformity in hypophosphatemic vitamin D-resistant rickets. *Clin Orthop* 1982;162:4.
 207. Mason RS, Rohl RG, Lissner D, et al. Vitamin D metabolism in hypophosphatemic rickets. *Am J Dis Child* 1982;136:909.
 208. Scriver CR, Reade TM, DeLuca HF, et al. Serum 1,25-dihydroxy vitamin D levels in normal subjects and in patients with hereditary rickets or bone disease. *N Engl J Med* 1978;299:976.
 209. Tsuchiya Y, Matsuo N, Cho H, et al. Vitamin D and vitamin dependency. *Contrib Nephrol* 1980;22:80.
 210. Balsan S, Garabedian M. 1,25-Dihydroxyvitamin D₃ and 1,α-hydroxy vitamin D₃ in children: biologic and therapeutic effects in nutritional rickets and different types of vitamin D resistance. *Pediatr Res* 1975;9:586.
 211. Delvin EE, Glorieux FH, Marie PJ, et al. Vitamin D dependency: replacement therapy with calcitriol. *J Pediatr* 1981;99:26.
 212. Eitches P, Pickering D, Smith R. Cystinotic rickets with vitamin D metabolites. *Arch Dis Child* 1977;52:661.
 213. Brooks MH, Bell NH, Love L, et al. Vitamin D-dependent rickets, type II: resistance of target organs to 1,25-dihydroxyvitamin D. *N Engl J Med* 1978;298:996.
 214. Colombo JP, Donath A. The effect of calcium infusions on renal handling of amino acids in hypophosphatemic vitamin D-resistant rickets. *Acta Paediatr Scand* 1975;64:703.
 215. Elkinton JR. Renal acidosis. *Am J Med* 1960;28:165.
 216. Elkinton JR, Huth EJ, Webster GD Jr, et al. The renal excretion of hydrogen ion in renal tubular acidosis. I. Quantitative assessment of the response to ammonium chloride as an acid load. *Am J Med* 1960;29:554.
 217. Relman AS. Renal acidosis and renal excretion of acid in health and disease. *Adv Intern Med* 1964;12:295.
 218. Baines GH, Barclay JA, Cooke WT. Nephrocalcinosis associated with hyperchloremia and low plasma bicarbonate. *Q J Med* 1945;14:113.
 219. Mautalen C, Montoreano R, LaBarrere C. Early skeletal effect of alkali therapy upon the osteomalacia of renal tubular acidosis. *J Clin Endocrinol Metab* 1976;42:875.
 220. Schreiner GE, Smith LH, Kye LH. Renal hyperchloremic acidosis: familial occurrence of nephrocalcinosis with hyperchloremia and low serum bicarbonate. *Am J Med* 1953;15:122.
 221. Cooke RE, Kleeman CR. Distal tubular dysfunction with renal calcification. *Yale J Biol Med* 1950;23:199.
 222. Cunningham J, Fraher LJ, Clemens TL, et al. Chronic acidosis with metabolic bone disease: effect of alkali on bone morphology and vitamin D metabolism. *Am J Med* 1982;73:199.
 223. Salassa RM, Jowsey J, Arnaud CD. Hypophosphatemic osteomalacia associated with "nonendocrine" tumors. *N Engl J Med* 1970;283:65.
 224. Swann GF. Pathogenesis of bone lesions in neurofibromatosis. *Br J Radiol* 1954;27:623.
 225. Dent CE, Gertner JM. Hypophosphatemic osteomalacia in fibrous dysplasia. *Q J Med* 1976;45:411.
 226. Halvorsen S, Aas K. Renal tubular defects in fibrous dysplasia of the bones: report of two cases. *Acta Paediatr Scand* 1961;50:297.
 227. Kunin AS. Polyostotic fibrous dysplasia with hypophosphatemia: a metabolic study. *Metab Clin Exp* 1962;11:978.
 228. McArthur RG, Hayles AG, Lambert PW. Albright's syndrome with rickets. *Mayo Clin Proc* 1979;54:313.
 229. Tanaka T, Swann S. A case of McCune-Albright syndrome with hyperthyroidism and vitamin D-resistant rickets. *Helv Paediatr Acta* 1977;32:263.
 230. Asnes RS, Berdon WE, Bassett VA. Hypophosphatemic rickets in an adolescent cured by excision of a non-ossifying fibroma. *Clin Pediatr* 1981;20:646.
 231. Daniels RA, Weisenfeld I. Tumorous phosphaturic osteomalacia.

- cia: report of a case associated with multiple hemangiomas of bone. *Am J Med* 1967;67:155.
232. Moncrieff MW, Brenton DP, Arthur LJ. Case of tumor rickets. *Arch Dis Child* 1978;53:740.
233. Pollack JA, Schiller AL, Crawford JD. Rickets and myopathy cured by removal of a nonossifying fibroma of bone. *Pediatrics* 1973;52:364.
234. Parker MS, Klein I, Haussler MR, et al. Tumor-induced osteomalacia: evidence of a surgically correctable alteration in vitamin D metabolism. *JAMA* 1981;245:492.
235. Cai Q, Hodgson SF, Kao PC, et al. Brief report. Inhibition of renal phosphate transport by a tumor product in a patient with oncogenic osteomalacia. *N Engl J Med* 1994;330:1645.
236. Aponte CJ, Petrelli MP. Anticonvulsants and vitamin D metabolism. *JAMA* 1973;225:1248.
237. Borgstedt AP, Bryson MF, Young LW, et al. Long-term administration of anti-epileptic drugs and the development of rickets. *J Pediatr* 1972;81:9.
238. Christiansen C, Kristensen M, Rodbro P. Latent osteomalacia in epileptic patients on anticonvulsants. *Br Med J* 1972;3:738.
239. Crosley CJ, Chee C, Berman PH. Rickets associated with long-term anticonvulsant therapy in a pediatric outpatient population. *Pediatrics* 1975;56:52.
240. Dent CE, Richens A, Rowe DJF, et al. Osteomalacia with long-term anticonvulsant therapy in epilepsy. *Br Med J* 1970;4:69.
241. Frame B. Hypocalcemia and osteomalacia associated with anticonvulsant therapy. *Ann Intern Med* 1971;74:294.
242. Morijiri Y, Sato T. Factors causing rickets in institutionalized handicapped children on anticonvulsant therapy. *Arch Dis Child* 1981;56:446.
243. Liakakos D, Papadopoulos Z, Vlachos P, et al. Serum alkaline phosphatase and urinary hydroxyproline values in children receiving phenobarbital with and without vitamin D. *J Pediatr* 1975;87:291.
244. Winters RW, Graham JB, Williams TF, et al. A genetic study of familial hypophosphatasia and vitamin D-resistant rickets with a review of the literature. *Medicine* 1958;37:97.
245. Gascon-Barre M, Core MG. Influence of phenobarbital and diphenylhydantoin on the healing of rickets in the rat. *Calcif Tissue Res* 1978;25:93.
246. Hoikka V, Savolainen K, Karjalainen P, et al. Treatment of osteomalacia in institutionalized epileptic patients on long-term anticonvulsant therapy. *Ann Clin Res* 1982;14:72.
247. Timperlake RW, Cook SD, Thomas KA, et al. Effects of anticonvulsant drug therapy on bone mineral density in a pediatric population. *J Pediatr Orthop* 1988;8:467.
248. Liu SH, Chu HI. Studies of calcium and phosphorus with special reference to pathogenesis and effects of dihydrotachysterol (AT10) and iron. *Medicine* 1943;22:103.
249. Mallick NP, Berlyne GM. Arterial calcification after vitamin D therapy in hyperphosphatemic renal failure. *Lancet* 1968;2:1316.
250. Blockey NJ, Murphy AV, Mocan H. Management of rachitic deformities in children with chronic renal failure. *J Bone Joint Surg Br* 1986;68:791.
251. Oppenheim WL, Salusky IB, Kaplan D, et al. Renal osteodystrophy in children. In: Castells S, Finberg L, eds. *Metabolic bone disease in children*. New York: Marcel Dekker, 1990:197.
252. Goldman R, Basset SH, Duncan GB. Phosphorus excretion in renal failure. *J Clin Invest* 1954;33:1623.
253. Brickman AS, Coburn JW, Norman AW. Action of 1,25-dihydroxycholecalciferol, a potent kidney-produced metabolite of vitamin D₃ in uremic man. *N Engl J Med* 1972;287:891.
254. DeLuca HF. The biochemical basis of renal osteodystrophy and post-menopausal osteoporosis: a view from the vitamin D system. *Curr Med Res Opin* 1981;7:279.
255. Mason RS, Lissner D, Wilkinson M, et al. Vitamin D metabolites and their relationship to azotemic osteodystrophy. *Clin Endocrinol* 1980;13:375.
256. Parfitt AM. Renal osteodystrophy. *Orthop Clin North Am* 1972;3:681.
257. Ritz E, Malluche HJ, Krempien B, et al. Pathogenesis of renal osteodystrophy: roles of phosphate and skeletal resistance to PTH. *Adv Exp Med Biol* 1978;103:423.
258. Brautbar N, Kleemna CR. Disordered divalent ion metabolism in kidney disease: comments on pathogenesis and treatment. *Adv Nephrol* 1979;8:179.
259. Coburn JW, Popovtzer MM, Massry SG, et al. The physicochemical state and renal handling of divalent ions in chronic renal failure. *Arch Intern Med* 1969;124:302.
260. Juttman JR, Hagenouw-Taal JC, Iameyer LD, et al. Intestinal calcium absorption, serum phosphate, and parathyroid hormone in patients with chronic renal failure and osteodystrophy before and during hemodialysis. *Calcif Tissue Res* 1978;26:119.
261. Kessner DM, Epstein FH. Effect of renal insufficiency on gastrointestinal transport of calcium. *Am J Physiol* 1965;209:141.
262. Kleeman CR, Massry SG, Coburn JW, et al. Calcium and phosphorus metabolism and bone disease in uremia. *Clin Orthop* 1970;68:210.
263. Stanbury SW. Bone disease in uremia. *Am J Med* 1968;44:714.
264. Stanbury SW, Lamb GA. Metabolic studies of renal osteodystrophy. I. Calcium, phosphorus, and nitrogen metabolism in rickets, osteomalacia, and hyperparathyroidism complicating uremia and in the osteomalacia of the adult Fanconi syndrome. *Medicine* 1962;41:1.
265. Berson SA, Yalow RS. Parathyroid hormone in plasma in adenomatous hyperparathyroidism, uremia, and bronchogenic carcinoma. *Science* 1966;154:907.
266. Stanbury SW, Lamb GA. Parathyroid function in chronic renal failure: a statistical survey of the plasma biochemistry in azotemic renal osteodystrophy. *Q J Med* 1966;35:1.
267. Brown DJ, Dawborn JK, Thomas DP, et al. Assessment of osteodystrophy in patients with chronic renal failure. *Aust NZ J Med* 1982;12:250.
268. Greenfield GB. Roentgen appearance of bone and soft-tissue changes in chronic renal disease. *AJR* 1972;116:749.
269. Craven JD. Renal glomerular osteodystrophy. *Clin Radiol* 1964;15:210.
270. Kaye M, Pritchard JE, Halpenny GW, et al. Bone disease in chronic renal failure with particular reference to osteosclerosis. *Medicine* 1960;39:157.
271. Lalli AF, Lapidus J. Osteosclerosis occurring in renal disease. *AJR* 1963;93:924.
272. Weller M, Edeiken J, Hodes PJ. Renal osteodystrophy. *AJR* 1968;104:354.
273. Abrams JD. Corneal and other findings in patients on intermittent dialysis for renal failure. *Proc R Soc Lond* 1966;59:533.
274. Berlyne GM. Microcrystalline conjunctival calcification in renal failure: a useful sign. *Lancet* 1968;2:366.
275. Berlyne GM, Shaw AG. Red eyes in renal failure. *Lancet* 1967;1:4.
276. Platt R, Owen TK. Renal dwarfism associated with calcification of arteries and skin. *Lancet* 1934;2:135.
277. Putkonen T, Wangel GA. Renal hyperparathyroidism with metastatic calcification of the skin. *Dermatologica* 1959;118:127.
278. Andersen DH, Schlesinger ER. Renal hyperparathyroidism with calcification of the arteries in infancy. *Am J Dis Child* 1942;63:102.
279. Friedman SA, Novack S, Thomson GE. Arterial calcification and gangrene in uremia. *N Engl J Med* 1969;280:1392.
280. Parfitt AM. Soft-tissue calcification in uremia. *Arch Intern Med* 1969;124:544.

281. Rosen H, Friedman SA, Raizner AE, et al. Azotemic arteriopathy. *Am Heart J* 1972;84:250.
282. Norman ME, Mazur AT, Borden S, et al. Early diagnosis of juvenile renal osteodystrophy. *J Pediatr* 1980;97:226.
283. Hsu AC, Kooh SW, Fraser D, et al. Renal osteodystrophy in children with chronic renal failure: an unexpectedly common and incapacitating complication. *Pediatrics* 1982;70:742.
284. David DS. Calcium metabolism in renal failure. *Am J Med* 1975;58:48.
285. Andersen J, Neilsen HJ. Renal osteodystrophy in non-dialysed patients with chronic renal failure. *Acta Radiol* 1980;21:803.
286. Debnam JW, Bates ML, Kopelman RC, et al. Radiological/pathological correlations in uremic bone disease. *Radiology* 1977;125:653.
287. Eastwood JB. Renal osteodystrophy: a radiological review. *CRC Crit Rev Diagn Imaging* 1977;9:77.
288. Anton HC. Thinning of the clavicular cortex in adults under the age of 45 in osteomalacia and hyperparathyroidism. *Clin Radiol* 1979;30:307.
289. Bonavita JA, Dalinka MK. Shoulder erosions in renal osteodystrophy. *Skeletal Radiol* 1980;5:105.
290. Kricun ME, Resnick D. Elbow abnormalities in renal osteodystrophy. *AJR* 1983;140:577.
291. Resnick D, Deftos LJ, Partemore JG. Renal osteodystrophy: magnification radiography of target sites of absorption. *AJR* 1981;136:711.
292. Sundaram M, Joyce PF, Shields JB, et al. Terminal phalangeal tufts: earliest site of renal osteodystrophy findings in hemodialysis patients. *AJR* 1981;136:363.
293. Sundaram M, Wolverson MK, Heiberg E, et al. Erosive azotemic osteodystrophy. *AJR* 1981;136:363.
294. Kricun ME, Resnick D. Patelofemoral abnormalities in renal osteodystrophy. *Radiology* 1982;143:667.
295. Koo WWK, Sherman R, Succop P, et al. Fractures and rickets in very low birth weight infants: conservative management and outcome. *J Pediatr Orthop* 1989;9:326.
296. Stamp WG, Whitesides TE, Field MH, et al. Treatment of vitamin D-resistant rickets: a long-term evaluation of its effectiveness. *J Bone Joint Surg Am* 1964;46:965.
297. Lee JJK, Lyne ED, Kleerekoper M, et al. Disorders of bone metabolism in severely handicapped children and young adults. *Clin Orthop* 1989;245:297.
298. Salenius P, Vankka E. The development of the tibio-femoral angle in children. *J Bone Joint Surg Am* 1975;57:259.
299. Staheli LT, Corbett M, Wyss C, et al. Lower-extremity rotational problems in children. *J Bone Joint Surg Am* 1985;67:39.
300. Kling TF Jr. Angular deformities of the lower limbs in children. *Orthop Clin North Am* 1987;18:513.
301. Rubinovitch M, Said SE, Glorieux FH, et al. Principles and results of corrective lower limb osteotomies for patients with vitamin D-resistant hypophosphatemic rickets. *Clin Orthop* 1988;237:264.
302. Paley D, Tetsworth K. Mechanical axis deviation of the lower limbs. *Clin Orthop* 1992;280:65.
303. Ferris B, Walker C, Jackson A, et al. The orthopaedic management of hypophosphataemic rickets. *J Pediatr Orthop* 1991;11:367.
304. Felts HJ, Whitley JE, Anderson DD, et al. Medical and surgical treatment of azotemic osteodystrophy. *Ann Intern Med* 1965;62:1272.
305. Esselstyn CB Jr, Popowniak KL. Parathyroid surgery in treatment of renal osteodystrophy and tertiary hyperparathyroidism. *Surg Clin North Am* 1971;51:1211.
306. Andress DL, Norris KC, Coburn JW, et al. Intravenous calcitriol in the treatment of refractory osteitis fibrosa of chronic renal failure. *N Engl J Med* 1989;321:274.
307. Crawford AH. Current concepts review. Slipped capital femoral epiphysis. *J Bone Joint Surg Am* 1988;70:1422.
308. Hagglund G, Bylander B, Hansson LI, et al. Bone growth after fixing slipped femoral epiphyses: brief report. *J Bone Joint Surg Br* 1988;70:845.
309. Nixon JR, Douglas JF. Bilateral slipping of the upper femoral epiphysis in end-stage renal failure. *J Bone Joint Surg Br* 1980;62:18.
310. Crawford AH. Correspondence. *J Bone Joint Surg Am* 1990;72:632.
311. Alper J. Boning up: newly isolated proteins heal bad breaks. *Science* 1994;263:324.
312. Stanitski DF. Treatment of deformity secondary to metabolic bone disease with Ilizarov technique. *Clin Orthop* 1994;301:38.
313. Huhne R, Schonfeld H. Eine eigenartige Wachstumsstörung im Kindesalter. *Monatsschr Kinderheilkd* 1929;42:267.
314. Rathbun JC. Hypophosphatasia. *Am J Dis Child* 1948;75:822.
315. Sobel EH, Clark LC, Fox RP, et al. Rickets: deficiency of "alkaline" phosphatase activity and premature loss of teeth in childhood. *Pediatrics* 1953;11:309.
316. McCane RA, Fairweather DVI, Barrett AM, et al. Genetic, clinical, biochemical, and pathological features of hypophosphatasia. *Q J Med* 1956;25:523.
317. Whyte MP, Teitelbaum SI, Murphy WA. Adult hypophosphatasia: clinical, laboratory, and genetic investigation of a large kindred with review of the literature. *Medicine* 1979;58:329.
318. Fraser D, Yendt ER, Christie FHE. Metabolic abnormalities in hypophosphatasia. *Lancet* 1955;1:286.
319. Pimstone B, Eissenberg E, Silverman S. Hypophosphatasia: genetic and dental studies. *Ann Intern Med* 1966;65:722.
320. Bartter FC. Hypophosphatasia. In: Stanbury JB, Wyngaarden JB, Fredrickson DS, eds. *The metabolic basis of inherited disease*, 2nd ed. New York: McGraw-Hill, 1966.
321. Bethune JD, Dent CD. Hypophosphatasia in the adult. *Am J Med* 1960;28:615.
322. Anderton JM. Orthopaedic problems in adult hypophosphatasia: a report of two cases. *J Bone Joint Surg Br* 1979;61:82.
323. Currarino G, Neuhauser EBD, Meyersback GC, et al. Hypophosphatasia. *AJR* 1957;78:392.
324. Kretschmer N, Stone M, Bauer C. Hereditary enzymatic effects as illustrated by hypophosphatasia. *Ann NY Acad Sci* 1958;75:279.
325. Fraser D. Hypophosphatasia. *Am J Med* 1957;22:730.
326. Goyer RA. Ethanolamine phosphate excretion in a family with hypophosphatasia. *Arch Dis Child* 1963;38:205.
327. McCane RA, Morrison AB, Dent CD. The excretion of phosphoethanolamine in hypophosphatasia. *Lancet* 1955;1:131.
328. Licata AA, Radfar N, Bartter FC. The urinary excretion of phosphoethanolamine in diseases other than hypophosphatasia. *Am J Med* 1978;64:133.
329. Jacobson DP, McClain EJ. Hypophosphatasia in monozygotic twins: a case report. *J Bone Joint Surg Am* 1967;49:377.
330. Coe JD, Murphy WA, Whyte MP. Management of femoral fractures and pseudofractures in adult hypophosphatasia. *J Bone Joint Surg Am* 1986;68:981.
331. Arnaud SB, Goldsmith RS, Stickler GB, et al. Serum parathyroid hormone and blood minerals: interrelationships in normal children. *Pediatr Res* 1973;7:485.
332. Bergman L, Hagberg S. Primary hyperparathyroidism in a child investigated by determination of ultrafiltrable calcium. *Am J Dis Child* 1972;123:174.
333. Bjernulf A, Hall K, Sjogren I, et al. Primary hyperparathyroidism in children. *Acta Paediatr Scand* 1970;59:249.

334. Cutler RE, Reiss E, Ackerman LV. Familial hyperparathyroidism. *N Engl J Med* 1964;270:859.
335. Randall C, Lauchlan SC. Parathyroid hyperplasia in an infant. *Am J Dis Child* 1963;105:364.
336. Stuart C, Acceto T Jr, Kuhn JP, et al. Intrauterine hyperparathyroidism: postmortem findings in two cases. *Am J Dis Child* 1979;133:67.
337. Bronsky D, Kiamko RT, Waldstein S. Familial idiopathic hyperparathyroidism. *Am J Med* 1974;57:34.
338. Whyte MP, Weldon W. Idiopathic hypoparathyroidism presenting with seizures during infancy: X-linked recessive inheritance in a large Missouri kindred. *J Pediatr* 1981;99:608.
339. Avioli LV. The therapeutic approach to hypoparathyroidism. *Am J Dis Child* 1974;57:34.
340. Albright F, Burnett C, Smith P, et al. Pseudohypoparathyroidism: an example of "Seabright-Bantam syndrome." Report of three cases. *Endocrinology* 1942;30:922.
341. Weinberg AG, Stone RT. Autosomal dominant inheritance in Albright's hereditary osteodystrophy. *J Pediatr* 1971;79:997.
342. Temtamy SA, McKusick VA. Brachydactyly as part of syndromes. In: Bergsma D, ed. *The genetics of hand malformations*. New York: Alan R. Liss, 1978:227.
343. Drezner M, Neelon FA, Lebovitz HE. Pseudohypoparathyroidism type II. A possible defect in the reception of the cyclic AMP signal. *N Engl J Med* 1973;289:1056.
344. Farfel Z, Brickman AS, Kaslow HR, et al. Defect of receptor-cyclase coupling protein in pseudohypoparathyroidism. *N Engl J Med* 1980;303:237.
345. Glass EJ, Barr DGD. Transient neonatal hyperparathyroidism secondary to maternal pseudohypoparathyroidism. *Arch Dis Child* 1981;56:555.
346. Marcus R, Wilber JF, Aurbach GD. Parathyroid hormone-sensitive adenyl cyclase from the renal cortex of a patient with pseudohypoparathyroidism. *J Clin Endocrinol Metab* 1971;33:537.
347. Cohn MJ, Izpisua-Belmonte JC, Abud H, et al. Fibroblast growth factors induce additional limb development from the flank of chick embryos. *Cell* 1995;80:739.
348. Zou H, Niswander L. Requirement for BMP signaling in interdigital apoptosis and scale formation. *Science* 1996;272:738.
349. Muragaki Y, Mundlos S, Upton J, et al. Altered growth and branching patterns in synpolydactyly caused by mutations in HOXD13. *Science* 1996;272:548.
350. Lefkowitz RJ. G proteins in medicine. *N Engl J Med* 1995;332:186.
351. Ringel MD, Schwindinger WF, Levine MA. Clinical implications of genetic defects in G proteins: the molecular basis of McCune-Albright syndrome and Albright hereditary osteodystrophy. *Medicine* 1996;75:171.
352. Wilson LC, Leverton K, Luttikhuis O, et al. Brachydactyly and mental retardation: an Albright hereditary osteodystrophy-like syndrome localized to 2q37. *Am J Hum Genet* 1995;56:400.
353. David NJ, Verner JV, Engel FL. The diagnostic spectrum of hypercalcemia. *Am J Med* 1962;33:88.
354. Forbes GB, Cafarelli C, Manning J. Vitamin D and infantile hypercalcemia. *Pediatrics* 1968;42:203.
355. Muggia F, Heineman HO. Hypercalcemia associated with neoplastic disease. *Ann Intern Med* 1970;73:281.
356. Powell D, Singer FR, Murray TM, et al. Nonparathyroid humoral hypercalcemia in patients with neoplastic diseases. *N Engl J Med* 1973;289:176.
357. Hyman LR, Boner G, Thomas JC, et al. Immobilization hypercalcemia. *Am J Dis Child* 1972;124:723.
358. King LR, Knowles HC, McLaurin RL. Calcium, phosphorus, and magnesium metabolism following head injury. *Ann Surg* 1973;177:126.
359. Lawrence GD, Loeffler RG, Martin LG, et al. Immobilization hypercalcemia. *J Bone Joint Surg Am* 1973;55:87.
360. Millard FJC, Nassim JR, Woollen JW. Urinary calcium excretion after immobilization and spinal fusion in adolescents. *Arch Dis Child* 1970;45:399.
361. Pezeshki C, Brooker AF Jr. Immobilization hypercalcemia. *J Bone Joint Surg Am* 1977;59:971.
362. Williams JCP, Baratt-Boyes BG, Lowe JB. Supravalvular aortic stenosis. *Circulation* 1961;24:1311.
363. Schipani E, Kruse K, Juppner H. A constitutively active mutant PTH-PTHrP receptor in Jansen-type metaphyseal chondrodysplasia. *Science* 1995;268:98.
364. Lanske B, Karaplis AC, Lee K, et al. PTH/PTHrP receptor in early development and Indian Hedgehog-regulated bone growth. *Science* 1996;273:663.
365. Warman ML, Abbott M, Apte SS, et al. A type X collagen mutation causes Schmid metaphyseal chondrodysplasia. *Nat Genet* 1993;5:79.
366. Chisholm JJ Jr. Increased lead absorption and lead poisoning. In: Behrman RE, Vaughan VC III, eds. *Nelson's textbook of pediatrics*, 12th ed. Philadelphia: WB Saunders, 1983:1684.
367. Kumar S, Shahabuddin S, Haboubi N, et al. Angiogenesis factor from human myocardial infarcts. *Lancet* 1983;2:364.

Organic Phase

368. Cruess RL. Physiology of bone formation and resorption. In: Cruess RL, ed. *The musculoskeletal system*. New York: Churchill Livingstone, 1982:219.
369. Frost HM. *Mathematical elements of lamellar bone remodeling*. Springfield, IL: Charles C Thomas, 1964.
370. Rasmussen H, Bordier P. The cellular basis of metabolic bone disease. *N Engl J Med* 1973;289:25.
371. Hollister DW, Byers PH, Holbrook KA. Genetic disorders of collagen metabolism. *Adv Hum Genet* 1982;12:1.
372. Gordon MK, Gerecke DR, Nishimura I, et al. A new dimension in the extracellular matrix. In: Glimcher MJ, Lian JB, eds. *The chemistry and biology of mineralized tissues: proceedings of the third international conference*. New York: Gordon and Breach, 1988:179.
373. Dunker AK, Zaleske DJ. Stereochemical considerations for constructing alpha-helical protein bundles with particular application to membrane proteins. *Biochem J* 1977;163:45.
374. Lane JM, Suda M, von der Mark K, et al. Immunofluorescent localization of structural collagen types in endochondral fracture repair. *J Orthop Res* 1986;4:318.
375. Hay ED. Embryonic induction and tissue interaction. *Excerpta Med Int Congr Ser* 1977;432:126.
376. Boskey AL. Current concepts of the physiology and biochemistry of calcification. *Clin Orthop* 1981;157:225.
377. Boskey AL. Mineral-matrix interactions in bone and cartilage. *Clin Orthop* 1992;281:244.
378. Buckwalter JA. Proteoglycan structure in calcifying cartilage. *Clin Orthop* 1983;172:207.

Osteogenesis Imperfecta

379. McKusick VA. *Heritable disorders of connective tissues*, 4th ed. St. Louis: Mosby, 1972.
380. Malebranche N. *Traite de la recherche de la verite*. Paris: Chez Andre Pralard, 1674.
381. Lobstein JF. De la fragilite des os, ou de l'osteopsathyrose. In: Levraut FG, ed. *Traite de l'anatomie pathologique*, vol 2. Paris: L.T. Cellot, 1833.
382. Vrolik W. *Tabulae ad illustradam embryogenesis hominis et mammalium, tam naturalem quam abnormen*. Amsterdam: GMP Londonck, 1949.
383. Castells S, Colbert C, Chakrabarti C, et al. Therapy of osteogenesis imperfecta with synthetic salmon calcitonin. *J Pediatr* 1979;95:807.

384. Looser E. Zur Kenntnis der Osteogenesis imperfecta congenita et tarda. *Mitt Grenzgebiet Med Chir* 1906;15:161.
385. Silience DO. Osteogenesis imperfecta: an expanding panorama of variance. *Clin Orthop* 1981;159:11.
386. Wynne-Davis R, Gormley J. Clinical and genetic patterns in osteogenesis imperfecta. *Clin Orthop* 1981;159:26.
387. Francis MJO, Bauze RJ, Smith R. Osteogenesis imperfecta: a new classification. *Birth Defects* 1985;11:99.
388. Silience DO, Senn A, Danks DM. Genetic heterogeneity in osteogenesis imperfecta. *J Med Genet* 1979;16:101.
389. Bauze RJ, Smith R, Francis MJO. A new look at osteogenesis imperfecta. *J Bone Joint Surg Br* 1975;57:2.
390. Minch CM, Kruse RW. Osteogenesis imperfecta: a review of basic science and diagnosis. *Orthopedics* 1998;21:558.
391. Dent JA, Paterson CR. Fractures in early childhood: osteogenesis imperfecta or child abuse. *J Pediatr Orthop* 1991;11:184.
392. DiCesare PE, Sew-Hoy A, Krom W. Bilateral isolated olecranon fractures in an infant as presentation of osteogenesis imperfecta. *Orthopedics* 1992;15:741.
393. Rao S, Patel A, Schildhauer T. Osteogenesis imperfecta as a differential diagnosis of pathologic burst fractures of the spine. *Clin Orthop* 1993;289:113.
394. Carty HML. Fractures caused by child abuse. *J Bone Joint Surg Br* 1993;75:849.
395. Kleinman PK, Blackburne BD, Marks SC, et al. Radiologic contributions to the investigation and prosecution of cases of fatal infant abuse. *N Engl J Med* 1989;320:507.
396. Kozlowki K, McCrossin R. Early osseous abnormalities in Menkes' kinky hair syndrome. *Pediatr Radiol* 1980;8:191.
397. Seedorff KS. *Osteogenesis imperfecta: a study of clinical features and heredity based on 55 Danish families comprising 180 affected persons*. Copenhagen: Ejnar Munksgaard, 1949.
398. Shapiro F. Consequences of an osteogenesis imperfecta diagnosis for survival and ambulation. *J Pediatr Orthop* 1985;5:456.
399. Duffrin H, Sundaram M. Radiologic case study: osteogenesis imperfecta. *Orthopedics* 1987;10:1304.
400. Cropp GJ, Meyers DN. Physiological evidence of hypermetabolism in osteogenesis imperfecta. *Pediatrics* 1972;49:375.
401. Marion MJ, Gannon FH, Fallon MD, et al. Skeletal dysplasia in perinatal lethal osteogenesis imperfecta. *Clin Orthop* 1993;293:327.
402. Smith R, Francis MJO, Bauze RJ. Osteogenesis imperfecta: a clinical and biochemical study of a generalized connective tissue disorder. *Q J Med* 1975;44:555.
403. Trelstad RL, Rubin D, Gross J. Osteogenesis imperfecta congenita: evidence for a generalized molecular disorder of collagen. *Lab Invest* 1977;36:501.
404. Pope FM, Nicholls AC, Eggleton C, et al. Osteogenesis imperfecta (lethal) bones contain types III and V collagen. *J Clin Pathol* 1980;33:534.
405. Barsh GS, David KE, Byers PH. Type I osteogenesis imperfecta: a nonfunctional allele for pro alpha (I) chains for type I procollagen. *Proc Natl Acad Sci USA* 1982;79:3838.
406. Peltonen L, Palotie A, Prockop DJ. A defect in the structure of type I procollagen in a patient who had osteogenesis imperfecta: excessive mannose in the COOH-terminal peptide. *Proc Natl Acad Sci USA* 1980;77:6179.
407. Pertinen RP, Lichtenstein JR, Martin GR, et al. Abnormal collagen metabolism in cultured cells in osteogenesis imperfecta. *Proc Natl Acad Sci USA* 1975;72:586.
408. Eyre DR, Upton M, Shapiro F, et al. Non-expression of cartilage type II collagen in a case of human achondrogenesis (Langer-Saldino variant). *Trans Orthop Res Soc* 1986;11:459.
409. Delvin EE, Glorieux FH, Lopez E. *In vitro* sulfate turnover in osteogenesis imperfecta congenita and tarda. *Am J Med Genet* 1979;4:349.
410. Turkainen J. Altered glycosaminoglycan production in cultured osteogenesis imperfecta skin fibroblasts. *Biochem J* 1983;213:171.
411. Cowell HR, Ray S. Talipes equinovarus and syndrome identification. *Contemp Orthop* 1984;9:51.
412. Huax JP, Lokietek W. Is APD a promising drug in the treatment of severe osteogenesis imperfecta? *J Pediatr Orthop* 1988;8:71.
413. Acito AJ, Kasra M, Lee JM, et al. Effects of intermittent administration of pamidronate on the mechanical properties of canine cortical and trabecular bone. *J Orthop Res* 1994;12:742.
414. Glorieux FH, Bishop NJ, Plotkin H, et al. Cyclic administration of pamidronate in children with severe osteogenesis imperfecta. *N Engl J Med* 1998;339:947.
415. Marini JC. Osteogenesis imperfecta: managing brittle bones [editorial]. *N Engl J Med* 1998;339:986.
416. Cole NL, Goldberg MH, Loftus M, et al. Surgical management of patients with osteogenesis imperfecta. *J Oral Maxillofac Surg* 1982;40:578.
417. King JD, Bobechko WP. Osteogenesis imperfecta: an orthopaedic description and surgical review. *J Bone Joint Surg Br* 1971;53:72.
418. Miller EA. Observation on the surgical management of osteogenesis imperfecta. *Clin Orthop* 1981;159:154.
419. Morefield WG, Miller GR. Aftermath of osteogenesis imperfecta: a disease in adulthood. *J Bone Joint Surg Am* 1980;62:113.
420. Quisling RW, Moore GR, Jahrsdoerfer RA. Osteogenesis imperfecta. *Arch Otolaryngol* 1979;105:207.
421. Roberts JM, Solomons CC. Management of pregnancy in osteogenesis imperfecta. *Obstet Gynecol* 1975;45:168.
422. Gerber LH, Binder H, Weintraub J, et al. Rehabilitation of children and infants with osteogenesis imperfecta. *Clin Orthop* 1990;251:254.
423. Letts M, Monson R, Weber K. The prevention of recurrent fractures of the lower extremities in severe osteogenesis imperfecta using vacuum pants: a preliminary report in four patients. *J Pediatr Orthop* 1988;8:454.
424. Ryoppy S, Alberty A, Kairila I. Early semiclosed intramedullary stabilization in osteogenesis imperfecta. *J Pediatr Orthop* 1987;7:139.
425. Sijbrandij S. Percutaneous nailing in the management of osteogenesis imperfecta. *Int Orthop* 1990;14:195.
426. Middleton RWD, Frost RB. Percutaneous intramedullary rod interchange in osteogenesis imperfecta. *J Bone Joint Surg Br* 1987;69:429.
427. Tiley F, Albright JA. Osteogenesis imperfecta: treatment by multiple osteotomy and intramedullary rod insertion. *J Bone Joint Surg Am* 1973;55:701.
428. Williams PF. Fragmentation and rodding in osteogenesis imperfecta. *J Bone Joint Surg Br* 1965;47:23.
429. Sofield HA, Millar EA. Fragmentation, realignment, and intramedullary rod fixation of deformities of the long bones in children: a ten-year appraisal. *J Bone Joint Surg Am* 1959;41:1371.
430. Nicholas RW, James P. Telescoping intramedullary stabilization of the lower extremities for severe osteogenesis imperfecta. *J Pediatr Orthop* 1990;10:219.
431. Gamble JG, Strudwick WJ, Rinsky LA, et al. Complications of intramedullary rods in osteogenesis imperfecta: Bailey-Dubow rods versus nonelongating rods. *J Pediatr Orthop* 1988;8:645.
432. Porat S, Heller E, Seidman DS, et al. Functional results of operation in osteogenesis imperfecta: elongating and nonelongating rods. *J Pediatr Orthop* 1991;11:200.
433. Morel G, Houghton GR. Pneumatic trouser splints in the treatment of severe osteogenesis imperfecta. *Acta Orthop Scand* 1982;53:547.

434. Herring JA. Indications, patient selection, and evaluation in pediatric orthopedics. In: Luque ER, ed. *Segmental spinal instrumentation*. Thorofare, NJ: Slack, 1984:64.
435. Lubicky JP. The spine in osteogenesis imperfecta. In: Weinstein SL, ed. *The pediatric spine*. New York: Raven, 1994:943.
436. Brenton DP, Dent CE. Idiopathic osteoporosis. In: Bickel H, Stern J, eds. *Inborn errors of calcium and bone metabolism*. Baltimore: University Park, 1976.
437. Cloutier MD, Hayles AB, Riggs BL, et al. Juvenile osteoporosis: report of a case including a description of some metabolic and microradiographic studies. *Pediatrics* 1967;40:649.
438. Dent CE. Idiopathic juvenile osteoporosis. *Birth Defects* 1969;5:134.
439. Jowsey J. *Metabolic diseases of bone*. Philadelphia: WB Saunders, 1977.
440. Jowsey J, Johnson KA. Juvenile osteoporosis: bone findings in seven patients. *J Pediatr* 1972;81:511.
441. Kooh SW, Cumming WA, Fraser D, et al. *Transient childhood osteoporosis of unknown cause*. Amsterdam: Excerpta Medica, 1973.
442. Teotia M, Teotia S, Singh RK. Idiopathic juvenile osteoporosis. *Am J Dis Child* 1979;133:894.
443. Evans RA, Dunstan CR, Hills E. Bone metabolism in idiopathic juvenile osteoporosis: a case report. *Calcif Tissue Int* 1983;35:5.
444. Gallagher CJ, Riggs BL, Eisman J. Intestinal calcium absorption and serum vitamin D metabolites in normal subjects and osteoporotic patients. *J Clin Invest* 1979;64:729.
445. Harris WH, Heaney RP. Skeletal renewal and metabolic bone disease. *N Engl J Med* 1969;280:193.
446. Marder HK, Tsang RC, Hug G, et al. Calcitriol deficiency in idiopathic juvenile osteoporosis in the young. *J Bone Joint Surg Br* 1980;62:417.
447. Greene WB. Idiopathic juvenile osteoporosis. In: Weinstein SL, ed. *The pediatric spine*. New York: Raven, 1994:933.
448. Jones ET, Hensinger RN. Spinal deformity in idiopathic juvenile osteoporosis. *Spine* 1981;6:1.
449. Manzke E, Gruber HE, Hines RW, et al. Skeletal remodeling and bone-related hormones in two adults with increased bone mass. *Metab Clin Exp* 1982;31:25.
450. Milgram JW, Jasty M. Osteopetrosis. *J Bone Joint Surg Am* 1982;64:912.
451. Shapiro F. Osteopetrosis: current clinical considerations. *Clin Orthop* 1993;294:34.
452. Albers-Schonberg H. Eine Bisher Nicht Beschriebene Allgemeinerkrankung Skelettes Im Rontgenbild. *Forsch Geb Rontgenstr* 1907;11:261.
453. Beighton P, Hamersma H. The orthopaedic implications of the sclerosing bone dysplasias. *S Afr Med J* 1980;11:600.
454. Hasenhuttl K. Osteopetrosis: review of the literature on comparative studies on a case with a 24-year follow-up. *J Bone Joint Surg Am* 1962;44:359.
455. Hinkel CL, Beiler DD. Osteopetrosis in adults. *AJR* 1955;74:46.
456. Milhaud G, Labat ML. Osteopetrosis reconsidered as a curable immune disorder. *Biomedicine* 1979;30:71.
457. Shapiro F, Glimcher MJ, Holtrop ME, et al. Human osteopetrosis: a histological, ultrastructural, and biochemical study. *J Bone Joint Surg Am* 1980;62:384.
458. Kramer B, Yuska H, Steiner MM. Marble bones. II. Chemical analysis of bone. *Am J Dis Child* 1939;57:1044.
459. Brown DM. Pathogenesis of osteopetrosis: a comparison of human and animal spectra. *Pediatr Res* 1971;5:181.
460. Dent CE, Smellie JM, Watson L. Studies in osteopetrosis. *Arch Dis Child* 1965;40:7.
461. Pearce L. Hereditary osteopetrosis of the rabbit. III. Pathological observations: skeletal abnormalities. *J Exp Med* 1950;92:591.
462. Pinchus JB, Gittleman IF, Kramer B. Juvenile osteopetrosis: metabolic studies in two cases and further observations on the composition of the bones in this disease. *Am J Dis Child* 1947;73:458.
463. Walker DG. Experimental osteopetrosis. *Clin Orthop* 1973;97:158.
464. Marks SC. Pathogenesis of osteopetrosis in the rat: reduced bone resorption due to reduced osteoclast function. *Am J Anat* 1973;138:165.
465. Walker DG. Bone resorption restored in osteopetrotic mice by transplants of normal bone marrow and spleen cells. *Science* 1975;190:784.
466. Walker DG. Osteopetrosis cured by temporary parabiosis. *Science* 1973;180:875.
467. Marks SC, Walker DG. The hematogenous origin of osteoclasts: experimental evidence from osteopetrotic (microphthalmic) mice treated with spleen cells from beige mouse donors. *Am J Anat* 1981;161:1.
468. Milhaud G, Labat ML, Parant M, et al. Immunologic defect and its correction in the osteopetrotic mutant rat. *Proc Natl Acad Sci USA* 1977;74:339.
469. Hofer M, Hirschel B, Kirschner P, et al. Brief report. Disseminated osteomyelitis from *Mycobacterium ulcerans* after a snakebite. *N Engl J Med* 1993;328:1007.
470. Ballet JJ, Griscelli C. Lymphoid cell transplantation in human osteopetrosis. In: Horton JE, Tarpley TM, Davis WF, eds. *Mechanisms of localized bone loss: proceedings of the first scientific evaluation workshop on localized bone loss*. Washington: Information Retrieval, 1978:399.
471. Ballet JJ, Griscelli C, Coutiris C, et al. Bone marrow transplantation in osteopetrosis. *Lancet* 1977;2:1137.
472. Coccia BF, Krivit W, Cervenka J. Successful bone marrow transplantation for infantile osteopetrosis. *N Engl J Med* 1980;302:701.
473. Kaplan FS, August CS, Fallon MD, et al. Successful treatment of infantile malignant osteopetrosis by bone-marrow transplantation. *J Bone Joint Surg Am* 1988;70:617.
474. Sieff CA, Levinsky RJ, Rogers DW, et al. Allogeneic bone-marrow transplantation in infantile malignant osteopetrosis. *Lancet* 1983;1:437.
475. Sorell M, Kapoor N, Kirkperuch C. Marrow transplantation for juvenile osteopetrosis. *Am J Med* 1981;70:1280.
476. Key LL Jr, Rodgriguez RM, Willi SM, et al. Long-term treatment of osteopetrosis with recombinant human interferon gamma. *N Engl J Med* 1995;332:1594.
477. Whyte MP. Chipping away at marble-bone disease. *N Engl J Med* 1995;332:1639.
478. Aegerter E, Kirkpatrick J. *Orthopaedic diseases*. Philadelphia: WB Saunders, 1975:440.
479. Talab YA, Mallouh A. Hyperostosis with hyperphosphatemia: a case report and review of the literature. *J Pediatr Orthop* 1988;8:338.
480. Naveh Y, Kaftori JK, Alan V, et al. Progressive diaphyseal dysplasia: genetics and clinical and radiographic manifestations. *Pediatrics* 1984;74:399.
481. Resnick D, Niwayama G. Osteomyelitis, septic arthritis, and soft tissue infection: the organisms. In: Resnick D, Niwayama G, eds. *Diagnosis of bone and joint disorders*, 2nd ed. Philadelphia: WB Saunders, 1988:2647.
482. Evans EB. Musculoskeletal changes complicating burns. In: Epps CH Jr, ed. *Complications in orthopaedic surgery*, 2nd ed. Philadelphia: Lippincott-Raven, 1986:1307.

Osteopetrosis

483. Caffey J. *Pediatric x-ray diagnosis*. Chicago: Year Book, 1972.
484. Caffey J. Infantile cortical hyperostosis: a review of the clinical and radiographic features. *Proc R Soc Lond* 1957;50:347.
485. Staheli LT, Church CC, Ward BH. Infantile cortical hyperostosis (Caffey's disease). *JAMA* 1968;203:96.
486. Bernstein RM, Zaleske DJ. Familial aspects of Caffey's disease: a report of a family and review of the English literature. *Am J Orthop* 1995;24:777.
487. Pazzaglia UE, Byers P, Beluffi G, et al. Pathology of infantile cortical hyperostosis (Caffey's disease). *J Bone Joint Surg Am* 1985;67:1417.
488. Blasier RB, Aronson DD. Infantile cortical hyperostosis with osteomyelitis of the humerus. *J Pediatr Orthop* 1985;5:222.
489. Frame B, Jackson CE, Reynolds WA, et al. Hypercalcemia and skeletal effects in chronic hypervitaminosis and skeletal effects in chronic hypervitaminosis A. *Ann Intern Med* 1974;80:44.
490. Gamble JG, Ip SC. Hypervitaminosis A in a child from megadosing. *J Pediatr Orthop* 1985;5:219.
491. Lim MO, Mukherjee AB, Hansen JW. Dysplastic cutaneous osteomatosis. *Arch Dermatol* 1981;117:797.
492. Banks SW. Bone changes in acute and chronic scurvy: an experimental study. *J Bone Joint Surg Am* 1943;25:553.
493. Hurwitz S. *Clinical pediatric dermatology*. Philadelphia: WB Saunders, 1981:185.
494. Heydemann JS, McCarthy RE. Tumoral calcinosis in a child. *J Pediatr Orthop* 1988;8:474.
495. Gregosiewicz A, Warda E. Tumoral calcinosis: successful medical treatment. *J Bone Joint Surg Am* 1989;71:1244.
496. Mozaffarian G, Lafferty FW, Pearson OH. Treatment of tumoral calcinosis with phosphorus deprivation. *Ann Intern Med* 1972;74:1745.
497. Mitnick PD, Goldfarb S, Slatopolsky E, et al. Calcium and phosphorus metabolism in tumoral calcinosis. *Ann Intern Med* 1980;92:482.
498. Aprin H, Sinha A. Tumoral calcinosis: report of a case in a one-year-old child. *Clin Orthop* 1984;185:83.
499. Kirk TS, Simon MA. Tumoral calcinosis: report of a case with successful medical management. *J Bone Joint Surg Am* 1981;63:1167.
500. Rodriguez-Peralto JL, Lopez-Barca F, Torres A, et al. Tumoral calcinosis in two infants. *Clin Orthop* 1989;242:272.
501. Cohen RB, Hahn GV, Tabas JA, et al. The natural history of heterotopic ossification in patients who have fibrodysplasia ossificans progressiva. *J Bone Joint Surg Am* 1993;75:215.
502. Kaplan FS, Tabas JA, Gannon F, et al. The histopathology of fibrodysplasia ossificans progressiva. *J Bone Joint Surg Am* 1993;75:220.
503. Kaplan FS, Hahn GV, Zasloff MA. Heterotopic ossification: two rare forms and what they can teach us. *J Am Acad Orthop Surg* 1994;2:288.
504. Brunet LJ, McMahon JA, McMahon AP, et al. Noggin, cartilage morphogenesis, and joint formation in the mammalian skeleton. *Science* 1998;280:1455.
505. Garland DE, Hanscom DA, Keenan MA, et al. Resection of heterotopic ossification in the adult with head trauma. *J Bone Joint Surg Am* 1985;67:1261.
506. Mital MA, Garber JE, Stinson JT. Ectopic bone formation in children and adolescents with head injuries: its management. *J Pediatr Orthop* 1987;7:83.
507. Ogilvie-Harris DJ, Fornasier VL. Pseudomalignant myositis ossificans: heterotopic new-bone formation without a history of trauma. *J Bone Joint Surg Am* 1980;62:1274.
508. Pazzaglia UE, Beluffi G, Colombo A, et al. Myositis ossificans in the newborn. *J Bone Joint Surg Am* 1986;68:456.
509. Ayers DC, Everts CM, Parkinson JR. The prevention of heterotopic ossification in high risk patients by low-dose radiation therapy after total hip arthroplasty. *J Bone Joint Surg Am* 1986;68:1423.
510. Pyeritz RE, McKusick VA. The Marfan syndrome: diagnosis and management. *N Engl J Med* 1979;300:772.
511. Tsipouras P, Del Mastro R, Sarfarazi M, et al. Genetic linkage of the Marfan syndrome, ectopia lentis, and congenital contractural arachnodactyly to the fibrillin genes on chromosomes 15 and 5. *N Engl J Med* 1992;326:905.
512. Keech MR, Wendt VE, Reed RC, et al. Family studies of the Marfan syndrome. *J Chronic Dis* 1966;19:57.
513. Steinberg I. A simple screening test for the Marfan syndrome. *AJR* 1966;97:118.
514. Parrish JG. Heritable disorders of connective tissue. *Proc R Soc Med* 1960;53:515.
515. Moe JH, Winter RB, Bradford DS, et al. Scoliosis in Marfan's syndrome. In: *Scoliosis and other spinal deformities*. Philadelphia: WB Saunders, 1978:315.
516. Amis J, Herring JA. Iatrogenic kyphosis: a complication of Harrington instrumentation in Marfan's syndrome. *J Bone Joint Surg Am* 1984;66:460.
517. Robins PR, Moe JH, Winter RB. Scoliosis in Marfan's syndrome. *J Bone Joint Surg Am* 1975;57:358.
518. Beighton P, Horan F. Orthopaedic aspects of the Ehlers-Danlos syndrome. *J Bone Joint Surg Br* 1969;51:444.
519. Ainsworth SR, Aulicino PL. A survey of patients with Ehlers-Danlos syndrome. *Clin Orthop* 1993;286:250.
520. Rames RD, Strecker WB. Recurrent elbow dislocations in a patient with Ehlers-Danlos syndrome. *Orthopedics* 1991;14:705.
521. Badelon O, Bensahel H, Csukonyi Z, et al. Congenital dislocation of the hip in Ehlers-Danlos syndrome. *Clin Orthop* 1990;255:138.
522. Pinnell SR, Krane SM, Kenzora JE, et al. A heritable disorder of connective tissue: hydroxylysine-deficient collagen disease. *N Engl J Med* 1972;386:1013.
523. Finkelstein JD. Methionine metabolism in mammals: the biochemical basis for homocystinuria. *Metab Clin Exp* 1974;23:387.
524. Gaull G, Sturman JA, Schaffner F. Homocystinuria due to cystathionine synthase deficiency: enzymatic and ultrastructural studies. *J Pediatr* 1974;84:381.
525. Brenton DP, Dow CJ, James JIP, et al. Homocystinuria and Marfan's syndrome. *J Bone Joint Surg Br* 1972;54:277.
526. Brill PW, Mitty JA, Gaull GE. Homocystinuria due to cystathionine synthetase deficiency: clinical roentgenologic correlations. *AJR* 1974;121:45.
527. Boers GHJ, Smals AGH, Trijbels FJM, et al. Heterozygosity for homocystinuria in premature peripheral and cerebral occlusive arterial disease. *N Engl J Med* 1985;313:709.
528. Clarke R, Daly L, Robinson K, et al. Hyperhomocystinemia: an independent risk factor for vascular disease. *N Engl J Med* 1991;324:1149.
529. Steegers-Theunissen RPM, Boers GHJ, Trijbels FJM, et al. Neural-tube defects and derangement of homocysteine metabolism. *N Engl J Med* 1991;324:199.

Endocrinopathies

530. Tanner JM, Goldstein H, Whitehouse RH. Standards for children's height at ages 2 to 9 years allowing for height of parents. *Arch Dis Child* 1970;45:755.
531. Tanner JM, Whitehouse RH, Takaishi M. Standards from birth to maturity for height, weight, height velocity, and weight velocity: British children, 1965. *Arch Dis Child* 1966;41:454-471.
532. Bunch WH, Dvornch VM. Pitfalls in the assessment of skeletal

- immaturity: an anthropologic case study. *J Pediatr Orthop* 1983; 3:220.
533. Tanner JM, Whitehouse RH, Marshall WA, et al. *Assessment of skeletal maturity and prediction of adult height (TW2 method)*. London: Academic, 1975.
 534. Hamill PV, Drizd TA, Johnson CL, et al. Physical growth: National Center for Health Statistics percentiles. *Am J Clin Nutr* 1979;32:607.
 535. Rudman D, Kutner MH, Blackston RD, et al. Children with normal variant short stature: treatment with human growth hormone for six months. *N Engl J Med* 1981;305:123.
 536. Vance ML, Mauras N. Growth hormone therapy in adults and children. *N Engl J Med* 1999;341:1206.
 537. Crawford JD. Meat, potatoes, and growth hormone. *N Engl J Med* 1981;305:163.
 538. Marshall WA. *Human growth hormone and its disorders*. London: Academic, 1977.
 539. Raisz LG, Kream B. Hormonal control of skeletal growth. *Annu Rev Physiol* 1981;43:225.
 540. Jennings AS, Liddle TW, Orth DN. Results of treating childhood Cushing's disease with pituitary irradiation. *N Engl J Med* 1977;297:957.
 541. Root AW, Bongiovanni AM, Eberlai WR. Diagnosis and management of growth retardation with special reference to the problem of hypopituitarism. *J Pediatr* 1971;78:737.
 542. Lin T, Tucci JR. Provocation tests of growth hormone release. *Ann Intern Med* 1974;80:464.
 543. Chaknakjian ZH, Marks JF, Fink CW. Effect of levodopa (L-dopa) on serum growth hormone in children with short stature. *Pediatr Res* 1973;7:71.
 544. Powell GF, Brasil JA, Blizzard RM. Functional deprivation and growth retardation simulating idiopathic hypopituitarism. I. Clinical evaluation of the syndrome. *N Engl J Med* 1967;276:1271.
 545. Powell GF, Brasil JA, Ruiti S, et al. Emotional deprivation and growth retardation simulating idiopathic hypopituitarism. II. Endocrinologic evaluation of the syndrome. *N Engl J Med* 1967; 276:1279.
 546. Soyka LF, Bode HH, Crawford JD, et al. Effectiveness of long term human growth therapy for short stature in children with human growth hormone deficiency. *J Clin Endocrinol Metab* 1970;30:1.
 547. Rivkees S, Bode HH, Crawford JD. Long-term growth in juvenile acquired hypothyroidism: the failure to achieve normal adult stature. *N Engl J Med* 1988;318:599.
 548. Wells D, King JD, Roe TF, et al. Review of slipped capital femoral epiphysis associated with endocrine disease. *J Pediatr Orthop* 1993;13:610.
 549. Zubrow AB, Lane JW, Parks JS. Slipped capital femoral epiphysis occurring during treatment for hypothyroidism. *J Bone Joint Surg Am* 1978;60:256.
 550. Neidel J, Boddenberg B, Zander D, et al. Thyroid function in Legg-Calve-Perthes disease: cross-sectional and longitudinal study. *J Pediatr Orthop* 1993;13:592.
 551. Kan K, Cruess RL, Posner B, et al. Receptor proteins for steroid and peptide hormones at the epiphyseal line. *Trans Orthop Res Soc* 1981;6:110.
 552. Simpson JL. *Disorders of sexual differentiation: etiology and clinical delineation*. New York: Academic, 1976.
 553. Zaleske DJ, Bode HH, Benz R, et al. Association of sciatica-like pain and Addison's disease: a case report. *J Bone Joint Surg Am* 1984;66:297.
 554. Sambrook P, Birmingham J, Kelly P, et al. Prevention of corticosteroid osteoporosis: a comparison of calcium, calcitriol, and calcitonin. *N Engl J Med* 1993;328:1747.
 555. Danon M, Crawford JD. The McCune-Albright syndrome. *Ergeb Inn Med Kinderheilkd* 1987;55:81.
 556. Harris WH, Dudley HR, Barry RJ. The natural history of fibrous dysplasia. *J Bone Joint Surg Am* 1962;44:207.
 557. Henry A. Monostotic fibrous dysplasia. *J Bone Joint Surg Br* 1969;51:300.
 558. Albin J, Wu R. Abnormal hypothalamic-pituitary function in polyostotic fibrous dysplasia. *Clin Endocrinol* 1981;14:435.
 559. Spiegel AM. The molecular basis of disorders caused by defects in G proteins. *Horm Res* 1997;47:89.
 560. Schnabel P, Bohm M. Mutations of signal-transducing G proteins in human disease. *J Mol Med* 1995;73:221.
 561. Alman BA, Greel DA, Wolfe HJ. Activating mutations of Gs protein in monostotic fibrous lesions of bone. *J Orthop Res* 1996;14:311.
 562. Motomura T, Kasayama S, Takagi M, et al. Increased interleukin-6 production in mouse osteoblastic MC3T3-E1 cells expressing activating mutant of the stimulatory G protein. *J Bone Miner Res* 1998;13:1084.
 563. Andrisano A, Soncini G, Calderoni PP, et al. Critical review of infantile fibrous dysplasia: surgical treatment. *J Pediatr Orthop* 1991;11:478.
 564. Connolly JF. Shepherd's crook deformities of polyostotic dysplasia treated by osteotomy and Zickel nail fixation. *Clin Orthop* 1977;123:22.
 565. Guille JT, Kumar SJ, MacEwen GD. Fibrous dysplasia of the proximal part of the femur. *J Bone Joint Surg Am* 1998;80:648.
 566. de Boer HH. The history of bone grafts. *Clin Orthop* 1988; 226:292.
 567. Virolainen P, Vuorio E, Aro HT. Gene expression at graft-host interfaces of cortical bone allografts and autografts. *Clin Orthop* 1993;297:144.
 568. Hopp SG, Dahners LE, Gilbert JA. A study of the mechanical strength of long bone defects treated with various bone autograft substitutes: an experimental investigation in the rabbit. *J Orthop Res* 1989;7:579.
 569. Pelker RR, McKay J Jr, Troiano N, et al. Allograft incorporation: a biomechanical evaluation in a rat model. *J Orthop Res* 1989;7:585.
 570. Jofe MH, Gebhardt MC, Tomford WW, et al. Reconstruction for defects of the proximal part of the femur using allograft arthroplasty. *J Bone Joint Surg Am* 1988;70:507.
 571. Shih HN, Chen YJ, Huang TJ, et al. Treatment of fibrous dysplasia involving the proximal femur. *Orthopedics* 1998;21: 1263.



8

THE SKELETAL DYSPLASIAS

PAUL D. SPONSELLER

GENERAL PRINCIPLES 244

Terminology 244
Classification 244
Prenatal Diagnosis 245
Evaluation 246
Treatment 246

ACHONDROPLASIA 246

Overview and Etiology 246
Etiology 247
Clinical Features 247
Growth and Development 247
Radiographic Characteristics 248
General Medical Treatment 250
Orthopaedic Treatment 250

HYPOCHONDROPLASIA 254

Etiology and Pathogenesis 254
Clinical Features 254
Radiographic Features 254
Differential Diagnosis 254
Treatment—General and Orthopaedic 254

METATROPIC DYSPLASIA 254

Clinical Features 255
Radiographic Features 256
Treatment/Orthopaedic Considerations 256

CHONDROECTODERMAL DYSPLASIA 257

Clinical Features 257
Radiographic Features 257
Orthopaedic Management 257

DIASTROPHIC DYSPLASIA 258

Clinical Features 258
Radiographic Features 260
Treatment 260

KNEIST DYSPLASIA 261

Clinical Features 262
Radiographic Features 262
Orthopaedic Treatment 262

SPONDYLOEPIPHYSEAL DYSPLASIA CONGENITA 263

Clinical Features 263
Radiographic Features 263
Medical Problems 264
Orthopaedic Problems and Treatment 264

SPONDYLOEPIPHYSEAL DYSPLASIA TARDA 265

Clinical Features 265
Radiographic Features 266
Orthopaedic Problems and Treatment 266

PSEUDOACHONDROPLASIA 266

Clinical Features 267
Radiographic Changes 268
Orthopaedic Problems and Treatment 268

MULTIPLE EPIPHYSEAL DYSPLASIA 269

Clinical Features 269
Radiographic Features 269
Orthopaedic Implications 270

CHONDRODYSPLASIA PUNCTATA 270

Clinical Features 270

Radiographic Features 271

Orthopaedic Implications 271

METAPHYSEAL CHONDRODYSPLASIAS 271

McKusick-type Metaphyseal Chondrodysplasia 271

Schmid-type Metaphyseal Chondrodysplasia 273

Jansen Metaphyseal Dysplasia 273

Kozlowski-type (Spondylometaphyseal Dysplasia) 273

**DIAPHYSEAL ACLASIA (MULTIPLE
OSTEOCARILAGINOUS EXOSTOSIS) 274**

Clinical Features 274

Radiographic Features 274

Orthopaedic Implications 275

**DYSCHONDROSTEOSIS (LERI-WEILL
SYNDROME) 275**

Clinical Features 275

Radiographic Features 275

Orthopaedic Implications 276

CLEIDOCRANIAL DYSPLASIA 276

Clinical Features 276

Radiographic Features 276

Orthopaedic Implications 277

LARSEN SYNDROME 278

Clinical Features 278

Radiographic Features 278

Orthopaedic Implications 278

PERINATAL LETHAL SKELETAL DYSPLASIAS 279**GENERAL PRINCIPLES****Terminology**

The skeletal dysplasias are a heterogeneous group including over 200 conditions recognized to date. In common, they are disorders of the growth and remodeling of bone and its cartilaginous precursor. The pathogenesis of many of these conditions is slowly being worked out, teaching us little by little about the growth of the skeleton. In the preface to his classic text, *Heritable Disorders of Connective Tissue*, McKusick quoted, "Nature is nowhere more openly to display her secret mysteries than in cases where she shows traces of her workings apart from the beaten path . . ." (1). It may even be true that there is a mutation and a disorder representing nearly each step of skeletal development. Most disorders result in short stature, defined as height more than two standard deviations below the mean for the population at a given age. The term "dwarfing condition" is used to refer to disproportionately short stature. The disproportion is commonly referred to as "short-trunk" or "short-limb." The short-limb types are further subdivided into categories based on which segment of the limb is short. "Rhizomelic" refers to shortening of the root (proximal) portion of the limb; "mesomelic," to the middle segment, and "acro-melic," to the distal segment. Achondroplasia is a classic example of rhizomelic involvement, with the femora and especially the humeri being most affected by shortening. Some of these disorders are named after the appearance of the skeleton (diastrophic means "to grow twisted," camptomelic means "bent limbs," and chondrodysplasia punctata refers to stippled cartilage). Eponyms are used to name others, such as Kneist, Morquio, and McKusick.

Classification

Classification of skeletal dysplasias has traditionally been done according to the pattern of bone involvement, as in

the International Classification of Osteochondrodysplasias (2) (Table 8-1). The newer trend, however, is to group them according to the specific causative protein, enzyme, or gene defect, in cases in which this is known (Table 8-2). A schematic representation of the effects of the known mutations on cartilage development is shown in Figure 8-1. It is also

**TABLE 8-1. INTERNATIONAL CLASSIFICATION OF
SKELETAL DYSPLASIAS, 1992 (A PARTIAL LIST)**

Defects of the tubular and flat bones and/or the axial skeleton
Achondroplasia group
Achondroplasia
Hypochondroplasia
Thanatophoric dysplasia
Metatropic dysplasia
Atelosteogenesis/diastrophic dysplasia group
Osteogenesis imperfecta
Kneist-Stickler group
Spondyloepiphyseal dysplasia congenita group
Other Spondyloepi-(metaphyseal) dysplasia group
Storage disorders
Mucopolysaccharidoses
Mucopolipidoses
Multiple epiphyseal dysplasia (MED)
Metaphyseal dysplasia
Dysplasias with defective mineralization
Hypophosphatasia
Hypophosphatemic rickets
Neonatal hypoparathyroidism
Dysplasias with increased bone density
Disorganized development of cartilaginous and fibrous components of the skeleton
Multiple cartilaginous exostoses
Dysplasia epiphysealis hemimelica
Enchondromatosis
Fibrous Dysplasia
Idiopathic osteolyses

TABLE 8-2. CLASSIFICATION OF DYSPLASIAS BASED ON ETIOLOGY

<i>FGFR3</i> group (local regulator of cartilage growth)
Achondroplasia
Hypochondroplasia
Thanatophoric dysplasia
<i>COL1A</i> group (structural osseous protein)
Osteogenesis imperfecta
<i>COL2A1</i> group (structural cartilage protein)
Spondyloepiphyseal dysplasia (SED)
Kniest dysplasia
Stickler dysplasia
Strudwick dysplasia
SED tarda
Diastrophic dysplasia sulfate transport-defective sulfate
transport enzyme group
Diastrophic dysplasia
Achondrogenesis
Collagen oligomeric matrix protein group (structural
cartilage protein)
Multiple epiphyseal dysplasia
Pseudoachondroplasia
Storage disorders
Mucopolysaccharidoses
Mucopolidoses

useful for the orthopaedic surgeon to mentally classify the dysplasias into those that are free from spinal deformity (for instance, hypochondroplasia and multiple epiphyseal dysplasia [MED] rarely have significant spinal abnormalities) versus those for which it is a frequent problem (such as spondyloepiphyseal dysplasia, diastrophic dysplasia, and metatropic dysplasia). Which disorders are free from epiphyseal involvement, and therefore from risk of degenerative joint disease down the road? Achondroplasia and hypochondroplasia, cleidocranial dysplasia, and diaphyseal aplasia rarely present these problems in adulthood, but spondyloepiphyseal dysplasia, multiple epiphyseal dysplasia, diastrophic dysplasia, and others commonly do.

Prenatal Diagnosis

With the increasing availability of prenatal screening, more patients with skeletal dysplasia are being diagnosed before birth. When ultrasound shows a fetus with shortening of the skeleton, femur length is the best biometric parameter to distinguish among the five most common possible conditions. Fetuses with femur length below 40% of the mean for gestational age most commonly had achondrogenesis; those with femur length between 40 and 60% most commonly had thanatophoric dysplasia or osteogenesis imper-

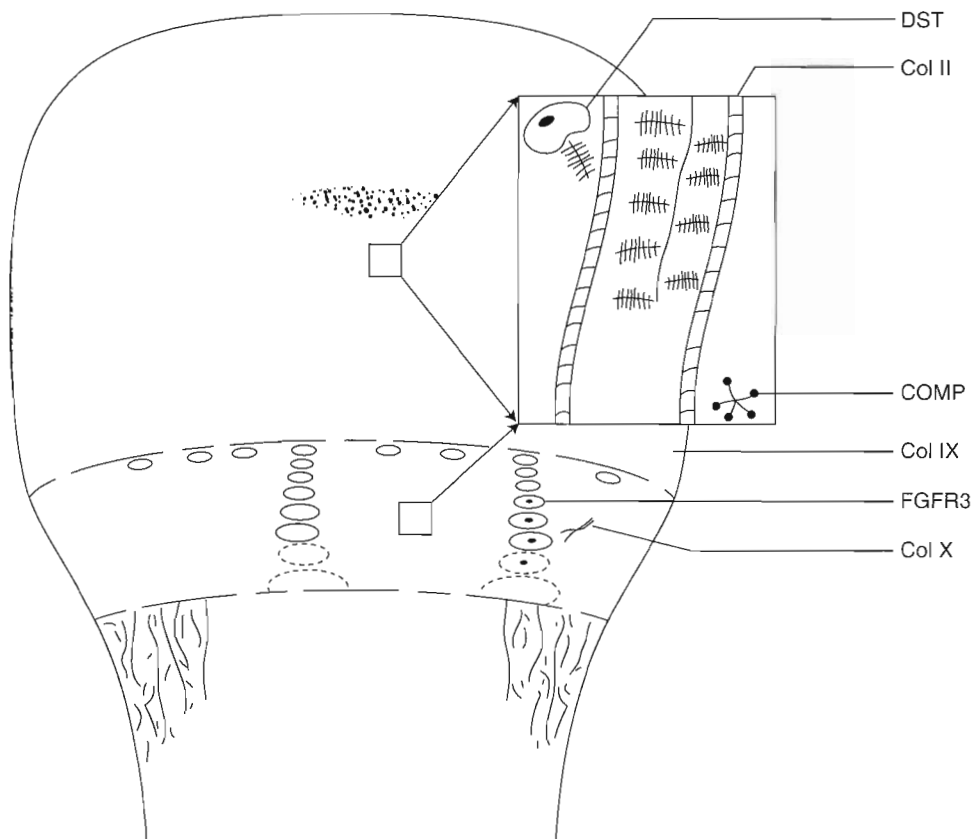


FIGURE 8-1. Schematic illustration of the sites and effects of the known cartilage defects in the skeletal dysplasias. Section of cartilage matrix of physis and epiphysis is simplified and enlarged; genetic abnormalities often affect both regions. *DST*, diastrophic sulfate transporter, deficiency of which leads to undersulfation of proteoglycans in epiphysis and physis of diastrophic dysplasia and achondrogenesis types 1B and 2; *Col II*, type II collagen, which is defective in Kniest dysplasia and spondyloepiphyseal dysplasia; *COMP*, cartilage oligomeric matrix protein, abnormal pseudoachondroplasia, and some forms of multiple epiphyseal dysplasia; *Col IX*, type IX collagen, which is closely linked to type II collagen, and is abnormal in some forms of multiple epiphyseal dysplasia; *FGFR3*, fibroblast growth factor receptor 3, which inhibits chondrocyte proliferation in achondroplasia, hypochondroplasia, and thanatophoric dysplasia; *Col X*, type X collagen, which is synthesized only by the hypertrophic cells of the growth plate, and is abnormal in Schmid-type metaphyseal chondrodysplasia.

fecta type II; and those with femur length over 80% most commonly had achondroplasia or osteogenesis imperfecta type III (3). Further testing may be performed, if indicated, by chorionic villous sampling and mutation analysis.

Evaluation

In evaluating a patient with short stature or abnormal bone development for skeletal dysplasia, several aspects of the medical history should be investigated for diagnosis and for coordination of care. Respiratory difficulty in infancy may occur as a result of restrictive problems in the syndromes with a small thorax, neurologic problems such as foramen magnum stenosis in achondroplasia, or upper airway obstruction in various conditions. A history of heart disease suggests the possibilities of chondroectodermal dysplasia, which may be associated with congenital heart malformations, or storage disorders such as Hurler or Morquio syndromes, in which cardiac dysfunction may be acquired. History of immune deficiency or malabsorption is common in cartilage-hair hypoplasia. Retinal detachment may occur with Kniest syndrome or spondyloepiphyseal dysplasia. Pertinent family history of short stature or dysmorphism should be sought, as well as any prior skeletal surgery the patient has had. Birth length, head circumference, and weight should be recorded. Unusual facial characteristics, cleft palate, and extremity malformations should be noted. Height percentile for age should be determined using standard charts. Measurement of the upper:lower segment ratio may be helpful in distinguishing disproportion early. This can be done by measuring the distance from the superior pubic ramus to the sole of the plantigrade foot, and subtracting it from the overall length. The normal ratio is 1.6 at birth (given that extremities develop later than the trunk), and diminishes to 0.93 in adults and teens. A thorough neurologic examination is needed because of the frequent incidence of spinal compromise—at the upper cervical level in spondyloepiphyseal dysplasia, diastrophic dysplasia, Larsen syndrome, metatropic dysplasia, or at any level in achondroplasia.

A skeletal survey should be ordered if one is not available: lateral film of head and neck, anteroposterior views of the entire spine, pelvis, arms, hands, and legs. Flexion–extension films of the cervical spine should be ordered if instability is suspected to be caused by delay in reaching milestones, or loss of strength or endurance. In many syndromes, such as spondyloepiphyseal dysplasia, in which cervical instability is common, these films should be ordered as a matter of course.

Laboratory tests may include calcium, phosphate, alkaline phosphatase, and protein, to rule out metabolic disorders such as hypophosphatemia or hypophosphatasia. The urine should be screened for storage products (under the guidance of a geneticist), if a progressive disorder is found. Serum thyroxine should be measured if the fontanels in an infant are bulging and bone development is delayed, to rule

out hypothyroidism. DNA testing for mutation analysis is not currently done in the clinical setting for skeletal dysplasias. When treating a child with a skeletal dysplasia, a geneticist should be consulted to help establish a diagnosis and, therefore, a prognosis, and to deal with medical problems. The geneticist sometimes functions as a primary physician for a patient with a genetic disorder, because a geneticist has the best overview of the medical issues facing the patient.

Treatment

The orthopaedic surgeon caring for the person with skeletal dysplasia should focus on several aspects: prevention of future limitations; treatment of current deformity, and treatment of pain. The patient's parents should be counseled about the mode of inheritance and risk of recurrence, so that they can make future family plans appropriately. In most cases, it is advisable to see these patients on a routine basis for surveillance, so that skeletal problems can be detected at the optimum time for treatment. Weight management is a continuing challenge for many, and reasonable attention should be paid to this.

If surgery becomes necessary on a person with skeletal dysplasia, special considerations apply. Anesthesia management is more difficult if the dysplasia involves oropharyngeal malformations, limited neck mobility cervical instability, or stenosis (4). Cervical instability is so common in the skeletal dysplasias that the surgeon should make a point of mentally ruling it out by knowledge of the patient, knowledge of the condition, and whether cervical instability is associated with it, or else by obtaining special radiographs in flexion and extension (5,6). Restrictive airway problems accompany some dysplasias, and laryngotracheomalacia affects many young diastrophic children. Skeletal distortion may make deep venous access challenging, and, in some cases, a general surgeon should be consulted in advance for this. Intraoperative positioning must accommodate both small stature and any contractures that are present. Postoperative planning must be done in advance, because most of these patients have decreased ability to accommodate postoperative immobilization, stiffness, or functional restrictions. In some situations, postoperative placement in a rehabilitative setting may be most helpful to the patient and family. The organization, Little People of America, may be a significant resource for information and support.*

ACHONDROPLASIA

Overview and Etiology

Achondroplasia is the most common form of skeletal dysplasia, although even it is uncommon, with an incidence of

* P.O. Box 9897, Washington DC, 20016.

approximately 1 in 30,000 to 1 in 50,000 (7,8). It is the only form of skeletal dysplasia that most physicians come in contact with. The name of the condition itself is not strictly accurate, since cartilage does develop both at the physes and at other locations. Whatever the origin of the term, bone that is formed from endochondral means is most underdeveloped in length, resulting in disproportionate short stature. The etiology of achondroplasia has recently been determined to be a mutation in the gene for fibroblast growth factor receptor-3 (*FGFR3*), which is present in cartilage (9–12).

Achondroplasia is transmitted as an autosomal dominant condition, and that information should be used to counsel the family and affected patient. However, looking backward, at least 80% of patients with achondroplasia have the disorder as the result of a spontaneous mutation (13). The risk of having a child with achondroplasia increases with increasing paternal age.

Etiology

The cause of achondroplasia is a point mutation in the gene for fibroblast growth factor receptor-3 (12). The gene for this receptor is on the short arm of chromosome 4. The mutation is always at the same nucleotide (1138), which is part of the transmembrane domain of this receptor. This is said to be the single most mutable nucleotide in humans. It causes a change in a single amino acid, from arginine to glycine. Fibroblast growth factor receptor is expressed in physal cartilage and in the central nervous system. *FGFR3* seems to limit endochondral bone formation in the proliferative zone of the physis, and this is a mutation that actually increases that inhibition (a so-called “gain-of-function” mutation). As discussed later in this chapter, this same receptor is also the site of different mutations, causing hypochondroplasia and thanatophoric dysplasia.

Histologically, the growth plates of persons with achondroplasia show a reduced hypertrophic cell zone and large collagen fibrils (14). However, intramembranous and periosteal ossification processes are normal (15).

Clinical Features

The appearance of a person with achondroplasia has numerous features that are uniform and predictable. Facial appearance is characterized by frontal bossing and midface hypoplasia (8,16). This hypoplasia develops because of the endochondral origin of the facial bones (16). The trunk length is within the lower range of normal, whereas the extremities are much shorter than normal (17), in a pattern which is termed “rhizomelic” (Fig. 8-2). The term “rhizo-” means “root.” The proximal segments (roots) of the extremities—the humeri and femora—are the most foreshortened. The fingertips usually reach only to the top of the greater trochanters, and this leads to difficulties in personal care

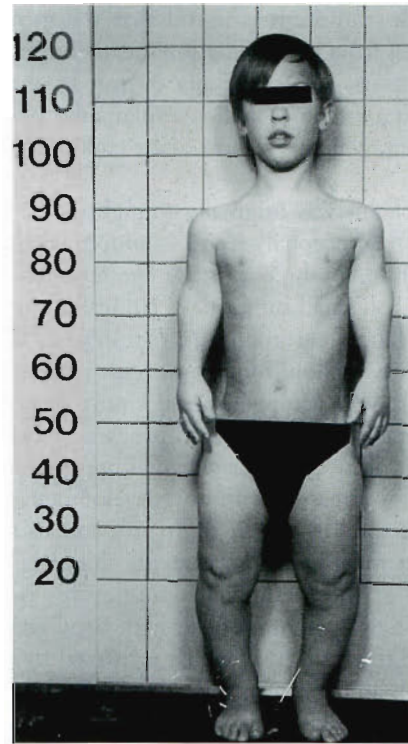


FIGURE 8-2. A 10-year-old boy with achondroplasia. Note pronounced shortening of proximal limb segments (rhizomelic pattern). The humeri are most affected. The elbows have a mild flexion contracture. There is mild genu varum.

(16). The digits of the hand have extra space between the third and the fourth rays, so that the digits are separated into three groups, including the thumb—the “trident hand.” There is usually a flexion contracture of the elbows, and the radial heads may be subluxated. Neither of these features causes functional impairment. Kyphosis at the thoracolumbar junction is common, especially in infancy. The condition usually improves with increasing patient age (18). Lumbar lordosis increases. Ligamentous laxity is common at the knees and ankles. The knees are most commonly in varus alignment, but may be in excessive valgus. The ankles usually have varus alignment, as well. Internal tibial torsion is common. The joints are otherwise not directly affected by this condition to any significant degree. The limbs generally have a muscular appearance. Intelligence is normal. Life expectancy is not significantly diminished in this condition.

Growth and Development

Growth curves are available for children with achondroplasia (17). The stature of children with achondroplasia is diminished proportionately throughout childhood, but the proportion declines during the adolescent growth spurt (19). The predicted adult height is 132 cm for men, and 122 cm women (13). When the growth pattern of specific

long bones is studied, it is found that the growth of the femur deviates from the population mean even more during the growth spurt, and the fibula overgrows the tibia (8). This latter fact is considered to explain the phenomenon of genu varum, which is seen in many children with achondroplasia.

Hydrocephalus was originally thought to be a cause of much of the macrocephaly seen in children with achondroplasia, but, although three-fourths of patients have ventriculomegaly, only a small subset have clinically important hydrocephalus (20). Charts of head circumference are available for children with achondroplasia to assist in following these features (21). Ventriculoperitoneal shunt surgery is indicated only for patients with rapidly progressive head enlargement or signs of increased intracranial pressure. Mental development is normal, but motor development is delayed (22). Muscle tone is low in the trunk and extremities in infancy. The most evident cause for this delay is neural compression at the foramen magnum. This occurs most likely because of asynchronous growth between the neural elements and the skull base, which is formed by endochondral bone (9). The foramen magnum is small for age in all infants with achondroplasia, although there is some "biologic variability" (23,24). Diminished foramen magnum measurements have been correlated with respiratory dysfunction and delayed motor development (20) (Fig. 8-3). Signs most predictive of severe stenosis of the foramen magnum requiring surgery are presence of clonus or hyperreflexia, and central hypopnea, as seen on sleep study. Developmental milestones are met later by children with achondroplasia than average-stature children. As an example, the mean age at which children with achondroplasia walk alone is 17 months. Normative tables for standard

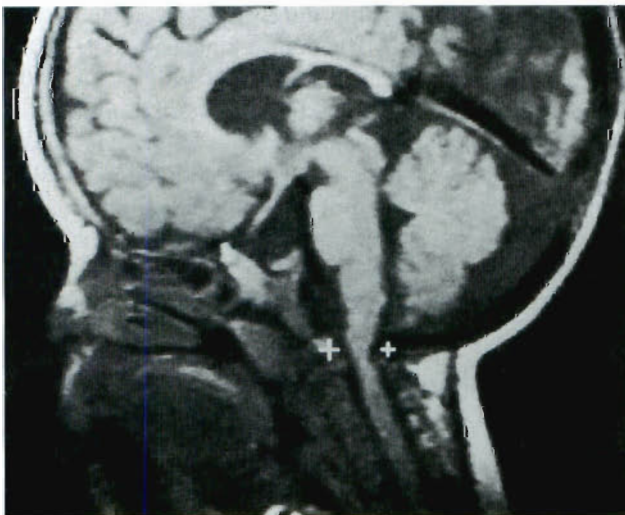


FIGURE 8-3. Magnetic resonance image of a child with achondroplasia shows stenosis at the foramen magnum. (Courtesy of George Bassett, M.D.)

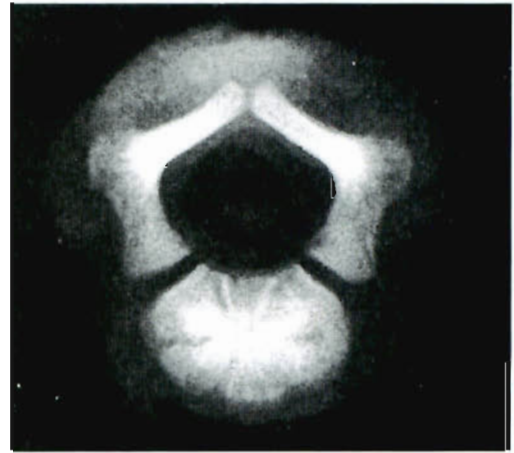


FIGURE 8-4. This specimen radiograph shows the obliquely oriented neurocentral synchondroses that contribute, by endochondral ossification, to both dimensions of the spinal canal. Because this process is impaired in achondroplasia, stenosis results.

milestones are available (22) and allow parents to detect complications. Development of spinal stenosis is explained by the formation of the spinal canal through endochondral ossification at the neurocentral synchondroses (Fig. 8-4). These obliquely oriented growth plates contribute to both the length of the pedicles and the distance between them. These dimensions are decreased at all levels of the achondroplastic spine. It remains a mystery why the dimensions are most diminished in the distal lumbar spine.

Radiographic Characteristics

The radiographic alterations involve regions in which the growth and development occur primarily through processes of endochondral ossification. Thus, in the skull, the facial bones, skull base, and foramen magnum are underdeveloped, whereas the cranial bones are normal in size and shape (8). There are growth curves available for the foramen magnum, which demonstrate that the dimensions of this aperture, as measured by computed tomography (CT), are reduced at birth in achondroplasia, accelerate in early childhood, but never quite reach normal (24). The spine displays central and foraminal stenosis, which becomes worse at progressively caudal levels (25,26). Although stenosis may occur at any level, it is most common in the lumbar spine. This is evident on plain films as a constant or diminishing distance between pedicles, from the first to the fifth lumbar levels on the anteroposterior view (Fig. 8-5), compared with the average-statured population, in whom 60% have increasing interpedicular distance at more caudal levels, and 40% have a constant distance. There is also decreased space between the vertebral body and the lamina on the lateral view. The stenosis of the spinal canal is best seen on CT, which graphically illustrates the tapering of the spinal

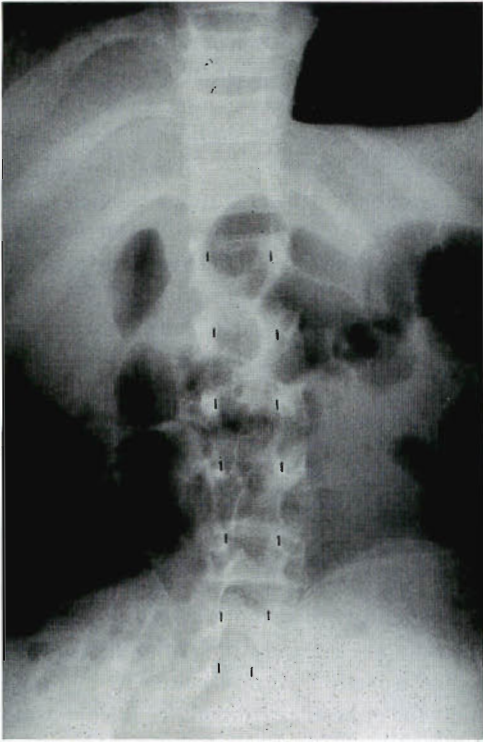

FIGURE 8-5. This anteroposterior view of the entire spine shows the progressive narrowing of the interpedicular distance at more caudal levels of the lumbar spine. This is the opposite of the normal pattern.

canal to a slit-like space at the lumbosacral junction (Fig. 8-6). The vertebral bodies have a scalloped appearance (13). If thoracolumbar kyphosis fails to resolve, the apical vertebrae develop a progressively round or wedge shape. Lumbar lordosis increases, and the sacrum may even become horizontal. Significant scoliosis is rare. A point to remember is that cervical instability, although so common in many forms

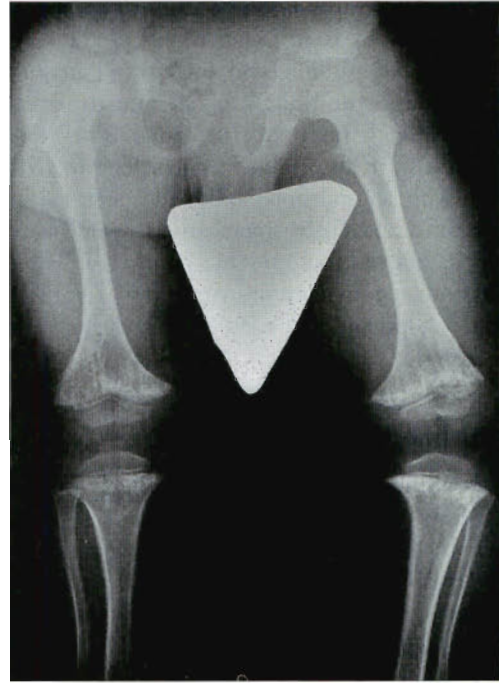

FIGURE 8-7. Radiograph of the lower extremities in a six-year-old with achondroplasia. The distal femoral physes have a pronounced inverted-"V" shape, and the knee is in varus. The acetabular roofs are horizontal.

of skeletal dysplasia, is not usually seen in this, the most common type of dysplasia.

The iliac wings have a squared appearance. The metaphyses of all long bones are flared in appearance. The diaphyses of all long bones are thick, despite being short, owing to subperiosteal bone apposition. Angulation at both the distal femoral and the proximal tibial metaphyses contributes to abnormal knee alignment (Fig. 8-7). The growth of the fibula is typically greater than that of the tibia, which also

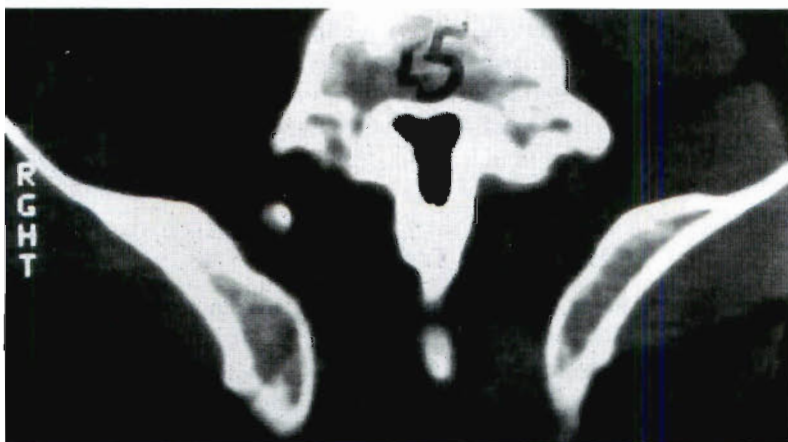

FIGURE 8-6. Computed tomogram of the fifth lumbar vertebra in achondroplasia, showing the slit-like spinal canal.

contributes to the varus in some cases. The shape of the distal femoral physis is an exaggeration of the normal inverted "V" in the midline, and the sites of major muscle insertions (such as the tibial tubercle and the greater trochanter) are more prominent than usual. The metacarpals and metatarsals are all of almost equal length. In 50% of individuals with achondroplasia, there is increased space between the third and fourth metacarpals, which is the basis for the appearance of the "trident" hand (13). The epiphyses throughout the skeleton are virtually normal in appearance and development, and consequently degenerative joint changes are rare.

General Medical Treatment

Infants with achondroplasia should be closely monitored in the first 2 years of life for signs of foramen magnum stenosis. These may include severe developmental delay, sleep apnea, persistent hypotonia, or spasticity. Sleep studies may be used, if this is suspected, to evaluate brain stem functions (27). If the diagnosis of foramen magnum stenosis is made, and the clinical picture persists, decompression of the brain stem should be undertaken by an experienced neurosurgeon. This consists of enlargement of the foramen magnum and sometimes laminectomy of the atlas. The clinical response is usually gratifying (23).

People with achondroplasia have a continuous challenge identifying and maintaining ideal body weight. Obesity is more common than in the general population, but standard curves of weight-for-height or weight-for-age used in the general population are not applicable to persons with achondroplasia. It is recommended that these individuals be followed using triceps skinfold thickness or weight/height squared, a measure that is less sensitive to short stature. Weight control measures should be instituted when these values exceed the 95% range for the general population (28).

Persons with achondroplasia are not deficient in growth hormone. Growth hormone has been used with only limited success in this disorder (11,29,30). The most noticeable results seem to be in those patients with the lowest growth velocities. Early data from the National Cooperative Growth Study has shown that treated children with achondroplasia gain a mean 0.3 standard deviations in height after 2 years of treatment, but the ability to maintain this over time is not known (11), nor is the effect on final height. One study (30) showed a significant increase in the growth rate during the first year of treatment, with a slower increase the second year, as well as variation in the response between patients. Clinically its use has not been widespread, to date.

A number of ear, nose, and throat problems occur as a result of underdevelopment of the midfacial skeletal structure. Maxillary hypoplasia leads to dental crowding and malocclusion, which may require orthodontic attention (31). The eustachian tubes may not function normally, and

this may lead to recurrent otitis media. Given that this may result in hearing loss, the physician should have a high index of suspicion, and early hearing screening should be performed in all children with achondroplasia (31). In one study, 60% of all achondroplastic children screened had hearing loss (32). Other causes of hearing deficit include ossicular chain abnormalities and neurologic causes, resulting from brain stem compression. Obstructive sleep apnea is found in three-fourths of children with achondroplasia when studied in the sleep laboratory (27,33). Treatment, if necessary, begins with adenotonsillectomy, and may progress to include more advanced procedures to enlarge the airway.

Respiratory complications are a greater risk in people with achondroplasia, due not only to upper airway obstruction, but also to decreased respiratory drive and decreased pulmonary function. Early correction of brain stem compression by decompression of critical foramen magnum stenosis may help preserve ventilatory potential. Spirometry shows that patients with achondroplasia also have decreased vital capacity (approximately 70% of predicted for height), although this is rarely a clinically limiting factor (34,35).

Enlargement of head circumference is the norm in individuals with achondroplasia. However, imaging studies have shown that the cerebrospinal fluid dynamics are variable. Examples of true megalencephaly, dilated ventricles without hydrocephalus, and communicating and noncommunicating forms of hydrocephalus have been identified. It is thought that intracranial venous pressure increases as a result of jugular foramen stenosis, causing arrested hydrocephalus without elevated intracranial cerebrospinal pressure. Treatment is not required. However, there are occasional patients who do appear to have clinical hydrocephalus, and it is recommended that head circumference should be measured throughout infancy and plotted against norms published for achondroplastic individuals (21). Those with progressive head enlargement should be seen by a neurosurgeon familiar with skeletal dysplasia, and they may benefit from treatment with a ventriculoperitoneal shunt.

Although patients with achondroplasia are among the most stable and healthy of those with skeletal dysplasias, nevertheless mortality rates are elevated in all age groups. The most common causes are sudden death in young infants, central nervous system events and respiratory problems in older children and young adults, and cardiovascular problems in older adults (28).

Orthopaedic Treatment

The major orthopaedic problems seen in children with achondroplasia include angular deformities of the knees, thoracolumbar kyphosis, and spinal stenosis. The former two are related to the pathogenetic factors of ligamentous laxity and muscular hypotonia. Genu varum is more com-

mon than valgus. Genu valgus almost never becomes severe or requires treatment. Varus may progress in some patients and appear to cause pain and difficulty walking. The fibula is long compared with the tibia, and it has been proposed that this differential growth between the long bones may be a cause of the deformity (15). However, the deformity involves the distal femur, as well as the proximal tibia. Often incomplete ossification of the epiphyses makes it impossible on plain films to determine the joint line, and to calculate the contributions of the tibia and the femur to the deformity. An arthrogram may be helpful in such cases. Along with the varus, there is often tibial torsion. Decision making about treatment is clouded by the fact that there are no natural history studies to suggest what degree of varus in young children is likely to progress, and what degree of varus, if any, is likely to cause degenerative problems in adulthood. The clinician should rely on the patient or parents for a history of walking difficulty or knee pain. Pain originating from the knee joint should be differentiated from the leg pain of spinal stenosis. In spinal stenosis, the aching is more diffuse and is relieved by decreasing the lumbar lordosis by flexing the lumbar spine, or "hunching over."

Treatment of genu varum, if it is severe, usually involves surgery. There is no evidence that bracing children with achondroplasia is effective. Their short thighs make it difficult to exert mechanical pressure unless the brace is extended to the waist. Lax ligaments make it difficult to transmit any force to the growth plates themselves. It does not seem wise to subject these children to unproven therapies, in light of all of the other medical problems they face. Tibial osteotomy may be done in any of several ways [6.1-6.4]: opening or closing, with internal or external fixation (36,37). Usually, a decision for surgery is not made until age 4 at the earliest. In skeletally immature patients, the osteotomy should be performed below the tibial tubercle. If internal tibial torsion exceeds 10 to 20 degrees, this should be corrected at the same time. Fibular shortening alone has been advocated as a treatment for young children with genu varum (15), but no long-term studies are available. Severe degenerative arthritis of the knee is not seen in adults with achondroplasia with any frequency.

Limb-lengthening for achondroplasia remains controversial, but is gradually gaining greater acceptance by patients and physicians. In contrast to most other skeletal dysplasias, conditions are favorable for extensive lengthening, in that the joints are normal and the musculotendinous units and nerves have excellent tolerance for stretch. Lengthening of 40 to 50% per segment has been reproducibly achieved for the femur and the tibia (38,39), with lengthening indices of between 30 and 40 days per centimeter. Care must be taken to minimize the complications of angular deformity and joint stiffness. The expected benefits of limb lengthening include increased function in the average-height world, improved self-image, and possibly a decrease in the lumbar

lordosis. The latter is purported to occur if the hip flexors are lengthened and an extension osteotomy is performed at the time of femoral lengthening (40). This combination of steps has been claimed to produce a relative pull of the pelvis into extension. However, most of these claims have not yet been clinically validated. The improved function has not been conclusively documented using standard outcome measures. This is important information to have, because lengthening may have an effect on muscle strength and joint status. Because most achondroplasts would need approximately 25 to 30 cm of additional height to enter the range of average stature, some do not quite achieve this goal. If the lower extremities are lengthened significantly, the humeri should be lengthened also to facilitate personal care. Six segments of major lengthening is a major time commitment, even when opposite limbs are lengthened at the same time. The total time required for such an undertaking may exceed 2 years, during a patient's critical years of adolescence or young adulthood. The effects on the lumbar spine require prospective study. The long-term effects of lengthening in this population also require study. In helping patients to come to a decision about whether limb-lengthening is personally appropriate, several discussions should be held with the involved family members to ensure that all the implications of the treatment plan have been discussed and that the information has been understood. Discussions with knowledgeable counselors, as well as with others with achondroplasia who have undergone lengthening, can be of help. In the proper setting, patients may be gratified with the results of lengthening.

Kyphosis

Kyphosis is present in most infants with achondroplasia, presumably due to low muscle tone, ligamentous laxity, and a large cranium. The kyphosis is noncongenital and is centered at the twelfth thoracic or first lumbar vertebrae. These vertebrae become wedge-shaped anteriorly, although this is a reversible phenomenon (Fig. 8-8). Most improve by the second or third year of life after walking begins and muscle strength increases (8,18,41,42). However, between 10 and 15% of patients retain kyphosis (Fig. 8-9), which can increase the risk of symptomatic stenosis through pressure on the conus, as well as the secondary lumbar lordosis that it induces. Therefore, treatment may be indicated at several phases of life: in infancy, to prevent development of kyphosis; in childhood, to assist in correction of those that do not correct with time; and in adulthood, to correct surgically those kyphoses that contribute to symptomatic spinal stenosis. Pauli et al. reported favorable results from early intervention (18). They recommend prevention of unsupported sitting, as well as keeping children from sitting up over 60 degrees, even with support, while kyphosis was present. We dispute the efficacy of this latter recommendation, because the drive to sit is irrepressible, and it seems to be more appropriate to provide earlier support, in the form of a firm-

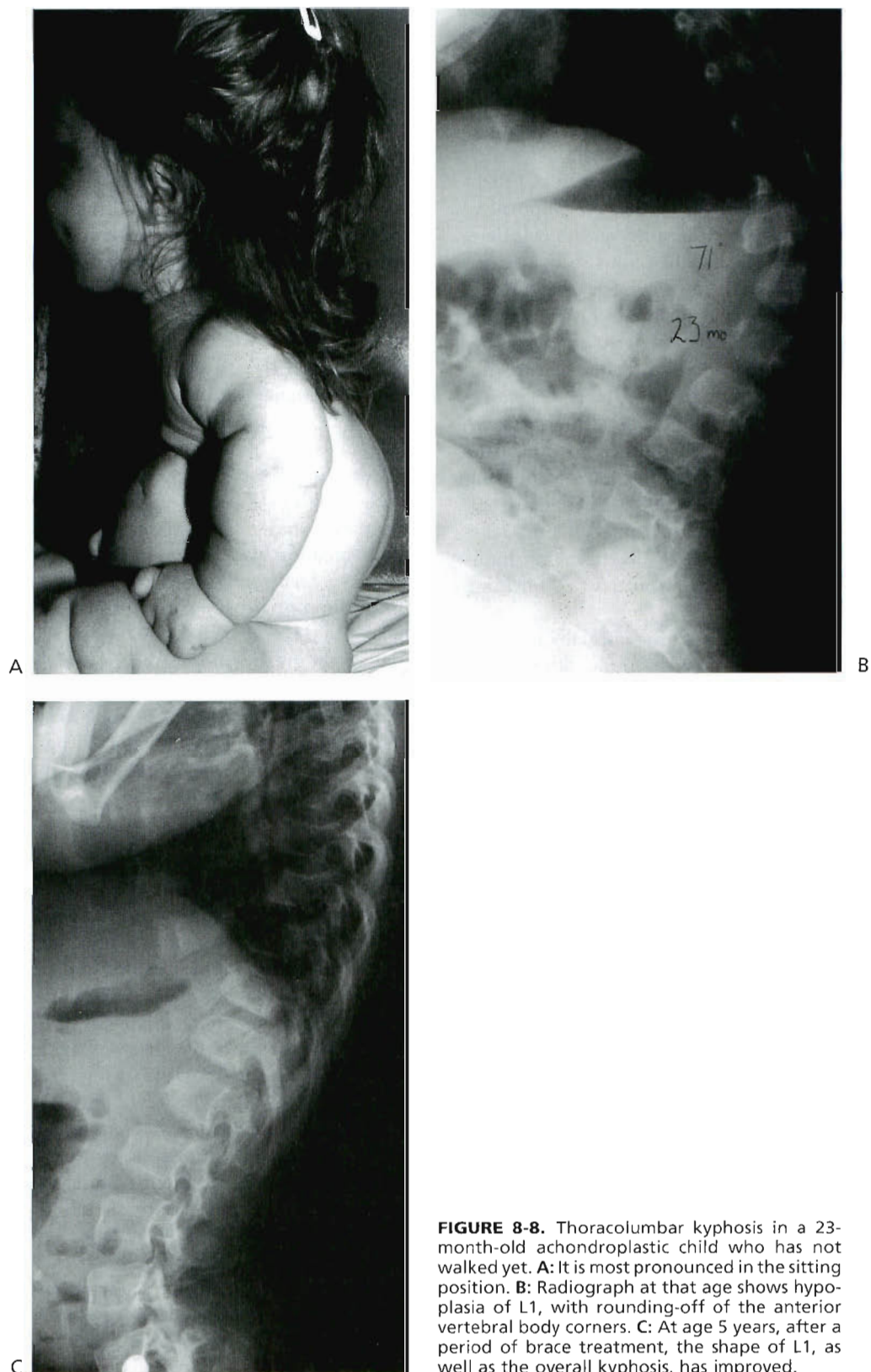

FIGURE 8-8. Thoracolumbar kyphosis in a 23-month-old achondroplastic child who has not walked yet. **A:** It is most pronounced in the sitting position. **B:** Radiograph at that age shows hypoplasia of L1, with rounding-off of the anterior vertebral body corners. **C:** At age 5 years, after a period of brace treatment, the shape of L1, as well as the overall kyphosis, has improved.

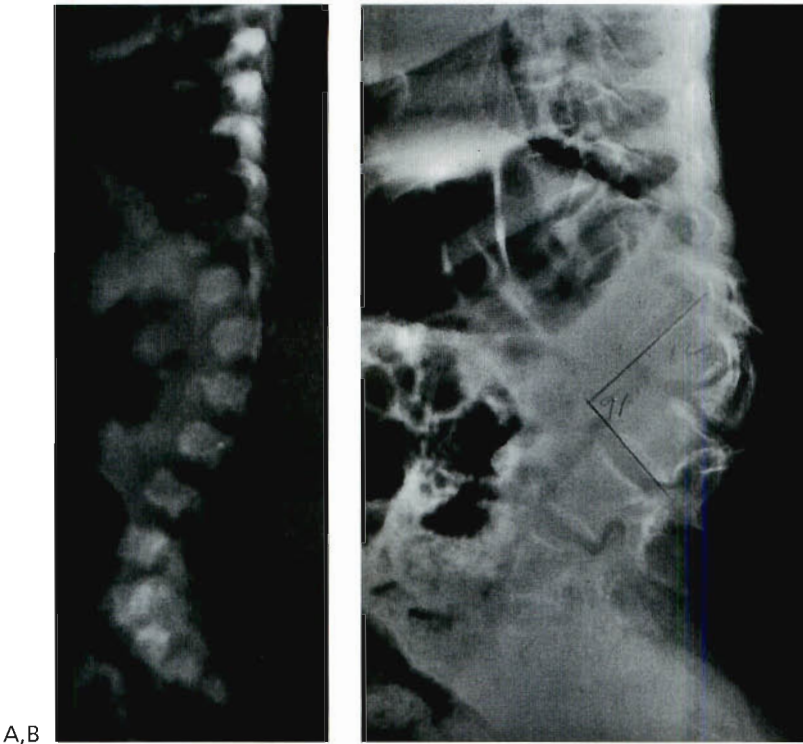


FIGURE 8-9. Thoracolumbar kyphosis has progressed in this patient, who had no medical follow-up between age 6 months (A) and 12 years (B). Although the latter figure resembles a congenital kyphosis, the former does not support it, and suggests that it was instead caused by compression over time.

backed chair, when sitting begins. Bracing is indicated if the kyphosis is accompanied by significant and progressive vertebral wedging, if it does not reduce below 30 degrees on prone hyperextension radiographs, or if it does not resolve by the age of 3 years. We prefer the use of a modified Knight brace; a double-upright thoracolumbosacral orthosis that has an adjustable posterior pad under the apex of the kyphosis and that does not constrain the thorax laterally. This should be worn full-time during waking hours until resolution of the vertebral wedging occurs, and a lateral film, taken while the patient is out of the brace, shows no significant kyphosis; then it should be gradually weaned. For children who fail treatment with a brace, we have had some success with a hyperextension cast incorporating the thighs, changed until elimination of the kyphosis in cast is achieved, and worn for several months, until the same end-point is achieved. This has the advantage of not being removable, and, consequently, a more sustained corrective force is applied to the spine. For patients in whom this therapy also fails, two options exist: prophylactic posterior fusion during childhood, or observation, with stabilization or correction of kyphosis only in those requiring decompression for spinal stenosis. Although there are no data directly comparing the two approaches, the former may be preferable for those with severe kyphosis because of the difficulty and risk of correcting a large kyphosis at an older age in these patients (43).

Stenosis

Spinal stenosis is the most common serious problem in individuals with achondroplasia. Most present with symptoms of neurogenic claudication. However, a small number develop muscle weakness alone, some of which is detected only on routine physical examination, thus emphasizing the importance of periodic neurologic screening. The neurologic deficit may involve upper or lower motor neuron signs, or both. Symptomatic stenosis usually develops in the third decade, although it has been noted as early as age 11 years. Diagnosis is best made by myelography performed through a cervical puncture with CT. This is, in many cases, more sensitive and specific than magnetic resonance imaging (MRI), to evaluate the site of block in a canal that is diffusely narrow. Spinal decompression is usually indicated as soon as the diagnosis has been confirmed. This decompression should extend from several levels above the myelographic block, down to the second sacral vertebra (44,45). The laminectomy should be done by a surgeon experienced in this procedure and should involve minimal use of instruments, such as rongeurs or probes, inside the canal. The laminae to be removed should be thinned with a high-speed bur. The dura often adheres to the lamina, and the incidence of dural tearing is high. The nerve roots, which are relatively long, often protrude through any hole in the dura. Careful foraminotomy should be done if there are signs of root stenosis.

HYPOCHONDROPLASIA

Etiology and Pathogenesis

Hypochondroplasia is an autosomal dominant disorder that has phenotypic and genotypic similarities to achondroplasia, but the two disorders are distinct, nevertheless. There are no known instances of achondroplasia and hypochondroplasia existing in the same family, except by marriage. The mutation causing most cases of hypochondroplasia has been found to be in the gene for fibroblast growth factor receptor-3 on the short arm of the fourth chromosome, just as in achondroplasia and thanatophoric dysplasia (9,46,47). In all these conditions, the mutation results in increased activation of factors that slow cell growth (48). In the case of hypochondroplasia, the mutation arises in a different portion of the gene (the tyrosine kinase domain, in contrast to the transmembrane domain in achondroplasia). However, there is more heterogeneity in this condition than in achondroplasia: between 30 and 40% of patients with hypochondroplasia have mutations in a different gene, instead. As mentioned earlier, almost all patients with achondroplasia have a uniform mutation in the same gene. This finding probably accounts for the clinical variability seen in hypochondroplasia. There does not appear to be an increased paternal age in fathers of children with hypochondroplasia.

Clinical Features

This is one of the most subtle of the skeletal dysplasias. The clinical abnormalities in hypochondroplasia are rather mild, and may go unnoticed until the pubertal growth spurt in some cases. The eventual height ranges from 118 to 160 cm (13,49). Head circumference is normal and frontal bossing is mild to absent. Because of the absence of obvious midface hypoplasia, these patients do not have a distinctive appearance. The limbs are not short in a rhizomelic pattern, but rather in a mesomelic one. Body proportions are closer to normal. The trident hand characteristic of achondroplasia is not seen in hypochondroplasia. Thoracolumbar kyphosis is also not a feature of this condition. Varus angulation of the knees is mild, and may resolve with growth. Joint laxity is mild. Spinal stenosis has been reported in about one-third of patients (13), but it is usually mild and does not require surgical treatment. Mental retardation has been reported in some of these patients.

Radiographic Features

Radiographic findings, as with clinical findings, are generally subtle. Hall and Spranger have proposed primary and secondary radiographic criteria (13,50). The primary criteria are narrowing of the lumbar pedicles, square iliac crests, short, broad femoral necks, mild metaphyseal flaring, and brachydactyly. Secondary criteria are shortening of the lum-

bar pedicles, mild posterior scalloping of the vertebral bodies, and elongation of the distal fibula and ulnar styloid. The pelvis has sciatic notches that are normally wide, in contrast to the narrowed notches seen in achondroplasia (51).

Differential Diagnosis

Although generally a mild skeletal dysplasia, hypochondroplasia has more variation than achondroplasia in its severity. In its more extreme form, it may resemble achondroplasia. Conversely, it may be mistaken for constitutionally short stature. It may also resemble Schmid metaphyseal dysplasia, in its mild short stature and mild genu varum. Dyschondrosteosis also produces mild short stature, but it is distinguished by Madelung deformity and triangular carpal bones.

Treatment—General and Orthopaedic

People with hypochondroplasia rarely have serious medical problems. The response to growth hormone administration in pharmacologic doses has been shown to persist up to 4 years, although decreasing with time. Studies with follow-up to maturity are still needed, but this treatment remains an option (30,52,53). Genetic counseling should be given about pattern of transmission for this autosomal dominant condition. If a female patient becomes pregnant, extra vigilance should be exercised for possible disproportion during childbirth.

Limb-lengthening is usually as successful as it is in achondroplasia in achieving significant gains without undue risks, because the joints are sound and the muscles tolerate lengthening (54). Because these patients are generally about 20 cm taller than patients with achondroplasia, limb-lengthening may place them within the normal range of stature. This is a personal decision for patients, who may benefit from talking to others who have considered it or undergone it. Long-term follow-up is still needed to determine the effects on the joints.

METATROPIC DYSPLASIA

The term “metatropic dwarfism” comes from the Greek word *metatropos*, or “changing form,” because patients with this condition appear to have short-limb dwarfism early in life, but later develop a short-trunk pattern as spinal length is lost to the development of kyphosis and scoliosis. The condition has been likened to Morquio syndrome, due to the enlarged appearance of the metaphyses and the con- tructures (55).

It is a rare condition, which may be inherited in an autosomal dominant or recessive manner. The cause of this dysplasia has not been elucidated. However, histologic abnor-

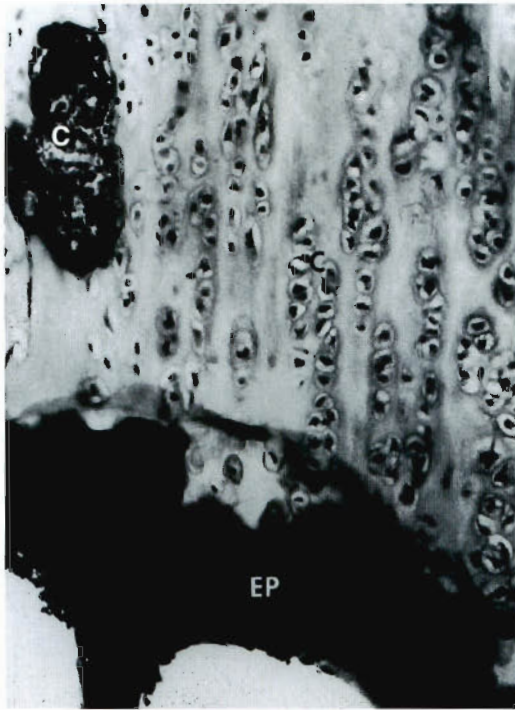
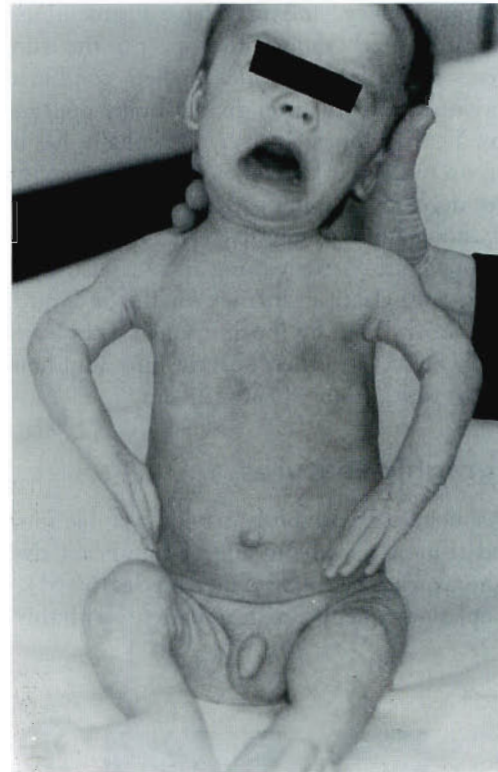

FIGURE 8-10. Histology of the growth plate in metatropic dysplasia, showing relatively normal columns of proliferating chondrocytes (C), but absence of the hypertrophic or degenerating zones, as well as a "seal," or bony end plate (EP), over the metaphysis. (From ref. 56, with permission.)

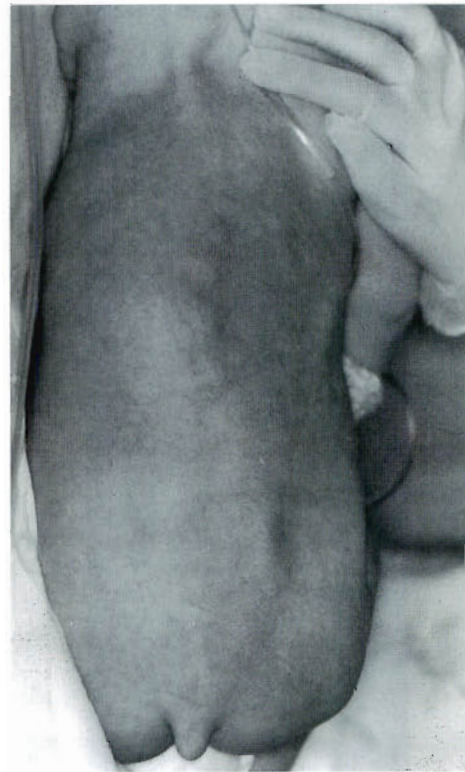malities of the growth plate have been studied and appear to be characteristic, as shown in the study published by a group led by Boden (56). The physis shows relatively normal columns of proliferating chondrocytes. However, there is an abrupt arrest of further development, with absence of a zone of hypertrophic or degenerating chondrocytes. Instead, there is a mineralized seal of bone over the metaphyseal end of the growth plate (Fig. 8-10). The perichondral ring remains intact, and circumferential growth was preserved. This uncoupling of endochondral and perichondral growth appears to account for the characteristic "knobby" metaphyses. Further understanding of the defect in this disorder will undoubtedly shed light on the normal maturation of the physis.

Clinical Features

One of the most characteristic features of this condition is the presence of the "coccygeal tail," a cartilaginous prolongation of the coccyx that is not present in other dysplasias (Fig. 8-11). It is usually a few centimeters long and arises from the gluteal fold. The facial appearance is not determined by the condition, although there may be a high arched palate. The sternum may display a pectus carinatum, and the limbs have flexion contractures of up to 30 to 40



A



B

FIGURE 8-11. A 1-year-old infant with metatropic dysplasia, illustrating knee-flexion contractures, "bulky" metaphyses (A), and a coccygeal tail (B).

degrees from infancy, and may have ligamentous laxity. They appear relatively short with respect to the trunk. The metaphyses are enlarged, which, when combined with underdeveloped musculature, gives a bulky appearance to the limbs. Ventriculomegaly or hydrocephalus has been reported in up to 25% of patients (57). Upper cervical spine instability develops in some patients. Scoliosis develops in early childhood and is progressive (58,59). Inguinal hernias are common. Some restrictive lung disease is usually present, which may cause death in infancy for the one-third of patients who are afflicted by the autosomal recessive form of the disease. However, others survive into adulthood, and adult height varies from 110 to 120 cm.

Radiographic Features

Prenatal sonographic diagnosis may be possible in the first or second trimester, with finding of significant dwarfism, narrow thorax, and the enlarged metaphyses (60,61). Odontoid hypoplasia frequently exists in patients with this condi-

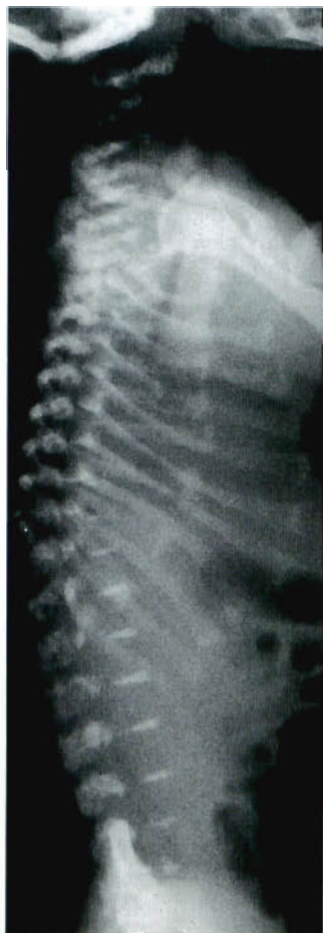

FIGURE 8-12. Newborn with metatropic dysplasia. Note platyspondyly with delayed vertebral ossification, and flared ribs. (Courtesy of Judy Hall, Vancouver, British Columbia.)

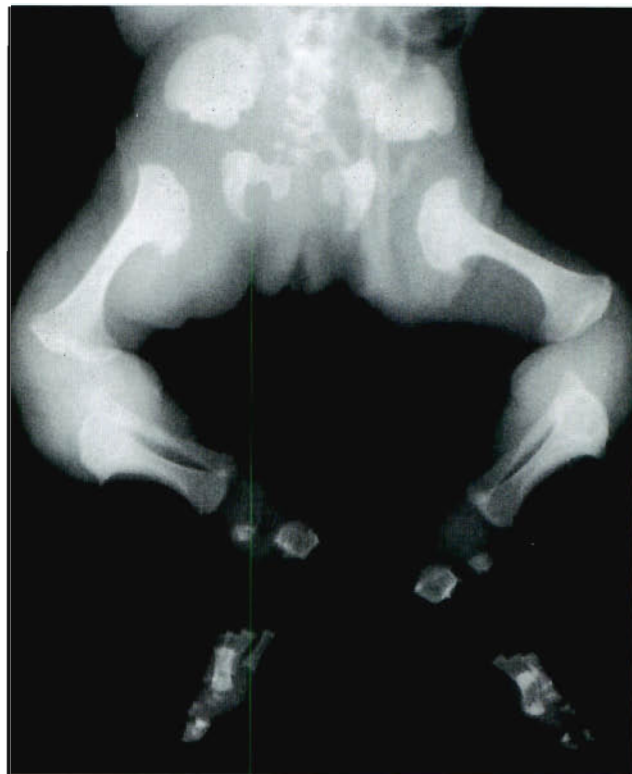

FIGURE 8-13. Newborn with metatropic dysplasia. The diaphyses are short and the metaphyses are broad, flared, and their appearance has been likened to dumbbells. The iliac wings are flared, and the acetabulae deep. (Courtesy of George S. Bassett, M.D.)

tion, as in many patients with skeletal dysplasia. In infancy, the vertebrae are markedly flattened throughout the spine, but normal in width. Kyphosis and scoliosis are almost always seen. The ribs are short and flared, with cupping at the costochondral junctions (Fig. 8-12).

The epiphyses and metaphyses are enlarged, giving the long bones an appearance that has been likened to that of a barbell (Fig. 8-13). The epiphyses have delayed and irregular ossification. Protrusio acetabuli has been reported. Genu varum of mild to moderate degree usually develops. Degenerative changes of major joints often occurs in adulthood.

Treatment/Orthopaedic Considerations

Respiratory problems often dominate infancy, and may be fatal. They result from the small thorax, and may also, in part, result from cervical instability. These children need to be observed on a follow-up basis at a center where pediatric pulmonary expertise is available. The neck should be imaged early with lateral flexion–extension radiographs. Because cervical quadriplegia has been reported from falls, fusion is recommended if the translation is greater than about 8 mm, or neurologic compromise is present. If a patient has atlan-

roaxial instability between 5 and 8 mm but is neurologically intact, MRI should be obtained in flexion and extension. Fusion should be recommended if cord compromise is seen [2.17].

The patients should be examined early for spinal curvature. There is no documentation of the efficacy of brace treatment for this condition. It may be tried in small curves (under 45 degrees) in young patients or those who need support to sit, but I do not recommend it for large curves, even if the patients are young and still actively growing. Spinal fusion for scoliosis may be advisable in patients with more severe curves. Deciding exactly when to intervene is more of an informed judgment than a science. This author recommends observation and accepting a larger curve threshold for surgery in younger patients (under age 10) to document medical health, and to have a chance of bone size adequate for instrumentation. However, progressive sharp angular kyphosis with paraparesis may occur in metatropic dysplasia, and should be treated early with fusion if, in the surgeon's estimation, neurologic compromise is a risk. When surgery is undertaken, anterior as well as posterior fusion is recommended if the patient is able to tolerate it, because of the high rate of pseudarthrosis in this condition (5). Given that the curves are often rigid, obtain only the amount of correction that can be achieved safely. Halo-cast immobilization is an option if patient size, stenosis, or poor bone density make instrumentation inadvisable.

CHONDROECTODERMAL DYSPLASIA

Disproportionately short stature and abnormalities in the mouth, teeth, limbs, and heart characterize this uncommon skeletal dysplasia, also known as Ellis-van Creveld syndrome (62). It is transmitted as an autosomal recessive condition, and is therefore more common in closely knit populations, most notably in the Pennsylvania Amish community. The basic defect is not known, but the chromosomal defect has been localized to the short arm of the fourth chromosome (63,64).

Clinical Features

About one-third of patients with this syndrome die in the neonatal period (the most severely affected age group). The cardiac defects are present in about one-half of patients, and most commonly consist of atrial septal defects or single atrium. As the name of this disorder would suggest, the teeth are also abnormal, both appearing and being lost early. The nails are hypoplastic. Urologic features include hypospadias and epispadias. The skeletal features are shortening of the middle and distal parts of the extremities (acromesomelic) in combination with a normal spine (65). This distal shortening is the opposite of that seen in achondroplasia (66–68). The chest is narrow. The ligaments are lax, and there is often sig-

nificant genu valgum. Rotational abnormalities often accompany this, such as external rotation of the femur and internal rotation of the tibia. The combination of these findings can give the limb an appearance of a flexion contracture, whereas in fact the problem is really valgus. Postaxial polydactyly is quite common, usually in the hands, and much less commonly in the feet.

Radiographic Features

The ribs are short and the chest is narrow. Bilateral knee valgus is usually relatively symmetric. It is partially due to uneven growth of the proximal tibial epiphysis, with the lateral side being underdeveloped (Fig. 8-14). An exostosis may arise medially from the proximal tibial metaphysis. The acetabulae have spike formation at the medial and lateral edges. The capital femoral epiphyses ossify early, and the greater trochanteric apophyses are pronounced. The wrists display fusion of the capitate and the hamate, and sometimes other bones. The carpal bones have delayed maturation but the phalanges are accelerated.

Orthopaedic Management

Reconstruction of the poly/syndactyly, performed when the cardiac status is stable, is usually successful. The angular and rotational disturbance of the lower extremities is usually addressed when it becomes clinically significant or rapidly progressing, usually at about 20 degrees of valgus (69). Unfortunately, bracing seems to have little or no effect, and

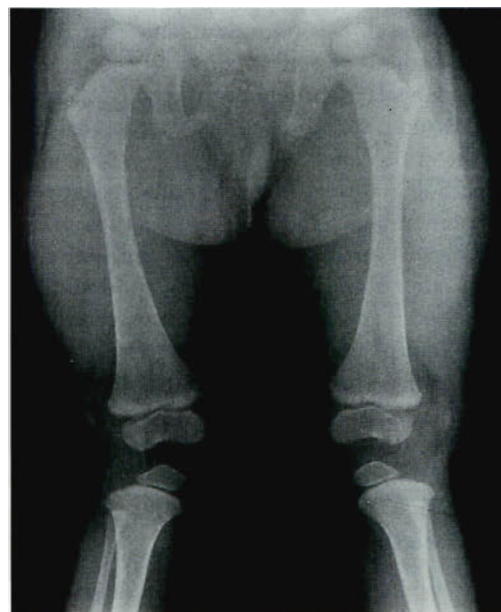

FIGURE 8-14. Lower extremities of a 5-year-old child with chondroectodermal dysplasia, demonstrating the characteristic pronounced hypoplasia of the lateral proximal tibial epiphysis with marked genu valgus. (Courtesy of Michael Ain, M.D.)

surgery remains the mainstay of treatment. Careful preoperative planning is needed, taking into account deformity at all locations from the proximal femur to the ankle and aiming to correct the mechanical axes and the malrotation with as few procedures as possible (70). Usually external fixation is the most expeditious way of handling the correction. If the deformity is one of simple valgus, simple medial hemi-epiphyseal stapling may be adequate.

DIASTROPHIC DYSPLASIA

Diastrophic dysplasia (DD) is perhaps the dysplasia with the most numerous, disparate, and severe skeletal abnormalities. The term “diastrophic” comes from a Greek root meaning “distorted,” which aptly describes the ears, spine, long bones, and feet. Before the current level of understanding of the skeletal dysplasias was developed, an early authority referred to this condition as “achondroplasia with clubbed feet” (71,72). Certainly the abnormalities are much more extensive than that.

The disorder is autosomal recessive and is extremely rare, except in Finland, where between 1 and 2% of the population are carriers, and there are over 160 people known to be affected due to an apparent founder effect. The defect is on chromosome 5 in the gene that codes for a sulfate transporter protein (aptly named “diastrophic dysplasia sulfate transporter”) (73,74). This protein is expressed in virtually all cell types. Decreased content of sulfate in cartilage from patients with DD has been demonstrated (75). It is presumed that a defect in this gene leads to undersulfation of proteoglycan in the cartilage matrix. If one considers proteoglycans to be the “hydraulic jacks” of cartilage at the ultrastructural level, it is understandable that there should be such impairment of performance of physeal, epiphyseal, and articular cartilage throughout the body. Achondrogenesis types 1B and 2 are more serious disorders causing mutations on the same gene.

Histopathology reveals that chondrocytes appear to degenerate prematurely, and collagen is present in excess (76,77). Tracheal cartilage has some of the same abnormalities seen in other cartilage types. This still does not explain some of the focal, specific malformations seen in DD, such as proximal interphalangeal joint fusion in the hands, short first metacarpal causing hitchhiker thumbs, or cervical spina bifida. Further work on the role of this sulfate transporter on skeletal growth and development must be done to explain these curious findings.

Clinical Features

Prominent cheeks and circumoral fullness gave rise to the previously used name “cherub dwarf” (Fig. 8-15). The nasal bridge is flattened. Up to one-half of patients have a cleft palate, which may contribute to aspiration pneumonia (76). The cartilage of the trachea is abnormally soft, and its

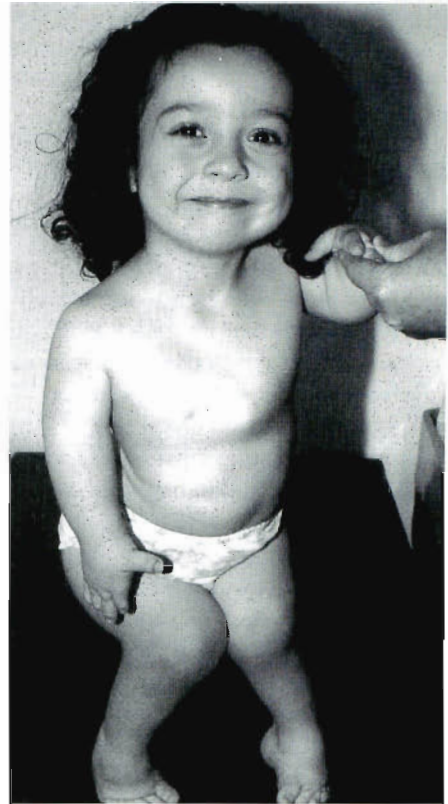

FIGURE 8-15. A 5-year-old girl with diastrophic dysplasia. Note prominent cheeks, circumoral fullness, equinovarus feet, valgus knees with flexion contracture, and abducted or “hitchhiker” thumbs.

diameter may be narrowed. The ear is normal at birth, but develops a peculiar acute swelling of the pinna at 3 to 6 weeks in 80 to 85% of cases. The reason for this event and this timing is not known. The cartilage hardens in a deformed shape—the “cauliflower ear,” which is one of the pathognomonic features of this dysplasia.

Patients with diastrophism have a slightly increased (approximately 5%) perinatal mortality as a result of respiratory problems, especially aspiration pneumonia and tracheomalacia.

The skeleton displays abnormalities from the cervical spine down to the feet (78). The posterior arches of the lower cervical spine are often bifid. There are no external clues to this underlying abnormality, which is occult. Cervical kyphosis is seen in one-third to one-half of patients (6,79). This may be present in infancy, and its course is variable. Spontaneous resolution has been reported in a number of patients, even with curves of up to 80 degrees (80,81) (Fig. 8-16A and B). However, others progress, and several reports of quadriplegia from this deformity exist (6,82). Scoliosis develops in at least one-third of patients (79), but many curves do not exceed 50 degrees. Tolo and Kopits state that the scoliosis may be one of two types:

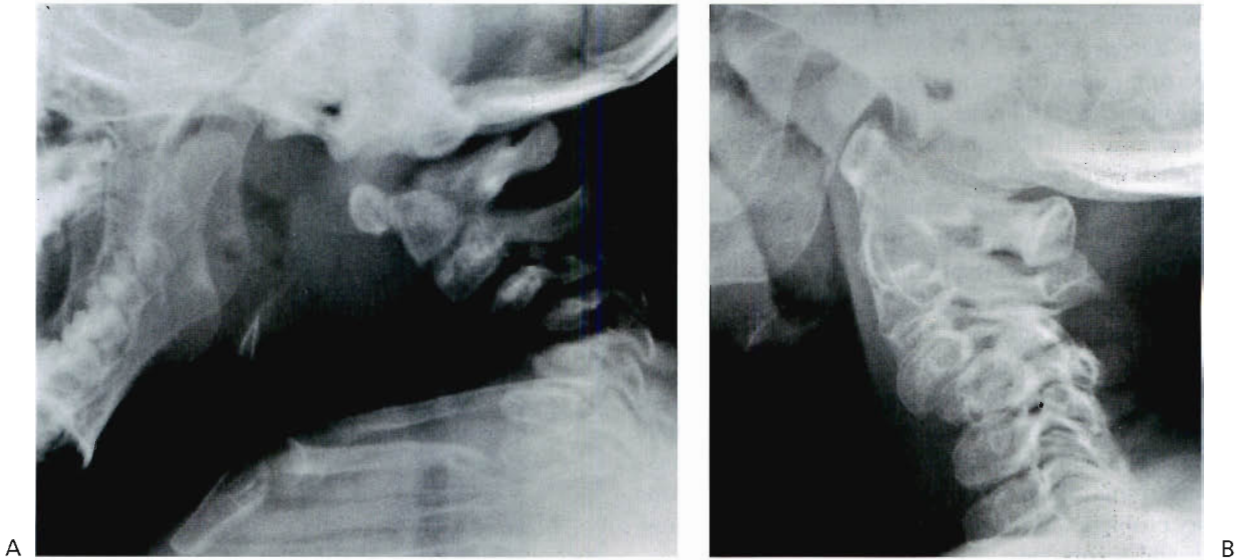


FIGURE 8-16. Cervical kyphosis, in a 1-year-old child (A) with diastrophic dysplasia, is pronounced, with marked deformity of C4. Results of findings on neurologic examination are normal. Four years later, it is markedly improved without any intervention (B).

idiopathic-like or sharply angular (83). The sharply angular type is usually characterized by kyphosis at the same level as the scoliosis. Spinal stenosis is not common, in contrast to achondroplasia. Most patients have significant lumbar lordosis, likely to compensate for the hip flexion contractures in diastrophism.

The extremities display rhizomelic shortening. The shoulders may be subluxated, as may the radial heads (possibly because of ulnar shortening). The hands are short, broad, and ulnarly deviated. The hitchhiker thumb is due to a short, proximally placed, often triangular, first metacarpal that may be hypermobile. This finding is seen in up to 95% of diastrophic persons. The proximal interphalangeal joints of the fingers are often fused (sympalangism).

The hips maintain a persistent flexion contracture. The proximal femoral epiphyses progressively deform, and even subluxate in some patients. Epiphyseal flattening and hinge abduction develop in many patients (84). Arthritic changes develop by early to middle adulthood. The knees usually have flexion contractures, which result from a combination of ligamentous contracture and epiphyseal deformation (Fig. 8-17). Excessive valgus is also common. As much as one-fourth of patients have a dislocated patella. Degenerative joint disease of the hips and knees develops in early to mid adulthood.

The feet of diastrophic persons are commonly described as being clubfeet, but many different variations exist. In the large Finnish series of Ryoppy, the most common finding was adduction and valgus (seen in 43%), followed in prevalence by equinovarus in 37%, then by pure equinus. The great toe may be in additional varus, beyond the degree

commonly seen in idiopathic clubfoot. This is analogous to the hitchhiker thumb. The navicular may not be so medially displaced as in typical clubfoot. The foot deformities are very stiff and involve bony malformations, as well as contracture and malalignment. These feet are as difficult to correct as any type of clubfoot.

There is great variation in severity of DD. Height is

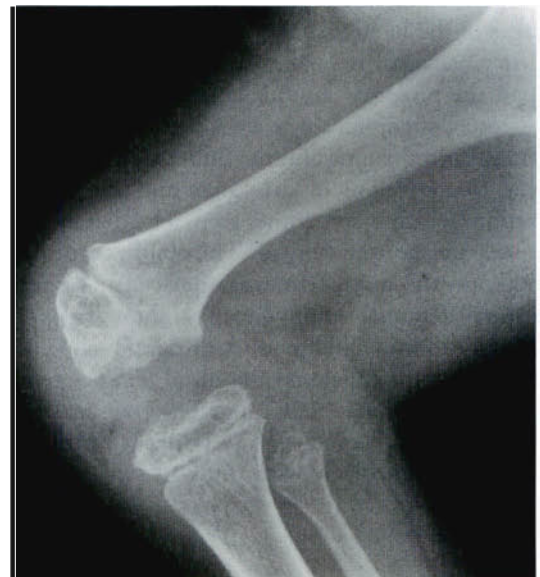

FIGURE 8-17. The joint contracture in diastrophic dysplasia is accompanied by epiphyseal deformity, as this knee radiograph illustrates.

related to overall severity of involvement, with taller people being less severely affected (85,86). These are part of the same spectrum of disorder. Growth curves for persons with DD are available (87). The median adult height is 136 cm for male patients and 129 cm for females (88). Therefore, people with achondroplasia are shorter in stature, and are approximately equal to those with pseudoachondroplasia and spondyloepiphyseal dysplasia congenita. The pubertal growth spurt is diminished or absent, so the overall growth failure is progressive, suggesting that the physes are unable to respond to normal hormonal influences.

The life expectancy of diastrophic persons is not significantly reduced, except for the small number of patients (approximately 8%) who die in infancy from respiratory causes, or during childhood from cervical myelopathy. Patients with severe spinal deformities are more prone to develop respiratory problems. Many patients are able to lead productive work and family lives.

Radiographic Features

Prenatal diagnosis may be made by sonography in the second trimester with demonstration of long-bone measurements at least three standard deviations below normal, as well as clubfeet and adducted thumbs. In infancy, calcification develops in the pinna of the ear, and later in the cranium and the costal cartilages. The vertebrae are poorly ossified. The lower cervical spine may demonstrate kyphosis. MRI may be necessary to judge the severity of this in relation to the spinal cord. Only one case of atlantoaxial instability has been reported in this condition. The interpediculate distances narrow only slightly at descending levels of the lumbar spine, unlike achondroplasia. Scoliosis may occur in the form of either a sharp, angular curve or a gradual, idiopathic-like one (Fig. 8-18).

Images of the hand are characterized by several findings. The first metacarpal is small, oval, and proximally placed. Although the proximal interphalangeal joints of the digits are ankylosed, a radiolucent space is present early on, which later fuses. Both the ulna and the fibula are shortened, contributing to the valgus of the knees and the radial head subluxation, which is sometimes seen. The diaphyses of the long bones are short and broad. The epiphyses of both the proximal and the distal femur are delayed in appearance. The capital femoral epiphyses may show signs of osteonecrosis well into childhood. Arthrograms show flattening of both the proximal and the distal femur, accounting for the stiffness observed clinically. The proximal femur is usually in varus, but, even so, hip dysplasia or subluxation may develop progressively with time.

Treatment

Cervical Spine

A neurologic examination should be performed periodically on all children. A lateral cervical radiograph should be per-

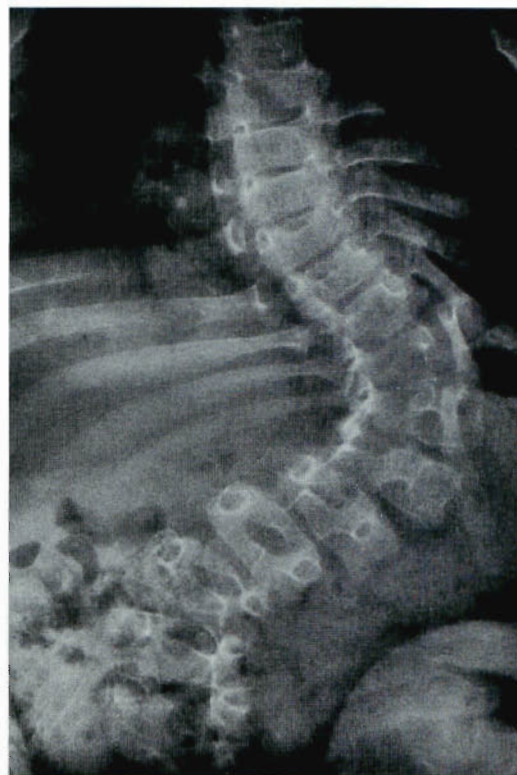

FIGURE 8-18. Significant scoliosis may occur early in diastrophic dysplasia, as in this 6-year-old child.

formed during the first 2 years of life, as well. If cervical kyphosis is noted, the patient should be followed with clinical and radiographic examinations every 6 months. If the kyphosis is nonprogressive, and there is no neurologic deficit, it should only be observed. If the kyphosis progresses, but there is no neurologic deficit, bracing may be employed. Successful control of cervical kyphosis by full-time use of the Milwaukee brace was reported by Bethem et al. (6,13). If the curve continues to progress despite the brace, or a neurologic deficit occurs, posterior fusion should be performed. The surgeon should be cognizant of the bifid lamina during the exposure. Instrumentation is usually technically not possible. If adequate bone graft is not available from the iliac crests, it may be taken from the proximal tibia(s) or other sources. Immobilization by a halo and vest is needed for 2 to 4 months. The pins should be inserted at a lower torque than in adults (4 inch-pounds), and the surgeon may elect to use a slight distractive moment and a slight posterior translation of the head. A pad may be used behind the apex of the kyphosis to help keep it from increasing. If neurologic deficit is present along with the curve, MRI in a neutral position and in extension will help to determine the degree of anterior compression and the type of procedure required. If there is severe anterior cord compression, corpectomy and strut graft may be indicated. Posterior fusion is indicated as well.

Thoracolumbar Spine

Scoliosis affects about one-half of diastrophic patients but often begins early in childhood. The success of bracing in preventing or slowing curve progression has not been documented. It seems reasonable to offer it to patients, if the curve is less than 45 degrees, but to discontinue it for those in whom there is no apparent benefit. Large curves often continue to progress in adulthood (79). Surgery has a role in preventing progression for curves over about 50 degrees [➔2.1-2.5]. Posterior fusion is the mainstay of treatment (83). For younger patients, or those whose associated kyphosis is over 50 degrees, anterior fusion may be added as well. Instrumentation should be used carefully, bearing in mind the short stature, the stiffness of the spine, and the slightly diminished bone density. Small hooks may be used if needed (83). Spinal stenosis is seen much less commonly than in achondroplasia, but it may occur if degenerative changes are superimposed on the baseline canal size. Mild stenosis may be masked in some cases by the patients' relative inactivity.

Hips

Hip flexion contractures and knee flexion contractures should be assessed together. If they are significant (over 40 degrees) release may be considered if an arthrogram shows no epiphyseal flattening and good potential for gaining range of motion. If there is epiphyseal flattening it is probably better to avoid releases, given that recurrence is likely. Hip dysplasia is often progressive because of deformation of the abnormal cartilage under muscle forces and body weight. No long-term series has been done to show the ability of surgery to arrest this process. Therefore, the surgeon should use individual judgment as to whether an acetabular augmentation or femoral osteotomy will help provide good coverage without restricting range of motion or function. Conservative treatment cannot be faulted in this condition.

Degenerative changes in the hip are one of the main reasons for decreasing walking ability in those with diastrophism. Hip joint arthroplasty is an option, usually after the patient reaches the midthirties. Small or custom components are needed. The femur often has an increased anterior bow, probably in compensation for the hip flexion contracture. The isthmus of the femur is only 13 mm on average. Contracture release may be needed along with the arthroplasty, but femoral nerve palsy may follow if it is done extensively. Autograft augmentation of the acetabulum is often necessary. The largest series of hip arthroplasty in this condition is by Peltonen et al., with 15 hips in 10 patients who had a mean age of 37 years (89). Three patients required femoral osteotomy or trochanteric transfer. Two had femoral palsies, which recovered. Hip range of motion was increased slightly.

Knees

The knees in diastrophism usually lack both flexion and extension. Complete correction of knee flexion contractures is prohibited by the shape of the condyles, which may be triangular, creating a bony block to flexion, extension, or both. Residual contracture at maturity may be diminished by distal femoral osteotomy. Patellar subluxation is present in one-fourth of diastrophic persons; correcting these may help improve extensor power.

Feet

Although the classic foot deformity in this condition is equinovarus, other types may be seen, including isolated equinus, forefoot adduction, or valgus. The feet are rigid, and cast treatment is usually futile. A plantigrade foot is the goal of treatment. Surgical treatment should be deferred until the feet are large enough to work on (usually after 1 year), and the neck is safe. If soft tissue release is performed, it should be as extensive as needed to correct the deformity [➔7.1]. Sometimes, this requires release of the posteroinferior tibiofibular ligament to bring the dome of the talus into the mortise. Partial recurrence of deformity is common (72), and salvage procedures include talectomy, talocalcaneal decancellation, or arthrodesis (in the older child).

KNEIST DYSPLASIA

Kneist syndrome is a profoundly affecting skeletal dysplasia characterized by typical facial features, and large, stiff joints with contractures (90,91). It has been likened by some to metatropic dysplasia, because of the enlarged stiff joints, and to spondyloepiphyseal dysplasia, because of the generalized disorder of both spinal and epiphyseal growth. It is now known to be due to a defect in type II collagen, the predominant protein of cartilage. Most mutations are between exons 12 and 24 of the *COL2A1* gene. Although numerous different mutations have been described, their phenotypic similarity results from the fact that they are all in this region, and that they tend to occur at splice sites, resulting in exon skipping, and thus in shorter type II collagen monomers (92,93). These combine with normal-length monomers from both ends to form heterotrimers with the missing segment excluded from the helix (94). This allows the mutation to express autosomal dominant behavior, in that one copy of the mutant allele disrupts the structure of the entire cartilage matrix. Most patients are affected as a result of a new mutation.

Pathologically, the cartilage has been termed "soft and crumbly," with a "Swiss-cheese" appearance (95). Scanning electron microscopy of cartilage demonstrates deficiency and disorganization of cartilage fibrils, and large, open cyst-like spaces.

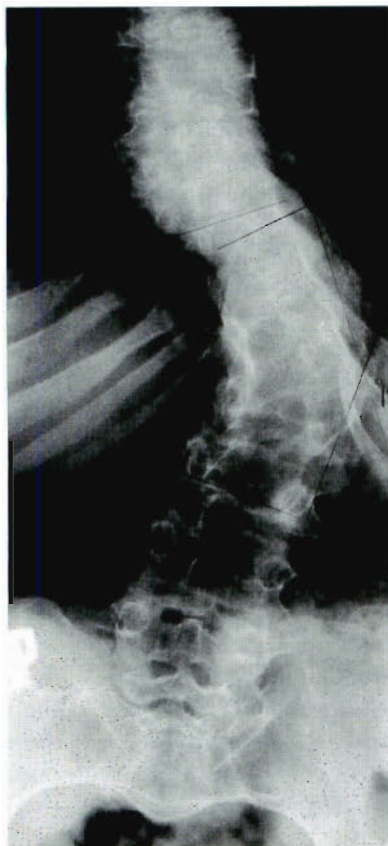

FIGURE 8-19. Scoliosis is common in Kneist dysplasia, but rarely severe enough to require intervention.

Clinical Features

As with many dysplasias, patients with this condition have a somewhat characteristic facial appearance, with prominent eyes and forehead and a depressed midface. Many patients have a cleft palate. The sternum may be depressed, and the

trunk is broad, unlike findings with metatropic dysplasia. However, as with that condition, the joints appear enlarged because of broad metaphyses of the long bones, and they are stiff—often lacking both extension and full flexion. This stiffness affects the hands as well as the large joints. Motor development may be delayed because of contractures or myelopathy. Intellectual development, however, is normal. Inguinal and abdominal hernias are also common.

Respiratory impairment may occur because of aspiration, which is made more likely by cleft palate or tracheomalacia. As with many other patients with skeletal dysplasia, otitis media may be a recurrent problem, and may even contribute to hearing impairment. Myopia is common, and retinal detachment and glaucoma may cause severe visual loss, as in Kneist's original patient, who became blind during adolescence (91). Adult height ranges from 106 to 145 cm.

Radiographic Features

There is osteopenia of both spine and extremities, perhaps as a result of disuse. All regions of the spine are affected, from atlantoaxial instability (due to odontoid hypoplasia) to hypoplasia of the cervical vertebrae and flattening of all vertebrae (96). The vertebral bodies have vertical clefts (97). There is kyphosis, and often mild scoliosis (Fig. 8-19), in the thoracolumbar spine. The femoral necks, as with all metaphyses, are short and broad. There are irregular calcifications in the epiphyseal and metaphyseal regions. Valgus deformities often develop in the distal femur or proximal tibia. The epiphyses are flattened and irregular (Fig. 8-20). Degenerative arthritis of the major weightbearing joints develops early, even in the second decade of life.

Orthopaedic Treatment

It is important to rule out cervical instability when the diagnosis is first made, when intubation is planned, or with

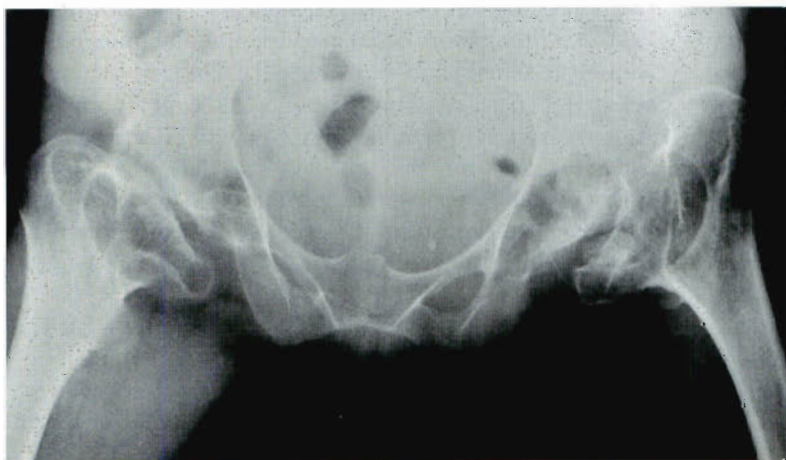

FIGURE 8-20. Like most epiphyses in Kneist dysplasia, the femoral heads are flattened and irregular. Also note the short, broad femoral necks.

any loss of milestones or of strength or coordination (98). Although kyphoscoliosis should be monitored, efficacy of brace treatment has never been studied, and remains doubtful. Surgery for spinal deformity is not often needed. Physical therapy has been recommended to increase joint mobility, but the efficacy of this too has not been proven.

Osteotomies about the hip or the knee may be helpful in certain circumstances. Osteotomy of the proximal femur may help improve joint congruity, if hinge abduction is developing [4,5]. An arthrogram in different positions may aid in making this decision. Any flexion deformity can be corrected at the same time by incorporating an extension component into the osteotomy, as long as adequate range of flexion will remain for sitting (at least 80 to 90 degrees). Osteotomy of the distal femur or proximal tibia is indicated if knee valgus is excessive. Equinovarus of the foot may be treated initially with casts, but surgery is often indicated [7,1]. If the stiffness of the first metatarsophalangeal joint produces hallux rigidus, traditional measures such as cheilectomy or arthrodesis may help.

SPONDYLOEPIPHYSEAL DYSPLASIA CONGENITA

Spondyloepiphyseal dysplasia congenita is a rare disorder with an estimated prevalence of about 3 to 4 per million population (8). Its key features include significant spinal and epiphyseal involvement, without metaphyseal enlargement or contractures of other joints (99). It is heritable in an autosomal dominant form, but most patients acquire the disease because of a new mutation. The genetic defect has recently been characterized as a defect in type II collagen, the gene for which is located on chromosome 1293. This is the predominant protein of cartilage, and mutations have been observed in the $\alpha 1$ chain, resulting in alteration in length (100). Like many skeletal dysplasias, electron microscopy has demonstrated intracellular inclusions, which are probably due to intracellular retention of procollagen (101).

Clinical Features

The severity of disease is variable. In general, the face is taut, the mouth small, and appearance somewhat characteristic. Cleft palate is common. The trunk and extremities are both shortened, although the extremities are more shortened proximally because of the coxa vara (Fig. 8-21). There is pectus carinatum, in part because the rib growth outpaces the increase in trunk height. There are many similarities to Morquio syndrome but a lack of visceral involvement. Scoliosis and kyphosis usually develop before the teen years. Back pain is common by this time, as well.

The hips are most commonly in varus, but this is variable. The degree of varus has been felt to be the best marker for the severity of the disease (102). If the varus is severe,

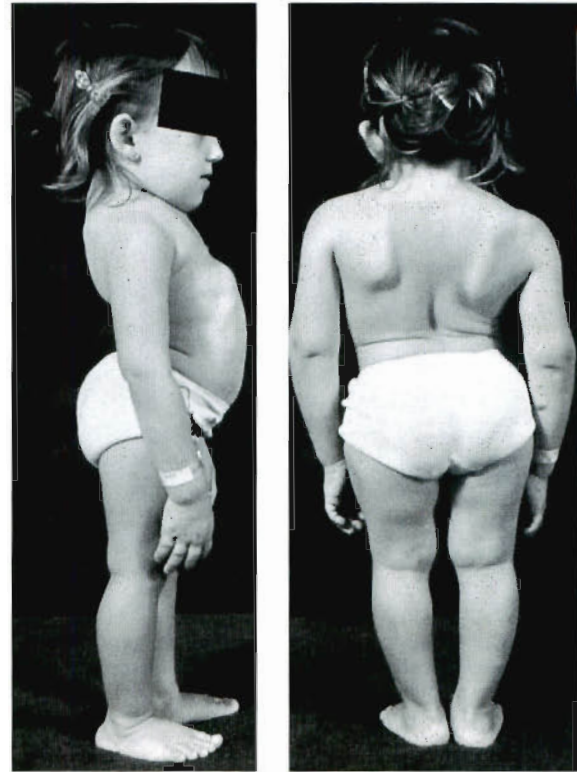


FIGURE 8-21. An 11-year-old child with spondyloepiphyseal dysplasia congenita. Markedly short stature is result of flattening of vertebrae at all levels, scoliosis, increased lumbar lordosis, and hip flexion contractures. Also note pectus carinatum. (Courtesy of George S. Bassett, M.D.)

it is often accompanied by a significant hip flexion contracture. Patients often walk with the trunk and head held back to compensate for this contracture. The knees are often in mild varus, and a combination of external rotation of the femora and internal rotation of the tibiae often coexists.

The most common foot deformity is equinovarus, but this is not nearly as stiff as the involvement with DD. Growth curves are available for this condition (102). Adult height varies from 90 to 125 cm.

Radiographic Features

One of the traits of this condition is that ossification is delayed in almost all regions (103,104). There is often odontoid hypoplasia or os odontoideum. Flattened vertebral ossification centers with posterior wedging give the vertebral appearance, on lateral view, a "pear shape." If scoliosis is present, it is often sharply angulated over a few vertebrae (Fig. 8-22). Disc spaces become narrow and irregular by maturity. Ossification of the pubis is delayed. The proximal femora are in varus with short necks, but the degree of this involvement varies. The proximal femur may not ossify for up to 9 years (102). Often, the varus is progressive (Fig. 8-

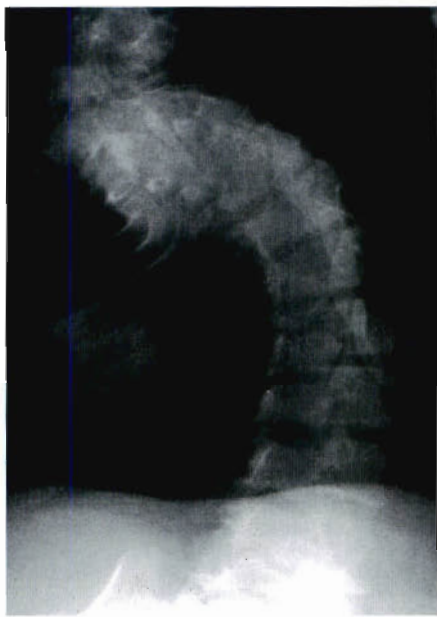

FIGURE 8-22. Scoliosis, with a sharp apex concentrated over a limited number of vertebrae, is characteristic of spondyloepiphyseal dysplasia congenita.

23). There is possible progressive extrusion of the femoral head. This may require an arthrogram to clearly demonstrate it. The distal femoral metaphyses are flared. Genu valgum is more common than genu varum. Early osteoarthritis is likely in the hips, more so than in the knee. The carpals are delayed in ossification, but the tubular bones of the hands are near normal.

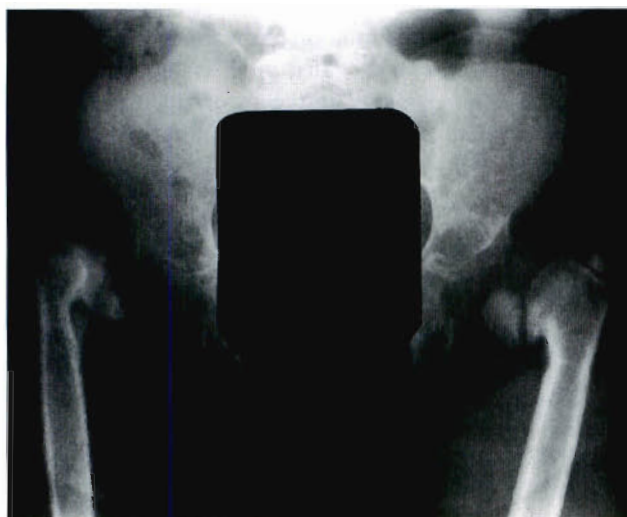

FIGURE 8-23. The hips in this patient with spondyloepiphyseal dysplasia congenita show severe coxa vara, with delayed ossification of the capital femoral epiphyses. (Courtesy of George S. Bassett, M.D.)

Medical Problems

Respiratory problems occur in infants due, in many cases, to a small thorax. The most common disabling problem in this syndrome involves the eyes: retinal detachment is common. It is reported to occur especially during the adolescent growth spurt. Regular ophthalmologic examinations are recommended. Hearing impairment is noted in a minority of patients.

Orthopaedic Problems and Treatment

Orthopaedically, the most potentially serious sequelae can involve neck instability. Os odontoideum, or odontoid hypoplasia, or aplasia may all cause instability and, potentially, myelopathy (Fig. 8-24A–C). Numerous cases have been reported (5). Careful neurologic examination should be done at each clinic visit. Flexion–extension radiographs should be performed about every 3 years if an upper cervical anomaly is identified. If the odontoid is difficult to see, one can use CT or MRI. Stenosis often coexists and makes subluxation more critical. It is recommended to fuse the atlantoaxial interval if instability exceeds 8 mm, or if symptoms develop [–2.17]. If severe stenosis exists, or if a fixed subluxation cannot be reduced, it may be necessary to perform an atlas decompression and, consequently, fusion to the occiput (105). Bone strength or canal size often make rigid internal fixation impractical or unsafe; in these cases, bone graft and halo-cast immobilization are usually successful. Scoliosis is present in more than one-half of patients with spondyloepiphyseal dysplasia. It may become severe. Curve control with a brace may be attempted if it is less than 40 degrees. However, long-term efficacy has not been demonstrated. Fusion may be necessary if the curve is progressive. Thoracolumbar stenosis is not as severe as in achondroplasia. Instrumentation is not contraindicated but should be used judiciously. If internal stabilization is not judged to be strong, consider use of a halo brace immobilization postoperatively. Correction is usually modest (17% in one series [5]). Anterior surgery should be used if the patient is young (under about age 11) or the curve is rigid (correcting to less than approximately 45 degrees). Kyphosis is also common; use of a Milwaukee brace has been shown to be effective if it can be worn until maturity (5).

Hip osteotomies are indicated if the neck-shaft angle is less than 100 degrees [–4.4]. Insufficient correction makes recurrence more likely. It is helpful to correct any flexion contracture at the same time if enough flexion will remain. Malrotation should be corrected as well. If a patient is experiencing painful hinge abduction, a valgus osteotomy may improve symptoms. An arthrogram may help in operative planning.

Dislocation may be reconstructed if done early. The surgeon may need a combination of femoral and iliac osteoto-

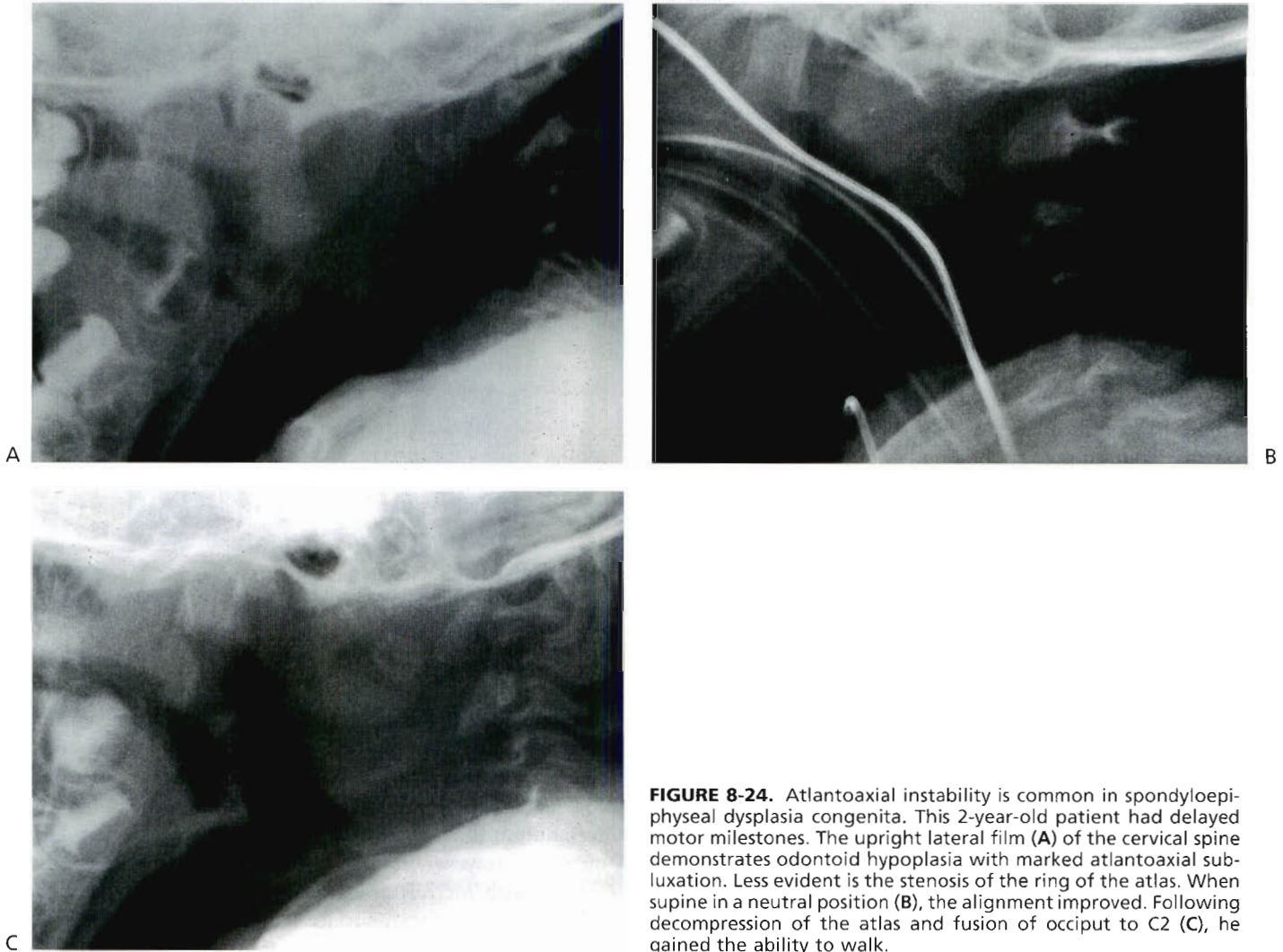


FIGURE 8-24. Atlantoaxial instability is common in spondyloepiphyseal dysplasia congenita. This 2-year-old patient had delayed motor milestones. The upright lateral film (A) of the cervical spine demonstrates odontoid hypoplasia with marked atlantoaxial subluxation. Less evident is the stenosis of the ring of the atlas. When supine in a neutral position (B), the alignment improved. Following decompression of the atlas and fusion of occiput to C2 (C), he gained the ability to walk.

mies. When doing any procedure on the hip, assess the knee alignment at the same time and correct it if necessary. The clinician should also consider the effect that knee angular correction will have on the hip. For instance, correction of severe knee valgus deformity has the same effect on hip congruity as does a varus osteotomy of the proximal femur.

Total joint replacement is a very difficult procedure: the hip is stiff, custom components are often needed, and concomitant osteotomy is sometimes necessary.

Foot deformities can usually be treated according to standard clubfoot principles [7.1]. If the foot is stiff, an osteotomy or decancellation of the talus, calcaneus, and/or cuboid may be needed.

SPONDYLOEPIPHYSEAL DYSPLASIA TARDA

Spondyloepiphyseal dysplasia (SED) tarda is distinguished from the congenita form by later age at diagnosis and more

mild features. Manifestations first appear in later childhood, or even in adulthood. The spine and only the larger joints are affected. Several genetic patterns of transmission have been reported (106–108). The most common is X-linked, in which male patients are more commonly or more severely affected and female patients may show milder manifestations. A recessive form has also been reported. SED-tarda is one of several conditions (termed the COL2A1 group or the SED family), which may result from a mutation in type II collagen (7,46). The mechanism by which the particular mutation for this condition produces the mildest phenotype in this family will doubtlessly be elucidated in the near future.

Clinical Features

Manifestations first are called to clinical attention at about 4 years old, in the earliest cases. Stature is mildly shortened. The condition may be first diagnosed as bilateral Perthes

syndrome (109). Back pain and hip or knee pain may be present in childhood. Joint range of motion is minimally limited, if at all. Varus or valgus deformities are rare. Degenerative changes may occur in the hip or the knee by young adulthood. Adult height may be to 60 in. or more (108).

Radiographic Features

Involvement of shoulders, hips, and knees predominates. The hips manifest varying degrees of coxa magna, flattening, or epiphyseal extrusion, differing markedly even within the same family (Fig. 8-25). A minority of patients present with bilateral coxa vara. Odontoid hypoplasia or os odontoideum may cause atlantoaxial instability. Spinal involvement ranges from mild platyspondyly (Fig. 8-26), with ax-like configuration of the vertebral bodies on the lateral view, to isolated disc-space narrowing. Mild-to-moderate scoliosis develops in a minority of cases.

Orthopaedic Problems and Treatment

The severity of orthopaedic conditions varies widely, even within a family. There are undoubtedly many affected individuals whose problems are so mild that no diagnosis is ever made. One large family was reported in which only 4 of the 31 affected members requested any orthopaedic treatment (110). This is one condition to consider whenever spine, hip, and/or knee pains run in a family, and the radiographs seem to be just a little atypical. Bracing may be recommended if scoliosis exceeds 30 degrees in the skeletally immature patient. Surgery should be offered for the rare patient in whom it exceeds 50 degrees. All patients should be screened for atlantoaxial instability. Fusion should be

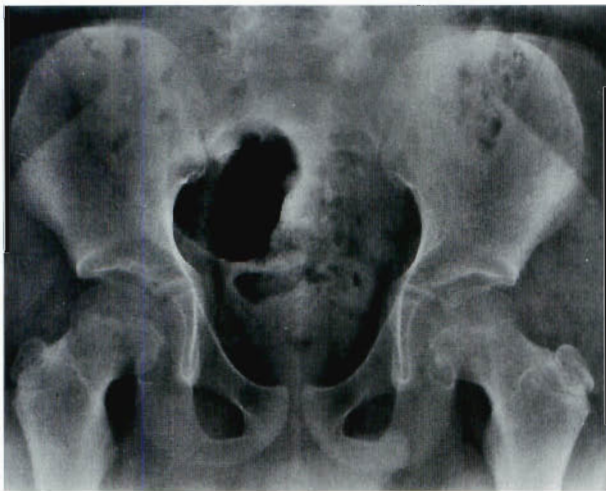

FIGURE 8-25. The pelvis in this patient with spondyloepiphyseal dysplasia tarda shows minimally small, flattened epiphyses.

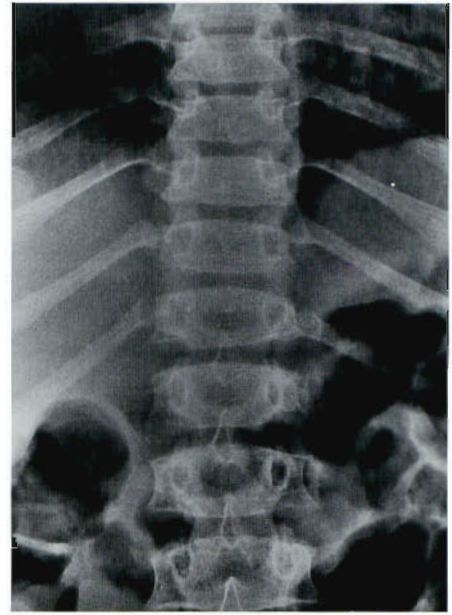


FIGURE 8-26. The spine in this patient with spondyloepiphyseal dysplasia tarda shows typical mild flattening of the vertebral bodies, but no scoliosis.

recommended if the spine is unstable in either flexion or extension, according to criteria given earlier for the congenita form [→2.17]. The role for procedures to increase coverage of the dysplastic, extruded femoral head by the acetabulum during the childhood years is not well documented. However, it may be helpful in the rare young patient with increasing extrusion and persistent pain, in whom the hip contact surface is markedly compromised. If hip pain becomes a problem after the femoral heads are mature or nearly mature, osteotomy may help to increase congruity or decrease hinge abduction. Usually, a valgus or valgus-extension osteotomy is most appropriate, so long as there is reasonable joint space and adequate contact remaining. A preoperative arthrogram is helpful in the younger patient to see the full outline of the articular surface. Osteotomies of knees or ankles are rarely needed. Total joint replacement is often needed for the hips or knees, at an age much younger than the general population.

PSEUDOACHONDROPLASIA

Pseudoachondroplasia was first described in 1959 by Maroteaux and Lamy as a form of spondyloepiphyseal dysplasia (111). It has subsequently been reclassified as being distinct from SED, because of late-onset physical findings and more mild spinal involvement. It involves the metaphyses, as well as the spine and epiphyses. The significant features are ligamentous laxity and “windswept” knees. With a prevalence of approximately four per million, it is one of the more

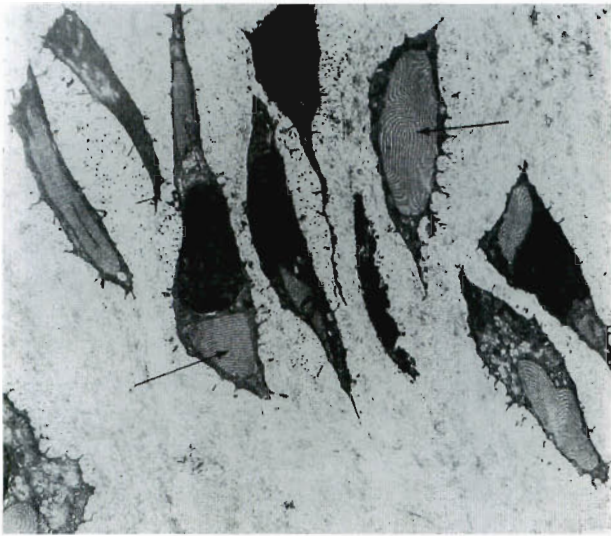

FIGURE 8-27. Abnormal lamellar inclusion bodies in endoplasmic reticulum of growth plate chondrocytes of a patient with pseudoachondroplasia. (From ref. 112, with permission.)

common skeletal dysplasias. Early histologic studies demonstrated that the chondrocytes of persons with pseudoachondroplasia contained lamellar inclusions within the endoplasmic reticulum (58,112). It has since been demonstrated that pseudoachondroplasia results from a mutation in cartilage oligomeric matrix protein (COMP), the same protein that is disordered in MED (113,114). COMP is normally a large extracellular matrix glycoprotein that is found in the territorial matrix surrounding chondrocytes. It is also found in the extracellular matrix of ligament and tendon tissues. A number of different mutations have been found in this gene (113). Some of the mutations involve a GAC trinucleotide repeat within this gene; it has been found that either expansions or deletions in this region may cause the disease. COMP accumulates in the rough endoplasmic reticulum of chondrocytes and tenocytes in persons with this disorder (115) (Fig. 8-27). Normal growth and development occur in mice whose *COMP* gene has been deleted, illustrating that it is accumulation of an abnormal form of COMP, not its absence, which causes pseudoachondroplasia. It is thought that the abnormality of the matrix does not maintain the shape of the cells, and allows them to become flatter (116,117). Three separate families have been reported who have somatic/germline mosaicism, which allows this dominant condition to behave like a recessive disorder, with up to a 50% recurrence risk, even from two normal-statured parents (114).

Clinical Features

Most patients with pseudoachondroplasia are not recognized as having a skeletal dysplasia at birth. The length at

birth is a mean of 49 cm, which is within normal limits. Growth tapers soon after this, however, so that the height falls to below the fifth percentile by the age of 2 years (118). The eventual height is the same as that of a person with DD. This pattern of progressive involvement is typical of storage disorders, which is essentially the nature of this condition. Usually, the diagnosis is made by the age of 2 to 4 years old.

Facial features have variously been termed "delicate" or normal (Fig. 8-28). In any event, they are not distinctive enough to be involved in the diagnostic process (119,120). Cervical instability is present in a minority of cases. Increased thoracic kyphosis and lumbar lordosis are often present (116). Mild scoliosis often occurs, but few cases become severe. The pattern of shortening of the extremities is rhizomelic and progresses with time. This finding helps explain why early writers often confused this disorder with achondroplasia. However, the hands are not tridentine. In almost all cases, the hips are dysplastic and the patient exhibits a waddling gait. Knees are most commonly in excessive valgus, or windswept (one in varus, one in valgus), due to lax ligaments, as well as epiphyseal and metaphyseal abnormalities. The joints may have flexion contractures or recurvatum. Adult height is a mean of 119 cm (range 106 to 130 cm) (118). No changes outside the skeletal system

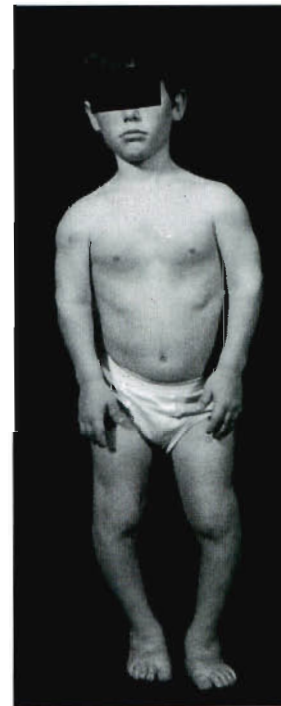

FIGURE 8-28. A 12-year-old patient with pseudoachondroplastic dysplasia. The head and trunk are normal, but there is rhizomelic shortening of the extremities. The hands and feet are short and broad. (Courtesy of George S. Bassett, M.D.)

have been noted as part of the disorder. Patients have normal intelligence, and a normal life expectancy (121).

Radiographic Changes

The vertebral bodies are very flat with anterior indentations, even in early childhood, and this may be one of the earliest ways to make the diagnosis, because affected babies are outwardly normal (Fig. 8-29). This flattening may be discovered if a routine chest radiograph is ordered, for instance. Almost one-half have odontoid hypoplasia or aplasia. Therefore, flexion–extension radiographs are advised at the initial evaluation. These should be repeated at intervals, because the degree of instability may increase with time. In the lumbar spine, the pedicles are not narrower caudally, as in achondroplasia, but are short in the sagittal plane. Sternal deformities may appear (carinatum or excavatum).

The long-bone metaphyses are broad, irregular at the ends, and flared at the edges. The epiphyses are late to ossify and irregular in appearance. There is progressively irregular ossification of epiphyses. Delayed maturation of triradiate cartilage is more common than in any other dysplasia. The pubic rami are delayed in closing, and the greater trochanteric apophysis is delayed also (122). The femoral head is enlarged, and undergoes progressive subluxation (Fig. 8-

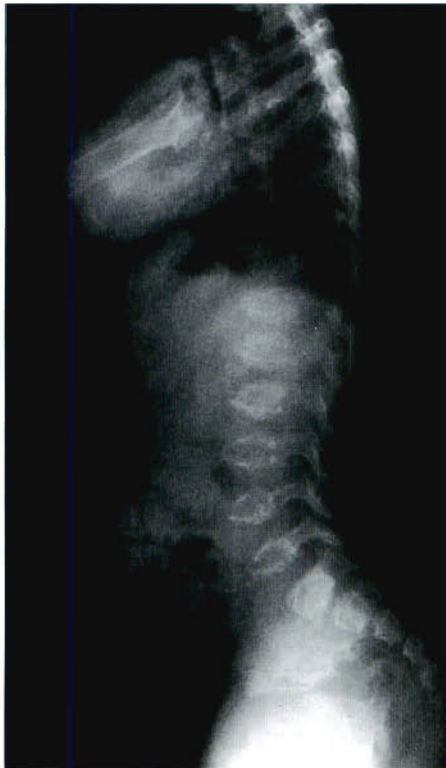

FIGURE 8-29. A 3-year-old child with pseudoachondroplastic dysplasia has platyspondyly with anterior beaking. (Courtesy of George S. Basset, M.D.)

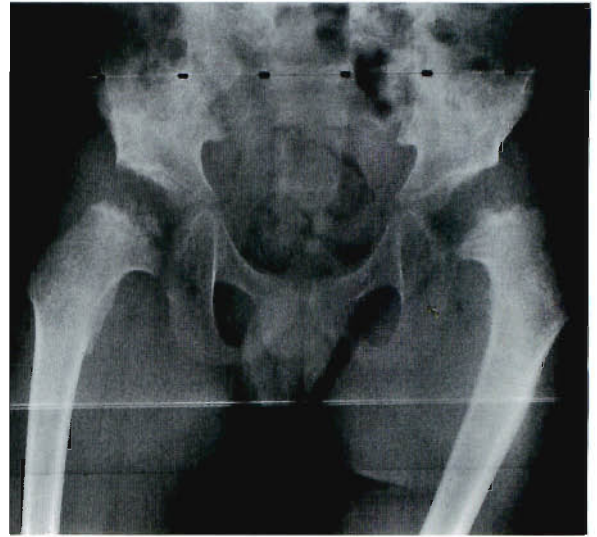

FIGURE 8-30. Deformation and delay in the ossification of the epiphyses are frequently seen in pseudoachondroplasia.

30). The metaphyses all show irregularity and beaking. The height of the epiphysis of the distal femur decreases (Fig. 8-31). An arthrogram may be helpful if operative intervention is planned, to visualize the joint surface and determine the location of the deformity(ies), because epiphyseal ossification is delayed, and this can be difficult to visualize. The tibial plateau may be depressed on one side, and the fibula may be relatively long. Delayed maturation of carpal bones makes predicting bone age or skeletal maturity difficult.

Orthopaedic Problems and Treatment

The cervical spine should be monitored and treated according to guidelines given earlier in this chapter. Myelopathy

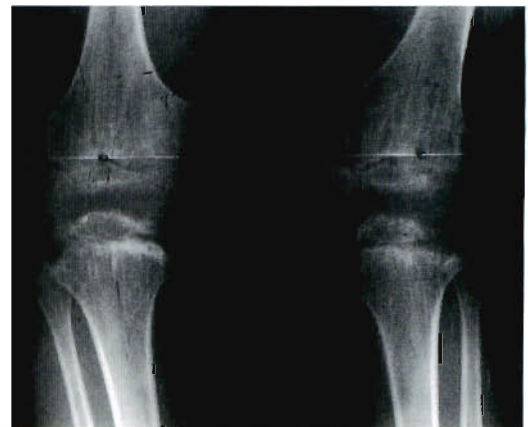

FIGURE 8-31. Epiphyseal flattening and a “windswept” alignment are characteristic of the knees in pseudoachondroplasia.

has been reported in several series. Posterior cervical fusion [➤2.17] may be indicated if translation of the atlas on the axis exceeds approximately 8 mm, or if neurologic signs are present. Many patients, surprisingly, have normal cervical spines.

If scoliosis is present, and is between 25 and 45 degrees in the skeletally immature individual, a trial of brace is warranted. Larger curves (over 50 degrees) may require surgery. Spinal stenosis is not a clinical problem, so the surgeon can use sublaminar fixation, if needed, to supplement other fixation methods [➤2.1-2.5].

Hip subluxation and dislocation may be due to intrinsic cartilage deformation to a hip adduction contracture or to valgus of the knee. It is recommended to try to arrest this process. A femoral osteotomy, as well as an iliac procedure, may be needed. Preoperatively, it is wise to make radiographs with the patient in corrected position, to see whether the hip will be congruous in this position. If it is aspherical or incongruous, one may need an acetabular augmentation to achieve coverage. This is generally a more versatile procedure than a rotational iliac osteotomy in the person with skeletal dysplasia. At the same time, the surgeon should look for and correct flexion and rotation contractures as well.

Valgus or varus deformities about the knee often need correction. It is up to the discretion of the patient and the surgeon when this should be done. The objective of the procedure is to obtain a horizontal joint surface with a well-aligned knee. Both tibial and femoral procedures may be necessary. The risk of recurrence is high, even with a well-done procedure, so it is wise to educate patients about this risk. Early onset of osteoarthritis often occurs—about one-half of adults in one long-term study had undergone at least one arthroplasty (116,121).

MULTIPLE EPIPHYSEAL DYSPLASIA

Multiple epiphyseal dysplasia is one of the most widely known and commonly occurring skeletal dysplasia. It is dominantly inherited. It affects many epiphyses, produces symptoms mainly in those with significant loadbearing, and has few changes in the physes or metaphyses. Historically, it was described as occurring in two separate forms, with eponyms that are still used today: Ribbing's dysplasia, having mild involvement, or Fairbank's dysplasia, a more severe type (123-125). With current understanding of the genetic basis, this may not be an absolute distinction.

Histologically, intracytoplasmic inclusions are seen that are similar to, but not so severe as, those seen in pseudoachondroplasia. Growth plate organization is still noticeably abnormal, despite the minimal changes seen in the metaphyses. The genetic basis for this disorder is now reasonably well understood. It is a genetically heterogeneous disorder. Mutations have been found in the gene for COMP on chromosome 19, as in pseudoachondroplasia. However, in other cases of MED, abnormalities have been found in the α_2

fibers of collagen type 9 (COL9A2). Collagen type 9 is normally a trimer that is found on the surface of type II collagen in cartilage. It may form a macromolecular bridge between type II collagen fibrils and other matrix components—it thus may be important for the adhesive properties of cartilage. A COL9A2 mutation has been described in one large family, with peripheral joint involvement only (126).

Clinical Features

Patients typically present later in childhood, for one of several reasons. They may be referred for joint pain in the lower extremities, decreased range of motion, gait disturbance, or angular deformities of the knees (127). There may be flexion contractures of knees or elbows. Symptoms may develop as late as adulthood. These patients have minimal short stature, ranging from 145 to 170 cm (57 to 67 in) (124). The face and spine are normal. There is no visceral involvement.

Radiographic Features

Most changes in MED involve the epiphyses; almost all of the ossification centers are delayed in appearance. There are occasional irregularities of streaking in the metaphyses, but they are minor. The appearances of the epiphyses in the immature and in the mature patient are different and characteristic (128). In the growing patient, the epiphyses are fragmented and small in size (Fig. 8-32). The epiphyseal

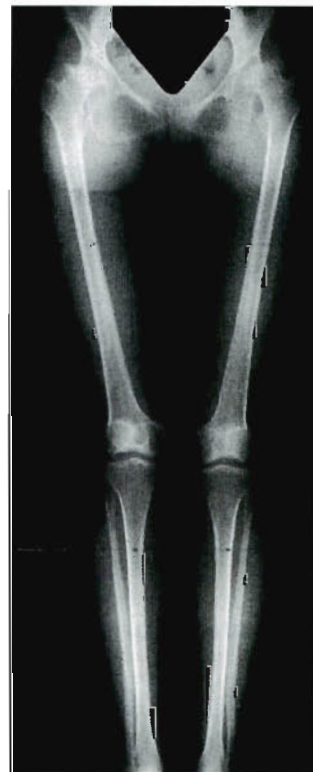

FIGURE 8-32. Multiple epiphyseal dysplasia.

ossification centers eventually coalesce, but the overall shape of the epiphysis is smaller. An arthrogram may be helpful when it is necessary to assess the shape of the joint surface. The more fragmentation there is in the capital femoral epiphysis, the earlier onset of osteoarthritis (129). Coxa vara occurs in some patients. After maturity, there is some degree of flattening of the major load-bearing epiphyses: flattening of the femoral condyles, an ovoid femoral head, decreased sphericity of the humeral head, and squaring of the talus. In adulthood, major joints develop premature osteoarthritis. This is most common and most severe in the hips.

Avascular necrosis may be superimposed on MED. This occurs in about one-half the femoral heads. It can be recognized by appearance of a crescent sign, resorption of bone that had already been formed, and, sometimes, by the presence of metaphyseal cysts (130). MRI at this time may show loss of signal in a portion of the femoral head. A “sagging rope sign” may develop later (121).

Any orthopaedic surgeon who examines children must be able to differentiate MED from Perthes disease (109). Several radiographic clues may be helpful. In MED, abnormalities in the acetabulum are primary, and are more pronounced. The radiographic changes are symmetric and fairly synchronous. It is also helpful to obtain radiographs of the knees, ankles, shoulders, and wrists.

Radiographs of the knees show that the femoral condyles are flattened, and may be in valgus. There may be irregular ossification, just as in the hip. The condyles are somewhat squared on lateral view. Osteochondritis dissecans may be superimposed. Some MED patients also show a double-layered patella on the lateral view (132). This is a complete or partial double radiodensity, which is rarely seen in other conditions. There may be a synovial-lined joint between the two layers of the patella.

The ankles in MED are also in valgus; changes occur more in the talus than in the distal tibia. Upper extremity involvement is less severe; there may be irregularities in the proximal and distal humerus and radius. The humeral head involvement in adulthood has been termed a “hatchet-head” appearance, and results from undergrowth of the head and neck. It occurs in children more severely affected with MED. Radial ray hypoplasia may occur sporadically (133). The carpal ossification centers are delayed in appearing. The hand and wrist involvement may predict stature (134). The spine may be normal, or may have slight endplate irregularities or ossification defects on the anterior margins of the vertebrae (135).

Orthopaedic Implications

The orthopaedic surgeon may become involved in the care of the patient with MED in either of two periods. There is a small role for realignment procedures in the early, deforming period of the hip if there is progressive subluxation or pain. Pain is more likely to occur in cases in which avascu-

lar necrosis has supervened (130). Although the principle of coverage is the same as that used in Perthes disease, there is often a degree of coxa vara preexisting in hips with MED, which contraindicates use of a femoral osteotomy. Acetabular shelf augmentation is a worthwhile procedure in these instances (136,137).

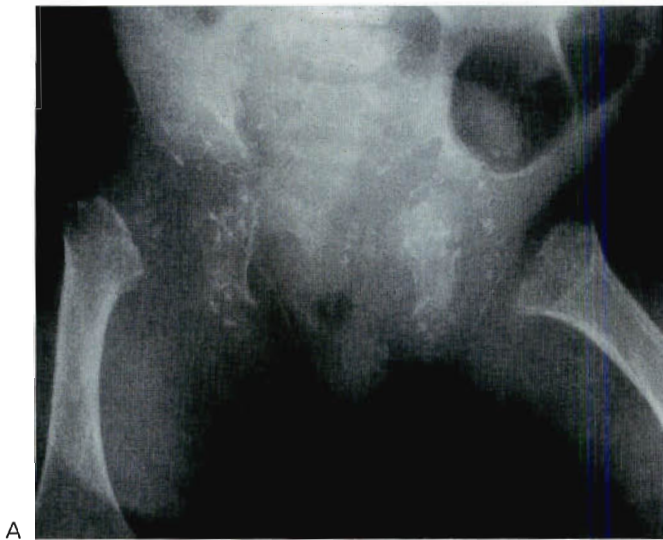
Not all patients need surgical treatment; however, some can be helped. Significant deformities may be corrected near maturity, either in the femur or tibia, depending on the site of abnormality. Degenerative joint disease is the biggest problem, and it occurs in the second or third decade. It results not so much from malalignment of the joints, but from intrinsic defect in cartilage. It produces stiffness, from an early age, and pain leading to a total joint **arthroplasty**. Even the shoulder is commonly affected by degeneration, and shoulder arthroplasty may be necessary (138).

CHONDRODYSPLASIA PUNCTATA

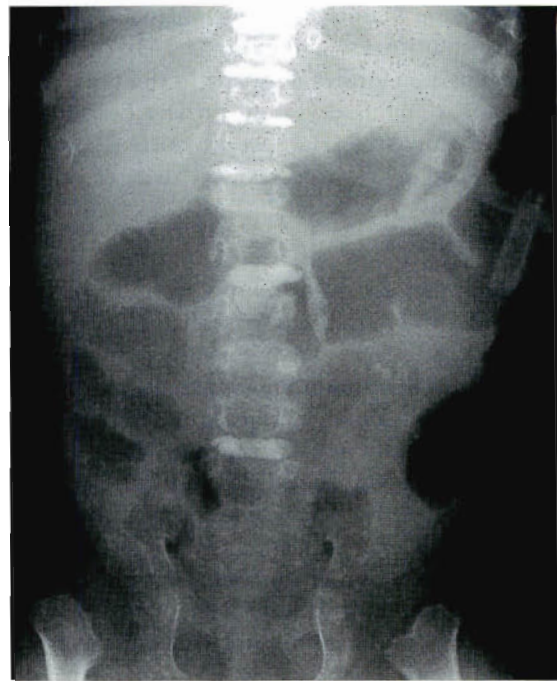This skeletal dysplasia is also known by the synonyms “congenital stippled epiphysis” and “chondrodystrophia calcificans congenita.” Key features include multiple punctate calcifications in infancy, which are best visualized on the newborn’s radiographs (139). It has been subclassified into three groups: an X-linked dominant type (Conradi-Hünermann syndrome), an autosomal recessive rhizomelic type, which is usually lethal in infancy, and a rare X-linked recessive type. Four others have been described that are even more rare (140). Although the appearance of neonatal epiphyseal calcification is striking, it is not very specific. Wulfsberg has listed various other conditions that may present with the same phenomenon: Zellweger (cerebrohepatorenal) syndrome, gangliosidosis, rubella, trisomy 18 or 21, vitamin K deficiency, hypothyroidism, or fetal alcohol or hydantoin syndromes (140–145). Rhizomelic chondrodysplasia punctata is a peroxisomal deficiency of dihydroxyacetone-phosphate acyltransferase; it is often (but not always) fatal in the first year of life (146,147). The genetic defect and pathogenesis of the Conradi-Hünermann syndrome has not been elucidated. Histologic examination shows perilacunar calcifications throughout the cartilage matrix (148).

Clinical Features

Patients with Conradi-Hünermann syndrome are characterized by hypertelorism, a depressed nasal bridge, and a bifid nasal tip (149–152). In addition, many have alopecia, congenital heart and/or renal malformations, and mental retardation. In rhizomelic chondrodysplasia punctata, findings include microcephaly, a high incidence of congenital cataracts, growth retardation, and a well-formed nasal bridge (153–156). Some have feeding difficulties, and most succumb to respiratory death or seizures in the first year. Diag-



A



B

FIGURE 8-33. A: Diffuse punctate epiphyseal calcifications in infancy are a hallmark for which chondrodysplasia punctata was named. B: At age 2-1/2 years, the epiphyseal calcifications are mostly resolved, but calcification of the intervertebral discs persists.

nosis may be made by amniocentesis, with measurement of plasmalogen biosynthesis and phytanic acid oxidation.

Skeletal findings in the extremities include limb-length inequality, coxa vara, and clubfoot or other foot deformities (157). Spinal findings include atlantoaxial instability, congenital scoliosis, or kyphosis (158).

Radiographic Features

Skeletal calcifications are visible at birth, but most disappear by 1 year. These involve the epiphyses, carpal bones, and pelvis (159) (Fig. 8-33A and B). Extraskelatal sites include the trachea and larynx. The appearance is of small flecks of calcium, "which appear as if paint had been flecked on by a brush" (160). The ossification centers themselves may be delayed in appearance. Coxa vara may affect one or both hips, or it may be absent (161). The fibula often overgrows the tibia significantly. Spine radiographs may show presence of a hemivertebra or a congenital bar. Calcification of the intervertebral discs may develop (Fig. 8-33B). Odontoid hypoplasia and os odontoideum have been described (158).

Orthopaedic Implications

Because of the risk of cervical instability, each patient should have a lateral cervical radiograph and, if instability appears possible, a flexion-extension view. Scoliosis may occur early due to secondary congenital anomalies. It may require early fusion if progression is documented and the patient, medically, is a candidate. Coxa vara should be treated

if the neck-shaft angle is less than 100 degrees [→4.4]. Lower limb-length inequality should be monitored and treated appropriately.

METAPHYSEAL CHONDRODYSPLASIAS

The metaphyseal chondrodysplasias are actually a group of disorders characterized by metaphyseal irregularity and deformity but preservation of epiphyseal structure, which, of course, is a contrast to almost all the dysplasias previously described in this chapter (162–164). The name may be a bit misleading, because it refers to the end result: radiographic changes in the metaphyses. Of course, logically, the real defect is in the growth plate itself, resulting in failure of uniform ossification of the cartilage columns, with persistence of cartilage islands, undergrowth, and deformity as the sequelae (165,166). There are many different named disorders that come under the heading of metaphyseal chondrodysplasia. We discuss here the commonest types: McKusick, Schmid and Jansen types, as well as Kozlowski-type spondylometaphyseal dysplasia, which has mild changes in the vertebral bodies.

McKusick-type Metaphyseal Chondrodysplasia

This condition is rather common in the Amish community of Lancaster County, Pennsylvania, as well as in Finland. It also occurs sporadically throughout the world. It is also

known by the term “cartilage-hair hypoplasia.” It is autosomal recessive and maps to chromosome 9 (167). Although etiology has not been further elucidated at this point, defects in hematopoietic colony development have been found in bone marrow samples of a number of patients, perhaps explaining the hematologic aspects of the disease.

Clinical Findings

The first thing that distinguishes this group of patients is their fine, light, and sometimes sparse hair (Figs. 8-34 and 8-35). This should serve as a clue to the more important medical problems that this group of patients may have. An alteration in T-cell immunity causes an increased risk of viral infection (especially *varicella zoster*, which may be more severe in these persons). Continued antibiotic prophylaxis in the first 6 months of life has been recommended (168,169). Anemia may develop, and 16% of patients require a blood transfusion (170). Bone marrow transplant has been reported in one infant with severe recurrent infections; it corrected the immune problem, but did not improve skeletal growth (171). Hematologic problems have a tendency to become less severe after childhood. Hirschsprung disease, intestinal malabsorption, and megacolon

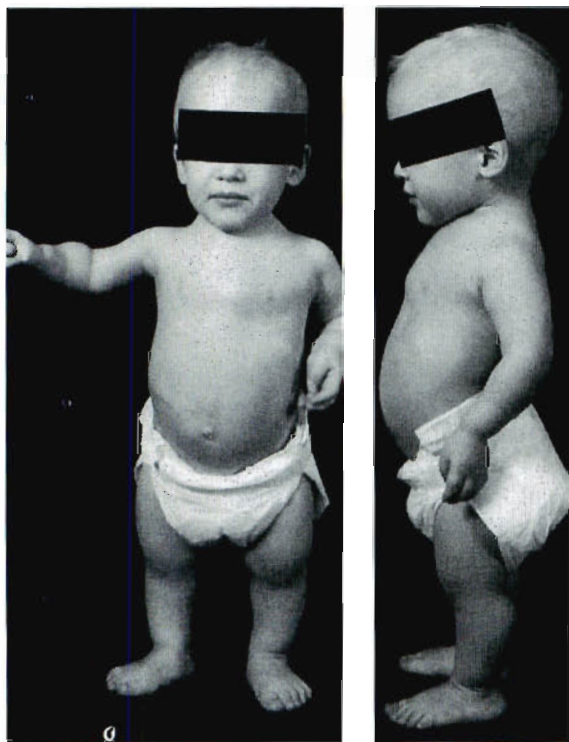


FIGURE 8-34. An 18-month-old child with McKusick-type metaphyseal chondrodysplasia. Notice the characteristic light, sparse hair, disproportionate short stature, pectus excavatum, and varus deformities of the lower extremities. Mild increased lumbar lordosis, flexion contractures of the elbows, and expansion of the wrists are also part of the deformity. (Courtesy of George S. Bassett, M.D.)

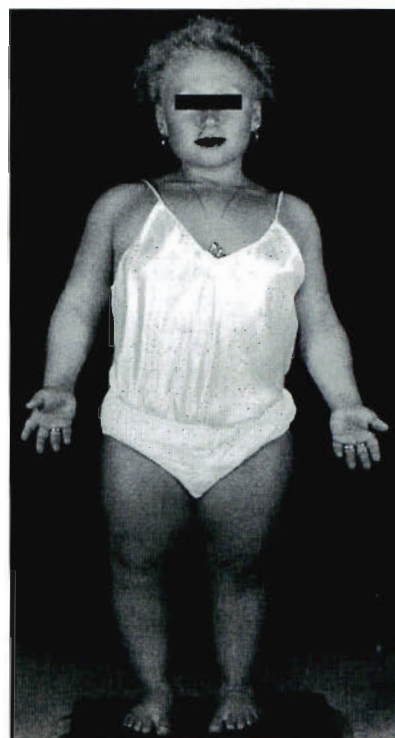

FIGURE 8-35. A 22-year-old woman with metaphyseal chondrodysplasia, McKusick type (cartilage-hair hypoplasia). Note disproportionately short stature, fine light hair, and genu varum.

may also develop. There is an increased risk of malignancy, such as lymphoma, sarcoma, and skin cancer. In the largest series reported, 8% of patients had malignancies (168,172). Clearly, then, these patients need medical surveillance into adulthood, more than would most patients with skeletal dysplasia.

Orthopaedically, these patients have generalized ligamentous laxity, but the elbows actually have flexion contractures. There is mild genu varum, which may bring them to see an orthopaedist. Pectus excavatum or carinatum may be observed. The adult height is 106–147 cm (42–58 in.).

Radiographic Features

In the McKusick type of metaphyseal chondrodysplasia (Fig. 8-36), there is more shortening and less varus of the long bones than seen in the Schmid type. The metaphyseal involvement is more evenly distributed, not all on the medial side of the knee. There is distal fibular overgrowth, perhaps because this bone is less inhibited by the forces of weightbearing. Atlantoaxial instability has been reported. The thoracolumbar spine shows some minimal changes, which are not of much clinical importance: columnization (increased height) of the vertebrae and increased lumbar lordosis.

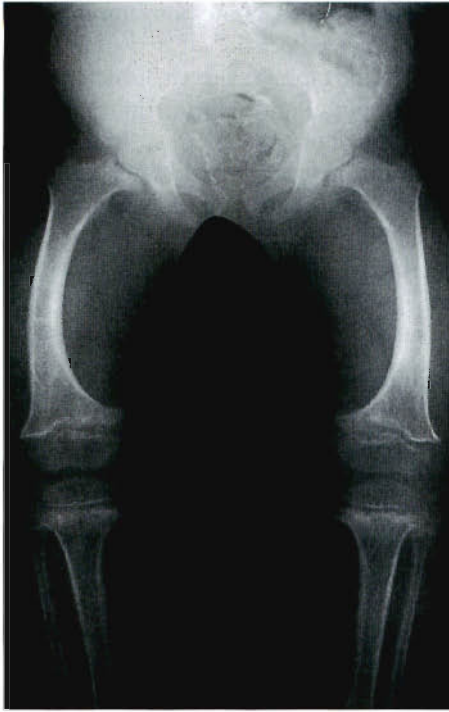

FIGURE 8-36. A 4-year-old patient with McKusick-type metaphyseal chondrodysplasia. Pelvis is normal, apart from silver clips from surgical treatment of megacolon. Mild coxa vara, bowing of the femurs and tibias with metaphyseal expansion, and irregular zones of provisional calcification are evident. (Courtesy of George S. Bassett, M.D.)

Orthopaedic Implications

It is prudent to obtain flexion–extension films for atlantoaxial instability, at least on the first visit. MRI in flexion and extension may be helpful, if the plain films seem equivocal diagnostically. Posterior spine fusion should be performed if there is more than 8 mm of translation, or if any signs of cord compression are present [2.17]. Congenital hip dislocation has been reported in 3% of patients, and successful closed reduction may be performed if detected early (168). In some patients (15%), the varus at knee or ankle should be corrected, if severe.

Schmid-type Metaphyseal Chondrodysplasia

The Schmid type is more common than the McKusick type, and is better understood at a genetic level (173). It is autosomal dominant. The defect is in the α_1 chain of type X collagen (174,175). Type X is a highly specialized extracellular matrix component, the synthesis of which is restricted only to hypertrophic chondrocytes in the calcifying zones of the growth plate and in zones of secondary ossification. It is a homotrimer of three α_1 chains, which has been implicated in morphogenetic events of endochondral ossification,

including calcification of hypertrophic cartilage prior to its replacement by bone. Many mutations described involve the C-terminal end, where joining of the three individual chains starts, and prevents the abnormal chains from forming trimeric structures (176). On histologic examination, one sees cartilage islands that extend into the metaphyses. The differential diagnosis for this and other forms of metaphyseal dysplasia, most importantly, includes various types of rickets and hypophosphatasia.

Clinical Features

Patients with the Schmid dysplasia show rather minimal clinical abnormalities. They are normal at birth. The facial appearance is normal. They may present to the orthopaedic surgeon with leg pains, varus knees and ankles, short stature, or a waddling gait. The adult height is minimally shortened, at an average 150 cm (59 inches).

Radiographic Features

The metaphyses of the long bones are widened and flared, and may have cysts. The physes are slightly widened. Weight-bearing may play a role in these changes—they have been reported to improve after rest or cast immobilization, and to recur after resumption of loading (173). There is a varus deformity of the knees. Atlantoaxial instability has been reported, but is rare.

Orthopaedic Implications

The epiphyses are normal, and patients rarely get degenerative changes. The orthopaedic surgeon may be called on to correct bowing of the knees if it becomes severe. Otherwise, there is little need for care in these patients.

Jansen Metaphyseal Dysplasia

This is a rarer type of dysplasia. It is an autosomal dominantly inherited disorder, which has been linked to a defect in the receptor for parathyroid hormone and parathyroid hormone related protein (177). This provides an interesting link between the skeletal dysplasias and the metabolic bone diseases. Patients with Jansen syndrome may have hypercalcemia, and they have more severe metaphyseal changes than the previous two types.

Kozlowski-type (Spondylometaphyseal Dysplasia)

Clinical Features

This uncommon autosomal dominant disorder has spinal, as well as metaphyseal, changes. It is recognized in preschool-age children by the findings of short stature and

mildly increased kyphosis. There may be slight limitation of joint movement, a Trendelenburg gait, and early osteoarthritis. Adult height reaches about 150 cm (54 in.).

Radiographic Features

There is mild platyspondyly, in contrast to the three disorders just described. There is a retarded bone age of the carpals and tarsals. The metaphyseal chondrodysplasia is most pronounced in the proximal femur.

DIAPHYSEAL ACLASIA (MULTIPLE OSTEOCARTILAGINOUS EXOSTOSIS)

Although solitary exostoses do not qualify as skeletal dysplasias, it is clear that patients with multiple exostoses have a generalized disturbance of skeletal growth. The condition has been localized to three different chromosomal locations: sites on chromosomes 8, 11, and 19. The specific genes have not been identified. The differing locations of mutation may account for the phenotypic variability of the condition. It is likely that tumor suppressor genes may be involved (7). Most cases are transmitted as autosomal dominant, but a large number of patients acquire it as a spontaneous mutation. The metaphysis of a person with multiple osteochondromas is characterized by thinning of the cortex, innumerable small bumps, and cartilage rests extending into the trabecular bone.

Clinical Features

The condition is not usually noted until age 3 to 4 years, when the first exostoses are noted and other features develop. The features become progressively more pronounced

until maturity, at which point bony prominences should cease to grow. Affected persons are at the low end of normal for stature. The metaphyses are circumferentially enlarged throughout the body, not only in regions where there are obvious exostoses. This gives a rather “stocky” appearance, which is then further exaggerated by the appearance of the exostoses. They may cause soreness when they arise under tendons or in an area vulnerable to bumping, such as the proximal humerus. The exostoses tend to steal from the longitudinal growth of the long bones. The categories of problems caused by this condition are fourfold:

1. Localized pressure on tendons and nerves, among other places. Peroneal palsy may arise from a lateral exostosis, and it may occur in such a way as to cause brachial plexus or spinal cord compression.
2. Angular growth of two-bone segments—the arms and forearms. Usually the thinner of these two bones is more inhibited in its growth than the wider one, so it tethers the growth of the latter. Valgus may develop at the wrist, knee, and ankle. The radial head may subluxate or dislocate.
3. Limb length inequality. Often one limb is more involved than the other with exostoses, and it may undergrow as much as 4 cm.
4. Malignant degeneration. Transformation to chondrosarcoma occurs in about 1% of patients after maturity. Such change may be signaled by increased growth of an exostosis, or pain over an exostosis. Bone scans every two years in adulthood have been advocated as one way to detect this change.

Radiographic Features

The metaphyses are very wide, and internal irregularities can be seen. The exostoses may be sessile or pedunculated,

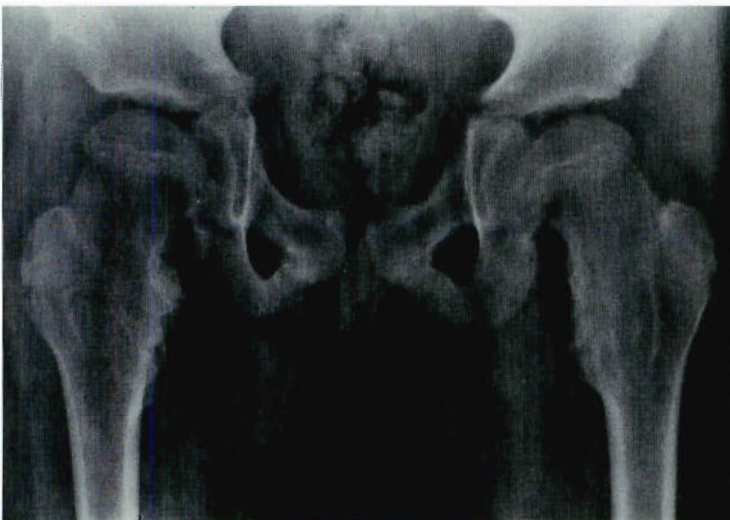

FIGURE 8-37. The hips in diaphyseal aclasia are characterized by broad, irregular femoral necks that are usually in valgus. There are osteochondromas and irregularities in formation of the pelvis also, which can be difficult to monitor over time.

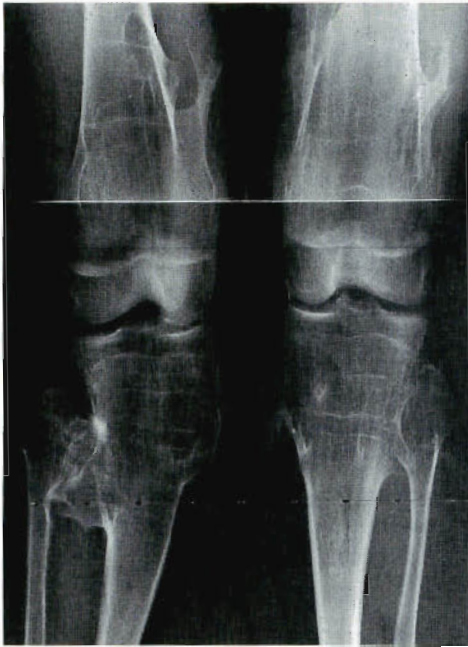

FIGURE 8-38. This figure of the knees in a patient with diaphyseal aclasia best illustrates that this defect is a systemic abnormality of bone formation, rather than a series of discrete tumors. The metaphyses are broad and irregular in the region where the exostoses are located. The knees are developing a valgus alignment, due to the short fibulae, as are the ankles.

and have continuity with the main cortex, like solitary exostoses do. Exostoses on the undersurface of the scapula may be identified on plain films, but are best evaluated by CT. The femoral necks are usually wide and in valgus (Fig. 8-37). Valgus is much more common than varus at the knee (Fig. 8-38), and the distal tibial epiphysis may be triangular if the fibula is pulling the ankle into valgus. Radial head subluxation may occur with ulnar shortening, and the resultant carpal subluxation can readily be identified by wrist films.

Orthopaedic Implications

Monitoring in childhood should mostly be done by clinical examination, because all bones are affected, and the lesions are too numerous to image routinely. Perform a brief neurologic examination, and check joint range of motion. Measure knee, ankle, elbow, and wrist angulation and limb lengths. Remove any exostoses that are causing significant symptoms, but warn the patients that the metaphyseal widening will persist, so the effect on appearance may not match expectations. Removal of lesions impairing radioulnar motion may result in slight increase in range, but not a dramatic improvement. Ulnar lengthening may help avert radial head subluxation. Hemiepiphysiodesis is a minimally invasive way to correct angulation at the wrist, knee, and ankle. If

the patient is near maturity and needs correction, osteotomy may be indicated. Limb-length inequality can be corrected by the standard algorithm, since the growth remains proportionate. Patients should be taught to examine themselves for signs of growth after maturity, because this may signal malignant degeneration. Bone scan may be a helpful adjunct if a problem is suspected.

DYSCHONDROSTEOSIS (LERI-WEILL SYNDROME)

Dyschondrosteosis, which was described by Leri and Weill in 1929 (178), is characterized by mild mesomelic short stature (middle segments are shortest). The growth disturbance of the middle segments is most notable in the distal radius, which usually develops a Madelung deformity (178–180). It is inherited in an autosomal dominant fashion, with about 50% penetrance (179,181). The expression is more severe in female patients than in males. It has been demonstrated to involve a mutation or deletion in the short-stature homeobox-containing gene *SHOX* (182).

Clinical Features

Patients usually present by age 8 years because of short stature, disproportion or deformity of the forearms, or wrist pain or deformity (183). The deformity of the distal forearm, or Madelung deformity, is characterized by a deficiency of growth of the volar-ulnar portion of the radius. The differential diagnosis of this phenomenon includes Turner syndrome, trauma, Ollier disease, or multiple hereditary exostoses. Most patients begin to experience pain in the wrist during adolescence, as well as limitation of pronation and supination. A variation on this theme, seen in some patients with dyschondrosteosis, is shortening of both radius and ulna, together without angulation. The mesomelic shortening also involves the lower extremities, specifically the tibio-fibular segments. Here, however, there is not so much angular deformity—only a mild genu varum or ankle valgus usually exists. Short stature is usually, but not always, a feature; adult height ranges from 135 to 170 cm (53 to 66 in.). In one series of patients, deficiency in growth hormone was found, and stature was increased by growth hormone supplementation (184).

Radiographic Features

Madelung deformity is a failure of development of the volar-ulnar part of the distal radial epiphysis. The distal radial epiphysis develops a triangular appearance and a tilt

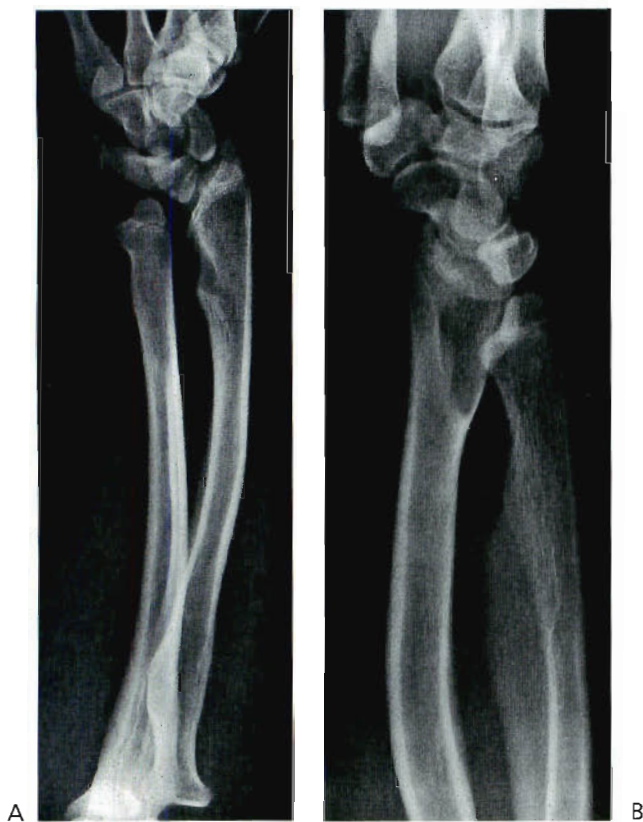

FIGURE 8-39. A: Madelung deformity in the forearm of a patient with dyschondrosteosis. B: The distal radial epiphysis has a markedly triangular epiphysis, and the ulna is dorsally subluxated.

of joint surface (185) (Fig. 8-39A and B). A physeal bar may be seen on CT at the lunate facet (183). The ulna is subluxated or dislocated dorsally. It is as long as, or longer than, the radius, in contrast to other causes of Madelung deformity mentioned in the differential diagnosis (186). The tibia and fibula are short, with the fibula longer than the tibia at the ankle and/or the knee. There may be some degree of genu varum or ankle valgus. Cubitus valgus, hypoplasia of the humeral head, and coxa valga have all been noted, but rarely do all occur in the same patient.

Orthopaedic Implications

Human growth hormone treatment may produce a sustained response, and patients concerned about short stature may be referred to an endocrinologist for discussion of this treatment (184,187). Patients who experience wrist pain may be treated initially by a wrist splint and antiinflammatory agents. If still symptomatic, a reconstruction with a double osteotomy of the distal radius and an ulnar recession, provides good results (188). This has shown improvement in symptoms and clinical appearance, but lunate subluxa-

tion, grip strength, and range of motion were minimally influenced (180). Although it has been described, it is unclear whether bar resection can allow normal growth to occur. Osteotomy of the tibia is occasionally indicated to correct genu varum (179).

CLEIDOCRANIAL DYSPLASIA

Cleidocranial dysplasia is a true skeletal dysplasia, because it affects the growth of many bones in all parts of the skeleton, primarily those of membranous origin. Classic features include a widening of the cranium, as well as dysplasia of the clavicle and the pelvis (189,190). The incidence is estimated at 1 : 200,000 (191). It is transmitted as an autosomal dominant condition, and the defect is in the *CFBA1* gene, which encodes a transcription factor required for osteoblast differentiation (192–194).

Clinical Features

Although the name suggests that only two bones are affected, there are numerous abnormalities. The patients have mildly to moderately diminished stature, with most female and some male patients below the fifth percentile for age. There is bossing in the frontal parietal and occipital regions. The maxillary region is underdeveloped, giving apparent exophthalmos and maxillary micrognathism. Cleft palate and dental abnormalities are common (195–198).

The clavicles are partially or completely absent (197); complete absence is present only 10% of the time. This causes the shoulders to drop and the neck to appear longer. The classic diagnostic feature is that the shoulders can be approximated, an ability which helped one college wrestler to escape holds (198). The pelvis is narrow. The hips are occasionally unstable at birth. Coxa vara may occur, causing limitation of abduction and a Trendelenburg gait. There is an increased incidence of scoliosis, and often a double thoracic curve. Syringomyelia has been reported in several patients with cleidocranial dysplasia and scoliosis (199–201). It has been recommended to perform MRI in patients with this dysplasia who have progressive scoliosis.

Radiographic Features

Prenatal radiographic diagnosis may be made on the basis of small or absent clavicles (Fig. 8-40). Nomograms are available for clavicular size during gestation (202). If a portion of the clavicle is present, it is usually the medial end. The skull of a newborn with this disorder has the maturation of a 20-week fetus (195). Wormian bones are present in the skull. The anterior fontanel may be open in adulthood (Fig. 8-41). In the vertebral column, spina bifida occulta and spondylolysis are common (203). The pelvis is narrow,

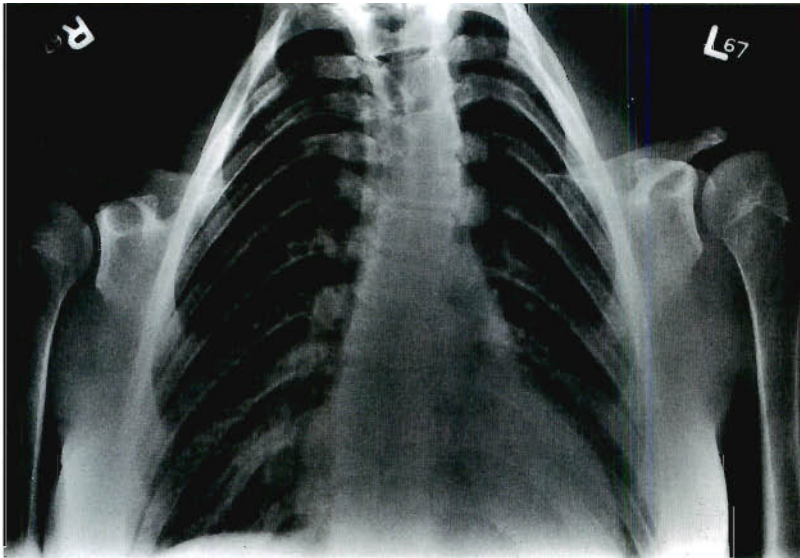


FIGURE 8-40. The clavicles are completely absent in the patient with cleidocranial dysplasia, although in many patients they are merely hypoplastic. There is also a characteristic mild scoliosis and an occult bifid lamina of T2.

and shows widening of the triradiate cartilage, delay in pubic ossification, and progressive deformation of the base of the femoral neck into varus (Fig. 8-42).

Orthopaedic Implications

No treatment is indicated for the clavicles. The coxa vara may be treated by valgus osteotomy if the neck shaft angle

is less than 100 degrees (204). If there is acetabular dysplasia, this should be corrected first. Scoliosis should be treated according to usual guidelines. MRI should be performed if the curve is progressive, because of the increased risk of syringomyelia.

Cesarean section is often necessary. Craniofacial surgery may be helpful in correcting the skull defects, and many dental problems may develop. Pregnant women may have cephalopelvic disproportion, especially if the fetus has the same disorder, because of the mother's narrow pelvis and the fetus' enlarged cranium.

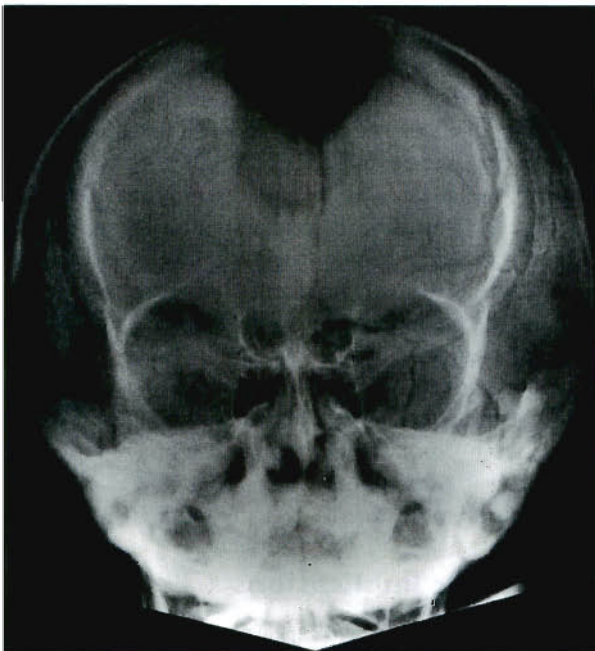

FIGURE 8-41. The skull in this teenager with cleidocranial dysplasia shows an enlarged cranium, widened sutures, and a persistent anterior fontanel.

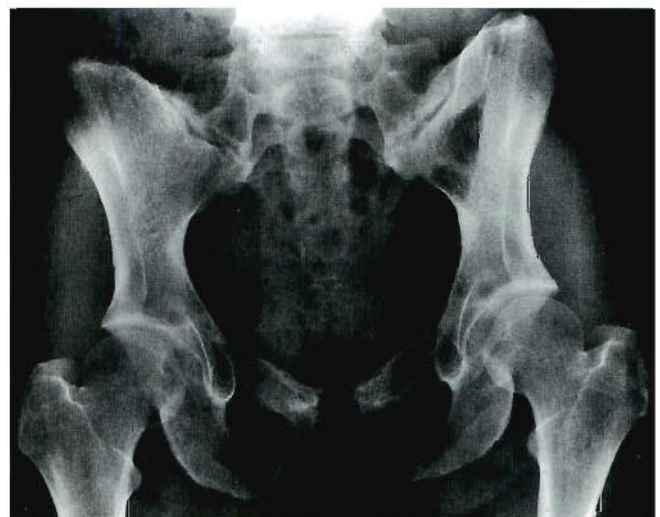

FIGURE 8-42. The pelvis in cleidocranial dysplasia is narrow. The symphysis pubis is widened, the ischiopubic synchondrosis is unossified, and there is mild coxa vara.

LARSEN SYNDROME

This syndrome was first described in 1950, when six cases were described having the unique combination of hypertelorism, multiple joint dislocations, and focal bone deformities (205). It has been reported in both autosomal dominant and recessive patterns. The gene is on chromosome 3 near, but distinct from, *COL7A1* locus 4,207; nothing more is currently known about it.

Clinical Features

The facial appearance involves widely spaced eyes, a depressed nasal bridge, and a prominent forehead. Cleft palate is common. The thumb has a wide distal phalanx and the fingers do not taper distally. Hypotonia has also been reported, but this may result from cervical compression (207). Sudden death has been reported (205,208), most was likely due to exacerbation of this compression. Dislocations most commonly involve the elbows (or radial heads), hips, and knees (Fig. 8-43), followed by the midfoot and shoulders. Characteristic foot deformities involve equinovarus or equinovalgus. Atrial and ventricular septal defects have been reported. Within the range of abnormalities just described, every patient with this syndrome is unique in his or her pattern of associated problems.

Radiographic Features

There does not appear to be a theme to the radiographic findings in this syndrome. Virtually every patient described,

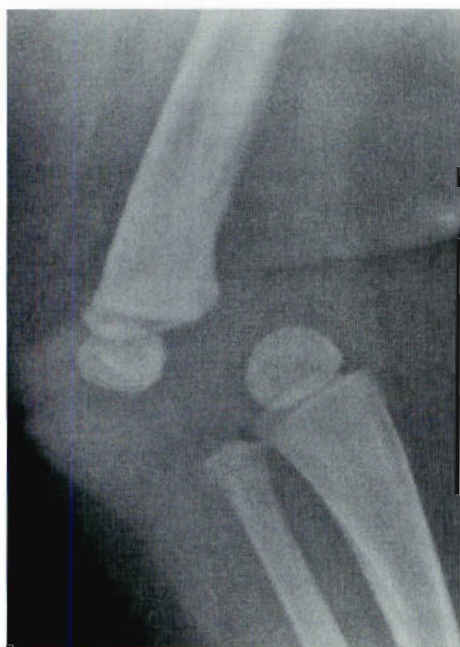

FIGURE 8-43. Congenital anterior knee dislocation is common in Larsen syndrome.

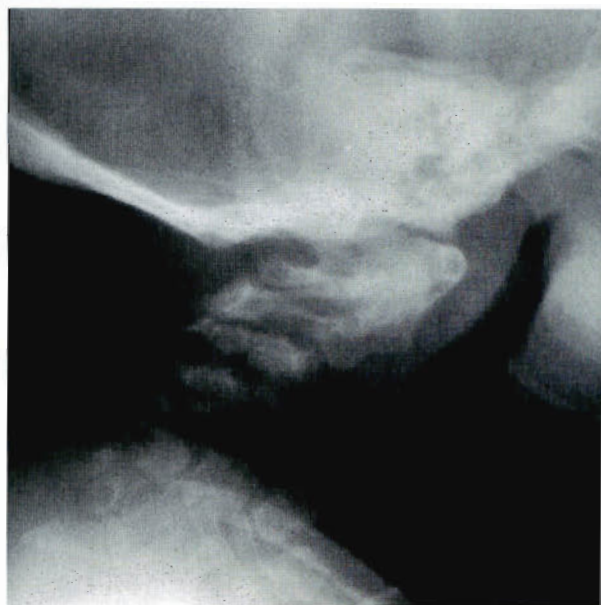

FIGURE 8-44. Cervical kyphosis occurs in many patients with Larsen syndrome, in association with spina bifida occulta of this region. The disorder is usually progressive. (Courtesy of George S. Bassett, M.D.)

however, has some abnormality in some part of the spine. The cervical spine is the most commonly and severely affected. Spina bifida is very common in the cervical spine. Perhaps because of this, the cervical vertebrae may develop a progressive kyphosis (Fig. 8-44). The vertebral bodies in this situation are very hypoplastic, especially C4 and C5. It is not clear whether this vertebral hypoplasia is a result of pressure from the kyphosis, or a separate, coincidental phenomenon that coexists with the posterior element deficiency. The incidence of cervical kyphosis in different series ranges from none to 60% (207,209,210). Other cervical problems that may occur include atlantoaxial or subaxial instability (209) and spondylolisthesis of vertebrae. The thoracic spine may also manifest spina bifida; scoliosis is seen in many, but it is usually mild and rarely requires treatment (209). In the lumbar spine, spondylolysis, kyphosis, scoliosis, and back pain may occur (209). Sacral spina bifida is common, but no neurologic compromise is reported.

One of the characteristic (although not universal) findings in Larsen syndrome is the presence of accessory calcaneal or carpal ossification centers (Fig. 8-45). Shortened metacarpals are also noted.

Orthopaedic Implications

At the beginning of treatment, the orthopaedic surgeon must rule out the cervical kyphosis that may accompany this syndrome, because of the catastrophic complications that have been reported. It may be easy to ascribe any developmental delay to the many other skeletal problems these

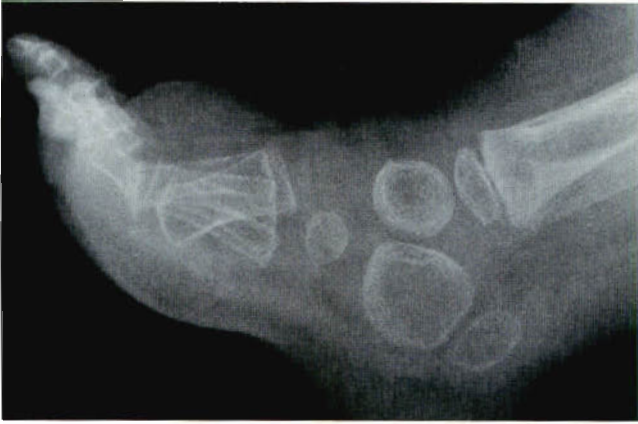

FIGURE 8-45. The feet in Larsen syndrome are usually in equinovarus, and show a characteristic accessory calcaneal ossification center.

children have, when in fact the cervical kyphosis may cause a neurologic basis for it. Because spontaneous improvement has not been reported in this kyphosis, as it has been in DD, it should be fused posteriorly if it exceeds about 35 to 45 degrees. At this level, posterior fusion alone over the involved segments may be successful, and may result in spontaneous correction with growth by acting as a posterior tether. If the kyphosis progresses to the point of myelopathy, an anterior corpectomy and fusion may be needed, and anterior growth will not occur. If enough iliac crest bone is not available for fusion, tibial bone may be used. After surgery, the patient should be in a brace or cast for 4 to 6 months (207). Laryngotracheomalacia may complicate induction of anesthesia.

The lower extremity problems are usually treated in a sequence beginning with the feet and the knees, then the hips. Treatment for clubfeet may be started early, inasmuch as some respond to manipulation and cast treatment with tenotomy. Recurrence is common, and should then be treated with complete subtalar release and shortening osteotomy or decancellation, as necessary. Knees that are hyperextended or subluxatable may be treated with casts as well, but this is unlikely to succeed in cases of complete dislocation. Such cases usually require open reduction with V-Y quadricepsplasty, anterior capsulotomy, and release of the anterior portions of the collateral ligaments. If cruciate deficiency leads to persistent anterior instability, reconstruction using parapatellar fascia is usually successful.

Whether to reduce hip dislocations in this condition remains controversial. Some series report that they are resistant to treatment (209,210), whereas others report some successful results (208,210). A failed treatment of a dislocated hip is less functional than one left untreated. A reasonable approach is to consider treatment of those hips in which the dislocation is not too high and the acetabulum is not too shallow, for patients with otherwise good prospects for activity. The medial approach [3.3, 3.4] may be used for

infants, but for older children or those with a shallow acetabulum, an anterolateral approach [3.2] is preferred, with osteotomy or augmentation. If the hip subluxates easily or has a narrow safe zone, the clinician should not hesitate to perform a femoral shortening and derotation. My preference is to begin cast treatment for the feet and knees together, then to operate on the knees if they are resistant, then the feet if they are resistant. By that time, the surgeon will have a better idea of the patient's potential and can decide on the most appropriate approach to the hips.

PERINATAL LETHAL SKELETAL DYSPLASIAS

With the increasing use of prenatal diagnostic tests, the orthopaedic surgeon may be questioned about some of the lethal dysplasias that would not otherwise be encountered in practice. These are mentioned here to provide passing familiarity. The combined incidence of lethal dysplasias has been estimated at 15 per 100,000 births in one population. The natural history of these conditions should be considered carefully if one is facing a decision to provide respiratory support.

Thanatophoric dysplasia is characterized by disproportionately small limbs, normal trunk length, a protuberant abdomen, and a large head with frontal bossing. The chest is narrow and the lungs hypoplastic. The femora are bowed, and their appearance has been likened to old-style telephone receivers. There is phenotypic resemblance to homozygous achondroplasia, and in fact this condition results from a mutation in the same gene, fibroblast growth factor receptor protein-3. Only a few children with this disorder have been reported to survive past age 2 years, even with full respiratory support.

Achondrogenesis is characterized by a short trunk, large head, distended abdomen, and severely underdeveloped limbs. It has been subclassified into four types. It may be autosomal dominant or recessive. In fact, achondrogenesis type I results from a mutation in the DD sulfate transporter.

Survival beyond birth is very rare. No treatment is available to prolong the life span at present. Atelosteogenesis, of which there are two types, is characterized by dislocations of large joints and in some cases, clubfeet. Midface hypoplasia, micrognathism, and a narrow chest are also seen. At least one of the two types results from a mutation in the DD sulfate transporter.

Short rib–polydactyly syndrome is autosomal recessive and is characterized by polydactyly, which is classically postaxial but may be preaxial, short horizontal ribs, and defects in the kidneys and lungs.

Osteogenesis imperfecta type II is arguably a skeletal dysplasia. Because of the poor prognosis, some of these children have been treated by bone marrow transplants, with reports of prolonged survival.

Conditions that may be, but are not always, lethal in the neonatal period include: achondroplasia (homozygous form), rhizomelic chondrodysplasia punctata, campromelic dysplasia, and a congenital form of hypophosphatasia.

Appendix 1: Clinical Summaries of Important Skeletal Dysplasias

Achondroplasia

Genetic Transmission: Autosomal dominant, but most patients have *de novo* mutation
 Gene Defect: Highly uniform mutation in fibroblast growth factor receptor-3
 Key Clinical Features: Stenosis of spine (esp. lumbar) or foramen magnum; thoracolumbar kyphosis; genu varum
 Key Treatment Points: Brace thoracolumbar kyphosis if over 2 years old; decompress symptomatic stenosis; C-spine is stable; osteotomies for genu varum if symptomatic

Hypochondroplasia

Genetic Transmission: Autosomal dominant
 Genetic Defect: Most in fibroblast growth factor receptor protein-3 (different domain)
 Key Clinical Features: Mild short stature; mild spinal stenosis
 Key Treatment Implications: May benefit from growth hormone and/or limb lengthening

Metatropic Dysplasia

Genetic Transmission: Autosomal dominant or recessive
 Genetic Defect: Unknown
 Key Clinical Features: Infant mortality risk; coccygeal tail, enlarged metaphyses, and contractures; kyphoscoliosis
 Key Treatment Points: Rule out cervical instability; possible role for spine fusion

Chondroectodermal Dysplasia

Genetic Transmission: Autosomal recessive
 Genetic Defect: Unknown
 Key Clinical Features: Cardiac defects, teeth and nails abnormal, postaxial polydactyly; genu valgus, external femoral rotation

Diastrophic Dysplasia

Genetic Transmission: Autosomal recessive
 Genetic Defect: Diastrophic dysplasia sulfate transporter abnormal in all cartilage
 Key Clinical Features: "Hitchhiker" thumbs and "cauliflower" ears; joint contractures, cervical kyphosis; scoliosis; degenerative joint disease, equinovarus feet
 Key Treatment Points: Monitor cervical kyphosis, fuse if increasing; correct feet; treat scoliosis, DJD

Kniest Dysplasia

Genetic Transmission: Autosomal dominant
 Genetic Defect: Type II collagen, *COL2A1*, usually exons 12–24
 Key Clinical Features: Large stiff joints; equinovarus; risk retinal detachment and odontoid hypoplasia

Spondyloepiphyseal Dysplasia Congenita

Genetic Transmission: Autosomal dominant
 Genetic Defect: Type II Collagen, *COL2A1*
 Key Clinical Features: Severely short stature, C1-2 instability, scoliosis, hip dysplasia, possible equinovarus foot

Spondyloepiphyseal Dysplasia Tarda

Genetic Transmission: X-linked most common
 Genetic Defect: Type II collagen (*COL2A1*)
 Key Clinical Features: Hip, back, or knee pain develop in later childhood/adolescence; mild scoliosis

Pseudoachondroplasia

Genetic Transmission: Autosomal dominant
 Genetic Defect: Cartilage oligomeric matrix protein (COMP)
 Key Clinical Features: Ligamentous laxity, windswept knees; size normal at birth, but falls behind

Multiple Epiphyseal Dysplasia

Genetic Transmission: Autosomal dominant
 Genetic Defect: Some forms from cartilage oligomeric matrix protein (COMP), other forms from type IX collagen
 Key Clinical Features: Near-normal stature; epiphyseal deformation of large joints with symptoms in late childhood or adulthood
 Key Treatment Points: Observation versus acetabular coverage in childhood; joint replacement in adulthood

Chondrodysplasia Punctata

Genetic Transmission: Multiple
 Genetic Defect: Rhizomelic form from peroxisomal enzyme deficiency; other forms unknown
 Key Clinical Features: Neonatal stippling of epiphyses; early mortality (most rhizomelic patients)
 Key Treatment Points: Evaluate and treat atlantoaxial instability, congenital scoliosis, coxa vara

Metaphyseal Chondrodysplasias

Mode of Inheritance: McKusick: autosomal recessive; Schmid, Jansen, and Kozlowski: autosomal dominant
 Key Clinical Features: Metaphyseal irregularities with normal epiphyses; genu varum, mild short stature, fine sparse hair; immune and GI disorders in McKusick type
 Key Treatment Points: Rule out rare atlantoaxial instability; correct genu varum if severe; monitor medical problems in McKusick type

Diaphyseal Aclasia (Multiple Osteocartilaginous Exostosis)

Genetic Transmission: Autosomal dominant
 Genetic Mutation: Mutations found on chromosomes 8, 11, and 19
 Key Clinical Features: Short stature, impingement on tendons and nerves, angular deformities, limb length inequality, malignant degeneration
 Key Treatment Implications: Monitor for growth disturbances, remove symptomatic exostoses, educate about signs of slight malignant degeneration

Dyschondrosteosis (Leri-Weill Syndrome)

Genetic Mutation: Short stature homeobox gene (*SHOX*)
 Key Treatment Points: Osteotomies may be indicated to correct forearm deformities

Cleidocranial Dysplasia

Genetic Transmission: Autosomal dominant
 Genetic Defect: Defect in human *CBFA1* gene
 Key Clinical Features: Widened cranium, clavicles partially or completely absent, unossified pubic rami; hip abnormalities
 Key Treatment Issues: Hip surgery for dysplasia or varus; care of dental, cranial, and obstetric problems

Larsen Syndrome

Genetic Transmission: Autosomal dominant or recessive
 Genetic Defect: Unknown
 Key Clinical Features: Widely spaced eyes, depressed nasal bridge, multiple joint dislocations, cervical kyphosis

References

General Principles

1. Beighton P. *McKusick's heritable disorders of connective tissue*. St. Louis: Mosby-Year Book, 1993.

2. Beighton P, Geidon A, Gorlin R, et al. International classification of osteochondrodysplasias. *Am J Med Genet* 1992;44:223.
3. Goncalves L, Jeanry P. Fetal biometry of skeletal dysplasias: a multicentric study. *J Ultrasound Med* 1994;13:767.
4. Tobias JD. Anesthetic implications of Larsen syndrome. *J Clin Anesth* 1996;8(3):255.
5. Bethem D, Winter RB, Lutter I, et al. Spinal disorders of dwarfism: review of the literature and report of eighty cases. *J Bone Joint Surg Am* 1981;63:1412.
6. Bethem D, Winter RB, Lutter I. Disorders of the spine in diastrophic dwarfism. *J Bone Joint Surg Am* 1981;62:529.

Achondroplasia

7. Dietz FR, Matthews KD. Current concepts review: update on the genetic bases of disorders with orthopaedic manifestations. *J Bone Joint Surg Am* 1996;78:1583.
8. Hall JG. The natural history of achondroplasia. *Basic Life Sci* 1988;48:3.
9. Horton WA. Fibroblast growth factor receptor 3 and the human chondrodysplasias. *Curr Opin Pediatr* 1997;9:437.
10. Muenke M, Schell U. Fibroblast growth factor receptor mutations in human skeletal disorders. *Trends Genet* 1981;11:308.
11. Seino Y, Moriwake T, Tanaka H, et al. Molecular defects in achondroplasia and the effects of growth hormone treatment. *Acta Pediatr* 1999;428(suppl):118.
12. Shiang R, Thompson LM, Zhu Y-Z, et al. Mutations in the transmembrane domain of FGFR3 cause the most common genetic form of dwarfism, achondroplasia. *Cell* 1994;78:335.
13. Wynn-Davies R, Walsh WK, Gormley J. Achondroplasia and hypochondroplasia: clinical variation and spinal stenosis. *J Bone Joint Surg Br* 1981;63:508.
14. Maynard JA, Ippolito EG, Ponseti IV, et al. Histochemistry and ultrastructure of the growth plate in achondroplasia. *J Bone Joint Surg Am* 1981;63:969.
15. Ponseti IV. Skeletal growth in achondroplasia. *J Bone Joint Surg Am* 1970;52:701.
16. Bailey JA. Orthopaedic aspects of achondroplasia. *J Bone Joint Surg Am* 1970;52:1285.
17. Nehme A-ME, Riseborough EJ, Tredwell SJ. Skeletal growth and development of the achondroplastic dwarf. *Clin Orthop* 1976;116:88.
18. Pauli RM, Breed A, Horton VK, et al. Prevention of fixed, angular kyphosis in achondroplasia. *J Pediatr Orthop* 1997;17:726.
19. Scott CI. Achondroplastic and hypochondroplastic dwarfism. *Clin Orthop* 1976;114:18.
20. Pauli RM, Horton VK, Glines LP, et al. Prospective assessment of risks for cervicomedullary-junction compression in infants with achondroplasia. *Am J Human Genet* 1995;56:732.
21. Pierre-Kahn A, Hirsch JF, Renier D. Hydrocephalus and achondroplasia: a study of 25 observations. *Childs Brain* 1980;7:205.
22. Todorov AB, Scott CI, Warren AE, et al. Developmental screening tests in achondroplastic children. *Am J Med Genet* 1981;9:19.
23. Hecht JT, Nelson FW, Butler IJ, et al. Computerized tomography of the foramen magnum: achondroplastic values compared to normal standards. *Am J Med Genet* 1985;20:355.
24. Hecht JT, Horton W, Reid CS, et al. Growth of the foramen magnum in achondroplasia. *Am J Med Genet* 1989;32:528.
25. Lutter LD, Lonstein JE, Winter RB, et al. Anatomy of the achondroplastic lumbar canal. *Clin Orthop* 1977;126:139.
26. Lutter LD, Langer LO. Neurological symptoms in achondroplastic. *J Bone Joint Surg Am* 1977;59:87.
27. Waters KA, Everett FM, Silience DO, et al. Treatment of obstructive sleep apnea in achondroplasia; evaluation of sleep, breathing and somatosensory-evoked potentials. *Am J Med Genet* 1995;59:460.
28. Hecht JA, Francomano C, Horton W, et al. Mortality in achondroplasia. *Am J Hum Genet* 1987;41:454.
29. Horton WA, Hecht JT, Hood OJ, et al. Growth hormone therapy in achondroplasia. *Am J Med Genet* 1992;42:667.
30. Tanaka H, Kubo T, Yamate T, et al. Effect of growth hormone therapy in children with achondroplasia: growth pattern, hypothalamic-pituitary function and genotype. *Eur J Endocrinol* 1998;138:275.
31. Berkowitz RG, Grundfast KM, Scott C, et al. Middle ear disease in childhood achondroplasia. *Ear Nose Throat J* 1991;70:305.
32. Glass L, Shapiro I, Hodge S, et al. Audiological findings of patients with achondroplasia. *J Pediatr Otorhinolaryngol* 1981;11:129.
33. Zucconi M, Weber G, Castronov V, et al. Sleep and upper airway obstruction in children with achondroplasia. *J Pediatr* 1996;129:743.
34. Stokes DC, Pyeritz RE, Wise RA, et al. Spirometry and chest wall dimensions in achondroplasia. *Chest* 1988;93:34.
35. Stokes DC, Woh ME, Wise RA, et al. The lungs and airways in achondroplasia. Do little people have little lungs? *Chest* 1988;98:145.
36. Dietz FR. Spike osteotomy for angular deformities of the long bones in children. *J Bone Joint Surg Am* 1988;70:848.
37. Rab GT. Oblique tibial osteotomy for tibia vara. *J Pediatr Orthop* 1988;8:715.
38. Aldighieri R. Femoral callorasis. *J Pediatr Orthop* 1997;17B:42.
39. Aldighieri R. Distraction osteogenesis for lengthening of the tibia in patients who have limb-length discrepancy of short stature. *J Bone Joint Surg Am* 1999;81:624.
40. Villarrubias JM, Ginebreda I, Jimeno E. Lengthening of the lower limbs and correction of lumbar hyperlordosis in achondroplasia. *Clin Orthop* 190;250:143.
41. Siebens AA, Hungerford DS, Kirgy NA. Curves of the achondroplastic spine: a new hypothesis. *Johns Hopkins Med J* 1978;142:205.
42. Kopits SE. Orthopaedic complications of dwarfism. *Clin Orthop* 1976;114:153.
43. Tolo VT. Surgical treatment of kyphosis In: Nicoletti B, ed. *Achondroplasia: human achondroplasia, a multidisciplinary approach*. New York: Plenum, 1986:257.
44. Pyeritz RE, Sack GH, Udvarhelyi GB. Thoracolumbosacral laminectomy in achondroplasia: long-term results in 22 patients. *Am J Med Genet* 1987;28:433.
45. Uematsu S, Hurko O. The subarachnoid fluid space in achondroplastic spinal stenosis: the surgical implications. In: Nicoletti B, ed. *Achondroplasia: human achondroplasia, a multidisciplinary approach*. New York: Plenum, 1986:275.

Hypochondroplasia

46. Horton WA. Evolution of the bone dysplasia family. *Am J Med Genet* 1996;63:4.
47. Rousseau F, Bonaventure J, Legeai-Mallet L, et al. Clinical and genetic heterogeneity of hypochondroplasia. *J Med Genet* 1996;33:749.
48. Su WC, Kitawaga M, Xue N, et al. Activation of Stat1 by mutant fibroblast growth-factor receptor in thanatophoric dysplasia type II dwarfism. *Nature* 1997;386:288.
49. Beals RK. Hypochondroplasia: a report of five kindreds. *J Bone Joint Surg Am* 1969;51:728.
50. Hall BD, Spranger J. Hypochondroplasia: clinical and radiological aspects in 39 cases. *Radiology* 1979;133: 95.
51. Fasanelli S. Hypochondroplasia: radiological diagnosis and differential diagnosis. In: Nicoletti B, ed. *Achondroplasia: human*

achondroplasia, a multidisciplinary approach. New York: Plenum, 1999:163.

52. Oberklaid F, Danks DM, Jansen F, et al. Achondroplasia and hypochondroplasia. Comments on frequency, mutation rate, and radiological features in skull and spine. *J Med Genet* 1979; 16:140.
 53. Ramaswami U, Hindmarsh PC, Brook CGD. Growth hormone therapy in hypochondroplasia. *Acta Paediatr* 1999;428(suppl): 116.
 54. Yasui N, Kawabata H, Kojimoto H, et al. Lengthening of the lower limbs in patients with achondroplasia and hypochondroplasia. *Clin Orthop* 1997;Nov(344):298.
- ### Metatropic Dysplasia
55. Rimoin DW, Siggers DC, Lachman RS, et al. Metatropic dwarfism, the Kneist syndrome and the pseudoachondroplastic dysplasias. *Clin Orthop* 1982;176:70.
 56. Boden SD, Kaplan FS, Fallon MD, et al. Metatropic dwarfism. uncoupling of endochondral and perichondral growth. *J Bone Joint Surg Am* 1987;69:174.
 57. Shohat M, Lachman R, Rimoin DL. Odontoid hypoplasia with vertebral subluxation and ventriculomegaly in metatropic dysplasia. *J Pediatr* 1989;114:239.
 58. Beck M, Roubicek M, Rogers JG, et al. Heterogeneity of metatropic dysplasia. *Eur J Pediatr* 1983;140:231.
 59. Maroteaux P, Sprange JW, Weidemann HR. Der metatrophische Zwergwuchs. *Arch Kinder* 1966;173: 211.
 60. Gordienko IY, Grechanin EY, Sopko NI, et al. Prenatal diagnosis of osteochondrodysplasias in high risk pregnancy. *Am J Med Genet* 1996;63:90.
 61. Manouvrier-Hanu S, Devisme L, Zelasko MC, et al. Prenatal diagnosis of metatropic dwarfism. *Prenatal Diag* 1995;15:753.
- ### Chondroectodermal Dysplasia
62. Ellis RWB, van Creveld S. A syndrome characterized by ectodermal dysplasia, polydactyly, chondrodysplasia and congenital morbis cordia. *Arch Dis Child* 1940;15:65.
 63. Ide SE, Ortiz de Luna RI, Francomano CA, et al. Exclusion of the MAX1 homeobox gene as the gene for the Ellis van Creveld syndrome in the Amish. *Hum Genet* 1996;98:572.
 64. Polymeropoulos MH, Ide SE, Wright M, et al. The gene for the Ellis-van Creveld syndrome is located on chromosome 4p16. *Genomics* 1996;35:1.
 65. Qureshi F, Jacques SM, Evans MI, et al. Skeletal histopathology in fetuses with chondroectodermal dysplasia (Ellis van Creveld syndrome). *Am J Med Genet* 1996;3:471.
 66. Kaitila H, Leisti JT, Rimoin DL. Mesomelic skeletal dysplasias. *Clin Orthop* 1976;114:94.
 67. McKusick VA, Egeland JA, Eldridge R. Dwarfism in the Amish. *Johns Hopkins Hosp Bull* 1964;115:125.
 68. Pinelli G, Cortefava F, Senes FM, et al. Ellis-van Creveld syndrome: description of four cases: orthopedic aspects. *Ital J Orthop Traumatol* 1990;16:113.
 69. Kruse RK, Bowen JR. Oblique tibial osteotomy in the correction of tibial deformity in children. *J Pediatr Orthop* 1989;9: 476.
 70. Paley D, Tetsworth K. Mechanical axis deviation of the lower limbs: preoperative planning of uniapical frontal plane angular and bowing deformities of the femur or tibia. *Clin Orthop* 1992; 280:65.
- ### Diastrophic Dysplasia
71. Hollister DW, Lachman RS. Diastrophic dwarfism. *Clin Orthop* 1976;114:61.
 72. Ryoeppey S, Poussa M, Merikanto J, et al. Foot deformities in diastrophic dysplasia. An analysis of 102 patients. *J Bone Joint Surg Br* 1992;74:441.
 73. Hastbacka J, Kaitila I, Sistonen P, et al. A linkage map spanning the locus for diastrophic dysplasia (DTD). *Genomics* 1991; 11:968.
 74. Hastbacka J, De la Chapelle A, Mahtani MM, et al. The diastrophic dysplasia gene encodes a novel sulfate transporter. *Cell* 1994;78:1073.
 75. Superti-Furga A, Rossi A, Steinmann B, et al. Achondrodysplasia family produced by mutations in the diastrophic dysplasia sulfate transporter gene: genotype/phenotype correlations. *Am J Med Genet* 1996;63:144.
 76. Lamy M, Maroteaux P. Le nanisme diastrophique. *Presse Med* 1990;68:1977.
 77. Qureshi F, Jacques SM, Johnson SF, et al. Histopathology of fetal diastrophic dysplasia. *Am J Med Genet* 1995;56:300.
 78. Walker BA, Scott CI, Hall JG, et al. Diastrophic dwarfism. *Medicine (Baltimore)* 1972;51:41.
 79. Poussa M, Merikanto J, Ryoeppey S, et al. The spine in diastrophic dysplasia. *Spine* 1991;16:881.
 80. Herring JA. The spinal disorders in diastrophic dwarfism. *J Bone Joint Surg Am* 1978;60:177.
 81. Remes V, Marttinen E, Poussa M, et al. Cervical kyphosis in diastrophic dysplasia. *Spine* 1999;24:1990.
 82. Kash IJ, Sane SM, Samaha FJ. Cervical cord compression in diastrophic dwarfism. *J Pediatr* 1974;84:862.
 83. Tolo VT, Kopits SE. Spinal deformity in diastrophic dysplasia. *Orthop Trans* 1983;7:1983.
 84. Vaara P, Peltonen J, Poussa M, et al. Development of the hip in diastrophic dysplasia. *J Bone Joint Surg Br* 1998;80:315.
 85. Horton WA, Rimoin DL, Lachman RS, et al. The phenotypic variability of diastrophic dysplasia. *J Pediatr* 1978;93:609.
 86. Merrill KD. Occipitoatlantal instability in a child with Kneist syndrome. *J Pediatr* 1990;116:596.
 87. Horton WA, Hall JG, Scott CL, et al. Growth curves for height for diastrophic dysplasia, spondyloepiphyseal dysplasia congenita and pseudoachondroplasia. *Am J Dis Child* 1982;136: 316.
 88. Makitie O, Kaitila I. Growth in diastrophic dysplasia. *J Pediatr* 1991;130:641.
 89. Peltonen JL, Hoikka V, Poussa M, et al. Cementless hip arthroplasty in diastrophic dysplasia. *J Arthroplasty* 1992; 7(suppl):369.
- ### Kneist Dysplasia
90. Kneist W. Zur abgrenzung der dysostoses endochondralis von der chondrodystrophie. *Z Kinder* 1952;70:633.
 91. Spranger J, Winterpracht A, Zabel B. Kneist dysplasia: Dr. W. Kneist, his patient, the molecular defect. *Am J Med Genet* 1997; 9:79.
 92. Cole WG. Abnormal skeletal growth in Kneist dysplasia caused by type II collagen mutations. *Clin Orthop* 1997;341:169.
 93. Wilkin DJ, Artz AS, South S, et al. Small deletions in the type II collagen triple helix produce Kneist dysplasia. *Am J Med Genet* 1999;85:105.
 94. Poole AR, Pidoux I, Reiner A, et al. Kneist dysplasia is characterized by an apparent abnormal processing of the C-propeptide of type II collagen resulting in imperfect fibril assembly. *J Clin Invest* 1988;81:579.
 95. Gilbert-Barnes E, Langer L. O. Kneist dysplasia: radiologic histopathologic and scanning EM findings. *Am J Med Genet* 1996; 63:34.
 96. Lachman R, Sillence D, Rimoin D. Diastrophic dysplasia: death of a variant. *Radiology* 1981;140:79.

97. Spranger JW, Maroteaux P. Kneist disease. *Birth Defects* 1974;10:50.
98. Siggers DC, Rimoin DL, Dorst JP, et al. The Kneist syndrome. *Birth Defects* 1974;10:193.

Spondyloepiphyseal Dysplasia Congenita

99. Cole WG, Hall RK, Rogers JG. The clinical features of spondyloepiphyseal dysplasia congenita resulting from the substitution of glycine 997 by serin in the alpha1 (II) chain of type II collagen. *J Med Genet* 1993;30:27.
100. Harrod MJ, Friedman JM, Currarino G, et al. Genetic heterogeneity in spondyloepiphyseal dysplasia congenita. *Am J Med Genet* 1984;18:311.
101. Tiller GE, Weis MA, Polumbo PA, et al. An RNA-splicing mutation in the type II collagen gene in a family with spondyloepiphyseal dysplasia congenita. *Am Hum Genet* 1995;56:388.
102. Wynne-Davies R, Hall C. Two clinical variants of spondyloepiphyseal dysplasia congenita. *J Bone Joint Surg Br* 1982;64:435.
103. Spranger JW, Langer LO Jr. Spondyloepiphyseal dysplasia congenita. *Radiology* 1970;94:313.
104. Williams B, Cranley RE. Morphologic observations on four cases of SED congenita. *Birth Defects* 1974;10:75.
105. LeDoux MS, Naftalis RC, Aronin PA. Stabilization of the cervical spine in spondyloepiphyseal dysplasia congenita. *Neurosurgery* 1991;28:580.

Spondyloepiphyseal Dysplasia Tarda

106. Yang SS, Chen H, Williams P, et al. Spondyloepiphyseal dysplasia congenita: a comparative study of chondrocyte inclusions. *Arch Pathol Lab Med* 1980;104:208.
107. Kaibara N, Takagishi K, Katsuki I. Spondyloepiphyseal dysplasia tarda with progressive arthropathy. *Skeletal Radiol* 1983;10:13.
108. Pinelli G, Cortefava F, Senes FM. Spondyloepiphyseal dysplasia tarda: linkage with genetic markers from the distal short arm of the X chromosome. *Hum Genet* 1988;81:61.
109. Crossan JF, Wynne-Davies R, Fulford GE. Bilateral failure of the capital femoral epiphysis: bilateral Perthes disease, multiple epiphyseal dysplasia, pseudoachondroplasia, and spondyloepiphyseal dysplasia. *Pediatr Orthop* 1986;8:197.
110. Diamond LS. A family study of spondyloepiphyseal dysplasia. *J Bone Joint Surg Am* 1970;52:1587.

Pseudoachondroplasia

111. Maroteaux P, Lamy M. Les formes pseudoachondroplastiques des dysplasies spondyloepisaires. *Presse Med* 1959;67:383.
112. Cooper RR, Ponseti IV, Maynard JA. Pseudoachondroplastic dwarfism. A rough-surfaced endoplasmic reticulum storage disorder. *J Bone Joint Surg Am* 1973;55:475.
113. Deere M, Sanford T, Francomano CA, et al. Identification of nine novel mutations in COMP in patients with pseudoachondroplasia and multiple epiphyseal dysplasia. *Am J Med Genet* 1999;85:486.
114. Ferguson HL, Deere M, Evans R, et al. Mosaicism in pseudoachondroplasia. *Am J Med Genet* 1997;70:287.
115. Stevens JW. Pseudoachondroplastic dysplasia: an Iowa review from human to mouse. *Iowa Orthop J* 1999;19:53.
116. Hecht JT, Montufar-Solis D, Decker G, et al. Retention of COMP and cell death in redifferentiated pseudoachondroplasia chondrocytes. *Matrix Biol* 1998;17:33.
117. Pedrini-Mille A, Maynard JA, Pedrinie VA. Pseudoachondroplasia: biochemical and histochemical studies of cartilage. *J Bone Joint Surg Am* 1984;66:1408.

118. Horton WA, Hall JG, Scott CI, et al. Growth curves for height for diastrophic dysplasia, spondyloepiphyseal dysplasia congenita and pseudoachondroplasia. *Am J Dis Child* 1982;136:316.
119. Hall JG. Pseudoachondroplasia. *Birth Defects* 1975;11:187.
120. Hall JG, Bailey JA, Dorst JP, et al. Pseudoachondroplastic SED, recessive Maroteaux-Lamy type. *Birth Defects* 1969;5:254.
121. McKeand J, Rotta J, Hecht JT. Natural history study of pseudoachondroplasia. *Am J Med Genet* 1996;63:406.
122. Wynne-Davies R, Hall CM, Young ID. Pseudoachondroplasia: clinical diagnosis at different ages and comparison of autosomal dominant and recessive types. A review of 32 patients. *J Med Genet* 1986;23:425.

Multiple Epiphyseal Dysplasia

123. Fairbank T. Dysplasia epiphysealis multiplex. *Br J Surg* 1947;34:325.
124. Ribbing S. Studien uber Hereditaire multiple Epiphysenstorungen. *Acta Radiol* 1937;(suppl):34.
125. Stanescu T, Stanescu V, Muriel ME, et al. Multiple epiphyseal dysplasia, Fairbank type: morphologic and biochemical study of cartilage. *Am J Med Genet* 1993;45:501.
126. Van Mourik JB, Hamel BC, Mariman EC. A large family with multiple epiphyseal dysplasia linked to COL9A2 gene. *Am J Med Genet* 1998;77:234.
127. Jacobs PA. Dysplasia epiphysealis multiplex. *Clin Orthop* 1968;58:117.
128. Schlesinger AE, Poznanski AK, Pudlowski RM, et al. Distal femoral epiphyses: normal standards for thickness and application to bone dysplasias. *Radiology* 1968;159:515.
129. Treble NJ, Jensen FO, Bankier A, et al. Development of the hip in multiple epiphyseal dysplasia. Natural history and susceptibility to premature osteoarthritis. *J Bone Joint Surg Br* 1990;72.
130. MacKenzie WG, Gassett GS, Mandell GA, et al. Avascular necrosis of the hip in multiple epiphyseal dysplasia. *J Pediatr Orthop* 1989;9:666.
131. Apley AG, Weintraub S. The sagging rope sign in Perthes disease and allied disorders. *J Bone Joint Surg Br* 1981;63:43.
132. Hodgkinson HM. Double layered patellae in multiple epiphyseal dysplasia. *J Bone Joint Surg Br* 1962;44:569.
133. Eddy MC, Steiner RD, McAlister WH, et al. Bilateral radial ray hypoplasia with multiple epiphyseal dysplasia. *Am J Med Genet* 1998;77:182.
134. Haga N, Nakamura K, Takikawa K, et al. Stature and severity in multiple epiphyseal dysplasia. *J Pediatr Orthop* 1998;18:394.
135. Spranger J. The epiphyseal dysplasias. *Clin Orthop* 1976;114:46.
136. Kruse RW, Guille JT, Bowen JR. Shelf arthroplasty in patients who have Legg-Calvé-Perthes disease. *J Bone Joint Surg Am* 1991;73:1338.
137. Willet K, Hudson I, Catterall A. Lateral shelf acetabuloplasty: an operation for older children with Perthes disease. *J Pediatr Orthop* 1992;12:563.
138. Ingram RR. The shoulder in multiple epiphyseal dysplasia. *J Bone Joint Surg Br* 1991;73:277.

Chondrodysplasia Punctata

139. Andersen PE, Justesen P. Chondrodysplasia punctata: report of two cases. *Skeletal Radiol* 1987;16:223.
140. Wulfsberg EA, Curtis J, Jayne CH. Chondrodysplasia punctata: a boy linked with X-linked recessive chondrodysplasia punctata due to an inherited x-y translocation with a current classification of these disorders. *Am J Med Genet* 1992;43:823.

141. Borg SA, Fitzner PM, Young LY. Roentgenologic aspects of adult cretinism. *AJR Am J Roentgenol* 1975;123:820.
 142. Hanson JW, Smith DW. The fetal hydantoin syndrome. *J Pediatr* 1975;87:285.
 143. Harrod MJ, Sherrod PS. Warfarin embryopathy in siblings. *Obstet Gynecol* 1981;57:673.
 144. Pauli RM, Lian JB, Mosher DF, et al. Association of congenital deficiency of multiple vitamin K-dependent coagulation factors and the phenotype of the warfarin embryopathy: clues to the mechanism of teratogenicity of coumarin derivatives. *Am J Med Genet* 1987;41:566.
 145. Pike MG, Applegarth DA, Dunn HG, et al. Congenital rubella syndrome associated with calcific epiphyseal stippling and peroxisomal dysfunction. *J Pediatr* 1990;116:88.
 146. Curry CJR, Magenis RE, Brown M, et al. Inherited chondrodysplasia punctata due to deletion of the terminal short arm of X-chromosome. *N Engl J Med* 1984;311:1010.
 147. Wardinsky TD, Pagon RA, Powell BR, et al. Rhizomelic chondrodysplasia punctata and survival beyond one year: a review of the literature and five case reports. *Clin Genet* 1990;38:84.
 148. Gilbert EF, Opitz JM, Spranger JW, et al. Chondrodysplasia punctata—rhizomelic form, pathologic and radiographic studies of three infants. *Eur J Pediatr* 1976;123:89.
 149. Happle R. X-linked dominant chondrodysplasia punctata. *Hum Genet* 1979;53:65.
 150. Mancke H, Christophers E, Wiedmann H-R. Dominant sex-linked inherited chondrodysplasia punctata. *Clin Genet* 1980;17:97.
 151. Silengo MC, Luzzatti L, Silverman FN. Clinical and genetic aspects of Conradi-Hunermann disease: a report of three familial cases and review of the literature. *J Pediatr* 1980;97:911.
 152. Spranger JW, Opitz JM, Bidder U. Heterogeneity of chondrodysplasia punctata. *Humangenetik* 1971;11:190.
 153. Heymans HAS, Oorthuys J, Nelck G, et al. Rhizomelic chondrodysplasia punctata: another peroxisomal disorder. *N Engl J Med* 1985;313:187.
 154. Hoeffler S, Hoeffler G, Moser AB, et al. Prenatal diagnosis of rhizomelic chondrodysplasia punctata. *Prenat Diagn* 1988;8:571.
 155. Mueller RF, Crowle PM, Jones R, et al. X-linked dominant chondrodysplasia punctata. *Am J Med Genet* 1985;20:137.
 156. Rittler M, Menger H, Spranger J. Chondrodysplasia punctata, tibia-metacarpal (TM) type. *Am J Med Genet* 1990;37:200.
 157. Burck U. Mesomelic dysplasia with punctate epiphyseal calcifications. *Eur J Pediatr* 1982;138:67.
 158. Bethem D. Os odontoideum in chondrodystrophia calcificans congenita. A case report. *J Bone Joint Surg Am* 1982;64:1385.
 159. Sheffield LJ, Halliday JL, Danks DM, et al. Clinical, radiologic, and biochemical classification of chondrodysplasia punctata. *Am J Med Genet* 1989;45(suppl A):A64.
 160. Fairbank HAT. Dysplasia epiphysealis punctata. Symptoms: stippled epiphyses, chondrodystrophia calcificans congenita Hünemann. *J Bone Joint Surg Br* 1949;31:114.
 161. Lawrence JJ, Schlensinger AE, Kozlowski K, et al. Unusual radiographic manifestations of chondrodysplasia punctata. *Skeletal Radiol* 1989;18:15.
 162. Cooper RR. Metaphyseal dysplasia: description of an ultrastructural defect in the epiphyseal plate chondrocytes. *J Bone Joint Surg Am* 1973;55:485.
 163. Evans R, Caffey J. Metaphyseal dysostosis resembling vitamin D-refractory rickets. *Am J Dis Child* 1958;95:640.
 164. Kozlowski K. Metaphyseal and spondylometaphyseal chondrodysplasia. *Clin Orthop* 1976;114:83.
 165. Maynard JA, Ippolito EG, Ponseti IV, et al. Histochemistry and ultrastructure of the growth plate in metaphyseal dysostosis: further observations on the structure of the cartilage matrix. *J Pediatr Orthop* 1981;1:161.
 166. Tiller GE, Polumbo PA, Weis MA, et al. Dominant mutations in the type II collagen gene, COL2A1, produce spondyloepimetaphyseal dysplasia, Strudwick type. *Nat Genet* 1995;11:87.
 167. Sulisalo T, van der Burgt I, Rimoin DL, et al. Genetic homogeneity of cartilage-hair hypoplasia. *Hum Genet* 1995;95:157.
 168. Makitie O, Kaitila I. Cartilage-hair hypoplasia—clinical manifestations in 108 Finnish patients. *Eur J Pediatr* 1993;152:211.
 169. Makitie O, Marttinen E, Kaitila I. Skeletal growth in cartilage-hair hypoplasia: a radiologic study of 82 patients. *Pediatr Radiol* 1992;22:434.
 170. Juvonen E, Makitie O, Mäkiperna E, et al. Defective in-vitro colony formation of haematopoietic progenitors in patients with cartilage-hair hypoplasia and history of anemia. *Eur J Pediatr* 1995;154:30.
 171. Berthet F, Siegrist CA, Ohsahin H, et al. Bone marrow transplantation in cartilage-hair hypoplasia. *Eur J Pediatr* 1996;155:286.
 172. van der Burgt I, Haraldsson A, Oosterwijk JC, et al. Cartilage hair hypoplasia. description of seven patients and review of the literature. *Am J Med Genet* 1991;41:371.
 173. Wasylenko MJ, Wedge JH, Houston CS. Metaphyseal chondrodysplasia, Schmid type. *J Bone Joint Surg Am* 1980;62:660.
 174. Paschalis EP, Jacenko O, Olsen B, et al. Fourier transform infrared microspectroscopic analysis identifies alterations in mineral properties in bones from mice transgenic for type X collagen. *Bone* 1996;19:151.
 175. Wallis GA, Rash B, Sykes B, et al. Mutations within the gene encoding the alpha1 (X) chain of type X collagen cause metaphyseal chondrodysplasia type Schmid but not several other forms. *J Med Genet* 1996;33:450.
 176. Chan D, Weng YM, Hocking AM, et al. Site-directed mutagenesis of type X collagen. *J Biol Chem* 1996;271:13566.
 177. Schipani E, Jensen GS, Pincus J, et al. Constitutive activation of the cyclic adenosine monophosphate signaling pathway by parathyroid hormone receptors mutated at the two loci for Jansen's metaphyseal chondrodysplasia. *Mol Endocrinol* 1997;11:851.
- ### Dyschondrosteosis (Leri-Weill Syndrome)
178. Leri A, Weill J. Une affection congenitale et symmetrique du developpement osseux: la dyschondrosteose. *Bull Med Soc Hosp Paris* 1929;53:1491.
 179. Dawe C, Wynne-Davies RW, Fulford GE. Clinical variation in dyschondrosteosis. *J Bone Joint Surg Br* 1982;64:377.
 180. Murphy MS, Linscheid RL, Dobyns JH, et al. Radial opening wedge osteotomy in Madelung's deformity. *J Hand Surg* 1996;21A:1035.
 181. Mohan V, Gupta RP, Helmi K, et al. Leri-Weill syndrome: a family study. *J Hand Surg Br* 1988;13:16.
 182. Shears DJ, Vassal HJ, Goodman FR, et al. Mutation and deletion of the pseudoautosomal gene SHOX causes Leri-Weill dyschondrosteosis. *Nat Genet* 1998;19:70.
 183. Cook PA, Yu JS, Wiand W, et al. Madelung deformity in skeletally immature patients: morphologic assessment using radiography, CT and MRI. *J Comput Assist Tomogr* 1996;20:505.
 184. Thuestad IJ, Ivarsson SA, Nilsson KO, et al. Growth hormone treatment in Leri-Weill syndrome. *J Pediatr Endocrinol Metab* 1996;9:201.
 185. Felman AH, Kirkpatrick JA. Dyschondrosteoses: mesomelic dwarfism of Leri and Weill. *Am J Dis Child* 1999;120:329.
 186. Langer LO. Dyschondrosteosis, a heritable bone dysplasia with

Metaphyseal Chondrodysplasias

- characteristic roentgenographic features. *AJR Am J Roentgenol* 1965;95:178.
187. Burren CP, Werther GA. Skeletal dysplasias: response to growth hormone therapy. *J Pediatr Endocrinol Metab* 1996;9:31.
 188. Vickers D, Nielsen G. Madelung deformity: surgical prophylaxis (physiolysis) during the late growth period by resection of the dyschondrosteosis lesion. *J Hand Surg Br* 1992;17:401.
- ### Cleidocranial Dysplasia
189. Bick EM, Marie P, Saiton P. The classic: on hereditary cleidocranial dysostosis. *Clin Orthop* 1968;58:5.
 190. Marie P, Seinton P. Observation d'hydrocephalie hereditaire par vice de developpement du crane et du cerveau. *Rev Neurol* 1897;5:394.
 191. Martinez-Frias ML, Herranz I, Salvador AI. Prevalence of dominant mutations in Spain: effect of changes in maternal age distribution. *Am J Med Genet* 1988;31:645.
 192. Geoffroy V, Corral DA, Ahou L, et al. Genomic organization, expression of the human CBFA1 gene, and evidence for an alternative splicing event affecting protein function. *Mamm Genome* 1999;9:54.
 193. Lee B, Thirunavukkarasu K, Zhou L, et al. Missense mutations abolishing DNA binding of the osteoblast-specific transcription factor OSF2/CBFA1 in cleidocranial dysplasia. *Nat Genet* 1997;16:307.
 194. Otto F, Thornell AP, Crompton T. *cfba1*, a candidate gene for cleidocranial dysplasia syndrome, is essential for osteoblast differentiation and bone development. *Cell* 1997;89:765.
 195. Jensen BL. Somatic development in cleidocranial dysplasia. *Am J Med Genet* 1990;35:69.
 196. Jensen BL. Development of the skull in infants with cleidocranial dysplasia. *J Craniofac Genet Dev Biol* 1993;13:89.
 197. Miles PW. Cleidocranial dysostosis: a survey of six new cases and 126 from the literature. *J Kansas Med Soc* 1940;41:462.
 198. Gupta SK, Sharma OP, Malhotra S, et al. Cleidocranial dysostosis—skeletal abnormalities. *Australas Radiol* 1992;36:238.
 199. Dore DD, MacEwen GD, Boulous MI. Cleidocranial dysostosis and syringomyelia: case report and review of the literature. *Clin Orthop* 1987;214:231.
 200. Tagliavero G, Fabris D, Agostini S. A case of progressive scoliosis in a patient with craniocleidopelvic dysostosis. *Ital J Orthop Traumatol* 1999;9:507.
 201. Vari R, Puca A, Meglio M. Cleidocranial dysplasia and syringomyelia. *J Neurol Sci* 1996;49:125.
 202. Hamner LH, Fabbri EL, Browne PC. Prenatal diagnosis of cleidocranial dysostosis. *Obstet Gynecol* 1994;83:856.
 203. Jarvis JL, Keats TE. Cleidocranial dysostosis: a review of 40 new cases. *Am J Radiol* 1974;21:5.
 204. Richie MF, Johnston CE II. Management of developmental coxa vara in cleidocranial dysostosis. *Orthopedics* 1989;12:1001.
- ### Larsen Syndrome
205. Larsen LJ, Schottstaedt ER, Bost FC. Multiple congenital dislocations associated with characteristic facial abnormality. *J Pediatr* 1950;37:574.
 206. Vujic M, Hallstenon K, Wahlstrom J, et al. Localization of a gene for autosomal dominant Larsen syndrome to chromosome region 3p21.1-14.1 in the proximity of, but distinct from, the COL7A1 locus. *Am J Hum Genet* 1999;57:1104.
 207. Johnston CE, Birch JG, Daniels JL. Cervical kyphosis in patients who have Larsen syndrome. *J Bone Joint Surg Am* 1996;78:538.
 208. Micheli LJ, Hall JE, Watts HG. Spinal instability in Larsen syndrome: report of three cases. *J Bone Joint Surg Am* 1976;58:562.
 209. Bowen JR, Ortega K, Ray S, et al. Spinal deformities in Larsen's syndrome. *Clin Orthop* 1985;197:159.
 210. Laville JM, Lakermore P, Limouzy F. Larsen's syndrome: review of the literature and analysis of thirty-eight cases. *J Pediatr Orthop* 1994;14:63.



9

SYNDROMES OF ORTHOPAEDIC IMPORTANCE

BENJAMIN A. ALMAN
MICHAEL J. GOLDBERG

NEUROFIBROMATOSIS 288

Cutaneous Markings 289
Neurofibroma 289
Osseous Lesions 289
Lisch Nodules 289
Etiology 291
Other Types of Neurofibromatosis 291
Orthopaedic Manifestations 291

PROTEUS SYNDROME 294

ARTHROGRYPOSIS 295

CONTRACTURE SYNDROMES INVOLVING ALL FOUR EXTREMITIES 296

Arthrogryposis Multiplex Congenita 296
Treatment 297
Larsen Syndrome 299

CONTRACTURE SYNDROMES INVOLVING PREDOMINANTLY THE HANDS AND FEET 301

Distal Arthrogryposis 301
Freeman-Sheldon Syndrome 303

CONTRACTURE SYNDROMES WITH SKIN WEBS 303

Pterygia Syndrome 303

DOWN SYNDROME 305

FETAL ALCOHOL SYNDROME 310

NAIL-PATELLA SYNDROME 311

DE LANGE SYNDROME 313

FAMILIAL DYSAUTONOMIA 314

RUBINSTEIN-TAYBI SYNDROME 315

PROGERIA 316

RUSSELL-SILVER DWARFISM 317

TURNER SYNDROME 318

NOONAN SYNDROME 318

PRADER-WILLI SYNDROME 319

BECKWITH-WIEDEMANN SYNDROME 320

VACTERLS AND VATER ASSOCIATION 321

GOLDENHAR SYNDROME 322

TRICHORHINOPHALANGEAL SYNDROME 323

MUCOPOLYSACCHARIDOSES 324

Mucopolysaccharidosis Type I 325
Mucopolysaccharidosis Type IV 325

HADJU-CHENEY SYNDROME 327

RETT SYNDROME 328

B. A. Alman: Department of Surgery, University of Toronto; Department of Orthopaedic Surgery/Developmental Biology, The Hospital for Sick Children, Toronto, Ontario M5G 1X8, Canada.

M. J. Goldberg: Department of Orthopaedics, Tufts University School of Medicine; Department of Orthopaedics, New England Medical Center, Boston, Massachusetts 02111.

The word “syndrome” is derived from a Greek word that means to run together. When several relatively uncommon anomalies occur in the same individual, it may be nothing more than coincidence. However, if they all result from the same cause, or occur in the same pattern in other children, that particular combination of birth defects is called a syndrome. A syndrome should be suspected if a characteristic orthopaedic malformation (e.g., radial clubhand) is encountered, if all four extremities are affected, if limb deformities are symmetric, if there are several associated nonorthopaedic anomalies, or if there is a familiar dysmorphic face (1–4). Children who have syndromes look more like each other than they do their parents.

It is not unusual for an orthopaedist to be the first physician to recognize that a child has features of a syndrome. In such cases, appropriate referrals should be made to a geneticist to assist in syndrome identification, order appropriate confirmatory tests, and arrange for management of the nonorthopaedic manifestations of the syndrome. The evaluation of a child for a syndrome includes a family history, a systems review, and a search for minor dysmorphic features, such as abnormal palm creases or abnormal shape of digits or toes. These may not be of immediate orthopaedic significance, but they are the clues to look further.

Syndromes can be caused by gene defects, environmental abnormalities during fetal development (a teratogen), or both. The relationship between the clinical (phenotypic) features and the cause of a syndrome is not always as simple as one would wish. There can be phenotypic variability, even within a family in which all the members carry the identical gene mutation. Some individuals are minimally affected, whereas others have all of the findings of the syndrome. This may be due to the presence of modifying genes, which may not be inherited in the same way as the gene mutation that causes the syndrome. Teratogenic agents present during fetal development can cause syndromes, such as the fetal alcohol syndrome. These teratogens affect developmental signaling pathways, which are cascades of genes expressed in a controlled fashion, to produce normal fetal development. A genetic defect can sometimes cause the same perturbation in such a pathway as a teratogen. Thus, some syndromes can be caused either by a gene defect or a teratogenic agent. A single gene can be responsible for a number of syndromes. This occurs because the products of different mutations have different cellular functions. Such is the case with the dystrophin gene, which causes both Duchenne and Becker muscular dystrophies.

Information about the etiology of a syndrome is important, because it has implications for the parents as to the risk of recurrence in subsequent pregnancies, and may hold the key to the development of novel treatments. The rapid pace of basic research in developmental biology and genetics makes it difficult for a traditional textbook to contain the most up-to-date information about syndrome etiology. The Internet is becoming an excellent source for such informa-

tion. One useful site is the On-Line Mendelian Inheritance in Man (OMIM), administered by the National Institutes of Health. This site can be accessed at <http://www.ncbi.nlm.nih.gov/Omim/>, and can be searched by syndrome name, causative gene, or clinical findings (5).

The care of children with syndromes involves multiple specialists (6). Discussions of the risk of subsequent pregnancies is in the realm of the genetic counselor. For parents, naming the condition often implies that it is then treatable or curable. This, sadly, is not the case. The importance of understanding syndromes is recognizing that associated medical abnormalities may adversely influence orthopaedic outcomes, and may influence surgical timing and management. The orthopaedic surgeon also needs information from the geneticist. Associated conditions may influence the outcome of orthopaedic problems and can affect anesthesia (e.g., cardiac or renal anomalies). Even if parents are not planning subsequent pregnancies, and if there are no plans for their child to undergo surgery in the near future, genetic evaluation is still important for proper syndrome diagnosis. Correct diagnoses are essential for research into syndrome etiology. Patients should be given the opportunity to participate in such research, especially in cases of relatively rare syndromes.

Nomenclature can confuse syndrome identification, because a single syndrome may have several names. Eponyms are not descriptive of the syndrome, nor do they give information about etiology. Classifying syndromes by the causative gene is problematic because some genes cause more than one syndrome, and some syndromes are caused by more than one gene. Furthermore, the gene names are frequently unrelated to clinical findings. A numbering system is used by most computer databases; the most widely used is that of the On-line Mendelian Inheritance in Man (5), but this is only helpful for database searches. The ideal nomenclature system would be descriptive, but also give information about etiology. Unfortunately, such a system has not yet been developed.

NEUROFIBROMATOSIS

There are several forms of neurofibromatosis (NF), the most common of which are type I and type II (NF1 and NF2). Orthopaedic manifestations are common in NF1, which is also called “von Recklinghausen disease,” whereas they are rare in NF2, which is also called “central neurofibromatosis” or “familial acoustic neuroma.” The clinical findings in NF1 are quite variable, and many of these findings develop over time. Children may exhibit none of the typical findings at birth, but the diagnosis can be made as they grow older and develop the characteristics necessary to confirm a

TABLE 9-1. NEUROFIBROMATOSIS TYPE 1: DIAGNOSTIC CRITERIA

At least two of the following are necessary to establish the diagnosis of NF1:

- At least six café-au-lait spots, larger than 5 mm in diameter for children, and larger than 15 mm for adults
- Two neurofibromas, or a single plexiform neurofibroma
- Freckling in the axillae or inguinal region
- An optic glioma
- At least two Lisch nodules (hamartoma of the iris)
- A distinctive osseous lesion, such as vertebral scalloping, or cortical thinning
- A first-degree relative with NF1

diagnosis of NF1 (7,8). This diagnosis is made by identifying at least two of the clinical findings in Table 9.1.

Cutaneous Markings

Café-au-lait spots are discrete, tan spots (Fig. 9-1). They often appear after 1 year of age, then the numbers and

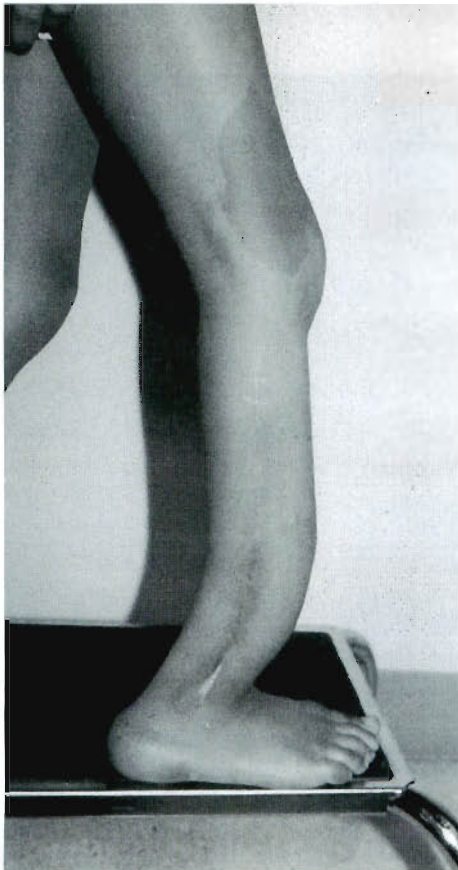

FIGURE 9-1. Neurofibromatosis in a 6-year-old child. Notice the large café-au-lait spot on the thigh and the anterior bowed tibia typical of pseudarthrosis. (From ref. 1, with permission.)

size steadily increase. The spots have a smooth edge, often described as similar to the coast of California, as opposed to the ragged edge of spots associated with fibrous dysplasia, which are described as similar to the coast of Maine. There exists great variation in the number of café-au-lait spots and their shape and size, although six lesions greater than 1 cm in size are required for the diagnostic criteria. Axillary and inguinal freckling is common, and serve as good diagnostic markers, because such freckling is exceptionally rare, except in people with NF. Hyperpigmented nevi are dark brown areas that are sensitive to touch. They typically overlie a deeper plexiform neurofibroma.

Neurofibroma

The two types of neurofibromas are different in their anatomic configuration and in clinical morbidity. The most common is the cutaneous neurofibroma, composed of benign Schwann cells and fibrous connective tissue (Fig. 9-2). They may occur anywhere, but are usually just below the skin. They may not be detectable until 10 years of age, and with puberty there is a rapid increase in their number. When many are grouped together on the skin, it is known as a fibroma molluscum. Plexiform neurofibromas are usually present at birth and are highly infiltrative in the surrounding tissues. The overlying skin is often darkly pigmented. They are highly vascular, and plexiform neurofibromas lead to limb gigantism, facial disfigurement, and invasion of the neuroaxis (Figs. 9-3 and 9-4).

Osseous Lesions

There are many skeletal manifestations, but the presence of an unusual scoliosis, nonunion of a long bone, overgrowth of a part, or a congenital pseudarthrosis lesion seen on radiographs should alert the physician to consider a diagnosis of NF (9). There are a variety of radiographic anomalies of bone observed, ranging from a scalloping of the cortex to cystic lesions in long bones that look much like nonossifying fibromas, to permeative bone destruction (Fig. 9-5). These radiographic findings can mimic benign and malignant bone lesions (10–12). Roentgenograms of the pelvis usually show various degrees of coxa valga, and in nearly 20% of patients there is radiographic evidence of protrusio acetabuli (13,14).

Lisch Nodules

Lisch nodules are hamartomas of the iris. They are present in 50% of all 5-year-olds with NF1, and in all adults with NF1. It is unusual for Lisch nodules to be present in individuals without NF1, and their detection can be used to aid in making this diagnosis. However, it may be difficult to

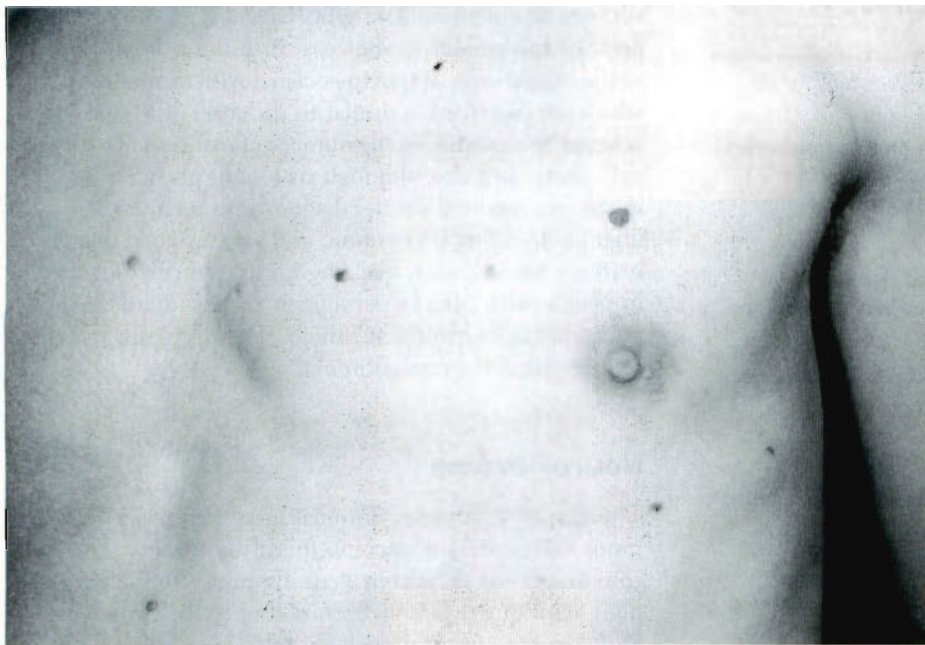


FIGURE 9-2. Neurofibromatosis in a 14-year-old patient. Cutaneous neurofibromas make their appearance with the onset of puberty. (From ref. 1, with permission.)

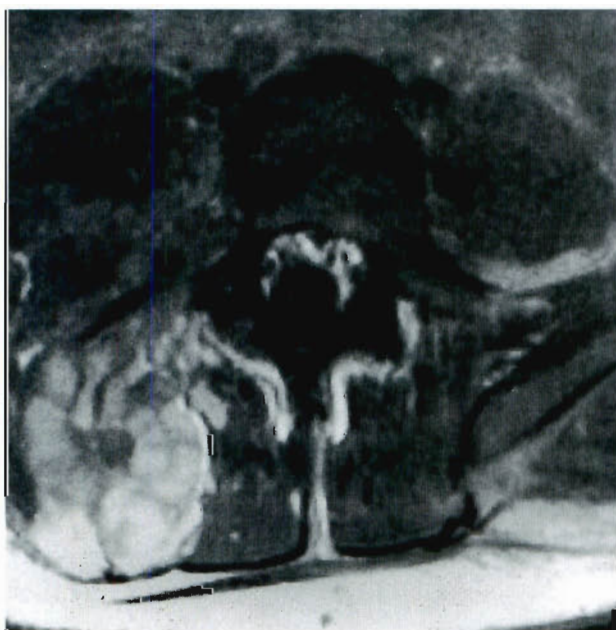

FIGURE 9-3. Neurofibromatosis in a 16-year-old patient. The magnetic resonance image at the level of L4-5 demonstrates a large plexiform neurofibroma that invades the neural axis. It extends from the level of L3 to the sacrum.

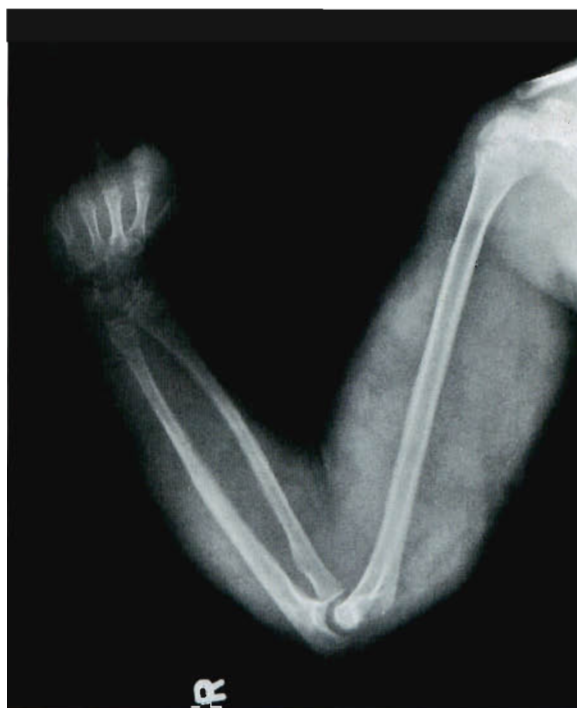

FIGURE 9-4. Neurofibromatosis in a 10-year-old patient. Hypertrophy affects the arm from the shoulder to the fingertips; the major component is soft tissue. Nodular densities throughout the upper arm are consistent with a plexiform neurofibroma. Notice the lack of skeletal overgrowth and some attenuation of the radius and ulna, from external compression by the neurofibroma. (From ref. 1, with permission.)

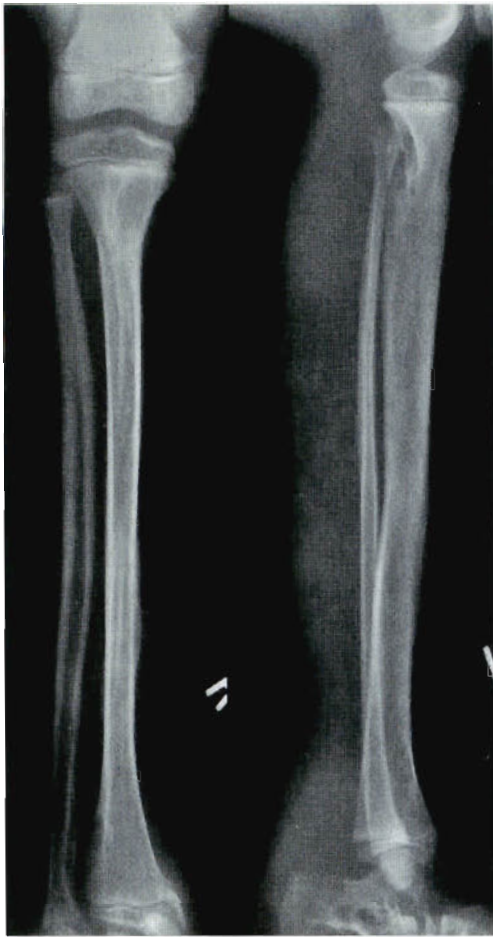

FIGURE 9-5. Neurofibromatosis in a 10-year-old patient. The radiograph shows an array of cystic and scalloped skeletal lesions in the tibia and os calcis of the right leg. Some of the lesions are characteristic of neurofibromatosis. Other lesions, occurring in isolation, can mimic benign fibrous tumors. Scalloped cortical erosion at the upper end of the femur, permeative bone destruction in the region of the os calcis, and metaphyseal cystic lesions are other features. (From ref. 1, with permission.)

detect these lesions, and individuals should be sent to an experienced ophthalmologist to make this diagnosis. The lesions do not cause any visual disturbances. Once the diagnosis is established further, ophthalmologic evaluation is not necessary (15,16).

Etiology

Neurofibromatosis is the most common single-gene disorder in humans, affecting 1 of 3,000 newborns (17–19). NF1 is an autosomal dominant disorder with 100% penetrance, but one-half of the cases are sporadic mutations and are associated with an older-than-average paternal age. The most renowned patient with NF, Joseph Merrick, called the Elephant Man, probably did not have this diagnosis and better fits Proteus syndrome (20). The *NF1* gene is located

on chromosome 17 (21). Its protein product is called neurofibrillin, and it acts as a tumor suppressor (22). There are also other potential genes within the *NF1* gene, located in introns, whose functional significance is unclear.

Neurofibrillin has similarity to the G-protein family of signal transduction proteins. These proteins convey messages from cell surface receptors to cytoplasmic effectors. Neurofibrillin plays such a role in the Ras signaling system, which is involved in the control of cell growth (23). Mutations in the *NF1* gene cause a disruption in its normal regulatory function of Ras signaling. This gives the affected cells an abnormal growth pattern.

Neurofibrillin is expressed at higher levels in the neural crest during development. Cells from the neural crest migrate to become pigmented cells of the skin, parts of the brain, spinal cord, peripheral nerves, and adrenals, thus explaining the common sites of abnormalities in the disorder. The gene defect gives a clue into potential novel therapies, because pharmacologic agents that block Ras signaling could be used to treat the disorder. Disruption of the normal Ras signaling cascade is probably responsible for the malignant potential in this disorder. Only one of the two copies of the *NF1* gene is mutated in affected patients; however, tumors from such individuals have been found to have only a mutated gene because of loss of the normal copy (24–27).

Other Types of Neurofibromatosis

Although patients with other forms of neurofibromatosis rarely present to an orthopaedist, one should be aware of these because musculoskeletal malformations occasionally are present. Patients with NF2 present with acoustic neuromas, central nervous system tumors, and rare peripheral manifestations. There are usually less than six café-au-lait spots, and no peripheral neurofibromata. These patients are very unlikely to present with an orthopaedic deformity. There are two much less common types of neurofibromatosis, type III and type IV (NF3 and NF4), which are more likely to develop a problem requiring orthopaedic intervention. Individuals with NF3 present with some of the characteristics of NF1, but also have acoustic neuromas, which are characteristic of NF2. These individuals often have spinal deformity, especially in the cervical region. NF4 presents with the same clinical findings as in NF1, except that one of the cardinal features of NF1, iris Lisch nodules, is absent (7,8). One reason to distinguish these types from NF1 is that they are probably caused by mutations in a different gene than that which causes NF1 (this has already been demonstrated in NF2), and thus will not be diagnosed using DNA testing for NF1.

Orthopaedic Manifestations

The common orthopaedic manifestations of NF, including scoliosis, limb overgrowth, pseudarthrosis, and radiographic

appearances of lesions, enable the initial diagnosis to be made, if the syndrome is kept in mind. Patients with NF often exhibit overgrowth, ranging from a single digit to an entire limb, and from mild anisomelia to massive giantism. Any child with focal giantism, such as macrodactyly, is best thought of as having NF until proven otherwise. When NF is compared with the more symmetric idiopathic hemihypertrophy, there is disproportional overgrowth involving the skin and subcutaneous tissue more than bone (see Fig. 9-4).

Scoliosis is common, and although there is no standard curve pattern, curves tend to fall into two behavioral patterns: a dystrophic curve and an idiopathic curve. Most curves in NF resemble idiopathic scoliosis curves. Their relation to NF is not understood, and their precise incidence debated. These curves can be managed like any other idiopathic curve.

The dystrophic scoliotic curve is a short, sharp, single thoracic curve typically involving four to six segments (Fig. 9-6) (13,28–35). It is associated with distortion of the ribs and vertebrae. The onset is early in childhood, and it is relentlessly progressive. Curves that initially appear to be

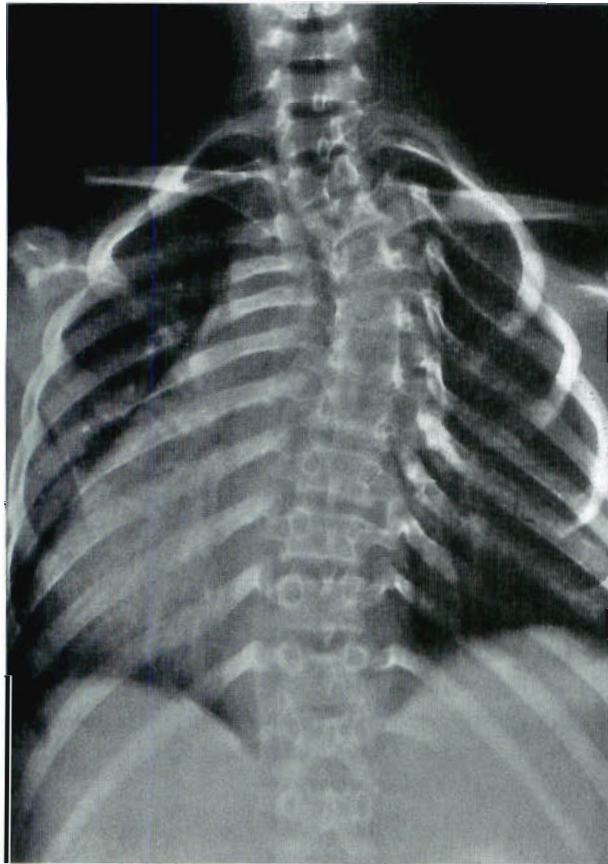


FIGURE 9-6. Neurofibromatosis in a 14-year-old patient. The dystrophic curve is produced by a short-segment scoliosis. Ribboned ribs show cystic irregularities. (From ref. 1, with permission.)

idiopathic in children under age 7 have almost a 70% chance of becoming dystrophic over time, although there may be subtle clues, for example mild rib penciling, that the curve is really dystrophic. The most important risk factors for progression is an early age of onset, a high Cobb angle, and an apical vertebrae that is severely rotated, scalloped, and located in the middle-to-lower thoracic area (32). The combination of curve progression and vertebral malformation mimics congenital scoliosis in appearance and behavior. Dystrophic curves are refractive to brace treatment. Sagittal plane deformities may occur, including an angular kyphosis (i.e., gibbus) and a scoliosis that has so much rotation that curve progression is more obvious on the lateral than on the anteroposterior roentgenogram (32). In those with angular kyphosis, there is a risk of paraplegia. Dystrophic curves are difficult to stabilize, and it is best to intervene with early surgery involving both anterior and posterior fusion (32,36–38). Kyphotic deformities are often the most difficult to manage surgically, and strut grafts across the kyphosis anteriorly may be necessary. In cases with extremely severe deformity, halo-femoral or halo-gravity traction may be necessary to safely straighten the spine to a more acceptable deformity, without producing neurologic sequelae.

There are several vertebral abnormalities evident on radiographs. These include scalloping of the posterior body, enlargement of the neural foramina, and defective pedicles, occasionally with a completely dislocated vertebral body (39–43). Such findings may mean that there is a dumbbell-shaped neurofibroma in the spinal canal extending out through a neural foramina. In NF patients, the dura behaves like the dura in patients with a connective tissue disorder, and dural ectasia is common, with pseudomeningoceles protruding through the neural foramina. Unlike neurofibromas, dural ectasia is an out-pouching of the dura, without an underlying tumor or overgrowth of spinal elements (Fig. 9-7) (44–47). The incidence of anterolateral meningoceles was underestimated until asymptomatic patients were screened with magnetic resonance imaging (MRI) (9,48). The erosion of the pedicles may lead to spinal instability, especially in the cervical spine. In rare cases, this can even lead to dislocation of the spine (49,50). MRI and computed tomography (CT) scans are helpful preoperatively to delineate the presence of defective vertebrae or dural abnormalities, and may assist in choosing the levels on which to place instrumentation.

Pseudarthrosis of a long bone is typically associated with NF (30). It usually affects the tibia, with a characteristic anterolateral bow obvious in infancy (Fig. 9-8) (51,52). Fracture usually follows, with spontaneous union rare and surgical union a challenge. An anterolateral bowed tibia should be managed with a total-contact orthosis to prevent fracture. Intramedullary rod fixation seems to offer the best results for the initial management of a pseudarthrosis [6.11]. The cause of the pseudarthrosis is not known;

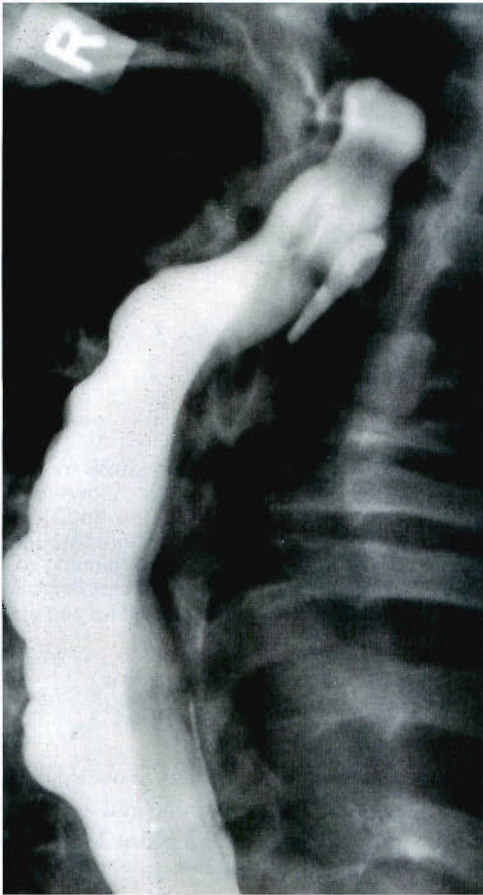

FIGURE 9-7. Myelogram of a young adult with neurofibromatosis and scoliosis with pseudomeningoceles and dural ectasia.

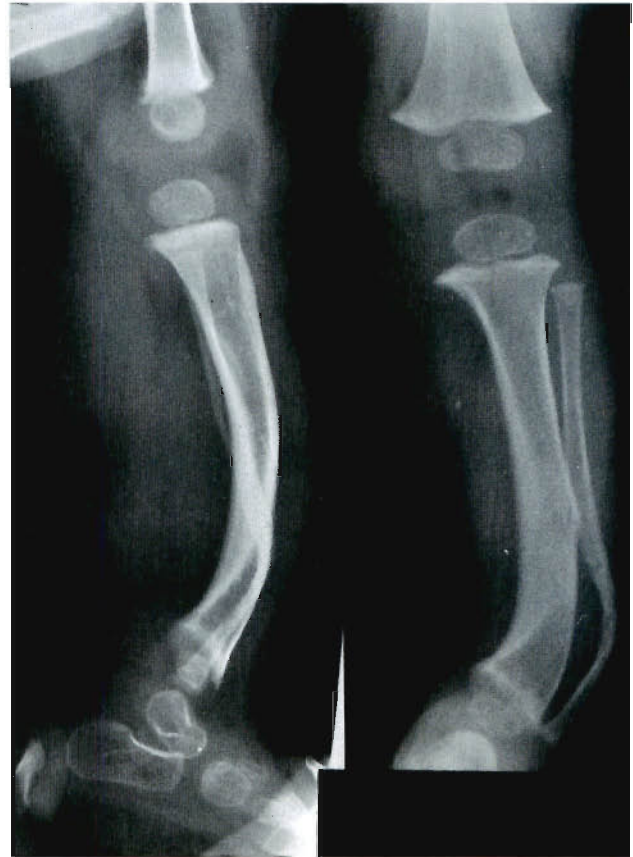

FIGURE 9-8. Neurofibromatosis in a 1-year-old patient. The anterolateral bow of the tibia and fibula warrant concern for impending fracture and pseudarthrosis. (From ref. 1, with permission.)

however, neurofibromas have not been identified at the pseudarthrosis site. The pseudarthrosis process may affect the ulna, radius, femur, or clavicle (53–59). In each of these locations, there is a course similar to that in the tibia, with bone loss and difficulty achieving union (Fig. 9-9). Not all pseudarthroses of the forearm require treatment (60), but if they are symptomatic, options include proximal and distal synostosis to produce a single-bone forearm, or the use of a vascularized fibula graft.

There are a variety of benign and malignant neoplastic processes that affect individuals with NF1. Most neurofibromas do not require treatment, but symptomatic lesions may require excision. Plexiform neurofibromas that become symptomatic are very difficult to manage. Their vascularity and infiltrative nature make complete extirpation almost impossible, with a substantial risk of uncontrollable hemorrhage and neurologic deficit. Although speculative, the use of angiogenesis inhibitors, such as interferon, or some experimental agents based on modulating the affect of the causative gene mutation, may be beneficial (61,62).

The exact incidence of malignancy in NF is controversial, with reported rates ranging from under 1% to over 20%

(63–67). The most common tumor location is in the central nervous system, with lesions such as optic nerve glioma, acoustic neuroma, and astrocytoma (68). There is a risk of malignant degeneration of a neurofibroma to a neurofibrosarcoma. This process can occur in a central or peripheral neurofibroma (69–72). It can be quite difficult to distinguish a malignant from a benign lesion. CT scans show areas of low-enhancing density in neurofibrosarcomas (73), but there are no studies determining the sensitivity and specificity of this finding. Similar patterns can also be visualized using MRI. Routine surveillance for sarcomatous change is impossible due to the large number of neurofibromas. Lesions that increase in size, or that develop new symptoms, should be investigated. There is a propensity for children with neurofibroma to develop other malignancies, such as Wilms tumors or rhabdomyosarcomas.

Hypertension, on the basis of renal artery stenosis or pheochromocytoma, is reported regularly, as is a curious type of metabolic bone disease similar to hypophosphatemic osteomalacia (74,75). Hypertension is a major risk factor for early death (67). Precocious puberty may occur due to

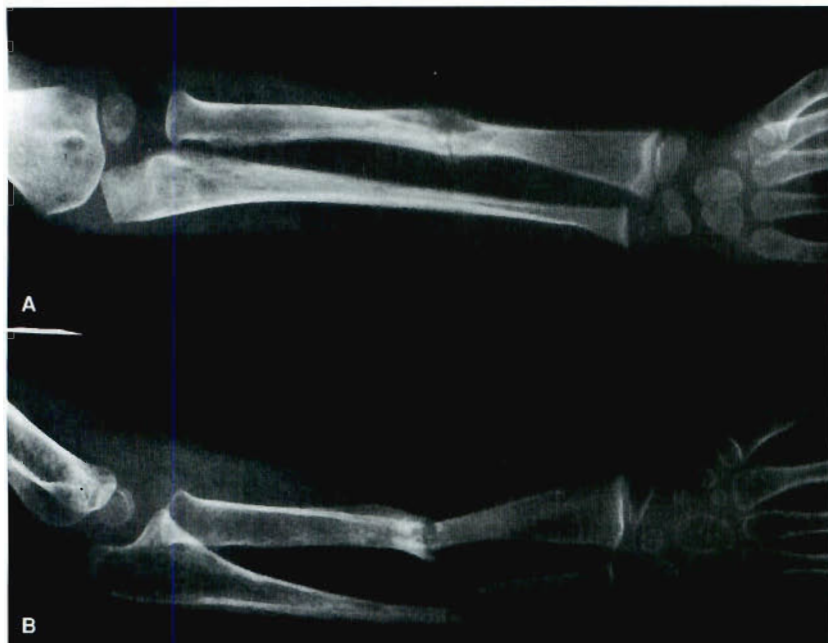

FIGURE 9-9. Neurofibromatosis in a 3-year-old patient. The radiograph shows progressive pseudarthrosis of the radius and ulna after a pathologic fracture. **A:** Fracture through the cystic lesion of the radius and thinning of the mid ulna. **B:** After 10 months of cast immobilization, pseudarthrosis affects the radius and ulna. (From ref. 1, with permission.)

an intracranial lesion (76). Affected children are short, but tend to have large heads. Approximately 50% have an intellectual handicap that varies from frank mental retardation to problems with school performance. Although mean IQ is low, there is quite a broad range of IQ (77). A high incidence of concentration problems may interfere with learning, more than a low IQ (78). The concentration problems can sometimes be managed pharmacologically.

PROTEUS SYNDROME

Proteus syndrome is an overgrowth condition, in which there is a bizarre array of abnormalities that include hemihypertrophy, macrodactyly, and partial giantism of the hands or feet, or both. The key to this diagnosis is worsening of existing features, and the appearance of new ones over time (79–82).

The cause of this syndrome is not known. Although there are case reports of familial occurrence, the vast majority of cases are sporadic (83–85). It is most likely due to a gene that is mutated in a mosaic manner (mutated in the affected tissues, but not the normal tissues), similar to McCune-Albright syndrome (polyostotic fibrous dysplasia). Such a mutation can occur very early in development in a single cell, which will divide to ultimately form various structures throughout the body.

The Proteus syndrome is named after the ancient Greek demigod who could change appearance and assume different shapes. The progressive nature of the deformities seen

in this syndrome can lead to grotesque overgrowth, facial disfigurement, angular malformation, and severe scoliosis (86). Joseph Merrick, called the Elephant Man, is thought to have had this syndrome, rather than NF (87).

The signs of Proteus syndrome overlap those other hamartomatous overgrowth conditions, such as idiopathic hemihypertrophy, Klippel-Trenaunay syndrome, Maffucci syndrome, and neurofibromatosis. However, unlike these other syndromes, the features here are more grotesque and involve multiple tissue types and sites. Proteus can be differentiated from NF1 by the lack of café-au-lait spots and Lisch nodules (88). A rating scale, which assigns points based on clinical findings (macrodactyly, hemihypertrophy, thickening of the skin, lipomas, subcutaneous tumors, verrucae, epidermal nevus, and macrocephaly) may be used to assist in diagnosis (89). However, the finding of worsening overgrowth features over time is usually sufficient to make this diagnosis.

Most children who present with macrodactyly do not have this as part of Proteus syndrome. In these sporadic cases, an isolated digit is involved, or, when multiple digits are involved, these are located adjacent to each other. Macrodactyly affecting nonadjacent toes or fingers or opposite extremities is almost always due to Proteus syndrome. There is a characteristic thickening and deep furrowing of the skin on the palms of the hands and soles of the feet. The array of cutaneous manifestations include hemangiomas and pigmented nevi of various intensities, and subcutaneous lipomas (Fig. 9-10). Varicosities are present, although true arteriovenous malformations are rare. There are cranial hyperostoses, and occasionally exostosis of the hands and feet.

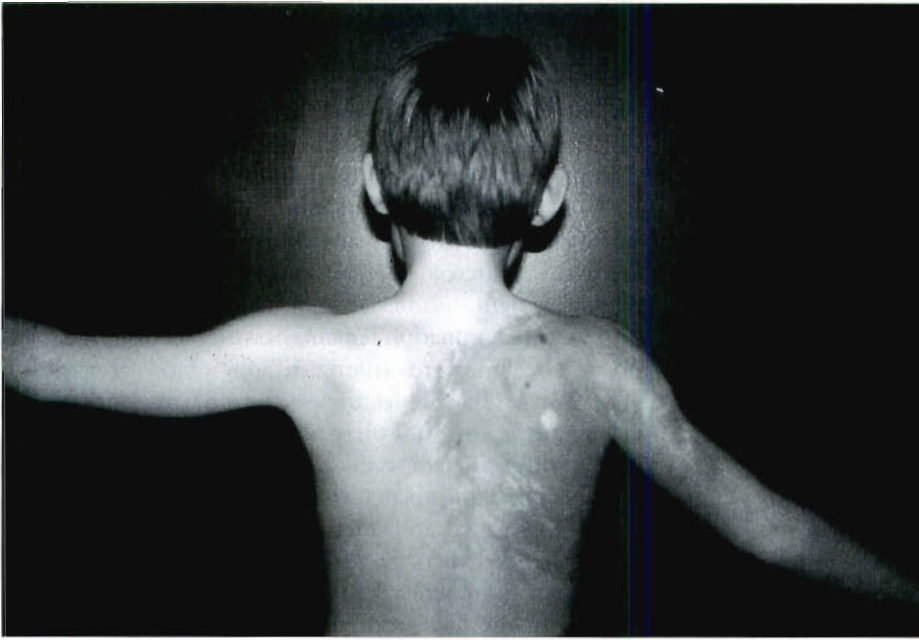

FIGURE 9-10. Proteus syndrome. Notice the cutaneous markings, large hemangioma of the shoulder, and lightly pigmented area on the back. There is some atrophy of the shoulder and arm muscles and a fixed contracture of the elbow.

Macroductyly seems to correspond to overgrowth along the terminal branches of a peripheral sensory nerve. Digital involvement in the hand favors the sensory distribution of the median nerve (1). The index is the most frequently affected finger, followed by the long finger and the thumb. It is the second toe that is most commonly macroductylous. The regional sensory nerve is greatly increased in size, taking a tortuous route through the fatty tissue.

There is a wide range of orthopaedic deformities, including focal and regional giantism, scoliosis, and kyphosis (90,91). Rather large vertebral bodies, known as megaspondylodysplasia, are present (92). Angular malformations of the lower extremities, especially genu valgum, are common. Because the genu valgum is often associated with restricted range of motion, joint stiffness, flexion contractures, and joint pain, it is postulated that an intraarticular growth disturbance contributes to the angular malformation. Roentgenographic hip abnormalities, such as acetabular dysplasia, are frequently discovered in asymptomatic patients. Deformities in the hindfoot are frequent and are usually heel valgus, but congenital equinovarus and "Z-foot" deformities have also been described (88,91).

Most of the literature on Proteus syndrome consists of case reports or case series, and there are no data comparing results of different types of treatments.

In addition, recurrences after surgical intervention are very common. This is probably due to an underlying growth advantage in affected tissues which cannot be corrected operatively. Thus, musculoskeletal deformities due to Proteus syndrome are very difficult to manage.

When the foot becomes difficult to fit into a shoe due to macroductyly, it is best managed by ablation rather than

debulking (93) [→7.22]. Anisomelia is best managed with epiphysiodesis [→4.19, 4.20, 6.12, 6.13], although limb-lengthening may be considered in cases with very large differences [→4.15, 4.16, 6.9, 6.10]. Osteotomies can correct angular malformations, but must be tempered by the chance of a rapid recurrence of deformity after corrective surgery (90,91). In some cases, sudden overgrowth of the operative limb have been reported. There are anecdotal reports of soft tissue procedures to "debulk" overgrown lesions; however, there are no series in the literature reporting results of these procedures, and our experience with them is that the results are only temporary. In rare cases, nerve or spinal cord impingement can occur. Nerve compression can be managed using decompression, but spinal cord compression is difficult, if not impossible, to successfully treat operatively (94,95). Mixed results are obtained from surgical treatment in this disorder, and operative treatment should be reserved for individuals who have exhausted nonsurgical management. Sometimes the operative procedures can be used as a temporizing measure, and patients may need to have repeat procedures performed throughout life.

Functional ability depends on the severity of the limb deformity and the presence of intracranial abnormalities (82,96). The life expectancy is unknown, but many adult patients are reported. Intubation can be difficult due to overgrowth of structures surrounding the trachea.

ARTHROGRYPOSIS

Arthrogryposis is really a physical finding, not a diagnosis, and represents a large group of disorders, all of which have

in common joint contractures present at birth. This term is used as a noun to describe specific diseases, and as an adjective, "arthrogrypotic," to refer to rigid joint contractures. There are 65 distinct syndromes coded under the term "arthrogryposis" in the On-Line Mendelian Inheritance in Man (5), illustrating the large variety of etiologies associated with this term. Most of the syndromes have different clinical courses, prognoses, genetics, causes, and pathologic processes, often making it difficult for the orthopaedist to determine management for an individual patient (97,98). A simple way to think about these disorders is to consider them as contracture syndromes, which can be grouped into a few general categories, each of which can be represented by a prototypic disease.

Contracture syndrome groups:

1. Involving all four extremities. This includes arthrogryposis multiplex congenita and Larsen syndrome, with more or less total body involvement.
2. Predominantly or exclusively involves the hands and feet. These are the distal arthrogryposes. Facial involvement can occur with some of these syndromes, and Freeman-Sheldon whistling face is included.
3. Pterygia syndromes in which identifiable skin webs cross the flexion aspects of the knees, elbows, and other joints. Multiple pterygias and popliteal pterygia fit in this group.

CONTRACTURE SYNDROMES INVOLVING ALL FOUR EXTREMITIES

Arthrogryposis Multiplex Congenita

Arthrogryposis multiplex congenita is the best-known of the multiple congenital contracture syndromes (99,100). Although attempts have been made to change the name "arthrogryposis multiplex congenita" to "multiple congenital contractures" or "amyoplasia," the popularity of arthrogryposis remains.

The etiology of arthrogryposis multiplex congenita is unknown. It was initially described in 1841 by Adolf Wilhelm Otto, who referred to his patient as a "human wonder with curved limbs" (101). The disorder is sporadic, with affected individuals having reproduced only normal children. There is, however, an increased incidence of classic arthrogryposis affecting only one of identical twins (102,103). The development of arthrogryposis may be influenced by an adverse intrauterine factor or the twinning process itself. Teratogens have been suggested, but none are proven, despite the multiple animal models that lend support to that theory (100,104–107). Some mothers of children with arthrogryposis have serum antibodies that inhibit fetal acetylcholine receptor function. One possibility is that maternal antibodies to these fetal antigens cause the disorder (108).

Histologic analysis discloses a small muscle mass with

fibrosis and fat between the muscle fibers. Myopathic and neuropathic features often are found in the same muscle biopsy specimen. The periarticular soft tissue structures are fibrotic, and in essence, there is a fibrous ankylosis. The number of anterior horn cells in the spinal cord is decreased, without an increase in the number of microglial cells (109–111). The pattern of motor neuron loss in specific spinal cord segments correlates with the peripheral deformities and the affected muscles, suggesting a primary central nervous system disorder as important in the cause (112).

Clinical examination remains best for establishing a diagnosis. The limbs are striking in appearance and position (Fig. 9-11). They are featureless and tubular. Normal skin creases are lacking, but there may be deep dimples over the joints. Muscle mass is reduced, although, in infancy, there is often abundant subcutaneous tissue. Typically, the shoulders are adducted and internally rotated, the elbow more often extended than flexed, and the wrist flexed severely, with ulnar deviation. The fingers are flexed, clutching the thumb. In the lower extremities, the hips are flexed, abducted, and externally rotated; the knees are typically in extension, although flexion is possible; and clubfeet are the rule. Joint motion is restricted. The condition is pain-free, with a firm, inelastic block to movement beyond a very

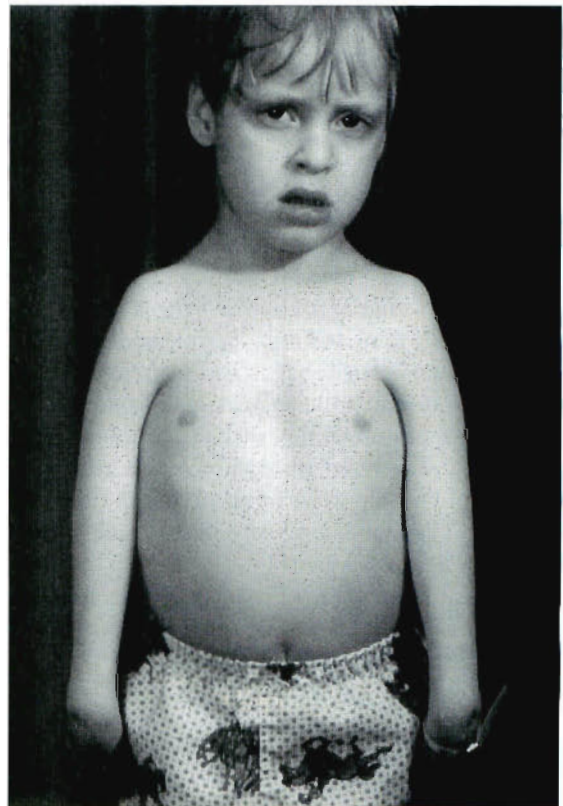


FIGURE 9-11. Arthrogryposis multiplex congenita. The picture shows the classic limb position and fusiform limbs lacking flexion creases.

limited range. In two-thirds of the patients, all four limbs are affected equally, but in one-third, lower-limb deformities predominate, and only on rare occasions do the upper extremities predominate. Deformities tend to be more severe and more rigid distally. The hips may be dislocated unilaterally or bilaterally.

The viscera usually are spared malformations, although gastroschisis has been reported. As a consequence of the general muscle weakness, there is a 15% incidence of inguinal hernia. Major feeding difficulties, due to a stiff jaw and an immobile tongue, are frequently encountered in infancy, and lead to respiratory infections and failure to thrive (113). The face is not particularly dysmorphic. A few subtle features, such as a small jaw, narrowing of the face, and occasionally, limited upward gaze (secondary to ocular muscle involvement), and a frontal midline hemangioma, may help with the diagnosis (see Fig. 9-11).

Radiographs reveal that the joints are normal, and that changes are adaptive and acquired over time as a consequence of fixed position (Fig. 9-12). There is evidence of a loss of subcutaneous fat and tissue. Electromyograms and muscle biopsies are of questionable diagnostic value. They have been used to separate patients with primarily neuro-

pathic changes from those with myopathic, but the clinical implications of such distinctions are not clear. A diagnosis of arthrogryposis can be suspected when prenatal ultrasound detects an absence of fetal movement, especially if seen in combination with polyhydramnios (104).

Despite every large medical center having treated patients with arthrogryposis, the natural history and long-term outcomes are not well known (114,115). Some contractures seem to worsen with age, and the joint becomes stiffer. No new joints become involved. At least 25% of affected patients are nonambulators, and many others are limited household walkers (116). As a rule, those with arthrogryposis who are very weak as infants stay weak, and those who appear stronger as infants stay strong. Adult interdependency seems to be related to education and coping skills, more than to the magnitude of joint contractures.

Treatment

Each of the multiple joints involved have their own unique opportunities for orthopaedic intervention, but at times an overview of the total patient must be borne in mind. The overall goals are lower-limb alignment and stability for ambulation, and upper extremity motion for self care (97,117,118). Outcomes seem better if joint surgery is done early, before adaptive intraarticular changes. Osteotomies are usually performed closer to the completion of growth. Early motion, and avoidance of prolonged casing, may increase joint motion, improving function. Many children require long-term bracing or other assistive devices (100).

Joint contractures make the birthing process difficult, and neonatal fractures may result (119). Physical therapy should not be initiated in the newborn until such fractures are ruled out (120). Mobilization of joints may be accomplished by early and frequent range of motion exercises and splinting of the joint in a position of function with a removable orthotic (100,120). There are no studies clearly demonstrating that early mobilization improves these patient outcomes, but such a program may improve passive range of motion, whereas active range of motion does not improve very much (100). In our experience, early mobilization seems to be useful primarily in the upper extremity. Fractures may accompany an overly vigorous range of motion program.

Approximately two-thirds of patients have developmental dysplasia of the hip or frank dislocation (100, 121–123) (see Fig. 9-12). At birth, the hips are flexed and abducted. There is considerable controversy about the management of the hips in these children. Closed reduction is rarely, if ever, successful. Operative reduction of a dislocated hip should be performed if it will improve function or decrease pain. Studies to date have not found pain to be a problem with these hips; however, only relatively short-term follow-up is reported. There is significant variability in function in these individuals due to the underlying severity of

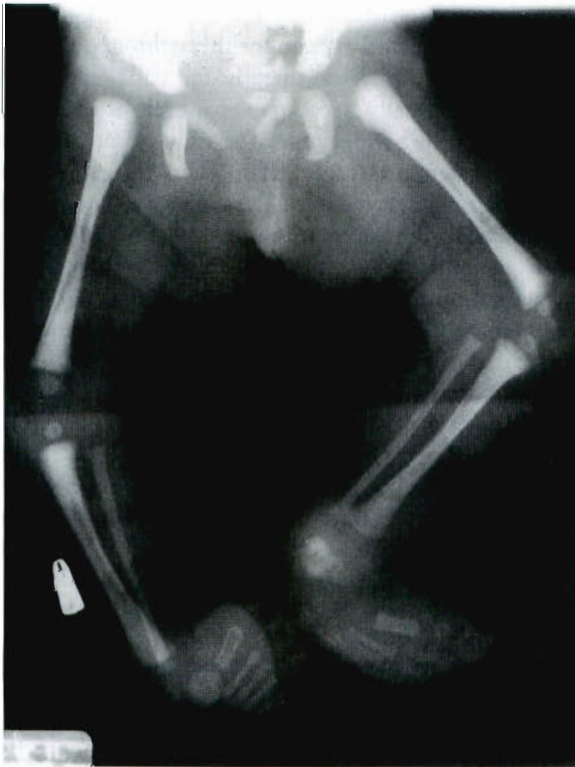

FIGURE 9-12. Arthrogryposis multiplex congenita at birth. Features include club feet, knee flexion deformity, and dislocated right hip. The articular surfaces are normal. Adaptive changes occur as a consequence of the fixed position. (From ref. 1, with permission.)

the disease, and this variability makes it difficult to determine any change in function from treating the hips. Range of motion of the hips may be important for function, because hip contractures, especially those causing flexion deformity, adversely affect the gait pattern. Operative procedures to locate dislocated hips, therefore, have the potential to worsen function if they produce significant contractures (122,124).

Studies of children with untreated dislocated hips concluded that those with bilateral dislocations frequently had satisfactory range of motion, their hips did not prevent them from walking, although rarely around the community, and pain was uncommon (121,123,124). Those with unilateral dislocations fared less well. More were limited to the household with walkers, and, although scoliosis was present in most patients, it was worse and more frequent in those with unilateral dislocations (100). In both groups, limitation of ambulation results more from the severe involvement of all four extremities than from the dislocated hips (100). These data, and case series suggesting little functional improvement with surgery for bilateral hip dislocations, supports the concept of leaving bilateral dislocated hips alone (100,121,122,124). However, in these studies, hip surgery was delayed until the knees were mobilized, and reductions did not occur until at least 1 year of age. This later age at reduction may be associated with higher rates of contractures, and worse function. Reports of early open reduction of unilateral and bilateral dislocated hips, with a reduced period of immobilization, show improved postoperative range of motion (123,125,126). Hip reduction may not benefit the child who is not an ambulator; however, there is no way to comfortably predict which children will become ambulators at the age early surgical treatment is contemplated. Thus, it seems reasonable to perform early open reduction in most children. Both medial and anterior approaches are advocated for early hip reduction (123,125,126) [➤3.2-3.4]. The key factor may be performing the hip reduction early in life, with minimal immobilization, rather than the specific operative approach utilized. This may be more easily accomplished using a medical approach.

Although the classic description of the knees is that they are hyperextended, most are in flexion (100,127-129) (Fig. 9-12). The precise plane of motion is often difficult to determine, and although physical therapy is recommended, medial lateral instability may result. Hyperextension deformity responds better to physical therapy and splinting than do flexion deformities. If the flexion deformity remains more than 30 degrees, ambulation is precluded because of the associated overall muscle weakness, especially of the quadriceps and gluteus maximus. Sometime before 2 years of age, soft tissue surgery, including posterior capsulotomy, should be performed. The actual procedure needs to be individualized, because each knee has a different degree of deformity. Posterior soft tissue procedures often need to be repeated

later in life, but before nearing skeletal maturity. Supracondylar osteotomies of the femur are recommended toward the end of growth to correct residual deformity (100,128-130). Femoral shortening may need to be added to the osteotomies. Many hyperextension deformities of the knee can be treated without surgery, but quadricepsplasty may be needed in cases with residual lack of motion. Traditional teaching is for correction of the knee deformity, before treating a dislocated hip, to allow stretching out of the muscles, which cross both joints. However, with early operative treatment of the hip, using a short period of immobilization, the hip may be operated upon at the same time as a surgical procedure to correct a hyperextended knee deformity. In this case, the hamstring muscles are relaxed by both procedures, and the knee can be immobilized, flexed in the hip spica cast. The flexed knee cannot be easily managed at the same time as hip surgery, because it is impossible to appropriately immobilize the hip with the knee held extended. Despite good initial nonoperative results in the hyperextended knee, there may be recurrence of the contracture over time, with surgery often needed later in life. An alternative technique of correction of the knee deformity is using an external fixator, with gradual correction (131); however, in most cases, an open procedure to release the contracted structures will be adequate. Late osteoarthritis seems more common in those with persistent hyperextension contracture.

A severe and resistant clubfoot is characteristic (100, 132,133) (Fig. 9-12). It is rare for the arthrogryptic clubfoot to respond to physical therapy and casts, and surgical intervention is usually necessary. However, as in the knee deformity, there is a wide range of severity. Some feet, therefore, respond better to surgery than others. Surgery for clubfoot is sometimes delayed until 1 year of age or later, as other joints, especially the knees, are attended to first. However, as in management of the hip, performing combined procedures, with minimal immobilization earlier in life, is gaining in popularity. Primary talectomy has been recommended because of the high incidence of failed soft tissue surgery (134,135); however, recent reports show good outcome with circumferential release alone, if performed before 1 year of age (136,137) [➤7.1]. This is probably a better initial approach, because salvage talectomy can always be performed later, if necessary. Positioning of the calcaneus is key to achieving a good result after talectomy (138). Residual deformity in the teenage years can be treated using a triple arthrodesis, or with multiple osteotomies, to maintain motion of the subtalar joints, while producing a plantigrade foot. A vertical talus is an unusual foot deformity in arthrogryposis multiplex congenita, and, if encountered, the physician must think of the distal arthrogryposes or pterygia syndromes.

Most patients do not require upper-extremity surgical procedures. The physician should never think of an individual joint in the upper extremity, but only the whole arm (139,140). Analysis needs to include each hand alone, and

how the two hands work together as an effective functional unit, and a functional assessment should be made before deciding on an operation. Because of this, surgical procedures on the upper extremity are usually delayed until the children are old enough to make such an assessment. There are two key goals in treatment of the upper extremities self-help skills, such as feeding and toileting, and mobility skills, such as pushing out of a chair and use of crutches.

The shoulder is usually satisfactory without treatment. For the elbow, it is ideal to achieve flexion to 90 degrees from the fixed extended position. However, when both elbows are involved, surgery to increase flexion should only be done on one side. The fibrotic joint capsule and the weak muscles make the prospect of achieving active elbow flexion unlikely. Passive elbow flexion to a right angle is a prerequisite for considering a tendon transfer for active elbow flexion. Restoration of elbow motion by capsulotomy and triceps-lengthening has had only fair success, diminishing the likelihood for success when an arthrogrypotic muscle is used to motor the joint (141). The triceps brachii and pectoralis have been the most frequently tried. Success is best in children greater than 4 years of age, and who have at least grade four strength of the muscle to be transferred (140,142–144). Distal humeral osteotomy, designed to place the elbow into flexion and correct some of the shoulder internal rotation deformity, may be performed toward the end of the first decade (124,140). It is designed to improve hand-to-mouth function. Care must be taken not to excessively externally rotate the distal humerus. The hand and wrist is usually flexed and ulna deviated, but variations within this pattern exist (145,146). In general, the ulna-side digits are more involved. Proximal interphalangeal flexion deformities rarely respond to physical therapy or surgery. The thumb is flexed and adducted into the palm, and responds better to surgery than do the other digits.

Approximately one-third of patients develop scoliosis (147). There are no comprehensive natural history studies of scoliosis in arthrogryposis, but the curves usually have a C-shaped, neuromuscular pattern and respond poorly to orthoses. Surgery is indicated for progressive curves interfering with balance or function that are generally greater than 50 degrees.

Intelligence is normal, and these children often have a natural ability to learn substitution techniques. There is, however, a strong association between initial feeding difficulties and subsequent language development, which should not be mistaken for retardation (113).

Larsen Syndrome

The essential features of Larsen syndrome are multiple congenital dislocations of large joints, a characteristic flat face, and ligamentous laxity (148) (Fig. 9-13). The cause of the facial flattening is unclear, but it is especially noticeable when observed in profile, and is associated with some hyper-

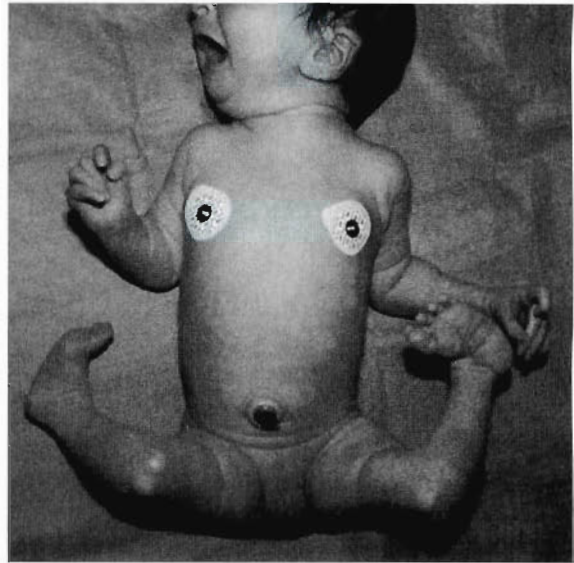


FIGURE 9-13. Larsen syndrome in a 1-week-old patient who has bilateral dislocated knees and clubfeet. (From ref. 1, with permission.)

telorism and a broad forehead. Dislocation of multiple joints appears in a characteristic pattern that includes bilateral dislocated knees, with the tibia anterior on the femur; bilateral dislocated hips; bilateral dislocated elbows; and bilateral clubfeet (149–153). The physician should think of this syndrome whenever dislocated knees are detected. The ligaments are lax or entirely absent. The ligamentous laxity is often so substantial that Larsen syndrome may be confused with Ehlers-Danlos syndrome.

On radiographs, the knees are dislocated, with the tibia anterior to the femur (151). Arthrograms show a small or absent suprapatellar pouch, absent cruciate ligaments, and a misaligned patella (Fig. 9-14). The elbows have complex radial–humeral, ulnar–humeral, and radial–ulnar dislocations. Radial–ulnar synostosis is common and usually associated with ulnar–humeral dislocation (Fig. 9-15B). A spheroid ossicle frequently occurs anterior to the elbow joint; its origin is unknown. There are an increased number of carpal centers (Fig. 9-15A), extra ossification centers in the foot, and a curious double ossification pattern of the calcaneus (Fig. 9-15C). Abnormal cervical spine segmentation, with instability, is typical, and kyphosis a complication often associated with myelopathy. Some cases are inherited in an autosomal dominant manner, aiding in the diagnosis.

Autosomal dominant and recessive inheritance are both reported in Larsen syndrome, although many cases are sporadic (154–156). Autosomal recessive inheritance may have the more severe phenotype. A linkage study of a large kindred from Sweden identified a region on chromosome 3, where the causative gene probably is located (157). The actual causative gene in this region has yet to be identified.

The large number of deformities of the lower extremities

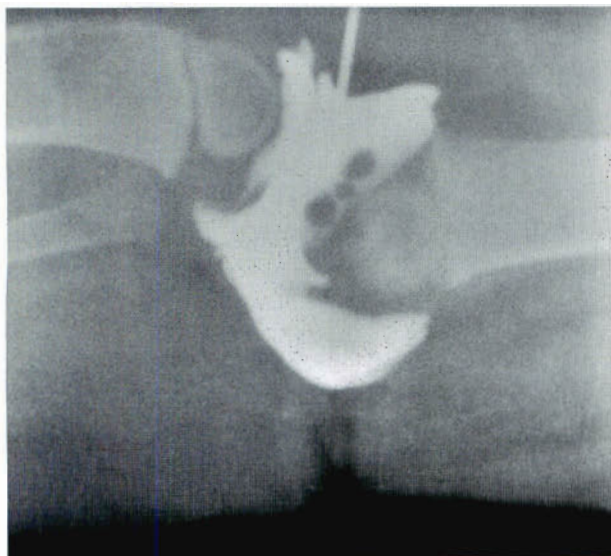
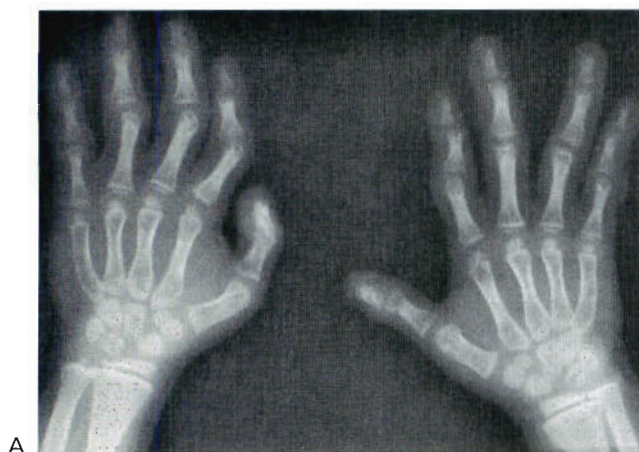

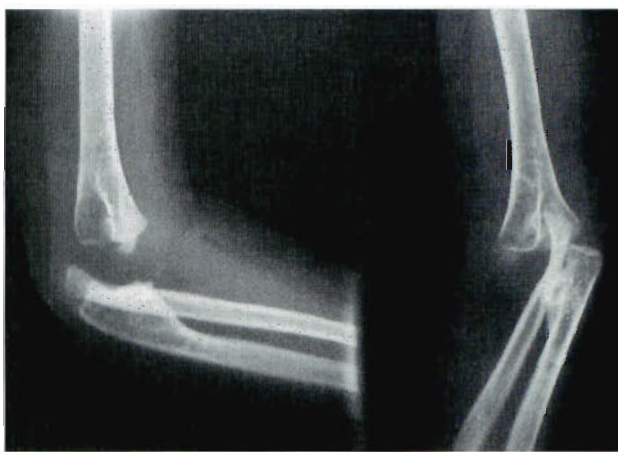
FIGURE 9-14. Larsen syndrome in a 5-month-old patient. The arthrogram of a knee shows anterior dislocation of the tibia on the femur and no suprapatellar pouch.

require treatment to achieve stable, located joints. Knee stability is necessary to achieve ambulation. Reduction almost always requires surgery. The knee may remain unstable after reduction because of the lack of major stabilizing ligaments, such as the anterior cruciate ligament. Long-term orthoses are often needed. Successful anterior cruciate ligament reconstruction has not been reported. The knee is usually reduced before the hips, although simultaneous procedures are possible (151,158). Although most knees do not respond to attempts at manipulation and cast correction, it has been traditional to try this approach initially. Too vigorous manipulations result in distal femoral metaphyseal–physeal fractures. Because manipulation has not been helpful in our hands for true dislocations, we believe that it can be abandoned once a dislocation is confirmed. Surgery may be undertaken as early as 3 to 4 months of age. Cautious restoration of the range of motion (gaining full extension is often a problem), while guarding against redislocation by using a flexion splint or brace may be required after operative reduction.

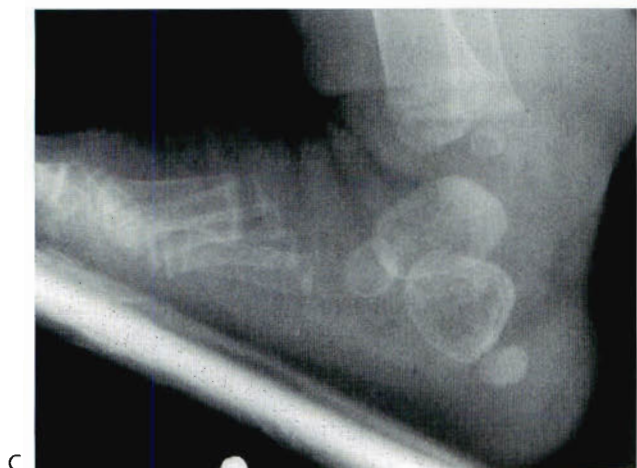The hips are dislocated, often despite a rather normal-appearing acetabulum. There is a sensation of good range of motion, although the hip may prove to be irreducible



A



B



C

FIGURE 9-15. A 4-year-old patient with Larsen syndrome. Characteristic roentgenograms. **A:** The hands show an increased number of carpal centers and interphalangeal joint subluxations. **B:** The elbow demonstrates total dislocation but full functional ability. (**A** and **B** from ref. 1, with permission.) **C:** The foot has an abnormal os calcis containing two ossification centers.

(153). The evolution of hip management in Larsen syndrome mirrors that in arthrogryposis multiplex congenita, and there is a trend toward earlier treatment. The relative rarity of this syndrome, however, accounts for the lack of good comparative data on how to best manage the hip dislocations. Reduction of the hip is associated with a high redislocation rate and revision surgery (151–153). For this reason, some advocate either leaving bilateral dislocated hips alone, or waiting until after 1 year of age and performing femoral and pelvic osteotomies, along with the open reduction. However, we prefer an approach similar to that in arthrogryposis, with early surgical relocation (usually through a medial approach) [►3.3, 3.4]. Because the knees are hyperextended when dislocated, and casted flexed after surgical relocation, both knees and hips can be operated on at the same time. Secondary osteotomy of the pelvis and femur can be performed later, if necessary.

The clubfeet can be managed in a cast until the knee deformity is corrected. Some feet can be corrected with serial casting, but long-term results suggest less residual deformity when the foot is treated surgically (151) [►7.1]. The foot may need to be braced to control ankle instability. Despite the dislocations of the elbow or shoulder, the arms remain functional and rarely require treatment. Crutches or walkers can be used despite the dislocations.

The major concern involving the spine is structural abnormalities of the cervical vertebrae (159,160). This manifestation may occur more frequently than previously recognized, and children should have cervical spine films taken in the first year of life to identify this deformity. Kyphosis is often due to hypoplasia of the vertebral bodies. A combination of cervical kyphosis and forward subluxation may result in quadriplegia and death. Posterior stabilization early (within the first 18 months of life) may avoid the significant problems associated with treatment after myelopathy has occurred, and allow for correction of a kyphotic deformity with growth (161).

Anesthesia complications are common. The mobile infolding arytenoid cartilage creates airway difficulties. The associated tracheomalacia can be especially problematic in the newborn, and may delay surgery for the hips and knees (162). The anesthesiologist should be aware of possible cervical spine instability, and a preoperative lateral film is recommended.

The children have normal intelligence. The prognosis is generally good with aggressive orthopaedic treatment, if the child survives the first year of life. The mortality figures for the first year may be as high as 40%. During the neonatal period, the cartilage-supporting structure of the larynx and trachea is soft, and there may be alarming elasticity of the thoracic cage at the costochondral junction, leading to respiratory failure and death. Cervical spine problems may also contribute to early mortality. Congenital cardiac septal defects and acquired lesions of the mitral valve and aorta,

similar to those found in Marfan syndrome, further complicate medical and anesthesia management (163).

CONTRACTURE SYNDROMES INVOLVING PREDOMINANTLY THE HANDS AND FEET

Distal Arthrogryposis

Children with distal arthrogryposis have characteristic fixed hand contractures and foot deformities, but the major large joints of the arms and legs are spared (164–166). Craniofacial abnormalities are often associated, which has caused distal arthrogryposis to be separated into several eponymic syndromes (e.g., Gordon syndrome), a situation that leads to confusion (167). The cardinal features of distal arthrogryposis are the hand deformity with ulna deviation of the fingers at the metacarpophalangeal joint, flexion deformities at the proximal interphalangeal and metacarpophalangeal joints, and a cup-like palm with a single palmar crease (Fig. 9-16). The thumb is flexed and adducted, with a web at its base (168). Distal arthrogryposis is common, and is sometimes incorrectly called multiple camptodactyly. The inheritance pattern of distal arthrogryposis is autosomal dominant, but there may be considerable variation in families, which leads to missing the diagnosis (167–170).

Linkage analysis shows that the causative gene in some families with distal arthrogryposis is located on chromosome 1 (5). Because there are a variety of subtypes of distal arthrogryposis, it is likely that a number of causative genes will be identified.

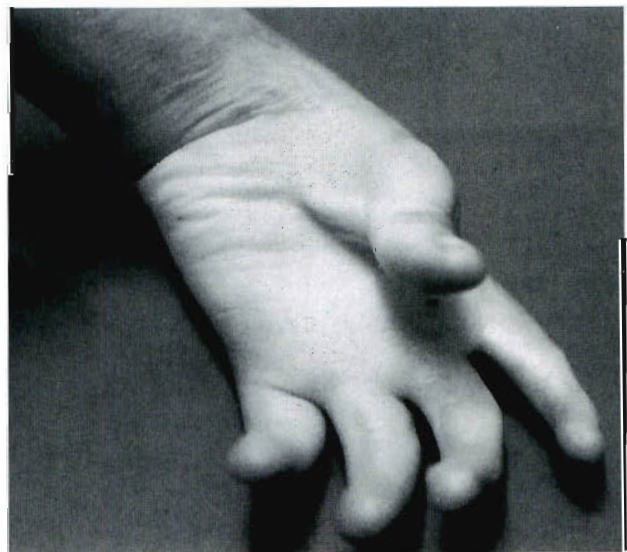

FIGURE 9-16. Distal arthrogryposis. Characteristic hand is the result of ulnar deviation at the metacarpophalangeal (MCP) joints. Notice the deeply cupped palm and webbing of the MCP joint of the thumb.

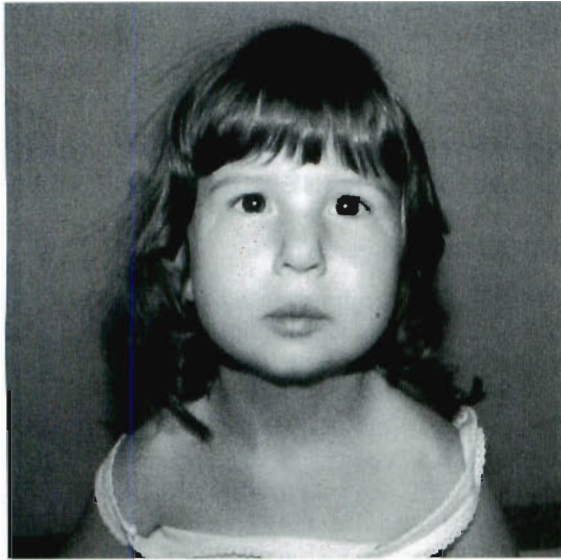

FIGURE 9-17. Freeman-Sheldon syndrome in a 3-year-old patient. Notice the small chin and mouth, long philtrum, puffy cheeks, deeply set eyes, and small chin cleft. (From ref. 1, with permission.)

Although the hand deformity is characteristic and constant, the feet may be clubbed, have stiff metatarsus adductus, and have a vertical talus. The major joints in the upper and lower extremities are otherwise normal, although a minor knee-flexion deformity may be found. Intelligence is normal. The associated craniofacial anomalies are cleft lip or cleft palate, and, in those families, the syndrome of distal arthrogryposis may have an eponymous name, such as Gordon syndrome (171,172). Radiographs show normal bony architecture, and only with persistence of deformities in the hand and feet are articular changes detected. This syndrome can be diagnosed prenatally in the fetus by detecting an unchanged position and lack of motion of the hands in contrast to the normal activity of the large uninvolved joints (173).

Overall, children with distal arthrogryposis have good function. The hands function well because the shoulders, elbows, and wrists are normal. Thumb surgery to lengthen the flexor pollicis longus and rebalance the extensor is the most common surgery. The feet more frequently require surgery. Some clubfeet can be corrected with manipulation and serial casts. Most are treated with circumferential releases [7.1]. The outcome of treatment of clubfoot is better in this syndrome than for other arthrogrypotic clubfeet.

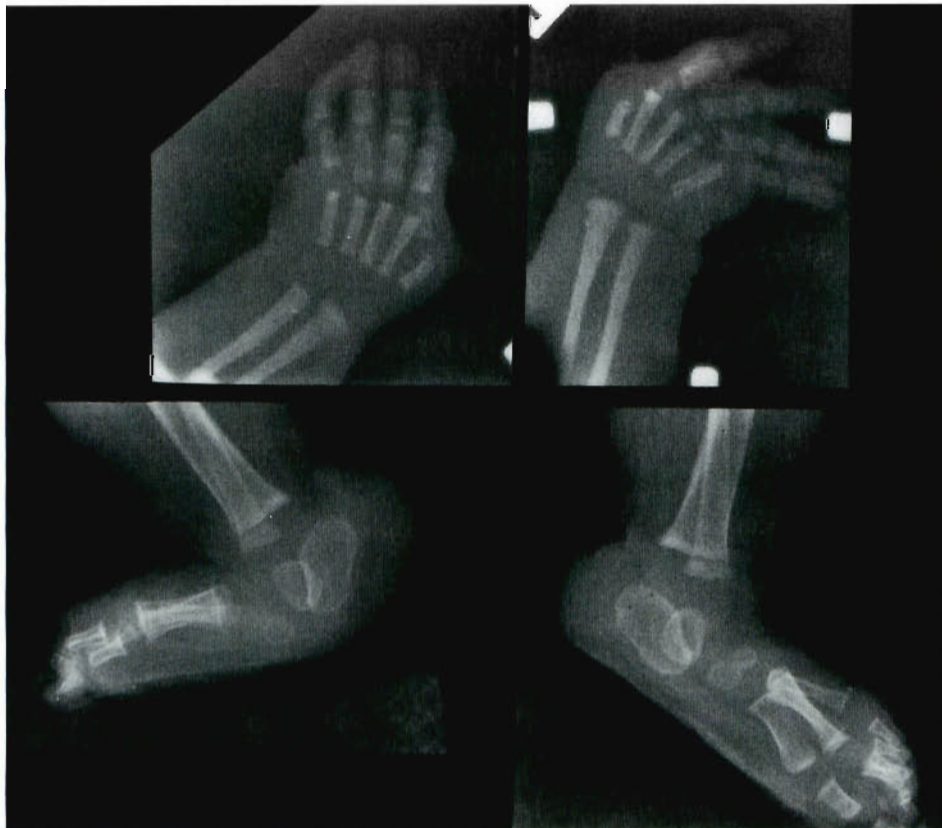

FIGURE 9-18. Freeman-Sheldon syndrome in a 5-year-old patient. Radiographs of the hands demonstrate ulnar deviation at the metacarpophalangeal joint, typical of a distal arthrogryposis syndrome. The feet show bilateral congenital vertical tali. All other joints in this patient were normal. (From ref. 1, with permission.)

Freeman-Sheldon Syndrome

Freeman-Sheldon syndrome is sometimes called “distal arthrogryposis type II,” because of the hand and foot deformities similar to distal arthrogryposis. It is recognized by its most characteristic feature, a “whistling face” (Fig. 9-17). The original name, “craniocarpotarsal dystrophy” is misleading, because it does not involve the cranium (174,175). This syndrome is usually sporadic, although there is evidence of autosomal dominant and autosomal recessive inheritance (176–178). The eyes are deeply set. The cheeks are fleshy, and pursed lips simulate whistling. There is a small mouth and a curious H-shaped dimple in the chin.

Scoliosis was not initially recognized as a common feature, but it affects more than one-half of the patients. The onset is in the first decade. It is often severe, with a left thoracic pattern reported regularly. The vertebrae are normally shaped. Although the scoliosis can be managed as in idiopathic scoliosis, the curves are more rigid, and may not respond well to brace treatment (177,179).

The hands demonstrate the classic distal arthrogryposis pattern described earlier (177,179,180). There are other contractures, including flexion deformities of the elbow and knee, decreased shoulder range of motion, decreased neck range of motion, and dislocated hips (181). Operative management principles for the upper extremity are similar to that with distal arthrogryposis. The hands are treated with physical and occupational therapy, but there is less improvement than seen with the other distal arthrogryposis syndromes (182). Most of the other associated contractures can be treated like those in the other arthrogrypotic syndromes.

Clubfoot is the most common foot deformity, with vertical talus being second most common (Fig. 9-18) (177,179,180). The clubfoot and vertical talus deformities are resistant to nonoperative measures.

During infancy, dysphagia and aspiration lead to failure to thrive, and to death. Surgery to permit adequate mouth opening for feeding may be necessary (183). Children who survive the neonatal period do well and have normal intelligence. Anesthesia complications are common; some are the result of abnormalities related to the laryngeal cartilages (183–186). The cause is unknown, but the buccinator muscle is hypoplastic, and electromyograms and muscle biopsies are identical to the peripheral muscle studies in classic arthrogryposis multiplex congenita (187), suggesting some similarity in pathophysiology.

CONTRACTURE SYNDROMES WITH SKIN WEBS

Pterygia Syndrome

“Pterygium” comes from a Greek word meaning “little wing.” A pterygium is a web. It can be seen as an isolated

malformation in some syndromes, such as the pterygium colli in the neck of patients with Klippel-Feil syndrome.

There are two clinically important pterygia syndromes: multiple pterygium syndrome and popliteal pterygia syndrome (188). Several pterygium syndromes are lethal, with the affected patients not surviving pregnancy or the newborn period (189,190). The web syndromes are separated genetically as autosomal recessive (i.e., lethal pterygium syndrome and multiple pterygium) and autosomal dominant (i.e., popliteal pterygium) (191). However, they often overlap. Lethal pterygium syndrome may be diagnosed prenatally by detecting hydrops and cystic hygroma colli (192).

Multiple pterygium syndrome (i.e., Escobar syndrome) is characterized by a web across every flexion crease in the extremities, most prominently across the popliteal space, the elbow, and in the axilla (193,194) (Fig. 9-19). There also are webs across the neck laterally and anteriorly from sternum to the chin, drawing the facial features down. The fingers are webbed. The webs can be obvious, but if they are not, the affected children can look very much like those with arthrogryposis multiplex congenita. The two features that differentiate this syndrome from classic arthrogryposis

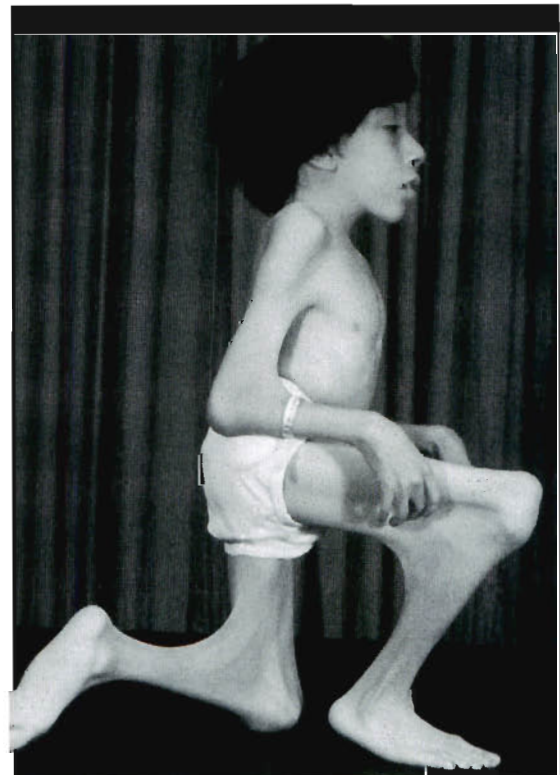


FIGURE 9-19. Multiple pterygium syndrome in a 12-year-old patient. Antecubital webs fix the elbows, and popliteal webs prevent ambulation. The patient had normal intelligence and became a college graduate. (From ref. 1, with permission.)

are vertical talus and congenital spine deformity. The vertical talus is fairly constant in multiple pterygium syndrome and can only be managed surgically. Circumferential release and prolonged protection, as in managing any arthrogryotic foot deformity, is necessary. The spine deformity is significant, with multiple segmentation abnormalities and a lordoscoliosis (195) (Figs. 9-20 and 9-21). The lordoscoliosis may be substantial enough to interfere with trunk and chest growth, leading to respiratory death during the first or second year of life (Fig. 9-21). Mobility depends much on the magnitude of the lower extremity webs and the remaining joint motion, with many patients limited to wheelchair for locomotion. The children have normal intelligence, and efforts for their independence should be maximized. Surgery is rarely needed for the upper extremities.

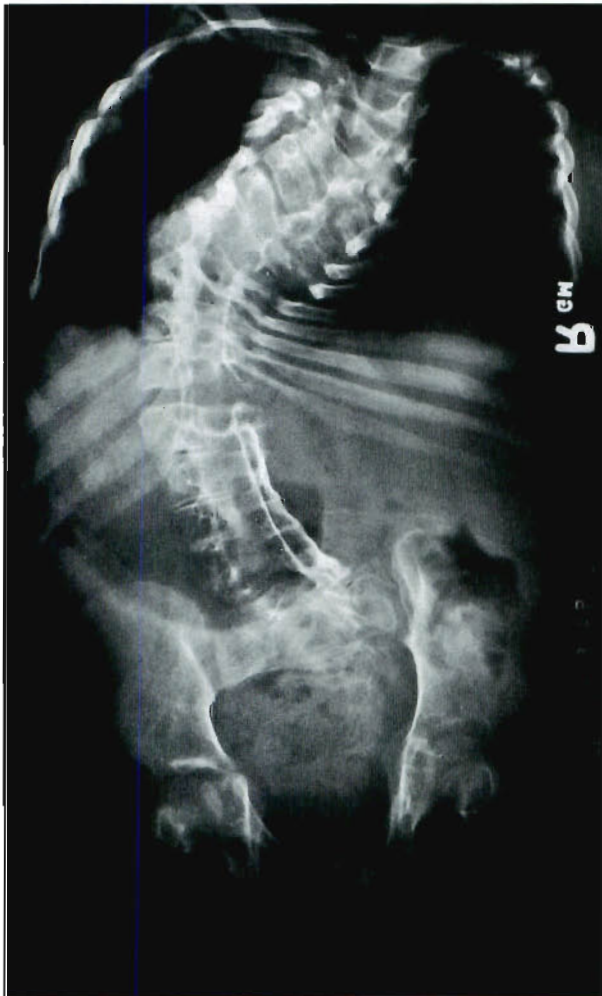


FIGURE 9-20. Multiple pterygium syndrome in a 13-year-old patient. Radiograph shows severe scoliosis, vertebral abnormalities, and an unsegmented bar from T9 to T12 and from L1 to S1, with an apparent gap between the bars. (From ref. 1, with permission.)

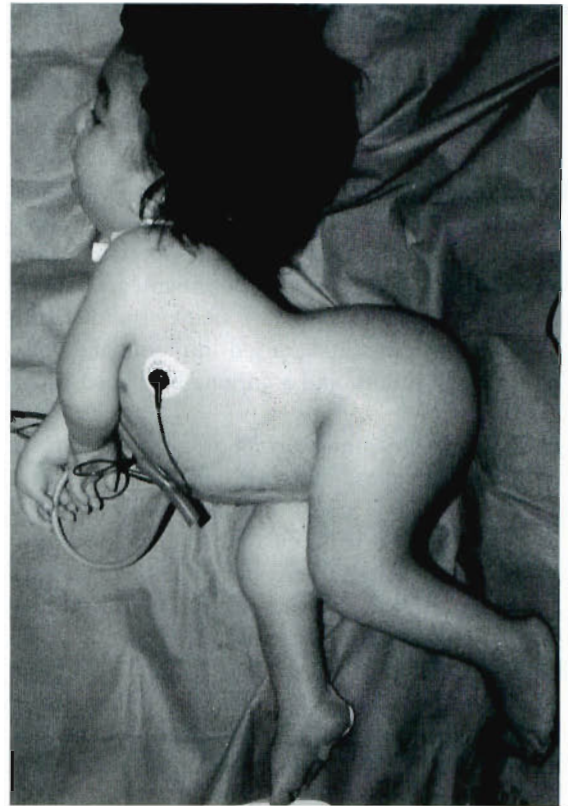

FIGURE 9-21. Multiple pterygium syndrome. Severe limitation of trunk growth was caused by vertebral fusions and lordoscoliosis. Death occurred at 24 months of age because of respiratory failure.

Popliteal pterygium syndrome (i.e., fascial-genital-popliteal syndrome) has recognizable features in the face, the genitals, and the knee (196–200). The features include a cleft lip and palate, lip pits, and intraoral adhesions (201,202). A fibrous band crosses the perineum and distorts the genitalia (203). A popliteal web is usually present bilaterally (200). It runs from ischium to calcaneus, resulting in a severe knee-flexion deformity. Tibia hypoplasia may be associated. Within the popliteal web is a superficial fibrous band, over which lies a tent of muscle running from the os calcis to the ischium, and known in the older literature as a “calcanoeischadicus muscle.” The popliteal artery and vein are usually deep, but the sciatic nerve is superficial in the web, just underneath the fibrous band (Fig. 9-22). There is a distinctive foot abnormality in this syndrome: a bifid great toenail and syndactyly of the lesser toes.

Although the original cases of multiple and popliteal pterygium syndromes were clearly defined, there is more phenotypic variation in both than originally thought. For example, mild webs in joints of the upper extremity may be found in patients with popliteal pterygium syndrome. Adaptive changes in the joints occur over time. Radiographically, the

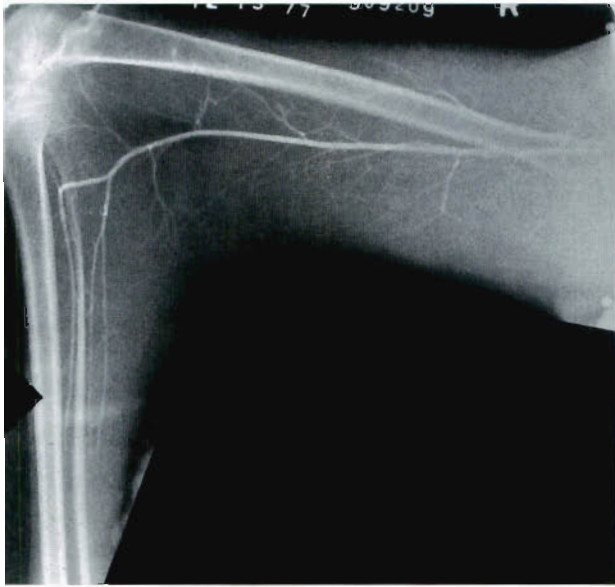


FIGURE 9-22. Popliteal pterygium in a 13-year-old patient. Arteriogram shows that the popliteal artery has been drawn up from its normal position. At the margin of the web is the sciatic nerve. (From ref. 1, with permission.)

patella becomes elongated, and the femoral condyles flattened, as a result of knee flexion deformity.

From a management perspective, the determining factors are the magnitude of scoliosis and the size of the web crossing the knee. The thoracic vertebral dysplasia, thoracic lordosis, and the small chest impairs lung development, resulting in death in the first years of life in those with multiple pterygium syndrome. For the longer-term survivor, management of the spine deformity is identical to those with nonsyndromic congenital scoliosis. Preoperative evaluation of intraspinal contents by MRI and ultrasound of the kidney are indicated.

The knee is the joint that limits mobility in both syndromes and is the joint that most determines future ambulatory potential (200,204–206). Traditionally, treatment of the knee begins with physical therapy, but its effectiveness is doubtful. Early popliteal web surgery is recommended before the onset of adaptive changes in the articular surfaces, and before further vascular shortening. The nerve is usually located just deep to the skin and web, and care must be taken to avoid nerve damage. The web is resected, and Z-plasty of the skin performed. There is a high recurrence rate despite braces. Femoral shortening and extension osteotomy are usually postponed until near or after maturity. However, if almost full knee extension cannot be achieved at surgery, even if during infancy or childhood, femoral shortening should be considered (207). Gradual distraction techniques can be used, but the advantage over traditional techniques has not been demonstrated (208). Posterior soft tissue pro-

cedures can be combined with distraction techniques to gradually extend the knee.

DOWN SYNDROME

Down syndrome is the most common and perhaps the most readily recognizable malformation in humans (209) (Fig. 9-23). Patients have a characteristic facial appearance including upward-slanting eyes, epicanthal folds, and a flattened profile. Examination of the hands reveals a single flexion crease, often referred to as a simian crease. There is also clinodactyly of the small finger. These hand malformations have no clinical significance (210). Milestones are delayed, with most children not walking until 2 to 3 years of age. The classic gait pattern is broad based, toed out, and waddling.

The bones in Down syndrome have subtle malformations. The best-studied changes are in the pelvis, which is characterized by flat acetabula and flared iliac wings (211). These pelvic changes are so characteristic that prior to use of chromosome analysis pelvic radiographs were used to confirm the diagnosis. Short stature is a cardinal feature; the average for male adults is 155 cm (61 in.), and the average for female adults is 145 cm (57 in.) (212). Bone changes can be used in prenatal diagnosis, in which a combination of bone length and maternal lab tests (human chorionic gonadotropin and alpha-fetoprotein levels) may predict the diagnosis, although the positive and negative predictive values are not as good as initially hoped (213). Cytogenetic study, which identifies complete trisomy 21 in 95% of cases, remains the best confirmative test.

Complete trisomies account for 95% of the cases, with 2% mosaics and 3% translocations. The overall risk is 1 per 660 live births, and the incidence is closely related to maternal age. If the mother is younger than 30 years of age, the risk is 1 of 5000 live births, and if the mother is older than 35 years of age, the incidence rises to 1 in 250. The critical region necessary for Down syndrome resides in part of the long arm of chromosome 21. Duplication of a 5-megabase region of chromosome 21 (located at 21q22.2–22.3) causes the classic phenotypic features, such as the characteristic facies, hand anomalies, congenital heart disease, and some aspects of the mental retardation (214). This region probably contains a number of genes whose duplication is necessary to produce the syndrome.

The general features of Down syndrome are well known. There is a characteristic flattened face. Mental retardation is typical, but performance is far better than expected from standard IQ testing. Congenital heart disease occurs in about one-half of patients, and is usually a septal defect (e.g., arteriovenous communis, ventricular septal defect). Duodenal atresia is found regularly. Leukemia occurs in about 1% (1,5). There is a high incidence of endocrinopathies, hypothyroidism in particular. Infections are common, although the precise molecular mechanism is not apparent.



FIGURE 9-23. Down syndrome. The child has the characteristic face, with upward-slanting eyes, epicanthal folds, open mouth of early childhood, and flattened profile. A: At 1 year of age. (Courtesy of Murray Feingold, M.D., Boston, MA.) B: At 10 years of age. (From ref. 1, with permission.)

The appearance of premature aging is obvious, and there often is an early onset of Alzheimer disease (215).

Approximately 10% of people with Down syndrome show an increased atlantodens interval on lateral spine films (216–220) (Fig. 9-24A). In most, the increased interval is

not associated with symptoms (217,221). In addition, there is a broad array of other abnormalities in the upper cervical spine, including instability at occiput and C1 (220, 222–224), odontoid dysplasia (217,225) (Fig. 9-24C), laminal defects at C1 (226) (Fig. 9-24B), spondylolisthesis (Fig.

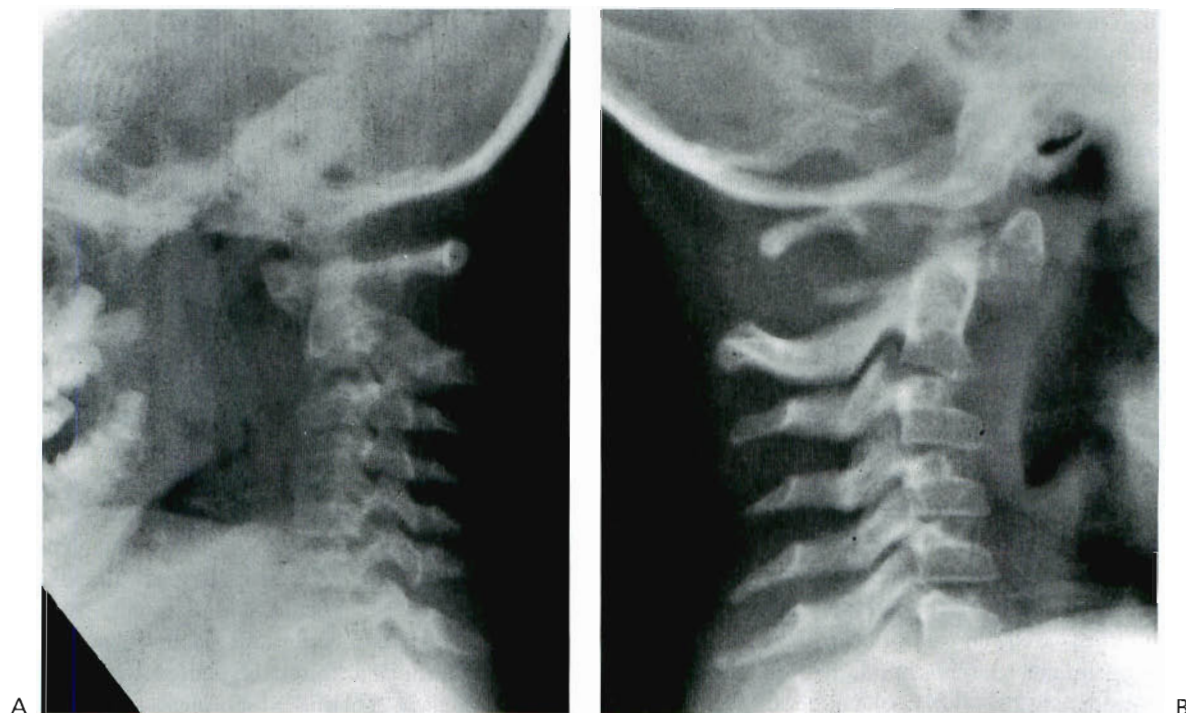


FIGURE 9-24. Cervical spine abnormalities in a patient with Down syndrome. A: Atlantodens instability at 8 years of age. B: Hypoplastic posterior elements of C1 at 3 years of age.

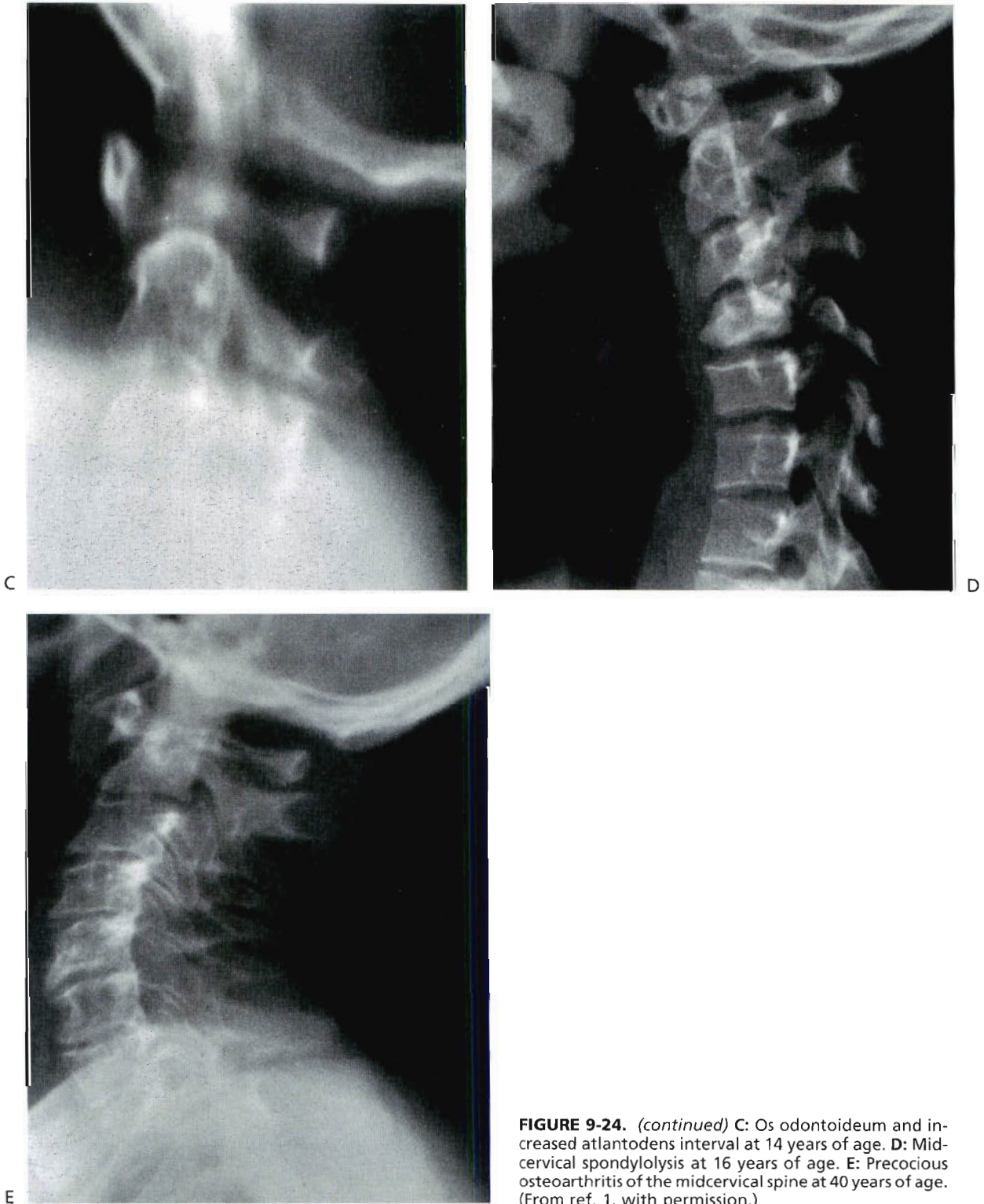

FIGURE 9-24. (continued) C: Os odontoideum and increased atlantodens interval at 14 years of age. D: Mid-cervical spondylolysis at 16 years of age. E: Precocious osteoarthritis of the midcervical spine at 40 years of age. (From ref. 1, with permission.)

9-24D), and precocious arthritis in the midcervical region (227,228) (Fig. 9-24E). These other abnormalities often complicate decision-making about spinal instability. Although routine screening radiographs often disclose these cervical spine abnormalities, radiographs are not reliable in predicting myelopathy (219,221,225,229–232). Thus, their use in the management of the cervical spine in patients with Down syndrome is uncertain. Details of managing the cervical spine in Down syndrome are found in Chapter 21 of this text.

About one-half the patients with Down syndrome have scoliosis, with an idiopathic pattern in most (233). Scoliosis is five times more likely to be detected in a severely retarded institutionalized population than in an ambulatory setting,

which suggests confounding variables of detection and neuromuscular factors. Management is the same as in idiopathic scoliosis. Spondylolisthesis occurs in about 6%, with the lower lumbar spine being most commonly involved. Spondylolisthesis can also occur in the cervical spine.

Congenital dislocated hips are rare, but progressive dysplasia may begin during later childhood. This loss of acetabular containment may lead to an acute or gradual complete dislocation (Fig. 9-25A, B). Although the onset of acetabular dysplasia is in late childhood, it can be progressive even after maturity, leading to adult dislocations (234–236) (Fig. 9-25C, D). Although hip instability and developmental dysplasia are thought to lead to functional disability, interfering with walking, and reducing independent mobility, there are

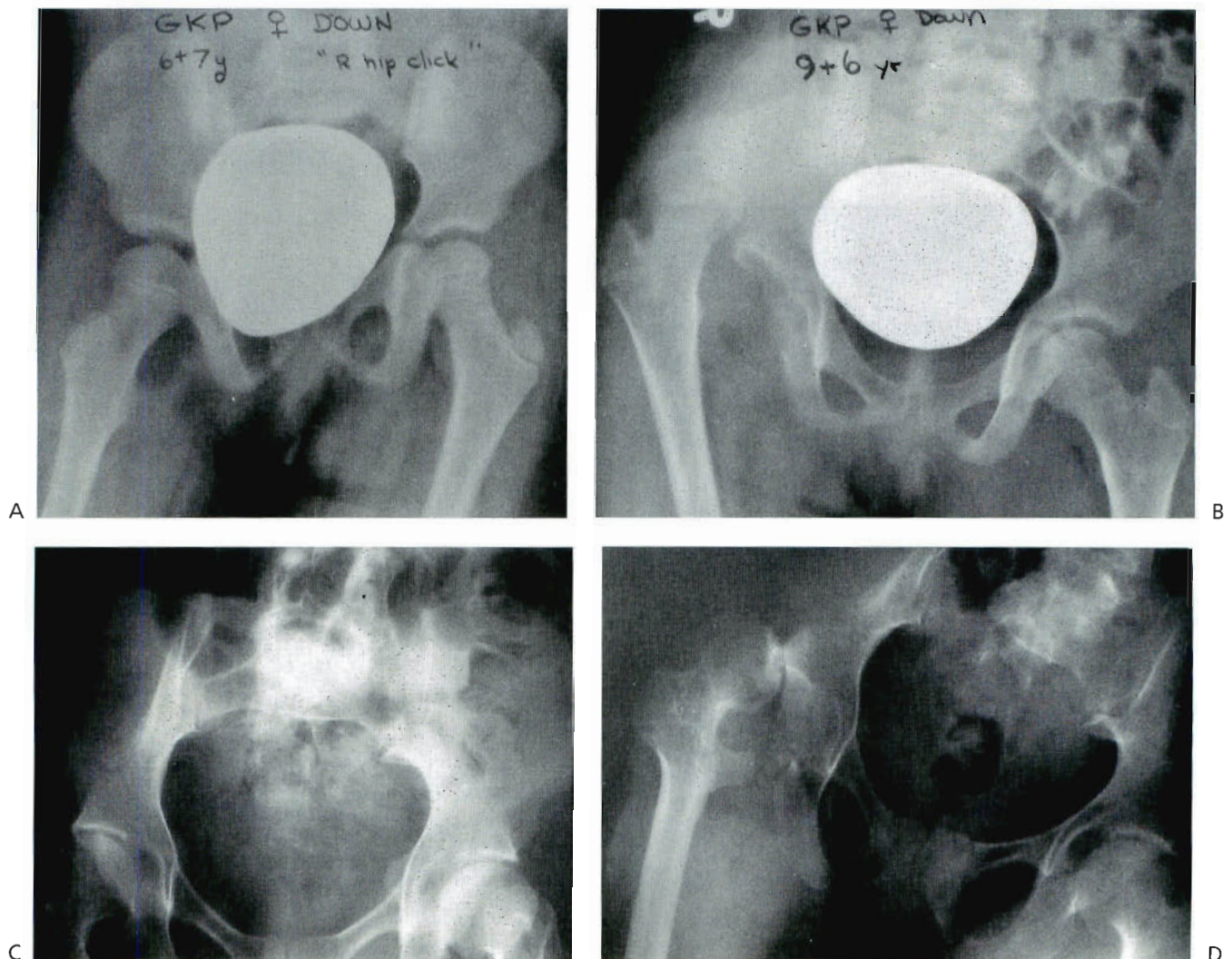


FIGURE 9-25. Down syndrome patient with late-onset developmental dysplasia of the hip, and dislocation. **A:** Standing radiograph of the pelvis at 6.5 years of age. **B:** At 9.5 years of age, the patient suddenly refused to walk because of hip dislocation. (From ref. 1, with permission.) **C:** Pelvic radiograph of a 31-year-old man with Down syndrome. **D:** Three years later, dislocation of right hip occurred. (From ref. 230, with permission.)

no studies showing this to be the case. The etiology of the hip instability is probably multifactorial, with ligamentous laxity, subtle changes in the shape of the pelvis and acetabular alignment, and behavior (some children become habitual dislocators) all contributing. Treatment of the unstable hip is difficult, and the multiple causative factors also contribute to higher treatment failure rates. Both operative and nonoperative treatment are reported. Prolonged bracing after reduction for the hip that acutely dislocates shows success in children under 6 years (237). In cases in which there are repeated dislocations, surgical reconstruction is warranted, especially in children over 6 years. Operative treatment is technically demanding, and requires correction of all the deforming factors. Reconstruction must take into account the abnormal bone alignment, and should include femoral [4.1, 4.2, 4.6] and acetabular osteotomies [3.5, 3.7, 3.8], as well as imbrication of the redundant capsule. The recurrence rate following hip surgery is high, suggesting that other factors related to the underlying disease, but not necessarily related to the hip anatomy itself, contribute to this high recurrence rate (238–240).

Slipped capital femoral epiphyses are reported in all Down syndrome series, although the precise incidence is unknown (233,241) (Fig. 9-26) [3.14]. There appears to be a higher-than-expected risk for avascular necrosis. The reasons are not clear, but the factors include an increased number of acute slips and more late diagnoses. It is tempting to speculate about an association with the hypothyroid

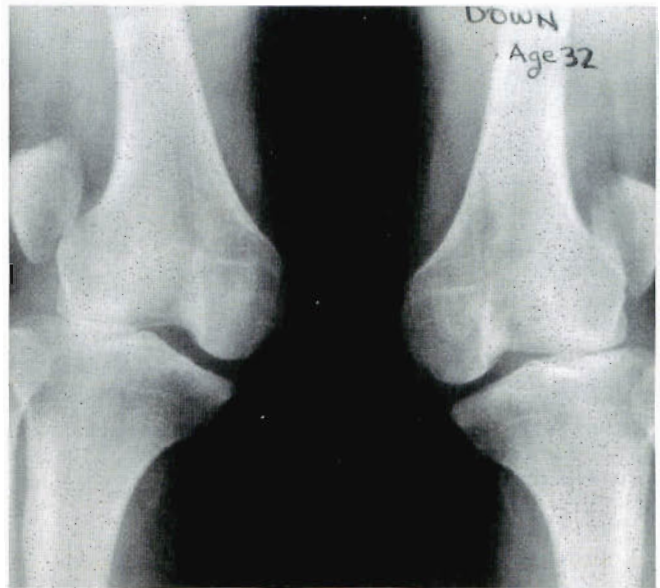


FIGURE 9-27. Down syndrome effects in a 32-year-old patient. The radiograph shows bilateral dislocated patellae and an oblique orientation of the joint line. The patient is fully ambulatory, but before standing, must manually reduce the patellae to the midline. (From ref. 1, with permission.)

state, which is common in Down syndrome. All children with Down syndrome should have thyroid function tests.

The configuration of the knee is that of genu valgum, with a subluxed and dislocated patella (Fig. 9-27). Many individuals will have asymptomatic patellar dislocations, and do not require treatment (242). Symptomatic cases should be initially managed with orthoses and a physiotherapy program. Individuals who continue to be symptomatic can be considered for operative treatment [5.1, 5.2]. As in hip dysplasia, operative interventions that correct all of the deformities (bone and soft tissue) have the best success.

The characteristic appearance of the feet in childhood is one of an asymptomatic flexible planovalgus shape, with an increased space between the great and second toes. Because maintaining mobility in adults with Down syndrome is important, foot impairment should be treated. This treatment is shoe-wear modification in many cases, but may require surgery in cases that are symptomatic despite appropriate shoe wear [7.4, 7.5, 7.11]. In many, hallux valgus develops in adolescence, and in adulthood bunions may become quite symptomatic. There is no evidence that prophylactic orthotics are beneficial in childhood. Repair of hallux valgus and bunion may be needed in late adolescence or young adulthood. Because of the hindfoot valgus, pronation, and external tibial torsion, the forces that produce bunions are obvious, and fusion of the first metatarsophalangeal joint should be considered, along with osteotomy, to correct hindfoot valgus [7.4].

A polyarticular arthropathy occurs in approximately 10%

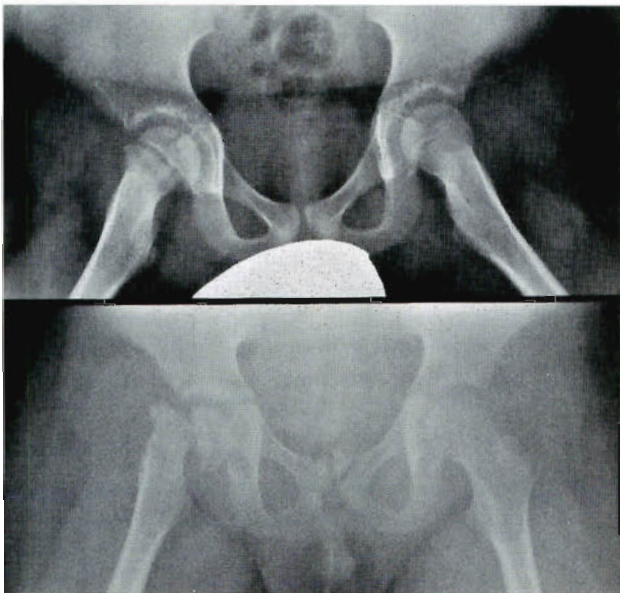


FIGURE 9-26. Effects of Down syndrome in a 12-year-old boy with 4 months of knee pain. The grade I slipped capital femoral epiphysis progressed to a total slip while the patient was undergoing preoperative evaluation and bed rest. (From ref. 1, with permission.)

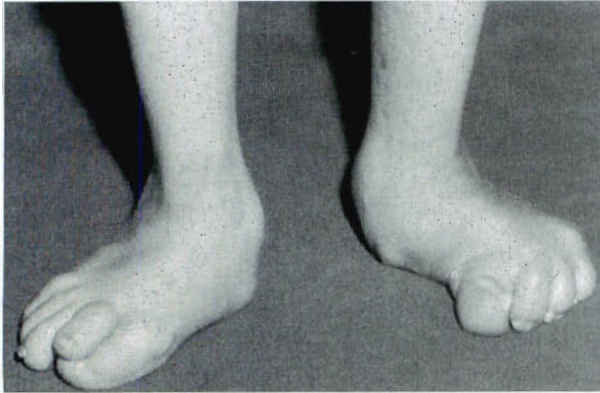

FIGURE 9-28. Polyarthrititis of Down syndrome and valgus feet led to significant deformity in a 16-year-old patient. (From ref. 1, with permission.)

of those with Down syndrome (243–245). Whether this is true juvenile rheumatoid arthritis, or a unique inflammatory arthritis due to genetic or immune defects, is unknown; the natural history is not documented. Delayed diagnosis is common. Nonsteroidal antiinflammatory drugs have been the mainstay of treatment. Foot symptoms are exceptionally frequent with the onset of polyarthropathy (Fig. 9-28).

Marked joint hypermobility is evident; the children are able to assume the most intriguing sitting postures. Ligamentous laxity was traditionally thought to be the cause of joint hypermobility and to predispose patients with Down syndrome to orthopaedic pathology. However, ligamentous laxity correlates poorly with joint hypermobility. This suggests that other factors, such as subtle malformations in the shapes of bones and insertion sites of ligaments, play a role in hypermobility (229,246).

The natural history of those with Down syndrome has changed in the last few decades. Longevity has increased because of the aggressive surgical approach to congenital heart disease, chemotherapy for leukemia, and antibiotics for infection. Survival into the sixties is common. Approximately 1 of 5 persons with Down syndrome has a musculoskeletal problem. Many, however, are merely radiographic abnormalities or curious physical findings. These patients often have excellent functional performance despite the abnormalities. There is a paucity of well-documented, long-term orthopaedic studies. Treatment programs should focus on functional performance rather than on radiographic findings.

FETAL ALCOHOL SYNDROME

Fetal alcohol syndrome is a pattern of malformations delineated in children of alcoholic mothers. The full-blown syndrome is usually only seen in children of chronic alcoholics

who drink throughout pregnancy. Lesser manifestations of the syndrome, known as fetal alcohol effects, may be related to more moderate alcohol ingestion (247). Although the risk to alcoholic mothers is known, there is substantial difference of opinion about the effects of moderate alcohol use during pregnancy (248–250). Alcohol is the most likely teratogen for a mother to encounter (251). The overall incidence of full-blown fetal alcohol syndrome is 0.33 per 1000 live births (252,253). For an alcoholic mother, there is a 30% risk for fetal alcohol syndrome in her child.

A cardinal clinical feature is disturbed growth; the children have intrauterine growth retardation, small weight, and small length at birth, and these limitations remain despite good nutrition during childhood (254,255) (Fig. 9-29). Their smallness and a loss of fat suggest a search for endocrine dysfunction; the patients often look similar to those who are growth hormone deficient. The second cardinal feature is disturbed central nervous system development. Many children with fetal alcohol syndrome are found in cerebral palsy clinics. The typical child has a small head, a small brain, and delayed motor milestones. Accomplishing fine motor skills is also delayed. Hypotonia is present early but many develop spasticity later. The typical face has three characteristic features: short palpebral fissures (i.e., the eyes

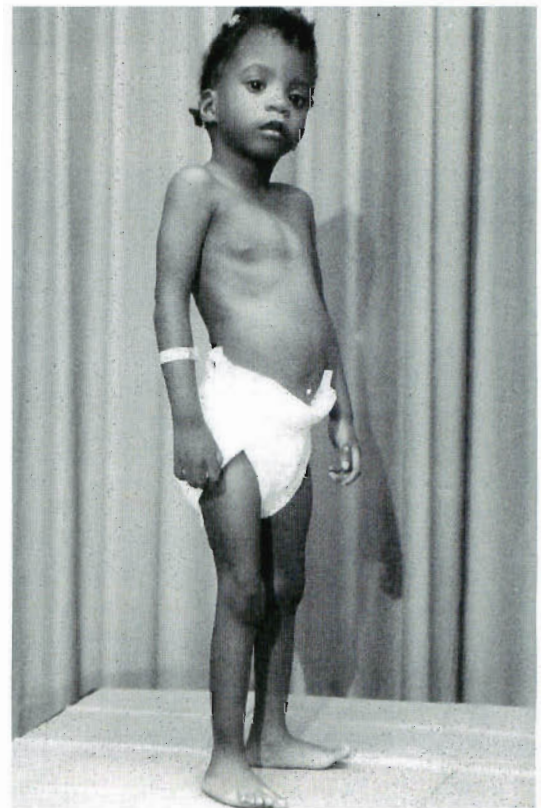

FIGURE 9-29. The 3-year-old patient is small and has the characteristic face of fetal alcohol syndrome. (From ref. 1, with permission.)

appear small), a flat philtrum (i.e., no groove below the nose), and a thin upper lip (256,257) (Fig. 9-29).

Approximately 50% have an orthopaedic abnormality, but most are not disabling (258–260). At birth, the range of motion is restricted, especially of the hands and feet, and occasionally these contractures are fixed. The contractures typically respond well to physical therapy, although residual stiffness in the proximal interphalangeal joints may remain. Clubfoot is common, and approximately 10% have developmental dysplasia of the hip. The clubfoot is usually not rigid (261). Cervical spine fusions, usually involving C2 and C3, may be indicated by radiographs (260,262–266). These may resemble the picture seen in Klippel-Feil syndrome, but there are usually none of the other findings associated with that syndrome. Synostoses are also common in the upper extremity, with fusions involving the radial-ulnar articulation and the carpal bones, all without disability (262,265,267). Stippled epiphyses may be seen in the lower extremities, but rarely in the upper extremities (268).

The orthopaedic problems associated with fetal alcohol syndrome can be managed the same as these problems in children without this syndrome. The future for children with fetal alcohol is dim, despite placement out of the alcoholic home. Intellect remains retarded, with little catch up. Social services departments should be involved in these children's care.

NAIL-PATELLA SYNDROME

Children with nail-patella syndrome have a quartet of findings that include nail dysplasia, patellar hypoplasia, elbow dysplasia, and iliac horns (269). The most prominent feature is dystrophic nails (Fig. 9-30A). The nail may be com-

pletely absent, hypoplastic, or show grooves and distortions in its surface (270). The thumb is more involved than the small finger, and the ulnar border more involved than the radial. The hands are often very symmetric, and fingernails are more involved than toenails.

The second cardinal feature is hypoplastic patellae (271). They are quite small, and may be entirely absent (Fig. 9-30B). They are unstable, and may be found in a position of fixed dislocation. The patellar abnormality highlights the total knee dysplasia, with an abnormal femoral condyle and a curious septum running from the patella to the intercondylar groove (septum interarticularis), dividing the knee into two compartments. Abnormalities in varus and valgus alignment occur, with valgus more common because of the small, flat lateral femoral condyle (271).

A third feature is a dislocated radial head (271,272) (Fig. 9-30C). The elbow joint is dysplastic, with abnormalities in the lateral humeral condyle, mimicking in many ways the dysplasia of the knee. The trochlea is large and the capitellum hypoplastic, creating an asymmetric shape that may predispose the radial head to dislocation.

The fourth and pathognomonic feature is iliac horns: bony exostoses on the posterior surface of the ilium (273) (Fig. 9-30D). They are asymptomatic and require no treatment.

Nail-patella syndrome is caused by a mutation in the *LMX1B* gene. This gene is a homeodomain protein, which plays a role regulating transcription in limb-patterning during fetal development. Mutation in the gene will disrupt normal limb patterning and alter kidney formation, resulting in extremity deformities and an associated nephropathy (274).

Children have short stature, with the height falling be-

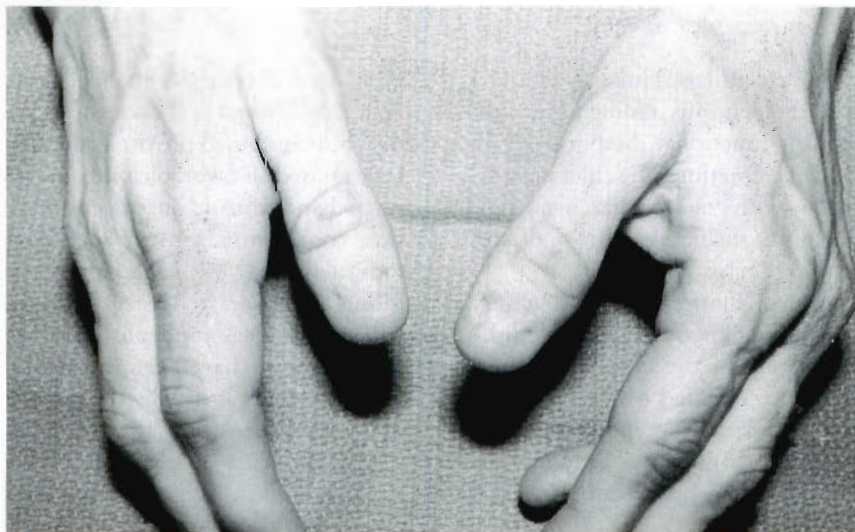


FIGURE 9-30. Nail-patella syndrome. The classic quartet of features consists of dystrophic nails shown in A. (continued)

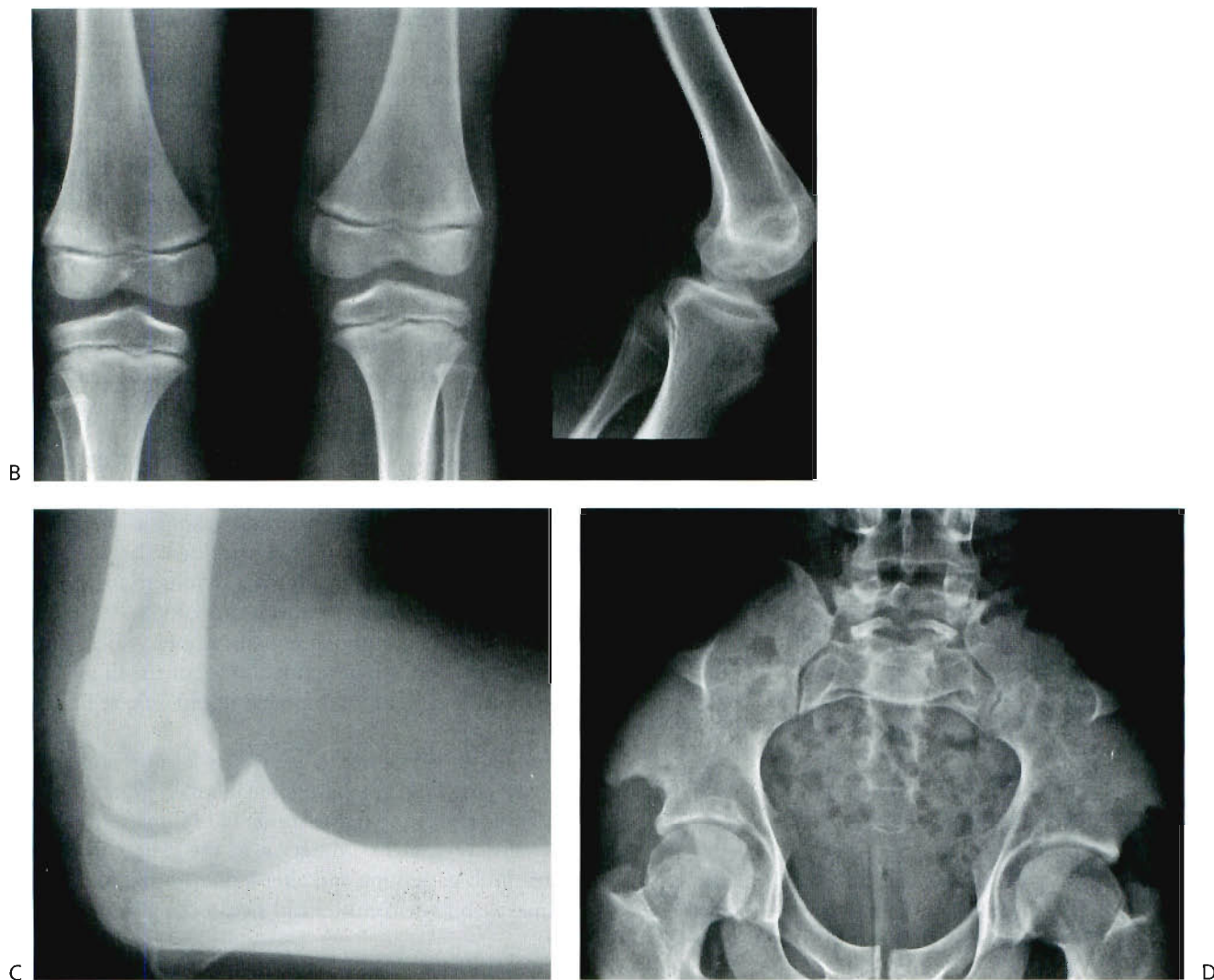


FIGURE 9-30. (continued) Absent patellae (notice the region of osteochondritis dissecans on the lateral film) are shown in B, posterior dislocation of the radial head in C, and iliac horns in D.

tween the third and tenth percentiles. There is shoulder girdle dysplasia that represents curious radiographic features, and not any significant functional disability (275). There is a foot deformity that is sometimes the chief presenting complaint of children with nail-patella syndrome (271,276). The foot deformities include variations of stiff calcaneal valgus, metatarsus adductus, and clubfeet.

There is a restricted range of motion and contractures affect several large joints, including knee-flexion deformities and external rotation contracture of the hip. When these contractures are severe and accompanied by stiff clubfeet, the diagnosis may be mistaken for arthrogryposis multiplex congenita. Madelung deformity, spondylolysis, and in some adults, inflammatory arthropathy may be present (269, 277, 278).

The knee disability is variable and related to the magnitude of quadriceps dysfunction and the dislocated patella.

Poor femoral condyles challenge achieving patella stability. As a rule, limited soft tissue or capsular releases are ineffective, but combined proximal and distal patella realignments have an overall favorable outcome [5.1, 5.2] (271). A contracted and fibrotic quadriceps may result in a knee extension contracture, and in such cases, quadricepsplasty is indicated along with the patella realignment. More commonly, an associated knee-flexion deformity may require hamstring release and posterior capsulotomy [4.23], although results have been inconsistent (271). Residual deformity, which is usually flexion or rotational, is managed by femoral osteotomy toward the end of the first decade. Osteochondritis dissecans of the femoral condyle is relatively common (Fig. 9-30B). An intraarticular septum makes arthroscopic management difficult, but the septum can be removed arthroscopically.

The radial head dislocation is asymptomatic in young

children, but may become symptomatic with time. In symptomatic individuals, excision of the radial head will improve symptoms arising from the prominent lateral bump, but the range of motion is rarely improved. Although traditional teaching advocates performing radial head excision after skeletal maturity, earlier excision in symptomatic children does not seem to be associated with significant problems (271). Clubfeet can be managed the same as idiopathic clubfeet [►7.1].

The most important nonorthopaedic condition is kidney failure. The nephropathy of nail-patella syndrome causes significant morbidity, affecting the patient's longevity. There is great variability in the age at onset and severity of the nephropathy (279). All patients should be referred for a nephrology evaluation when this diagnosis is made. Patients can go on to chronic renal failure, requiring long-term nephrology management.

DE LANGE SYNDROME

The exceptionally characteristic face of a child with growth retardation makes the clinical diagnosis of de Lange syndrome reasonably reliable (280). The face has immediately recognizable down-turned corners of the mouth, single eyebrow (synophrys), elongated philtrum, and long eyelashes (281,282) (Fig. 9-31).

The syndrome itself is clinically defined, with the cause unknown. Duplication or deletion of the chromosome band 3q25-29 produces a phenotype similar to de Lange syndrome (283,284). In these instances, the mother is always the transmitting parent, suggesting genomic imprinting. The syndrome is relatively common, occurring 1 in 10,000 live births, and it is possible to make a prenatal diagnosis by ultrasound (285,286).

Most have mild orthopaedic deformities of the upper extremities (286–292) (Fig. 9-32). They form a curious constellation of a small hand, a proximally placed thumb, clinodactyly of the small finger, and decreased elbow motion, usually caused by a dislocated radial head. This combination rarely causes any disability. Some patients, however, have severe deformities of the upper extremity in the form of an absent ulna and a monodigital hand, a condition that can be unilateral or bilateral (Fig. 9-32).

The lower extremities are usually spared. Tight heel cords and other cerebral palsy-like contractures are seen occasionally. Syndactyly of the toes is fairly constant. Aplasia of the tibia has been reported rarely. There is possibly a higher incidence of Legg-Perthes disease, approaching about 10%.

The small size begins with intrauterine growth retardation. Children remain small, with a delayed skeletal age. The mortality rate in the first year of life is high because of defective swallowing mechanisms (293), gastroesophageal reflux (294), aspiration, and respiratory infections. If the children survive their first year, they usually do well, but the long-term outcome is not well known. Almost all walk, but their milestones are delayed. There is retarded mentation, but the added features of no speech and no interactions cause major disability (295). Self-mutilating behavior can be an obstacle to orthopaedic care (296,297).

Because of the mental retardation, the failure of developing speech and paucity of social interactions raise questions about the suitability of these patients for some types of orthopaedic treatment. Braces, physical therapy, and surgery for tight heel cords are justifiable. Upper-extremity surgery is not indicated unless improved performance capacity is ensured. Patients with de Lange syndrome do not use upper-extremity prostheses. Lower-extremity prostheses, however, should be prescribed for the rare case with tibial deficiency. Because the gastroesophageal reflux and swallowing disorder

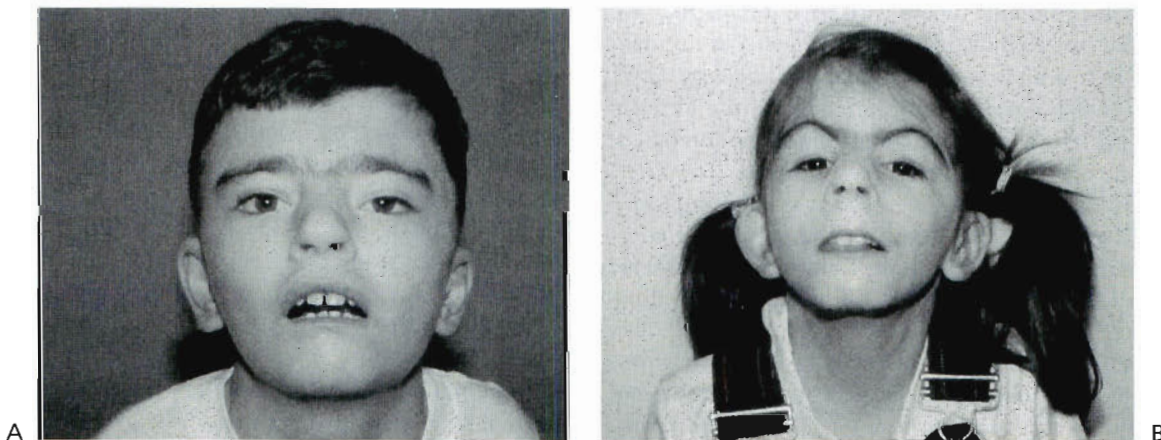


FIGURE 9-31. Cornelia de Lange syndrome. Notice the classic facial features of heavy eyebrows meeting in the midline, upturned nose, downturned corners of the mouth, and long eyelashes in a 13-year-old boy (A) and a 7-year-old girl (B). (From ref. 1, with permission.)

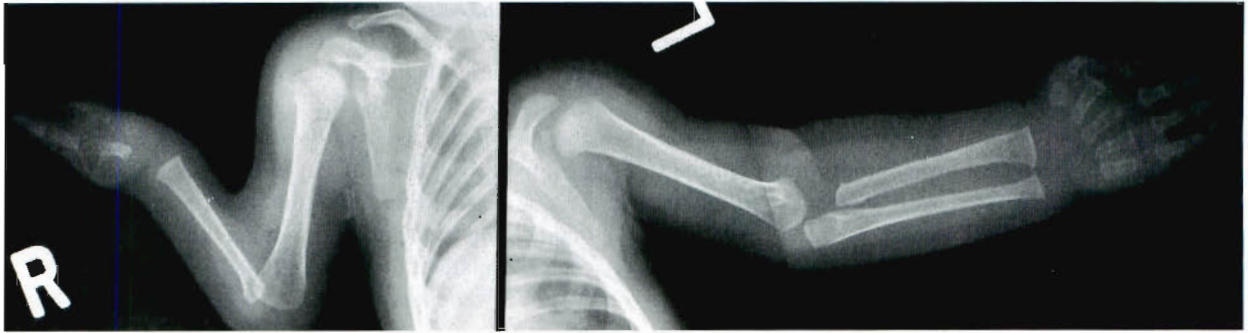


FIGURE 9-32. Cornelia de Lange syndrome in a child demonstrating a severely affected upper extremity on her right side (i.e., absent ulna and fingers) and a mildly affected arm on her left (i.e., short thumb and dysplasia of proximal radius). (From ref. 1, with permission.)

ders may persist well past the first year, there is a higher risk of anesthesia complications (298).

FAMILIAL DYSAUTONOMIA

Familial dysautonomia, also called Riley-Day syndrome, is an autosomal recessive disorder occurring primarily in Jews tracing their ancestry to Eastern Europe. Among such individuals, the incidence is estimated to be about 1 in 3,700. The clinical manifestations are caused by defective functioning of the autonomic nervous system and sensory system. The autonomic dysfunction causes labile blood pressure, dysphagia, abnormal temperature control, and abnormal gastrointestinal motility. Infants have difficulty swallowing, with misdirected fluids going to the lungs, resulting in pneumonia. There is a poor suck response and a curious absence of tears. During childhood, the autonomic dysfunction becomes more apparent, with wide swings in blood pressure and body temperature. There are cyclic vomiting episodes; these crises often last hours or days. Swallowing remains poor. The skin is blotchy. There is relative insensitivity to pain, and poor hot-cold distinction. Intelligence is normal, but the children exhibit emotional lability, and may have unusual personality development, especially in the teenage years. The diagnosis is made on clinical findings, and based on the presence of five signs: (i) lack of axon flare after intradermal injection of histamine, (ii) absence of fungiform papillae on the tongue, (iii) miosis of the pupil after conjunctival installation of methacholine chloride, (iv) absent deep tendon reflexes, and (v) diminished tear flow (299–301).

Linkage studies show the gene locus to be on chromosome 9 (9q31–33), but the actual gene has not yet been identified (302). The information about the locus, however, has been successfully utilized in prenatal diagnosis. Pathologic anatomy reveals a paucity of neurons in cervical sympathetic ganglia, dorsal sensory roots, and abdominal para-

sympathetic nerves (303). The number of small axons is depleted from the sensory nerves and the dorsal columns. Because of a primary failure to develop axons, the symptoms are present at birth, and there is a loss of nerve cells and progression of symptoms as the patient ages.

Musculoskeletal manifestations include scoliosis, fracture susceptibility, avascular necrosis, and a Charcot joint-like process. Although scoliosis affects a majority of patients, approximately one-fourth will need operative intervention (302,304–306) [↗2.9]. It has an early onset, and progression is often rapid. Kyphosis, accentuated by tight anterior pectoralis muscles, appears in approximately one-half of patients. Bracing does not work well, because of the underlying gastrointestinal and emotional problems. Anesthesia can be challenging in individuals with such autonomic lability, but with proper techniques, operative intervention is successful. Surgery seems to give better results if performed early in the course of the disease (307–309).

Fractures occur frequently, and often go unrecognized because of the insensitivity to pain (310). The physician should be suspicious of occult fractures in patients who have had trauma and swelling, but experience minimal tenderness. Fractures usually heal quite well, but early diagnosis and avoiding displacement is the goal.

Radiographic evidence of avascular necrosis is common, but the pathobiology is entirely unknown (302,306,311). There are Legg-Perthes changes in the hips. Osteochondritis dissecans of the knees is often extensive, involving both femoral condyles (Fig. 9-33). It may be difficult to differentiate the ossification changes in the knee due to osteochondritis dissecans from what may be an early Charcot joint (312,313). Hip dysplasia may be seen in patients with this syndrome.

The natural history of familial dysautonomia is characterized by a relatively high mortality rate in infancy, attributed to aspiration pneumonia (301). Sudden death in childhood and adolescence occurs because the child is unable to respond appropriately to stress or hypoxia. Early recognition

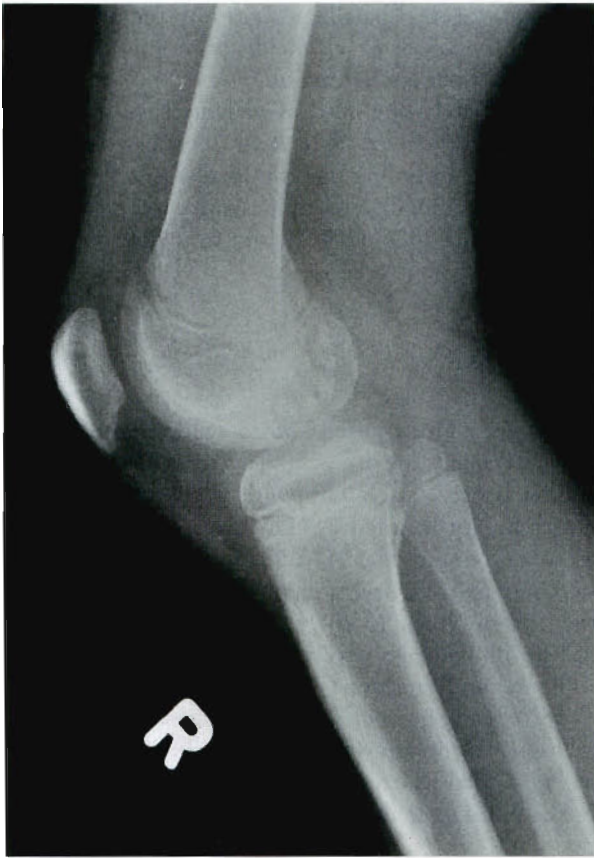

FIGURE 9-33. Familial dysautonomia. Irregular ossifications of the distal femoral epiphysis mimic osteochondritis dissecans.

of this syndrome and appropriate care, lead to a life expectancy of many decades. Management of the gastrointestinal problems, and the use of gastrostomy and funduplications have been extremely successful in this regard. There have been successful pregnancies brought to term in affected mothers (314).

RUBINSTEIN-TAYBI SYNDROME

The Rubinstein-Taybi syndrome is characterized by mental retardation associated with characteristic digital changes, consisting mainly of broad thumbs and large toes (315). It is relatively common in the mentally retarded population, with an incidence of 1 in 500 in this population (316). Most cases are sporadic, although there is the possibility of autosomal dominant inheritance (317).

One of the most characteristic clinical features is the comical face with a Cyrano de Bergerac-like nose and the nasal septum extending below the nostrils (Fig. 9-34). The face may change with time, making this a less reliable finding (318). Broad terminal phalanges of the thumb are present in 87% of patients, and the great toe is affected in 100%.

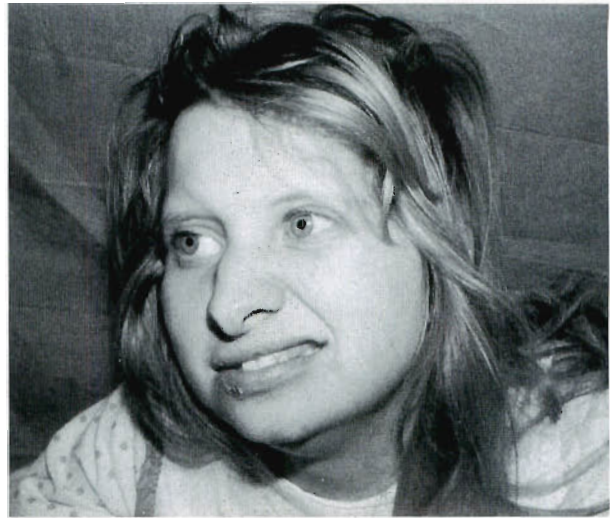

FIGURE 9-34. Rubinstein-Taybi syndrome. In a 10-year-girl, the characteristic Cyrano de Bergerac-like nose has a septum that extends below the nostrils.

One-half of the patients have radially angulated thumbs, a source of disability. Hallux varus is common, and the physician should consider Rubinstein-Taybi syndrome whenever congenital hallux varus is encountered. Patients have ligamentous laxity and pronated feet, and an increased incidence of fractures (316).

The radiographs are rather characteristic. The thumb shows a wide distal phalanx, with soft tissue hypertrophy and a triangular proximal phalanx (i.e., delta phalanx) that accounts for the radial deviation (Fig. 9-35A). The toe demonstrates duplicated or broad distal phalanx, but true polydactyly is not part of this syndrome (Fig. 9-35B). There is an assortment of insignificant other skeletal anomalies, many in the axial skeleton (319).

Patients with Rubinstein-Taybi syndrome have been shown to have breakpoints in, and microdeletions of, chromosome 16p13.3. This region contains the gene for CREB-binding protein, a nuclear protein participating as a co-activator in cyclic-AMP-regulated gene expression. This protein plays an important role in the development of the central nervous system, head, and neck, thus explaining the facial malformation and mental retardation. The propensity to develop tumors in these regions is probably caused by malregulation of cyclic-AMP-regulated gene expression (320).

Birth weight and size are normal, but growth retardation is noticed at the end of the first year, and there is no true pubertal growth spurt (321). The patients are mentally retarded, many with microcephaly. IQ can range from 35 to 80, with a delay in acquiring skills. However, these features vary. Associated medical problems include visual disturbances, congenital heart disease, and gastrointestinal abnormalities. Later in life, frequent upper respiratory infections

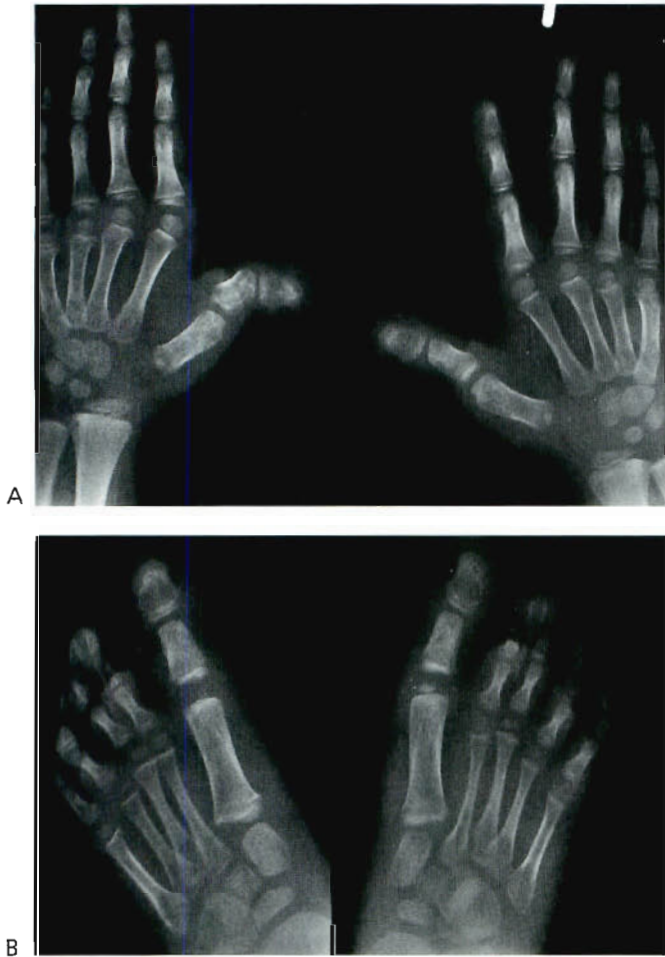


FIGURE 9-35. Rubinstein-Taybi syndrome in a 7-year-old patient. **A:** The thumbs are malformed, with a trapezoid proximal phalanx. The epiphysis extends around the radial side. **B:** The feet are more symmetric. Notice the broadening of the distal phalanx of the great toe. (From ref. 1, with permission.)

are related to abnormal craniofacial features, severe dental caries are common, and other infections lead to morbidity (322–324). Individuals with this syndrome are predisposed to certain types of central nervous system and head and neck tumors (325).

The thumb is treated if the radial deviation interferes with pinch, in which case osteotomy of the proximal phalanx should be performed. The deformity is progressive, and recurrence is common, as with any delta phalanx. The toe rarely requires treatment unless there is a significant congenital hallux varus. Patellar dislocation occurs in this syndrome. Although reports suggest that early surgical intervention might improve function, there are no data comparing early treatment with other managements to support this concept. If surgery is performed, the addition of an extensive quadriceps mobilization seems to decrease the revision rate (326,327) [5.1, 5.2]. We reserve surgical in-

tervention for the patella dislocation for symptomatic cases, or for cases in which the dislocation is clearly interfering with a patient's function.

Approximately one-third of patients have structural or conductive heart defects. Patients are sensitive to many anesthesia drugs, including neuromuscular blocking agents, which tend to induce arrhythmias and prolong awakening from anesthesia (328,329). Keloid formation is common (330).

PROGERIA

Progeria (i.e., Hutchinson-Gilford syndrome) is the best-known of many syndromes characterized by premature aging. It is exceedingly rare, with fewer than 30 affected children in North America. The cause is entirely unknown. Autosomal dominant (331) and autosomal recessive (332) inheritance patterns have been proposed, but a sporadic mutation is more likely (333).

These individuals have very abnormal levels of growth hormones, and hormone supplementation will increase growth velocity, but not result in improved survival (334). The cause is not known, but tissues from these patients have been used in a variety of reports to study the aging process. Fibroblasts from cultures derived from these indi-

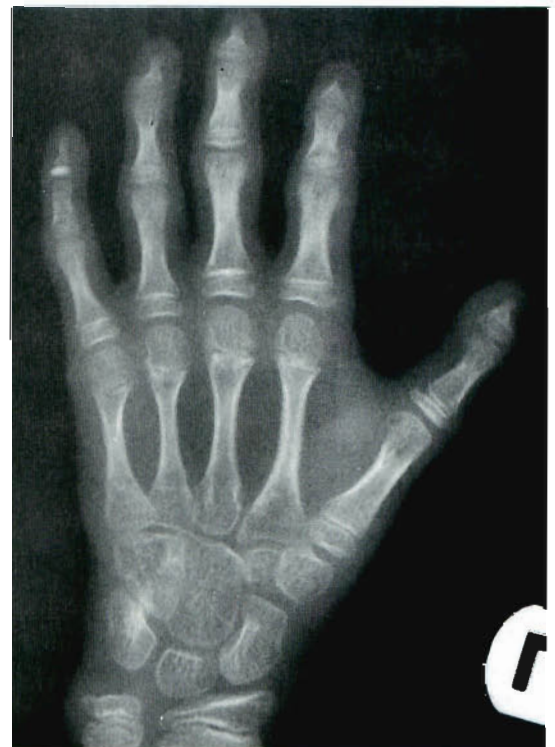

FIGURE 9-36. Progeria. The radiograph shows distal acrolysis, with resorption of the distal phalanges. (From ref. 1, with permission.)

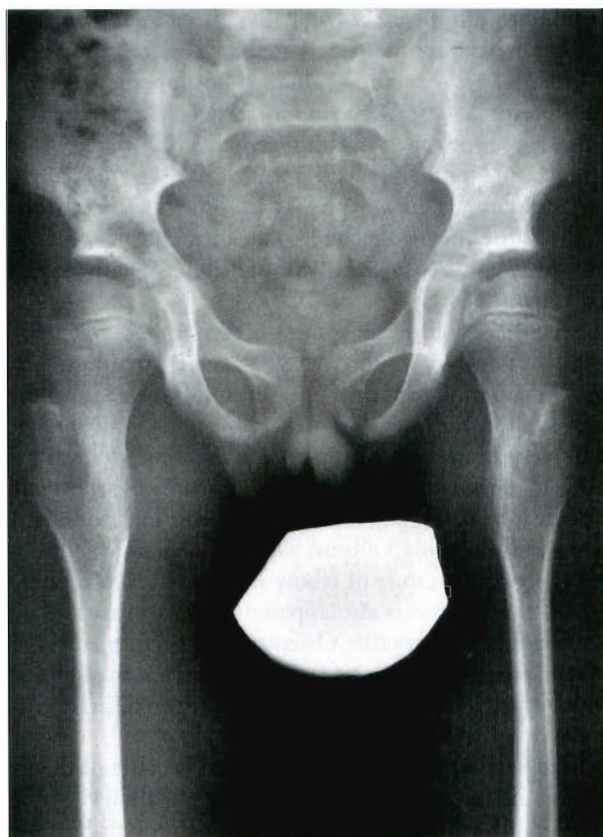

FIGURE 9-37. Progeria in an 11-year-old patient. The radiograph shows a marked degree of coxa valgus and some femoral head uncovering.

viduals have a variety of abnormalities, including a deficient ability to clear free radicals (335).

Children with progeria are diagnosed between 1 and 2 years of age, according to their clinical features alone. There is severe growth retardation and an inability to gain weight. If there is survival to adolescence, there is no pubertal growth spurt. Alopecia and a loss of subcutaneous fat is dramatic, and accounts for the distinctive appearance of a skinny old man or woman (336,337). These patients have joint stiffness that is not arthritis; it is a periarticular fibrosis. Osteolysis occurs in the fingertips, clavicle, and proximal humerus (331,338,339) (Fig. 9-36). The vertebrae may become osteopenic, creating fish-mouth vertebral bodies on radiographs (331,337,340). Fractures are common, often with delayed union. There is late developmental dysplasia of the hip, and the onset of a rather significant coxa valga (340,341) (Fig. 9-37). The children do not live long enough to develop arthritis secondary to the acetabular dysplasia. Not all systems age. There are no cataracts; there is no senility. Rather than aging, the normal tissues undergo an atrophic or degenerative change that mimics normal aging. The principal histopathologic atrophic changes occur in the skin, subcutaneous tissue, bone, and cardiovascular system. Ath-

erosclerosis with myocardial infarction by 10 years of age is the rule, and life expectancy rarely exceeds 20 years.

The children are vital until struck down by myocardial infarction. Despite a short life, it is imperative not to permit any suffering. Hip surgery is indicated only if there is a documented functional impairment. Surgery is not indicated to prevent future arthritis. There is no medical treatment for the basic disease process.

RUSSELL-SILVER DWARFISM

The patient with Russell-Silver syndrome is defined clinically as a short child with body asymmetry and a characteristic face (342–344) (Fig. 9-38). The cause is unclear. Some suggest autosomal dominant inheritance, and others an abnormal intrauterine environment (343,344). The associated genitourinary malformations and the variation in the pattern of sexual maturation chemically (increased gonadotropin secretion) or clinically (precocious sexual development) have suggested hypothalamic or other endocrine disturbance contributing to the pathogenesis. Affected children are small at birth and remain below the third percentile throughout growth, with a marked delay in skeletal maturation. Body asymmetry with hemihypertrophy affects 80%. It averages about 2 cm at maturity, but can be as much as 6 cm. Regardless of the magnitude of the discrepancy, it is clinically more apparent because the child is small. The face is characteristically triangular and seemingly too small for the cranial vault. There have been several reports of variations in sexual maturation pattern, chemically or clinically. Malformations of the genitourinary systems have been described (345,346).

Radiologic analysis discloses a remarkable array of orthopaedic findings, but it is not clear which are part of the



FIGURE 9-38. Russell-Silver syndrome. The triangular face is seemingly small for the size of the skull.

syndrome and which are coincidental (347–349). Scoliosis is usually idiopathic. Hand and foot abnormalities include clinodactyly, polydactyly, and hallux varus. Developmental hip dysplasia, avascular necrosis of the femoral head, and slipped capital femoral epiphysis may be present (332). Many radiographic changes, such as the minor hand abnormalities, suggest a disturbed morphogenesis.

Treatment consists of managing leg-length equality. This can be difficult because individual growth curves may vary, the skeletal age is very retarded, and puberty may be very abnormal. It is easy to miss the appropriate timing for epiphyseal fusion. Growth hormone has been administered to improve stature. Although the use of growth hormone will increase growth velocity, it is not yet known if ultimate height is increased (350).

It is not known if screening for Wilms tumor, as is performed in other forms of hemihypertrophy, is necessary. However, there is a case report of Wilms tumor in an affected patient (351). Thus, it is safest to screen these patients as one would with any other hemihypertrophy (see Beckwith-Wiedemann syndrome below).

TURNER SYNDROME

This syndrome is present only in girls, and consists of short stature, sexual infantilism, a webbed neck, and cubitus valgus. It is a relatively common chromosome disorder affecting 1 of 2,500 live births, but the rate of intrauterine lethality is 95%. The syndrome is caused by a single X chromosome. In two-thirds of cases, all cells are XO, and parental origin of the single X chromosome is the mother in 70% of the cases (352). XO mosaicism occurs in about one-third of patients, and in 1% there is deletion of only a part of an X chromosome (352,353). Cytogenetic studies will confirm this diagnosis.

The effect of the single X chromosome may be different, depending on whether it is derived from the father or from the mother, which is probably the result of imprinting (354). Recent studies, based on individuals with partial loss of the X chromosome, suggest a critical region at Xp11.2–p22.1 responsible for the disease (355).

The identification of particular features at a particular age raises suspicion for this syndrome. At birth, the child has a webbed neck, widely spaced nipples, and edema of the hands and feet. The foot edema may persist for several months. During childhood, the low hairline, webbed neck, cubitus valgus, and short stature become more apparent. The adolescent has short stature and sexual infantilism. The most important features that call for chromosome analysis are edema of the hands and feet at birth, short stature in childhood, and sexual infantilism as an adolescent.

Growth retardation is a cardinal feature, with an ultimate height of about 140 cm (56 in.) (356). Bone maturation is

normal until 8 to 9 years of age, then, because sex hormone stimulation is absent, there is neither skeletal maturation nor pubertal growth spurt. There is no puberty at all, and the girls remain without secondary sexual characteristics unless exogenous estrogen is administered. The web neck looks like a feature of Klippel-Feil syndrome, but the cervical spine radiographs are normal. It is a cutaneous web only, and the cause may be related to an intrauterine cystic hygroma (357). It is cosmetically unsightly, and plastic surgery is effective (358).

Idiopathic scoliosis is common, and the curve usually develops in juveniles. The delayed skeletal maturation allows a long period for curve progression. Growth hormone, which is almost always administered to girls with this syndrome, accelerates curve progression. Although the scoliosis can be managed the same way as idiopathic scoliosis, patients must be observed more frequently during growth hormone administration. Cubitus valgus is present in 80%, but there is a normal range of elbow motion and no disability (359). Genu valgum is also apparent, but the vast majority of cases are asymptomatic. Osteotomy is performed for the rare symptomatic case [4.17, 4.19]. There is a medial bony protuberance not unlike an osteochondroma, arising off the proximal tibia in some (360).

Osteoporosis is a significant problem because of the low estrogen and an altered renal vitamin D metabolism, which is correctable with the administration of growth hormone and sex steroid supplementation (361–364). Even in childhood, there may be the sequelae of osteoporosis, with a high incidence of wrist fractures reported (365).

Intelligence is normal, but there is a high frequency of learning disabilities (366,367). The life expectancy is normal, overall medical status is excellent, and social acceptance is good (368). There are some heart and kidney abnormalities reported at a somewhat higher incidence than for the normal population (369). Having only one X chromosome enables the patient to have X-linked recessive disorders, such as Duchenne muscular dystrophy.

Children with Turner syndrome are treated with growth hormone through adolescence, which results in a modest increase in growth velocity and final height from an average of 140 cm (55 in.) to just under 149 cm (58.5 in.) (370,371). Cyclic sex hormones are administered during adolescence and throughout adulthood. Estrogen is necessary for the development of secondary sexual characteristics, and the estrogen, and possibly the previously administered growth hormone, help to prevent osteoporosis. Many with Turner syndrome marry, and obstetric techniques of hormone supplementation and ovum transplantation can result in pregnancy.

NOONAN SYNDROME

The phenotype of Noonan syndrome is reminiscent of Turner syndrome, with short stature, webbed neck, cubitus

valgus, and sexual immaturity (372,373). However, the chromosomes are normal. This syndrome affects boys and girls. The incidence is 1 in 1,000, and it is an autosomal dominant disorder (374). Many clinical features are shared with the Turner phenotype, but what distinguishes this syndrome are the normal gonads, a high incidence of mental retardation, and right-sided congenital heart defects, often with hypertrophic cardiomyopathy (375,376). Scoliosis is more common (40%) than in Turner patients, and more severe (377). Minor to major vertebral abnormalities may be seen on radiographs. Skeletal maturation is delayed despite normal puberty and menarche. Noonan syndrome is often misdiagnosed, and most frequently confused with King-Denborough syndrome, a myopathic arthrogryposis syndrome characterized by short stature, web neck, spinal deformity, and contractures. Recognizing the difference is important, because a malignant hyperthermia-like picture is part of the King-Denborough syndrome. Linkage analysis identified loci for Noonan syndrome at 12q22, and at 12q24 (378).

PRADER-WILLI SYNDROME

Prader-Willi is a syndrome of hypotonia, obesity, hypogonadism, short stature, small hands and feet, and mental deficiency (379–381). The incidence is 1 in 5,000 births, with a prevalence in the population of 1 in 16,000 to 25,000. As newborns, those with Prader-Willi syndrome are floppy babies, having hypotonia, poor feeding, and delayed milestones (382). They may mimic infants with spinal muscular atrophy. Approximately 10% have developmental dysplasia of the hip. The syndrome may be remembered with an “H” mnemonic: hypotonia, hypogonadism, hyperphagia, hypomentation, and small hands, all probably based on a hypothalamic disorder.

After 1 or 2 years of age, a different clinical picture appears (383). A characteristic face of upward-slanting, almond-shaped eyes becomes apparent (Fig. 9-39). Obesity begins, and a Prader-Willi diagnosis is usually suspected because of the onset of a voracious eating disorder. The patient has a preoccupation with food and an insatiable appetite (384,385). Obesity has a central distribution, sparing the distal limbs. Complex behavioral modification programs are occasionally effective, and a trial using fenfluramine has had limited success (386). The patient has short stature, below the 10th percentile, with an ultimate height of 150 cm (59 in.). There is no adolescent growth spurt. The genitalia are hypoplastic, and the patient has small hands and feet (387). Mental retardation is present, but it is extremely variable. Nevertheless, skills for independent living are almost nonexistent, and most reside in sheltered homes (384,388).

Prader-Willi syndrome is caused by a deletion of a

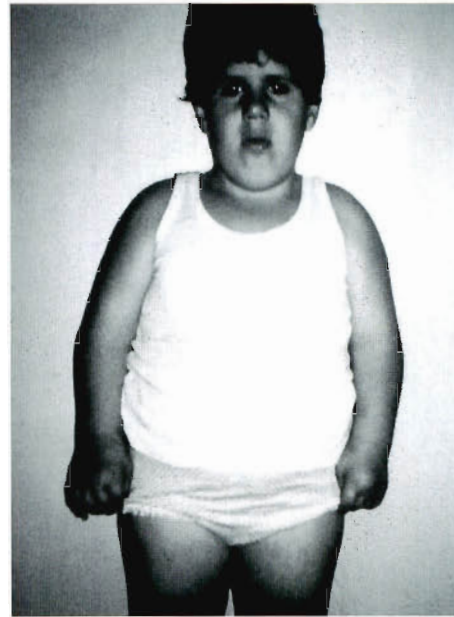


FIGURE 9-39. Prader-Willi syndrome in a 7-year-old patient. The features include truncal obesity and a round face with almond-shaped eyes. (From ref. 1, with permission.)

small part of chromosome 15 (15q11-13) of paternal origin (389,390). This is an example of genomic imprinting, because only missing DNA from the father causes the syndrome (391). Genomic imprinting is a process by which genes of maternal origin have different effects than genes of paternal origin. Angelman syndrome, or happy puppet syndrome, is phenotypically dissimilar to Prader-Willi syndrome. Angelman syndrome patients are small and mentally retarded, and they have athetosis and seizures. However, they have the exact chromosome deletion that occurs in Prader-Willi syndrome (15q11-13), except that the deleted DNA is of maternal origin (390).

The most significant orthopaedic problem is juvenile-onset scoliosis, which affects 50 to 90% (Fig. 9-40). It is difficult to control with an orthosis because of the truncal fat (392–395). Those who come to surgery have a significant anesthesia risk because of morbid obesity (396) [■2.9]. The legs are malaligned, with genu valgum and pes planus, but the condition has limited or no effect on functional health and physical performance.

Although comparative studies are not available, case series suggest that growth hormone improves body composition, fat utilization, physical strength and agility, and growth in this syndrome (397,398). The lack of controlled trials, and ethical issues related to its use in this patient population, make the use of growth hormone in Prader-Willi syndrome of uncertain benefit.

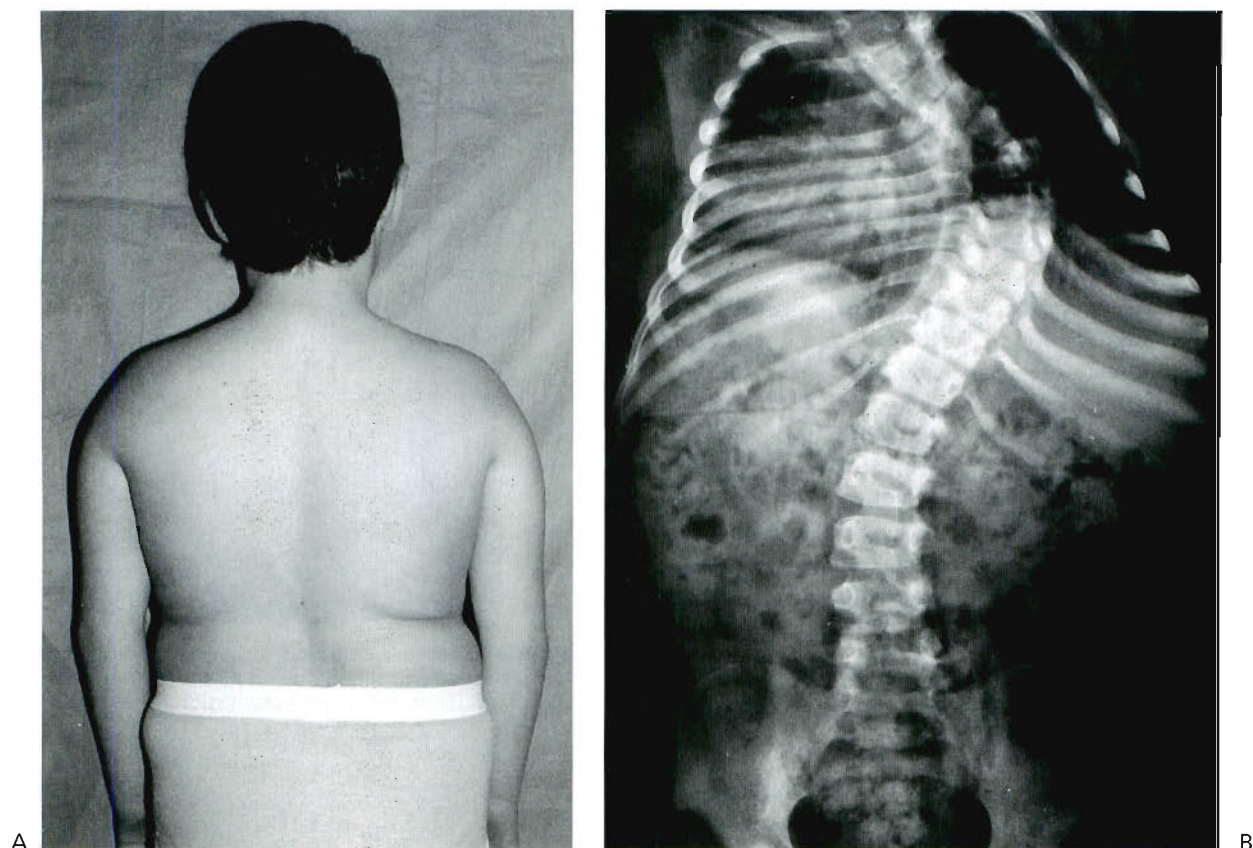


FIGURE 9-40. Prader-Willi syndrome in a 6-year-old patient. **A:** Scoliosis is difficult to detect because of the truncal obesity. **B:** The roentgenogram of this patient discloses a 50-degree thoracic curve. (B from ref. 1, with permission.)

BECKWITH-WIEDEMANN SYNDROME

Beckwith-Wiedemann syndrome is a triad of organomegaly, omphalocele, and a large tongue (399). The incidence is 1 in 14,000, and it is probably an autosomal dominant trait of variable expression. Patients are large, although this feature is not always noticed at birth (400). The child is in the 97th percentile by 1 year of age. The tongue is gigantic at birth, and although it tends to regress, hemiglossectomy is sometimes needed. Omphalocele is common, and 15% of the babies born with omphaloceles have Beckwith-Wiedemann syndrome. The abdominal viscera are enlarged, and a single-cell hypertrophy accounts for the large organs: in the adrenals, giant cortical cells; in the gonads, increased number of interstitial cells; and in the pancreas, islet cell hyperplasia. This underlies the 10% risk of developing benign or malignant tumors. Wilms tumor is the most common.

Beckwith-Wiedemann is linked to chromosome 11p15, which is near the Wilms tumor gene (11p13) and the insulin-like growth factor gene (11p15.5) (401). There may be some paternal genomic imprinting (see the section on

Prader-Willi Syndrome, above) (402,403). The closeness of the Beckwith-Wiedemann gene locus and the embryonal tumor gene loci accounts for the higher incidence of tumors seen in this syndrome.

Pancreatic islet cell hyperplasia causes hypoglycemia. It is critical for the neonatologist to diagnose this syndrome early to prevent the consequences of hypoglycemia. If it is not managed properly, seizures occur at day 2 or 3. Central nervous system damage from the hypoglycemia leads to a cerebral palsy-like picture. The cerebral palsy-like findings confuse the diagnosis of this syndrome, and make the management of these patients more complex. The diagnosis can occasionally be made prenatally by ultrasound (404,405).

The clinical feature that make the orthopaedist suspect this diagnosis is the unusual combination of two otherwise common problems: spastic cerebral palsy and hemihypertrophy (Fig. 9-41). The spasticity is thought to be a result of the neonatal hypoglycemic episodes, especially if accompanied by neonatal seizures, but spastic hemiplegia is most commonly seen. In general, children with cerebral palsy tend to be small; Beckwith-Wiedemann syndrome should be suspected if a large child has spastic cerebral palsy. Asym-

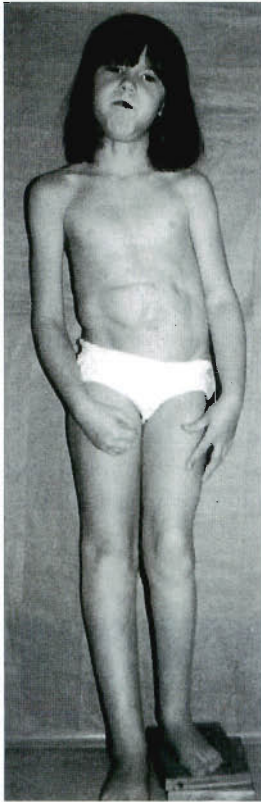

FIGURE 9-41. Beckwith-Wiedemann syndrome in an 8-year-old patient. Hemihypertrophy on right, a part of this syndrome, is combined with hemiatrophy on left, due to acquired encephalopathy secondary to hypoglycemic seizures as a newborn, yielding a significant leg-length discrepancy of 4.6 cm. Abdominal scars are a consequence of omphalocele repair. (From ref. 1, with permission.)

metric growth affects about 20%. It is usually true hemihypertrophy, but it can be significant if the spastic hemiplegia affects the smaller side.

Children with Beckwith-Wiedemann syndrome are predisposed to a variety of neoplasms, most notably Wilms tumor. Abdominal ultrasounds at regular intervals until the age of 6, to screen for Wilms tumor, are advocated. A series comparing a screened population (ultrasounds every 4 months) with a population that was not screened, showed that none of the children in the screened group presented with late-stage Wilms tumor, although one-half of the children who developed Wilms tumor in the nonscreened group presented with late-stage disease. This study suggests that screening every 4 months will identify early disease. However, a larger study is needed to determine if screening improves patient survival (406,407).

Scoliosis is common; it is usually idiopathic, but there may be insignificant morphogenic variations, such as 13 ribs. It is managed as any idiopathic curve. Other orthopaedic findings include cavus feet, dislocated radial heads, and occasional cases of polydactyly (408).

VACTERLS AND VATER ASSOCIATION

VATER, as the syndrome was previously known, has been expanded to VACTERLS (409). The letters of VACTERLS in this syndrome's name constitute an acronym for the systems and defects involved: vertebral, anus, cardiac, tracheal, esophageal, renal, limb, and single umbilical artery. The physician does not need to find examples of all seven categories of anomalies to diagnose the syndrome. The syndrome can be diagnosed prenatally by visualizing several of the malformations on ultrasound. The most obvious physical finding at birth is the radial ray defect. Between 5 and 10% of radial club hands are associated with VACTERLS.

The cause is unknown, but it is a nonrandom association, whose simultaneous occurrence by chance is unlikely (410). The current thought is that these structures are either all formed at the same time, or are all patterned by the same developmental signaling pathway. An event occurring during fetal development that disrupts either the common signaling pathway, or a variety of susceptible pathways operating at the same time, is probably responsible for the associated malformations.

The vertebral defects include disturbed spinal segmentation, with vertebral bars and blocks (411,412). Thoracic anomalies are worse in those with tracheoesophageal fistula, and lumbar anomalies are more common with those who have an imperforate anus. Occult intraspinal pathology is common (413,414), and a screening MR study of the spine is recommended, especially in patients who require operative management for their scoliosis. The curves can be managed like other types of congenital scoliosis [↗2.9, 2.11, 2.12].

Congenital heart defects are present in one-half of these patients. Ventricular septal defect is the most common problem. Duodenal atresia may be found in this syndrome. The VACTERLS patient often has a single kidney. Other collecting-system anomalies occur frequently among this group.

The limb anomalies range from a hypoplastic thumb to a radial club hand. The defect may be unilateral or bilateral; bilateral defects are always asymmetric (411). The legs are spared 80% of the time. When the lower extremities are involved, a duplicated hallux is the most common finding.

The normal umbilical cord has two arteries and one vein. The absence of an artery, detectable only at the time of delivery or in the immediate newborn period, reflects the broad range of morphologic defects dating back to placental formation.

Developmental delay may be observed, and is thought to be the consequence of skeletal anomalies of the arms, scoliosis, and surgery for gastrointestinal or genitourinary malformations. Nevertheless, several central nervous system malformations (e.g., encephalocele hydrocephalus) may be associated with VACTERLS, and must be excluded (413,414). If the patient survives the gastrointestinal anom-

alies and correction of the cardiac defects, the prognosis for a normal life is excellent. Each orthopaedic abnormality can be treated as an isolated problem. Sections on congenital scoliosis (see Chapter 18) and radial clubhand (see Chapter 22) contain detailed information. The key point is to recognize this association, and to identify other abnormalities that might interfere with treatment.

GOLDENHAR SYNDROME

The name "ocular-auricular-vertebral dysplasia" points to the areas in which anomalies are found: the eye, ear, and vertebrae (415). The defects vary in severity and frequently are associated with other malformations (416,417). It is not a rare syndrome, with an incidence of 1 in 3,000 to 5,000

births. The cause is unknown, but marked geographic variation and segregation analysis suggests a genetic disorder (418).

The typical eye defect is an epibulbar dermoid on the conjunctiva (Fig. 9-42A). Preauricular fleshy skin tags are found in front of the ear, and pits extend from the tragus to the corner of the mouth (Fig. 9-42B). In some patients, the ear may be hypoplastic or absent. The eye and ear anomalies are unilateral in 85% of these children, and facial asymmetry is the result of a hypoplastic mandibular ramus, invariably on the same side as the ear anomalies (Fig. 9-42C).

The vertebral anomalies may occur anywhere along the spine, although the lower cervical and upper thoracic predominate (Fig. 9-42C). Hemivertebrae are the most common defect, with an occasional block fusion found. Neural tube defect occurs more often than expected in the general

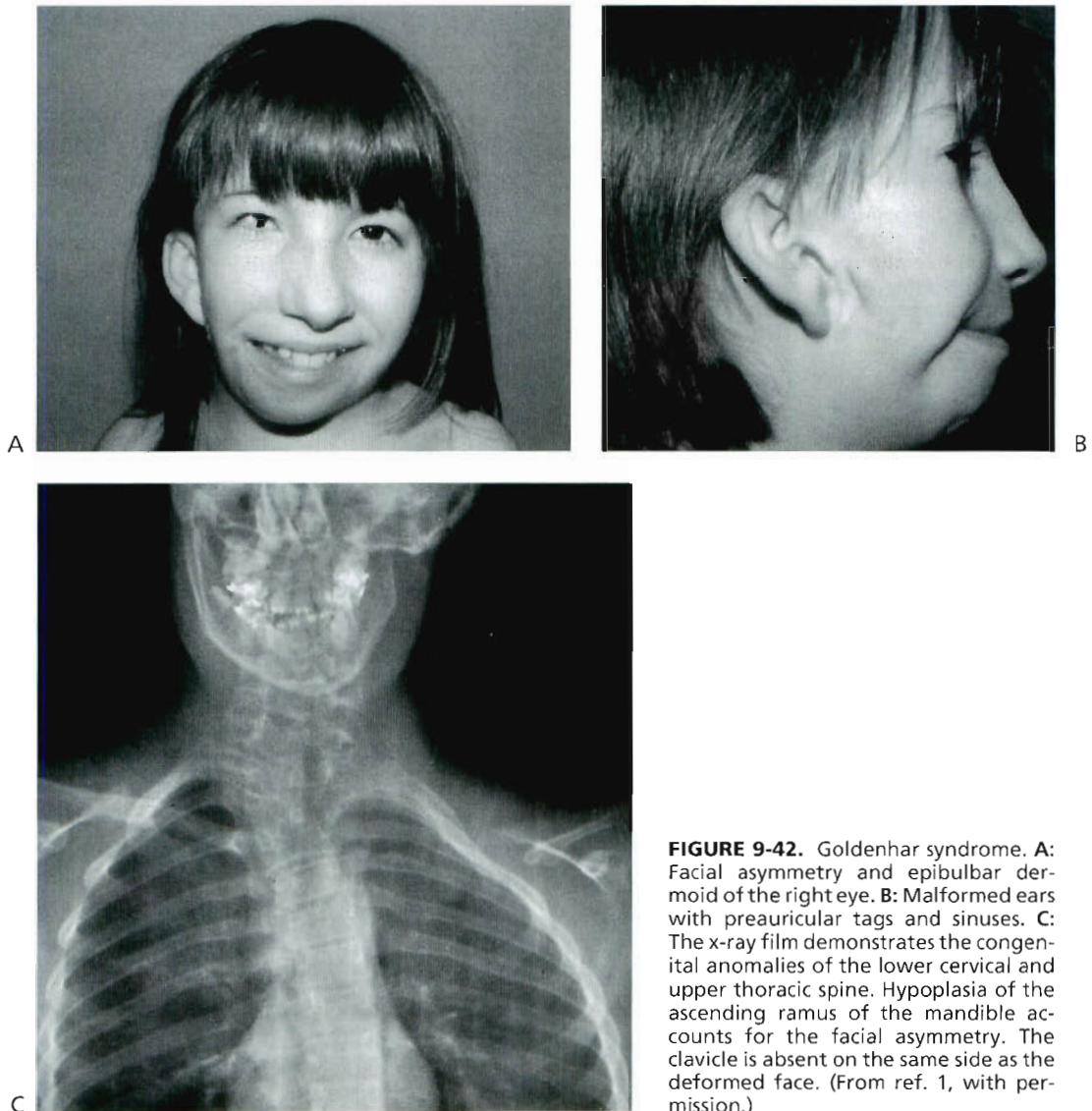


FIGURE 9-42. Goldenhar syndrome. **A:** Facial asymmetry and epibulbar dermoid of the right eye. **B:** Malformed ears with preauricular tags and sinus. **C:** The x-ray film demonstrates the congenital anomalies of the lower cervical and upper thoracic spine. Hypoplasia of the ascending ramus of the mandible accounts for the facial asymmetry. The clavicle is absent on the same side as the deformed face. (From ref. 1, with permission.)

population, and it may involve lumbar spine, cervical spine, or the skull (i.e., encephalocele). Approximately one-half of patients have clinically detectable scoliosis (419). An idiopathic, compensatory curve below the congenital curve is often more troublesome than the congenital curve itself. Sprengel deformity and rib anomalies may be present in association with the congenital curves in the cervical-thoracic region. Orthotic management of scoliosis is difficult, and has no effect on the congenital portion of the curve. The location of the scoliosis is often too high for brace management. Early fusion should be performed for progression of the congenital curve. Preoperative CT and MRI are recommended to delineate the anatomy of the congenital curve and determine if there is any intraspinal pathology. There may be occult posterior element defects that will also be identified on CT.

Intubation for anesthesia may be difficult because of the small jaw, stiff neck, and upper airway dysmorphology (420). Other anomalies include congenital heart disease (e.g., ventricular septal defect) (416), cleft lip, and cleft palate (421). Mental retardation, affecting 10 to 25% of patients, is usually limited to cases involving microphthalmia or an encephalocele (422).

TRICHORHINOPHALANGEAL SYNDROME

The name of this syndrome causes confusion, because textbooks describe trichorhinophalangeal syndrome, trichorhinophalangeal syndrome with exostosis, and Langer-Giedion syndrome. It is best to think of two relatively distinct trichorhinophalangeal (TRP) syndromes: types I and II. Despite the clinical overlaps between the two, there are enough features to separate them into distinct syndromes.

Patients with TRP-I have a pear-shaped, bulbous nose, prominent ears, sparse hair, and cone epiphyses. They have mild growth retardation. The thumbs are broad, and the fingers are often angled at the distal interphalangeal and proximal interphalangeal joints. The hips mimic a Perthes-like disease in radiographs and symptoms (423). There may be lax ligaments.

The key feature distinguishing TRP-II from TRP-I is the presence of multiple exostoses, especially involving the lower extremities. Those with TRP-II have facial features and cone epiphyses similar to patients with TRP-I. There is a higher chance of mental retardation in TRP-II. Langer-Giedion syndrome and TRP-II are identical (424). Patients with TRP-II also have microcephaly, large and protruding ears, a bulbous nose, and sparse scalp hair. In infancy, the skin is redundant and loose, which may be severe enough to mimic Ehlers-Danlos syndrome. Marked ligamentous laxity may further support this error in diagnosis. There is a tendency toward fractures. Similar to TRP-I, the Perthes-like picture is expressed in TRP-II, as well as all the hand anomalies (425).

Both TRP-I and TRP-II are due to mutation or loss of

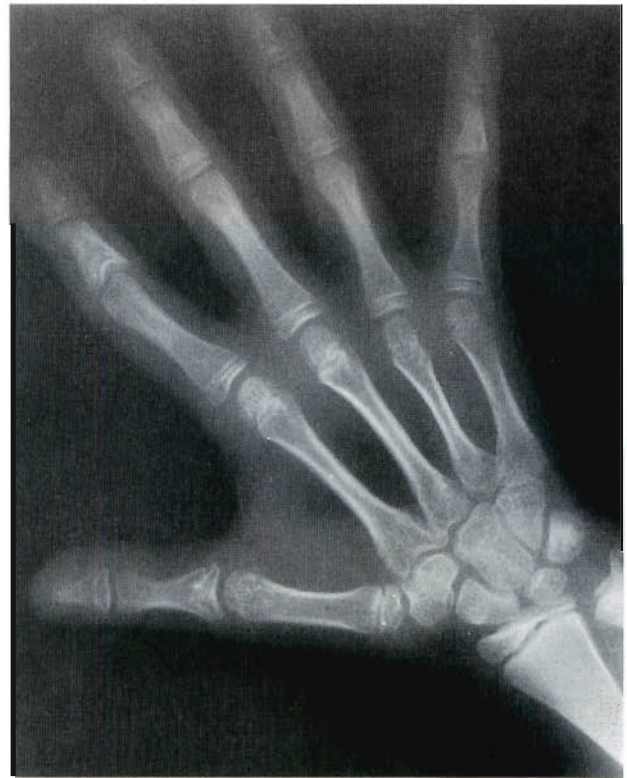

FIGURE 9-43. Trichorhinophalangeal syndrome. This 11-year-old patient has cone- or chevron-shaped epiphyses in the hand, and a broad thumb and distal phalanx.

the *TRSP1* gene (424). However, TRP-II is due to a larger loss of the chromosomal region, with loss of the adjacent gene, *EXT-1*, as well. The *EXT-1* gene is one of the genes responsible for hereditary exostoses, explaining the associated exostoses. The *TRSP1* gene is responsible for the fascial malformation and cone epiphyses present in both disorders. Individuals with loss of a large portion of a chromosome are more likely to have mental retardation, thus explaining the mental retardation in some patients with TRP-II, which has a larger region of chromosomal deletion. TRP-II is one of the few disorders actually known to be due to two contiguous genes (5).

Radiographically, the hand in a patient with TRP-I or TRP-II shows short fourth and fifth metacarpals, cone epiphyses, a short and broad thumb, and fingers with angled proximal and distal interphalangeal joints (426) (Fig. 9-43). The cone epiphyses, so characteristic of this syndrome, are not seen until after 3 or 4 years of age. The pelvis shows the unilateral or bilateral changes of Perthes in TRP-I and TRP-II, but rather than resolution, the Perthes-like picture persists, evolving into a pattern more like multiple epiphyseal dysplasia with precocious arthritis (Fig. 9-44). Despite the wealth of radiographic abnormalities, the hands rarely have functional disturbances. Osteotomy of the thumb is occasionally needed. If symptomatic, we recommend man-

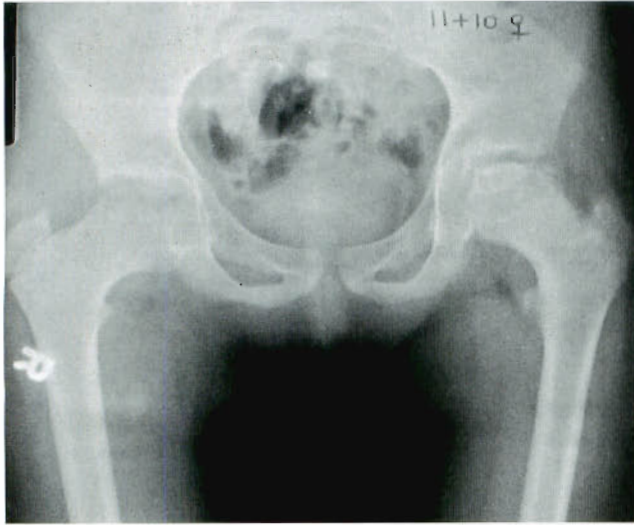

FIGURE 9-44. Trichorhinophalangeal syndrome, type I. The changes mimic Legg-Perthes disease, but by 12 years of age, they did not resolve. On the right is a small but spherical epiphysis. On the left, the changes are similar to those seen in Perthes disease and in multiple epiphyseal dysplasia.

aging the hips as in symptomatic Perthes, but there are insufficient data about outcome. Occasionally, an exostosis may be large or symptomatic enough to require excision.

MUCOPOLYSACCHARIDOSES

This group of genetic disorders is characterized by mucopolysaccharide excretion in the urine (427). There are at least 13 types (Table 9-2). The mild-to-severe mucopolysaccharidoses have similar radiographs and various clinical fea-

tures, but each produces a particular sugar in the urine because of a specific enzyme defect (427,428). Changes in the naming and numbering of systems over the years have introduced considerable confusion in understanding the mucopolysaccharidoses. The incidence is 1 in 10,000.

The patients have somewhat thickened and coarse facial features and short stature, and many develop stiff joints (Fig. 9-45), especially in the hands. Stiffness is postulated to be the result of the deposition of mucopolysaccharide in the capsule and periarticular structures, and to reflect the loss of joint congruity. Radiographs reveal oval vertebral bodies that often are beaked anteriorly; a pelvis with wide, flat ilia; capacious acetabuli; unossified femoral head cartilage; and coxa valga. The radiographic and clinical features are usually not apparent at birth, but become more apparent as the child gets older. Thus, it may be difficult to diagnose a mucopolysaccharidosis during the first year of life.

All the mucopolysaccharidoses are autosomal recessive except for mucopolysaccharidosis type II (Hunter syndrome), which is X-linked. The most common mucopolysaccharidoses are type I (Hurler syndrome) and type IV (Morquio syndrome).

The mucopolysaccharidoses can be diagnosed by urine screening, using a toluidine blue-spot test. If the initial results are positive, specific blood testing is done for the associated sugar abnormality. Although spot tests are quick and inexpensive, they have high false-positive and high false-negative rates. They are the initial test that should be ordered.

The pathobiologic mechanisms are similar for the mucopolysaccharidoses. Each has a deficiency of a specific lysosomal enzyme that degrades the sulfated glycosamine glycans: heparan sulfate, dermatan sulfate, keratan sulfate, and chondroitin sulfate. The incomplete degradation product accumulates in the lysosomes themselves. The mucopolysac-

TABLE 9-2. MUCOPOLYSACCHARIDOSES

Designation	Name	Enzyme Defect	Stored Substance	Inheritance Pattern
MPS I	Hurler/Scheie	α -L-iduronidase	HS + DS	autosomal recessive
MPS II	Hunter	Iduronidase-2-sulfatase	HS + DS	X-linked recessive
MPS IIIA	Sanfilippo A	Heparin-sulfatase (sulfamidase)	HS	autosomal recessive
MPS IIIB	Sanfilippo B	α -N-acetylglucosamidase	HS	autosomal recessive
MPS IIIC	Sanfilippo C	Acetyl-CoA: α -glucosaminide-N-acetyltransferase	HS	autosomal recessive
MPS IIID	Sanfilippo D	Glucosamine-6-sulfatase	HS	autosomal recessive
MPS IVA	Morquio A	N-acetyl galactosamine-6-sulfate sulfatase	KS, CS	autosomal recessive
MPS IVB	Morquio B	β -D-galactosidase	KS	autosomal recessive
MPS IVC	Morquio C	Unknown	KS	autosomal recessive
MPS V	Formerly Scheie disease, no longer used.			
MPS VI	Moroteux-Lamy	Arylsulfatase B, N-acetylgalactosamine-4-sulfatase	DS, CS	autosomal recessive
MPS VII	Sly	β -D-glucuronidase	CS, HS, DS	autosomal recessive
MPS VIII		Glucuronate-2-sulphatase	CS, HS	autosomal recessive

CS, chondroitin sulfate; DS, dermatan sulfate; HS, heparin sulfate; KS, keratin sulfate; MPS, mucopolysaccharidosis.

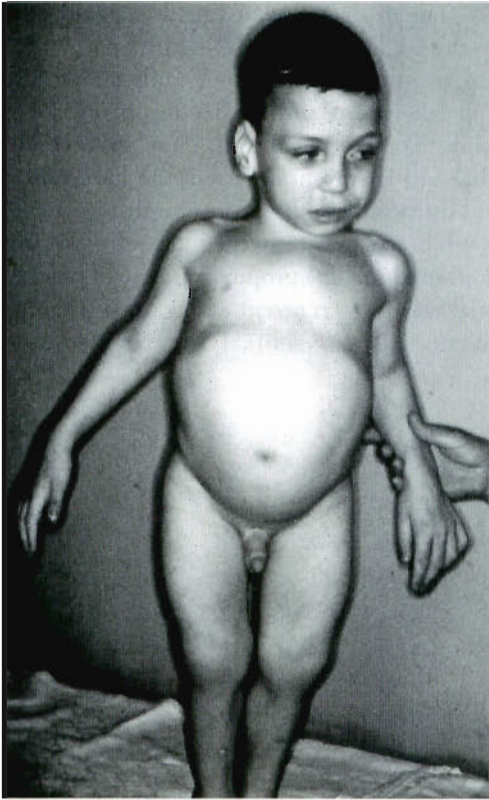

FIGURE 9-45. The classic appearance of a mucopolysaccharidosis in a 3-year-old patient includes facial features that are mildly coarsened, an abdominal protuberance from an enlarged spleen and liver, a short trunk, and stiff interphalangeal joints of the fingers.

charidoses are part of a larger group of disorders known as the lysosomal storage diseases. The incomplete product accumulates in the tissues, such as the brain, the viscera, and the joints. This unremitting process leads to the clinical progression of the disease. The child is normal at birth, but a problem may be chemically detectable by 6 to 12 months of age, and clinical progression is apparent by 2 years of age.

Mucopolysaccharidosis Type I

Mucopolysaccharidosis type I is the clinical prototype. It is characterized by a deficiency of L-iduronidase, the enzyme that degrades dermatan sulfate and heparan sulfate. The Hurler and Scheie forms represent the severe and mild ends of the clinical spectrum in mucopolysaccharidosis type I. Children with the Hurler form have progressive mental retardation; severe, multiple skeletal deformities; considerable organ and soft tissue deformities; and death before 10 years of age. The Scheie form is characterized by joint stiffness, corneal clouding, and no mental retardation; the diagnosis is usually made at about 15 years of age, and the patient

has a normal life expectancy. Many patients with mucopolysaccharidosis I fall in the middle of this clinical spectrum. The clinical variation is determined by where and what kind of mutation occurs along the gene for L-iduronidase (429,430).

Marrow transplantation is used in more severe forms (Hurler syndrome), however, the results on the bones are variable (431). This may be due to the poor penetration of the enzyme derived from the transplanted leukocytes to the osseous cells (431). Initial studies suggested an improvement in most of the nonosseous manifestations of the disease with marrow transplant. More recent, longer-term studies cast doubt on the long-term effectiveness (432). Despite these disappointing longer-term results, marrow transplant may provide short-term improvement, especially in the nonosseous manifestations. The musculoskeletal deformities that persist after marrow transplant still require treatment.

Malalignment of the limbs can occur, and epiphyseal stapling, or osteotomies, may be necessary for genu valgum (433) [4.17, 4.19, 6.1–6.4, 6.14]. Approximately one-fourth have an abnormality of the upper cervical spine. Odontoid hypoplasia and a soft tissue mass in the canal can be managed like those in Morquio syndrome (below). The accumulation of degradation products in closed anatomic spaces, such as the carpal tunnel, causes triggering of the fingers and carpal tunnel syndrome. These can be managed operatively (434,435).

Mucopolysaccharidosis Type IV

Between 1929 and 1959, there was a miscellany of skeletal diseases described as “Morquio syndrome,” including several types of spondyloepiphyseal dysplasia. Morquio syndrome is an autosomal recessive disorder with an incidence of 3 per 1,000,000 members of the population. Three types of Morquio syndrome are classified as subtypes of mucopolysaccharidosis type IV. All are caused by enzyme defects involved in degradation of keratan sulfate (427–429).

Patients with severe classic mucopolysaccharidosis type IVA are short-trunked dwarfs, although they appear normal at birth. They develop corneal opacities. The bone dysplasia is radiographically obvious, and the final height is less than 125 cm (50 in.). Patients have abnormal dentition. The deficient enzyme is *N*-acetylgalactosamine-6-sulfate sulfatase, and the chromosomal defect occurs at 16q24.3 (436). Patients with intermediate mucopolysaccharidosis type IVB have the same but milder phenotypes as those with type IVA. They are taller, with final heights greater than 125 cm (50 in.), and they have normal dentition. Here the enzyme defect is β -D-galactosidase. Patients with mild mucopolysaccharidosis type IVC have very mild clinical manifestations.

The three forms of Morquio mucopolysaccharidoses type IV can be separated by the severity of symptoms and the

patient's age at detection. All patients are normal at birth. For patients with the severe type IVA, the diagnosis is made between 1 and 3 years of age; those with the mild type IV are diagnosed as teenagers; and those with the intermediate form are diagnosed somewhere in the middle of this age range. The three forms may also be separated by the severity of the radiographic changes.

Intelligence is normal in all of the mucopolysaccharidosis IV types, and only rarely are the facial features coarsened. Similarly, all are short-trunked dwarfs with ligamentous laxity; the laxity is rather profound in mucopolysaccharidosis

type IVA. The degree of genu valgus is significant, aggravated by the lax ligaments (437–440).

Management of the knee proves difficult because of the osseous malalignment and the lax ligaments. Despite the observation that the fingers and joints are becoming stiff, the medial and lateral instability of the knee remains. Realignment osteotomies can restore plumb alignment [→4.17, 6.1–6.5], but braces may be needed to control the instability during ambulation. The prophylactic use of braces, to prevent initial valgus or recurrent deformity after surgery, has not been effective (437–440). The hips and knees develop

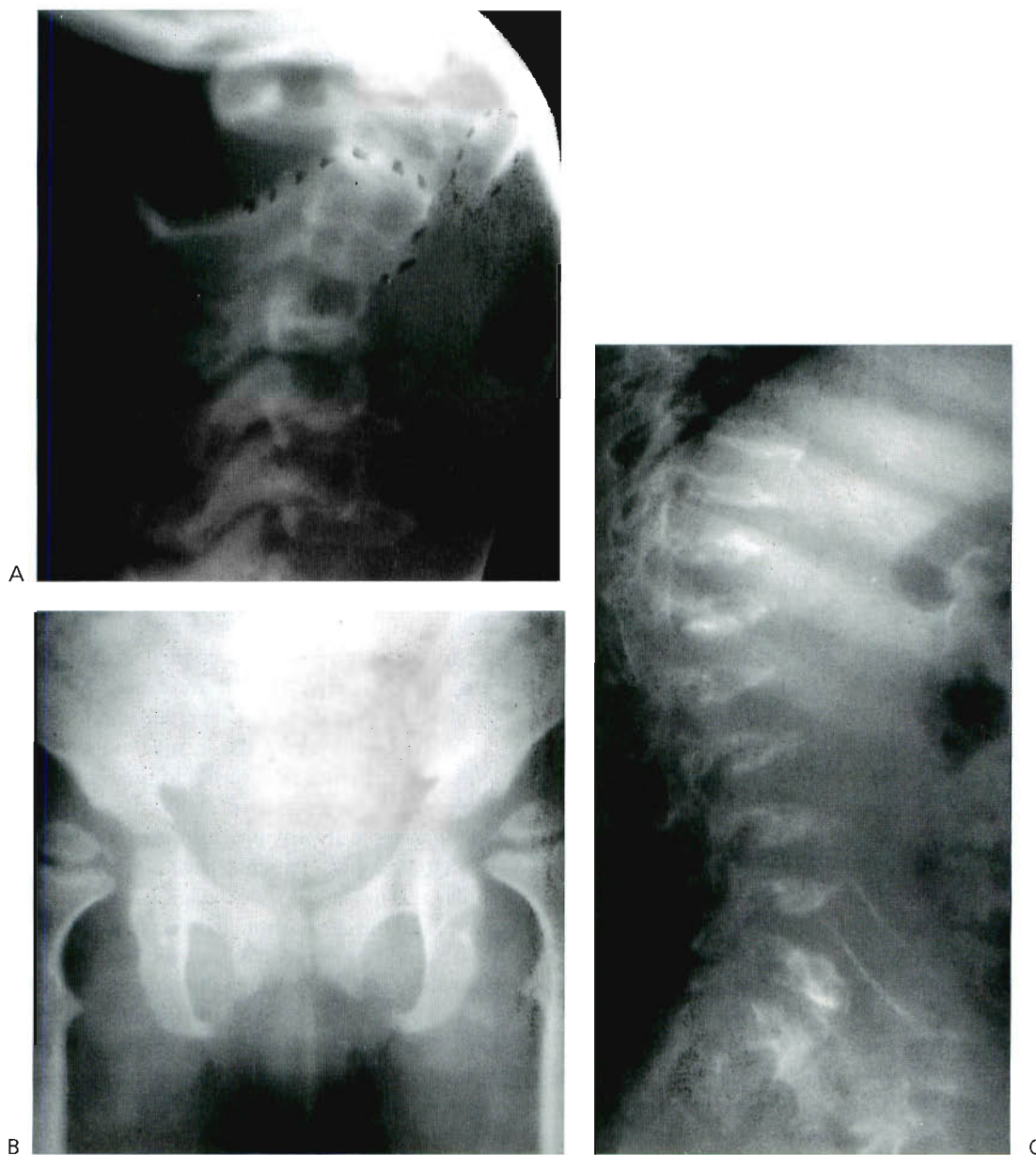


FIGURE 9-46. Morquio syndrome. The radiographic features include an absent odontoid (A), a pelvis with capacious acetabuli and coxa valga (B), and a marked platyspondyly at 12 years of age (C). It is difficult to imagine these vertebrae were normal at birth.

early arthritis. The hips show a progressive acetabular dysplasia. Early arthrograms may show substantial cartilage modeling within the capacious bony acetabulum, but in time, it disappears. The femoral capital epiphyses are initially advanced for the patient's age, but between 4 and 9 years of age, the femoral heads grow smaller, then disappear altogether (Fig. 9-46B, C). The pathophysiology of the progressive hip disease is not completely understood, and neither medication nor surgery have been shown to improve the prognosis (437–440).

Odontoid hypoplasia or aplasia is universal, with resultant C1–2 instability (439–442) (Fig. 9-46A). There is a soft tissue mass in the spinal canal, contributing to cord compression (442,443). This soft tissue mass can make the space available for the cord smaller than one would expect, based on radiographs alone. Neurologic function, especially of upper-extremity strength and tone, is probably more important than measuring distances on dynamic cervical spine films. The upper and lower extremity findings are often of flaccidity, rather than spasticity. The onset of the myelopathy can occur as early as the first decade of life, progressing as the soft tissue hypertrophies, with the C1–2 instabilities aggravating the situation. Sudden deaths of patients with Morquio disease have been reported, and they are typically attributed to the C1–2 subluxation. C1–2 fusion before the onset of symptoms is controversial, but promoted by some (442,443) [↗2.17]. Others think the best surgery is occipital cervical fusion because it reduces the anterior soft tissue mass (443,444) [↗2.18]. There are no comparative studies evaluating the outcomes of each of the different management approaches. Based on the available information, it is reasonable to obtain MRI studies on symptomatic individuals, or on those with radiographic evidence of instability. C1–2 fusions are recommended for asymptomatic in-

dividuals with MRI evidence of cord compression. Symptomatic individuals should be fused throughout the region of instability and cord compression.

Elsewhere in the spine, the vertebrae show a progressive platyspondylia with a thoracic kyphosis. No treatment is effective. Despite these problems, many patients with Morquio disease live for decades. Cardiorespiratory disease is common, but the problems at the upper cervical spine account for most disabilities.

HADJU-CHENEY SYNDROME

Hadju-Cheney syndrome, also called arthrodontosteodysplasia, consists of acroosteolysis, with osteoporosis and hypoplastic changes in the skull and mandible. The osteoporosis leads to multiple fractures of the skull, spine, and digits. The cranial sutures persist; wormian bones are seen on the skull radiographs. Basilar impression is a common finding, often requiring operative intervention. The terminal digits exhibit gradual loss of bone mass, sometimes called "pseudo-osteolysis." Patients tend to have a deep voice (445–449).

Orthopaedic manifestations include loose jointedness, patellar dislocations, scoliosis, frequent fractures, and basilar impression (449). The basilar invagination can cause hydrocephalus and an Arnold-Chiari malformation (450). This is usually managed by decompression and an occiput to upper cervical spine fusion (Fig. 9-47) [↗2.18]. Little data is available on the management of other musculoskeletal problems. Scoliosis can be managed as in idiopathic scoliosis, although the underlying osteopenia and associated spinal fractures may make nonoperative management more difficult.

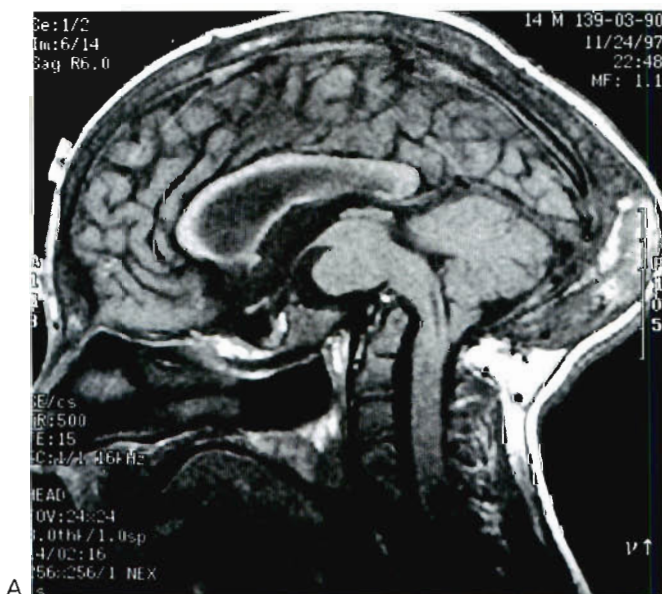


FIGURE 9-47. Hadju-Cheney syndrome. A: MRI of the head shows marked basilar invagination with an associated syrinx in the cervical cord. (continued)

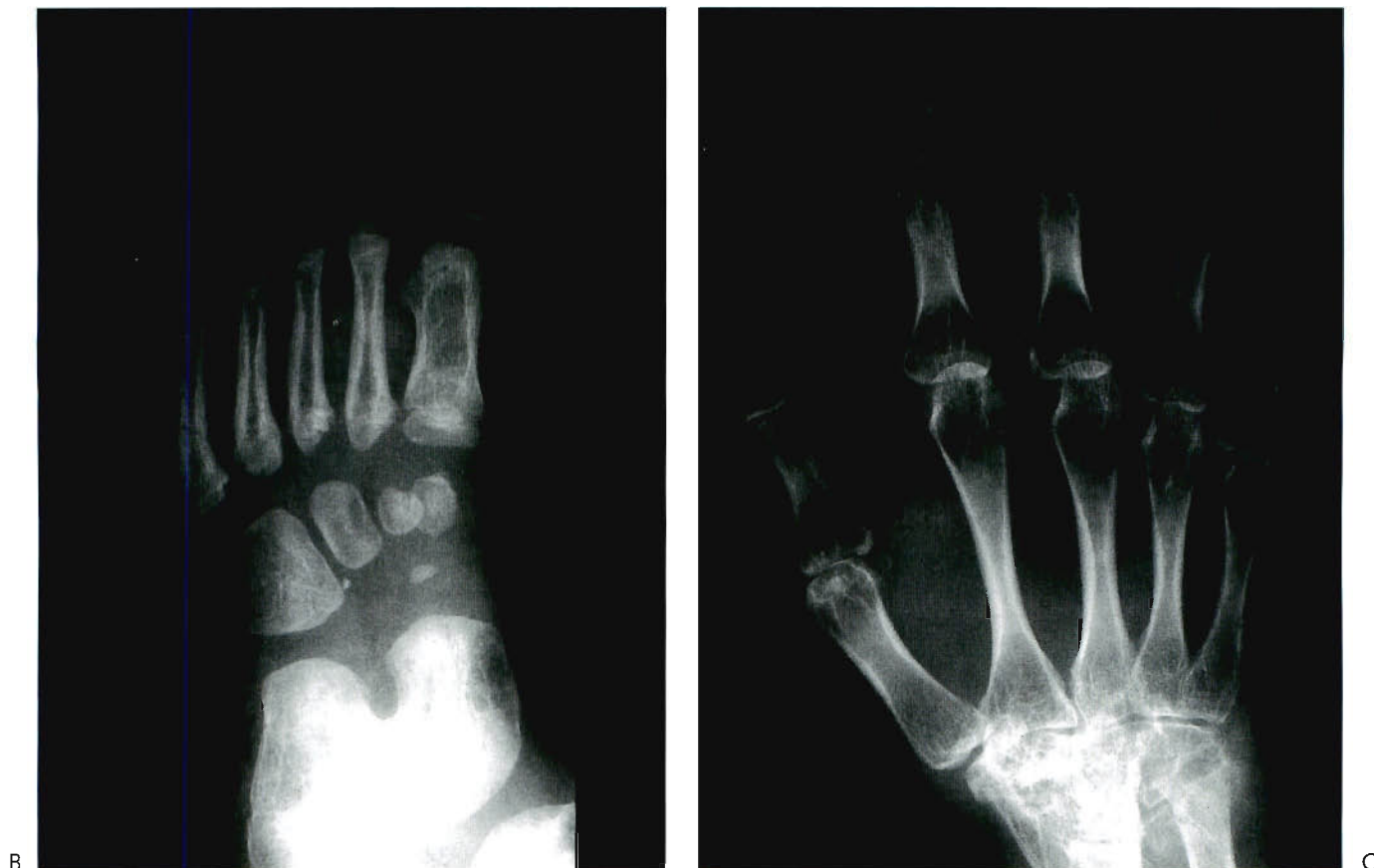

FIGURE 9-47. (continued) Radiographs show osteoporosis with pathologic fractures (B) and loss of bone mass in the terminal digits (C), termed "pseudo-osteolysis."

Polycystic kidney disease and cardiac valvular disease are reported in some individuals, and cardiac and renal function should be evaluated before undergoing anesthesia (451,452). The disorder can be inherited in an autosomal dominant manner, but the causative gene is unknown.

RETT SYNDROME

Rett syndrome is an X-linked disorder, present almost exclusively in girls, that is characterized by normal development for the first 6 to 18 months, followed by rapid deterioration of higher brain functions. This is accompanied by dementia, autism, loss of purposeful use of the hands, and ataxia. After the initial rapid decline, the deterioration slows dramatically, so that affected individuals may have a relatively stable picture for several decades (453). There is variability in the severity of the decline, so that some girls are still walking as teenagers, whereas others stop ambulating in early childhood. A hand radiograph may help with the diagnosis, because 60% will have either negative ulnar variance or a short fourth metacarpal (454,455).

Children with this syndrome were initially thought to

have cerebral palsy with a movement disorder. Andreas Rett, a pediatrician practicing in Austria, noted that these girls all had normal development in the first month of life, and was thus able to separate them from cerebral palsy. This is an X-linked disorder, occurring with an incidence of 1 in 40,000. In some patients, it is caused by a mutation in the *MECP2* gene, which encodes X-linked methyl-CpG-binding protein 2. MeCP2 binds to a certain DNA sequence, and, through interaction with other factors, alters the way certain genes are transcribed. Mutations in this gene likely change the expression pattern of a wide variety of other genes (456), ultimately resulting in Rett syndrome. X-linked dominant diseases are more severe in boys, and Rett is probably fatal in the vast majority of male cases. Despite this, there are few cases of affected males reported (457).

Children with Rett syndrome present to the orthopaedist with a clinical picture similar to that of a total-body-involved cerebral palsy patient. Scoliosis occurs in over half the affected girls (457–461). Orthotic management probably does not alter the progression of the curve. There is a typical, usually long "c" pattern to the curves. These can be stabilized surgically, when they reach a magnitude that

interferes with sitting or balance [2.1, 2.5, 2.6, 2.9]. However, as in cerebral palsy, there are no comparative studies showing improved function following spinal surgery. Spinal instrumentation and fusion should include the whole curve and any kyphotic segments. Although walking ability theoretically can worsen following extensive fusions, this has not occurred in the relatively small number of cases in which spinal surgery was undertaken in ambulatory girls with Rett syndrome (456,458). Coxa valga and lower-extremity contractures can occur, and these should be managed as in cerebral palsy, with emphasis placed on operative procedures that will improve function or decrease pain (459,461,462).

The life span in Rett syndrome is not known, but there are some affected individuals with a normal life span. There are a variety of nonorthopaedic problems, including cardiac conduction abnormalities, epilepsy, and vasomotor instability of the lower limbs. Some of these put the patients at increased risk when undergoing anesthesia (453).

References

- Goldberg MJ. *The dysmorphic child: an orthopedic perspective*. New York: Raven, 1987.
- Hecht JT, Scott CI Jr. Genetic study of an orthopedic referral center. *J Pediatr Orthop* 1984;4:208.
- Jones KL. *Smith's recognizable patterns of human malformation*. 4th ed. Philadelphia: WB Saunders, 1992.
- Jones KL, Robinson LK. An approach to the child with structural defects. *J Pediatr Orthop* 1983;3:238.
- Online Mendelian Inheritance in Man, OMIM. Center for Medical Genetics, Johns Hopkins University and National Center for Biotechnology Information, National Library of Medicine (Bethesda, MD), 1999. Available at: <http://www.ncbi.nlm.nih.gov/omim>. Accessed February 24, 2000.
- Van Regemorter N, Dodion J, Druart C, et al. Congenital malformations in 10,000 consecutive births in a university hospital: need for genetic counseling and prenatal diagnosis. *J Pediatr* 1984;104:386.
- Riccardo VM, Eichner JE. *Neurofibromatosis: phenotype, national history, and prognosis*. Baltimore: Johns Hopkins University Press, 1986.
- Riccardo WM. Neurofibromatosis: clinical heterogeneity. *Curr Probl Cancer* 1982;7:34.
- Elster AD. Radiologic screening in the neurocutaneous syndromes: strategies and controversies. *Am J Neuroradiol* 1992;13:1078.
- Kaufman A, Sherman FC, Black W, et al. Osseous destruction by neurofibroma diagnosed in infancy as "desmoplastic fibroma." *J Pediatr Orthop* 1984;4:239.
- Kozlowski K, Lipson A. Bony tuberculosis misinterpreted—a cautionary tale. *Aust Radiol* 1993;37:119.
- Locht RC, Huebert HT, McFarland DF. Subperiosteal hemorrhage and cyst formation in neurofibromatosis: a case report. *Clin Orthop* 1981;155:141.
- Joseph KN, Bowen JR, MacEwen GD. Unusual orthopedic manifestations of neurofibromatosis. *Clin Orthop Rel Res* 1992;278:17.
- Mandell GA, Harcke T, Scott CI, et al. Protrusion acetabuli in neurofibromatosis: nondysplastic and dysplastic forms. *Neurosurgery* 1992;30:552.
- Lubs MC, Bauer MS, Formes ME, Djokic B. Lisch nodules in neurofibromatosis type I. *N Engl J Med* 1991;324:1266.
- Riccardo VM. Neurofibromatosis: past, present and future. *N Engl J Med* 1991;324:1285.
- Huson SM, Compston DAS, Harper PS. A genetic study of von Recklinghausen neurofibromatosis in south east Wales. II. Guidelines for genetic counseling. *J Med Genet* 1989;26:712.
- Riccardi VM. Type I neurofibromatosis and the pediatric patient. *Curr Probl Pediatr* 1992;66.
- Samuelsson B, Riccardi VM. Neurofibromatosis in Gothenburg, Sweden. *Neurofibromatosis* 1989;2:78.
- Graham PW, Oehlschlaeger FH. *Articulating the Elephant Man. Joseph Merrick and his interpreters*. Baltimore: Johns Hopkins University Press, 1992.
- Xu G, O'Connell P, Viskochil D. The neurofibromatosis type 1 gene encodes a protein related to GAP. *Cell* 1990;62:608.
- Li Y, Bollag G, Clark R. Somatic mutations in the neurofibromatosis 1 gene in human tumors. *Cell* 1992;69:281.
- The I, Hannigan GE, Cowley GS. Rescue of a drosophila NF1 mutant phenotype by protein kinase A. *Science* 1997;276:794.
- Gutmann DH, Collins FS. Recent progress toward understanding the molecular biology of von Recklinghausen neurofibromatosis. Brief review. *Ann Neurol* 1992;31:555.
- Hruban RH, Shiu MH, Senie RT, et al. Malignant peripheral nerve sheath tumors of the buttock and lower extremity. A study of 43 cases. *Cancer* 1990;66:1253.
- Viskochil D, White R, Cawthon R. The neurofibromatosis type 1 gene. *Ann Rev Neurosci* 1993;16:183.
- Zlotogora J. Mutations in von Recklinghausen neurofibromatosis: an hypothesis. *Am J Med Genet* 1993;46:182.
- Akbarnia BA, Gabriel KR, Beckman E, et al. Prevalence of scoliosis in neurofibromatosis. *Spine* 1992;17:S244.
- Calvert PT, Edgar MA, Webb PJ. Scoliosis in neurofibromatosis. The natural history with and without operation. *J Bone Joint Surg Br* 1989;71:246.
- Crawford AH Jr, Bagamery N. Osseous manifestations of neurofibromatosis in childhood. *J Pediatr Orthop* 1986;6:72.
- Grawford AH. Pitfalls of spinal deformities associated with neurofibromatosis in children. *Clin Orthop Rel Res* 1989;245:29.
- Funasaki H, Winter RB, Lonstein JB, et al. Pathophysiology of spinal deformities in neurofibromatosis. An analysis of 71 patients who had curves associated with dystrophic changes. *J Bone Joint Surg Am* 1994;76:692.
- Sirois JL III, Drennan JC. Dystrophic spinal deformity in neurofibromatosis. *J Pediatr Orthop* 1990;10:522.
- Winter RB, Moe JH, Bradford DS, et al. Spine deformity in neurofibromatosis. A review of one hundred and two patients. *J Bone Joint Surg Am* 1979;61:677.
- Kim HW, Weinstein SL. Spine update. The management of scoliosis in neurofibromatosis. *Spine* 1997;22:2770.
- Betz RR, Iorio R, Lombardi AV, et al. Scoliosis surgery in neurofibromatosis. *Clin Orthop Rel Res* 1989;245:53.
- Hsu LCS, Lee PC, Leong JCY. Dystrophic spinal deformities in neurofibromatosis. Treatment by anterior and posterior fusion. *J Bone Joint Surg Br* 1984;66:495.
- Shufflebarger HL. Cotrel-Dubousset instrumentation in neurofibromatosis spinal problems. *Clin Orthop Rel Res* 1989;245:24.
- Craig JB, Govender S. Neurofibromatosis of the cervical spine. *J Bone Joint Surg Br* 1992;74:575.
- Isu T, Miyasaka K, Abe H, et al. Atlantoaxial dislocation associated with neurofibromatosis. Report of three cases. *J Neurosurg* 1983;58:451.
- Rockower S, McKay D, Nason S. Dislocation of the spine in neurofibromatosis. A report of two cases. *J Bone Joint Surg Am* 1982;64:1240.
- Winter RB. Spontaneous dislocation of a vertebra in a patient

- who had neurofibromatosis. Report of a case with dural ectasia. *J Bone Joint Surg Am* 1991;73:1402.
43. Wong-Chung J, Gillespie R. Lumbosacral spondyloptosis with neurofibromatosis. *Spine* 1991;16:986.
 44. Bensaid AH, Dietemann JL, Kastler B, et al. Neurofibromatosis with dural ectasia and bilateral symmetrical pedicular clefts: report of two cases. *Neuroradiology* 1992;34:107.
 45. Chee CP. Lateral thoracic meningocele associated with neurofibromatosis: total excision by posterolateral extradural approach. A case report. *Spine* 1989;14:129.
 46. Dolynchuk KN, Teskey J, West M. Intrathoracic meningocele associated with neurofibromatosis: case report. *Neurosurgery* 1990;27:485.
 47. Egelhoff JC, Bates DJ, Ross JS, et al. Spinal MR findings in neurofibromatosis types 1 and 2. *AJNR Am J Neuroradiol* 1992;13:1071.
 48. So CB, Li DKB. Anterolateral cervical meningocele in association with neurofibromatosis: MR and CT studies. *J Comput Assist Tomogr* 1989;13:692.
 49. Winter R. Spontaneous dislocation of a vertebrae in a patient who had neurofibromatosis: report of a case with dural ectasia. *J Bone Joint Surg Am* 1991;73:1404.
 50. Eichorn C, Wendt G, Staudte H-W, et al. Dural ectasia in von Recklinghausen's disease of the lumbar spine: a case report. *J Bone Joint Surg Br* 1995;77:835.
 51. Morrissy RT, Riseborough EJ, Hall JE. Congenital pseudarthrosis of the tibia. *J Bone Joint Surg Br* 1981;63:367.
 52. Morrissy RT. Congenital pseudarthrosis of the tibia. A long-term follow-up study. *Clin Orthop* 1982;166:14.
 53. Alldred AJ. Congenital pseudarthrosis of the clavicle. *J Bone Joint Surg Br* 1963;45:312.
 54. Bayne LG. Congenital pseudarthrosis of the forearm. *Hand Clin* 1985;1:457.
 55. Gregg PJ, Price BA, Ellis HA, Stevens J. Pseudarthrosis of the radius associated with neurofibromatosis. A case report. *Clin Orthop* 1982;171:175.
 56. Kaempffe FA, Gillespie R. Pseudarthrosis of the radius after fracture through normal bone in a child who had neurofibromatosis. A case report. *J Bone Joint Surg Am* 1989;71:1419.
 57. Kameyama O, Ogawa R. Pseudarthrosis of the radius associated with neurofibromatosis: report of a case and review of the literature. *J Pediatr Orthop* 1990;10:128.
 58. Maffulli N, Fixsen JA. Pseudoarthrosis of the ulna in neurofibromatosis. A report of four cases. *Arch Orthop Trauma Surg* 1991;110:204.
 59. Ostrowski DM, Eilert RE, Waldsten G. Congenital pseudarthrosis of the ulna: a report of two cases and a review of the literature. *J Pediatr Orthop* 1985;5:463.
 60. Craigen MA, Clarke NM. Familial congenital pseudarthrosis of the ulna. *J Hand Surg Br* 1995;20:331.
 61. Ezekowitz RA, Mulliken JB, Folkman J. Interferon alpha-2a therapy for life threatening hemangiomas of infancy. *N Engl J Med* 1992;326:1456.
 62. Folkman J. Successful treatment of an angiogenic disease. *N Engl J Med* 1989;320:1211.
 63. Brill CB. Neurofibromatosis: clinical overview. *Clin Orthop Rel Res* 1989;245:10.
 64. Mapstone TB. Neurofibromatosis and central nervous system tumors in childhood. *Neurosurg Clin North Am* 1992;3:771.
 65. Sorensen SA, Mulvihill JJ, Nielsen A. Long-term follow-up of von Recklinghausen neurofibromatosis. Survival and malignant neoplasms. *N Engl J Med* 1986;314:1010.
 66. Warrier RP, Kini KR, Ragu U, et al. Neurofibromatosis and malignancy. *Clin Pediatr* 1985;24:584.
 67. Zoller M, Rembeck B, Akesson HO. Life expectancy, mortality and prognostic factors in neurofibromatosis type 1. A twelve-year follow-up of an epidemiological study in Goteborg, Sweden. *Acta Derm Venereol* 1995;75:140.
 68. Listernick R, Charrow J, Greenwald M. Emergence of optic pathway gliomas in children with neurofibromatosis type 1 after normal neuroimaging results. *J Pediatr* 1992;121:584.
 69. Coleman BG, Arger PH, Dalinka MK, et al. CT of sarcomatous degeneration in neurofibromatosis. *AJR Am J Roentgenol* 1983;140:383.
 70. Gutmann DH, Collins FS. The neurofibromatosis type 1 gene and its protein product, neurofibromin. Review. *Neuron* 1993;10:335.
 71. Meis JM, Enzinger FM, Martz KL, Neal JA. Malignant peripheral nerve sheath tumors (malignant schwannomas) in children. *Am J Surg Pathol* 1992;16:694.
 72. Wanebo JE, Malik JM, Vandenberg SR, et al. Malignant peripheral nerve sheath tumors. A clinicopathologic study of 28 cases. *Cancer* 1993;71:1247.
 73. Coleman BG, Arger PH, Dalinka MK. CT of sarcomatous degeneration in neurofibromatosis. *AJR Am J Roentgenol* 1983;140:387.
 74. Konishi K, Nakamura M, Yamakawa H, et al. Case report: hypophosphatemic osteomalacia in von Recklinghausen neurofibromatosis. *Am J Med Sci* 1991;301:322.
 75. Weinstein RS, Harris RL. Hypercalcemic hyperparathyroidism and hypophosphatemic osteomalacia complicating neurofibromatosis. *Calcif Tissue Int* 1990;46:361.
 76. Habiby R, Silverman B, Listernick R. Precocious puberty in children with neurofibromatosis type 1. *J Pediatr* 1995;126:367.
 77. Hofman KJ, Harris EL, Bryan RN. Neurofibromatosis type 1: the cognitive phenotype. *J Pediatr* 1994;124:S8.
 78. Ferner RE, Hughes RA, Weinman J. Intellectual impairment in neurofibromatosis 1. *J Neurol Sci* 1996;138:133.

Proteus Syndrome

79. Barkmakian JT, Posner MA, Silver L, et al. Proteus syndrome. *J Hand Surg* 1992;17:32.
80. Kalen V, Burwell DS, Omer GE. Macrodactyly of the hands and feet. *J Pediatr Orthop* 1988;8:311.
81. Lacombe D, Taieb A, Vergnes P, et al. Proteus syndrome in 7 patients: clinical and genetic considerations. *Genet Couns* 1991;2:93.
82. Biesecker LG, Happle R, Milliken JB, et al. Proteus syndrome: diagnostic criteria, differential diagnosis, and patient evaluation. *Am J Med Genet* 1999;84:389.
83. Aylsworth AS, Friedmann PA, Powers SK, et al. New observations with genetic implications in two syndromes: (1) father to son transmission of the Nager acrofacial dysostosis syndrome and (2) parental consanguinity in the Proteus syndrome. *Am J Hum Genet* 1987;41:A43.
84. Cremin BJ, Viljoen DL, Wynchank S, et al. The Proteus syndrome: the magnetic resonance and radiological features. *Pediatr Radiol* 1987;17:486.
85. Goodship J, Redfearn A, Milligan D, et al. Transmission of Proteus syndrome from father to son? *J Med Genet* 1991;28:781.
86. Wiedemann HR, Burgio GR, Alenjoy P, et al. The Proteus syndrome: partial gigantism of the hands and/or feet, nevi, hemihypertrophy, subcutaneous tumors, macrocephaly or other skull anomalies and possible accelerated growth and visceral affections. *Eur J Pediatr* 1983;140:5.
87. Tibbles JA, Cohen MM. The Proteus syndrome: the Elephant Man diagnosed. *Br Med J* 1986;293:683.
88. Clark RD, Donnai D, Rogers J, et al. Proteus syndrome: an expanded phenotype. *Am J Med* 1987;25:99.

89. Horamisliligil GS. Proteus syndrome and hamartoses with overgrowth. *Dysmorphol Clin Genet* 1990;4:87.
90. Demetriades MD, Hager J, Nikolaides N, et al. Proteus syndrome: musculoskeletal manifestations and management: a report of two cases. *J Pediatr Orthop* 1992;12:106.
91. Stricker S. Musculoskeletal manifestations of Proteus syndrome: report of two cases with literature review. *J Pediatr Orthop* 1992;12:667.
92. Azouz EM, Costa T, Fitch N. Radiologic findings in the Proteus syndrome. *Pediatr Radiol* 1987;17:481.
93. Turra S, Santini S, Cagnoni G. Gigantism of the foot: our experience in seven cases. *J Pediatr Orthop* 1998;18:337.
94. Ring D, Snyder B. Spinal canal compromise in Proteus syndrome: a case report and review of the literature. *Am J Orthop* 1997;26:275.
95. Choi ML, Wey PD, Borah GL. Pediatric neuropathy in Proteus syndrome. *Ann Plast Surg* 1998;40:528.
96. Malamitsi-Puchner A, Dimitriadis D, et al. Proteus syndrome: course of a severe case. *Am J Med Genet* 1990;35:283.

Arthrogryposis

97. Goldberg MJ. *The dysmorphic child: an orthopedic perspective*. New York: Raven, 1987:1.
98. Hall JG. Genetic aspects of arthrogryposis. *Clin Orthop* 1985;194:44.

Contracture Syndromes Involving All Four Extremities

99. Hall JG, Reed SD, Driscoll EP. Part I. Amyoplasia: a common, sporadic condition with congenital contractures. *Am J Med Genet* 1983;15:571.
100. Sarwark JF, MacEwen GD, Scott CI. Current concepts review. Amyoplasia (a common form of arthrogryposis). *J Bone Joint Surg Am* 1990;72:465.
101. Otto AW. A human monster with inwardly curved extremities. *Clin Orthop* 1985;194:4.
102. Hall JG, Reed SD, McGillvray BC, et al. Part II. Amyoplasia: twinning in amyoplasia—a specific type of arthrogryposis with an apparent excess of discordantly affected identical twins. *Am J Med Genet* 1983;15:591.
103. Weston PJ, Ives EJ, Honore RL. Monochromic diamniotic minimally conjoined twins. *Am J Med Genet* 1990;37:558.
104. Fahy MJ, Hall JG. A retrospective study of pregnancy complications among 828 cases of arthrogryposis. *Genet Couns* 1990;1:3.
105. Hall JG, Reed SD. Teratogens associated with congenital contractures in humans and animals. *Teratology* 1982;25:173.
106. Robertson WL, Glinski LP, Kirkpatrick SJ, et al. Further evidence that arthrogryposis multiplex congenita in the human sometimes is caused by an intrauterine vascular accident. *Teratology* 1992;45:345.
107. Swinyard CA, Bleck EE. The etiology of arthrogryposis (multiplex congenita contracture). *Clin Orthop* 1985;194:15.
108. Jacobson L, Polizzi A, Morris-Kay G. Plasma from human mothers of fetuses with severe arthrogryposis multiplex congenita causes deformities in mice. *J Clin Invest* 1999;103:1038.
109. Banker BQ. Neuropathologic aspects of arthrogryposis multiplex congenita. *Clin Orthop* 1985;194:30.
110. Clarren SK, Hall JG. Neuropathologic findings in the spinal cords of 10 infants with arthrogryposis. *J Neurol Sci* 1983;58:89.
111. Quinn CM, Wigglesworth JS, Heckmatt J. Lethal arthro-

- gryposis multiplex congenita: a pathological study of 21 cases. *Histopathology* 1991;19:155.
112. Brown LM, Robson MJ, Sharrard WJW. The pathology of arthrogryposis multiplex congenita neurologica. *J Bone Joint Surg Br* 1980;62:291.
113. Robinson RO. Arthrogryposis multiplex congenita: feeding, language and other health problems. *Neuropediatrics* 1990;21:177.
114. Carlson WO, Speck GJ, Vicari V, et al. Arthrogryposis multiplex congenita. A long-term follow-up study. *Clin Orthop* 1985;194:115.
115. Davidson J, Beighton P. Whence the arthrogryposis? *J Bone Joint Surg Br* 1976;58:492.
116. Hoffer MM, Swank S, Eastman F, et al. Ambulation in severe arthrogryposis. *J Pediatr Orthop* 1983;3:293.
117. Hahn G. Arthrogryposis. Pediatric review and rehabilitative aspects. *Clin Orthop* 1985;194:105.
118. Thompson GH, Bilenker RM. Comprehensive management of arthrogryposis multiplex congenita. *Clin Orthop* 1985;194:6.
119. Diamond LS, Alegado R. Perinatal fractures in arthrogryposis multiplex congenita. *J Pediatr Orthop* 1981;1:189.
120. Palmer PM, MacEwen GD, Brown JR, et al. Passive motion therapy for infants with arthrogryposis. *Clin Orthop* 1985;194:54.
121. Huurman WW, Jacobsen ST. The hip in arthrogryposis multiplex congenita. *Clin Orthop* 1985;194:81.
122. St. Clair HS, Zimble S. A plan of management and treatment results in the arthrogryposis hip. *Clin Orthop* 1985;194:74.
123. Staheli LT, Chow DE, Elliott JS, et al. Management of hip dislocations in children with arthrogryposis. *J Pediatr Orthop* 1987;7:681.
124. Williams P. The management of arthrogryposis. *Orthop Clin North Am* 1978;9:67.
125. Akazawa H, Oda K, Mitani S. Surgical management of hip dislocation in children with arthrogryposis multiplex congenita. *J Bone Joint Surg Br* 1998;80:636.
126. Szoke G, Staheli LT, Jaffer K, et al. Medial-approach open reduction of hip dislocation in amyoplasia-type arthrogryposis. *J Pediatr Orthop* 1996;16:127.
127. Guidera JK, Kortright L, Barber V, et al. Radiographic changes in arthrogryposis knees. *Skeletal Radiol* 1991;20:193.
128. Sodergard J, Ryoppy S. The knee in arthrogryposis multiplex congenita. *J Pediatr Orthop* 1990;10:177.
129. Thomas B, Schopler S, Wood W, et al. The knee in arthrogryposis. *Clin Orthop* 1985;194:87.
130. Murray C, Fixsen JA. Management of knee deformity in classical arthrogryposis multiplex congenita (amyoplasia congenita). *J Pediatr Orthop B* 1997;6:191.
131. Brunner R, Hefli F, Tgetgel JD. Arthrogryposis joint contracture at the knee and the foot: correction with a circular frame. *J Pediatr Orthop B* 1997;6:192.
132. Guidera KJ, Drennan JC. Foot and ankle deformities in arthrogryposis multiplex congenita. *Clin Orthop* 1985;194:93.
133. Zimble S, Craig CL. The arthrogryposis foot. Plan of management and results of treatment. *Foot Ankle* 1983;3:211.
134. Green ADL, Fixsen JA, Lloyd-Roberts GC. Talectomy for arthrogryposis multiplex congenita. *J Bone Joint Surg Br* 1984;66:697.
135. Hsu LCS, Jaffray D, Leong JCY. Talectomy for club foot in arthrogryposis. *J Bone Joint Surg Br* 1984;66:694.
136. Niki H, Staheli LT, Mosca VS. Management of clubfoot deformity in amyoplasia. *J Pediatr Orthop* 1997;17:803.
137. Chang CH, Huang SC. Surgical treatment of clubfoot deformity in arthrogryposis multiplex congenita. *J Formos Med Assoc* 1997;96:30.

138. D'Souza H, Aroojis A, Chawara GS. Talectomy in arthrogryposis: analysis of results. *J Pediatr Orthop* 1998;18:760.
139. Bennet JB, Hansen PE, Granberry WM, et al. Surgical management of arthrogryposis in the upper extremity. *J Pediatr Orthop* 1985;5:281.
140. Williams PF. Management of upper limb problems in arthrogryposis. *Clin Orthop* 1985;194:60.
141. Doyle JR, James PM, Larsen W, et al. Restoration of elbow flexion in arthrogryposis multiplex congenita. *J Hand Surg* 1980;5:149.
142. Van Heest A, Waters PM, Simmons BP. Surgical treatment of arthrogryposis of the elbow. *J Hand Surg Am* 1998;23:1063.
143. Axt MW, Niethard FU, Doderlein L. Principles of treatment of the upper extremity in arthrogryposis multiplex congenita type I. *J Pediatr Orthop B* 1997;6:179.
144. Atkins RM, Bell MJ, Sharrard WJW. Pectoralis major transfer for paralysis of elbow flexion in children. *J Bone Joint Surg Br* 1985;67:640.
145. Bayne LG. Hand assessment and management of arthrogryposis multiplex congenita. *Clin Orthop* 1985;194:68.
146. Yonenobu K, Tada K, Swanson B. Arthrogryposis of the hand. *J Pediatr Orthop* 1984;4:599.
147. Daher YH, Lonstein JE, Winter RB, et al. Spinal deformities in patients with arthrogryposis. A review of 16 patients. *Spine* 1985;10:608.
148. Larsen LJ, Schottstaedt ER, Bost FC. Multiple congenital dislocations associated with characteristic facial abnormality. *J Pediatr* 1950;37:574.
149. Houston CS, Reed MH, Desautels JEL. Separating Larsen syndrome from the "arthrogryposis basket." *J Can Assoc Radiol* 1981;32:206.
150. Klenn PJ, Iozzo RV. Larsen's syndrome with novel congenital anomalies. *Hum Pathol* 1991;22:1055.
151. Laville JM, Lakermance P, Limouzy F. Larsen's syndrome: review of the literature and analysis of thirty-eight cases. *J Pediatr Orthop* 1994;14:63.
152. Oki T, Terashima Y, Murachi S, et al. Clinical features and treatment of joint dislocations in Larsen's syndrome. Report of three cases in one family. *Clin Orthop* 1976;119:206.
153. Steel HH, Koh EJ. Multiple dislocations associated with other skeletal anomalies (Larsen's syndrome) in three siblings. *J Bone Joint Surg Am* 1972;54:75.
154. Habermann ET, Sterling A, Dennis RI. Larsen's syndrome: a heritable disorder. *J Bone Joint Surg Am* 1976;58:558.
155. Marques MdeNT. Larsen's syndrome: clinical and genetic aspects. *J Genet Hum* 1980;28:83.
156. Stanley D, Seymour N. The Larsen syndrome occurring in four generations of one family. *Int Orthop* 1985;8:267.
157. Vujic M, Hallstenson K, Wahlstrom J. Localization of a gene for autosomal dominant Larsen syndrome to chromosome region 3p21.1-14.1 in the proximity of, but distinct from, the COL7A1 locus. *Am J Hum Genet* 1995;57:1113.
158. Munk S. Early operation of the dislocated knee in Larsen's syndrome. A report of two cases. *Acta Orthop Scand* 1988;59:582.
159. Bowen JR, Ortega K, Ray S, et al. Spinal deformities in Larsen's syndrome. *Clin Orthop* 1985;197:159.
160. Micheli LJ, Hall JE, Watts HG. Spinal instability in Larsen's syndrome. Report of three cases. *J Bone Joint Surg Am* 1976;58:562.
161. Johnston CE 2nd, Birch JG, Daniels JL. Cervical kyphosis in patients who have Larsen syndrome. *J Bone Joint Surg Am* 1996;78:545.
162. Stevenson GW, Hall SC, Palmieri J. Anesthetic considerations for patients with Larsen's syndrome. *Anaesthesia* 1991;75:142.
163. Kiel EA, Frias JL, Victorica BE. Cardiovascular manifestations in the Larsen syndrome. *Pediatrics* 1983;71:942.
164. Dhaliwal AS, Myers TL. Digitotalar dysmorphism. *Orthop Rev* 1985;14:90.
165. Kasai T, Oki T, Nogami H. Familial arthrogryposis with distal involvement of the limbs. *Clin Orthop* 1982;166:182.
166. Salis JG, Beighton P. Dominantly inherited digito-talar dysmorphism. *J Bone Joint Surg Br* 1972;54:509.
167. Hall JG, Reed SD, Greene G. The distal arthrogryposes: delineation of new entities—review and nosologic discussion. *Am J Med Genet* 1982;11:185.
168. Zancolli E, Zancolli E Jr. Congenital ulnar drift of the fingers. Pathogenesis, classification, and surgical management. *Hand Clin* 1985;1:443.
169. Hageman G, Jenekens FGI, Vette JK, et al. The heterogeneity of distal arthrogryposis. *Brain Dev* 1984;6:273.
170. McCormack MK, Coppola-McCormack P, Lee M. Autosomal-dominant inheritance of distal arthrogryposis. *Am J Med Genet* 1980;6:163.
171. Robinow M, Johnson GF. The Gordon syndrome: autosomal dominant cleft palate, camptodactyly, and club feet. *Am J Med Genet* 1981;9:139.
172. Rozin MM, Hertz M, Goodman RM. A new syndrome with camptodactyly, joint contractures, facial anomalies, and skeletal defects: a case report and review of syndromes with camptodactyly. *Clin Genet* 1984;26:342.
173. Bui TH, Lindholm H, Demir N, et al. Prenatal diagnosis of distal arthrogryposis type I by ultrasonography. *Prenat Diagn* 1992;12:1047.
174. Freeman EA, Sheldon JH. Cranio-carpo-tarsal dystrophy. An undescribed congenital malformation. *Arch Dis Child* 1938;13:277.
175. Walker BA. Whistling face-windmill vane syndrome (craniocarpotarsal dystrophy; Freeman-Sheldon syndrome). *Birth Defects* 1969;5:228.
176. Dallapiccola B, Giannotti A, Lembo A, Sagni L. Autosomal recessive form of whistling face syndrome in sibs. *Am J Med Genet* 1989;33:542.
177. Malkawi H, Tarawneh M. The whistling face syndrome, or craniocarpotarsal dysplasia. Report of two cases in a father and son and review of the literature. *J Pediatr Orthop* 1983;3:364.
178. Wettstein A, Buchinger G, Braun A, Bazan UB. A family with whistling face syndrome. *Hum Genet* 1980;55:177.
179. Rinsky LA, Bleck EE. Freeman-Sheldon ("whistling face") syndrome. *J Bone Joint Surg Am* 1976;58:148.
180. Estrada R, Rosenfeld W, Salazar JD, et al. Freeman-Sheldon syndrome with unusual hand and foot anomalies. *J Natl Med Assoc* 1981;73:664.
181. O'Connell DJ, Hall CM. Cranio-carpo-tarsal dysplasia. A report of seven cases. *Radiology* 1977;123:719.
182. Wenner SM, Shalvoy RM. Two stage correction of thumb adductor contracture in Freeman-Sheldon syndrome. *J Hand Surg* 1989;14:937.
183. Marasovich WA, Mazaheri M, Stool SE. Otolaryngologic findings in whistling face syndrome. *Arch Otolaryngol Head Neck Surg* 1989;115:1373.
184. Duggar RG, DeMars PD, Bolton VE. Whistling face syndrome: general anesthesia and early postoperative caudal analgesia. *Anesthesiology* 1989;70:545.
185. Galaini CA, Marr BH. Laryngomalacia and intraneural striated muscle in an infant with Freeman-Sheldon syndrome. *Int J Pediatr Otolaryngol* 1993;25:243.
186. Jones R, Dolcourt JL. Muscle rigidity following halothane in two patients with Freeman-Sheldon. *Anesthesiology* 1992;77:599.

Contracture Syndromes Involving Predominantly the Hands and Feet

187. Sauk JJ, Delaney JR, Reaume C, et al. Electromyography of oral-facial musculature in craniocarpotarsal dysplasia (Freeman-Sheldon syndrome). *Clin Genet* 1974;6:132.

Contracture Syndromes with Skin Webs

188. Hall JG, Reed SD, Rosenbaum KN, et al. Limb pterygium syndromes: a review and report of 11 patients. *Am J Med Genet* 1982;12:377.
189. De Die-Smulders CE, Schrander-Stompel CT, Fryns JP. The lethal multiple pterygium syndrome: a nosological approach. *Genet Couns* 1990;1:13.
190. De Die-Smulders CE, Vonsee MJ, Zandvoort JA, Fryns JP. The lethal multiple pterygium syndrome: prenatal ultrasonographic and postmortem findings. *Eur J Obstet Gynecol Reprod Biol* 1990;35:283.
191. Hall JG. Genetic aspects of arthrogryposis. *Clin Orthop* 1985;194:44.
192. Hartwig NG, Vermeij-Keers C, Bruijn JA, et al. Case of lethal multiple pterygium syndrome with special references to the origin of pterygia. *Am J Med Genet* 1989;33:537.
193. McCall RE, Buddon J. Treatment of multiple pterygium syndrome. *Orthopedics* 1992;15:1417.
194. Penchaszadeh VB, Salszberg B. Multiple pterygium syndrome. *J Med Genet* 1981;18:451.
195. Winter RB. Scoliosis and the multiple pterygium syndrome. *J Pediatr Orthop* 1983;3:125.
196. Escobar V, Weaver D. Popliteal pterygium syndrome. A phenotypic and genetic analysis. *J Med Genet* 1978;15:35.
197. Froster-Iskenens VG. Popliteal pterygium syndrome. *J Med Genet* 1990;27:320.
198. Herold HZ. Popliteal pterygium syndrome. *Clin Orthop* 1986;299:194.
199. Hunter A. The popliteal pterygium syndrome: report of a new family and review of literature. *Am J Med Genet* 1990;36:196.
200. Oppenheim WL, Larson KR, McNabb MB, et al. Popliteal pterygium syndrome: an orthopaedic perspective. *J Pediatr Orthop* 1990;10:58.
201. Koch H, Grzonka M, Koch J. Popliteal pterygium syndrome with special consideration of the cleft malformation. Cleft palate. *Craniofac J* 1992;29:80.
202. Wynne JM, Fraser AG, Herman R. Massive oral membrane in the popliteal web syndrome. *J Pediatr Surg* 1982;17:59.
203. Cunningham LN, Keating MA, Snyder HM, et al. Urologic manifestations of the popliteal pterygium syndrome. *J Urol* 1989;141:910.
204. Addison A, Webb PJ. Flexion contractures of the knee associated with popliteal webbing. *J Pediatr Orthop* 1983;3:376.
205. Crawford A. Treatment of popliteal pterygium syndrome. *J Pediatr Orthop* 1982;2:443.
206. Hansson LI, Hansson V, Jonsson K. Popliteal pterygium syndrome in a 74-year-old woman. *Acta Orthop Scand* 1976;47:525.
207. Saleh M, Gibson MF, Sharrard WJ. Femoral shortening in correction of congenital knee flexion deformity with popliteal webbing. *J Pediatr Orthop* 1989;9:609.
208. Brunner R, Hefti F, Tgetgel JD. Arthrogryptic joint contracture at the knee and the foot: correction with a circular frame. *J Pediatr Orthop B* 1997;6:192.
211. Caffey J, Ross S. Pelvic bones in infantile mongoloidism: roentgenographic features. *AJR Am J Roentgenol* 1958;80:458.
212. Cronk C, Crocker AC, Pueschel SM, et al. Growth charts for children with Down syndrome: 1 month to 18 years of age. *Pediatrics* 1988;81:102.
213. Wald NJ, Watt HC, Hackshaw AK. Integrated screening for Down's syndrome on the basis of tests performed during the first and second trimesters. *N Engl J Med* 1999;341:461.
214. Brock DJH. *Molecular genetics for the clinician*. Cambridge, UK: Cambridge University Press, 1993.
215. Kolata G. Down syndrome—Alzheimer's linked. *Science* 1985;230:1152.
216. MacLachlan RA, Fidler KE, Yeh H, et al. Cervical spine abnormalities in institutionalized adults with Down's syndrome. *J Intellect Disabil Res* 1993;37:277.
217. Pueschel SM, Scola FH, Tupper TB, et al. Skeletal anomalies of the upper cervical spine in children with Down syndrome. *J Pediatr Orthop* 1990;10:607.
218. Pueschel SM, Moon AC, Scola FH. Computerized tomography in persons with Down syndrome and atlantoaxial instability. *Spine* 1992;17:735.
219. Selby KA, Newton RW, Gupta S, et al. Clinical predictors and radiological reliability in atlantoaxial subluxation in Down's syndrome. *Arch Dis Child* 1991;66:876.
220. Tredwell SJ, Newman DE, Lockitch G. Instability of the upper cervical spine in Down syndrome. *J Pediatr Orthop* 1990;10:602.
221. White KS, Ball WS, Prenger EC, et al. Evaluation of the cranio-cervical junction in Down syndrome: correlation of measurements obtained with radiography and MR imaging. *Radiology* 1993;186:377.
222. Gabriel KR, Mason DE, Carango P. Occipito-atlantal translation in Down's syndrome. *Spine* 1990;15:997.
223. Menezes AH, Ryken TC. Craniovertebral abnormalities in Down's syndrome. *Pediatr Neurosurg* 1992;18:24.
224. Stein SM, Kirchner SG, Horev G, et al. Atlanto-occipital subluxation in Down syndrome. *Pediatr Radiol* 1991;21:121.
225. Ohsawa T, Izawa T, Kuroki Y, et al. Follow-up study of atlanto-axial instability in Down's syndrome without separate odontoid process. *Spine* 1989;14:1149.
226. Martich V, Ben-Ami T, Youssefzadeh DK, et al. Hypoplastic posterior arch of C-1 in children with Down syndrome: a double jeopardy. *Radiology* 1992;183:125.
227. Fidone GS. Degenerative cervical arthritis and Down's syndrome. *N Engl J Med* 1986;314:320.
228. Tangerud A, Hestnes A, Sand T, et al. Degenerative changes in the cervical spine in Down's syndrome. *J Ment Defic Res* 1990;34:179.
229. Cremers MJ, Beijer HJ. No relation between general laxity and atlantoaxial instability in children with Down syndrome. *J Pediatr Orthop* 1993;13:318.
230. Pueschel SM, Herndon JH, Gelch MM, et al. Symptomatic atlanto-axial subluxation in persons with Down syndrome. *J Pediatr Orthop* 1984;4:682.
231. Pueschel SM, Scola FH, Pezzullo JC. A longitudinal study of atlanto-dens relationships in asymptomatic individuals with Down syndrome. *Pediatrics* 1992;89:1194.
232. Pueschel SM. Should children with Down syndrome be screened for atlantoaxial instability? *Arch Pediatr Adolesc Med* 1998;152:123.
233. Diamond LS, Lynne D, Sigman B. Orthopedic disorders in patients with Down's syndrome. *Orthop Clin North Am* 1981;12:57.
234. Hresko MT, McCarthy JC, Goldberg MJ. Hip disease in adults with Down syndrome. *J Bone Joint Surg Br* 1993;75:604.
235. Roberts GM, Starey N, Harper P, et al. Radiology of the pelvis

- and hips in adults with Down's syndrome. *Clin Radiol* 1980; 31:475.
236. Shaw ED, Beals RK. The hip joint in Down's syndrome. A study of its structure and associated disease. *Clin Orthop Rel Res* 1992;278:101.
 237. Greene WB. Closed treatment of hip dislocation in Down syndrome. *J Pediatr Orthop* 1998;18:643.
 238. Aprin H, Zink WP, Hall JE. Management of dislocation of the hip in Down syndrome. *J Pediatr Orthop* 1985;5:428.
 239. Bennet GC, Rang M, Roye DP, et al. Dislocation of the hip in trisomy 21. *J Bone Joint Surg Br* 1982;64:289.
 240. Gore DR. Recurrent dislocation of the hip in a child with Down's syndrome. *J Bone Joint Surg Am* 1981;63:823.
 241. Nogi J. Hip disorders in children with Down's syndrome. *Dev Med Child Neurol* 1985;27:86.
 242. Dugdale TW, Renshaw TS. Instability of the patellofemoral joint in Down syndrome. *J Bone Joint Surg Am* 1986;68:405.
 243. Herring JA, Fielding JW. Cervical instability in Down's syndrome and juvenile rheumatoid arthritis. *J Pediatr Orthop* 1982; 2:205.
 244. Miele JF, Piasio MA, Goldberg MJ. Orthopedic deformity occurring in Down syndrome patients with juvenile rheumatoid arthritis. *Orthop Trans* 1986;10:130.
 245. Sherk HH, Pasquariello PS, Watters WC. Multiple dislocations of the cervical spine in a patient with juvenile rheumatoid arthritis and Down's syndrome. *Clin Orthop* 1982;162:37.
 246. Levack B, Roper BA. Dislocation in Down's syndrome. *Dev Med Child Neurol* 1984;26:122.
 261. Halmesmaki E, Raivio K, Ylikorkala O. A possible association between maternal drinking and fetal clubfoot. *N Engl J Med* 1985;312:790.
 262. Cremin BJ, Jaffer Z. Radiological aspects of the fetal alcohol syndrome. *Pediatr Radiol* 1981;11:151.
 263. Lowry RB. The Klippel-Feil anomaly as part of the fetal alcohol syndrome. *Teratology* 1977;16:53.
 264. Neidengard L, Carter TE, Smith DW. Klippel-Feil malformation complex in fetal alcohol syndrome. *Am J Dis Child* 1978; 132:929.
 265. Spiegel PG, Pekman WM, Rich BH, et al. The orthopedic aspects of the fetal alcohol syndrome. *Clin Orthop* 1979;139: 58.
 266. Tredwell SJ, Smith DF, MacLeod PJ, Wood BJ. Cervical spine anomalies in fetal alcohol syndrome. *Spine* 1982;7:331.
 267. Jaffer Z, Nelson M, Beighton P. Bone fusion in the foetal alcohol syndrome. *J Bone Joint Surg Br* 1981;63:569.
 268. Leicher-Duber A, Schumacher R, Spranger J. Stippled epiphyses in fetal alcohol syndrome. *Pediatr Radiol* 1990;20:369.

Fetal Alcohol Syndrome

247. Day NL, Richardson GA. Prenatal alcohol exposure: a continuum of effects. *Semin Perinatol* 1991;4:271.
248. Ernhart CB. Clinical correlations between ethanol intake and fetal alcohol syndrome. *Recent Dev Alcohol* 1991;9:127.
249. Knupfer G. Abstaining for foetal health: the fiction that even light drinking is dangerous. *Br J Addiction* 1991;86:1057.
250. Rosett HL, Weiner L, Lee A, et al. Patterns of alcohol consumption and fetal development. *Obstet Gynecol* 1983;61:539.
251. Rosett HL, Weiner L. Prevention of fetal alcohol effects. *Pediatrics* 1982;69:813.
252. Abel EL, Sokol RJ. A revised conservative estimate of the incidence of FAS and its economic impact. *Alcoholism* 1991;15: 514.
253. Little RE, Wendt JK. The effects of maternal drinking in the reproductive period: an epidemiologic review. *J Subst Abuse* 1991;3:187.
254. Smith DF, Sandor GG, MacLeod PM, et al. Intrinsic defects in the fetal alcohol syndrome: studies on 76 cases from British Columbia and the Yukon Territory. *Neurobehav Toxicol Teratol* 1981;3:145.
255. Streissguth AP, Clarren SK, Jones KL. Natural history of the fetal alcohol syndrome: a 10-year follow-up of eleven patients. *Lancet* 1985;2:85.
256. Autti-Ramo I, Gaily E, Granstrom ML. Dysmorphic features in offspring of alcoholic mothers. *Arch Dis Child* 1992;67:712.
257. Rostand A, Kaminski M, Lelong N, et al. Alcohol use in pregnancy, craniofacial features, and fetal growth. *J Epidemiol Commun Health* 1990;44:302.
258. Crain LS, Fitzmaurice NE, Mondry C. Nail dysplasia and fetal alcohol syndrome. *Am J Dis Child* 1983;137:1069.
259. Van Rensburg LJ. Major skeletal defects in the fetal alcohol syndrome. *J Afr Med J* 1981;59:687.
260. West JR, Black AC Jr, Reimann PC, et al. Polydactyly and polysyndactyly induced by prenatal exposure to ethanol. *Teratology* 1981;24:13.
269. Beals RK, Eckhardt AL. Hereditary onycho-osteodysplasia (nail-patella syndrome). A report of nine kindreds. *J Bone Joint Surg Am* 1969;51:505.
270. Daniel CR III, Osment LS, Noojin RL. Triangular lunulae. A clue to nail-patella syndrome. *Arch Dermatol* 1980;116:448.
271. Guidera KJ, Satterwhite Y, Ogden JA, et al. Nail-patella syndrome: a review of 44 orthopaedic patients. *J Pediatr Orthop* 1991;11:737.
272. Yakish SD, Fu FH. Long-term follow-up of the treatment of a family with nail-patella syndrome. *J Pediatr Orthop* 1983;3:360.
273. Darlington D, Hawkins CF. Nail-patella syndrome with iliac horns and hereditary nephropathy. Necropsy report and anatomical dissection. *J Bone Joint Surg Br* 1967;49-B:164.
274. Dreyer SD, Zhou G, Baldini A, et al. Mutations in LMX1B cause abnormal skeletal patterning and renal dysplasia in nail-patella syndrome. *Nat Genet* 1998;19:47.
275. Loomer RL. Shoulder girdle dysplasia associated with nail-patella syndrome. A case report and literature review. *Clin Orthop Rel Res* 1989;238:112.
276. Hogg J, Macnical MF. Foot deformities associated with onycho-osteodysplasia. A familial study and a review of associated features. *Int Orthop* 1985;9:135.
277. Letts M. Hereditary onycho-osteodysplasia (nail-patella syndrome). A three generation familial study. *Orthop Rev* 1991; 20:267.
278. Papadakos VT, Swan A, Bhalla AK. Nail-patella syndrome associated with mixed crystal deposition arthropathy. *Clin Rheumatol* 1992;11:413.
279. Lommen EJ, Hamel BC, te Slaa RL. Nephropathy in hereditary osteo-onycho dysplasia (HOOD): variable expression or genetic heterogeneity. *Prog Clin Biol Res* 1989;305:157.

Nail-patella Syndrome

de Lange Syndrome

280. Filippi G. The de Lange syndrome. Report of 15 cases. *Clin Genet* 1989;35:343.
281. De Die-Smulders C, Theunissen P, Schranter-Stumpel C, et al. On the variable expression of the Brachmann-de Lange syndrome. *Clin Genet* 1992;41:42.
282. Greenberg F, Robinson LK. Mild Brachmann-de Lange syndrome: changes of phenotype with age. *Am J Med Genet* 1989; 32:90.
283. Ireland M, English C, Cross I, et al. A de novo translocation t(3;17)(q26.a3;q3.1) in a child with Cornelia de Lange syndrome. *J Med Genet* 1991;28:639.

284. Lakshminarayana P, Nallasivam P. Cornelia de Lange syndrome with ring chromosomes 3. *J Med Genet* 1990;27:405.
285. Bruner JP, Hsia YE. Prenatal findings in Brachmann-de Lange syndrome. *Obstet Gynecol* 1990;76:966.
286. Drolshagen LF, Durmon G, Berumen M, et al. Prenatal ultrasonographic appearance of "Cornelia de Lange" syndrome. *J Clin Ultrasound* 199;220:470.
287. Condrion CJ. Limb anomalies in Cornelia de Lange syndrome infant patient. *Birth Defects* 1969;5:226.
288. Curtis JA, O'Hara AE, Carpenter GG. Spurs of the mandible and supracondylar process of the humerus in Cornelia de Lange syndrome. *AJR Am J Roentgenol* 1977;129:156.
289. Filippi G, Renuart AW. Limb anomalies in the Cornelia de Lange syndrome: adult patient. *Birth Defects* 1969;5:228.
290. Halal F, Preus M. The hand profile in de Lange syndrome: diagnostic criteria. *Am J Med Genet* 1979;3:317.
291. Joubin J, Pettrone CF, Pettrone FA. Cornelia de Lange's syndrome. A review article (with emphasis on orthopedic significance). *Clin Orthop* 1982;171:180.
292. Pashayan HM, Fraser FC, Pruzansky S. Variable limb malformations in the Brachmann-Cornelia de Lange syndrome. *Birth Defects* 1975;11:147.
293. Rosenbach Y, Zahavi I, Dinari G. Gastroesophageal dysfunction in Brachmann-de Lange syndrome. *Am J Med Genet* 1992;42:379.
294. Cates M, Billmire DF, Bull MJ, Grosfeld JL. Gastroesophageal dysfunction in Cornelia de Lange syndrome. *J Pediatr Surg* 1989;24:248.
295. Fraser WI, Campbell BM. A study of six cases of de Lange Amsterdam dwarf syndrome, with special attention to voice, speech and language characteristics. *Dev Med Child Neurol* 1978;20:189.
296. Dossetor DR, Couryer S, Nicol AR. Massage for very severe self-injurious behaviour in a girl with Cornelia de Lange syndrome. *Dev Med Child Neurol* 1991;33:636.
297. Shear CS, Nyhan WL, Kirman BH, et al. Self-mutilative behavior as a feature of the de Lange syndrome. *J Pediatr* 1971;78:506.
298. Sargent WW. Anesthetic management of a patient with Cornelia de Lange syndrome. *Anesthesiology* 1991;74:1162.
308. Robin GC. Scoliosis in familial dysautonomia. *Bull Hosp Joint Dis Orthop Inst* 1984;44:26.
309. Rubery PT, Speilman JH, Hester P. Scoliosis in familial dysautonomia. *J Bone Joint Surg Am* 1995;77:1369.
310. Guidera KJ, Multhopp H, Ganey T, et al. Orthopaedic manifestations in congenitally insensate patients. *J Pediatr Orthop* 1990;10:514.
311. Mitnick JS, Axelrod FB, Genieser NB, et al. Aseptic necrosis in familial dysautonomia. *Radiology* 1982;142:89.
312. Brunt PW. Unusual cause of Charcot joints in early adolescence (Riley-Day syndrome). *Br Med J* 1967;4:277.
313. Chillag KJ, Stevens DB. Idiopathic neurogenic arthropathy. *J Pediatr Orthop* 1985;5:597.
314. Porges RF, Axelrod FB, Richards M. Pregnancy in familial dysautonomia. *Am J Obstet Gynecol* 1978;132:485.

Rubinstein-Taybi Syndrome

315. Rubinstein JH. Broad thumb-hallux (Rubinstein-Taybi) syndrome 1957-1988. *Am J Med Genet* 1990;6(suppl):3.
316. Hennekam RC, Van Den Boogaard MJ, Sibbles BJ, et al. Rubinstein-Taybi syndrome in The Netherlands. *Am J Med Genet* 1990;6(suppl):17.
317. Marion RW, Garcia DM, Karasik JB. Apparent dominant transmission of the Rubinstein-Taybi syndrome. *Am J Med Genet* 1993;46:284.
318. Allanson JE. Rubinstein-Taybi syndrome: the changing face. *Am J Med Genet* 1990;6(suppl):38.
319. Robson MJ, Brown LM, Sharrad WJW. Cervical spondylolysis syndrome and other skeletal abnormalities in Rubinstein-Taybi syndrome. *J Bone Joint Surg Br* 1980;62:297.
320. Petrij F, Giles RH, Dauwerse HG. Rubinstein-Taybi syndrome caused by mutations in the transcriptional co-activator CBP. *Nature* 1995;376:351.
321. Stevens CA, Hennekam RC, Blackburn BL. Growth in the Rubinstein-Taybi syndrome. *Am J Med Genet* 1990;6(suppl):51.
322. Hennekam RC, Van Doorne JM. Oral aspects of Rubinstein-Taybi syndrome. *Am J Med Genet* 1990;6(suppl):42.
323. Partington MW. Rubinstein-Taybi syndrome: a follow-up study. *Am J Med Genet* 1990;6(suppl):65.
324. Stevens CA, Carey JC, Blackburn BL. Rubinstein-Taybi syndrome: a natural history study. *Am J Med Genet* 1990;6(suppl):30.
325. Miller RW, Rubinstein JH. Tumors in Rubinstein-Taybi syndrome. *Am J Med Genet* 1995;56:115.
326. Mehlman CT, Rubinstein JH, Roy DR. Instability of the patellofemoral joint in Rubinstein-Taybi syndrome. *J Pediatr Orthop* 1998;18:511.
327. Stevens CA. Patellar dislocation in Rubinstein-Taybi syndrome. *Am J Med Genet* 1997;72:190.
328. Stirt JA. Anesthetic problems in Rubinstein-Taybi syndrome. *Anesth Analg* 1981;60:534.
329. Stirt JA. Succinylcholine in Rubinstein-Taybi syndrome. *Anesthesiology* 1982;57:429.
330. Selmanowitz VJ, Stiller MJ. Rubinstein-Taybi syndrome. Cutaneous manifestations and colossal keloids. *Arch Dermatol* 1981;117:504.
329. Axelson FB, Porges RF, Stein ME. Neonatal recognition of familial dysautonomia. *J Pediatr* 1987;110:946.
330. Clayson D, Welton W, Axelson FB. Personality development and familial dysautonomia. *Pediatrics* 1980;65:274.
331. Axelson FB, Abularrage JJ. Familial dysautonomia: a prospective study of survival. *J Pediatr* 1982;101:234.
332. Blumenfeld A, Slangenaupt SA, Liebert CB, et al. Precise genetic mapping and haplotype analysis of the familial dysautonomia gene on human chromosome 9q31. *Am J Hum Genet* 1999;64:1110.
333. Pearson J, Pytel BA, Grover-Johnson N, et al. Quantitative studies of dorsal root ganglia and neuropathologic observations on spinal cords in familial dysautonomia. *J Neurol Sci* 1978;35:77.
334. Hensinger RN, MacEwen GD. Spinal deformity associated with heritable neurological conditions: spinal muscular atrophy, Friedreich's ataxia, familial dysautonomia, and Charcot-Marie-Tooth disease. *J Bone Joint Surg Am* 1976;58:13.
335. Robin GC. Scoliosis in familial dysautonomia. *Bull Hosp Joint Dis Orthop Inst* 1984;44:16.
336. Yoslow W, Becker MH, Bartels J, et al. Orthopaedic defects in familial dysautonomia. A review of sixty-five cases. *J Bone Joint Surg Am* 1971;53:1541.
337. Albanese SA, Babecko WP. Spine deformity in familial dysautonomia (Riley-Day syndrome). *J Pediatr Orthop* 1979;7:183.
331. Monu JU, Benka-Coker LB, Fatunde Y. Hutchinson-Gilford progeria syndrome in siblings. Report of three new cases. *Skeletal Radiol* 1990;19:585.
332. Khalifa MM. Hutchinson-Gilford progeria syndrome: report of

- a Libyan family and evidence of autosomal recessive inheritance. *Clin Genet* 1989;35:125.
333. Brown WT. Progeria: a human-disease model of accelerated aging. *Am J Clin Nutr* 1992;55(suppl 6):1222S.
 334. Abdenur JE, Brown WT, Friedman S, et al. Response to nutritional and growth hormone treatment in progeria. *Metabolism* 1997;46:851.
 335. Yan T, Li S, Jiang X, et al. Altered levels of primary antioxidant enzymes in progeria skin fibroblasts. *Biochem Biophys Res Commun* 1999;257:163.
 336. Badame AJ. Progeria. *Arch Dermatol* 1989;125:540.
 337. Gillar PJ, Kaye CI, McCourt JW. Progressive early dermatologic changes in Hutchinson-Gilford progeria syndrome. *Pediatr Dermatol* 1991;8:199.
 338. Moen C. Orthopaedic aspects of progeria. *J Bone Joint Surg Am* 1982;64:542.
 339. Reichel W, Bailey JA II, Zigel S, et al. Radiological findings in progeria. *J Am Geriatr Soc* 1971;19:657.
 340. Fernandez-Palazzi F, McLaren AT, Slowie DF. Report on a case of Hutchinson-Gilford progeria, with special reference to orthopedic problems. *Eur J Pediatr Surg* 1992;2:378.
 341. Gamble JG. Hip disease in Hutchinson-Gilford progeria syndrome. *J Pediatr Orthop* 1984;4:585.

Russell-Silver Dwarfism

342. Angehrn V, Zachmann M, Prader A. Silver-Russell syndrome. Observations in 20 patients. *Helv Paediatr Acta* 1979;34:297.
343. Saal HM, Pagon RA, Pepin MG. Reevaluation of Russell-Silver syndrome. *J Pediatr* 1985;107:733.
344. Tanner JM, Lejarraga H, Cameron N. The natural history of the Silver-Russell syndrome: a longitudinal study of thirty-nine cases. *Pediatr Res* 1975;9:611.
345. Escobar V, Gleiser S, Weaver DD. Phenotypic and genetic analysis of the Silver-Russell syndrome. *Clin Genet* 1978;13:278.
346. Samn M, Lewis K, Blumberg B. Monozygotic twins discordant for the Russell-Silver syndrome. *Am J Med Genet* 1990;37:543.
347. Limbird TJ. Slipped capital femoral epiphysis associated with Russell-Silver syndrome. *South Med J* 1989;82:902.
348. Moss SH, Switzer HE. Congenital hypoplastic thumb in the Silver syndrome: a case report and review of upper extremity anomalies in the world literature. *J Hand Surg* 1983;8:480.
349. Spect EE, Hazelrig PE. Orthopaedic considerations of Silver's syndrome. *J Bone Joint Surg Am* 1973;55:1502.
350. Stanhope R, Ackland F, Hamill G, et al. Physiological growth hormone secretion and response to growth hormone treatment in children with short stature and intrauterine growth retardation. *Acta Paediatr Scand* 1989;349(suppl):47.
351. Bruckheimer E, Abrahamov A. Russell-Silver syndrome and Wilms tumor. *J Pediatr* 1993;122:165.

Turner Syndrome

352. Jacobs PA, Betts PR, Cockwell AE, et al. A cytogenetic and molecular reappraisal of a series of patients with Turner's syndrome. *Ann Hum Genet* 1990;54:209.
353. Gicquel C, Cabrol S, Schneid H, et al. Molecular diagnosis of Turner's syndrome. *J Med Genet* 1992;29:547.
354. Pagel M. Mother and father in surprise genetic agreement. *Nature* 1999;397:19.
355. Zinn AR, Tonk VS, Chen Z, et al. Evidence for a Turner syndrome locus or loci at Xp11.2-p22.1. *Am J Human Genet* 1998;63:1757.
356. Naeraa RW, Nielsen J. Standards for growth and final height in Turner's syndrome. *Acta Paediatr Scand* 1990;79:182.
357. Mostello DJ, Bofinger MK, Siddigi TA. Spontaneous resolution of fetal cystic hygroma and hydrops in Turner syndrome. *Obstet Gynecol* 1989;73:862.
358. Thomson SJ, Tanne NS, Mercer DM. Web neck deformity: anatomical considerations and options in surgical management. *Br J Plast Surg* 1990;43:94.
359. Beals RK. Orthopedic aspects of the XO (Turner's) syndrome. *Clin Orthop* 1973;97:19.
360. Kosowicz J. The deformity of the medial tibial condyle in nineteen cases of gonadal dysgenesis. *J Bone Joint Surg Am* 1960;42:600.
361. Mora S, Weber G, Guarneri MP, et al. Effect of estrogen replacement therapy on bone mineral content in girls with Turner syndrome. *Obstet Gynecol* 1992;79:747.
362. Naeraa RW, Nielsen J. Standards for growth and final height in Turner's syndrome. *Acta Paediatr Scand* 1990;79:182.
363. Neely EK, Marcus R, Rosenfeld RG, et al. Turner syndrome adolescents receiving growth hormone are not osteopenic. *J Clin Endocrinol Metab* 1993;76:861.
364. Saggese G, Federico G, Bertelloni S, et al. Mineral metabolism in Turner's syndrome: evidence for impaired renal vitamin D metabolism and normal osteoblast function. *J Clin Endocrinol Metab* 1992;75:998.
365. Ross JL, Long LM, Feuillan P, et al. Normal bone density of the wrist and spine and increased wrist fractures in girls with Turner's syndrome. *J Clin Endocrinol Metab* 1991;73:355.
366. Rovet JF. The psychoeducational characteristics of children with Turner syndrome. *J Learn Disabil* 1993;26:333.
367. Swillen A, Fryns JP, Kleczkowska A, et al. Intelligence, behaviour and psychosocial development in Turner syndrome. A cross-sectional study of 50 pre-adolescent and adolescent girls (4-20 years). *Genet Couns* 1993;4:7.
368. Sylven L, Hagenfeldt K, Brondum-Neilsen K, et al. Middle-aged women with Turner's syndrome. Medical status, hormonal treatment and social life. *Acta Endocrinol* 1991;125:359.
369. Subramaniam PN. Turner's syndrome and cardiovascular anomalies: a case report and review of the literature. *Am J Med Sci* 1989;297:260.
370. Rosenfeld RG. Growth hormone therapy in Turner's syndrome: an update on final height. *Acta Paediatr* 1992;383(suppl):3.
371. Rosenfeld RG, Frane J, Attie KM, et al. Six year results of a randomized, prospective trial of human growth hormone and oxandrolone in Turner syndrome. *J Pediatr* 1992;121:49.

Noonan Syndrome

372. Collins E, Turner G. The Noonan syndrome: a review of the clinical and genetic features of 27 cases. *J Pediatr* 1973;83:941.
373. Sharland M, Burch M, McKenna WM, et al. A clinical study of Noonan syndrome. *Arch Dis Child* 1992;67:178.
374. Sharland M, Morgan M, Smith G, et al. Genetic counselling in Noonan syndrome. *Am J Med Genet* 1993;45:437.
375. Burch M, Mann JM, Sharland M, et al. Myocardial disarray in Noonan syndrome. *Br Heart J* 1992;68:586.
376. Campbell AM, Bousfield JD. Anaesthesia in a patient with Noonan's syndrome and cardiomyopathy. *Anaesthesia* 1992;47:131.
377. Wedge JH, Khalifa MM, Shokeir MHK. Skeletal anomalies in 40 patients with Noonan's syndrome. *Orthop Trans* 1987;11:40.
378. Legius E, Schollen E, Matthijs G, Fryns J-P. Fine mapping of Noonan/ cardio-facio cutaneous syndrome in a large family. *Eur J Hum Genet* 1998;6:32.

Prader-Willi Syndrome

379. Cassidy SB. Prader-Willi syndrome. *Curr Probl Pediatr* 1984;14:1.

380. Gavranich J, Selikowitz M. A survey of 22 individuals with Prader-Willi syndrome in New South Wales. *Aust Paediatr J* 1989;25:43.
381. Holm VA, Cassidy SB, Butler MG, et al. Prader-Willi syndrome: consensus diagnostic criteria. *Pediatrics* 1993;91:398.
382. Aughton DJ, Cassidy SB. Physical features of Prader-Willi syndrome in neonates. *Am J Dis Child* 1990;144:1251.
383. Char F. A photographic study: the natural history of Prader-Willi syndrome. *J Clin Dysmorphol* 1984;2:2.
384. Borghgraef M, Fryns JP, Van den Berghe H. Psychological profile and behavioral characteristics in 12 patients with Prader-Willi syndrome. *Genet Couns* 1990;1:141.
385. Curfs LM, Verhulst FC, Fryns JP. Behavioral and emotional problems in youngsters with Prader-Willi syndrome. *Genet Couns* 1991;2:33.
386. Selikowitz M, Sunman J, Pendergast A, et al. Fenfluramine in Prader-Willi syndrome: a double blind, placebo controlled trial. *Arch Dis Child* 1990;65:112.
387. Hudgins L, Cassidy SB. Hand and foot length in Prader-Willi syndrome. *Am J Med Genet* 1991;41:5.
388. Waters J, Clarke DJ, Corbett JA. Educational and occupational outcome in Prader-Willi syndrome. *Child Care Health Dev* 1990;16:271.
389. Cassidy SB, ed. *Prader-Willi syndrome and other chromosome 15q deletion disorders. NATO ASI series H: cell biology*. vol 61. Heidelberg: Springer, 1992:265.
390. Knoll JH, Wagstaff J, Lalande M. Cytogenetic and molecular studies in the Prader-Willi and Angelman syndromes: an overview. *Am J Med Genet* 1993;46:2.
391. Nicholls RD. Genomic imprinting and uniparental disomy in Angelman and Prader-Willi syndromes: a review. *Am J Med Genet* 1993;46:16.
392. Gurd AR, Thompson TR. Scoliosis in Prader-Willi syndrome. *J Pediatr Orthop* 1981;1:317.
393. Holm VA, Larnen EL. Prader-Willi syndrome and scoliosis. *Dev Med Child Neurol* 1981;23:192.
394. Rees D, Jones MW, Owen R, et al. Scoliosis surgery in the Prader-Willi syndrome. *J Bone Joint Surg Br* 1989;71:685.
395. Soriano RM, Weisz I, Houghton GR. Scoliosis in the Prader-Willi syndrome. *Spine* 1988;13:211.
396. Mayhew JF, Taylor B. Anaesthetic considerations in the Prader-Willi syndrome. *Can Anaesth Soc J* 1983;30:565.
397. Carrel AL, Myers SE, Whitman BY. Growth hormone improves body composition, fat utilization, physical strength and agility, and growth in Prader-Willi syndrome: A controlled study. *J Pediatr* 1999;134:221.
398. Davies PS, Evans S, Broomhead S. Effect of growth hormone on height, weight, and body composition in Prader-Willi syndrome. *Arch Dis Child* 1998;78:476.

Beckwith-Wiedemann Syndrome

399. Martinez y Martinez R, Martinez-Carboney R, Ocampo-Campos R, et al. Wiedemann-Beckwith syndrome: clinical, cytogenetical and radiological observations in 39 new cases. *Genet Couns* 1992;3:67.
400. Goldberg MJ. Beckwith-Wiedemann syndrome. In: Goldberg MJ, ed. *The dysmorphic child. An orthopedic perspective*. New York: Raven, 1987:175.
401. Ping AJ, Reeve AE, Law DJ, et al. Genetic linkage of Beckwith-Wiedemann syndrome to 11p15. *Am J Hum Genet* 1989;44:720.
402. Brown KW, Gardner A, Williams JC, et al. Paternal origin of 11p15 duplications in the Beckwith-Wiedemann syndrome. A new case and review of the literature. *Cancer Genet Cytogenet* 1992;58:66.

403. Viljoen D, Ramesar R. Evidence for paternal imprinting in familial Beckwith-Wiedemann syndrome. *J Med Genet* 1992;29:221.
404. Lodeiro JG, Byers JW III, Chuipke S, et al. Prenatal diagnosis and perinatal management of the Beckwith-Wiedemann syndrome: a case and review. *Am J Perinatol* 1989;6:446.
405. Shah YG, Metlay L. Prenatal ultrasound diagnosis of Beckwith-Wiedemann syndrome. *J Clin Ultrasound* 1990;18:597.
406. Shah KJ. Beckwith-Wiedemann syndrome: role of ultrasound in its management. *Clin Radiol* 1983;34:313.
407. Choyke PL, Siegel MJ, Craft AW. Screening for Wilms tumor in children with Beckwith-Wiedemann syndrome or idiopathic hemihypertrophy. *Med Pediatr Oncol* 1999;32:200.
408. Lee FA. Radiology of the Beckwith-Wiedemann syndrome. *Radiol Clin North Am* 1972;10:261.

VACTERLS and VATER Association

409. Quan L, Smith DW. The VATER association: vertebral defects, anal atresia, T-E fistula with esophageal atresia, radial and renal dysplasia: a spectrum of associated defects. *J Pediatr* 1973;82:104.
410. Beals RK, Rolfe B. VATER association. A unifying concept of multiple anomalies. *J Bone Joint Surg Am* 1989;71:948.
411. Lawhorn SM, MacEwen GD, Bunnell WP. Orthopaedic aspects of the VATER association. *J Bone Joint Surg Am* 1986;68:424.
412. Wulfsberg EA, Phillips-Dawkins TL, Thomas RL. Vertebral hypersegmentation in a case of the VATER association. *Am J Med Genet* 1992;42:766.
413. Chestnut R, James HE, Jones KL. The VATER association and spinal dysraphia. *Pediatr Neurosurg* 1992;18:144.
414. Raffel C, Litofsky S, McComb JG. Central nervous system malformations and the VATER association. *Pediatr Neurosurg* 1990;16:170.

Goldenhar Syndrome

415. Sherk HH, Whitaker LA, Pasquariello PS. Facial malformations and spinal anomalies. A predictable relationship. *Spine* 1982;7:526.
416. Morrison PJ, Mulholland HC, Craig BG, et al. Cardiovascular abnormalities in the oculo-auriculo-vertebral spectrum (Goldenhar syndrome). *Am J Med Genet* 1992;44:425.
417. Van Bever Y, van den Ende JJ, Richieri-Costa A. Oculo-auriculo-vertebral complex and uncommon associated anomalies: report on 9 unrelated Brazilian patients. *Am J Med Genet* 1992;44:683.
418. Kaye CI, Martin AO, Rollnick BR, et al. Oculoauriculovertebral anomaly: segregation analysis. *Am J Med Genet* 1992;43:913.
419. Darling DB, Feingold M, Berkman M. The roentgenological aspects of Goldenhar's syndrome (oculoauriculovertebral dysplasia). *Radiology* 1968;91:254.
420. Madan R, Trikha A, Venkataraman RK, et al. Goldenhar's syndrome: an analysis of anaesthetic management. A retrospective study of seventeen cases. *Anaesthesia* 1990;45:49.
421. Sherk HH, Whitaker LA, Pasquariello PS. Facial malformations and spinal anomalies. A predictable relationship. *Spine* 1982;7:526.
422. Schrander-Stumpel CT, de Die-Smulders CE, Hennekam RC, et al. Oculoauriculovertebral spectrum and cerebral anomalies. *J Med Genet* 1992;29:326.

Trichorhinophalangeal Syndrome

423. Minguella I, Ubierna M, Escola J, et al. Trichorhinophalangeal syndrome, type I, with avascular necrosis of the femoral head. *Acta Paediatr* 1993;82:329.

424. Ludecke HJ, Johnson C, Wagner MJ, et al. Molecular definition of the shortest region of deletion overlap in the Langer-Giedion syndrome. *Am J Hum Genet* 1991;49:1197.
425. Bauermeister S, Letts M. The orthopaedic manifestations of the Langer-Giedion syndrome. *Orthop Rev* 1992;21:31.
426. Burgess RC. Trichorhinophalangeal syndrome. *South Med J* 1991;84:1268.

Mucopolysaccharidoses


427. Hopwood JJ, Morris CP. The mucopolysaccharidoses. Diagnosis, molecular genetics and treatment. *Mol Biol Med* 1990;7:381.
428. Scriver CR, Beaudet AL, Sly WS, Valle D, eds. *The metabolic basis of inherited disease*, 6th ed. New York: McGraw-Hill, 1989.
429. Fukada S, Tomatsu S, Masue M, et al. Mucopolysaccharidosis type IVA. N-acetyl galactosamine-6-sulfate sulfatase exonic point mutations in classical Morquio and mild cases. *J Clin Invest* 1992;90:1049.
430. Jin WD, Jackson CE, Desnick RJ. Mucopolysaccharidosis type VI: identification of three mutations in the arylsulfatase B gene of patients with severe and mild phenotypes provides molecular evidence for genetic heterogeneity. *Am J Hum Genet* 1992;50:795.
431. Field RE, Buchanan JA, Coppemans MG, et al. Bone marrow transplantation in Hurler's syndrome. Effect on skeletal development. *J Bone Joint Surg Br* 1994;76:957.
432. Guffon N, Souillet G, Maire I, et al. Follow-up of nine patients with Hurler syndrome after bone marrow transplantation. *J Pediatr* 1998;133:119.
433. Odunusi E, Peters C, Krivit W, et al. Genu valgum deformity in Hurler syndrome after hematopoietic stem cell transplantation: correction by surgical intervention. *J Pediatr Orthop* 1999;19:270.
434. Haddad FS, Hill RA, Jones DH. Triggering in the mucopolysaccharidoses. *J Pediatr Orthop B* 1998;7:138.
435. Haddad FS, Jones DH, Vellodi A, et al. Carpal tunnel syndrome in the mucopolysaccharidoses and mucopolipidoses. *J Bone Joint Surg Br* 1997;79:576.
436. Baker E, Guo XH, Orsborn AM, et al. The Morquio A syndrome (mucopolysaccharidosis IVA) gene maps to 16q24.3. *Am J Hum Genet* 1993;52:96.
437. Bassett GS. Orthopaedic aspects of skeletal dysplasias. *Instruct Course Lect, AAOS*. 1990;39:389.
438. Bassett GS. Lower-extremity abnormalities in dwarfing conditions. *Instruct Course Lect* 1990;39:389.
439. Goldberg MJ. Orthopaedic aspects of bone dysplasia. *Orthop Clin North Am* 1976;7:445.
440. Kopits SE. Orthopaedic complications of dwarfism. *Clin Orthop* 1976;114:153.
441. Berthel D, Winter RB, Luther L, et al. Spinal disorders of dwarfism: review of the literature and report of eighty cases. *J Bone Joint Surg Am* 1981;63:389.
442. Nelson J, Thomas PS. Clinical findings in 12 patients with MPS IVA (Morquio's disease): further evidence for heterogeneity. Part III: odontoid dysplasia. *Clin Genet* 1988;33:126.
443. Stevens JM, Kendall BE, Crockard HA. The odontoid process in Morquio-Brailsford disease. The effects of occipitocervical fusion. *J Bone Joint Surg Br* 1991;73:851.
444. Stevens JM, Kendall BE, Crockard HA, et al. The odontoid process in Morquio-Brailsford's disease. The effects of occipitocervical fusion. *J Bone Joint Surg Br* 1991;73:851.

Hadju-Cheney Syndrome

445. Brown DM, Bradford DS, Gorlin RJ. The acro-osteolysis syndrome: morphologic and biochemical studies. *J Pediatr* 1976;88:580.
446. Elias AN, Pinals RS, Anderson HC. Hereditary osteodysplasia with acro-osteolysis (the Hadju-Cheney syndrome). *Am J Med* 1978;65:636.
447. Kawamura J, Miki Y, Yamazaki S. Hadju-Cheney syndrome: MR imaging. *Neuroradiology* 1991;33:442.
448. O'Reilly MAR, Shaw DG. Hadju-Cheney syndrome. *Ann Rheum Dis* 1994;53:279.
449. Weleber RG, Beals RK. Hadju-Cheney syndrome report of 2 cases and review of literature. *J Pediatr* 1976;88:249.
450. Ades LC, Morris LL, Haan EA. Hydrocephalus in Hadju-Cheney syndrome: brief report. *J Bone Joint Surg Br* 1988;70:674.
451. Kaler SG, Geggel RL, Sadehgi-Nejad A. Hadju-Cheney syndrome associated with severe cardiac valvular and conduction disease. *Am J Med Genet* 1995;56:30.
452. Kaplan P, Ramos F, Zackai EH. Cystic kidney disease in Hadju-Cheney syndrome. *Am J Med Genet* 1995;56:30.

Rett Syndrome

453. Hagberg B, Aicardi J, Dias K. A progressive syndrome of autism, dementia, ataxia, and loss of purposeful hand use in girls: Rett's syndrome: report of 35 cases. *Brain Dev* 1985;14:479.
454. Leonard H, Thomson M, Bower C. Skeletal abnormalities in Rett syndrome: increasing evidence for dysmorphogenetic defects. *Am J Med Genet* 1995;58:285.
455. Leonard H, Thomson M, Glasson E. Metacarpophalangeal pattern profile and bone age in Rett syndrome: further radiological clues to the diagnosis. *Am J Med Genet* 1999;83:95.
456. Amir RE, Van den Veyver IB, Wan M, et al. Rett syndrome is caused by mutations in X-linked MECP2, encoding methyl-CpG-binding protein 2. *Nat Genet* 1999;23:185.
457. Coleman M. Is classical Rett syndrome ever present in males? *Brain Dev* 1990;12:32.
458. Huang TJ, Lubicky JP, Hammerberg KW. Scoliosis in Rett syndrome. *Orthop Rev* 1994;23:937.
459. Guidera KJ, Borrelli J Jr, Raney E. Orthopaedic manifestations of Rett syndrome. *J Pediatr Orthop* 1991;11:208.
460. Harrison DJ, Webb PJ. Scoliosis in the Rett syndrome: natural history and treatment. *Brain Dev* 1990;12:156.
461. Loder RT, Lee CL, Richards BS. Orthopaedic aspects of Rett syndrome: a multicenter review. *J Pediatr Orthop* 1989;9:562.
462. Roberts AP, Conner AN. Orthopaedic aspects of Rett's syndrome: brief report. *J Bone Joint Surg Br* 1988;70:674.



10

LOCALIZED DISORDERS OF BONE AND SOFT TISSUE

WILLIAM G. MACKENZIE
PETER G. GABOS

CONGENITAL AND DEVELOPMENTAL DISORDERS 339

Vascular Tumors and Malformations 339
Vascular Malformations 340
Complex-combined Vascular Malformations 343
Disorders Involving Joint and Bone 355

ACQUIRED DISORDERS 366

Myositis Ossificans 366
The Osteochondroses 368
Infantile Quadriceps Fibrosis 369
Reflex Sympathetic Dystrophy 370

This chapter focuses on the congenital, developmental or acquired disorders that affect localized or regional areas of the pediatric musculoskeletal system. These entities often share a common clinical presentation and underlying pathologic process, yet are not confined to any one part of the skeleton nor are caused by a recognized systemic abnormality.

CONGENITAL AND DEVELOPMENTAL DISORDERS

Vascular Tumors and Malformations

Vascular anomalies are seen commonly in orthopaedic practice. Most are of no clinical importance, but, occasionally

these anomalies can be deforming or life threatening and require interdisciplinary management. These anomalies may be solitary or the organizing features of various syndromes (1).

The term "vascular anomalies" is used here to describe pediatric vascular disorders with primarily dermatologic or visceral manifestations, excluding abnormalities of the heart and great vessels. The term "hemangioma" has been traditionally used for every type of vascular anomaly, but Mulliken et al. have recently devised a classification system to better clarify these lesions based on their endothelial characteristics (2–4). Two main groups of disorders have been identified; the hemangiomas of infancy, vascular tumors with an early proliferative and later involuting stage; and vascular malformations, a heterogeneous group of vascular lesions comprised of dysplastic vessels, which can be capillary, venous, arterial, lymphatic, or a combination.

Vascular Tumors

Hemangiomas may be cutaneous, subcutaneous, intramuscular, or visceral. The location is most commonly in the

W. G. Mackenzie: Orthopaedic Department, Thomas Jefferson Medical College, Philadelphia, Pennsylvania 19107; Department of Orthopaedics, Alfred I. duPont Hospital for Children, Wilmington, Delaware 19803.

P. G. Gabos: Department of Orthopaedic Surgery, Jefferson Medical College, Thomas Jefferson University Hospital, Philadelphia, Pennsylvania 19107; Department of Orthopaedic Surgery, Alfred I. duPont Hospital for Children, Wilmington, Delaware 19899.

head and neck (60%) followed in frequency by the trunk and extremities. The majority occur singly but 20% proliferate in multiple sites.

Cutaneous hemangiomas (formerly called “strawberry” or “capillary hemangiomas”) are present in up to 12% of children at 1 year of age (5). A small cutaneous mark is present early in life, which grows rapidly to become a raised, bosselated, vivid red color that blanches poorly. Subsequent slow, spontaneous involution occurs with complete regression in 70% of children by 7 years (3). Lumbosacral hemangiomas and other lesions such as hypertrichosis and dimpling should alert the orthopaedist to an underlying occult spinal dysraphism.

Deep hemangiomas (formerly termed “cavernous hemangiomas”) occur in the lower dermis or muscle. The overlying skin may be only slightly raised or bluish. On palpation, the mass is fibrofatty, similar to the superficial hemangioma. These deep hemangiomas can be confused with venous or lymphatic malformations which are usually soft and compressible unless thrombosed. Spontaneous involution usually occurs with deep hemangiomas. Sonography can differentiate between a hemangioma and vascular malformation but MRI is considered the gold standard (5,6).

Most hemangiomas resolve uneventfully with occasional scarring. Superficial ulceration and bleeding is uncommon. Up to 20% of hemangiomas can have significant complications including destruction of involved tissues or obstruction of a vital structure such as the eye or airway (5). High-

output congestive heart failure can result from large hemangiomas and gastrointestinal bleeding from intestinal involvement. Kasabach-Merritt syndrome or thrombocytopenic coagulopathy was recently shown to be associated with a rare vascular tumor known as “kaposiform hemangioendothelioma,” and not with the common hemangioma (7).

Intralesional or systemic corticosteroids and interferon-alpha are used for large, problematic or life-threatening hemangiomas (5). Factors that inhibit growth of endothelial cells will likely be used in the future (8).

Vascular Malformations

Vascular malformations are subcategorized by the type of vessel abnormality and its flow characteristics (5). The slow-flow anomalies include capillary malformations (CM) (port wine stains and telangiectasias), venous malformations (VM), and lymphatic malformations (LM) (previously known as “lymphangiomas” and “cystic hygromas”). Arterial (AM) and arteriovenous malformations (AVM) are fast-flow anomalies. Unlike the vascular tumors, vascular malformations do not regress spontaneously but can worsen depending on the type. Combined, complex malformations occur. An example of this is the Klippel-Trenaunay syndrome, a slow-flow, capillary-venous and often lymphatic malformation (CVLM), which results in limb overgrowth. Typical vascular malformations are outlined in Table 10-1.

Capillary malformations are usually referred to as “port wine stains.” Most are cosmetic vascular birthmarks but

TABLE 10-1. ASSOCIATIONS OF VASCULAR MALFORMATIONS IN CHILDREN

Syndrome	Type and Location	Clinical Problems	Orthopaedic Concerns	Mode of Inheritance
Vascular malformations on limbs				
Klippel-Trenaunay	Capillary venous malformation anywhere, arteriovenous malformations in the extremities	Varicose veins, cardiac overload	Limb hypertrophy, macrodactyly	
Blue rubber bleb nevus	Multifocal cutaneous and visceral venous malformations	Gastrointestinal bleeding	Limb hypertrophy, hemarthrosis	Autosomal dominant
Maffucci	Venous malformations in subcutaneous tissue and intraosseous enchondromas	Malignant tumors	Enchondroma with skeletal deformity, overgrowth, and sarcoma	
Central hemangiomas with indirect effects on skeleton				
Rendu-Osler-Weber (hereditary hemorrhagic telangiectasia)	Capillary malformations on the lips, tongue, mucous membranes, and gastrointestinal and genitourinary systems	Bleeding from all sites, anemia, pulmonary arteriovenous malformations	Skeletal vascular malformations (hands, wrist, axial skeleton)	Autosomal dominant
Sturge-Weber	Capillary malformation on face, vascular malformation on brain	Seizures, mental retardation, glaucoma	Hemiplegia, hemiatrophy (neurogenic)	
Ataxia-telangiectasia	Capillary malformations on conjunctivae, face, neck, and arms	Progressive ataxia, sinus and pulmonary infections, lymphomas	Mimics Friedreich ataxia: foot and ankle contractures	Autosomal recessive

some indicate an underlying condition such as Sturge-Weber syndrome. This is a nonhereditary syndrome characterized by a capillary malformation in the trigeminal nerve distribution, and more importantly, an associated vascular anomaly of the ipsilateral choroid and leptomeninges (1,4,5). These children may develop seizures, hemiplegia, developmental delay and retinal damage. This disorder must be considered when assessing a child with apparent cerebral palsy. Magnetic resonance imaging (MRI) of the brain is usually diagnostic. Facial and limb capillary malformations can be associated with soft tissue and bone hypertrophy, which are usually seen at birth. These malformations may be part of a complex vascular anomaly such as Klippel-Trenaunay syndrome, which will be discussed later. Pulsed dye laser will improve the appearance of these lesions.

Cutis marmorata telangiectatica congenita is a rare disorder seen at birth, characterized by a deep purple, serpiginous, reticulated cutaneous pattern, usually involving the trunk and extremities (4,9). The cutaneous findings usually improve spontaneously but venous dilation becomes more prominent and atrophy of the involved limb with leg-length discrepancy can occur (9). There are no reports in the literature on the efficacy of epiphysiodesis in this disorder.

Hereditary hemorrhagic telangiectasia or Rendu-Osler-Weber syndrome is an autosomal dominant disorder characterized by spider-like, red maculopapules on the face and mucous membrane in the first decade (5). The resultant arteriovenous fistulas in the lungs and gastrointestinal tract can lead to hemorrhage and cardiac failure.

Ataxia-telangiectasia or Louis-Bar syndrome is an autosomal recessive condition that causes cerebellar ataxia followed by progressive neuromotor degeneration. Telangiectasias develop on the upper part of the body: the face, neck, arms, and conjunctiva. Contractures may develop at the foot and ankle.

Venous malformations are the most common of all vascular anomalies. They are typically cutaneous but can also be skeletal or visceral. Most are solitary but multiple lesions can occur which may indicate an autosomal dominant condition called "multiple glomangiomas" (5). Venous malformations manifest as easily compressible masses with blue coloration if superficial (Fig. 10-1A-C). The swelling is worse when the limb is dependent and improves with elevation. These lesions cause aching discomfort and usually enlarge gradually as the child matures. Subcutaneous lesions can cause local sensory nerve irritation (10). Activity-related pain mimicking a chronic compartment syndrome is often associated with intramuscular lesions and diagnosis can be difficult (10). Thrombosis is common and phleboliths can be present as early as 2 years of age (4,5). Periarticular lesions can cause recurrent hemarthroses.

The options for imaging include plain films, which show abnormalities in most cases of deep venous malformations including phleboliths and enlargement or distortion of soft tissue planes (1,11). Ultrasound and computed tomography

(CT) scans with intravenous contrast demonstrate similar findings but do not add significant new information to the plain films. They may be used to direct aspiration or needle biopsy if a limited specimen is useful. MRI and magnetic resonance angiography add significant anatomic detail and are the most informative diagnostic modalities (6). Hemangiomas produce a very high T2 signal, presumably because of the pooling of blood with low flow. The signal is non-uniform because of the fibrous and fatty septae within the hemangioma. MRI can determine the extent of deep hemangiomas and differentiate the vascular elements from surrounding tissues. However, MRI cannot differentiate feeding arteries from veins, and angiography is the only way to obtain this information. Venography may not demonstrate the lesion if the flow is slow (12,13). Angiography is helpful if an arteriovenous fistula is suspected, if sclerotherapy is planned or if surgical resection is being considered.

A low-grade, localized intravascular coagulopathy can occur in children with extensive venous malformations (2,5,14). The platelet count is normal in contrast to the Kasabach-Merritt phenomenon, and the prothrombin time and D-dimers are elevated. Heparin may be required for treatment (2).

Elastic support stockings control swelling and discomfort in the extremity. Sclerotherapy, the injection of an irritating solution, is an effective intervention, but the venous malformations can recur (5). Surgical resection, often done after sclerotherapy, is considered for large, painful lesions. Incomplete exsanguination under tourniquet control allows dissection in a relatively bloodless field and better visualization of the margins (10). Recurrence is common, and was noted in 48% of patients in one study (10). Pharmacologic treatment is indicated in vascular tumors with active angiogenesis but has not been successful in the management of vascular malformations (2).

Blue rubber bleb nevus syndrome, or Bean syndrome, is a multifocal, cutaneous, and visceral venous malformation (2,4,15,16). The lesions are usually present at birth and are raised soft, blue, compressible nodules that blanch. The nodules become more numerous as the child grows older. The main risk arises from gastrointestinal hemorrhage but there are significant orthopaedic problems. The cutaneous lesions in the hands and feet cause pain and interfere with function (15,17). Hemarthrosis and stiffness can result from articular involvement. Skeletal deformities may be secondary to pressure from adjacent lesions or hypertrophy may occur because of hypervascularity (15). Significant hypertrophy may require amputation.

Maffucci syndrome is characterized by venous malformations in the subcutaneous tissues, along with multiple intraosseous enchondromas. There is no consistent genetic basis (1). The hemangiomas are present at birth in only 25% of patients; in the remainder, the lesions become evident by 5 years of age. The clinical appearance is of a blue discoloration on the skin. X-ray films may show calcified thrombi in

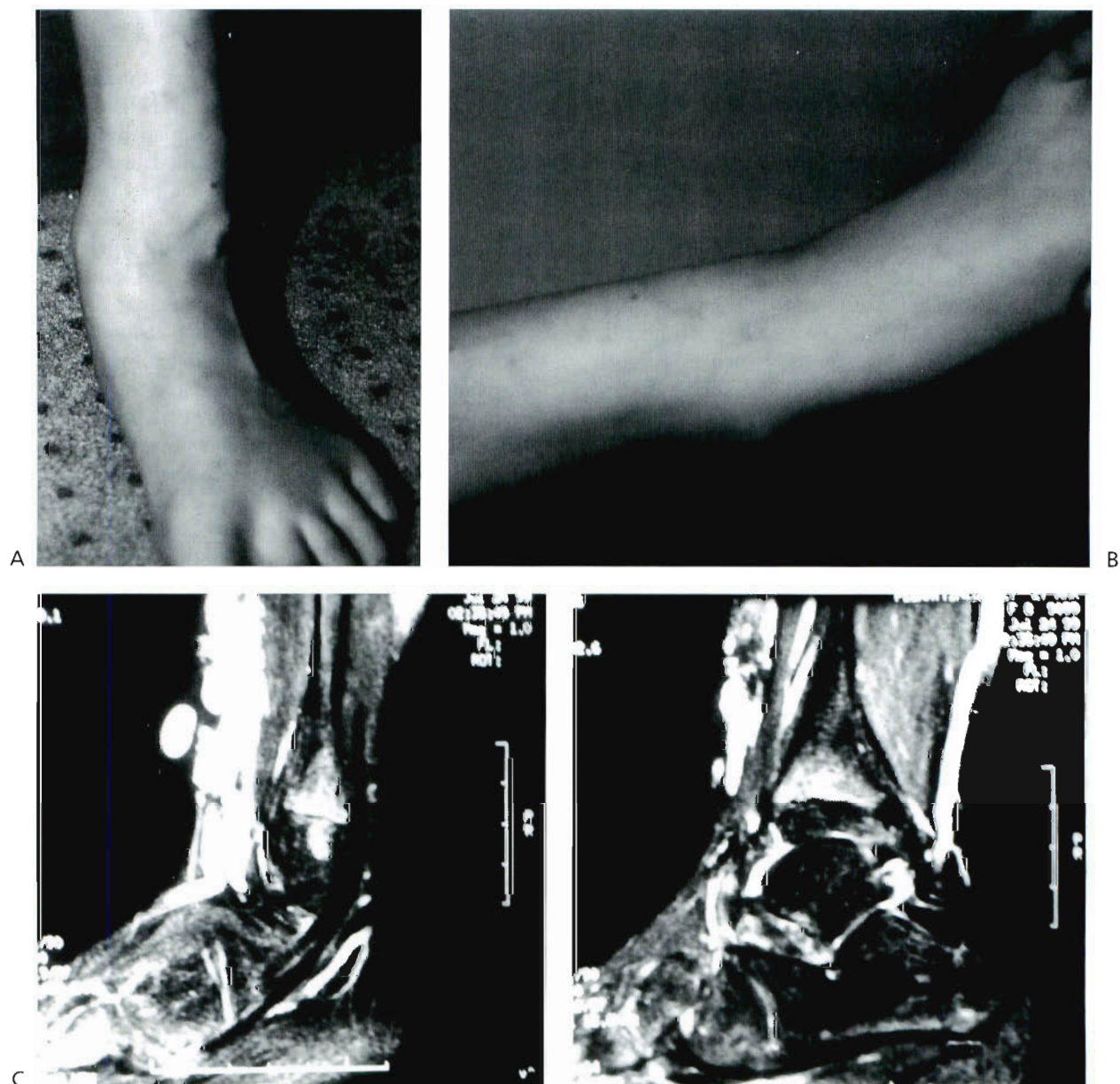


FIGURE 10-1. Eight-year-old girl with vascular malformation complaining of aching discomfort above the ankle. **A:** Standing clinical photograph demonstrating swelling and superficial irregularity over the anterolateral aspect of the ankle. This was nontender and easily compressible. **B:** With elevation of the limb, the lesion drained and was not palpable except for deep thick structures. **C:** MRI demonstrating high T2 signal typical of a vascular malformation.

addition to the enchondromas. The skeletal manifestations include short stature, limb-length inequality, angular deformities, and scoliosis. The patient's risk potential for malignant transformation is 30%; this may include the vascular lesions undergoing transformation to spindle cell hemangioendothelioma (2).

Lymphatic malformations may affect any area of the body, although they are most commonly seen in the cervicofacial region, axilla, mediastinum, and pelvis (18,19). Al-

though usually falling within the province of the general pediatric surgeon, a lymphatic malformation may first be noticed as a mass of unknown origin in a limb or as a cause of osteolysis or nerve compression. Most are present at birth or are detected in the first two years of life (5).

These malformations are slow-flow lesions that consist of anomalously formed lymphatic channels, described as microcystic, macrocystic, or a combination thereof (3–5). Superficial lymphatic malformations are recognized by

clear, small vesicles. Intravascular bleeding often occurs resulting in red nodules that are seen typically in combined lesions such as Klippel-Trenaunay syndrome. Large, deep malformations (also known as cystic hygromas or lymphangiomas) present as ballottable masses with an underlying blue hue. Although they are benign, they are locally aggressive and may compress adjacent structures. Airway compression by cervicofacial lesions can be life-threatening. Soft tissue and skeletal overgrowth is seen in association with these lesions. Chronic disseminated intravascular coagulation, as described previously in venous malformations, can also occur in large lymphatic malformations (2,5).

Diagnosis may be aided by transillumination, ultrasound, nuclear imaging, CT, or MRI. Lymphangiomas tend to have a characteristic MRI appearance, with a heterogeneous low signal on T1-weighted images, lower than that of muscle, but a very high T2-weighted signal, greater than that of fat (20). Enhancement with gadolinium did not occur in pure lymphatic malformations (6,21). Other congenital anomalies may affect these children.

A small percentage of lymphatic malformations may regress spontaneously. Staged surgical resection of the involved tissues should be done for symptomatic lesions. Sclerotherapy is useful in isolated lesions. Radical procedures, with removal of important adjacent structures, are not indicated to alter the course of the disease.

Lymphedema may occur at various ages. If present in childhood, it is called Milroy disease, a congenital lymphedema, which is autosomal dominant. Cases with onset slightly later in the first or in the second decade are called Meige disease and have the same inheritance pattern. Lymphedema is also seen as part of Turner syndrome and Noonan syndrome (i.e., Turner phenotype with normal-appearing chromosomes and mental retardation). Treatment in all of these cases is conservative: elevation when possible and compression with a Jobst stocking or intermittent pneumatic compression (13,22).

Osseous lymphatic malformations may include solitary intraosseous or more extensive forms. Solitary intraosseous lesions are extremely rare (23). They are lytic and well-demarcated but variably circumscribed. The appearance resembles a simple cyst, but involvement within bone is more extensive. Curettage and bone grafting has been reported with success (23).

Complex-combined Vascular Malformations

Several complex, combined vascular malformations exist, which have a mix of capillary, venous, lymphatic, or arterial malformations. They share a propensity for soft tissue and skeletal overgrowth.

Klippel-Trenaunay Syndrome

In 1900, Klippel and Trenaunay described their eponymous disorder, which has three essential features: a cutaneous cap-

illary-venous malformation, varicose veins, and hypertrophy of soft tissue and bone in the involved limbs (Fig. 10-2A–C). The vascular malformation is usually seen early in life and typically does not cross the midline of the body (24–27). The entire limb is not uniformly affected. The severity of the varicose veins varies, but they tend to get larger with age and are always present by 12 years (28). Abnormalities in arteries and lymphatic vessels are also frequently seen. If clinically significant arteriovenous shunting is present in addition to the typical triad, the additional name “Parkes-Weber” has been applied (Klippel-Trenaunay-Parkes-Weber) (29). Some authors suggest that the Parkes-Weber syndrome should be considered distinct from Klippel-Trenaunay syndrome (5). Overgrowth usually occurs on the limb affected by the vascular malformations but may not. The mechanism leading to overgrowth involves increased bulk or girth and increased length and width of the bone. Most of the size discrepancy seen is in girth, secondary to soft tissue hypertrophy (sparing muscles) and lymphatic abnormalities (28).

Klippel-Trenaunay syndrome may be due to a somatic mutation for a factor critical to the endothelial activity necessary for vasculogenesis and angiogenesis in embryonic development (28,30,31). It is presumed that this vascular malformation induces the hypertrophy of other tissues, but there also may be primary mesodermal abnormalities in these cases (32). The absence of deep venous drainage and venous hypertension is not likely to be a causative factor, because deep veins are missing in only 14% of patients and venous flow is normal (24). Baskerville et al. suggest that increased flow through the abnormal capillary network and venous channels may promote overgrowth (24).

Clinical Features. Although most cases are evident from the time of birth or infancy, a few cases have been reported in which features appeared as late as 6 years of age. There is no recognized pattern of inheritance. The lower extremities are affected at least ten times more often than the upper extremities. The affected limb is longer than normal in 90% of patients (11,28,33). Usually, all bones and soft tissues are involved in the hypertrophy (Fig. 10-2).

The growth patterns of the involved limbs have not been rigorously studied over time, but there are enough reported cases of nonuniform overgrowth to caution the physician that prediction of an eventual discrepancy should be done only as a rough estimate. McCullough and Kenwright described two patients with a decreasing discrepancy with growth (34). Severe leg-length discrepancy is uncommon. In one study only 10% of the children had a discrepancy greater than 3 cm (28). In addition to the extremity hypertrophy, there is evidence of fundamental embryologic regulatory defects, especially distally, with 25% of patients having anomalies of fingers or toes, such as macrodactyly, syndactyly, polydactyly, and clinodactyly (33). Scoliosis affects at least 5% of patients, although it rarely requires sur-

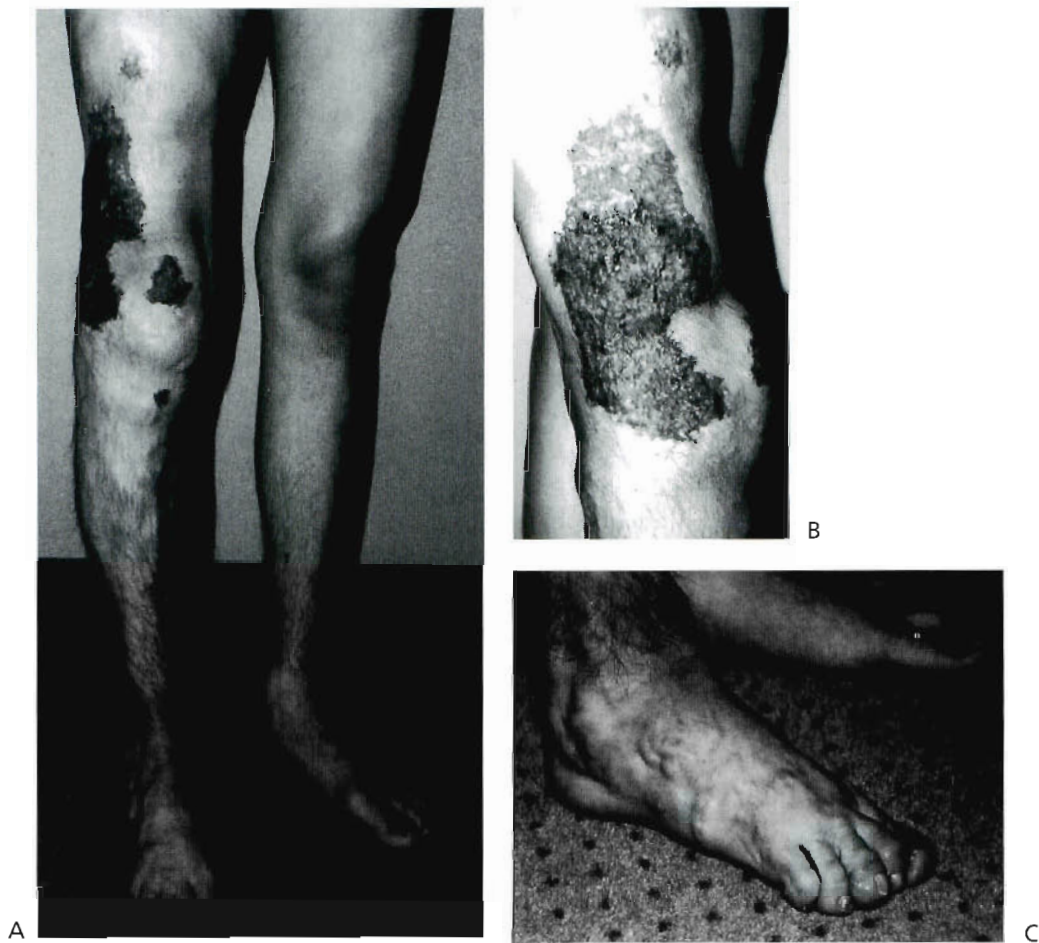

FIGURE 10-2. A: Fifteen-year-old boy with Klippel-Trenaunay syndrome of his right lower extremities with typical findings of hypertrophy, varicosities, and superficial complex combined vascular malformations. B, C: He had aching discomfort from the varicosities, intermittent pain from thrombophlebitis and drainage from the superficial vascular malformations.

gery. Systemic involvement may occur. In the central nervous system, arteriovenous malformations and cerebral and cerebellar hypertrophy have been described (35,36). The gastrointestinal and genitourinary system may be involved, resulting in bleeding in some cases. Surface bleeding from the hemangioma occurs in 25% of patients, and 15% have clinical pulmonary emboli, spontaneously or after operation (24). Congestive heart failure may occur in patients with large vascular malformations. Despite these complications, the life expectancy is not markedly decreased. The impact of this complex medical condition on the child's psychosocial development cannot be underestimated.

Pathology. Most notably, venous fibromuscular dysplasia, consisting of hypertrophied, irregular, or absent medial layers of the veins, allows dilatation. Valves are anomalous; they are absent or obstructed. Deep venous channels are usually present, and arteriovenous malformations are uncommon (31). Lymphatic hypoplasia is common. Other

tissues, such as nerve and subcutaneous tissue, may be hypertrophied.

Differential Diagnosis. Neurofibromatosis may produce massive hypertrophy without prominent nevi. Maffucci syndrome often includes limb-length inequality with vascular malformations, but it is differentiated by the presence of intraosseous enchondromas. Beckwith-Wiedemann syndrome involves localized overgrowth but also includes neonatal hypoglycemia, visceromegaly, macroglossia, and a predisposition for Wilms tumor. Proteus syndrome is a more severe disorder involving virtually all the features of Klippel-Trenaunay, but it also includes soft tissue tumors, pigmented skin lesions, and thickened palms and soles (25). Bannayan-Zonana syndrome is characterized by thoracic and abdominal lipomatosis, vascular malformations, and macrocephaly (37).

Imaging. Plain radiographs, limb-length evaluation, color duplex ultrasonography, MRI, MR angiography, MR

lymphangiography, and lymphoscintigraphy can provide sufficient information for diagnosis and planning in most cases (21,28,37–39). Lymphatic imaging is particularly useful in the evaluation of children with massive hypertrophy (28). Arteriography may be helpful in planning for hemipelvectomy or hip disarticulation to map major vessels and anticipate significant bleeding (11). Contrast angiography is also useful for percutaneous treatment of a vascular malformation.

Treatment. The skeletal and vascular abnormalities of Klippel-Trenaunay syndrome are usually not dramatically progressive. Surgery has a limited role in this condition. It should be done only for disabling problems and when the benefit is fairly predictable (39). Instead, initial therapy of the aching, hypertrophic limb with varicosities should consist of compression. Intermittent pneumatic compression should be applied at night, using a custom-fitted garment and a home pump, inflated every 90 s to a pressure midway between diastolic and systolic (40). Just before arising, a Jobst compression garment is applied, then worn throughout the day. A marked decrease in limb girth, resolution of cardiac overload and dependent syncope, reduced discomfort, and marked improvement in function can be seen. A technique of manual lymphatic drainage can also be used, if there is a significant lymphatic component to the malformation (22). Thrombophlebitis and pulmonary embolism are common. Consultation with a vascular surgeon may be beneficial for most of these patients.

Surgery is beneficial in selected situations, including cardiac failure from shunting in children, not responding to compressive therapy; rapid enlargement in limb size; bleeding from abnormal vessels in the gut, kidney, or genitalia; coagulopathy; reconstruction of selected cases of syndactyly or polydactyly; and for severely disfiguring dysfunctional limbs, for which reconstruction is not an option and amputation may provide a more functional limb. The level of amputation is often dictated by the extent and severity of the vascular malformation. A knee disarticulation is preferred to a midthigh amputation because it is an end-bearing stump with rotational control, better suspension, the distal femoral physis is preserved and overgrowth is avoided. Midthigh amputation requires ischial weightbearing, which may be a problem in the presence of any scarring or gluteal vascular malformations (25,41,42). Risks of surgery include infection, particularly in children with abnormal lymphatic drainage and delayed wound healing, which is common after transverse amputations (43). Occasionally, a proximal limb disarticulation is needed in neonates as a lifesaving procedure. For patients in this age group, hypothermia and total circulatory arrest for up to 60 min has been successful as an adjunct to minimize blood loss (44). Pulsed-dye laser treatments can be used to treat the cutaneous vascular malformations over limited areas (28).

Certain procedures have low success rates. Surgery to

debulk the extremities has usually resulted in recurrence or minimal improvement. Varicose vein ligation may provide relief of local symptoms, but the varicosities often recur, and ligation should be avoided if the deep venous system is not patent. Epiphysiodesis has a limited role because growth patterns are unpredictable, and the procedure does not decrease width of the involved extremities. Limb-shortening at skeletal maturity may be the most accurate technique. If surgery is planned, the involved skin should be protected, and the increased risk of deep thrombosis borne in mind.

Proteus Syndrome

Proteus syndrome is a sporadic vascular, skeletal, and soft tissue disorder characterized by vascular anomalies, macrodactyly, exostoses, asymmetric hypertrophy, subcutaneous tumors, scoliosis, and other anomalies (45–49). The name is derived from the Greek god, Proteus, who could change shape at will to avoid capture. This syndrome may result from somatic mosaicism (45). The cutaneous vascular malformations include capillary, lymphatic, capillary-venous, and capillary-lymphatic-venous types. Subcutaneous tumors, found most commonly on the trunk, are composed of adipose and fibrous tissue, Schwann cell structures, and vascular tissue. A symptomatic lipofibromatosis hamartoma of the median nerve in the carpal tunnel has been described in a child (50). MRI is helpful in delineating the nature and extent of the subcutaneous tumors as well as aiding in the diagnosis of the syndrome (45,51).

Macrodactyly is a common manifestation and can occur in the hands and feet (45). The enlarged digits may not be located on the same side of the hemihypertrophy. The macrodactyly progresses rapidly in the first few years of life, and slows in later childhood and adolescence. Severe cosmetic and functional problems can result. The histology is a hamartomatous proliferation of all mesenchymal tissues, especially the osseous and fibrofatty components (48). Treatment will be discussed in the section on macrodactyly later in this chapter. Another striking finding in the foot is plantar hypertrophy, resulting in cerebriform or gyriform creasing (Fig. 10-3).

Hemihypertrophy may be partial, complete, or crossed, and results in limb-length discrepancy, which varies greatly. Overgrowth and progressive atrophy have been described (46). Because skeletal age may be delayed and the rate of progression is not well understood, planning treatment can be difficult. Extensive overgrowth and joint contractures can result in amputation.

Angular upper- and lower-limb deformities are seen in Proteus syndrome. Genu valgum occurs commonly, recurs after bracing, and has required repeated osteotomies (46,48) (Fig. 10-4) [►6.1–6.5]. Joint contractures and angular deformities may be caused by epiphyseal exostoses (46).

Scoliosis or kyphoscoliosis occurs in approximately 50% of children with Proteus syndrome and may require fusion (45–49). The effect of bracing is not known. Spondylomeg-

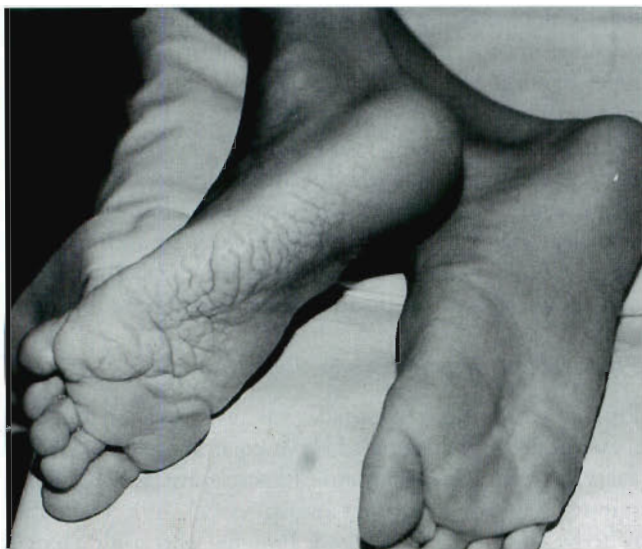

FIGURE 10-3. Adolescent male with Proteus syndrome with typical gyriform creasing of the sole of his foot.

ally, or localized spinal overgrowth, has been reported. This can result in progressive compressive neuropathy (48).

Gorham Disease

Gorham disease, or massive osteolysis, has also been called “disappearing bone disease” (52). This has been classified here as a complex, combined lymphatic venous malformation but the pathogenesis has not been fully elucidated. Osteolysis is initially localized to one bone and may subsequently involve adjacent bones. The joints and intervertebral discs do not act as barriers to extension. Progressive

bone resorption typically occurs and the bone is replaced by fibrous tissue. The resorption can stop spontaneously on rare occasions. Peak age of onset is in the second and third decades of life (53). Gorham disease is differentiated from other forms of idiopathic osteolysis based on its lack of association with neuropathy or a genetic mode of transmission (54). It may involve any area of the skeleton but is most common in the shoulder, pelvic girdles, and spine (53,55–57). It may present as dull, aching weakness in involved segments, with increasing deformity, or with pathologic fracture. Patients with lesions extending outside of bone have a high mortality rate, approaching 50% from chylothorax, chylopericardium, chyloperitoneum, and cachexia (18,55,58).

Radiographic Findings. On plain radiographs, single or multiple intramedullary and subcortical radiolucent foci are seen, which eventually coalesce (59). There is subsequent disappearance of contiguous bones and tapering of the bony remnants (Fig. 10-5A). No sclerosis or osteoblastic reaction is seen. If a pathologic fracture occurs, the bony lesion may be overlooked initially, if the lysis is minimal. Unlike normal fracture healing, the bone ends eventually become tapered, and there is no evidence of new callus forming. Computerized tomography is the best method to evaluate the extent of bone destruction. Arteriography, venography, and lymphangiography do not demonstrate the intraosseous lesion (56). Nuclear medicine scans are inconsistent in showing the lesion; MRI is very helpful, but the signal characteristics vary, depending on the stage of the disease process (54,55). The neovascular tissue is bright on T1 and T2 imaging early, but the predominant fibrous tissue present late in the process is dark on T1 and T2 imaging (Fig. 10-5B). The differential diagnosis includes other rare causes of idiopathic osteolysis, including hereditary multicentric

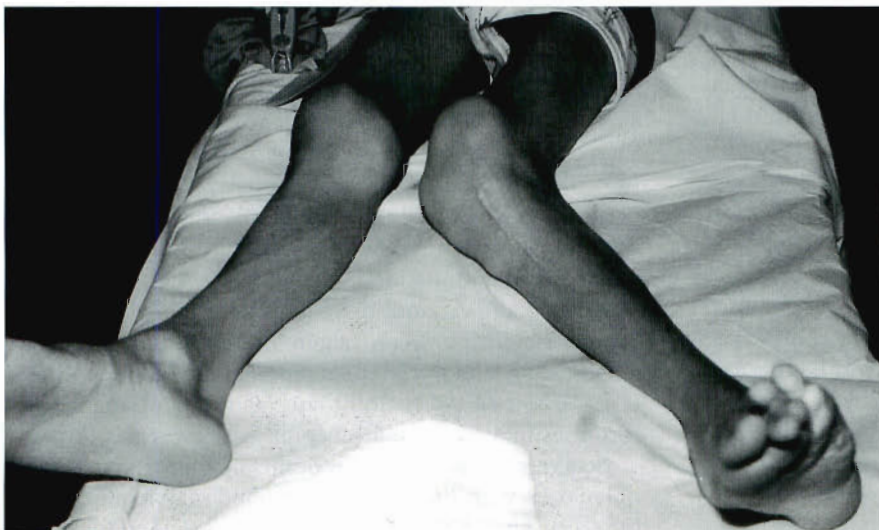

FIGURE 10-4. Adolescent male with Proteus syndrome with recurrent left genu valgum after a high tibial osteotomy just prior to repeat osteotomy.

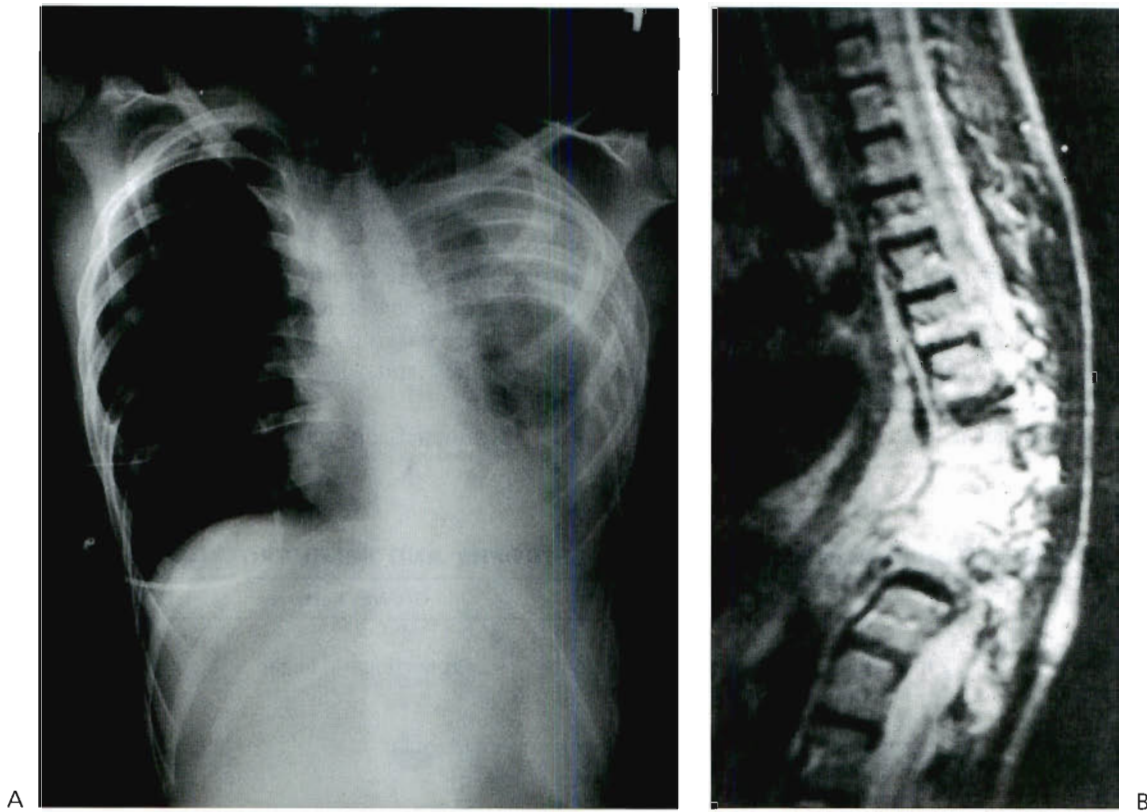


FIGURE 10-5. Twelve-year-old male with Gorham disease. **A:** Chest x-ray demonstrates loss of ribs 8, 9, and 10, and a chylothorax. **B:** The neovascular tissue is bright on T2 and on this MRI, there is extensive vertebral destruction and paravertebral involvement. This boy died from this process.

osteolysis (i.e., carpotarsal type), nonhereditary multicentric osteolysis with nephropathy, and others.

Histopathology. Histologic studies demonstrate numerous thin-walled vessels, lined by endothelial cells. The vessels may be empty or contain proteinaceous fluid and/or blood cellular elements (58). Fibrous connective tissue replaces the bone. There is no evidence of malignancy or inflammation. The histologic changes are similar to benign hemangioma or venous malformation of bone, but there is much more extensive bone destruction (53). The bone shows extensive osteoclastic activity. The cause is unclear, but perivascular cells of the lesion show the characteristics of osteoclast precursors (56).

Treatment. No treatment has been shown to be consistently successful, but surgery, with or without radiation therapy, has been the mainstay of treatment. Some cases, especially those without significant involvement of chest or abdominal cavities, stabilize spontaneously, although return of the “vanished” bone does not occur. This complicates the evaluation of published treatment protocols. Local resection and bone grafting, with or without internal fixation, has not been consistently successful (53). Most grafts are re-

sorbed, but there is one report of the successful use of a vascularized fibular graft in pelvic-femoral reconstruction (60). Wide resection and limb salvage, with or without prosthetic reconstruction, can be successful (53,54). Amputation has been required to achieve a satisfactory margin and improved function (53,60). Radiation therapy has proven effective in some cases, when doses of 30 Gy or more are used (53,61). Management of vertebral and rib involvement with chylothorax is frustrating. Resection with adequate margins is usually not possible. Pleural adhesion therapy with bleomycin and irradiation successfully managed the chylothorax in one patient (55).

Hemihypertrophy and Hemihypotrophy

Hemihypertrophy and hemihypotrophy are defined as asymmetries between the right and left sides of the body to a greater degree than can be attributed to normal variation. This may involve the length and girth of the limbs as well as the head, trunk, and internal organs.

The difficulty for the surgeon is deciding what is normal and what is not, that is, to determine whether the larger limbs are hypertrophic or the smaller limbs hypotrophic (62). Differentiation of overgrowth from undergrowth is

based on comparison of the limb with its expected length, in proportion to the rest of the body. This may be visually obvious and straightforward for typical cases, or it may be difficult to discern in milder cases. The examiner may search for anomalies that herald the abnormal limb. Vascular malformations and associated digital malformations or macrodactyly usually signify overgrowth conditions; obvious muscle hypotrophy, focal neurologic abnormality, mental retardation, or joint abnormality may accompany undergrowth. If no such clues are found, a graph of normative sitting heights can be used to determine the patient's trunk height percentile, and a graph of normal lengths of the tibia and femur can be used to see which side falls on a percentile that most closely matches it (34).

To determine normal variation in limb size, Pappas and Nehme referred to an unpublished survey from the growth study at Children's Hospital, Boston (63). The maximum mean discrepancy seen at different ages for 95.5% of the population was approximately 1.4% (0.4 centimeter difference at 1 year, 0.8 centimeter at 10 years, and 1.1 centimeters at skeletal maturity) (63). Similar data have been reported in a group of young adult army recruits (64). Pappas and Nehme have defined abnormal asymmetry as a 5% or greater difference in length and/or circumference (63). MRI and other imaging techniques can assess the tissues in the extremities and aid in establishment of the diagnosis (37,62).

Hemihypertrophy and hypotrophy can be initially classi-

TABLE 10-2. DIFFERENTIAL DIAGNOSIS OF HEMIHYPERTROPHY AND HEMIHYPOTROPHY

Condition	Features	Growth Pattern	Treatment Implication
Hypertrophy of normal tissues			
Idiopathic hemihypertrophy	Increase in length and breadth of one extremity or one-half of body \pm renal malformation	Proportionate, linear	Monitor for increased risk of Wilms or other neoplasm
Beckwith-Weidemann Syndrome	Large body size, hemihypertrophy of whole body, macroglossia, omphalocele, pancreatic hyperplasia	Irregular	Risk of Wilms or embryonal tumors
Hamartomatous disorders			
Klippel-Trenaunay syndrome	Limb-length discrepancies; combined, complex vascular malformation (may be on long or short side); varicosities	Often irregular, does not affect all segments equally	Prediction for epiphysiodesis inaccurate; operate for function; amputation sometimes needed; compression therapy
Neurofibromatosis	Café-au-lait spots (>5) plus family history of subcutaneous neurofibroma, dystrophic bone changes	Irregular	
Proteus syndrome	Vascular anomalies, asymmetric hypertrophy, macrodactyly, exostoses, subcutaneous masses	Irregular	Valgus often coexists; skeletal age delayed or disassociated
Hemi-3 syndrome	Hemihypertrophy, hemihyperesthesia, hemiareflexia	Hypertrophy of girth, not length	
Undergrowth of limb			
Idiopathic hemihypotrophy	Greater dysmorphism than hemihypertrophy, congenital scoliosis, genitourinary malformation	Proportionate	Discrepancy rarely exceeds 2 cm by maturity; treatment rarely indicated
Turner/mosaic (XO/XX)	Short stature, low hairline, peripheral edema, valgus of knees or elbows	Discrepancy accelerated near puberty	Keloids common
Russell-Silver syndrome	Very short stature (<3%), small, triangular face, one limb or whole side short, developmental dysplasia of the hip, scoliosis, genitourinary anomalies common	Eventual limb length discrepancy of 1–6 cm	Skeletal age is delayed
Neurogenic (e.g., hemiplegic, polio)	Undergrowth if proportional to weakness	Proportionate, affects weakest limb segments	Lengthening rarely indicated in weak limb
Skeletal dysplasia or dyostoses	Polyostotic fibrous dysplasia, multiple exostoses, multiple enchondromas		

fied as congenital or acquired. Acquired asymmetry can result from injury, infection, radiation, or inflammation (65,66). Congenital forms may be classified as total or limited, total having involvement of all organ systems, including the ipsilateral paired organs. Limited forms have only muscular, vascular, skeletal, or neurologic involvement and are also subdivided by the area of involvement: classic (ipsilateral upper and lower limbs), segmental (a single limb), facial or crossed (65–67). These disorders can also be classified as nonsyndromic (isolated) or syndromic (part of a clinical syndrome). Table 10-2 outlines the differential diagnosis of hemihypertrophy and hemihypotrophy.

Overgrowth may be seen in idiopathic or nonsyndromic hypertrophy, associated with Beckwith-Wiedemann syndrome, neurofibromatosis, Bannayan-Zonana syndrome, or vascular malformations such as Klippel-Trenaunay and Proteus syndromes and lymphatic malformations (see Table 10-2). Undergrowth may be secondary nonsyndromic hypotrophy, mosaicism for Turner syndrome, Russell-Silver syndrome, neurologic asymmetry (cerebral palsy, polio), osteochondromatosis, enchondromatosis, or polyostotic fibrous dysplasia (68).

Idiopathic or nonsyndromic hemihypertrophy is a condition of unknown cause affecting approximately 1 per 50,000 people (63,65,67,69). There is no clear inheritance pattern.

The hemihypertrophy is rarely apparent at birth but becomes evident during the early years of growth. The unilateral enlargement may include the ear, one-half of the tongue, the pupil, the nipple, the thorax, the abdomen, the internal organs, and the arm and leg (66,70) (Fig. 10-6A and B). Mental capacities are usually normal, unlike those of patients with idiopathic hemihypotrophy, and contrary to earlier reports (48,69). Cutaneous vascular lesions are not associated with nonsyndromic hemihypertrophy. Compensatory scoliosis secondary to the leg-length discrepancy is common but the incidence of structural scoliosis is also increased, even after leg-length equalization and may be the result of vertebral body asymmetry. Uncommon skeletal anomalies are syndactyly, lobster-claw hand, developmental dysplasia of the hip, and clubfoot (68). Genitourinary abnormalities are a common association, and can include inguinal hernias, cryptorchidism, and medullary sponge kidney (65,69).

These children are at increased risk for malignant tumors, such as Wilms, adrenal carcinoma, hepatoblastoma, and leiomyosarcoma (65). A recent study suggested an incidence of 5.9% (71). It is possible that the same abnormal cellular growth control mechanism that results in overgrowth also predisposes these children to tumor formation (65,71). Abdominal sonographic screening has been recommended for

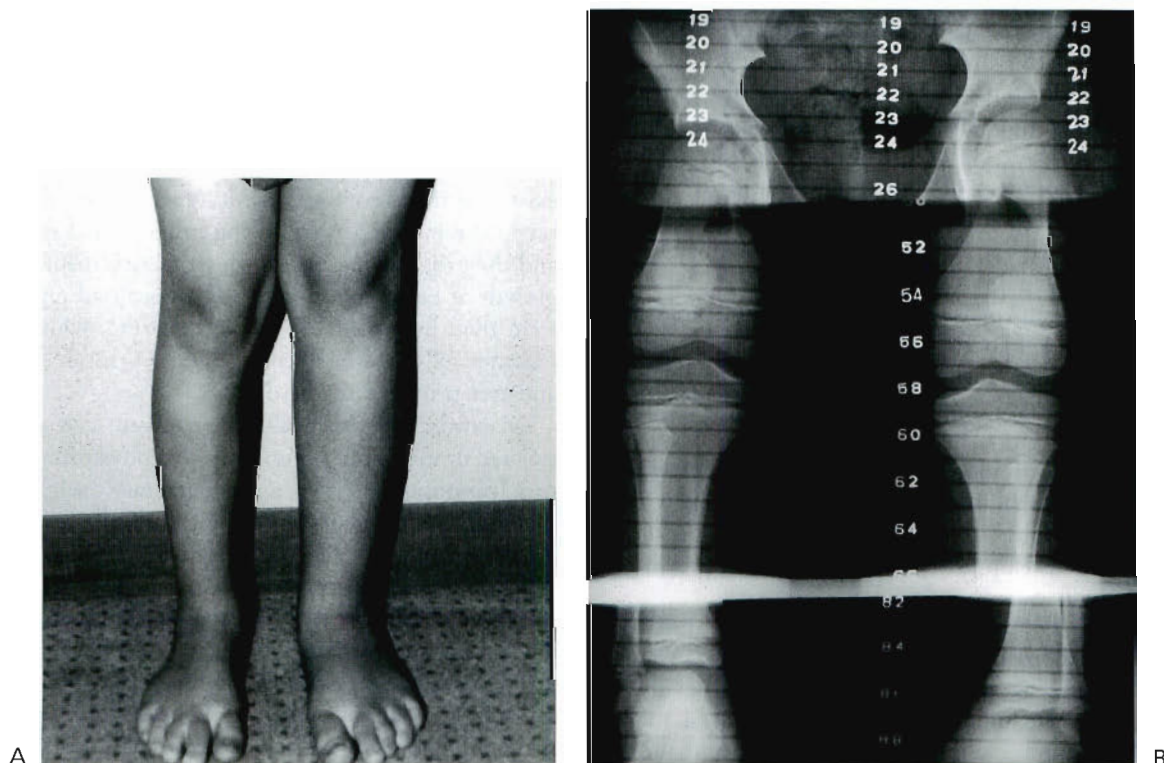


FIGURE 10-6. Eight-and-a-half-year-old boy with idiopathic hemihypertrophy. **A:** Note enlargement of the entire left lower extremity. The left upper extremity was enlarged as well. **B:** The lower extremity orthoentgenogram demonstrates the leg-length discrepancy.

children with hemihypertrophy, to detect these tumors as early as possible (65,72). This is controversial, because there is little evidence that this results in a better clinical outcome for children with Wilms or other tumors, it will not diagnose extraabdominal tumors, and the hemihypertrophy is only recognized in 30% of children prior to the tumor diagnosis (65,73,74). Nevertheless, current recommendations are for regular screening: abdominal ultrasound every 3 months until age 7, then physical exam every 6 months, until skeletal maturity (72).

The leg-length discrepancy in nonsyndromic hemihypertrophy rarely exceeds 5 cm by skeletal maturity (34,63,70,75). The discrepancy usually increases continually with time, at the same proportionate rate (75). There are cases of resolution of inequality in early childhood and those with reduction of the rate of increase in adolescence, which can make an accurate prediction of discrepancy difficult (34,67). The tibia is overgrown as much as, or slightly more than, the femur (63). Limb girth is increased by an average of 10%, primarily due to muscle hypertrophy (63). Epiphysiodesis [➔4.19, 4.20, 6.12, 6.13] has resulted in satisfactory limb equalization at skeletal maturity in most children (63,70).

Beckwith-Wiedemann syndrome is a congenital overgrowth syndrome usually diagnosed at birth, and characterized by neonatal hypoglycemia, macroglossia, visceromegaly, omphalocele, hemihypertrophy, and a predisposition for embryonal tumors, most frequently Wilms tumor (76). The risk of Wilms tumor, hepatoblastoma, and neuroblastoma is higher than in nonsyndromic hemihypertrophy, and in one study, 13 of 183 children developed a tumor by age 4 years (77). Hemihypertrophy only occurs in about 13% of these children but puts them at greater risk of developing a cancer (77,78). These children must be carefully monitored for the development of embryonal tumors.

Other disorders with limb-length inequality include neurofibromatosis, Proteus syndrome, Klippel-Trenaunay syndrome, and lymphangiomas (51).

A rare disorder, known as the hemi-3 syndrome, may be associated with hemihypertrophy, mostly of limb width (79). Its other features include hemihyperesthesia, hemi-areflexia, and scoliosis. It appears to be a neural crest disorder.

Hemihypotrophy is more likely to be associated with diffuse skeletal abnormalities than is hemihypertrophy (67). The term "hypotrophy" is preferred to atrophy, because there is decreased development, instead of a loss of previous normal tissue bulk.

Idiopathic hemihypotrophy appears to be about one-half as frequent as idiopathic hemihypertrophy (67). These patients, however, have a higher incidence of other dysmorphic features, including cleft palate and facial malformations, congenital scoliosis, and genitourinary malformations. Mental retardation is common, but Wilms tumor is not associated with the condition (80). Rarely does this syndrome require orthopaedic treatment, because, in most cases, the discrepancy is less than 2.5 cm.

Russell-Silver syndrome has some features in common with idiopathic hemihypotrophy, but it is characterized by overall short stature, with most patients never exceeding a height of 152 cm (5 feet). These patients have a characteristic small, triangular face, and renal and genital malformations (80). Scoliosis is common and may be congenital or idiopathic-like. The limb hypotrophy is usually minimal, but as much as 5 cm has been reported.

Patients who are mosaic for the Turner syndrome (XO/XX) may have hemihypotrophy, as may patients who have multiple enchondromas or osteochondromas, with mean discrepancies of 9 and 3.5 cm, respectively, for those patients with limb-length inequality. Neurogenic inequalities vary in proportion to the asymmetry of the neurologic involvement, rarely exceeding 2.5 cm in the lower extremities in cerebral palsy or 6 centimeters in polio patients (75). In assessing patients with localized overgrowth or undergrowth, it should not be assumed that the growth alteration is proportional. Shapiro described five patterns of limb-length discrepancy, and, even within a given diagnosis, multiple patterns may be seen (75). Periodic assessment should be done, if possible, during growth to determine the pattern being followed. Predictions are then more accurate. If significant joint contractures are present, plain radiographs or scans may not measure limb length accurately, and CT scans may be needed. For treatment of significant upper-extremity inequalities, normative growth data is also available (81).

Localized Gigantism and Macrodactyly

Macrodactyly is an uncommon anomaly characterized by an increase in the size of the constituent elements of a single or several adjacent digits of the hand or foot. Two types exist: the more common static type, which enlarges from birth; the increase in size being proportional with growth; and the progressive type, in which there is disproportionate growth of the involved digit (82). Localized gigantism is a term used inconsistently in the literature, which describes macrodactyly, as well as enlargement of tissues of the hands and feet proximal to the digits.

Macrodactyly, or localized gigantism, can occur as an isolated or idiopathic condition. Macrodystrophia-lipomatosa (fibrolipomatosis) is a nonhereditary overgrowth of all mesenchymal elements of the digit, particularly the fibroadipose tissue (37,83). Macrodactyly may also occur in association with neurofibromatosis and vascular malformations (capillary, venous, arterial, or lymphatic), such as Klippel-Trenaunay and Proteus syndrome (82–85). Children with multiple enchondromatosis, Maffucci syndrome, and tuberous sclerosis can have enlarged digits. It may be difficult to make a diagnosis in infancy because of the delayed manifestations in these syndromes such as the café-au-lait spots in neurofibromatosis. MRI evaluation of the tissues involved in the macrodactyly can be helpful in establishing a diagnosis in the absence of specific clinical features (37).

Clinical Features. Most cases of macrodactyly are evident soon after birth, although occasionally the dynamic type may not become apparent until later in infancy, when relentless enlargement occurs (Fig. 10-7A–D). The upper extremities are more commonly affected than lower extremities. Unilateral involvement occurs in 95% of cases,

although, in two-thirds of patients, more than one digit on the involved side, usually adjacent, is affected (82). The second ray is the most commonly enlarged, followed in descending frequency by the third, first, fourth, and very rarely fifth rays. Syndactyly may coexist. Usually, the palmar or plantar surface is more hypertrophied than the dorsal,

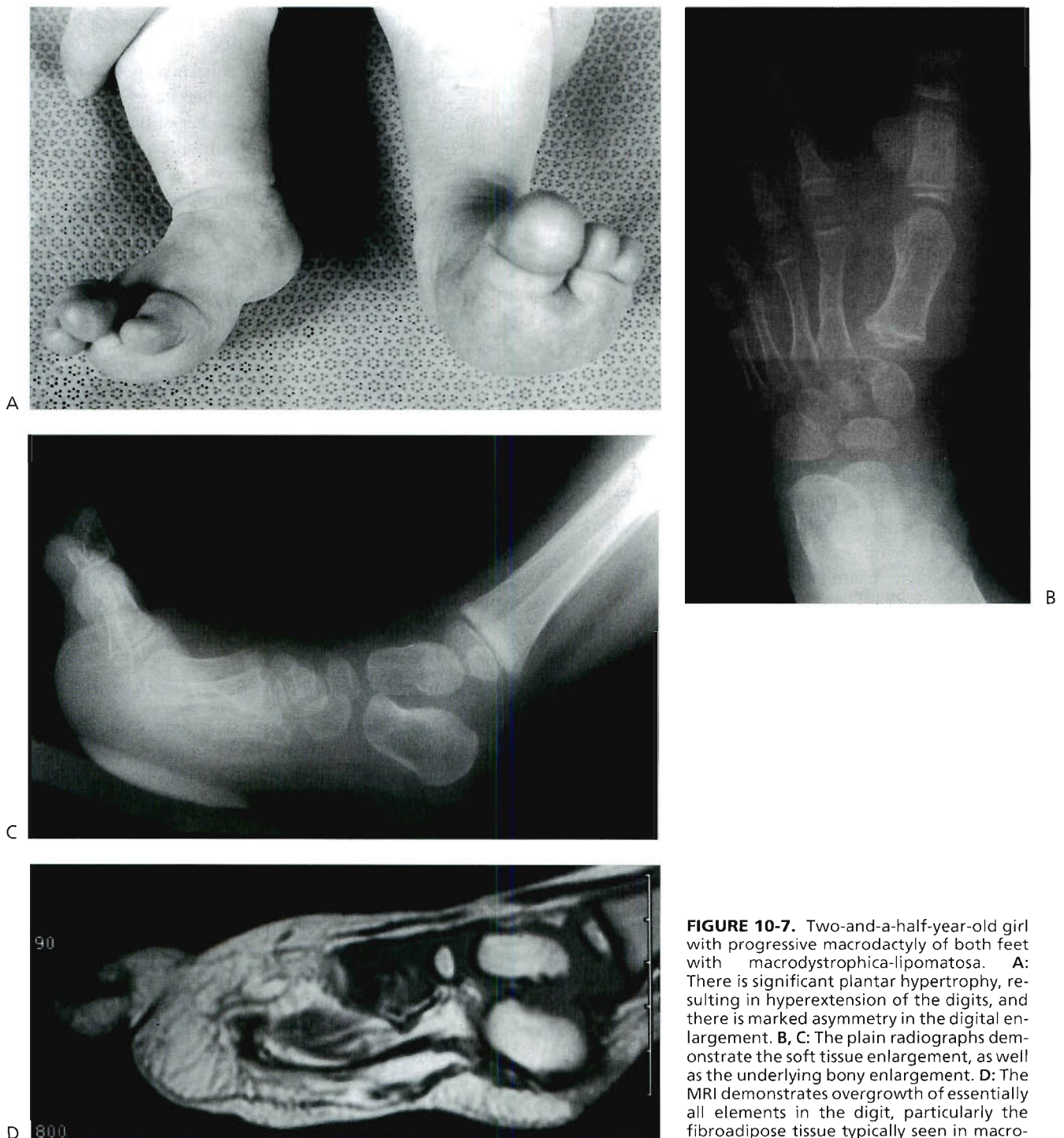


FIGURE 10-7. Two-and-a-half-year-old girl with progressive macrodactyly of both feet with macrodystrophia-lipomatosa. **A:** There is significant plantar hypertrophy, resulting in hyperextension of the digits, and there is marked asymmetry in the digital enlargement. **B, C:** The plain radiographs demonstrate the soft tissue enlargement, as well as the underlying bony enlargement. **D:** The MRI demonstrates overgrowth of essentially all elements in the digit, particularly the fibroadipose tissue typically seen in macrodystrophia-lipomatosa.

resulting in hyperextension of the metatarsal or metacarpophalangeal joints (86,87). If two adjacent digits are affected, they grow apart from each other. In static macrodactyly, the involved digits are about 1½ times the normal length and width. In the dynamic type, even more striking enlargement may occur. The bone age may be advanced in the involved phalanges (86,88). The metacarpals or metatarsals can be enlarged, widening the hand or foot (86). The width of the unilateral forearm, leg, thigh, or arm may also be subtly increased (88). Not long after skeletal maturity, interphalangeal joint stiffness and degenerative changes may supervene prematurely, even in untreated cases (82).

Pathology. The pathology varies, depending on the etiology of the macrodactyly. The most consistent feature is overgrowth of the fibro-fatty tissue but all tissues are enlarged in the involved digit (82,86,88). Fibrous bands and hypertrophied adipose tissue infiltrate muscle and nerve. A proliferation of fibroblastic tissue between the cortex and periosteum may account for the phalangeal overgrowth (86,88). The digital nerves are more prominent than usual, particularly in the hand, with proliferation of epineural and perineural tissue (82,83,86). Plexiform neurofibromas are typical in neurofibromatosis (83). Macrodactyly in children who have met strict criteria for the diagnosis of Proteus syndrome is not associated with enlarged digital nerves or fibroadipose tissue proliferation (85).

The pathogenesis of macrodactyly is unknown but neuroinduction is considered a possibility (83,86). Occult neurofibromatosis was once thought to be the cause, but long-term follow-up studies, including one of 26 years, have failed to reveal development of other features of neurofibromatosis besides the macrodactyly itself (89).

Treatment. The operative treatment varies, depending on the location, type, and severity of the macrodactyly. Management considerations are very different for the hand and foot. In the hand, function is paramount, and a significant increase in the width and length of a digit can be tolerated, whereas, in the foot, accommodating even a small excess of width in a shoe may be difficult. A good cosmetic result can be difficult to achieve. In the static type of macrodactyly, debulking and shortening procedures, such as phalangeal resection and epiphysiodesis, are successful. In contrast, the deformity seen in progressive forms will usually require ray resection. Extensive debulking can interfere with the blood supply to the skin and result in delayed wound healing.

Mild-to-moderate macrodactyly can be managed by a two stage (3 months apart) soft tissue debulking procedure, if length is not a problem (82). If length is a problem, then epiphysiodesis of the proximal phalanx, and the metacarpal or metatarsal, if involved, will be effective in the young child (less than 6–8 years) (82,86,90,91). In the older child, bone shortening by phalangeal resection can be combined with staged debulking (92,93). Ligament reconstruction or fu-

sion with Kirschner wire fixation will avoid the reported complications of floppy toes or secondary deformities (89). Isolated phalangeal amputation should be avoided because of subsequent angular deformities of the adjacent toes (84,89).

Digital shortening and debulking has not been effective, in the long term, for excessive forefoot widening. Ray resection is a more definitive solution to the multiple dimensions of enlargement often encountered (83,89,94,95). One or two rays may be taken, although the first ray of the foot should not be amputated in isolation because of its unique function in balance and weightbearing. To improve correction and avoid recurrence, it has been suggested to resect a wedge of adjacent tarsal bones, when doing a ray resection (83). Ray resection prevents crossover of the adjacent digits and eliminates “gap” formation and soft tissue enlargement. A three-ray foot is the minimum that is functionally serviceable. In the foot, more extensive involvement would necessitate midfoot or Syme disarticulation, depending on the extent of overgrowth.

As the patient matures, a subtle increase in width may be seen in all levels of the limb. Herring reported a case of macrodactyly with width increase, in the absence of any overall limb-length discrepancy (96). The family should be counseled from the first visit that this condition is complex and involves multiple tissues and levels. They need to know that multiple procedures may be necessary and that early, appropriate, aggressive resections, involving all affected dimensions, may decrease the total number of surgeries required. For example, as soon as it becomes apparent that length and width may be excessive, resection of one or several rays, with shortening or epiphysiodesis of an adjacent ray, may be appropriate. Often, several consultations with one or different surgeons may be necessary to help families achieve this realization.

Congenital Constriction Band Syndrome

Congenital constriction band syndrome, otherwise known as amniotic band syndrome, is a common cause of terminal congenital malformation of limbs, with a reported incidence of 1 in 5,000 to 10,000 children (97,98). The three main manifestations include acrosyndactyly, superficial or deep constriction bands involving a digit or extremity, and intrauterine amputation (97,99–101).

Clinical Features. The clinical presentation of congenital constriction band syndrome is quite variable. The bands may be superficial and incomplete or extend deeply to the underlying bone, and be circumferential. Two bands may be present in one extremity. Distal to the band, there may be significant neurovascular impairment (98–103). Impaired venous and lymphatic drainage causes swelling of the limb distal to the constriction. With growth, the constriction band occasionally gets more severe and becomes symptom-

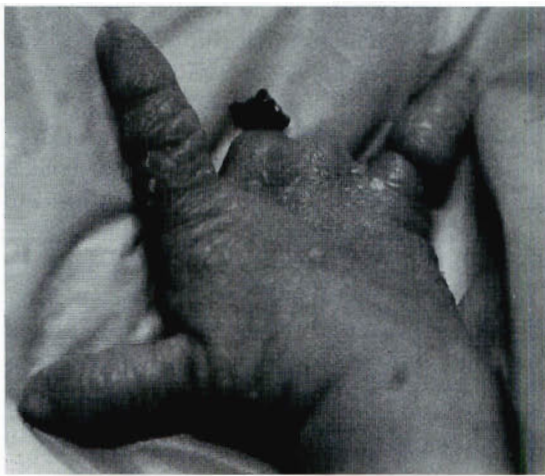atic (98). Upper-extremity involvement is more frequent than the lower extremity. Head, neck, or trunk constriction bands are very uncommon (104). The distal aspect of the limb, particularly the longest digits (index, long, and ring fingers, and great, second, and third toes) are most frequently affected (97–99,105).

Patterson developed a classification system based on the severity of the syndrome: simple constriction rings; constriction rings associated with deformity of the distal part, with or without lymphedema; and constriction rings associated with syndactyly and intrauterine amputation (106).

Amputations and syndactyly are seen in more than one-

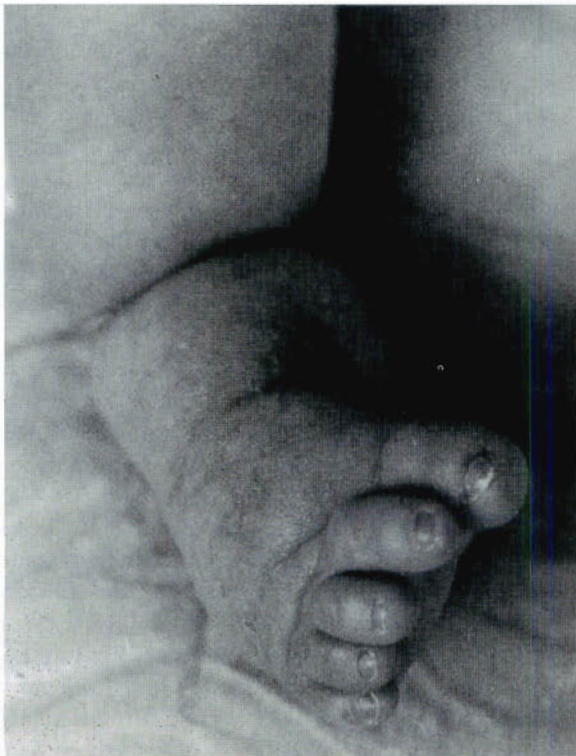half of affected children. Transverse, terminal, digital amputations, with normal proximal skeletal development, are typical (97–99,105) (Fig. 10-8A). Simple syndactyly is common, whereas complex syndactyly with bony fusions is rare (99). Acrosyndactyly or fenestrated syndactyly, in which there is an open cleft between digits joined distally, can be seen. Hypoplastic or absent nails are consistently present.

The incidence of clubfoot in constriction band syndrome ranges from 12 to 56% (97–99,101,102,106) (Fig. 10-8B). These feet are often rigid and more difficult to treat than the idiopathic clubfoot. Approximately 30 to 50% of the clubfeet are classified as paralytic (100,101,103,107). These

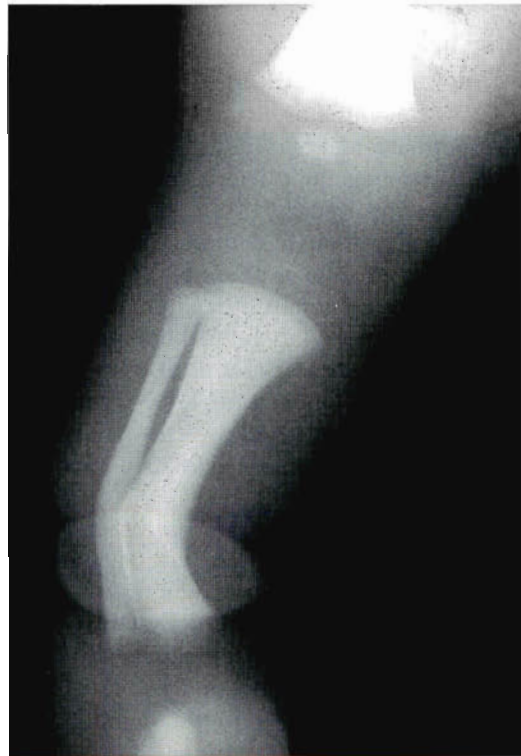

A

FIGURE 10-8. Child with congenital constriction band syndrome. **A:** Clinical photo demonstrating autoamputation of the long and ring digits through the proximal phalanges, and a circumferential constriction band in the proximal segment of the small finger. **B:** Clinical photograph demonstrating circumferential constriction band involving the distal lower leg, and an associated talipes equinovarus deformity. **C:** The radiograph of the same patient demonstrates an uncommon finding of angulation of the bone underlying the circumferential band.



B



C

feet have weakness of the peroneal muscles and are always associated with ipsilateral constriction bands. The deep constriction bands are thought to cause a compression neuropathy, direct muscle injury or perhaps a compartment syndrome. The nonparalytic clubfeet may or may not have ipsilateral constriction bands and are considered to be idiopathic clubfeet or resulting from oligohydramnios (99).

Angular deformity, bone dysplasia, and pseudarthrosis can occur deep to constriction bands in the upper and lower extremities (106,108,109). The anterolateral tibial bowing appears similar to that seen in congenital pseudarthrosis of the tibia associated with neurofibromatosis but in contrast remodeling can occur and realignment osteotomies, if required, will heal (108) (Fig. 10-8C). Rapid, spontaneous healing of osseous defects in the forearm and tibia of infants have been described (108,109). Zions et al. prefer the term "discontinuity," rather than "pseudarthroses," in describing these defects, because of the spontaneous healing (109).

Leg-length discrepancy exceeding 2.5 cm, in 25% of children with constriction bands, has been reported (99). Surgical management will be required in some of these children, depending on the predicted discrepancy at skeletal maturity. Craniofacial abnormalities, including cleft lip and palate, are seen in 7% of children with constriction band syndrome (98,101).

Etiology. Despite many theories, the etiology and pathogenesis of constriction band syndrome remains unclear. Although the two main conflicting theories focus on whether the band formation is the result of factors intrinsic or extrinsic to the embryo or fetus, the disorder may be more heterogeneous than considered in the past.

The extrinsic theories have the widest acceptance. Torpin has proposed that entanglement of the limbs in defects or free strands of amnion result in constriction band syndrome (110,111). Supportive evidence includes the lack of hereditary factors, the ultrasonographic demonstration of prenatal amniotic bands, the involvement of the longer digits and the histologic demonstration of amnion in constriction bands. Amniocentesis in animals produces fetal malformations that resemble constriction band syndrome in humans. Kino demonstrated in rats that the malformations result from subcutaneous hemorrhages that are caused by excessive uterine contractions after amniocentesis (97). In a study reviewing children with clubfeet and constriction band syndrome, there was a history of attempted first-trimester abortion in 60% of the children (103).

The intrinsic theory by Streeter proposed that a defect of the subcutaneous germ plasma caused soft tissue necrosis and subsequent healing, with the formation of constriction bands (112). There is evidence that *in utero* vascular disruption from the death of a co-twin, or from placentally derived embolic infarcts, can cause constriction band syndrome (113). In these children, there was no ultrasound evidence of amniotic bands. It appears this syndrome may result from factors other than amniotic entanglement.

The differential diagnosis is limited, but there are some interesting conditions to consider. The "Michelin tire baby syndrome" consists of multiple benign circumferential skin creases. This is an autosomal dominant condition that has been traced through as many as four generations in one family. These creases are present from birth, disappear by 5 years of age, and predominantly involve the extremities (114). Hair-thread constriction may occur in infants, usually younger than 2 years of age, and cause circulatory compromise (115). Strands of hair or fabric strands may become wrapped around fingers and toes tightly enough to cause distal swelling and circumferential laceration of the skin. At that time, it may be difficult to visualize the hair causing the problem to differentiate it from congenital constriction bands. Ainhum is a disorder characterized by ulceration at the base of the fifth toe on the plantar surface, which progresses to a circumferential constriction ring with autoamputation. It is mainly seen in Africa (116).

Treatment. Superficial, asymptomatic constriction bands do not require treatment. Excision of the band, and closure with multiple Z-plasties, is indicated in bands that extend to the deep subcutaneous tissue or fascia, if there is edema distal to the band, in the presence of vascular insufficiency or neurologic deficit, and if the band is increasing in severity [►1.3]. The surgical release has been traditionally staged, releasing one-half of the band at a time with a 6- to 12-week interval (99,106,117). There was concern that impaired venous or lymphatic flow and skin-flap necrosis would result, if the band was released in one stage, but single-stage release of constriction bands can be done safely (117) (Fig. 10-9A and B).

The constriction band and underlying fibrous tissue in the subcutaneous tissue, fascia, and muscle should be completely excised with an adjacent 1- to 2-mm cuff of normal tissue. The compressed neurovascular structures can be difficult to distinguish, and may be inadvertently damaged. To avoid injury, the nerves and vessels should be exposed proximally or distally and followed under the band. The wound should be closed with Z-plasties fashioned with large flaps at a 60-degree angle. In children with ischemia of the distal limb, a fasciotomy may be required.

Clubfeet in neonates with an ipsilateral constriction band can be treated by serial manipulation and casting, if there is no significant foot edema or evidence of neurovascular compromise. Resection of the constriction band should be done prior to surgical release of the clubfoot. Nonoperative management is rarely successful in these children (102,103,107). The severity of the clubfoot is more important than the presence or severity of the constriction band in predicting the outcome of surgical treatment (102,107). Rigid clubfoot with deep bands usually has a poor outcome. Muscle imbalance of the foot, resulting from peroneal weakness, should be managed by a split transfer of the tibialis anterior tendon (101,107).

Surgical intervention in children with acrosyndactyly is

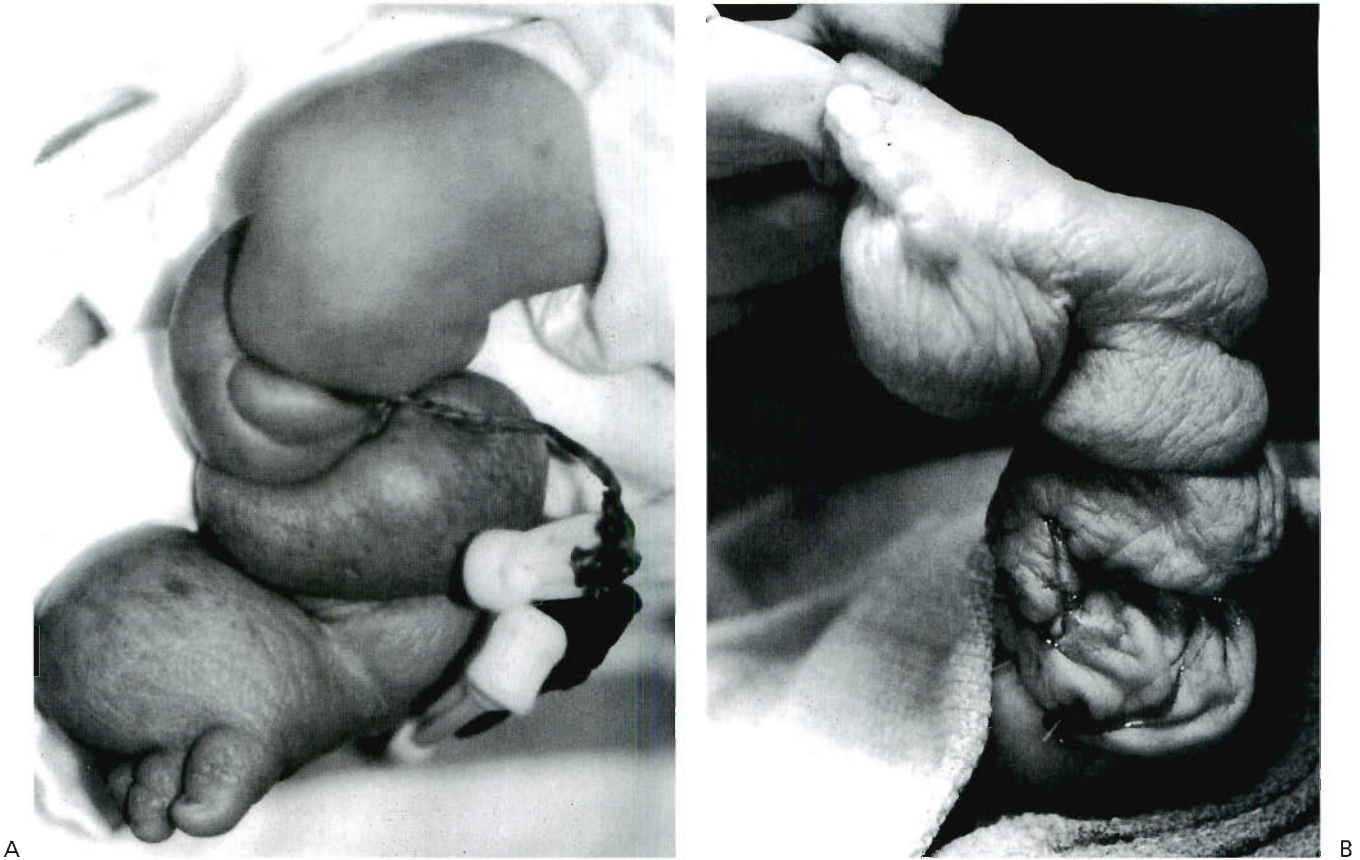


FIGURE 10-9. One-day-old female born at 28 weeks' gestation. An amniotic band around the umbilical cord led to fetal distress and precipitous delivery. **A:** Clinical photograph of the right lower extremity, with multiple deep circumferential bands. Marked distal swelling and vascular compromise with petechial formation is present. **B:** Clinical photograph immediately following emergent single-stage circumferential release of amniotic bands, with Z-plasty of the skin. Note decompression and reperfusion of all segments distal to the resected bands.

generally done between the ages of 6 months and 1 year because of the severity of the deformity and to allow for longitudinal growth and function (105).

Disorders Involving Joint and Bone

Progressive Diaphyseal Dysplasia

Progressive diaphyseal dysplasia, or Camurati-Engelmann syndrome, is a sclerosing bone dysplasia characterized by progressive diaphyseal thickening and sclerosis, bone pain and weakness (118,119).

Clinical Features. This autosomal dominant disorder is very rare (1 per 1 million) with boys being affected more often than girls (3:2 ratio) (120). The age at the onset of symptoms is highly variable, with the majority presenting in the first decade. In one study, the mean age of onset was 15 years and 4 months, with the age range from 1 to 70 years (120). The clinical and radiological manifestations are also variable. The most common symptoms are limb pain,

easy fatigability, headache, poor appetite, and difficulty running. Clinical signs include muscle weakness and atrophy, thickening of the long bones, genu valgum, waddling gait, and exophthalmus (120). These children can have mistaken diagnoses of neuromuscular disorders when radiographs are not done (121). Basilar skull sclerosis can lead to narrowing of cranial foramina with symptomatic auditory and optic nerve compression (122). Progression usually occurs in a slow, unpredictable fashion but occasionally will spontaneously stop. There is a normal life span.

Laboratory studies are not helpful for diagnosis. The alkaline phosphatase is elevated in 40% of patients (123). Biochemical markers of bone turnover may be useful for assessment of disease activity.

Radiographic Features. The plain radiographs demonstrate symmetric, periosteal and endosteal diaphyseal sclerosis and diaphyseal widening. The tibia is most frequently involved, but all the long bones in the upper and lower extremities, and the clavicle, can be affected early in the course of the disease. The cortex becomes wide and irregular

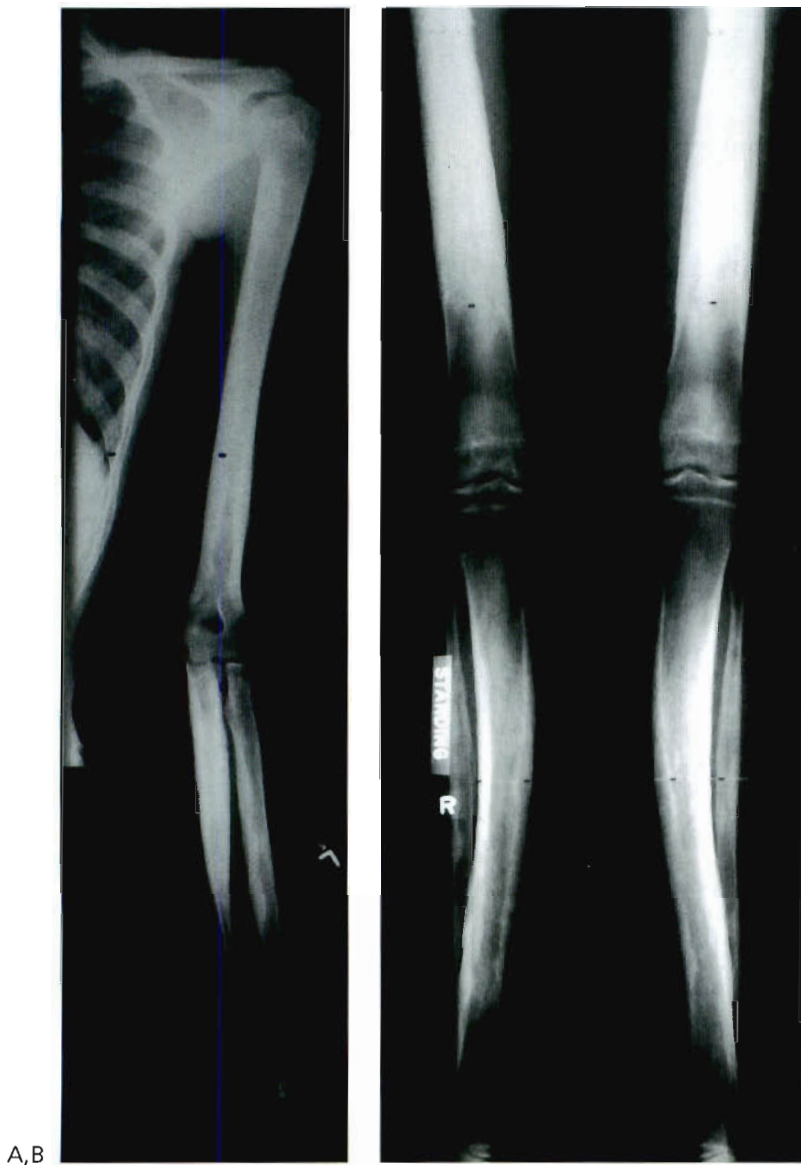

FIGURE 10-10. A, B: Seventeen-year-old female with diaphyseal dysplasia. Radiographs demonstrate wide and irregular cortices and marked narrowing of the medullary cavity of the long bones in the upper and lower extremities; typical finding of genu valgum is demonstrated.

with narrowing of the medullary cavity (Fig. 10-10A and B). Computerized tomography has shown that the thickening and sclerosis are not uniformly distributed in the long bones (124). Sclerosis at the base of the skull is common but is not an early finding. The radiological evolution is usually progressive, increasing sclerosis of the bone, with extension to the metaphysis and epiphysis and eventual involvement of the metacarpals and metatarsals, pelvis, and spine (120,123,125,126). In the spine, only the posterior elements and the posterior aspect of the vertebral body are affected with no stenosis (124,126). Technetium-99m bone scans demonstrate uptake in the middiaphysis of the involved long bones early in the disease, often before changes on the plain radiographs. MRI shows cortical involvement with sparing of the medullary cavities but is not helpful for diagnosis or management (126).

Pathology. Other than the thickened cortex, there is no histologic abnormality unique to progressive diaphyseal dysplasia. Early changes are typical of recent bone formation, with woven bone and lack of haversian system development, but later modeling occurs (122). Marrow fibrosis and narrowing of the medullary canal can occur, which may explain the occasional patient with anemia (125).

Etiology. The cause of this autosomal dominant disorder and the variability of its expression has not yet been explained. The more severe involvement in males who inherited the disease from the father has suggested the presence of a dynamic mutation with triplet repeat expansion (122). The candidate gene should have a function in endochondral and intramembranous bone formation.

Differential Diagnosis. Other sclerosing bone dysplasias with normal stature should be considered. Considerable overlap exists in the classification of sclerosing bone dysplasias (127). The diagnosis can be made by determining the inheritance pattern, clinical and radiological characteristics, and laboratory findings or lack thereof. Ribbing disease has a similar radiological appearance but affects only the lower extremities and is not always symmetrical. Extensive early cranial and facial involvement, an autosomal recessive inheritance pattern, and mental retardation differentiates craniodiaphysal dysplasia from progressive diaphyseal dysplasia. Osteopetrosis is differentiated by sclerosis throughout the skeleton. Hyperphosphatasia can have similar radiological findings but the alkaline phosphatase level is markedly increased. Hardcastle syndrome is an autosomal dominant disorder with diaphyseal medullary stenosis and sclerosis with pathologic fractures and malignant transformation (128). Juvenile Paget disease, infantile cortical hyperostosis, hypervitaminosis A, and fluorosis should also be considered in the differential diagnosis.

Treatment. There is no cure for this disorder but treatment can improve pain and function. Nonsteroidal antiinflammatories will alleviate limb pain and physical therapy may maximize function.

Corticosteroid administration results in reduced pain and fatigue and better function, such as the ability to run (129). It does not alter the natural history of the osseous changes.

Successful surgical realignment of the lower extremities has been described by Clawson and Loop (125). Knee flexion deformities, genu valgum, and external tibial torsion were corrected by distal femoral and proximal tibial and fibular osteotomies. The bone was described as being soft and vascular but healed uneventfully.

Melorheostosis

Melorheostosis, first described by Leri and Joanny in 1922, is a rare sclerosing skeletal dysplasia characterized by soft tissue contractures in childhood overlying slowly evolving linear hyperostosis (130). The name is derived from the Greek words *melos* meaning "limb" and *rhein* meaning "to flow," as in wax.

Clinical Features. This nonhereditary disorder affects both sexes equally. The typical presentation is with painless, asymmetric joint contractures prior to 6 years of age (131,132). The lower extremities are much more frequently involved than the upper extremities. The underlying hyperostosis develops slowly and progresses with age, usually more rapidly in childhood. The overlying soft tissues may be thickened with lymphedema, or have sclerodermatous skin changes or vascular malformations (133–136). There is also associated muscle atrophy and periarticular fibrosis

with contractures. Flexion contractures at the knee, hip, finger, ankle equinus and patellar dislocation are the most common joint deformities (132). Paraarticular ossification and synovitis can further impair joint motion (137,138). Limb-length discrepancy, and varus and valgus deformity about the knee and ankle, are caused by fibrosis and physal abnormalities. A mean of 4 centimeters of shortening was noted in one study of 11 children but one patient had overgrowth of the affected limb (132). Melorheostosis does not shorten life span but the morbidity may be considerable.

Etiology. The etiology of this disorder is not known. It has been observed that distribution of the lesions correspond to sclerotomes (138). A hypothesis is that an infection, analogous to herpes zoster, occurs and lesions spread along the distribution of affected nerve roots with resultant scarring and osseous changes.

Radiographic Features. The classic radiographic appearance of melorheostosis is asymmetrical bands of sclerosis in an irregular, linear pattern often described as molten wax flowing down the side of a candle (Fig. 10-11A–C). In children the hyperostosis is endosteal, unlike adults, in whom it is in an extracortical, subperiosteal location (136,137). The hyperostosis can be located throughout the skeleton, typically on one side of the diaphysis of long bones, the pelvis and in the hands and feet. The ribs, skull, and spine are affected least often. Patches of hyperostosis, rather than a linear pattern, are present in the carpal and tarsal bones and the epiphyses. This is similar to that seen in osteopoikilosis. Increased uptake is noted in involved areas on bone scan.

The hyperostosis consists of woven or nonlamellar dense bone with thickened, sclerotic and irregular laminae (137).

Differential Diagnosis. The differential diagnosis includes osteomyelitis, osteopetrosis, osteopoikilosis, and osteopathia striata, all of which can have similar radiographic findings. Mixed sclerosing bone dysplasia is comprised of melorheostosis, osteopoikilosis and/or osteopathia striata in the same individual (127). These three rare bone dysplasias are postulated to have a close association. The transient periosteal reaction in infantile cortical hyperostosis is less dense and is found in different locations. Focal scleroderma may cause soft tissue fibrosis and contractures but the bones are radiologically normal (139).

Treatment. The soft tissue contractures are resistant to manipulation, bracing and serial casting (140). Nonsteroidal antiinflammatory medications can improve the discomfort. Surgical treatment including soft tissue releases, capsulotomies, and osteotomies are difficult and incomplete correction or rapid recurrence of the deformity is common, sometimes necessitating an amputation (132,137). Distal limb ischemia can occur when the chronically contracted and

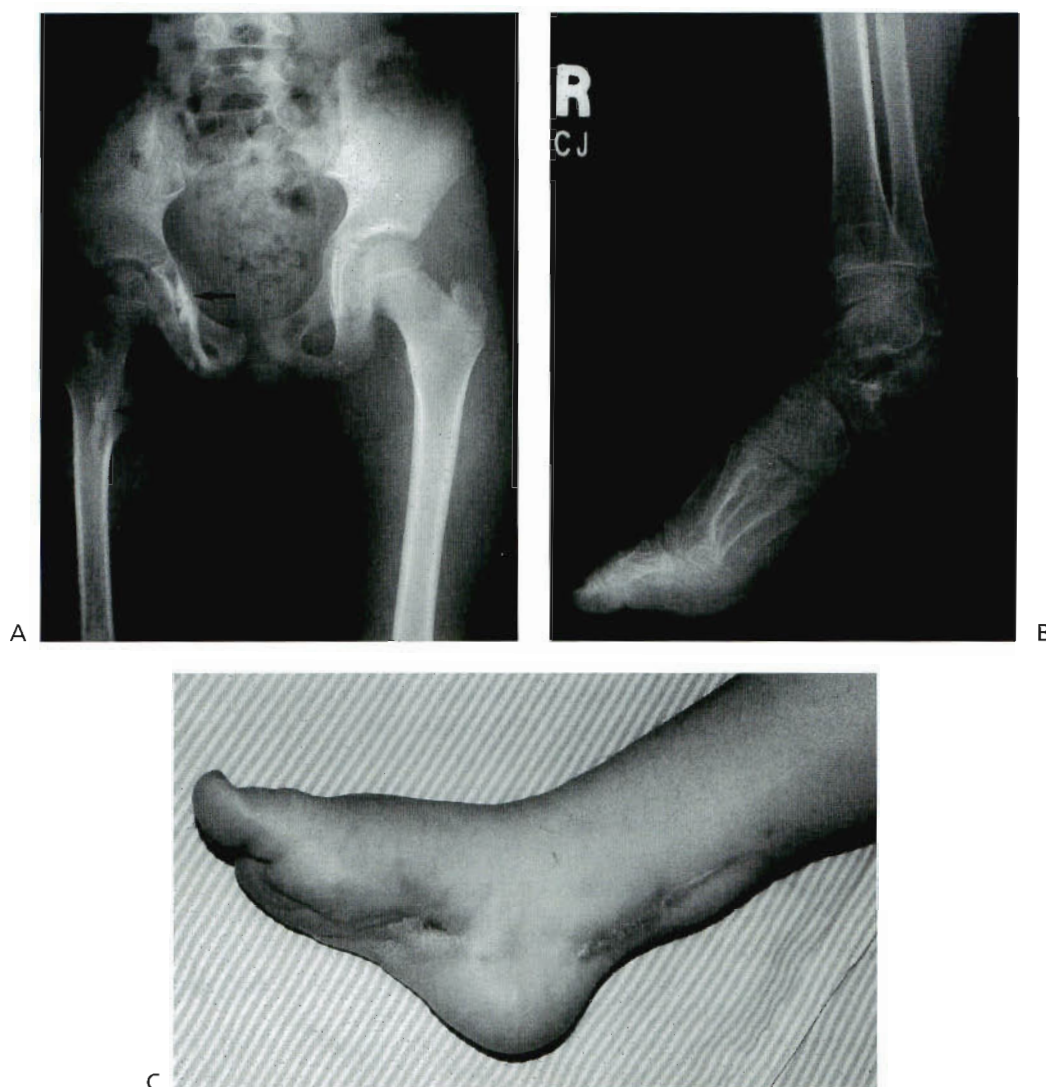


FIGURE 10-11. Eight-year-old girl with melorheostosis who presented with an equinovarus foot deformity. **A:** The classical findings of irregular linear hyperostosis are seen at the arrows. **B:** Patches of hyperostosis are seen in the talus and calcaneus and this is typical of melorheostotic involvement of the tarsals. **C:** There was pain and swelling about the equinovarus foot. Previous surgical releases resulted in rapid recurrence of the deformity.

flexed joint is extended. Osteotomies that permit shortening may avoid this complication.

The Ilizarov technique has been used in a small number of children for lengthening [4,16,6,9], realignment of angular deformities and correction of joint contractures (140–143). Realignment and lengthening have been done successfully but complications include pseudarthrosis, and, in one child, ischemia with pain and loss of function and eventual amputation (141,143).

Osteopoikilosis

Osteopoikilosis, or osteopathia condensans disseminata, is an uncommon, autosomal dominant, sclerosing bone dys-

plasia characterized by numerous small foci of increased radiodensity in the periarticular regions.

Clinical Features. This disorder develops during childhood and persists through life. The children have normal stature and most are asymptomatic, but up to 20% will have mild articular discomfort with a joint effusion (144). The diagnosis is often made as an incidental radiological finding. Fractures heal uneventfully and pathological fractures have not been reported. The risk of malignancy is probably not higher than the normal population. Osteopoikilosis is frequently seen in association with a hereditary dermatologic condition, dermatofibrosis lenticularis disseminata, or Buschke-Ollendorf syndrome, which is marked

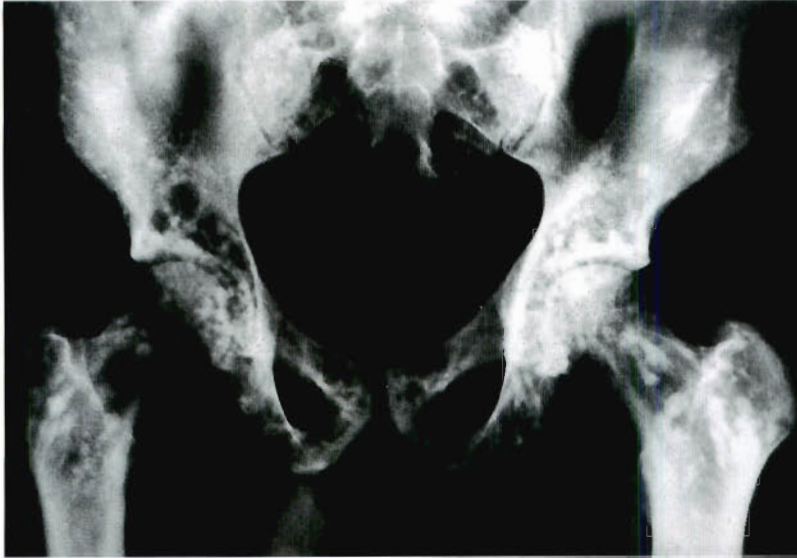

FIGURE 10-12. Osteopoikilosis. Extensive involvement of the pelvis in this asymptomatic patient.

by the presence of papular fibromas (145,146). This syndrome is usually asymptomatic but soft tissue fibrosis and joint contractures can occur in these children that appear clinically similar to that seen in melorheostosis.

Radiographic Features. The osteosclerotic nodules are well-defined, homogeneous, bilateral, circular- to ovoid-shaped from 1 to 15 mm, and are located in the metaphyses and epiphyses of long bones, the carpus, the tarsus, the pelvis, and the scapulae (Fig. 10-12). The ribs, clavicle, and skull are not involved (144,147). The lesions may increase or decrease in size or number (147).

The bone scan usually does not demonstrate increased uptake in the lesions (148). This is useful, to differentiate this condition from metastatic breast or prostate carcinoma. Mastocytosis should also be considered in the differential diagnosis.

The etiology and pathogenesis of osteopoikilosis is not clear. The sclerotomal distribution and association with abnormalities of mesodermal tissues suggests a relationship between this condition and other osteosclerotic disorders (145,147,149).

Pathologic Features. The sclerotic areas consist of focal condensations of compact lamellar bone within the spongiosa (144,149).

Treatment. There is no treatment for this benign disorder. In the rare cases of associated fibrosis and joint contracture, the management is the same as for melorheostosis.

Osteopathia Striata

Osteopathia striata, or Voorhoeve disease, is another of the sclerosing bone dysplasias and is characterized by dense linear striations in bone (150,151).

Clinical Features. This is a rare, autosomal dominant disorder that exhibits no physical or laboratory abnormalities. The diagnosis is usually made on an incidental radiograph.

Radiographic Features. The radiographic hallmark is dense linear striations in the tubular and flat bones with the exception of the skull and clavicles. These lesions do not change with time. In the long bones, the striations are parallel to the long axis and affect principally the metaphyses but may extend into the epiphyses (Fig. 10-13A and B). A fan-shaped pattern of linear striations can be seen in the iliac wings, likely reflecting the growth pattern of the pelvis (151). There is no increased uptake on the bone scan.

Osteopathia striata occasionally is an osseous constituent in more complex sclerosing bone dysplasias, such as osteopathia striata with cranial sclerosis and mixed sclerosing bone dysplasia; nonsclerosing bone dysplasias, such as spondylometaphyseal dysplasia; and congenital malformation syndromes, such as focal dermal hypoplasia (149,151,152).

Treatment. Treatment is not required for asymptomatic isolated osteopathia striata.

Congenital Pseudarthrosis of the Clavicle

Congenital pseudarthrosis of the clavicle is a rare disorder of formation of the clavicle that is recognizable at birth. The right clavicle is most commonly affected, although bilateral involvement has been reported in approximately 10% of cases, and rare examples of isolated left-sided involvement have been documented. The absence of birth trauma and subsequent lack of exuberant early callus formation distinguish it from acute neonatal fracture. The roentgenographic appearance of the clavicular defect and lack of other charac-

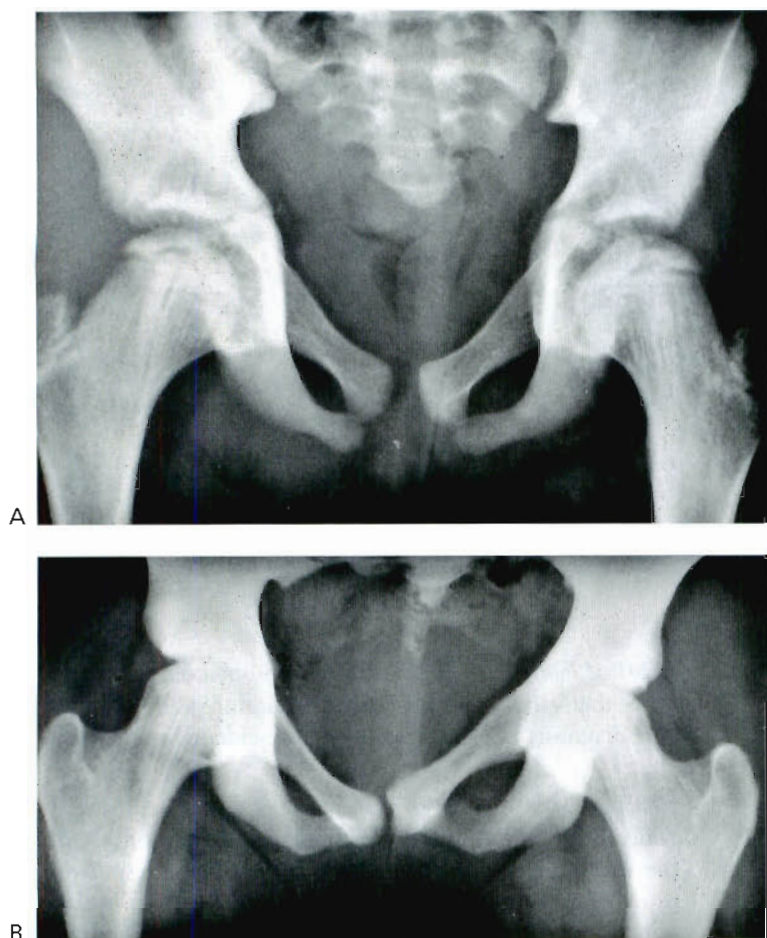


FIGURE 10-13. Osteopathia striata. The streaking of the proximal femurs did not change much in this patient between the ages of 12 years (A) and 25 years (B). Note the flattened femoral epiphysis.

teristic bony malformations of the skull and pelvis distinguish it from cleidocranial dysplasia.

Etiology. A genetic basis for congenital pseudarthrosis of the clavicle is unclear. Most cases are felt to arise sporadically, although familial cases demonstrating autosomal dominant inheritance have been reported (153,154). Congenital pseudarthrosis of the clavicle is thought to occur either by a primary intrinsic failure of clavicular development or as a result of external compressive forces. The development of the clavicle from two separate centers of intramembranous ossification was first recognized by Mall (154), and has been confirmed by others (155,156). It has been postulated that an intrinsic failure of coalescence of these two centers is responsible for the development of the pseudarthrosis (157). Lloyd-Roberts and colleagues postulated that extrinsic compression by the subclavian artery, alone or in combination with a cervical rib, was responsible for the defect. This interesting concept is supported by the overwhelming frequency of right-sided involvement, and the normally higher location of the right subclavian artery compared to the left, and the location of the artery directly

below the area of the defect. Rare cases of left-sided involvement have been associated with dextrocardia, and bilateral cases have been associated with cervical ribs (158).

Clinical Features. Congenital pseudarthrosis of the clavicle typically presents in infancy or in early childhood, with a painless prominence and hypermobile segment over the middle-third of the clavicle. Radiographs may be necessary to distinguish the lesion from birth fracture or cleidocranial dysplasia. The majority of lesions involve only the right clavicle, although bilateral cases and rarer left-sided cases have been described. The cosmetic deformity tends to be slowly progressive, with an increase in noticeable prominence over the pseudarthrosis and foreshortening and dropping of the shoulder girdle over time. The pseudarthrosis can become painful with certain overhead activities, or with direct compression or palpation. Shoulder motion is typically regarded as normal, and significant functional disability is unusual. Several cases of later development of thoracic outlet compression syndrome have been reported in association with congenital pseudarthrosis of the clavicle (153,159–164).

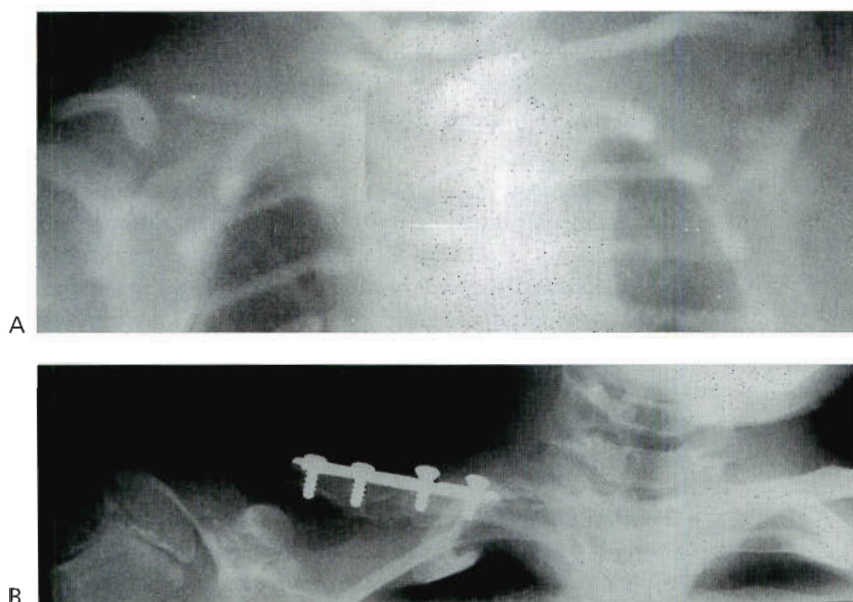


FIGURE 10-14. Pseudarthrosis of the right clavicle. **A:** Congenital pseudarthrosis of the right clavicle. There are no signs of healing. **B:** Radiographic appearance after solid union achieved by open reduction, internal fixation, and autogenous bone grafting in a different 8-year-old boy.

Radiographic Features. The radiographic findings in congenital pseudarthrosis are characteristic. The clavicle typically displays a definite separation in its midportion, with the medial aspect lying superior to the lateral aspect, owing to muscle forces and the weight of the upper extremity. The bone ends appear bulbous, with sclerotic closure of the marrow cavity and no evidence of callus formation or reactive bones (Fig. 10-14A). The disorder is easily distinguishable from cleidocranial dysplasia, due to the lack of other characteristic radiographic abnormalities of the skull and pelvis, including wide cranial sutures, coxa vara, failure of pubic ossification, and hypoplastic ilia. If necessary, subsequent radiographs of the clavicle will fail to demonstrate callus formation, thereby distinguishing early cases from acute neonatal fracture.

Histopathology. Histopathologic specimens from resected lesions have demonstrated hyaline cartilaginous caps at both ends of the pseudarthrosis, often joined by dense fibrous and fibrocartilaginous tissue (165). Hirata and colleagues demonstrated columnar distribution of chondrocytes in different stages of maturation at the ends of the pseudarthrosis, similar to that seen in a developing cartilaginous physis. Endochondral ossification at these terminal ends was confirmed by tetracycline labeling (166).

Treatment. Most cases of congenital pseudarthrosis of the clavicle that are described in the literature have undergone some form of operative treatment [►1.2], and therefore the true natural history of untreated cases is unknown. Indications for operative management have included progressive pain and unacceptable cosmetic deformity at the site of the pseudarthrosis, functional limitations and later onset

of thoracic outlet compression syndrome (153,157, 159–168). Most authors advocate delaying surgery until the patient is approximately 3 to 6 years of age, using a technique of resection of the pseudarthrosis, bone grafting, and internal fixation, most commonly with use of a plate and screws (153,156,162,168) (Fig. 10-14B). Solid union of the pseudarthrosis and acceptable cosmesis using these methods has been uniformly achieved. However, the patient should be counseled preoperatively that they would effectively be trading a “bump” for a “scar.” Grogan and colleagues reported on early operative treatment of this condition, with 6 of 8 patients below the age of 30 months (167). They demonstrated union in all 8 patients using a technique of careful preservation of the periosteal sleeve, resection of the pseudarthrosis, and approximation of the bone ends without bone grafting or internal fixation. Toledo and MacEwen pointed out the hazards of using an intramedullary pin for fixation after operative treatment of this condition (169).

Dysplasia Epiphysealis Hemimelica

Dysplasia epiphysealis hemimelica is a rare disorder of localized osteochondral overgrowth, involving single or multiple epiphyses or ossification centers. First reported by Mouchet and Belot as “tarsomegalie,” the disorder was later clarified by Trevor, who termed the disorder “tarso-epiphysal aclasis” (170,171). Fairbank later suggested the term “dysplasia epiphysialis hemimelica,” to deemphasize tarsal involvement, and to describe the predilection for unilateral involvement of the medial or lateral aspect of one or more epiphyses (172). Although the lesion most commonly affects the medial aspect of the epiphysis, lateral involvement,

as well as involvement of entire epiphyses, has been reported. Unilateral distribution when multiple sites are involved is common, and the lesion can present on both sides of an affected joint.

Etiology. The etiology of dysplasia epiphysealis hemimelica is unknown. Trevor considered dysplasia epiphysealis hemimelica to be a congenital error of skeletal development, in which an altered process of cell division at the superficial zone of articular cartilage allows for persistent proliferation and production of a large cartilaginous mass (171). Fairbank hypothesized that the disorder was due to a localized disturbance of the pre- or postaxial part of the apical cap of the limb bud in early fetal development (172). To date, no clear genetic transmission of the disorder has been described.

Clinical Features. The incidence of the disorder has been estimated at 1 per 1 million, with the majority of cases affecting males. Presentation is usually in childhood or early adolescence, although presentations in older adulthood have been described (173). In cases of multiple sites of involvement, the lesions are characteristically unilateral, although bilateral cases are reported. Azouz et al. classified dysplasia epiphysealis hemimelica into three types: localized (involving only one epiphysis), classic (involving more than one bone in a single limb), and generalized (involving an entire lower extremity from the pelvis to foot), with the classic form being most common (174). Clinical features vary, depending on the location of the lesion, but patients typically complain of painless swelling or a mass on one side of a joint, limitation of motion, and occasionally locking, angular deformity, limp, regional muscle wasting, or limb-length discrepancy. The lower extremities are affected most commonly, predominantly at the knee and ankle (171,172,175,176). Other reported sites have included the capital femoral epiphysis and acetabulum, sacroiliac joint, metacarpophalangeal joint, wrist, shoulder, and subtalar joint (177–183).

Radiographic Features. The radiographic features of dysplasia epiphysealis hemimelica can vary depending on the age of the patient and maturation of the lesion. The radiologic diagnosis is fairly straightforward when the lesion is fully calcified or ossified, appearing as an irregular, often multicentric, lobulated mass protruding directly from one side of the affected epiphysis or tarsal bone (Fig. 10-15A–C). The affected ossification center will often appear prematurely, and may be larger than the contralateral side. Modeling abnormalities of the adjacent metaphysis have also been reported. However, early lesions may present only with joint space enlargement or small foci of irregular calcification, and may resemble paraarticular tumors or other disorders with ectopic ossification or calcification. With maturation, the lesion enlarges and ossifies, and becomes

confluent with the underlying epiphyseal bone (184). MRI has proven useful in demonstrating the extent of the lesion, and in identifying a potential cleavage plane between the lesion and the underlying epiphysis (175,184–186).

Histopathology. On gross and microscopic examination, the lesion will resemble an osteochondroma, although no discrete stalk is present. Microscopically, one may find a boundary of cartilage separating the lesion from the underlying bony epiphysis, if the lesion has not yet fully ossified. A thick zone of hyperplastic cartilage is distinguishable from the rest of the cartilaginous epiphysis only by some irregularity in the size and distribution of the chondrocytes (172). Malignant degeneration of the lesion has not been reported.

Treatment. Treatment of dysplasia epiphysealis hemimelica should be directed at addressing the patient's complaints, while preserving the integrity of the affected joint as much as possible. Most of the reported cases of dysplasia epiphysealis hemimelica have been treated surgically, and therefore the long-term prognosis for untreated lesions involving the weightbearing surface of the joint (i.e., articular lesions) is mostly unknown. Fairbank predicted that involved joints would go on to early degenerative joint disease, and this has been demonstrated in some patients after surgical intervention (175,176,181,187). If the cartilaginous overgrowth is not on the weightbearing surface of the joint (i.e., juxtaarticular lesions), simple excision is warranted to relieve pain and improve function. However, recurrence of the lesion prior to skeletal maturity has been reported (176,177). Fairbank described spontaneous correction of associated angular deformities after excision, but this has not been a consistent finding (154). The treatment of articular lesions remains somewhat controversial. Kuo and colleagues did not recommend excision of articular lesions due to unsatisfactory results in 3 of 9 patients with lesions involving the distal tibia and talus (176). Keret and colleagues performed corrective osteotomies without excision for angular deformity associated with articular lesions if an arthrogram demonstrated a smooth joint surface (175). The authors noted recurrence of valgus deformity at the knee after varus osteotomy in 1 of 3 patients, requiring repeat osteotomy.

Fibrodysplasia Ossificans Progressiva

Fibrodysplasia ossificans progressiva is a genetic disorder characterized by congenital malformations of the great toes and by later development of a predictable pattern of heterotopic endochondral osteogenesis of tendons, ligaments, fasciae and striated muscles. Although most patients present as new mutations, autosomal dominant transmission and variable expressivity has been confirmed by several authors (188–191). The incidence of this condition is extremely rare, affecting less than 1 in 1 million persons (192).

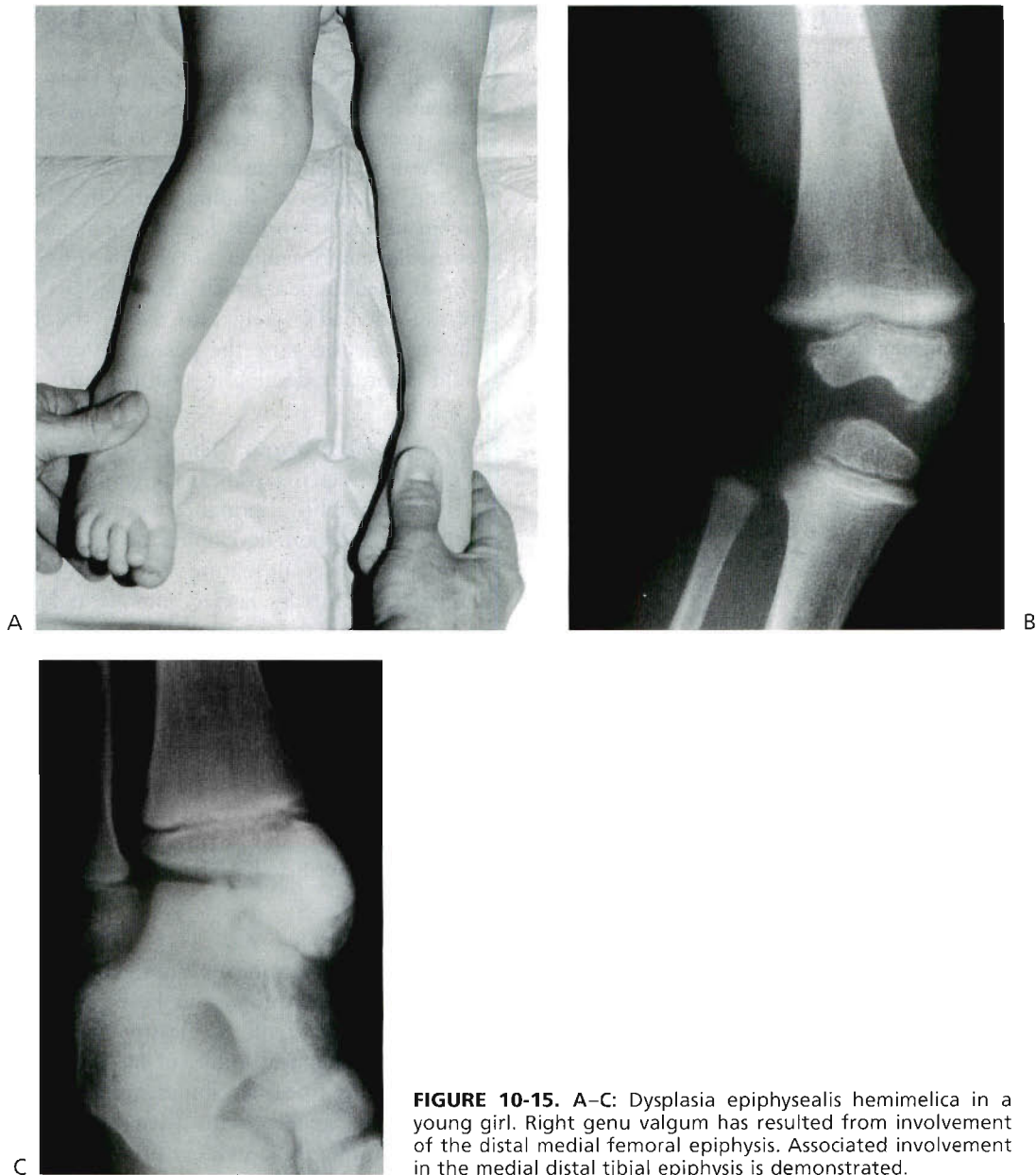


FIGURE 10-15. A–C: Dysplasia epiphysealis hemimelica in a young girl. Right genu valgum has resulted from involvement of the distal medial femoral epiphysis. Associated involvement in the medial distal tibial epiphysis is demonstrated.

Etiology. The genetic defect and pathophysiology responsible for fibrodysplasia ossificans progressiva are unknown at this time. The combination of the congenital malformation of the great toe and the postnatal development of heterotopic bone, in characteristic patterns of developmental gradients, suggests a possible role of the bone morphogenetic proteins in the etiology of fibrodysplasia ossificans progressiva. Bone morphogenetic proteins have been implicated in several embryonic epithelial and mesenchymal interactions, such as limb formation, and have the potential to transdifferentiate myoblasts in culture into osteoblast-like cells. Shafritz and colleagues demonstrated overexpres-

sion of bone morphogenetic protein 4 (BMP 4) and its messenger ribonucleic acid (mRNA) in cells derived from an early fibroproliferative lesion in a patient with fibrodysplasia ossificans progressiva (193). Expression of this mRNA was noted in lymphoblastoid cell lines from 26 of 32 patients with the disorder, compared to only 1 of 12 normal subjects. Lanchoney and colleagues have identified elevated steady-state levels of BMP 4 mRNA and BMP 4 receptor mRNA in lesional and nonlesional muscle cell lines from patients with fibrodysplasia ossificans progressiva, suggesting that molecular deregulation of BMP 4 signaling pathways could lead to the disease phenotype (194). Although the gene for

BMP 4 has been mapped to chromosome 14q22-q23, Xu and Shore were unable to identify a mutation in the *BMP 4* gene or its upstream flanking region, in a family showing autosomal-dominant inheritance of fibrodysplasia ossificans progressiva (195).

Clinical Features. The earliest recognizable manifestation of fibrodysplasia ossificans progressiva involves aberrant morphology of the great toe, which demonstrates shortening of the first ray, delta-shaped proximal phalanx, interphalangeal joint fusion, and varying degrees of hallux valgus, either alone or in combination (196). Progressive heterotopic ossification becomes evident at a mean age of 5 years, but may be seen shortly after birth, or as late as the second decade of life. Most lesions arise spontaneously, although blunt trauma can trigger the onset. Individual nodules can regress, although most progress to form mature bone. In their review of 44 patients with fibrodysplasia ossificans progressiva, Cohen and colleagues noted a predictable pattern of involvement of heterotopic ossification, proceeding from axial to appendicular, cranial to caudad, and proximal to distal (197). Dorsal involvement preceded ventral involvement, with the initial lesion characteristically occurring as a painful, erythematous, subfascial nodule in the posterior aspect of the neck, spine, or shoulder girdle. Kaplan and colleagues described the early, intermediate, and late progression of a typical lesion in fibrodysplasia ossificans progressiva (191). The early lesion is heralded by pain, erythema, swelling, warmth, and tenderness, and may resemble an infectious process. After several weeks, the swelling and pain begin to subside, but an increase in induration occurs (the intermediate lesion). The late lesion is present by 12 weeks, and consists of a hard, painless mass that is evident roentgenographically (Fig. 10-16A–G).

Severe disability ensues secondary to extraarticular ankylosis of the major diarthrodial joints. Hip and knee involvement can impair walking and sitting ability. Progressive spinal deformity is common, and can be particularly severe when unilateral pelvis-to-chest-wall synostosis is present (198). Humeral-to-chest-wall synostosis can lead to superior subluxation of the glenohumeral joint (199). Involvement of the temporomandibular joint may lead to inanition with resultant poor nutrition. Decubiti often develop due to a combination of underlying bony prominences, poor nutrition, and lack of mobility. Other associations have included shortened thumbs, fifth-finger clinodactyly, conductive hearing loss, diffuse thinning of the hair on the scalp, premature cessation of menses in female patients, and, uncommonly, mental retardation. Exacerbating factors may include trauma to the muscles, biopsy of lesions, surgical attempts at bone removal, intramuscular injections, careless venipuncture, and dental therapy (196). New lesions can occur throughout the patient's lifetime, and most patients become completely immobilized and confined to a wheelchair by their third decade. The diaphragm, extraocular

muscles, cardiac muscle, and smooth muscle are characteristically spared in the disorder.

Cardiopulmonary dysfunction can play a role in the shortened survival of some patients with fibrodysplasia ossificans progressiva. Heterotopic ossification involving the chest wall and spine can lead to impaired chest wall dynamics and reliance on diaphragmatic breathing (192,197). Kussmaul and coworkers found a high incidence of right ventricular abnormalities on electrocardiographic evaluation of their patients with fibrodysplasia ossificans progressiva who had severely restrictive chest wall disease (200). The investigators raise the possibility that cor pulmonale could eventually develop in such patients.

Radiographic Features. The areas of heterotopic ossification in fibrodysplasia ossificans progressiva are initially similar in radiographic appearance to myositis ossificans, with diffuse calcification developing progressive zonal osseous maturation. Sheets of mature skeletal bone eventually form along striated muscles, fasciae, tendons, and ligaments, causing ankylosis of the joints. Solid extraosseous bridges can form between bones, leading to characteristic synostoses of the cervical spine to occiput, scapula and chest wall to humerus, spine to pelvis, and pelvis to femur. In addition to the characteristic great toe deformities, abnormal cervical vertebrae with small bodies, large posterior elements and fused lateral masses, shortened first metacarpals, fifth-finger clinodactyly, short and broad femoral necks, and exostoses of the proximal tibiae have been reported (Fig. 10-16C–F) (196).

Histopathology. Erroneous biopsies of the lesions in fibrodysplasia ossificans progressiva have provided insight into the pathogenesis of the ossification. Histopathologic and immunohistochemical studies of specimens from early preosseous lesions reveal an abundance of primitive vascular cells and angiogenesis, with a conspicuous absence of an acute or chronic inflammatory process. The clinician may be misled toward a presumptive diagnosis of aggressive fibromatosis or low-grade sarcoma at this stage, if fibrodysplasia ossificans progressiva is not considered. Intermediate lesions exhibit scattered cartilaginous foci and evidence of endochondral ossification, proceeding in a sequence that appears entirely normal. Late lesions demonstrate histologically normal lamellar bone, with fatty marrow encased in fibrous connective tissue (201).

Treatment. There is presently no effective treatment for fibrodysplasia ossificans progressiva. Treatment is largely supportive, with attempts at limiting the exacerbating factors of ectopic bone formation, such as trauma, intramuscular injections, careless venipuncture and dental extractions. Padding of bony prominences and nutritional support may be useful in preventing decubiti. Biopsy of lesions or surgery

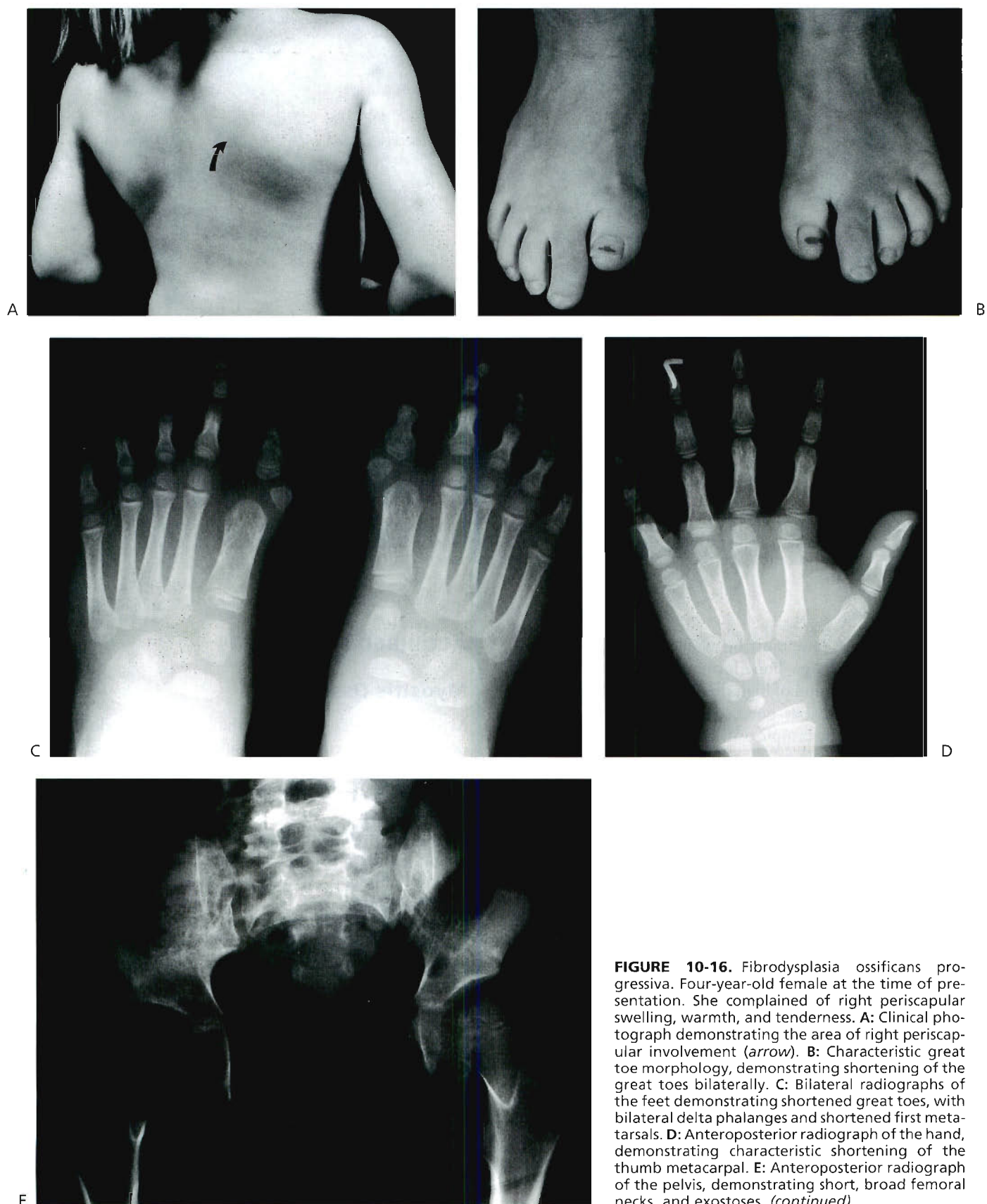
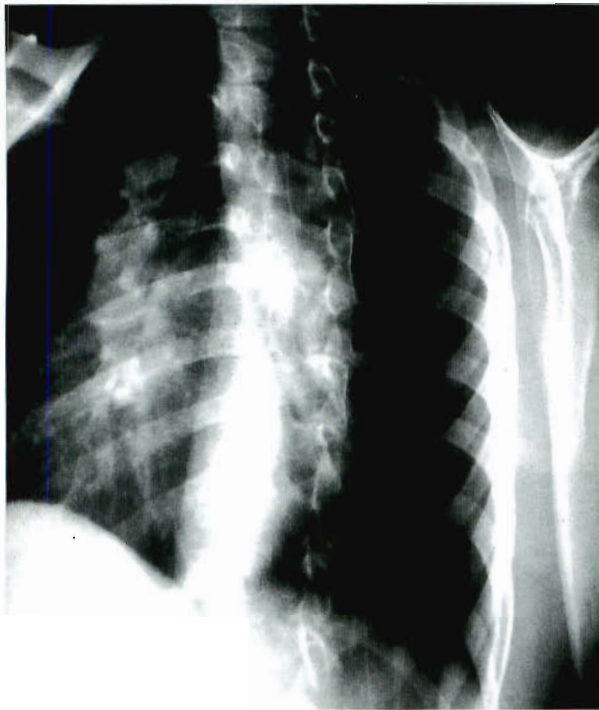
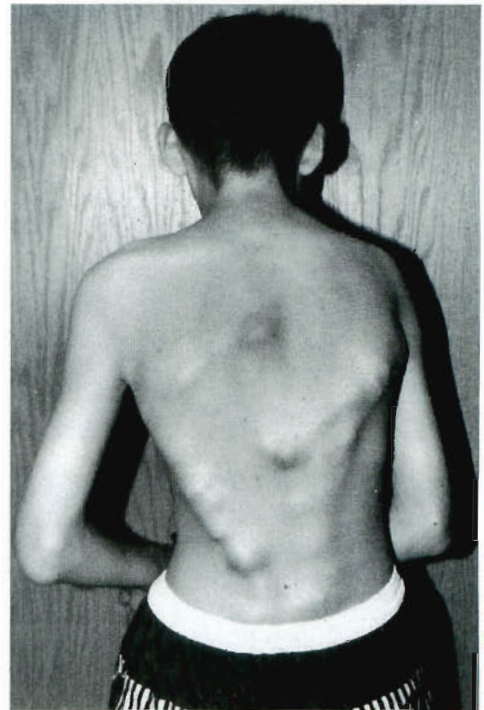


FIGURE 10-16. Fibrodysplasia ossificans progressiva. Four-year-old female at the time of presentation. She complained of right periscapular swelling, warmth, and tenderness. **A:** Clinical photograph demonstrating the area of right periscapular involvement (*arrow*). **B:** Characteristic great toe morphology, demonstrating shortening of the great toes bilaterally. **C:** Bilateral radiographs of the feet demonstrating shortened great toes, with bilateral delta phalanges and shortened first metatarsals. **D:** Anteroposterior radiograph of the hand, demonstrating characteristic shortening of the thumb metacarpal. **E:** Anteroposterior radiograph of the pelvis, demonstrating short, broad femoral necks, and exostoses. (*continued*)



F



G

FIGURE 10-16. (continued) F: Early spontaneous fusion along the posterior elements and lateral masses is demonstrated. G: Clinical appearance of an older individual with advanced subcutaneous ossification and characteristic dorsal-to-ventral pattern.

to excise ectopic bone must be avoided, because they uniformly precipitate new bone formation (196).

The administration of high doses of oral diphosphonates and corticosteroids has not been shown to influence the development of the ectopic ossifications. Brantus and Meunier evaluated the effects of intravenous administration of ethane-1-hydroxy-1-diphosphonate and oral prednisone on early flare-ups in patients with fibrodysplasia ossificans progressiva (202). During a mean follow-up of 6 years in seven patients with the disorder, the symptoms of local swelling and pain during 29 of 31 acute flare-ups were ameliorated, and, in 21 flare-ups, no ossification appeared. However, the percentage of acute flare-ups that normally result in ossification is unknown, and so the effect of intravenous diphosphonates during early flare-ups on subsequent progression to ossification cannot be confirmed. As well, during the period of study, 10 new ossifications were observed that resulted in severe deterioration of joint mobility, and there was no change in the radiographic appearance of preexisting ossifications.

Future direction of medical therapies in fibrodysplasia ossificans progressiva will likely center around inhibitors of endochondral osteogenesis. Proposed treatments have included the use of *BMP 4* inhibitors, isotretinoin (an inhibitor of mesenchymal tissue differentiation into cartilage and bone), and antiangiogenic factors (202–205). To date, such treatments should be regarded as investigational.

ACQUIRED DISORDERS

Myositis Ossificans

Myositis ossificans refers to the acquired development of nonneoplastic heterotopic ossification within soft tissues, most often in response to localized trauma. Although the process most commonly develops within skeletal muscle, the term itself is a misnomer, because nonmuscular tissue may be involved, and inflammation is rare. Adolescents and young adults, predominantly male, are affected most frequently, although myositis ossificans has been reported in infancy (206).

Etiology

Precipitating factors in myositis ossificans include single or repetitive trauma in up to 70% of cases (207). The development of heterotopic ossification has also been reported after severe thermal injury, in neurologic diseases, and posttraumatic paraplegia and brain injury, and after some orthopaedic operations, such as total hip arthroplasty (208–216). Rarer genetic and developmental forms of heterotopic ossification exist, including fibrodysplasia ossificans progressiva, progressive osseous heteroplasia, pseudomalignant heterotopic ossification, Albright hereditary osteodystrophy, and parosteal fasciitis (196,203,217–220).

The origin of the bone-forming cells in myositis ossificans remains unknown. Recent investigations into the role of extraskelatal osteogenic precursor cells, and the local factors that induce them, may provide insight into the origins of ectopic bone formation in myositis ossificans, and in other disorders characterized by the formation of heterotopic ossification (221,222).

Clinical Features

Signs and symptoms of myositis ossificans typically include localized pain and a palpable mass which begin to occur approximately 1 to 3 weeks after injury. Increased warmth, swelling, and limitation of motion of the affected area may be noted. A low-grade fever and a mildly elevated erythrocyte sedimentation rate may be present. Limb involvement predominates, most commonly in the quadriceps or brachialis muscles, although virtually any region of the body can be affected. A decrease in pain and increased firmness to the lesion occur over an 8- to 12-week period, with the development of varying degrees of contracture of the affected part.

Radiographic Features

Early plain radiographs in myositis ossificans may demonstrate a noncalcified mass in the soft tissues, typically over the diaphyseal region of the extremity. Within 2 to 4 weeks from injury, floccular calcifications begin to appear within the mass, and a periosteal reaction of the underlying bone may be seen if the cambium layer of the periosteum was involved in the initial injury. Over a 6- to 8-week period, serial radiographs obtained at 1- to 2-week intervals characteristically demonstrate peripheral osseous maturation of the lesion, with a central lucent zone and a lucent line separating it from the underlying cortex, and should be helpful in distinguishing the lesion from an extraosseous sarcoma (Fig. 10-17A and B). By 5 to 6 months, mature bone is evident, and the lesion may show a decrease in overall size. Computed tomography may be particularly helpful in delineating the zonal maturation and cortical separation in myositis ossificans, when the diagnosis is unclear (Fig. 10-18A and B) (207). Other imaging modalities that have been utilized in the diagnosis of myositis ossificans include bone scintigraphy, ultrasound, MRI, leukocyte scanning, and angiography, particularly in early lesions or in difficult cases (207,220). In cases with the typical history of trauma and localized findings, and with roentgenographic evidence of progressive peripheral osseous maturation, the use of these other imaging modalities is infrequently required.

Histopathology

The hallmark of myositis ossificans on histopathologic examination is the presence of zonal phenomenon, as de-

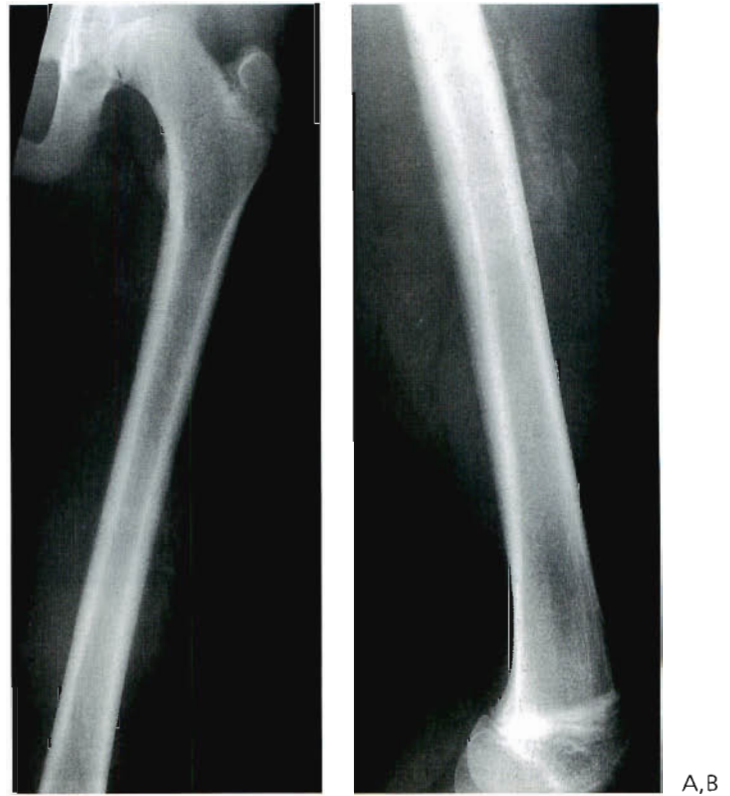

FIGURE 10-17. Adolescent male complaining of quadriceps tightness, swelling, and discomfort, 6 weeks after sustaining an impact to his thigh during a football game. **A, B:** Anteroposterior and lateral radiographs of the femur demonstrate floccular calcifications within the soft tissue of the thigh, with underlying periosteal reaction in the femoral diaphysis.

scribed by Ackerman (223). The typical lesion consists of a central (inner) zone of undifferentiated cells and atypical myotonic figures, which may be impossible to distinguish from a sarcoma; an adjacent (middle) zone of well-oriented osteoid formation in a nonneoplastic stroma; and a peripheral (outer) zone of well-oriented lamellar bone, clearly demarcated from the surrounding tissue. Although rarely required, when biopsy is performed in cases of myositis ossificans, a specimen of sufficient size and orientation is important in establishing the architectural pattern of the lesion.

Treatment

Prevention of heterotopic ossification at the site of initial injury would ideally be preferable. Nonsteroidal antiinflammatory agents can be utilized to help diminish symptomatology in the early stages of myositis ossificans. Hughston and colleagues suggested that strict rest of the affected part, through the use of splinting, would allow for more complete resorption of the hematoma, and discourage formation of heterotopic bone (224). Thorndike advocated a combina-

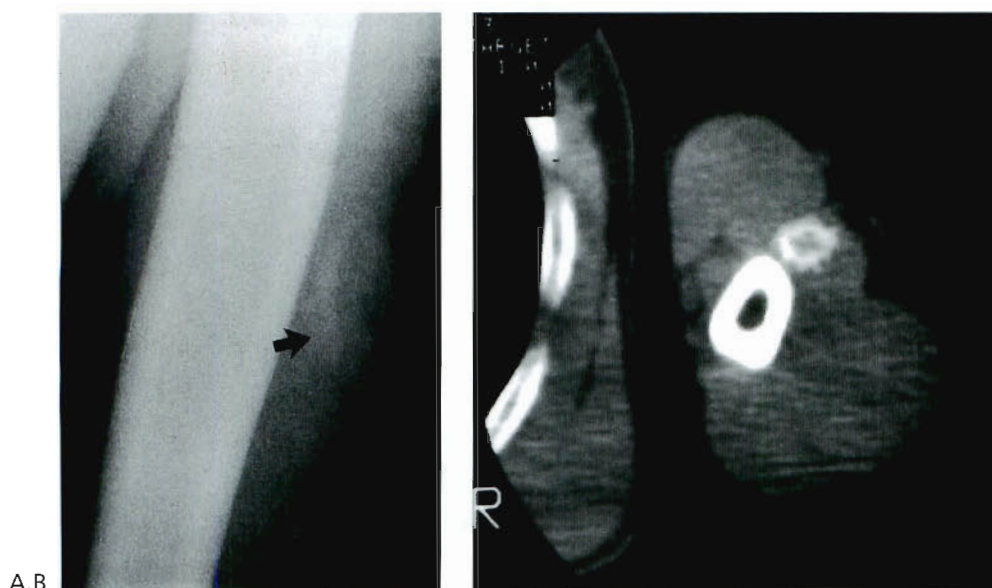


FIGURE 10-18. Myositis ossificans. **A:** Anteroposterior radiograph demonstrating myositis ossificans in the left upper arm (arrow). **B:** CT scan of the same patient, delineating peripheral maturation and clear separation of the lesion from the underlying cortex of the humerus.

tion of rest, icing, compression bandaging, and avoidance of massage therapy (225). Jackson and Feagin developed a treatment strategy for the prevention of myositis ossificans after quadriceps contusions in young athletes (226). They recommended a three-phase program of 24 to 48 h of strict rest of the extremity, elevation and icing (phase I), followed by restoration of motion (phase II), and progressive resistance strengthening (phase III). However, there is presently no clear evidence that such measures alter the development of myositis ossificans, or modify its severity.

The extent of the ossification in myositis ossificans can be deceiving until maturation of the lesion occurs. Similarly, areas of mature ossification can regress partially or totally over time. Many of these lesions will become asymptomatic, and not interfere with function of the affected part. It is therefore advisable, when considering excision of heterotopic bone, to wait until full maturation of the lesion is demonstrated roentgenographically, or on bone scintigraphy (typically 12 to 18 months after injury), and to remove lesions only when they interfere with function or cause persistent local symptomatology.

The Osteochondroses

Osteochondrosis is characterized by a disturbance in endochondral ossification, including both chondrogenesis and osteogenesis, in a previously normal endochondral growth region. The condition is considered idiopathic, and has been described in nearly every growth center of the body, including epiphyses, apophyses, and physes. The various osteochondroses often have associated eponyms, and their clinical features are related to their area of occurrence. As a group, the osteochondroses have relatively well-defined natural his-

stories, and generally predictable outcomes (227). The more clinically significant osteochondroses are described throughout this text according to anatomic region, but are highlighted here for their features as localized disorders of bone and cartilage (Table 10-3).

Etiology

The initial event, or combination of events, leading to the process of disordered endochondral ossification and subsequent necrosis remains unknown. Traumatic and vascular etiologies have been proposed. It has been suggested that the normal process of chondrification of cartilage canals in

TABLE 10-3. EXAMPLES OF OSTEOCHONDROSES BY REGION

Upper Extremity
Capitulum (Panner)
Carpal navicular (Kienboch)
Phalangeal epiphysis (Theemann)
Distal radial epiphysis (Madelung)
Vertebral end plates
Schuermann
Lower extremity
Capital femoral epiphysis (Legg-Perthes)
Proximal tibial physis (Blount)
Tibial tubercle (Osgood-Schlatter)
Calcaneal apophysis (Sever)
Tarsal navicular (Köhler)
Metatarsal heads, 2, 3, or 4 (Freiberg)
General
Osteochondritis dissecans, especially knee, ankle, elbow

the growth center fails, leading to necrosis of cartilage canal vessels in the subchondral bone and adjacent epiphyseal cartilage, or to failed enlargement of the bony centrum and disordered proliferation of cartilage cells within the epiphysis (227,228). In the case of lesions involving segmental epiphyseal necrosis of the subchondral bone and overlying cartilage, so-called “osteochondritis dissecans,” it is not clear whether the vascular necrosis precedes or is subsequent to necrosis of the cartilage. The osteochondroses affecting non-articular cartilage, so-called “traction apophysitis,” may be related to mechanical disruption of the endochondral mechanism from longitudinally directed shear forces along tendinous or ligamentous attachments.

Clinical Features

The clinical presentation of the various osteochondroses are dependent on the site and degree of involvement, but may include local or referred pain, inflammation, effusion, limitation of motion, gait disturbance, or, in the case of physeal involvement such as Blount disease, visible disturbance in growth.

Radiographic Features

Although the exact imaging features of an osteochondrosis are characteristic for the anatomic area involved, they do share some common radiographic features. Early involvement may appear as a decrease in size, increase in density, or irregular architecture of the involved centrum. Resorption of necrotic bone may lead to apparent worsening of the radiographic appearance, with return of radiographically evident bone, as revascularization and reossification occurs (Fig. 10-19A–C). The resultant area may come to appear radiographically normal, or demonstrate permanently altered anatomy. Delay in complete revascularization of a fragmented necrotic centrum may result in separation of an ununited segment, as in osteochondritis dissecans.

Histopathology

In general, all stages of the process have been described, including necrosis of bone and cartilage, revascularization, granulation tissue invasion, osteoclastic resorption of necrotic segments, osteoid replacement along necrotic trabeculae, and, eventually, formation of mature lamellar bone (227). Biopsy of an area of involvement is rarely indicated, however, due to the characteristic clinical and radiographic findings. Of interest is that in osteochondritis dissecans, in which it is largely accepted that necrosis of the underlying subchondral bone leads to the separation of an osteocartilaginous fragment from the surrounding viable bone, the specimen may be purely cartilaginous, and if bone is present, it is not always necrotic (229).

Treatment

In children, the majority of osteochondroses are self-limiting, and will respond to symptomatic, nonoperative treatment with complete resolution (229–232). A combination of rest, icing, and rehabilitation of the affected part can help decrease the duration of symptoms, but may not influence the final outcome (230). Surgical intervention is typically reserved for more clinically severe forms, often to reduce causative stress, such as bony realignment in some cases of Blount disease, or to stimulate healing or remove intraarticular fragments, as in some cases of osteochondritis dissecans.

Infantile Quadriceps Fibrosis

Infantile quadriceps fibrosis refers to a condition of congenital or acquired contracture of all or part of the extensor mechanism of the knee. This entity has been called “congenital fibrosis” by some authors; however, we prefer the term “infantile quadriceps fibrosis” to distinguish this entity from congenital dislocation of the knee, which may have quadriceps fibrosis as a feature (233–235).

Clinical Features

The clinical features include varying degrees of limitation of knee flexion, thigh atrophy, genu valgum or recurvatum, high-riding patella, and habitual patellar dislocation, which are felt to be directly related to the extent of the quadriceps fibrosis (233,234,236). In some patients, increases in knee flexion are possible only after obligate lateral dislocation of the patella (236). There may be a history of repeated intramuscular injections of the thigh and gluteal muscles in early infancy, often in relation to severe or prolonged illness (236–238). In some children, the etiology cannot be established, but may be due to some other form of direct or indirect injury to the quadriceps mechanism. The physician should consider mild forms of arthrogryposis, congenital dislocation of the knee or patella, or spinal dysraphism, in the differential diagnosis.

Etiology

Early descriptions of infantile quadriceps fibrosis implied that the disorder was due to a muscular dysplasia of congenital origin, superficially resembling an incomplete syndrome of arthrogryposis (233,234,239). Gunn established the role of intramuscular injections in infancy as the major cause of the fibrosis, and this has since been confirmed by others (236–238,240,241).

Pathology

On gross and histologic examination, diffuse fibrosis and fatty replacement of muscle are present, most commonly

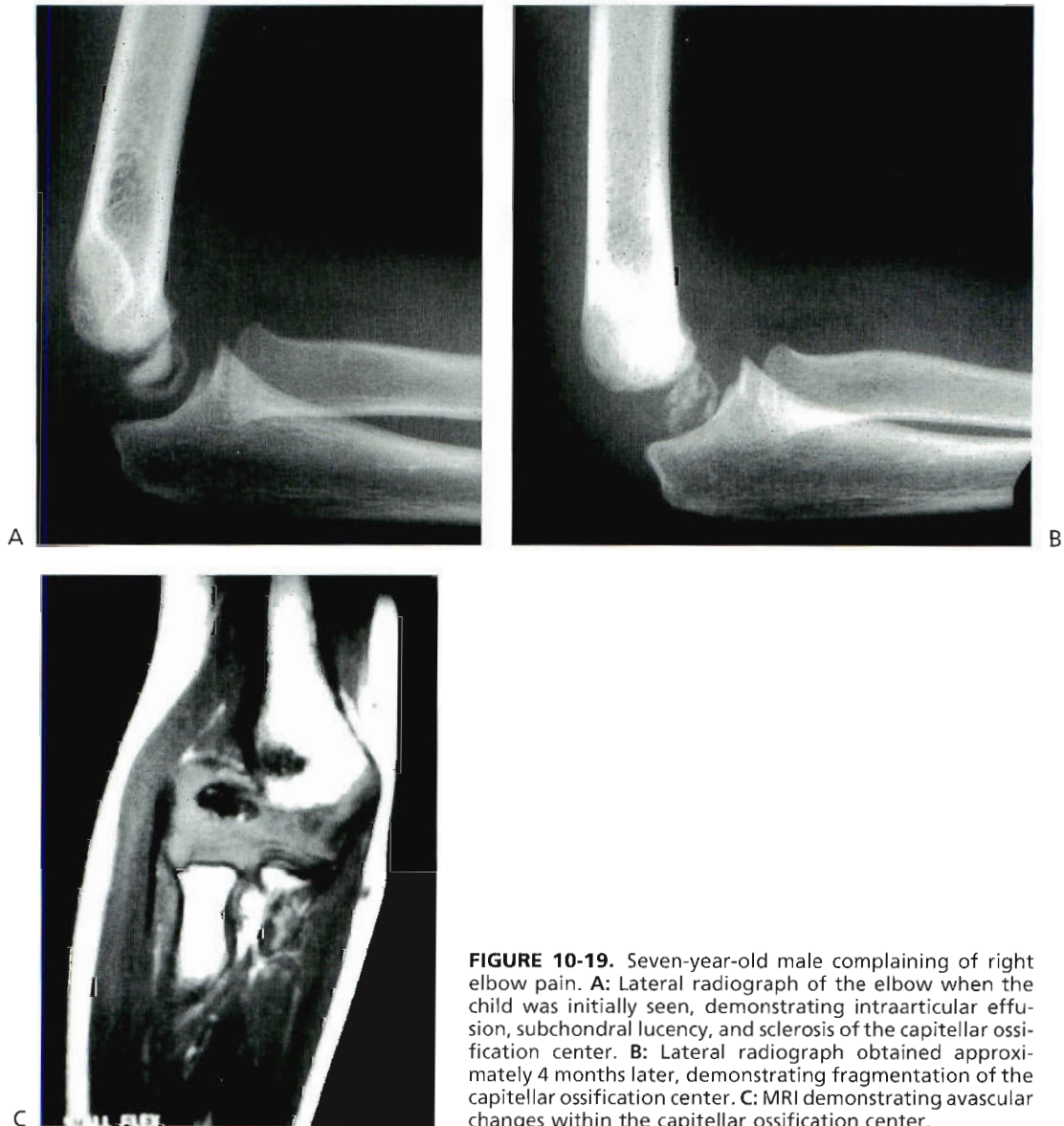


FIGURE 10-19. Seven-year-old male complaining of right elbow pain. **A:** Lateral radiograph of the elbow when the child was initially seen, demonstrating intraarticular effusion, subchondral lucency, and sclerosis of the capitellar ossification center. **B:** Lateral radiograph obtained approximately 4 months later, demonstrating fragmentation of the capitellar ossification center. **C:** MRI demonstrating avascular changes within the capitellar ossification center.

involving the vastus lateralis, vastus intermedius, and iliotibial tract (233,236). An “abnormal” attachment of the iliotibial tract to the superolateral patella was noted by Jeffreys, which more likely represented a mechanically hypertrophied epicondylopatellar ligament (242,243).

Treatment

Nonoperative treatment, in the form of manipulation, splinting, and stretching, has not been successful in addressing the condition (233). Surgical intervention has included various forms of distal muscle and fascia release, lengthening of the quadriceps tendon, and rebalancing of the extensor mechanism, depending on the extent of involvement and clinical features (233,234,236,244). In selected cases, early

release of the muscles, through a limited subtrochanteric exposure, has been described, with good results reported (237).

Reflex Sympathetic Dystrophy

Reflex sympathetic dystrophy is a syndrome characterized by pain in an extremity and associated dysfunction of the autonomic nervous system. This syndrome usually follows a minor trauma, but has been associated with many medical and surgical conditions, and with certain drugs. Although thought to be rare in children, it is being recognized with increasing frequency (245,246). The syndrome has been given a variety of names, including posttraumatic pain syndrome, algoneurodystrophy, shoulder–hand syndrome, Su-

deck atrophy, and causalgia. The term “causalgia” has been primarily used to describe the burning pain following a peripheral nerve injury, while “reflex sympathetic dystrophy” has been reserved for cases that resemble causalgia, but do not have a vascular or neural lesion (247). To clarify the picture, the term “complex regional pain syndrome” has been proposed to correspond with “reflex sympathetic dystrophy (type I)” and “causalgia (type II)” (248).

Clinical Features

Girls are much more likely to be affected with reflex sympathetic dystrophy than boys, and the lower extremities are much more frequently involved than the upper extremities (245,246,249,250).

The cardinal symptoms and signs include pain, vasomotor abnormalities, trophic changes, and motor manifestations (251). The pain is disproportionate in duration, severity, and distribution to that which would be expected in response to the initiating noxious event. It may be spontaneous and aggravated by dependency or touch, or evoked by mechanical or thermal stimuli. Hyperpathia, or pain that persists after the stimulus has been removed, and allodynia, or pain that is produced by a nonnoxious stimulus, such as light touch, are common complaints. Edema is a common early finding. The temperature of the affected extremity may be colder or warmer than the uninvolved side, and have a different skin color. Although chronic trophic changes are reported as being rare in children (249), one study reported a 15% incidence of trophic changes (245). Skin, hair, and nail growth changes, subcutaneous tissue and muscle atrophy, and leg-length discrepancy can be seen. Motor changes include weakness, tremor, dystonia, and reduced movement.

Although it has been commonly held that children who develop this syndrome have predisposing psychogenic factors (252), several recent studies have concluded there are no predisposing traits (245,253). Psychological stressors can modify the severity of the symptoms and the continuous pain, and accompanying disability may result in anxiety disorders and depression.

Reflex sympathetic dystrophy has been classically described as evolving through characteristic stages: the acute stage, followed by the dystrophic period, and, finally, by atrophy (254). The staging system has been shown recently to not consistently describe the evolution of the disorder (255).

The diagnosis of reflex sympathetic dystrophy is primarily clinical. The current diagnostic criteria (256) require:

1. The presence of an initiating noxious event or a cause of immobilization.
2. Continuing pain, allodynia, or hyperalgesia in which the pain is disproportionate to the inciting event.
3. Evidence at some time of edema, changes in skin blood flow, or abnormal sudomotor activity in the painful region.

4. The diagnosis is excluded by the existence of conditions that would otherwise account for the degree of pain and dysfunction.

There are no specific diagnostic studies available. Plain radiographs, bone scan, and thermography are rarely required for diagnosis in children.

The diagnosis is typically delayed, occasionally for a year or more (245,246,250,257). Reflex sympathetic dystrophy can be localized to the knee, and may be misdiagnosed as anterior knee pain syndrome.

The differential diagnosis includes trauma, stress fracture, infection, tumor (such as osteoid osteoma), and psychological disorders with somatic manifestations.

Radiographic Features

Plain radiographs may be normal or demonstrate osteopenia in children (250). The patchy osteopenia typical in adults is not often present in children. Bone scan has been advocated as a diagnostic tool in adults, however, in children, the results are highly variable, demonstrating increased, decreased, or normal uptake in the involved extremities (250,258). The sensitivity and specificity of the bone scan are not sufficient for its routine use in the diagnosis of reflex sympathetic dystrophy (246,250). The bone scan is useful though, to rule out occult skeletal disorders such as stress fracture or neoplasm (245).

Etiology

The etiology and pathogenesis of reflex sympathetic dystrophy is unknown. Many theories suggest dysfunction of the sympathetic nervous system but this is controversial (247). Ochoa has demonstrated, in human studies that the pain and accompanying features that resemble sympathetically mediated disturbances may be due instead to sensitization of peripheral nociceptors and mechanoreceptors, and to the effects of vasoactive substances released at the endings of small sensory afferent fibers (259).

Treatment

The goal of treatment is to restore function. This is ideally achieved through a coordinated, staged, progressive approach that uses treatment modalities required to achieve both remission and rehabilitation (245,251,260).

A 1998 consensus report, by Stanton-Hicks and others, outlines a treatment algorithm for reflex sympathetic dystrophy in adults and children (251). It focuses on the principles of patient motivation, mobilization, and desensitization facilitated by the relief of pain. Physical therapy is the cornerstone of treatment, with pharmacologic management (nonsteroidal antiinflammatories, opioids, tricyclic antidepressants, steroids, and drugs such as carbamazepine), re-

gional anesthesia (for analgesia and sympathetic blockade), neuromodulation, and psychotherapy used as adjuncts to facilitate management. Casts and splints should not be used in the treatment because immobilization may exacerbate the problem (249). An interdisciplinary team approach is most likely to succeed. The initial treatment for children should be physical therapy. It is necessary to educate the patient and the family about the nonprotective nature of the neuropathic pain to help them work through the discomfort (251). More than 50% of the children will respond to physical therapy alone (249,250), or in combination with transcutaneous electrical nerve stimulation (TENS), psychotherapy, and the use of oral medication (245). Treatment early in the course of the disease gives the best results. Sympathetic nerve blocks may be useful if the abovementioned treatment is not successful. A continuous block with a catheter technique may be preferable to intermittent blocks (251,261). Physical rehabilitation and behavioral therapy are continued under the sympathetic nerve block.

The typical outcome is one of improvement, but children can have long-term persistent pain and dysfunction (245).

References

Congenital and Developmental Disorders

Vascular Tumors and Malformations

- Goldberg M. Hemangioma syndromes. In: Goldberg M, ed. *The dysmorphic child*. New York: Raven, 1987.
- Enjolras O. Vascular tumors and vascular malformations: are we at the dawn of a better knowledge? *Pediatr Derm* 1999;16:238.
- Mulliken JB, Glowacki J. Hemangiomas and vascular malformations in infants and children: a classification based on endothelial characteristics. *Plast Reconstr Surg* 1982;69:412.
- Mulliken JB, Young AE, et al. *Vascular birthmarks: hemangiomas and malformations*. Philadelphia: WB Saunders, 1988.
- Fishman SJ, Mulliken JB. Vascular anomalies, a primer for pediatricians. *Pediatr Clin North Am* 1998;45:455.
- Meyer JJ, Hoffer FA, Barnes PD, et al. Biologic classification of soft tissue vascular anomalies: MR correlation. *Am J Radiol* 1991;157:559.
- Enjolras O, Wassef M, Majoyer E, et al. Infants with Kasabach-Merritt syndrome do not have "true" hemangiomas. *J Pediatr* 1997;130:631.
- Folkman J. Angiogenesis in cancer, vascular, rheumatoid and other diseases. *Nature Med* 1995;1:27.

Vascular Malformations

- Dutkowsky JP, Kasser JR, Kaplan LC. Leg length discrepancy associated with vivid cutis marmorata. *J Pediatr Orthop* 1993;13:456.
- Rogalski R, Hensinger R, Loder R. Vascular abnormalities of the extremities: clinical findings and management. *J Pediatr Orthop* 1993;13:9.
- Yousem DM, Scott WW Jr, Fishman EK. Case report 440: Klippel-Trenaunay syndrome of right lower extremity. *Skeletal Radiol* 1987;16:652.
- Levine C. Imaging of body asymmetry and hemihypertrophy. *Crit Rev Diagn Imaging* 1990;31:1.

- Stringel G. Hemangiomas and lymphangiomas. In: Ashcroft KW, Haldor TM, eds. *Pediatric surgery*. Philadelphia: WB Saunders, 1993.
- Enjolras O, Ciabrini D, Mazoyer E, Laurian C. Pure venous malformations in the limbs (27 cases). *J Am Acad Dermatol* 1997;36:219.
- McCarthy JE, Goldberg MJ, Zimble S. Orthopaedic dysfunction in the blue rubber-bleb nevus syndrome. *J Bone Joint Surg Am* 1982;64:280.
- Moodley M, Ramdial P. Blue rubber bleb nevus syndrome: case report and review of the literature. *Pediatrics* 1993;92:160.
- Pasaboc LG, Gibbs PM, Kwan W. Blue rubber bleb nevus syndrome in the foot. *J Foot Ankle Surg* 1994;33:271.
- Gupta AK, et al. Mediastinal and skeletal lymphangiomas in a child. *Pediatr Radiol* 1991;21:129.
- Hoefel JG, Marchal AC, Pierre E, et al. Cystic lymphangioma of the pelvis in childhood. *Br Radiol* 1990;63:813.
- Siegel MJ, Glazer HS, St. Amour TF, et al. Lymphangiomas in children: MRI imaging. *Radiology* 1989;170:467.
- Mandell GA, Alexander MA, Harcke HT. A multiscentigraphic approach to imaging of lymphedema and other causes of the congenitally enlarged extremity. *Semin Nucl Med* 1993;23:334.
- Boris M, Weindorf S, Lasinski B, et al. Lymphedema reduction by non-invasive complex lymphedema therapy. *Oncology* 1994;8:95.
- Jumbelic M, Feuerstein M, Dorfman HD. Solitary intraosseous lymphangioma. *J Bone Joint Surg Am* 1984;66:1479.

Complex-combined Vascular Malformations

- Baskerville PA, Ackroyd JS, Lea Thomas M, et al. The Klippel-Trenaunay syndrome. Clinical, radiological and hemodynamic features and management. *Br J Surg* 1985;72:232.
- Guidera KJ, Brinker MR, Koussoff BG, et al. Overgrowth management in Klippel-Trenaunay and Proteus syndromes. *J Pediatr Orthop* 1993;13:459.
- Klippel M, Trenaunay P. Du naevus variqueux ostéophytrophique. *Arch Gen Med (Paris)* 1900;185:641.
- Lindenauer SM. The Klippel-Trenaunay syndrome. *Ann Surg* 1965;162:303.
- Berry SA, Peterson C, Mize W, et al. Klippel-Trenaunay syndrome. *Am J Med Gen* 1998;79:312.
- Parkes-Weber F. Hemangiectatic hypertrophy of limbs: congenital phlebarteriectasis and so-called congenital varicose veins. *Br J Child Dis* 1918;15:13.
- Baskerville PA, Ackroyd JS, Browne NL. The etiology of the Klippel-Trenaunay syndrome. *Ann Surg* 1985;292:624.
- Lie JT. Pathology of angiodysplasia in Klippel-Trenaunay syndrome. *Pathol Res Pract* 1988;183:747.
- Pelleren D, Martelli H, Lutoiche X, et al. Congenital soft tissue dysplasia: a new malformation entity and concept. *Prog Pediatr Surg* 1989;22:1.
- Moor JJ, Warren FH, Arensman RM. Klippel-Trenaunay syndrome: rarely a surgical disease. *South Med J* 1988;81:83.
- McCullough CJ, Kenwright J. The prognosis in congenital lower limb hypertrophy. *Acta Orthop Scand* 1979;50:307.
- Anlar B, Yalaz R, Erzen C. Klippel-Trenaunay-Weber syndrome: a case with cerebral and cerebellar hemihypertrophy. *Neuro Radiology* 1988;30:360.
- Oyesiku NM, Gahm NJ, Goldman RL. Cerebral arteriovenous fistula in Klippel-Trenaunay-Weber syndrome. *Dev Med Child Neurol* 1988;30:245.
- D'Costa H, Hunter JD, O'Sullivan G, et al. Magnetic resonance imaging in macromelia and macrodactyly. *Br J Radiol* 1996;69:502.
- Laor T, Hoffer FA, Burrows PE, Kozakewick HP. MR lymph-

- angiography in infants, children and young adults. *AJR Am J Roentgenol* 1998;171:1111.
39. McCarthy RE, Lytle JD, VanDevanter S. The use of total circulatory arrest in the surgery of giant hemangioma and Klippel-Trenaunay syndromes in neonates. *Clin Orthop* 1983;289:237.
 40. Stringel G, D'Astous J. Klippel-Trenaunay syndrome and other cases of lower limb hypertrophy: pediatric surgical implications. *J Pediatr Surg* 1987;22:645.
 41. Letts RM. Orthopaedic treatment of hemangiomatous hypertrophy of the lower extremity. *J Bone Joint Surg* 1997;59:777.
 42. Sooriakumaran S, Landham TL. The Klippel-Trenaunay syndrome. *J Bone Joint Surg* 1991;73B:169.
 43. Gates PE, Drvaric DM, Kruger L. Wound healing in orthopaedic procedures for Klippel-Trenaunay syndrome. *J Pediatr Orthop* 1996;16:723.
 44. McGroty BJ, Amadio PC, Dobyns JH, et al. Anomalies of the fingers and toes associated with Klippel-Trenaunay syndrome. *J Bone Joint Surg Am* 1991;73:1537.
 45. Biesecker LG, Happle R, Mulliken JB, et al. Proteus syndrome: diagnostic criteria, differential diagnosis, and patient evaluation. *Am J Med Genet* 1999;84:389.
 46. Demetriades D, Hager J, Nikolaides N, et al. Proteus syndrome: musculoskeletal manifestations and management: a report of two cases. *J Pediatr Orthop* 1992;12:106.
 47. Samlaska CP, Levin SW, James WD, et al. Proteus syndrome. *Arch Dermatol* 1989;125:1109.
 48. Stricker S. Musculoskeletal manifestations of Proteus syndrome: report of two cases with literature review. *J Pediatr Orthop* 1992;12:667.
 49. Wiedemann HR, Burgio GR, Aldenhoff P. The Proteus syndrome. *Eur J Pediatr* 1983;140:5.
 50. Choi ML, Wey PD, Borah GL. Pediatric peripheral neuropathy in proteus syndrome. *Ann Plast Surg* 1998;40:528.
 51. Cremin BJ, Viljoen DL, Wynchank S, et al. The Proteus syndrome: MR and radiological features. *Pediatr Radiol* 1987;17:486.
 52. Gorham LW, Stout AP. Massive osteolysis. *J Bone Joint Surg Am* 1955;37:985.
 53. Shives TC, Beabout JW, Unni KK. Massive osteolysis. *Clin Orthop Rel Res* 1993;294:267.
 54. Remia LF, Richolt J, Buckley KM, et al. Pain and weakness of the shoulder in a 16-year-old boy. *Clin Orthop Rel Res* 1998;347:268.
 55. Aoki M, Kato F, Saito H, et al. Successful treatment of chylothorax by bleomycin for Gorham's disease. *Clin Orthop Rel Res* 1996;330:193.
 56. Heyden G, Knudblom LG, Nielson M. Disappearing bone disease. *J Bone Joint Surg Am* 1977;59:57.
 57. Mendez AA, Keret D, Robertson W, et al. Massive osteolysis of the femur. *J Pediatr Orthop* 1989;9:604.
 58. Joseph J, Barta EG. Disappearing bone disease. *J Pediatr Orthop* 1987;7:584.
 59. Johnson PM, McClure JG. Observations on massive osteolysis. *Radiology* 1958;71:28.
 60. Picault C, Comtet JJ, Imbert JC, et al. Surgical repair of extensive idiopathic osteolysis of the pelvic girdle. *J Bone Joint Surg Br* 1984;66:148.
 61. Dunbar SF, Rosenberg A, Mankin H, et al. Gorham's massive osteolysis. The role of radiation therapy and a review of the literature. *Int Radiol Oncol Biol Phys* 1993;26:491.
 62. Levine CL. The imaging of body asymmetry and hemihypertrophy. *Crit Rev Diagn Imaging* 1990;31:1.
 63. Pappas AM, Nehme AM. Leg length discrepancy associated with hypertrophy. *Clin Orthop* 1979;144:198.
 64. Rush WA, Steiner HA. A study of lower extremity length inequality. *AJR Am J Roentgenol* 1946;56:616.
 65. Ballock RT, Wiesner GL, Myers MT, et al. Hemihypertrophy. Concepts and controversies. *J Bone Joint Surg Am* 1997;79:1731.
 66. Ward J, Lerner HH. A review of the subject of congenital hemihypertrophy and a complete case report. *J Pediatr* 1947;31:403.
 67. Beals RK. Hemihypertrophy and hemihypotrophy. *Clin Orthop* 1992;166:200.
 68. Phelan EM, Carty HM, Kalos S. Generalized enchondromatosis associated with hemangiomas, soft tissue calcifications and hemihypertrophy. *Br J Radiol* 1986;59:69.
 69. Viljoen D, Pearn J, Beighton P. Manifestations and natural history of idiopathic hemihypertrophy. *Clin Genet* 1984;26:81.
 70. MacEwen GD, Case JL. Congenital hemihypertrophy. *Clin Orthop* 1967;50:147.
 71. Hoyme HE, Seaver LH, Jones KL, et al. Isolated hemihyperplasia (hemihypertrophy): report of a prospective multicenter study of the incidence of neoplasia and review. *Am J Med Genet* 1998;79:274.
 72. Clericuzio CL, Johnson C. Screening for Wilms tumor in high risk individuals. *Hematol Oncol Clin North Am* 1995;9:1253.
 73. Green DM, Breslow NE, Beckwith JB, et al. Screening of children with hemihypertrophy, aniridia and Beckwith-Wiedemann syndrome in patients with Wilms tumor: a report from the national Wilms tumor study. *Med Pediatr Oncol* 1993;21:188.
 74. Janik JS, Steeler RA. Delayed onset of hemihypertrophy in Wilms' tumor. *J Pediatr Surg* 1976;11:581.
 75. Shapiro F. Developmental patterns in lower extremity length discrepancies. *J Bone Joint Surg Am* 1992;64:639.
 76. Elliot M, Bayley R, Cole T, et al. Clinical features and natural history of Beckwith-Wiedemann syndrome: presentation of 74 new cases. *Clin Genet* 1994;46:168.
 77. Debaun MR, Zucker MA. Risk of cancer during the first four years of life in children from the Beckwith-Wiedemann syndrome registry. *J Pediatr* 1998;132:398.
 78. Wiedemann HR. Tumors and hemihypertrophy associated with Wiedemann-Beckwith syndrome. *Eur J Pediatr* 1983;141:129.
 79. Nudleman K, Andermann E. Hemi-3 syndrome. *Brain* 1984;107:533.
 80. Goldberg MJ. Syndromes of overgrowth. In: Goldberg M, ed. *The dysmorphic child*. New York: Raven, 1987.
 81. Bortel DT, Pritchett JW. Straight-line graphs for prediction of growth of the upper extremity. *J Bone Joint Surg Am* 1993;75:885.
 82. Barsky AJ. Macroductyly. *J Bone Joint Surg Am* 1967;49:1255.
 83. Turra S, Santini S, Cagnoni G, et al. Gigantism of the foot: our experience in seven cases. *J Pediatr Orthop* 1998;18:337.
 84. Ackland MK, Urthoff HK. Idiopathic localized gigantism: a 26-year follow-up. *J Pediatr Orthop* 1988;8:618.
 85. Miura H, Uchida Y, Iharak, et al. Macroductyly in Proteus syndrome. *J Hand Surg Br* 1993;18:308.
 86. Dennyson WG, Bear JN, Bhoola KD. Macroductyly in the foot. *J Bone Joint Surg Br* 1977;59:355.
 87. Stevens PM. Toe deformities. In: Drennan JC, ed. *The child's foot and ankle*. New York: Raven, 1984.
 88. Ben-Bassat M, Casper J, Laron Z. Congenital macroductyly. *J Bone Joint Surg Br* 1966;48:359.
 89. Grogan DP, Bernstein RM, Habal MB, et al. Congenital lipofibromatosis associated with macroductyly of the foot. *Foot Ankle Int* 1991;12:40.
 90. Jones KG. Megalodactylism. *J Bone Joint Surg Am* 1963;45:1704.
 91. Topoleski TA, Ganel G, Grogan DP. Effect of proximal phalangeal epiphysodesis in the treatment of macroductyly. *Foot Ankle Int* 1997;18:500.

92. Kotwal PP, Farooque M. Macroductyly. *J Bone Joint Surg Br* 1998;18:337.
93. Tsuge K. Treatment of macroductyly. *Plast Reconstr Surg* 1967;39:590.
94. Dedrick DP, Kling TF Jr. Ray resection in the treatment of macroductyly of the foot in children. *Orthop Trans* 1985;9:145.
95. Kalen V, Burwell DS, Omer GE. Macroductyly of the hands and feet. *J Pediatr Orthop* 1988;8:311.
96. Herring JA, Tolo VT. Instructional case: macroductyly. *J Pediatr Orthop* 1984;4:503.
97. Kino Y. Clinical and experimental studies of the congenital constriction band syndrome with an emphasis on its etiology. *J Bone Joint Surg Am* 1975;57:636.
98. Moses JM, Platt AE, Cooper RR. Annular constricting bands. *J Bone Joint Surg Am* 1979;61:562.
99. Askins G, Ger E. Congenital constriction band syndrome. *J Pediatr Orthop* 1988;8:461.
100. Cowell HR, Hensinger RN. The relationship of clubfoot to congenital annular bands. In: Bateman JE, ed. *Foot science*. Philadelphia: WB Saunders, 1976.
101. Tada K, Yonenobu K, Swanson AB. Congenital constriction band syndrome. *J Pediatr Orthop* 1984;4:726.
102. Allington NJ, Jay Kumar S, Guille JT. Clubfeet associated with congenital constriction bands of the ipsilateral lower extremity. *J Pediatr Orthop* 1995;15:599.
103. Gomez VR. Clubfeet in congenital annular constricting bands. *Clin Orthop* 1996;323:155.
104. Bahadoran Ph, Lacour J Ph, Terrisse A, et al. Congenital constriction band of the trunk. *Pediatr Dermatol* 1997;6:470.
105. Wiedrich TA. Congenital constriction band syndrome. *Hand Clin* 1998;14:29.
106. Patterson TJS. Congenital ring constrictions. *Br J Plast Surg* 1961;14:1.
107. Chang C, Huang S. Clubfoot deformity in congenital constriction band syndrome: manifestations and treatment. *J Formos Med Assoc* 1998;97:328.
108. Bourne MH, Klassen RA. Congenital annular constricting bands. *J Bone Joint Surg* 1987;7:218.
109. Zions LE, Osterkamp JA, Crawford TO, Harvey JP. Congenital annular bands in identical twins. *J Bone Joint Surg Am* 1984;56:450.
110. Torpin R. Amniochorionic mesoblastic fibrous strings and amniotic bands: associated constricting fetal malformations or fetal death. *Am J Obstet Gynecol* 1965;91:65.
111. Torpin R. *Fetal malformations caused by amnion rupture during gestation*. Springfield, IL: Charles C Thomas, 1968.
112. Streeter GL. Focal deficiencies in fetal tissues and their relationship to intrauterine amputation. *Contrib Embryol* 1930;22:1.
113. VanAllen MI, Siegel-Bartelt J, Dixon J, et al. Constriction bands and limb reduction defects in two newborns. *Am J Med Genet* 1992;44:598.
114. Bass HN, Caldwell S, Brooks BS. Michelin tire baby syndrome. *Am J Med Genet* 1993;45:370.
115. Abel M, McFarland R. Hair and thread constriction in infants. *J Bone Joint Surg Am* 1993;75:915.
116. Keane BH, Tucker HA. Etiologic concepts and pathologic aspects of ainhum. *Arch Pathol* 1986;41:639.
117. Greene WB. One-stage release of congenital circumferential constriction bands. *J Bone Joint Surg Am* 1993;75:650.
120. Naveh Y, Kaftori JK, Alon U, et al. Progressive diaphyseal dysplasia: genetics and clinical and radiologic manifestations. *Pediatrics* 1984;74:399.
121. Stenzler S, Grogan DP, Frenchman SM, et al. Progressive diaphyseal dysplasia presenting as neuromuscular disease. *J Pediatr Orthop* 1989;9:463.
122. Saraiva JM. Progressive diaphyseal dysplasia: a three-generation family with markedly variable expressivity. *Am J Med Gen* 1997;71:348.
123. Hundley JD, Wilson FC. Progressive diaphyseal dysplasia: review of the literature and report of seven cases in one family. *J Bone Joint Surg Am* 1973;55:461.
124. Kaftori JK, Kleinhaus A, Naveh Y. Progressive diaphyseal dysplasia: radiographic follow-up and CT findings. *Radiology* 1987;164:772.
125. Clawson DK, Loop JW. Progressive diaphyseal dysplasia (Engelmann's disease). *J Bone Joint Surg Am* 1964;46:143.
126. Grey AC, Wallace R, Crone M. Engelmann's disease. A 45 year follow-up. *J Bone Joint Surg Br* 1996;78:488.
127. Nevin NC, Thomas PS, Davis RI, et al. Melorheostosis in a family with autosomal dominant osteopoikilosis. *Am J Med Genet* 1999;82:409.
128. Norton KI, Wagrreich JM, Granowetter L, Martignetti JA. Diaphyseal medullary stenosis (sclerosis) with bone malignancy (malignant fibrous histiocytoma): Hardcastle syndrome. *Pediatr Radiol* 1996;26:675.
129. Naveh Y, Alon U, Kaftori JK, Berant M. Progressive diaphyseal dysplasia: evaluation of corticosteroid therapy. *Pediatrics* 1985;75:321.
130. Leri A, Joanny J. Un affection non decrite des os: Hyperostose "en coulee: sur toute la longueur d'un membre ou melorheostose." *Bul Mem Soc Hop Paris* 1922;46:1141.
131. Rozencwaig R, Wilson NR, McFarland GB Jr. Melorheostosis. *Am J Orthop* 1997;26:83.
132. Younge D, Drummond D, Herring J, et al. Melorheostosis in children. Clinical features and natural history. *J Bone Joint Surg Br* 1979;61:415.
133. Alvarez MJ, Lazaro MA, Espada G, et al. Linear scleroderma and melorheostosis: case presentation and literature review. *Clin Rheumatol* 1996;15:389.
134. Fryns JP, Pedersen JC, Vanfleteren L, et al. Melorheostosis in a 3-year-old girl. *Acta Pediatr Belg* 1980;33:185.
135. Ippolito V, Mirra JM, Morta C, et al. Case report 771: melorheostosis in association with desmoid tumor. *Skeletal Radiol* 1993;22:284.
136. Moris JM, Samilson RL, Corley CL. Melorheostosis: review of the literature and report of an interesting case with a nineteen year follow-up. *J Bone Joint Surg Am* 1963;45:1191.
137. Campbell CJ, Papademetriou T, Bonfiglio M. Melorheostosis: a report of clinical, roentgenographic and pathological findings in fourteen cases. *J Bone Joint Surg Am* 1968;50:1281.
138. Murray RO, McCreadie J. Melorheostosis and sclerotomes: a radiological correlation. *Skeletal Radiol* 1979;4:57.
139. Buckley SL, Skinner S, James P, Ashley RK. Focal scleroderma in children. *J Pediatr Orthop* 1993;13:784.
140. Atar D, Lehmann WB, Grant AD, et al. The Ilizarov apparatus for treatment of melorheostosis. *Clin Orthop* 1992;281:163.
141. Griffter J, El Hayek T, Giborn P. Melorheostosis: complications of a tibial lengthening with the Ilizarov apparatus. *Eur J Pediatr Surg* 1998;8:186.
142. Marshall JH, Bradish CF. Callotasis in melorheostosis: a case report. *J Bone Joint Surg Br* 1993;75:155.
143. Naudie D, Hamdy RC, Fassier F, et al. Complications of limb lengthening in children who have an underlying bone disorder. *J Bone Joint Surg Am* 1998;80:18.
144. Benli IT, Akalin S, Boysan E, et al. Epidemiological, clinical

Disorders Involving Joint and Bone

118. Camurati M. Diluluraro caso di osteite simmetrica ereditaria degli arti inferiori. *Chir Organi Mov* 1922;6:662.
119. Engelmann G. Ein von osteopathia hyperostica (sclerotisans) multiples infantiles. *Fortschr Rontgenstr* 1929;39:1101.

- and radiological aspects of osteopoikilosis. *J Bone Joint Surg Br* 1992;74:504.
145. Al Attia HM, Sherif AM. Buschke-Ollendorf syndrome in a grade multipara: a case report and short review of the literature. *Clin Rheumatol* 1998;17:172.
 146. Walpole IR, Manners PJ. Clinical considerations in Buschke-Ollendorf syndrome. *Clin Genet* 1990;37:59.
 147. Chigira M, Kati K, Mishio K, et al. Symmetry of bone lesions in osteopoikilosis. *Acta Orthop Scand* 1991;62:495.
 148. Whyte MP, Murphy WA, Siegel BA. 99m Tc-pyrophosphate bone imaging in osteopoikilosis, osteopathia striata and melorheostosis. *Radiology* 1988;127:439.
 149. Walker GF. Mixed sclerosing bone dystrophies. *J Bone Joint Surg Br* 1964;46:546.
 150. Fairbanks HAT. Osteopathia striata. *J Bone Joint Surg Br* 1950;32:117.
 151. Greenspan A. Sclerosing bone dysplasias. A target-site approach. *Skeletal Radiol* 1991;20:561.
 152. Nishimura G, Okada T, Tachibana K, et al. Osteopathia striata short stature, and characteristic facies: a previously unknown skeletal dysplasia. *Eur J Pediatr* 1997;156:631.
 153. Gibson DA, Carroll N. Congenital pseudarthrosis of the clavicle. *J Bone Joint Surg Br* 1970;52:629.
 154. Mall FP. On ossification centers in human embryos less than one hundred days old. *Am J Anat* 1906;5:433.
 155. Gardner E. The embryology of the clavicle. *Clin Orthop Rel Res* 1968;58:9.
 156. Lombard JJP. Pseudarthrosis of the clavicle. *South Afr Med J* 1984;66:151.
 157. Alldred AJ. Congenital pseudarthrosis of the clavicle. *J Bone Joint Surg Br* 1963;45:312.
 158. Lloyd-Roberts GC, Apley AG, Pyrford OR. Reflections on the etiology of congenital pseudarthrosis of the clavicle. *J Bone Joint Surg Br* 1975;57:24.
 159. Bargar WL, Marcus RE, Ittleman FP. Late thoracic outlet syndrome secondary to pseudarthrosis of the clavicle. *J Trauma* 1984;24:857.
 160. de Gauzy JS, Baunin C, Puget C, et al. Congenital pseudarthrosis of the clavicle and thoracic outlet syndrome in adolescence. *J Pediatr Orthop* 1999;8:299.
 161. Hahn K, Shah R, Shalev Y, et al. Congenital clavicular pseudarthrosis associated with vascular thoracic outlet syndrome: case presentation and review of the literature. *Cathet Cardiovasc Diagn* 1995;35:321.
 162. Schoenecker PL, Johnson GE, Howard B, et al. Congenital pseudarthrosis. *Orthop Rev* 1992;21:855.
 163. Valette H. Pseudarthrose congenitale de la clavicule et syndrome de la traverse thoraco-brachiale. Revue de la litterature a propos d'un cas. *J Mal Vasculaires* 1995;20:51.
 164. Young MC, Richards RR, Hudson AR. Thoracic outlet syndrome with congenital pseudarthrosis of the clavicle: treatment by brachial plexus decompression, plate fixation and bone grafting. *Can J Surg* 1988;31:131.
 165. Behringer BR, Wilson FC. Congenital pseudarthrosis of the clavicle. *Am J Dis Child* 1972;123:511.
 166. Hirata S, Miya H, Mizuno K. Congenital pseudarthrosis of the clavicle. Histologic examination for the etiology of the disease. *Clin Orthop Rel Res* 1995;315:242.
 167. Grogan DP, Love SM, Guidera KJ, et al. Operative treatment of congenital pseudarthrosis of the clavicle. *J Pediatr Orthop* 1991;11:176.
 168. Schnall SB, King JD, Marrero G. Congenital pseudarthrosis of the clavicle: a review of the literature and surgical results of six cases. *J Pediatr Orthop* 1988;8:316.
 169. Toledo LC, MacEwen GD. Severe complications of surgical treatment of congenital pseudarthrosis of the clavicle. *Clin Orthop Rel Res* 1979;139:64.
 170. Mouchet A, Belot J. La tarsomegalie. *J Radiol Electrologie* 1926;10:289.
 171. Trevor D. Tarso-epiphyseal aklasis. A congenital error of epiphyseal development. *J Bone Joint Surg Br* 1950;32:204.
 172. Fairbank TJ. Dysplasia epiphysealis hemimelica. *J Bone Joint Surg Br* 1956;32:237-257.
 173. DeVine JH, Rooney RC, Carpenter C, et al. Dysplasia epiphysealis hemimelica in an elderly patient. *Am J Orthop* 1997;26:223.
 174. Azouz RM, Slomic AM, Marton D, et al. The variable manifestations of dysplasia epiphysealis hemimelica. *Pediatr Radiol* 1985;15:44.
 175. Keret D, Spatz DK, Caro PA, et al. Dysplasia epiphysealis hemimelica: diagnosis and treatment. *J Pediatr Orthop* 1992;12:365.
 176. Kuo RS, Bellemore MC, Monsell FP, et al. Dysplasia epiphysealis hemimelica: clinical features and management. *J Pediatr Orthop* 1998;18:543.
 177. Graves SC, Kuester DJ, Richardson EG. Dysplasia epiphysealis hemimelica (Trevor disease) presenting as peroneal spastic flat-foot deformity: a case report. *Foot Ankle* 1991;12:55.
 178. Heiple KG. Carpal osteochondroma. *J Bone Joint Surg Am* 1961;43:861.
 179. Levi N, Ostgaard SE, Lund B. Dysplasia epiphysealis hemimelica (Trevor's disease) of the distal radius. *Acta Orthop Belgica* 1998;64:104.
 180. Maylack FH, Manske PR, Strecker WB. Dysplasia epiphysealis hemimelica at the metacarpophalangeal joint. *J Hand Surg Am* 1988;13:916.
 181. Mendez AA, Keret D, MacEwen GD. Isolated dysplasia epiphysealis hemimelica of the hip joint. *J Bone Joint Surg Am* 1988;70:921.
 182. Saxton HM, Wilkinson JA. Hemimelica skeletal dysplasia. *J Bone Joint Surg Br* 1964;46:608.
 183. Segal LS, Vrahas MS, Schwentker EP. Dysplasia epiphysealis hemimelica of the sacroiliac joint. *Clin Orthop Rel Res* 1996;333:202.
 184. Iwasawa T, Aida N, Kobayashi N, et al. MRI findings of dysplasia epiphysealis hemimelica. *Pediatr Radiol* 1996;26:65.
 185. Lang IM, Azouz EM. MRI appearances of dysplasia epiphysealis hemimelica of the knee. *Skeletal Radiol* 1997;26:226.
 186. Peduto AJ, Frawley KJ, Bellemore MC, et al. MR imaging of dysplasia epiphysealis hemimelica: bony and soft-tissue abnormalities. *Am J Radiol* 1999;172:819.
 187. Connor JM, Horan FT, Beighton P. Dysplasia epiphysealis hemimelica: clinical and genetic study. *J Bone Joint Surg Br* 1983;65:350.
 188. Burton-Fanning FW, Vaughan AL. A case of myositis ossificans. *Lancet* 1901;2:849.
 189. Gaster A. A case of myositis ossificans. *West London Med J* 1905;10:37.
 190. Harris NH. Myositis ossificans progressiva. *Proc R Soc Med* 1961;54:70.
 191. Kaplan FS, McCluskey W, Hahn G, et al. Genetic transmission of fibrodysplasia ossificans progressiva. *J Bone Joint Surg Am* 1993;75:1214.
 192. Connor JM, Evans CC, Evans DAP. Cardiopulmonary function in fibrodysplasia ossificans progressiva. *Thorax* 1981;36:419.
 193. Shafritz AB, Shore EM, Gannon FH, et al. Overexpression of an osteogenic morphogen in fibrodysplasia ossificans progressiva. *N Engl J Med* 1996;335:555.
 194. Lanchoney TF, Olmstead EA, Shore EM, et al. Characterization of bone morphogenetic protein 4 receptor in fibrodysplasia ossificans progressiva. *Clin Orthop Rel Res* 1998;346:38.
 195. Xu M, Shore EM. Mutational screening of the bone morpho-

- genetic protein 4 gene in a family with fibrodysplasia ossificans progressiva. *Clin Orthop Rel Res* 1998;346:53.
196. Connor JM, Evans DAP. Fibrodysplasia ossificans progressiva: the clinical features and natural history of 34 patients. *J Bone Joint Surg Br* 1982;64:76.
 197. Cohen RB, Hahn GV, Tabas JA, et al. The natural history of heterotopic ossification in patients who have fibrodysplasia ossificans progressiva. A study of forty-four patients. *J Bone Joint Surg Am* 1993;75:215.
 198. Shah PB, Zasloff MA, Drummond D, et al. Spinal deformity in patients who have fibrodysplasia ossificans progressiva. *J Bone Joint Surg Am* 1994;76:1442.
 199. Sawyer JR, Klimkiewicz JJ, Iannotti JP, et al. Mechanism for superior subluxation of the glenohumeral joint in fibrodysplasia ossificans progressiva. *Clin Orthop Rel Res* 1998;346:130.
 200. Kussmaul WG, Esmail AN, Sagar Y, et al. Pulmonary and cardiac function in advanced fibrodysplasia ossificans progressiva. *Clin Orthop Rel Res* 1998;346:104.
 201. Kaplan FS, Tabas JA, Gannon FH, et al. The histopathology of fibrodysplasia ossificans progressiva. An endochondral process. *J Bone Joint Surg Am* 1993;75:220.
 202. Brantus J, Meunier PJ. Effects of intravenous etidronate and oral corticosteroids in fibrodysplasia ossificans progressiva. *Clin Orthop Rel Res* 1998;346:117.
 203. Kaplan FS, Sawyer J, Connors S, et al. Urinary basic fibroblast growth factor. A biochemical marker for preosseous fibroproliferative lesions in patients with fibrodysplasia ossificans progressiva. *Clin Orthop Rel Res* 1998;346:59.
 204. Olmstead EA, Gannon FH, Wang Z, et al. Embryonic overexpression of c-fos protooncogene. A murine stem cell chimera applicable to the study of fibrodysplasia ossificans progressiva in humans. *Clin Orthop Rel Res* 1998;346:81.
 205. Zasloff MA, Rocke DM, Crofford LJ, et al. Treatment of patients who have fibrodysplasia ossificans progressiva with isotretinoin. *Clin Orthop Rel Res* 1998;346:121.
 218. Kaplan FS, Craver R, MacEwen GD, et al. Progressive osseous heteroplasia: a distinct developmental disorder of heterotopic ossification. *J Bone Joint Surg Am* 1994;76:425.
 219. Letts M, Pang E, Carpenter B, et al. Parosteal fasciitis in children. *Am J Orthop* 1995;24:119.
 220. Ogilvie-Harris DJ, Fornasier VL. Pseudomalignant myositis ossificans. Heterotopic new bone formation without a history of trauma. *J Bone Joint Surg Am* 1980;62:1274.
 221. Illes T, Dubouset J, Szendroi M, et al. Characterization of bone-forming cells in post-traumatic myositis ossificans by lectins. *Pathol Res Pract* 1992;188:172.
 222. Reilly TM, Seldes R, Luchetti W, et al. Similarities in the phenotype expression of pericytes and bone cells. *Clin Orthop Rel Res* 1998;346:95.
 223. Ackerman LV. Extra-osseous localized non-neoplastic bone and cartilage formation. *J Bone Joint Surg Am* 1958;40:279.
 224. Hughston J, Whatley G, Stone M. Myositis ossificans traumatica. *South Med J* 1962;55:1167.
 225. Thorndike A. Myositis ossificans traumatica. *J Bone Joint Surg* 1940;22:315.
 226. Jackson P, Feagin JA. Quadriceps contusion in young athletes: relationship of severity of injury to treatment and prognosis. *J Bone Joint Surg Am* 1973;55:95.
 227. Siffert RS. Classification of the osteochondroses. *Clin Orthop Rel Res* 1981;158:10.
 228. Carlson CS, Meuten DJ, Richardson DC. Ischemic necrosis of cartilage in spontaneous and experimental lesions of osteochondrosis. *J Orthop Res* 1991;9:317.
 229. Chiroff RT, Cooke CP. Osteochondritis dissecans: a histologic and microradiographic analysis of surgically excised lesions. *J Trauma* 1975;15:689.
 230. Borges JLP, Guille JT, Bowen JR. Kohler's bone disease of the tarsal navicular. *J Pediatr Orthop* 1995;15:596.
 231. Green WT, Banke HH. Osteochondritis dissecans in children. *J Bone Joint Surg Am* 1953;35:26.
 232. Van Demark RE. Osteochondritis dissecans with spontaneous healing. *J Bone Joint Surg Am* 1952;34:143.
 233. Hnekvovsky O. Progressive fibrosis of the vastus intermedius muscle in children. *J Bone Joint Surg Br* 1961;43:318.
 234. Karlen A. Congenital fibrosis of the vastus intermedius muscle. *J Bone Joint Surg Br* 1984;46:488.
 235. Uthoff HK, Ogata S. Early intrauterine presence of congenital dislocation of the knee. *J Pediatr Orthop* 1994;14:254.
 236. Gunn DR. Contracture of the quadriceps muscle. A discussion on the etiology and relationship to recurrent dislocation of the patella. *J Bone Joint Surg Br* 1964;46:492.
 237. Sengupta S. Pathogenesis of infantile quadriceps fibrosis and its correction by proximal release. *J Pediatr Orthop* 1985;5:187.
 238. Shanmugasundaram TK. Post-injection fibrosis of skeletal muscle: a clinical problem. A personal series of 169 cases. *Int Orthop* 1980;4:31.
 239. Fairbank TJ, Barrett AM. Vastus intermedius contracture in early childhood. *J Bone Joint Surg Br* 1961;43:326.
 240. Hollaert P, Adjans P, Destoop N, et al. Review of the literature on quadriceps fibrosis and study of 11 cases. *Acta Orthop Belg* 1975;41:255.
 241. Makhani JS. Quadriceps fibrosis. A complication of intramuscular injections in the thigh. *Indian J Pediatr* 1971;38:54.
 242. Fulkerson JP, Gossling HR. Anatomy of the knee joint lateral retinaculum. *Clin Orthop Rel Res* 1980;153:183.
 243. Jeffreys TE. Recurrent dislocation of the patella due to abnormal attachment of the iliotibial tract. *J Bone Joint Surg Br* 1963;45:740.
 244. Williams PF. Quadriceps contractures. *J Bone Joint Surg Br* 1968;50:278.

Acquired Disorders

206. Heifetz SA, Galliana CA, DeRosa GP. Myositis (fasciitis) ossificans in an infant. *Pediatr Pathol* 1992;12:223.
207. Cushner FD, Morwessel RM. Myositis ossificans traumatica. *Orthop Rev* 1992;21:1319.
208. Boyd BM Jr, Roberts WM, Miller GR. Periarticular ossification following burns. *South Med J* 1959;52:1048.
209. Costello FV, Brown A. Myositis ossificans complicating anterior poliomyelitis. *J Bone Joint Surg Br* 1951;33:594.
210. Damanski M. Heterotopic ossification in paraplegia. A clinical study. *J Bone Joint Surg Br* 1961;43:286.
211. Evans EB. Orthopaedic measures in the treatment of severe burns. *J Bone Joint Surg Am* 1966;48:661.
212. Garland DE, Blum CE, Waters RL. Periarticular heterotopic ossification in head-injured adults. *J Bone Joint Surg Am* 1980;62:1143.
213. Hardy AG, Dickson JW. Pathological ossification in traumatic paraplegia. *J Bone Joint Surg Br* 1963;45:76.
214. Ritter MA, Vaughn RB. Ectopic ossification after total hip arthroplasty. Predisposing factors, frequency, and effect on results. *J Bone Joint Surg Am* 1977;59:345.
215. Warren SB. Heterotopic ossification after total hip replacement. *Orthop Rev* 1990;19:603.
216. Wharton GW, Morgan TH. Ankylosis in the paralyzed patient. *J Bone Joint Surg Am* 1970;52:105.
217. Brook CG, Valman HB. Osteoma cutis and Albright's hereditary osteodystrophy. *Br J Dermatol* 1971;85:471.

245. Wilder RT, Berde CB, Wolohan M, et al. Reflex sympathetic dystrophy in children. *J Bone Joint Surg Am* 1992;74:910.
246. Cimaz R, Matucci-Cerinic M, Zulian F, et al. Reflex sympathetic dystrophy in children. *J Child Neurol* 1999;14:363.
247. Schott GD. An unsympathetic view of pain. *Lancet* 1995;345:634.
248. Stanton-Hicks M, Janig W, Hassenbusch S, et al. Reflex sympathetic dystrophy: changing concepts and taxonomy. *Pain* 1995;63:127.
249. Bernstein BH, Singsen BH, Kent TJ, et al. Reflex sympathetic dystrophy in children. *J Pediatr* 1978;43:211.
250. Dierz FR, Matthews KD, Montgomery WJ. Reflex sympathetic dystrophy in children. *Clin Orthop* 1990;258:225.
251. Stanton-Hicks M, Barn R, Boas R, et al. Complex regional pain syndromes: guidelines for therapy. *Clin J Pain* 1998;14:155.
252. Sherry DD, Weisman R. Psychological aspects of childhood reflex neurovascular dystrophy. *Pediatrics* 1988;81:572.
253. Lynch ME. Psychological aspects of reflex sympathetic dystrophy: a review of the adult and paediatric literature. *Pain* 1992;49:337.
254. Schwartzman RJ, McLellan TL. Reflex sympathetic dystrophy: a review. *Arch Neurol* 1987;44:555.
255. Veldman PHJM, Reynen HM, Arntz IE, et al. Signs and symptoms of reflex sympathetic dystrophy: prospective study of 829 patients. *Lancet* 1993;342:1012.
256. Merskey H, Bagduk N, eds. *Classification of chronic pain*, 2nd ed. Seattle, WA: IASP, 1994.
257. Pillemer FG, Micheli LJ. Psychological considerations in youth sports. *Clin Sports Med* 1988;7:679.
258. Laxer RM, Allen RC, Malleson PN. Technetium 99m-methylene diphosphonate bone scans in children with reflex neurovascular dystrophy. *J Pediatr* 1985;106:437.
259. Ochoa JL. Pain mechanisms in neuropathy. *Curr Opin Neurol* 1994;7:407.
260. Silber JJ, Magid M. Reflex sympathetic dystrophy in children and adolescents. *Am J Dev Child* 1988;142:1325.
261. Berde CB, Sethna NF, Micheli LJ. A technique for continuous lumbar sympathetic blockade for severe reflex sympathetic dystrophy in children and adolescents. *Anesth Analg* 1988;67(suppl):514.



DISEASES RELATED TO THE HEMATOPOIETIC SYSTEM

WALTER B. GREENE

BONE MARROW FAILURE SYNDROMES 379

Fanconi Anemia 380
Diamond-Blackfan Anemia 380
Schwachman-Diamond Syndrome 380
Cartilage-hair Hypoplasia 381
Thrombocytopenia with Absent Radius Syndrome 381

DISORDERS OF ERYTHROCYTES 383

Iron-deficiency Anemia 383
Sickle Cell Disease 383
Thalassemia 389
Anemia of Chronic Inflammation 391

DISORDERS OF NEUTROPHILS 392

Chronic Granulomatous Disease 392

DISORDERS OF LYMPHOCYTES AND THE IMMUNE SYSTEM 394

X-linked Agammaglobulinemia 394
Acquired Immunodeficiency Syndrome 394

DISORDERS OF THE MONOCYTE-MACROPHAGE SYSTEM 395

Gaucher Disease 395
Langerhans Cell Histiocytosis 402

DISORDERS OF HEMOSTASIS 407

Hemophilia 408

ACUTE LEUKEMIA 416

The hematopoietic system includes the circulating blood, the bone marrow, the spleen, the lymph nodes, and reticulo-endothelial cells scattered throughout the body. The multiple cells that compose the hematopoietic system lead to a large number and variety of disorders. This chapter focuses on pediatric disorders of the hematopoietic system that affect the musculoskeletal system

BONE MARROW FAILURE SYNDROMES

Erythrocytes, granulocytes, and platelets develop in the bone marrow, and bone marrow failure syndromes are characterized by failure of the bone marrow to produce these cells (1). Some of these disorders cause a pancytopenia, and some syndromes affect only one or two of the bone marrow cell lines. Fanconi anemia, Diamond-Blackfan anemia, Schwachman-Diamond syndrome, cartilage-hair hypoplasia, and thrombocytopenia with absent radius syndrome are the five inherited bone marrow failure syndromes that have a significant association with congenital skeletal abnormalities (2). It is important for the orthopaedic surgeon to un-

derstand these syndromes, because the hematologic abnormalities associated with these disorders typically present after the skeletal problems have been diagnosed.

Fanconi Anemia

Fanconi anemia is an autosomal recessive disorder that ultimately causes pancytopenia (1,3). Onset of the pancytopenia is typically delayed, and in 995 patients, the average age at diagnosis of aplastic anemia was 7.8 years in boys and 8.8 years in girls (1). A few patients have onset of hematologic abnormalities in either infancy or the adult years, with 4% having these disorders diagnosed in the first year of life and 10% after 15 years of age.

The classic anomalies associated with Fanconi anemia include short stature, hypoplastic or absent thumbs, café-au-lait or hypopigmented spots, and a characteristic facial appearance with a broad nose, epicanthal folds, and micrognathia. Children who develop the pancytopenia at an early age are more likely to have associated abnormalities. For example, upper-limb anomalies occur in 48% of all patients, but are noted in 68% of patients who are diagnosed before 1 year of age (1). The most common skeletal anomaly is hypoplasia, or absence of the thumb. Radial hemimelia may also occur. In a review of 68 patients with Fanconi anemia, hypoplasia was seen in 25 patients, and radial hemimelia associated with absence or deficiency of the thumb was observed in 9 patients (3). Other skeletal abnormalities are less frequent, and include Klippel-Feil syndrome, Sprengel deformity, hip dislocation, and syndactyly of the second and third toes.

Thrombocytopenia is usually the first hematologic manifestation. Granulocytopenia and anemia follow, in that order. The cause of the anemia is not well understood, but the diagnosis of Fanconi anemia can be confirmed by detecting chromosome breaks after culturing the lymphocytes with DNA cross-linking agents.

If treatment of the pancytopenia is limited to blood transfusions, 80% of patients die within 2 years. Androgens, combined with corticosteroids, are the first line of therapy, and may result in remission; however, almost all responders must remain on androgen therapy. Bone marrow transplantation offers a cure for the aplastic anemia and leukemia. The International Bone Marrow Transplant Registry reported a 66% 2-year probability of survival in 151 patients transplanted from a human leukocyte antigen (HLA)-identical sibling, and 29% survival in 48 patients transplanted from an alternative donor (4).

Fanconi anemia is a premalignant condition; at least 15% of patients develop leukemia, myelodysplastic syndrome, liver tumors, or other cancers (1). To decrease the risk of DNA damage to other tissues, pretransplantation preparation of patients with Fanconi anemia should include a lower dose of cyclophosphamide, and no irradiation. However, a

secondary malignancy after transplantation is still relatively common in Fanconi anemia (5).

Diamond-Blackfan Anemia

Diamond-Blackfan anemia is a rare, single cytopenic type of bone marrow failure. The anemia develops by 1 year of age in 90% of patients (6). In a review of 527 cases, associated malformations were observed in 24% of patients (1). Dysmorphic facial features, upper limb anomalies, and short stature are most common. Anomalies of the thumb are the most common skeletal abnormality, with triphalangeal thumbs present in 19 of the 527 patients (1). Other anomalies of the radial aspect of the hand include subluxed or hypoplastic thumbs, and flattening of the thenar eminence. Incomplete radial hemimelia has been reported, but forearm deficits are uncommon in Diamond-Blackfan anemia (7). Klippel-Feil syndrome occurs in approximately 1% of patients.

Infants with Diamond-Blackfan syndrome typically are healthy at birth, but develop the insidious onset of listlessness, irritability, and pallor by the age of 2 to 3 months, or later in the first year of life. The anemia, however, may be present at birth, or may develop after 1 year of age. Laboratory studies demonstrate a striking normocytic anemia, with hemoglobin levels of 3 to 4 g/dL. Platelet and white blood cell counts are usually normal. Bone marrow aspirates typically show erythroid hypoplasia, but no depression of granulocyte or platelet precursors. Some cases are familial, and some of the inherited cases have been linked to chromosome 19q (6). The pathogenesis of Diamond-Blackfan anemia is uncertain, but the variable presentations and the variable responses to hematopoietic growth factors suggest multiple causes (1,8).

The first line of therapy is corticosteroids, and the overall response rate is approximately 70%. The most common pattern of the responders is a long-term dependence on steroid medications, but at a reduced dosage. Supportive transfusions and chelation therapy are necessary for patients who do not respond to steroids. Experience with bone marrow transplantation is limited, but six of eight children who underwent transplantation from HLA-identical siblings were reported to be alive 5 to 87 months after surgery, with no evidence of anemia (9). Leukemia (nine cases) and osteogenic sarcoma (one case) have been described in patients who did not respond to steroids (10).

Schwachman-Diamond Syndrome

Schwachman-Diamond syndrome is an autosomal recessive disorder characterized by exocrine pancreatic insufficiency and neutropenia. Except for cystic fibrosis, Schwachman-Diamond syndrome is the most common cause of pancreatic insufficiency in children (1). These children present during the first year of life with failure to thrive, malabsorp-

tion, steatorrhea, and frequent respiratory and cutaneous infections (1,11,12).

Musculoskeletal problems are common in Schwachman-Diamond syndrome (1,11–13). In a review of 21 patients that included routine skeletal surveys, all patients were noted to have skeletal abnormalities, ranging from metaphyseal chondrodysplasia to delayed bone maturation (11). Proportionate short stature and delayed bone age were always present, and were initially noted between the first and second year of life. Metaphyseal chondrodysplasia, mainly affecting the hips, was observed in 13 of the 21 patients; however, this may be an underestimation, because the radiographic features of metaphyseal chondrodysplasia may not be obvious in older adolescents or adults. Marked coxa vara was noted in 4 of the 13 patients with metaphyseal chondrodysplasia. Clinodactyly (48%), long-bone tubulation associated with genu varum (33%), and abnormally short ribs with flared anterior ends (47%) also were observed (11). A type II bifid thumb also has been reported (14).

In addition to the pancreatic insufficiency, neutropenia associated with skin and respiratory infections is typically found during infancy or early childhood. Laboratory studies show normal sweat chloride tests, but excessive fecal fat and deficient pancreatic trypsin, lipase, and amylase in the stool and duodenal secretions. Pancreatic biopsies demonstrate preservation of the islets of Langerhans, but fatty tissue replacement of the remainder of the organ.

Intermittent neutropenia, with the neutrophil count periodically being less than $1500/\text{mm}^3$, is seen in approximately two-thirds of patients, and is constant in the remainder. Impaired chemotaxis is present in all patients (12). Intermittent thrombocytopenia and mild anemia also may develop. Pancytopenia was noted in 44 of 200 patients, at an average age of 9 years (1). Bone marrow aspirates may appear normal, but they usually show decreased cellularity or myeloid maturation arrest.

Treatment for patients with Schwachman-Diamond syndrome includes high doses of oral pancreatic enzymes (1). This significantly improves the malabsorption, but does not affect either limb growth or neutropenia. Respiratory and sinus tract infections are frequent, but these respond to prompt treatment with antibiotics. Although the malabsorption seems to improve with age, infections continue to be a problem.

Leukemia develops in 5 to 10% of patients (1), but this may be an underestimation, because in one study, myelodysplastic syndrome was found in 7 of 21 patients (12).

Cartilage-hair Hypoplasia

Cartilage-hair hypoplasia is an autosomal recessive, short-limbed, metaphyseal chondrodysplasia associated with defective cell-mediated immunity. McKusick and colleagues (15) originally described the clinical and genetic characteristics of this disorder in 77 patients belonging to the Old

Amish sect. Cartilage-hair hypoplasia has subsequently been described in the non-Amish population, and a review of 63 such patients found similar clinical and laboratory manifestations to those of the Amish population (16). Of note, more than 100 Finnish patients have also been described (17).

Hair that is fine, sparse, and unpigmented, as well as short stature (lower than the third percentile), are consistent findings (15,16). The limbs are disproportionately short. These patients superficially resemble people with achondroplasia; however, the sparse, unpigmented hair and normalized skull permit ready differentiation. Furthermore, narrowing of the interpedicular distance is absent.

Immunodeficiency in cartilage-hair hypoplasia was first suspected because of an atypical response to varicella infection. McKusick and colleagues (15) observed that two patients died of this disease, and three others had such virulent attacks that smallpox was seriously considered. The immunologic defects are quite variable, ranging from mild lymphopenia to severe combined immunodeficiency syndrome. Chronic neutropenia and anemia may also occur (16–18). Recurrent viral respiratory tract infections are common during childhood, but in many patients the impaired cellular immunity is mild enough that adults with cartilage-hair hypoplasia have no health problems. Some children, however, have severe problems with recurrent respiratory tract infections and failure to thrive. Bone marrow transplantation may be required (19,20). Although bone marrow transplantation may correct the immune deficiency, it does not change the deficient growth and chondrodysplasia (19). Because vaccine-related illness may occur, vaccination should be performed only with attenuated virus.

The gene for cartilage-hair hypoplasia has been localized to 9p21-p13 (21). Selective defective expression of early-activation genes may be the underlying defect in cartilage-hair hypoplasia (20). This could explain the multisystem nature of the disease.

Thrombocytopenia with Absent Radius Syndrome

Thrombocytopenia with absent radius (TAR) syndrome is a unique autosomal recessive condition characterized by bilateral absence of the radius, with the thumbs being present. Retention of the thumbs distinguishes TAR from Fanconi anemia and trisomy 18. In the latter two diseases, the thumbs are absent if the radius is absent (1). The diagnosis of TAR also is aided by early manifestations of thrombocytopenia (22,23). Sixty percent of these patients have hemorrhagic problems within the first week of life, and 95% by 4 months (1).

The anomalies in 100 patients with TAR have been reviewed and summarized (24) (Table 11-1). In addition to the intercalary radial hemimelia, other anomalies of the upper extremity may occur, including hypoplasia of the

TABLE 11-1. SKELETAL DEFICIENCY IN THROMBOCYTOPENIA WITH ABSENT RADIUS SYNDROME

Deficiency	Presence/Number of Patients with Adequate Documentation
Upper extremity	
Bilateral absent radius	99/100
Unilateral absent radius	1/100
Thumbs present	100/100
Thumbs hypoplastic	48/92
Ulnar involvement	50/68
Short and bowed	35
Unilaterally absent	3
Bilaterally absent	12
Humerus involvement	36/87
Hypoplastic	22
Absent	14
Shoulder girdle involvement (hypoplastic or absent scapula and clavicle)	10/49
Middle phalanx of the little finger (hypoplastic and absent)	35/41
Lower extremity	
Hip dislocation	6/79
Lower extremity phocomelia	5/100
Stiff knee	9/100
Genu varum	29/92
Patella abnormalities	13/92
Clubfoot	4/100
Face	
Mandibular hypoplasia	11/79

(Adapted from ref. 24, with permission.)

thumb, clinodactyly of the little finger associated with hypoplasia of the middle phalanx, ulnar shortening and bowing, and short or absent humeri that are typically bilateral. Klippel-Feil syndrome and/or scapular hypoplasia also is observed.

Lower-extremity abnormalities occur in 40% of patients (1). Most lower-extremity abnormalities in TAR syndrome are concentrated at the knee, but dislocation of the hip and clubfoot may occur. Genu varum, associated with flexion contracture and internal tibial torsion, was the most common abnormality recorded by Schoenecker and colleagues (25) in their detailed description of 21 patients. Absence or hypoplasia of the patella, sometimes accompanied by either lateral or medial dislocation, also was observed.

Hypoplasia of the medial femoral condyle is a primary factor in the genu varum and joint malalignment. Recurrent varus is a frequent finding after osteotomies and patella realignment procedures (25). Gounder and colleagues (26) reported on soft tissue release of the knee, followed by post-operative bracing, but did not provide adequate information concerning long-term follow-up to determine whether soft tissue release performed at an early age is better than osteotomy for the knee deformities in TAR.

Micrognathia secondary to mandibular hypoplasia also may be present (Table 11-1). Cardiac anomalies have been reported in 10% of patients, with tetralogy of Fallot, atrial septal defect, and ventricular septal defect being the most common lesions (1).

Thrombocytopenia may necessitate a delay in centralization of the hand and wrist (Fig. 11-1). Early and prolonged splinting, combined with frequent stretching exercises, will prevent progressive contractures (27). With shortening of the humerus and the ulna, centralization may be contraindicated.

Thrombocytopenia in patients with TAR syndrome tends to be episodic and is precipitated by nonspecific stresses, such as upper respiratory tract infections and gastrointestinal disturbances (1,23). During infancy, the platelet count is typically in the range of 15,000 to 30,000/mm³ but may be more depressed. Periodic leukemoid reactions may be observed, and may temporally correlate with the thrombocytopenic episodes. Because platelet function is normal, bleeding tendencies correlate with platelet counts. Supportive therapy with platelet transfusions has significantly altered the mortality risk during infancy. Steroids or splenectomy is not necessary.

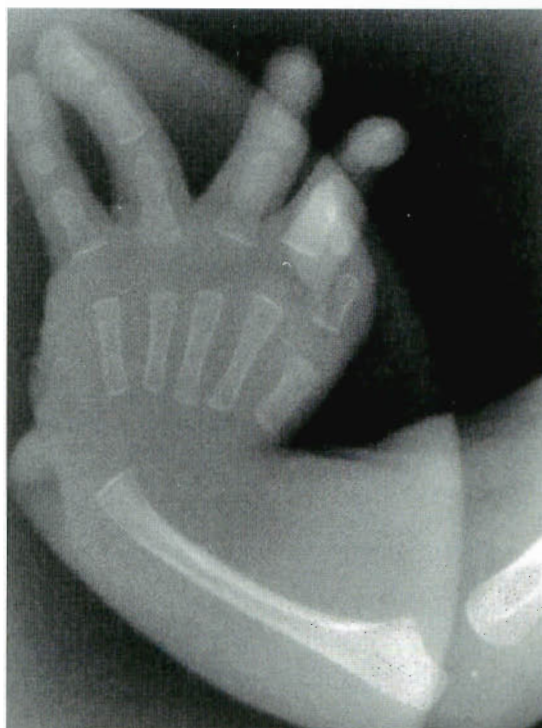


FIGURE 11-1. Anteroposterior radiograph of the left hand of a 1-month-old infant with bilateral radial hemimelia and essentially normal thumbs. Patient was started on a program of progressive casting and splinting, with anticipation of centralization at 6 months of age. At age 2 months, laboratory studies, obtained for evaluation of gastroenteritis, revealed thrombocytopenia with a platelet count of 17,000/mm³. Low platelet count continued, and centralization of the wrist was delayed.

The prognosis for patients with TAR syndrome is good. Only one case of leukemia has been reported (28). The thrombocytopenia typically resolves by early childhood, and platelet counts of more than 100,000 cells/ μ L are typical after the first year. Reconstructive operations can be performed at that time.

DISORDERS OF ERYTHROCYTES

The erythrocyte, with its unique hemoglobin molecule, delivers oxygen from the lungs to the tissue, and transports carbon dioxide in the opposite direction. The intravascular journey of an erythrocyte is approximately 175 miles in its normal life span of 120 days. Anemia is the result of a reduced number of erythrocytes, or of a reduced life span of the erythrocyte, or both. Any process that disrupts production, alters the structure of the erythrocyte, or impairs the function of the hemoglobin molecule can cause anemia.

Iron-deficiency Anemia

Iron-deficiency anemia (IDA) is the most common nutritional deficiency in the western world, and the most common cause of anemia (29). The peak incidence is between 4 months and 3 years of age, and during adolescence. Iron-deficiency anemia causes lethargy, easy fatigability, blue sclerae, koilonychia, and, during infancy, growth retardation and impaired cognitive development. The mechanism by which IDA impairs cognitive development is unclear. Marrow hyperplasia accompanies severe IDA, and radiographs of the skull may show widening of the diploic space with striations (30). Although skeletal abnormalities and low body weight resolve with treatment, developmental deficiencies, secondary to chronic IDA in young children, are not fully reversible (31,32).

Prevention is critically important, and includes iron supplementation during pregnancy, and selective screening (29,33,34). Risk factors during early childhood include the following: premature and low-birth-weight infants; infants fed a diet of non-iron-fortified infant formula for more than 2 months; infants introduced to cow's milk before age 12 months; breast-fed infants who, after age 6 months, do not receive supplemental iron-fortified food or formula; children who consume more than 24 oz of cow's milk daily; and children who have special health care needs (29,33). Adolescent girls also develop IDA. Risk factors for this group include poor nutrition, increased duration or frequency of menstrual flow, chronic use of certain analgesic medications, and prolonged training for long-distance running (35,36).

The orthopaedic surgeon most likely will encounter iron-deficiency anemia during the preoperative evaluation; however, determination of hemoglobin levels for all preoperative patients is not necessary (37). The author performs this test

on adolescent girls who have started menstruating, or who have other risk factors, on infants at risk, who did not receive adequate supplementation, and on any patient whose history or physical examination suggests anemia. Hemoglobin levels of less than 11 g/dL in infants, and less than 12 g/dL in adolescents, should be evaluated and treated. Patients who have mild anemia can be given a 4-week therapeutic trial of iron. An increase in hemoglobin of 1 g/dL is considered diagnostic of iron-deficiency anemia (29). Severe anemia, or anemia occurring during the middle period of growth, requires more extensive laboratory studies to exclude other diagnostic possibilities.

Sickle Cell Disease

Approximately 1 of every 300 African-American people has sickle cell disease (38). The three common genotypes for sickle cell disease are:

- SS disease, which is homozygous for hemoglobin S
- SC disease, which is heterozygous for hemoglobin S and hemoglobin C
- S β disease, which is heterozygous for hemoglobin S and hemoglobin β -thalassemia

People with the sickle cell trait are heterozygous for hemoglobin S and a normal β -globulin chain. They have no clinical problems under physiologic conditions, and may participate in athletic events without restriction.

Hemoglobin S results from an abnormality of the β -globulin gene on chromosome 11, which causes substitution of valine for glutamic acid at the sixth codon from the amino terminus (39). Hemoglobin C occurs when lysine is substituted for the same glutamic acid affected in hemoglobin S (40). Patients with SC disease have similar, but less frequent, complications than patients with SS disease. The β -thalassemia gene causes reduced synthesis of the β -globulin polypeptide. Patients with S β disease have clinical manifestations that depend on the output of the β -thalassemia gene. If no hemoglobin A is produced, the patients are listed as having S β^0 disease, and have a clinical course comparable to that of patients with SS disease. If there is some production of hemoglobin A from the β -thalassemia gene, the patients are classified as having S β^+ disease, and have a milder clinical course, similar to that seen with SC disease.

Vasooclusion and hemolysis are the basic pathologic events in sickle cell disease. When hemoglobin S is deoxygenated, it polymerizes and changes to a gel of intertwined fibers (39). As a result, the erythrocyte becomes distorted, fragile, and is rapidly destroyed. The paradox is that sickle cells are not only more fragile, but are relatively rigid and more viscous. Therefore, in addition to increased hemolysis, these erythrocytes clog small blood vessels and infarct tissues. Other factors, such as cellular dehydration from enhanced potassium chloride cotransport, and adhesion of SS

erythrocytes to the endothelium, play a role in the vaso-occlusion.

The rate and extent of polymer formation depends on the degree of deoxygenation of the cell, the intracellular concentration of hemoglobin, and the amount of hemoglobin F. Because the transit time in the microcirculation is typically short, polymers do not form in most SS cells as they complete the circulatory route. However, anything that retards the transit time can affect the degree of polymerization. In addition, the relatively slow circulation in bone makes it a target organ for vasoocclusion.

Considerable heterogeneity is observed in patients with sickle cell disease. The basis of this clinical variability is not fully understood, but probably involves a variety of genetic and environmental factors. Patients who have hereditary persistence of fetal hemoglobin have mild disease. The concomitant presence of α -thalassemia genes in patients with hemoglobin SS causes the erythrocytes to be smaller and lighter. These patients have higher hemoglobin levels and fewer reticulocytes, but are at greater risk for vasoocclusive disorders (41). Environmental factors, such as nutrition, public health measures, rates of immunization, and access to medical care, affect the rate and degree of complications. In the United States, 50% of patients with sickle cell disease survive beyond the fifth decade, but less than 2% survive to the age of 5 years in parts of Africa (42,43).

The clinical manifestations of sickle cell disease in children are listed in Table 11-2. Good pediatric preventive care minimizes the risk of some of these complications (44).

Vaccinations for pneumococcus, hepatitis B, and *Haemophilus influenzae* should be given in a timely fashion. Prophylactic penicillin, started at the time of diagnosis and continued until 5 years of age, diminishes the risk of bacteremia. Early evaluation and treatment of febrile illnesses reduces the risk of sepsis.

Although their birth weight is normal, subsequent growth and development are delayed in children with sickle cell disease. The salient findings of the Cooperative Study of Sickle Cell Disease, sponsored by the National Institutes of Health, include the following: weight is affected more than height; patients with SS and $S\beta^0$ disease demonstrate more delay in growth than patients with SC and $S\beta^+$ disease; and, in general, by the end of adolescence patients have caught up with controls in height, but not weight (45). Increased hemolysis and greater metabolic requirements for erythropoiesis, as well as a greater number of infectious episodes, probably explain the delay in growth. Sexual development is also delayed in sickle cell disease, and the delay in attaining different Tanner stages also is affected by the type of sickle cell disease (45).

Sickle cell disease is the most common cause of stroke in children (46), and, in 4,082 patients, the incidence of cerebrovascular events was highest during the childhood years (47). Exchange transfusion at the time of the acute infarction minimizes the risk of permanent impairment (40). The risk of recurrent stroke is approximately 50 to 70%, if children with sickle cell disease are untreated. A prophylactic transfusion program, which keeps hemoglobin

TABLE 11-2. CLINICAL FEATURES OF SICKLE CELL DISEASE IN CHILDREN

Vasoocclusive complications	
Crises	Frequent in some, uncommon in others
Dactylitis	In children younger than 6 years old
Osteonecrosis	Prognosis and manifestations less severe, compared with adults
Priapism	Onset after age 10 years; in children, episodes tend to be multiple short episodes
Splenic sequestration	More common in children younger than 2 years of age, often preceded by infection
Stroke	Four to 8% of children with SS disease; peak incidence is at 3 to 8 years of age; silent central nervous system damage and cognitive impairment more frequent
Acute chest syndrome	More common in children, but more severe in adults; may occur in postoperative period; most common cause of death after 10 years of age
Complications of hemolysis	
Anemia	Hematocrit = 15 to 30 in SS disease, higher in SC disease
Cholelithiasis	May occur in children, present in most adults
Acute aplastic episodes	Associated with parvovirus
Infection complications	
Sepsis	Most common cause of death in young children; <i>Streptococcus pneumoniae</i> most common
Osteomyelitis	<i>Salmonella</i> and <i>Staphylococcus aureus</i>
Septic arthritis	Relatively uncommon
Reactive arthritis	May be triggered by <i>Salmonella enteritidis</i>

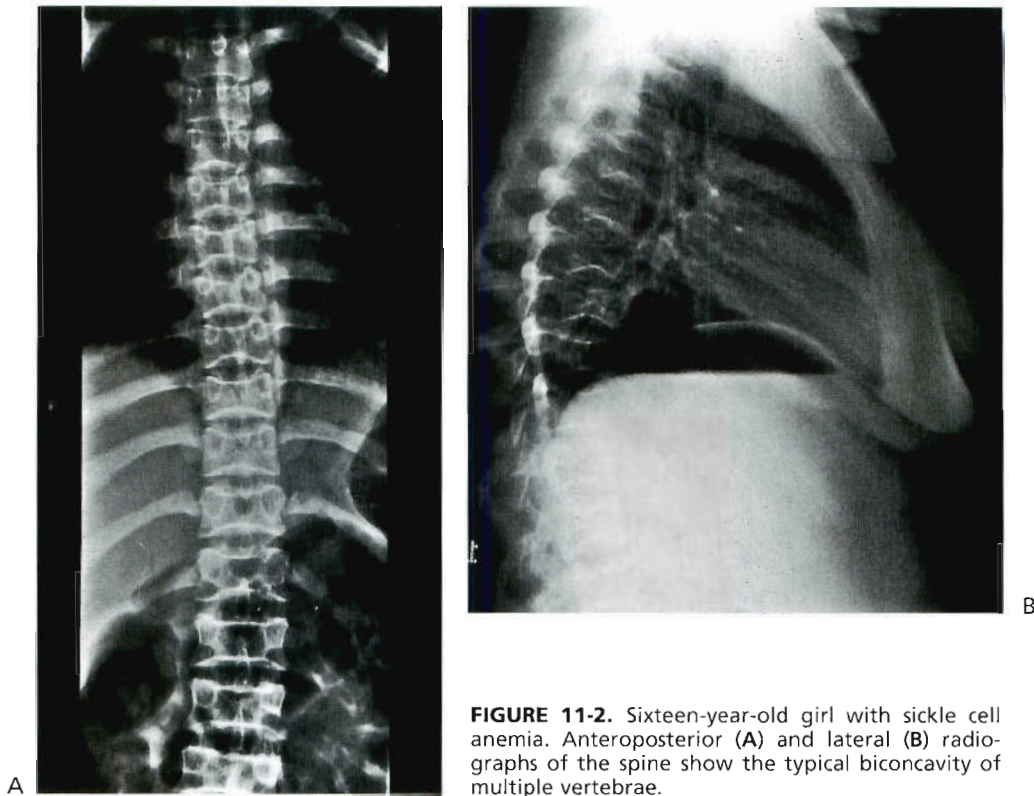


FIGURE 11-2. Sixteen-year-old girl with sickle cell anemia. Anteroposterior (A) and lateral (B) radiographs of the spine show the typical biconcavity of multiple vertebrae.

S levels at less than 30%, reduces the rate of recurrent infarction to approximately 10 to 15% (40,48). More controversial is whether children at risk for stroke, as identified by Doppler ultrasonography, should undergo the potentially harmful long-term prophylactic transfusion therapy (49,50).

Bone and joint problems in sickle cell disease include the sickle cell crises, dactylitis, osteonecrosis, osteomyelitis, septic arthritis, reactive arthritis, and leg ulcers. In addition, hemolytic anemia in these patients causes erythroid hyperplasia of the bone marrow, with resultant increased size of the medullary spaces, and osteopenia. The spine is more likely to demonstrate the effect of marrow hyperplasia. Thinning of the cortices and trabeculae lead to collapse, with development of a biconcave "fish" vertebra and mild structural changes (Fig. 11-2). Two studies have shown decreased bone mineral density in children with sickle cell disease (51,52), but, fortunately, the osteopenia in most patients has limited clinical significance.

A sickle cell crisis is the most common cause of extremity and spinal pain in patients with sickle cell disease. In a study of 3,578 patients, the average rate of crisis requiring medical treatment was 0.8 per year in SS disease, 1.0 per year in $S\beta^0$ disease, and 0.4 per year in SC and $S\beta^+$ disease (53). An elevated fetal hemoglobin level was associated with a lower rate of crises. Considerable variation, however, occurs

within groups, and 39% of the SS disease patients recorded no painful episodes requiring treatment.

A sickle cell crisis results from a localized area of infarction. Back or extremity pain is secondary to bone marrow infarction, whereas abdominal pain is most likely secondary to infarction in the intestines (54,55). The excruciating pain associated with a crisis is secondary to the resultant inflammatory response. Levels of substance P, a known stimulator of tumor necrosis factor and interleukin-8, are elevated in patients with sickle cell disease, and increase further during a crisis (56).

The humerus, tibia, and femur are the most common sites of long-bone infarction in children (54). Swelling and limitation of motion are typically mild. Temperature elevation is usually low grade, but 21% of the episodes reported by Keeley and Buchanan (54) involved a temperature greater than 39°C. A sickle cell crisis typically lasts 3 to 5 days. Supportive measures are the mainstay of therapy. With severe pain, parenteral opiates should be given at frequent, fixed intervals until the pain has diminished (43).

Dactylitis, or hand-foot syndrome, is secondary to infarction of a bone in the hand or foot, and frequently is the first clinical manifestation seen after hemoglobin F has been replaced by hemoglobin S. The typical patient is a child younger than 2 years of age, who presents with an acutely swollen hand or foot (57-59). In a prospective study, Ste-

vens and colleagues (59) reported a 45% incidence of dactylitis, with 41% of the affected patients demonstrating recurrent episodes until 4 years of age. Radiographic findings are similar in dactylitis and osteomyelitis, with initial radiographs demonstrating soft tissue swelling, and subsequent examinations characterized by periosteal elevation, subperiosteal bone reaction, bone lysis, and ultimately, bone reformation (58). The problem of dactylitis ceases with the disappearance of hematopoietic marrow in the hands and feet,

and no series has reported this condition in patients older than 6 years of age.

The risk of osteomyelitis and other infections is more common in patients with sickle cell disease. This is attributable to a combination of factors, including splenic dysfunction, defective mechanisms of opsonization and complement function, and episodes of bacteremia secondary to localized bowel infarction. Fortunately, the rate of osteomyelitis is relatively low, compared with the incidence of

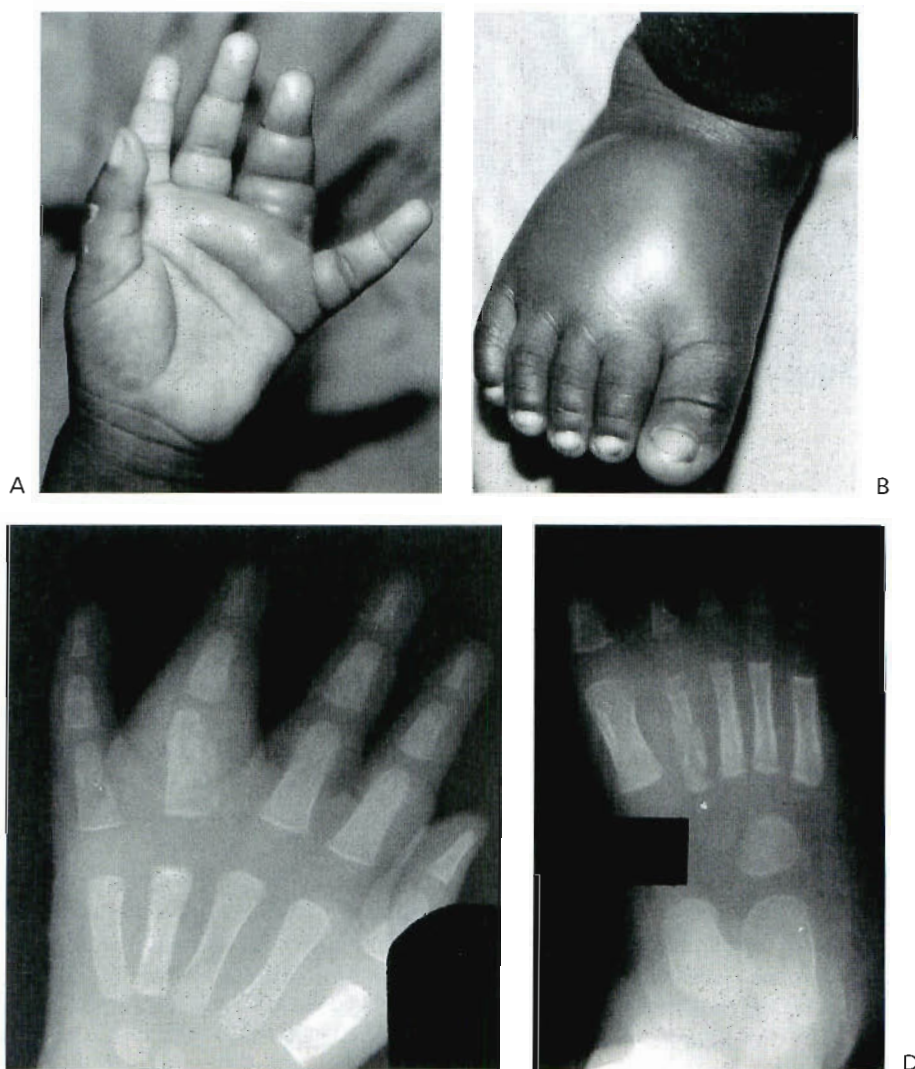


FIGURE 11-3. Osteomyelitis in a 7-month-old boy with sickle cell anemia. Patient presented with swelling of the hand and foot. Initial diagnosis was dactylitis. Because of persistent swelling and elevated temperature, aspiration was performed 48 h after admission. Purulent material was obtained, and cultures demonstrated *Salmonella* organisms. Antibiotic therapy, and surgical drainage of the hand and foot, successfully resolved the infection. **A:** Forty-eight h after admission, the hand shows marked swelling in the region of the ring finger. **B:** Forty-eight h after admission, there is swelling on the dorsum of the foot. **C:** Anteroposterior radiograph of the hand on the 15th hospital day. **D:** Anteroposterior radiograph of the foot on the 15th hospital day. Osteolysis and periosteal elevation are noted in the proximal phalanx of the ring finger and the second metatarsal. Although this patient had osteomyelitis, the radiographic appearance also is consistent with a healing dactylitis. (From ref. 62, with permission.)

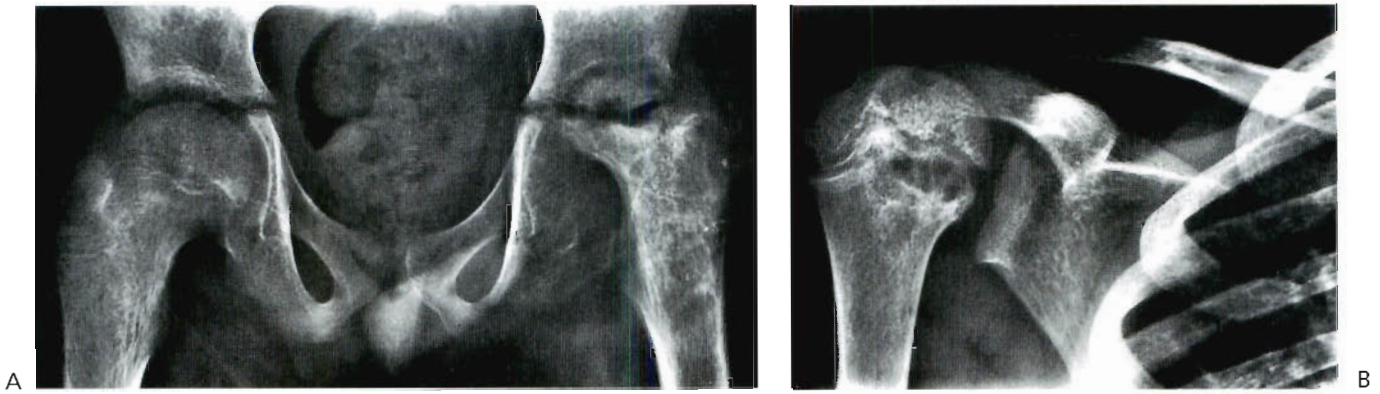

FIGURE 11-4. Eight-year-old boy with sickle cell anemia, who presented with high fever and bilateral shoulder and left hip pain. Cultures from the left hip and right shoulder demonstrated *Salmonella* organisms. **A:** Pelvic radiograph 4 months after diagnosis demonstrates progressive destruction of the left femoral head, as a result of osteonecrosis from the concomitant septic arthritis and osteomyelitis. **B:** Anteroposterior radiograph of the right shoulder demonstrates osteolytic changes in the humeral head and the metaphysis. Similar changes were observed on the contralateral side.

sickle cell crises. Dalton and colleagues (60) observed a 1.6% incidence of osteomyelitis per admission for musculoskeletal complaints in children with sickle cell disease.

The unique features of osteomyelitis in sickle cell anemia include a high incidence of *Salmonella* and multifocal infections, and delay in diagnosis. In reviewing the nine studies of osteomyelitis in sickle cell anemia, published from 1981 to 1996, Burnett et al. (61) observed that *Salmonella* was the most common infecting organism, and that the overall ratio of *Salmonella* to *Staphylococcus aureus* was 1.4 to 1. Interestingly, the incidence of *Salmonella* was relatively high in studies from centers in the United States, the ratio of *Salmonella* to *S. aureus* being 5.1 to 1 in this population. Other Gram-negative enteric bacilli are almost as common as *S. aureus* as a cause of osteomyelitis in sickle cell disorders. Capillary occlusion and infarction of gut mucosa account for the high incidence of both *Salmonella* and the other Gram-negative enteric organisms.

The key to minimizing complications, such as chronic osteomyelitis and multifocal sites, is early recognition (Figs. 11-3 and 11-4). However, differentiating a sickle cell crisis or dactylitis from osteomyelitis may be difficult. The degrees of fever and leukocytosis overlap, and the initial radiographs do not show abnormalities in either disorder. In addition, because of the shape of the erythrocyte, the erythrocyte sedimentation rate is unreliable in sickle cell disorders. Furthermore, the usual radionuclide and magnetic resonance imaging studies are inconclusive (63). As a result, appropriate treatment of osteomyelitis may be delayed (62,64,65). Although various combinations, such as sequential gallium scans, have been reported to be useful, the reliability and radiation exposure of these techniques have led experienced observers to comment that these tests, as well as magnetic

resonance imaging, do not reliably differentiate infarction from infection (63,66,67).

Osteomyelitis should be considered when a child presenting with an apparent crisis or dactylitis, has a temperature greater than 39°C, an unusual degree of pain, and a “left shift” in the peripheral leukocyte count (62,66). Blood cultures, as well as aspiration or open biopsy of the affected bone, may be necessary to differentiate these two clinical problems, and should be performed whenever the diagnosis is uncertain. Ultrasonography also should be considered in the evaluation process. In a recent study, Sadat-Ali et al. (68) observed that ultrasonography routinely demonstrated periosteal elevation in sickle cell patients who had osteomyelitis, but did not show abnormalities in patients with infarction.

If osteomyelitis is a possibility, antibiotic therapy is instituted with chloramphenicol or ampicillin to cover *Salmonella*, and with oxacillin to provide protection against *S. aureus*. The emergence of resistant *Salmonella* species has caused some authors to suggest that a newer β -lactam or quinolone should be used as the initial antibiotic (69,70). With a delay in diagnosis, surgical drainage and prolonged parenteral antibiotic therapy is needed. The wound should be left open when a large subperiosteal abscess is present (65).

Pathologic fractures complicating long-bone osteomyelitis are more common in patients with sickle cell anemia (65,71), and occurred in 10% of patients in one large series (69). In that study, fractures were more common in the first decade of life, in acute, compared with chronic, osteomyelitis, and in patients whose treatment was delayed. Delayed union, malunion, or joint stiffness complicated approximately 10 to 15% of the fractures.

Compared with osteomyelitis, septic arthritis is relatively

uncommon in sickle cell disease (58,72). Unless the joint infection is secondary to direct penetration from an adjacent osteomyelitis, most cases of septic arthritis are caused by organisms other than *Salmonella* (72). Because of delay in diagnosis, septic arthritis of the hip in patients with sickle cell disease is more likely to be complicated by avascular necrosis or dislocation (71).

Reactive arthritis, causing a sterile joint effusion, also may occur in children with sickle cell anemia (73,74). The knees and elbows are most frequently involved, but symptoms may occur in other joints. Acute onset of pain occurs in one or more joints. Fever is commonly present, and may range from low-grade to greater than 39°C. Synovial fluid analysis typically reveals a leukocyte count of less than 20,000/mm³. Joint effusions usually last 1 to 2 weeks, and the duration of arthralgia ranges from a few days to 2 months. The cause of reactive arthritis is unknown, but may be associated with minor episodes of *Salmonella* enteritis or microvascular thrombosis in the synovial tissue. Treatment for reactive arthritis is splinting and analgesic medication.

Osteonecrosis of the femoral and humeral heads is common in sickle cell disease. In radiographic studies of more than 2,500 patients older than 5 years of age, the prevalence was dependent on the patient's age and the type of sickle cell disease (75,76). The prevalence was higher in the proximal femur, averaging 9.7% at this location, compared with 5.6% in the humerus (Tables 11-3 and 11-4). Patients with the SC or $S\beta^+$ genotype had a lower incidence of osteonecrosis, and tended to develop this problem at a later age. Within the SS group, patients homozygous for the α -thalassemia gene were more likely to develop osteonecrosis. This provides further evidence that the association of the α -thalassemia gene increases the risk of vasoocclusion. Bilateral osteonecrosis of the humeral head was more common, occurring in 67% of patients, compared with a 54% incidence of bilateral involvement of the femoral head. Concomitant humeral and femoral head osteonecrosis was common, occurring in 76% of SS patients and 75% of SC patients.

Osteonecrosis of the femoral head may not cause symp-

TABLE 11-4. PREVALENCE OF HUMERAL HEAD OSTONECROSIS IN SICKLE CELL DISEASE

Age (years)	Percent with Humeral Head Osteonecrosis	Type of Sickle Cell Disease	
		Genotype	Percent ^a
5-9	1.2	SS	6.0
10-14	2.6	$S\beta^0$	5.7
15-24	3.8	SC	4.6
25-34	9.7	$S\beta^+$	3.6
35-44	18.7		
≥45	22.0		

^a Age-adjusted rate.

(Adapted from ref. 76, with permission.)

toms for several years. In a large radiographic study, almost one-half of the patients were asymptomatic at the time of diagnosis, but 21% of this group became symptomatic in the follow-up period, which averaged 5.6 years (75). Children have a better prognosis. In the study by Hernigou and colleagues (77), when the osteonecrosis developed before 10 years of age, only 5 of 14 hips had a Harris hip score lower than 80 points, at an average follow-up of 19 years. In comparison, 51 of 81 hips had a low hip rating when the osteonecrosis developed between 10 and 14 years of age. Therefore, young children with sickle cell disease have a reasonable potential for healing avascular necrosis of the femoral head, but the prognosis is guarded when osteonecrosis develops during adolescence.

Although not particularly useful in the very early detection of osteonecrosis, magnetic resonance imaging (MRI) is helpful in defining the extent of the infarct (78) (Fig. 11-5). Furthermore, MRI frequently shows that segments of the femoral head are involved to varying degrees, suggesting that different segments of the femoral head are infarcted at different times (80).

Several series have documented poor results after total joint arthroplasty in patients with sickle cell disease (81-83). Both acute and late complications are increased, with the incidence of infection and early revision being alarmingly high. This factor, and the poor long-term results for children older than 10 years of age, necessitate consideration of realignment osteotomy for this group. Radiography and MRI should define the extent of the avascular necrosis. With extensive involvement of the femoral head, or deficiency of the lateral pillar, a femoral or pelvic osteotomy should be considered. Abduction bracing is a better alternative for younger children (Fig. 11-5), but loss of motion and total head involvement require consideration of other therapeutic alternatives.

Compared with osteonecrosis of the femoral head, disability and pain are less frequent with osteonecrosis of the humeral head. In a large radiographic survey, more than 79% of the patients were asymptomatic at diagnosis (76).

TABLE 11-3. PREVALENCE OF FEMORAL HEAD OSTONECROSIS IN SICKLE CELL DISEASE

Age (years)	Percent with Femoral Head Osteonecrosis	Type of Sickle Cell Disorder	
		Genotype	Percent ^a
5-9	1.3	$S\beta^0$	13.1
10-14	4.6	SS	10.2
15-24	8.2	SC	8.8
25-34	18.8	$S\beta^+$	5.8
35-44	21.9		
≥45	32.5		

^a Age-adjusted rate.

(Adapted from ref. 75, with permission.)

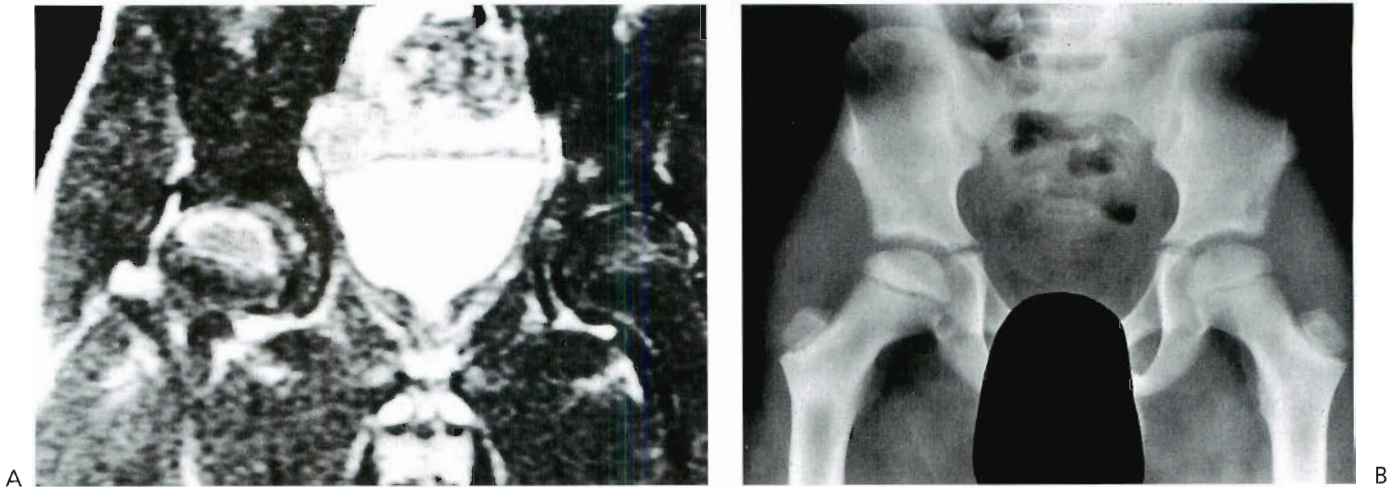


FIGURE 11-5. A: Magnetic resonance image of a 7-year, 4-month-old boy with sickle cell anemia. Patient complained of pain in the right hip. The T2-weighted image is consistent with avascular necrosis of the right femoral head. On other views, abnormal signals also were present in the left femoral head, although not to the degree seen in the right femur. B: Anteroposterior radiograph of the pelvis 5 months later demonstrates sclerosis of the lateral and inferior margins of the epiphysis, consistent with the creeping substitution healing of osteonecrosis. Patient had been maintained in an abduction brace. (Adapted from ref. 79, with permission.)

The disease process, however, may progress. The crescent sign and collapse of the humeral head typically begin in the superior medial quadrant. Further fragmentation and joint incongruity will cause symptoms and restricted motion, but the need for prosthetic replacement is uncommon.

Hydroxyurea stimulates hemoglobin F synthesis in many patients with sickle disease, and in a study of 299 adult patients, the frequency of crisis, acute chest syndrome, and hospitalization and the need for blood transfusion were significantly reduced by hydroxyurea (84). Similar findings have been observed in children, although these studies involved an earlier phase (85–87). The major short-term toxicity of hydroxyurea is reversible neutropenia, but whether this drug will prove to be carcinogenic over the long term is unknown. For that reason, hydroxyurea is not used in patients with minimal symptoms. It is hoped that hydroxyurea and other medications will prevent the organ damage and mortality associated with sickle cell disorders.

The use of bone marrow transplantation in patients with sickle cell disease is controversial (88). Complications are less frequent if the patient is young without major chronic organ damage, and is being transplanted from a healthy HLA-identical relative. In a series of 22 children with sickle cell disease who received marrow transplants from HLA-matched siblings, Walters et al. (89) observed that 15 were cured, 4 had recurrent disease with unknown effect of the conditioning chemotherapy on their sickle cell disease, 1 had mixed results, and 2 died after transplantation. Successful transplantation will cure the patient of the sickle cell disease and its associated pain. Furthermore, Hernigou et al. (90) reported significant healing of humeral head os-

teonecrosis after bone marrow transplantation in a 13-year-old boy. On the other hand, even if transplantation is successful, these patients are likely to be infertile, and to have an uncertain future risk of chemotherapy inducing malignancy.

Intraoperative considerations for patients with sickle cell disease include adequate hydration, avoidance of hypothermia and deoxygenation, and maintenance of blood volume. The use of a tourniquet does not cause increased sickling (91), but special efforts should be made to exsanguinate the limb before inflating the pneumatic tourniquet. In a study of 1,079 surgical procedures performed on 717 sickle cell patients, the only association between preoperative hemoglobin A level and complication rate was the reduction in painful crises (92). Of note, complications after operation were more common in patients receiving regional, rather than general, anesthesia.

Thalassemia

The thalassemias are an extremely heterogeneous group of inherited anemias caused by mutations in the synthesis of hemoglobin (93). Normal hemoglobin is a tetramer consisting of two α -like and two β -like globin polypeptides. Hemoglobin A, a highly soluble and stable polypeptide formed by two α -globulin and two β -globulin chains, is the predominant hemoglobin found in normal red blood cells after the age of 6 months. Two minor hemoglobins, hemoglobin A2 ($\alpha_2\delta_2$) and hemoglobin F ($\alpha_2\gamma_2$), normally constitute a small fraction of the hemoglobin found in red blood cells, with the proportion of hemoglobin A2 being about 2.5%

and that of hemoglobin F being less than 1% after the age of 6 months.

Thalassemia is characterized by absent or deficient synthesis of one or more globin chains. The consequences range from severe anemia to laboratory abnormalities of no clinical significance.

The gene for α -globulin is duplicated on chromosome 16. Therefore, each human cell contains four copies of the α -globulin gene. The four α -thalassemia syndromes are based on whether one, two, three, or four of the α -globulin genes are defective (93). If all four α -globulin genes are affected, the result is hydrops fetalis and death *in utero*. Otherwise, patients with α -thalassemia have significantly fewer problems than patients with β -thalassemia. This is because unpaired β -globulin chains can form a relatively stable tetramer (hemoglobin H). A person with one affected gene has the silent carrier syndrome, which is characterized by no anemia and normal red blood cells. In the thalassemia trait syndrome, two genes are affected; these patients have mild anemia with hypochromic and microcytic red blood cells. In practical terms, thalassemia trait at the time of diagnosis requires differentiation from iron-deficiency anemia (94). Patients with three affected α -globulin genes have hemoglobin H disease, a syndrome characterized by moderate anemia, chronic hemolysis, and a relatively benign course. As a result of different mutations, clinical heterogeneity is seen within each α -thalassemia syndrome. Individuals who are heterozygous for β -thalassemia are sometimes classified as having thalassemia minor.

Cooley anemia or severe β -thalassemia is secondary to homozygous mutations of the β -globulin gene, with a resultant absent or severely deficient synthesis of the β -polypeptide chain. Therefore, in β -thalassemia, many of the hemoglobin molecules are composed of unpaired α -globulin chains. This molecule is extremely insoluble and causes intracellular precipitates. The circulating erythrocytes are distorted, extremely small, and have a markedly reduced amount of hemoglobin. In addition, increased hemolysis occurs because these damaged erythrocytes are removed at an accelerated rate. The clinical consequences are severe anemia, growth retardation, hepatosplenomegaly, and bone marrow expansion, with its associated complications.

Current use of the term "thalassemia major" implies a homozygous β -thalassemia that requires regular blood transfusion (93). "Thalassemia intermedia" is applied to a group of homozygous β -globin patients who maintain hemoglobin levels of 6 to 10 g/dL, except during periods of infection or surgery. Severity of disease is related to the relative imbalance between α -globin and total non- α -globin synthesis. This is determined by the specific mutation(s) in the β - and α -globin genes, as well as by the ability of the individual to synthesize hemoglobin F.

Untreated patients with thalassemia major present with severe anemia during the first months of life, and most will die during the first 5 years of life. Transfusion programs to

maintain hemoglobin levels between 9.5 and 11.5 mg/dL, and chelation therapy to minimize the effect of iron overload, have markedly altered life expectancy and other problems seen in thalassemia; however, even when serial transfusions are begun at an early age, patients still may develop growth retardation and endocrine abnormalities, and may die of cardiac dysfunction in middle age (95).

Skeletal abnormalities seen in sporadically treated thalassemia result from extreme erythroid hyperplasia, which causes widening of the marrow space, thinning of the cortex, and striking osteoporosis (96). The earliest changes are noted in the hands and feet. The metacarpals, metatarsals, and phalanges are expanded to a rectangular, then a convex shape. The changes observed in these peripheral areas diminish in older children as the distal red marrow is replaced by fatty marrow; however, the skull, the spine, and the pelvis in these patients may show progressive radiologic changes (Figs. 11-6 and 11-7).

Earlier studies noted that fractures after minimal trauma occurred in 40 to 50% of patients with thalassemia at an average age of 10 to 16 years (97–99). Transfusion therapy has decreased the incidence and nature of this complication. For example, Michelson and Cohen (100) recorded a fracture incidence of 21%, at an average age of 25 years, when a transfusion program was started during early childhood. Furthermore, fractures in these patients occurred after a more appropriate level of trauma, and healed within an expected time and without the deformity commonly seen in earlier studies.

Premature fusion of the physis also was observed in earlier studies of thalassemia patients (97,101). This problem was noted in 15 to 20% of the patients, and was particularly common in the proximal humeral physis. The cause of the premature physal fusion was unclear, but the problem was observed more frequently in the patients who had a delay in beginning transfusion therapy (101).

Iron overload in thalassemia results from transfusion therapy and excessive absorption of iron in the gut (102). Excessive catabolic iron overwhelms the iron-binding capacity of transferrin. Free iron is toxic to cells, promoting hydroxyl radical formation. Hemosiderin deposits accumulate in the reticuloendothelial cells, leading to hepatomegaly. Iron deposition also occurs in the central and peripheral bone marrow (103). Most importantly, free iron in the heart impairs the function of the mitochondrial respiratory chain. As a result, fatal cardiomyopathy occurs during the adolescent years unless treatment is instituted. Chelation therapy with deferoxamine markedly delays or prevents cardiac disease. The prognosis for survival without cardiac disease is particularly good for patients whose serum ferritin concentrations remain less than 2,500 ng/mL (104). Chelation therapy is best started at a young age, but even then it may not always prevent growth failure and/or delayed or absent puberty (105).

Spinal cord compression, secondary to extramedullary

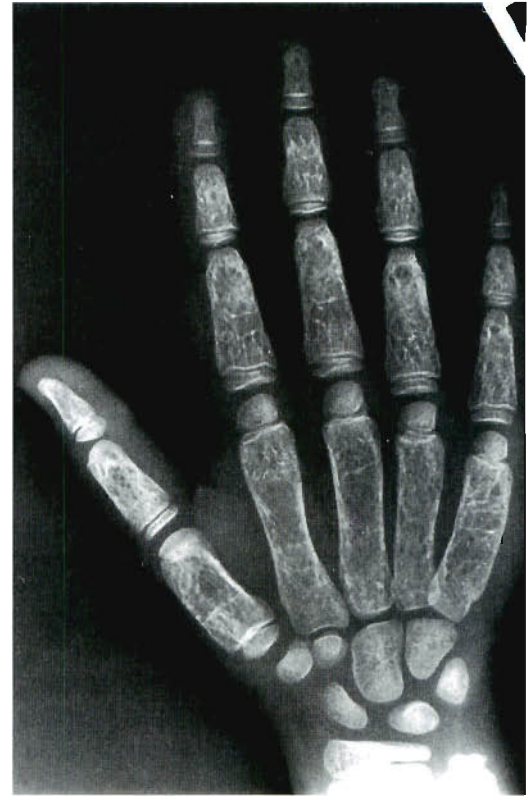
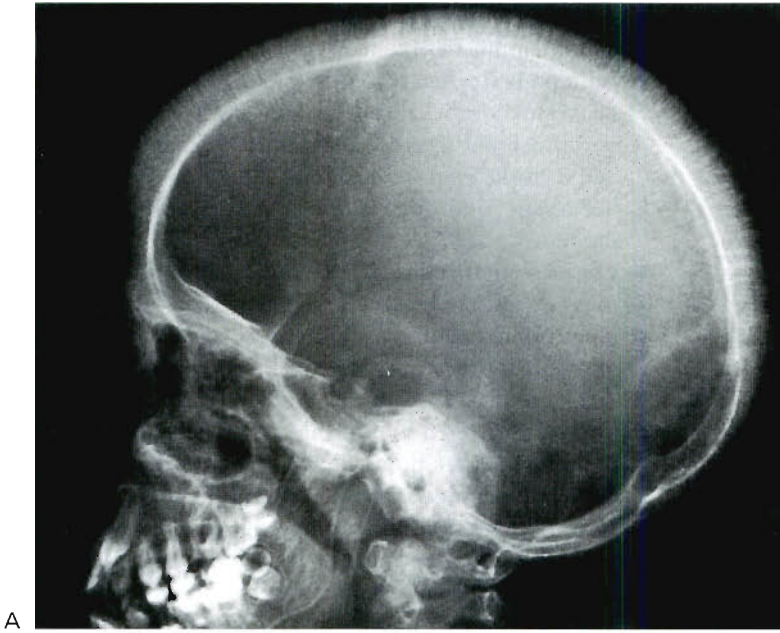
FIGURE 11-6. A: Lateral radiograph of the skull, showing the radial striations of the calvarium in an 11-year-old boy with thalassemia major. B: Note the widened marrow cavities of the metacarpals and phalanges, and the marked osteoporosis.

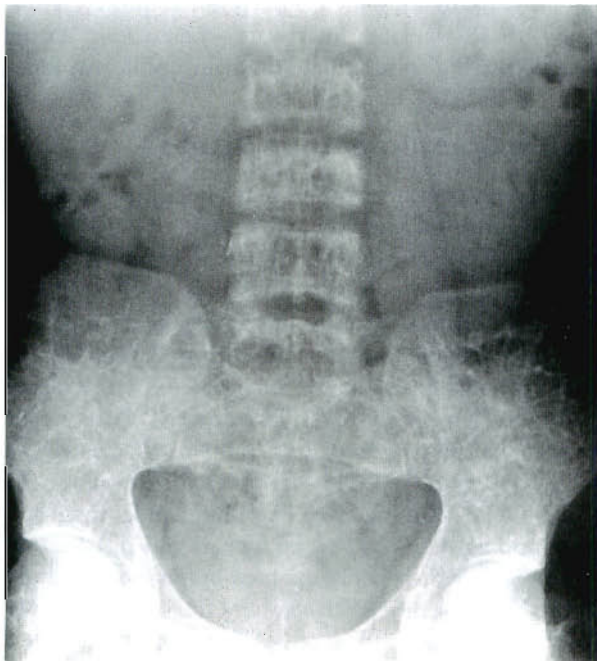


FIGURE 11-7. Anteroposterior radiograph of the lumbar spine and pelvis in a 26-year-old man with homozygous β -thalassemia. Radiographs show marked osteoporosis and lacy trabeculae secondary to marrow hypoplasia. (From ref. 79, with permission.)

hematopoiesis, is an uncommon complication typically seen in adult patients with thalassemia intermedia (106–108). Treatment is controversial. MRI should be performed. Surgical decompression, radiotherapy, and transfusion therapy are treatment alternatives.

Owing to the long-term problems of chronic transfusion therapy and the risk of blood-borne diseases, bone marrow transplantation increasingly is being used for patients with thalassemia major (93,109). The best results are seen in patients younger than 16 years who have not developed hepatomegaly or portal fibrosis, who have received regular chelation treatment before transplantation, and who receive a bone marrow transplant from an HLA-identical donor after undergoing a preoperative conditioning regimen. In this group, 12-year Kaplan-Meier analysis in 111 patients showed a 96% survival rate, a 90% disease-free survival rate, a 7% rejection mortality, and a 4% nonrejection mortality. After successful bone marrow transplantation, chelation treatment may improve liver and cardiac function (110).

Anemia of Chronic Inflammation

Anemia of chronic inflammation (ACI) is a well-recognized, but imperfectly understood, disorder associated with disorders of chronic infection, serious trauma, malignancy, and inflammation, such as juvenile rheumatoid arthritis (94,111,112). Although, in the past this disorder was fre-

quently called anemia of chronic disease, the change in nomenclature reflects a shift in understanding that inflammation is the key component. Chronic diseases without an inflammatory component are not ACI (111). Furthermore, within a particular disease, the patients who develop anemia are the patients who have a more serious course of their underlying disease (113).

In patients with ACI, the anemia is typically mild (hemoglobin greater than 9 g/dL) and nonprogressive. The erythrocytes are normocytic or mildly microcytic. However, the most characteristic laboratory findings in ACI are an elevated plasma ferritin level and normal-to-low transferrin saturation. These parameters allow differentiation from iron-deficiency anemia, in which both ferritin and transferrin levels are low, and distinguish ACI from iron-overload disorders, in which both levels are high.

ACI is a multifactorial process reflecting impaired release of iron from storage sites, and inhibition of erythroid progenitors. In ACI, large deposits of iron remain stored as hemosiderin in the reticuloendothelial cells (111,112). Inflammatory mediators, such as interleukin-1 and tumor necrosis factor, stimulate ferritin synthesis, and excessive ferritin shells are probably the cause of iron remaining in storage (114). As a result, there is impaired transport of iron from storage sites to developing erythrocytes. Patients with ACI also have low levels of erythropoietin, which is consistent with cell culture studies demonstrating suppression of erythropoietin production by inflammatory cytokines (115).

Treatment of ACI is most effective when the source of inflammation can be eliminated. Iron therapy is of no value, and observation is often chosen when the anemia is mild. Blood transfusion or erythropoietin may be necessary when the anemia is compromising postoperative management or other aspects of treatment (94,111).

DISORDERS OF NEUTROPHILS

Phagocytic white blood cells include two groups: granulocytes (neutrophils, eosinophils, and basophils) and mononuclear cells (monocytes and tissue macrophages). Neutrophils are the first line of defense against bacterial and fungal infections, and as such, their specialized machinery is focused to seek out, ingest, and kill microorganisms (116,117). While circulating in the bloodstream, neutrophils detect and respond to chemotactic substances released from a site of infection. As a result, a chain of complex and overlapping reactions ensue (117):

- Loose adhesions are made and broken between the neutrophil and the postcapillary venule endothelium. As a result, neutrophil movement is slowed (leukocyte rolling), and the cells gain a more intense exposure to the activating factors.
- Blood flow is reduced by tighter adhesions formed be-

tween neutrophils and platelets, between neutrophils and endothelium, and by neutrophils adhering to each other.

- Adhesions are then loosened, and the neutrophils migrate between endothelial cells to sites of infection, in a complex process of receptor engagement, signal transduction, and cytoskeleton remodeling. Secretion of gelatinase, heparinase, and other enzymes facilitates this migratory process.
- On reaching the site of infection, neutrophils adhere to microorganisms by several different types of receptors.
- Neutrophils engulf most bacteria (phagocytosis), with the microorganism sequestered in a closed vacuole called a "phagosome." Organisms that are too large, such as fungi, are covered by a firmly adherent layer of neutrophils, which then proceed with phagocytosis in a similar, collective manner at the neutrophil-hyphae interface.
- Neutrophils have different types of granules, which contain a variety of antimicrobial proteins. Optimal killing requires concurrent degranulation and activation of nicotinamide adenine dinucleotide phosphate (NADPH) oxidase, with injection of their products into the phagosome.
- Activation of NADPH oxidase at the phagosome membrane sets off the respiratory burst reaction. NADPH reacts with oxygen to generate superoxide, which combines with water to produce hydrogen peroxide (H_2O_2). Myeloperoxidase, an azurophil granule component, catalyzes H_2O_2 to combine with chloride anions to form hypochlorous acid (HOCl). The oxidants H_2O_2 and HOCl not only kill bacteria, but also activate neutrophil granule proteases and, more importantly, denature bacterial proteins, making them susceptible to proteolysis. Finally, these oxidants inactivate chemotactic factors, thereby serving to terminate the neutrophil invasion.

Chronic Granulomatous Disease

Inherited defects of neutrophils may affect various components of neutrophil function and structure (117). Chronic granulomatous disease (CGD) is the most common congenital disorder of neutrophils, occurring in 1 per 200,000 to 250,000 live births. Osteomyelitis is relatively common in CGD and has some unique features in this disorder.

CGD is actually a group of four related diseases characterized by deficiency in NADPH oxidase. Defects in four *phox* proteins (phagocyte oxidase proteins that participate in the activation of NADPH) have been identified as causes of CGD (117–120). Inactive NADPH includes three cytosolic components (p47 *phox*, p67 *phox*, and p21 *rac*) and cytochrome *b*, which is plasma-membrane-bound, and is composed of the larger gp91 *phox* and the smaller p22 *phox* subunits. During activation of NADPH oxidase, the cytosolic components migrate and attach to the membrane components.

CGD is most commonly transmitted by sex-linked recessive inheritance as a result of a mutation in the X chromo-

some gene for gp91 *phox* (117). Other types of CGD are autosomal recessive disorders. Approximately 60 to 65% of CGD is secondary to a defect in gp91 *phox*, and 30% is secondary to a defect in the gene encoding p47 *phox* (chromosome 7). Defects in p67 *phox* (chromosome 1) or p22 *phox* (chromosome 16) account for the remaining cases of CGD.

Phagocytosis is normal in CGD, but the neutrophils have decreased ability to kill microbes that are catalase-positive. Therefore, infections with *Staphylococcus aureus*, *Aspergillus* species, *Escherichia coli*, *Klebsiella* species, *Salmonella* species, *Berkholderia cepacia*, *Pseudomonas aeruginosa*, *Serratia marcescens*, *Enterobacter* species, *Proteus* species, and *Nocardia* species are common in CGD. With an infection by a catalase-negative microbe, the H_2O_2 produced by the bacterium may be used by the CGD neutrophils as a bypass to complete the killing process.

A typical patient with CGD is a boy who develops symptoms of recurrent skin and pulmonary infections associated with persistent lymphadenopathy in the first or second year of life. Girls may be affected if the CGD is secondary to the less common autosomal recessive disorders. Nitroblue tetrazolium dye is a useful screening test for CGD, but it is being supplanted by the more accurate flow cytometry test using dihydrorhodamine 123 fluorescence, which detects oxidant production (117).

Recurrent infections include superficial infections, such as skin abscess, lymphadenitis, and perirectal abscess, or deep infections, such as pneumonia, otitis media, osteomyelitis, and liver abscess (116,121) (Fig. 11-8). The severity of CGD is not uniform. An adverse prognostic indicator is development of symptoms before 1 year of age (122), a factor that probably reflects the site of mutation, and whether any residual NADPH oxidase activity is present.

Osteomyelitis can be particularly problematic in CGD, and has been noted in 20 to 30% of these patients (116). Earlier reports of osteomyelitis in CGD indicated that the bones of the hands and feet were most commonly involved (123), but in a later review of 13 children who developed 20 episodes of osteomyelitis (124), the spine and the ribs were the most common sites of infection. Direct spread from a contiguous lung or hepatic abscess is the usual cause of spine or rib involvement, whereas hematogenous spread causes long-bone infections. *Aspergillus* is a common cause of vertebral osteomyelitis in CGD (116,124), and, as one might expect, the diagnosis of vertebral osteomyelitis is often delayed in these children. Sponseller and colleagues (124) found that these patients did not respond to antibiotics alone, and noted that their best results were obtained with preoperative imaging to define the extent of the bony infection, temporary withholding of antibiotics to obtain reliable intraoperative cultures, thorough debridement of the infected tissue, and leaving the wound open to allow healing by secondary intention. However, other authors have reported successful medical cure of extensive *Aspergillus*

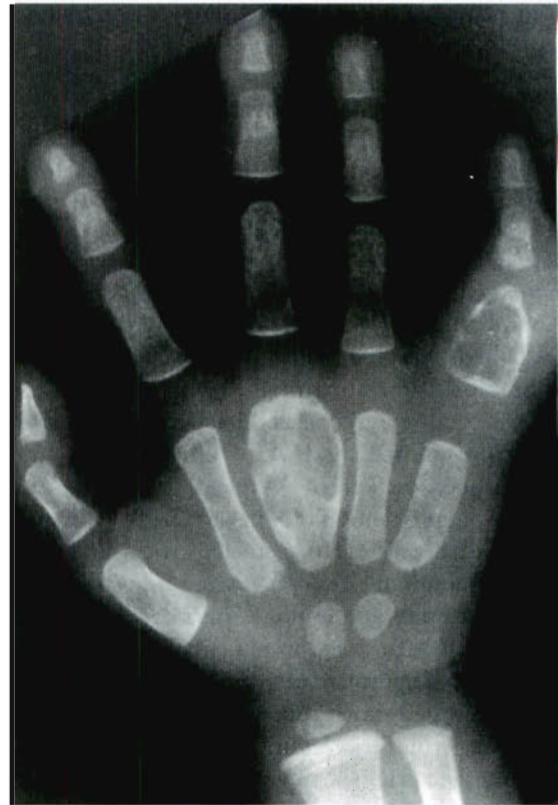

FIGURE 11-8. Fifteen-month-old boy with a 2-month history of progressive swelling of the right hand. Anteroposterior radiograph of the hand demonstrates fusiform swelling and osteolysis of the third metacarpal and proximal phalanx of the little finger. The patient had a past history of tuberculosis meningitis. Because the chest radiograph demonstrated infiltrates, the preoperative diagnosis was tuberculosis dactylitis. A drainage procedure was performed. Cultures demonstrated *Serratia marcescens*; subsequent tests confirmed the diagnosis of chronic granulomatous disease.

osteomyelitis of the spine, using recombinant γ -interferon and antifungal agents (125–127).

A 50% survival rate at 10 years of age was noted in one retrospective study published in 1989 (128), but most CGD patients now survive into adulthood (117). Principles of the comprehensive management of a child with CGD include the following (117):

- Prevention of infections by timely immunizations, compulsive hygiene (hand washing, dental cleaning, careful anal washing, prompt cleansing of any skin damage), and avoidance of possible sources of pathogens (passive smoke, bedside humidifiers, decaying plants)
- Prophylaxis with trimethoprim-sulfamethoxazole or dicloxacillin; studies have shown an approximately 50% reduction in infections in children with CGD on prophylactic antibiotics
- Use of recombinant human γ -interferon; a multicenter, double-blind, randomized study demonstrated a 70% re-

duced infection risk when interferon was administered prophylactically (129)

- Early administration of parenteral antibiotics that cover *S. aureus*, as well as Gram-negative bacteria
- Prompt drainage of abscesses and selected surgical biopsy for culture and definitive diagnosis; the latter is particularly true with suspected fungal infections.

Formation of granulomas, probably secondary to chronic inflammation from inadequate immunologic debridement, may complicate CGD. As a result, gastric outlet obstruction, ileocolitis, chronic cystitis, hepatosplenomegaly, and other chronic inflammatory problems may develop. Cyclosporine has been reported as an effective treatment for retractable colitis in one child with CGD (130).

Heterozygous carriers of X-linked CGD may sustain some infectious problems if they have a relatively large number of abnormal cells (116). Female carriers may also develop the autoimmune disorder discoid lupus erythematosus. This and other autoimmune disorders, although less likely, also have been noted in patients with CGD (131).

Bone marrow transplantation is controversial in CGD, but it has been performed successfully with an HLA-compatible sibling and preconditioning therapy (132,133). Clinical trials of gene therapy are under way in patients with CGD. Neutrophil function has been augmented in a small percentage of cells for a few months (134), but high-level, permanent gene transfer to hematopoietic cells has not been achieved.

DISORDERS OF LYMPHOCYTES AND THE IMMUNE SYSTEM

Lymphocytes can be divided into two main categories. Bone marrow-derived lymphocytes, the B cells, are precursors for humoral immunity cells (i.e., plasma cells that secrete antibodies). Thymus-derived lymphocytes, or T cells, control cell-mediated immunity, and have both effector and regulatory functions. Effector functions include delayed hypersensitivity and graft-versus-host reactivity. Regulatory functions include enhancement and suppression of both cell-mediated and humoral immunity.

X-linked Agammaglobulinemia

X-linked agammaglobulinemia is a sex-linked recessive disorder manifested by recurrent bacterial infections that typically begin after 6 months of age, when maternal immunoglobulins have essentially disappeared (135). Physical findings are sparse. Tonsils and palpable lymph nodes are virtually absent. The history of recurrent dermatitis, otitis media, pneumonia, and meningitis initiates appropriate laboratory studies. The disease is confirmed by profound hypo-

gammaglobulinemia, absence of B lymphocytes, and a normal number of T cells and lymphocytes (136). Defective production of cytoplasmic tyrosine kinase, a signaling protein that is necessary for the maturation at the pre-B-cell stage, is the cause of X-linked agammaglobulinemia (137).

Without circulating B lymphocytes, children are susceptible to infection by pyogenic encapsulated bacteria (135,137). Response to fungal and viral infections is normal, except for enterovirus and vaccine-associated poliomyelitis. Delayed hypersensitivity and allograft rejection are also normal. Untreated, patients with agammaglobulinemia usually develop bronchiectasis and die of pulmonary complications. The prognosis is significantly improved with immunoglobulin therapy and prompt institution of antibiotics for infections.

The unique musculoskeletal problem seen in agammaglobulinemia, and in other disorders causing hypogammaglobulinemia, is an arthropathy that resembles juvenile rheumatoid arthritis. In a review of 69 patients with X-linked agammaglobulinemia, 11 had aseptic arthritis and 4 had septic arthritis at presentation, and 3 patients subsequently developed aseptic arthritis (138). The arthritis is usually nonerosive, and either oligoarticular or polyarticular, and it most commonly affects the knees, the wrists, the ankles, and the fingers (139). The cause of the arthritis is unclear, but the presence of excessive suppressor T cells in the synovial tissue clearly makes the arthritis in these patients different from classic rheumatoid arthritis (140).

Although the arthritis in most patients responds to immunoglobulin therapy, chronic synovitis persists in a few patients (139). Atypical infections undoubtedly account for some of these cases. In a survey of 358 patients with primary antibody deficiency, Franz and colleagues (141) found that mycoplasmal infection was the most common cause of severe chronic erosive arthritis.

Acquired Immunodeficiency Syndrome

Through 1997, it is estimated that 12 million people worldwide have died of acquired immunodeficiency syndrome (AIDS), and 3 million of these deaths were in children (142). Children younger than 13 years of age account for 1% of the AIDS cases in the United States, but even in this country, AIDS is one of the top ten causes of death between the ages of 1 and 13 years (143). The rate in children is much higher in sub-Saharan Africa, where two-thirds of the 30 million people with human immunodeficiency virus (HIV) infections reside.

Perinatal transmission is the cause of most HIV infections in children younger than 13 years of age. Congenital HIV infection can be acquired in the intrauterine environment, during delivery, or after delivery (through breast feeding) (144). Studies suggest that the most common route of

vertical transmission is intrapartum, and the least common is by breast feeding.

When the patient is infected, viremia occurs. HIV binds to cells expressing CD4 molecules on their surface, primarily CD4 lymphocytes, but also cells of the monocyte-macrophage lineage (144). Cells of the central nervous system, such as microglia, astrocytes, and oligodendroglia, also may be affected. CD4 lymphocytes accumulate in the lymph nodes, where they proliferate, resulting in a generalized lymphadenopathy. During this period of clinical latency, there is a reduction in the measurable level of HIV in the blood but also a gradual deterioration of the immune system, which is characterized by depletion of CD4 cells trapped in the lymph nodes. In the later phase of the disease, the dendritic meshwork of the lymph nodes deteriorates, and HIV levels in the bloodstream again increase.

Untreated, the duration between infection and AIDS-related illnesses is shorter in children than in adults (144,145). However, great strides have been made in the prevention of vertical HIV transmission, as well as in the treatment of infected infants (146–148). In one study, antiretroviral treatment of the mother, during pregnancy, and of the infant decreased the transmission rate from 25.5% in the placebo group to 8.3% in the group receiving zidovudine (147). The use of prophylactic antibiotics, a consistent immunization program, and aggressive therapy for *Pneumocystis carinii* pneumonia and other infections, also extend the life expectancy of these infants. Approximately 70% survive until their fifth birthday, and these figures are continuing to change (149). As a result, the diagnosis of congenital HIV infection by itself should not be a contraindication to elective surgery.

Encephalopathy is common in congenital HIV infection (144,145). The most common manifestation is a progressive disorder, but some children have a static encephalopathy that is similar to spastic diplegic or quadriplegic cerebral palsy. If gross motor development is stymied by muscle imbalance and contractures, and if the immunologic status is satisfactory, then surgical procedures will improve motor function. The CD4 count and viral load should be assessed preoperatively. Absolute CD4 counts are higher in infants, and severe depression of CD4 lymphocytes is considered to be present when there are counts of less than $750/\text{mm}^3$ in children younger than 12 months of age, less than $500/\text{mm}^3$ in children 1 to 5 years old, and less than $200/\text{mm}^3$ in children 6 years of age or older.

Although the incidence of vertical transmission of HIV infection is decreasing in the United States, the incidence in adolescents is increasing (150). In addition, compared with adults, the infection rate is higher in adolescent girls, indicating a larger proportion of heterosexual transmission in this group. The elimination of contaminated clotting factors has virtually eradicated HIV infection in children with hemophilia.

DISORDERS OF THE MONOCYTE-MACROPHAGE SYSTEM

The mononuclear phagocytic system includes monocytes and macrophages, cells that are critical components of the immune system. Macrophages ingest and kill invading organisms, and also are important in tissue breakdown and remodeling. The mononuclear phagocytic system also functions in antigen presentation, cellular cytotoxicity, and modulation of lymphocytes.

Cells of the monocyte-macrophage system arise from a common stem cell in the bone marrow. After differentiation into monocytes, these cells circulate in the peripheral blood, and migrate to different tissues where they reside, and may change and develop highly specialized functions. Although widely distributed, macrophages are particularly abundant in the spleen, liver (Kupffer cells), lymph nodes, lungs, and bone. Osteoclasts are also derived from monocytes, and, as such, are an example of a highly specialized resident macrophage. Osteopetrosis (Chapter 7) is secondary to a deficiency in osteoclast function, and, therefore, could be classified as a disorder of the monocyte-macrophage system.

Dendritic cells are clearly derived from bone marrow cells. Furthermore, there is supporting but not conclusive evidence that monocytes and dendritic cells develop from a common precursor. Dendritic cells are antigen-presenting but are nonphagocytic. Types of dendritic cells include: (a) follicular dendritic cells found in germinal centers, and thought to function as presenting antigens to B cells; (b) interdigitating reticulum cells, also found in lymph nodes, and thought to function as presenting antigens to T cells; and (c) Langerhans cells of the skin (151).

Storage diseases of the reticuloendothelial system, also called "lysosomal storage diseases," have profound effects on the mononuclear phagocytic system, including the organs housing the reticuloendothelial system. Storage diseases may affect other organ systems, particularly the central nervous system. The common pathogenesis in the storage diseases is a deficiency of a catabolic enzyme normally found in lysosomal particles of the cell cytoplasm (151,152). As a result, products of cellular metabolism accumulate, which would normally be degraded and excreted. The lysosomes are overloaded, and the cell eventually disrupts. Abnormal accumulation of macrophages and organ dysfunction subsequently occur.

The different types of lysosomal storage diseases seen in children and their associated skeletal abnormalities are listed in Table 11-5. Type 1 Gaucher disease, as well as various types of mucopolysaccharidosis and mucopolipidosis, are commonly evaluated and treated by orthopaedic surgeons. Gaucher disease will be discussed in this chapter.

Gaucher Disease

Gaucher disease, initially described in 1882 by Philippe Charles-Ernest Gaucher, is the most common lysosomal

TABLE 11-5. STORAGE DISEASES IN CHILDREN, AND ASSOCIATED MUSCULOKELETAL ABNORMALITIES

Disease	Age at Onset	Stored Material	Enzyme Deficiency	Presenting Symptoms	Additional Skeletal Manifestations
Sphingolipidoses					
Gaucher disease, type 1	Childhood	Glucocerebroside	Glucocerebrosidase	Splenomegaly, anemia, thrombocytopenia	Gaucher crises, widened metaphysis, osteopenia, pathologic fracture, osteonecrosis
Gaucher disease, type 2	Infancy	Glucocerebroside	Glucocerebrosidase	Central nervous system signs, failure to thrive, hepatomegaly	Not significant, death by age 2 years
Gaucher disease, type 3	Adolescence	Glucocerebroside	Glucocerebrosidase	Hepatosplenomegaly, neurologic manifestations	Most have only neurologic manifestations
Niemann-Pick disease, type A (acute neuronopathic form)	Infancy	Sphingomyelin	Sphingomyelinase (severe)	Developmental delay, hepatosplenomegaly	Wasting of the extremities
Niemann-Pick disease, type B (chronic without central nervous system involvement)	Second year	Sphingomyelin	Sphingomyelinase (severe)	Hepatosplenomegaly	Osteopenia, modeling defects with metaphyseal flaring, sea-blue histiocytes in bone marrow, long vertebral pedicles secondary to sphingomyelin in spinal cord
Niemann-Pick disease, types C and D (chronic neuropathic)	Childhood	Sphingomyelin; unesterified cholesterol accumulates in lysosomes	Sphingomyelinase	Considerable variability; infantile group has psychomotor delay; juvenile has ataxic gait; late onset has apparent psychiatric disturbance	No apparent problems from bone marrow infiltration
Farber disease	Infancy	Ceramide	Ceramidase	Painful swelling in the hands and feet, hoarseness, vomiting	Periarticular nodules associated with joint contractures
G _{M1} -gangliosidosis, type 1	Infancy	G _{M1} -ganglioside, glycoprotein	G _{M1} -ganglioside- β -galactosidase	Slow development, spastic quadriplegia, hepatosplenomegaly	Stubby hands, broad wrists, widening of the midshaft of the humerus, anterior breaking of the lumbar vertebrae, spatulate ribs
G _{M1} -gangliosidosis, type 2	1–3 years of age	G _{M1} -ganglioside, glycoprotein	G _{M1} -ganglioside- β -galactosidase	Cessation and regression of motor development	Not significant
G _{M1} -gangliosidosis, type 3	3–30 years of age	G _{M1} -ganglioside, glycoprotein	G _{M1} -ganglioside- β -galactosidase	Progressive pyramidal and extrapyramidal disease	Not significant
G _{M2} -gangliosidosis	Infancy	G _{M2} -ganglioside, globoside	Hexosaminidase A (Tay-Sach disease), hexosaminidase A and B (Sandhoff disease)	Slow development, progressive motor dysfunction, cherry-red macula	Sandhoff disease has foam cells in bone marrow

TABLE 11-5. (continued)

Disease	Age at Onset	Stored Material	Enzyme Deficiency	Presenting Symptoms	Additional Skeletal Manifestations
Mucopolysaccharidoses					
Type I, Hurler syndrome	Infancy	Dermatan sulfate, heparan sulfate	α -Iduronidase	Coarse facial features, corneal opacities, hearing loss, enlarged tongue, frontal bossing, hepatosplenomegaly, joint stiffness	Dysostosis multiplex with rounding and anterior beaking of vertebrae, lumbar kyphosis secondary to hypoplasia of the lumbar vertebrae, shortening of metacarpals and phalanges
Type 1, Scheie syndrome	After 5 years of age	Dermatan sulfate, heparan sulfate	α -Iduronidase	Joint stiffness, claw hands and feet	Carpal tunnel syndrome
Type I, Hurler-Scheie syndrome	3–8 years of age	Dermatan sulfate, heparan sulfate	α -Iduronidase	Progressive corneal clouding, deafness, hepatosplenomegaly, joint stiffness, valvular heart disease	Skeletal changes similar, but less severe than Hurler syndrome, progressive mental retardation
Type II, Hunter syndrome	2–4 years of age	Dermatan sulfate, heparan sulfate	Iduronate sulfatase	Coarse facial features, progressive deafness, stiff joints, hepatosplenomegaly	Dysostosis multiplex as in type I, short stature, degenerative arthritis of the hips
Type III, Sanfilippo syndrome types A, B, C, and D	2–6 years of age	Heparan sulfate	A, heparan- <i>N</i> -sulfatase; B, <i>N</i> -acetyl- α -glucosaminidase; C, acetyl coenzyme A; α -glucosaminide acetyltransferase; D, <i>N</i> -acetyl- α -glucosamine-6-sulfatase	Delayed development, marked hyperactivity, sleep disorders, hirsutism, joint stiffness	Mild dysostosis multiplex with thickening of the calvaria and biconvex configuration of thoracolumbar vertebrae, stature within normal limits
Type IV, Morquio syndrome (type A)	1–2 years of age (severe form)	Keratan sulfate	Galactosamine-6-sulfatase	Short stature, dwarfism, loose joints	Short neck, aplasia odontoid process with C1–C2 subluxation, kyphosis, waddling gait, bowed knee
Type IV, Morquio syndrome (type B)	Variable, usually later than type A	Keratan sulfate	β -galactosidase	Similar but usually less severe than type A Morquio syndrome	Similar but usually less severe than type A Morquio syndrome
Type VI, Maroteaux syndrome	1–2 years of age (severe form)	Dermatan sulfate	Galactosamine-4-sulfatase	Coarse facies, joint stiffness, corneal clouding, deafness	Short stature, C1–C2 subluxation, crouched stance with hip and knee contractures
Type VII, Sly syndrome	Variable	Dermatan sulfate, keratan sulfate	β -Glucuronidase	Coarse facies, cloudy corneas, short stature	Dysostosis multiplex
Mucosulfatidosis (multiple sulfatase deficiency)	Neonatal, late infantile, and juvenile forms	Sulfatides, mucopolysaccharides	Arylsulfatase A, B, and C, other sulfatases	Prominent forehead, flattened nose, short neck, delayed development, hepatomegaly	Dysostosis multiplex

(continued)

TABLE 11-5. (continued)

Disease	Age at Onset	Stored Material	Enzyme Deficiency	Presenting Symptoms	Additional Skeletal Manifestations
Mucopolidoses					
Sialidosis type I	Late childhood	Sialyloligosaccharides, glycoproteins	Neuraminidase specific for glycoproteins and oligosaccharides, with a terminal sialic acid	Falls, decreased visual acuity, myoclonus	Often absent, scoliosis may develop
Sialidosis type II	Congenital, infantile, and juvenile types	Sialyloligosaccharides, glycoproteins	Same as above	Dysmorphic facies, short stature, developmental delay	Dysostosis multiplex, stippled epiphyses, ovoid vertebral bodies
Type II mucopolidosis (I-cell disease)	Infancy	Sialyloligosaccharides, glycoproteins, glycolipids	High serum, but deficient fibroblast levels of variety of acid hydrolases	Wizened face at birth, gingival hyperplasia, stiff joints	Delayed conversion of cartilage to bone, osteopenia, V-shaped deformity of the wrist, acetabular dysplasia, short rounded vertebral bodies, anteroinferior beaking T12 or L1
Type III mucopolidosis (pseudo-Hurler polydystrophy)	2–4 years of age	Glycoproteins, glycolipids	Same as above	Stiffness in hands and shoulders	Short stature, scoliosis, progressive joint stiffness, destruction of hip joints, carpal tunnel syndrome, claw hands
Type IV mucopolidosis (short stature)	Infancy	Glycolipids, glycoproteins	Unknown	Slow development, corneal clouding	
Other Diseases					
Fucosidosis	Type 1, 6–18 months; type 2, 2–3 years; type 3, later childhood	Fucoglycolipids, fucosyloligosaccharides	α -Fucosidase	Slow development, developmental deterioration	Dysostosis multiplex
α -Mannosidosis	Type 1, infantile; type 2, juvenile-adult	Mannosyloligosaccharides	α -Mannosidase	Slow development, coarse facies, hepatosplenomegaly	Dysostosis multiplex, severe in type 1 and mild in type 2
Aspartylglucosaminosis	Second year	Aspartylglucosamine	Aspartylglucosaminase	Recurrent infection, diarrhea, hernias, hypotonia, progressive mental retardation	Mild dysostosis multiplex with wedge-shape vertebrae
Wolman disease	Infancy	Cholesterol esters, triglycerides	Acid lipase	Vomiting, diarrhea, hepatosplenomegaly, calcified adrenals	Not significant
Neuronal ceroid lipofuscinoses (five types)	Variable, related to type	Ceroid lipofuscin pigments	CLN-1-palmitoyl-protein thioesterase; others unknown	Progressive neurologic dysfunction	Not significant

storage disease, with an overall incidence of approximately 1 per 40,000 (152). A sentinel study by Brady and colleagues (153) proved that Gaucher disease was caused by a deficiency of glucocerebrosidase, the lysosomal enzyme that hydrolyzes glucocerebroside, an important component of cell wall membranes. In patients with Gaucher disease, the normal necrosis of cells, especially leukocytes, causes a gradual accumulation of glucocerebroside in macrophages. The resultant Gaucher cell is a large, lipid-laden cell found mostly in the red pulp of the spleen, the liver sinusoids, and the bone marrow. Clinical manifestations of Gaucher

disease are either attributable to accumulation of these abnormal macrophages or a secondary consequence of the resultant organ dysfunction. For example, thrombocytopenia and clotting deficiency resulting from hepatosplenomegaly may precipitate severe leg or back pain, the so-called “bone or Gaucher crisis.”

Three forms of Gaucher disease are recognized. All are characterized by autosomal recessive inheritance. Type I is by far the most common, and is characterized by splenomegaly with resultant pancytopenia, hepatomegaly, and infiltration of the bone marrow, with multiple skeletal mani-

festations. Type II disease, also known as the acute neuropathic or infantile type, is rare, involves the central nervous system, and causes death before age 2 years. Type III disease, also called the chronic neuronopathic type, is typified by the development of hepatosplenomegaly during the first decade, and by neurologic problems during adolescence. All types of Gaucher disease are panethnic, but type I is particularly prevalent among Ashkenazi Jews. The incidence of Gaucher disease in this population has been calculated to be 1 per 450 live births, with a carrier frequency of 9% (154). The prevalence of type III is particularly high in Norrbotten, a northern district of Sweden.

The gene for glucocerebrosidase has been mapped, and more than 109 mutations have been described in patients with Gaucher disease (155). Most are missense mutations causing substitution of one amino acid for another, but insertions, deletions, and crossover recombinations also occur (152). The most common mutations in Jewish patients are 1226G and 84G, whereas 1448C and 1226G are most common in non-Jewish patients (156). The 1226G mutation is an alanine-to-glycine transition at base 1226 that results in an asparagine-to-serine substitution at amino acid 370. This substitution is associated with residual enzyme activity, and patients homozygous for 1226G either remain asymptomatic or have onset of symptoms in the adult years. In contrast, patients homozygous for the 1448T allele have severe loss of enzyme activity, and develop either type II or type III disease. Individuals carrying a 1226G/1448T combination have type I disease, with earlier and more severe involvement. Of note, the presence of the 1226G mutation precludes the development of neurologic problems (157).

Obviously, the type of mutation and its effect on enzyme activity correlate best with clinical severity and age at presentation. However, considerable heterogeneity also is noted among patients with the same genotype (157,158). Possible explanations for this variability include the effect of unknown modifying genes that link with the cerebroside enzyme, and the effect of nongenetic events, such as the influence of viral infections on splenomegaly, and traumatic injuries on the skeletal manifestations of the disease.

Age at onset of symptoms ranges from early childhood to the older adult years. In the study by Zimran and colleagues (158), the age at diagnosis averaged 25 years (range, 8 months to 70 years). The most common symptom at presentation was an abnormality of coagulation, such as epistaxis, easy bruising, or prolonged bleeding after superficial wounds. An incidental finding of splenomegaly or thrombocytopenia prompted diagnosis in some patients before symptoms occurred. Bone pain or fracture may herald the disease, but this was uncommon, noted in only 13% of patients.

Splenomegaly is a cardinal feature of Gaucher disease (158,159). The spleen may be enormous, occupying one-half of the abdomen, with resultant protuberant abdomen,

aching pain, and altered posture. Pancytopenia may occur, although thrombocytopenia and mild anemia are more common. Drug therapy has virtually eliminated the development of hypersplenism and the need for splenectomy in Gaucher disease.

Hepatomegaly also occurs, because glucocerebroside accumulates in Kupffer cells, the specialized macrophage cells that line the walls of the sinusoids of the liver. Compared with the spleen, the degree of liver dysfunction is not as severe (152). Abnormal liver function tests are common, but these abnormalities are of limited consequence. An exception is the effect of liver dysfunction on clotting factors. The resultant coagulopathy may complicate treatment of fractures or operations for arthritic conditions. Drug therapy can reverse these abnormalities.

The skeletal changes seen in Gaucher disease include abnormal widening of the metaphysis, osteopenia, Gaucher crisis or pseudoosteomyelitis, osteomyelitis, pathologic fractures, hemorrhagic cysts, avascular necrosis, and subsequent arthritis.

Infiltration of the bone marrow by the Gaucher cells is the primary cause of the skeletal problems. Triglyceride-rich adipocytes in the bone marrow are progressively replaced by Gaucher cells, and MRI studies show decreased intensity of involved marrow signals on both the T1 and T2 images (160,161). Quantitative MRI studies also correlate with disease severity, as measured by splenic enlargement and other complications (161–163).

Abnormal flaring of the metaphysis, the so-called Erlenmeyer-flask deformity, develops in approximately 70% of patients (158) (Fig. 11-9). This bony deformity most likely

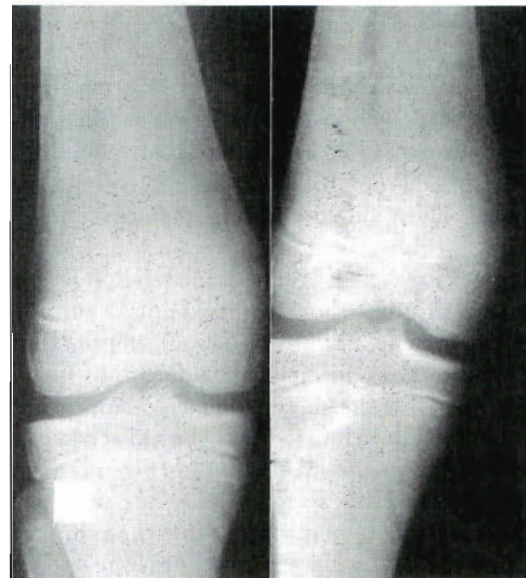

FIGURE 11-9. Flaring of the distal femoral metaphysis, known as Erlenmeyer-flask deformity, in a child with Gaucher disease. (Courtesy of Henry J. Mankin, M.D.)

results from expansion of a relatively weak metaphyseal cortex by the abundant Gaucher cells. The distal femur is most often involved, but the proximal tibia and the proximal humerus also may exhibit a widened metaphysis (164).

Osteopenia is most obvious in the axial and proximal portions of the appendicular skeleton. The osteopenia, however, is diffuse. Bone density measurements in 61 adult patients showed significant decrease at the lumbar spine, femoral neck, and distal radius, and the severity of the osteoporosis correlated with other disease indicators (165). Patients with osteopenia may complain of aching in the bones or loss of height secondary to vertebral wedging; however, the primary consequence of osteopenia is its predisposition to pathologic fractures.

A Gaucher crisis is characterized by acute, intense pain that is relatively well localized (159,166,167). Common sites include the distal femur, the proximal tibia, and the proximal femur. Mild swelling, localized tenderness, and fever are often present. The leukocyte count is elevated, ranging from 13,100 to 19,800 units in one series (166). Likewise, the erythrocyte sedimentation rate is elevated, typically in the range of 40 to 120 mm/h. These symptoms mimic osteomyelitis; hence, the alternative term for a Gaucher crisis is “pseudoosteomyelitis.” Although uncommon, a crisis may be the first clinical manifestation of Gaucher disease. The finding of concomitant splenomegaly will suggest the correct diagnosis.

The cause of a crisis is hemorrhage in the intramedullary canal and, on occasion, the subperiosteal space (161,168). Thrombocytopenia and deficient clotting factors, in the environment of bone marrow crowded with Gaucher cells, lead to intramedullary bleeding. Blood under pressure and the inflammatory reaction explain the intense pain, and why the acute symptoms mimic osteomyelitis. Intramedullary hemorrhage also may cause localized ischemia and subsequent osteonecrosis.

At the onset of a crisis, radiographs are normal, but technetium bone scans demonstrate decreased uptake, and MRI scans show edema, as well as intramedullary and subperiosteal hemorrhage (166–168). Consistent with the subsequent inflammatory and remodeling responses, radiographs a few weeks after onset demonstrate periosteal elevation and lytic areas within the medullary canal (164) (Fig. 11-10). Bone scans at this time show increased uptake surrounding a central photopenic area (166). Several months later, the bone scans return to normal, but radiographs may show areas of sclerosis in the intramedullary canal, or areas of osteonecrosis in the femoral head, the tibial plateau, the femoral condyles, or the humeral head (Fig. 11-11).

Treatment for a crisis is supportive. The pain is typically severe for 1 to 3 days, and, during this time, intravenous narcotics are required. High-dose prednisolone has been reported to be effective at providing pain relief within a few hours (169). This therapy theoretically reduces bone and subperiosteal edema. With conventional treatment, the pain

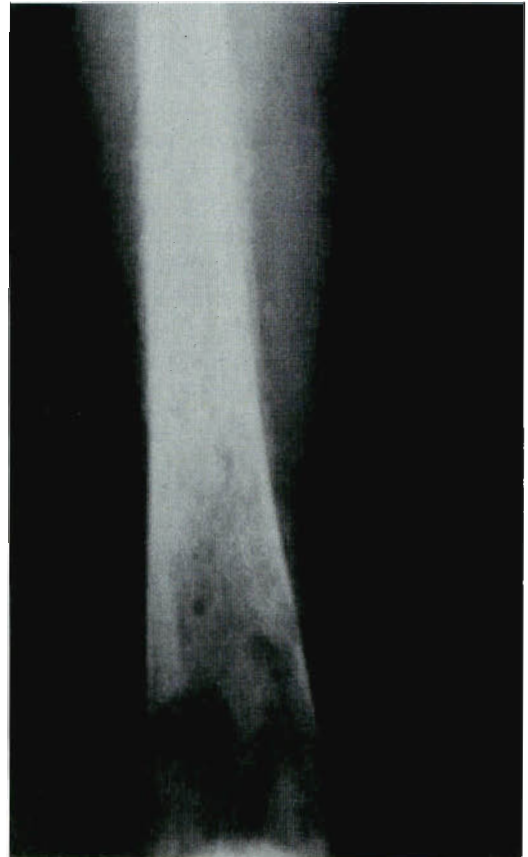

FIGURE 11-10. Bone destruction, sclerosis, and periosteal new bone formation in the femoral shaft after a Gaucher crisis. (Courtesy of Henry J. Mankin, M.D.)

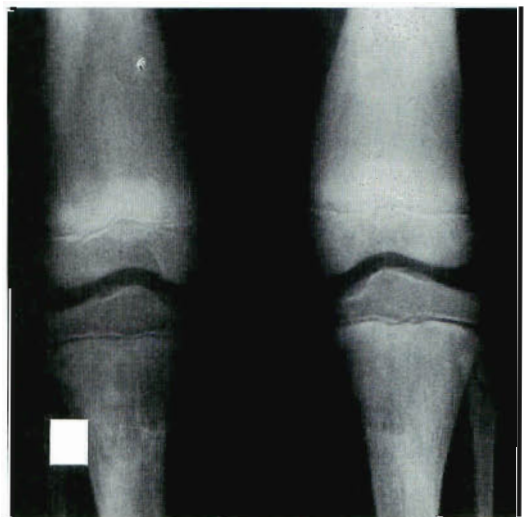

FIGURE 11-11. Radiolucency and osteosclerosis in the proximal tibial metaphysis are a result of Gaucher crisis. Note the Erlenmeyer-flask appearance of the distal femur. (Courtesy of Henry J. Mankin, M.D.)

gradually subsides over 2 to 4 weeks. Continued observation is needed to determine whether a complication, such as osteonecrosis of the femoral head, develops.

Osteomyelitis in Gaucher disease is uncommon, but it is characterized by a delay in diagnosis because it often follows a crisis. Furthermore, there is an increased prevalence of anaerobic organisms that is most likely related to the ischemic bone marrow. Laboratory and imaging studies may not differentiate a crisis from osteomyelitis. A bone biopsy may be required, but should be performed with caution, and using strict aseptic technique, because these patients are susceptible to developing infections after aspiration or surgical drainage (170).

Pathologic fractures may occur in children with Gaucher disease. Katz and colleagues (171) analyzed 23 fractures occurring in nine children with an average age of 12 years (range, 6 to 18 years). Common locations included the distal femur, the proximal tibia, and the base of the femoral neck. Fifteen fractures (65%) occurred at a site that had been affected by a crisis 2 to 12 months previously. Fractures of the femoral neck occur more often in children younger than 10 years of age, and may be complicated by coxa vara, pseudarthrosis, and avascular necrosis (164). Delayed union and nonunion are common in patients with Gaucher disease who are not on drug therapy.

Back pain in patients with Gaucher disease may be severe and secondary to either a crisis or a pathologic fracture (Fig. 11-12), or the pain may be mild and presumably secondary to osteopenia. In a series of 19 children and adolescents with spinal involvement, 9 episodes of nonspecific mild pain, which lasted for 2 to 5 days, occurred in the thoracic

spine, and 3 patients had severe pain that was typical of a Gaucher crisis (172). One of the latter patients developed increased kyphosis. Pathologic fractures presented with an insidious onset of pain 1 to 2 months before diagnosis. The most common fracture pattern was rectangular compression and a "bone-within-a-bone" appearance of two to three adjacent vertebrae. In these patients, the vertebra healed with a central depression, and kyphosis or scoliosis was an infrequent complication. Anterior wedge compression fracture of one or more vertebrae also may occur, and these patients may develop severe kyphosis and spinal cord compression (172).

Osteonecrosis may develop in the femoral head, the femoral condyles, the tibial plateau, and the humeral head (159,164,167). In 53 patients evaluated at an average age of 33 years (range, 1 to 72 years), Zimran and colleagues (158) observed avascular necrosis of the femoral head in 11 patients. Two patients had total hip arthroplasty, and two patients had total knee replacement. Children who develop avascular necrosis of the femoral head have a guarded prognosis (Fig. 11-13). By their young adult years, they are mostly asymptomatic with daily activities, but have poor radiographic ratings (173). Osteonecrosis of the humeral head in patients with Gaucher disease is similar to sickle cell anemia, in that joint incongruity may cause limitation of motion, but the disability usually is not severe enough to limit routine activities or require total joint arthroplasty.

In the past, operative intervention in patients with Gaucher disease was complicated by excessive bleeding and

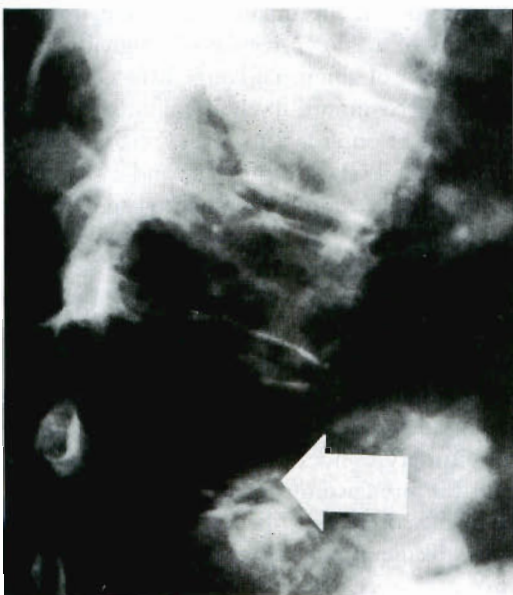


FIGURE 11-12. Compression fracture of a vertebra in Gaucher disease. (Courtesy of Henry J. Mankin, M.D.)

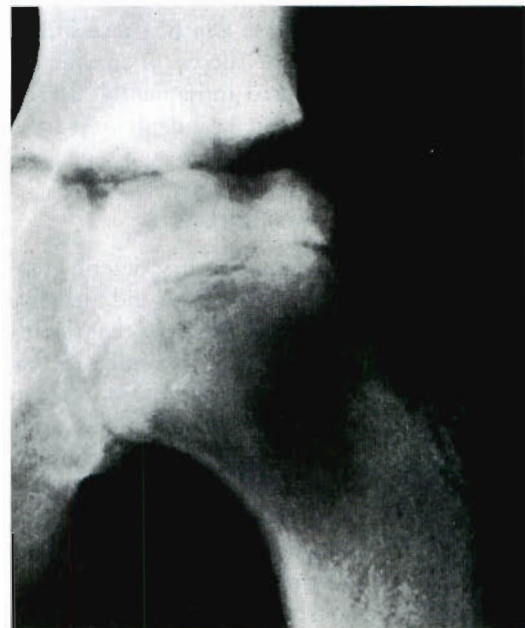


FIGURE 11-13. Late phases of osteonecrosis of the femoral head demonstrate flattening and incongruity. (Courtesy of Henry J. Mankin, M.D.)

osteopenic bone-limiting fixation (164,167). New drug therapy markedly decreases these problems.

Developments in medical therapy are exciting but expensive. In 1991, Barton and colleagues (174) reported that glucocerebrosidase could be altered, and the resultant enzyme, alglucerase, could be transported across the cell membrane. In addition to the placenta-derived enzyme, a recombinant form of the enzyme is now available. Studies of patients treated with alglucerase have consistently found normalization of hematologic parameters, decreased splenomegaly and hepatomegaly volume, and increased hemoglobin concentrations (175,176). Changes in the skeleton were not obvious in early studies, but with therapy for more than 3.5 years, Rosenthal and colleagues (177) noted marked improvement in both marrow composition and bone mass.

The cost of enzyme replacement therapy for Gaucher disease is very expensive, particularly when administered using a regimen of 60 U/kg every 2 weeks, which is the amount initially described. For a 70-kg patient, the wholesale cost of the medication alone is \$382,000 (U.S.) per year. Several studies have reported that a low-dose/high-frequency protocol (2.3 U/kg three times per week; 30 U/kg/month) provides equivalent normalization of blood counts and decrease in the size of the liver and spleen (178–181). Indeed, some patients are satisfactorily managed using 15 U/kg/month. Home transfusion is a necessary component of this treatment. Skeletal symptoms are also reduced on the low-dose/high-frequency protocols, but whether the reduced dosage will be as effective in altering the skeletal changes is still unanswered. In addition, normalization of growth retardation was only noted in children receiving higher doses (60 to 120 U/kg/month) of alglucerase (182).

Bone marrow transplantation can be successful in type I Gaucher disease, but with the success of enzyme therapy, this treatment modality is used infrequently (183). Gene transfer trials have been initiated, and preliminary results are encouraging (184).

Langerhans Cell Histiocytosis

Eosinophilic granuloma of bone was first described in 1940 by Lichenstein and Jaffe (185) and Otani and Ehrlich (186). Green and Faber (187), in 1942, observed that the histopathology of eosinophilic granuloma was similar to that seen in Hand-Schüller-Christian disease and the more severe Letterer-Siwe disease. Because proliferating histiocytes are common to all three disorders, Lichenstein (188) designated this group of diseases “histiocytosis X.” Because the Langerhans cell histiocyte is unique to these disorders, the Histiocyte Society, in 1985, recommended the term “Langerhans cell histiocytosis” (189), and that term is preferred.

Langerhans cell histiocytosis (LCH) is a disease complex characterized by infiltration of one or more organs by large mononuclear cells with benign-appearing nuclei that often have a central groove (151). Compared with other histio-

cytes, the unique structural aspect of the Langerhans cell is tubular or racket-shaped granules seen on electron microscopy. These granules, or organelles, apparently result from internalization of antigen complexes formed at the cell membrane (190). Enzymatic and monoclonal antibody studies have confirmed that these Langerhans cells have features of dendritic cells (191,192).

Not all of the histiocytes in LCH lesions are Langerhans cells; the typical granules are found in 2 to 79% of the histiocytes (193). Other cell types found in LCH lesions include lymphocytes, eosinophils, neutrophils, and, on occasion, multinucleated giant cells. Eosinophils are the predominant other cells, although they may be sparse or virtually absent.

Histopathologic features vary depending on the stage of the disease, the tissue involved, and unknown factors (151,194). Early in the disease process, the bony lesions typically are dominated by histiocytes. More mature lesions may be difficult to differentiate from a subacute or chronic osteomyelitis, but foci of necrosis, granulomatous changes with variable amounts of fibrosis, multinucleated giant cells, and the presence of the Langerhans cell usually distinguish the lesion as LCH.

The pathogenesis of LCH is still speculative. The disease is not a neoplasm, at least not in the classic sense; there is no evidence of aneuploidy and, although Langerhans cells within a lesion are clonal, this is not enough to define LCH as a neoplasm (195). A reactive immunologic process, causing bone and soft tissue destruction, is the probable cause. Some stimulus, perhaps a virus, triggers proliferation of the Langerhans cells; however, sensitive *in situ* hybridization and polymerase chain reaction techniques failed to find evidence of viruses in 56 cases of LCH (196). Cytokines are abundant in LCH tissue (197), and these enzymes probably play a major role in the inflammatory and osteolysis response. A loss of a “down-regulatory” signal could result in a proliferation of abnormal Langerhans cells.

LCH is more common in children, and, in this group, the median age of onset is 2 to 3 years (151). The clinical manifestations of LCH are protean, and every patient at presentation needs a thorough evaluation to determine the extent of the disease. Furthermore, ongoing evaluation is needed because the extent of the disease and its classification may change. The extent of the disease is classified as solitary bone involvement, multiple bone involvement without soft tissue involvement, bone and soft tissue involvement, or soft tissue involvement alone. Common sites of soft tissue involvement include the skin, lymph nodes, lungs, liver, ears, and pituitary stalk. The extent of soft tissue involvement, and the presence of organ dysfunction, usually are classified by the criteria described by Lahey (198) (Table 11-6). Skin involvement may vary from a few discrete pinhead lesions to a generalized pustular eczematous eruption. Generalized skin disease is a typical presenting feature in children younger than 2 years of age, and is a poor prognostic

TABLE 11-6. CRITERIA OF ORGAN DYSFUNCTION IN LANGERHANS CELL HISTIOCYTOSIS

Liver
Albumin < 2.5 g/dL
Bilirubin > 1.5 mg/dL
Edema
Ascites
Pulmonary system ^a
Cough
Cyanosis
Dyspnea
Pleural effusion
Pneumothorax
Hematopoietic system
Anemia < 10 mg/dL ^b
Leukopenia < 4,000/dL
Neutropenia < 1,500/dL
Thrombocytopenia < 100,000/dL

^a Not secondary to pulmonary infection.^b Not attributable to iron-deficiency anemia.

(Adapted from ref. 198, with permission.)

factor (199). Fatal dissemination occurs more often in children younger than 2 years of age at onset, but it also may occur when the disease is diagnosed in later childhood, or even in the adult years (200). Failure of organs, such as the lungs, liver, spleen, and bone marrow, is the usual cause of death (198,199,201–203). Generalized involvement of the brain often occurs in adults and in children with disseminated disease.

Diabetes insipidus occurs in 12 to 50% of children with multiple system involvement (201,204). It may be the only abnormality at the onset of the disease (205), but more often it occurs after LCH has been diagnosed. Diabetes insipidus is the most frequent abnormality that subsequently develops in patients who have only bone involvement at the onset of disease (206).

Skeletal lesions are common, occurring in 80 to 97% of patients with LCH (199,203,204,207,208). The skull, spine, pelvis, ribs, and femur are the common sites of bony lesions (209). Other long bones may be involved, but lesions in the hands and feet are rare. Skull lesions have a well-defined, punched-out appearance (Fig. 11-14). Vertebra plana, first described by Compere and colleagues (210), is the typical spinal lesion. The vertebral body is markedly collapsed, but in contrast to an infectious process, the adjacent disc space is preserved. Posterior elements usually are spared. In the series by Ruppert and colleagues (211), a thoracic vertebra was most often affected (54%), and a cervical vertebra was least often involved (11%).

Long-bone lesions are typically lytic, and located in the diaphysis or metaphysis (Fig. 11-14). Other radiographic features include endosteal scalloping, cortical thinning, and widening of the medullary cavity (211). Lamellated eleva-

tion of the periosteum (onion skinning), simulating Ewing sarcoma or osteomyelitis, accounts for approximately 5% of the solitary eosinophilic granulomas (Fig. 11-15). In a series of 25 children presenting with diaphyseal periosteal elevation, ten cases were secondary to Ewing sarcoma and seven were diagnosed as eosinophilic granuloma (212). Patients with Ewing sarcoma are more likely to show definite Codman triangles, as well as intramedullary and cortical destruction. Epiphyseal or transphyseal involvement is uncommon, but has been reported (211,213,214). In a series of 15 solitary lucent epiphyseal lesions, only one case was secondary to eosinophilic granuloma (213).

Skeletal surveys should be combined with bone scans, because both modalities can give false-negative results (207,215). In a study that compared bone scans with skeletal surveys in 42 patients, 36 (19%) of the 191 lesions were missed on bone scans, and 55 (29%) were missed on routine skeletal surveys (215). Bone scans were more sensitive in detecting LCH lesions in the ribs, spine, and pelvis, but less sensitive in detecting lesions in the skull. Both modalities have similar sensitivity in the extremities. MRI changes are nonspecific, because the low signal intensity on T1-weighted images, and the high signal intensity on T2-weighted images, do not differentiate eosinophilic granuloma from osteomyelitis or Ewing sarcoma (216). On the other hand, bone scans, computed tomography, and MRI may be useful in localizing a site of unexplained pain, or in finding spinal cord compression.

A bony lesion without soft tissue involvement is the most common presentation of LCH, accounting for 50 to 77% of the pediatric cases (203,204,207,208). Patients with solitary bone involvement at disease onset have the best prognosis, and, in this group, no deaths have been reported (201,203,204,207,217). In comparison, patients with organ dysfunction at disease onset have a mortality rate of 30 to 70% (201–204). Evolution to multiple bone lesions or soft tissue involvement is also uncommon. Bollini and colleagues (207) reviewed 216 patients from eight series who had solitary bone involvement. Evolution to multiple bone lesions occurred in 7% of patients, mostly during the first year after diagnosis, and only 1% of patients developed soft tissue involvement. Dimentberg and Brown (208) found a 30% incidence of new bony lesions in patients with initial solitary involvement. Their protocol, however, included periodic skeletal surveys, and 55% of their new lesions were asymptomatic.

Multiple bone involvement without soft tissue involvement has a good prognosis. However, the incidence of additional bone lesions and subsequent soft tissue involvement is higher in this group (208). Development of diabetes insipidus is the most common soft tissue problem. The mortality rate of this group is low, being only 1 of 22 patients in the series reported by Raney and D'Angio (203).

The presenting complaints of patients with a solitary

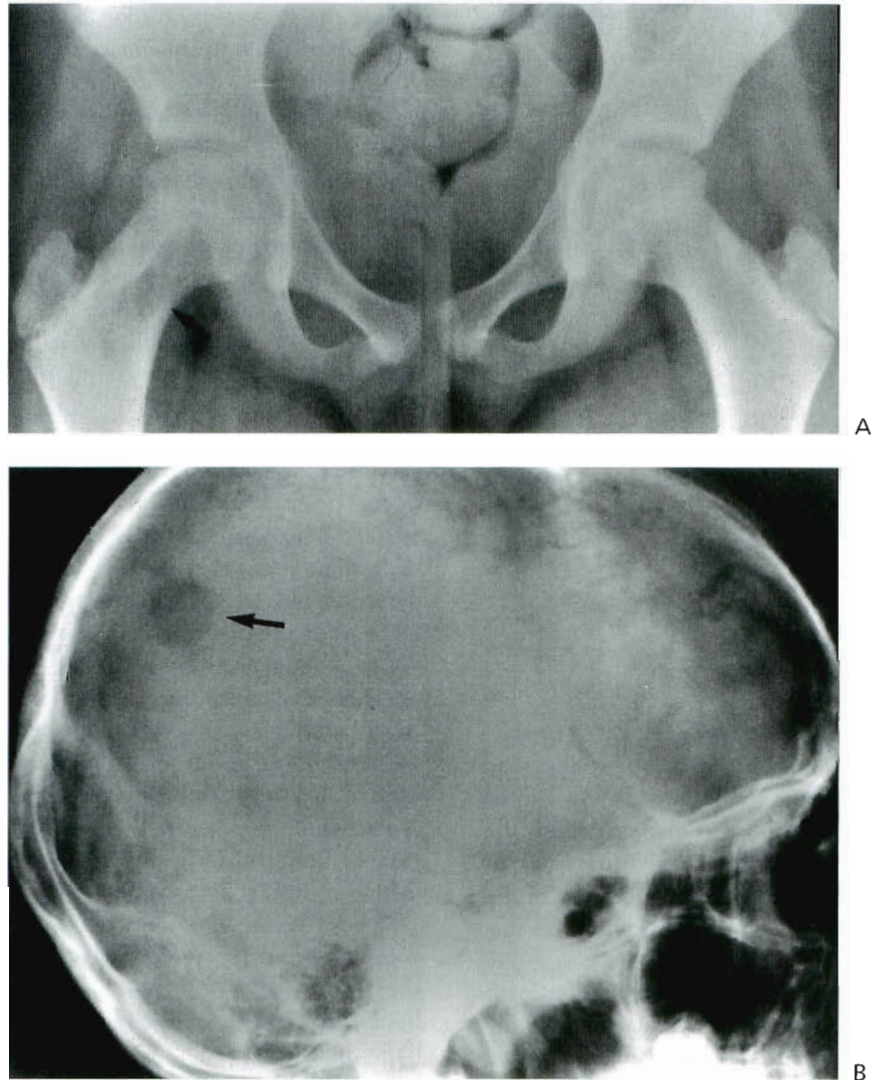


FIGURE 11-14. Eosinophilic granuloma, with multiple bone involvement, in a 9-year-old girl who had progressive symptoms of pain and limp involving the right hip. **A:** Anteroposterior radiograph of the pelvis demonstrates a lytic lesion in the right femoral neck. Biopsy defined the diagnosis. Follow-up radiographs, taken 5 months later, show complete resolution of the lesion. **B:** Lateral radiograph of the skull 5 months after biopsy of the femur. At that time, the patient had a sore spot on the back of the head. Radiographs show the typical "punched-out" appearance of eosinophilic granuloma. Three months later, the patient developed a third bony lesion in the left proximal femur. Subsequent follow-up showed a full resolution of symptoms without therapy.

bone lesion are localized swelling, pain, or limp (Fig. 11-16). The child also may be asymptomatic, with the diagnosis being made from radiographs obtained for unrelated reasons. In any circumstance, these patients should be evaluated for possible additional bone lesions. Inquire concerning symptoms of lethargy, polyuria or polydipsia, chronic cough, dyspnea, and feeding difficulties. Examine for the possibility of skin rash, otitis, exophthalmos, tachypnea, sinusitis, hepatomegaly, jaundice, splenomegaly, growth retardation, and swelling or tenderness over the skull, facial bones, spine, and extremities. A lateral skull radiograph is

a good screening study for a child with a solitary bone lesion of unknown cause. Additional laboratory studies that should be considered for a child with known LCH include a complete blood count and smear, liver function tests, serum and urine osmolality, and radiographic survey of the chest and skeleton (208). Unless clinically indicated, hand and foot radiographs are not necessary because these regions are rarely involved. For patients with significant risk of organ dysfunction, such as those with obvious soft tissue involvement or those younger than 3 years of age who have multiple bone lesions, Dimentberg and Brown (208) recommend

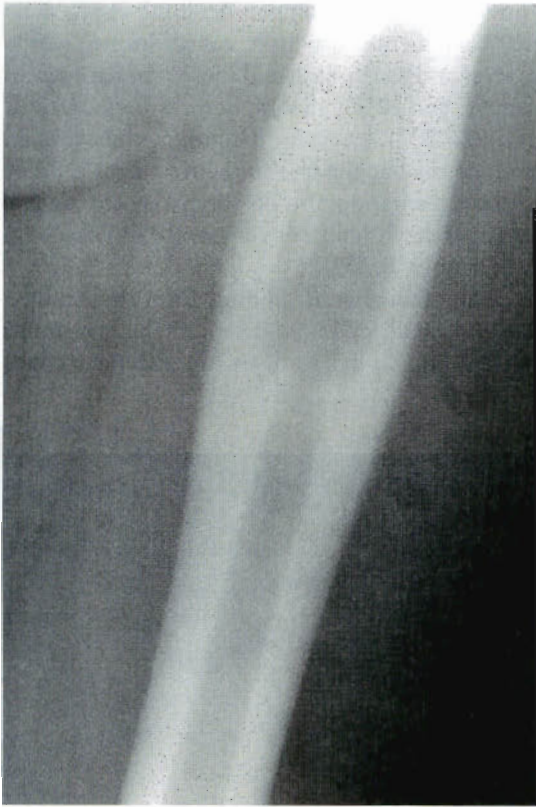

FIGURE 11-15. Eosinophilic granuloma in a 12-year-old girl who had pain in the thigh for 3 to 4 months. Radiograph of the femur shows an expansile lesion with periosteal reaction.

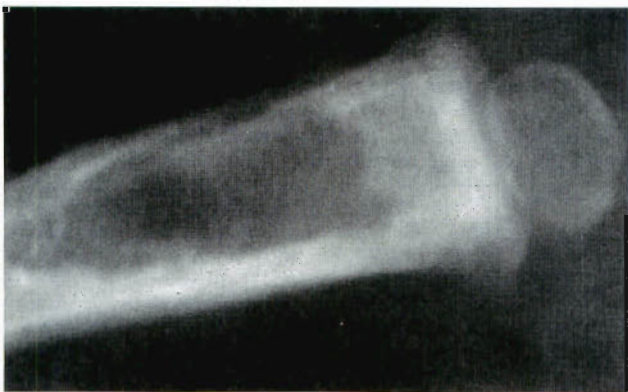


FIGURE 11-16. Eosinophilic granuloma in a 9-month-old boy who had a 2-week history of a mass in the thigh. Before transfer, the patient had received several days of antibiotic therapy. Lateral radiograph of the distal femur shows a large lytic lesion with periosteal elevation. After biopsy and curettage, the femur was protected with a spica cast. No other lesions developed, and follow-up 10 years later demonstrated no abnormalities.

additional studies, including arterial blood gas, bone marrow aspirate, computed tomography of the chest, abdominal ultrasonography, audiology assessment, dental assessment, and immunologic profile.

A biopsy is necessary to confirm the suspected diagnosis. The exception is the patient with classic multifocal radiographic findings. When the skin is involved, it is the preferred site of biopsy. A typical lytic lesion of bone can be biopsied by transcutaneous needle aspiration (207). Open biopsy is preferred when curettage is indicated, or for mid-diaphyseal lesions characterized by periosteal elevation.

Treatment of bone lesions in patients without soft tissue involvement should be limited to observation, medical management, steroid injection, or curettage. The rate of healing was not significantly different in a study evaluating treatment versus observation of bony lesions (218). Observation is indicated when the patient is asymptomatic or has only mild symptoms, and when the lesion does not have a high risk of fracture. Curettage is an adjunct to open biopsy. In addition, this mode of therapy, with or without supplemental bone grafting, may be selected for lesions associated with intense pain or significant risk of fracture. Intralesional steroid injections have been reported to provide good results (219). Owing to the variable rate of healing and the self-limited nature of LCH, it is difficult to know whether this treatment influences the natural history. Steroid injections, however, may be preferred for lesions with persistent pain and slow healing after curettage. Based on the abundant production of cytokines and prostaglandin E_2 in bone lesions of LCH, Munn and colleagues (220) treated ten symptomatic children with indomethacin (1 to 2.5 mg/kg/day in divided doses). Eight patients had complete response to treatment. Whether indomethacin has a specific role in slowing disease progression or merely acts as an analgesic has not yet been established. Of note, low-dose radiotherapy should not be used because there are two reports documenting secondary malignancy after this therapy was used for solitary bone involvement (208,221).

Solitary spinal lesions typically cause pain, and may be associated with postural adaptations, such as torticollis or scoliosis. However, LCH in the spine may also be asymptomatic. Indeed, multiple sites of asymptomatic spinal involvement may be present in patients with disseminated soft tissue involvement. Vertebra plana without posterior arch involvement is the most common pattern, but cases have been reported of lesions limited to the posterior arch, of lesions involving the vertebral body that did not cause collapse, and of lesions in the spinal cord without bony involvement (211,222,223). Most patients do not have neurologic deficits, and can be treated symptomatically by short-term immobilization in plaster casts, and orthoses after the diagnosis has been confirmed (224). Reconstitution of vertebral height to a variable but effective amount is the natural history, and long-term follow-up studies have not observed back or neck dysfunction (223).

Although uncommon, eosinophilic granuloma of the spine may cause neurologic deficit (223,225). In these patients, clinical and MRI examinations should be able to differentiate nerve root involvement from spinal cord compression. With nerve root impingement, treatment should include bed rest, immobilization, and perhaps steroid injection. For patients with spinal cord compression, surgical decompression and stabilization should be considered, unless there is disseminated disease and an unfavorable prognosis. Radiotherapy may be indicated with this degree of involvement.

Chemotherapy has a limited role in LCH, and most au-

thors now agree that systemic chemotherapy generally is reserved for patients who have constitutional symptoms, such as fever and weight loss, and those who have severe skin involvement and organ dysfunction, as defined by Lahey (198,202,226,227). Even in this group, a short course of prednisolone may be the best initial treatment (202). Bone marrow transplantation also has been reported in isolated cases of patients who did not respond to multiple-regimen chemotherapy (228,229).

The earliest radiographic finding denoting healing of appendicular skeletal lesions is development of a trabecular pattern (Fig. 11-17). In a study by Alexander and colleagues

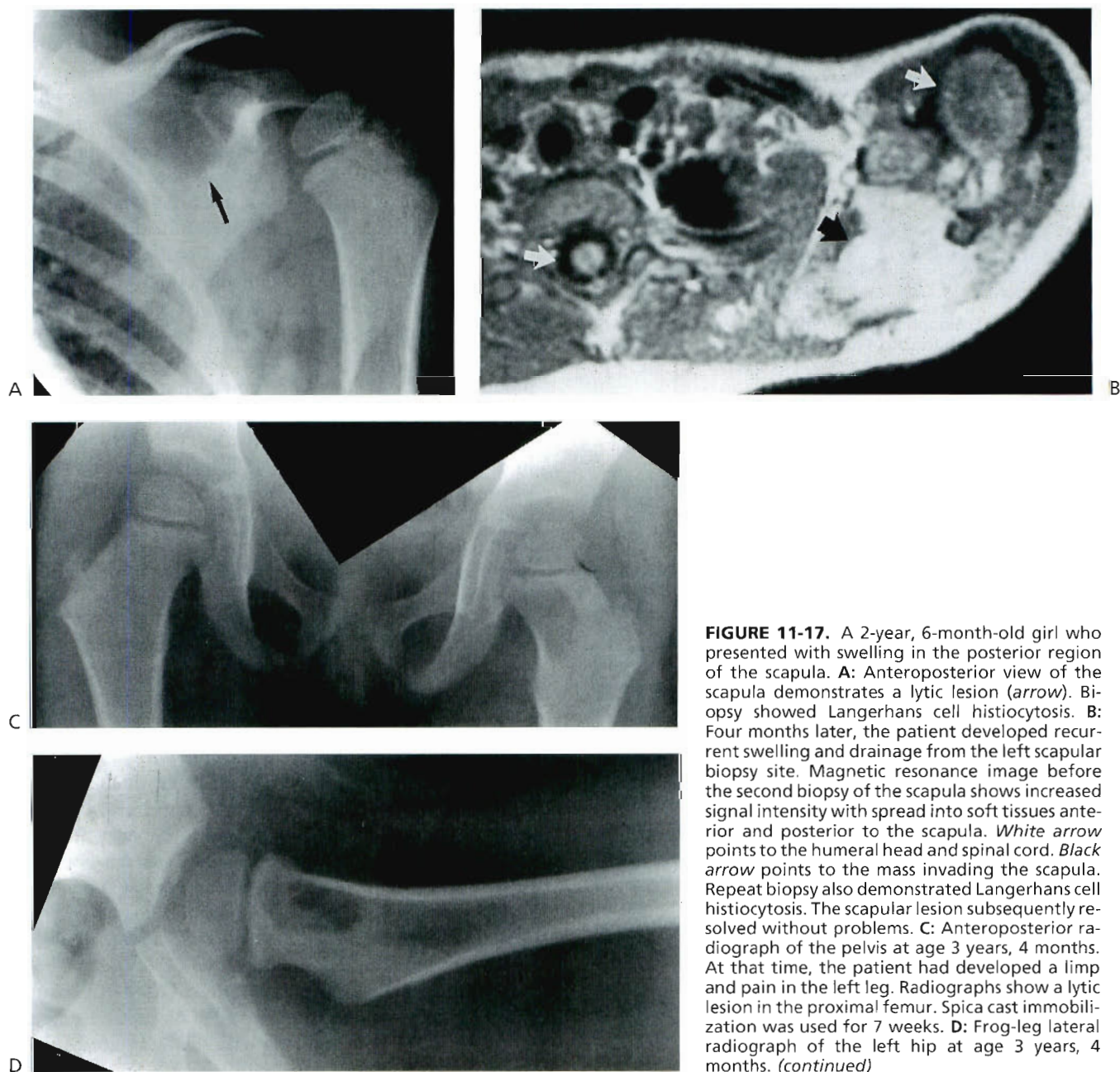

FIGURE 11-17. A 2-year, 6-month-old girl who presented with swelling in the posterior region of the scapula. **A:** Anteroposterior view of the scapula demonstrates a lytic lesion (arrow). Biopsy showed Langerhans cell histiocytosis. **B:** Four months later, the patient developed recurrent swelling and drainage from the left scapular biopsy site. Magnetic resonance image before the second biopsy of the scapula shows increased signal intensity with spread into soft tissues anterior and posterior to the scapula. White arrow points to the humeral head and spinal cord. Black arrow points to the mass invading the scapula. Repeat biopsy also demonstrated Langerhans cell histiocytosis. The scapular lesion subsequently resolved without problems. **C:** Anteroposterior radiograph of the pelvis at age 3 years, 4 months. At that time, the patient had developed a limp and pain in the left leg. Radiographs show a lytic lesion in the proximal femur. Spica cast immobilization was used for 7 weeks. **D:** Frog-leg lateral radiograph of the left hip at age 3 years, 4 months. (continued)

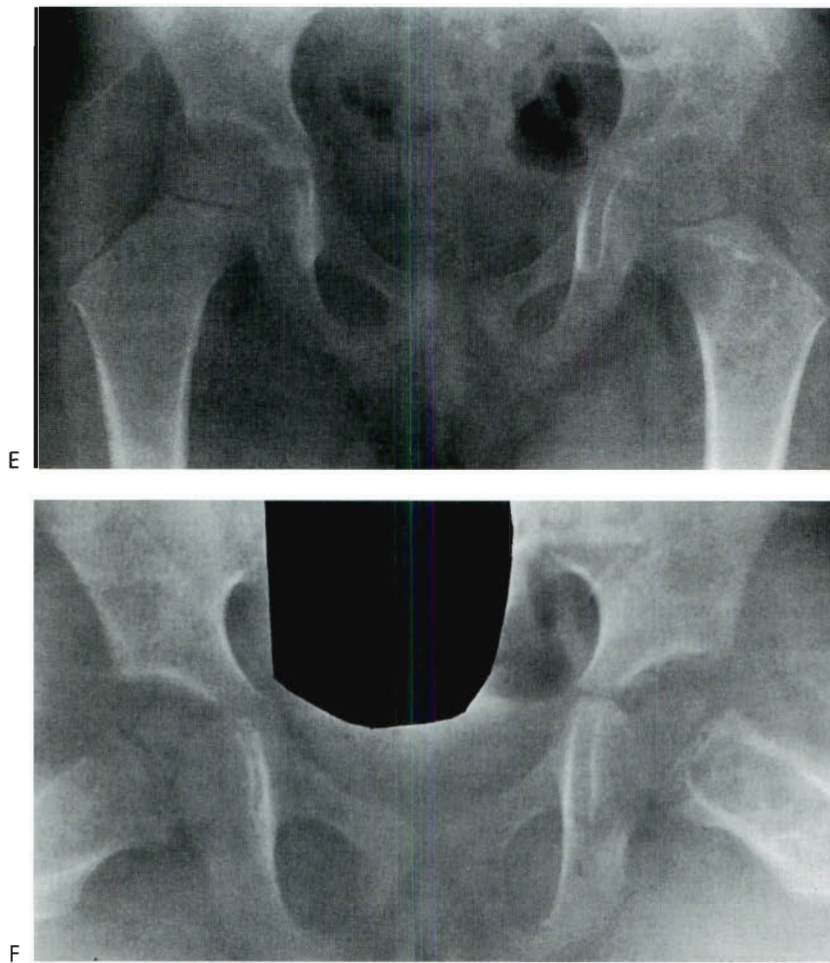


FIGURE 11-17. (continued) E: Anteroposterior radiograph of the pelvis at age 3 years, 6 months. F: Frog-leg lateral radiograph of the pelvis at age 3 years, 6 months. Trabecular pattern indicates progressive healing of the Langerhans cell histiocytosis. (Courtesy of Gary D. Bos, M.D.)

(230), the trabecular pattern was observed 6 to 10 weeks after diagnosis in patients who had uneventful healing. Complete healing then occurred within the next 36 to 40 weeks. Therefore, it is reasonable to repeat radiographs of the involved lesion approximately 2 months after diagnosis. If a trabecular pattern has developed, the next radiologic examination can be scheduled at the 6-month interval. However, if no evidence of trabeculation has occurred, repeat radiographs are warranted in another 2 months. If there is no evidence of healing at 4 months after diagnosis, additional therapy may be indicated. Routine skeletal surveys, as well as a complete physical examination, should be performed every 6 months for at least 2 years (208). These surveys will diagnose new bony and soft tissue lesions in a timely fashion.

In summary, Langerhans cell histiocytosis is a fascinating disorder that is probably secondary to an aberrant reactive immunologic process. Solitary bony involvement is most common. In these patients, treatment probably does not

influence healing, and making a diagnosis and classifying the extent of involvement is more important. Periodic reexamination is needed, because the disease classification may change. Patients with organ dysfunction have a guarded prognosis, and systemic chemotherapy is indicated.

DISORDERS OF HEMOSTASIS

Hemostasis protects us from the many bumps of everyday activity and permits safe surgery. Injury to a blood vessel initiates a highly integrated set of reactions to restore hemostasis. Although the reactions overlap, it is helpful to divide the clotting process into vascular, platelet, and plasma components.

The vascular component includes the grossly evident vasoconstriction, as well as exposure of tissue elements that activate platelets, and the coagulation cascade. The platelet component includes adhesion of platelets to vascular tissues

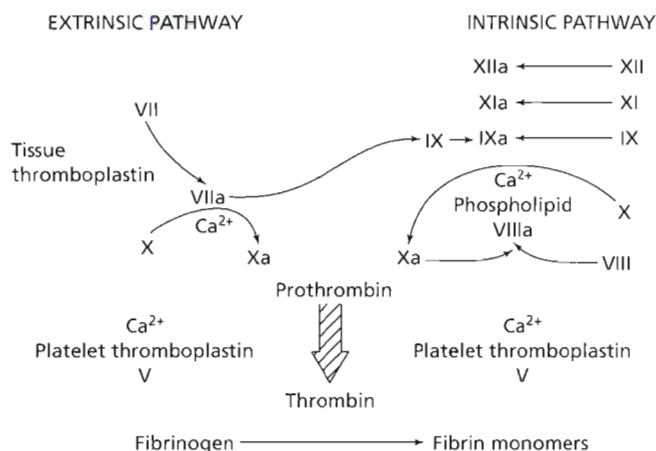


FIGURE 11-18. Formation of thrombin.

(assisted by factor VIII–related von Willebrand factor), aggregation of platelets to each other to form a platelet plug, and stabilization of the platelet plug by deposition of fibrin within it.

The plasma component of restoration of hemostasis has an extrinsic or membrane surface pathway and an intrinsic pathway. Because it is now evident that activated factor VII can activate both factor X and factor IX, the relative value of the intrinsic versus the extrinsic pathway is considered less important. In the extrinsic pathway, tissue factor binds activated factor VII on membrane surfaces. The tissue factor–factor VIIa complex can then activate factor IX in the intrinsic pathway and factor X in the standard extrinsic pathway (Fig. 11-18). Factor IXa combines with activated factor VIII to form a complex that also activates factor X. In the intrinsic pathway, exposure to collagen activates factor XII, which then activates factor XI; this is followed by activation of factor IX. Factor VIII is important, because once it is activated, this factor accelerates the activation of factor X by activated factor IX. Activated factor Xa forms a complex with activated factor V, to convert prothrombin to thrombin, which then converts fibrinogen to fibrin.

Hemophilia

Any of the 14 coagulation factors may be deficient, but musculoskeletal problems are primarily found in patients with deficits of either factor VIII, also known as hemophilia A, or factor IX, also known as hemophilia B. Both factor VIII and factor IX deficiencies are transmitted by a sex-linked recessive gene; therefore, both disorders are largely restricted to the male population. The other inherited coagulation disorders are very uncommon, and, more importantly, are characterized by mucosal hemorrhages, such as epistaxis and menorrhagia, and rarely demonstrate hemorrhage into a joint, except after major trauma. A surveillance

study of people with hemophilia A or B in six U.S. states found that 2,156 (79%) had factor VIII deficiency (231). The age-adjusted prevalence of hemophilia A and B was 13.4 cases per 100,000 males, and the average incidence was estimated to be 1 in 5,032 live male births. Hemophilia occurs in all ethnic groups, and shows no significant racial predilection.

The diagnosis of hemophilia is suggested in infants who have atypical bleeding at the time of circumcision or atypical bruising with neonatal immunizations, and in toddlers who develop lip lacerations and unusual bruising while learning to walk. A history of affected males on the maternal side of the family is another clue. The partial thromboplastin time is abnormal in both factor VIII and IX deficiency, and specific factor assays are used to establish the diagnosis and its degree of severity.

Coagulation factors are quantitated in units: 1 U is equal to the activity of the clotting factor in 1 mL of pooled, normal plasma. The concentration of factors VIII and IX is commonly designated as a percentage of activity, representing units per deciliter. Therefore, factor VIII and IX activity in a normal person should be 100%, but a range from 50 to 200% is within normal limits. Deficiencies of coagulation factors are graded as severe (less than 1% activity), moderate (1 to 5% activity), and mild (more than 5% activity) (232). In a surveillance study, 43% of patients had severe, 26% had moderate, and 31% had mild hemophilia (231). In patients with severe hemophilia, a hemarthrosis may occur with minimal trauma, or spontaneously during normal daily activities, but joint bleeds rarely develop in patients with mild deficiency, unless significant trauma occurs. Patients with moderate deficiency have intermediate symptoms but typically develop significantly less arthropathy than patients with severe disorders.

Neither acute bleeding episodes nor surgery can be managed effectively in hemophiliacs without appropriate replacement of the missing clotting factor. When only whole blood or plasma was available, the volume requirements for even a single transfusion were so great that transfusions were administered only in limb-threatening and life-threatening situations. The discovery of cryoprecipitate, in 1965 (233), and the subsequent development of concentrates (234,235), radically expanded treatment options for hemophiliacs. With concentrates, it was possible to deliver a total blood volume of clotting factor in a 50-mL solution. As a result, transfusion therapy at home and elective operations were widely instituted in the 1970s.

Both factor VIII and factor IX concentrates were initially prepared from plasma that was pooled from many donors, a process that allowed transmission of blood-borne diseases. In the 1970s, hepatitis was a recognized complication of transfusion therapy, and most hemophiliacs at that time had hepatitis-associated antibodies. In the early 1980s, AIDS clearly was identified in hemophiliacs. Heat treatment of the concentrates, however, virtually eliminated HIV, so

that hemophiliacs who received their initial transfusion after 1984 were not infected by HIV (232). Both factor VIII and factor IX can now be manufactured using recombinant DNA techniques that produce a purified product. Therefore, virtually all pediatric patients with hemophilia are now seronegative for both HIV and hepatitis viruses.

Inhibitors are antibodies that develop to the infused product. They develop in about 15% of patients with severe factor VIII deficiencies, but their frequency is much lower in patients with factor IX deficiency (236,237). Patients with an inhibitor do not bleed more frequently, but have limited options for transfusion. The potency of a patient's inhibitor status is defined in Bethesda units per milliliter of plasma. High responders have inhibitor titers of greater than 10 Bethesda units, and develop an anamnestic response with subsequent exposure. Low responders maintain an inhibitor titer of less than 10 Bethesda units, even when exposed to repeated doses of factor VIII. Of note, the likelihood of developing a high-titer inhibitor is remote if a patient has received 100 transfusions, and elective surgery may proceed in these patients without apprehension that this complication will develop in the postoperative period (232).

Low responders can undergo elective surgery, using higher doses of factor VIII transfusion. In high responders, elective surgery is not feasible unless the patient has undergone multiple, sequential transfusions to induce immune tolerance. The overall success rate for immune tolerance in hemophilia A is 63 to 83% (238). Daily factor transfusions increase the likelihood of success, and the duration of transfusions is typically several months. The other option under investigation is activated factor VII. Factor VIIa is thought to interact with tissue factor at the site of bleeding, then to activate factor X, thereby bypassing factor VIII. Intraoperative hemostasis was achieved with recombinant factor VIIa

in 28 of 29 inhibitor patients undergoing elective surgery (239).

Hemophilic arthropathy begins with a hemarthrosis, particularly when two or three bleeding episodes occur in a joint within a short period. As the blood inside the joint is catabolized, the breakdown products must be absorbed by the synovium. Iron is the most damaging element (232,240–242). Synovial cells can absorb a limited amount of iron, but when that quantity is exceeded, the cell disintegrates and releases lysosomes that not only destroy articular cartilage, but inflame the synovial tissue. The result is a hypertrophic and hypervascular synovium that, in a person with a clotting deficiency, is friable, and tends to bleed easily (Fig. 11-19). Thus begins a vicious cycle of recurrent hemarthrosis followed by more synovitis and joint destruction.

Blood-breakdown products also affect the chondrocytes. Even in the early stage of joint disease, the chondrocytes contain siderosomes (secondary lysosomes containing iron ferritin granules), and show intracellular evidence of cell disruption (232,243). With disintegration of the chondrocyte, not only are lysosomes released to destroy the matrix of the cartilage, but the factory (the chondrocyte) also is destroyed (Fig. 11-20).

As hemophilic arthropathy progresses, the synovium loses its marked villous formation, and is mostly replaced by fibrous tissue. This, in combination with erosion of the articular surfaces, causes loss of joint motion. The end result may be a disabling arthritis at an early age (Fig. 11-21).

Radiographic changes in the early stages of hemophilic arthropathy are similar to those observed in rheumatoid arthritis. Soft tissue swelling, osteopenia, and overgrowth of the epiphysis are observed with the initiation of synovitis. As the disease progresses, marginal erosions, subchondral cysts, subchondral irregularity, widening of the intercondylar notch of the femur, squaring of the patella, enlargement

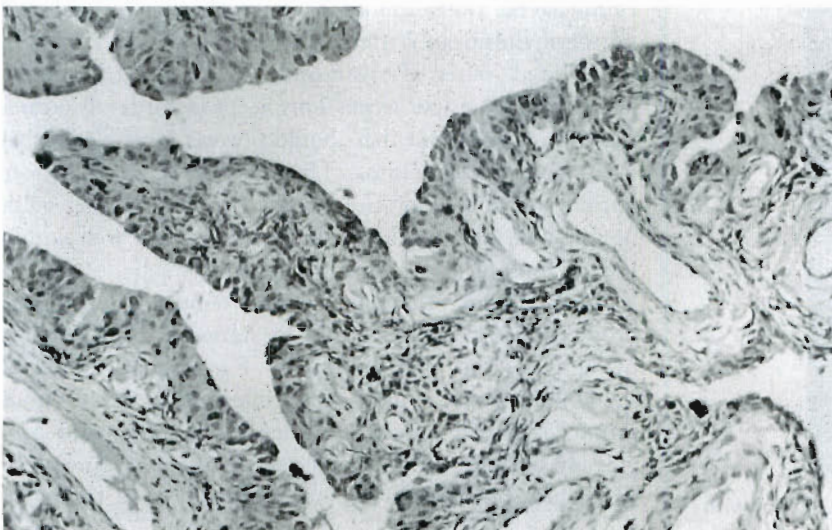


FIGURE 11-19. Synovium from an 8-year-old boy with hemophilia who had an 18-month history of hypertrophic synovitis and recurrent hemarthrosis in the knee. Note villous formation, markedly increased vascularity, and chronic inflammatory cell infiltrates. (From ref. 232, with permission.)

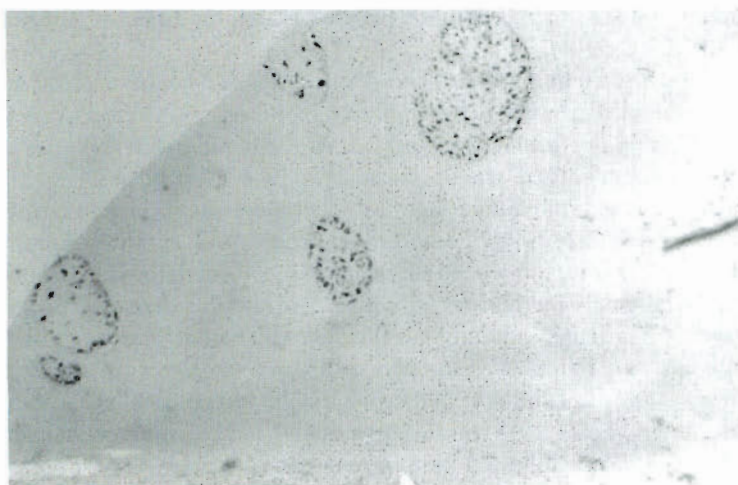


FIGURE 11-20. Cartilage shaving from patellar erosions in an 11-year-old boy with factor IX hemophilia. The patient had only a 9-month history of difficulty with this knee. Chondrocytes demonstrate disintegration, with iron deposition around the periphery (Perls stain). (From ref. 232, with permission.)

of the radial head, and widening of the trochlear notch of the olecranon are characteristic changes (Fig 11-22). With end-stage arthropathy, narrowing of the articular cartilage is obvious, but the subchondral bone is more sclerotic in hemophiliacs than in patients with rheumatoid arthritis. Hemophilic arthropathy may be staged by radiographs, and a four-part, seven-point classification has shown good correlation with joint function, as measured by range of motion and muscle torque (244) (Table 11-7).

The knee, ankle, and elbow are the joints most commonly affected in hemophiliacs (245–247). In small children, the ankle is frequently the target. In one series (245), the elbow was the most common site of bleeding during

adolescence, but other studies (246,247) have noted that the knee is more frequently affected at that age. The shoulder, hip, and wrist rarely are affected by a hemarthrosis, and, in this era of home therapy, these joints rarely progress to significant arthropathy.

The physical signs of hemarthrosis include increased warmth, swelling, and some limitation of motion. A prodrome of pain or discomfort frequently is perceived before the joint swelling is obvious. Transfusion as soon as possible is most critical in the management of any bleeding episode, and with concentrates home therapy is feasible. For routine treatment of muscle or joint hemorrhage, the patient or the patient's parents transfuse 20 to 25 U of factor per kilogram of body weight. This amount of transfusion typically keeps the clotting factor greater than 1% for at least 48 hours (Fig. 11-23).

Home transfusion therapy, with treatment on demand, has certainly reduced the severity and incidence of hemophilic arthropathy, but has not eliminated this problem. Prophylactic transfusions, a concept initiated in some northern European centers, are being used increasingly in the United States. Transfusions (25 U/kg) are typically given three times per week. This keeps factor levels greater than 1%, an amount that should prevent joint bleeds that occur with trivial trauma. Theoretically, if the joints are normal at the end of childhood, then the mature, adult person with hemophilia could function quite well within the confines of his or her coagulopathy.

To maintain essentially normal radiologic outcomes, prophylactic transfusions must be started in most patients by the age of 2 to 3 years (248,249). Even a small number of joint bleeds (one to four), before the initiation of continuous prophylaxis, will adversely influence the subsequent progression of arthropathy. Venous access, therefore, is a problem when transfusions are administered three times per week in a small child. Implantable devices are required.

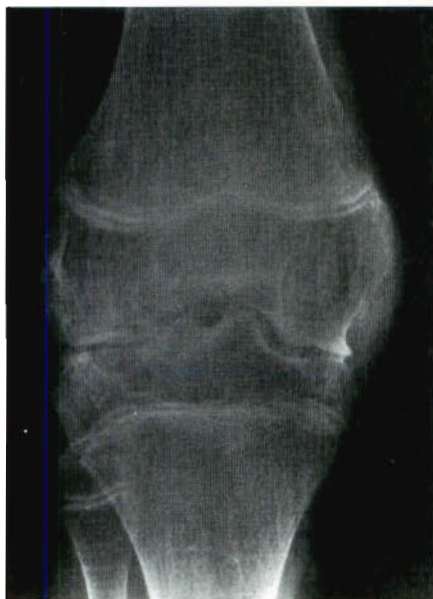

FIGURE 11-21. Radiograph of the knee of a 14-year-old boy with advanced hemophilic arthropathy.

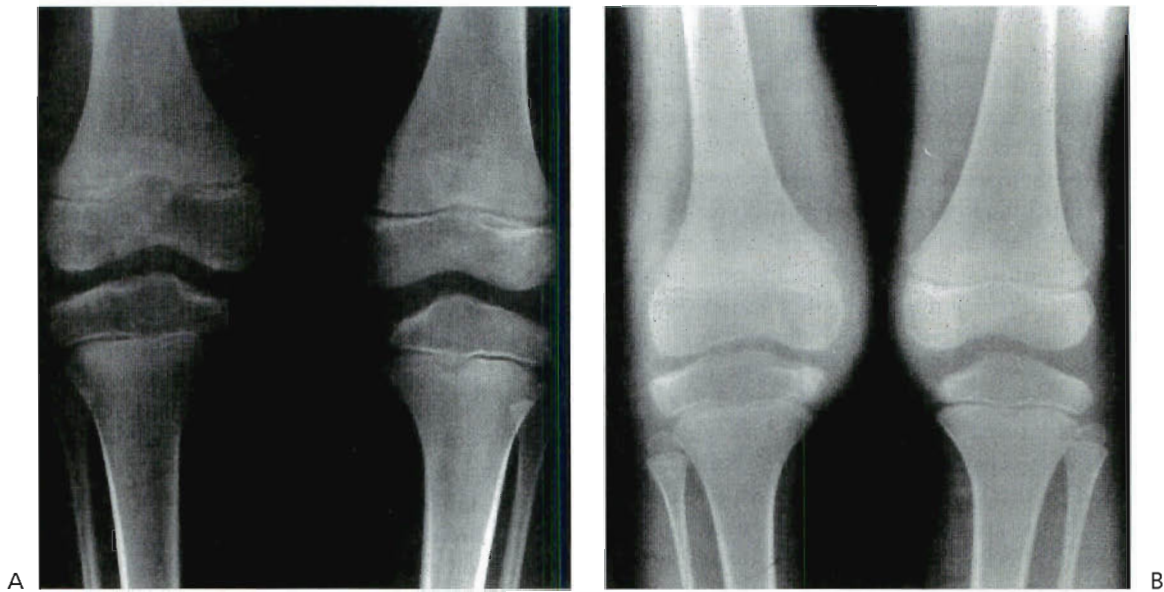

FIGURE 11-22. **A:** Anteroposterior standing radiograph of the knee in a 7-year, 2-month-old boy with factor VIII deficiency. Early changes of hypertrophic synovitis and hemophilic arthropathy are present in the right knee. Note the widening of the intercondylar notch. **B:** Anteroposterior standing radiograph of both knees 8 months later. The arthropathy has progressed despite good compliance with home transfusion therapy and 6 months of prophylactic transfusions. Significant joint narrowing and cartilage erosions are observed in the right knee. (From ref. 79, with permission.)

These devices are effective, but have a risk of bacteremia with long-term use, the rate, over approximately 3 years, ranging from 12 to 56% (250–252). The treatment is also expensive, primarily because of the cost of recombinant factors VIII and IX. The cost of the factor itself, if administered three times per week between the ages of 2 and 18 years in

TABLE 11-7. RADIOGRAPHIC GRADING OF HEMOPHILIC ARTHROPATHY

Classification	Score
Subchondral irregularity	
Absent	0
Mild ($\leq 50\%$ of joint surface)	1
Pronounced	2
Joint space narrowing	
Absent	0
$\leq 50\%$	1
$> 50\%$	2
Joint margin erosion	
Absent	0
Present	1
Joint surface incongruity	
Absent	0
Mild	1
Pronounced	2

(Adapted from ref. 244, with permission.)

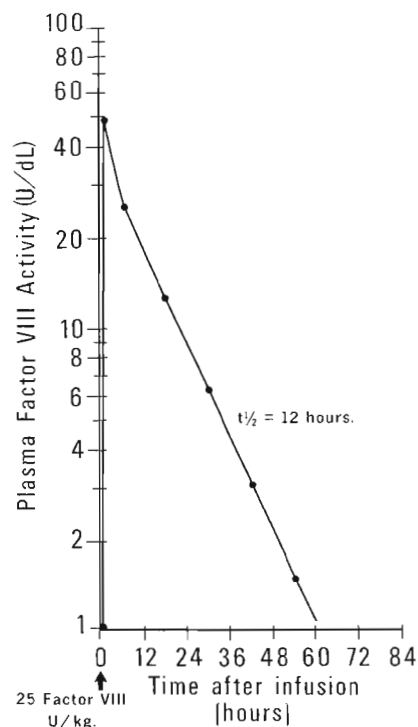


FIGURE 11-23. Typical falloff curve after infusion of 25 U/kg body weight of factor VIII in a patient with severe hemophilia. $t_{1/2}$, half-life. (From ref. 79, with permission.)

an average-size child, is approximately \$3 million (U.S.). Therefore, studies that include issues such as costs of hospitalization, surgery, and days lost from school or work still find that prophylactic transfusion is significantly more expensive than episodic care (253,254).

Another approach to preventing disabling hemophilic arthropathy is to use different treatment protocols for minor versus major joint bleeds. A minor hemarthrosis can be treated at home by transfusing the appropriate concentrate as soon as possible. Ice packs, mild analgesics, crutches, and splints are useful adjuncts in controlling pain and swelling.

A major hemarthrosis is different. This type of bleed usually occurs after significant trauma, or as a recurrent hemarthrosis in a joint that already is affected by synovitis. A major hemarthrosis is painful. Furthermore, with a large amount of blood in the joint, hypertrophic synovitis and recurrent hemarthrosis are likely sequelae. In addition to transfusion, a major hemarthrosis should be treated with aspiration, short-term splinting, a defined rehabilitation program, and, most importantly, repeated transfusions, to minimize the risk of developing hypertrophic synovitis.

Aspiration is critical in treating a major hemarthrosis (232). Removing the bulk of blood within the joint greatly reduces the amount of iron that must be absorbed, the risk of developing hypertrophic synovitis, and recurrent hemorrhage. Aspiration also dramatically reduces the severe pain associated with a major hemarthrosis. After routine factor transfusion (25 U/kg), the joint is aspirated using local anesthetic agents and other analgesic measures.

Prophylactic transfusions are needed to protect the joint while it is recovering from a major hemarthrosis. Transfusions are repeated every 48 hours. This schedule keeps factor levels greater than 1%, an amount that usually prevents recurrent hemorrhage. The prophylactic transfusions are continued for 10 to 28 days, or even longer if synovitis is still present. For patient comfort, and to minimize risk of an early rebleed, the joint is splinted for 2 days. The splint is removed immediately after the second transfusion. This enables the initiation of joint motion at a time when factor levels are high. A program of muscle strengthening and range of motion is prescribed, so that the joint is fully rehabilitated when the prophylactic transfusions are discontinued.

When synovitis develops, the affected joint is swollen by the hypertrophic, boggy synovium. Joint motion, however, is not particularly painful or restricted at this early stage, unless a hemarthrosis recently has occurred. Recurrent hemarthroses, however, are typical. Furthermore, between episodes of obvious joint bleeds, ongoing oozing of blood from the hypervascular friable synovium perpetuates the synovitis and joint effusion.

The principle of nonoperative management of hypertrophic synovitis in hemophiliacs is intended to prevent joint bleeds so that the synovitis may resolve. In a study of prophylactic transfusions for hypertrophic synovitis and recurrent hemarthrosis, the rate of hemarthrosis in the affected

joint was reduced, but only 36% (12 of 33 joints) achieved a good result (defined as 0 to 0.5 bleeding episodes per month and decreased synovial hypertrophy) (255). It is uncommon for prophylactic transfusions to resolve subacute synovitis completely, particularly if the synovial hypertrophy is moderate or severe.

Synovectomy in hemophiliacs initially was reported by Storti and colleagues (256) in 1969. Since then, many centers have reported the results of this operation in hemophiliacs. Reduction in the rate of hemarthrosis is a consistent result, and is the only noncontroversial aspect of this procedure. This is important, however, because reducing the incidence of joint bleeds has both functional and economic benefits. An acute hemarthrosis is painful, and will limit ambulation and function for 1 to 10 days, even when transfusions are administered promptly (245). Therefore, when hemarthroses are occurring three to six times per month, the child is severely disabled. In addition, by 1 year after synovectomy, the reduction in transfusion requirements actually offsets the cost of transfusion required to perform the operation (257).

Whether synovectomy stops the progression of hemophilic arthropathy is more difficult to answer. Although the data are not conclusive, the reports of knee synovectomy, with long-term follow-up (258–265), and my personal observations, support the concept that the procedure delays but does not eliminate the progression of arthropathy. Joints with less-advanced changes at the time of synovectomy have demonstrated less progression (258,260,262,265). Although recurrent synovitis is uncommon, it is not surprising that the arthropathy continues to progress because articular cartilage erosions already are present in many hemophiliacs at the time of synovectomy.

Most synovectomies have been performed on the knee. The initial technique was an open procedure managed with conventional postoperative therapy. In these cases, loss of motion was common and significant, even with prolonged inpatient therapy. For example, in a series of 13 patients, Montane and colleagues (260) observed that 11 patients lost an average of 43 degrees of motion. Continuous passive motion, and the use of arthroscopic technique to perform the operation, have improved the results of knee synovectomy in hemophiliac patients (258,265–269). Most authors who advocate arthroscopic knee synovectomy also recommend postoperative continuous passive motion (258,266,268,269). By using these techniques, the range of knee motion can be maintained. Arthroscopic synovectomy of the knee in a hemophiliac is a demanding and time-consuming procedure. The hypertrophic, fibrotic synovium can be difficult to remove, and thorough removal is necessary to prevent recurrent hemarthroses. In addition, arteriovenous fistula has been reported after this procedure in hemophiliac patients (270).

Open synovectomy of the knee has some advantages. It permits more effective and less traumatic removal of the

synovium, particularly where the synovium inserts at the margin of the articular cartilage. Joint motion is maintained by preserving the joint capsule in the suprapatellar region and instituting continuous passive motion immediately after the operation. Preserving the suprapatellar capsule provides an interface for movement of the quadriceps tendon over the distal femur. This tissue, however, has become attenuated by the hypertrophic synovium, and must be dissected carefully from the underlying synovium. Because articular erosions and fibrillations typically are present in these patients at the time of synovectomy, it is mandatory that an arc of motion be established immediately. Otherwise, adhesions develop and it is difficult to rehabilitate the joint.

Elbow synovectomy usually is accompanied by radial head excision in the older adolescent or adult. The enlarged and incongruent radial head is probably secondary to the hypervascular synovium stimulating aberrant growth. After the radial head has been removed, it is easy to excise the remainder of the synovium. For a younger child, excision of the radial head is contraindicated. In this situation, it is difficult to perform an open synovectomy without taking down the collateral ligaments. Arthroscopic synovectomy would seem to be a better approach in younger children, and Busch and Kurczynski (271) have reported good results in three patients treated with arthroscopic synovectomy of the elbow.

The limited experience with ankle synovectomy in children suggests that the results are good and that rehabilitation is relatively easy, using either open or arthroscopic technique. Greene (272) described a three-incision technique that allowed a complete synovectomy. Continuous passive motion was not required, and rehabilitation was easy and effective, even though three of the five children were younger than 5 years of age. The rate of hemarthrosis in the involved ankle averaged 3.4 per month before synovectomy, compared with 0.1 per month after the operation. In addition, the range of ankle motion increased by an average of 10 degrees. Busch and Kurczynski (271) have presented similar results after arthroscopic synovectomy of the ankle. Of note, 1 of their 17 ankle synovectomy patients developed a pseudoaneurysm of the anterior tibial artery.

Radiosynovectomy is an alternative and may be the only option for a patient with an inhibitor. Radioactive isotopes cause fibrosis of synovial tissue; however, articular cartilage is relatively resistant to the effects of radiation, and joint function is maintained. The cost of a radiosynovectomy is significantly lower. The procedure can be performed on an outpatient basis, and, more importantly, transfusion of the expensive clotting factor is only necessary for 1 to 3 days. Therefore, even a patient with a high-responding inhibitor can undergo radiosynovectomy. The disadvantages are the higher rate of recurrent hemarthrosis and the theoretical concerns of causing chromosomal damage and subsequent malignancy.

Gold (^{198}Au), yttrium (^{90}Y), rhenium (^{186}Re), chromic

phosphate (^{32}P), and dysprosium (^{165}Dy) are the radioisotopes that have been used in hemophilic patients. ^{165}Dy has a short half-life (2.3 h) and therefore can be used only in centers that are adjacent to nuclear reactors. For that reason, it has been reported in only a few patients with hemophilia (273). ^{198}Au and ^{186}Re have relatively short half-lives (2.7 and 3.7 days, respectively) and have been used successfully in patients with hemophilia (274–276). These agents, however, have the disadvantage of a relatively shallow depth of penetration; therefore, they may not be optimal for large joints. Furthermore, leakage outside the joint may be higher with these agents.

Good results in patients with hemophilia have been reported with ^{90}Y (277–279), an agent that has a relatively short half-life of 2.7 days, but a greater depth of penetration (mean of 3.6 versus 1.2 mm for ^{198}Au and ^{186}Re). Heim and colleagues (279) used ^{90}Y in 50 joints of 43 hemophilia patients, 4 of whom had inhibitors. The rate of hemarthrosis of the affected joint decreased from one bleed per week to one bleed per month. Eight joints required a second injection. Erken (278) reported on 58 joints in 35 hemophiliacs, ranging in age from 5 to 20 years. Factor levels were increased to 80% at the time of injection and were maintained at more than 50% for 3 days. An estimated dose of 5 mCi of ^{90}Y was injected into the knee joint, and less into smaller joints. The joints were immobilized for 48 to 60 h to minimize leakage of radioisotope from the joint. The frequency of hemorrhage decreased from 4 per month, before the injection, to 0.2 per month at a mean follow-up of 7 years. Eight patients required repeat injection. After the second injection, the rate of hemarthrosis was decreased in four patients and unchanged in four patients.

Some authors favor ^{32}P , a radioactive agent that has a half-life of 14 days. The theoretical advantage of a prolonged half-life is that an acute inflammatory reaction and subsequent hemorrhage would not occur. Therefore, ^{32}P could be safer for patients with an inhibitor. The long half-life also means that only a single transfusion is necessary before the injection. The theoretical disadvantage is the greater risk of this agent accumulating in tissues outside the joint. Two centers have reported good results with ^{32}P in patients with hemophilia (280,281).

The role of radioactive synovectomy in hemophilia is evolving. The percentage of patients with recurrent hemarthrosis is higher than that observed after surgical synovectomy, but the results are acceptable. The expense of transfusion therapy for surgical synovectomy, and the low morbidity of the procedure, are obvious advantages that are particularly germane in developing countries. In centers performing these procedures, careful monitoring is needed to document the possible side effects of radiotherapy on children.

Muscle hemorrhages are common in patients with severe factor VIII or IX deficiency, and may occur after minimal trauma. Characteristic sites include the volar compartment

of the forearm, the iliopsoas, the quadriceps, and the anterior and posterior calf muscles. Clinical symptoms progress from stiffness, to pain on movement, to pain at rest. In a study of lower-extremity muscle bleeds in children, the quadriceps muscle was involved in 44%, the posterior calf muscles in 35%, the adductors in 7%, and the anterior calf muscles in 7% (282). Most patients with bleeding episodes in this study were transfused within 3 h, and the time for complete restoration of joint motion averaged 3.5 days.

Home transfusion therapy is effective for minor muscle bleeds. A single infusion usually is adequate if it is administered soon after the onset of the hemorrhage. For lower-extremity bleeds, crutches are used until normal range of motion has been regained. Patients or parents are instructed to call their physicians if they have symptoms of severe pain or neurologic dysfunction. With symptoms suggestive of a compartment syndrome in a hemophiliac who does not have an inhibitor, the factor levels are increased to 100%, then evaluation and management should be routine. This means that compartment pressures are measured, and fasciotomy is performed when indicated.

Patients with a high-titer inhibitor are at increased risk for complications from muscle hemorrhage (Fig. 11-24). These patients should seek medical attention early, so that alternative transfusions can be started. To minimize the risk of a compartment syndrome and contractures, nonoperative modalities, such as protective dressings, elevation, and splinting, should be aggressively pursued.

An iliopsoas bleed, sometimes called a “retroperitoneal hemorrhage,” may be associated with femoral nerve paralysis and, as such, demands more intensive therapy. Hemorrhage into the iliacus compartment causes femoral nerve paralysis. Because the iliacus muscle is confined between

the pelvic wall and the overlying fascia, a relatively small hemorrhage in this muscle also will cause marked pain. The patient holds the hip in a flexed position, and the pain is markedly increased by attempts at hip extension. Hemarthrosis into the hip joint can be differentiated by flexing the hip. In this position, rotation of the hip will be relatively normal with an iliopsoas hemorrhage, but rotation will remain limited with a bleed into the joint. If the location of the hemorrhage is unclear, ultrasonography or computed tomography may be used to define the site of bleeding. In the 1970s, femoral nerve palsies were found in approximately 60% of iliacus bleeds (247). The increased use of home therapy has reduced the incidence of this complication.

The standard treatment for femoral nerve palsy associated with an iliopsoas bleed is bed rest and continuous transfusion, to maintain factor levels at 50% or higher, for 7 to 14 days. With this therapy, the femoral nerve paralysis resolves, but several months may elapse before the quadriceps muscle regains sufficient strength to extend the knee against gravity. Growe and Meek (283) reported a case that was treated by open decompression of the iliopsoas muscle. This patient had symptoms for 5 days, a severe flexion contracture, paralysis of the femoral nerve, and a compartment pressure measurement of 166 mm Hg with the hip in extension, and 60 mm Hg with the hip flexed. At operation, a large organized clot was evacuated from the interval between the psoas and iliacus muscles. The patient's hip flexion contracture resolved within 1 week, and the quadriceps muscle function was normal within 1 month.

An equinus contracture may develop after hemorrhage into the gastrocnemius soleus muscle, particularly when there is a delay in transfusion for more than 6 to 12 hours (Fig. 11-25). Aggressive use of sequential splints and casts prevents this problem, even in patients with inhibitors. After a single transfusion, the leg should be immobilized in a compressive dressing and posterior splint. If an equinus contracture is present after 48 hours, a short-leg walking cast is applied with the ankle held in maximum dorsiflexion. The cast aids ambulation, but more importantly, minimizes the establishment of an equinus contracture, as the hematoma organizes. The cast is changed every few days, until the ankle can be positioned in neutral dorsiflexion with the knee extended. Stretching exercises then are used to gain further dorsiflexion.

Fixed knee-flexion contractures rarely develop in patients on home transfusion therapy. The exception is the patient with an inhibitor. In these patients, the alternatives to transfusion are not always effective, and an acute hemarthrosis may evolve into a fixed knee-flexion contracture. Traction, if instituted in an early and timely fashion, will allow the patient to regain full knee extension in 3 to 7 days.

Severe knee-flexion contractures that are chronic may be complicated by posterior subluxation of the tibia (232,285). If the patient also has an inhibitor that precludes elective

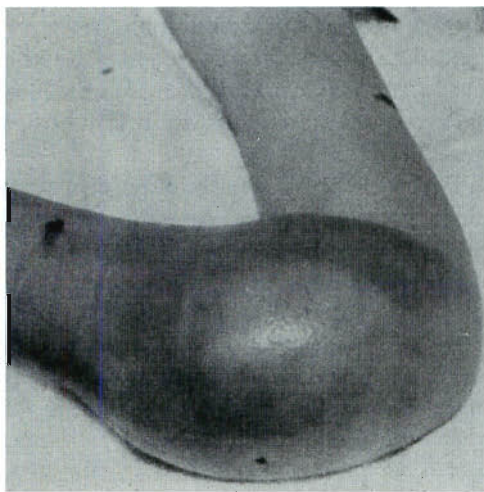


FIGURE 11-24. Massive soft tissue hemorrhage in the forearm of a 5-year-old patient with hemophilia can lead to Volkmann contractures.

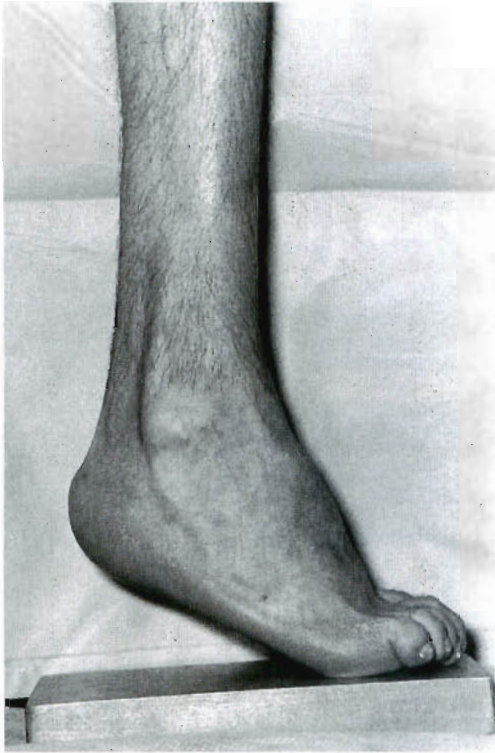


FIGURE 11-25. A 29-year-old man, with hemophilia and high-titer inhibitor, sustained multiple calf hemorrhages during childhood, which resulted in a fixed equinus contracture. Consistent and persistent treatment with serial casts could have greatly minimized the deformity and enhanced the patient's lower extremity function. (From ref. 284, with permission.)

surgery, the flexion contracture and subluxation of the tibia may be corrected with a Quengel cast (232) (Fig. 11-26). Offset subluxation hinges pull the proximal tibia forward, and the toggle stick allows windlass correction of the flexion deformity. The Quengel cast usually can correct the contracture to approximately 15 degrees. Further extension is attained with standard cast-wedging techniques.

Whether using traction or casting, the goal is to correct the knee-flexion contracture to 5 to 10 degrees. If less correction is attained, recurrent contractures are more likely. Furthermore, a typical patient will subsequently lose a few degrees of correction, but if the knee-flexion contracture remains less than 15 degrees, knee function is maximized, and stress across the joint is minimized. Therefore, after the contracture is corrected, a period of bracing is necessary. Over several months, the patient gradually is weaned from the brace, while a program of strengthening and range of motion is instituted.

The necessity of Quengel casting and bracing for a chronic contracture does not mean that the knee will be ankylosed. In my experience, approximately half of the patients ultimately regained more than 100 degrees of knee

motion, despite having a flexion contracture of more than 40 degrees at the start of treatment (285). Factors associated with good results included no significant joint erosions at the initiation of therapy, no breakthrough bleeding during treatment, and good compliance during the period of bracing.

A pseudotumor, or hemophilic cyst, starts as a hemorrhage that is intramuscular, subperiosteal, or intraosseous. A fibrous capsule eventually surrounds and sequesters the large mass of blood, which ultimately is transformed to necrotic erythrocytes and reactive tissues. Pseudotumors continue to enlarge. The capsule of the pseudotumor has a relatively sparse vasculature, but the coagulation defects in these patients allow ongoing small and asymptomatic hemorrhages, probably secondary to altered pressure gradients that develop when the extravasated blood is catabolized. As the pseudotumor expands, the surrounding soft tissue is displaced and erosion of adjacent bones occurs (Fig. 11-27). Eventually, a clinically apparent mass or pathologic fracture causes the patient to seek evaluation. The radiographs of a pseudotumor typically demonstrate a soft tissue mass, areas of soft tissue calcification, varying degrees of osseous destruction, and reactive new bone formation. The differential diagnosis includes aneurysmal bone cysts, osteomyelitis, and some types of sarcoma.

Pseudotumors were more common before the development of effective concentrates. At that time, pseudotumors in young children were more likely in the bones of the hands and feet. In a series of 19 pseudotumors, Martinson (287) observed that 9 occurred in the carpometacarpal or tarsometatarsal bones. In my experience, which is during the era of concentrates and home transfusion therapy, most pseudotumors have been located in the pelvis, and probably originated from a bleed in the iliacus muscle. Other sites may be involved, however, and I have treated hemophiliacs with pseudotumors of the proximal humerus, the olecranon, and the proximal femur.

The pseudotumor should be excised, if at all possible. Delay in operation will only allow further expansion of the pseudotumor and destruction of surrounding structures. Computed tomography is adequate to demonstrate the extent of the mass (288). In most situations, a lesional excision is indicated, but in large pseudotumors of the pelvis, some of the inner wall of the pseudotumor capsule may be left to minimize the risk of massive hemorrhage from adherent internal iliac vessels.

Fracture patterns are different in hemophiliacs who have significant arthropathy of the lower extremities. Limited mobility of their lower extremities, coupled with disuse osteoporosis, make supracondylar fracture of the femur and fractures of the femoral neck more likely. Fracture in these patients, even if nondisplaced, will cause more bleeding, swelling, and risk of compartment syndrome. Transfusion therapy should be instituted immediately, and most of these

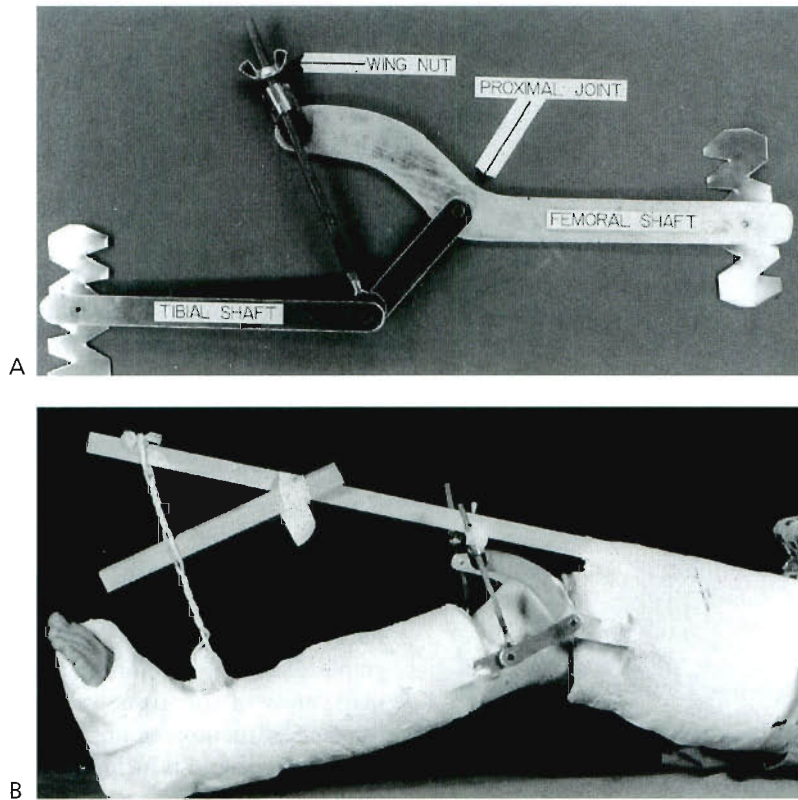


FIGURE 11-26. A: Quengel cast antisubluxation hinge. B: Completed Quengel cast applied to a patient. (From ref. 286, with permission.)

patients will need to be admitted to the hospital at least overnight for observation. For fractures that can be treated by nonoperative means, the amount and duration of trans-

fusion are individualized, depending on the location of the fracture, the amount of apparent hemorrhage, and the social situation. Patients who require open reduction should be transfused using standard protocols for surgical procedures.

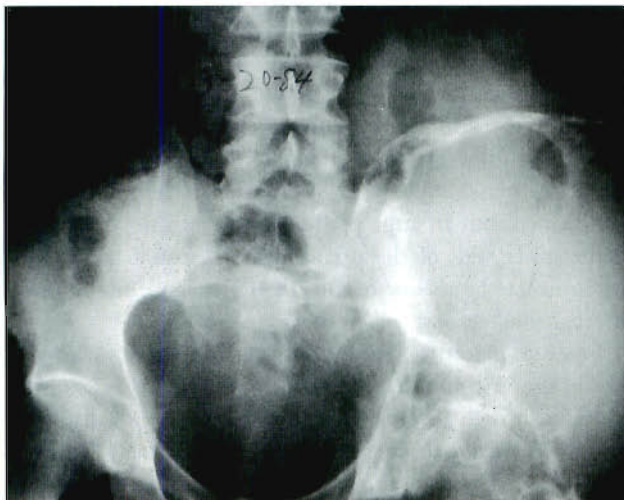

FIGURE 11-27. Pseudotumor of the ilium in a 39-year-old man with severe factor VIII deficiency and low-titer inhibitor. There is marked destruction of the left ilium.

ACUTE LEUKEMIA

Acute leukemia is the most common neoplasm in children, accounting for approximately one-third of pediatric cancer cases (289). "Acute leukemia" is used for diseases that have a predominance of immature hematopoietic or lymphoid precursors, whereas "chronic leukemia" describes conditions characterized by proliferation of mature marrow elements. Acute lymphoblastic leukemia (ALL) accounts for approximately 80% of the leukemias seen in children. The peak incidence of ALL is between the ages of 1 and 5 years, and the frequency declines progressively in the older childhood age groups. With intensive combination chemotherapy and central nervous system prophylaxis, the survival rate of ALL has improved significantly, and the current rate of cure is approximately 80% (290). Adverse risk factors include a white blood cell count greater than 50,000/mm³ at

TABLE 11-8. SIGNS AND SYMPTOMS OF DIAGNOSIS OF ACUTE LYMPHOBLASTIC LEUKEMIA IN 137 CHILDREN

Signs and Symptoms	Patients ^a (%)
Lethargy or malaise	36
Fever or infection	31
Extremity or joint pain	23
Bleeding manifestation	18
Anorexia	12
Abdominal pain	7
Central nervous system manifestation	2

^a Some patients presented with more than one sign or symptom.
(Adapted from ref. 291, with permission.)

diagnosis, patients with mature B-cell ALL, specific genetic abnormalities, age younger than 1 year at diagnosis, and a poor early response to induction therapy.

Although ALL is primarily a disease of the bone marrow, any organ may be infiltrated by the malignant cells. For that reason, the signs and symptoms at diagnosis can vary (Table 11-8). Pain in the extremities, or a limp, may be the initial manifestation of ALL, and the first physician evaluating these children may be an orthopaedic surgeon. In a representative study of 296 patients, a limp or extremity pain was the chief complaint at diagnosis in 52 patients (18%), and was an associated symptom in 65 patients (22%) (292). In another study of 40 ALL patients, 5 presented with refusal to walk and 13 had gait abnormalities (293). Pain is most common in the lower extremities, but it also may be present in the upper extremities. A history of night pain is significant, but is not always present or obtainable in these young children. Back pain also may be noted, and pathologic fracture of the vertebral body is found at diagnosis in 2 to 7% of children with ALL (294–296) (Fig. 11-28).

Arthritis or painful swelling of a joint may herald the onset of leukemia (298,299), and in one series, they were observed in 11% of ALL patients (299). Multiple joints may be involved, and migratory joint pain may occur. Asymmetric involvement of the large joints is characteristic. The cause of the arthritis is uncertain, but may be related to infiltration of the synovium by leukemic cells or by the hyperuricemia often observed at diagnosis.

Infiltration of the bone marrow by the leukemic cells explains the limb and back pain. Radiographic changes at diagnosis are even more frequent than musculoskeletal symptoms (294,295,300,301). Characteristic findings include localized and generalized osteoporosis, radiolucent metaphyseal bands, osteolytic defects, cortical defects, osteosclerosis, and periosteal reactions (Figs. 11-29 and 11-30). Osteopenia and metaphyseal lucent bands are the most common findings. Fractures also may be present. Typical patterns include: impaction fracture in the femur or tibia and vertebral compression fractures. Radiologic skeletal

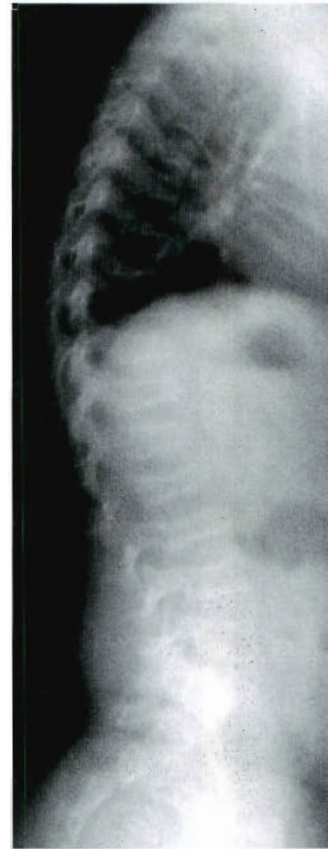

FIGURE 11-28. A 6-year-old girl presented with acute pain and an inability to walk. Radiographic examination revealed diffuse osteopenia and multiple compression fractures. Diagnostic evaluation revealed acute leukemia. (From ref. 297, with permission.)

changes do not portend a worse prognosis (300), and some studies have observed that, on average, ALL children with skeletal changes have more normal hematologic indexes and enhanced survival (294). However, the presence of five or more skeletal lesions at diagnosis is associated with a delay in diagnosis, and decreased survival (294,300).

Mineral homeostasis may be abnormal at diagnosis. In a prospective study of 40 children with ALL, low levels of 1,25-dihydroxyvitamin D and osteocalcin with hypercalciuria, were observed in approximately two-thirds of the patients (302). Bone density Z scores correlated with plasma 1,25-dihydroxyvitamin D concentrations. The cause of the defective mineralization at diagnosis is unclear, because renal tubular studies and 25-vitamin D levels were normal.

Children with ALL who present with bone pain often incur a delay in diagnosis, and may be misdiagnosed as having osteomyelitis, septic arthritis, or juvenile rheumatoid arthritis (292,295,298). This possibility may be minimized by inquiring about symptoms such as lethargy, fever, headache, vomiting, night pain, and easy bruising, and by including examination of the lymph nodes and abdominal organs in a child who presents with unexplained limb or

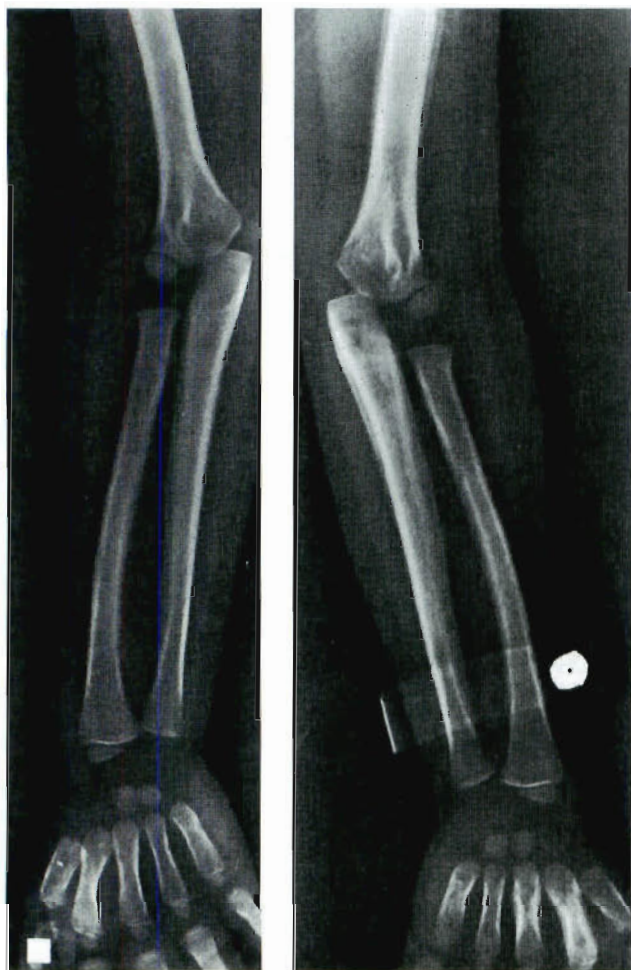


FIGURE 11-29. A 3-year-old boy with acute lymphocytic leukemia shows periosteal new bone formation, involving large segments of the radius, the ulna, and the humerus. A metaphyseal band is present at the distal radius.

back pain. A complete blood count may be helpful, particularly if the white blood cell count is markedly elevated or significantly depressed, or if blast forms are noted. However, children with ALL also may have a nondiagnostic leukocyte count that is normal or only slightly elevated, as well as an elevated erythrocyte sedimentation rate. In this situation, radiographs showing a greater degree of osteopenia than one would expect will suggest the correct diagnosis. Radiographs also should be carefully examined for the presence of more characteristic lesions, such as metaphyseal lucent bands. Bone scans in children with leukemia are inconsistent, and may show increased uptake in an asymptomatic region, or normal or decreased uptake in areas that have obvious lysis on plane radiographs (289). With any suspicion, diagnostic bone marrow aspiration should be considered.

Distinguishing systemic juvenile rheumatoid arthritis from ALL in children who present with fever and multiple joint pain may be challenging. Lymphadenopathy, spleno-

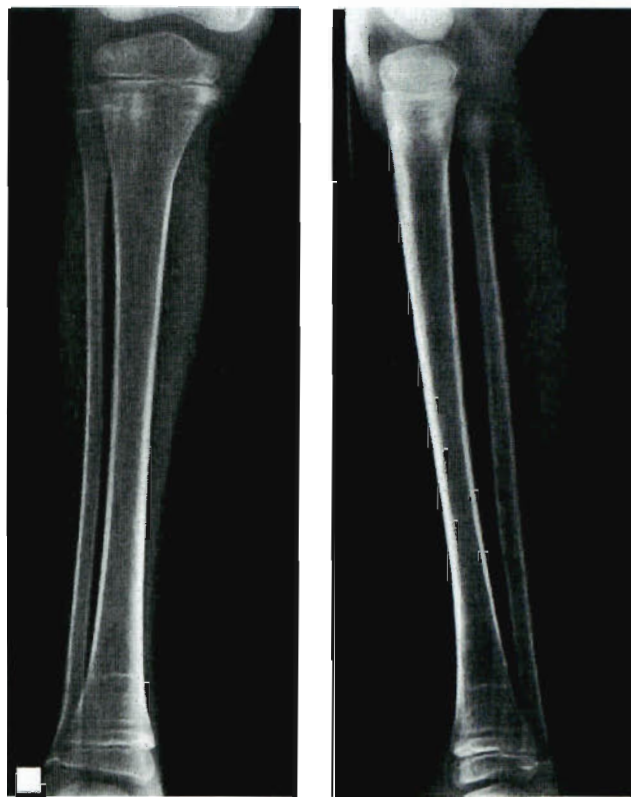


FIGURE 11-30. A 6-year-old girl with acute myelogenous leukemia shows multiple growth rest lines, generalized osteopenia, and a metaphyseal band.

megaly, and hepatomegaly are equivalent in both groups (298). Musculoskeletal night pain, however, is observed frequently in ALL, whereas morning stiffness is common in juvenile rheumatoid arthritis. Nonarticular bone pain, in addition to the joint symptoms, is found in ALL, but is absent in juvenile rheumatoid arthritis. Radiographic findings are limited to joint effusions in juvenile rheumatoid arthritis patients, whereas other abnormalities are frequently observed in children with leukemia.

The basic approach to therapy for leukemia involves a relatively brief induction phase, followed by intensification (consolidation) treatment, then prolonged continuation therapy (289,290). The goal of induction therapy is to reduce the leukemic cell load, so that there are normal blood cell counts and a normocellular bone marrow with less than 5% blasts. A typical regimen includes a glucocorticoid (dexamethasone), vincristine, and asparaginase. Intrathecal chemotherapy is included. Intensification therapy also incorporates combination chemotherapy. To prevent relapse, therapy at lower dosage levels is continued for 2.5 to 3 years, even in children showing a good response.

Leukemic bone and joint pain typically resolves with the institution of chemotherapy; however, during chemotherapy, osteoporosis may increase and pathologic fractures may

occur. In a prospective study of 40 ALL children during 24 months of chemotherapy, Atkinson and colleagues (302) observed that 64% had a significant reduction in bone mineral content, as measured by Z scores. Bone density was most severely affected in children older than 11 years of age. During the 2-year treatment period, fractures occurred in 15 patients, and a reduction in bone mineral content during the first 6 months of treatment had a 64% positive predictive value for this complication. Although rare, severe osteoporosis and multiple vertebral body collapse during treatment of ALL also have been reported (303). After therapy is completed, the bone mineral content improves, but long-term survivors of ALL remain relatively osteopenic compared with controls (304,305). Whether this will have any long-term consequences is unclear at this time.

Symptomatic osteonecrosis is more likely to develop in adults with leukemia, but has also been reported in the pediatric population. Murphy and Greenberg (306) found multifocal, symptomatic osteonecrosis in 5 of 228 children with ALL. Sites of involvement included the femoral condyle, femoral head, humeral condyle, talus, and capitellum. These patients were older at diagnosis, ranging from 9.5 to 16.7 years of age. Dexamethasone was thought to be the causative agent. Recent MRI studies indicate that osteonecrosis is more common than previously realized. In a prospective MRI study of 24 ALL patients, 9 patients (38%) developed osteonecrosis during treatment, and 6 of them were asymptomatic (307).

Allogenic bone marrow transplantation, with its greater risk of osteonecrosis, may be necessary for ALL patients who relapse, or who are in high-risk categories. Multiple osteochondromas were observed in nine ALL patients (23%) at a mean 6 years after total body irradiation (308). At a mean follow-up of 2.5 years after diagnosis of the osteochondromata, no lesion had demonstrated malignant change. Short stature also occurs as a consequence of treating ALL. This complication has been greatly reduced by treatment protocols that lessen the need for or the degree of cranial irradiation (309).

References

Bone Marrow Failure Syndromes

1. Alter BP, Young NS. The bone marrow failure syndromes. In: Nathan DG, Oski SH, eds. *Hematology of infancy and childhood*, 5th ed. Philadelphia: WB Saunders, 1998:237.
2. Alter BP. Arms and the man or hands and the child: congenital anomalies and hematologic syndromes. *J Pediatr Hematol Oncol* 1997;19:287.
3. Minagi H, Steinbach HL. Roentgen appearance of anomalies associated with hypoplastic anemias of childhood: Fanconi's anemia and congenital hypoplastic anemia (erythrocytopenia). *Am J Roentgenol* 1966;97:100.
4. Gluckman E, Auerbach AD, Horowitz MM, et al. Bone marrow transplantation for Fanconi anemia. *Blood* 1995;86:2856.
5. Deeg HJ, Socie G, Schock G, et al. Malignancies after marrow transplantation for aplastic anemia and Fanconi anemia: a joint Seattle and Paris analysis of results in 700 patients. *Blood* 1996; 87:386.
6. Willig TN, Ball SE, Tchernia G. Current concepts and issues in Diamond-Blackfan anemia. *Curr Opin Hematol* 1998;5:109.
7. Hurst JA, Baraitser M, Wonke B. Autosomal dominant transmission of congenital erythroid hypoplastic anemia with radial abnormalities. *Am J Med Genet* 1991;40:482.
8. McGuckin CP, Ball SE, Gordon-Smith EC. Diamond-Blackfan anemia: three patterns of in vitro responses to haemopoietic growth factors. *Br J Hematol* 1995;89:457.
9. Mugishima H, Gale RP, Rowlings PA, et al. Bone marrow transplantation for Diamond-Blackfan anemia. *Bone Marrow Transplant* 1995;15:55.
10. Aquino VM, Buchanan GR. Osteogenic sarcoma in a child with transfusion-dependent Diamond-Blackfan anemia. *J Pediatr Hematol Oncol* 1996;18:230.
11. Aggett PJ, Cavanagh NPC, Matthew DJ, et al. Schwachman's syndrome. *Arch Dis Child* 1980;55:331.
12. Smith OP, Hann IM, Chessells JM, et al. Haematological abnormalities in Schwachman-Diamond syndrome. *Br J Haematol* 1996;94:279.
13. Dhar S, Anderton JM. Orthopaedic features of Schwachman syndrome. *J Bone Joint Surg Am* 1994;76:278.
14. Dror Y, Durie P, Marcon P, et al. Duplication of distal thumb phalanx in Schwachman-Diamond syndrome. *Am J Med Genet* 1998;78:67.
15. McKusick VA, Eldridge R, Hostetler JA, et al. Dwarfism in the Amish. *Bull Johns Hopkins* 1965;116:285.
16. van der Burgt I, Haraldsson A, Oosterwijk JC, et al. Cartilage hair hypoplasia, metaphyseal chondrodysplasia type McKusick: description of seven patients and review of the literature. *Am J Med Genet* 1991;41:371.
17. Makitie O, Kaitila I. Cartilage-hair hypoplasia: clinical manifestations in 108 Finnish patients. *Eur J Pediatr* 1993;152:211.
18. Beals RK. Cartilage-hair hypoplasia: a case report. *J Bone Joint Surg Am* 1968;50:1245.
19. Berthet F, Siegrist CA, Ozsahin H, et al. Bone marrow transplantation in cartilage-hair hypoplasia: correction of the immuno-deficiency but not of the chondrodysplasia. *Eur J Pediatr* 1996;155:286.
20. Castigli E, Irani AM, Geha RS, et al. Defective expression of early activation genes in cartilage-hair hypoplasia (CHH) with severe combined immunodeficiency (SCID). *Clin Exp Immunol* 1995;102:6.
21. Sulisalo T, Francomano CA. High-resolution genetic mapping of the cartilage-hair hypoplasia (CHH) gene in Amish and Finnish families. *Genomics* 1994;20:347.
22. Hall JG, Levin J, Kuhn JP, et al. Thrombocytopenia with absent radius (TAR). *Medicine* 1969;48:411.
23. Hall JG. Thrombocytopenia and absent radius (TAR). *J Med Genet* 1987;24:79.
24. Hedberg VA, Lipton JM. Thrombocytopenia with absent radii. *Am J Pediatr Hematol Oncol* 1988;10:51.
25. Schoenecker PL, Cohn AK, Sedgwick WG, et al. Dysplasia of the knee associated with the syndrome of thrombocytopenia and absent radius. *J Bone Joint Surg Am* 1984;66:421.
26. Gounder DS, Ockelford PA, Pullon HW, et al. Clinical manifestations of the thrombocytopenia and absent radii (TAR) syndrome. *Aust NZ J Med* 1989;19:479.
27. Dell PC, Sheppard JE. Thrombocytopenia, absent radius syndrome: report of two siblings and a review of the hematologic and genetic features. *Clin Orthop* 1982;162:129.
28. Camitta BM, Rock A. Acute lymphoid leukemia in a patient

with thrombocytopenia/absent radii (Tar) syndrome. *Am J Pediatr Hematol Oncol* 1993;15:335.

Disorders of Erythrocytes

29. Oski FA. Iron deficiency in infancy and childhood. *N Engl J Med* 1993;329:190.
30. Lanzkowsky P. Radiological features of iron-deficiency anemia. *Am J Dis Child* 1968;116:16.
31. Filer LJ. Iron needs during rapid growth and mental development. *J Pediatr* 1990;117:S143.
32. Hurtado EK, Claussen AH, Scott KG. Early childhood anemia and mild or moderate mental retardation. *Am J Clin Nutr* 1999; 69:115.
33. Morey SS. CDC guidelines for prevention, detection, and treatment of iron deficiency. *Am Fam Physician* 1998;58:1475.
34. Preziosi P, Prual A, Galan P, et al. Effect of iron supplementation on the iron status of pregnant women: consequences for newborns. *Am J Clin Nutr* 1997;66:1178.
35. Ballin A, Berar M, Rubinstein U, et al. Iron state in female adolescents. *Am J Dis Child* 1991;146:803.
36. Raunekar RA, Sabio H. Anemia in the adolescent athlete. *Am J Dis Child* 1992;146:1201.
37. Roy WL, Lerman J, McIntyre BG. Is preoperative haemoglobin testing justified in children undergoing minor elective surgery? *Can J Anaesth* 1991;38:700.
38. Schneider RG, Hightower B, Hosty TS, et al. Abnormal hemoglobins in a quarter million people. *J Am Soc Hematol* 1976; 48:629.
39. Bunn HF. Pathogenesis and treatment of sickle cell disease. *N Engl J Med* 1997;337:762.
40. Dover GJ, Platt OS. Sickle cell disease. In: Nathan DG, Oski SH, eds. *Hematology of infancy and childhood*, 5th ed. Philadelphia: WB Saunders, 1998:762.
41. Serjeant GR. Natural history and determinants of clinical severity of sickle cell disease. *Curr Opin Hematol* 1995;2:103.
42. Steinberg MH. Management of sickle cell disease. *N Engl J Med* 1998;340:1021.
43. Platt OS, Brambilla DJ, Rosse WF, et al. Mortality in sickle cell disease: life expectancy and risk factors for early death. *N Engl J Med* 1994;330:1639.
44. McKie VC. Sickle cell anemia in children: practical issues for the pediatrician. *Pediatr Ann* 1998;27:521.
45. Platt OS, Rosenstock W, Espeland MA. Influence of sickle cell hemoglobinopathies on growth and development. *N Engl J Med* 1984;311:7.
46. Earley CJ, Kittner SJ, Feaser BR, et al. Stroke in children and sickle-cell disease: Baltimore-Washington cooperative young stroke study. *Neurology* 1998;51:169.
47. Ohene-Frempong K, Weiner SJ, Sleeper LA, et al. Cerebrovascular accidents in sickle cell disease: rates and risk factors. *Blood* 1998;91:288.
48. Pegelow CH, Adams RJ, McKie V, et al. Risk of recurrent stroke in patients with sickle cell disease treated with erythrocyte transfusions. *J Pediatr* 1995;126:896.
49. Adams RJ, McKie VC, Hsu L. Prevention of a first stroke by transfusions in children with sickle cell anemia and abnormal results on transcranial Doppler ultrasonography. *N Engl J Med* 1998;339:5.
50. Cohen AR. Sickle cell disease: new treatments, new questions. *N Engl J Med* 1998;339:42.
51. Brinker MR, Thomas KA, Meyers SJ, et al. Bone mineral density of the lumbar spine and proximal femur is decreased in children with sickle cell anemia. *Am J Orthop* 1998;27:43.
52. Soliman AT, Berehi H, Darwish A, et al. Decreased bone mineral density in prepubertal children with sickle cell disease: correlation with growth parameters, degree of siderosis and secretion of growth factors. *J Trop Pediatr* 1998;44:194.
53. Platt OS, Thorington BD, Brambilla DJ, et al. Pain in sickle cell disease: rates and risk factors. *N Engl J Med* 1991;325:11.
54. Keeley K, Buchanan GR. Acute infarction of long bones in children with sickle cell anemia. *J Pediatr* 1982;101:170.
55. Mankad VN, Williams JP, Harpen MD, et al. Magnetic resonance imaging of bone marrow in sickle cell disease: clinical, hematologic, and pathologic correlations. *Blood* 1990;75:274.
56. Michaels LA, Ohene-Frempong K, Zhao H, et al. Serum levels of substance P are elevated in patients with sickle cell disease and increase further during vaso-occlusive crisis. *Blood* 1998; 92:3148.
57. Babhulkar SS, Pande K, Babhulkar S. The hand-foot syndrome in sickle-cell haemoglobinopathy. *J Bone Joint Surg Br* 1995; 77:310.
58. Diggs LW. Bone and joint lesions in sickle-cell disease. *Clin Orthop* 1967;52:119.
59. Stevens MCG, Padwick M, Serjeant GR. Observations on the natural history of dactylitis in homozygous sickle cell disease. *Clin Pediatr* 1981;20:311.
60. Dalton GP, Drummond DS, Davidson RS, et al. Bone infarction versus infection in sickle cell disease in children. *J Pediatr Orthop* 1996;16:540.
61. Burnett NW, Bass JW, Cook BA. Etiology of osteomyelitis complicating sickle cell disease. *Pediatrics* 1998;101:296.
62. Greene WB, McMillan CW. *Salmonella* osteomyelitis and hand-foot syndrome in a child with sickle cell anemia. *J Pediatr Orthop* 1987;7:716.
63. Bonnerot V, Sebag G, de Montalembert M, et al. Gadolinium-DOTA enhanced MRI of painful osseous crises in children with sickle cell anemia. *Pediatr Radiol* 1994;24:92.
64. Bennett OM, Namnyak SS. Bone and joint manifestations of sickle cell anemia. *J Bone Joint Surg Br* 1990;72:494.
65. Epps CH Jr, Bryant DOD III, Coles MJM, et al. Osteomyelitis in patients who have sickle-cell disease. *J Bone Joint Surg Am* 1991;73:1281.
66. Buchanan GR. Differentiation of bone infarct from infection in a child with sickle cell disease. *Pediatr Infect Dis J* 1996;15: 725.
67. Kahn CE Jr, Ryan JW, Hatfield MK, et al. Combined bone marrow and gallium imaging: differentiation of osteomyelitis and infarction in sickle hemoglobinopathy. *Clin Nucl Med* 1998;13:443.
68. Sadat-Ali M, al-Umrani K, al-Habdan I, et al. Ultrasonography: can it differentiate between vasoocclusive crisis and acute osteomyelitis in sickle cell disease? *J Pediatr Orthop* 1998;18:552.
69. Anand AJ, Glatt AE. *Salmonella* osteomyelitis and arthritis in sickle cell disease. *Semin Arthritis Rheum* 1994;24:211.
70. Bryan JP, Rocha H, Scheld WM. Problems in salmonellosis: rationale for clinical trials with lower β -lactam agents and quinolones. *Rev Infect Dis* 1986;8:189.
71. Ebong WW. Pathological fracture complicating long bone osteomyelitis in patients with sickle cell disease. *J Pediatr Orthop* 1986;6:177.
72. Syrogiannopoulos GA, McCracken GH, Nelson JD. Osteoarticular infections in children with sickle cell disease. *Pediatrics* 1986;78:1090.
73. Hanissian AS, Silverman A. Arthritis of sickle cell anemia. *South Med J* 1974;67:28.
74. Schumacher HR, Andrews R, McLaughlin G. Arthropathy in sickle-cell disease. *Ann Intern Med* 1973;78:203.
75. Milner PF, Kraus AP, Sebes JL, et al. Sickle cell disease as a cause of osteonecrosis of the femoral head. *N Engl J Med* 1991; 325:1476.

76. Milner PF, Kraus AP, Sebes JJ, et al. Osteonecrosis of the humeral head in sickle cell disease. *Clin Orthop* 1993;289:136.
77. Hernigou P, Galacteros F, Bachir D, et al. Deformities of the hip in adults who have sickle-cell disease and had avascular necrosis in childhood. *J Bone Joint Surg Am* 1991;73:81.
78. Ware HE, Brooks AP, Toye R, et al. Sickle cell disease and silent avascular necrosis of the hip. *J Bone Joint Surg Br* 1991;73:947.
79. Grecne WB. Disease of the hematopoietic system and chronic inflammatory arthritides: musculoskeletal complications in children. In: Bowen JR, Epps CE, eds. *Complications in pediatric orthopaedic surgery*. Philadelphia: JB Lippincott, 1995:715.
80. Rao VM, Mitchell DG, Steiner RM, et al. Femoral head avascular necrosis in sickle cell anemia: MR characteristics. *Magn Reson Imaging* 1988;6:661.
81. Acurio MT, Friedman RJ. Hip arthroplasty in patients with sickle-cell haemoglobinopathy. *J Bone Joint Surg Br* 1992;74:367.
82. Bishop AR, Roberson JR, Eckman JR, et al. Total hip arthroplasty in patients who have sickle-cell hemoglobinopathy. *J Bone Joint Surg Am* 1988;70:853.
83. Clarke HJ, Jinnah RH, Brooker AF, et al. Total replacement of the hip for avascular necrosis in sickle cell disease. *J Bone Joint Surg Br* 1989;71:465.
84. Charache S, Terrin ML, Moore RD, et al. Effect of hydroxyurea on the frequency of painful crises in sickle cell anemia. Investigators of the Multicenter Study of Hydroxyurea in Sickle Cell Anemia. *N Engl J Med* 1995;332:1317.
85. Ohene-Frempong K, Smith-Whitley K. Use of hydroxyurea in children with sickle cell disease: what comes next? *Semin Hematol* 1997;34(Suppl 3):30.
86. Olivieri NF, Vichinsky EP. Hydroxyurea in children with sickle cell disease: impact on splenic function and compliance with therapy. *J Pediatr Hematol Oncol* 1998;20:26.
87. Rogers ZR. Hydroxyurea therapy for diverse pediatric populations with sickle cell disease. *Semin Hematol* 1997;34(Suppl 3):42.
88. Platt OS, Guinan EC. Bone marrow transplantation in sickle cell anemia: the dilemma of choice. *N Engl J Med* 1996;335:426.
89. Walters MC, Patience M, Leisenring W, et al. Bone marrow transplantation for sickle cell disease. *N Engl J Med* 1996;335:369.
90. Hernigou P, Bernaudin F, Reinert P, et al. Bone-marrow transplantation in sickle cell disease: effect on osteonecrosis. A case report with a four-year follow-up. *J Bone Joint Surg Am* 1997;79:1726.
91. Stein RE, Urbaniak J. Use of the tourniquet during surgery in patients with sickle cell hemoglobinopathies. *Clin Orthop* 1980;151:231.
92. Koshy M, Weiner SJ, Miller ST, et al. Surgery and anesthesia in sickle cell disease. Cooperative Study of Sickle Cell Diseases. *Blood* 1995;86:3676.
93. Orkin SH, Nathan DG. The thalassemias. In: Nathan DG, Oski SH, eds. *Hematology of infancy and childhood*, 5th ed. Philadelphia: WB Saunders, 1998:811.
94. Abramson SD, Abramson N. 'Common' uncommon anemias. *Am Fam Physician* 1999;59:851.
95. Kattamis C, Liakopoulou T, Kattamis A. Growth and development in children with thalassaemia major. *Acta Paediatr Scand Suppl* 1990;366:111.
96. Caffey J. Cooley's anemia: a review of the roentgenographic findings in the skeleton. *Am J Roentgenol* 1957;78:381.
97. Dines DM, Canale VC, Arnold WD. Fractures in thalassemia. *J Bone Joint Surg Am* 1976;58:662.
98. Exarchou E, Polirou G, Vretou E, et al. Fractures and epiphyseal deformities in beta-thalassemia. *Clin Orthop* 1984;189:229.
99. Finsterbush A, Farber I, Mogle P, et al. Fracture patterns in thalassemia. *Clin Orthop* 1985;192:132.
100. Michelson J, Cohen A. Incidence and treatment of fractures in thalassemia. *J Orthop Trauma* 1988;2:29.
101. Colavita N, Orazi C, Danza SM, et al. Premature epiphyseal fusion and extramedullary hematopoiesis in thalassemia. *Skeletal Radiol* 1987;16:533.
102. Hershko C, Link G, Cabantchik I. Pathophysiology of iron overload. *Ann NY Acad Sci* 1998;850:191.
103. Levin TL, Sheth SS, Ruzal-Shapiro C, et al. MRI marrow observations in thalassemia: the effects of the primary disease, transfusional therapy, and chelation. *Pediatr Radiol* 1995;25:607.
104. Olivieri NF, Nathan DG, MacMillan JH, et al. Survival in medically treated patients with homozygous beta-thalassemia. *N Engl J Med* 1994;331:574.
105. Giardina PJ, Grady RW. Chelation therapy in beta-thalassemia: the benefits and limitations of desferrioxamine. *Semin Hematol* 1995;34:304.
106. Aydingoz U, Oto A, Cila A. Spinal cord compression due to epidural extramedullary hematopoiesis in thalassemia: MRI. *Neuroradiology* 1997;39:870.
107. Coskun E, Keskin A, Suzer T, et al. Spinal cord compression secondary to extramedullary hematopoiesis in thalassemia. *Eur Spine J* 1998;7:501.
108. Lau SK, Chan CK, Chow YYN. Cord compression due to extramedullary hemopoiesis in a patient with thalassemia. *Spine* 1994;19:2467.
109. Lucarelli G, Giardini C, Baronciani D. Bone marrow transplantation in thalassemia. *Semin Hematol* 1995;32:297.
110. Mariotti E, Angelucci E, Agostini A, et al. Evaluation of cardiac status in iron-loaded thalassemia patients following bone marrow transplantation: improvement in cardiac function during reduction in body iron burden. *Br J Haematol* 1998;103:916.
111. Andrews NC, Bridges KR. Disorders of iron metabolism and sideroblastic anemia. In: Nathan DG, Oski SH, eds. *Hematology of infancy and childhood*, 5th ed. Philadelphia: WB Saunders, 1998:423.
112. Konijn M. Iron metabolism in inflammation. *Baillieres Clin Haematol* 1994;7:829.
113. Peeters HR, Jongen-Lavrencic M, Raja AN, et al. Course and characteristics of anaemia in patients with rheumatoid arthritis of recent onset. *Ann Rheum Dis* 1996;55:162.
114. Means RT Jr. Pathogenesis of the anemia of chronic disease: a cytokine-mediated anemia. *Stem Cells* 1995;13:32.
115. Means RT Jr. Erythropoietin in the treatment of anemia in chronic infectious, inflammatory, and malignant diseases. *Curr Opin Hematol* 1995;2:210.

Disorders of Neutrophils

116. Dinanuer MC. The phagocyte system and disorders of granulopoiesis and granulocyte function. In: Nathan DG, Oski SH, eds. *Hematology of infancy and childhood*, 5th ed. Philadelphia: WB Saunders, 1998:889.
117. Malech HL, Nauseef WM. Primary inherited defects in neutrophil function: etiology and treatment. *Semin Hematol* 1997;34:279.
118. Forehand JR, Johnston RB Jr. Chronic granulomatous disease: newly defined molecular abnormalities explain disease variability and normal phagocyte physiology. *Curr Opin Pediatr* 1994;6:668.
119. Meischl C, Ross D. The molecular basis of chronic granulomatous disease. *Springer Semin Immunopathol* 1998;19:417.
120. Verhoeven AJ. The NADPH oxidase: lessons from chronic

- granulomatous disease neutrophils. *Ann NY Acad Sci* 1997;832:85.
121. Eckert JW, Abramson SL, Starke J, et al. The surgical implications of chronic granulomatous disease. *Am J Surg* 1995;169:320.
 122. Finn A, Hadzic N, Morgan G, et al. Prognosis of chronic granulomatous disease. *Arch Dis Child* 1990;65:942.
 123. Wolfson JJ, Kane WJ, Laxdal SD, et al. Bone findings in chronic granulomatous disease of childhood: a genetic abnormality of leukocyte function. *J Bone Joint Surg Am* 1969;51:1573.
 124. Sponseller PD, Malech HL, McCarthy EF, et al. Skeletal involvement in children who have chronic granulomatous disease. *J Bone Joint Surg Am* 1991;73:37.
 125. Heinrich SD, Finney T, Craver R, et al. *Aspergillus* osteomyelitis in patients who have chronic granulomatous disease. *J Bone Joint Surg Am* 1991;73:456.
 126. Kline MW, Bocobo FC, Paul ME, et al. Successful medical therapy of *Aspergillus* osteomyelitis of the spine in an 11-year-old boy with chronic granulomatous disease. *Pediatrics* 1994;93:830.
 127. Pasic S, Abinun M, Pistignat B, et al. *Aspergillus* osteomyelitis in chronic granulomatous disease: treatment with recombinant gamma-interferon and itraconazole. *Pediatr Infect Dis J* 1996;15:833.
 128. Mouy R, Fischer A, Vilmer E, et al. Incidence, severity, and prevention of infections in chronic granulomatous disease. *J Pediatr* 1989;114:555.
 129. The International Chronic Granulomatous Disease Cooperative Study Group. Controlled trial of interferon gamma to prevent infection in chronic granulomatous disease. *N Engl J Med* 1991;324:504.
 130. Rosh JR, Tang HB, Mayer L, et al. Treatment of intractable gastrointestinal manifestations of chronic granulomatous disease with cyclosporine. *J Pediatr* 1995;126:143.
 131. Lee BW, Yap HK. Polyarthritis resembling juvenile rheumatoid arthritis in a girl with chronic granulomatous disease. *Arthritis Rheum* 1994;37:773.
 132. Calvino MC, Maldonado MS, Ortheo E, et al. Bone marrow transplantation in chronic granulomatous disease. *Eur J Pediatr* 1996;155:877.
 133. Ho CM, Vowels MR, Lockwood L, et al. Successful bone marrow transplantation in a child with X-linked chronic granulomatous disease. *Bone Marrow Transplant* 1996;18:213.
 134. Malech HL, Bauer TR Jr, Hickstein DD. Prospects for gene therapy of neutrophil defects. *Semin Hematol* 1997;34:355.
 - in patients with primary immunoglobulin deficiency: clinical features and outcome in 18 patients. *Br J Rheumatol* 1997;36:661.
 142. Horowitz HW, Telzak EE, Sepkowitz KA, et al. Human immunodeficiency virus infection. Part I. *Dis Mon* 1998;44:545.
 143. Centers for Disease Control. AIDS among children: United States, 1996. *MMWR* 1996;45:1005.
 144. Chadwick EG, Yogev R. Pediatric AIDS. *Pediatr Clin North Am* 1995;42:969.
 145. Miller CR. Pediatric aspects of AIDS. *Radiol Clin North Am* 1997;35:1191.
 146. Andiman WA. Medical management of the pregnant woman infected with human immunodeficiency virus type 1 and her child. *Semin Perinatol* 1998;22:72.
 147. Connor EM, Sperling RS, Gelber R, et al. Reduction of maternal-infant transmission of human immunodeficiency virus type 1 with zidovudine treatment. Pediatric AIDS Clinical Trials Group Protocol 076 Study Group. *N Engl J Med* 1994;331:1173.
 148. Wu LR, Capparelli EV, Connor JD. Therapy of pediatric AIDS. *Curr Opin Pediatr* 1995;7:214.
 149. Cooper A. Human immunodeficiency virus and acquired immunodeficiency syndrome: recent developments and their implications for pediatric surgeons. *Semin Pediatr Surg* 1995;4:252.
 150. Lindegren ML, Hanson C, Miller K, et al. Epidemiology of human immunodeficiency virus infection in adolescents, United States. *Pediatr Infect Dis J* 1994;13:525.

Disorders of the Monocyte-macrophage System

Disorders of Lymphocytes and the Immune System

135. Bonilla FA, Rosen FS, Geha RS. Primary immunodeficiency diseases. In: Nathan DG, Oski SD, eds. *Hematology of infancy and childhood*, 5th ed. Philadelphia: WB Saunders, 1998:1023.
136. Conley ME. X-linked immunodeficiencies. *Curr Opin Genet Dev* 1994;4:401.
137. Manis J, Schwartz RS. Agammaglobulinemia and insights into B-cell differentiation. *N Engl J Med* 1996;335:1523.
138. Hansel TT, Haeney MR, Thompson RA. Primary hypogammaglobulinemia and arthritis. *Br Med J* 1987;295:174.
139. Lee AH, Levinson AI, Schumacher HR Jr. Hypogammaglobulinemia and rheumatic disease. *Semin Arthritis Rheum* 1993;22:252.
140. Chattopadhyay C, Natvig JB, Chattopadhyay H. Excessive suppressor T-cell activity of the rheumatoid synovial tissue in X-linked hypogammaglobulinemia. *Scand J Immunol* 1980;11:455.
141. Franz A, Webster AD, Furr PM, et al. Mycoplasmal arthritis
151. Sullivan JL, Woda BA. Lymphohistiocytic disorders. In: Nathan DG, Orkin SH, eds. *Hematology of infancy and childhood*, 5th ed. Philadelphia: WB Saunders, 1998:1359.
152. Kolodny EH, Lebron D. Storage diseases of the reticuloendothelial system. In: Nathan DG, Oski SH, eds. *Hematology of infancy and childhood*, 5th ed. Philadelphia: WB Saunders, 1998:1461.
153. Brady RO, Kanfer JN, Shapiro D. Metabolism of glucocerebrosides. II. Evidence of an enzymatic deficiency in Gaucher's disease. *Biochem Biophys Res Commun* 1965;18:221.
154. Beutler E, Nguyen NJ, Henneberger MW, et al. Gaucher disease: gene frequencies in the Ashkenazi Jewish population. *Am J Hum Genet* 1993;51:85.
155. Beutler E, Gelbart T. Hematologically important mutations: Gaucher disease. *Blood Cells Mol Dis* 1998;24:2.
156. Beutler E, Gelbart T. Gaucher disease mutations in non-Jewish patients. *Br J Haematol* 1993;85:401.
157. Beutler E. Gaucher disease. *Curr Opin Hematol* 1997;4:19.
158. Zimran A, Kay A, Gelbart T, et al. Gaucher disease: clinical, laboratory, radiologic, and genetic features of 53 patients. *Medicine* 1992;71:337.
159. Stowens DW, Teitelbaum SL, Kahn AJ, et al. Skeletal complications of Gaucher disease. *Medicine* 1985;64:310.
160. Miller SP, Zirzow GC, Doppelt SH, et al. Analysis of the lipids of normal and Gaucher bone marrow. *J Lab Clin Med* 1996;127:353.
161. Herman G, Shapiro RS, Abdelwahab IF, et al. MR imaging in adults with Gaucher disease type I: evaluation of marrow involvement and disease activity. *Skeletal Radiol* 1993;22:247.
162. Johnson LA, Hoppel BE, Gerard EL, et al. Quantitative chemical shift imaging of vertebral bone marrow in patients with Gaucher disease. *Radiology* 1992;182:451.
163. Rosenthal DI, Barton NW, McKusick KA, et al. Quantitative imaging of Gaucher disease. *Radiology* 1992;185:841.

164. Amstutz HC, Carey EJ. Skeletal manifestations and treatment of Gaucher's disease. *J Bone Joint Surg Am* 1966;48:670
165. Pastores GM, Wallenstein S, Desnick RJ, et al. Bone density in type I Gaucher disease. *J Bone Miner Res* 1996;11:1801.
166. Katz K, Mechlis-Frish S, Cohen IJ, et al. Bone scans in the diagnosis of bone crisis in patients who have Gaucher disease. *J Bone Joint Surg Am* 1991;73:513.
167. Mankin HJ, Doppelt SH, Rosenberg AE, et al. Metabolic bone disease in patients with Gaucher's disease. In: Avioli LA, Krane SM, eds. *Metabolic bone disease and clinically related disorders*, 2nd ed. Philadelphia: WB Saunders, 1990:730.
168. Horev G, Kornreich L, Hadar H, et al. Hemorrhage associated with "bone crisis" in Gaucher's disease identified by magnetic resonance imaging. *Skeletal Radiol* 1991;20:479.
169. Cohen IJ, Kornreich L, Mekhmandarov S, et al. Effective treatments of painful bone crises in type I Gaucher's disease with high dose prednisone. *Arch Dis Child* 1996;75:218.
170. Bell RS, Mankin HJ, Doppelt SH. Osteomyelitis in Gaucher disease. *J Bone Joint Surg Am* 1986;68:1380.
171. Katz K, Cohen IJ, Ziv N, et al. Fractures in children who have Gaucher disease. *J Bone Joint Surg Am* 1987;69:1361.
172. Katz K, Sabato S, Horev G, et al. Spinal involvement in children and adolescents with Gaucher disease. *Spine* 1993;18:332.
173. Katz K, Horev G, Grunebaum M, et al. The natural history of osteonecrosis of the femoral head in children and adolescents with Gaucher disease. *J Bone Joint Surg Am* 1996;78:14.
174. Barton NW, Brady RO, Dambrosia JM, et al. Replacement therapy for inherited enzyme deficiency: macrophage-targeted glucocerebrosidase for Gaucher's disease. *N Engl J Med* 1991;324:1464.
175. Barton NW, Brady RO, Dambrosia JM, et al. Dose-dependent responses to macrophage-targeted glucocerebrosidase in a child with Gaucher disease. *J Pediatr* 1992;120:277.
176. Pastores GM, Sibille AR, Grabowski GA. Enzyme therapy in Gaucher disease type I: dosage efficacy and adverse effects in 33 patients treated for 6 to 24 months. *Blood* 1993;82:408.
177. Rosenthal DI, Doppelt SH, Mankin JH, et al. Enzyme replacement therapy for Gaucher disease: skeletal responses to macrophage-targeted glucocerebrosidase. *Pediatrics* 1995;96:629.
178. Beutler E, Demina A, Laubscher K, et al. The clinical course of treated and untreated Gaucher disease: a study of 45 patients. *Blood Cells Mol Dis* 1995;21:86.
179. Beutler E. Enzyme replacement therapy for Gaucher's disease. *Baillieres Clin Haematol* 1997;10:751.
180. Elstein D, Hadas-Halpern I, Itzhaki M, et al. Effect of low-dose enzyme replacement therapy on bones in Gaucher disease patients with severe skeletal involvement. *Blood Cells Mol Dis* 1996;22:104.
181. Zimran A, Hadas-Halpern I, Zevin S, et al. Low-dose high-frequency enzyme replacement therapy for very young children with severe Gaucher disease. *Br J Haematol* 1993;85:783.
182. Kaplan P, Mazur A, Manor O, et al. Accelerating of retarded growth in children with Gaucher disease after treatment with alglucerase. *J Pediatr* 1996;129:149.
183. Kaye EM. Therapeutic approaches to lysosomal storage diseases. *Curr Opin Pediatr* 1995;7:650.
184. Barranger JA, Rice EO, Dunigan J, et al. Gaucher's disease: studies of gene transfer to haematopoietic cells. *Baillieres Clin Haematol* 1997;10:765.
185. Lichenstein L, Jaffe H. Eosinophilic granuloma of bone with report of a case. *Am J Pathol* 1940;16:595
186. Otani S, Ehrlich J. Solitary granuloma of bone simulating primary neoplasm. *Am J Pathol* 1940;16:479
187. Green WT, Faber S. Eosinophilic or solitary granuloma of bone. *J Bone Joint Surg Am* 1942;24:499
188. Lichenstein L. Histiocytosis X (eosinophilic granuloma of bone, Letterer-Siwe disease, and Schüller-Christian disease). *J Bone Joint Surg Am* 1964;46:76.
189. D'Angio GJ, Favara BE, Ladisch W. Workshop on the childhood histiocytosis: concepts and controversies. *Med Pediatr Oncol* 1986;14:104.
190. Favara BE. Langerhans' cell histiocytosis pathobiology and pathogenesis. *Semin Oncol* 1991;18:3.
191. Beckstead JH, Wood GS, Turner RR. Histiocytosis X cells and Langerhans cells: enzyme histochemical and immunologic similarities. *Hum Pathol* 1984;15:826.
192. Cambazard F, Dezutter-Dambuyant C, Straquet MJ, et al. Eosinophilic granuloma of bone and biochemical demonstration of 49-kDa Cdla molecule expression by Langerhans cell histiocytosis. *Clin Exp Dermatol* 1991;16:377.
193. Mierau GW, Favara BE, Brenman JM. Electron microscopy in histiocytosis X. *Ultrastruct Pathol* 1982;3:137.
194. Makley JT, Carter JR. Eosinophilic granuloma of bone. *Clin Orthop* 1986;204:37.
195. Dehner LP. Morphologic findings in the histiocytic syndromes. *Semin Oncol* 1991;18:8.
196. McClain K, Jin H, Gresik V, et al. Langerhans cell histiocytosis: lack of a viral etiology. *Am J Hematol* 1994;47:16.
197. de Graaf JH, Tamminge RY, Dam-Meiring A, et al. The presence of cytokines in Langerhans' cell histiocytosis. *J Pathol* 1996;180:400.
198. Lahey ME. Histiocytosis X: an analysis of prognostic factors. *J Pediatr* 1975;87:184.
199. Broadbent V. Favourable prognostic features in histiocytosis X: bone involvement and absence of skin disease. *Arch Dis Child* 1986;61:1219.
200. Novice FM, Collison DW, Kleinsmith DM, et al. Letterer-Siwe disease in adults. *Cancer* 1989;63:166.
201. Berry DH, Gresik MV, Humphrey GB, et al. Natural history of histiocytosis X: a pediatric oncology study. *Med Pediatr Oncol* 1986;14:1.
202. McLelland J, Broadbent V, Yeomans E, et al. Langerhans cell histiocytosis: the case for conservative treatment. *Arch Dis Child* 1990;65:301.
203. Raney RB, D'Angio GJ. Langerhans' cell histiocytosis (histiocytosis X): experience at the Children's Hospital of Philadelphia, 1970-1984. *Med Pediatr Oncol* 1989;17:20.
204. Leavey P, Varughese M, Breatnach F, et al. Langerhans cell histiocytosis: a 31-year review. *Ir J Med Sci* 1991;160:271.
205. Schmitts S, Martin E, Zachmann M, et al. Pituitary stalk thickening with diabetes insipidus preceding typical manifestations of Langerhans cell histiocytosis in children. *Eur J Pediatr* 1993;152:399.
206. Grois N, Barkovich AJ, Rosenau W, et al. Central nervous system disease associated with Langerhans' cell histiocytosis. *Am J Pediatr Hematol Oncol* 1993;15:245.
207. Bollini G, Jouve JL, Genter JC, et al. Bone lesions in histiocytosis X. *J Pediatr Orthop* 1991;11:469.
208. Dimentberg RA, Brown KLB. Diagnostic evaluation of patients with histiocytosis X. *J Pediatr Orthop* 1990;10:733.
209. Greis PE, Hankin FM. Eosinophilic granuloma: the management of solitary lesions of bone. *Clin Orthop* 1990;257:204.
210. Compere EL, Johnson WE, Coventry MB. Vertebra plana (Calve's disease) due to eosinophilic granuloma. *J Bone Joint Surg Am* 1954;36:969.
211. Ruppert D, Oria RA, Kumar R, et al. Radiologic features of eosinophilic granuloma of bone. *Am J Roentgenol* 1989;153:1021.
212. Kozlowski K, Diard F, Padovani J, et al. Unilateral mid-femoral periosteal new bone of varying aetiology in children. *Pediatr Radiol* 1986;16:475.
213. Gardner DJ, Azouz EM. Solitary lucent epiphyseal lesions in children. *Skeletal Radiol* 1988;17:497.

214. Leeson MC, Smith A, Carter JR, et al. Eosinophilic granuloma of bone in the growing epiphysis. *J Pediatr Orthop* 1985;5:147.
215. Dogan AS, Conway JJ, Miller JH, et al. Detection of bone lesions in Langerhans cell histiocytosis: complementary roles of scintigraphy and conventional radiography. *J Pediatr Hematol Oncol* 1996;18:51.
216. Beltran J, Aparisi F, Bonmati LM, et al. Eosinophilic granuloma: MRI manifestations. *Skeletal Radiol* 1993;22:157.
217. Fiorillo A, Sadile F, De Chiara C, et al. Bone lesions in Langerhans cell histiocytosis. *Clin Pediatr* 1993;32:118.
218. Womer RB, Raney RB, D'Angio GJ. Healing rates of treated and untreated bone lesions in histiocytosis X. *Pediatrics* 1985;76:286.
219. Egeler RM, Thompson RC Jr, Voute PA, et al. Intralesional infiltration of corticosteroids in localized Langerhans' cell histiocytosis. *J Pediatr Orthop* 1992;12:811.
220. Munn SE, Olliver L, Broadbent V, et al. Use of indomethacin in Langerhans cell histiocytosis. *Med Pediatr Oncol* 1999;32:247.
221. Greenberger JS, Crocker AC, Vawter G, et al. Results of treatment of 127 patients with systemic histiocytosis (Letterer-Siwe disease, Schüller-Christian syndrome and multifocal eosinophilic granuloma). *Medicine* 1981;60:311.
222. Baber WW, Numaguchi Y, Nadell JM, et al. Eosinophilic granuloma of the cervical spine without vertebrae plana. *J Comput Tomogr* 1987;11:346.
223. Robert H, Duboussier J, Miladi L. Histiocytosis X in the juvenile spine. *Spine* 1987;12:167.
224. Mammano S, Candiotti S, Balsano M. Cast and brace treatment of eosinophilic granuloma of the spine: long-term follow-up. *J Pediatr Orthop* 1997;17:821.
225. Alley RM, Sussman MD. Rapidly progressive eosinophilic granuloma. *Spine* 1992;17:1517.
226. Raney RB. Chemotherapy for children with aggressive fibromatosis and Langerhans' cell histiocytosis. *Clin Orthop* 1991;262:58.
227. Starling KA. Chemotherapy of histiocytosis-X. *Hematol Oncol Clin North Am* 1987;1:119.
228. Greinix HT, Storb R, Sanders JE, et al. Marrow transplantation for treatment of multisystem progressive Langerhans cell histiocytosis. *Bone Marrow Transplant* 1992;10:39.
229. Ringdén O, Åhrström L, Lönnqvist B, et al. Allogeneic bone marrow transplantation in a patient with chemotherapy-resistant progressive histiocytosis X. *N Engl J Med* 1987;316:733.
230. Alexander JE, Seibert JJ, Berry DH, et al. Prognostic factors for healing of bone lesions in histiocytosis X. *Pediatr Radiol* 1988;18:326.
231. Soucie JM, Evatt B, Jackson D. Occurrence of hemophilia in the United States. The Hemophilia Surveillance System Project Investigators. *Am J Hematol* 1998;59:288.
232. Greene WB, McMillan CW. Nonsurgical management of hemophilic arthropathy. *Instructional Course Lect* 1989;38:367.
233. Pool JG, Shannon AE. Production of high-potency concentrates in antihemophilic globulin in a closed-bag system: assay in vitro and in vivo. *N Engl J Med* 1965;273:1443.
234. Brinkhouse KM, Shanbrom E, Roberts HR, et al. A new high-potency glycine-precipitated antihemophilic factor (AHF) concentrate. *JAMA* 1968;205:613.
235. Wagner RH, McLester WD, Smith M, et al. Purification of antihemophilic factor (factor VIII) by amino acid precipitation. *Thromb Diath Haemorrh* 1964;11:64.
236. McMillan CW, Green WB, Blatt PM, et al. The management of musculoskeletal problems in hemophilia. *Instructional Course Lect* 1983;33:210.
237. Shapiro SS. Antibodies to blood coagulation factors. *Clin Haematol* 1979;8:207.
238. DiMichele DM. Immune tolerance: a synopsis of the international experience. *Haemophilia* 1998;4:568.
239. Shapiro AD, Gilchrist GS, Hoots WK, et al. Prospective, randomized trial of two doses of rFVIIa (NovoSeven) in haemophilia patients with inhibitors undergoing surgery. *Thromb Haemost* 1998;80:773.
240. Mainardi CL, Levine PH, Werb Z, et al. Proliferative synovitis in hemophilia: biochemical and morphologic observations. *Arthritis Rheum* 1978;21:137.
241. Roosendaal G, Vianen ME, Wenting MJ, et al. Iron deposits and catabolic properties of synovial tissue from patients with haemophilia. *J Bone Joint Surg Br* 1998;80:540.
242. Stein H, Duthie RB. The pathogenesis of chronic haemophilic arthropathy. *J Bone Joint Surg Br* 1981;63:601.
243. Roy S. Ultrastructure of articular cartilage in experimental haemarthrosis. *Arch Pathol* 1968;86:69.
244. Greene WB, Yankaskas BC, Guilford WB. Comparison of radiologic classification of hemophilic arthropathy with clinical parameters. *J Bone Joint Surg Am* 1989;71:237.
245. Aronstam A, Browne RS, Wassef M, et al. Clinical features of early haemarthroses in severely affected adolescent haemophiliacs. *Clin Lab Haematol* 1984;6:9.
246. Gamble JG, Bellah J, Rinsky LA, et al. Arthropathy of the ankle in hemophilia. *J Bone Joint Surg Am* 1991;73:1008.
247. Houghton GR, Duthie RB. Orthopaedic problems in hemophilia. *Clin Orthop* 1979;138:197.
248. Funk M, Schmidt H, Escuriola-Ettingshausen C, et al. Radiological and orthopedic score in pediatric hemophilic patients with early and late prophylaxis. *Ann Hematol* 1998;77:171.
249. Kreuz W, Escuriola-Ettingshausen C, Funk M, et al. When should prophylactic treatment in patients with haemophilia A and B start? The German experience. *Haemophilia* 1998;4:413.
250. Ljung R, van den Berg M, Petrini P, et al. Port-A-Cath usage in children with haemophilia: experience of 53 cases. *Acta Paediatr* 1998;87:1051.
251. Miller K, Buchanan GR, Zappa S, et al. Implantable venous access devices in children with hemophilia: a report of low infection rates. *J Pediatr* 1998;132:934.
252. Perkins JL, Johnson VA, Osip JM, et al. The use of implantable venous access devices (IVAD's) in children with hemophilia. *J Pediatr Hematol Oncol* 1997;19:339.
253. Bohn RL, Avorn J, Glynn RJ, et al. Prophylactic use of factor VIII: an economic evaluation. *Thromb Haemost* 1998;75:932.
254. Smith PS, Teutsch SM, Shaffer PA, et al. Episodic versus prophylactic infusions for hemophilia A: a cost-effective analysis. *J Pediatr* 1996;129:424.
255. Greene WB, McMillan CW, Warren MW. Prophylactic transfusion for hypertrophic synovitis in children with hemophilia. *Clin Orthop* 1997;343:19.
256. Storti E, Traldi A, Tosatti E, et al. Synovectomy, a new approach to hemophilic arthropathy. *Acta Haematol* 1969;41:193.
257. Wilson FC, Mayhew DE, McMillan CW. Surgical management of musculoskeletal problems in hemophilia. *Instructional Course Lect* 1983;32:233.
258. Klein KS, Aland CM, Him HC, et al. Long-term follow-up of arthroscopic synovectomy for chronic hemophilic synovitis. *Arthroscopy* 1987;3:231.
259. Matsuda Y, Duthie DB. Surgical synovectomy for hemophilic arthropathy of the knee joint: long-term follow-up. *Scand J Haematol* 1984;33(Suppl 40):237.
260. Montane I, McCollough NC, Lian EC. Synovectomy of the

Disorders of Hemostasis

- knee for hemophilic arthropathy. *J Bone Joint Surg Am* 1986; 68:210.
261. O'Connell FD. Open surgical synovectomy of the knee in hemophilia: long-term follow-up. In: Gilbert MS, Greene WB, eds. *Musculoskeletal problems in hemophilia*. New York: The National Hemophilia Foundation, 1989:91.
 262. Post M, Watts G, Telfer M. Synovectomy in hemophilic arthropathy: a retrospective review of 17 cases. *Clin Orthop* 1986; 202:139.
 263. Scarponi R, Silvello L, Landonio G, et al. Long-term evaluation of knee-joint function after synovectomy in haemophilia. *Br J Haematol* 1982;52:337.
 264. Storti E, Ascari E, Gamba G. Postoperative complications of joint function after knee synovectomy in haemophiliacs. *Br J Haematol* 1982;50:544.
 265. Triantafyllou SJ, Hanks GA, Handal JA, et al. Open and arthroscopic synovectomy in hemophilic arthropathy of the knee. *Clin Orthop* 1992;283:196.
 266. Casscells CD. Commentary: the argument for early arthroscopic synovectomy in patients with severe hemophilia. *Arthroscopy* 1987;3:78.
 267. Greene WB. Use of continuous passive slow motion in the postoperative rehabilitation of difficult pediatric knee and elbow problems. *J Pediatr Orthop* 1983;3:419.
 268. Limbird TJ, Dennis SC. Synovectomy and continuous passive motion (cpm) in hemophilic patients. *Arthroscopy* 1987;3:74.
 269. Wiedel JD. Arthroscopic synovectomy of the knee in hemophilia. *Clin Orthop* 1996;328:46.
 270. Cohen B, Griffiths L, Dandy DJ. Arteriovenous fistula after arthroscopic synovectomy in a patient with haemophilia. *Arthroscopy* 1992;8:373.
 271. Busch M, Kurczynski E. The role of arthroscopic synovectomy in the treatment of children with hemophilia. Presented at the Pediatric Orthopaedic Society of North America meeting, May 4, 1993, White Sulphur Springs, WV.
 272. Greene WB. Synovectomy of the ankle for hemophilic arthropathy. *J Bone Joint Surg Am* 1994;76:812.
 273. Zuckerman JD, Solomon GE, Shortkroff S, et al. Principles of radiation synovectomy. In: Gilbert MS, Greene WB, eds. *Musculoskeletal problems in hemophilia*. New York: The National Hemophilia Foundation, 1990:93.
 274. Fernandez-Palazzi F, de Boscl NB, de Vargas AF. Radioactive synovectomy in haemophilic haemarthrosis: follow-up of fifty cases. *Scand J Haematol* 1984;33(Suppl 40):291.
 275. Löfqvist T, Petersson C, Nilsson IM. Radioactive synoviorthesis in patients with hemophilia with factor inhibitor. *Clin Orthop* 1997;343:37.
 276. Merchan EC, Magallon M, Martin-Villar J, et al. Long-term follow-up of haemophilic arthropathy treated by AU-198 radiation synovectomy. *Int Orthop* 1993;17:120.
 277. Dawson TM, Ryan PF, Street AM, et al. Yttrium synovectomy in haemophilic arthropathy. *Br J Rheumatol* 1994;33:351.
 278. Erken EHW. Radiocolloids in the management of hemophilic arthropathy in children and adolescents. *Clin Orthop* 1991;264: 129.
 279. Heim M, Horoszowski H, Lieberman L, et al. Methods and results of radionucleotide synovectomies. In: Gilbert MS, Greene WB, eds. *Musculoskeletal problems in hemophilia*. New York: The National Hemophilia Foundation, 1990:98.
 280. Rivard GE, Girard M, Belanger R, et al. Synoviorthesis with colloidal ³²P chromic phosphate for the treatment of hemophilic arthropathy. *J Bone Joint Surg Am* 1994;76:482.
 281. Siegel ME, Siegel HJ, Luck JV Jr. Radiosynovectomy's clinical applications and cost effectiveness: a review. *Semin Nucl Med* 1997;27:364.
 282. Aronstam A, Rainsford SG, Painter MJ. Patterns of bleeding in adolescents with severe haemophilia A. *Br Med J* 1979;1: 469.
 283. Grove GH, Meek R. Decompression of the iliopsoas muscle. In: Gilbert MS, Greene WB, eds. *Musculoskeletal problems in hemophilia*. New York: The National Hemophilia Foundation, 1990:45.
 284. Greene WB. Chronic inflammatory arthritides and diseases related to the hematopoietic system. In: Drennan JC, ed. *The child's foot and ankle*. New York: Raven, 1992:461.
 285. Greene WB, Howes CL, Mathewson AB. Treatment of knee flexion contractures in hemophiliacs with inhibitors and pre-existent arthropathy. In: Gilbert MS, Greene WB, eds. *Musculoskeletal problems in hemophilia*. New York: The National Hemophilia Foundation, 1990:74.
 286. Greene WB, Wilson FC. Nonoperative management of hemophilic arthropathy and muscle hemorrhage. *Instructional Course Lect* 1983;32:223.
 287. Martinson A. Hemophilic pseudotumors. In: Boone DC, ed. *Comprehensive management of hemophilia*. Philadelphia: FA Davis, 1976:94.
 288. Hermann G, Yeh HC, Gilbert MS. Computed tomography and ultrasonography of the hemophilic pseudotumor and their use in surgical planning. *Skeletal Radiol* 1986;15:123.

Acute Leukemia

289. Niemeyer CM, Sallan SE. Acute lymphoblastic leukemia. In: Nathan DG, Orkin SH, eds. *Hematology of infancy and childhood*, 5th ed. Philadelphia: WB Saunders, 1998:1245.
290. Pui CH, Evans WE. Acute lymphoblastic leukemia. *New Engl J Med* 1998;339:605.
291. Sallan SE, Weinstein HJ. Childhood acute leukemia. In: Nathan DG, Oski FA, eds. *Hematology of infancy and childhood*, 3rd ed. Philadelphia: WB Saunders, 1987:1028.
292. Jonsson OG, Sartain P, Ducore JM, et al. Bone pain as an initial symptom of childhood acute lymphoblastic leukemia: association with nearly normal hematologic indexes. *J Pediatr* 1990;117:233.
293. Halton JM, Atkinson SA, Fraher L, et al. Mineral homeostasis and bone mass at diagnosis in children with acute lymphoblastic leukemia. *J Pediatr* 1995;126:557.
294. Heinrich SD, Gallagher D, Warrior R, et al. The prognostic significance of the skeletal manifestations of acute lymphoblastic leukemia of childhood. *J Pediatr Orthop* 1994;14:105.
295. Rogalsky RJ, Black GB, Reed MH. Orthopaedic manifestations of leukemia in children. *J Bone Joint Surg Am* 1986;68:494.
296. Santangelo JR, Thomson JD. Childhood leukemia presenting with back pain and vertebral compression fractures. *Am J Orthop* 1999;28:257.
297. Greene WB. Idiopathic juvenile osteoporosis. In: Weinstein SL, ed. *The pediatric spine*. New York: Raven, 1994:933.
298. Ostrov BE, Goldsmith DP, Athreya BH. Differentiation of systemic juvenile rheumatoid arthritis from acute leukemia near the onset of disease. *J Pediatr* 1993;122:595.
299. Saulsbury FT, Sabio H. Acute leukemia presenting as arthritis in children. *Clin Pediatr* 1985;24:625.
300. Appell RG, Buhler T, Willich E, et al. Absence of prognostic significance of skeletal involvement in acute lymphocytic leukemia and non-Hodgkin lymphoma in children. *Pediatr Radiol* 1985;15:245.
301. Masera G, Carnelli V, Ferrari M, et al. Prognostic significance of radiological bone involvement in childhood acute lymphoblastic leukemia. *Arch Dis Child* 1977;52:530.
302. Atkinson SA, Halton JM, Bradley C, et al. Bone and mineral abnormalities in childhood acute lymphoblastic leukemia: influence of disease, drugs and nutrition. *Int J Cancer* 1998;11:35.

303. D'Angelo P, Conter V, Di Chiara G, et al. Severe osteoporosis and multiple vertebral collapses in a child during treatment for B-ALL. *Acta Haematol* 1993;38:38.
304. Arikoski P, Komulainen J, Voutilainen R, et al. Reduced bone mineral density in long-term survivors of childhood acute lymphoblastic leukemia. *J Pediatr Hematol Oncol* 1998;20:234.
305. Warner JT, Evans WD, Webb DK, et al. Relative osteopenia after treatment for acute lymphoblastic leukemia. *Pediatr Res* 1999;45:544.
306. Murphy RG, Greenberg ML. Osteonecrosis in pediatric patients with acute lymphoblastic leukemia. *Cancer* 1990;65:1717.
307. Ojala AE, Paakko E, Lanning FP, et al. Osteonecrosis during the treatment of childhood acute lymphoblastic leukemia: a prospective MRI study. *Med Pediatr Oncol* 1999;32:11.
308. Harper GD, Dicks-Mireaux C, Leiper AD. Total body irradiation-induced osteochondromata. *J Pediatr Orthop* 1998;18:356.
309. Mohnike K, Dorffle W, Timme J, et al. Final height and puberty in 40 patients after antileukaemic treatment during childhood. *Eur J Pediatr* 1997;156:272.



JUVENILE IDIOPATHIC ARTHRITIS

DOWAIN A. WRIGHT

OVERVIEW OF PEDIATRIC RHEUMATIC DISEASE ENCOUNTERED BY THE PEDIATRIC ORTHOPAEDIC SURGEON 428

CLASSIFICATION AND DIAGNOSIS OF JUVENILE IDIOPATHIC ARTHRITIS 428

Oligoarthritis 429
Polyarthritis (RF-) 430
Polyarthritis (RF+) 430
Systemic Arthritis 430
Psoriatic Arthritis 430
Enthesitis-related Arthritis 430
Other Juvenile Idiopathic Arthritides 430

APPROACH TO THE EVALUATION OF CHILDREN WITH LIMB PAIN, LIMP, OR JOINT PAIN WITH OR WITHOUT SWELLING 430

Timing of Pain or Disability 431
Duration of Pain 432
Location of Pain 432
Intensity of Pain 432
Age of the Child 432
Response to Activity or Rest and Immobilization 432
Associated Symptoms 432
Family History 432
Physical Exam 433
Labs and Tests 433
Synovial Fluid Analysis 434
Radiographic Studies 434

DIFFERENTIAL DIAGNOSIS OF JOINT PAIN AND SWELLING IN CHILDREN 434

Arthritis and Limb Pain Associated with Other
Conditions 434
Infectious Arthritis 435
Lyme Disease 435
Postinfectious Arthritis 435
Transient Synovitis of the Hip 435
Acute Rheumatic Fever 435
Poststreptococcal Arthritis 436
Serum Sickness 437
Other Inflammatory Arthropathies 437
Coagulopathies and Hemoglobinopathies 438
Malignancies 438
Benign Tumors 438
Benign Pains of Childhood 438

JUVENILE IDIOPATHIC ARTHRITIS 439

Epidemiology 440
Etiology 441
Genetics 441
Infection as Trigger 441

CLINICAL SYNDROMES OF JIA 441

Clinical Onset Types 441
Systemic Arthritis 442
Oligoarthritis 444
Polyarthritis 444
Psoriatic Arthritis 445
Enthesitis-related Arthritis 446
Juvenile Ankylosing Spondylitis 447
Inflammatory Bowel Disease-associated Arthritis 447

RADIOLOGIC FINDINGS IN JIA 448**TREATMENT OF JIA 450**

Medications 450

Nonsteroidal Antiinflammatory Drugs 450

Corticosteroids 451

Methotrexate 451

Sulfasalazine 451

Physical and Occupational Therapy 451

Surgical Interventions for Complications of JIA 451

Synovectomy 452

Soft Tissue Release 452

Arthrodesis 452

Osteotomy 452

Epiphysiodesis 452

Total Joint Arthroplasty 452

OVERVIEW OF PEDIATRIC RHEUMATIC DISEASE ENCOUNTERED BY THE PEDIATRIC ORTHOPAEDIC SURGEON

Pain is a common complaint in childhood. Each year, as many as 1% of all children will have pains severe enough to be evaluated (1). Approximately 15% of healthy children reported episodes of musculoskeletal pain on a health questionnaire (2). Healthy children in daycare centers have approximately one painful episode every 3 h, related to play, discipline, or interaction with peers (3). The orthopaedic surgeon is often the first specialist to encounter the child with joint, limb, or back pain. They must be able to identify the most likely cause of the pain and initiate treatment or referral to an appropriate medical specialist.

Juvenile arthritis is the most common rheumatic disease of childhood. It is one of the most common chronic illnesses occurring in children. The annual incidence ranges from 10 to 14 per 100,000, with an overall prevalence of 1 to 2 per 1,000 (4,5). Although only 1 in 100 children evaluated by a physician for joint pain will ultimately be diagnosed with arthritis, the frequency of arthritis presenting to the orthopaedic specialist is surely higher.

The purpose of this chapter is to provide the orthopaedic surgeon with an in-depth understanding of the presentation, differential diagnosis, and management of children with arthritis. With this framework, the orthopaedic specialist should be able to identify children with juvenile arthritis, and to differentiate arthritis from benign pains of childhood, psychogenic pain syndromes, infection, malignancy, or other systemic autoimmune diseases (lupus, dermatomyositis, and vasculitis). Infection and malignancies, as well as congenital, mechanical, or traumatic causes of limb or joint pain, are presented only as a contrast to juvenile arthritis, because detailed presentations on these subjects are found elsewhere in this text.

CLASSIFICATION AND DIAGNOSIS OF JUVENILE IDIOPATHIC ARTHRITIS

The cause(s) of juvenile arthritis is not known. With the great heterogeneity of presentation and course, there will likely be multiple initiating factors in the setting of a suscep-

tible host. There is no laboratory test that will make a definitive diagnosis of arthritis. A diagnosis of juvenile arthritis is made by taking a thorough history, performing a skilled and comprehensive physical examination, utilizing directed laboratory tests and imaging procedures, and following the child over time.

There have been two major sets of criteria for the diagnosis and classification for juvenile arthritis. The diagnostic criteria for juvenile chronic arthritis (JCA) were defined by the European League Against Rheumatism (EULAR) (6) (Table 12-1). In the EULAR criteria, JCA is differentiated into onset types of pauciarticular, polyarticular, juvenile rheumatoid (positive rheumatoid factor [RF]), systemic, juvenile ankylosing spondylitis, and juvenile psoriatic arthritis. In North America, the most frequently used criteria have been those by the American College of Rheumatology (ACR) for juvenile rheumatoid arthritis (JRA) (7) (Table 12-1). These criteria define the subtypes of JRA to be oligoarticular (pauciarticular), polyarticular, and systemic. They exclude other causes of juvenile arthritis, including spondyloarthropathies (juvenile ankylosing spondylitis, inflammatory bowel disease-associated arthritis, and related diseases), juvenile psoriatic arthritis, arthritis associated with other systemic inflammatory diseases (systemic lupus erythematosus, dermatomyositis, sarcoidosis, etc.) and infectious or neoplastic disorders.

These criteria, although similar, do not identify identical populations or spectra of disease, but have often been used interchangeably. This has led to confusion in interpretation of studies of the epidemiology, treatment, and outcome of juvenile arthritis. Recently, the International League of Associations of Rheumatologists (ILAR) has proposed (8) and revised (9) criteria for the diagnosis and classification of juvenile arthritis, or "Durban Criteria" (Table 12-2). The term "juvenile idiopathic arthritis" (JIA) has been proposed to replace both JRA and JCA, and will encompass all juvenile arthritides lasting greater than 6 weeks that are of unknown cause. This international compromise will allow uniform interpretation of clinical and therapeutic data. Although these criteria are not definitive, and some children will fit into either no category or two or more categories, they should be thought of as a work in progress. As techniques become available to better define the genetic risk factors and specific triggers of juvenile arthritis, uniform modifica-

TABLE 12-1. COMPARISON OF ACR AND EULAR CLASSIFICATION OF JUVENILE IDIOPATHIC ARTHRITIS

	ACR	EULAR
Age at onset:	<16 years	<16 years
Arthritis:	One or more joints	One or more joints
Duration of disease:	6 weeks or longer	3 months or longer
Onset type:	In first 6 months	
	Polyarthritis: 5 or more joints	Pauciarticular <5 joints
	Oligoarthritis: <5 joints	Polyarticular >4 joints, RF negative
	Systemic: arthritis with characteristic fever at onset	Juvenile rheumatoid arthritis >4 joints, RF positive
		Juvenile ankylosing spondylitis
		Juvenile psoriatic arthritis
Exclusions:	Other forms of juvenile arthritis	

ACR, American College of Rheumatology; EULAR, European League Against Rheumatism; RF, rheumatoid factor.

tions to the criteria can be made. At least now we are all starting with the same basic set of assumptions. In the remaining sections of this chapter, the term “juvenile arthritis” is used to denote any type of arthritis in childhood, “JIA” will be used as defined above, and the terms “JRA” and “JCA” will be used only when referring to specific epidemiologic, therapeutic, or outcome data.

Oligoarthritis

Oligoarticular onset of JIA is defined as arthritis affecting one to four joints during the first 6 months of disease. There are two subcategories: persistent oligoarthritis affects no more than four joints throughout the entire course of arthritis. Extended oligoarthritis affects a cumulative total of five

TABLE 12-2. CRITERIA FOR CLASSIFICATION OF JUVENILE IDIOPATHIC ARTHRITIS: DURBAN, 1997

Age at onset: before 16th birthday

Arthritis in one or more joints

Duration of disease: at least 6 weeks

Onset type:

Systemic Arthritis

Arthritis with or preceded by daily fever of at least 2 weeks' duration, accompanied by one or more of the following:

1. Evanescent, nonfixed erythematous rash
2. Generalized lymph node enlargement
3. Hepatomegaly or splenomegaly
4. Serositis

Polyarthritis (RF-negative)

Arthritis affecting five or more joints during the first 6 months of disease; tests for RF are negative

Psoriatic Arthritis

1. Arthritis and psoriasis, or
2. Arthritis and at least two of:
 - a. dactylitis
 - b. nail abnormalities (pitting or onycholysis)
 - c. family history of psoriasis confirmed by a dermatologist in at least one first-degree relative

Other Arthritis

Children with arthritis of unknown cause that persists for at least 6 weeks, but that either:

1. does not fulfill criteria for any of the other categories, or
2. fulfills criteria for more than one of the other categories

Oligoarthritis

1. Persistent oligoarthritis: no more than four joints involved
2. Extended oligoarthritis: affects a cumulative total of five or more joints after the first 6 months of disease

Polyarthritis (RF-positive)

Arthritis affecting five or more joints during the first 6 months of disease, associated with positive RF tests on two occasions at least 3 months apart

Enthesitis-related Arthritis

Arthritis and enthesitis, or arthritis or enthesitis with at least two of:

1. Sacroiliac joint tenderness and/or inflammatory spinal pain
2. Presence of HLA-B27
3. Family history of HLA-B27-associated disease in at least one first- or second-degree relative
4. Anterior uveitis that is usually associated with pain, redness, or photophobia
5. Onset of arthritis in a boy after the age of 8 years

RF, rheumatoid factor; CRP, C-reactive protein.

joints or more after the first 6 months of disease. A child will be excluded from this diagnostic category if any of the following five conditions are met: a family history of psoriasis, confirmed by a dermatologist, in at least one first- or second-degree relative; family history of medically confirmed HLA-B27-associated disease in at least one first- or second-degree relative; HLA-B27-positive male with onset of arthritis after 8 years of age; a positive RF test; or systemic arthritis. Characteristics include the age at onset of arthritis. Also, the patterns of arthritis should be noted, including: large joints only, small joints only, limb predominance (upper, lower, both), specific joint involvement, and symmetry of arthritis. Finally, the occurrence of anterior uveitis, presence of antinuclear antibody (ANA), and any human leukocyte antigens (HLA) class I and II showing predisposing or protective alleles should be considered. This diagnostic subgroup will certainly contain some children with psoriatic arthritis who have not yet developed a psoriatic dermatitis. It will also exclude the few children with oligoarticular disease and a positive RF. However, these children are likely to have an early onset of RF-positive polyarticular arthritis, or at least would be predicted to have a more prolonged and severe course, and as such, should be excluded from the oligoarticular group.

Polyarthritis (RF –)

Polyarticular onset (RF-negative) JIA is defined as arthritis affecting five or more joints during the first 6 months of disease with a negative RF, and the absence of systemic arthritis. Descriptors for RF-negative polyarticular JIA include age at onset, symmetry of arthritis, presence of ANA, and occurrence of uveitis.

Polyarthritis (RF +)

RF-positive polyarticular JIA is defined as arthritis affecting five or more joints during the first 6 months of disease, associated with a positive RF test on two occasions at least 3 months apart, and the absence of systemic arthritis. Descriptors include age at onset of arthritis, symmetry, presence of ANA, and immunogenetic characteristics. This disease is likely to be the equivalent of early-onset adult rheumatoid arthritis.

Systemic Arthritis

Systemic JIA is characterized by arthritis with or preceded by daily fever of at least 2 weeks' duration, which is documented to be quotidian for at least 3 days, and accompanied by one or more of the following: evanescent, nonfixed, erythematous rash; generalized lymphadenopathy; hepato- or splenomegaly; or serositis. This type of arthritis can be described in terms of age at onset of arthritis and the pattern

of arthritis during and after the first 6 months: oligoarthritis, polyarthritis, or arthritis present only after the first 6 months of systemic illness. Other descriptors include the features of systemic disease after the first 6 months of disease, the presence of RF, and the level of C-reactive protein (CRP).

Psoriatic Arthritis

Psoriatic arthritis is defined as arthritis and psoriasis, or arthritis and at least two other criteria, including: dactylitis, nail abnormalities (pitting or onycholysis), or a family history of psoriasis documented by a dermatologist in at least one first-degree relative. Exclusions include the presence of RF and systemic arthritis. Descriptors include the age at onset of arthritis or psoriasis, pattern of joint involvement, oligoarticular or polyarticular course, presence of ANA, or uveitis.

Enthesitis-related Arthritis

Enthesitis-related arthritis (ERA) is defined as arthritis and enthesitis (pain at insertion sites of tendons and ligaments), or arthritis or enthesitis with at least two of the following characteristics: sacroiliac joint tenderness and/or inflammatory spinal pain, presence of HLA-B27, family history in at least one first- or second-degree relative of a medically confirmed HLA-B27-associated disease (e.g., ankylosing spondylitis, sacroiliitis with inflammatory bowel disease, or acute [symptomatic] anterior uveitis associated with pain, redness, or photophobia), or onset of arthritis in a boy after the age of 8 years. Enthesitis is defined as tenderness at the insertion of tendon, ligament joint capsule, or fascia to bone. Descriptors for enthesitis-related arthritis include age at onset of arthritis or enthesitis, patterns of arthritis, symmetry of arthritis, oligoarticular or polyarticular disease course, and the presence of inflammatory bowel disease.

Other Juvenile Idiopathic Arthritides

Despite our best attempts to categorize children with idiopathic arthritis, there will inevitably be children who do not fit into any known category. This group of children with JIA will be considered to have undifferentiated or overlap arthritis. This category of other arthritis is defined as children with arthritis of unknown cause that persists for at least 6 weeks, but that either does not fulfill criteria for any other category, or fulfills criteria for more than one of the other categories.

APPROACH TO THE EVALUATION OF CHILDREN WITH LIMB PAIN, LIMP, OR JOINT PAIN WITH OR WITHOUT SWELLING

The evaluation of children with limb or back pain, a new limp, or joint pain with or without swelling, requires a comprehensive history and physical examination. The first

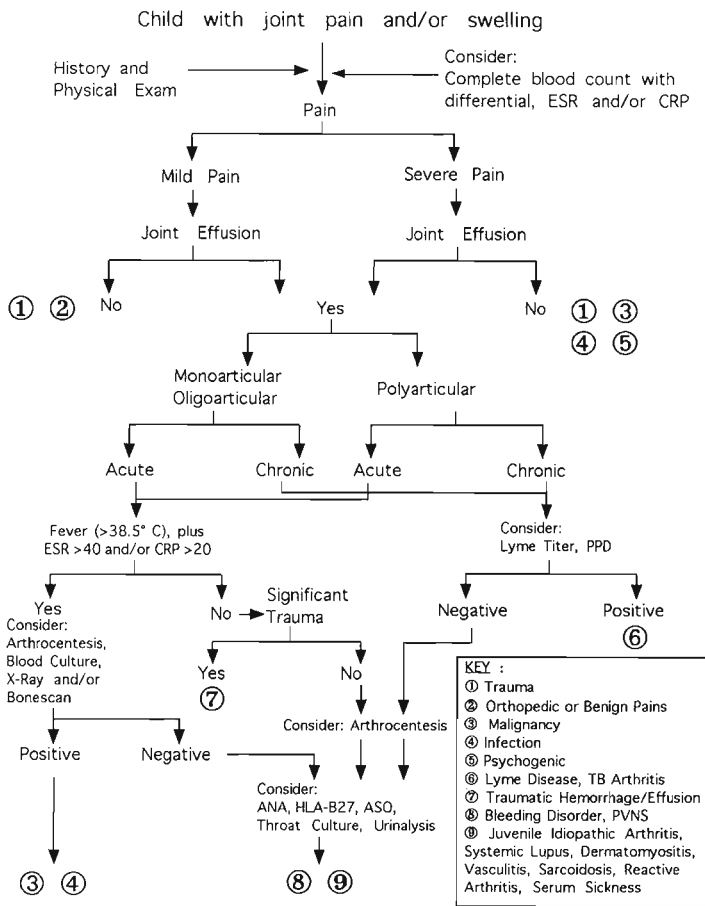


FIGURE 12-1. Algorithm for evaluation of a child with joint pain and/or swelling. Chronic is considered <6 weeks. ANA, antinuclear antibody; ASO, antistreptolysin-O; PPD, tuberculin skin test; PVNS, pigmented villonodular synovitis; ESR, erythrocyte sedimentation rate; CRP, C-reactive protein.

priority is to rule out an infection (osteomyelitis, septic arthritis, discitis), malignancy, or orthopaedic abnormality requiring prompt intervention. The causes of arthritis in children are extensive and many are rare. There are no pathognomonic presentations, and there is extensive overlap of all types of juvenile arthritis. Laboratory tests and radiologic studies are often uninformative, and should not be used to make or dismiss the diagnosis of juvenile arthritis. The purpose of this section is to provide the orthopaedist with an overview of the ways children present with arthritis, and to generate a framework for the logical identification of the appropriate diagnosis with a minimum of diagnostic procedures. The algorithm in Figure 12-1 provides a guide for the evaluation of children presenting with limb or joint pain. The first step in any evaluation of a child with possible arthritis is to obtain a thorough history and review of systems.

Timing of Pain or Disability

The timing of the pain is important. Children with arthritis will frequently have mild-to-moderate pain and stiffness

(gelling) in the mornings, after a nap, sitting in class, after a long automobile ride, or other periods of inactivity. These complaints will generally improve within minutes or hours of renewed activity. Although there may be some residual limp or mild complaints of pain or stiffness, many children with JIA will be entirely asymptomatic on presentation to the physician's office. The major exception to this is the child with enthesitis-related arthritis, who may have morning pain and stiffness, but who will worsen throughout the day or with activities, because of repeated stress on inflamed tendons and entheses. A minority of children with JIA will have significant pain throughout the day, and the physical exam is likely to reveal severe arthritis in those with increased pain. It would be very unusual for the pain associated with JIA to keep a child from falling asleep or to wake the child from sleep. When a child has only afternoon, evening, and/or nighttime pains that resolve in the morning, this is typical for benign pains of childhood (growing pains). When pain is present both day and night, and interferes with sleep, it is unlikely to be due to JIA, but, depending on the duration and location, may be associated with malignancy, infection, or psychogenic pain syndromes.

Duration of Pain

The duration of pain is also important. Severe pain of new onset, which prompts immediate evaluation, may be due to infection, malignancy, or trauma. Pain that is slowly worsening or unchanged over weeks or months is typical of JIA. When pain has been present for many years, the cause is often psychogenic or mechanical. It is not unusual for a parent to note that a child has had pain, clumsiness, or difficulty walking from the time the child's first steps were taken. When neurologic abnormalities, including cerebral palsy, are excluded, the majority of these children have benign mechanical problems, or parental anxiety can be considered.

Location of Pain

The location of the pain is an important part of the history. Children with JIA will rarely have muscular pains. True weakness should suggest either an inflammatory or congenital myopathy. Long-bone or periarticular pain is often seen with trauma or malignancies. When pain is random, intermittent, or migratory, especially if it comes and goes during the clinic visit, it is often psychogenic in origin. Pain with JIA can be additive, and can have spontaneous improvement, but it is usually present consistently over weeks or months.

Intensity of Pain

The quality or intensity of the pain can be difficult to determine in children, especially for the preverbal child. Pain-rating scales for children have been developed to be sensitive to the cognitive-developmental conceptualizations of children (10). Children are asked to rate their pain on a visual analog scale (VAS), in terms of present pain and worst pain intensity for the previous week. Each VAS is a 10-cm horizontal line with no numbers or descriptors. The child VAS is anchored with the developmentally appropriate pain descriptors: happy and sad faces, corresponding to no pain and severe pain, respectively.

In general, the intensity of pain reported by children with JIA ranges from moderate to absent (11). Rarely, the child will report severe pain. Most children with JIA will maintain near-normal function. Acute arthritis, such as postinfectious reactive arthritis, including acute rheumatic fever, is typically much more painful than JIA. Intense pain that is nonmigratory and present night and day is more likely to represent infection or malignancy. However, severe pain that is intermittent or migratory, interferes with school, and causes sleep disturbance in a child with normal laboratories and growth, is usually psychogenic in origin. Children with psychogenic pain syndromes are often unable to perform normal daily activities, due to the high level of perceived pain.

Age of the Child

The age of the patient is important. The majority of children with JIA have the onset of arthritis before 6 years of age (12). This age group is far less likely to have psychogenic pain syndromes. A frequent complaint on first presentation is that a fall or injury caused a sudden swelling and pain in a joint. However, most children under 6 years of age fall frequently, whereas children aged 1 to 4 fall nearly every day. Although young children may have fractures from even innocent falls, nonaccidental trauma should not be considered as the most likely cause of true joint swelling in this age group.

Response to Activity or Rest and Immobilization

In children in whom it is possible that a significant injury or repetitive stress has caused joint or tendon pain, resting the limb and immobilization are often attempted. Although children with arthritis can have minimal pain when the affected joint is immobilized, they are uniformly worse when the cast or splint is removed. If the child has joint pain with effusion and stiffness, prolonged immobilization will often result in severe restriction in range of motion and increased pain. Children with arthritis usually improve with activities, and every attempt should be made to keep them mobile. We do not limit athletic activities but do encourage noncontact sports.

Associated Symptoms

Other associated symptoms can often be useful in guiding your evaluation of joint pain. Fevers, whether continuous or periodic, can be associated with infection and malignancies or systemic inflammatory disease. Weight loss, with laboratory evidence of inflammation, suggests the presence of a systemic illness, such as infection, malignancy, inflammatory bowel disease, or systemic onset JIA. Persistent fatigue, sleep disturbance, and depression are often signs of a psychogenic pain syndrome. Fatigue should not be confused with true weakness, which could represent the onset of an inflammatory myositis.

Family History

The family history is important in evaluation for suspected JIA. The presence of HLA-B27–associated diseases, chronic back pains, or psoriasis could suggest the onset of an associated disease. Other systemic autoimmune disorders, including adult rheumatoid arthritis, often group in families, but have no direct pattern of inheritance. Children with psychogenic pain syndromes are often found to have a relative, usually the mother, who has chronic pain and acts as a role model for the pain behavior.

Physical Exam

A comprehensive physical exam, when combined with a complete history and screening laboratory tests, will often be sufficient to diagnose the child with arthritis. The musculoskeletal exam will often allow differentiation between mechanical or psychogenic causes of pain and inflammatory etiologies. Children with functional pain syndromes will often have complaints of pain that are out of proportion to the exam and often are migratory or transient, even during the exam.

Arthritis

Arthritis is defined as swelling within a joint, or limitation in range of joint movement with joint pain or tenderness, that is observed by a physician, and which is not due to a primary mechanical disorder. Young children will often be difficult to examine, and should be observed closely for limp or joint swelling prior to approaching the child. It is often instructive to observe the child playing in the waiting area and walking to or from the exam room. All children with joint pain or swelling should have a comprehensive joint exam. Often, children with joint pain will be quite apprehensive about the exam. When a child presents with the complaint of a single swollen or tender joint, it is important to evaluate all joints for signs of arthritis. It is not infrequent that joints other than the presenting joint will be involved with arthritis. As such, it is wise to begin the exam at sites distant from the point of pain, and gain the trust of the child prior to approaching the painful site. Examination of a painful site will often end your ability to further examine the child.

Labs and Tests

There are no multitest panels appropriate for the evaluation of children with joint pain and swelling. Specific laboratory evaluations should be guided by the history and physical examination. For most children, a complete blood count with differential, CRP, and erythrocyte sedimentation rate (ESR) are indicated. This will help to identify hematologic abnormalities suggesting malignancy, and to document the presence or absence of systemic inflammation. The CRP is an acute-phase protein synthesized in the liver in response to proinflammatory cytokines. The ESR is an indirect measure of systemic inflammation and the acute-phase response. In most children, the ESR is below 15 mm/h. The ESR rises in response to the relative decline in concentration of serum albumin and increase in acute-phase proteins, including fibrinogen and others. The ESR may be elevated due to marked anemia, or by a low serum concentration of albumin due to decreased production or loss, as in nephrotic syndrome. Most children with arthritis will have an ESR less than 100 mm/h, whereas systemic arthritis, malignan-

cies, and infections are more likely with an ESR greater than 100 mm/h. However, many children with oligoarticular and some with polyarticular arthritis will have a normal ESR and CRP. The addition of a CRP can be helpful in situations in which infection is highly suspected, because the short half-life of this acute-phase protein results in a rapid decline in concentration with effective antibiotic treatment, whereas the ESR may even continue to rise.

The antinuclear antibody (ANA) titer is a measure of serum antibodies that can bind to one of many potential antigens present in the nucleus of normal human cells. ANA titers are usually considered to be elevated when they can be identified at a dilution of 1:40, or with an absolute value of 7.5 IU/mL. The presence of an elevated ANA should never be used to diagnose arthritis. However, the ANA does have some utility as a screening test for JIA (13,14). The frequency of ANA positivity is greatest in younger girls with oligoarticular disease, and represents an increased risk for anterior uveitis (15). When arthritis is suspected by history and physical exam, the presence of a positive ANA should prompt immediate referral to an ophthalmologist for a slit-lamp exam to evaluate for the presence of uveitis. Even in the absence of an ANA, children with confirmed arthritis should have a routine ophthalmologic exam with slit lamp. However, it is known that elevated ANA titers may be present in up to 20% of normal children (typically, at titers of 1:40 to 1:80), and may be induced by recent illness, or be present in first- or second-degree relatives of patients with systemic lupus erythematosus (SLE) (16,17). Children who have an ANA elevated to any level, with no evidence of systemic inflammation, and no arthritis on examination by a pediatric rheumatologist, are extremely unlikely to subsequently develop a significant autoimmune disease (16,18).

The rheumatoid factor (RF) is an autoreactive antibody, usually IgM, recognizing IgG that has bound to antigen. RF positivity is infrequent in children with arthritis, and rarely occurs in children younger than 7 years of age. When present in children with arthritis, the RF signifies a chronic inflammatory state, and has been associated with a higher frequency of erosive synovitis and poor prognosis (19,20). Studies in children and adults demonstrated that a positive RF is as likely to be present in children with diseases other than JIA as it is in those with JIA (21,22). Thus, there is no role for RF testing in the orthopaedic or pediatric office evaluation of children with possible arthritis.

The presence of HLA-B27 is highly associated with transient reactive arthritis, inflammatory bowel disease, and enthesitis-related arthritis. The high familial occurrence of ankylosing spondylitis is directly related to the presence of HLA-B27 (23). Although HLA-B27 is found in nearly 8% of the white population, it can be useful in the diagnosis of enthesitis-related arthritis. It is especially important in boys after the age of 8, when there is a family history of HLA-B27-associated illness, or sacroiliac joint or spinal inflammatory pain.

On rare occasions and in specific circumstances, children may develop gout (24). However, there is no utility in obtaining uric acid levels as a screening test for arthritis. The diagnosis of gout is made by documentation of the presence of urate crystals in synovial fluid, irrespective of serum uric acid levels.

Synovial Fluid Analysis

Arthrocentesis with synovial fluid analysis and culture should be performed in all children with an acute febrile monoarthritis. Infection should also be considered when a child with polyarticular arthritis has an acutely swollen and tender joint, usually accompanied by fever, because this may represent a secondary septic arthritis. The diagnosis and treatment of septic arthritis are discussed in detail in Chapter 13.

Synovial fluid analysis in children with JRA usually shows an inflammatory fluid. However, the total white blood cell count can range from 150 to greater than 100,000 cells/mm³ (25–27), with average counts of between 10,000 and 12,000 cells/mm³. There is often a neutrophil predominance, with a range of 18 to 88% and average of 56% (25). Synovial biopsy is obtained if the tuberculin test is positive, or if the diagnosis of sarcoidosis is being considered.

Radiographic Studies

Initial evaluation of children with joint pain and/or swelling by plain radiographs is useful, predominantly to identify periarticular osteopenia, fractures, or other bony lesions. In early JIA, there are no pathognomonic radiographic findings. The diagnosis of JIA is typically made long before bony changes are apparent. Ultrasound is often a rapid and noninvasive way to identify an intraarticular effusion. Radionuclide imaging with ^{99m}Tc to evaluate for osteomyelitis will occasionally identify other joints with subclinical inflammation, suggesting a diagnosis of JIA. Although rarely required for diagnosis, magnetic resonance imaging

is the most sensitive technique for detecting early articular changes in JIA (28–30).

DIFFERENTIAL DIAGNOSIS OF JOINT PAIN AND SWELLING IN CHILDREN

A comprehensive differential diagnosis of arthritis in childhood is beyond the scope of this chapter. There are over 100 disorders in which arthritis may be a significant manifestation (31). The most common classes of disorders that must be considered in the differential diagnosis of JIA include mechanical or orthopaedic conditions, infection, trauma, psychogenic, and inflammatory. Often, the differential diagnostic considerations will be determined by whether the presentation is acute, subacute, or chronic, whether the child has monoarticular or polyarticular arthritis, and by the presence of systemic signs such as fever (Table 12-3).

Arthritis and Limb Pain Associated with Other Conditions

Children with an acute inflammatory oligo- or polyarthritis will often present with a sudden swollen and/or painful joint. This is in contrast to most children with JIA who, with the exception of systemic onset, often have a subacute or insidious onset. Children with injuries can often describe the exact time and place where the injury occurred, whereas children with benign pains will frequently have a history of pain from the time they could walk. Conversely, children with psychogenic pain frequently can also describe an event, minor or major injury, or illness as the initiator of their pain. However, many children fail to fit the expected profiles, and atypical presentations often occur. It is important to evaluate children with limb and joint pain with a broad differential diagnosis, which can be better defined with a thorough history and comprehensive physical exam. The presence or absence of fever, the age and sex of the child, and associated signs and symptoms will aid the con-

TABLE 12-3. CLASSES OF DISORDERS IN THE DIFFERENTIAL DIAGNOSIS OF JIA

Monoarticular	Polyarticular	Febrile Syndromes
Oligoarthritis	Polyarthritis	Systemic arthritis
Psoriatic arthritis	Psoriatic arthritis	Malignancy
Enthesitis-related arthritis	Enthesitis-related arthritis	Lymphoid
Sarcoidosis	Sarcoidosis	Neuroblastoma
Transient synovitis of the hip	Systemic lupus erythematosus	Systemic lupus erythematosus
Trauma	Juvenile dermatomyositis	Juvenile dermatomyositis
Hemophilia	Systemic vasculitis	Systemic vasculitis
Pigmented villonodular synovitis	Scleroderma	Infection: viral or bacterial
Septic arthritis	Gonococcal septic arthritis	Inflammatory bowel disease
Reactive arthritis	Reactive arthritis	Reactive arthritis

sultant in determining the optimal strategy for the selection of diagnostic testing.

Infectious Arthritis

Septic arthritis generally affects a single joint and is associated with fever, elevated neutrophil count, ESR, and CRP. This is in contrast to monoarticular JIA, which seldom has significant systemic inflammatory signs. Gonococcal arthritis in sexually active children, however, can present with an oligoarticular, polyarticular, or migratory pattern, with significant tenosynovitis. There are instances in which organisms such as *Staphylococcus aureus* can present with a subacute arthritis. However, this presentation is most common for mycobacterial infections or Lyme disease. In most cases, septic joints are extremely painful, but in JIA, swelling is often out of proportion to reported pain.

Lyme Disease

In early Lyme disease, the signs and symptoms of infection include fever and migratory arthralgia, with little or no joint swelling. Early localized disease is typically manifest by the presence of erythema migrans, the classic expanding rash that occurs most often at the site of the tick bite and develops within 7 days to 1 month after infection (32). Lyme arthritis occurs months to years after the initial infection. Many patients with untreated Lyme disease will complain of migratory arthralgias or arthritis (33). In a recent retrospective study of 90 children with Lyme arthritis, Gerber et al. (34) noted that the majority (63%) had monoarticular disease, but no children had greater than four joints involved. The knee was affected most often (90%), followed by hip (14%), ankle (10%), wrist (9%), and elbow (7%), whereas small joints were rarely involved. The majority of children with Lyme arthritis do not recall a tick bite or erythema migrans (34,35). This is in contrast to prospective studies in which 90% of children diagnosed with Lyme disease had a history of erythema migrans. The most likely reason for this discrepancy is that the majority of children with erythema migrans are identified and treated with antibiotics, and do not develop late complications of Lyme disease. Lyme arthritis is typically a low-grade inflammatory synovitis with a large and relatively painless joint effusion. The ESR can be normal or elevated, and 25% can have values greater than 60 mm/h (34). In both children and adults, a chronic form of Lyme arthritis can persist after treatment, and is associated with *HLA-DR4* and *HLA-DR2* alleles (36). The majority of children with Lyme arthritis can be effectively treated with a single, 4-week course of orally administered amoxicillin or doxycycline (34).

Postinfectious Arthritis

Postinfectious or reactive arthritis results in a sterile synovitis that occurs as the result of the immune response to a

nonarticular infection. Most children have reactive arthritis following upper respiratory or gastrointestinal infections, rather than genitourinary disease, which is more common in adults (37–39). The classic presentation of reactive arthritis is the triad of conjunctivitis, urethritis, and arthritis found in Reiter's syndrome (RS). The complete triad of RS is very uncommon in childhood. Children account for less than 1% of all patients with complete RS, and the ratio of boys to girls is 4:1 (39,40). A history of sexual activity could suggest infection with *Chlamydia* (41). In patients with classic RS and other postinfectious reactive arthritis, a large majority carry the *HLA-B27* allele (39,42).

Transient Synovitis of the Hip

Transient synovitis of the hip (TSH) is a self-limited, post-infectious, inflammatory arthritis. TSH has a peak incidence, predominantly in boys (70%), between 3 and 10 years of age. It is an idiopathic disorder often preceded by a nonspecific upper respiratory tract infection (43). Trauma has frequently been associated with TSH, and may be a predisposing factor (44). The onset of pain is often gradual, may be focused to the hip, thigh, or knee, and lasts for an average of 6 days. Occasionally, TSH can be bilateral (4%). The child often presents with inability to walk or with a severe limp. There is a loss of internal rotation of the hip, and it is usually held in flexion, abducted, and externally rotated. There is often low-grade fever. The ESR and white blood cell count are normal to mildly elevated (45). Plain radiographs are often normal, or may show mild widening of the joint space. Ultrasound is a sensitive and reliable method to confirm the presence of an effusion (45). With rest and nonsteroidal antiinflammatory drugs (NSAIDs), the majority of children will have complete resolution of symptoms within 2 weeks. The majority of children with TSH will have a single event, with 4 to 17% having a recurrence usually within the first 6 months after the initial onset (44).

Acute Rheumatic Fever

Acute rheumatic fever (ARF) occurs as a postinfectious reaction to infection of the oropharynx with group A beta-hemolytic streptococcus. The incidence of ARF has remained relatively constant at around 1 per 100,000 children between the ages of 5 and 17 years (46). It is very unusual for ARF to occur before the age of 4 years. Although ARF is rare in developed countries, it remains the most common cause of acquired heart disease in the developing world. In South Africa, the prevalence of ARF has been estimated to be 690 per 100,000 (47).

Clinical Features of ARF

Arthritis. The classic arthritis of ARF is a migratory polyarthritis, usually affecting the legs first, and later the arms.

Joint involvement is the most common (75%) and often the first manifestation of the disease (48). The affected joints are often red and swollen, with pain out of proportion to the physical examination. The arthritis of ARF is exquisitely responsive to aspirin, and dramatic relief is often obtained within several hours after the first dose. Residual synovitis does not commonly develop.

Carditis. Rheumatic carditis occurs in nearly 65% of children with ARF (48), and is the only cause of significant morbidity and mortality. The use of Doppler echocardiography has increased the sensitivity of detection of valvar involvement in ARF, and abnormalities have been found in as many as 90% of patients with ARF (46). Arthralgia cannot be used as a minor criteria if arthritis is present. A prolonged PR interval is often seen in ARF, but is not associated with increased risk for carditis.

Subcutaneous Nodules. The subcutaneous nodules of ARF are typically small (<1 cm in diameter) and painless. They typically are present for 1 to 2 weeks. The overlying skin is not inflamed nor attached to the nodule. The most typical locations are over bony prominences. Nodules occur in less than 10% of patients, but are often associated with carditis.

Erythema Marginatum. Erythema marginatum is an irregular, nonpruritic skin rash, pink-to-red in color, usually affecting the trunk and occasionally the proximal limbs, but never the face. The rash occurs early in the disease, and when present may persist after all other manifestations of disease have resolved. It occurs in less than 10% of children with ARF, but is also associated with carditis.

Chorea. Sydenham's chorea is a neurologic disorder with choreiform movements and emotional lability. The movement disorder can often be unilateral. It cannot be suppressed voluntarily, but is not present during sleep. Chorea occurs in nearly 15% of children with ARF. The interval between the streptococcal pharyngitis and the onset of chorea can be as long as 3 months. When chorea is the only major manifestation there may be no markers of inflammation, and streptococcal pharyngitis can be difficult to identify.

The diagnosis of ARF is based on the application of the modified Jones criteria (49) (Table 12-4). The diagnosis requires the presence of two major criteria, or one major criterion and two minor criteria, and requires supportive evidence of a preceding streptococcal infection (increased ASO/anti-DNase B, positive rapid streptococcal antigen test or throat culture). It is clear that not all children who meet the Jones criteria will have ARF, and conversely, a small number of children with ARF will not meet these criteria.

Treatment. Treatment of ARF is usually with aspirin, 80 to 100 mg/kg/d in children (8 gm/day maximum), and

TABLE 12-4. THE MODIFIED JONES CRITERIA FOR DIAGNOSIS OF ACUTE RHEUMATIC FEVER

Major Manifestations	Minor Manifestations
Carditis	Fever
Polyarthritides	Arthralgia
Subcutaneous nodules	Prolonged PR interval
Erythema marginatum	Increased ESR or CRP
Chorea	

Diagnosis requires the presence of two major criteria, or one major and two minor criteria, with supporting evidence of a preceding streptococcal infection (rising streptococcal antibody titers, positive throat culture or rapid streptococcal test).

ESR, erythrocyte sedimentation rate; CRP, C-reactive protein.

serum salicylate concentrations of 20 to 30 mg/dL. In the presence of carditis, congestive heart failure, or heart block, corticosteroid therapy is added. The typical treatment doses are 2 mg/kg/day of prednisone for 2 to 3 weeks, then tapered over an additional 3 weeks. The aspirin is typically discontinued 3 weeks after stopping the corticosteroids. Eradication of streptococci by treatment with penicillin is indicated in all patients with ARF, even in the absence of a positive throat culture. Children with a history of ARF should receive prophylactic antibiotics: intramuscular benzathine penicillin every 3 to 4 weeks, oral penicillin V twice daily, or sulfadiazine once per day. Patients with documented rheumatic heart disease should continue prophylaxis indefinitely.

Poststreptococcal Arthritis

Recently, the entity of poststreptococcal-reactive arthritis (PSRA) has been characterized, and many investigators feel that it is a variant of ARF (50–52). PSRA typically presents as a nonmigratory oligo- or polyarthritides. It is differentiated from ARF by the frequent presence of tenosynovitis and the poor response to aspirin or other nonsteroidal drugs. In addition to arthritis, other clinical manifestations include erythema nodosum, livedo reticularis, cutaneous vasculitis, and systemic polyarteritis nodosa (53,54). Limited studies have suggested that there is increased risk for ARF and rheumatic carditis with further episodes of streptococcal pharyngitis, and that streptococcal prophylaxis is indicated (50,52). Children with PSRA were found to have a statistically significant increased frequency of HLA-DRB1*01, while those with ARF had an increased frequency of HLA-DRB1*16, and the frequency of HLA-B27 was not different than controls (55). The association of PSRA with HLA-DRB1*01, but not with HLA-B27, suggests that its pathogenesis may be more similar to that of ARF than to reactive arthritis. This would again support the recommendation for prophylaxis.

Serum Sickness

Serum sickness is a clinical syndrome resulting from an adverse immunologic response to foreign antigens mediated by the deposition of immune complexes. Although serum sickness was first described after injection of heterologous serum, today the most common causes are antibiotics (penicillins and sulfonamides) and viral infections (56–58). Serum sickness is characterized by fever, arthralgia or arthritis, lymphadenopathy, cutaneous eruptions (urticarial or morbilliform), and angioedema. Both serum sickness and allergic angioedema can be confused with acute-onset juvenile arthritis. However, the majority of children with serum sickness will spontaneously improve within a few days to weeks. For mild disease, removal of the offending antigen, and treatment with antihistamines and nonsteroidal antiinflammatory medications, is sufficient. In severe cases, a several-week course of corticosteroids may be required.

Other Inflammatory Arthropathies

Gout

Gouty arthritis is characterized by hyperuricemia and deposition of monosodium urate crystals into the joint. The major clinical manifestations include acute mono- or oligoarthritis, frequently involving the first metatarsophalangeal joint, resulting in podagra. Gout may result from either increased production or decreased excretion of uric acid. Gout is extremely rare in children (24). The diagnosis of gout can only be confirmed by demonstration of negatively birefringent, monosodium urate crystals in the synovial fluid when viewed under a polarized light microscope. Acute gout is treated with nonsteroidal antiinflammatory medications, colchicine, and occasionally prednisone. After the acute event has subsided, allopurinol is utilized to prevent recurrences by decreasing serum levels of uric acid. The use of allopurinol in acute gout is not recommended due to a paradoxical worsening of gout with a sudden decrease in uric acid levels.

Cystic Fibrosis-associated Arthritis

Children and young adults with cystic fibrosis (CF) have an increased incidence of musculoskeletal disorders. CF-associated arthritis is a transient reactive arthritis often associated with pulmonary exacerbations (59–63). Teenagers and older patients with CF have a higher-than-expected occurrence of RF-positive polyarticular JIA or adult rheumatoid arthritis (64). Finally, some children with CF develop secondary hypertrophic osteoarthropathy, demonstrable on radiographs (65,66).

Systemic Autoimmune Diseases

Many of the systemic autoimmune diseases can cause an acute or chronic arthritis. There are often signs, symptoms,

or laboratory abnormalities that will aid in the diagnosis of these conditions. For a thorough discussion of these diseases in children, several excellent texts and reviews are available (31,67,68).

Systemic lupus erythematosus (SLE) is an episodic, autoimmune inflammatory disease characterized by multiorgan system inflammation. Arthralgia and arthritis affect 75% of the children with SLE. It is usually polyarticular, and the joint pain is often out of proportion to physical findings. The arthritis typically responds readily to corticosteroids, is rarely erosive (69), and does not typically result in deformity.

Sarcoidosis is uncommon in childhood (70). However, arthritis is frequent in childhood-onset sarcoidosis, and typically presents as an oligoarthritis affecting the knees, ankles, and/or elbows. It is characterized by very large effusions and boggy synovitis with minimal pain or loss of motion. A synovial biopsy will often be diagnostic, showing the presence of noncaseating sarcoid granulomas.

Vasculitis in childhood can be associated with arthritis. However, the disease most likely to be seen by the orthopaedic surgeon is Henoch-Schönlein purpura (HSP). HSP is the most common vasculitic syndrome in childhood, occurring in slightly more than 1 in 10,000 children per year (71). The classic manifestations of HSP are nonthrombocytopenic palpable purpura, arthritis, abdominal pain, gastrointestinal hemorrhage, and glomerulonephritis. In the complete syndrome the diagnosis is often clear. However, the arthritis can precede the appearance of the rash, and the rash may be unrecognized if a comprehensive skin examination is not done. The rash of HSP often begins on the lower extremities as an urticarial eruption, followed by petechiae and purpura, which are most often concentrated on the buttocks and lower extremities, especially the ankles. The purpura will frequently recur in crops over several weeks, resulting in multiple lesions in different stages of evolution. The arthritis of HSP presents as a periarticular swelling and tenderness, most commonly of large joints, with severe pain and limitation of motion. The younger child will often refuse to use the affected joint. The arthritis is usually transient, and resolves without sequelae in a few days to weeks. In most children, HSP will resolve completely within 4 weeks from onset.

Foreign Body Synovitis

Plant thorns and wood splinters may be introduced onto the joint space and cause a chronic synovitis or tendonitis (72). Typically, the injury has been long forgotten, because many months may pass between entry of the thorn into the skin and egress into the joint. Often, a careful history will uncover the past trauma. Surgical removal of the splinter and synovectomy are the only effective treatments.

Coagulopathies and Hemoglobinopathies

Children with congenital coagulopathies (hemophilia) and hemoglobinopathies (sickle cell disease) will present with acute joint pain and swelling, resulting from hemarthrosis and localized ischemia, respectively. A comprehensive discussion of these conditions is found in Chapter 11.

Malignancies

Leukemia in childhood frequently presents with musculoskeletal pain and arthritis (73,74). Although a joint effusion can occur, the pain is usually localized to the metaphyses of the long bones. The pain in children with malignancies is typically more severe than in JIA and will frequently be continuous. Another feature of children with malignancies is the extreme elevation of the ESR (often >100), whereas in JIA, the ESR is usually only moderately elevated, and may be normal. Plain radiographs may show subperiosteal elevation, osteolytic reaction, or metaphyseal rarefaction. In a recent study of 29 children with malignancy who were referred to pediatric rheumatologists, features suggestive of malignancy included nonarticular “bone” pain (68%), back pain as a major presenting feature (32%), bone tenderness (29%), severe constitutional symptoms (32%), and atypical clinical features (48%) (75). Atypical features included night sweats (14%), ecchymoses and bruising (14%), abnormal neurologic signs (13%), and abnormal masses (7%). Children with malignancy were more likely to have the combination of an elevated ESR with a low platelet count (28%).

Benign Tumors

Pigmented villonodular synovitis (PVNS) is a benign tumor of the synovium. Although PVNS is rare in childhood, it does frequently result in recurrent joint swelling (76,77). This usually results in recurrent effusions that are minimally painful, with progressive cartilage destruction and erosion of bone. A frequent finding is chocolate brown synovial fluid on joint aspiration. The diagnosis is often confirmed by synovial biopsy showing nodular hypertrophy, with proliferating fibroblasts and synovial cells and hemosiderin-laden macrophages. Surgical excision can be curative. However, many patients have recurrences, and occasionally multifocal disease can occur.

Benign Pains of Childhood

Growing Pains

Growing pains, or benign pains of childhood are common, and may affect up to 20% of all children at some time (78). The diagnosis of growing pains should be reserved for those children, typically from 2 to 12 years of age, who have

benign pain, precipitated by exercise and routine physical activities. These pains usually occur in the afternoon, evening, or middle of the night, but are never present in the morning. They often respond well to massage or analgesics. The physical examination shows no sign of synovitis, and laboratory studies are always normal. Therapy for growing pains includes gentle massage and stretching. Children with recurring or daily pains often have significant benefit from a single bedtime dose of acetaminophen, ibuprofen, or naproxen. Frequently, acetaminophen 1 h before and after exercise can be beneficial.

Exaggerated Benign Pains of Childhood

There are children who have exaggerated but benign pains that are similar to growing pains. These pains are often more frequent, more intense, can be present at any time of the day, and are typically increased by physical activity. These children often have distinct physical exam findings that aid in diagnosis of this syndrome: hypermobile joints, pes planus, and/or leg-length discrepancy.

Hypermobility, either generalized or localized, is a common finding in children with pain (79). The diagnosis of hypermobility requires three of the following: opposition of the thumb to the flexor aspect of the forearm, hyperextension of the fingers parallel to the extensor aspect of the forearm, hyperextension of the elbows or knees by more than 10 degrees, or excessive dorsiflexion of the ankle and eversion of the foot (80). Children with hypermobility will often benefit from weight training, with strengthening about the hypermobile joints.

Ligamentous laxity in the feet can result in pes planus, with pronation and pain in the medial side of the arch. There are often associated mechanical strains resulting in pain in the ankles, knees, hips, and lower back. These children may benefit from the use of orthotic shoe inserts.

A congenital leg-length discrepancy is also frequently associated with benign pains of childhood. These children will often have a leg-length difference of less than 2.5 cm. However, this difference is more significant in proportion in small children. These children are often reported as clumsy from the time they began to walk. They will frequently benefit from the temporary use of sole inserts for the shoe of the shorter leg.

Pain Amplification Syndromes

Pain is an unpleasant sensory and emotional experience associated with real or potential injury, or is perceived in terms of such injury. The sensation of pain is a complex process dependent on multiple factors, including degree of injury, personal experience or knowledge of others' experience, and current emotional, as well as physical health. Psychogenic pain can develop without obvious cause, as a consequence of an acute or chronic illness, or following a severe or even

mild injury, but persists or worsens long after any inciting factor has been relieved. This type of pain can be localized or diffuse. It is frequently described as more intense than other types of pain, and is often associated with changes in mood, sleep patterns, and vocational and avocational function. A comprehensive discussion of the psychogenic pain syndromes in childhood is beyond the scope of this chapter, so I refer the reader to a number of excellent reviews (81–86).

Chronic pain syndromes in children are a frequent diagnostic dilemma for pediatricians and pediatric subspecialists. Nearly all of these children present with the belief of the parents, and occasionally the child, that the pain must be due to arthritis. Much of the difficulty in categorization of children with chronic musculoskeletal pain results from the variable nomenclature used by different clinicians and researchers. Malleson et al. (87) have suggested the use of diffuse idiopathic pain syndrome, which includes primary fibromyalgia syndrome, and localized idiopathic pain syndrome, which includes reflex sympathetic dystrophy (RSD).

An alternative proposal (81) is to use the term “pain amplification syndrome” for all chronic idiopathic pain syndromes of childhood, and to subclassify them as: (a) with autonomic dysfunction (complex regional pain syndrome type 1 or 2, reflex neurovascular dystrophy, reflex sympathetic dystrophy, algodystrophy, sympathetically mediated pain syndrome, Sudeck atrophy, localized idiopathic pain syndrome); (b) without autonomic dysfunction—constant (psychogenic, psychosomatic, pseudodystrophy, localized idiopathic pain syndrome, diffuse idiopathic pain syndrome); (c) without autonomic dysfunction—intermittent (psychogenic, psychosomatic, growing pains); (d) with multiple painful points (fibromyalgia, diffuse idiopathic pain syndrome); and (e) hypervigilant (psychogenic, psychosomatic, growing pains). This system has some advantages in allowing classification of chronic pain that does not meet the well-defined criteria for fibromyalgia or RSD (88–90).

Despite the difficulty with nomenclature, the common symptomatology that pervades all these pain syndromes is the presence of noninflammatory pain that is disproportional to physical exam findings, and that most children display *la belle indifférence*, an appearance of unconcern regarding the severe pain and disability they are experiencing. The majority of patients are female (80%), with onset typically after 6 years of age, but may be present in children as young as 3 years (83,86,91). Another very important aspect of these pain syndromes is the ability to move from one symptom complex to another, or to have characteristics of multiple psychogenic syndromes simultaneously. A child may present with localized limb pain without autonomic signs, then develop classic RSD, which resolves, only to be followed by diffuse pain with multiple painful points or fibromyalgia.

Reflex Sympathetic Dystrophy

RSD is likely underrecognized in children (84,86,91,92). The onset of RSD is often after minor trauma, or after a fracture that has healed and the cast has been removed. There is an initial pain that causes the child to stop using the affected limb. The disuse perpetuates the pain and the involved extremity becomes painful to even light touch (allodynia), swollen, cold, and discolored. Plain radiographs of the affected limb can show soft tissue swelling, and, after 6 to 8 weeks, a generalized osteoporosis. Technetium 99m bone scans can show either a diffuse increase or decrease in uptake of isotope (Fig. 12-2). Outcome for children with RSD is thought to be generally good when intensive physical and psychologic therapy is instituted within the first year (83,84,91). However, others have shown that more than 50% of children with RSD who presented after 1 year had elapsed between onset of symptoms and diagnosis continued to have pain and prolonged dysfunction (91). The most effective treatment for RSD is vigorous physical therapy and careful attention to the underlying psychosocial stressors (83,84,86). The affected limb should never be immobilized, because this will uniformly cause a worsening of the pain during or after the period of immobilization.

Childhood-onset Fibromyalgia

Fibromyalgia syndrome (FMS) is a common noninflammatory disorder characterized by chronic diffuse pain, and localized tender points with a decreased pain threshold. FMS accounted for 2.1% of new patient diagnoses by pediatric rheumatologists in a U.S. pediatric rheumatology disease registry (93). Childhood-onset FMS is similar to the adult disorder, which is characterized by diffuse pain, tender/trigger points, irritable bowel syndrome, headaches, fatigue, and nonrestorative sleep (89). Yunus and Masi (88) defined criteria for pediatric FMS, including diffuse pain and five or more tender points. They found prominent symptoms were nonrestorative sleep (100%), fatigue (91%), stiffness (79%), subjective swelling (61%), headaches (54%), paresthesias (36%), and irritable bowel syndrome (27%). It is the morning stiffness and generalized pains that may prompt the referral of a child with FMS to an orthopaedic surgeon. Therapy for FMS consists of physical therapy with stretching and aerobic exercise (including aqua therapy), stress reduction, and psychologic counseling.

JUVENILE IDIOPATHIC ARTHRITIS

Juvenile arthritis is one of the most frequent chronic illnesses of children. The majority of children with JIA have syndromes that are unique to childhood. Even in those types of JIA that have an adult equivalent, such as ankylosing spondylitis and psoriatic arthritis, children often have a dif-

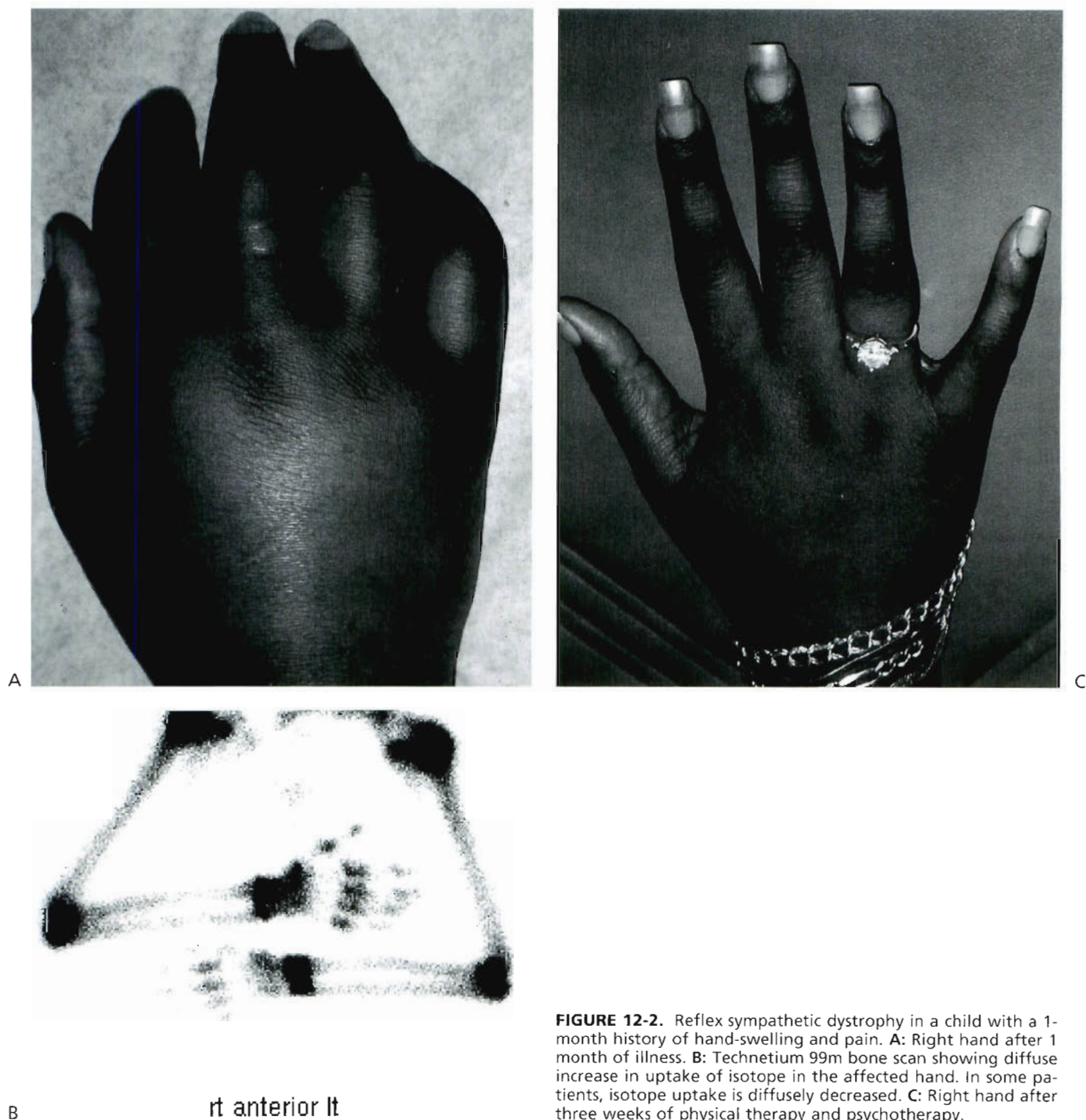


FIGURE 12-2. Reflex sympathetic dystrophy in a child with a 1-month history of hand-swelling and pain. **A:** Right hand after 1 month of illness. **B:** Technetium 99m bone scan showing diffuse increase in uptake of isotope in the affected hand. In some patients, isotope uptake is diffusely decreased. **C:** Right hand after three weeks of physical therapy and psychotherapy.

ferent pattern of onset and course than adults. Children with arthritis are also uniquely affected by articular inflammation which, due to their skeletal immaturity, can result in growth disturbances. As a result of localized inflammation, there can be acceleration of ossification centers, accelerated growth, or premature closure of epiphyses, resulting in diminished length.

Epidemiology

Juvenile arthritis is the most common rheumatic disease of childhood. The worldwide incidence ranges from 7 to 20 cases per 100,000 children at risk per year (1,5,94,95). Recent studies have suggested that the incidence of JRA may be decreasing (5). Alternatively, the improved recognition

of Lyme disease, and the exclusion of psoriatic arthritis and juvenile spondyloarthropathies, may be a contributing factor.

The overall prevalence of JRA in the United States has been estimated to be between 57 and 113 per 100,000 children younger than 16 years old (96). The prevalence of childhood-onset psoriatic arthritis and enthesitis-related arthritis (spondyloarthropathies) is less well characterized. The prevalence of juvenile ankylosing spondylitis is reported to be 2 to 10 per 100,000, whereas juvenile psoriatic arthritis has a prevalence of 2 to 12 per 100,000 (97). The incidence of juvenile spondyloarthropathies in whites of Northern European ancestry is slightly greater than 1 per 100,000 (94,98). However, spondyloarthropathy is the most common form of juvenile arthritis in some Mexican and North American Indian children (99,100).

Etiology

The etiology of JIA is unknown. Chronic arthritis is a complex disorder requiring inappropriate immunologic activation, with failure of self-tolerance, in the setting of multiple host genetic and environmental factors. JIA is a heterogeneous disorder with multiple ages and patterns of onset, and with a highly variable course. It is likely that multiple initiating factors are involved, including infection, trauma, and autoimmunity, all in conjunction with genetic predilection for arthritis.

Genetics

There are many reported associations between HLA types and juvenile arthritis. Other than HLA-B27, the majority of the associations of JIA have been with the HLA class II antigens, which are restricted to cells of lymphoid origin (102). In oligoarticular arthritis, there is an increased association with HLA-DR8, HLA-DR6, and HLA-DR5, with relative risks of 2 to 27. This means that a child who carries one or more of these genes has a 2- to 27-fold increased risk of developing the disease, compared to the population as a whole. The presence of uveitis is correlated with HLA-DR5, whereas protection from uveitis is correlated with HLA-DR1 (102). Chronic uveitis has also been associated with HLA-DRB1 and HLA-DQA1 (103). Polyarticular onset with positive rheumatoid factor is associated with HLA-DR4, which parallels the association with adult rheumatoid arthritis, whereas HLA-DR7 seems protective. Rheumatoid factor negative polyarticular disease is associated with HLA-DR8, HLA-DPw3, and HLA-DQw4, with relative risk factors of 3 to 10. Systemic-onset disease has overlapping risk factors, showing an association with HLA-DR4, HLA-DR5, and HLA-DR8, with relative risks ranging from around 2 to 7 (101).

Juvenile ankylosing spondylitis (JAS) and related diseases show a striking familial occurrence. The only immunogenic factor in common in this class of diseases has been shown

to be HLA-B27. Data from multiple immunogenetic studies have shown that 90% of patients with JAS express the HLA-B27 antigen (104,105). These data are supported by an animal model in which spontaneous inflammatory disease of the gastrointestinal tract, peripheral and vertebral joints, male genital tract, skin, nails, and heart were seen in transgenic rats expressing a functional human HLA-B27 allele (106).

Imbalances in levels of proinflammatory and antiinflammatory cytokines may be associated with chronic inflammation. A polymorphism in the *IL-1 α* gene was found to be associated with uveitis and pauciarticular arthritis in Norwegians (107). Children who have an *IL-6* genotype, which has a relatively higher transcription rate when stimulated, may be at greater risk for systemic arthritis (108).

Infection as Trigger

Infection has been implicated in both the onset and exacerbation of chronic arthritis in children (109). Of all types of JIA, systemic onset has clinical features most consistent with an infectious process: acute onset, high fever, rash, lymphadenopathy, and arthritis. However, there has to date been no convincing laboratory evidence of infection in this relatively homogeneous disease. Multiple viral and bacterial agents have been associated with JIA (110). However, no single or even large group of agents has been convincingly implicated in any form of JIA. It is more probable that multiple conserved viral and bacterial antigens, with epitopes that crossreact with human antigens, may promote an inappropriate autoimmune response. This association is strongest for the HLA-B27-associated diseases (111) in which arthritogenic peptides from enteric pathogens have generated specific B27-restricted CD8⁺ T lymphocytes that were isolated from arthritic joints (112).

CLINICAL SYNDROMES OF JIA

Clinical Onset Types

The relative prevalence of each of the subtypes of juvenile arthritis vary widely, depending on whether the EULAR or ACR are utilized. The onset diagnosis of children with JRA, over many years, has been relatively consistent, with approximately 50% of children having oligoarticular disease, 30 to 40% with polyarticular disease, and 10 to 20% systemic onset. Only recently has psoriatic arthritis been separated from the spondyloarthropathies and differentiated from JRA. The subtypes of JCA show similar figures for oligoarticular (50%) and systemic onset (11%). However, the prevalence of polyarticular disease is only 20% and the remaining is divided among undifferentiated spondyloarthropathy, JAS, juvenile psoriatic arthritis, and inflammatory bowel disease-associated arthritis (94) (Table 12-5). The most current summary of the prevalence of individual subtypes uti-

TABLE 12-5. FREQUENCY OF JUVENILE ARTHRITIS SUBTYPES

Subtypes	Symmons et al. (94) (%)	Subtypes	Bowyer and Roettcher (93) (%)
Systemic JCA	11	Systemic JRA	11
Polyarticular JCA		Polyarticular JRA	
RF-positive	3	RF-positive	1
RF-negative	17	RF-negative	24
Oligoarticular JCA	50	Oligoarticular JRA	38
Spondyloarthropathy ^a	11	Spondyloarthropathy ^a	24
Psoriatic arthritis	7	Psoriatic arthritis	3

^a All spondyloarthropathies, including juvenile ankylosing spondylitis and inflammatory bowel disease-associated arthritis.

lizing the ACR criteria is from the Pediatric Rheumatology Data Base (93) (Table 12-5). Of 2,828 children with arthritis, 11% had systemic onset, 24% polyarticular (RF-), 1% polyarticular (RF+), 38% pauciarticular, 24% spondyloarthritis (11% JAS), and 3% psoriatic arthritis. Each subtype of juvenile arthritis has individual characteristics, and each type can have widely different courses and outcomes, which further emphasizes the heterogeneity of JIA.

Systemic Arthritis

Systemic onset juvenile arthritis (113) was first completely described by Still in 1897, and systemic arthritis has often been called “Still’s disease.” His classic article was reprinted in 1978 (114). Systemic arthritis is characterized by the presence of daily or twice-daily spiking fevers, usually to 39°C or higher (115). Children with systemic arthritis are frequently quite ill-appearing while febrile. The fever often responds poorly to NSAIDs, but will typically respond well to corticosteroids. In most children, the fever is accompanied by a characteristic rash (116) (Fig. 12-3). The rash consists of discrete, erythematous macules, which are blanching, transient, and frequently nonpruritic. The rash is often more pronounced on the trunk, but is often present on the extremities, and may occur on the face. Many children with systemic arthritis will have extraarticular manifestations, including hepatosplenomegaly, pericarditis, pleuritis, lymphadenopathy, and abdominal pain. The extraarticular features may be present for weeks, months, and occasionally, years prior to the onset of arthritis. Usually, the extraarticular manifestations of systemic arthritis are self-limited, and will resolve spontaneously or with corticosteroid therapy. Occasionally, the pericarditis can result in tamponade. Systemic arthritis can occur at any age, but is slightly more common before 6 years of age (94), and can occur rarely in adulthood, when it is referred to as “adult-onset Still’s disease.” There is an equal ratio of males to females, which may support the premise that there is an infectious trigger for systemic arthritis (117).

The laboratory features of systemic arthritis are notable for elevated acute-phase reactants. The ESR and CRP are

greatly elevated. The disease is often accompanied by anemia of chronic disease (118–120), a leukocytosis, and a marked thrombocytosis, which may exceed 1 million/mm³. Clinical experience has shown that, when the platelet count remains greater than 500,000/mm³ after 5 years, remission is unlikely. Elevation of serum ferritin has been correlated with active inflammation in some children with systemic arthritis (121). Patients with systemic arthritis can have coagulation abnormalities with generation of fibrin split products, which have also been correlated with active disease (122). Children with systemic arthritis are rarely ANA- or RF-positive.

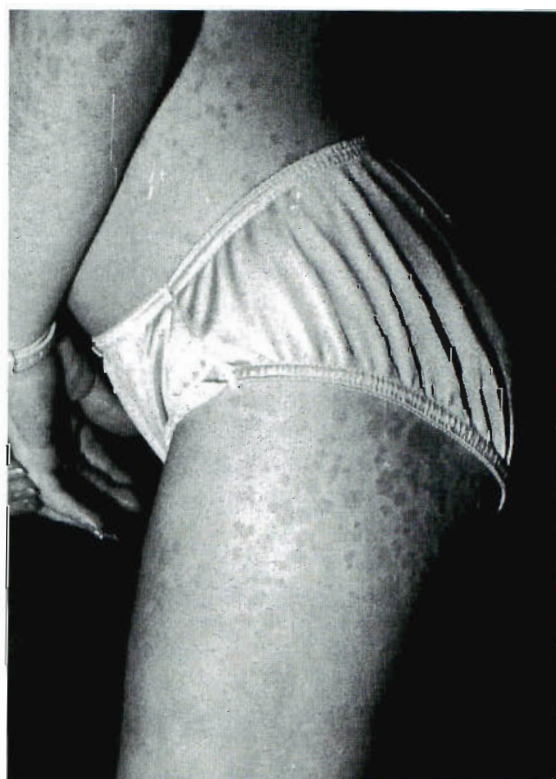

FIGURE 12-3. Rash of systemic-onset juvenile idiopathic arthritis.

The differential diagnosis of systemic arthritis is essentially the same as for fever of unknown origin. Systemic arthritis often presents the greatest challenge to the clinician during the phase prior to the onset of arthritis. The diagnostic possibilities that must be considered include infections, malignancy, inflammatory bowel disease, systemic lupus erythematosus, and vasculitides (polyarteritis nodosa, Kawasaki disease).

Clinical Course

One striking feature of systemic arthritis is arrest of linear growth during periods of active disease (123,124) (Fig. 12-4). The use of glucocorticoids also may result in growth retardation, as well as Cushing syndrome, in this same group of patients. When children with systemic arthritis have active inflammatory disease the use of human growth hormone fails to significantly increase linear growth (125,126). The prognosis of systemic arthritis is determined predominantly by the course of arthritis. Nearly 50% of children with systemic arthritis will have an oligoarticular course that is typically mild, and in the majority of these children, the

arthritis will ultimately remit. The remaining half of the children with systemic onset will develop a polyarticular arthritis that can remit, but progresses in approximately 50% of cases (25% of all systemic-onset JIA) to a severe, unrelenting, and destructive course despite all current therapeutic interventions (127). Chronic anterior uveitis is extremely rare in systemic arthritis. Systemic amyloidosis, usually presenting with the onset of proteinuria and hypertension, can occur as a result of any chronic inflammatory disease. Nearly 8% of children with systemic arthritis, and to a lesser degree, the other subtypes of JIA, have been shown to develop this life-threatening complication (128). The incidence of amyloidosis in North America is significantly lower than that seen in Europe. The reason for this discrepancy remains unclear.

Macrophage activation syndrome (MAS) is a severe, potentially life-threatening complication seen nearly exclusively in systemic arthritis. It is characterized by macrophage activation with hemophagocytosis, and is associated with hepatic dysfunction, disseminated intravascular coagulation with a precipitous fall in the ESR secondary to hypofibrinogenemia, and encephalopathy (129). It has been suggested

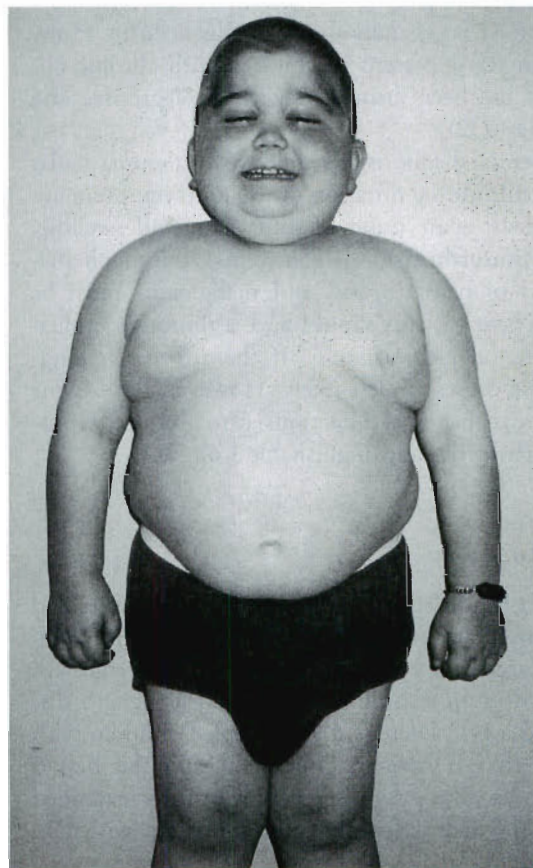
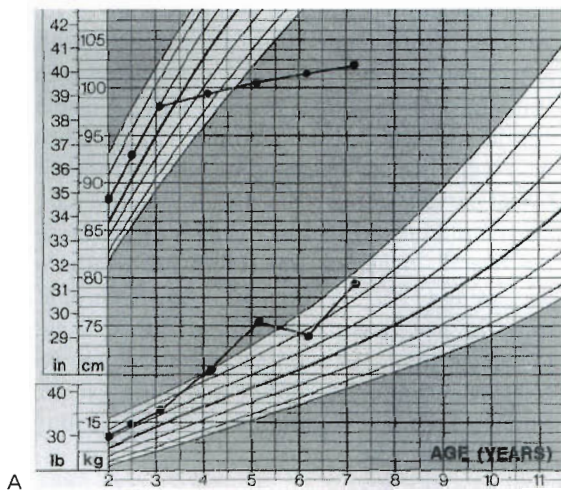


FIGURE 12-4. Child with systemic-onset juvenile idiopathic arthritis. **A:** Growth arrest due to systemic inflammation and chronic steroid use. **B:** The same child at age 7 with chronic polyarthritis, growth arrest, and Cushing syndrome.

B

that antiinflammatory medications and viral infections can induce this syndrome. High-dose corticosteroids and cyclosporine A have been shown to improve the outcome of MAS (130,131).

Oligoarthritis

Oligoarthritis is the most common subtype of JIA, and is characterized by arthritis in four or fewer joints during the first 6 months of disease. These children rarely have complaints of pain, do not have associated fever, and are not systemically ill. The knee is the most common joint affected, followed by ankles and elbows. The hips are only rarely affected. Small joints of the hands and feet are seldom affected in oligoarthritis. Asymmetric oligoarticular involvement of small joints, with or without large-joint arthritis, is most characteristic of psoriatic arthritis. The majority of children with oligoarthritis present before 6 years of age, and girls predominate (4 to 1). Although oligoarthritis can present in older children, the late-onset type, in which there is a male predominance and high incidence of HLA-B27, now should be classified as enthesitis-related arthritis.

Most children with oligoarthritis will have a mild elevation of the ESR (rarely above 80 mm/h), but it can be normal. The CRP is usually normal or mildly elevated. Antinuclear antibodies are found in 40 to 80% of children with oligoarthritis, and are associated with increased risk for anterior uveitis. An RF is generally absent in oligoarthritis. However, when an RF is present in children with chronic oligoarthritis, it has been associated with an aggressive and erosive disease (132).

The differential diagnosis of a child with a monoarticular arthritis depends on the duration of the joint involvement. In children with acute onset of joint pain and swelling, infections (septic arthritis or osteomyelitis), trauma, hematologic causes of hemarthrosis, and malignancy must be considered. These patients should have a thorough evaluation, including an arthrocentesis. If the arthritis is longstanding, these causes are less likely. However, both Lyme disease and mycobacterial infections can produce a prolonged monoarthritis indistinguishable from JIA.

Clinical Course

The majority of children with oligoarthritis have a mild and remitting course. However, in untreated children with longstanding unilateral knee arthritis, there can be overgrowth of the affected limb, resulting in a marked leg-length discrepancy (133,134). There is a subgroup of children with oligoarthritis that is indistinguishable within the first 6 months of disease, but progresses to polyarthritis (extended oligoarticular), which is usually most consistent with RF-negative polyarticular JIA.

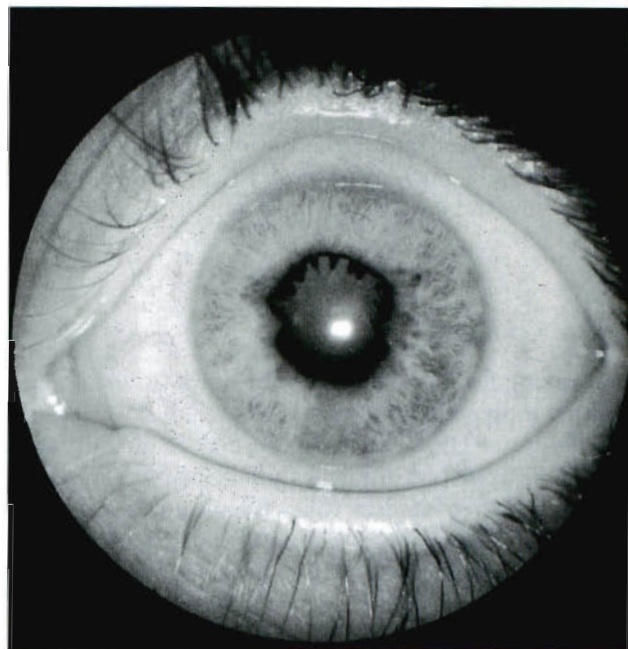

FIGURE 12-5. Iritis in oligoarticular juvenile idiopathic arthritis. Posterior synechiae are finger-like adhesions between the iris and lens, and result in an irregular pupil.

Chronic uveitis (Fig. 12-5) is the most serious complication seen in oligoarthritis, and occurs in 13 to 34% of all patients with juvenile arthritis. Nearly 80% of all cases of anterior uveitis in childhood are associated with JIA (135). Initially, the eyes of most patients with JIA-associated uveitis appear normal, and are asymptomatic. Of those children who will ultimately develop uveitis, it is already present in 6% of patients at onset of arthritis, but develops in a majority of children within 4 to 7 years after diagnosis. Although the overall incidence and severity of uveitis seems to be decreasing (136,137), even a low-grade chronic uveitis can result in a poor visual outcome (138). Current guidelines for ophthalmologic examination in children with juvenile arthritis recommend routine screening examinations, including slit-lamp evaluation, based on age and type of onset (139) (Table 12-6).

Polyarthritis

Polyarticular-onset JIA is characterized by the insidious, but occasionally acute, onset of a generally symmetric arthritis in five or more joints. It can involve both large and small joints, and frequently affects the cervical spine and temporomandibular joints. Typically, girls outnumber boys 3 to 1. Mild systemic features can be present in children with polyarthritis. They may have low-grade fevers, lymphadenopathy, and hepatosplenomegaly. The fevers are not typically the high quotidian temperature spikes that are diagnostic of systemic arthritis, and rash is rarely seen (7). There

TABLE 12-6. GUIDELINES FOR INITIAL FREQUENCY OF SCREENING EYE EXAMS IN JIA

Juvenile Arthritis Onset Type	Minimum Screening Frequency	
	Age at Onset	
	<7 years	≥7 years
Oligoarthritis		
ANA-positive	3 to 4 months	6 months
ANA-negative	6 months	6 months
Polyarthritis		
ANA-positive	3 to 4 months	6 months
ANA-negative	6 months	6 months
Systemic arthritis	1 year	1 year
Psoriatic arthritis		
[†] ANA-positive	3 to 4 months	6 months
ANA-negative	6 months	6 months
Enthesitis-related arthritis	1 year	1 year

All patients with an irregular iris, or an acute red, painful, or photophobic eye, should be examined immediately.

ANA, antinuclear antibodies.

are at least two distinct subgroups of polyarthritis: those with and without the presence of RF.

RF-negative polyarthritis can occur at any age, with the median age of onset at 6.5 years (94). This subgroup can be ANA-positive (40 to 50%), and this is associated with an increased incidence of uveitis (5%) (135).

The second subgroup of polyarthritis includes those with a positive RF. This subtype occurs predominantly in older girls (>8 years) who are HLA-DR4-positive, and is indistinguishable from adult rheumatoid arthritis. These children are more likely to have a symmetric small-joint arthritis, rheumatoid nodules, and early erosive synovitis with a chronic course. However, these children rarely develop chronic uveitis.

Most patients with active polyarthritis will have an elevated ESR, typically 20 to 80 mm/h. The ESR is often a useful measure of disease activity in children with polyarthritis (14,140). Children with significant joint disease will often develop anemia of chronic disease, with hemoglobin in the range of 7 to 10 g/dL, although this is more marked in systemic arthritis (118,119).

The differential diagnosis of polyarthritis is quite different from that of monoarticular disease. Polyarticular septic arthritis is unusual, although an asymmetric polyarthritis and tenosynovitis can be caused by *Neisseria gonorrhoeae*. Systemic lupus should be considered, especially in adolescent and preadolescent girls. Reactive arthritis, inflammatory bowel-related arthritis, juvenile psoriatic arthritis, and enthesitis-related arthritis, including juvenile ankylosing spondylitis, should be considered. Although juvenile dermatomyositis and scleroderma may present with polyarthritis, the associated signs and symptoms of these disorders usually lead to a correct diagnosis.

Clinical Course

Children with polyarthritis that is rheumatoid-factor-positive are at risk for a prolonged and destructive course. These children are typically older girls with multiple joints involved (20 or greater), including the small joints of the hands and feet, early erosions, and rheumatoid nodules. The presence of hip arthritis has been shown to be a poor prognostic sign, and may lead to destruction of the femoral heads (141). If polyarthritis persists longer than 7 years remission is unlikely. The onset of puberty seems to have no relation to disease activity or remission (67). Severe polyarticular (polyarticular and systemic JIA) disease, with involvement of the temporomandibular joints prior to 5 years of age, can result in micrognathia (142).

Psoriatic Arthritis

The diagnosis of juvenile psoriatic arthritis was considered to be rare in children. Prior to 1982, there were fewer than 80 cases described in the English literature, when Shore and Ansell (143) published the first large collection of 60 children with psoriatic arthritis. The rarity of juvenile psoriatic arthritis was unusual, due to the relatively large number of children with psoriasis, and the fact that 7% of adults with psoriasis have arthritis (144). Juvenile psoriatic arthritis has historically been considered a juvenile spondyloarthropathy. However, recent studies have shown the juvenile psoriatic arthritis is a distinct entity that has been underdiagnosed, often due to the long period from onset of arthritis to onset of psoriasis (144,145).

Psoriatic arthritis may account for up to 7% of JIA. There is a mild female predominance (1.6 to 2.3 girls to 1 boy) and it often affects young children, with a median onset age of 5.9 to 10.1 years. The arthritis is often an asymmetric oligo- or polyarthritis affecting both large and small joints. At onset, the majority have nail pitting (67%) (Fig. 12-6), a family history of psoriasis (69%), or dactylitis (39%), and less than one-half of the children have the rash of psoriasis (13 to 43%) (94,144,145). Current criteria do not require the development of psoriasis to confirm a diagnosis of psoriatic arthritis (9) (Table 12-2).

Children with psoriatic arthritis usually do not develop an RF, but a positive ANA can be seen in 50%, and is a risk factor for uveitis. HLA-DR1 and HLA-DR6 were statistically significant risk factors for development of juvenile psoriatic arthritis (145). There is a mild, but not statistically significant, increase in the presence of HLA-B27 in children with psoriatic arthritis, and these children are more likely to have axial arthritis (143–145). The presentation of children under 5 years of age is often heralded by the involvement of a small number of fingers or toes that are relatively asymptomatic, but result in marked overgrowth of the digit(s).

The differential diagnosis of psoriatic arthritis is essentially the same as for polyarthritis. However, the diagnosis

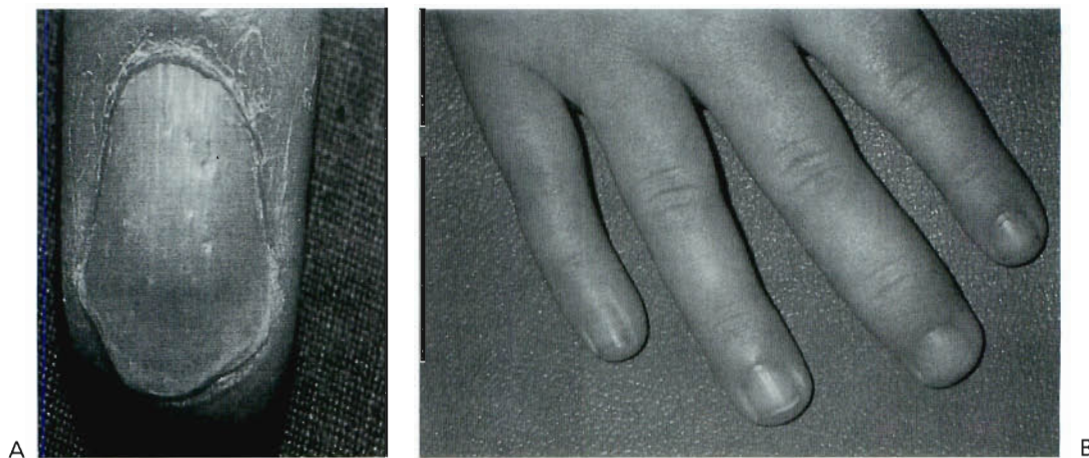


FIGURE 12-6. Juvenile psoriatic arthritis. **A:** Nail pitting associated with psoriasis. **B:** Swelling of a single distal interphalangeal joint in a child with juvenile psoriatic arthritis.

of psoriatic arthritis should be suspected in a child with dactylitis, nail pitting, asymmetric involvement of large and small joints, arthritis of the distal interphalangeal (DIP) joints (Fig. 12-6), or a first- or second-degree relative with psoriasis. There is rarely fever or systemic illness as may be seen in septic arthritis caused by *Neisseria gonorrhoeae*.

Clinical Course

Children with psoriatic arthritis can have a chronic lifelong arthritis that may follow a relapsing and remitting course. Arthritis mutilans and predominant DIP joint disease are unusual. However, many of the children will have prolonged polyarthritis that may result in irreversible joint damage (143). Amyloidosis has been noted in the European literature, and has resulted in the death of at least 3 children (143,146). Chronic anterior uveitis has been observed in up to 17% of children (144,145), is associated with a positive ANA titer, and is clinically indistinguishable from the uveitis in oligo- and polyarthritis. The uveitis associated with psoriatic arthritis may be more resistant to treatment than the other forms of chronic uveitis associated with childhood arthritis (67).

Enthesitis-related Arthritis

The criteria for classification of enthesitis-related arthritis (ERA) describes a group of arthritides that includes undifferentiated spondyloarthritis, ankylosing spondylitis, and inflammatory bowel disease-associated arthritis. At the onset, juvenile spondyloarthropathies are often undifferentiated, preventing the application of adult-onset criteria for diagnosis. The addition of criteria for the presence of HLA-B27, a family history of HLA-B27-associated disease, and

the onset of arthritis in a boy after 8 years of age, will increase the number of children included in this category (9). However, in an effort to better define the group of children who have psoriatic arthritis, the Durban criteria now excludes children from the diagnosis of ERA, even those with ankylosing spondylitis, if they have a first- or second-degree relative with psoriasis. This will likely contribute a significant number of children to the "Other Arthritis" category, in that they either fulfill no criteria or fulfill criteria for more than one category. It is probable that families with a genetic propensity for psoriasis, who also carry the *HLA-B27* gene, may have two distinct mechanisms contributing to the development of arthritis. These disorders will be better defined as the underlying mechanisms are elucidated by molecular and genetic research. The current criteria will include many of those children previously diagnosed with a syndrome of seronegativity, enthesopathy, and arthropathy (SEA syndrome), who were shown to be at increased risk for development of classic spondyloarthritis or juvenile ankylosing spondylitis (147,148).

ERA is often associated with enthesitis and arthralgias or arthritis long before any axial skeletal involvement is identified (148). Enthesitis is identified when marked tenderness is noted at the 6, 10, and 2 o'clock positions on the patella, at the tibial tuberosity, iliac crest, or the attachments of the Achilles tendon or plantar fascia (67). In some children the only manifestation of ERA may be severe enthesopathy of the heel(s) (149) (Fig. 12-7).

Laboratory evaluation of children with ERA is relatively unremarkable. There is often systemic inflammation with thrombocytosis and an elevated ESR. A highly elevated ESR (>100) is more likely to be associated with inflammatory bowel disease in a child who meets the criteria for ERA. The RF is uniformly negative, but ANAs can be present in

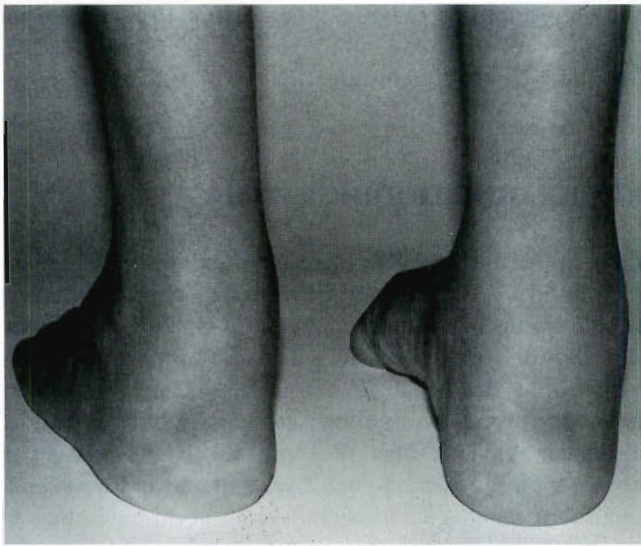


FIGURE 12-7. Achilles tendonitis and enthesitis in a child with enthesitis-related arthritis. (Courtesy of Dr. Ruben Burgos-Vargas.)

the same proportion as the childhood population (16,17,67).

The primary extraarticular manifestation of ERA is acute anterior uveitis (AAU), which can occur in up to 27% of children with ankylosing spondylitis (150). AAU is highly associated with the presence of HLA-B27 (50%) (151). It typically presents with an acute, painful, red, photophobic eye. Although AAU may resolve with no ocular residua, some children will have a persistent uveitis that is relatively resistant to therapy, and can result in blindness (152,153).

Juvenile Ankylosing Spondylitis

Children with juvenile ankylosing spondylitis (JAS) have often been diagnosed based on adult criteria that require radiographic evidence of sacroiliitis. JAS most often presents in late childhood or adolescence. Children with JAS and sacroiliac (SI) involvement are often HLA-B27-positive (82 to 95%), and the male-to-female ratio is 6:1 (97). Most children ultimately diagnosed with JAS will initially have an episodic arthritis of large joints of the lower extremities and the tarsal bones. Regardless of axial disease, the most reliable predictors to differentiate JAS from oligo- or polyarticular JIA are the presence of enthesitis and tarsal disease in children who have arthritis of the lower, but not of the upper extremities (154).

The presentation of JAS is most remarkable for the absence of axial involvement. Only 12.8 to 24% of children with JAS have pain, stiffness, or limitation of motion of the sacroiliac or lumbosacral spine at onset. A peripheral arthropathy or enthesopathy, affecting predominantly the lower limb joints and entheses, is seen in 79 to 89.4%.

These children tend to have fewer than five joints involved, and rarely more than ten. At presentation, the joint involvement is usually asymmetric, or even unilateral (155). Small joints of the toes are commonly involved in JAS, but are seldom affected in other forms of JIA, with the exception of psoriatic arthritis.

The diagnosis of JAS is often difficult at onset. However, the combination of peripheral joint arthritis, with a lower-extremity predominance, enthesitis, and SI, or lumbosacral disease, would strongly suggest the diagnosis of ERA and possible JAS. Septic SI joint disease and osteomyelitis can present with SI pain and limitation of motion.

Examination of the axial skeleton is important in the diagnosis of JAS. Pain may be elicited over the SI joints by direct pressure, lateral compression of the pelvis, or distraction of the SI joints (Patrick test). Quantitation of the normal lumbar spine flexion, by Macrae and Wright's modification of the Schober test (156), can identify children with limitation of lumbar spine flexion. With the child standing upright, an anchoring mark is made at the lumbosacral junction (dimples of Venus). A mark is then made 5 cm below and 10 cm above the lumbosacral junction. Then, with the child in maximal forward flexion, the distance between the upper and lower points is measured. In general, a modified Schober measurement of greater than 21 cm (i.e., an increase of 6 cm) is within normal limits (67). The measurement of fingertip to floor distance on forward flexion is not reproducible, reflects both hip and back flexion, and does not correlate with the Schober index. Chest expansion is also not a reliable test for spine involvement in JAS (155).

Clinical Course

The initial course of JAS is characterized by remitting and relapsing symptoms, which are frequently mild. This can not be differentiated from the child who seems to have recurrent bouts of reactive arthritis. However, the pattern of joint disease (which often progresses to become polyarticular) and axial disease is usually evident after the third year of illness (155). Children with long-standing JAS have been shown to develop tarsal bone coalition that has been termed "ankylosing tarsitis" (157) (Fig. 12-8).

Outcome data for JAS are incomplete and at times contradictory. The prognosis of JAS has been reported as both worse and better than adult-onset ankylosing spondylitis (158,159). Peripheral joint arthritis tends to be more common than that seen in adults (67). Hip disease had been associated with a poor functional outcome (158,160), and may require total hip arthroplasty.

Inflammatory Bowel Disease-associated Arthritis

The prevalence of arthritis in children with inflammatory bowel disease (IBD) has been reported to be 7 to 21%,

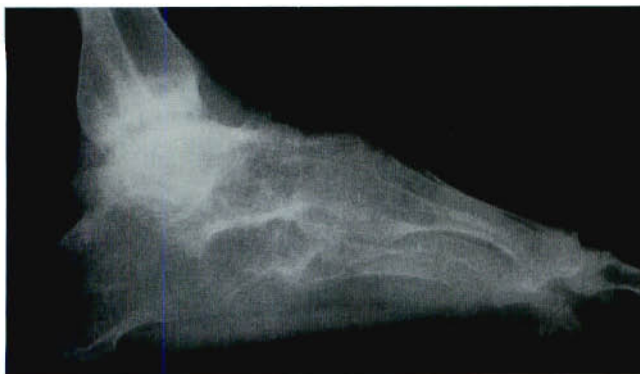

FIGURE 12-8. Ankylosing tarsitis, a complex disorder resulting in ankylosis of the foot in a child with juvenile ankylosing spondylitis. (Courtesy of Dr. Ruben Burgos-Vargas.)

and usually occurs after the diagnosis of the bowel disease (161–163). There are two different patterns of arthritis seen (67). The most common type is an oligo- or polyarticular arthritis of the lower limbs. This group is less likely to meet the criteria for ERA. This arthritis is often episodic, with exacerbation lasting 4 to 6 weeks, and rarely, for months. The activity of the peripheral arthritis often reflects the underlying activity of the IBD. The less-common type of IBD-associated arthritis is a HLA-B27-associated oligoarticular arthritis of the lower limbs, with sacroiliitis and enthesitis,

and no relationship to bowel inflammation (67). This form is more likely to persist and progress, despite control of the bowel disease, and seems identical to other ERAs.

RADIOLOGIC FINDINGS IN JIA

Early in the course of JIA, there are often no specific radiologic findings. As the disease progresses, there is often periarticular osteopenia, localized soft tissue swelling, and occasionally, joint space widening due to effusion or synovial hypertrophy. Late changes seen in JIA include joint space narrowing from cartilage loss, erosions, subluxation, and ultimately ankylosis (Figs. 12-9 and 12-10). Erosive changes do not typically occur before 2 years of active disease, and significant changes in radiographs rarely occur in less than 6 months. Children with chronic polyarthritis will frequently develop bony ankylosis of the carpal and tarsal joints, and in the cervical spine.

Radiologic abnormalities of cervical spine (Fig. 12-11) can result from apophyseal joint inflammation and bony fusion, often initially at the C2–C3 level. Atlantoaxial instability can be seen with chronic arthritis of the cervical spine. Symptoms can range from minimal to severe neck pain and limitation of movement of the cervical spine, to neurologic damage due to impingement of the spinal cord. Special precautions for children with JIA and cervical spine arthritis must be made prior to anesthesia, due to the rigid cervical spine and atlantoaxial instability, to avoid serious injury.

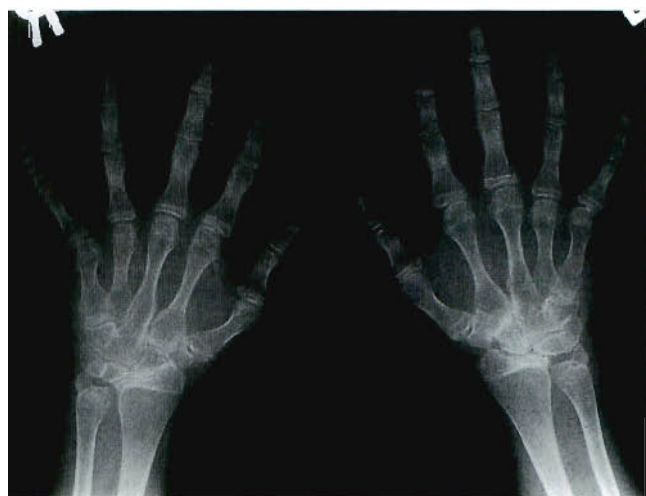
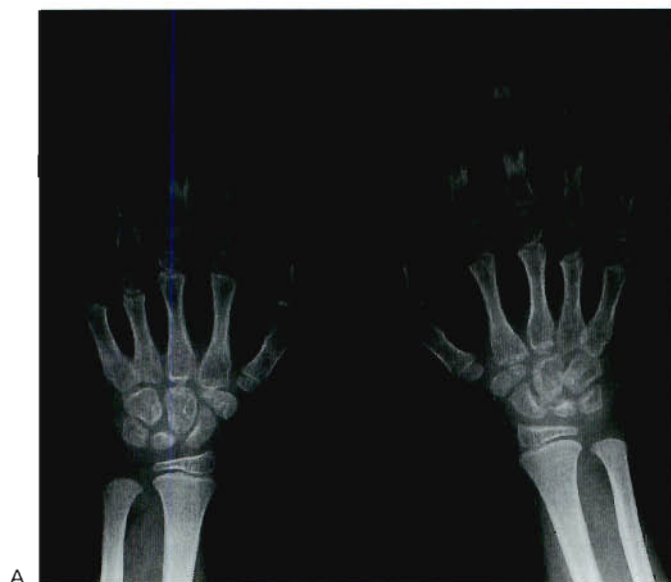
FIGURE 12-9. Polyarticular juvenile idiopathic arthritis with wrist and finger involvement. **A:** At 6 years of age, there is periarticular osteopenia and diffuse swelling of the wrist and fingers. **B:** At 20 years of age, there is significant carpal and carpometacarpal fusion.

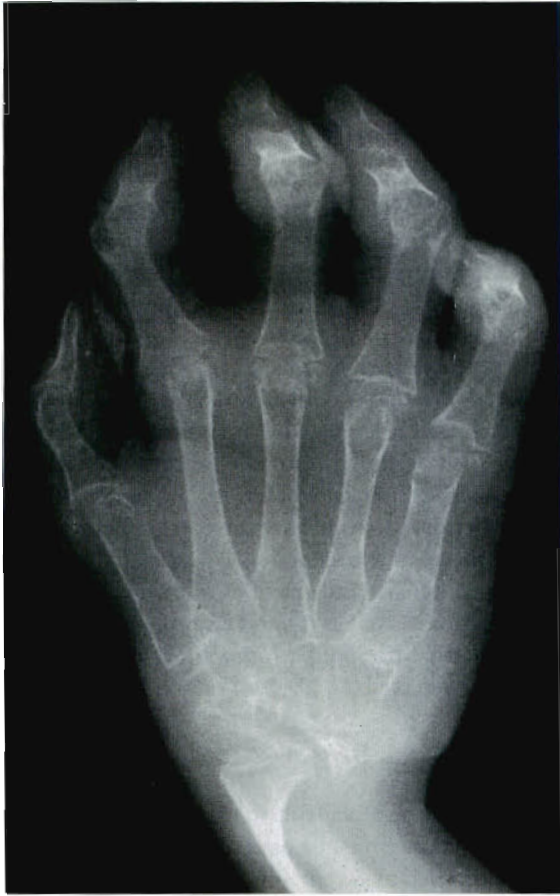
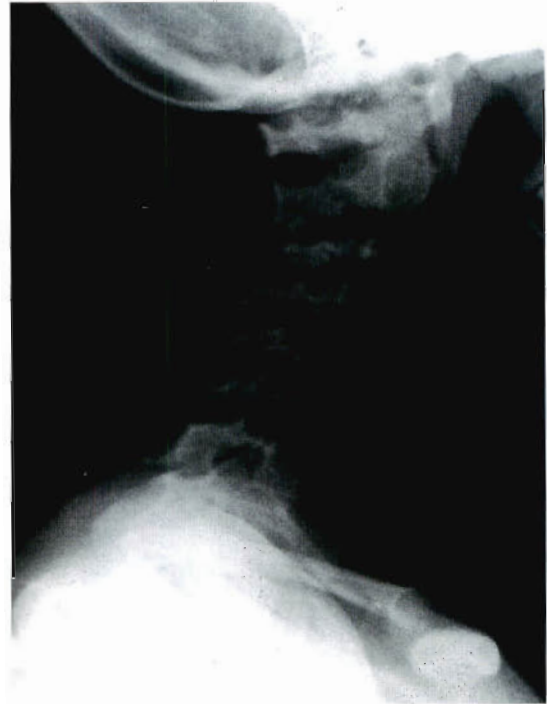
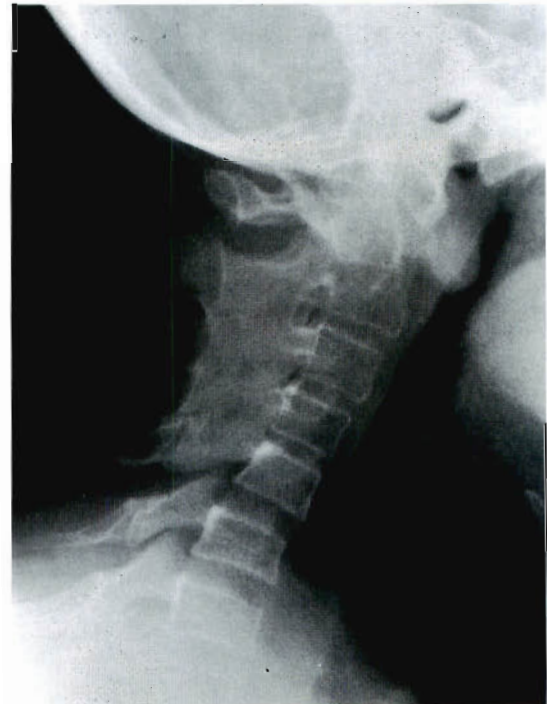FIGURE 12-10. Systemic-onset polyarticular juvenile idiopathic arthritis with prolonged arthritis, resulting in severe osteopenia and destructive changes in the hand and wrist, with severe ulnar deviation.



A



B

FIGURE 12-11. The cervical spine in a child with polyarticular JIA. A: At 6 years of age, there are no radiographic abnormalities. B: At 21 years of age, there is ankylosis of C2–C5.

Likewise, serious traumatic injuries have occurred after spontaneous cervical spinal fusion as a consequence of JIA, highlighting the vulnerable nature of these children (164).

Radiographs in psoriatic arthritis can show both asymmetric erosive disease, with or without regional osteoporosis, and periosteal new bone formation. The periostitis can lead to overgrowth of the affected bone. Although erosive changes of the DIP joints can be seen, this is a rare occurrence (67) (Fig. 12-12).

Children with ankylosing spondylitis will develop radiographic changes in the SI joints, but this may not occur for 1 to 15 (average 6.5) years after diagnosis (150). These findings can include pseudowidening due to erosions, sclerosis, and fusion (Fig. 12-13). Radiologic changes in the lumbosacral spine occur later in the course of JAS, and are less frequent (165). Chronic enthesitis, particularly at the

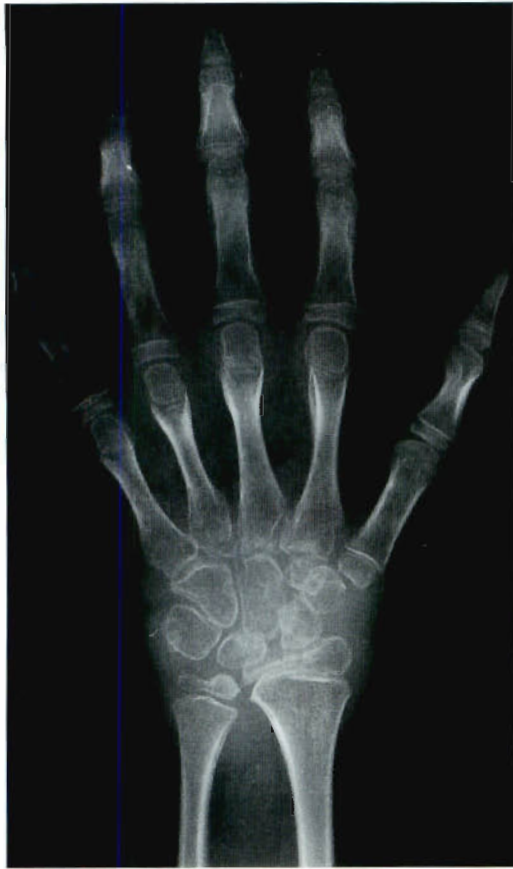

FIGURE 12-12. Juvenile psoriatic arthritis affecting the hand, with metacarpophalangeal, proximal, and distal interphalangeal joint involvement, with marked fusiform swelling, and periostitis.

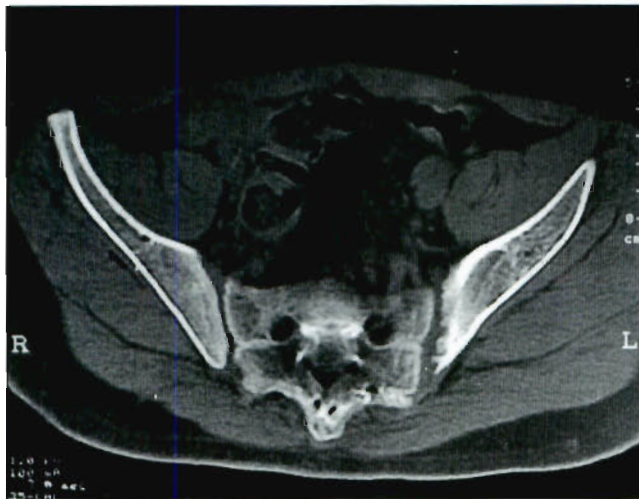


FIGURE 12-13. CT scan of the SI joints in a child with juvenile ankylosing spondylitis, showing erosions and sclerosis of the SI joints. (Courtesy of Dr. Ruben Burgos-Vargas.)

calcaneus, can result in erosion at the insertion of the Achilles tendon or plantar fascia.

TREATMENT OF JIA

The treatment of juvenile arthritis is best achieved with a multidisciplinary team approach. First and foremost, the child and family must participate in informed decision-making. The team of health care professionals can provide comprehensive care of all facets of this chronic disease. The team should include the primary care physician, to coordinate medical care, and the rheumatologist, for diagnosis and treatment plans. Other valuable members of the treatment team may include the rheumatology nurse, for education and family support; social worker, for monetary and school advocacy; dietitian, to minimize the effects of corticosteroid therapy; physical and occupational therapists, to maintain and improve strength and range of joint motion; ophthalmologist, for uveitis screening and treatment; and occasionally the pediatric orthopaedic surgeon, when surgical interventions are indicated.

Medications

There are many drugs available to treat arthritis. Often, two or more drug classes must be used simultaneously to achieve disease control. Many recent advances in understanding the mechanisms of inflammation in arthritis have led to novel therapeutic strategies. The fundamental purpose of pharmacologic therapy is to achieve pain control, decrease inflammation, promote, then maintain remission. The medications used are individualized for each patient, depending on their subtype of arthritis, degree of inflammation, and previous response to medications.

Nonsteroidal Antiinflammatory Drugs

The mechanism of action of NSAIDs is by inhibition of the biosynthesis of prostaglandins, by direct action on the enzyme cyclooxygenase (COX) (166). The recent discovery of a second COX enzyme (COX-2), which is induced in the proinflammatory cascade, and the differential inhibition of the two COX isoforms (COX-1 and COX-2) by individual NSAIDs, has provided the basis for the development of safer NSAIDs (167). At this time, no COX-2-specific NSAID is approved for use in children. However, this exciting scientific advance will likely change NSAID use in children in the near future.

NSAIDs are the initial therapeutic intervention in most children with JIA. NSAIDs provide both analgesia and an antiinflammatory effect. The average time-course for response to NSAIDs is 4 to 12 weeks (168). Thus, an NSAID is usually given for 4 to 8 weeks before substituting another, if there has not been sufficient improvement. NSAIDs are

TABLE 12-7. NSAIDS FOR THE TREATMENT OF JIA

Drug (brand)	Dosage (usual number of daily doses)
Choline magnesium trisalicylate ^{a,c} (Trilisate)	50 mg/kg/day (2)
Salicylsalicylic acid ^{a,b} (Disalcid)	50–100 mg/kg/day (2)
Ibuprofen ^{a,c} (Motrin, Advil, etc.)	40 mg/kg/day (4)
Naproxen ^{a,c} (Naprosyn)	10–20 mg/kg/day (2)
Tolmetin ^a (Tolectin)	15–30 mg/kg/day (3)
Indomethacin ^{a,c} (Indocin)	1–3 mg/kg/day (3)
Diclofenac (Voltaren)	2–3 mg/kg/day (2)
Nabumetone (Relafen)	20–25 mg/kg/day (1–2)

^a FDA-labeled for use in children.^b No inhibition of platelet aggregation.^c Liquid preparation available.

generally safe and well tolerated in most children. Abdominal pain, nausea, and vomiting are common side effects, but gastrointestinal hemorrhage is rare (169). However, gastroduodenal injury is more frequent in children receiving high doses, or more than one NSAID (170). The use of aspirin for JIA is no longer recommended due to the risk of Reye syndrome, increased hepatotoxicity, bleeding, and four-times-per-day dosing.

The doses of NSAIDs in children are based on body weight, and are proportionally greater than in adult rheumatic diseases (Table 12-7). Preparations that come in a liquid form and have once to twice-daily dosing are preferred. In the United States, the most commonly used NSAID for JIA is naproxen (10 to 20 mg/kg/day, b.i.d.). In children with fevers and serositis associated with systemic arthritis and with JAS, indomethacin is often the most effective NSAID (67). Children on chronic NSAID therapy should have a complete blood count, renal and liver function tests, and urine analysis every 6 months.

Nearly two-thirds of children with juvenile arthritis are inadequately treated with NSAIDs alone (171). These children require additional pharmacologic interventions.

Corticosteroids

Intraarticular corticosteroid injections had been shown to be safe and effective in controlling the synovitis in JIA (172,173). Triamcinolone hexacetonide (1 mg/kg for large joints and 0.5 mg/kg for medium joints) is the most commonly used agent, and often provides long-term control of inflammation. The most frequent adverse consequence of intraarticular corticosteroids is development of subcutaneous atrophy at the site of injection. Systemic corticosteroids can be used for rapid control of severe arthritis. However, long-term use should be restricted to those children with severe arthritis or systemic features that do not respond to other interventions.

Methotrexate

Methotrexate is the most commonly used second-line agent for treatment of juvenile arthritis. It is typically given at 0.5 to 1 mg/kg (with a maximum of 20 to 30 mg) once weekly by mouth or subcutaneous injection. It has been shown to be superior to placebo in polyarticular and extended oligoarticular, but not systemic arthritis (174,175), and can produce radiologic improvement of erosions (176). Methotrexate has been shown to decrease the severity of uveitis in children with JIA who were dependent on topical corticosteroids (177).

The major side effects with methotrexate use are nausea, diarrhea, and oral ulcers. Supplementation with folic acid (1 mg/day) can usually prevent gastrointestinal complications. One of the most significant long-term side effects of methotrexate use is the development of liver fibrosis and cirrhosis (178–180). Serial abnormalities of hepatic enzymes were significantly associated with liver fibrosis in children taking methotrexate for juvenile arthritis (181), suggesting that the current guidelines for patients with rheumatoid arthritis are applicable to patients with JIA (182).

Sulfasalazine

Sulfasalazine has been used extensively in Europe, and increasingly in North America, for treatment of both spondyloarthropathies and JRA/JCA (183,184). It is typically given in the enteric-coated form, at a dose of 50 mg/kg/day in two divided doses. Recently, a randomized, double-blind, placebo-controlled trial showed that sulfasalazine is both safe and effective for the treatment of oligo- and polyarticular JCA (185). Serious side effects have been noted in children with systemic arthritis, and the routine use of sulfasalazine is not recommended for this subgroup (186,187).

Physical and Occupational Therapy

All children with prolonged arthritis should be evaluated by a physical and/or occupational therapist to provide an appropriate teaching and treatment program. Most treatment programs for JIA will include active and passive range of motion exercises, strengthening, and other modalities, such as a hot paraffin bath for relief of hand stiffness. Swimming has the advantage of providing muscle-strengthening and active range of motion without significant weight-bearing. Splinting may be used to maintain alignment, provide rest, and reduce flexion contractures. For children with severe flexion contractures, a dynamic tension splint or serial casting can be used to correct the contracture. Physical therapy for range of motion in JAS is primarily to prevent loss of mobility and poor functional positioning.

Surgical Interventions for Complications of JIA

For the majority of children with JIA, orthopaedic surgery has a limited role in the management plan. With early detec-

tion and aggressive medical management, including intra-articular corticosteroid injections, the majority of children with juvenile arthritis have a satisfactory outcome without significant disability. However, for those children with persistent arthritis, treated or untreated, continued presence of pain, joint contractures, and mechanical instability, there is often significant benefit from individualized orthopaedic surgical intervention. Many of the reports of surgery for juvenile arthritis actually refer to adults who have had arthritis since childhood. Surgical intervention in JIA presents several problems to the management team. The small size and growth potential of children must be considered. Also, in the postsurgical period, prolonged immobilization can lead to decreased strength and range of motion, with or without active arthritis. Often after a surgical procedure there will be intensive physical therapy required to mobilize the child's joints. There is no universal agreement about which procedures are indicated for the treatment of complications of chronic arthritis in childhood. However, the overall goal is to provide symptomatic relief and increased function.

Synovectomy

Synovectomy may be indicated in a minority of children with JIA for relief of pain, swelling, and impaired joint motion related to synovial hypertrophy. There may be short-term benefit in joint-swelling and pain, but range of motion may not improve, or may even worsen (188–192). The greatest benefit has been seen in large joints (193,194). But recurrences are common, and the ultimate outcome of children with JIA is not altered by prophylactic synovectomy (195,196).

Soft Tissue Release

Soft tissue release may rarely be useful in a child with a severe contracture of the knee or hip that has been resistant to splinting or serial casting. Initial observations regarding soft tissue release were encouraging (197). However, more recent reports have been less striking, with only a modest benefit and a tendency to deteriorate (198,199). In most cases, vigorous physical therapy will avoid the need for this frequently unsuccessful operation.

Arthrodesis

Arthrodesis is indicated for treatment of severe joint destruction of the ankle after prolonged synovitis in oligo- or poly-articular JIA. After puberty, a fixed and painful deformity of the ankle is best corrected by performing a triple arthrodesis. Occasionally, in children with isolated damage of the subtalar or talonavicular joint, a single joint fusion may be appropriate (200) [➔7.10, 7.11]. If required, these procedures may be later converted to a triple arthrodesis [➔7.9].

Although many children with JIA have cervical spine

arthritis and atlantoaxial instability, there is no consensus on the indications for prophylactic fusion. In many cases a simple cervical orthosis may stabilize the neck and prevent further subluxation. However, fusion of the cervical spine (C1–C2) is indicated in children who have progressive neurologic involvement (201,202) [➔2.17].

Osteotomy

Osteotomy has only occasional utility in children with arthritis. In a younger child with a fixed deformity of the knee but good remaining joint surface and minimal active synovitis, a knee osteotomy may result in correction of the deformity (203). Unfortunately, the osteotomy makes a subsequent total knee arthroplasty more difficult due to the distorted anatomy.

Infrequently, a shortening osteotomy of the radius or lengthening of the ulna may be utilized to correct length discrepancies of the forearm bones. Recently, distraction lengthening of the ulna in six children (eight wrists), with severe destructive changes in the wrist due to JCA, was reported (204). This procedure was found to adequately correct the deformity with improved function, and in the majority no further splinting was required with an average follow-up of 70 months (range 12 to 152).

Epiphysiodesis

An appropriately timed epiphysiodesis has been successfully used to correct leg-length discrepancies in oligoarticular arthritis (205,206). The discrepancy can be predicted using the method of Moseley (207). Simon et al. (206) reported that 15 patients followed to skeletal maturity had satisfactory results.

Total Joint Arthroplasty

Total joint arthroplasty is indicated for children with JIA who have severe destructive joint changes with functional impairment or disabling pain. The most common joints replaced are the hip and knee, but there may be indications for shoulder and elbow arthroplasty.

Total hip replacement is typically performed due to severe destruction or ankylosis, resulting in functional impairment. Initial series using predominantly cemented hip replacements showed reduction in pain and improved functional ability, but with a significant rate of loosening and subsequent revision (208,209). Recent results have suggested an improved outcome with cementless arthroplasty of the hip, but poor bone stock remains an indication for cementing (210,211).

The knee is frequently involved in JIA, and when there is significant pain, deformity, and functional incapacity, a total knee replacement is indicated. Initial results of total knee arthroplasty in JIA have been encouraging, with few

revisions required (212–214). Recent long-term follow-up of total knee arthroplasty in young adults and children with arthritis has been equally encouraging (215). Cementless total knee arthroplasty has been used in selected cases (216).

Total elbow replacement may be indicated in children with severe destruction of the elbow joint. In a recent review, Connor and Morrey (217) evaluated the long-term outcome of 19 children (23 elbows), who had been managed with total elbow arthroplasty and followed for at least 2 years. Only three (13%) had a poor result due to late complications: aseptic loosening, instability, and worn bushings.

Shoulder replacement in juvenile arthritis is indicated when there is prolonged pain, limitation of function, and significant joint destruction. There are not sufficient data to evaluate the efficacy of total shoulder arthroplasty in children. However, in studies of adults with rheumatoid arthritis, and in some including children, the results have been promising (218,219).

References

Overview of Pediatric Rheumatic Disease Encountered by the Pediatric Orthopaedic Surgeon

1. Kunnamo I, Kallio P, Pelkonen P. Incidence of arthritis in urban Finnish children: a prospective study. *Arthritis Rheum* 1986;29:2132.
2. Goodman JE, McGraft PJ. The epidemiology of pain in children and adolescents: a review. *Pain* 1991;46:247.
3. McGrath PJ, McAlpine L. Psychologic perspectives on pediatric pain. *J Pediatr* 1993;122:S2.
4. Kaipiainen-Seppanen O, Savolainen A. Incidence of chronic juvenile rheumatic diseases in Finland during 1980–1990. *Clin Exp Rheumatol* 1996;14:441.
5. Peterson LS, Mason T, Nelson AMO, et al. Juvenile rheumatoid arthritis in Rochester, Minnesota 1960–1993. Is the epidemiology changing? *Arthritis Rheum* 1996;39:1385.

Classification and Diagnosis of Juvenile Idiopathic Arthritis

6. European League Against Rheumatism (EULAR). Bulletin 4. Nomenclature and classification of arthritis in children. Basel: National Zeitung AG, 1977.
7. Cassidy JT, Levinson JE, Bass JC, et al. A study of classification criteria for a diagnosis of juvenile rheumatoid arthritis. *Arthritis Rheum* 1986;29:274.
8. Fink CW. Proposal for the development of classification criteria for idiopathic arthritides of childhood (published erratum appears in *J Rheumatol* 1995;22:2195). *J Rheumatol* 1995;22:1566.
9. Petty RE, Southwood TR, Baum J, et al. Revision of the proposed classification criteria for juvenile idiopathic arthritis: Durban, 1997. *J Rheumatol* 1998;25:1991.

Approach to the Evaluation of Children with Limb Pain, Limp, or Joint Pain with or without Swelling

10. Varni JW, Thompson KL, Hanson V. The Varni/Thompson Pediatric Pain Questionnaire. I. Chronic musculoskeletal pain in juvenile rheumatoid arthritis. *Pain* 1987;28:27.

11. Sherry DD, Bohnsack J, Salmonson K, et al. Painless juvenile rheumatoid arthritis. *J Pediatr* 1989;116:921.
12. Sullivan DB, Cassidy JT, Petty RE. Pathogenic implications of age of onset in juvenile rheumatoid arthritis. *Arthritis Rheum* 1975;18:251.
13. Haynes DC, Gershwin ME, Robbins DL. Autoantibody profiles in juvenile arthritis. *J Rheumatol* 1986;13: 58.
14. Petty RE, Cassidy JT, Sullivan DB. Serologic studies in juvenile rheumatoid arthritis. A review. *Arthritis Rheum* 1977;20(suppl): 260.
15. Rosenberg AM. Uveitis associated with juvenile rheumatoid arthritis. *Semin Arthritis Rheum* 1987;16:158.
16. Cabral DA, Petty RE, Fung M, et al. Persistent antinuclear antibodies in children without identifiable inflammatory, rheumatic or autoimmune disease. *Pediatrics* 1992;89:441.
17. Allen RC, Dewez P, Stuart L. Antinuclear antibodies using HEp-2 cells in normal children and in children with common infections. *J Paediatr Child Health* 1991;27:39.
18. Deane PMG, Liard G, Siegel DM, et al. The outcome of children referred to a pediatric rheumatology clinic with a positive antinuclear antibody test but without an autoimmune disease. *Pediatrics* 1995;95:892.
19. Stillman JS, Barry PE. Juvenile rheumatoid arthritis: series 2. *Arthritis Rheum* 1977;20(suppl):171.
20. Schaller JG. Juvenile rheumatoid arthritis: series 1. *Arthritis Rheum* 1977;20(suppl):165.
21. Eichenfield AH, Athreya BH, Boughty RA. Utility of rheumatoid factor in the diagnosis of juvenile rheumatoid arthritis. *Pediatrics* 1986;78:480.
22. Shmerling RH, Delbanco TL. How useful is the rheumatoid factor? *Arch Intern Med* 1992;152:2417.
23. Petty R. HLA-B27 and rheumatic diseases of childhood. *J Rheumatol* 1990;17:7.
24. Howell RR. Juvenile gouty arthritis. *Am J Dis Child* 1985;139: 547.
25. Cassidy JT, Brody GL, Martel W. Monarticular juvenile rheumatoid arthritis. *J Pediatr* 1967;70:867.
26. Baldassare AR, Chang F, Zuckner J. Markedly raised synovial fluid leukocyte counts not associated with infectious arthritis in children. *Ann Rheum Dis* 1978;37:404.
27. Zuckner J, Baldassare A, Chang F, et al. High synovial fluid leukocyte counts of noninfectious etiology. *Arthritis Rheum* 1977;20(suppl):270.
28. Senac MO, Deutsch D, Bernstein BH. MR imaging in juvenile rheumatoid arthritis. *AJR Am J Roentgenol* 1988;150:873.
29. Verbruggen LA, Shahabpour M, Van Roy P, et al. Magnetic resonance imaging of articular destruction in juvenile rheumatoid arthritis. *Arthritis Rheum* 1990;33:1426.
30. Yulish BD, Lieberman JM, Newman AJ. Juvenile rheumatoid arthritis: assessment with MR imaging. *Radiology* 1987;165: 149.

Differential Diagnosis of Joint Pain and Swelling in Children

31. Klippel JH, Weyand CM, Wortmann RL. *Primer on the rheumatic diseases*. 11th ed. Atlanta: Arthritis Foundation, 1997:1.
32. Steere AC, Bartenhagen NH, Craft JE. The early clinical manifestations of Lyme disease. *Ann Intern Med* 1983;99:76.
33. Steere AC, Schoen RT, Taylor E. The clinical evolution of Lyme arthritis. *Ann Intern Med* 1987;107:725.
34. Gerber MA, Zemel LS, Shapiro ED. Lyme arthritis in children: clinical epidemiology and long-term outcomes. *Pediatrics* 1998; 102:905.
35. Huppertz HI, Karch H, Suschke HJ, et al. Lyme arthritis in

- European children and adolescents. *Arthritis Rheum* 1995;38:361.
36. Steere AC, Dwyer E, Winchester R. Association of chronic Lyme arthritis with HLA-DR4 and HLA-DR2 alleles. *N Engl J Med* 1990;323:219.
 37. Cuttita JJ, Schenines EJ, Garay SM, et al. Juvenile onset Reiter's syndrome: a retrospective study of 26 patients. *Clin Exp Rheumatol* 1992;10:285.
 38. Smith RJ. Evidence for *Chlamydia trachomatis* and *Ureaplasma urealyticum* in a patient with Reiter's disease. *J Adolesc Health Care* 1989;10:155.
 39. Rosenberg AM, Petty RE. Reiter's disease in children. *Am J Dis Child* 1979;133:394.
 40. Wright V. Reiter's disease. In: Scott JT, ed. *Copeman's textbook of the rheumatic diseases*. London: Longmans Green, 1978:549.
 41. Keat A, Maini RN, Nkwazi GC. Role of *Chlamydia trachomatis* and HLA B27 in sexually acquired reactive arthritis. *Br Med J* 1978;1:605.
 42. Keat AC, Maini RN, Pegrum GD, et al. The clinical features and HLA associations of reactive arthritis associated with non-gonococcal urethritis. *Q J Med* 1979;190:323.
 43. Harrersen D, Weiner D, Weiner S. The characterization of "transient synovitis of the hip" in children. *J Pediatr Orthop* 1986;6:11.
 44. Koop S, Quanbeck D. Three common causes of childhood hip pain. *Pediatr Clin North Am* 1996;43:1053.
 45. Wingstrand H. Transient synovitis of the hip in the child. *Acta Orthop Scand* 1986;57(suppl):219.
 46. Veasy LG, Wiedmeier SE, Orsmond GS. Resurgence of acute rheumatic fever in the intermountain area of the United States. *N Engl J Med* 1987;316:280.
 47. McLaren MJ, Hawkins DM, Koorhop HJ. Epidemiology of rheumatic heart disease in black school children of Soweto, Johannesburg. *Br Med J* 1975;3:474.
 48. Veasy LG, Tani LY, Hill HR. Persistence of acute rheumatic fever in the intermountain area of the United States. *J E Pediatr* 1994;124:9.
 49. Dajani AS, Ayoub E, Bierman FZ. Guidelines for the diagnosis of rheumatic fever. Jones criteria, 1992 update. *JAMA* 1992;268:2069.
 50. Schaffer FM, Agarwal R, Helm J, et al. Post-streptococcal-reactive arthritis and silent carditis: a case report and review of the literature. *Pediatrics* 1994;93:837.
 51. Arnold MH, Tyndall A. Post-streptococcal-reactive arthritis. *Ann Rheum Dis* 1989;48:681.
 52. De Cunto CL, et al. Prognosis of children with poststreptococcal reactive arthritis. *Pediatr Infect Dis J* 1988;7:683.
 53. Bont L, Brus F, Dijkman-Neerincx RHM, et al. The clinical spectrum of post-streptococcal syndromes with arthritis in children. *Clin Exp Rheumatol* 1998;16:750.
 54. Fink CW. The role of the *Streptococcus* in post-streptococcal reactive arthritis and childhood polyarteritis nodosa. *J Rheumatol* 1991;18(suppl.29):14.
 55. Ahmed S, et al. Poststreptococcal reactive arthritis: clinical characteristics and association with HLA-DR alleles. *Arthritis Rheumatol* 1998;41:1096.
 56. Beilory L, et al. Human serum sickness: a prospective analysis of 35 patients treated with equine anti-thymocyte globulin for bone marrow failure. *Medicine* 1988;67:40.
 57. Weston WL, Brice SL, Jester JD, et al. Herpes simplex virus in childhood erythema multiforme. *Pediatrics* 1992;89:32.
 58. Fiffmeyer JE. Serum sickness. *Ann Allergy* 1986;56:105.
 59. Schidlow DV, Goldsmith DP, Palmer J, et al. Arthritis in cystic fibrosis. *Arch Dis Child* 1984;59:377.
 60. Summers GD, Webley M. Episodic arthritis in cystic fibrosis: a case report. *Br J Rheumatol* 1986;31:535.
 61. Pertuiset E, Menkes CJ, Lenoir G. Cystic fibrosis arthritis. A report of five cases. *Br J Rheumatol* 1992;28:341.
 62. Newman AJ, Ansell BM. Episodic arthritis in children with cystic fibrosis. *J Pediatr* 1979;94: 594.
 63. Dixey J, Redington AN, Butler RC. The arthropathy of cystic fibrosis. *Ann Rheum Dis* 1988;47:218.
 64. Sagransky DM, Greenwald RA. Seropositive rheumatoid arthritis in a patient with cystic fibrosis. *Am J Dis Child* 1980;129:634.
 65. Nathanson I, Riddlesberger MMJ. Pulmonary hypertrophic osteoarthropathy in cystic fibrosis. *Radiology* 1980;135:649.
 66. Athreya BH, Borns P, Roselund ML. Cystic fibrosis and hypertrophic osteoarthropathy in children. *Am J Dis Child* 1973;129:634.
 67. Cassidy JT, Petty RE. *Textbook of pediatric rheumatology*. 3rd ed. Philadelphia: WB Saunders, 1995.
 68. Isenberg DA, Miller JJ, eds. *Adolescent rheumatology*. London: Martin Dunitz, 1999.
 69. Ragsdale CG, Petty RE, Cassidy JT. The clinical progression of apparent juvenile rheumatoid arthritis to systemic lupus erythematosus. *J Rheumatol* 1980;17:777.
 70. Patrishall EN, Strobe GL, Spinola AM. Childhood sarcoidosis. *J Pediatr* 1986;108:169.
 71. Steward M, Savage JM, Bell B. Long term renal prognosis of Henoch-Schonlein purpura in an unselected childhood population. *Eur J Pediatr* 1988;147:113.
 72. Barton LL, Saied KR. Thorn-induced arthritis. *J Pediatr* 1978;93:322.
 73. Costello PB, Brecker ML, Starr JL. A prospective analysis of the frequency, course, and possible prognostic significance of the joint manifestations of childhood leukemia. *J Rheumatol* 1983;10:753.
 74. Saulsbury FT, Sabio G. Acute leukemia presenting as arthritis in children. *Clin Pediatr* 1985;24:625.
 75. Cabral DA, Tucker LB. Malignancies in children who initially present with rheumatic complaints. *J Pediatr* 1999;134:53.
 76. Flandry F, Hughston JC. Pigmented villonodular synovitis. *J Bone Joint Surg Am* 1987;69:942.
 77. Walls JP, Nogi J. Multifocal pigmented villonodular synovitis in a child. *J Pediatr Orthop* 1985;5:229.
 78. Peterson H. Growing pains. *Pediatr Clin North Am* 1986;33:1356.
 79. Gedalia A, Person DA, Brewer EJ. Hypermobility of the joints in juvenile episodic arthritis/arthritis. *J Pediatr* 1985;107:873.
 80. Carter C, Wilkinson J. Persistent joint laxity and congenital dislocation of the hip. *J Bone Joint Surg Br* 1964;46:40.
 81. Sherry DD. Pain syndromes. In: Isenberg DA, Miller JJ, eds. *Adolescent rheumatology*. London: Martin Dunitz, 1999:197.
 82. Yunus MB, Masi AT. Juvenile primary fibromyalgia syndrome. A clinical study of thirty-three patients and matched normal controls. *Arthritis Rheumatol* 1985;28:138.
 83. Sherry DD, Weisman R. Psychologic aspects of childhood reflex neurovascular dystrophy. *Pediatrics* 1988;81:572.
 84. Sherry DD, McGuire T, Mellins E, et al. Psychosomatic musculoskeletal pain in childhood: clinical and psychological analyses of 100 children. *Pediatrics* 1991;88:1093.
 85. Sherry DD. Musculoskeletal pain in children. *Curr Op Rheumatol* 1997;9:465.
 86. Bernstein BH, Singsen BH, Kent JT, et al. Reflex neurovascular dystrophy in childhood. *J Pediatr* 1978;93:211.
 87. Malleson PN, Al-Matar M, Petty RE. Idiopathic musculoskeletal pain syndromes in children. *J Rheumatol* 1992;19:1786.
 88. Yunus MB, Masi AT. Juvenile primary fibromyalgia syndrome. A clinical study of thirty-three patients and matched normal controls. *Arthritis Rheum* 1985;28:138.
 89. Wolfe F, Smythe HA, Yunus MB, et al. The American College

- of Rheumatology 1990 Criteria for the Classification of Fibromyalgia. Report of the Multicenter Criteria Committee. *Arthritis Rheum* 1990;33:160.
90. Bernstein BH, Singen BH, Kent JT, et al. Reflex neurovascular dystrophy in childhood. *J Pediatr* 1978;93:211.
 91. Wilder RT, Berde CB, Wolohan M, et al. Reflex sympathetic dystrophy in children. Clinical characteristics and follow-up of seventy patients. *J Bone Joint Surg Am* 1992;74:910.
 92. Silber TJ, Majd M. Reflex sympathetic dystrophy syndrome in children and adolescents. Report of 18 cases and review of the literature. *Am J Dis Child* 1988;142:1325.
 93. Bowyer S, Roettcher P. Pediatric rheumatology clinic populations in the United States: results of a 3 year survey. Pediatric Rheumatology Database Research Group. *J Rheumatol* 1996;23:1968.
- ### Juvenile Idiopathic Arthritis
94. Symmons DP, Jones M, Osborne J, et al. Pediatric rheumatology in the United Kingdom: data from the British Pediatric Rheumatology Group National Diagnostic Register. *J Rheumatol* 1996;23:1975.
 95. Towner SR, Michet CJJ, O'Fallen WM, et al. The epidemiology of juvenile arthritis in Rochester, Minnesota. *Arthritis Rheum* 1983;26:1208.
 96. Singen BH. Rheumatic diseases of childhood. *Rheum Dis Clin North Am* 1990;16:581.
 97. Cabral DA, Malleson PN, Petty RE. Spondyloarthropathies of childhood. *Pediatr Clin North Am* 1995;42:1051.
 98. Malleson PN, Fung MY, Rosenberg AM, et al. The incidence of paediatric rheumatic diseases: results from the Canadian Paediatric Rheumatology Association Disease Registry. *J Rheumatol* 1996;23:1981.
 99. Burgos-Vargas R, Lardizabal-Sanabria J, Katona G. Ankylosing spondylitis and related diseases in the Mexican Mestizo. *Spine* 1990;4:665.
 100. Gofen JP, Chalmers A, Price GE, et al. HLA-B27 and ankylosing spondylitis in BC Indians. *J Rheumatol* 1975;2:328.
 101. De Inocencio J, Giannini EH, Glass DN. Can genetic markers contribute to the classification of juvenile rheumatoid arthritis? *J Rheumatol* 1993;40(suppl):12.
 102. Malagon C, Van Kerckhove C, Giannini EH. The iridocyclitis of early onset pauciarticular juvenile rheumatoid arthritis: outcome in immunogenetically characterized patients. *J Rheumatol* 1992;19:160.
 103. Ploski R, Vinje O, Ronningen KS, et al. HLA class II alleles and heterogeneity of juvenile rheumatoid arthritis. *Arthritis Rheum* 1993;36:465.
 104. Rubin LA, Amos CI, Wade JA, et al. Investigating the genetic basis for ankylosing spondylitis. Linkage studies with the major histocompatibility complex region. *Arthritis Rheum* 1994;37:1212.
 105. Burgos-Vargas R, Pacheco-Tena C, Vazquez-Mellado J. Juvenile-onset spondyloarthropathies. *Rheum Dis Clin North Am* 1997;23:569.
 106. Hammer RE, Maika SD, Richardson JA, et al. Spontaneous inflammatory disease in transgenic rats expressing HLA-B27 and human β_2m : an animal model of HLA-B27-associated human disorders. *Cell* 1990;63:1099.
 107. McDowell TL, Symons JA, Ploski R, et al. A genetic association between juvenile rheumatoid arthritis and a novel interleukin-1 alpha polymorphism. *Arthritis Rheum* 1995;38:221.
 108. Martin K, Woo P. Juvenile idiopathic arthritides. In: Isenberg DA, Miller JJ, eds. *Adolescent rheumatology*. London: Martin Dunitz, 1999:78.
 109. Kunnamo I. Infections and related risk factors of arthritis in children. *Scand J Rheumatol* 1987;16:93.
 110. Pugh MT, Southwood TR, Gaston JS. The role of infection in juvenile chronic arthritis. *Br J Rheumatol* 1993;32:838.
 111. Sieper J, Braun J. Pathogenesis of spondylarthropathies. *Arthritis Rheum* 1995;38:1547.
 112. Hermann E, Yu DTY, Meyer KH, et al. HLA-B27-restricted CD8 T cells derived from synovial fluids of patients with reactive arthritis and ankylosing spondylitis. *Lancet* 1993;342:646.
- ### Clinical Syndromes of JIA
113. Schneider R, Laxer RM. Systemic onset juvenile rheumatoid arthritis. *Baillieres Clin Rheum* 1998;12:245.
 114. Still GF. On a form of chronic joint disease in children. *Am J Dis Child* 1978;132:195.
 115. Calabro JJ, Marchesano JM. Fever associated with juvenile rheumatoid arthritis. *N Engl J Med* 1967;276:11.
 116. Calabro JJ, Marchesano JM. Rash associated with juvenile rheumatoid arthritis. *J Pediatr* 1968;72:611.
 117. Lang B, Shore A. A review of current concepts on the pathogenesis of juvenile rheumatoid arthritis. *J Rheumatol* 1990;17(suppl 21):1.
 118. Vreugdenhil G, Baltus CAM, Van Eijk HG, et al. Anaemia of chronic disease: diagnostic significance of erythrocyte and serological parameters in iron deficient rheumatoid arthritis. *Hum Nutr Clin Nutr* 1990;40C:57.
 119. Prouse PJ, Harvey AR, Bonner B. Anaemia in juvenile chronic arthritis: serum inhibition of normal erythropoiesis in vitro. *Ann Rheum Dis* 1986;36:127.
 120. Koerper MA, Stempel DA, Dallman PR. Anemia in patients with juvenile rheumatoid arthritis. *J Pediatr* 1980;92:930.
 121. Pelkonen P, Swanljung K, Siimes MA. Ferritinemia as an indicator of systemic disease activity in children with systemic juvenile rheumatoid arthritis. *Acta Paediatr Scand* 1986;75:64.
 122. Bloom BJ, Tucker LB, Miller LC, et al. Fibrin D-dimer as a marker of disease activity in systemic onset juvenile rheumatoid arthritis. *J Rheumatol* 1998;25:1620.
 123. Bernstein BH, Stobie D, Singen BH, et al. Growth retardation in juvenile rheumatoid arthritis (JRA). *Arthritis Rheum* 1977;20(suppl):212.
 124. Woo PM. Growth retardation and osteoporosis in juvenile chronic arthritis. *Clin Exp Rheum* 1994;12(suppl 10):S87.
 125. Davies UM, Rooney M, Preece MA, et al. Treatment of growth retardation in juvenile chronic arthritis with recombinant human growth hormone. *J Rheumatol* 1994;21:153.
 126. Davies UM, Jones J, Reeve J, et al. Juvenile rheumatoid arthritis. Effects of disease activity and recombinant human growth hormone on insulin-like growth factor 1, insulin-like growth factor binding proteins 1 and 3, and osteocalcin. *Arthritis Rheum* 1997;40:332.
 127. Schneider R, Lang BA, Reilly BJ. Prognostic indicators of joint destruction in systemic-onset juvenile rheumatoid arthritis. *J Pediatr* 1992;120:200.
 128. David J, Vouyiouka O, Ansell BM, et al. Amyloidosis in juvenile chronic arthritis: a morbidity and mortality study. *Clin Exp Rheum* 1993;11:85.
 129. Prieur AM, Stephan JL. Macrophage activation syndrome in children with joint diseases. *Rev Rheum Engl Ed* 1994;61:385.
 130. Ravelli A, De Benedetti F, Viola S, et al. Macrophage activation syndrome in systemic juvenile rheumatoid arthritis successfully treated with cyclosporine. *J Pediatr* 1996;128:275.
 131. Mouy R, Stephan JL, Pillet P, et al. Efficacy of cyclosporine A in the treatment of macrophage activation syndrome in juvenile arthritis: report of five cases. *J Pediatr* 1996;129:750.
 132. Sailer M, Cabral D, Petty RE, et al. Rheumatoid factor positive,

- oligoarticular onset juvenile rheumatoid arthritis. *J Rheumatol* 1997;24:586.
133. Bunger C, Bulow J, Tondebold E. Microcirculation of the juvenile knee in chronic arthritis. *Clin Orthop* 1986;204:294.
 134. Vostrejs M, Hollister JR. Muscle atrophy and leg length discrepancies in pauciarticular juvenile rheumatoid arthritis. *Am J Dis Child* 1988;142:343.
 135. Kanski JJ. Uveitis in juvenile chronic arthritis. *Eye* 1988;2:641.
 136. Sherry DD, Mellins ED, Wedgewood RJ. Decreasing severity of chronic uveitis in children with pauciarticular arthritis. *Am J Dis Child* 1991;145:1026.
 137. Chalom EC, Goldsmith DP, Koehler MA, et al. Prevalence and outcome of uveitis in a regional cohort of patients with juvenile rheumatoid arthritis. *J Rheumatol* 1997;24:2031.
 138. Nguyen QD, Foster S. Saving the vision of children with juvenile rheumatoid arthritis-associated uveitis. *JAMA* 1998;280:1133.
 139. American Academy of Pediatrics Section on Rheumatology and Section on Ophthalmology. Guidelines for ophthalmologic examinations in children with juvenile rheumatoid arthritis. *Pediatrics* 1993;92:295.
 140. Olshaker JS, Jerrard DA. The erythrocyte sedimentation rate. *J Emerg Med* 1997;15:869.
 141. Blane CE, Ragsdale CG, Hensinger RN. Late effects of JRA on the hip. *J Pediatr Orthop* 1987;7:677.
 142. Olson L, Echerdal O, Hallonsten AL. Craniomandibular function in juvenile chronic arthritis. A clinical and radiographic study. *Swed Dent J* 1991;15:71.
 143. Shore A, Ansell BM. Juvenile psoriatic arthritis—an analysis of 60 cases. *J Pediatr* 1982;100:529.
 144. Southwood TR, Petty RE, Malleson PN, et al. Psoriatic arthritis in children. *Arthritis Rheum* 1989;32:1007.
 145. Robertson DM, Cabral DA, Malleson PN, et al. Juvenile psoriatic arthritis: followup and evaluation of diagnostic criteria. *J Rheumatol* 1996;23:166.
 146. Wesolowska H. Clinical course of psoriatic arthropathy in children. *Mater Med Pol* 1985;55:185.
 147. Rosenberg AM, Petty RE. A syndrome of seronegative enthesopathy and arthropathy in children. *Arthritis Rheum* 1982;25:1041.
 148. Cabral DA, **Oen KG, Petty RE**. SEA syndrome revisited: a longterm followup of children with a syndrome of seronegative enthesopathy and arthropathy. *J Rheumatol* 1992;19:1282.
 149. Gerster JC, Piccinin P. Enthesopathy of the heels in juvenile onset seronegative B-27 positive spondyloarthropathy. *J Rheumatol* 1984;12:310.
 150. Ansell BM. Ankylosing spondylitis. In: Moll JMH, ed. *Juvenile spondylitis and related disorders*. Edinburgh: Churchill Livingstone, 1980:120.
 151. Derhaag PJFM, Feltkamp TEW. Acute anterior uveitis and HLA-B27. *Inter Ophth* 1990;14:19.
 152. Rosenbaum JT. Acute anterior uveitis and spondyloarthropathies. *Rheum Dis Clin North Am* 1992;18:143.
 153. Power WJ, Rodriguez A, Pedroza-Seres M, et al. Outcomes in anterior uveitis associated with the HLA-B27 haplotype. *Ophthalmology* 1998;105:1646.
 154. Burgos-Vargas R, Vazquez-Mellado J. The early clinical recognition of juvenile-onset ankylosing spondylitis and its differentiation from juvenile rheumatoid arthritis. *Arthritis Rheum* 1995;38:835.
 155. Burgos-Vargas R, Petty RE. Juvenile ankylosing spondylitis. *Rheum Dis Clin North Am* 1992;18:123.
 156. Macrae IF, Wright V. Measurement of back movement. *Ann Rheum Dis* 1969;28:584.
 157. Burgos-Vargas R. Spondyloarthropathies and psoriatic arthritis in children. *Curr Opin Rheum* 1993;5:634.
 158. Garcia-Morteo O, Maldonado-Cocco JA, Suarez-Almazor ME, et al. Ankylosing spondylitis of juvenile onset: comparison with adult onset disease. *Scand J Rheumatol* 1983;12:246.
 159. Calin A, Elswood J. The natural history of juvenile-onset ankylosing spondylitis: a 24-year retrospective case-control study. *Br J Rheumatol* 1988;27:91.
 160. Marks SH, Barnett M, Calin A. A case-control study of juvenile- and adult-onset ankylosing spondylitis. *J Rheumatol* 1982;9:739.
 161. Farmer RG, Michener WM. Prognosis of Crohn's disease with onset in childhood and adolescence. *Dig Dis Sci* 1979;24:752.
 162. Lindsley C, Schaller J. Arthritis associated with inflammatory bowel disease in children. *J Pediatr* 1974;84:16.
 163. Hamilton JR, Bruce MD, Abdourhamam M. Inflammatory bowel disease in children and adolescents. *Adv Pediatr* 1979;26:311.

Radiologic Findings in JIA

164. Vogel LC, Lubicky JP. Cervical spine fusion: not protective of cervical spine injury and tetraplegia. *Am J Orthop* 1997;26:636.
165. Ladd JR, Cassidy JT, Martel W. Juvenile ankylosing spondylitis. *Arthritis Rheum* 1971;14:579.

Treatment of JIA

166. Vane JR. Inhibition of prostaglandin synthesis as a mechanism of action for aspirin-like drugs. *Nat New Biol* 1971;231:232.
167. Vane J. Towards a better aspirin. *Nature* 1994;367:215.
168. Lovell D, Giannini E, Brewer E. Time course of response to nonsteroidal anti-inflammatory drugs in patients with juvenile rheumatoid arthritis. *Arthritis Rheum* 1984;27:1433.
169. Lindsley C. Uses of nonsteroidal anti-inflammatory drugs in pediatrics. *Am J Dis Child* 1993;147:229.
170. Mulberg AE, Linz C, Bern E, et al. Identification of nonsteroidal antiinflammatory drug-induced gastroduodenal injury in children with juvenile rheumatoid arthritis. *J Pediatr* 1993;122:647.
171. Giannini EH, Cawkwell GD. Drug treatment in children with juvenile rheumatoid arthritis. Past, present, and future. *Pediatr Clin North Am* 1995;42:1099.
172. Huppertz HI, Tschammler A, Horwitz AE, et al. Intraarticular corticosteroids for chronic arthritis in children: efficacy and effects on cartilage and growth. *J Pediatr* 1995;127:317.
173. Padeh S, Passwell JH. Intraarticular corticosteroid injection in the management of children with chronic arthritis. *Arthritis Rheum* 1998;41:1210.
174. Giannini EH, Brewer EJ, Kuzmina N, et al. Methotrexate in resistant juvenile rheumatoid arthritis. Results of the U.S.A.-U.S.S.R. double-blind, placebo-controlled trial. *N Engl J Med* 1992;326:1043.
175. Woo P, Wilkes H, Southwood T, et al. Low dose methotrexate is effective in extended oligoarticular arthritis but not in systemic arthritis of children. *Arthritis Rheum* 1997;40:S47.
176. Ravelli A, Viola S, Ramenghi B, et al. Radiologic progression in patients with juvenile chronic arthritis treated with methotrexate. *J Pediatr* 1998;133:262.
177. Weiss AH, Wallace CA, Sherry DD. Methotrexate for resistant chronic uveitis in children with juvenile rheumatoid arthritis. *J Pediatr* 1998;133:266.
178. Wallace CA, Sherry DD. A practical approach to avoidance of methotrexate toxicity. *J Rheumatol* 1995;22:1009.
179. Hashkes PJ, Balistreri WF, Bove KE, et al. The long-term effect of methotrexate therapy on the liver in patients with juvenile rheumatoid arthritis. *Arthritis Rheum* 1997;40:2226.
180. Kugathasan S, Newman AJ, Dahms BB, et al. Liver biopsy

- findings in patients with juvenile rheumatoid arthritis receiving long-term, weekly methotrexate therapy. *J Pediatr* 1996;128:149.
181. Hashkes PJ, Balistreri WF, Bove KE, et al. The relationship of hepatotoxic risk factors and liver histology in methotrexate therapy for juvenile rheumatoid arthritis. *J Pediatr* 1999;131:47.
 182. Kremer JM, Alarcon GS, Lightfoot RW, et al. Methotrexate for rheumatoid arthritis. Suggested guidelines for monitoring liver toxicity. *Arthritis Rheum* 1994;37:316.
 183. Huang JL, Chen LC. Sulphasalazine in the treatment of children with chronic arthritis. *Clin Rheumatol* 1998;17:359.
 184. Imundo LF, Jacobs JC. Sulfasalazine therapy for juvenile rheumatoid arthritis. *J Rheum* 1996;23:360.
 185. van Rossum MA, et al. Sulfasalazine in the treatment of juvenile chronic arthritis: a randomized, double-blind, placebo-controlled, multicenter study. Dutch Juvenile Chronic Arthritis Study Group. *Arthritis Rheum* 1998;41:808.
 186. Ansell BM, Hall MA, Loftus JK, et al. A multicenter pilot study of sulphasalazine in juvenile chronic arthritis. *Clin Exp Rheumatol* 1991;9:201.
 187. Hertzberger-ten Cate R, Cats A. Toxicity of sulfasalazine in systemic juvenile chronic arthritis. *Clin Exp Rheumatol* 1991;9:85.
 188. Eyring EJ, Longert A, Bass J. Synovectomy in juvenile rheumatoid arthritis. *J Bone Joint Surg Am* 1971;53:638.
 189. Granberry WM, Brewer EJJ. Results of synovectomy in children with rheumatoid arthritis. *Clin Orthop* 1974;101:120.
 190. Larsen EH, Reiman I, Revig O. Synovectomy in infantile arthritis. Proceedings of the British Orthopaedic Association. *J Bone Joint Surg Br* 1968;50:221.
 191. McMaster M. Synovectomy of the knee in juvenile rheumatoid arthritis. *J Bone Joint Surg Br* 1972;54:263.
 192. Mogensen B, Brattstrom H, Ekelund L, et al. Synovectomy of the hip in juvenile chronic arthritis. *J Bone Joint Surg Br* 1982;64:295.
 193. Rydholm U, Elborgh R, Ranstam J, et al. Synovectomy of the knee in juvenile chronic arthritis. A retrospective consecutive follow-up study. *J Bone Joint Surg Br* 1986;68:223.
 194. Kampner S, Ferguson AB. Efficacy of synovectomy in juvenile rheumatoid arthritis. *Clin Orthop* 1972;88:94.
 195. Jacobsen ST, Levinson JE, Crawford AH. Late results of synovectomy in juvenile rheumatoid arthritis. *J Bone Joint Surg Am* 1985;67:8.
 196. Kvien TK, Pahle JA, Hoyeraal HM. Comparison of synovectomy and no synovectomy in patients with juvenile rheumatoid arthritis. A 24-month controlled study. *Scand J Rheumatol* 1987;16:81.
 197. Ansell BM. The management of chronic arthritis of children. *J Bone Joint Surg Br* 1983;65:536.
 198. Rydholm U, Brattstrom H, Lidgren L. Soft tissue release for knee flexion contracture in juvenile chronic arthritis. *J Pediatr Orthop* 1986;6:448.
 199. Swann M, Ansell BM. Soft-tissue release of the hips in children with juvenile chronic arthritis. *J Bone Joint Surg Br* 1986;68:404.
 200. Sammarco GJ, Tablante EB. Subtalar arthrodesis. *Clin Orthop Rel Res* 1998;349:73.
 201. Hensinger RN, Devito PD, Ragsdale CG. Changes in the cervical spine in juvenile rheumatoid arthritis. *J Bone Joint Surg Am* 1986;68:189.
 202. Fried JA, Athreya B, Gregg JR. The cervical spine in juvenile rheumatoid arthritis. *Clin Orthop* 1983;179:102.
 203. Swann M. Juvenile chronic arthritis. *Clin Orthop* 1987;219:38.
 204. Mink van der Molen AB, Hall MA, Evans DM. Ulnar lengthening in juvenile chronic arthritis. *J Hand Surg Br* 1998;23:438.
 205. Rydholm U, Brattstrom H, Bylander B, et al. Stapling of the knee in juvenile chronic arthritis. *J Pediatr Orthop* 1987;7:63.
 206. Simon S, Whiffen J, Shapiro F. Leg-length discrepancies in monoarticular and pauciarticular juvenile rheumatoid arthritis. *J Bone Joint Surg Am* 1981;63:209.
 207. Moseley CF. A straight line graph for leg length discrepancies. *J Bone Joint Surg Am* 1977;59:174.
 208. Chmell MJ, Scott RD, Thomas WH, et al. Total hip arthroplasty with cement for juvenile rheumatoid arthritis. Results at a minimum of ten years in patients less than thirty years old. *J Bone Joint Surg Am* 1997;79:44.
 209. Witt JD, Swann M, Ansell BM. Total hip replacement for juvenile chronic arthritis. *J Bone Joint Surg Br* 1991;73:770.
 210. Kumar MN, Swann M. Uncemented total hip arthroplasty in young patients with juvenile chronic arthritis. *Ann Royal Col Surg Eng* 1998;80:203.
 211. Haber D, Goodman SB. Total hip arthroplasty in juvenile chronic arthritis: a consecutive series. *J Arthroplasty* 1998;13:259.
 212. Carmichael E, Chaplin DM. Total knee arthroplasty in juvenile rheumatoid arthritis. A seven-year follow-up study. *Clin Orthop* 1986;210:192.
 213. Sarokhan AJ, Scott RD, Thomas WH, et al. Total knee arthroplasty in juvenile rheumatoid arthritis. *J Bone Joint Surg Am* 1983;65:1071.
 214. Stuart MJ, Rand JA. Total knee arthroplasty in young adults who have rheumatoid arthritis. *J Bone Joint Surg Am* 1988;70:84.
 215. Dalury DF, Ewald FC, Christie MJ, et al. Total knee arthroplasty in a group of patients less than 45 years of age. *J Arthroplasty* 1995;10:598.
 216. Boublik M, Tsahakis PJ, Scott RD. Cementless total knee arthroplasty in juvenile onset rheumatoid arthritis. *Clin Orthop* 1993;286:88.
 217. Connor PM, Morrey BF. Total elbow arthroplasty in patients who have juvenile rheumatoid arthritis. *J Bone Joint Surg Am* 1998;80:678.
 218. Stewart MPM, Kelly IG. Total shoulder replacement in rheumatoid disease. *J Bone Joint Surg Br* 1997;79:68.
 219. Thomas BJ, Amstutz HC, Cracchiolo A. Shoulder arthroplasty for rheumatoid arthritis. *Clin Orthop* 1990;265:125.



13

BONE AND JOINT SEPSIS

RAYMOND T. MORRISSY

BONE AND JOINT INFECTION 459

Definition 460
Epidemiology 460
Etiology 460
Pathophysiology of Osteomyelitis 461
Pathophysiology of Septic Arthritis 465

DIAGNOSIS 466

History 466
Examination 467
Laboratory 467
Imaging 469
Aspiration 473

DIFFERENTIAL DIAGNOSIS 474

Osteomyelitis 474
Septic Arthritis 475

TREATMENT 476

Organism Identification 476
Select Correct Antibiotic 476

Antibiotic Delivery 478
Route of Administration 478
Penetration 479
Efficacy of Antibiotic 479
Duration of Administration 480
Surgery 480

RESULTS 482

SPECIAL CONDITIONS 482

Spine 482
Pelvis and Sacroiliac Joint 484
The Neonate 486
Sickle Cell Disease 488
Chronic Recurrent Multifocal Osteomyelitis 490
Subacute Osteomyelitis 492
Puncture Wounds of the Foot 494
Gonococcal Arthritis 496
Tuberculosis 497

BONE AND JOINT INFECTION

Bone and joint sepsis is a relatively common disorder in the pediatric population. This makes it likely that all orthopaedic surgeons will be faced with the problems inherent in the diagnosis and treatment of these disorders. If diagnosis

was always easy this would be of little concern, but bone and joint sepsis in childhood is characterized by protean manifestations. The infant may only appear to be septic. The cause of the limp may not be obvious. The bone changes may resemble a tumor. The joint swelling may be due to an acute onset of juvenile rheumatoid arthritis (JRA).

After diagnosis, other problems remain. What antibiotic is correct for use before culture results are known? What should be done if the cultures are negative? What is the best way to administer the antibiotic, and for how long? When is surgery indicated? The diversity of organisms, the variety

of locations where infection is possible, and the numerous conditions associated with bone and joint sepsis increase the difficulty.

Definition

Osteomyelitis is an inflammation of the bone, and arthritis is an inflammation of the joint. Although it is assumed that osteomyelitis and septic arthritis are caused by bacteria, in certain cases the bacteria cannot be isolated, making it necessary to develop criteria that establish the diagnosis in the absence of a bacteria. A useful definition of osteomyelitis is proposed by Peltola and Vahvanen (1). They consider the diagnosis to be firm when two of the following four criteria are present: pus aspirated from bone; positive bone or blood culture; classic symptoms of localized pain, swelling, warmth, and limited range of motion (ROM) of the adjacent joint; and radiographic changes typical of osteomyelitis. Another useful classification is that proposed by Morey and Peterson (2) in which the diagnosis is considered to be definite, when an organism is isolated from the bone or adjacent soft tissue, or there is histologic evidence of osteomyelitis; probable, when there is a positive blood culture, in addition to clinical and roentgenographic features of osteomyelitis; or likely, when there are typical clinical findings in addition to definite roentgenographic evidence of osteomyelitis and a response to antibiotics.

Because so many patients with septic arthritis have negative cultures, it is important to use criteria that include those patients. Morey et al. included those patients with negative cultures when five of the following six criteria are present: temperature greater than 38.3°C, pain in the suspected joint that is made worse with motion, swelling of the suspected joint, systemic symptoms, absence of other pathologic processes, and a satisfactory response to antibiotics (3).

Epidemiology

Knowledge of the epidemiology of osteomyelitis and septic arthritis is derived from institutional studies and governmental morbidity data (4–6).

Osteomyelitis shows a clearly increased incidence in childhood, with a slight increase after 50 years of age. In contrast, the incidence of septic arthritis, although greatest in childhood, is markedly increased in the older age groups (7). In childhood, septic arthritis occurs about twice as often as osteomyelitis and tends to have its peak incidence in the early years of the first decade, whereas osteomyelitis has a peak incidence in the later years of the first decade. The disease is more common in males, and actually tends to increase with age through adolescence, according to hospital morbidity data (8).

There is an impression among clinicians, and in some institutional reports, of a seasonal variation in the incidence of acute hematogenous osteomyelitis (AHO). Gillespie (7) confirmed this, showing an increase in the early autumn

and late summer, in both the Northern and Southern hemispheres.

Gillespie (7) has shown that incidence of AHO varies among races, with a higher incidence in New Zealand Maoris and Australian aboriginals than in children of European descent in these countries. At the same time, groups of similar ethnic background show differences in the incidence of AHO for which social or environmental factors may be responsible.

The idea that osteomyelitis is a changing disease is not new, and perhaps indicates that it is a disease that is capable of continuous change, depending on various circumstances. In the city of Glasgow, Scotland, the incidence of AHO in children younger than 13 years of age has dropped by more than 50%, due mainly to a decrease in long-bone infections. At the same time, the incidence of subacute infections increased from 12 to 42% during the period of study (4). Jones and colleagues (9) also suggest that the incidence of subacute osteomyelitis is increasing, while the incidence of acute AHO is decreasing. In a review of 60 patients having AHO between 1980 and 1985, 35% had subacute infection.

A study from Denmark, which reviewed 30 years' experience with bone and joint infection due to *Staphylococcus aureus*, found that although *S. aureus* bacteremia had increased over the last decade of the study (coinciding with an increase in hospital admissions), the prevalence of AHO in patients 1 to 20 years of age decreased. There was a significant increase in joint infections among patients between 1 and 20 years of age during a 4-year period in this decade. The investigators thought this likely to be due to a change in the type of *S. aureus* that was predominant during this period, illustrating the complex bacterial–host interaction (5).

In the 1970s, a change in the causative organism in septic arthritis was noted, with *Haemophilus influenzae* type B becoming the most common cause in children 1 and 4 years of age (5). The reason for this is not clear. Currently, *H. influenzae* has virtually disappeared as a cause of joint sepsis where the vaccine against *H. influenzae* has been administered (10). It has been replaced by *Kingella kingae* in the same age group. This is discussed later.

Etiology

Koch's postulates are the basis of the germ theory of infections:

- The organism must be identified at the site of the disease
- The organism must not be found in other diseases
- The organism must be able to produce the disease in other animals
- The organism must be identified in the disease that is produced (11).

Pasteur (12) failed to satisfy Koch postulates when he injected staphylococci intravenously into guinea pigs, as did

many others after him. In attempting to produce hematogenous osteomyelitis, Rodet (13) was reportedly successful, but details in his report are sketchy. Others have reported variable success in producing hematogenous osteomyelitis (14).

The reproducible creation of a bone or joint infection requires some other intervention, usually something that has the potential to change the local environment. The standard model for the study of antibiotics for treatment of osteomyelitis involves the injection of sodium morrhuate directly into the bone to produce necrosis, followed by the injection of bacteria directly into the area (15).

Some of the earliest attempts to produce osteomyelitis in animals involved trauma to the bone, and many of these were reportedly successful. Trauma to the growth plate, followed by the intravenous injection of *S. aureus*, has produced an AHO that resembles the human form of the disease (16,17). These studies allow observations on the pathology of AHO.

How bacteria lodge in a bone or joint, then establish a clinical infection, cannot be completely explained. There are numerous bacteria in and on the body, and bacteremia is a daily event in childhood, giving ample opportunity for bacteria to gain access to the bones and joints (18). The answer lies in a better understanding of the factors that influence host resistance, of bacteria pathogenicity, and of factors that relate both—an exploration of which is beyond the scope of this chapter.

Among the factors that have been observed to be associated with infection, none is so common as trauma. The idea of trauma as a predisposing factor to infection is not new. As mentioned, it was one of the earliest methods in experimental efforts to produce AHO. The entire subject was summarized by Burrows (19) in 1932, when he popularized the term *locus minoris resistentiae*, to describe the effect injury had on decreasing resistance to infection. Clinically, trauma to the affected part is noted in 30 to 50% of those who have clinical AHO (20–24). Although there are no similar clinical data for septic arthritis, experimental models demonstrate the role of trauma in the production of the disease (25,26). The conclusion that may be drawn from the clinical and laboratory data is that trauma is not always essential for an infection to be established, but that it makes it easier in some circumstances.

Just as trauma is a factor, so is the function of the immune system. This is easily illustrated by the increased susceptibility to infections of all types in those patients with diseases characterized by deficient or altered immune function, and in the neonate with immature immune function.

More mysterious are those factors that may cause temporary and transient depression of immune function (e.g., intercurrent viral illness, anesthesia, surgery, trauma, and malnutrition); all are known to impair certain aspects of immune function, and have been related to an increased incidence of clinical infection.

Despite partial understanding of the interrelated factors

between host and bacteria, many aspects of AHO and septic arthritis in children remain unexplained; for example, the predilection for males, increased incidence of infection in the lower extremities, and peak age incidence.

Pathophysiology of Osteomyelitis

Bone is unique as a tissue and as an organ, not only for its rigid and variable structure, but also for its ability to heal and replace itself with entirely normal tissue without scar.

There are two types of cortical bone that are especially evident in childhood. That which is found in the metaphyseal region is little more than a compact version of cancellous bone. Its maze-like structure allows easy communication between the subperiosteal space and the medullary space. The cortical bone of the diaphysis is dense lamellar bone, which is relatively acellular. Consequently, it is impenetrable and renews itself more slowly. This structure is more obvious in the larger bones (Fig. 13-1A).

The cancellous bone that makes up the central part is also differentiated both by structure and function. The central cellular part, known as the medullary cavity, has little bone, but contains a rich reticuloendothelial system. The metaphyseal region has more bone structure, but is relatively acellular, containing few cells of the reticuloendothelial system. These differences are more pronounced in the long bones, particularly at the rapidly growing ends (Fig. 13-1A and B).

The periosteum of a child's bone is thick. Although it is easily separated from the bone, it is not easily penetrated by infection. Because its blood supply is from the outside, elevation from the bone does not impair function, and it continues to produce osteoid and bone. In children, this response of an elevated periosteum is often dramatic, producing a layer of bone around the original bone that is called the involucrum.

In a classic article, Hobo (27) described his experiments on the localization of both India ink particles and bacteria in bone after intravenous injection. He noted that, although most bacteria lodged in the medullary cavity, they were rapidly phagocytized, and no infection resulted. In the area beneath the epiphyseal plate, few bacteria lodged. These bacteria were not phagocytized, however, due to the absence of phagocytic cells in this region of the bone, and infection subsequently developed. Hobo thought that the vessels beneath the physal plate were small arterial loops that emptied into venous sinusoids, and that the resulting turbulence was the cause of localization. However, electron microscopic studies have shown these to be small terminal branches (28). In addition, it has been demonstrated that the endothelial wall of new metaphyseal capillaries have gaps that allow the passage of blood cells and presumably, bacteria (29).

How and why bacteria lodge in the area beneath the epiphyseal plate and establish an infection in this region, is poorly understood. In closed experiments with trauma as a model, infection did not develop in fractures of the

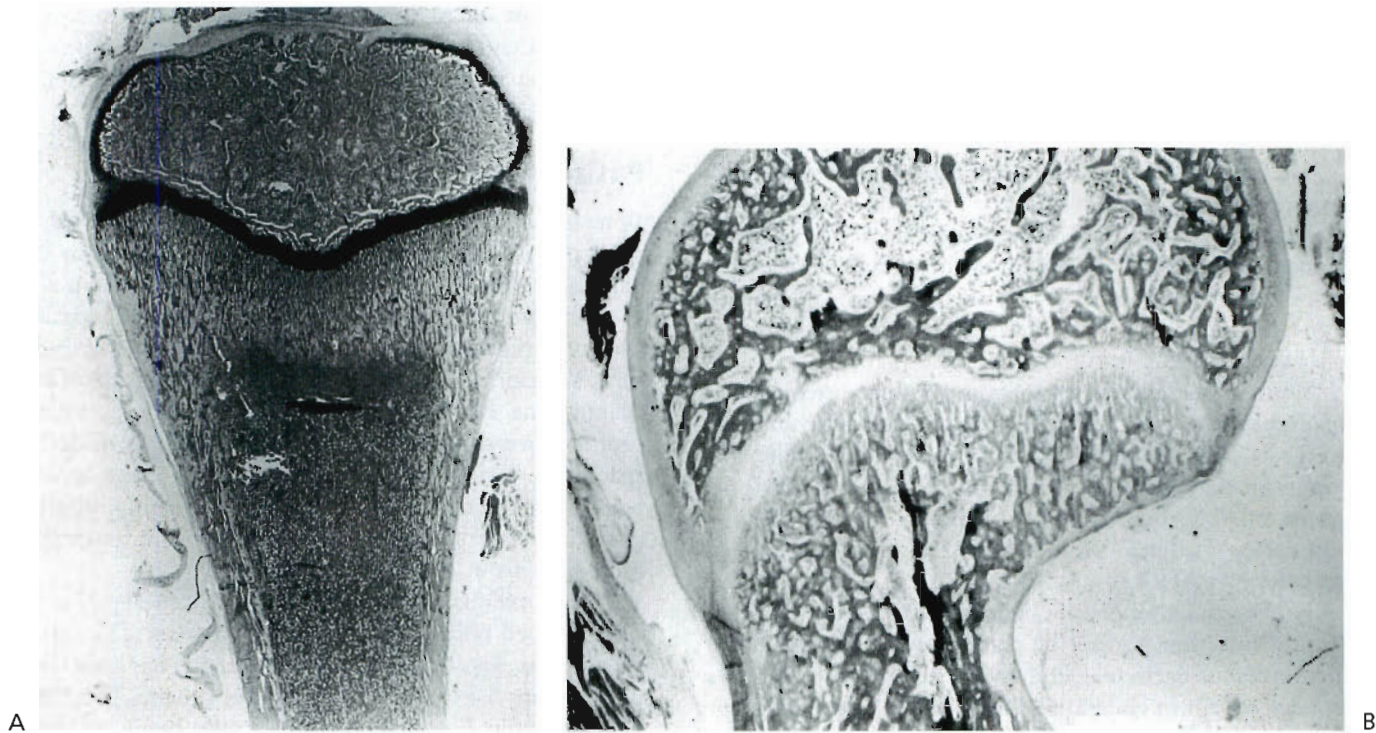


FIGURE 13-1. Proximal tibia (A) and proximal radius (B) of a 6-week-old rabbit, demonstrating the difference in the cortical bone between the metaphysis and the diaphysis. The diaphyseal cortex is composed of thick, relatively acellular bone, whereas the metaphyseal cortex is a condensation of the spongy metaphyseal bone. Also note the difference in the cellularity between the metaphyseal and the diaphyseal areas. The size of this metaphyseal area, separating the cellular marrow from the area beneath the epiphyseal plate, is different in the rapidly growing bones, such as the proximal tibia, than in the slow-growing bones, such as the proximal radius.

diaphysis of the fibula, or in the uninjured metaphysis of the tibia, but developed in the injured metaphysis (16,17). Thus, bacterial seeding of a hematoma cannot be the explanation. It is possible that specific bacteria–substrate interactions play a role (e.g., those that occur for the localization of certain bacteria in the nasopharynx or on damaged heart valves). This is illustrated in experiments with mice which suggest that substrate production by certain strains of *S. aureus* was related to their ability to lodge in the bone following intravenous administration (30). Possibly, the injury to the unique physal plate cartilage produces a new substrate that is attractive to certain bacteria—specifically, those that cause AHO. There are numerous other as yet unexplored possibilities.

Trueta (31) was the first to note the importance of the changing anatomy of the interosseous blood supply with age. In the infant, before the ossific nucleus is formed, the vessels from the metaphysis penetrate directly into the cartilaginous anlage of the epiphysis (Fig. 13-2A). As the ossific nucleus develops, a separate blood supply to this epiphysis develops, and the metaphyseal vessels crossing the developing physal plate disappear (Fig. 13-2B). The change is signaled by the development of the ossification of the epi-

physis, and is generally complete with the distinct formation of a physal plate (Fig. 13-2C).

Because of this blood supply pattern in the infant, the initial bacterial localization is in the cartilaginous precursor of the epiphysis. Infection results in its early destruction, with the consequent alteration of future growth. When the physal plate is formed, it provides a temporary barrier to the spread of infection into the epiphysis because the vessels end beneath the plate.

A unique characteristic of hematogenous osteomyelitis is its predilection for the most rapidly growing end of the large long bones, especially those of the lower extremity. This may be explained by the observation that in rapidly growing bones the phagocytic cells are further from where the bacteria localize, because of the structure of these bones (Fig. 13-1A,B). Thus, the inflammatory response takes longer to reach the bacteria, allowing a clinical infection to become established.

Bone formation and resorption are integrally linked. Diseases that result in net bone loss may be viewed as being processes that alter this linkage. The earliest change observed in osteomyelitis is the death of the osteoblasts, followed by resorption of the bony trabeculae by numerous osteoclasts

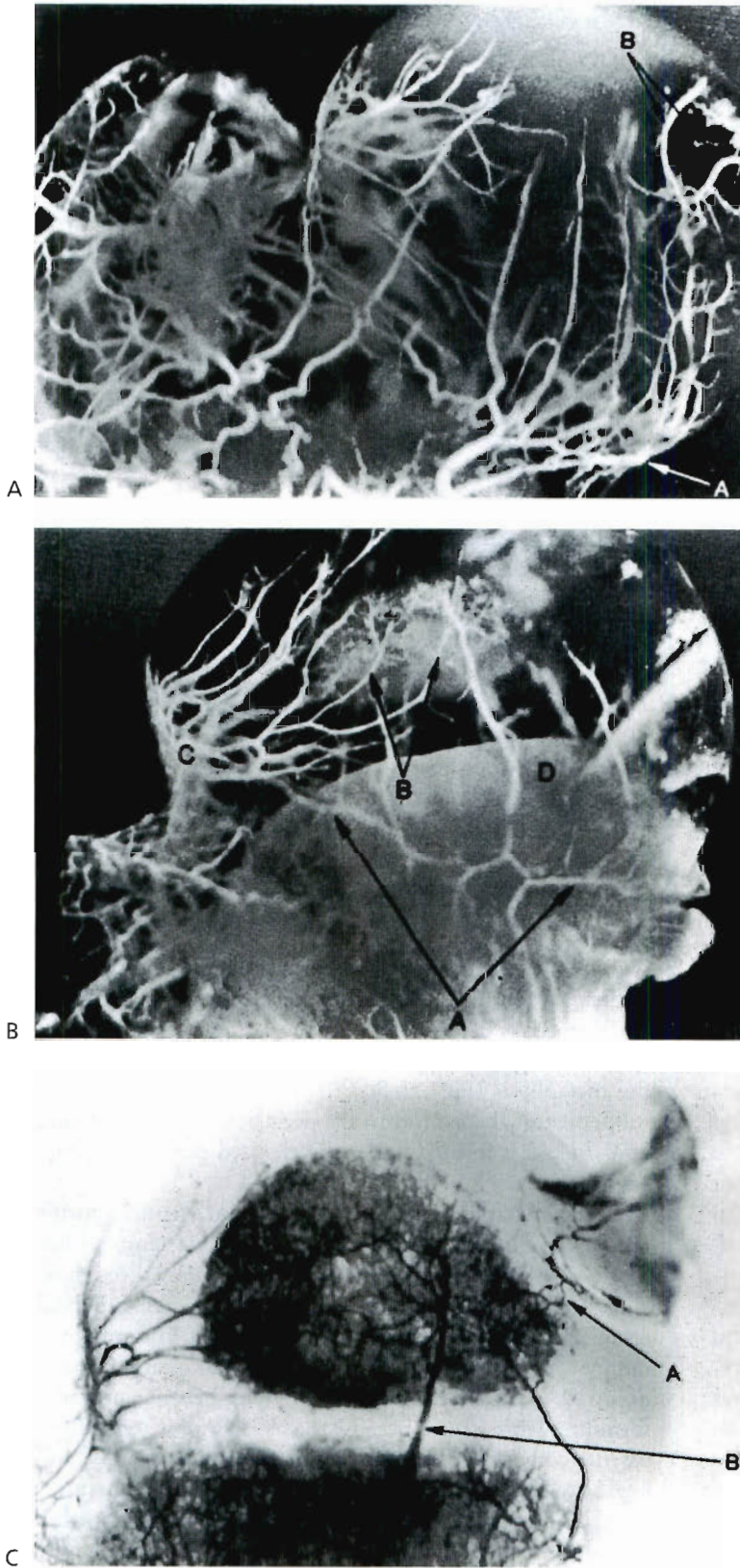


FIGURE 13-2. Human specimens of the proximal femur, which are injected with barium sulfate, demonstrate the changing blood supply to the developing femoral head with growth. **A:** In the 3-day-old infant, the vessels proceed directly from the metaphysis into the cartilaginous precursor of the femoral head. **B** represents two arteries penetrating from the ligamentum teres. **B:** By 9 months of age, separate vessels have developed to supply the ossifying nucleus of the femoral head. **A** represents a subsynovial ring that is intracapsular. **B** illustrates the separate vessels, which have developed to supply the ossific nucleus. These arteries in turn come from the ascending cervical arteries, which cross the periphery of the epiphysis (**C**). **C:** At 3 years, 4 months of age, the vessels crossing from the metaphysis have disappeared. Only peripheral vessels remain to supply the epiphysis. The supply from the ligamentum teres (**A**) is decreasing. The vessel **B** is actually a branch of the anterior cervical artery, which enters at the periphery, as seen on other views of the same specimen. (From ref. 182, with permission.)

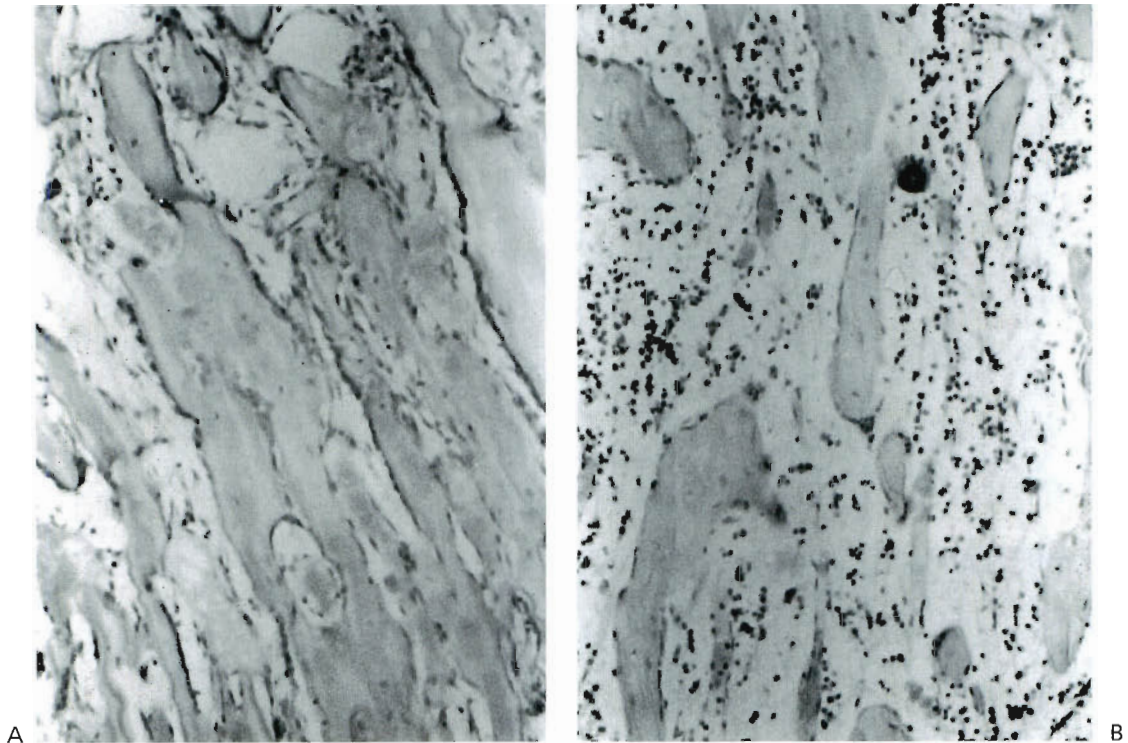


FIGURE 13-3. A: A photomicrograph of the proximal tibial metaphysis of a 6-week-old rabbit demonstrates trabecular bone lined with osteoblasts. B: Twenty-four hours after induction of experimental hematogenous osteomyelitis by injury to the physis and intravenous injection of *Staphylococcus aureus*, the osteoblasts have disappeared, and the trabeculae are being resorbed by osteoclasts.

(Fig. 13-3A and B). This occurs over a wide area of the metaphysis surrounding the infection, beginning within 12 to 18 h. In experimental situations, it has also been shown that lymphocytes may release an osteoclastic activating factor, whereas macrophages, monocytes, and vascular endothelial cells may all directly resorb both the crystalline and matrix components of bone.

Although the complete mechanism of this finding is yet to be elucidated, it is known that, in response to toxins and bacterial antigens, interleukin-1 is produced by macrophages and polymorphonuclear leukocytes (32). Interleukin-1 is known to cause most of the events known as inflammation, and to stimulate the production of prostaglandin E_2 , which stimulates osteoclast bone resorption (33). In response to these stimuli, inflammatory cells accumulate and migrate to the area of bacterial localization beneath the physis. As these inflammatory cells migrate to the accumulating bacteria, the bone in the path of the migration is resorbed (Fig. 13-4A and B).

In response to products liberated by the increasing number of bacteria, as well as host factors, inflammatory cells begin to accumulate (34). Because there are few such cells in the area of bacterial localization beneath the physal plate, this response begins in a region closer to the medullary

cavity. Over the next few days, this inflammatory response migrates to the area of the bacteria, and the bone in its path is resorbed (Fig. 13-5A). As the accumulation of pus continues, it finds egress through the maze-like cortex of the metaphysis (Fig. 13-5A). If the infection continues, a subperiosteal abscess forms, the periosteum is elevated, and new osteoid is formed under the elevated periosteum (Fig. 13-5B).

If the metaphysis lies within the joint, septic arthritis results early in the process, because the periosteum within the joint is thin, and the pus quickly ruptures through it. This occurs in four locations in the older child: proximal femur, proximal humerus, distal lateral tibia, and proximal radius. As the periosteum is elevated, the cortical bone is deprived of its blood supply, and may become necrotic, forming a sequestrum. Because the blood supply to the periosteum comes from the muscle side, it remains healthy, and begins to lay down new bone, known as the involucrum.

It is important to note that the pus does not usually spread down the medullary cavity, because it is successfully walled off by the inflammatory response (Fig. 13-5B). Contrary to how it may first appear, in the presence of a healthy inflammatory response the path of least resistance is through the metaphyseal cortex. The spread of pus into the medul-

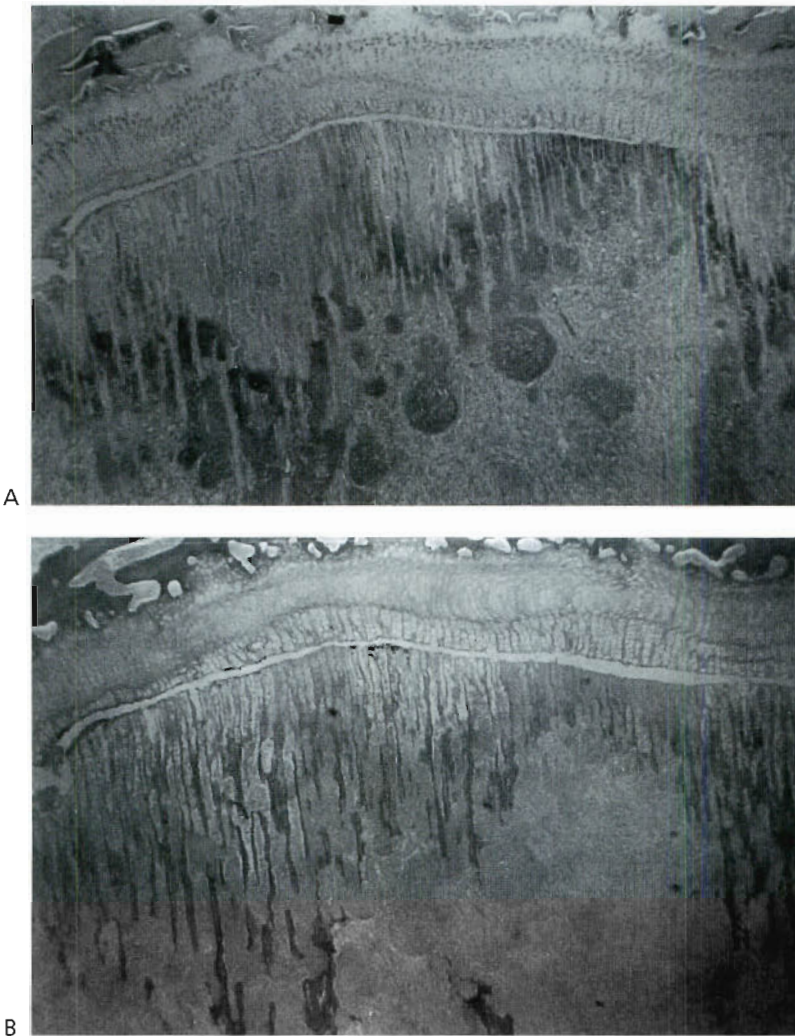


FIGURE 13-4. A: In a hematoxylin and eosin-stained specimen of a 3-day-old hematogenous infection in the proximal tibia of a rabbit, the accumulation of inflammatory cells and microabscesses can be seen. B: In an adjacent Gram-stained section, the remaining bony and cartilaginous columns and microabscesses can be seen. In addition, small clumps of organisms can be seen beneath the physis.

lary cavity is seen either in a neglected case or in a patient whose immunity is impaired.

Pathophysiology of Septic Arthritis

As in bone, the unique anatomic features of a joint should be considered in relation to infection. The synovial lining of the joint is a unique and vascular tissue that does not have a basement membrane. It secretes a fluid that is essentially a transudate of serum. The remainder of the joint surface is avascular cartilage. The interior of the joint provides a avascular environment for bacterial proliferation, similar to a culture tube.

It is probable that the transient bacteremia experienced by children results in bacteria entering the joint. It has been demonstrated that the joint has the ability to clear bacteria from itself, thus avoiding clinical infection (35). There are two important limitations to this ability: The mechanism is not so effective with pathogenic bacteria (e.g., *S. aureus*),

and there is a limit to the amount of bacteria that can be cleared.

Localization of bacteria in a joint is not so well understood as it is in bone. Although trauma has been implicated as being a factor (26), it may not completely explain the propensity for large joints and those of the lower extremity to be involved. What is apparent, however, is that bacteria are present not only in the synovium, but they also gain access to the joint cavity early in the process. Within a matter of hours, this is associated with a synovitis and fibrinous exudate, followed shortly by areas of synovial necrosis.

The mechanisms of cartilage destruction have been extensively studied in both bacterial and nonbacterial arthritis. Although the specific mechanisms of cartilage destruction may differ depending on the infecting organism, it is important that the clinician understand the biology of the process that she/he is attempting to alter.

A large variety of enzymes (e.g., proteases, peptidases, collagenases) are released from the leukocytes, the synovial

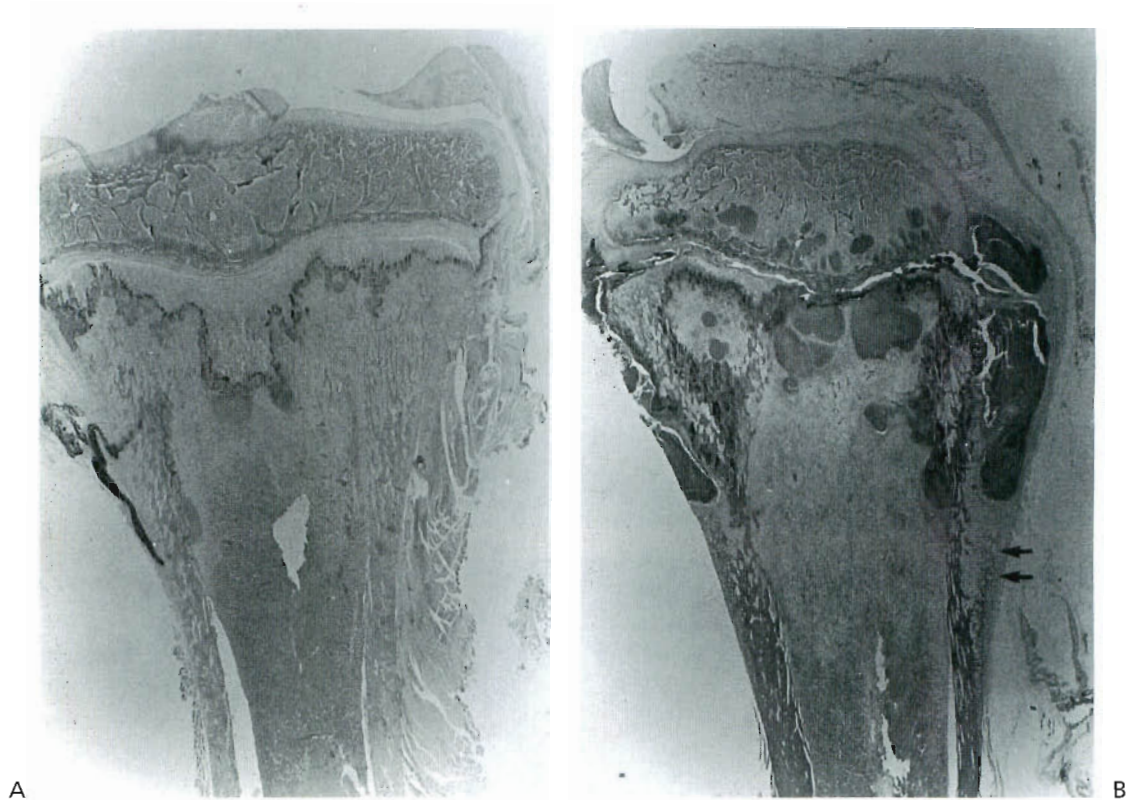


FIGURE 13-5. **A:** Rabbit's tibia with 3-day-old hematogenous osteomyelitis. A small amount of pus has found its way through the metaphyseal cortex into the subperiosteal space. **B:** Rabbit's tibia with 7-day-old infection. Note the well-developed intraosseous abscesses, in addition to the large subperiosteal abscess. New bone formation is occurring beneath the elevated periosteum (arrows). (From ref. 16, with permission.)

cells, and the cartilage. These enzymes are capable of degrading the matrix and the collagen of articular cartilage. In addition, organisms (e.g., *S. aureus*, several Gram-negative bacteria) liberate extracellular proteolytic enzymes (36–41).

These enzymes initiate the first measurable change in the articular cartilage, the loss of glycosaminoglycan. This can occur as early as 8 h in experimental models, and is not detectable by visual inspection (42). It renders the cartilage less stiff and perhaps subject to increased wear. Collagen destruction occurs later in the process, and is responsible for the visual changes that may be seen (43–45). It is important to understand that these destructive mechanisms do not require the continued presence of live organisms to be sustained.

DIAGNOSIS

History

Among the expected symptoms in any case of bone or joint sepsis, pain leads the list (46,47). This common symptom is not always verbalized by children. Thus, it is important

for the physician to realize that it may be expressed in many different ways: refusal to walk, refusal to bear weight, limping, or simple disuse of a part.

A careful history should do more than lead to a suspicion of infection. It should lead to the consideration of the possible organism and to any circumstances that may predispose to that organism, the duration of the infectious process, and the likely location of the process.

Although it is difficult to relate the stage of infection seen in experimental animals to the onset of clinical symptoms of a child, there seems to be a relatively close correlation, which suggests that symptoms begin shortly after the establishment of the inflammatory reaction in the bone or joint. The ease of access to expert medical care in some parts of the United States demonstrates this. It is no longer unusual to see children within 12 h of the onset of limp, who have only normal or mildly elevated laboratory values and a positive bacterial aspirate from the bone or joint.

A good clinical correlation is that pus is seldom found on aspiration of bone with fewer than 3 days of symptoms. The same is not true for joints, wherein elevated leukocyte counts are found in the joint fluid within 24 h of symptoms.

This response is frequently blunted by the unintentional

or ill-advised use of antibiotics before establishing the diagnosis of bone or joint infection. Thus, when recent antibiotic administration is a part of the history, care must be taken in interpreting each clinical symptom, sign, and laboratory value.

In the history, a careful search should be made for concomitant infections, recent infection, or reasons for lowered resistance to infection. A history of recent upper respiratory infection or other seemingly unrelated illness is frequent, and may explain an organism's access to the circulation. Recent rashes or swollen nodes are important for their association with diseases such as rheumatoid arthritis, Lyme arthritis, or leukemia.

Chickenpox is probably the most common childhood illness that produces a temporary suppression of immunity, leading to an increased incidence of skin infections, usually due to *S. aureus* and group A *Streptococcus*. This in turn leads to an increased opportunity for bone or joint infections with these organisms (48).

Trauma has been mentioned as a possible etiologic factor in both osteomyelitis and septic arthritis. Its importance in the history is twofold. First, it should be recognized that symptoms after trauma may not be due to trauma, particularly when they are more severe day-by-day or fail to improve as expected. Second, the history of trauma may successfully direct the search for the location in children too young to communicate.

Examination

The entire purpose of the examination is to search for signs of infection and to localize the process. The typical child who is seen in the first 3 to 4 days of osteomyelitis or septic arthritis may appear unhappy and out of sorts, but rarely appears to be ill or moribund, as has often been described. Fever is not a consistent accompaniment of what would seem to be such a serious infection (46,47). Children with subacute osteomyelitis may remain relatively active, favoring only the affected part, and showing no systemic symptoms of infection.

Because most cases of AHO and septic arthritis involve the lower extremities, a common finding is limp. This usually is an antalgic limp, defined by a shortened stance phase on the affected leg. Failure to use an upper extremity in the usual manner, or discomfort noted by the parent in dressing the child, are common symptoms in the upper extremity.

Swelling and erythema, cardinal signs of infection, are of value early in the process only in bones that are not covered by muscles and in joints that are easily palpated. Loss of normal concavities and loss of normal skin wrinkles may be the only subtle clues. Visual comparison of the normal and affected limb, symmetrically positioned, should always be done.

After the affected part is identified by limp or disuse, palpation of the bones and joints is used to identify the

specific location of the inflammation. In the case of small children who cry at the mere presence of a stranger and panic at being touched, it is often beneficial to instruct the parent how to elicit the tender area. After showing the parent how to palpate the area, the physician should leave the room and allow the parent to first examine the unaffected, then the affected part, and report the results.

Joints are more effectively examined by ROM than tenderness, although palpation of those joints that are not covered by muscle may reveal both the presence of an effusion, and tenderness. Involvement of large joints covered by large amounts of tissue is detected by a decreased ROM. In the axial skeleton, such as the spine and the sacroiliac (SI) region, percussion and compression, respectively, are more effective in eliciting symptoms than is palpation.

An infected joint usually has neither full flexion nor extension, and may be painful through anything but a small ROM. In the case of the hip, internal rotation, abduction, and extension, all of which tighten the hip capsule, are painful and limited.

Laboratory

The leukocyte count is not a reliable indication of inflammation in its early stages, and when normal, often leads the physician away from the correct diagnosis of sepsis. In a series from the Mayo clinic, only 25% of infants and children with osteomyelitis had a leukocyte count above normal for their age, and only in 65% was the differential count abnormal (2). The results were similar for a series of patients from the same institution with septic arthritis (3). This has been confirmed in other series (20,46,47).

The most useful laboratory tests used in the diagnosis of bone or joint sepsis are those that measure the acute phase response. These responses are discussed in recent review articles (49,50). This acute phase response is actually the increase or decrease in a variety of plasma proteins, in response to cytokine production secondary to acute or chronic inflammation. In addition to being responsible for many of the systemic symptoms seen in infection, e.g., fever, anorexia, lethargy, and anemia, an increase of many of these proteins can be measured in the blood. The two most common tests to measure the acute phase response today are the C-reactive protein (CRP) and the erythrocyte sedimentation rate (ESR). There is evidence that this acute phase response may differ in different inflammatory conditions. For example, CRP will be elevated in trauma whereas the ESR will not.

The ESR is one of the nonspecific acute-phase reactants found in the serum in response to inflammation. The test measures the rate at which the erythrocytes fall through plasma, and is dependent mostly on the concentration of fibrinogen. However, the result can be greatly affected by the size, shape, and number of erythrocytes present, as well as other proteins in the plasma. The ESR is unreliable in

the neonate, in the presence of significant anemia, in patients with sickle cell disease, or when the patient is taking steroids.

The ESR is almost always elevated within 48 to 72 h of the onset of infection, and returns to normal over a period of 2 to 4 weeks after elimination of the infection. The ESR is less reliable in the first 48 h of the infection than after 48 h. In the Mayo clinic series, the ESR was below 20 mm/hr in only 5 of 76 patients with septic arthritis (3). It appears that an elevated ESR can be anticipated in about 90% of cases that subsequently prove to be AHO (46,47). Although noted to be elevated just as often in patients with osteomyelitis, the ESR was significantly higher in those with septic arthritis (3). Those authors did not find the value of the ESR diminished by previous antibiotic therapy.

An additional problem in the clinical usefulness of the ESR is that it continues to rise for 3 to 5 days after institution of successful therapy. Although a continuing rise beyond the fourth to fifth day of treatment is an indication of failure to eradicate the infection, it is because of this delayed response that the ESR is not a good means of assessing the resolution of sepsis during the first week of treatment (51).

The CRP is a substance found in the serum in response to inflammation and trauma. The CRP may begin to rise within 6 h of the triggering stimulus, then increases several hundred-fold, reaching a peak within 36–50 h. Because of the short half-life of the protein (47 h), it will also fall quickly to normal with successful treatment, in contrast to the ESR. This makes the CRP of greater value than the ESR, not only for earlier diagnosis of infection, but also for determining resolution of the inflammation (52).

One report comparing serial determinations of ESR and CRP in 44 children with proved bacteriologic osteomyelitis demonstrated the ESR to be elevated initially in 92% of the patients, and the CRP to be elevated in 98% (53). The peak ESR was measured on days 3 through 5, whereas the peak CRP was measured on day 2. Thereafter, it took the ESR about 3 weeks to return to normal, whereas the CRP returned to normal within 1 week. Thus, the CRP is more likely to be helpful in diagnosing the early case of infection, and is more useful after its resolution.

The question is often raised as to whether or not the CRP is useful in separating a musculoskeletal infection from an otitis media, which is commonly seen in children. Elevated CRP values are reported in 22% of those with a bacteria otitis media, and 65% of those with a viral otitis media (54). Thus, it would seem that an elevated CRP may be due to otitis media.

Blood cultures are indispensable, because they frequently demonstrate the organism. In most series, the yield from blood culture ranges between 30 and 50% in both septic arthritis and osteomyelitis (47). The yield from both blood culture and aspirated material decreases with previous antibiotic therapy (3). Even with previous antibiotic treatment,

however, the chances of obtaining positive cultures, when all sources (blood, bone, and joint fluid) are cultured, remain high (47).

The importance of needle aspiration of the bone or direct biopsy at the time of surgery, before antibiotic administration, is emphasized by the frequency with which positive cultures are obtained. In 91 aspirations of bone for osteomyelitis, pus was obtained in 58%, and positive cultures were obtained in 70% of these aspirates, yielding 40 positive cultures from all aspirates (47). In other series, the yield of positive cultures from bone has been even higher, ranging from 51 to 73% (46,51).

Aspiration of joint fluid provides the opportunity to gather more information than does bone aspiration. The question, however, is which tests, in addition to the culture and Gram stain, are worthwhile. The answer appears to be that only the leukocyte count and the percentage of polymorphonuclear cells are of value (55,56). Because fluid from an infected joint frequently clots, it may be helpful to rinse the syringe with heparin before aspirating the joint. Because only a small amount of fluid may be obtained, care must be taken not to leave any significant volume of heparin in the syringe, which may alter the cell count.

Although it is generally assumed that septic joints have a leukocyte count from 80,000/mL to more than 100,000/mL, and other inflammatory disorders in the differential diagnosis have counts of 50,000/mL and less, there is considerable overlap (Table 13-1). In a series of 126 bacteriologically proved cases of septic arthritis, Fink and Nelson (55) found leukocyte counts of 50,000/mL or less in 55%, with 34% having counts less than 25,000/mL. Only 44% of the patients had counts of 100,000/mL. At the same time, inflammatory diseases (e.g., rheumatoid arthritis) may have counts in excess of 80,000/mL (58).

As in osteomyelitis, the frequency of positive cultures seems to be slightly higher with open biopsy than with needle biopsy, but the difference is not great. In addition,

TABLE 13-1. SYNOVIAL FLUID ANALYSIS

Disease	Leukocytes*	Polymorphs* (%)
Normal	<200	<25
Traumatic	<5,000 with many erythrocytes	<25
Toxic synovitis	5,000–15,000	<25
Acute rheumatic fever	10,000–15,000	50
Juvenile rheumatoid arthritis	15,000–80,000	75
Septic arthritis	>80,000	>75

* The leukocyte count and percentage of polymorphs can vary in most diseases, depending on the severity and duration of the process. Overlap greater than shown in these averages is possible. (From ref. 57, with permission.)

the positive yields are generally not as high as in osteomyelitis, ranging in various reports from 36 to 80% (46,51,59).

The importance of obtaining material from blood and bone or joint aspiration is emphasized in a report by Vaughan and colleagues (60), in which many children with osteomyelitis had only positive blood cultures, whereas others had only positive bone cultures.

Gram staining is the only opportunity for presumptive identification of the organism within a few hours of initial patient contact, and is thus a valuable test that should not be ignored. It appears from reports of both septic arthritis and osteomyelitis that the Gram stain demonstrates an organism in about one-third of the bone or joint aspirates (46,47,55).

Certain bacteria growing in the body release their type-specific polysaccharide capsule into the circulation. Detection of this antigen, by either counterimmunoelectrophoresis or cold agglutination tests, can provide presumptive evidence for the organism (61,62). The release of this antigen does not depend on the presence of live organisms. Therefore, this test has the potential of rapid identification of the organism, and may be especially useful in patients who have received previous antibiotics. However, the yield from this test has been low, and it is not used in the diagnosis of bone or joint sepsis.

Offering promise for the future are molecular diagnostic tests to identify the presence of bacteria, along with the species and its sensitivities. These tests rely on the identification of specific DNA and RNA in the samples. The tests can be performed in an hour (rather than a day or more) for positive cultures. They also have the theoretical advantage of identifying the organism even if treatment with antibiotics has begun, since they do not depend on live bacteria for culture. However, to date these tests have not proven specific or sensitive enough for reliable clinical use (63).

Imaging

The imaging of musculoskeletal sepsis is discussed in more detail in Chapter 3.

Plain Radiographs

Deep soft tissue swelling is the earliest radiographic evidence of osteomyelitis (64). The role of radiography in the diagnosis of early bone and joint sepsis is often undervalued. This is because it is often considered only to seek changes in the bone, which in osteomyelitis may not occur for at least 5 to 7 days after the onset of symptoms. Radiographs are a two-dimensional representation of density difference, and as such, can detect changes in the soft tissues as well as in the bone. Because the inflammation in the bone or joint produces edema in the soft tissues adjacent to the area of inflammation, there is swelling in this region, with enlargement of this muscle layer detectable on the radiograph. In addition, the edema obliterates the normal fat planes that can be seen between the muscle layers. All of this can be detected with routine radiographs if they are properly obtained.

Detection of deep soft tissue swelling and loss of normal fat planes depends on comparison of one limb with the other. Therefore, radiographs of symmetrically positioned views of both limbs should be ordered, using a technique to demonstrate the soft tissues (Fig. 13-6).

Radiographs to detect deep soft tissue swelling are of most value in suspected sepsis of the long bones. The technique becomes less useful in the axial skeleton, because of the large overlapping muscles. An additional problem in interpretation occurs around the hip. In this location, the normal external rotation and abduction position assumed by the irritable hip (regardless of the cause) causes the appearance of capsular bulging (65). Another sign that is often

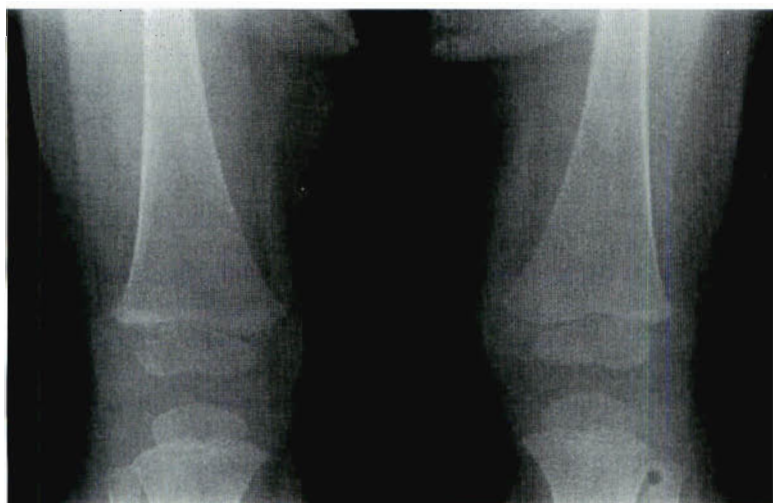

FIGURE 13-6. Plain radiograph of a 16-month-old toddler with a 36-h history of increasing difficulty bearing weight and pain in the region of the left knee. Note the deep soft tissue swelling about the medial side of the distal left femur. Deep soft tissue swelling is the earliest finding in osteomyelitis.

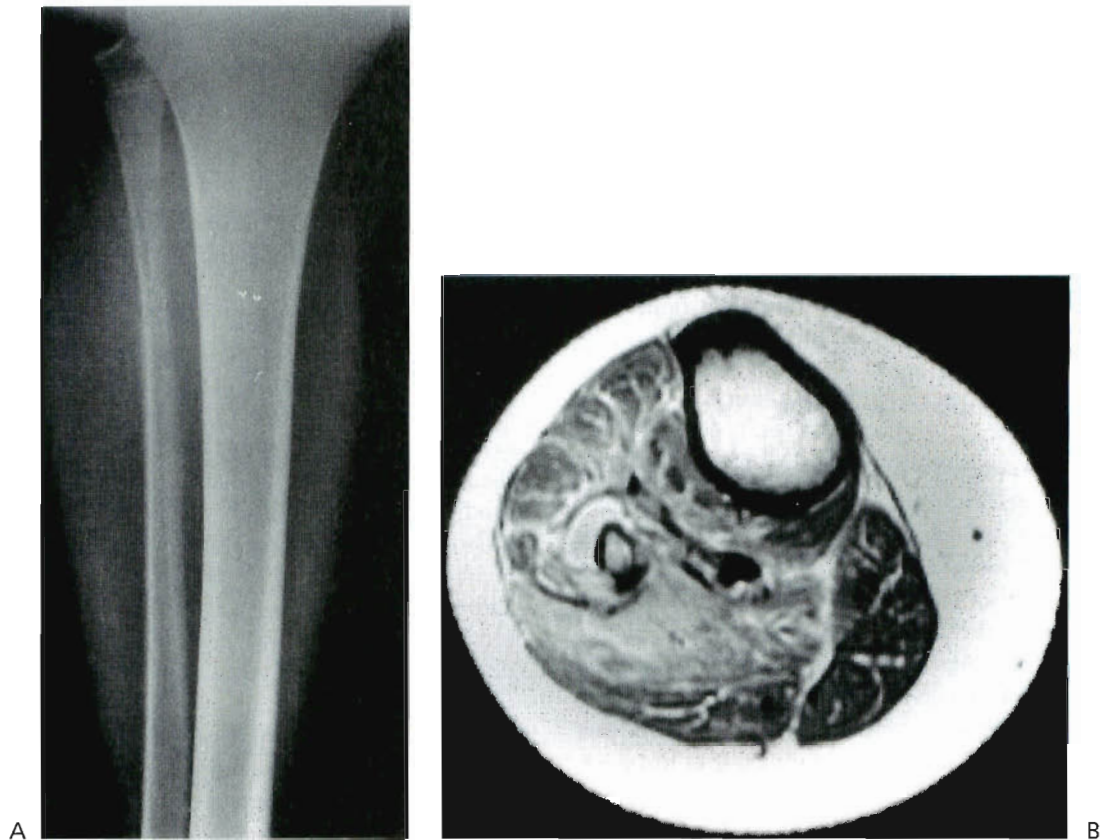


FIGURE 13-7. A: Radiograph of the leg of a 14-year-old boy who presented with swelling and pain for the past 6 weeks. He related the onset to twisting his leg when he fell into a hole. Is this osteomyelitis or tumor? Note the deep soft tissue swelling, the bone destruction, and the periosteal new bone around the fibula. B: The magnetic resonance imaging scan demonstrated bone destruction, fluid in one area around the fibula, and extensive edema in the surrounding muscles, all of which suggest that osteomyelitis is more likely. The fibula was biopsied as though the lesion were malignant. Pus and Gram-positive staphylococci were identified.

sought in suspected sepsis of the hip joint is joint space widening. Although this may be seen frequently in the neonate, it is often lacking in older children. It is a late sign, and its absence is not to be interpreted as lack of sepsis (66).

The more classic radiographic signs of osteomyelitis—resorption of bone and periosteal new bone formation—are easily recognized. The forms that the bone destruction can take are myriad, however, and particularly in children, can be confused with bone neoplasms (67–69). This is another point that illustrates the importance of a definitive tissue or bacteriologic diagnosis before treatment can be confidently pursued (Fig. 13-7).

Bone Scan

Radionuclide scanning of the skeleton is done with three different radiopharmaceuticals: technetium 99m (^{99m}Tc) diphosphonate, gallium 67 citrate, and indium 111. Because of ^{99m}Tc diphosphonate's high diagnostic accuracy, easy availability, relatively low cost compared with other

methods, and rapidity, it is the clear choice for detecting physiologic alterations in the skeletal tissues of children. Bone scintigraphy is discussed in more detail in Chapter 3.

There are several facts about bone scintigraphy that the orthopaedist needs to understand and evaluate. First is the mechanism of isotope uptake. Isotope uptake depends on both vascularity and calcium phosphate deposition (70). Isotope uptake is greater, the newer the calcium phosphate deposition. Second, the bone scan consists of three phases: an angiogram, performed immediately after injection; immediately followed by the second or "blood pool" phase; and 2 to 3 h later, the mineral phase, which reflects uptake in the bone. All three phases are helpful, especially in distinguishing cellulitis from osteomyelitis. Third, the quality of the bone scan should be evaluated. The bladder should be empty, so that accumulated isotope does not obstruct the sacrum. It is important that symmetrically positioned views of both sides be obtained. In children, it is important that pinhole or converging-collimator images be obtained of suspected areas of infection. Because most AHO occurs in the

metaphysis adjacent to the physal plate, such views are necessary to separate early metaphyseal changes from the large amount of uptake found in the physal plate (Fig. 13-8A and B). Because these images are time-consuming to obtain and may require that the child be sedated, it is important that the physician communicate the desired areas of interest to the radiologist.

The value of radionuclide scans differs in children with suspected bone or joint sepsis, depending on the diagnosis. In a large series of 280 patients referred with a clinical diagnosis of osteomyelitis, the scan correctly identified osteomyelitis at 55 of 62 sites of proved osteomyelitis in the appendicular skeleton (71). This report demonstrated a sensitivity of 89% and a specificity of 94%, with an overall accuracy of 92% for this method. Considering differences in populations and methodologies, these results are not too different from other reports in the literature.

The accepted criterion for diagnosis of septic arthritis on radionuclide scan is equally increased uptake on both sides of the joint. The interpretation is not so simple in practice. Compared with osteomyelitis, the diagnosis of septic arthritis presents a different problem: Although the scan may correctly identify the site of joint sepsis in about 90% of infected joints, it does not accurately separate bone from

joint sepsis, nor differentiate infectious from noninfectious arthritis (71,72). This is a particular problem in the hip, in which the differential diagnoses may include transient synovitis, septic arthritis, or osteomyelitis of the femoral neck.

Not all positive scans indicate infection, and because skeletal scintigraphy is interpreted, it suggests that many factors need to be included if the scan is to be helpful (73,74). Foremost among these factors is that the scan should be interpreted in the context of the clinical facts. This was illustrated by McCoy and colleagues, who demonstrated improved specificity and sensitivity when the scan was interpreted with knowledge of the clinical findings and initial laboratory studies, compared to when the interpretation was a blind reading of the scan (75). The importance of this has been emphasized by others (71,72).

The interpretation of the scan is important. There is a tendency on the part of many orthopaedic surgeons to call a bone scan "positive" or "negative," depending on areas of increased, normal, or decreased uptake. Linking knowledge of the pathophysiology of the disease process to the scan, which actually reflects localized physiologic changes in the bone, is more useful and more accurate.

Although localized increased isotope uptake may be due

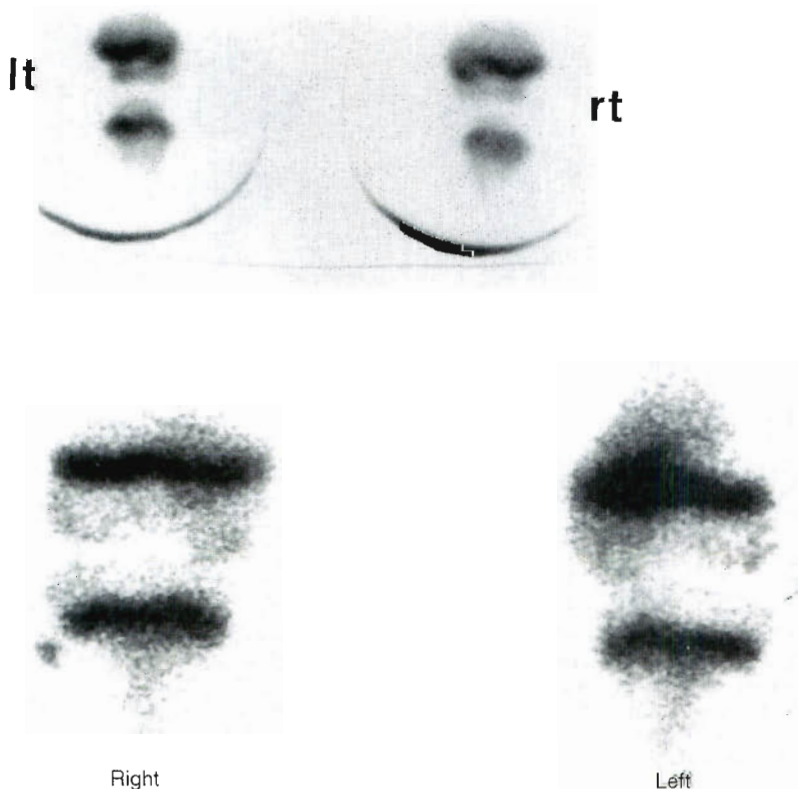


FIGURE 13-8. A: Bone scan of lower extremities of the same patient in Fig. 13-6. Note the activity around the physis. Differences in isotope uptake between the two sides are equivocal. B: Pinhole views of the distal femurs clearly demonstrate a difference between the left and right. In addition, the pattern of "peaking" in the metaphysis is typical of early osteomyelitis and corresponds to the expected pathologic process.

to osteomyelitis, it may also be due to any other process that increases the vascularity or deposition of calcium phosphate. Among the most common disorders seen in children are tumors and bone resorption due to disuse. Therefore, the bone scan can localize the area of the skeleton where there is altered physiology, but it cannot determine the cause (Fig. 13-9A and B).

The importance of a cold scan, in which there is an area of decreased isotope uptake, has been recognized as a serious problem, indicating acute devascularization of the bone caused by subperiosteal abscess (71,72,76,77).

The diagnosis and treatment of an acute bone or joint infection should not be delayed by the bone scan. In many institutions today, it may be easier to obtain an MRI during the evening or weekend hours. This, and the value of the MRI in detecting marrow changes early, may change the role of bone scintigraphy. Regardless of these changes, bone scintigraphy is still the method of choice when multiple sites are in question, or the site is unknown.

In requesting or waiting for a bone scan, the question often arises whether aspiration of the bone or joint alters the results of the scan. McCoy and colleagues (75) demonstrated in the clinical situation that the aspiration did not alter the scan, whereas Canale and colleagues (78) showed the same results in an experimental situation. This suggests that when the site of pathology is known and aspiration is

indicated it need not, and in many cases probably should not, be delayed while waiting for a bone scan.

Computed Tomography

CT is valuable in the detection of focal areas of bone destruction, as well as detection and delineation of soft tissue abscess associated with bone and joint infection. Positive bone scans of the spine and pelvis often fail to provide the surgeon with the exact location of the lesion, which would permit either aspiration or planning of a surgical approach. In such circumstances, CT examination of the area localized by the bone scan can prove useful (79). Compared to MRI, its advantages are its greater availability and lower cost, both of which come at the disadvantage of being unable to detect early changes within the marrow in early cases.

Magnetic Resonance Imaging

MRI is a useful technique in the evaluation of both acute and chronic osteomyelitis because of its ability to provide good anatomic detail in many planes, and to detect pathologic changes within the marrow and soft tissues. Its actual use, however, is mitigated by its cost and the frequent necessity for sedation or general anesthesia in small children. It is simply not necessary for the diagnosis and treatment of the usual case of osteomyelitis or septic arthritis, but can

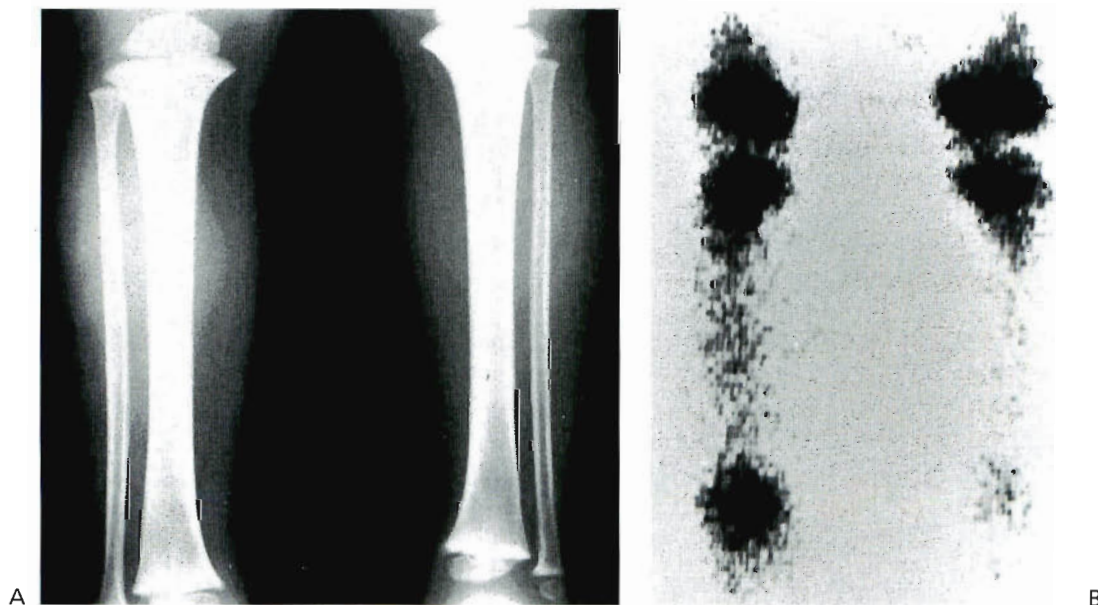


FIGURE 13-9. A: A seven-year-old girl complained of pain in her leg for about 24 hours. Examination revealed diffused swelling in the leg and a rapidly spreading erythema. Radiographs show superficial soft tissue swelling on the right leg, but the deep soft tissue layers are not swollen. This appearance indicates cellulitis. B: Bone scan was obtained on this patient and mistakenly interpreted as showing osteomyelitis. The diffused pattern of uptake is not typical of osteomyelitis, but represents the effects of increased circulation throughout the bone, secondary to inflammation and acute disuse.

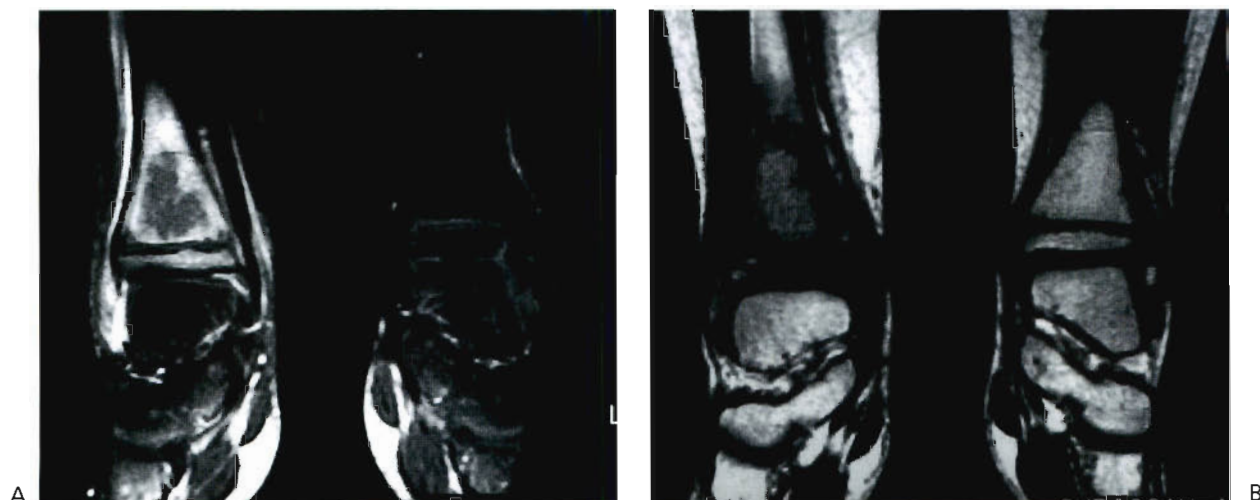


FIGURE 13-10. A: T1 MRI of the distal tibia in an 11-year-old female with right ankle pain and limp. She was started on oral antibiotic, but failed to resolve. The MRI demonstrates the edema in the distal right tibia, compared to the normal marrow signal from the left tibia. B: The spin echo postcontrast T1 images show enhancement due to the contrast material, and the absence of the bright fat signal. Note the center of the lesion, which suggests abscess formation.

prove very helpful in those cases in which uncertainty exists but the location of the disease process is known.

MRI for the evaluation of sepsis should include both T1- and T2-weighted sequences, because the difference between the two is important (Fig. 13-10). In acute osteomyelitis the low-intensity signal seen on the T1-weighted image becomes a high-intensity signal on the T2-weighted image. These changes reflect the increased water in the marrow produced by the edema, hyperemia, and purulent exudate that characterize the pathologic process (80) (see Chapter 3).

In a group of 43 children admitted to the hospital with the diagnosis of musculoskeletal infection, Mazur and colleagues showed the MRI had a sensitivity of 97% and a specificity of 92% (81). The indications for MRI in the diagnosis of acute bone or joint sepsis remain those cases in which the diagnosis cannot be made by the usual means. These will be cases in which there is confusion with neoplasia, cases previously treated, suspected sepsis in the axial skeleton, or when there is conflicting information (Fig. 13-7).

Ultrasound

Following its use in evaluation of developmental dislocation of the hip, ultrasound examination has been suggested as a tool for diagnosis of septic arthritis of the hip. Several reports leave no doubt that ultrasound can detect the presence of fluid within the hip, as well as the presence of a bulging capsule (82–84).

Ultrasound examination can be useful when the physician is unable to elicit the clinical signs of an irritable hip

(limited and painful internal rotation) that accompany a joint effusion. Despite reports to the contrary, it does not seem possible to separate pus in septic arthritis from synovial fluid due to toxic synovitis, thus limiting the value of the test once irritability of the hip is established by clinical examination (85,86). It would seem to find it greatest use in the irritable hip that may be secondary to extracapsular irritation, e.g., early pelvic osteomyelitis with irritation of the surrounding muscles.

Ultrasound also has been applied to the diagnosis of osteomyelitis, based on the ultrasound detection of the soft tissue changes in the periosteum and surrounding soft tissues, including subperiosteal abscess (87). This may prove of value in guiding aspiration in some cases, but is of limited value due to its inability to detect changes within the bone.

Aspiration

The history, physical examination, and all of the radiographic procedures have been used to locate the area of abnormality. None of these examinations has the ability to confirm whether this abnormal area is caused by infection or some other process, such as neoplasia. In addition, none of these modalities allow identification of the organism—an essential step in confirming the diagnosis, selecting the correct antibiotic, and determining the need for surgical debridement.

Aspiration is the step most often omitted in the workup of a suspected osteomyelitis and, to a lesser extent, septic arthritis. The reasons are many: The physician is reluctant to introduce a needle into the bone or joint for fear of causing an infection; the physician is afraid of hurting the

patient; the physician does not believe that it is necessary. None of these are valid reasons. There is little risk of introducing new organisms when sterile technique is used. With intravenous sedation and local anesthetic the aspiration of bone or joint can be performed with little discomfort. Aspiration of the bone or joint often yields organisms that are not found by culture of blood and other materials (46,47,51).

Aspiration of joints is a relatively simple matter, causing no more discomfort than placing an intravenous needle. Aspiration of the bone may be more difficult. Depending on the age and cooperation of the patient, various amounts of sedation may be necessary. Oral or intravenous midazolam (Versed) has proven to be quick and effective. After the area is prepared with a skin disinfectant, sterile towels are used to drape the area. A large-bore, cannulated, shallow tapered needle is used. The needle is first inserted into the most likely area until it contacts bone. Aspiration at this point may withdraw pus, indicating a subperiosteal abscess. If no pus is obtained, the needle is twisted like a drill until it is felt to penetrate the bone. Aspiration is again performed. The needle easily penetrates the thin metaphyseal bone.

Any material obtained should be sent for both culture and Gram staining, even if it does not appear to be purulent, because it may contain organisms. It is an unfortunate mistake to think that it is only blood and to discard it. The next most common error is to be too far from the metaphysis. Fear of being in the physis or epiphysis, coupled with difficulty in discerning the landmarks in a small, fat, and swollen extremity, leads to this error. The physician knows this is the case when it is difficult to penetrate the bone with the needle because the metaphyseal bone is easy to penetrate, whereas the cortical bone of the diaphysis is impenetrable with the usual needle (Fig. 13-1A).

DIFFERENTIAL DIAGNOSIS

Osteomyelitis

Although most cases of osteomyelitis in infants and children are relatively easy to diagnose, there are always cases having an atypical presentation and appearance, and osteomyelitis can be a great imitator. It is therefore helpful for the physician to always keep in mind those conditions that may present with the characteristics of bone infection, and thus be mistaken for infection.

Trauma is perhaps the most common. It is easily confused with osteomyelitis, because the latter often presents with a history of injury to the part, and is characterized by the same features: pain, swelling, tenderness, and soft tissue swelling on radiographs. In trauma, the symptoms are of sudden onset, whereas in infection, the symptoms usually begin more gradually. Trauma may be associated with an elevation of the CRP, but not of the ESR, whereas both are usually elevated in osteomyelitis. The pain of trauma

usually improves within 36 to 48 h, whereas that of osteomyelitis worsens.

Most troublesome are those cases that are difficult to distinguish from neoplasia (68,69). The most common malignancy in childhood is leukemia, and approximately 30% of these children present with bone pain (88). To complicate matters even more, 39% of these children present with constitutional symptoms such as lethargy, 18% with fever, and 60% have an elevated leukocyte count and elevated ESR (89). Although lucent metaphyseal bands are said to be characteristic of leukemia, other bone changes are also seen. One study found lytic lesions in 19%, sclerotic lesions in 4%, and periosteal new bone in 2% (89).

The treating physician should be suspicious when other signs associated with leukemia are noted (e.g., bleeding, easy bruising, bone pain in multiple sites). A low leukocyte count, seen in 35% of patients presenting with leukemia, should also raise suspicion, although this finding may also indicate serious systemic sepsis. An anemia that is not explained by acute symptoms of osteomyelitis or abnormally low platelets should also arouse suspicion. An additional clue is when the bone scan does not demonstrate the findings that would be expected in the presence of osteomyelitis. The typical finding in leukemia is a lytic lesion without increased uptake, because the lesion is purely lytic, without new bone formation or reaction (90).

Other less common neoplasms may mimic osteomyelitis (67–69). Whenever the characteristic appearance of one of these neoplasms is recognized, the physician should immediately run through the differential diagnosis in his or her mind, remembering that the differential diagnosis is the possibilities arranged in order of probability. In the younger child, an irregular lytic lesion and/or the presence of periosteal new bone, with or without a lytic lesion, should always suggest osteomyelitis, metastatic neuroblastoma, and eosinophilic granuloma, along with leukemia. In the older child and adolescent, the various forms of subacute osteomyelitis, discussed below, most often mimic tumors. The most difficult to differentiate from osteomyelitis, when periosteal new bone characterizes the lesion, is Ewing sarcoma (91). In all such cases, the diagnosis must be established before treatment is begun. The lesion should be approached as a malignancy, with complete radiographic staging and a biopsy approach that would not jeopardize limb salvage surgery, if the lesion is malignant. In cases in which trauma or infection is as likely as tumor, and the situation is not acute, it may be advisable to follow the course for 1 or 2 weeks. In this situation, occult trauma will show rapid resolution of symptoms and maturation of new bone, while the signs of infection will become more obvious.

Bone infarction can mimic AHO. (The differential diagnosis of bone infarct and osteomyelitis in sickle cell disease is discussed later.) Gaucher disease is another less-common disorder in which acute bone infarction occurs. Similar to those with sickle cell disease, these patients can also have

AHO, although it is less common than bone infarction. In one series of 49 patients with Gaucher disease, 11 were admitted to the hospital with acute lower-extremity pain, constitutional symptoms, fever, an elevated leukocyte count, and an elevated ESR (92). Of these, 5 were diagnosed as AHO, whereas the others had a bone infarction. There was no difference between the clinical signs and laboratory data for the two groups. Because bone destruction was rapid in those with osteomyelitis, the authors recommended early biopsy for culture. Because these patients seem to be unusually susceptible to infection after bone surgery, it is best to perform this biopsy by aspiration and in the sterile environment of the operating room.

Septic Arthritis

The differential diagnoses of septic arthritis, which is that of an acutely swollen and painful joint, include many more possibilities than that for osteomyelitis. The culture results are even more important, because many disorders mimicking septic arthritis are not diagnosed by biopsy but by many complex laboratory tests, and often by the passage of time. In considering the differential diagnoses of septic arthritis, the urgency of making the correct diagnosis is important. The physician should always consider what must be diagnosed today, what can be diagnosed tomorrow, and what can be diagnosed next week. For example, septic arthritis, particularly of the hip, should be diagnosed as soon as possible, whereas there is little harm to the patient if JRA is diagnosed next week.

One of the most difficult and yet important differentials is between septic arthritis of the hip and toxic synovitis, a

condition thought to be caused by a postinfectious arthritis (see Chapter 12). The importance of this diagnosis is the need for immediate drainage of the hip in the presence of bacterial sepsis, whereas the treatment of toxic synovitis is observation. Both may present with a history of a few to several days of hip pain, with limp progressing to the inability to walk. The physical signs are similar in both, with limited and painful internal rotation, abduction, and extension. A longer history of symptoms, with cyclic improvement and worsening, suggests toxic synovitis. The pain is usually worse and the motion more restricted in septic arthritis.

One study comparing 94 patients with toxic synovitis and 38 with septic arthritis found that there was significant overlap of the temperature, leukocyte count, and ESR between the two groups (93). That the ESR is often elevated in toxic synovitis is not always appreciated. A more recent study by Kocher et al. found four independent multivariate clinical predictors to help distinguish septic arthritis from toxic synovitis: history of fever, nonweightbearing, ESR greater than 40 mm/h, and WBC greater than 12,000/mm³ (94). An algorithm for the probability of a patient having septic arthritis is shown in Table 13-2.

JRA is frequently a consideration, especially when it presents as a single acutely swollen joint (see Chapter 12). Clinically different from septic arthritis, the history is often a more gradual onset, particularly regarding pain. The patient usually remains ambulatory. The examination is characterized by motion that is good with surprisingly little pain, compared with the large amount of swelling that is usually present. The joint is only mildly tender and the synovium may be thickened. Initial laboratory tests are not helpful in

TABLE 13-2. ALGORITHM FOR PROBABILITY OF SEPTIC ARTHRITIS

Multivariate Predictor				Predicted Probability of Septic Arthritis (%)
History of Fever	Nonweight- bearing	Erythrocyte Sedimentation Rate ≥ 40 mm per hr	Serum White Blood Cell Count >12,000 cells per mm ³ (12.0×10^9 cells per L)	
Yes	Yes	Yes	Yes	99.8
Yes	Yes	Yes	No	97.3
Yes	Yes	No	Yes	95.2
Yes	Yes	No	No	57.8
Yes	No	Yes	Yes	95.5
Yes	No	Yes	No	62.2
Yes	No	No	Yes	44.8
Yes	No	No	No	5.3
No	Yes	Yes	Yes	93.0
No	Yes	Yes	No	48.0
No	Yes	No	Yes	33.8
No	Yes	No	No	3.4
No	No	Yes	Yes	35.3
No	No	Yes	No	3.7
No	No	No	Yes	2.1
No	No	No	No	0.1

(From ref. 107, with permission.)

the differential diagnosis. The synovial fluid leukocyte count usually contains fewer than 100,000 leukocytes/mL, whereas in sepsis, the count is typically more than 100,000 leukocytes/mL. This is not always true, however, and the leukocyte count can be more than 100,000 leukocytes/mL in JRA (58). In many cases, the aspirate from the joint has the appearance of pus from a septic joint; in such cases, the physician has little choice but to begin treatment for septic arthritis, while searching for other clues.

Rheumatic fever, a sequela of group A streptococcal infection, is another childhood illness that often is associated with swollen and painful joints. For reasons that are not clear, there was a resurgence of rheumatic fever beginning in the late 1980s, after years of decline (95). The problem for the orthopaedic surgeon is to think of this disorder in the initial evaluation, because those additional findings that lead to the diagnosis must be sought. The joint pain is typically in the large joints (knees, ankles, elbows, and wrists), and is evanescent and migratory. Also characteristic is that the pain, which is severe, is out of proportion to the amount of swelling, which is usually mild. The history should seek evidence of an untreated pharyngitis or febrile illness, a rash, or some other infection due to group A *Streptococcus* approximately 2 weeks before the onset of joint swelling. Inquiry should also be made about any joint symptoms preceding the presenting complaint, especially the involvement of multiple joints.

The diagnosis of rheumatic fever is based on the Jones criteria. The major criteria are carditis, arthritis, chorea, subcutaneous nodules, and erythema marginatum. The minor criteria are fever; arthralgia; elevated ESR or CRP; heart block, as evidenced on an electrocardiogram; and a previous history of rheumatic fever. The diagnosis is made when there are two major or one major and two minor criteria. A heart murmur usually is not present this early in the course of the disease. Rheumatic fever is one diagnosis that must be considered in the differential diagnosis of any patient with septic arthritis.

Another disorder that causes either arthralgia or arthritis is Henoch-Schönlein purpura. This disorder is a vasculitis of unknown origin (possibly allergic), which affects mainly children between the ages of 2 and 11 years of age. In the full-blown case having all of the clinical manifestations (nonthrombocytopenic purpuric rash, abdominal pain, arthritis, and nephritis), the diagnosis is not difficult. The joint manifestations, which occur in up to 75% of the patients, precede the other symptoms in about 25% of those affected. For this reason, the orthopaedist should be familiar with the features of the joint findings. The joints most commonly involved are the knees and ankles. The swelling and tenderness are more periarticular than that in septic arthritis, and if an effusion is present, it is usually mild. Joint fluid will not contain blood. The earliest signs of purpura must be sought, which may be fine pinpoint hemorrhagic lesions, usually seen below the waist. The joint symptoms do not require treatment, and usually disappear within days. These

patients require medical management for the other, sometimes more serious, manifestations of the disease.

There are many other causes of joint swelling that merit consideration. Enteroarthritis secondary to *Salmonella* or *Yersinia* infection may be suspected when abdominal symptoms coincide. The arthritis may precede the abdominal symptoms, however. These patients can be confused with those having septic arthritis, because as with septic arthritis, the ESR and CRP are often elevated to high levels. Kawasaki disease, a vasculitis of unknown etiology, may present with joint symptoms in its early stage. It is characterized by a rash with red eyes and lips, erythema of the palms and soles with edema, and lethargy. The child does not like to be moved, and may seem to be more ill than the visible signs suggest. Serum sickness, which is often manifest by joint swelling and an urticarial rash, usually affects more than one joint, and most commonly follows treatment with penicillin or a cephalosporin antibiotic, especially Ceclor. Other considerations are discussed later in this chapter.

TREATMENT

There are four principles that the physician must always keep in mind when treating an infection:

1. Identify the organism.
2. Select the correct antibiotic.
3. Deliver the antibiotic to the organisms.
4. Stop the tissue destruction.

Organism Identification

The first principle, to identify the organism, is the ultimate purpose of diagnosis. The diagnosis of musculoskeletal sepsis, and septic arthritis in particular, is difficult to establish with certainty unless an organism is identified. Likewise, it is even more difficult to treat the infection with certainty until the specific organism is identified.

Select Correct Antibiotic

The value of knowing the relative incidence of causative organisms in a particular case is to aid in selecting a likely effective antibiotic before the organism is positively identified by culture, and to understand the unique characteristics of the organism, including antibiotic resistance, so that initial treatment may be modified accordingly. The antibiotics commonly used in the treatment of musculoskeletal sepsis are listed in Table 13-3.

When hematogenous osteomyelitis and septic arthritis are considered apart from any unique circumstances, age is the most important factor in the incidence of a particular organism. In reviewing different series, there are often wide variations in the percentage of cases caused by a particular

TABLE 13-3. ANTIBIOTICS COMMONLY USED IN THE TREATMENT OF BONE AND JOINT SEPSIS

Drug ¹	Route	Dosage ^{2,3}	Comments
Amoxicillin	Oral	80 mg/kg/d q8h	
Ampicillin	IV	100–150 mg/kg/d q6h	
Dicloxacillin	Oral	100 mg/kg/d q6h	
Methicillin	IV	150 mg/kg/d q6h	
Nafcillin	IV	150 mg/kg/d q6h	
Penicillin G	IV	150,000 U/kg/d q4–6h	
Penicillin V	Oral	100 mg/kg/d q6h	
Oxacillin	IV	150 mg/kg/d q6h	
Cefazolin (Ancef, Kefzol)	IV	100 mg/kg/d q8h	Max dose 6 gm/d
Cephalexin (Keflex)	Oral	100 mg/kg/d q6h	
Cefotaxime (Claforan)	IV	150 mg/kg/d q6–8h	
Cefprozil (Cefzil)	Oral	60 mg/kg/d q12h	
Ceftazidime (Fortaz)		100–150 mg/kg/d q8h	Max dose 8 gm/d
Ceftriaxone (Rocephin)	IV/IM	50–75 mg/kg/d q24h	Max dose 2 gm/d
Cefuroxime (Zinacef)	IV	100–150 mg/kg/d q8h	
Cefuroxime axetil (Ceftin)	Oral	60 mg/kg/d q12h	
Ciprofloxacin (Cipro)	IV/Oral	30 mg/kg/d q12h	Max 800 mg/d
		30 mg/kg/d q12h	Max 1500 mg/d
Clindamycin	IV/Oral	25–40 mg/kg/d q6h	
Gentamicin	IV	7.5 mg/kg/d q8h	Monitor peak and trough start at third dose
Vancomycin	IV	40 mg/kg/d q6h	Administer over 1 h monitor peak and trough start at fourth dose
Bactrim	IV/Oral	10 mg/kg/d (of trimethoprim component) bid	

¹ CBC should be monitored weekly for neutropenia or anemia, in any patient on high-dose IV penicillin or cephalosporin therapy. It should be monitored monthly on high-dose oral therapy.

² Doses recommended are for normal children with normal renal function for the treatment of bone and joint infections. Recommended doses for the treatment of other conditions may be lower or higher.

³ For doses in the neonatal period, see: Nelson, JD. *Pocket book of pediatric antimicrobial therapy*, 10th ed. Baltimore: Williams & Wilkins, 1998–1999.

organism. This may be because of the years over which the data were gathered, the population being evaluated, on the diligence in identifying the organisms. Despite these variations, some generalizations can be made based on age that are very useful in the initial selection of an antibiotic.

The most useful age divisions are: premature neonates, term neonates, children under 3 to 4 years of age, and children older than 4 years of age. The reasons for this have to do with the organisms that predominate in these age groups. The premature infant is discussed later as a special problem.

The term “neonate” may be considered as any child from birth to 6 weeks of age. Although the neonatal period is considered the first 28 days it is more helpful, when thinking of infection, to think of the neonate being any infant up to 6 weeks of age. The particular organisms that affect this population are group A and group B streptococcus, *Streptococcus pneumoniae*, and *Escherichia coli*, in addition to *Staphylococcus aureus*. In this age group, cefotaxime (Claforan) is the first drug of choice. Ceftriaxone (Rocephin) is also a good choice in a child without jaundice.

Prior to the use of the vaccine against *H. influenzae* type b (HIB), it was the most common organism causing septic arthritis in patients younger than 5 years of age, whereas *S.*

aureus was, and remains, the most common organism in children older than 5 years of age (55,96,97). This made it important to select an initial antibiotic that was effective against HIB in this age group. Today, HIB is a rare cause of bone or joint sepsis because of the immunization. HIB may still be suspected in the newborn or in the unusual child who today has not received immunization. It is important to recognize that as many as 30% of children with HIB septic arthritis may also have meningitis (97,98). This is especially likely to occur in children younger than 2 years of age. Several other organisms (e.g., group B streptococci and *Escherichia coli*) found in septic arthritis also show a predilection for the younger age groups, and may also cause meningitis.

An organism that is increasingly identified in osteoarticular infections, particularly in the younger child under the age of 3 or 4 years, is *Kingella kingae* (99). This organism was initially identified and characterized in the late 1960s. It has been isolated in slightly more than 1% of pharyngeal cultures, but may be more prevalent. In one series of infections due to *K. kingae*, 56% of the patients had a respiratory infection (100). This predilection for the respiratory tract, and the increased incidence of musculoskeletal infection

with this organism during the winter months, is noted in other reports (59,99). The organism is described as an opportunistic pathogen, and is thought to colonize the nasopharynx then invade the bloodstream. Favored sites are bone, joints, disc spaces, and heart.

The increased incidence of *K. kingae* infection may be due to better methods of isolation. It has been demonstrated that inoculation of the material into a BACTEC culture bottle (Johnston Laboratories, Towson, MD) can dramatically increase the rate of recovery of *K. kingae* (100).

Like *H. influenzae*, *K. kingae* infections most often occur in children younger than 4 years of age. Most children are healthy before the onset of the infection. The organism affects joints most frequently. The clinical course and laboratory findings do not differ significantly from septic arthritis caused by other organisms. The bone infections are often insidious and frequently occur in the epiphysis.

K. kingae is sensitive to penicillin and many of the semisynthetic penicillins and cephalosporins that are used to treat bone and joint infections (101,102). It is possible that in the past many of the culture-negative cases of musculoskeletal sepsis resolved with these commonly used antibiotics, without *K. kingae* being identified. A second organism seen in septic arthritis in this age group is *Streptococcus pneumoniae*. Currently 30 to 50% of these organisms are relatively resistant to the semisynthetic penicillins and cephalosporins (103).

Today, ceftriaxone (Rocephin) is an excellent drug for initial treatment of bone and joint sepsis in children under the age of 4 years of age. The fact that it is effective against most of the common organisms seen in this age group; the fact that it can be administered once a day, significantly reducing costs; and the very high minimal inhibitory concentrations that are reached in the blood, all favor this antibiotic.

It is important to remember that despite the variety of organisms responsible for bone and joint sepsis in the younger child, *S. aureus* is still the most common causative organism in AHO after infancy, and particularly over the age of 5 years. The reported incidence ranges between 25 and 64%, depending largely on the age mix of the patients in the study (20,46,47,51). However, streptococcal organisms, including group A *Streptococcus* and *S. pneumoniae*, are also found in the child older than 5 years of age, with the reported incidence ranging from 4 to 21%. Infections with streptococcal organisms tend to occur in the younger age range (20,49,51,165), whereas *Staphylococcus aureus* becomes more common with increasing age. In this older age range in which *Staphylococcus* predominates, a semisynthetic penicillin, e.g., oxacillin or a cephalosporin, e.g., cefazolin (Ancef, Kefzol) or cefuroxime (Zinacef), are good initial choices.

Preferably, children between birth and 2 to 3 years of age are managed along with a pediatrician or pediatric specialist. One of the important reasons, other than the management of the antibiotics, is that these children more frequently have other sites of involvement, e.g., meningitis. They require a

good clinical examination for meningitis and other problems which may not be commensurate with the best skills of the orthopaedist.

It needs to be understood that these are initial choices which are made before culture results are available. Once the organism is identified, the antibiotic choice is changed to one that is effective but narrower in its range of activity. The antibiotics most commonly used to treat bone and joint infections in children are listed in Table 13-3.

The selection of an oral antibiotic should be based on Gram stain and culture results. For the child younger than the age of 5 years, cefuroxime axetil (Ceftin) and cefprozil (Cefzil) are good choices. For the older child, cephalexin suspension or dicloxacillin capsules are a good choice (see Table 13-3).

Antibiotic Delivery

Giving an antibiotic to a patient who has an infection is not sufficient. The physician must ensure that the antibiotic both reaches all of the organisms and effectively kills them. This involves several issues. Does it matter whether the antibiotic is given intravenously or orally? How long should the antibiotic be given, and why? Where can the antibiotic be expected to penetrate? Can it kill the organism when it gets there? In this era of cost containment, and with the worthwhile goal of keeping children out of the hospital, the real questions are, how long does the patient have to remain in the hospital, and when can intravenous administration of antibiotic be switched to oral administration?

Route of Administration

Initial antibiotic therapy for bone or joint infections should always begin with intravenous administration. The question of how soon the intravenous route can be switched to the oral, in any particular case, is a question for which no data are available. Intravenous administration is more expensive than oral administration, however, and certainly less convenient for the patient (104). An advantage to intravenous administration is that high concentrations of antibiotic can be achieved quickly with certainty. These levels exceed those usually necessary, whereas the levels achieved with oral administration are usually adequate. The difficulty with oral administration is in ensuring that absorption from the gut is adequate, and that the patient is compliant. Despite these potential pitfalls, the efficacy of oral antibiotics in the treatment of bone and joint sepsis has been well documented (104–107), and represents an acceptable method of treatment following an initial course of intravenous antibiotics.

An additional troublesome problem with prolonged intravenous administration in small children, is maintaining vascular access. This usually requires that these children have a peripheral indwelling catheter (PIC line) placed. While lessening the problems, these lines are not without

problems, e.g., clotting and becoming infected, as well as requiring a certain level of skill on the part of the home health agency that is managing the line. Thus, they are not a reason to give intravenous antibiotic longer than necessary.

The successful administration of oral therapy requires the same conditions as for intravenous therapy, i.e., that the antibiotic reach the organisms in sufficient concentration and be in the bone for a sufficient length of time to kill the organisms. Patients may generally be switched to oral antibiotics therapy when the course of the disease is resolving, abscess formation is not present or has been debrided, or the antibiotic is well-tolerated orally by the patient, and the parents are reliable.

In one series about 10% of the patients failed to achieve adequate serum concentrations of the antibiotic after oral administration (107). Reports such as this led to the recommendation that the peak serum level be measured to verify that adequate antibiotic was present. There is some evidence that it may actually be the trough level that is more significant (109,110). In practices in which measurement of bactericidal concentration of antibiotic has been measured as a routine in the past, it is now used more often only for more difficult situations. This has evolved because, with adequate oral doses, it is very unusual to find insufficient levels of antibiotic or treatment failures that can be attributed to insufficient levels of antibiotic. Experience has taught that, to achieve adequate serum levels of antibiotic, larger oral doses (usually two times larger) are needed than those commonly recommended (Table 13-3).

Although it is decreasing as a routine practice, at times it will be necessary or advisable to measure the concentration of the antibiotic. Because the direct measurement in the blood of the level of commonly used antibiotics (e.g., semi-synthetic penicillins, cephalosporins) is not feasible, it is measured indirectly by the serum bactericidal test. This test uses serial dilutions of patient serum to test against the bacteria, which is isolated to determine the minimal dilution that is bactericidal for the organism (111,112).

Blood is drawn after the administration of the oral antibiotic to determine the peak level. For antibiotic given in suspension, the blood is drawn 1 h after administration; for antibiotic administered in capsule or tablet, blood is drawn approximately 1.5 to 2 h after administration. If the trough level is to be measured, blood is drawn just before the next dose. Dilutions of the serum are prepared and tested against the isolated organism. If an organism is not isolated, a representative laboratory strain of the presumed organism is used. Although it is controversial regarding how much the peak serum level should exceed the bactericidal concentration, a 1:8 dilution is generally accepted as being effective. When adequate levels are not present, the dose may be increased: probenecid (Benemid) to inhibit renal excretion may be added, or intravenous therapy may be reinstituted.

The serum level of other antibiotics (e.g., gentamicin, vancomycin) can and should be monitored in all cases. These antibiotics can be measured directly in the blood.

Not only does the blood level of these intravenous antibiotics vary significantly between individuals, but their toxic side effects are significant. Both the peak and trough levels need to be measured and monitored. For gentamicin, blood is drawn approximately 30 min after administration, and just before the next dose. The peak level should be between 5 and 10 $\mu\text{g/mL}$, and the trough should be 1.9 $\mu\text{g/mL}$ or less. For vancomycin, blood is drawn 1 h after administration, and just before the next dose. The peak level should be between 20 and 40 $\mu\text{g/mL}$ and the trough between 5 and 10 $\mu\text{g/mL}$.

Generally, blood levels of gentamicin or vancomycin should be measured every 3 to 4 days, in addition to those of blood urea nitrogen (BUN) and creatinine. For prolonged (longer than 3 weeks) or recurrent therapy with these drugs, it is wise to monitor the patient for ototoxicity also. Vancomycin should be infused over no less than 1 h to avoid the release of histamine by the drug (red man syndrome) or serious hypotension. If a rash occurs, it usually can be circumvented by administering the drug over 90 to 120 min, or by the use of intravenous diphenhydramine (Benadryl) 1 mg/kg (total dose not to exceed 50 mg) just before the infusion.

Penetration

After an adequate serum level of the antibiotic is achieved, it must reach all of the areas harboring bacteria. In evaluating data on antibiotic penetration, it is necessary to consider the antibiotic in addition to the methods used to measure its concentration (113). Methicillin, dicloxacillin, cephaloridine, and cefazolin all penetrate into pus and bone in children with osteomyelitis in concentrations several times greater than the mean inhibitory and mean bactericidal concentrations for *S. aureus* (114). The same is true for orally administered ampicillin, cephalexin, cloxacillin, dicloxacillin, and penicillin G in the synovial fluid of children with septic arthritis (115). There is no evidence that antibiotics penetrate into dead bone.

Efficacy of Antibiotic

The treatment of musculoskeletal sepsis presents a paradox. If the antibiotics kill the bacteria, and there is a sufficient serum concentration in the absence of dead bone, why is not antibiotic administration more rapidly and universally successful? The answer lies in understanding that there are several factors that may interfere with the antibiotic action. One factor that is poorly studied is the effect the local environment has on the ability of the antibiotic to kill bacteria. It is known that the interaction of purulent material from some Gram-negative organisms can interfere with the action of certain antibiotics (116,117).

With a large inoculum and the production of large amounts of β -lactamase, β -lactam antibiotics, such as semi-

synthetic penicillins and cephalosporins, are susceptible to breakdown, rendering them ineffective (118–120). In addition, the low pH at the site of infection is known to interfere with the action of some antibiotics. These factors suggest that the local environment is important to the effective action of the antibiotic, and that the site of infection may not be the ideal environment.

Duration of Administration

There are no good data that indicate how long antibiotics should be administered in any particular case. The old recommendation of 6 weeks of intravenous administration is often based on difficult and complicated referral cases from large tertiary medical centers, which do not represent the “usual” case (121). Conversely, there is no evidence, other than clinical experience, that a shorter duration can be effective. More important than rigid rules is an understanding of the pathophysiology of each case, so that the treatment can be based on the particulars of that case. The correct answer is that the antibiotic should be continued until all of the organisms have been killed.

To illustrate, consider two different cases. A 5-year-old boy presents with a history of increasing pain in the distal thigh for 3 days, and inability to walk on the day of presentation. His radiographs are normal, except for deep soft tissue swelling. Aspiration demonstrates pus, and he undergoes surgical debridement the same day. He is started on the correct antibiotic. Over the next 5 days, the pain, swelling, and fever subside, the CRP is falling, and he begins to walk. He can be safely treated with 5 days (perhaps less) of intravenous antibiotics, followed by oral antibiotics for an additional 3 or 4 weeks.

Another 5-year-old boy is seen 2 weeks after the onset of pain in the distal thigh. His physician had placed him on oral antibiotics after 3 days, but the pain and limp continued to worsen. His radiographs show extensive involvement of the distal femoral metaphysis, with radiolucent areas and periosteal new bone. He undergoes surgical debridement, but it is not deemed possible to debride all of the bone that is involved. At the end of 7 days, his fever is decreasing, the CRP has not fallen, and although his signs and symptoms are improving, he still has some swelling and tenderness. This patient should remain on intravenous antibiotics.

These two cases illustrate the factors to consider when deciding the duration of antibiotic therapy. How long has the infection been present, and how much bone is involved? Is there abscess formation? Has the patient had adequate surgical debridement to remove the pus and other materials that interfere with effective antibiotic action? Has all of the dead bone been removed to expose organisms to antibiotic? Is the patient getting better? These clinical observations can be aided to a limited extent by radiographic and laboratory studies, remembering that radiographic changes lag behind the actual bone changes, and that the ESR and, to a lesser

degree, the CRP also lag behind resolving infection during the first week (51).

Current practice is a sequential course of intravenous antibiotic, followed by an oral course. Clinical parameters determine when oral antibiotics begin. In the typical case which resolves quickly with treatment, oral therapy starts after 5 days of intravenous antibiotic administration; in the case of osteomyelitis, it continues for 4 to 6 weeks and, in septic arthritis, for an additional 2 to 3 weeks.

Surgery

Destruction of tissue is the final result of infection. Although bone has the ability to repair itself, articular and epiphyseal cartilage do not. Therefore, one of the main goals of treatment is to stop tissue destruction. Killing the bacteria is the first part of the treatment, but not the only part. Tissue destruction is mainly the result of the complex process known as the “inflammatory reaction.” Although this reaction is initiated by bacteria, the presence of live bacteria is not necessary for its continuation. It is well recognized that the products liberated by bacteria, cell wall fragments of dead bacteria, products liberated from leukocytes, and products of tissue destruction are all capable of causing an inflammatory reaction, which results in tissue destruction (37,40,122–124).

With an understanding of the mechanisms of tissue destruction and the delivery of antibiotic to the bacteria in an environment where it can be effective, the basis for surgery becomes more meaningful. Surgery is for debridement. It removes the inflammatory products more rapidly than the host defense mechanisms. In so doing, it provides a more effective environment in which antibiotics can work. It reduces the size of the inoculum, ensuring more effective antibiotic action of many commonly used antibiotics. Lastly, it removes all of the dead and avascular bone or the thick fibrinous exudate from joints, thus exposing all of the organisms to antibiotic. This provides a more rapid end to tissue destruction, and requires a shorter course of antibiotic therapy.

The indications for surgical debridement of AHO remain controversial and in flux. Difficulty in evaluating published reports and recommending various points of view arise because of failure to identify the important characteristics of those who were treated with surgery and those who were not. Among those factors that are important to evaluate are the duration and severity of infection, the type of organism, appropriateness of antibiotic use, the duration of intravenous antibiotic versus oral, and length of hospitalization.

The author has used the aspiration of pus, or failure of signs and symptoms to resolve within 36 to 48 h, as an indication for surgical debridement. This practice is based on the same principles used to treat infection in other parts of the body. Especially important is the age-old wisdom of draining an abscess, regardless of location. With these crite-

ria, many cases avoid surgery, few require prolonged intravenous therapy, and recurrence is distinctly unusual. This is a mainstream opinion that is evolving in clinical practice, and that is supported by others (125,126).

Surgical debridement of a focus of hematogenous osteomyelitis requires an incision only large enough to expose the area of bone involved. Incision of the periosteum in the involved area is performed first, to drain the subperiosteal abscess. Stripping of the periosteum to expose additional periosteal abscess should be done sparingly, to avoid devascularization of the bone. Next, using a drill an entry hole is made into the bone. This can be enlarged with a rongeur to allow access with a curet, but this hole should not be any larger than necessary to curet the involved bone. The diseased area is easily distinguished from more normal bone by "feel" with the curet and the appearance of the material removed.

Specimens should be sent for both culture and routine histology. The importance of routine histologic examination of material from the bone is twofold. Some tumors have a tendency to become necrotic and, when surgically explored, may look similar to pus; the most common is metastatic neuroblastoma, followed by Ewing sarcoma. In addition, if positive identification of the organism is not obtained, it is reassuring to have a histologic diagnosis of osteomyelitis.

The indications for arthrotomy in the treatment of septic arthritis are perhaps even more controversial (except for the hip), although more sharply divided between the orthopaedic and pediatric literature. Experimental evidence supports lavage of the joint, but individual experiences constitute the evidence that drives clinical decisions.

In experimental staphylococcal septic arthritis in rabbits that were treated with antibiotic, the beneficial effect of

surgical lavage was demonstrated (45). During the first arthrotomy at 4 days, all of the material in the knee could be washed out; at 7 days, it had to be removed manually. All cultures were negative at 7 days. Both the surgically treated and nonsurgically treated animals showed loss of glycosaminoglycan. There was no collagen degradation in those treated by surgical lavage, however. A similar study has shown that arthrotomy and irrigation may be more effective than repeated aspirations, as the above data suggest (127).

In the author's experience, there is no question that some joint infections can be cured with antibiotics alone. This seems to be especially true in the smaller joints, such as the wrist, and in younger children. Attempts to treat joints such as the knee without drainage have never been as prompt to resolve as those treated with a small arthrotomy and irrigation, followed by a brief period of splinting.

Effective drainage of most joints can be performed through a small incision. The incision should be large enough to permit a small retractor to be inserted into the joint. On the knee of a small child, this can be accomplished with an incision of no more than 2.5 cm. After suctioning the purulent material from the joint, a swab of the synovium is obtained for culture. A small biopsy of the synovium may also be sent for culture. Irrigation is then performed with saline through a small rubber catheter directed into all of the recesses of the joint. A drain (or irrigation system, if preferred) is inserted into the joint, and the wound is closed (128,129).

Repeated aspiration has been recommended, but suffers from two drawbacks: it is ineffective in draining the joint (Fig. 13-11), and it becomes a difficult trial for both the patient and the physician because it must be repeated at least daily for several days. Arthroscopy has also been recommended (130,131). Morbidity following arthroscopy does

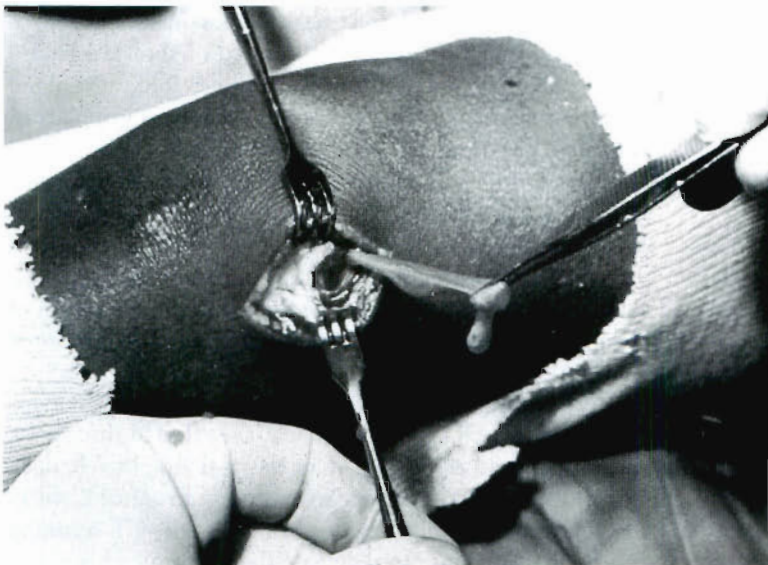


FIGURE 13-11. This patient with 3 days of symptoms was diagnosed as having septic arthritis after aspiration of the joint. Within 2 h of aspiration, the knee joint was opened through a small arthrotomy, with the patient under general anesthesia. Before and after irrigation, large amounts of thick fibrinous pus were removed with a forceps, illustrating the inadequacy of aspiration as a method to debride the joint.

not seem to be any different than for open arthrotomy in septic joints, whereas the operative time and resources are more costly for arthroscopy.

RESULTS

Most children who are seen for AHO or septic arthritis can expect to recover without sequelae. These disorders are curable. Untoward consequences are usually due to advanced disease at the time of presentation, or problems in the initial management. Other than these two factors, the literature sheds little light on other reasons for failure, because the reports cover decades during which organisms, antibiotics, and principles of management changed (20,60,120,126,132–134).

Most complications from musculoskeletal sepsis occur in the hip for reasons documented elsewhere in this chapter. Other than the hip, joint destruction is expected only in the late-presenting and neglected case. Chronic osteomyelitis remains distinctly unusual, probably because of the rapid bone turnover in children. Epiphyseal destruction with growth arrest is occasionally seen, but usually in cases in which appropriate treatment is delayed.

SPECIAL CONDITIONS

Spine

For decades, physicians have recognized hematogenous infections of both the disc space and the vertebral body. Descriptions of the disorder as “a benign form of osteomyelitis of the spine” provide a clue to its natural history (135), whereas the various descriptions in the literature of vertebral osteomyelitis and discitis, over the past several decades, reflect the uncertainty that these are indeed two separate conditions (136,137). Modern imaging modalities, such as scintigraphy, CT scanning, and MRI have resolved the confusion by demonstrating evidence of bone involvement in children with the clinical presentation of discitis (138,139). It thus appears that both vertebral osteomyelitis and discitis are the result of a hematogenous infection beginning in the bone adjacent to the cartilaginous vertebral end plate.

The vascular anatomy of the vertebral body and disc has been well studied (140–143). These studies demonstrate that the blood supply to the disc comes from the contiguous bone of the vertebral bodies. In the young child, vessels can be identified traversing the cartilaginous vertebral end plate and entering the annulus. By the age of 8 years, these vessels have largely disappeared, but a rich anastomotic network of vessels remains along the periphery of the disc that can persist until 30 years of age.

The etiology of the syndrome of discitis is most likely infectious. Occasionally, the question of traumatic injury to

the vertebral end plate, similar to a Salter-Harris I fracture, is raised; however, substantial proof is lacking. The different presentations, the characteristic age range (average age, 7 years), and the isolation of bacteria from many cases also militates against this being a traumatic disorder. It is recognized, however, that this is an infection that behaves differently than most musculoskeletal infections.

The presentation of patients with discitis is variable and insidious, with fewer than one-half presenting with the characteristic symptoms of refusal to walk or back pain (144). In addition, signs of infection, such as fever, are usually minimal or absent. Despite this, three different patterns of clinical presentation have been described (145,146). The first presentation is in the younger child, usually younger than 3 years of age, who has difficulty walking. In the very young child this may begin with a reluctance, then refusal to walk, and may be confused with more common causes, such as a septic hip. In the child who is attempting to walk, there is often a characteristic gait, with the child bending forward and hands on the thighs for support.

The second presentation, usually occurring in children 7 to 15 years of age, is abdominal pain. This can be vague and associated with a poor appetite and listlessness. Sometimes the pain radiates anteriorly and can be confused with an intraabdominal condition, although localized physical signs in the abdomen are lacking.

The final presentation is back pain. In the classic presentation, the patient complains of back pain, has loss of the normal lumbar lordosis, and is painful to percussion. In some children, this onset may be gradual, whereas in others who often have radiographic evidence of vertebral osteomyelitis, the onset may be rapid and may suggest infection. In most cases, fever is absent or low. It is also important to remember that these presentations may overlap greatly in age, symptoms, and findings.

The laboratory evaluation, as with most cases of skeletal sepsis, is not helpful unless the underlying disease is suspected and all of the correct tests are obtained. The leukocyte count may or may not be elevated or show a leftward shift. The ESR and CRP are usually elevated, and blood cultures may be positive, but not so reliably as in the usual infection involving a major bone or joint.

Radiographs at the initial presentation are often normal, and usually show no changes in the first 1 to 3 weeks of symptoms. One of the earliest findings, often seen only in retrospect, is an irregularity of the vertebral end plate. This is followed by narrowing of the disc space, then erosion of the vertebral end plate, as evidence of involvement of more than just the disc space (Fig. 13-12).

Bone scintigraphy is useful in suspected cases, demonstrating increased isotope uptake at the affected disc space. This usually occurs sooner than the radiographic changes, but the author has seen negative bone scans after 2 weeks of symptoms in patients with proved discitis. CT scanning is a useful technique to delineate the anatomic changes in

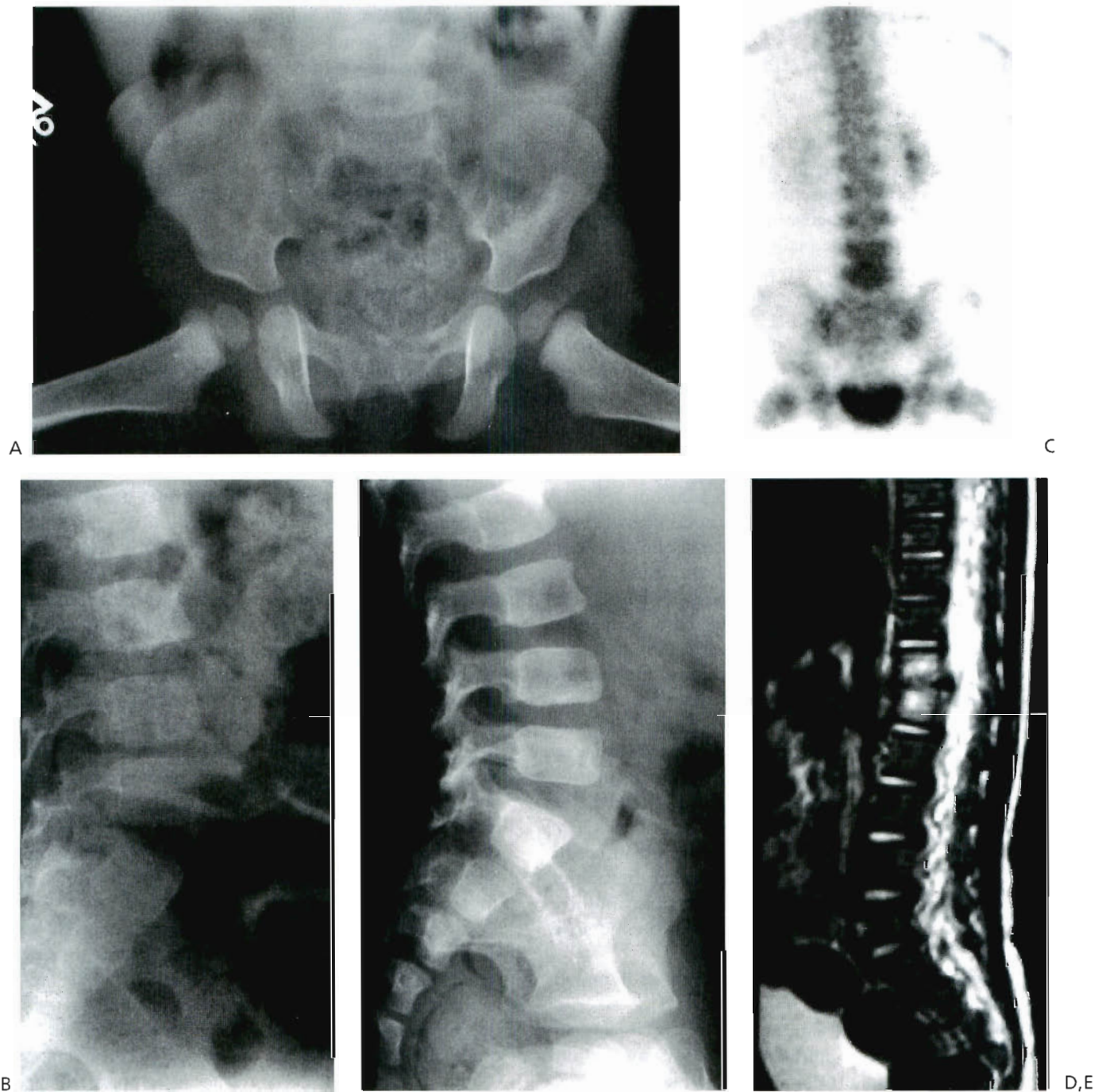


FIGURE 13-12. A: AP view of the pelvis of a 14-month-old child who stopped walking after several days of limping, falling, and irritability. This radiograph was ordered by the initial treating physician because of the suspicion of hip infection. Note the narrowing of the L4–L5 disc space. B: The lateral view was taken subsequently, when examination by the orthopaedic surgeon demonstrated pain on percussion of the lower spine. Again, note the narrowing of the L4–L5 disc space. C: Increased isotope uptake in the vertebral bodies of L4 and L5, which is typical of discitis, is demonstrated. D: At 10-month follow-up, the disc space has almost recovered its normal height. E: A fast spin-echo T2 MRI of a 22-month-old child with a similar story. Note the more significant changes in the disc than expected on the radiographs. The enhancement of the vertebral bodies demonstrates that the process is not confined to the disc as described in the past.

the vertebral bodies. When performed on patients having classic disc space narrowing, it usually shows unsuspected areas of vertebral involvement. Although it is not often necessary, MRI is a useful tool in the case that is difficult to diagnose. In addition, it gives so much clear information that it is hard to resist using this as the first imaging test following the plain radiograph. MRI clearly demonstrates the involvement of the adjacent vertebrae (138,139).

Differential diagnosis between tumor and infection is usually not difficult on the plain radiographs. Collapse of the vertebral body, with preservation of the disc space, is seen in eosinophilic granuloma (vertebra plana) and, to a lesser extent, in leukemia. Neither of these conditions demonstrates increased isotope uptake on bone scan early in their course. Destruction of bone, with subsequent involvement of one or two disc spaces, suggests infection. A large amount of bone destruction, especially in adjacent vertebrae, suggests tuberculosis. Primary bone tumors of the spine are unusual in childhood, but must also be considered when bone destruction is present. MRI offers more detail about the extent of both bone and surrounding soft tissue involvement, and for that reason is a very useful test when a question arises as to the possibility of tumor (147).

In almost all other cases of musculoskeletal infection, aspiration or biopsy for culture is considered to be mandatory. With infections of the vertebrae and disc, however, difficulty, potential complications, morbidity, and cost are factors that usually lead to treatment without biopsy. This course is supported by the usually benign natural history of this condition, and by the excellent results that are achieved with empiric treatment in the absence of positive cultures. In those series in which biopsy has been performed, the yield of positive cultures is slightly less than 50%. Open biopsy is more likely to yield positive cultures than needle biopsy, and there is a trend toward better identification of organisms in more recent series. The results of the positive biopsies show a preponderance of *S. aureus* as the causative organism (144–146,148).

The treatment of disc space infections reflects both past observations and contemporary knowledge. Past observations of this disease demonstrated that it was largely self-limited, with occasional morbidity, and was successfully treated with rest, despite recognition of a likely infectious etiology (136,149). Current treatment consists of antistaphylococcal antibiotics (e.g., a semisynthetic penicillin or first-generation cephalosporin, as used in the initial treatment of AHO) (146). This has resulted in less morbidity (138). Antibiotic therapy is usually started intravenously, with hospitalization and bed rest. Careful observation for the onset of neurologic signs that would indicate epidural abscess formation is advisable until the patient shows resolution of symptoms. Immobilization may also be used, but the trend is to avoid it. If the patient's symptoms resolve, intravenous antibiotics are switched to oral antibiotics after 5 to 7 days. Oral antibiotics are continued for 3 to 5 weeks.

Resolution of symptoms usually occurs within the first 72 h. If this is not the case, the physician should begin to question the diagnosis or the specific bacterial etiology. Further imaging studies, such as CT scan or MRI, may be justified in such circumstances to search for tumor or abscess formation. Biopsy is indicated in a patient who fails to respond to antibiotics and bed rest, or has findings on imaging studies that suggest a diagnosis other than typical discitis.

Pelvis and Sacroiliac Joint

Infections of the pelvis and SI joint share two features with each other and with discitis: They present with a wide variety of symptoms, and are thus difficult to diagnose, and they can usually be treated successfully without surgery. However, unlike discitis, pelvic infections can occur in many locations within the pelvis, making diagnosis and localization more difficult. The debate over whether the process in the SI joint is an osteomyelitis or true septic arthritis is largely irrelevant to the clinician. Both are possible and probably occur, and both are treated in the same way.

The presentation is not always acute, as in most forms of septic arthritis and osteomyelitis. In one series, only one-third of the cases were acute, and the average time from onset to diagnosis was 3.9 weeks (150). Morgan and Yates (151) described four different presentations of osteomyelitis of the pelvis, depending on the initial area of pain: hip joint, abdominal, buttocks, and sciatic. In addition, they described a systemic presentation with malaise and fever. Beaupre and Carroll (152) described three presentations of SI joint osteomyelitis, which they termed gluteal, abdominal, and lumbar disc. The lumbar disc syndrome presents with pain in the lower back, hip, and thigh; the gluteal syndrome presents with pain, and possibly a mass in the buttocks; and the abdominal syndrome can mimic acute appendicitis.

The most important step in the diagnosis of pelvic osteomyelitis is to consider it as a possibility. Failure to perform an adequate examination for symptoms in the SI joint by compression and careful palpation of the other pelvic bones is a common cause of delay in diagnosis and confusion with other sites of infection. At the same time, it is important to remember that the pelvis and the SI joint are the site for many different pathologic processes, of which infection is only one (153).

Perhaps the most common diagnosis that is confused with SI joint sepsis is septic hip. SI joint infection is generally seen in older children, with the mean age being 10 years, whereas septic hip is more common in the younger child (150). Despite the complaint of pain around the hip, children with SI joint infection often remain ambulatory, and have relatively free internal rotation of the hip, in contrast to those with a septic hip. Conversely, patients with SI joint infection frequently experience greater pain on external rotation of the hip than internal rotation. If the

FABER test (flexion, abduction, external rotation) is performed, it usually elicits pain in the presence of SI joint sepsis, as does compression of the pelvis (Gaenslen test). Tenderness almost always is found over the SI joint, if sought. Other areas (e.g., the ischium, pubis, ilium) should always be palpated for tenderness in children with gait disturbance or hip pain.

It is important to remember that osteomyelitis can occur in any location in any pelvic bone, and failure to elicit symptoms in the SI joint does not rule out pelvic osteomyelitis (154,155). Bony tenderness is usually present at the site of involvement, emphasizing the importance of suspicion, followed by a careful examination (155).

Osteomyelitis of the ischiopubic synchondrosis presents a confusing picture, despite tenderness being present. This synchondrosis, which fuses between 5 and 12 years of age, and occasionally later, shows a radiographic picture of expansion, and uneven mineralization before fusion. In addition, it is often asymmetric to the opposite side, which may have fused earlier, and radioisotope uptake is increased in many cases (156). Kloiber and colleagues report that, if the radioisotope activity at the ischiopubic synchondrosis is equal to or greater than that adjacent to the triradiate cartilage, or if the activity extends into the adjacent pubic ramus or ischium, it is indicative of a pathologic process (157).

Oblique radiographic views demonstrating the SI joint may be obtained, but their value today in making an early diagnosis with better imaging techniques is doubtful. In most cases of pelvic osteomyelitis, the initial radiographs are normal. This is especially true when symptoms have been present for fewer than 1 or 2 weeks. The earliest sign of infection on the radiograph is disappearance of the subchondral margins and erosion; however, this should be considered to be a late finding. If radiographic changes are present with less than 1 week of symptoms, careful consideration should be given to other disorders, such as tumor or chronic inflammatory SI disease. Until recently, the ^{99m}Tc bone-scanning was the most effective test in localizing a focus of pathology within the pelvic bones, but this may be changing, with further experience with MRI (158–161). Single photon emission computed tomography (SPECT) scanning should be utilized in the pelvis, as in the spine.

CT scans likewise can be helpful in several respects, but are not necessary in all cases (159,161,162). CT scans can better delineate the extent of bone involvement than can the radionuclide scan.

More recently, the value of MRI has become apparent in not only localizing the location and extent of bone involvement, but also in better delineating soft tissue changes, e.g., abscess formation (163) (Fig. 13-13).

Schaad and colleagues reported that the bacterial etiology was established in 57% of the cases they studied from their own patients, and from a literature review (150). In most cases, *S. aureus* is the organism that is cultured from blood, direct aspiration, or biopsy (150,152,159,161,164). *Staphy-*

lococcus epidermidis and *Streptococcus* species are also reported, but, in many cases, may be contaminants (159). An occasional *Salmonella* species may be isolated in patients who are not otherwise predisposed (150,161,165).

Laboratory findings in SI joint sepsis and pelvic osteomyelitis parallel other bone and joint infections, with the leukocytes often being normal and the ESR and CRP levels usually elevated. Blood cultures are positive in about 50% of cases; therefore, considering the difficulty in obtaining cultures from the SI joint and pelvis, they should always be obtained. *Salmonella* is always a possibility, even in those not predisposed to this organism, and, thus, stool cultures should be obtained. Joint aspirates are positive for the organism less often than in other cases of bone and joint sepsis (150,153,164). Although this is partly due to the difficulty in entering the joint, even biopsy specimens and pus seem to yield positive culture results less often than would be expected.

In the report by Reilly and colleagues (161), six of ten cultures from aspiration or biopsy of the SI joint were positive; the same yield as obtained from blood cultures. The technique for aspirating the SI joint has been described (166,167).

The author prefers to aspirate only those cases that do not respond promptly to antibiotics, or that exhibit atypical features, for the following reasons:

- Morbidity and expense associated with this procedure, which usually requires general anesthesia, are high
- Blood or stool culture can identify at least 60% of the organisms
- Most organisms are *S. aureus*
- The literature indicates that most of these patients respond to antistaphylococcal antibiotics.

Reports in the literature demonstrate that surgical debridement of pelvic osteomyelitis is usually not necessary (152,153,164). This contradicts reports in the older literature. The ability of this process to resolve with antibiotic therapy alone is probably due to a variety of factors: the large and diffuse blood supply to the bones, which makes sequestrum formation unlikely; the rigid ligament structure around the SI joint, which contains the spread of infection; and negligible long-term morbidity, even when the joint becomes ankylosed (164). Indications for surgery are those for biopsy in the case of suspected tumor, an unusual presentation, or failure to achieve resolution of the symptoms in a reasonable amount of time. Drainage of a large abscess may be necessary, especially in the presence of systemic symptoms.

Initial antibiotic therapy should be with an intravenous semisynthetic penicillin or first-generation cephalosporin, as used in the treatment of AHO (see Table 13-3). If symptoms resolve and the CRP begins to fall, the patient may be switched to oral antibiotics in 5 to 7 days, if adequate

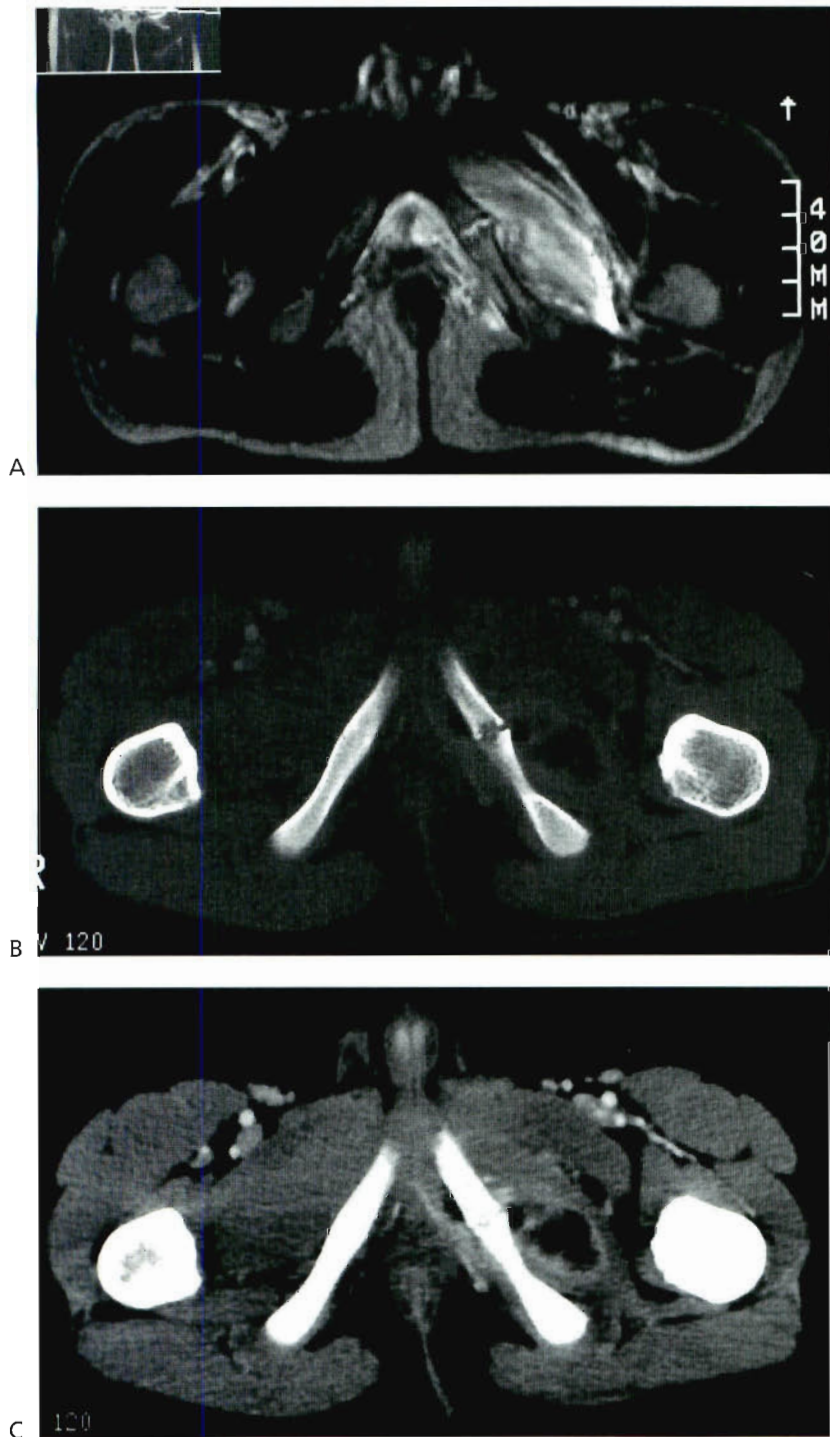

FIGURE 13-13. A: A T2 MR image of a 9-year-old boy with a history of increasing limp and hip pain for 1 week. The edema in the obturator muscle, the increased signal intensity around the ischiopubic synchondrosis, and the suggestion of abscess formation all suggest pelvic osteomyelitis. When the symptoms failed to resolve with intravenous antibiotics, CT-guided needle aspiration of the abscess was performed. B: Note the changes in the bone around the ischiopubic synchondrosis seen on the bone windows. C: Note the abscess seen on the soft tissue windows. Although MRI might still be the best choice for an initial imaging study in suspected pelvic osteomyelitis because of its ability to detect early changes within the bone, a great deal of information can be obtained from a good CT scan.

blood levels are obtained with oral administration. Initial and subsequent antibiotics should be adjusted to reflect information from blood and stool cultures, in addition to biopsy material, if that has been obtained. Failure of a response suggests that the antibiotic is not effective against the causative organism, a large abscess persists, or the etiology is not infectious.

The Neonate

Both AHO and septic arthritis can occur in the neonatal period. The classic definition of the neonatal period is the first 28 days of life. For the purposes of antibiotic selection in community-acquired infection, however, the physician is well advised to consider this period to extend to the first

8 weeks of life. The pathogenesis, diagnosis, and treatment of bone and joint sepsis differ significantly in the neonate.

The immune system in the neonate is immature. The factors are multiple, with some being specific and others nonspecific, and many of them are incompletely understood (168,169). There are two important effects of this lack of well-developed immunity. First, neonates are susceptible to a wide range of organisms that are less virulent under normal circumstances. Second, because they lack a well-developed immune system, neonates do not have the usual inflammatory response that creates the signs and symptoms so important to early diagnosis.

In most circumstances, the organisms reach the bone or joint by the hematogenous route. In addition to their unusual susceptibility to many organisms that may be considered normal flora, neonates may be subjected to a wider range of organisms and to opportunities for these organisms to gain access to the circulation. This is particularly true of the neonate (especially the premature infant) who is sick and remains in the intensive care unit in the presence of nosocomial pathogens, coupled with invasive monitoring, intravenous feeding, drug administration, and blood sampling. Indwelling vascular catheters, particularly those in the umbilical vessels, have long been recognized as being one of the main sources of infection (170).

There appears to be two types of infection in the neonate: that recognized in the hospital in premature infants, and that which becomes apparent after discharge from the nursery in otherwise healthy, full-term neonates. The type manifest in the hospital usually occurs in premature infants undergoing invasive monitoring. These infants are more likely to have infection caused by *S. aureus* or Gram-negative organisms, to have multiple sites of involvement, and to be systemically ill. More than 40% of affected infants have more than one site of involvement (171,172). The other type is usually manifest between 2 and 4 weeks of life (sometimes as late as 8 weeks), in infants who are not systemically ill, and are developing and feeding normally. These infections are more likely to be due to group B *Streptococcus*, and involve a single site.

Most cases of bone and joint sepsis in the neonate are caused by *S. aureus*, with group B *Streptococcus* being the next most common. Gram-negative organisms probably comprise 10 to 15% of the infections (171–172). *Candida albicans* is not uncommon, but usually occurs along with or after other infection, often in patients on prolonged antibiotic therapy or hyperalimentation (179). It is characterized by an even greater lack of the usual symptoms (e.g., increased warmth, tenderness).

A unique feature of neonatal bone and joint sepsis is the frequent association of contiguous bone and joint involvement and high morbidity due to the subsequent destruction of the growth plate or joint. This association, which has been reported to be as high as 76% (171,172), leads to another important difference between the neonate and the

older child, regarding the changing anatomy with growth and maturation. Trueta (31,180) described the changing vascular anatomy of the physis, and particularly the femoral head, during growth. Ogden (181) extensively studied the role that this unique vascular anatomy plays in neonatal osteomyelitis, and Chung (182) beautifully demonstrated this changing anatomy with injected human specimens.

The changing anatomy of the blood supply within the physis has been addressed previously in this chapter. Its importance in neonatal osteomyelitis is that the vascular channels penetrating the physis and the chondroepiphysis (cartilaginous anlage of the epiphysis) permit an early destruction of both, with consequent disturbance of growth and joint congruity. This probably occurs both by lysis of the cartilage, through the direct action of the organisms, and by destruction of the blood vessels (and the consequent avascular changes) by the inflammatory process (181,183).

Ogden's studies led him to conclude that the frequent association of bone and joint involvement was the result of primary bone infection, and was mainly due to the vascular canals traversing the physal plate and the chondroepiphysis, allowing early abscess formation in the chondroepiphysis, which could rupture into the joint. An additional factor is that the metaphysis in neonates may lie within the capsule of the joint, thus creating septic arthritis when the pus penetrates the metaphysis and elevates the periosteum (181,183). The lesson for the physician is that, when a septic joint is diagnosed in the neonate, a thorough search for osteomyelitis in an adjacent metaphysis or epiphysis is mandatory.

The diagnosis of bone and joint sepsis in the neonate is not easy, largely because of the absence of signs and symptoms secondary to the immature immune system. In one report on the value of bone scintigraphy in detection of neonatal osteomyelitis, the sensitivity for diagnosing focal disease by clinical findings was 20%, radiography 65%, and bone scintigraphy 90%. This illustrates the need for a high index of suspicion and reliance on tests other than examination, for the localization of the disease (184).

The most common presenting findings are swelling, followed by pseudoparalysis and tenderness. The large amount of fat surrounding the limbs of the neonate often makes detection of swelling difficult, whereas the lack of apparent illness often leads the unsuspecting physician to ascribe the lack of motion or apparent pain to some other cause. The diagnosis in the septic premature neonate is often delayed while other causes, such as meningitis or pneumonia, are sought.

Because early diagnosis is so important, the evaluation of the septic infant for osteomyelitis or septic arthritis should be serial, and not sequential. Any neonate with sepsis should be suspected of musculoskeletal sepsis. Any infant who exhibits disuse, discomfort of a joint with motion, or tenderness of a limb should be suspected of having bone or joint sepsis.

Other than possible soft tissue swelling, radiographic changes do not accompany an early diagnosis. The ^{99m}Tc bone scan is useful because it can survey the entire skeleton and detect changes before they are radiographically apparent. Ash and Gilday (185), however, found that only 32% of proved sites of osteomyelitis in 10 neonates were positive on the bone scan. This lack of ability to detect osteomyelitis may be partly due to the lack of inflammatory response to the infection, or because the infectious focus lies adjacent to the active growth plate, and is thus obscured by the uptake of the isotope in the growth plate. Subsequently, Bresler and colleagues (186) reported a more favorable experience, detecting all 25 sites of proved osteomyelitis in 15 affected infants. The improved results appear to be due to higher-resolution equipment and magnification views of all suspected areas.

Routine laboratory evaluation is of little value. The leukocyte count and differential leukocyte count are not reliably elevated. The sedimentation rate is usually elevated, but is a nonspecific finding. The blood cultures are positive in about 50% of patients with proven infection.

Once the area of involvement is identified, aspiration is mandatory. This permits confirmation, either through obtaining pus, a positive Gram-stain, or a positive culture. The author strongly believes that in any neonate with known osteomyelitis or septic arthritis, both hip joints should be aspirated because:

- Multiple sites of involvement are common
- The proximal femur and hip joint are frequently involved
- Symptoms and signs are often subtle or lacking
- The hip is the most difficult joint to examine
- The window of opportunity for effective treatment is small
- The hip joint is the most frequent site of permanent sequelae.

The antibiotic management of the neonate is difficult, and should be undertaken in conjunction with a physician having such experience. The selection of the antibiotic is guided by the probable causative organisms, and modified by positive Gram-staining and culture. The dosage varies, depending on the degree of prematurity and the status of hepatic or renal function. Because penicillinase-resistant forms of *S. aureus*, in addition to Gram-negative enteric organisms, are possible, initial antibiotic selection should cover these organisms, as well as group B *Streptococcus*. Choices may include oxacillin, along with gentamicin or a third-generation cephalosporin such as cefotaxime or ceftazidime. Ceftriaxone (Rocephin) may also be used if there is no jaundice. If methicillin-resistant *S. aureus* is suspected, vancomycin should be considered in the initial therapy.

Some authors have implied that surgical drainage may worsen the result (172), and others have implied success without surgical drainage (174). Such studies suffer from treatment of only the most severe cases with surgery, accep-

tance of a high incidence of complications, and inadequate follow-up to detect the magnitude of growth alteration. It would seem to be even more imperative to treat the neonate with surgical debridement because adequate immune mechanisms are lacking. Therefore, when pus is found its removal is advised. This cannot be adequately accomplished with repeated aspiration, and therefore this form of therapy is not recommended.

Sickle Cell Disease

Sickle cell disease is the result of an autosomal recessive gene that produces abnormal hemoglobin, with numerous effects. Marrow hyperplasia, as a mechanism to compensate for the reduced oxygen-carrying capacity of the erythrocytes, resorbs both trabeculae and cortex, whereas reactive bone formation thickens the existing trabeculae. Susceptibility to infections other than osteomyelitis (e.g., sepsis, pneumonia) is increased, growth and sexual development are retarded, and infarction of bone and other organs is common. This section discusses only those factors relating to bone and joint infection.

The gene responsible for production of the abnormal hemoglobin (hemoglobin S gene) occurs predominantly in those of African descent, but is also present in whites in Greece, Turkey, Italy, and India. It is estimated that between 8 and 30% of African-Americans carry the hemoglobin S gene. About 2.5% of African-Americans are estimated to be homozygous for the gene that produces the clinical picture of sickle cell anemia. Although patients who are homozygous for the sickle cell gene are those most likely to be affected with bone infarction and infection, those who have hemoglobin SC disease, or hemoglobin *S. thalassemia*, are also predisposed. The pathophysiologic effects of the abnormal hemoglobin molecule are discussed in Chapter 11.

Although the orthopaedist is most familiar with the bone manifestations of this disease, it is important to remember that the most serious, common, and important infections result from the *Pneumococcus* organism. This is because those children who are homozygous for the sickle gene have defects in the alternate complement pathway, defects in opsonic activity, and impaired splenic function, which renders them susceptible to infection from pneumococci (187). In addition, these children may have an increased susceptibility to *H. influenzae*. Neither of these organisms play a large role in the bone and joint sepsis seen by the orthopaedist.

The incidence of osteomyelitis in patients with sickle cell anemia is low (particularly in the United States), despite the attention it receives in the literature. In 1971, Specht (188) found only 82 cases in the literature, whereas the few cases reported over several years in other large centers attest to the infrequent occurrence (189,190). This low incidence is even more important to the orthopaedist, when considered relative to the number of admissions for sickle cell crisis, a clinically similar presentation (190).

The presentation of osteomyelitis or sickle cell crisis in patients with sickle cell disease does not differ significantly. Because infection is thought to follow bone infarction, both conditions may coexist. The patient with known sickle cell disease in crisis presents as an uncomfortable child with pain in one or more joints or bones. Mild swelling is often present, joint effusions are not uncommon, and bone tenderness is usual. A late but differentiating feature is that with proper management the pain of infarction is usually markedly diminished by 3 to 5 days, whereas that of infection is not, unless antibiotics are also administered.

The leukocyte count and differential are not helpful in distinguishing infection from infarction. The ESR must be interpreted with caution, because it is elevated in both infarction and infection. In addition, the ESR tends to be falsely low in patients with sickle cell disease. The ESR is more likely to be above 20 mm/h in those with infection (191,192), and significant elevations should raise the suspicion of sepsis.

The initial radiologic manifestations of osteomyelitis in sickle cell disease are indistinguishable from those of bone infarction, and consist of periosteal new bone along the diaphysis. As the infection proceeds, however, a diffuse moth-eaten appearance of the bone occurs, with longitudinal fissuring and increasing periosteal bone formation. This results in the typical radiographic findings of a chronic diaphyseal bone infection with involucrum and sequestrum. Frequently, the other changes of sickle cell disease are seen also—the result of marrow hyperplasia and previous bone infarction (Fig. 13-14).

The role of bone scintigraphy to differentiate marrow infarction from infection has been controversial (190, 193,194). An understanding of the local pathophysiology in both conditions explains the problem and the potential usefulness of this modality. Bone infarction initially produces an area of decreased vascularity, and thus decreased isotope uptake. Once the inflammatory reaction to the in-

farction is established, however, the vascularity around the infarction results in increased isotope uptake. This probably occurs between 3 and 7 days after the infarction. Once it occurs, the scintigraphic appearance is the same as that of infection, which also produces increased vascularity and increased isotope uptake.

Therefore, if bone scintigraphy is to be useful, it must be performed early, preferably within 72 h of the onset of symptoms. Two different scans must be used: a ^{99m}Tc bone scan, followed by a bone marrow scan with a different isotope. Increased uptake on the ^{99m}Tc scan, with decreased uptake on the marrow scan, suggests infection (190,195). Although gallium 67 citrate scanning after ^{99m}Tc scanning has been recommended, it has not been found useful by others (190), and its high radiation dose to the child is an additional factor to consider.

The use of MRI has not proven to be of great value. This is in part because the findings of marrow infarction, as well as those in the soft tissues, are not reliably distinguished from sepsis (196). At the same time, other reports value ultrasonography in the differentiation of osteomyelitis from vasoocclusive crisis by demonstrating subperiosteal fluid and thickening of the periosteum (197,198). The answer as to why ultrasonography was successful when MRI failed lies in the details of these reports. In the reports of ultrasound diagnosis, many other parameters were actually used to arrive at the diagnosis.

A unique manifestation of this disorder is a condition known as sickle cell dactylitis, or hand-foot syndrome (24,199). The condition occurs in infants and young children, usually those younger than 4 years of age. No case of a child older than 7 years of age has been reported. It may precede the diagnosis of sickle cell disease. The actual incidence is probably between 10 and 20% of children with sickle cell disease, and it seems to be more common in Africa. Although it is logical to assume that it is due to infarction, there is also evidence that it may be secondary to acute marrow hyperplasia, because it is not seen once the hands and feet are no longer the site of active hematopoietic production.

Patients present with acute symmetric or asymmetric painful swelling of the hands and feet. Although considered to be a benign condition, obviating further evaluation (199), *Salmonella* osteomyelitis has been associated with this condition (200,201). Laboratory tests do not help in the differential diagnosis. Radiographic findings in the hand-foot syndrome at first demonstrate only soft tissue swelling, followed in 7 to 14 days by the formation of subperiosteal new bone. This is followed by medullary resorption and the appearance of irregular densities, in addition to cortical thinning. The changes revert to normal in weeks to months. Thus, radiographs do not help in the differential diagnosis.

With so few objective findings and tests to help in the differential diagnosis of bone infarction and osteomyelitis, how should the orthopaedist approach the patient in a clini-

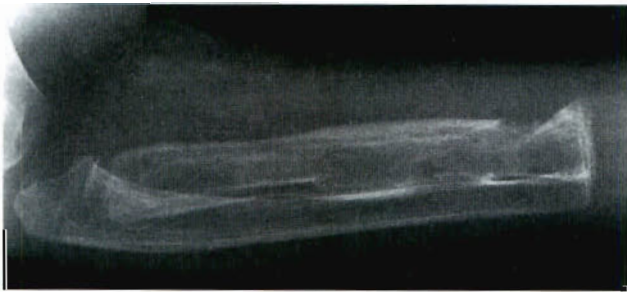


FIGURE 13-14. Lateral radiograph of the forearm in this infant demonstrate the typical changes of sickle cell osteomyelitis: longitudinal fissuring, diaphyseal location of the infection, and developing involucrum. These changes would be expected in any chronic infection of bone, and are not unique to sickle cell osteomyelitis.

cal situation, wherein the diagnosis could be either? Awareness, repeated examination, and blood cultures are basic and important. High fever, an elevated ESR, and a sequential bone scan early in the course of the disease may raise the suspicion of osteomyelitis. Aspiration of the suspected bone, with Gram-staining and culturing of all material, should not be postponed when the orthopaedist or another caring for the child suspects infection. This is the only test that confirms the diagnosis, and allows appropriate early treatment.

In the literature, recommendations for or against surgical debridement are variable: Some believe it to be the best treatment (202), some believe that patients do well without surgery (191,192,203), and others report surgery without specific indications (191,192). A close look at the outcomes and complications of this disease lead the modern orthopaedist to question the treatment of osteomyelitis without surgical drainage. Although in children the diaphyseal infections eventually heal, the contemporary standard of care seeks to avoid the diaphyseal destruction commonly seen, and the morbidity of prolonged hospitalization, intravenous antibiotic administration, and late sequelae. In other words, early diagnosis (not common in reports in the literature) and prompt drainage of an abscess, especially in an area of infarction, may result in outcomes comparable with normal children having the usual course of pyogenic osteomyelitis.

The question of using a tourniquet in patients with sickle cell disease who are undergoing extremity surgery is frequently raised because of the possibility that the ischemia may provoke thrombosis. This does not seem to be a problem; when the patient is properly prepared for surgery, no complications from the use of a tourniquet should result (204,205).

Which organism is the most common cause of osteomyelitis in sickle cell disease: *S. aureus* or *Salmonella*? This is a frequent test question, although it has little relevance in practice because both are so common that antibiotics must be given against both organisms until cultures establish the etiology. In addition, the literature is contradictory on which organism is the most common (191,203,205). A recent article reviewing the world literature since 1959 found *Salmonella* to be the most common (207).

Initial antibiotic choices are cefotaxime (Claforan) or ceftriaxone (Rocephin), each of which covers both *S. aureus* and *Salmonella* species, including those *Salmonella* resistant to ampicillin, chloramphenicol, or trimethoprim-sulfamethoxazole (Bactrim) (Table 13-3).

Arthritis may be seen in various forms in patients with sickle cell disease (208). The most common is an aseptic arthritis, most likely due to the sickle cell disease. It may be seen during crisis, but is more often a transient synovitis, usually involving the knee, which resolves within 5 days (209,210). A second form of aseptic arthritis is that associ-

ated with a remote *Salmonella* infection. This may be seen with other organisms, and the exact mechanism is not clear. Finally, the patient with sickle cell disease may have a septic arthritis. When this is the case, *Salmonella* is not the most likely organism. *Salmonella* is a rare organism in septic arthritis (210); when it occurs, it is most often in patients without sickle cell disease. When *Salmonella* septic arthritis occurs in sickle cell patients, it is most often from contiguous spread of osteomyelitis. More likely organisms in septic arthritis are *Staphylococcus* species (202,212). As with osteomyelitis, there is a difference of opinion on the advisability of arthrotomy for drainage (202,212).

Chronic Recurrent Multifocal Osteomyelitis

In 1972, a condition described as "subacute and chronic symmetrical osteomyelitis" was reported in the radiology literature (213). Since then, more than 50 cases of this disorder, which has come to be known as "chronic recurrent multifocal osteomyelitis" (CRMO) have been described. Females are affected in about 70% of the cases (214). This entity is distinct from pyogenic osteomyelitis, and is associated with a variety of other curious disorders of bone and skin. These associations include chronic sclerosing osteomyelitis of Garré, condensing osteitis of the clavicle, sternocostoclavicular hyperostosis, and palmoplantar pustulosis.

The clinical picture is characterized by the insidious onset of pain, often with swelling and occasionally erythema, suggesting infection of the bone. In a retrospective review of 14 patients with CRMO, 86% presented with a single tender swollen periarticular site (215). Patients usually remain ambulatory. Although more often multifocal, the initial presentation may be unifocal, progressing to multifocal. Although arthritis is more common in adults, it may be seen in adolescents (216). This and subsequent attacks are usually associated with symptoms of malaise and occasionally low-grade fever.

A curious, associated condition is palmoplantar pustulosis, a descriptive term for vesicles that may appear on the hands or feet. The association of these lesions with a variety of bone lesions is common, and all of these various conditions, previously described as being associated with palmoplantar pustulosis, are probably the same disease (217). These lesions do not occur in all cases, but seem to recur with recurrence of the bone symptoms. The bone lesions and the clinical course do not seem to differ between patients with and without these skin manifestations.

The subsequent course of resolution, then recurrence months later, is characteristic of this disease. Subsequent flare-ups are associated with the same findings and symptoms of the initial attack. The same or different bones may be involved. Generally, the symptoms recur over a period of 2 years; however, symptoms may recur as many as 5 years

later. Growth arrest has been both absent (216) and present (218) in different series.

Laboratory findings are distinct from the usual findings in pyogenic osteomyelitis because the leukocyte count remains normal. The sedimentation rate is elevated, and cultures of bone and blood are negative. It has been noted that the chemotactic activity of the polymorphonuclear cells is increased, whereas in the presence of bacterial infection, this activity is decreased (214).

The descriptions of the pathology in the bony lesions vary in the literature (214,217,218). This variation probably results from sampling differences and the stage of the lesion at the time of the biopsy. It seems that early lesions consist of infiltration predominantly with neutrophils. This is followed by infiltration with fibrovascular tissue and inflam-

matory cells (predominantly lymphocytes and plasma cells). Osteoblasts and trabecular thickening follow.

At the time of presentation, the characteristic metaphyseal lesions are usually well developed. These lesions consist of poorly delimited eccentric metaphyseal lucencies along the physal border. These lesions have been shown to cross into the epiphysis (216,221). The most common sites for these lesions are the distal and proximal metaphyses of the tibia and femur. Other affected sites are the distal radius and ulna, the distal fibula, and the metatarsals (Fig. 13-15). From a review of the literature, it seems that almost every bone has been reported as being involved, including the pelvis.

As healing occurs, sclerosis surrounds the lesion. When the lesion extends into the cortex, periosteal reaction may

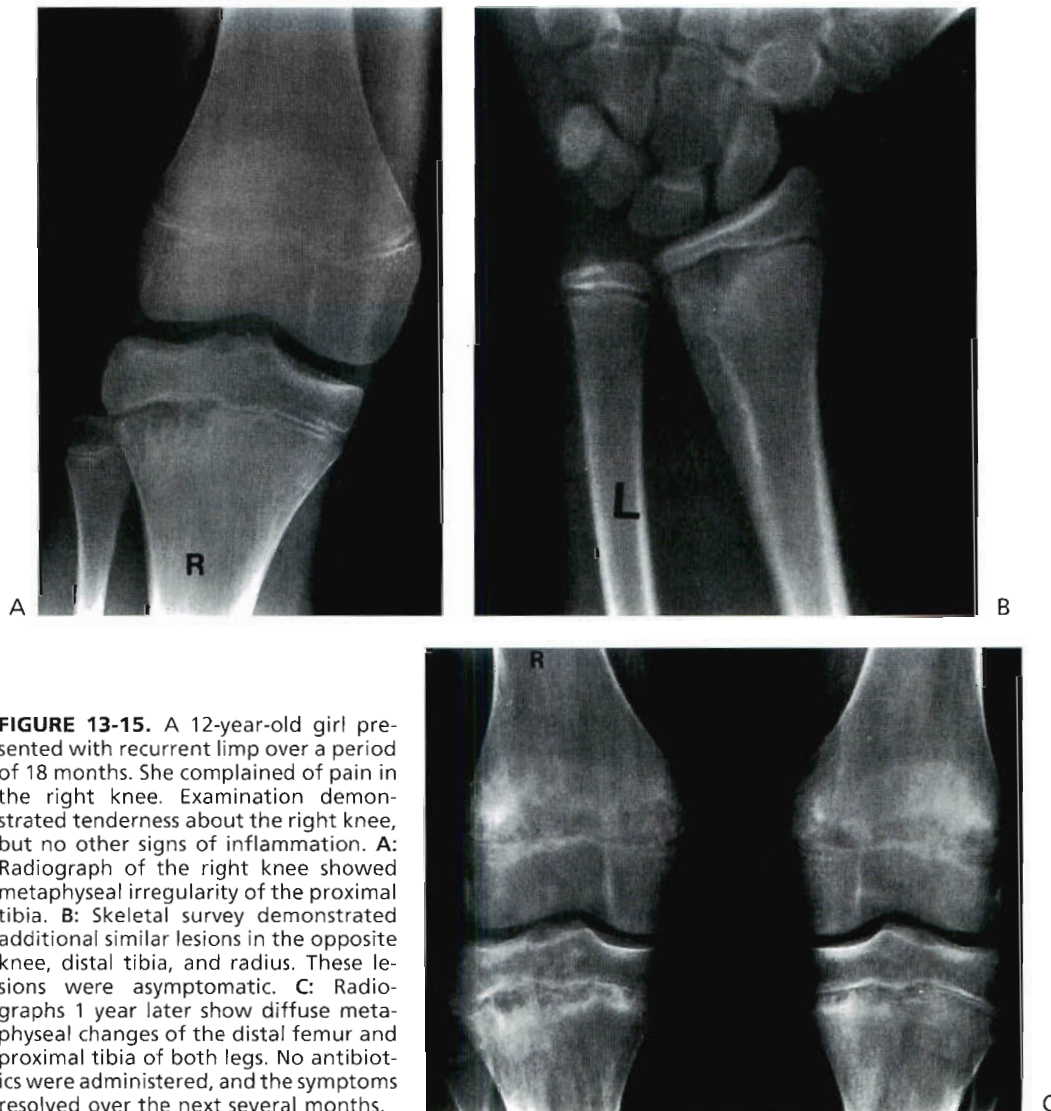


FIGURE 13-15. A 12-year-old girl presented with recurrent limp over a period of 18 months. She complained of pain in the right knee. Examination demonstrated tenderness about the right knee, but no other signs of inflammation. **A:** Radiograph of the right knee showed metaphyseal irregularity of the proximal tibia. **B:** Skeletal survey demonstrated additional similar lesions in the opposite knee, distal tibia, and radius. These lesions were asymptomatic. **C:** Radiographs 1 year later show diffuse metaphyseal changes of the distal femur and proximal tibia of both legs. No antibiotics were administered, and the symptoms resolved over the next several months.

occur. This is more likely to be seen early in the course in the small tubular and flat bones. This picture can be confused with bony neoplasm, such as leukemia, Ewing sarcoma, or eosinophilic granuloma.

The clavicle is frequently involved, presenting as a chronic sclerosing osteomyelitis (220). When present, this starts in the medial end of the clavicle and may present with both lucencies and an onionskin periosteal reaction.

Bone scintigraphy shows increased uptake in radiographically apparent lesions, and also helps to identify lesions that are not apparent on plain radiographs. In one report, bilateral lesions were found in 64% of the patients, and bone scintigraphy was very useful in finding the asymptomatic lesions (215).

It is doubtful that every case needs to undergo biopsy. If the picture is characteristic, little is to be gained. There may well be circumstances wherein the diagnosis is in doubt, in which case biopsy is necessary to rule out a malignancy, or to obtain culture from a lesion suspected of being pyogenic or tuberculous.

The most likely confusion is between subacute osteomyelitis and chronic recurrent multifocal osteomyelitis. Gamble and Rinsky (222) compared groups of patients with each other. From their data, the only helpful initial finding is the presence of multiple bone lesions in patients with chronic recurrent multifocal osteomyelitis. The age, symptoms, and laboratory findings were similar in both groups. Occasionally the periosteal reaction can indicate a more serious bone lesion, such as Ewing sarcoma, when it is the only lesion.

There is no specific treatment for this disorder, and the symptoms resolve without treatment. In most cases, nonsteroidal antiinflammatory medications ameliorate the pain. Antibiotics have not been demonstrated to have any effect on the course of the disorder, and are not indicated.

Subacute Osteomyelitis

In 1965, Harris and Kirkaldy-Willis (223) called attention to a subacute form of pyogenic osteomyelitis in which there had been no acute symptoms and the patient had received no antibiotics. Four years later, King and Mayo (224) reported a similar group of patients. The characteristic presenting features were no previous acute attack to suggest evolution of an acute osteomyelitis to a chronic form, insidious onset of pain, absence of systemic signs, and radiographic presence of a bone lesion at the time of presentation. They found these lesions in both the epiphysis and diaphysis, and described the various radiographic presentations.

Regardless of the location within the bone, the presentation is usually the same: weeks to months of worsening pain that started insidiously, and limp and tenderness with swelling visible, depending on the location. In addition, the laboratory findings are similar in most cases, and are distinct from AHO. The leukocyte count is usually normal or only slightly elevated. The ESR is usually elevated, although usu-

ally not as high as in AHO. Blood cultures are usually negative, although curetings from the lesions are frequently culture-positive, usually for *S. aureus*. Histology is compatible with acute and chronic inflammation.

Radiographic lesions are usually seen at the time of presentation. Far from being uniform, these lesions can present in many different locations and with a plethora of radiographic features. This highlights the main problem that faces the treating physician: the differential diagnosis of the lesion. Gledhill's classification (225) was further expanded by Roberts and colleagues (226) (Fig. 13-16). Differentiating some of these lesions from tumor is the most difficult part of the diagnosis (227).

The most common type of subacute osteomyelitis in the pediatric age group is the metaphyseal lesion (types IA and IB) (228). This represents a true Brodie abscess, a localized abscess of bone without previous acute illness. The lesion is located eccentrically in the metaphysis, frequently with visible extension into the epiphysis (Fig. 13-17). The lesion may have a sclerotic border, or may be irregular and ill-defined. The second most common type is the epiphyseal lesion (type V) (229–231). The radiographic appearance is similar to the lesion in the metaphysis; it also may extend across the plate into the metaphysis. The other lesions—erosion of the metaphyseal cortex (type II); localized conical and periosteal reaction (type III); onionskin cortical reaction in the diaphysis (type IV); and those involving the vertebral body (type VI)—are seen less commonly.

Increasingly seen in patients presenting with a limp is the presence of these lesions in the tarsal bones (232). The lesions most often are lytic in the talus and calcaneus, and sclerotic in the other bones.

As mentioned, the differential diagnosis of these lesions is the most important step in correct treatment, and is often the most difficult. In a series of 71 children with subacute osteomyelitis, Ross and Cole (233) divided the lesions into two categories: aggressive lesions (26) and cavities in the region of the metaphysis and epiphysis (45). All of the lesions in the aggressive group that were in the diaphysis or metaphysis demonstrated onionskin periosteal new bone. Two lesions were in the spine. The other lesions were all in the metaphysis or epiphysis, and had the typical radiologic features of type I and V lesions described above. The differential diagnoses of a type V lesion in the epiphysis include chondroblastoma and osteoid osteoma (and osteoblastoma), with eosinophilic granuloma, enchondroma, and chondromyxoid fibroma being less common. Of these, only chondroblastoma produces a periosteal response. The differential diagnoses of the typical type I lesion include eosinophilic granuloma, and perhaps giant cell tumor. Computerized tomography can be useful in the questionable case. The type III metaphyseal lesion, with erosion of the cortex, can be confused with osteosarcoma. A recent report of a characteristic finding on T1-weighted MR images may prove helpful in some cases. While not pathognomonic, the finding

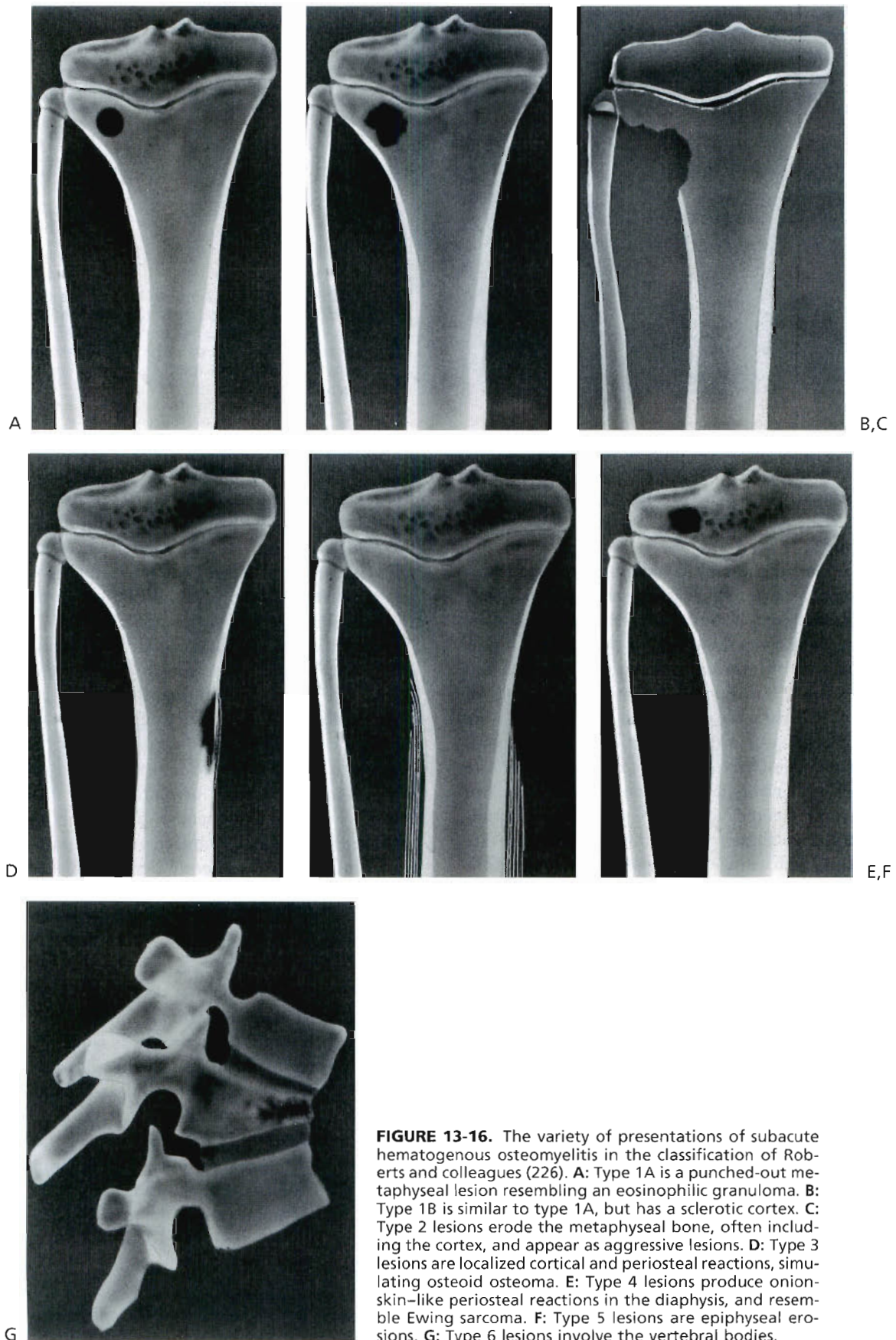


FIGURE 13-16. The variety of presentations of subacute hematogenous osteomyelitis in the classification of Roberts and colleagues (226). **A:** Type 1A is a punched-out metaphyseal lesion resembling an eosinophilic granuloma. **B:** Type 1B is similar to type 1A, but has a sclerotic cortex. **C:** Type 2 lesions erode the metaphyseal bone, often including the cortex, and appear as aggressive lesions. **D:** Type 3 lesions are localized cortical and periosteal reactions, simulating osteoid osteoma. **E:** Type 4 lesions produce onion-skin-like periosteal reactions in the diaphysis, and resemble Ewing sarcoma. **F:** Type 5 lesions are epiphyseal erosions. **G:** Type 6 lesions involve the vertebral bodies.

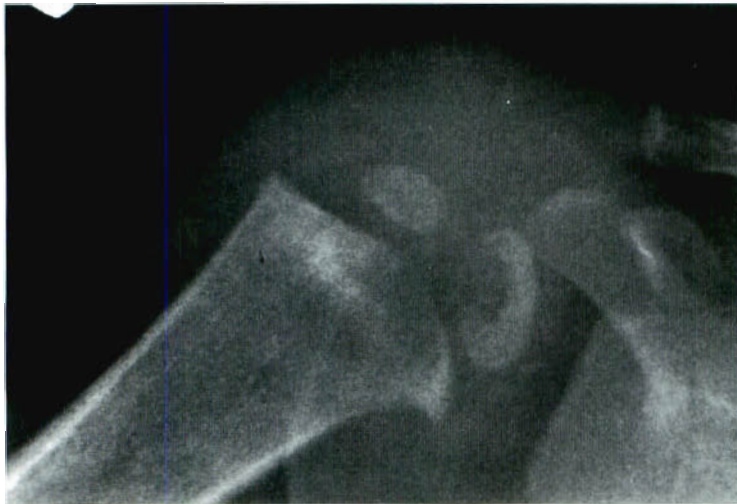


FIGURE 13-17. A 13-month-old girl presented for examination when her mother noted the child experienced discomfort when lifting her arms while her mother changed the child's clothes. *Haemophilus influenzae* was cultured from the lesion. The epiphyseal lesion communicates with the metaphyseal lesion.

of a rim of tissue, which is hyperintense relative to the main cavity, called the "penumbra sign," suggests infection as opposed to tumor (234).

The appearance of the typical lesion of a bone abscess in the epiphysis or metaphysis is so characteristic that Ross and Cole believed that it was diagnostic, and could be treated without biopsy or curettage. For these patients, they recommended 48 h of intravenous semisynthetic penicillin or first-generation cephalosporin, followed by 6 weeks of oral antibiotic. Eighty-seven percent of 37 children were healed with one course of antibiotics. Failure increased with the age of the child, and led to curettage and a further course of antibiotic. The authors do not mention the dosage of oral antibiotic, nor whether adequate serum levels of antibiotic, were verified in these patients. This 13% failure rate may be improved with a longer course of intravenous antibiotic, without resort to surgical treatment. All of the cases of aggressive lesions underwent biopsy and curettage. Hamdy et al. have subsequently reviewed 24 cases treated with antibiotics only, and 20 with surgical debridement and antibiotics, and concluded that there was no difference in the results (235).

Puncture Wounds of the Foot

Since Johanson's 1968 report (236), orthopaedic surgeons have become increasingly aware of the association between puncture wounds of the foot and *Pseudomonas aeruginosa* as the causative organism of deep infections that follow. It was subsequently demonstrated that *Pseudomonas* can be recovered from the inner spongy sole of well-worn tennis shoes (237). *P. aeruginosa* is a Gram-negative aerobic organism with anaerobic tolerance, which is found widely in soil, water, and on the skin. As a human pathogen seen in orthopaedic conditions, it seems to have an affinity for cartilage.

However, despite the common isolation of *Pseudomonas*

from puncture wound of the foot, it is important to remember that *S. aureus* is the most common soft tissue infection following puncture wound. In addition, *Aeromonas hydrophila* is common when puncture wounds or lacerations occur in fresh water, e.g., ponds (238). Gentamicin or Bactrim are effective against this organism.

Fitzgerald and Cowan (239) identified puncture wounds of the foot as the reason for an emergency room visit in 0.8% of children younger than the age of 15 years. Of the total number with puncture wounds, 8.4% who were seen within the first 24 h after the injury, either had cellulitis at the time of presentation or returned within the first 4 days with cellulitis. Of those presenting 1 to 7 days after the injury, cellulitis was present in 57%. Only 0.6% of those who were not referred to the emergency room for an established infection subsequently developed osteomyelitis. Of 132 patients seen with soft tissue infection after puncture wound of the foot, 112 had a prompt response to soaks, rest, elevation, and antibiotics.

The importance of these data is that most infections after puncture wounds of the foot do not develop osteomyelitis or septic arthritis. This has been confirmed by a more recent report, which found osteomyelitis in only 16% of 44 children admitted to the hospital with puncture wounds of the foot (240). The cases of cellulitis that do not develop osteomyelitis or septic arthritis after puncture wounds of the foot represent the denominator usually not seen by the orthopaedist. Most of these infections respond to nonoperative therapy, such as rest, elevation, and oral antibiotics.

A major dilemma is the initial management of the puncture wound. Suggestions for "debridement and irrigation with loose closure over small irrigation tubes" are impractical, given the number of puncture wounds occurring annually in the United States, and the infrequency of serious infection (236). Similarly, the recommendation that "any

deep wounds should be surgically debrided" seems impractical, because the treating physician would not know how deep the puncture wound is without anesthesia and surgical exploration (241).

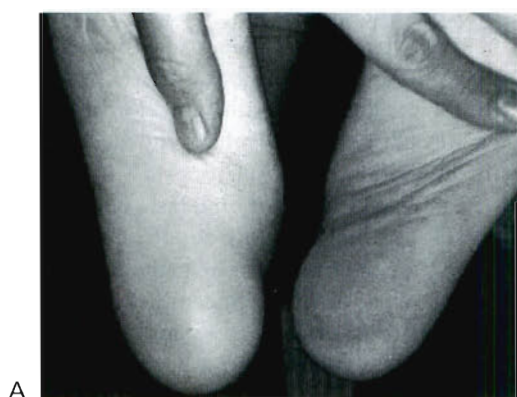Given the data on the development of cellulitis and osteomyelitis after puncture wounds, it appears that subsequent development of osteomyelitis and septic arthritis is mostly determined by whether the nail punctures the bone or joint. It is usually impossible for the initial treating physician to know this, although there should be a high degree of suspicion if the wound is over the metatarsal heads, the lateral border of the foot, or the heel—areas where the bone is in close approximation to the skin of the sole of the foot.

A reasonable approach to the initial management of a puncture wound of the foot includes superficial debridement of the skin and inspection for a foreign body, because a foreign body is found in almost 3% of cases (239). Tetanus prophylaxis is important. Because of the possibility of cellulitis developing in the first several days, patients should be advised to return at the first sign of infection. There does not seem to be any solid evidence either for or against the routine use of antibiotics in the initial management. They can be used effectively in the management of cellulitis, and

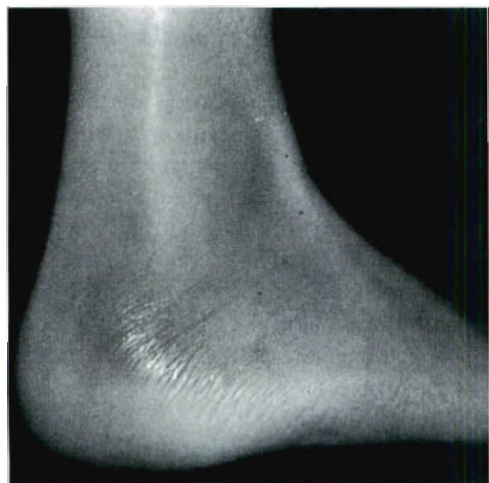there is no effective oral antibiotic for *Pseudomonas* osteomyelitis or septic arthritis in the pediatric age group.

The typical course of osteomyelitis or septic arthritis is the onset of pain and swelling 2 to 5 days after the puncture, when the initial symptoms should be gone. At this time, soaks, elevation, and an oral antistaphylococcal antibiotic are prescribed. If the patient has cellulitis, this regimen usually results in a cure. When osteomyelitis or septic arthritis is present the symptoms may improve, but do not disappear. This is probably due to the mixed flora in these infections. Finally, either continued pain and swelling or radiographic changes prompt the correct diagnosis. Good treatment includes close follow-up of those puncture wounds having signs of infection, and appropriate treatment if signs and symptoms of cellulitis do not resolve promptly on oral antibiotic treatment.

Initially, the signs and symptoms of cellulitis and osteomyelitis or septic arthritis can be difficult to differentiate. Pain on motion of a specific metatarsophalangeal joint is usually indicative of a septic arthritis in that joint. Dorsal swelling on the forefoot, or swelling laterally and medially around the heel, is often an additional sign of a serious deep infection (Fig. 13-18). Aspiration is helpful, not only in

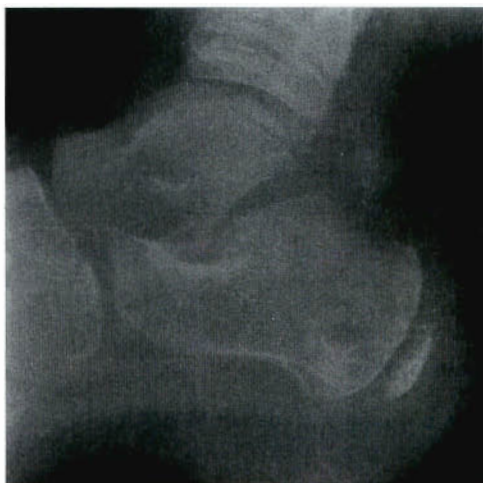

A



B

FIGURE 13-18. This patient was seen with pain 2 weeks after a puncture wound of the heel. He returned to the emergency department 3 days after the puncture wound because of increasing pain and swelling. Therapy was begun with a first-generation cephalosporin antibiotic. He experienced temporary improvement, but later the pain became worse. **A:** Note the swelling of the affected heel, when compared with the opposite contralateral heel side. **B:** Because of the dense septated tissue in the heel, osteomyelitis of the calcaneus usually is seen laterally. The swelling and erythema on the lateral side of the heel indicates deep infection. **C:** A radiograph demonstrates a lytic lesion of the heel, in addition to the soft tissue swelling. *Pseudomonas aeruginosa* was cultured from the infected site.



C

locating pus, but in obtaining material for culture. If no pus is obtained, bone scintigraphy may help in the early differentiation of cellulitis from osteomyelitis or septic arthritis. More recently, it has been suggested that MRI may be a more cost-effective way of diagnosing early osteomyelitis in the foot, following puncture wounds (242).

Pseudomonas infection of a bone or joint is a surgical disease; the failure of antibiotics alone to resolve these infections has been adequately demonstrated (243). The surgical approach may be either dorsal or volar, but must give adequate access to both the bones and joints in the region of the puncture, because *P. aeruginosa* is a cartilage-seeking organism. Some surgeons believe that the volar approach leaves a potentially painful scar. When properly placed, however, this should not be the case. This approach has the advantage of directly exposing the puncture track, which is an essential part of the surgery, because of the high incidence of foreign material found at surgical debridement (239,244). The dorsal approach allows direct access to the joints and bones through a more anatomic and easier-to-extend approach, which is not limited by the considerations of placement on the sole of the foot. This can be combined with a limited debridement of the volar puncture wound. Except in the most extensive cases of destruction of the calcaneus, in which the "cloven hoof" incision can be used, this bone should be approached from a medial or lateral incision, or from both.

Infections due to puncture wounds have two characteristics: They are caused by multiple organisms, and *P. aeruginosa* is usually one of them. For this reason, it makes sense to begin antibiotic therapy with a combination of antibiotics effective against both Gram-positive organisms and Gram-negative organisms, including *P. aeruginosa*. An initial choice may be ceftazidime (Fortaz) and gentamicin or oxacillin and gentamicin (Table 13-3). Jacobs and coworkers (243,244) suggest that 7 days of intravenous antibiotics after adequate surgical debridement are sufficient, although others recommend longer treatment (e.g., 10 days to 2 weeks).

Ciprofloxacin is another antibiotic that is effective against *Pseudomonas*. However, its use in children has been limited by reports of interfering with the growth plate in animal studies. Despite this, it has been used in cystic fibrosis and other serious infections in children, without reports of ill effects on cartilage or growth.

In cases that fail to respond to the above treatment, the fast-growing mycobacteria (e.g., *Mycobacterium chelonae* and *Mycobacterium fortuitum*) should be considered as possible pathogens.

Gonococcal Arthritis

Gonococcal arthritis is usually a sexually transmitted disease caused by the Gram-negative diplococcus, *Neisseria gonorrhoeae*. In the newborn, the disease is contracted from the

mother during passage through the birth canal, and results most commonly in conjunctivitis and scalp abscesses. When the disease is noted after the newborn period, before puberty, and in sexually inactive adolescents, sexual abuse should be suspected. Gonococcal infection is most common in women in the second and third decade, and therefore is seen frequently in the adolescent age group. Although gonococcal infection can take many forms, the orthopaedist is most likely to encounter this infection as septic arthritis in the disseminated form of the disease.

In the adolescent, the infection most often results from dissemination of a genitourinary infection, which is frequently asymptomatic. The delay between the genitourinary infection and the arthritis is variable, ranging from a few days to several weeks. In adolescence, the disseminated form of the disease is associated with pregnancy and menstruation, periods of low progesterone activity (245).

The orthopaedist needs to be especially aware of the possibility of sexual abuse in patients with gonococcal arthritis. Sexual abuse may occur in as many as 10% of all abuse cases, and it is estimated that between 5 and 20% of sexually abused children have a sexually transmitted disease, most commonly gonococcal infection (246,247). Children who are identified with or suspected of having a gonococcal infection should have cultures of all mucous membranes, including pharynx, vagina, and rectum, before the administration of antibiotics. These cultures should be handled in a manner that permits them to be used as evidence in court. In addition, reporting of suspected cases is mandated by the Child Abuse Reporting Law. For all of these reasons, the orthopaedist should involve a knowledgeable pediatrician in the evaluation of these patients.

The classic presentation is rash, tenosynovitis, and migratory polyarthralgia. Only about one-third of the cases develop a distinctive, but not pathognomonic rash, which is a result of gonococcal septicemia. The initial lesion is a small erythematous macule. This may disappear or develop a small vesicle, followed by a necrotic center that may form a pustule. The tenosynovitis, when seen, often affects the dorsal surface of the wrist and hand. This finding, like the skin rash, is nonspecific and can be caused by other organisms.

The clinical presentation of the disseminated disease with septic arthritis begins with chills and fever in about three-fourths of the patients. Joint involvement is polyarticular in 80% of cases. The knee is most often affected, but it is important to remember that any joint, large or small, can be involved. The size of the effusion may vary widely, and may even be absent. The involved joints are usually painful. The nature of the arthritis does not appear to have changed over the past several decades, although treatment with antibiotics has resulted in the virtual elimination of joint destruction (248–252). Osteomyelitis still may be seen as an occasional complication (221).

The leukocyte count is elevated in two-thirds of the pa-

tients. Culture is the only way to confirm the diagnosis. Culture and Gram-staining of joint fluid, and of the cervix of postpubertal girls and the vagina of prepubertal girls, should be performed. Any urethral or prostatic discharge in the male should also be cultured and examined by Gram-staining. Blood cultures should be routine. The organism may occasionally be isolated from skin lesions, but Gram-staining gives a higher yield.

N. gonorrhoeae is a difficult organism to grow, and special care is needed in the handling of the material for culture. Because the organism is sensitive to cold, material for culture should be plated directly onto a warm medium, whenever possible. Special culture tubes for transport of gonococcal cultures are available, and should be used, in addition to prompt delivery of specimens to the bacteriology laboratory, when direct-plating is not feasible. Cultures from sterile sites (e.g., blood, synovial fluid) are plated on chocolate blood agar. Cultures from nonsterile sites (e.g., the vagina, skin lesions) should be plated on selective media (e.g., Thayer-Martin agar) that contains antibiotics to inhibit the growth of other organisms. Cultures are grown in a 5 to 10% CO₂ atmosphere.

The increasing resistance of *N. gonorrhoeae* to penicillin and tetracycline makes parenteral administration of a third-generation cephalosporin (e.g., ceftriaxone, 50 mg/kg/day, intramuscularly or intravenously, once daily) the initial drug of choice (Table 13-3). If the organism is demonstrated to be sensitive to penicillin, it can be used. Recommendation for drainage of the joints remains variable. In the hip joint, there is no controversy; surgical drainage, as for pyogenic septic arthritis caused by any organism, is required. In other large joints with large amounts of purulent fluid, surgical drainage may be preferable to repeated needle aspiration. If surgical drainage is used, it is wise to leave a closed suction drain in the joint, because the tendency to reaccumulate fluid is greater than with other forms of septic arthritis.

Tuberculosis

Fewer cases of tuberculosis were reported in the United States in 1985 since reporting began in 1953. Between 1985 and 1991, the incidence rose sharply, only to slightly decrease in both 1992 and 1993 for all age groups except those younger than 15 years of age. During this period, the largest increase was reported for patients born outside of the United States and its territories. In 1993, these patients comprised almost 30% of the reported cases. California, New York, and Texas saw the largest increases. The increased incidence has been accompanied by human immunodeficiency virus infection and multi-drug-resistant organisms.

Because extrapulmonary tuberculosis is more common among children, particularly those younger than 5 years of age, the orthopaedic surgeon must again become aware of this possibility when evaluating chronic joint inflammation or chronic bone lesions.

Patients who are exposed to tuberculosis may or may not become infected, and those who are infected may or may not become diseased. There is a time lag between infection and diagnosis of the extrapulmonary disease of about 1 year.

Most patients are infected by human contact because bovine tuberculosis has been eliminated in this country by the pasteurization of milk. The lungs are the most common site of initial infection in children; the kidneys are not. The tubercle bacilli may disseminate to bones or joints during the lymphatic and hematogenous spread of the initial infection. If the initial lung infection remains untreated, involvement of the bones and/or joints occurs in 5 to 10% of children (253). The development of the lesions in bone is time- and location-related. Dactylitis may occur within a few months in younger children. Long-bone involvement may occur in 1 to 3 years.

The initial focus in the bone is usually the epiphysis or metaphysis, and rarely the diaphysis. As the osteomyelitis develops, it enlarges the area of bone destruction in a centrifugal fashion, producing a characteristic round cystic lesion with ill-defined margins. These lesions are filled with an inflammatory granulation tissue, creating a reactive hyperemia, which produces a wide area of osteopenia surrounding the lesion. This process is almost purely destructive or lytic, with little or no bone reaction (Fig. 13-19)—thus, the lack of sclerotic margins and a periosteal response. Because of the chronicity and hyperemia, widening and accelerated growth of the epiphysis may be seen. The physal plate offers little resistance to the spread of the infection, as it does in other pyogenic infections. Before extraosseous abscess formation the bone lesions may mimic pyogenic infection or tumors such as eosinophilic granuloma.

Most skeletal tuberculosis affects the spine. The infection almost always begins in the vertebral body, usually the anterior one-third. The most frequent site of involvement in the spine is the lower thoracic and upper lumbar spine. Paravertebral abscess formation is characteristic, and calcification developing within the abscess is almost diagnostic of a tuberculous abscess. The discs become involved when two adjacent vertebral bodies are affected. The bone lesions in the vertebral bodies are mainly destructive (Fig. 13-20).

Skeletal tuberculosis outside of the axial skeleton usually affects the major joints, particularly the hip and knee. Isolated joint infections, unusual in childhood, are initially characterized by effusion, in addition to synovial proliferation and thickening. In the early stages there are no radiographic characteristics that separate tuberculous arthritis from any chronic inflammation of the joint. As with the bone lesions, the hyperemia causes widespread osteopenia, and may cause overgrowth of the epiphyses. The infection proceeds both by pannus formation over the articular cartilage and by erosion of the subchondral bone, beginning at the synovial margins (254). The result is joint space narrowing and subchondral cystic erosion. Early in the process, the clinical and radiologic findings may closely resemble

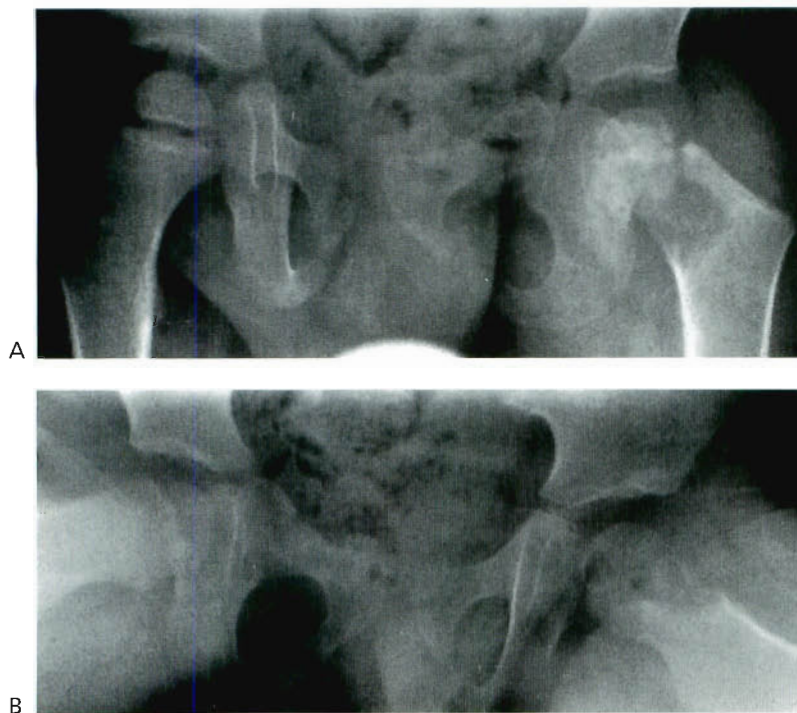


FIGURE 13-19. A and B: Radiographs of a 3-year-old boy who recently moved to the United States from Mexico. The child had complaints of increasing limp on the left, pain that worsened at night, and no significant limitation of activity. Examination demonstrated limited motion with irritability. Laboratory studies showed a normal complete blood count, erythrocyte sedimentation rate of 25 mm/h, and a positive purified protein derivative test. Open biopsy confirmed the diagnosis of tuberculosis by histology and culture. (Courtesy of Hugh Watts, M.D.)

those of JRA or pigmented villonodular synovitis. Laboratory studies, however, should easily separate these entities.

As the infection continues untreated, large amounts of caseous material and pus accumulate and dissect along normal tissue planes. Eventually, a sinus track to the surface is formed—a hallmark of a long-standing neglected case. The abscess formed by tuberculous infection is called a “cold abscess,” because of the lack of any signs of acute inflammation.

Two other presentations occur in childhood. The first, tuberculous dactylitis, may resemble sickle cell dactylitis, with swelling of the phalanges, metacarpals, and metatarsals. Tuberculous dactylitis is usually not very painful, however, and onset is usually consecutive, rather than simultaneous. Before the availability of radiographs, this was called *spina* (Latin for “a short bone”) *ventosa* (meaning “inflated with air”). The radiographs show a cyst-like expansion of the tubular bones, with thinning of the cortex (255). A second presentation is with multifocal cystic involvement of the bone. This is characterized by areas of simultaneous destruction in the shafts of long bones and in flat bones, with a strong tendency to symmetry (256).

The first and most important step in the diagnosis of tuberculous infection of the bone or joint is to consider it as a possibility. In addition, when tuberculosis is diagnosed, underlying HIV infection must also be considered. Tuberculosis should be considered whenever a chronic-appearing bone lesion is encountered. Early diagnosis is important to prevent spread to a contiguous joint. The clinical picture

is variable, depending on the location and the stage of the disease. It is characterized by its insidious onset; lack of characteristic inflammatory features, such as erythema; and bone destruction or joint involvement greater than the symptoms would suggest.

Laboratory studies usually show a normal leukocyte count and an elevated ESR. The purified protein derivative skin test usually is positive. Radiographic changes are usually present at the time of presentation. The diagnosis depends on the identification of the organism, *Mycobacterium tuberculosis*. Positive cultures are obtained in 85.5% of patients who have both pulmonary and extrapulmonary disease, in 83.5% of those with only pulmonary disease, and in 76.5% of those who have only extrapulmonary disease (257).

Tuberculosis produces a widespread inflammatory response which may mislead the surgeon in obtaining biopsy material, especially if the synovium is to undergo biopsy. In cases with bone lesions, the granulation tissue filling the cystic bone lesion is the best material for biopsy. In tuberculosis arthritis without bone involvement, the biopsy should be taken from the peripheral junction of the synovium with the bone, or preferably from the junction of the synovium with a cyst (258).

The treatment of skeletal tuberculosis is medical. Surgical debridement of the bone lesions is not necessary for a cure, although drainage of large abscesses often improves the patient's overall constitutional symptoms (256,258,259). In addition, open surgical biopsy is often necessary. Because of the effectiveness of drug therapy, there is little chance

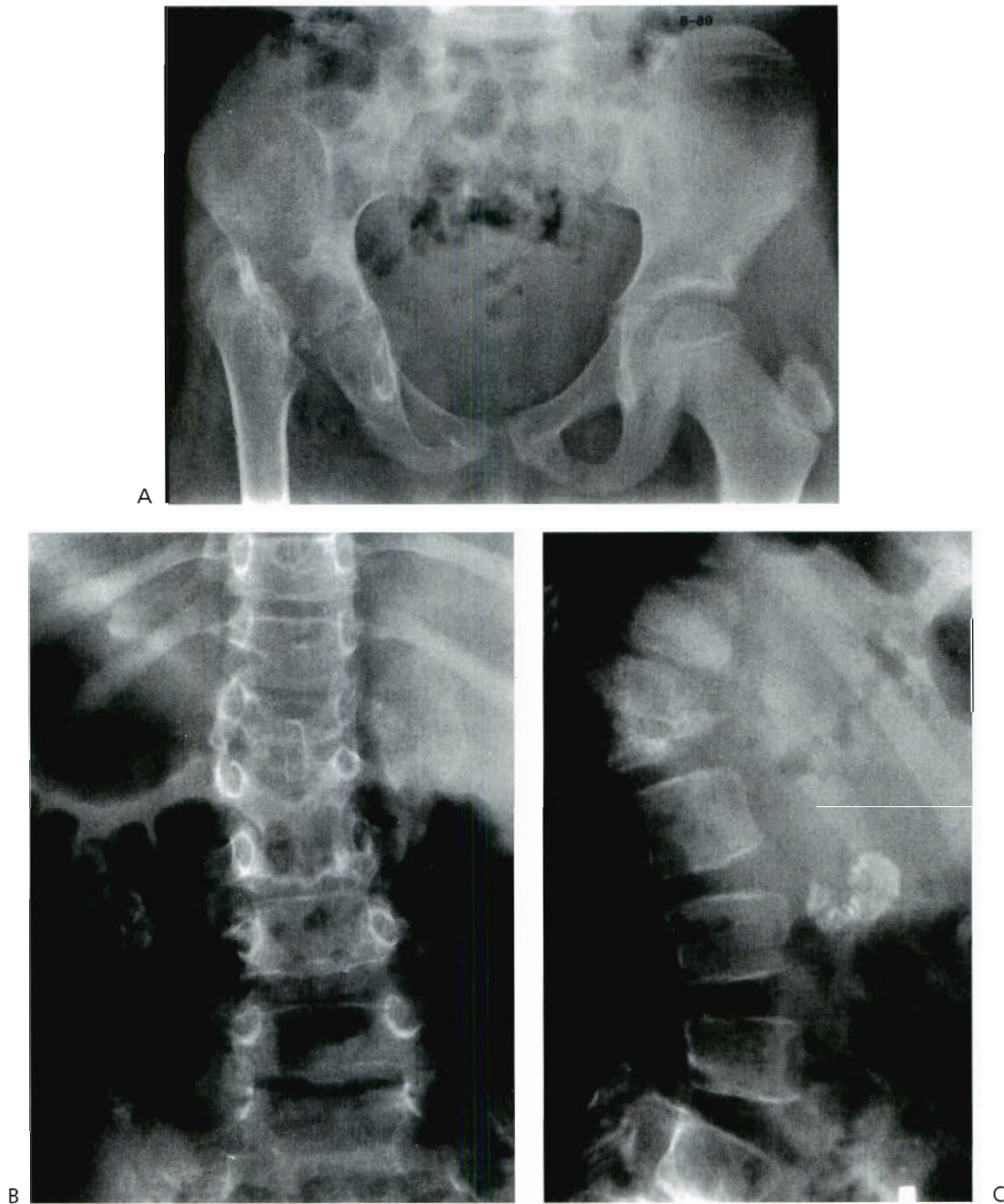


FIGURE 13-20. A: Anteroposterior (AP) radiograph of a 10-year-old girl from Mexico who had a past history of several operations on the right hip for tuberculosis presented with increasing back pain and kyphosis. B and C: AP and lateral views of the spine show bony destruction of the vertebral body, with relative preservation of the intervertebral disc and the calcified node; both are features of tuberculosis. Open biopsy confirmed the diagnosis of tuberculosis. (Courtesy of Hugh Watts, M.D.)

that surgical biopsy will lead to sinus formation. It is important to always be aware that superinfection with pyogenic organisms can occur, and this may be a reason for apparent treatment failure with antitubercular drugs. This is particularly true when a sinus has formed (259).

Several studies on tuberculous spondylitis demonstrate that surgery is necessary primarily to treat the kyphosis and not the tuberculosis; many cases do well with only medical management (260–262). Indications for surgery remain relative, and include neurologic involvement, spinal insta-

bility, and failure of medical treatment. Although patients with neurologic involvement can recover with medical management, they seem to do so faster with surgical management (260). Surgical treatment of the kyphosis produces a higher rate of union and less deformity than regimens without surgical stabilization (261,262). Thus, it appears that with contemporary surgical and anesthetic techniques tuberculous kyphosis is best treated early with anterior surgery for debridement and strut grafting. The treatment of spinal instability, especially that spanning more than two disc spaces, is difficult and probably requires both anterior arthrodesis with strut-grafting and posterior arthrodesis with instrumentation (263).

Although the effectiveness of ambulatory drug treatment has been demonstrated (261,262), there is evidence of an increasing incidence of resistant strains, due most likely to inadequate treatment of the initial infection (257). This emphasizes both the need for constant surveillance for drug resistance and the importance of careful supervision of outpatient oral therapy, to be certain that compliance is optimal.

Initial antimicrobial agent selection depends on the likelihood of drug-resistant organisms, whereas long-term selection should be guided by susceptibility testing. In those who are not at high risk for drug-resistant organisms, various regimens of isoniazid, rifampin, and pyrazinamide are recommended (264). In children who come from areas where antibiotics are sold over the counter, where high rates of drug-resistant tuberculosis occur, and when incomplete treatment may have resulted in multidrug-resistant strains, ethambutol or streptomycin should be added to the standard three-drug regimen. Treatment of bone and joint tuberculosis in children should be continued for 1 year.

References

Bone and Joint Infection

1. Peltola H, Vahvanen V. A comparative study of osteomyelitis and purulent arthritis with special reference to aetiology and recovery. *Infection* 1984;12:75.
2. Morey BF, Peterson HA. Hematogenous pyogenic osteomyelitis in children. *Orthop Clin North Am* 1975;6:935.
3. Morey BF, Bianco AJ Jr, Rhodes KH. Septic arthritis in children. *Orthop Clin North Am* 1975;6:923.
4. Craigen MA, Watters J, Hackett JS. The changing epidemiology of osteomyelitis in children. *J Bone Joint Surg Br* 1992;74:541.
5. Espersen F, Frimodt MN, Thamdrup RV, et al. Changing pattern of bone and joint infections due to *Staphylococcus aureus*: study of cases of bacteremia in Denmark, 1959–1988. *Rev Infect Dis* 1991;13:347.
6. Gillespie WJ. Epidemiology in bone and joint infection. *Infect Dis Clin North Am* 1990;4:361.
7. Gillespie WJ. The epidemiology of acute haematogenous osteomyelitis of childhood. *Int J Epidemiol* 1985;14:600.
8. Gillespie WJ, Nade SML. *Musculoskeletal infections*. Melbourne, Australia: Blackwell Scientific, 1987.
9. Jones NS, Anderson DJ, Stiles PJ. Osteomyelitis in a general hospital. A five-year study showing an increase in subacute osteomyelitis. *J Bone Joint Surg Br* 1987;69:779.
10. Bowerman SG, Green NE, Mencia GA. Decline of bone and joint infections attributable to *Haemophilus influenzae* type b. *Clin Orthop* 1997;341:128.
11. Koch R. Die aetiologie der tuberkulose. *Berl Klin Wochenschr* 1882;19:779.
12. Pasteur L. De l'extension de la theorie des germes a l'etiology de quelques maladies communes. *Bull Acad Med* 1880;9:435.
13. Rodet A. Etude experimental aur l'osteomyelite infectieuse. *Acad Sci* 1884;99:569–571. In: Bick EM, ed. *Classics of orthopaedics*. Philadelphia: JB Lippincott, 1976:461.
14. Weaver JB, Tyler MW. Experimental staphylococcaemia and hematogenous osteomyelitis. *J Bone Joint Surg* 1943;25:791.
15. Norden CW. Experimental osteomyelitis. (I) S description of the model. *J Infect Dis* 1970;122:410.
16. Morrissy RT, Haynes DW. Acute hematogenous osteomyelitis: a model with trauma as an etiology. *J Pediatr Orthop* 1989;9:447.
17. Whalen JL, Fitzgerald RHJ, Morrissy RT. A histological study of acute hematogenous osteomyelitis following physeal injuries in rabbits. *J Bone Joint Surg Am* 1988;70:1383.
18. Everett ED, Hirschmann JV. Transient bacteremia and endocarditis prophylaxis: a review. *Medicine* 1977;56:61.
19. Burrows H. *Some factors in the localization of disease in the body*. New York: William Wood, 1932.
20. Dich VQ, Nelson JD, Haltalin KC. Osteomyelitis in infants and children. *Am J Dis Child* 1975;129:1273.
21. Gilmour WN. Acute hematogenous osteomyelitis. *J Bone Joint Surg Br* 1962;44:842.
22. Manche E, Rombouts GV, Rombouts JJ. Acute hematogenous osteomyelitis due to ordinary germs in children with closed injuries. Study of a series of 44 cases. *Acta Orthop Belg* 1991;57:91.
23. Shandling B. Acute hematogenous osteomyelitis: a review of 300 cases treated during 1953–1959. *South Afr Med* 1960;34:520.
24. Watson RJ, Burko H, Megas H, et al. The hand-foot syndrome in sickle cell disease in young children. *Pediatrics* 1963;31:975.
25. Olney BW, Papasian CJ, Jacobs RR. Risk of iatrogenic septic arthritis in the presence of bacteremia: a rabbit study. *J Pediatr Orthop* 1987;7:524.
26. Schurman DJ, Mirra J, Ding A, et al. Experimental *E. coli* arthritis in the rabbit: a model of infectious and post-infectious inflammatory synovitis. *J Rheumatol* 1977;4:118.
27. Hobo T. Zur pathogenese de akuten haematogenen osteomyelitis, mit berucksichtigung der vitalfarbungs lehrer. *Acta Scola Med Kioto* 1921;4:1.
28. Schenk RK, Wiener J, Spiro D. Fine structural aspects of vascular invasion of the tibial epiphyseal plate of growing rats. *Acta Anat* 1968;69:1.
29. Speers DJ, Nade SML. Ultrastructural studies of *Staphylococcus aureus* in experimental acute haematogenous osteomyelitis. *Infect Immun* 1985;49:443.
30. Matusuhita K, Hamabe M, Matsuoka M, et al. Experimental hematogenous osteomyelitis by *Staphylococcus aureus*. *Clin Orthop* 1997;334:291.
31. Trueta J. The normal vascular anatomy of the human femoral head during growth. *J Bone Joint Surg Br* 1957;39:358.
32. Tiku K, Tiku ML, Skosey JL. Interleukin-1 production by human polymorphonuclear neutrophils. *J Immunol* 1986;136:3677.
33. Dinarello CA, Cannon JG, Mier JW, et al. Multiple biological activities of human recombinant interleukin-1. *J Clin Invest* 1986;77:1734.

34. Malech HL, Gallin JI. Neutrophils in human disease. *N Engl J Med* 1987;317:687.
 35. Johnson AH, Campbell WG, Callahan BC. Infection of rabbit knee joints after intra-articular injection of *Staphylococcus aureus*. *Am J Pathol* 1970;60:165.
 36. Arvidson S, Holme T, Lindholm B. The formation of extracellular proteolytic enzymes by *Staphylococcus aureus*. *Acta Pathol Microbiol Scand* 1972;80:835.
 37. Dingle JT. The role of lysosomal enzymes in skeletal tissue. *J Bone Joint Surg Br* 1973;55:87.
 38. Harris EDJ, Parker HG, Radin EL, et al. Effects of proteolytic enzymes on structural and mechanical properties of cartilage. *Arthritis Rheum* 1972;15:497.
 39. Harris ED, McCroskery PA. The influence of temperature and fibril stability on degradation of cartilage collagen by rheumatoid synovial collagenase. *N Engl J Med* 1974;290:1.
 40. Oronsky A, Ignarro L, Perrer R. Release of cartilage mucopolysaccharide-degrading neutral protease from human leukocytes. *J Exp Med* 1973;138:461.
 41. Steinberg JJ, Sledge CB. Co-cultivation models of joint destruction. In: Dingle JT, Gordon JL, ed. *Cellular interactions*. Amsterdam: Elsevier/North-Holland, 1981:263.
 42. Smith L, Schurman DJ, Kajiyama G, et al. The effect of antibiotics on the destruction of cartilage in experimental infectious arthritis. *J Bone Joint Surg Am* 1987;69:1063.
 43. Curtiss PHJ, Klein L. Destruction of articular cartilage in septic arthritis. I. In vitro studies. *J Bone Joint Surg Am* 1963;45:797.
 44. Curtiss PHJ, Klein L. Destruction of articular cartilage in septic arthritis. II. In vivo studies. *J Bone Joint Surg Am* 1965;47:1595.
 45. Daniel D, Akeson W, Amiel D, et al. Lavage of septic joints in rabbits: effects of chondrolysis. *J Bone Joint Surg Am* 1976;58:393.
- Diagnosis**
46. Faden H, Grossi M. Acute osteomyelitis in children. Reassessment of etiologic agents and their clinical characteristics. *Am J Dis Child* 1991;145:65.
 47. Scott RJ, Christofersen MR, Robertson WWJ, et al. Acute osteomyelitis in children: a review of 116 cases. *J Pediatr Orthop* 1990;10:649.
 48. Griebel M, Nahlen B, Jacobs RF, et al. Group A streptococcal postvaricella osteomyelitis. *J Pediatr Orthop* 1985;5:101.
 49. Gabay C, Kushner I. Acute-phase proteins and other systemic responses to inflammation. *New Engl J Med* 1999;340:448.
 50. Jaye DL, Waites KB. Clinical applications of C-reactive protein in pediatrics. *Pediatr Infect Dis J* 1997;16:735.
 51. Peltola H, Vahvanen V, Aalto K. Fever, C-reactive protein, and erythrocyte sedimentation rate in monitoring recovery from septic arthritis: a preliminary study. *J Pediatr Orthop* 1984;4:170.
 52. Pepys MB. C-reactive protein fifty years on. *Lancet* 1981;1:653.
 53. Unkila-Kallio L, Kallio MJT, Eskola J, et al. Serum C-reactive protein, erythrocyte sedimentation rate, and white blood cell count in acute hematogenous osteomyelitis of children. *Pediatrics* 1994;93:59.
 54. Tejani N, Chonmaitree T, Rassin DK, et al. Use of C-reactive protein in differentiation between acute bacterial and viral otitis media. *Pediatrics* 1995;95:664.
 55. Fink CW, Nelson JD. Septic arthritis and osteomyelitis in children. *Clin Rheum Dis* 1986;12:423.
 56. Shmerling RH, Delbanco TL, Tosteson AN, et al. Synovial fluid tests. What should be ordered? *JAMA* 1990;264:1009.
 57. Morrissy RT. Septic arthritis. In: Gustilo RB, Genninger RP, Tsukayama DT, eds. *Orthopaedic infection: diagnosis and treatment*. Philadelphia: WB Saunders, 1989.
 58. Baldassare AR, Chang F, Zuckner J. Markedly raised synovial fluid leucocyte counts not associated with infectious arthritis in children. *Ann Rheum Dis* 1978;37:404.
 59. Wilson NIL, DiPaola M. Acute septic arthritis in infancy and childhood. *J Bone Joint Surg Br* 1986;68:584.
 60. Vaughan PA, Newman NM, Rosman MA. Acute hematogenous osteomyelitis in children. *J Pediatr Orthop* 1987;7:652.
 61. Kohler RB, Wheat LJ. Rapid diagnosis by the detection of microbial antigens. *Med Microbiol* 1982;1:327.
 62. Merritt K, Boyle WE, Dye SK, et al. Counter immunoelectrophoresis in the diagnosis of septic arthritis caused by *Haemophilus influenzae*. *J Bone Joint Surg Am* 1976;58:414.
 63. Hoeffel DP, Hinrichs SH, Garvin KL. Molecular diagnostics for the detection of musculoskeletal infection. *Clin Orthop* 1999;360:37.
 64. Capitanio MA, Kirkpatrick JA. Early roentgen observations in acute osteomyelitis. *Am J Roentgenol Radium Ther Nucl Med* 1970;108:488.
 65. Brown I. A study of the "capsular" shadow in disorders of the hip in children. *J Bone Joint Surg Br* 1975;57:175.
 66. Volberg FM, Sumner TE, Abramson JS, et al. Unreliability of radiographic diagnosis of septic hip in children. *Pediatrics* 1984;74:118.
 67. Cabanela ME, Sim FH, Beabout JW, et al. Osteomyelitis appearing as neoplasms: a diagnostic problem. *Arch Surg* 1974;109:68.
 68. Lindenbaum S, Alexander H. Infections simulating bone tumors. *Clin Orthop* 1984;184:193.
 69. Willis RB, Rozencwaig R. Pediatric osteomyelitis masquerading as skeletal neoplasia. *Orthop Clin North Am* 1996;27:625.
 70. Francis MD, Fogelman I. ^{99m}Tc diphosphonate uptake mechanism on bone. In: Fogelman I, ed. *Bone scanning in clinical practice*. London: Springer-Verlag, 1987:7.
 71. Howie DW, Savage JP, Wilson TG, et al. The technetium phosphate bone scan in the diagnosis of osteomyelitis in childhood. *J Bone Joint Surg Am* 1983;65:431.
 72. Sundberg SB, Savage JP, Foster BK. Technetium phosphate bone scan in the diagnosis of septic arthritis in childhood. *J Pediatr Orthop* 1989;9:579.
 73. Sullivan DC, Rosenfield NS, Ogden J, et al. Problems in the scintigraphic detection of osteomyelitis in children. *Radiology* 1980;135:731.
 74. Sullivan JA, Vasileff T, Leonard JC. An evaluation of nuclear scanning in orthopaedic infections. *J Pediatr Orthop* 1980;1:73.
 75. McCoy JR, Morrissy RT, Seibert J. Clinical experience with the technetium-99 scan in children. *Clin Orthop* 1981;154:175.
 76. Berkowitz ID, Wenzel W. "Normal" technetium bone scans in patients with acute osteomyelitis. *Am J Dis Child* 1980;134:828.
 77. Trackler RT, Miller KE, Sutherland DH, et al. Childhood pelvic osteomyelitis presenting as a "cold" lesion on bone scan: case report. *J Nucl Med* 1976;17:620.
 78. Canale ST, Harkness RM, Thomas PA, et al. Does aspiration of bones and joints affect results of later bone scanning? *J Pediatr Orthop* 1985;5:23.
 79. Hernandez RJ, Conway JJ, Poznanski AK, et al. The role of computed tomography and radionuclide scintigraphy in the localization of osteomyelitis in flat bones. *J Pediatr Orthop* 1985;5:151.
 80. Tang JS, Gold RH, Bassett LW, et al. Musculoskeletal infection of the extremities: evaluation with MR imaging. *Radiology* 1988;166:205.
 81. Mazur JM, Ross G, Cummings RJ, et al. Usefulness of magnetic resonance imaging for the diagnosis of acute musculoskeletal infections in children. *J Pediatr Orthop* 1995;15:144.

82. Alexander JE, Seibert JJ, Glasier CM, et al. High-resolution hip ultrasound in the limping child. *J Clin Ultrasound* 1989;17:19.
83. Zawin JK, Hoffer FA, Rand FF, et al. Joint effusion in children with an irritable hip: US diagnosis and aspiration. *Radiology* 1993;187:459.
84. Zieger MM, Dorr U, Schulz RD. Ultrasonography of hip joint effusions. *Skeletal Radiol* 1987;16:607.
85. Dorr U, Zieger M, Hauke H. Ultrasonography of the painful hip. Prospective studies in 204 patients. *Pediatr Radiol* 1988;19:36.
86. Royle SG. Investigation of the irritable hip. *J Pediatr Orthop* 1992;12:396.
87. Howard CB, Einhorn M, Dagan R, et al. Ultrasound in diagnosis and management of acute haematogenous osteomyelitis in children. *J Bone Joint Surg Br* 1993;75:79.

Differential Diagnosis

88. Hann IM, Gupta S, Palmer MK, et al. The prognostic significance of radiological and symptomatic bone involvement in childhood acute lymphoblastic leukemia. *Med Pediatr Oncol* 1979;6:51.
89. Rogalsky RJ, Black GB, Reed MH. Orthopaedic manifestations of leukemia in children. *J Bone Joint Surg Am* 1986;68:494.
90. Clausen N, Gotze H, Pedersen A, et al. Skeletal scintigraphy and radiography at onset of acute lymphocytic leukemia in children. *Med Pediatr Oncol* 1983;11:291.
91. McCormack LJ, Dockerty MB, Ghormley RK. Ewing's sarcoma. *Cancer* 1952;5.
92. Bell RS, Mankin HJ, Doppelt SH. Osteomyelitis in Gaucher disease. *J Bone Joint Surg Am* 1986;68:1380.
93. Del BMA, Champoux AN, Bockers T, et al. Septic arthritis versus transient synovitis of the hip: the value of screening laboratory tests. *Ann Emerg Med* 1992;21:1418.
94. Kocher MS, Zurakowski D, Kasser JR. Differentiating between septic arthritis and transient synovitis of the hip in children: an evidence-based clinical prediction algorithm. *J Bone Joint Surg Am* 1999;81:1662.
95. Bisno AL. Group A streptococcal infections and acute rheumatic fever. *N Engl J Med* 1991;325:783793.

Treatment

96. Barton LL, Dunkle LM, Habib FH. Septic arthritis in childhood. A 13-year review. *Am J Dis Child* 1987;141:898.
97. Shaw BA, Kasser JR. Acute septic arthritis in infancy and childhood. *Clin Orthop* 1990;257(Aug):21.2.
98. Rotbart HA, Glode MP. *Haemophilus influenzae* type b septic arthritis in children: report of 23 cases. *Pediatrics* 1985;75:254.
99. Lundy KW, Kehl DK. Increasing prevalence of *Kingella kingae* in osteoarticular infections in young children. *J Pediatr Orthop* 1998;18:262.
100. Yagupsky P, Dagan R, Howard CW, et al. High prevalence of *Kingella kingae* in joint fluid from children with septic arthritis revealed by the BACTEC blood culture system. *J Clin Microbiol* 1992;30:1278.
101. Gamble JG, Rinsky LA. *Kingella kingae* infection in healthy children. *J Pediatr Orthop* 1988;8:445.
102. Lacour M, Duarte M, Beutler A, et al. Osteoarticular infections due to *Kingella kingae* in children. *Eur J Pediatr* 1991;150:612.
103. Bradley JS, Kaplan SL, Tan TQ, et al. Pediatric pneumococcal bone and joint infections. *Pediatrics* 1998;102:1376.
104. Eisenberg JM, Kitz DS. Savings from outpatient antibiotic therapy for osteomyelitis. Economic analysis of a therapeutic strategy. *JAMA* 1986;255:1584.
105. Bryson VJ, Connor JD, Leuers M, et al. High dose dicloxacillin treatment of acute staphylococcal osteomyelitis in children. *J Pediatr* 1979;94:673.
106. Kolyvas E, Shronheim G, Marks MI, et al. Oral antibiotic therapy of skeletal infections in children. *Pediatrics* 1980;65:867.
107. Kocher MS, Zurakowski D, Kasser JR. Differentiating between septic arthritis and transient synovitis of the hip in children: an evidence-based clinical prediction algorithm. *J Bone Joint Surg Am* 1999;81:12.
108. Nelson JD, Bucholz RW, Kusmiesz H, et al. Benefits and risks of sequential parenteral-oral cephalosporin therapy for suppurative bone and joint infections. *J Pediatr Orthop* 1982;2:255.
109. Weinstein MP, Stratton CW, Hawley HB, et al. Multicenter collaborative evaluation of a standardized serum bactericidal test as a predictor of therapeutic efficacy in acute and chronic osteomyelitis. *Am J Med* 1987;83:218.
110. Wolfson JS, Swartz MN. Serum bactericidal activity as a monitor of antibiotic therapy. *N Engl J Med* 1985;312:968.
111. MacLowry JD. Perspective: the serum dilution test. *J Infect Dis* 1989;160:624.
112. Stratton CW. Serum bactericidal test. *Clin Microbiol Rev* 1988;1:19.
113. Smith BR, Rolston KV, LeFrock JL, et al. Bone penetration of antibiotics. *Orthopaedics* 1983;6:187.
114. Tetzlaff TR, Howard JB, McCracken GH, et al. Antibiotic concentrations in pus and bone of children with osteomyelitis. *J Pediatr* 1978;92:135.
115. Nelson JD, Howard JB, Shelton S. Oral antibiotic therapy for skeletal infection of children. I. Antibiotic concentration in suppurative synovial joint. *J Pediatr* 1978;92:131.
116. Bryan RE, Hammond D. Interaction of purulent material with antibiotics used to treat pseudomonas infection. *Antimicrob Agents Chemother* 1974;6:700.
117. Bryan LE, Van den Elzen HM. Streptomycin accumulation in susceptible and resistant strains of *Escherichia coli* and *Pseudomonas aeruginosa*. *Antimicrob Agents Chemother* 1976;9:928.
118. Donowitz GR, Mandell GL. Beta-lactam antibiotics. *New Engl J Med* 1988;318:419.
119. Farrar WE, O'Dell NM. Comparative β -lactamase resistance and antistaphylococcal activities of parenterally and orally administered cephalosporins. *J Infect Dis* 1978;137:490.
120. Sabath LD, Garner C, Wilcox C, et al. Effect of inoculum and of beta-lactamase on the anti-staphylococcal activity of thirteen penicillins and cephalosporins. *Antimicrob Agents Chemother* 1975;8:344.
121. Waldvogel FA, Medoff G, Swartz MN. Osteomyelitis: a review of clinical features, therapeutic considerations and unusual aspects. *N Engl J Med* 1970;282:198.
122. Braude AI, Jones JL, Douglas HI. The behavior of *Escherichia coli* endotoxin (somatic antigen) during infectious arthritis. *J Immunol* 1963;90:297.
123. Ginsburg I, Sela MN. The role of leukocytes and their hydrolases in the persistence, degradation, and transport of bacterial constituents in tissues: relation to chronic inflammatory processes in staphylococcal, streptococcal, and mycobacterial infections and in chronic periodontal disease. *CRC Crit Rev Microbiol* 1976;4:249.
124. Ginsburg J, Goulchian A, Stabholtz N, et al. Streptococcal and staphylococcal arthritis. *Agents Actions* 1980;7:260.
125. Green NE, Edwards K. Bone and joint infections in children. *Orthop Clin North Am* 1987;18:555.
126. LaMont RL, Anderson PA, Dajani AS, et al. Acute hematogenous osteomyelitis in children. *J Pediatr Orthop* 1987;7:579.
127. Goldstein WM, Gleason 'II', Barmada R. A comparison between arthrotomy and irrigation and multiple aspirations in the treatment of pyogenic arthritis. *Orthopaedics* 1983;6:1309.
128. Letts RM, Wong E. Treatment of acute osteomyelitis in chil-

- dren by closed-tube irrigation: a reassessment. *Can J Surg* 1975; 18:60.
129. Patterson DC. Acute suppurative arthritis in infancy and childhood. *J Bone Joint Surg Br* 1970;52:474.
 130. Skyhar MJ, Mubarak SJ. Arthroscopic treatment of septic knees in children. *J Pediatr Orthop* 1987;7:647.
 131. Stanitski CL, Harvell JC, Fu FH. Arthroscopy in acute septic knees. Management in pediatric patients. *Clin Orthop* 1989; 241:209.

Results

132. Blockley NJ, Watson JT. Acute osteomyelitis in children. *J Bone Joint Surg Br* 1970;52:77.
133. Cole WG, Dalziel RE, Leidl S. Treatment of acute osteomyelitis in childhood. *J Bone Joint Surg Br* 1982;64:218.
134. Molan RAB, Piggot J. Acute osteomyelitis in children. *J Bone Joint Surg Br* 1977;59:2.

Special Conditions

Spine

135. Smith AIDF. A benign form of osteomyelitis of the spine. *JAMA* 1933;101:335.
136. Bremner AE, Neligan GA. Benign form of acute osteitis of the spine in young children. *BMJ* 1953;1:856.
137. Ghormley RK, Bickel WH, Dickson DD. A study of acute infectious lesions of the intervertebral disks. *South Med J* 1940; 33:347.
138. Ring D, Johnston CE, Wenger KR. Pyogenic infectious spondylitis in children: the convergence of discitis and vertebral osteomyelitis. *J Pediatr Orthop* 1995;15:652.
139. Song KS, Ogden JA, Ganey T, et al. Contiguous discitis and osteomyelitis in children. *J Pediatr Orthop* 1997;17:470.
140. Coventry MB, Ghormley RK, Kernohan JW. The intervertebral discitis microscopic anatomy and pathology. Part I. Anatomy, development and physiology. *J Bone Joint Surg* 1945;27:105.
141. Crock HV, Yoshizawa H. *The blood supply of the vertebral column and spinal cord in man*. New York: Springer-Verlag, 1977.
142. Hassler O. The human intervertebral disc: a microangiographical study on its vascular supply at various ages. *Acta Orthop Scand* 1969;40:765.
143. Wiley AM, Trueta J. The vascular anatomy of the spine and its relationship to pyogenic vertebral osteomyelitis. *J Bone Joint Surg Br* 1959;41:796.
144. Rocco HD, Eyring EJ. Intervertebral disk infections in children. *Am J Dis Child* 1972;123:448.
145. Spiegel PG, Kengla KW, Isaacson AS, et al. Intervertebral disc-space inflammation in children. *J Bone Joint Surg Am* 1972;54: 284.
146. Wenger DR, Bobechko WP, Gilday DL. The spectrum of intervertebral disc-space infection in children. *J Bone Joint Surg Am* 1978;60:100.
147. An HS, Vaccaro AR, Dolinskas CA, et al. Differentiation between spinal tumors and infections with magnetic resonance imaging. *Spine* 1991;16(suppl 8):334.
148. Boston HC, Bianco AJJ, Rhodes KH. Disk space infections in children. *Orthop Clin North Am* 1975;6:953.
149. Menelaus MB. Discitis: an inflammation affecting the intervertebral disc in children. *J Bone Joint Surg Br* 1964;46:16.

Pelvis and Sacroiliac Joint

150. Schaad UB, McCracken GH, Nelson JD. Pyogenic arthritis of the sacroiliac joint in pediatric patients. *Pediatrics* 1980;66:375.

151. Morgan A, Yates A. The diagnosis of acute osteomyelitis of the pelvis. *Postgrad Med J* 1966;42:74.
152. Beaupre A, Carroll N. The three syndromes of iliac osteomyelitis in children. *J Bone Joint Surg Am* 1979;61:1087.
153. Reilly JP, Gross RH, Emans JB, et al. Disorders of the sacroiliac joint in children. *J Bone Joint Surg Am* 1988;70:31.
154. Chung SMK, Borns P. Acute osteomyelitis adjacent to the sacroiliac joint in children. *J Bone Joint Surg Am* 1973;55:630.
155. Edwards MS, Baker CJ, Granberry WM, et al. Pelvic osteomyelitis in children. *Pediatrics* 1978;61:62.
156. Jarvis J, McIntyre W, Udjus K, et al. Osteomyelitis of the ischiopubic synchondrosis. *J Pediatr Orthop* 1985;5:163.
157. Kloiber R, Udjus K, McIntyre W, et al. The scintigraphic and radiographic appearance of the ischiopubic synchondroses in normal children and in osteomyelitis. *Pediatr Radiol* 1988;18: 57.
158. Ailsby RL, Staheli LT. Pyogenic infections of the sacroiliac joint in children. Radioisotope bone scanning as a diagnostic tool. *Clin Orthop* 1974;100:96.
159. Farley T, Conway J, Shulman ST. Hematogenous pelvic osteomyelitis in children. *Am J Dis Child* 1985;139:946.
160. Miller JH, Gates GF. Scintigraphy of sacroiliac pyarthrosis in children. *JAMA* 1977;238:2701.
161. Reilly JP, Gross RH, Emans JB, et al. Disorders of the sacroiliac joint in children. *J Bone Joint Surg Am* 1988;70:31.
162. Morgan JG, Schlegelmilch JG, Spiegel PK. Early diagnosis of septic arthritis of the sacroiliac joint by use of computed tomography. *J Rheumatol* 1981;8:879.
163. Viani RM, Bromberg K, Bradley JS. Obturator internus muscle abscess in children: report of seven cases and review. *Clin Infect Dis* 1999;28:117.
164. Coy JTI, Wolf CR, Brower TD, et al. Pyogenic arthritis of the sacroiliac joint: long-term follow-up. *J Bone Joint Surg Am* 1976; 58:845.
165. Sucato DJ, Gillespie R. *Salmonella* pelvic osteomyelitis in normal children: report of two cases and a review of the literature. *J Pediatr Orthop* 1997;17:463.
166. Hendrix RW, Lin P-J, Kane WJ. Simplified aspiration or injection technique for the sacro-iliac joint. *J Bone Joint Surg Am* 1982;64:1249.
167. Miskew DB, Block RA, Witt PF. Aspiration of infected sacroiliac joints. *J Bone Joint Surg Am* 1979;61:1071.

The Neonate

168. Gotoff SP. Neonatal immunity. *J Pediatrics* 1974;85:149.
169. Kuo KN, Lloyd-Roberts GC, Orme IM, et al. Immunodeficiency and infantile bone and joint infection. *Arch Dis Child* 1975;50:51.
170. Lim MO, Gresham EL, Franken EAJ, et al. Osteomyelitis as a complication of umbilical artery catheterization. *Am J Dis Child* 1977;131:142.
171. Bergdahl S, Ekengren K, Eriksson M. Neonatal hematogenous osteomyelitis: risk factors for long-term sequelae. *J Pediatr Orthop* 1985;5:564.
172. Fox L, Sprunt K. Neonatal osteomyelitis. *Pediatrics* 1978;62: 535.
173. Edwards MS, Baker CJ, Wagner ML, et al. An etiologic shift in infantile osteomyelitis: the emergence of the group B streptococcus. *J Pediatr* 1978;93:578.
174. Ish-Horowicz MR, McIntyre P, Nade S. Bone and joint infections caused by multiply resistant *Staphylococcus aureus* in a neonatal intensive care unit. *Pediatr Infect Dis J* 1992;11:82.
175. Knudsen CJM, Hoffman EB. Neonatal osteomyelitis. *J Bone Joint Surg Br* 1990;72:846.
176. Memon IA, Norman MB, Jacobs NM, et al. Group B strepto-

- coccal osteomyelitis and septic arthritis. *Am J Dis Child* 1979; 133:921.
177. Monk PM, Reilly BJ, Ash JM. Osteomyelitis in the neonate. *Radiology* 1982;145:677.
 178. Weissberg ED, Smith AL, Smith DH. Clinical features of neonatal osteomyelitis. *Pediatrics* 1974;53:505.
 179. Yousefzadeh DK, Jackson JH. Neonatal and infantile candidal arthritis with or without osteomyelitis: a clinical and radiographical review of 21 cases. *Skeletal Radiol* 1980;5:77.
 180. Trueta J. The three types of acute haematogenous osteomyelitis. A clinical and vascular study. *J Bone Joint Surg Br* 1959;41:671.
 181. Ogden JA. Pediatric osteomyelitis and septic arthritis: the pathology of neonatal disease. *Yale J Biol Med* 1979;52:423.
 182. Chung SMK. The arterial supply of the developing proximal end of the human femur. *J Bone Joint Surg Am* 1976;58:961.
 183. Kemp HBS, Lloyd-Roberts GC. Avascular necrosis of the capital epiphysis following osteomyelitis of the proximal femoral metaphysis. *J Bone Joint Surg Br* 1974;56:688.
 184. Aigner RM, Fueger GF, Ritter G. Results of three-phase bone scintigraphy and radiography in 20 cases of neonatal osteomyelitis. *Nucl Med Commun* 1996;17:20.
 185. Ash JM, Gilday DL. The futility of bone scanning in neonatal osteomyelitis: concise communication. *J Nucl Med* 1980;21:417.
 186. Bressler EL, Conway JJ, Weiss SC. Neonatal osteomyelitis examined by bone scintigraphy. *Radiology* 1984;152:685.
- ### Sickle Cell Disease
187. Landesman SH, Rao SP, Ahonkhai VI. Infections in children with sickle cell anemia. *Am J Pediatr Hemat Oncol* 1982;4:407.
 188. Specht EE. Hemoglobinopathic *salmonella* osteomyelitis. *Clin Orthop* 1971;79:110.
 189. Engh CA, Hughes JL, Abrams RC, et al. Osteomyelitis in the patient with sickle-cell disease. *J Bone Joint Surg Am* 1971;53:1.
 190. Keely K, Buchanan GR. Acute infarction of long bones in children with sickle cell anemia. *J Pediatr* 1982;101:170.
 191. Mallouh A, Talab Y. Bone and joint infection in patients with sickle cell disease. *J Pediatr Orthop* 1985;5:158.
 192. Syrogiannopoulos GA, McCracken GHJ, Nelson JD. Osteoarticular infections in children with sickle cell disease. *Pediatrics* 1986;78:1090.
 193. Kim HC, Alavi A, Russell MO, et al. Differentiation of bone and bone marrow infarcts from osteomyelitis in sickle cell disorders. *Clin Nucl Med* 1989;14:249.
 194. Rao S, Solomon N, Miller S, et al. Scintigraphic differentiation of bone infarction from osteomyelitis in children with sickle cell disease. *Pediatrics* 1985;107:685.
 195. Kim HC, Alavi A, Russell MO, et al. Differentiation of bone and bone marrow infarcts from osteomyelitis in sickle cell disorders. *Clin Nuclear Med* 1989;14:249.
 196. Frush DP, Heyneman LE, Ware RE, et al. MR features of soft tissue abnormalities due to acute marrow infarction in five children with sickle cell disease. *AJR Am J Roentgenol* 1999;173:989.
 197. Sadat-Ali M, al-Umran K, al-Habdan I, et al. Ultrasonography: can it differentiate between vasoocclusive crisis and acute osteomyelitis in sickle cell disease? *J Pediatr Orthop* 1998;18:552.
 198. Booz MM, Hariharan V, Aradi AJ, et al. The value of ultrasound and aspiration in differentiating vaso-occlusive crisis and osteomyelitis in sickle cell disease patients. *Clin Radiol* 1999;54:636.
 199. Worrel VT, Burera V. Sickle-cell dactylitis. *J Bone Joint Surg Am* 1976;58:1161.
 200. Greene WB, McMillan CW. *Salmonella* osteomyelitis and hand-foot syndrome in a child with sickle cell anemia. *J Pediatr Orthop* 1987;7:716.
 201. Noonan WJ. *Salmonella* osteomyelitis presenting as "hand-foot syndrome" in sickle-cell disease. *BMJ* 1982;284:1464.
 202. Sankaran KM, Sadat AM, Kutty MK. Septic arthritis in sickle cell disease. *Int Orthop* 1988;12:255.
 203. Adeyokunnu AA, Hendrickse RG. *Salmonella* osteomyelitis in childhood. *Arch Dis Child* 1980;55:175.
 204. Adu-Gyamfi Y, Sankarankutty M, Marwa S. Use of a tourniquet in patients with sickle-cell disease. *Can J Anesth* 1993;40:24.
 205. Stein RE, Urbaniak J. Use of the tourniquet during surgery in patients with sickle cell hemoglobinopathies. *Clin Orthop* 1980;151:231.
 206. Sadat-Ali M, Sankaran-Kutty M, Kutty K. Recent observations on osteomyelitis in sickle-cell disease. *Int Orthop* 1985;9:97.
 207. Burnett MW, Bass JW, Cook BA. Etiology of osteomyelitis complicating sickle cell disease. *Pediatrics* 1998;10:296.
 208. Henderson RC, Rosenstein BD. *Salmonella* septic and aseptic arthritis in sickle-cell disease. A case report. *Clin Orthop* 1989;248:261.
 209. Espinoza LR, Spilberg I, Osterland CK. Joint manifestations of sickle-cell disease. *Medicine* 1974;53:295.
 210. Orozoco-Alcala J, Baum J. Arthritis during sickle cell crisis. *N Engl J Med* 1973;288:420.
 211. Jackson MA, Nelson JD. Etiology and medical management of acute suppurative bone and joint infections in pediatric patients. *J Pediatr Orthop* 1982;2:313.
 212. Ebong WW. Septic arthritis in patients with sickle-cell disease. *Br J Rheumatol* 1987;26:99.
- ### Chronic Recurrent Multifocal Osteomyelitis
213. Giedion A, Holthusen W, Masel LF, et al. Subacute and chronic "symmetrical" osteomyelitis. *Ann Radiol* 1972;15:329.
 214. Jurik AG, Helmig O, Ternowitz T, et al. Chronic recurrent multifocal osteomyelitis: a follow-up study. *J Pediatr Orthop* 1988;8:49.
 215. Madnell GA, Contreras SJ, Conard K, et al. Bone scintigraphy in the detection of chronic recurrent multifocal osteomyelitis. *J Nucl Med* 1998;39:1778.
 216. Carr AJ, Cole WG, Robertson DM, et al. Chronic multifocal osteomyelitis. *J Bone Joint Surg Br* 1993;75:582.
 217. Kawai K, Doita M, Tateishi H, et al. Bone and joint lesions associated with pustulosis palmaris et plantaris: a clinical and histological study. *J Bone Joint Surg Br* 1988;70:117.
 218. Manson D, Wilmot DM, King S, et al. Physal involvement in chronic recurrent multifocal osteomyelitis. *Pediatr Radiol* 1989;20:76.
 219. Bjorksten B, Boquist L. Histopathological aspects of chronic recurrent multifocal osteomyelitis. *J Bone Joint Surg Br* 1980;62:376.
 220. Jurik AG, Moller BN. Chronic sclerosing osteomyelitis of the clavicle: a manifestation of chronic recurrent multifocal osteomyelitis. *Arch Orthop Trauma Surg* 1987;106:144.
 221. Manson D, Wilmot DM, King S, et al. Physal involvement in chronic recurrent multifocal osteomyelitis [see comments]. *Pediatr Radiol* 1989;20:76.
 222. Gamble JG, Rinsky LA. Chronic recurrent multifocal osteomyelitis: a distinct clinical entity. *J Pediatr Orthop* 1986;6:579.
- ### Subacute Osteomyelitis
223. Harris NG, Kirkaldy-Willis WH. Primary subacute pyogenic osteomyelitis. *J Bone Joint Surg Br* 1965;47:526.
 224. King DM, Mayo KM. Subacute haematogenous osteomyelitis. *J Bone Joint Surg Br* 1969;51:458.

225. Gledhill RB. Subacute osteomyelitis in children. *Clin Orthop* 1973;96:57.
 226. Roberts JM, Drummond DS, Breed AL, et al. Subacute hematogenous osteomyelitis in children: a retrospective study. *J Pediatr Orthop* 1982;2:249.
 227. Cortias P, Tomeno B, Anract P, et al. Subacute osteomyelitis presenting as a bone tumour. A review of 21 cases. *Int Orthop* 1997;21:243.
 228. Bogoch E, Thompson G, Salter RB. Foci of chronic circumscribed osteomyelitis (Brodie's abscess) that traverse the epiphyseal plate. *J Pediatr Orthop* 1984;4:162.
 229. Azouz EM, Greenspan A, Marton D. CT evaluation of primary epiphyseal bone abscesses. *Skeletal Radiol* 1993;22:17.
 230. Green NE, Beauchamp RD, Griffin PP. Primary subacute epiphyseal osteomyelitis. *J Bone Joint Surg Am* 1981;63:107.
 231. Sorensen TS, Hedeboe J, Christensen ER. Primary epiphyseal osteomyelitis in children. Report of three cases and review of the literature. *J Bone Joint Surg Br* 1988;70:818.
 232. Ezra E, Wientroub S. Primary subacute haematogenous osteomyelitis of the tarsal bones in children. *J Bone Joint Surg Br* 1997;79:983.
 233. Ross ERS, Cole WG. Treatment of subacute osteomyelitis in childhood. *J Bone Joint Surg Br* 1985;67:443.
 234. Grey AC, Davies AM, Mangham DC, et al. The "penumbra sign" on T1-weighted MR imaging in subacute osteomyelitis: frequency, cause and significance. *Clin Radiol* 1998;53:587.
 235. Hamdy RC, Lawton L, Carey T, et al. Subacute hematogenous osteomyelitis: are biopsy and surgery always indicated? *J Pediatr Orthop* 1996;16:220.
- Puncture Wounds of the Foot**
236. Johanson PH. Pseudomonas infections of the foot following puncture wounds. *JAMA* 1968;204:170.
 237. Fisher MC, Goldsmith JF, Gilligan PH. Sneakers as a source of *Pseudomonas aeruginosa* in children with osteomyelitis following puncture wounds. *Pediatrics* 1985;106:607.
 238. Weber CA, Wertheimer SJ, Ognjan A. *Aeromonas hydrophila*—its implications in freshwater injuries. *J Foot Ankle Surg* 1995;34:442.
 239. Fitzgerald RH, Cowan JDE. Puncture wounds of the foot. *Orthop Clin North Am* 1975;6:965.
 240. Laughlin TJ, Armstrong DG, Caporusso J, et al. Soft tissue and bone infections from puncture wounds in children. *West J Med* 1997;166:126.
 241. Reichl M. Septic arthritis following puncture wound of the foot. *Arch Emerg Med* 1989;6:277.
 242. Lau LS, Bin G, Jaovisidua S, et al. Cost effectiveness of magnetic resonance imaging in diagnosing *Pseudomonas aeruginosa* infection after puncture wound. *J Foot Ankle Surg* 1997;36:36.
 243. Jacobs RF, Adelman L, Sack CM, et al. Management of *Pseudomonas* osteochondritis complicating puncture wounds of the foot. *Pediatrics* 1982;69:432.
 244. Jacobs RF, McCarthy RE, Elser JM. *Pseudomonas* osteochondritis complicating puncture wounds of the foot in children: a 10-year evaluation. *J Infect Dis* 1989;160:657.
- Gonococcal Arthritis**
245. Holmes K, Counts G, Beatty H. Disseminated gonococcal infection. *Ann Intern Med* 1971;74:979.
 246. Rimsza M, Niggemann E. Medical evaluation of sexually abused children: a review of 311 cases. *Pediatrics* 1982;69:8.
 247. White ST, Loda FA, Ingram DL. Sexually transmitted diseases in sexually abused children. *Pediatrics* 1983;72:16.
 248. Cooperman MB. Gonococcus arthritis in infancy. A clinical study of forty-four cases. *Am J Dis Child* 1927;33:932.
 249. Cooperman MB. End results of gonorrheal arthritis. A review of seventy cases. *Am J Surg* 1928;5:241.
 250. Spink WW, Keefer CS. Gonococcal arthritis: pathogenesis, mechanism of recovery and treatment. *JAMA* 1938;109:1448.
 251. Wehrbein HL. Gonococcus arthritis—a study of six hundred cases. *Surg Gyn Obstet* 1929;49:105.
 252. Wise CM, Morris CR, Wasilaukas BL, et al. Gonococcal arthritis in an era of increasing penicillin resistance. Presentations and outcomes in 41 recent cases (1985–1991). *Arch Intern Med* 1994;154:2690.
- Tuberculosis**
253. Smith MJD, Stack KR, Marquis JR. Tuberculosis and opportunistic mycobacterial infections. In: Fegin RO, Cherry JD, eds. *Pediatric infectious diseases*. 3rd ed. Philadelphia: WB Saunders, 1992:1327.
 254. Phemister DB, Hatcher CH. Correlation of pathological and roentgenological findings in the diagnosis of tuberculous arthritis. *AJR Am J Roentgenol* 1933;29:736.
 255. Hardy JB, Hartmann JR. Tuberculous dactylitis in childhood. *J Pediatr* 1947;30:146.
 256. Shannon BF, Moore M, Houkom JA, et al. Multifocal cystic tuberculosis of bone. *J Bone Joint Surg Am* 1990;72:1089.
 257. Jereb JA, Cauthen GM, Kelly GD, et al. The epidemiology of tuberculosis. In: Friedman LN, ed. *Tuberculosis: current concepts and treatment*. Boca Raton, FL: CRC, 1994:17.
 258. Versfeld GA, Solomon A. A diagnostic approach to tuberculosis of bones and joints. *J Bone Joint Surg Br* 1982;64:446.
 259. Martini M, Adjrad A, Boudjemaa A. Tuberculous osteomyelitis. A review of 125 cases. *Int Orthop* 1986;10:201.
 260. Lifeso RM, Weaver P, Harder EH. Tuberculous spondylitis in adults. *J Bone Joint Surg Am* 1985;67:1405.
 261. Medical Research Council Working Party on Tuberculosis of the Spine. Five-year assessment of controlled trials of ambulatory treatment, debridement and anterior spinal fusion in the management of tuberculosis of the spine; studies in Bulawayo (Rhodesia) and in Hong Kong. *J Bone Joint Surg Br* 1978;60:163.
 262. Medical Research Council Working Party on Tuberculosis of the Spine. Five-year assessment of controlled trials of inpatient and outpatient treatment and of plaster-of-Paris jackets for tuberculosis of the spine in children on standard chemotherapy. Studies in Masan and Pusan, Korea. *J Bone Joint Surg Br* 1976;58:399.
 263. Rajasekaran S, Soundarapandian S. Progression of kyphosis in tuberculosis of the spine treated by anterior arthrodesis. *J Bone Joint Surg Am* 1989;71:1314.
 264. Pediatrics AAO. Tuberculosis. In: Peter G, ed. *Report of the Committee on Infectious Diseases*, 23. Elk Grove Village, IL: American Academy of Pediatrics, 1994:488.



BONE AND SOFT TISSUE TUMORS

DEMPSEY S. SPRINGFIELD
MARK C. GEBHARDT

MOLECULAR BIOLOGY OF TUMORS 507

EVALUATION 510

Chief Complaint 510
Medical History 511
Review of Systems 511
Physical Examination 512
Plain Radiograph Examination 512
Additional Diagnostic Studies 513
Staging 515
Biopsy 517

SPECIFIC BONE TUMORS 518

Bone-forming Tumors 518

CHEMOTHERAPY FOR MUSCULOSKELETAL TUMORS 527

Cartilaginous Tumors 528
Lesions of Fibrous Origin 534
Miscellaneous Lesions 537
Soft Tissue Tumors 544

Primary bone and soft tissue tumors in the pediatric age group are uncommon and when they occur, usually benign. There are two primary malignant tumors of bone, osteosarcoma and Ewing sarcoma/peripheral (or primitive) neuroectodermal tumor (PNET), and one soft tissue sarcoma, rhabdomyosarcoma, which occur predominantly in the pediatric patient. The orthopaedist must remain alert because the malignant tumor is an unexpected event, and its infrequency can result in improper or delayed initial management. The orthopaedist who sees pediatric patients, but is not prepared to manage a malignant or aggressive benign

musculoskeletal tumor, must be comfortable with evaluating patients with musculoskeletal tumors, and know whom to refer and whom to manage. This chapter reviews the common bone and soft tissue tumors of childhood; it discusses how the patients present, what physical findings to expect, and how the plain radiographs should look; and it suggests additional diagnostic and staging evaluations and treatment. This chapter is not intended to be a definitive text of musculoskeletal pathology, and includes only the more common tumors of childhood.

MOLECULAR BIOLOGY OF TUMORS

Dramatic improvements in the survival of children with previously lethal sarcomas have occurred in the last 30 years from the use of adjuvant chemotherapy. One of the intriguing aspects about childhood sarcomas is that despite similar histologies, stages, and prognostic factors, some patients re-

D. S. Springfield: Leni and Peter W. May Department of Orthopaedics, Mount Sinai School of Medicine; Department of Orthopaedics, Mount Sinai Hospital, New York, New York 10029.

M. C. Gebhardt: Department of Orthopaedic Surgery, Harvard Medical School, Boston, Massachusetts 02115; Orthopaedic Service, Massachusetts General Hospital, Boston, Massachusetts 02114.

spond well to treatment, whereas others seem to be resistant to chemotherapy. To date, patients with good prognoses cannot be distinguished from those with poor prognoses except by crude clinical characteristics, such as the presence of metastatic disease at diagnosis. Recent molecular findings in sarcomas may shed light on the biologic behavior of sarcomas and their response to chemotherapy.

One method of seeking genetic alterations in tumors is to examine the chromosomes by karyotype analysis. The identification of recurrent chromosomal abnormalities provides clues regarding sites of potential gene mutations. Normally, there are 23 pairs of chromosomes in the human cell nucleus. Osteosarcomas in general have multiple, bizarre karyotypic abnormalities: Some chromosomes are missing, some are duplicated, and some are grossly altered. All high-grade osteosarcomas studied to date have complex karyotypes and nonclonal chromosome aberrations superimposed on complex clonal events (1,2). Low-grade parosteal osteosarcoma, on the other hand, is characterized by the presence of a ring chromosome, accompanied by no or few other abnormalities. Although it is usually possible to distinguish high-grade from low-grade osteosarcoma by standard histology, in other tumors the karyotype information can be diagnostically useful. In addition to possibly providing prognostic information, the specific chromosomal aberrations provide clues that assist molecular biologists looking for gene mutations (2).

In contrast to osteosarcoma, Ewing sarcomas, PNETs, and alveolar rhabdomyosarcomas have single chromosomal translocations characteristic of their respective histologies. In these tumors, part of one chromosome is transposed to part of another chromosome through a breakpoint. In these tumors, a novel gene and gene protein product are created that presumably give the cell a growth advantage. The most common translocations for these tumors are listed in Table 14-1.

The demonstration of translocations has been useful in the differential diagnosis of round cell tumors. Under the light microscope, there is little to distinguish one of these tumor types from the other, and although immunohistochemistry helps to an extent, it is at times difficult to be sure

of the diagnosis. Demonstration of these characteristic karyotypic findings makes pathologists more secure in their diagnosis, and has helped with the classification of these tumors. To perform a karyotype analysis, short-term cultures and metaphase spreads are necessary, but these are labor-intensive and require fresh tissue (4). More recent techniques, with fluorescent *in situ* hybridization and reverse transcriptase-polymerase chain reaction, allow rapid analysis for the presence of translocations, and these techniques can be performed on frozen and sometimes paraffin-embedded tissue (5,6).

These translocations have import beyond establishing the diagnosis. For several years, the distinction between Ewing sarcoma and PNET was difficult, and clinicians were not sure whether to treat them differently. The observation that both Ewing sarcoma, a poorly differentiated mesenchymal tumor of uncertain cell lineage, and PNET, a tumor believed to be of neural crest origin, shared the same chromosomal translocation led pathologists to believe that both were related neuroectodermal tumors (7,8). There is debate regarding whether one or the other has a better prognosis, but the treatment strategies used today are the same for both tumors (9–11).

More recently, these markers have been used in staging and follow-up of high-risk patients (12). Using reverse transcriptase-polymerase chain reaction technology, one can detect small numbers of tumor cells in a bone marrow or peripheral blood cell population. This makes the interpretation of bone marrow aspirates more precise, and may provide a means of earlier detection of relapses after treatment. It is hoped that the gene products of these translocations can also be used in treatment strategies. Because the novel genes formed from the translocation make a novel protein that normal cells do not make, antibodies or targeted T cells can be generated to specifically kill tumor cells. This is being tried in early-phase trials of relapsed patients with rhabdomyosarcoma and Ewing sarcoma/PNET, and if it works, it may be a way of treating patients who fail standard drug therapy.

Genetic alterations in the DNA of sarcomas have been well demonstrated. Mutations in genes, called “oncogenes,” give some evidence relative to the pathogenesis of these tumors, and may have some prognostic and therapeutic import (13,14). Oncogenes are normal cellular genes (*protooncogenes*) that are necessary for the normal development and function of the organism (15). When they are mutated, they may produce a protein capable of inducing the neoplastic state. Oncogenes act through a variety of mechanisms to deregulate cell growth. This is obviously a very complex process and may involve more than one genetic event.

There are two categories of oncogenes: *dominant oncogenes* and *tumor-suppressor genes* (15). The dominant oncogenes encode proteins that are involved in signal transduction, i.e., transmitting an external stimulus from outside the cell to the machinery controlling replication in the cell

TABLE 14-1. CYTOGENETIC FINDINGS IN EWING SARCOMA/PERIPHERAL (OR PRIMITIVE) NEUROECTODERMAL TUMOR AND ALVEOLAR RHABDOMYOSARCOMA

Tumor	Translocation	Genes
Ewing sarcoma/peripheral (or primitive)	t(11;22)(q24;q12)	<i>EWS-FLI-1</i>
neuroectodermal tumor	t(21;22)(q22;q12)	<i>EWS-ERG</i>
Alveolar rhabdomyosarcoma	t(2;13)(q35;q14)	<i>PAX3-FKHR</i> <i>PAX7-FKHR</i>

(From ref. 3, with permission.)

nucleus. Mutant cellular signal transduction genes keep the cell permanently "turned on." The protein products of oncogenes also function as aberrant growth factors, growth factor receptors, or nuclear transcription factors. These types of genes seem to have a lesser role in osteosarcomas.

A second class of genes, the tumor suppressor genes, are genes that encode proteins whose normal role is to restrict cell proliferation (16–20). They act as brakes rather than accelerators of growth. Their normal role is to regulate the cell cycle and keep it in check.

The retinoblastoma gene (*RB1*) was the first gene recognized in this class (21,22). Osteosarcomas are very frequent in patients with hereditary retinoblastoma, both in the orbit and in the extremities, unrelated to irradiation. It was subsequently learned that osteosarcomas in these patients as well as spontaneous osteosarcomas carry mutations or deletions of the *RB1* gene. It was one of the first clues that osteosarcomas had a genetic cause. It is estimated that approximately 60 to 75% of sporadic osteosarcomas have an abnormality of the *RB1* gene, or do not express a functional RB1 product (14). The retinoblastoma gene is located on the long arm of chromosome 13 (13q14), and is 200 kilobases in length. Its product is a 105- to 110-kilodalton nuclear phosphoprotein (pRB) that appears to have a cell cycle regulatory role. The retinoblastoma protein acts as a signal protein to connect the cell cycle with the transcription of genes that mediate the cell cycle. Deactivation of the *RB1* gene or absence of pRB allows cells to enter the cell cycle in an unregulated fashion, a condition that imparts a growth advantage to the affected cell. It should be noted that one copy of the gene is sufficient for a normal phenotype. A child born with a normal and a mutant or absent allele will not manifest retinoblastoma until some event occurs in retinoblasts to alter the normal allele. If both copies thus become deranged, the normal check on the cell cycle disappears and the conditions for the neoplastic state are met.

The second tumor suppressor gene to be identified was the *p53* gene (23–25). Located on the short arm of chromosome 17 (17p), its product is a nuclear phosphoprotein that has a cell cycle regulatory role similar to that of the Rb protein. Like RB, inactivation of *p53* gives the cell a growth advantage, probably as a result of loss of cell cycle regulation. *p53* may be inactivated by a variety of mutations, including a single base change (point mutation) that increases the half-life of the protein, allelic loss, rearrangements, and deletions of the *p53* gene. Each of these mechanisms can result in tumor formation by loss of growth control. It is estimated that about 25% of osteosarcomas have detectable mutations of the *p53* gene (26).

The *p53* protein is a transcription factor, meaning that it binds to regions of other genes (DNA), and controls the expression of genes responsible for cell cycle control (cell growth), apoptosis (programmed cell death), and other metabolic functions, such as control of repair of DNA damage. *p53* acts in concert with Rb, and a variety of other proteins,

to regulate the cell cycle by a complex cascade of enzymes, of which Rb probably has the central role. Apoptosis has recently become recognized as an important mechanism by which chemotherapy and radiotherapy kill cancer cells. *p53* is involved in this process, and appears to arrest cell division after sublethal damage (e.g., by radiation), to give the cell time to repair DNA defects before the next division (27–29). If repair does not take place, the cell undergoes apoptosis and dies. If *p53* is not functional, the cell may survive and accumulate genetic defects, leading to malignant transformation. Osteosarcomas have been shown to have a variety of mutations of the *p53* gene (30–39). Preliminary evidence suggests that overexpression of mutant *p53* protein, detected by immunohistochemistry or loss of heterozygosity of the *p53* gene, is related to outcome in human osteosarcoma (40,41).

In sarcomas, genetic defects other than *p53* and Rb have been detected. One example is a gene called *mdm-2*, which is a zinc finger protein amplified in some sarcomas (23,42–44). It inactivates *p53* protein by binding to *p53*, and prevents its transcription factor activity. Cordon-Cardo et al. (45) studied 211 adult soft tissue sarcomas by immunohistochemistry, using monoclonal antibodies to *mdm-2* and *p53*, and demonstrated a correlation between overexpression of *mdm-2/p53* and poor survival. Patients without mutations in either gene (*mdm-2/p53* –) had the best survival, those with one mutation (either *mdm-2* +/*p53* – or *mdm-2* –/*p53* +) had intermediate survival, and those with mutations in both genes (*mdm-2* +/*p53* +) had the worst survival.

Not only are genetic mutations found in the tumors of patients with sarcomas, but mutations may also be present in all somatic cells (*germline mutations*) in patients with heritable cancer (46–53). Although such defects do not appear to be common in the general population, germline *p53* mutations are present in patients who are part of a familial cancer syndrome. These families have a variety of cancers, often at an early age, and osteosarcomas and soft tissue sarcomas are a fairly common occurrence in these kindreds. Identification of patients with *p53* germline mutations can be useful in determining which patients in an affected family are at risk for developing cancers, but much more work is needed in genetic counseling to determine how best to use this information. A recent study showed that germline mutations were present in approximately 3 to 4% of children with osteosarcoma, and that the detection of these mutations was more accurate than family history in predicting family cancer susceptibility (54).

How is this information useful for treatment? One possibility is that *p53* mutations may be a potential biologic marker of prognosis and response to treatment (chemotherapy). There is some preliminary evidence that *p53* mutations in the tumor may portend a worse prognosis in osteosarcoma. More recently, the association of *p53* and apoptosis has suggested possible strategies for chemother-

apy, based on the status of the p53 pathway (28,29). Gene therapy (replacing the missing or mutated gene by transfection with viral carriers) is often discussed, but there are major technical hurdles to overcome before this technology can be used to treat cancers in humans. However, it might be possible to make tumor cells more antigenic, or to make them more sensitive to antineoplastic drugs, by gene transfer. Another strategy would be to alter normal cells to make them less sensitive to damage by chemotherapeutic agents. Currently, these techniques pose technical challenges, but they offer realistic promise for the near future.

Another exciting area in the molecular biology of sarcomas is multidrug resistance (MDR). MDR probably explains why some patients respond to chemotherapy and others do not. Drug resistance may be intrinsic (present at diagnosis) or acquired (appearing after treatment of a tumor) (55,56). At least four basic mechanisms of drug resistance are now recognized under the category of the MDR phenotype. They are (a) changes in glutathione metabolism, (b) alterations in topoisomerase II, (c) non-P-glycoprotein (P-gp)-mediated mechanisms, and (d) P-gp-mediated mechanisms (1,2). Recent evidence has suggested that P-gp may be of particular relevance to osteosarcoma.

P-gp is a glycoprotein encoded by the MDR-1 gene on the long arm of chromosome 7 in humans (55,57,58). MDR-1 is one member of the aneurysmal bone cyst (ABC) superfamily of genes that encode membrane transport proteins, which function as unidirectional membrane pumps using adenosine triphosphate hydrolysis to work against a concentration gradient. P-gp is a 170-kilodalton protein located in the cell membrane that functions as an energy (adenosine triphosphate)-requiring pump that excludes certain classes (amphipathic compounds) of drugs from the cell. This physiologic mechanism is believed to be important in certain organ systems, such as the blood-brain barrier, placenta, liver, kidney, and colon for ridding the cell of unwanted toxins, but it is also responsible for actively excluding chemotherapeutic agents, such as *Vinca* alkaloids, anthracyclines, colchicine, etoposides, and taxol (many of which are active in osteosarcoma protocols) from the cancer cell. Another feature of the P-gp mechanism which may have some relevance to therapeutic strategies is that some classes of drugs can reverse the MDR phenotype by blocking the action of the pump. These drugs include verapamil, cyclosporin A, tamoxifen, and others.

Several studies have demonstrated that some (25 to 69%) sarcomas display the MDR phenotype at diagnosis, and that relapsed sarcomas show higher incidence and intensity of MDR expression (59–64). These studies suffer from small numbers of patients and a variety of methods by which MDR was tested, so comparisons of studies and accurate determination of the incidence of MDR expression are difficult to accomplish. In addition, the age of the patient and the sarcoma type appear to be related to the incidence of detectable P-gp at diagnosis. One study showed that osteo-

sarcomas have a higher incidence of MDR than other types of adult sarcomas (65). Serra et al. (61) demonstrated that overexpression of P-gp protein was evident in 23% of primary and 50% of metastatic osteosarcomas.

Recently, Baldini et al. (66) reported on 92 patients with nonmetastatic extremity osteosarcoma treated with chemotherapy and surgery, and related immunohistochemically determined P-gp expression to event-free survival. They found that P-gp expression predicted a decreased probability of remaining event-free, and was more predictive than histologic response to preoperative chemotherapy.

Findings such as these are important in planning future protocols in human osteosarcoma. The drug-resistant tumor is becoming better identified as one that has a poor histologic response to preoperative chemotherapy and that expresses P-gp. Undoubtedly, it is more complex than this, and other mechanisms will pertain. Several caveats exist. One is the complexity of defining the resistant tumor. Preoperative chemotherapy requires 10 to 12 weeks to provide an estimate of histologic necrosis unless ways can be found to accurately predict percentage of necrosis by positron emission tomographic scans, thallium scans, and/or gadolinium-enhanced magnetic resonance imaging. Detection of P-gp at diagnosis is difficult, and no one method has proven superior. It is probably not sufficient to demonstrate the presence of P-gp; also important is whether the pump is functioning to exclude cytotoxic agents from the tumor cell. Ideally, one would like to reverse the action of the P-gp mechanism, but just as there are not new agents to rescue patients who have poor histologic response, the agents currently available to reverse MDR are of limited benefit. They are potentially problematic in that they make the normal cell less tolerant to chemotherapy, and thereby increase toxicity, and in other tumors their use has not proven to be effective (56,58). The future probably lies in developing more effective reversing agents, and in defining other drug-resistant mechanisms.

EVALUATION

The differential diagnosis for patients who present with a bone or soft tissue mass includes neoplasia, infection, and trauma. Infection and trauma are more common than neoplasia, and one of these is usually the explanation of a mass or abnormality seen on a radiograph. Neoplasia should not be forgotten. The consequences of the mismanagement of a patient with a musculoskeletal tumor can be grave (Fig. 14-1).

Chief Complaint

Pain is the most common presenting complaint of a patient with a musculoskeletal tumor. The characteristics of the pain can help determine the diagnosis. Ask the patient:

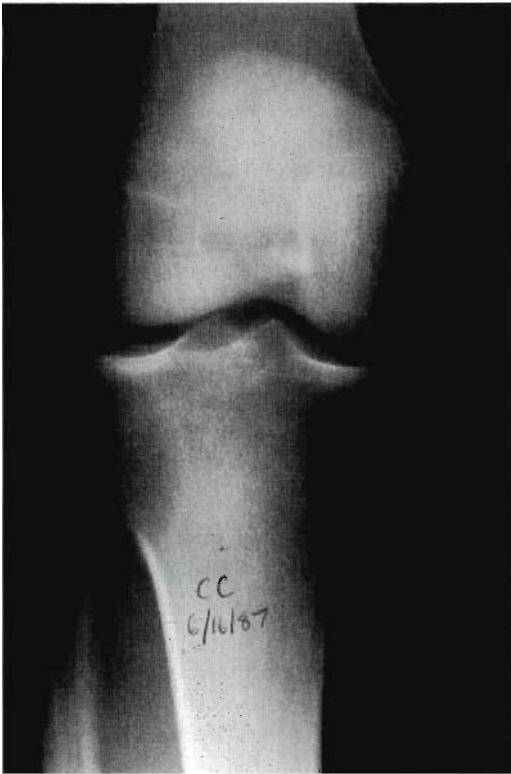


FIGURE 14-1. Anteroposterior radiograph of the knee of a young man who complained of it "giving way." The orthopaedist who saw the patient suspected a derangement, and the patient eventually had arthroscopic surgery. A radiolucent lesion can easily be seen in the lateral aspect of the proximal tibial metaphysis and epiphysis. This giant cell tumor of bone was missed because the physician did not consider this diagnosis when he was examining the patient or the radiograph. By the time the tumor was recognized, it had grown so large that resection and allograft reconstruction were required. Had it been treated when this radiograph was taken, a curettage and bone graft packing, or polymethyl methacrylate packing probably would have been done.

Where is the pain? How did it begin? Is it sharp, dull, radiating, or constant? Is it associated with activity? Is there a particular activity that makes the pain worse? What makes the pain better? Does it wake you at night? Is the intensity of the pain increasing, staying the same, or diminishing?

Patients who have active benign tumors (e.g., ABCs, chondroblastoma, and chondromyxofibroma) usually have a mild, dull, slowly progressive pain that is worse at night and aggravated by activity. Patients with malignant musculoskeletal tumors complain of a more rapidly progressive symptom complex, not specifically related to activity, which often awakens them at night. Occasionally, the pain pattern is diagnostic. The pain of an osteoid osteoma is so typical that the diagnosis should be strongly suspected from the history. This pain is a constant intense pain that is worse at night, and it is almost always relieved by aspirin or nonsteroidal antiinflammatory drugs (NSAIDs). The pain caused by a Brodie abscess is similar to that of an osteoid osteoma, but the Brodie abscess pain is rarely relieved by aspirin.

Most children and parents date the onset of symptoms to a traumatic event. The specific nature of the trauma and the relation of the trauma to the current symptoms must be evaluated thoroughly. Trauma without a definitive fracture can be the explanation for an abnormal radiograph but should not be used as the explanation, even for a periosteal reaction, unless the history is perfectly consistent. With the increased level of organized sports for children, there has been an increased incidence of fatigue fractures, and these fractures can be confused with neoplasias. Be cautious about ascribing a lesion to trauma.

The child presenting with a fracture should be questioned about the specifics of the injury that produced the fracture. Most lesions that lead to a pathologic fracture are easily recognized on a plain radiograph, but occasionally they may not be obvious. When the traumatic event seems insignificant, a pathologic fracture should be suspected. The patient should be asked about symptoms, no matter how minimal, before the fracture. Most aggressive benign tumors and malignant tumors produce pain before the bone is weakened enough to fracture. Inactive benign tumors are almost always asymptomatic until the bone breaks.

Medical History

Most children have no significant past medical history, but inquiries should be made. Has the child had a previous fracture? Has the child had other illnesses? Have radiographs been taken previously? Do not assume that the patient or the family will volunteer significant past medical history. Ask specific questions.

Review of Systems

Ask specifically about systemic symptoms of fever, decreased appetite, irritability, and decreased activity. Most patients with musculoskeletal tumors do not have systemic symptoms, and the presence of a systemic illness should alert the physician to the possibility of an underlying generalized disorder or osteomyelitis. Patients with Ewing sarcoma may have elevated temperature, weight loss, and malaise, but this is the exception rather than the rule. Even children with large primary malignant musculoskeletal tumors usually appear healthy. Patients with cancer do not always present with obvious signs of the underlying malignancy.

Most children with a soft tissue mass do not have symptoms. If the patient is younger than 5 years of age, the mass usually is noted first by a parent. The parent is convinced that the mass appeared overnight, but this is rarely the case. Teenagers may report the presence of a mass, but often only after a few weeks or months of waiting for it to resolve spontaneously. Painful soft tissue masses are most often abscesses. The majority of even malignant soft tissue tumors do not produce significant symptoms until they are large. Although most of the soft tissue masses seen in children

prove to be benign, all soft tissue masses, even those in children, should be considered malignant tumors until proven otherwise. The consequences of mistaking a malignant soft tissue tumor for a benign tumor can be devastating, whereas the consequences of approaching a benign tumor as if it were a malignancy are minimal.

Physical Examination

All patients with musculoskeletal complaints, especially those in the pediatric age group, should have a complete physical examination. Not only can important information be gained about the specific disorder being evaluated, but other significant abnormalities may be found. Café-au-lait lesions of the skin are a clue that the patient has fibrous dysplasia or neurofibromatosis. Numerous hard, nontender, fixed masses near the ends of long bones are diagnostic of multiple osteochondroma. Exophthalmos and otitis media indicate that the patient has Hand-Schüller-Christian disease.

The affected extremity should be examined carefully. The gait pattern should be recorded, muscular atrophy measured, and abnormalities in the vascular supply and motor and sensory innervation noted. The range of motion of the adjacent joint should be measured. If there is a mass present it should be measured, and the presence of erythema, tenderness, pulsations, bruit, or increased temperature should be noted.

Soft, movable, nontender masses, especially those in the subcutaneous tissues, usually are benign. These can be felt best when lubricant is applied on the overlying skin. Firm-to-hard, fixed or tethered, tender masses, especially those deep to the superficial fascia, are more likely to be malignant, but neurofibroma, deep lipoma, and cyst usually are firm to the touch. Transilluminate the mass; if light is transmitted more easily through the mass than through the surrounding tissue, the mass is a fluid-filled cyst.

Plain Radiograph Examination

Patients with musculoskeletal complaints should have at least anteroposterior and lateral plain radiographs. Good-quality plain radiographs (at least two views, preferably at 90 degrees) are necessary. The entire lesion must be observed. The radiograph should be reviewed systematically. Look at the bone, all of it, and every bone on the radiograph. Ask yourself these questions: Is there an area of increased or decreased density? Is there endosteal or periosteal reaction, and if there is, what are the characteristics of the reaction? Is there cortical destruction? Is it localized or are there multiple defects? Is the margin in the tumor well defined or poorly defined? Is there a reactive rim of bone surrounding the lesion? Are there densities within a radiolucent lesion? Is the bone of normal, increased, or decreased overall density? Is the joint normal? Is there loss of articular

cartilage? Is the subchondral bone normal, thick, or thin? Are there abnormalities in the bone on both sides of the joint? Are there intraarticular densities? Is there a soft tissue mass? Are there calcifications or ossifications in the soft tissue? By looking specifically for abnormalities, it is unlikely that an abnormality will be missed. The pelvis and the scapula are exceptions to this rule. Large tumors involving the pelvis or the scapula, even those with marked destruction of bone, can be extremely difficult or impossible to see on a plain radiograph. If there is a suggestion that the patient has a pelvic or a scapular tumor, bone scanning and computed axial tomography (CT) or magnetic resonance imaging (MRI) are recommended.

Enneking (67) teaches that four sets of questions should be asked when looking at plain radiographs of a possible bone tumor.

1. Where is the tumor? This refers to the lesion's anatomic location: long bone or flat bone; epiphyseal, metaphyseal, or diaphyseal; and medullary canal, intracortical, or surface.
2. What is the tumor doing to the bone? Is there erosion of the bone, and if so, what is the pattern?
3. What is the bone doing to the tumor? Is there periosteal or endosteal reaction? Is it well-developed? Is it sharply defined?
4. Are there intrinsic characteristics within the tumor that indicate its histology? Is there bone formation by the tumor? Is there calcification? Is the lesion completely radiolucent?

The examination of a radiograph should not be a casual glance, but a detailed study of all tissue present. Do not forget to specifically examine the soft tissues visible on the radiograph.

Most bone tumors can be diagnosed correctly after obtaining the history, performing a physical examination, and examining the plain radiograph. When the specific diagnosis is made from these examinations, additional studies are requested only if they are necessary for treatment. Specific treatment often can be planned from only the history, physical examination, and plain radiographs. For example, a 16-year-old boy with a hard, fixed mass in the distal femur that has not increased in size for more than 1 year, and has been present for 9 years, complains of pain after direct trauma to this mass. Plain anteroposterior and lateral radiographs confirm the clinically suspected diagnosis of osteochondroma. Further evaluation to make the diagnosis is not necessary, but if surgical resection is elected as the treatment, CT or MRI may be useful in planning the operative procedure.

When the specific diagnosis cannot be made, it should be possible to limit the differential to three or four diagnoses, and appropriate additional evaluations can be requested. CT, MRI, nuclear bone scanning (technetium, gallium, thallium, and indium), and positron emission

tomography may reveal findings that are diagnostic, or that provide needed information with which to plan a subsequent biopsy. For example, a 10-year-old boy complains of mild knee pain that has been present for 3 months, has loss of knee flexion, and on the lateral radiograph of the distal femur there is a bone density lesion attached to the posterior femoral cortex. From this information, the lesion is recognized as either a parosteal osteosarcoma or an osteocartilaginous exostosis. A technetium bone scan, with increased activity in the area of the lesion does not distinguish between these two, but both CT and MRI allow one to distinguish between a parosteal osteosarcoma and an osteocartilaginous exostosis. A parosteal osteosarcoma is attached to the cortex of the bone, whereas an osteocartilaginous exostosis arises from the cortex, and has a medullary canal continuous with the medullary canal of the bone. CT or MRI is critical in the evaluation of a patient in this clinical setting.

Additional Diagnostic Studies

Laboratory Examinations

Urine and serum laboratory values in musculoskeletal neoplasia are usually normal. Only a few musculoskeletal disorders are associated with abnormal laboratory values. The erythrocyte sedimentation rate (ESR), or sedimentation rate, is nonspecific but sensitive. Patients with infections or malignant tumors usually have an elevated ESR, but patients with benign disease should have a normal value. A normal ESR value can be used to increase the physician's confidence that a suspected benign, inactive lesion is just that. A markedly elevated value (>180 mm/h) supports a diagnosis of infection, and may be just what is needed to justify an early aspiration of a bone or soft tissue lesion. Patients with active benign or malignant musculoskeletal tumors, particularly those with Ewing sarcoma, often have an elevated ESR, but it is rarely greater than 80 mm/h. C-reactive protein is another serum value that indicates systemic inflammation. It increases and returns to normal more quickly than ESR.

Serum alkaline phosphatase is present in most tissues in body, but the bone and the hepatobiliary system are the predominant sources. In the pediatric age group conventional high-grade osteosarcoma is associated with elevated serum alkaline phosphatase (68). Not all patients with osteosarcoma have elevated serum alkaline phosphatase, and therefore, a normal value does not exclude osteosarcoma from the diagnosis. A minimal elevation can be observed with numerous processes, even a healing fracture. Adults with elevated serum alkaline phosphatase secondary to bone disease are most likely to have Paget disease of bone or diffuse metastatic carcinoma. Patients with a primary liver disorder have elevated serum alkaline phosphatase as well, but they also have elevated serum 5-nucleotidase, elevated

leucine aminopeptidase, and glutamyl transpeptidase deficiency. These are not elevated in primary bone tumors.

Serum and urine calcium and phosphorus should be measured, especially if a metabolic bone disorder is suspected. Serum lactic dehydrogenase (LDH) is elevated in some patients with osteosarcoma, and Ewing sarcoma patients with elevated levels have a worse prognosis (69–71). Elevated LDH may also indicate relapse in a patient who has been treated for these tumors. Patients entering chemotherapy treatment protocols will need to have LDH levels determined to stratify them on the protocol. Other laboratory determinations are not helpful, and are not recommended.

Radionuclide Scans

Technetium bone scanning is readily available, safe, and an excellent method to evaluate the activity of the primary lesion (Fig. 14-2). In addition, bone scanning is the most practical method to survey the entire skeleton. Technetium 99 attached to a polyphosphate is injected intravenously, and after a delay of 2 to 4 h the polyphosphate, with its attached technetium, concentrates in the skeleton proportional to the production of new bone. A disorder that is associated with an increase in bone production increases the local concentration of technetium 99 and produces a "hot spot" on the scan. The technetium bone scan can be used to evaluate the activity of a primary lesion, to search for other bone lesions, and to indicate extension of a lesion beyond what is seen on the plain radiograph. The polyphosphate–technetium 99 compound also concentrates in areas of increased blood flow, and soft tissue tumors usually have increased activity compared with normal soft tissues. The technetium scan can be used to evaluate blood flow if images are obtained during the early phases immediately after injection of the technetium. The polyphosphate–technetium 99 is cleared and excreted by the kidneys, so the kidneys and the bladder have more activity than other organs. The technetium scan is sensitive but nonspecific. The principal value of a radionuclide scan is as a means of surveying the entire skeleton for clinically unsuspected lesions. In approximately 25% of cases of Langerhans cell histiocytosis and plasmocytoma, the bone scan is normal, or there is decreased activity at the site of the lesion (72–74).

Gallium 67 imaging is another radionuclide study to evaluate both bone and soft tissue tumors (75). This examination takes longer to perform (24 to 72 h) than technetium 99 scanning (2 h), but it is believed to be useful in the evaluation of musculoskeletal tumors (76) because it can help differentiate a musculoskeletal infection from a neoplasia. Gallium scans are most useful when evaluating a patient suspected of having an occult infection. Scanning should be performed before a surgical procedure, because the operative site has increased uptake on the radionuclide scan.

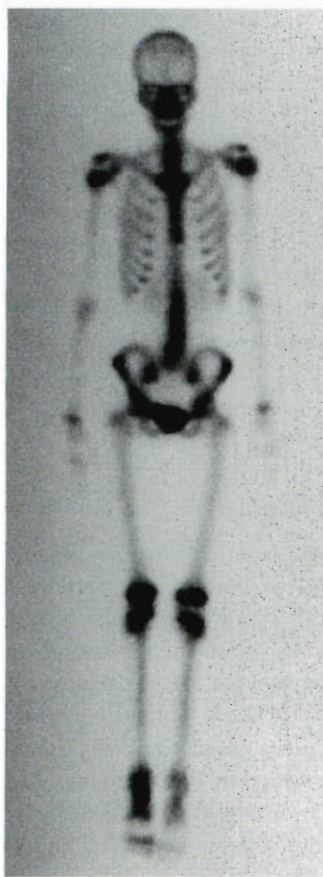

FIGURE 14-2. This is an anterior view of a whole body technetium 99 bone scan. This patient has an osteoid osteoma of her talus, and there is increased activity in the talus. There is also increased activity in the distal tibia, which is thought to be a reaction to the local increased blood flow. Technetium 99 bone scanning is an efficient means of evaluating the entire skeleton of a patient with a bone lesion. It is important to have the entire skeleton scanned, rather than limit the scan to a small part of the skeleton.

Thallium scans have been used to evaluate a tumor's response to therapy before resection (77,78). Because thallium uptake correlates well with the vascular supply of a tumor, decreased thallium uptake after therapy is a reflection of tumor necrosis, which is the best evidence that the chemotherapy is working. Unfortunately, to date the accuracy of thallium scanning is not sufficient for it to be completely reliable.

Positron emission tomography (PET) is being used more frequently in the evaluation of musculoskeletal tumors (79). Fluoro-2-deoxy-D-glucose (FDG) PET is the type of PET used most frequently in the musculoskeletal system. Because there is a differential uptake of FDG between neoplastic tissue and normal tissue (neoplastic tissue has greater uptake), it is possible to identify neoplastic tissue on a PET scan. The role of PET in the evaluation and monitoring of patients with musculoskeletal neoplasia is under investigation.

Computed Axial Tomography

When introduced in the late 1970s, CT dramatically improved the evaluation of bone and soft tissue tumors. Anatomic location and extent could be determined accurately. This improved the accuracy of anatomic localization, so that less radical surgery can be performed safely. Often, a specific diagnosis can be made or a suspected diagnosis can be confirmed after seeing the CT scan. Smaller nodules are seen on whole-lung CT scans than are seen with plain chest radiographs or whole-lung linear tomographs. With CT the abdomen can be evaluated thoroughly without surgical exploration.

The most common error made when requesting CT is not asking specific questions of the radiologist. Radiologists do not know what specific information the orthopaedist wants; only if specific questions are asked is the maximum value of CT realized. A specific differential diagnosis should be made from the presentation and plain radiographs. Only then can a decision be made regarding whether to request CT, MRI, both, or neither. Ask the radiologist to determine the lesion's location and its density and vascularity, and to search for intralesional characteristics that may provide a diagnostic clue. Have the radiologist include the contralateral normal extremity on the CT scan for comparisons.

The density of a bone or soft tissue mass on a CT scan is called its "attenuation coefficient" and is measured in Hounsfield units (HU) (Fig. 14-3). The density of water is 0 HU; tissues more dense than water have a positive value, and tissues less dense than water have a negative value. The vascularity of a lesion can be evaluated by measuring the increase in the attenuation coefficient of a lesion after intravenous infusion of contrast, and comparing this increase to that in an adjacent muscle. Normal muscle has an attenuation coefficient of approximately 60 HU, and increases 5 to 10 HU with a bolus of intravenous contrast. Fat has an attenuation coefficient of approximately -60 HU, and cortical bone usually has a value of more than 1,000 HU.

CT can be performed quickly with the newer "spiral" scanners and is less anxiety-producing, so sedation is less likely to be needed compared with MRI. CT remains most useful in the evaluation of small lesions in or immediately adjacent to the cortex (e.g., osteoid osteoma on the surface) and lesions with fine mineralization or calcifications (e.g., chondroblastoma). Percutaneous biopsies of musculoskeletal lesions can be performed with the assistance of localization obtained with CT. For all other situations, MRI has replaced CT.

Magnetic Resonance Imaging

MRI does not expose the patient to radiation, and has proved to be the most useful tool in the evaluation of musculoskeletal lesions. MRI produces images of the body in

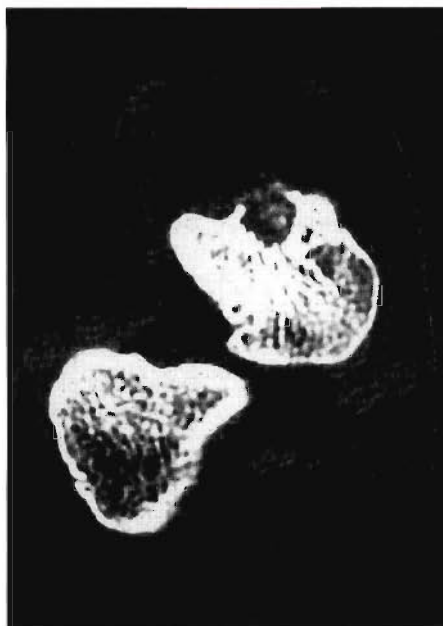


FIGURE 14-3. The density of a lesion can be measured on a computed tomography scan. This cortical bone lesion is an osteoid osteoma. The radiologist can measure the actual density of the lesion and provide information regarding the type of tissue. The measurements are made in Hounsfield units, after a developer of computed tomography. Zero Hounsfield units is the density of water. Negative units are less dense than water (fat measures approximately -70 Hounsfield units), and positive units are more dense than water (cortical bone measures greater than $1,000$ Hounsfield units).

all three planes (axial, sagittal, and coronal) as easily as in a single plane, and possesses no known hazards to the patient.

The images are produced by a computer program that converts the reactions of tissue hydrogen ions in a strong magnetic field excited by radio waves. By adjusting excitation variables, images that are T1- and T2-weighted are obtained. A variety of techniques have been used to produce images of improved quality compared with routine T1- and T2-weighted images. The use of gadolinium as an intravascular contrast agent allows one to judge the vascularity of a lesion, providing even more information about the tumor. Fat suppression images with gadolinium enhancement often are especially useful to demonstrate a soft tissue neoplasia. As with CT, it is important for the orthopaedist requesting MRI to discuss the case with the radiologist. The radiologist can then determine the optimal setting to see the lesion.

MRI is the single most important diagnostic test after physical examination and plain radiography for evaluating a musculoskeletal lesion. The ability to view the lesion in three planes, determine its intraosseous extent, see the soft tissue component clearly, and have an idea of the tissue type from one diagnostic test makes MRI a powerful tool (80). Unfortunately, variations in technique mean that it is important that the examination be planned carefully if the

most information possible is to be obtained (see Chapter 3). The radiologist must understand what questions need to be answered from the MRI. As a rule, it is important that the image be reviewed while it is being made, to ensure that the entire lesion is examined. Image the entire bone. T1-weighted (with and without gadolinium), T2-weighted, and fat-suppression techniques are the minimal images needed.

Staging

Patients with neoplasia can be separated into groups based on the extent of their tumor and its potential for metastasis. These groups are called stages. Grouping patients by their stage helps the physician predict a patient's risk of local recurrence and metastasis. This facilitates making treatment decisions about individual patients and helps in the comparison of treatment protocols. Staging systems are based on the histologic grade of the tumor, the tumor's size and location, and the presence of regional or distant metastasis. The presence of a metastasis at the time of presentation is a bad prognostic sign, and, regardless of other findings, puts the patient in the highest-risk stage. For patients without metastasis at presentation, the histologic grade of the tumor is the principle prognostic predictor. Size is next in importance. Higher histologic grade and larger tumors are associated with the worst prognosis.

There are two common staging systems used for musculoskeletal tumors. The task force on malignant bone tumors of the American Joint Commission on Staging and End Result Studies published a staging system for soft tissue tumors in 1977 (81). This system was revised in 1987 (82,83). This staging system is based on the histologic grade (G), local extent or size (T), whether or not there is involvement of nodes (N), and metastases (M). The tumors are separated into three histologic grades (G1, low grade; G2, medium grade; G3, high grade) and two sizes (T1 for less than 5 cm, T2 for equal to or greater than 5 cm). Patients with nodal involvement are designated N1, and those without nodal involvement are designated N0. Patients with metastatic disease are designated M1, and those without metastatic disease are designated M0. There are four stages, with subclasses in each stage. The patient with stage 1 has the best prognosis, and the patient with stage 4 has the worst prognosis (Table 14-2).

Enneking and colleagues (84) also proposed a musculoskeletal staging system. This system is used more often by orthopaedists involved in the management of patients with musculoskeletal tumors. It was designed to be simple, straightforward, and clinically practical. The tumors are separated into only two histologic grades (I, low grade; II, high grade) and two anatomic extents (A, intracompartmental; B, extracompartmental). Patients with metastatic disease in either a regional lymph node or a distant site are grouped together as stage III. Each bone is defined as its own separate

TABLE 14-2. REVISED AMERICAN JOINT COMMISSION STAGING SYSTEM FOR SOFT TISSUE SARCOMA

Stage	Description
Stage I	
IA—G1, T1, N0, M0	Grade 1 tumor, <5 cm in diameter with no regional lymph node or distant metastasis
IB—G1, T2, N0, M0	Grade 1 tumor, ≥5 cm in diameter with no regional lymph node or distant metastasis
Stage II	
IIA—G2, T1, N0, M0	Grade 2 tumor, <5 cm in diameter with no regional lymph node or distant metastasis
IIB—G2, T2, N0, M0	Grade 2 tumor, ≥5 cm in diameter with no regional lymph node or distant metastasis
Stage III	
IIIA—G3, T1, N0, M0	Grade 3 tumor, <5 cm in diameter with no regional lymph node or distant metastasis
IIIB—G3, T2, N0, M0	Grade 3 tumor, ≥5 cm in diameter with no regional lymph node or distant metastasis
Stage IV	
IVA—G1–3, T1–2, N1, M0	Tumor of any grade or size with histologically verified metastasis to regional lymph nodes, but no distant metastasis
IVB—G1–3, T1–2, N0–1	Clinically diagnosed distant metastasis

G1, low grade; G2, medium grade; G3, high grade; T1, <5 cm; T2, ≥5 cm; N0, no nodal involvement; N1, nodal involvement; M0, no metastases; M1, metastases.

(From ref. 82, with permission.)

anatomic compartment. The soft tissue anatomic compartments are defined as muscle groups separated by fascial boundaries (Table 14-3). There are five stages in this system (Table 14-4).

Enneking and colleagues (84) also introduced four terms to indicate the surgical margin of a tumor resection. These terms are commonly used, and provide a means of describing the relation between the histologic extent of the tumor and the resection margin. The surgical margins are defined as intralesional, marginal, wide, and radical. An intralesional margin is the surgical margin achieved when a tumor's pseudocapsule is violated and gross tumor is removed from within the pseudocapsule. An incisional biopsy and a curettage are two common examples of an intralesional margin.

TABLE 14-3. SURGICAL SITES

Intracompartmental	Extracompartmental
Intraosseous	Extraosseous soft tissue extension
Intraarticular	Extraparticular soft tissue extension
Superficial to deep fascia	Deep fascial extension Intraosseous or extrafascial extension
Paraosseous	
Intrafascial compartments	Extrafascial planes or spaces
Ray of hand or foot	Midfoot and hindfoot
Posterior calf	Popliteal space
Anterolateral leg	Groin-femoral triangle
Anterior thigh	Intrapelvic
Medial thigh	Midhand
Posterior thigh	Antecubital fossae
Buttocks	Axilla
Volar forearm	Periclavicular
Dorsal forearm	Paraspinal
Anterior arm	Head and neck
Posterior arm	
Periscapular	

(From ref. 84, with permission.)

A marginal surgical margin is achieved when a tumor is removed by dissecting between the normal tissue and the tumor's pseudocapsule. This is a surgical margin obtained when a tumor is "shelled out." A wide surgical margin is achieved when the tumor is removed with a surrounding cuff of normal, uninvolved tissue. This is often referred to as *en bloc* resection. A radical surgical margin is achieved when the tumor and the entire compartment (or compartments) are removed together. This usually is accomplished only with an amputation that is proximal to the joint just proximal to the lesion (e.g., an above-knee amputation for a tibial tumor). As a rule, benign lesions can be managed with an intralesional or marginal surgical margin, but malignant tumors require a wide surgical margin. Radical surgical margins are reserved for recurrent tumors and the most infiltrative malignancies.

TABLE 14-4. SURGICAL STAGES

Stage	Grade	Site and Size
IA	Low	Intracompartmental (T1)
IB	Low	Extracompartmental (T2)
IIA	High	Intracompartmental (T1)
IIB	High	Extracompartmental (T2)
III	Any grade; regional or distant metastasis	Any site or size

T1, <5 cm; T2, ≥5 cm.

(From ref. 84, with permission.)

Biopsy

Biopsy should be the last step in the evaluation of a patient with a bone or soft tissue tumor, and it should be performed only after careful planning (85–87). Often, biopsy proves unnecessary after the patient has been thoroughly evaluated, the diagnosis having been made by the clinical setting and radiographic findings. When a biopsy is required, the pre-biopsy evaluation improves the chance that adequate and representative tissue will be obtained, the least amount of normal tissue will be contaminated, and the pathologist will make an accurate diagnosis. Biopsies performed without an adequate prebiopsy evaluation are more likely to produce unsatisfactory results.

The purpose of the biopsy is to confirm the diagnosis suspected by the physician after the evaluation, or to determine which diagnosis, among a limited differential diagnosis, is correct. In addition to providing confirmation for a specific diagnosis, the tissue obtained must be sufficient for histologic grading. It must be representative of the tumor, and because many musculoskeletal tumors are heterogeneous, the specific site from which the tissue is taken is important. The surgeon who is willing to assume the surgical management of the patient, regardless of the diagnosis, should biopsy the patient's tumor. The biopsy incision and the tissue exposed during the biopsy must be excised with the tumor, if a wide surgical margin resection proves to be necessary. If the surgeon who performs the resection has planned and performed the biopsy, the patient has a better chance of limb salvage and less risk of local recurrence (86). The surgeon should consult with the radiologist and the pathologist before performing the biopsy to get their suggestions of the best tissue to obtain. Discussing the case with the pathologist the day before the biopsy also allows the pathologist to be better prepared when he or she is expected to make a diagnosis from a frozen section.

Needle biopsy and fine-needle aspirate biopsy often are suggested (88–91). Usually, they can be performed without general anesthesia and hospital admission, saving money and the need for general anesthesia. The needle track can be seeded with tumor, and should be excised at the time of the definitive resection. Needle biopsy and fine-needle aspirate biopsy must be planned just as open biopsy is planned, and the responsible surgeon should decide how the biopsy is to be performed. Needle biopsy and fine-needle aspirate biopsy are most useful for lesions whose clinical presentations are diagnostic, and when treatment is either nonsurgical or requires presurgical therapy. Although an experienced pathologist usually can make the correct diagnosis from a well-done needle biopsy or a fine-needle aspirate biopsy, more mistakes are made with these techniques than with open biopsy, and histologic grading can be difficult or impossible without open biopsy (88,89,91).

Plan the biopsy carefully. Think about possible future treatment, especially limb-salvage resection. The skin inci-

sion and deep dissection should be made so that they can be resected with the tumor at the time of definitive limb-salvage operation. Longitudinal skin incisions are better than transverse skin incisions. The dissection should be as limited as possible, flaps should not be raised, and neurovascular bundles should not be exposed. The dissection should be through a muscle, not between muscles. The tumor's pseudocapsule and a portion of the tumor should be excised as a block and sent to the pathologist. A frozen section analysis should be done, even when there are no plans for immediate additional surgery. The pathologist should be certain that adequate and diagnostic tissue is available. Only when dense bone is biopsied is it impossible to obtain a frozen section analysis. The pathologist should set aside tissue for subsequent examination with an electron microscope. Some tissue should be kept frozen in the event that immunohistochemistry is required.

A tourniquet can be used during the biopsy, but deflate the tourniquet before closure. The tumor should be manipulated as little as possible, and do not use a compressive bandage to exsanguinate the extremity, but rather elevate the extremity for 3 to 5 min before inflating the tourniquet.

Extra care should be taken to achieve hemostasis before closing the wound. The hematoma from the biopsy may contain tumor cells, and will require resection if surgery is the treatment. The wound can be drained, but the exit site of the drain must be in line with the incision and close to it. The drain track is resected with the tumor and the biopsy incision.

Occasionally an excisional biopsy, rather than an incisional biopsy, is indicated. An excisional biopsy is appropriate when the lesion is small, and can be excised with a cuff of normal tissue. An excisional biopsy may be appropriate even when a major resection is required. If the preoperative evaluation strongly supports the diagnosis of a malignancy, particularly one for which a frozen section analysis will be difficult to do, an excisional biopsy should be considered. The choice between an incisional biopsy and an excisional biopsy usually is easy to make. A clinically obvious exostosis on the proximal tibia should have an excisional biopsy, if it is biopsied at all. A surface osteosarcoma, diagnosed based on the results of plain radiography and CT or MRI, can be excisionally biopsied with a resection. A large aggressive lesion within the distal femur and invading the adjacent soft tissues should be biopsied incisionally. This decision is more difficult when the evaluation reveals a small, active, possibly low-grade malignancy on the proximal humerus or the distal radius. An incisional biopsy exposes uncontaminated tissues to the tumor, and if the tumor proves to be a malignancy, the definitive resection is more complicated. If the lesion can be treated with curettage or a marginal excision, the incisional biopsy leads to the least functional loss. The final decision is made for each patient based not only on the tumor's characteristics, but also on the patient's desires. Some patients want to take the least chances, and

are willing to accept the possibility of slight overtreatment, whereas others choose to take one step at a time. It is the surgeon's responsibility to inform the patient so that an informed decision can be made.

An added advantage of the excisional biopsy is that the pathologist is able to examine the entire lesion, improving the accuracy of the pathologic examination. Musculoskeletal tumors often are heterogeneous, and the amount of tissue obtained with an incisional biopsy always is limited. It can be particularly difficult to distinguish active benign cartilage tumors from low-grade chondrosarcomas. When the entire lesion, especially its connection with the adjacent bone and soft tissue, is seen the distinction is made more easily.

A final note of caution is offered with regard to the biopsy: Osteomyelitis is more common than bone tumors, especially in children, and osteomyelitis often mimics neoplasia. The reverse also is true; whenever performing a biopsy, even when the diagnosis seems obvious, culture the tumor and biopsy the infection.

SPECIFIC BONE TUMORS

This text is not designed to be a definitive musculoskeletal pathology text, and only those tumors that are common are discussed. The authors have tried to confine the discussion to pertinent information regarding the tumors, their evaluation, and their treatment.

Bone-forming Tumors

Osteoid Osteoma

Jaffe (92) is credited with the initial description of osteoid osteoma, distinguishing it from a sterile abscess called a Brodie abscess, and from Garré osteomyelitis. It is a benign tumor and accounts for 11% of the benign bone tumors in Dahlin's series from the Mayo Clinic (93). The patient is usually a young boy (males are affected more commonly than females, at a ratio of 3:1; 80% are between 5 and 24 years of age at the time of their initial symptoms) complaining of an intense pain at the site of the lesion.

The pain is an unrelenting, sharp, boring pain, worse at night and, almost without exception, completely relieved by aspirin or NSAIDs. The pain is not related to activity. The pain is thought to be attributable to prostaglandins produced by the nidus. The relief obtained with aspirin and NSAIDs is most likely the result of their ability to block prostaglandin's action. If a patient has the typical pain of an osteoid osteoma, but is not relieved by aspirin, the diagnosis of an osteoid osteoma should be doubted. The patient may have pain before any abnormality appears on the plain radiograph, and often the patient has had an electromyogram, a myelogram, or an arthrogram, before the typical plain radiographic changes are seen. Some patients are sus-

pected of having a psychosomatic disorder before the osteoid osteoma is found.

Osteoid osteomas may arise in any bone, but one-half of them are found in the femur or the tibia, whereas the other half are distributed throughout the rest of the skeleton (Fig. 14-4). The proximal femur is a common site. It is also a site at which it may be difficult to find the lesion. Young patients with persistent pain in the groin, the middle thigh, or the knee should be suspected of having an osteoid osteoma. The other common location of an occult osteoid osteoma is the spine. When osteoid osteoma arises in the spine, usually it is located in the posterior elements (Fig. 14-5). The osteoid osteoma in the spine does not elicit a significant bony reaction, and is very difficult to see on plain radiographs. The patient presents most commonly with a painful scoliosis (94,95). When a patient with scoliosis complains of back pain, osteoid osteoma should be considered. A technetium bone scan is particularly useful when the clinical presentation suggests an osteoid osteoma but the lesion cannot be found on the plain radiograph. It reveals an area of increased uptake, supporting a diagnosis of osteoid osteoma, and shows the lesion's location.

Patients with osteoid osteoma show few abnormalities on physical examination, with the exception of scoliosis in patients with osteoid osteoma of the spine. The child may walk with a limp and have atrophy of the involved extremity. If the bone with the osteoid osteoma can be palpated directly, it will be tender. Local erythema or increased temperature are not seen, and joint motion is normal. Serum and urine laboratory values are normal.

The plain radiographic appearance of an osteoid osteoma is of dense reactive bone, and usually is diagnostic. The lesion itself (the nidus, less than 15 mm in diameter) is radiolucent, but often is not seen on the plain radiograph, because of the density of the intense bone reaction that surrounds it. The nidus may be on the surface of the bone, within the cortex, or on the endosteal surface. Lesions on the endosteal surface have less reaction than lesions within or on the cortex. The lesion and the reaction are associated with increased uptake on the radionuclide study (technetium bone scan) (96). The nidus is best demonstrated by CT (97). The distance between the CT scan sections should be small (1 to 2 mm), so that the nidus is not missed. The window settings of the CT scanner should be adjusted so that the dense reaction around the lesion does not obscure the small, low-density nidus. When the nidus is found, it helps to have the distance from a bony landmark to the nidus measured on the scan, so that the nidus can be found at the time of surgical removal. MRI has been used to examine osteoid osteoma, and the diagnosis may be suspected, but the associated edema and reaction make the diagnosis less specific than with CT.

On gross inspection, the nidus of an osteoid osteoma is red and surrounded by dense white bone. The nidus is small, usually not more than 5 to 10 mm in diameter. A lesion that is identical histologically to the nidus of an osteoid

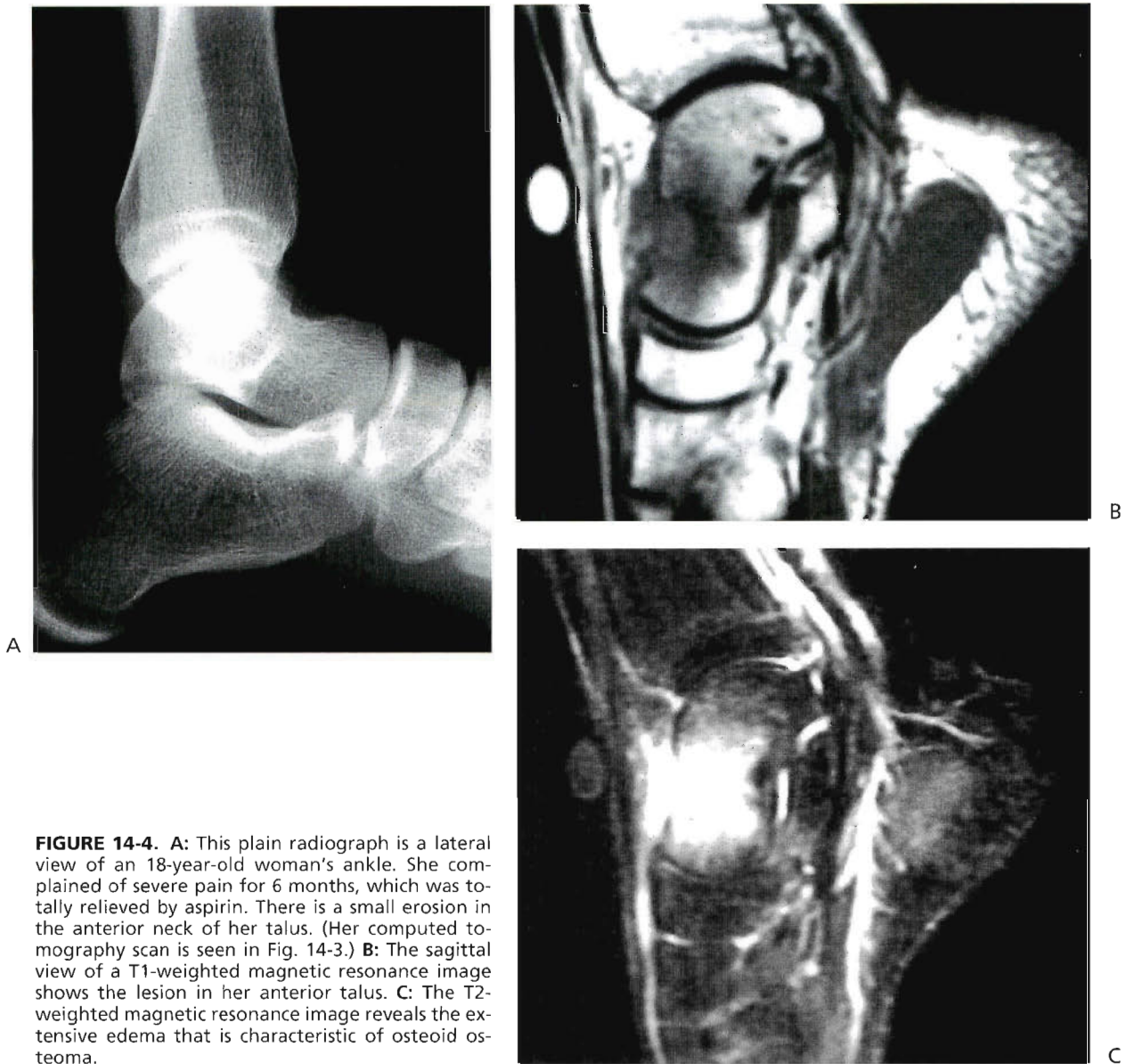


FIGURE 14-4. **A:** This plain radiograph is a lateral view of an 18-year-old woman's ankle. She complained of severe pain for 6 months, which was totally relieved by aspirin. There is a small erosion in the anterior neck of her talus. (Her computed tomography scan is seen in Fig. 14-3.) **B:** The sagittal view of a T1-weighted magnetic resonance image shows the lesion in her anterior talus. **C:** The T2-weighted magnetic resonance image reveals the extensive edema that is characteristic of osteoid osteoma.

osteoma, but larger than 2 cm, is called an osteoblastoma. The nidus is composed of numerous vascular channels, osteoblasts, and thin, lace-like osteoid seams (Fig. 14-6). Multinucleated giant cells can be seen, but are not common.

The pain of an osteoid osteoma can resolve spontaneously (98). Kneisl and Simon (99) treated 24 patients with osteoid osteoma. Thirteen were operated on immediately, and all had complete relief of pain. Nine were treated with NSAIDs. Three subsequently elected to have surgery, but six eventually became free of pain (an average of 33 months). It is believed that osteoid osteoma is a spontaneously healing lesion that eventually involutes over a period of years, and the nidus completely ossifies. Occasionally, a patient uses aspirin or NSAIDs to control the symptoms

until the pain disappears, but most often the intensity of pain, the time it takes for the lesion to heal spontaneously, and the amount of medication required is not tolerable, and the patient elects to have surgery. Complete removal of the nidus relieves the patient's pain. Partial removal may provide temporary relief, but the pain usually returns (100). Only the nidus needs to be excised, whereas the reactive bone around the nidus does not need to be removed.

There are two surgical methods of removing the nidus. The conventional method is a block resection of the nidus and most of the surrounding reactive bone. The other is a curettage of the nidus. The advantage of the block resection is the greater assurance that all of the nidus is removed, but this technique requires removal of a segment of the cortex,

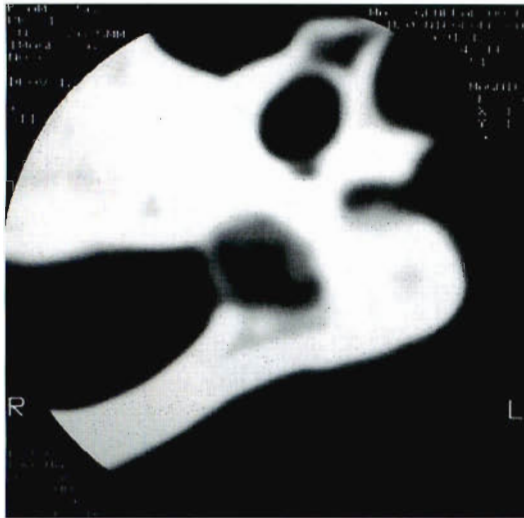


FIGURE 14-5. This is a computed tomography scan cut through a lesion in the pedicle of a teenager with neck pain. The lesion has all of the characteristics of osteoid osteoma. It could not be seen clearly on the plain radiograph, but there was a discrete focus of increased uptake on a technetium 99 bone scan.

and produces a marked reduction in the strength of the bone. The defect created by the excision may need to be bone-grafted, and the patient's extremity may need to be protected for an extended period of time. The advantage of the curettage technique is that the bone is not weakened significantly, and bone grafting is not required. However, with curettage it is more difficult to be certain that all of the nidus is removed.

If curettage is the excision technique used, the nidus must be accurately localized preoperatively, and seen intraoperatively. When the nidus cannot be localized accurately pre-

operatively, or seen intraoperatively, block excision is preferred. Intraoperative radionuclide scanning and intraoperative tetracycline-fluorescence demonstration have been reported as methods of finding the nidus in the operating room and assuring the surgeon of its complete removal (101–104). The authors have not found these techniques necessary. Preoperative planning and careful localization of the nidus is the most important means of ensuring that the nidus can be found during the operation.

Radiofrequency ablation has become an accepted means of treating osteoid osteoma (105–107). The procedure is performed under general anesthesia, but usually can be done without hospitalization. Using CT to control placement, a needle biopsy is performed to confirm the diagnosis. Then, through the same needle track a radiofrequency electrode with an internal thermistor is placed in the nidus. The patients were not protected, nor were their activities limited after the heat ablation, and there have been no complications. Other closed methods of treatment have been reported (108).

Osteoblastoma

Osteoblastoma is sometimes called “giant osteoid osteoma” because it is histologically identical to osteoid osteoma, but larger. Unlike osteoid osteoma, osteoblastoma is not surrounded by dense reactive bone. Cementoblastoma of the jaw is histologically identical to osteoblastoma. Osteoblastoma is less common than osteoid osteoma, accounting for less than 1% of the primary bone tumors in Dahlin's series (93).

The typical patient is a boy in the second decade of life (50% of the patients are between 10 and 20 years of age, although the age range is from 5 to 35 years of age) complaining of back pain (approximately 50% of the lesions

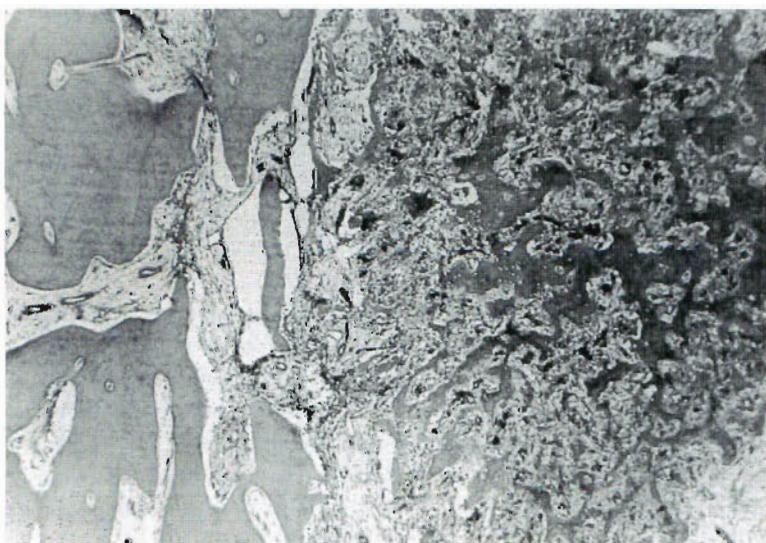


FIGURE 14-6. Histologic appearance of an osteoid osteoma. The bone tissue on the left is reactive trabeculae surrounding the nidus (right). The nidus is composed of osteoid, multinucleated giant cells, osteoblasts, and vessels. A thorough curettage of the nidus was done, and the patient's pain resolved completely. (Original magnification $\times 10$.)

are in the spine). The pain of an osteblastoma is not as severe as the pain of an osteoid osteoma, and aspirin or NSAIDs do not have such a dramatic effect. There are no physical findings characteristic of osteblastoma. When the tumor is in the spine, the patient has decreased motion of the spine in the involved area. Osteblastomas are tender, and direct palpation often localizes a lesion, even when it cannot be seen on a plain radiograph.

Extremity lesions are usually diaphyseal; the patient often has a limp and mild atrophy, and complains of pain directly over the lesion. Blood and urine laboratory examinations are normal. The appearance of osteblastoma on a radiograph is variable. It is usually a mixed radiolucent, radiodense lesion, more lucent than dense. There is minimal reaction in the surrounding bone. Lesions in the spine may be difficult or impossible to see when initially examining the plain radiograph, but when located by other studies, the subtle abnormality on the plain radiograph can usually be appreciated.

Clues to look for on the plain radiograph to indicate the location of an osteblastoma are an irregular cortex, loss of pedicle definition, and enlargement of the spinous process. As with osteoid osteoma, CT is the best method of localization. On the CT scan, the lesion usually "expands the bone" and has intralesional stippled ossifications and a high attenuation coefficient (100 HU or more). Osteblastoma on the radionuclide scan has increased uptake, and technetium bone scanning is an excellent method of initially screening a patient suspected of having an osteblastoma. The bone scan localizes the lesion, but it is not specific enough to plan a surgical resection for lesions in the spine.

Osteblastomas should be excised surgically. They continue to enlarge and damage the bone and adjacent structures if left untreated. A wide surgical resection is preferred when practical, but an extended curettage is sufficient for most cases. As much of the surrounding bone should be removed as possible. Most osteblastomas are controlled by the extended curettage, but recurrence is not uncommon, and some can be locally aggressive. It is difficult to give a percentage risk of local recurrence, but in the authors' experience, it is less than 10% of cases. Although irradiation has been used in the management of these patients, there is little evidence that it is of benefit.

The histology of an osteblastoma is identical to the nidus of an osteoid osteoma. There should not be abnormal mitoses, although mitotic activity can be observed. There are osteoblasts, multinucleated giant cells, seams of osteoid, and a rich vascular bed. Schajowicz and Lemos (109) suggested that a subset of osteblastoma be termed malignant osteblastoma. They believe that this subset has histologic features that are worse than those of the usual osteblastoma, is more aggressive locally, and is more likely to recur after limited surgery. A rare osteblastoma metastasizes but still meets the histologic definitions of a benign tumor, although it probably should be classified as low-grade osteosarcoma.

Osteosarcoma

Osteosarcoma is defined as a tumor in which malignant spindle cells produce bone. There are two major variants that have significantly different clinical presentations and prognoses. The more common osteosarcoma is classic high-grade or conventional, and the other is juxtacortical. Some authors separate juxtacortical osteosarcomas into parosteal and periosteal. Less common variants of osteosarcoma (e.g., intracortical, soft tissue, radiation-induced, Paget) are not discussed in this text.

Classic High-grade Osteosarcoma. The patient is usually a teenager (about 50% of the patients present during the second decade of life; more than 75% are between 8 and 25 years of age) complaining of pain and a mass around the knee (Figs. 14-7 and 14-8). Half of the lesions are located in the distal femur or the proximal tibia. The proximal humerus, proximal femur, and pelvis are the next most common sites. The pain precedes the appreciation of the mass by a few weeks to 2 or 3 months. Boys and girls are affected with equal frequency. The patient does not have systemic symptoms, and usually feels well. The mass is slightly

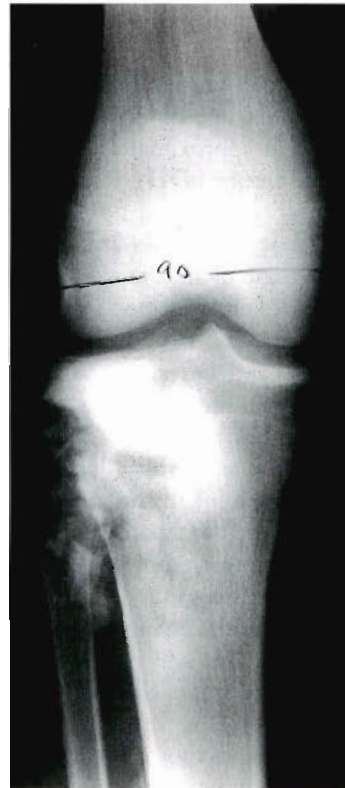

FIGURE 14-7. This is an anteroposterior plain radiograph of an 18-year-old man with an osteosarcoma of his proximal tibia. There is increased density in the proximal tibia associated with cortical destruction and extraosseous bone formation. Biopsy was confirmatory.

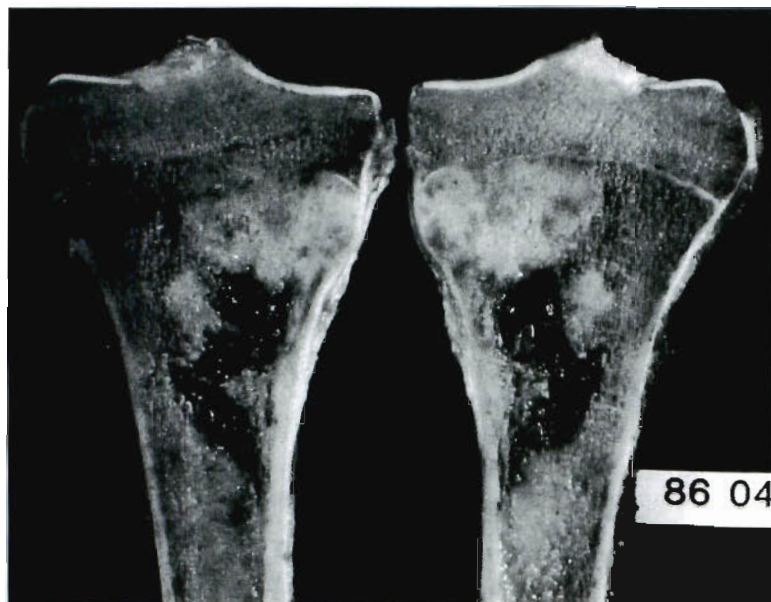

FIGURE 14-8. Classic high-grade osteosarcoma of the proximal tibia. The tibia was bisected for examination. The tumor is composed of an osteoblastic component in the metaphysis, which is up to, and just through, the epiphyseal plate; there also is a more distal cystic component. The tumor has penetrated the cortex, and has a small extracortical component. The patient had not received preoperative chemotherapy, but was treated successfully with limb salvage resection and knee arthrodesis. The patient received postoperative adjuvant chemotherapy, and has been continuously free of disease for 4 years.

tender, firm-to-hard, and fixed to the bone but not inflamed. The adjacent joint usually has restricted motion.

The remainder of the physical examination is normal, except in the rare (less than 1%) patient who presents with metastases or multiple focal osteosarcoma. One-half of all patients have elevated serum alkaline phosphatase (extremely high serum alkaline phosphatase values indicate a worse prognosis), and approximately one-fourth of all patients have elevated serum LDH (an elevated LDH also is associated with a worse prognosis). The remainder of the blood and urine laboratory values are normal.

The plain radiograph of an osteosarcoma is usually diagnostic. The typical lesion is located in the metaphysis, involves the medullary canal, is both lytic (radiolucent) and blastic (radiodense), and has an extrasosseous component and a periosteal reaction suggestive of a rapid growth (Codman triangle or sunburst pattern). Many osteosarcomas have a soft tissue component, with a fluffy density suggestive of neoplastic bone, adjacent to the more obvious bone lesion. Those osteosarcomas that consist primarily of cartilage or fibrous tissue are almost purely radiolucent. Telangiectatic osteosarcoma, a histologic variant of classic high-grade osteosarcoma, may be mistaken on a radiograph for an ABC or a giant cell tumor. This will not be a clinical problem for the pathologist if adequate clinical information is provided by the surgeon.

MRI is the method of choice for evaluating suspected osteosarcoma. The lesion's extent is more clearly defined by MRI, especially the intraosseous component. The lesion can be seen in all three planes, and its soft tissue extension is easily appreciated. It is critical that the entire bone be included on at least one plane (usually the coronal view). The

tumor should be viewed with a minimum of T1-weighted (with and without gadolinium), T2-weighted, and fat-suppressed images.

Osteosarcomas should be resected with at least a wide surgical margin, and the anatomic extent of the tumor is the principal determinant of what operation will be required. MRI is the best method to determine the anatomic extent of an osteosarcoma. The relation of osteosarcoma to the major neurovascular bundle must be determined. The muscles invaded by the soft tissue component must be identified. Involvement of the adjacent joint must be looked for, the intraosseous extent measured, and the presence of metastasis noted. Talking to the radiologist before MRI is performed helps to ensure that all this information is obtained.

Chest radiography and whole lung CT are performed because of the relatively high incidence of patients presenting with pulmonary metastasis (approximately 10%).

The technetium bone scan shows increased uptake in the area of the tumor. Occasionally it is useful in determining the intraosseous extent, although MRI is more accurate. More importantly, technetium scanning is an excellent screen of the entire skeleton for occult bone lesions. On rare occasions a lung metastasis is seen on the bone scan, but usually a hot spot in the chest on the bone scan is secondary to involvement of a rib.

There are five major histologic types of conventional osteosarcoma, and each is graded for the degree of malignancy. The histologic type is determined by the predominant cell type of the tumor. Although initially it was thought that the different types had distinct prognoses, it is now recognized that if matched for size and histologic grade, all types

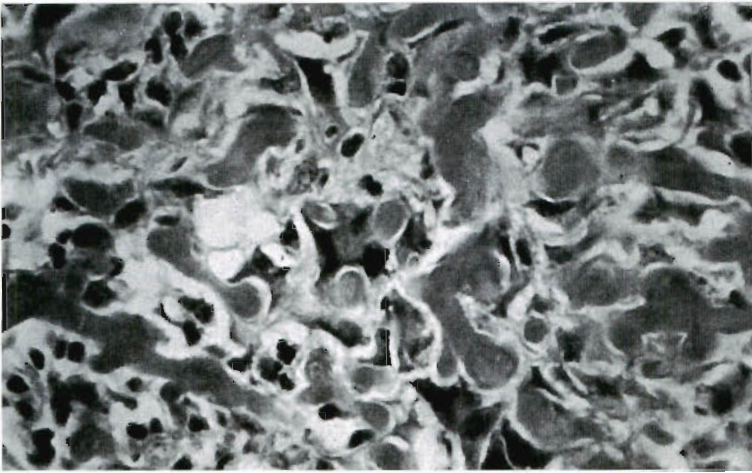


FIGURE 14-9. Histologic appearance of classic high-grade osteosarcoma. The malignant spindle cells are recognized by their abnormal variation in size and shape. No mitotic figures are seen in this photomicrograph, but abnormal mitoses usually are seen in high-grade conventional osteosarcoma. (Original magnification $\times 40$.)

have the same prognosis. Even telangiectatic osteosarcoma, which was originally described as having a particularly poor prognosis, is thought to have the same prognosis as the other classic high-grade osteosarcomas.

The five types are osteoblastic, chondroblastic, fibroblastic, mixed, and telangiectatic osteosarcomas. These tumors are graded on a scale of either 1 to 3 or 1 to 4. The higher the histologic grade, the worse the prognosis. Most osteosarcomas are grade 3 or 4, and of the mixed type. The tumor is composed of a mixture of neoplastic cells, but must have malignant spindle cells making osteoid. Atypical mitoses are common, and small areas of necrosis are usually seen (Fig. 14-9).

Treatment of classic high-grade osteosarcoma includes adjuvant chemotherapy and surgical resection. The standard protocol consists of chemotherapy (neoadjuvant; usually three or four courses of a multidrug regimen), then surgical resection, and finally additional chemotherapy (Fig. 14-10). The entire treatment takes almost 1 year. The surgical resection can almost always be done without an amputation of the extremity, and less radical surgery is being performed now compared with only a few years ago. Recently, Picci and associates suggested that patients whose tumors have more than 90% necrosis after preoperative chemotherapy do not require as wide a surgical margin as patients with less necrosis (110,111). The use of neoadjuvant chemotherapy has not produced increased survival compared with postoperative adjuvant chemotherapy, but it does seem to make surgery easier, and gives the pediatric oncologist a predictor of survival.

The three most important drugs used for osteosarcoma are doxorubicin (Adriamycin), high-dose methotrexate, and cisplatin. The majority of chemotherapy protocols include these three drugs in various dosage schedules, in addition to one or more other drugs. The development of granulocyte-stimulating factor to counteract bone marrow suppression, has allowed increased intensification of the treatment with

fewer complications; granulocyte-stimulating factor is now used routinely. Overall survival has increased to more than 60%, with even better survival for those patients with greater than 90% necrosis after chemotherapy (112–122).

Limb-salvage surgery is being performed for all but the largest of osteosarcomas. Amputation is done in less than

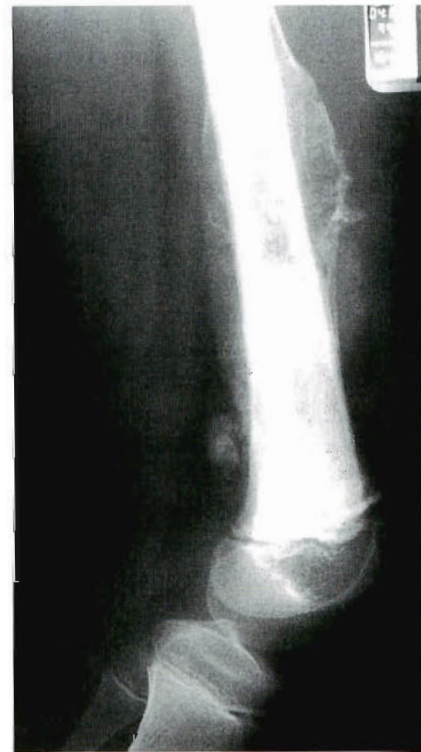

FIGURE 14-10. This plain radiograph is a lateral view of the distal femur of a patient who has had standard preoperative chemotherapy. The original lesion had a large extraosseous component that has been reduced in size, and there has been "maturing" of the periosteal reaction. The patient's pain diminished, and the range of motion in her knee returned to normal.

20% of cases (122–126). The accepted incidence of local recurrence is between 5 and 10%, which does not seem to increase the incidence of death (125). This is an area of concern, however, because it appears that the vast majority of patients with local recurrence die of their disease (123,125). One explanation is that local recurrence is a sign of a more aggressive tumor, not solely the consequence of poor surgery. That being said, however, the insistence on wide margins is paramount. The tumor with a small amount of surrounding normal tissue is resected. This usually means 1 or 2 cm of normal bone proximal and/or distal to the extent of the tumor and a small cuff of muscle directly on the tumor and bone. It is uncommon to perform extraarticular resection unless there is gross extension of tumor into a joint, and increasingly close bone margins are accepted in an attempt to save a young child's growth plate or a patient's articular cartilage.

The management of patients with pathologic fractures is controversial. There is an increased incidence of local recurrence if limb-salvage resection is performed, but this increased incidence of local recurrence does not seem to increase the risk of death (123,127–130). The usual management of a patient with a pathologic fracture and osteosarcoma is to treat the fracture closed, give neoadjuvant chemotherapy, and perform limb salvage if negative surgical margins can be obtained.

The patient younger than 10 or 11 years, whose tumor resection requires the removal of a major growth plate (distal femur, proximal tibia, or proximal humerus), presents a special problem (131–135). Older patients with limb-length inequality can be managed with a combination of initial lengthening, opposite-side growth arrest, and heel lifts. A variety of techniques have been developed to manage the patient who has so much growth left in his or her extremity that these simple methods are insufficient. Some patients will have a conventional amputation, and this remains an excellent method for many patients. There have been advances in prosthetic design during the past decade, and patients with amputations do not require additional operations (as patients with limb salvage do), and remain the most physically active patients. Variations on a conventional amputation (either a rotationplasty or a tibial turn-up) can be done, particularly for the young patient with an osteosarcoma in the femur, to improve function, compared with conventional amputation (136–156). Limb salvage for the patient younger than 10 years is particularly difficult. All methods require repeated operations, and their long-term success has yet to be completely documented. The most common method currently used involves a "growing" endoprosthesis (131,133,157–165). There are a number of methods to make the endoprosthesis grow, but they all require a repeat operation every 8 to 12 months. In addition, as the child grows in length, the bone grows in diameter, and fixation is problematic.

Juxtacortical Osteosarcoma. Osteosarcomas that arise from or are adjacent to the external surface of the bone behave differently than those that arise from within the medullary canal. They are less aggressive locally, have less potential for distant metastasis, and are less common than conventional osteosarcoma. There seem to be two distinct juxtacortical osteosarcomas, parosteal and periosteal, but neither is common, and how distinct they are from one another remains a topic of debate. Parosteal osteosarcoma is most commonly located in the posterior aspect of the distal femur, and is composed of bone and low-grade malignant fibrous tissue. Periosteal osteosarcoma is more often located in the diaphysis, and is composed of bone and cartilage with malignant spindle cells.

Geschickter and Copeland (166) were the first to describe osteosarcoma. They thought that there were two distinct lesions, a benign parosteal bone-forming tumor and a malignant bone-forming tumor, but all osteosarcomas are defined as malignant, and have the potential to metastasize. The patient's age at presentation varies over a greater range (10 to 45 years) than in classic high-grade osteosarcoma, and the median age of presentation tends to be slightly older (167–171). The patient usually complains of a painless mass that blocks motion in the adjacent joint. This is most often knee flexion, because the posterior distal femur is the most common site of a juxtacortical osteosarcoma (93). Occasionally the patient complains of a mild, dull ache in the area of the tumor, but symptoms are minimal. The mass is fixed, hard, and nontender. The adjacent joint may have limited passive and active motion as a result of the mechanical block from the tumor. Inflammation is not observed. The patient's laboratory values are normal.

The plain radiograph is almost always diagnostic, but the findings may be mistaken for osteocartilaginous exostosis (Fig. 14-11). The lesion arises from the cortex, which may be normal or thickened. The juxtacortical osteosarcoma often wraps around the bone, with the periosteum between the tumor and the underlying cortex. This growth pattern (wrapping around the bone) produces the "string sign" on the plain radiograph, with a thin radiolucent line between the lesion and the cortex of the bone. The lesion itself is dense, and has the pattern of bone. There is increased uptake on the technetium bone scan. The appearance of the lesion on a CT scan is characteristic, and distinguishes a juxtacortical osteosarcoma from an exostosis. Juxtacortical osteosarcoma is attached to the cortex growing out into the soft tissue and may invade the cortex, but the normal cortex is intact (167,168,171). An exostosis arises from the cortex, and the cortex of the normal bone becomes the cortex of the exostosis, with the medullary canal of the bone communicating with the medullary canal of the exostosis. Intraosseous extension of the tumor is seen more easily with MRI than with CT.

An incisional biopsy of a juxtacortical osteosarcoma can be difficult to interpret, and based on histology alone, the

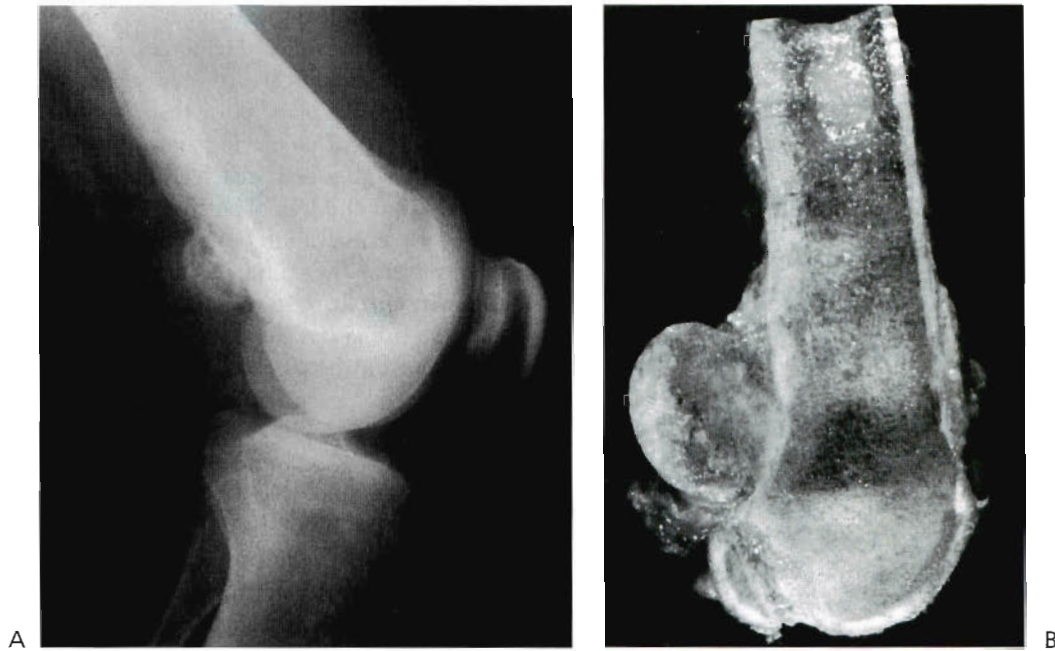


FIGURE 14-11. **A:** Lateral radiograph of the distal femur and knee of a patient with a parosteal osteosarcoma. The posterior distal femoral cortex is thickened and slightly irregular. The radiodensity adjacent to the posterior cortex is the central portion of the parosteal osteosarcoma. Surrounding this bony mass is a nonossified component of the tumor, composed primarily of fibrous tissue, but with some cartilage. This patient was treated with limb-salvage wide resection of the distal femur, and underwent reconstruction with an osteoarticular allograft. No chemotherapy was used, and the patient has remained free of disease for 5 years. **B:** The parosteal osteosarcoma is larger than it appears on the plain radiograph. The cap of fibrous tissue and cartilage can be seen covering the bony center. The tumor is attached to the cortex, but does not extend through it. This gross relation is similar to that of an exostosis, and may lead to a mistaken histologic diagnosis. The gross difference between an exostosis, and a parosteal osteosarcoma is that the stalk of an exostosis is cortical bone that blends with the cortex of the host bone, and the medullary canal of the stalk and host bone are connected (see Fig. 14-13B). The parosteal osteosarcoma, conversely, is attached to the cortex, but the cortex of host bone is intact, and the medullary canal does not communicate with the parosteal osteosarcoma.

lesion can be mistaken for an exostosis. This is particularly true when juxtacortical osteosarcoma is not suspected by the clinician, or when the pathologist does not examine the radiograph. This lesion, more than most, is diagnosed by its clinical and radiographic presentation, and is confirmed by histology. An excisional biopsy is recommended in most cases. The lesion is composed of regularly arranged bone, with a background of usually bland spindle cells and fibrous tissue. A cartilage cap is often present. Parosteal osteosarcomas are graded histologically on a scale of 1 to 3 (170). Higher-grade lesions, especially those with medullary involvement, have a greater risk of metastasizing (usually to the lung) than those of lower grade without medullary extension (169,173–177).

When the diagnosis can be relatively certain from the preoperative studies, a wide excisional biopsy is recommended. The cortical margin should be generous and the tumor pseudocapsule not disturbed. When a lesion from the posterior distal femur is resected, the neurovascular bundle usually can be freed from the lesion without dissecting the

pseudocapsule, but the posterior capsule of the knee and the posterior aspect of the femoral condyle usually must be resected with the tumor. Those lesions that wrap around the bone and have gross invasion of the medullary canal may require a resection that includes the entire end of the bone.

The initial resection is the best opportunity to control the lesion without an amputation. Most patients do not need adjuvant chemotherapy because the cure with surgery alone is approximately 80% (167,168,170,171,178,179). Patients with histologic grade 3 lesions probably should receive adjuvant chemotherapy, especially if the medullary canal has been invaded, although the data are limited (170).

The periosteal osteosarcoma is another type of juxtacortical osteosarcoma (93,180,181). It is most common in the anterior proximal tibia, and it tends to be diaphyseal in location. It has a sunburst appearance on the plain radiograph, and is composed of malignant cartilage and bone (182). A wide surgical resection is recommended (169, 180,181,183). The place of adjuvant chemotherapy is con-

troversial; as with parosteal osteosarcoma, probably only patients with grade 3 lesions should receive it.

Local Control of Extremity Sarcomas. The “gold standard” for achieving local control in patients with bone and soft tissue sarcomas in the extremities is amputation. However, no one wants to lose a limb if it can be prevented, and the authors have learned that sarcomas can be safely resected as long as a cuff of normal tissue can be kept surrounding the resected specimen. This is called “achieving a wide margin of resection.” Usually adjuvant therapies such as chemotherapy are used either before or after these resections.

There is a fairly wide experience with limb salvage in adults. Children have the added problems of growth, small size, and (it is hoped) more longevity, which make reconstruction more challenging. The options for limb salvage include osteoarticular and intercalary allografts, metallic prostheses, and vascularized and nonvascularized autograft transplants. All of these are used at various times by the tumor surgeon. Rotationplasty is another option somewhere between limb salvage and amputation; it is occasionally useful in very young patients.

The child must first be a limb-salvage candidate. This means that the tumor is located such that the major nerves and vessels can be preserved, and enough muscle will remain to make the limb functional. MRI is the best imaging test to aid in the decision (80). It shows the extent of the tumor within the medullary cavity, the extent of the soft tissue mass, and the relationship of the mass to the joint, nerves, and vessels. Most of the time the adjacent joint is not involved, but the epiphysis is frequently involved with tumor (184,185). This must be carefully assessed. Usually, the patient will have received chemotherapy preoperatively, which makes the resection easier in tumors without a matrix, such as Ewing sarcoma/PNET, because the mass becomes smaller.

In some locations, such as the fibula and clavicle, no bony reconstruction is necessary. Very young children with bone tumors of the foot and ankle are usually best treated by ray, Syme, or below-knee amputation. Soft tissue sarcomas at these sites may be resectable without amputation, if it is possible to achieve wide margins with or without adjuvant irradiation. A method of using a metatarsal head in the tibial stump to prevent stump overgrowth has been described, and seems to be useful (186,187).

For tumors of the distal femur or proximal tibia, the resection will almost certainly include an epiphyseal center. In children near skeletal maturity, this will not lead to a major limb-length inequality. An allograft or prosthesis 1 to 2 cm longer than the length of bone that is resected can be used, and a contralateral epiphysiodesis can be performed at a later date, if necessary. As long as the predicted discrepancy is less than 2 cm, no special reconstruction is necessary. In younger children, limb length is more of a concern. One option is to reconstruct with an osteoarticular allograft, and

treat the limb-length discrepancy using standard methods of epiphysiodesis, closed femoral shortening, or limb lengthening. The allograft has the advantage of not disturbing the adjacent growth plate. Growth arrest of the adjacent growth plate may occur by placing a prosthetic stem across it. One difficulty with this approach is obtaining a graft of appropriate size. For children older than 10 years, it is usually possible to use a small adult bone. Use of grafts with open growth plates is not advised because they will fracture through the allograft physis. Use of an osteoarticular allograft for the proximal tibia has the advantage of providing a site of attachment for the patellar ligament. The results of allografts for limb salvage in osteosarcoma are reasonable, but the patient should not expect normal limb function (131, 188–194). A good or excellent result, based on a functional evaluation system devised by Mankin et al. (195), can be expected in about 65 to 70% of patients. It should be noted that there are no ideal measures of function after limb salvage (although several have been developed), and this remains an area of investigation. In general, if patients can return to normal walking activities without supports or braces, it is considered to be a good result. Seldom can they return to contact sports or running activities (196). Complications include infection, nonunion, fracture, and joint instability (195,197,198). If the patient survives, he or she may need joint arthroplasty at some time in the future, but by then the patient should be old enough that growth is no longer a consideration. Growth equalization can be achieved by contralateral epiphysiodesis, limb shortening, or ipsilateral lengthening (132,134). The experience with limb lengthening in these patients is limited because limb length is seldom a major issue.

Another option is the use of a metallic prosthesis. Modular prostheses are now available that allow the surgeon to construct an implant of suitable length in the operating room (133,199). Custom implants are seldom necessary. Some prostheses have the ability to be expanded as the child grows (131,133,157,159,160,162–165). There are a variety of types, but perhaps the best is the modular prosthesis that can be lengthened by removing one of the body segments and replacing it with another segment 1 to 2 cm longer (133). This is not a simple operation because the soft tissues form a dense fibrous layer around the implant, which must be resected or released to achieve lengthening. The neurovascular structures are difficult to identify in these lengthening procedures, and are at risk for direct and stretching injury. Usually it is possible to achieve at least 2 cm of length per procedure. In very young patients, this must be repeated every 6 months until maturity, at which point revision to an adult prosthesis may be necessary. There are few data on these prostheses, but at least one report shows that it is possible to gain 2 to 18 cm in length, and to have equal limb lengths at skeletal maturity (162). The issues of prosthetic failure, loosening, wear of polyethylene, and infection remain unresolved. The choice of implant or re-

constructive method is up to the surgeon and the family. Prostheses are more functional initially, but their longevity is unknown. Expandable prostheses have a high failure rate (133). More than 80% of these will require revision by 5 years, and the revision rate appears to be higher in uncemented prostheses. Many of these patients will have knee stiffness and the infection rate, especially in the tibia, may be as high as 38%, although this can be improved with the liberal use of gastrocnemius flaps (133). The modular prosthesis has been reported to have a 5-year revision-free and amputation-free survival rate of 75%, presumably because it is mechanically stronger and less complex (133). Function appears better in children who are older than 8 years at the time of the reconstruction. Allografts require more difficult rehabilitation, but they hold the promise of superior longevity. It is very important to tell the patient in either case that the function will not be normal, and that neither reconstruction is meant to return the patient to sports activities. For lower-extremity sarcomas about the knee or hip, it is the authors' feeling that patients older than 8 to 10 years with open growth plates, are best treated with allografts to preserve the adjacent growth center, but that skeletally mature patients may be better served by prostheses because of the easier recovery and rehabilitation. In either case, subsequent revisions or eventual amputation may be necessary.

For diaphyseal lesions, an intercalary resection can be performed that spares the adjacent joints and occasionally the epiphyseal plates. These patients can be reconstructed with intercalary allografts and/or vascularized fibulae (191,192,200). Recently, a method of using an allograft to provide initial stability, augmented by a vascularized fibular graft to achieve quicker union and long-term healing potential, was described (201–203). This technique is especially helpful when only a small segment of the epiphysis remains after the resection.

For lesions of the proximal humerus, intraarticular or extraarticular resection is usually performed (204–207). If the rotator cuff and part of the deltoid can be preserved, reconstruction with an osteoarticular allograft yields good results (208,209). Some surgeons prefer to use an endoprosthesis with the allograft to prevent late joint collapse and fracture (188,210). In either case, the allograft position allows attachment of the rotator cuff, which is an advantage over the use of a prosthesis. For extraarticular resections when both the deltoid and the rotator cuff are sacrificed, arthrodesis, using allograft, vascularized fibula, or both, is indicated (211). It is difficult to achieve an arthrodesis, but when it works, it is very functional. When a formal Tikhoff-Linberg resection, which includes the scapula, is necessary, the reconstruction is more difficult; leaving a flail upper extremity may be the only option (204,207,212,213).

For very young patients with tumors of the distal femur, or older patients who want to be athletically active, rotationplasty is an option (136–140,143,145–147,150,151,

156). In these patients, above-knee amputation would lead to a very short stump with a poor lever arm (214). Rotationplasty, by taking advantage of the tibia and foot, provides a longer lever arm and an active “knee” joint. It also avoids resection of the major nerves, so that phantom pain is not an issue. The physical appearance without the prosthesis is disturbing to some patients, but with a prosthesis they look similar to other amputees and function much better than above-knee amputees (139,142,144,145,152, 215). The technical details are well described elsewhere (143), and the technique has been described for lesions of the proximal tibia and the proximal femur (141,149,153); more recently, similar procedures have been described for the upper extremity (216). It is very important to have frank discussions with the patient and his or her family about the appearance and expected outcome of this reconstruction. Having the patient meet another patient who has undergone rotationplasty, or at least viewing a video and meeting with an experienced physical therapist and prosthetist, can be very helpful. Interestingly, young patients do not view this as an amputation, because the foot is still present, and the long-term psychological outcomes of these patients has been very good.

CHEMOTHERAPY FOR MUSCULOSKELETAL TUMORS

It was not until the 1970s that chemotherapy was believed to be effective for malignant tumors of the musculoskeletal system. The extremely high incidence of metastatic disease in patients with osteosarcoma (more than 80%) and Ewing sarcoma (more than 85%), and some promising results in patients with metastatic sarcoma, prompted the use of adjuvant chemotherapy in patients who did not have documented disease but in whom the risk of having subclinical metastases was high (217). The early results were exciting, and even the use of what was considered minimal amounts of less-than-optimal drugs improved survival. These early studies led to the acceptance of adjuvant chemotherapy for Ewing sarcoma, osteosarcoma, and rhabdomyosarcoma (218–230). There are no chemotherapeutic agents believed to be effective for chondrosarcoma (231), and the use of chemotherapy for soft tissue sarcomas (except rhabdomyosarcoma) remains controversial (232–234).

In the 1980s, preoperative chemotherapy was introduced, and preoperative administration is now standard for the initial chemotherapy for patients with Ewing sarcoma, osteosarcoma, and rhabdomyosarcoma (26,115,116,119, 217,235–248). “Neoadjuvant chemotherapy” is a term used to indicate that the patient receives chemotherapy before the definitive treatment of the primary lesion. This was initially used as a means of treating patients with osteosarcoma who were waiting for the production of a custom prosthesis. The effect of chemotherapy on the tumor was

significant and of prognostic significance, leading to the routine use of preoperative chemotherapy.

There are numerous chemotherapeutic protocols for the three skeletal malignancies for which chemotherapy is used (Ewing sarcoma, osteosarcoma, and rhabdomyosarcoma). All use more than one drug, and usually three to five. Most protocols are between 9 and 12 months long. Approximately one-third of the chemotherapy is given preoperatively, and the remainder is given after surgery.

The drugs used for musculoskeletal tumors include:

Doxorubicin (Adriamycin), a cytotoxic anthracycline antibiotic that passively enters the cell to diffuse into the nucleus, where it binds nucleic acids and prohibits DNA synthesis (217). It is cardiotoxic, myelosuppressive, and produces alopecia. It is given intravenously in divided doses over 6 months, with 450 mg/m² recommended as the maximum dose.

Methotrexate is an antimetabolite that inhibits dihydrofolic acid reductase. This interferes with DNA synthesis and repair, and alters cellular replication. When administered in high doses (12 mg/m² intravenously), leucovorin or citrovorum factor is given to the patient to rescue the normal cells. Leucovorin is a chemically reduced derivative of folic acid and is used by the cells to complete normal cell functions without the need for dihydrofolic acid reductase. Tumor cells seem less able to use leucovorin than normal cells, and this difference allows methotrexate to be effective against malignant tumors. The primary side effects of methotrexate are gastrointestinal, including nausea, vomiting, and loss of appetite.

Cisplatin is a heavy metal that is thought to cause intrastrand cross-links in DNA, and therefore interference with the DNA. It is given intravenously in doses of 75 to 100 mg/m² repeatedly over the course of the treatment. The principal side effect of cisplatin is nephrotoxicity.

Cyclophosphamide (Cytoxan) is a synthetic drug chemically related to nitrogen mustard. It cross-links DNA and interferes with DNA functions. It is given intravenously at a dose of 40 to 50 mg/kg in divided doses over 4 to 5 days. The major side effects of cyclophosphamide are gastrointestinal disorders and myelosuppression.

Ifosfamide is a synthetic analog of cyclophosphamide, with similar actions. It is given intravenously at 1.2 g/m²/day for 5 days.

Vincristine is an alkaloid from the periwinkle plant. It is thought to arrest dividing cells in the metaphase state by inhibiting microtubule formation in the mitotic spindle. It is given intravenously at weekly intervals at doses of 1.4 mg/m² in adults and 2.0 mg/m² in children. The major side effect of vincristine is peripheral neuropathy.

Bleomycin is a cytotoxic glycopeptide antibiotic from a strain of *Streptomyces verticillus* that inhibits DNA synthesis. It also probably inhibits RNA and protein synthesis. It is given intravenously at 0.25 to 0.50 U/kg once or twice per

week. The most serious side effect of bleomycin is a 10% incidence of severe pulmonary fibrosis.

Actinomycin D (dactinomycin) is one of a number of actinomycin antibiotics from *Streptomyces*. It binds to DNA by intercalation with the phenoxazone ring. This inhibits the DNA from being a template for RNA and synthesizing itself. It is given intravenously at 0.5 mg/day for 5 days. Dactinomycin produces nausea and vomiting, and is myelosuppressive.

These drugs are given in various combinations and doses, depending on the specific diagnosis, the protocol, the response of the patient, and the aggressiveness of the medical oncologist.

Cartilaginous Tumors

Cartilaginous tumors include enchondroma, exostosis (osteocartilaginous exostosis, osteochondroma), chondromyxofibroma, periosteal chondroma, chondroblastoma, and chondrosarcoma. The benign tumors are common, especially enchondroma and exostosis, whereas chondrosarcoma is extremely rare in the pediatric age group (93,249,250).

Enchondroma

The origin of enchondroma is debatable, and it probably is not a true neoplasia. It may be the result of epiphyseal growth cartilage that does not remodel and persists in the metaphysis, or it may result from persistence of the original cartilaginous anlage of the bone (251). Both possibilities have been suggested as explanations of the cause of this common benign tumor. The majority of patients with a solitary enchondroma present with either a pathologic fracture through a lesion in the phalanx, which is the most common location (251) (the proximal humerus and the distal femur are the other common locations for enchondroma), or the history that the lesion was an incidental finding on a radiograph taken for another reason (Fig. 14-12). Enchondromas are common lesions that account for 11% of benign bone tumors (93,253). They do not need to be removed. The problem they present is diagnostic. Usually, the diagnosis can be made from the clinical setting and the plain radiograph. Forty percent of enchondromas are found in the bones of the hand or feet—usually a phalanx. An enchondroma should not produce symptoms unless there is a pathologic fracture. There are no associated blood or urine abnormalities. The femur and proximal humerus are the next most common sites. Enchondromas are located in the metaphysis and are central lesions in the medullary canal. The bone may be wider than normal, but this is caused by the lack of remodeling in the metaphysis rather than by expansion of the bone by the tumor. The cortex may be thin or normal; the lesion is radiolucent in the pediatric age group, but later has intralesional calcifications. There should be no periosteal reaction. In the pediatric pa-

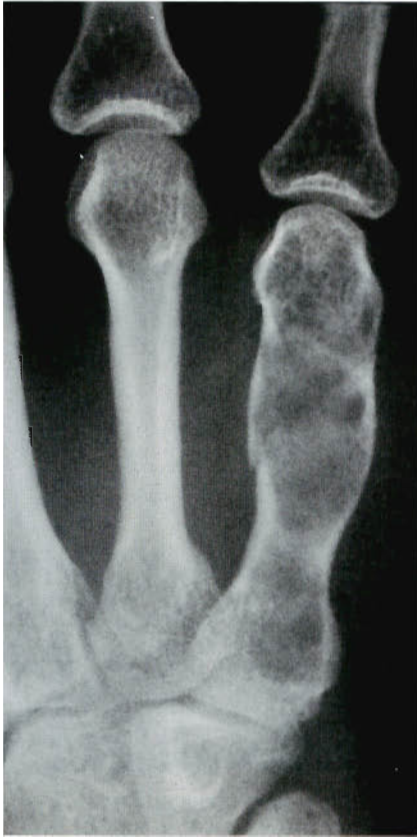

FIGURE 14-12. This enchondroma of the fifth metacarpal is typical. The shaft is enlarged, and the lesion is radiolucent. This patient had been aware of this lesion since she was 10 years of age. She had sustained numerous pathologic fractures, and decided to have it curetted. The curettage was done after the fracture had healed.

tient, unicameral bone cysts have a similar radiographic appearance, but they are most common in the proximal femur and the proximal humerus. The appearance of an enchondroma on MRI is typical. The cartilage matrix has an intermediate signal intensity on the T1-weighted image and a high signal intensity on the T2-weighted image (80, 254–258). It should have a sharp margin with the adjacent bone without peripheral edema.

When the findings are typical for an enchondroma, no biopsy is necessary. Repeat plain radiography and physical examination should be performed in approximately 6 weeks, then every 3 to 6 months for 2 years. Although there are reports of solitary enchondromas differentiating into chondrosarcomas, usually late in adult life, this does not occur frequently enough to justify the removal of all enchondromas. The patient should be advised that after age 30 years if the lesion becomes painful or enlarges, it should be considered a low-grade chondrosarcoma and be surgically resected.

Incisional biopsy usually is contraindicated. Pathologists

have difficulty distinguishing between active enchondroma (most pediatric-age patients have active lesions) and low-grade chondrosarcoma. The clinical course is the best measure of the lesion's significance, and an incisional biopsy alters the status of the lesion and makes subsequent evaluation difficult. If the patient or the patient's parents insist on biopsy, it is best that the entire lesion be removed.

Patients with multiple enchondroma (Ollier disease) are much less common than those with solitary enchondromas. Multiple enchondroma was originally described in the late 1800s by Ollier (259). Most patients with Ollier disease have bilateral involvement, but with unilateral predominance. These patients have growth deformities, both angular and in length. Their extremity deformities should be managed surgically to maintain the function of the limbs without specific regard to the enchondroma. Patients with Ollier disease have an increased risk of developing secondary chondrosarcoma later in life, and should be so advised (260–262). The incidence of secondary chondrosarcoma in patients with Ollier disease is not known, but may be as high as 25%. The pelvis and shoulder girdle are the most common locations of secondary chondrosarcoma.

Maffucci disease consists of multiple enchondroma and soft tissue hemangioma (263). Patients with this disorder have an even greater risk of developing malignant cartilage tumors than patients with Ollier disease; more importantly, they have a great risk of developing carcinoma of an internal organ (264).

Exostosis

The terms “osteochondroma,” “osteocartilaginous exostosis,” and “exostosis” are used interchangeably. This lesion was first described in the early 1800s. It is common. Although the pathogenesis of this lesion is not known, an abnormality or injury to the periphery of the growth plate has been suggested as the cause (251). It has been shown in an experimental animal study that the periphery of the growth plate can be traumatized and a typical exostosis produced.

The patient with a solitary exostosis usually is brought in by a parent who has just noticed a mass adjacent to a joint. The patient usually has no symptoms. An occasional patient has loss of motion in the adjacent joint, attributable to the size of the mass. The patient often has been aware of the mass for months to years, and reports that it has been slowly enlarging. Some patients have pain resulting from irritation of an overlying muscle, repeated trauma, pressure on an adjacent neurovascular bundle, or inflammation in an overlying bursa. On physical examination, the mass is nontender, hard, and fixed to the bone. The rest of the physical examination is normal.

Exostoses are so characteristic on a plain radiograph that they should be diagnosed from their radiographic appearance alone (Fig. 14-13). The mass is a combination of a radiolucent cartilaginous cap with varying amounts of ossifi-

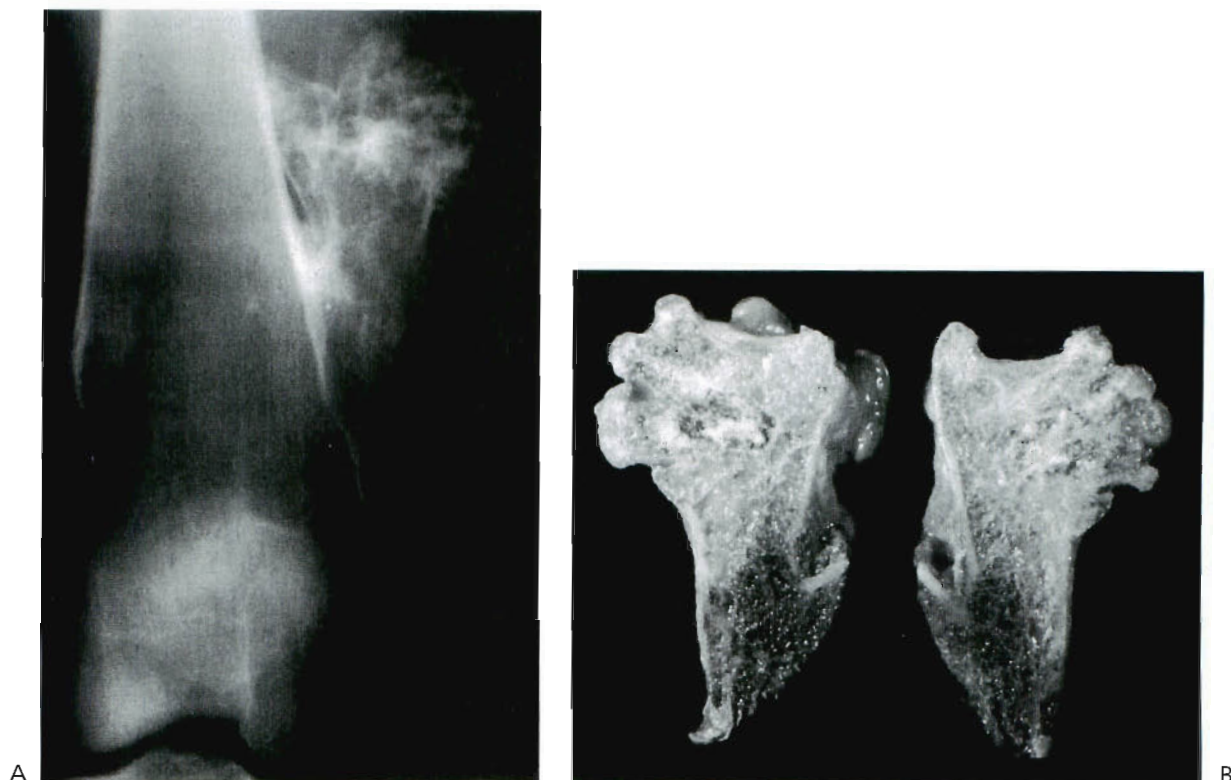

FIGURE 14-13. **A:** Anteroposterior radiograph of the distal femur with a typical pedunculated exostosis. The cortex of the lesion blends into the cortex of the femur. The exostosis has an irregular proximal end that is covered by a cartilaginous cap. The pathologic material is the cartilage, but what is seen on the radiograph is the bone formed by enchondral ossification of the cartilage. This patient repeatedly hit the mass while playing football, and it was marginally excised. A small rim of the cortex of the femur was removed along with the exostosis because occasionally any residual cartilage that lies at the base of the stalk can lead to a recurrence. **B:** Gross bisected specimen from the same patient. The femoral attachment is inferior, and the cortex of the femur can be seen blending with the cortex of the exostosis. The medullary canal of the femur is filled with hematopoietic marrow, and appears dark. The hematopoietic marrow extends into the base of the exostosis, but most of the marrow of the exostosis is fatty. There is a thin, cartilaginous cap. In a child, a cartilaginous cap more than 1 cm thick is of no concern, but in an adult a cartilaginous cap of more than 1 cm is considered to indicate early malignant degeneration to secondary chondrosarcoma.

cation and calcification. The amount of calcification and bone formation increases with age. The base may be broad (sessile exostosis) or narrow (pedunculated exostosis). In both types, the cortex of the underlying bone opens to join the cortex of the exostosis, so that the medullary canal of the bone is in continuity. This usually can be appreciated on the plain radiograph, but if not, CT or MRI establishes this finding and confirms the diagnosis.

In the pediatric age group exostoses should be expected to grow. They may continue to grow well into the third decade of life. This is not a sign of malignancy. Only after 30 years of age should growth of an exostosis be thought to indicate malignant degeneration. The growth rate is not steady, and occasionally a lesion grows more rapidly than expected. Removal of the lesion in a child is indicated only for those patients who have symptoms attributable to pres-

sure on a neurovascular bundle or irritation of the overlying muscle. Removal in a young child may result in damage to the growth plate and recurrence of the lesion. Malignant degeneration is extremely rare in children and uncommon in adults. Malignant degeneration is more common in lesions of the scapula, the pelvis, and the proximal femur. Although it is often stated that the risk of malignant degeneration is as high as 20%, the real incidence is not known. It is probably less than 5%.

Gross examination of an exostosis reveals a lesion that looks like a cauliflower. It has an irregular surface covered with cartilage. The cartilage is usually less than 1 cm thick, except in the young child, in which it may be 2 or 3 cm thick. In an adult, when the cartilaginous cap is thicker than 1 cm a secondary chondrosarcoma should be suspected (253,257,265–269). Deep in the cartilaginous cap there is

a variable amount of calcification, enchondral ossification, and normal bone with a cortex and cancellous marrow cavity. The microscopic appearance of the cartilaginous cap typically is benign hyaline cartilage.

Some patients have multiple exostoses (270–272). A patient may have three or four lesions, but more often there are 10 to 15. Usually, the patient has exostoses of all shapes and sizes. They are concentrated in the metaphysis of the long bones, but may be in the spine, the ribs, the pelvis, and the scapula. On physical examination, they are hard, fixed masses adjacent to joints. Patients with multiple exostoses usually are shorter than average but not below the normal range. They have loss of motion in the affected joints, especially forearm rotation, elbow extension, hip abduction and adduction, and ankle inversion and eversion.

Multiple heritable exostosis is transmitted by an autosomal dominant gene with a variable penetrance, and usually half of the children of an affected parent have clinical manifestations (270,273,274). An extensively involved parent may have a child with minimal involvement, or vice versa. In the majority of patients with multiple heritable exostoses, the radiographic appearance of the proximal femur is diagnostic. The femoral neck is short and broad with multiple bony excrescences.

After the age of 30 years, patients with multiple heritable exostoses have an increased risk of developing secondary chondrosarcoma (266,267,273,275–281). Secondary chondrosarcoma in the pediatric age group is extremely rare (282,283). Occasionally, one or more of the exostoses are removed to relieve the pain related to repeated local trauma, or to improve the motion of the adjacent joint. Those lesions in the pelvis and the spine should be observed closely because they have the greatest risk of undergoing malignant degeneration. The authors do not recommend removing these lesions simply because they are present.

The authors advise patients with exostosis, whether single or multiple, to be examined and to undergo radiography at least yearly. Patients are told to report symptoms or increasing size immediately. Patients older than 30 years of age with an enlarging exostosis should have it removed as if it were a secondary chondrosarcoma, because this usually is the case (284).

Chondromyxofibroma

Chondromyxofibroma is a rare tumor. The patient is usually a male (males are more frequently affected than females at a ratio of 2 to 1) in the second or third decade of life (93,285). The patient complains of a dull, steady pain that is usually worse at night. The only positive physical finding is tenderness over the involved area, and occasionally a deep mass can be appreciated. Approximately one-third of chondromyxoid fibromas occur in the tibia, usually proximally. It is a radiolucent lesion that involves the medullary canal, but is eccentric and erodes the cortex (253,286) (Fig. 14-

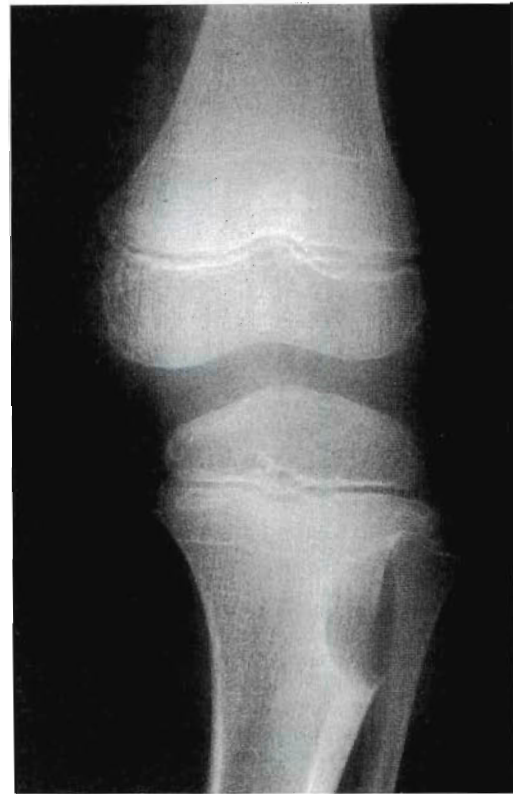

FIGURE 14-14. Anteroposterior radiograph of a chondromyxofibroma of the proximal lateral tibia. The lesion is typically an eccentric, radiolucent abnormality that usually destroys the cortex but is contained by the periosteum. As in this case, the radiographic appearance of chondromyxofibroma is often similar to that of an aneurysmal bone cyst.

14). It may be covered by only periosteum, and is often mistaken for the more common ABC. The solid nature of chondromyxofibroma versus the cystic nature of an ABC, as seen on MRI, is a means of differentiating between these two lesions. The natural history is not known because of infrequency and the fact that surgical treatment is nearly universal. Thorough curettage and bone grafting are recommended.

Chondroblastoma

Chondroblastoma, or Codman tumor, initially was thought to be a variant of giant cell tumor of bone. Codman's detailed description in 1931 was of an "epiphyseal chondromatous giant cell tumor" (287). Jaffe and Lichtenstein in 1942 (288) suggested that it be called "benign chondroblastoma," and separated it from giant cell tumor of bone. Codman was particularly interested in the shoulder, and he thought that this lesion was found principally in the proximal humerus (Fig. 14-15). It has since become clear that chondroblastoma is found in many bones, but the proximal

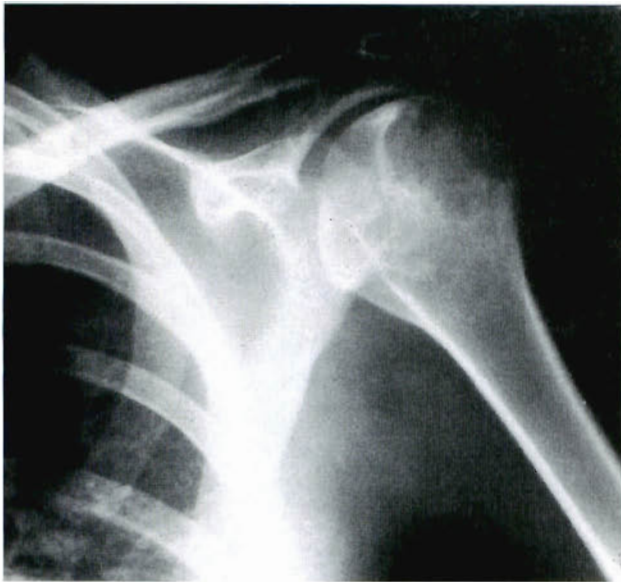

FIGURE 14-15. Radiograph of a chondroblastoma in the proximal humeral epiphysis. This is a typical Codman tumor. The lesion is both epiphyseal and metaphyseal, has an irregular reactive border, and has intralesional calcifications, although these are difficult to see on plain radiographs. Giant cell tumor of bone is similar to chondroblastoma, except that there are no intralesional calcifications. This patient was treated with curettage and bone grafting.

humerus is the most common site (approximately 20%) (93,289–291).

Chondroblastoma accounts for 1% of bone tumors (93). The patient with a chondroblastoma is usually in the second decade of life, with an open growth plate, but it occurs in older patients as well. The initial symptoms are of pain in the joint adjacent to the lesion, and the patient usually presents with joint complaints. The findings on physical examination also may suggest an intraarticular disorder because most patients have an effusion and diminished motion in the adjacent joint. Frequently the patient is believed to have chronic synovitis; he or she does not have other symptoms or abnormal physical findings. The patient's laboratory data are normal.

The lesion arises in the secondary ossification center. In children, it is the most common neoplastic lesion of the secondary ossification center (292), and in adults, only giant cell tumor of bone involves the secondary ossification center more often. (Osteomyelitis is the most common diagnosis in adults to produce a lesion in the secondary ossification center.) On the plain radiograph, the lesion is radiolucent, usually with small foci of calcification (293). The calcification is best seen on a CT scan. There is usually a reactive rim of bone surrounding the lesion, and sometimes metaphyseal periosteal reaction. The edema associated with chondroblastoma can be appreciated on MRI (Fig. 14-16). There is increased uptake on a technetium bone scan. Chest radiog-

raphy or CT should be performed, because chondroblastoma is one of the benign bone tumors that can have lung implants and still be considered benign (294). Chondroblastoma and osteochondritis dissecans can have a similar appearance on plain radiographs, but they should not be confused with one another. Osteochondritis dissecans produces an abnormality in the subchondral bone, but with chondroblastoma the subchondral bone is almost always normal. Patients with chondroblastoma have more of an effusion than patients with osteochondritis dissecans, and their pain is constant and not related to activity as it is in patients with osteochondritis dissecans.

The histologic appearance of chondroblastoma is typical, and this disorder is rarely confused with other diagnoses. It consists of small cuboidal cells (chondroblasts) closely packed together to give the appearance of a cobblestone street (288–291). In addition, there are areas with varying amounts of amorphous matrix that often contains streaks of calcification, and usually there are numerous multinucleated giant cells. Chondroblastoma is not as vascular as osteoblastoma, and there are few, if any, mitoses, and no abnormal mitoses (Fig. 14-17).

Chondroblastomas progress and invade the joint. They should be treated when found. Curettage is the treatment of choice, but it must be a thorough curettage and extend beyond the reactive rim (291). The lesion should be seen adequately at the time of the curettage, which usually means that the joint must be opened. Iatrogenic seeding of a joint is not a significant risk, and intraarticular surgical exposure is recommended if this facilitates visualization. The majority of recurrences are cured with a second curettage, but a rare lesion can be locally aggressive, and requires a wide resection (290). Chondroblastoma of the pelvis frequently behaves more aggressively than that in long bones, and an initial wide excision is recommended.

Most patients are close to skeletal maturity when the diagnosis is made, and the risk of growth disturbance from the tumor or its treatment is minimal. When the patient is younger than 10 years old care should be taken not to damage the growth plate.

Periosteal Chondroma

This is an uncommon lesion that arises from the surface of the cortex, deep in the periosteum (295–297). The patient usually complains of pain at the site of the lesion. More than half of these lesions are found in the proximal humerus, and the others are evenly dispersed through the long bones. The lesion often can be palpated. It is a nontender, hard mass that is fixed to the bone. The plain radiograph is typical (Fig. 14-18). Periosteal chondroma is a scalloped defect on the outer surface of the cortex, occasionally with intralesional calcifications and minimal periosteal reaction. Microscopically, periosteal chondroma is benign cartilage, but it appears more active than enchondroma. It has been mis-

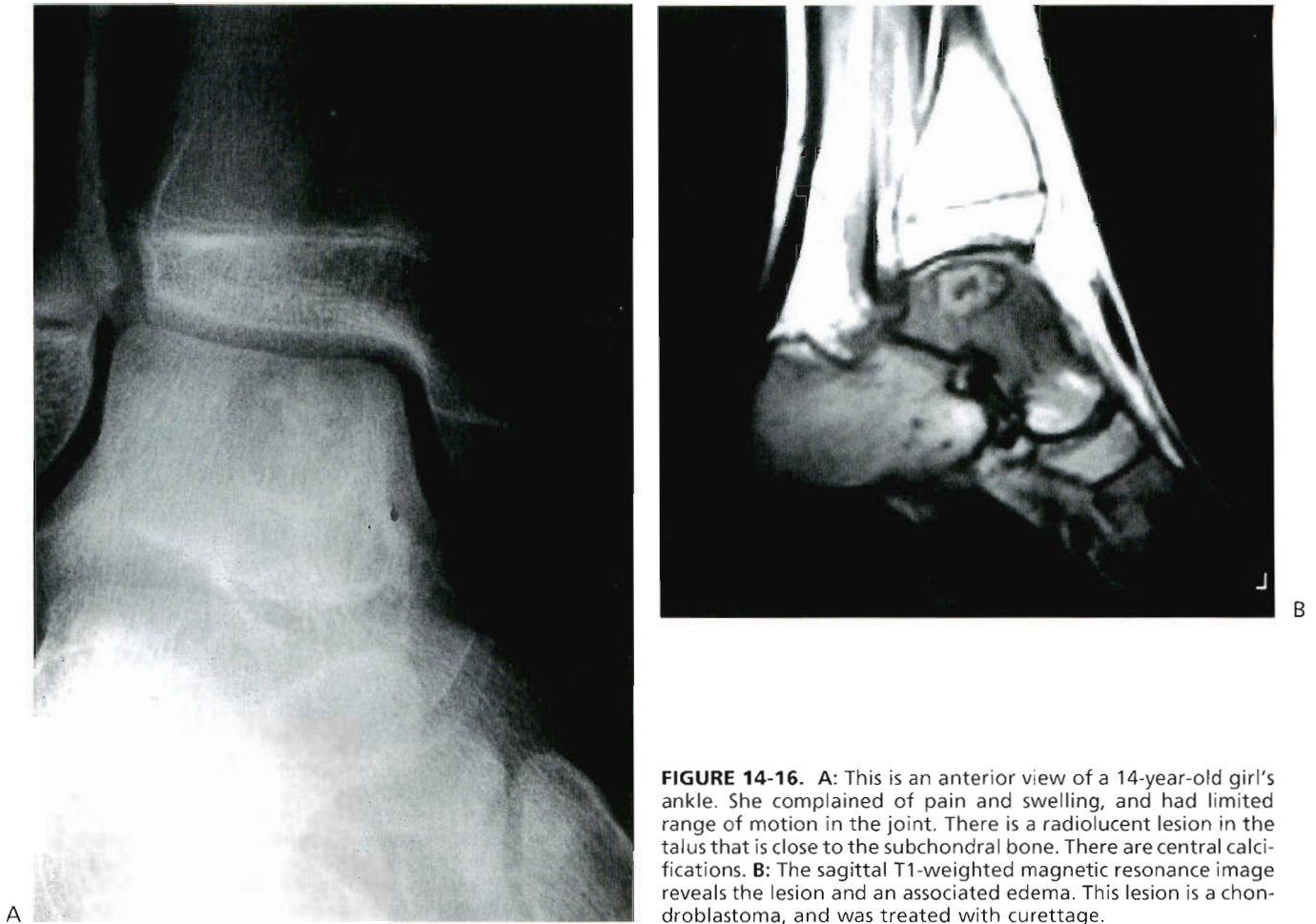


FIGURE 14-16. A: This is an anterior view of a 14-year-old girl's ankle. She complained of pain and swelling, and had limited range of motion in the joint. There is a radiolucent lesion in the talus that is close to the subchondral bone. There are central calcifications. B: The sagittal T1-weighted magnetic resonance image reveals the lesion and an associated edema. This lesion is a chondroblastoma, and was treated with curettage.

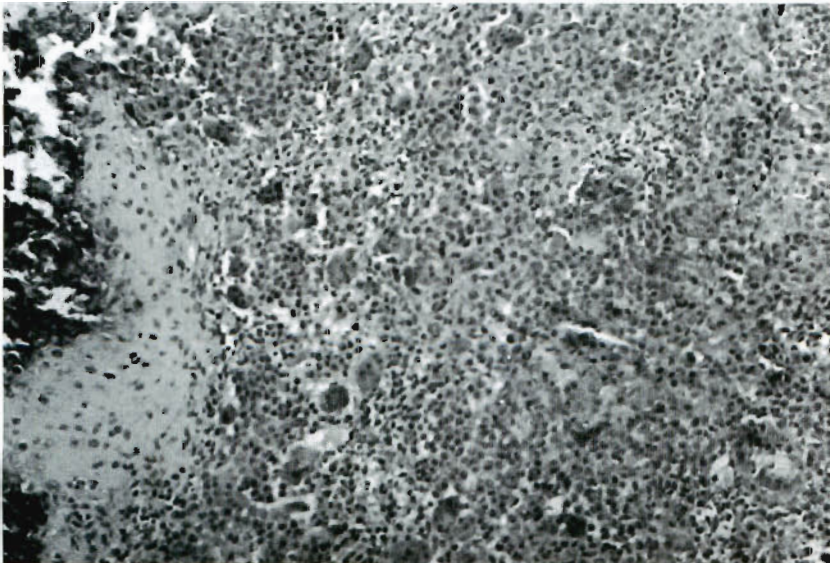


FIGURE 14-17. Histologic appearance of a chondroblastoma. The tumor consists of cuboidal cells (i.e., chondroblasts), varying amounts of amorphous matrix (some of which is calcified), and multinucleated giant cells. Calcification is seen (left). The cuboidal cells fit together in such a manner that they have the appearance of cobblestones. (Original magnification $\times 10$.)

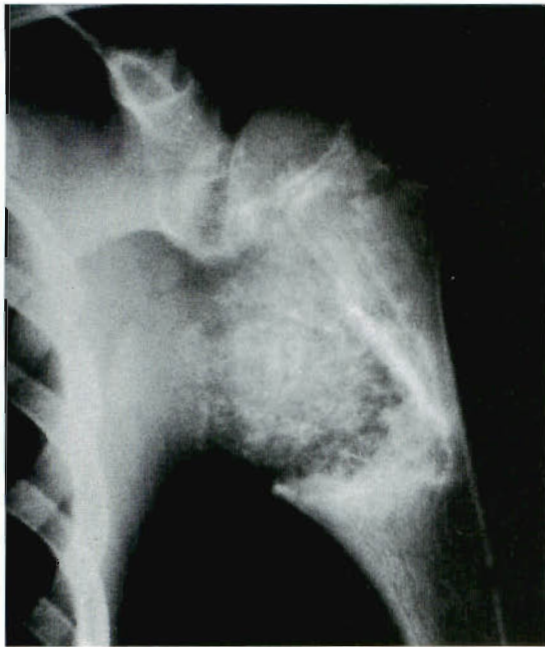

FIGURE 14-18. Radiograph of the shoulder of a 12-year-old boy. The large periosteal chondroma involves the medial aspect of the metaphysis. Most such tumors are smaller. This patient had no symptoms; the lesion was found by the boy's pediatrician on routine physical examination, and an incisional biopsy confirmed the diagnosis. The lesion was only partially removed. The tumor did not change appreciably during 2 years of follow-up.

taken for chondrosarcoma. Because local recurrence is a risk, a wide excision, including the underlying cortex, is the treatment of choice.

Lesions of Fibrous Origin

Nonossifying Fibroma

Nonossifying fibroma, which is also known as fibroma of bone, nonosteogenic fibroma, metaphyseal fibrous defect, and fibrous cortical defect, is probably the most common lesion of bone (298–302). Up to 40% of children have this lesion, which is found most often between the ages of 4 and 8 years (303). Ninety percent are in the distal femur. These are asymptomatic lesions that are found only if a radiograph is taken for another reason or when the patient has a pathologic fracture. The patient has no abnormal physical findings, and the serum and urine chemistries are normal.

Nonossifying fibroma should be recognized based on the clinical presentation and plain radiographic findings (298). Biopsy for diagnosis is rarely necessary. Two radiographic appearances are seen. The more common fibroma is a small (less than 0.5 cm) radiolucent lesion within the cortex, with a sharply defined border. Most authors call this lesion a “fibrous cortical defect” (93). There is little or no increased uptake on the technetium bone scan.

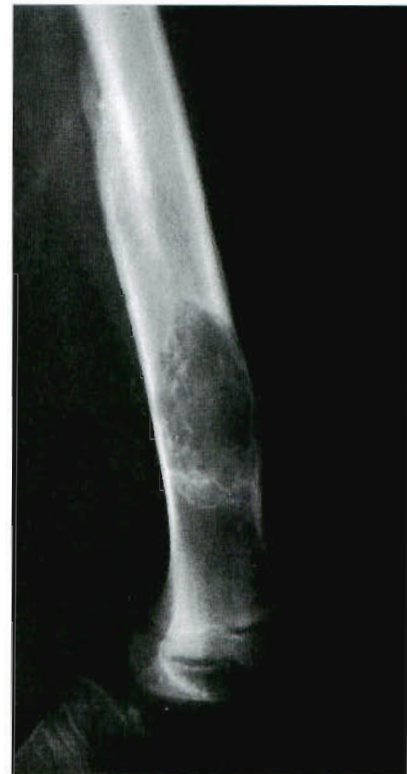

FIGURE 14-19. Lateral radiograph of the distal femur with a large nonossifying fibroma (NOF). The patient had sustained a pathologic fracture that had healed, but the lesion persisted. NOF is usually a metaphyseal, radiolucent, irregular lesion surrounded by a reactive rim of bone. As is often the case, the cortex surrounding a large NOF is thin and appears to be expanded. Although this lesion eventually heals spontaneously, its large size and persistence after pathologic fracture indicated that curettage and bone grafting were necessary. NOFs that replace more than half of the bone should be curetted and grafted.

The other appearance is that of a metaphyseal lesion eccentrically located (Fig. 14-19). This lesion probably started out as a fibrous cortical defect, but continued to enlarge. It appears to have arisen from within the cortex, expanding into the medullary cavity and raising the periosteum. The lesion is surrounded by a well-defined thin rim of reactive bone. There should be no acute periosteal reaction unless there has been a fracture. There may be slightly increased uptake on the technetium bone scan. Multiple nonossifying fibromas occur in approximately 20% of patients. Usually they are found in the lower extremities, so investigators suggest obtaining plain radiographs of both lower extremities, whenever a nonossifying fibroma is found.

Both lesions consist of benign, spindle, fibroblastic cells arranged in a storiform pattern (298,299) (Fig. 14-20). Multinucleated giant cells are common, and areas of large, lipid-laden macrophages often can be seen. Hemosiderin within the fibroblastic stromal cells and multinucleated giant cells is usual. There is no bone formation within the lesion, and mitoses are not seen.

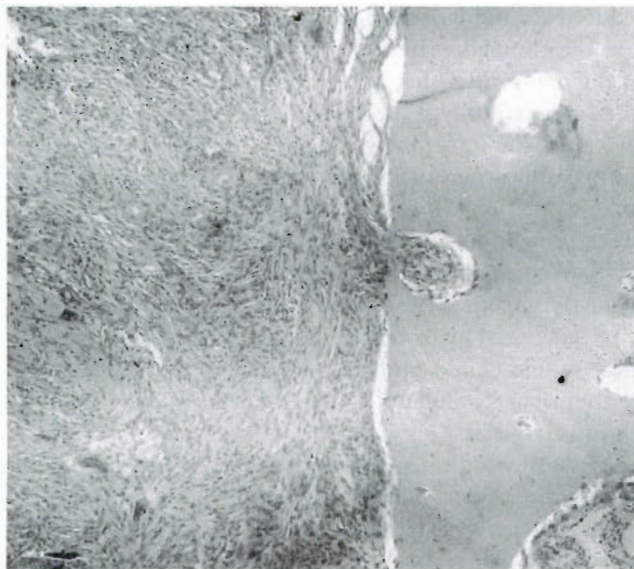


FIGURE 14-20. Low-power histologic view of a typical nonossifying fibroma. The fibroma is composed of benign fibrous tissue and multinucleated giant cells. Hemosiderin is often present. The nonossifying fibroma is invading cortical bone (right). (Original magnification $\times 10$.)

The small cortical lesion (fibrous cortical defect) needs no treatment, but should be observed. Repeat radiographs at 3- to 6-month intervals for 1 to 2 years are suggested. These lesions should heal spontaneously. Nonossifying fibroma may need surgery. Nonossifying fibromas that are less than 50% of the diameter of the bone can be merely observed, but curettage and packing with bone graft should be considered if they enlarge (304–306). Patients who present with nonossifying fibromas that are more than 50% of the diameter of the bone should consider having the lesions curetted and packed with bone graft. According to Arata and colleagues (306), these patients have an increased risk of developing pathologic fractures. Many patients with these large nonossifying fibromas elect not to have surgery, and reduce their activity instead. This is an alternative treatment.

Patients who present with pathologic fractures should have the fractures treated nonoperatively if possible. The fracture should heal without difficulty in a normal length of time. There is no evidence that the healing of the fracture increases the chances of spontaneous healing of a nonossifying fibroma, or of any other benign lesion. Nonossifying fibroma usually heals spontaneously, which may happen after the fracture, but usually the fracture callus obscures the radiolucent lesion and the physician is fooled into thinking that the lesion is healing. When the callus has remodeled and the cortices become distinct on the radiograph, the lesion can be seen again. Patients with pathologic fractures must be followed until the callus has remodeled sufficiently so that a final determination can be made about the status of the underlying nonossifying fibroma. If it per-

sists after the fracture has healed, curettage and bone grafting are suggested.

Fibrous Dysplasia

Fibrous dysplasia may not be a true neoplasia, but a developmental abnormality caused by a somatic mutation with a defect in the formation of bone (see Chapter 7). It is a common disorder that produces a variety of complaints and physical findings. The majority of patients (approximately 85%) have a single skeletal lesion (monostotic fibrous dysplasia), whereas the remainder have numerous lesions (polyostotic fibrous dysplasia). The patients with polyostotic fibrous dysplasia may have only two or three small areas of involvement, or may have extensive skeletal abnormalities with grossly deformed bones.

The patient with monostotic fibrous dysplasia usually presents without symptoms, and the lesion is found when a radiograph is taken for unrelated reasons (307–310). Occasionally the child presents with a pathologic fracture or angular deformity. A rib is the most common location of monostotic fibrous dysplasia, but any bone can be involved. There are no physical findings associated with monostotic fibrous dysplasia, and the café-au-lait lesions and endocrine abnormalities sometimes found in patients with polyostotic fibrous dysplasia, do not occur in patients with the monostotic variant. Serum and urine chemistries are normal in patients with fibrous dysplasia.

The plain radiograph is often diagnostic, although the radiographic appearance of fibrous dysplasia is variable (Fig. 14-21A). It is a medullary process that typically produces a ground-glass appearance on the radiograph. The lesion is usually diaphyseal. The diaphysis is larger than normal, and the ground-glass appearance of the medullary canal blends into the thinned cortex so that it is difficult to define the border between the medullary canal and the cortex. When typical-appearing lesions are seen in a single bone or in a single limb, the diagnosis is almost certain. There may be an angular deformity in the bone, especially when the lesion is large. The lesions may mature with age and become radiodense or cystic. Fibrous dysplasia shows excessive uptake on a technetium bone scan out of proportion to what one might predict from the plain radiographic appearance.

The patient with polyostotic fibrous dysplasia usually presents around the age of 10 years, complaining of an angular deformity of a bone (307,311–314). The most common deformity is varus of the proximal femur, or shepherd's crook deformity. The light brown skin lesions with irregular borders are called "coast of Maine" café-au-lait spots. The lesions with smooth borders associated with neurofibromatosis are called "coast of California" café-au-lait spots.

Hyperthyroidism and diabetes mellitus have been reported as associated endocrinopathies, and vascular tumors have been seen in association with fibrous dysplasia (313,315–318). Albright syndrome is a triad of fibrous dys-

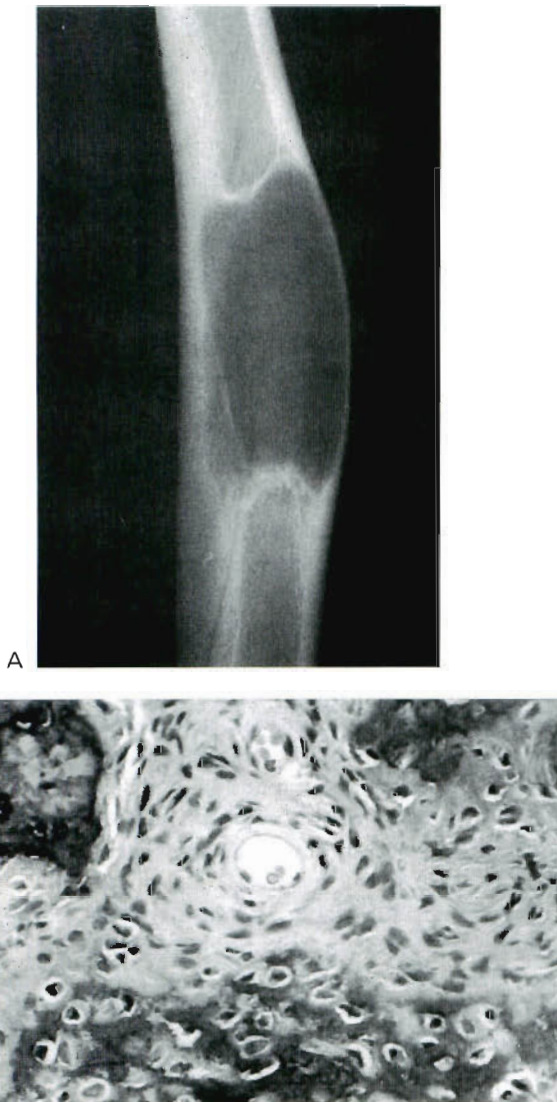


FIGURE 14-21. **A:** Radiograph of a fibrous dysplasia in the diaphysis of a long bone. The ground-glass appearance, the thin cortex, and the angular deformity of the bone are all typical features of fibrous dysplasia. Because this lesion was large and the patient had an angular deformity, a cortical bone graft was placed within the cortex to increase the strength of the bone. Curettage of the lesion probably does not increase local control, but should be performed if it can be carried out easily. Fibrous dysplastic bone is structurally weak, and cortical grafts are more likely to improve the strength of the bone and not be resorbed by the host. **B:** Histologic appearance of fibrous dysplasia. The tumor is mostly fibrous tissue composed of collagen and fibroblast. Small bits of bone and osteoid, often having a "C" or an "O" shape, seem to have been sprinkled on the fibrous tissue. Osteoblasts are not seen, and the bone seems to be produced by the fibroblastic cells. (Original magnification $\times 40$.)

plasia, café-au-lait spots, and precocious puberty (315). The lesions in polyostotic fibrous dysplasia tend to be more unilateral than bilateral. The radiographic appearance of the lesion is the same as in patients with monostotic disease. The structural strength of bones with fibrous dysplasia is

reduced as a result of the poorly organized trabecular pattern and the thinned cortex. The weakness of the bones leads to the deformities that are usually present.

Microscopically, fibrous dysplasia, both the monostotic and polyostotic forms, is composed of fibrous tissue with normal-appearing nuclei and irregularly shaped strands of osteoid and bone (Fig. 14-21B). There are few if any osteoblasts present, and the osteoid and bone seem to arise directly from the background fibrous stroma. The bone is irregularly organized, and often has a "C" or an "O" shape. Multinucleated giant cells are rare in fibrous dysplasia, and there should be few mitoses, and none of these cells should be abnormal. Nodules of cartilage may be present in typical fibrous dysplasia.

Monostotic fibrous dysplasia usually does not need surgical treatment. Occasionally, a solitary lesion will be painful and curettage with grafting is required. Small lesions can be packed with cortical cancellous bone graft (autogenous or allogenic), whereas large lesions are probably better treated with cortical bone grafts. A special circumstance is a lesion in the femoral neck. These lesions seem to have a risk of developing fatigue fractures, and cortical bone grafting is recommended (319). Resorption of the bone graft with recurrence of fibrous dysplasia can occur, and the patient should be seen in follow-up for up to 5 years. Occasionally it is necessary to augment the bone with long-term or permanent internal fixation to prevent repeated fractures and relieve pain. Progressive bone deformity is unusual in patients with monostotic fibrous dysplasia. Patients with polyostotic fibrous dysplasia are more often in need of surgical therapy. Bone deformity is the most common indication. The proximal femur is the most challenging bone to manage. Once a varus deformity develops, it is important not only to bone graft (preferably cortical bone), but to correct the angular deformity with a valgus osteotomy. Rigid internal fixation is recommended (307,320–328).

Osteofibrous Dysplasia

Kempson (329) described the osteofibrous dysplasia lesion, which is found in the mandible and the anterior cortex of the tibia of children. It is benign, but may be locally aggressive. It is *not* a healing nonossifying fibroma. The patients usually do not have symptoms, and usually are brought to the physician's attention by a parent who has noticed an anterior bowing or mass in the tibia. The lesion is almost always located within the anterior cortex of the tibia, and is best seen on the lateral radiograph (Fig. 14-22). There are usually numerous radiolucent lesions with a rim of reactive bone. There is increased uptake on the technetium bone scan in the area of the lesion.

Although Kempson (329) suggested the name "ossifying fibroma," the more commonly used term is "osteofibrous dysplasia" (330–334). Some authors believe that osteofibrous dysplasia is a type of fibrous dysplasia, but this is

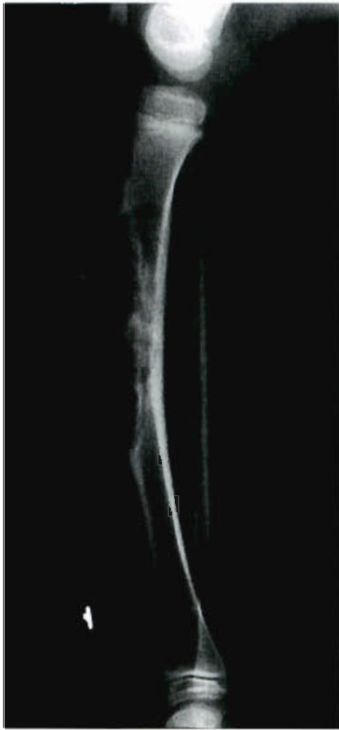

FIGURE 14-22. Lateral radiograph of the leg of a patient with osteofibrous dysplasia. Found almost exclusively in the tibia, this lesion involves the anterior cortex, and can extend into the medullary canal. The tibia commonly has an anterior bow.

controversial. Fibrous dysplasia has numerous characteristics that osteofibrous dysplasia does not have. Fibrous dysplasia arises from the medullary canal, and rarely produces bowing of the tibia. It rarely recurs after curettage, and is not an aggressive lesion unless the patient has polyostotic disease. Osteofibrous dysplasia, on the other hand, arises from the cortex and involves the medullary canal late in the disease process. It usually is associated with a bowed tibia, and quickly recurs if curetted. Usually it requires a resection for control. There have been few studies of patients with osteofibrous dysplasia with adequate follow-up, but many of these lesions slowly progress, and are eventually resected.

The authors recommend observation of the lesion when it is found in a patient younger than 10 years of age. Incisional biopsy is not necessary in most cases, because the clinical presentation is diagnostic. In addition, the biopsy reveals only a small portion of the lesion, and does not change the initial management. Bracing may not prevent progressive bowing, but can be tried if there is an angular deformity. If the lesion progresses before closure of the growth plate, biopsy and resection are suggested. If the patient presents after closure of the growth plate, especially if the lesion is large (more than 3 or 4 cm in diameter) or has aggressive features on plain radiographs, a biopsy is sug-

gested. If an adamantinoma is found a wide resection is recommended. If the biopsy reveals osteofibrous dysplasia, it is best to excise the entire lesion for a complete histologic examination to rule out the possibility of there being a focus of adamantinoma. If the lesion is small (less than approximately 3 cm) and the patient has no symptoms, continued observation is suggested.

Adamantinoma has a clinical presentation similar to osteofibrous dysplasia. In adamantinoma, however, usually the patient is older (third decade of life), and the lesion appears more aggressive on the radiographs (e.g., soft tissue extension, acute periosteal reaction, large size, involvement of the medullary canal), but this is not always the case. It has been suggested that there is another type of adamantinoma that looks extremely similar to osteofibrous dysplasia, even with histologic examination. One must be suspicious of the diagnosis of osteofibrous dysplasia, especially in a progressive lesion in a patient older than 10 years of age (335,336).

If a lesion suspected of being an osteofibrous dysplasia is going to be observed, the patient should undergo radiography at least every 6 months until the lesion heals or is resected. Typical adamantinoma has a risk of metastasizing, but it is not known if the adamantinoma that looks like osteofibrous dysplasia can metastasize (333).

Miscellaneous Lesions

Langerhans Cell Histiocytosis

“Langerhans cell histiocytosis” is the name selected to refer to what we once called “histiocytosis X,” and includes the syndromes eosinophilic granuloma, Hand-Schüller-Christian disease, and Letterer-Siwe disease (337,338). In 1941 Farber suggested that eosinophilic granuloma, Hand-Schüller-Christian disease, and Letterer-Siwe disease were related (339). Later, Lichtenstein published an article agreeing with Farber, and suggested the term “histiocytosis X” (340). This is a disorder of the Langerhans histiocytes, and although eosinophils are a common component of the lesion, they are not necessary for the diagnosis (Fig. 14-23).

Eosinophilic granuloma usually occurs in patients between the ages of 5 and 15 years. The skull is the most commonly involved site (341) (Fig. 14-24). Many of the skull lesions probably are not diagnosed because the only abnormality is a painless, small, spontaneously resolving lump in the scalp. The vertebral bodies and the ilium are the next most common sites of involvement (342–344). Those lesions in long bones may weaken the bone sufficiently that the patient presents with activity-related pain suggestive of a fatigue fracture, or with a pathologic fracture. The lesion is a radiolucent abnormality with sharp borders of transition and often no reaction by the host bone. An apparent central sequestrum of bone may be seen. Eosinophilic granuloma usually results in increased uptake on a technetium bone scan, but as many as 25% of lesions will

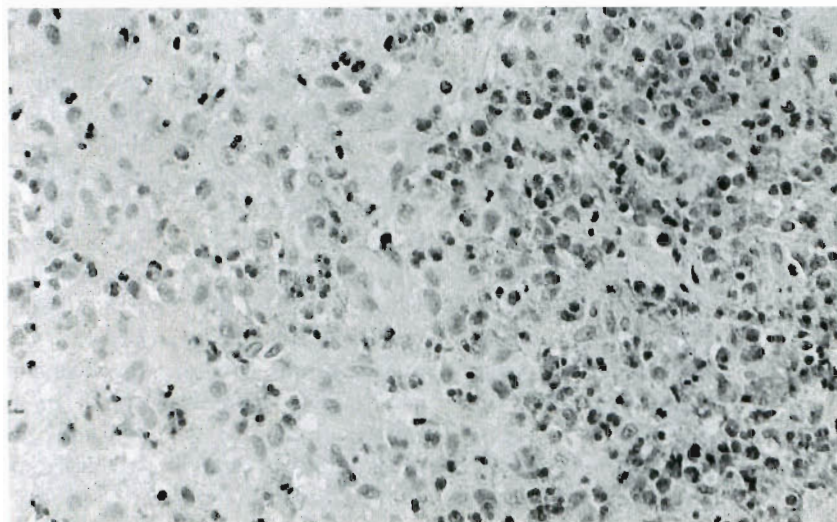


FIGURE 14-23. Low-power view of an eosinophilic granuloma (Langerhans granuloma). The eosinophils are numerous, but it is the presence of histiocytes that defines this tumor. The histiocytes are large cells with a clear, folded nucleus and a prominent nucleolus. (Original magnification $\times 10$.)

not be associated with abnormal bone scans (72,73, 345–350) (Fig. 14-25).

Patients with eosinophilic granuloma do not progress to Hand-Schüller-Christian disease, but should be evaluated on presentation to exclude the presence of that syndrome.

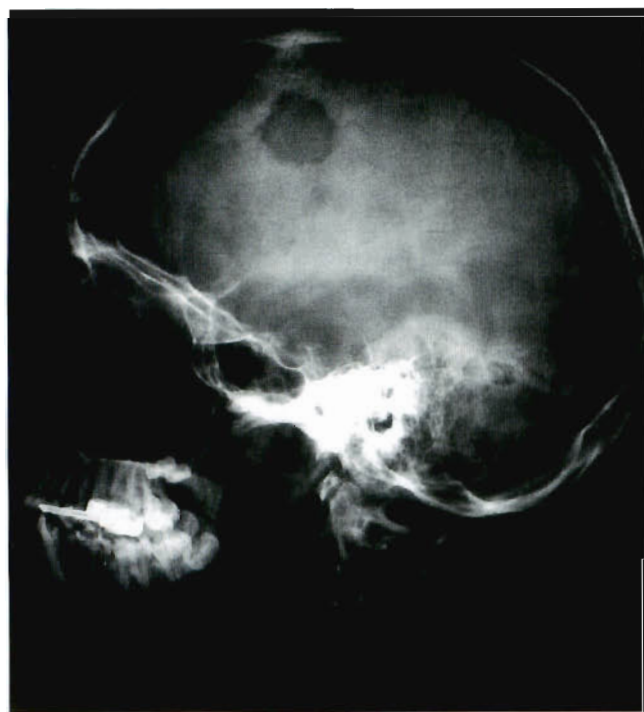

FIGURE 14-24. This is a lateral plain radiograph of the skull of a patient with a solitary Langerhans cell histiocytosis (eosinophilic granuloma). The skull is the single most common site of involvement for eosinophilic granuloma. Plain radiographs of the skull are recommended when eosinophilic granuloma is suspected. These lesions rarely require treatment.

Obtaining a lateral skull film to observe the size of the sella turcica, and a first voided urine specimen after overnight fluid restriction to prove that the patient can concentrate his or her urine, is the easiest way to evaluate the patient for diabetes insipidus. Liver enzymes should be determined. A skeletal survey also should be done to look for other lesions. Multiple lesions can be seen in eosinophilic granuloma. If any of these parameters are abnormal, the patient should be referred to a pediatric hematologist. The authors routinely seek a consultation from a pediatric hematologist for all patients with Langerhans cell histiocytosis.

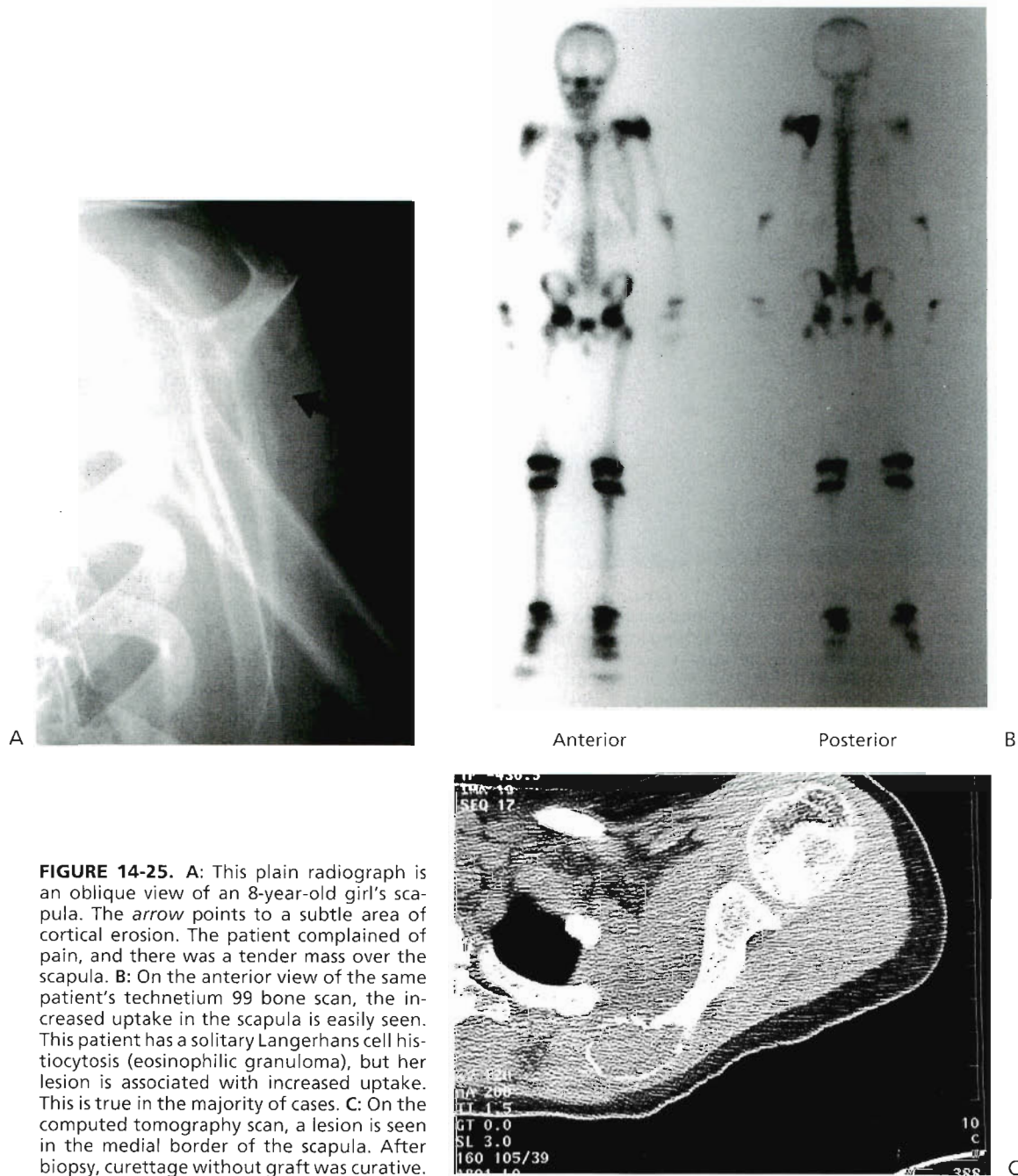
It was believed that eosinophilic granuloma needed to be treated, and many children underwent irradiation, curettage, or excision. At present, it is believed that the majority of these lesions are self-healing, and that no specific treatment is necessary (338). Intralesional injection of corticosteroids has been recommended by some physicians (351–353).

Hand-Schüller-Christian disease is a combination of bone lesion, exophthalmos, and diabetes insipidus. Patients with this disorder should be treated with systemic corticosteroids or chemotherapy (354–357).

Letterer-Siwe disease is a malignant form of Langerhans cell histiocytosis. Most patients present before 3 years of age with skin, visceral, and brain lesions, and they may or may not have bone lesions. They require aggressive chemotherapy (341,358–360).

Unicameral Bone Cysts

Unicameral bone cysts are not always unicameral. They also are called “simple bone cysts,” but they may not be simple to treat. These common lesions usually are found when the patient sustains a pathologic fracture. Their radiographic appearance is so typical that most can be diagnosed without



a biopsy (Fig. 14-26). The proximal humerus and the proximal femur account for 90% of unicameral bone cysts (361–365). The cysts seem to arise from the epiphyseal plate, and are immediately adjacent to the plate extending into the metaphysis (366–369). The metaphyseal bone does not remodel and the metaphysis is broader than normal, but not broader than the width of the epiphyseal plate. A thin rim of bone borders the unicameral bone cyst. The surrounding bone is not reactive, and there is no acute peri-

osteal reaction. When the cyst becomes mature (latent), usually after the patient reaches the age of 10 years, the epiphysis grows away from the lesion. The unicameral bone cyst eventually heals spontaneously and fills in with bone. No evidence of its previous existence is seen.

Treatment is to prevent a pathologic fracture. Some lesions remain small and do not present a significant risk to the patient. Other lesions are large (e.g., proximal humeral lesions), are in high-stress anatomic sites (e.g., the femoral

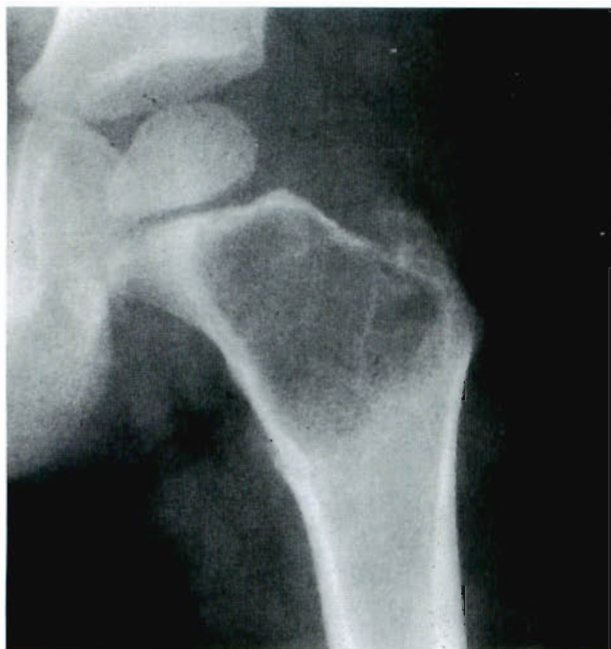

FIGURE 14-26. Anteroposterior radiograph of a proximal femoral unicameral bone cyst (UBC). UBCs are radiolucent lesions immediately adjacent to the growth plate that extend into the metaphysis. This UBC is considered active because it is immediately adjacent to the growth plate and the patient is younger than 10 years old. Large lesions in the proximal femur should be treated because of the risk of pathologic fracture. Initial treatment should be a corticosteroid injection.

neck), or persist after the patient has become a young adult, and in these cases treatment is indicated. Only those patients who have unicameral bone cysts that are at risk for pathologic fracture should be treated (370–375). Injection is recommended rather than an operative procedure because the results of injection are equal to those of curettage and bone grafting, whereas the risk, recovery, and cost are less. Intracystic injection of corticosteroids is the treatment of choice as an initial means of stimulating the cyst to heal (376,377). Before the common use of corticosteroid injections, curettage and autogenous bone grafting had been the most common treatment. Operative treatment with curettage and autogenous bone grafting is reserved for those lesions that do not respond to repeated injections of corticosteroid (361,376,378–380). The number of injections that should be tried before deciding to operate is not agreed upon. The authors give at least three injections approximately 1 month apart before resorting to an open operative procedure. The injection of autogenous bone marrow is a technique advocated by some (381). In a study of ten patients whose unicameral bone cysts were treated with autogenous marrow, all were free of pain within 2 weeks of the injection, and all healed completely within 1 year.

The injection of corticosteroid was introduced by Scaglicetti and colleagues (377,382). It has been used extensively

and is an established method of treatment of a unicameral bone cyst. It should be performed with anesthesia (usually general anesthesia), and with the aid of fluoroscopic visualization. An 18- or 20-gauge spinal needle is passed percutaneously into the cyst. The wall of the cyst is penetrated easily by an 18-gauge needle with the stylet in place. Rotating the needle as it is pushed through the bone often helps it penetrate the cortex. Clear yellow or slightly bloody fluid should be obtained. If no fluid is aspirated, the diagnosis of unicameral bone cyst should be questioned and the lesion biopsied.

Once the fluid has been withdrawn a second needle is introduced into the cyst as far from the first as possible. A radiopaque dye (usually Renografin 60) is injected into the cyst to confirm that it is unicameral, and that all parts fill with dye. Frequently the draining veins are seen shortly after the cyst is injected. If the cyst has more than one cavity, each one should be injected.

It is not known if the type of corticosteroid used is important, but methylprednisolone acetate (Depo-Medrol) is probably the most commonly used steroid. There is no standard amount of corticosteroid. Usually, 80 mg is sufficient for a small cyst, and up to 160 mg may be used for large cysts. There are two techniques for corticosteroid injection. One is to inject the corticosteroid under pressure, with the second needle occluded, to rupture the cyst wall. The other is to inject the corticosteroid without pressure, using the second needle as a vent. It is unclear which method is better. A repeat radiograph is taken in 1 month, and if there is no evidence of early healing (e.g., increased thickness of the reactive wall), a repeat injection is done. Repeated injections are often needed, but more than three to five probably are not beneficial.

The rare unicameral bone cyst that requires operative treatment should be curetted and packed with bone graft. When the cyst is adjacent to the growth plate, care should be taken not to damage the epiphyseal cartilage during curettage (383). Autogenous bone or allograft cortical cancellous bone can be used to pack the cavity (361,378,384,385). Freeze-dried cortical cancellous allograft is particularly advantageous because it is associated with an excellent healing rate and little, if any, incidence of complications, and no secondary incision is required to obtain the autogenous bone graft. Calcium sulfate tablets are an alternative material that can be used to fill the cavity (386,387).

Aneurysmal Bone Cysts

An ABC is a controversial lesion (361,363,388–391). Some investigators believe that this lesion occurs only in association with another bone tumor, whereas others recognize ABCs as a primary diagnosis (389,392,393). ABCs often occur in association with a number of benign tumors (e.g., giant cell tumor, chondroblastoma, osteoblastoma), or with osteosarcoma (389). When it is a secondary lesion, the pri-

mary lesion usually is obvious, and the ABC component is limited to only a small portion of the tumor. Secondary ABCs are classified with their underlying diagnosis. The presence of a secondary ABC does not change the therapy or prognosis of the underlying primary tumor.

A primary ABC occurs most commonly in teenagers (80%). More than 50% of these cysts arise in large tubular bones, and almost 30% occur in the spine. The patient usually complains of a mild, dull pain, and only rarely is there a clinically apparent pathologic fracture. The patient's physical examination is usually normal, and there are no abnormal laboratory findings associated with ABC.

On the plain radiograph an ABC is a radiolucent lesion arising eccentrically within the medullary canal of the metaphysis (Fig. 14-27). It resorbs the cortex and elevates the periosteum, generally making the bone wider than the epiphyseal plate. Usually, there is a thin shell of reactive periosteal bone, but occasionally this bone cannot be seen. When ABC arises in a long bone, it is metaphyseal. When it arises in the spine, it originates in the posterior elements but it

may extend into the body, and not uncommonly will extend to an adjacent vertebral body or rib. Giant cell tumor of the bone and telangiectatic osteosarcoma may have identical radiographic appearances as an ABC (379,389). The periosteal reaction has an aggressive appearance, and the lesion may be mistaken for an aggressive or malignant tumor (363). ABCs may arise in the cortex and elevate the periosteum with or without involving the medullary canal.

The CT scan is helpful in making the diagnosis of ABC. The lesion should have a density of approximately 20 HU, and this does not increase with intravenous contrast injection. When the patient lies still for 20 to 30 min, the cells in the fluid within the cyst cavity settle, and a fluid/fluid level can be seen (394). Similar findings can be seen on MRI. Fluid/fluid level was originally described in ABC but has subsequently been seen in a number of other lesions. It cannot be considered diagnostic of ABC. An ABC has an increased uptake of technetium on the bone scan, but often the scan has a central area of decreased uptake (395).

ABCs should be biopsied to establish the diagnosis, then curetted and packed with bone graft. The pathologist should be advised in advance, and the possibility of a telangiectatic osteosarcoma should be discussed. It is uncommon for the histologic appearance of an ABC to be confused with that of a telangiectatic osteosarcoma, although the radiographic and gross appearances can be identical. On gross inspection, an ABC is a cavitory lesion with a villous lining. Microscopic examination reveals the lining to be composed of hemosiderin-laden macrophages, multinucleated giant cells, a fibrous stroma, and usually small amounts of woven bone (Fig. 14-28). The microscopic appearance of the lining of the ABC is similar to that of a giant cell tumor of bone.

The majority of ABCs are treated successfully with curettage and packing of bone graft. The first recurrence can be recuretted and grafted. Embolization has been used to decrease blood loss during surgery, and has been associated with fewer recurrences (396,397). Whether embolization is necessary or of help is debatable. Cryosurgery has also been reported (361,388,398). Cryosurgery has associated complications, and it is not considered necessary in most cases. It may play a role in the treatment of recurrent lesions. Definitive resection can be performed when the consequences of the resection are minimal, but it is absolutely necessary only when the lesion has a particularly aggressive clinical growth pattern.

An ABC of the spine (approximately 30% of cases) can present a particularly challenging problem. The lesion always involves the posterior elements, but can also involve the vertebral body. The patients complain initially of pain at the site of the lesion, but the ABC often is not found until the patient has nerve root or cord compression. Radiotherapy has been used in the management of patients with ABC of the spine, but surgery is recommended for all patients as the initial means of treatment. Most cases are controlled with simple curettage. Usually the posterior ele-

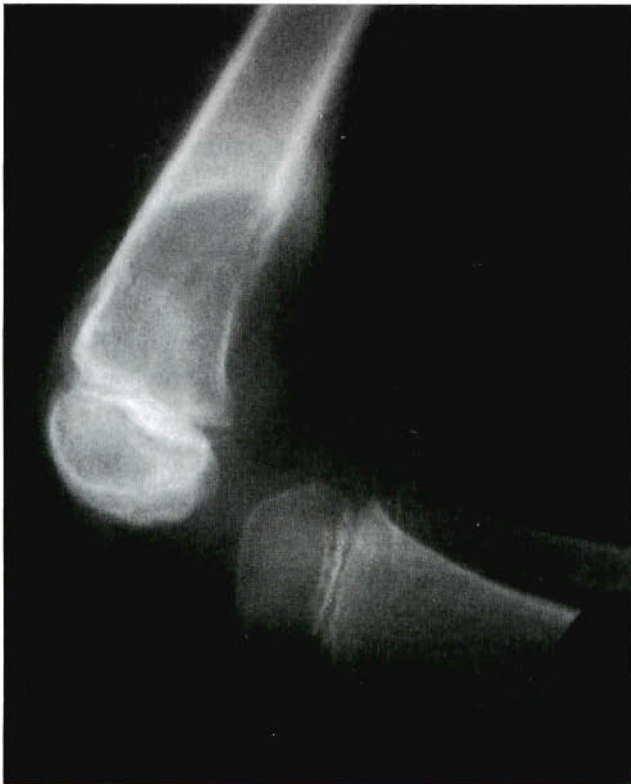

FIGURE 14-27. Radiograph of a distal femur with an aneurysmal bone cyst involving the distal metaphysis, and extending through the posterior cortex. As in this patient, an aneurysmal bone cyst may have the appearance of an aggressive tumor. When the cyst erodes through the cortex it usually is contained by the periosteum, which reacts and produces bone. The differential diagnosis should include aneurysmal bone cyst, osteosarcoma (telangiectatic variant), Ewing sarcoma, and osteomyelitis. This patient was successfully treated with curettage and bone grafting.

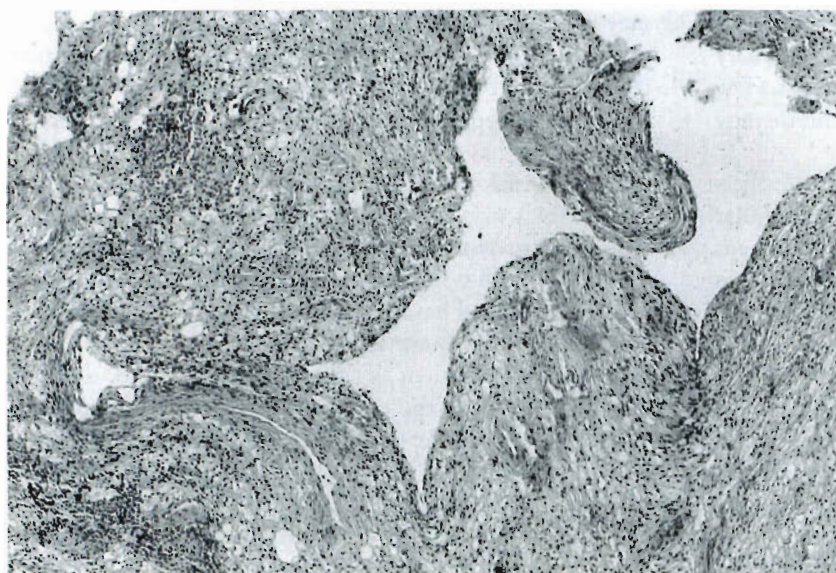


FIGURE 14-28. Low-power view of the tissue lining an aneurysmal bone cyst. The lining is composed of fibrous tissue with multinucleated giant cells, foamy histiocytes, hemosiderin, and, often, spicules of immature bone (not seen). The fronds and spaces are typical. (Original magnification $\times 10$.)

ments are resected, and involvement of the pedicles or the body is curetted. If complete laminectomy is performed, a short posterior fusion is advised. Radiotherapy can be used in the postoperative period, but usually this is reserved for the rare case of rapid recurrence with soft tissue infiltration. Postoperative MRI or CT is recommended as a baseline study with which to compare any later scans.

Ewing Sarcoma/Peripheral Neuroectodermal Tumor

Ewing sarcoma and peripheral (or primitive) neuroectodermal tumor (EWS/PNET) are discussed together because they are closely related (247,399). Both have the same chromosomal translocation between chromosomes 11 and 22, similar presentations, identical treatments, and almost identical histologic characteristics. PNET is also called Askin tumor, and was originally identified from tumors classified as Ewing sarcoma. EWS/PNETs are thought to arise from the neural crest. At least 90% have a characteristic chromosomal translocation [$t(11:22)(q24;q12)$]. This translocation leads to a novel fusion protein called EWS-FLI1 (400,401).

EWS/PNET was the most lethal of all primary bone tumors before the routine use of adjuvant chemotherapy, with a 5-year survival of approximately 15% (402). Before the use of adjuvant chemotherapy, most patients were treated with irradiation alone. With improved survival associated with adjuvant chemotherapy the role of surgery has been reevaluated, and there is evidence, albeit only from retrospective studies, that surgical resection combined with chemotherapy produces improved survival compared with survival after irradiation and chemotherapy (239,402–413).

The patient with EWS/PNET initially complains of pain. Some have generalized symptoms of fever, weight loss, and malaise, but this is not the usual presentation. Males are affected at a 3:2 ratio over females, and most patients are between the ages of 5 and 30 years. Any bone may be affected. The femur is the most common site of origin (20%); the pelvis and the humerus are also common sites. There is usually a soft tissue mass associated with the bone lesion, and on physical examination this mass often can be palpated. The mass is warm, firm, and tender, and it may be pulsatile. There are no specific abnormal laboratory values diagnostic of EWS/PNET, but the sedimentation rate often is increased. Elevated LDH is a poor prognostic sign (247,399).

The typical plain radiograph of a EWS/PNET reveals diffuse destruction of the bone, extension of the tumor through the cortex, a soft tissue component, and a periosteal reaction (414) (Fig. 14-29). The periosteal reaction may produce a Codman triangle, an “onionskin” appearance, or a sunburst appearance. These suggest an aggressive lesion that has rapidly penetrated the cortex and elevated the periosteum. The extraosseous soft tissue mass and medullary canal involvement can be seen on CT and MRI scans, and usually are more extensive than what was expected from the plain radiograph (80,415,416).

MRI has proved to be more accurate in determining the intramedullary extent of EWS than CT. The inflammation around the tumor is seen with MRI more easily than with other studies, and its extent is often more than expected from the other tests. The technetium bone scan is most useful in finding occult bone metastasis. Approximately 5% of these patients present with pulmonary metastasis.

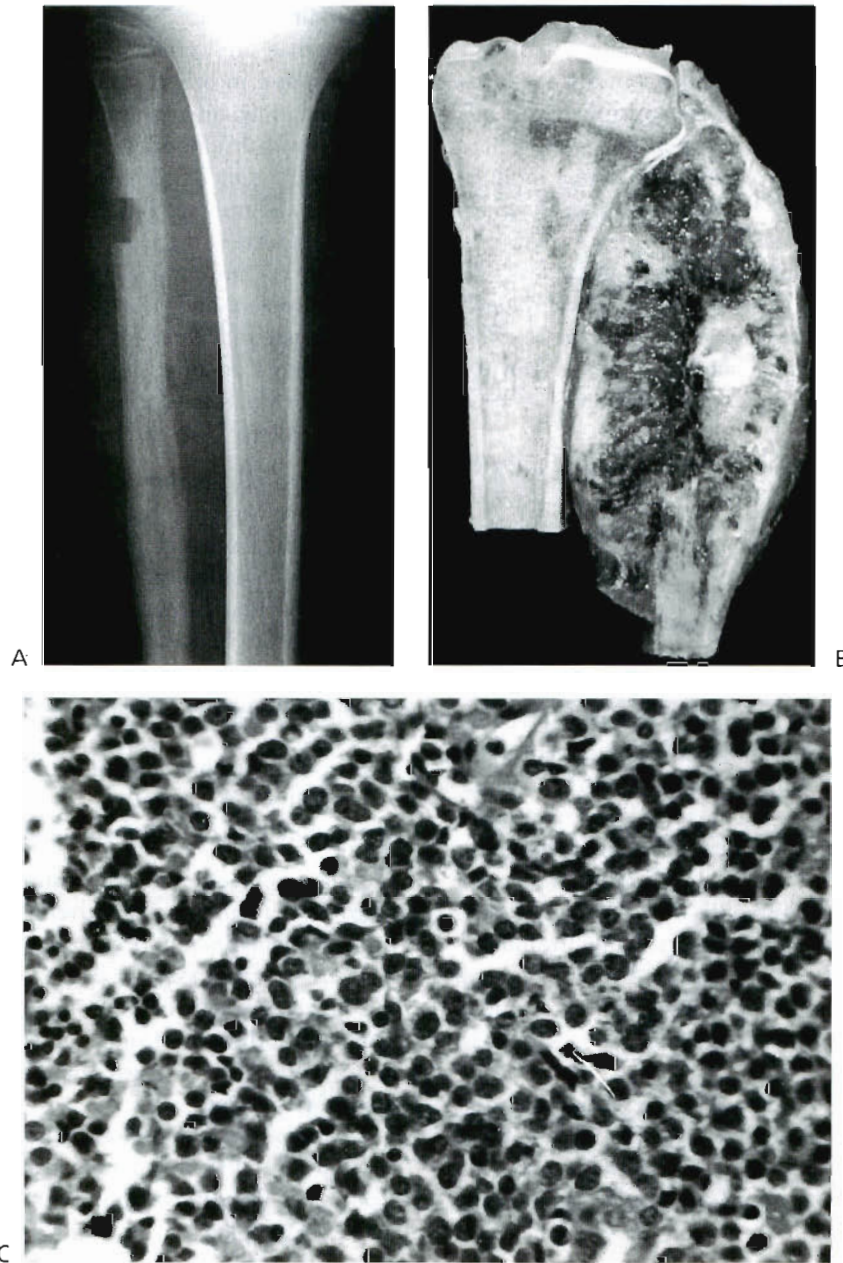


FIGURE 14-29. A: Anteroposterior radiograph of the proximal tibia and fibula of a patient with Ewing sarcoma involving the proximal fibula. The fibular cortical detail is lost, and erosion of the medial surface, soft tissue mass, and periosteal reaction—all typical findings of Ewing sarcoma—are present. The combination of these findings is indicative of an aggressive process. Acute osteomyelitis may have this appearance, but the patient usually has other signs of infection. The defect in the lateral aspect of the fibula is attributable to an incisional biopsy of the bone. The bone should not be biopsied if there is sufficient soft tissue extension. This will lessen the chance of pathologic fracture. In addition, the extraosseous tumor is usually more easily cut, and the histologic appearance is better. B: Gross specimen of Ewing sarcoma of the proximal fibula, similar to the case in A. The tumor has replaced the proximal fibula, and there is a large soft tissue mass, with invasion of surrounding muscles and no involvement of the tibia. This patient chose to have an immediate amputation, although this is not standard treatment. C: Histologic appearance of Ewing sarcoma. The nuclei are easily seen, and there are nucleoli within each nucleus. The cells are small and round, with very little variation in nuclear appearance. Mitoses are rare. The cytoplasm is faint and difficult to see, and the cytoplasmic borders are poorly defined. (Original magnification $\times 10$.)

The histologic appearance of EWS/PNET is that of a small, round, cell tumor. The EWS/PNET cell has a distinct nucleus with minimal cytoplasm and an indistinct cytoplasmic border (7,417–419). The cells are similar and mitoses are uncommon. Necrotic areas usually are seen. There are glycogen granules in the cytoplasm, and these produce the positive periodic acid Schiff (PAS) stain on routine histologic examination. The intracellular glycogen granules are diastase positive (i.e., exposure to diastase will break the glycogen down, eliminating PAS staining). The glycogen can be seen as dense cytoplasmic granules with the electron microscope. Increasingly, genetic analysis is being done for EWS/PNET to identify the 11:22 translocation as a means of establishing the diagnosis.

Treatment of EWS/PNET is a combination of chemotherapy and either irradiation or surgery (245,412, 420–432). The drugs commonly used include vincristine, doxorubicin, cyclophosphamide, ifosfamide, and etoposide. Actinomycin D, a drug used previously, is currently used less often. Most protocols begin with two to four courses of chemotherapy before deciding how to manage the primary tumor. This usually results in a significant reduction in the size of the primary tumor. Surgical resection is recommended if the functional consequences of the resection are acceptable (406–408,433–435). If the margins are close and viable tumor is present in the resected specimen, postoperative irradiation is recommended. If the primary tumor cannot be resected without undue morbidity, irradiation alone can be used (223,224,423,436–445). The total dosage should be kept as low as possible, usually around 50 gray (Gy), and certainly less than 60 Gy, because dosages of more than 60 Gy are associated with an unacceptable incidence of later irradiation-associated sarcomas (446–453).

Current survival statistics for patients presenting without metastasis reveal a 5-year disease-free survival of greater than 65% (444). Patients who present with metastasis have less chance of being cured but should be treated aggressively because some will survive.

Soft Tissue Tumors

The majority of soft tissue tumors in children are benign (454). Only rhabdomyosarcoma in the younger age group and synovial cell sarcoma in teenagers and older patients occur with any frequency, and they are both rare tumors (455). Hemangioma, the fibromatoses, neurilemoma, and neurofibroma are more common. The physician must be aware of the possibility of malignant soft tissue tumor in the child and evaluate any lump carefully (456).

Hemangioma

Hemangioma may be a true neoplasia, a hamartoma, or an arteriovenous malformation. Its origin is controversial. It is

important that the abnormality be recognized as a benign lesion that in certain circumstances regresses spontaneously, and in others infiltrates the muscle and occasionally bone. Hemangiomas are the most common tumors in infancy and childhood, and account for 7% of benign soft tissue tumors in all age groups. They are most common in the head and neck regions, but also may be found in internal organs, especially the liver. Often an intrahepatic hemangioma can be seen on a CT scan of the abdomen taken for another reason, and its existence is of little concern.

Enzinger and Weiss (457) provide a classification of vascular tumors of soft tissue. The borderline malignant and malignant vascular tumors are not pertinent to this discussion; therefore, only the benign tumors are included:

- localized hemangioma
- capillary hemangioma (including juvenile type)
- cavernous hemangioma
- venous hemangioma
- arteriovenous hemangioma (racemose hemangioma)
- epithelioid hemangioma (angiolymphoid hyperplasia, Kimura disease)
- hemangioma of granulation tissue type (pyogenic granuloma)
- miscellaneous hemangiomas of deep soft tissue (synovial, intramuscular, neural)
- angiomatosis (diffuse hemangioma)

Capillary hemangioma constitutes the largest group of benign vascular tumors. The juvenile hemangioma variant of capillary hemangioma occurs in 1 of every 200 live births. They may be cutaneous or deep, and usually are seen within the first few weeks of life, often enlarging for the first 6 months but then regressing and becoming 75 to 95% involute by the age of 7 years. Capillary hemangiomas do not require treatment.

Cavernous hemangiomas are not as common as the capillary type, but do not spontaneously regress and may require treatment. They most commonly arise within muscle, and invade tissue planes extensively. The patient often presents with complaints of swelling, tenderness, and inflammation secondary to thrombophlebitis within the hemangioma. This inflammation resolves within a few days, and can be treated with local heat and oral aspirin. The noninflamed hemangioma is soft and ill defined. The patient may have no symptoms or the sensation of heaviness or a tight feeling in the extremity. On the plain radiograph there are often small, smooth, round calcifications called “phleboliths.” The appearance of hemangiomas on MRI is virtually diagnostic, because they are composed of smooth, regular blood vessels and normal fat.

The cavernous hemangiomas have an indirect communication with the major vascular tree, and are not easily filled with contrast for angiography or venography; they are better visualized with MRI. Occasionally a tourniquet proximal to the hemangioma permits filling of the tumor veins

at the time of venography or angiography (Fig. 14-30). If an intravenous injection does not demonstrate the hemangioma, the dye can be injected directly into the hemangioma. CT, particularly if performed with intravenous contrast, is almost always diagnostic. The hemangioma has varying densities with multiple dye-filled areas. Biopsy is performed only to confirm the diagnosis, and resection is not necessary unless the patient has repeated bouts of inflammation or complaints of discomfort (usually a full or tight feeling), or the parents are anxious about the mass.

Surgical excision usually is not required. When surgery is performed the hemangioma often recurs unless the entire muscle (or muscles) involved is resected. These lesions are probably best considered congenital abnormalities that involve most of the veins in the extremity. When the grossly involved veins are resected the surrounding vessels dilate, resulting in clinical recurrence. Hemangiomas do not undergo malignant degeneration, and although they can produce significant abnormalities in the extremity surgical resection is rarely curative, although it may reduce the symptoms. Irradiation has been used with varying benefit. Embolization also has been used for patients who have severe pain.

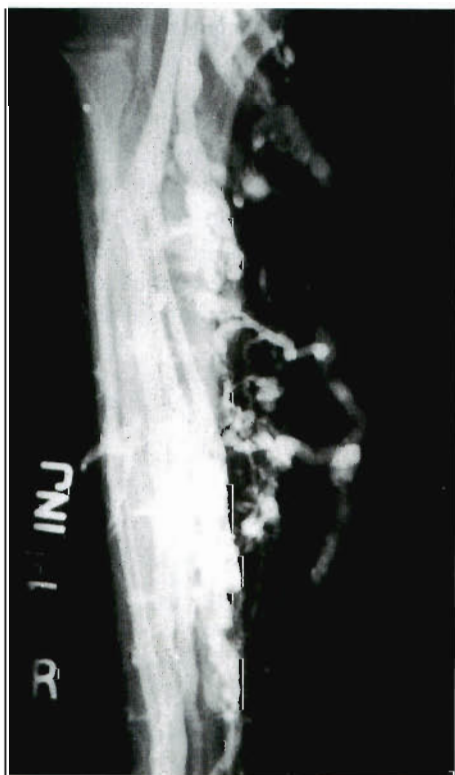

FIGURE 14-30. Venogram of a patient with hemangioma of the calf. The hemangioma communicated with the deep venous system and was easily filled when normal veins were injected with contrast; this is not always the case. This patient had two pulmonary emboli, and the hemangioma was confined to the gastrocnemius muscle. Therefore, the entire gastrocnemius muscle was resected.

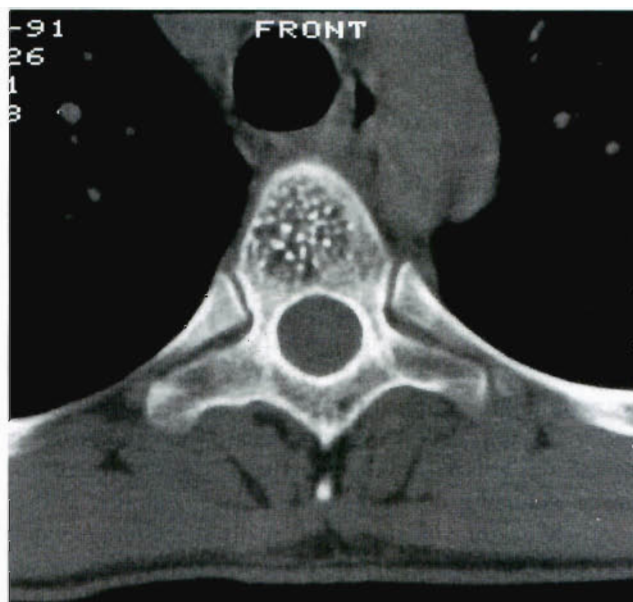


FIGURE 14-31. Computed tomography scan of a typical hemangioma of the vertebral body. The small foci of increased density are thickened trabeculae of bone, and the low-density areas are filled with the hemangiomatous tissue.

Direct injections have been used, but there are few data regarding the results, and published reports of this management have not been found.

Hemangioma of bone, either solitary or diffuse, is a hamartoma, and not a true neoplasia. The solitary lesions are more frequent, especially in the vertebral bodies where they are most often found (Fig. 14-31). Solitary lesions may occur in any bone, but the skull is the second most common site. These lesions do not produce symptoms, and usually are found when a radiograph is taken for another reason. The radiograph and CT scan are diagnostic. The bone has a honeycomb appearance, with increased trabecular markings around radiolucencies.

Patients with multiple lesions are more likely to present during the first or second decade of life, with either mild discomfort or pathologic fracture. These patients can have involvement of their viscera and skin. When multiple sites are involved they are usually the long bones of the extremities and the short bones of the hands and feet. Treatment should be symptomatic, with curettage and bone grafting for lesions that weaken the bone. Lesions that do not produce symptoms, or that are not at risk for fracture should be observed. They should resolve with time.

Fibromatoses

Benign fibrous lesions in children are relatively common and rarely malignant. Extraabdominal desmoid, or aggressive fibromatosis, is the most common benign fibrous lesion

seen in children (458). The less common lesions are not discussed in this text. Enzinger and Weiss (457) discuss these elsewhere.

Extraabdominal desmoid or aggressive fibromatosis is the most common benign fibrous tumor seen in patients older than 10 years of age (459). The patient presents with mild pain and a slowly enlarging mass. The mass is deep, firm, and slightly tender, but it is not inflamed. The adjacent joint is normal. A soft tissue mass can be seen on a plain radiograph, but there are no distinguishing features. Calcifications within the mass are not expected.

There is usually increased activity in the lesion on the technetium bone scan, although some large masses will not display increased uptake. Often, even when the lesion is immediately adjacent to the bone, there is no increased uptake of technetium. The mass has a density similar to that of muscle on the CT scan, but usually it is more vascular and can be distinguished best from the surrounding tissue by performing CT while the patient is infused with intravenous contrast. The classic collagen bundles produce a relative signal void (dark on T1- and T2-weighted images) on MRI, but because the cellularity varies, fibromatoses may have an appearance on MRI similar to any soft tissue neoplasia (460,461).

Histologically, fibromatosis has the appearance of scar tissue (457,462). It is composed of dense bundles of collagen with evenly dispersed benign cells (Fig. 14-32). The cell of origin is believed to be the myofibroblast. The histologic appearance and cell of origin of fibromatosis are identical to those of plantar fibromatosis and Dupuytren contracture, but the latter conditions are not as clinically aggressive as fibromatosis. Although they recur, they do not extend proximally out of the feet or hands as seen in aggressive fibromatosis.

Aggressive fibromatosis is an infiltrative lesion, and local

excision rarely removes the entire tumor. Often what in the operating room appears to be the extent of the tumor is found to have microscopic tumor when examined by the pathologist. Fortunately, the presence of a positive margin at the initial resection does not always lead to a local recurrence, and it is recommended to observe the patient for a local recurrence. Approximately half of the patients will develop recurrent disease regardless of the histologic margin. Those patients whose lesions recur must be widely excised if local control is to be expected. Patients younger than 10 years of age have a greater risk of developing a local recurrence than older patients. When a wide surgical margin is accomplished with the resection of the recurrence, local control is usually achieved. When the second surgical margin is microscopically positive, irradiation is recommended (459). The majority of a patient's lesions will be controlled with this combination. Low-dose methotrexate and vinblastine (355,463) have been used to treat some patients with aggressive fibromatosis, and the initial reports have been encouraging, but the effect of this treatment is unpredictable. Fibromatosis has a variable clinical course, and the treatment needs to be individualized for each patient.

Benign Tumors of Nerve Origin

There are two common benign tumors that arise from nerves: neurilemoma and neurofibroma (457,462). Neurilemmomas, or schwannomas, arise from the nerve sheath. They occur most often in early adulthood, and usually are solitary and slow-growing. The patient usually presents with a painless mass, and has a Tinel sign when the mass is tapped. The mass may be from any nerve, but it is often in the superficial tissue arising from a small sensory nerve. When arising from a spinal nerve root, the foramen may be enlarged because of the pressure of the tumor on the



FIGURE 14-32. Histologic appearance of fibromatosis. The lesion infiltrates a muscle, and is more cellular than the typical fibromatosis. A wide resection was attempted, but this patient had a microscopically positive margin. One year later, the patient had not had a recurrence. (Original magnification $\times 10$.)

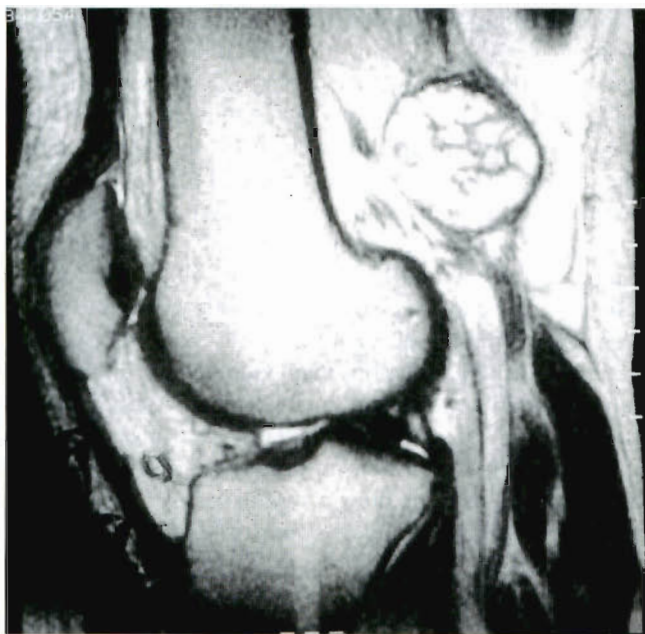


FIGURE 14-33. This is a sagittal view of a T1-weighted magnetic resonance image. The round, well-circumscribed mass posterior to the femur is within the peroneal nerve. It proved to be a schwannoma. Schwannomas have a typical appearance on magnetic resonance images. If they arise from a major nerve, as is the case in this patient, the nerve can usually be traced into the lesion. The schwannoma is smooth, slightly oblong, and has both bright and intermediate signals.

bone. Nerve dysfunction is uncommon, and is seen only when the nerve is compressed between the tumor and an adjacent rigid structure. Patients with superficial nerve lesions usually present early with small tumors, but deep-seated lesions may be large before they are discovered (Fig.

14-33). Neurilemoma rarely is seen in patients with von Recklinghausen disease because neurofibroma is the common type in these patients. Neurilemmomas are nodular masses with a distinct capsule, and are easily separated from the nerve of origin. Their microscopic appearance is a combination of a cellular area (Antoni A) and a myxoid area (Antoni B). The Antoni A area is composed of benign spindle cells that tend to have their nuclei stacked with intervening cytoplasm (Fig. 14-34). The nuclear stacking is called a "palisaded appearance," and the arrangement of alternating nuclei and cytoplasm is called a "Verocay body." The Antoni B area is composed of myxomatous tissue with less cellularity than the Antoni A area. Neurilemmomas are treated by marginal excision without sacrificing the affected nerve. Neurilemmomas should not recur.

Neurofibromas may arise as a solitary lesion or multiple lesions. The majority, maybe as many as 90%, are solitary and are not characteristic of von Recklinghausen disease. They may arise in the skin or be associated with a recognizable peripheral nerve. Like neurilemmomas, they usually present as a painless mass with a Tinel sign. Unlike neurilemmomas, they tend to be intimately associated with the nerve fibers. Fortunately, most arise from small cutaneous nerves and can be removed without loss of nerve function. Histologically, neurofibromas are not encapsulated and invade the nerve fibers and, rarely, the adjacent soft tissue. The cells are elongated, wavy, and have dark-staining nuclei. There is a collagen matrix composed of stringy-appearing fibers. Neurites usually are seen within the lesion. Surgical resection is recommended for those lesions that are solitary and not associated with a major nerve. Lesions arising from a major nerve can be resected, but the nerve fascicles must be split and the neurofibroma removed from between them. Neither solitary neurilemoma nor neurofibroma has a sig-



FIGURE 14-34. Histologic appearance of a neurilemoma (Antoni A area). The nuclei are stacked, giving the lesion a palisaded appearance. (Original magnification $\times 10$.)

nificant incidence of malignant degeneration, although patients with neurofibromatosis have a small risk of developing neurofibrosarcoma.

Rhabdomyosarcoma

Rhabdomyosarcoma is a malignant tumor of muscle (3,246,464–466). It was once thought to occur in adults and children with almost equal frequency, but, since the middle 1970s, most of the adult tumors once called rhabdomyosarcoma have been reclassified as malignant fibrous histiocytoma. Rhabdomyosarcoma is believed to be extremely rare in adults, but it is the most common malignant soft tissue tumor in patients younger than 15 years of age. It accounts for approximately 3.5% of children's malignancies, and there are approximately 350 new cases per year in the United States (246,467). There are four histologic patterns: embryonal, botryoid-type, alveolar, and pleomorphic (468–470).

Botryoid-type rhabdomyosarcoma is histologically identical to the embryonal pattern, but is considered a separate entity because of its gross appearance. A botryoid rhabdomyosarcoma is an embryonal cell type that involves a hollow viscus. Pleomorphic rhabdomyosarcoma is a histologic type seen in adults, and is the least common. Embryonal rhabdomyosarcoma is the most common type, and usually arises in the head, the neck, the genitourinary tract, and the retroperitoneum. It is rare in the extremities. Botryoid rhabdomyosarcoma tends to occur in the first decade of life. The current treatment is a combination of chemotherapy, surgery, and, if not totally excised, irradiation. When chemotherapy is given preoperatively, the surgery required is less radical, and adequate surgical margins are more easily achieved.

Alveolar rhabdomyosarcoma is more common in the extremities than in the trunk, and is seen in older children and young adults usually between 10 and 25 years of age (227,246,471–476). The patient presents with a rapidly growing, painless mass deep within the muscle. This occurs with equal frequency in the upper and lower extremities. There are no clinical or laboratory findings that distinguish rhabdomyosarcoma from other soft tissue tumors.

Characteristic chromosomal abnormalities have been identified in the alveolar subtype (5,477–479). Approximately 70% of the tumors will have a translocation between chromosome 13 and chromosome 2, whereas another 30% will have the translocation between chromosome 13 and chromosome 1. Prognostic variables include histologic subtype, size of the tumor, site of the tumor, and age of the patient (480–483). Alveolar subtype, larger tumors, patients older than 10 years of age, and extremity location are associated with a poor prognosis. Therefore, the patients that the orthopaedist treats tend to do worse than those treated by the urologist and the otolaryngologist. Alveolar rhabdomyosarcoma, like the other subtypes, is treated with

a combination of chemotherapy and surgery (226,227, 246,484–488). Irradiation can be used if total surgical resection cannot be achieved without excessive morbidity. If the lesion is small it should be totally resected initially. Unlike in rhabdomyosarcoma at other sites, preoperative chemotherapy should be considered, because this often makes total resection of an extremity lesion possible when it was not possible before chemotherapy. A wide surgical margin is recommended (230,487,489–491). Unless the patient has palpable regional lymph node enlargement, biopsy of the lymph nodes is not necessary. Preoperative irradiation is reserved for lesions that would require an amputation to obtain a wide margin. Postoperative irradiation is used when no preoperative irradiation was given and the surgical margins are positive for tumor (486,492–494). Survival is related to stage, but the overall survival for a patient with extremity rhabdomyosarcoma is approximately 60% (3,464,481,485,486,495,496).

The histologic appearance of embryonal rhabdomyosarcoma can vary (473,475). This lesion consists of poorly differentiated rhabdomyoblasts with limited collagen matrix. The rhabdomyoblasts are small, round-to-oval cells with dark-staining nuclei and limited amounts of eosinophilic cytoplasm. Cross-striations are not seen regularly. Alveolar rhabdomyosarcoma is composed of small, round-to-oval tumor cells loosely arranged together in groups by dense collagen bundles. This arrangement of cells in groups produces an alveolar appearance; hence the name.

The Intergroup Rhabdomyosarcoma Committee, with representation from both the Pediatric Oncology Group and the Children's Cancer Study Group, has been the dominant group treating rhabdomyosarcoma in the United States. Their management and cooperative efforts have resulted in major advances in the management of this malignancy (230). Their staging system for patients with rhabdomyosarcoma is currently in use (474,476,483,497) (Table 14-5).

Synovial Cell Sarcoma

Synovial cell sarcoma is a malignant tumor of soft tissue whose cellular characteristics suggest that the tumor arises from primitive synovial cells, but it rarely occurs within a joint (233,457). Unlike other soft tissue sarcomas, synovial cell sarcomas occur frequently in the hand and foot (498). They usually are in the deep soft tissues near a joint. These tumors account for 10% of all soft tissue sarcomas (457). Most patients are between 15 and 35 years of age, and males predominate slightly. Patients with synovial cell sarcoma often complain of pain before they have palpable masses, and many patients give a history of having complained of pain for 2 to 4 years before the lesion was found. Synovial cell sarcoma, although rare, may be the explanation for persistent pain in a young patient (454,499–502).

The usual physical finding is the firm, slightly tender

TABLE 14-5. INTERGROUP RHABDOMYOSARCOMA STAGING SYSTEM

Stage	Site	Size	Nodes	Metastases
1	Orbit Head and neck Genitourinary (not bladder or prostate)	Any	Any	None
2	Bladder and prostate Extremity Cranial parameningeal Other	≤5 cm	None or unknown	None
3	Bladder and prostate Extremity Cranial parameningeal Other	≤5 cm ≥5 cm	Clinically involved Any	None None
4	All	Any	Any	Present

mass. Up to 25% of these patients have metastasis to regional lymph nodes, and the lymph nodes should be examined carefully (503). The patient's blood and urine laboratory values are normal.

The lesion occurs in all parts of the body. The head, the neck, and the trunk account for approximately 15% of the lesions, whereas the upper and lower extremities account for more than 50% of them. Almost 10% of the lesions arise in the hands or feet.

Synovial cell sarcomas may have calcifications or ossifications within the tumor, and these often are seen on plain radiographs. The radiodensities are usually very small. Small, irregular calcific foci, or irregular ossification within a soft tissue tumor should suggest the diagnosis of synovial cell sarcoma. The CT scan demonstrates a soft tissue mass, with these calcified densities deep within the tumor. Although the small foci of calcification or mineralization are not seen as well with MRI as with CT, MRI is preferred over CT as the staging test (504). This is true for all soft tissue masses. Neurofibrosarcoma and fibrosarcoma also can have intralesional calcification, but synovial cell sarcoma is the most common tumor with intralesional densities.

The characteristic histologic findings are of a biphasic tumor with areas of epithelioid or glandular appearance mixed with areas having spindle cell appearance (457). Usually the spindle cell component predominates (Fig. 14-35). Some synovial cell sarcomas have only the spindle cell component and are called monophasic synovial cell sarcomas. There seem to be no clinically significant differences between the two types. Mitoses are usually present, but the tumor is more difficult to grade histologically than other soft tissue sarcomas. Synovial cell sarcoma is almost always a high-grade soft tissue sarcoma.

Surgical resection is, and has been, the principal treatment of synovial cell sarcoma (499–502,505–510). Adju-

vant chemotherapy is used, but the data regarding the efficacy in synovial cell sarcoma are equivocal at best (500, 509,511,512). In adults and older children with synovial cell sarcoma, as in those with other soft tissue sarcomas, preoperative radiotherapy is used in conjunction with non-radical surgery in an attempt to salvage more extremities. Approximately 15% of synovial sarcomas occur in the feet (498). It was believed that the scarring from irradiation precluded its use in the feet and hands, but with modern techniques adjuvant irradiation and marginal resection can be performed in the majority of sarcomas of the feet or hands with preservation of a functioning extremity. Preoperative irradiation and surgery are recommended for most soft tissue sarcomas of the feet. This has been successful in saving extremities and controlling the disease locally, but the incidence of metastatic disease remains high, at slightly more than 50% (233,455,500,501,505,508,512,513).

Benign Synovial Tumors

There are only two neoplasias that arise from the synovial lining of a joint. Synovial cell sarcoma has been reported to have arisen from within a joint, but this is decidedly rare, and the majority of synovial sarcomas arise within periarticular soft tissues and do not invade joints. Synovial chondromatosis and pigmented villonodular synovitis arise from synovial tissue and are found in joints, bursa, and tendon sheaths. They are the only two neoplasias that commonly occur in the joint.

Synovial Chondromatosis. Synovial chondromatosis is a disorder of the synovial tissues (457). It is most common in the knee but can arise in any joint, tendon sheath, or bursa. Its cause is unknown, and it has no recognized familial pattern of occurrence. The subliminal lining of the joint

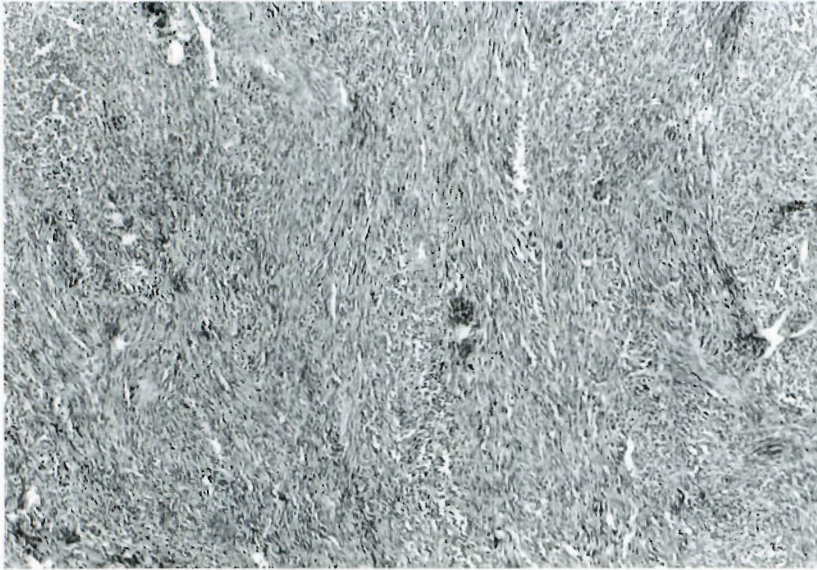


FIGURE 14-35. Low-power view of the spindle component of a synovial cell sarcoma. This lesion is composed of malignant spindle cells with a minimal amount of matrix. At a higher power, mitotic figures are seen. Other areas of this tumor have a glandular appearance, which is the reason that this synovial cell sarcoma is a biphasic tumor. (Original magnification $\times 10$.)

produces small nodules of hyaline-appearing cartilage that are extruded from the synovial lining to become loose bodies within the joint (Fig. 14-36). The cartilage may become necrotic if they become large, or they may undergo enchondral ossification if they have a blood supply. In both cases, they can be seen on plain radiographs. Without the calcification or the ossification, the cartilage is radiolucent and not visible on routine radiographs.

The disease is rare in children, and presents most commonly between the ages of 20 and 50 years. The most common joint involved is the knee, with the elbow next in frequency, and the hip third. The patient usually presents

with mild discomfort, minimal loss of motion, and a joint effusion. There may be a history of locking. The knee may appear normal on examination, but usually there is a moderate-to-large effusion, limited motion, and a boggy synovium. The plain radiographs show nothing abnormal or small intraarticular calcified bodies. The arthrogram is diagnostic with an irregular synovial surface and normal-to-thinned synovial fluid. The MRI scan is usually diagnostic.

Most patients have sufficient symptoms and require removal of loose bodies. Usually synovectomy is performed, but recurrence is common as the synovial lining is regenerated (514). The process seems to have a limited natural

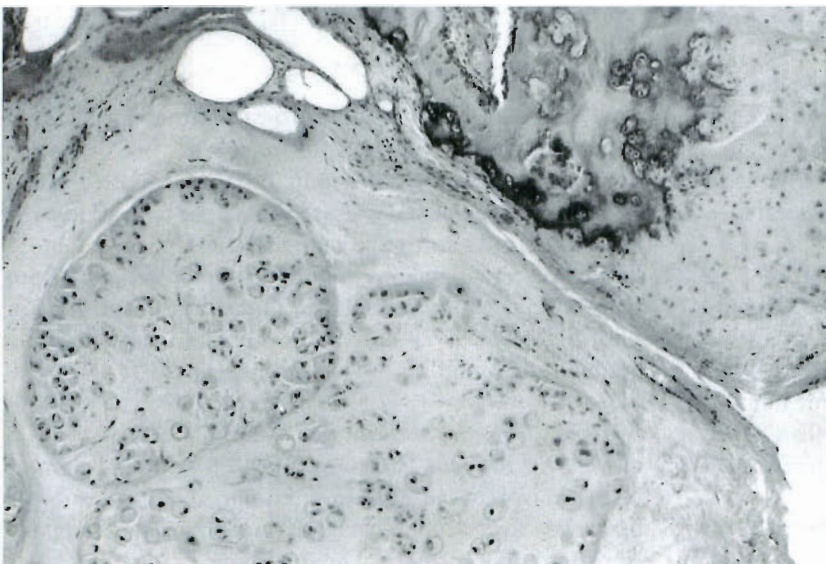


FIGURE 14-36. Low-power view of synovial chondromatosis. The nodules of cartilage are formed within the synovial lining and extruded into the joint to produce loose bodies. The nodules can undergo enchondral ossification if they have a blood supply (top right).

history, and the production of new loose bodies ceases after 1 or 2 years.

Pigmented Villonodular Synovitis. Pigmented villonodular synovitis (PVNS) is a rare disorder of the synovial tissues that may be a true neoplasia, although it has been suggested that it is caused by an infectious process (457,515). The synovial lining becomes proliferative and hypertrophic. It can involve a joint (most commonly the knee) or a tendon sheath. When tendon sheaths are involved, PVNS usually occurs in the hand or the foot. The patient presents with a swollen joint that is usually painless. The synovial tissue is boggy on examination. The joint fluid has old, dark blood in it, and it is common for the diagnosis to be suspected first when the joint is aspirated just before the injection of contrast material for arthrography. The arthrogram or MRI scan is diagnostic, with a thickened shaggy lining and demonstration of dark pigment signal on MRI (516).

The majority of the patients with PVNS are between 20 and 40 years of age (515). The plain radiograph is usually normal except for the soft tissue swelling, but occasionally the proliferative synovial tissues invade the bones adjacent to the joint. This happens most frequently when the hip joint is involved. MRI is the best radiographic method to evaluate the extent of the lesion. Bone invasion can be appreciated, as can the extent of enlargement of the synovial cavity. Synovectomy is the treatment of choice, but there is a high incidence of recurrence (approximately 50%) (515). Intraarticular injection of radioactive materials (dysprosium or yttrium) has been used successfully as a means of controlling recurrent disease. Some patients have minimal symptoms with their recurrence and accept the chronic swelling. As long as the bones remain uninvolved, there is no absolute indication for surgical removal. Patients are followed with clinical examination and plain radiography. For patients with diffuse involvement, recurrence is common (more than 75%), but most have no or little progression or symptoms and do not need treatment.

References

Molecular Biology of Tumors

1. Fletcher JA, Gebhardt MC, Kozakewich HP. Cytogenetic aberrations in osteosarcomas: nonrandom deletions, rings, and double-minute chromosomes. *Cancer Genet Cytogenet* 1994;77:81.
2. Bridge JA, Nelson M, McComb E, et al. Cytogenetic findings in 73 osteosarcoma specimens and a review of the literature. *Cancer Genet Cytogenet* 1997;95:74.
3. Arndt CA, Crist WM. Common musculoskeletal tumors of childhood and adolescence. *N Engl J Med* 1999;341:342.
4. Fletcher JA, Kozakewich HP, Hoffer FA, et al. Diagnostic relevance of clonal cytogenetic aberrations in malignant soft-tissue tumors. *N Engl J Med* 1991;324:436.
5. Barr FG, Chatten J, D'Cruz CM, et al. Molecular assays for chromosomal translocations in the diagnosis of pediatric soft tissue sarcomas. *JAMA* 1995;273:553.
6. Kumar S, Pack S, Kumar D, et al. Detection of EWS-FLI-1 fusion in Ewing's sarcoma/peripheral primitive neuroectodermal tumor by fluorescence in situ hybridization using formalin-fixed paraffin-embedded tissue. *Hum Pathol* 1999;30:324.
7. Dehner LP. Primitive neuroectodermal tumor and Ewing's sarcoma. *Am J Surg Pathol* 1993;17:1.
8. Navarro S, Cavazzana AO, Lombart-Bosch A, et al. Comparison of Ewing's sarcoma of bone and peripheral neuroepithelioma: an immunocytochemical and ultrastructural analysis of two primitive neuroectodermal neoplasms. *Arch Pathol Lab Med* 1994;118:608.
9. Schmidt D, Herrmann C, Jurgens H, et al. Malignant peripheral neuroectodermal tumor and its necessary distinction from Ewing's sarcoma: a report from the Kiel Pediatric Tumor Registry. *Cancer* 1991;68:2251.
10. Terrier P, Henry-Amar M, Triche TJ, et al. Is neuro-ectodermal differentiation of Ewing's sarcoma of bone associated with an unfavourable prognosis? *Eur J Cancer* 1995;31A:307.
11. Hartman KR, Triche TJ, Kinsella TJ, et al. Prognostic value of histopathology in Ewing's sarcoma: long-term follow-up of distal extremity primary tumors. *Cancer* 1991;67:163.
12. West DC, Grier HE, Swallow MM, et al. Detection of circulating tumor cells in patients with Ewing's sarcoma and peripheral primitive neuroectodermal tumor. *J Clin Oncol* 1997;15:583.
13. Gebhardt MC. Molecular biology of sarcomas. *Orthop Clin North Am* 1996;27:421.
14. Hansen MF. Molecular genetic considerations in osteosarcoma. *Clin Orthop* 1991:237.
15. Varmus J, Weinberg R. *Genes and the biology of cancer*. New York: Scientific American Library, 1993:67.
16. Cavenee WK, Koufos A, Hansen MF. Recessive mutant genes predisposing to human cancer. *Mutat Res* 1986;168:3.
17. Hatakeyama M, Herrera RA, Makela T, et al. The cancer cell and the cell cycle clock. *Cold Spring Harbor Symp Quant Biol* 1994;59:1.
18. Hinds PW, Weinberg RA. Tumor suppressor genes. *Curr Opin Genet Dev* 1994;4:135.
19. Weinberg RA. Tumor suppressor genes. *Science* 1991;254:1138.
20. Weinberg RA. The molecular basis of oncogenes and tumor suppressor genes. *Ann NY Acad Sci* 1995;758:331.
21. Dryja TP, Friend S, Weinberg RA. Genetic sequences that predispose to retinoblastoma and osteosarcoma. *Symp Fundam Cancer Res* 1986;39:115.
22. Friend SH, Bernards R, Rogelj S, et al. A human DNA segment with properties of the gene that predisposes to retinoblastoma and osteosarcoma. *Nature* 1986;323:643.
23. Hung J, Anderson R. p53: functions, mutations and sarcomas. *Acta Orthop Scand Suppl* 1997;273:68.
24. Lane DP. Cancer: p53, guardian of the genome. *Nature* 1992;358:15.
25. Miller C, Koeffler HP. P53 mutations in human cancer. *Leukemia* 1993;7(Suppl 2):S18.
26. Link M, Eilber F. Osteosarcoma. In: Pizzo P, Poplack D, eds. *Principles and practice of pediatric oncology*. Philadelphia: JB Lippincott, 1997:889.
27. Ding HF, Fisher DE. Mechanisms of p53-mediated apoptosis. *Crit Rev Oncol* 1998;9:83.
28. Fisher DE. Apoptosis in cancer therapy: crossing the threshold. *Cell* 1994;78:539.
29. Lowe SW, Bodis S, Bardeesy N, et al. Apoptosis and the prognostic significance of p53 mutation. *Cold Spring Harbor Symp Quant Biol* 1994;59:419.
30. Ueda Y, Dockhorn-Dworniczak B, Blasius S, et al. Analysis of mutant P53 protein in osteosarcomas and other malignant and benign lesions of bone. *J Cancer Res Clin Oncol* 1993;119:172.
31. Andreassen A, Oyjord T, Hovig E, et al. p53 abnormalities in different subtypes of human sarcomas. *Cancer Res* 1993;53:468.

32. Lonardo F, Ueda T, Huvos AG, et al. p53 and MDM2 alterations in osteosarcomas: correlation with clinicopathologic features and proliferative rate. *Cancer* 1997;79:1541.
33. Smith-Sorensen B, Gebhardt MC, Kloen P, et al. Screening for TP53 mutations in osteosarcomas using constant denaturant gel electrophoresis (CDGE). *Hum Mutat* 1993;2:274.
34. Diller L, Kassel J, Nelson CE, et al. p53 functions as a cell cycle control protein in osteosarcomas. *Mol Cell Biol* 1990;10:5772.
35. Toguchida J, Yamaguchi T, Ritchie B, et al. Mutation spectrum of the p53 gene in bone and soft tissue sarcomas. *Cancer Res* 1992;52:6194.
36. Miller CW, Aslo A, Won A, et al. Alterations of the p53, Rb and MDM2 genes in osteosarcoma. *J Cancer Res Clin Oncol* 1996;122:559.
37. Miller CW, Aslo A, Tsay C, et al. Frequency and structure of p53 rearrangements in human osteosarcoma. *Cancer Res* 1990;50:7950.
38. Masuda H, Miller C, Koeffler HP, et al. Rearrangement of the p53 gene in human osteogenic sarcomas. *Proc Natl Acad Sci USA* 1987;84:7716.
39. Mulligan LM, Matlashewski GJ, Scoble HJ, et al. Mechanisms of p53 loss in human sarcomas. *Proc Natl Acad Sci USA* 1990;87:5863.
40. Abudu A, Mangham DC, Reynolds GM, et al. Overexpression of p53 protein in primary Ewing's sarcoma of bone: relationship to tumour stage, response and prognosis. *Br J Cancer* 1999;79:1185.
41. Yamaguchi T, Toguchida J, Yamamuro T, et al. Allelotype analysis in osteosarcomas: frequent allele loss on 3q, 13q, 17p, and 18q. *Cancer Res* 1992;52:2419.
42. Chen J, Lin J, Levine AJ. Regulation of transcription functions of the p53 tumor suppressor by the mdm-2 oncogene. *Mol Med* 1995;1:142.
43. Chen J, Wu X, Lin J, et al. mdm-2 inhibits the G1 arrest and apoptosis functions of the p53 tumor suppressor protein. *Mol Cell Biol* 1996;16:2445.
44. Ladanyi M, Cha C, Lewis R, et al. MDM2 gene amplification in metastatic osteosarcoma. *Cancer Res* 1993;53:16.
45. Cordon-Cardo C, Latres E, Drobnjak M, et al. Molecular abnormalities of mdm2 and p53 genes in adult soft tissue sarcomas. *Cancer Res* 1994;54:794.
46. Porter DE, Holden ST, Steel CM, et al. A significant proportion of patients with osteosarcoma may belong to Li-Fraumeni cancer families. *J Bone Joint Surg Br* 1992;74:883.
47. Birch JM, Hartley AL, Blair V, et al. Cancer in the families of children with soft tissue sarcoma. *Cancer* 1990;66:2239.
48. Toguchida J, Yamaguchi T, Dayton SH, et al. Prevalence and spectrum of germline mutations of the p53 gene among patients with sarcoma. *N Engl J Med* 1992;326:1301.
49. Diller L, Sexsmith E, Gottlieb A, et al. Germline p53 mutations are frequently detected in young children with rhabdomyosarcoma. *J Clin Invest* 1995;95:1606.
50. Li FP, Fraumeni JF Jr. Prospective study of a family cancer syndrome. *JAMA* 1982;247:2692.
51. Malkin D. p53 and the Li-Fraumeni syndrome. *Cancer Genet Cytogenet* 1993;66:83.
52. Malkin D, Li FP, Strong LC, et al. Germ line p53 mutations in a familial syndrome of breast cancer, sarcomas, and other neoplasms. *Science* 1990;250:1233.
53. Knudson AG. Antioncogenes and human cancer. *Proc Natl Acad Sci USA* 1993;90:10914.
54. McIntyre JF, Smith-Sorensen B, Friend SH, et al. Germline mutations of the p53 tumor suppressor gene in children with osteosarcoma. *J Clin Oncol* 1994;12:925.
55. Kartner N, Ling V. Multidrug resistance in cancer. *Sci Am* 1989;260:44.
56. Kuttesch JF Jr. Multidrug resistance in pediatric oncology. *Invest New Drugs* 1996;14:55.
57. Chan HS, Grogan TM, Haddad G, et al. P-glycoprotein expression: critical determinant in the response to osteosarcoma chemotherapy. *J Natl Cancer Inst* 1997;89:1706.
58. Chan HS, Grogan TM, DeBoer G, et al. Diagnosis and reversal of multidrug resistance in paediatric cancers. *Eur J Cancer* 1996;32A:1051.
59. Vergier B, Cany L, Bonnet F, et al. Expression of MDR1/P-glycoprotein in human sarcomas. *Br J Cancer* 1993;68:1221.
60. Kusuzaki K, Hirata M, Takeshita H, et al. Relationship between P-glycoprotein positivity, doxorubicin binding ability and histologic response to chemotherapy in osteosarcomas. *Cancer Lett* 1999;138:203.
61. Serra M, Scotlandi K, Manara MC, et al. Analysis of P-glycoprotein expression in osteosarcoma. *Eur J Cancer* 1995;31A:1998.
62. Suto R, Abe Y, Nakamura M, et al. Multidrug resistance mediated by overexpression of P-glycoprotein in human osteosarcoma *in vivo*. *Int J Oncol* 1998;12:287.
63. Scotlandi K, Serra M, Nicoletti G, et al. Multidrug resistance and malignancy in human osteosarcoma. *Cancer Res* 1996;56:2434.
64. Stein U, Walther W, Wunderlich V. Point mutations in the mdrl promoter of human osteosarcomas are associated with *in vitro* responsiveness to multidrug resistance relevant drugs. *Eur J Cancer* 1994;30A:1541.
65. Stein U, Wunderlich V, Haensch W, et al. Expression of the mdrl gene in bone and soft tissue sarcomas of adult patients. *Eur J Cancer* 1993;29A:1979.
66. Baldini N, Scotlandi K, Barbanti-Brodano G, et al. Expression of P-glycoprotein in high-grade osteosarcomas in relation to clinical outcome. *N Engl J Med* 1995;333:1380.

Evaluation

67. Enneking W. *Musculoskeletal tumor surgery*. New York: Churchill Livingstone, 1983.
68. Bacci G, Dallari D, Battistini A, et al. The prognostic value of serum alkaline phosphatase in osteosarcoma of the limbs. *Chir Organi Mov* 1992;77:171.
69. Link MP, Goorin AM, Horowitz M, et al. Adjuvant chemotherapy of high grade osteosarcoma of the extremity. *Clin Orthop Relat Res* 1991;270:8.
70. Luksch R, Sampietro G, Collini P, et al. Prognostic value of clinicopathologic characteristics including neuroectodermal differentiation in osseous Ewing's sarcoma family of tumors in children. *Tumori* 1999;85:101.
71. Glaubiger DL, Makuch RW, Schwarz J. Influence of prognostic factors on survival in Ewing's sarcoma. *Natl Cancer Inst Monogr* 1981;285.
72. Parker BR, Pinckney L, Etcubanas E. Relative efficacy of radiographic and radionuclide bone surveys in the detection of the skeletal lesions of histiocytosis X. *Radiology* 1980;134:377.
73. Siddiqui AR, Tashjian JH, Lazarus K, et al. Nuclear medicine studies in evaluation of skeletal lesions in children with histiocytosis X. *Radiology* 1981;140:787.
74. Woolfenden JM, Pitt MJ, Durie BG, et al. Comparison of bone scintigraphy and radiography in multiple myeloma. *Radiology* 1980;134:723.
75. Kirchner PT, Simon MA. The clinical value of bone and gallium scintigraphy for soft-tissue sarcomas of the extremities. *J Bone Joint Surg Am* 1984;66:319.
76. Simon MA, Kirchner PT. Scintigraphic evaluation of primary bone tumors: comparison of technetium-99m phosphonate and gallium citrate imaging. *J Bone Joint Surg Am* 1980;62:758.
77. Imbriaco M, Yeh SD, Yeung H, et al. Thallium-201 scintigra-

- phy for the evaluation of tumor response to preoperative chemotherapy in patients with osteosarcoma. *Cancer* 1997;80:1507.
78. Ramanna L, Waxman A, Binney G, et al. Thallium-201 scintigraphy in bone sarcoma: comparison with gallium-67 and technetium-MDP in the evaluation of chemotherapeutic response. *J Nucl Med* 1990;31:567.
 79. Leskinen S, Lapela M, Lindholm P, et al. Metabolic imaging by positron emission tomography in oncology. *Ann Med* 1997;29:271.
 80. Jaramillo D, Laor T, Gebhardt MC. Pediatric musculoskeletal neoplasms: evaluation with MR imaging. *Magn Reson Imaging Clin North Am* 1996;4:749.
 81. Russell WO, Cohen J, Enzinger F, et al. A clinical and pathological staging system for soft tissue sarcomas. *Cancer* 1977;40:1562.
 82. Suit HD, Mankin HJ, Wood WC, et al. Treatment of the patient with stage M0 soft tissue sarcoma. *J Clin Oncol* 1988;6:854.
 83. Peabody TD, Gibbs CP Jr, Simon MA. Evaluation and staging of musculoskeletal neoplasms. *J Bone Joint Surg Am* 1998;80:1204.
 84. Enneking WF, Spanier SS, Goodman MA. A system for the surgical staging of musculoskeletal sarcoma. *Clin Orthop Relat Res* 1980;153:106.
 85. Mankin HJ, Lange TA, Spanier S. The hazards of biopsy in patients with malignant primary bone and soft-tissue tumors. *J Bone Joint Surg Am* 1982;64:1121.
 86. Mankin HJ, Mankin CJ, Simon MA. The hazards of the biopsy, revisited. Members of the Musculoskeletal Tumor Society. *J Bone Joint Surg Am* 1996;78:656.
 87. Simon MA, Biermann JS. Biopsy of bone and soft-tissue lesions. *J Bone Joint Surg Am* 1993;75:616.
 88. Akerman M, Rydholm A, Persson BM. Aspiration cytology of soft-tissue tumors: the 10-year experience at an orthopedic oncology center. *Acta Orthop Scand* 1985;56:407.
 89. Ball AB, Fisher C, Pittam M, et al. Diagnosis of soft tissue tumours by Tru-Cut biopsy. *Br J Surg* 1990;77:756.
 90. Ghelman B, Lospinuso MF, Levine DB, et al. Percutaneous computed-tomography-guided biopsy of the thoracic and lumbar spine. *Spine* 1991;16:736.
 91. Kissin MW, Fisher C, Carter RL, et al. Value of Tru-Cut biopsy in the diagnosis of soft tissue tumours. *Br J Surg* 1986;73:742.
- ### Specific Bone Tumors
92. Jaffe H. "Osteoid osteoma": a benign osteoblastic tumor composed of osteoid and atypical bone. *Arch Surg* 1935;31:709.
 93. Unni K. *Dablin's bone tumors: general aspects and data on 11,087 cases*. Philadelphia: Lippincott-Raven, 1996:143.
 94. Keim HA, Reina EG. Osteoid-osteoma as a cause of scoliosis. *J Bone Joint Surg Am* 1975;57:159.
 95. Freiburger R. Osteoid osteoma of the spine: a cause of backache and scoliosis in children. *Radiology* 1960;75:232.
 96. Smith FW, Gilday DL. Scintigraphic appearances of osteoid osteoma. *Radiology* 1980;137:191.
 97. Herrlin K, Ekelund L, Lovdahl R, et al. Computed tomography in suspected osteoid osteomas of tubular bones. *Skeletal Radiol* 1982;9:92.
 98. Golding J. The natural history of osteoma with a report of twenty cases. *J Bone Joint Surg Br* 1954;36:218.
 99. Kneisl JS, Simon MA. Medical management compared with operative treatment for osteoid-osteoma. *J Bone Joint Surg Am* 1992;74:179.
 100. Norman A. Persistence or recurrence of pain: a sign of surgical failure in osteoid-osteoma. *Clin Orthop* 1978:263.
 101. Ayala AG, Murray JA, Erling MA, et al. Osteoid-osteoma: intraoperative tetracycline-fluorescence demonstration of the nidus. *J Bone Joint Surg Am* 1986;68:747.
 102. Ghelman B, Thompson FM, Arnold WD. Intraoperative radioactive localization of an osteoid-osteoma: case report. *J Bone Joint Surg Am* 1981;63:826.
 103. Gore DR, Mueller HA. Osteoid-osteoma of the spine with localization aided by 99 mTc-polyphosphate bone scan: case report. *Clin Orthop* 1975:132.
 104. Rinsky LA, Goris M, Bleck EE, et al. Intraoperative skeletal scintigraphy for localization of osteoid-osteoma in the spine: case report. *J Bone Joint Surg Am* 1980;62:143.
 105. Tillotson CL, Rosenberg AE, Rosenthal DI. Controlled thermal injury of bone: report of a percutaneous technique using radio-frequency electrode and generator. *Invest Radiol* 1989;24:888.
 106. Rosenthal DI, Alexander A, Rosenberg AE, et al. Ablation of osteoid osteomas with a percutaneously placed electrode: a new procedure. *Radiology* 1992;183:29.
 107. Rosenthal DI, Hornicek FJ, Wolfe MW, et al. Percutaneous radiofrequency coagulation of osteoid osteoma compared with operative treatment. *J Bone Joint Surg Am* 1998;80:815.
 108. Voto SJ, Cook AJ, Weiner DS, et al. Treatment of osteoid osteoma by computed tomography guided excision in the pediatric patient. *J Pediatr Orthop* 1990;10:510.
 109. Schajowicz F, Lemos C. Malignant osteoblastoma. *J Bone Joint Surg Br* 1976;58:202.
 110. Picci P, Sangiorgi L, Rougraff BT, et al. Relationship of chemotherapy-induced necrosis and surgical margins to local recurrence in osteosarcoma. *J Clin Oncol* 1994;12:2699.
 111. Picci P, Bohling T, Bacci G, et al. Chemotherapy-induced tumor necrosis as a prognostic factor in localized Ewing's sarcoma of the extremities. *J Clin Oncol* 1997;15:1553.
 112. Souhami RL, Craft AW, Van der Eijken JW, et al. Randomized trial of two regimens of chemotherapy in operable osteosarcoma: a study of the European Osteosarcoma Intergroup. *Lancet* 1997;350:911.
 113. Bramwell VH. The role of chemotherapy in the management of non-metastatic operable extremity osteosarcoma. *Semin Oncol* 1997;24:561.
 114. Provisor AJ, Ettinger LJ, Nachman JB, et al. Treatment of non-metastatic osteosarcoma of the extremity with preoperative and postoperative chemotherapy: a report from the Children's Cancer Group. *J Clin Oncol* 1997;15:76.
 115. Bacci G, Ferrari S, Mercuri M, et al. Neoadjuvant chemotherapy for extremity osteosarcoma: preliminary results of the Rizzoli's 4th study. *Acta Oncol* 1998;37:41.
 116. Bacci G, Ferrari S, Donati D, et al. Neoadjuvant chemotherapy for osteosarcoma of the extremity in patients in the fourth and fifth decade of life. *Oncol Rep* 1998;5:1259.
 117. Link MP, Goorin AM, Horowitz M, et al. Adjuvant chemotherapy of high-grade osteosarcoma of the extremity: updated results of the Multi-Institutional Osteosarcoma Study. *Clin Orthop* 1991:8.
 118. Link MP, Goorin AM, Miser AW, et al. The effect of adjuvant chemotherapy on relapse-free survival in patients with osteosarcoma of the extremity. *N Engl J Med* 1986;314:1600.
 119. Uchida A, Myoui A, Araki N, et al. Neoadjuvant chemotherapy for pediatric osteosarcoma patients. *Cancer* 1997;79:411.
 120. Eilber F, Giuliano A, Eckardt J, et al. Adjuvant chemotherapy for osteosarcoma: a randomized prospective trial. *J Clin Oncol* 1987;5:21.
 121. Goorin AM, Andersen JW. Experience with multiagent chemotherapy for osteosarcoma: improved outcome. *Clin Orthop* 1991:22.
 122. Meyer WH, Malawer MM. Osteosarcoma: clinical features and evolving surgical and chemotherapeutic strategies. *Pediatr Clin North Am* 1991;38:317.

123. Bacci G, Ferrari S, Mercuri M, et al. Predictive factors for local recurrence in osteosarcoma: 540 patients with extremity tumors followed for minimum 2.5 years after neoadjuvant chemotherapy. *Acta Orthop Scand* 1998;69:230.
124. Gherlinzoni F, Picci P, Bacci G, et al. Limb sparing versus amputation in osteosarcoma: correlation between local control, surgical margins and tumor necrosis. Istituto Rizzoli experience. *Ann Oncol* 1992;3(Suppl 2):S23.
125. Rougraff BT, Simon MA, Kneisl JS, et al. Limb salvage compared with amputation for osteosarcoma of the distal end of the femur: a long-term oncological, functional, and quality-of-life study. *J Bone Joint Surg Am* 1994;76:649.
126. Springfield DS, Schmidt R, Graham-Pole J, et al. Surgical treatment for osteosarcoma. *J Bone Joint Surg Am* 1988;70:1124.
127. Scully SP, Temple HT, O'Keefe RJ, et al. The surgical treatment of patients with osteosarcoma who sustain a pathologic fracture. *Clin Orthop* 1996:227.
128. Jaffe N, Spears R, Eftekhari F. Pathological fracture in osteosarcoma: impact of chemotherapy on primary tumor and survival. *Cancer* 1987;59:701.
129. Abudu A, Sferopoulos NK, Tillman RM, et al. The surgical treatment and outcome of pathological fractures in localised osteosarcoma. *J Bone Joint Surg Br* 1996;78:694.
130. Pochanugool L, Subhadharaphandou T, Dhanachai M, et al. Prognostic factors among 130 patients with osteosarcoma. *Clin Orthop* 1997:206.
131. Finn HA, Simon MA. Limb-salvage surgery in the treatment of osteosarcoma in skeletally immature individuals. *Clin Orthop* 1991:108.
132. Gonzalez-Herranz P, Burgos-Flores J, Ocere-Guzman JG, et al. The management of limb-length discrepancies in children after treatment of osteosarcoma and Ewing's sarcoma. *J Pediatr Orthop* 1995;15:561.
133. Ward WG, Yang RS, Eckardt JJ. Endoprosthetic bone reconstruction following malignant tumor resection in skeletally immature patients. *Orthop Clin North Am* 1996;27:493.
134. Moseley CF. Management of leg-length disparities after tumor surgery (Editorial). *J Pediatr Orthop* 1995;15:559.
135. Rao BN, Champion JE, Pratt CB, et al. Limb salvage procedures for children with osteosarcoma: an alternative to amputation. *J Pediatr Surg* 1983;18:901.
136. Hanlon M, Krajchich JJ. Rotationplasty in skeletally immature patients: long-term followup results. *Clin Orthop* 1999:75.
137. Merkel KD, Gebhardt M, Springfield DS. Rotationplasty as a reconstructive operation after tumor resection. *Clin Orthop* 1991:231.
138. Kotz R. Rotationplasty. *Semin Surg Oncol* 1997;13:34.
139. Steenhoff JR, Daanen HA, Taminiau AH. Functional analysis of patients who have had a modified Van Nes rotationplasty. *J Bone Joint Surg Am* 1993;75:1451.
140. Gortsauner-Wolf F, Kotz R, Knahr K, et al. Rotationplasty for limb salvage in the treatment of malignant tumors at the knee: a follow-up study of seventy patients. *J Bone Joint Surg Am* 1991;73:1365.
141. Winkelmann WW. Hip rotationplasty for malignant tumors of the proximal part of the femur. *J Bone Joint Surg Am* 1986;68:362.
142. Murray MP, Jacobs PA, Gore DR, et al. Functional performance after tibial rotationplasty. *J Bone Joint Surg Am* 1985;67:392.
143. Kotz R, Salzer M. Rotation-plasty for childhood osteosarcoma of the distal part of the femur. *J Bone Joint Surg Am* 1982;64:959.
144. Catani F, Capanna R, Benedetti MG, et al. Gait analysis in patients after Van Nes rotationplasty. *Clin Orthop* 1993:270.
145. Cammisia FP Jr, Glasser DB, Otis JC, et al. The Van Nes tibial rotationplasty: a functionally viable reconstructive procedure in children who have a tumor of the distal end of the femur. *J Bone Joint Surg Am* 1990;72:1541.
146. Heeg M, Torode IP. Rotationplasty of the lower limb for childhood osteosarcoma of the femur. *Aust NZ J Surg* 1998;68:643.
147. Badhwar R, Agarwal M. Rotationplasty as a limb salvage procedure for malignant bone tumours. *Int Orthop* 1998;22:122.
148. Merkel KD, Reinus WR, Miller G, et al. Modification of the Van Nes rotationplasty: report of a case. *Clin Orthop* 1997:195.
149. Winkelmann WW. Rotationplasty. *Orthop Clin North Am* 1996;27:503.
150. Kawai A, Hamada M, Sugihara S, et al. Rotationplasty for patients with osteosarcoma around the knee joint. *Acta Med Okayama* 1995;49:221.
151. Capanna R, Del Ben M, Campanacci DA, et al. Rotationplasty in segmental resections of the femur. *Chir Organi Mov* 1992;77:135.
152. van der Windt DA, Pieterse I, van der Eijken JW, et al. Energy expenditure during walking in subjects with tibial rotationplasty, above-knee amputation, or hip disarticulation. *Arch Phys Med Rehabil* 1992;73:1174.
153. Krajchich JJ. Modified Van Nes rotationplasty in the treatment of malignant neoplasms in the lower extremities of children. *Clin Orthop* 1991:74.
154. de Bari A, Krajchich JJ, Langer F, et al. Modified Van Nes rotationplasty for osteosarcoma of the proximal tibia in children. *J Bone Joint Surg Br* 1990;72:1065.
155. Krajchich JJ, Carroll NC. Van Nes rotationplasty with segmental limb resection. *Clin Orthop* 1990:7.
156. Schwartz HS, Frassica FJ, Sim FH. Rotationplasty: an option for limb salvage in childhood osteosarcoma. *Orthopedics* 1989;12:257.
157. Kenan S, Bloom N, Lewis MM. Limb-sparing surgery in skeletally immature patients with osteosarcoma. *Clin Orthop Relat Res* 1991;270:223.
158. Unwin PS, Walker PS. Extendible endoprosthesis for the skeletally immature. *Clin Orthop Relat Res* 1966;322:179.
159. Kenan S, Lewis MM. Limb salvage in pediatric surgery: the use of the expandable prosthesis. *Orthop Clin North Am* 1991;22:121.
160. Cool WP, Grimer RJ, Carter SR, et al. Longitudinal growth following a growing endoprosthesis replacement of the distal femur in the skeletally immature. In: *Eighth International Symposium on Limb Salvage (ISOLS)*, Florence, Italy, 1995.
161. Schindler OS, Cannon SR, Briggs TW, et al. Use of extendable total femoral replacements in children with malignant bone tumors. *Clin Orthop* 1998:157.
162. Schiller C, Windhager R, Fellingner EJ, et al. Extendable tumour endoprostheses for the leg in children. *J Bone Joint Surg Br* 1995;77:608.
163. Schindler OS, Cannon SR, Briggs TW, et al. Stanmore custom-made extendible distal femoral replacements: clinical experience in children with primary malignant bone tumours. *J Bone Joint Surg Br* 1997;79:927; erratum 1998;80:562.
164. Verkerke GJ, Schraffordt Koops H, Veth RP, et al. First clinical experience with a noninvasively extendable endoprosthesis: a limb-saving procedure in children suffering from a malignant bone tumor. *Artif Organs* 1997;21:413.
165. Eckardt JJ, Safran MR, Eilber FR, et al. Expandable endoprosthetic reconstruction of the skeletally immature after malignant bone tumor resection. *Clin Orthop* 1993:188.
166. Geschickter C, Copeland M. Parosteal osteoma of bone: a new entity. *Ann Surg* 1951;133:790.
167. Campanacci M, Picci P, Gherlinzoni F, et al. Parosteal osteosarcoma. *J Bone Joint Surg Br* 1984;66:313.

168. Okada K, Frassica FJ, Sim FH, et al. Parosteal osteosarcoma: a clinicopathological study. *J Bone Joint Surg Am* 1994;76:366.
169. Schajowicz F, McGuire MH, Santini Araujo E, et al. Osteosarcomas arising on the surfaces of long bones. *J Bone Joint Surg Am* 1988;70:555.
170. Ahuja SC, Villacin AB, Smith J, et al. Juxtacortical (parosteal) osteogenic sarcoma: histological grading and prognosis. *J Bone Joint Surg Am* 1977;59:632.
171. Unni KK, Dahlin DC, Beabout JW, et al. Parosteal osteogenic sarcoma. *Cancer* 1976;37:2644.
172. Hudson TM, Springfield DS, Benjamin M, et al. Computed tomography of parosteal osteosarcoma. *Am J Roentgenol* 1985;144:961.
173. Bertoni F, Present D, Hudson T, et al. The meaning of radiolucencies in parosteal osteosarcoma. *J Bone Joint Surg Am* 1985;67:901.
174. Wold LE, Unni KK, Beabout JW, et al. Dedifferentiated parosteal osteosarcoma. *J Bone Joint Surg Am* 1984;66:53.
175. Shuhaibar H, Friedman L. Dedifferentiated parosteal osteosarcoma with high-grade osteoclast-rich osteogenic sarcoma at presentation. *Skeletal Radiol* 1998;27:574.
176. Wold LE, Unni KK, Beabout JW, et al. High-grade surface osteosarcomas. *Am J Surg Pathol* 1984;8:181.
177. Picci P, Campanacci M, Bacci G, et al. Medullary involvement in parosteal osteosarcoma: a case report. *J Bone Joint Surg Am* 1987;69:131.
178. Enneking WF, Springfield D, Gross M. The surgical treatment of parosteal osteosarcoma in long bones. *J Bone Joint Surg Am* 1985;67:125.
179. Sheth DS, Yasko AW, Raymond AK, et al. Conventional and dedifferentiated parosteal osteosarcoma: diagnosis, treatment, and outcome. *Cancer* 1996;78:2136.
180. Hall RB, Robinson LH, Malawar MM, et al. Periosteal osteosarcoma. *Cancer* 1985;55:165.
181. Ritts GD, Pritchard DJ, Unni KK, et al. Periosteal osteosarcoma. *Clin Orthop* 1987:299.
182. deSantos LA, Murray JA, Finklestein JB, et al. The radiographic spectrum of periosteal osteosarcoma. *Radiology* 1978;127:123.
183. Unni KK, Dahlin DC, Beabout JW. Periosteal osteogenic sarcoma. *Cancer* 1976;37:2476.
184. Simon MA, Bos GD. Epiphyseal extension of metaphyseal osteosarcoma in skeletally immature individuals. *J Bone Joint Surg Am* 1980;62:195.
185. Enneking WF, Kagan AD. Transepiphyseal extension of osteosarcoma: incidence, mechanism, and implications. *Cancer* 1978;41:1526.
186. O'Neal ML, Bahner R, Ganey TM, et al. Osseous overgrowth after amputation in adolescents and children. *J Pediatr Orthop* 1996;16:78.
187. Benevnia J, Makley JT, Leeson MC, et al. Primary epiphyseal transplants and bone overgrowth in childhood amputations. *J Pediatr Orthop* 1992;12:746.
188. Dick HM, Malinin TI, Mnaymneh WA. Massive allograft implantation following radical resection of high-grade tumors requiring adjuvant chemotherapy treatment. *Clin Orthop* 1985:88.
189. Mnaymneh W, Malinin TI, Makley JT, et al. Massive osteoarticular allografts in the reconstruction of extremities following resection of tumors not requiring chemotherapy and radiation. *Clin Orthop* 1985:76.
190. Dick HM, Strauch RJ. Infection of massive bone allografts. *Clin Orthop* 1994:46.
191. Gebhardt MC, Flugstad DI, Springfield DS, et al. The use of bone allografts for limb salvage in high-grade extremity osteosarcoma. *Clin Orthop* 1991:181.
192. Alman BA, De Bari A, Krajchich JI. Massive allografts in the treatment of osteosarcoma and Ewing sarcoma in children and adolescents. *J Bone Joint Surg Am* 1995;77:54.
193. Hornicek FJ Jr, Mnaymneh W, Lackman RD, et al. Limb salvage with osteoarticular allografts after resection of proximal tibia bone tumors. *Clin Orthop* 1998:179.
194. Gitelis S, Piasecki P. Allograft prosthetic composite arthroplasty for osteosarcoma and other aggressive bone tumors. *Clin Orthop Relat Res* 1991;270:197.
195. Mankin HJ, Gebhardt MC, Jennings LC, et al. Long-term results of allograft replacement in the management of bone tumors. *Clin Orthop* 1996:86.
196. Enneking WF, Dunham W, Gebhardt MC, et al. A system for the functional evaluation of reconstructive procedures after surgical treatment of tumors of the musculoskeletal system. *Clin Orthop* 1993:241.
197. Berrey BH Jr, Lord CF, Gebhardt MC, et al. Fractures of allografts: frequency, treatment, and end-results. *J Bone Joint Surg Am* 1990;72:825.
198. Lord CF, Gebhardt MC, Tomford WW, et al. Infection in bone allografts: incidence, nature, and treatment. *J Bone Joint Surg Am* 1988;70:369.
199. Freedman EL, Eckardt JJ. A modular endoprosthesis system for tumor and non-tumor reconstruction: preliminary experience. *Orthopedics* 1997;20:27.
200. Ortiz-Cruz E, Gebhardt MC, Jennings LC, et al. The results of transplantation of intercalary allografts after resection of tumors: a long-term follow-up study. *J Bone Joint Surg Am* 1997;79:97.
201. Manfrini M, Gasbarrini A, Malaguti C, et al. Intraepiphyseal resection of the proximal tibia and its impact on lower limb growth. *Clin Orthop* 1999:111.
202. Innocenti M, Ceruso M, Manfrini M, et al. Free vascularized growth-plate transfer after bone tumor resection in children. *J Reconstr Microsurg* 1998;14:137.
203. Capanna R, Manfrini M, Ceruso M, et al. A new reconstruction for metadiaphyseal resections: a combined graft (allograft shell plus vascularized fibula). Preliminary results. In: Brown KLB, ed. *Complications of limb salvage: prevention, management and outcome*. Montreal: International Symposium of Limb Salvage, 1991:319.
204. Capanna R, van Horn JR, Biagini R, et al. The Tikhoff-Linberg procedure for bone tumors of the proximal humerus: the classical extensive technique versus a modified transglenoid resection. *Arch Orthop Trauma Surg* 1990;109:63.
205. Malawar MM. Tumors of the shoulder girdle: technique of resection and description of a surgical classification. *Orthop Clin North Am* 1991;22:7.
206. Cheng EY, Gebhardt MC. Allograft reconstructions of the shoulder after bone tumor resections. *Orthop Clin North Am* 1991;22:37.
207. Voggenteiter G, Assenmacher S, Schmit-Neuerburg KP. Tikhoff-Linberg procedure for bone and soft tissue tumors of the shoulder girdle. *Arch Surg* 1999;134:252.
208. O'Connor MI, Sim FH, Chao EY. Limb salvage for neoplasms of the shoulder girdle: intermediate reconstructive and functional results. *J Bone Joint Surg Am* 1996;78:1872.
209. Gebhardt MC, Roth YF, Mankin HJ. Osteoarticular allografts for reconstruction in the proximal part of the humerus after excision of a musculoskeletal tumor. *J Bone Joint Surg Am* 1990;72:334.
210. Jensen KL, Johnston JO. Proximal humeral reconstruction after excision of a primary sarcoma. *Clin Orthop* 1995:164.
211. Scarborough MT, Helmsstedter CS. Arthrodesis after resection of bone tumors. *Semin Surg Oncol* 1997;13:25.
212. Kumar VP, Satku SK, Mitra AK, et al. Function following limb

- salvage for primary tumors of the shoulder girdle: 10 patients followed 4 (1–11) years. *Acta Orthop Scand* 1994;65:55.
213. Malawer MM, Sugarbaker PH, Lampert M, et al. The Tikhoff-Linberg procedure: report of ten patients and presentation of a modified technique for tumors of the proximal humerus. *Surgery* 1985;97:518.
 214. Jacobs PA. Limb salvage and rotationplasty for osteosarcoma in children. *Clin Orthop* 1984;217.
 215. McClenaghan BA, Krajchich JL, Pirone AM, et al. Comparative assessment of gait after limb-salvage procedures. *J Bone Joint Surg Am* 1989;71:1178.
 216. Windhager R, Millesi H, Kotz R. Resection-replantation for primary malignant tumours of the arm: an alternative to fore-quarter amputation. *J Bone Joint Surg Br* 1995;77:176.
- ### Chemotherapy for Musculoskeletal Tumors
217. Balis F, Holcenberg J, Poplack D. General principles of chemotherapy. In: Pizzo P, Poplack D, eds. *Principles and practice of pediatric oncology*. Philadelphia: JB Lippincott, 1997:215.
 218. Sutow WW, Sullivan MP, Fernbach DJ, et al. Adjuvant chemotherapy in primary treatment of osteogenic sarcoma: a Southwestern Oncology Group study. *Cancer* 1975;36:1598.
 219. Jaffe N, Frei EL, Traggis D, et al. Adjuvant methotrexate and citrovorum-factor treatment of osteogenic sarcoma. *N Engl J Med* 1974;291:994.
 220. Rosenberg SA, Cabner BA, Young RC, et al. Treatment of osteogenic sarcoma. I. Effect of adjuvant high-dose methotrexate after amputation. *Cancer Treat Rep* 1979;63:739.
 221. Rosen G, Murphy ML, Huvos AG, et al. Chemotherapy, en bloc resection, and prosthetic bone replacement in the treatment of osteogenic sarcoma. *Cancer* 1976;37:1.
 222. Tepper J, Glaubiger D, Lichter A, et al. Local control of Ewing's sarcoma of bone with radiotherapy and combination chemotherapy. *Cancer* 1980;46:1969.
 223. Graham-Pole J. Ewing sarcoma: treatment with high dose radiation and adjuvant chemotherapy. *Med Pediatr Oncol* 1979;7:1.
 224. Tefft M, Razek A, Perez C, et al. Local control and survival related to radiation dose and volume and to chemotherapy in non-metastatic Ewing's sarcoma of pelvic bones. *Int J Radiat Oncol Biol Phys* 1978;4:367.
 225. Jaffe N, Paed D, Traggis D, et al. Improved outlook for Ewing's sarcoma with combination chemotherapy (vincristine, actinomycin D and cyclophosphamide) and radiation therapy. *Cancer* 1976;38:1925.
 226. Maurer HM, Moon T, Donaldson M, et al. The Intergroup Rhabdomyosarcoma Study: a preliminary report. *Cancer* 1977;40:2015.
 227. Hays DM, Soule EH, Lawrence W Jr, et al. Extremity lesions in the Intergroup Rhabdomyosarcoma Study (IRS-I): a preliminary report. *Cancer* 1982;49:1.
 228. Hays DM, Sutow WW, Lawrence W Jr, et al. Rhabdomyosarcoma: surgical therapy in extremity lesions in children. *Orthop Clin North Am* 1977;8:883.
 229. Frei ED, Jaffe N, Gero M, et al. Adjuvant chemotherapy of osteogenic sarcoma: progress and perspectives. *J Natl Cancer Inst* 1978;60:3.
 230. Lawrence W Jr, Hays DM, Heyn R, et al. Surgical lessons from the Intergroup Rhabdomyosarcoma Study (IRS) pertaining to extremity tumors. *World J Surg* 1988;12:676.
 231. Eriksson AI, Schiller A, Mankin HJ. The management of chondrosarcoma of bone. *Clin Orthop* 1980:44.
 232. McCoy DM, Levine EA, Ferrer K, et al. Pediatric soft tissue sarcomas of nonmyogenic origin. *J Surg Oncol* 1993;53:149.
 233. Miser J, Triche T, Kinsella T, et al. Other soft tissue sarcomas of childhood. In: Pizzo P, Poplack D, eds. *Principles and practice of pediatric oncology*. Philadelphia: JB Lippincott, 1997:865.
 234. Donaldson SS. The value of adjuvant chemotherapy in the management of sarcomas in children. *Cancer* 1985;55:2184.
 235. Winkler K, Beron G, Delling G, et al. Neoadjuvant chemotherapy of osteosarcoma: results of a randomized cooperative trial (COSS-82) with salvage chemotherapy based on histological tumor response. *J Clin Oncol* 1988;6:329.
 236. Pignatti G, Bacci G, Picci P, et al. Telangiectatic osteogenic sarcoma of the extremities: results in 17 patients treated with neoadjuvant chemotherapy. *Clin Orthop Relat Res* 1991;270:99.
 237. Winkler K, Bieling P, Bielack S, et al. Local control and survival from the Cooperative Osteosarcoma Study Group studies of the German Society of Pediatric Oncology and the Vienna Bone Tumor Registry. *Clin Orthop Relat Res* 1991;270:79.
 238. Bacci G, Picci P, Ruggieri P, et al. Neoadjuvant chemotherapy for the treatment of osteosarcoma of the limbs: preliminary results in 100 patients treated preoperatively with high doses of methotrexate i.v. followed by cisplatin (i.a.) and adriamycin. *Chir Organi Mov* 1991;76:1.
 239. Aparicio J, Munarriz B, Pastor M, et al. Long-term follow-up and prognostic factors in Ewing's sarcoma: a multivariate analysis of 116 patients from a single institution. *Oncology* 1998;55:20.
 240. Ferrari S, Mercuri M, Rosito P, et al. Ifosfamide and actinomycin-D, added in the induction phase to vincristine, cyclophosphamide and doxorubicin, improve histologic response and prognosis in patients with non metastatic Ewing's sarcoma of the extremity. *J Chemother* 1998;10:484.
 241. Bacci G, Picci P, Mercuri M, et al. Predictive factors of histological response to primary chemotherapy in Ewing's sarcoma. *Acta Oncol* 1998;37:671.
 242. Bacci G, Picci P, Ferrari S, et al. Primary chemotherapy and delayed surgery for nonmetastatic osteosarcoma of the extremities: results in 164 patients preoperatively treated with high doses of methotrexate followed by cisplatin and doxorubicin. *Cancer* 1993;72:3227.
 243. Bacci G, Picci P, Pignatti G, et al. Neoadjuvant chemotherapy for nonmetastatic osteosarcoma of the extremities. *Clin Orthop* 1991:87.
 244. Juergens H, Kosloff C, Nirenberg A, et al. Prognostic factors in the response of primary osteogenic sarcoma to preoperative chemotherapy (high-dose methotrexate with citrovorum factor). *Natl Cancer Inst Monogr* 1981:221.
 245. Bacci G, Picci P, Ferrari S, et al. Neoadjuvant chemotherapy for Ewing's sarcoma of bone: no benefit observed after adding ifosfamide and etoposide to vincristine, actinomycin, cyclophosphamide, and doxorubicin in the maintenance phase. Results of two sequential studies. *Cancer* 1998;82:1174.
 246. Wexler L, Helman L. Rhabdomyosarcoma and the undifferentiated sarcomas. In: Pizzo PA, Poplack D, eds. *Principles and practice of pediatric oncology*. Philadelphia: JB Lippincott, 1997:799.
 247. Horowitz M, Malawer M, Woo S, et al. Ewing's sarcoma family of tumors: Ewing's sarcoma of bone and soft tissue and the peripheral primitive neuroectodermal tumors. In: Pizzo P, Poplack D, eds. *Principles and practice of pediatric oncology*. Philadelphia: JB Lippincott, 1997:831.
 248. Winkler K, Beron G, Kotz R, et al. Neoadjuvant chemotherapy for osteogenic sarcoma: results of a cooperative German/Austrian study. *J Clin Oncol* 1984;2:617.
- ### Cartilaginous Tumors
249. Campanacci M. *Bone and soft tissue tumors*. New York: Springer-Verlag, 1990:433.

250. Schajowicz F. *Tumors and tumorlike lesions of bone*. Berlin: Springer-Verlag, 1994:71.
251. Milgram JW. The origins of osteochondromas and enchondromas: a histopathologic study. *Clin Orthop* 1983;264.
252. Noble J, Lamb DW. Enchondromatosis of bones of the hand: a review of 40 cases. *Hand* 1974;6:275.
253. Giudici MA, Moser RP Jr, Kransdorf MJ. Cartilaginous bone tumors. *Radiol Clin North Am* 1993;31:237.
254. van der Woude HJ, Bloem JL, Pope TL Jr. Magnetic resonance imaging of the musculoskeletal system. Part 9. Primary tumors. *Clin Orthop* 1998;272.
255. Geirnaerdt MJ, Bloem JL, Eulderink F, et al. Cartilaginous tumors: correlation of gadolinium-enhanced MR imaging and histopathologic findings. *Radiology* 1993;186:813.
256. Golfieri R, Baddeley H, Pringle JS, et al. Primary bone tumors: MR morphologic appearance correlated with pathologic examinations. *Acta Radiol* 1991;32:290.
257. Masciocchi C, Sparvoli L, Barile A. Diagnostic imaging of malignant cartilage tumors. *Eur J Radiol* 1998;27(Suppl 1):S86.
258. Bohndorf K, Reiser M, Lochner B, et al. Magnetic resonance imaging of primary tumours and tumour-like lesions of bone. *Skeletal Radiol* 1986;15:511.
259. Ollier M. Exostoses osteogeniques multiples. *Lyon Med* 1898;88:484.
260. Cowan WK. Malignant change and multiple metastases in Ollier's disease. *J Clin Pathol* 1965;18:650.
261. Schwartz HS, Zimmerman NB, Simon MA, et al. The malignant potential of enchondromatosis. *J Bone Joint Surg Am* 1987;69:269.
262. Cannon SR, Sweetnam DR. Multiple chondrosarcomas in dyschondroplasia (Ollier's disease). *Cancer* 1985;55:836.
263. Bean W. Dyschondroplasia and hemangiomata (Maffucci's syndrome). *Arch Intern Med* 1955;95:767.
264. Lewis RJ, Kercham AS. Maffucci's syndrome: functional and neoplastic significance. Case report and review of the literature. *J Bone Joint Surg Am* 1973;55:1465.
265. Norman A, Sissons HA. Radiographic hallmarks of peripheral chondrosarcoma. *Radiology* 1984;151:589.
266. Garrison RC, Unni KK, McLeod RA, et al. Chondrosarcoma arising in osteochondroma. *Cancer* 1982;49:1890.
267. Canella P, Gardini F, Boriani S. Exostosis: development, evolution and relationship to malignant degeneration. *Ital J Orthop Traumatol* 1981;7:293.
268. Lee JK, Yao L, Wirth CR. MR imaging of solitary osteochondromas: report of eight cases. *Am J Roentgenol* 1987;149:557.
269. Lange RH, Lange TA, Rao BK. Correlative radiographic, scintigraphic, and histological evaluation of exostoses. *J Bone Joint Surg Am* 1984;66:1454.
270. Solomon L. Hereditary multiple exostosis. *J Bone Joint Surg Am* 1963;45:292.
271. Jaffe H. Hereditary multiple exostosis. *Arch Pathol* 1943;36:335.
272. Shapiro F, Simon S, Glimcher MJ. Hereditary multiple exostoses: anthropometric, roentgenographic, and clinical aspects. *J Bone Joint Surg Am* 1979;61:815.
273. Schmale GA, Conrad EU 3rd, Raskind WH. The natural history of hereditary multiple exostoses. *J Bone Joint Surg Am* 1994;76:986.
274. Peterson HA. Multiple hereditary osteochondromata. *Clin Orthop* 1989;222.
275. Merchan EC, Sanchez-Herrera S, Gonzalez JM. Secondary chondrosarcoma: four cases and review of the literature. *Acta Orthop Belg* 1993;59:76.
276. Saunders C, Szabo RM, Mora S. Chondrosarcoma of the hand arising in a young patient with multiple hereditary exostoses. *J Hand Surg Br* 1997;22:237.
277. Du YK, Shih HN, Wang JM, et al. Dedifferentiated chondrosarcoma arising from osteochondromatosis: a case report. *Chang Keng I Hsueh* 1991;14:130.
278. Solomon L. Chondrosarcoma in hereditary multiple exostosis. *S Afr Med J* 1974;48:671.
279. Wuisman PI, Jutte PC, Ozaki T. Secondary chondrosarcoma in osteochondromas: medullary extension in 15 of 45 cases. *Acta Orthop Scand* 1997;68:396.
280. Kilpatrick SE, Pike EJ, Ward WG, et al. Dedifferentiated chondrosarcoma in patients with multiple osteochondromatosis: report of a case and review of the literature. *Skeletal Radiol* 1997;26:370.
281. Sharma SR, Chandra P, Gadekar NG. Sarcomatous change in diaphyseal aclasis (report of two cases). *Indian J Cancer* 1967;4:95.
282. Aprin H, Riseborough EJ, Hall JE. Chondrosarcoma in children and adolescents. *Clin Orthop* 1982;226.
283. Young CL, Sim FH, Unni KK, et al. Chondrosarcoma of bone in children. *Cancer* 1990;66:1641.
284. Hudson T. *Radiographic-pathologic correlation of musculoskeletal lesions*. Baltimore: Williams & Wilkins, 1987.
285. Rahimi A, Beabout JW, Ivins JC, et al. Chondromyxoid fibroma: a clinicopathologic study of 76 cases. *Cancer* 1972;30:726.
286. Bertoni F, Bacchini P. Classification of bone tumors. *Eur J Radiol* 1998;27(Suppl 1):S74.
287. Codman E. Epiphyseal chondromatous giant cell tumor of the upper end of the humerus. *Surg Gynecol Obstet* 1931;52:543.
288. Jaffe H, Lichtenstein L. Benign chondroblastoma of bone: a reinterpretation of the so-called calcifying or chondromatous giant cell tumor. *Am J Pathol* 1942;18:969.
289. Dahlin DC, Ivins JC. Benign chondroblastoma: a study of 125 cases. *Cancer* 1972;30:401.
290. Huvo AG, Marcove RC. Chondroblastoma of bone: a critical review. *Clin Orthop* 1973;95:300.
291. Springfield DS, Capanna R, Gherlizoni F, et al. Chondroblastoma: a review of seventy cases. *J Bone Joint Surg Am* 1985;67:748.
292. Gardner DJ, Azouz EM. Solitary lucent epiphyseal lesions in children. *Skeletal Radiol* 1988;17:497.
293. McLeod RA, Beabout JW. The roentgenographic features of chondroblastoma. *Am J Roentgenol* 1973;118:464.
294. Green P, Whittaker RP. Benign chondroblastoma: case report with pulmonary metastasis. *J Bone Joint Surg Am* 1975;57:418.
295. Boriani S, Bacchini P, Bertoni F, et al. Periosteal chondroma: a review of twenty cases. *J Bone Joint Surg Am* 1983;65:205.
296. Lichtenstein L, Hall J. Periosteal chondroma: a distinctive benign cartilage tumor. *J Bone Joint Surg Am* 1952;34:691.
297. Rockwell MA, Saiter ET, Enneking WF. Periosteal chondroma. *J Bone Joint Surg Am* 1972;54:102.

Lesions of Fibrous Origin

298. Friedland JA, Reinus WR, Fisher AJ, et al. Quantitative analysis of the plain radiographic appearance of nonossifying fibroma. *Invest Radiol* 1995;30:474.
299. Bullough PG, Walley J. Fibrous cortical defect and non-ossifying fibroma. *Postgrad Med J* 1965;41:672.
300. Hudson TM, Stiles RG, Monson DK. Fibrous lesions of bone. *Radiol Clin North Am* 1993;31:279.
301. Marks KE, Bauer TW. Fibrous tumors of bone. *Orthop Clin North Am* 1989;20:377.
302. Brower AC, Culver JE Jr, Keats TE. Histological nature of

- the cortical irregularity of the medial posterior distal femoral metaphysis in children. *Radiology* 1971;99:389.
303. Caffé J. On fibrous defects in cortical walls of growing tubular bones. In: Levine S, ed. *Advances in pediatrics*, vol 7. Chicago: Year Book, 1955:13.
 304. Easley ME, Kneisl JS. Pathologic fractures through nonossifying fibromas: is prophylactic treatment warranted? *J Pediatr Orthop* 1997;17:808.
 305. Peterson HA, Fitzgerald EM. Fractures through nonossifying fibromata in children. *Minn Med* 1980;63:139.
 306. Arata MA, Peterson HA, Dahlin DC. Pathological fractures through non-ossifying fibromas: review of the Mayo Clinic experience. *J Bone Joint Surg Am* 1981;63:980.
 307. Grabias SL, Campbell CJ. Fibrous dysplasia. *Orthop Clin North Am* 1977;8:771.
 308. Henry A. Monostotic fibrous dysplasia. *J Bone Joint Surg Br* 1969;51:300.
 309. Stanton RP, Montgomery BE. Fibrous dysplasia. *Orthopedics* 1996;19:679.
 310. Steward M, Gilmer W, Edmunson A. Fibrous dysplasia of bone. *J Bone Joint Surg Am* 1962;44:302.
 311. Lichtenstein L. Polyostotic fibrous dysplasia. *Arch Surg* 1938;36:874.
 312. Gurler T, Alper M, Gencosmanoglu R, et al. McCune-Albright syndrome progressing with severe fibrous dysplasia. *J Craniofac Surg* 1998;9:79.
 313. Lee PA, Van Dop C, Migeon CJ. McCune-Albright syndrome: long-term follow-up. *JAMA* 1986;256:2980.
 314. Harris W, Dudley H, Barry R. The natural history of fibrous dysplasia: an orthopaedic, pathological, and roentgenographic study. *J Bone Joint Surg Am* 1962;44:207.
 315. Albright F, Butler A, Hampton A, et al. Syndrome characterized by osteitis fibrosa disseminata, area of pigmentation and endocrine dysfunction, with precocious puberty in females. *N Engl J Med* 1937;216:727.
 316. Danon M, Robboy SJ, Kim S, et al. Cushing syndrome, sexual precocity, and polyostotic fibrous dysplasia (Albright syndrome) in infancy. *J Pediatr* 1975;87:917.
 317. Mauras N, Blizzard RM. The McCune-Albright syndrome. *Acta Endocrinol Suppl* 1986;279:207.
 318. MacMahon HE. Albright's syndrome: thirty years later. (Polyostotic fibrous dysplasia.) *Pathol Annu* 1971;6:81.
 319. Enneking WF, Gearen PF. Fibrous dysplasia of the femoral neck: treatment by cortical bone-grafting. *J Bone Joint Surg Am* 1986;68:1415.
 320. Breck LW. Treatment of fibrous dysplasia of bone by total femoral plating and hip nailing: a case report. *Clin Orthop* 1972;82:82.
 321. Bryant DDD, Grant RE, Tang D. Fibular strut grafting for fibrous dysplasia of the femoral neck. *J Natl Med Assoc* 1992;84:893.
 322. Connolly JF. Shepherd's crook deformities of polyostotic fibrous dysplasia treated by osteotomy and Zickel nail fixation. *Clin Orthop* 1977:22.
 323. DePalma AF, Ahmad I. Fibrous dysplasia associated with Shepherd's crook deformity of the humerus. *Clin Orthop* 1973;97:38.
 324. Funk FJ Jr, Wells RE. Hip problems in fibrous dysplasia. *Clin Orthop* 1973;90:77.
 325. Freeman BH, Bray EWD, Meyer LC. Multiple osteotomies with Zickel nail fixation for polyostotic fibrous dysplasia involving the proximal part of the femur. *J Bone Joint Surg Am* 1987;69:691.
 326. Guille JT, Kumar SJ, MacEwen GD. Fibrous dysplasia of the proximal part of the femur: long-term results of curettage and bone-grafting and mechanical realignment. *J Bone Joint Surg Am* 1998;80:648.
 327. Jaffe KA, Dunham WK. Treatment of benign lesions of the femoral head and neck. *Clin Orthop* 1990;134.
 328. Shih HN, Chen YJ, Huang TJ, et al. Treatment of fibrous dysplasia involving the proximal femur. *Orthopedics* 1998;21:1263.
 329. Kempson R. Ossifying fibroma of long bones. *Arch Pathol* 1966;82:218.
 330. Campanacci M, Laus M. Osteofibrous dysplasia of the tibia and fibula. *J Bone Joint Surg Am* 1981;63:367.
 331. Campbell CJ, Hawk T. A variant of fibrous dysplasia (osteofibrous dysplasia). *J Bone Joint Surg Am* 1982;64:231.
 332. Kozor D, Stoss H, Wagner H, et al. Jaffe-Campanacci syndrome: case report and review of literature. *Clin Dysmorphol* 1994;3:328.
 333. Springfield DS, Rosenberg AE, Mankin HJ, et al. Relationship between osteofibrous dysplasia and adamantinoma. *Clin Orthop* 1994:234.
 334. Wang JW, Shih CH, Chen WJ. Osteofibrous dysplasia (ossifying fibroma of long bones): a report of four cases and review of the literature. *Clin Orthop* 1992:235.
 335. Schajowicz F, Santini-Araujo E. Adamantinoma of the tibia masked by fibrous dysplasia: report of three cases. *Clin Orthop* 1989:294.
 336. Hazelbag HM, Taminiau AH, Fleuren GJ, et al. Adamantinoma of the long bones: a clinicopathological study of thirty-two patients with emphasis on histological subtype, precursor lesion, and biological behavior. *J Bone Joint Surg Am* 1994;76:1482.

Miscellaneous Lesions

337. Stull MA, Kransdorf MJ, Devaney KO. Langerhans cell histiocytosis of bone. *Radiographics* 1992;12:801.
338. Sessa S, Sommelet D, Lascombes P, et al. Treatment of Langerhans-cell histiocytosis in children: experience at the Children's Hospital of Nancy. *J Bone Joint Surg Am* 1994;76:1513.
339. Farber S. The nature of "solitary or eosinophilic granuloma" of bone. *Am J Pathol* 1941;17:625.
340. Lichtenstein L. Histiocytosis X: integration of eosinophilic granuloma of bone, "Letterer-Siwe disease," and "Schuller-Christian disease" as related manifestations of a single nosologic entity. *Arch Pathol* 1953;56:84.
341. Kilpatrick SE, Wenger DE, Gilchrist GS, et al. Langerhans' cell histiocytosis (histiocytosis X) of bone: a clinicopathologic analysis of 263 pediatric and adult cases. *Cancer* 1995;76:2471.
342. Levine SE, Dormans JP, Meyer JS, et al. Langerhans' cell histiocytosis of the spine in children. *Clin Orthop* 1996:288.
343. Ippolito E, Farsetti P, Tudisco C. Vertebra plana: long-term follow-up in five patients. *J Bone Joint Surg Am* 1984;66:1364.
344. O'Donnell J, Brown L, Herkowitz H. Vertebra plana-like lesions in children: case report with special emphasis on the differential diagnosis and indications for biopsy. *J Spinal Disord* 1991;4:480.
345. Crone-Munzbrock W, Brassow F. A comparison of radiographic and bone scan findings in histiocytosis X. *Skeletal Radiol* 1983;9:170.
346. Dogan AS, Conway JJ, Miller JH, et al. Detection of bone lesions in Langerhans cell histiocytosis: complementary roles of scintigraphy and conventional radiography. *J Pediatr Hematol Oncol* 1996;18:51.
347. Howarth DM, Mullan BP, Wiseman GA, et al. Bone scintigraphy evaluated in diagnosing and staging Langerhans' cell histiocytosis and related disorders. *J Nucl Med* 1996;37:1456.
348. Schaub T, Eissner D, Hahn K, et al. Bone scanning in the

- detection and follow-up of skeletal lesions in histiocytosis X. *Ann Radiol* 1983;26:407.
349. Van Nieuwenhuysen JP, Clapuyt P, Malghem J, et al. Radiographic skeletal survey and radionuclide bone scan in Langerhans cell histiocytosis of bone. *Pediatr Radiol* 1996;26:734.
 350. Westra SJ, van Woerden H, Postma A, et al. Radionuclide bone scintigraphy in patients with histiocytosis X. *Eur J Nucl Med* 1983;8:303.
 351. Egeler RM, Thompson RC Jr, Voute PA, et al. Intralesional infiltration of corticosteroids in localized Langerhans' cell histiocytosis. *J Pediatr Orthop* 1992;12:811.
 352. Schreuder HW, Pruszczyński M, Lemmens JA, et al. Eosinophilic granuloma of bone: results of treatment with curettage, cryosurgery, and bone grafting. *J Pediatr Orthop B* 1998;7:253.
 353. Bernstrand C, Bjork O, Ahstrom L, et al. Intralesional steroids in Langerhans cell histiocytosis of bone. *Acta Paediatr* 1996;85:502.
 354. Raney RB Jr, D'Angio GJ. Langerhans' cell histiocytosis (histiocytosis X): experience at the Children's Hospital of Philadelphia, 1970-1984. *Med Pediatr Oncol* 1989;17:20.
 355. Raney RB Jr. Chemotherapy for children with aggressive fibromatosis and Langerhans' cell histiocytosis. *Clin Orthop* 1991:58.
 356. West WO. Velban as treatment for disseminated eosinophilic granuloma of bone: follow-up note after seventeen years. *J Bone Joint Surg Am* 1984;66:1128.
 357. Womer RB, Raney RB Jr, D'Angio GJ. Healing rates of treated and untreated bone lesions in histiocytosis X. *Pediatrics* 1985;76:286.
 358. Nezelof C, Basset F. Langerhans cell histiocytosis research: past, present, and future. *Hematol Oncol Clin North Am* 1998;12:385.
 359. Conter V, Reciputo A, Arrigo C, et al. Bone marrow transplantation for refractory Langerhans' cell histiocytosis. *Haematologica* 1996;81:468.
 360. Morgan G. Myeloablative therapy and bone marrow transplantation for Langerhans' cell histiocytosis. *Br J Cancer Suppl* 1994;23:S52.
 361. Campanacci M, Capanna R, Picci P. Unicameral and aneurysmal bone cysts. *Clin Orthop* 1986:25.
 362. Baker DM. Benign unicameral bone cyst: a study of forty-five cases with long-term follow up. *Clin Orthop* 1970;71:140.
 363. Capanna R, Campanacci DA, Manfrini M. Unicameral and aneurysmal bone cysts. *Orthop Clin North Am* 1996;27:605.
 364. Neer C, Francis K, Marcove R, et al. Treatment of unicameral bone cyst: a follow-up study of one hundred seventy-five cases. *J Bone Joint Surg Am* 1966;48:731.
 365. Makley JT, Joyce MJ. Unicameral bone cyst (simple bone cyst). *Orthop Clin North Am* 1989;20:407.
 366. Cohen J. Unicameral bone cysts: a current synthesis of reported cases. *Orthop Clin North Am* 1977;8:715.
 367. Chigira M, Maehara S, Arita S, et al. The aetiology and treatment of simple bone cysts. *J Bone Joint Surg Br* 1983;65:633.
 368. Cohen J. Etiology of simple bone cyst. *J Bone Joint Surg Am* 1970;52:1493.
 369. Lokiec F, Wientroub S. Simple bone cyst: etiology, classification, pathology, and treatment modalities. *J Pediatr Orthop B* 1998;7:262.
 370. Kruls HJ. Pathological fractures in children due to solitary bone cysts. *Reconstr Surg Traumatol* 1979;17:113.
 371. Lee JH, Reinus WR, Wilson AJ. Quantitative analysis of the plain radiographic appearance of unicameral bone cysts. *Invest Radiol* 1999;34:28.
 372. Ahn JI, Park JS. Pathological fractures secondary to unicameral bone cysts. *Int Orthop* 1994;18:20.
 373. Kaelin AJ, MacEwen GD. Unicameral bone cysts: natural history and the risk of fracture. *Int Orthop* 1989;13:275.
 374. McGlynn FJ, Mickelson MR, El-Khoury GY. The fallen fragment sign in unicameral bone cyst. *Clin Orthop* 1981:157.
 375. Reynolds J. The "fallen fragment sign" in the diagnosis of unicameral bone cysts. *Radiology* 1969;92:949.
 376. Oppenheim WL, Galleno H. Operative treatment versus steroid injection in the management of unicameral bone cysts. *J Pediatr Orthop* 1984;4:1.
 377. Scaglietti O, Marchetti PG, Bartolozzi P. Final results obtained in the treatment of bone cysts with methylprednisolone acetate (Depo-Medrol) and a discussion of results achieved in other bone lesions. *Clin Orthop* 1982:33.
 378. Farber JM, Stanton RP. Treatment options in unicameral bone cysts. *Orthopedics* 1990;13:25.
 379. Hecht AC, Gebhardt MC. Diagnosis and treatment of unicameral and aneurysmal bone cysts in children. *Curr Opin Pediatr* 1998;10:87.
 380. Spence KF Jr, Bright RW, Fitzgerald SP, et al. Solitary unicameral bone cyst: treatment with freeze-dried crushed cortical-bone allograft. A review of one hundred and forty-four cases. *J Bone Joint Surg Am* 1976;58:636.
 381. Yandow SM, Lundeen GA, Scott SM, et al. Autogenic bone marrow injections as a treatment for simple bone cyst. *J Pediatr Orthop* 1998;18:616.
 382. Scaglietti O, Marchetti PG, Bartolozzi P. The effects of methylprednisolone acetate in the treatment of bone cysts: results of three years follow-up. *J Bone Joint Surg Br* 1979;61:200.
 383. Stanton RP, Abdel-Mota'al MM. Growth arrest resulting from unicameral bone cyst. *J Pediatr Orthop* 1998;18:198.
 384. Spence KF, Sell KW, Brown RH. Solitary bone cyst: treatment with freeze-dried cancellous bone allograft. A study of one hundred seventy-seven cases. *J Bone Joint Surg Am* 1969;51:87.
 385. Neer CS, Francis KC, Johnston AD, et al. Current concepts on the treatment of solitary unicameral bone cyst. *Clin Orthop* 1973;97:40.
 386. Altermatt S, Schwobel M, Pochon JP. Operative treatment of solitary bone cysts with tricalcium phosphate ceramic: a 1 to 7 year follow-up. *Eur J Pediatr Surg* 1992;2:180.
 387. Peltier LF, Jones RH. Treatment of unicameral bone cysts by curettage and packing with plaster-of-Paris pellets. *J Bone Joint Surg Am* 1978;60:820.
 388. Biesecker JL, Marcove RC, Huvos AG, et al. Aneurysmal bone cysts: a clinicopathologic study of 66 cases. *Cancer* 1970;26:615.
 389. Martinez V, Sissons HA. Aneurysmal bone cyst: a review of 123 cases including primary lesions and those secondary to other bone pathology. *Cancer* 1988;61:2291.
 390. Tillman BP, Dahlin DC, Lipscomb PR, et al. Aneurysmal bone cyst: an analysis of ninety-five cases. *Mayo Clin Proc* 1968;43:478.
 391. Lichtenstein L. Aneurysmal bone cysts. *Cancer* 1950;3:279.
 392. Nguyen BD, Lugo-Olivieri CH, McCarthy EF, et al. Fibrous dysplasia with secondary aneurysmal bone cyst. *Skeletal Radiol* 1996;25:88.
 393. Szendroi M, Arato G, Ezzati A, et al. Aneurysmal bone cyst: its pathogenesis based on angiographic, immunohistochemical and electron microscopic studies. *Pathol Oncol Res* 1998;4:277.
 394. Hudson TM. Fluid levels in aneurysmal bone cysts: a CT feature. *Am J Roentgenol* 1984;142:1001.
 395. Hudson TM. Scintigraphy of aneurysmal bone cysts. *Am J Roentgenol* 1984;142:761.
 396. Green JA, Bellemore MC, Marsden FW. Embolization in the treatment of aneurysmal bone cysts. *J Pediatr Orthop* 1997;17:440.
 397. DeRosa GP, Graziano GP, Scott J. Arterial embolization of

- aneurysmal bone cyst of the lumbar spine: a report of two cases. *J Bone Joint Surg Am* 1990;72:777.
398. Marcove RC, Sheth DS, Takemoto S, et al. The treatment of aneurysmal bone cyst. *Clin Orthop* 1995;157.
 399. Grier HE. The Ewing family of tumors: Ewing's sarcoma and primitive neuroectodermal tumors. *Pediatr Clin North Am* 1997;44:991.
 400. Delattre O, Zucman J, Melot T, et al. The Ewing family of tumors: a subgroup of small-round-cell tumors defined by specific chimeric transcripts. *N Engl J Med* 1994;331:294.
 401. Meier VS, Kuhne T, Jundt G, et al. Molecular diagnosis of Ewing tumors: improved detection of EWS-FLI-1 and EWS-ERG chimeric transcripts and rapid determination of exon combinations. *Diagn Mol Pathol* 1998;7:29.
 402. Pritchard DJ, Dahlin DC, Dauphine RT, et al. Ewing's sarcoma: a clinicopathological and statistical analysis of patients surviving five years or longer. *J Bone Joint Surg Am* 1975;57:10.
 403. Damron TA, Sim FH, O'Connor MI, et al. Ewing's sarcoma of the proximal femur. *Clin Orthop* 1996;232.
 404. Li WK, Lane JM, Rosen G, et al. Pelvic Ewing's sarcoma: advances in treatment. *J Bone Joint Surg Am* 1983;65:738.
 405. Terek RM, Brien EW, Marcove RC, et al. Treatment of femoral Ewing's sarcoma. *Cancer* 1996;78:70.
 406. Horowitz ME, Neff JR, Kun LE. Ewing's sarcoma: radiotherapy versus surgery for local control. *Pediatr Clin North Am* 1991;38:365.
 407. Sudanese A, Toni A, Ciaroni D, et al. The role of surgery in the treatment of localized Ewing's sarcoma. *Chir Organi Mov* 1990;75:217.
 408. Toni A, Sudanese A, Ciaroni D, et al. The role of surgery in the local treatment of Ewing's sarcoma of the extremities. *Chir Organi Mov* 1990;75:262.
 409. Wilkins RM, Pritchard DJ, Burgert EO Jr, et al. Ewing's sarcoma of bone: experience with 140 patients. *Cancer* 1986;58:2551.
 410. Pritchard DJ. Surgical experience in the management of Ewing's sarcoma of bone. *Natl Cancer Inst Monogr* 1981;169.
 411. Sailer SL, Harmon DC, Mankin HJ, et al. Ewing's sarcoma: surgical resection as a prognostic factor. *Int J Radiat Oncol Biol Phys* 1988;15:43.
 412. Bacci G, Toni A, Avella M, et al. Long-term results in 144 localized Ewing's sarcoma patients treated with combined therapy. *Cancer* 1989;63:1477.
 413. O'Connor MI, Pritchard DJ. Ewing's sarcoma: prognostic factors, disease control, and the reemerging role of surgical treatment. *Clin Orthop* 1991;78.
 414. Gebhardt MC. Bone tumors in children: differential characteristics and treatment. *Postgrad Med* 1984;76:87.
 415. Hudson TM, Hamlin DJ, Enneking WF, et al. Magnetic resonance imaging of bone and soft tissue tumors: early experience in 31 patients compared with computed tomography. *Skeletal Radiol* 1985;13:134.
 416. Rosenthal DI. Computed tomography of orthopedic neoplasms. *Orthop Clin North Am* 1985;16:461.
 417. Terrier P, Llombart-Bosch A, Contesso G. Small round blue cell tumors in bone: prognostic factors correlated to Ewing's sarcoma and neuroectodermal tumors. *Semin Diagn Pathol* 1996;13:250.
 418. Brinkhuis M, Wijnaendts LC, van der Linden JC, et al. Peripheral primitive neuroectodermal tumour and extra-osseous Ewing's sarcoma: a histological, immunohistochemical and DNA flow cytometric study. *Virechows Arch* 1995;425:611.
 419. Shimada H, Newton WA Jr, Soule EH, et al. Pathologic features of extraosseous Ewing's sarcoma: a report from the Intergroup Rhabdomyosarcoma Study. *Hum Pathol* 1988;19:442.
 420. Gururangan S, Marina NM, Luo X, et al. Treatment of children with peripheral primitive neuroectodermal tumor or extraosseous Ewing's tumor with Ewing's-directed therapy. *J Pediatr Hematol Oncol* 1998;20:55.
 421. Raney RB, Asmar L, Newton WA Jr, et al. Ewing's sarcoma of soft tissues in childhood: a report from the Intergroup Rhabdomyosarcoma Study, 1972 to 1991. *J Clin Oncol* 1997;15:574.
 422. Bacci G, Ferrari S, Avella M, et al. Non-metastatic Ewing's sarcoma: results in 98 patients treated with neoadjuvant chemotherapy. *Ital J Orthop Traumatol* 1991;17:449.
 423. Goldman A. Ewing's sarcoma: treatment with high-dose radiation and adjuvant chemotherapy. *Recent Results Cancer Res* 1982;80:115.
 424. Rosen G, Caparros B, Nirenberg A, et al. Ewing's sarcoma: ten-year experience with adjuvant chemotherapy. *Cancer* 1981;47:2204.
 425. Vietti TJ, Gehan EA, Nesbit ME Jr, et al. Multimodal therapy in metastatic Ewing's sarcoma: an intergroup study. *Natl Cancer Inst Monogr* 1981;279.
 426. Nesbit ME Jr, Perez CA, Tefft M, et al. Multimodal therapy for the management of primary, nonmetastatic Ewing's sarcoma of bone: an intergroup study. *Natl Cancer Inst Monogr* 1981:255.
 427. Craft A, Cotterill S, Malcolm A, et al. Ifosfamide-containing chemotherapy in Ewing's sarcoma. The Second United Kingdom Children's Cancer Study Group and the Medical Research Council Ewing's Tumor Study. *J Clin Oncol* 1998;16:3628.
 428. Craft AW, Cotterill SJ, Bullimore JA, et al. Long-term results from the first UKCCSG Ewing's Tumour Study (ET-1). United Kingdom Children's Cancer Study Group (UKCCSG) and the Medical Research Council Bone Sarcoma Working Party. *Eur J Cancer* 1997;33:1061.
 429. Wexler LH, DeLaney TF, Tsokos M, et al. Ifosfamide and etoposide plus vincristine, doxorubicin, and cyclophosphamide for newly diagnosed Ewing's sarcoma family of tumors. *Cancer* 1996;78:901; erratum 1997;79:867.
 430. Antman K, Crowley J, Balcerzak SP, et al. A Southwest Oncology Group and Cancer and Leukemia Group B phase II study of doxorubicin, dacarbazine, ifosfamide, and mesna in adults with advanced osteosarcoma, Ewing's sarcoma, and rhabdomyosarcoma. *Cancer* 1998;82:1288.
 431. Ahrens S, Hoffmann C, Jabar S, et al. Evaluation of prognostic factors in a tumor volume-adapted treatment strategy for localized Ewing sarcoma of bone: the CESS 86 experience. Cooperative Ewing Sarcoma Study. *Med Pediatr Oncol* 1999;32:186.
 432. Sauer R, Jurgens H, Burgers JM, et al. Prognostic factors in the treatment of Ewing's sarcoma. The Ewing's Sarcoma Study Group of the German Society of Paediatric Oncology CESS 81. *Radiother Oncol* 1987;10:101.
 433. Frieden RA, Ryniker D, Kenan S, et al. Assessment of patient function after limb-sparing surgery. *Arch Phys Med Rehabil* 1993;74:38.
 434. Kimber C, Michalski A, Spitz L, et al. Primitive neuroectodermal tumours: anatomic location, extent of surgery, and outcome. *J Pediatr Surg* 1998;33:39.
 435. Givens SS, Woo SY, Huang LY, et al. Non-metastatic Ewing's sarcoma: twenty years of experience suggests that surgery is a prime factor for successful multimodality therapy. *Int J Oncol* 1999;14:1039.
 436. Arai Y, Kun LE, Brooks MT, et al. Ewing's sarcoma: local tumor control and patterns of failure following limited-volume radiation therapy. *Int J Radiat Oncol Biol Phys* 1991;21:1501.
 437. Perez CA, Tefft M, Nesbit ME Jr, et al. Radiation therapy in the multimodal management of Ewing's sarcoma of bone: report of the Intergroup Ewing's Sarcoma Study. *Natl Cancer Inst Monogr* 1981:263.

438. Tefft M. Treatment of Ewing's sarcoma with radiation therapy. *Int J Radiat Oncol Biol Phys* 1981;7:277.
439. Razek A, Perez CA, Tefft M, et al. Intergroup Ewing's Sarcoma Study: local control related to radiation dose, volume, and site of primary lesion in Ewing's sarcoma. *Cancer* 1980;46:516.
440. Lewis RJ, Marcove RC, Rosen G. Ewing's sarcoma: functional effects of radiation therapy. *J Bone Joint Surg Am* 1977;59:325.
441. Tefft M, Chabora BM, Rosen G. Radiation in bone sarcomas: a re-evaluation in the era of intensive systemic chemotherapy. *Cancer* 1977;39:806.
442. Dunst J, Sauer R, Burgers JM, et al. Radiation therapy as local treatment in Ewing's sarcoma: results of the Cooperative Ewing's Sarcoma Studies CESS 81 and CESS 86. *Cancer* 1991; 67:2818.
443. Perez CA, Tefft M, Nesbit M, et al. The role of radiation therapy in the management of non-metastatic Ewing's sarcoma of bone: report of the Intergroup Ewing's Sarcoma Study. *Int J Radiat Oncol Biol Phys* 1981;7:141.
444. Dunst J, Jurgens H, Sauer R, et al. Radiation therapy in Ewing's sarcoma: an update of the CESS 86 trial. *Int J Radiat Oncol Biol Phys* 1995;32:919.
445. Donaldson SS, Torrey M, Link MP, et al. A multidisciplinary study investigating radiotherapy in Ewing's sarcoma: end results of POG #8346. Pediatric Oncology Group. *Int J Radiat Oncol Biol Phys* 1998;42:125.
446. Tucker MA, D'Angio GJ, Boice JD Jr, et al. Bone sarcomas linked to radiotherapy and chemotherapy in children. *N Engl J Med* 1987;317:588.
447. Greene MH, Glaubiger DL, Mead GD, et al. Subsequent cancer in patients with Ewing's sarcoma. *Cancer Treat Rep* 1979;63: 2043.
448. Smith LM, Cox RS, Donaldson SS. Second cancers in long-term survivors of Ewing's sarcoma. *Clin Orthop* 1992;275.
449. Freeman CR, Gledhill R, Chevalier LM, et al. Osteogenic sarcoma following treatment with megavoltage radiation and chemotherapy for bone tumors in children. *Med Pediatr Oncol* 1980;8:375.
450. Kuttresch JF Jr, Wexler LH, Marcus RB, et al. Second malignancies after Ewing's sarcoma: radiation dose-dependency of secondary sarcomas. *J Clin Oncol* 1996;14:2818.
451. Smith LM, Donaldson SS. Incidence and management of secondary malignancies in patients with retinoblastoma and Ewing's sarcoma. *Oncology* 1991;5:135; discussion 142, 147.
452. Bechler JR, Robertson WW Jr, Meadows AT, et al. Osteosarcoma as a second malignant neoplasm in children. *J Bone Joint Surg Am* 1992;74:1079.
453. Le Vu B, de Varhaire F, Shamsaldin A, et al. Radiation dose, chemotherapy and risk of osteosarcoma after solid tumours during childhood. *Int J Cancer* 1998;77:370.
454. Smith JT, Yandow SM. Benign soft-tissue lesions in children. *Orthop Clin North Am* 1996;27:645.
455. Pappo AS, Pratt CB. Soft tissue sarcomas in children. *Cancer Treat Res* 1997;91:205.
456. Meyer JS, Dormans JP. Differential diagnosis of pediatric musculoskeletal masses. *Magn Reson Imaging Clin North Am* 1998; 6:561.
457. Enzinger F, Weiss S. *Soft tissue tumors*. New York: CV Mosby, 1993.
458. Jaffe H. *Tumors and tumorous conditions of the bones and joints*. Philadelphia: Lea & Febiger, 1968:256.
459. Faulkner LB, Hajdu SI, Kher U, et al. Pediatric desmoid tumor: retrospective analysis of 63 cases. *J Clin Oncol* 1995;13:2813.
460. Eich GF, Hoeffel JC, Tschappeler H, et al. Fibrous tumours in children: imaging features of a heterogeneous group of disorders. *Pediatr Radiol* 1998;28:500.
461. Sundaram M, McGuire MH, Herbold DR. Magnetic resonance imaging of soft tissue masses: an evaluation of fifty-three histologically proven tumors. *Magn Reson Imaging* 1988;6:237.
462. Hajdu S. *Pathology of soft tissue tumors*. Philadelphia: Lea & Febiger, 1979.
463. Weiss AJ, Lackman RD. Low-dose chemotherapy of desmoid tumors. *Cancer* 1989;64:1192.
464. Dagher R, Helman L. Rhabdomyosarcoma: an overview. *Oncologist* 1999;4:34.
465. Malogolowkin MH, Ortega JA. Rhabdomyosarcoma of childhood. *Pediatr Ann* 1988;17:251, 254.
466. Maurer HM. Rhabdomyosarcoma in childhood and adolescence. *Curr Probl Cancer* 1978;2:1.
467. Stiller CA, Parkin DM. International variations in the incidence of childhood soft-tissue sarcomas. *Paediatr Perinat Epidemiol* 1994;8:107.
468. Pappo AS. Rhabdomyosarcoma and other soft tissue sarcomas of childhood. *Curr Opin Oncol* 1995;7:361.
469. Pappo AS, Shapiro DN, Crist WM, et al. Biology and therapy of pediatric rhabdomyosarcoma. *J Clin Oncol* 1995;13:2123.
470. Pappo AS, Shapiro DN, Crist WM. Rhabdomyosarcoma: biology and treatment. *Pediatr Clin North Am* 1997;44:953.
471. Triche TJ. Diagnosis of small round cell tumors of childhood. *Bull Cancer* 1988;75:297.
472. LaQuaglia MP. Extremity rhabdomyosarcoma: biological principles, staging, and treatment. *Semin Surg Oncol* 1993;9:510.
473. Dodd S, Malone M, McCulloch W. Rhabdomyosarcoma in children: a histological and immunohistochemical study of 59 cases. *J Pathol* 1989;158:13.
474. Tsokos M. The diagnosis and classification of childhood rhabdomyosarcoma. *Semin Diagn Pathol* 1994;11:26.
475. Newton WA Jr, Soule EH, Hamoudi AB, et al. Histopathology of childhood sarcomas: Intergroup Rhabdomyosarcoma Studies I and II. Clinicopathologic correlation. *J Clin Oncol* 1988;6: 67.
476. Andrassy RJ, Corpron CA, Hays D, et al. Extremity sarcomas: an analysis of prognostic factors from the Intergroup Rhabdomyosarcoma Study III. *J Pediatr Surg* 1996;31:191.
477. Noguera R. Cytogenetics and tissue culture of small round cell tumors of bone and soft tissue. *Semin Diagn Pathol* 1996;13: 171.
478. Scrabble H, Witte D, Shimada H, et al. Molecular differential pathology of rhabdomyosarcoma. *Genes Chromosomes Cancer* 1989;1:23.
479. Barr FG. Molecular genetics and pathogenesis of rhabdomyosarcoma. *J Pediatr Hematol Oncol* 1997;19:483.
480. Ghavimi F, Mandell LR, Heller G, et al. Prognosis in childhood rhabdomyosarcoma of the extremity. *Cancer* 1989;64:2233.
481. Crist WM, Garnsey L, Beltangady MS, et al. Prognosis in children with rhabdomyosarcoma: a report of the Intergroup Rhabdomyosarcoma Studies I and II. Intergroup Rhabdomyosarcoma Committee. *J Clin Oncol* 1990;8:443.
482. Raney RB Jr, Crist WM, Maurer HM, et al. Prognosis of children with soft tissue sarcoma who relapse after achieving a complete response: a report from the Intergroup Rhabdomyosarcoma Study I. *Cancer* 1983;52:44.
483. Tsokos M, Webber BL, Parham DM, et al. Rhabdomyosarcoma: a new classification scheme related to prognosis. *Arch Pathol Lab Med* 1992;116:847.
484. Antman K, Crowley J, Balcerzak SP, et al. An intergroup phase III randomized study of doxorubicin and dacarbazine with or without ifosfamide and mesna in advanced soft tissue and bone sarcomas. *J Clin Oncol* 1993;11:1276.

485. Maurer HM, Gehan EA, Beltangady M, et al. The Intergroup Rhabdomyosarcoma Study-II. *Cancer* 1993;71:1904.
486. Crist W, Gehan EA, Ragab AH, et al. The Third Intergroup Rhabdomyosarcoma Study. *J Clin Oncol* 1995;13:610.
487. Hays DM, Raney RB, Crist WM, et al. Secondary surgical procedures to evaluate primary tumor status in patients with chemotherapy-responsive stage III and IV sarcomas: a report from the Intergroup Rhabdomyosarcoma Study. *J Pediatr Surg* 1990;25:1100.
488. Pratt CB, Hustu HO, Kumar AP, et al. Treatment of childhood rhabdomyosarcoma at St. Jude Children's Research Hospital, 1962-78. *Natl Cancer Inst Monogr* 1981;93.
489. LaQuaglia MP, Ghavimi F, Penenberg D, et al. Factors predictive of mortality in pediatric extremity rhabdomyosarcoma. *J Pediatr Surg* 1990;25:238; discussion 243.
490. Johnson DG. Trends in surgery for childhood rhabdomyosarcoma. *Cancer* 1975;35:916.
491. Corpron CA, Andrassy RJ. Surgical management of rhabdomyosarcoma in children. *Curr Opin Pediatr* 1996;8:283.
492. Wharam MD, Hanfelt JJ, Tefft MC, et al. Radiation therapy for rhabdomyosarcoma: local failure risk for clinical group III patients on Intergroup Rhabdomyosarcoma Study II. *Int J Radiat Oncol Biol Phys* 1997;38:797.
493. Raney RB Jr, Gehan EA, Hays DM, et al. Primary chemotherapy with or without radiation therapy and/or surgery for children with localized sarcoma of the bladder, prostate, vagina, uterus, and cervix: a comparison of the results in Intergroup Rhabdomyosarcoma Studies I and II. *Cancer* 1990;66:2072.
494. Ransom JL, Pratt CB, Shanks E. Childhood rhabdomyosarcoma of the extremity: results of combined modality therapy. *Cancer* 1977;40:2810.
495. Pedrick TJ, Donaldson SS, Cox RS. Rhabdomyosarcoma: the Stanford experience using a TNM staging system. *J Clin Oncol* 1986;4:370.
496. Hays DM. Rhabdomyosarcoma. *Clin Orthop* 1993;36.
497. Lawrence W Jr, Gehan EA, Hays DM, et al. Prognostic significance of staging factors of the UICC staging system in childhood rhabdomyosarcoma: a report from the Intergroup Rhabdomyosarcoma Study (IRS-II). *J Clin Oncol* 1987;5:46.
498. Gross E, Rao BN, Bowman L, et al. Outcome of treatment for pediatric sarcoma of the foot: a retrospective review over a 20-year period. *J Pediatr Surg* 1997;32:1181.
499. Henderson SA, Davis R, Nixon JR. Synovial sarcoma: a clinicopathological review. *Int Orthop* 1991;15:251.
500. Marcus KC, Grier HE, Shamberger RC, et al. Childhood soft tissue sarcoma: a 20-year experience. *J Pediatr* 1997;131:603.
501. Pappo AS, Fontanesi J, Luo X, et al. Synovial sarcoma in children and adolescents: the St. Jude Children's Research Hospital experience. *J Clin Oncol* 1994;12:2360.
502. Schmidt D, Thum P, Harms D, et al. Synovial sarcoma in children and adolescents: a report from the Kiel Pediatric Tumor Registry. *Cancer* 1991;67:1667.
503. Gaakker HA, Albus-Lutter CE, Gortzak E, et al. Regional lymph node metastases in patients with soft tissue sarcomas of the extremities: what are the therapeutic consequences? *Eur J Surg Oncol* 1988;14:151.
504. Morton MJ, Berquist TH, McLeod RA, et al. MR imaging of synovial sarcoma. *Am J Roentgenol* 1991;156:337.
505. Horowitz ME, Pratt CB, Webber BL, et al. Therapy for childhood soft-tissue sarcomas other than rhabdomyosarcoma: a review of 62 cases treated at a single institution. *J Clin Oncol* 1986;4:559.
506. Ladenstein R, Treuner J, Koscielniak E, et al. Synovial sarcoma of childhood and adolescence: report of the German CWS-81 study. *Cancer* 1993;71:3647.
507. Ferrari A, Casanova M, Massimino M, et al. Synovial sarcoma: report of a series of 25 consecutive children from a single institution. *Med Pediatr Oncol* 1999;32:32.
508. Lee SM, Hajdu SI, Exelby PR. Synovial sarcoma in children. *Surg Gynecol Obstet* 1974;138:701.
509. Blakely ML, Spurbeck WW, Pappo AS, et al. The impact of margin of resection on outcome in pediatric nonrhabdomyosarcoma soft tissue sarcoma. *J Pediatr Surg* 1999;34:672.
510. Philippe PG, Rao BN, Rogers DA, et al. Sarcomas of the flexor fossae in children: is amputation necessary? *J Pediatr Surg* 1992;27:964.
511. Marcus RB Jr. Current controversies in pediatric radiation oncology. *Orthop Clin North Am* 1996;27:551.
512. Fontanesi J, Pappo AS, Parham DM, et al. Role of irradiation in management of synovial sarcoma: St. Jude Children's Research Hospital experience. *Med Pediatr Oncol* 1996;26:264.
513. Ryan JR, Baker LH, Benjamin RS. The natural history of metastatic synovial sarcoma: experience of the Southwest Oncology Group. *Clin Orthop* 1982:257.
514. Shpitzer T, Ganel A, Engelberg S. Surgery for synovial chondromatosis: 26 cases followed up for 6 years. *Acta Orthop Scand* 1990;61:567.
515. Goldman AB, DiCarlo EF. Pigmented villonodular synovitis: diagnosis and differential diagnosis. *Radiol Clin North Am* 1988;26:1327.
516. Steinbach LS, Neumann CH, Stoller DW, et al. MRI of the knee in diffuse pigmented villonodular synovitis. *Clin Imaging* 1989;13:305.



15

CEREBRAL PALSY

THOMAS S. RENSHAW

BASIC BRAIN DEVELOPMENT 563

ETIOLOGY 564

PREVALENCE 564

CLASSIFICATION 565

Neuropathic Types 565
Anatomic Patterns 565

ASSOCIATED PROBLEMS IN OTHER SYSTEMS 566

Central Nervous System 566
Gastrointestinal System 566
Genitourinary System 566

DIAGNOSIS 566

History 567
Physical Examination 567
Other Tests 567

COMMON TYPES OF CEREBRAL PALSY AND THEIR MANAGEMENT 568

Spastic Quadriplegia 569
Spastic Diplegia 577
Spastic Hemiplegia 589
Athetoid Cerebral Palsy 590

UPPER EXTREMITY INVOLVEMENT 590

Nonsurgical Treatment 591
Surgical Treatment 591

Cerebral palsy is a generic term used to describe certain clinical syndromes whose common feature is the abnormal control of motor function by the brain. The abnormal control results in a nonprogressive disorder of movement and/or posture, but the manifestations can change with growth, development, and maturation. Often, sensory and other brain functions are involved.

The etiologic agents of cerebral palsy afflict the immature brain to produce neuropathologic lesions that do not worsen. Although some parts of brain development con-

tinue throughout childhood, Gage has defined the "immature brain" as being younger than age 2 years. Accepting this definition, one may classify and code a brain lesion occurring thereafter as producing static encephalopathy, with a specific cause, instead of cerebral palsy, which may be coded without a known causative agent (1). In general, this differentiation does not affect the prognosis, and most clinicians refer to both as cerebral palsy.

BASIC BRAIN DEVELOPMENT

An excellent overview of brain development has been provided by Goldberg (2). During the first trimester of embryonic life, the brain differentiates into a grossly recognizable cerebrum, cerebellum, and other structures. An insult dur-

T. S. Renshaw: Department of Orthopaedic Surgery, Yale University, New Haven, Connecticut 06520; Department of Orthopaedic Surgery, Yale-New Haven Hospital, New Haven, Connecticut 06510.

ing this period usually produces a structural lesion that is detectable by magnetic resonance imaging (MRI).

Neurons begin to develop early in the second trimester, originating in the periventricular regions and migrating toward the surface of the cerebral cortex. By the fifteenth week of gestation fetal reflex movements can be detected. At the end of the second trimester all neurons have been formed and any damage or loss cannot be replaced.

Synaptic connections begin to be established early in the third trimester and intensify after birth. Glialization, which begins in the second trimester, occurs at least until age 2 years (3). Myelination in the brain does not begin until late in the third trimester, but continues into adolescence in a well-defined pattern. As more pathways become myelinated, primitive reflexes drop out, mostly during the first 6 months of life, and normal postural reflexes appear. As myelination continues pathology in the brain becomes apparent. Brain morphologic maturation, as detectable by MRI, has been reported to continue through at least age 10 years (4).

As Goldberg points out, only after the neuronal pathways from brain lesions have become myelinated and can be tested and found to be abnormal can such lesions be detected. Because different pathways are myelinated at different times, spastic diplegia usually is not detected until at least 8 to 10 months of age, hemiplegia usually at about 20 to 24 months, and athetosis usually after 24 months (2).

ETIOLOGY

In most cases of cerebral palsy only risk factors can be identified, and not specific causes. The etiology is not necessarily the result of a brain insult that occurred in the prenatal or perinatal period. Only approximately 10 to 15% of patients in one large group had documented perinatal hypoxia or other problems (5). Cerebral palsy is not solely the result of prematurity because 60 to 65% of afflicted children were born at full term (1). Although only approximately 10% of cerebral palsy patients weigh less than 1,500 grams at birth, in this low birth weight group the risk of having cerebral palsy is 90 per 1,000, compared with 3 per 1,000 if weighing more than 2,500 grams and appropriate for gestational age (1,5,6). Low birth weight for gestational age and prematurity are commonly associated with the development of spastic diplegia (6).

Maternal risk factors in the prenatal period include infection, drug or alcohol abuse, epilepsy, mental retardation, hyperthyroidism, severe toxemia, an incompetent cervix, and third-trimester bleeding (4). Genetic abnormalities, teratologic agents, or congenital malformations of the child's brain may play a causative role, and in some patients, there may be multiple contributing agents (7–9).

Risk factors in the perinatal period include trauma; kernicterus; vaginal bleeding at the time of admission; placental complications such as abruptio, premature rupture of membranes, and chorionitis; and hypoxia or anoxia. It has been suggested that four questions must have positive answers in order to establish birth asphyxia as the probable cause of cerebral palsy (10):

1. Was there evidence of marked and prolonged intrapartum asphyxia?
2. Did the newborn exhibit signs of moderate or severe hypoxic-ischemic encephalopathy?
3. Is the neurologic condition one that intrapartum asphyxia could explain?
4. Has the clinical evaluation been extensive enough to exclude other conditions?

Oxytocin augmentation, cord prolapse, and breech presentation also have been associated with increased risk for cerebral palsy, but only if accompanied by low apgar scores (1).

Postnatally, an insult can come from head trauma (11); vascular accidents in the brain; central nervous system infections; kernicterus; hypoxia or anoxia from such causes as near drowning, suffocation, and cardiac arrest; and other problems. The long-term manifestations of cerebral palsy, caused by different specific agents, have not been extensively studied, but there is evidence that postnatal infectious causes commonly produce more severe orthopaedic deformities than do many other agents (12).

The brain lesion is permanent and nonprogressive, but the natural history of cerebral palsy is not static. Growth and maturation of not only the central nervous system but other systems as well often result in changing musculoskeletal problems in the child.

PREVALENCE

Cerebral palsy is found in from 1 to 7 per 1,000 children throughout most of the world, theoretically being more common in geographic regions where prenatal maternal and perinatal infant care are poor (3,13). In regions where sophisticated neonatal intensive care units exist, the risk of brain damage may be reduced by early treatment of certain problems, but also the lives of very premature infants and those with other life-threatening problems are often saved. In this latter group, the incidence of cerebral palsy is higher than in the general population. The result is that the incidence of cerebral palsy is only slightly reduced by preventing some cases, while saving others who have cerebral palsy who would not have survived (3). Twin pregnancies result in a child with cerebral palsy about 12 times more commonly than do single pregnancies. This is largely related to low birth weight (14). The prevalence of the neuropathic

types and anatomic patterns of cerebral palsy varies greatly in many reports because of the widely differing populations studied. For example, a study containing the residents of state institutions shows many more severely involved individuals than does a study derived from a large private medical practice.

CLASSIFICATION

Cerebral palsy is classified by the neuropathic type of motor dysfunction and by the anatomic region of involvement.

Neuropathic Types

Spastic

This is the most common type of motor dysfunction. In cerebral palsy spasticity is an upper motor neuron syndrome caused by a lesion of the pyramidal system of the brain. The manifestations are a velocity-dependent increase in muscle tone and hyperexcitable tonic stretch reflexes. Spasticity is usually accompanied by weakness, loss of muscle control or dexterity, interference with balance, fatigability, and often the simultaneous contracting of antagonistic muscles (15). Severe spasticity is often referred to as rigidity. Joint contractures are common in spastic cerebral palsy.

Athetoid

Athetosis is a type of dyskinesia (abnormal movement) caused by an extrapyramidal brain lesion. It is characterized by purposeless writhing movements which become intensified when the child is frightened or excited. With pure athetosis, joint contractures are uncommon and muscle tone may not be increased. Tendon lengthenings in children with athetosis are often unpredictable, and may result in the creation of an opposite deformity that is more difficult to treat. Decades ago athetosis comprised about 25% of the cases of cerebral palsy because a major cause, Rh incompatibility with resulting kernicterus, was not so easily detected and prevented as is now the case. Dystonia, a phenomenon of increased general muscle tone, distorted postures, and abnormal positions that are induced by voluntary movements can occur together with athetosis.

Ataxic

Ataxic cerebral palsy is uncommon. It is a disturbance of coordinated movement, most noticed when walking, and is usually the result of cerebellar dysfunction. A mild intention tremor may be present, contractures are rare, and except for the treatment of scoliosis and hip dysplasia, surgery is rarely necessary.

Mixed

Children with mixed cerebral palsy have both pyramidal and extrapyramidal motor control abnormalities. Variable amounts of spasticity, athetosis, and/or ataxia occur together in this form. Sometimes the athetoid component is barely detectable, but it may nevertheless make surgical treatment less predictable.

Hypotonic

Generalized hypotonia may last for 2 or 3 years, and is most often a stage through which an infant passes before developing overt spasticity or ataxia. The brain lesion is present but masked by lack of myelination of the pathways that will carry its abnormal messages. Occasionally, mentally retarded children are erroneously referred to as having hypotonic cerebral palsy.

Anatomic Patterns

Quadriplegia

Quadriplegia, also known as tetraplegia, implies involvement of all four limbs. Many of these children have global involvement with mental retardation; bulbar dysfunction, manifested by drooling, dysarthria, and dysphagia; and seizures. The usual cause is severe hypoxia. After initially presenting as a floppy baby, the child shows delayed developmental milestones. The spectrum of severity is variable, from having no sitting ability or head control to being able to walk independently.

Diplegia

With diplegia, both lower extremities are always involved to a greater extent than the upper extremities, which are affected to some degree. A substantial percentage of diplegia results from prematurity. There has often been associated periventricular hemorrhage in and/or around the third ventricle, producing the characteristic lesion of diplegia (periventricular leukomalacia) in the motor fibers to the lower extremities before they enter the internal capsule (1). Intelligence is usually normal.

Hemiplegia

In hemiplegia, one side of the body is involved, the upper limb being more affected than the lower. The diagnosis is not often made until after walking has begun or fine motor hand control is noted to be deficient. A focal traumatic, vascular, or asymmetric infectious lesion is likely to be the cause of hemiplegia.

Seizure disorders are most frequently seen in this type of involvement, probably because of the focal brain lesion (4). The seizures usually begin in the first 2 years of life (16). Children with hemiplegia are also more likely to have homonymous hemianopsia and stereognostic deficits than are those with other types of involvement (4). Asymmetry of upper and lower limb growth, with the involved side being smaller, is also a common finding and probably is related to the trophic factor of sensory loss (17).

Other Types

Anatomic patterns of involvement are not always clear-cut, and some patients do not fit these common types. Blair and Stanley found only 55% intraobserver agreement in a cerebral palsy classification study (18).

Double hemiplegia refers to bilateral, usually symmetric involvement, with the upper extremities being more afflicted than the lower extremities. Triplegia implies difficulty with any three limbs, usually both lower and one upper. Monoplegia means only one limb is affected.

Paraplegia is used to describe involvement of the lower extremities only. This is a rare occurrence as the result of a brain injury, and such a pattern of motor dysfunction should alert the physician to the possibility of pathology in the spinal cord or canal.

ASSOCIATED PROBLEMS IN OTHER SYSTEMS

Central Nervous System

Other central nervous system problems occur as the result of global brain involvement, but the spinal cord usually is spared. Seizures afflict about 30% of children with cerebral palsy, and are most often seen with patients who have hemiplegia and quadriplegia, with mental retardation, or in postnatally acquired syndromes (19).

Mental retardation, defined as IQ less than 50, occurs in 30 to 65% of children with cerebral palsy (19). It is most prevalent in those with spastic quadriplegia. Other problems include behavioral and emotional difficulties; perceptual disorders; learning disorders; bulbar involvement with drooling, difficulty swallowing, and speech impairment; sensory deafness (which is most often seen in those with extrapyramidal involvement); and visual difficulties, such as perceptual problems, strabismus, nystagmus, and cortical blindness. Visual problems affect about 50% of children with cerebral palsy (1), so visual screening examinations are important for young children.

Gastrointestinal System

Problems with this system are particularly common in more severely involved children. Constipation and fecal impaction are common problems in children with global involvement. Impaired swallowing, vomiting, esophageal reflux, and hiatal hernia can cause aspiration and the risk of severe pneumonia, epigastric pain, profound feeding problems, and poor nutrition (20). Children with cerebral palsy who are malnourished have soft tissue wasting and interference with growth (21,22). When they undergo surgery they are at higher risk for postoperative infections (23).

Assessment of nutrition includes composition of the diet, especially regarding calorie and protein intake, and the feeding history. Can the child feed him- or herself, and if not, who is the feeder? Is the swallowing competent or does frequent aspiration occur? A radiologic contrast study of swallowing and to rule out gastroesophageal reflux may be helpful. Nutritional status can be poor despite obesity, and therefore studies such as total serum proteins and albumin; iron, iron-binding capacity, and transferrin levels; hemoglobin and erythrocyte mean corpuscular volume; and total lymphocyte count may be helpful to assess nutritional status (24,25). This is routinely done preoperatively with patients who will undergo extensive spinal surgery, but is not necessary for all preoperative workups. Keep in mind, however, that no single study is an absolute indicator of malnutrition.

Correction of malnutrition is best accomplished by enteric feeding augmentation, if possible. If swallowing is impaired, a tube-feeding program should be considered. When oral or tube-feeding supplementation is not feasible, the child should be referred to an appropriate surgeon for consideration for a feeding gastrostomy or jejunostomy. Gastroesophageal reflux sometimes can be managed successfully by medical means, but may require surgical fundoplication.

Genitourinary System

Bladder dysfunction and urinary incontinence are common in severely afflicted children. They also have a higher incidence of urinary tract infections than the normal population. This may relate to bladder dysfunction and retrograde colonization from frequent diaper soiling, or to urolithiasis, probably caused by dehydration and urinary stasis.

McNeal and colleagues, in a study of cerebral palsy patients, noted that 28% complained of enuresis, 26% had stress incontinence, 18% had urgency, and 36% had more than one symptom (26).

DIAGNOSIS

The diagnosis usually is established by a pediatrician or a neurologist before the child has had occasion to visit the

orthopaedic surgeon. In some instances, however, an unexplained abnormal posturing, limp, toe walking, limb asymmetry, joint tightness, developmental delay, or other finding enables the orthopaedist to make the diagnosis of cerebral palsy.

History

Except for familial spastic paraparesis and congenital ataxia which are inherited conditions, cerebral palsy is not a genetic disease. The medical history begins with a search for possible causes and risk factors, including environmental agents, abnormal events during the pregnancy, the details of the birth, and assessment of the neonatal and infantile periods. Next, it is important to assess some benchmark physical developmental milestones, such as sitting, crawling, cruising, and walking (Table 15-1). These may be normal with hemiplegia. The review of systems should be thorough to detect any of the commonly related problems. A history of previous treatment, including surgery, is essential.

Physical Examination

The main goals of the physical examination are:

- to determine the grades of muscle strength and selective control;
- to evaluate the muscle tone and determine whether it is normal, hypotonic, spastic, athetoid, or mixed;
- to assess reflexes and sensory function;
- to evaluate the degree of deformity or muscle contracture at each of the major joints;
- to assess linear, angular, and torsional deformation of the spine and long bones, and fixed hand or foot deformities;
- to appraise balance, equilibrium, and standing or walking postures.

Physical assessment begins with observation of the child while taking the history. Next, as a dynamic examination evaluate the head control, sitting balance, the ability to crawl, the ability to pull up to stand, standing posture and balance, and the ability to walk. Observational gait assess-

ment is imperative in those who can walk. The remainder of the examination is performed on the examining table, or, better yet, on the parent's lap, if the child is age 4 or 5 years or younger. The primitive neurologic reflexes, tendon reflexes, sensation, muscle strength, muscle tone, joint range of motion, contractures, torsional abnormalities, and spine should be assessed (1,27,28). Remember that motor dysfunction in the extremities can also be a manifestation of a brain or spinal cord tumor, infection, or other problem.

At the end of the initial history and physical examination formulate a functional assessment of the patient for documentation at that time and for communicating with other health care professionals. The following is an example of such an assessment: "The patient is a 5-year-old boy with spastic quadriplegic cerebral palsy. He is the product of a 32-week uncomplicated pregnancy, and was delivered by emergency cesarean section because of uncontrolled uterine bleeding. He has fair head control, poor sitting balance, and has never pulled to stand, or walked. He is able to communicate discomfort only, and does not participate in any activities of daily living."

Other Tests

Specialized gait analysis, valuable in the management of certain patients with cerebral palsy, is rarely necessary for diagnostic purposes. It may be useful in differentiating between idiopathic toe walking and mild spastic diplegia (29–31).

The diagnosis of conditions such as dysmorphic syndromes or congenital metabolic, neurologic, and muscular diseases, usually can be differentiated from global involvement with cerebral palsy, by clinical examination, and, if necessary, chromosomal analysis. Special imaging techniques, including MRI, positron emission tomography (PET), and computed tomography (CT), are useful in the evaluation of intracranial pathology.

Plain radiographs may be important. If there is any sign of a spinal deformity, radiographs in the coronal or sagittal planes, or both, document the degree, and sometimes the cause (e.g., a congenital vertebral anomaly), of the deformity. It can be argued that a periodic (every 12 months) coronal plane radiograph of the pelvis is necessary for the early detection of hip pathology, such as acetabular dysplasia or subluxation, in children with spastic diplegia or quadriplegia who are not walking (Fig. 15-1). These problems may not be clinically detectable, and are more easily managed and have better outcomes if treated early. Weight-bearing radiographs of the feet and ankles in the anteroposterior and maximally dorsiflexed lateral projections document the status of foot deformities when surgical intervention is being considered.

TABLE 15-1. SIMPLE DEVELOPMENTAL MILESTONES

Milestone	Average Age Achieved (mo)	95th Percentile
Head control	3	6
Independent sitting	6	9
Crawling	8	Some never do
Pull up to stand	8	12
Independent walking	12	17

(From ref. 3, with permission.)

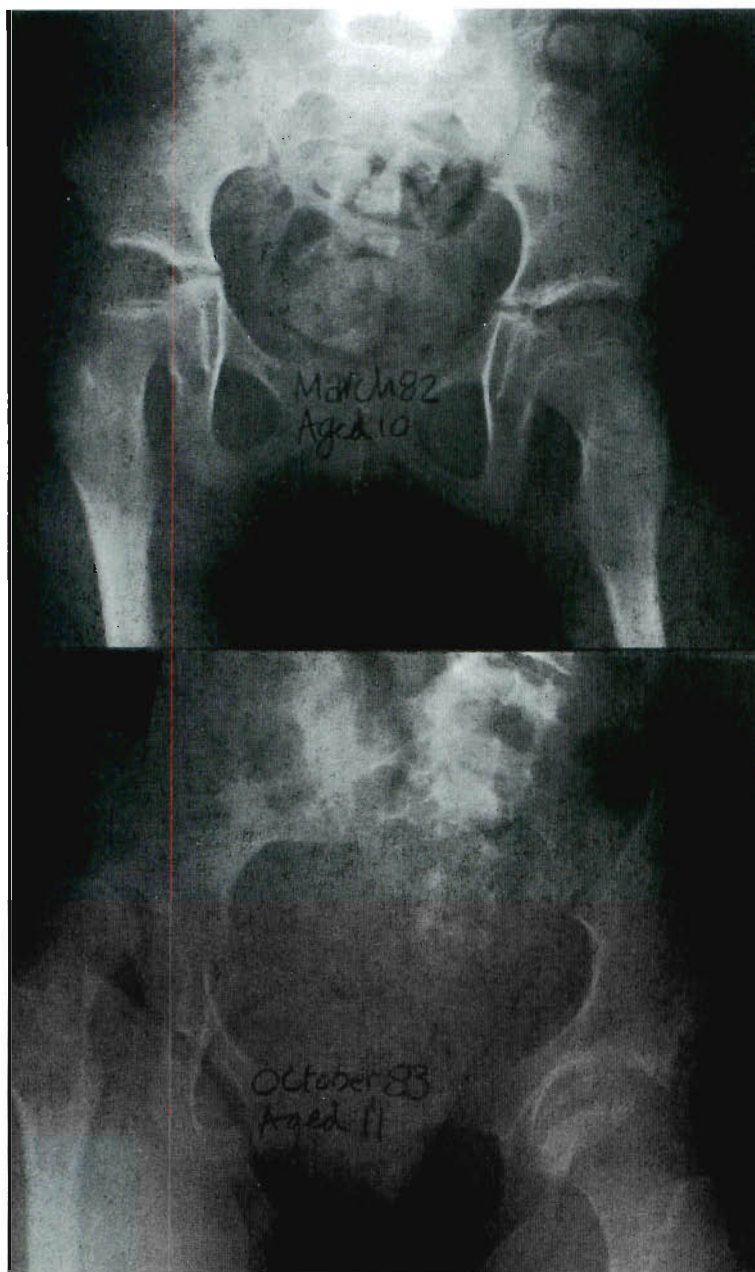


FIGURE 15-1. Radiographs showing substantial changes in the right hip, including dislocation, which developed over a few months at age 10 years. Annual hip evaluations, including radiographs, are important in detecting such problems.

COMMON TYPES OF CEREBRAL PALSY AND THEIR MANAGEMENT

The remainder of this chapter uses the formats of spastic quadriplegia, diplegia, and hemiplegia; athetoid cerebral palsy; and the upper extremity, to discuss the principles and techniques of management of common problems.

Many centers have developed cerebral palsy management programs conducted by teams of knowledgeable specialists. Team members usually include a pediatrician, orthopaedic surgeon, neurologist, consultant neurosurgeon, clinical nurse specialist, physical therapist, occupational therapist,

speech–language specialist, social worker, educator, and psychologist (4). It is especially important for the team members to frequently communicate and confirm that they are in agreement, at least substantially, so that the family does not receive mixed or conflicting messages about their child's problems or care. The family is the most important member of the team.

Assessment of Treatment Results. Unfortunately, most treatment methods in cerebral palsy are not grounded in databased research, but rather are based on empiricism, opinions, and experience, as the best that can be done. For-

tunately, physicians now recognize that treatment must be measured in terms of technical outcomes, functional health assessments, and patient satisfaction (2). Many measurement instruments now have been developed and validated (32). These include gait analysis, the Gross Motor Function Measure, the Pediatric Orthopaedic Society of North America's Health Status Questionnaire (33), the Gillette Children's Specialty Healthcare Normalcy Index and Functional Assessment Questionnaire, and the WeeFIM. In time, these and others should provide the needed data to base clinical care on reliable critical pathways.

Spastic Quadriplegia

An example for spastic quadriplegia is a patient with global involvement who is unable to walk and who requires nearly total care. Of paramount importance are the priorities of such a person which are, in order of importance:

- communication with others;
- the ability to take care of activities of daily living, especially personal hygiene;
- mobility in the environment; and
- walking (29).

Only about 20% of children with spastic quadriplegia will eventually walk. Realistic goals for nonambulatory orthopaedic care are directed toward maintaining balanced, comfortable sitting. The specific objectives are achievement and maintenance of:

- a straight spine and a level pelvis;
- located, mobile, painless hips that flex to at least 90 degrees for comfortable sitting, and extend to at least 30 degrees of flexion, to accomplish pivot transfers;
- mobile knees that flex for sitting, and can extend enough (to <20 degrees or less of flexion) to be controlled by orthoses for transfers;
- plantigrade feet for wearing shoes and for comfort on the footplates of wheelchairs;
- an appropriate wheelchair;
- management of problems in the other systems.

It is important to understand that it is in the wheelchair that the patient with spastic quadriplegia will spend most waking hours. The chair should be considered a total body orthosis, to be fitted and maintained by an expert (Fig. 15-2). The ability to independently transfer in and out of a wheelchair greatly facilitates the ability to live in a group-home setting for an adult with spastic quadriplegia. It is beneficial for all concerned to have a physical therapist experienced with patients in wheelchairs collaborate in developing the wheelchair prescription. The following should be considered in wheelchair design:

Foot rests:

- should be long enough for the shoes,
- either should support the entire foot in a plantigrade

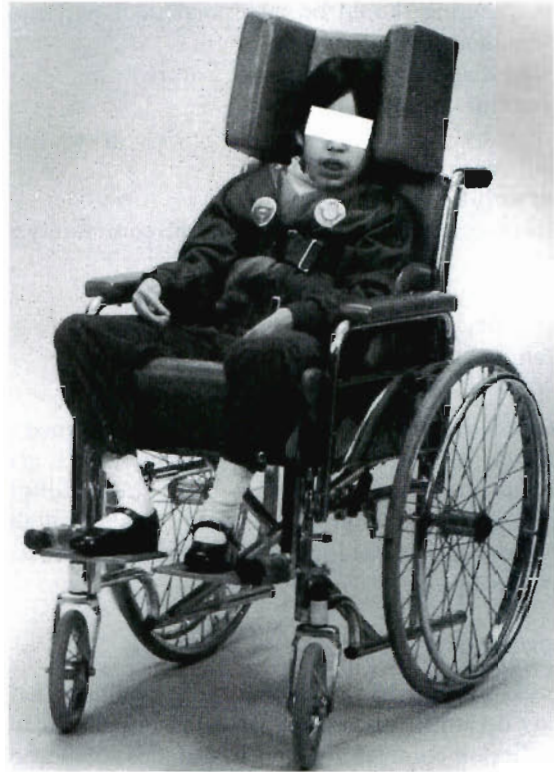

FIGURE 15-2. An appropriately fitted wheelchair provides proper body positioning, including head control.

position or be removed to allow free dangling of fixed deformities, such as severe equinus, to avoid increased pressure over a small area of contact,

should be able to swing out of the way for entering and exiting the chair, and

should accommodate foot restraint straps if needed.

Seat:

height must allow the feet to correctly contact the foot rests,

depth should entirely support each of the thighs, which may not be of equal lengths, but not compress the popliteal area,

width should not compress the trochanters, but also should not allow lateral shifting or excessive tilting of the pelvis,

firmness should be as much as tolerated by the patient to provide maximum pelvic stability without creating excessive skin pressure over bony prominences,

contour should be incorporated, if necessary, for comfort.

Chairback:

height should support the patient's trunk from the pelvis to the midscapular region,

width should accommodate the trunk and any needed thoracic support pads,

firmness should be as firm as is comfortable to aid in preventing collapsing kyphosis,

contouring should be incorporated, if necessary, to accommodate scoliosis, reclining may be a necessary feature.

Restraint components:

may be necessary for foot, leg, pelvic, trunk, arm, or head control.

Portability:

is necessary if transportation in the community is desired.

Propulsion method:

the patient's arms,
an attendant,
motorization.

Because the child's waking activities are performed while sitting, the spine and hips are of prime importance, and are often the site of major problems in spastic quadriplegia. Other lower extremity problems specific to the ambulatory patient with spastic quadriplegia are addressed in the section on spastic diplegia.

Hyperlordosis

Increased lordosis in the lumbar spine is almost never a primary deformity in cerebral palsy. It is usually secondary to hip flexion contractures, and it responds to appropriate correction of those contractures by such means as stretching exercises or surgical lengthening of the psoas tendon. Hyperlordosis can also be a compensatory deformity below a rigid thoracic hyperkyphosis, and it usually responds to correction of the primary problem. When surgical spinal fusion is necessary to correct severe scoliosis, it is essential to consider the sagittal plane spinal balance and to preserve adequate lumbar lordosis by avoiding overdistraction across the lumbar spine.

Hyperkyphosis

Hyperkyphosis is most commonly seen in the young child with cerebral palsy who has weak spinal extensor musculature and a resultant long, C-shaped kyphotic posturing of the entire spine. This is almost always flexible, correcting fully on prone lying. It is best controlled by proper seating adaptation such as restraint straps on the wheelchair, slight reclining of the back, or, less often, by a thoracolumbosacral orthosis to provide sitting support. There is debate regarding whether increasing sitting support inhibits the function in the spinal extensor muscles and weakens them further, and whether physical therapy or muscle stimulation is helpful in maintaining or enhancing spinal extensor muscle strength.

Kyphosis occasionally occurs in the lumbar spine as the result of overly tight hamstring muscles. This kyphosis disappears with proximal lengthening of the hamstrings.

Children with cerebral palsy are not immune to the spinal deformities that afflict other children, so thoracic hyperkyphosis as the result of the Scheuermann condition, or postural juvenile kyphosis may also occur. Indications for orthotic treatment in these kyphotic conditions are simi-

lar to those in other children, but spinal orthotics are not likely to be as well tolerated.

Scoliosis

Scoliosis is more prevalent in all types of cerebral palsy compared with the general population, and varies directly with the severity of motor involvement. With patients who have mild hemiplegia, scoliosis occurs in fewer than 5%; with patients with severe spastic quadriplegia, its occurrence is much greater; in all cerebral palsy patients, it is about 25%. Specific increased risk factors for curve progression are quadriplegia, younger age, poor sitting balance, pelvic obliquity, and the presence of multiple curves.

Scoliosis in cerebral palsy is different from idiopathic scoliosis. It develops earlier; is more likely to be progressive; progresses beyond skeletal maturity, especially when the curve exceeds 40 degrees; is markedly less responsive to orthotic control; and is more likely to require surgical treatment.

As with idiopathic or other types of scoliosis, there are only three appropriate options for management. These are observation with documentation, orthotic treatment, or surgical stabilization. Observation alone is indicated for a curve that is of insufficient magnitude to require treatment (25–30 degrees), or is present in a patient whose best interests may not be served by active surgical intervention. The latter category is difficult to define: It would include the most severely involved individuals who are unable to perceive or interact with their environment in any meaningful fashion, based on severe and global compromise of their cognitive and sensory perceptual abilities. Only careful study by members of the cerebral palsy team and the patient's family can lead to this assessment. In such cases, the overall management goals are the patient's safety and comfort.

The orthotic treatment of scoliosis in quadriplegic cerebral palsy was based mostly on hope and empiricism until two studies showed that it rarely succeeds in controlling a curve (34,35). Most quadriplegic patients from each center did not experience any meaningful curve control from orthotic treatment. In some cases, however, an orthosis may slow curve progression, particularly in curves of 30 to 60 degrees, allowing beneficial growth in an immature spine before definitive surgical stabilization. At best no more than 15% of brace-treated curves stop progressing, and this may simply reflect the natural history of some cases of scoliosis in cerebral palsy (35). Ambulatory patients with spastic diplegia may develop idiopathic-type scoliotic curves. In these milder cases of cerebral palsy, brace control may be successful. Orthoses and other types of external devices for trunk support may be of value in improving sitting balance, particularly for those patients in whom surgery is not indicated. If the patient can tolerate a total-contact low-profile orthosis, this is the most effective and economical means of providing improved trunk support, even if it is a relatively soft

orthosis (36). This is often not the case, however, and a custom-molded trunk or total-body-supporting wheelchair insert is required. These devices are difficult to fit properly, often quickly outgrown, and expensive. They must provide adequate pelvic alignment, trunk control, and head support (37). Nevertheless, the ability to sit as erectly and comfortably as possible is essential for a totally involved patient. Good sitting improves the patient's mental outlook, communication ability, respiratory function, ease of feeding, gastrointestinal function, hand usage, and mobility in the environment (38).

Surgical stabilization of progressing scoliosis is the only way to stop such a curve, in most cases (39,40). The benefit of a procedure of this magnitude and expense has been questioned by some (41), but most orthopaedic surgeons strongly believe that the surgery is worthwhile particularly in preventing loss of the ability to sit (Figure 15-3). Postoperative patients with reasonably balanced nonprogressive scoliosis have much better endurance for sitting; this greatly improves their quality of life when they can sit up comfortably for several hours, or even all day, and not have frequent substantial back pain that requires recumbency most of their waking hours. According to their caregivers they also are

much easier to feed, dress, and transport than those with severe untreated scoliosis. Most likely, after fusion they have less back discomfort, better pulmonary function, and less decubitus skin ulceration than similarly involved patients with severe untreated scoliosis (but this has not been proven) (42).

Once a curve exceeds 40 to 45 degrees magnitude it is likely to continue progressing, and surgery is usually indicated. Posterior internal fixation with a segmental system, such as double rods with cross-links connected to the spine by multiple hooks; sublaminar wires; interspinous wires; pedicle screws; or combinations of these techniques and an adequate posterior fusion mass is usually employed[2.6]. This is needed to achieve a balanced spine over a reasonably level pelvis, the objective of such surgery (42–45). Whenever possible, a larger and more rigid rod is preferable to provide better correction, resist deforming forces, and promote a solid arthrodesis. It is essential to achieve spinal balance in both the coronal and sagittal planes to maximize sitting balance. An abundance of allograft bone or an effective bone graft substitute should be available to generate the strong fusion mass.

Fusion limits are usually from the upper thoracic region

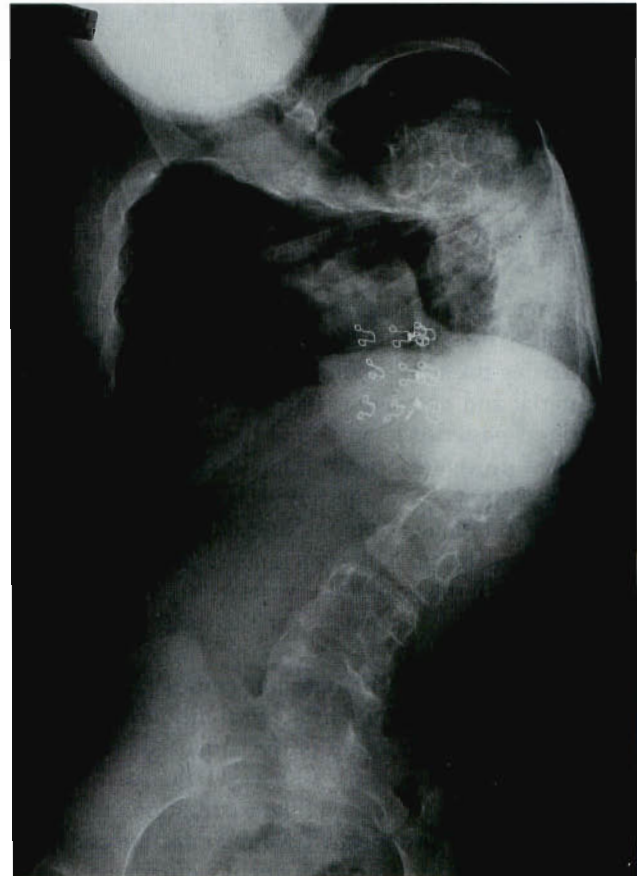
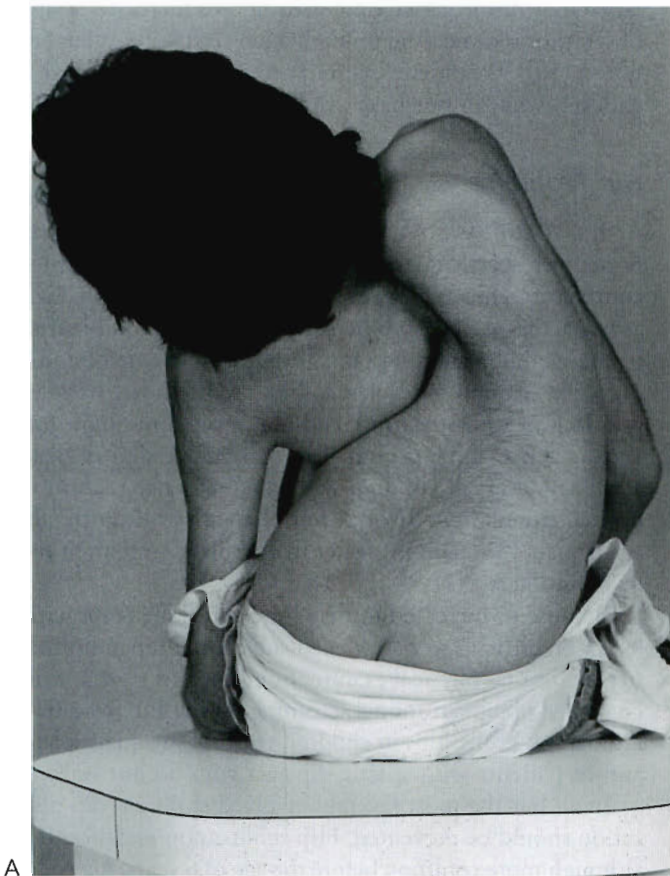
FIGURE 15-3. Clinical (A) and radiographic (B) images of a girl with cerebral palsy who has severe, untreated scoliosis. She is unable to sit for more than a few minutes.

(T1–T3) to L5, or more commonly, to the pelvis. When the fusion does not extend to the upper thoracic region there is an increased risk of developing a substantial junctional kyphosis cephalad to it. This may interfere with the ability of the patient to see at or above the horizontal, or may require constant and eventually painful neck hyperextension to do so. No matter how cephalad the upper fusion level or what type the fixation, some patients still develop a junctional kyphosis. Although applying a bilateral two-level clawed-hook configuration at the cephalad end of the rods (Fig. 15-4) with preservation of the uppermost posterior ligaments may help to prevent a junctional kyphosis, this has not been consistently successful.

Fusions should include the pelvis, if pelvic obliquity exceeds 10 degrees from the intercrestal iliac line to the top of L5 or L4, when measured on a sitting anteroposterior radiograph. Otherwise, pelvic obliquity may continue to progress and make sitting more difficult. Various techniques for pelvic fixation are available, including hooks, rods, and screws anchored to various bones, but none have withstood the test of time better than the Galveston technique [■2.6–2.7] (46).

Routine anterior spinal surgery is not necessary in cerebral palsy. The most common indication for anterior spinal surgery in this condition is to improve curve correctability. Increased correction may be needed:

- to level the pelvis when pelvic obliquity is rigid and severe;
- to balance the spine in large, rigid curves that do not correct to less than 50 or 60 degrees during supine bending or maximum traction radiographs;
- to release the anterior tether of a kyphosis; or
- to attempt to improve respiratory function or decrease the likelihood of the development of a pseudarthrosis in severe curves.

In such cases, a release of the deforming structures is accomplished by dividing the anterior longitudinal ligament, excising the annulus fibrosis, and removing all of the disc material and endplate cartilage back to the posterior annulus and posterior longitudinal ligament, and packing bone graft into the disc spaces. This may be done via an open thoracotomy, or, perhaps with less morbidity, by an endoscopic technique. Anterior internal fixation is rarely necessary when strong, rigid posterior fixation is performed. The anterior and the posterior operations are accomplished at the same surgical setting rather than staging them by several days or weeks (27).

There are several other important considerations when managing a spinal deformity by surgical means in a patient with cerebral palsy. One-third of the patients are malnourished (47) and may have gastroesophageal reflux, as discussed earlier. Detecting and correcting these conditions preoperatively helps prevent postoperative wound infection and healing problems by improving the patient's nutritional status (48). Determination of the serum transferrin level, albumin

level, and total lymphocyte count are commonly used to assess nutritional status. An index using transferrin and albumin levels to identify malnourished patients has been developed (49).

Intraoperative blood loss should be calculated carefully, expressed in terms of percentage of blood volume, and appropriately replaced to avoid hypovolemia or dangerous coagulopathies, especially when blood loss nears 50% of the blood volume. With this method preoperative blood volume must be accurately estimated, and suctioned blood loss plus blood in weighed sponges should be carefully measured. Another means of monitoring blood loss and replacement is by calculating erythrocyte mass and considering hematocrit measurements in the lost blood as well as in the replacement source.

Postoperative pulmonary problems, such as hypoventilation, atelectasis, aspiration pneumonia, and the adult respiratory distress syndrome may occur, and every preventive effort, including rapid mobilization of the patient, must be enlisted.

Spondylolysis and Spondylolisthesis

Although spondylolysis and spondylolisthesis do not occur in nonambulatory patients, they have been reported in ambulatory patients with cerebral palsy with an incidence similar to that in the general population. No increased severity of symptoms or relation to hip flexion contractures has been noted (50). Treatment is similar to that recommended for children who do not have cerebral palsy.

Hip Problems

About 70 to 90% of the hip problems in cerebral palsy occur with spastic quadriplegia. The common problems are contractures, hip at risk, subluxation, and dislocation. Causative factors of hip problems are probably combinations of muscle imbalance, acetabular dysplasia, pelvic obliquity, excessive femoral anteversion, increased femoral neck valgus, lack of weightbearing, and maldirected resultant force vectors across the hip joint. Femoral anteversion is greater at all age levels in children with cerebral palsy than in the normal population. It does not change significantly after age 6 years (51), and is greater in ambulatory children than in nonwalkers (52).

Because of increased muscle tone and some contracture, it can be difficult to detect even substantial hip abnormalities by routine physical examination. For this reason it may be wise to obtain an annual screening supine anteroposterior radiograph of the hips in children with spastic quadriplegia, and in patients with spastic diplegia who do not walk.

In all but the most severely involved children, hip dislocation should be prevented. Hip subluxation or dislocation, although more common before the age of 6 years, may occur at any age. Hips at risk and hips that are subluxated rarely

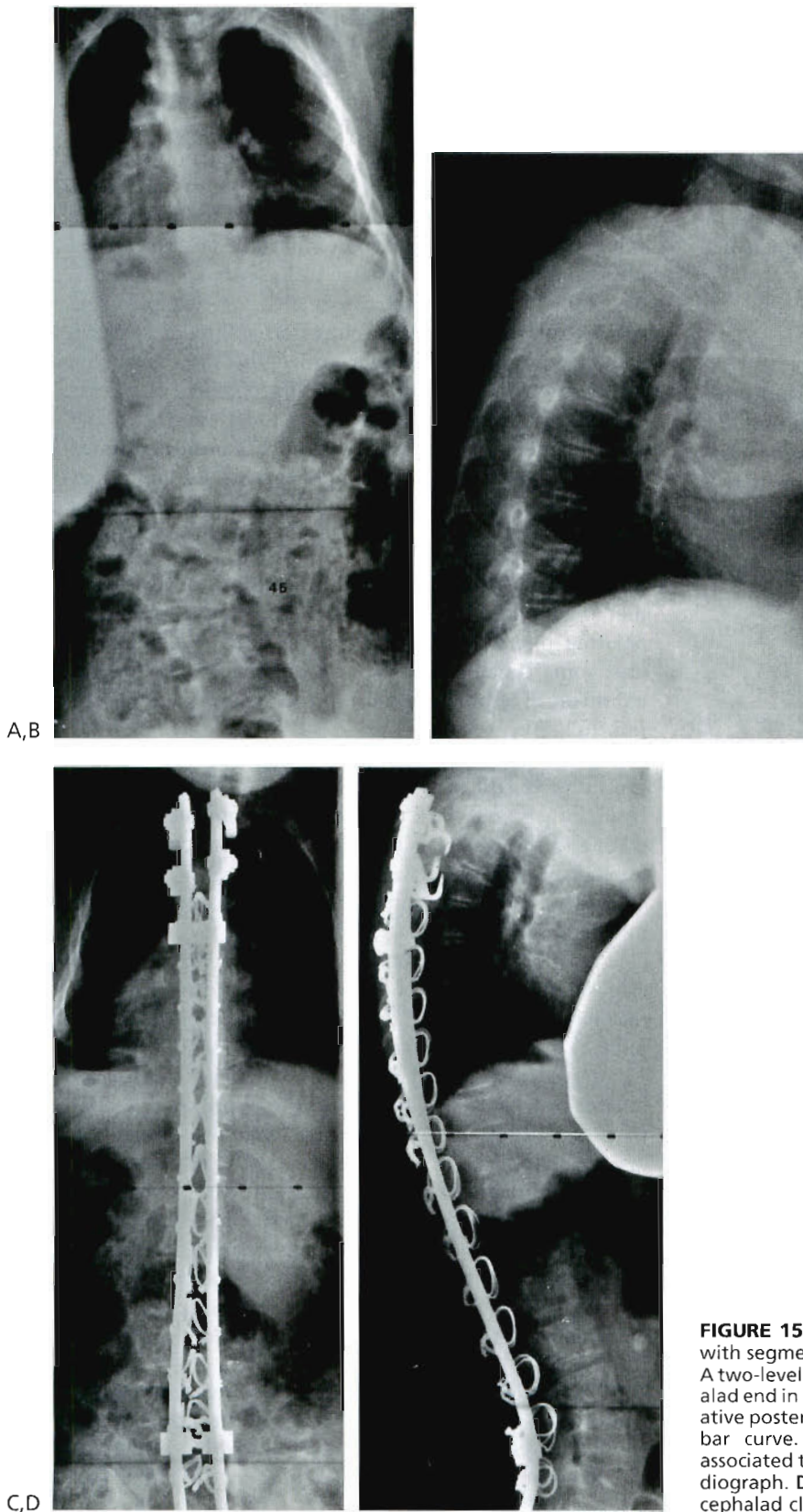


FIGURE 15-4. Treatment of scoliosis by posterior spinal fusion with segmental instrumentation, using mostly sublaminar wires. A two-level, transverse process, pedicle claw was used at the cephalad end in an attempt to prevent junctional kyphosis. **A:** Preoperative posteroanterior radiograph demonstrates a 45-degree lumbar curve. **B:** Preoperative lateral radiograph demonstrates associated thoracic kyphosis. **C:** Postoperative posteroanterior radiograph. **D:** Postoperative lateral radiograph demonstrates the cephalad claw configuration of the hooks.

cause discomfort, but dislocation can lead to pain. Studies have reported pain in approximately 50% of cerebral palsy patients with dislocated hips (53,54), and the associated increased contractures may make care more difficult and worsen sitting balance. One study, however, found that surgical reduction of dislocated hips did not improve pain or sitting ability (55). Until more studies with longer follow-up are available regarding treatment of dislocated hips in cerebral palsy, most surgeons follow the management described in the following section.

Hip Management

Hip at Risk. The hip at risk has increased valgus and anteversion and a shallow acetabulum, but no subluxation. Tightness and contractures in the adductor and flexor muscles are usually present. Without treatment, hips at risk often progress to subluxation or dislocation, particularly if there is less than 30 degrees of abduction in flexion or extension, and/or with hip flexion contractures of greater than 20 degrees. Such progression may be very slow (months to years) or occur much more rapidly. Because the literature lacks valid data regarding the likelihood of such hips worsening, it is not possible to predict the natural history of every hip at risk in cerebral palsy. That leaves the surgeon with the options of closely following hips at risk or intervening. Unless the patient is so cerebrally compromised as to preclude surgical treatment most surgeons will intervene, realizing that at least in some cases the hip pathology would not have been progressive. The use of stretching exercises alone as treatment for hips at risk is rarely, if ever, successful. In young children with hips at risk and mild or absent muscle tightness, night splinting, in an attempt to improve acetabular depth, is an option that some surgeons might choose. That night splinting can reliably increase acetabular depth, however, has not been confirmed by a well-controlled study.

Surgical treatment of the hip at risk consists of lengthening and weakening of the tight adductors and flexors [3.17] (56–58). The adductor longus may be all that needs releasing, especially in those who walk, but the gracilis, and occasionally part of the adductor brevis muscles also, may require release in order to gain abduction to at least 45 degrees for each extended hip and 60 degrees abduction for each hip in flexion. The issue of whether to release or transfer the adductors is discussed in the section on spastic diplegia. Tenotomy or elongation of the psoas tendon, sparing the iliacus fibers, should be performed. Psoas tenotomy, in a nonambulatory patient with spastic quadriplegia, may be performed either at the pelvic brim or at the lesser trochanter. Tenotomy at the more caudal site may produce more hip flexor weakness, a situation of no consequence to a nonwalker, but one that may be detrimental to an ambulatory patient who needs adequate hip flexor power to lift the limb for step climbing (2). Psoas tenotomy at the pelvic brim is performed in the manner

described by Sutherland et al. (59). On rare occasions the psoas may not be tendinous at that level, and the tenotomy must be done more distally. Then it is wise to suture the proximal cut end of the tendon to the hip capsule in an attempt to maintain better hip flexor strength.

Postoperatively, some surgeons use abduction splinting for several months. This is applied at night, and always within the child's range of comfortable abduction. The value of such splinting is questionable. Postoperatively, physical therapy is begun as soon as the second postoperative day (60). In the past, anterior branch, or even complete, obturator neurectomy has been performed to denervate the adductor muscles, in addition to lengthening them. Now this is rarely done because most surgeons believe it to be unnecessary when an adequate adductor release (i.e., allowing 60 degrees of passive abduction) has been performed. If the child has an athetoid component, in addition to spasticity, obturator neurectomy should never be done. That can result in a severe, disabling abduction contracture.

Subluxation. Hip subluxation is defined as uncovering of more than one-third of the femoral head and a break in the Shenton line, but with the femoral head maintaining at least some contact with the acetabulum (45,61). Surgical treatment of a subluxation can prevent subsequent dislocation (62,63).

Soft tissue releases and prolonged splinting sometimes can be successful in very young children. When only soft tissue surgery is deemed necessary to treat unilateral subluxation and the patient is younger than 9 years, bilateral releases may be best because the contralateral hip is usually at least somewhat abnormal or likely to become so, if only unilateral surgery is done (64).

The subluxated hip most often has increased femoral valgus, anteversion, or both, and requires corrective proximal femoral osteotomy (63,65–67). To stabilize the hip joint, varus of the femoral neck is usually reduced to about 115 degrees in an ambulatory child, or even less in a nonambulator [4.1–4.3, 4.6]. In addition to appropriate tendon releases, derotation of the excessive femoral anteversion to approximately 10 to 20 degrees (or 30 to 45 degrees of passive internal hip rotation) is performed to prevent posterior subluxation (68,69) (Fig. 15-5). The younger the patient, the more likely is the valgus and anteversion to recur postoperatively, especially if the child is under age 4 years (70). If the magnitude of the subluxation exceeds 50%, an open reduction and capsulorrhaphy will improve the result (71).

If bony surgery (a varus rotational osteotomy with or without a pelvic osteotomy) is required, prophylactic surgery on a well-covered contralateral hip with adequate abduction is not necessary, regardless of the age or ambulatory status of the patient (72).

If acetabular dysplasia is present (acetabular index >25 degrees) (73), it almost always should be corrected surgically. An exception might be a child younger than 4 or 5 years with very mild dysplasia and recently fully corrected abnor-

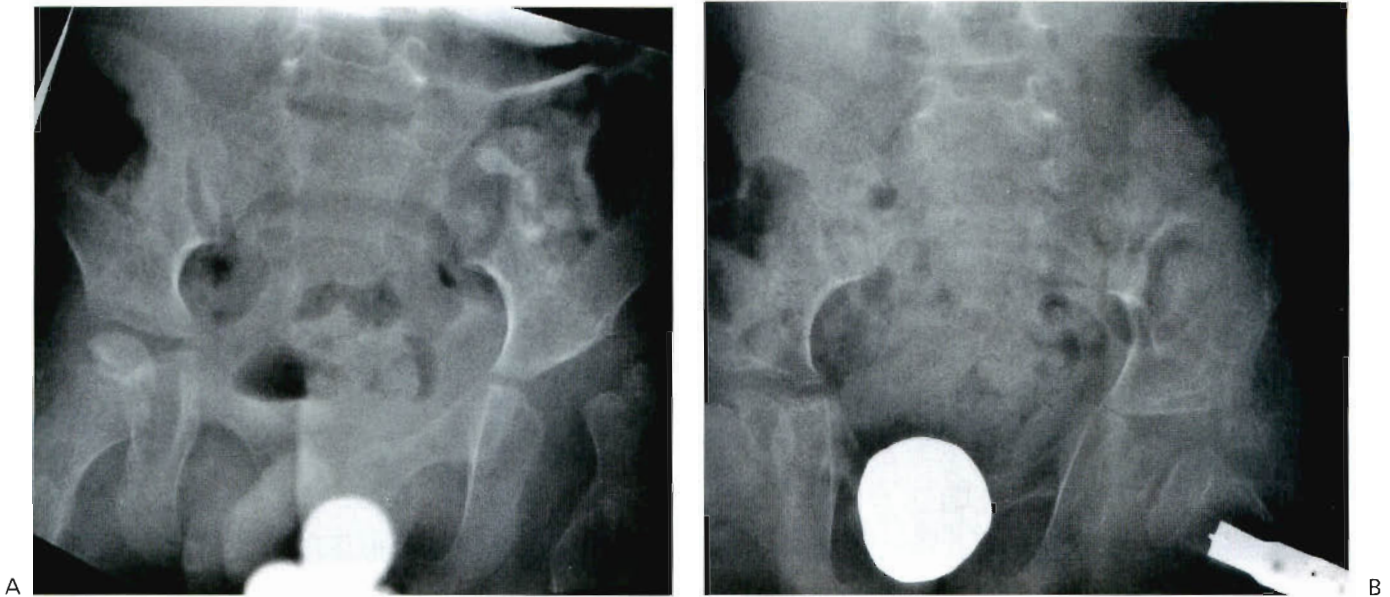


FIGURE 15-5. Dislocation of the left hip in this patient with spastic quadriplegia was treated by varization-derotation osteotomy and innominate osteotomy. **A:** Complete dislocation of left hip. **B:** Status, post-open reduction and femoral and pelvic osteotomies.

mal valgus and anteversion. In this situation acetabular remodeling may occur from the stimulation of redirecting the force vector across the hip joint from the lateral acetabular rim to the center of the acetabulum. Older children have much less potential for biologic remodeling to normalize the acetabulum after femoral varization and rotation osteotomies.

The dysplastic acetabulum in cerebral palsy is shallow. In nonambulators, the acetabular deficit is superior, posterior, and usually more severe than in ambulatory patients. It is almost always associated with an increase in the femoral neck-shaft angle and femoral anteversion. The femoral anteversion is greater in ambulators (52).

Acetabular dysplasia is corrected surgically by choosing the appropriate pelvic osteotomy and being certain that its prerequisites are met. Arthrographic evaluation and, if necessary to define the pathoanatomy, three-dimensional reformatted CT scanning images can be helpful in the decision-making process (52,74).

The Salter, Steel, Sutherland, Pemberton, pericapsular, Dega (75), and Chiari osteotomies, and shelf augmentation of the acetabular rim, all have been successful in cerebral palsy when appropriate indications are met [→3.7–3.12] (45,76–82). If the acetabulum is found to be deficient superiorly and anteriorly, or purely superiorly, an antero-lateral rotational osteotomy, such as a Salter, Steel, or Sutherland procedure, or a Pemberton osteotomy, is appropriate. Often, there is superior and posterior deficiency, in which case, restoration of lateral and posterior coverage by a shelf-augmentation procedure, an Albee shelf, a Dega procedure (83), or a pericapsular osteotomy (68,73) may

be more appropriate. The Chiari osteotomy can be performed if the superior acetabular rim has not been so proximally eroded that the cut will enter the sacroiliac joint.

Dislocation. Hip dislocation may be addressed by relocation procedures (84), by accepting the dislocation, by proximal femoral resection (85), or, less commonly, by hip arthrodesis or total hip replacement arthroplasty (86,87). If the dislocation occurred within 1 year, and/or if the anatomy does not appear excessively distorted, most surgeons elect to perform anterior open reduction and capsulorrhaphy, combined with appropriate soft tissue releases (usually adductors and psoas tendon) and a proximal femoral shortening, varization, and rotation osteotomy. Often, a degree of acetabular dysplasia is associated with the dislocation, and it is wise to correct this at the same time. The pelvic procedure should be tailored to the situation, as described in the previous discussion of the subluxated hip.

If the hip has been dislocated for longer than 1 year, achieving a painless, mobile, stable hip from open reduction and other surgery is less likely because of joint incongruity and eroded articular cartilage on the femoral head. When such a hip is painless, no treatment is required. When the hip is painful, proximal femoral resection with muscle interposition, as described by Castle and Schneider, has a high success rate [→3.16] (85,88). This resection is performed at the subtrochanteric level, the thickened capsule and gluteus medius muscle are sewn over the acetabular inlet, and a muscle cuff of vastus lateralis is sewn over the beveled femoral stump (Fig. 15-6). It is critical to carefully save as much vastus lateralis as possible during the initial dissec-

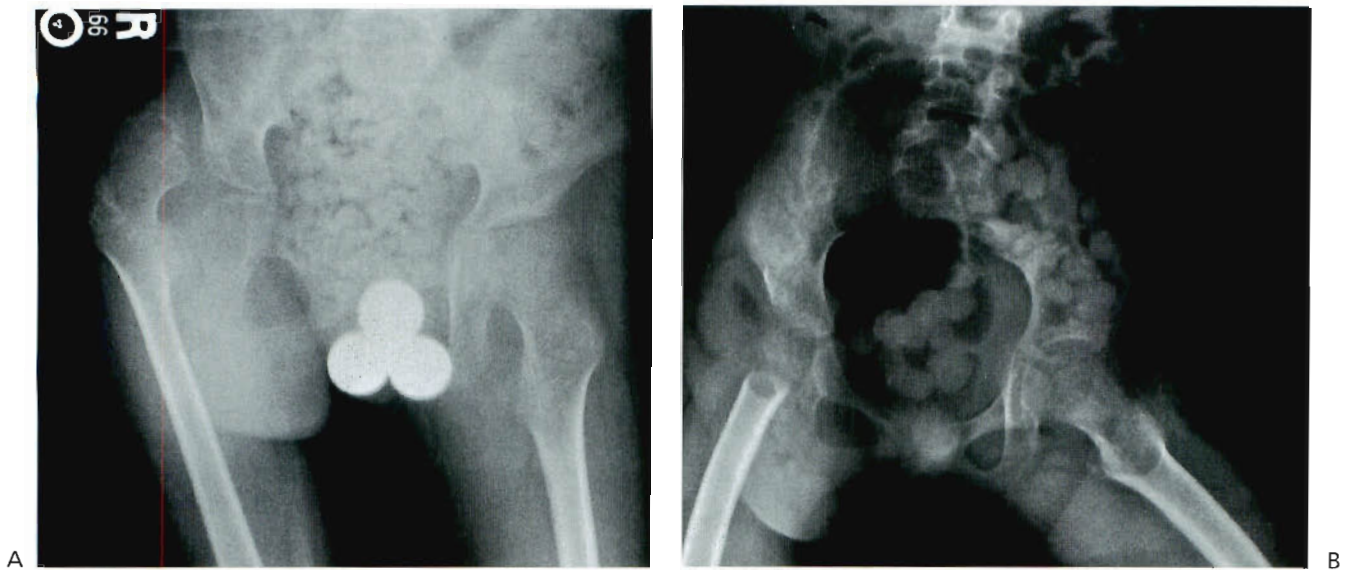


FIGURE 15-6. This nonambulatory child's painful dislocated right hip was treated by resection of the proximal femur just distal to the lesser trochanter and oversewing muscle flaps. This is known as the Castle procedure. His pain was relieved. **A:** Preoperative anteroposterior radiograph shows the dislocated right hip with femoral head deformity and acetabular dysplasia. **B:** Postoperative radiograph. The proximal femur has been resected at the distal end of the lesser trochanter.

tion, and to provide a good, thick muscle covering over the femoral stump. Postoperative management should consist of a bilateral pantaloons or a one-and-a-half-hip spica cast for about 3 to 4 weeks, then comfortable but effective exercises to assure maintenance of the desired range of hip motion. This range is the minimal flexion contracture: at least 100 degrees of flexion, neutral rotation, and abduction to at least 20 degrees. Postoperative traction or external fixators are rarely necessary. The result is usually good motion and good pain relief, but definite thigh-shortening, which must be accommodated in the seat of the wheelchair. Following proximal femoral resection, it is very common to have spasm and discomfort for several days, weeks, or even months. This usually will eventually resolve, but analgesics and antispasmodic medications may be necessary for a prolonged time. A successful trial of an intrathecal baclofen injection may indicate the use of a baclofen pump during this period. Heterotopic ossification about the hip is almost universally seen after proximal femoral resection, and single-dose radiation therapy should be considered to minimize its magnitude.

Femoral head resection, combined with subtrochanteric valgus pelvic support osteotomy, has been successful in relieving the pain of chronic hip dislocation (89,90).

The Girdlestone intertrochanteric resection has been tried for the painful dislocated hip. The likelihood of continuing postoperative pain from femoral-iliac impingement has caused most surgeons to abandon this procedure.

Arthrodesis is another option, but may be difficult to accomplish in nonambulatory patients with severe spasticity. When enough flexion is provided to make sitting

comfortable, it may limit the ability to comfortably lie supine. Arthrodesis, therefore, is not often performed.

The reported experience is small with replacement arthroplasty for painful dislocated hips (89). This procedure is indicated most often for the ambulatory adult with mild to moderate spasticity and severe degenerative arthritis of the hip.

Osteoarthritis. The located osteoarthritic hip in cerebral palsy need not be treated surgically, unless it is painful and nonsurgical methods have failed. In that case, arthrodesis and replacement arthroplasty have both been successful, the latter being preferred because of less postoperative morbidity and easier management (91). Arthrodesis [→3.13] is usually performed in a position appropriate for walking, sitting, and lying: 30 degrees of flexion, 5 to 10 degrees abduction, and neutral rotation for an ambulatory patient, and 45 degrees of flexion for a nonambulator. Leg-length equalization should be considered in walking patients because it may defer the development of back pain (92).

Extension Contracture. Extension contracture of the hip occasionally occurs in the severely spastic child with quadriplegia. The probable cause is tightly contracted hamstrings, which are hip extensors, as well as knee flexors. Often it is seen with extensor thrust, a rigid and sustained hip extension that can greatly interfere with comfortable sitting, because the extension contracture does not allow adequate hip flexion. When severe it can literally push and slide the child out of the wheelchair. The treatment options for mild exten-

sion contracture are proximal lengthening of the hamstrings [➔3.19] or injections into the hamstrings of neuromotor blocking agents, such as botulinum A toxin or alcohol. For more than mild extension contractures, lengthening of the proximal hamstrings is indicated (21,42). If this is not adequate, posterior capsulotomy of the hip and release of the external rotator muscles may also be necessary. Unfortunately, recurrence of extension contractures is common and often rapid following proximal hamstring lengthening.

Extension Plus Abduction Contracture. Extension plus abduction contracture of the hip is not common. It most often occurs after injudicious release of the flexors and adductors in patients who have athetosis, and is also seen after aggressive flexor and adductor releases in patients who have severe spasticity or rigidity and previously undetected co-spasticity in the hip extensor and abductor muscles. Co-spasticity can be difficult to detect even by careful physical examination, but both flexion and extension of the joint are substantially limited, as are abduction and adduction. Gait analysis may detect co-spasticity in ambulatory patients.

Because of their writhing movements patients who have athetosis rarely develop contractures that require surgical releasing. The problem is with the mixed spastic–athetoid patient with tightness, in whom the surgeon cannot determine precisely just how much to weaken the spastic muscle. It is definitely better to err on the side of underrelease.

The treatment of mild cases of extension plus abduction contracture of the hip consists of stretching exercises and proper seating in the wheelchair. Data regarding the use of tone-reducing measures in this situation are currently lacking, but a trial of intrathecal baclofen may be useful. With more severe involvement, surgical treatment is necessary. This involves release of the proximal hamstrings, the femoral and iliotibial band insertions of the gluteus maximus, the external rotator muscles, and even posterior capsulotomy of the hip joint, if necessary. In long-standing severe contractures, femoral shortening may be necessary to prevent overstretching of the sciatic nerve (93).

Spastic Diplegia

Most children with spastic diplegia walk, although late walking is the rule, and it is not unusual for a diplegic child not to begin ambulation until age 4 years or even later (94). Motor improvement often reaches a plateau at about age 7 years, so that if a child is not walking by then there is little likelihood that he or she will walk (27,95). The severity of lower extremity involvement is the most important factor in walking ability. A seizure disorder, marked flaccidity, persistent abnormal primitive reflexes, or a dislocated hip are deterrents to walking, whereas intelligence, upper extremity severity index, or birth weight do not correlate closely with walking prognosis (95). Mental retardation has little or no effect on walking ability (27,96).

TABLE 15-2. BLECK'S WALKING PROGNOSIS CRITERIA

1. Asymmetric tonic neck reflex (ATNR)
2. Neck-righting reflex (NRR)
3. Moro reflex (MR)
4. Symmetric tonic neck reflex (STNR)
5. Parachute reaction (PR)
6. Foot-placement reaction (FPR)
7. Extensor thrust (ET)

These tests are performed in order on nonambulatory children after the age of 12 months. When one of the following is present (ATNR, NRR, MR, STNR, ET) or absent (PR, FPR), one point is given. A score of zero gives a good prognosis for walking; patients with one point have a guarded prognosis; and two or more points indicates a poor prognosis.

(From ref. 27, with permission.)

Bleck (Table 15-2) and Beals (Table 15-3) have described criteria for predicting the likelihood of walking in children with cerebral palsy (95,97–99), and Campos da Paz studied 272 children with cerebral palsy and found that achievement of head balance before age 9 months, independent sitting by 24 months, and crawling by 30 months were good prognostic indicators for walking, whereas lack of head control by age 20 months indicated a poor prognosis (100). Conversely, Molnar and Gordon, in a study of 233 children with cerebral palsy, found that in children younger than age 2 years, independent sitting was not a good predictor for walking ability, but that after age 4 years inability to sit predicted nonambulation (96).

Hoffer and colleagues classified ambulation for meningo-myelocoele into four functional levels. This classification is also appropriate for use in children with cerebral palsy:

1. Community ambulators: These patients walk indoors and outdoors for most of their activities, and may need crutches, braces, or both. They use a wheelchair only for long trips out of the community.
2. Household ambulators: These patients walk only indoors and with apparatus. They are able to get in and out of the chair and bed with little or no assistance. They may use the wheelchair for some indoor activities at home and school, and for all activities in the community.

TABLE 15-3. BEALS' WALKING PROGNOSIS CRITERIA

Severity Index*	Walking Prognosis
>18	Free walking by age 3 years
12–18	Free walking by age 7 years
10–11	Free or crutch walking by age 6 years
0–9	Crutch or no walking

* The severity index is defined as the motor age in months at the chronologic age of 3 years.

(From ref. 27, with permission.)

3. Nonfunctional ambulators: Walking for these patients is a therapeutic exercise at home, in school, or in the hospital. Afterward, they use their wheelchairs to get from place to place and to satisfy all their needs for transportation.
4. Nonambulators: These patients are wheelchair-bound, but usually can transfer from chair to bed (101).

Children with spastic diplegia are less-often afflicted with scoliosis, seizures, speech impediments, and major problems in other systems than are those with quadriplegia. Hip dislocation is also less likely, but excessive valgus and anteversion of the proximal femur, acetabular dysplasia, and hips at risk or subluxated are not uncommon.

The majority of children with cerebral palsy have problems with balance. In diplegia, posterior equilibrium is most often affected, but this does not obviate walking or require the use of cane or crutches. Crutches are necessary if anterior balance is defective. If lateral balance is significantly involved, a walker will be needed. Severe lateral equilibrium disturbances usually preclude any walking.

Gait Analysis. Gait analysis in cerebral palsy is an objective and well-established method of documentation that allows the careful study of the various components of pathologic gait, the energy expended (102), and the outcomes of treatment protocols. Gait analysis is discussed in Chapter 5 of this textbook, and in others devoted exclusively to the subject (1).

A recent study indicates that when experienced physicians added gait analysis data to their own clinical evaluations, they changed their surgical recommendations about half the time, with more decreases than increases in procedures (103). Whether this will improve surgical outcomes and reduce costs has not been studied. Although preoperative gait analysis is theoretically desirable, it is neither possible nor necessary for every child who undergoes surgery. Nevertheless, every surgeon who treats children with cerebral palsy should have a good knowledge of normal and pathologic human gait, and understand gait analysis and pattern recognition (104) (Fig. 15-7). The application of his or her observational gait assessment then will be more accurate.

The prerequisites for normal gait are:

- stability of the foot and entire lower extremity in stance phase;
- clearance of the ground by the foot in swing phase;
- appropriate prepositioning of the foot at the end of swing phase;
- adequate step length; and
- maximization of energy conservation (1).

Observational gait analysis is done by watching the child walk repeatedly while viewing the gait from the front, back, and side. Study only one component at a time (e.g., cadence, stride length, the foot, the knee, the hip, lower-extremity

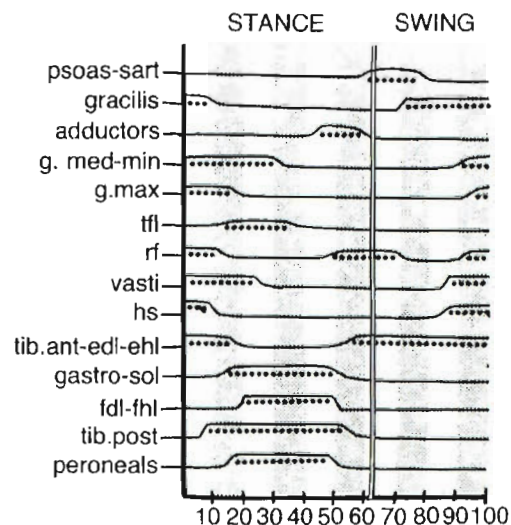


FIGURE 15-7. Chart of normal muscle-firing patterns (*dotted lines*) for the lower extremities. The patterns of a child with cerebral palsy are compared with these normal data.

rotational alignment, the pelvis, the trunk), recognizing that often there are differences between the sides. Gage has described observational gait analysis in detail (1). For a given child, intraobserver observations are more accurate than interobserver observations (105). In either situation, the opportunity to study a videotape of the gait from the front, back, and sides, with zoom capability for the feet, increases accuracy.

Pattern recognition allows the surgeon to observe the gait cycles of the walking child, look for the priorities of gait and deviations from normal, and correlate this information to the findings on static physical examination. If all this information is consistent with a recognized standard pattern (e.g., one of the types of hemiplegia or a diplegic gait with equinovalgus feet, tight hamstrings, tight hip flexors and adductors, and increased femoral anteversion) there is a strong likelihood of success after applying the proper surgical procedures to address each problem.

It would be ideal to review a high-tech gait analysis on every ambulatory cerebral palsy patient preoperatively if cost and accessibility to sophisticated gait labs were not a problem. In reality, surgeons will be most comfortable without gait analysis with those patients who have apparently straightforward patterns of gait pathology (Fig. 15-8). Nevertheless, gait analysis provides a more precise definition of the gait abnormality in more complex cases, such as those with severe diplegia and those who have had previous surgery with little success.

Treatment Methods

The treatment categories for patients with spastic diplegia are modulation of spasticity (oral medications, intramuscu-




FIGURE 15-8. An example of a common spastic diplegic gait pattern. Note the ankle equinus, knee flexion, hip flexion, internal rotation of the entire limb, and compensatory lumbar lordosis.

lar injections, intrathecal injections, selective dorsal rhizotomy), physical therapy, orthotics and/or manipulation and casting, and musculoskeletal surgery. These modalities are discussed in this section.

Oral Medications. Ideally, an orally administered medication would appropriately temper spasticity and allow nearly normal voluntary muscle control to occur over the long term. Unfortunately, such an agent does not exist. Many types of muscle relaxants, antispasmodics, and neuroinhibitory medications have been tried to little or no avail, mostly because therapeutic doses are so large that the substantial accompanying drowsiness is unacceptable (106). Oral pharmacotherapy, widely accepted as effective for problems in cerebral palsy, has been limited to anticonvulsants for seizures and diazepam for superimposed postoperative myo-

spasms, by its probable effect of increasing presynaptic inhibition (107), and perhaps for its tranquilizing effect on pain perception.

Intramuscular Injections. The purposes of injecting various substances into muscles or around nerves are:

- to weaken a muscle and improve the balance of forces across a joint in order to assess whether this will improve function. This is a temporary effect, but in some cases it may be of value to allow a stretching and strengthening physical therapy program to perhaps avoid or, more likely, defer the need for surgery;
- to separate severe spasticity from fixed-joint contracture;
- to determine which muscle is the major contributor to an abnormal posture; and
- to assess the performance of antagonistic muscles (108).

The most common lower-extremity muscle injected is the gastrocnemius to reduce equinus deformity. Other common sites are the hamstrings and hip adductors. Repeated injections may be necessary to achieve the desired effect, and injecting some substances can be painful unless general anesthesia is used.

The shortest-acting drug is a local anesthetic agent, injected in the immediate vicinity of a specific nerve to block its fibers and allow the physician to observe the effect. If the effect is beneficial, then repeating the injection with another longer-acting agent should reproduce the effect (109). If the goal is to make the effect permanent, phenol is used to destroy the nerve fibers.

Another means of weakening the muscle is to inject 45% alcohol into its fibers in a more regional distribution to inhibit nerve transmission and, thereby, muscle contraction. This is painful and requires general anesthesia. When successful, the effect of alcohol injection lasts for a variable period, but usually approximately 6 weeks (27,110).

Botulinum-A Toxin. A newer agent for intramuscular injection is botulinum-A toxin (BTX), a neurotoxin produced by *Clostridia* bacteria. It is delivered into or near sites of nerve arborization, and blocks the release of acetylcholine from presynaptic vesicles at the myoneural junction. Recovery of tone results from the sprouting of new nerve terminals, which peaks at about 60 days (111,112). The agent is injected using a 23- or 25-gauge needle, usually without local or general anesthesia, but topical anesthesia will prevent the discomfort that rarely lasts more than 5 minutes. The muscles are located by palpation. To reach muscles that are deep or difficult to localize, electromyographic guidance and electrical stimulation have been used (113). BTX diffuses readily, so the injection should be placed in the muscle belly (114).

BTX is quite expensive, and optimal dosage regimens have not been agreed upon. It has been shown to be a safe technique, whose effects on muscles begin in 12 to 72 h,

and usually last for 3 to 6 months or longer (115–117). Injections may be repeated after 2 or more weeks, and up to six injections may be given at a site, until the desired response in muscle tone reduction has been achieved. This treatment is contraindicated in the presence of fixed joint contractures. It is most useful in very young patients when a limited number of muscles are involved (117), and the surgeon wishes to defer surgical intervention until the child is older, has a stabilized gait pattern, or other components of the child's problem can be more precisely identified and addressed. A double-blind trial in 12 patients with equinovarus or equinovagis foot deformities showed improvement in five of six treated patients, and improvement in two of six placebo-injected patients (118). A report of 14 children who had BTX treatment for equinus showed marked improvement (mean 6.7 months) in six, mild improvement in three, and no improvement in five (119). Other studies have found it to be longer-lasting with fewer side effects, and equally, or more efficient, at improving equinus gait than serial casting (110,120), but combining the two may be beneficial (121). In the upper extremity BTX has shown beneficial effects, particularly in relieving tight elbow flexors and thumb flexors. This has improved hygiene and cosmesis, but not fine motor function (122). Independent of motor function, BTX is usually effective in relieving pain from muscle spasms (119). Unanswered but essential questions are:

- whether or not the expensive and temporary tone reduction will allow physical therapy efforts to succeed in avoiding, rather than just delaying, the need for surgery;
- what is the optimal dosage protocol;
- when and what are the effects of BTX antibody formation; and
- what aberrations and their controlling muscles are most appropriate for this treatment?

Intrathecal Injections. Baclofen (Lioresal) is an agonist of the neuroinhibitor gamma-aminobutyric acid which interferes with release of excitatory transmitters that cause spasticity (107). When injected intrathecally, it acts on the spinal cord synaptic reflexes to broadly decrease lower-extremity spasticity for about 8 h (1). In the upper extremity, there is a lesser reduction of tone, about equal to that achieved by selective posterior rhizotomy, but no change in joint range of motion (123). It has poor lipid solubility and does not cross the blood–brain barrier very effectively, so when given orally large doses are required, and excessive lethargy is the result. Beneficial long-term effects are realized when administered intrathecally by a refillable, subcutaneously implanted pump. This provides a ten-times greater concentration in the spinal fluid than does comparable oral dosing (124). Problems and complications from using the pump are decreasing as experience improves, and include

infection, catheter breakage, fistula, equipment malfunction, and the need for frequent refilling with the medication.

Large long-term outcome studies are not yet available. It appears that this treatment may be most helpful for patients with dystonia and spasticity who have hygiene problems or difficulty with sitting (121). Another group of patients may be those who are ambulatory and have underlying weakness. This second group cannot tolerate the additional weakness imposed by selective dorsal rhizotomy. Recognizing that adequate data on which to base a recommendation for its use in specific patients is weak or lacking, it appears that intrathecal baclofen is of definite benefit in about one-half the patients in studies thus far reported (124–126). It also may be of some aid in assessing the potential benefit of selective posterior rhizotomy. In the doses used to treat spasticity, baclofen has no effect on athetosis (127).

Selective Posterior Rhizotomy. This procedure has been employed for several decades (128), but only in the past 15 years has it been widely used in North America (129,130). Unlike earlier attempts to surgically or electrically alter the central nervous system beneficially (e.g., cerebellar stimulation) (131), it has met with growing acceptance. The principle of selective posterior rhizotomy is to reduce spasticity and balance muscle tone by altering the control exhibited by the anterior horn cells in the spinal cord. The normal inhibitory influences on the gamma efferent system, produced by higher centers in the brain and carried to the anterior horn cell by long intraspinal tracts are deficient in cerebral palsy, as is the ability to coordinate movement as mediated through the extrafusal fibers from the alpha motor neurons. Selective posterior rhizotomy attempts to limit the stimulatory inputs from the muscle spindles in the lower limbs that arrive by the afferent fibers in the dorsal roots. This is done by sectioning only those dorsal rootlets whose impulses exert excessive facilitatory influence on the anterior horn cell, and thus better balance these influences.

The operation is performed under general anesthesia without relaxants. The lumbar laminae and the intervening ligaments are removed as an en bloc laminoplasty from L1 to S1, preserving the facet joints. Then, individual posterior rootlets from the L1 to S1 posterior roots are carefully dissected out and electrically stimulated. The electromyographic and physical responses are noted, and those rootlets that supply the offending muscles are surgically divided. Rootlets are spared if they show decremental and squared-type electromyographic responses. They are divided if the responses are incremental, clonic, multiphasic, sustained, or contralateral, although this determination is not always easy. In most cases, up to 70 rootlets per root are stimulated, and 25 to 50% are sectioned. The laminae and ligament complex are then replaced. The theoretical advantages of laminoplasty compared to laminectomies, at each level, are that it is faster, may result in less scarring in the spinal canal,

and replacement of the intact laminae may prevent some cases of lumbar instability or deformity.

The patient best served by selective posterior rhizotomy is the young child (age 3–8 years) with:

- spastic diplegic involvement;
- voluntary motor control;
- reasonable intelligence and motivation;
- no fixed contractures;
- good trunk control;
- the ability to walk with good underlying strength and balance; and who has
- severe, pure spasticity; and was
- preterm or of low birth weight (132).

Full-term children are more likely to have rigidity plus spasticity, and therefore may not respond as favorably to selective posterior rhizotomy (1,128). Availability for, and cooperation with, postoperative physical therapy are prerequisites for the procedure because therapy may be required three or four times per week for as long as a year to regain strength. The procedure is not indicated in children with athetosis, ataxia, rigidity, dystonia, antigravity muscle and truncal weakness or hypotonia, overlengthened tendons, and severe fixed contractures. Information regarding any benefits in those with spastic quadriplegia is limited (133). The results of unilateral rhizotomy in spastic hemiplegia are not available, but at least one source does not recommend it (128).

In the early postoperative period, the patient is weaker than before surgery and requires intensive physical therapy, but once the acute rehabilitation are complete, improvement in the lower extremities may be dramatic and perhaps lasting. Sometimes even improvements in upper-extremity function, seizure control, bladder function, swallowing, speech, and personality are seen after an overall reduction in muscle tone (134). Results thus far show lasting reduction in spasticity; increased hip, knee, and ankle range of motion; often a plantigrade foot in stance; increased stride length and walking speed; and no increase in sensory deficits (128,134–138). Three randomized trials comparing rhizotomy with physical therapy have now been published (139–141). These indicate that rhizotomy is more successful at reducing muscle tone, and often at improving motor function.

Although this procedure reduces spasticity and tone, it does not affect joint contractures or the overly contracted musculotendinous unit. These must be treated by orthopaedic surgical procedures after rehabilitation from the rhizotomy. It is estimated that up to 65% of patients require additional procedures, with those older than 4 years at the time of rhizotomy requiring more orthopaedic procedures (129,142,143).

Selective posterior rhizotomy can be beneficial, but it is not a miracle procedure, nor does it cure cerebral palsy. The patient will still have poor motor control and balance, muscle weakness, contractures, sensory involvement, and/

or persisting primitive reflexes if he or she did so preoperatively.

As with virtually everything else in medicine, there are some caveats. An occasional patient develops rapid and severe hip subluxation or dysplasia after this type of rhizotomy (144). Heterotopic ossification around the hip has been reported to occur after varus derotation osteotomy of the proximal femur, with patients who have spastic quadriplegia who have previously had selective posterior rhizotomy (145). Patients with preexisting lumbar lordosis of more than 60 degrees on a sitting lateral radiograph are at risk for the development of postoperative lumbar hyperlordosis (146,147). Spondylolysis and spondylolisthesis have also been reported (148). Another study noted that after rhizotomy, its only consistent negative effect is some increase in sagittal plane anterior pelvic tilt in independent ambulators (137). Perhaps the most common problem after rhizotomy, other than weakness, is the development of planovalgus foot deformities reported in up to 50% of cases (143,149). The deformity is often severe enough to require surgical correction.

Long-term results with many patients followed over several decades are not yet available, but thus far an increased risk of developing scoliosis or kyphosis has not been reported. Another question remaining to be answered is whether late neuropathic arthropathy will occur, but this seems unlikely.

Selective posterior rhizotomy is a demanding procedure for the patient, the family, and the professional staff. Although there is little risk involved, it is expensive, long-term results are not known, and careful patient selection and surgical technique are mandatory. Nevertheless, it can be of substantial benefit to many children.

Physical Therapy. There are several possible roles for physical therapy in cerebral palsy, some generally well accepted and some not. The brain lesion impacts on motor function in four major ways, with individual variation in the involvement of each. These are:

- loss of selective motor control and dependence on primitive reflexes;
- abnormal muscle tone that is influenced by posture, position, or movement;
- muscle imbalance between agonists and antagonists; and
- impaired body-balance mechanisms.

Numerous attempts to modify the central nervous system, and to alter substantial motor dysfunction by external physical means, have been employed exhaustively over the past several decades. The goal is to produce major improvement in voluntary control, tone, and muscle and body balance. In general, most therapists work in a cephalocaudal sequence to try to establish head control, trunk balance for sitting, then reciprocal lower-extremity mobility for crawling, pulling to stand, and, hopefully, functional walking.

The treatment methods include neurodevelopmental therapy, sensory integration therapy, patterning, conductive education, pressure-point stimulation, bracing, and stretching, and many recreation-based therapies (150). For any of these techniques to succeed, the brain probably has to be modified or reprogrammed to make new connections that function almost as well as those it originally made (2), and this may not be possible.

The results and benefits of most of these methods continue to be debated (151–155). There is considerable difference of opinion regarding which modalities should be employed, at what age, how often (from once per week to virtually continuous therapy for 18 h a day), by whom, and how the results are to be measured, documented, and assessed. Some published studies suggest that certain physical therapy programs can improve a cerebral palsy child's joint contractures, motor status, and social motivation (4,156,157), whereas others suggest that they do not (153). Significant problems with the literature include small heterogeneous samples, nonrandomized treatment, lack of controlled data, and patient attrition from many studies (153). In many instances it is difficult or impossible to determine whether the therapy was of benefit, or if improvement in motor skills was the result of the child's obligatory neurologic maturation and the learning of substitution patterns and coping methods completely independent from any restructuring of neurocentral control patterns. For some children, certain therapy programs may make a difference. In this regard, it is important that motor function be documented periodically by the therapist during the child's early growth years. This can be done using such systems as the Movement Analysis of Infants, the Gross Motor Performance Measure, Pediatric Evaluation of Disability Inventory, and WeeFIM (158,159).

Much less controversial is that during the first 3 years of life a program that focuses on compensation techniques, showing parents how positioning can facilitate mobility, maintaining joint range of motion, and educating parents about cerebral palsy is helpful. A major source of psychological stress in mothers of handicapped children is the dependency of the child on the mother for accomplishing the activities of daily living. A therapy program that teaches mothers easier ways to work with their child is of great value (160).

Whenever possible, it is beneficial that a parent perform much of the physical therapy, and not rely totally on the physical therapist (4). This saves professional fees, minimizes trips to the therapist and interference with school time, and positively involves parents and even siblings with the child. Many parents, however, decline such involvement because of other family or career demands, or simply because they are too tired to commit the time and effort necessary.

Frequent sessions and protracted therapy programs are expensive and time-consuming, and generate hopes and expectations for all involved. If not of benefit, or if ineffective

modalities are employed, the therapy process can raise false hopes, increase frustrations for the child and the family, waste large sums of money, and sometimes unbalance interactions among the members of the family unit (4,151).

There is general agreement that postoperative rehabilitative physical therapy is not only helpful but it is usually essential to maximize the benefits of most types of orthopaedic surgery in cerebral palsy. The patient and the therapist are the ones who will overcome the early postoperative weakness, stiffness, and discomfort. The goals are to maintain or improve joint range of motion, regain preoperative muscle strength, maximize ambulation, and improve function, if possible. How long should the postoperative therapy continue, and how frequently should it be done? This varies with the magnitude of the surgery performed. It may be necessary for as little as 1 or 2 weeks, or as long as several months. The family may be able to provide the treatments on a daily basis. If all treatments must be provided by the therapist, two or three times per week is standard.

Another potential benefit of physical therapy is the prevention of joint contractures by the supervision of a daily range of motion program for those who lack the motor strength and voluntary control to maintain their own ranges. This type of program can be done by a parent, an aide, or a caretaker, and does not require the services of a physical therapist, other than to develop and monitor the program. As previously noted, however, data proving the benefit of such a program are lacking. In some severely involved children, it is impossible to prevent contractures no matter how aggressive the treatment.

An unresolved issue is the duration of maintenance physical therapy. Although some parents want and even demand therapy two or three times a week for the life of their child, there is no evidence that any type of physical therapy can have a beneficial, lasting effect on motor function beyond early-to-middle childhood (age 4–8 years). Children older than this no doubt benefit more by devoting their time (and their families' and society's resources) to the development of communication, cognitive, and recreational skills, instead of endless therapy sessions.

It is irrefutable that the physical therapist can be of great benefit to the child and family. She or he is a resource, and sometimes a case manager for:

- adaptive and therapeutic equipment, including seating systems;
- fabricating some types of splints and basic orthotics;
- educating the family about cerebral palsy and the child's deficits and potential;
- advising the family regarding modifications in the home using community resources;
- acting as liaison with the school; and
- as a realistic, supportive health care professional (161).

Of great importance is a good two-way communication pathway between the therapist and the physician. The thera-

pist is often the primary person who documents the child's neuromotor status, monitors progress, and may recommend surgery or other treatments.

A different therapy approach, described in a pilot study, is that of using low-intensity transcutaneous electric stimulation in an attempt to strengthen weaker antagonistic lower-extremity muscles. The treatment is applied only at night. In a small group of patients, some motor improvement was noted, but was lost after the stimulation was withdrawn (162). More investigation of this approach is necessary before its clinical relevance is determined.

Orthotics. Orthotic devices are classically used to prevent deformity, to improve function by substituting for a weakened muscle, or to protect a weakened part. In cerebral palsy, they are most commonly used to:

- stabilize feet, ankles, and knees;
- maintain nighttime hip abduction to prevent subluxation;
- possibly slow the progression of spinal deformity, to obtain beneficial growth or improve sitting balance; and
- as night splints to prevent hand and wrist deformity.

Progress has been made in understanding the biomechanics of the lower extremities in cerebral palsy, and developing strong, lightweight, comfortable new materials for the orthoses. Lower-extremity orthotics almost never will have to extend above the knee with patients who have spastic diplegia (163). For foot control, the UCBL (University of California Biomechanics Laboratory) orthosis is most popular. This can maintain forefoot, hindfoot, and subtalar alignment in a supple, not rigid, foot, but cannot control the ankle.

Various types of ankle-foot orthoses (AFOs) include the solid-ankle type, to control the entire foot, provide mediolateral ankle stability, and maintain the ankle in a rigid plantigrade position to preserve the plantar flexion-knee extension couple. The solid-ankle AFO is the best choice for the spastic foot, and can be used in almost any instance. Modifications to the solid-ankle AFO have been made to improve foot and ankle function. An example is the posterior leaf-spring AFO, which does not provide mediolateral ankle stability, but allows some plantar flexion and dorsiflexion from neutral, while preventing footdrop. This type is used when spasticity is minimal. It stores minimal kinetic energy during dorsiflexion, and gives back minimal energy at push-off. Articulated AFOs have hinged ankles and plantar flexion stops, which prevent equinus and excessive extensor thrust while allowing free dorsiflexion during gait. They also allow more tibialis anterior muscle function. Although articulated AFOs better allow dorsiflexion activities, such as bending over and stair climbing, they provide less ankle support, are bulky, and do not fit into shoes well, and are more likely to cause heel irritation. They may also prevent a needed plantar flexion-knee extension couple, and may

allow triggering of the gastrocnemius stretch reflex, causing the patient to fight the brace (158). Another type of AFO is the floor-reaction type, of which there are several varieties. It uses the plantar flexion-knee extension couple to prevent knee-flexion crouch and gain appropriate stance-phase knee extension during gait, provided that the foot is plantigrade, no significant knee flexion contracture is present (<10 degrees), hip extension is full, and no major rotational malalignments are present in the limb. This approach has essentially eliminated the need to ever prescribe a KAFO (knee-ankle-foot orthosis) in an ambulatory child with cerebral palsy. The main indication for KAFOs is to brace the lower limbs for ease of transfer in a nonambulatory patient.

Manipulation and Casting. Obtaining beneficial elongation of tight or contracted musculotendinous units or joint capsules can sometimes be accomplished by gentle, non-painful, repeated passive stretching, followed by maintaining the correction with casts, splints, or adjustable orthotic devices. This treatment method has the potential to cause pain to the child, and to raise false hopes for improvement when applied to more than mild spasticity, tightness, or contractures, or when used in patients who are unable to accurately communicate their discomfort.

With properly selected patients, manipulation and casting can sometimes improve, at least temporarily, contractures of the ankle, knee, elbow, wrist, or hand (164). The process may be repeated from every few days to a week, and various casting materials, dropout casts, removable splints, and orthotics with dial-lock or ratchet hinges may be used. The use of nerve or muscle blocks as an adjunct may sometimes be worthwhile.

Another method, known as "inhibition casting," has been employed for several years. This treatment is applied to the lower-extremities by carefully molding bilateral plaster below-knee casts in an attempt to inhibit certain normal tonic plantar reflexes, especially grasp, and thus reduce overall lower-extremity tone. A probable added benefit is stabilization of the foot and ankle by the well-molded cast. The casts are either left in place or changed weekly for 3 or 4 weeks, during which time intensive physical therapy is performed. Hinged AFOs are then substituted for the casts. This method has reportedly been successful in some hands (165–169), but because the noted improvement may not be maintained for more than a few months, others have not considered it to be of value (170).

Orthopaedic Surgery. Surgical treatment is a rapid and dramatic means of altering the structure and function of the musculoskeletal system in children with cerebral palsy. It is almost always the only effective means when fixed myostatic contracture exists. Lengthening a muscle also weakens it. This may help to gain muscle balance about a joint, but strengthening an antagonist may still be desirable, and

difficult or impossible. In most cases, the muscles that contract eccentrically, producing deceleration and shock absorption, are the most appropriate for lengthening, and loss of function rarely occurs. Concentric or accelerator muscles initiate, rather than modulate, movement, and may be substantially weakened by lengthening. In these situations, such as with the iliopsoas muscle, it may be better to intramuscularly lengthen the tendinous portion and accept some residual contracture in exchange for preserving needed strength. What follows are recommendations for the treatment of the most common problems and deformities in an ambulatory child who has spastic diplegia.

Treatment of Specific Problems

In most cases, the patient has several abnormal elements in the disturbed gait. Best results are obtained from surgery if all of the abnormalities are identified preoperatively and corrected during the same surgical setting (171,172), requiring only one rehabilitation period. Little or no benefit is derived by simply performing one procedure, such as a triceps surae lengthening, and waiting to assess its effect on other abnormal elements of the child's gait before proceeding to correct them. This strategy does not improve the final result, and inflicts unnecessary discomfort, hospitalization, and rehabilitation on the child.

The best age to perform the surgery varies with the patient and the problems. Ideally it would be after the gait pattern has stabilized, which is about age 4 or 5 years in nonaffected children, and then or later in children with cerebral palsy, but before age 8 years. Certainly, surgery can be successful in older children and adults. In cases in which the hips are at risk for dislocation, or when there is progressive or substantial acetabular dysplasia, surgery should not be delayed, regardless of age.

In the immediate postoperative period, the major concerns related to the orthopaedic surgical procedures are pain management, relief of superimposed myospasms, and minimization of the child's anxiety. Giving the analgesic medication through the existing intravenous access line, using patient-controlled analgesia when possible, routinely administering diazepam for 48 to 72 h to lessen myospasms, providing continuous caudal analgesia through a small catheter, and the presence of kind, supportive personnel, are most helpful to the child.

Overall, the postoperative management is aimed at restoration of joint motion, muscle strength, and improved gait as rapidly as possible. During this period, it may be beneficial to use night splints for comfort, and to prevent joint positioning that could contribute to recurrent contractures. Such splinting should never exceed the comfort tolerance of the child. In this regard, it is sometimes necessary to alternate control of one ankle and the opposite knee on successive nights, or use splinting only during the day, when it can be effectively monitored. The value of night splinting

is not universally accepted, and valid well-controlled studies proving its efficacy are lacking. It is expensive and can be burdensome and uncomfortable for the patient because of malfitting splints, the frustration of substantially restricted mobility, or maintenance of a continuous overstretch on muscles.

When only soft tissue surgery has been done, ambulation may begin within a few days postoperatively. If osteotomies or subtalar arthrodeses were performed, partial weightbearing may begin as soon as 3 weeks postoperatively, assuming that the internal fixation is adequate. Full, unrestricted weightbearing should probably be deferred until radiographic evidence of adequate early bony healing is seen, usually by about 6 weeks. It may take at least 3 months, and sometimes longer, to regain the preoperative level of strength after most multiple lower-extremity surgical procedures with patients who have spastic diplegia.

Hallux Valgus. Hallux valgus and bunions occur commonly in cerebral palsy, most likely because of a combination of muscle imbalance with adductor hallucis overactivity and externally applied forces, such as inadequate clearance resulting from equinovalgus deformity of the foot and ankle, forcing the phalanges of the great toe into valgus (173,174). Equinus, and particularly valgus, of the foot must be corrected first to achieve a lasting good result from hallux valgus surgery in cerebral palsy.

Indications for surgery in this condition are pain and difficulty with proper shoeing; rarely is cosmesis alone an indication. There are myriad operations for the correction of hallux valgus, and most have been used with varying degrees of success in cerebral palsy [→7.12–7.14]. When spasticity is mild, such procedures as ostectomy, capsulorrhaphy, adductor hallucis release or transfer, and proximal or distal first metatarsal osteotomy can be successful (175–179). With recurrence, or with patients who have more severe spasticity, the McKeever metatarsophalangeal arthrodesis (180), with the joint in a few degrees of valgus and 10 degrees of dorsiflexion relative to the floor, is an excellent procedure (174).

Ankle Equinus. Pure equinus of the ankle, without associated valgus or varus, is not common. It is the result of overactivity or contracture of the triceps surae group, which is normally six times stronger than the ankle dorsiflexors (181). Most of the overactivity is in the gastrocnemius muscle. The soleus is usually not the major problem. The equinus deformity can be treated by serial manipulation and casting, which is most successful with patients who are young, have less spasticity, and whose equinus is mild. Recurrence of the equinus deformity after several months is not uncommon after manipulation and casting.

Another nonsurgical method is the intramuscular injection of botulinum-A toxin into the gastrocnemius. This will not help in fixed myostatic contracture, but can improve or correct equinus temporarily in mild cases. Mostly, it simply

delays the need for surgery. Further study is necessary to determine if patients who will realize permanent correction can be identified.

Lasting correction most often requires surgical elongation of the gastrocnemius unit, which, if performed as an isolated procedure, usually can be done as outpatient surgery (173,183). Elongation is most commonly done by lengthening the Achilles tendon (which also lengthens the soleus), by either multiple partial tenotomies, the Hoke triple-cut (184), or White double-cut (185,186) techniques (either percutaneously or open), or by an open step-cut lengthening [➔7.16–7.17]. When percutaneous techniques are employed, care should be taken to avoid completely dividing the Achilles tendon. Some surgeons have advocated methods of attempting to quantify the exact amount of lengthening necessary (187,188). These methods have not gained wide acceptance.

Some authors advocate the Baker (189,190) or Vulpinus (191,192) fascial division type of lengthening of the gastrocnemius aponeurosis alone. This method has the advantage of not only preserving, but actually generating more soleus strength for pushoff (193). Whether it results in a higher recurrence rate is debatable (194). Similar results have been reported in studies comparing tendon lengthening with muscle lengthening in the treatment of equinus deformity (195,196).

A less popular method is Achilles tendon advancement anteriorly (i.e., closer to the talus) on the calcaneus to decrease its power by decreasing its lever arm (197–199). This procedure is more complex than the tendon lengthenings, and has not been demonstrated to be superior. Its best results occur when it is combined with other procedures (195).

Regardless of the surgical technique selected, the result is usually good (200). Recurrence rates are inversely proportional to the age of the child at the time of surgery; lower rates are seen in older children. Before age 4 years, the recurrence rate is about 25%, whereas it approaches zero when the surgery is done after age 8 years (201,202). After surgical lengthening, some believe it is beneficial to control the ankle with a night splint and an orthosis to prevent recurrent deformity and improve function (203). Others have shown that orthotics do not prevent recurrent deformity (204). A reasonable approach is to use an AFO to improve functional stability or control weakness in those who need it, and to reserve night splinting for those who show signs of early recurrent tightness. If the patient has voluntary active foot dorsiflexion to more than 10 degrees, there is a good likelihood that an AFO will not be necessary.

The patient is treated with a below-knee cast for 2 to 3 weeks if only the gastrocnemius aponeurosis has been lengthened or an incomplete Achilles tenotomy (e.g., the Hoke technique) has been done. The below-knee cast is left in place for 4 to 6 weeks after step-cut lengthening of the Achilles tendon.

A problem to be avoided is the postoperative develop-

ment of a calcaneus deformity from overlengthening the heel cord, particularly in a patient with athetosis. Treatment for an overlengthened heel cord is difficult, but some have had success with shortening the Achilles tendon by surgical reattachment or imbrication, and Tardieu and Tardieu suggest a period of casting the ankle in plantar flexion, followed by orthotic control at plantigrade during the day and in equinus at night (204).

Foot and Ankle Equinovarus. Ankle equinus, varus of the hindfoot, and, often, varus and supination of the forefoot are present in this deformity. It is most often seen in hemiplegia, but also may occur in children with diplegia and quadriplegia. The hindfoot varus is most likely caused by overactivity of the tibialis posterior muscle, whereas varus and supination of the forefoot are more likely the result of overactivity of the tibialis anterior, which may also contribute to hindfoot varus. Peroneal muscle weakness may also be a factor.

For treatment of hindfoot equinovarus, correction of the equinus, as described above, must be combined with lengthening or split transfer of the tibialis posterior tendon [➔7.18]. Lengthening may be by the step-cut method or by intramuscular tenotomy cephalad to the musculotendinous junction, which is also known as the “Frost procedure” (163,205). Some surgeons prefer to split the tendon and transfer the lateral half to the peroneus brevis tendon (206,207) in order not to weaken the muscle as much as would a lengthening. Others believe that some weakening is desirable. There are several reports of good results with the split transfer, and many indicate that preoperative gait analysis is not necessary for a successful outcome (208).

Although anterior transfer of the tibialis posterior tendon through the interosseous membrane to the dorsum of the foot has been advocated (150,209), it should not be done in cerebral palsy patients. This transfer can result in a calcaneovalgus deformity that is very difficult to correct (210).

In varus and supination foot deformities caused by overactivity of the tibialis anterior muscle, a split transfer of the lateral half of its tendon to the cuboid bone usually successfully balances the foot (211). DeGnore and Greene use hindfoot varus, which occurs in the swing phase of gait, and a positive confusion test as their indication for split anterior tibialis tendon transfer (212). The validity of the confusion test, however, has been questioned because it does not predict ankle kinematics in the swing phase of gait (213).

Nonrigid varus of the hindfoot often occurs with varus and supination of the forefoot. In this situation, split anterior tibialis tendon transfer, combined with posterior tibialis tendon lengthening, is appropriate.

When the hindfoot varus is rigid, bony surgery, in addition to addressing the triceps surae and tibialis posterior units, is necessary to correct the deformity (214). This can be accomplished by a laterally based, closing-wedge osteot-

omy of the calcaneus with staple or screw fixation, which is technically difficult to reduce and adequately fix. Easier and very effective is obliquely dividing the calcaneus in the coronal plane, posterior and parallel to the peroneal tendons, sliding the posterior fragment laterally, and fixing it with a cannulated or cancellous screw or pins. Assuming adequate internal fixation with either procedure, a below-knee cast is necessary until bony healing has occurred (usually 6–8 weeks). Subsequent orthotic control of the foot and ankle may or may not be necessary.

Foot and Ankle Equinovalgus. This is the most common situation with patients who have diplegia, followed by equinovarus and calcaneus with about equal prevalence (215). Its cause is probably muscle imbalance, with triceps surae overactivity and weakness of the tibialis posterior muscle, with relative overpull of the peroneal musculature (216). The equinus is addressed as described above. It should not be assumed that the valgus originates at the subtalar joint. It may be coming from the ankle, so weightbearing radiographs of the ankle should be studied as part of the surgical planning. If the ankle valgus is really in the distal tibia, it may be corrected by osteotomy, or, in some cases, by hemiepiphysodesis, screw fixation, or stapling of the medial side of the physis, if sufficient growth remains.

Subtalar valgus, which is mild and supple, can be controlled by an orthosis, either an AFO or a UCBL type. The orthosis may be augmented by intramuscular lengthening of the peroneus brevis tendon which decreases the power of the muscle by one grade (217). The peroneus longus tendon should not be lengthened because a varus deformity may ensue. Transfer of the peroneus brevis to the tibialis

posterior tendon has been performed, but published series with evaluations of results are lacking (216).

With more severe valgus that is passively correctable, surgery is usually required, because orthotic control rarely succeeds. This is particularly true if there has been failure of an orthosis to control the hindfoot valgus, such that painful calluses and blisters result on the medial side of the foot.

Most surgeons prefer either an Evans or modified Evans lateral opening-wedge lengthening osteotomy of the distal calcaneus (218), or a subtalar arthrodesis using internal fixation and bone grafting [7.4, 7.10, 7.11] (219) (Fig. 15-9). Calcaneal lengthening restores support of the talus, and does not involve fusion of a joint. It should be combined with medial plication and peroneal lengthening, as described by Mosca (220). Subtalar fusion with internal fixation rigidly fixes the subtalar joint, and yields a higher fusion rate than the classic Grice procedure or modifications thereof, which rely on bone graft alone (221–225).

Stabilization also may be accomplished by arthroereisis, using a staple or an inert plastic block (226). This technique may be effective in some very young children, but it is not widely accepted. Multiple series with adequate long-term follow-up are lacking.

Another method of correcting a supple valgus hindfoot deformity is by medial displacement of an oblique osteotomy of the calcaneus with screw or pin fixation. Although limited experience with this procedure has been reported, the osteotomy heals rapidly, preserves subtalar motion, and is easy to perform (227).

When rigid, nonreducible hindfoot valgus is present the options are a sliding medial-displacement calcaneal osteotomy (228), a lateral opening-wedge or medial closing-wedge

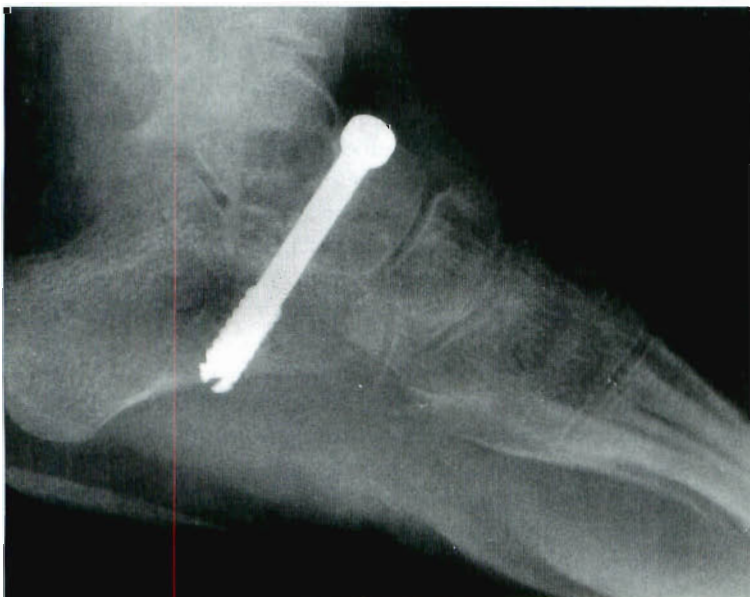

FIGURE 15-9. Postoperative lateral radiograph of a subtalar arthrodesis stabilized by a cannulated screw and augmented by iliac autograft bone.

osteotomy of the proximal calcaneus, a combined calcaneal-cuboid-cuneiform osteotomy (229) or a triple arthrodesis. Triple arthrodesis provides correction (230), but is best avoided in very young patients in whom growth of the foot will be substantially inhibited. For this reason, it probably should not be performed on a child who is not within about 2 years of the end of growth. Triple arthrodesis [➔7.9] appears to be successful over the long term with patients who have mild involvement and are community ambulators. It has been reported not to increase the risk of later development of midfoot and ankle osteoarthritis as the result of abnormal mechanical forces being transferred to those joints over a long period (231). It is always important to achieve the best possible muscle balance at the foot and ankle; otherwise, even a triple arthrodesis may deform in time.

External Tibial Torsion. External (lateral) tibial torsion is usually associated with excessive femoral anteversion and pes planovalgus. Inadequate foot clearance may also be a factor.

Profound external tibial torsion substantially shortens the lever-arm effect of the foot in generating the plantar flexion-knee extension couple, which facilitates knee extension in the midstance and late stance phases of gait and helps to prevent crouch. Stance phase is often shortened, the base of support is unstable, and pushoff power is compromised. The solution to this problem is distal derotational osteotomies of the tibia and fibula at the supramalleolar level to align the ankle and foot progression angle with the direction of gait and the axis of the knee [➔6.8]. The fibula is divided transversely just proximal to the syndesmosis, and the tibia is divided about 2.5 cm above the physis. In younger children fixation by crossed smooth Steinmann pins, cut and bent extracutaneously, and an above-knee cast is adequate. The pins are removed, and the cast changed to below-knee at 6 weeks. In older children, the surgeon may choose to use a T-plate and screws and a short-leg cast. As with any surgical procedure near to an open physis, care must be taken to avoid inadvertent damage to the growth plate.

Knee-flexion Deformity. Knee-flexion deformity may be a true flexion contracture, but is more often simply caused by spastic and tight hamstring muscles, without fixed capsular contracture (232). The medial hamstrings usually are the major problem (233). Very often there is an associated hip flexion contracture and a crouched gait. Rarely, knee flexion may be a coping mechanism for calcaneus deformity (hyperdorsiflexion) at the ankle. More often, the ankle is neutral or in equinus. Equinus must be corrected when hamstrings are lengthened or genu recurvatum may result. It is essential to assess and address all factors to appropriately manage a crouched gait.

As a general rule, the hamstrings require lengthening when straight-leg raising cannot exceed 70 degrees above

the horizontal, or when the popliteal angle (i.e., the sagittal femorotibial angle with maximum knee extension, the patient supine, and the hip first flexed to 90 degrees) is less than 135 degrees (i.e., 45 degrees short of full extension). Lengthening the medial hamstrings is performed by incising the fascial aponeurosis of the semimembranosus muscle at a minimum of two levels, and step-cut lengthening or tenotomizing the semitendinosus and gracilis tendons [➔4.23]. If after these procedures the lateral hamstrings are still tight (popliteal angle less than 160 degrees), they may also require aponeurotic lengthening (234,235).

Postoperatively, hamstring lengthenings with or without distal rectus femoris transfers are managed in removable knee-immobilizer splints, which can easily fit over a below-knee cast. Passive range of motion exercises may begin on the second or third postoperative day. If no bony surgery has been performed walking training may begin as early as the fifth postoperative day. When adequate quadriceps strength has been regained, usually by the fourth postoperative week, the knee immobilizers may be discarded or used as night splints. Between physical therapy sessions sitting should be done with the knees alternately in extension and flexion.

Good results at the knee can sometimes be obtained by lengthening the hamstrings proximally (236) [➔3.19]. It has been found, however, that lumbar lordosis may increase after this procedure because of the overactive hip flexors; also, the desired effect on the distal hamstring tightness may not be achieved (237). It must be remembered that the hamstrings are also hip extensors, sometimes contributing up to a one-third of the extensor torque (238,239). Hip extensor power is somewhat lessened by hamstring lengthening, especially proximal hamstring lengthening. Therefore, this procedure may increase a preexisting hip flexion contracture, as well as increase the lumbar lordosis, if the iliopsoas unit is not addressed concomitantly. Gait analysis has shown that in some patients with a crouch gait, the hamstrings may be of normal or even excessive length. This is seen with simultaneous hyperflexion of the hip. In this situation hamstring lengthening alone may further weaken hip extensor power and increase the already severe hip-flexion deformity. To preserve some of the hip extensor power of the hamstrings, Gage has recommended transfer of the distal semitendinosus to the lateral femoral metaphysis. This may minimally augment external rotation at the hip (1).

Rectus Femoris Transfer. A finding commonly associated with knee-flexion deformity is cospasticity of the rectus femoris muscle and the hamstrings. The rectus may be firing continuously throughout the gait cycle, or mostly during swing phase, but the result often is a stiff-knee gait with less than 80% of normal knee motion. In this situation when the hamstrings alone are lengthened, a stiff, extended-knee gait frequently results. There is lack of adequate knee flexion in swing phase, and that interferes with foot clear-

ance so that circumduction or vaulting may be necessary to compensate (240). The stiff-knee gait may be prevented by transferring the distal rectus femoris tendon medially and posteriorly [➔4.24]. The transfer does not affect gait abnormalities in the transverse plane (i.e., intoeing or out-toeing), and it makes no difference whether the transfer is attached to the sartorius, gracilis, semitendinosus, or iliotibial band (241,242). This transfer is successful in restoring adequate (60 degrees) knee flexion in the swing phase of gait. It has been shown that transfer is necessary to accomplish this, not just tenotomy of the distal rectus femoris tendon (242,243). The indication for distal rectus femoris transfer is a preoperative range of knee motion during gait of less than 80% of normal (less than 45 to 50 degrees) and hamstring–rectus femoris cocontracture, with nonphasic activity of the rectus during the swing phase of gait (243–245).

Unfortunately the static assessment of hamstring tightness by straight-leg raising or by measuring the popliteal angle, does not correlate with the dynamic range of knee motion during gait (246).

Without gait analysis, one is left to assess knee motion during gait either by clinical observation or the study of a videotape of gait. Recent work also suggests that a positive Duncan-Ely test does not predict abnormal EMG activity, and neither the type of abnormal EMG activity in the rectus nor the magnitude of the restricted preoperative knee range of motion are significant variables in determining the success of the transfer (242). The beneficial effects of rectus transfer (increased velocity, stride length, and knee range of motion) may diminish significantly over time (247).

Hip Adduction Contracture. Tightness in the hip adductors can result in a scissoring type of gait pattern, and predisposes the patient to hip dysplasia or subluxation. Generally, when the hips cannot be abducted beyond 30 degrees in flexion or extension, adductor release or transfer (either posteriorly to the ischial tuberosity, which has its advocates [87,248] or posteriorly and distally to the gracilis [249]) is indicated [➔3.18]. There seems to be little difference in the results from release or transfer (250,251), but one study reports a high incidence of pelvic obliquity and hip subluxation after adductor transfer to the ischium (252). Neurectomy of the anterior branch of the obturator nerve is rarely indicated in diplegic patients who can walk, because it excessively weakens the adductor brevis muscle and can result in a wide-based gait with hyperabduction of the hips (253). The hip adductors function to stabilize the hip against excessive abduction during gait, running, and in activities such as skiing, skating, and horseback riding. The gait stability they provide allows more effective hip flexor and extensor activity. Thus, it is important not to “go for broke” and overlengthen or overweaken the adductors in ambulatory patients.

Release of the tight adductors [➔3.17] is performed with the patient supine, through either a longitudinal or trans-

verse incision, depending on the preference of the surgeon. The adductor longus is always completely divided. Often, this is adequate to accomplish the objective of adductor release for most surgeons. This is at least 60 degrees of passive abduction on each side, with the hip and knee flexed to 90 degrees, or at least 45 degrees of passive abduction with the hip and knee extended (the medial hamstrings are also hip adductors). At times, some of the adductor brevis may also need to be released, and it may be necessary to divide the gracilis muscle to achieve the desired abduction.

Hip Flexion Contracture. A hip flexion contracture is best detected by the Thomas test, the prone extension test, or both (254). When the contracture exceeds about 20 to 25 degrees it should be released. Most contractures are caused by a spastic, contracted iliopsoas unit, and often hamstring lengthenings and rectus femoris transfers are necessary, and are combined with psoas recessions. This combination of procedures has very little or no significant effect on pelvic tilt (255).

In ambulatory children release of the iliopsoas tendon by tenotomy at the lesser trochanter weakens hip flexor power excessively, and may prohibit enough hip flexion strength to lift the limb in climbing stairs (256). Ambulatory children should have tenotomy of the psoas tendon alone, not the iliacus fibers, performed over the brim of the pelvis (257). Care must be exercised to differentiate the psoas tendon from the femoral nerve. Occasionally, the psoas is not tendinous at this level. Then a recession to the anterior hip capsule is performed via an adductor approach.

Hip flexor releases are treated postoperatively by lying prone several times per day. Painful muscle spasms are particularly common in the first few days after hip surgery, and may be treated with diazepam and analgesics. It is desirable to begin gentle passive range of motion exercises by the second or third day after flexor or adductor releases, and gait training may begin 5 to 7 days postoperatively. After 3 weeks, more vigorous muscle strengthening exercises are tolerated.

Lumbar Hyperlordosis. Hyperlordosis is usually the result of compensation for bilateral hip flexion contractures. Correcting the contractures corrects the excessive lordosis. It should be remembered that other conditions, such as compensation for a rigid thoracic kyphosis, also produce lumbar hyperlordosis.

Intoeing. Intoeing is most commonly the result of excessive femoral anteversion (frequently measuring 60 to 70 degrees), but occasionally is caused by increased spasticity in the internal rotator muscles of the hip (the medial hamstrings or the anterior fibers of the gluteus medius and tensor fascia lata) (233). Excessive femoral anteversion, causing intoeing, rarely exists as an isolated finding in spastic diplegia.

It is usually accompanied by lower-extremity musculotendinous tightness or contractures that also require correction.

Derotational osteotomy of the femur is the treatment for increased femoral anteversion. The appropriate age for the osteotomy is whenever other lower-extremity surgery is being done. This usually means after age 4 years. The derotation may be at the supracondylar region [➔4.18] in younger children with mild to moderate spasticity, and may be secured either by crossed Steinmann pins (42) and a hip spica cast, or by an external fixator. In older children, and at any age with substantial spasticity, it is best to perform the osteotomy at the intertrochanteric level [➔4.6] and to preserve the attachment of the iliopsoas. Fixation with a strong blade-plate or screw-plate may avoid the need for a postoperative spica cast and allow early hip motion with patients who have adequate bone stock. Such strong internal fixation obviates the problems of loss of fixation and malunion, which occasionally occur after the pin and cast fixation of distal femoral osteotomies. The proximal osteotomy is facilitated by placing the patient in the prone position and using the approach described by Root and Siegal (258). If subluxation and/or coxa valga are present, varus can be added to the osteotomy. Another option for derotation in children older than age 10 years is in the subtrochanteric region with fixation by a locked intramedullary rod, but this cannot be combined with varization.

Femoral derotational osteotomies to correct excessive anteversion require external rotation of the distal segment, which tightens the medial hamstrings. To prevent this increased medial hamstring tightness, which may actually increase internal rotation, these hamstrings usually need to be lengthened when femoral derotation is performed.

Other methods of treating intoeing gait in children with cerebral palsy have been advocated. Two of these are transfer of the semitendinosus tendon to the distal lateral femur (1) and posteromedial transfer of the distal tendon of the rectus femoris. These techniques have not been shown to be effective for intoeing (241). It should be remembered that transfer of the distal tendon of the rectus femoris, either medially or laterally, does improve knee flexion for foot clearance during the swing phase of gait (241). Another reported technique is transfer of the greater trochanter [➔4.9], with its attached gluteus medius muscle to the anterior proximal femur, so that it may function as an external rotator, as well as an abductor (259). This abductor transfer, although sometimes successful, can produce an abductor weakness type of gait and has not been widely adopted (42).

Spastic Hemiplegia

Children afflicted with spastic hemiplegia have involvement of one side of the body, with the arm and hand more severely involved than the lower extremity. On closer evaluation, very mild involvement on the contralateral side is often found, especially in those with more severe affliction (1).

The hemiplegia type comprises about 30% of all cerebral

palsy cases. About 1 in 3 patients have a seizure disorder, and almost one-half have some degree of mental retardation (3). More common than mental retardation is an attention deficit, learning, or behavioral disorder (260). A history of head trauma or intracranial hemorrhage is frequently found in spastic hemiplegia. Virtually all patients are community ambulators, although only about half can walk by 18 months of age (3). Some limb-length inequality and a difference in foot size are the rule, but rarely require any treatment.

The stereotyped concept of the patient with hemiplegia includes equinovarus at the foot and ankle, flexion at the knee and hip, internal rotation of the lower limb, internal rotation at the shoulder, flexion at the elbow, pronation of the forearm, flexion and ulnar deviation at the wrist, and thumb-in-palm with finger flexion in the hand. Actually, the degree of involvement with spastic hemiplegia is a spectrum, which has been separated into four subtypes (155). It is essential in planning treatment to quantify the involvement. Surgical results should be predictably good.

Type I hemiplegia is characterized by weakness of the tibialis anterior muscle, and the triceps surae group is not tight. This type is manifest as a footdrop and a steppage gait, with plantar flexion disappearing during stance phase. It is easily treated with an appropriate AFO. A posterior leaf spring or an articulated ankle type is usually superior to a solid-ankle AFO in this condition (261). The most difficult part of management is to get the child to wear the orthosis if he or she has no other noticeable variation from normality. One reported surgical approach to this type of hemiplegic problem has been transfer of the flexor digitorum longus and flexor hallucis longus tendons to the dorsum of the foot (262). Experience with this technique is limited, and meaningful long-term results are not available.

Type II hemiplegia has tibialis anterior muscle weakness plus spasticity in the triceps surae group, and usually in the tibialis posterior muscle. This produces an equinovarus deformity of the foot and ankle, which persists throughout all phases of gait, and can produce some knee hyperextension late in stance phase. The problem is addressed by lengthening the gastrocnemius aponeurosis or the Achilles tendon, lengthening or performing a split transfer of the tibialis posterior tendon (206,207), and providing an AFO if needed. Split posterior tibial tendon transfer is useful for correction of the varus heel in stance phase when there is no fixed deformity and the muscle is firing in phase (during stance). Often the tibialis posterior is active throughout the gait cycle. In that case it is better to lengthen its tendon rather than perform the split transfer (3). Rarely, the tibialis anterior muscle, instead of being weak, is overactive during the swing phase of gait. Then, a split anterior tibialis tendon transfer can be effective in achieving transverse plane balance of the foot (211). This is usually combined with tibialis posterior tendon-lengthening.

Postoperatively, an AFO may be needed to assist a weak tibialis anterior, or to aid in preventing recurrent equinus

deformity. Some children are orthosis-free after the surgery. The risk of recurrence of the equinus deformity in hemiplegia decreases as the child grows older, being reported at about 25% below the age of 4 years and 12% thereafter (3).

In type III hemiplegia, not only are the triceps surae and tibialis posterior muscles spastic and usually contracted, but hamstring involvement is also present, often with cospasticity of the rectus femoris. This produces a stiff, flexed knee gait with equinovarus foot and ankle deformity. Successful treatment includes the tendon surgery discussed for type II and the addition of medial hamstring lengthenings, often combined with a distal rectus femoris tendon transfer, as described in the section on spastic diplegia. Again, the appropriate AFO may be necessary postoperatively, sometimes temporarily, and sometimes permanently.

Type IV hemiplegia has the features of type III, with the addition of hip flexor and adductor spasticity or contracture. Iliopsoas lengthening, by release of the psoas tendon over the pelvic brim, and appropriate adductor releases are added to the treatment recommended for those with type III involvement.

This classification is helpful in the management of most patients with spastic hemiplegia. It is not infallible, however, and patients occasionally are encountered who have profound equinus with little or no varus; who have increased ipsilateral femoral anteversion, in addition to type IV involvement; or who have other abnormalities.

Athetoid Cerebral Palsy

Children with athetoid cerebral palsy have abnormal muscle tension and tone, which may increase with voluntary activity. Their resting state often includes limb movements that are purposeless, involuntary, and almost continuously changing. The movements are coarse and irregular, often give the child the appearance of squirming or writhing, and extensor tone predominance is the rule. The movements disappear during sleep (263).

The muscle tension often changes with the emotional state. The athetoid movements are greater in the more distal parts of the limbs, and often rapidly flow from flexion to extension, adduction to abduction, and pronation to supination. Because of the almost constant motion, most of the joints are put through a full range of motion, and contractures are not common unless there is an asymmetric component of mixed spasticity present.

Most children with substantial athetosis are not able to walk. Their mobility is by power wheelchair, often with an adapted steering mechanism. The therapeutic focuses for these children should be on communication methods, on facilitating their control over activities of daily living, and on wheelchair mobility (264).

The gait pattern of those few patients with athetosis who can walk is random, inconsistent, and influenced by many external stimuli. Without a consistent baseline, the results

of soft tissue surgery are unpredictable. Tenotomies and muscle releases should be done infrequently, and then very carefully with patients who have significant athetosis, because often the result is a severe, almost untreatable deformity opposite the one originally addressed.

Scoliosis is not uncommon in athetoid patients, and responds well to the internal fixation and spinal fusion techniques described earlier. Adult athetoid patients may develop profoundly painful degenerative spondylosis and myelopathy in the cervical spine, sometimes with upper-extremity weakness and even instability. One study identified two-thirds of athetoid patients by age 44 years, and all patients older than age 55 years, with moderate or severe cervical disc degeneration (265). The most common motion segment is C5–C6. This usually responds well to anterior cervical fusion (266), but severe athetosis and dystonia can make postoperative immobilization very difficult. In this situation, the use of BTX injections into the neck muscles can be extremely beneficial in eliminating involuntary neck motions (267).

UPPER EXTREMITY INVOLVEMENT

Most upper-extremity involvement occurs with patients who have spastic hemiplegia and quadriplegia. When considering treatment, it is essential to consider the function of the entire upper limb, and of the child to whom it is attached. It has long been reported that the problems of spasticity, weakness, poor motor control, poor proprioception and stereognosis, and joint contractures, reduce or eliminate the possible benefits of tendon lengthenings, transfers, or other surgical treatment in most cases. Patients with hemiplegia have been reported to have better results than do patients who have quadriplegia, and postoperative function is usually better with right hemiplegia than with left (268). Mental retardation, visual deficits, behavioral problems, and particularly dyskinetic involvement also may contraindicate upper extremity surgery. Fewer than 5% of patients are appropriate candidates for such surgery (269). Nevertheless, a recent report of 718 procedures in 134 patients over a 25-year period indicates that only high motivation and fair-to-good motor control affect upper-extremity surgical outcome, and mentation, sensibility, and the type of cerebral palsy do not influence the surgical result (270).

Patients with hemiplegic involvement often have functional improvement after upper-extremity surgery. Substantial cosmetic improvement or facilitation of care, such as dressing and gloving, can be achieved in severely involved patients. Patients who are most likely to benefit from upper-extremity surgery in cerebral palsy are those with:

- spasticity, not athetosis;
- reasonable intelligence and good motivation;
- stable trunk and body position;

- good hand proprioception, stereognosis, touch, and other sensations;
- no fixed contractures and adequate passive range of motion of all upper-extremity joints;
- reasonable hand function, with good hand placement capability and voluntary control; and
- age between 5 and 20 years (111,271).

In some instances, the use of preoperative dynamic electromyographic studies aids in decision-making regarding lengthening or transferring musculotendinous units (272–274).

An important indication for surgical correction of wrist and elbow contractures can be cosmesis. Older children and adolescents with reasonable intelligence who function well in public may have a negative body image, with a rigid, contracted wrist and elbow. This may also have a negative effect on peer group acceptance. In such cases, correction of those deformities, although having no benefit for upper-extremity function, can be of immense psychological value to the patient.

Nonsurgical Treatment

Traditional nonsurgical treatment modalities include passive range of motion exercises and passive night splinting to attempt to prevent contractures and serial casting, or judiciously applied dynamic splinting to attempt correction of mild contractures in the absence of much spasticity. The daytime use of splints in attempts to improve function almost always meets with failure in hands with poor sensation and control, and may actually increase spasticity. Outcome studies of splinting are lacking. It is doubtful that the satisfaction of “doing something” alone justifies the cost.

Recently, BTX injections have shown promise in selected upper-extremity muscles, but the effects are temporary unless a stretching program or another means of lengthening the muscles succeeds during the temporary period. BTX will probably most help a hemiplegic child with spasticity, no joint contractures, and reasonable hand function. The best early results have involved blocking the biceps, pronator teres, flexor carpi ulnaris, and thumb flexors and adductors (114,122). Whether surgery is merely deferred or can sometimes be avoided with BTX treatment is not yet known.

Surgical Treatment

Before undertaking an upper-extremity surgery program it is essential for patients and families to understand that realistic goals are improved function and appearance. Normality is not a possible result, and any improvement will require careful evaluation and planning. As with the lower extremity, it is wise to perform all needed procedures at one operative setting. It is certainly possible to have different surgical teams operating on the upper and lower extremities at the

same time. Some common upper-extremity surgical procedures and their indications in spastic patients follow. Those patients with athetosis almost never have enough voluntary control to benefit from upper-extremity surgery.

Shoulder

Although it is rarely necessary to operate on the shoulder with severe spasticity, adduction and internal rotation contractures may develop, caused by tightness of the subscapularis and pectoralis major muscles. If hand function is reasonable but the ability to position the hand in space is compromised, correction of shoulder contractures is appropriate. This is accomplished by releasing the tendon of the subscapularis and lengthening the tendon of the pectoralis major. If this does not provide the needed correction, a proximal humeral derotational osteotomy, fixed with a compression plate, usually solves the problem (269,271).

An uncommon problem for people with hemiplegia is shoulder abduction when running, caused by deltoid muscle spasticity. This may be relieved by musculotendinous lengthening of the deltoid (114).

Elbow

The elbow is prone to develop flexion and pronation contractures in children with substantial spasticity. The flexion contracture is caused by the spasticity of the biceps, brachialis, and brachioradialis. Serial casting, dropout casts (long-arm casts with the posterior plaster above the elbow removed to allow further extension while blocking further flexion), dynamic splints, and BTX have been discussed already.

Surgery is usually necessary to gain lasting correction. The indications are to improve the ability to position a functional hand in space, to improve hygiene or prevent skin breakdown, and to improve appearance. Most flexion contractures of the elbow can be corrected by resecting the lacertus fibrosus, and by fractional lengthening of the brachialis and the biceps, plus release of the brachioradialis origin (114). Occasionally, step-cut lengthening of the biceps and anterior capsulotomy of the elbow is necessary (269).

Pronation deformity of the elbow is the result of overactivity of the pronator teres, perhaps the pronator quadratus, and weakness of supination. When combined with a flexion contracture in a young child, dislocation of the radial head may occur. The pronation component forces the dorsum of the hand or forearm to assist in bimanual tasks. Correcting the contracture to permit supination allows use of the hand. Surgical treatment of pronation contracture consists either of distal release or transfer of the pronator teres muscle (269). If passive supination is full, some advocate transfer of the pronator teres tendon through the interosseous membrane (114) or posterior to the radius to an anterolateral insertion so that it can function as a supinator (268). Results

of this transfer are not always good, and a fixed supination deformity is a larger problem than a pronation deformity (268). Release of the pronator alone is usually successful, and is preferred by most surgeons.

Wrist

Prior to operating across the wrist, the status of the finger flexors and extensors must be determined. Flexion deformity or contracture with some ulnar deviation is the usual finding at the wrist in spastic upper extremities. This is usually associated with pronation of the forearm and weakness of the wrist extensor muscles. If flexor spasticity is minimal and finger extension is good, simply lengthening the flexor carpi ulnaris or the flexor carpi radialis, but not both, may be helpful. Another usually effective means of weakening spastic wrist and finger flexors is the flexor and pronator release procedure (271,276). The disadvantage of this operation is that it is nonselective, releasing all wrist and finger flexors and the pronator teres from the medial epicondyle of the distal humerus (42).

Flexor spasticity often is very severe, and extensor weakness is profound. In such cases, flexor carpi ulnaris transfer is recommended [1.7] (276,277). Before transfer an electromyogram can be performed to determine the phase of the muscle if that cannot be determined by clinical examination. Transfer of the flexor carpi ulnaris tendon around the ulnar border of the wrist and into the extensor carpi radialis brevis, is indicated if the transferred muscle is active during grasp, and the patient has poor wrist extension and poor grasp but can actively extend the fingers with the wrist in neutral or dorsiflexion (8,278) (Fig. 15-10). If the flexor carpi ulnaris muscle is active during release and there is adequate grasp but poor release, it is transferred to the extensor digitorum communis tendons. At least one long-term follow-up study has indicated that transfer to the wrist extensor is less predictable than transfer to the finger extensors (279). Regardless of the site of transfer, the flexor carpi radialis tendon should not be lengthened in association with flexor carpi ulnaris transfer because that risks overly weakening wrist flexion.

Wrist arthrodesis eliminates any useful compensatory or functional motion of the wrist, and prevents the wrist from any helpful participation in grasp and release by a tenodesis effect of the extrinsic muscles. It is indicated most often for the markedly deformed carpus in severely involved patients for hygienic or cosmetic reasons, such as putting the hand through a sleeve or into a pocket or a mitten.

Ulnar deviation of the wrist may be caused by overactivity in the extensor carpi ulnaris muscle with volar displacement of its tendon. Split transfer of its tendon to the extensor carpi radialis brevis has been recommended (271).

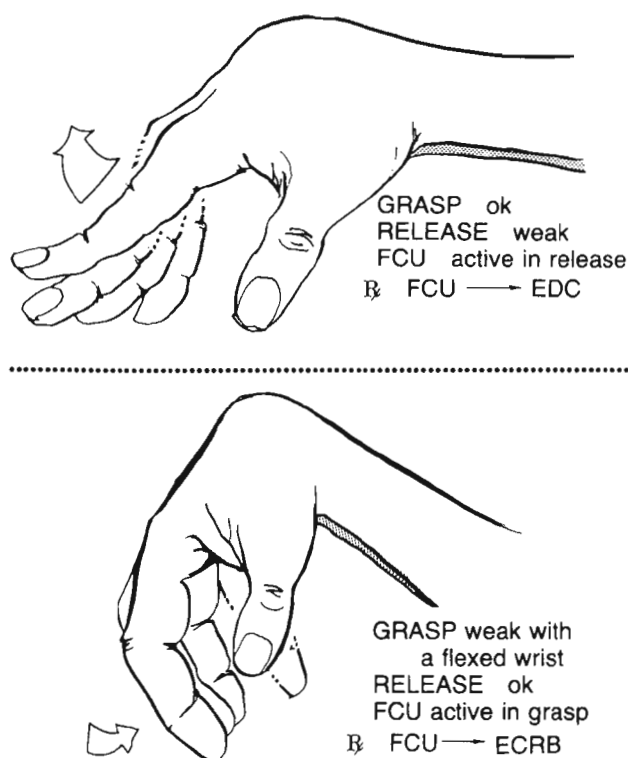


FIGURE 15-10. The spastic hemiplegic hand. The hand at top will benefit from transfer of the flexor carpi ulnaris (FCU) to augment the extensor digitorum communis (EDC). At the bottom, the hand needs augmentation of wrist extension by transferring the flexor carpi ulnaris to the extensor carpi radialis brevis (ECRB).

Hand

The common hand deformities are:

- flexion and adduction of the thumb; and
- either clawing with hyperextension of the finger metacarpophalangeal joints, with flexion contractures of the distal finger joints; or
- full flexion at all finger joints; or
- swan-neck deformities of the fingers.

Thumb-in-palm deformities are complex, and require careful assessment before the appropriate treatment can be recommended. In most cases, the adductor pollicis and first dorsal interosseus muscles overpower the abductor pollicis longus and the extensor pollicis longus and brevis muscles. Common patterns of deformity are:

- metacarpal adduction contracture;
- metacarpal adduction contracture with metacarpophalangeal (MCP) flexion contracture;
- metacarpal adduction contracture with MCP hyperextension contracture; and
- metacarpal adduction contracture with MCP and interphalangeal joint flexion contractures.

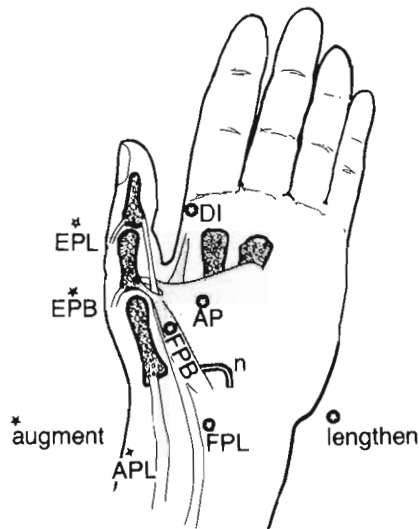


FIGURE 15-11. The repertoire of operations for the thumb-in-palm deformity. Shortened muscles should be lengthened, and weak long muscles should be shortened and augmented. An unstable metacarpophalangeal joint should be stabilized. AP, adductor pollicis; APL, abductor pollicis longus; DI, first dorsal interosseous; EPB, extensor pollicis brevis; EPL, extensor pollicis longus; FPL, flexor pollicis longus.

In all types, there are contractures of the skin of the first web and tight fascial bands in the first dorsal interosseous and adductor aponeuroses (114). There are different ways to surgically treat these deformities, but in principle all involve release of contractures of the skin, joints, and spastic muscles; joint stabilization; and augmentation of the weakened muscles [→1.8] (269,271,280) (Fig. 15-11).

Often the problem in the claw hand with wrist flexion and metacarpophalangeal hyperextension is imbalance between the wrist flexors and extensors. This is usually addressed by transferring either the flexor carpi radialis or the flexor carpi ulnaris to the extensor carpi radialis brevis (271).

If finger flexion deformity is a mild but functional problem, fractionally lengthening the flexor digitorum sublimis and profundus muscles is of benefit. This is done by complete transverse circumferential release of their aponeuroses in the proximal third of the forearm. In tightly flexed fingers that cannot be extended, even with the wrist flexed, an effective treatment is tenotomies of the flexor digitorum profundus and sublimis tendons at different levels in the distal forearm. With the fingers extended the proximal ends of the sublimis tendons are then sutured to the distal ends of the profundus tendons (sublimis to profundus transfers). Tenotomies of the wrist flexors usually are also necessary. With more severe involvement proximal row carpectomy can be used to gain additional length in the soft tissues, or wrist arthrodesis may be necessary to stabilize the hand for assisting.

The often seen swan-neck deformities of the fingers result from intrinsic muscle spasticity and extrinsic extensor overpull, partly caused by the wrist-flexion deformity, by compensation for weak wrist extensors, or by both, with resultant overpull on the central slip of the extensor mechanism. With time the volar plate becomes incompetent and the proximal interphalangeal joint may subluxate and become fixed. In the latter situation it is unlikely that function can be improved with surgery. With early or mild deformities correction of the wrist flexion alone may suffice, and splinting may be added if the deformities are <40 degrees. With more severe deformities the surgical treatment is much more complex (114,269,271).

Appropriate postoperative care, especially after tendon transfers, is essential to the success of hand and upper extremity surgery in cerebral palsy. Recommended treatment for most patients is 4 weeks of complete immobilization, then an intensive exercise program with emphasis on reach, grasp, and release. Removable splints are used for several months during the day, and often at night, for several years (269). Although it is realized that only a small percentage of children with spastic cerebral palsy benefit from upper-extremity surgery, such reconstruction can be of substantial benefit for the appropriate patient.

References

1. Gage JR. *Gait analysis in cerebral palsy*. London: MacKeith, 1991.

Basic Brain Development

2. Goldberg MJ. Measuring outcomes in cerebral palsy. *J Pediatr Orthop* 1991;11:682.
3. Rang M. Cerebral palsy. In: Morrissy RT, ed. *Lovell and Winter's pediatric orthopaedics*. 3rd ed. Philadelphia: JB Lippincott, 1990.
4. Russman BS, Gage JR. Cerebral palsy. *Curr Probl Pediatr* 1989; 19:65.

Etiology

5. Nelson KB, Ellenberg JH. Antecedents of cerebral palsy II. Multivariate analysis of risk. *N Engl J Med* 1986;315:81.
6. Atkinson S, Stanley FJ. Spastic diplegia among children of low and normal birthweight. *Dev Med Child Neurol* 1983;25:693.
7. Delong MR. Possible involvement of central pacemakers in clinical disorders of movement. *Fed Proc* 1978;37:2171.
8. *Orthopaedic Knowledge Update 3*. Park Ridge, IL: American Academy of Orthopaedic Surgeons, 1990:286.
9. Weindling AM, Rochefort MJ, Claverty SA, et al. Development of cerebral palsy after ultrasonographic detection of periventricular cysts in the newborn. *Dev Med Child Neurol* 1985;27:800.
10. Freeman JM, Nelson KB. Intrapartum asphyxia and cerebral palsy. *Pediatrics* 1988;82:240.
11. Diamond LJ, Jaudes PK. Child abuse in a cerebral palsied population. *Dev Med Child Neurol* 1983;25:169.
12. Loder RT. Orthopaedic aspects of children with infectious (central nervous system) postnatal cerebral palsy. *J Pediatr Orthop* 1992;12:527.

Prevalence

13. Nelson KB, Ellenberg JH. Epidemiology of cerebral palsy. In: Schoenberg BS, ed. *Advances in neurology*, vol. 19. New York: Raven, 1978:421.
14. Grether JK, Nelson KB, Cummins SK. Twinning and cerebral palsy: experience in four northern California counties, births 1983 through 1985. *Pediatrics* 1993;92:854.

Classification

15. Young RR, Wiegner AW. Spasticity. *Clin Orthop* 1987;219:50.
16. Cohen ME, Duffner PK. Prognostic indicators in hemiparetic cerebral palsy. *Ann Neurol* 1981;9:953.
17. Aram DM, Ekelman BL, Satz P. Trophic changes following early unilateral injury to the brain. *Dev Med Child Neurol* 1986;28:165.
18. Blair E, Stanley FJ. An epidemiologic study of cerebral palsy in Western Australia 1956–1975. III: postnatal aetiology. *Dev Med Child Neurol* 1982;27:615.

Associated Problems in Other Systems

19. Gibbs FA, Gibbs EL, Perstein MA, Rich CL. Electroencephalographic and clinical aspects of cerebral palsy. *Pediatrics* 1963;32:73.
20. Cadman D, Richards J, Feldman W. Gastro-esophageal reflux in severely retarded children. *Dev Med Child Neurol* 1978;20:95.
21. Elmer E, Wenger DR, Mubarak SJ, et al. Proximal hamstring lengthening in the sitting cerebral palsy patient. *J Pediatr Orthop* 1992;12:329.
22. Patrick J, Boland M, Sroski D, Burray GE. Rapid correction of wasting in children with CP. *Dev Med Child Neurol* 1986;28:734.
23. Jevsevar DS, Karlin LI. The relationship between preoperative nutritional status and complications after an operation for scoliosis in patients who have cerebral palsy. *J Bone Joint Surg Am* 1993;75:880.
24. Jensen JE, Jensen TG, Smith TK, et al. Nutrition in orthopaedic surgery. *J Bone Joint Surg Am* 1982;64:1263.
25. Lonstein JE. Cerebral palsy. In: Weinstein SL, ed. *The pediatric spine—principles and practice*. New York: Raven, 1994.
26. McNeal DM, Hawtrey CE, Wolraich MG. Symptomatic neurogenic bladder in a cerebral palsied population. *Dev Med Child Neurol* 1983;25:612.

Diagnosis

27. Bleck EE. *Orthopaedic management of cerebral palsy*. Philadelphia: WB Saunders, 1979.
28. Thompson G, Rubin I, Bilenker R. *Comprehensive management of cerebral palsy*. New York: Grune & Stratton, 1983.
29. Hicks R, Durinick N, Gage JR. Differentiation of idiopathic toe-walking and cerebral palsy. *J Pediatr Orthop* 1988;8:160.
30. Kalen V, Adler N, Bleck EE. Electromyography of idiopathic toe walking. *J Pediatr Orthop* 1986;6:31.
31. Pape KE, Kirsch SE, Galil A, et al. Neuromuscular approach to the motor deficits of cerebral palsy: a pilot study. *J Pediatr Orthop* 1993;13:628.

Common Types of Cerebral Palsy and Their Management

32. Campbell SK. Quantifying the effects of interventions for movement disorders resulting from cerebral palsy. *J Child Neurol* 1997;11S:S61.

33. Daltroy LH, Liang MH, Fossel AH, et al. The POSNA Pediatric Musculoskeletal Functional Health Questionnaire: Report on Reliability, Validity, and Sensitivity to Change. *J Pediatr Orthop* 1998;18:561.
34. Olafsson Y, Saraste H, Al-Dabbagh Z. Brace treatment in neuromuscular spine deformity. *J Pediatr Orthop* 1999;19:376.
35. Renshaw TS, Larkin J. Results of orthotic treatment of scoliosis in cerebral palsy (abstract). *Orthop Trans* 1987;11:38.
36. Letts RM, Rathbone MD, Yamashita T, et al. Soft Boston orthosis in management of neuromuscular scoliosis: a preliminary report. *J Pediatr Orthop* 1992;12:470.
37. Rang M, Douglas G, Benner GC, Koreska J. Seating for children with cerebral palsy. *J Pediatr Orthop* 1981;1:279.
38. Nwaobi OM, Smith PD. Effect of adaptive seating on pulmonary function of children with CP. *Dev Med Child Neurol* 1986;28:351.
39. Gersoff W, Renshaw TS. Treatment of scoliosis in CP by posterior spinal fusion with Luque-rod segmental instrumentation. *J Bone Joint Surg Am* 1988;70:41.
40. Thometz JG, Simon SR. Progression of scoliosis after skeletal maturity in institutionalized adults who have cerebral palsy. *J Bone Joint Surg Am* 1988;70:1290.
41. Kalen V, Conklin M, Sherman I. Untreated scoliosis in severe cerebral palsy. *J Pediatr Orthop* 1992;12:337.
42. Green NE. Cerebral palsy. In: Canale ST, Beary JH, eds. *Operative pediatric orthopaedics*. St. Louis: Mosby-Year Book, 1991: 611.
43. Allen BL, Ferguson RL. Technique: L-rod instrumentation for scoliosis in cerebral palsy. *J Pediatr Orthop* 1982;2:87.
44. Lonstein JE, Akbarnia BA. Operative treatment of spinal deformities in patients with cerebral palsy or mental retardation. *J Bone Joint Surg Am* 1983;65:43.
45. Sponseller PD, Whiffen JR, Drummond DS. Interspinous process segmental spinal instrumentation for scoliosis in cerebral palsy. *J Pediatr Orthop* 1986;6:559.
46. Allen BL, Ferguson RL. The Galveston technique for L-rod instrumentation of the scoliotic spine. *Spine* 1982;7:276.
47. Tredwell SJ. Complications of Spinal Surgery. In: Weinstein SL, ed. *The pediatric spine*. New York: Raven, 1994;1761.
48. Drvaric DM, Roberts JM, Burke SW, et al. Gastroesophageal evaluation in totally involved cerebral palsy patients. *J Pediatr Orthop* 1987;7:187.
49. Rainey-Macdonald CG, Holiday RL, Wells GA, et al. Validity of a two-variable nutritional index for use in selecting candidates for nutritional support. *JPEN* 1983;7:15.
50. Hennrikus WL, Rosenthal RK, Kasser JR. Incidence of spondylolisthesis in ambulatory cerebral palsy patients. *J Pediatr Orthop* 1993;13:37.
51. Laplaza FJ, Root L, Tassanawipas A, Glasser DB. Femoral torsion and neck-shaft angles in cerebral palsy. *J Pediatr Orthop* 1993;13:192.
52. Abel MF, Wenger DR, Mubarak SJ, Sutherland DH. Quantitative analysis of hip dysplasia in cerebral palsy: a study of radiographs and 3-D reformatted images. *J Pediatr Orthop* 1994;14:283.
53. Cooperman DR, Bartucci E, Dietrick E, Millar EA. Hip dislocation in spastic cerebral palsy: long term consequences. *J Pediatr Orthop* 1987;7:268.
54. Moreau MJ, Drummond DS, Rogala E, et al. Natural history of the dislocated hip in spastic cerebral palsy. *Dev Med Child Neurol* 1979;21:749.
55. Pritchett JW. Treated and untreated unstable hips in severe cerebral palsy. *Dev Med Child Neurol* 1990;32:3.
56. Onimus M, Allamel G, Manyone P, Laurain JM. Prevention of hip dislocation in cerebral palsy by early psoas and adductors tenotomies. *J Pediatr Orthop* 1991;11:432.

57. Phelps W. Prevention of acquired dislocation of the hip in cerebral palsy. *J Bone Joint Surg Am* 1959;41:440.
58. Silver RL, Rang M, Chan J, et al. Adductor release in non ambulant children with cerebral palsy. *J Pediatr Orthop* 1985; 5:672.
59. Sutherland DH, Zilberfarb JL, Kaufman KR, et al. Psoas release at the pelvic brim in ambulatory patients with cerebral palsy: operative technique and functional outcome. *J Pediatr Orthop* 1997;17:563.
60. Miller F, Dias RC, Dabney KW, et al. Soft-tissue release for spastic hip subluxation in cerebral palsy. *J Pediatr Orthop* 1997; 17:571.
61. Sharrard WJW, Allen MH, Heany SH, et al. Surgical prophylaxis of subluxation and dislocation of the hip in cerebral palsy. *J Bone Joint Surg Am* 1975;57:160.
62. Bagg MR, Farber J, Miller F. Long-term follow-up of hip subluxation in cerebral palsy patients. *J Pediatr Orthop* 1993;13: 32.
63. Hoffer MM, Stein GA, Koffman M, Prietto M. Femoral varus-derotation osteotomy in spastic cerebral palsy. *J Bone Joint Surg Am* 1985;67:1229.
64. Carr C, Gage JR. The fate of the non operated hip in cerebral palsy. *J Pediatr Orthop* 1987;7:262.
65. Houkom JA, Roach JW, Wenger DR, et al. Treatment of acquired hip subluxation in CP. *J Pediatr Orthop* 1986;6:285.
66. Kalen V, Bleck EE. Prevention of spastic paralytic dislocation of the hip. *Dev Med Child Neurol* 1985;27:17.
67. Lonstein JE, Beck K. Hip dislocation and subluxation in CP. *J Pediatr Orthop* 1986;6:521.
68. Bleck EE. I. Cerebral palsy hip deformities: is there a consensus? (editorial). *J Pediatr Orthop* 1994;14:281.
69. Brunner R, Baumann JU. Clinical benefit of reconstruction of dislocated or subluxated hip joints in patients with spastic cerebral palsy. *J Pediatr Orthop* 1994;14:290.
70. Brunner R, Baumann JU. Long-term effects of intertrochanteric varus-derotation osteotomy on femur and acetabulum in spastic cerebral palsy: an 11 to 18 year follow-up study. *J Pediatr Orthop* 1997;17:585.
71. Mubarak SJ, McNerney NP, Wenger DR. Pericapsular acetabuloplasty for treatment of the dysplastic hip in cerebral palsy: results and complications in one hundred and four patients. Lake Buena Vista, FL: Presented at the Pediatric Orthopaedic Society of North America, 1999.
72. Gordon JE, Parry SA, Capelli AM, et al. The effect of unilateral varus rotational osteotomy with or without pelvic osteotomy on the contralateral hip in patients with perinatal static encephalopathy. *J Pediatr Orthop* 1998;18:734.
73. Mubarak SJ, Valencia FG, Wenger DR. One-stage correction of the spastic dislocated hip. *J Bone Joint Surg Am* 1992;74: 1347.
74. Heinrich S, MacEwen GD, Zembo M. Hip dysplasia, subluxation, and dislocation in cerebral palsy: an arthrographic analysis. *J Pediatr Orthop* 1991;11:488.
75. Morrissy RT. *Atlas of pediatric orthopaedic surgery*. 2nd ed. Philadelphia: Lippincott-Raven, 1996.
76. Chiari K. Medial displacement osteotomy of the pelvis. *Clin Orthop* 1974;98:55.
77. Osterkamp J, Caillouette JT, Hoffer MM. Chiari osteotomy in cerebral palsy. *J Pediatr Orthop* 1988;8:274.
78. Pemberton PA. Pericapsular osteotomy for congenital dislocation of the hip. *J Bone Joint Surg Am* 1965;47:65.
79. Staheli LT. Technique: slotted acetabular augmentation. *J Pediatr Orthop* 1981;1:321.
80. Steel HH. Triple osteotomy of the innominate bone. *Clin Orthop* 1977;122:116.
81. Sutherland DH, Greenfield R. Double innominate osteotomy. *J Bone Joint Surg Am* 1977;59:1082.
82. Zuckerman JD, Staheli LT, McLaughlin JF. Acetabular augmentation for progressive hip subluxation in CP. *J Pediatr Orthop* 1984;4:436.
83. Dega W. Osteotomia trans-iliakalne w leczeniu wrodzonej dysplazji biodra. *Chir Narz Ruchu Ortop Polska* 1974;39:601.
84. Gross MS, Ibrahim K, Wehner J, et al. Combined surgical procedure for treatment of hip dislocation in CP (abstract). *Dev Med Child Neurol* 1984;26:255.
85. Castle ME, Schneider C. Proximal femoral resection-interposition arthroplasty. *J Bone Joint Surg Am* 1978;60:1051.
86. Koffman M. Proximal femoral resection or THR in severely disabled cerebral spastic patients. *Orthop Clin North Am* 1981; 12:91.
87. Root L, Spero C. Hip adductor transfer compared with adductor tenotomy in cerebral palsy. *J Bone Joint Surg Am* 1981;63: 767.
88. McCarthy RE, Simon S, Zawacky R, Reese N. Proximal femoral resection to allow adults who have severe cerebral palsy to sit. *J Bone Joint Surg Am* 1988;70:1011.
89. McHale KA, Bagg M, Nason SS. Treatment of the chronically dislocated hip in adolescents with cerebral palsy with femoral head resection and subtrochanteric valgus osteotomy. *J Pediatr Orthop* 1990;10:504.
90. Segal LS, Reighard C. Subtrochanteric valgus osteotomy and femoral head resection for chronic painful dislocated hips in patients with cerebral palsy. Lake Buena Vista, FL: Presented at the Pediatric Orthopaedic Society of North America, 1999.
91. Root L, Goss JR, Mendes J. The treatment of the painful hip in cerebral palsy by total hip replacement or hip arthrodesis. *J Bone Joint Surg Am* 1986;68:590.
92. Benaroch TE, Richards BS, Haideri N, et al. Intermediate follow-up of a simple method of hip arthrodesis in adolescent patients. *J Pediatr Orthop* 1996;16:30.

Extension Plus Abduction Contracture

93. Szalay EA, Roach JW, Houkom JA, et al. Extension-abduction contracture of the spastic hip. *J Pediatr Orthop* 1986;6:1.
94. Norlin R, Odenrick P. Development of gait in spastic children with CP. *J Pediatr Orthop* 1986;6:674.
95. Beals R. Spastic paraplegia and diplegia: an evaluation of the non-surgical and surgical factors influencing the prognosis for ambulation. *J Bone Joint Surg Am* 1966;48:827.
96. Molnar GE, Gordon SV. Predictive value of clinical signs for early prognostication of motor function in cerebral palsy. *Arch Phys Med* 1976;57:153.
97. Bleck EE. Locomotor prognosis in cerebral palsy. *Dev Med Child Neurol* 1975;17:18.
98. Bleck EE. Orthopaedic management in cerebral palsy. *Clin Dev Med* 1987;99/100:17.
99. Renshaw TS, Green NE, Griffin PP, et al. Cerebral palsy: orthopaedic management. *Instr Course Lect* 1996;45:475.
100. Campos da Paz A Jr. Walking prognosis in cerebral palsy: a 22-year retrospective. Sun Valley, ID: Presented at the American Orthopaedic Association 107th Annual Meeting, June 1994.
101. Hoffer MM, Felwell E, Perry R, et al. Functional ambulation in patients with myelomeningocele. *J Bone Joint Surg Am* 1973; 55:137.
102. Rose J, Medeiros JM, Parker R. Energy cost index as an estimate of energy expenditure of CP children during assisted ambulation. *Dev Med Child Neurol* 1985;27:485.
103. DeLuca PA, Davis RB, Ounpuu S, et al. Alterations in surgical decision making in patients with cerebral palsy based on three-dimensional gait analysis. *J Pediatr Orthop* 1997;17:608.

104. Sutherland DH, Oishen R, Cooper L, Woo SL-Y. The development of mature gait. *J Bone Joint Surg Am* 1980;62:336.
105. Krebs DE, Edelstein JE, Fishman S. Reliability of observational kinematic gait analysis. *Phys Ther* 1985;65:1027.
106. Pransatelli MR. Oral pharmacology for the movement disorders of cerebral palsy. *J Child Neurol* 1996;11S:13S.
107. Wright T, Nicholson J. Physiotherapy for the spastic child: an evaluation. *Dev Med Child Neurol* 1973;15:146.
108. Gracies JM, Elovic E, McGuire J, et al. Traditional pharmacological treatments for spasticity. Part I: local treatments. *Muscle Nerve Suppl* 1997;6:S61.
109. Carpenter EB. Role of nerve blocks in the foot and ankle in cerebral palsy: therapeutic and diagnostic. *Foot Ankle* 1983;4:164.
110. Carpenter EB, Seltz DB. Intramuscular alcohol as an aid in management of spastic cerebral palsy. *Dev Med Child Neurol* 1980;22:497.
111. Cosgrove AP, Corr TS, Graham HK, et al. Botulinum toxin in the management of the lower limb in cerebral palsy. *Dev Med Child Neurol* 1994; 36:386.
112. Lagueny A, Burbaud P. Mechanism of action, clinical indication and results of treatment of botulinum toxin. *Neurophysiol Clin* 1996;26:216.
113. O'Brien CF. Injection techniques for botulinum toxin using electromyography and electrical stimulation. *Muscle Nerve Suppl* 1997;6:S176.
114. Waters PM, Van Heest A. Spastic hemiplegia of the upper extremity in children. *Hand Clin* 1998;14:119.
115. Cosgrove AP, Graham HK. Botulinum toxin-A in the management of children with cerebral palsy (abstract). *Orthop Trans* 1993;16:625.
116. Koman LA, Mooney JF, Smith B, Goodman A, Mulvaney T. Management of cerebral palsy with botulinum-A toxin: preliminary investigation. *J Pediatr Orthop* 1993;13:489.
117. Pullman SL, Greene P, Fahn S, et al. Approach to the treatment of limb disorders with botulinum toxin A. Experience with 187 patients. *Arch Neurol* 1996;53:617.
118. Koman LA, Mooney JF, Smith B, et al. Management of cerebral palsy with botulinum-A toxin: preliminary investigation. *J Pediatr Orthop* 1993;13:489.
119. Zelnik N, Giladi N, Goikhman I, et al. The role of botulinum toxin in the treatment of lower limb spasticity in children with cerebral palsy—a pilot study. *Isr J Med Sci* 1997;33:129.
120. Corry IS, Cosgrove AP, Duffy CM, et al. Botulinum toxin A compared with stretching casts in the treatment of spastic equinus: a randomised prospective trial. *J Pediatr Orthop* 1998;18:304.
121. Sanchez-Carpintero R, Narbona J. Botulinum toxin in spastic infantile cerebral palsy: results in 27 cases during one year. *Rev Neurol* 1997;25:531.
122. Corry IS, Cosgrove AP, Walsh EG, et al. Botulinum toxin A in the hemiplegic upper limb: a double-blind trial. *Dev Med Child Neurol* 1997;39:185.
123. Albright AL, Barry MJ, Fasick MP, et al. Effects of continuous intrathecal baclofen infusion and selective posterior rhizotomy on upper extremity spasticity. *Pediatr Neurosurg* 1995;23:82.
124. Armstrong RW. Intrathecally administered baclofen for treatment of children with spasticity of cerebral origin. *J Neurosurg* 1997;87:409.
125. Gerszten PC, Albright AL, Barry MJ. Effect on ambulation of continuous intrathecal baclofen infusion. *Pediatr Neurosurg* 1997;27:40.
126. Gerszten PC, Albright AL, Johnstone GF. Intrathecal baclofen infusion and subsequent orthopedic surgery in patients with spastic cerebral palsy. *J Neurosurg* 1998;88:1009.
127. Albright AL, Cervi A, Singletary J. Intrathecal baclofen for spasticity in cerebral palsy. *JAMA* 1991;265:1418.
128. Oppenheim WL, Peacock WJ. Selective dorsal rhizotomy (abstract). *J Pediatr Orthop* 1991;11:690.
129. Peacock WJ, Arlens L, Berman B. CP spasticity: selective posterior rhizotomy. *Pediatr Neurosci* 1987;13:61.
130. Peacock WJ, Staudt LA. Functional outcomes following selective posterior rhizotomy in children with cerebral palsy. *J Neurosurg* 1991;74:380.
131. Davis R, Schulman J, Delahanty A. Cerebellar stimulation for cerebral palsy: double blind study. *Acta Neurochir Suppl* 1987; 39:126.
132. Staudt LA, Peacock WJ. Selective posterior rhizotomy for the treatment of spastic cerebral palsy. In: Long T, ed. *Pediatric physical therapy*, vol. 1. Baltimore: Williams & Wilkins, 1989.
133. Bretas CT, Dias LS, Gaebler-Spira D. Selective posterior rhizotomy in spastic quadriplegia: results (abstract). *Orthop Trans* 1993;16:627.
134. Oppenheim WL. Selective posterior rhizotomy for spastic cerebral palsy—a review. *Clin Orthop* 1990;253:20.
135. Berman B, Peacock WJ, Vaughan CL, et al. Assessment of patients with spastic cerebral palsy before and after rhizotomy (abstract). *Dev Med Child Neurol* 1987;55(suppl):24.
136. Boscarino LF, Ounpuu S, Davis RB III, et al. Effects of selective dorsal rhizotomy on gait in children with cerebral palsy. *J Pediatr Orthop* 1993;13:174.
137. Perry J, Adams J, Cahan LD. Foot-floor contact patterns following selective dorsal rhizotomy (abstract). *Dev Med Child Neurol Suppl* 1989;31:19.
138. Tippets RH, Walker ML, Liddell KL. Long-term follow-up of selective dorsal rhizotomy for relief of spasticity in cerebral-palsied children (abstract). *Dev Med Child Neurol Suppl* 1989; 31:19.
139. Steinbok P, Reiner AM, Beauchamp R, et al. A randomized clinical trial to compare selective posterior rhizotomy plus physiotherapy with physiotherapy alone in children with spastic diplegic cerebral palsy. *Dev Med Child Neurol* 1997;39:178.
140. McLaughlin JF, Bkornson KF. Selective dorsal rhizotomy. *Dev Med Child Neurol* 1998;40:220.
141. Wright FV. Evaluation of selective dorsal rhizotomy. *Dev Med Child Neurol* 1998;40:227.
142. Chicoine MR, Park TS, Vogler GP, et al. Predictors of ability to walk after selective dorsal rhizotomy in children with cerebral palsy. *Neurosurgery* 1996;38:711.
143. Carroll KL, Moore KR, Stevens PM. Orthopedic procedures after rhizotomy. *J Pediatr Orthop* 1998;18:69.
144. Greene WB, Dietz FR, Goldberg MJ, et al. Rapid progression of hip subluxation in cerebral palsy after selective posterior rhizotomy. *J Pediatr Orthop* 1991;11:494.
145. Payne LZ, DeLuca PA. Heterotopic ossification after rhizotomy and femoral osteotomy. *J Pediatr Orthop* 1993;13:733.
146. Crawford K, Karol LA, Herring JA. Severe lumbar lordosis after dorsal rhizotomy. *J Pediatr Orthop* 1996;16:336.
147. Millis MB. Rapidly progressive lumbar hyperlordosis following selective posterior rhizotomy for spastic quadriplegia (abstract). *Orthop Trans* 1993;16:10.
148. Peter IC, Hoffman EB, Arens L, et al. Spondylolysis and spondylolisthesis after five-level lumbosacral laminectomy for selective posterior rhizotomy in cerebral palsy. *Child's Nervous Sys* 1993;9:285.
149. Arens L, Peacock W, Peter J. Selective posterior rhizotomy: a long-term follow-up study. *Child Nerv Syst* 1989;5:148.
150. Roor L, Miller SR, Kirz P. Posterior tibial tendon transfer in patients with cerebral palsy. *J Bone Joint Surg Am* 1987;69: 1133.
151. Herndon WA, Troup P, Yngve DA, et al. Effects of neurodevel-

- opmental treatment on movement patterns of children with cerebral palsy. *J Pediatr Orthop* 1987;7:395.
152. Kanda T, Yuge M, Yamori Y, et al. Early physiotherapy in the treatment of spastic diplegia. *Dev Med Child Neurol* 1984;26:438.
 153. Palmer FB, Shapiro BK, Wachtel RC, et al. The effects of physical therapy on cerebral palsy: a controlled trial in infants with spastic diplegia. *N Engl J Med* 1988;318:803.
 154. Piper MC, Kumos VI, Willis DM, et al. Early physical therapy effects on the high risk infant: a randomized control trial. *Pediatrics* 1986;78:216.
 155. Winters TF, Gage JR, Hicks R. Gait patterns in spastic hemiplegia in children and young adults. *J Bone Joint Surg Am* 1987;69:437.
 156. Paine RS. On the treatment of cerebral palsy: the outcome of 177 patients, 74 totally untreated. *Pediatrics* 1962;29:605.
 157. Scherzer AL, Mike V, Ilson J. Physical therapy as a determinant of change in the cerebral palsied infant. *Pediatrics* 1976;58:47.
 158. Loder RT. The ambulatory child with cerebral palsy. *Orthopaedic knowledge update pediatrics*. Rosemont: American Academy of Orthopaedic Surgeons, 1996:19.
 159. Young NL, Wright JG. Measuring pediatric physical function. *J Pediatr Orthop* 1995;15:244.
 160. Breslaw N, Starvich KS, Mortimer EA. Psychological stress in mothers of disabled children. *Am J Dis Child* 1982;136:682.
 161. Sussman MD. Role of the physical therapist in treatment of children with cerebral palsy (abstract). *J Pediatr Orthop* 1991;11:688.
 162. Papariello SG, Skinner SR. Dynamic electromyography analysis of habitual toe walkers. *J Pediatr Orthop* 1985;5:171.
 163. Ruda R, Frost HM. Cerebral palsy: spastic varus and forefoot adductus treated by intramuscular posterior tibial tendon lengthening. *Clin Orthop* 1971;79:61.
 164. Bleck EE. Management of the lower extremities in children who have cerebral palsy. *J Bone Joint Surg Am* 1990;72:140.
 165. Cusick B, Sussman M. Short leg casts: their role in the management of cerebral palsy. *Phys Occup Ther Pediatr* 1982;2:93.
 166. Duncan W, Mott D. Foot reflexes and the use of the "inhibitive cast." *Foot Ankle* 1983;4:145.
 167. Otis JC, Root L, Kroll MA. Measurement of plantar flexor spasticity during treatment with tone-reducing casts. *J Pediatr Orthop* 1985;5:682.
 168. Sussman MD. Casting as an adjunct to neurodevelopmental therapy in cerebral palsy. *Dev Med Child Neurol* 1983;25:804.
 169. Sussman MD, Cusick B. The role of short-leg, tone reducing casts as an adjunct to physical therapy of patients with cerebral palsy. *Johns Hopkins Med Bull* 1979;145:112.
 170. Watt J, Sims D, Harckham F, et al. A prospective study of inhibitive casting as an adjunct to physiotherapy for cerebral palsied children. *Dev Med Child Neurol* 1986;28:480.
 171. Browne AO, McManus F. One-session surgery for bilateral correction of lower limb deformities in spastic diplegia. *J Pediatr Orthop* 1987;7:259.
 172. Norlin R, Tkaczuk H. One-session surgery for correction of lower extremity deformities in children with cerebral palsy. *J Pediatr Orthop* 1985;5:208.
 173. Holstein A. Hallux valgus: an acquired deformity of the foot in cerebral palsy. *Foot Ankle* 1980;1:33.
 174. Renshaw TS, Sirkin RB, Drennan JC. The management of hallux valgus in cerebral palsy. *Dev Med Child Neurol* 1979;21:202.
 175. Ball J, Sullivan JA. Treatment of the juvenile bunion by Mitchell osteotomy. *Orthopedics* 1985;10:1249.
 176. Bleck EE. Forefoot problems in cerebral palsy—diagnosis and management. *Foot Ankle* 1984;4:188.
 177. Helal B. Surgery for adolescent hallux valgus. *Clin Orthop* 1981;157:50.
 178. Luba R, Rosman M. Bunions in children—treatment with a modified Mitchell osteotomy. *J Pediatr Orthop* 1984;4:44.
 179. Scranton PE, Zuckerman JD. Bunion surgery in adolescents—results of surgical treatment. *J Pediatr Orthop* 1984;4:39.
 180. McKeever DC. Arthrodesis of the first metatarsophalangeal joint for hallux valgus, hallux rigidus, and metatarsus primus varus. *J Bone Joint Surg Am* 1952;34:129.
 181. Silver RL, de la Garza J, Rang M. The myth of muscle imbalance: a study of relative strengths and excursions of normal muscles about the foot and ankle. *J Bone Joint Surg Br* 1985;67:432.
 182. Greene WB. Achilles tendon lengthening in cerebral palsy: comparison of inpatient versus ambulatory surgery. *J Pediatr Orthop* 1987;7:256.
 183. Moreau MJ, Lake DM. Outpatient percutaneous heel cord lengthening in children. *J Pediatr Orthop* 1987;7:253.
 184. Hoke M. An operation for stabilizing paralytic feet. *J Orthop Surg* 1921;3:494.
 185. Graham HK, Fixsen JA. Lengthening of the calcaneal tendon in spastic hemiplegia by the White technique: a long term review. *J Bone Joint Surg Br* 1988;70:472.
 186. White JW. Torsion of the Achilles tendon: its surgical significance. *Arch Surg* 1943;46:784.
 187. Gaines RW, Ford TB. A systematic approach to the amount of Achilles tendon lengthening in CP. *J Pediatr Orthop* 1985;4:448.
 188. Garbarino JL, Clancy M. A geometric method of calculating tendo Achillis lengthening. *J Pediatr Orthop* 1985;5:573.
 189. Baker LD, Hill LM. Foot alignment in the cerebral palsy patient. *J Bone Joint Surg Am* 1964;46:1.
 190. Baker LD. A rational approach to the surgical needs of the cerebral palsy patient. *J Bone Joint Surg Am* 1956;38:313.
 191. Javors JR, Klaaren HE. The Vulpius procedure for correction for equinus deformity in CP. *J Pediatr Orthop* 1987;7:191.
 192. Vulpius O, Stoffel A. *Orthopaedische Operationslehre*. Stuttgart: Ferdinand Enke, 1913.
 193. Rose SA, DeLuca PA, Davis RB III, et al. Kinematic and kinetic evaluation of the ankle after lengthening of the gastrocnemius fascia in children with cerebral palsy. *J Pediatr Orthop* 1993;13:727.
 194. Olney BW, Williams PF, Menelaus MB. Treatment of spastic equinus by aponeurosis lengthening. *J Pediatr Orthop* 1988;8:422.
 195. Etnyre B, Chambers CS, Scarborough NH, Cain TE. Preoperative and postoperative assessment of surgical intervention for equinus gait in children with cerebral palsy. *J Pediatr Orthop* 1993;13:24.
 196. Sharrard WJW, Bernstein S. Equinus deformity in cerebral palsy: a comparison between elongation of the tendo calcaneus and gastrocnemius recession. *J Bone Joint Surg Br* 1972;54:272.
 197. Stevens DB, Opfell AR, Stanley N, Walker JL. Heel cord advancement for treatment of spastic equinus deformity in children (abstract). *Orthop Trans* 1993;16:625.
 198. Strecker WB, Via MW, Oliver SK, Schoenecker PL. Heel cord advancement for treatment of equinus deformity in cerebral palsy. *J Pediatr Orthop* 1990;10:105.
 199. Throop FB, DeRosa GP, Reeck C, Waterman S. Correction of equinus in cerebral palsy by the Murphy procedure of tendo calcaneus advancement: a preliminary communication. *Dev Med Child Neurol* 1975;17:182.
 200. Grant AD, Feldman R, Lehman WB. Equinus deformity in CP. A retrospective analysis of treatment and function in 39 cases. *J Pediatr Orthop* 1985;5:678.
 201. Rattey TE, Leahey L, Hyndman J, et al. Recurrence after Achil-

- les tendon lengthening in cerebral palsy. *J Pediatr Orthop* 1993; 13:184.
202. Taussig G, Pilliard D. Triceps lengthening in children with cerebral palsy performed before the age of six years. Results at the end of growth. *Rev Chir Orthop* 1988;74:79.
203. Banks HH. Equinus and cerebral palsy—its management. *Foot Ankle* 1983;4:149.
204. Tardieu G, Tardieu C. Cerebral palsy: mechanical evaluation and conservation correction of limb joint contractures. *Clin Orthop* 1987;219:63.
205. Majestro TC, Ruda R, Frost HM. Intramuscular lengthening of the posterior tibialis tendon. *Clin Orthop* 1963;79:59.
206. Green NE, Griffin PP, Shiavi R. Split posterior tibial tendon transfer in spastic cerebral palsy. *J Bone Joint Surg Am* 1983; 65:748.
207. Kling TF, Kaufer HA, Hensinger RN. Split posterior tibial tendon transfers in children with cerebral spastic paralysis and equinovarus deformity. *J Bone Joint Surg Am* 1985;67:186.
208. Snyder M, Kumar SJ, Stecyk MD. Split tibialis posterior tendon transfer and tendo-Achilles lengthening for spastic equinovarus feet. *J Pediatr Orthop* 1993;13:20.
209. Bisia RS, Louis HJ, Albano P. Transfer of tibialis posterior tendon in cerebral palsy. *J Bone Joint Surg Am* 1976;58:497.
210. Schneider M, Balon K. Deformity of the foot following anterior transfer of the posterior tibial tendon and lengthening of the Achilles tendon for spastic equinovarus. *Clin Orthop* 1977;125: 113.
211. Hoffer MM, Barakat G, Koffman M. 10 year follow-up of split anterior tibial tendon transfer in cerebral palsied patients with spastic equinovarus deformity. *J Pediatr Orthop* 1985;5:432.
212. DeGnore LT, Greene WB. Split anterior tibialis tendon transfer in cerebral palsy (abstract). *Orthop Trans* 1993;16:785.
213. Davids JR, Holland WC, Sutherland DH. Significance of the confusion test in cerebral palsy. *J Pediatr Orthop* 1993;13:717.
214. Silver CM, Simon SD, Lichtman HM. Long-term follow-up observations on calcaneal osteotomy. *Clin Orthop* 1974;99:181.
215. O'Connell PA, D'Souza L, Dudeney S, et al. Foot deformities in children with cerebral palsy. *J Pediatr Orthop* 1998;18:743.
216. Bennet GC, Rang M, Jones D. Varus and valgus deformities of the foot in cerebral palsy. *Dev Med Child Neurol* 1982;24: 499.
217. Nather A, Fulford GE, Stewart K. Treatment of valgus hindfoot in cerebral palsy by peroneus brevis lengthening. *Dev Med Child Neurol* 1984;26:335.
218. Evans D. Calcaneo-valgus deformity. *J Bone Joint Surg Br* 1975; 57:270.
219. Dennyson WG, Fulford GE. Subtalar arthrodesis by cancellous grafts and metallic internal fixation. *J Bone Joint Surg Br* 1976; 58:507.
220. Mosca VS. Calcaneal lengthening for valgus deformity of the hindfoot. *J Bone Joint Surg Am* 1995;78:500.
221. Barrasso JA, Wile PB, Gage JR. Extra-articular subtalar arthrodesis with internal fixation. *J Pediatr Orthop* 1984;4:555.
222. Grice DS. The role of subtalar fusion in the treatment of valgus deformities of the feet. *AAOS Instr Course Lect* 1959;16:127.
223. McCall RE, Lillich JS, Harris JR, Johnston FA. The Grice extra-articular arthrodesis: a clinical review. *J Pediatr Orthop* 1985; 5:442.
224. Moreland JR, Westin WG. Further experience with Grice subtalar arthrodesis. *Clin Orthop* 1986;207:113.
225. Scott SM, Janes PC, Stevens PM. Grice subtalar arthrodesis followed to skeletal maturity. *J Pediatr Orthop* 1988;8:176.
226. Crawford AH, Kucharzuk D, Roy DR, Blibo J. Subtalar stabilization of the planovalgus foot by staple arthroereisis in young children who have neuromuscular problems. *J Bone Joint Surg Am* 1990;72:840.
227. Koman LA, Mooney JF, Goodman A. Management of valgus hindfoot deformity in pediatric cerebral palsy patients by medial displacement osteotomy. *J Pediatr Orthop* 1993;13:180.
228. Schwend RM, Millis MB, Hall JE. Calcaneal displacement osteotomy for correction of hindfoot deformities. San Francisco, CA: Presented at the American Academy of Orthopaedic Surgeons 60th Annual Meeting, 1993.
229. Rathjen KE, Mubarak SJ. Calcaneal-cuboid-cuneiform osteotomy for the correction of valgus foot deformities in children. *J Pediatr Orthop* 1998;18:775.
230. Tenuta J, Shelton YA, Miller F. Long-term follow-up of triple arthrodesis in patients with cerebral palsy. *J Pediatr Orthop* 1993;13:713.
231. Aiona M. Triple arthrodesis in cerebral palsy: long-term results (abstract). *Orthop Trans* 1993;16:626.
232. Damron T, Breed A, Roecker E. Hamstring tenotomies in cerebral palsy: long-term retrospective analysis. *J Pediatr Orthop* 1991;11:514.
233. Sutherland DH, Schottstaedt ER, Larsen LJ, et al. Clinical and EMG study of seven spastic children with internal rotation gait. *J Bone Joint Surg Am* 1969;51:1070.
234. Hsu L, Helena L. Distal hamstring elongation in the management of spastic cerebral palsy. *J Pediatr Orthop* 1990;10:378.
235. Relmers J. Contracture of the hamstrings in spastic cerebral palsy. A study of three methods of operative correction. *J Bone Joint Surg Br* 1974;56:102.
236. Sharps CH, Clancy M, Steel HH. A long term retrospective study of proximal hamstring release for hamstring contracture. *J Pediatr Orthop* 1984;4:443.
237. Drummond DS, Rogala E, Templeton J, Cruess R. Proximal hamstring release for knee flexion and crouched gait in cerebral palsy. *J Bone Joint Surg Am* 1974;56:1598.
238. Hoffinger SA, Rab GT, Abou-Ghaida H. Hamstrings in cerebral palsy crouch gait. *J Pediatr Orthop* 1993;13:722.
239. Waters RL, Perry J, McDaniels JM, House K. The relative strength of the hamstrings during hip extension. *J Bone Joint Surg Am* 1974;56:1592.
240. Perry J. Distal rectus femoris transfer. *Dev Med Child Neurol* 1987;29:153.
241. Ounpuu S, Mulk E, Davis RB III, et al. Rectus femoris surgery in children with cerebral palsy. Part I: the effect of rectus femoris transfer location on knee motion. *J Pediatr Orthop* 1993;13: 325.
242. Chambers H, Lauer AL, Kaufman K, et al. Prediction of outcome after rectus femoris surgery in cerebral palsy: the role of cocontraction of the rectus femoris and vastus lateralis. *J Pediatr Orthop* 1998;18:703.
243. Ounpuu S, Mulk E, Davis RB III, et al. Rectus femoris surgery in children with cerebral palsy. Part II: a comparison between the effect of transfer and release of the distal rectus femoris on knee motion. *J Pediatr Orthop* 1993;13:331.
244. Gage JR, Perry J, Hicks RR, et al. Rectus femoris transfer to improve knee function of children with cerebral palsy. *Dev Med Child Neurol* 1987;29:159.
245. Sutherland DH, Santi M, Abel MF. Treatment of stiff-kneed gait in cerebral palsy: a comparison by gait analysis of distal rectus femoris transfer versus proximal rectus release. *J Pediatr Orthop* 1990;10:433.
246. Ferguson RL, Gulliford PT, McMullin M, et al. Clinical correlation between static straight leg raise and popliteal angular measurements vs. dynamic gait lab measurements of knee extension. Lake Buena Vista, FL: Presented at the Pediatric Orthopaedic Society of North America, 1999.
247. Bruno RJ, Sirirungruangasarn Y, Berzins A, et al. Gait analysis after rectus femoris transfer in children with cerebral palsy. Lake

- Buena Vista, FL: Presented at the Pediatric Orthopaedic Society of North America, 1999.
248. Baumann J, Meyer E, Schurmann E. Hip adductor transfer to the ischial tuberosity in spastic and paralytic hip disorders. *Arch Orthop Trauma Surg* 1978;92:107.
 249. Beals TC, Thompson NE, Beals RK. Modified adductor muscle transfer in cerebral palsy. *J Pediatr Orthop* 1998;18:522.
 250. Griffin PP, Wheelhouse WW, Shiavi R. Adductor transfer for adductor spasticity: clinical and EMG gait analysis. *Dev Med Child Neurol* 1979;19:783.
 251. Reimers J, Poulsen S. Adductor transfer versus tenotomy for stability of the hip in spastic cerebral palsy. *J Pediatr Orthop* 1984;4:52.
 252. Scott A, Chambers C, Cain TE, et al. Adductor transfers in cerebral palsy: long-term results studied by gait analysis (abstract). *Orthop Trans* 1993;16:626.
 253. Matsuo T, Tada S, Hajime T. Insufficiency of the hip adductor after anterior obturator neurectomy in 42 children with cerebral palsy. *J Pediatr Orthop* 1986;6:686.
 254. Staheli LT. The prone hip extension test. *Clin Orthop* 1977; 123:12.
 255. DeLuca PA, Ounpuu S, Davis RB, et al. Effect of hamstring and psoas lengthening of pelvic tilt in patients with spastic diplegic cerebral palsy. *J Pediatr Orthop* 1998;18:712.
 256. Matsuo T, Hara H, Tada S. Selective lengthening of the psoas and rectus femoris and preservation of the iliacus for flexion deformity of the hip in cerebral palsy patients. *J Pediatr Orthop* 1987;7:690.
 257. Sutherland DH, Zilberfarb JL, Kaufman KR, et al. Psoas release at the pelvic brim in ambulatory patients with cerebral palsy: operative technique and functional outcome. *J Pediatr Orthop* 1997;17:563.
 258. Root L, Siegal T. Osteotomy of the hip in children: posterior approach. *J Bone Joint Surg Am* 1980;62:571.
 259. Steel HH. Gluteus medius and minimus insertion advancement for correction of internal rotation gait in cerebral palsy. *J Bone Joint Surg Am* 1980;62:919.
 260. Silver LB. Controversial approaches to treating learning disabilities and attention deficit disorders. *Am J Dis Child* 1986;140: 1045.
 261. Brunner R, Meier G, Ruepp T. Comparison of a stiff and a spring-type ankle-foot orthosis to improve gait in spastic hemiplegic children. *J Pediatr Orthop* 1998;18:719.
 262. Hiroshima K, Hamada S, Shimizu N, et al. Anterior transfer of the long toe flexors for the treatment of spastic equinovarus and equinus foot in cerebral palsy. *J Pediatr Orthop* 1988; 8: 164.
 263. DeJong RN. *The neurologic examination*. New York: Hoeber-Harper, 1958.
 264. Butler C. Effects of powered mobility on self initiated behaviors of very young children with locomotor disability. *Dev Med Child Neurol* 1986;28:325.
 265. Harada T, Ebara S, Kajiura I, et al. Cervical spondylosis in patients with athetoid cerebral palsy (abstract). *Orthop Trans* 1993;16:790.
 266. Samilson RL. Orthopaedic aspects of cerebral palsy. *Clin Dev Med* 1975;52/53:142.
 267. Racette BA, Laurysen C, Perlmutter JS. Preoperative treatment with botulinum toxin to facilitate cervical fusion in dystonic cerebral palsy. Report of two cases. *J Neurosurg* 1998;88:328.

Upper Extremity Involvement

268. *Orthopaedic knowledge update 2*. Park Ridge, IL: American Academy of Orthopaedic Surgeons, 1987:191.
269. Skoff H, Woodbury DF. Current concepts review: management of the upper extremity in cerebral palsy. *J Bone Joint Surg Am* 1985;67:500.
270. Van Heest AE, House JH, Cariello C. Upper extremity surgical treatment of cerebral palsy. *J Hand Surg* 1999;24A:323.
271. Mital MA, Sakellarides HT. Surgery of the upper extremity in the retarded individual with spastic cerebral palsy. *Orthop Clin North Am* 1981;12:127.
272. Hoffer MM, Perry J, Melkonian G. Dynamic EMG and decision-making for surgery in the upper extremity of patients with cerebral palsy. *J Hand Surg* 1979;4:424.
273. Mowery CA, Gelberman RH, Rhoades C. Upper extremity tendon transfers in cerebral palsy: electromyographic and functional analysis. *J Pediatr Orthop* 1985;5:69.
274. Perry J, Hoffer MM. Preoperative and postoperative dynamic EMG as an aid in planning tendon transfers in children with cerebral palsy. *J Bone Joint Surg Am* 1977;59:531.
275. Inglis AE, Cooper W. Release of the flexor-pronator origin for flexion deformities of the hand and wrist in spastic paralysis. *J Bone Joint Surg Am* 1966;48:847.
276. Ono CM, Lipp EB. Green-Banks flexor carpi ulnaris transfer to wrist extensors for spastic cerebral palsy (abstract). *Orthop Trans* 1993;16:325.
277. Thometz JG, Tachdjian MO. Long term follow-up of the flexor carpi ulnaris transfer in spastic hemiplegia children. *J Pediatr Orthop* 1988;8:407.
278. Beach W, Strecker WB, Coe J, et al. Use of the Green transfer in treatment of patients with spastic cerebral palsy: 17 year experience. *J Pediatr Orthop* 1991;11:731.
279. Hoffer MM, Ichman M, Mitani M. Long-term follow-up on tendon transfers to the extensors of the wrist and fingers in patients with cerebral palsy. *J Hand Surg* 1986;11:836.
280. House J, Gwathmey G, Fidler M. A dynamic approach to the thumb-in-palm deformity in cerebral palsy. *J Bone Joint Surg Am* 1981;63:216.



16

MYELOMENINGOCELE

RICHARD E. LINDSETH

CLASSIFICATION AND PATHOLOGY 601

NEUROLOGIC ABNORMALITY 603

GENETICS, ETIOLOGY, AND PRENATAL DIAGNOSIS 604

NATURAL HISTORY 604

Hydrocephaly 605
Arnold-Chiari Deformity 605
Tethered Cord Syndrome 605
Latex Hypersensitivity 606

EFFECT OF MYELOMENINGOCELE ON DEVELOPMENTAL SEQUENCE 606

TREATMENT 607

Spine 608
Thoracic Paraplegia 617
Upper Lumbar Paraplegia 619
Middle and Lower Lumbar Paraplegia 619
Knee 621
Foot 622
Orthotic Devices 628

Myelomeningocele is the most complex treatable congenital malformation of the central nervous system. Its effect on the child, the parents, and the medical community may be devastating. The initial treatment, which consists of closure of the meningocele and insertion of a ventriculoperitoneal shunt, is straightforward and well within the capability of most neurosurgeons. The child is then referred to the orthopaedist for rehabilitation.

The orthopaedic care of these patients is strongly influenced by factors beyond an orthopaedist's control, including changes in the neurologic system, urologic abnormalities, societal pressures, education, and the availability of medical resources. It is almost impossible to carry out the necessary treatment program without a coordinated interdisciplinary team consisting of a neurosurgeon, an orthopaedist, a urolo-

gist, a social worker, physical and occupational therapists, educators, a pediatrician, and a nurse specialist. If these services cannot be provided, the child should be referred to a clinic that can provide them.

CLASSIFICATION AND PATHOLOGY

The pathologic description of spina bifida and associated neurologic abnormalities was made by von Recklinghausen in 1886 (1). His observations remain current, and only recently have we begun to understand the pathologic processes that lead to the formation of myelomeningocele and other associated diseases.

Neural tube defects are grouped together under the generic terms "myelodysplasia," "spinal dysraphia," and "spina bifida aperta." These are not to be confused with "spina bifida occulta," which is a common radiographic finding of a lack of fusion of the spinous process of the lower lumbar and sacral spine without neurologic abnormalities. Neural tube defects

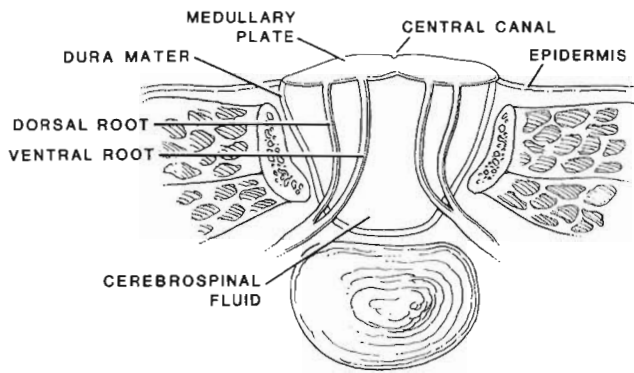


FIGURE 16-1. Cross-section of myelomeningocele. The abnormal cord is part of the sac, and is elevated out of the canal.

can be divided into four subtypes: meningocele, myelomeningocele, lipomeningocele, and rachischisis.

A cyst involving only the meninges but not any neural elements is called a “meningocele.” It often requires surgical excision and closure by a neurosurgeon. However, it does not cause neurologic or orthopaedic abnormalities, and further treatment is not needed.

A myelomeningocele includes the abnormal neural elements as a part of the sac (Fig. 16-1). The sac may assume any size, form, or location along the spine. It is less likely to be epithelialized than a meningocele sac. The neural elements are abnormal, and pronounced peripheral neurologic deficits are common. Central nervous system abnormalities, including Arnold-Chiari deformity and hydrocephalus, are common.

A “lipomeningocele” is a lesion in which the sac contains a lipoma that is intimately involved with the sacral nerves. These lesions often are epithelialized at birth. Children with lipomeningocele may not have hydrocephaly or other central nervous system abnormalities. Neurologic function, which is almost normal at birth, may become impaired with growth. This abnormality is similar to other abnormalities of the spine, including dermoid sinus, dermoid cyst, and diastematomyelia. When paralysis occurs, it rarely extends above the lumbosacral area. Progressive neurologic loss should be the major concern in the treatment of these children.

“Rachischisis” is a complete absence of the skin and sac, with exposure of the muscle and the presence of a dysplastic spinal cord without evidence of a covering. Occasionally even the bone is exposed, but usually there is a thin covering of muscle.

The embryologic development of myelomeningocele is unknown. There are two opposing schools of thought that have existed since the initial description of the disease (1): von Recklinghausen’s hypothesis that the defect was caused by lack of closure of the spine, and Morgagni’s proposal that it was caused by a rupture of a previously closed neural tube (2–7). Proponents of each theory have gained prominence.

The formation of the myelomeningocele occurs early in life, probably between the third and fourth weeks of gestation. This has two implications. The first is that if myelo-

meningocele is to be prevented by eliminating teratogenic factors and providing a nutritional supplement it must be done very early—preconception—if possible. The second implication is that the lesion has occurred before limb bud development, yet most often the limb bud of the lower extremity is essentially normal. This seems to suggest that at least initially neurologic function is normal and remains so until late in prenatal development. This has led some investigators to evaluate the benefit of delivery by cesarean section when maturity of the lungs permits, avoiding the trauma to the neural plate caused by the decrease in amniotic fluid as maturity progresses, and by the birth process itself (8). However, the studies are inconclusive.

The roof of the myelomeningocele is composed of the spinal cord. It is open from the central canal posteriorly through the dorsal columns (Fig. 16-1). The anterior roots are intact, whereas the posterior roots to the dorsal cord are more likely to be involved in the pathologic process. The central canal of the cord is open and communicates with the fourth ventricle of the brain; this allows the cerebral spinal fluid to flow to the outside. Because of the probable involvement of the posterior columns, sensory and proprioception abnormalities probably are worse than the motor abnormalities. This abnormality of sensory feedback and crossing nerve fibers around the central cord may explain the lack of coordinated reciprocal functioning and the presence of spasticity frequently observed in children with myelomeningocele.

The attachment of the spinal cord to the meningocele sac prevents the normal upward migration of the spinal cord with growth. This produces the tethered cord. Even with surgical release of the spinal cord from all adhesions at the time of sac closure, there is a likelihood of reattachment of the cord during the healing process with recurrence of tethered cord syndrome later in life. The incidence of symptomatic retethering is unknown. However, it seems that the more it is looked for the more common it becomes.

Because of tethered cord, brain development, or hydrocephaly, almost all children with myelomeningocele have displacement of the brain stem through the foramen magnum into the cervical neural canal, known as Arnold-Chiari type II malformation. The extent of the displacement determines the type of deformity. Type I malformation has minimal deformity; type II deformity consists of the displacement of the medulla oblongata and the spinal cord to the extent that the cervical nerve roots must take an upward course to reach their outlet foramina (Fig. 16-2). This is the most common deformity in myelomeningocele. The type III deformity is more severe in displacement and includes part of the cerebellum.

The final pathologic abnormality is hydrocephaly, which consists of excessive cerebral spinal fluid in the ventricles of the brain. Almost 90% of children with myelomeningocele develop hydrocephaly, which communicates to a persistently open central canal of the cord, which in turn communicates with the meningocele sac. This open communication of the central canal and the fourth ventricle permits the

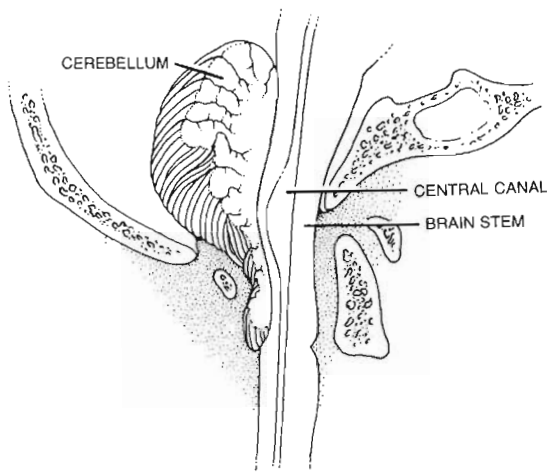


FIGURE 16-2. Arnold-Chiari type II malformation of the brain stem. This is the most common type of malformation seen in myelomeningocele. The medulla oblongata is displaced distally through the foramen magnum into the cervical neural canal. The ventricle communicates with the still-open central canal of the cord.

outflow of the cerebral spinal fluid, decompresses the ventricular pressure, and relieves the hydrocephaly. However, at the time of sac closure the fluid flow from the central canal is stopped and hydrocephaly returns. If hydrocephaly is not shunted, the fluid pressure increases in the brain and the spinal cord, which causes brain atrophy, hydromyelia, and eventually syringomyelia.

NEUROLOGIC ABNORMALITY

The neurologic abnormality defies simple classification (9) because of the complex abnormalities of the central nervous

system, which include hydrocephaly, Arnold-Chiari deformity, hydrosyringomyelia, tethered cord, and injury to the posterior column of the spinal cord. Attempts to classify the level of paralysis by muscle function as though the defect is similar to a spinal cord injury seen in vertebral fractures are unsuccessful. Sharrard and Grosfield (10) initially formulated the classification by lumbar segmental levels based on motor segmental innervation using the level of the anterior horn cells in the spinal cord. This classification does not match the clinical observation of function in the lower extremities. For example, there is confusion in the literature about what is an L4 versus an L5 level of paralysis. The problem is using muscle activity to describe the level of paralysis when central nervous system dysfunction is common. If sensation, the most severely damaged nerve function, is used to describe the level of paralysis the classification better describes what is seen clinically. Muscles that can communicate with the brain through sensory feedback are functional. Muscles that cannot do this may be ignored by the brain and become flaccid or spastic, and function only by reflex. The author recommends that classification of function be made by sensory level, rather than motor level, because it will be more consistent between patients and between different observers. Another area of confusion is whether the level of paralysis is based on which muscles are working or upon which muscles are paralyzed.

Another confounding variable is abnormality of coordinated muscle function due to brain stem abnormalities. On manual testing the muscles contract to simple commands, such as "Extend (or flex) the knee." However, on complex coordinated activities such as walking, the leg muscles do not contract as expected, but contract and relax simultaneously in a co-contraction rather than sequentially, as seen in normal gait (Fig. 16-3). This dynamic co-contraction is

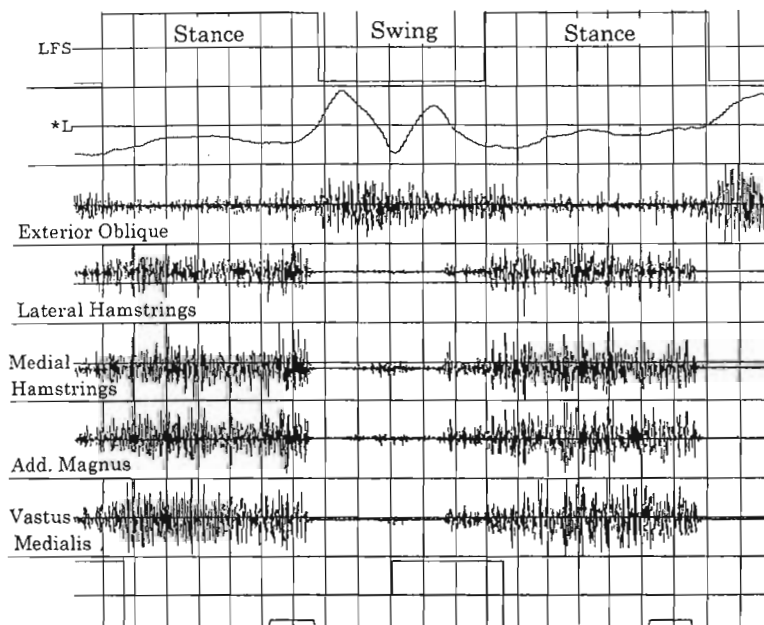


FIGURE 16-3. Dynamic electromyograms taken during a gait assessment analysis of a 5-year-old child with an L4 level of paraplegia and a type II Arnold-Chiari malformation. Surface electrodes were used during this analysis. The external oblique muscle is a swing phase muscle. The medial and lateral hamstrings, the adductor magnus, and the vastus medialis contract simultaneously throughout the stance phase. This observation has been checked using fine-wire electrodes, which show that the simultaneous contraction is not caused by crosstalk between the surface electrodes.

very common in the L3 to L5 level of paralysis, and may explain the knee flexion contractures in these patients, despite normal quadriceps strength. The author observed this phenomenon in a child with hydrocephalus and Arnold-Chiari deformity without myelomeningocele. This may suggest that it is related to the brain stem rather than to the meningocele itself.

Other common neurologic defects that are not well understood, are decreased perceptual motor function of the hands and attention deficit disorder manifested by short attention span at school (11).

GENETICS, ETIOLOGY, AND PRENATAL DIAGNOSIS

Approximately 6,000 infants in the United States are born each year with neural tube defects. This includes anencephaly, myelomeningocele, and related abnormalities. Gradual decrease in incidence worldwide has occurred over the last 30 years (12). The reason for this fluctuation is not clear, and probably involves both genetic and environmental factors.

Most neural tube defects occur as isolated malformations caused by a variety of factors, both inherited and acquired (13,14). This pattern is known as "multifactorial inheritance." In the United States, the overall incidence of neural tube defects is 0.15% among whites and 0.04% among African-Americans. After the birth of one affected child, the risk of a second affected child is higher (15,16). In the United States the occurrence of a neural tube defect in first-degree relatives of an affected member was 3.2%, in second-degree relatives, 0.5%, and in third-degree relatives, 0.17% (14).

Not all neural tube defects are multifactorially inherited; some are caused by chromosome abnormalities, and others are caused by single-gene abnormalities. Usually, children with chromosomal or single-gene abnormalities have other birth defects. Some cases of spina bifida and anencephaly are entirely produced environmentally. These abnormalities are caused by exposure during pregnancy to teratogenic agents such as valproic acid taken for seizure control (17).

Yates and colleagues (11) have shown an association between susceptibility of offspring with neural tube defects and depressed red cell folate levels which cannot be attributed entirely to low dietary intake of folate. They postulate that a factor that predisposes a person to the current neural tube defect is an inherent disorder of folate metabolism. This theory is supported by a study by Sellar and Nevin (18) in which a decreased incidence of neural tube defects was found in children of mothers taking periconceptional vitamin supplementation. The FDA recommends that all women of child-bearing age receive 0.4 mg folate before conception and during early pregnancy. The Centers for Disease Control and Prevention (17) recommends that women who fall into the high-risk group of bearing a child

with a neural tube defect because of giving birth to a prior affected child, or having a first-degree relative with a neural tube defect, receive a larger dose of folate, 4.0 mg/day.

Prenatal diagnosis of a neural tube defect allows the family, in consultation with the medical community, to make informed decisions about its child. These decisions range from termination of pregnancy to attempts to improve the outcome of pregnancy by improved perinatal care in institutions medically prepared to provide optimal care for the child. The aim of any prenatal screen for open neural tube defect is to be able to pinpoint women with a sufficiently high risk of having an affected infant to justify carrying out special diagnostic procedures such as amniocentesis for amniotic fluid, alpha-fetoprotein and acetylcholinesterase determinations, and detailed ultrasonography for examination of the fetus (19). Women who have had an infant with a neural tube defect carry enough risk of having another affected child to justify undergoing amniocentesis. Longitudinal ultrasound examination of the fetal spine provides vital information about the presence or absence of neural tube defect. The sensitivity of ultrasound examination is excellent for studying women at high risk for carrying a fetus with neural tube defect. In almost all fetuses with anencephaly, and in at least 80% of fetuses with open spina bifida, diagnoses are correct. When no abnormalities are found on detailed ultrasound examination, amniocentesis is recommended for evaluation for alpha-fetoprotein and acetylcholinesterase (20).

NATURAL HISTORY

Most children born with myelomeningocele die in early infancy if left untreated. This has been documented in several series of untreated children in the late 1950s and early 1960s. The mortality rates range from 90 to 100% (21,22). The cause of death in most infants is meningoventriculitis. Surgical treatment is not necessary for survival if antibiotics are administered and nutrition is maintained. However, the surviving children are disabled further by a high level of paralysis and increased mental retardation resulting from the continued trauma to the spinal cord and the uncontrolled hydrocephaly, which would not have been present if surgical treatment had been carried out.

During the 1970s, there was an attempt to select patients for treatment according to the criteria suggested by Lorber (22). However, most neurosurgeons have had great difficulty in withholding all forms of treatment from selected infants with myelomeningocele. They are performing initial sac closure and ventriculoperitoneal shunts on most infants with myelomeningocele.

Because most patients are treated with initial closure and ventriculoperitoneal shunt, a new and different natural history of the disease following this early treatment is being studied and documented. Studies conducted in the 1960s

cannot be equated with the disease course of the children of this decade. An important discovery about the nature of myelomeningocele during the last 15 years is that the disease is not static but may undergo progressive neurologic degeneration, manifested by increasing levels of paralysis and decreasing upper-extremity function (23–25). Neurologic deterioration can be sudden and dramatic, or very slow and insidious. It is extremely important that the orthopaedist carry out a detailed neurologic evaluation including upper and lower extremities and motor function at each clinic visit, and any change in function requires a referral to the neurosurgeon for appropriate diagnosis and treatment. Three major areas of deterioration of the central nervous system have been found: hydrocephaly and associated hydrosyringomyelia, Arnold-Chiari deformity, and tethered cord syndrome.

Hydrocephaly

Hydrocephaly is a common disabling abnormality found in myelomeningocele due to obstruction of fluid movement by complex deformities of the posterior fossa and brain stem. In 1974, Lorber showed that, of patients *without* hydrocephaly, 30% had IQs above 100, 50% had IQs between 80 and 99, 12% had IQs between 60 and 79, and 8% had IQs under 60. In contrast, of patients *with* hydrocephaly, only 20% had IQs above 100, 30% had IQs between 80 and 99, 30% had IQs between 60 and 79, and 20% had IQs under 60 (22). Perceptual motor abnormalities appeared to be the biggest factor in intellectual function. Most of these children perform well in their verbal scores but are considerably below average in their perceptual motor and hand function scores.

Although, in some children with myelomeningocele the hydrocephaly becomes arrested in infancy without evidence of increasing head size or symptoms of acute intracranial pressure, most children require a ventriculoperitoneal or ventriculoatrial shunt (26). Considerable improvements in the design and construction of the shunt have been achieved; however, it is still an unsophisticated device for controlling the right amount of ventricular pressure. Shunt failure can occur at any age, and must be evaluated at each clinic visit.

In the young child shunt failure is accompanied by the typical symptoms of hydrocephaly. However, in the older age groups shunt malfunction rarely is associated with signs of acute hydrocephaly, such as nausea, vomiting, and severe headache, except first thing in the morning (24,26,27).

Because of the communication of the fourth ventricle with the persistent central canal of the cord, increased hydrocephaly results in fluid entering the central canal, causing dilation and pressure in the cord when the child is upright (6). If left unresolved, this eventually causes the formation of hydrosyringomyelia. Three problems have been shown to result from hydrosyringomyelia. The first problem is in-

creasing paralysis of the lower extremities, occasionally associated with increased spasticity and, to a lesser extent, back pain. This problem is seen usually when the child is in his or her early school-age years. The second problem is progressive scoliosis which may occur as early as 5 years of age, but is more likely to be seen in the 7-to-10-year-old group (26,27). The third problem is weakness of the hands and upper extremity (24). This occurs when the child is in the teenage years. Most of these symptoms are resolved by early correction of the hydrocephalus by shunt replacement.

Arnold-Chiari Deformity

Associated with hydrocephaly is the Arnold-Chiari deformity, which is classified into three types according to the degree of displacement of the brain stem and hindbrain through the foramen magnum. Most of these affected children have a type II anomaly, which is characterized by displacement of the medulla oblongata into the cervical neural canal through the foramen magnum, requiring the cervical roots to take an upward course to reach their outlet foramina (Fig. 16-2).

The symptoms of an Arnold-Chiari type II deformity in infants includes periodic apnea, stridor, nystagmus, weak or absent cry, and upper-extremity spasm and weakness. Symptoms come in episodes between which the infant may show minimal involvement. The cause of the episodic nature of the symptoms is not determined. During childhood symptoms include spastic weakness of the upper extremities and, occasionally, leg involvement. Children also have nystagmus, stridor, difficulties in swallowing, and depressed or absent cough reflex. Symptoms in older patients still are being determined, and probably include scoliosis, decreased upper-extremity function, neck pain, and decreased respiratory function. The most serious difficulties appear to be present in infancy and decrease as the child matures.

In many children, following initial placement of the ventriculoperitoneal shunt to control hydrocephalus brain stem symptoms usually resolve on their own and do not require surgical decompression procedures. In a few infants and children in whom the brain stem compressive symptoms persist or progress, the posterior fossa and upper spinal region are decompressed surgically. The effect of aggressive treatment of Arnold-Chiari deformity on overall survival and function has yet to be determined.

Tethered Cord Syndrome

Tethered cord syndrome is another major cause of decreased nerve function (28). During the formation of the myelomeningocele, the open neural elements are attached to the ectoderm at its periphery. This prevents it from migrating cephalad during the growth of the fetus. Consequently, all children with myelomeningocele have a degree of tethered cord at the time of birth. During closure of the sac, the

everted spinal cord is dissected from the skin and allowed to fall back inside the neural canal. If any dermal elements are left attached to the spinal cord, dermoid cysts may develop and eventually cause decreasing function in the lumbosacral roots by direct pressure on the nerve elements.

After sac closure there still is a tendency for the spinal cord to become adherent to the meningocele repair. As the child grows this adherence again produces a tethered cord and prevents the spinal cord from migrating cephalad during growth. Although many children have a tethering of their spinal cord, only a few actually have symptoms of the condition and require surgical release. Because the posterior part of the spinal cord is adherent to the meningocele repair, and the cord proximal to the meningocele is held posteriorly where it is compressed by the posterior neural arch in the area of the lumbar lordosis, most symptoms are associated with posterior column abnormalities.

Pain appears to be a prominent symptom of the tethered cord syndrome and may occur in the lower lumbar spine, in the area of the myelomeningocele, or the sacral roots, with pain in the buttock and the posterior thigh. The pain is also activity-related, and becomes worse after walking long distances. In addition, increasing spasticity and decreasing function of the lower extremities are frequently present. Occasionally there is an associated progressive scoliosis associated with marked lordosis. Changes in dermatomal somatosensory-evoked potentials are present, and are helpful in making the diagnosis if serial examinations have been made (29). Changes in bladder function are common. The diagnosis of tethered cord syndrome is made on clinical evaluation, not by the presence or absence of a tethered cord on radiographic MRI study. The MRI describes the nature of the tether and confirms the diagnosis. The diagnosis of tethered cord syndrome in thoracic level paraplegics is rare, and becomes more common the lower the level of paralysis. In the author's experience surgical release of the tethered cord rarely provides complete return of lost function. The diagnosis must be made early, and appropriate care must be provided before major loss occurs.

Latex Hypersensitivity

During the past 10 years there have been increasing reports of severe immediate-type allergic reactions to latex exposure (30). Although anyone may become sensitized to latex, three groups appear to have a high risk: children with myelomeningocele, health care workers, and workers in the latex industry. The reported incidence is as high as 34% in myelomeningocele children, and may increase in the future (31).

All patients should be questioned about a history of latex allergy. A history suggesting sensitivity includes swelling or itching of the lips from blowing up balloons or after dental examinations, and swelling or itching of the skin after contact with any rubber products. Other information that may

suggest increased risk of latex allergy includes hand eczema; oral itching after eating bananas, chestnuts, or avocados; and multiple surgical procedures in infancy.

There is no standard test for latex allergy. Skin testing with a latex extract or glove extract may be the best test available. However, anaphylaxis has occurred in spina bifida patients during skin testing. In vitro tests may not be sensitive enough to detect all persons who may be at risk for latex contact.

Because of the high incidence of latex allergy in myelomeningocele it is recommended that all patients, regardless of history, should have their surgery performed in a latex-free environment. There have been several lists published of latex-containing items. However, they are being revised almost daily, and no list should be considered complete. Some things that are labeled "latex," such as latex paint, are not latex based. It is best to ask the manufacturer if there is any question. If the child is known to be allergic, the parents will be able to tell what things need to be avoided in the hospital environment. However, in surgery, it must be assumed that the child is sensitive to all latex material. A latex-free environment is one in which no latex gloves are used by any personnel in the operating room, and there should be no latex accessories (e.g., catheters, adhesives, tourniquets, anesthesia equipment) that come into direct contact with the patient.

EFFECT OF MYELOMENINGOCELE ON DEVELOPMENTAL SEQUENCE

The normal child undergoes a sequential development of fine motor, gross motor, personal, social, language, and cognitive skills, which are the result of the child's physical abilities and his or her interaction with the environment (11). Three major areas that interfere with normal development of the myelomeningocele child are residual physical deformity, iatrogenic factors, and restrictions by society.

Medical treatment of children with myelomeningocele contributes greatly to their delayed development. Prolonged and frequent hospitalization during the first years of life, although often necessary, considerably interferes with the learning experiences of the child. Hoppenfield (32) pointed out that because of this environmental deprivation a 1-month-old infant with myelomeningocele frequently cannot follow a light to a midline, fix both eyes on the light, and respond to the sound of a rattle.

Along with the frequent shunt malfunctions and repeated hospitalizations the child also is placed in casts and splints to treat physical deformity, which further interferes with mobility and physical contact with parents, and prevents parent-child bonding. As the child becomes older, individuality often is denied as he or she is treated as a disease entity rather than a person. In the clinic the children

frequently are undressed to their diapers then paraded before members of the clinic without regard for their embarrassment. The tendency is to treat them as asexual beings. If it is necessary to present a physical function abnormality to a group for discussion or education, a picture or a video recording should be used.

The last impediment to normal development is the resistance of society to accept and accommodate handicapped persons. Although there have been considerable improvements in treatment of children with myelomeningocele during the last 10 years, there still are considerable societal barriers to these children. For example, access to schools, playgrounds, amusement parks, sporting events, movie theaters, and private homes are limited to some extent. Also, acceptance of handicapped people in the employment market is restricted.

Although many previously mentioned factors are beyond control, these myelomeningocele patients can be helped to overcome their handicap. Hospitalization and treatment programs must be planned to interfere as little as possible with the normal developmental sequence, particularly in infancy. We must work within the clinics, schools, and to a larger extent, society, to promote acceptance of these patients as individuals, and help them carry out the four principle tasks of childhood and adolescence: establishment of a stable self-image, acceptance of an adult sexual role, development of independence, and choice of a career (33).

Development of a positive self-image and adult sexuality is a difficult task. Because of the physical impairment of children with myelomeningocele, personal interactions among peers is severely restricted, beginning in early childhood and extending into adolescence. The child with myelomeningocele looks different because of braces, orthopaedic shoes, wheelchairs, and deformities; these are barriers to peer acceptance. These feelings of being different may never be erased, even if the cause of these feelings is eliminated (34). Sexual information for these patients often is avoided or erroneous. Shurtleff et al. (8) showed that many adults with myelomeningocele could have sexual relationships, including procreation; however, knowledge about the specific problems in myelomeningocele is meager, and a local resource person may be difficult to find.

Development of independence is a complex issue between the parents and their dependent, handicapped child. The parents are often overprotective of the child. This protective attitude is also present in school and in society at large, especially if the child is confined to a wheelchair.

The choice of a career is also difficult. High school counselors are not trained to advise disadvantaged children, especially those with perceptual motor abnormalities of the hands. Government programs are not available until the patient is 18 years old or has graduated from high school. This is too late. Employment opportunities also are limited by the lack of ability to get health insurance.

TREATMENT

Treatment of children with myelomeningocele is not a matter of what can be done, but what should be done for each child. The decision-making may begin prenatally if the diagnosis is made by alpha-fetoprotein testing or ultrasound examination. The option to continue or terminate the pregnancy can be made at this time. If it is continued, decisions must be made on how to improve the prognosis of the child. These include referral, before delivery, to a center experienced in the care of these children so that adequate planning and preparation for the family can be carried out. If the diagnosis is made after birth then the next decision is whether the meningocele should be closed and the child treated. Most children are treated unless there are other deformities present that are not compatible with life, such as anencephaly, congenital heart disease, pulmonary insufficiency, and other congenital malformations. In some cases, the lesion may be surgically untreatable.

Orthopaedic treatment is intertwined with the neurosurgical treatment. It is also tied in with urologic treatment. Almost all of these children have urologic abnormalities that require bladder drainage by conduits or intermittent catheterization. Frequent infection may spread to orthopaedic surgical areas, and the orthopaedic treatment of spine deformity influences the ability of the patient for self-catheterization.

Orthopaedic treatment of myelomeningocele has three major goals. The first goal is to provide for maximal use of residual ability to maintain range of motion and stability of the spine and extremities. The second is to provide for mobility by means of a wheelchair and other wheeled devices or by ambulation. The third goal is to prevent deterioration of neurologic function. Although it is true that the actual treatment of the central nervous system is performed by the neurosurgeon, the diagnosis of decreased function is made from observations of the spine and extremities by the orthopaedist. It cannot be assumed, because these patients are being seen and followed-up by neurosurgeons, that subtle changes in function are going to be observed. Teamwork is essential in treatment of children with myelomeningocele.

The ability to walk is important and often necessary in our society, despite recent advances in wheelchair design and wheelchair accessibility in the community. It also is the desire of every child with spina bifida. Although it is possible for most paraplegic children to walk to some degree during preschool and school age, many adults are not able to continue walking. Abnormalities of the spine and legs are often the cause for this inability. There are four necessary requirements of walking: alignment of trunk and legs; range of motion; control of the hip, knee, and ankle joints; and power to provide forward motion.

The alignment of the spine and the legs must be such that the center of gravity passes through the joints of the pelvis, the hip, the knee, and the foot. Deformities of the spine, such as scoliosis, kyphosis, and pelvic obliquity, pre-

vent the center of gravity from passing through the center of the hip joint. Contractures of the hip or knee also will prevent stable weightbearing.

Motion of the lumbosacral spine and the hip are essential for functional walking. Motion of the knee is less important, and is useful only in clearing the swing leg. Mobility of the spine must allow the center of gravity to be shifted from side to side over the stance leg. Motion of the hip is the most important part of walking. Analysis of spina bifida children who maintain walking ability has shown normal flexion/extension of the hip. Thirty degrees of motion is necessary for forward progression. If there is less motion than this, then pelvic motion must help compensate for this decreased motion.

The child must be able to control the position of the trunk and hip, knee, and ankle joints, during the gait cycle. If this cannot be performed by muscle activity then it must be provided by an orthotic device. The determination of available muscles to control the joints is dependent on the level of paralysis.

The thoracic-level paraplegic has no active muscle contraction across the hip joint, and no feeling below the groin or in the hip. The child has no control of the hip, and the hip is unstable, even though it may be reduced and appear stable on radiograph examination. Stability for walking can only be provided by an orthosis that crosses the hip joint.

The upper lumbar paraplegic child has several muscles crossing the hip joint. These muscles include the hip flexors and the hip adductors. These children have some sensation crossing the hip joint. Contraction of the hip flexors causes the hip to flex, pitching the child forward. In order to keep from falling it is necessary to place most of his or her weight on the arms and crutches or walker. This is not a useful posture for walking and must be corrected. There is no way of surgically providing stability to this hip, and, similar to the thoracic-level paraplegic, the stability must be provided by an orthosis.

The middle and lower lumbar paraplegic child has hip flexors and adductors, knee extensors, and weak knee flexors. These children do not have normal hip extension or hip abduction, which are the most important muscles for standing and walking. Their weak hamstring muscles have a tendency to extend the hip and make these children walk without the need for orthotic control of the hip. The result of this is knee-flexion contracture. The force imbalance around the hip results in eventual hip dislocation. A decrease in the force imbalance, and increase of the control of the hip, can be obtained only by moving muscles to a more functional position or by adding muscles to the hip. Muscles available for transfer include the iliopsoas, the abdominal muscles, and the adductor muscles. Control of the hip and knee can be achieved by muscle activity; however, the ankle requires an orthosis.

The sacral-level paraplegic child has sufficient muscle control around the hip, the knee, and the ankle to provide the necessary stability.

The force necessary to move forward is beyond the muscle contraction needed to control the joint. In normal individuals it is provided by the calf muscle, which pushes people forward into their next step, and the hip extensors, which pull forward after the foot hits the floor. Both of these muscles have sacral level innervation and are paralyzed in almost all spina bifida children. In the thoracic and upper-lumbar levels of paraplegia the arms become the power producers to move forward. The arms are not designed for this activity and are inefficient. Weight gain is also a problem because many of these patients become obese. Consequently, it takes increased energy to walk and the walking pace is much slower than normal. Eventually, most thoracic and upper lumbar-level paraplegic people discover that the wheelchair is a much more efficient means of transportation.

The middle and lower lumbar-level paraplegics substitute trunk shift and sway to produce the forward motion. Much of the motion is from side to side, rather than forward. This also is an inefficient method of walking, and some children abandon it for a wheelchair when they become adults. The use of muscle transfers to increase hip extension does aid in the efficiency of walking and may keep the patient walking longer.

Spine

Spine deformity is so common in myelomeningocele that it should be considered part of the disease complex (35). The spine deformities usually are progressive and may cause severe disability, interfere with rehabilitation, and negate previous treatment to maintain ambulation.

The most obvious and consistent abnormality of myelomeningocele spinal deformity is the incomplete posterior arch in the lumbosacral spine. This abnormality affects many aspects of scoliosis and kyphosis treatment. Other congenital malformations also may be present (36). Hemivertebrae and diastematomyelia may occur at any level along the spine. Similarly, unsegmented bars may occur at any level. They are particularly difficult to identify and evaluate if they occur in the area of the spina bifida, where the facet joints, lamina, and spinous processes are difficult to identify on standard radiographs.

The spinal curvature often appears at a younger age than that typical for most developmental abnormalities. It may be present by 2 to 3 years of age, becoming severe by age 7. Because of the early onset of the deformity, treatment plans need to anticipate growth of the spine. However, the projections for growth in children with myelomeningocele are different from those for children with normal growth potential. Children with myelomeningocele may have slow growth due to growth hormone deficiency, and mature earlier than usual, often by 9 to 10 years of age in girls and 11 to 12 years in boys. The cause of the hormonal abnormalities has not been discerned, but they are treatable if it is necessary for the overall management of the child.

Another factor that needs to be considered in the surgical treatment of these patients is the high infection rate (35,37–39). These patients are subject to frequent septicemias due to urinary tract infections. Most of these children have chronic contamination of the urinary tract, which always has the potential to progress into an infection. During surgical procedures adequate drainage of the bladder and appropriate antibiotics should be a routine part of the surgical management. The skin in the area of the meningocele repair is often of poor quality, and gives minimal coverage to the instrumentation.

These children also have deformity of the pelvis and hips that affects spine balance. For example, asymmetric hip contractures may cause lumbar scoliosis, pelvic obliquity, and abnormal lordosis in the standing or sitting position. Similarly, correction of the spine in the treatment of scoliosis can position the legs in a way that prevents functional sitting or standing.

As with all children with spinal deformities, the goals of treatment are the prevention of further deformity and the creation of a stable, balanced spine. Children with myelomeningocele, however, require more precise correction of the deformities. Residual deformity may prevent them from sitting, standing, or walking. Pressure sores are likely to develop if pelvic obliquity remains, and their sagittal plane alignment must allow them to perform intermittent self-catheterization.

Scoliosis and Lordosis

Scoliosis occurs in almost 100% of patients with thoracic-level paraplegia (40). Eighty-five percent of these curves are greater than 45 degrees. As the paralysis level lowers, so does the incidence of scoliosis. At the fourth lumbar level of paraplegia the instance of curvature decreases to about 60%, with only 40% requiring surgical intervention (40) (Fig. 16-4). Lordosis without concurrent scoliosis is rare, and usually is caused by hip-flexion contractures. Historically it has been seen after spinal-peritoneal shunting for hydrocephalus; however, this procedure is rarely performed.

Several causes for the scoliosis have been identified. A C-shaped scoliosis is usually caused by muscle weakness associated with high-level paraplegia. It also may be associated with asymmetric levels of paralysis or a spastic hemiplegia due to the hydrocephalus. This type of scoliosis may be associated with kyphosis rather than lordosis. Typically, this curve pattern occurs at a young age, often in infancy, and is usually progressive. If severe spasticity is present an intraspinal rhizotomy or cordectomy may be necessary (42).

Hydromyelia, or hydrosyringomyelia associated with uncompensated hydrocephalus, can cause scoliosis (24–27). The scoliosis is usually in the thoracic or the thoracolumbar region, and it is typically S-shaped. Because of stiffness in the area of the myelomeningocele in the lumbar spine, the compensation for the major curve may be incomplete and associated with pelvic obliquity. Scoliosis may be the only

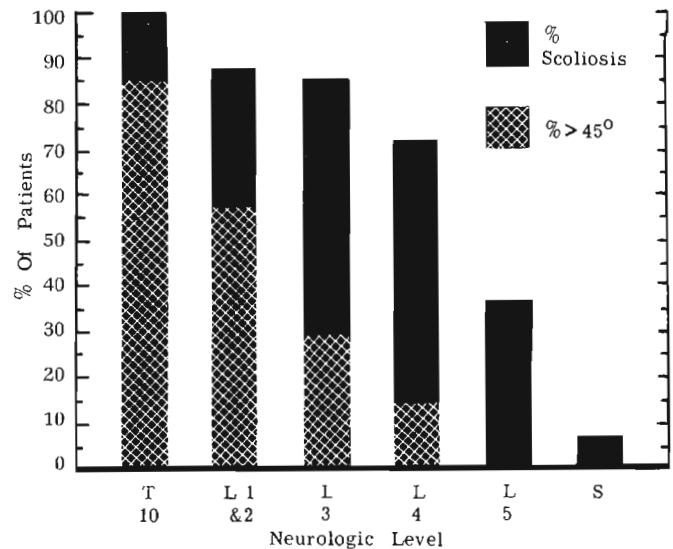


FIGURE 16-4. Incidence and severity of scoliosis, based on the level of paraplegia. (From ref. 41, with permission.)

clinical sign of shunt malfunction or progressive hydromyelia, and may occur at any age, even early in childhood. Headache, nausea, vomiting, and vision changes—the usual signs of hydrocephalus—may be absent. Other symptoms of hydromyelia are back pain, weakness of the upper extremities, and increasing paralysis of the legs. It has been shown that reinserting a functional shunt may decrease the scoliosis if it is less than 50 degrees (27).

Another cause of scoliosis is the tethered cord syndrome (23,28,43). This abnormality is caused by attachment of the spinal cord to the area of the myelomeningocele, preventing its upward migration with growth. This syndrome may be associated with other intraspinal pathologies, such as dermoid tumors, lipomas, and diastematomyelia. The scoliosis is usually in the dorsal lumbar or lumbar spine with a marked increase in lumbar lordosis. Results of releasing the tethered cord are variable, but frequently curve progression is stopped; in a few cases, it improves. If the curve is more than 50 degrees, the scoliosis should be corrected and stabilized with spine fusion.

Congenital malformations, including the lack of formation and the lack of segmentation (36,44), may exist in combination with hydromyelia, tethered cord, or muscle paralysis. When evaluating a child with scoliosis the physician must consider each component of the scoliosis in the treatment program. Because of the high number of neurologic abnormalities associated with scoliosis a referral to a neurosurgeon should be made at the first sign of increasing scoliosis. It may be necessary to reinsert the shunt, untether the spinal cord, and treat the congenital scoliosis, if all are present.

Diagnostic Studies. At each visit a thorough neurologic examination of muscle strength, levels of sensation, and re-

flex activity of the upper and lower extremities should be carefully documented. If scoliosis is developing, the documented changes in neurologic function are of major diagnostic importance to the etiology of the scoliosis.

Radiographic evaluation should be carried out annually from the age of 1 year. These radiographs should be taken while the child is sitting, when the child can do so. This eliminates the problems related to hip flexion contracture and asymmetric abduction and adduction. If there is documented progressive scoliosis, additional radiographic examination is indicated. Magnetic resonance imaging (MRI) probably gives the most information without requiring invasive studies (45). MRI of the head and cervical spine evaluates the hydrocephalus and the degree of Arnold-Chiari malformation. The cervical, thoracic, and lumbar spine also should be scanned. The cervical and thoracic spine are evaluated for the appearance of syrinx or hydromyelia. The scan of the lumbar spine provides information on the posterior displacement of the conus and the presence of intraspinal tumors, such as lipoma or dermoid cysts. The MRI studies must be interpreted in association with the clinical findings to determine the cause of the scoliosis. The presence of a tethered cord is common, and it alone may not be the cause of the deformity. In the author's experience the scoliosis is in the lumbar spine with the apex at the last intact neural arch; the lordosis is in excess of 90 degrees; and other signs of tethered cord, such as changes in bladder function and neurologic function of the legs, are present.

Computed tomography (CT) also can be used. However, to get the maximum benefit from the study contrast material is usually necessary for evaluation of the spinal cord. Both MRI and CT studies usually require sedation or anesthesia in young children.

Treatment. If the scoliosis continues to progress after neurologic problems have been corrected, orthopaedic treatment is indicated. If the spine is balanced and the curve is 30 degrees or less, observation probably is indicated. However, if the curve is unbalanced or greater than 30 degrees the center of gravity falls outside of the pelvic base of support, the spine will become unstable, and progression of the deformity is almost assured. A trial of bracing is indicated in children younger than the age of 7 years if the curve is supple and can be corrected easily. However, because bracing in paralytic scoliosis is passive, the brace tends to deform the rib cage and produce pressure sores in the area of insensate skin. In infants special care is needed to avoid abdominal compression, which may make it difficult for the child to breathe and eat. Although the use of a brace is only temporary, it may delay the necessity of surgery until the child is 8 or 9 years old, when many of these children are beginning adolescence (36,46).

The most effective spinal orthosis is a two-piece, polypropylene, bivalved, molded body jacket. This design allows the brace to be expanded or contracted throughout the day, to allow for eating, and allows some adjustability for growth.

Meticulous care is required because pressure sores are frequent, and once they develop, it is almost impossible to continue using the brace for control of the curve. In general, the child begins orthosis wear slowly, starting at 1 h intervals, after which the skin should be inspected. If any redness does not disappear within 4 h, the orthosis must be modified. The time in the brace is gradually increased over 2 to 3 weeks until the child is wearing it throughout the day except for naps and nighttime. If the family or caregivers are unable to provide this degree of care an orthosis is probably not indicated.

Most of these children require surgical correction and spinal fusion. Levels of fusion depend on the age of the child, the location of the curve, the level of paralysis, and the ambulatory status. As with all children with spinal deformities, the goals of treatment are the prevention of further deformity and the creation of a stable, balanced spine. Children with myelomeningocele, however, require more precise correction of their deformities; because of their paralysis, they are unable to compensate for any residual deformity, which may prevent them from sitting or from standing and walking. Pressure sores are likely to develop if pelvic obliquity remains, and their sagittal plane alignment must allow them to perform intermittent self-catheterization.

The treatment of the tethered cord, even if it is not symptomatic when correction of the scoliosis is performed, is an unsettled issue. Correction of the scoliosis lengthens the posterior spine, and puts the tethered cord on stretch. This may produce neurologic changes, even if they were absent before. Therefore, the neurosurgeons at the author's clinic believe that the tethered cord should be released either before or during the scoliosis surgery. If it is done before, the time between release and the spine surgery should probably be no more than 6 months because of the frequent retethering.

Generally, the same guidelines for instrumentation and fusion of idiopathic scoliosis are applicable to the myelomeningocele spine. The fusion should go from neutral vertebra to neutral vertebra, and the end vertebra should be located within the stable zone. This holds true for thoracic and thoracolumbar curves. However, in double curves, uncompensated curves, and primary lumbar curves, the decision becomes more difficult. The guidelines for fusion and instrumentation in these cases differ from those for idiopathic scoliosis. In general, it is a mistake to fuse short; if there is a question, fuse long. A compensatory thoracic curve should be fused for its entire length, and the fusion should not end in the middle of a sagittal curve or at a junctional kyphosis.

The selection of the level at the distal end usually is complicated by the open vertebral arch, which prevents attachment of the instrumentation to the end vertebra. Lumbar hyperlordosis usually is present, compounding the problem of deciding on the distal level of fusion. In the past, the instrumentation was extended to the pelvis because of the difficulty of getting a firm attachment to the lower lumbar vertebrae [2.5, 2.6] (47). With the newer methods of

pedicle fixation it may be possible to control some curves without fusing the lumbosacral joint. The indications for extending the fusion mass to the sacrum are not well established. Lumbosacral arthrodesis is difficult to obtain because of the lack of posterior vertebral arch to fuse [2.6–2.8]. Consequently, pseudoarthroses and instrumentation failures are common (39). Attempts to correct these problems require repeated surgical procedures and have an uncertain outcome. If a successful fusion to the sacrum is obtained it may deprive ambulatory patients of the ability to walk (48). In wheelchair-bound patients a lumbosacral fusion may cause difficulty because of increased occurrence of pressure sores if the residual pelvic obliquity is 15 degrees or greater. Movement in the lumbosacral spine absorbs much of the angular and rotational movements of the trunk during wheelchair activities. If the lumbosacral spine is fused, these torsional movements are transmitted to the pelvis, creating increased shear between the pelvis, the skin, and the wheelchair seat.

If the lumbosacral joint is not fused, the scoliosis tends to increase, unless the lumbar scoliosis can be corrected to less than 20 degrees and the pelvic obliquity to less than 15 degrees. Therefore, it is important to treat the scoliosis while the curve is small and can be corrected to less than a 20-degree lumbar curve and a 15-degree pelvic obliquity, whether fusion to the sacrum is planned or not. The delay of surgical correction of the scoliosis to allow the spine to grow may lead to an unsatisfactory correction. After spine correction residual pelvic obliquity greater than 15 degrees and less than 35 degrees can be corrected by a bilateral posterior iliac osteotomy, with transfer of a wedge of bone from the long side to the short side. The correction of the pelvic obliquity is necessary if there is difficulty sitting or an ischial ulcer develops (49).

Children with a thoracic or upper lumbar level of paraplegia should be fused to the sacrum (Fig. 16-5). In children with low lumbar and sacral levels of paraplegia, the lumbo-

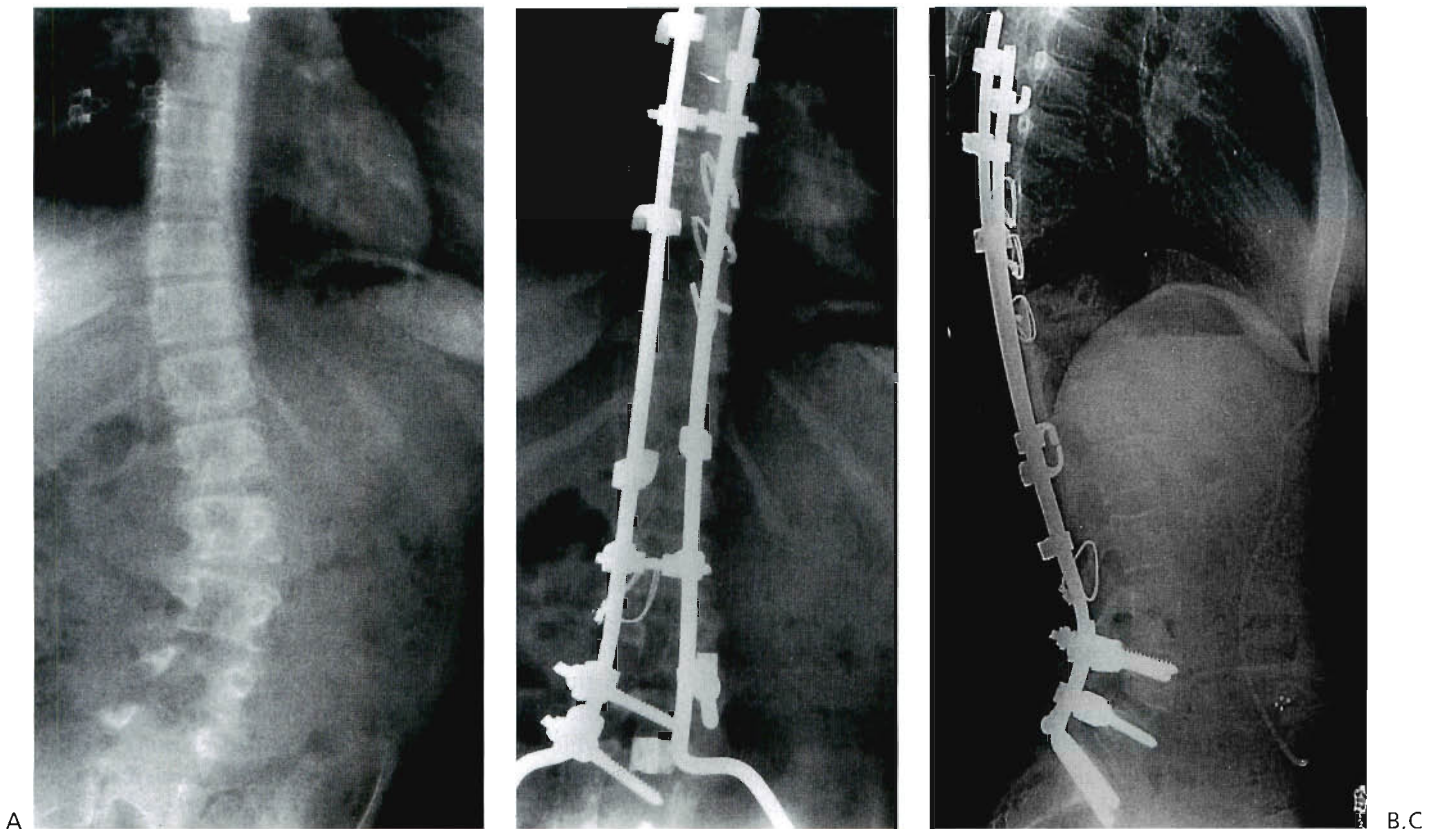


FIGURE 16-5. A 13-year-old girl has an L3-level paraplegia, but is not ambulatory. She is obese and has a progressive lumbar scoliosis and pelvic obliquity. A tethered spinal cord previously was released. **A:** Anteroposterior radiograph shows a 50-degree uncompensated lumbar scoliosis resulting in 35-degrees of pelvic obliquity. There is excessive lumbar lordosis. **B:** Postoperative anteroposterior radiograph shows complete correction of the scoliosis. The sacrum was included in the fusion because the lumbar scoliosis included the first sacral vertebra and the child was not ambulatory. Pedicle screws were used to secure the segmental instrumentation to L4 and L5. Anterior interbody fusion was performed from T10 to the sacrum. **C:** Postoperative radiograph shows restoration of normal sagittal alignment. Lumbar lordosis now measures 55 degrees. The patient has full extension of her hips, and is able to perform intermittent self-catheterization. (From ref. 59, with permission.)

sacral joint should be spared if they are walkers, and the spine can be aligned satisfactorily (Fig. 16-6).

The sagittal deformity also must be evaluated because increased lumbar lordosis is a common deformity. Assessment of sitting, supine, and standing posture must be made before correcting the lumbar lordosis. These children often require a greater degree of lordosis than normal. Restoring the lumbar lordosis to the normal range may uncover a hip-flexion contracture and prevent the child from standing or walking. If too much lordosis is fused into the lumbar spine of a female patient she may not be able to carry out intermittent self-catheterization. The degree of lordosis left in the spine after fusion needs to be tailored to each patient. It is best to treat the hip contractures before correcting the spine. If the hip deformity is not corrected first, positioning of the spine on the operating table will be difficult and torque the spine postoperatively, leading to instrument failure and pseudarthrosis.

Ischial pressure sores also should be treated before spinal fusion to lessen the chance of infection. This is often difficult to do because the pelvic obliquity is a major cause of the ulceration and unless it is corrected, pressure cannot be relieved from the ulcer. In this circumstance, a gluteus maximus myocutaneous flap can be used to promote primary healing. The patient is maintained on an air mattress bed until the spinal correction can be performed. This may seem extreme, but is much less of a problem than an infected spinal fusion that requires instrument removal.

The age of the child at the time of surgery is an important consideration. If the child has not yet reached adolescence, as determined by the beginning of the appearance of pubic hair and a Risser sign of I, there is an almost 100% assurance that the curve will continue to progress despite posterior fusion unless the anterior spine is fused to the same level. The lumbar spine usually is fused anteriorly as well as posteriorly because of the deficient posterior vertebral arch, but if the posterior fusion extends up into the thoracic spine, it must be fused anteriorly as well.

In a child with a progressive curve that cannot be controlled by a brace and who is younger than 8 years old, the preferred treatment is extraperiosteal segmental Luque instrumentation without spinal fusion. Distal fixation of the rods in the area of the open spine is difficult. The author prefers use of the first sacral foramen as the anchor point. The "S" rod attached to the ala is also a possibility. The ilium is also a possibility, although the author has experienced loosening of the rod in the ilium with loss of fixation and erosion of the rod through the skin. Postoperative brace treatment is still indicated, and complications from this approach include rod breakage, wire breakage, and spontaneous fusion. To provide a definitive solution, reoperation is often necessary when the child reaches maturity.

Instrumentation. Spinal fusion is still the most important part of surgical treatment of scoliosis despite the recent ad-

vances in spinal instrumentation. The role of the instrumentation is to improve spinal alignment and the fusion rate, and reduce the need for recumbency or postoperative immobilization. Whatever the instrumentation used, the degree of correctability of the curve is limited. It is important to carry out an early fusion when the deformity is manageable. The amount of correction that is possible is probably limited to about 60 degrees, despite the size of the curve. Occasionally it is possible to produce amazing degrees of correction, but this is not the rule. It is better to correct completely a 60-degree curve than to correct a 120-degree curve to 60 degrees.

It is agreed that anterior and posterior fusion is necessary in the area of the lumbar spine (40,50–52). However, there is no agreement about whether the anterior spine needs to be instrumented. The more severe the deformity to be corrected the greater the indication for using anterior instrumentation. However, there is still a great risk of producing kyphosis of the lumbar spine or at least flattening the normal lumbar lordosis, although some of the newer devices using thicker rods may control the sagittal alignment of the lumbar spine. Anterior instrumentation to the sacrum is difficult, and it is questionable whether an anterior interbody fusion of L5-S1 is necessary. Normally this is a very stable joint, and adequate posterior fusion can be obtained by grafting from the lamina and transverse process of L5 to the sacral ala. However, if the anterior longitudinal ligament is destroyed along with the annulus fibrosis, instability and severe deformity of this joint may occur if the child develops a pseudarthrosis of the lumbosacral joint. Because repair of this deformity and pseudarthrosis can be difficult, it is preferable to end the anterior instrumentation at L4 [➤2.11] in those patients who have a dorsal lumbar curve that ends or is stable at L3-L4. If it is necessary to extend the fusion down to the pelvis, perform an anterior fusion only down to L5, and posteriorly to the pelvis.

Posterior instrumentation has evolved considerably over the last 20 years. Initially, Harrington instrumentation was used [➤2.2–2.4], but because of the lack of posterior vertebral arch, distal fixation of the fusion was difficult unless the instrumentation was extended down to the sacral ala. The alar hooks frequently became displaced, and the pseudarthrosis and complication rates were unacceptably high (52). The child also required postoperative immobilization which increased the occurrence of pressure sores.

Luque instrumentation has become the standard instrumentation for these children (47). Because of the segmental fixation to each vertebra, there is much better control over the spine and postoperative immobilization is not required [➤2.5]. However, it does not fix the length of the spine as a rod with hooks does; therefore, the spine may settle or collapse along the rod, with loss of some correction in the immediate postoperative period. If the rod is contoured to maintain a normal sagittal alignment there is a tendency for the rod to twist into the coronal plane deformity with

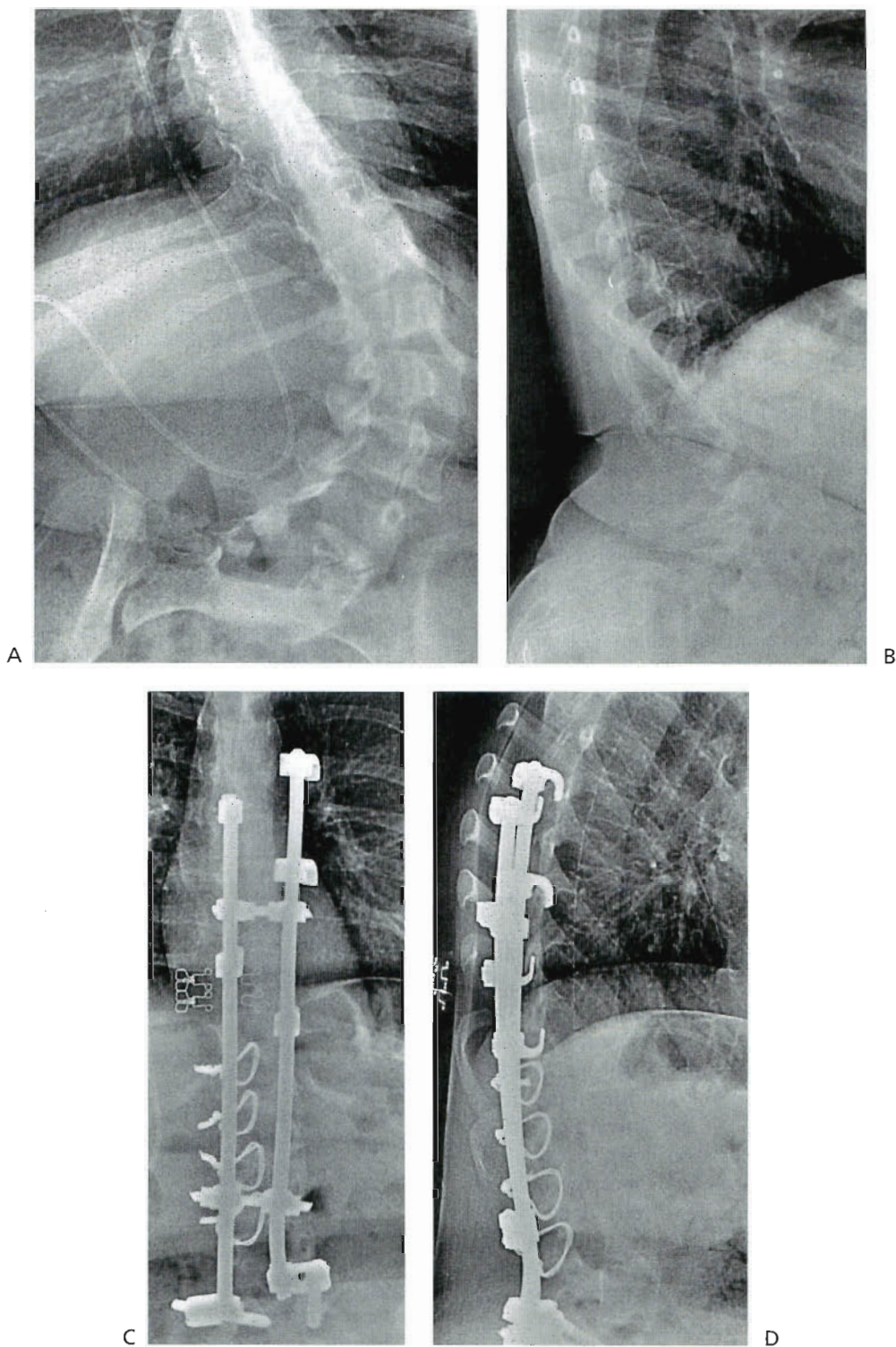


FIGURE 16-6. A mature 12-year-old girl with progressive lumbar scoliosis is an L4-level paraplegic, and is a community walker with ankle-foot orthoses and crutches. **A:** Anteroposterior radiograph shows 55-degree lumbar scoliosis from T10 to L3. There is a 20-degree compensatory curve from L4 to the sacrum. There is residual 30-degree pelvic obliquity. The last intact vertebral arch is L2. **B:** Lateral radiograph shows severe 120-degree lordosis, which is typical of the deformity associated with tethered cord. **C:** Anteroposterior radiograph shows correction of the scoliosis and pelvic obliquity. Pelvic screws are used to fix the distal end vertebrae at L5. The lumbosacral joint was left unfused to allow the patient enough pelvic mobility to continue walking. Release of the tethered cord was performed at the same time as the spine fusion. An anterior interbody fusion was performed from T9 to L5, without instrumentation. **D:** Lateral radiograph shows correction of the lordosis to 45 degrees and the achievement of a normal sagittal alignment. (From ref. 59, with permission.)

loss of correction. This is lessened by the use of the unit rod or multiple transverse rod connectors. Fixation to the open posterior spine in the lumbar area by wires around the pedicle is weak, and extension of the instrumentation to the ilium is usually necessary. Even this distal attachment of the Luque rods is weak because there may be significant osteoporosis of the pelvis. Loosening of the instrumentation and pseudarthrosis of the lumbosacral joint is frequent. Although this is not usually symptomatic, the author has observed increased scoliosis, pelvic obliquity, and pressure sores.

The development of instrumentation that allows segmental fixation [➡2.9], distraction, and compression on the same rod, along with the use of pedicle screws [➡2.8], may solve many problems of instrumentation of the distal spine. The pedicle screws allow the end vertebra to be positioned in three planes, and provide stable segmental instrumentation. This instrumentation may lessen the desirability of anterior instrumentation. Long-term studies have not yet been performed, but early experience indicates that satisfactory results can be obtained (Figs. 16-5 and 16-6).

Whatever the instrumentation used posteriorly, it should be low-profile in design. In the area of the meningocele sac there is poor skin and soft tissue coverage. Prominence of hardware invariably leads to ulceration over the hardware, eventual infection, and the need to remove the instrumentation.

Congenital Scoliosis

Congenital scoliosis may occur anywhere along the spine, including the cervical, the thoracic, and the lumbosacral spines. Congenital malformations may be caused by the lack of formation or segmentation, or a combination of the two. If the malformation occurs in the lumbosacral area the progression of deformity is usually rapid and uncompensated, causing severe pelvic obliquity. Nonoperative methods of treatment do not correct congenital scoliosis, or even prevent it from worsening. These children, because of their neurologic abnormalities, are unable to tolerate an unbalanced spine. Therefore, it is important that treatment be carried out in infancy when the deformity is small, rather than waiting until the child is older and heroic measures are needed to obtain satisfactory alignment.

Posterior fusion of the malformation is rarely successful in preventing progression. Anterior and posterior fusion is the procedure of choice, and it should be performed when a diagnosis of progressive scoliosis is made, usually at 1 year of age. The spine may be approached in staged or separate anterior and posterior procedures, or anterior and posterior interbody fusions may be performed through a posterior approach, using the pedicle as the access conduit to the anterior spine (53). The posterior approach is useful when the malformation is in the upper thoracic spine, where the anterior approach is difficult. If the lumbar curve is already so severe that the pelvic obliquity is greater than 15 degrees,

an osteotomy of the spine to correct the deformity should be considered. Another possibility in a child over 10 years of age is to perform a bilateral posterior iliac osteotomy to balance the pelvis after the spine has been fused (49).

Kyphosis

Lumbar kyphosis is a major deformity that occurs in 8 to 15% of patients with myelomeningocele (32,38,54–57). It often measures 80 degrees or more at birth, and usually progresses with growth. Children with extensive kyphosis are unable to wear braces, have trouble sitting in a wheelchair, and often have ulcerations over the prominent kyphos. Progression of the kyphosis may lead to breathing difficulty because the abdominal contents are crowded into the chest cavity by increasing upward pressure on the diaphragm. These children also have difficulty eating because of loss of abdominal size, which results in a failure to thrive. They are underweight and short in stature. The increased flexion of the trunk also may interfere with drainage of urine if the child has a urethrostomy, a vesicotomy, or an ileostomy.

Kyphosis is almost always progressive, and attempts to delay definitive treatment until the child is older leads to a more severe deformity (7,58). The aorta and the vena cava do not follow the anterior border of the spine across the kyphosis (59); they take the short route, like a bowstring, limiting the amount of surgical correctability. Therefore, it is important to carry out treatment early, even though it may be only a temporizing procedure. A more definitive procedure can be performed later.

The goals of treatment is to increase abdominal height, to allow more room for the abdominal contents, and relieve pressure on the diaphragm and the lungs. In addition, the kyphosis must be minimized to lessen the incidence of pressure sores and move the center of gravity posteriorly to center it over the ischium. This improves the child's ability to sit without using the arms for support.

The kyphosis deformity can be divided into two types (60) (Fig. 16-7). The first type is a collapsing kyphosis; it is often C-shaped and supple, at least during the initial stages. The apex may occur anywhere from the lower dorsal spine to the lumbosacral joint. The second type is a rigid S-shaped lumbar kyphosis with a proximal dorsal lordosis. The kyphosis is usually centered at L2 and the proximal rigid lordosis at about T10. This is the most common variety in the older child because the C-shaped curve often progresses to the S-shaped curve with time.

Collapsing Kyphosis. Conservative treatment, which consists of observation, is usually futile. The curve progresses rapidly, and it is not unusual to see a 2- or 3-year-old child with a kyphosis greater than 100 degrees. In those few instances in which the collapsing curve does not progress rapidly and is less than 20 to 30 degrees, an initial period of

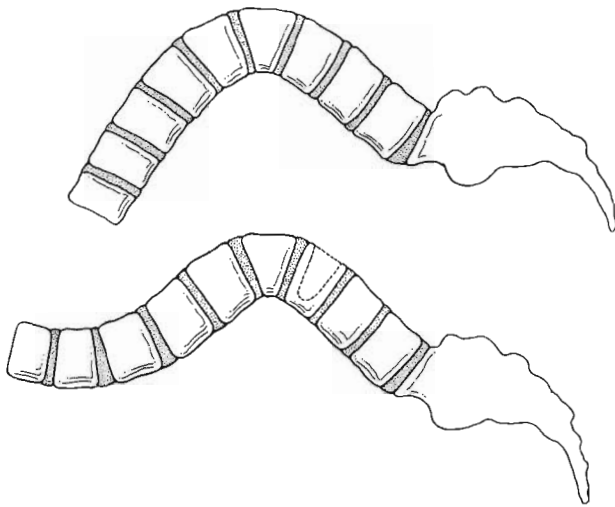


FIGURE 16-7. Two types of lumbar kyphosis: the C-shaped collapsing curve (**top**) and the S-shaped curve (**bottom**). (From ref. 59, with permission.)

observation may be worthwhile. If the curve is supple and the skin is in excellent condition, a brace can be tried. However, because any orthotic device must push over the apical vertebra posteriorly and against the protuberant abdomen anteriorly, it may lead to pressure sores over the gibbus and increased pressure on the abdominal contents. The kyphosis almost always requires surgical correction; this should not be delayed if brace treatment is unsatisfactory.

Collapsing scoliosis in the immature child is difficult to treat surgically. Posterior spinal fusion without instrumentation usually fails because of tension forces in the fusion mass. When instrumentation is used instrument failure is common. Attempts to provide stability by anterior strut fusion with a strut graft also tend to fail in young patients. The fusion creates an anterior unsegmented bar, with growth potential remaining posteriorly. As the child grows, the kyphosis increases. If the surgeon waits until the child is older to carry out anteroposterior fusion with instrumentation along the dorsal lumbar spine, the curve is often so severe that satisfactory correction is difficult if not impossible to obtain. If the anteroposterior fusion is carried out in infancy the resulting spine is too short to allow sufficient room for abdominal volume and respiratory sufficiency.

The anterior structures, including the abdominal wall, the aorta, and the vena cava, are of insufficient length to allow correction to occur without shortening the spine to remove tension from these structures (61,62). Many different procedures have been described to shorten the posterior spine to allow the spine to be straightened and put into more normal sagittal alignment (55–57,63–66). Most of these techniques require fusion of the spine to maintain correction, and therefore should be performed only in an

adolescent child; otherwise, the lumbar spine will be too short.

A method used to shorten the spine which does not require spinal fusion is to remove the ossific nuclei from the vertebrae above and below the apical vertebra, which is left intact (Fig. 16-8A,B). The pedicle and posterior arch are removed from these two vertebrae. The apical vertebra is pushed forward, correcting the kyphosis (60) (Fig. 16-8C). Approximately 100 degrees of kyphosis can be corrected. Because the vertebral body growth centers are left intact the growth of the spine continues, often producing a gradual increase in the lordosis. The spine is not fused so the procedure can be performed in children of any age, even in newborns. It is also possible to perform this surgery without mobilizing the spinal cord or dividing any of the nerve roots. Therefore, it can be performed when nerve function is intact below the level of the kyphosis. If the child is younger than 1 year old, tension-band wiring between the pedicles of the apical vertebra and the vertebrae above and below the osteotomy appears to be sufficient. If the child is older than 1 year Luque instrumentation, placed extraperiosteal and

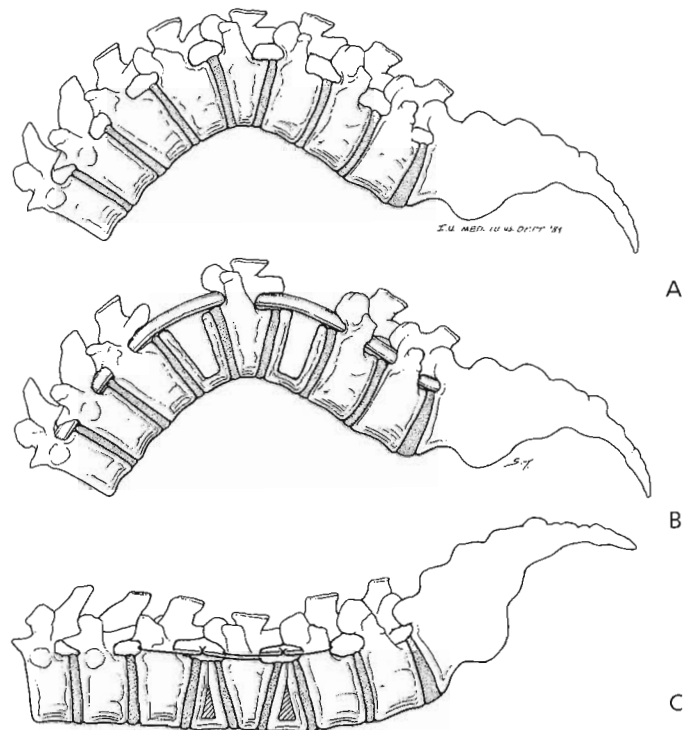


FIGURE 16-8. The C-shaped curve is corrected by removing the ossific nucleus of the vertebrae above and below the apical vertebrae. **A:** The C-shaped kyphosis before removal of the ossific nucleus from the vertebrae. **B:** Spinous processes, laminae, pedicles, and ossific nucleus have been removed from the vertebrae above and below the apical vertebrae. The growth plate, disc, and anterior cortex are left intact. **C:** The deformity is reduced by pushing the apical vertebra forward. Tension band wiring around the pedicles maintains the reduction. (From ref. 67, with permission.)

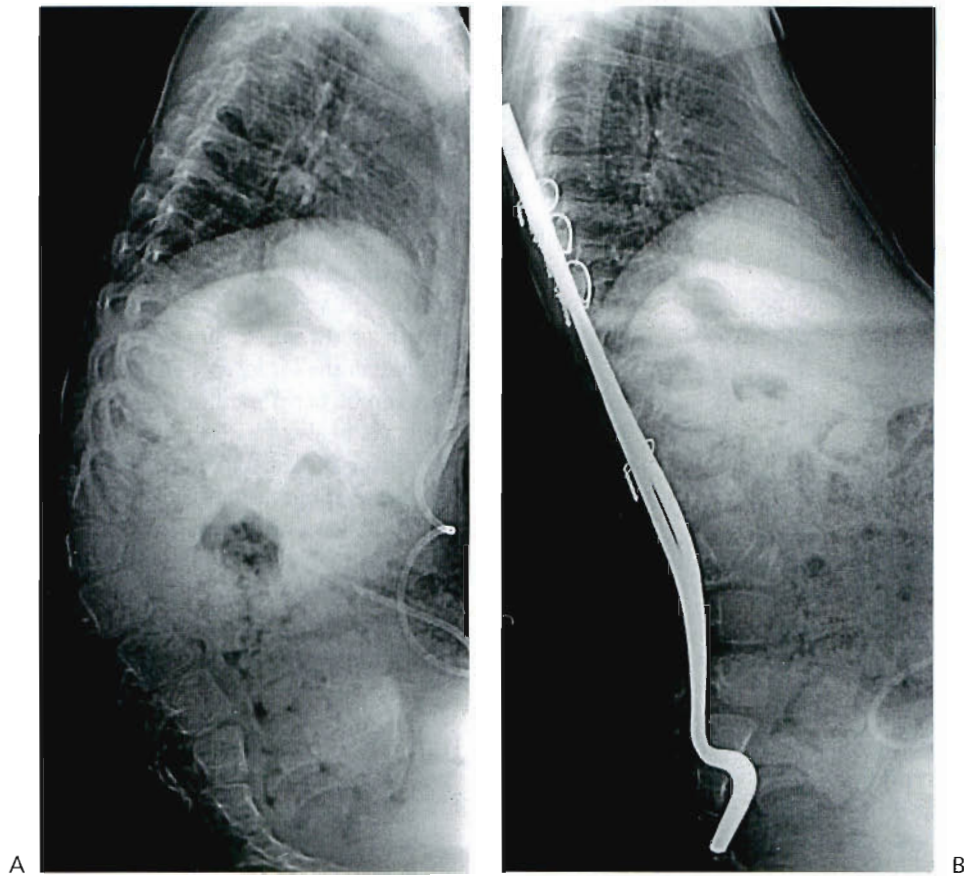


FIGURE 16-9. A 2-year-old child with 65 degrees of progressive kyphosis. **A:** After excision of the ossific nucleus above and below the apical vertebrae the correction is held with a specially modified Luque rod which is inserted into the first sacral foramen.

modified to attach to the sacrum without fusion, should be performed (68) [➔2.7]. At least three sublaminar wires on each rod superior to the kyphosis are needed to provide sufficient support (Fig. 16-9). If the child is an adolescent, posterior spinal fusion can be added to the instrumentation.

Skin coverage is often a problem. If the skin is exceedingly scarred or ulcerated over the kyphosis wound breakdown and infection are likely. The problem with skin coverage should be addressed prior to the spinal correction. A myocutaneous flap should be planned and prepared beforehand (69).

Rigid S-shaped Kyphosis. Treatment of the rigid form of upper lumbar kyphosis is difficult and controversial. Conservative nonoperative treatment invariably leads to an increased deformity and difficulty in later correction. In 1968, Sharrard (57) first described resection of the apical vertebral body for the treatment of kyphosis; since then, most authors have recommended vertebral excision as a part of the operative treatment (69). Most of these reports also showed that excision of the apical vertebra may lead to initial correction

of the deformity. However, the deformity has a tendency to recur, often to a worse degree than the initial kyphosis (56), leading to feelings of futility and frustration.

Treatment of the rigid form of kyphosis requires a different approach. Because both the kyphosis and the proximal lordosis are rigid it is necessary to correct both deformities at the same time. This can be accomplished by excising the vertebra(e) (usually two) between the kyphosis and lordosis (56,62,64) (Fig. 16-10) and fusing the apical vertebra to the distal end of the thoracic spine at the level of the resection. In a young child, this is the only area fused, and the osteotomy is held in position by tension-band wiring around the pedicle above and below the resected vertebrae (55,62) (Fig. 16-11). It is important that the paraspinal muscles be sutured behind the area of the spine in order to add a corrective force, decreasing the likelihood of recurrence of the deformity. The correction can also be held by use of rods anchored in the first sacral foramen distally and sublaminar wires proximally, similar to the fixation used in the collapsing kyphosis. If the child is Risser sign I or above, the spine may be fused along the length of the instrumentation.

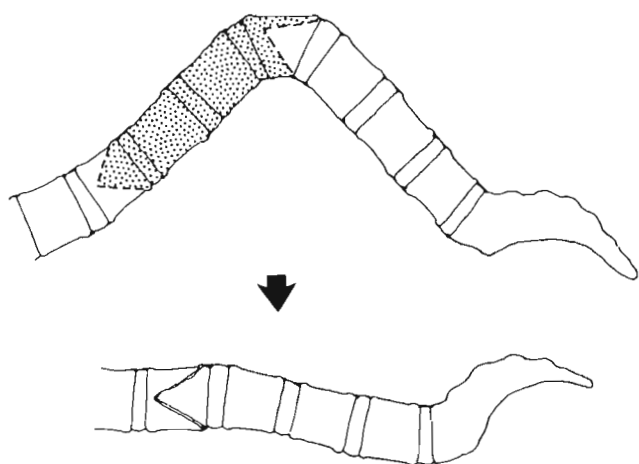


FIGURE 16-10. Bone is removed for correction of a rigid dorsal kyphosis (*shaded area*). The area removed usually includes one or two vertebrae proximal to the apical vertebrae in the area of the fixed lordosis. The vertebrae proximal to the resection and the apical vertebrae are shaped to receive each other in a tongue-and-groove joint to provide stability until bony union is achieved.

Hip

The function of the hip joint depends on neurologic level. The treatment program therefore is based on the level of sensory and motor paralysis (70–72). In a large proportion of myelomeningocele patients, the hips are reduced at birth, with the exception of those children who are breech position

(Fig. 16-12). Following birth, normal hips may become dislocated or dysplastic because of the position of the infant following closure of the back. If the infant is laid on his or her side, continued adduction of the superior hip eventually leads to dislocation. However, if the child can be placed in the prone position with the hips in the “human position” of flexion and 60 degrees of abduction, the hips can be maintained in the reduced position while the spine heals without being soiled by urine or feces (Fig. 16-13). This position also does not preclude placement of a shunt and the therapist can have access to the feet and knees. If abduction splinting is maintained during nap time and night-time after discharge from the hospital most children survive the first year of life with their hips reduced. Generally, the author does not maintain the splinting after the first 3 months of life; however, in other medical centers splints are maintained throughout the first year.

Thoracic Paraplegia

The thoracic-level paraplegic child does not have sensation or muscle control over the lower extremities. Surgery cannot provide stability; it must be provided by an orthosis. Without sensation and motor control reduction of the hip is not necessary for sitting and walking using orthotic aids (74). However, the child needs a functional range of motion without contracture (51). Surgical procedures should be used to provide range of motion so that the child can sit satisfactorily.

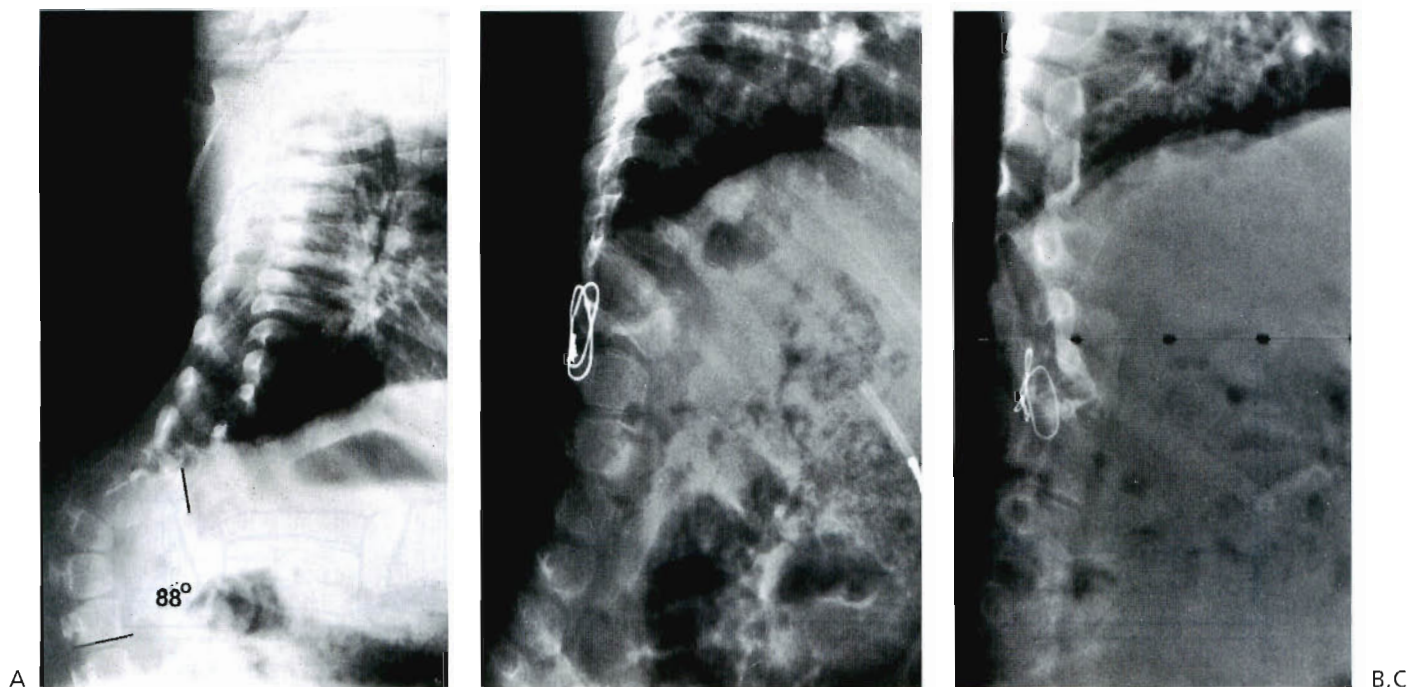


FIGURE 16-11. A: A 1-year, 10-month-old child with an 88-degree kyphosis. B: Two years after surgery, the kyphosis is at 13 degrees, and the lumbar spine has increased in height from 6.1 to 9 cm. C: Twelve years after surgery, the kyphosis is unchanged, and the spine height has increased to 14 cm.

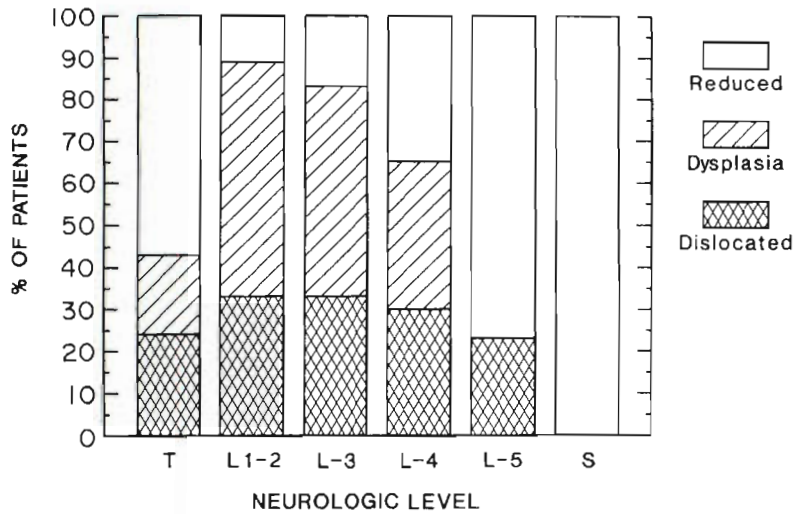


FIGURE 16-12. An evaluation of 100 consecutive infants with myelomeningocele who had not received treatment for their hips.

ily in a wheelchair, lie comfortably in bed, and use orthoses for standing and walking, if indicated.

Treating hip contractures in paraplegics is often frustrating because many contractures return promptly, often to a worse degree than before surgical release. A simple sectioning of tight tendons and release of tight ligamentous structures does not appear to be sufficient. The use of a free fat graft to fill the dead space formed by the release of tendon and capsule has helped prevent the recurrence of contracture

in a few of the author's patients. It is important that prolonged bracing and physical therapy be used to maintain whatever motion has been obtained by surgery.

Fortunately, dislocation of the hip is not usually found in the thoracic-level paraplegic person because of the lack of muscle function. If a hip is becoming dysplastic or is dislocating the cause should be found and treated. Increased muscle tone or spasticity should be treated by muscle release, or perhaps by neurectomy. Pelvic obliquity caused by devel-

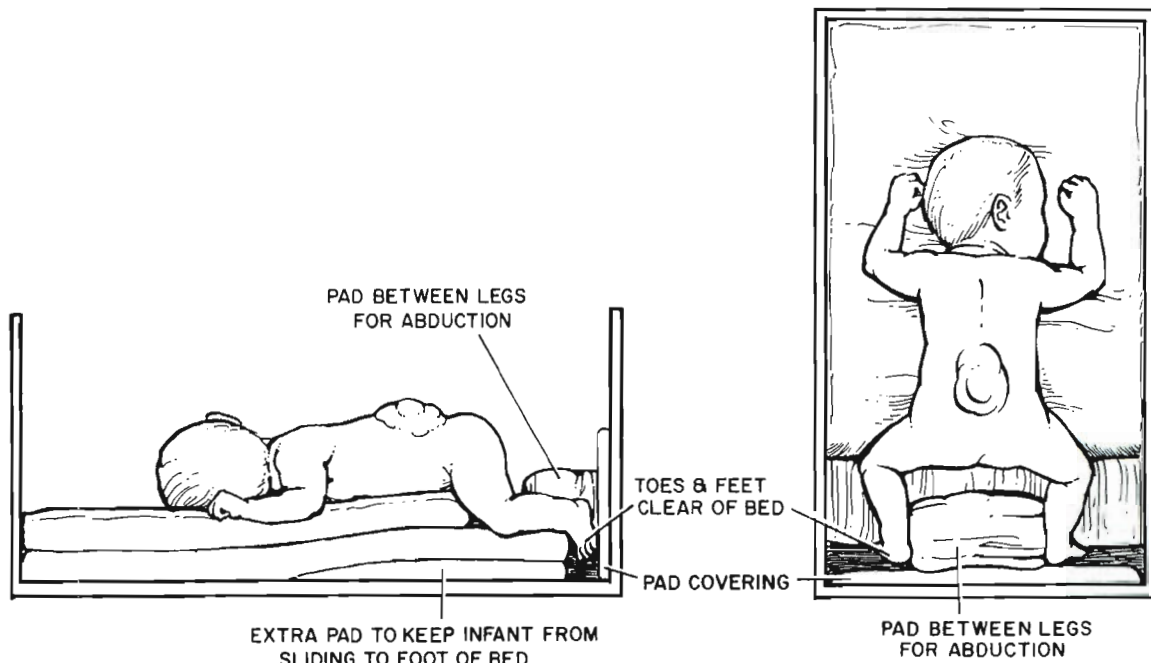


FIGURE 16-13. Position of infant after closure of the spine. This position allows gentle abduction of the hips in the neonatal period. (From ref. 73, with permission.)

oping scoliosis should be treated. Attempts to reduce a dislocated hip are difficult and often unsuccessful. The principal risk of surgically reducing the hip is stiffness. Multiple surgical procedures should be avoided because the risk of stiffness increases with each surgical procedure. It is better to have a supple dislocated hip than a stiff located hip.

The limitation of motion from a dislocated hip usually does not interfere with the overall function of the child. Even in unilateral dislocation, a dislocated hip does not prevent standing in an orthosis, sitting, or lying down, unless an associated adduction contracture is present.

The increased incidence of pressure sores, because of unilateral or bilateral hip dislocation in the absence of contractures or pelvic obliquity, has not been documented. Because of the loss of the greater trochanter as a pressure-accepting area, more pressure is placed on the ischium and sacrum. This would seem to increase the possibility of ulceration. In the presence of hip dislocation, special attention must be made to wheelchair seating.

The orthosis must provide pelvic, hip, knee, ankle, and foot stability. The standing frame, the parapodium, the swivel walker, and hip control orthosis all provide stability (75). At approximately 18 to 24 months of age, if the child has developed head control and sitting balance, a standing orthosis is prescribed. Orthotic devices are needed to provide stability to the lower extremity. The child usually finds these devices to be confining because they are too slow, they require too much energy, and they are too difficult to apply. Consequently, most of these children give up walking by the time they are 8 or 9 years of age, and use a wheelchair for their mobility (72).

Two designs in orthotic devices may change this prognosis for walking. The first is a *reciprocating orthosis* that allows controlled flexion and extension of the hip during walking (76). This decreases the energy requirement and increases walking speed (77). However, this orthosis allows for almost no contractures of the hips or knee, and orthotic breakage may be a frequent occurrence. The second development is a *hip guidance orthosis*, which allows for limited hip motion, while still providing stability (78). These braces may be tried after the age of 3 years and the child is large enough to fit into the smallest size of the orthosis. However, these devices are quite expensive and need to be replaced frequently.

Upper Lumbar Paraplegia

The upper lumbar paraplegic (L1–L2) has sensation in the anterior hip joint and thigh. Motor function includes the iliopsoas and the adductors producing hip flexion and adduction. Flexion adduction contracture of the hip, because of the unrestricted contraction of the hip flexors and adductors, is typical. There is a high incidence of hip dislocation. Attempts to reduce the hip without correcting the muscle imbalance are doomed to failure, and severe ankylosis of

the hips often results. Although providing hip stability for the child without the use of orthosis is possible, up to the present surgical attempts have been unsuccessful. Iliopsoas transfer is contraindicated in children with upper lumbar paraplegia, and often leads to severe extension contractures and increased disability (79,80).

The preferred treatment of children with upper lumbar paraplegia is obtaining range of motion by release of the contracture, including the iliopsoas and adductor tendons, then treating the child in a manner similar to that done for a thoracic-level paraplegic. If range of motion can be obtained, the dislocated hip does not cause disability for either walking or sitting (74,80). Because of the intact sensation across the hip joint, the reciprocating brace and the hip guidance orthosis are useful, and often succeed in continued walking as a mode of mobility into young adulthood (77,78).

Middle and Lower Lumbar Paraplegia

The middle to lower lumbar paraplegic (L3–L5) patient has sensation to below the knee. Muscle function includes hip flexion and adduction, knee extension, and weak knee flexion. Foot dorsiflexion and eversion also may be present. These patients have the potential for control of the hip and knee, and therefore the potential for independent walking.

Gait studies show almost normal sagittal plane motion of the hip, which is responsible for the movement of the child forward. There is an associated increase in hip rotation and abduction and adduction more than normal. This indicates that range of motion and control of the hip are probably the most important factors in walking for these children.

The hip in the middle to lower lumbar-level paraplegic is also a major source of deformity and disability. The natural history of the hip is to undergo progressive dysplasia and dislocation associated with hip-flexion contracture, which becomes evident when the child begins to walk. Muscle imbalance is caused by strong hip flexors, adductors, and absent or weak hip abductors and extensors. This muscle imbalance is exaggerated by the forces of walking when the hip flexors and adductors are used to stabilize the hip during the stance phase of walking, instead of during their typical function in the swing phase. The contraction of the hip flexors and adductors during the stance phase of gait causes the hip to flex and adduct, which produces a shear force across the acetabulum. It is not unusual for these paraplegic children to survive infancy with hips that are not dislocated, then to have them become dislocated at age 3 or 4 years. Attempts to reduce the hip and correct the progressive deformity are unsuccessful unless there is correction of the forces around the hip.

Historically, muscle balance has been obtained at the hip by performing muscle releases. However, taking the muscle control away from the hip does not increase its stability although the hip stays reduced, but increases its instability

because of weakness, and requires the use of an orthosis to stabilize the hip for walking (74). This conclusion is not surprising, considering the severely weakened hip made unstable by surgical procedures.

Sharrard initiated another approach to hip instability by transferring the iliopsoas tendon to the greater trochanter, a modification of procedures suggested by Garceau and Mustard to treat instability of the hip following poliomyelitis (81,82,84). The purpose of the tendon transfer was to produce an abduction force across the hip joint during the stance phase of walking, and thereby eliminate the deforming hip flexion force of the iliopsoas. Long-term studies have shown that this transfer is successful in maintaining hip reduction and decreasing the hip-flexion contracture (79,81,83). However, the iliopsoas is transferred out of phase to normal walking, and may decrease the necessary sagittal plane motion necessary for walking, stepping up on a curb, or climbing stairs. The weakness of the hip flexion requires the child to use the rectus femoris and sartorius muscles to flex the hip. This in turn results in extension of the knee, which also makes stair climbing difficult. Because the iliopsoas normally is used as a hip flexor, it continues to contract during the flexion activity of the hip, and also may prevent the hip from flexing, leading to an extension contracture.

Bunch and Hakala (79) have shown that with careful selection of patients preservation of the nerve to the sartorius muscle and intensive physical therapy, stair climbing can be achieved. In many instances, in the lower lumbar-level paraplegic person without pelvic or hip deformity, without spasticity, and with good knee control, gait can be improved to the point that patients may be able to "cruise the mall" using their braces, crutches, or walker, rather than a wheelchair (85).

Transfer of the external oblique muscle from the abdomen to the greater trochanter; posterior transfer of the adductor longus, brevis, and gracilis to the ischium [↗3.18]; and transfer of the tensor fascia lata muscle posteriorly on the ilium and to the tendon of the gluteus maximus, have been used to control the hip (86–88). Studies have shown a maintenance of hip reduction and improvement in the acetabular index and the cente–edge angle after those muscle transfers, similar to the results obtained with Sharrard iliopsoas transfer (Fig. 16-14). In addition, after the three muscle transfers children with L3–L5 paraplegia have shown marked improvement in their walking ability, 70% of whom demonstrated a marked increase in endurance and walking speed. They also have required less bracing. Fifty percent of these children have developed enough stability around their hip to learn to walk independently

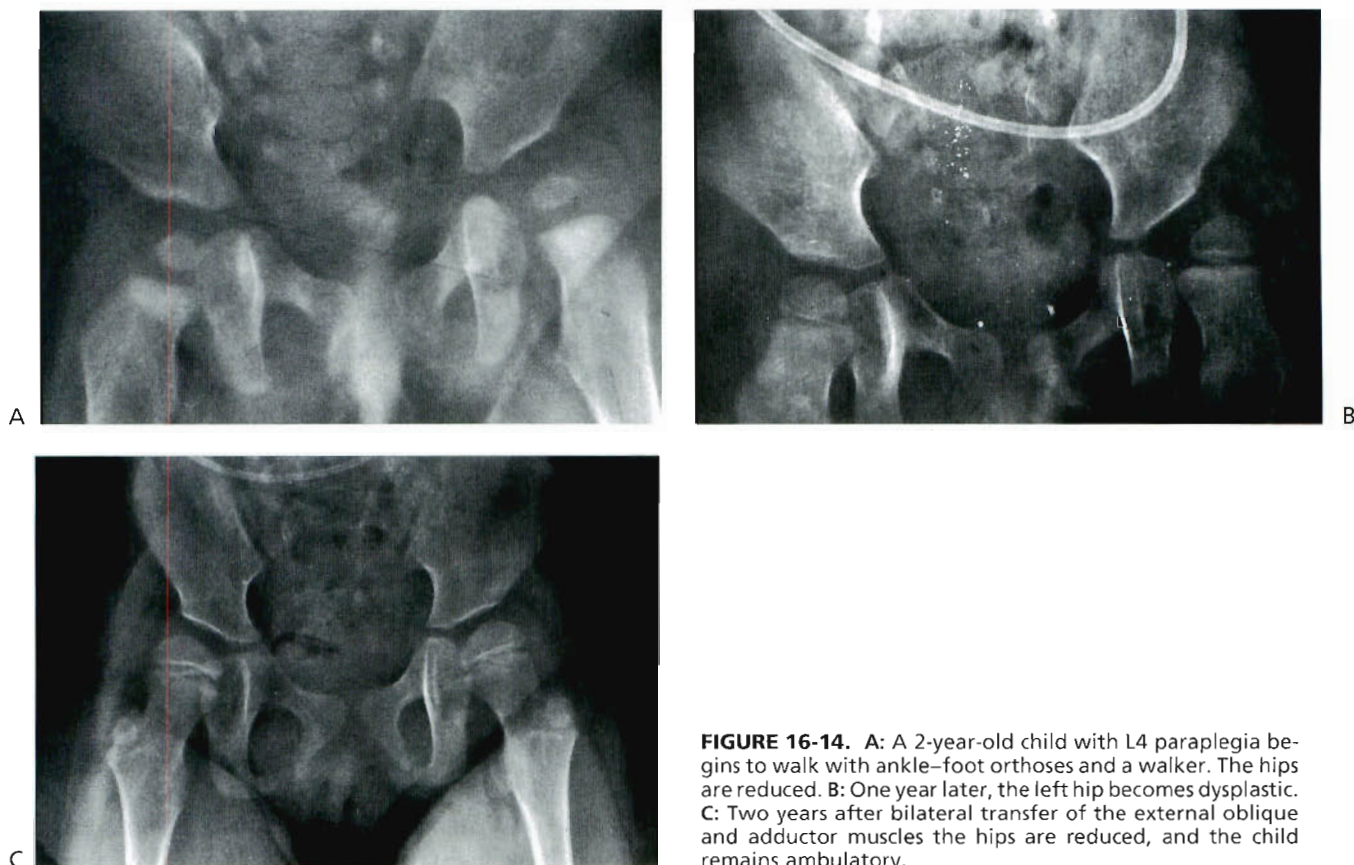


FIGURE 16-14. A: A 2-year-old child with L4 paraplegia begins to walk with ankle-foot orthoses and a walker. The hips are reduced. B: One year later, the left hip becomes dysplastic. C: Two years after bilateral transfer of the external oblique and adductor muscles the hips are reduced, and the child remains ambulatory.

without crutches or a walker (86). These muscle transfers are performed after the child has reached 2 years of age and learned to walk.

Although improvement in the hip indices can be produced by muscle transfers around the hip, they are not sufficiently forceful to correct major anatomic deformities. It is therefore necessary to reduce the hip and correct femoral and acetabular deformity at the time of, or prior to, the muscle transfer. Continued radiographic evaluation must be made following the reconstruction because recurrent dysplasia is possible.

If the hip is dislocated at birth the author prefers to wait until the child is 1 year of age before carrying out hip reduction to avoid interfering with motor development. If the child is between 1 and 6 years of age an open reduction and capsular plication are carried out to provide stability [3.2]. If there is deformity of the femoral neck, a varus femoral shortening osteotomy is indicated [4.1-4.3]. Pelvic osteotomy is indicated for severe acetabular dysplasia (89). The type of pelvic osteotomy performed depends on the deformity and the surgeon's preference [3.7-3.12]. An arthrogram and a CT scan may help to establish the area of acetabular insufficiency so that a correct procedure can be selected. The muscle transfers are then performed to help maintain reduction. The muscle transfers work better on a reduced hip than a dislocated one. Therefore, the author reduces the hips, even bilateral dislocations, before the age of 4 years. After that age the dysplasia is so great that the success rate is poor and the hips are left dislocated.

Sacral-level paraplegics have intrinsic stability to their hip with sensation and motor control. Dislocation of the hip in these children is rare; however, when it occurs it should be treated as a developmental dislocation of the hip.

Knee

The function of the knee is important to a child with myelomeningocele. Function of the knee is dependent on both the absence of deformity and the presence of stability. It must be stable during stance to accept the weight of the child without buckling, and flex sufficiently during swing to clear the foot. However, it is possible to walk with a stiff knee, and stability is more important than motion. The three deformities that may seriously diminish the ambulatory ability are extension or hyperextension contractures, flexion contractures, and valgus rotational deformities.

In a study of 16 patients with residual hyperextension contractures of the knee, only three were able to walk (72). These children also had difficulty sitting. Fortunately, the incidence of extension contractures is relatively low. There are several causes of extension contractures. One of the most common causes is seen in a child born with a breech presentation and with hyperflexed hips, hyperextended knees, and clubfoot. In these infants, the hamstring tendons usually have displaced anterior to the knee axis perpetuating the hyperextension deformity, although the child may be an L4

or L5 level paraplegic. The next most common cause appears in the middle lumbar level paraplegic person in which the child has quadriceps function, but no perceptible knee flexors. The least-common cause is seen in high-level paraplegic people in whom there is spasticity of the quadriceps muscle. Most of these cases can be treated by passive range of motion and splinting during the neonatal period of life. Although normal range of motion is rarely achieved, 60 to 70 degrees of flexion is common.

For those paraplegic children who do not respond to physical therapy, surgical treatment is indicated. If the child has voluntary function of the quadriceps, a modification of the V-Y plasty of the quadriceps tendons should be performed (Fig. 16-15). This procedure is modified by detaching the vastus medialis and the vastus lateralis from the medial and lateral hamstrings, which slide posterior to the knee axis. This approach often restores the hamstring function, and the child develops both active flexion and exten-

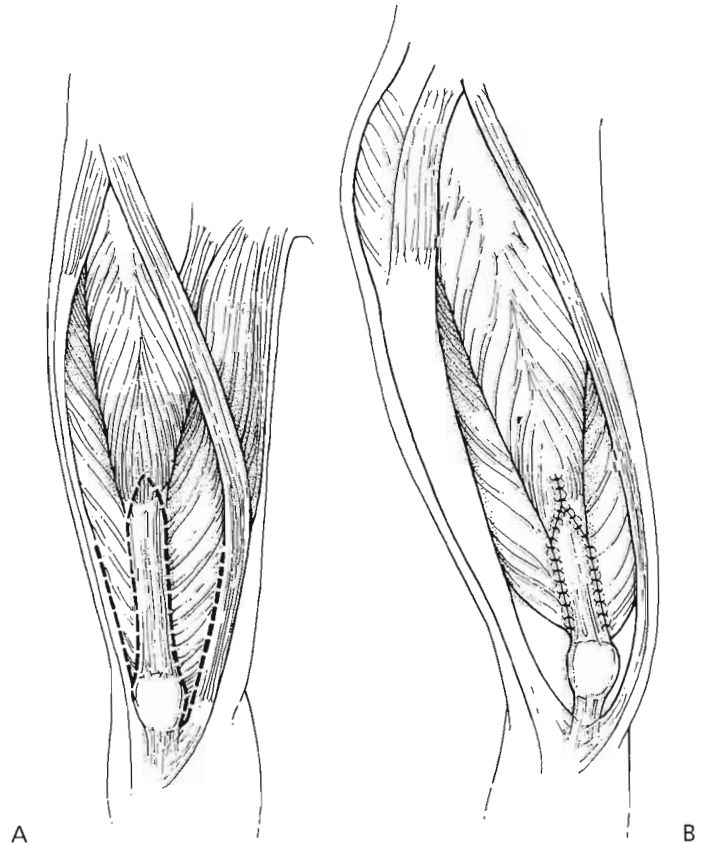

FIGURE 16-15. The V-Y quadricepsplasty for hyperextension contracture of the knee. **A:** In addition to the detachment of the rectus femoris tendon from the muscle of the rectus femoris, the vastus medialis and the vastus lateralis muscles, the vastus medialis and lateralis muscles are separated from the iliotibial band, the lateral hamstrings, the medial hamstrings, and the sartorius muscles. **B:** When the knee is flexed, the hamstring muscles and tensor fascia lata slip posterior to the knee axis, restoring their normal function. The quadriceps muscles are then repaired in the lengthened position. (From ref. 90, with permission.)

sion of the knee. If the quadriceps are not under voluntary control and are spastic, use sectioning of the patellar tendon and the retinaculum.

Flexion deformities are common in these children, even in the face of normal quadriceps function (91). A small degree of contracture, below 20 degrees, seems to be tolerated well, but contraction greater than 30 degrees decreases the likelihood that the child will continue to walk. Contractures over 20 degrees in the adult have a high incidence of patellofemoral pain (92).

The cause of the flexion contracture is not always apparent. In some children spasticity of the hamstrings or gastrocnemius can be implicated. In most middle and low lumbar paraplegic people, the cause appears to be a co-contraction of the hamstring and the quadriceps during the entire stance phase of gait. This lack of coordinated activity occurs only during walking and may not be present during manual testing of muscle activity during the neurologic examination. It appears to be related to brain stem abnormalities. The result of the tug of war between the knee flexors and extensors is persistent knee flexion during stance and decreased knee flexion during swing. A gait study, including EMGs, may be helpful in deciding the cause and treatment of the contracture. However, in most cases, the gait study is for research purposes and the treatment decision is made on clinical evaluation.

In the neonatal period and in infancy, physical therapy may be helpful in decreasing the flexion contracture. In those children who do not respond to physical therapy by 18 months to 2 years of age, surgical correction is indicated.

If the child with flexion contractures has some voluntary function of the medial hamstrings, the hamstrings should be lengthened rather than sectioned. The biceps femoris and the posterior part of the iliotibial band can be sectioned. The gastrocnemius origin should be resected. Almost all children with this deformity need to have a posterior capsulotomy extending from the posterior aspect of the medial collateral ligament to the posterior aspect of the lateral collateral ligament [►4.23]. In most patients, the anterior cruciate ligament also needs to be partially, if not completely, resected to allow the tibia to slide forward on the femur into extension.

In most children functioning at the low lumbar level the hamstring muscles contract at the same time as the quadriceps muscle throughout the stance phase of walking (Fig. 16-3). For these children the author transfers the insertion of the biceps femoris and the semimembranosus muscles to the cut end of the gastrocnemius muscle on the distal femur. This transfer will assist in extension without flexing the knee. The transfer can be performed at any age because the attachment to the distal femoral epiphysis will allow for future growth. By removing two of the hamstring muscles from the knee flexion, the quadriceps usually will be able to maintain knee extension during stance.

Postoperatively, the patient must wear an above-the-knee orthosis for a prolonged period to prevent the development

of knee instability. In the child older than 6 or 7 years, sufficient deformity may have developed in the femoral condyles to preclude satisfactory soft tissue correction of the contracture, and a distal femoral osteotomy is needed. The osteotomy must be as close to the knee as possible to prevent an anteriorly offset knee joint. There is a tendency for recurrence of deformity with growth, and repeat surgery may be necessary.

Valgus and rotational deformities of the knee primarily are caused by tightness of the iliotibial band and the forces of ambulation. During the Trendelenburg gait pattern, the shift of weight lateral to the hip joint, along with contraction of the adductors and fixed position of the foot to the floor, produce a valgus thrust to the knee. The young child is best treated by muscle transfers to the hip to stabilize his or her gait pattern; by sectioning of the distal iliotibial band if it is contracted; and by placing the child in a knee-ankle-foot orthosis to resist the valgus thrust to the knee. If the deformity becomes fixed, a distal femoral osteotomy [►4.17] is required to realign the knee.

Stability for the knee in thoracic and upper lumbar paraplegics is provided by an orthosis. Sufficient sensation and motor control of the knee is not present unless the child has functioning of the L4–L5 nerve roots. Without a good quadriceps, some medial hamstring function, and sensation to the tibial tubercle, the child cannot control the knee adequately. Attempts to stabilize the thoracic upper and middle lumbar-level paraplegic patients with a below-the-knee orthosis by means of equinus positioning or with other types of foot positioning should be avoided. Because the child is unable to raise his or her center of gravity to vault over a plantar flexed foot the knee must hyperextend or externally rotate, producing degenerative changes because of a lack of protective sensation (Fig. 16-16).

Foot

The function of the foot of a child paralyzed by myelomeningocele is significantly impaired (120). The severe deformity of the leg and foot, limited ankle and subtalar motion, absent weak or spastic muscles, and the lack of sensation make it almost impossible for the foot to function normally by providing shock absorption, control of floor reaction forces, and the transfer of weight that is necessary for gait (93). Almost all of the myelomeningocele children require treatment of their feet. Even nonambulatory children require adequate positioning of the foot to accept shoe wear, placement on wheelchair foot rests, and prevent pressure sores. Ambulatory children require an accurate correction of deformity. They are unable to compensate for malposition of the foot because of weakness of the trunk, the hip, and the knee, which causes the weightbearing line and the floor reaction force to fall outside the zone of stability of the hip, the knee, and the ankle. For example, a foot that has residual inward rotation produces a varus deformity at

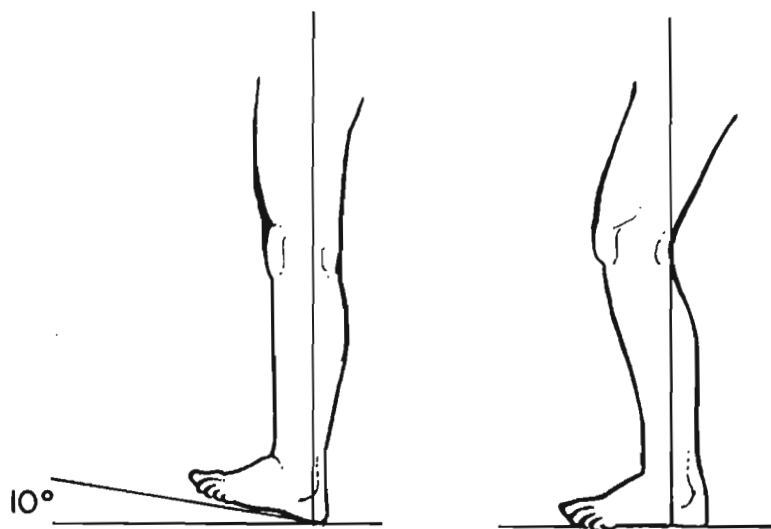


FIGURE 16-16. A 10-degree dorsiflexion of the foot is needed for the leg to progress beyond midstance. If the foot is held in neutral or plantar flexion the tibia cannot progress beyond the vertical without raising of the body—a difficult activity for a paraplegic. Dorsiflexion can be provided by manufacturing the orthosis in dorsiflexion or by elevating the heel of the shoe.

the knee and inward rotation of the leg during the stance phase of gait. Outward rotation of the foot causes a valgus deformity to the knee and an exaggerated outward rotation of the leg during stance. Residual equinus deformity causes hyperextension of the knee and the inability of the child to move the center of gravity beyond midstance. On the other hand, calcaneus deformity allows the tibia to fall forward during midstance, producing knee flexion and a crouched gait. The foot must also be able to compensate for deformity of the knee. For example, a knee-flexion contracture requires the ability of the ankle to dorsiflex so that the heel will contact the floor.

The correction of the deformity by itself is not sufficient. Muscle balance must be achieved in the foot as well. If this muscle imbalance is left uncorrected when the alignment of the foot is obtained the deformity will recur. There are only two choices available to correct the muscle imbalance: removing the muscle force by excising the tendon or transferring the force to another location by tendon transfer. The preservation or removal of muscle activity must be considered carefully in relation to the function of the foot during walking. If the child needs an orthosis to walk then muscle control of the foot is of little importance, and the deforming forces should be eliminated; however, if the child has enough muscular control and sensation to walk without an orthosis, the muscle balance must be obtained by performing the appropriate tendon transfer.

The goals of treatment are to align the foot to allow transfer of the floor reaction force through the center of the ankle and to produce stability of the knee and hip during the stance phase of gait. The motion of the joints in the foot should be preserved which allows preservation of the shock-absorptive capacity of the foot and lessens the possibility of joint degenerations. A rigid foot also has a high incidence of ulceration even if the deformity has been corrected

by subtalar arthrodesis or triple arthrodesis (94). It is also important to avoid bony prominences in the weightbearing area to lessen the likelihood of pressure sores (25).

Talipes Equinovarus Deformity

Talipes equinovarus, or clubfoot, is the most common deformity in these children and occurs in well over 50% (10). It is present in all levels of paraplegia, but the treatment differs at each level as a result of the muscle function that may be present. The correction of the equinovarus deformity in myelomeningocele patients is rarely accomplished by nonoperative means. An attempt to manipulate the foot and cast the deformity during the newborn period is worth a try if the foot is reasonably supple, and can be manipulated into a satisfactory position prior to the casting (1). However, most of these feet are rigid and the success rate with manipulation and casting has been poor. The cast cannot be used to obtain correction because pressure sores will develop. Occasionally after cast treatment the foot appears to be in satisfactory position; however, evaluation of the foot—thigh axis shows that the foot is still internally rotated approximately 45 degrees. This is the result of the severe deformity of the neck of the talus. As the foot is manipulated into the proper relation to the axis of the leg the calcaneus is moved laterally from underneath the talus, depriving it of its support and allowing the talar head to drop plantarward, producing a foot that resembles a congenital vertical talus. If this occurs then further attempts at nonoperative treatment should be abandoned. If satisfactory correction has been achieved then the child must be placed in splints to prevent recurrence of deformity. The splints must be worn continuously until the age of standing. If the foot has not achieved satisfactory correction by the time the infant is 3 months of age the author abandons conservative treatment and rec-

ommends surgical correction when the child is 1 year old. This interim period between nonoperative and surgical treatment allows for normal development of the child without the problem of constant cast change and braces. The advantage of performing surgery at the time the child is ready to stand is that weightbearing can be used to maintain the correction along with the orthosis used for ambulation.

The surgical correction of the clubfoot [➔7.1] rarely is accomplished by limited surgery. A radical complete circumferential subtalar release is necessary in order to allow the calcaneus to rotate sufficiently underneath the talus to align the axis of the foot to the axis of the ankle and knee (95). Because of the deformity of the neck of the talus it is then necessary to displace the calcaneus medially beneath the talus so that the posterior facet and the anterior facets are reduced, in order to prevent the talar head from sagging or falling into a vertical position. It is important to repair the tibial calcaneal ligaments with nonabsorbable suture to prevent lateral migration of the calcaneus into valgus. A plantar release and capsulotomy of the calcaneal cuboid joint is usually necessary as well.

Unless the child has a sacral level of paralysis all of the contracted tendons should be resected rather than lengthened because they are spastic and nonfunctional. A simple cutting of the tendons often results in the tendon being caught in the scar, then acting as a tether as the foot grows. This causes recurrence of the deformity. In the L5-level paraplegic person, the anterior tibialis and peroneal tendons also should be released. Leaving them intact often results in a calcaneal valgus deformity. It is better to have a flaccid braceable foot than a deformed foot with muscle activity that is inappropriate for standing. This aggressive treatment gives a satisfactory result in the majority of patients (96).

A major problem during surgical correction of the deformity is skin coverage for the posteromedial aspect of the foot. Many incisions have been tried, but no one incision is free of complications. For the relatively mild deformity, a Cincinnati incision gives adequate results (97). It provides excellent exposure to the medial and lateral side of the subtalar joint. The drawback to this incision is exposure of the heel cord; however, in most of these children, the tendon is sectioned rather than lengthened, and lack of exposure is not critical. The medial and lateral calcaneal vessels must be carefully preserved to provide circulation to the heel. Other incisions, such as the Turco or the two incisions described by Carroll, are equally effective (91,98,99).

With severe deformity, the Cincinnati incision does not appear to be sufficient. The axis of the foot often must rotate almost 90 degrees in relation to its ankle at the time of surgery. The skin on the medial aspect of the foot is insufficient to allow this degree of correction. If the skin is closed with excessive tension it will slough and heal by scar. This scar then contracts as the foot grows and causes recurrent deformity. On the other hand, if the deformity

is not completely corrected in order to allow skin closure, then a satisfactory position of the foot is not obtained. The author now uses a modified posterior medial incision (Fig 16-17). It starts posterolaterally, approximately 5 cm above the ankle at the posterior edge of the fibula. It curves obliquely downward to 1 cm below the medial malleolus. It then curves distally along the medial border of the foot to the first cuneiform, where it curves dorsally over the dorsum of the foot to a point just in front of the lateral malleolus. The incision over the dorsal aspect of the foot is only through the skin, preserving the dorsal veins and nerves of the foot. After the foot has been positioned and pinned in the corrected position an assessment is made about the integrity of the medial skin. If the skin is excessively tight, the incision is extended across the dorsum of the foot. The proximal flap is freed by blunt dissection from the fascia for a distance of 2 cm. There is no subcutaneous dissection of the distal skin. The skin is then allowed to find its normal position without tension. This permits the skin of the proximal flap to keep its normal relation with the leg while the foot rotates underneath it. The incision is then closed with interrupted subcutaneous sutures and a running dermal stitch. This incision relieves the tension on the medial side of the incision and decreases the redundant skin on the lateral aspect of the foot.

Another approach to obtain skin coverage is to insert a subcutaneous balloon (i.e., tissue expander), well before the planned correction of the foot (100). The balloon is gradually expanded by the injection of saline, stretching the skin and subcutaneous tissue. At the time of correction of the foot deformity the balloon is removed and the redundant skin is used to close the incision without tension.

It is rarely possible to correct the metatarsus adductus at the same time as the correction of the hindfoot. The author prefers to do this as a separate procedure when the child is 3 or 4 years of age. Although not always necessary, it needs to be done more often than in idiopathic clubfoot. Soft tissue release is rarely effective in achieving a permanent correction of the metatarsus adductus. A closing-wedge osteotomy of the cuboid and an opening osteotomy of the first cuneiform, with transfer of the wedge of bone from the cuboid to the first cuneiform, is preferred (101,102). The metatarsals II and III are then osteotomized at their base [➔7.6]. The correction is held with multiple pins that are removed in 1 month. The child is held in a walking cast for 1 additional month then placed in suitable orthoses, as needed, for ambulation.

Recurrent equinovarus deformity may be treated by talectomy; however, the deformity has a tendency to recur, and its short distance from the medial malleolus in the plantar aspect of the foot makes it difficult to fit with an orthotic device (95). Another problem with brace wear is that the pressure in the plantar surface of the foot is not distributed evenly, although the foot appears plantigrade. These areas of high pressure may predispose these patients to ulcerations

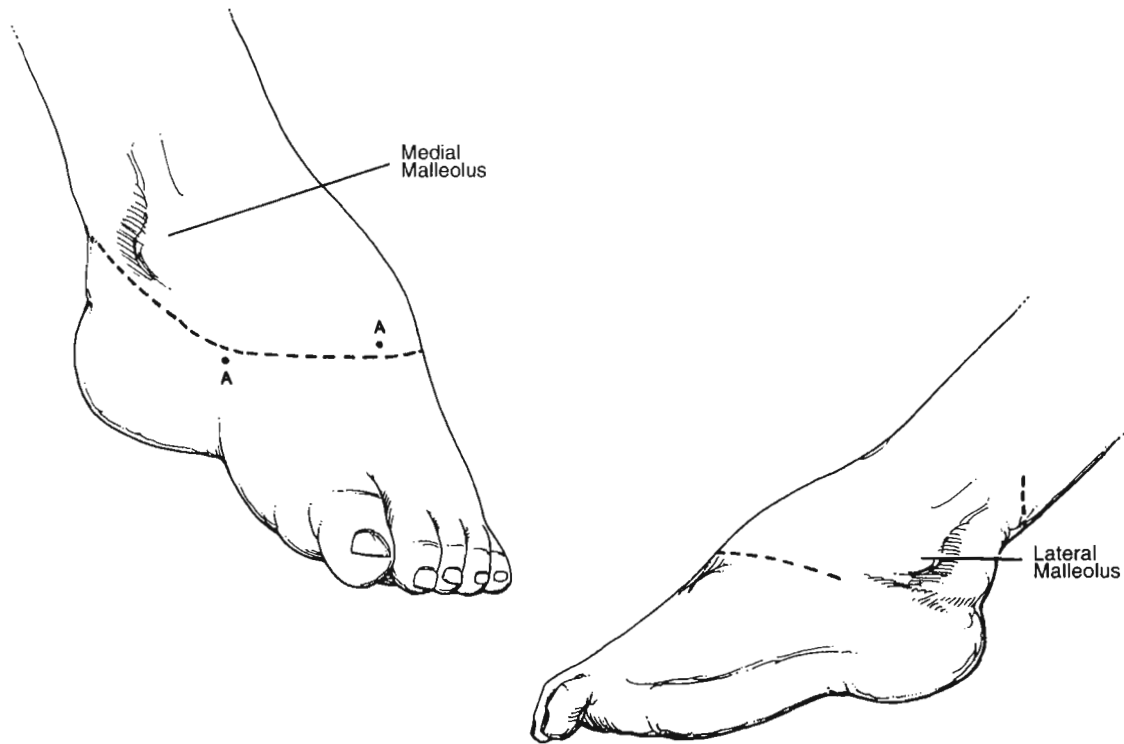


FIGURE 16-17. The incision begins posterolaterally, approximately 5 cm above the ankle at the posterior edge of the fibula. It extends obliquely downward to 1 cm below the medial malleolus. It then curves distally along the medial border of the foot to a point 1 cm distal to the anterior border of the medial malleolus. After the correction of the foot deformity the incision is extended to the first cuneiform, where it curves dorsally over the dorsum of the foot to a point at the anterior edge of the lateral malleolus. The incision over the dorsum of the foot is only through the skin, preserving the dorsal veins and nerves of the foot. The proximal flap is freed by blunt dissection from the fascia for a distance of 2 cm. There is no dissection of the distal skin. The skin is then allowed to find its position relative to the tibia and foot without tension. Usually the two points marked "A" will come together.

(103–105). Persistent wear of an orthosis is essential despite the difficult fit. In the older child severe residual deformity may be corrected by a triple arthrodesis (106). This procedure should be limited to only the extreme cases because of the danger of joint degeneration and skin ulceration caused by the stiffness of the foot. Less severe deformities may be managed by a tarsal metatarsal osteotomy to correct the midfoot deformity and a calcaneal osteotomy to correct the varus deformity of the heel (99).

Calcaneus Deformity

Calcaneal deformities of the foot in the newborn are primarily due to the unopposed contraction of the anterior tibial muscle, the toe extensor muscles, or the peroneal muscles (107). There is flaccid paralysis of the triceps surae. The deformity may be calcaneal valgus, calcaneus, or calcaneal varus, depending on the predominant muscle activity. The deformity is usually progressive, and the calcaneus eventually becomes positioned vertically underneath the talus (Fig.

16-18). The deformity prevents the forefoot from contacting the floor, interfering with balance, preventing the floor reaction force from stabilizing the knee, and causing the child to walk in a flexed-knee or crouched gait. Because of the lack of sensation this deformity leads to heel ulcerations in the teenage years.

Nonoperative treatment is rarely successful. Manipulations of the foot in the newborn period, and bracing as the child becomes older, may provide satisfactory position. However, in most cases the muscles continue to shorten, making brace and shoe wear difficult. In the child younger than 5 years of age with a minor deformity, which includes vertical alignment of the calcaneus, the anterior tibial tendon should be transferred through the interosseous membrane and attached to the calcaneus or released if the deformity is not severe. The decision to transfer or release is made by the strength of the toe extensors. If they are strong, transfer the anterior tibial tendon. At the time of surgery the deformity can be fully corrected; often the anterior tibial tendon is sectioned; then the tendon is not transferred. The

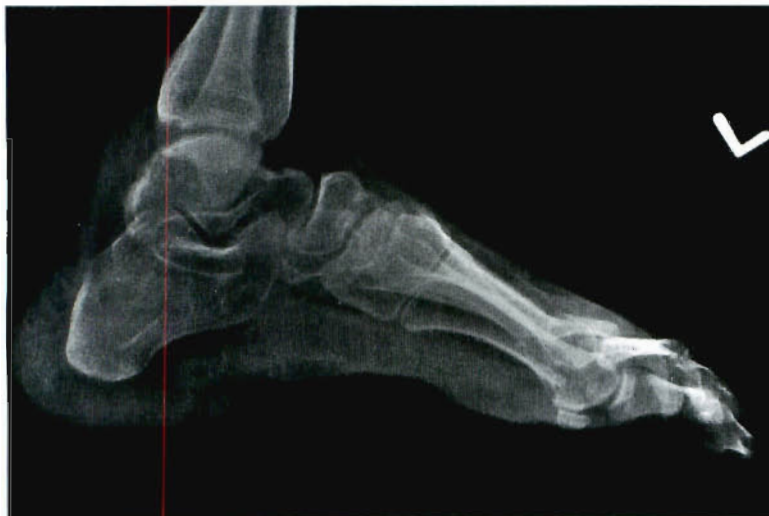

FIGURE 16-18. Lateral radiograph of an L5 paraplegic patient shows the vertical position of the os calcis. Note the hypertrophy of the heel pad.

remaining tight anterior structures should be released so that the foot can be brought into satisfactory position for bracing (108,109). The purpose of the anterior tendon transfer is to relieve a deforming force and to counteract the function of the toe extensors. The transfer is insufficient in power to substitute for the gastrocnemius soleus muscles. Although these patients may learn to walk without an orthosis following the tendon transfer, gait studies have shown they walk better with, than without, the orthosis (110).

In children older than 5 years of age soft tissue procedures rarely are sufficient. These patients also require osteotomy of the calcaneus with posterior displacement of the posterior fragment (111).

If the child has already developed ulceration underneath the calcaneus the treatment must provide correction of the foot deformity, followed by removal of the prominent part of the calcaneus, excision of the ulcer, and primary closure by means of a local flap. To allow the ulcer to heal by secondary intention will not provide reconstitution of the normal weightbearing fat pad. Repeat ulcerations are common. The weightbearing skin and fat pad must be restored in order to prevent recurrence of the ulceration. Posthealing orthotic wear is essential.

Valgus Deformity in the Newborn

Valgus deformities usually are associated with contracture of the lateral musculature of the foot, equinus deformity of the calcaneus, and a lateral displacement of the calcaneus from beneath the talus (112,113). The external appearance of the foot resembles that of a congenital vertical talus, but usually it is less rigid. Nonoperative treatment is rarely successful, despite the observation that the foot often can be manipulated back into a satisfactory position by plantar flexing the foot and rotating the calcaneus beneath the talus.

The lack of active function of the posterior tibial muscle and the spastic activity of the peroneal muscles cause frequent recurrence. Occasionally a rigid form of congenital vertical talus may be found in myelodysplasia (103).

If the foot cannot be manipulated passively into the correct deformity and held with an orthosis, then an aggressive surgical approach is needed at about 1 year of age. The author prefers an extensive subtalar release to allow reduction of the calcaneus beneath the talus. This may require resection of the Achilles tendon and the peroneal tendons. The posterior ankle capsule is divided along with the fibular calcaneal ligaments. The anterior tibial tendon can be resected or transferred back to the neck of the talus. The author prefers to resect the tendon and do the subtalar arthrodesis. The function of the anterior tibial muscle is difficult to determine and it may not perform as expected. In most cases an extraarticular subtalar arthrodesis is needed (31,114,115).

Valgus Deformity in the Older Child

Valgus deformity is common in the ambulatory child and frequently is associated with outward rotation deformity of the foot and the ankle (112,116). The cause of the deformity is undetermined, but is probably related to the floor reaction force during stance without the appropriate muscle control of the posterior tibial muscle. There usually is a lateral tilt to the ankle mortis with shortening of the fibula. The subtalar joint may be deformed as well. The location of the deformity can be determined by standing anteroposterior radiographs of the ankle mortis and foot. The outward rotation of the ankle axis in relation to the knee should be assessed. It may exceed 60 degrees. Pressure sores caused by shoes and orthotic devices are common.

Nonoperative care, including casts, manipulation, and orthoses, will not correct or prevent the deformity. Most

children will require surgical correction. The deformity in the tibia and fibula can be corrected by supramalleolar osteotomy that corrects both the valgus and rotation [➔6.8]. If there is minimal outward rotation of the ankle the valgus deformity of the ankle mortis can be treated by a medial tibial epiphysiodesis (117). If the child is young then staples can be used, so they can be removed later after the correction has been obtained. If the valgus deformity is mild and associated with a calcaneus deformity and a minimal outward tibial rotation, a calcaneal fibular tendo Achilles tenodesis can prevent progression of the deformity in about 70% of the patients (117,118). However, stretching of the tenodesis is a major problem, and Shafer and Dias recommend the addition of an anterior tibial tendon transfer to the calcaneus (25). If there is subtalar valgus the foot should be treated like the valgus deformity in the newborn.

Cavus Deformity

Cavus deformity of the foot usually is accompanied with claw toe deformity, and is seen in the sacral-level paraplegic child. These children have normal strength of the anterior tibial and toe extensor muscles, which pull up the midfoot at the base of the first metatarsal and dorsiflex or hyperextend the metatarsal phalangeal joints. The normal functioning peroneus longus plantar flexes the first metatarsal. The paralysis of the gastrocnemius soleus muscles leave the hindfoot in calcaneus position. Active toe flexors flex the interphalangeal joints, and with paralysis the foot intrinsic muscles cannot flex the metacarpal phalangeal joints or extend the interphalangeal joints. These children have enough sensation and muscle control to walk without an orthosis, but frequently develop progressive deformity and ulcerations under their toes, their metatarsal heads, and their heels. Their gait is also abnormal, because of the lack of sufficient power in the gastrocnemius soleus muscles. The cavus deformity is often progressive and may be associated with secondary varus deformity of the foot as the child attempts to use flexor hallucis and digitorum longus muscles to compensate for paralysis of the gastrocnemius soleus muscles.

Conservative treatment by means of an ankle-foot orthosis often provides a temporary solution; however, once the child can walk without the brace, it is difficult to get him or her to wear it again. Therefore, most of these children come to surgical correction.

Surgical treatment must include correction of the bone deformity and soft tissue contracture and restoration of the muscle imbalance. In the young child with mild deformation a plantar fascia release, followed by an ankle-foot orthosis, may provide satisfactory correction of the deformity. Rigid cavus, due to midfoot deformity, can be corrected by a tarsal metatarsal osteotomy associated with plantar release [➔7.7, 7.8]. If the deformity is due to a dorsiflexion deformity of the calcaneus, a calcaneal osteotomy is necessary (119). The calcaneus is moved backward or laterally, as

needed, to correct the cavus or cavovarus deformities. Muscle-balancing procedures must consider the phase of the muscle during gait, the power of the muscle available, and the required muscle power necessary for walking (120,121). The primary goal is to have a plantigrade braceable foot without recurrent deformity or pressure sores. If the residual muscle power in the foot is in the poor-to-fair range, then the foot cannot be made functional by muscle transfers, and it is best to lengthen or resect the tendon of the deforming muscle and brace the foot. However, if there is sensation on the sole of the foot and the strength of the toe flexor is good-to-normal, it may be possible to transfer the muscles to the heel to achieve force balance and a satisfactory brace-free gait.

The anterior tibial muscle is a swing-phase muscle, and cannot be made into a stance-phase muscle to substitute for the gastrocnemius soleus muscle unless electromyogram gait studies show the contrary. In most circumstances it is better to lengthen the tendon and preserve its necessary function of foot clearance during swing. If the foot is in varus, then transfer of its anterior tibial tendon to the midfoot may be useful. Muscle imbalance of the toes can be helped by transfer of the long extensor tendons to the metatarsal heads, with fusion of the interphalangeal joints. This transfer helps elevate the metatarsal heads and prevent recurrent cavus. When the foot is in cavovalgus deformity, the peroneus brevis also can be transferred to the calcaneus.

Charcot Arthropathy

Charcot, or neurotrophic, arthropathy is a progressive degeneration of a joint caused by a lack of protective sensation. This is a problem that primarily affects ambulatory young adult patients who have decreased sensation of the knee, the ankle, and the foot. Because of the pathologic anatomy of the myelomeningocele, the sensory level is usually higher than the motor level. Consequently, these patients often are able to stand and walk, but do not have protective sensation. The patient with paralysis at the L4–L5 level appears to be the most vulnerable (Fig. 16-19). The pathologic process begins following an initial traumatic episode. The initial episode may follow a minor fall that the patient does not consider to be a major injury-producing event. Following this initial traumatic episode, there usually is a considerable amount of swelling and redness around the joint. The appearance of the joint resembles an infection and cellulitis. There may be some minor discomfort but usually no severe pain. Because of the lack of pain the patient often does not seek medical advice and continues to walk on the joint, causing further microfractures to occur. Even if the patient obtains medical consultation the initial radiographs often are unremarkable and the patient is often given antibiotics for the mistaken diagnosis of infection. Once the joint degeneration has become evident on radiograph the joint has been destroyed, and satisfactory outcome is difficult to achieve.

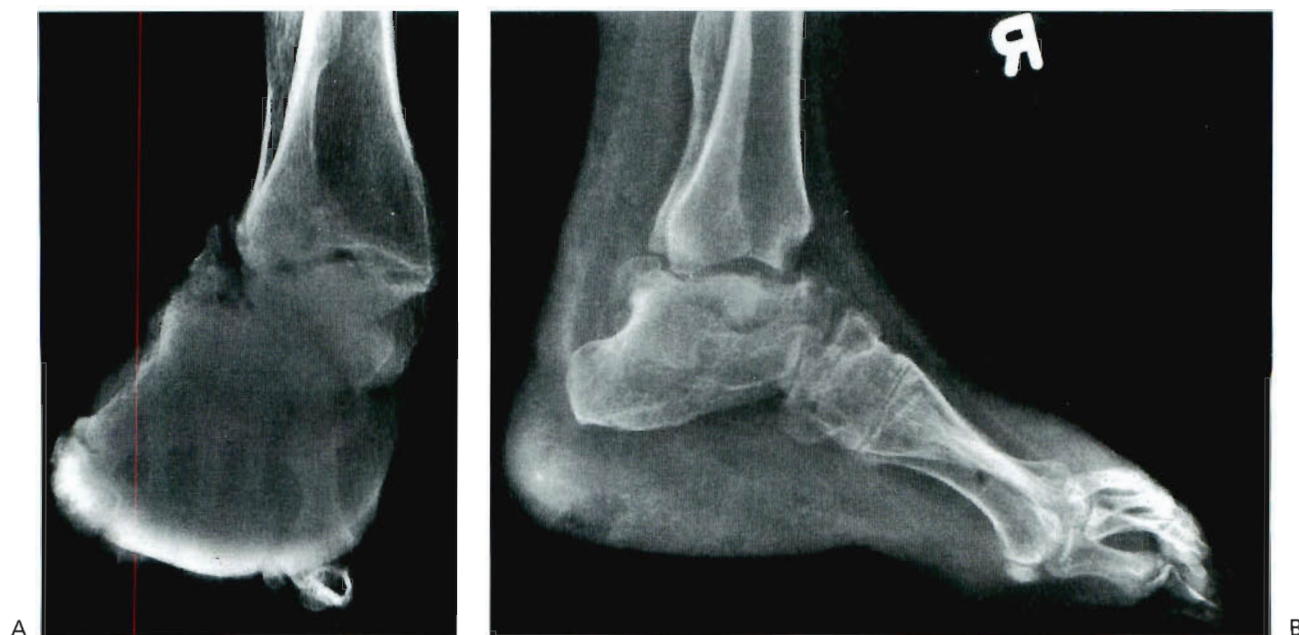

FIGURE 16-19. This Charcot degeneration occurred in a 16-year-old, L5 paraplegic girl who refused to wear her ankle-foot orthosis.

Treatment of the Charcot arthropathy must be instituted early and based on suspicion rather than waiting for radiographic confirmation. The best treatment is a vigorous protection of the joint following the initial episode before additional injury occurs. This may be accomplished by a splint or a cast and by nonweightbearing. If the early treatment has been successful radiographic changes may never be identified. Typically the swelling and erythema subside after 1 or 2 weeks. If they recur after the beginning of weight bearing, then the protection must be resumed for a longer time. The healing usually takes 6 to 8 weeks. However, if the diagnosis and treatment are delayed until the radiograph becomes positive for joint deformity or degeneration, prolonged immobilization and protection must be provided until the process has run its course. This may take 6 to 8 months or longer. The joint protection should be maintained until there is radiographic evidence of healing of the avascular segment of the joint and all swelling and erythema has disappeared. Continued orthotic protection of the foot and ankle or knee is essential.

Orthotic Devices

The goal of treatment of the myelomeningocele foot is a braceable plantigrade foot. Only the sacral-level paraplegic has sufficient sensation and muscle control to gain stability of the foot and ankle without orthotic support. The orthosis must provide stability to the foot and ankle, and ideally should be lightweight and cosmetically acceptable. It should limit all unwanted motion of the foot and ankle, and trans-

mit the floor reaction force to the anterior shin where the child has sensation. The ideal orthosis has not been developed. The closest we can come is a brace made of polypropylene that controls and limits the ankle motion (122). If the ankle is in valgus, or if there is instability of the subtalar joint, the brace can be modified with a supramalleolar strap which uses the principle of the T-strap of the double upright style of orthosis (123). This helps release the pressure on the medial malleolus and the head of the talus.

The author prefers the floor reaction force ankle-foot orthosis that is closed anteriorly over the tibial tubercle so that the floor reaction force can be transmitted directly to the area of intact sensation (Fig. 16-20). It also gives a firm support to the tibia to help extend the knee during midstance (124). Because the orthosis is in part a cylinder, it is much more resistant to rotation and valgus deformation during walking than the more common posterior polypropylene ankle-foot orthosis. Because the ankle is rigid the heel of the shoe must act as the shock absorber at heel strike, and should be of a relatively soft, shock-absorbing material. The foot also must be allowed to simulate 10 degrees of dorsiflexion in order to get the tibia beyond midstance to take the next step (125) (Fig. 16-16). This can be adjusted by the height of the heel or the position of the foot when the mold is made for the brace. The drawback to the floor reaction orthosis is that it is difficult to make and requires a skilled orthotist. There is little margin of error permitted, or maximum gait cannot be achieved.

The downside to an ankle-foot orthosis is that the ankle-foot joint complex cannot absorb the transverse plane

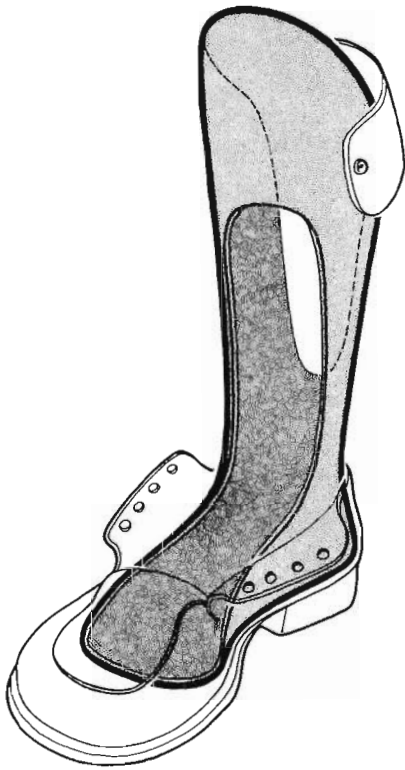


FIGURE 16-20. An ankle-foot orthosis made of a polypropylene shell with a Plastizote lining. The orthosis is closed anteriorly over the tibial tubercle so that the floor reaction force can be transmitted directly to the area of intact sensation. (From ref. 117, with permission.)

forces of gait. The forces are consequently transferred to the knee which is not designed to accept them. A recent study showed that in the S1–2-level paraplegic the brace may be more detrimental to the knee than a benefit to the gait pattern (96).

Shoe inserts and modifications are rarely successful in providing correction of alignment and position deformities of the foot. Most of these children do not have the muscle control or the sensation to take advantage of these devices. They may be helpful in protecting the foot of an S1 level paraplegic.

Fractures of the Femur and Tibia

Fractures of the femur and tibia occur commonly in children with myelomeningocele (66,125). The trauma needed to produce the fracture is often minimal, particularly after cast immobilization. The fractures are usually epiphyseal or metaphyseal (126–129). The peak incidence of fracture appears to be between the ages of 3 and 7 years, but fracture may occur at any age. Fracture is related to the level of paralysis and postoperative immobilization. Metabolic abnormalities have been investigated and found not to be present (130).

Diagnosis of fracture often is missed because of the minimal trauma. If the fracture is not diaphyseal, no instability of the leg may be present, which aids in the diagnosis. The local and systemic response to the fracture also is exaggerated, and consists of swelling of the leg, local warmth, erythema, and fever (131). These signs and symptoms often are misdiagnosed as cellulitis or osteomyelitis. Any unexplained fever in these children in association with a swollen warm leg that appears to be cellulitis should be treated as a fracture until radiographs prove otherwise.

Fracture following postoperative cast immobilization is common, and several studies have reported an incidence of 18 to 45%. Prevention of fractures in the postoperative period include starting the child on weightbearing as soon as possible, and keeping the plaster immobilization time to a minimum. After the cast has been removed extreme caution must be exercised for at least 1 week. Once a fracture has occurred it is best to carry out minimal immobilization and begin weightbearing as soon as possible. If these children are treated with the usual routine of plaster cast and inactivity the osteopenia increases, and repeated fractures are more likely to occur.

In most instances the author prefers a soft cast made of cast padding about 1 inch thick, followed by an elastic bandage and, if necessary, a single lightweight plaster splint. The swelling decreases rapidly, and the soft cast has to be reapplied within 2 or 3 days. The family rewraps the elastic bandage daily. Usually, there is sufficient callus to begin weightbearing in 2 or 3 weeks after casting. If a plaster cast is used weightbearing should be started as soon as possible. If the fracture is close to the hip internal fixation may be necessary to obtain early mobility.

References

Classification and Pathology

1. Walker G. The early management of varus feet in myelomeningocele. *J Bone Joint Surg Br* 1971;53:462.
2. Gardner WJ. Anatomic features common to the Arnold-Chiari and the Dandy-Walker malformations suggest a common origin. *Cleve Clin Q* 1959;26:206.
3. Gardner WJ. Myelocoele—rupture of the neural tube? *Clin Neurosurg* 1968;15:57.
4. Gardner WJ. Embryologic origin of spinal malformations. *Acta Radiol (Stockh)* 1966;5:1012.
5. Gardner WJ. Diastematomyelia and the Klippel-Feil syndrome. *Cleve Clin Q* 1964;31:19.
6. Gardner WJ. Myelomeningocele—the result of rupture of the embryonic neural tube. *Cleve Clin Q* 1960;27:88.
7. Morgagni JB. *The seats and causes of diseases investigated by anatomy*. vol. 3. London: A Millar & T Cadell, 1797.
8. Shurtleff DB, Lutly DA, Benedetti TJ, et al. The outcome of pregnancies diagnosed as having a fetus with myelomeningocele. *Kinderchir* 1987;42(suppl):50.

Neurologic Abnormality

9. McDonald CM, Jaffe KM, Shurtleff DB, et al. Modifications to the traditional description of neurosegmental innervation in myelomeningocele. *Dev Med Child Neurol* 1991;33:473.

10. Sharrard WJ, Grosfield I. The management of deformity and paralysis of the foot in myelomeningocele. *J Bone Joint Surg Br* 1968;50:456.
11. Wolfe PH. Development and motivational concepts in Piaget's sensory-motor theory of intelligence. *J Am Acad Child Adolesc Psychiatry* 1963;2:225.

Genetics, Etiology, and Prenatal Diagnosis

12. Stein SC, Feldman JG, Friedlander M, et al. Is myelomeningocele a disappearing disease? *Pediatrics* 1982;69:511.
13. Carter CO. Spina bifida and anencephaly—a problem in genetic-environmental interaction. *J Biosoc Sci* 1969;1:71.
14. Toriello HV, Higgins JV. Occurrence of neural tube defects among first, second, and third degree relatives of proband—results of a USA study. *Am J Med Genet* 1987;15:601.
15. Carter CO, Roberts JA. The risk of recurrence after two children with central nervous system malformations. *Lancet* 1967;1:306.
16. Lawrence KM. Clinical and ethical considerations on alpha-fetoprotein estimated for early prenatal diagnosis of neural tube malformations. *Dev Med Child Neurol* 1974;16(suppl 32):117.
17. Centers for Disease Control and Prevention. Recommendations for the use of folic acid to reduce the number of cases of spina bifida and other neural tube defects. *MMWR Morb Mortal Wkly Rep* 1992;RR-14:41.
18. Seller MJ, Nevin NC. Periconceptional vitamin supplementation and the prevention of neural tube defects in southeast England and North Ireland. *J Med Genet* 1984;21:325.
19. Alan LD, Donald I, Gibson AA, et al. Amniotic fluid alpha-fetoprotein in the antenatal diagnosis of spina bifida. *Lancet* 1973;2:522.
20. Lawrence KM. The recurrence risk in spina bifida cystica and anencephaly. *Dev Med Child Neurol* 1969;11(suppl 20):23.
21. Hide DW, Williams HP, Ellis HL. The outlook for the child with a myelomeningocele for whom early surgery was considered inadvisable. *Dev Med Child Neurol* 1972;14:304.

Natural History

22. Lorber J. Selective treatment of myelomeningocele—to treat or not to treat? *Pediatrics* 1974;53:307.
23. Bunch WH, Scarff TB, Dvonch VM. Progressive loss in myelomeningocele patients. *Orthop Trans* 1983;7:185.
24. Hall PV, Campbell RH, Kalsbeck JE. Myelomeningocele and progressive hydromyelia—progressive paresis in myelodysplasia. *J Neurosurg* 1975;43:457.
25. Schafer MF, Dias LS. *Myelomeningocele—orthopaedic treatment*. Baltimore: Williams & Wilkins, 1983:168.
26. Hall PV, Lindseth RE, Campbell RH, et al. Scoliosis and hydrocephalus in myelocoele patients. The effect of ventricular shunting. *J Neurosurg* 1979;50:174.
27. Hall PV, Lindseth RE, Campbell RL, et al. Myelodysplasia and developmental scoliosis. *Spine* 1976;1:48.
28. Heinz ER, Rosenbaum AE, Scarff TB, et al. Tethered spinal cord following myelomeningocele repair. *Radiology* 1979;131:153.
29. Scarff TB, Toleikis JR, Bunch WH, et al. Dermatomes and somatosensory evoked potentials in children with myelomeningocele. *Z Kinderchir Grenzgeb* 1979;28:384.
30. Tosi LL, Slater JE, Shafer C, et al. Latex allergy in spina bifida patients—prevalence and surgical implications. *J Pediatr Orthop* 1993;13:709.
31. Aronson DD, Middleton DL. Extra-articular subtalar arthrodesis with cancellous bone graft and internal fixation for children with myelomeningocele. *Dev Med Child Neurol* 1991;33:232.

Effect of Myelomeningocele on Developmental Sequence

32. Hoppenfeld S. Congenital kyphosis in myelomeningocele. *J Bone Joint Surg Br* 1967;49:276.
33. Hammar SL. The approach to the adolescent patient. *Pediatr Clin North Am* 1973;20:799.
34. Johnson WR. Sex education of the mentally retarded. In: Curz F, Levic GD, eds. *Human sexuality and the mentally retarded*. New York: Brunner Mazel, 1973:57.

Treatment

35. Hull WJ, Moe JN, Winter RB. Spinal deformity in myelomeningocele—natural history, evaluation, treatment. *J Bone Joint Surg Am* 1974;56:1767.
36. Bunch WH. Treatment of the myelomeningocele spine. *Instr Course Lect* 1976;25:93.
37. Drummond DS, Moreau M, Cruess RL. The results and complications of surgery for the paralytic hip and spine in myelomeningocele. *J Bone Joint Surg Br* 1980;62:49.
38. Raycroft JE, Curtis BH. *Spinal curvature in myelomeningocele: natural history and etiology*. St. Louis: CV Mosby, 1972.
39. Sriram K, Bobrtchko WT, Hall JE. Surgical management of spinal deformities in spina bifida. *J Bone Joint Surg Br* 1972;54:666.
40. Mackel JL, Lindseth RE. Scoliosis in myelodysplasia. *J Bone Joint Surg Am* 1975;57:1031.
41. Lindseth RE. Scoliosis etiology and conservative treatment. In: McLaurin RL, et al., eds. *Spina bifida: a multidisciplinary approach*. New York: Praeger, 1986:439.
42. McLaughlin TP, Banta JV, Gahm NH, Raycroft JF. Intraspinal rhizotomy and distal cordectomy in patients with myelomeningocele. *J Bone Joint Surg Am* 1986;68:88.
43. McLone DG, Herman JM, Gabrieli AP, et al. Tethered cord as a cause of scoliosis in children with a myelomeningocele. *Pediatr Neurosurg* 1990;16:8.
44. Winter RB, Moe JN, Eilers VE. Congenital scoliosis. A study of 234 patients treated and untreated. Part I. Natural history. Part II. Treatment. *J Bone Joint Surg Am* 1968;50:1.
45. Brenningstall GN, Marker SM, Tubman DE. Hydrosyringomyelia and diastematomyelia detected by MRI in myelomeningocele. *Pediatr Neurol* 1992;8:267.
46. Bunch WH. The Milwaukee brace in paralytic scoliosis. *Clin Orthop* 1975;110:63.
47. Allen BL Jr. The operative treatment of myelomeningocele spinal deformity. *Orthop Clin North Am* 1979;10:845.
48. Mazur JM, Menelaus MB, Dickson DR, et al. Efficacy of surgical management for scoliosis in myelomeningocele—correction of deformity and alteration of functional status. *J Pediatr Orthop* 1986;6:568.
49. Lindseth RE. Posterior iliac osteotomy for fixed pelvic obliquity. *J Bone Joint Surg Am* 1978;60:17.
50. Banta JV. Combined anterior and posterior fusion for spinal deformity in myelomeningocele. *Spine* 1990;15:946.
51. Menelaus MB. Progress in the management of the paralytic hip in myelomeningocele. *Orthop Clin North Am* 1980;11:17.
52. Osebold WR, Mayfield JK, Winter RB, et al. Surgical treatment of the paralytic scoliosis associated with myelomeningocele. *J Bone Joint Surg Am* 1982;64:841.
53. Lindseth RE, Graziano GP. One-stage anterior transpedicular and unilateral fusion for congenital scoliosis. *Orthop Trans* 1988;12:184.
54. Drennan JC. The role of muscles in the development of human lumbar kyphosis. *Dev Med Child Neurol* 1970;12:33.

55. Eyring EJ, Wanken JJ, Sayers MP. Spinal osteotomy for kyphosis in myelomeningocele. *Clin Orthop* 1972;88:24.
56. Lindseth RE, Selzer L. Vertebral excision for kyphosis in children with myelomeningocele. *J Bone Joint Surg Am* 1979;61:699.
57. Sharrard WJ, Drennan JC. Osteotomy-excision of the spine for lumbar kyphosis in older children with myelomeningocele. *J Bone Joint Surg Br* 1972;54:50.
58. Banta JV, Hamanda JS. Natural history of the kyphotic deformity in myelomeningocele. *J Bone Joint Surg Am* 1976;58:279.
59. Loder RT, Shapiro P, Towbin R, et al. Aortic anatomy in children with myelomeningocele and congenital lumbar kyphosis. *J Pediatr Orthop* 1991;11:31.
60. Lindseth RE. Myelomeningocele spine. In: Weinstein SL, ed. *The pediatric spine: principles and practice*. New York: Raven, 1994.
61. Fromm B, Carstens C, Niethard FU, et al. Aortography in children with myelomeningocele and lumbar kyphosis. *J Bone Joint Surg Br* 1992;74:691.
62. Lintner SA, Lindseth RE. The long-term follow up after proximal resection in children with myelomeningocele and a kyphosis deformity. *Orthop Trans* 1993;17:123.
63. Dunn HK. Kyphosis of myelodysplasia—operative treatment based on pathophysiology. *Orthop Trans* 1983;7:19.
64. Hall JE, Poitra B. The management of kyphosis in patients with myelomeningocele. *Clin Orthop* 1977;128:33.
65. Lubicky JP, Fredrickson BE. The combined use of kyphectomy, spinal cord resection, Luque instrumentation, and myocutaneous flaps for severe kyphosis in the myelomeningocele. *Orthop Trans* 1985;9:495.
66. Warner WC Jr, Fackler CD. Comparison of two instrumentation techniques in treatment of lumbar kyphosis in myelodysplasia. *J Pediatr Orthop* 1993;13:704.
67. Lindseth RE. Spine deformity in myelomeningocele. *Inst Course Lect* 1991;40:276.
68. Weisl H. Coxa vara in spina bifida. *J Bone Joint Surg Br* 1983;65:128.
69. Heydermann JS, Gillespie R. Management of myelomeningocele kyphosis in the older child by kyphectomy and segmental spinal instrumentation. *Spine* 1987;12:37.
70. Asher M, Olson J. Factors affecting the ambulatory status of patients with spina bifida cystica. *J Bone Joint Surg Am* 1983;65:350.
71. Lee EH, Carroll NC. Hip stability and ambulatory status in myelomeningocele. *J Pediatr Orthop* 1985;5:522.
72. Lindseth RE. Treatment of the lower extremity in children paralyzed by myelomeningocele. *Instr Course Lect* 1976;25:76.
73. Passo SD. Positioning infants with myelomeningocele. *Am J Nurs* 1974;74:165.
74. Feiwell E, Sakar D, Blatt T. The effect of hip reduction on function in patients with myelomeningocele—potential gains and hazards of surgical care. *J Bone Joint Surg Am* 1978;60:169.
75. Lough LK, Nielsen DH. Ambulation of children with myelomeningocele—parapodium versus parapodium with Orlau swivel modification. *Dev Med Child Neurol* 1986;28:489.
76. McCall RE, Schmidt WT. Clinical experience with the reciprocal gait orthosis in myelodysplasia. *J Pediatr Orthop* 1986;6:157.
77. Yngve DA, Douglas R, Roberts JM. The reciprocating gait orthosis in myelomeningocele. *J Pediatr Orthop* 1984;4:304.
78. Rose GK, Sankarankutt M, Stallard J. A clinical review of the orthotic treatment of myelomeningocele patients. *J Bone Joint Surg Br* 1983;65:242.
79. Bunch WH, Hakala MW. Iliopsoas transfers in children with myelomeningocele. *J Bone Joint Surg Am* 1984;66:224.
80. Hoffer MM, Feiwell E, Perry R, et al. Functional ambulation in patients with myelomeningocele. *J Bone Joint Surg Am* 1973;55:137.
81. Carroll NC, Sharrard WJ. Long term follow up of posterior iliopsoas transplantation for paralytic dislocation of the hip. *J Bone Joint Surg Am* 1972;54:551.
82. Garceau GJ, Kinzel JW. Transplantation of the iliacus muscle for loss of hip abduction power. *Q Bull Indiana Univ Med Center* 1951;13:27.
83. Stillwell A, Menelaus MB. Walking ability after transplantation of the iliopsoas—a long term follow up. *J Bone Joint Surg Br* 1984;66:656.
84. Mustard WT. Iliopsoas transfer for weakness of hip abduction. *J Bone Joint Surg Am* 1952;34:647.
85. Raycroft TF. Posterior iliopsoas transfer—long-term results in patients treated at Newington Children's Hospital. *Orthop Trans* 1987;11:454.
86. Phillips DP, Lindseth RE. Ambulation after transfer of adductors, external oblique, and tensor fascia lata in myelomeningocele. *J Pediatr Orthop* 1992;12:712.
87. Thomas LI, Thompson TC, Strub LR. Transplantation of the external oblique muscle for adductor paralysis. *J Bone Joint Surg Am* 1950;32:207.
88. Yngve DA, Lindseth RE. Effectiveness of muscular transfer in myelomeningocele hips measured by radiographic indices. *J Pediatr Orthop* 1982;2:121.
89. Canale TS, Hammond NL III, Cotler JM, et al. Pelvic displacement osteotomy for chronic hip dislocation in myelodysplasia. *J Bone Joint Surg Am* 1975;57:177.
90. Lindseth RE. Extension contracture of the knee. In: McLaurin RL, Oppenheimer S, Dias L, et al., eds. *Spina bifida: a multidisciplinary approach*. New York: Praeger, 1986:40.
91. Dias LS. Surgical management of knee contractures in myelomeningocele. *J Pediatr Orthop* 1982;2:127.
92. Williams JJ, Graham GP, Dunne KB, et al. Late knee problems in myelomeningocele. *J Pediatr Orthop* 1993;13:701.
93. Turco VJ. Surgical correction of the resistant clubfoot: one stage posteromedial release with internal fixation: a preliminary report. *J Bone Joint Surg Am* 1971;53:477.
94. Burke SW, Weinse LS, Maynard MJ. Neuropathic foot ulcers in myelodysplasia. *Orthop Trans* 1991;15:102.
95. Menelaus MB. Talcotomy for equinovarus deformity in arthrogryposis and spina bifida. *J Bone Joint Surg Br* 1971;53:468.
96. de Carvalho Neto J, Dias LS, Gabrieli AP. Congenital talipes equinovarus in spina bifida: treatment and results. *J Pediatr Orthop* 1996;16:782.
97. Crawford AH, Marxen JL, Osterfield DL. The Cincinnati Incision—a comprehensive approach for surgical procedures of the foot and ankle in childhood. *J Bone Joint Surg Am* 1982;64:1355.
98. Carroll NC. Pathoanatomy and surgical treatment of the resistant clubfoot. *Instr Course Lect* 1988;37:93.
99. Trieshmann H, Millis M, Hall J, et al. Sliding calcaneal osteotomy for treatment of hindfoot deformity. *Orthop Trans* 1980;4:305.
100. Grant AD, Silver L, Lehman WB, Altar D. The use of tissue expander in clubfoot surgery. Presented at: Pediatric Orthopaedic Society of North America Meeting, May 7, 1990; San Francisco, CA.
101. Kling TF Jr, Schmidt TL, Conklin, MJ. Open wedge osteotomy of the first cuneiform for severe metatarsus adductus. Presented at: Pediatric Orthopaedic Society of North America Meeting, May 7, 1990; San Francisco, CA.
102. McKay DW. New concept of and approach to clubfoot treatment. Section II. Correction of the clubfoot. *J Pediatr Orthop* 1983;3:10.
103. Dias LS, Stern LS. Talcotomy in the treatment of resistant tali-

- pes equinovarus deformity in myelomeningocele and arthrogryposis. *J Pediatr Orthop* 1987;7:39.
104. Sherk HH, Ames MD. Talectomy in the treatment of the myelomeningocele patient. *Clin Orthop* 1975;75:218.
 105. Sherk HH, Marchinski LJ, Clancy M, et al. Ground reaction forces on the plantar surface of the foot after talectomy in the myelomeningocele. *J Pediatr Orthop* 1989;9:269.
 106. Duncan JW, Lovell WW. Hoke triple arthrodesis. *J Bone Joint Surg Am* 1978;60:795.
 107. Fraser RK, Hoffman EB. Calcaneus deformity in the ambulant patient with myelomeningocele. *J Bone Joint Surg Br* 1991;73:994.
 108. Bliss DG, Menelaus MB. The results of transfer of the tibialis anterior to the heel in patients who have a myelomeningocele. *J Bone Joint Surg Am* 1986;68:1258.
 109. Rodrigues RC, Dias LS. Calcaneus deformity in spina bifida—results of anterolateral release. *J Pediatr Orthop* 1992;12:461.
 110. Banta JV, Sutherland DH, Wyatt M. Anterior tibial transfer to the os calcis with Achilles tenodesis for calcaneal deformity in myelomeningocele. *J Pediatr Orthop* 1982;1:125.
 111. Coleman SS. *Complex foot deformities in children*. Philadelphia: Lea & Febiger, 1983:147.
 112. Dias LS, Jasty MJ, Collins P. Rotational deformities of the lower limb in myelomeningocele—evaluation and treatment. *J Bone Joint Surg Am* 1984;66:215.
 113. Menelaus MB. Pes plano-valgus. In: McLaurin RL, Oppenheimer S, Dias L, et al., eds. *Spina bifida—a multidisciplinary approach*. New York: Prager, 1986:431.
 114. Diamond L. Dowel type subtalar arthrodesis in children. *J Bone Joint Surg Am* 1976;58:725.
 115. Lee YF, Grogan TJ, Moseley CF. Extra-articular subtalar arthrodesis in myelodysplasia. *Orthop Trans* 1990;14:590.
 116. Malhotra D, Puri R, Owen R. Valgus deformity of the ankle in children with spina bifida aperta. *J Bone Joint Surg Br* 1984;66:381.
 117. Burkus JK, Moore DW, Raycroft JF. Valgus deformity of the ankle in myelodysplastic patients. Correction of stapling of the medial part of the distal tibial physis. *J Bone Joint Surg Am* 1983;65:1157.
 118. Stevens PM, Toomey E. Fibular-Achilles tenodesis for paralytic ankle valgus. *J Pediatr Orthop* 1988;8:169.
 119. Bradley GW, Coleman SS. The treatment of the calcaneocavus foot deformity. *J Bone Joint Surg Am* 1981;63:1159.
 120. Sutherland DH. *Gait disorders in childhood and adolescence*. Baltimore: Williams & Wilkins, 1984:631.
 121. Sutherland DH. An electromyographic study of the plantar flexors of the ankle in normal walking on the level. *J Bone Joint Surg Am* 1966;48:66.
 122. Glancy JC, Lindseth RE. The polypropylene solid-ankle orthosis. *Orthot Prosthet* 1972;26:16.
 123. Lin RS. Application of varus T-strap principle to the polypropylene ankle—foot orthosis. *Orthot Prosthet* 1982;36:67.
 124. Lindseth RE. Myelomeningocele. In: Drennan JC, ed. *The child's foot and ankle*. New York: Raven, 1992.
 125. Hullin MG, Robb JE, Loudon IR. Ankle-foot orthosis function in low level myelomeningocele. *J Pediatr Orthop* 1992;12:518.
 126. Cuxart A, Iborra J, Melendez M, et al. Physeal injuries in myelomeningocele patients. *Paraplegia* 1992;30:791.
 127. Edvardsen P. Physeo-epiphyseal injuries of lower extremities in myelomeningocele. *Acta Orthop Scand* 1972;43:550.
 128. Korhonen BJ. Fractures in myelodysplasia. *Clin Orthop* 1971;79:145.
 129. Kumar SJ, Cowell HR, Townsend P. Physcal, metaphyseal, and diaphyseal injuries of the lower extremities in children with myelomeningocele. *J Pediatr Orthop* 1984;4:25.
 130. Repasky D, Richard K, Lindseth RE. Ascorbic acid and fractures in children with myelomeningocele. *J Am Diet Assoc* 1976;69:511.
 131. Drummond DS, Moreau M, Cruess RL. Postoperative neuropathic fractures in patients with myelomeningocele. *Dev Med Child Neurol* 1981;23:147.



17

OTHER NEUROMUSCULAR DISORDERS

GEORGE H. THOMPSON
FRANK R. BERENSON

HISTORY 634

PHYSICAL EXAMINATION 635

DIAGNOSTIC STUDIES 635

Hematologic Studies 635
Electromyography 635
Nerve Conduction Studies 635
Muscle Biopsy 635
Nerve Biopsy 636
Other Studies 636

GENETIC AND MOLECULAR BIOLOGY STUDIES 636

MUSCULAR DYSTROPHIES 636

SEX-LINKED MUSCULAR DYSTROPHIES 637

Duchenne Muscular Dystrophy 637
Becker Muscular Dystrophy 644
Emery-Dreifuss Muscular Dystrophy 644

AUTOSOMAL RECESSIVE MUSCULAR DYSTROPHIES 646

Limb-girdle Muscular Dystrophy 646
Infantile Fascioscapulohumeral Muscular Dystrophy 646

G. H. Thompson: Department of Orthopaedic Surgery and Pediatrics, Case Western Reserve University; Pediatric Orthopaedics, Rainbow Babies and Children's Hospital, Cleveland, Ohio 44106.

F. R. Berenson: Department of Pediatrics, Mercer University, Macon, Georgia 31207; Department of Pediatrics, Children's Healthcare of Atlanta at Scottish Rite, Atlanta, Georgia 30342.

AUTOSOMAL DOMINANT MUSCULAR DYSTROPHIES 647

Fascioscapulohumeral Muscular Dystrophy 647
Distal Muscular Dystrophy 648
Ocular Muscular Dystrophy 648
Oculopharyngeal Muscular Dystrophy 648

MYOTONIA 648

Myotonic Dystrophy 648
Congenital Myotonic Dystrophy 649
Myotonia Congenita 649

CONGENITAL MYOPATHIES AND CONGENITAL MUSCULAR DYSTROPHY 649

CONGENITAL MYOPATHIES 649

Central Core Disease 649
Nemaline Myopathy 650
Centronuclear Myopathy 650
Congenital Fiber-type Disproportion 650
Metabolic Myopathies 650

CONGENITAL MUSCULAR DYSTROPHY 651

SPINAL MUSCULAR ATROPHY 652

Clinical Classification 652
Functional Classification 653
Genetic and Molecular Biology Studies 653
Clinical Features 653
Diagnostic Studies 653
Radiographic Evaluation 653
Treatment 653

FRIEDREICH ATAXIA 656

Clinical Features 656

Genetic and Molecular Biology Studies 656

Treatment 656

HEREDITARY MOTOR SENSORY NEUROPATHIES 657

Classification 657

Diagnostic Studies 658

Genetic and Molecular Biology Studies 658

Treatment 658

POLIOMYELITIS 662

Pathology 663

Disease Stages 663

Treatment 664

Treatment Guidelines 665

POSTPOLIOMYELITIS SYNDROME 668

Neuromuscular disorders other than cerebral palsy and myelodysplasia are less common, but nevertheless appear in pediatric orthopaedic and neuromuscular clinics. These disorders include the muscular dystrophies and congenital myopathies, spinal muscular atrophy, Friedreich ataxia, hereditary motor sensory neuropathies (HMSN), and poliomyelitis. It is important that an accurate diagnosis be established so that an effective treatment program can be planned and initiated. Delaying the diagnosis may lead to inappropriate treatment and perhaps further pregnancies with involved children in the presence of genetic diseases (1). Accurate diagnosis requires a careful history, physical examination, and appropriate diagnostic studies (2).

HISTORY

The history should include the details of pregnancy, delivery, and growth and development of the involved child. Questions regarding *in utero* activity, complications of delivery, birth weight, Apgar score, problems during the neonatal period, age at achievement of developmental motor milestones, age at onset of the current symptoms, and information regarding whether the condition is static or progressive should be asked. Systemic symptoms, such as cardiac disease, cataracts, seizures, or other abnormalities, should also be ascertained.

The family history is important in diagnosis because these disorders, with the exception of poliomyelitis, are genetic in origin. Family members of an involved child or adolescent may need to be examined for subtle expressions of the same disorder. These same family members may also require hematologic or other studies to arrive at an accurate diagnosis.

PHYSICAL EXAMINATION

Most children who present for evaluation of a suspected neuromuscular disorder have either a delay in developmental milestones, abnormal gait, or foot deformity. There

usually is a history of progression. Physical examination consists of a thorough musculoskeletal and neurologic evaluation. Observing the child walking and performing simple tasks, such as arising from a sitting position on the floor, can be beneficial. Observing the gait may reveal decreased arm swing, circumduction of the legs, scissoring, or short cadence. Standing posture may reveal increased lumbar lordosis or wide base position for balance. Also, in the standing position the appearance of the feet should be observed. Pes cavus or cavovarus deformities are common physical findings in many of these disorders. Having the child walk on the heels and toes gives a gross assessment of motor strength, whereas having the child run may reveal an increase in muscle tone or ataxia.

Inspection of the skin should be performed for evidence of skin rashes or other abnormalities. Typical facies of the patient with spinal muscular atrophy and congenital myotonic dystrophy should become familiar to orthopaedic surgeons. The tongue should be examined to detect evidence of fasciculation suggestive of anterior horn cell diseases. Excessive drooling is common in both cerebral palsy and congenital myotonic dystrophy. In the latter, nasal speech may also be present. A thorough ophthalmologic examination is necessary to elicit external ophthalmoplegia or retinitis pigmentosa. Cataracts may develop during adolescence in myotonic dystrophy.

Muscle testing should be carefully performed. Generally, myopathic disorders selectively affect proximal limb muscles before distal muscles. They also demonstrate proportionally greater weakness than the degree of atrophy early in the disease process. The converse is true in neuropathies.

A careful neurologic evaluation usually completes the musculoskeletal examination. Sensory responses must be checked individually and recorded. Decreased vibratory sensation may be present in HMSN, such as Charcot-Marie-Tooth disease. In spinal muscular atrophy the deep tendon reflexes may be absent, but they are increased in cerebral palsy. A positive Babinski sign confirms upper motor neuron disease. Abnormalities in the Romberg test and rapid alternating movements may indicate cerebellar involvement. Mental function evaluation may be necessary, because

organic mental deterioration may be part of some neurologic syndromes. In many cases the assistance of a pediatric neurologist can be invaluable in performing a careful neurologic and mental evaluation because minor subtleties may be a clue to diagnosis.

DIAGNOSTIC STUDIES

Appropriate diagnostic studies are imperative in the accurate diagnosis of the myopathic and neuropathic disorders (3–6). These can be divided into hematologic studies, electromyography (EMG) with both nerve conduction studies and needle electrode exam, muscle biopsy, and nerve biopsy. Molecular diagnostic studies have become available for several disorders, such as Duchenne and Becker muscular dystrophies.

Hematologic Studies

The measurement of serum creatine phosphokinase (CPK) is the most sensitive test for demonstrating abnormalities of striated muscle function (7,8). The level of elevation parallels the rate and amount of muscle necrosis and decreases with time as the muscle is replaced by fat and fibrous tissue. The highest CPK levels are typically seen in the earliest stages of Duchenne or Becker muscular dystrophy in which increases of 20 to 200 times normal may be found (4). The level of elevation does not correlate with the severity or rate of progression of the disorder. The highest levels are usually found in Duchenne muscular dystrophy. Umbilical cord blood CPK levels should be obtained in all male infants who are suspected of having this disorder (9). Birth trauma may elevate the CPK in umbilical cord blood, but in the normal child this elevation disappears promptly. The enzyme level remains elevated in true muscular dystrophy. Serum CPK may be mildly or moderately elevated in other dystrophic disorders, such as fascioscapulohumeral muscular dystrophy, Emery-Dreifuss muscular dystrophy, and spinal muscular atrophy. It is also mildly elevated in female carriers of Duchenne muscular dystrophy, although they are asymptomatic. In congenital myopathies and peripheral neuropathies, the CPK levels are usually normal to only mildly elevated. In other neuromuscular disorders that do not directly affect striated muscle, the CPK levels are normal. Serum enzymes, such as aldolase and serum glutamic oxaloacetic transaminase (SGOT), are also important in the study of striated muscle function. Aldolase levels correlate well with the CPK levels (6).

Electromyography

EMG can differentiate between a myopathic and neuropathic process but is rarely helpful in establishing a definitive

diagnosis. Characteristics of neuropathic disorders include the presence of fibrillation potentials, increased insertional activity, and high amplitude and increased-duration motor unit potentials (4). The fibrillation potential represents denervated individual muscle fibers firing spontaneously.

Myopathic EMG is characterized by low-voltage, short-duration polyphasic motor unit potentials (4). Myopathies rarely demonstrate EMG changes characteristic of a neuropathy, although in an inflammatory muscle disease with significant muscle breakdown there may be prominent fibrillations. The use of an experienced electromyographer is imperative in the accurate performance and interpretation of EMG data.

Nerve Conduction Studies

Nerve conduction studies are important in the establishment of the diagnosis of peripheral neuropathy in children. Nerve conduction velocities are normal in children with anterior horn cell diseases, nerve root diseases, and myopathies. The normal value in the child older than 5 years of age is 45 to 65 m/s. In infants and younger children, the velocity is lower because myelination is incomplete.

Motor conduction velocity may be lowered in HMSN (e.g., Charcot-Marie-Tooth disease) before clinical deficits are present. The nerve conduction studies can help determine whether the neuropathy involves an isolated nerve or is a disseminated process.

Muscle Biopsy

Muscle biopsy is the most important test in determining the diagnosis of a neuromuscular disorder (10,11). Muscle biopsy material is usually examined by routine histology, special histochemical stains, and electron microscopy. The criterion for selecting the muscle for biopsy is clinical evidence of muscle weakness. Muscles that are involved but are functioning are selected in chronic diseases such as Duchenne muscular dystrophy because they demonstrate the greatest diagnostic changes. A more severely involved muscle may be chosen in an acute illness because the process has not had sufficient time to progress to extensive destruction. In patients who have proximal lower extremity muscle weakness biopsy of the vastus lateralis is performed, whereas in those with distal weakness the gastrocnemius is biopsied. Biopsy of the deltoid, biceps, or triceps is performed for shoulder girdle or proximal upper extremity weakness.

Muscle biopsies can be performed as an open procedure (10,12) or by percutaneous needle (13). The open technique as described by Banker is preferred (10). The biopsies are obtained under general anesthesia, spinal anesthetic, regional nerve block, or with a field block surrounding the area of incision. It is important that local anesthetic not be infiltrated into the muscle because this may alter the

morphology of the muscle. The vastus lateralis is the most common muscle chosen. A 4-cm incision is made and the underlying fascia is incised longitudinally. The muscle is looked at directly to avoid including normal fibrous septae in the specimens. Muscle clamps are used to obtain three specimens. The clamps are oriented in the direction of the muscle fibers. A 2- to 3-mm piece of muscle is grasped in each end of the clamp. The muscle is cut at the outside edge of each clamp and a cylinder of muscle excised. Using a muscle clamp keeps the muscle at its resting length and minimizes artifact. One specimen is quickly frozen in liquid nitrogen (-160°C) to prevent loss of soluble enzymes. This specimen is used for light microscopy with a variety of special preparations. The other specimens are used for routine histology and electron microscopy. The wound is subsequently closed in layers. Electrocautery may be used during the closure. If it is used before the biopsy, it may inadvertently damage the specimens and alter the morphology.

Nerve Biopsy

Occasionally biopsy of a peripheral nerve is helpful in demyelinating disorders. Usually the sural nerve is selected for biopsy because of its distal location and lack of autogenous zone of innervation. The patient notices no sensory change or only a mild diminution after excision of the 3- to 4-cm segment of the nerve. Hurley et al. (12) reported a single incision for combined muscle and sural nerve biopsy. An incision over the posterolateral aspect of the calf allows access to the nerve and either the soleus or the peroneal muscles. This avoids the necessity for two incisions. This technique was demonstrated to be accurate in diagnosing disorders in which both a muscle and nerve biopsy may be necessary.

Other Studies

Other studies that may be beneficial in establishing the diagnosis of a neuromuscular disorder include electrocardiogram (ECG), pulmonary function studies, magnetic resonance imaging (MRI), ophthalmologic evaluation, amniocentesis, and pediatric neurology evaluation.

Duchenne muscular dystrophy, Friedreich ataxia, and myotonic dystrophy demonstrate ECG abnormalities. Duchenne muscular dystrophy frequently has mitral valve prolapse secondary to papillary muscle involvement (14,15). Arrhythmias under anesthesia have been reported with both Duchenne and Emery-Dreifuss muscular dystrophies (16,17).

Pulmonary function studies demonstrate involvement of respiratory muscles but do not establish the diagnosis. If respiratory muscle involvement is present the rate of deterioration can be followed with periodic studies. This is important if surgery is contemplated in children or adolescents with muscular dystrophy, spinal muscular atrophy, or

Friedreich ataxia. The forced vital capacity (FVC) is the most important study after arterial blood gas measurements (18).

MRI has been demonstrated to distinguish muscles in neuropathic and myopathic disorders (19). Imaging estimates of the disease severity by degree of muscle involvement correlate well with clinical staging. MRI may also be important in selecting appropriate muscles for biopsy.

Ophthalmologic evaluation may demonstrate subtle or more obvious ocular changes associated with specific disorders.

GENETIC AND MOLECULAR BIOLOGY STUDIES

Genetic research through molecular biologic techniques has tremendously enhanced our understanding of the genetic aspects of many of these disorders (20,21). The exact location of chromosomal and gene defects has led to the possibility of genetic engineering with correction of these disorders. In each of the various disorders, the current status of genetic and molecular biology research, if any, is discussed.

MUSCULAR DYSTROPHIES

The muscular dystrophies are a group of noninflammatory inherited disorders with progressive degeneration and weakness of skeletal muscle without apparent cause in the peripheral or central nervous system. These have been divided by clinical distribution, severity of muscle weakness, and pattern of genetic inheritance (Table 17-1). An accurate diagnosis is important, both for prognosis and management of the individual patient and for identification of genetic factors that may be crucial in planning for subsequent children by the involved family.

TABLE 17-1. CLASSIFICATION OF MUSCULAR DYSTROPHIES

Sex-linked Muscular Dystrophy
Duchenne
Becker
Emery-Dreifuss
Autosomal Recessive Muscular Dystrophy
Limb-girdle
Infantile fascioscapulohumeral
Autosomal Dominant Muscular Dystrophy
Fascioscapulohumeral
Distal
Ocular
Oculopharyngeal

SEX-LINKED MUSCULAR DYSTROPHIES

Duchenne Muscular Dystrophy

Duchenne muscular dystrophy is the most common form of muscular dystrophy. Transmission is by an X-linked recessive trait. A single gene defect is found in the short arm of the X chromosome. The disease is characterized by its occurrence in males, except for rare cases associated with Turner syndrome. In this rare event, the XO karyotype who carries the defective gene may demonstrate the phenotype found in involved males (4). This disorder has a high mutation rate, and a positive family history is present in approximately 65% of cases. Duchenne muscular dystrophy occurs in about 1 in 3,500 live male births, with about one-third of involved children having the disease based on a new mutation.

Becker muscular dystrophy is a similar but less common and less severe form of muscular dystrophy. It occurs in about 1 in 30,000 live male births, becomes apparent later in childhood, and has a more protracted and variable course than Duchenne muscular dystrophy. This disorder is discussed later but is introduced here because of the similar inheritance pattern and molecular biology abnormality.

Clinical Features

Duchenne muscular dystrophy is generally clinically evident when the child is between 3 and 6 years of age. Earlier onset may also occur. The family may have observed that the child's ability to achieve independent ambulation was delayed or that he has become a toe walker. Children 3 years of age or older may demonstrate frequent episodes of tripping and falling, in addition to difficulty in reciprocal motion, such as running or climbing stairs. Inability to hop and jump normally is commonly present.

In Duchenne muscular dystrophy there is progressive weakness in the proximal muscle groups which descends symmetrically in both lower extremities, particularly the gluteus maximus, gluteus medius, quadriceps, and tibialis anterior muscles. The abdominal muscles are involved. Involvement of the shoulder girdle muscles (i.e., trapezius, deltoid, and pectoralis major muscles) and lower facial muscles occurs later. Pseudohypertrophy of the calf muscles caused by the accumulation of fat is common but not invariably present. Most patients have cardiac involvement, most commonly a sinus tachycardia and right ventricular hypertrophy. Life-threatening dysrhythmia or heart failure ultimately develops in about 10% of patients. Many also have a static encephalopathy, with mild or moderate mental retardation (22). Death from pulmonary failure and occasionally from cardiac failure occurs during the second or third decades of life.

During gait the child's cadence is slow and he or she develops compensatory changes in gait and stance as weak-

ness progresses. Sutherland et al. (23,24) documented disease progression by measuring the gait variables of cadence, swing phase, ankle dorsiflexion, and anterior pelvic tilt. The hip extensors, primarily the gluteus maximus, are the first muscle group to be involved. Initially the patient compensates by carrying the head and shoulders behind the pelvis, maintaining the weight line posterior to the hip joint and center of gravity (Fig. 17-1). This produces an anterior pelvic tilt and increases lumbar lordosis. Cadence and swing-phase ankle dorsiflexion decrease, and the patient develops a waddling, wide-based gait with shoulder sway to compensate for gluteus medius weakness. Muscle weakness requires that the force line remain behind the hip joint and in front of the knee joint throughout single limb support (23-25), and hip abductors and quadriceps muscles force the patient to circumduct during the swing phase of gait, while at the same time shifting the weight directly over the hip joint. The generalized pelvic weakness requires considerable forward motion to be generated by the spine for the patient to advance. Ankle plantar flexion becomes fixed and the stance phase is reduced to the forefoot, resulting in even more difficulty with balance and cadence. Foot inversion develops as peroneal strength diminishes. The tibialis posterior muscle, which is one of the last muscles to be involved, is responsible for the inversion or varus deformity of the foot.

Weakness in the shoulder girdle, which occurs 3 to 5 years later, precludes crutch usage to aid in ambulation. It also makes it difficult to lift the patient from under the arms. This tendency for the child to slip a truncal grasp has been termed "Meyerson sign." As the weakness in the upper extremities increases, the child becomes unable to move his or her arms. Although the hands retain strength longer than the arms, use of the hands is limited because of weakness of the arms.

Clinical diagnosis of Duchenne muscular dystrophy is established by physical examination, including gait and specific muscle weakness, and by the absence of sensory deficits. The upper extremity and knee deep-tendon reflexes are lost early in the disease, whereas the ankle reflexes remain positive until the terminal phase. A valuable clinical sign is the Gower sign. The patient is placed prone or in the sitting position on the floor and asked to rise. This is usually difficult, and the patient may require the use of a chair for assistance. The patient is then asked to use his or her hands to grasp the lower legs and force the knees into extension. The patient then walks his or her hands up their extremities to compensate for the quadriceps and gluteus maximum weakness. This sign may also be found in congenital myopathies and spinal muscular atrophy. Appreciation of the contracture of the iliotibial band can be measured by the Ober test. To perform this test, the child is placed on his or her side with both hips flexed. The superior leg is then abducted and extended and allowed to fall into adduction. The degree of abduction contracture can be measured by the number

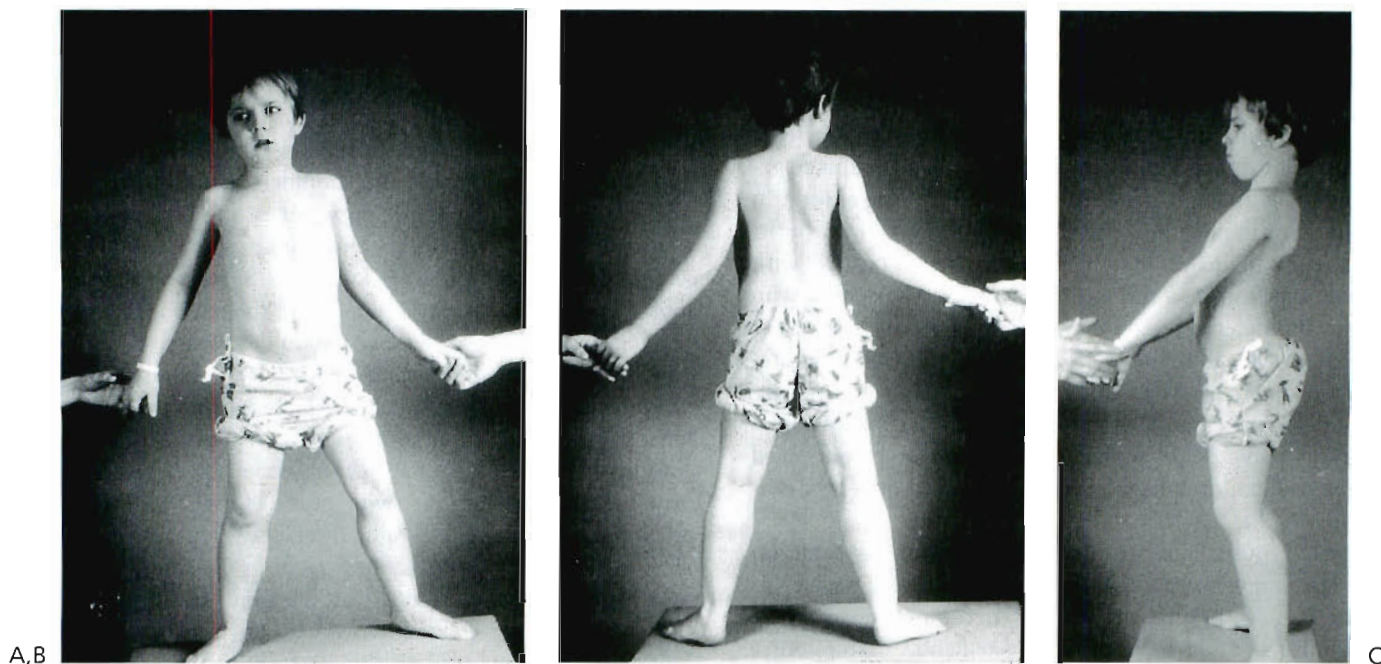


FIGURE 17-1. A: A 7-year-old boy with Duchenne muscular dystrophy demonstrates precarious stance due to mild hip abduction contractures. Observe the pseudohypertrophy of the calves. B: Posterior view demonstrates mild ankle equinus in addition to the calf pseudohypertrophy. C: Side view shows an anterior tilt to the pelvis and increased lumbar lordosis, and the head and the shoulders are aligned posterior to the pelvis. This characteristic posture maintains the weight line posterior to the pelvis and center of gravity, compensates for the muscle weakness, and helps maintain balance.

of degrees the leg lacks in coming to the neutral position. Tendo Achillis contractures also occur. Contracture of the tendo Achillis and the iliotibial band are the most consistent deformities noted during the physical examination. Macroglossia is also a common finding.

Duchenne muscular dystrophy progresses slowly but continuously. A rapid deterioration may be noted after immobilization in bed, even for short periods after respiratory infections or perhaps extremity fractures. Every effort should be made to maintain a daily ambulatory program. Children are usually unable to ambulate effectively by 10 years of age in the absence of treatment (3,26–28). With loss of standing ability, the child becomes wheelchair-dependent. This results in a loss of the accentuated lumbar lordosis, which protects the child from kyphoscoliosis (28). As a consequence most develop a progressive spinal deformity.

Myocardial deterioration is also a constant finding. ECG changes are present in more than 90% of children with Duchenne muscular dystrophy. The average intelligence quotient of these patients has been shown to be about 80 (22).

Hematologic Studies

The serum CPK is markedly elevated in the early stages of Duchenne muscular dystrophy. This may be 200 to 300

times normal, but decreases as the disease progresses and muscle mass is reduced. CPK levels are also elevated in female carriers, although not as high as in affected boys (two to three times that in normal women and girls). There is an 80% accuracy when the CPK level is repeated at three consecutive monthly intervals (30). Aldolase and SGOT levels also may be elevated, but the elevations are not unique to striated muscle disease.

Electromyography

EMG shows characteristic myopathic changes with reduced amplitude, short duration, and polyphasic motor action potentials (4).

Muscle Biopsy

The muscle biopsy specimen reveals degeneration with subsequent loss of fiber, variation in fiber size, proliferation of connective tissue, and subsequently, of adipose tissue (10,11). Increased cellularity with occasional internal migration of the sarcolemmal nuclei is present. Histochemical loss of clear-cut subdivisions to fiber types, especially with adenosine triphosphatase reaction and tendency toward type I fiber predominance, are also seen.

Genetic and Molecular Biology Studies

A single gene defect in the short arm of the X chromosome has been identified as being responsible for both Duchenne and Becker muscular dystrophies (31,32). The status of genetic and molecular biology in Duchenne muscular dystrophy has been summarized by Shapiro and Specht (4). The gene is located at the Xp21.2 region and spans 2 million base pairs (20,23). It includes 65 exons (i.e., coding regions) and encodes the 400-kd protein dystrophin (33,34). The large size of the gene correlates with the high rate of spontaneous mutation. Dystrophin is a component of cell membrane cytoskeleton and represents 0.01% of skeletal muscle protein. Its distribution within skeletal, smooth, and cardiac muscle and within the brain correlates well with the clinical features in Duchenne and Becker muscular dystrophies. A structural role for the dystrophin protein is suggested by studies demonstrating concentration of the protein in a lattice organization in the cytoplasmic membrane of skeletal muscle fibers (35,36). Demonstrable mutations, deletions, or duplications of dystrophin are found in 70 to 80% of involved males (33,34,37,38). The reading frame hypothesis defines which mutations correlate with the more severe Duchenne muscular dystrophy or with the less severe Becker muscular dystrophy. Mutations that disrupt the translational reading frame or the promoter (i.e., the specific DNA sequence that signals where RNA synthesis should begin) result in a presumably unstable protein, which correlates with Duchenne muscular dystrophy. In contrast, mutations that do not disrupt the translational reading frame or the promoter have a lower molecular weight and semifunctional dystrophin, which correlates with the less severe Becker muscular dystrophy (33,39).

Dystrophin testing (dystrophin immunoblotting), DNA mutation analysis (polymerase chain reaction or DNA [Southern] blot analysis), or both provide an aid to differentiate between Duchenne and Becker muscular dystrophies, and other initially similar disorders, such as dermatomyositis, limb-girdle muscular dystrophy, Emery-Dreifuss muscular dystrophy, and congenital muscular dystrophy (38,40,41). In the latter disorders the dystrophin is normal. In patients with Duchenne muscular dystrophy there is a complete absence of dystrophin, whereas in Becker muscular dystrophy, dystrophin is present but is altered in size, decreased in amount, or both. Nicholson et al. (42) reported a positive relation between the amount of dystrophin and the age at loss of independent ambulation in 30 patients with Duchenne muscular dystrophy and 6 patients with Becker muscular dystrophy. They found that even low concentrations of dystrophin in Duchenne muscular dystrophy may have functional significance and may explain the variability of age when ambulation ceases. The presence of partially functional dystrophin protein is sufficient for minimizing the phenotypic expression leading to the milder disorder of Becker muscular dystrophy (33,37,40). The

same tests can be used to improve detection of female carriers (38,41). Based on smaller-than-normal dystrophin protein, two atypical forms of Becker muscular dystrophy have been recognized. These include myalgia without weakness in male patients similar to metabolic myopathy, and cardiomyopathy in male patients with little or no weakness (43).

Research involves the possibility of dystrophin replacement in diseased muscles. This involves the implantation of myoblasts, or muscle precursor cells, into the muscles of patients with Duchenne muscular dystrophy (44). This has been successful in producing dystrophin in the murine mdx model of Duchenne muscular dystrophy (45). Unfortunately, the results in involved males has been disappointing (46–50).

Several forms of experimental treatment of Duchenne muscular dystrophy are being investigated. Prednisone has been demonstrated to have short-term benefits in slowing the progressive weakness for at least 3 years (51,52). However, the associated side effects of weight gain, osteoporosis and myopathy limit its usefulness (53–55). Azathioprine has also been evaluated in Duchenne muscular dystrophy, but has not shown beneficial effects (56).

Treatment

The orthopaedic problems in children with Duchenne muscular dystrophy include decreasing ambulatory ability, soft tissue contractures, and spinal deformity (2–4,57). The goals of treatment should be designed to improve or maintain the functional capacity of the involved child or adolescent.

The treatment modalities in Duchenne muscular dystrophy have been outlined by Drennan (58) and include physical therapy, functional testing, orthoses, fracture management, surgery, wheelchair, cardiopulmonary management, and genetic and psychologic counseling.

Physical Therapy. Physical therapy is directed toward prolongation of functional muscle strength, prevention or correction of contractures by passive stretching, gait training with orthoses and transfer techniques, ongoing assessment of muscle strength and functional capacity, and wheelchair and equipment measurements.

After the diagnosis of Duchenne muscular dystrophy has been established and before muscle strength has deteriorated, a program of maximum-resistance exercises performed several times daily, should be instituted (5,59). This may help prolong strength and delay the onset of soft tissue contractures. Contractures are more effectively delayed or prevented than corrected by physical therapy. Contractures develop in the ambulatory patient because muscle weakness progression results in development of adaptive posturing to maintain lower extremity joint stability. A home exercise program can be effective in minimizing hip and ankle soft tissue contractures. Drennan recommended that exercises

be performed twice daily on a firm surface and should include stretching of the tensor fascia lata, hamstrings, knee flexors, and ankle plantar flexors (58). Occasionally serial casting may be useful to correct existing deformities before physical therapy. Knee flexion contractures of less than 30 degrees may benefit by serial or wedge casting. This enhances the use of knee-ankle-foot orthoses (KAFOs). Unless orthoses are used after casting and in conjunction with physical therapy, these contractures rapidly recur.

Functional Testing. Functional testing predominantly involves periodic muscle testing. Muscle strength is tested by measurement of the active range of motion of a joint against gravity. This type of testing allows assessment of the rate of deterioration as well as the functional capacity of the individual.

Orthoses. Lightweight molded plastic ankle-foot orthoses (AFOs) or KAFOs are used in independently ambulatory patients when gait becomes precarious, when early soft tissue contractures of the knees and ankle are developing, and after surgical correction of these deformities (60–63). KAFOs usually are supplemented with a walker because of the excessive weight and the fear of falling. Important prescription components include partial ischial weightbearing support, posterior thigh cuff, and a spring-loaded, drop-lock knee joint with an ankle joint set at a right angle. Ambulation may be extended for up to 3 years by the combined use of surgery and orthoses. The maintenance of a straight lower extremity also enables the nonwalking patient to stand with support and thereby assist in transfers.

Spinal orthoses are usually of no value in progressive spinal deformities, but wheelchair-bound patients, especially those with severe cardiopulmonary compromise and severe scoliosis, may benefit from the use of a custom wheelchair, a thoracic suspension orthosis, or custom thoracic-lumbar spinal orthosis (TLSO) (52). A mobile arm support orthosis attached to the wheelchair may benefit the patient in performing personal hygiene tasks and self-feeding activities (64,65).

Fracture Management. Fractures of the lower extremities occur frequently in children with Duchenne muscular dystrophy. This occurs predominantly after ambulation has ceased and the child is wheelchair-bound. These fractures are best treated by closed reduction and cast immobilization. Occasionally open reduction and internal fixation may be needed. In children who are still ambulatory, it is important that they be placed on a program of early mobilization to allow weightbearing. This may require the use of an electrically powered circle bed. Once early healing is present, the child can be returned to the KAFO to decrease weight and enhance mobility.

Surgery. Contractures of the lower extremities and progressive weakness impair ambulation. Surgery is indicated

when independent ambulation becomes precarious and when contractures are painful or interfere with essential daily activities. The major contractures amenable to surgical intervention include equinus and equinovarus contractures of the ankle and foot, knee flexion contractures, and hip flexion and abduction contractures. In thin individuals, these contractures may be released by percutaneous techniques (57,66,67). Orthotic measurements for ambulatory patients should be obtained before surgery. This allows them to be applied shortly after surgery to assist in rapid restoration of ambulation. Correction of contractures and the use of orthoses can prolong effective ambulation by 1 to 3 years (3,25,60–63,67–74). Hsu and Furumasu (25) reported a mean prolongation of walking of 3.3 years in 24 patients with Duchenne muscular dystrophy, ranging in age from 8 to 12 years at the time of surgery. It is usually not possible to restore functional ambulation once the patient has been unable to walk for more than 3 to 6 months (60,68,70). Each patient must be individually assessed to determine the functional needs and the best procedures. Common contraindications for correction of lower extremity contractures include obesity, rapidly progressive muscle weakness, or poor motivation in those who prefer to use a wheelchair rather than attempt ambulation (4).

Foot and Ankle. Equinus contractures occur first, then equinovarus contractures. This is due to a combination of tendo Achillis contracture and muscle imbalance induced by the stronger tibialis posterior muscle. This latter muscle retains good function despite the progression of muscle weakness in other areas. These equinovarus deformities can be managed by a combination of tendo Achillis lengthening (percutaneous open tenotomy [57,60,62,63,69,71] [↗7.17], with or without resection [70]; Vulpius [3,75]; or open Z-lengthening [68,74] [↗7.16]) and tibialis posterior lengthening, tenotomy, or transfer through the interosseous membrane to the dorsum of the foot [↗7.19] (3,5,28,57,61–63,68–71,76–78). Tibialis posterior transfer prevents recurrence of equinovarus deformities and maintains active dorsiflexion of the foot. Some authors, however, have questioned the necessity of a transfer because it is a more extensive procedure and they prefer tenotomy, recession, or lengthening (5,57,61,69). Postoperative gait analysis has shown that the transferred tibialis posterior muscle is electrically silent (79). Greene (76) has reported that tibialis posterior myotendinous junction recession in 6 patients (12 feet) had an increased recurrence rate when compared with transfer in 9 patients (18 feet), which made the former a less desirable procedure. Percutaneous tendo Achillis lengthening under local anesthesia has been reserved for nonambulatory patients who have a typically equinus deformity and cannot wear shoes. The nonambulatory patient with a moderately severe equinovarus deformity may require open tenotomies of the tendo Achillis, the tibialis posterior, and long toe flexors. Severe

equinovarus contractures have been managed effectively by talectomy.

Knee. Knee flexion contractures coexist with hip flexion contractures and develop rapidly when the patient is wheelchair-bound. These contractures limit proper positioning in bed and may lead to the development of hamstring spasm, causing considerable discomfort when the patient attempts to transfer. A Yount procedure (80), (release of the distal aspect of the tensor fascia lata and iliotibial band) is the most common procedure used in correcting knee flexion contractures (57,61–63). Hamstring tenotomies (68), recession or Vulpius-type lengthening (75), and formal Z-lengthening may also be necessary [➔4.23]. These procedures enhance quadriceps power and function as well as relieve symptoms. Postoperatively KAFOs are necessary to prevent recurrence.

Hip. Hip flexion and abduction contractures increase lumbar lordosis and interfere with the ability to stand and to lay comfortably supine. Patients with hip flexion contractures may complain of low back pain. Correction of flexion contractures involves release of the tight anterior muscles, including the sartorius, rectus femoris, and tensor fascia femoris (4,57). Abduction contractures are improved by release of the tensor fasciae lata proximally with use of the Ober procedure (81), modified Soutter release (82), the Yount procedure distally (80), or by complete resection of the entire iliotibial band (28,72).

Upper Extremity. Upper extremity contractures are common in adolescents with Duchenne muscular dystrophy but usually do not require treatment. These contractures include shoulder adduction, elbow flexion, forearm pronation, wrist flexion, metacarpophalangeal and proximal interphalangeal joint flexion, and others. These usually do not preclude the use of wheelchairs. Muscle weakness is the most devastating aspect of upper extremity involvement. Wagner et al. (83) demonstrated wrist ulnar deviation and flexion contractures in addition to contractures of the extrinsic and intrinsic muscles of the fingers, producing boutonniere and swan-neck deformities and hyperextension of the distal interphalangeal joints in adolescents with Duchenne muscular dystrophy. The treatment of upper extremity contractures involves physical therapy with daily passive range of motion exercises. When passive wrist dorsiflexion is limited to neutral, a nighttime extension orthosis may be beneficial. Surgery for these contractures is rarely indicated.

Spinal Deformity. Approximately 95% of patients with Duchenne muscular dystrophy develop progressive scoliosis (29,72,84–91). This typically begins to occur when ambulation ceases, and it is rapidly progressive. About 25% of older ambulating patients, however, have mild scoliosis (26,92). Prolongation of ambulation by appropriate soft tissue releases of the lower extremity contractures, which maintains accentuated lumbar lordosis, can delay the onset of scoliosis (73). The curves are usually thoracolumbar, associated with kyphosis, and lead to pelvic obliquity. Scoliosis cannot be controlled by orthoses or wheelchair seating sys-

tems (72,84,93–97). Orthotic management, although it may slow curve progression, does not slow the systemic manifestations of Duchenne muscular dystrophy (e.g., decreasing pulmonary function and cardiomyopathy). These may complicate spinal surgery at a later time. As the scoliosis progresses, it can result in a loss of sitting balance, produce abnormal pressure, and occasionally cause the patient to become bedridden (98). Heller et al. (99) reported improved sitting support with an orthosis in 28 patients who either refused surgery or who were felt to be inoperable.

Surgical correction of scoliosis both improves sitting balance and minimizes pelvic obliquity (84,85,96–98,100,101). It is usually recommended that a posterior spinal fusion be performed once the curve is greater than 20 degrees (84,85,95–98,101–104). Fusion extends from the upper thoracic spine (T2 or T4) to L5 or the pelvis. It is important to center the patient's head over the pelvis in both the coronal and sagittal planes. This usually allows complete or almost complete correction of the deformity. This maintains sitting balance, improves head control, and allows more independent hand function. Although autogenous bone grafting is used in most patients, there appears to be no difference in fusion rates when allograft bone is used (105–108). Segmental spinal instrumentation techniques using Luque rod instrumentation are most commonly used [➔2.5,2.6] (57,84,85,88,95,100,101,105,106,109–112). Other segmental instrumentation systems, such as Cotrel-Dubousset, TSRH, Isola, and others, can also be used (105,106,110,113). These allow sufficient fixation, so that postoperative immobilization is not necessary (Fig. 17-2). Fixation to the pelvis is achieved using the Galveston or other techniques (102,105,109,110,112,113,115). The latter is felt to maintain better correction of pelvic obliquity. Some authors believe that fusion to L5 is sufficient and that there will be no spinopelvic deformity throughout the remainder of the patient's life (55,107,116,117). However, a postoperative spinopelvic deformity can occur and progress and most authors recommend fusion to the pelvis. Mubarak et al. (88,116) recommend fusion to L5 if the curve is greater than 20 degrees, the FVC is greater than 40%, and the patient is using a wheelchair full time, except for occasional standing. If the patient's curve is greater than 40 degrees or if there is pelvic obliquity greater than 10 degrees, then fusion to the sacropelvis is recommended.

Careful preoperative evaluation, including pulmonary function studies and cardiology consultation, is mandatory because of the associated pulmonary and cardiac abnormalities and the risk for malignant hyperthermia (98,118–121). Children with Duchenne muscular dystrophy have a decreased FVC beginning when they are about 10 years of age due to weakness of the intercostal muscles and associated contractures. There is a linear decrease over time (18,85,91,98,101,104,118). Kurz et al. (18) observed a 4% decrease in percentage of FVC for each year of age or each 10 degrees of scoliosis. It stabilizes at about 25% of normal

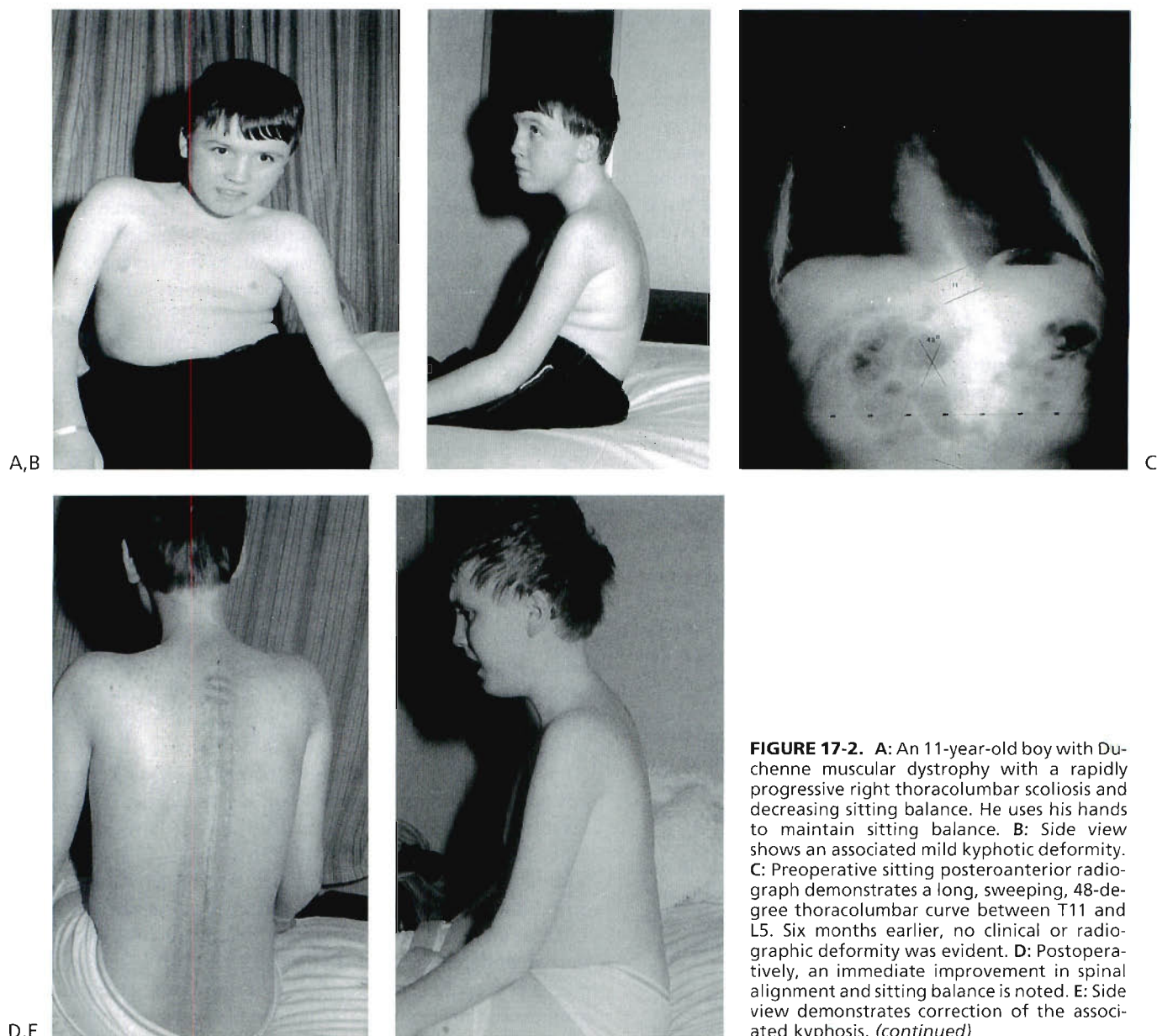


FIGURE 17-2. A: An 11-year-old boy with Duchenne muscular dystrophy with a rapidly progressive right thoracolumbar scoliosis and decreasing sitting balance. He uses his hands to maintain sitting balance. B: Side view shows an associated mild kyphotic deformity. C: Preoperative sitting posteroanterior radiograph demonstrates a long, sweeping, 48-degree thoracolumbar curve between T11 and L5. Six months earlier, no clinical or radiographic deformity was evident. D: Postoperatively, an immediate improvement in spinal alignment and sitting balance is noted. E: Side view demonstrates correction of the associated kyphosis. (*continued*)

until death. The presence of severe scoliosis may increase the rate of decline in the FVC. Jenkins et al. reported that when the FVC is 30% or less there is an increasing risk for postoperative complication, such as pneumonia and respiratory failure (118). Other authors have made similar observations (18,98,101). Smith et al. (91) found that most patients with curves of more than 35 degrees had FVC less than 40% of predicted normal values, and therefore recommended that spinal arthrodesis be considered for all patients with Duchenne muscular dystrophy when they can no longer walk. Nevertheless, successful surgery can be performed in many patients with FVC as low as 20% of predicted normal values (106).

It is debated whether spinal stabilization increases the quantity of life, although it definitely increases the quality of the remaining life (85,106,109). In a study of 55 patients with Duchenne muscular dystrophy, of which 32 underwent spinal fusion and 23 did not, Galasko et al. (85) found that FVC remained stable in the operated group for 36 months postoperatively and then fell slightly. In the nonoperated group it progressively declined. The survival data showed that a significantly higher mortality rate was seen in the nonoperated group. This study indicated that spinal stabilization can increase survival for several years if it is done early before significant progression has occurred. Other studies, however, have shown that posterior spinal

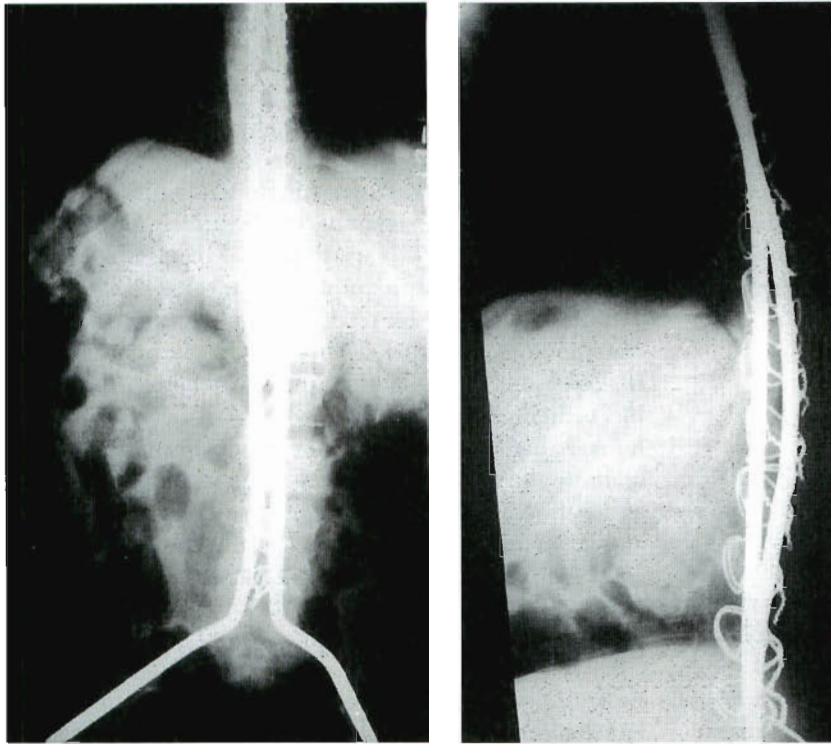


FIGURE 17-2. (continued) F: Postoperative sitting radiograph after posterior spinal fusion and Luque rod instrumentation from T4 to the sacrum. The Galveston technique, with insertion of the Luque rod into the wing of the ilium, was used for pelvic fixation. Almost complete correction of his spinal deformity was achieved. G: Postoperative lateral radiograph shows improved sagittal alignment.

fusion has no effect on the steady decline in pulmonary function when compared with unoperated patients (103,106,122–124). In addition to correction and stabilization of the spine, patients experience improved quality of life measures, such as function, self image, and cosmesis (103,109,110,125). Parents also reported improved ability to provide care to their child.

Complications are common during and following surgery (85,95–97,103,110,116). These include excessive intraoperative blood loss, neurologic injury, cardiopulmonary compromise, postoperative infection, wound healing, curve progression, hardware problems, and late pseudarthrosis. With respect to intraoperative blood loss, this can be minimized by early surgery and the use of hypotensive anesthesia (107). The increased intraoperative blood loss in patients with Duchenne muscular dystrophy appears to be due to the lack of dystrophin in the smooth muscle, which inhibits normal vasocontraction (126).

The role of intraoperative spinal cord monitoring in children with Duchenne muscular dystrophy is controversial. Noordeen et al. reported that a 50% decrease in amplitude was suggestive of neurologic impairment (127).

Wheelchair. A wheelchair is necessary for patients who are no longer capable of independent ambulation. This is typically a motorized wheelchair to allow the patient to be independent of parents or aides, especially while attending

school. The wheelchair may be fitted with a balanced mobile arm orthosis for the purpose of facilitating personal hygiene and feeding (64,65).

Cardiopulmonary Management. Respiratory failure in Duchenne muscular dystrophy is a constant threat and is the most common cause of death early in the third decade of life. Kurz et al. (18) found the vital capacity peaks at the age when standing ceases, then declines rapidly thereafter. The development of scoliosis compounds the problems and leads to further diminution of the vital capacity (123). The complication rate in spinal surgery increases when the FVC is less than 30% of expected. Programs of vigorous respiratory therapy and the use of home negative-pressure and positive-pressure ventilators may allow patients with Duchenne muscular dystrophy to survive into the third and fourth decades of life (128–131).

Cardiac failure may also occur in the second decade of life. After initially responding to digitalis and diuretics, the involved cardiac muscle becomes flabby and the patient goes into congestive heart failure. Myocardial infarction has been reported in boys as young as 10 years of age. There is no correlation between the severity of pulmonary dysfunction and cardiac function or between age and cardiac function (132). The cardiomyopathy of Duchenne muscular dystrophy exists clinically as a separate entity.

Genetic and Psychologic Counseling

Proper diagnosis and early genetic counseling may help prevent birth of additional male infants with Duchenne muscular dystrophy. It must be remembered that approximately 20% of families have already conceived and delivered a second involved male infant before the diagnosis is made in the first (63,133). Genetic counseling with parents and family groups is important in the management of psychological problems arising when the genetic nature of the diagnosis becomes known.

Becker Muscular Dystrophy

Becker muscular dystrophy is similar to Duchenne muscular dystrophy in clinical appearance and distribution of weakness, but it is less severe (134,135). Onset is generally after the age of 7 years and the rate of progression is slower. The patients usually remain ambulatory until adolescence or early adult years. The Gower maneuver may occur as the weakness progresses (Fig. 17-3). Pseudohypertrophy of the calf is common, and eventually equinus and cavus foot deformities develop (Fig. 17-4). Cardiac involvement is frequent. There may be a family history of atypical muscular dystrophy. Pulmonary problems are less severe and the patient's life expectancy is longer.

Treatment

The treatment of the musculoskeletal deformities associated with Becker muscular dystrophy is essentially the same as with Duchenne muscular dystrophy. Ankle and forefoot equinus occur commonly. Shapiro and Specht (4) have reported good success with the Vulpius tendo Achillis lengthening in patients with equinus contractures. A tibialis posterior tendon transfer is performed if necessary [7.19]. Forefoot equinus may require a plantar release and possibly a midfoot dorsal-wedge osteotomy for correction. The use of orthotics is also beneficial because the rate of progression is slower and the remaining muscle strength greater than in Duchenne muscular dystrophy. The incidence of scoliosis is high, especially in those adolescents who have ceased walking. These patients require careful evaluation and periodic spinal radiographs. Posterior spinal fusion and segmental instrumentation, usually Luque, are beneficial when progression occurs [2.5,2.6] (134).

Emery-Dreifuss Muscular Dystrophy

Emery-Dreifuss muscular dystrophy is an uncommon sex-linked recessive disorder characterized by early contractures and cardiomyopathy (16). The typical phenotype is seen only in males, although milder or partial phenotypes have been reported in female carriers (137–140). Involved males

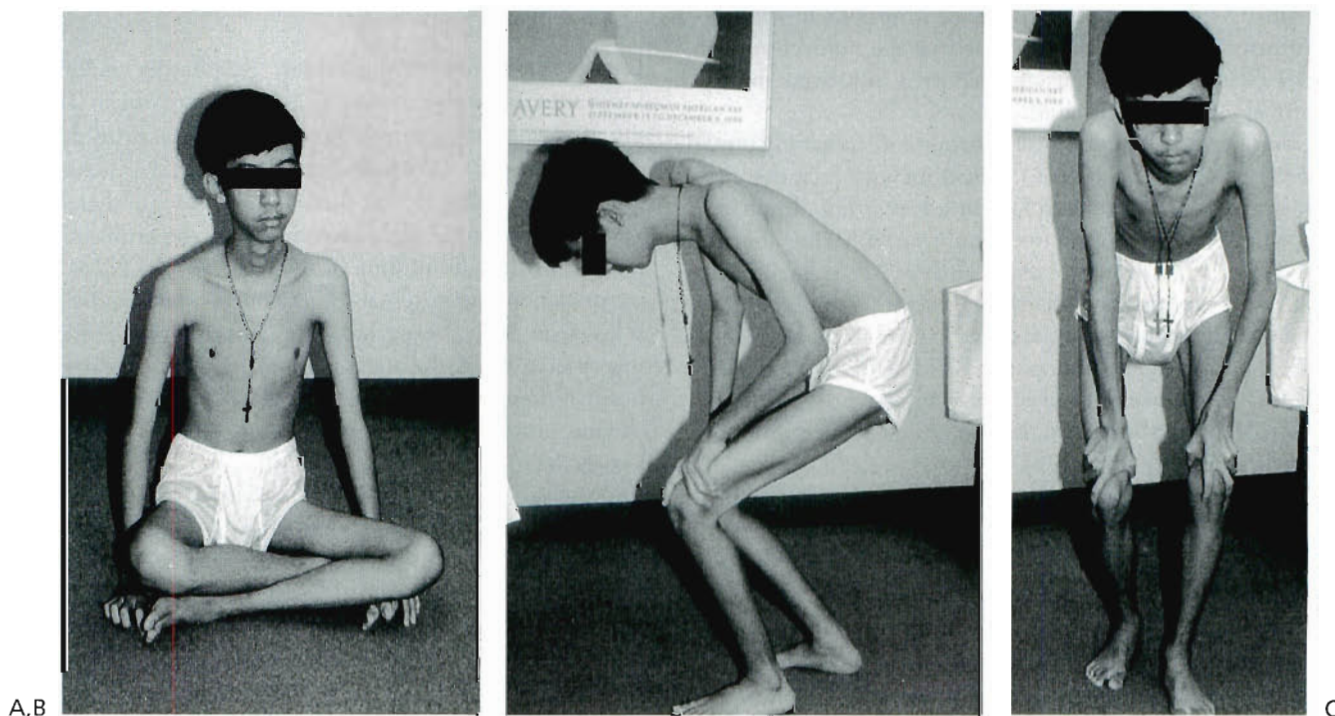


FIGURE 17-3. A: A 13-year-old boy with suspected Becker muscular dystrophy uses the Gower maneuver to stand from a sitting position. B: Manually assisted knee extension is necessary to achieve upright stance. C: Front view.

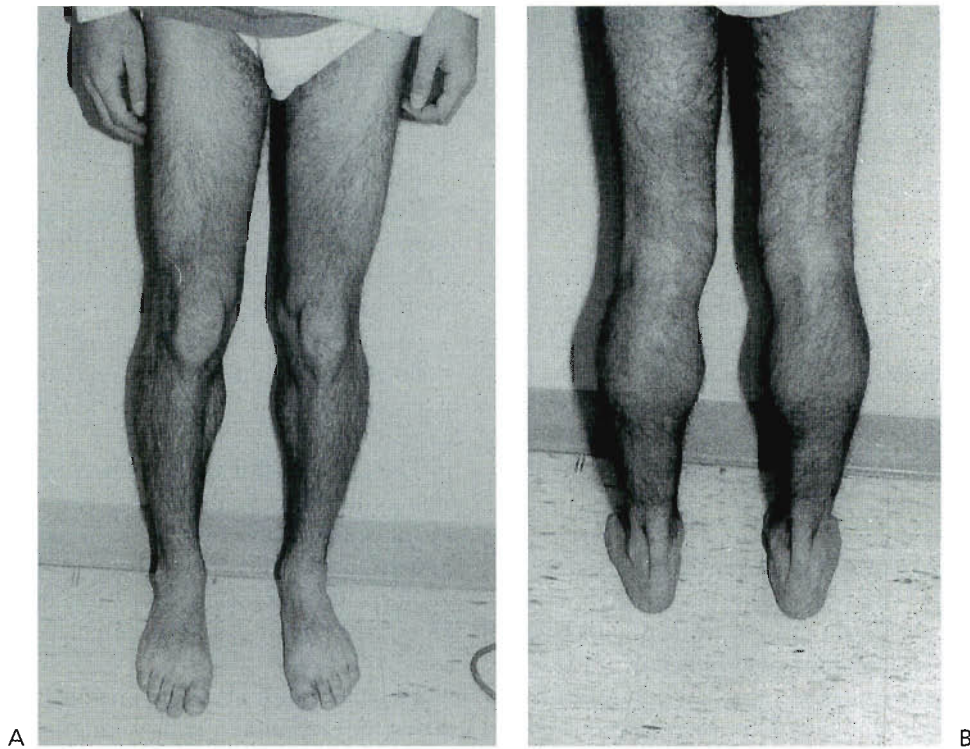

FIGURE 17-4. A: Pseudohypertrophy of the calves in an 18-year-old man with Becker muscular dystrophy. He is a brace-free ambulator. B: Posterior view.

show mild muscle weakness in the first 10 years of life and a tendency for toe walking. The Gower maneuver may be present in young children. The distinctive clinical criteria occur in late childhood or early adolescence. These include tendo Achillis contractures, elbow flexion contractures, neck extension contracture, tightness of the lumbar paravertebral muscles, and cardiac abnormalities involving bradycardia and first-degree, and eventually complete, heart block (139–141). The muscle weakness is slowly progressive but there may be some stabilization in adulthood. Most patients are able to ambulate into the fifth and sixth decades of life. Obesity and untreated equinus contractures can lead to the loss of ambulatory ability at an earlier age (4).

The CPK level in patients with Emery-Dreifuss muscular dystrophy is only mildly or moderately elevated. EMG and muscle biopsy are myopathic. The diagnosis of this form of muscular dystrophy should be considered in patients with a myopathic phenotype after Duchenne and Becker muscular dystrophies have been ruled out, usually by dystrophin testing (4). The condition must also be distinguished from scapuloperoneal muscular dystrophy and the rigid spine syndrome (142).

Genetic and Molecular Biology Studies

The gene locus for Emery-Dreifuss muscular dystrophy has been localized to the long arm of the X chromosome at Xq28 in linkage studies (143,144).

Treatment

The treatment of Emery-Dreifuss muscular dystrophy is similar to that used for other forms of muscular dystrophy. The goals are to prevent or correct deformities and maximize function. Treatment modalities include physical therapy, correction of soft tissue contractures, spinal stabilization, and cardiologic intervention.

Physical Therapy. This can be useful in the management of neck extension contractures, elbow flexion contractures, and the tightness of the lumbar paravertebral muscles. Decreased neck flexion, which is characteristic of this disorder, can begin as early as the first decade, but usually is not present until the second decade. This is due to contracture of the extensor muscles and the ligamentum nuchae. According to Shapiro and Specht (4), this does not progress past neutral. Lateral bending and rotation of the neck also become limited as the extensor contractures progress. Physical therapy can be beneficial in maintaining limited flexion of the neck.

Soft Tissue Contractures. Tendo Achillis lengthening and posterior ankle capsulotomy combined with anterior transfer of the tibialis posterior tendon can be beneficial in providing long-term stabilization of the foot and ankle [7.1,7.16,7.19] (4,139). Elbow flexion contractures usu-

ally do not require treatment. These contractures can be as severe as 90 degrees, although most do not exceed 35 degrees (4,98). Full flexion from this position and normal forearm pronation and supination are preserved. Physical therapy may be beneficial to slow the progress of the elbow flexion contractures. Surgery has not been shown to be beneficial.

Spinal Stabilization. Scoliosis is common in this form of muscular dystrophy, but it has a lower incidence of progression. This has been attributed to contractures at the lumbar and ultimately the thoracic paravertebral muscles, which seem to prevent progression (4,139). Those patients with scoliosis need to be followed closely, but most do not require treatment. Curves that progress beyond 40 degrees may require surgical stabilization.

Cardiologic Intervention. Sudden death due to severe bradycardia caused by complete heart block has been a major cause of death in these patients. Most do not have cardiac symptoms preceding death. Merlini et al. (141) reported that 30 of 73 patients with Emery-Dreifuss muscular dystrophy died suddenly, and only four were symptomatic. It is recommended that a cardiac pacemaker be inserted shortly after confirmation of the diagnosis (141,145).

AUTOSOMAL RECESSIVE MUSCULAR DYSTROPHIES

Limb-girdle Muscular Dystrophy

Limb-girdle muscular dystrophy is common and may be more benign than the other forms of muscular dystrophy. It is a rather heterogeneous group of disorders with various classifications proposed for it over the years. The age of onset and rate of progression of muscle weakness are variable. It usually begins in the second or third decade of life. It is transmitted as an autosomal recessive trait, but an autosomal dominant pattern of inheritance has been reported in some families (146,147).

The symptoms of limb-girdle muscular dystrophy are similar to fascioscapulohumeral muscular dystrophy, except that the facial muscles are not involved. The initial muscle weakness involves either the pelvic or shoulder girdle. The rate of progression is usually slow, with soft tissue contractures and disability developing 20 years or more after the onset. The patients remain ambulatory for many years.

The distribution of weakness is similar to that seen in Duchenne and Becker muscular dystrophies. The iliopsoas, gluteus maximus, and quadriceps muscles are involved early in the disease process. Usually, shoulder girdle involvement occurs at about the same time. The serratus anterior, trapezius, rhomboid, latissimus dorsi, and sternal portions of pectoralis major muscles are affected most often. The disease

later spreads to involve other muscles, such as the biceps brachia and the clavicular portion of the pectoralis major. Deltoid involvement may occur but is usually late. Weakness may involve the distal muscles of the limbs, such as the wrist and finger flexors and extensors, in the more severely involved individuals.

Two forms of limb-girdle muscular dystrophy include a more common pelvic-girdle type and a scapulohumeral form. The latter is rare, with symptoms involving primarily the shoulder girdle. Involvement of the pelvic girdle may not occur for many years. In the pelvic-girdle type, there is weakness of the hip extensors and abductors, resulting in accentuated lumbar lordosis, gait abnormalities, and hip instability.

The CPK level is moderately elevated in patients with limb girdle muscular dystrophy. The clinical characteristics are indistinguishable from those of sporadic Becker muscular dystrophy, carriers of Duchenne or Becker muscular dystrophies, and those of childhood acid-maltase deficiency (4). Thus, a dystrophin assay is essential in establishing the diagnosis.

Treatment of limb-girdle muscular dystrophy is similar to that for Duchenne and Becker muscular dystrophies. Significant scoliosis rarely occurs because of the late onset of the disease process. When present, it usually is mild and does not require treatment (136). Involved individuals usually succumb to their disease process before 40 years of age.

Genetic and Molecular Biology Studies

The autosomal recessive form has been linked to chromosome 15q and the autosomal dominant form to 5q (148,149).

Infantile Fascioscapulohumeral Muscular Dystrophy

Infantile fascioscapulohumeral muscular dystrophy (IFSH MD) has been recognized with increasing frequency. It is a more severe variant of the more common later-onset fascioscapulohumeral muscular dystrophy (150–153). It appears to be autosomal recessive, but the affected gene has not been identified. Facial diplegia is noted in infancy, followed by sensorineural hearing loss in childhood (mean age, 5 years). A Möbius type of facial weakness may also be present and progress asymptotically at a relatively slow pace (154). Ambulation begins at a normal age, but because of progressive muscle weakness, most patients become wheelchair-bound during the second decade of life. Weakness causes the child to walk with the hands and forearms folded across the upper buttocks to provide support for the weak gluteus maximus muscles (4,150,153). This marked lumbar lordosis is progressive and is almost pathognomonic for IFSH



FIGURE 17-5. Marked lumbar lordosis in a 15-year-old girl with infantile fascioscapulohumeral muscular dystrophy. She is still ambulatory but having increasing back pain.

MD (Fig. 17-5). The lordosis leads to fixed hip flexion contractures after the patient is wheelchair-dependent. Equinus or equinovarus deformities and scoliosis occur less frequently.

Treatment

The treatment of patients with IFSH MD is individualized because most patients do not have significant orthopaedic deformities. These patients usually have severely compromised pulmonary functions and succumb in early adolescence. Shapiro et al. outlined the possible treatment modalities for children with IFSH MD. Flexible equinus and equinovarus deformities respond well to AFOs (153). Occasionally, a Vulpius-type tendo Achillis lengthening may be necessary (75). Hip flexion contractures usually do not require treatment in ambulatory patients and it may decrease function. Spinal orthoses control the lordosis but do not provide correction because the spine remains flexible early in the course of the disorder. Because an orthosis interferes with ambulation it is usually not employed. When wheelchair use is full-time, a modified wheelchair with an orthosis may be beneficial, or perhaps a posterior spinal fusion and segmental instrumentation, depending on the severity of the deformity (88). Scapulothoracic stabilization is not necessary because the severity of dysfunction is so severe that

minimal or no improvement in shoulder function can be achieved.

AUTOSOMAL DOMINANT MUSCULAR DYSTROPHIES

Fascioscapulohumeral Muscular Dystrophy

Fascioscapulohumeral muscular dystrophy is an autosomal dominant disorder having variable expression (155). The disease is manifest by muscular weakness of the face, shoulder girdle, and upper arm. It is caused by a gene defect, *FRG1*, on chromosome 4q35 (156,157). There is selective sparing of the deltoid, the distal part of the pectoralis major muscle, and the erector spinae muscles. This results in decreased scapulothoracic motion, with scapular winging and a marked decrease in shoulder flexion and abduction. Glenohumeral motion is usually preserved. The onset may occur at any age but is most common in late childhood or early adulthood. It occurs in both genders but is more common in females. Abortive or mild cases are common. Progression is insidious and periods of apparent arrest may occur. Cardiac involvement and central nervous system involvement are absent. Life expectancy is relatively good.

Initially, the face and shoulder girdle muscles are involved but they may be affected only mildly for many years. Facial signs, which may be present at infancy, include lack of mobility, incomplete eye closure, pouting lips with a transverse smile, and absence of eye and forehead wrinkles. It tends to produce a “popeye” appearance. The shoulder girdle weakness leads to scapular winging. The weight of the upper extremities, together with the weakness of the trapezius, permits the clavicles to assume a more horizontal position. It also leads to a forward-sloping appearance of the shoulders. As the disease progresses, pelvic girdle and tibialis anterior muscle involvement may also occur (150). Scoliosis is rare because of the late onset of the disease process (5).

The CPK levels in patients with fascioscapulohumeral muscular dystrophy are usually normal. The diagnosis is made by physical examination and muscle biopsy (158).

Treatment

The winging of the scapula, with weakness of shoulder flexion and abduction, is the major orthopaedic problem in fascioscapulohumeral muscular dystrophy. The deltoid, supraspinatus, and infraspinatus muscles are usually normal, however, or minimally involved. Posterior scapulothoracic fusion or stabilization (scapuloplexy) by a variety of techniques can be beneficial in restoring mechanical advantage of the deltoid and rotator cuff muscles (159–165). This can result in increased active abduction and forward flexion of the

shoulder and improved function, as well as cosmesis. Jakab and Gledhill (162) reported the results of a simplified technique for scapulocostal fusion. The technique involves wiring of the medial border of the scapula to ribs three through seven. Internal fixation is achieved with 16-gauge wire. The wires ensure firm fixation and eliminate the need for postoperative immobilization and subsequent rehabilitation. The child uses a sling for 3 to 4 days postoperatively, then begins a physical therapy program. They found that shoulder flexion increased 28 degrees (range, 20–40 degrees) and abduction 27 degrees (range, 20–35 degrees) at a mean follow-up of 2.9 years. This allowed all patients to raise their arms and hands above their heads, conferring a greater mechanical advantage. The beneficial effects do not seem to deteriorate with time (159–161,165).

Distal Muscular Dystrophy

This is a rare form of muscular dystrophy. It is also known as Gower muscular dystrophy. It typically begins after 45 years of age. It is transmitted as an autosomal dominant trait. The initial involvement is in the intrinsic muscles of the hand. The disease process spreads proximally. In the lower extremities the calves and tibialis anterior are first involved. The absence of sensory, especially vibratory, abnormalities differentiates this from Charcot-Marie-Tooth disease.

Ocular Muscular Dystrophy

Ocular muscular dystrophy, also known as “progressive external ophthalmoplegia,” is another rare form of muscular dystrophy. It typically begins in the adolescent years. The extraocular muscles are affected, resulting in diplopia and ptosis. This is followed by limitation of ocular movement (166). The upper facial muscles are often affected. The disease is slowly progressive and may involve the proximal upper extremities. The pelvis can be involved late in the disease process. Most patients with this disorder have an identifiable mitochondrial myopathy (167).

Oculopharyngeal Muscular Dystrophy

This form of muscular dystrophy begins in the third decade of life and is particularly common in French Canadians (168,169). Pharyngeal muscle involvement results in dysarthria and dysphasia, which leads to repetitive regurgitation and weight loss. This condition necessitates cricopharyngeal myotomy, which does not alter pharyngeal function (170,171). Ptosis develops in middle life. This disorder is inherited in an autosomal dominant pattern with complete penetrance (168).

MYOTONIA

Myotonia is a group of disorders characterized by the inability of skeletal muscle to relax after a strong contraction from either voluntary movement or mechanical stimulation. This is best demonstrated by a slow relaxation of a clenched fist. The most common myotonias include myotonic dystrophy, congenital myotonic dystrophy, and myotonia congenita. These are all rare disorders that are transmitted by autosomal dominant inheritance (4,20).

Myotonic Dystrophy

Myotonic dystrophy is a systemic disorder characterized by myotonia, progressive muscle weakness, gonadal atrophy, cataracts, frontal baldness, heart disease, and dementia (172). The genetic defect is located on chromosome 19q (19,173). The distal musculature is affected first and the myotonia begins to disappear as muscle weakness progresses. Onset is usually in late adolescence or early adulthood. In women the diagnosis is frequently made only after they have given birth to a child who is more severely involved. The disease spreads slowly proximally and involves the quadriceps, hamstrings, and eventually the hip extensors. The lower extremities are more involved than the upper extremities. The most common presenting symptoms are weakness of the hands and difficulty in walking. Patients may be unable to relax the fingers after shaking hands and may need to palmar flex the hand to open the fingers. Muscles of the face, mandible, eyes, neck, and distal limbs may also be affected. The levels of serum enzymes are normal. Muscle biopsies show type I atrophy of the muscle fibers and the presence of some internal nuclei (11). These are nonspecific findings. The “dive-bomber” pattern on EMG is diagnostic (4).

Examination reveals an expressionless face, ptosis, and a fish mouth that is difficult to close. There is marked wasting of the temporal, masseter, and sternocleidomastoid muscles. Deep tendon reflexes are diminished or lost. Slit lamp examination of the eyes reveals that most patients have lenticular opacities, cataracts, and retinopathy. Cardiac involvement is also common and includes mitral valve prolapse and arrhythmias (174). Organic brain deterioration may also occur. Frontal baldness in men and glaucoma in both genders occurs in midadult life. The course of the disease is one of steady deterioration. Most patients lose the ability to ambulate within 15 to 20 years of onset of symptoms (174). There are no characteristic orthopaedic deformities, although a slight tendency toward increased hindfoot varus has been observed (4). Life span is shortened, and death is usually caused by pneumonia or cardiac failure.

Treatment of myotonic dystrophy is primarily orthotic because the onset is usually after skeletal maturity. An AFO may be beneficial in patients with a drop foot due to weakness of the tibialis anterior and peroneal muscles.

Congenital Myotonic Dystrophy

This is a relatively common muscle disorder of variable expression that occurs most frequently with a mother who has either a forme fruste or mild clinical involvement (175–178). Although it has autosomal dominant transmission, it is predominantly transmitted maternally (177). This is an exception in autosomal dominant disorders and indicates additional maternal factors. Approximately 40% of patients have severe involvement or die in infancy, whereas 60% will be affected later (179). The child may have an expressionless, long, narrow face; hypotonia; delayed developmental milestones; facial diplegia; difficulty feeding due to pharyngolaryngeal palsy; respiratory failure; and mild mental retardation (180). Swallowing improves with growth but the hypotonia persists. Examination shows diffuse weakness and absent deep tendon reflexes. It can appear to be similar to spinal muscular atrophy. Ambulation is usually delayed. If the mother is the carrier, there may be other organic disorders later in life (180). Cataracts usually occur after 14 years of age.

The defective gene has been localized to chromosome 19, and a test for prenatal diagnosis is available (181). There appears to be an expansion of a highly repeated sequence of three nucleotides: cytosine, thymine, and guanine. The trinucleotide repeat is at the 3' end of a protein kinase gene on chromosome 19, which lengthens as it passed from one generation to another. The length of the sequence correlates with the severity of the disorder.

Orthopaedic problems in congenital myotonia dystrophy include congenital hip dislocation and talipes equinovarus (i.e., clubfeet). There is a tendency to develop soft tissue contractures of other major joints of the lower extremities. Clubfeet may behave like those in arthrogryposis multiplex congenita (182). Serial casting may be tried, but most require surgery, such as an extensive, complete release [→7.11]. If this fails, a talectomy or Verebelyi-Ogston procedure may be useful (183). Scoliosis is also common and may require orthotic or surgical intervention (136). Because life expectancy is at least to the early adult years, aggressive orthopaedic management improves the quality of life.

Myotonia Congenita

Myotonia congenita is usually present at birth, but does not become clinically apparent until after 10 years of age. In some cases it may present as low back pain or impaired athletic ability (184–186). The severity of the myotonia varies considerably. The distribution is widespread, although it is more marked in the lower extremities than the upper extremities (187). Myotonia is most evident with initial movement. Repetitive movement decreases the myotonia and facilitates later movements. Usually, within 3 to 4 minutes stiffness disappears and normal activities including running are possible. Some patients appear herculean be-

cause of generalized muscle hypertrophy, particularly in the buttocks, thighs, and calves. Children with myotonia congenita have no associated weakness and no other endocrine or systemic abnormalities. The disease is compatible with a normal life span. A patient's disability is not great when the limits of the disease have been accepted. Procainamide and diphenylhydantoin (Dilantin) have been used with some success to decrease the myotonia, but they should be used only in severe cases (188). There are no characteristic orthopaedic deformities (4). The disorder, a chloride channelopathy, is caused by various mutations in the skeletal muscle voltage-gated chloride channel gene *CLC-1* (189,190).

CONGENITAL MYOPATHIES AND CONGENITAL MUSCULAR DYSTROPHY

Congenital myopathies and congenital muscular dystrophy present as a hypotonic or floppy baby at birth or in early infancy. When these conditions occur in an older child, they can present as muscle weakness (191–194). These disorders are not well understood clinically or at the molecular level. The diagnostic categorization is not uniform or predictive. They are defined histologically from muscle biopsies (4,10,11,192,194–196). When the biopsy findings are abnormal but not dystrophic, the patient is diagnosed as having a nonspecific myopathy (4). When considerable fibrosis is present along with necrotic fibers, congenital muscular dystrophy may be diagnosed (194).

CONGENITAL MYOPATHIES

The congenital myopathies include: central core disease, nemaline myopathy (rod-body myopathy), myotubular myopathy (centronuclear), congenital fiber-type disproportion and metabolic myopathies. Differentiation between these types can be accomplished through histochemical analysis and electron microscopy of muscle biopsy specimens (4,10,11,194–196).

Central Core Disease

Central core disease is a nonprogressive autosomal dominant congenital myopathy that frequently presents in infancy with hypotonia or in young children with delayed motor developmental milestones (10,192,195–198). Independent ambulation may not be achieved until 4 years of age. The distribution of muscle involvement is similar to that found in Duchenne muscular dystrophy, with the trunk and lower extremities being more involved than upper extremities and the proximal muscles more than the distal muscle groups. The pelvic girdle is more involved than the shoulder. Use of the Gower maneuver is common. No dete-

rioration in strength occurs with time, sensation is normal, and the deep tendon reflexes are either decreased or absent. Muscle wasting is a common finding, but progression of muscle weakness is rare. Muscle biopsies show mostly type I fibers containing central round or oval regions that are devoid of oxidative enzymes, adenosine triphosphate activity, and mitochondria. Serum CPK and nerve conduction studies are normal, whereas EMGs show myopathic abnormalities. Scoliosis, soft tissue contractures, congenital hip subluxation and dislocation, talipes equinovarus, pes planus, and hypermobility of joints (especially the patella) are the most common musculoskeletal problems and can require treatment (197–201). Scoliotic deformities have patterns similar to those of idiopathic scoliosis, progress rapidly, and tend to be rigid. Posterior spinal fusion and segmental instrumentation yields satisfactory results [↗2.9] (200). Soft tissue contractures about the hip and knee may need to be released. Clubfeet require extensive soft tissue releases to achieve correction [↗7.1]. Congenital dislocation of the hip can be treated by open or closed reduction techniques, but the recurrence rate is high and may require osseous procedures, such as pelvic or proximal femoral osteotomies (201). Central core disease is one of the disorders in which patients are susceptible to malignant hyperthermia. This association with malignant hyperthermia has led to linkage of both disorders to the long arm of chromosome 19 (202,203).

Nemaline Myopathy

Nemaline, or rod-body myopathy, is a variable congenital myopathy that usually begins in infancy or early childhood, with hypotonia affecting all skeletal muscles (4,10, 194–196,204–206). There is no involvement of cardiac muscle. Elongated facies, with a high-arched palate and a nasal, high-pitched voice, frequently are noted. Skeletal changes may resemble those seen in arachnodactyly. Martinez and Lake, in a review of the literature regarding 99 patients, recognized these forms: neonatal (severe), congenital (moderate), and adult onset (204). The neonatal form is characterized by severe hypotonia, with 90% mortality in the first 3 years of life due to respiratory insufficiency. The mean survival after birth was 16 months. The moderate congenital form, which is the most common and prototypic, is diagnosed during or after the neonatal period and has mild or moderate hypotonia, weakness, and delayed developmental milestones. Most patients begin to walk at 2 to 4 years of age, and the weakness is usually nonprogressive or only slowly progressive. The mortality rate is about 5%. Those who die are usually neonates. Death is typically from severe involvement of the pharyngeal and respiratory muscles (207–209). The adult-onset form is characterized by proximal weakness that occasionally progresses acutely. There is no correlation between the number of rods and the phenotype in nemaline myopathy (205).

Soft tissue contractures are uncommon in nemaline my-

opathy. The major musculoskeletal problems are scoliosis and lumbar lordosis. Posterior spinal fusion and segmental instrumentation [↗2.9] may be indicated in progressive scoliotic deformities (4). Lower extremity orthoses can be beneficial in providing joint stability and aiding ambulation. Because of diminished pulmonary function and a risk for malignant hyperthermia, patients undergoing surgery require careful administration of anesthesia and monitoring (210).

Centronuclear Myopathy

Centronuclear (i.e., myotubular) myopathy is a disorder of considerable variability (10,195,196,211). Muscle biopsies demonstrate persistent myotubes of fetal life (212,213). There are X-linked recessive, autosomal recessive, and autosomal dominant forms (211,214). The defect in the X-linked recessive form is at the locus Xq28. Children have varying degrees of weakness, generally noted in infancy. Patients with X-linked recessive forms are usually severely involved and die in infancy. The autosomal recessive form is hypotonic at birth, but is not progressive and may improve with time. Most of these children are able to walk. They may have a myopathic facies, high-arched palate, and proximal muscle weakness. There is an increased incidence of cavovarus foot deformities, scoliosis, lumbar lordosis, and scapular winging (10). By late adolescence or early adult life, some patients lose their ability to ambulate.

Congenital Fiber-type Disproportion

Congenital fiber-type disproportion is characterized by generalized hypotonia at or shortly after birth. The histologic criteria from muscle biopsies to diagnose this disorder include a predominance in number and a reduction in size of type I fibers and relatively large type II fibers (10,11). It is recognized as a nonspecific pathologic change that occurs in many patients and has a myopathic, neuropathic, or central nervous system origin (10,215). The degree of weakness is variable, and sequential examinations determine the prognosis. Most patients become ambulatory. The most serious problem is life-threatening respiratory infections during the first years of life. Proximal muscle weakness is frequently associated with acetabular dysplasia (215,216). To prevent postural contractures from developing an appropriate lower extremity splint should be used until the patient achieves ambulation. Severe, rigid scoliosis can occur. Orthoses are usually ineffective, and early spinal arthrodesis may be necessary (4).

Metabolic Myopathies

These myopathies represent a broad spectrum of metabolic abnormalities that are generally clinically evident in the first two decades of life (217). These include disorders of glycogenesis and mitochondrial dysfunction. Myopathies caused

by metabolic error in the first step of glycolysis are clinically associated with exercise intolerance, in which there are myophosphorylase and phosphofructokinase deficiencies, or with progressive muscle weakness and wasting, in which there are acid maltase or debrancher enzyme deficiencies (218). Defects in the second step of glycogenesis are associated with exercise intolerance. Myopathies caused by deficiencies in mitochondrial enzymes are less well defined and may be associated with severe benign exercise intolerance and progressive myopathic syndromes (218–220).

CONGENITAL MUSCULAR DYSTROPHY

Congenital muscular dystrophy is a rare disorder that generally presents as a floppy baby during infancy, with generalized muscle weakness with involvement of respiratory and facial muscles (221). It is a muscle disorder in which the muscle biopsy demonstrates dystrophic features characterized by considerable perimysial and endomysial fibrosis (194). It is different from Duchenne muscular dystrophy and Becker muscular dystrophy because it affects both males and females, is not associated with massively elevated levels

of CPK, does not involve abnormalities of the dystrophin gene or protein, and is associated with a more variable prognosis (4). There are several forms of congenital muscular dystrophy. In one, the infant is weak at birth. Many have severe stiffness of joints, whereas others do not. A few infants have rapid progression and do not survive after the first year of life. Most, however, stabilize and survive into adulthood (222). Another type is seen in Japanese infants and has been termed “Fukuyama congenital muscular dystrophy.” It is characterized by a marked developmental defect in the central nervous system (223,224). There is progressive muscle degeneration and mental retardation. Severe joint contractures develop, and many involved children die in the first decade of life. Merosin-deficient congenital muscular dystrophy is associated with white matter changes on brain MRI, and has been linked to chromosome 6q2 (225,226).

Common orthopaedic problems include congenital hip dislocation and subluxation, tendo Achillis contractures, and talipes equinovarus (Fig. 17-6). Because most survive, aggressive orthopaedic management is warranted. This may include physical therapy, orthoses, soft tissue releases, and perhaps osteotomy (4,227). Early physical therapy may be beneficial in the prevention of soft tissue contractures. Soft

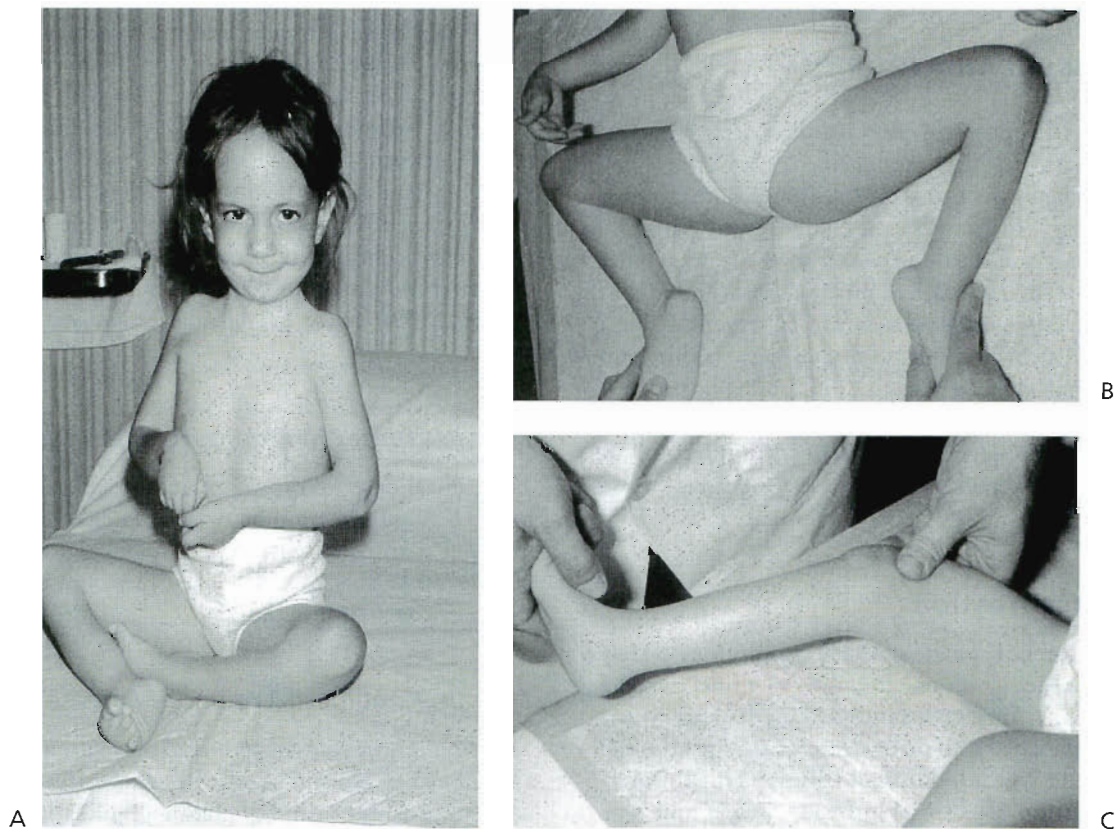


FIGURE 17-6. A: Clinical photograph of a 3-year-old girl with congenital muscular dystrophy. Observe the position of the upper and lower extremities. B: The hips are flexed, abducted, and externally rotated. C: Moderate knee flexion contractures are present.

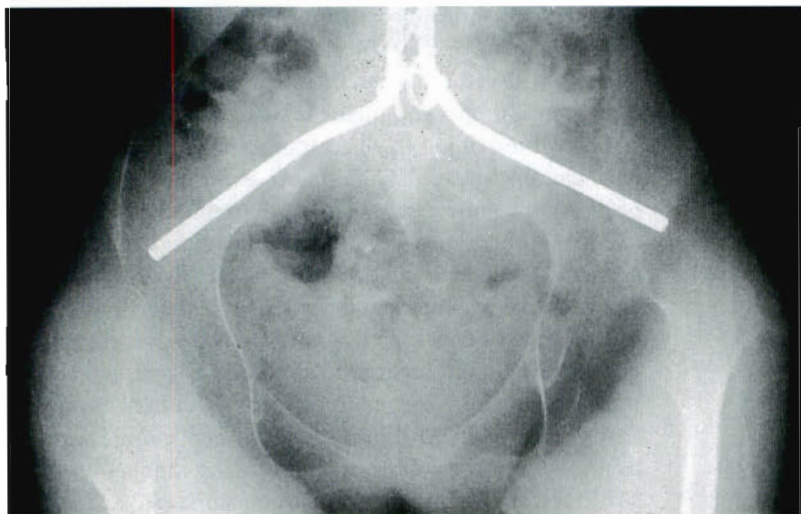


FIGURE 17-7. Pelvic radiograph of an 11-year-old girl with congenital muscular dystrophy, 3 years after posterior spinal fusion and Luque rod instrumentation, including the Galveston technique. She is wheelchair-dependent and has developed bilateral asymptomatic hip dislocations despite extensive soft tissue releases in early childhood.

tissue releases in the treatment of congenital dislocation of the hip are characterized by a high incidence of recurrent dislocation (Fig. 17-7) (227). Progressive scoliosis may be initially treated by an orthosis, although most require surgical stabilization similar to other forms of muscular dystrophy.

SPINAL MUSCULAR ATROPHY

Spinal muscular atrophy is a group of disorders characterized by degeneration of the anterior horn cells of the spinal cord and occasionally the neurons of the lower bulbar motor nuclei, resulting in muscle weakness and atrophy (228–232). They are autosomal recessive disorders that occur in about 1 in 20,000 live births (233). The loss of anterior horn cells is considered to be an acute event without progression. The neurologic deterioration may stabilize and remain unchanged for long periods (234,235). The progression of muscle weakness is a reflection of normal growth that exceeds muscle reserve. Respiratory function is compromised, and atelectasis and pneumonia are the usual causes of death.

Clinical Classification

The clinical features of spinal muscular atrophy vary widely and are based on the age at onset and the functional capacity of the child at the time of diagnosis. This has led to the disorder being classified into three types. These include type I (severe), or acute Werdnig-Hoffman disease; type II (intermediate), or chronic Werdnig-Hoffman disease; and type III (mild), or Kugelberg-Welander disease (236,237). All three are a spectrum of the same disorder, but each has specific diagnostic criteria and prognosis. There is a consid-

erable overlap between these three disorders, however, and most authors consider them to be a single disorder—spinal muscular atrophy (238). Generally, the earlier the onset, the worse the prognosis.

Type I, Acute Werdnig-Hoffman Disease

The Type I spinal muscular atrophy is characterized by clinical onset between birth and 6 months of age. These children typically have severe involvement with marked weakness and hypotonia. They usually die from respiratory failure between 1 and 24 months of age. Because of their young age and severe involvement, they usually do not require orthopaedic intervention. Pathologic multiple fractures may occur due to *in utero* osteoporosis secondary to decreased movement at birth and suggest osteogenesis imperfecta (239). These fractures heal rapidly with immobilization.

Type II, Chronic Werdnig-Hoffman Disease

The clinical onset of type II spinal muscular atrophy varies between 6 and 24 months of age. These children are less involved than those with type I spinal muscular atrophy, but are never able to walk. They may, however, live into the fourth and fifth decades.

Type III, Kugelberg-Welander Disease

The clinical onset of type III spinal muscular atrophy occurs after 2 years of age and usually before age 10 years. Walking is usually possible until late childhood or early adolescence. These patients usually are not able to run. Their motor capacity decreases with time, however, and they have difficulty rising from the floor because of weakness of the pelvic-

girdle muscles; this is known as the Gower sign. There is atrophy of the lower limbs, with pseudohypertrophy of the calves. Cranial nerve muscles are usually not affected. They have normal intelligence and may function effectively in society. Both the quality and quantity of life may be extended in type II and type III spinal muscular atrophy by the use of nighttime or full-time assisted ventilation (240).

Functional Classification

Evans et al. (241) have developed a four-group functional classification that may be useful prognostically.

Group I

Children never sit independently, have poor head control, and develop early progressive scoliosis.

Group II

Children have head control and the ability to sit if placed in a sitting position but are unable to stand or walk, even with orthotics.

Group III

Children have the ability to pull to stand and to walk with external support, such as orthoses.

Group IV

Children have the ability to walk and run independently.

Other studies have supported the use of this classification (230,235,237,242).

Genetic and Molecular Biology Studies

Linkage studies have established that the genetic homogeneity for the three types of spinal muscular atrophy occur at the same locus on chromosome 5q (19,228,233,243–245). Two genes have been found to be associated with disease, the survival motor neuron gene (*SMN*) and the neuronal apoptosis inhibitory protein gene (*NAIP*) (229,246,247). The presence of large-scale deletions involving both genes corresponds to a more severe phenotype. Prenatal diagnosis is available with the use of polymerase chain reaction amplification assays. No specific gene therapy is available.

Clinical Features

The clinical features of spinal muscular atrophy vary according to the clinical classification. The clinical characteristics common to all groups are relatively symmetric limb and trunk weakness and muscle atrophy that affects the lower extremities more than the upper extremities and the proxi-

mal muscles more than the distal muscles. Hypotonia and areflexia are present. Sensation and intelligence are normal. In infants, gross fasciculations of the tongue and fine tremors of the fingers are commonly present (234,248). The only muscles not involved are the diaphragm, sternothyroid, sternohyoid, and the involuntary muscles of the intestine, bladder, heart, and sphincters (228,237).

Diagnostic Studies

The studies used in the initial diagnosis of spinal muscular atrophy include laboratory studies, EMG, nerve conduction studies, and muscle biopsies. Hematologic studies in spinal muscular atrophy are not particularly useful (232). The CPK and aldolase levels are normal to only slightly elevated. Electrophysiologic studies, such as EMG, in patients with spinal muscular atrophy show typical neuropathic changes, such as increased amplitude and duration of response (232). Nerve conduction studies in spinal muscular atrophy are typically normal. Muscle biopsies are usually diagnostic, demonstrating muscle fiber degeneration and atrophy of fiber groups (232). However, with the recent advent of genetic testing for this disorder muscle biopsy is usually not necessary.

Radiographic Evaluation

There are no specific radiographic characteristics that are useful in making the diagnosis of spinal muscular atrophy. The most common radiographic abnormalities are nonspecific and include hip subluxation or dislocation and progressive spinal deformity (232). Bowen and Forlin (249) recommended that spinal radiographs, posteroanterior and lateral, be obtained in the sitting position to avoid the compensations seen in the standing and supine positions.

Treatment

The major orthopaedic abnormalities associated with spinal muscular atrophy include the presence of soft tissue contractures of the lower extremities, hip subluxation and dislocation, and spinal deformity (231,232,235).

Lower Extremity Soft Tissue Contractures

Soft tissue contractures of the lower extremities are the result of progressive muscle degeneration and replacement with fibrous tissue. Ambulation may be promoted and soft tissue contractures delayed by the use of orthoses, such as KAFOs (250). Contractures tend to occur most frequently after the child becomes wheelchair-bound. The prolonged sitting posture enhances hip and knee flexion contractures. Hip soft tissue contractures may also result in abnormal growth of the proximal femur and predisposes the patient to coxa valga and progressive hip subluxation. Soft tissue con-

tractures without an associated osseous deformity usually do not require treatment. Even when they are released, the sitting posture of the child enhances their recurrence.

Hip Subluxation and Dislocation

Progressive hip subluxation leading to dislocation occurs predominantly in spinal muscular atrophy types II and III. It is important that this be prevented to provide comfort, sitting balance, and maintain pelvic alignment. A comfortable sitting posture is important if the adolescent or young adult is to function in society. Periodic anteroposterior radiographs of the pelvis, beginning in midchildhood to late childhood, are important to allow early recognition of coxa valga and subluxation. Once diagnosed, it is usually progressive because of the continued muscle weakness and soft tissue contractures. Procedures that have been used with some success in the past include soft tissue releases, such as adductor tenotomy, iliopsoas recession, and medial hamstring lengthening [↗3.17,3.18]. This restores some balance to the proximal musculature. Most children will benefit by varus derotation osteotomy if the hip is severely subluxated [↗4.2,4.3] (232). If the hip is dislocated, an open reduction with capsulorrhaphy [↗3.2] and pelvic osteotomy of the Chiari type may be beneficial [↗3.11]. The usual rotation osteotomies (e.g., Salter, Sutherland, Steel) sacrifice posterior coverage to gain lateral (superior) and anterior coverage. In the child who will be predominantly in a sitting position, this lack of posterior coverage may predispose the patient to a posterior subluxation. Therefore, the pelvic osteotomy method chosen must allow improved posterior coverage. This is usually accomplished with the Chiari osteotomy [↗3.11] or perhaps a shelf procedure [↗3.12]. Even after satisfactory alignment of the hip, resubluxation and dislocation can occur due to the progressive degeneration of the proximal muscles (251). These children require annual clinical and radiographic evaluation to assess the hips postoperatively. Thompson and Larsen (251) reported four cases of recurrent hip dislocation after corrective surgery. Two patients had second operations followed by recurrent dislocation. They questioned the advisability of treatment of hip dislocations in patients with spinal muscular atrophy.

Spinal Deformity

Most children who survive into adolescence develop a progressive spinal deformity. This occurs in 100% of the spinal muscular atrophy children and adolescents with type II and most of those with type III, especially when they lose their ability to walk (235,241,249,252–255). As in other neuromuscular disorders, as the curve progresses there is an adverse effect on pulmonary function (249,255).

The deformity typically begins in the first decade due to severe truncal weakness. Once the deformity begins, it is steadily progressive and can reach severe magnitude unless

appropriately managed. The thoracolumbar paralytic C-shaped and single thoracic patterns, usually curved to the right, are most common. About 30% of children also have an associated kyphosis, which is also progressive (253,256). In type II spinal muscular atrophy, the mean expected increase in scoliosis is 8.3 degrees per year, whereas in type III it is 2.9 degrees per year.

Orthotic Management. Bracing is ineffective in preventing or halting the progression of scoliosis or kyphosis in children with spinal muscular atrophy (231,235,241,242, 253, 254, 256–260). However, it can be effective in improving sitting balance and slowing the rate of progression in young ambulatory children (249,260). This has the advantage of allowing them to reach an older, more suitable age for undergoing surgical intervention. Bowen and Forlin (249) recommended orthotic treatment to help maintain posture or slow curve progression in a child 9 years of age or younger with a deformity between 20 and 40 degrees. The thoracolumbar spinal orthosis (TLSO) is the most common orthosis used in children with spinal muscular atrophy. This orthosis must be carefully molded to distribute the forces over a large surface area to prevent skin irritation and breakdown, a major problem for children with neuromuscular diseases. Furumasu et al. (261) found that orthoses decreased function because of less spinal flexibility.

Occasionally, wheelchair modifications can also be effective in controlling truncal alignment and improving sitting posture (232). This also may be beneficial in slowing the rate of curve progression.

Surgery. The criteria for surgical spinal stabilization in spinal muscular atrophy include curve magnitude greater than 40 degrees, satisfactory flexibility on supine lateral bending radiographs, and an FVC greater than 40% of normal (232). When these criteria are met, a posterior spinal fusion using segmental spinal instrumentation techniques, such as Luque rod instrumentation and sublaminar wires [↗2.5,2.6], is used (Fig. 17-8) (100,109,111,112,231,235, 242,249,252–254,257–259,261,263,264). Other segmental systems, such as Cotrel-Dubousset, TSRH, Isola, and others, can also be utilized. These, however, do not usually distribute the forces of instrumentation throughout the spine as well as the Luque rods with sublaminar wiring. The spine is usually osteopenic, and there is a risk for bone failure unless the forces of instrumentation are minimized through extensive distribution. Fixation to the pelvis using the Galveston technique (113,114) or other techniques is common (115,263). In most children who are nonambulatory and have pelvic obliquity, fusion to the pelvis provides improved spinopelvic stability and alignment. Anterior spinal fusion and instrumentation are rarely indicated because of the compromised pulmonary status of these children. This may predispose the patient to pulmonary complications postoperatively (242,257). Anterior fusions alone are also too short and do not ade-

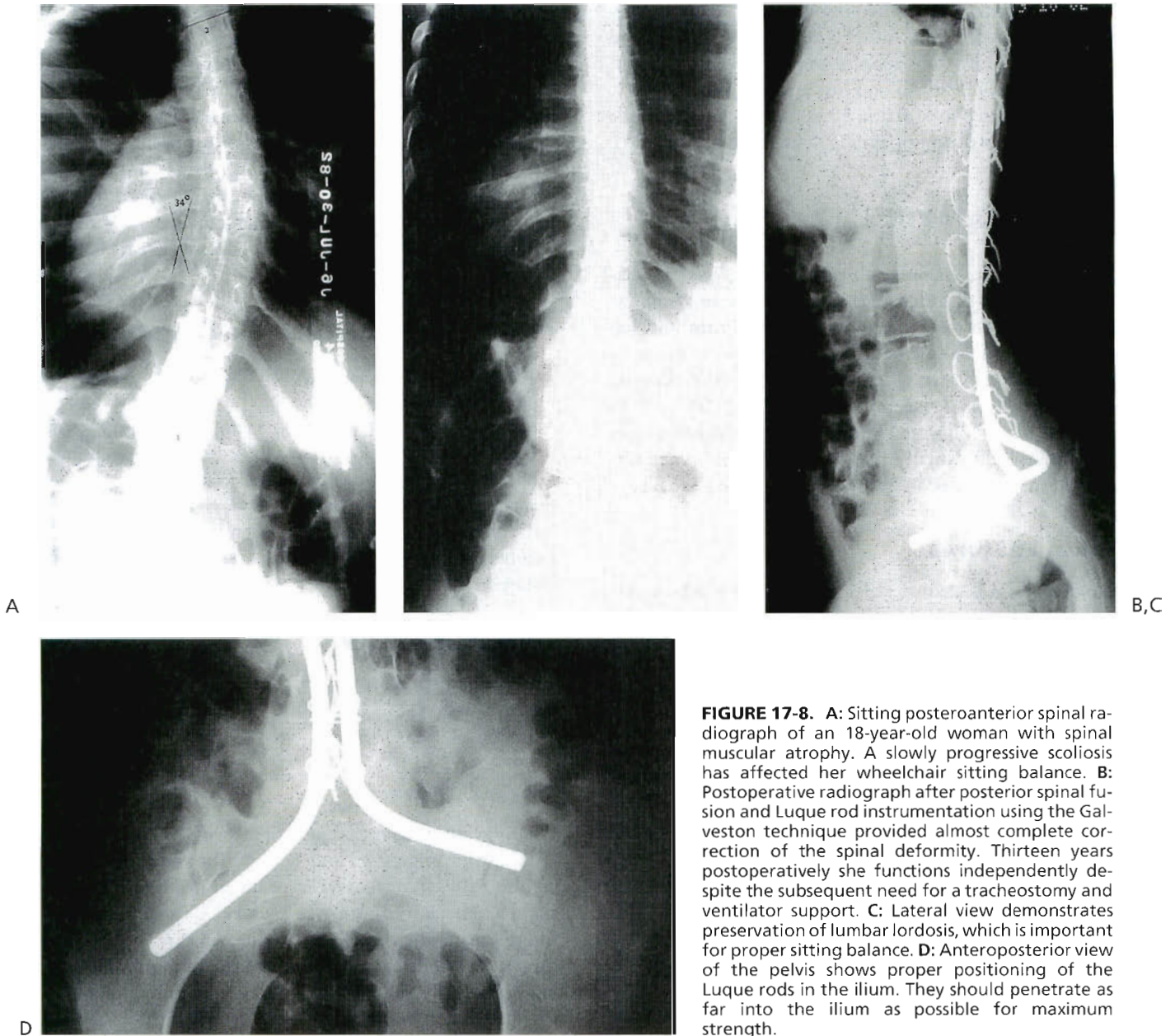


FIGURE 17-8. A: Sitting posteroanterior spinal radiograph of an 18-year-old woman with spinal muscular atrophy. A slowly progressive scoliosis has affected her wheelchair sitting balance. B: Postoperative radiograph after posterior spinal fusion and Luque rod instrumentation using the Galveston technique provided almost complete correction of the spinal deformity. Thirteen years postoperatively she functions independently despite the subsequent need for a tracheostomy and ventilator support. C: Lateral view demonstrates preservation of lumbar lordosis, which is important for proper sitting balance. D: Anteroposterior view of the pelvis shows proper positioning of the Luque rods in the ilium. They should penetrate as far into the ilium as possible for maximum strength.

quately stabilize the entire spine. When performed, it is combined with a simultaneous or staged posterior spinal fusion, usually with Luque rod instrumentation (100,249). Whatever posterior instrumentation system is used, it is important that no postoperative immobilization be necessary; this enhances sitting balance and pulmonary status and makes transfers easier.

Decreased function has been observed after spine fusion (252,261). Although spinal alignment and sitting balance are improved, the loss of spinal mobility decreases the function of the upper extremities and activities of daily living, such as performing transfers and personal hygiene. Askin et al. (262) recommended early surgery to preserve function.

They too found that patient function may not improve following surgery, but the cosmetic results were gratifying, and there may be improved caregiver ability. However, Bridwell et al. (109) reported improved function, self-image, cosmesis, and caregiver ability in 21 patients with spinal muscular atrophy followed for a mean of 7.8 years postoperatively (range 2 to 12.6 years).

Operative complications are similar to other neuromuscular disorders. These include excessive blood loss, pulmonary complications, neurologic injury, wound infection, loss of fixation due to osteopenia, pseudarthrosis, and death (100,111,127,252,254,256,257,259,263). The use of segmental spinal instrumentation techniques and aggressive

preoperative and postoperative respiratory therapy can result in decreased complications. Hypotensive anesthesia and intraoperative spinal cord monitoring may be beneficial in decreasing intraoperative blood loss and neurologic injury. Noordeen et al. reported that a 50% decrease in amplitude may be indicative of an impending neurologic injury (127).

FRIEDREICH ATAXIA

Spinocerebellar degenerative diseases are a group of relatively uncommon disorders that are hereditary and progressive. Friedreich ataxia is the most common form and has orthopaedic implications because of its high incidence of scoliosis. Friedreich ataxia is characterized by slow, progressive spinocerebellar degeneration. It occurs in about 1 in 50,000 live births (265). It is autosomal recessive and occurs most commonly in North America in people of French Canadian heritage. Males and females are affected equally.

Clinical Features

Friedreich ataxia is characterized by a clinical triad consisting of ataxia (which is usually the presenting symptom), areflexia of the knees and ankles, and a positive plantar response, or the Babinski sign (232,266). Geoffroy et al. (267) established strict criteria for the clinical diagnosis of typical Friedreich ataxia. This has been modified by Harding (268). The primary symptoms and signs that occur in all involved patients include onset before the age of 25 years; progressive ataxia of limbs and gait; absent knee and ankle deep tendon reflexes; positive plantar response; decreased nerve conduction velocities in the upper extremities, with small or absent sensory action potentials; and dysarthria. The secondary symptoms and signs that are present in more than 90% of cases include scoliosis, pyramidal weakness in the lower extremities, absent reflexes in the upper extremities, loss of position and vibratory sense in the lower extremities, and an abnormal ECG. Accessory symptoms and signs present in fewer than 50% of cases include optic atrophy, nystagmus, distal weakness and wasting, partial deafness, pes cavus, and diabetes mellitus.

The mean age at onset is between 7 and 15 years, although the range is wide, from 4 years to as late as 25 years of age (232,266–271). Most involved individuals lose their ability to walk and are wheelchair-bound by the second or third decade. Labelle et al. (272) demonstrated that the muscle weakness is always symmetric, initially proximal rather than distal, more severe in the lower extremities, and rapidly progressive when the patients become nonambulatory. The first muscle to be involved is the hip extensor (gluteus maximus). They also demonstrated that muscle weakness is not the primary cause of loss of ambulatory function. Ataxia and other factors also play a role. Death usually occurs in the fourth or fifth decade, due to progres-

sive hypertrophic cardiomyopathy, pneumonia, or aspiration (266,268,273).

Nerve conduction studies show decreased or absent sensory action potentials in the digital and sural nerves. Conduction velocity in the motor and sensory fibers of the median and tibial nerves are moderately slowed. An EMG shows a loss of motor units and an increase in polyphasic potentials. The ECG in adults typically shows a progressive hypertrophic cardiomyopathy. Hematologic tests such as CPK are normal, but there is increased incidence of clinical and chemical diabetes mellitus.

Genetic and Molecular Biology Studies

Chamberlain et al. have demonstrated that individuals with Friedreich ataxia have a defect on chromosome 9q13 (274). Additional studies have identified two loci on chromosome 9 (*D9S5* and *D9S15*) that are linked to Friedreich ataxia (265). It is now known that Friedreich is due to a trinucleotide repeat of GAA, which results in loss of expression of the frataxin protein. There is an inverse relationship between number of trinucleotide repeats and age of onset of the disease (275).

Treatment

The major orthopaedic problems in Friedreich ataxia are pes cavovarus, spinal deformity, and painful muscle spasms (232,266).

Pes Cavovarus

Pes cavovarus is common in patients with Friedreich ataxia. It is slowly progressive and tends to become rigid. When combined with ataxia, it can result in decreased ability to stand and walk. Orthotic management is usually ineffective in preventing the deformity, but an AFO can be used after surgery to stabilize the foot and ankle and to prevent recurrent deformity. Surgical procedures can be used in ambulatory patients to improve balance and walking ability. Procedures that have been shown to be effective include tendo Achillis lengthening and tibialis posterior tenotomy, lengthening, or anterior transfer to the dorsum of the foot [➔7.16,7.19] (232,266). The tibialis anterior muscle may also be involved and may require either tenotomy, lengthening, or centralization to the dorsum of the foot to prevent recurrence. In fixed, rigid deformities, a triple arthrodesis [➔7.9] may be necessary to achieve a plantigrade foot.

Spinal Deformity

Scoliosis occurs in essentially all patients with Friedreich ataxia (266,268,269,271,276,277). The age at onset is variable and usually begins while the patient is still ambulatory. The incidence of curve progression has been shown to corre-

late to the age at clinical onset of the disease process. Labelle et al. (277) demonstrated that when disease onset is before 10 years of age and scoliosis occurs before 15 years of age, most patient curves progress to greater than 60 degrees and require surgical intervention. When the disease onset is after 10 years of age and the scoliosis occurs after 15 years of age, curve progression is not as severe; most do not reach 40 degrees by skeletal maturity or progress thereafter. There was no correlation between curve progression, degree of muscle weakness, level of ambulatory function, and duration of the disease process. The patterns of scoliosis in patients with Friedreich ataxia are similar to those of adolescent idiopathic scoliosis, rather than to those of neuromuscular scoliosis. The pathogenesis of scoliosis in Friedreich ataxia appears to be not muscle weakness but the ataxia that causes a disturbance of equilibrium and postural reflexes. Double major (i.e., thoracic and lumbar) and single thoracic or thoracolumbar curves are the most common curve patterns (269,270,277,278). Only a few patients have lumbar or long C-shaped thoracolumbar curves. About two-thirds of patients with Friedreich ataxia develop an associated kyphosis greater than 40 degrees (270,277). The treatment of scoliosis in Friedreich ataxia can be either by orthotic or surgical methods.

Orthoses. A thoracolumbar spinal orthosis may be tried in ambulatory patients having 25- to 40-degree curves. It is usually not well tolerated, but it may slow the rate of progression, although rarely does it stabilize the curve (266,269,278). In ambulatory patients, an orthosis may interfere with walking because it prevents compensatory truncal movement necessary for balance and movement.

Surgery. In progressive curves greater than 60 degrees, especially in older adolescents confined to a wheelchair, a single-stage posterior spinal fusion stabilizes the curve and yields moderate correction. Curves between 40 and 60 degrees can be either observed or treated surgically, depending on the patient's age at clinical onset, the age when scoliosis was first recognized, and evidence of curve progression. Posterior segmental instrumentation using Harrington rods and sublaminar wires [➔2.3] or Luque rod instrumentation [➔2.5] has been demonstrated to be effective in achieving correction and a solid arthrodesis (100,111,269,270,276,278). Other segmental systems (e.g., Cotrel-Dubousset, Isola, TSRH) should also be effective [➔2.9]. Fusions are typically from the upper thoracic (T2 or T3) to lower lumbar regions. Fusion to the sacrum is usually unnecessary, except in C-shaped thoracolumbar curves with associated pelvic obliquity (270,278). Autogenous bone supplemented with banked bone, when necessary, usually produces a solid fusion. Anterior surgery, with or without instrumentation, usually followed by a posterior spinal fusion and instrumentation is limited to rigid curves greater than 60 degrees associated with poor sitting balance (278). Surgery is performed only after a thorough cardiopulmo-

nary evaluation and under careful intraoperative and postoperative monitoring. Postoperative immobilization should be avoided. Vertebral osteopenia and spinal stenosis is not a problem in Friedreich ataxia.

Painful Muscle Spasms

Painful muscle spasms occur in some patients with Friedreich ataxia (232). They usually begin in the late adolescent or early adult years and worsen with time. The spasms are characterized by a sudden onset and short duration. The hip adductors and the knee extensors are commonly involved. Initial treatment is usually by massage, heat, and perhaps muscle relaxants, such as diazepam and baclofen. In adults, if the adductor or quadriceps spasms are interfering with perineal care or sitting balance, the patient may benefit by tenotomies. This is rarely necessary.

HEREDITARY MOTOR SENSORY NEUROPATHIES

HMSNs are a large group of variously inherited neuropathic disorders (232,266,279). Charcot-Marie-Tooth disease is the prototype, but there are other disorders with similar but different manifestations.

Classification

The classification system for HMSN is presented in Table 17-2. HMSN types I, II, and III are encountered predominantly in pediatric orthopaedic and neuromuscular clinics, whereas HMSN types IV, V, VI, and VII tend to be late-onset and occur in adults (232).

HMSN type I is an autosomal dominant disorder and includes disorders referred to as peroneal atrophy, Charcot-

TABLE 17-2. CLASSIFICATION OF HEREDITARY MOTOR SENSORY NEUROPATHIES

Type	Terminology	Inheritance
I	Charcot-Marie-Tooth syndrome (hypertrophic form) or Roussy-Levy syndrome (areflexic dystaxia)	Autosomal dominant
II	Charcot-Marie-Tooth syndrome (neuronal form)	Variable
III	Dejerine-Sottas disease	Autosomal recessive
IV	Refsum disease	
V	Neuropathy with spastic paraplegia	
VI	Optic atrophy with peroneal muscle atrophy	
VII	Retinitis pigmentosa with distal muscle weakness and atrophy	

Marie-Tooth disease (hypertrophic form), or Roussy-Levy syndrome. It is a demyelinating disorder that is characterized by peroneal muscle weakness, absent deep tendon reflexes, and slow nerve conduction velocities. HMSN type II is the neuronal form of Charcot-Marie-Tooth disease. It is characterized by persistently normal reflexes, sensory and motor nerve conduction times that are only mildly abnormal, and variable inheritance patterns (232). These two types are clinically similar, although HMSN type II often causes less severe weakness and has a later onset than HMSN type I. HMSN type III is the autosomal recessive disorder, Dejerine-Sottas disease. This disorder begins in infancy and is characterized by more severe alterations in nerve conduction and by sensory disturbances that are more extensive than in HMSN types I and II. The HMSN types I and III are due to demyelination of peripheral nerves. These are characterized by muscle weakness in the feet and hands, absent deep tendon reflexes, and diminution of distal sensory capabilities, particularly light touch position and vibratory sensation (232).

The four additional types are late onset and rarely seen by pediatric orthopaedists or in pediatric neuromuscular clinics: HMSN type IV, Refsum disease, is characterized by excessive phytanic acid; HMSN type V is an inherited spastic paraplegia, with distal weakness in the limbs presenting in the second decade of life with an awkward gait and equinus foot deformities; HMSN type VI is characterized by optic atrophy in association with peroneal muscle atrophy; and HMSN type VII has retinitis pigmentosa, with distal weakness in the limbs and muscle atrophy.

Diagnostic Studies

Diagnosis of HMSN is made by physical examination in combination with EMG with nerve conduction studies and genetic testing. The EMG findings in HMSN show typical neuropathic changes, with increased amplitude and duration of response. Nerve conduction studies show marked slowing of the rate of impulse conduction in the involved muscles. A biopsy specimen of muscles such as the gastrocnemius demonstrates typical neuropathic findings, including atrophy of the fiber group, with all of the fibers in an abnormal group having uniformly small diameter. A biopsy specimen of a peripheral nerve, usually the sural nerve, shows typical demyelination, confirming the diagnosis of peripheral neuropathy.

Genetic and Molecular Biology Studies

Many individuals with the HMSN type I have a DNA duplication of a portion of the short arm of chromosome 17 in the region of p 11.2 to p 12 (20,280–282). Additional studies have shown a human peripheral myelin protein-22 gene to be contained within the duplication (283–285). It is thought that the abnormality in the peripheral myelin

protein-22 gene, which encodes the myelin protein, has a causative role in Charcot-Marie-Tooth disease. Either a point mutation in peripheral myelin protein-22 or duplication of the region that contains the peripheral myelin protein-22 gene can result in the disorder (286).

Treatment

Children with HMSN typically present with gait disturbance or foot deformities. The severity of involvement is variable. In severe involvement, there may be proximal muscle weakness. The major orthopaedic problems include pes cavovarus, hip dysplasia, spinal deformity, and hand and upper extremity dysfunction.

Pes Cavovarus

The pathogenesis of cavovarus deformities in children with HMSN and other neuromuscular disorders is becoming better understood (287–292). The components of the pes cavovarus deformity include claw toes; plantar flexed first metatarsal with adduction and inversion of the remaining metatarsals; midfoot malposition of the navicular, cuboid and cuneiforms, leading to a high arch (cavus); and hindfoot varus malposition between the talus and calcaneus (Fig. 17-9). Initially HMSNs affect the more distal muscles. The mildest cases affect the toes and forefoot, whereas the midfoot and hindfoot are progressively affected with progression of the disease process. In a computed tomography study of 26 patients with HMSN I, II, or III, Price et al. (293) found that the interossei and lumbrical muscles of the feet demonstrated earlier and more severe involvement compared with the extrinsic muscles. These intrinsic muscles have the most distal innervation. Even with minimal weakness the invertor muscles, such as the tibialis anterior and tibialis posterior muscles, are stronger than the evertors, such as the peroneus longus; this relation favors the development of adduction and varus deformities.

Pes cavovarus deformities are progressive, but the rate is variable, even among involved family members. Initially, the deformity is flexible but later becomes rigid. Shapiro and Specht point to the plantar flexed first metatarsal as the key finding (232). As the first metatarsal becomes increasingly plantar flexed, this is followed by increasing hindfoot varus and forefoot and midfoot supination and cavus. The block test is useful in defining the mobility of the remainder of the foot in children with a rigid plantar flexed first metatarsal (291).

The goals in the treatment of foot deformities in children with HMSN include maintenance of a straight, plantigrade, and relatively flexible foot during growth (288). This maximizes function and minimizes the development of osseous deformities that may require more extensive surgery in adolescence and early adult years, such as triple arthrodesis.

The treatment options for the management of foot de-

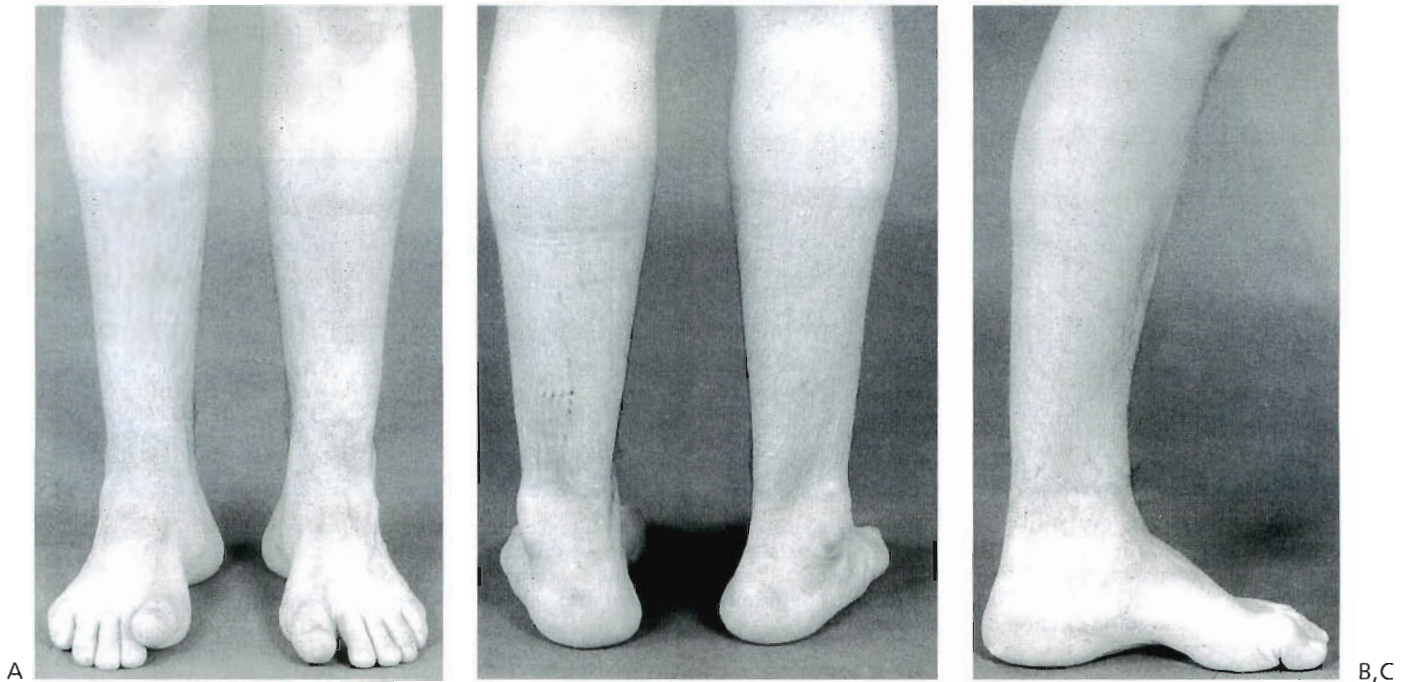

FIGURE 17-9. A: Front view of the lower legs and feet of a 16-year-old boy with hereditary motor sensory neuropathy type I (i.e., Charcot-Marie-Tooth disease). His calves are thin, and he has mildly symptomatic cavus feet. Clawing of the toes is minimal. B: Posterior view demonstrates moderate heel varus. C: The cavus foot deformity is most apparent when viewed from the medial side. A mild flexion deformity of the great toe interphalangeal joint is present.

formities include: plantar release, plantar-medial release, tendon transfers, calcaneal osteotomy, midtarsal osteotomy, triple arthrodesis, and correction of toe deformities.

Plantar Release. In children younger than 10 years of age who have a mild cavovarus deformity, a plantar release may be beneficial in correcting the plantar flexed first metatarsal and providing correction of the associated flexible hindfoot and midfoot deformities (294). In the radical plantar release described by Paulos et al. (291), selective Z-lengthening of the long toe flexor tendons and tibialis posterior tendon is performed if there is a bowstring effect after plantar release.

Plantar-medial Release. If the hindfoot deformity in the child younger than 10 years of age is rigid, leading to fixed varus deformity, the plantar release may be combined with a medial release (291). The medial structures to be released include the ligamentous and capsular structures between the talus and calcaneus [➔7.1] (except the posterior talocalcaneal ligament), and the capsule of the talonavicular joints. The navicular is then reduced onto the head of the talus and secured with a smooth Steinmann pin. The posterior ankle and subtalar joint ligaments and the tendo Achillis are not disturbed because they are necessary for counter-resistance during postoperative serial casting. Once the incision has healed a series of corrective weightbearing casts

are applied. Excellent correction of the entire foot has been reported after this technique.

Tendon Transfers. In children and adolescents who have a flexible cavovarus deformity in which active inversion is associated with relative weakness of the evertor muscles, a transfer of the tibialis anterior tendon to the dorsum of the midtarsal region in line with the third metatarsal may be helpful (295). The transfer is designed to balance strength, but the foot must be aligned initially by a plantar release and perhaps the plantar-medial release.

Other tendinous procedures that may be used depend on the individual needs of the patient. These may include tendo Achillis lengthening [➔7.16], anterior transfer at the tibialis posterior tendon [➔7.19], long toe extensors to the metatarsals or midfoot, and flexor-to-extensor tendon transfers for claw toes (288,291,295,296). Tendo Achillis lengthening is rarely necessary, as the equinus is due to the plantar flexed first metatarsal and forefoot. The hindfoot is typically in a calcaneus position.

Calcaneal Osteotomy. In children who are younger than 10 years of age and who have mild but fixed deformity, a calcaneal osteotomy may be beneficial in correcting the varus deformity of the hindfoot (232). This osteotomy does not interfere with growth because it is not made through

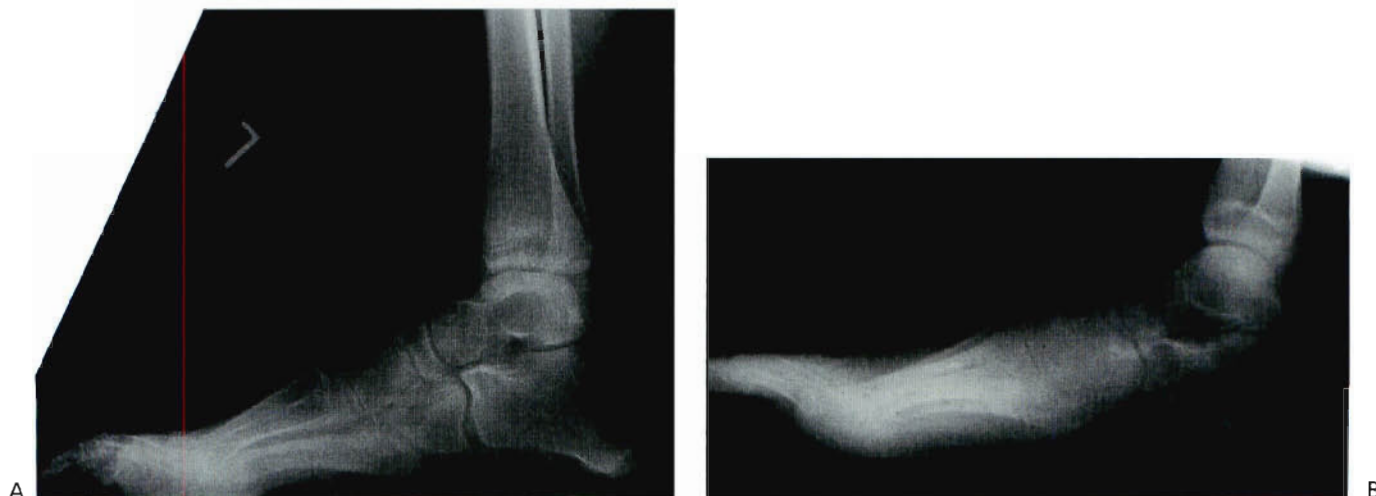

FIGURE 17-10. A: Moderate cavovarus deformity of the left foot in a 14-year-old male with Charcot-Marie-Tooth disease. He was managed by a closing wedge valgus osteotomy at the calcaneus, an opening wedge, plantar-based osteotomy of the medial cuneiform, and soft tissue balancing. B: Postoperatively, the cavovarus deformity has been improved. He is a brace-free ambulator due to restoration of muscle balance.

a cartilaginous growth area. To allow lateral translation, the osteotomy is cut slightly obliquely, passing from a superior position on the lateral surface to a more inferior position on the medial surface. It is possible to translate the distal fragment as much as one-third of its transverse diameter, thus allowing conversion of weightbearing from varus to slight valgus. In patients who are older than 10 years of age or who are more severely affected, a lateral closing-wedge calcaneal osteotomy, with lateral translation of the distal and posterior fragments, is performed (Fig. 17-10) (232). In both procedures the osteotomy is stabilized with staples or Steinmann pins.

Midtarsal Osteotomy. The midtarsal osteotomy provides correction by removal of a dorsal and slightly laterally based wedge, with the proximal osteotomy cut through the navicular and cuboid bones and the distal cut through the cuboid and three cuneiforms (296). Moderate deformities can be corrected satisfactorily with this procedure, especially if it is augmented with a plantar release, calcaneal osteotomy, and perhaps an anterior transfer of the tibialis anterior tendon. Equinus deformities of the midfoot and varus deformities of the forefoot can be corrected with appropriate wedge resections. Growth retardation and limitation of mobility are minimal compared with after a triple arthrodesis.

Triple Arthrodesis. In adolescents who have reached skeletal maturity and have a severe deformity, walk with difficulty, and cannot run, a triple arthrodesis [■7.9] may be performed. Every attempt should be made to avoid this procedure because of the associated complications of undercorrection, overcorrection, pseudarthrosis of the talo-

navicular joint, and degenerative changes in the ankle and midfoot joints (297–301).

Wetmore and Drennan (300) reported unsatisfactory results in 23 of 30 feet (16 patients) at a mean follow-up at 21 years. The progressive muscle imbalance resulted in recurrent pes cavovarus deformities. There was also an increased incidence of degenerative osteoarthritis of the ankle as a consequence to the deformity and the loss of subtalar joint motion. They felt triple arthrodesis should be limited to patients with severe, rigid deformities. Saltzman et al. reported similar results in 67 feet in 57 patients, including 6 feet in patients with Charcot-Marie-Tooth disease at 25 and 44 years of mean follow-up (302). However, 95% of the patients were satisfied with their clinical results. Ghanem et al. also reported long-term satisfactory results in children who had a triple arthrodesis (288).

The Ryerson triple arthrodesis is preferred because the joint surfaces of the talocalcaneal, talonavicular, and calcaneal cuboid joints are removed, along with appropriate-sized wedges to correct the various components of the hindfoot and midfoot deformities (Fig. 17-11) (296). In patients who have marked equinus of the midfoot and forefoot in relation to a relatively well-positioned hindfoot, the Lambrinudi triple arthrodesis may be performed (296,303). Once an arthrodesis has been performed to straighten the foot, tendon transfers to balance muscle power are of great importance.

Toe deformities in adolescents or after a triple arthrodesis may be corrected by proximal and distal interphalangeal fusion or flexor-to-extensor tendon transfer (304). The great toe may require an interphalangeal joint fusion and transfer of the extensor hallucis longus from the proximal phalanx

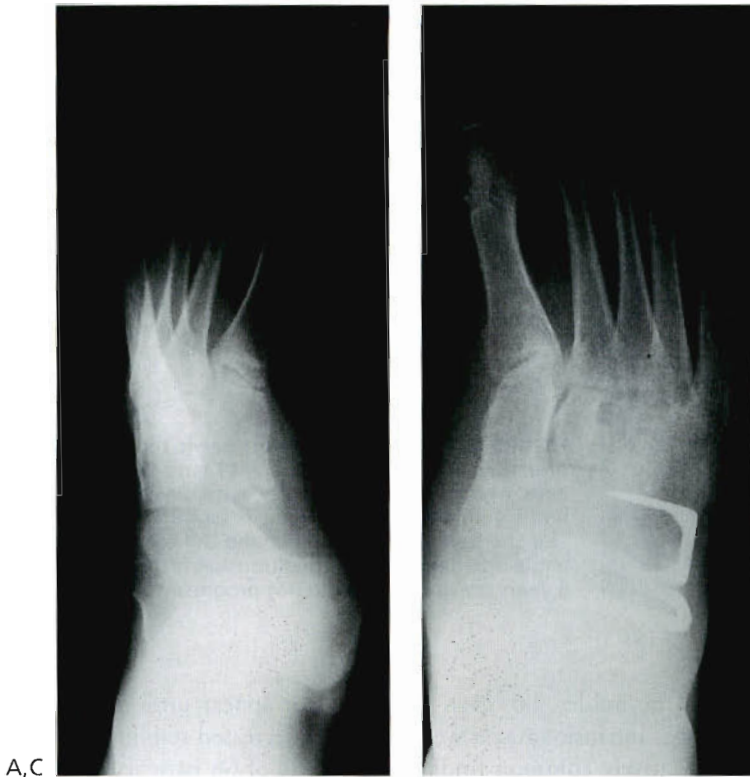
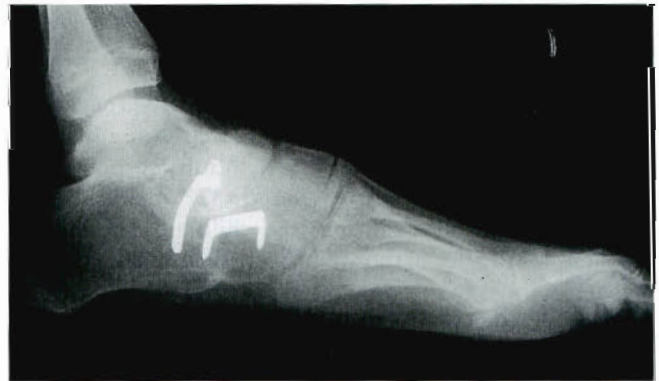
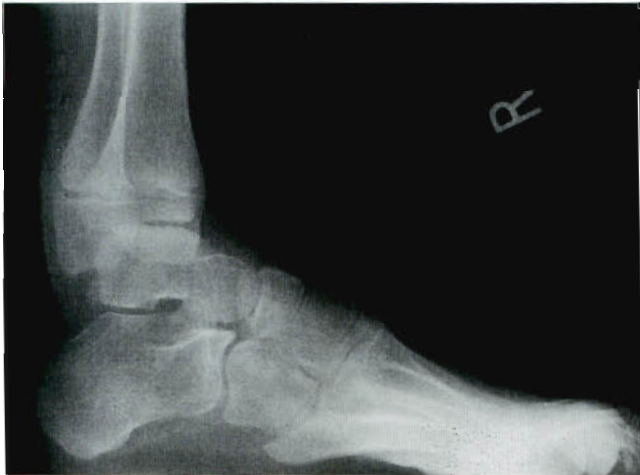FIGURE 17-11. A: Standing anteroposterior radiograph of severe cavovarus deformity of the right foot in a 14-year-old male with Charcot-Marie-Tooth disease. B: Lateral radiograph demonstrates a varus hindfoot and midfoot, and a plantar flexed first metatarsal. C: Postoperative standing anteroposterior radiograph following a Ryerson triple arthrodesis, soft tissue balancing, and correction of his claw toe deformities. D: Lateral radiographs show markedly improved alignment.

A,C



B

D

to the neck of the first metatarsal (Jones procedure). The latter then serves as a foot dorsiflexor.

Hip Dysplasia

Hip dysplasia in HMSN occurs in about 6 to 8% of involved children (305,306). Occasionally, hips may be dislocatable at birth, although the neuropathy does not become apparent for several years. It is more likely to occur in HMSN type I than HMSN type II because of the more severe neurologic involvement in the former. Walker et al. (306) thought that the slight muscle weakness about the

hip in growing children with HMSN may be sufficient to distort growth and development, leading to dysplasia. Usually, hip dysplasia is diagnosed between 5 and 15 years of age because of mild discomfort (305,306,308). Dysplasia may be present in asymptomatic patients, however (Fig. 17-12). Annual anteroposterior radiographs of the pelvis have been recommended to allow early diagnosis and treatment. Typical radiographic findings include acetabular dysplasia, coxa valga, and subluxation. The treatment of HMSN hip dysplasia includes soft tissue releases to correct contractures and restore muscle balance and pelvic or proximal femoral varus derotation osteotomies or both to stabilize and ade-

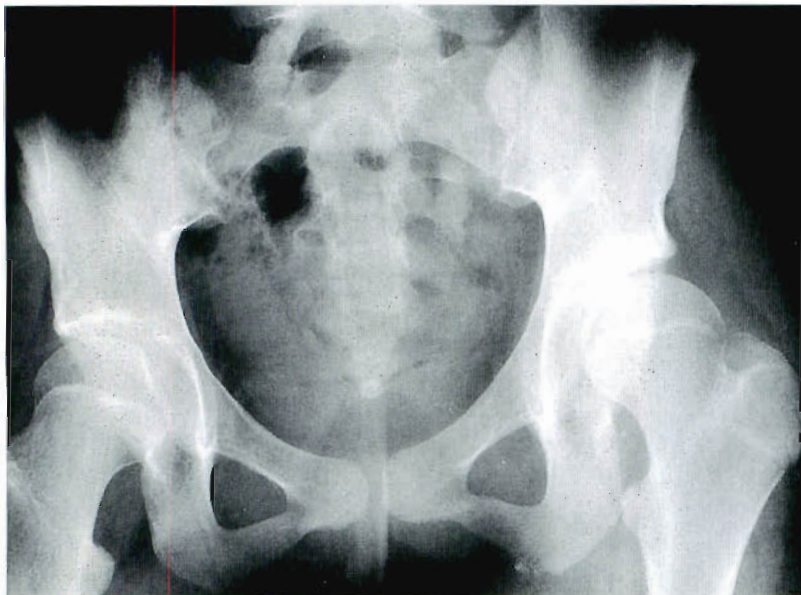


FIGURE 17-12. Anteroposterior pelvic radiograph of a 15-year-old girl with Charcot-Marie-Tooth disease. Asymptomatic acetabular dysplasia of the left hip is visible. The medial joint is slightly widened. The Shenton line is disrupted, and the center-edge angle is 16 degrees. This condition was first observed 6 years previously and did not progress.

quately realign the hip (305,307–310). The type of pelvic osteotomy is determined by the patient's age and severity of the dysplasia. Rotational osteotomies (Salter, Steel) [→3.5,3.10] are useful in many children with mild dysplasia, while periacetabular osteotomies are useful in adolescents and young adults, and the Chiari osteotomy [→3.11] when there is severe dysplasia.

Spinal Deformity

Scoliosis was initially thought to occur in about 10% of children with HMSN (311,312). These children were usually ambulatory, with age of onset of spinal deformity of about 10 years. A study by Walker et al. (313) found a 37% incidence of scoliosis or kyphoscoliosis in involved children. The incidence increases to 50% in those who were skeletally mature. Spinal deformity is more common in girls and HMSN type I. Curve progression requiring orthoses or surgery is uncommon. The curve patterns and management are similar to those for idiopathic adolescent scoliosis, except for an increased incidence of kyphosis. As a consequence, orthotic management can be effective in arresting progression of the deformity. If progression reaches 45 to 50 degrees, a posterior spinal fusion and segmental spinal instrumentation can effectively stabilize and partially correct the deformity [→2.9] (311,312). Intraoperative spinal cord monitoring with somatosensory cortical evoked potentials may show no signal transmission. This is due to the demyelination of the peripheral nerves and perhaps to degeneration of the dorsal root ganglion and dorsal column of the spinal cord (314). A wake-up test may need to be performed.

Hand and Upper Extremity Dysfunction

The upper extremities are involved in about two-thirds of individuals with HMSN (315,316). The involvement tends

to be milder, however, and does not appear until a later age. Intrinsic muscle weakness with decreased stability is a relatively common finding. In a study of 68 patients with Charcot-Marie-Tooth disease, the mean age at onset of symptoms in the hands and upper extremities was 19 years. Intrinsic muscle function was initially impaired, and patients became aware of motor weakness and a lack of dexterity. Sensory changes such as numbness are usually present concomitantly. Physical and occupational therapy may be helpful. In some patients operative intervention, such as transfer of the flexor digitorum sublimis to restore opposition, nerve compression releases, soft tissue contracture releases, and joint arthrodeses, may be effective in improving function. Preoperative EMG has been shown to aid in selecting optimal forearm muscles for tendon transfers to the hand (317).

POLIOMYELITIS

Acute poliomyelitis results from an acute viral infection, with localization in the anterior horn cells of the spinal cord and certain brain stem motor nuclei. It is caused by one of three polioviruses known as Brunhilde (type 1), Lansing (type 2), and Leon (type 3). Humans are the natural host for poliovirus, transmitting the disease by the oropharyngeal route. Each one of the polioviruses has varying virulence. Most poliovirus infections have an abortive course, with only mild gastrointestinal symptoms. Fewer than 1% of infections develop the paralytic form of the disease. Development of prophylactic vaccines has greatly reduced the incidence of polio, although the disease remains a major health problem in developing countries. Fewer than 10 cases

occur in the United States annually, and these most commonly result from the use of the active oral polio vaccine (318,319).

Pathology

The poliovirus invades the body through the oropharyngeal route and multiplies in the gastrointestinal tract lymph nodes before spreading to the central nervous system by the hematogenous route. The incubation period ranges from 6 to 20 days. Motoneuron cells of the anterior horn cells of the spinal cord and brain stem are acutely attacked. In the spinal cord, the lumbar and cervical regions are particularly involved. The medulla, cerebellum, and midbrain may be involved also. Except for the motor areas, the white matter of the spinal cord and the cerebral cortex are uninvolved.

Damage to the anterior horn cells may be due directly to viral multiplication, toxic byproducts of the virus, or indirectly from ischemia, edema, and hemorrhage in the glial tissues surrounding the anterior horn cells. In addition to acute inflammatory cellular reaction, edema with perivascular mononuclear cuffing occurs.

The inflammatory response gradually subsides, and the necrotic ganglion cells are surrounded and partially dissolved by macrophages and neutrophils. After 4 months, the spinal cord is left with residual areas of gliosis and lymphocytic cell collections occupying the area of the destroyed motor cells. Evidence exists of continuous disease activity in spinal cord segments examined two decades after the onset of the disease. Histopathologic sections demonstrate a loss or atrophy of motor neurons, severe reaction gliosis, and mild-to-moderate perivascular interparenchymal inflammation, with sparing of corticospinal tracts. Skeletal muscle demonstrates gross atrophy and replacement by fat and connective tissue histologically. The percentage of motor units destroyed in an individual muscle varies markedly, and the resultant clinical weakness is proportionate to the number of lost motor units. Sharrard has stated that clinically detectable weakness is present only when more than 60% of the motor nerve cells supplying the muscle have been destroyed (320). Involved muscles can range from those of one extremity to those of all four extremities, the trunk, and the bulbar musculature.

Muscles innervated by the cervical and lumbar segments are most frequently involved. However, involvement occurs twice as frequently in the lower extremity than in the upper extremity muscles. Sharrard (321,322) combined clinical and histologic studies which demonstrated that muscles with short motor nerve cell columns often are severely paralyzed, whereas those with long motor cell columns are more frequently left paretic or weak. The quadriceps, tibialis anterior, medial hamstrings, and hip flexors are the lumbar innervated muscles most frequently involved. The deltoid, triceps, and pectoralis major are most frequently affected in the upper extremities. The sacral nerve roots are usually

spared, resulting in the characteristic preservation of the intrinsic muscles of the foot (323).

Recovery of muscle function depends on return to function of those anterior horn cells damaged but not destroyed. Clinical recovery begins during the first month after the acute illness and is nearly complete by the sixth month, although there is limited potential for additional recovery through the second year. Sharrard has stated that the mean final grade of a muscle is two grades above its assessment at 1 month and one grade above it at 6 months (320).

Disease Stages

Management of poliomyelitis varies according to the stage of the disease process. These are designated acute, convalescent, and chronic stages. Because the acute and convalescent stages are rarely encountered in this country, orthopaedic management is usually confined to the chronic stage. Most pediatric orthopaedic programs see several children or more per year with poliomyelitis in the chronic stage. These children are usually adopted from nonindustrialized nations or from parents who have immigrated from such countries.

Acute Stage

Acute poliomyelitis may cause symptoms ranging from mild malaise to generalized encephalomyelitis with widespread paralysis. Diagnosis is based on clinical findings because there are no diagnostic laboratory tests. This phase generally lasts 7 to 10 days. The return to normal temperature for 48 h and the absence of progressive muscle involvement indicates the end of the acute phase. This phase is usually managed by pediatricians because there may be medical problems, especially respiratory, that may be life-threatening.

The orthopaedist should be familiar with the clinical signs of acute poliomyelitis. Meningismus is reflected in the characteristic flexor posturing of the upper and lower extremities. Involved muscles are tender, even to gentle palpation. Clinical examination can be difficult because of pain during the acute stage.

Orthopaedic treatment during this phase emphasizes prevention of deformity and comfort. This approach consists of physical therapy with gentle, passive range of motion exercises and splinting. Muscle spasms, which can lead to shortening and contractures, may respond to the application of warm, moist heat. This can relieve muscle sensitivity and discomfort. Sharrard (320) emphasized that rapid loss of elasticity, coupled with shortening of tendons, fascia, and ligaments, leads to contractures.

Convalescent Stage

The convalescent phase of poliomyelitis begins 2 days after the temperature returns to normal and progression of the

paralytic disease ceases. The phase continues for 2 years, during which spontaneous improvement of muscle power occurs. The assessment of the rate of recovery in poliomyelitis is made by serial examination of the muscle strength. Muscle assessment should be performed monthly for 6 months and then at 3-month intervals during the remainder of the convalescent stage.

Johnson (324) demonstrated that an individual muscle demonstrating less than 30% of normal strength at 3 months should be considered to be permanently paralyzed. Muscles showing evidence of more than 80% return of strength require no specific therapy. He emphasized that muscles that fall between these two parameters retain the potential for useful function and that therapy should be directed toward recreating hypertrophy of the remaining muscle fibers.

The treatment goals during this phase include efforts to prevent contractures and deformity, restoration and maintenance of normal joint range of motion, and assisting individual muscles in achieving maximum recovery (316). Physical therapy and orthotics are the main treatment modalities. Physical therapy is directed toward having individual muscles assume maximum capability within their pattern of normal motor activity and not permitting adaptive or substitute patterns of associated muscles to persist. Hydrotherapy can also be helpful in achieving these goals. Orthoses, both ambulatory and nighttime, are necessary to support the extremity during this phase.

Chronic Stage

The chronic stage of poliomyelitis begins after 2 years, and it is during this stage that the orthopaedist assumes responsibility for the long-term management resulting from muscle imbalance.

The management goal during the chronic stage is to achieve maximal functional capacity. This is accomplished by restoring muscle balance, preventing or correcting soft tissue contractures, correcting osseous deformities, and directing allied personnel, such as physical therapists, occupational therapists, and orthotists.

Treatment

Soft Tissue Contractures

Flaccid paralysis, muscle imbalance, and growth all contribute to soft tissue contractures and fixed deformities in poliomyelitis. Contractures occur from increased mechanical advantage of the stronger muscles and continue the attenuation of their weaker antagonists. The greater the disparity in muscle balance, the sooner a contracture may develop.

Joint instability does not result in fixed deformity, except in cases in which it is allowed to occur over a period of years in a growing child. Static instability can be controlled readily and indefinitely by orthoses. Dynamic joint instabil-

ity readily produces a fixed deformity, and orthotic control is difficult. Deformities are initially confined to soft tissues, but later, bone growth and joint alignment may be affected.

The age at onset of poliomyelitis is important. The osseous growth potential of young children makes them more vulnerable to secondary osseous deformities. The worst deformities occur in young children and those with severe muscle imbalance. Release of soft tissue contractures and appropriate tendon transfers performed in a young child are important in preventing structural changes.

Tendon Transfers

Achievement of muscle balance in patients with dynamic instability effectively halts progression of paralytic deformity (326). Tendon transfers are performed when dynamic muscle imbalance is sufficient to produce deformity and when orthotic protection is required. Transfers should be delayed until the paralyzed muscle has been given adequate postural treatment to ensure that it has regained maximum strength and that the proposed tendon transfer is required. The objectives of tendon transfer are to provide active motor power to replace function of a paralyzed muscle or muscles, to eliminate the deformity caused by a muscle when its antagonist is paralyzed, and to produce stability through better muscle balance. The principles of tendon transfer have been well established (327,328).

The muscle to be transferred should rate good or fair before transfer and must have adequate strength to actively perform the desired function. On the average, one grade of motor power is lost after muscle transfer. The length and range of motion of the transferred muscle and that of the muscle being replaced must be similar. Loss of original function resulting from tendon transfers must be balanced against potential gains. Free passive range of motion is essential in the absence of deformity at the joint to be moved by the tendon transfer. A transfer as an adjunct to bony stabilization cannot be expected to overcome a fixed deformity (329). The smooth gliding channel for the tendon transfer is essential. Atraumatic handling of the muscle tissue can prevent injury to its neurovascular supply and prevent adhesions. The tendon should be rooted in a straight line between its origin and new insertion. Attachment of the tendon transfer should be under sufficient tension to correspond to normal physiologic conditions and should allow the transferred muscle to achieve a maximum range of contraction.

Osteotomies

Osseous deformities may produce joint deformities that impair extremity alignment and limit function. This most commonly occurs in the lower extremity. Osteotomies can be beneficial in restoring extremity alignment and improving function. Because of possible recurrence during subsequent growth, these procedures are usually postponed, if possible, until late childhood or early adolescence.

Arthrodeses

Arthrodeses are usually performed for salvage, except in the foot where a subtalar, triple, or pantalar arthrodesis may be useful in stabilization and realignment.

Treatment Guidelines

The basic treatment guidelines for chronic or postpoliomyelitis in children have been outlined by Watts (330). These guidelines include restoring ambulation, correcting factors that cause deformities with growth, correcting factors that obviate or reduce dependency on orthoses, correcting upper extremity problems, and treating spinal deformities. Understandably, these guidelines allow the child or adolescent to achieve maximum functional level. The specific methods to achieve each guideline are multiple, sometimes complex, and based on careful evaluation of the patient. Because children with previous poliomyelitis are infrequently encountered, specific details on the various procedures are not presented. Such information can be obtained from the references in the various sections.

The orthopaedist must establish a comprehensive plan for each child based on a thorough musculoskeletal examination—in particular, joint range of motion, existing deformities, and manual testing of the individual muscles of the extremities and trunk. The latter should be individually recorded on a worksheet so that it can be used for future reference. It is important to remember that a muscle normally loses one grade of power when transferred. To be functionally useful, a muscle grade of at least 4 is necessary, although a grade 3 muscle, when transferred, may be an effective tenodesis in preventing deformity by balancing an opposing muscle.

Upper Extremity

In polio upper extremity involvement tends to be less severe than in the lower extremity. A stable upper extremity, especially the shoulder, is necessary for support of the body weight with a walker or crutches. It is also necessary for transfers or shifting the trunk if wheelchair-bound. A functional elbow, wrist, and hand is necessary for maximum independent function.

Shoulder. Shoulder stability is essential for all upper extremity activities. Satisfactory level of function of the hand, forearm, and elbow is a prerequisite for any shoulder reconstructive surgery. The major problems affecting the shoulder are predominantly muscle paralysis of the deltoid, pectoralis major, subscapularis, supraspinatus, and infraspinatus muscles. Rarely are all muscles involved because of the multiple levels of innervation. Tendon transfers can occasionally be effective in restoring shoulder stability. When there is extensive weakness, shoulder arthrodesis may be helpful. It can also be indicated whether there is a painful subluxation or dislocation. A strong trapezius serratus anterior muscle is necessary to allow increased function after fusion.

Elbow. The major problem affecting the elbow is loss of flexion. When the biceps and brachialis are paralyzed, a tendon transfer may be helpful in restoring useful elbow flexion. Possible procedures include a Steindler flexorplasty, which transfers the origin of the wrist flexors to the anterior aspect of the distal humerus (331). The best functional results occur in patients whose elbow flexors are only partially paralyzed and whose fingers and wrist flexors are normal. Transfer of the sternal head of the pectoralis major also may be considered. Other possible procedures include transfer of the sternocleidomastoid, latissimus dorsi, and anterior transfer of the triceps brachii. Paralysis of the triceps brachii muscle may occur in poliomyelitis, but seldom interferes with elbow function because gravity passively extends the elbow. Triceps brachii function is necessary, however, in activities in which the body weight is shifted to the hands, such as in transferring from bed to wheelchair or in crutch walking.

Forearm. Fixed deformities of the forearm seldom create major functional disabilities in children and adolescents with poliomyelitis. Pronation contractures are the most common disability. Function can be improved with release of the pronator teres and transfer of the flexor carpi ulnaris muscle.

Hand. Tendon transfers and fusions to improve hand function can be considered in selected cases. The number of possible transfers is extensive, and each patient requires a careful evaluation to ensure maximum functional improvement. Carpal tunnel syndrome has also been reported as a long-term sequela of poliomyelitis (332). This is associated with prolonged use of crutches or cane.

Lower Extremity

Lower extremity problems are most common in poliomyelitis. They can have a significant impact on function, especially ambulation.

Leg-length Discrepancy. This is a common problem when there is asymmetrical neurologic involvement. If the discrepancy is greater than 2 cm, this can produce a great disturbance. An appropriately timed contralateral epiphysiodesis is the usual procedure of choice (see Chapter 28). Greater discrepancy may be treated orthotically. Lengthening is rarely a consideration. However, D'Souza and Shah recently demonstrated that circumferential periosteal sleeve resection of the distal femur and/or distal tibia can produce a transient growth stimulation that can be beneficial in mild discrepancies, usually 2 to 3 cm (325).

Hip. Hip problems in poliomyelitis include muscle paralysis, soft tissue contractures, internal or medial femoral torsion, coxa valga, and hip subluxation and dislocation. Periodic anteroposterior radiographs of the pelvis are necessary to assess growth and the relation between the femoral head and acetabulum. Function can be improved and subluxa-

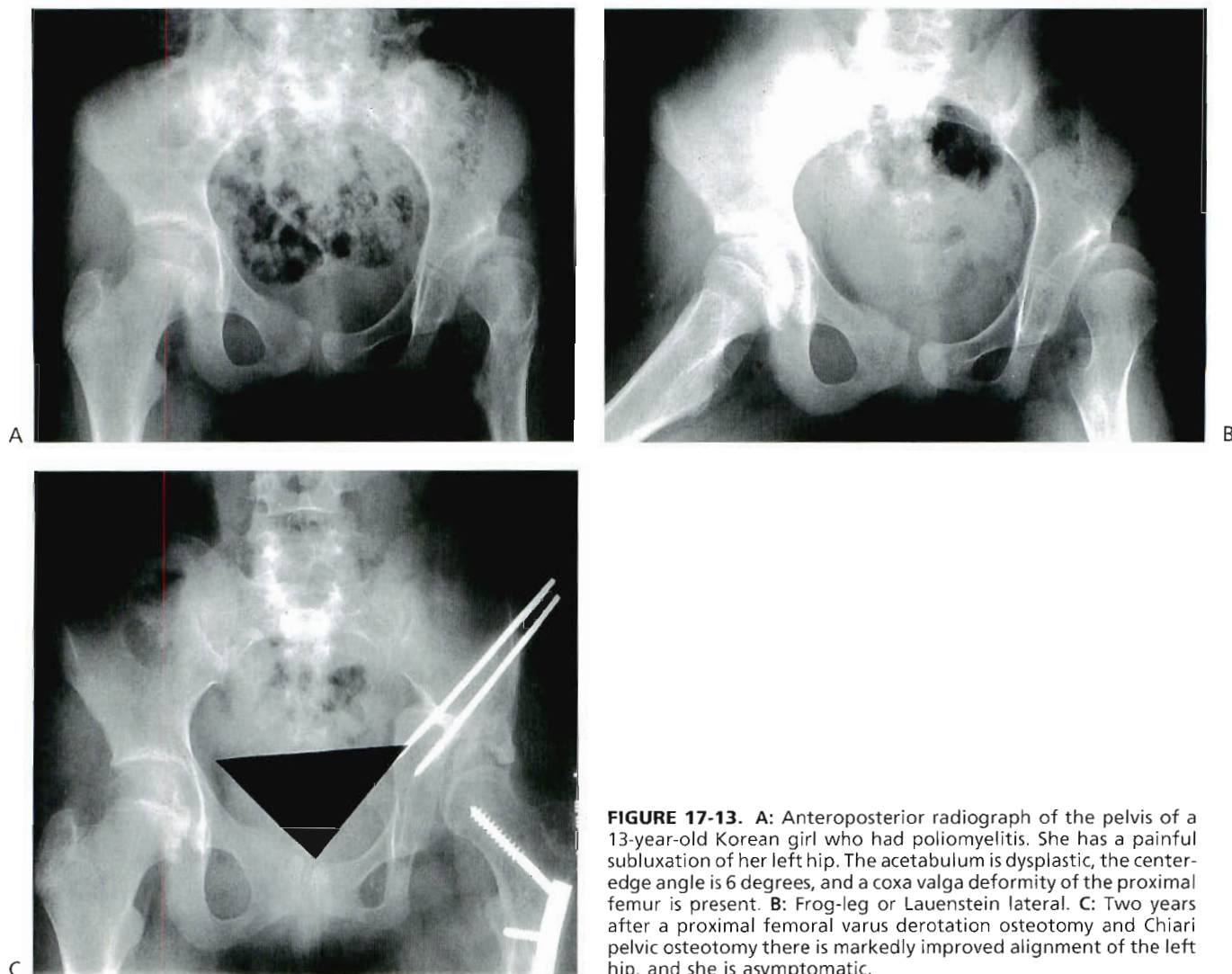


FIGURE 17-13. A: Anteroposterior radiograph of the pelvis of a 13-year-old Korean girl who had poliomyelitis. She has a painful subluxation of her left hip. The acetabulum is dysplastic, the center-edge angle is 6 degrees, and a coxa valga deformity of the proximal femur is present. B: Frog-leg or Lauenstein lateral. C: Two years after a proximal femoral varus derotation osteotomy and Chiari pelvic osteotomy there is markedly improved alignment of the left hip, and she is asymptomatic.

tion-dislocation prevented with appropriate soft tissue releases, tendon transfers, proximal femoral varus derotation osteotomy, and pelvic osteotomy (Fig. 17-13) (322,323). It is important that the procedures be coordinated to provide as balanced a musculature as possible so that hip stability can be maintained. Lau et al. (333) reported good or satisfactory results in 70% of patients with paralytic hip instability due to poliomyelitis. The key factors for success were muscle balance, the femoral neck shaft and anteversion angles, and the acetabular geometry.

Knee. Flexion contractures, extension contractures, genu valgum, and external rotation of the tibia are common knee deformities in poliomyelitis that can have an adverse effect on functional ambulation. Hamstring release, distal femoral extension osteotomy, proximal femoral extension osteotomy, and rotational tibial osteotomies are common procedures (334–337). One of the most common soft tissue procedures is that described by Yount, in which the distal iliotibial band, including the intermuscular septum, is re-

leased (80). This may be combined with an Ober release proximally if hip flexion contractures are also present (81). Shahcheraghi et al. recently reported that anterior hamstring tendon transfer significantly improved active knee extension and function in patients with paralysis of the quadriceps femoris muscle following poliomyelitis (338).

Foot and Ankle. Deformities of the foot and ankle are among the most common in adolescents with poliomyelitis. Drennan has discussed possible procedures to correct the deformities and improve muscle balance (339). This is again achieved with a combination of correction of soft tissue contractures, tendon transfers, and bone-stabilizing procedures, such as calcaneal osteotomy, subtalar arthrodesis, triple arthrodesis, and pantalar arthrodesis (340–345). The patient requires a careful evaluation to determine the appropriate procedures. Arthrodeses produce good long-term results with a low incidence of ankle-degenerative arthritis, due to lower functional demands and stresses of patients with poliomyelitis (302,340,342).

Spine

Scoliosis occurs in about one third of patients with poliomyelitis (346). The type and severity of the curvature depends on the extent of paralysis and residual muscle power of the involved trunk muscles and pelvic obliquity. The most common curve patterns are the double major thoracic and lumbar curves, followed by the long paralytic C-shaped thoracolumbar curve (347). Pelvic obliquity occurs in about 50% of cases of spinal deformity. Because of severe rotation, kyphosis in the lumbar spine and lordosis in the thoracic spine are also common.

The goals of treatment are to obtain a balanced vertical torso over a level pelvis. This permits stable sitting and hands-free activities. It also helps prevent decubiti and paralytic hip dislocation. In young children with curves between 20 and 40 degrees orthotic management with a TLSO can be tried. It rarely provides complete stability, but can be effective in slowing the rate of progression and allowing the child to reach a more suitable age for surgery. In severe cases in young children segmental spinal instrumentation without fusion may be considered. Eberle (348), however, reported failure of segmental spinal instrumentation in 15 of 16 chil-

dren with poliomyelitis between 5 and 12 years of age. Thus, children who undergo instrumentation without fusion should be treated with TLSO and undergo fusion as soon as possible to prevent late complications. For adolescents with a supple spine and a curve of less than 60 degrees a posterior spinal fusion with segmental instrumentation, usually Luque rod instrumentation, provides stability and a low pseudarthrosis rate [→2.5] (100,346,347,349). Other segmental systems (e.g., TSRH, Cotrel-Dubousset, Isola) should also be effective [→2.9]. In severe curves of 60 to 100 degrees, a combined anterior and posterior spinal fusion is usually necessary. Anterior spinal instrumentation with a Dwyer or Zielke system may be used in thoracolumbar and lumbar curves [→2.11]. Anterior discectomy and fusion is preferred for thoracic curves. The posterior spinal fusion and instrumentation may be performed the same day or performed 1 or 2 weeks later. Leong et al. (350) and others (349,351) have demonstrated that combined anterior and posterior spinal fusions provide excellent correction for postpoliomyelitis spinal deformity, including the associated pelvic obliquity (Fig. 17-14). Rarely is preoperative traction or traction between staged anterior and posterior procedures necessary for additional correction. Fusion to

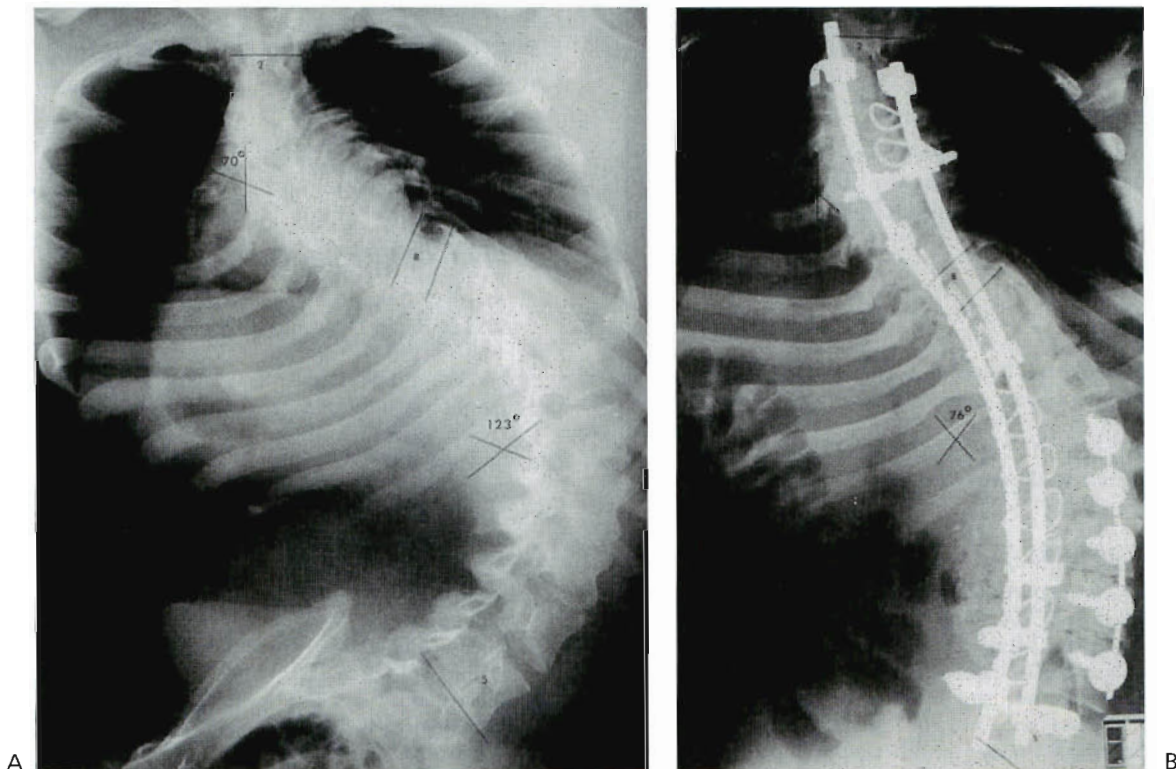


FIGURE 17-14. A: Anteroposterior sitting spinal radiograph of a 17-year-old girl from the Middle East who has a severe paralytic scoliosis. There is a 123-degree left thoracolumbar scoliosis and a 70-degree right thoracic scoliosis. She contracted poliomyelitis at the age of 2 years, which left her with flail lower extremities and essentially normal upper extremities. She is wheelchair-dependent and has pain from rib-pelvis impingement. B: Postoperative radiograph after staged anterior spinal fusion and Zielke instrumentation and posterior spinal fusion using Isola instrumentation from T3 to the sacrum. Pain relief was complete and sitting balance improved. The left thoracolumbar curve has been reduced to 70 degrees and the right thoracic curve to 47 degrees.

the pelvis or sacrum is usually necessary in patients with severe pelvic obliquity (346,352,353).

POSTPOLIOMYELITIS SYNDROME

Postpoliomyelitis syndrome is a true entity occurring in adults, and a sequela to previous poliomyelitis. Reactivation of the poliovirus has been confused with amyotrophic lateral sclerosis. Postpoliomyelitis syndrome is thought to be an overuse syndrome (354). Diagnosis is based on five criteria and is essentially a diagnosis of exclusion. The criteria include:

1. A confirmed history of previous poliomyelitis.
2. Partial to fairly complete neurologic and functional recovery.
3. A period of neurologic and functional stability of at least 15 years duration.
4. Onset of two or more of the following health problems since achieving a period of stability: unaccustomed fatigue, muscle and joint pain or both, new weakness in muscles previously affected or unaffected, functional loss, cold intolerance, and new atrophy.
5. No other medical diagnosis to explain the aforementioned health problems (170).

Postpoliomyelitis syndrome is more likely to develop in those with onset later than 10 years of age because older children are more likely to have severe poliomyelitis. Management of these patients is conservative and consists of muscle strengthening, decreasing the duration of effort, and orthotics (354). Reconstructive surgery is rarely indicated or necessary.

References

1. Read L, Galasko CS. Delay in diagnosing Duchenne muscular dystrophy in orthopaedic clinics. *J Bone Joint Surg Br* 1986;68:481.
2. Florence JM, Brocke MH, Carroll JE. Evaluation of the child with muscular weakness. *Ortho Clin North Am* 1978;9:409.

Diagnostic Studies

3. Shapiro F, Bresnan MJ. Current concepts review. Orthopaedic management of childhood neuromuscular disease. Part III: diseases of muscle. *J Bone Joint Surg Am* 1982;64:1102.
4. Shapiro F, Specht L. Current concepts review. The diagnosis and orthopaedic treatment of inherited muscular diseases of childhood. *J Bone Joint Surg Am* 1993;75:439.
5. Siegel IM. Diagnosis, management and orthopaedic treatment of muscular dystrophy. *AAOS Instr Course Lect* 1981;30:3.
6. Vignos PJ Jr. Diagnosis of progressive muscular dystrophy. *J Bone Joint Surg Am* 1967;49:1212.
7. Munsar TL, Baloh R, Pearson CM, et al. Serum enzyme alterations in neuromuscular disorders. *JAMA* 1973;226:1536.
8. Thomson WH, Leyburn P, Walton JN. Serum enzyme activity in muscular dystrophy. *Br Med J* 1960;2(5208):1276.

9. Zellweger H, Antonik A. Newborn screening for Duchenne muscular dystrophy. *Pediatrics* 1975;55:30.
10. Banker BQ. *Myology. Basic and clinical*. New York: McGraw-Hill, 1986:1527.
11. Dubowitz V. *Muscle biopsy*, 2nd ed. London: Bailliere Tindall, 1985.
12. Hurley ME, Davids JR, Mubarak SJ. Single-incision combination biopsy (muscle and nerve) in the diagnosis of neuromuscular disease in children. *J Pediatr Orthop* 1994;14:740.
13. Mubarak SJ, Chambers HG, Wenger DR. Percutaneous muscle biopsy in the diagnosis of neuromuscular disease. *J Pediatr Orthop* 1992;12:191.
14. Sanjal SK, Leung RK, Tierney RC, et al. Mitral valve prolapse syndrome in children with Duchenne's progressive muscular dystrophy. *Pediatrics* 1979;63:116.
15. Yazawa Y. Mitral valve prolapse related to geometrical changes of the heart in cases of progressive muscular dystrophy. *Clin Cardiol* 1984;7:198.
16. Emery AEH. X-linked muscular dystrophy with early contractures and cardiomyopathy [Emery-Dreifuss type]. *Clin Genet* 1987;32:360.
17. Seay AR, Ziter FA, Thompson JA. Cardiac arrest during induction of anesthesia in Duchenne muscular dystrophy. *J Pediatr* 1978;93:88.
18. Kurz LT, Mubarak SJ, Schultz P, et al. Correlation of scoliosis and pulmonary function in Duchenne muscular dystrophy. *J Pediatr Orthop* 1983;3:347.
19. Schreiber A, Smith WL, Ionasescu V, et al. Magnetic resonance imaging of children with Duchenne muscular dystrophy. *Pediatr Radiol* 1987;17:495.

Genetic and Molecular Biology Studies

20. Dietz FR, Mathews KD. Current concepts review. Update on genetic bases of disorders with orthopaedic manifestations. *J Bone Joint Surg Am* 1996;78:1583.
21. Specht LA. Molecular basis and clinical applications of neuromuscular disease in children. *Curr Opin Pediatr* 1991;3:966.

Sex-linked Muscular Dystrophies

22. Marsh GG, Munsar TL. Evidence for early impairment of verbal intelligence in Duchenne muscular dystrophy. *Arch Dis Child* 1974;49:118.
23. Sutherland DH, Olshen R, Cooper L, et al. The pathomechanics of gait in Duchenne muscular dystrophy. *Dev Med Child Neurol* 1981;23:3.
24. Sutherland DH. Gait analysis in neuromuscular diseases. *AAOS Instr Course Lect* 1990;39:333.
25. Hsu JD, Furumasa J. Gait and posture changes in the Duchenne muscular dystrophy child. *Clin Orthop* 1993;288:122.
26. Brooke MH, Fenichel GM, Griggs RC, et al. Duchenne muscular dystrophy. Patterns of clinical progression and effects of supportive therapy. *Neurology* 1989;39:475.
27. Emery AEH. *Duchenne muscular dystrophy*. 2nd ed. New York: Oxford University Press, 1988.
28. Rideau Y, Glorion B, Duport G. Prolongation of ambulation in the muscular dystrophies. *Acta Neurol* 1983;38:390.
29. Wilkins KE, Gibson DA. The patterns of spinal deformity in Duchenne muscular dystrophy. *J Bone Joint Surg Am* 1976;58:24.
30. Roses AD, Roses MJ, Miller SE, et al. Carrier detection in Duchenne muscular dystrophy. *N Engl J Med* 1976;294:193.
31. Kunkel LM, Monaco AP, Hoffman E, et al. Molecular studies of progressive muscular dystrophy (Duchenne). *Enzyme* 1987;38:72.

32. Slater GR. The missing link in Duchenne muscular dystrophy. *Nature* 1987;330:693.
33. Hoffman EP, Brown RH Jr, Kunkel LM. Dystrophin. The protein product of the Duchenne muscular dystrophy locus. *Cell* 1987;51:919.
34. Hoffman EP, Kunkel LM. Dystrophin abnormalities in Duchenne/Becker muscular dystrophy. *Neuron* 1989;2:1019.
35. Darras BT. Molecular genetics of Duchenne and Becker muscular dystrophy. *J Pediatr* 1990;117:1.
36. Uchino M, Araki S, Miike T, et al. Localization and characterization of dystrophin in muscle biopsy specimens for Duchenne muscular dystrophy and various neuromuscular disorders. *Muscle Nerve* 1989;12:1009.
37. Beggs AH, Hoffman EP, Snyder JR, et al. Exploring the molecular basis for variability among patients with Becker muscular dystrophy. Dystrophin gene and protein studies. *Am J Hum Genet* 1991;49:54.
38. Specht LA, Kunkel LM. Duchenne and Becker muscular dystrophies. In: Rosenberg RN, Prusiner SB, DiMauro S, et al., eds. *The molecular and genetic basis of neurological disease*. Boston: Butterworth-Heinemann, 1993:613.
39. Hoffman EP, Kunkel LM, Angelini C, et al. Improved diagnosis of Becker muscular dystrophy by dystrophin testing. *Neurology* 1989;39:1011.
40. Hoffman EP, Fischbeck KH, Brown RH, et al. Characterization of dystrophin in muscle-biopsy specimens from patients with Duchenne's or Becker's muscular dystrophy. *N Engl J Med* 1988;318:1363.
41. Specht LA, Beggs AH, Korf B, et al. Prediction of dystrophin phenotype by DNA analysis in Duchenne/Becker muscular dystrophy. *Pediatr Neurol* 1992;8:432.
42. Nicholson LVB, Johnson MA, Bushby KMD, et al. Functional significance of dystrophin positive fibres in Duchenne muscular dystrophy. *Arch Dis Child* 1993;68:632.
43. Gospe SM Jr, Lazaro RP, Lava NS, et al. Familial X-linked myalgia and cramps. A nonprogressive myopathy associated with a deletion in the dystrophin gene. *Neurology* 1989;39:1277.
44. Partridge TA. Invited review. Myoblast transfer. A possible therapy for inherited myopathies? *Muscle Nerve* 1991;14:197.
45. Partridge TA, Morgan JE, Coulton GR, et al. Conversion of mdx myofibres from dystrophin-negative to -positive by injection of normal myoblasts. *Nature* 1989;337:176.
46. Gussoni E, Pavlath GK, Lantot AM, et al. Normal dystrophin transcripts detected in Duchenne muscular dystrophy patients after myoblast transplantation. *Nature* 1992;356:435.
47. Huard J, Bouchard JP, Roy R, et al. Human myoblast transplantation; preliminary results of 4 cases. *Muscle Nerve* 1992;15:550.
48. Karpati G, Ajdukovic D, et al. Myoblast transfer in Duchenne muscular dystrophy. *Ann Neurol* 1993;34:8.
49. Law PK, Goodwin TG, Fang Q, et al. Feasibility, safety and efficacy of myoblast transfer therapy on Duchenne muscular dystrophy boys. *Cell Transplant* 1992;1:235.
50. Mendell JR, Kissel JT, Amato AA, et al. Myoblast transfer in the treatment of Duchenne's muscular dystrophy. *N Engl J Med* 1995;333:832.
51. DeSilva S, Drachman D. Prednisone treatment in Duchenne muscular dystrophy. *Arch Neurol* 1987;44:818.
52. Heckmatt J, Rodillo E, Dubowitz V. Management of children. Pharmacological and physical. *Br Med Bull* 1989;45:788.
53. Dubowitz V. Prednisone in Duchenne dystrophy (editorial). *Neuromuscul Disord* 1991;1:161.
54. Fenichel GM, Florence JM, Pestronk A, et al. Long-term benefit from prednisone therapy in Duchenne muscular dystrophy. *Neurology* 1991;41:1874.
55. Mendell JR, Moxley RT, Griggs RC, et al. Randomized double-blind six-month trial of prednisone in Duchenne's muscular dystrophy. *N Engl J Med* 1989;320:1592.
56. Griggs RC, Moxley RT, Mendell JR, et al. Duchenne dystrophy: randomized, controlled trial of prednisone (18 months) and azathioprine (12 months). *Neurology* 1993;43:520.
57. Green NE. The orthopaedic care of children with muscular dystrophy. *AAOS Instr Course Lect* 1987;36:267.
58. Drennan JC. Neuromuscular disorders. In: Morrissy RT, ed. *Lovell and Winter's pediatric orthopaedics*. Philadelphia: JB Lippincott, 1990:381.
59. Johnson EW, Kennedy JH. Comprehensive management of Duchenne muscular dystrophy. *Arch Phys Med Rehabil* 1971;52:110.
60. Heckmatt JZ, Dubowitz V, Hyde SA, et al. Prolongation of walking in Duchenne muscular dystrophy with lightweight orthoses; review of 57 cases. *Dev Med Child Neurol* 1985;27:149.
61. Spencer GE Jr, Vignos PJ Jr. Bracing for ambulation in childhood progressive muscular dystrophy. *J Bone Joint Surg Am* 1962;44:234.
62. Spencer GE Jr. Orthopaedic care of progressive muscular dystrophy. *J Bone Joint Surg Am* 1967;49:1201.
63. Vignos PJ, Wagner MB, Karlinchak B, Katirji B. Evaluation of a program for long-term treatment of Duchenne muscular dystrophy. Experience at the University Hospitals of Cleveland. *J Bone Joint Surg Am* 1996;78:1844.
64. Chyatte SB, Long C, Vignos PJ. The balanced forearm orthosis in muscular dystrophy. *Arch Phys Med Rehabil* 1965;46:633.
65. Yasuda YL, Bowman K, Hsu JD. Mobile arm supports: criteria for successful use in muscle disease patients. *Arch Phys Med Rehabil* 1986;67:253.
66. Siegel IM, Miller JE, Ray RD. Subcutaneous lower limb tenotomies in treatment of pseudohypertrophic muscular dystrophy. *J Bone Joint Surg Am* 1968;50:1437.
67. Smith SE, Green NE, Cole RJ, et al. Prolongation of ambulation in children with Duchenne muscular dystrophy by subcutaneous lower limb tenotomy. *J Pediatr Orthop* 1993;13:331.
68. Bonnet I, Burgot D, Bonnard C, Glorion B. Surgery of the lower limbs in Duchenne muscular dystrophy. *Fr J Orthop Surg* 1991;5:160.
69. Bowker JH, Halpin PJ. Factors determining success in reambulation of the child with progressive muscular dystrophy. *Ortho Clin North Am* 1978;9:431.
70. Dubouset J, Queneau P. Place et indication de la chirurgie dans la dystrophie musculaire de Duchenne de boulogne a evolution rapide. *Rev Chir Orthop* 1983;69:207.
71. Hsu JD. The management of foot deformity in pseudohypertrophic muscular dystrophy (DMD). *Ortho Clin North Am* 1976;7:979.
72. Rideau Y, Duport G, Delaubier A. Premieres remissions reproductibles dans l'evolution de la dystrophie musculaire de Duchenne. *Bull Acad Natl Med* 1986;170:605.
73. Rodillo EB, Fernandez-Bermejo E, Heckmatt JZ, Dubowitz V. Prevention of rapidly progressive scoliosis in Duchenne muscular dystrophy by prolongation of walking with orthoses. *J Child Neurol* 1988;3:269.
74. Williams EA, Read L, Ellis A, et al. The management of equinus deformity in Duchenne muscular dystrophy. *J Bone Joint Surg Br* 1984;66:546.
75. Vulpius O, Stoffel A. Orthopaedische operationslehre. 2nd ed. Stuttgart: Ferdinand Enke, 1920.
76. Greene WB. Transfer versus lengthening of the posterior tibial tendon in Duchenne's muscular dystrophy. *Foot Ankle* 1992;13:526.
77. Hsu JD, Hoffer MM. Posterior tibial tendon transfer through the interosseous membrane. A modification of the technique. *Clin Orthop* 1978;131:202.

78. Miller GM, Hsu JD, Hoffer MM, Rentfro R. Posterior tibial tendon transfer. A review of the literature and analysis of 74 procedures. *J Pediatr Orthop* 1982;2:363.
79. Melkonian GJ, Cristafaro RL, Perry J, et al. Dynamic gait electromyography study in Duchenne muscular dystrophy (DMD) patients. *Foot Ankle* 1983;1:78.
80. Yount CC. The role of the tensor fasciae femoris in certain deformities of the lower extremities. *J Bone Joint Surg Am* 1926; 8:171.
81. Ober FR. The role of the iliotibial band and fascia lata as a factor in the causation of low back disabilities and sciatica. *J Bone Joint Surg* 1936;18:105.
82. Soutter R. A new operation for hip contractures in poliomyelitis. *Boston Med Surg J* 1914;170:380.
83. Wagner MB, Vignos PJ Jr, Carlozzi C. Duchenne muscular dystrophy: a study of wrist and hand function. *Muscle Nerve* 1989;12:236.
84. Cambridge W, Drennan JC. Scoliosis associated with Duchenne muscular dystrophy. *J Pediatr Orthop* 1987;7:436.
85. Galasko CSB, Delaney C, Morris P. Spinal stabilisation in Duchenne muscular dystrophy. *J Bone Joint Surg Br* 1992;74:210.
86. Gibson DA, Wilkins KE. The management of spinal deformities in Duchenne muscular dystrophy. A new concept in spinal bracing. *Clin Orthop* 1975;108:41.
87. Hsu JD. The natural history of spine curvature progression in the nonambulatory Duchenne muscular dystrophy patient. *Spine* 1983;8:771.
88. Mubarak SJ, Miller LS. Muscular dystrophy. In: Weinstein SL, ed. *The pediatric spine. Principles and practice*. New York: Raven, 1994:1101.
89. Robin GC, Brief LP. Scoliosis in childhood muscular dystrophy. *J Bone Joint Surg Am* 1971;53:4666.
90. Siegel IM. Scoliosis in muscular dystrophy: some comments about diagnosis, observations on prognosis, suggestions for therapy. *Clin Orthop* 1973;93:235.
91. Smith AD, Koreska J, Moseley CF. Progression of scoliosis in Duchenne muscular dystrophy. *J Bone Joint Surg Am* 1989;71: 1066.
92. Lord J, Behrman B, Varzos N, et al. Scoliosis associated with Duchenne muscular dystrophy. *Arch Phys Med Rehabil* 1990; 71:13.
93. Colbert AP, Craig C. Scoliosis management in Duchenne muscular dystrophy. Prospective study of modified Jewett hyperextension brace. *Arch Phys Med Rehabil* 1987;68:302.
94. Seeger BR, Sutherland AD, Clark MS. Orthotic management of scoliosis in Duchenne muscular dystrophy. *Arch Phys Med Rehabil* 1984;65:83.
95. Sussman MD. Advantage of early spinal stabilization and fusion in patients with Duchenne muscular dystrophy. *J Pediatr Orthop* 1984;4:532.
96. Swank SM, Brown JC, Perry RE. Spinal fusion in Duchenne's muscular dystrophy. *Spine* 1982;7:484.
97. Weimann RL, Gibson DA, Moseley CF, Jones DC. Surgical stabilization of the spine in Duchenne muscular dystrophy. *Spine* 1983;8:776.
98. Shapiro F, Sethna N, Colan S, et al. Spinal fusion in Duchenne muscular dystrophy: a multidisciplinary approach. *Muscle Nerve* 1992;15:604.
99. Heller KD, Forst R, Forst J, Hengstler K. Scoliosis in Duchenne muscular dystrophy: aspects of orthotic treatment. *Prosthet Orthot Int* 1997;21:202.
100. Boachie-Adjei O, Lonstein JE, Winter RB, et al. Management of neuromuscular spinal deformities with Luque segmental instrumentation. *J Bone Joint Surg Am* 1989;71:548.
101. Rideau Y, Glorion B, Delaubier A, et al. The treatment of scoliosis in Duchenne muscular dystrophy. *Muscle Nerve* 1984; 7:281.
102. Marchesi D, Arlet V, Stricker U, Aebi M. Modification of the original Luque technique in the treatment of Duchenne's neuromuscular scoliosis. *J Pediatr Orthop* 1997;17:743.
103. Miller F, Moseley CF, Koreska J. Spinal fusion in Duchenne muscular dystrophy. *Dev Med Child Neurol* 1992;34:775.
104. Oda T, Shimizu N, Yonenobu K, et al. Longitudinal study of spinal deformity in Duchenne muscular deformity. *J Pediatr Orthop* 1993;13:478.
105. Bridwell KH, O'Brien MF, Lenke LG, et al. Posterior spinal fusion supplemented with only allograft bone in paralytic scoliosis. Does it work? *Spine* 1994;19:2658.
106. Brook PD, Kennedy JD, Stern LM, et al. Spinal Fusion in Duchenne's muscular dystrophy. *J Pediatr Orthop* 1996;16:324.
107. Fox HJ, Thomas CH, Thompson AG. Spinal instrumentation for Duchenne's muscular dystrophy: experience of hypotensive anesthesia to minimize blood loss. *J Pediatr Orthop* 1997;17: 750.
108. Yazici M, Asher MA. Freeze-dried allograft for posterior spinal fusion in patients with neuromuscular spinal deformities. *Spine* 1997;22:1467.
109. Bridwell KH, Baldus C, Iffrig TM, et al. Process measures and patient/parent evaluation of surgical management of spinal deformities in patients with progressive flaccid neuromuscular scoliosis (Duchenne's muscular dystrophy and spinal muscular atrophy). *Spine* 1999;24:1300.
110. Ramirez N, Richards SB, Warren PD, Williams GR. Complications after posterior spinal fusion in Duchenne's muscular dystrophy. *J Pediatr Orthop* 1997;17:109.
111. Taddonio RF. Segmental spinal instrumentation in the management of neuromuscular spinal deformity. *Spine* 1982;7:305.
112. Broom MJ.
113. Lonstein JE. The Galveston technique using Luque or Correl-Dubousset rods. *Ortho Clin North Am.* 1994;25:311-320.
114. Allen BL Jr, Ferguson AL. The Galveston technique for L-rod instrumentation of the scoliotic spine. *Spine* 1982;7:119.
115. McCarthy RE, Bruffett WL, McCullough FL. S rod fixation to the sacrum in patients with neuromuscular spinal deformities. *Clin Orthop* 1999;364:26.
116. Mubarak SJ, Morin WD, Leach J. Spinal fusion in Duchenne muscular dystrophy—fixation and fusion to the sacropelvis? *J Pediatr Orthop* 1993;13:752.
117. Rice JJ, Jeffers BL, Devitt AT, McManus F. Management of the collapsing spine for patients with Duchenne muscular dystrophy. *Ir J Med Sci* 1998;167:242.
118. Jenkins JG, Bohn D, Edmonds JF, et al. Evaluation of pulmonary function in muscular dystrophy patients requiring spinal surgery. *Crit Care Med* 1982;10:645.
119. Rideau Y, Jankowski LW, Grellet J. Respiratory function in the muscular dystrophies. *Muscle Nerve* 1981;4:155.
120. Rideau Y, Delaubier A. Neuromuscular respiratory deficit. Setting back mortality. *Semin Orthop* 1987;2:203.
121. Smith PEM, Calverley PMA, Edwards RHT, et al. Practical problems in the respiratory care of patients with muscular dystrophy. *N Engl J Med* 1987;316:1197.
122. Kennedy JD, Staples AJ, Brook PD, et al. Effect of spinal surgery on lung function in Duchenne muscular dystrophy. *Thorax* 1995;50:1173.
123. Miller F, Moseley CF, Koreska J, et al. Pulmonary function and scoliosis in Duchenne dystrophy. *J Pediatr Orthop* 1988;8: 133.
124. Miller RG, Chalmers AC, Dao H, et al. The effects of spine fusion on respiratory function in Duchenne muscular dystrophy. *Neurology* 1991;41:38.

125. Granata C, Merlini L, Cervellati S. Long-term results of spine surgery in Duchenne muscular dystrophy. *Neuromuscul Disord* 1996;6:61.
126. Noordeen MH, Hoddad FS, Muntoni F, et al. Blood loss in Duchenne muscular dystrophy: vascular smooth muscle dysfunction. *J Pediatr Orthop B* 1999;8:212.
127. Noordeen MHH, Lee J, Gibbons CER, et al. Spinal cord monitoring in operations for neuromuscular scoliosis. *J Bone Joint Surg Br* 1997;79:53.
128. Alexander MA, Johnson EW, Petty J, et al. Mechanical ventilation of patients with late stage Duchenne muscular dystrophy. Management in the home. *Arch Phys Med Rehabil* 1979;60:289.
129. Bach JR, O'Brien J, Krolenberg R, et al. Muscular dystrophy. Management of end stage respiratory failure in Duchenne muscular dystrophy. *Muscle Nerve* 1987;10:177.
130. Curran FJ. Night ventilation by body respirators for patients in chronic respiratory failure due to late stage Duchenne muscular dystrophy. *Arch Phys Med Rehabil* 1981;62:270.
131. Hilton T, Orr RD, Perkin RM, et al. End of life care in Duchenne muscular dystrophy. *Pediatr Neurol* 1993;9:165.
132. Stewart CA, Gilgoff Baydur A, Prentice W, et al. Gated radionuclide ventriculography in the evolution of cardiac function in Duchenne's muscular dystrophy. *Chest* 1988;94:1245.
133. Emery AEH, Watt MS, Clack ER. The effects of genetic counseling in Duchenne muscular dystrophy. *Clin Genet* 1972;3:147.
134. Becker PE. Two new families of benign sex-linked recessive muscular dystrophy. *Rev Can Biol* 1962;21:551.
135. Bradley WG, Jones MZ, Mussini JM, et al. Becker-type muscular dystrophy. *Muscle Nerve* 1978;1:111.
136. Daher YH, Lonstein JE, Winter RB, et al. Spinal deformities in patients with muscular dystrophy other than Duchenne. A review of 11 patients having surgical treatment. *Spine* 1985;10:614.
137. Dickey RP, Ziter FA, Smith RA. Emery-Dreifuss muscular dystrophy. *J Pediatr* 1984;104:555.
138. Miller RG, Layzer RB, Mellenthin MA, et al. Emery-Dreifuss muscular dystrophy with autosomal dominant transmission. *Neurology* 1985;35:1230.
139. Shapiro F, Specht L. Orthopedic deformities in Emery-Dreifuss muscular dystrophy. *J Pediatr Orthop* 1991;11:336.
140. Specht LA. Case records of the Massachusetts General Hospital. Case 34-1992. *N Engl J Med* 1992;327:548.
141. Merlini L, Granata C, Dominici P, et al. Emery-Dreifuss muscular dystrophy. Report of five cases in a family and review of the literature. *Muscle Nerve* 1986;9:481.
142. Goto I, Ishimoto S, Yamada T, et al. The rigid spine syndrome and Emery-Dreifuss muscular dystrophy. *Clin Neurol Neurosurg* 1986;88:293.
143. Consalez GG, Thomas NST, Stayton CL, et al. Assignment of Emery-Dreifuss muscular dystrophy to the distal region of Xq28. The results of a collaborative study. *Am J Hum Genet* 1991;48:468.
144. Thomas NS, Williams H, Elsas LJ, et al. Localization of the gene for Emery-Dreifuss muscular dystrophy to the distal long arm of the X-chromosome. *J Med Genet* 1986;23:596.
145. Hopkins LC, Jackson JA, Elsas LJ. Emery-Dreifuss humeroperoneal muscular dystrophy. An X-linked myopathy with unusual contractures and bradycardia. *Ann Neurol* 1981;10:230.
- workshop—the 'limb-girdle' muscular dystrophies. *Neuromuscul Disord* 1992;2:3.
148. Beckman JS, Richard I, et al. A gene for limb-girdle muscular dystrophy maps to chromosome 15 by linkage. *C R Acad Sci III* 1991;312:141.
149. Speer MC, Yamaoka LH, Gilchrist JH, et al. Confirmation of genetic heterogeneity in limb-girdle muscular dystrophy: linkage of an autosomal dominant form to chromosome 5q. *Am J Hum Genet* 1992;50:1211.
150. Bailey RO, Marzulo DC, Hans MB. Muscular dystrophy. Infantile fascioscapulohumeral muscular dystrophy. New observations. *Acta Neurol Scand* 1986;74:51.
151. Carroll JE, Brooke MH. Infantile fascioscapulohumeral dystrophy. In: Serratrice G, Roux H, eds. *Peroneal atrophies and related disorders*. New York: Masson, 1978:305.
152. Korf BR, Bresnan MJ, Shapiro F, et al. Fascioscapulohumeral dystrophy presenting in infancy with facial diplegia and sensorineural deafness. *Ann Neurol* 1985;17:513.
153. Shapiro F, Specht L, Korf BR. Locomotor problems in infantile fascioscapulohumeral muscular dystrophy. Retrospective study of 9 patients. *Acta Orthop Scand* 1991;62:367.
154. Hanson PA, Rowland LP. Möbius syndrome and fascioscapulohumeral muscular dystrophy. *Arch Neurol* 1971;24:31.

Autosomal Dominant Muscular Dystrophies

155. Kazakov VM, Bogorodinsky DK, Znoyko ZV, et al. The fascioscapulo-limb (or the fascioscapulohumeral) type of muscular dystrophy. Clinical and genetic study. *Eur Neurol* 1974;11:236.
156. Fisher J, Upadhyaya M. Molecular genetics of fascioscapulohumeral muscular dystrophy (FSHD). *Neuromuscul Disord* 1997;7:55.
157. Wijmenga C, Frants RR, Brouwer OF, et al. Location of fascioscapulohumeral muscular dystrophy gene on chromosome 4. *Lancet* 1990;336:651.
158. Bodensteiner JB, Schochet SS. Fascioscapulohumeral muscular dystrophy. The choice of a biopsy site. *Muscle Nerve* 1986;9:544.
159. Bunch WH, Siegal IM. Scapulothoracic arthrodesis in fascioscapulohumeral muscular dystrophy. Review of seventeen procedures with three to twenty-one year follow-up. *J Bone Joint Surg Am* 1993;75:372.
160. Copeland SA, Howard RC. Thoracoscaphular fusion for fascioscapulohumeral dystrophy. *J Bone Joint Surg Br* 1978;60:547.
161. Copeland SA, Levy O, Warner GC, et al. The shoulder in patients with muscular dystrophy. *Clin Orthop* 1999;368:80.
162. Jakab E, Gledhill RB. Simplified technique for scapulocostal fusion in fascioscapulohumeral dystrophy. *J Pediatr Orthop* 1993;13:749.
163. Ketenjian AY. Scapulocostal stabilization for scapular winging in fascioscapulohumeral muscular dystrophy. *J Bone Joint Surg Am* 1978;60:476.
164. Kocalkowski A, Frostick SP, Wallace WA. One-stage bilateral thoracoscaphular fusion using allografts. A case report. *Clin Orthop* 1991;273:264.
165. Letournel E, Fardieu M, Lytle JO, et al. Scapulothoracic arthrodesis for patients who have fascioscapulohumeral muscular dystrophy. *J Bone Joint Surg Am* 1990;72:78.
166. Wosick WF, Alker G. CT manifestation of ocular muscular dystrophy. *Comput Radiol* 1984;8:391.
167. Olson W, Engel WK, Walsh GO, et al. Oculocraniosomatic neuromuscular disease with "ragged-red" fibers. *Arch Neurol* 1993;26:193.
168. Barbeau A. The syndrome of hereditary late onset ptosis and dysphagia in French Canada. In Kuhn E, ed. *Symposium uber*

Autosomal Recessive Muscular Dystrophies

146. Arikawa E, Hoffman EP, Kaido M, et al. The frequency of patients with dystrophin abnormalities in a limb-girdle patient population. *Neurology* 1991;41:1491.
147. Bushby K. Report on the 12th ENMC sponsored international

Progressive Muskeldystrophie, Myotonie, Myasthenie. Berlin: Springer-Verlag, 1966;102.

169. Pratt MF, Meyers PK. Oculopharyngeal muscular dystrophy. Recent ultrastructural evidence for mitochondrial abnormalities. *Laryngoscope* 1986;96:368.
170. Dobrowski JM, Zajchuck JT, LaPiana FG, et al. Oculopharyngeal muscular dystrophy. Clinical and histopathologic correlations. *Otolaryngol Head Neck Surg* 1986;95:131.
171. Duranceau A, Forand MD, Fautaux JP. Surgery in oculopharyngeal muscular dystrophy. *Am J Surg* 1980;139:33.
192. Dubowitz V. *Muscle disorders in childhood.* Philadelphia: WB Saunders, 1978.
193. Zellweger H, McCormick WF, Mergner W. Severe congenital muscular dystrophy. *Am J Dis Child* 1967;114:591.
194. Banker BQ. *Myology. Basic and clinical.* vol. 2. New York: McGraw-Hill, 1986:1367.
195. Goebel HH. Congenital myopathies. In: Adachi M, Ser JH, eds. *Neuromuscular disorders.* New York: Igaku-Schoin, 1990: 197.
196. Goebel HH. Congenital myopathies. *Semin Pediatr Neurol* 1996;3:152.

Myotonia

172. O'Brien TA, Harper PS. Course, prognosis and complications of childhood-onset myotonic dystrophy. *Dev Med Child Neurol* 1984;26:62.
173. Cook AW, Bird TD, Spence AM, et al. Myotonic dystrophy, mitral-valve prolapse and stroke. *Lancet* 1978;1:335.
174. Schonk D, Coerwinkel-Driessen M, van Dalen I, et al. Definition of subchromosomal intervals around the myotonic dystrophy gene region at 19q. *Genomics* 1989;4:384.
175. Bell DB, Smith DW. Myotonic dystrophy in the neonate. *J Pediatr* 1972;81:83.
176. Carroll JE, Brooke MH, Kaiser K. Diagnosis of infantile myotonic dystrophy. *Lancet* 1975;2:608.
177. Hanson PA. Myotonic dystrophy in infancy and childhood. *Pediatr Ann* 1984;13:123.
178. Vanier TM. Dystrophia myotonica in childhood. *Br Med J* 1960; 2(5208):1284.
179. Zellweger H, Ionasescu V. Early onset of myotonic dystrophy in infants. *Am J Dis Child* 1973;125:601.
180. Calderon R. Myotonic dystrophy. A neglected cause of mental retardation. *J Pediatr* 1966;68:423.
181. Speer MC, Pericak-Vance MA, Yamaoka L, et al. Presymptomatic and prenatal diagnosis in myotonic dystrophy by genetic linkage studies. *Neurology* 1990;40:671.
182. Bowen RS Jr, Marks HG. Foot deformities in myotonic dystrophy. *Foot Ankle* 1984;5:125.
183. Gross RH. The role of the Verebelyi-Ogston procedure: the management of the arthrogrypotic foot. *Clin Orthop* 1985;194: 99.
184. Burnham R. Unusual causes of stiffness in two hockey players. *Clin J Sport Med* 1997;7:137.
185. Haig AJ. The complex interactions of myotonic dystrophy in low back pain. *Spine* 1991;16:580.
186. Weinberg J, Curl LA, Kuncl RW, et al. Occult presentation of myotonia congenita in a 15-year-old athlete. *Am J Sports Med* 1999;27:529.
187. Winters JL, McLaughlin LA. Myotonia congenita. *J Bone Joint Surg Am* 1970;52:1345.
188. Geschwind N, Simpson JA. Procaine amide in the treatment of myotonia. *Brain* 1955;78:81.
189. Kubisch C, Schmidt-Rose T, Fontaine B, et al. CIC-1 chloride channel mutations in myotonia congenita: variable penetrance of mutations shifting the voltage dependence. *Hum Mol Genet* 1998;7:1753.
190. Plassart-Schiss E, Gervais A, Eymard B, et al. Novel muscle chloride channel (CICN1) mutations in myotonia congenita with various modes of inheritance including incomplete dominance and penetrance. *Neurology* 1998;50:1176.

Congenital Myopathies and Congenital Muscular Dystrophy

191. Brooke MH. *A clinician's view of neuromuscular diseases.* Baltimore: Williams & Wilkins, 1977.

Congenital Myopathies

197. Gamble JG, Rinsky LA, Lee JH. Orthopaedic aspects of central core disease. *J Bone Joint Surg Am* 1988;70:1061.
198. Shuaib A, Paasuke RT, Brownell KW. Central core disease. Clinical features in 13 patients. *Medicine* 1987;66:389.
199. Armstrong RM, Koenigsberg R, Mellinger J, et al. Central core disease with congenital hip dislocation: study of two families. *Neurology* 1971;21:369.
200. Kumano K. Congenital non-progressive myopathy, associated with scoliosis: clinical, histological, histochemical and electron microscopic studies of seven cases. *Nippon Seikeigeka Gakkai Zasshi* 1980;54:381.
201. Ramsey PL, Hensinger RN. Congenital dislocation of the hip associated with central core disease. *J Bone Joint Surg Am* 1975; 57:648.
202. Frank JP, Harati Y, Butler IJ, et al. Central core disease and malignant hyperthermia syndrome. *Ann Neurol* 1980;7:11.
203. Haan EA, Freemantle CJ, McCure JA, et al. Assignment of the gene for central core disease to chromosome 19. *Hum Genet* 1990;86:187.
204. Martinez BA, Lake BD. Childhood nemaline myopathy: a review of clinical presentation in relation to prognosis. *Dev Med Child Neurol* 1987;29:815.
205. Shimomura C, Nonaka I. Nemaline myopathy: comparative muscle histochemistry in the severe neonatal, moderate congenital and adult-onset forms. *Pediatr Neurol* 1989;5:25.
206. Shy GM, Engel WK, Somers JE, et al. Nemaline myopathy. A new congenital myopathy. *Brain* 1963;86:793.
207. Eeg-Olofsson O, Henriksson KG, Thornell LE, et al. Early infant death in nemaline (rod) myopathy. *Brain Dev* 1983;5: 53.
208. Maayan C, Springer C, Armon T, et al. Nemaline myopathy as a cause of sleep hypoventilation. *Pediatrics* 1986;77:390.
209. McComb RD, Markesbery WR, O'Connor WN. Fatal neonatal nemaline myopathy with multiple congenital anomalies. *J Pediatr* 1979;95:47.
210. Cunliffe M, Burrows FA. Anesthetic implications of nemaline rod myopathy. *Can Anaesth Soc J* 1985;32:543.
211. Wallgren-Pettersson C, Clarke A, Samson F, et al. The myotubular myopathies: differential diagnosis of the X-linked recessive, autosomal dominant and autosomal recessive forms and present state of DNA studies. *J Med Genet* 1995;32:673.
212. Munsat TL, Thompson LR, Coleman RF. Centronuclear ("myotubular") myopathy. *Arch Neurol* 1969;20:120.
213. Spiro AJ, Shy GM, Gonatas NK. Myotubular myopathy. Persistence of fetal muscle in an adolescent boy. *Arch Neurol* 1966; 14:1.
214. Darnsfor C, Larsson HEB, Oldfors A, et al. X-linked myotubular myopathy: a linkage study. *Clin Genet* 1990;37:335.
215. Cavanagh NPC, Lake BD, McMeniman P. Congenital fibre type disproportion myopathy. A histological diagnosis with an uncertain clinical outlook. *Arch Dis Child* 1979;54:735.
216. Brooke MH. A neuromuscular disease characterized by fiber

- types disproportion. In: Kakulas BA, ed. *Proceedings of the Second International Congress on Muscle Diseases*. Perth, Australia, November 1971. Amsterdam: Excerpta Medica, 1973.
217. Gullotta F. Metabolic myopathies. *Pathol Res Pract* 1985;80:10.
 218. Cornelio F, DiDonato S. Myopathies due to enzyme deficiencies. *J Neurol* 1985;232:321.
 219. Kearns TP, Sayre GP. Retinitis pigmentosa, external ophthalmoplegia and complete heart block. *Arch Ophthalmol* 1958;60:280.
 220. Mechler F, Mastaglia FL, Serena M, et al. Mitochondrial myopathies. A clinico-pathological study of cases with and without extra-ocular muscle involvement. *Aust NZ J Med* 1986;16:185.
- ### Congenital Muscular Dystrophy
221. Leyten QH, Gabreels FJ, Renier WO, et al. Congenital muscular dystrophy: a review of the literature. *Clin Neurol Neurosurg* 1996;98:267.
 222. McManamin JB, Becker LE, Murphy EG. Congenital muscular dystrophy: a clinicopathologic report of 24 cases. *J Pediatr* 1982;100:692.
 223. Fukuyama Y, Osawa M, Suzuki H. Congenital progressive muscular dystrophy of the Fukuyama type—clinical, genetic and pathological considerations. *Brain Dev* 1981;3:1.
 224. Fukuyama Y, Osawa M. A genetic study of the Fukuyama type congenital muscular dystrophy. *Brain Dev* 1983;6:373.
 225. Hillaire D, Leclerc A, Faure S, et al. Localization of merosin-negative congenital muscular dystrophy to chromosome 6q2 by homozygosity mapping. *Hum Mol Genet* 1994;3:1657.
 226. Philpot J, Sewry C, Pennock J, Dubowitz V. Clinical phenotype in congenital muscular dystrophy: correlation with expression of merosin in skeletal muscle. *Neuromuscul Disord* 1995;5:301.
 227. Jones R, Kahn R, Hughes S, Dubowitz V. Congenital muscular dystrophy. The importance of early diagnosis and orthopaedic management in the long-term prognosis. *J Bone Joint Surg Br* 1979;61:13.
- ### Spinal Muscular Atrophy
228. Gordon N. The spinal muscular atrophies. *Dev Med Child Neurol* 1991;33:930.
 229. Iannaccone ST. Spinal muscular atrophy. *Sem Neurol* 1998;18:19.
 230. Russman BS, Melchreit R, Drennan, JC. Spinal muscular atrophy. The natural course of the disease. *Muscle Nerve* 1983;6:179.
 231. Shapiro F, Bresnan MJ. Current concepts review. Orthopaedic management of childhood neuromuscular disease. Part I. Spinal muscular atrophy. *J Bone Joint Surg Am* 1982;64:785.
 232. Shapiro F, Specht L. Current concepts review. The diagnosis and orthopaedic treatment of childhood spinal muscular atrophy, peripheral neuropathy, Friedreich ataxia and arthrogryposis. *J Bone Joint Surg Am* 1993;75:1699.
 233. Brzustowicz LM, Lehner T, Castilla LH, et al. Genetic mapping of chronic childhood-onset spinal muscular atrophy to chromosome 5q 11.2. *Nature* 1990;334:540.
 234. Iannaccone ST, Browne RH, Samaha FJ, et al. Prospective study of spinal muscular atrophy before age 6 years. *Pediatr Neurol* 1993;9:187.
 235. Schwentker EP, Gibson DA. The orthopaedic aspects of spinal muscular atrophy. *J Bone Joint Surg Am* 1976;58:32.
 236. Brooke MH. *A clinician's view of neuromuscular diseases*. 2nd ed. Baltimore: Williams and Wilkins, 1986:36.
 237. Pearn J. Classifications of spinal muscular atrophies. *Lancet* 1980;1:919.
 238. Russman BS, Iannaccone ST, Buncher CR, et al. Spinal muscular atrophy. New thoughts on the pathogenesis and classification schema. *J Child Neurol* 1992;7:347.
 239. Burke SW, Jameson VP, Roberts JM, et al. Birth fractures in spinal muscular atrophy. *J Pediatr Orthop* 1986;6:34.
 240. Gilgoff IS, Kahlstrom E, McLaughlin E, Keens TG. Long-term ventilatory support in spinal muscular atrophy. *J Pediatr* 1989;115:904.
 241. Evans GA, Drennan JC, Russman BS. Functional classification and orthopaedic management of spinal muscular atrophy. *J Bone Joint Surg Br* 1981;63:516.
 242. Merlini L, Granata C, Bonfiglioli S, et al. Scoliosis in spinal muscular atrophy. Natural history and management. *Dev Med Child Neurol* 1989;31:301.
 243. Gilliam TC, Brzustowicz LM, Castilla LH, et al. Genetic homogeneity between acute and chronic forms of spinal muscular atrophy. *Nature* 1990;345:823.
 244. Melki J, Sheth P, Abdelhak S, et al. The French spinal muscular atrophy investigators. Mapping of acute (type 1) spinal muscular atrophy to chromosome 5q12 q14. *Lancet* 1990;336:271.
 245. Melki J, Abdelhak S, Sheth P, et al. Gene for chronic proximal spinal muscular atrophies maps to chromosome 5q. *Nature* 1990;344:767.
 246. Burlet P, Burglen L, Clermont O, et al. Large scale deletions of the 5q13 region are specific to Werdnig-Hoffman disease. *J Med Genet* 1996;33:281.
 247. Stewart H, Wallace A, McGaughan J, et al. Molecular diagnosis of spinal muscular atrophy. *Arch Dis Child* 1998;78:531.
 248. Miles JM. Diagnosis and discussion. Type I spinal muscular atrophy (Werdnig-Hoffman disease). *Am J Dis Child* 1993;147:908.
 249. Bowen JR, Forlin E. Spinal muscular atrophy. In: Weinstein SL, ed. *The pediatric spine. Principles and practice*. New York: Raven, 1994:1025.
 250. Granata C, Cornelio F, Bonfiglioli S, et al. Promotion of ambulation of patients with spinal muscular atrophy by early fitting of knee-ankle-foot orthoses. *Dev Med Child Neurol* 1987;29:221.
 251. Thompson CE, Larsen LJ. Recurrent hip dislocation in intermediate spinal atrophy. *J Pediatr Orthop* 1990;10:638.
 252. Brown CJ, Zeller JL, Swank SM, et al. Surgical and functional results of spine fusion in spinal muscular atrophy. *Spine* 1989;14:763.
 253. Granata C, Merlini L, Magni E, et al. Spinal muscular atrophy. Natural history and orthopaedic treatment of scoliosis. *Spine* 1989;14:760.
 254. Phillips DP, Royce DP Jr, Farcy J-P, et al. Surgical treatment of scoliosis in a spinal muscular atrophy population. *Spine* 1990;15:942.
 255. Rodillo E, Marini ML, Heckmatt JZ, Dubowitz V. Scoliosis in spinal muscular atrophy. Review of 63 cases. *J Child Neurol* 1989;4:118.
 256. Riddick MF, Winter RB, Lutter LD. Spinal deformities in patients with spinal muscle atrophy. A review of 36 patients. *Spine* 1982;7:476.
 257. Aprin H, Bowen JR, MacEwen GD, et al. Spine arthrodesis in patients with spinal muscular atrophy. *J Bone Joint Surg Am* 1982;64:1179.
 258. Hensinger RN, MacEwen GD. Spinal deformity associated with heritable neurological conditions. Spinal muscular atrophy. Friedreich's ataxia, familial dysautonomia, and Charcot-Marie-Tooth disease. *J Bone Joint Surg Am* 1976;58:13.
 259. Piasecki JO, Mahinpour S, Lovine DB. Long-term follow-up of spinal fusion in spinal muscular atrophy. *Clin Orthop* 1986;207:44.
 260. Letts M, Rathbone D, Yamashita T, et al. Soft Boston orthosis

- in management of neuromuscular scoliosis. *J Pediatr Orthop* 1992;12:470.
261. Furumasa J, Swank SM, Brown JC, et al. Functional activities in spinal muscular atrophy patients after spinal fusion. *Spine* 1989;14:771.
 262. Askin GN, Hallett R, Hare N, Webb JK. The outcome of scoliosis surgery in the severely physically handicapped child. An objective and subjective assessment. *Spine* 1997;22:44.
 263. Daher YH, Lonstein JE, Winter RB, Bradford DS. Spinal surgery in spinal muscular atrophy. *J Pediatr Orthop* 1985;5:391.
 264. Liu GT, Specht LA. Progressive juvenile segmental spinal muscular atrophy. *Pediatr Neurol* 1992;9:54.
- ### Friedreich Ataxia
265. Fujita R, Hanauer A, Vincent A, et al. Physical mapping of two loci (D9S5 and D9S15) tightly linked to Friedreich ataxia locus (FRDA) and identification of nearby CpG Islands by pulse-field gel electrophoresis. *Genomics* 1991;10:915.
 266. Shapiro F, Bresnan MJ. Current concepts review. Orthopaedic management of childhood neuromuscular disease. Part II: peripheral neuropathies, Friedreich's ataxia and arthrogryposis multiplex congenita. *J Bone Joint Surg Am* 1982;64:949.
 267. Geoffroy G, Barbeau A, Breton G, et al. Clinical description and roentgenologic evaluation of patients with Friedreich's ataxia. *Can J Neurol Sci* 1976;3:279.
 268. Harding AE. Friedreich's ataxia. A clinical and genetic study of 90 families with an analysis of early diagnostic criteria and intrafamilial clustering of clinical features. *Brain* 1981;104:589.
 269. Cady RB, Bobechko WP. Incidence, natural history and treatment of scoliosis in Friedreich's ataxia. *J Pediatr Orthop* 1984;4:673.
 270. Daher YH, Lonstein JE, Winter RB, et al. Spinal deformities in patients with Friedreich ataxia. A review of 19 patients. *J Pediatr Orthop* 1985;5:553.
 271. Filla A, DeMichele G, Caruso G, et al. Genetic data and natural history of Friedreich's disease. A study of 80 Italian patients. *J Neurol* 1990;237:345.
 272. Labelle H, Beauchamp M, LaPierre Duhaime M, Allard P. Pattern of muscle weakness and its relation to loss of ambulatory function in Friedreich's ataxia. *J Pediatr Orthop* 1987;7:496.
 273. Hewer RL. Study of fatal cases of Friedreich's ataxia. *Br Med J* 1968;3:649.
 274. Chamberlain S, Shaw J, Rowland A, et al. Mapping of mutation causing Friedreich's ataxia to human chromosome 9. *Nature* 1988;334:248.
 275. Campuzano V, Montermini L, Molto MD, et al. Friedreich's ataxia: autosomal recessive disease caused by an intronic GAA triplet repeat expansion. *Science* 1996;271:1423.
 276. Hensinger RN, MacEwen GD. Spinal deformity associated with heritable neurological conditions. Spinal muscular atrophy, Friedreich's ataxia, familial dysautonomia, and Charcot-Marie-Tooth disease. *J Bone Joint Surg Am* 1976;58:13.
 277. Labelle H, Tohme S, Duhaime M, et al. Natural history of scoliosis in Friedreich's ataxia. *J Bone Joint Surg Am* 1986;68:564.
 278. Labelle H, Duhaime M, Allard P. Spinal deformities in Friedreich's ataxia. In: Weinstein SL, ed. *The pediatric spine: principles of practice*. New York: Raven, 1994:999.
 280. Lupski JR, de Oca-Luna RM, Slaugenhaupt S, et al. DNA duplication associated with Charcot-Marie-Tooth disease type 1A. *Cell* 1991;66:219.
 281. Vance JM, Nicholson GA, Yamaoka LH, et al. Linkage of Charcot-Marie-Tooth neuropathy type 1A to chromosome 17. *Exp Neurol* 1989;104:186.
 282. Vance JM. Hereditary motor and sensory neuropathies. *J Med Genet* 1991;28:1.
 283. Patel PI, Roa BB, Welcher AA, et al. The gene for the peripheral myelin protein pmp-22 is a candidate for Charcot-Marie-Tooth disease type 1A. *Nat Genet* 1992;1:159.
 284. Timmerman V, Nelis E, Van Hul W, et al. The peripheral myelin protein gene pmp-22 is contained within the Charcot-Marie-Tooth disease type 1A duplication. *Nat Genet* 1992;1:171.
 285. Valentijn LJ, Bolhuis PA, Zorn I, et al. The peripheral myelin gene PMP-22/GAS-3 is duplicated in Charcot-Marie-Tooth disease type 1A. *Nat Genet* 1992;1:166.
 286. Roa BB, Garcia CA, Suter U, et al. Charcot-Marie-Tooth disease type 1A. Association with a spontaneous point mutation in the PMP22 gene. *N Engl J Med* 1993;329:96.
 287. Alexander TJ, Johnson KA. Assessment and management of pes cavus in Charcot-Marie-Tooth disease. *Clin Orthop* 1989;246:273.
 288. Ghanem I, Zeller R, Seringe R. The foot in hereditary motor and sensory neuropathies in children. *Rev Chir Orthop Reparatrice Appar Mot* 1996;82:152.
 289. Mann RA, Missirian J. Pathophysiology of Charcot-Marie-Tooth disease. *Clin Orthop* 1988;234:221.
 290. McCluskey WP, Lovell WW, Cummings RJ. The cavovarus foot deformity. Etiology and management. *Clin Orthop* 1989;247:27.
 291. Paulos L, Coleman SS, Samuelson KM. Pes cavovarus. Review of a surgical approach using selective soft-tissue procedures. *J Bone Joint Surg Am* 1980;62:942.
 292. Sabir M, Lyttle D. Pathogenesis of Charcot-Marie-Tooth disease. Gait analysis and electrophysiologic, genetic, histopathologic, and enzyme studies in a kinship. *Clin Orthop* 1984;184:223.
 293. Price AE, Maisel R, Drennan JC. Computed tomographic analysis of the pes cavus. *J Pediatr Orthop* 1993;13:646.
 294. Bost FC, Schottstaedt ER, Larsen LJ. Plantar dissection. An operation to release the soft tissues in recurrent or recalcitrant talipes equinovarus. *J Bone Joint Surg Am* 1960;42:151.
 295. Roper BA, Tibrewal SB. Soft tissue surgery in Charcot-Marie-Tooth disease. *J Bone Joint Surg Br* 1989;71:17.
 296. Richardson EG. Neurogenic disorders. In: Crenshaw AH, ed. *Campbell's operative orthopaedics*. 8th ed, vol. 4. St. Louis: CV Mosby, 1992:2777.
 297. Angus PD, Cowell HR. Triple arthrodesis. A critical long-term review. *J Bone Joint Surg Br* 1986;68:260.
 298. Mann DC, Hsu JD. Triple arthrodesis in the treatment of fixed cavovarus deformity in adolescent patients with Charcot-Marie-Tooth disease. *Foot Ankle* 1992;13:1.
 299. Gould N. Surgery in advanced Charcot-Marie-Tooth disease. *Foot Ankle* 1984;4:267.
 300. Wetmore RS, Drennan JC. Long-term results of triple arthrodesis in Charcot-Marie-Tooth Disease. *J Bone Joint Surg Am* 1989;71:417.
 301. Wukich DK, Bowen JR. A long-term study of triple arthrodesis for correction of pes cavovarus in Charcot-Marie-Tooth disease. *J Pediatr Orthop* 1989;9:433.
 302. Saltzman CL, Fehrle MJ, Cooper RR, Spencer EC, Ponseti IV. Triple arthrodesis: twenty-five and forty-four-year average follow-up of the same patients. *J Bone Joint Surg Am* 1999;81:1391.
- ### Hereditary Motor Sensory Neuropathies
279. Warner LE, Garcia CA, Lupski JR. Hereditary peripheral neuropathies: clinical forms, genetics, and molecular mechanisms. *Ann Rev Med* 1999;50:263.

303. Hall JE, Calvert PT. Lambrinudi triple arthrodesis. A review with particular reference to the technique of operation. *J Pediatr Orthop* 1987;7:19.
304. Cole WH. The treatment of claw-foot. *J Bone Joint Surg* 1940; 22:895.
305. Pailthorpe CA, Benson MKD'A. Hip dysplasia in hereditary motor and sensory neuropathies. *J Bone Joint Surg Br* 1992;74: 538.
306. Walker JL, Nelson KR, Heavilon JA, et al. Hip abnormalities in children with Charcot-Marie-Tooth disease. *J Pediatr Orthop* 1994;14:54.
307. Kumar SJ, Marks HG, Bowen JR, MacEwen GD. Hip dysplasia associated with Charcot-Marie-Tooth disease in the older child and adolescent. *J Pediatr Orthop* 1985;5:511.
307. Fuller JE, DeLuca PA. Acetabular dysplasia and Charcot-Marie-Tooth disease in a family. A report of four cases. *J Bone Joint Surg Am* 1995;77:1087.
309. Osebold WR, Lester EL, Watson P. Dynamics of hip joint remodeling after Chiari steotomy. 10 patients with neuromuscular disease followed for 8 years. *Acta Orthop Scand* 1997;68: 128.
310. Trumble SJ, Mayo KA, Mast JW. The periacetabular osteotomy. Minimum 2-year follow-up in more than 100 hips. *Clin Orthop* 1999;363:54.
311. Daher YH, Lonstein JE, Winter RB, Bradford DS. Spinal deformities in patients with Charcot-Marie-Tooth disease. A review of 12 patients. *Clin Orthop* 1986;202:219.
312. Hensinger RN, MacEwen GD. Spinal deformity associated with heritable neurological conditions. Spinal muscular atrophy, Friedreich's ataxia, familial dysautonomia, and Charcot-Marie-Tooth disease. *J Bone Joint Surg Am* 1976;58:13.
313. Walker JL, Nelson KR, Stevens DB, et al. Spinal deformity in Charcot-Marie-Tooth disease. *Spine* 1994;19:1044.
314. Krishna M, Taylor JF, Brown MC, et al. Failure of somatosensory-evoked-potential monitoring in sensorimotor neuropathy. *Spine* 1991;16:479.
315. Brown RE, Zamboni WA, Zook EG, Russell RC. Evaluation and management of upper extremity neuropathies in Charcot-Marie-Tooth disease. *J Hand Surg* 1992;17-A:523.
316. Miller MJ, Williams LL, Slack SL, Nappi JF. The hand in Charcot-Marie-Tooth disease. *J Hand Surg Br* 1991;16:191.
317. Mackin GA, Gordon MJ, Neville HE, Ringel SP. Restoring hand function in patients with severe polyneuropathy: the role of electromyography before tendon transfer surgery. *J Hand Surg Am* 1999;24:732.
318. Gaebler JW, Kleiman MB, French ML, et al. Neurologic complications in oral polio vaccine recipients. *J Pediatr* 1986;108: 878.
319. Strebel PM, Sutter RW, Cochi SL, et al. Epidemiology of poliomyelitis in the United States one decade after the last reported case of indigenous wild virus-associated disease. *Clin Infect Dis* 1992;14:568.
320. Sharrard WJW. Muscle recovery in poliomyelitis. *J Bone Joint Surg Br* 1955;37:63.
321. Sharrard WJW. The segmental innervation of the lower limb musculature in man. *Ann R Coll Surg Engl* 1964;35:106.
322. Sharrard WJW. Posterior iliopsoas transplantation in the treatment of paralytic dislocation of the hip. *J Bone Joint Surg Br* 1964;46:426.
323. Kojima H, Furuta Y, Fujita M, et al. Onuf's motor neuron is resistant to poliovirus. *J Neurol Sci* 1989;93:85.
324. Johnson EW Jr. Results of modern methods of treatment of poliomyelitis. *J Bone Joint Surg* 1945;27:223.
325. D'Souza H, Shah NM. Circumferential periosteal sleeve resection: results in limb-length discrepancy secondary to poliomyelitis. *J Pediatr Orthop* 1999;19:215.
326. Schottstaedt ER, Larsen LJ, Bost FC. Complete muscle transportation. *J Bone Joint Surg Am* 1955;37:897.
327. Herndon CH. Tendon transplantation of the knee and foot. *Instr Course Lect* 1961;18:145.
328. Mayer L. The physiologic method of tendon transplants. Review after forty years. *AAOS Instr Course Lect* 1956;13:116.
329. Kuhlmann RF, Bell JF. A clinical evaluation of tendon transplantations for poliomyelitis affecting the lower extremities. *J Bone Joint Surg Am* 1952;34:915.
330. Watts HG. Management of common third world orthopaedic problems. Paralytic poliomyelitis, tuberculosis of bones and joints, Hansen's disease (leprosy), and chronic osteomyelitis. *Instr Course Lect* 1992;41:471.
331. Liu T-K, Yang R-S, Sun J-S. Long-term results of the Steindler flexorplasty. *Clin Orthop* 1993;276:104.
332. Waring WP, Werner RA. Clinical management of carpal tunnel syndrome in patients with long-term sequelae of poliomyelitis. *J Hand Surg Am* 1989;14:865.
333. Lau JHK, Parker JC, Hsu LCS, Leong JCY. Paralytic hip instability in poliomyelitis. *J Bone Joint Surg Br* 1986;68:528.
334. Asirvatham R, Watts HG, Rooney RJ. Rotation osteotomy of the tibia after poliomyelitis. *J Bone Joint Surg Br* 1990;72: 409.
335. Asirvatham R, Rooney RJ, Watts HG. Proximal tibial extension medial rotation osteotomy to correct knee flexion contracture. *J Pediatr Orthop* 1991;11:646.
336. Mehta SN, Mukherjee AK. Flexion osteotomy of the femur for genu recurvatum after poliomyelitis. *J Bone Joint Surg Br* 1991; 73:200.
337. Men H-X, Bian C-H, Yang C-D, et al. Surgical treatment of the flail knee after poliomyelitis. *J Bone Joint Surg Br* 1991;73: 195.
338. Shahcheraghi GH, Jarid M, Zeighami B. Hamstring tendon transfer for quadriceps femoris transfer. *J Pediatr Orthop* 1996; 16:765.
339. Drennan JC. Poliomyelitis. In: Drennan JC, ed. *The child's foot and ankle*. New York: Rowen Press, 1992:305.
340. Adelaar RS, Dannelly EA, Meunier PA, et al. A long-term study of triple arthrodesis in children. *Orthop Clin North Am* 1996; 4:895.
341. Asirvatham R, Watts HG, Rooney RJ. Tendoachilles tenodesis to the fibula. A retrospective study. *J Pediatr Orthop* 1991;11: 652.
342. DeHeus JAC, Marti RK, Besselaar PP, et al. The influence of subtalar in triple arthrodesis on the tibiotalar joint. A long-term follow-up study. *J Bone Joint Surg Br* 1997;79:644.
343. El-Batonty MM, Aly El-S, El-Lakkany MR, et al. Triple arthrodesis for paralytic valgus; a modified technique: brief report. *J Bone Joint Surg Br* 1988;70:493.
344. Pandey AK, Pandey S, Prasnd V. Calcaneal osteotomy and tendon sling for the management of calcaneus deformity. *J Bone Joint Surg Am* 1989;71:1192.
345. Westin GW, Dingeman RD, Gausewitz SH. The results of tendodesis of the tendo achillis to the fibular for paralytic pes calcaneus. *J Bone Joint Surg Am* 1988;70:320.
346. Chen P-Q, Shen Y-S. Poliomyelitis scoliosis. In: Weinstein SL, ed. *The pediatric spine. Principles and practice*. New York: Raven, 1994:1069.
347. Mayer PJ, Edwards JW, Dove J, et al. Post-poliomyelitis paralytic scoliosis. A review of curve patterns and results of surgical treatment in 118 consecutive patients. *Spine* 1981;6:573.
348. Eberle CF. Failure of fixation after segmental spinal instrumentation without arthrodesis in the management of paralytic scoliosis. *J Bone Joint Surg Am* 1988;70:696.

Poliomyelitis

349. DeWald RL, Faut M. Anterior and posterior spinal surgery for paralytic scoliosis. *Spine* 1979;4:401.
350. Leong JCY, Wilding K, Mok CD, et al. Surgical treatment of scoliosis following poliomyelitis: a review of 110 cases. *J Bone Joint Surg Am* 1981;63:726.
351. O'Brien JP, Yau APMC, Gertzbiel S, et al. Combined staged anterior and posterior correction of the spine in scoliosis following postmyelitis. *Clin Orthop* 1975;110:81.
352. Eberle CF. Pelvic obliquity and the unstable hip after poliomyelitis. *J Bone Joint Surg Br* 1982;64:300.
353. Gau YL, Lonstein JE, Winter RB, et al. Luque-Galveston procedure for correction and stabilization of neuromuscular scoliosis and pelvic obliquity. A review of 68 patients. *J Spinal Disord* 1991;4:399.

Postpoliomyelitis Syndrome

354. Perry J, Barnes G, Gronley JK. The postpolio syndrome. An overuse phenomenon. *Clin Orthop* 1988;233:145.



18

IDIOPATHIC AND CONGENITAL SCOLIOSIS

PETER O. NEWTON
DENNIS R. WENGER

CHILDHOOD AND ADOLESCENT SCOLIOSIS 677

Definitions 678
Etiology 678
Classification 681
Clinical Features 682

IDIOPATHIC SCOLIOSIS—DETAILS OF DIAGNOSIS AND TREATMENT 693

Prevalence and Natural History of Idiopathic Scoliosis 693

School Screening for Scoliosis 697
Treatment of Idiopathic Scoliosis 698
Complications 721

CONGENITAL SCOLIOSIS—DETAILS OF DIAGNOSIS AND TREATMENT 724

Definition 724
Classification 725
Natural History 727
Treatment 727

CHILDHOOD AND ADOLESCENT SCOLIOSIS

“Idiopathic scoliosis” defines a common and potentially severe musculoskeletal disorder of unknown etiology, the diagnosis and treatment of which have been central in the development of orthopaedic surgery as a specialty. In its milder forms scoliosis may produce only trunk shape change, but when severe, can be markedly disfiguring as well as producing cardiac and pulmonary compromise (Fig. 18-1). The goal of this chapter is to present the key elements in diagnosis, natural history, and treatment of both idiopathic and congenital scoliosis.

The etiology of typical adolescent scoliosis remains unknown; thus, the term “idiopathic” remains appropriate. Scoliosis can also be classified based on associated conditions, since it occurs in many neuromuscular disorders (cerebral palsy, muscular dystrophy, and others) as well as in association with generalized diseases and syndromes (neurofibromatosis, Marfan syndrome, and bone dysplasia). Congenital scoliosis, caused by failure in vertebral formation or segmentation, causes a more mechanically understandable type of scoliosis.

The etiology of a scoliotic deformity (idiopathic, neuromuscular, syndrome related, and congenital) largely dictates its natural history, including the risk for and rate of curve progression, as well as the effect the curve will have on the cardiopulmonary function, mobility, and appearance. Although scoliosis includes both sagittal plane and torsional malalignment of the spinal column, the deformity is most readily noted as frontal plane deformity. Better understand-

P. O. Newton: Department of Orthopaedic Surgery, University of California—San Diego; Department of Orthopaedic Surgery, Children’s Hospital and Health Center, San Diego, California 92123.

D. R. Wenger: Department of Orthopaedic Surgery, University of California—San Diego; Pediatric Orthopedics, Children’s Hospital and Health Center, San Diego, California 92123.

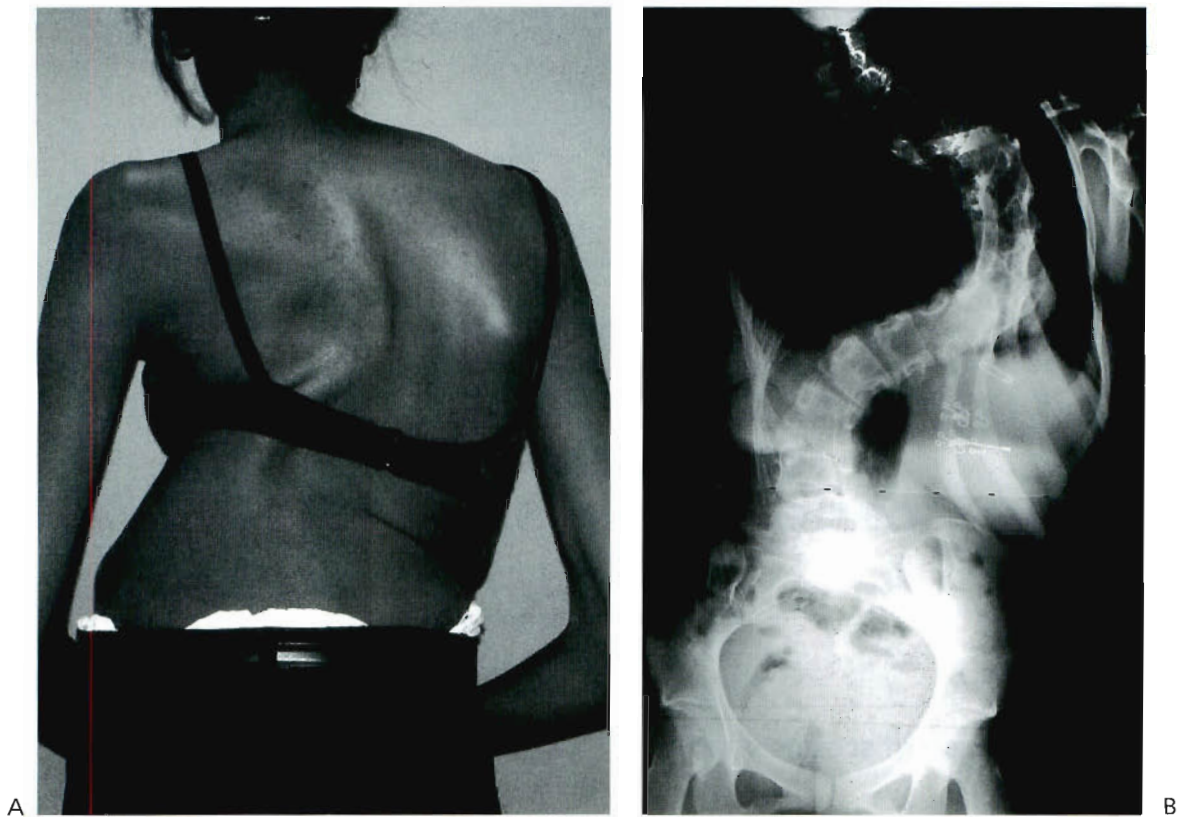


FIGURE 18-1. A: This 16-year-old female with severe scoliosis refused early surgical treatment and had severe curve progression. Her clinical examination demonstrates marked trunk and rib cage deformity, and she had reduced pulmonary function. B: The posteroanterior radiograph demonstrates a right thoracic curvature of 125 degrees.

ing of the three-dimensional nature of scoliosis has led to many recent advances in its treatment.

Definitions

The normal spine is straight in the frontal plane, but has sagittal plane contours including thoracic kyphosis averaging 30 to 35 degrees (range 10 to 50 degrees, T5–T12) and lumbar lordosis averaging 50 to 60 degrees (range 35 to 80 degrees, T12–S1) (1–3). The scoliotic spine deviates from midline in the frontal plane, and rotates maximally at the apex of the curve (4). The vertebral rotation toward the convexity of the curve, through the attached ribs, produces the typical chest wall prominence (Adams sign) that allows early diagnosis (5,6) (Fig. 18-2).

In the past, it was thought that the lateral curvature of scoliosis was also kyphotic (increased roundback). It is now understood that the apparent “hump” on the back is due to rib prominence secondary to the rotational deformity of the vertebrae and rib cage, and that most thoracic idiopathic scoliosis is associated with a *decrease* in normal thoracic kyphosis (7,8). Dickson and others have postulated that an early evolution to lordosis in the normally kyphotic thoracic spine leads to an unstable mechanical environment, leading

to rotational collapse (9,10) (Fig. 18-3). This is not to say that all thoracic scoliosis is hypokyphotic, since many congenital, neuromuscular, and a few idiopathic cases have a true kyphotic component.

In addition to global deformity of the spine and trunk, wedging of individual discs and vertebral bodies develops, due to the Hueter-Volkman effect (suppression of growth on the concave side of the curve) (11) (Fig. 18-4). This includes asymmetric growth and/or remodeling of the vertebral bodies, pedicles, laminae, and facet joints, as well as the transverse and spinous processes.

Etiology

Although the etiology of idiopathic scoliosis remains unknown, substantial research has been performed with many theories proposed. These range from genetic factors to disorders of bone, muscles, and disc, as well as growth abnormalities and central nervous system causes.

Genetic Factors

Several studies have demonstrated an increased incidence of scoliosis in the family members of affected individuals,

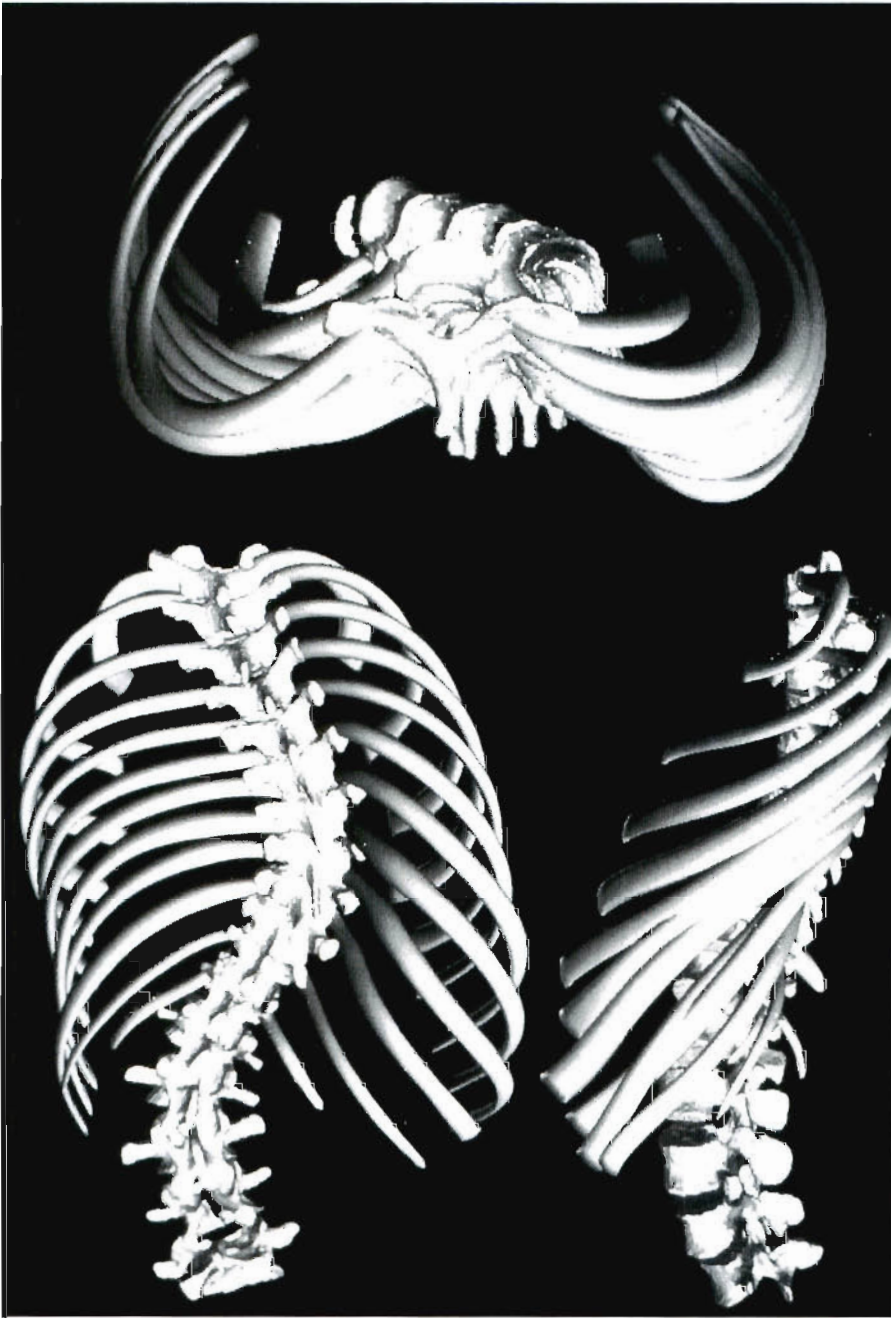


FIGURE 18-2. A three-dimensional reconstruction of the scoliotic spine and trunk demonstrates the three-plane deformity of the spine and attached ribs. The torsional deformity is maximal at the apex of the curvature. (Courtesy of St. Justine Hospital, Montreal, Canada.)

confirming a genetic etiologic component to the etiology of scoliosis (12–16). Risenborough and Wynne-Davies found scoliosis in 11.1% of first-degree relatives of 207 patients with idiopathic scoliosis (16). These familial studies suggest a polygenic inheritance pattern.

Examination of scoliosis in birth twins has led to further confirmation of genetic etiologic factors. In a meta-analysis of scoliosis in twins, Kesling and Reinker demonstrated 73% concordance in 37 pairs of monozygotic twins. They found that in 37 pairs of identical twins in which at least one twin was identified with scoliosis, 27 of the pairs had

both twins affected. However, only 36% of the 31 dizygotic twins were concordant. In addition, the severity of the scoliosis was statistically similar for the monozygotic twins, but not for the dizygotic twins (17). Inoue et al. demonstrated even greater concordance in twins. DNA fingerprinting confirmed the zygosity, and found concordance of idiopathic scoliosis in 92% of monozygotic and 63% of dizygotic twins (18). Despite this confirming evidence of a genetic etiology, the genes and gene products responsible for the development of idiopathic scoliosis remain unknown.

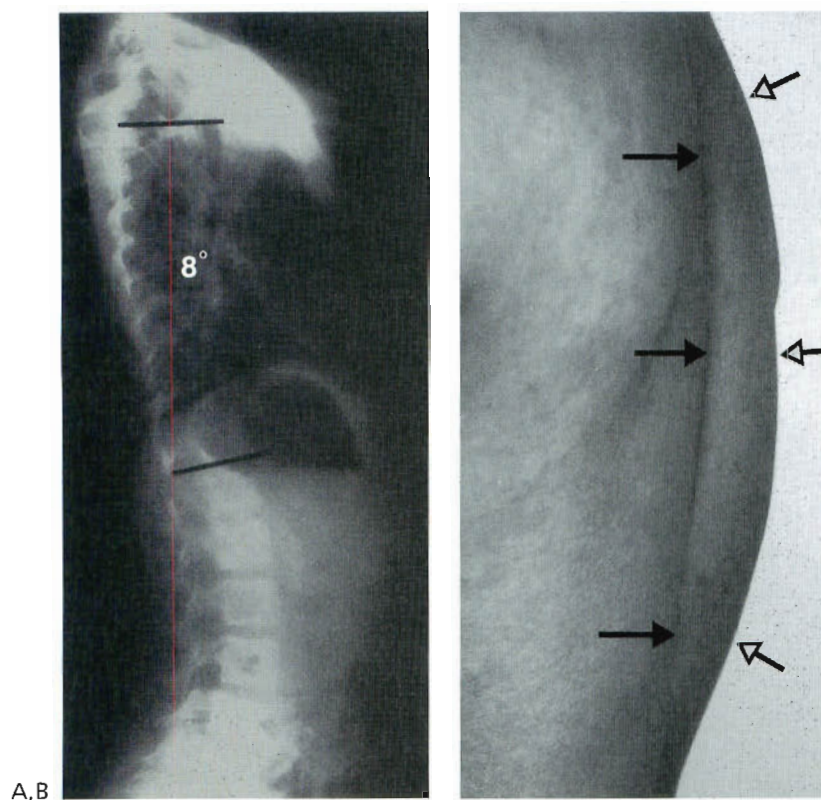


FIGURE 18-3. A: This standing lateral radiograph demonstrates the decreased kyphosis of the thoracic spine ("hypokyphosis"), commonly seen in thoracic curves in patients with idiopathic scoliosis. B: An oblique view clinical photograph of the patient demonstrates both the prominence of the rib cage due to the rotational deformity (open arrows), as well as the flattening of the thoracic kyphosis along the midline (closed arrows).

Tissue Deficiencies

Competing theories propose that the primary pathology of scoliosis is centered in each of the structural tissues of the spine (bone, muscle, ligament/disc). There are known con-

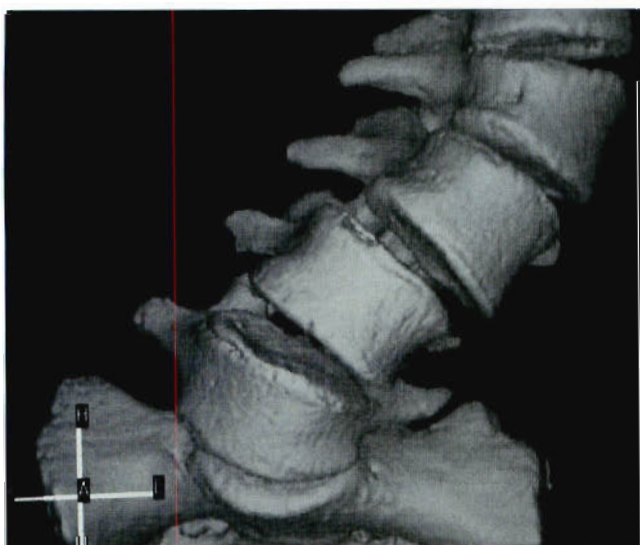


FIGURE 18-4. A three-dimensional CT scan in a patient with severe lumbar scoliosis demonstrates the wedging of both the discs and vertebral bodies, which occurs through asymmetric loading and growth (Hueter-Volkman effect).

ditions in which each of these tissues are pathologic and associated with scoliosis. For example, fibrous dysplasia (bone collagen abnormality) resulting in dysplastic, misshapened vertebrae (19); muscle disorders such as Duchenne muscular dystrophy leading to a collapsing scoliosis; and soft tissue-collagen disorders, such as Marfan syndrome, each have a clear association with the development of scoliosis.

In Marfan syndrome there is a defective gene coding for fibrillin. Fibrillin is found in many soft tissues including ligament, cartilage, and periosteum (20). The fibrillin abnormality found in Marfan syndrome is associated with scoliosis in 55 to 63% of cases (21,22). Although fibrillin has been ruled out as a cause of idiopathic scoliosis (23), similar subtle deficiencies in any of the tissues of the spine could result in idiopathic scoliosis (24). For instance, several (25–27) have suggested that adolescent idiopathic scoliosis (AIS) may be related to osteopenia. They found the vertebral bone mineral density to be lower in girls ages 12 to 14 years with scoliosis compared to matched controls, with the density lower not only in the vertebrae, but also in the proximal femur (25). The mechanism by which osteopenia alone leads to scoliosis, however, remains undefined.

Vertebral Growth Abnormality Theories

Abnormalities of spinal growth mechanisms also provide an attractive etiology theory because scoliosis development and

progression are temporally related to the time of rapid adolescent growth (28,29). Differential growth rates between the right and left sides of the spine could generate an asymmetry that would be accentuated with asymmetric biomechanical loading and the Heuter-Volkman effect (11,30,31). Milner and Dickson (32), as well as others (10,31,33–35), have postulated that the etiology of scoliosis relates to the development of relative thoracic lordosis. Dickson believes that anterior spinal growth outpaces posterior growth, producing hypokyphosis with subsequent buckling of the vertebral column, leading to the rotational deformity of scoliosis; however, the cause for this theorized “mismatch” of anterior and posterior spinal column growth has not been presented, and may be secondary rather than primary. Interestingly, it has been documented that thoracic kyphosis tends to decrease in normal children during the normal adolescent growth spurt (36). Thus, irregularities in the changing sagittal shape of the spine during the rapid period of adolescent growth may be important in the development of scoliosis.

Several studies suggest that adolescents with scoliosis are taller than their peers (37–42). Increased levels of growth hormones (43,44) and characteristic body morphometry (thin, physically less developed appearance) (45–49) may also relate to scoliosis development.

Central Nervous System Theories

Clearly, disorders of the brain, spinal cord, and muscles may result in scoliosis with the role of the central nervous system in idiopathic scoliosis having been studied in detail (50–57). Goldberg et al. noted greater asymmetry of the cerebral cortices in scoliotic patients (55). Also, abnormalities in equilibrium and vestibular function have been noted in patients with scoliosis (50,58–63); however, it is difficult to know if these findings are primary or secondary (64). Woods et al. have suggested a neurologic etiology to scoliosis based on the surprising finding that hearing-impaired children seem to have a lower incidence of scoliosis (63). Syringomyelia is associated with an increased incidence of scoliosis (65,66) possibly due to direct pressure on the sensory or motor tracts of the spinal cord. Alternatively, there may be no relation to the dilation of the central canal, but instead, brain stem irritation from an associated Chiari malformation or enlargement of the fourth ventricle of the brain as the cause.

Recently, it has been postulated that melatonin and the pineal gland may be related to scoliosis. This is based on research of pinealectomy in chickens that resulted in a high incidence of severe scoliosis (67–69). In these studies, presumably melatonin deficiency led to scoliosis in the chicken (70). Melatonin receptors are located in the brainstem and spinal cord dorsal gray matter, areas associated with postural control. Subsequent studies of human melatonin levels have been conflicting and inconclusive. Machida et al. found

lower than normal melatonin concentration in the serum of patients with progressive scoliosis compared to those with stable curves (71). In contrast, Hilibrand et al. (72) and Fagan et al. (73) found no difference in urine melatonin levels between patients with scoliosis and normal control subjects. In addition, Bagnall et al. found no difference in serum melatonin levels of patients with scoliosis (74). Thus confirmation that melatonin deficiency in humans is associated with scoliosis, as seen in chickens, is lacking.

Histologic analysis of paraspinous muscles has revealed denervation changes suggestive of a neuropathic cause (75), as well as ultrastructural changes in the sarcolemma at the myotendinous junction, supporting the concept of a primary muscle disorder (76). As in the findings relating to equilibrium, it is difficult to determine a causal relationship, and the findings in muscle could be secondary, reflecting the muscle's response to asymmetric spine loading (77).

In summary, the etiology of scoliosis remains puzzling. From a biomechanical standpoint the vertebral column is a naturally unstable construct, made of multiple mobile segments. As Stagnara has noted, one should not be surprised that a minor disturbance in the structure, support system, or growth of the spine could lead to scoliosis, particularly in a complex structure where the “normal” state includes multiple curves (sagittal plane), and is based on an oblique foundation (the sacrum) (78). There are likely several causes of idiopathic scoliosis, and active research continues in an attempt to find a unifying theory as to its cause.

Classification

Curve Location

Scoliotic deformities assume a variety of curve patterns, and several useful classification systems have been developed. The terminology committee of the Scoliosis Research Society (SRS) defines the following technical description of curve locations (this is in contrast to curve pattern descriptions developed for the purpose of planning surgical correction; see “Surgical Correction of Idiopathic Scoliosis”):

- Cervical: apex between C2 and C6
- Cervicothoracic: apex between C7 and T1
- Thoracic: apex between T2 and T11
- Thoracolumbar: apex between T12 and L1
- Lumbar: apex between L2 and L4
- Lumbosacral: apex at L5 or below

The apex of a curve defines its center, and is the most laterally deviated disc or vertebra of the curve. Usually a single vertebra can be defined, but in other cases a pair of vertebrae are at the apex (in this case the “apical disc” is used to define the level of the apex). The apical vertebra(e) are also the most horizontal. The end vertebrae of a curve define the proximal and distal extent of a curve, and are

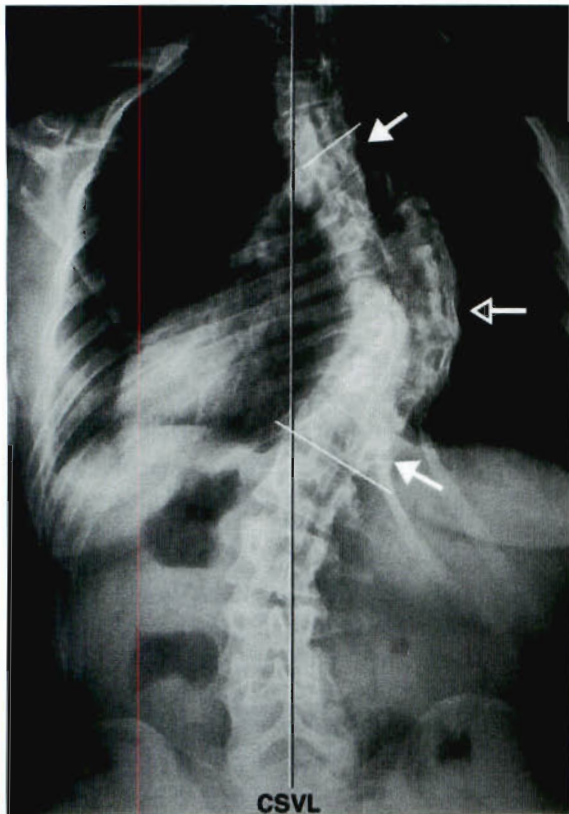


FIGURE 18-5. The end vertebrae (solid arrows), apical vertebra (open arrow), and central sacral vertical line (CSVL) are demonstrated on this upright film. The CSVL is commonly used to determine the distal-most extent of a spinal fusion that classically extends to the “stable vertebra.” In this radiograph, the stable vertebra is arguably L1 or L2.

determined by locating the vertebrae most tilted from the horizontal (these vertebrae are used to make the Cobb measurement). The central sacral vertical line, a vertical line which bisects the sacrum, is used to assess the balance of the spine in relation to its base (the pelvis) (Fig. 18-5).

Age at Onset

Age at diagnosis is also used to define idiopathic scoliosis groups as follows:

- Infantile (ages 0 to 3 years)
- Juvenile (age 4 to 10 years)
- Adolescent (11 to 17 years)
- Adult (≥ 18 years)

The age when idiopathic scoliosis develops is one of the most important factors in determining the natural history of the disorder, with early onset cases more likely to be progressive. Scoliosis onset before the adolescent growth spurt is more likely to have an underlying spinal cord abnormality as the cause of the deformity with the incidence of

abnormality approximately 20% in the juvenile group and as high as 50% in the infantile group (79).

Primary and Secondary, Structural and Nonstructural Curves

Curves may also be described as primary or secondary. The primary curve is the first to develop; however, at times two or even three curves of equal severity exist that make the determination of a primary versus secondary curve difficult. Secondary or compensatory curves develop after formation of the primary curve as a means of balancing the head and trunk over the pelvis. Similar compensation occurs in the sagittal plane in which the typical lordotic thoracic curve may end both cranially and caudally with a junctional kyphosis. Sagittal plane abnormalities have only recently been well understood and considered when planning surgical correction.

The terms structural and nonstructural have also been used to describe the flexibility of scoliotic curves with structural curves being more rigid (i.e., do not correct well with side-bending). The degree of curve rigidity that differentiates a structural and nonstructural curve, however, has not been clearly defined.

Etiologic Classification

Classification of scoliosis by etiology may be broadly described as idiopathic (or idiopathic-like), neuromuscular, syndrome related, and congenital. It is important to consider a patient presenting with scoliosis as a patient presenting with a sign (i.e., scoliosis), rather than a diagnosis. Most scoliosis (approximately 80%) is idiopathic; however, the remaining cases are associated with a wide variety of disorders in which scoliosis is often the presenting complaint.

The SRS has classified scoliosis as associated with each of the diagnoses seen in Table 18-1. The scoliosis associated with these conditions is discussed in other chapters of this text. Neuromuscular disorders of either neuropathic or myopathic etiology make up a large proportion of the non-idiopathic causes of scoliosis in childhood. Intra- or extraspinal tumors or abnormalities must also be considered as a cause of scoliosis. Congenital scoliosis and kyphosis also may lead to progressive spine deformity. An awareness of each potentially associated condition helps when analyzing the various proposed etiologic factors in idiopathic scoliosis, and, more importantly, the diagnosis of idiopathic scoliosis requires the exclusion of these conditions.

Clinical Features

History

Understanding what prompted a physician visit for evaluation of scoliosis is key. For example, in North America, a

TABLE 18-1. CLASSIFICATION OF SCOLIOSIS

Idiopathic	Fiber-type disproportion	Osteochondrodystrophies
Infantile	Congenital hypotonia	Achondroplasia
Resolving	Myotonia dystrophica	Spondyloepiphyseal dysplasia
Progressive	Other	Diastrophic dwarfism
Juvenile	Congenital	Mucopolysaccharidoses
Adolescent	Failure of formation	Other
Muscular	Wedge vertebra	Tumor
Neuropathic	Hemivertebra	Benign
Upper motor neuron	Failure of segmentation	Malignant
Cerebral palsy	Unilateral bar	Rheumatoid disease
Spinocerebellar degeneration	Bilateral (fusion)	Metabolic
Friedreich disease	Mixed	Rickets
Charcot-Marie-Tooth disease	Associated with neural tissue defect	Juvenile osteoporosis
Roussy-Levy disease	Myelomeningocele	Osteogenesis imperfecta
Syringomyelia	Meningocele	Related to lumbosacral area
Spinal cord tumor	Spinal dysraphism	Spondylolysis
Spinal cord trauma	Diastematomyelia	Spondylolisthesis
Other	Other	Other
Lower motor neuron	Neurofibromatosis	Thoracogenic
Poliomyelitis	Mesenchymal	Postthoracoplasty
Other viral myelitides	Marfan syndrome	Postthoracotomy
Traumatic	Homocystinuria	Other
Spinal muscular atrophy	Ehlers-Danlos syndrome	Hysterical
Werdig-Hoffmann disease	Other	Functional
Kugelberg-Welander disease	Traumatic	Postural
Myelomeningocele (paralytic)	Fracture or dislocation (nonparalytic)	Secondary to short leg
Dysautonomia (Riley-Day syndrome)	Postirradiation	Due to muscle spasm
Other	Other	Other
Myopathic	Soft tissue contractures	
Arthrogryposis	Postemphyema	
Muscular dystrophy	Burns	
Duchenne (pseudohypertrophic)	Other	
Limb-girdle		
Fascioscapulohumeral		

screening examination (either in school or at a routine primary care visit) often leads to referral. History-taking should include questions about family history of scoliosis, recent growth, and the physical changes of puberty (onset of menses). When an affected sibling or parent has scoliosis, prevalence increases seven times (sibling) and three times (parent), respectively, compared to the general population (14). A record of height increases over the prior few years is important in predicting remaining spinal growth and the risk for curve progression (80). This information may be available from the primary care physician or, at times, from measurements on the wall/door marked in the family's home. The onset of menses forms an important maturational time point in females (81). The family history, as well as the review of systems, should identify disorders known to be associated with scoliosis (Table 18-1).

The presence or absence of severe back pain is important, because most idiopathic scoliosis patients have only mild discomfort. Patients seen after scoliosis has been diagnosed (in a screening setting) commonly develop "pain" that continues until the exact diagnosis, and particularly the prog-

nosis, have been clarified by an orthopaedic consultant who can provide reassurance. Despite the common belief that mild idiopathic scoliosis is not painful, a recent study suggests that adolescents with mild curves often report discomfort of a mild fatigue variety. Ramirez et al. noted back pain in 23% of 2,442 patients with "idiopathic" scoliosis. Only 9% of those with pain were subsequently found to have an underlying pathologic condition to explain it (diagnoses such as spondylolysis/spondylolisthesis, Scheuermann kyphosis, syringomyelia, herniated disc, tethered cord, and intraspinal tumor) (82).

In evaluating a child with scoliosis, a significant complaint of back pain is a clue that should raise one question, "Is this truly an idiopathic curve?" A child or adolescent who presents with *severe* back pain, and is subsequently found to have scoliosis requires a very careful history, physical examination, and radiographic study (a bone scan and MRI study may be required), because an underlying etiologic cause is more likely (82–84). However, the clinician must distinguish between "severe pain" (requiring further workup) and the mild fatigue pain (noted above) reported

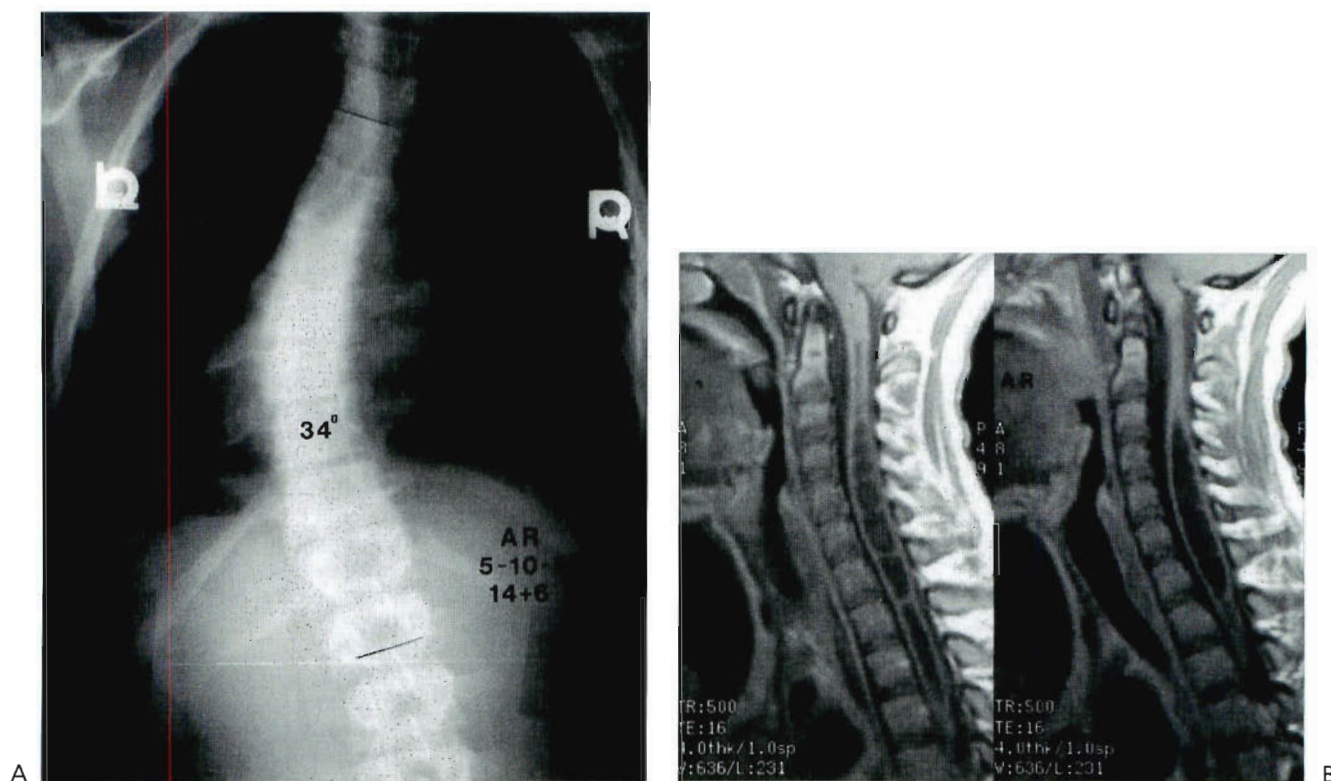


FIGURE 18-6. A: This 14-year-6-month-old male who presented with a 34 degree left thoracic scoliosis was asymptomatic with a normal physical examination, except for the absence of a left abdominal reflex. This finding, in addition to the presence of a left thoracic curve—an “abnormal” pattern for idiopathic scoliosis—was the indication for further evaluation with an magnetic resonance imaging (MRI) scan. B: The sagittal MRI scan showed a large cervical spinal cord syrinx.

by Ramirez et al. and others (82,85). During adolescence, activity-related musculoskeletal low back pain occurs at a frequency greater than in childhood, but less than in adults (86,87).

Age at onset, rate of curve progression, and the presence of neurologic symptoms and signs are the most useful findings in identifying nonidiopathic scoliosis. In younger patients (less than 10 years) with a neurologic cause, actual neurologic findings on physical examination are often absent, and often the spinal curvature itself must be considered the initial sign of a neural axis abnormality (79,88–90). The most common intraspinal abnormality found in this age group is syringomyelia (dilation of the central spinal canal) with an associated Chiari malformation (brain stem below the level of the foramen magnum) (Fig. 18-6).

Rapid development of a severe curve suggests a nonidiopathic type of scoliosis. Neurologic symptoms such as weakness, sensory changes, and balance/gait disturbance suggest intraspinal pathology (syringomyelia, tethered cord, tumor, etc.) as the cause of spinal curvature (83,89,90). The neurologic history should therefore focus on difficulties with walking, running, and stair-climbing. A history of radiating pain, numbness, and tingling in the limbs, and difficulties with bowel or bladder control, should also be sought.

Physical Examination

Physical examination of a scoliosis patient includes evaluation of trunk shape, trunk balance, the neurologic system, limb length, skin markings, and associated skeletal abnormalities. Assessment of pubertal development includes assessment of the stages of breast development and the presence of axillary/pubertal hair (Tanner stages). This can be done discretely without fully undressing the patient. Examination of girls while dressed in a two-piece swimsuit (patient instructed at time of telephone appointment to wear a swimsuit for the examination) reduces anxiety and apprehension, yet allows assessment of breast development and axillary hair.

With the patient standing, the back and trunk are inspected for asymmetry of shoulder height, scapular position, and shape of the waist (Fig. 18-7) viewed from both behind and in front. Potential pelvic tilt, (an indicator of limb-length difference) is determined by palpating the iliac crests and posterior inferior iliac spines bilaterally in the standing patient with both hips and knees fully extended. Lateral translation of the head can be measured in centimeters of deviation from the gluteal cleft by dropping a plumb line from C7 (Fig. 18-8). Deviation of the chest cage (trunk

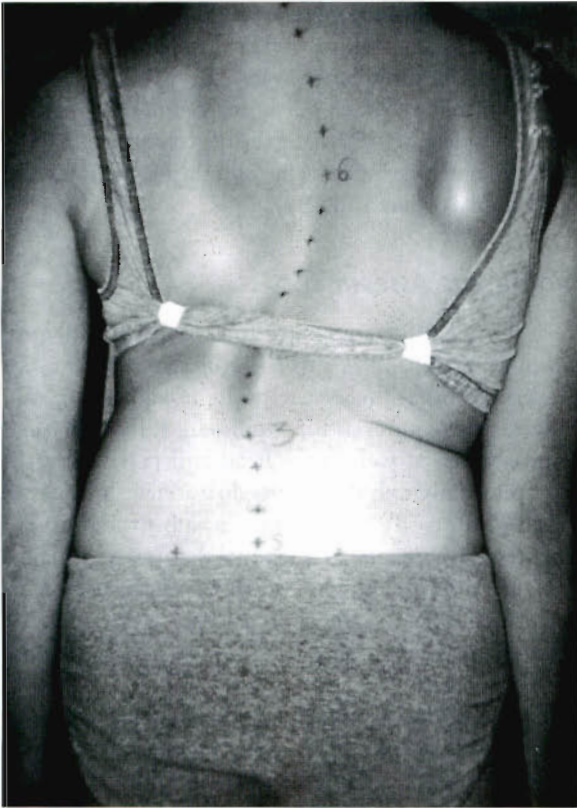

FIGURE 18-7. The clinical appearance of this 11-year-old female with right thoracic scoliosis demonstrates asymmetry of the waistline and scapulae as well as slight elevation of the right shoulder.

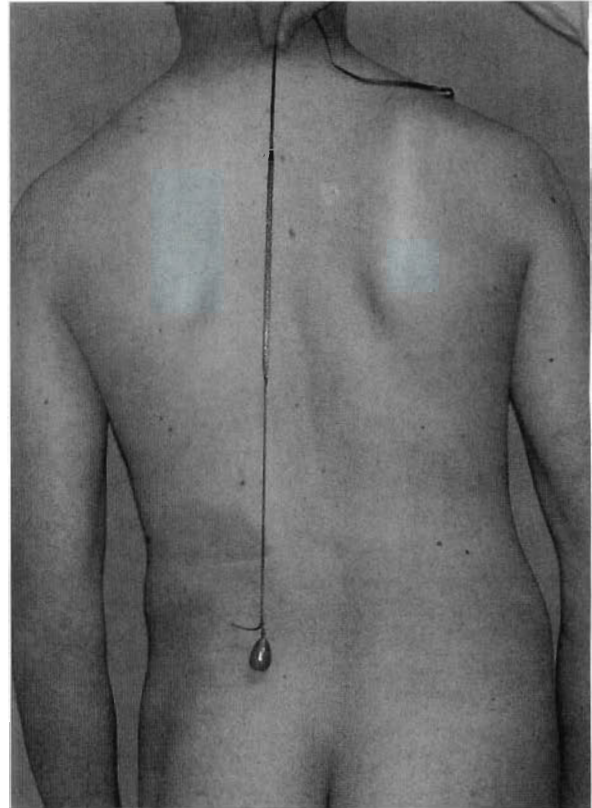


FIGURE 18-8. A small weight hanging from a string ("plumb bob") serves as a simple tool for quantifying trunk deviation. In this case, the plumb line is measured from C7 and quantified as a deviation in centimeters from the gluteal cleft below (5 cm).

shift) should also be assessed, since patients can have full head compensation (return of the head and neck back to midline), yet have marked lateralization of the trunk.

Forward-bend Test. The forward-bend test, first described by Adams in Britain (91), has the patient bend forward at the waist, with their knees straight and palms together. This examination should be performed from behind (to assess lower trunk rotation), from in front (to assess upper trunk rotation), as well as from the side (to assess kyphosis). Any asymmetry of the upper thoracic, midthoracic, thoracolumbar, and lumbar regions should be quantitated with a scoliometer (92) (angle of trunk rotation—ATR), or by measuring the height of the prominence in centimeters (Fig. 18-9). This prominence reflects the rotational deformity of the spine associated with scoliosis (93,94). Although not always exactly correlated, in general an angle of trunk rotation of 5 to 7 degrees is associated with a radiographic Cobb angle measurement of 15 to 20 degrees. (This is a guideline—occasionally patients have little trunk rotation yet have significant radiographic scoliosis, and vice versa (95)).

An inability to bend directly forward at the waist, or decreased range with forward/side bending, may be due to

pain, lumbar muscle spasm, and/or hamstring tightness; any of which should suggest underlying pathology. These findings, plus abnormalities in straight-leg-raise testing suggests irritation of the lumbar roots due to spondylolysis, disc herniation, infection, neoplasm, or other causes.

Skin, Limb Length. Additional components of a comprehensive scoliosis examination include inspection of the skin (both on the back and elsewhere) for cutaneous evidence of an associated disease. Café au lait spots and/or axillary freckles suggest possible neurofibromatosis, while dimpling or a hairy patch in the lumbosacral area may suggest an underlying spinal dysraphism. Excessive skin or joint laxity may be related to a connective tissue disorder, such as Marfan or Ehlers-Danlos syndrome.

Limb length should also be measured in the supine position if pelvic tilt is noted on the standing examination. A spinal curvature which results from a limb-length difference is usually compensatory and serves to rebalance the trunk over the pelvis. A short right leg results in a compensatory right lumbar curve. There is no rotational deformity of the spine with these curves, and in the lumbar region the rotational prominence noted on the forward-bend test is on the

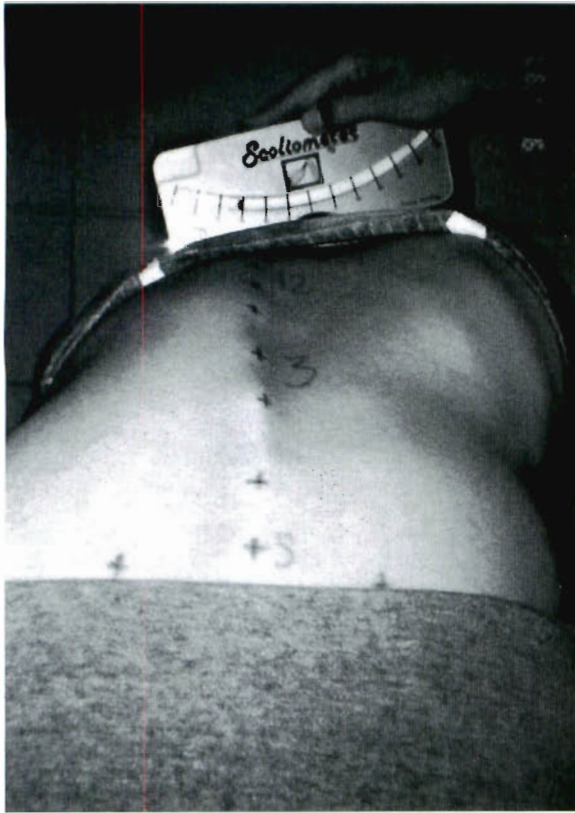


FIGURE 18-9. The Adams forward bend test is performed to detect small degrees of trunk rotation frequently associated with scoliosis. The scoliometer is used to quantify the angle of trunk rotation in degrees. This simple device is utilized in screening patients for scoliosis, as well as for quantifying the degree of trunk rotation in patients being followed clinically.

concave side of the curve (the long leg makes the iliac crest and lumbar spine more prominent on that side). This is the opposite of what is seen in true lumbar scoliosis, in which the rotational prominence noted on the bending test is found on the side of the curve convexity. Presence of the bending-test rotational prominence, on the “wrong” side in a lumbar curve, is almost always diagnostic of limb-length discrepancy spinal asymmetry, rather than true scoliosis. The prominence disappears if the pelvis is leveled with an appropriately sized block underneath the short leg.

Neurologic Examination

The neurologic examination should evaluate balance, motor strength in the major muscle groups of all four extremities, as well as sensation. Watching the patient walk, toe and heel walk, tandem walk, squat deeply, and single-leg hop allows rapid assessment of balance and motor strength. Reflex testing includes upper- and lower-extremity deep-tendon reflexes, as well as abdominal reflexes that are obtained by lightly stroking the abdominal wall with a blunt instrument (key, end of reflex hammer) adjacent to the umbilicus,

with the patient supine and relaxed. The expected brisk and symmetric unilateral contraction of the abdominal musculature, pulling the umbilicus toward the side being stroked, indicates normalcy. When persistently abnormal (reflex absent on one side and present on the other), intraspinal disorders, particularly syringomyelia, should be considered and an MRI study ordered (65,96).

Radiographic Assessment

The ideal screening radiograph for scoliosis is an upright (standing) posteroanterior (PA) projection of the entire spine exposed on a single cassette. In an adolescent, due to body size, this requires a three-foot length film to visualize the entire spine, as well as the head and pelvis on a single radiograph. Many radiology units do not have long cassettes and a chest-film-size cassette can be substituted, with the film centered on the area of maximal deformity (usually the thorax). If a lumbar curve is present, a separate film must be performed. Clearly, the child is better served if they can be referred to a center that uses long cassettes, allowing a single film.

The patient must be standing, since diagnostic and treatment standards developed over the years are based on upright films. In young patients, or those with severe neuromuscular involvement, sitting or even supine radiographs may be the only position possible. Curve magnitude is greater when the patient is upright (compared to supine), and is of particular importance in infantile and congenital curves with films taken before and after walking age. “Curve progression” may be noted with the first upright radiograph, compared to prior supine views, when in fact one has simply documented that gravity causes a curve to be more severe. A lateral film is not required as part of the initial x-ray screening of a thoracic curve, unless back pain or sagittal deformity are noted. A lateral view of the lumbosacral junction is often performed in lumbar scoliosis to assess for spondylolysis/spondylolisthesis as a possible cause (Fig. 18-10).

Radiographic techniques used to minimize radiation of sensitive organs (breast, thyroid, ovaries, bone marrow) include taking only the required number of x-rays, utilizing rare earth radiographic enhancing screens with fast film, and a posterior to anterior exposure (97–99). The lifetime risk for developing cancer of the breast and thyroid has been suggested to increase by 1 to 2% for patients exposed to multiple x-rays associated with scoliosis treatment; however, this rate was generated in the 1960s and 1970s, before new radiation reducing techniques were available. The greatest reduction to breast and thyroid exposure is associated with the posteroanterior exposure (compared to the anteroposterior), which reduces breast/thyroid exposure 3- to 7-fold (99). Shielding of the breasts with anteroposterior (AP) projection is possible, but not recommended, because of the increased thyroid exposure (shielding the thyroid obstructs the view of the upper spine) (Fig. 18-11). Wise doctors

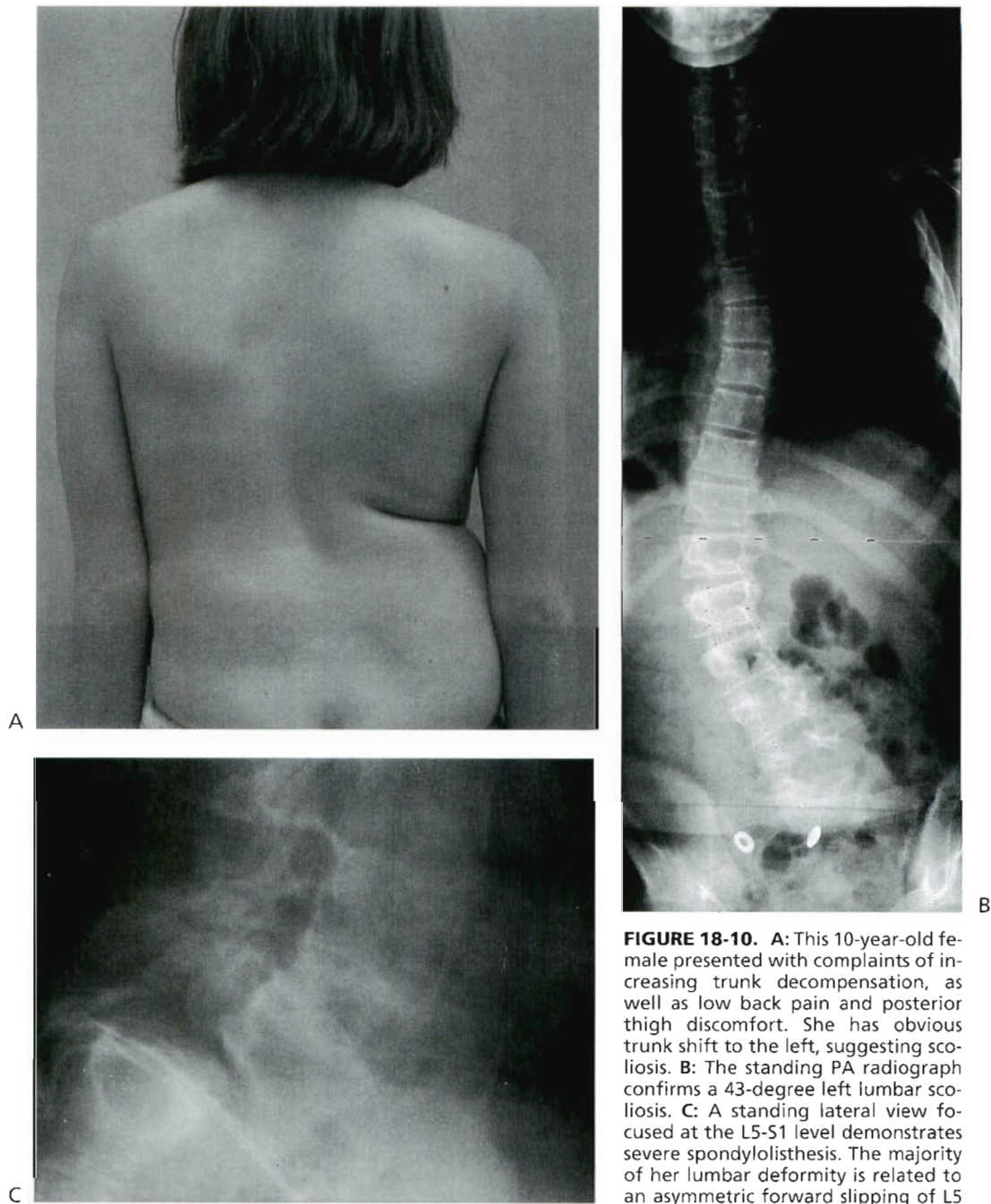


FIGURE 18-10. **A:** This 10-year-old female presented with complaints of increasing trunk decompensation, as well as low back pain and posterior thigh discomfort. She has obvious trunk shift to the left, suggesting scoliosis. **B:** The standing PA radiograph confirms a 43-degree left lumbar scoliosis. **C:** A standing lateral view focused at the L5-S1 level demonstrates severe spondylolisthesis. The majority of her lumbar deformity is related to an asymmetric forward slipping of L5 on S1, with the rotational deformity translated to the lumbar spine above.

counsel their patients by telling them that only the minimum number of x-rays required to treat the disorder correctly will be performed, and that the benefit of having the x-rays outweighs the risk of not knowing the type and severity of the scoliosis.

When surgical treatment is being considered, lateral-bend radiographs to assess curve flexibility as well as a standing lateral view are required. Side-bending radiographs allow one to determine curve flexibility, and to decide what levels

to include in the instrumented and fused segment. Controversy remains regarding the best method for obtaining bending films, with supine AP views (patient maximally bent to the right and left) being standard at many institutions (Fig. 18-12), whereas others believe that a standing bend film is a better indicator, particularly in the lumbar spine. Lateral bending over a bolster provides somewhat greater correction, and has been proposed as a more accurate predictor of the correction obtained with the more powerful modern surgi-

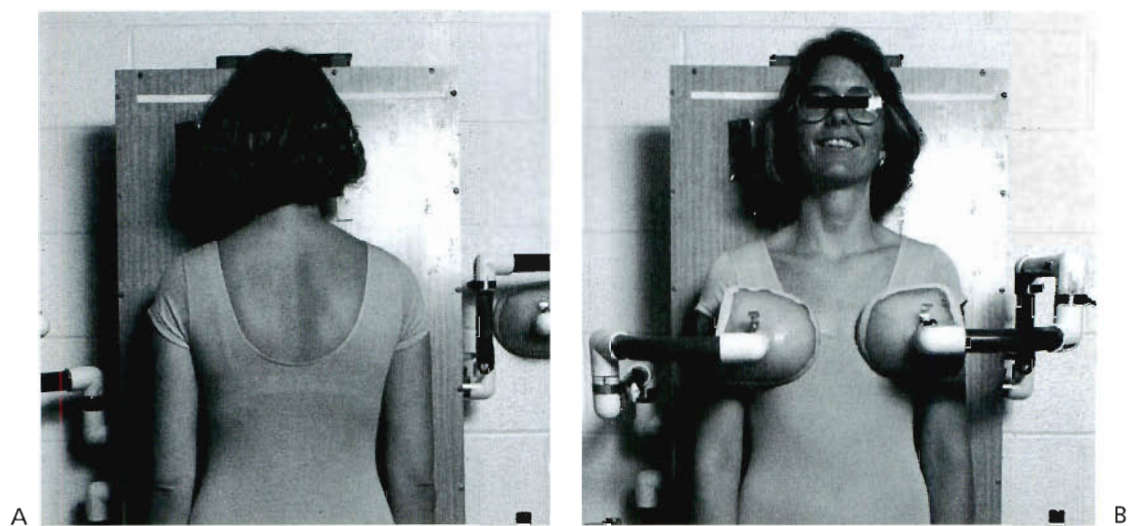


FIGURE 18-11. A: Positioning of a patient for a posteroanterior radiograph. B: Positioning of a patient for an anteroposterior radiograph with breast shielding.

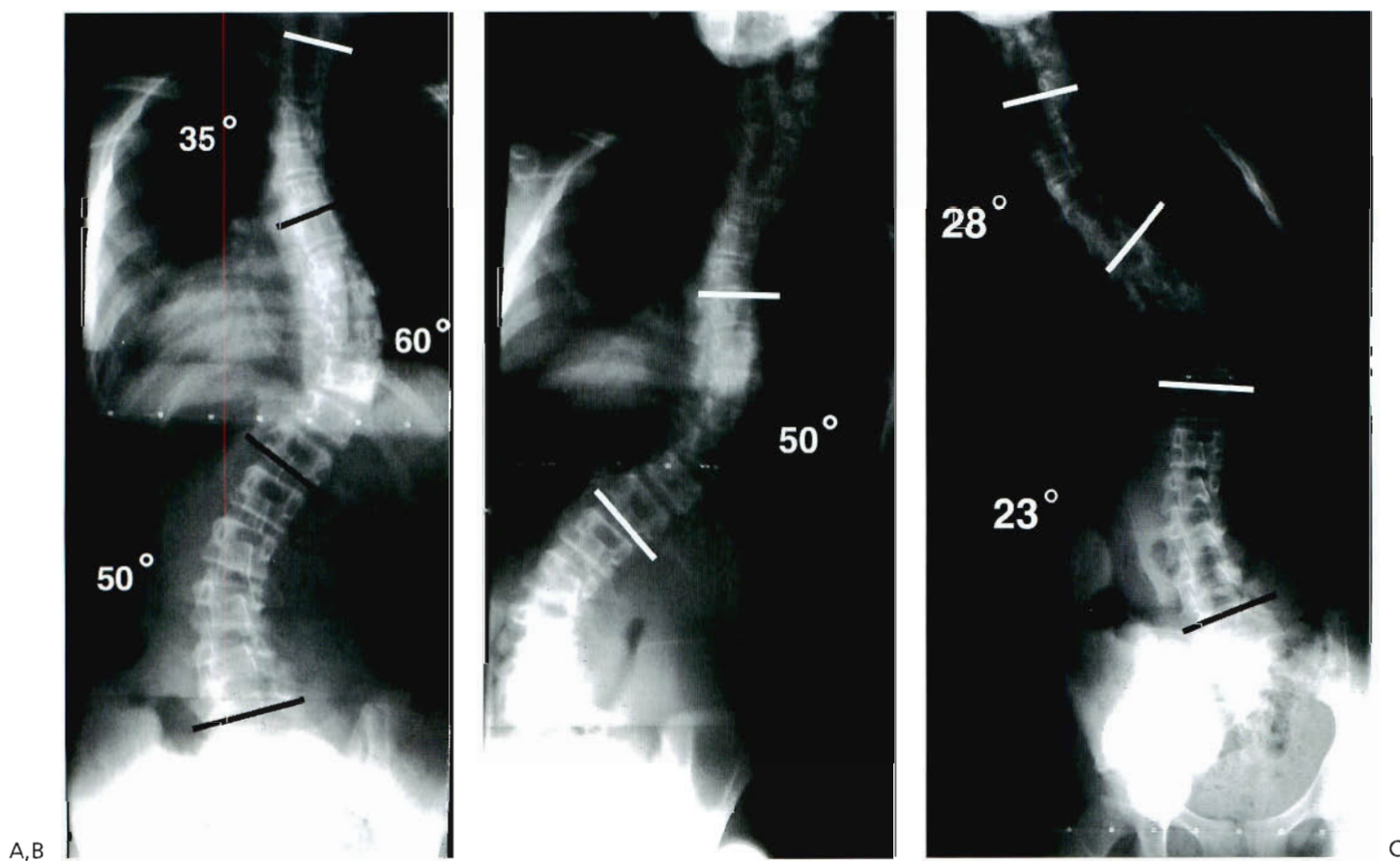


FIGURE 18-12. A: Standing PA radiograph of a premenarchal female demonstrating a 35-degree left upper thoracic scoliosis, 60-degree right thoracic scoliosis, and 50-degree left lumbar scoliosis. B: The bend film to the right is useful in determining the flexibility of the main right thoracic curve. In this case, the right thoracic curve decreased only to 50 degrees on supine side bending. C: The side-bending film to the left is useful in determining the curve flexibility of the left upper thoracic curve, which decreased to 28 degrees, and the left lumbar curve, which decreased to 23 degrees.

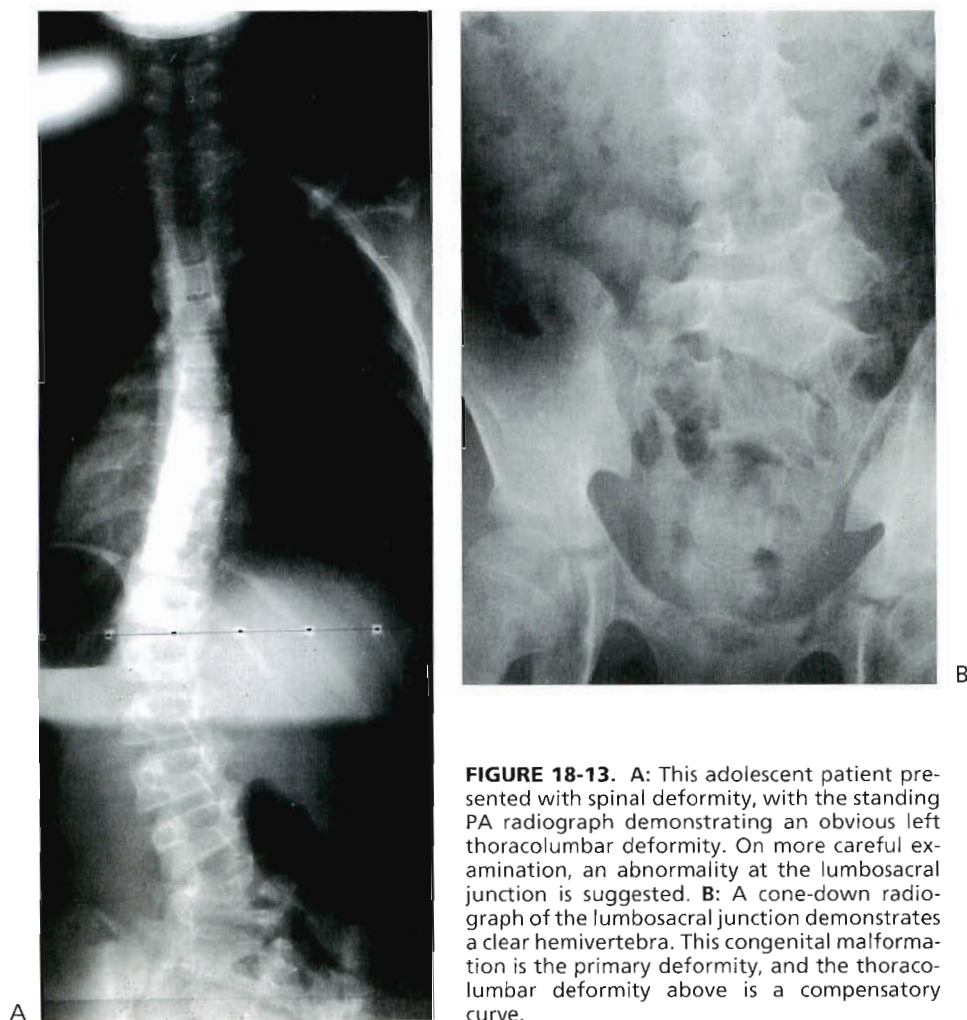

FIGURE 18-13. A: This adolescent patient presented with spinal deformity, with the standing PA radiograph demonstrating an obvious left thoracolumbar deformity. On more careful examination, an abnormality at the lumbosacral junction is suggested. B: A cone-down radiograph of the lumbosacral junction demonstrates a clear hemivertebra. This congenital malformation is the primary deformity, and the thoracolumbar deformity above is a compensatory curve.

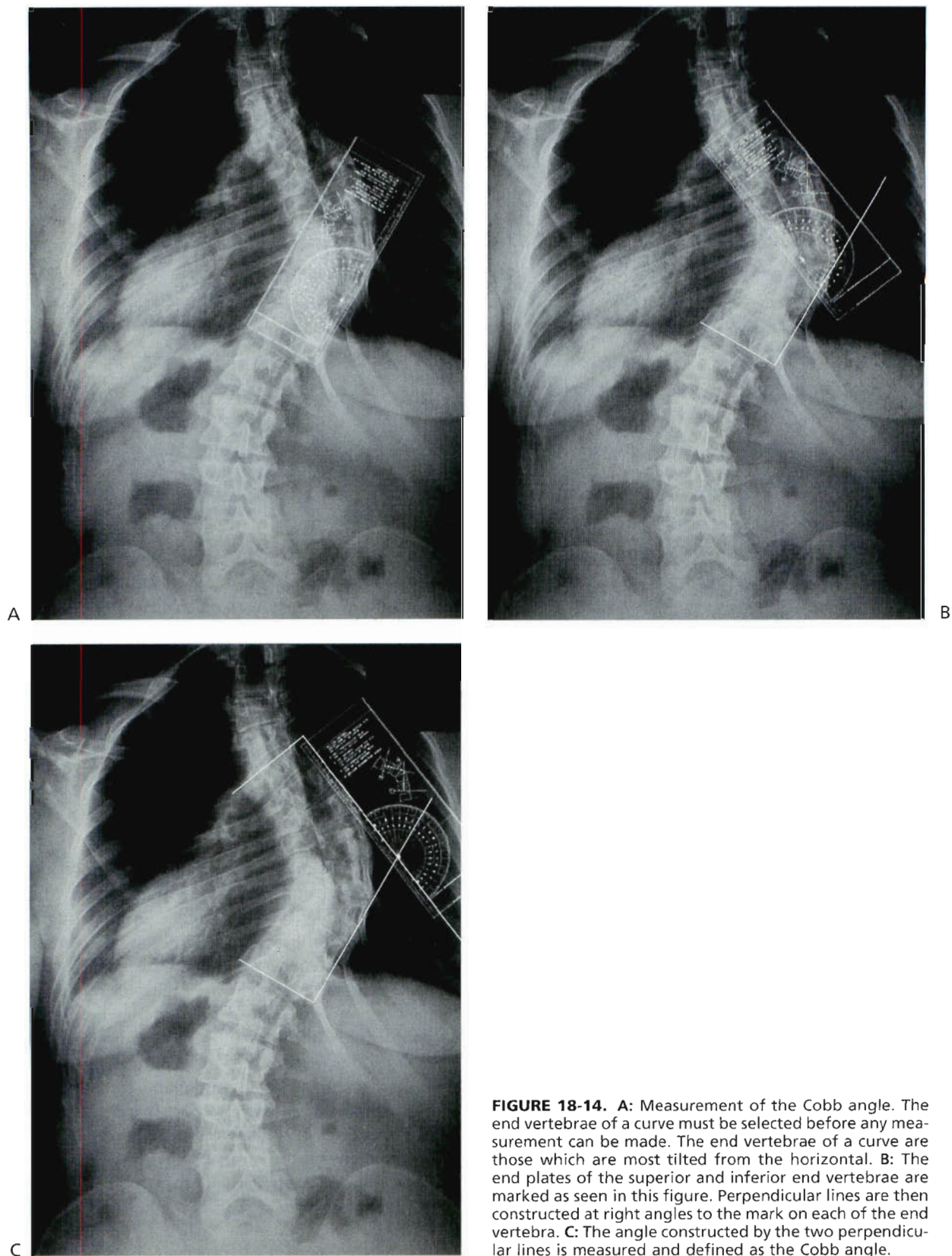
cal instrumentation methods (100,101). In curves greater than 60 to 70 degrees, longitudinal traction films may also be helpful in evaluating curve flexibility (102,103).

The Stagnara oblique view, taken perpendicular to the rib prominence rather than in the PA direction, provides a more accurate picture of large curves with a large rotational component. Taken in this manner the true magnitude of the scoliosis can be measured (104).

Reading Scoliosis Films. Assessment of the standing PA film begins by looking for soft tissue abnormalities, congenital bony abnormalities (wedged vertebra, etc.), then by assessing curvature (coronal plane deviation). Bone assessment includes looking for wedged or hemivertebrae (Fig. 18-13), bar formation bridging a disc space, as well as midline irregularities, such as spina bifida or a bony spike suggesting diastematomyelia. The pedicles should be inspected to be certain that they are present bilaterally and that the interpedicular distance is not abnormally increased, suggesting an intraspinal mass (105,106). Absent pedicles or vertebral

body lucency are associated with lytic processes, such as tumor or infection. If a curve is noted, the symmetry and levelness of the pelvis are analyzed. A limb length discrepancy can be estimated by determining iliac wing and hip joint height differences, assuming the patient had both hips and knees fully extended when the film was exposed.

Curve measurement by the Cobb method (107) allows quantification of the curve. A protractor with single-degree demarcations that is not bent or warped allows more accurate measurements. The caudal and cranial end vertebrae to be measured are the vertebrae that are the most tilted, with the degree of tilt between these two vertebrae defining the Cobb angle (in a normal spine this angle is 0 degrees). One outlines the superior end plate of the cranial end vertebra and the inferior end plate of the caudal end vertebra, constructs a perpendicular to these lines, then measures the angle where the perpendicular lines cross. When more than one curve exists, a Cobb angle measurement is made for each curve (Fig. 18-14). When comparing serial radiographs of the same patient, the end vertebra chosen should gener-



ally remain constant; however, adjustments may be required over time, due to brace-influenced change or other curve pattern changes. The wide variation of inter- and intraobserver error (about 5 degrees for any curve measurement) should be understood by the surgeon and the anxious parents (and patient) (108–110). Carman et al. state that to be 95% certain that two measurements are truly different, a 10-degree change must be measured (111). A useful maneuver for both the neophyte and expert surgeon includes viewing the current film, the prior-visit film, and the original film side by side. (A good scoliosis clinic needs at least three long view boxes mounted side-by-side). Then, before making a Cobb measurement, one should use the “eyeball method” to see whether the radiographic curve appears to be getting worse. Patients and their parents often want to make this assessment with you. This type of exercise puts the Cobb measurement in perspective (and sometimes humbles you as to your accuracy and reproducibility in measurement).

Vertebral rotation, maximal at the apex of a curve, is demonstrated radiographically by asymmetry of the pedicles and a shift of the spinous processes toward the concavity. Two methods are available for quantifying it: Nash and Moe (112), and Perdriolle (113). Vertebral rotation is not routinely measured clinically, and both methods have substantial inaccuracies, which limit their usefulness (114).

Skeletal maturity should be assessed radiographically to estimate remaining spinal growth, an important predictor of risk for curve progression. The most widely used method in scoliosis patients is that of Risser (115), who noted that the iliac crest apophysis ossifies in a predictable fashion, from lateral to medial, and that its fusion to the body of the ilium mirrors the fusion of the vertebral ring apophysis, signifying completion of spinal growth. The lateral to medial ossification of the iliac crest apophysis occurs over a period of 18–24 months, finally capping the entire iliac wing. Risser classified the extent of apophyseal ossification in stages, with Risser 0 indicating absence of ossification in the apophysis and Risser 5 indicating fusion of the fully ossified apophysis to the ilium (spinal growth complete) (116). Risser 1 through 4 are assigned to the intermediate levels of maturity as seen in Fig. 18-15.

The status of the triradiate cartilage of the acetabulum also provides a landmark for assessing growth potential. The triradiate growth cartilage usually closes before the iliac apophysis appears (Risser 0) at about the time of maximal spinal growth (117,118). Skeletal age can also be measured using the Greulich and Pyle atlas to compare hand radiographs against illustrated standards, although these readings become less accurate (large standard deviations) in the adolescent age group (119).

Specialized Imaging Studies

Most idiopathic scoliosis cases do not require imaging beyond plain radiography. Specialized imaging methods that

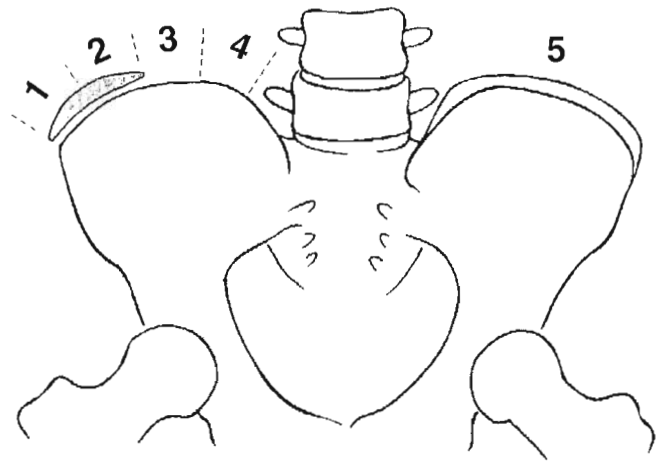
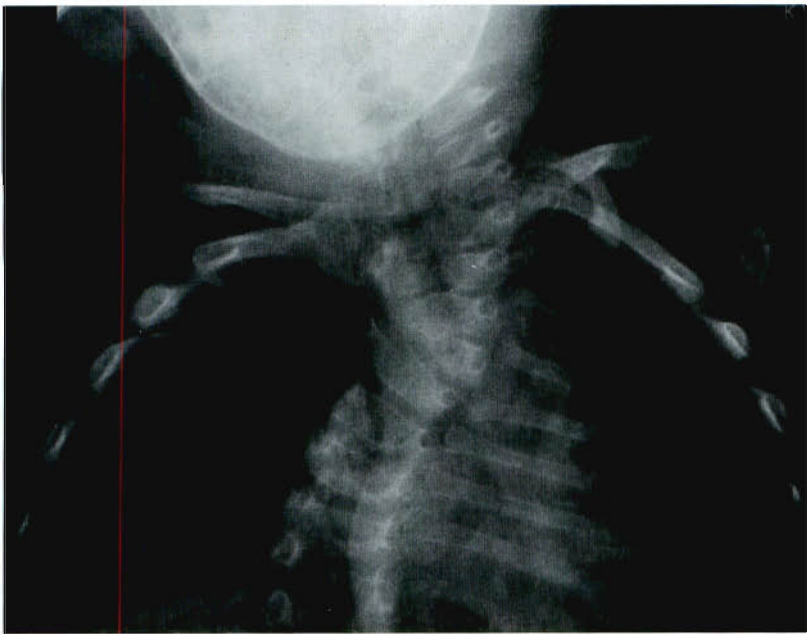

FIGURE 18-15. Risser sign. The iliac apophysis ossifies in a predictable manner, beginning laterally and progressing medially. This capping of the iliac wing is correlated with slowing and completion of spinal growth occurring over an 18- to 24-month period.

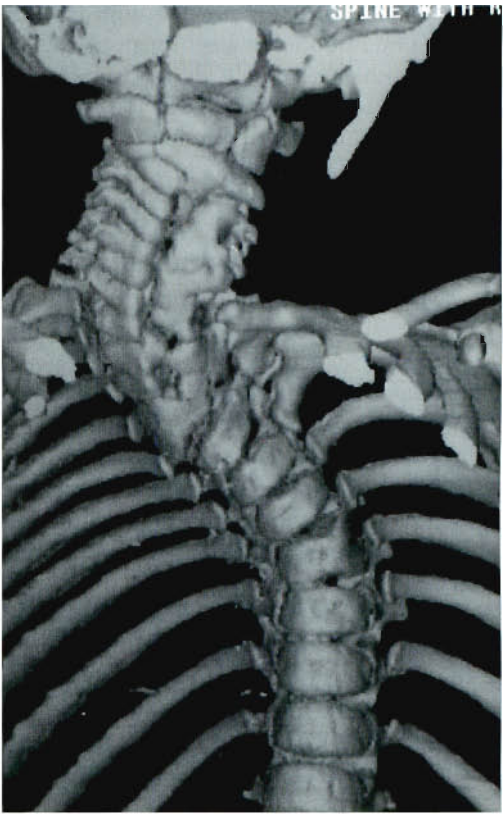can be used to evaluate cases with unusual features include magnetic resonance imaging (MRI), computed tomography (CT), and bone scintigraphy, each with specific indications and advantages.

In the developed world, MRI has almost completely replaced myelography for the study of the neural elements in spine disorders. An exception is the patient who has had prior placement of stainless steel hardware (making MRI visualization nearly impossible) who has continued or new symptoms that require study.

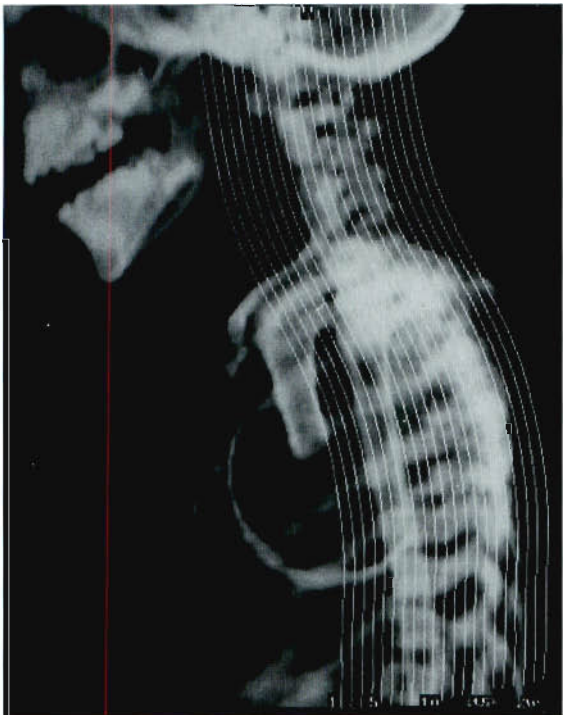MRI study of the spine is indicated for all infantile and juvenile idiopathic patients (79,120,121), as well as those with congenital bony anomalies, if surgical correction is planned (122,123). Left thoracic curves and scoliosis in boys have been shown to have an increased association with spinal cord anomalies and may be an indication for MRI study (120,124). Indications for routine MRI study in patients with typical idiopathic scoliosis prior to corrective surgery (and who have a normal clinical neurologic examination), remain unclear (125). At present there is no prospective study that confirms the efficacy of MRI screening for preoperative assessment (spine and brain) of all patients with idiopathic scoliosis, although a few centers have made this the routine for all operative cases. Clearly, patients with an abnormality in the neurologic examination (120), or with cutaneous findings (suggesting dysraphism or neurofibromatosis), should have an MRI study of the spine and/or brain. Severe angular and rotational deformities may be difficult to analyze with an MRI, because the spinal canal deviates into and out of the planar cuts of the sagittal and coronal images. CT myelography that produces a dye column may be better for revealing stenosis or an intraspinal filling defect in extremely severe cases of scoliosis.



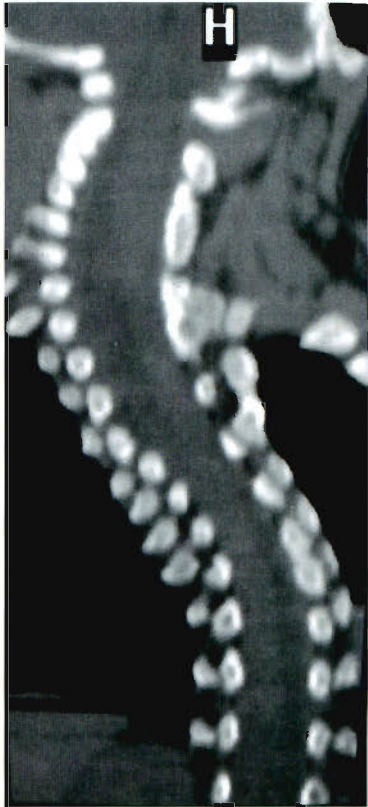
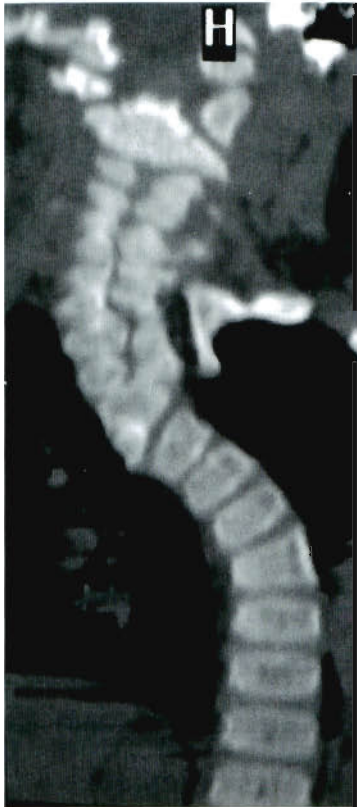A



B



C,D



E

The workup of patients with substantial back pain with no obvious cause may require a bone scan to evaluate for possible tumor, infection, or spondylolysis. The bone scan is an excellent screening test for studying the painful scoliotic patient, allowing one to screen for conditions ranging from osteoid osteoma to hydronephrosis. A single photon emission computed tomography (SPECT) type bone scan (computerized tomographic enhancement) is very useful in identifying spondylolysis and its varying presentations (unilateral, bilateral, cold scan, hot scan, etc.). If an area of increased activity is noted on the bone scan, additional imaging (either MR or CT) may be required. CT studies can be performed with increasing sophistication, and provide the best method for imaging the bony anatomy in complex deformities and congenital anomalies. Standard two-dimensional transverse images are less helpful in scoliosis, compared to coronal, sagittal, and three-dimensional reformatted images. Additional multiplanar (curved along the deformity) reformatted coronal and sagittal images are particularly helpful in imaging the scoliotic spine when congenital anomalies are suspected (Fig. 18-16).

Imaging the kidneys and urologic collecting system is important in patients with congenital scoliosis (126,127), because identification of a congenital spinal deformity may be the first clue of an abnormality of the genitourinary (GU) system (which, if unrecognized, could lead to permanent kidney damage). An ultrasound study is the most practical screening test for detecting GU system abnormalities and should be obtained once a congenital spinal abnormality has been identified (126).

IDIOPATHIC SCOLIOSIS—DETAILS OF DIAGNOSIS AND TREATMENT

Idiopathic scoliosis makes up the largest subset of patients with spinal deformity, and because its etiology is unknown, this diagnosis is one of exclusion made only after a careful evaluation has ruled out other causes of scoliosis. Clinical features and treatment vary by age group (infantile, juvenile, adolescent), and are summarized below.

Prevalence and Natural History of Idiopathic Scoliosis

The prevalence of idiopathic scoliosis (with a curve of greater than 10 degrees) in a childhood and adolescent population has been reported to be from 0.5 to 3 per 100 (128–134). The reported prevalence of larger curves (greater than 30 degrees) ranges from 1.5 to 3 per 1,000 (135,136) (Table 18-2). Thus small to moderate curves are common, and severe (life threatening) curves are rare.

The percentage of cases seen in each age group demonstrates a strong predominance of adolescent curves, with a series of patients from Boston showing 0.5% infantile, 10.5% juvenile, and 89% adolescent (16). The natural history for each group varies substantially.

Although classically idiopathic scoliosis has been divided into three groups according to the age of onset (infantile, juvenile, adolescent), there is a movement in Britain to simplify this to early-onset scoliosis (before age 10 years) and late-onset scoliosis (typical adolescent scoliosis) (131). Dickson and Weinstein believe that only early-onset scoliosis has the potential for evolution to severe thoracic deformity with cardiac and pulmonary compromise (137). This simpler classification has not been fully evaluated, thus the traditional three-age-group division remains the standard in North America.

Infantile Idiopathic Scoliosis

Infantile idiopathic scoliosis (IIS) cases have been more commonly reported from Britain, compared to North America (16,138,139). More recent reports, however, have suggested a decrease in the frequency of infantile cases more closely paralleling the North American experience (140).

IIS presents as a left thoracic curve in approximately 90% of cases with a male:female ratio of 3:2 (138,139,141,142). The curvature is associated with plagiocephaly, hip dysplasia, congenital heart disease, and mental retardation (14,143). The series from Britain suggests that the vast majority (up to 90%) of these curves are self-limited and resolve spontaneously (142); however, the few that are progressive can be difficult to manage (Fig. 18-17).

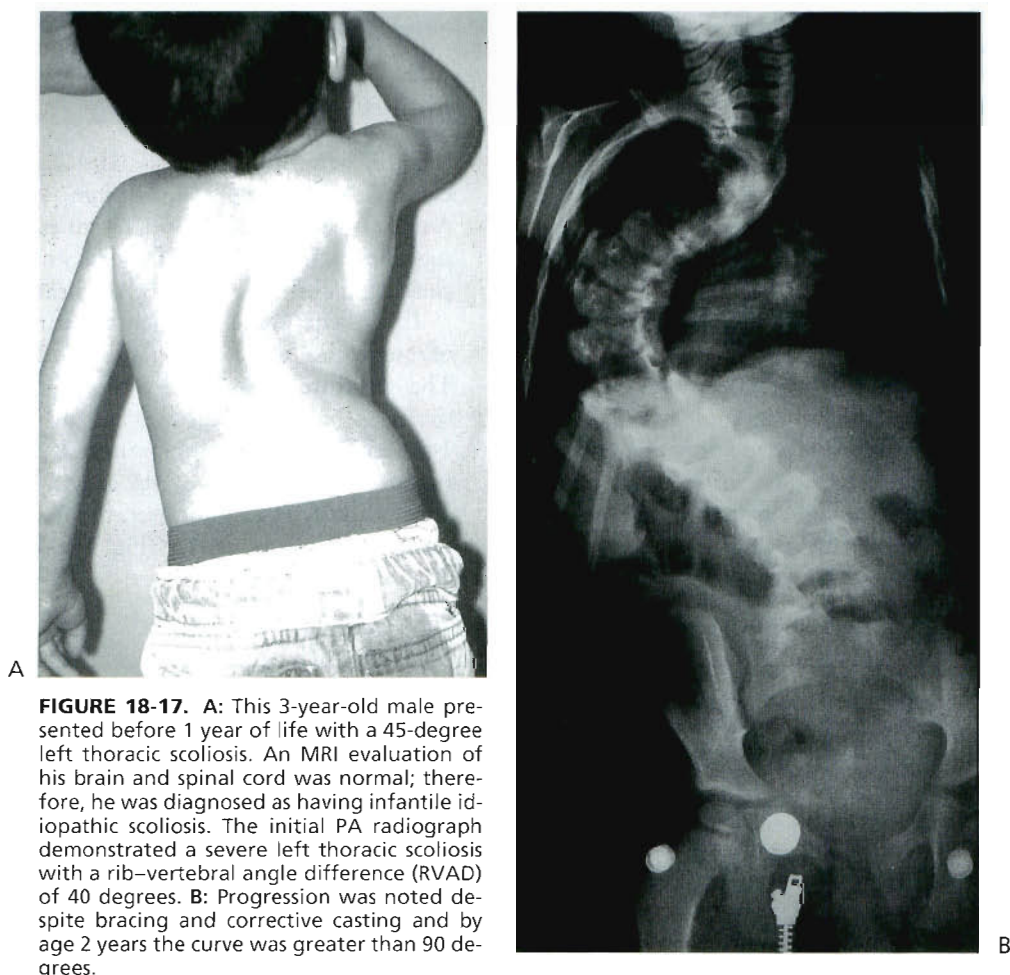
FIGURE 18-16. A: This 3-year-old patient presented with severe cervicothoracic scoliosis. The AP radiograph demonstrates a congenital etiology to the deformity; however, the details of the malformation are difficult to appreciate on the plain radiograph. **B:** A three-dimensional CT scan demonstrates much more clearly the anatomic deformities in the vertebral bodies. **C:** Frontal plane reformatted images are helpful in analyzing the size and number of hemivertebrae, as well as detecting unsegmented bars. The ability to obtain these images along a curved surface (produced with special software) is particularly useful in following the curvature of the spine in either the AP or lateral projections. Here the sagittal plane (lateral) curved scout film is seen. **D:** The anteroposterior reformatted images through the mid-portion of the vertebral bodies allows identification of the hemivertebrae and associated wedged vertebrae throughout the cervical and upper thoracic spine. **E:** An anteroposterior reformatted image, through the level of the pedicles, demonstrates two areas of an unsegmented bar in the concavity of the cervicothoracic deformity.

TABLE 18-2. PREVALENCE OF SCOLIOSIS

Author (Ref)	No. Patients	(% of Patients with Curves of this Magnitude)			
		>5 degrees	>10 degrees	>20 degrees	>30 degrees
Stirling et al. (131)	15,799	2.7	0.5		
Bruszezski & Kamza (130)	15,000	3.8	3.0	0.5	0.15
Rogala et al. (133)	26,947	5.3	2.2		
Shands & Eisberg (129)	50,000	1.9	1.4	0.5	0.29
Kane & Moe (128)	75,290				0.13
Huang (94)	33,596		1.5	0.2	0.04
Morais et al. (134)	29,195		1.8	0.3	
Soucacos et al. (171)	82,901		1.7	0.2	0.04

Prediction of Progression in Infantile Curves. Risk factors which predict a high likelihood for curve progression have been identified by Mehta who, in a study of 135 patients with infantile idiopathic scoliosis, determined radiographic prognostic factors: 1) rib vertebral angle difference (RVAD) and 2) phase of the rib head (144). The RVAD

is the most commonly utilized measure, and is determined at the apical vertebra on an AP radiograph. The difference in the obliquity between the two ribs attaching to the apical vertebra (right versus left) is known as the RVAD. The ribs in the concavity of progressive infantile scoliosis are relatively horizontal, while those on the convex side are



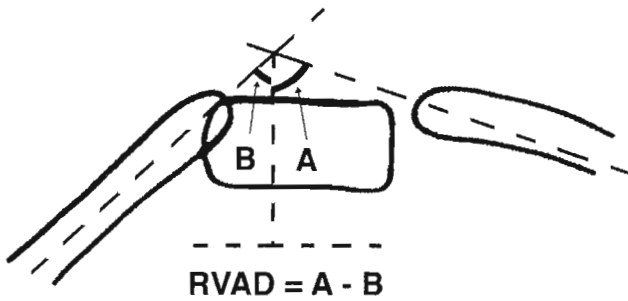


FIGURE 18-18. In infantile idiopathic scoliosis the rib-vertebral angle difference (RVAD) helps in predicting curve progression. The RVAD is constructed by first determining the angle of the right and left ribs at the apical level of the deformity. The slope of the ribs relative to the transverse plane is measured for each rib. The difference in the angle between the right and left sides is the RVAD.

more vertically aligned (Fig. 18-18). Eighty-three percent of Mehta's reported cases resolved when the RVAD was less than 20 degrees compared to 84% progressing when the RVAD was greater than 20 degrees (144,145).

Juvenile Idiopathic Scoliosis

Juvenile idiopathic scoliosis (JIS), defined as scoliosis with an onset between the age of 4 to 10 years, makes up approximately 8 to 16% of the childhood idiopathic scoliosis (146–148), and in many respects, represents a transitional group between the infantile and adolescent groups. Curves with onset in this age group are often progressive with potential for trunk deformity and eventual cardiac and pulmonary compromise. Many patients who present in adolescence (previously undiagnosed and untreated), with severe thoracic curves requiring immediate surgery, have had the onset of their curve in the juvenile age period, making differentiation of the juvenile versus adolescent grouping problematic.

In JIS, boys seem to be affected earlier than girls (146,149). In a series of 109 patients evaluated by Robinson and McMaster, the boys presented at a mean age of 5 years 8 months, compared to an age of 7 years 2 months for the girls. The ratio of girls to boys was 1:1.6 for those younger than 6 years and 2.7:1 for those older than 6 years at presentation. Additionally, there were equal numbers of right- and left-sided curves in the younger group (less than 6 years), with a predominance of right sided curves (3.9:1) in the patients older than 6 years (146). When curves reach 30 degrees they are nearly always progressive if left untreated (150). The rate of progression is 1 to 3 degrees per year before age 10 years, and sharply increases to 4.5 to 11 degrees per year after that age (146). This is particularly true for thoracic curves, which despite brace treatment, require arthrodesis greater than 95% of the time (146,150). The surgical treatment of JIS is similar to that for adolescent

idiopathic scoliosis; however, anterior growth ablation (fusion), in addition to posterior instrumentation and fusion, is more commonly indicated to prevent "crankshaft" rotational growth following posterior fusion (see p. 729). In very young cases, instrumentation using a system that can be periodically lengthened is sometimes used (instrumentation without fusion-fusion only at proximal and distal hook sites).

Adolescent Idiopathic Scoliosis

This most common category of adolescent idiopathic scoliosis (AIS) theoretically develops a curve after the age of 10 years, associated with the rapid growth of adolescence. Again, the separation of adolescent and juvenile curves is somewhat arbitrary, since an 11-year-old girl who presented with a 70-degree scoliosis almost certainly had the onset of scoliosis in the juvenile age period. Thus the European view is that scoliosis should be considered either early-onset or late-onset. As noted previously, the prevalence data range between 0.5 and 3% for curves ≥ 10 degrees. These data have been collected from a variety of sources, including screening chest x-rays as well as school screening programs (Table 18-2). Roughly 2% of adolescents have a scoliosis of ≥ 10 degrees, but only 5% of these cases have progression of the curve to greater than 30 degrees. The ratio of boys to girls is equal for minor curves, yet is dominated by girls as the curve magnitude increases, reaching 1:8 for those requiring treatment (151).

Risk Factors for Progression

Knowledge of which curves will likely worsen and which will not is critical in deciding whom to treat. Risk factors for scoliosis progression that have been identified include gender, remaining skeletal growth, curve location, and curve magnitude with scoliosis progression being most rapid during peak skeletal growth (early infancy and adolescence). The peak growth velocity of adolescence averages 6 to 8 cm of overall height gain per year (28,118) with half of this growth coming from the trunk (spine) (152) (Fig. 18-19). Several determinants are useful in predicting the remaining growth. The age of the patient is obvious; however, substantial variation in skeletal growth exists for patients of the same chronologic age; therefore, bone age is a more consistent indicator (153). Menarchal status helps determine the growth spurt in females with the onset of menses generally following the most rapid stage of skeletal growth by approximately 12 months.

The Risser sign, associated with the stages of vertebral body end-plate growth, has been demonstrated to be a useful measure for assessing risk for curve progression. When the Risser sign is 1 or less, the risk for progression is up to 60 to 70%, while if the patient is Risser 3, the risk is reduced to less than 10% (29,154).

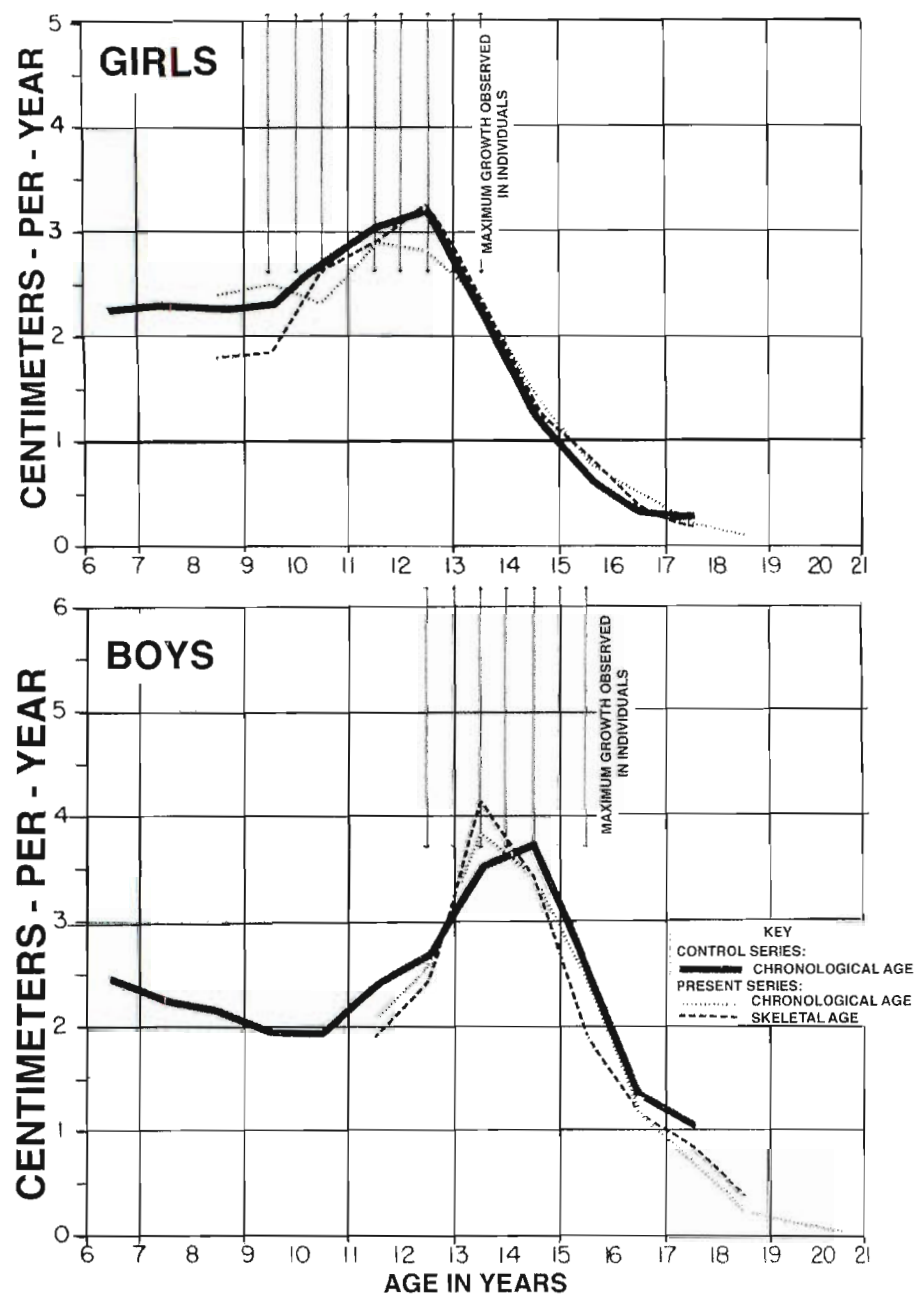


FIGURE 18-19. Increase in sitting height during the adolescent growth spurt for girls and boys is noted in this graph. The peak gain in trunk height ranges between 3 and 6 cm per year. (From ref. 152, with permission.)

Unfortunately many of the readily identified markers of maturity (menarchal status and Risser sign) are quite variable, and appear just after the adolescent growth spurt. It is therefore impossible to tell if a premenarchal, Risser 0 patient is approaching, in the midst of, or past the time of most rapid growth and risk for scoliosis progression, if there is no accurate record of prior growth. Recently, closure of the triradiate cartilage of the acetabulum has been identified as a radiographic sign which more closely approximates the time of peak growth velocity (118).

Curve pattern has also been identified as an important variable for predicting the probability of progression. Curves with an apex above T12 are more likely to progress than isolated lumbar curves (154). Curve magnitude at initial diagnosis appears to be a factor predicting progression (29,155) (Fig. 18-20). In a series of skeletally immature patients (Risser 0 or 1), curve progression occurred in 22% of cases with a curve at initial diagnosis of 5 to 19 degrees compared to 68% incidence of curve progression when the initial curve was 20 to 29

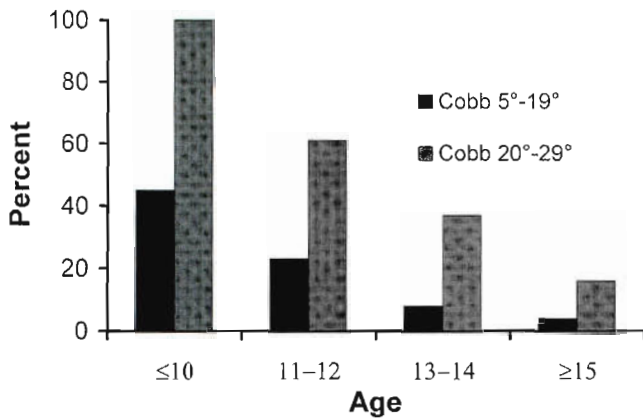


FIGURE 18-20. The incidence of scoliosis curve progression is greatest at a younger age and for larger curves. (From ref. 29, with permission.)

degrees (29). This rate increases to 90% when the initial curve is 30 to 59 degrees (156).

Natural History in Adulthood

The long-term effects of idiopathic scoliosis in adults should be understood when considering treatment in childhood and adolescence. The risk of curve progression is greatest during the rapid phases of growth as discussed above; however, not all curves stabilize after growth stops. In the long-term studies performed at the University of Iowa, greater than two-thirds of patients experienced curve progression following skeletal maturity. Curves of less than 30 degrees tended not to progress with the most marked progression occurring in curves that were between 50 and 75 degrees at the completion of growth (continuing at a rate of nearly 1 degree/year). Lumbar curves generally progressed if they were greater than 30 degrees at skeletal maturity (157,158). Several studies have been performed which provide insight into what the future holds for affected individuals. Early studies of untreated scoliosis patients, with up to 50-year follow-up, claimed a mortality rate twice that expected in the general population with cardiopulmonary problems as the most common cause of death (159,160). Disability and back pain were common in the living patients (160,161). Unfortunately the etiology of the scoliosis in these studies was mixed (idiopathic, congenital, neuromuscular), and the severity of the scoliosis was not known for many of the patients, making correlations to those with idiopathic scoliosis impossible.

In more recent studies in which only adolescent idiopathic scoliosis patients were included, the increased mortality rate reported previously has not been confirmed (162). Mortality from cor pulmonale and right heart failure was seen only in severe thoracic curves (>90 to 100 degrees) (162,163).

Pulmonary function becomes limited as thoracic scoliosis becomes more severe (>80 to 90 degrees curve) (162,164,165). Forced vital capacity (FVC) and forced expiratory volume in one second (FEV₁) decrease linearly with approximately a 20% reduction in predicted values with curves of 100 degrees (162) (Fig. 18-21). The associated deformity of the chest cavity causes restrictive lung disease. Thoracic lordosis also decreases lung volume and increases the deleterious effects of scoliosis on pulmonary function (166).

Estimates regarding the frequency of back pain and associated disability in adults with scoliosis vary, but most studies have demonstrated slightly higher rates of back pain compared to control groups (162,167–169). The 1,476 patients with AIS surveyed in Montreal had more frequent and more severe back pain than did 1,755 control subjects (167). Disability rates have been higher (160,167) in some series and similar in others (162).

The social impact of scoliosis varies with the individual and the cultural setting. Many current patients have substantial concern about the appearance of their back and seek medical treatment for correction of their deformity (170). The rate of marriage for females with scoliosis is lower in some studies implying a psychosocial effect of the deformity (159,160). Many modern parents are unwilling to accept significant deformity of any type in their child whether it be dental, dermatologic, or orthopedic, particularly if there is a reasonable and safe way to correct the condition.

School Screening for Scoliosis

School screening programs to detect scoliosis at an early stage have been instituted in many countries, with a goal of detecting childhood scoliosis early enough to allow brace treatment, rather than in its late stages, when surgical correc-

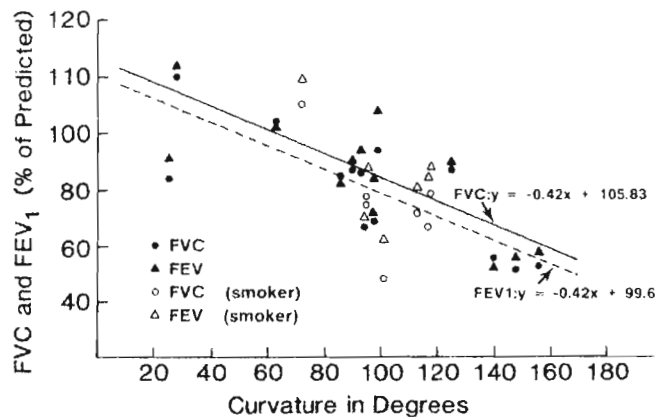


FIGURE 18-21. Pulmonary function as it relates to curve severity in both nonsmoking and smoking patients. (From ref. 162, with permission.)

tion and fusion would be needed (171–173). Screening programs for any disease are indicated if effective early treatment methods exist, and if the disorder is frequent enough to justify the cost. Although screening programs for scoliosis are widespread in North America, the variable sensitivity and specificity of the screening exam, and the borderline efficacy of brace treatment, have caused some to suggest that school screening is not justified (137,172,174–177).

Despite these concerns, scoliosis screening is commonly performed on school children between the fifth and sixth grades (age 10 to 12 years) (178). The Adams forward-bend test is employed in combination with scoliometer (179) measurement of the maximum angle of trunk rotation (ATR) (Fig. 18-9). A referral and radiograph are recommended when the ATR is >7 degrees (93,94,179,180). The 7-degrees ATR standard detects nearly all curves greater than 30 degrees, yet leads to a large number of patient referrals (2 to 3 per 100 children screened) (93,179) for radiographs in adolescents who have only spinal asymmetry (Cobb <10 degrees) or mild scoliosis (Cobb <25 degrees) not needing treatment. Overall, in screening programs the incidence of curves of >10 degrees (Cobb angle) is approximately 3%, and of curves >25 degrees, about 0.3%.

Both the Adams forward-bend test and measurement of the ATR with a scoliometer have been shown to have reasonable intraexaminer agreement (95,180–182). Although there is an overall linear correlation between the ATR and Cobb angles (95,183), precise prediction of the magnitude of deformity is not possible without a radiograph. The positive predictive value (the probability of having scoliosis with an abnormal screening test) of the forward-bend test is highly variable (94,134,174,176,184) and thought by many to be too low to warrant current scoliosis screening practices.

Despite the criticism leveled at school screening (cost and over-referral), many experts believe that the emphasis placed on screening for early diagnosis has greatly increased awareness of scoliosis, not only in the lay public, but also among primary care physicians. It appears that the combination of increased awareness plus the efficacy of screening programs has reduced the number of patients who do not see a physician until they have marked deformity (171,173,185,186). This remains controversial, and others have presented longitudinal data following the institution of a screening program which reject this idea (135,176).

Treatment of Idiopathic Scoliosis

Analysis of idiopathic scoliosis treatment is dependent on understanding the natural history of the condition in the untreated state compared to the outcome with intervention. As in many pediatric conditions, the short-term outcomes of treatment are reasonably well known; however, the long-term results are less well defined. Due to this lack of knowl-

edge, controversy continues regarding treatment choices in any individual patient.

Nonoperative Treatment of Idiopathic Scoliosis

Because most patients with idiopathic scoliosis have curves of less than 20 degrees, and only a few progress to require treatment, most patients are simply monitored. Idiopathic curves of less than 25 degrees should be monitored every 4 to 12 months (depending on the age and growth rate of the patient) with clinical and radiographic examination. Those in the rapid phases of growth are seen at more frequent intervals (every 4 to 6 months). Curves of greater than 30 degrees should be monitored for progression after skeletal maturity with radiographs obtained approximately every 5 years. Curve progression in the mature patient (when it occurs) is slow enough (approximately 1 degree per year) that more frequent follow-up is not indicated.

Indications for Orthotic (Brace) Treatment. In growing children, a spinal orthosis (brace) is generally indicated when a curve progresses to 25 to 30 degrees (187–189). Scoliosis braces of many different styles and corrective mechanical principles have been developed with each having in common the goal of modifying spinal growth by applying an external force. Because brace treatment depends on spinal growth modulation, treatment is prescribed only for patients with substantial spinal growth remaining (Risser 2–3 or less). The upper limit of curve magnitude amenable to brace treatment is approximately 45 degrees. Most studies have confirmed that, even in the most cooperative patients, the final result of brace treatment is maintenance of the curve at the degree of severity present at the onset of bracing. Correction may occur while in the brace, but when the brace is discontinued, the curve will generally settle to its pre-treatment severity (190–192). Scoliosis patients and their parents should be advised of this, because most anticipate that the brace will provide permanent correction, as is seen in orthodontic correction, a common point of reference for the layperson. In more severe curves with trunk deformity already present, this information may cause some patients and their parents to select surgical correction rather than brace maintenance.

In general, a brace is indicated for growing adolescents with a curve between 25 and 45 degrees. Most surgeons insist that curve progression of more than 5 degrees be documented before bracing curves of less than 30 degrees. These indications may need to be altered depending on the clinical circumstance; for example, a 10-year-old premenarchal female, with a curve that has increased from 14 to 22 degrees in the prior 6 months, should probably be braced before reaching 25 degrees. Early bracing may also be considered when a strong positive family history for progressive scoliosis exists (mother or sibling required treatment).

Brace Types. The Milwaukee brace, developed by Walter Blount at Milwaukee Children's Hospital in the 1940s, became the standard to which other designs were compared (193). This brace remained popular into the 1980s (194), and remains an option in selected situations. The original design provided longitudinal traction between the skull and pelvis with lateral translational forces directed through pads on the chest wall (Fig. 18-22). The brace uprights can be adjusted in length to accommodate growth—a feature useful in treating infantile and juvenile patients. In addition, it remains one of the few designs that has the potential to maintain upper thoracic curves.

Underarm braces (e.g., Boston (195,196) and Wilmington (197,198)) (Fig. 18-23) have replaced the Milwaukee brace in most centers due to increased acceptance by the patients. Because no upright or neckpiece is used, the brace is less conspicuous, a feature highly important to the adolescent. The stigma of wearing a visible scoliosis brace produces a negative self-image in many teenagers (199,200). Despite improvements in brace appearance (brace worn under clothes—no visible neckpiece), many teenagers will not cooperate with brace wear. Factors for failure include pain (201), poor fit, heat, family environment, and concerns

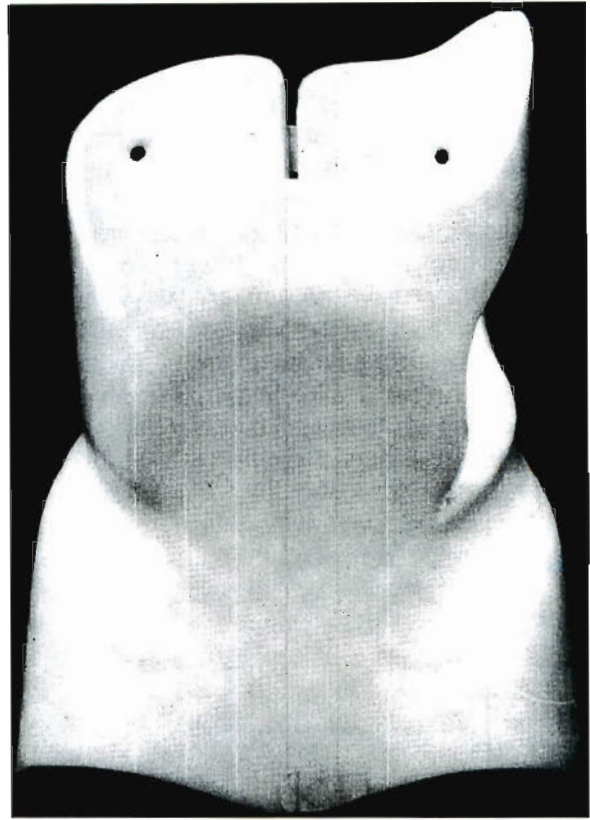


FIGURE 18-23. Boston brace.

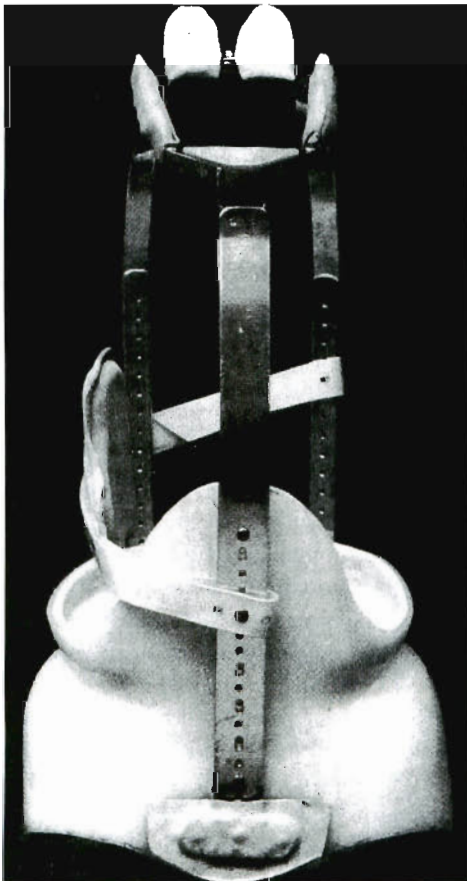


FIGURE 18-22. Milwaukee brace.

about self-esteem. The brace must be acceptable to the patient if it is to be worn and have any chance of limiting curve progression.

The Charleston nighttime bending brace (202), an alternative that attempts to create a more complete correction of the curve (Fig. 18-24), requires a trunk bend so severe that it precludes walking. This brace is therefore only prescribed for nighttime wear and is best suited for single curves that are more distal (thoracolumbar and lumbar curves).

Wearing Schedule. Correction by a brace is thought to be due to the constant corrective molding of the trunk and spine during growth. As such, full-time (23 h per day) brace wear was first advised by Blount, and continues to be recommended by many who prescribe scoliosis braces. About 15 years ago, certain centers began to treat patients for only 16 h per day, allowing the child to go to school without the brace, hoping that the abbreviated schedule would lead to greater patient compliance (197,203). This schedule is popular with many surgeons (and patients); however, one must question the biomechanical validity of the concept since the preponderance of brace wear is at night when the curve is least severe (patient supine). Alternatively, during daytime hours, when the curve is at its greatest (upright, forces of gravity), the curve is uncorrected. A metaanalysis

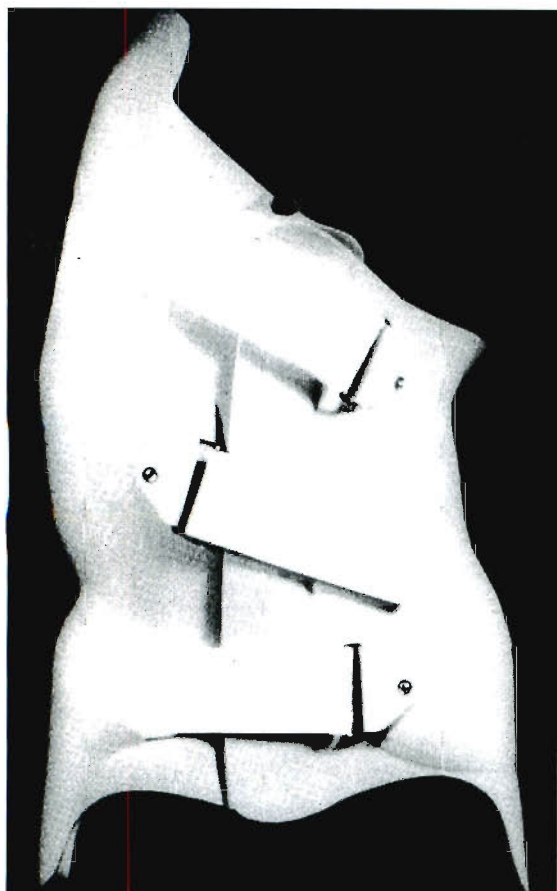


FIGURE 18-24. Charleston brace (nighttime bending brace).

performed by the Scoliosis Research Society Prevalence and Natural History Committee found a dose dependent relationship between the time per day in brace and success in preventing curve progression (204), suggesting that more hours of brace wear per day provides more effective correction. This contradicted a study of the Wilmington brace, which did not demonstrate a difference in efficacy between part-time and full-time bracing (197).

This recommendation for full-time brace wear is in sharp contrast to the Charleston nighttime bending brace philosophy, which attempts to produce hypercorrection. In a series reported by Price et al., the average curve correction while in the brace was 73% (205), and they postulated that less time per day of wear was required because of the marked correction while in the brace.

Brace Efficacy. The effectiveness of bracing for idiopathic scoliosis has been presumed for many years, yet controlled treatment trials with and without bracing had not been completed until recently (187,206). Earlier studies reporting high success rates for brace treatment were subsequently

noted to have included many patients who were at low risk for progression. Lonstein and Winter evaluated 1,020 patients treated with a Milwaukee brace, over half who were at substantial risk for progression, and for whom the natural history was known. In the group with an initial curve between 20 and 29 degrees, and at high risk for progression, the brace was found to be effective compared to natural history data (194). This is in contrast to the findings of Noonan et al. who have recently called into question the efficacy of the Milwaukee brace (207).

In 1995 the results of a prospective controlled study of bracing by the Scoliosis Research Society was published. The results in 286 patients age 10 to 15 years, with an initial curve of 25 to 35 degrees, treated with either observation alone (129 patients), an underarm brace (111 patients), or nighttime electrical stimulation (46 patients) were compared. Curve progression at the end of bracing (skeletal maturity) was limited to less than 5 degrees in 74% of those treated with a brace, compared to 34% of those followed without treatment. The group treated with electrical stimulation had a success rate of only 33% (187). Although critics (137) site flaws in this and other studies, most centers have accepted the results, and continue to advise brace treatment for progressive curves in skeletally immature adolescents.

Data regarding the efficacy of various brace designs are mixed with differing inclusion criteria making direct comparisons impossible (203,204). However, in two recent studies a full-time underarm brace was more successful than a nighttime Charleston bending brace both in preventing curve progression and in preventing surgery (188,208). Both of these studies were retrospective with potential biases, and no prospective comparison of various braces has been performed to confirm these conclusions. In the series from Dallas, the nighttime Charleston brace equaled the efficacy of a Boston brace for single lumbar and thoracolumbar curves (188).

For each of these braces correction of the curve should be maximized in the brace with careful fitting, and adjustment of the pads by an experienced orthotist with an interest in scoliosis treatment. Efficacy is increased when the in-brace radiographic Cobb angle is reduced by 20% or more, compared to the pre-brace Cobb measurement (207).

In summary, although brace treatment for progressive curves provide the standard of care in most of the developed world, the scientific basis for brace efficacy is not powerful. When to intervene remains problematic, because very mild curves are easier to control with a brace, yet wholesale adoption of this policy leads to many children being braced unnecessarily. Waiting until the curve reaches 30 degrees allows one to brace the least number of patients, yet the margin between a curve of 30 degrees (brace instituted) and 40 to 45 degrees (surgery required) is distressingly small. Finally, many adolescents strongly resist brace wear, and their resistance is understandable (209,210), particularly in teenage

boys with scoliosis, who might have to wear a brace for as long as 5 years (skeletal maturity often age >18 years). Each of these factors make the brace treatment of scoliosis a continuing challenge.

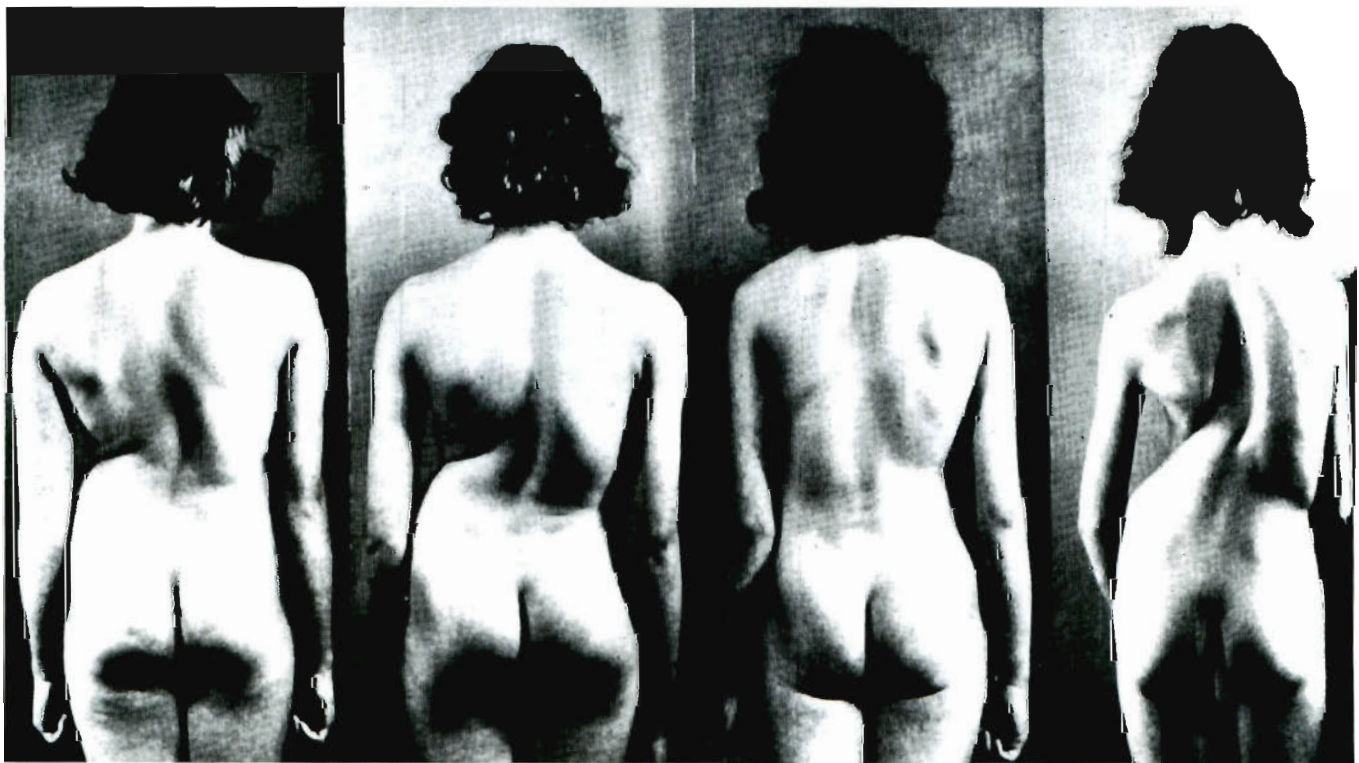Surgical Correction of Idiopathic Scoliosis

Introduction and Indications. Goals for surgical treatment of idiopathic scoliosis include improved spinal alignment/balance and prevention of subsequent curve progression. Corrective instrumentation plus arthrodesis (fusion) provides the best method for achieving lasting correction, and can be used either anteriorly or posteriorly to restore spinal alignment, as well as to provide postoperative stabilization while the fusion mass progressively solidifies. All current methods rely on the development of a stable bony fusion mass to maintain the correction over time with the rods serving as internal struts while fusion occurs. Application of a rod system without a bony fusion predictably leads to rod fracture and loss of correction.

The indications for surgical correction of scoliosis are

based on curve magnitude, clinical deformity, risk for progression, skeletal maturity, and curve pattern. In general, thoracic curves of greater than 40 to 50 degrees (Cobb angle) in skeletally immature patients should have surgical correction, while in mature patients (i.e., risk of progression decreased), surgical correction is reserved for curves of 50 degrees or more. These Cobb angle ranges are meant as guidelines rather than absolute indications and are based on the natural history of untreated scoliosis in immature and mature patients. Factors other than Cobb angle should be considered when deciding between operative and nonoperative treatment. Trunk deformity (rotation), as well as trunk balance, are important factors in deciding when to advise surgical correction. A patient with a lumbar curve of 35 degrees may have such a severe lateral trunk shift that surgical correction is indicated. The curve pattern has a great impact on the cosmetic deformity associated with the scoliosis, with single curves producing a more noticeable unbalanced trunk, compared to double or triple curves (Fig. 18-25).

When recommending surgical treatment of scoliosis, it is implied that both early and long-term outcome will be



Lumbar

Thoracolumbar

Double Major

Thoracic

FIGURE 18-25. This classic series of photographs from J.I.P. James demonstrates the clinical appearance of four patients, each with a 70-degrees magnitude curvature, although with different curve patterns. The clinical deformity is greater in single curves, particularly in the thoracic curve. (From ref. 141, with permission.)

improved compared to the nonoperative treatment. The short-term results of surgical treatment are well known with a variety of surgical techniques having been studied for most curve types. Midterm (5 to 10 years) outcomes for modern corrective surgery are becoming available (211,212), but like all advancing technologies, the surgical methods tend to change faster than the results can be collected. The study by Dickson et al. of Harrington's surgically treated patients, with 20-year follow-up, showed good long-term results. Although the methods of Harrington (single distraction rod) have been replaced in many parts of the world, the fusion of patients with scoliosis in that era led to lasting stabilization in most cases (213).

Posterior Spinal Instrumentation. Paul Harrington of Houston introduced posterior spinal instrumentation in the early 1960s to make spine fusions more predictable (214). Prior to this, *in situ* fusions with body cast correction were performed (215) to correct the deformity and immobilize

the spine while the fusion occurred. The addition of Harrington instrumentation improved scoliosis correction and greatly reduced the incidence of pseudarthrosis following scoliosis surgery.

Harrington Instrumentation. The Harrington instrumentation system consists of a ratcheted concave distraction rod with hooks at either end and a threaded compression rod attached to the transverse processes on the convex side of the curve [➡2.2]. Coronal plane improvement provided by the Harrington distraction rod was often gained at the expense of decreased thoracic kyphosis and flattening of the lumbar spine (so-called "flat-back deformity"), as noted in the sagittal plane (Fig. 18-26). Subsequent modifications of the Harrington concept included the use of sublaminar wires or a square-ended rod to allow rod contouring (in an attempt to maintain thoracic kyphosis and lumbar lordosis) while preventing rod rotation with distraction [➡2.3] (216).

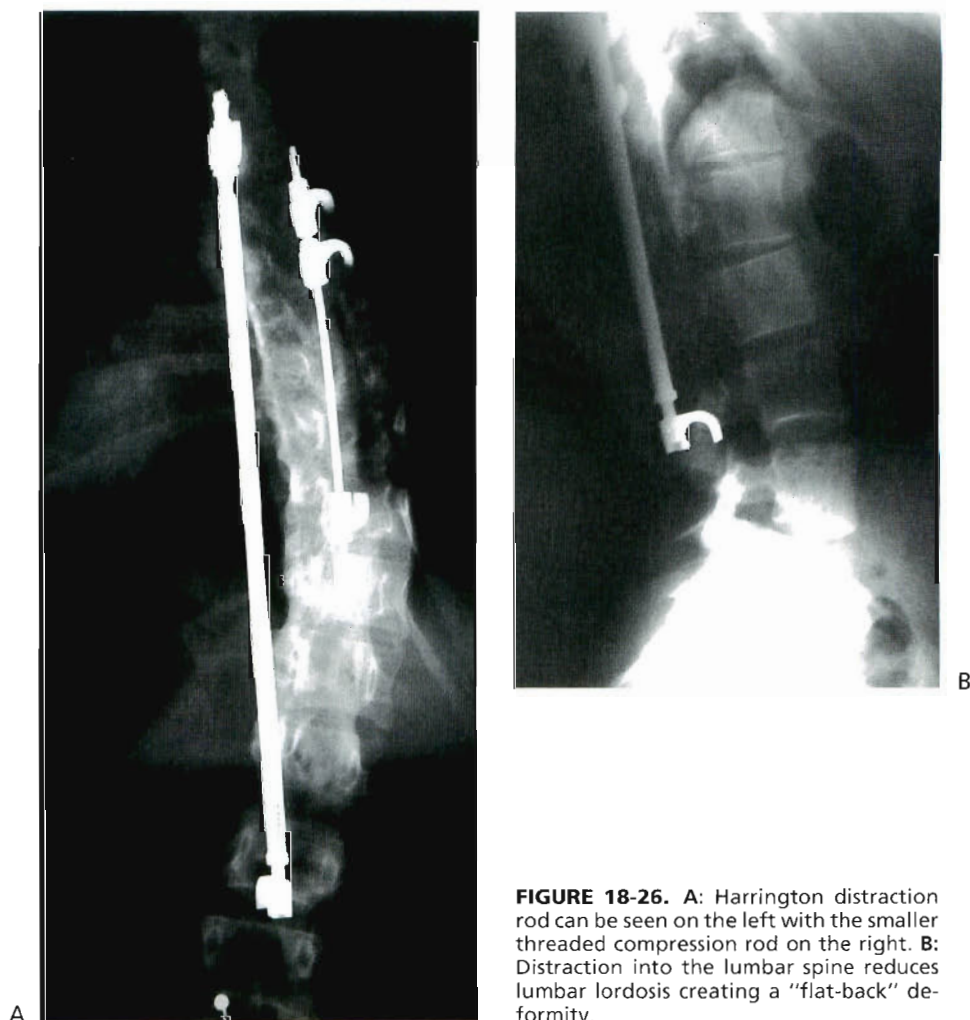


FIGURE 18-26. A: Harrington distraction rod can be seen on the left with the smaller threaded compression rod on the right. B: Distraction into the lumbar spine reduces lumbar lordosis creating a "flat-back" deformity.

The trend toward protecting normal lumbar contour was greatly advanced by Moe's clarification that most scoliosis (with apparent double curves) requiring surgical correction did *not* require fusion of the lumbar curve. He clarified that the lumbar curve is very often secondary, and does not require fusion (the so-called King-Moe type 2 curve). Application of the King-Moe curve classification is emphasized later in this chapter (217).

Cotrel-Dubousset and Other Double Rod, Multiple Hook Systems. Nearly 20 years after the Harrington method was introduced, Cotrel and Dubousset (France) introduced a multi-hook system that allowed distraction and compression on the same rod (218). Sagittal plane contouring of the rods and segmental hook fixation improved curve correction, as well as postoperative stability. Many additional segmental fixation posterior instrumentation systems utilizing similar concepts are now available for surgical correction of scoliosis. Current options for attachment to the posterior spine include hooks (for attachment to the transverse processes, laminae, and pedicles), sublaminar wires (Luque), and pedicle screws [➤2.9].

The introduction of pedicle screw fixation into posterior scoliosis constructs distally, allows greater correction compared to distal hook constructs, and allows fewer levels to be instrumented caudally (219,220). The utility of pedicle screw attachment to vertebra was first recognized in Europe (221), and was initially quite controversial in North America because of an increased potential for neurologic injury associated with screw insertion. Pedicle screw attachment is highly effective, but the surgeon must have appropriate training and skill when using them to safely improve the stability of corrective scoliosis constructs. In North America they are generally used only in the lower thoracic and upper lumbar spine when used at all for scoliosis correction. The use of pedicle screws in mid and even upper thoracic vertebrae in scoliosis has been advocated by Suk et al., but this more demanding technique has not been widely adopted (222,223).

It must be emphasized that with all of these procedures the goal is to obtain fusion, and one must first perform careful subperiosteal exposure of the spine as well as meticulous facet excision [➤2.1]. The spine must also be decorticated prior to adding bone graft. The complexity of modern instrumentation sometimes causes surgeons to pay too little attention to the details required to obtain a successful fusion.

Mechanisms of Correction. Several strategies can be utilized when implanting posterior instrumentation systems. Frontal plane realignment of the spine can be accomplished by translating the vertebra to the concave rod. This translational movement may be performed by connecting the concave rod, precontoured to the desired sagittal profile to each fixation site along the spine, then rotating the rod into the sagittal plane. This rod rotation maneuver, popularized by

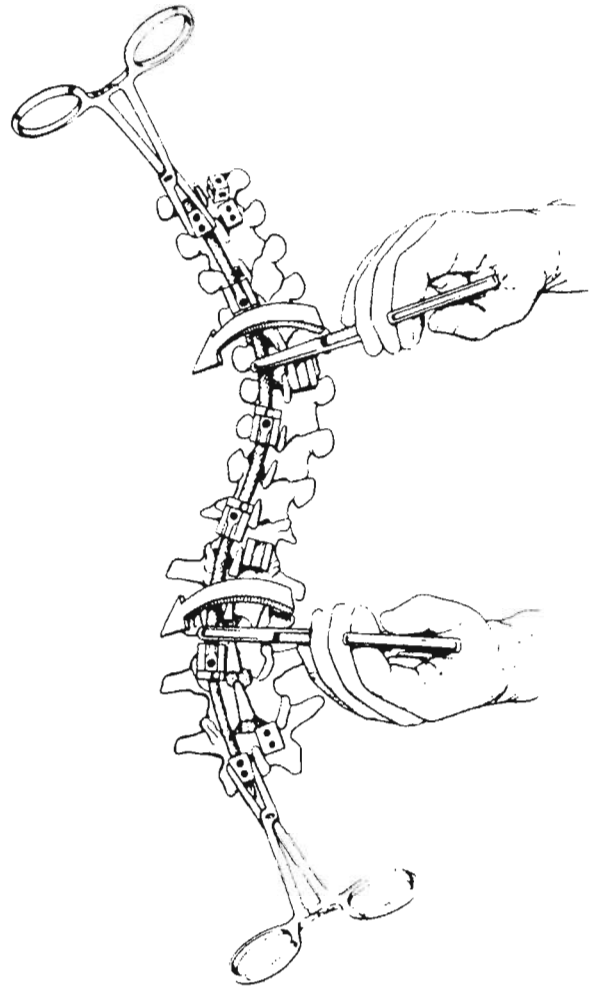
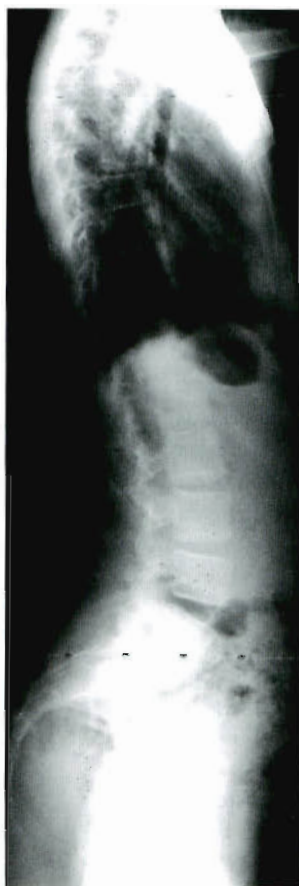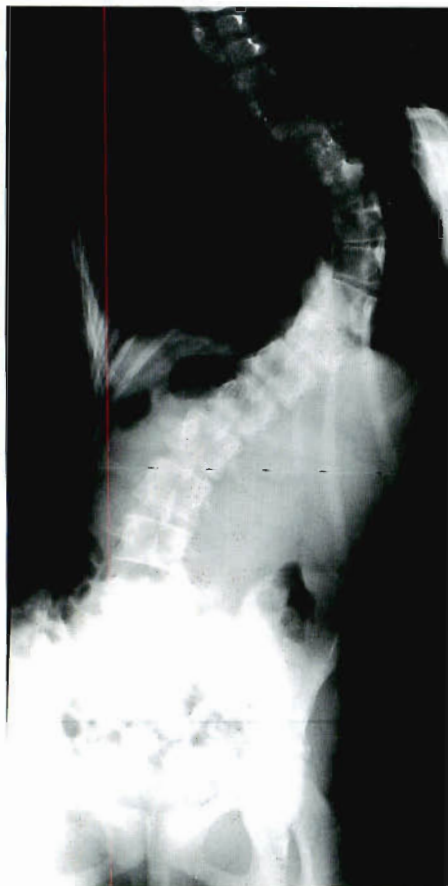


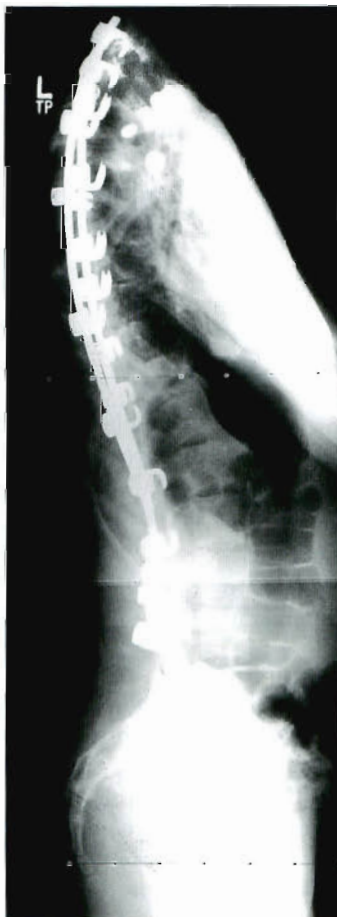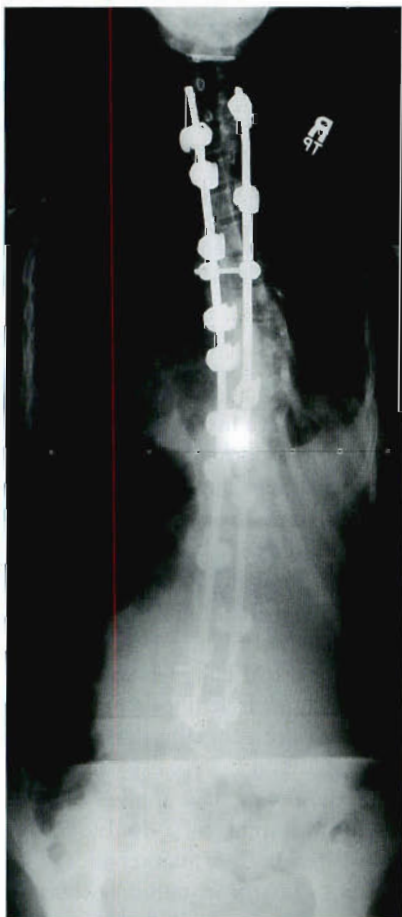FIGURE 18-27. Example of the rod derotation maneuver popularized by Dubousset. The rod, first contoured to match the scoliosis, is then secured to the hooks and rotated 90 degrees to recreate thoracic kyphosis and lumbar lordosis.

Dubousset, remains an effective method for translating the apex of the curve into a more normal position (Fig. 18-27). Another method for translating the apex in space involves locking the concave rod into the position of anticipated correction, then sequentially (with hooks) or incrementally (with sublaminar wires) drawing the spine to the rod. Compression and distraction forces are then added to enhance both frontal and sagittal plane correction.

Distraction on the concave (usually left sided) rod in the thoracic spine increases thoracic kyphosis and decreases a right-sided scoliosis. Both are generally desired, given the frequent loss of normal thoracic kyphosis noted in idiopathic scoliosis. Similarly, *compression* applied on the same left-sided rod in the lumbar spine (of a double curve) corrects scoliosis and allows restoration/maintenance of lumbar lordosis. In most posterior instrumentation systems used to correct a right thoracic curve, the left-sided (concave) tho-



A,B



C,D

FIGURE 18-28. A: This adolescent female presented with a 90-degrees right thoracic scoliosis with marked trunk shift to the right. She corrected to 60 degrees on bending to the right. B: Preoperative lateral radiograph. C: Following thoracoscopic release and fusion the patient underwent a posterior spinal instrumentation and fusion, with correction of her deformity. A distraction was used through the concavity of the thoracic curve on the left rod with lumbar compression to restore trunk balance and maintain sagittal alignment through the lumbar spine. D: Postoperative lateral radiograph demonstrates maintenance of appropriate sagittal alignment.

racic rod that is placed first provides the majority of the deformity correction. The second rod, placed on the right side, primarily adds stability and resistance to fatigue failure. In most modern systems, the two rods are then cross-linked to improve stability.

Anterior Release and Fusion. Indications for a combined anterior and posterior approach in idiopathic scoliosis include patients with large (greater than 75 degrees), rigid (bend correction less than 50 degrees) curves, and those at risk for post-fusion crankshaft deformity. Curve flexibility is increased by anterior disc excision, allowing greater correction with posterior instrumentation, and the bone graft used anteriorly leads to a very stable fusion (anterior and posterior). The procedure involves anterior disc excision with release of the anterior longitudinal ligament, removal

of the annulus fibrosis and nucleus pulposus, excision of the vertebral endplate cartilage, and occasionally (in severe cases), excision of the rib head (at the costovertebral joint) (Fig. 18-28).

The term “crankshaft deformity” (117,224–227) identifies a circumstance in which anterior spinal growth continues despite successful posterior fusion, resulting in worsening rotational deformity even after successful posterior fusion (Fig. 18-29). The problem occurs only in skeletally immature patients (Risser 1 or less, triradiate cartilage open). Defining and measuring crankshaft growth is difficult, and has been defined as an increase in the Cobb measurement of >10 degrees, or an increase in apical rotation despite successful posterior fusion. This largely axial rotational deformity is difficult to measure with routine radiog-

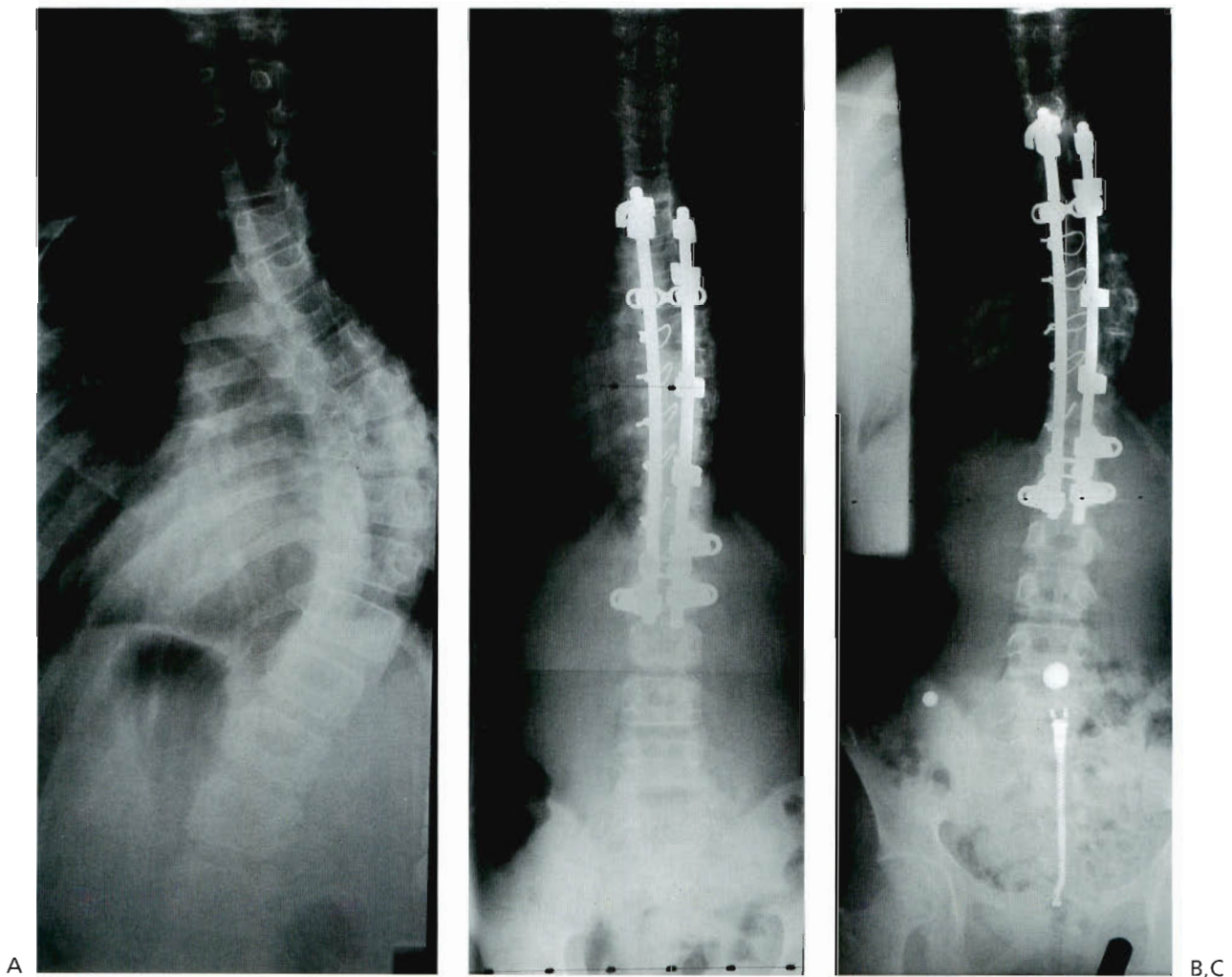


FIGURE 18-29. A: This 8-year, 9-month-old female (clearly skeletally immature) presented with a 60-degree right thoracic scoliosis. B: She underwent an isolated posterior instrumentation and fusion with correction to 22 degrees. C: Due to continued anterior spinal growth, a crankshaft deformity developed with curve progression, and the trunk decompensated despite a successful posterior fusion. One year postoperatively her curve measured 34 degrees. In this illustration (taken two years postoperatively), her curve has progressed to 43 degrees.

raphy. Recent reports suggest that anterior fusion arrests the anterior growth center and limits the development of this late deformity (228).

An additional advantage of anterior release and fusion is the increased area for the arthrodesis (vertebral end plates) presumably reducing the risk of pseudarthrosis. The thoracoscopic approach is being developed as a means of accomplishing anterior disc excision and fusion with minimally invasive methods (229–231).

Anterior Spinal Instrumentation. At the time of anterior disc excision and fusion, anterior corrective instrumentation with vertebral body screw fixation and a single or double anterolateral rod construct can be considered for some curve patterns [→2.11]. The first anterior instrumentation systems, introduced by Dwyer (232) and then Zielke (233), were both flexible rod compression systems that generated kyphosis within the instrumented segments. This production of kyphosis may be desirable in the scoliotic thoracic

spine (that has become relatively lordotic), but is generally undesirable in the lumbar region.

Subsequently, more rigid solid-rod anterior systems were developed in an attempt to improve the sagittal alignment, particularly when used for thoracolumbar and lumbar curves. Scoliotic curve patterns that are amenable to corrective anterior instrumentation and fusion generally include those with a single structural deformity (thoracic, thoracolumbar, or lumbar).

The greatest experience with anterior scoliosis correction has been gained in the treatment of thoracolumbar and lumbar scoliosis (234–237). Direct access to the vertebral bodies and intervertebral discs is possible via an open anterior thoracoabdominal approach. Anterior disc excision creates mobility, which enhances correction in the frontal and axial planes, but decreases sagittal plane lordosis. Special attention to the sagittal plane is required when anterior compression instrumentation is used distal to the thoracolumbar junction to avoid production of an

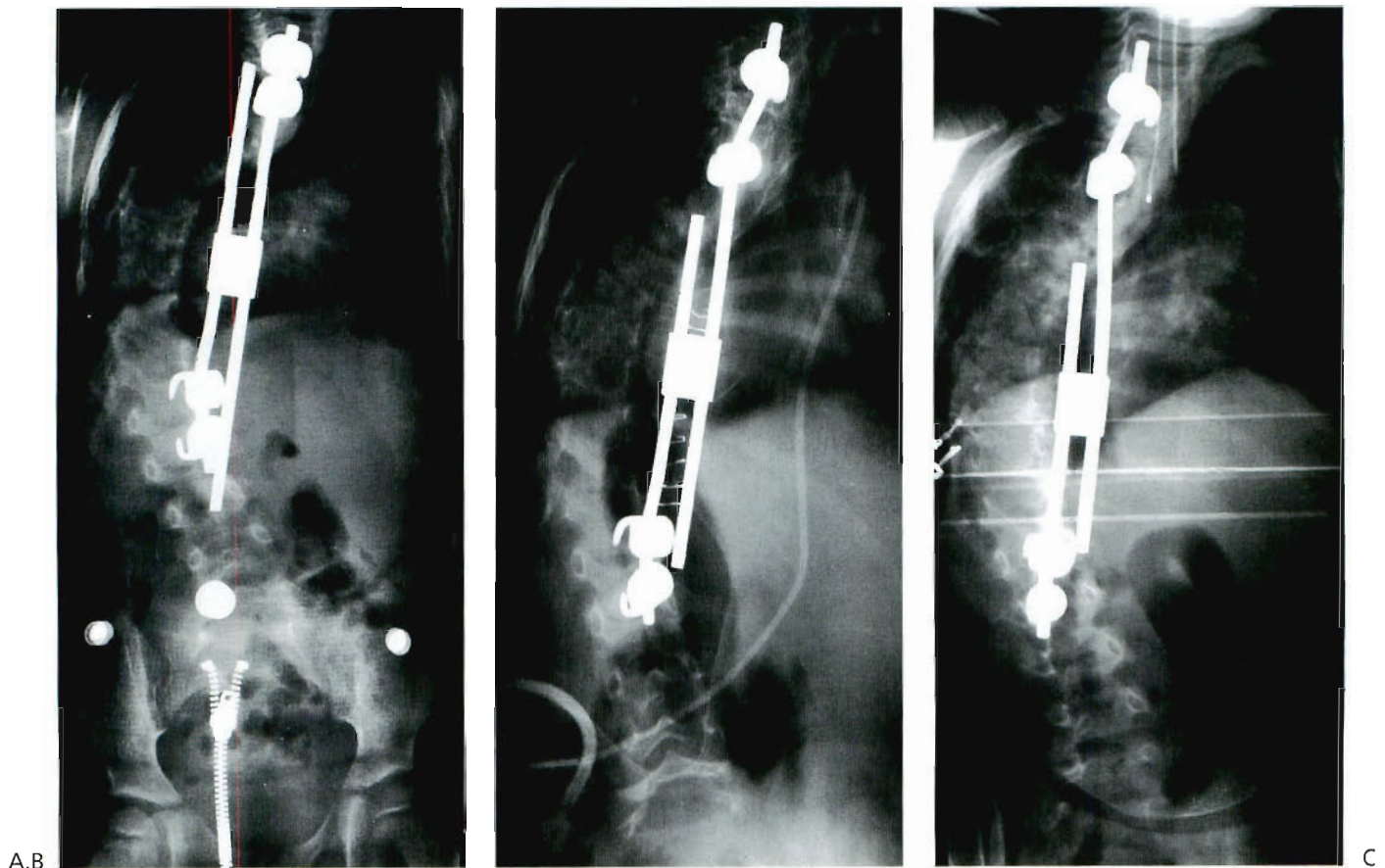


FIGURE 18-30. A: This patient with infantile idiopathic scoliosis (seen also in Fig. 18-17) underwent apical anterior and posterior hemiepiphysiodesis with posterior instrumentation at age 4 years. B, C: At the first repeat lengthening procedure, he achieved an increase in spine length of 2.5 cm. Additional lengthening procedures were performed every 6 months with a total length gain of 6 cm (some from deformity correction, some from growth of the spine) achieved 2½ years following the initial procedure.

iatrogenic flat-back deformity (due to loss of desired lordosis). Structural interbody support, by use of a structural bone graft or an interbody “cage,” has been advocated as a means of maintaining sagittal alignment (238). Double-rod, double-screw anterior systems have also been introduced as a means of providing additional sagittal plane control (239,240). In most cases, anterior instrumentation can achieve similar or greater correction (than posterior instrumentation for the same curve) with fewer levels instrumented (241,242).

The selection of the most appropriate approach for correction of idiopathic scoliosis (anterior versus posterior) is dependent on the curve pattern, sagittal deformity, age of the patient, and experience of the surgeon. The selection of the fusion levels for any given patient is also dependent on several factors and remains a topic of much controversy. The fusion should be as short as possible, minimizing the changes in spinal mobility, yet be long enough to ensure optimal correction and lasting spinal balance (both coronal and sagittal).

Instrumentation without Fusion. Instrumentation without fusion, a technique utilized in young children with curves that progress relentlessly despite aggressive brace treatment, includes a subcutaneously positioned distraction construct that spans the deformity (243). At the proximal and distal hook sites, a limited fusion is performed to decrease the incidence of hook dislodgment. In the intervening segments, the spine is *not* stripped subperiosteally, since exposure alone may lead to spontaneous fusion in a young child (thus the concept of a “subcutaneous” rod). Sequential distraction is performed every 6 to 12 months during growth, until no further correction can be obtained. The height gained with these procedures is usually modest, and complications are common (243) (hook dislodgement, spontaneous fusion (244), and infection); therefore, these systems are presently used in children less than 5 to 6 years of age in whom there are few other options. The internal splint (spinal rods) requires external protection with a brace throughout the period of sequential rod distraction. Eventually, a formal instrumentation and fusion are performed. A short convex hemiepiphysiodesis (anterior and posterior) over the apical levels may also be included in the subcutaneous rod technique (224,245) (Fig. 18-30).

Surgical Correction According to Curve Pattern

Idiopathic scoliosis takes on several typical and distinct curve patterns with the most common being a right thoracic curve. To surgically correct scoliosis one must understand these curve patterns. The most widely used classification, developed by Moe as reported by King et al. (King-Moe

TABLE 18-3. CURVE PATTERNS OF THORACIC CURVES

Type I

Double thoracic and lumbar curves
Thoracic and lumbar prominences clinically
Both curves cross the midline
Lumbar curve may be larger than the thoracic curve
Both curves are structural with nearly equal flexibility on supine side bending
True double-major curve, both require fusion

Type II

Thoracic and lumbar curves
Minimal lumbar prominence clinically
Both curves cross the midline
Lumbar curve is more flexible on supine side-bending examination
False double-major pattern allowing selective fusion of the thoracic curve

Type III

Thoracic curve
Minimal or no decompensation
Lumbar curve does not cross the midline

Type IV

Long thoracic curve
Marked decompensation
Curve reaches the midline at L4, which tilts into the curve

Type V

Double thoracic curve
Positive tilt of T1 with prominent left neckline
High left and right thoracic prominences clinically
Upper left curve structural on side-bending examination

(From ref. 217, with permission.)

Classification) (Table 18-3, Fig. 18-31), was designed primarily to decide when to instrument the thoracic curve alone (in patients with apparent double curves), and when to instrument both the thoracic and lumbar curves. Despite the common use of this classification when planning surgery, the system was not designed as a comprehensive classification of idiopathic scoliosis curve patterns.

Primary lumbar and thoracolumbar curves, as well as triple curves, are not included in the King-Moe classification. Others have designed classification systems that are more comprehensive (246,247). The system proposed by Lenke et al. considers both frontal and sagittal plane deformity and is designed to guide surgical treatment decision-making for all curve patterns. This classification system is currently being evaluated at several scoliosis centers around the world with the practicality and usefulness of such a classification system yet to be proven (Fig. 18-32).

Right Thoracic Curve Pattern. The common idiopathic right thoracic curve pattern is most often corrected with posterior spinal instrumentation and fusion of the thoracic curve. Selection of the best cranial and caudal vertebrae to attach to is critical, with the goal to fuse as short as possible,

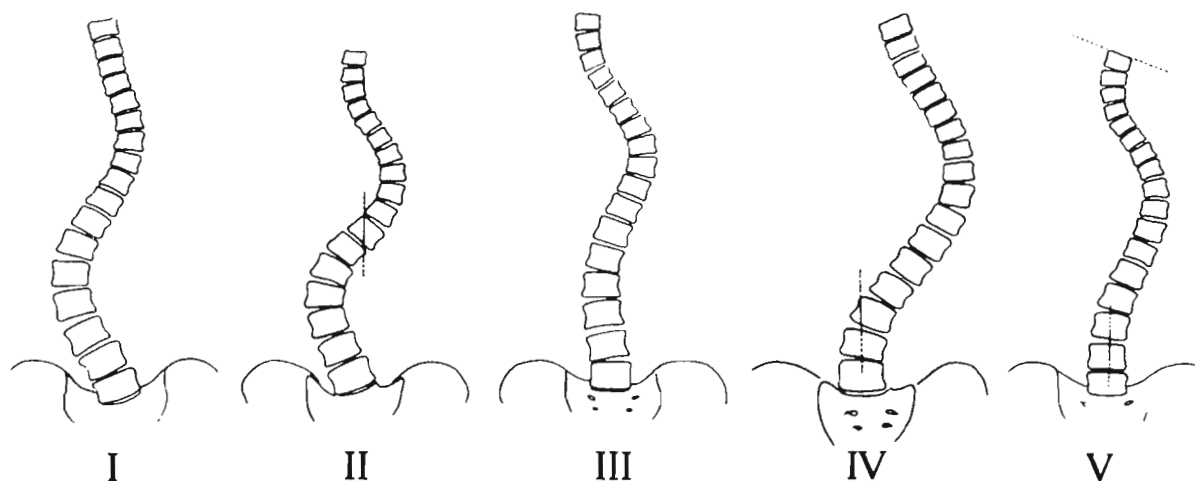


FIGURE 18-31. Diagrammatic representation of the King-Moe classification system for thoracic idiopathic scoliosis. (From ref. 217, with permission.)

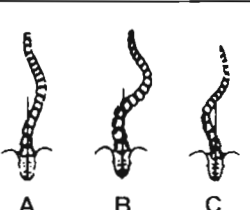
Lumbar Spine Modifier	Curve Type (1 - 6)					
	Type 1 (Main Thoracic)	Type 2 (Double Thoracic)	Type 3 (Double Major)	Type 4 (Triple Major)	Type 5 (TL/L)	Type 6 (TL/L- MT)
A (No to Minimal Curve)	 1A*	 2A*	 3A*	 4A*		
B (Moderate Curve)	 1B*	 2B*	 3B*	 4B*		
C (Large Curve)	 1C*	 2C*	 3C*	 4C*	 5C*	 6C*
Possible Sagittal structural criteria (to determine specific curve type)	 Normal	 PT Kyphosis	 TL Kyphosis	 PT + TL Kyphosis	 Normal	 TL Kyphosis

* T5-12 sagittal alignment modifier: —, N, or +
 —: <10°
 N : 10-40°
 + : >40°

FIGURE 18-32. A, B: This comprehensive scoliosis classification scheme has been proposed by Lenke et al. to classify all forms of adolescent idiopathic scoliosis. Each curve is given a type 1 to 6, as well as a lumbar spine modifier A to C, and a thoracic sagittal profile modifier —, N, +. (continued)

Curve Type				
Type	Proximal Thoracic	Main Thoracic	Thoracolumbar / Lumbar	Curve Type
1	Non-Structural	Structural (Major)	Non-Structural	Main Thoracic (MT)
2	Structural	Structural (Major)	Non-Structural	Double Thoracic (DT)
3	Non-Structural	Structural (Major)	Structural	Double Major (DM)
4	Structural	Structural (Major)	Structural	Triple Major (TM)
5	Non-Structural	Non-Structural	Structural (Major)	Thoracolumbar / Lumbar (TL/L)
6	Non-Structural	Structural	Structural (Major)	Thoracolumbar / Lumbar - MT (TL/L-MT) (Lumbar Curve > Thoracic by $\geq 10^\circ$)

STRUCTURAL CRITERIA		LOCATION OF APEX (SRS definition)	
Proximal Thoracic:	- Side Bending Cobb $\geq 25^\circ$ - T2 - T5 Kyphosis $\geq +20^\circ$	CURVE	APEX
Main Thoracic:	- Side Bending Cobb $\geq 25^\circ$ - T10 - L2 Kyphosis $\geq 25^\circ$	THORACIC	T2 - T11-12 DISC
Thoracolumbar / Lumbar:	- Side Bending Cobb $\geq 25^\circ$ - T10 - L2 Kyphosis $\geq +20^\circ$ - > 1 Nash-Moe (Apical S.B.)	THORACOLUMBAR	T12 - L1
		LUMBAR	L1-2 DISC - L4

Modifiers		
Lumbar Spine Modifier	CSVL to Lumbar Apex	
A	CSVL Between Pedicles	
B	CSVL Touches Apical Body(ies)	
C	CSVL Completely Medial	

Thoracic Sagittal Profile T5 - T12	
- (Hypo)	< 10°
N (Normal)	10° - 40°
+ (Hyper)	> 40°

Curve Type (1-6) + Lumbar Spine Modifier (A, B, or C) + Thoracic Sagittal Modifier (-, N, or +)
Classification (e.g. 1B+): _____

FIGURE 18-32. (continued)

yet long enough to minimize residual trunk imbalance or late curve progression. For typical correction of a thoracic curve the most distal hook is attached to the vertebra that is one level proximal to the stable vertebra (vertebra bisected by the central sacral vertical line). Multiple hooks or sublaminar wires on the concave side of the spine are used to draw up the apex of the curve from its lordoscoliotic position into a more normal kyphotic alignment. The concave (left-sided) rod is placed first; setting the hooks in distraction on the concavity provides both scoliosis correction and also aids in restoration of more normal kyphosis with posterior distraction. The convex (right-sided) rod is then added, and the two rods are connected with a cross-link (Fig. 18-33).

Thoracic curves can also be corrected by anterior instrumentation. This concept, more commonly used for thoracolumbar and lumbar curves in North America, has been regularly employed to also correct thoracic curves in multiple European centers for at least two decades. Advantages include greater correction, a shorter fusion, and ease of recreating normal kyphosis in the hypokyphotic thoracic spine. Most recently, several American centers have begun to correct thoracic cases with anterior instrumentation (241,248). The levels selected for fusion in anterior instrumentation to correct thoracic scoliosis include all vertebrae within the measured Cobb angle. The thoracotomy required for this approach, which results in at least a temporary decrease of

pulmonary function, is a disadvantage of the method (Fig. 18-34). Also, in most systems only a single rod is used with the vertebral screw attached to the vertebral body, which is relatively more cancellous in nature compared to posterior fixation sites. This may increase the risk for screw–bone separation, especially at the cranial end of a thoracic curve, where the vertebral bodies are smaller.

Anterior thoracic corrective instrumentation is being developed for thoracoscopic implantation, and may be a future option for correction of thoracic scoliosis in patients with only moderately severe curves.

Right Thoracic, Left Lumbar Curve Pattern. The lumbar curve (usually convex to the left) that often presents in association with a right thoracic curve, may vary substantially in both magnitude (Cobb angle) and severity of rotation. Either the thoracic or lumbar curve may dominate such a double-curve pattern, although the thoracic curve is more often primary. In deciding on surgical treatment, one must determine which of the curves requires instrumentation and fusion (thoracic, lumbar, or both). When the thoracic curve is larger and/or more rigid than the lumbar curve (King II), selective fusion of the thoracic curve only should be considered (217,249) (Fig. 18-35). There are situations, however, in which the lumbar curve is large enough to require fusion if a well-balanced spine is to be achieved after correction.

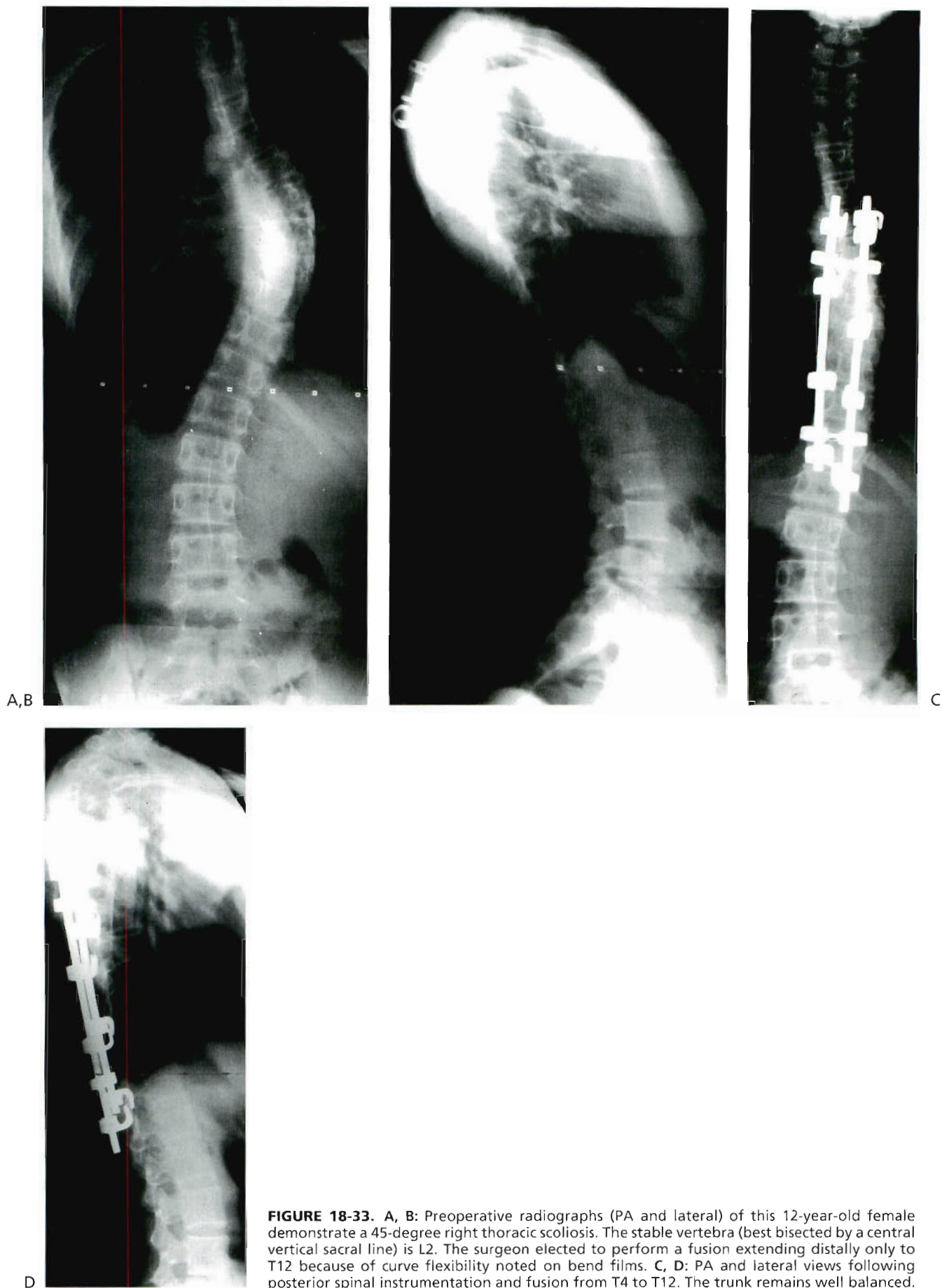


FIGURE 18-33. A, B: Preoperative radiographs (PA and lateral) of this 12-year-old female demonstrate a 45-degree right thoracic scoliosis. The stable vertebra (best bisected by a central vertical sacral line) is L2. The surgeon elected to perform a fusion extending distally only to T12 because of curve flexibility noted on bend films. C, D: PA and lateral views following posterior spinal instrumentation and fusion from T4 to T12. The trunk remains well balanced.

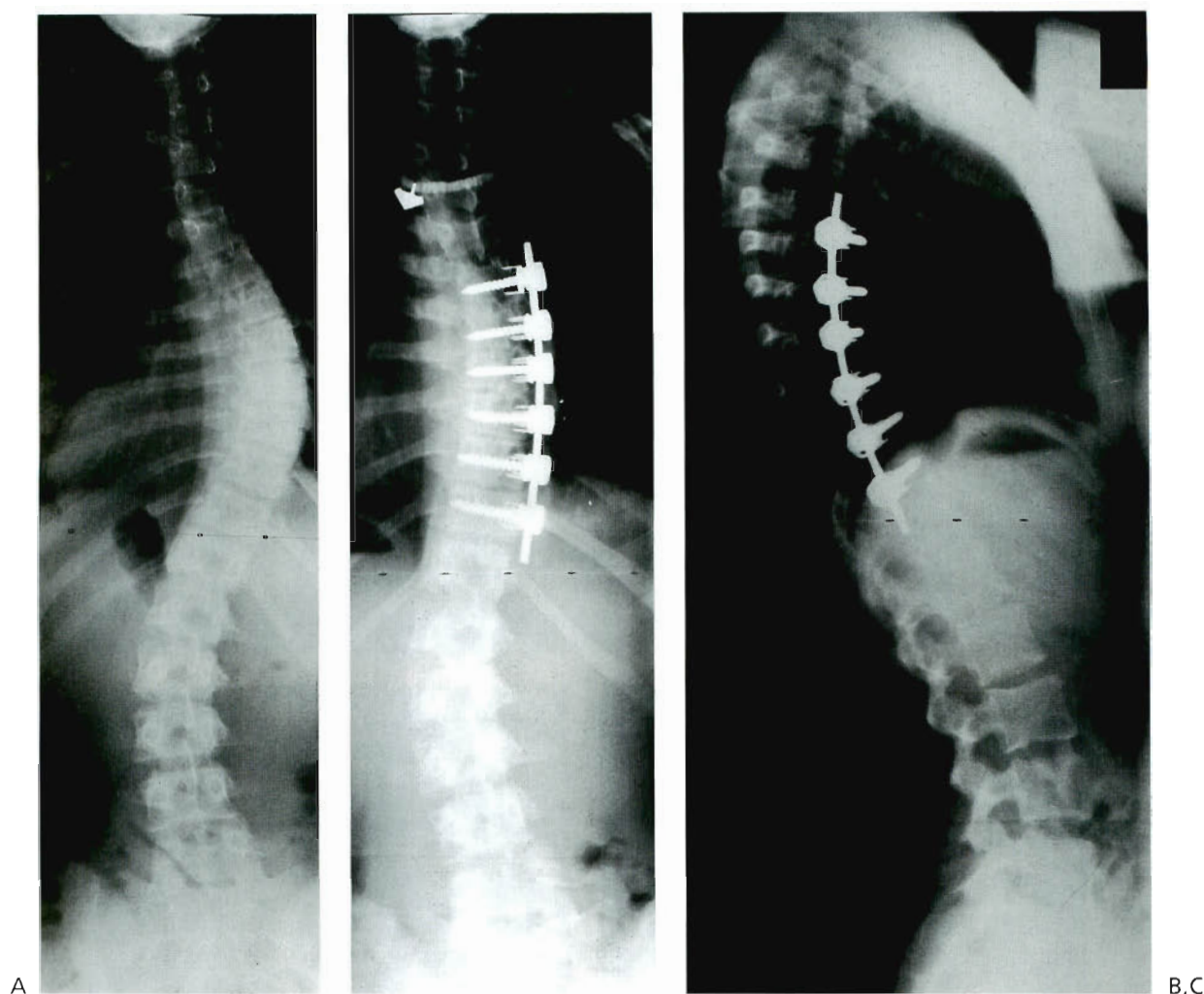


FIGURE 18-34. A: This 13-year-old female presented with a typical right thoracic curve. B, C: Postoperative PA and lateral radiographs demonstrate correction with limited anterior thoracic instrumentation and fusion from T6 to T11.

Several authors have provided criteria for selective fusion of the thoracic curve alone (249–251). Although universal agreement has not been reached, several factors should be understood. The instrumentation should not end inferiorly just above a “junctional kyphosis” (as noted on the lateral view). The junction between the thoracic and lumbar curves (approximately T12) may be focally kyphotic in the sagittal plane. A selective fusion of the thoracic spine in such a case will exaggerate the kyphosis at the thoracolumbar junction. When the lateral view demonstrates junctional kyphosis, the corrective instrumentation should extend distal to the kyphosis. If the lumbar curve is greater than 45 to 50 degrees, vigorous correction of only the thoracic curve with a posterior instrumentation system may result in postoperative truncal decompensation to the left (252,253). If selective fusion is elected in these cases, correction of the thoracic curve should be modest to minimize the chance of residual trunk imbalance (251).

When instrumentation of both the thoracic and the lumbar curves is required, the distal extent is usually to the L3 or L4 level (Fig. 18-36). Ideally, the distal extent of the fusion should be as proximal as possible to preserve lumbar motion segments, yet long enough to avoid creating trunk imbalance. Choosing between L3 and L4 can be difficult. The most predictable spinal balance occurs when the fusion/instrumentation extends distally to the stable vertebra (the vertebra best bisected by the central sacral vertical line). In patients with limited remaining growth and a left-sided lumbar curve, fusion to L3 may be considered, if there is minimal axial rotation of L3 as noted on the bend film to the left, and L3 levels above the pelvis with side bending to the right. With posterior instrumentation, laminar hook, or pedicle screw, fixation can be used to attach to lumbar vertebrae. When required to achieve thoracic and lumbar curve balance, pedicle screws provide an option that allows greater control and correction of a lumbar curve. Again, the

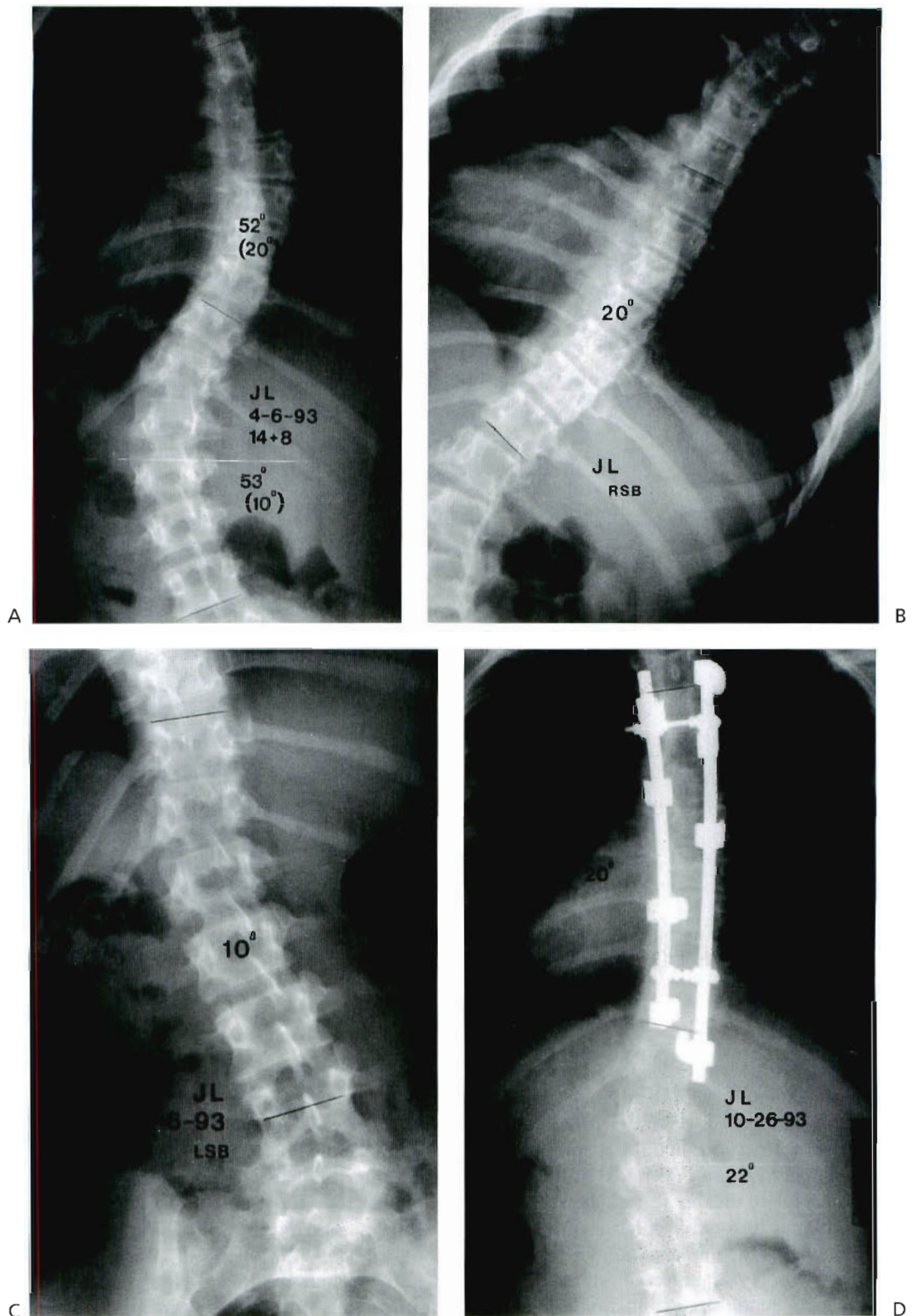


FIGURE 18-35. A: This 14-year-old female presented with idiopathic scoliosis and a right thoracic curve of 52 degrees and a left lumbar curve of 53 degrees. Clinically, she was balanced with level shoulders, and primarily a thoracic prominence on forward-bending. B: Supine-side bending to the right demonstrated correction of the right thoracic curve to 20 degrees. C: Supine side-bending to the left demonstrated lumbar curve correction to 10 degrees. Selective fusion of the thoracic curve alone is possible in this case, as long as there is not overcorrection of the right thoracic curve. The lower end vertebra of the curve (T11) is neutrally rotated and stable (bisected by the center sacral vertical line). D: Instrumentation and fusion were performed from T4 to T11. The thoracic curve was corrected to 20 degrees, and the lumbar curve spontaneously corrected to 22 degrees.

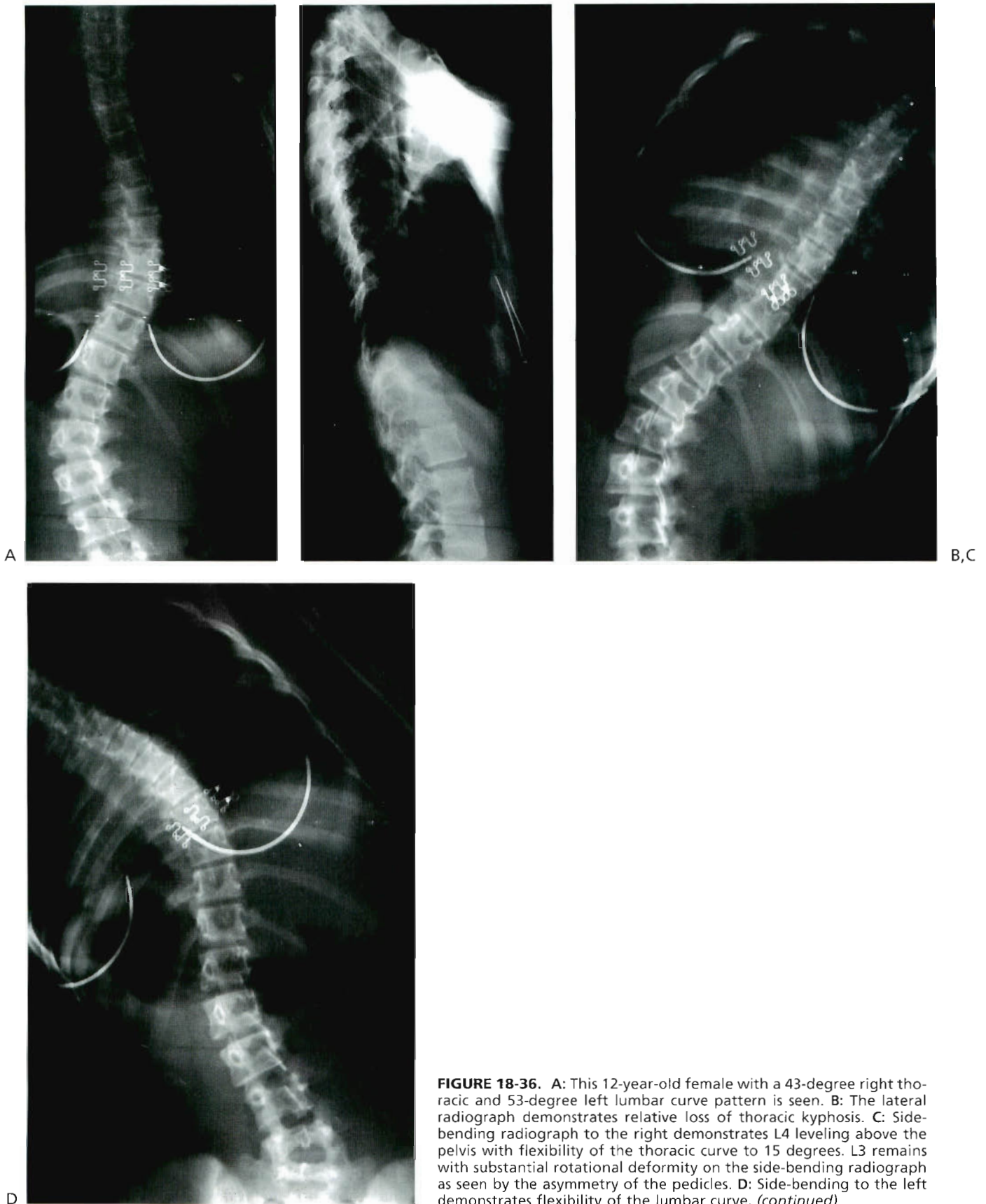


FIGURE 18-36. A: This 12-year-old female with a 43-degree right thoracic and 53-degree left lumbar curve pattern is seen. B: The lateral radiograph demonstrates relative loss of thoracic kyphosis. C: Side-bending radiograph to the right demonstrates L4 leveling above the pelvis with flexibility of the thoracic curve to 15 degrees. L3 remains with substantial rotational deformity on the side-bending radiograph as seen by the asymmetry of the pedicles. D: Side-bending to the left demonstrates flexibility of the lumbar curve. (*continued*)

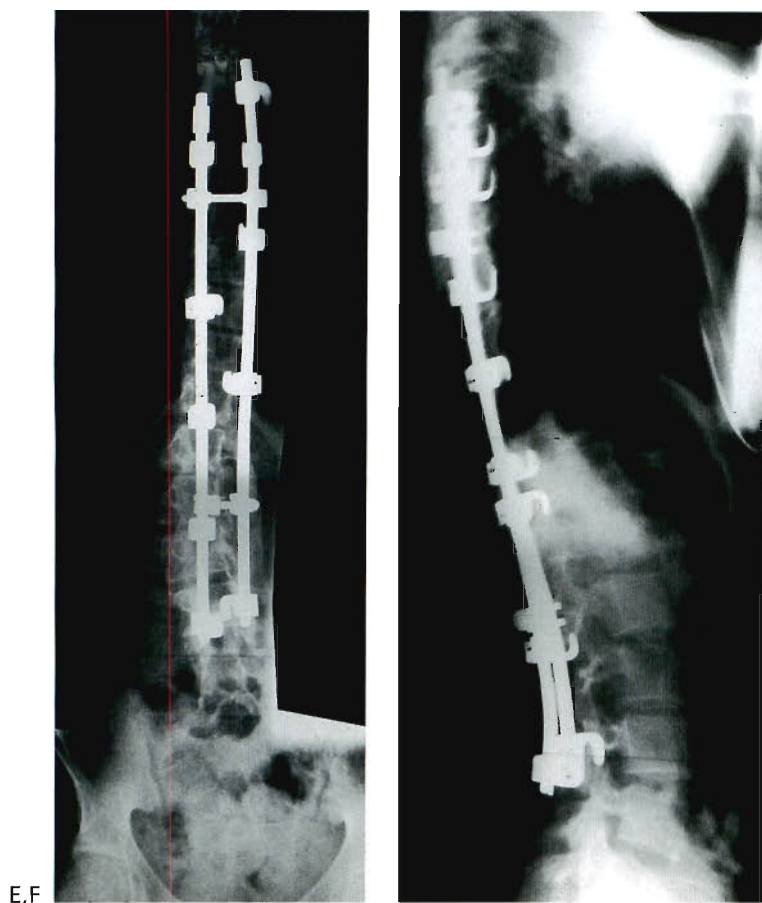


FIGURE 18-36. (continued) E: Given the magnitude of the lumbar curve relative to the thoracic curve, both curves required instrumentation and fusion. The standing PA radiograph 2 years postoperatively demonstrates correction of the thoracic curve to 10 degrees and the lumbar curve to 15 degrees. F: Standing lateral radiograph demonstrates maintenance of lumbar lordosis and slight improvement in the thoracic kyphosis.

surgical goal is to achieve improved spinal alignment with global truncal balance, with both C7 and the trunk well-centered over the pelvis in both the sagittal and coronal planes (Fig. 18-37).

Double Thoracic Curve Pattern. The double thoracic curve is recognized by the presence of an elevated left shoulder, whereas an isolated right thoracic curve is typically associated with an elevated right shoulder. If the left shoulder is higher, an upper thoracic curve to the left should be suspected. A left upper thoracic curve that is relatively rigid (reduces to >20 to 25 degrees on bend film) generally requires instrumentation beginning proximally at T1 or T2 (254). If the double pattern is not recognized, and the right thoracic curve alone is straightened, the left shoulder elevation is often worse following the surgery (255).

Left Lumbar or Thoracolumbar Curve Pattern. A primary lumbar or thoracolumbar curve pattern does not have a significant thoracic component and is usually convex to the left with a trunk shift to the left. In these cases, isolated fusion of a lumbar or thoracolumbar curve

is appropriate, and can be accomplished by either anterior or posterior methods. Correction with posterior hook constructs has not been as successful in achieving derotation of the lumbar curve, compared to anterior instrumentation. Limited anterior instrumentation of the apical 3 or 4 vertebrae has been proposed by Bernstein and Hall with satisfactory early outcomes in the majority of patients [2.11] (242). Longer anterior constructs (256) some with the use of bone graft or a structural cage in the disc space, have become popular in the treatment of these curves (Fig. 18-38). Pedicle screw fixation has allowed better control and correction of these curves when corrected with posterior instrumentation (Fig. 18-39). In severe cases, both anterior and posterior instrumentation may be indicated (Fig. 18-40).

Triple Curve Pattern. Not infrequently, a combined curve pattern includes curves in all three locations: left upper thoracic, right thoracic, left lumbar/thoracolumbar. Although it may not be necessary to surgically treat all three curves, each should be considered individually to determine if they are structural (relatively rigid), and treated accordingly

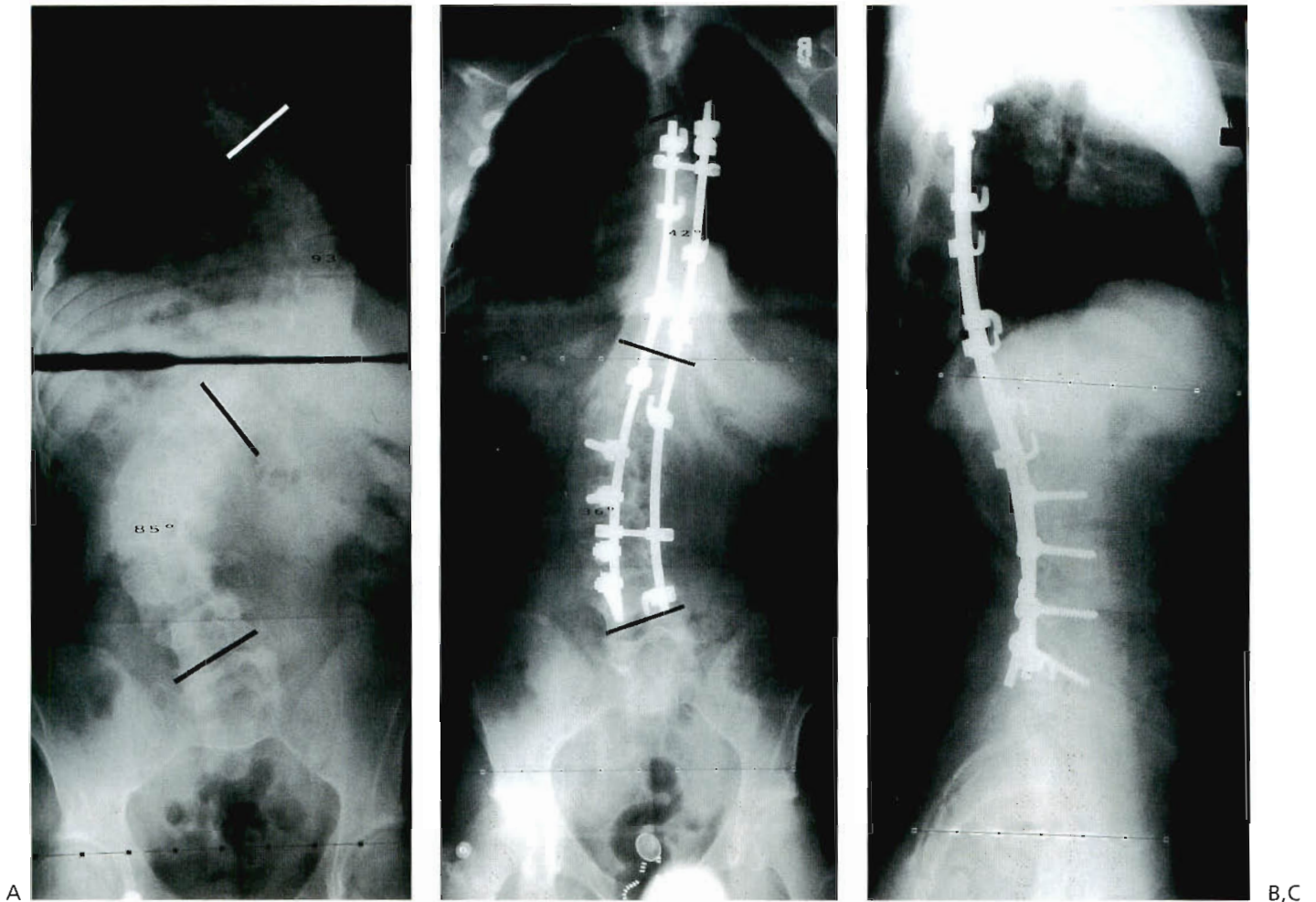


FIGURE 18-37. A: This 16-year-old male presented with severe double major scoliosis, with a right thoracic curve of 93 degrees and a left lumbar curve of 85 degrees. On side-bending radiographs to the right, the thoracic curve decreased to 68 degrees. On side-bending to the left the lumbar curve corrected to 52 degrees. B: The patient underwent a thoracoscopic anterior spinal release from T5 to T12, followed by a posterior spinal instrumentation and fusion of both curves. The lumbar curve was corrected to 36 degrees with pedicle screw fixation on the convex side of the curve. Coronal balance was maintained with correction of the thoracic curve to 42 degrees. C: The lateral radiograph demonstrates restoration of alignment in the sagittal plane.

(Fig. 18-41). In these triple curves the lower thoracic curve, if dominant, is certainly included in the arthrodesis. The inclusion criteria for the upper thoracic and lumbar curves are the same as those used for the corresponding double-curve patterns. For example, elevation of the left shoulder, in an upper thoracic curve with a curve that remains greater than 20 to 25 degrees on side-bending, should be considered for inclusion within the levels of fusion. Similarly, the lumbar curve should be instrumented when its Cobb angle magnitude is equal to or greater than the thoracic curve. The greater the difference in magnitude and rotation between the thoracic and lumbar curves (i.e., thoracic greater than lumbar), the more likely the lumbar curve can be spared from fusion (249,251).

Outcomes of Surgical Treatment

Given the relatively new methods used for surgical correction of adolescent idiopathic scoliosis (Harrington instrumentation in the 1960s, Cotrel-Dubousset instrumentation in the 1980s), very long-term outcome data are not yet available. Spinal instrumentation techniques continue to undergo modification and improvement almost faster than outcome studies can be performed. The Scoliosis Research Society has recently developed an outcomes instrument which will allow more careful functional outcomes analysis of patients treated with scoliosis (257).

Outcome after Posterior Surgery. The longest follow-up exists for patients treated with Harrington instrumentation

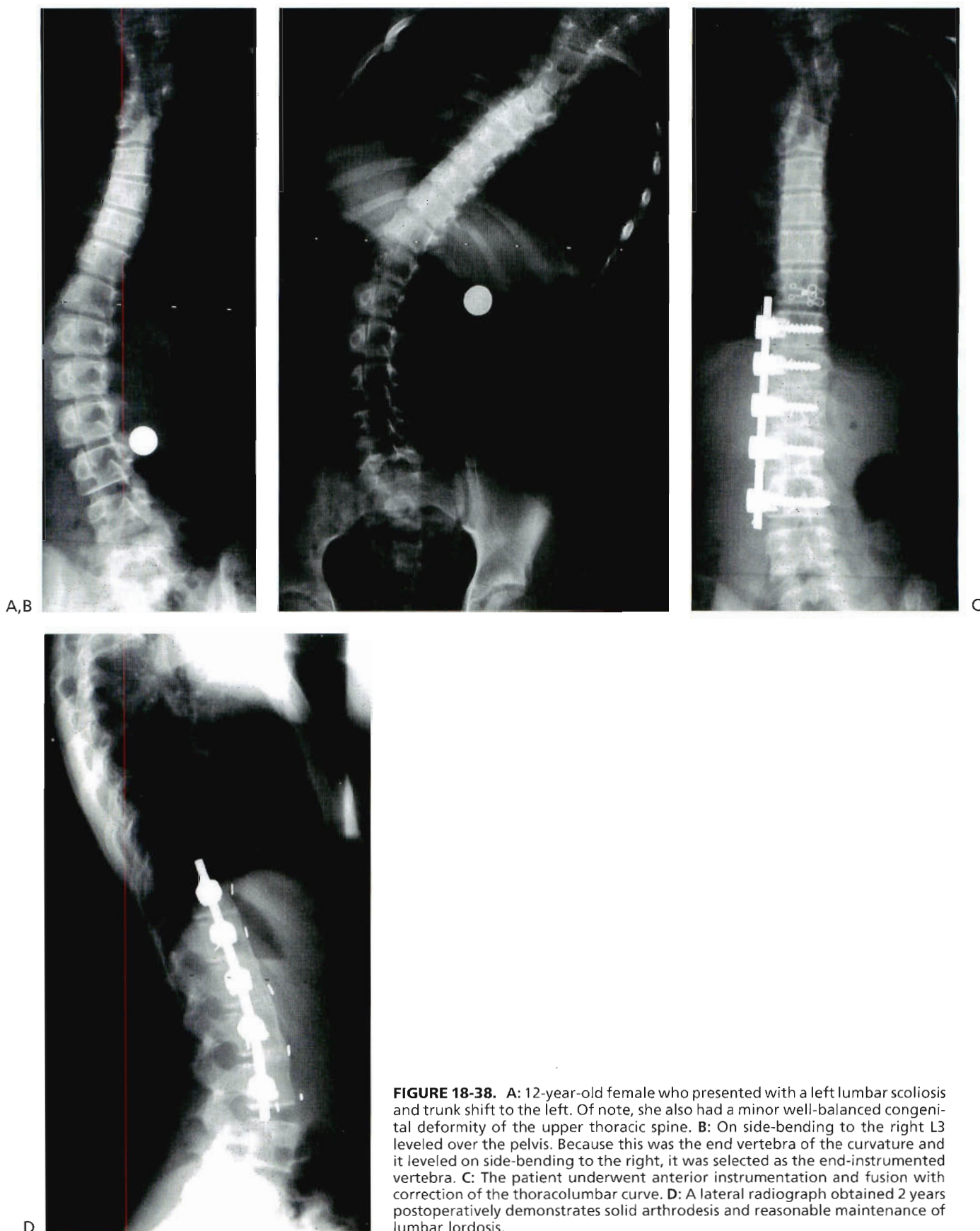


FIGURE 18-38. A: 12-year-old female who presented with a left lumbar scoliosis and trunk shift to the left. Of note, she also had a minor well-balanced congenital deformity of the upper thoracic spine. B: On side-bending to the right L3 leveled over the pelvis. Because this was the end vertebra of the curvature and it leveled on side-bending to the right, it was selected as the end-instrumented vertebra. C: The patient underwent anterior instrumentation and fusion with correction of the thoracolumbar curve. D: A lateral radiograph obtained 2 years postoperatively demonstrates solid arthrodesis and reasonable maintenance of lumbar lordosis.

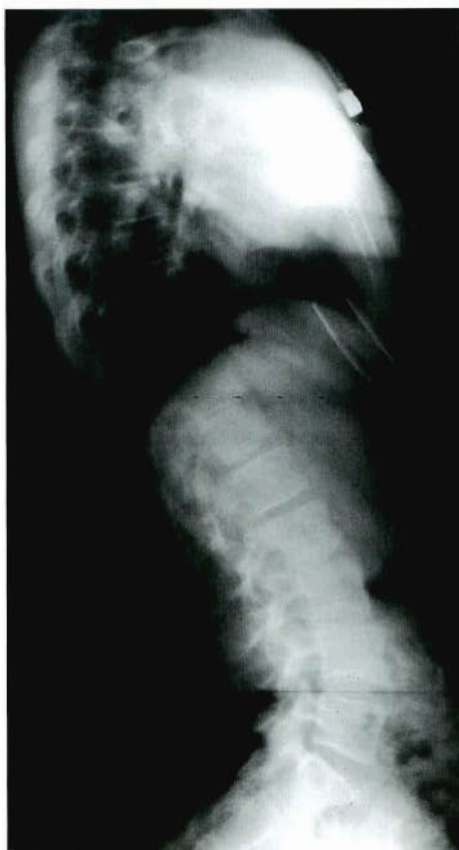
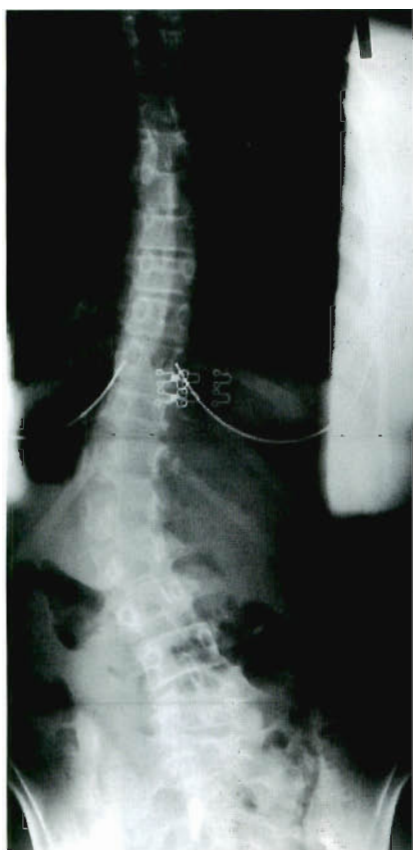
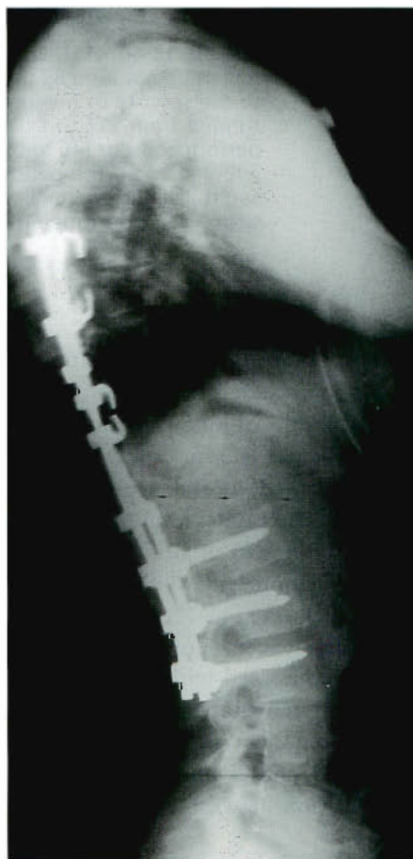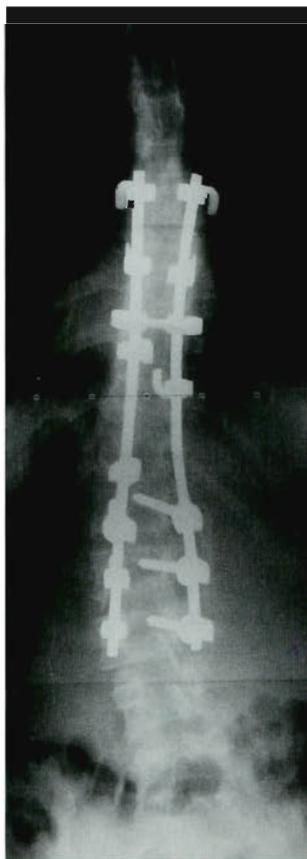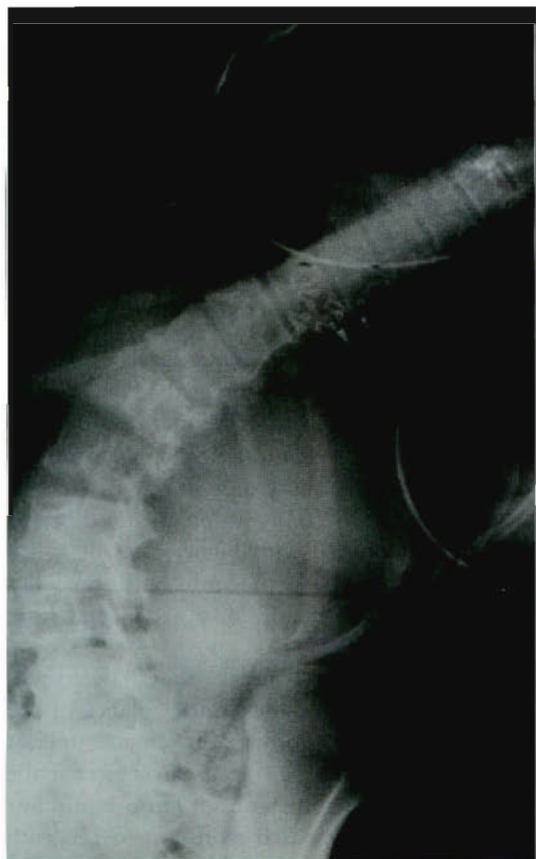


FIGURE 18-39. A: This 13-year-old female presented with a progressive left thoracolumbar scoliosis associated with trunk shift to the left. B: The lateral radiograph demonstrates maintenance of relatively normal sagittal alignment. C: Side-bending to the right demonstrates that L3 is level with the top of the pelvis. D: Posterior instrumentation and fusion were performed utilizing pedicle screw fixation through the apex of the lumbar spine at L1, L2, and L3 bilaterally. This provided correction of her lumbar deformity and improved her trunk shift, resulting in a balanced spine. E: Postoperative lateral radiograph demonstrates maintenance of lumbar lordosis in the instrumented segments.



A,B

C,D

E

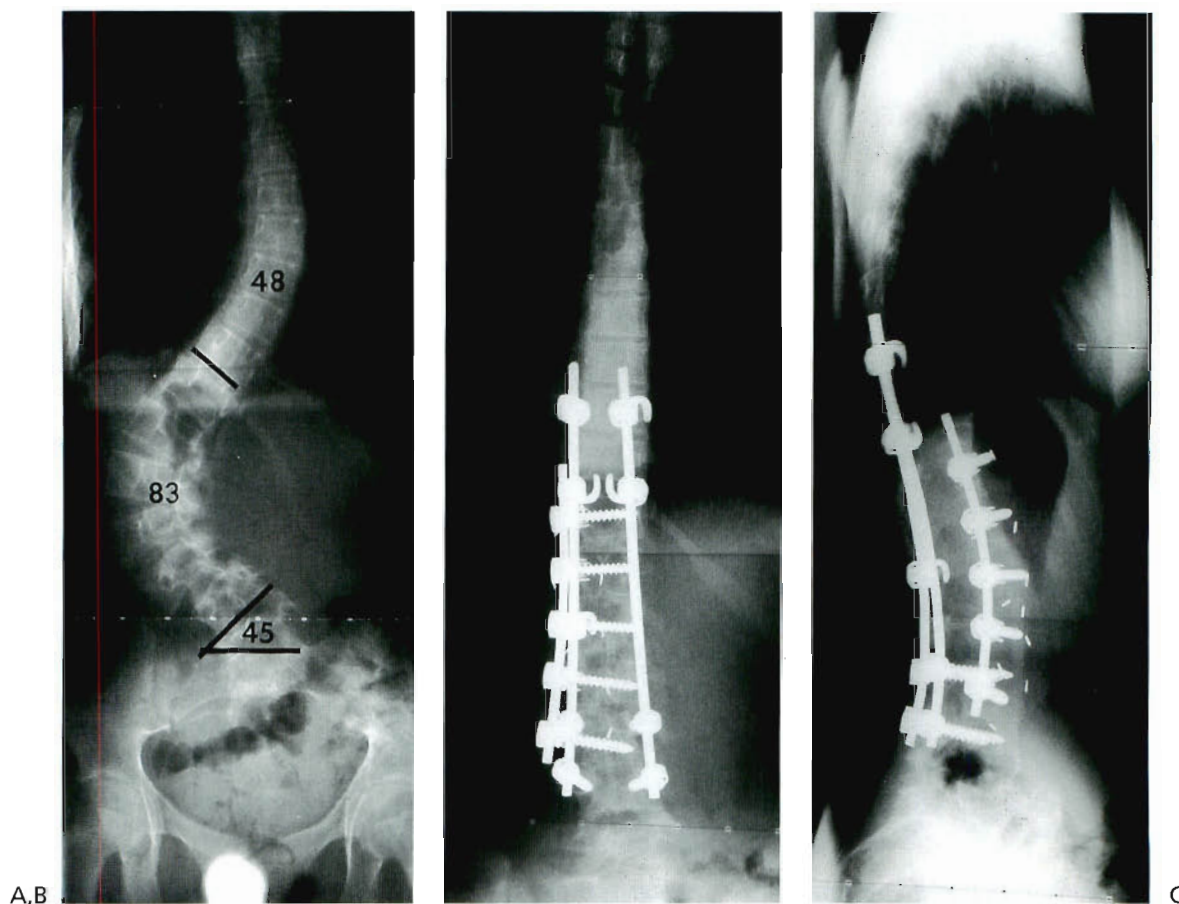


FIGURE 18-40. **A:** This 13-year-old female presented with previously untreated severe left lumbar scoliosis measuring 83 degrees. She had a flexible compensatory right thoracic deformity. **B:** Due to the severity of the lumbar curvature, an anterior disc excision with instrumentation was performed from T12 to L4. Following this procedure an additional posterior instrumentation was performed from T10 to L5, further correcting the inferior aspect of the lumbar spine with pedicle screw fixation. The patient has a sixth lumbar vertebra below the lowest instrumented level. **C:** Sagittal alignment has been restored and maintained with solid anterior and posterior arthrodesis seen 2 years postoperatively.

and fusion. An average coronal plane improvement of 48% of the Cobb angle has been reported (258). The long-term functional results of long posterior fusions have focused on the prevalence of late-onset low back pain. Conflicting results regarding the prevalence of pain and the correlation of pain with the caudal level of instrumentation have been reported. Moskowitz et al. (259) found no increase in pain or any correlation with the caudal level of arthrodesis. In contrast, Dickson et al. (168) found an increased incidence of back pain an average of 21 years after Harrington instrumentation compared with a control population. Cochran et al. (260) noted an increased frequency of pain in patients fused to L4 or L5 compared to those fused to L3 or above. Dickson et al. and Connolly et al. however, found no statistical correlation between the level of fusion and back pain (168,261).

Despite conflicting results regarding the increased poten-

tial for low back pain with more caudal levels of instrumentation and fusion, it seems intuitive that one should minimize the caudal extent of a fusion. Winter et al. demonstrated a significant loss of spinal motion when an arthrodesis included L4 compared to those only fused inferiorly to upper or midlumbar levels (262). Fusion to more caudal levels has also been associated with higher rates of radiographic degenerative changes in the unfused distal levels (spondylolisthesis, lateral olisthesis, disc narrowing, facet sclerosis) (261) (Fig. 18-42).

In addition to minimizing the caudal extent of the fusion, alignment in both the coronal and sagittal planes of the unfused segments should be optimized. It remains unclear whether the long-term functional results are better if the spine is fused to L4, with maintenance of lordosis and improved coronal position, compared to fusion to L3, with slightly greater residual deformity of the remaining caudal

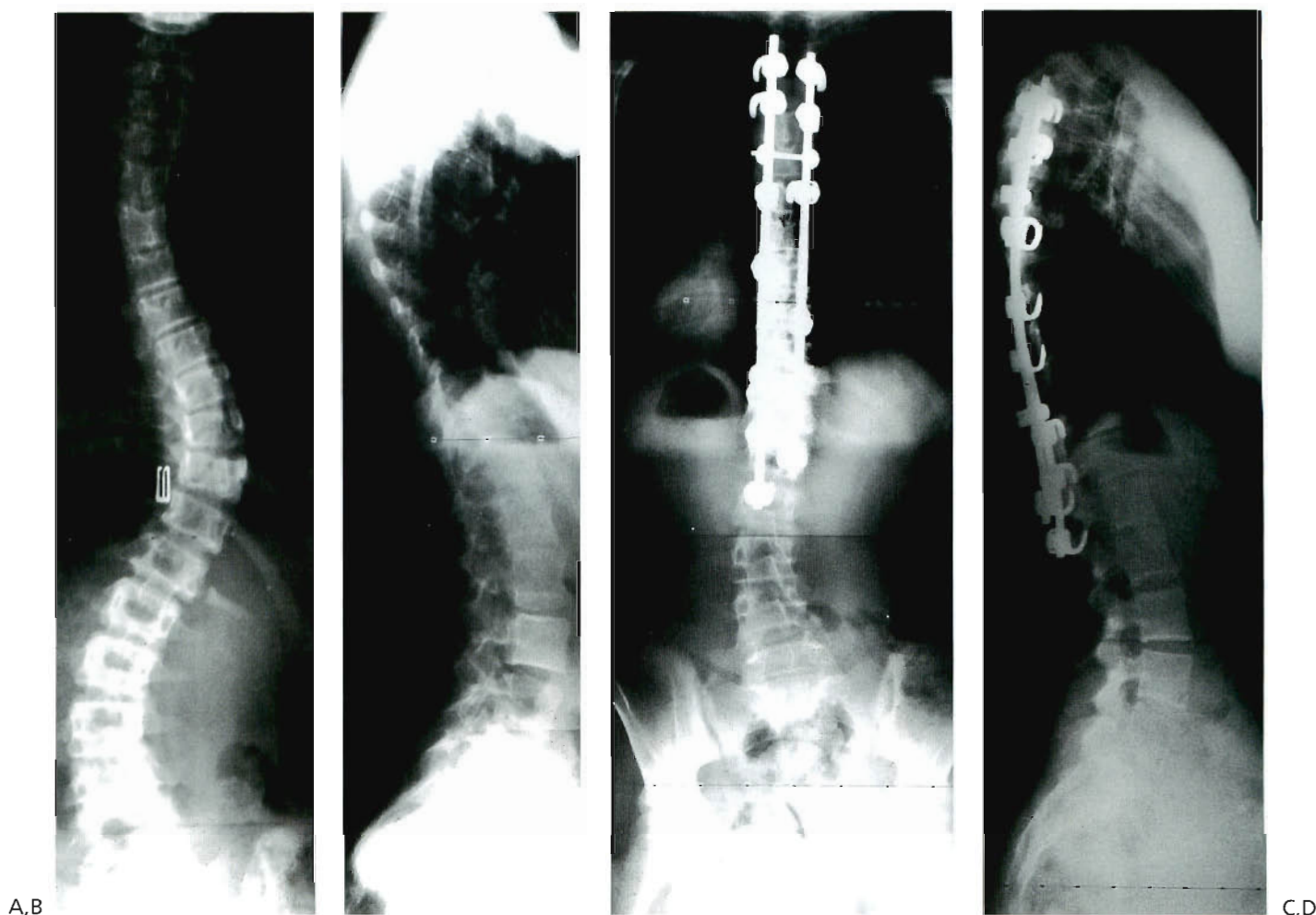


FIGURE 18-41. **A:** This premenarchal female had progressive scoliosis with a triple curve pattern. The left upper thoracic curve is seen with tilt of T1 and a 35-degree left upper thoracic deformity. The main right thoracic scoliosis measures 60 degrees and the left lumbar deformity 50 degrees. **B:** The lateral radiograph demonstrates hypokyphosis without a thoracolumbar junction kyphosis. The side-bending radiographs for this patient can be seen in Figure 18-12B and C. **C:** Given the clinical elevation of the left shoulder, it was elected to include the left upper thoracic curve in the instrumented segment to prevent further elevation of this shoulder. The main right thoracic deformity was larger than the left lumbar curve; therefore, the lumbar curve was not included in the instrumentation. Postoperative radiograph demonstrates spontaneous improvement of the lumbar curve with balance of C7 over the pelvis. The shoulders are now more level. **D:** The lateral radiograph demonstrates restoration of a more normal sagittal profile. Hook reversal at L1 on the left rod was used to initiate lumbar lordosis, as well as limit the risk of significant trunk decompensation.

levels. The relationship of alignment and degenerative changes to the development of low back pain requires additional follow-up and analysis.

The early (253,263) and midterm (212) (5 to 10-year follow-up) results of CD instrumentation suggest improved coronal and sagittal plane correction, compared to Harrington instrumentation (264). An average correction of 61% can be expected when considering all curve types (258). The segmental hook constructs have provided clear improvement in postoperative sagittal alignment (265), although little improvement in the axial rotation deformity

has been appreciated despite the early promise that systems such as the CD type would greatly derotate the spine by an intraoperative rotational maneuver as the instrumentation is applied (266–269). Postoperative immobilization has been minimal at most centers using the CD system, compared to Harrington instrumentation, yet the incidence of pseudarthrosis and loss of correction has been less with the newer system (212,264).

Early in the experience with CD instrumentation, truncal decompensation to the left was commonly noted in King type II curves when selective thoracic fusion was performed

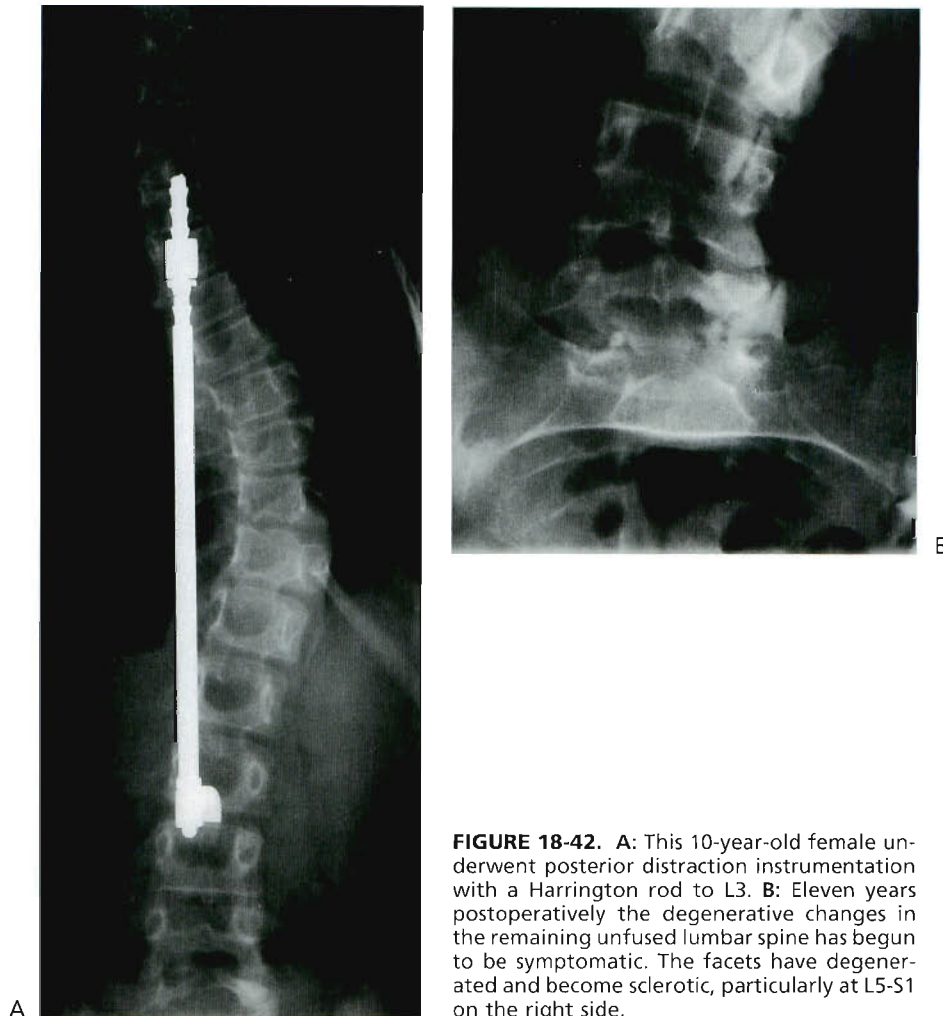


FIGURE 18-42. A: This 10-year-old female underwent posterior distraction instrumentation with a Harrington rod to L3. B: Eleven years postoperatively the degenerative changes in the remaining unfused lumbar spine has begun to be symptomatic. The facets have degenerated and become sclerotic, particularly at L5-S1 on the right side.

(250,253,270). Several techniques have been suggested to avoid this difficulty (249,252). The most important is to avoid over-correction of the thoracic spine beyond a degree that the unfused lumbar curve can adapt to. Also, hook reversal at the lower-most hook of the concave rod (most inferior hook upgoing) initiates coronal plane balance and lumbar lordosis, minimizing the risk for trunk decompensation (250,251,253) (Fig. 18-43).

Outcome after Anterior Surgery. Until recently, anterior correction of scoliosis has been primarily used for the correction of lumbar and thoracolumbar scoliosis. The percentage of frontal plane correction, with either Dwyer, Zielke, TSRH (Texas Scottish Rite Hospital) or Kaneda instrumentation, has been reported between 67 and 98% (234–238,242,271). Some authors have noticed a loss of sagittal plane lumbar lordosis with anterior compressive systems (272,273). Even solid $\frac{1}{4}$ " rod systems, such as the TSRH system have not been able to entirely preserve normal lordosis when used without anterior interbody structural

support (234). Sweet et al. have reported that sagittal alignment in the lumbar spine can be maintained if interbody structural support is added (238); however, even with this interbody support, if a pseudarthrosis develops eventual rod breakage and collapse into increased scoliosis and kyphosis will occur (Fig. 18-44). Two rod anterior systems also provide an option that may allow better maintenance of lumbar lordosis (240,256), although reported follow-up remains limited.

The results of anterior instrumentation in the thoracic spine are beginning to be reported with Betz et al. having made a nonrandomized comparison of anterior versus posterior thoracic instrumentation for thoracic idiopathic scoliosis. The anterior 3.2- or 4.0-mm threaded rods resulted in comparable coronal plane scoliosis correction, compared to posterior hook systems, but were associated with a 31% incidence of rod breakage. The distal level of fusion in the anterior fusion group was on average two segments proximal to the those in the posterior group (241). Lenke et al. have also reported a greater spontaneous improvement of the

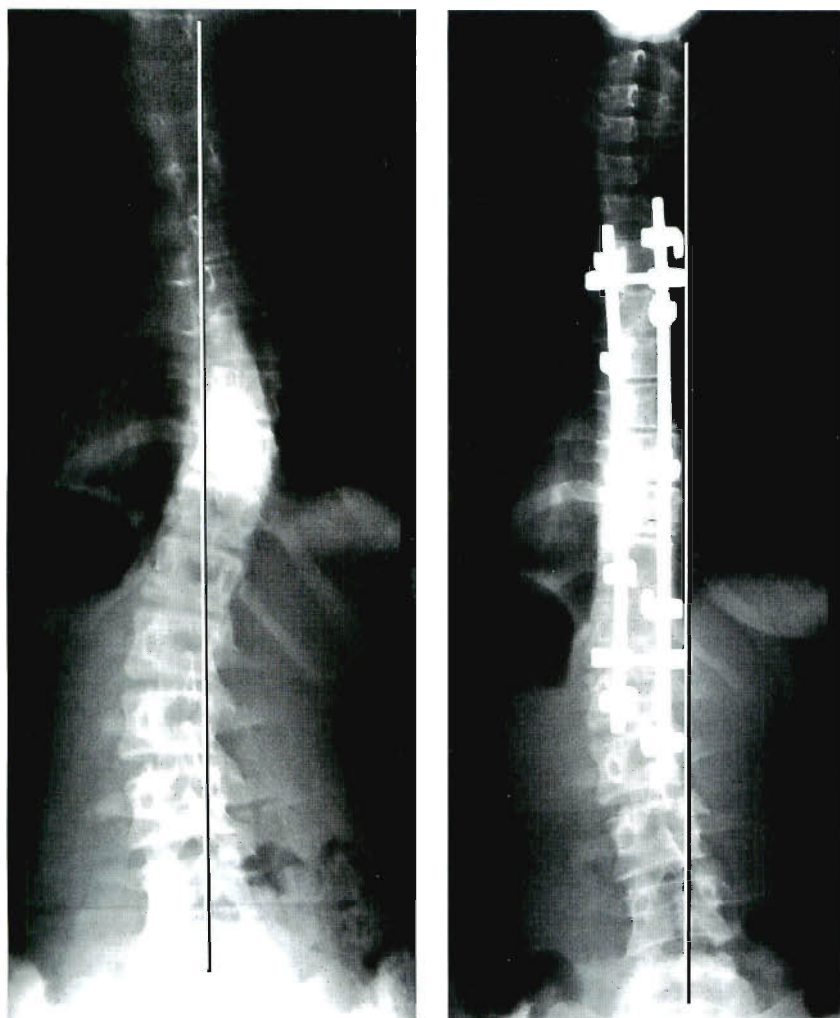


FIGURE 18-43. **A:** The preoperative PA radiograph demonstrates the stable vertebra to be at T12. **B:** The patient was instrumented posteriorly to L1 with a down-going hook at the distal end on the left side, resulting in decompensation to the left. This could have been prevented by either stopping the instrumentation at T12 or reversing the direction of the left-sided L1 hook to up-going.

uninstrumented portion of the lumbar spine when the thoracic instrumentation was anterior (and shorter), as compared to posterior in treating thoracic curves that had a compensatory lumbar curve pattern. At 2-year follow-up the thoracic curves were corrected 58% and the lumbar curves (uninstrumented) 56% in the anterior instrumentation group, compared to 38 and 37%, respectively, for the posterior instrumentation group (248). The rate of pseudarthrosis and rod breakage appears to be greatly reduced with the introduction of solid (nonthreaded) rods for thoracic curves, although proximal screw pull out can be more problematic as the rod stiffness is increased.

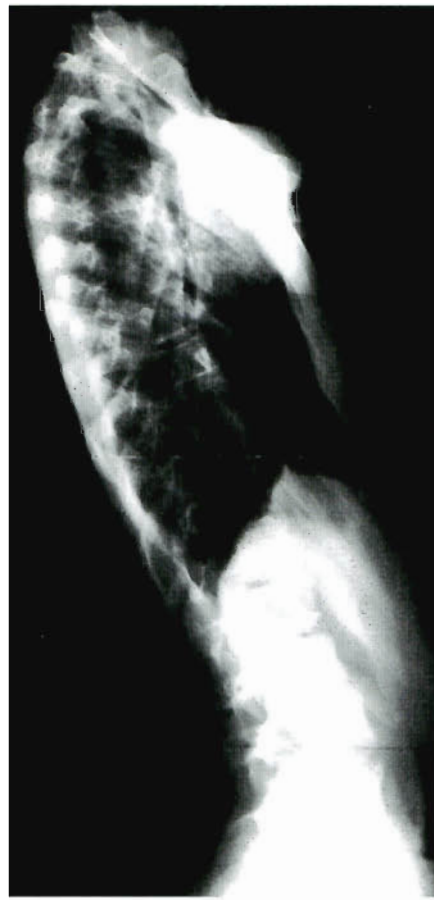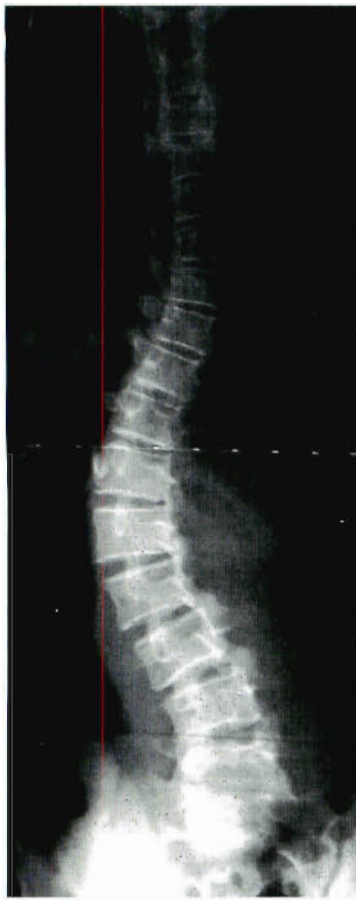Complications

The complications of scoliosis surgery can be serious, although over the last 20 years these procedures have become much safer due to advances in anesthesia, blood loss management, instrumentation systems, and neurologic monitoring.

The remarkable corrective power of the new instrumentation methods, coupled with better surgical skills, spinal cord monitoring, and methods to minimize blood loss have changed how one advises patients regarding possible complications following scoliosis surgery. In the past, the surgeon focused on blood loss, hook dislodgment, infections, and paraplegia or other neurologic deficits. Although all potential complications must be mentioned in the current era, patients are more likely to experience problems such as postoperative trunk imbalance or a need for subsequent metal removal. Due to the size, complexity, and modularity of the implants, they are more likely to produce muscle irritation, bursitis, or even a late low-grade infection in the bursitic area (274–276).

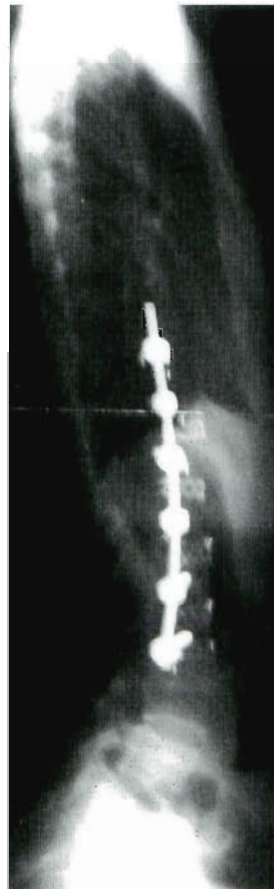
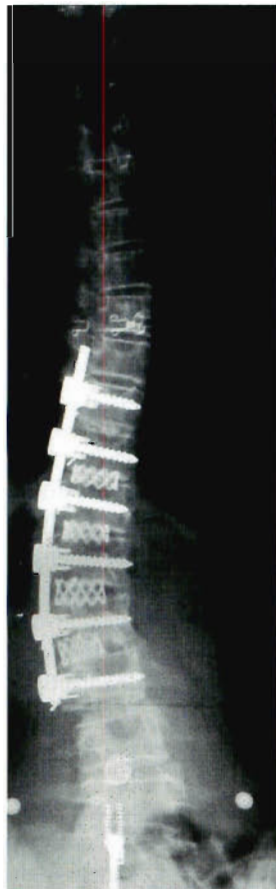
Neurologic Injury

The risk for neurologic injury during idiopathic scoliosis surgery is not well documented in a large series, although data from the membership of the Scoliosis Research Society

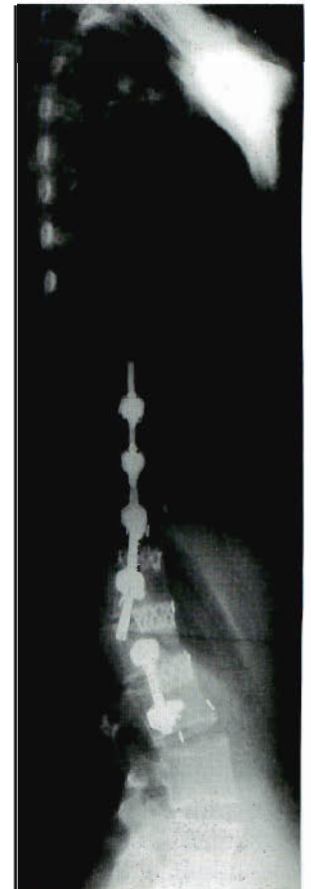



A,B

FIGURE 18-44. A: This 13-year-old female presented with a lumbar curve and trunk shift to the left. B: The preoperative lateral view demonstrates decreased lumbar lordosis. C, D: This was addressed with an anterior approach utilizing a single rod with interbody support to increase lumbar lordosis. E, F: She returned 1 year after the surgery asymptomatic but with loss of correction and fracture of the rod. This demonstrates that a single-rod anterior system may not always be strong enough to maintain correction while the bone graft is maturing, particularly in a very active patient.



C,D



E,F

is collected annually. In 1995 the reported incidence of neurologic injury after surgery was 1% in all types of scoliosis surgery in all ages. One of the 1,643 patients undergoing surgery for idiopathic scoliosis developed a complete spinal cord injury. The incidence of partial spinal cord and nerve root injury was 10 of 1,643 for the idiopathic scoliosis group, compared to 7 of 211 for the congenital scoliosis group. More than one-half of these patients had subsequent recovery of normal neurologic function. In a series of 1,090 patients undergoing spinal deformity correction by Bridwell et al., four patients developed a neurologic deficit postoperatively. However, only one of these patients had idiopathic scoliosis, and the total number of idiopathic scoliosis cases is not reported (277).

The etiology of spinal cord dysfunction can be classified as a result of direct trauma (contusion) to the cord, excessive traction to the neural elements produced by corrective instrumentation, and vascular insufficiency to the cord. The blood supply to the spinal cord is segmental and enters via the neural foramina. There has been some controversy as to the risk of vascular insufficiency to the cord associated with ligation of the anterior segmental blood vessels in anterior spine surgery. Winter et al. reported 1,197 cases in which segmental vessels were divided with no neurologic sequelae noted (278). There have, however, been other reports suggesting a possible vascular cause of spinal cord dysfunction postoperatively after segmental vessel ligation (279). Those at greatest risk appear to be patients with congenital malformations and hyperkyphosis (279–281). If an anterior procedure requires division of the segmental vessels, they should be ligated in the midvertebral body area rather than near the neural foramen. In high risk cases (congenital, kyphosis, revision surgery), temporary clamping of the vessels with concomitant spinal cord monitoring has been suggested by some as a means of detecting a potentially critical source of spinal cord blood supply (280).

Induced hypotension is a well-accepted standard in scoliosis to minimize operative blood loss; however, the mean arterial pressure must be maintained at a safe level to assure adequate blood flow to the spinal cord. In extremely complex corrections (kyphosis, osteotomies, revision surgery) in which the risk for cord ischemia is greater, the surgeon may elect to keep the blood pressure higher (even though blood loss will be greater) to assure cord perfusion (279).

Spinal Cord Monitoring

The wake-up test described by Stagnara was the first widely used method for monitoring spinal cord function after deformity correction. This technique includes decreasing the level of anesthesia intraoperatively to a level that allows the patient to follow commands. The patient is instructed to move their feet/toes, confirming the competency of the spinal cord motor tracts (282).

Subsequently, continuous electrical spinal cord monitor-

ing has become almost standard in surgical correction of spine deformity. Monitoring of sensory and motor pathways is possible; however, from a technical standpoint sensory monitoring is simpler and more widely accepted. Somatosensory evoked potentials (SSEPs) are obtained by stimulating distally (legs) and measuring the response proximally (brain), and have been very reliable in detecting changes in spinal cord function, providing the surgeon relatively rapid feedback about any effect that deformity correction is having on neurologic function (283). The lag time between the insult to the spinal cord and the resulting monitoring changes may be 10 to 20 min. Other factors (besides injury to the cord that have been found to affect spinal cord monitoring) resulting in false-positive indications of injury include hypotension, hypothermia, and dislodgment of the monitoring leads, as well as other technical malfunctions in the system. If changes are noted these factors should be evaluated and corrected, and if the monitoring abnormalities persist, a wake-up test should be performed to confirm the findings. Loosening of the implants to remove any corrective forces, or complete removal of the implants, should be performed as soon as a deficit is confirmed. Institution of the methylprednisolone steroid spinal cord injury protocol (284) also seems warranted, although the efficacy in this specific group of spinal cord injury patients has not been carefully studied.

Blood Loss and Transfusion

Scoliosis surgery may be associated with blood loss requiring transfusion. This requires appropriate anticipation by the surgeon based on the type of deformity and the extent of the planned surgery. Preoperative autologous donation may be the most reliable way to avoid exposure to allogenic blood products, although this is not possible in all patients (too small, psychologic stress of donating too great, long distance to the blood bank, preoperative anemia, congenital heart disease, and/or expense). Alternatives to minimize allogenic blood exposure include intraoperative blood salvage, preoperative erythropoietin administration (285), intraoperative hemodilution (286), and (used with the precautions noted above) controlled hypotensive anesthesia (287).

Early Postoperative—In-hospital Complications

Complications in the early postoperative period include respiratory compromise, wound infection, and delayed neurologic injury. The incidence of respiratory complications in idiopathic scoliosis is approximately 1%, whereas wound infection occurs in approximately 2% of cases (childhood and adult surgery). The incidence for infection in childhood and adolescent surgery is probably lower (288). Delayed neurologic injury has been recognized with increasing frequency, and the importance of careful neurologic monitoring of lower-extremity function for the 48 h following cor-

A,B

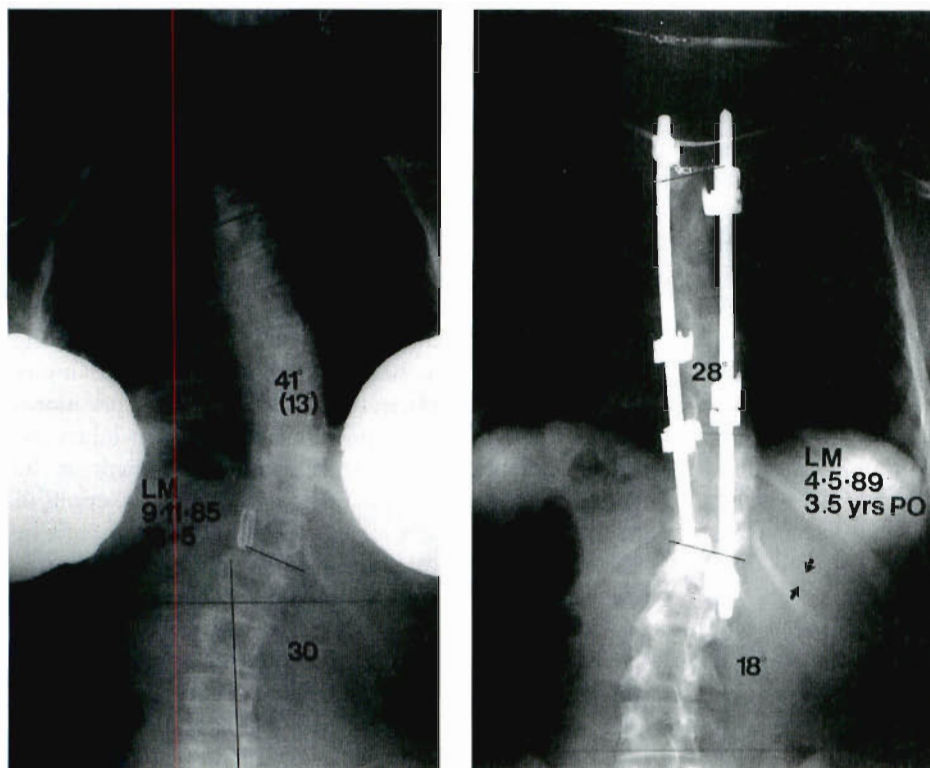


FIGURE 18-45. A: This 13-year-old female presented with a 41-degree right thoracic idiopathic scoliosis. The stable vertebra is probably L2. B: The patient was fused from T5 to T12. This radiograph 1 year postoperatively shows correction of the deformity to 13 degrees, but with acute angulation at T12-L1 and a 2-cm decompensation to the right. This case demonstrates the pitfalls of fusing too short.

rective surgery must be emphasized. Cases have been reported that confirmed intact neurologic function after the surgery with loss of motor and sensory function in the days following surgery (277,289,290). The etiology of delayed-onset paraplegia is unclear, and may be vascular due to postoperative hypotension, or mechanical resulting from a compressive hematoma.

Implant–Hardware Complications

Complications related to the hardware may present early or late in the postoperative period. Despite greatly improved implant systems, there is still a potential for early failure of the bone–hardware interface by either implant dislodgment or bony fracture. If a pseudarthrosis develops, late hardware failure can be anticipated. The time to hardware failure depends to some degree on the size and number of the rods used (Fig. 18-44). Small single-rod systems may fatigue and fracture in less than a year, compared to a double-rod system that may not fail for up to 5 years, if a pseudarthrosis is present. Rod fracture is diagnostic of pseudarthrosis; however, pseudarthrosis and rod failure may not be associated with any clinical problems. If pain or curve progression are noted revision surgery may be necessary.

Due to their prominence, the newer instrumentation systems have increased the need for late hardware removal, compared to the experience with Harrington rods. Another problem with new systems has been the development of

delayed infection and/or metal reaction (274–276). The cause of these problems likely relates to the bulk of the systems and their modularity. Loosening of any one component of the complex system can lead to formation of a bursa, which can then eventually become infected.

Late Alignment Problems

Postoperative spinal alignment may not match what was anticipated preoperatively. The problems and causes of trunk decompensation have been discussed above. The correction of spinal deformities should result in a harmonious transition from the instrumented to the noninstrumented regions of the spine. Abrupt changes in sagittal or coronal alignment may result in junctional problems (Fig. 18-45). Levels adjacent to a fused segment of spine are subjected to increased mechanical stresses, and this is likely increased if malalignment exists. The use of new multisegmental, powerfully corrective instrumentation has the potential for increasing the incidence of postsurgical trunk imbalance.

CONGENITAL SCLIOSIS—DETAILS OF DIAGNOSIS AND TREATMENT

Definition

Congenital scoliosis is the result of abnormally formed vertebral elements with the altered vertebral shape producing

deviations in spinal alignment. These deficiencies occur in the embryonic period of intrauterine development (before 48 days gestation), and are commonly associated with cardiac and urologic abnormalities that develop during the same period (126,127). The etiology is unknown in humans; however, in animal studies congenital scoliosis has been produced by transient exposure to toxic elements during the fetal period (291). Congenital deformities are classified broadly into failures of vertebral formation and failures of segmentation between the vertebrae. Congenital scoliosis, by definition, involves anomalous vertebral elements, and when these anomalies are identified, the curve should be classified as congenital, even if the scoliosis is not diagnosed until adolescence. Similarly, patients noted early in life to have scoliosis without abnormally formed vertebrae should not be diagnosed as having congenital scoliosis. Occasionally, in infants with significant curves with the vertebrae not yet fully ossified, differentiation between an idiopathic and a congenital curve can be difficult.

Classification

Congenital scoliosis classification (based on the developmental anomaly of the spine) includes deficiencies in vertebral formation, segmentation, or a combination of the two (mixed) (Fig. 18-46). Failures of formation and segmentation may occur on either the right or left side of the body resulting in “pure” scoliosis, or in the anterior and posterior elements resulting in “pure” kyphosis or lordosis, respectively. Combined deficiencies are common, and associated sagittal plane deformity is important to recognize (292) (Fig. 18-47).

In the classic failure of formation anomaly, hemivertebra (a triangular-shaped vertebra) forms on only one side, and can be subclassified into those that have disc and growth potential on: a) both the superior and inferior ends of the vertebra—*fully segmented*, b) either the superior or inferior end only—*semi-segmented*, or c) those that are fused to the vertebrae above and below—*nonsegmented* (Fig. 18-48).

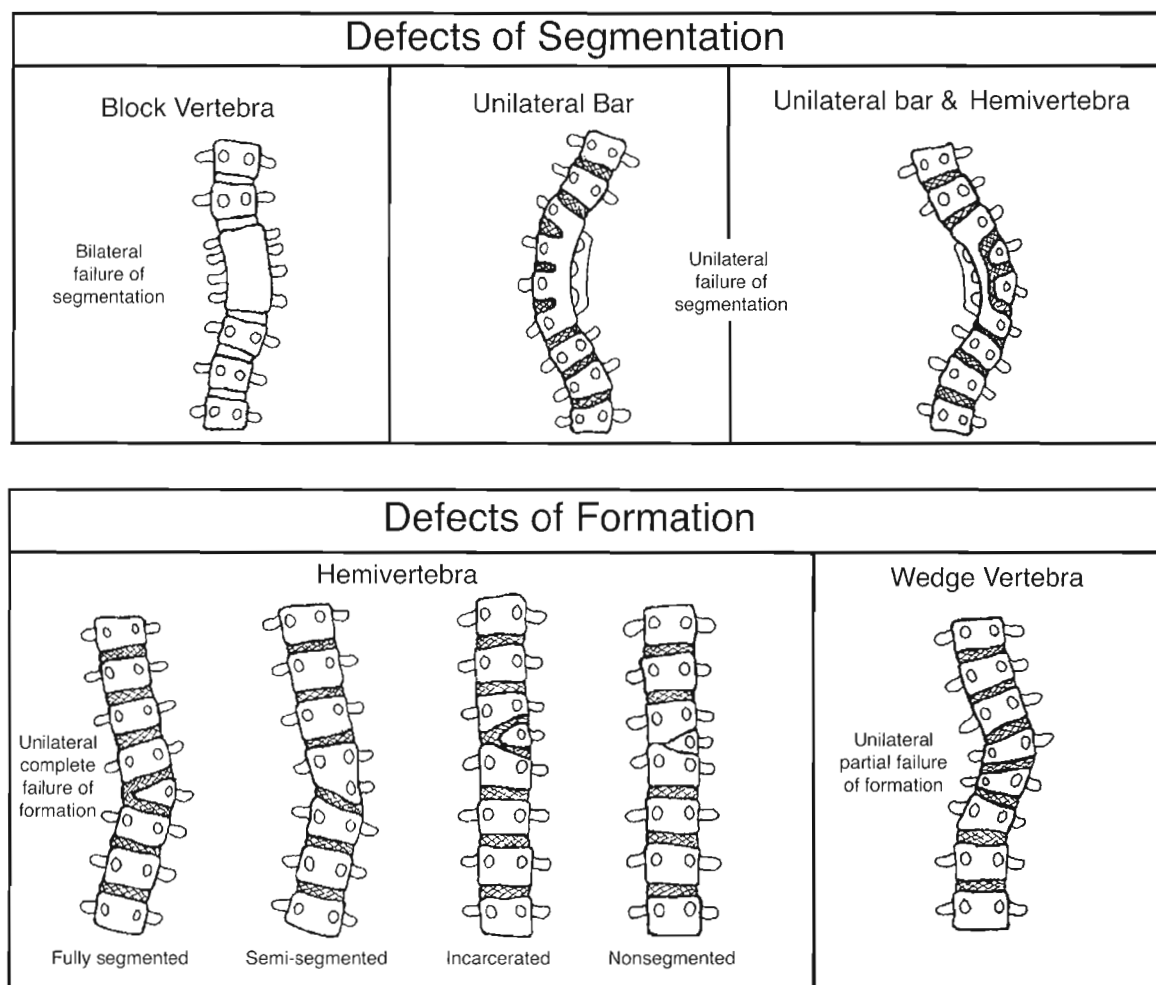


FIGURE 18-46. Diagrammatic representation of classification system of congenital scoliosis. (From ref. 294, with permission.)

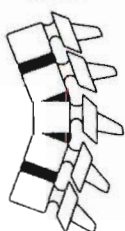
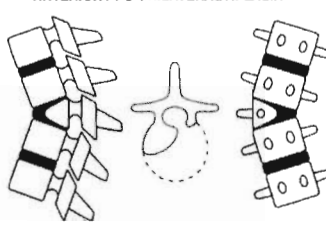
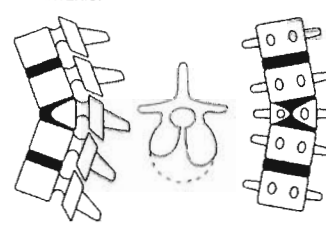

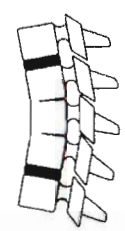
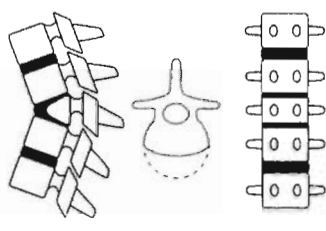
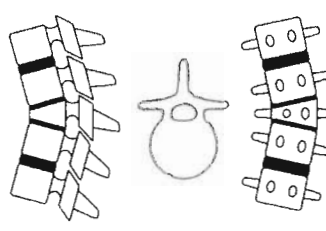
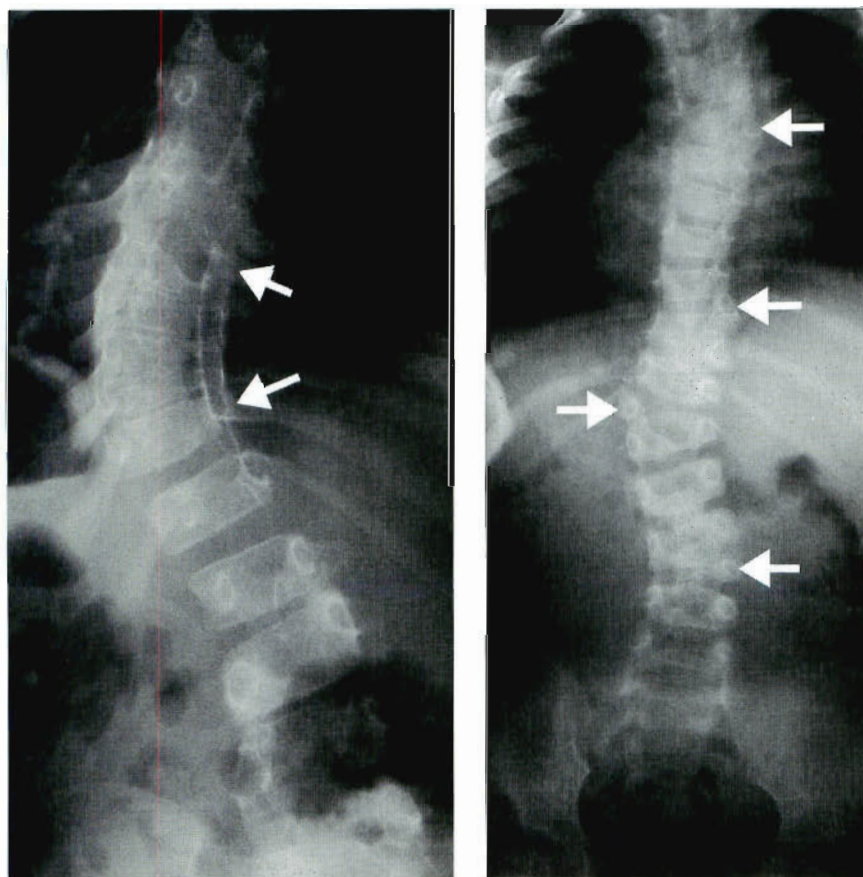
DEFECTS OF VERTEBRAL-BODY SEGMENTATION	DEFECTS OF VERTEBRAL-BODY FORMATION		MIXED ANOMALIES
<p>PARTIAL</p>  <p>ANTERIOR UNSEGMENTED BAR</p>	<p>ANTERIOR AND UNILATERAL APLASIA</p>  <p>POSTEROLATERAL QUADRANT VERTEBRA</p>	<p>ANTERIOR AND MEDIAN APLASIA</p>  <p>BUTTERFLY VERTEBRA</p>	 <p>ANTEROLATERAL BAR AND CONTRALATERAL QUADRANT VERTEBRA</p>
<p>COMPLETE</p>  <p>BLOCK VERTEBRA</p>	<p>ANTERIOR APLASIA</p>  <p>POSTERIOR HEMIVERTEBRA</p>	<p>ANTERIOR HYPOPLASIA</p>  <p>WEDGE VERTEBRA</p>	

FIGURE 18-47. Diagrammatic representation of the failure of formation and segmentation in congenital kyphosis. (From ref. 292, with permission.)



A,B

FIGURE 18-48. A: This radiograph demonstrates a long unilateral unsegmented bar (arrows). B: This radiograph demonstrates multiple hemivertebrae, both fully segmented and semi-segmented, as well as incarcerated and non-incarcerated varieties.

The degree of deficiency in unilateral formation is variable, and in the mildest form, a “wedge” vertebra develops. The vertebral width is normal, although the height of the vertebra is asymmetric on the right and left side. Rib deficiencies tend to match the vertebral deficiencies, and when the number of ribs on the right and left sides do not match, a hemivertebra or other congenital anomalies should be suspected.

Failure of normal segmentation of the vertebral column may occur on both sides of the spine symmetrically or unilaterally. Segmentation deficiencies result in inhibition of longitudinal growth, and result in little deformity if they occur circumferentially around the spine (block vertebra). A unilateral unsegmented bar, however, produces a growth tether that often results in marked scoliosis due to growth only on one side of the spine. Mixed deformities are common, and at times exact classification of congenital scoliosis is difficult.

Identifying a congenital malformation on the spinal radiographs requires careful assessment of the films. Asymmetry of the size or number of the pedicles may suggest a failure of formation, and an absent rib is often associated with a deficiency of the vertebral elements. An unsegmented bar is suggested when the corresponding ribs and/or pedicles are conjoined. Segmentation defects can also be presumed when the disc space is narrowed. A three-dimensional CT study often helps to clarify the diagnosis in an older child with a complex deformity (293) (see Fig. 18-16).

Natural History

The likelihood of any single case of congenital scoliosis developing progressive deformity is difficult to state with certainty. There are, however, known anomalies and curve locations that make some generalizations possible. McMaster and Ohtsuka reviewed 251 patients with congenital scoliosis, documenting curve progression during growth

(292,294). Three-fourths of the patients' curves progressed substantially, and they were able to relate this to curve location and type. Those with a thoracic location progressed the greatest, and the curve types with the poorest prognosis were those with multiple hemivertebrae and a convex unilateral bar (failure of segmentation) opposite the hemivertebrae.

A summary of the median annual rate of curve progression is seen in Figure 18-49. Block and wedge vertebrae progressed <1 degree per year and generally did not require treatment. Hemivertebrae, however, increased between 1 degree and 2.5 degrees per year. Double hemivertebrae increased at roughly twice that rate. Unilateral unsegmented bars progressed at rates up to 6 to 9 degrees per year in the thoracolumbar junction, whereas the unilateral unsegmented bars with a contralateral hemivertebra were at the greatest risk of progression, at times exceeding 10 degrees per year (294) (Fig. 18-50).

Despite the information gained from the review of these patients, the growth potential of a curve may be difficult to classify and/or predict in any single case. Careful monitoring of radiographs is required to document and detect progression. The most likely times of increasing deformity match the phases of normally rapid spinal growth (the first 2 to 3 years of life and the adolescent years). Cobb angle measurement remains the method of following curves for progression, yet it is more difficult to apply in complex congenital curves (296), and the use of patient photographs can at times be helpful in addition.

Treatment

Nonoperative Treatment—Observation

The presence of a congenital spinal anomaly requires close monitoring of spinal growth until maturity. Initially, most

Site of curvature	Type of congenital anomaly					
	Block vertebra	Wedge vertebra	Hemivertebra		Unilateral unsegmented bar	Unilateral unsegmented bar and contralateral hemivertebrae
			Single	Double		
Upper thoracic	<1°–1°	★–2°	1°–2°	2°–2.5°	2°–4°	5°–6°
Lower thoracic	<1°–1°	2°–3°	2°–2.5°	2°–3°	5°–6.5°	6°–7°
Thoracolumbar	<1°–1°	1.5°–2°	2°–3.5°	5°–★	6°–9°	>10°–★
Lumbar	<1°–★	<1°–★	<1°–1°	★	>5°–★	★
Lumbosacral	★	★	<1°–1.5°	★	★	★

□ No treatment required ■ May require spinal surgery □ Require spinal fusion ★ Too few or no curves

Ranges represent the degree of derotation before and after 10 years of age

FIGURE 18-49. The annual rates of curve progression for each of the congenital anomalies are shown. The shaded areas represent the likelihood of spinal fusion based on the predicted increase in deformity. (From ref. 294, with permission.)

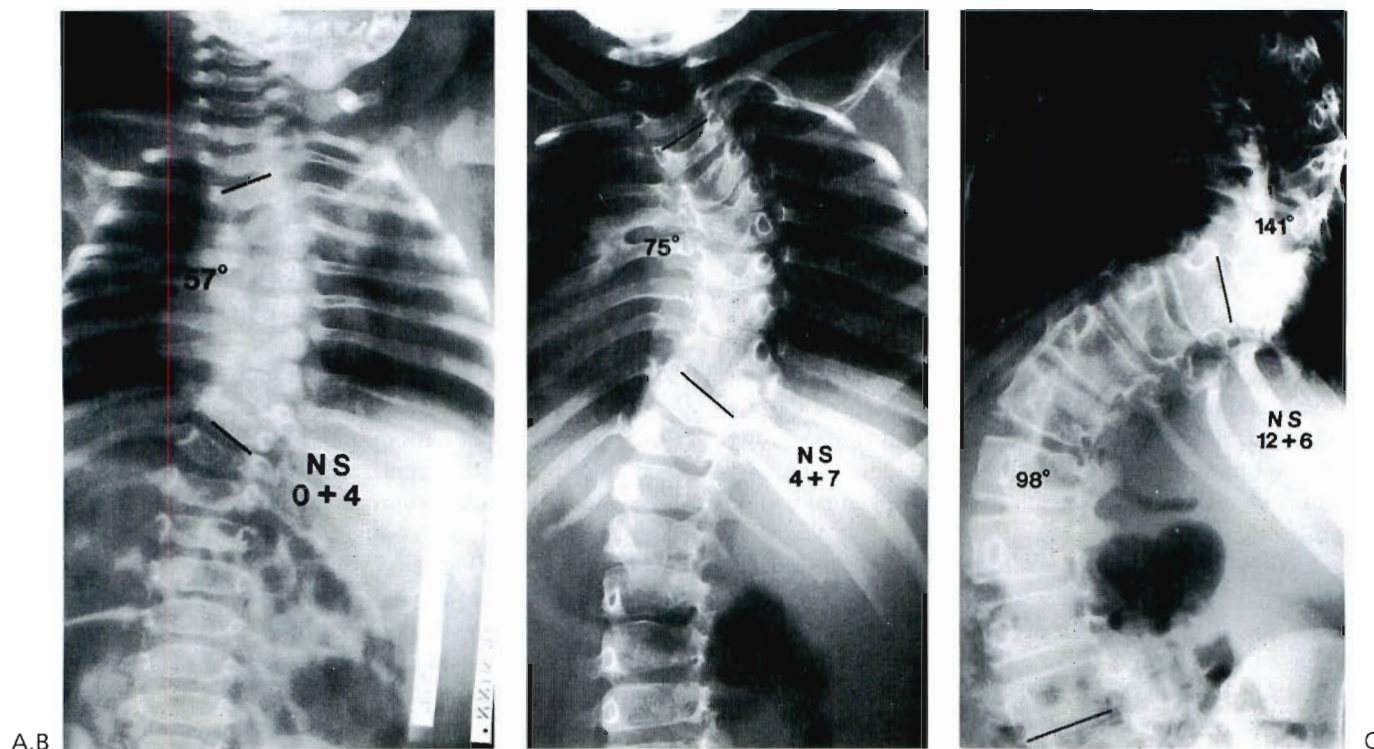


FIGURE 18-50. A: Four-month-old female presented with a 57-degree congenital right thoracic scoliosis. There is a hemivertebra on the right and a segmentation defect on the left (*unsegmented bar*). She did not receive treatment. B: At 4 years of age, the curve had progressed to 75 degrees. The congenital bar on the left is more easily seen, as well as the fusion between the ribs. C: By 12 years of age her curve progressed to 141 degrees with a 98-degree compensatory lumbar curve developing. (From ref. 295, with permission.)

curves are simply monitored, with radiographic assessment performed every 4 to 12 months, depending on the age of the patient and the suspicion (based on curve type) that progression is likely. Early in life, supine radiographs are the most reproducible; however, when old enough to cooperate (approximately age 2 years), upright radiographs should be taken. The landmarks used for Cobb angle determination are often difficult to mark, and Loder et al. found the interobserver error in Cobb angle measurement of congenital scoliosis curves to be as high as 10 degrees (296). Sequential analysis of trunk shift and Cobb measurement of the compensatory curves are also useful in determining if progression is occurring. Often, the compensatory curve which has no vertebral anomalies is easier to measure than is the congenital curve, and serves as an accurate “biomechanical indicator” about what is happening in the primary congenital curve.

In general, brace treatment has not been shown to be very effective in managing the primary curve in congenital scoliosis, because the curves tend to be short with little flexibility. Certain curves with a long flexible component may be amenable to orthotic management. On occasion, the compensatory curves which develop above or below a con-

genital deformity become problematic, and bracing to aid trunk balance may be helpful in these circumstances (297).

Surgical Treatment

Operative management is the standard treatment for progressive congenital scoliosis; however, because of the relative inflexibility of these curves, correction with instrumentation is less feasible than in idiopathic deformities. Because significant correction can usually not be obtained within the anomalous segments of the spine, surgical intervention is required earlier in the development of the curve (compared to surgery for idiopathic scoliosis). Surgical treatment options include: posterior fusion (*in situ* or with instrumentation), combined anterior and posterior fusion, convex hemiepiphysiodesis (anterior and/or posterior hemiarthrodesis), and hemivertebra excision. Each of these methods has its own indications, risks, and benefits, and the principles of each must be understood in order to optimize the outcome.

Preoperative Assessment. The most important aspect of preoperative documentation is sequential radiographs con-

firming progressive deformity. An exception is an unsegmented bar with a contralateral hemivertebra that has been suggested as an indication for surgery at the time of initial diagnosis (298). As discussed previously, the genitourinary system should be screened with an ultrasound examination, looking for a treatable cause of urinary tract outflow obstruction. Prior to undertaking surgical treatment of a congenital spinal deformity, an MRI of the entire spinal cord should be considered, especially if distraction instrumentation is planned. Associated intraspinal malformations, such as a diastematomyelia or a tethered cord, have been noted in cases of congenital scoliosis (298,299) (Fig. 18-51). A detethering procedure should be performed before a corrective spinal fusion procedure if neurologic symptoms are present. The treatment of asymptomatic patients with MRI findings only is more controversial. If there is a large compensatory curve (with normal motion segments) that will be straightened with instrumentation and included in the fusion, a prophylactic detethering procedure is indicated.

Goals of Surgery in Congenital Scoliosis. The goal for the variety of surgical procedures used in congenital scoliosis is to limit progression of a deformity that has been documented to be increasing with growth. Removing or modifying this growth potential in a young patient will limit curve progression, but may also affect ultimate spinal length. A recent study by Goldberg et al. has shown that children with congenital scoliosis are usually both small for their age and remain very small (compared to their peers) into adulthood, even if they do not require surgery. Discussion of surgical methods and their potential effect on final height must be tempered with the knowledge that final height may be limited by these poorly understood constitutional factors that are associated with congenital scoliosis (300). In addition, the surgeon and the parents must accept that growth of abnormally shaped vertebrae does not generate increased trunk height if deformity is allowed to progress. Trunk height will be greatest if a progressive curve is fused early, and the adjacent segments allowed to grow straight, rather than becoming part of a large compensatory curve.

Although the goal for most cases is limiting curve progression with the use of instrumentation or vertebral excision, one can surgically *reduce* the degree of deformity in some cases. These procedures carry somewhat greater risk for neurologic injury, the degree of which varies with the procedure, the curve pattern, flexibility, the location within the spine (cervical, thoracic, and lumbar), and the experience of the surgeon. It is for this reason that many patients with congenital scoliosis are treated with *in situ* fusion.

Posterior Fusion. Posterior *in situ* arthrodesis is the simplest approach to the surgical treatment of congenital scoliosis with the resultant large posterior fusion mass designed to limit progression of congenital curves (298,301,302). The fusion must include all of the vertebrae of the measured

Cobb angle, and extend laterally to the transverse processes. Without instrumentation, a postoperative cast or vigorously worn rigid plastic jacket is required for 4 to 6 months after the procedure. The expected correction, by placement of a molded Risser cast, is generally modest in most congenital deformities; thus, the method is referred to as an *in situ* fusion. The neurologic risks associated with the technique are minimal.

The success of this procedure in preventing further deformity (increase in the Cobb angle or increase in the rotational deformity) depends on the nature of the malformation and the growth potential of the remaining unfused anterior vertebral bodies. Increased rotational deformity after a posterior spinal fusion (the “crankshaft phenomenon”) (225), first described in idiopathic scoliosis, has also been documented to occur in skeletally immature patients with congenital (301,303) and neuromuscular scoliosis (227,303,304). Predicting which curves are likely to develop late crankshaft deformity is difficult, and relates to the curve pattern and anterior growth potential; however, understanding that congenital curves—fused posteriorly only—are at risk for it has led many surgeons to also perform anterior fusion in cases in which the risk for progression is perceived to be high.

Use of Posterior Instrumentation. The addition of instrumentation to a posterior arthrodesis can be considered in older children. Pediatric-sized instrumentation systems are available for children older than approximately age 3 years, which makes limited deformity correction possible in selected cases. Postoperative immobilization may be avoided in cases with secure internal fixation (juvenile and adolescent patients), whereas in the younger group, extended immobilization may be required to protect the instrumentation from dislodgment. The risk of neurologic injury increases with more aggressive attempts at instrumented deformity correction (302). The dimension of the spinal canal, as well as the blood supply to the spinal cord may also be congenitally deficient, both of which make the placement of hooks and distraction rods somewhat more dangerous than in typical idiopathic deformities. Careful spinal cord monitoring is required (see Idiopathic Scoliosis section).

Anterior Fusion. Anterior *in situ* arthrodesis may be required when substantial anterior vertebral growth is expected. Anterior growth potential in congenital deformities appears dependent both on the age of the patient (as in idiopathic scoliosis) and on the presence and orientation of anterior growth cartilage. The width of the disc space can be used to make inferences regarding growth potential. For example, a hemivertebra that is semisegmented (fused to one of the adjacent vertebra anteriorly) has less growth potential than one that is fully segmented with growth cartilage on both the superior and inferior end plates. Anterior fusion is usually combined with a posterior procedure (posterior

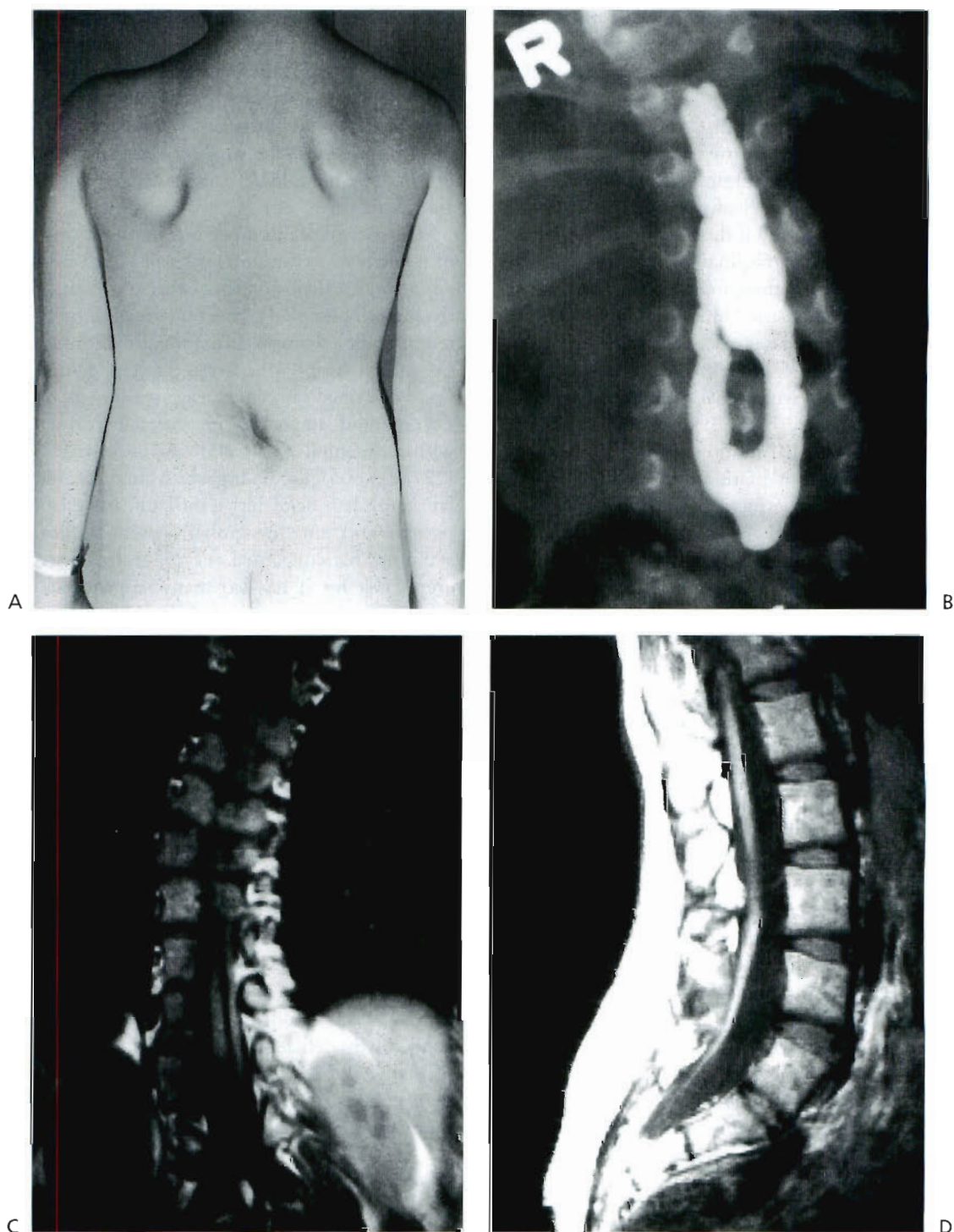


FIGURE 18-51. A: This patient presented with right thoracic scoliosis with a prominent right scapula and hair patch in the lumbar area. One foot was smaller than the other, and the ankle reflex was absent on that side. B: A myelogram demonstrates a diastematomyelia. C: Magnetic resonance imaging (MRI) scan also shows a diastematomyelia with a split in the spinal cord. D: On the sagittal MRI the cord extended to the sacral area with a tight filum terminale for each hemicord.

fusion with or without instrumentation), and is most commonly used for young patients with highly progressive deformities (e.g., hemivertebra and a contralateral bar). This gives the best chance for limiting growth in the circumstances known to be at greatest risk for rapid progressive deformity (305).

A fully segmented hemivertebra also may require an anterior fusion, because the additional growth centers of an anterior and laterally placed hemivertebra may generate substantial rotational deformity in the presence of a posterior fusion alone. The age at the time of surgery also plays a roll in this decision. Block vertebrae, semisegmented hemivertebrae, and wedge vertebrae are less likely to be progressive from the outset, and if they do progress, can often be treated with a posterior fusion alone.

Anterior procedures are designed primarily to limit growth of the vertebrae; however, some degree of flexibility may be obtained following discectomies in deformities which do not have a segmentation deficiency. The surgical exposure must allow for complete removal of the disc and end plate growth cartilage of the levels involved. The disc spaces are filled with autogenous rib or cancellous allograft bone to ensure an arthrodesis between the vertebrae. The risk of surgically related paralysis due to vascular insuffi-

ciency seems greatest in congenital scoliosis surgery (280) as compared to surgery on other curve types.

Partial Fusion, Growth Modulation, and Hemiepiphysiodesis. Methods for obtaining correction of a congenital deformity by modifying the growth of the involved levels have been proposed by many authors (306–310), with the principal of a Blount-type hemiepiphysiodesis (used to correct a long-bone deformity) applied to the spine. Convex hemiarthrodesis (hemiepiphysiodesis), a technique that includes performing a fusion only on the convex side of the curve, both anteriorly and posteriorly, has led to mixed results. Depending on the growth potential of the concave vertebral elements, the hemiarthrodesis may need to be extended one level above and below the measured curve. This technique has been most useful when utilized early in life (before age 5 years). Additionally, it should be employed when curves have proven to be progressive yet remain less than 50 degrees (Fig. 18-52). Beyond these levels, the results are less predictable. This procedure should not be used if a significant kyphotic component to the deformity exists, because the anterior fusion may lead to worsening of the kyphosis. It is similarly important to be certain that the anterior hemiarthrodesis component is extended posteriorly

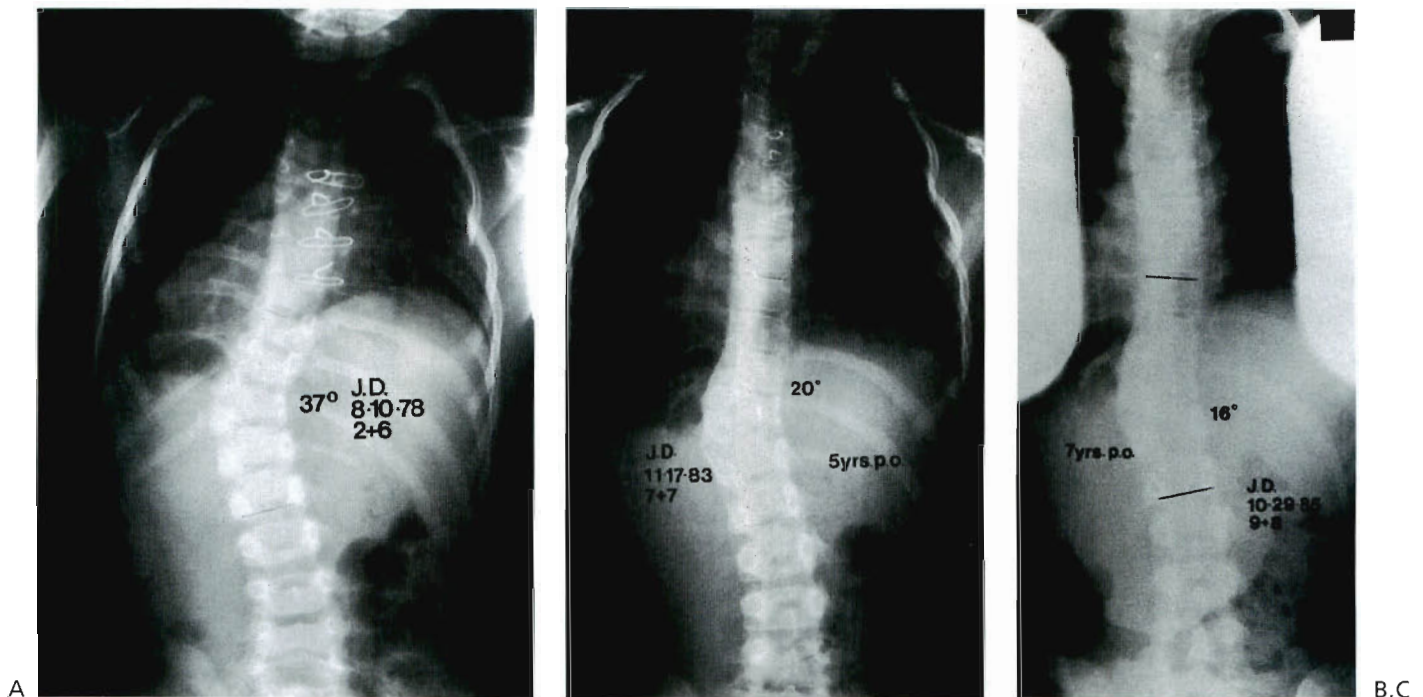
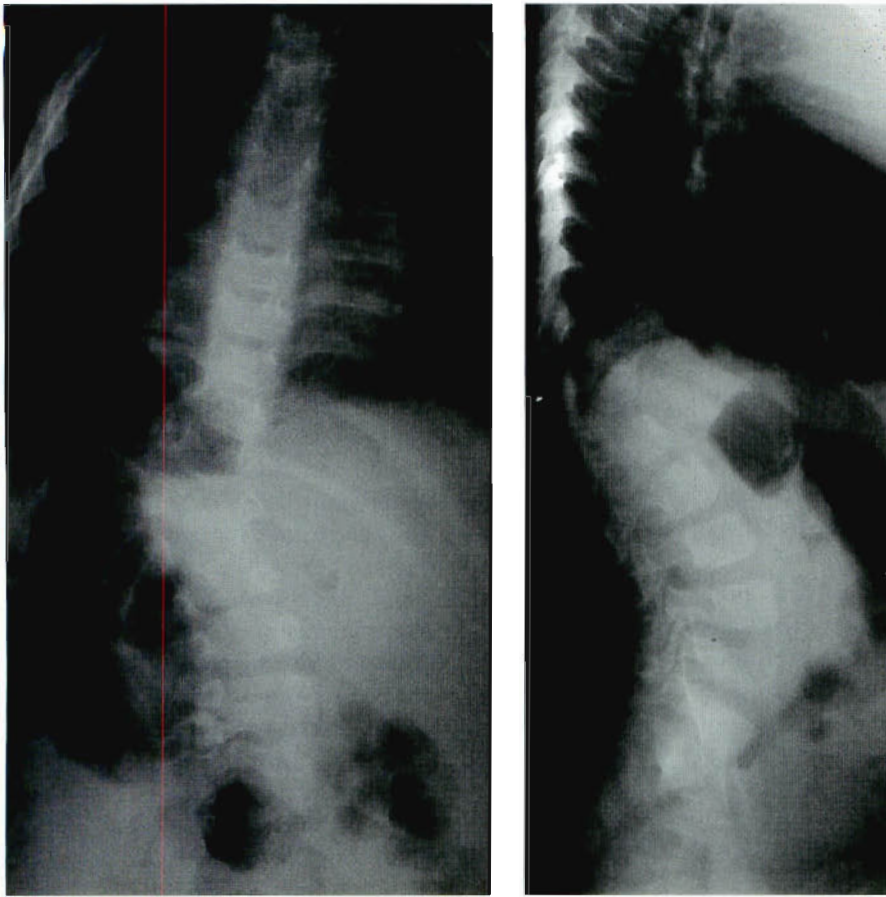
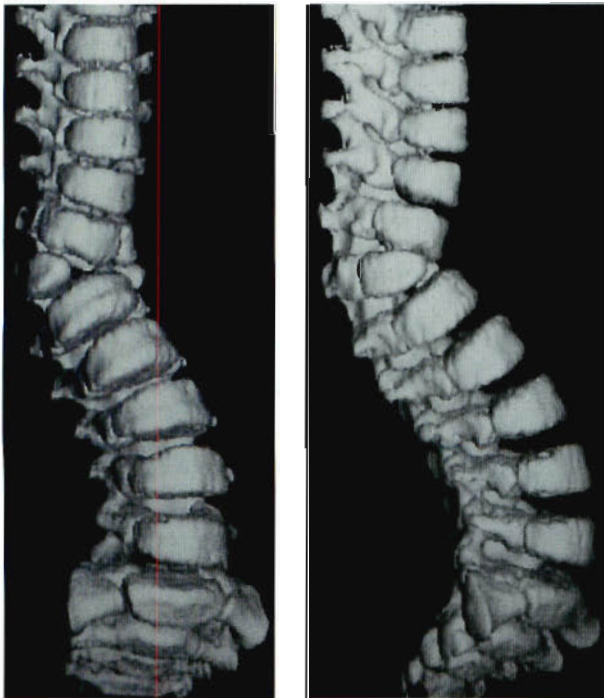


FIGURE 18-52. A: A 2-year, 6-month-old girl presented with progressive congenital thoracolumbar scoliosis caused by a hemivertebra. Treatment options included anterior and posterior fusion, epiphysiodesis, posterior fusion only, and hemivertebra excision. She underwent a convex anterior and posterior growth arrest (hemiepiphysiodesis). B: Five years after surgery the curve was 20 degrees. C: Seven years after surgery the curve was 16 degrees. Nine years after her surgery the curve was 10 degrees.

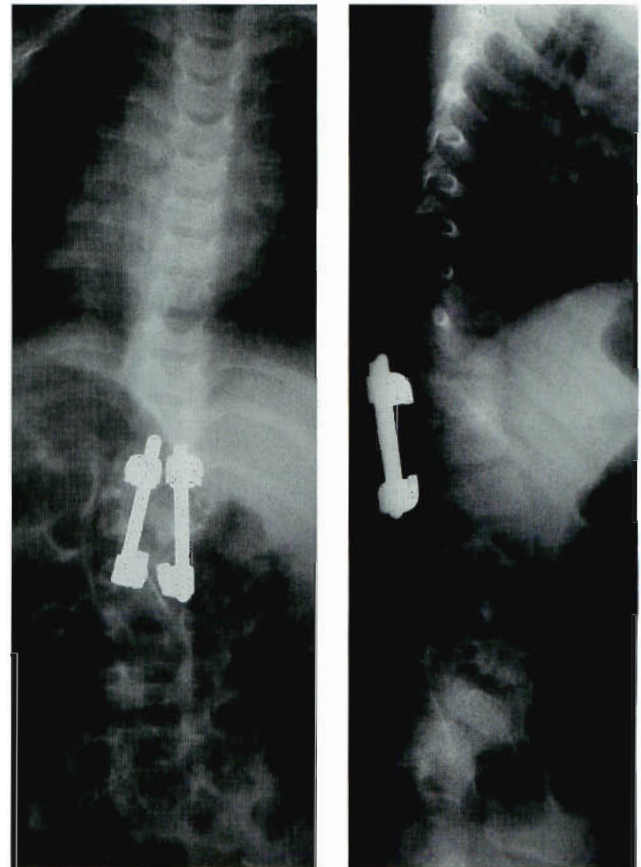


A,B

FIGURE 18-53. A: Preoperative radiograph in a 6-year-old male with progressive congenital scoliosis due to an apparent T12 hemivertebra. B: Lateral view demonstrates focal kyphosis centered at the T12 level. C: Anterior view on a three-dimensional CT study demonstrates that the hemivertebra may have a small "butterfly" component (small residual of body on the opposite side). The absence of body anteriorly is leading to severe kyphosis. D: Sagittal view on three-dimensional CT study. The cause of the kyphosis is clear. E: PA radiograph after vertebral body excision and corrective instrumentation. F: Lateral view after vertebral body excision and corrective instrumentation.



C,D



E,F

to the posterior longitudinal ligament. If not, growth in the posterior remainder of the vertebral end plates may result in a progressive kyphotic deformity.

Hemivertebra Excision. Hemivertebra excision, [➔2.12] a procedure that allows for acute deformity correction as well as stabilization with arthrodesis, is associated with greater neurologic risk and is technically much more demanding than the options discussed above. Resection of a hemivertebra is safest (neurologically) when performed below the tip of the cord (conus), and has the greatest impact on trunk balance when applied to lower lumbar or lumbosacral deformities. Thus, the procedure is most commonly used for lower lumbar hemivertebrae associated with truncal decompensation (311), although it has also been effectively applied to severe deformities of the thoracic and thoracolumbar spine (298,312) (Fig. 18-53).

Surgical exposure may be either by simultaneous anterior and posterior exposure or by staged anterior and posterior procedures. The combined approach allows removal under direct vision of all the bony components of the hemivertebra, with anterior and posterior grafting between the remaining superior and inferior vertebrae and is preferred. If an unsegmented bony bar exists an osteotomy may be required. When possible, compression instrumentation is used on the convex side of the curve to close down the wedge resection. A Risser cast may be used for immobilization in the corrected position, and is also generally required even when instrumentation is used to prevent hook dislodgment. Unrecognized compression of neural elements can occur with hemivertebra excision, and reliable spinal cord monitoring or a wake-up test is mandatory. The results of several series suggest that in experienced hands this is a safe and effective approach to the deformity caused by a hemivertebra (309,312–314).

ACKNOWLEDGMENTS

Grateful appreciation is extended to Candy McGinley and J. D. Bomar for their invaluable assistance in preparation of this manuscript.

References

Childhood and Adolescent Scoliosis

- Bernhardt M, Bridwell KH. Segmental analysis of the sagittal plane alignment of the normal thoracic and lumbar spines and thoracolumbar junction. *Spine* 1989;14:717.
- Propst-Proctor SL, Bleck EE. Radiographic determination of lordosis and kyphosis in normal and scoliotic children. *J Pediatr Orthop* 1983;3:344.
- Vedantam R, Lenke LG, Keeney JA, et al. Comparison of standing sagittal spinal alignment in asymptomatic adolescents and adults. *Spine* 1998;23:211.
- Stokes IA, Bigalow LC, Moreland MS. Measurement of axial rotation of vertebrae in scoliosis. *Spine* 1986;11:213.
- Stokes IA, Armstrong JG, Moreland MS. Spinal deformity and back surface asymmetry in idiopathic scoliosis. *J Orthop Res* 1988;6:129.
- Asher MA, Cook LT. The transverse plane evolution of the most common adolescent idiopathic scoliosis deformities. A cross-sectional study of 181 patients. *Spine* 1995;20:1386.
- Lawton JO, Dickson RA. The experimental basis of idiopathic scoliosis. *Clin Orthop* 1986;9.
- Ohlen G, Aaro S, Bylund P. The sagittal configuration and mobility of the spine in idiopathic scoliosis. *Spine* 1988;13:413.
- Dickson RA. The aetiology of spinal deformities. *Lancet* 1988;1:1151.
- Somerville EW. Rotational lordosis: the development of the single curve. *J Bone Joint Surg Br* 1952;34:421.
- Stokes IA, Laible JP. Three-dimensional osseo-ligamentous model of the thorax representing initiation of scoliosis by asymmetric growth. *J Biomech* 1990;23:589.
- Robin GC, Cohen T. Familial scoliosis. A clinical report. *J Bone Joint Surg Br* 1975;57:146.
- Miller NH. Cause and natural history of adolescent idiopathic scoliosis. *Orthop Clin North Am* 1999;30:343.
- Wynne-Davies R. Familial (idiopathic) scoliosis. A family survey. *J Bone Joint Surg Br* 1968;50:24.
- Wynne-Davies R. Genetic aspects of idiopathic scoliosis. *Dev Med Child Neurol* 1973;15:809.
- Risenborough EJ, Wynne-Davies R. A genetic survey of idiopathic scoliosis in Boston, Massachusetts. *J Bone Joint Surg Am* 1973;55:974.
- Kesling KL, Reinker KA. Scoliosis in twins. A meta-analysis of the literature and report of six cases. *Spine* 1997;22:2009; 2015 (discussion).
- Inoue M, Minami S, Kitahara H, et al. Idiopathic scoliosis in twins studied by DNA fingerprinting: the incidence and type of scoliosis. *J Bone Joint Surg Br* 1998;80:212.
- Guille JT, Bowen JR. Scoliosis and fibrous dysplasia of the spine. *Spine* 1995;20:248.
- Peyeritz RE. The Marfan syndrome. In: Royce PM, Steinmann B, eds. *Connective tissue and its heritable disorders: molecular, genetic, and medical aspects*. New York: Wiley-Liss; 1993:437.
- Robins PR, Moe JH, Winter RB. Scoliosis in Marfan syndrome. Its characteristics and results of treatment in thirty-five patients. *J Bone Joint Surg Am* 1975;57:358.
- Sponseller PD, Hobbs W, Riley LH 3rd, et al. The thoracolumbar spine in Marfan syndrome. *J Bone Joint Surg Am* 1995;77:867.
- Miller NH, Mims B, Child A, et al. Genetic analysis of structural elastic fiber and collagen genes in familial adolescent idiopathic scoliosis. *J Orthop Res* 1996;14:994.
- Ponseti IV, Pedrini V, Wynne-Davies R, Duval-Beaupere G. Pathogenesis of scoliosis. *Clin Orthop* 1976;00:268.
- Cheng JC, Guo X. Osteopenia in adolescent idiopathic scoliosis. A primary problem or secondary to the spinal deformity? *Spine* 1997;22:1716.
- Burner WL, Badger VM, Sherman FC. Osteoporosis and acquired back deformities. *J Pediatr Orthop* 1982;2:383.
- Cook SD, Harding AF, Morgan EL, et al. Trabecular bone mineral density in idiopathic scoliosis. *J Pediatr Orthop* 1987;7:168.
- Loncar-Dusek M, Pecina M, Prebeg Z. A longitudinal study of growth velocity and development of secondary gender characteristics versus onset of idiopathic scoliosis. *Clin Orthop* 1991:278.
- Lonstein JE, Carlson JM. The prediction of curve progression in untreated idiopathic scoliosis during growth. *J Bone Joint Surg Am* 1984;66:1061.

30. Roaf R. Rotation movements of the spine with special reference to scoliosis. *J Bone Joint Surg Br* 1958;40:312.
31. Roaf R. The basic anatomy of scoliosis. *J Bone Joint Surg Br* 1966;48:786.
32. Millner PA, Dickson RA. Idiopathic scoliosis: biomechanics and biology. *Eur Spine J* 1996;5:362.
33. Cruickshank JL, Koike M, Dickson RA. Curve patterns in idiopathic scoliosis. A clinical and radiographic study. *J Bone Joint Surg Br* 1989;71:259.
34. Smith RM, Dickson RA. Experimental structural scoliosis. *J Bone Joint Surg Br* 1987;69:576.
35. Murray DW, Bulstrode CJ. The development of adolescent idiopathic scoliosis. *Eur Spine J* 1996;5:251.
36. Willner S, Johansson B. Thoracic kyphosis and lumbar lordosis during the growth period in boys and girls. *Acta Paediatr Scand* 1983;72:873.
37. Nordwall A, Willner S. A study of skeletal age and height in girls with idiopathic scoliosis. *Clin Orthop* 1975;6.
38. Willner S. A study of growth in girls with adolescent idiopathic structural scoliosis. *Clin Orthop* 1974;101:129.
39. Leong JC, Low WD, Mok CK, et al. Linear growth in southern Chinese female patients with adolescent idiopathic scoliosis. *Spine* 1982;7:471.
40. Archer IA, Dickson RA. Stature and idiopathic scoliosis. A prospective study. *J Bone Joint Surg Br* 1985;67:185.
41. Buric M, Momcilovic B. Growth pattern and skeletal age in school girls with idiopathic scoliosis. *Clin Orthop* 1982;238.
42. Drummond DS, Rogala EJ. Growth and maturation of adolescents with idiopathic scoliosis. *Spine* 1980;5:507.
43. Skogland LB, Miller JA. Growth related hormones in idiopathic scoliosis. An endocrine basis for accelerated growth. *Acta Orthop Scand* 1980;51:779.
44. Willner S, Nilsson KO, Kastrup K, et al. Growth hormone and somatomedin A in girls with adolescent idiopathic scoliosis. *Acta Paediatr Scand* 1976;65:547.
45. Saji MJ, Upadhyay SS, Leong JC. Increased femoral neck-shaft angles in adolescent idiopathic scoliosis. *Spine* 1995;20:303.
46. LeBlanc R, Labelle H, Rivard CH, Poitras B. Relation between adolescent idiopathic scoliosis and morphologic somatotypes. *Spine* 1997;22:2532.
47. LeBlanc R, Labelle H, Forest F, Poitras B. Morphologic discrimination among healthy subjects and patients with progressive and nonprogressive adolescent idiopathic scoliosis. *Spine* 1998;23:1109.
48. Upadhyay SS, Hsu LC, Ho EK, et al. Disproportionate body growth in girls with adolescent idiopathic scoliosis. A longitudinal study. *Spine* 1991;16:S343.
49. Normelli H, Sevastik J, Ljung G, et al. Anthropometric data relating to normal and scoliotic Scandinavian girls. *Spine* 1985;10:123.
50. Wiener-Vacher SR, Mazda K. Asymmetric otolith vestibulo-ocular responses in children with idiopathic scoliosis. *J Pediatr* 1998;132:1028.
51. Burwell RG, Cole AA, Cook TA, et al. Pathogenesis of idiopathic scoliosis. The Nottingham concept. *Acta Orthop Belg* 1992;58(suppl)1:33.
52. Wyatt MP, Barrack RL, Mubarak SJ, et al. Vibratory response in idiopathic scoliosis. *J Bone Joint Surg Br* 1986;68:714.
53. Thomsen M, Steffen H, Sabo D, et al. Juvenile progressive scoliosis and congenital horizontal gaze palsy. *J Pediatr Orthop B* 1996;5:185.
54. Dretakis EK. Scoliosis associated with congenital brain-stem abnormalities. A report of eight cases. *Int Orthop* 1984;8:37.
55. Goldberg CJ, Dowling FE, Fogarty EE, et al. Adolescent idiopathic scoliosis and cerebral asymmetry. An examination of a nonspinal perceptual system. *Spine* 1995;20:1685.
56. Gregoric M, Pecak F, Trontelj JV, et al. Postural control in scoliosis. A statokinesimetric study in patients with scoliosis due to neuromuscular disorders and in patients with idiopathic scoliosis. *Acta Orthop Scand* 1981;52:59.
57. Geissele AE, Kransdorf MJ, Geyer CA, et al. Magnetic resonance imaging of the brain stem in adolescent idiopathic scoliosis. *Spine* 1991;16:761.
58. Herman R, Mixon J, Fisher A, et al. Idiopathic scoliosis and the central nervous system: a motor control problem. The Harrington lecture, 1983. Scoliosis Research Society. *Spine* 1985;10:1.
59. Keessen W, Crowe A, Hearn M. Proprioceptive accuracy in idiopathic scoliosis. *Spine* 1992;17:149.
60. Lidstrom J, Friberg S, Lindstrom L, et al. Postural control in siblings to scoliosis patients and scoliosis patients. *Spine* 1988;13:1070.
61. Sahlstrand T, Ortengren R, Nachemson A. Postural equilibrium in adolescent idiopathic scoliosis. *Acta Orthop Scand* 1978;49:354.
62. Yamada K, Yamamoto H, Nakagawa Y, et al. Etiology of idiopathic scoliosis. *Clin Orthop* 1984;50.
63. Woods LA, Haller RJ, Hansen PD, et al. Decreased incidence of scoliosis in hearing-impaired children. Implications for a neurologic basis for idiopathic scoliosis. *Spine* 1995;20:776; 781 (discussion).
64. O'Beirne J, Goldberg C, Dowling FE, et al. Equilibrium dysfunction in scoliosis—cause or effect? *J Spinal Disord* 1989;2:184.
65. Zadeh HG, Sakka SA, Powell MP, et al. Absent superficial abdominal reflexes in children with scoliosis. An early indicator of syringomyelia. *J Bone Joint Surg Br* 1995;77:762.
66. Samuelsson L, Lindell D. Scoliosis as the first sign of a cystic spinal cord lesion. *Eur Spine J* 1995;4:284.
67. Wang X, Jiang H, Raso J, et al. Characterization of the scoliosis that develops after pinealectomy in the chicken and comparison with adolescent idiopathic scoliosis in humans. *Spine* 1997;22:2626.
68. Coillard C, Rivard CH. Vertebral deformities and scoliosis. *Eur Spine J* 1996;5:91.
69. Machida M, Dubousset J, Imamura Y, et al. An experimental study of chickens for the pathogenesis of idiopathic scoliosis. *Spine* 1993;18:1609.
70. Machida M, Dubousset J, Imamura Y, et al. Role of melatonin deficiency in the development of scoliosis in pinealectomized chickens. *J Bone Joint Surg Br* 1995;77:134.
71. Machida M, Dubousset J, Imamura Y, et al. Melatonin. A possible role in pathogenesis of adolescent idiopathic scoliosis. *Spine* 1996;21:1147.
72. Hilibrand AS, Blakemore LC, Loder RT, et al. The role of melatonin in the pathogenesis of adolescent idiopathic scoliosis. *Spine* 1996;21:1140.
73. Fagan AB, Kennaway DJ, Sutherland AD. Total 24-hour melatonin secretion in adolescent idiopathic scoliosis. A case-control study. *Spine* 1998;23:41.
74. Bagnall KM, Raso VJ, Hill DL, et al. Melatonin levels in idiopathic scoliosis. Diurnal and nocturnal serum melatonin levels in girls with adolescent idiopathic scoliosis. *Spine* 1996;21:1974.
75. Spencer GS, Zorab PA. Spinal muscle in scoliosis. Part I. Histology and histochemistry. *J Neurol Sci* 1976;30:137.
76. Khosla S, Tredwell SJ, Day B, et al. An ultrastructural study of multifidus muscle in progressive idiopathic scoliosis. Changes resulting from a sarcolemmal defect at the myotendinous junction. *J Neurol Sci* 1980;46:13.
77. Zetterberg C, Bjork R, Ortengren R, et al. Electromyography of the paravertebral muscles in idiopathic scoliosis. Measurements of amplitude and spectral changes under load. *Acta Orthop Scand* 1984;55:304.

78. Stagnara P. *Spinal deformity*. Dove J., translator; Butterworth, 1988.
79. Gupta P, Lenke LG, Bridwell KH. Incidence of neural axis abnormalities in infantile and juvenile patients with spinal deformity. Is a magnetic resonance image screening necessary? *Spine* 1998;23:206.
80. Duval-Beaupere G, Lamireau T. Scoliosis at less than 30 degrees. Properties of the evolutivity (risk of progression). *Spine* 1985;10:421.
81. Soucacos PN, Zacharis K, Gelalis J, et al. Assessment of curve progression in idiopathic scoliosis. *Eur Spine J* 1998;7:270.
82. Ramirez N, Johnston CE, Browne RH. The prevalence of back pain in children who have idiopathic scoliosis. *J Bone Joint Surg Am* 1997;79:364.
83. Barnes PD, Brody JD, Jaramillo D, et al. Atypical idiopathic scoliosis: MR imaging evaluation. *Radiology* 1993;186:247.
84. Mehta MH. Pain provoked scoliosis. Observations on the evolution of the deformity. *Clin Orthop* 1978:58.
85. Fairbank JC, Pynsent PB, Van Poortvliet JA, et al. Influence of anthropometric factors and joint laxity in the incidence of adolescent back pain. *Spine* 1984;9:461.
86. Mierau D, Cassidy JD, Yong-Hing K. Low-back pain and straight leg raising in children and adolescents. *Spine* 1989;14:526.
87. Turner PG, Green JH, Galasko CS. Back pain in childhood. *Spine* 1989;14:812.
88. Lewonowski K, King JD, Nelson MD. Routine use of magnetic resonance imaging in idiopathic scoliosis patients less than eleven years of age. *Spine* 1992;17:S109.
89. Baker AS, Dove J. Progressive scoliosis as the first presenting sign of syringomyelia. Report of a case. *J Bone Joint Surg Br* 1983;65:472.
90. Citron N, Edgar MA, Sheehy J, et al. Intramedullary spinal cord tumours presenting as scoliosis. *J Bone Joint Surg Br* 1984;66:513.
91. Adams W. *Lectures on pathology and treatment of lateral and other forms of curvature of the spine*. London: Churchill Livingstone; 1865.
92. Bunnell WP. Outcome of spinal screening. *Spine* 1984;18:1572.
93. Grossman TW, Mazur JM, Cummings RJ. An evaluation of the Adams forward bend test and the scoliometer in a scoliosis school screening setting. *J Pediatr Orthop* 1995;15:535.
94. Huang S-C. Cut-off point of the scoliometer in school scoliosis screening. *Spine* 1997;22:1985.
95. Korovessis PG, Stamatakis MV. Prediction of scoliotic Cobb angle with the use of the scoliometer. *Spine* 1996;21:1661.
96. Yngve D. Abdominal reflexes. *J Pediatr Orthop* 1997;17:105.
97. Levy AR, Goldberg MS, Hanley JA, et al. Projecting the lifetime risk of cancer from exposure to diagnostic ionizing radiation for adolescent idiopathic scoliosis. *Health Phys* 1994;66:621.
98. Lescreve JP, Van Tiggelen RP, Lamoureux J. Reducing the radiation dosage in patients with a scoliosis. *Int Orthop* 1989;13:47.
99. Levy AR, Goldberg MS, Mayo NE, et al. Reducing the lifetime risk of cancer from spinal radiographs among people with adolescent idiopathic scoliosis. *Spine* 1996;21:1540.
100. Cheung KM, Luk KD. Prediction of correction of scoliosis with use of the fulcrum bending radiograph. *J Bone Joint Surg Am* 1997;79:1144.
101. Luk KD, Cheung KM, Lu DS, et al. Assessment of scoliosis correction in relation to flexibility using the fulcrum bending correction index. *Spine* 1998;23:2303.
102. Vaughan JJ, Winter RB, Lonstein JE. Comparison of the use of supine bending and traction radiographs in the selection of the fusion area in adolescent idiopathic scoliosis. *Spine* 1996;21:2469.
103. Takahashi S, Passuti N, Delecree J. Interpretation and utility of traction radiography in scoliosis surgery. Analysis of patients treated with Cotrel-Dubousset instrumentation. *Spine* 1997;22:2542.
104. Stagnara P. Medical observation and tests for scoliosis. *Rev Lyon Med* 1968;17:391.
105. Papp T, Porter RW, Aspden RM. The growth of the lumbar vertebral canal. *Spine* 1994;15:2770.
106. Larsen JL. The lumbar spinal canal in children. Part II: the interpedicular distance and its relation to the sagittal diameter and transverse pedicular width. *Eur J Radiol* 1981;1:312.
107. Cobb J. Outline for the study of scoliosis. *Instr Course Lect* 1948;5:261.
108. Oda M, Rauh S, Gregory PB, et al. The significance of roentgenographic measurement in scoliosis. *J Pediatr Orthop* 1982;2:378.
109. Goldberg MS, Poitras B, Mayo NE, et al. Observer variation in assessing spinal curvature and skeletal development in adolescent idiopathic scoliosis. *Spine* 1988;13:1371.
110. Morrissey RT, Goldsmith GS, Hall EC, et al. Measurement of the Cobb angle on radiographs of patients who have scoliosis. Evaluation of intrinsic error. *J Bone Joint Surg Am* 1990;72:320.
111. Carman DL, Browne RH, Birch JG. Measurement of scoliosis and kyphosis radiographs. Intraobserver and interobserver variation. *J Bone Joint Surg Am* 1990;72:328.
112. Nash CL Jr, Moe JH. A study of vertebral rotation. *J Bone Joint Surg Am* 1969;51:223.
113. Perdriolle R. *La scoliose*. In: Maloine SA, ed; 1979.
114. Richards BS. Measurement error in assessment of vertebral rotation using the Perdriolle torsionmeter. *Spine* 1992;17:513.
115. Risser JC. The iliac apophysis: an invaluable sign in the management of scoliosis. *Clin Orthop* 1958;11:111.
116. Noordeen MH, Haddad FS, Edgar MA, et al. Spinal growth and a histologic evaluation of the Risser grade in idiopathic scoliosis. *Spine* 1999;24:535.
117. Sanders JO, Herring JA, Browne RH. Posterior arthrodesis and instrumentation in the immature (Risser-grade-0) spine in idiopathic scoliosis. *J Bone Joint Surg Am* 1995;77:39.
118. Sanders JO, Little DG, Richards BS. Prediction of the crankshaft phenomenon by peak height velocity. *Spine* 1997;22:1352.
119. Greulich W, Pyle S. *Radiographic atlas of skeletal development of the hand and wrist*. 2nd ed. Stanford CA: Stanford University Press; 1959.
120. Schwend RM, Hennrikus W, Hall JE, et al. Childhood scoliosis: clinical indications for magnetic resonance imaging. *J Bone Joint Surg Am* 1995;77:46.
121. Evans SC, Edgar MA, Hall-Craggs MA, et al. MRI of 'idiopathic' juvenile scoliosis. A prospective study. *J Bone Joint Surg Br* 1996;78:314.
122. Bradford DS, Heithoff KB, Cohen M. Intraspinal abnormalities and congenital spine deformities: a radiographic and MRI study. *J Pediatr Orthop* 1991;11:36.
123. McMaster MJ. Occult intraspinal anomalies and congenital scoliosis. *J Bone Joint Surg Am* 1984;66:588.
124. Mejia EA, Hennrikus WL, Schwend RM, et al. A prospective evaluation of idiopathic left thoracic scoliosis with magnetic resonance imaging. *J Pediatr Orthop* 1996;16:354.
125. Cheng JC, Guo X, Sher AH, et al. Correlation between curve severity, somatosensory evoked potentials, and magnetic resonance imaging in adolescent idiopathic scoliosis. *Spine* 1999;24:1679.
126. Drvaric DM, Ruderman RJ, Conrad RW, et al. Congenital

scoliosis and urinary tract abnormalities: are intravenous pyelograms necessary? *J Pediatr Orthop* 1987;7:441.

127. MacEwen GD, Winter RB, Hardy JH. Evaluation of kidney anomalies in congenital scoliosis. *J Bone Joint Surg Am* 1972; 54:1451.

Idiopathic Scoliosis—Details of Diagnosis and Treatment

Prevalence and Natural History of Idiopathic Scoliosis

128. Kane WJ, Moe JH. A scoliosis-prevalence survey in Minnesota. *Clin Orthop* 1970;69:216.
129. Shands AR, Eisberg HB. The incidence of scoliosis in the State of Delaware. A study of 50,000 minifilms of the chest made during a survey for tuberculosis. *J Bone Joint Surg Am* 1955; 37:1243.
130. Bruszewski J, Kamza A. Czestosc wystepowania Skolizoz na Podstawie Anacizy Zdec maxoobrakowych. *Chir Narzadow Ruchu Ortop Pol* 1957;22:115.
131. Stirling AJ, Howel D, Millner PA, et al. Late-onset idiopathic scoliosis in children six to fourteen years old. A cross-sectional prevalence study. *J Bone Joint Surg Am* 1996;78:1330.
132. Dickson RA. Scoliosis in the community. *Br Med J* 1983;286: 615.
133. Rogala EJ, Drummond DS, Gurr J. Scoliosis: incidence and natural history. A prospective epidemiological study. *J Bone Joint Surg Am* 1978;60:173.
134. Morais T, Bernier M, Turcotte F. Age and sex-specific prevalence of scoliosis and the value of school screening programs. *Am J Public Health* 1985;75:1377.
135. Montgomery F, Willner S. The natural history of idiopathic scoliosis. Incidence of treatment in 15 cohorts of children born between 1963 and 1977. *Spine* 1997;22:772.
136. Kane WJ. Scoliosis prevalence: a call for a statement of terms. *Clin Orthop* 1977:43.
137. Dickson RA, Weinstein SL. Bracing (and screening)—yes or no? *J Bone Joint Surg Br* 1999;81:193.

Infantile Idiopathic Scoliosis

138. James JIP, Lloyd-Roberts GC, Pilcher MF. Infantile structural scoliosis. *J Bone Joint Surg Br* 1959;41:719.
139. Scott JC, Morgan TH. The natural history and prognosis of infantile idiopathic scoliosis. *J Bone Joint Surg Br* 1955;37:400.
140. McMaster MJ. Infantile idiopathic scoliosis: can it be prevented? *J Bone Joint Surg Br* 1983;65:612.
141. James JIP. Idiopathic scoliosis: The prognosis, diagnosis, and operative indications related to curve patterns and the age of onset. *J Bone Joint Surg Br* 1954;36:36.
142. Lloyd-Roberts GC, Pilcher MF. Structural idiopathic scoliosis in infancy. *J Bone Joint Surg Br* 1965;47:520.
143. Hooper G. Congenital dislocation of the hip in infantile idiopathic scoliosis. *J Bone Joint Surg Br* 1980;62:447.
144. Mehta MH. The rib vertebral angle in the early diagnosis between resolving and progressive infantile scoliosis. *J Bone Joint Surg Br* 1972;54:230.
145. Ceballos T, Ferrer-Torrelles M, Castillo F, et al. Prognosis in infantile idiopathic scoliosis. *J Bone Joint Surg Am* 1980;62:863.
146. Robinson CM, McMaster MJ. Juvenile idiopathic scoliosis. Curve patterns and prognosis in one hundred and nine patients. *J Bone Joint Surg Am* 1996;78:1140.
147. Moe JH, Kettleson DN. Idiopathic scoliosis. Analysis of curve patterns and the preliminary results of Milwaukee-brace treatment in one hundred sixty-nine patients. *J Bone Joint Surg Am* 1970;52:1509.

148. Ponseti IV, Friedman B. Prognosis in idiopathic scoliosis. *J Bone Joint Surg Am* 1950;32:381.
149. Mannherz RE, Betz RR, Clancy M, et al. Juvenile idiopathic scoliosis followed to skeletal maturity. *Spine* 1988;13:1087.
150. Tolo VT, Gillespie R. The characteristics of juvenile idiopathic scoliosis and results of its treatment. *J Bone Joint Surg Br* 1978; 60:181.
151. Bunnell WP. The natural history of idiopathic scoliosis. *Clin Orthop* 1988:20.
152. Anderson M, Hwang S-C, Green WT. Growth of the normal trunk in boys and girls during the second decade of life. Related to age, maturity, and ossification of the iliac epiphyses. *J Bone Joint Surg Am* 1965;47:1554.
153. Biondi J, Weiner DS, Bethem D, et al. Correlation of Risser sign and bone age determination in adolescent idiopathic scoliosis. *J Pediatr Orthop* 1985;5:697.
154. Peterson LE, Nachemson AL. Prediction of progression of the curve in girls who have adolescent idiopathic scoliosis of moderate severity. Logistic regression analysis based on data from The Brace Study of the Scoliosis Research Society. *J Bone Joint Surg Am* 1995;77:823.
155. Karol LA, Johnston CE 2nd, Browne RH, et al. Progression of the curve in boys who have idiopathic scoliosis. *J Bone Joint Surg Am* 1993;75:1804.
156. Nachemson A, Lonstein J, Weinstein S. Report of the Prevalence and Natural History Committee of the Scoliosis Research Society. Denver, CO: Annual Meeting of the Scoliosis Research Society, 1982.
157. Weinstein SL, Ponseti IV. Curve progression in idiopathic scoliosis. *J Bone Joint Surg Am* 1983;65:447.

Natural History in Adulthood

158. Weinstein SL. Idiopathic scoliosis. Natural history. *Spine* 1986; 11:780.
159. Nachemson A. A long term follow-up study of non-treated scoliosis. *Acta Orthop Scand* 1968;39:466.
160. Nilsson U, Lundgren KD. Long-term prognosis in idiopathic scoliosis. *Acta Orthop Scand* 1968;39:456.
161. Fowles JV, Sliman N, Nolan B, et al. The treatment of idiopathic scoliosis in Tunisia. A review of the first five years. *Acta Orthop Belg* 1978;44:416.
162. Weinstein SL, Zavala DC, Ponseti IV. Idiopathic scoliosis: long-term follow-up and prognosis in untreated patients. *J Bone Joint Surg Am* 1981;63:702.
163. Pehrsson K, Larsson S, Nachemson A, et al. A long term follow-up of patients with untreated scoliosis. A study of mortality, cause of death, and symptoms. Minneapolis, MN: Annual Meeting of the Scoliosis Research Society, 1991.
164. Pehrsson K, Bake B, Larsson S, et al. Lung function in adult idiopathic scoliosis: a 20 year follow up. *Thorax* 1991;46:474.
165. Upadhyay SS, Mullaji AB, Luk KD, et al. Relation of spinal and thoracic cage deformities and their flexibilities with altered pulmonary functions in adolescent idiopathic scoliosis. *Spine* 1995;20:2415.
166. Winter RB, Lovell WW, Moe JH. Excessive thoracic lordosis and loss of pulmonary function in patients with idiopathic scoliosis. *J Bone Joint Surg Am* 1975;57:972.
167. Mayo NE, Goldberg MS, Poitras B, et al. The Ste-Justine Adolescent Idiopathic Scoliosis Cohort Study. Part III: Back pain. *Spine* 1994;19:1573.
168. Dickson JH, Erwin WD, Rossi D. Harrington instrumentation and arthrodesis for idiopathic scoliosis. A twenty-one-year follow-up. *J Bone Joint Surg Am* 1990;72:678.
169. Collis DK, Ponseti IV. Long-term follow-up of patients with

idiopathic scoliosis not treated surgically. *J Bone Joint Surg Am* 1969;51:425.

170. Payne WK 3rd, Ogilvie JW, Resnick MD, et al. Does scoliosis have a psychological impact and does gender make a difference? *Spine* 1997;22:1380.

School Screening for Scoliosis

171. Soucacos PN, Soucacos PK, Zacharis KC, et al. School-screening for scoliosis. A prospective epidemiological study in north-western and central Greece. *J Bone Joint Surg Am* 1997;79:1498.
172. Pruijs JE, van der Meer R, Hageman MA, et al. The benefits of school screening for scoliosis in the central part of The Netherlands. *Eur Spine J* 1996;5:374.
173. Lonstein JE, Bjorklund S, Wanninger MH, et al. Voluntary school screening for scoliosis in Minnesota. *J Bone Joint Surg Am* 1982;64:481.
174. U.S. Preventive Services Task Force. Screening for adolescent idiopathic scoliosis. Policy statement. *JAMA* 1993;269:2664.
175. U.S. Preventive Services Task Force. Screening for adolescent idiopathic scoliosis. Review article. *JAMA* 1993;269:2667.
176. Goldberg CJ, Dowling FE, Fogarty EE, et al. School scoliosis screening and the United States Preventive Services Task Force. An examination of long-term results. *Spine* 1995;20:1368.
177. Morrissy RT. School screening for scoliosis. A statement of the problem. *Spine* 1988;13:1195.
178. Scoliosis Research Society. *Scoliosis: A handbook for patients*. Park Ridge, IL, 1986.
179. Bunnell WP. Outcome of spinal screening. *Spine* 1993;18:1572.
180. Pruijs JE, Keessen W, van der Meer R, et al. School screening for scoliosis: the value of quantitative measurement. *Eur Spine J* 1995;4:226.
181. Murrell GA, Coonrad RW, Moorman CT, et al. An assessment of the reliability of the Scoliometer. *Spine* 1993;18:709.
182. Cote P, Kreitz BG, Cassidy JD, et al. A study of the diagnostic accuracy and reliability of the Scoliometer and Adam's forward bend test. *Spine* 1998;23:796; 803 (discussion).
183. Duval-Beaupere G. Threshold values for supine and standing Cobb angles and rib hump measurements: prognostic factors for scoliosis. *Eur Spine J* 1996;5:79.
184. Burwell RG, Dangerfield PH. Arthropometry. In: Findlay MD, Owens HJ, eds. *Surgery of the spine*. Oxford: Blackwell, 1992: 191.
185. Winter RB. The pendulum has swung too far. Bracing for adolescent idiopathic scoliosis in the 1990s. *Orthop Clin North Am* 1994;25:195.
186. Winter RB. Adolescent idiopathic scoliosis [editorial]. *N Engl J Med* 1986;314:1379.

Treatment of Idiopathic Scoliosis

187. Nachemson AL, Peterson LE. Effectiveness of treatment with a brace in girls who have adolescent idiopathic scoliosis. A prospective, controlled study based on data from the Brace Study of the Scoliosis Research Society. *J Bone Joint Surg Am* 1995; 77:815.
188. Katz DE, Richards BS, Browne RH, et al. A comparison between the Boston brace and the Charleston bending brace in adolescent idiopathic scoliosis. *Spine* 1997;22:1302.
189. Nash CL Jr. Current concepts review: scoliosis bracing. *J Bone Joint Surg Am* 1980;62:848.
190. Willers U, Normelli H, Aaro S, et al. Long-term results of Boston brace treatment on vertebral rotation in idiopathic scoliosis. *Spine* 1993;18:432.
191. Carr WA, Moe JH, Winter RB, et al. Treatment of idiopathic

scoliosis in the Milwaukee brace. *J Bone Joint Surg Am* 1980; 62:599.

192. Mellencamp DD, Blount WP, Anderson AJ. Milwaukee brace treatment of idiopathic scoliosis: late results. *Clin Orthop* 1977: 47.
193. Blount W, Schmidt A. The Milwaukee brace in the treatment of scoliosis. *J Bone Joint Surg Am* 1957;37:693.
194. Lonstein JE, Winter RB. The Milwaukee brace for the treatment of adolescent idiopathic scoliosis. A review of one thousand and twenty patients. *J Bone Joint Surg Am* 1994;76:1207.
195. Emans JB, Kaelin A, Bancel P, et al. The Boston bracing system for idiopathic scoliosis. Follow-up results in 295 patients. *Spine* 1986;11:792.
196. Watts HG, Hall JE, Stanish W. The Boston brace system for the treatment of low thoracic and lumbar scoliosis by the use of a girdle without superstructure. *Clin Orthop* 1977;87.
197. Allington NJ, Bowen JR. Adolescent idiopathic scoliosis: treatment with the Wilmington brace. A comparison of full-time and part-time use. *J Bone Joint Surg Am* 1996;78:1056.
198. Piazza MR, Bassett GS. Curve progression after treatment with the Wilmington brace for idiopathic scoliosis. *J Pediatr Orthop* 1990;10:39.
199. Apter A, Morein G, Munitz H, et al. The psychosocial sequelae of the Milwaukee brace in adolescent girls. *Clin Orthop* 1978: 156.
200. MacLean WE Jr., Green NE, Pierre CB, et al. Stress and coping with scoliosis: psychological effects on adolescents and their families. *J Pediatr Orthop* 1989;9:257.
201. Ramirez N, Johnston CE 2nd, Browne RH, et al. Back pain during orthotic treatment of idiopathic scoliosis. *J Pediatr Orthop* 1999;19:198.
202. Price CT, Scott DS, Reed FR Jr, et al. Nighttime bracing for adolescent idiopathic scoliosis with the Charleston Bending Brace: long-term follow-up. *J Pediatr Orthop* 1997;17:703.
203. Green NE. Part-time bracing of adolescent idiopathic scoliosis. *J Bone Joint Surg Am* 1986;68:738.
204. Rowe DE, Bernstein SM, Riddick MF, et al. A meta-analysis of the efficacy of non-operative treatments for idiopathic scoliosis [see comments]. *J Bone Joint Surg Am* 1997;79:664.
205. Price CT, Scott DS, Reed FE Jr, et al. Nighttime bracing for adolescent idiopathic scoliosis with the Charleston bending brace. Preliminary report. *Spine* 1990;15:1294.
206. Fernandez-Feliberti R, Flynn J, Ramirez N, et al. Effectiveness of TLSO bracing in the conservative treatment of idiopathic scoliosis. *J Pediatr Orthop* 1995;15:176.
207. Noonan KJ, Weinstein SL, Jacobson WC, et al. Use of the Milwaukee brace for progressive idiopathic scoliosis. *J Bone Joint Surg Am* 1996;78:557.
208. Howard A, Wright JG, Hedden D. A comparative study of TLSO, Charleston, and Milwaukee braces for idiopathic scoliosis. *Spine* 1998;23:2404.
209. Climent JM, Sanchez J. Impact of the type of brace on the quality of life of adolescents with spine deformities. *Spine* 1999; 24:1903.
210. Wickers FC, Bunch WH, Barnett PM. Psychological factors in failure to wear the Milwaukee brace for treatment of idiopathic scoliosis. *Clin Orthop* 1977:62.
211. Edgar MA, Mehta MH. Long-term follow-up of fused and unfused idiopathic scoliosis. *J Bone Joint Surg Br* 1988;70:712.
212. Lenke LG, Bridwell KH, Blanke K, et al. Radiographic results of arthrodesis with Cotrel-Dubousset instrumentation for the treatment of adolescent idiopathic scoliosis. A five- to ten-year follow-up study. *J Bone Joint Surg Am* 1998;80:807.
213. Dickson JH, Mirkovic S, Noble PC, et al. Results of operative treatment of idiopathic scoliosis in adults. *J Bone Joint Surg Am* 1995;77:513.

214. Harrington PR. Treatment of scoliosis: correction and internal fixation by spine instrumentation. *J Bone Joint Surg Am* 1962; 44:591.
215. Hibbs RA. A report of fifty-nine cases of scoliosis treated by the fusion operation. By Russell A. Hibbs, 1924. *Clin Orthop* 1988;4.
216. Winter RB. Harrington instrumentation into the lumbar spine: technique for preservation of normal lumbar lordosis. *Spine* 1986;11:633.
217. King HA, Moe JH, Bradford DS, Winter RB. The selection of fusion levels in thoracic idiopathic scoliosis. *J Bone Joint Surg Am* 1983;65:1302.
218. Cotrel Y, Dubousset J, Guillaumat M. New universal instrumentation in spinal surgery. *Clin Orthop* 1988;227:10.
219. Barr SJ, Schuette AM, Emans JB. Lumbar pedicle screws versus hooks. Results in double major curves in adolescent idiopathic scoliosis. *Spine* 1997;22:1369.
220. Hamill CL, Lenke LG, Bridwell KH, et al. The use of pedicle screw fixation to improve correction in the lumbar spine of patients with idiopathic scoliosis. Is it warranted? *Spine* 1996; 21:1241.
221. Boos N, Webb JK. Pedicle screw fixation in spinal disorders: a European view. *Eur Spine J* 1997;6:2.
222. Suk SI, Lee CK, Min HJ, et al. Comparison of Cotrel–Dubousset pedicle screws and hooks in the treatment of idiopathic scoliosis. *Int Orthop* 1994;18:341.
223. Suk SI, Kim WJ, Kim JH, et al. Restoration of thoracic kyphosis in the hypokyphotic spine: a comparison between multiple-hook and segmental pedicle screw fixation in adolescent idiopathic scoliosis. *J Spinal Disord* 1999;12:489.
224. Andrew T, Piggott H. Growth arrest for progressive scoliosis. Combined anterior and posterior fusion of the convexity. *J Bone Joint Surg Br* 1985;67:193.
225. Dubousset J, Herring JA, Shufflebarger H. The crankshaft phenomenon. *J Pediatr Orthop* 1989;9:541.
226. Roaf R. Vertebral growth and its mechanical control. *J Bone Joint Surg Br* 1960;42:40.
227. Roberto RF, Lonstein JE, Winter RB, et al. Curve progression in Risser stage 0 or 1 patients after posterior spinal fusion for idiopathic scoliosis. *J Pediatr Orthop* 1997;17:718.
228. Lapinsky AS, Richards BS. Preventing the crankshaft phenomenon by combining anterior fusion with posterior instrumentation. Does it work? *Spine* 1995;20:1392.
229. Regan JJ, Mack MJ, Picetti GD 3rd. A technical report on video-assisted thoracoscopy in thoracic spinal surgery. Preliminary description. *Spine* 1995;20:831.
230. Newton PO, Wenger DR, Mubarak SJ, Meyer RS. Anterior release and fusion in pediatric spinal deformity. A comparison of early outcome and cost of thoracoscopic and open thoracotomy approaches. *Spine* 1997;22:1398.
231. Crawford AH, Wall EJ, Wolf R. Video-assisted thoracoscopy. *Orthop Clin North Am* 1999;30:367, viii.
232. Dwyer AF. Experience of anterior correction of scoliosis. *Clin Orthop* 1973;93:191.
233. Zielke K, Berthet A. [VDS—ventral derotation spondylodesis—preliminary report on 58 cases]. *Beitr Orthop Traumatol* 1978;25:85.
234. Turi M, Johnston CE, Richards BS. Anterior correction of idiopathic scoliosis using TSRH instrumentation. *Spine* 1993; 18:417.
235. Suk SI, Lee CK, Chung SS. Comparison of Zielke ventral derotation system and Cotrel–Dubousset instrumentation in the treatment of idiopathic lumbar and thoracolumbar scoliosis. *Spine* 1994;19:419.
236. Kaneda K, Fujiya N, Satoh S. Results with Zielke instrumentation for idiopathic thoracolumbar and lumbar scoliosis. *Clin Orthop* 1986;195.
237. Luk KD, Leong JC, Reyes L, et al. The comparative results of treatment in idiopathic thoracolumbar and lumbar scoliosis using the Harrington, Dwyer, and Zielke instrumentations. *Spine* 1989;14:275.
238. Sweet FA, Lenke LG, Bridwell KH, et al. Maintaining lumbar lordosis with anterior single solid-rod instrumentation in thoracolumbar and lumbar adolescent idiopathic scoliosis. *Spine* 1999;24:1655.
239. Kaneda K, Shono Y, Satoh S, et al. Anterior correction of thoracic scoliosis with Kaneda anterior spinal system. A preliminary report. *Spine* 1997;22:1358.
240. Hopf CG, Eysel P, Dubousset J. Operative treatment of scoliosis with Cotrel–Dubousset–Hopf instrumentation. New anterior spinal device. *Spine* 1997;22:618; 627 (discussion).
241. Betz RR, Harms J, Clements DH 3rd, et al. Comparison of anterior and posterior instrumentation for correction of adolescent thoracic idiopathic scoliosis. *Spine* 1999;24:225.
242. Bernstein RM, Hall JE. Solid rod short segment anterior fusion in thoracolumbar scoliosis. *J Pediatr Orthop B* 1998;7:124.
243. Moe JH, Kharrat K, Winter RB, et al. Harrington instrumentation without fusion plus external orthotic support for the treatment of difficult curvature problems in young children. *Clin Orthop* 1984;35.
244. Fisk JR, Peterson HA, Laughlin R, et al. Spontaneous fusion in scoliosis after instrumentation without arthrodesis. *J Pediatr Orthop* 1995;15:182.
245. Marks DS, Iqbal MJ, Thompson AG, et al. Convex spinal epiphyseodesis in the management of progressive infantile idiopathic scoliosis. *Spine* 1996;21:1884.
246. Coonrad RW, Murrell GA, Motley G, et al. A logical coronal pattern classification of 2,000 consecutive idiopathic scoliosis cases based on the scoliosis research society–defined apical vertebra. *Spine* 1998;23:1380.
247. Lenke LG, Betz RR, Harms J, et al. A new comprehensive classification system of adolescent idiopathic scoliosis. Presented at: 32nd Annual Meeting of the SRS, 1997.
248. Lenke LG, Betz RR, Bridwell KH, et al. Spontaneous lumbar curve coronal correction after selective anterior or posterior thoracic fusion in adolescent idiopathic scoliosis. *Spine* 1999;24: 1663; 1672 (discussion).
249. Lenke LG, Bridwell KH, Baldus C, et al. Preventing decompensation in King type II curves treated with Cotrel–Dubousset instrumentation. Strict guidelines for selective thoracic fusion. *Spine* 1992;17:S274.
250. Thompson JP, Transfeldt EE, Bradford DS, et al. Decompensation after Cotrel–Dubousset instrumentation of idiopathic scoliosis. *Spine* 1990;15:927.
251. Bridwell KH, McAllister JW, Betz RR, et al. Coronal decompensation produced by Cotrel–Dubousset “derotation” maneuver for idiopathic right thoracic scoliosis. *Spine* 1991;16:769.
252. Richards BS. Lumbar curve response in type II idiopathic scoliosis after posterior instrumentation of the thoracic curve. *Spine* 1992;17:S282.
253. Richards BS, Birch JG, Herring JA, et al. Frontal plane and sagittal plane balance following Cotrel–Dubousset instrumentation for idiopathic scoliosis. *Spine* 1989;14:733.
254. Lenke LG, Bridwell KH, O’Brien MF, et al. Recognition and treatment of the proximal thoracic curve in adolescent idiopathic scoliosis treated with Cotrel–Dubousset instrumentation. *Spine* 1994;19:1589.
255. Winter RB. The idiopathic double thoracic curve pattern. Its recognition and surgical management. *Spine* 1989;14:1287.
256. Kaneda K, Shono Y, Satoh S, et al. New anterior instrumentation for the management of thoracolumbar and lumbar scoliosis.

Application of the Kaneda two-rod system. *Spine* 1996;21:1250;1261 (discussion).

Outcomes of Surgical Treatment

257. Haher TR, Merola A, Zipnick RI, et al. Meta-analysis of surgical outcome in adolescent idiopathic scoliosis. A 35-year English literature review of 11,000 patients. *Spine* 1995;20:1575.
258. Stasikelis PJ, Pugh LI, Ferguson RL, et al. Distraction instrumentation outcomes in scoliosis. *J Pediatr Orthop B* 1998;7:106.
259. Moskowitz A, Moe JH, Winter RB, et al. Long-term follow-up of scoliosis fusion. *J Bone Joint Surg Am* 1980;62:364.
260. Cochran T, Irtast L, Nachemson A. Long-term anatomic and functional changes in patients with adolescent idiopathic scoliosis treated by Harrington rod fusion. *Spine* 1983;8:576.
261. Connolly PJ, Von Schroeder HP, Johnson GE, et al. Adolescent idiopathic scoliosis. Long-term effect of instrumentation extending to the lumbar spine. *J Bone Joint Surg Am* 1995;77:1210.
262. Winter RB, Carr P, Mattson H. A study of functional spinal motion in women after instrumentation and fusion for deformity or trauma. *Spine* 1997;22:1760.
263. Lenke LG, Bridwell KH, Baldus C, et al. Cotrel-Dubousset instrumentation for adolescent idiopathic scoliosis. *J Bone Joint Surg Am* 1992;74:1056.
264. Humke T, Grob D, Scheier H, et al. Cotrel-Dubousset and Harrington Instrumentation in idiopathic scoliosis: a comparison of long-term results. *Eur Spine J* 1995;4:280.
265. Bridwell KH, Betz R, Capelli AM, et al. Sagittal plane analysis in idiopathic scoliosis patients treated with Cotrel-Dubousset instrumentation. *Spine* 1990;15:921.
266. Sawatzky BJ, Tredwell SJ, Jang SB, et al. Effects of three-dimensional assessment on surgical correction and on hook strategies in multi-hook instrumentation for adolescent idiopathic scoliosis. *Spine* 1998;23:201.
267. Labelle H, Dansereau J, Bellefleur C, et al. Preoperative three-dimensional correction of idiopathic scoliosis with the Cotrel-Dubousset procedure. *Spine* 1995;20:1406.
268. Aronsson DD, Stokes IA, Ronchetti PJ, et al. Surgical correction of vertebral axial rotation in adolescent idiopathic scoliosis: prediction by lateral bending films. *J Spinal Disord* 1996;9:214.
269. Willers U, Transfeldt EE, Hedlund R. The segmental effect of Cotrel-Dubousset instrumentation on vertebral rotation, rib hump and the thoracic cage in idiopathic scoliosis. *Eur Spine J* 1996;5:387.
270. Benli IT, Tuzuner M, Akalin S, et al. Spinal imbalance and decompensation problems in patients treated with Cotrel-Dubousset instrumentation. *Eur Spine J* 1996;5:380.
271. Kohler R, Galland O, Mechin H, et al. The Dwyer procedure in the treatment of idiopathic scoliosis. A 10-year follow-up review of 21 patients. *Spine* 1990;15:75.
272. Lowe TG, Peters JD. Anterior spinal fusion with Zielke instrumentation for idiopathic scoliosis. A frontal and sagittal curve analysis in 36 patients. *Spine* 1993;18:423.
273. Kostuik JP, Carl A, Ferron S. Anterior Zielke instrumentation for spinal deformity in adults. *J Bone Joint Surg Am* 1989;71:898.

Complications

274. Richards BS. Delayed infections following posterior spinal instrumentation for the treatment of idiopathic scoliosis. *J Bone Joint Surg Am* 1995;77:524.

275. Clark CE, Shufflebarger HL. Late-developing infection in instrumented idiopathic scoliosis. *Spine* 1999;24:1909.
276. Wimmer C, Gluch H. Aseptic loosening after CD instrumentation in the treatment of scoliosis: a report about eight cases. *J Spinal Disord* 1998;11:440.
277. Bridwell KH, Lenke LG, Baldus C, et al. Major intraoperative neurologic deficits in pediatric and adult spinal deformity patients. Incidence and etiology at one institution. *Spine* 1998;23:324.
278. Winter RB, Lonstein JE, Denis F, et al. Paraplegia resulting from vessel ligation. *Spine* 1996;21:1232.
279. Bridwell KH. Normalization of the coronal and sagittal profile in idiopathic scoliosis: options of treatment. *J Orthop Sci* 1998;3:125.
280. Apel DM, Marrero G, King J, et al. Avoiding paraplegia during anterior spinal surgery. The role of somatosensory evoked potential monitoring with temporary occlusion of segmental spinal arteries. *Spine* 1991;16:S365.
281. Glassman SD, Johnson JR, Shields CB, et al. Correlation of motor-evoked potentials, somatosensory-evoked potentials, and the wake-up test in a case of kyphoscoliosis. *J Spinal Disord* 1993;6:194.
282. Hall JE, Levine CR, Sudhir KG. Intraoperative awakening to monitor spinal cord function during Harrington instrumentation and spine fusion. Description of procedure and report of three cases. *J Bone Joint Surg Am* 1978;60:533.
283. Szalay EA, Carollo JJ, Roach JW. Sensitivity of spinal cord monitoring to intraoperative events. *J Pediatr Orthop* 1986;6:437.
284. Bracken MB. Methylprednisolone in the management of acute spinal cord injuries. *Med J Aust* 1990;153:368.
285. Vitale MG, Stazzone EJ, Gelijns AC, et al. The effectiveness of preoperative erythropoietin in averting allogenic blood transfusion among children undergoing scoliosis surgery. *J Pediatr Orthop B* 1998;7:203.
286. Olsfanger D, Jedeikin R, Metser U, et al. Acute normovolaemic haemodilution and idiopathic scoliosis surgery: effects on homologous blood requirements. *Anaesth Intensive Care* 1993;21:429.
287. McNeill TW, DeWald RL, Kuo KN, et al. Controlled hypotensive anesthesia in scoliosis surgery. *J Bone Joint Surg Am Weekly* 1974;56:1167.
288. Scoliosis Research Society. *Morbidity and Mortality Report*. 1995.
289. Johnston CE, Happel LT Jr, Norris R, et al. Delayed paraplegia complicating sublaminar segmental spinal instrumentation. *J Bone Joint Surg Am* 1986;68:556.
290. Mineiro J, Weinstein SL. Delayed postoperative paraparesis in scoliosis surgery. A case report. *Spine* 1997;22:1668.

Congenital Scoliosis—Details of Diagnosis and Treatment

291. Singh J, Aggison L Jr, Moore-Cheatum L. Teratogenicity and developmental toxicity of carbon monoxide in protein-deficient mice. *Teratology* 1993;48:149.

Classification


292. McMaster MJ, Singh H. Natural history of congenital kyphosis and kyphoscoliosis. A study of one hundred and twelve patients. *J Bone Joint Surg Am* 1999;81:1367.
293. Bush CH, Kalen V. Three-dimensional computed tomography in the assessment of congenital scoliosis. *Skeletal Radiol* 1999;28:632.

Natural History

294. McMaster MJ, Ohtsuka K. The natural history of congenital scoliosis. A study of two hundred and fifty-one patients. *J Bone Joint Surg Am* 1982;64:1128.
295. Winter RB. *Congenital deformities of the spine*. New York: Thieme-Stratton, 1983:55.
296. Loder RT, Urquhart A, Steen H, et al. Variability in Cobb angle measurements in children with congenital scoliosis. *J Bone Joint Surg Br* 1995;77:768.

Treatment

297. Winter RB, Moe JH. Orthotics for spinal deformity. *Clin Orthop* 1974;0:72.
298. McMaster MJ. Congenital scoliosis caused by a unilateral failure of vertebral segmentation with contralateral hemivertebrae. *Spine* 1998;23:998.
299. Winter RB, Haven JJ, Moe JH, Lagaard SM. Diastematomyelia and congenital spine deformities. *J Bone Joint Surg Am* 1974;56:27.
300. Goldberg CJ, Moore DP, Fogarty EE, et al. Growth patterns in children with congenital vertebral anomalies. New York: Annual Meeting Scoliosis Research Society, 1998:58.
301. Terek RM, Wehner J, Lubicky JP. Crankshaft phenomenon in congenital scoliosis: a preliminary report. *J Pediatr Orthop* 1991;11:527.
302. Winter RB, Moe JH, Lonstein JE. Posterior spinal arthrodesis for congenital scoliosis. An analysis of the cases of two hundred and ninety patients, five to nineteen years old. *J Bone Joint Surg Am* 1984;66:1188.
303. Lopez-Sosa F, Guille JT, Bowen JR. Rotation of the spine in congenital scoliosis. *J Pediatr Orthop* 1995;15:528.
304. Sanders JO, Evert M, Stanley EA, et al. Mechanisms of curve progression following sublamina (Luque) spinal instrumentation. *Spine* 1992;17:781.
305. McMaster MJ, David CV. Hemivertebra as a cause of scoliosis. A study of 104 patients. *J Bone Joint Surg Br* 1986;68:588.
306. Thompson AG, Marks DS, Sayampanathan SR, et al. Long-term results of combined anterior and posterior convex epiphysiodesis for congenital scoliosis due to hemivertebrae. *Spine* 1995;20:1380.
307. Marks DS, Sayampanathan SR, Thompson AG, et al. Long-term results of convex epiphysiodesis for congenital scoliosis. *Eur Spine J* 1995;4:296.
308. Kieffer J, Dubousset J. Combined anterior and posterior convex epiphysiodesis for progressive congenital scoliosis in children aged \leq 5 years. *Eur Spine J* 1994;3:120.
309. King AG, MacEwen GD, Bose WJ. Transpedicular convex anterior hemiepiphysiodesis and posterior arthrodesis for progressive congenital scoliosis. *Spine* 1992;17:S291.
310. Winter RB, Lonstein JE, Denis F, et al. Convex growth arrest for progressive congenital scoliosis due to hemivertebrae. *J Pediatr Orthop* 1988;8:633.
311. Winter RB. Congenital scoliosis. *Orthop Clin North Am* 1988;19:395.
312. Holte DC, Winter RB, Lonstein JE, et al. Excision of hemivertebrae and wedge resection in the treatment of congenital scoliosis. *J Bone Joint Surg Am* 1995;77:159.
313. Leatherman KD, Dickson RA. Two-stage corrective surgery for congenital deformities of the spine. *J Bone Joint Surg Br* 1979;61:324.
314. Callahan BC, Georgopoulos G, Eilert RE. Hemivertebral excision for congenital scoliosis. *J Pediatr Orthop* 1997;17:96.



19

KYPHOSIS

WILLIAM C. WARNER, JR.

POSTURAL KYPHOSIS 744

CONGENITAL KYPHOSIS 744

Patient Presentation 746
Treatment 747
Complications of Treatment 749

SEGMENTAL SPINAL DYSGENESIS 749

SACRAL AGENESIS 749

PROGRESSIVE ANTERIOR VERTEBRAL FUSION 749

SCHEUERMANN DISEASE 750

Classification 750
Epidemiology 750
Etiology 751
Natural History 752
Associated Conditions 752
Clinical Presentation 752
Physical Examination 753
Radiographic Examination 753
Treatment 754

POSTLAMINECTOMY KYPHOSIS 758

Evaluation 760
Treatment 760

RADIATION KYPHOSIS 760

Treatment 761

MISCELLANEOUS CAUSES OF KYPHOTIC DEFORMITIES 763

Achondroplasia 763
Pseudoachondroplasia 763
Spondyloepiphyseal Dysplasia Congenita 765
Diastrophic Dwarfism 765
Mucopolysaccharidosis 765
Marfan Syndrome 765
Larsen Syndrome 765
Posttraumatic Deformities 766
Neurofibromatosis 767
Tuberculosis 768
Juvenile Osteoporosis 768

Kyphosis is a curvature of the spine in the sagittal plane, in which the convexity of the curve is directed posteriorly. Lordosis is a curvature of the spine in the sagittal plane, in which the convexity of the curve is directed anteriorly. The

thoracic spine and the sacrum normally are kyphotic, and the cervical spine and the lumbar spine normally are lordotic (1). Although several authors have tried to define normal kyphosis of the thoracic spine and normal lordosis of the lumbar spine, these studies have shown much variability in what is considered normal (2–8). The ranges of normal kyphosis and lordosis change with increasing age, and vary according to gender and the area of the spine involved (2–5). The degree of kyphosis or lordosis that is considered normal or abnormal depends on the location of the curva-

ture and the age of the patient. For example, 30 degrees of kyphosis is normal in the thoracic spine, but abnormal at the thoracolumbar junction.

For the purposes of this chapter, the guidelines established by the Scoliosis Research Society for normal thoracic kyphosis and lordosis are used. The normal range of thoracic kyphosis is defined as 20 to 40 degrees, and that of lumbar lordosis as 30 to 60 degrees (9). The thoracolumbar junction should have no kyphosis or lordosis (10). Lumbar lordosis begins at L1–L2 and increases gradually until the L3–L4 disc space. The apex of normal thoracic kyphosis is the T6–T7 disc space (10,11).

Initially during fetal and intrauterine development the entire spine is kyphotic. During the neonatal period the thoracic, lumbar, and sacral portions of the spine remain in a kyphotic posture. Cervical lordosis begins to develop when a child starts holding the head up. When an upright posture is assumed, the primary and secondary curves begin to develop. The primary curves are thoracic and sacral kyphosis, and the secondary or compensatory curves in the sagittal plane are cervical and lumbar lordosis. These curves

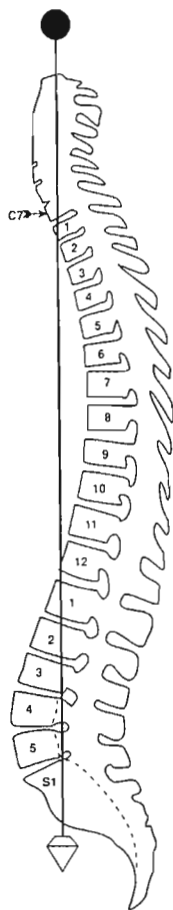

FIGURE 19-1. A plumb line is made from the middle of the C7 vertebral body to the posterosuperior corner of the S1 vertebral body. (From ref. 16, with permission.)

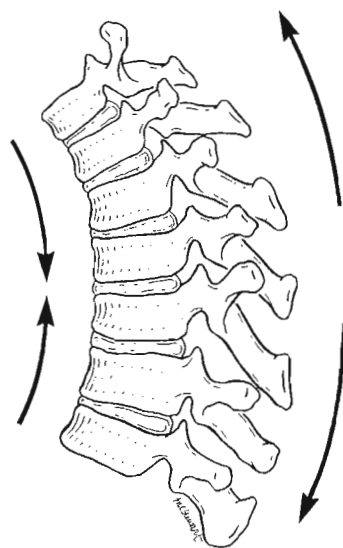


FIGURE 19-2. Forces that contribute to kyphotic deformity of the thoracic spine. The anterior vertebral bodies are in compression, and the posterior vertebral elements are in tension. (From ref. 17, with permission.)

balance each other so that the head is centered over the pelvis (2,12,13).

Cutler et al. (14) and Fon et al. (15) showed that the ranges of normal thoracic kyphosis and lumbar lordosis are dynamic, progressing gradually with growth. During the juvenile and adolescent growth periods thoracic kyphosis and lumbar lordosis become more pronounced and take on a more adult appearance. Differences also exist between male and female spines (6). Thoracic kyphosis and spine mobility are different in boys and girls. Mellin and others (3,11) have shown that during the juvenile and adolescent periods (ages 8 to 16 years) girls have less thoracic kyphosis and thoracic spinal mobility than do boys of the same age. Thoracic kyphosis also tends to progress with age. Fon et al. (15) showed that from 30 to 70 years of age women have a progressive increase in kyphosis, from a mean of 25 to 40 degrees. Men also show a definite progression with age, but at a lower rate.

Normal sagittal balance is defined as a plumb line dropping from C7 and intersecting the posterosuperior corner of the S1 vertebral body (Fig. 19-1). Positive sagittal balance occurs when the plumb line falls in front of the sacrum, and negative sagittal balance occurs when the plumb line falls behind the sacrum (16).

Different forces are exerted on the spine, depending on the presence of kyphosis or lordosis. In the upright position the spine is subjected to the forces of gravity, and several structures maintain its stability: the disc complex (nucleus pulposus and annulus), the ligaments (anterior longitudinal ligament, posterior longitudinal ligament, ligamentum flavum, apophyseal joint ligaments, and interspinous ligament), and the muscles (the long spinal muscles, the short

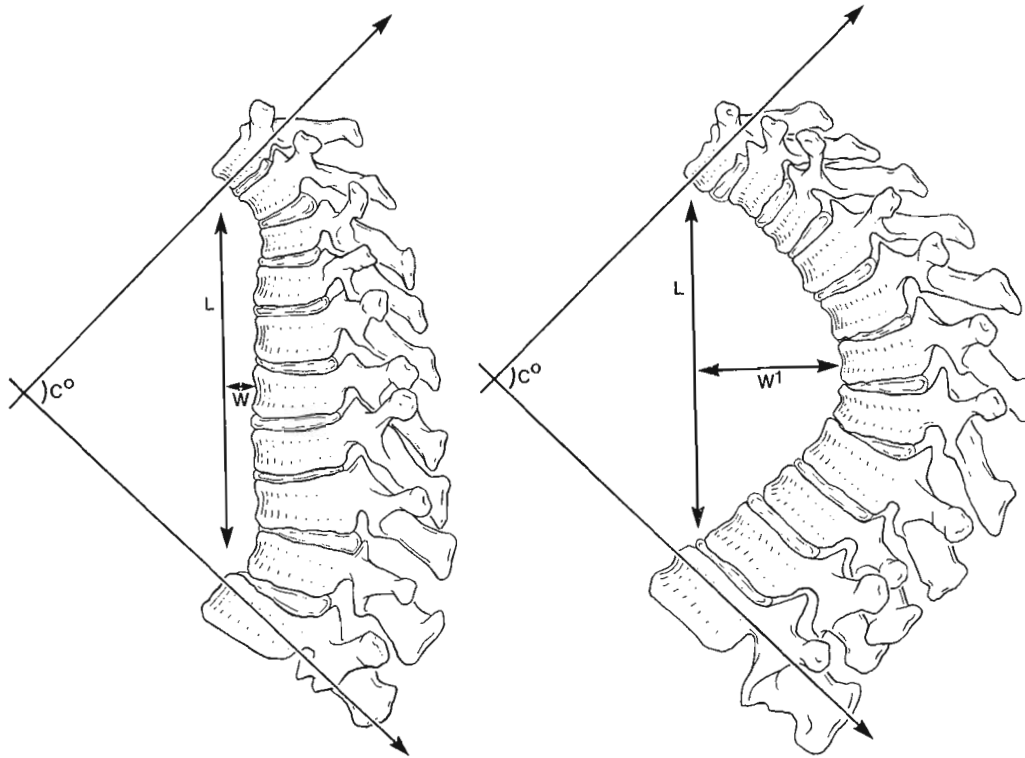


FIGURE 19-3. The two spinal curvatures represented by these drawings are different in magnitude; however, using Cobb's method to measure the deformities, the degrees of curvature are identical. The differences in the curves are more accurately reflected when the length of the curves (L) and their respective widths (W and $W1$) are taken into consideration. (From ref. 19, with permission.)

intrinsic spinal muscles, and the abdominal muscles). Alteration in function resulting from paralysis, surgery, tumor, or infection, or alteration in growth potentials, can cause a progressive kyphotic deformity in a child (17). Both compressive and tensile forces are produced by the action of gravity on an upright spine (Fig. 19-2). With normal thoracic kyphosis, the compressive forces borne by the anterior element are balanced by the tensile forces borne by the posterior element. In a lordotic spine, the compressive forces are posterior and the tensile forces are anterior. These forces of compression and tension on the spinal physes can cause changes in normal growth, and a growth deformity can be added to a biomechanical deformity to cause a pathologic kyphosis (17,18).

Voutsinas and MacEwen (19) believe that relative differences in forces applied to the spine are reflected more accurately by the length and width of a kyphotic curve than by just the degree of the curve. For example, curves that are longer and wider (farther from the center of gravity) are more likely to cause deformity in an immature spine (Fig. 19-3). Winter and Hall (20) classified disorders that result in kyphosis of the spine. Only the more common causes are presented in this chapter; the other causes are discussed elsewhere in this text (Table 19-1).

TABLE 19-1. DISORDERS AFFECTING THE SPINE THAT RESULT IN KYPHOSIS

I. Postural disorders
II. Scheuermann kyphosis
III. Congenital disorders
a. Defect of formation
b. Defect of segmentation
IV. Paralytic disorders
a. Poliomyelitis
b. Anterior horn cell disease
V. Myelomeningocele
VI. Posttraumatic
a. Acute
b. Chronic
c. With or without cord damage
VII. Inflammatory
a. Tuberculosis
b. Other infection
VIII. Postsurgical
a. Postlaminectomy
b. Post-body (tumor) excision

(continued)

TABLE 19-1. (continued)

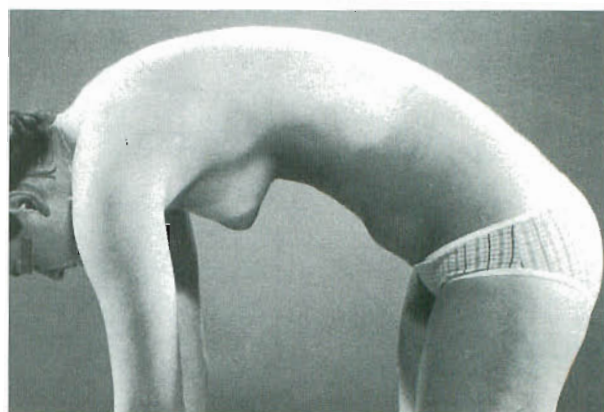IX. Inadequate fusion
a. Too short
b. Pseudoarthrosis
X. Postirradiation
a. Neuroblastoma
b. Wilms tumor
XI. Metabolic
a. Osteoporosis
1. Senile
2. Juvenile
b. Osteogenesis imperfecta
XII. Developmental
a. Achondroplasia
b. Mucopolysaccharidosis
c. Other
XIII. Collagen disease (e.g., Marie-Strümpell)
XIV. Tumor
a. Benign
b. Malignant
XV. Neurofibromatosis

(From ref. 20, with permission.)

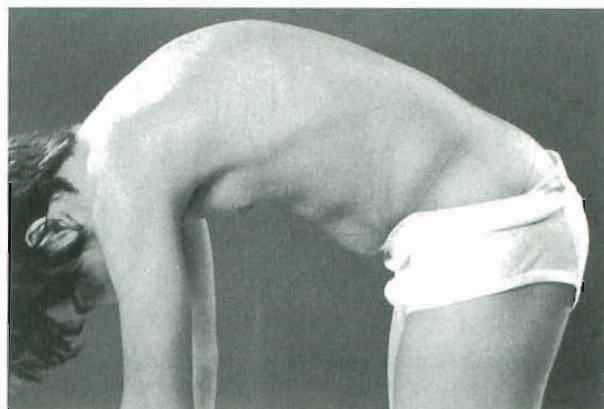
POSTURAL KYPHOSIS

Postural kyphosis is a flexible deformity of the spine, and is a common complaint of juvenile and adolescent patients. Usually, the parents are more concerned about the postural roundback deformity than the adolescent is, and these parental concerns typically are what bring the patient to the physician's office. The physician's role in this situation is to rule out more serious causes of kyphosis. Postural kyphosis should be differentiated from pathologic types of kyphosis, such as Scheuermann disease or congenital kyphosis. When observed from the side, patients with postural roundback have a gentle rounding of the back while bending forward (Fig. 19-4). Patients with Scheuermann disease and congenital kyphosis have a sharp angular kyphosis or gibbus on forward bending when observed from the side. Radiographs usually are necessary to rule out pathologic types of kyphosis. Patients with postural kyphosis do not have radiographic vertebral body changes, and the deformity is completely correctable by changes in position or posture. This deformity is common in patients who are taller than their peers, and in young adolescent girls undergoing early breast development who tend to stoop because they are self-conscious about their bodies (21).

No active medical treatment is necessary. Bracing is not indicated. Exercises have been suggested and may help maintain better posture, but adherence to such a therapy program is difficult for juveniles and young adolescents. This problem is treated best by patient and, more important, parent education and observation (22).



A



B

FIGURE 19-4. A: Lateral view of normal spinal contour on forward bending. B: Lateral view of a patient with Scheuermann disease on forward bending. Note the break in the normal contour of the spine. (Courtesy of Robert Winter, M.D., Minneapolis.)

CONGENITAL KYPHOSIS

Congenital kyphosis is an uncommon deformity, but despite its rare occurrence, neurologic deficits as a result of this deformity are frequent.

Congenital kyphosis occurs because of abnormal development of the vertebrae, including a failure of developing segments of the spine to form or to separate properly (23). The spine can be stable or unstable, or it can become unstable with growth (24). Spinal deformity in congenital kyphosis usually progresses with growth, and the amount of progression is directly proportional to the number of vertebrae involved, the type of involvement, and the amount of remaining normal growth in the affected vertebrae (24,25).

Van Schrick in 1932 (26) and Lombard and LeGenissel in 1938 (27) initially described two basic types of congenital kyphosis: a failure of formation of part or all of the vertebral body, and a failure of segmentation of part or all of the vertebral body. Winter and associates (23,28) developed the most useful classification of congenital kyphosis, which divides the deformity into three types (Table 19-2). Type I is failure of formation of all or part of the vertebral body

TABLE 19-2. WINTER'S CLASSIFICATION OF CONGENITAL DEFORMITY

Type I	Failure of formation of all or part of the vertebral body
Type II	Failure of segmentation of one or multiple vertebral levels
Type III	Mixed form, with elements of both failure of formation and failure of segmentation

(Fig. 19-5A); type II is failure of segmentation of one or multiple vertebral levels (Fig. 19-5B); and type III is a mixed form, with elements of both failure of formation and failure of segmentation.

Dubousset and Zeller et al. (29,30) also classified congenital kyphosis. Their classification is similar to that of Winter, except that their type III includes rotary dislocation of the spine. Shapiro and Herring (31) also described a type III congenital kyphosis, but further divided the displacement into type A (sagittal plane only) and type B (rotary, transverse, and sagittal plane). Either classification can be subdivided further into deformities with and without neurologic compromise. Both classifications and the presence or absence of neurologic compromise are useful for making treatment decisions, because each type of congenital kyphosis has a distinct natural history and risk of progression. The presence of neurologic compromise also affects the type of treatment recommended.

Most vertebral malformations that cause spinal deformity occur between the twentieth and thirtieth days of fetal development (24,28,32). The somatic mesoderm, which is devoted to the formation of the vertebral column and rib cage, undergoes segmentation into discrete, bilateral, 38 to 44 paired somites. Formation of a vertebra depends on contributions of cells from two separate and successive pairs of

sclerotomes. This condensation of the paired sclerotomes occurs around 5 weeks of gestation. If one side of the pair of sclerotomes fails to develop, this will cause a hemivertebra to be formed, and result in congenital scoliosis (33,34). Tsou (35) concluded that congenital kyphosis and congenital scoliosis occur during different periods of spinal development. He divided the development of the spine into an embryonic period (the first 56 days) and a fetal period (from 57 days to birth). During the embryonic period, hemivertebra formation from aplasia of part of the vertebrae, and failure of segmentation, caused scoliosis.

Tsou (35) believes that the causes of congenital kyphosis occur in the fetal period, during the cartilaginous phase of development. Failure of formation occurs in this cartilaginous phase when the cartilaginous centrum of the vertebral body forms a functionally inadequate growth cartilage.

Failure of formation varies from complete aplasia, which involves the pars and the facet joints, and makes the spine unstable to involvement of only the anterior one-third to one-half of the vertebral body. This abnormal development is thought to be the result of inadequate vascularization of the vertebral body during the fetal period, leading to hypoplasia or aplasia of the anterior vertebral body. If one side of the vertebra is involved more than the other side, scoliosis also may occur (Fig. 19-6). Unlike hemivertebral anomalies that occur in the embryonic period as a result of maldevelopment of corresponding pairs of somites, causing congenital scoliosis, posterior arch anomalies are almost universally absent in pure congenital kyphosis.

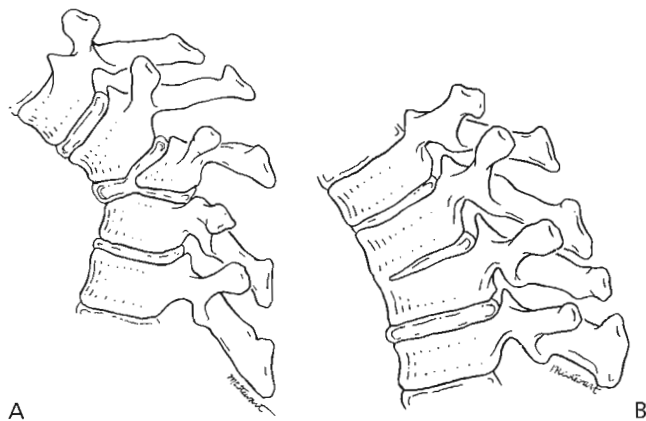


FIGURE 19-5. A: Congenital kyphosis caused by failure of formation of the vertebral body (type I). B: Congenital kyphosis caused by failure of segmentation (type II). (Courtesy of Robert Winter, M.D., Minneapolis.)

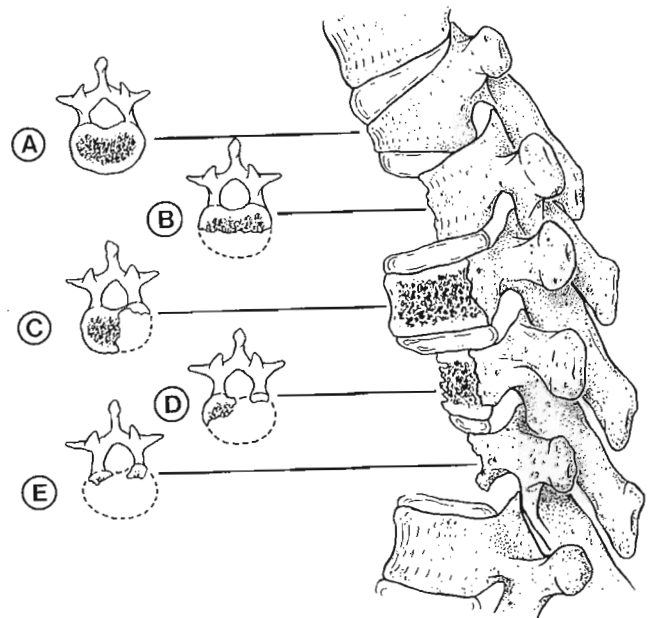


FIGURE 19-6. The five most common patterns of congenital vertebral hypoplasia and aplasia are illustrated in lateral and transverse views. Types B and E tend to produce pure congenital kyphosis. (From ref. 35, with permission.)

Failure of segmentation is believed by Tsou (35) to be an osseous metaplasia of the annulus fibrosus (35,36), which acts as a tether against normal growth and causes spinal deformity. The height of the vertebral bodies is relatively normal, but the depth of the ossification of the annulus fibrosus varies. Ossification also may be delayed, with a period of normal growth followed by spontaneous ossification. Morin et al. (37) believes that kyphosis caused by a "segmentation defect" represents a developmental defect of the perivertebral structures (the annulus fibrosis, the ring apophysis, and the anterior longitudinal ligament), rather than a true intervertebral bar.

The natural history of congenital kyphosis is well known, and based on the type of congenital kyphosis: failure of formation (type I), or failure of segmentation (type II). The natural history of type III congenital kyphosis is less well understood. Both type I and type II deformities tend to be progressive, with the greatest rate of progression occurring during the adolescent growth spurt. Failure of formation (type I deformity) produces a much more malignant kyphosis, with a rate of progression that averages 7 degrees a year (28). Type I deformities have a much higher incidence of neurologic involvement and paraplegia than do type II deformities (28). Neurologic problems are increased in patients with these types of deformity because they tend to have an acute angular kyphosis over a short segment, which places the spinal cord at high risk for compression at the level of acute angulation. Type II deformities generally progress an average of 5 degrees per year and rarely result in neurologic problems because involvement of several segments produces a more gradual kyphosis, and vertebral body height usually is maintained with little or no vertebral body wedging. The most frequent location of congenital kyphosis is from T10 to L1 (28).

Patients with congenital kyphosis can have other anomalies. Intraspinous abnormalities have been reported to occur in 5 to 18% of patients with congenital kyphosis and congenital scoliosis (38). A study by Bradford et al. (39) indicates that this incidence may be greater. They found that six of eight patients with congenital kyphosis had spinal cord abnormalities visible on magnetic resonance imaging (MRI). Even though the proposed time of development of deformity may be different from that of congenital scoliosis other nonskeletal anomalies, such as cardiac, pulmonary, renal, and auditory disorders, or Klippel-Feil syndrome (40,41) can be associated with congenital kyphosis. Dubousset (29) has suggested that certain forms of type II congenital kyphosis (failure of segmentation) may be inherited. The patients have a failure of segmentation, with delayed fusion of the anterior vertebral elements, which is not visible on radiographs until 8 or 10 years of age. Dubousset (29) described one family in which three individuals had delayed ossification and congenital kyphosis, and another family in which the grandmother, mother, and two sisters had the deformity. Progression of congenital kyphosis can be significant during the adolescent growth spurt.

Patient Presentation

The diagnosis of a congenital spine problem usually is made by a pediatrician before the patient is seen by an orthopaedist. The deformity may be detected before birth on prenatal ultrasonography (42), or noted as a clinical deformity in the newborn nursery. If the deformity is mild, congenital kyphosis can be overlooked until a rapid growth spurt makes the condition more obvious. Some mild deformities are found by chance on radiographs that are obtained for other reasons. Physical examination usually reveals a kyphotic deformity at the thoracolumbar junction or in the lower thoracic spine. An attempt should be made to determine the rigidity of the deformity by flexion and extension of the spine. A detailed neurologic examination should be done, looking for any subtle signs of neurologic compromise. Associated musculoskeletal and nonmusculoskeletal anomalies should be sought on physical examination.

High-quality, detailed anteroposterior and lateral radiographs provide the most information in the evaluation of congenital kyphosis (Fig. 19-7). Failure of segmentation and the true extent of failure of formation may be difficult to detect on early films because of incomplete ossification.

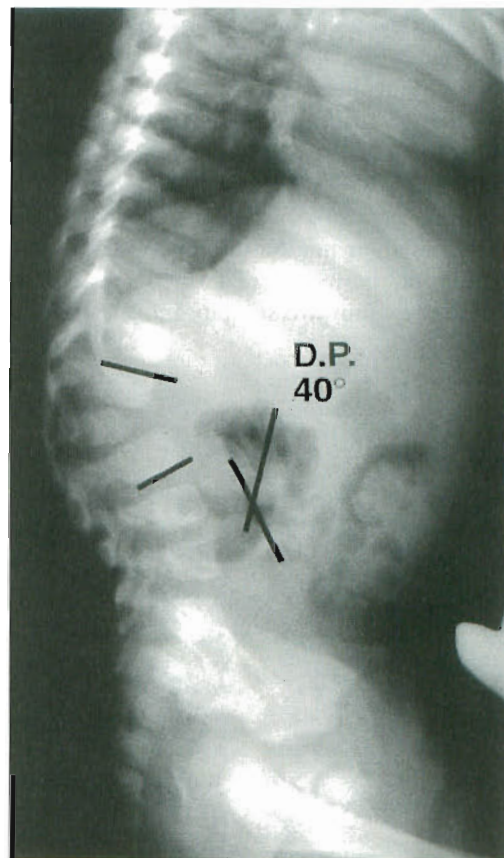


FIGURE 19-7. A 2-year-old child with type I congenital kyphosis measuring 40 degrees. Radiograph demonstrates failure of formation of the anterior portion of the first lumbar vertebra.

Flexion and extension lateral radiographs are helpful to determine the rigidity of the kyphosis and possible instability of the spine. Computed tomographic (CT) scans with three-dimensional reconstructions have replaced tomography in most cases, and can identify the amount of vertebral body involvement as well as determine whether more kyphosis or scoliosis might be expected. CT scans can only identify the nature of the bony deformity and the size cartilage anlage. They do not show the amount of growth potential in the cartilage anlage, and therefore only an estimate of possible progression can be made. MRI should be obtained in most cases because of the significant incidence of intraspinal abnormalities. In addition, the location of the spinal cord and any areas of spinal cord compression caused by the kyphosis can be seen on MRI. The cartilage anlage will be well defined by MRI in patients with failure of formation (Fig. 19-8); however, as with CT scans and plain radiographs, MRI cannot reveal how much growth potential is present in the cartilage anlage, and can only help to estimate the probability of a progressive deformity.

Ultrasonography has been used in the early prenatal (20 weeks of gestation) diagnosis of this condition, and is help-

ful for evaluating the renal system for any occult abnormalities (42). Myelograms have been used to document spinal cord compression, but have been mostly replaced by MRI. If myelography is used, images should be taken in the prone and supine positions. Myelograms obtained in only the prone position may miss information about spinal cord compression because of pooling of dye around the apex of the deformity. Myelography can be used in conjunction with CT scanning to add to the diagnostic information obtained.

Treatment

Because the natural history of this condition is continued progression with an increased risk of neurologic compromise, surgery usually is the preferred method of treatment (23). If the deformity is mild or if the diagnosis is uncertain close observation may be a treatment option. However, observation of a congenital kyphotic deformity must be used with caution, and the physician must not be lulled into a false sense of security if the deformity progresses only 3 to 5 degrees over a 6-month period. If the deformity is observed over 2 to 3 years, it will have progressed 20 to 30 degrees and cannot be easily corrected. Bracing has no role in the treatment of congenital kyphosis, unless compensatory curves are being treated above or below the congenital kyphosis (23,40,43). Bracing a rigid structural deformity, such as congenital kyphosis, neither corrects the deformity nor stops the progression of kyphosis.

Surgery is the recommended treatment for congenital kyphosis. The type of surgery depends on the type of deformity, the size of the deformity, the age of the patient, and the presence of neurologic deficits. Procedures can include posterior fusion, anterior fusion, both anterior and posterior fusions, and anterior osteotomy and posterior fusion. Fusion can be performed with or without instrumentation.

Treatment of Type I Deformities

Treatment of type I deformities can be divided into three stages: early with mild deformity, late with moderate or severe deformity, and late with severe deformity and spinal cord compression.

Early Treatment of Mild Deformities. For type I deformities, with a known average progression rate of 7 degrees a year, the best treatment is early posterior fusion. If the deformity is less than 50 or 55 degrees and the patient is younger than 5 years of age, posterior fusion alone, extending from one level above the kyphotic deformity to one level below, is recommended (23,28,40,44). Winter and Moe (44,45) recommend that a hyperextension cast be worn for 6 months. At 6 months from the initial fusion a second procedure with exploration of the fusion mass and a possible second fusion may be needed, followed by another 6 months

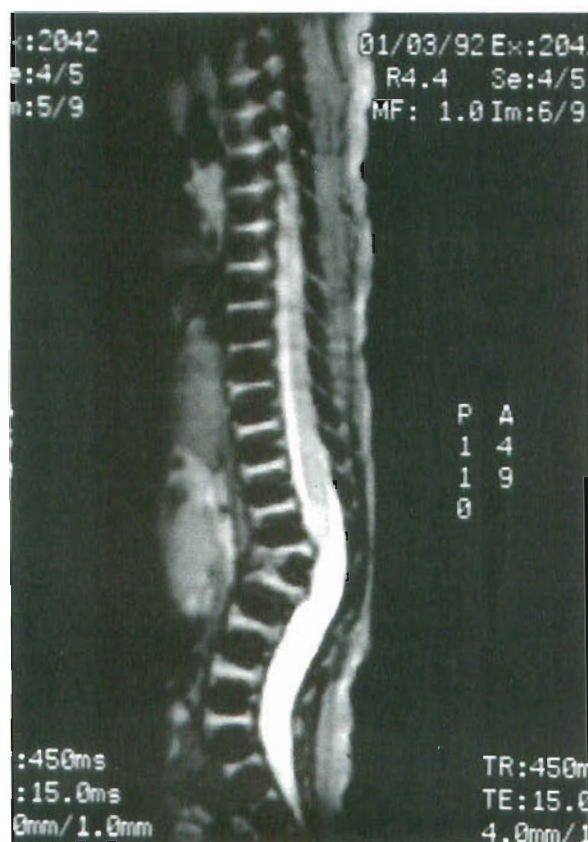

FIGURE 19-8. Magnetic resonance image of type I congenital kyphosis. Failure of formation of the anterior vertebral body is demonstrated, but the growth potential of the involved vertebra cannot be determined. Note the pressure on the dural sac.

of casting. Winter and Moe (44,45) found that this predictably controlled the progressive kyphotic deformity and that the deformity improved, with growth in many cases. The improvement seen with growth probably is due to normal growth from the anterior end plates of the vertebrae one level above and below the congenital kyphotic vertebrae that are included in the posterior fusion. Anterior and posterior fusion predictably halts the progression of the kyphotic deformity, but does not allow for the possibility of some correction of the deformity with growth because of ablation of the anterior physes. (30,44).

Late Treatment of Moderate to Severe Deformities. In older patients with type I kyphotic deformities posterior arthrodesis alone may be successful if the kyphosis is less than 50 to 55 degrees (28,46). If the deformity is more than 55 degrees (which usually is the case in deformities detected late), anterior and posterior fusion produces more reliable results (28,46). Anterior arthrodesis alone will not correct the deformity. Any correction of the deformity requires anterior strut grafting with temporary distraction and posterior fusion, with or without posterior compression instrumentation. The posterior instrumentation should be regarded more as an internal stabilizer than as a correction device (23). Correction by instrumentation should be avoided in rigid, angular curves because of the high incidence of neurologic complications. If anterior strut grafting is performed the strut graft should be placed anteriorly under compression. When an associated scoliosis is present the kyphosis should be approached from the concave side of the scoliosis to place the strut grafts under compression.

If no correction is attempted and the goal of surgery is just to stop progression of the kyphosis, a simple anterior interbody fusion combined with a posterior fusion can be performed. The use of skeletal traction (halo-pelvic, halo-femoral, or halo-gravity) to correct the deformity is tempting but is not recommended because of the risk of paraplegia (47). In a patient with a rigid gibbus deformity traction pulls the spinal cord against the apex of the rigid kyphosis, which can result in neurologic compromise (Fig. 19-9).

Late Treatment of Severe Deformities with Cord Compression. Late treatment of a severe congenital kyphotic deformity with spinal cord compression is difficult. If congenital kyphosis causes spinal cord compression, anterior decompression is indicated. The compression is created by bone or disc material pressing into the front of the spinal cord, and this can be decompressed only by an anterior procedure; laminectomy has no role in the treatment of this condition (20). For associated scoliosis the anterior approach should be on the concavity of the scoliosis, to allow the spinal cord to move both forward and into the midline after decompression [→2.12]. After adequate decompression has been achieved the involved vertebrae are fused with an anterior strut graft. This is followed by a posterior fusion, with or without posterior stabilizing, instrumentation. Postoperative support with a cast, brace, or halo cast, usually is required.

Treatment of Type II Deformities

Treatment of type II deformities can be divided into early treatment of mild deformities and late treatment of severe

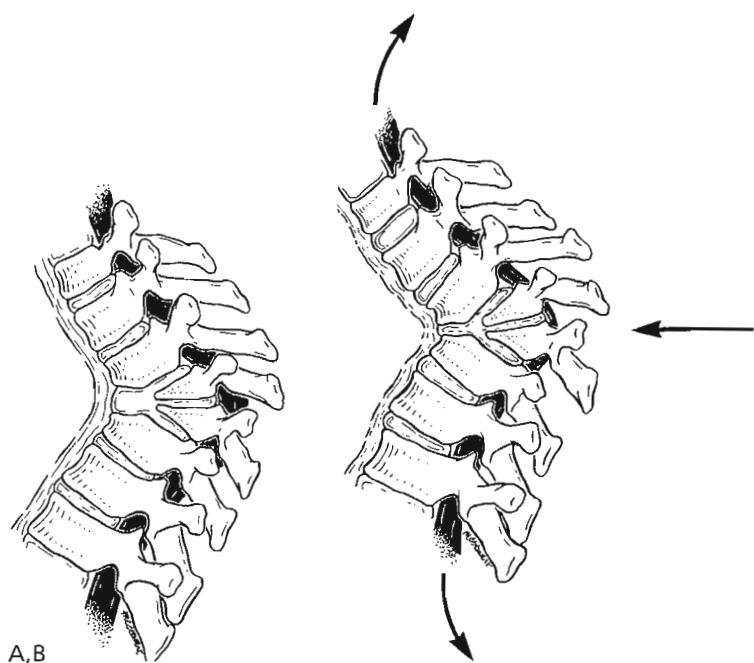


FIGURE 19-9. The effect of traction on a rigid congenital kyphosis. **A:** The apical area does not change with traction, but the adjacent spine is lengthened. **B:** The spine, and thus the spinal cord, lengthen, producing increased tension in the spinal cord and aggravation of any neurologic deficits. (From ref. 262, with permission.)

deformities as outlined by Mayfield et al. (48). If a type II kyphosis is mild and detected early, posterior fusion with compression instrumentation can be performed. The kyphosis must be less than 50 degrees for a posterior fusion alone to have a good chance of success. The posterior fusion should include all the involved vertebrae, plus one vertebra above and one vertebra below the congenital kyphosis.

Compression instrumentation can be used more safely in type II deformities because the kyphosis is more rounded and over several segments, instead of sharply angular, as in type I deformities [→2.13, 2.14]. If the deformity is severe and detected late correction can be obtained only by performing anterior osteotomies and fusion, followed by posterior fusion and compression instrumentation (48).

Complications of Treatment

Some of the more frequent complications of treatment of congenital kyphosis are pseudarthrosis, progression of kyphosis, and paralysis. Pseudarthrosis and progression of the kyphotic deformity can be minimized by performing anterior and posterior fusions for deformities of more than 50 degrees. The posterior fusion should extend from one level above to one level below the involved vertebrae. This may allow for some correction with growth.

Paralysis is perhaps the most feared complication of spinal surgery. The risk of this complication can be lessened by not attempting to correct the deformity with instrumentation. Instrumentation should just be used for stabilization of rigid deformities. The use of halo traction in rigid congenital kyphotic deformities, has been associated with an increased risk of neurologic compromise (47). Another long-term problem is low back pain that occurs in 38% of patients, because of increased lumbar lordosis which is needed to compensate for the kyphotic deformity (49).

SEGMENTAL SPINAL DYSGENESIS

Segmental spinal dysgenesis is a congenital anomaly of the lumbar or thoracolumbar spine, consisting of focal agenesis or dysgenesis of the spine that results in severe spinal stenosis and instability (50). A progressive kyphosis occurs at the site of segmental spinal dysgenesis. This condition often is confused with other spinal anomalies, such as type I congenital kyphosis, sacral agenesis, lumbosacral agenesis, or lumbar agenesis. Faciszewski et al. (51) have described detailed radiographic and clinical definitions of this condition. Segmental spinal dysgenesis is characterized by severe focal stenosis of the spinal canal at the involved segment, and is associated with significant narrowing of the thecal sac and absence of adjacent nerve roots. At the involved level, a ring of bone encircles the posteriorly positioned spinal canal, causing stenosis. The spinal canal has limited potential for enlargement with growth because of the absence of neuro-

central junctions, where growth occurs. No pedicles or spinous or transverse processes are present at this level. Anterior to the bony ring is a fat-filled space. The distal bony anatomy and spinal canal usually are normal, although spina bifida has been noted in a few cases (52). Neurologic function can range from normal to complete paraplegia. Associated anomalies are common, and there is a high incidence of a neurogenic bladder.

The etiology of segmental spinal dysgenesis is unknown. The diagnosis can be made on the basis of plain radiographs, but MRI and CT scans and three-dimensional reconstructions usually are needed to fully show the extent of this condition. A progressive kyphosis will occur with this condition. Progressive neurologic deterioration has been noted by Flynn et al. (53) and Faciszewski et al. (51). Early anterior and posterior fusion, with or without decompression, is recommended. The use of spinal instrumentation is controversial because of the small size of the patient. Hughes et al. (52) believe that treatment should be directed toward the establishment and maintenance of spinal stability first, and toward decompression of the cord secondarily.

SACRAL AGENESIS

Sacral agenesis consists of a complete or partial absence of the sacrum (54–57). Rarely is it associated with absence of the most caudal segment of the lumbar spine. The association with maternal diabetes has been well documented (54–57). Kyphosis may occur with this condition, although it is usually not progressive and does not require treatment (58,59).

PROGRESSIVE ANTERIOR VERTEBRAL FUSION

Progressive anterior vertebral fusion (PAVF) is rare and an uncommon cause of kyphosis in pediatric patients; however, if discovered late it may be confused with type II congenital kyphosis. Knutsson (60), in 1949, was the first to describe PAVF in the English literature, and a total of 80 cases have since been reported. This condition is distinguishable from type II congenital kyphosis because the disc spaces and vertebral bodies are normal at birth and later become affected with an anterior fusion. Although the etiology is unknown, PAVF is probably a distinct clinical condition, even though consideration has been given to the possibility that it may represent a delayed type II congenital kyphosis. Kharrat and Dubousset (61) found this condition to be familial in 6 of 15 patients, and Van Buskirk et al. (62) reported associated anomalies in 46% of 15 patients, including heart defects, tibial agenesis, foot deformities, Klippel-Feil syndrome, Ito syndrome, pulmonary artery stenosis, and hemisacralization of L5.

Neurologic deficits usually are not seen in PAVF, but Smith (63) reported one case of spinal cord compression resulting from an acutely angled kyphosis. Van Buskirk et al. (62) and Dubousett (24,29) described five stages of PAVF: stage 1 is disc space narrowing, which occurs to a greater extent anteriorly than posteriorly; stage 2 is increased sclerosis of the vertebral end plates of the anterior and middle columns; stage 3 is fragmentation of the anterior vertebral end plates; stage 4 is fusion of the anterior and sometimes the middle columns; and stage 5 is development of a kyphotic deformity.

Kyphosis is the last stage in PAVF, and is caused by the anterior disc space fusing while part of the posterior disc space remains open, allowing for continued growth in the posterior disc space and the posterior column. Bollini et al. (64) found that patients with thoracic PAVF had a relatively good prognosis, while those with lumbar involvement had a poor prognosis. Involvement of the thoracic spine is better tolerated by patients than is involvement of the lumbar area because of the normal kyphotic posture of the thoracic spine. Therefore, nonoperative treatment for most thoracic PAVF deformities is recommended. For PAVF in the lumbar spine a posterior spinal fusion is indicated in stages 1, 2, and 3. In stages 4 and 5 lumbar PAVF, the kyphotic deformity has already occurred in a normally lordotic lumbar spine. Posterior fusion will only stop progression of kyphotic deformity. If normal sagittal alignment is to be obtained an anterior osteotomy, followed by posterior fusion and instrumentation, is recommended (60–67).

SCHEUERMANN DISEASE

Scheuermann disease is a common cause of structural kyphosis in the thoracic, thoracolumbar, and lumbar spine. Scheuermann originally described this rigid juvenile kyphosis in 1920; it is characterized by vertebral body wedging that is believed to be caused by a growth disturbance of the vertebral end plates (68,69) (Fig. 19-10).

Classification

Scheuermann disease can be divided into two distinct groups: a typical form and an atypical form. These two types are determined by the location and natural history of the kyphosis, including symptoms occurring during adolescence and after growth is completed. Typical Scheuermann disease usually involves the thoracic spine, with a well-established natural history during adolescence and after skeletal maturity (70). This classic form of Scheuermann kyphosis will have three or more consecutive vertebrae, each wedged 5 degrees or more, producing a structural kyphosis. In contrast, atypical Scheuermann disease usually is located in the thoracolumbar junction or in the lumbar spine, and its natural history is less well understood. The atypical type is char-

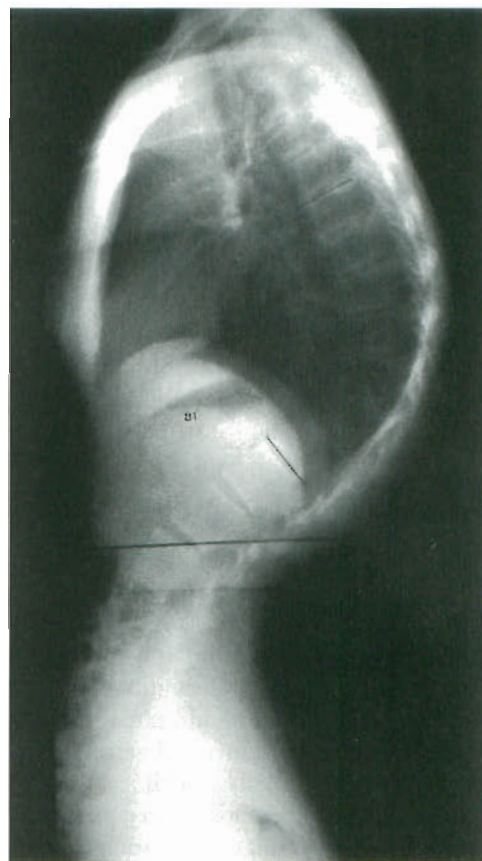


FIGURE 19-10. Lateral radiograph of a patient with Scheuermann disease and an 81-degree kyphotic deformity. Note the narrowing of the intervertebral disc spaces and the irregularity of the vertebral end plates. There is an associated increase in lumbar lordosis below the kyphotic deformity.

acterized by vertebral end plate changes, disc space narrowing, and anterior Schmorl nodes, but does not necessarily fulfill Sorenson's criteria of three consecutively wedged vertebrae of 5 degrees. Thoracic Scheuermann is the most common form, with the atypical form less frequently seen.

Epidemiology

Typical Scheuermann disease consists of a rigid thoracic kyphosis in a juvenile or adolescent spine. The apex of kyphosis is located between T7 and T9 (10). The reported incidence of Scheuermann deformities in the general population ranges from 0.4 to 8.3% (71–74). Reported male-to-female ratios vary in the literature. Scheuermann originally reported a male preponderance of 88% (68). Most reports in the literature note either a slight male preponderance or an equal male-to-female ratio (34,73–77). Bradford et al. (72) has been the only one to report an increased incidence of Scheuermann disease in women.

The age at onset of Scheuermann kyphosis is difficult to establish. Sorensen (74) described a Scheuermann pro-

drome in patients who have a lax, asthenic posture from the age of approximately 4 to 8 years, and in whom, within a few years, a fixed kyphosis developed. The clinical detection of Scheuermann disease occurs at about 10–12 years of age. Radiographic evidence of Scheuermann disease usually is not detectable in patients younger than 10 years of age because the ring apophysis is not yet ossified. Until the ring apophysis ossifies, vertebral body wedging and irregularity of the end plate are difficult to measure on radiographs.

Etiology

Many possible etiologies have been suggested for Scheuermann disease, but the true cause remains unknown. Etiologic factors that have been suggested as causes of Scheuermann kyphosis include genetic, vascular, hormonal, metabolic, and mechanical. Sorensen (74) noted a high familial predilection, and Halal et al. (78), in a study of 5 families, and McKenzie and Sillence (79), in a study of 12 families, suggested that the disease may be inherited in an autosomal dominant fashion with a high degree of penetrance. Additional support for a genetic basis for this condition is provided in a report by Carr et al. (80,81) of Scheuermann disease occurring in identical twins. Halal et al. (78), McKenzie et al. (79), and Carr et al. (81) have reported on possible autosomal dominant inheritance of Scheuermann kyphosis.

Scheuermann believed that the kyphosis was caused by a form of avascular necrosis of the ring apophysis, which led to a growth disturbance resulting in a progressive kyphosis with growth (68,69). The problem with this theory is that the ring apophysis contributes little to the longitudinal growth of the vertebrae (81,82). Bick and Copel (83) demonstrated that the ring apophysis lies outside the true cartilaginous physis and contributes nothing to the longitudinal growth of the vertebral body. Therefore, a disturbance in the ring apophysis should not affect growth of the vertebrae or cause vertebral wedging.

Schmorl (84) described a herniation of disc material through the cartilaginous end plate, known as Schmorl nodes. He believed that the herniation of disc material occurred because of a weakened end plate. The disc herniation was thought to damage the anterior end plate, resulting in abnormal growth, which in turn caused the kyphosis. There is a definite increased incidence of Schmorl nodes in patients with Scheuermann kyphosis, but the problem with this theory is that Schmorl nodes were found outside the area of kyphosis, and in patients who had asymptomatic normal spines and did not have a kyphotic deformity.

Ferguson (85) suggested that persistence of an anterior vascular groove altered the anterior growth of the vertebral body, but Aufdermaur and Spycher (86,87) and Ippolito and Ponseti (88) were unable to document growth disturbances around the anterior vascular groove, and concluded

that persistence of an anterior vascular groove was a sign of immaturity of the spine. Lambrinudi (89) postulated that Scheuermann disease resulted from upright posture and a tight anterior longitudinal ligament. The fact that no cases of Scheuermann disease have been found in quadruped animals lends support to this theory (90). This has led to the more popular belief that the anterior end plate changes are caused by mechanical forces in response to Wolff's law or the Heuter-Volkman principle. Compression forces in the anterior growth plate cause a decrease in growth in the area of kyphosis. Indirect support for this argument can be found in the changes in the wedging of the involved vertebral bodies and the reversal of these changes when bracing or casting is used in the immature spine. Scoles et al. (90) also support this theory by demonstrating disorganized endochondral ossification in involved vertebrae, similar to that seen in Blount disease. They conclude that the changes in endochondral ossification are the result of increased pressure on the vertebral growth plate.

Ascani et al. (91,92) found that patients with Scheuermann disease tended to be taller than normal for their chronologic and skeletal ages, and that their bone age tended to be more advanced than their chronologic age. Because they found increased growth hormone levels in these patients they suggested that the increased height and the advanced skeletal age could be caused by the increased growth hormone (91,92). The increased height and more rapid growth may make the vertebral end plates more susceptible to increased pressure and result in the changes seen in Scheuermann disease. The increased growth hormone levels noted by Ascani et al. also may lead to a relative osteoporosis of the spine, which may predispose the spine to the development of Scheuermann disease.

Bradford et al. (71,93), Burner et al. (94), and Lopez et al. (95) reported that Scheuermann kyphosis may be caused by a form of juvenile osteoporosis. Lopez et al. noted a similar association between osteoporosis and Scheuermann disease, on dual photon absorptiometry (95). Gilsanz et al. (96), on quantitative CT scans, found no evidence of osteoporosis in patients with Scheuermann kyphosis, when compared to normal research subjects. They suggested that the differences in his report, and reports showing osteoporosis, could be related to the technique used to determine osteoporosis. Scoles et al. (90), on single-photon absorptiometric analysis, in a study of cadaver vertebrae from patients with Scheuermann kyphosis, also found no evidence of osteoporosis.

What is shown by the histologic studies of Ascani et al. (91), Ippolito et al. (88,97), and Scoles et al. (90) is that an alteration in endochondral ossification occurs. Whether this altered endochondral ossification is the cause or the result of kyphosis is not known. Ippolito and Ponseti (88) found a decrease in the number of collagen fibers and an increase in proteoglycan content, and the collagen fibers were thinner than normal. Some areas of the altered end

plate showed direct bone formation from cartilage instead of the normal growth plate sequences for ossification. These studies help support the belief that Scheuermann kyphosis is an underlying growth problem of the anterior vertebral end plates, which results in kyphosis.

Natural History

Many early studies suggested a poor natural history for Scheuermann disease, and recommended early treatment to prevent severe deformity, pain, impaired social functioning, embarrassment about physical appearance, myelopathy, degeneration of the disc spaces, spondylolisthesis, and cardio-pulmonary failure. Despite these reports, few long-term follow-up studies of Scheuermann disease were performed until that of Murray et al. (73). Findings by Travaglini and Conti (34,98), Murray et al. (73), and Lowe (99) suggest that the natural history of the disease tends to be benign.

The kyphotic deformity progresses rapidly during the adolescent growth spurt. Bradford et al. (100) noted that more than half of his patients who required brace treatment had progression of their deformities during this growth spurt before brace treatment was begun. Little is known about progression of the kyphosis after growth is completed, and whether it is similar to that in scoliosis. Whether the kyphosis will continue to progress during adulthood, after a certain degree of kyphosis has been reached, is not well documented. Travaglini and Conte (34) found that the kyphosis did progress during adulthood, but few patients developed severe deformities. What is known is that patients with Scheuermann kyphosis have more intense back pain, jobs that require relatively little physical activity, less range of motion of the trunk in extension, and different localization of back pain than the general population that does not have Scheuermann kyphosis (73). Even with these findings, when compared with normal individuals patients with Scheuermann kyphosis have no significant differences in self-esteem, social limitations, or level of recreational activities. The number of days they miss from work because of back pain also is similar. The data regarding the natural history of Scheuermann disease suggest that, although patients may have some functional limitations, their lives are not seriously restricted, and they have few clinical or functional problems. Pulmonary function actually increases in these patients, probably because of the increased diameter of the chest cavity, until their kyphosis is more than 100 degrees. Patients with kyphosis of more than 100 degrees had restrictive pulmonary function. Another finding in patients with Scheuermann kyphosis was that disc degeneration was five times more likely to be seen on MRI in patients with Scheuermann, compared with controls (101). The clinical significance of this finding is not known (73).

Associated Conditions

Mild to moderate scoliosis is present in about one-third of patients with Scheuermann disease (99), but the curves tend

to be small, about 10 to 20 degrees. Scoliosis associated with Scheuermann disease usually has a benign natural history. The scoliotic curve rarely is progressive, and usually does not require treatment. Deacon et al. (102,103) divided scoliotic curves found in patients with Scheuermann disease into two types, based on the location of the curve and the rotation of the vertebrae into or away from the concavity of the scoliotic curve. In the first type of curves, the apices of scoliosis and kyphosis are the same, and the curve is rotated toward the convexity. The rotation of the scoliotic curve is opposite that normally seen in idiopathic scoliosis. Deacon et al. (102,103) suggested that the difference in direction of rotation is caused by scoliosis occurring in a kyphotic spine, instead of the hypokyphotic or lordotic spine that is common in idiopathic scoliosis. In the second type of curves, the apex of scoliosis is above or below the apex of kyphosis, and the scoliotic curve is rotated into the concavity of the scoliosis, more like idiopathic scoliosis. This type of scoliosis seen with Scheuermann kyphosis is the most common, and rarely progresses or requires treatment.

Lumbar spondylolysis is a frequent associated finding in Scheuermann kyphosis. The suggested reason for the increased incidence of spondylolysis is that increased stress is placed on the pars interarticularis as a result of the associated compensatory hyperlordosis of the lumbar spine in Scheuermann disease. This increased stress causes a fatigue fracture at the pars interarticularis, resulting in spondylolysis. Ogilvie and Sherman (104) found a 50% incidence of spondylolysis in the 18 patients he reviewed. Stoddard and Osborn reported a 54% incidence of spondylolysis in their patients with Scheuermann kyphosis (105).

Other conditions reported in patients with Scheuermann disease include endocrine abnormalities (106), hypovitaminosis (107), inflammatory disorders (105,106), and dural cysts (90,108).

Clinical Presentation

Clinical signs of Scheuermann disease occur around the time of puberty. The clinical feature that distinguishes postural kyphosis from Scheuermann kyphosis is rigidity. Often, mild Scheuermann disease is believed to be postural because the kyphosis may be more flexible in the early stages than in later stages. Usually the patient seeks treatment because of a parent's concern about poor posture. Sometimes, the poor posture has been present for several months or longer, or the parents may have noticed a recent change during a growth spurt. Attributing kyphotic deformity in a child to poor posture often causes a delay in diagnosis and treatment.

Pain may be the predominant clinical complaint rather than deformity. The pain generally is located over the area of the kyphotic deformity, but also occurs in the lower lumbar spine if compensatory lumbar lordosis is severe. Back pain usually is aggravated by standing, sitting, or physical

activity. The distribution and intensity of the pain vary according to the age of the patient, the stage of the disease, the site of the kyphosis, and the severity of the deformity. Pain usually subsides with the cessation of growth, although pain in the thoracic spine can sometimes continue, even though the patient is skeletally mature (73,109). More commonly, after growth is completed patients complain of low back pain caused by the compensatory or exaggerated lumbar lordosis.

Most symptoms related to Scheuermann disease occur during the rapid growth phase. During the growth spurt, pain is reported by 22% of patients, but as the end of the adolescent growth spurt approaches, this figure reaches 60%. Some authors believe that when growth is complete the pain recedes completely, except for well-circumscribed perispinal discomfort (110–112). In adult patients with Scheuermann disease, pain may be located in and around the posterior iliac crest. This pain is thought to result from arthritic changes at T11 and T12, because the posterior crest is supplied by this dermatome. Stagnara (113) believes that the mobile areas above and below the rigid segment are the source of pain.

Symptoms also depend on the apex of kyphosis. Murray et al. (73) noted that if the apex of kyphosis was in the upper thoracic spine patients had more pain with everyday activities. The degree of kyphosis also has been correlated with symptoms. It seems logical that the larger the kyphosis, the more likely it is to be symptomatic, but Murray et al. (73) found that curves between 65 and 85 degrees produced the most symptoms, whereas curves of more than 85 degrees and less than 65 degrees produced fewer symptoms. However, in patients with thoracolumbar or lumbar kyphosis (atypical Scheuermann disease), activity decreased as the degree of kyphosis increased.

Lumbar Scheuermann

Patients with lumbar Scheuermann disease differ from those with thoracic deformity. These patients usually have low back pain, but, unlike patients with the more common form of Scheuermann disease, their kyphotic deformity is not as noticeable. Pain is associated with spinal movement. Lumbar Scheuermann is especially common in males involved in competitive sports, and in farm laborers, suggesting that this may be an injury to the vertebral physes from repeated trauma (114).

Physical Examination

In a patient with Scheuermann disease, a thorough examination of the back and a complete neurologic evaluation are essential. With the patient standing the shoulders appear to be rounded and the head protrudes forward. The anterior bowing of the shoulders is caused by tight pectoralis muscles. Angular kyphosis is seen best when the patient is viewed

from a lateral position and is asked to bend forward. Normally, the back exhibits a gradual rounding with forward bending, but in patients with Scheuermann disease an acute increase in the kyphosis of the thoracic spine, or at the thoracolumbar junction, is evident. Stagnara et al. (115) found cutaneous pigmentation to be common at the most protruding spinous process at the apex of the kyphosis, probably the result of friction exerted by the backs of chairs and clothing. Compensatory lumbar and cervical lordosis, with forward protrusion of the head, further increases the anterior flexion of the trunk. Associated hamstring and hip flexor muscle tightness often are present.

The kyphotic deformity has some form of rigidity, and will not correct completely with hyperextension. Larger degrees of kyphosis are not necessarily more rigid, and the amount of rigidity will vary with the age of the patient (73).

The neurologic evaluation usually is normal, but must not be overlooked. Spinal cord compression has been reported occasionally in patients with Scheuermann disease (116–120). Three types of neural compression have been reported: ruptured thoracic disc (121), intraspinal extradural cyst, and mechanical cord compression at the apex of kyphosis. However, spinal cord compression and neurologic compromise are rare (122). Bouchez et al. (66) found that only 1% of patients with a paralyzing disc herniation had Scheuermann disease. In patients with spinal cord compression caused by the kyphosis alone, Ryan and Taylor (119) suggest that the factors influencing the onset of cord compression are the angle of kyphosis, the number of segments involved, and the rate of change of the angle of kyphosis. This may be why neurologic findings are rare in Scheuermann kyphosis—the kyphosis occurs gradually over several segments, without acute angulation.

Radiographic Examination

The most important radiographic views are standing anteroposterior and lateral views of the spine. The amount of kyphosis present is determined by the Cobb method on a lateral radiograph of the spine. This is accomplished by selecting the cranial- and caudal-most tilted vertebrae in the kyphotic deformity. A line is drawn along the superior end plate of the most cranial vertebra and the inferior end plate of the most caudal vertebra. Lines are drawn perpendicular to the lines along the end plates, and the angle they form is the degree of kyphosis (123). Normal kyphosis is between 20 and 40 degrees (9).

The criterion for diagnosis of Scheuermann disease on a lateral radiograph is more than 5 degrees of wedging of at least three adjacent vertebrae (74). The degree of wedging is determined by drawing one line parallel to the superior end plate and another line parallel to the inferior end plate of the vertebra, and measuring the angle formed by their intersection. Bradford believes that three wedged vertebrae

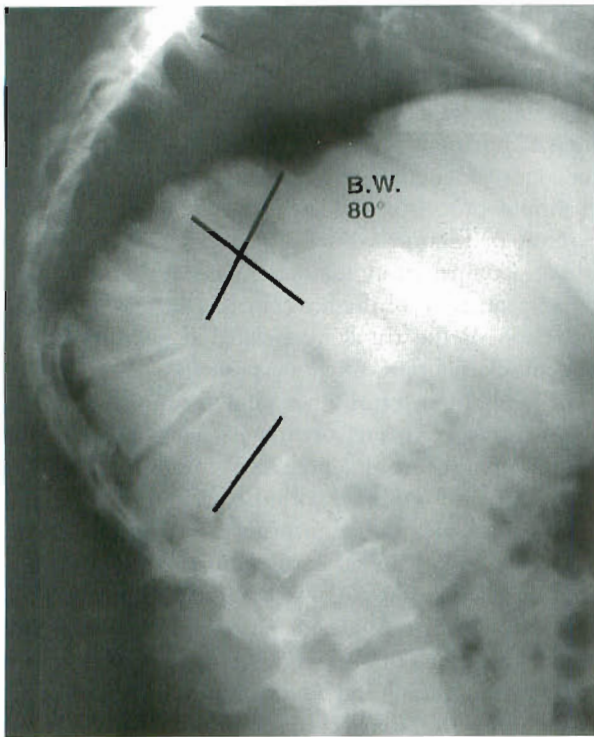


FIGURE 19-11. Lateral radiograph of a patient with Scheuermann disease demonstrates the kyphotic deformity seen in this disorder. Note the irregularity of the vertebral end plates and the anterior vertebral wedging.

are not necessary for the diagnosis, but rather an abnormal, rigid kyphosis is indicative of Scheuermann disease (124).

The vertebral end plates are irregular, and the disc spaces are narrowed. The anteroposterior diameter of the apical vertebra frequently is increased (90) (Fig. 19-11). Associated Schmorl nodes often are seen in the vertebrae in the kyphosis. Flexibility is determined by taking a lateral radiograph with the patient lying over a bolster placed at the apex of the deformity, to hyperextend the spine. The bolster should be placed at the apex of the deformity to maximize the amount of correction seen on a hyperextension radiograph. On the lateral radiographs, most patients will be in negative sagittal balance (125). Sagittal balance is measured radiographically by dropping a plumb line from the center of the C7 vertebral body and measuring the distance from this line to the sacral promontory, with a positive value indicating the plumb line lies anterior to the promontory of the sacrum. Normal sagittal balance values are ± 2 cm to the sacral promontory. On a lateral radiograph of lumbar Scheuermann kyphosis irregular end plates, Schmorl nodes, and disc-space narrowing will be seen, but rarely vertebral-body wedging. MRI and CT scans are necessary only if the patient has unusual symptoms or positive neurologic findings. An anteroposterior or posteroanterior radiograph

of the spine should be obtained to look for associated scoliosis or vertebral anomalies. The patient's skeletal maturity can be estimated from a radiograph of the left hand and wrist, or from the Risser sign on the anteroposterior radiograph of the spine.

Treatment

The indications for the treatment of patients with Scheuermann kyphosis can be grouped into five general categories: pain, progression of deformity, neurologic compromise, cardiopulmonary compromise, and cosmesis.

Treatment options include observation, nonoperative methods, and surgery. Observation is an active form of treatment. If the deformity is mild and nonprogressive, the kyphosis can be observed every 6 months with lateral radiographs. The parents and patient must understand the need for regular follow-up visits. If the deformity begins to progress another form of treatment, such as bracing, casting, or surgery, may be indicated.

Nonoperative methods include exercise, physical therapy, electrical stimulation, bracing, and casting. Exercise and physical therapy alone will not permanently improve kyphosis that is caused by skeletal changes. The improvement seen with these methods is due to improved muscle tone and correction of bad posture. The goals of physical therapy are to increase flexibility of the spine, correct lumbar hyperlordosis, strengthen extensor muscles of the spine, and stretch tight hamstring and pectoralis muscles. The efficacy of this treatment method has not been proven, and although it may improve the postural component of Scheuermann disease, its effect on a rigid kyphosis is questionable.

Although electrical stimulation has been reported in a small number of patients with scoliosis or kyphosis, (126), its use has not been reported in patients with Scheuermann disease. The general consensus at this time is that electrical stimulation is of no benefit in these patients (99).

Other nonoperative treatment methods can be divided into active correction systems (braces) and passive correction systems (casts). For either a brace or a cast to be effective, the kyphotic curve must be flexible enough to allow correction of at least 40% (92,127).

The Milwaukee brace is the brace recommended for the treatment of Scheuermann disease (128) (Fig. 19-12). The Milwaukee brace functions as a dynamic three-point orthosis that promotes extension of the thoracic spine. The neck ring maintains proper alignment of the upper thoracic spine, and the padded poster uprights apply pressure over the apex of the kyphosis. The pelvic girdle stabilizes the lumbar spine by flattening the lumbar lordosis. A low-profile brace, without a chin ring and with anterior shoulder pads, can be used for curves, with an apex at the level of T9 or lower. The indications for brace treatment are spine immaturity and kyphosis of 50 to 70 degrees, with radiologic evidence

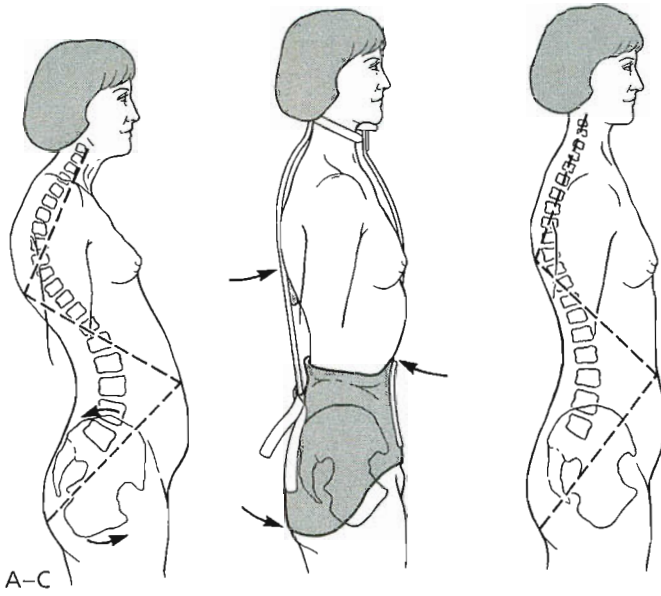


FIGURE 19-12. A: Patient with Scheuermann kyphosis has thoracic kyphosis, compensatory lumbar lordosis, anterior protrusion of the head, and rotation of the pelvis. B: Patient with Scheuermann kyphosis in a Milwaukee brace. The placement of the pelvic girdle, posterior thoracic pads, occipital pads, and neck ring encourage correction of the kyphosis. C: Correction of kyphosis after Milwaukee brace treatment. (Courtesy of Robert Winter, M.D., Minneapolis.)

of Scheuermann disease. The brace initially is worn full-time for an average of 12 to 18 months. If the curve is stabilized and no progression is noted after this time, a part-time brace program can be started. If no progression is noted with part-time bracing, a nighttime bracing program is used until skeletal maturity is reached. However, Gutowski and Renshaw (129) reported that part-time bracing (16 h/day) is as effective as full-time bracing, and is associated with improved patient compliance. In this study, a Boston lumbar kyphosis orthosis was used. The rationale for correction in this orthosis was reduction of the lumbar lordosis, which caused the patient to dynamically straighten the thoracic kyphosis to maintain an upright posture. This presupposes a flexible thoracic kyphosis, a normal neurovestibular axis, and the absence of hip flexion contractures.

Despite initial improvement, several authors have noted a significant loss of correction after the discontinuation of brace treatment (46,130). Montgomery and Erwin (77) believe that if permanent correction of kyphosis is possible, a change in vertebral body wedging should be seen before bracing is discontinued. Even though some loss of correction can occur after bracing is discontinued, it still is effective in obtaining some correction of the kyphosis, and possibly reversing vertebral body wedging, or at least preventing any progression of the kyphotic deformity (77) (Fig. 19-13). Poor brace results were noted by Bradford in patients in whom the kyphosis exceeded 75 degrees, the wedging of the vertebral bodies was more than 10 degrees, or the patient was near or past skeletal maturity (124).

De Mauroy and Stagnara (131) developed a therapeutic regimen for patients with Scheuermann disease that uses serial casts for correction. This method consists of three

stages. First, a physical therapy program is started in preparation for the casts. Next, three antigavity casts are applied on separate occasions. The casts are changed at 45-day intervals, to obtain gradual correction of the deformity at each cast change. The third stage involves the use of a plastic maintenance brace that is worn until skeletal maturity is reached. Although the reported results of this method of treatment have been good (131), the Milwaukee brace is still the preferred nonoperative treatment method in North America.

Surgical correction of kyphosis may be a posterior approach, an anterior approach, or a combined anterior and posterior approach. The combined anterior and posterior approach is the most frequently recommended and reliable procedure for surgical correction of kyphosis (132–135) (Fig. 19-14). A posterior procedure alone can be considered if the kyphosis can be corrected to, and maintained at, less than 50 degrees, while a posterior fusion occurs (136–138). The spine can be instrumented with Harrington compression rods (73,139) or a posterior Cotrel-Dubousset type of instrumentation system (140). If Harrington compression rods are used for posterior instrumentation, the $\frac{1}{4}$ -inch rods are used. Even when $\frac{1}{4}$ -inch Harrington compression rods are used, a brace or cast should be applied after surgery to prevent rod breakage until a solid fusion is obtained. Prolonged immobilization is necessary, however, and there are potential complications. When a Cotrel-Dubousset or similar type of instrumentation system is used, postoperative immobilization may not be required. Anterior instrumentation for Scheuermann disease has been reported by Kostuik (141), consisting of an anterior interbody fusion and anterior instrumentation, with a Harrington distraction system

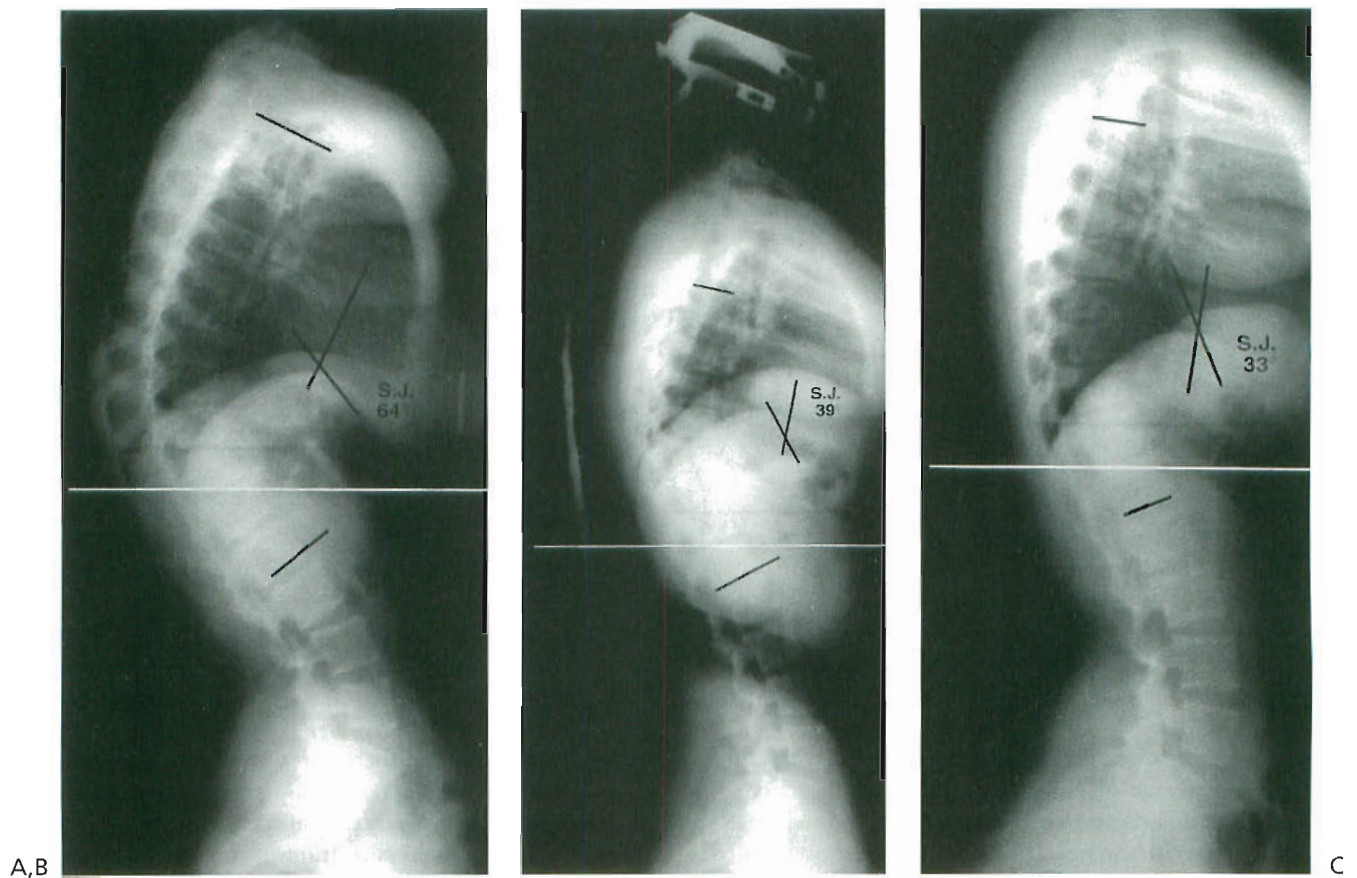


FIGURE 19-13. A: A 15-year-old girl with a 64-degree thoracic kyphosis secondary to Scheuermann disease. B: Lateral radiograph of the patient in a Milwaukee brace with the kyphotic deformity improved to 39 degrees. C: Lateral radiograph obtained after the patient completed brace treatment; the kyphotic deformity has improved to 33 degrees.

augmented by postoperative bracing. A single rod and multiple bone screws, available in the present-day spine instrumentation systems, may be used instead of the Harrington distraction system. Although Kostuik has reported good results with this technique, the anterior instrumentation approach for treatment of Scheuermann kyphosis is not widely used (141).

When anterior and posterior surgery is performed for Scheuermann disease, the anterior release and fusion are performed first, followed by the posterior fusion and instrumentation. The posterior fusion and instrumentation can be done on the same day as the anterior release and fusion, or they can be done as a staged procedure. Harrington compression rods can be used for posterior instrumentation, but usually rods with multiple hooks are used. Lowe (134) and Coscia et al. (142) have reported a high complication rate after using Luque rods and wires for posterior fixation, because this system does not allow for any compression. The posterior instrumentation should include at least three sets of hooks above the apex and at least two sets of hooks

below the apex of the kyphosis. The fusion and instrumentation should include the proximal vertebra in the measured kyphotic deformity and the first lordotic disc distally. If the fusion and instrumentation end in the kyphotic deformity, a junctional kyphosis at the end of the instrumentation is likely to develop.

Lowe emphasized that overcorrection of the deformity should be avoided to prevent proximal junctional kyphosis (134). He recommended that no more than 50% of the preoperative kyphosis be corrected, and that the final kyphosis should never be less than 40 degrees. He also found that patients with Scheuermann disease tend to be in negative sagittal balance and become further negatively balanced after surgery, which may predispose them to the development of junctional kyphosis. Reinhardt and Bassett (143) recommended fusion to the first square vertebra distally if the end vertebra distally was wedged to prevent junctional kyphosis. The type of instrumentation used will determine whether postoperative immobilization is needed. This immobilization can consist of a brace or a Risser body cast.

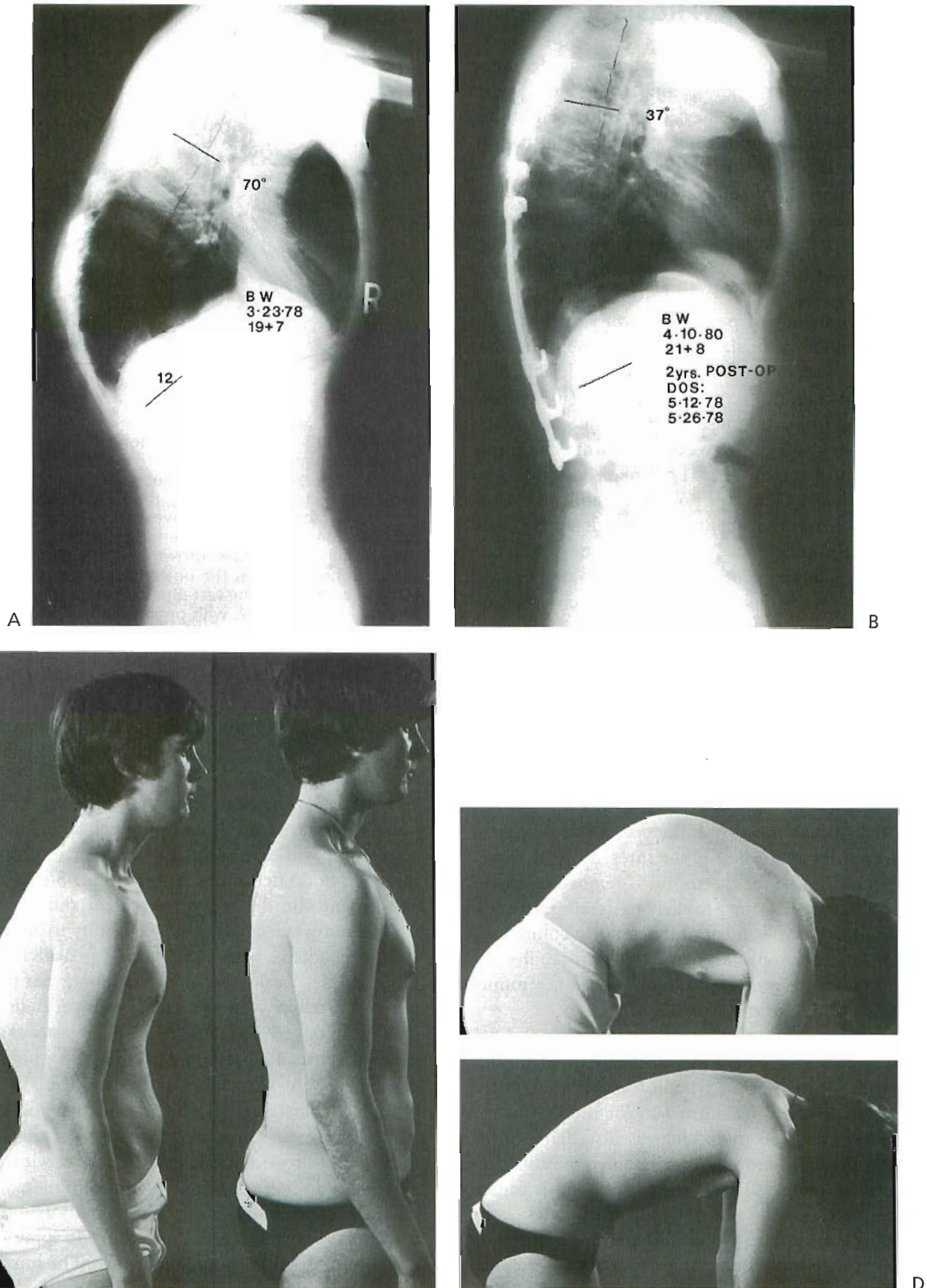


FIGURE 19-14. A: A 19-year-old man with a 70-degree lower thoracic Scheuermann kyphosis was treated by anterior ligament release and interbody fusion, followed by posterior instrumentation and fusion. B: Two years after surgery the kyphosis is 37 degrees. C: Standing photographs before and 2 years after surgery. D: Forward-bending photographs before and 2 years after surgery. (Courtesy of Robert Winter, M.D., Minneapolis.)

POSTLAMINECTOMY KYPHOSIS

A laminectomy or multiple laminectomies are needed most often in children for the diagnosis and treatment of spinal cord tumors, but also may be needed for other conditions, such as neurofibromatosis, Arnold Chiari malformation, and syringomyelia (144,145). Although deformity after laminectomy is unusual in adults, it is common in children because of the unique and dynamic nature of the growing spine (121,146–150). Postlaminectomy deformities usually result in kyphotic deformity, but a scoliotic deformity also may occur (147).

The pathophysiology of postlaminectomy kyphotic deformity can be multifactorial. Deformity of the spine after multiple laminectomies can be caused by (i) skeletal deficiencies (anterior column, facet joint, laminae), (ii) ligamentous deficiencies, (iii) neuromuscular imbalance, (iv) effects of gravity, and (v) progressive osseous deformity resulting from growth disturbances (144,151). Panjabi and colleagues (152) showed that with loss of posterior stabilizing structures caused by removal of the interspinous ligaments, spinous processes, and laminae, the normal flexion forces placed on the spine will produce kyphosis. Gravity places a flexion moment on the spine, producing compression force on the anterior vertebrae and discs, and a tensile force on the remaining posterior structures. This may explain why postlaminectomy deformities occur most often in the cervical and thoracic spine, and rarely in the lumbar spine. Gravity tends to cause a kyphosis in the cervical and thoracic spine, whereas it accentuates the usual lordosis of the lumbar spine.

Skeletal deficiencies also can produce deformity. The most important factor noted to influence the development of postlaminectomy deformity is the integrity of the facet joint (147,152–154). If the facet joint is removed or damaged during surgery, deformity is likely to develop. In addition, any secondary involvement of the anterior column, by tumor or surgical resection, adds to the risk of instability and deformity after laminectomy. Also, multiple laminectomies increase the risk of deformity (155).

Paralysis of muscles that help stabilize the spine also can add to a postlaminectomy deformity, because these muscles are unable to resist the normal flexion forces placed on the spine by gravity and by the normal flexor muscles of the spine. Yasuoka et al. (156) noted increased wedging of the vertebrae and excessive motion after laminectomy in children, but not in adults. This increased wedging is caused by increased pressure on the cartilaginous end plates of the vertebral bodies. With time the increased pressure will cause a decrease in growth of the anterior portion of the vertebrae, according to the Heuter-Volkman principle (Fig. 19-15). Excessive spinal motion in children after laminectomy can be attributed to the facet joint anatomy in the cervical spine and the increased ligamentous laxity of growing children. Orientation of the cervical joint in a child is more horizontal

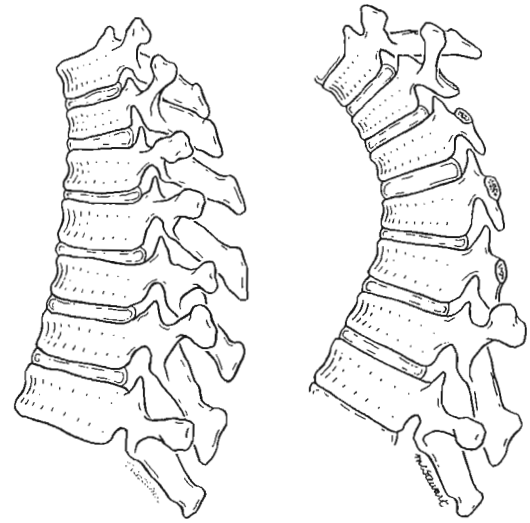


FIGURE 19-15. Drawings of the thoracic spine before and after repeated laminectomy demonstrate the effects on growth of the vertebral bodies. **A:** Before laminectomy, the anterior vertebral bodies are rectangular in configuration. **B:** The spine that has had multiple laminectomies will have increased compression anteriorly because of loss of posterior supporting structures. This compression results in less growth in the anterior portion of the vertebral body than in the posterior portion. In time, this will result in wedging of the vertebral bodies, causing a kyphotic deformity. (From ref. 157, with permission.)

than that seen in an adult. This horizontal orientation offers less resistance to forces that tend to cause kyphosis in the cervical spine.

Kyphosis is the most common deformity, although scoliosis also can occur, either as the primary deformity or in association with kyphosis. The incidence of postlaminectomy kyphotic deformity ranges from 33 to 100% (157), and depends on the age of the patient and the level of the laminectomy. Generally, the deformity is more likely in younger patients, and after more cephalad laminectomy. For example, Yasuoka et al. (156) found that spinal deformity occurred in 46% of patients younger than 15 years of age, but in only 6% of patients 15 to 24 years of age. All the patients between 15 and 24 years of age in whom deformity developed were 18 years of age or younger. Yasuoka et al. (156) and Fraser et al. (158) found that higher levels of laminectomy were associated with a greater chance of deformity. Deformity occurred after 100% of cervical spine laminectomies, in 36% of thoracic laminectomies, and in none of the lumbar laminectomies, in their study.

Kyphosis in the cervical and thoracic spine is the most common postlaminectomy deformity. The lumbar spine is normally in lordosis, and this may protect the lumbar spine from developing kyphosis after multiple lumbar laminectomies. Papagelopoulos et al. (159) reported that hyperlordosis occurred in children who had lumbar laminectomies for intraspinal tumors. If the laminectomies extended

into the thoracolumbar junction, kyphosis at the thoracolumbar junction occurred in 33% of his patients. Peter et al. (160) found that most of his patient did not develop a significant deformity after multiple lumbar laminectomies for selective posterior dorsal root rhizotomy, but he did find that 9% developed spondylolysis. This may be the result of increased lordosis in this patient population (161).

Postlaminectomy deformity can occur early in the postoperative period or gradually over time. Kyphotic deformities have been reported to occur as late as 6 years after surgery (146,161). Progression also can be sudden or gradual, or the deformity may progress significantly only during the adolescent growth spurt.

The natural history of postlaminectomy spinal deformity is varied, and depends on the age of the patient at the time of surgery, the location of the laminectomy or laminectomies, and the integrity of the facet joint. Three types of postlaminectomy kyphosis have been described in children: (i) instability after facetectomy, (ii) hypermobility between vertebral bodies associated with gradual rounding of the spine, and (iii) wedging of vertebral bodies caused by growth disturbances (157).

Kyphosis from instability after facetectomy tends to be sharp and angular, and usually occurs in the immediate or early postoperative period, causing associated loss of neurologic function (Fig. 19-16). Gradual rounding of the ky-

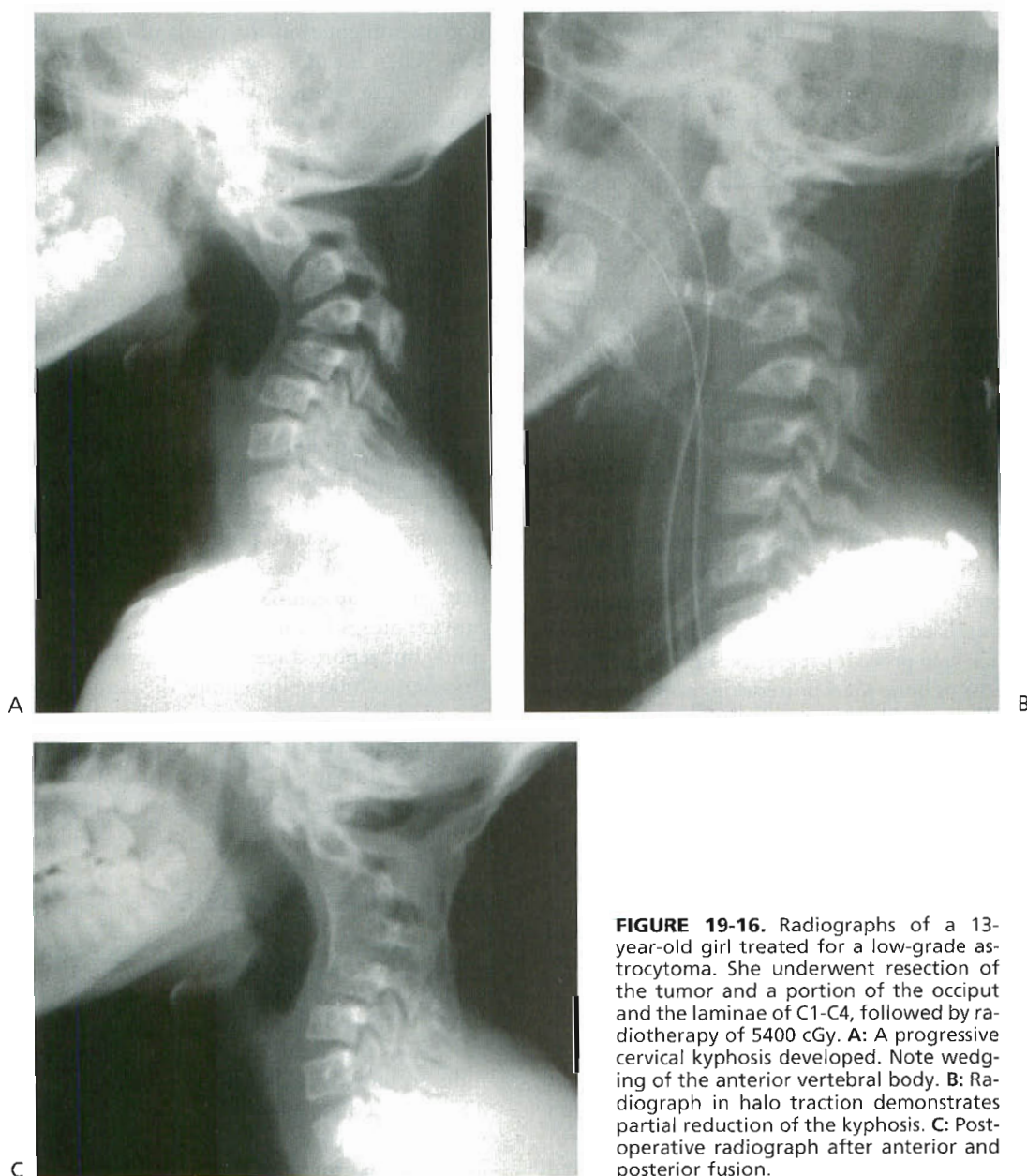


FIGURE 19-16. Radiographs of a 13-year-old girl treated for a low-grade astrocytoma. She underwent resection of the tumor and a portion of the occiput and the laminae of C1-C4, followed by radiotherapy of 5400 cGy. **A:** A progressive cervical kyphosis developed. Note wedging of the anterior vertebral body. **B:** Radiograph in halo traction demonstrates partial reduction of the kyphosis. **C:** Postoperative radiograph after anterior and posterior fusion.

photic deformity is seen more often when the facet joints are preserved. Kyphosis increases gradually over time because of the stress placed on the remaining posterior structures. If the spine is immature when the laminectomy is performed, the resulting kyphosis can inhibit the growth of the anterior growth plates of the involved vertebrae. Unequal growth results in wedging of the vertebrae and a progressive kyphotic deformity that is accelerated during the adolescent growth spurt.

Other associated conditions also can add to or cause kyphotic deformities, including persistence of spinal cord tumors, neurologic deficits, intraspinal pathology (hydromyelia), and radiation therapy (162,163).

Evaluation

The evaluation of a postlaminectomy deformity should focus on (i) the flexibility of the deformity, (ii) loss of spinal structures, and (iii) determination of future deformity with growth. The flexibility of a deformity can be estimated by flexion and extension lateral radiographs. If these cannot be obtained then a lateral traction film can be used. CT scans and three-dimensional reconstruction views may better delineate which bony elements are missing. MRI may be used, but gives more information about the spinal cord, disc, and surrounding soft tissue. To aid in preoperative planning, Lonstein recommends drawing the spine preoperatively (144). The lines should represent the spinous processes and intact laminae and facet joints. This may aid in predicting progression of a postlaminectomy deformity.

Treatment

Treatment of postlaminectomy kyphosis is difficult, and it is best to prevent the deformity from occurring (164). The facet joints should be preserved whenever possible during laminectomy. Localized fusion at the time of facetectomy or laminectomy may help prevent progressive deformity (165). Because of the loss of bone mass posteriorly, however, localized fusion may not produce a large enough fusion mass to prevent kyphosis. Even so, this approach is advocated, because it may produce enough bone mass posteriorly to stabilize what otherwise would be a severe progressive deformity.

After surgery in which the laminae have been removed, bracing has been suggested to prevent deformity (166,167), although no studies have documented the efficacy of this form of treatment. After the deformity has occurred and started to progress, bracing is ineffective in preventing further progression (144,147).

For progressive or marked deformity, spinal fusion is recommended, although the patient's long-term prognosis should be considered before making definitive treatment plans. If the prognosis for survival is poor, spinal fusion may not be appropriate. However, given the availability of effective treatment protocols for tumors and the improved

survival rates, fusion usually is indicated for progressive deformity. Combined anterior and posterior spinal fusion is preferred in most patients, because of the frequency of pseudarthrosis after either procedure alone.

Lonstein (144) reported pseudarthrosis in 57% of patients after posterior fusion, and in 15% of patients after anterior fusion. Anterior and posterior fusion can be performed on the same day, or as staged procedures. When the anterior procedure is performed, care must be taken to remove all the physes back to the posterior longitudinal ligament. Leaving some of the physes in the vertebral body can cause an increase in the deformity. When the posterior procedure is performed, instrumentation of the involved spine is desirable, but not always possible, because of the absence of posterior elements. The development of pedicle screw fixation has been helpful in allowing the use of posterior instrumentation for postlaminectomy kyphosis [↗2.8, 2.9]. When it can be performed safely, this procedure provides secure fixation while the spinal fusion is maturing. Torpey et al. recommend a posterior fusion, using titanium rod instrumentation at the time of laminectomy. The instrumentation provides stability postoperatively, and the titanium rods allow for postoperative MRI to evaluate spinal cord tumors. In certain cases, anterior instrumentation with rod and bone screws or plates may be used to obtain stability and correction of the deformity (168). If the deformity is severe or long-standing, anterior release, followed by halo traction or a halo cast with an Ilizarov device, can be used to obtain gradual correction (169,170).

A technique known as "laminoplasty" may lessen the chance of progressive deformity. This approach involves suturing the laminae back in place after removal, or removing just one side of the laminae and allowing them to hinge open like a book to expose the spinal cord, then suturing that side of the laminae back in place (171–173). This may provide only a fibrous tether connecting the laminae to the spine, but reported results have been promising (174,175). Another technique is to hinge the laminae open in a lateral direction, after dividing the laminae in the midline. This provides a lateral trough for the placement of bone graft for a lateral fusion (176). Hopefully, the use of these techniques will decrease the incidence of postlaminectomy deformity.

RADIATION KYPHOSIS

The relative radiosensitivity of growing cartilage was discovered by investigators during the 1940s. Animal studies by Engel (177,178), Gall et al. (179), Hinkel (180), Barr et al. (181), and Reidy et al. (182) documented radiation-induced growth inhibition in growing cartilage and bone. The longitudinal growth of a vertebral body takes place through normal endochondral ossification, similar to the longitudinal growth of the metaphyses of long bones. Bick

and Copel (82,83) demonstrated this on histologic sections in fresh autopsy specimens of vertebral bodies, taken from research subjects ranging in age from 14 weeks of fetal development to 23 years of age. This endochondral ossification at the physal growth plate is radiosensitive (82,83,177, 178,180,182,183). Engel (177,178) and Arkin and Simon (184) were able to produce spinal deformities in experimental animals, using radiation. Arkin et al. (185) were the first to report a case of spinal deformity caused by radiation in humans. Since these reports, it has become clear that exposing an immature spine to radiation can produce spinal deformity, including scoliosis, kyphoscoliosis, lordoscoliosis, and kyphosis.

The three most common solid tumors of childhood in which radiation therapy is part of the treatment regimen, and in which the vertebral column is included in the radiation fields, are neuroblastoma, Wilms tumor, and medulloblastoma. Early in the history of radiation therapy, survival rates were poor and spinal deformities were not as prevalent. With improved treatment protocols and survival rates, the incidence of spinal deformities has increased. The degree of growth inhibition of the spine is related to the accumulated radiation dose and the age of the child when the spine is irradiated. Progression is directly dependent on the remaining growth potential in the irradiated vertebrae. The younger the child and the greater the accumulated radiation dose, the greater the chance of deformity (186–191). The most severe growth changes occur in patients who are 2 years of age or younger at the time of irradiation. Initial vertebral changes usually occur 6 months to 2 years after radiation exposure (192), but the deformity may not become apparent until years later, after a period of growth (187,190).

Reports of radiation involving the spinal column show that an accumulated dose less than 1,000 cGy does not produce a detectable inhibition of vertebral growth, whereas a dose of 1,000 to 2,000 cGy causes a temporary inhibiting effect on growth. Sometimes, this is manifested as a transverse growth arrest line in the vertebra, which gives the appearance of a bone within a bone. A dose of radiation between 2,000 and 3,000 cGy causes irregularity or scalloping of vertebral end plates, diminishing axial height, and sometimes leads to a flattened, beaked vertebra (187, 188,190,192–195). A dose of 5,000 cGy causes bone necrosis (188). The effect that radiation has on soft tissue also affects the progression of spinal deformity. The soft tissue anterior to the spine and the abdominal muscle can become fibrotic and act as a tether with growth, adding to the deformity of the spine as the child grows (196).

The incidence of spinal deformity after irradiation of the spine has been reported to range from 10 to 100% (187,190,191,193,197–200). These rates are decreasing because of shielding of growth centers, symmetric field selection, and decreased total accumulated radiation doses. The last of these changes has resulted from an increase in the

use and effectiveness of chemotherapeutic regimens that reduce the need for large doses of radiation. Early reports showed an increased incidence of scoliotic deformities with the use of asymmetric fields, but the incidence of kyphotic postirradiation deformities has increased with the use of symmetric radiation fields (201).

Any child who has received irradiation to the spine should be observed carefully for the development of spinal deformity. Because the development of deformity is related to the amount of disordered growth in the vertebral bodies that were affected by irradiation, it depends to a large extent on the amount of growth left in the spine, when irradiation was started, and the amount of damage to the physes caused by irradiation, which correlates directly with the accumulated radiation dose. If the dose of radiation is large enough to cause permanent damage to the physes the deformity will be progressive. Postirradiation scoliosis and kyphosis both progress more rapidly during the adolescent growth period (190,191,194,201). Before the adolescent growth spurt, the deformity may remain relatively stable or progress at a steady rate. Severe curves can continue to progress even after skeletal maturity, and these patients may require continued observation.

Radiographic evaluation of a postirradiation deformity should include standard posteroanterior and lateral radiographs of the spine. Occasionally, tomograms or CT scans with sagittal or coronal reconstruction, are needed for better delineation of the vertebral body deformities. The spinal cord is evaluated best with MRI. Neuhauser et al. (188) described the roentgenographic changes seen in irradiated spines. The earliest changes were alterations in the vertebral bodies within the irradiated section of the spine, caused by impairment of endochondral growth at the vertebral end plates. Growth arrest lines produced a bone-within-a-bone picture. This occurred in 28% of the 81 patients in the study by Riseborough et al. (190). Other radiographic changes were end plate irregularity with an altered trabecular pattern, and decreased vertebral body height. This pattern was the most common radiographic change reported by Riseborough et al. (83%) (190). Contour abnormalities, causing anterior narrowing and beaking of the vertebral bodies, much like those seen in patients with conditions that affect endochondral ossification (e.g., Morquio syndrome, achondroplasia), were the third type of radiographic change noted by Neuhauser et al. (188).

Treatment

Milwaukee brace treatment has been recommended for progressive curves, but generally has been ineffective for postirradiation kyphosis (190,201), especially in patients with soft tissue contractures contributing to the deformity. The irradiated skin also may be of poor quality, making long-term brace wear difficult. If progression occurs, spinal fusion with or without instrumentation should be performed, re-

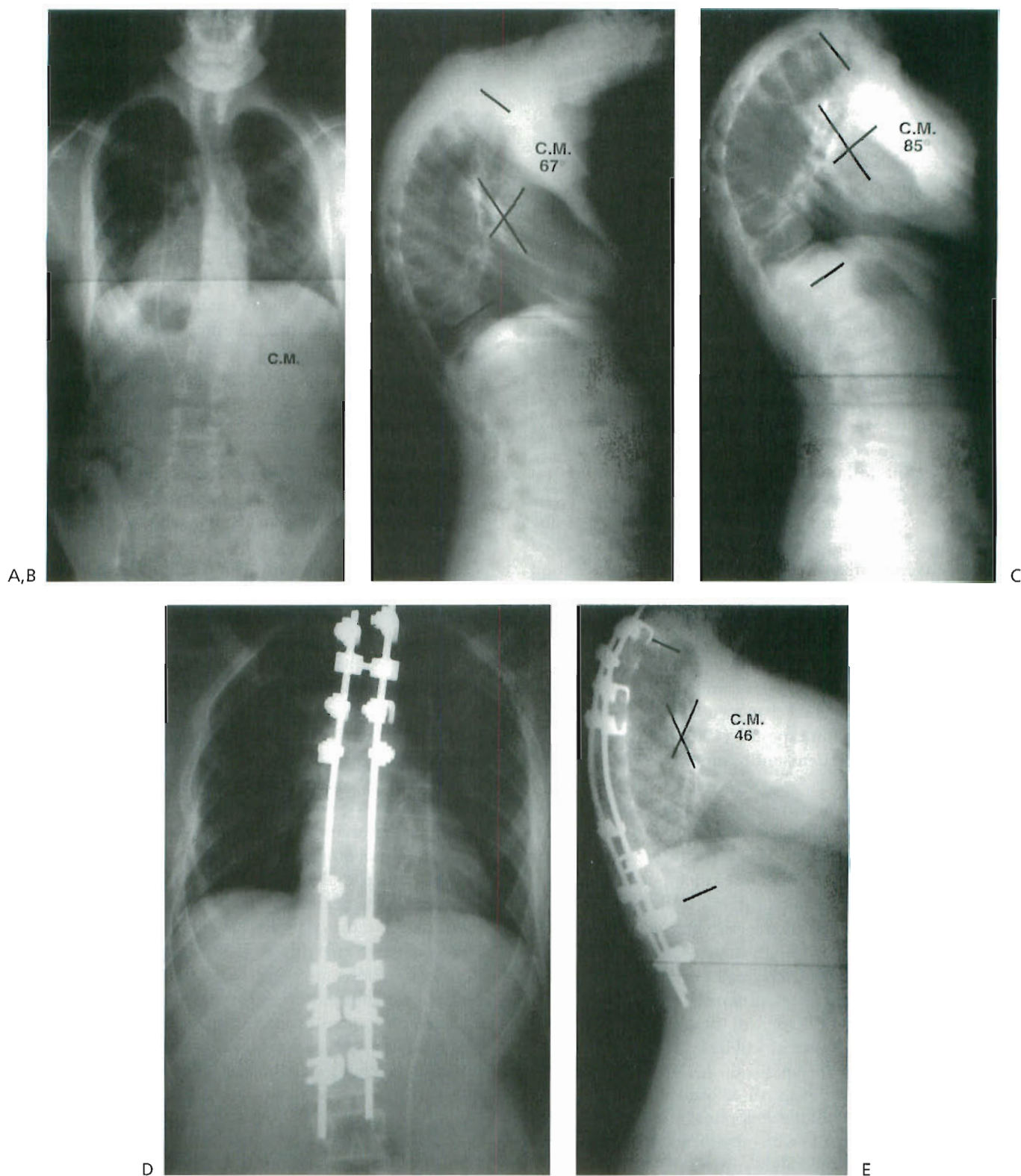


FIGURE 19-17. A and B: Anteroposterior (AP) and lateral radiographs of a 16-year-old child with a suprasellar germinoma treated with resection and 3400 cGy of radiation to the base of the skull and the entire spine. Radiographs demonstrate a 67-degree kyphosis with associated scoliosis. C: The kyphosis progressed to 85 degrees over 18 months despite bracing. D and E: AP and lateral radiographs after anterior and posterior fusion with posterior instrumentation. The kyphosis has been corrected to 46 degrees.

ardless of the age of the patient. Because bone quality is poor, fusion can be difficult to obtain after a single attempt. Anterior and posterior fusion are recommended, and should extend at least one or two levels above and below the end of the kyphosis (157,190,201–204). The posterior fusion mass may require reexploration and repeated bone grafting at 6 months, and cast immobilization may need to be prolonged for 6 to 12 months. Posterior instrumentation should be used whenever feasible because it adds increased stability while the fusion mass is maturing, and may allow for some limited correction of the kyphotic deformity (Fig. 19-17) [■ 2.13, 2.14]. Although anterior instrumentation can be used in certain cases, as a result of the radiation the vertebral bodies usually remain in an infantile form, and instrumentation with bone screws may be difficult.

Correction of postirradiation kyphosis is difficult. Typically, these curves are rigid, and soft tissue scarring and contractures often further hamper correction. Healing can be prolonged and pseudarthrosis is common. Infection is a frequent complication in these patients because of poor vascularity of the irradiated tissue (190). Riseborough et al. (190) reported a pseudarthrosis rate of 37% and an infection rate of 23% in his patients after surgery. King and Stowe (201) also reported a high complication rate in patients who were treated surgically. Because viscera also can be damaged by irradiation, bowel obstruction, perforation, and fistula formation may occur after spinal fusion. This can be difficult to differentiate from postoperative cast syndrome, and the treating physician should be aware of this complication (205). Radiation myelopathy also can occur in this patient population (206). King and Stowe (201) reported postoperative paraplegia in 2 of 7 patients after radiation treatment for neuroblastoma and correction of their kyphotic spine deformity. They believed that these two patients had a subclinical form of radiation myelopathy, and with spinal correction what little vascular supply was present to the cord was compromised. Therefore, the surgeon should be aware of this possibility and try to avoid overcorrection.

MISCELLANEOUS CAUSES OF KYPHOTIC DEFORMITIES

Spinal deformity in the sagittal plane can occur in patients with skeletal dysplasia (207,208). The natural history of spinal deformity varies with the type of deformity and the type of dysplasia. Some sagittal plane deformities that appear severe at birth or in infancy improve spontaneously with growth, whereas others continue to progress and eventually can cause paraplegia. A knowledge of the various skeletal dysplasias and the natural history of sagittal plane deformities in each is necessary to prevent overtreatment and undertreatment.

Achondroplasia

Treatment of spinal problems is required most often in patients with achondroplasia. The most common sagittal plane deformity in achondroplastic dwarfs is thoracolumbar kyphosis (209,210,213). The kyphosis usually is detected at birth, and is accentuated when the child is sitting, because of the associated hypotonia in these infants (211). Ambulation is delayed until about 18 months of age, but after ambulation begins, the thoracolumbar kyphosis tends to improve. According to Lonstein (212), thoracolumbar kyphosis resolves in 70% of achondroplastic dwarfs, and persists in 30%. One-third of these patients, or 10% of achondroplastic dwarfs with thoracolumbar kyphosis, have progressive kyphosis (212) (Fig. 19-18).

A lateral radiograph of the thoracolumbar spine during infancy shows anterior wedging of the vertebrae at the apex of the kyphosis (213). In patients whose thoracolumbar kyphosis resolves, the anterior vertebral body wedging also improves. When the kyphosis is progressive, anterior vertebral body wedging persists.

If no improvement in the thoracolumbar kyphosis is evident by 3 years of age, a thoracolumbosacral orthosis (TLSO) is recommended, to try to prevent progression of the kyphosis (214–217). Early treatment to prevent the development of a progressive kyphosis has been recommended by Pauli et al. (218). They developed an algorithm for treatment in the young achondroplastic patient, first counseling the parents against unsupported sitting and for close follow-up. If kyphosis develops, and is less than 30 degrees, TLSO bracing is begun and continued until the child is walking independently and there is evidence of improvement of vertebral body wedging and kyphosis. Using this form of early intervention, Pauli et al. (218) reported no occurrences of progressive kyphosis.

Indications for surgery are documented progression of a kyphotic deformity, kyphosis of more than 40 degrees in a child older than 5 or 6 years of age, or neurologic deficits related to the spinal deformity (210,211,219). Distinguishing between neurologic deficits that result from a kyphotic deformity and those associated with lumbar stenosis, which is common in achondroplastic dwarfs, can be difficult. A thorough physical examination and diagnostic studies, such as myelography, CT, and MRI, are necessary to determine appropriate treatment. Most patients with progressive thoracolumbar kyphosis require combined anterior and posterior fusion. Instrumentation is not recommended in these patients because of the small size of the spinal canal and the lack of epidural fat, which make instrumentation hazardous.

Pseudoachondroplasia

Kyphotic deformities also can occur in children with pseudoachondroplasia, and are caused by multiple vertebral body wedging in the thoracolumbar and thoracic spine. The

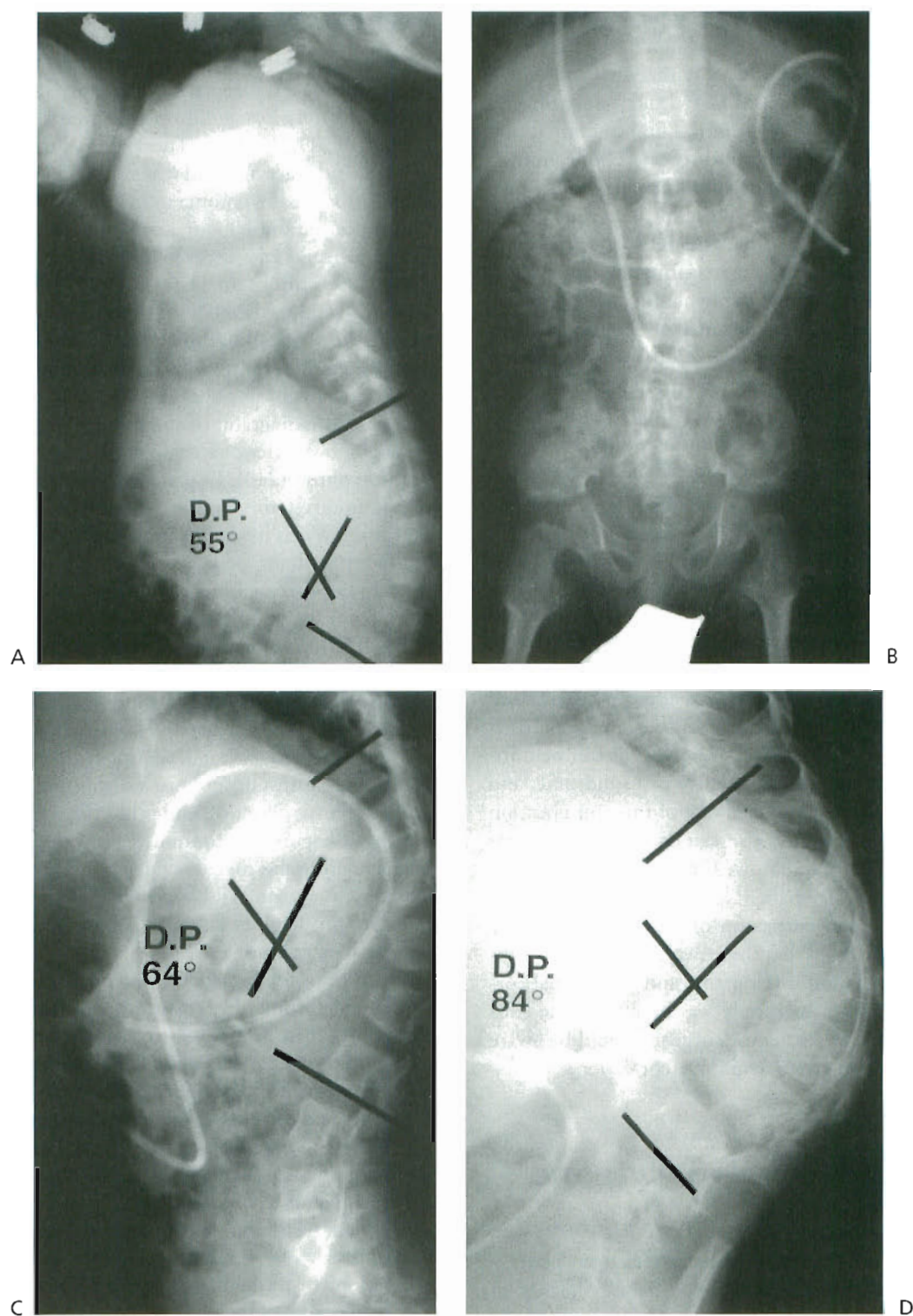


FIGURE 19-18. Achondroplastic dwarf with progressive thoracolumbar kyphosis. **A:** Lateral radiograph at 1 year of age shows a 55-degree thoracolumbar kyphosis. **B:** Anteroposterior radiograph at 5 years of age shows narrowing of the lumbar interpedicular distance characteristic of achondroplasia. **C:** Lateral radiograph at 5 years of age reveals a 64-degree kyphosis. **D:** Lateral radiograph at 9 years of age shows an 84-degree thoracolumbar kyphotic deformity.

kyphotic deformity in patients with pseudoachondroplasia differs from that in patients with achondroplasia. In patients with pseudoachondroplasia, the kyphosis involves multiple levels, and is less acutely angular than the deformity in patients with achondroplasia, which involves only one or two levels. Bracing may prevent progression of this deformity, but surgery is indicated if progression occurs. Spinal fusion with instrumentation can be performed safely in patients with pseudoachondroplasia, because there is no associated stenosis of the spinal canal as in patients with achondroplasia (211,220,221).

Spondyloepiphyseal Dysplasia Congenita

Thoracolumbar kyphotic deformities in patients with spondyloepiphyseal dysplasia congenita usually are mild and nonprogressive, and seldom require treatment (211,221).

Diastrophic Dwarfism

Midcervical kyphosis frequently occurs in patients with diastrophic dwarfism. Progressive cervical kyphosis can be stabilized with a spinal fusion (211,221,222). There are insufficient data to recommend posterior fusion alone or combined anterior and posterior fusion. If a posterior fusion is performed, the increased incidence of cervical spina bifida in diastrophic dwarfism must be considered during dissection.

Mucopolysaccharidosis

Patients with any of the mucopolysaccharidoses can develop kyphotic spine deformities at the thoracolumbar junction. In patients with Hurler syndrome (type I), the vertebral bodies have an anterior beaking at the level of the kyphotic deformity. This kyphosis usually is not progressive and rarely requires treatment, because most children with Hurler syndrome die before 10 years of age. Kyphotic deformities in patients with Hunter syndrome (type II) also rarely require treatment, because the kyphosis rarely is progressive, and patients do not often survive past 20 years of age (223). Thoracolumbar kyphosis in patients with Morquio syndrome (type IV) is associated with anterior vertebral body defects in the form of anterior beaking of the vertebrae. This kyphosis remains constant with growth, and rarely progresses. Patients with Maroteaux-Lamy syndrome (type VI) have a longer life span, and can develop progressive kyphosis, which should be treated with bracing. If progression is not halted with bracing, anterior and posterior fusion may be indicated (211,221).

Marfan Syndrome

Marfan syndrome is a generalized disorder of connective tissue that affects the supporting structures of the body,

especially those in the musculoskeletal system. This syndrome is caused by mutations in coding of the genes for the glycoprotein fibrillin (224,225). Spinal deformity is the most common skeletal abnormality in Marfan syndrome, and scoliosis is the most common spinal deformity in patients with Marfan syndrome (112,226–231). Thoracic lordosis has been traditionally reported as the most common sagittal plane deformity (232,233). In some patients, the thoracic lordosis becomes severe enough to compromise respiration. With the lordotic posture of the thoracic spine, an associated kyphosis or relative kyphosis may develop in the lumbar spine. A third common spinal deformity associated with Marfan syndrome is thoracolumbar kyphosis, which affects about 10% of patients (Fig. 19-19). These spinal deformities usually occur during the juvenile growth period, before the adolescent growth spurt (233). Sponseller et al. found that 41% of his patients with Marfan syndrome had a kyphotic deformity of more than 50 degrees, with a tendency for longer kyphoses extending through the thoracolumbar junction (234).

Brace treatment has been recommended to try to halt the progression of spinal deformity, but Birch and Herring (235) found this approach to be ineffective in their patients. Correction of kyphotic deformities requires anterior and posterior spinal fusion with segmental instrumentation (235). Thoracic lordosis is corrected by posterior segmental instrumentation to correct the lordotic deformity, followed by posterior fusion (236). Complications are more frequent after surgical correction of spinal deformity in patients with Marfan syndrome than after spinal surgery in other patients (235).

Cervical spinal abnormalities also are common in patients with Marfan syndrome, but clinical problems from these abnormalities are rare. Basilar impression and focal cervical kyphosis are the most frequently reported cervical spine abnormalities. Focal cervical kyphosis usually is associated with a lordotic thoracic spine (237).

Because of the increased incidence of cervical spine abnormalities, Hobbs et al. (237) has recommended that patients with Marfan syndrome avoid sports with risks of high-impact loading of the cervical spine.

Larsen Syndrome

Larsen et al. (238), in 1950, described a congenital malformation syndrome (239) consisting of facial dysmorphism and hyperelasticity of the joints, with congenital dislocation of the knees and frequent dislocation of the hips and elbows (112,240–243). Equinovarus or valgus foot deformities and ancillary calcaneal nuclei also are characteristic features of this syndrome. Abnormalities of the cervical spine, specifically cervical kyphosis, were not emphasized in the original description, and often this life-threatening finding is overlooked (169,240,244). Johnston et al. (239) reported cervical kyphosis and vertebral body anomalies in 5 of 9 patients

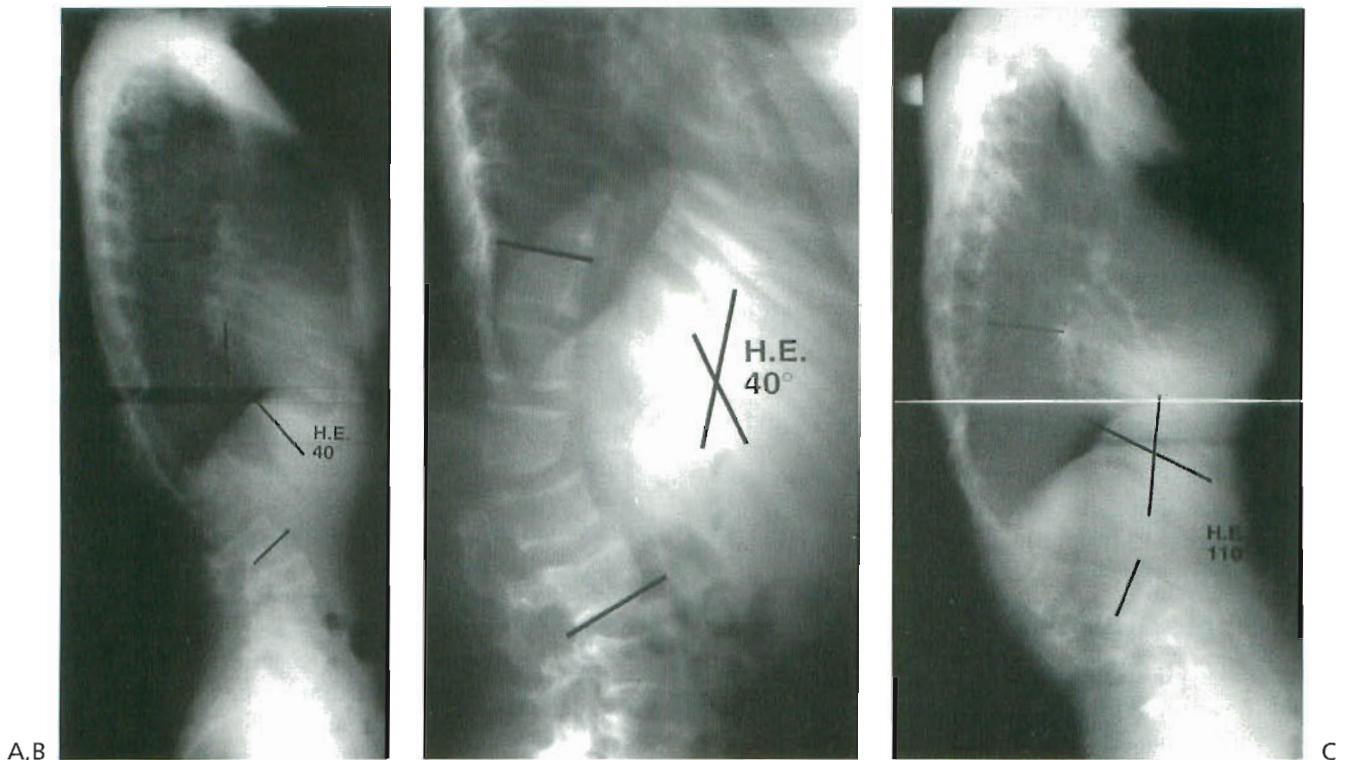


FIGURE 19-19. A and B: Lateral radiographs of a 17-year-old child with Marfan syndrome and a 40-degree progressive thoracolumbar kyphosis. C: Lateral radiograph of the same patient 3 years later shows that the thoracolumbar kyphosis has progressed to 110 degrees.

with Larsen syndrome. The apex of the kyphosis usually occurs at the fourth or fifth cervical vertebra, with marked hypoplasia of one or two of the vertebral bodies (Fig. 19-20). Cervical kyphosis is present in infants with Larsen syndrome. Developmental delay may be attributed to hypotonia and dislocation of the knees or hips, but the underlying cause for developmental delay may be a chronic myelopathy from the cervical kyphosis. Cervical kyphosis and vertebral hypoplasia are easily demonstrated on lateral C-spine radiographs. Flexion and extension views usually are not needed, and may be difficult to obtain safely in an infant. MRI scans will demonstrate spinal cord compression or compromise.

Treatment recommendations for cervical kyphosis in Larsen syndrome is an early posterior arthrodesis to stabilize the spine. An *in situ* posterior arthrodesis, with autogenous iliac crest bone graft, followed by immobilization in either a halo or Minerva cast or custom orthosis, is recommended. The only reduction of the kyphosis is that obtained in the postoperative halo or Minerva cast or orthosis. Johnston et al. (239) found that over time, after a solid posterior arthrodesis a gradual correction of the kyphosis occurs because of continued anterior vertebral body growth. Because the posterior arthrodesis is performed at a young age, the patient must be followed for potential complications from continued anterior growth, resulting in lordosis. John-

ston and Schoenecker (245) reported a patient who developed neurologic symptoms from this growth-related lordosis.

Posttraumatic Deformities

Kyphosis can occur as a direct result of trauma to the spinal column or the spinal cord. Deformity can occur at the fracture site, or as a result of paralysis after spinal cord injury or anterior growth arrest at the fracture site (246–250). Kyphosis at the fracture site is acute and spans a short segment of vertebrae. Paralytic kyphosis is a long, C-shaped deformity that spans many vertebral segments.

Kyphosis at a fracture site requires surgical intervention for correction. Anterior, posterior, and combined anterior and posterior procedures have been described for correction of posttraumatic kyphosis (251–255). Brace treatment has been ineffective for progressive paralytic kyphosis (246), and surgery is indicated for paralytic kyphosis of more than 60 degrees. If the kyphosis is flexible, and can be reduced to less than 50 degrees, posterior fusion with segmental instrumentation can be performed. If the kyphosis is rigid and cannot be reduced to less than 50 degrees on preoperative bending x-ray films, anterior release and fusion should be

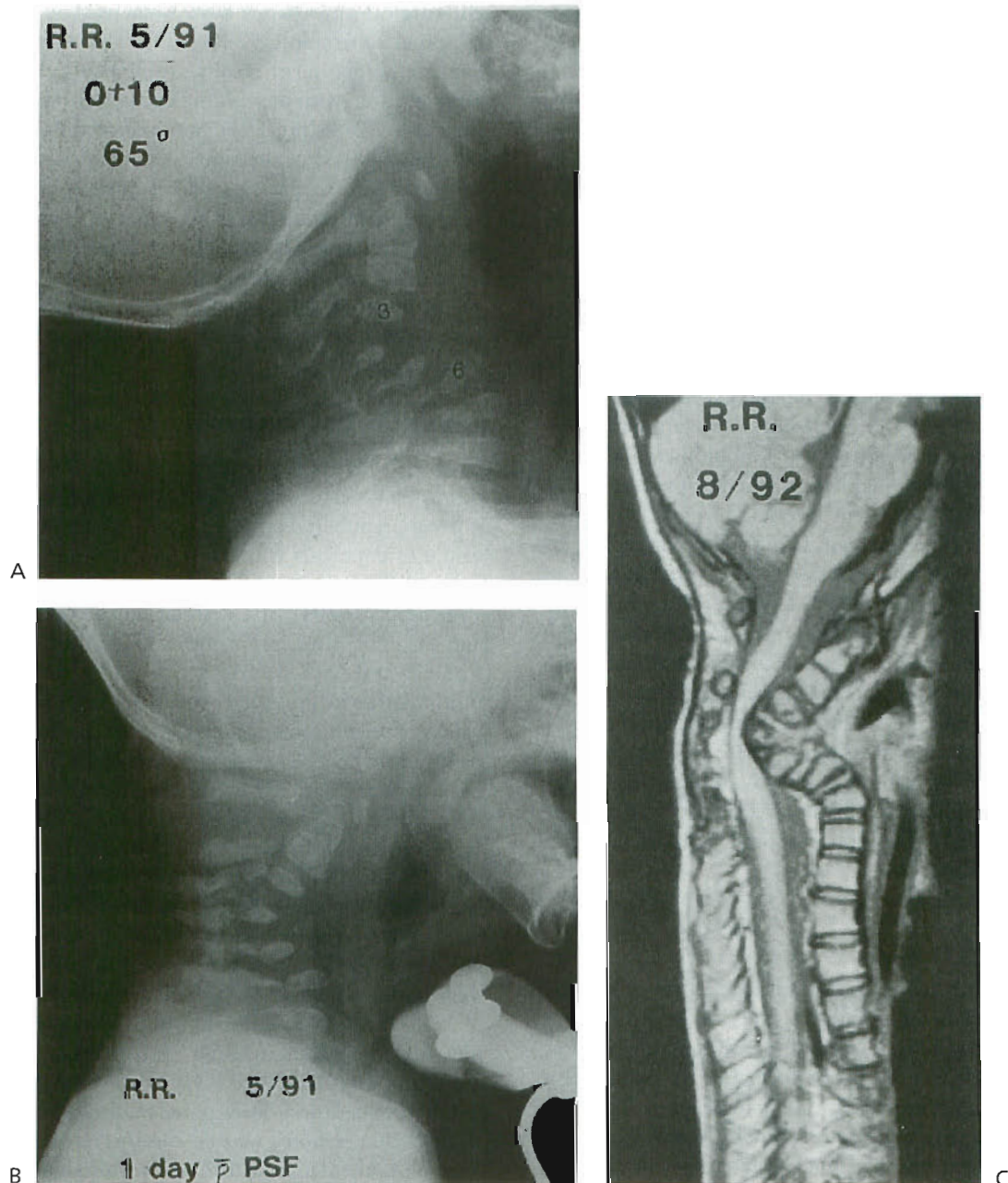


FIGURE 19-20. Larsen syndrome. **A:** Lateral radiograph of a 10-month-old patient showing kyphosis of 65 degrees, with correction to only 48 degrees in extension. **B:** Lateral radiograph immediately after posterior arthrodesis, showing patient with orthosis and correction of kyphosis to 39 degrees. **C:** T2-weighted magnetic resonance image 15 months postoperatively shows severe impingement on spinal cord. Kyphosis had progressed to 110 degrees, and patient was quadriplegic after a fall. (From ref. 239, with permission.)

followed by posterior fusion and segmental instrumentation (246,250).

Neurofibromatosis

Kyphoscoliosis is common in patients with neurofibromatosis, although kyphosis may be the predominant deformity (256).

Funasaki et al. (257) found that 50% of their patients with neurofibromatosis and spinal deformity had an abnormal sagittal curve. The vertebral bodies frequently are deformed and attenuated at the apex of the kyphosis. Dystrophic vertebral body changes may develop over time (258,259). Crawford (258) described this as modulation of the deformity, from a nondystrophic curve to a dystrophic

curve. The kyphosis typically is sharp and angular over a relatively small number of vertebral segments. Severely angular kyphosis can cause neurologic compromise (260,261). Lonstein et al. (262) found cord compression, due to spinal curvature from neurofibromatosis, to be second only to congenital kyphosis as a cause of spinal cord compression. The kyphosis in patients with neurofibromatosis typically involves the thoracic spine or upper thoracic spine. Involvement of the cervical and cervicothoracic vertebrae also have been reported (260,263–267).

Kyphotic deformities with dystrophic changes tend to be progressive, and more commonly lead to neurologic compromise.

Treatment of kyphoscoliosis in patients with neurofibromatosis begins with a thorough physical examination for neurologic abnormalities. MRI scans should be obtained to demonstrate any intraspinal lesions, such as pseudomeningocele, dural ectasia, or neurofibroma, which may cause impingement on the spinal cord (268). Any intraspinal lesions should be treated as necessary before spinal fusion and instrumentation are undertaken. Because posterior fusion alone has resulted in a high rate of pseudarthrosis (65%) (269), anterior and posterior spinal fusion, combined with posterior instrumentation, is recommended. Abundant autogenous bone graft and prolonged immobilization may be required to obtain a solid fusion in these patients, and repeated bone grafting 6 months after the initial surgery may be required. Vascularized fibular or rib grafts also may be used for anterior fusion and structural support (93,258,263,266,270–272).

Tuberculosis

Spinal tuberculosis is the most dangerous form of skeletal tuberculosis, because of its ability to cause bone destruction, deformity, and paraplegia. In childhood spinal tuberculosis, the extent and degree of abscess formation is greater than that seen in adult tuberculosis, but paraplegia is less common in children than adults with spinal tuberculosis (273). The most frequent site of spinal tuberculosis in children is the thoracolumbar junction and its adjacent segments. Tuberculosis infection usually destroys the anterior elements of the spine, and results in a significant angular kyphosis at the infected site. With differential growth of the intact posterior elements, kyphosis may increase with growth (273).

All forms of active spinal tuberculosis are treated with a complete course of chemotherapy. First-line drugs are streptomycin, isoniazid, and rifampicin, and second-line drugs are ethambutol and pyrazinamide (274). Even with adequate medical treatment of spinal tuberculosis, problems arising from bone destruction, such as spinal deformity or paraplegia, must be treated surgically. Chemotherapy alone can be used when there is little bone destruction or risk of deformity, or in medically high-risk patients. Several differ-

ent surgical approaches have been used in the treatment of spinal tuberculosis (275–279). The surgery with most consistent long-term results is anterior debridement and strut grafting, with or without a posterior fusion and instrumentation (274,280–291). Some correction of the kyphosis may be obtained at the time of surgery. Kyphosis also can be a problem in patients with healed spinal tuberculosis (292). The infected area of the anterior spine usually fuses, and continued growth posteriorly causes progressive kyphosis that can result in paraplegia. The presence of neurologic symptoms is an indication for anterior decompression and fusion, which can be followed by posterior fusion and instrumentation.

Juvenile Osteoporosis

Idiopathic juvenile osteoporosis is an acquired systemic condition that consists of generalized osteoporosis in otherwise normal prepubertal children (293). Although idiopathic juvenile osteoporosis is uncommon, associated kyphosis and back pain are common in patients with this condition.

Schippers (294) first described this condition in 1939, and since that time, other authors have described its clinical findings and natural history (134,295–301). The etiology of idiopathic juvenile osteoporosis is unknown. Laboratory values of serum calcium, phosphorus, alkaline phosphatase, parathyroid hormone, and osteocalcin are normal. The collagen type and ratios from skin biopsy samples also are normal. There have been some reports of a slight decrease in 1,25-dihydroxyvitamin D (299,302,303), but the significance of this finding is not known. Low serum calcitonin levels also have been reported, but treatment with calcitonin has not proven to be beneficial (297,304). In contrast, Saggese et al. (300) noted normal serum calcitonin levels in their patients. Green (305) believes that a mild deficiency of 1,25-dihydroxyvitamin D can explain most of the findings in idiopathic juvenile osteoporosis. During rapid growth phases the deficiency is discovered because growth requirements cannot keep pace, causing a relative osteoporosis. When puberty occurs, the increase in sex hormone overcomes the deficit in 1,25-dihydroxyvitamin D, and the relative osteoporosis improves. This theory has yet to be proved.

Clinically, these patients complain of insidious onset of low back pain (306), lower-extremity pain or fractures, and difficulty walking (63,224,307,308). Difficulty walking may sometimes be the only finding. This condition occurs during the prepubertal period, and is slightly more common in boys than girls. Vertebral collapse or wedging, with resulting kyphosis, is common. Brenton and Dent (304) classified idiopathic juvenile osteoporosis into mild, moderate, and severe types. Patients with the mild type had only back pain and vertebral fractures; those with the moderate type had back and lower-extremity pain and fractures, with some limitation of activities, but eventual return to normal function; and those with the severe form had back and lower-

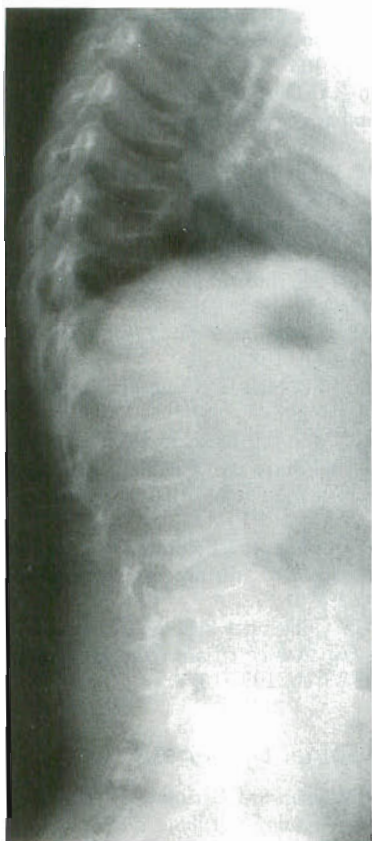


FIGURE 19-21. Standing lateral radiograph of a 10-year-old girl with idiopathic juvenile osteoporosis shows diffuse osteopenia, multiple "codfish" vertebrae in the thoracic and lumbar spine, and "coin" vertebrae in the upper thoracic spine secondary to extreme collapse. (From ref. 305, with permission.)

extremity pain and fractures. Both metaphyseal and diaphyseal fractures can occur in the lower extremities. Patients with severe disease improve clinically, but do not return to normal activity after puberty.

Plain radiographs show wedging or collapse of the vertebral bodies. A "codfish" appearance of the vertebral bodies can occur, with the superior and inferior borders of the vertebrae becoming biconcave (Fig. 19-21). Because of the osteoporosis, tomograms may be necessary to better delineate the spinal deformity. Other studies that can be useful for following the progress of this disease are single-photon absorptiometry, dual-photon absorptiometry, and quantitative CT scanning (297,299,300). The problems with these tests are that normal ranges for adolescents and children are variable and have not been standardized.

Idiopathic juvenile osteoporosis is a diagnosis of exclusion. Other diseases that must be considered include metabolic bone diseases, leukemia, Cushing syndrome, lysinuric protein intolerance, type I homocystinuria, and osteogenesis imperfecta. The natural history of this condition is spontaneous improvement or remission at the onset of puberty.

Associated kyphosis tends to improve after the onset of puberty.

Treatment of idiopathic juvenile osteoporosis involves modification of activities, possible calcium supplementation and vitamin D supplementation, and supportive treatment of spinal deformities. A balance must be obtained between restriction of activities to prevent fractures and excessive restriction of activities that will increase osteoporosis. If a significant progressive kyphosis develops, the Milwaukee brace is the treatment of choice (298). The brace is worn until there is evidence of improvement of the osteoporosis. Operative therapy for this condition has been associated with a high complication rate, because the poor bone quality makes instrumentation and fusion difficult (309).

References

1. O'Rahilly R, Benson D. The development of the vertebral column. In: Bradford DS, Hensinger RN, eds. *The pediatric spine*. New York: Thieme, 1985:3.
2. DiMeglio A, Bonnel F. Growth of the spine. In: Raimondi AJ, Choux M, Di Rocco C, eds. *The pediatric spine, vol. 1*. New York: Springer-Verlag, 1989:39.
3. Mellin G, Harkonen H, Poussa M. Spinal mobility and posture and their correlations with growth velocity in structurally normal boys and girls aged 13 to 14. *Spine* 1988;3:152.
4. Mellin G, Poussa M. Spinal mobility and posture in 8- to 16-year-old children. *J Orthop Res* 1992;10:211.
5. Probst-Proctor SL, Bleck EE. Radiographic determination of lordosis and kyphosis in normal and scoliotic children. *J Pediatr Orthop* 1983;3:344.
6. Schultz AB, Sorensen SE, Andersson GBJ. Measurements of spine morphology in children, ages 10–16. *Spine* 1984;9:70.
7. Stagnara P, DeMauroy JC, Dran G, et al. Reciprocal angulation of vertebral bodies in the sagittal plane: approach to references in the evaluation of kyphosis and lordosis. *Spine* 1982;7:335.
8. Willner S, Johnson B. Thoracic kyphosis and lumbar lordosis during the growth period in children. *Acta Paediatr Scand* 1983; 72:873.
9. Lowe T. Mortality-morbidity committee report. Vancouver, British Columbia: Scoliosis Research Society, 1987.
10. Bernhardt M, Bridwell KH. Segmental analysis of the sagittal plane alignment of the normal thoracic and lumbar spines and the thoracolumbar junction. *Spine* 1989;14:717.
11. Hammerberg KW. Kyphosis. In: Bridwell KH, DeWald RL, eds. *The textbook of spinal surgery*. Philadelphia: JB Lippincott, 1991:501.
12. LeMire RJ. Intrauterine development of the vertebrae and spinal cord. In: Raimondi AJ, Choux M, DiRocco C, eds. *The pediatric spine, vol. 1*. New York: Springer-Verlag, 1989:20.
13. Schijman E. Comparative anatomy of the spine in the newborn infant and toddler. In: Raimondi AJ, Choux M, Di Rocco C, eds. *The pediatric spine, vol. 1*. New York: Springer-Verlag, 1989: 1.
14. Cutler WB, Friedman E, Genovese-Stone E. Prevalence of kyphosis in a healthy sample of pre and postmenopausal women. *Am J Phys Med Rehabil* 1993;72:219.
15. Fon GT, Pitt MJ, Thies AC Jr. Thoracic kyphosis: range in normal subjects. *AJR Am J Roentgenol* 1980;134:979.
16. Bernhardt M. Normal spinal anatomy: normal sagittal plane alignment. In: Bridwell KH, DeWald RL, eds. *The textbook of spinal surgery*, 2nd ed. Philadelphia: Lippincott-Raven, 1997: 185.

17. White AA III, Panjabi MM. Practical biomechanics of scoliosis and kyphosis. In: White AA III, Panjabi MM, eds. *Clinical biomechanics of the spine*. Philadelphia: JB Lippincott, 1990:127.
18. Roaf R. Vertebral growth and its mechanical control. *J Bone Joint Surg* 1960;42B:40
19. Voutsinas SA, MacEwen GD. Sagittal profiles of the spine. *Clin Orthop* 1986;210:235.
20. Winter RB, Hall JE. Kyphosis in childhood and adolescence. *Spine* 1978;3:285.

Postural Kyphosis

21. Wenger DR. Roundback. In Wenger DR, Rang M, eds. *The art and practice of children's orthopaedics*. New York: Raven, 1993:422.
22. Winter RB. Spinal problems in pediatric orthopaedics. In: Morrissey RT, ed. *Lovell & Winter's pediatric orthopaedics*, 3rd ed. Philadelphia: JB Lippincott, 1990:673.

Congenital Kyphosis

23. Winter R. Congenital kyphosis. *Clin Orthop* 1977;128:26.
24. Dubousset J. Congenital kyphosis and lordosis. In: Weinstein SL, ed. *The pediatric spine: principles and practice*. New York: Raven, 1994:245.
25. McMaster MJ, Ohtsuk AK. The natural history of congenital scoliosis: a study of two hundred and fifty-one patients. *J Bone Joint Surg Am* 1982;64:1128.
26. Van Schrick FG. Dir Angeborene kyphose. *Zentr Orthop Chir* 1932;56:238.
27. Lombard P, LeGenissel M. Cyphoses congenitales. *Rev Orthop* 1938;22:532.
28. Winter RB, Moe JH, Wang JF. Congenital kyphosis: its natural history and treatment as observed in a study of one hundred and thirty patients. *J Bone Joint Surg Am* 1973;55:223.
29. Dubousset J. Congenital kyphosis. In: Bradford DS, Hensinger RM, eds. *The pediatric spine*. New York: Thieme, 1985:196.
30. Zeller RD, Ghanem I, Dubousset J. The congenital dislocated spine. *Spine* 1996;21:1235.
31. Shapiro J, Herring J. Congenital vertebral displacement. *J Bone Joint Surg Am* 1993;75:656.
32. Rivard CH, Narbaiz R, Uthoff HK. Congenital vertebral malformations: time of induction in human and mouse embryo. *Orthop Rev* 1979;8:135.
33. Philips MF, Dormans J, Drummond D. Progressive congenital kyphosis: report of five cases and review of the literature. *Pediatr Neurosurg* 1997;26:130.
34. Travaglini F, Conte M. Cifosi 25 anni. Progressi in patologia vertebrale. In: Goggia A, ed. *Le cifosi*, vol 5. Bologna: Goggia, 1982:163.
35. Tsou PM. Embryology of congenital kyphosis. *Clin Orthop* 1977;128:18.
36. Tsou PM, Yau A, Hodgson AR. Embryogenesis and prenatal development of congenital vertebral anomalies and their classification. *Clin Orthop* 1980;152:211.
37. Morin B, Poitras B, Duhaime M, et al. Congenital kyphosis by segmentation defect: etiologic and pathogenic studies. *J Pediatr Orthop* 1985;5:309.
38. Blake NS, Lynch AS, Dowling FE. Spinal cord abnormalities in congenital scoliosis. *Ann Radiol Paris* 1986;29:377.
39. Bradford DS, Heithoff KB, Cohen M. Intraspinous abnormalities and congenital spine deformities: a radiographic and MRI study. *J Pediatr Orthop* 1991;11:36.
40. Guille JT, Forlin E, Bowen JR. Congenital kyphosis. *Orthop Rev* 1993;22:235.

41. Winter RB, Moe JH, Lonstein JE. The incidence of Klippel-Feil syndrome in patients with congenital scoliosis and kyphosis. *Spine* 1984;9:363.
42. Broekman BA, Dorr JP. Congenital kyphosis due to absence of two lumbar vertebral bodies. *JCU J Clin Ultrasound* 1991;19:303.
43. Lubicky JP, Shook JE. Congenital spinal deformity. In: Bridwell HK, DeWald RL, eds. *The textbook of spinal surgery*. Philadelphia: JB Lippincott, 1991:365.
44. Winter RB, Moe JH. The results of spinal arthrodesis for congenital spinal deformity in patients younger than five years old. *J Bone Joint Surg Am* 1982;64:419.
45. Winter RB. *Congenital deformities of the spine*. New York: Thieme-Stratton, 1983.
46. Montgomery SP, Hall JE. Congenital kyphosis. *Spine* 1982;7:360.
47. Winter RB, Moe JH, Lonstein JE. The surgical treatment of congenital kyphosis: a review of 94 patients age 5 years or older, with 2 years or more follow-up in 77 patients. *Spine* 1985;10:224.
48. Mayfield JK, Winter RB, Bradford DS, et al. Congenital kyphosis due to defects of anterior segmentation. *J Bone Joint Surg Am* 1980;62:1291.
49. Winter RB. Congenital kyphosis. In: Bridwell KH, DeWald RL, eds. *The textbook of spinal surgery*, 2nd ed. Philadelphia: Lippincott-Raven, 1997:1077.

Segmental Spinal Dysgenesis

50. Scott RM, Wolpert SM, Bartoshesky LE, et al. Segmental spinal dysgenesis. *Neurosurgery* 1988;22:739.
51. Faciszewski T, Winter RB, Lonstein JE. Segmental spinal dysgenesis. A disorder different from spinal agenesis. *J Bone Joint Surg Am* 1995;77:530.
52. Hughes LO, McCarthy RE, Glasier CM. Segmental spinal dysgenesis: a report of three cases. *J Pediatr Orthop* 1998;18:227.
53. Flynn JM, Otsuka NY, Emans JB, et al. Segmental spinal dysgenesis: early neurologic deterioration and treatment. *J Pediatr Orthop* 1997;17:100.

Sacral Agenesis

54. Andrich J, Kalamchi A, MacEwen GD. Sacral agenesis: a clinical evaluation of its management, heredity, and associated anomalies. *Clin Orthop* 1979;139:52.
55. Blumel J, Evans ER, Eggers GWN. Partial and complete agenesis or malformation of the sacrum with associated anomalies. Etiologic and clinical study with special reference to heredity. A preliminary report. *J Bone Joint Surg Am* 1959;41:497.
56. Rusnak SL, Driscoll SG. Congenital spinal anomalies in infants of diabetic mothers. *Pediatrics* 1965;35:989.
57. Banta JV, Nichols O. Sacral agenesis. *J Bone Joint Surg Am* 1969;51:693.
58. Pang D. Sacral agenesis and caudal spinal cord malformations. *Neurosurgery* 1993;32:755.
59. Phillips WA, Cooperman DR, Lindquist TC, et al. Orthopaedic management of lumbosacral agenesis. *J Bone Joint Surg Am* 1964;64:1282.

Progressive Anterior Vertebral Fusion

60. Knutsson F. Fusion of vertebrae following non-infectious disturbance in the zone of growth. *Acta Radiol* 1949;32:404.
61. Kharat K, Dubousset J. Bloc vertebrale anterieur progressif chez l'enfant. *Rev Chir Orthop* 1980;66:485.

62. Van Buskirk CS, Zeller RD, Dubousset JF. Progressive anterior vertebral fusion; a frequently missed diagnosis. Paper presented at: Scoliosis Research Society; 1998; New York.
 63. Smith R. Idiopathic juvenile osteoporosis: experience of twenty-one patients. *Br J Rheumatol* 1995;34:68.
 64. Bollini G, Jowe JL, Zeller R. Progressive spontaneous anterior fusion of the spine. A study of seventeen patients. Presented at: 15th Meeting of the European Pediatric Orthopaedic Society; 1996; Prague, Czech Republic.
 65. Andersen J, Rostgaard-Christensen E. Progressive noninfectious anterior vertebral fusion. *J Bone Joint Surg Br* 1991;73:859.
 66. Bouchez B, Arnott G, Combelles G, et al. Compression medullaire par hernie kistale dorsale. *Rev Neurol Paris* 1986;142:154.
 67. Smith JRG, Martin IR, Shaw DG, et al. Progressive non-infectious anterior vertebral fusion. *Skel Radiol* 1986;15:599.
- Scheuermann Disease**
68. Scheuermann HW. Kyphosis dorsalis juvenilis. *Z Orthop Chir* 1921;41:305.
 69. Scheuermann HW. Kyphosis dorsalis juvenilis. *Ugeskr Laeger* 1920;82:385.
 70. Bradford DS. Juvenile kyphosis. *Clin Orthop* 1977;128:45.
 71. Bradford DS, Ahmed KB, Moe JH, et al. The surgical management of patients with Scheuermann's disease: a review of twenty-four cases managed by combined anterior and posterior spine fusion. *J Bone Joint Surg Am* 1980;62:705.
 72. Bradford DS, Moe JH, Winter RB. Kyphosis and postural roundback deformity in children and adolescents. *Minn Med* 1973;56:114.
 73. Murray PM, Weinstein SL, Spratt KF. The natural history and long-term follow-up of Scheuermann kyphosis. *J Bone Joint Surg Am* 1993;75:236.
 74. Sorensen KH. *Scheuermann's juvenile kyphosis. Clinical appearances, radiography, aetiology and prognosis*. Copenhagen: Munksgaard, 1964.
 75. Fisk JW, Raigent ML, Hill PD. Incidence of Scheuermann's disease. Preliminary report. *Am J Phys Med Rehabil* 1982;61:32.
 76. Fisk JW, Baigent ML, Hill PD. Scheuermann's disease. Clinical and radiological survey of 17 and 18 year olds. *Am J Phys Med Rehabil* 1984;63:18.
 77. Montgomery SP, Erwin WE. Scheuermann's kyphosis: long-term results of Milwaukee brace treatment. *Spine* 1981;6:5.
 78. Halal F, Gledhill RB, Fraser FC. Dominant inheritance of Scheuermann's juvenile kyphosis. *Am J Dis Child* 1978;132:1105.
 79. McKenzie L, Sillence D. Familial Scheuermann disease: a genetic and linkage study. *J Med Genet* 1992;29:41.
 80. Carr AJ. Idiopathic thoracic kyphosis in identical twins. *J Bone Joint Surg Br* 1990;72:144.
 81. Carr AJ, Jefferson RJ, Turner-Smith AR, et al. Surface stereophotogrammetry of thoracic kyphosis. *Acta Orthop Scand* 1989;60:177.
 82. Bick EM, Coepl JW, Spector S. Longitudinal growth of the human vertebra. A contribution to human osteogeny. *J Bone Joint Surg Am* 1950;32:803.
 83. Bick EM, Copel JW. The ring apophysis of the human vertebra. Contribution to human osteogeny II. *J Bone Joint Surg Am* 1951;33:783.
 84. Schmorl G. The pathogenesis der juvenilen kyphose. *Fortschr Roentgen* 1930;41:359.
 85. Ferguson AB Jr. The etiology of pre-adolescent kyphosis. *J Bone Joint Surg Am* 1956;38:149.
 86. Aufdermaur M. Juvenile kyphosis (Scheuermann's disease): radiology, histology and pathogenesis. *Clin Orthop* 1981;154:166.
 87. Aufdermaur M, Spycher M. Pathogenesis of osteochondrosis juvenilis Scheuermann. *J Orthop Res* 1986;4:452.
 88. Ippolito E, Ponseti IV. Juvenile kyphosis: histological and histochemical studies. *J Bone Joint Surg Am* 1981;63:175.
 89. Lambrinudi L. Adolescent and senile kyphosis. *BMJ* 1934;2:800.
 90. Scoles PV, Latimer BM, Digiovanni BF, et al. Vertebral alterations in Scheuermann's kyphosis. *Spine* 1991;16:509.
 91. Ascani E, Borelli P, Larosa G, et al. Malattia di Scheuermann. I: studio ormonale. In: Gaggia A, ed. *Progressi in patologia vertebrale*, vol 5. Bologna: Le Cifosi, 1982:97.
 92. Ascani E, LaRossa G. *Scheuermann's kyphosis*. New York: Raven, 1994.
 93. Bradford DS, Daher YH. Vascularized rib grafts for stabilisation of kyphosis. *J Bone Joint Surg Br* 1986;68:357.
 94. Burner WL, Badger VM, Sherman FC. Osteoporosis and acquired back deformities. *J Pediatr Orthop* 1982;2:383.
 95. Lopez RA, Burke SW, Levine DB, et al. Osteoporosis in Scheuermann's disease. *Spine* 1988;13:1099.
 96. Gilsanz V, Gibbens DT, Carlson M, et al. Vertebral bone density in Scheuermann disease. *J Bone Joint Surg Am* 1989;71:894.
 97. Ippolito E, Bellocci M, Montanaro A, et al. Juvenile kyphosis: an ultrastructural study. *J Pediatr Orthop* 1985;5:315.
 98. Travaglini F, Conte M. Untreated kyphosis: 25 years later. In Gaggia A, ed. *Kyphosis*. Bologna: Italian Scoliosis Research Group, 1984:21.
 99. Lowe TG. Current concepts review, Scheuermann disease. *J Bone Joint Surg Am* 1990;72:940.
 100. Bradford DS, Moe JH, Montalvo FJ, et al. Scheuermann's kyphosis. Results of surgical treatment by posterior spine arthrodesis in twenty-two patients. *J Bone Joint Surg Am* 1975;57:439.
 101. Pajanen H, Alanen A, Erkkila BM, et al. Disc degeneration in Scheuermann disease. *Skel Radiol* 1989;18:523.
 102. Deacon P, Berkin C, Dickson R. Combined idiopathic kyphosis and scoliosis. An analysis of the lateral spinal curvature associated with Scheuermann's disease. *J Bone Joint Surg Br* 1985;67:189.
 103. Deacon P, Flood BM, Dickson RA. Idiopathic scoliosis in three dimensions: a radiographic and morphometric analysis. *J Bone Joint Surg Br* 1984;66:509.
 104. Ogilvie JW, Sherman J. Spondylolysis in Scheuermann's disease. *Spine* 1987;12:251.
 105. Stoddard A, Osborn JF. Scheuermann's disease or spinal osteochondrosis. Its frequency and relationship with spondylolysis. *J Bone Joint Surg Br* 1979;61:56.
 106. Muller R, Gschwend N. Endokrine Störungen und Morbus Scheuermann. *Acta Med Scand* 1969;65:357.
 107. Kemp FH, Wilson DC. Some factors in the aetiology of osteochondritis of the spine. *Br J Radiol* 1947;20:410.
 108. Cloward RB, Bucy PC. Spinal extradural cyst and kyphosis dorsalis juvenilis. *AJR Am J Roentgenol* 1937;38:681.
 109. Roland M, Morris R. A study of the natural history of back pain. Part I: Development of a reliable and sensitive measure of disability in low-back pain. *Spine* 1983;8:141.
 110. Greene TL, Hensinger RN, Hunter LY. Back pain and vertebral changes simulating Scheuermann's disease. *J Pediatr Orthop* 1985;5:1.
 111. Huskisson EC. Measurement of pain. *Lancet* 1974;9:1127.
 112. Kaijser R. Übert kongenitale Kniegelenksluxationen. *Acta Orthop Scand* 1935;6:120.
 113. Stagnara P. In: Gaggia A, ed. *Modern trends in orthopaedics. Cyphoses thoraciques regulieres pathologiques*, 1982.
 114. Blumenthal SL, Roach J, Herring JA. Lumbar Scheuermann's. A clinical series and classification. *Spine* 1987;12:929.

115. Stagnara P, Faucher R, Dupeloux J, et al. Maladie des Scheuermann. *Pediatrics* 1966;21:361.
116. Bhojraj SY, Dandawate AV. Progressive cord compression secondary to thoracic disc lesions in Scheuermann's kyphosis managed by posterolateral decompression, interbody fusion, and pedicular fixation. A new approach to management of a rare clinical entity. *Eur Spine J* 1994;3:66.
117. Klein DM, Weiss RL, Allen JE. Scheuermann's dorsal kyphosis and spinal cord compression: case report. *Neurosurgery* 1986;18:628.
118. Lesoin F, Leys D, Rousseaux M, et al. Thoracic disk herniation and Scheuermann's disease. *Eur Neural* 1987;26:145.
119. Ryan MD, Taylor TKF. Acute spinal cord compression in Scheuermann's disease. *J Bone Joint Surg Br* 1982;64:409.
120. Yablon JD, Kasdon DL, Levine H. Thoracic cord compression in Scheuermann's disease. *Spine* 1988;13:896.
121. Chiu KY, Luk KDK. Cord compression caused by multiple disc herniations and intraspinal cyst in Scheuermann's disease. *Spine* 1995;20:1075.
122. Bradford DS, Garcia A. Neurological complications in Scheuermann's disease. *J Bone Joint Surg Am* 1969;51:567.
123. Cobb J. Outline for the study of scoliosis. *Instr Course Lect* 1948;5:261.
124. Bradford DS. Vertebral osteochondrosis (Scheuermann's kyphosis). *Clin Orthop* 1981;158:83.
125. Lowe TG, Kasten MD. An analysis of sagittal curves and balance after Cotrel-Dubousset instrumentation for kyphosis secondary to Scheuermann's disease. A review of 32 patients. *Spine* 1994;19:1680.
126. Axelgaard J, Nordwall A, Brown JC. Correction of spinal curves by transcutaneous electrical muscle stimulation. *Spine* 1983;8:463.
127. Sachs B, Bradford D, Winter R, et al. Scheuermann kyphosis: follow-up of Milwaukee brace treatment. *J Bone Joint Surg Am* 1987;69:50.
128. Bradford DS, Moe JH, Montalvo FJ, et al. Scheuermann's kyphosis and roundback deformity: results of Milwaukee brace treatment. *J Bone Joint Surg Am* 1974;56:740.
129. Gutowski WT, Renshaw TS. Orthotic results in adolescent kyphosis. *Spine* 1988;13:485.
130. Farsetti P, Tudisco C, Caterini R, et al. Juvenile and idiopathic kyphosis. Long-term follow-up of 20 cases. *Arch Orthop Trauma Surg* 1991;110:165.
131. De Mauroy JC, Stagnara P. Resultats a long terme du traitement orthopedique. *Aix en Provence* 1978;60.
132. Bradford DS, Brown DM, Moe JH, et al. Scheuermann's kyphosis. A form of osteoporosis? *Clin Orthop* 1976;118:10.
133. Herndon WA, Emans JB, Micheli LG, et al. Combined anterior and posterior fusion for Scheuermann's kyphosis. *Spine* 1981;6:125.
134. Lowe TG. Double L-rod instrumentation in the treatment of severe kyphosis secondary to Scheuermann's disease. *Spine* 1987;12:336.
135. Nerubay J, Katznelson A. Dual approach in the surgical treatment of juvenile kyphosis. *Spine* 1986;11:101.
136. Otsuka NY, Hall JE, Mah JY. Posterior fusion for Scheuermann's kyphosis. *Clin Orthop* 1990;251:134.
137. Speck GR, Chopin DC. The surgical treatment of Scheuermann's kyphosis. *J Bone Joint Surg Br* 1986;68:189.
138. Sturm PF, Dobson JC, Armstrong GWD. The surgical management of Scheuermann's disease. *Spine* 1993;18:685.
139. Johnston CE II: *TSRH Instrumentation Update*, vol. 1. Texas Scottish Rite Hospital, 1997.
140. Shufflebarger HL. Cotrel-Dubousset instrumentation for Scheuermann's kyphosis. *Orthop Trans* 1989;13:90.
141. Kostuik JP. Anterior Kostuik-Harrington distraction systems. *Orthopedics* 1985;11:1379.
142. Coscia MF, Bradford DS, Ogilvie JW. Scheuermann's kyphosis: results in 19 cases treated by spinal arthrodesis and L-rod instrumentation. *Orthop Trans* 1988;12:255.
143. Reinhardt P, Bassett GS. Short segmental kyphosis following fusion for Scheuermann's disease. *J Spinal Disord* 1990;3:162.

Postlaminectomy Kyphosis

144. Lonstein JE. Post-laminectomy kyphosis. *Clin Orthop* 1977;128:93.
145. McLaughlin MR, Wahlig JB, Pollack IF. Incidence of postlaminectomy kyphosis after Chiari decompression. *Spine* 1997;22:613.
146. Haft H, Ransohoff J, Carter S. Spinal cord tumors in children. *Pediatrics* 1959;23:1152.
147. Lonstein JE, Winter RB, Moe JH, et al. Post-laminectomy spine deformity. *J Bone Joint Surg Am* 1976;58:727.
148. Mikawa Y, Shikata J, Yamamuro T. Spinal deformity and instability after multilevel cervical laminectomy. *Spine* 1987;12:6.
149. Tachdjian MO, Matson DD. Orthopaedic aspects of intraspinal tumors in infants and children. *J Bone Joint Surg Am* 1965;47:223.
150. Katsumi Y, Honma T, Nakamura T. Analysis of cervical instability resulting from laminectomies for removal of spinal cord tumor. *Spine* 1989;14:1171.
151. Cattell HS, Clark GL Jr. Cervical kyphosis and instability following multiple laminectomies in children. *J Bone Joint Surg Am* 1967;49:713.
152. Panjabi MN, White AAI, Johnson RM. Cervical spine mechanics as a function of transection of components. *J Biomech* 1975;8:327.
153. Butler MS, Robertson WW Jr, Rate W, et al. Skeletal sequelae of radiation therapy for malignant childhood tumors. *Clin Orthop* 1990;251:235.
154. Saito T, Yamamuro T, Shikata J, et al. Analysis and prevention of spinal column deformity following cervical laminectomy I. Pathogenetic analysis of postlaminectomy deformities. *Spine* 1991;16:494.
155. Bell DF, Walker JL, O'Connor G, et al. Spinal deformity after multiple-level cervical laminectomy in children. *Spine* 1994;19:406.
156. Yasuoka S, Peterson HA, Laws ER Jr, et al. Pathogenesis and prophylaxis of post-laminectomy deformity of the spine after multiple level laminectomy: difference between children and adults. *Neurosurgery* 1981;9:145.
157. Peterson HA. Iatrogenic spinal deformities. In: Weinstein SL, ed. *The pediatric spine: principles and practice*. New York: Raven, 1994:651.
158. Fraser RD, Paterson DC, Simpson DA. Orthopaedic aspects of spinal tumours in children. *J Bone Joint Surg Br* 1977;59:143.
159. Papagelopoulos PJ, Peterson HA, Ebersold MJ, et al. Spinal column deformity and instability after lumbar or thoracolumbar laminectomy for intraspinal tumors in children and young adults. *Spine* 1997;22:442.
160. Peter JC, Hoffman EB, Arens LJ, et al. Incidence of spinal deformity in children after multiple level laminectomy for selective posterior rhizotomy. *Child's Nerv Syst* 1990;6:30.
161. Yasuoka S, Peterson HA, MacCarty CS. Incidence of spinal column deformity after multilevel laminectomy in children and adults. *J Neurosurg* 1982;57:441.
162. Donaldson DH. Scoliosis secondary to radiation. In: Bridwell HK, DeWald RL, eds. *The textbook of spinal surgery*. Philadelphia: JB Lippincott, 1991:485.
163. Whitehouse WM, Lampe I. Osseous damage in irradiation of

- renal tumors in infancy and childhood. *AJR Am J Roentgenol* 1953;70:721.
164. Butler JC, Whitecloud TS. Postlaminectomy kyphosis: causes and surgical management. *Orthop Clin North Am* 1992;23:505.
 165. Callahan RA, Johnson RM, Margolis RN, et al. Cervical facet fusion for control of instability following laminectomy. *J Bone Joint Surg Am* 1977;59:991.
 166. Sim FH, Svien JH, Bickel WH, et al. Swan-neck deformity following extensive cervical laminectomy: a review of twenty one cases. *J Bone Joint Surg Am* 1974;56:564.
 167. Steinbok P, Boyd M, Cochrane D. Cervical spinal deformity following craniotomy and upper cervical laminectomy for posterior fossa tumors in children. *Childs Nerv Syst* 1989;5:25.
 168. Torpey BM, Dormans JP, Drummond DS. The use of MRI-compatible titanium segmental spinal instrumentation in pediatric patients with intraspinal tumor. *J Spinal Disord* 1995;8:76.
 169. Francis WR Jr, Noble DP. Treatment of cervical kyphosis in children. *Spine* 1988;13:883.
 170. Graziano GP, Herzenberg JE, Hensinger RN. The halo-Ilizarov distraction cast for correction of cervical deformity. *J Bone Joint Surg Am* 1993;75:996.
 171. Ishida Y, Suzuki K, Ohmori K, et al. Critical analysis of extensive cervical laminectomy. *Neurosurgery* 1989;24:215.
 172. Raimondi AJ, Gutierrez FA, Di Rocco C. Laminotomy and total reconstruction of the posterior spinal arch for spinal canal surgery in childhood. *J Neurosurg* 1976;45:555.
 173. Rama B, Markakis E, Kolenda H, et al. Reconstruction instead of resection: laminotomy and laminoplasty. *Neurochirurgia Stuttg* 1990;33(suppl 1):36.
 174. Kehrli P, Bergamaschi R, Maitrot D. Open-door laminoplasty in pediatric spinal neurosurgery. *Childs Nerv Syst* 1996;12:551.
 175. Mimatsu K. New laminoplasty after thoracic and lumbar laminectomy. *J Spinal Disord* 1997;10:20.
 176. Shikata J, Yamamuro T, Shimizu K, et al. Combined laminoplasty and posterolateral fusion for spinal canal surgery in children and adolescents. *Clin Orthop* 1990;259:92.
 187. Katzman H, Waugh T, Berdon W. Skeletal changes following irradiation of childhood tumors. *J Bone Joint Surg Am* 1969;51:825.
 188. Neuhauser EBD, Wittenborg MH, Berman CZ, et al. Irradiation effects of roentgen therapy on the growing spine. *Radiology* 1952;59:637.
 189. Rate WR, Butler MS, Robertson WWJ, et al. Late orthopaedic effects in children with Wilms' tumor treated with abdominal irradiation. *Med Pediatr Oncol* 1991;19:265.
 190. Riseborough EH, Grabias SL, Burton RI, et al. Skeletal alterations following irradiation for Wilms' tumor: with particular reference to scoliosis and kyphosis. *J Bone Joint Surg Am* 1976;58:526.
 191. Wallace WHB, Shalet SM, Morris-Jones PH, et al. Effect of abdominal irradiation on growth in boys treated for a Wilms tumor. *Med Pediatr Oncol* 1990;18:441.
 192. Rutherford H, Dodd GD. Complications of radiation therapy: growing bone. *Semin Roentgenol* 1974;9:15.
 193. Riseborough EJ. Irradiation induced kyphosis. *Clin Orthop* 1977;128:101.
 194. Smith R, Daviddson JK, Flatman GE. Skeletal effects of orthovoltage and megavoltage therapy following treatment of nephroblastoma. *Clin Radiol* 1982;33:601.
 195. Vaeth JM, Levitt SH, Jones MD, et al. Effects of radiation therapy in survivors of Wilms' tumor. *Radiology* 1962;79:560.
 196. Maki-pernaa A, Heikkila JT, Merikanto J, et al. Spinal deformity induced by radiotherapy for solid tumors in childhood: a long-term follow-up study. *Eur J Pediatr* 1993;152:197.
 197. Barrera M, Roy LP, Stevens M. Long-term follow-up after unilateral nephrectomy and radiotherapy for Wilms' tumour. *Pediatr Nephrol* 1989;3:430.
 198. Butler RW. The nature and significance of vertebral osteochondritis. *Proc Royal Soc Med* 1955;48:895.
 199. Pastore G, Antonelli R, Fine W, et al. Late effects of treatment of cancer in infancy. *Med Pediatr Oncol* 1982;10:369.
 200. Rubin P, Duthie RB, Young LW. The significance of scoliosis in postirradiated Wilms' tumor and neuroblastoma. *Radiology* 1962;79:539.
 201. King J, Stowe S. Results of spinal fusion for radiation scoliosis. *Spine* 1982;7:574.
 202. Donaldson WF, Wissinger HA. Axial skeletal changes following tumor dose radiation therapy. *J Bone Joint Surg Am* 1967;49:1469.
 203. Mayfield JK. Post-radiation spinal deformity. *Orthop Clin North Am* 1979;10:829.
 204. Otsuka NY, Hey L, Hall JE. Postlaminectomy and postirradiation kyphosis in children and adolescents. *Clin Orthop Rel Res* 1998;354:189.
 205. Shah M, Eng K, Engler GL. Radiation enteritis and radiation scoliosis. *NY State J Med* 1980;80:1611.
 206. Eyster EF, Wilsin CB. Radiation myelopathy. *J Neurosurg* 1970;32:414.
- ### Radiation Kyphosis
177. Engel D. An experimental study on the action of radium on developing bones. *Br J Radiol* 1938;11:779.
 178. Engel D. Experiments on the production of spinal deformities by radium. *AJR Am J Roentgenol* 1939;42:217.
 179. Gall EA, Luigley JR, Hilken JA. Comparative experimental studies of 200 kilovolt and 1000 kilovolt roentgen rays. I. The biological effects on the epiphyses of the albino rat. *Am J Pathol* 1940;16:605.
 180. Hinkel CL. The effect of roentgen rays upon the growing long bones of albino rats. Quantitative studies of the growth limitation following irradiation. *AJR Am J Roentgenol* 1942;47:439.
 181. Barr JS, Lingley JR, Gall EA. The effect of roentgen irradiation on epiphyseal growth. I. Experimental studies upon the albino rat. *AJR Am J Roentgenol* 1943;49:104.
 182. Reidy JA, Lingley JR, Gall EA, et al. The effect of roentgen irradiation on epiphyseal growth. II. Experimental studies upon the dog. *J Bone Joint Surg* 1947;29:853.
 183. Hinkel CL. The effect of roentgen rays upon the growing long bones of albino rats II. Histopathological changes involving endochondral growth centers. *AJR Am J Roentgenol* 1943;49:321.
 184. Arkin AM, Simon N. Radiation scoliosis: an experimental study. *J Bone Joint Surg Am* 1950;32:396.
 185. Arkin AM, Pack GT, Ransohoff NS, et al. Radiation-induced scoliosis: a case report. *J Bone Joint Surg Am* 1950;32:401.
 186. Katz LD, Lawson JP. Radiation-induced growth abnormalities. *Skel Radiol* 1990;19:50.
- ### Miscellaneous Causes of Kyphotic Deformities
207. Hensinger RN. Kyphosis secondary to skeletal dysplasias and metabolic disease. *Clin Orthop Rel Res* 1977;128:113.
 208. Tolo VT. Spinal deformity in short-stature syndromes. *Instr Course Lect* 1990;39:399.
 209. Herring JA. Kyphosis in an achondroplastic dwarf. *J Pediatr Orthop* 1983;3:250.
 210. Tolo VT. Surgical treatment of kyphosis in achondroplasia. In: Nicoletti B, Kopits SE, Ascani E, et al., eds. *Human achondroplasia: a multidisciplinary approach*. New York: Plenum, 1988:257.
 211. Tolo VT. Spinal deformity in skeletal dysplasia. In: Weinstein

- SL, ed. *The pediatric spine: principles and practice*. New York: Raven, 1994:369.
212. Lonstein JE. Treatment of kyphosis and lumbar stenosis in achondroplasia. *Basic Life Sci* 1986;48:283.
213. Eulert J. Scoliosis and kyphosis in dwarfing conditions. *Arch Orthop Trauma Surg* 1983;102:45.
214. Kopits SE. Thoracolumbar kyphosis and lumbosacral hyperlordosis in achondroplastic children. In: Nicoletti B, Kopits SE, Ascani E, et al., eds. *Human achondroplasia: a multidisciplinary approach*. New York: Plenum, 1988:241.
215. Siebens AA, Hungerford DS, Kirby NA. Achondroplasia: effectiveness of an orthosis in reducing deformity of the spine. *Arch Phys Med Rehabil* 1987;68:384.
216. Siebens AA, Kirby N, Hungerford DS. Orthotic correction of sitting abnormality in achondroplastic children. In: Nicoletti B, Kopits SE, Ascani E, et al., eds. *Human achondroplasia: a multidisciplinary approach*. New York: Plenum, 1988:313.
217. Winter RB, Hall JE. Kyphosis in an achondroplastic dwarf. *J Pediatr Orthop* 1983;3:250.
218. Pauli RM, Breed A, Horton VK, et al. Prevention of fixed, angular kyphosis in achondroplasia. *J Pediatr Orthop* 1997;17:726.
219. Shikata J, Yamamuro T, Iida H, et al. Surgical treatment of achondroplastic dwarfs with paraplegia. *Surg Neurol* 1988;29:125.
220. Cooper RR, Ponseti IV, Maynard JA. Pseudoachondroplastic dwarfism. *J Bone Joint Surg Am* 1973;55:475.
221. Jones ET, Hensinger RN. Spinal deformity in individuals with short stature. *Orthop Clin North Am* 1979;10:877.
222. Herring JA. The spinal disorders in diastrophic dwarfism. *J Bone Joint Surg Am* 1978;60:177.
223. Benson PF, Burton LR, Fensom AH, et al. Lumbar kyphosis in Hunter's disease (MPS II). *Clin Genet* 1979;16:317.
224. Dietz HC, Cutting GR, Pyeritz RE, et al. Marfan syndrome caused by a recurrent de novo missense mutation in the fibrillin gene. *Nature* 1991;352:337.
225. Dietz HC, Pyeritz RE, Hall BD, et al. The Marfan syndrome locus: confirmation of assignment to chromosome 15 and identification of tightly-linked markers at 15 q 15-921.3. *Genomics* 1991;9:355.
226. Amis J, Herring JA. Iatrogenic kyphosis: a complication of Harrington instrumentation in Marfan syndrome. *J Bone Joint Surg Am* 1984;66:460.
227. Beneux J, Rigault P, Poliquen JC. Les deviations rachidiennes de la maladie de Marfan chez l'enfant. Etude de 10 cas. *Rev Chir Orthop Reparatrice Appar Mot* 1978;64:471.
228. Joseph KN, Kane HA, Milner RS, et al. Orthopaedic aspects of the Marfan phenotype. *Clin Orthop* 1992;277:251.
229. Robins PR, Moe JH, Winter RB. Scoliosis in Marfan syndrome: its characteristics and results of treatment in thirty-five patients. *J Bone Joint Surg Am* 1975;57:358.
230. Savini R, Cervellati S, Beroaldo E. Spinal deformities in Marfan syndrome. *Ital J Orthop Traumatol* 1980;6:19.
231. Taneja DK, Manning CW. Scoliosis in Marfan syndrome and arachnodactyly. In: Zorab PA, ed. *Scoliosis*. London: Academic, 1977:261.
232. Goldberg MJ. Marfan and the marfanoid habitus. In: Goldberg MJ, ed. *The dysmorphic child: an orthopaedic perspective*. New York: Raven, 1987:83.
233. Kumar SJ, Guille JT. Marfan syndrome. In: Weinstein SL, ed. *The pediatric spine: principles and practice*. New York: Raven, 1994:665.
234. Sponseller PD, Hobbs W, Riley LE, Ryeritz RE. The thoracolumbar spine in Marfan syndrome. *J Bone Joint Surg Am* 1995;77:867.
235. Birch JG, Herring JA. Spinal deformity in Marfan syndrome. *J Pediatr Orthop* 1987;7:546.
236. Winter RB. Thoracic lordoscoliosis in Marfan syndrome: report of two patients with surgical correction using rods and sublaminar wires. *Spine* 1990;15:233.
237. Hobbs WR, Sponseller PD, Weiss A-PC, et al. The cervical spine in Marfan syndrome. *Spine* 1997;22:983.
238. Larsen LJ, Schottstaedt ER, Bost FC. Multiple congenital dislocations associated with characteristic facial abnormality. *J Pediatr* 1950;37:574.
239. Johnston CE, Birch JG, Daniels JL. Cervical kyphosis in patients who have Larsen syndrome. *J Bone Joint Surg Am* 1996;78:538.
240. Muzumdar AS, Lowry RB, Robinson CE. Quadriplegia in Larsen syndrome. *Birth Defects* 1977;13:202.
241. Harris R, Cullen CH. Autosomal dominant inheritance in Larsen's syndrome. *Clin Genet* 1971;2:87.
242. Dudding BA, Gorlin RJ, Langer LD. The oro-palato-digital syndrome. A new symptom-complex consisting of deafness, dwarfism, cleft palate, characteristic facies, and generalized bone dysplasia. *Am J Dis Child* 1967;113:214.
243. McKusick VA. *Mendelian inheritance in man*, 4th ed, Baltimore: Johns Hopkins University Press, 1975.
244. Micheli LJ, Hall JE, Watts HG. Spinal instability in Larsen's syndrome. Report of three cases. *J Bone Joint Surg Am* 1976;58:562.
245. Johnston CE II, Schoenecker PL. Correspondence to the editor. *J Bone Joint Surg Am* 1997;79:1590.
246. Renshaw TS. Spinal cord injury and posttraumatic deformities. In: Weinstein SL, ed. *The pediatric spine: principles and practice*. New York: Raven, 1994:767.
247. Dearolf WWI, Betz RR, Vogel LC, et al. Scoliosis in pediatric spinal cord-injured patients. *J Pediatr Orthop* 1990;10:214.
248. Malcolm BW. Spinal deformity secondary to spinal injury. *Orthop Clin North Am* 1979;10:943.
249. Mayfield JK, Erkkila JC, Winter RB. Spine deformity subsequent to acquired childhood spinal cord injury. *J Bone Joint Surg Am*. 1981;63:1401.
250. Renshaw TS. Paralysis in the child: orthopaedic management. In: Bradford DS, Hensinger RM, eds. *The pediatric spine*. New York: Thieme, 1985:118.
251. Böhm H, Harms J, Donk R, Zielke K. Correction and stabilization of angular kyphosis. *Clin Orthop Rel Res* 1990;258:56.
252. Gertzbein SD, Harris MB. Wedge osteotomy for the correction of posttraumatic kyphosis. *Spine* 1992;17:374.
253. McAfee PC, Bohlman HH, Yuan HA. Anterior decompression of traumatic thoracolumbar fractures with incomplete neurological deficit using a retroperitoneal approach. *J Bone Joint Surg Am* 1985;67:89.
254. Roberson JR, Whitesides TF Jr. Surgical reconstruction of late post-traumatic thoracolumbar kyphosis. *Spine* 1985;10:307.
255. Wu SS, Hwa SY, Lin LC, et al. Management of rigid post-traumatic kyphosis. *Spine* 1996;21:2260.
256. Craig JB, Govender S. Neurofibromatosis of the cervical spine. A report of eight cases. *J Bone Joint Surg Br* 1992;74:575.
257. Funasaki H, Winter RB, Lonstein JB, et al. Pathophysiology of spinal deformities in neurofibromatosis. Pathophysiology of spinal deformities in neurofibromatosis. *J Bone Joint Surg Am* 1994;76:692.
258. Crawford AH. Pitfalls of spinal deformities associated with neurofibromatosis in children. *Clin Orthop* 1989;245:29.
259. Hsu LCS, Lee PC, Leong JCY. Dystrophic spinal deformities in neurofibromatosis, treated by anterior and posterior fusion. *J Bone Joint Surg Br* 1984;66:495.
260. Crawford AH. Neurofibromatosis. In: Weinstein SL, ed. *The pediatric spine: principles and practice*. New York: Raven, 1994:619.

261. Curtis BH, Fisher RL, Butterfield WL, et al. Neurofibromatosis with paraplegia: report of 8 cases. *J Bone Joint Surg Am* 1969; 51:843.
262. Lonstein JE, Winter RB, Moe JH, et al. Neurologic deficit secondary to spinal deformity. *Spine* 1980;5:331.
263. Asazuma T, Yamagishi M, Nemoto K, et al. Spinal fusion using a vascularized fibular bone graft for a patient with cervical kyphosis due to neurofibromatosis. *J Spinal Disord* 1997;10:537.
264. Gioia G, Mandelli D, Capaccioni B, et al. Poslaminectomy cervical dislocation in von Recklinghausen's disease. *Spine* 1998; 23:273.
265. Kokubun S, Ozawa H, Sakurai M, et al. One-stage anterior and posterior correction of severe kyphosis of the cervical spine in neurofibromatosis. A case report. *Spine* 1993;18:2332.
266. Nijland EA, van den Berg MP, Wuisman PIJM, et al. Correction of a dystrophic cervicothoracic spine deformity in Recklinghausen's disease. *Clin Orthop Rel Res* 1998;349:149.
267. Ward BA, Harkey L, Parent AD, et al. Severe cervical kyphotic deformities in patients with plexiform neurofibromas: case report. *Neurosurgery* 1994;35:960.
268. Schorry EK, Stowens DW, Crawford AH, et al. Summary of patient data from a multidisciplinary neurofibromatosis clinic. *Neurofibromatosis* 1989;2:129.
269. Winter RB, Moe JH, Bradford DS, et al. Spine deformities in neurofibromatosis. *J Bone Joint Surg Am* 1979;61:677.
270. Bradford DS. Anterior vascular pedicle bone grafting for the treatment of kyphosis. *Spine* 1980;5:318.
271. Bradford DS, Ganjavian S, Antonious D, et al. Anterior strut-grafting for the treatment of kyphosis. *J Bone Joint Surg Am* 1982;64:680.
272. Rose GK, Sanderson JM. Transposition of rib with blood supply for the stabilisation of a spinal kyphosis. *J Bone Joint Surg Br* 1975;57:112.
273. Ho EKW, Leong JCY. Tuberculosis of the spine. In: Weinstein SL, ed. *The pediatric spine: principles and practice*. New York: Raven, 1994:837.
274. Antituberculosis regimens of chemotherapy. *Bull Int Union Tuberc Lung Dis* 1988;63:60.
275. Schultz K-P, Kothe R, Leong JCY, et al. Growth changes of solidly fused kyphotic block after surgery for tuberculosis. Comparison of four procedures. *Spine* 1997;22:1150.
276. Medical Research Council Working Party on Tuberculosis of the Spine. A controlled trial of anterior spinal fusion and debridement in the surgical management of tuberculosis of the spine in patients on standard chemotherapy: studies in Hong Kong. *Br J Surg* 1974;61:853.
277. Medical Research Council Working Party on Tuberculosis of the Spine. A controlled trial of debridement and ambulatory treatment in the management of tuberculosis of the spine in patients on standard chemotherapy. *J Trop Med Hyg* 1974;77: 72.
278. Medical Research Council Working Party on Tuberculosis of the Spine. Five-year assessments of controlled trials of ambulatory treatment, debridement and anterior spinal fusion in the management of tuberculosis of the spine: studies in Bulawayo (Rhodesia) and in Hong Kong. *J Bone Joint Surg Br* 1978;60: 163.
279. Medical Research Council Working Party on Tuberculosis of the Spine. A ten-year assessment of a controlled trial comparing debridement and anterior spinal fusion in the management of tuberculosis of the spine in patients on standard chemotherapy in Hong Kong. *J Bone Joint Surg Br* 1982;64:393.
280. Altman GT, Altman DT, Frankovitch KF. Anterior and posterior fusion for children with tuberculosis of the spine. *Clin Orthop Rel Res* 1996;325:225.
281. Bailey HL, Gabriel M, Hodgson AR, et al. Tuberculosis of the spine in children: operative findings and results in one hundred consecutive patients treated by removal of the lesion and anterior grafting. *J Bone Joint Surg Am* 1972;54:1633.
282. Hsu LCS, Leong JCY. Tuberculosis of the lower cervical spine (C2-7): a report on forty cases. *J Bone Joint Surg Br* 1984;66: 1.
283. Ito H, Tsuchiya J, Asami G. A new radical operation for Pott's disease. *J Bone Joint Surg* 1934;16:499.
284. Moon M-S. Spine update. Tuberculosis of the spine. Controversies and a new challenge. *Spine* 1997;22:1791.
285. Moon M-S, Woo Y-K, Lee K-S. Posterior instrumentation and anterior interbody fusion for tuberculous kyphosis of dorsal and lumbar spines. *Spine* 1995;20:1910.
286. Medical Research Council Working Party on Tuberculosis of the Spine. A controlled trial of ambulant outpatient treatment and inpatient rest in bed in the management of tuberculosis of the spine in young Korean patients on standard chemotherapy: a study in Masan, Korea. *J Bone Joint Surg Br* 1973;55:678.
287. Medical Research Council Working Party on Tuberculosis of the Spine. A ten-year assessment of controlled trials of inpatient and outpatient treatment and plaster-of-Paris jackets for tuberculosis of the spine in children on standard chemotherapy: studies in Masan and Pusan, Korea. *J Bone Joint Surg Br* 1985;67: 103.
288. Upadhyay SS, Saji MJ, Sell P, et al. The effect of age on the change in deformity after anterior debridement surgery for tuberculosis of the spine. *Spine* 1996;21:2356.
289. Upadhyay SS, Saji MJ, Sell P, et al. Spinal deformity after childhood surgery for tuberculosis of the spine. A comparison of radical surgery and debridement. *J Bone Joint Surg Br* 1994;76: 91.
290. Upadhyay SS, Saji MJ, Sell P, et al. The effect of age on the change in deformity after radical resection and anterior arthrodesis for tuberculosis of the spine. *J Bone Joint Surg Am* 1994; 76:701.
291. Upadhyay SS, Sell P, Saji MJ, et al. 17-year prospective study of surgical management of spinal tuberculosis in children. Hong Kong operation compared with debridement surgery for short- and long-term outcome of deformity. *Spine* 1993;18:1704.
292. Hsu LCS, Cheng CL, Leong JCY. Pott's paraplegia of late onset: the cause of compression and results after anterior decompression. *J Bone Joint Surg Br* 1988;70:534.
293. Dent CE, Friedman M. Idiopathic juvenile osteoporosis. *Q J Med* 1965;134:177.
294. Schippers JC. Over een geval van "spontane" algemeene osteoporose bij een klein meisje. *Maandschrift voor Kindergeneeskunde* 1939;8:108.
295. Evans RA, Dunstan CR, Hills E. Bone metabolism in idiopathic juvenile osteoporosis: a case report. *Calcif Tissue Int* 1983;35: 5.
296. Hoekman K, Papapoulos SE, Peters ACB, et al. Characteristics and bisphosphonate treatment of a patient with juvenile osteoporosis. *J Clin Endocrinol Metab* 1985;61:952.
297. Jackson EC, Strife CF, Tsang RC, et al. Effect of calcitonin replacement therapy in idiopathic juvenile osteoporosis. *Am J Dis Child* 1988;142:1237.
298. Jones ET, Hensinger RN. Spinal deformity in idiopathic juvenile osteoporosis. *Spine* 1981;6:1.
299. Marder HK, Tsang RC, Hug G, et al. Calcitriol deficiency in idiopathic juvenile osteoporosis. *Am J Dis Child* 1982;136:914.
300. Saggese G, Bartelloni S, Baroncelli GI, et al. Mineral metabolism and calcitriol therapy in idiopathic juvenile osteoporosis. *Am J Dis Child* 1991;145:457.
301. Smith R. Idiopathic osteoporosis in the young. *J Bone Joint Surg Br* 1980;62:417.
302. Roskamp R, Sell G, Emmons D, et al. Idiopathic juvenile

- osteoporose-Bericht über zwei Fälle. *Klin Pädiatr*, 1987;199:457.
303. Samuda GM, Cheng MY, Yeung CY. Back pain and vertebral compression: an uncommon presentation of childhood acute lymphoblastic leukemia. *J Pediatr Orthop* 1987;7:175.
 304. Brenton DP, Dent CE. Idiopathic juvenile osteoporosis. In: Bickel H, Stern J, eds. *Inborn errors of calcium and bone metabolism*. Baltimore: University Park, 1976:222.
 305. Green WB. *Idiopathic juvenile osteoporosis*. New York: Raven, 1994.
 306. Dimar JR II, Campbell M, Glassman SD. Idiopathic juvenile osteoporosis. An unusual cause of back pain in an adolescent. *Am J Orthop* 1995;11:865.
 307. Marhaug G. Idiopathic juvenile osteoporosis. *Scand J Rheumatol* 1993;22:45.
 308. Villaverde V, De Inocencio J, Merino R, et al. Difficulty walking. A presentation of idiopathic juvenile osteoporosis. *J Rheumatol* 1998;25:173.
 309. Bartal E, Gage J. Idiopathic juvenile osteoporosis and scoliosis. *J Pediatr Orthop* 1982;2:295.



SPONDYLOLYSIS AND SPONDYLOLISTHESIS

JOHN E. LONSTEIN

CLASSIFICATION 777

NATURAL HISTORY 779

Progression 779
Pain 779

ETIOLOGY 779

Hereditary Factors 779
Trauma 780
Growth 780

PATIENT EVALUATION 780

History 780
Physical Examination 780

RADIOLOGIC EVALUATION 781

Routine Views 781
Bone Scan 781
CT or MRI Scan 782
Measurement 782

TREATMENT 783

Spondylolysis 783
Spondylolisthesis 785

COMPLICATIONS 793

Pseudarthrosis 793
Increased Slippage 793
Neurologic Complications 793

"Spondylolysis" is the term used to refer to a defect in the pars interarticularis of the vertebra, being most common at L5 in the child or adolescent. The term is from the Greek *spondylos*, or vertebra, and *lysis*, or break or defect. Spondylolisthesis is from the Greek words *spondylos*, or vertebra, and *olisthesis*, meaning "movement" or "slipping," and refers to the slipping forward of one vertebra on the next caudal vertebra, being first described by a Belgium obstetrician, Herbiniaux, in 1782 (1). Because the defect is most common at L5, the resultant slip is most common at this level, with L5 slipping forward on S1.

CLASSIFICATION

The most well-known classification of spondylolisthesis is that of Wiltse, who divided it into five types (2):

Type I—Dysplastic or congenital. This type of spondylolisthesis is due to a congenital abnormality of the L5-S1 facet joints, consisting of a more transverse orientation of the facets than normal. This allows forward slipping of the vertebrae with the intact neural arch.

Type II—Isthmic. There is a defect of the pars interarticularis that permits the forward slippage, the articular facets being normal. There are three subtypes that describe the nature of the defect in the pars:

1. Lytic fracture of the pars
2. Elongated but intact pars
3. Acute pars fracture

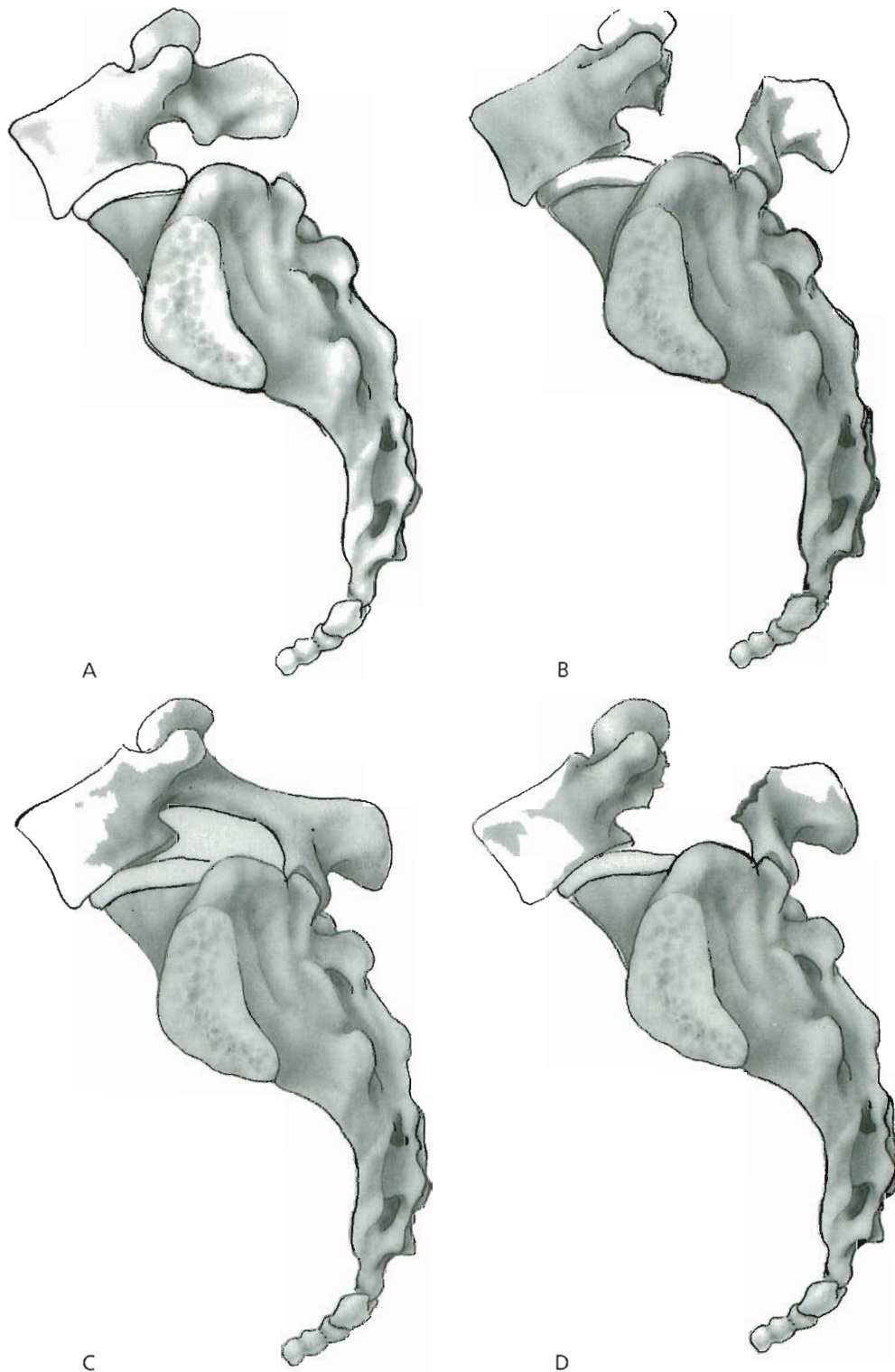


FIGURE 20-1. In type I, or dysplastic spondylolisthesis, there is a congenital deficiency of the L5-S1 facet joints that allows forward slippage of L5 on S1 (**A**). In type II, or isthmic spondylolisthesis, there is a lesion of the pars interarticularis that permits the forward slippage. This condition is divided into three groups: (**B**) a lytic lesion of the pars, (**C**) an elongated but intact pars, or (**D**) an acute fracture of the pars.

Type III—Degenerative. Degenerative arthritis of the facet joints, as well as degeneration of the disc.

Type IV—Traumatic. An acute fracture in an area of the vertebra other than the pars.

Type V—Pathologic. A lesion of the pars or pedicle due to generalized bone disease that allows forward slippage.

Only two of these types, Types I and II, occur in children and adolescents, and these are discussed in this chapter (Fig. 20-1).

NATURAL HISTORY

With one exception (3), a defect in the pars has never been found at birth (4–8). The incidence of spondylolysis is 4.4% at age 6 years, rising to the adult rate of 5.5 to 6% by the age of 14 years (4,9). There have been cases reported in the first year of life with scattered cases reported under age 2 years (6,7,10). The incidence is higher in males, with a lower incidence in blacks (4,11). The highest incidence is in Alaskan Eskimos, with a rate of 26%, with the highest rate being in Eskimos from north of the Yukon River (12).

Of the two types of spondylolisthesis seen in children and adolescents, dysplastic or congenital is the least common. This type of spondylolisthesis has a 2:1 female:male ratio (13,14) and makes up between 14 and 21% of the cases in various series (13,15). Most do not progress beyond 50% slippage because of the severe symptoms produced by the intact neural arch impinging on the neural elements. These children are at higher risk for neurologic injury, e.g., cauda equina syndrome, than those with isthmic spondylolisthesis.

Isthmic spondylolisthesis is much more common, and although most authors mix both types of spondylolisthesis with spondylolysis in their reports, most of the data in the literature refer to this type of spondylolisthesis. The percentage of cases with spondylolysis that develop spondylolisthesis is documented in only one longitudinal study, that of Fredrickson et al. (4). In a radiographic study of school children, they reported the incidence of spondylolysis to be 4.4% at 6 years of age, increasing to 6% in adulthood. This agrees with other studies (9–11). They also found that 68% of the 5-year-old children had an associated slip or spondylolisthesis, increasing slightly to 74% in adulthood (4). This would indicate that the number of children with spondylolysis who will develop spondylolisthesis after 6 years of age is small.

Saraste, in her 20-year follow-up review of 255 patients with spondylolysis and spondylolisthesis, reported that 40% of adults showed no progression of the slip, 40% slipped an additional 1 to 5 mm, and 15% 11 to 15 mm (16). Her data also suggest that spondylolisthesis is more common than spondylolysis, with approximately 22% of patients having only spondylolysis at initial presentation.

Osterman et al. noted in their report the following severity of slipping in those with spondylolisthesis: grade I, 79%; grade II, 20%; grade III, 1% (17). Others report a slightly higher incidence of more severe slips (18).

Rowe and Roche report a difference in the incidence of spondylolisthesis between the races and sexes: 6.4% in white males, 2.8% in black males, 2.3% in white females, and 1.1% in black females (11). The difference in natural history between the sexes is illustrated by the fact that, although the incidence is twice as high in males, high-grade slips are four more times as common in females.

There are two questions related to the natural history of spondylolysis and spondylolisthesis, the answers to which have a major impact on clinical decision-making: How frequently does the slip in spondylolisthesis progress? and How often does pain or other symptoms become a problem?

Progression

Progression occurs in a low percentage of cases, occurring in 4% of Frennered et al.'s series, and 5% of Saraste's cases (16,19). In the series of Fredrickson et al. it appeared that progression was unlikely after adolescence (4), whereas other authors reported progression in adolescence, often related to disc degeneration (20–22). In adolescence, progression is most likely to occur during the growth spurt, and is more common in females, and in dysplastic spondylolisthesis (4).

Some radiographic features have related to a greater chance of progression. The degree of slip on presentation has been found to be associated with chance of progression by some authors (9,23,24), and not by others (16,19). The amount of lumbosacral kyphosis, or the slip angle, especially when severe, is associated with progression in the growing child. Other changes are found with high-grade slips, e.g., dome-shaped sacrum and trapezoidal L5, these being secondary to the slip, and not prognostic for slip progression (19).

Pain

Because pain is the most common presenting symptom, are there any prognostic features for this? Saraste found that there were radiographic features that correlated with low back symptoms. These were a slip of greater than 25%, L4 spondylolysis or spondylolisthesis, or early disc degeneration at the level of the slip (16).

ETIOLOGY

The exact etiology of this condition is unknown, theories being related to hereditary factors, a congenital predisposition, trauma, posture, growth, and biomechanical factors.

Hereditary Factors

Family studies have shown a high incidence of spondylolysis and spondylolisthesis in first-degree relatives of children with these conditions, the incidence varying from 19 to 69% (7,25–28). Wynne-Davies and Scott noted an in-

creased incidence of dysplastic lesions in affected relatives, in addition to a higher incidence of spina bifida of S1 (28).

Trauma

Trauma is considered to be a factor in etiology of spondylolysis and spondylolisthesis. Acute trauma is obviously the cause of the acute traumatic type of spondylolysis. In addition, many cases present after a traumatic episode. Is the trauma the cause of the lesion, or does it make an asymptomatic defect symptomatic? Wiltse et al. theorized that spondylolysis is a stress fracture in the pars, so that repetitive microtrauma or microstresses are generally considered to be the factor in the etiology (29). Repetitive hyperextension motion, in which the caudal edge of the inferior articular facet makes contact with the pars interarticularis, is considered to be the causative trauma. This is confirmed by the higher incidence of spondylolysis in certain sports (female gymnasts [30], college football linemen [31,32], weight lifters [33]), and in Scheuermann disease (34). In addition, spondylolysis has not been reported in adults who have never walked (35), pointing to the mechanical effects of the upright posture.

Growth

Growth definitely plays a role in the etiology of spondylolysis, as evidenced by the fact that defects do not occur in the newborn, and reach an incidence of 4% at age 6 years, rising to the adult incidence by age 14 years. This increase is more marked during the adolescent growth spurt (4).

The etiology is thus multifactorial, with an inherited predisposition that leads to the defect occurring with repeated microtrauma. This predisposition may be an inherent weakening of the pars itself, or may result in a certain structure of the facets that creates the stress fracture with repetitive hyperextension. The dysplastic variety, with an elongated pars, has a strong familial pattern with abnormal facet orientation and spina bifida of S1.

PATIENT EVALUATION

History

Spondylolysis and spondylolisthesis, when asymptomatic, are usually detected as an incidental finding on a pelvis or spine radiograph. However, they are frequently found as the cause of low back pain in children and adolescents. The most common time for this is the adolescent growth spurt, ages 10 to 15 years. The pain may be of a chronic nature, generally being exacerbated by sports or other physical activity, and relieved by rest or restriction of activities. The pain may also follow an acute traumatic episode, often involving hyperextension during sports participation. The pain is a

dull, aching, low back discomfort, either localized to the low back, or with some radiation into the buttock and posterior thighs. This pain is probably due to the instability due to the pars defect. Radicular pain is unusual in the adolescent and more common in the adult, and is usually in the L5 distribution due to nerve compression by the hypertrophic callus at the pars defect, or due to the foraminal stenosis accompanying the spondylolisthesis.

The child can present with parents noting a change in posture or gait, with or without accompanying pain. This is usually with spondylolisthesis, especially with more marked degrees of slip. The postural changes noted are a flattening of the buttocks, increased lumbar lordosis, and gait alterations, described as a waddling gait.

Occasionally, these cases present with scoliosis. This can be as adolescent idiopathic scoliosis, with the spondylolysis or spondylolisthesis detected incidentally on radiographic assessment of the scoliosis. On the other hand, the curve pattern may be atypical, and may be spasm scoliosis associated with the spondylolisthesis or an olisthetic curve due to asymmetric slip at the lumbosacral area.

Physical Examination

The physical findings depend on whether pain is part of the presenting symptoms, as well as on the degree of slip in spondylolisthesis. Back and gait examination may be completely normal with no hamstring tightness. With spondylolisthesis there is usually some degree of hamstring tightness with restriction of forward bending. The cause of this hamstring tightness is unknown. It usually resolves with a solid fusion. When it does not, decompression of the roots and sacroplasty may also be curative (36).

With spondylolisthesis and associated pain, there is usually a restriction of spine motion in addition to restriction of forward bending. With greater degrees of slip there is shortening of the waistline, with a flattening of the buttocks. In addition, a step-off at the lumbosacral area may be visible as well as palpable (Fig. 20-2). A localized area of tenderness to deep palpation may also be elicited in the lumbosacral area. In addition, in these severe slips the child stands with hips and knees flexed due to the anterior rotation of the pelvis, and the gait is one of short steps due to inability to extend the hips.

Straight-leg raising is severely restricted due to the tight hamstrings. Neurologic examination is usually completely normal, but may show diminished or absent ankle deep-tendon reflex, and weakness of the extensor hallucis longus. Sphincter dysfunction is very rare.

Scoliosis may be a part of the presentation, either a typical idiopathic type, or with more decompensation and spasm, indicative of a spasm or olisthetic scoliosis. It is important to recognize that the pain complaints and/or the neurologic findings may be due to some pathology other than the spondylolysis or spondylolisthesis, e.g., bone, spinal cord, conus or cauda tumor, disc herniation, or disc-

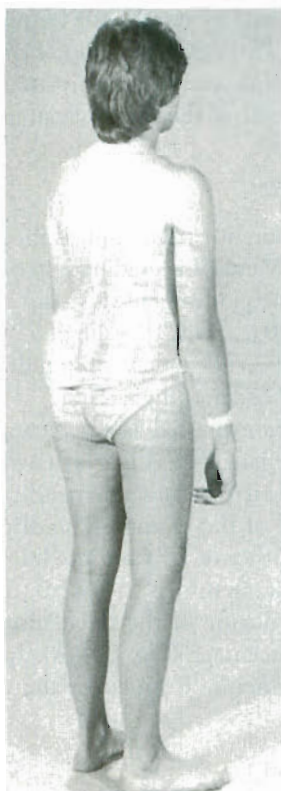

FIGURE 20-2. The typical findings of spondylolisthesis include flattening of the buttocks, lumbosacral kyphosis, a step-off in the lower lumbar area, and the lumbar lordosis.

space infection. It is thus incumbent on the physician to rule out other causes of the back pain with a detailed history, physical examination, radiographs, and adjunctive tests.

RADIOLOGIC EVALUATION

Routine Views

The initial radiographic evaluation consists of standing posteroanterior and lateral lumbosacral spine films. Full-length views are taken in addition in the presence of scoliosis, and a full-length lateral is taken with larger degrees of slip to evaluate the sagittal spine alignment. The spot lateral film usually shows the defect, especially with bilateral pars defects, and the degree of slip in spondylolisthesis is appreciated. It is important to recognize that the degree of slip differs in the supine and standing position, and that the standing view shows a greater slip, and should always be taken (37). In cases of a unilateral defect there may be sclerosis of the facet, lamina, or pars on the intact side opposite the defect.

To better visualize the pars defect oblique views of the lumbosacral area are often necessary. The view is an oblique of the lumbosacral area and not of the lumbosacral spine,

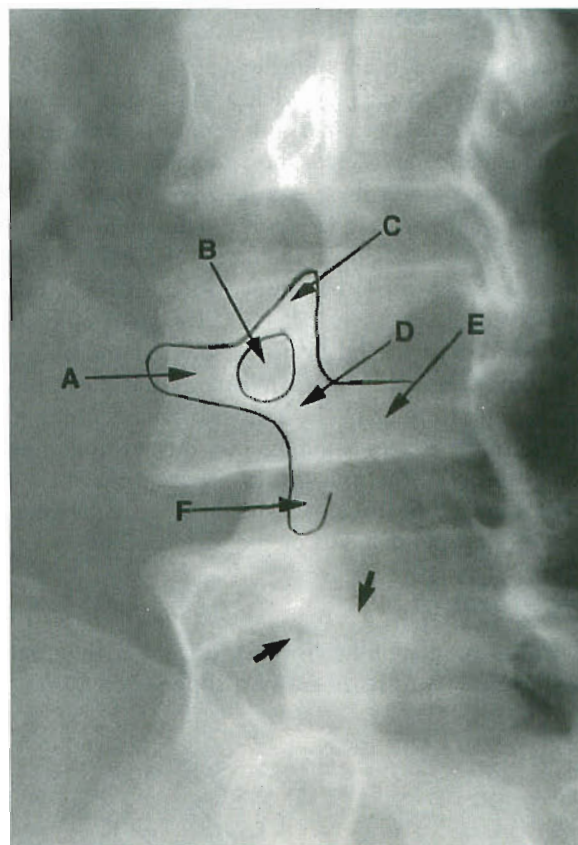


FIGURE 20-3. Oblique lumbosacral radiograph showing the "Scotty dog," which is made up of the following anatomic structures: the nose is the transverse process (A), the eye is the pedicle (B), the ear is the superior articular process (C), the neck is the pars (D), the back is the lamina (E), and the front leg is the inferior articular process (F). At L5, there is a "collar" on the dog (arrows), which is the isthmic defect in the pars.

so the central x-ray beam must be in the lumbosacral area and not in the midlumbar spine. The defect is seen as the well known "collar" on the "Scotty dog" (Fig. 20-3). In cases in which the defect is strongly suspected but is not seen on the oblique views, a CT scan may be used to visualize the defect.

Supine flexion and extension views are useful in demonstrating the mobility of the spondylolisthesis—both of the amount of slip and of the reduction of the lumbosacral kyphosis. This is useful information for assessing the instability and in planning treatment.

Bone Scan

A bone scan is used in cases with a recent onset of pain or with a distinct history of trauma, to detect an acute fracture of the pars or exclude a bony tumor. This is best performed using single photon emission computed tomography (SPECT) scan because of the greater detail.

CT or MRI Scan

Additional imaging is occasionally necessary. A CT scan is the method of choice when a defect in the pars is strongly suspected on clinical grounds, but cannot be identified on the oblique radiographs. This should be done with fine cuts 1.5-mm apart. When there is a neurologic deficit, or the symptoms suggest a diagnosis other than spondylolysis or spondylolisthesis, imaging of the neural elements should be performed. Today this is best done with an MRI, although special circumstances may call for CT myelography. The area assessed must extend from the lower thoracic area to the sacrum. Cases with spondylolisthesis and a neurologic deficit due to a tumor of the conus or cauda equina have occurred. In these cases elimination of this possibility, with imaging studies of the spinal canal, is essential.

MRI done for low back pain should be carefully assessed for changes of spondylolysis or spondylolisthesis.

Measurement

The deformity in spondylolisthesis, usually at the lumbosacral junction, consists of forward slippage of L5 on S1,

usually accompanied by rotation of L5 on S1 into lumbosacral kyphosis. The degrees of slip, kyphosis, and other changes in the lumbosacral anatomy are evaluated on the standing spot lateral of the lumbosacral area (38).

Slip Percentage

The amount of anterior translation is most commonly described using the Meyerding grading system (39). This classifies the slip into five grades: grade I is a slip of 1 to 25%, grade II a slip of 26 to 50%, grade III a slip of 51 to 75%, grade IV a slip of 76 to 100%, and grade V, or spondyloptosis, slippage past the anterior border of the sacrum.

The slip can be expressed as a percentage following the description of Talliard (40). A line is drawn along the posterior border of the sacrum, and a perpendicular line is drawn at the upper end of the sacrum. The displacement of the posteroinferior corner of L5 from the line along the posterior border of the sacrum is measured. The width of S1 forms the denominator of the calculation, the slip being expressed as a percentage (Fig. 20-4A). In many cases the upper end of the sacrum is rounded, and the measurement

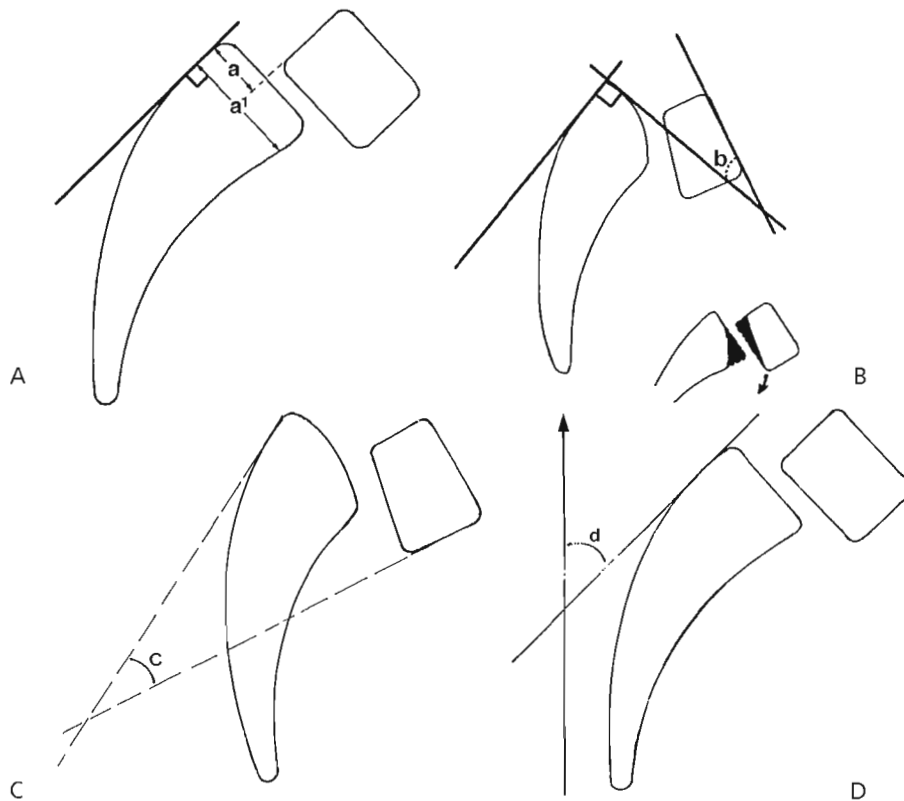


FIGURE 20-4. Measurement of spondylolisthesis. **A:** Measurement of the amount of forward displacement (a) and of the sagittal diameter of S1 (a') allows calculation of the percent slip. **B:** Measurement of the slip angle (b), which is the kyphosis at the area of the slip (i.e., the L5-S1 kyphosis). As the slip increases, there is a growth inhibition of the anterior lip of S1 and the posterior lip of L5. Because of this, the vertebra becomes trapezoidal, and using the bottom of L5 does not accurately measure the angular deformity. **C:** Measurement of the sagittal rotation angle (c), which also represents the L5-S1 kyphosis and equals the slip angle. **D:** Measurement of the sacral inclination (d).

of the width of S1 is inaccurate, so the anteroposterior width of L5 is used instead.

Slip Angle

The slip angle measures the amount of lumbosacral kyphosis or sagittal rotation. The kyphosis is measured using the relationship of L5 to S1. A perpendicular to the line at the back of the sacrum, as drawn above, forms the sacral measuring line. A line is drawn along the upper end plate of L5, and the angle formed by these two lines is the slip angle, which normally is in lordosis and expressed by a negative sign (38) (Fig. 20-4B). Boxall et al. (15) have used the line along the inferior edge of L5 for their measurement, but this edge is often difficult to visualize accurately. In addition, with more marked slips L5 is often trapezoidal in shape, and using the lower edge gives the additive measurement of the kyphosis and the wedging of L5.

Sagittal Rotation

The amount of sagittal rotation can also be measured as the angle between the lines drawn along the back of the sacrum and along the back of L5. This sagittal rotation angle (SRA) should equal the slip angle measured above (Fig. 20-4C).

In larger degrees of slip (either translation or angulation), it is seen that L4 shows retrolisthesis on L5. In these severe slips (more than 50%), the slip angle of L4, in relation to the sacrum is also measured, because, after an L4-to-sacrum fusion this is the effective lumbosacral slip angle.

Sacral Inclination

The inclination of the sacrum to the vertical is measured by the angle of a line along the posterior edge of the sacrum and the vertical (a line drawn parallel to the edge of the x-ray film) (Fig. 20-4D).

Anatomic Changes

There are changes in the shape of L5 and S1 that are noted. The contour of S1 is altered, in that it is rounded and dome-shaped. The fifth lumbar vertebra becomes trapezoidal in shape, being narrower posteriorly and wider anteriorly.

TREATMENT

There are a large number of treatment choices for the child with spondylolysis or spondylolisthesis. These include doing nothing, observation, limitation of activities, exercises, bracing, casting, repair of a pars defect, fusion, decompression, and reduction of the slip. The problem is selecting the specific treatment for the child. In making this choice, the following factors are considered: the presenting complaint,

age, growth potential, and physical findings, especially neurologic signs and the amount of displacement and slip (slip percentage and slip angle). The different treatment choices in spondylolysis and spondylolisthesis are discussed, along with the indications for each treatment method.

Spondylolysis

Nonoperative

Observation. As noted above, many cases of spondylolysis are asymptomatic. The follow-up depends on the child's growth potential. In a child who has completed growth no follow-up is necessary. In the growing child, on the other hand, regular annual visits with radiographs taken are necessary until the end of growth. The child is allowed to participate in all sports without restriction (Fig. 20-5).

Bracing. When the child presents with pain the question is whether the symptoms are of recent origin, following an acute injury, or whether they are chronic and of long duration. In the cases with pain following a definite injury a SPECT bone scan is performed to determine whether the pars defect is of recent origin, and is an acute fracture. In cases in which the scan is positive, immobilization in a cast or brace is used to aid in healing of the pars defect. The best method to immobilize this area is with a body cast with a leg extension. Healing of the defect has been described with varying success, with healing taking 3 to 4 months, and being documented with oblique views or repeat bone scans, but seldom with CT scans (41–44) (Fig. 20-6).

Following healing of the defect, or when the child becomes asymptomatic with immobilization, even with a persistent pars defect, resumption of all activities is allowed. This includes participation in all sporting or athletic activities with no restriction.

Reduction of Activities. In general, when symptomatic the child with spondylolysis presents with a long history of pain with activity. These cases are treated with restriction of activity and abdominal and spinal muscle-strengthening exercises, with rest being used in the rare case that is very symptomatic. This restriction continues until the child is asymptomatic, at which time gradual resumption of activities is initiated. This treatment plan is also used in the case of spondylolysis with a history of a recent injury in which the bone scan is negative or cold.

If there is no relief with reduction of activities, the use of an orthosis may be suggested to the child and family. Only a very symptomatic child may agree to this treatment alternative. In cases that do not respond to nonoperative treatment, surgery should be offered as an alternative.

Operative

Arthrodesis. A one-level L5 to S1 posterolateral lumbosacral arthrodesis is performed for cases not responsive to

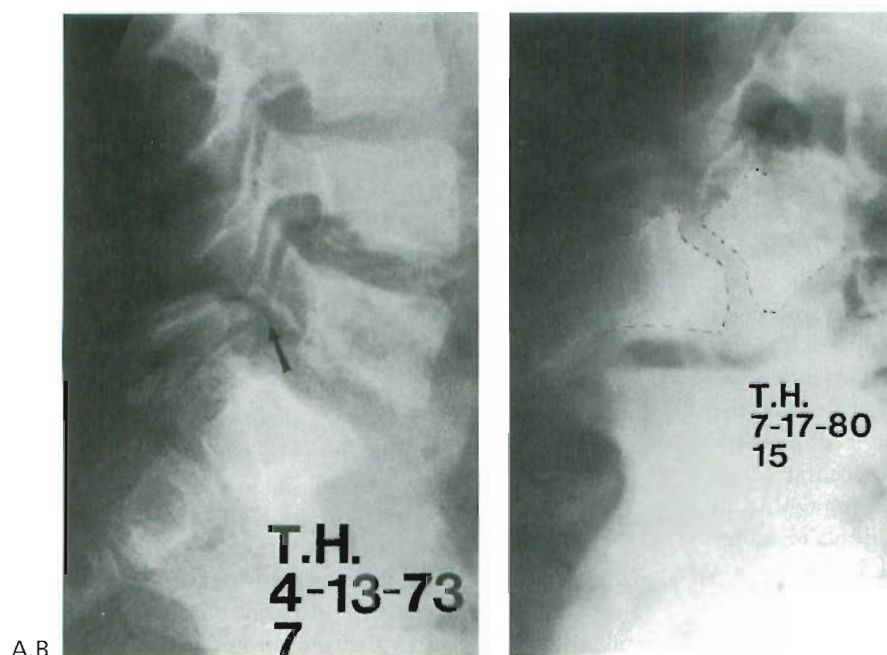


FIGURE 20-5. A: This 7-year-old boy was seen for lordosis. He was completely asymptomatic, and the radiograph showed a pars defect. He was treated with periodic observation. B: At 15 years of age, he was still asymptomatic, and was an outstanding high school athlete.

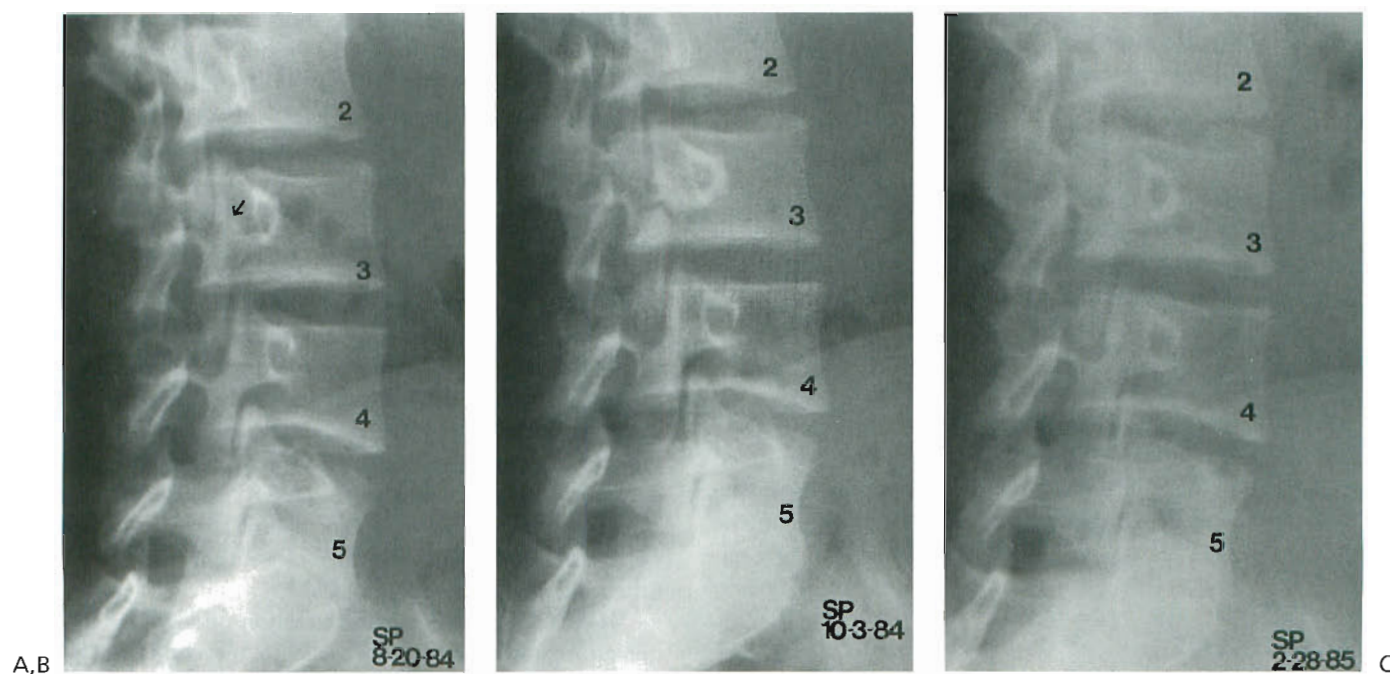


FIGURE 20-6. A: This high school soccer player was seen for mild, generalized low back pain. Physical examination and radiographs, including this oblique view, were normal. B: Two months later, 10 days after an acute back injury suffered during a soccer game, a pars defect at L3 is clearly visible. C: The patient was placed in an orthosis for 3 months, and 1 month later the lesion had healed, the symptoms had resolved, and the patient had returned to playing sports. (From ref. 45, with permission.)

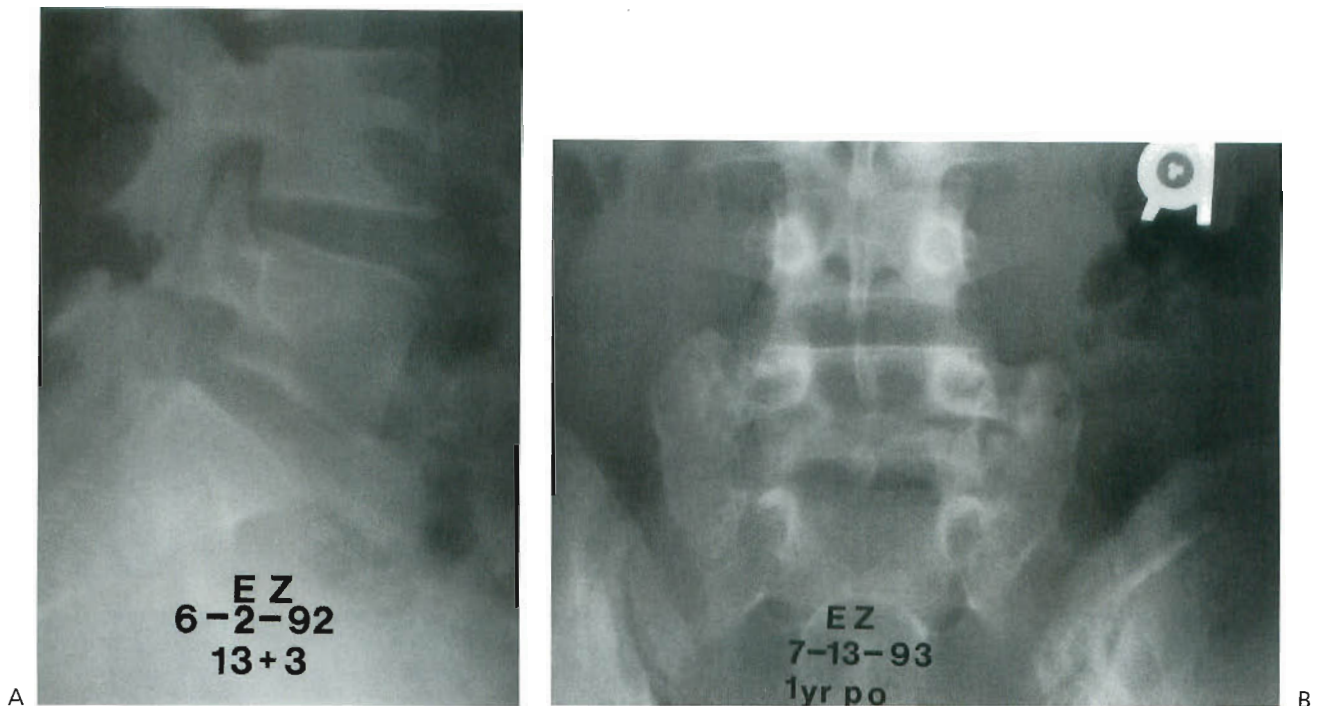


FIGURE 20-7. A patient was seen at the age of 13 years 3 months, with a 1-year history of low back pain. She was a competitive figure skater, and initially reduction in the amount of time spent skating reduced her symptoms. On this presentation, however, the pain interfered with her daily life. **A:** The spot lateral lumbar radiograph showed an L5 spondylolysis. **B:** The patient underwent a one-level posterolateral lumbar arthrodesis, with postoperative immobilization in a one-leg spica cast for 3 months. One year later, she was free of pain and had returned to figure skating, and the radiograph showed a solid posterolateral fusion.

nonoperative treatment. This is performed through a mid-line skin incision with approach to the transverse process and sacral ala via a muscle-splitting incision, as described by Wiltse and Jackson (14) [➔ 2.15], with the addition of autologous iliac bone graft. Postoperative immobilization may or may not be used depending on the surgeon's preference and the patient's symptomatology. Many reports recommend spica casting for 3 months based on their results (15,36,46–50). Others report good results with no immobilization (44), immobilization in a corset (51), or immobilization in a Boston brace (52). I prefer immobilizing these children with a thoracolumbosacral orthosis (TLSO) or body cast with a leg extension, the latter being used in the more painful case, or when the child is very active (Fig. 20-7). Although the rate of success for fusion in spondylolisthesis is superior when a cast with a leg extension is used, no such data exist for fusion for spondylolysis.

Repair of Defect. In cases in which the pars defect is at L4 or higher the preferred technique is direct repair of the pars defect to maintain normal lumbar motion. This technique is used only in those cases of spondylolysis without any slippage. This technique was first described by Buck (53) and popularized by Scott, Johnson and Thompson

(54). Several techniques have been described (55–58). These authors emphasize the careful selection of patients and the learning curve associated with this procedure. The defect is first cleaned of all soft tissue and, if necessary, the nerve root is decompressed with a laminotomy. Then the defect is grafted, and some form of fixation is used to compress the proximal pedicle portion of the pars to the caudal laminar portion (Fig. 20-8).

Good results, with healing in all cases, have been described by Bradford and Iza, who reported good or excellent results in 17 of 21 patients using the Scott technique (59). Others have reported similar results, but follow-up for most patients is short and a large number of these procedures were done for L5 spondylolysis (60–62).

Spondylolisthesis

Nonoperative

Nonoperative treatment is indicated for slips of less than 30 to 50% in the growing child, and for some larger slips in the mature adolescent.

Observation. An asymptomatic slip of less than 30 to 50% in an actively growing child is observed for progression with standing lateral lumbar radiographs. This is also the

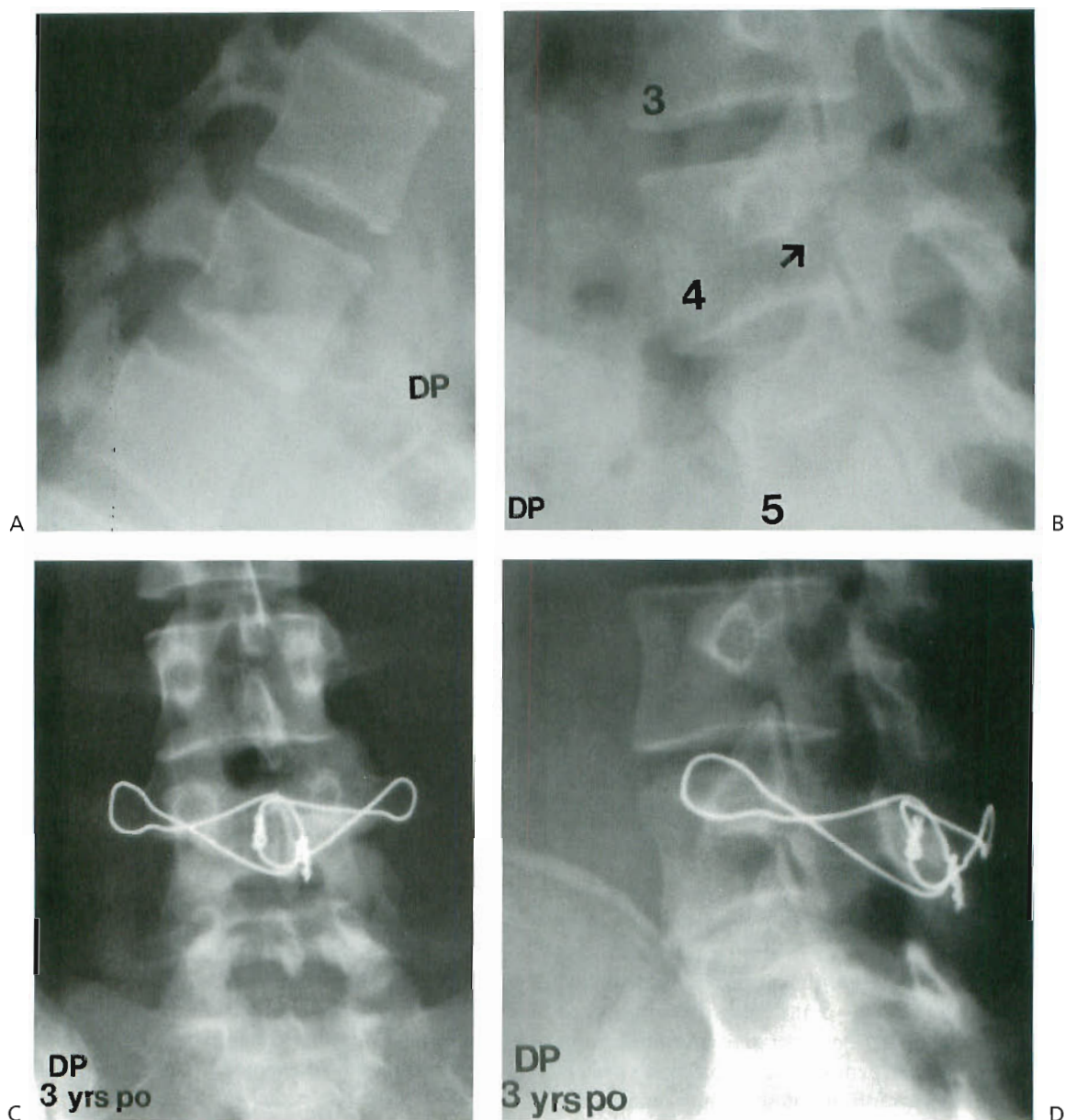


FIGURE 20-8. A 14-year-old girl was seen for chronic low back pain. She had bilateral pars fractures at L4, as seen on (A) lateral and (B) oblique radiographs (arrow, pars defect). The patient underwent bone grafting, with wiring of the defect with a spinous process transverse process wire. The wire position is seen on the posteroanterior view (C), and the solid fusion is seen on the oblique view (D). She was rendered free of pain and returned to full activity.

treatment of an asymptomatic mature adolescent with a slip of less than 50%. If there is no change in the slip angle or the amount of the slip, the observation continues. With an increase in the spondylolisthesis, surgical stabilization is indicated.

Reduction of Activities. A growing child who presents with low back pain and a slip of less than 30 to 50% is advised to limit exercise and sporting activities. After the symptoms subside these activities are resumed.

Bracing. If with restricting the activities the pain does not resolve, the use of a TLSO may be beneficial (43,63,64). This usually requires a period of 6 to 12 weeks in a brace. Once the symptoms are relieved, gradual resumption of activities occurs.

Operative Treatment

Surgical stabilization of the spondylolisthesis should be considered for the symptomatic child who does not respond

to nonoperative management, and the pain prevents full participation in normal activities. In addition, the growing child with a slip of more than 30 to 50%, or the mature adolescent with a slip of more than 75%, should be treated surgically even if there are no symptoms.

Arthrodesis. The surgical procedure used to treat spondylolisthesis is a posterolateral arthrodesis. The approach is with a midline skin incision, and a midline or paramedian approach to the spine. The midline approach is used when decompression is performed [→ 2.15]. When no decompression is necessary the approach is paraspinous, with an incision through the fascia midway between the posterior iliac crest and the midline. The transverse processes and sacral ala are approached either through or around the paraspinous musculature. Iliac bone graft is placed in this prepared bed on the decorticated transverse process and adjacent lateral aspect of the superior articular process, and on the decorticated sacral ala. In decorticating the sacral ala, it has been found best to create a cavity in the ala to place the strips of cancellous graft in this cavity, as described by Hensinger et al. (48). This places the bone graft more vertically, and there is a larger surface area for fusion to the sacrum.

Decision-making. In the surgical treatment of spondylolisthesis, decisions have to be made regarding the levels to be fused, the role of decompression, the role of reduction, the need for an anterior fusion, the use of instrumentation, and decisions regarding immobilization and bed rest. These decisions depend on the degree of the deformity (slip percentage and kyphosis), neurologic symptoms and signs, and on the mobility of the spondylolisthesis shown on flexion and extension radiographs.

Levels to Be Fused. The basic procedure is a posterolateral one-level L5-S1 fusion. The fusion is extended to L4 with greater degrees of slip (i.e., more than 50%) for two reasons. With this degree of slip the transverse process of L5 is displaced anterior to the sacral ala, and it is impossible to expose the transverse process of L5 without exposing the L4 transverse process. In addition, bone graft placed from L5 to the ala will be horizontal and under shear forces, whereas graft from the ala to the L4 transverse process will lie more vertically. A two-level arthrodesis will be necessary in a slip of less than 50%, where the transverse process of L5 is very small, and thus provides an insufficient bed for the fusion.

Decompression. True nerve root compression is evidenced by motor weakness and a sensory deficit, and is confirmed with further imaging studies, which also eliminate other possible causes of the neurologic changes, e.g., a spinal cord or cauda tumor. Usually the L5 root is involved, being compressed at the foraminal level by the proximal part of the pars as it slips forward with the vertebral body, or by the

fibrocartilaginous tissue at the pars defect. In rare cases with a more marked slip the nerve root can be trapped between the transverse process of L5 and the sacral ala. These cases with true root compression are an indication for nerve root decompression. Tight hamstrings are not a sign of root compression, and no correlation has been found between tight hamstrings and the objective neurologic findings of weakness, sensory deficit, or reflex changes (15). Cases with tight hamstrings alone require a fusion without decompression, and after the fusion is solid the tightness resolves with time in the majority of cases.

The basis of decompression is the Gill procedure, with removal of the loose lamina (65). This alone does not decompress the nerve root, additional dissection and a formal root decompression being necessary. Nerve root decompression alone is contraindicated in the growing child and should always be accompanied by a spinal fusion (65,66). Wiltse believes that root decompression is rarely necessary, and that tight hamstrings, abnormal reflexes, and motor weakness recover after a posterior fusion alone (14). The author believes that a formal decompression of the nerve gives the nerve the best chance of recovery. This must be weighed against the chance of increased slip, which follows a decompression and fusion (see below).

Reduction. When treating spondylolisthesis the question of reduction is always brought up. Reasons given for reduction, rather than *in situ* fusion, are reduced pseudarthrosis rate, elimination of the risk for postoperative slip progression, saved motion segments, and reduced clinical deformity. A large number of articles have been written about different techniques for reduction, without in fact demonstrating that the results in these areas are improved following reduction; the majority of these articles include adolescents as well as adults. Muschik et al. compared anterior fusion with anterior and posterior fusion, and reduction with transpedicular screws in 59 children (67). In addition to the expected radiographic improvement, they reported a lower rate of pseudarthrosis (7 versus 24%). However, the complication rate was the same, and there was no difference subjectively for the patient or objectively on clinical examination. This highlights the dilemma for the surgeon in recommending a bigger operation.

Many different techniques have been described to reduce spondylolisthesis, following the initial description of Jenkins in 1936 (68). The techniques include halo-femoral traction (6,40,69), cast reduction (70), instrumentation (71,72), and the combined anterior and posterior approach (33,73–75).

Distraction instrumentation across the lumbar spine has been shown to be bad because it reduces the lumbar lordosis and has a major deleterious effect on sagittal balance. Of the two deformities in spondylolisthesis (translation and kyphosis), the kyphosis is the more important problem and should be focused on. In addition, the degree of instability as shown on flexion/extension x-rays is important, as well as the magnitude of the symptoms.

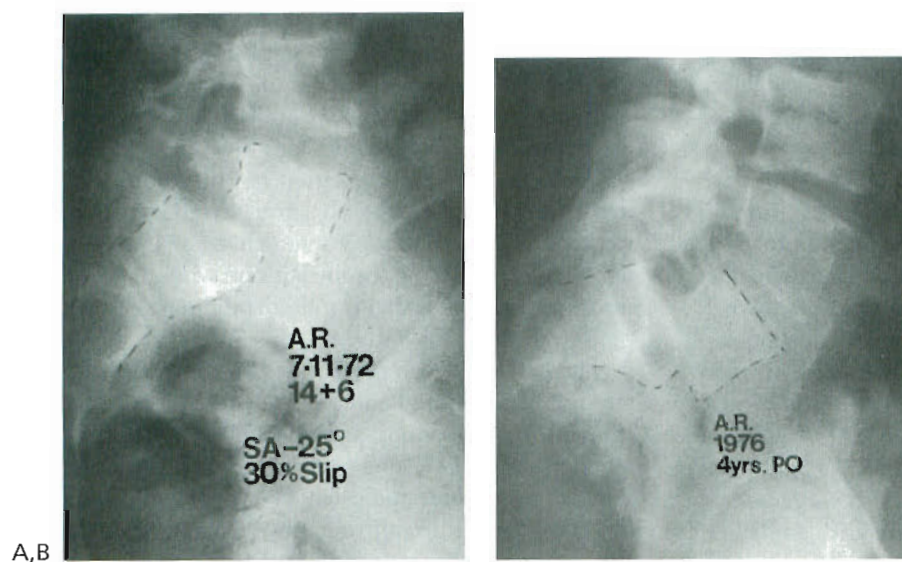


FIGURE 20-9. A patient was seen at the age of 14 years 6 months with chronic low back pain. **A:** The lateral lumbosacral view showed spondylolisthesis with a 30% slip and a -25 -degree slip angle. An L4-to-sacrum fusion was performed, followed by postoperative immobilization in a cast. **B:** Four years after operation, a radiograph shows a solid fusion with no alteration in displacement or slip: a fusion *in situ*. The patient had complete pain relief.

Minor degrees of slip (less than 25%) are treated with fusion *in situ*, unless there is instability on flexion/extension views [► 2.15] (Fig. 20-9). In those with demonstrated instability, in larger degrees of slip translation, or with kyphosis, cast reduction can be used. The cast is a single leg spica that is applied 5 to 7 days postoperatively on a Risser frame, with the child in traction and a support under the sacrum, and the thigh (and pelvis) in extension (70) (Fig. 20-10). In these greater degrees of slip, even with slips over 75%, the relationship of L4 to the sacrum is important as the fusion extends to L4. This includes the sagittal relationship, and slip angle of L4 to the sacrum, because this becomes the effective lumbosacral joint after fusion (77).

With more marked deformity, especially increased lumbosacral kyphosis and spondyloptosis, some degree of reduction may be necessary to realign the lumbar spine over the sacrum in a position to achieve a solid fusion. Closed reduction with halo-femoral traction or spinous process wiring can result in some reduction, with the reduction held with a posterior fusion; and some authors describe the addition of an anterior fusion (73,74,78–80). An L5 vertebral body resection, or vertebrectomy, has been described for spondyloptosis. This shortens the lumbar spine, allowing reduction of L4 onto the sacrum, where it is fused (81,82). All these more complex reduction techniques have as a complication a significant incidence of radiculopathy, which must be borne in mind in the decision-making process (79,83–85).

The role of the combined techniques for the treatment of these severe grades of spondylolisthesis is small, as the majority of cases of spondylolisthesis in children and adolescents are of lesser grades, and can be adequately treated with a posterior fusion and cast reduction alone. The posture in children with severe slips is due in part to the spasm associated with the slip and to pain. When the fusion is solid, the pain disappears and the posture improves.

The need to resort to more complex reduction techniques with instrumentation in children and adolescents is thus rare. In those children in whom it is necessary to reduce the kyphosis or the amount of slipping to restore the balance of L3 over the sacrum, combined anterior and posterior arthrodesis with instrumentation may be necessary. However, it remains controversial as to whether this approach improves the ultimate clinical outcome.

Anterior Fusion. The role of an anterior fusion in the treatment of spondylolisthesis is reserved for the more severe grades. This can be part of a two-staged approach, with the anterior fusion being via the trans- or retroperitoneal approach (86–89). A useful method of anterior arthrodesis, which is becoming more popular for *in situ* fusion of severe or partially reduced slips, is with a fibular graft inserted posteriorly through the sacrum into the body of L5 (90,91) [► 2.16]. This technique requires mobilization of the thecal sac so that the graft can be inserted from the midline, and thus some neurologic complications, usually temporary, can be expected (92).

Instrumentation. The initial use of instrumentation in the treatment of spondylolisthesis was with Harrington distraction instrumentation to reduce the slip. This use has disappeared due to the effect of distraction on reducing the lumbar lordosis. Transpedicular fixation is commonly used in the lumbar spine in adults for lumbar fusions for various conditions, including spondylolisthesis [► 2.8 & 2.9]. The use in adolescents can be for stabilization of the lumbosacral spine, taking the place of the spica cast. Reduction of the spondylolisthesis is possible with positioning on the operative table, and the lumbosacral relationship being maintained internally with the instrumentation (93) (Fig. 20-11). The use of transpedicular instrumentation to maintain the reduced position is becoming more com-

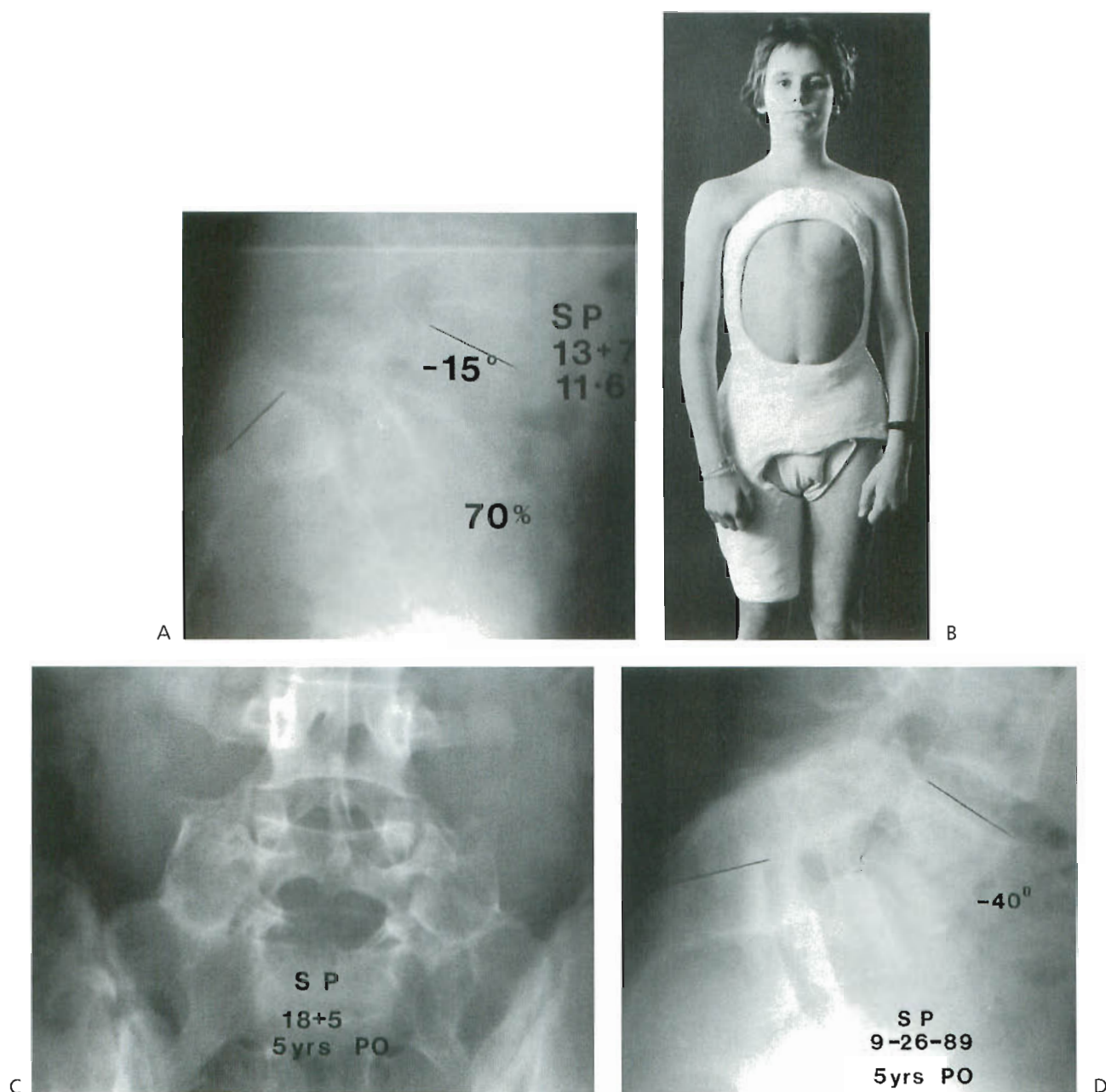


FIGURE 20-10. A patient was seen at the age of 13 years 7 months with severe low back and leg pain and inability to bend forward. **A:** The spot lateral lumbar view showed a 70% spondylolisthesis with an L5 slip angle of 15 degrees, but an L4 slip angle of -15 degrees. He underwent a posterolateral L4-to-sacrum fusion, and 5 days after operation had reduction on a Risser frame, and was placed in a single-leg spica cast (**B**). He wore the leg extension for 4 months and a body cast for an additional 3 months. (From ref. 76, with permission.) **C:** Five years after the operation, he was free of pain, and his fusion was solid. **D:** The lateral view showed reduction of the displacement and slip angle, with improvement of the L4-to-sacrum slip angle. Note the retrolisthesis of L4 on L5.

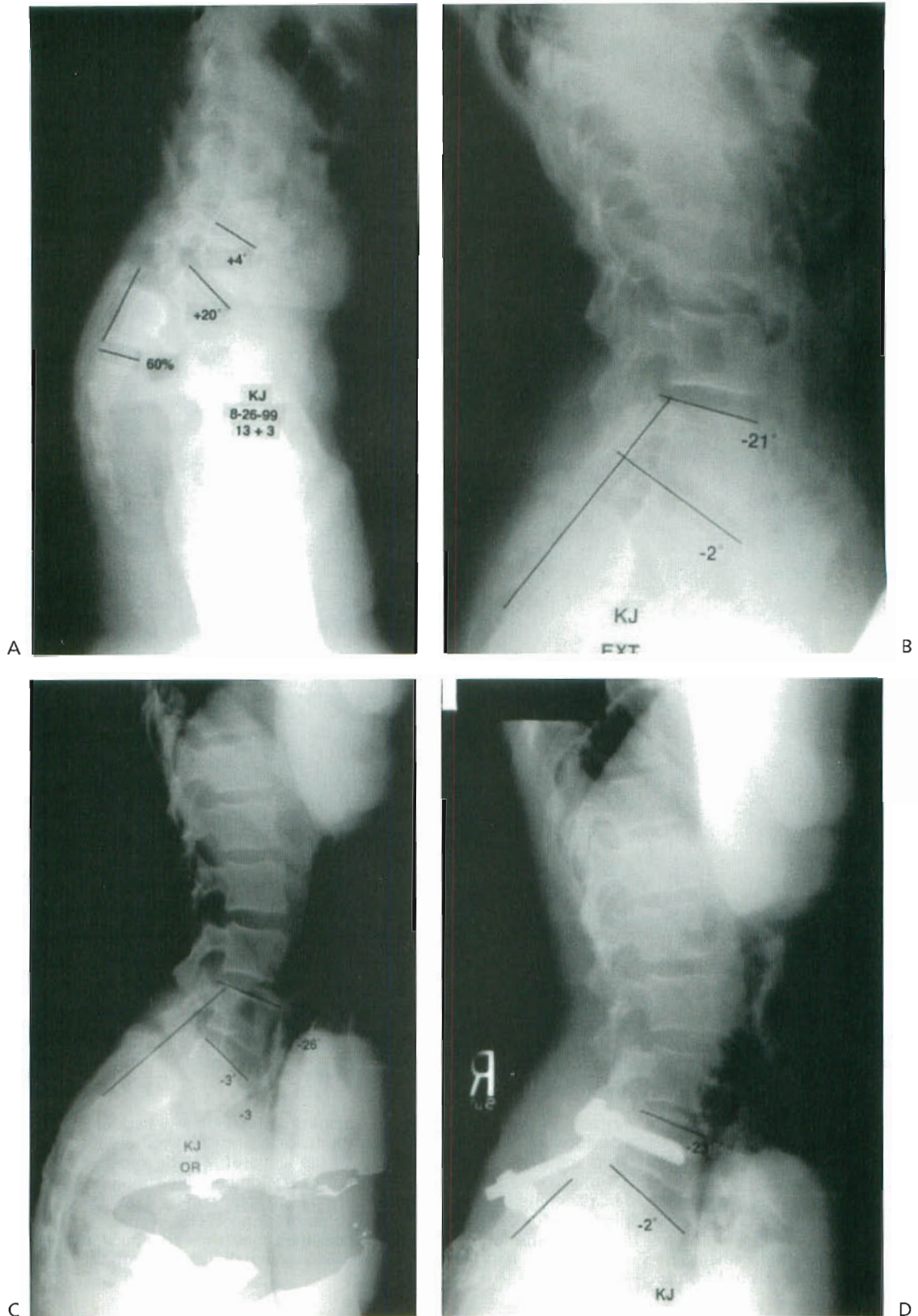


FIGURE 20-11. A patient presented at the age of 13 years 3 months with increasing lumbosacral pain that was restricting her activities. **A:** A standing spot lateral of the lumbosacral area showed a 60% L5-S1 spondylolisthesis with an L5 slip angle of +20 degrees and an L4 slip angle of +4 degrees. **B:** An extension radiograph showed that this was very mobile, correcting to a slip angle of L4 of -21 degrees. **C:** She was positioned on the operating table with supports under her thighs, which extended her hips and spine, reducing the L4 slip angle to -26 degrees. **D:** She underwent a L4 to S1 posterolateral fusion with transpedicular instrumentation, and the postoperative radiograph shows maintenance of the correction with a L4 slip angle of -23 degrees.

monly used because it replaces a spica cast and is more acceptable to adolescents.

Amundson et al. have described a technique of intraoperative reduction of spondylolisthesis using the instrumentation on grades I to IV. This is time-consuming, has a high incidence of radiculopathy, and the need for these complete reductions has never been proven (83).

Immobilization and Bed Rest. The possible immobilization following fusion varies from no immobilization (8,94) or a brace, to a single or bilateral spica cast (7,48), with the patient ambulatory or on a period of bed rest postoperatively. As fusion is performed for symptoms, the author prefers to use some immobilization postoperatively, both to slow the patient down and to improve the fusion rate. For a routine fusion there is usually cast reduction, with the patient ambulatory in a single leg spica cast, and immobilization being continued for 4 months. The patient who is in a great deal of pain, with marked spasm, or who has a larger degree of slip (more than 50 to 75%) with significant kyphosis, requires a period of bed rest following the fusion, which is usually performed posteriorly, or may be used with a combined approach. Five to seven days after the fusion, a spica cast is applied with cast reduction, with the patient being nonambulatory for 3 to 4 months. After this, the

patient is ambulatory in a body cast or brace without a leg extension. After fusion with instrumentation the author prefers to use a body brace (TLSO) with a thigh extension and hinge hip joint for 3 to 4 months until the fusion is solid.

Scoliosis Associated with Spondylolisthesis

Scoliosis may be associated with spondylolisthesis in two scenarios—it may be spondylolisthesis with adolescent idiopathic scoliosis, two common conditions that may coexist, or the scoliosis may be due to the spondylolisthesis. The latter may be a spasm curve or may be due to an asymmetric slip, the so-called olisthetic scoliosis. In a study of 500 consecutive cases with adolescent idiopathic scoliosis, Fisk et al. found the incidence of pars defects was 6.2%, the same as the incidence in the general population (95). In this case, the scoliosis and the spondylolysis or spondylolisthesis are assessed separately and treated independently. If the scoliosis needs fusion it should be treated accordingly; the same holds true for the spondylolisthesis. There is no current evidence that a long fusion to L4 results in increased stress on spondylolisthesis with an increase in the slip. Whenever possible, the caudal extent of the fusion should be to L3 to preserve

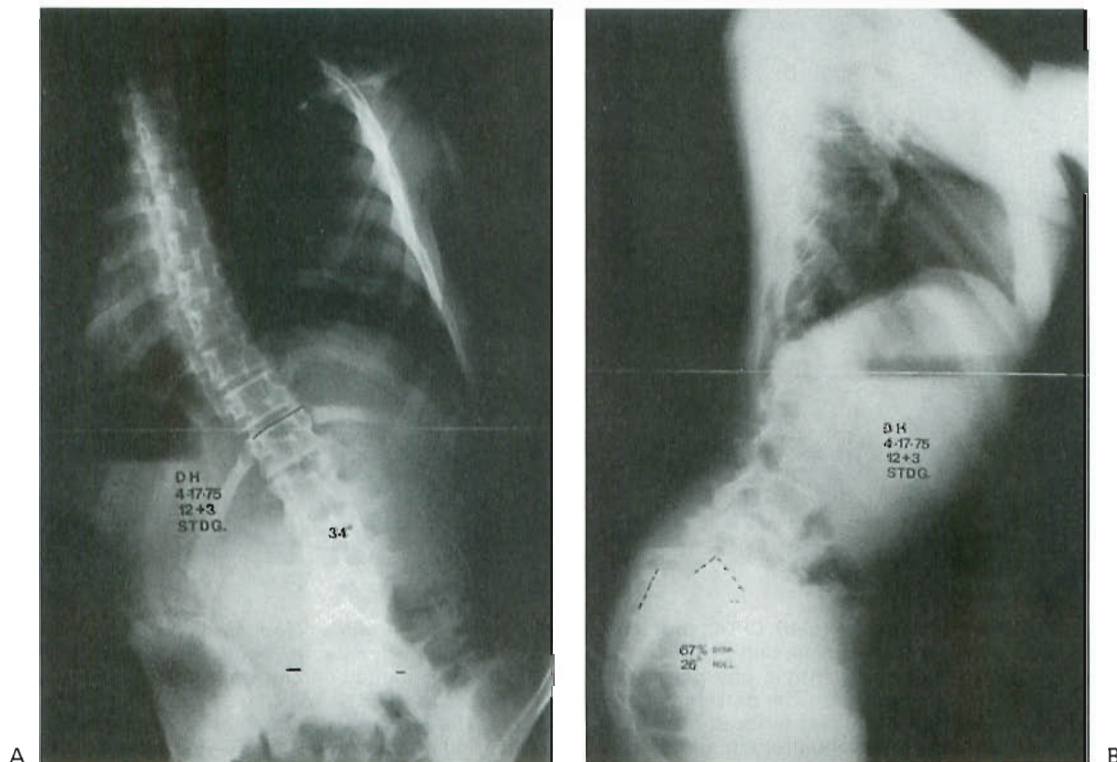


FIGURE 20-12. A patient was seen at the age of 12 years 3 months with a “spasm” scoliosis, lumbosacral pain, and sciatica. B: The lateral standing radiograph showed a relatively vertical sacrum, 67% displacement, a 26-degree slip angle, and total lordosis from T1 to L5. Note how the torso is displaced forward in relation to the pelvis. (*continued*)

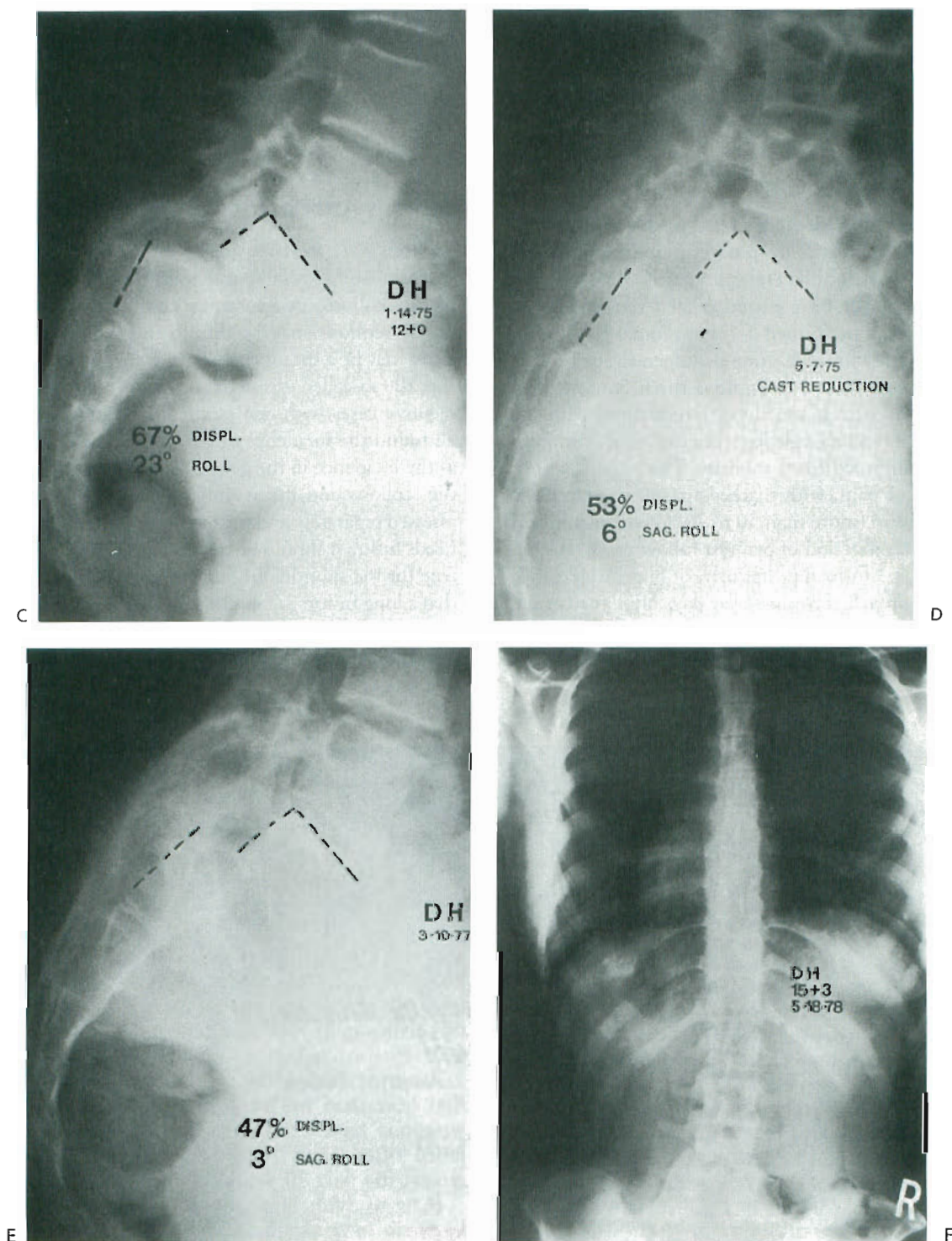


FIGURE 20-12. (continued) C: The spot lateral lumbar view shows an elongated pars of L5, with a pars defect near the pedicle. D: The patient was treated by nerve root decompression, L4-S1 transverse process fusion, and partial reduction by double pantaloons cast application in a hyperextended position. The percentage of slip was reduced from 67 to 53%, but, more importantly, the slip angle was reduced from 23 to 6 degrees. The patient was nonambulatory for 3 months, then was ambulatory in a body cast for an additional 3 months. E: At a 2-year follow-up visit the patient's fusion was solid, she was free of pain, and there was no loss of correction. F: An anteroposterior view 3 years after surgery shows the solid lumbosacral fusion and total disappearance of the scoliosis.

motion segments, even though no concrete scientific evidence exists for possible problems with a fusion to L4. Careful observation of the spondylolisthesis below a fusion is necessary till the end of growth. The possible occurrence of scoliosis requiring fusion to L4 and an asymptomatic slip requiring fusion to L4 is very rare, and the author knows of no such occurrence. If this does occur all attempts must be made to fuse the scoliosis to the upper lumbar spine, with an anterior fusion and instrumentation for the lumbar curve, and a posterior fusion for both curves and the spondylolisthesis.

A spasm scoliosis consists of a long, sweeping curve with a curve pattern atypical for adolescent idiopathic scoliosis. It is usually due to spasm, or rarely due to an unequal slip with rotation at the lumbosacral junction. The curve reduces or disappears when the patient is supine. These cases benefit from a period of being supine in a cast postoperatively, and the curve disappears with a solid fusion (Fig. 20-12).

COMPLICATIONS

Pseudarthrosis

The pseudarthrosis rate in the literature varies from 0 to 25% (15,18,36,46,48,96,97), the majority being under

15%, with the higher rate attributed to severe spondylolisthesis (15). Most of the studies in the literature are small, and no statistical correlation was found between the degree of slip and the pseudarthrosis rate, although the studies suggest a higher pseudarthrosis rate with higher grades of slip.

Increased Slippage

Increased slip, as measured by the amount of displacement or kyphosis, can increase in the presence of a solid fusion (14,15,23,47,49,96). However, it should be noted that these fusions were assessed with radiographs, and not CT scans, which may demonstrate that at least some cases of increased slipping are due to the fact that the fusion was not solid. This further slip following surgery is more common following a posterior dissection, especially after decompression, all tending to remove the midline-stabilizing structures and thus increase lumbosacral instability. This is also more common with higher degrees of spondylolisthesis, with more displacement or kyphosis (Fig. 20-13). Burkus et al. have shown that slippage is less common following cast reduction, compared to the cases with lesser immobilization postoperatively (46).

Neurologic Complications

Radiculopathy has been described following the reduction of spondylolisthesis, and this complication must be appreci-

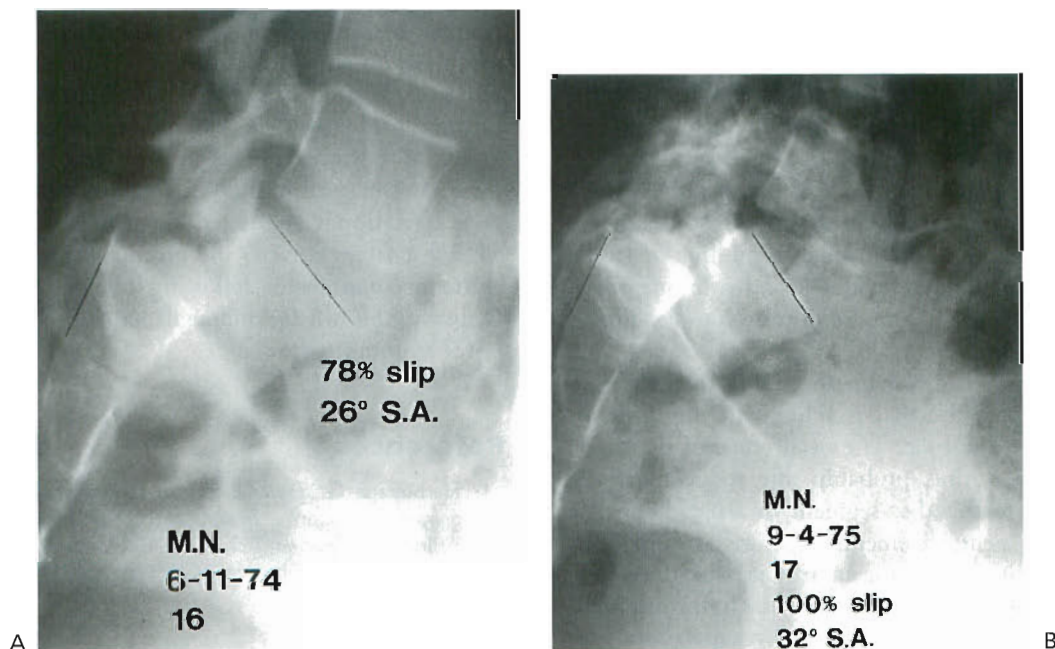


FIGURE 20-13. A: A patient was seen at the age of 16 years with low back pain and sciatica. A: The spot lateral lumbosacral radiograph showed a 78% displacement and a slip angle of 26 degrees. The patient was treated with decompression and L4-to-S1 posterolateral fusion, and after operation was ambulatory in a brace. B: Two months later, a standing radiograph in the brace showed an increase in the displacement to 100% and a slight increase in the slip angle to 32 degrees. (continued)

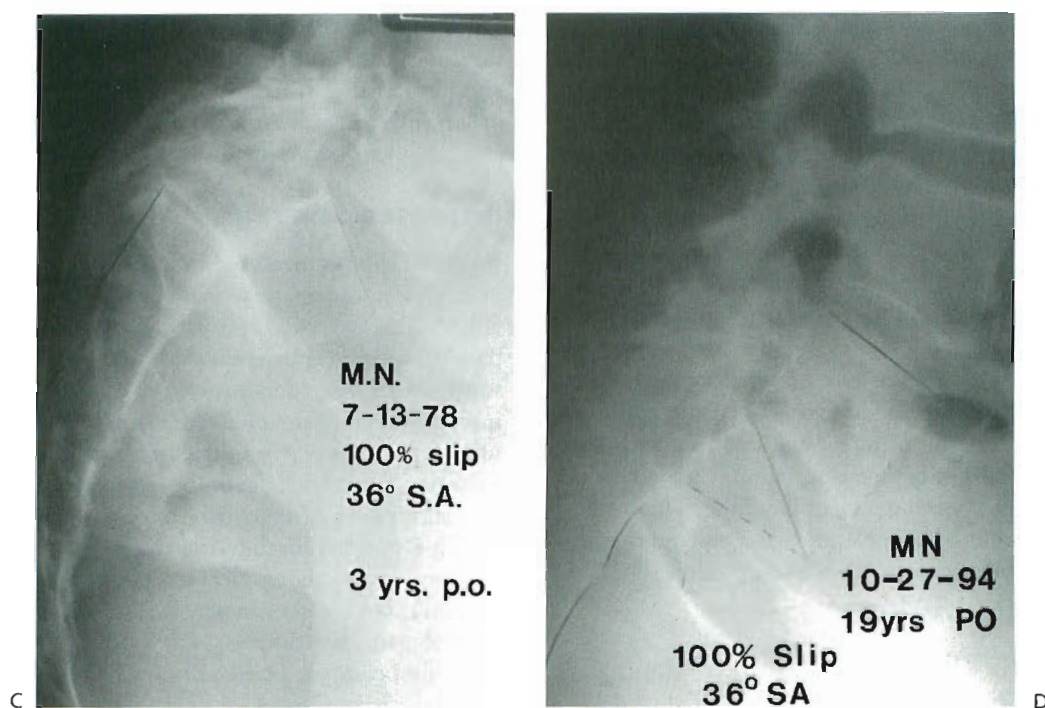


FIGURE 20-13. (continued) **C:** Three years after operation the fusion was solid, the patient was free of pain, and the lumbosacral relation was unchanged. **D:** Nineteen years after operation the patient remains free of pain, without a single degree of change detectable in her radiographs.

ated if this treatment plan is used (79,83–85). This is usually an L5 lesion with varying recovery rates.

In addition, acute postoperative cauda equina syndrome has been reported after a simple posterolateral fusion, without decompression or reduction (98,99). All but three of the patients in the multicenter report of Schoenecker et al. had severe slips of grade III or IV, and preoperative neurologic symptoms or signs implicating the L5 root or cauda. This complication can occur through a midline or lateral muscle-splitting incision, and with the patient prone or lateral (36,99). The cause of this significant complication is not definitely known.

It has been found that in these severe slips the MRI scan shows a lumbosacral disc that is split, with the posterior half indenting the dural sac. The occurrence of the cauda equina syndrome is thus probably due to acute neural compression due to this disc segment in a patient with a marked slip and neural elements that are already compressed, and thus at risk. During anesthesia, with the relaxation of muscle tone, an acute change occurs in the lumbosacral relationship with acute cauda equina compression. This may explain at least some of the cases that develop cauda equina syndrome, and suggests that MRI should be performed on all severe slips prior to surgery. It must be noted that this complication can occur in the absence of presenting neurologic signs or symptoms (98,99).

Even with immediate decompression in these cases, permanent neurologic deficits may still remain. If possible, this complication should be prevented. Any neurologic deficit in a case of spondylolisthesis should be investigated with further imaging studies. Any root compression in a case of severe spondylolisthesis should be decompressed; any of these cases may be an ideal indication for stabilization with pedicle fixation. Careful neurologic follow-up is essential in all cases postoperatively, and prompt evaluation and appropriate decompression following imaging studies, follow. Only with knowledge and vigilance can this rare complication be minimized.

References

1. Herbiniaux G. *Traite sur divers accouchemens labprieux, et sur polypes de la matrice*. Bruxelles: JL DeBoubers, 1782.
2. Wiltse LL, Newman PH, Macnab I. Classification of spondylolysis and spondylolisthesis. *Clin Orthop Rel Res* 1976;117:23.

Natural History

3. Borkow SE, Kleiger B. Spondylolisthesis in the newborn. A case report. *Clin Orthop Rel Res* 1971;81:73.
4. Fredrickson BE, Baker D, McHolick WJ, et al. The natural history of spondylolysis and spondylolisthesis. *J Bone Joint Surg Am* 1984;66:699.

5. Newnan PH. The etiology of spondylolisthesis. *J Bone Joint Surg Br* 1963;45:39.
6. Taillard WF. Etiology of spondylolisthesis. *Clin Orthop Rel Res* 1976;117:30.
7. Turner RH, Bianco A Jr. Spondylolysis and spondylolisthesis in children and teen-agers. *J Bone Joint Surg Am* 1971;53:1298.
8. Wiltse L. Spondylolisthesis in children. *Clin Orthop Rel Res* 1961;21:156.
9. Baker D, Mc Hollick W. Spondylolysis and spondylolisthesis in children. *J Bone Joint Surg Am* 1956;38:933.
10. Wiltse LL. Spondylolisthesis, classification and etiology: symposium on the spine, American Academy of Orthopedic Surgeons. St. Louis, MO: CV Mosby, 1969:143.
11. Roche M, Rowe C. The incidence of separate neural arch and coincident bone variations. *J Bone Joint Surg Am* 1952;34:491.
12. Stewart T. The age incidence of neural arch defects in Alaskan natives, considered from the standpoint of etiology. *J Bone Joint Surg Am* 1953;35:937.
13. Newman PH. Surgical treatment for spondylolisthesis in the adult. *Clin Orthop Rel Res* 1976;117:106.
14. Wiltse LL, Jackson DW. Treatment of spondylolisthesis and spondylolysis in children. *Clin Orthop Rel Res* 1976;117:92.
15. Boxall D, Bradford DS, Winter RB, et al. Management of severe spondylolisthesis in children and adolescents. *J Bone Joint Surg Am* 1979;61:479.
16. Saraste H. Long-term clinical and radiological follow-up of spondylolysis and spondylolisthesis. *J Pediatr Orthop* 1987;7:631.
17. Osterman K, Schlenzka D, Poussa M, et al. Isthmic spondylolisthesis in symptomatic and asymptomatic subjects, epidemiology, and natural history with special reference to disk abnormality and mode of treatment. *Clin Orthop Rel Res* 1993;297:65.
18. Velikas EP, Blackburne JS. Surgical treatment of spondylolisthesis in children and adolescents. *J Bone Joint Surg Br* 1981;63:67.
19. Frennered AK, Danielson BI, Nachemson AL. Natural history of symptomatic isthmic low-grade spondylolisthesis in children and adolescents: a seven-year follow-up study. *J Pediatr Orthop* 1991;11:209.
20. Henson J, McCall IW, O'Brien JP. Disc damage above a spondylolisthesis. *Br J Radiol* 1987;60:69.
21. Schlenzka D, Poussa M, Seitsalo S, et al. Intervertebral disc changes in adolescents with isthmic spondylolisthesis. *J Spinal Dis* 1991;4:344.
22. Szypryt EP, Twining P, Mulholland RC, et al. The prevalence of disc degeneration associated with neural arch defects of the lumbar spine assessed by magnetic resonance imaging. *Spine* 1989;14:977.
23. Hensinger RN. Spondylolysis and spondylolisthesis in children and adolescents (review). *J Bone Joint Surg Am* 1989;71:1098.
24. Seitsalo S, Osterman K, Hyvarinen H, et al. Progression of spondylolisthesis in children and adolescents. A long-term follow-up of 272 patients. *Spine* 1991;16:417.
25. Wiltse LL, Widell E Jr, Jackson DW. Fatigue fracture: the basic lesion is isthmic spondylolisthesis. *J Bone Joint Surg Am* 1975;57:17.
26. Jackson DW, Wiltse LL, Cirincione RJ. Spondylolysis in the female gymnast. *Clin Orthop Rel Res* 1976;117:68.
27. Ferguson RJ, McMaster JH, Stanitski CL. Low back pain in college football linemen. *J Sports Med* 1975;2:63.
28. Semon RL, Spengler D. Significance of lumbar spondylolysis in college football players. *Spine* 1981;6:172.
29. Bradford D. Management of spondylolysis and spondylolisthesis. In: Evarts C, ed. *Instructional course lectures, American Academy of Orthopedic Surgeons*, vol 32. St. Louis: CV Mosby, 1983:151.
30. Ogilvie JW, Sherman J. Spondylolysis in Scheuermann's disease. *Spine* 1987;12:251.
31. Rosenberg NJ, Bargar WL, Friedman B. The incidence of spondylolysis and spondylolisthesis in nonambulatory patients. *Spine* 1981;6:35.

Patient Evaluation

32. Newton PA, Johnston CEI. Analysis and treatment of poor outcomes following in situ arthrodesis in adolescent spondylolisthesis. *J Pediatr Orthop* 1997;17:754.

Radiologic Evaluation

33. Lowe RW, Hayes TD, Kaye J, et al. Standing roentgenograms in spondylolisthesis. *Clin Orthop Rel Res* 1976;117:80.
34. Wiltse LL, Winter RB. Terminology and measurement of spondylolisthesis. *J Bone Joint Surg Am* 1983;65:768.
35. Meyerding H. Spondylolisthesis. *Surg Gynecol Obstet* 1932;54:371.
36. Taillard W. Les spondylolisthesis chez l'enfant et l'adolescent. *Acta Orthop Scand* 1955;24:115.

Treatment

37. Blanda J, Berthem D, Moats W, et al. Defects of pars interarticularis in athletes: a protocol for nonoperative treatment. *J Spinal Dis* 1993;6:406.
38. Morita T, Ikata T, Katoh S, et al. Lumbar spondylolysis in children and adolescents. *J Bone Joint Surg Br* 1985;72:620.
39. Steiner ME, Micheli LJ. Treatment of symptomatic spondylolysis and spondylolisthesis with the modified Boston brace. *Spine* 1985;10:937.
40. Wiltse L. Proceedings: lumbar spine: posterolateral fusion. *J Bone Joint Surg Br* 1975;57:261.
41. Winter RB. Spondylolysis and spondylolisthesis in the adolescent: when to do what. *Iowa Orthop J* 1986;6:36.
42. Burkus JK, Lonstein JE, Winter RB, et al. Long-term evaluation of adolescents treated operatively for spondylolisthesis. A comparison of in situ arthrodesis only with in situ arthrodesis and reduction followed by immobilization in a cast. *J Bone Joint Surg Am* 1992;74:693.
43. Freeman BD, Donati NL. Spinal arthrodesis for severe spondylolisthesis in children and adolescents. A long-term follow-up study. *J Bone Joint Surg Am* 1989;71:594.
44. Hensinger R, Lang L, MacEwen G. Surgical management of the spondylolisthesis in children and adolescents. *Spine* 1976;1:207.
45. Pizzutillo PD, Mirenda W, MacEwen GD. Posterolateral fusion for spondylolisthesis in adolescence. *J Pediatr Orthop* 1986;6:311.
46. Dubousset J. Treatment of spondylolysis in children and adolescents. *Clin Orthop* 1997;337:77.


Etiology

47. Albanese M, Pizzutillo PD. Family study of spondylolysis and spondylolisthesis. *J Pediatr Orthop* 1982;2:496.
48. Friberg S. Studies on spondylolisthesis. *Acta Chir Scand* 1939;82(suppl):56.
49. Laurent L, Einola S. Spondylolisthesis in children and adolescents. *Acta Orthop Scand* 1961;31:45.
50. Wynne-Davies R, Scott JH. Inheritance and spondylolisthesis: a radiographic family survey. *J Bone Joint Surg Br* 1979;1979:301.

51. Bosworth D, Fielding J, Demarest L, et al. Spondylolisthesis: a critical review of a consecutive series of cases treated by arthrodesis. *J Bone Joint Surg Am* 1955;37:767.
52. Frennered AK, Danielson BI, Nachemson AL, et al. Midterm follow-up of young patients fused in situ for spondylolisthesis. *Spine* 1991;16:409.
53. Buck JE. Direct repair of the defect in spondylolisthesis. Preliminary report. *J Bone Joint Surg Br* 1970;52:432.
54. Johnson G, Thompson A. The Scott wiring technique for direct repair of lumbar spondylolysis. *J Bone Joint Surg Br* 1992;74:426.
55. Gillet P, Petit M. Direct repair of spondylolysis without spondylolisthesis, using a rod-screw construct and bone grafting of the pars defect. *Spine* 1999;24:1252.
56. Kakiuchi M. Repair of the defect in spondylolysis. Durable fixation with pedicle screws and laminar hooks. *J Bone Joint Surg Am* 1997;79:818.
57. Morshcher E, Gerber B, Fasel J. Surgical treatment of spondylolisthesis by bone grafting and direct stabilization of spondylolysis by means of a hook screw. *Arch Orthop Trauma Surg* 1984;103:175.
58. Songer MN, Rovin R. Repair of the pars interarticularis defect with a cable-screw construct. A preliminary report. *Spine* 1998;23:236.
59. Bradford DS, Iza J. Repair of the defect in spondylolysis or minimal degrees of spondylolisthesis by segmental wire fixation and bone grafting. *Spine* 1985;10:673.
60. Hambly M, Lee CK, Gutteling E, et al. Tension band wiring—bone grafting for spondylolysis and spondylolisthesis. A clinical and biomechanical study. *Spine* 1989;14:455.
61. Nicol RO, Scott JH. Lytic spondylolysis. Repair by wiring. *Spine* 1986;11:1027.
62. Roca, J, Moretta D, Fuster S, et al. Direct repair of spondylolysis. *Clin Orthop Rel Res* 1988;236:192.
63. Bell DF, Ehrlich MG, Zaleske DJ. Brace treatment for symptomatic spondylolisthesis. *Clin Orthop Rel Res* 1988;236:192.
64. Pizzutillo PD, Hummer CD. Nonoperative treatment for painful adolescent spondylolysis or spondylolisthesis. *J Pediatr Orthop* 1989;9:538.
65. Gill G, Manning J, White H. Surgical treatment of spondylolisthesis without spine fusion. *J Bone Joint Surg Am* 1955;37:493.
66. Gill GG. Long-term follow-up evaluation of a few patients with spondylolisthesis treated by excision of the loose lamina with decompression of the nerve roots without spinal fusion. *Clin Orthop Rel Res* 1984;182:215.
67. Muschik M, Zippel H, Perka C. Surgical management of severe spondylolisthesis in children and adolescents. Anterior fusion in situ versus anterior spondylolysis with posterior transpedicular instrumentation and reduction. *Spine* 1997;22:2036.
68. Jenkins J. Spondylolisthesis. *Br J Surg* 1936;24:80.
69. Harris R. Spondylolisthesis. *Ann R Coll Surg Engl* 1951;8:259.
70. Scaglieri O, Frontino G, Bartolozzi P. Technique of anatomical reduction of lumbar spondylolisthesis and its surgical stabilization. *Clin Orthop Rel Res* 1976;117:165.
71. Harrington PR, Dickson JH. Spinal instrumentation in the treatment of severe progressive spondylolisthesis. *Clin Orthop Rel Res* 1976;117:157.
72. Edwards C. Reduction of spondylolisthesis: biomechanics and fixation. *Orthop Trans* 1986;10:543.
73. DeWald RL, Faut MM, Taddonio RF, et al. Severe lumbosacral spondylolisthesis in adolescents and children. Reduction and staged circumferential fusion. *J Bone Joint Surg Am* 1981;63:619.
74. Ohki I, Inoue S, Murata T, et al. Reduction and fusion of severe spondylolisthesis using halo-pelvic traction with a wire reduction device. *Int Orthop* 1980;4:107.
75. Sijbrandij S. Reduction and stabilisation of severe spondylolisthesis. A report of three cases. *J Bone Joint Surg Br* 1983;65:40.
76. Lonstein JE. Cast techniques. In: Lonstein JE, Bradford DS, Winter RB, et al., eds. *Moe's textbook of scoliosis and other spinal deformities*. 3rd ed. Philadelphia: WB Saunders, 1994:129.
77. Bradford D. Spondylolysis and spondylolisthesis. In: Lonstein J, Bradford D, Winter R, et al., eds. *Moe's textbook of scoliosis and other spinal deformities*. 3rd ed. Philadelphia: WB Saunders, 1994:415.
78. Balderston RA, Bradford DS. Technique for achievement and maintenance of reduction for severe spondylolisthesis using spinous process traction wiring and external fixation of the pelvis. *Spine* 1985;10:376.
79. Bradford DS, Gotfried Y. Staged salvage reconstruction of grades IV and V spondylolisthesis. *J Bone Joint Surg Am* 1987;69:191.
80. Bradford DS, Boachie-Adjei O. Treatment of severe spondylolisthesis by anterior and posterior reduction and stabilization. A long-term follow-up study. *J Bone Joint Surg Am* 1990;72:1060.
81. Gaines RW, Nichols WK. Treatment of spondyloptosis by two stage L5 vertebrectomy and reduction of L4 onto S1. *Spine* 1985;10:680.
82. Huizenga B. Reduction of spondyloptosis with two-stage vertebrectomy. *Orthop Trans* 1983;7:21.
83. Amundson G, Edwards C, Garfin S. Spondylolisthesis. In: Rothman R, Simeone F, ed. *The spine*. 3rd ed. Philadelphia: WB Saunders, 1992:913.
84. Matthiass HH, Heine J. The surgical reduction of spondylolisthesis. *Clin Orthop Rel Res* 1986;203:34.
85. Transfeldt EE, Dendrinos GK, Bradford DS. Paresis of proximal lumbar roots after reduction of L5-S1 spondylolisthesis. *Spine* 1989;14:884.
86. Freebody D, Bendall R, Taylor RD. Anterior transperitoneal lumbar fusion. *J Bone Joint Surg Br* 1971;53:617.
87. Bradford DS. Treatment of severe spondylolisthesis. A combined approach for reduction and stabilization. *Spine* 1979;4:423.
88. Sevastikoglou JA, Spangfort E, Aaro S. Operative treatment of spondylolisthesis in children and adolescents with tight hamstrings syndrome. *Clin Orthop Rel Res* 1980;147:192.
89. Verbiest H. The treatment of lumbar spondyloptosis or impending lumbar spondyloptosis accompanied by neurologic deficit and/or neurogenic intermittent claudication. *Spine* 1979;4:68.
90. Bohlman HH, Cook SS. One-stage decompression and posterolateral and interbody fusion for lumbosacral spondyloptosis through a posterior approach. Report of two cases. *J Bone Joint Surg Am* 1982;64:415.
91. Smith MD, Bohlman HH. Spondylolisthesis treated by a single-stage operation combining decompression with in situ posterolateral and anterior fusion. An analysis of eleven patients who had long-term follow-up. *J Bone Joint Surg Am* 1990;72:415.
92. Esses SI, Natout N, Kip P. Posterior interbody arthrodesis with a fibular strut graft in spondylolisthesis. *J Bone Joint Surg Am* 1995;77:172.
93. Emans JB, Waters PM, Hall JE. Technique for maintenance of reduction of severe spondylolisthesis using L4-S4 posterior segmental hyperextension fixation. *Orthop Trans* 1987;11:113.
94. Nachemson A. Repair of the spondylolisthetic defect and intertransverse fusion for young patients. *Clin Orthop Rel Res* 1976;117:101.
95. Fisk JR, Moe JH, Winter RB. Scoliosis, spondylolysis, and spondylolisthesis. Their relationship as reviewed in 539 patients. *Spine* 1978;3:234.

Complications

96. Seitsalo S, Osterman K, Poussa M. Scoliosis associated with lumbar spondylolisthesis. A clinical survey of 190 young patients. *Spine* 1988;13:899.
97. Sherman FC, Rosenthal RK, Hall JE. Spine fusion for spondylolysis and spondylolisthesis in children. *Spine* 1979;4:59.
98. Maurice HD, Morley TR. Cauda equina lesions following fusion in situ and decompressive laminectomy for severe spondylolisthesis. Four case reports. *Spine* 1989;14:214.
99. Schoenecker PL, Cole HO, Herring JA, et al. Cauda equina syndrome after in situ arthrodesis for severe spondylolisthesis at the lumbosacral junction (see comments). *J Bone Joint Surg Am* 1990;72:369.



THE CERVICAL SPINE

RANDALL T. LODER

NORMAL EMBRYOLOGY, GROWTH, AND DEVELOPMENT 799

Embryology 799

Growth and Development 800

Normal Radiographic Parameters 800

CONGENITAL AND DEVELOPMENTAL PROBLEMS 804

Torticollis 804

Klippel-Feil Syndrome 814

Os Odontoideum 815

Developmental and Acquired Stenoses and Instabilities 815

Other Syndromes 820

TRAUMA 822

Fractures and Ligamentous Injuries of the Occipital
Complex to the C1-C2 Complex 823

Fractures and Ligamentous Injuries of C3-C7 827

Spinal Cord Injury without Radiographic Abnormality 827

Transient Quadriplegia 829

Special Injury Mechanisms 829

INFLAMMATORY AND SEPTIC CONDITIONS 830

Juvenile Rheumatoid Arthritis 830

Intervertebral Disc Calcification 831

Pyogenic Osteomyelitis and Discitis 832

Tuberculosis 832

HEMATOLOGIC AND ONCOLOGIC CONDITIONS 833

Benign Tumors 833

Malignant Tumors 835

Many of the diseases and congenital anomalies affecting the pediatric cervical spine are simply a reflection of aberrant growth and developmental processes. This chapter discusses these diseases and anomalies in this framework. A basic knowledge of the normal embryology, growth, and development of the pediatric cervical spine is helpful to understand these conditions. Most of the anomalies and diseases involving the pediatric cervical spine are easily divided into those of the upper (occiput, C1, C2) and lower (C3-C7) segments.

NORMAL EMBRYOLOGY, GROWTH, AND DEVELOPMENT

Embryology

Occipitoaxioatlas Complex

The occiput is formed from at least four or five somites. All definitive vertebrae develop from the caudal sclerotome half of one segment and the cranial sclerotome half of the succeeding segment (1). These areas of primitive mesenchyme separate from each other during fetal growth, then undergo chondrification and subsequent ossification. This chondrification and ossification is a passive process that follows the blueprint laid down by the mesenchymal anlage.

Because of this sequencing the cranial half of the first cervical sclerotome remains as a half segment between the occipital and atlantal rudiments, and is known as the proatlas. The primitive centrum of this proatlas becomes the tip of the odontoid process, whereas its arch rudiments assist in the formation of the occipital condyles (2). The vertebral arch of the atlas separates from its respective centrum, becoming the ring of C1; the separated centrum fuses with the proatlas above and the centrum of C2 below, to become the odontoid process and body of C2. The axis forms from the second definitive cervical vertebral mesenchymal segment. The odontoid process is the fusion of the primitive centra of the atlas and the proatlas half segment. The posterior arches of C2 form from only the second definitive cervical segment.

Thus, the atlas is made up of three main components: the body and the two neural arches. The axis is made up of four main components: the body, the two neural arches, and the odontoid (or five components, if the proatlas rudiment is considered).

Vertebrae C3-C7

These vertebrae follow the normal formation scheme of all vertebrae (3). A portion of the mesenchyme from the sclerotomal centrum creates two neural arches that migrate posteriorly and around the neural tube. This eventually forms the pedicles, the laminae, the spinous processes, and a very small portion of the body. The majority of the body is formed by the centrum. An ossification center develops in each of the two neural arches and one in the vertebral center, with a synchondrosis formed by the cartilage between the ossification centers.

Growth and Development

Atlas

Ossification is present only in the two neural arches at birth (4). These ossification centers extend posteriorly toward the rudimentary spinous process to form the posterior synchondrosis, and anteriorly into the articular facet region to form all of the bone present in the facets. Anteromedial to each facet the neurocentral synchondroses form, joining the neural arches and the body; this occurs on each side of the expanding anterior ossification center. The body starts to ossify between 6 months and 2 years, usually in a single center. By 4 to 6 years the posterior synchondrosis fuses, followed by the anterior synchondroses slightly thereafter. The final internal diameter of the pediatric C1 spinal canal is determined by 6 to 7 years of age. Further growth is obtained only by periosteal appositional growth on the external surface, which leads to thickening and increased height, but without changing the size of the spinal canal.

Axis

The odontoid develops two primary ossification centers that usually coalesce within the first 3 months of life; these centers are separated from the C2 centrum by the dentocentral synchondrosis (5,6). This synchondrosis is below the level of the C1-C2 facets, and contributes to the overall height of the odontoid, as well as to the body of C2. It is continuous with the vertebral body and facets, and it coalesces with the anterior neurocentral synchondroses. These synchondroses progressively close, starting first in the regions of the facets, next at the neurocentral synchondroses, and finally at the dentocentral synchondrosis. This closure occurs between 3 and 6 years of age. The tip of the dens is composed of a cartilaginous region similar to an epiphysis, the chondrum terminale, which develops an ossification center between 5 and 8 years of age, becoming the ossiculum terminale. The ossiculum terminale fuses to the remainder of the odontoid between 10 and 13 years of age.

The posterior neural arches are partially ossified at birth, joined by the posterior synchondrosis. By 3 months of age these arches, growing more posteriorly, form the rudimentary spinous process. By 1 year of age, ossification fills the spinous process, and by 3 years of age, the posterior synchondrosis has fused. Thus, both the posterior and the anterior synchondroses are closed by 6 years of age, and there is no further increase in spinal canal size after this age.

C3-C7

At birth all three ossification centers are present. The anterior synchondrosis (i.e., neurocentral synchondrosis) is slightly anterior to the base of the pedicles; it usually closes between 3 and 6 years of age. The posterior synchondrosis is at the junction of the two neural arches; it usually closes by 2 to 4 years of age. In the neonate and young child the articular facets are horizontal; they become more vertically oriented as the child ages and reaches the normal adult configuration. They are also more horizontal in the upper cervical spine than in the lower cervical spine. The vertebral bodies enlarge circumferentially by periosteal appositional growth, whereas they grow vertically by endochondral ossification. Secondary ossification centers develop at the tips of the spinous processes and the cartilaginous ring apophyses of the bodies around the time of puberty. These ring apophyses are involved in the vertical growth of the body. These secondary ossification centers fuse with the vertebral body around age 25 years.

Normal Radiographic Parameters

Certain radiographic parameters that indicate pathology of the cervical spine in adults represent normal developmental processes in children. These parameters are the atlantooccipital motion and atlanto-dens interval (ADI), pseudosublux-

ation and pseudoinstability, variations in the curvature of the cervical spine that may resemble spasm and ligamentous injury, variations in the presence of skeletal growth and growth centers that may resemble fractures, and anterior soft tissue widening. Normal cervical spine motion in children, is also discussed.

Atlanto-dens Interval and Atlantooccipital Motion

These intervals are determined on lateral flexion and extension radiographs, which should be made voluntarily with the patient awake. The ADI is the space between the anterior aspect of the dens and the posterior aspect of the anterior ring of the atlas (Fig. 21-1). An ADI of more than 5 mm on flexion and extension lateral radiographs indicates instability (7,8). This is more than the 3-mm adult value because of the increased cartilage content of the odontoid and ring of the atlas in children, as well as the increased ligamentous laxity in children. In extension, overriding of the anterior arch of the atlas on top of the odontoid also can be seen in up to 20% of children (9).

A mild increase in the ADI may indicate a subtle disruption of the transverse atlantal ligament. In adults, this ligament ruptures around an interval of 5 mm (10). In chronic atlantoaxial conditions (e.g., rheumatoid arthritis, Down syndrome, congenital anomalies), the ADI is less useful. In children with these disorders who are frequently hypermobile but do not have ruptured transverse atlantal ligaments, the ADI is increased beyond the 3- to 5-mm range. The complement of the ADI, the space available for the cord (SAC), is a more useful measure in this situation. This

space is the distance between the posterior aspect of the dens and the anterior aspect of the posterior ring of the atlas or the foramen magnum. A SAC of less than 13 mm may be associated with neurologic problems (11).

In patients in whom there is an attenuation of the transverse atlantal ligament without rupture, the alar ligament provides some stability. It acts like a checkrein (12), first tightening up in rotation, then becoming completely taut as the odontoid process continues to move posteriorly for a distance equivalent to its full transverse diameter. This safety zone between the anterior wall of the spinal canal of the atlas, the axis, and the neural structures is an anatomic constant equal to the transverse diameter of the odontoid. This constant defines Steel's rule of thirds: one-third cord, one-third odontoid, and one-third space (12). This rule remains constant throughout the growth of the cervical spine (13). The cord can move into this space (safe zone) when the odontoid moves posteriorly because of an attenuated transverse atlantal ligament. It is here that the alar ligament becomes taut, acting as a checkrein and secondary restraint, preventing further movement of the odontoid into the cord. In the chronic situation, it is important to recognize when this safe zone has been exceeded and the child enters the region of impending spinal cord compression. In the case of trauma, the alar ligament is insufficient to prevent a fatal cord injury in the event of another neck injury similar to the one that caused the initial interruption of the transverse atlantal ligament.

Normal ranges of motion at the atlantooccipital joint are not well defined. In a series of 40 normal college freshmen, the tip of the odontoid remained directly below the basion of the skull in both flexion and extension (14). Thus, the

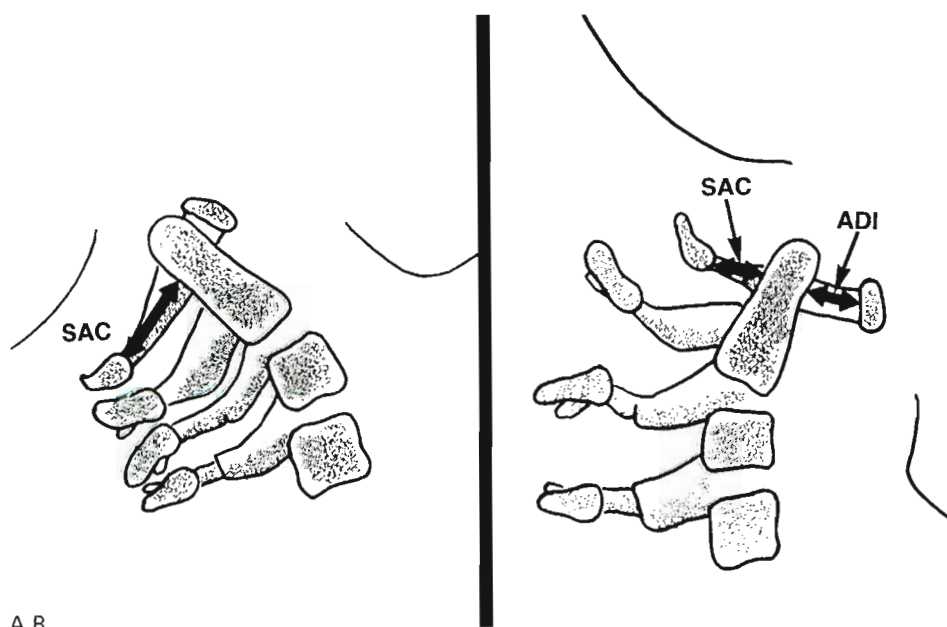


FIGURE 21-1. Lateral view of the atlantoaxial joint. The atlanto-dens interval (ADI) is the distance between the anterior aspect of the dens and the posterior aspect of the anterior portion of the ring of the atlas. The space available for the cord (SAC) is the distance between the posterior aspect of the dens and the anterior aspect of the posterior portion of the ring of the atlas. In children, an ADI of 5 mm or larger is abnormal. In teenagers and adults, a SAC of 13 mm or smaller may be associated with canal compromise. In younger children, spinal cord impingement is imminent if the SAC is equal to or less than the transverse diameter of the odontoid. **A:** The relations in extension. **B:** The relations in flexion.

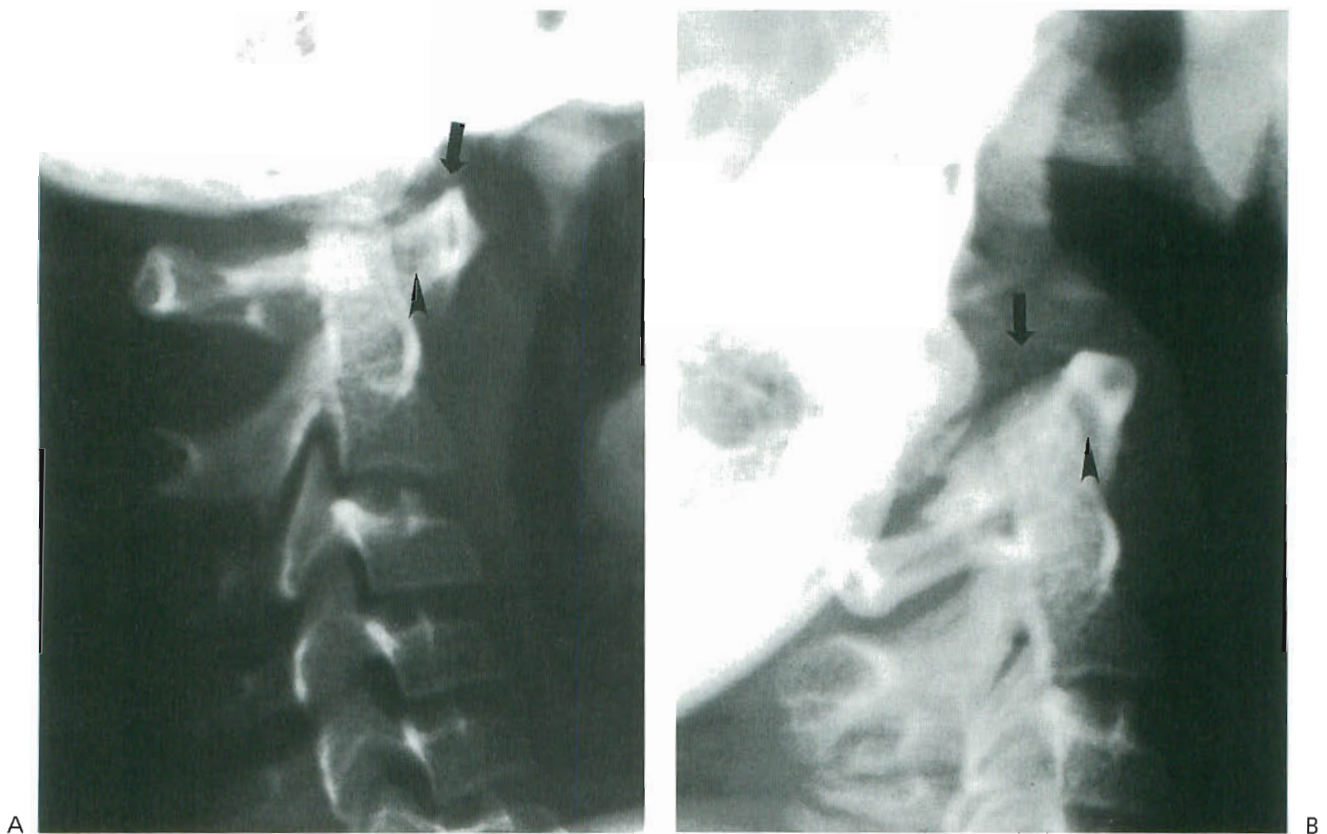


FIGURE 21-2. Lateral flexion (A) and extension (B) radiographs of an 11-year-old boy with Down syndrome. The child presented with loss of hand control when flexing his neck. Using the method of Tredwell and colleagues (15), the atlantooccipital distance is measured as the distance between the anterior margin of the condyles at the base of the skull and the sharp contour of the anterior aspect of the concave joint of the atlas. More than 4 mm of posterior translation is abnormal. The atlantooccipital distance (arrows) measured 10 mm in extension and 1 mm in flexion. The atlantodens interval was 1 mm in extension and 6 mm in flexion, for a total of 5 mm of motion (arrowheads). The space available for the cord was 17 mm in flexion and 20 mm in extension. Both occipitoatlantal instability (more than 4 mm of posterior translation) and atlantodens hypermobility (5-mm atlantodens interval in flexion) were present.

joint should not allow any horizontal translation during flexion and extension. Tredwell and colleagues (15) believe that a posterior subluxation of the atlantooccipital relation in extension of more than 4 mm indicates instability (Fig. 21-2). This can be measured as the distance between the anterior margin of the condyles at the base of the skull and the sharp contour of the anterior aspect of the concave joint of the atlas anteriorly, or as the distance between the occipital protuberance and the superior arch of the atlas posteriorly. Another method to measure posterior subluxation of the atlantooccipital joint is that of Wiesel and Rothman (16) (Fig. 21-3). With this technique, occiput–C1 translation from maximum flexion to maximum extension should be no more than 1 mm in normal adults. These norms in children have not yet been established.

Pseudosubluxation

The C2–C3 interspace, and, to a lesser extent the C3–C4 interspace in children, have a normal physiologic displace-

ment. In a study of 161 children (9), marked anterior displacement of C2 on C3 was observed in 9% of children between 1 and 7 years old. In some children, the anterior physiologic displacement of C2 on C3 is so pronounced that it appears pathologic (pseudosubluxation). To differentiate this from pathologic subluxation, Swischuk (18) has used the posterior cervical line (Fig. 21-4) drawn from the anterior cortex of the posterior arch of C1 to the anterior cortex of the posterior arch of C3. In physiologic displacement of C2 on C3, the posterior cervical line may pass through the cortex of the posterior arch of C2, touch the anterior aspect of the cortex of the posterior arch of C2, or come within 1 mm of the anterior cortex of the posterior arch of C2. In pathologic dislocation of C2 on C3, the posterior cervical line misses the posterior arch of C2 by 2 mm or more.

The planes of the articular facets change with growth. The lower cervical spine facets change from 55 to 70 degrees, whereas the upper facets (i.e., C2–C4) may have initial angles as low as 30 degrees, which gradually increase to 60

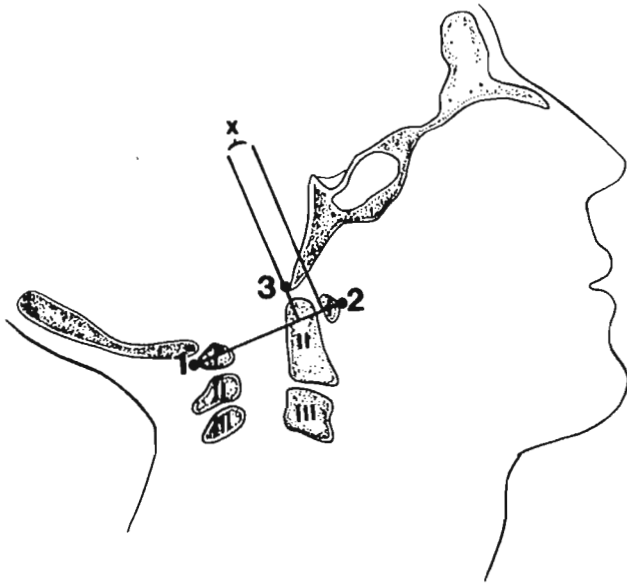


FIGURE 21-3. The method of measuring atlantooccipital instability, according to Wiesel and Rothman (16). The atlantal line joins points 1 and 2. A perpendicular line to the atlantal line is made at the posterior margin of the anterior arch of the atlas. The distance (x) from the basion (3) to the perpendicular line is measured in flexion and extension. The difference between flexion and extension represents the anteroposterior translation at the occipitoatlantal joint; in normal adults, this translation should be no more than 1 mm. (From ref. 17, with permission.)

to 70 degrees. This variation in facet angulation, along with normal looseness of the soft tissues, intervertebral discs, and the relative increase in the size and weight of the skull compared with the trunk, are the major factors responsible for

this pseudosubluxation. No treatment is needed for this normal physiologic subluxation.

Variations in the Curvature and Growth of the Cervical Spine That Can Resemble Injury

In the classic study of Catell and Filtzer (9), 16% of normal children showed a marked angulation at a single interspace, suggestive of injury to the interspinous or posterior longitudinal ligament; 14% showed an absence of the normal lordosis in the neutral position; and 16% showed an absence of the flexion curvature between the second and seventh cervical vertebrae, which could be erroneously interpreted as splinting secondary to injury.

Spina bifida of the posterior arch, or multiple ossification centers of the ring of C1, may mimic fractures. They can be delineated from fractures by their smooth cortical margins. In some children, the posterior ring of C1 remains cartilaginous, which is usually of no clinical significance (20). Spina bifida also may occur at other cervical levels, and the overlapping lucent areas on anteroposterior radiographs, when crossing a vertebral body, may mimic a vertical fracture of the body.

The dentocentral synchondrosis of C2 begins to close between 5 to 7 years of age (5). However, it may be visible in vestigial forms up to 11 years of age (9), and may be erroneously interpreted as an undisplaced fracture. Similarly, the apical odontoid epiphysis (i.e., ossiculum terminale) may appear by 5 years of age, although it most typically appears around 8 years of age. This also can be misinterpreted as an odontoid tip fracture.

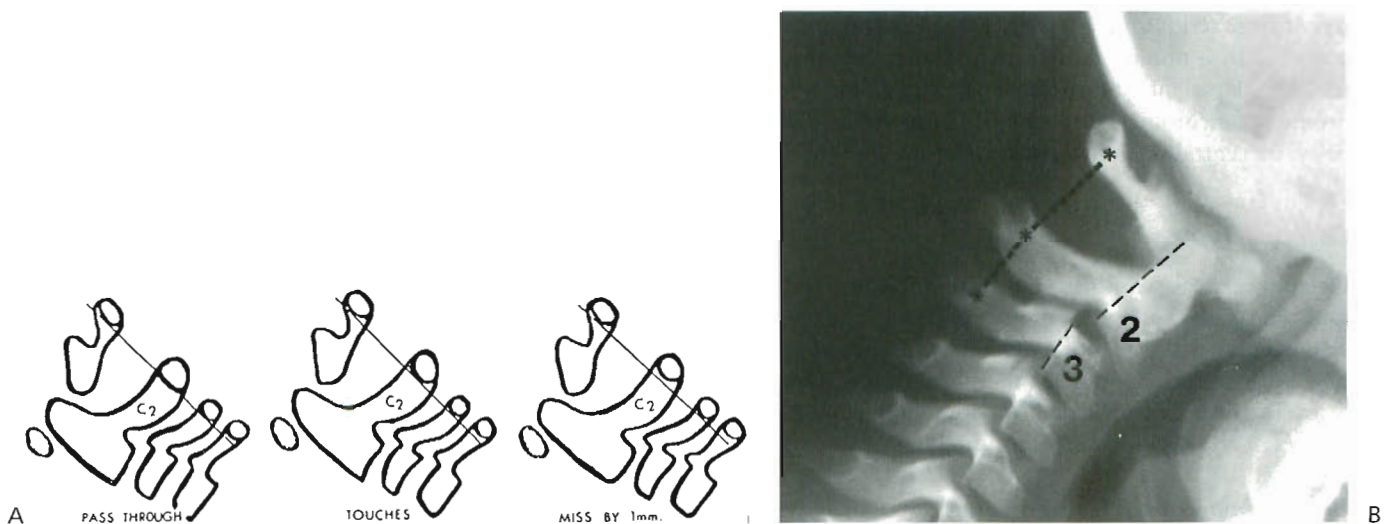


FIGURE 21-4. A: The posterior line of Swischuk showing the normal limits: passing through or just behind the anterior cortex of C2 (left); touching the anterior aspect of the cortex of C2 (center); coming within 1 mm of the anterior aspect of the cortex of C2 (right). (From ref. 18, with permission.) B: Lateral cervical radiograph of a child with pseudosubluxation at C2-C3, shown by a stepoff at C2-C3 (dashed line), but with a normal posterior cervical line (asterisk line). Also note the anterior wedging of the C3 vertebral body. (From ref. 19, with permission.)

Wedging of the C3 vertebral body is a normal radiographic finding in 7% of younger children (21) (Fig. 21-4B). If it is not known whether the wedging is a normal variation or a true compression fracture in the face of a traumatic history, a computed tomography (CT) scan will demonstrate fracture lines through the body if a fracture is present. In the lower cervical levels, secondary centers of ossification of the spinous processes may resemble avulsion fractures (9).

Normal Lower Cervical Spine Motion

Generally, the interspinous distances increase with increasing age, being the smallest at C4–C5 and the largest at C6–C7, until 15 years of age, when this distance is largest at C5–C6 (8). The anteroposterior displacement, from hyperflexion to hyperextension, decreases from C2–C3 to C6–C7. The angular displacement is greatest (15 degrees) at C3–C4 and C4–C5 for children 3 to 8 years of age; is greatest (17 degrees) at C4–C5 for children 9 to 11 years of age; and is greatest (15 degrees) at C5–C6 for children 12 to 15 years of age.

CONGENITAL AND DEVELOPMENTAL PROBLEMS

Torticollis

Torticollis is a combined head tilt and rotatory deformity. Torticollis indicates a problem at C1–C2, because 50% of the cervical spine rotation occurs at this joint. A head tilt alone indicates a more generalized problem in the cervical spine. The differential diagnosis of torticollis is large, and can be divided into osseous and nonosseous types. In a recent large series from a tertiary care pediatric orthopaedic center (22), a nonmuscular cause of torticollis was found in 18% of patients, most frequently the Klippel-Feil syndrome or a neurologic disorder (ocular pathology, obstetric palsy, or central nervous system lesion).

Osseous Types

Occipitocervical synostosis, basilar impression, and odontoid anomalies are the most common congenital/developmental malformations of the occipitovertebral junction, with an incidence of 1.4 to 2.5 per 100 children (23). These lesions arise from a malformation of the mesenchymal anlagen at the occipitovertebral junction.

Basilar Impression. Basilar impression is an indentation of the skull floor by the upper cervical spine. The tip of the dens is more cephalad, and sometimes protrudes into the opening of the foramen magnum. This may encroach on the brainstem, risking neurologic damage from direct injury,

vascular compromise, or alterations in cerebrospinal fluid flow (24).

Basilar impression can be primary or secondary. Primary basilar impression, the most common type, is a congenital abnormality often associated with other vertebral defects (e.g., Klippel-Feil syndrome, odontoid abnormalities, atlantooccipital fusion, atlas hypoplasia). The incidence of primary basilar impression in the general population is 1% (25).

Secondary basilar impression is a developmental condition attributed to softening of the osseous structures at the base of the skull. Any disorder of osseous softening can lead to secondary basilar impression. These include metabolic bone diseases (e.g., Paget disease [26], renal osteodystrophy, rickets, osteomalacia [27]), bone dysplasias and mesenchymal syndromes (e.g., osteogenesis imperfecta [28], achondroplasia [29], hypochondroplasia [30], neurofibromatosis [31]), and rheumatologic disorders (e.g., rheumatoid arthritis, ankylosing spondylitis). The softening allows the odontoid to migrate cephalad and into the foramen magnum.

These patients typically present with a short neck (78% in one series) (32). This shortening is only an apparent deformity because of the basilar impression. Asymmetry of the skull and face (68%), painful cervical motion (53%), and torticollis (15%) can also occur. Neurologic signs and symptoms are often present (33). Many children will have acute onset of symptoms precipitated by minor trauma (34). In cases of isolated basilar impression, the neurologic involvement is primarily a pyramidal syndrome associated with proprioceptive sensory disturbances (motor weakness, 85%; limb paresthesias, 85%). In cases of basilar impression associated with Arnold-Chiari malformations, the neurologic involvement is usually cerebellar, and symptoms include motor incoordination with ataxia, dizziness, and nystagmus. In both types the patients may complain of neck pain and headache in the distribution of the greater occipital nerve and the involvement of cranial nerves, particularly those that emerge from the medulla oblongata (trigeminal [V], glossopharyngeal [IX], vagus [X], and hypoglossal [XII]). Ataxia is a very common finding in children with basilar impression (34). Hydrocephalus may develop as a result of obstruction of the cerebrospinal fluid flow by obstruction of the foramen magnum from the odontoid.

Basilar impression is difficult to assess radiographically. The most commonly used lines are Chamberlain's (35), McRae's (36), and McGregor's (37) (Fig. 21-5). McGregor's line is the best line for screening because the landmarks can be clearly defined at all ages on a routine lateral radiograph. McRae's line is helpful in assessing the clinical significance of basilar impression because it defines the opening of the foramen magnum; in patients who are symptomatic, the odontoid projects above this line. At present, CT with sagittal plane reconstructions can show the osseous relations at the occipitocervical junction more clearly, and magnetic

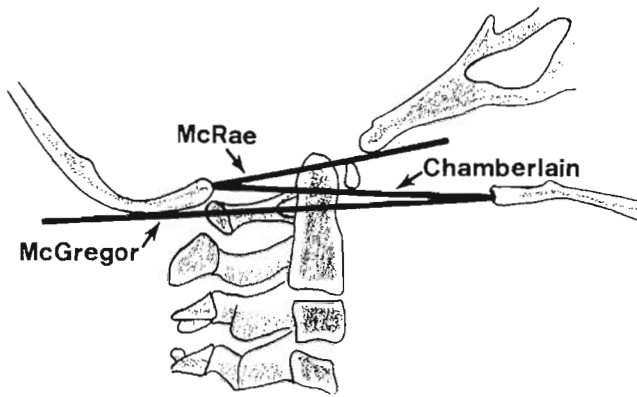


FIGURE 21-5. These landmarks on a lateral radiograph of the skull and upper cervical spine are used to assess basilar impression. McRae's line defines the opening of the foramen magnum. Chamberlain's line is drawn from the posterior lip of the foramen magnum to the dorsal margin of the hard palate. McGregor's line is drawn from the upper surface of the posterior edge of the hard palate to the most caudad point of the occipital curve of the skull. McGregor's line is the best line for screening because of the clarity of the radiographic landmarks in children of all ages.

resonance imaging (MRI) clearly delineates the neural anatomy. Occasionally, vertebral angiography is needed (38).

Treatment of basilar impression can be difficult, and requires a multidisciplinary approach (orthopaedic, neurosurgical, and neuroradiologic) (39). The symptoms rarely can be relieved with customized orthoses (40); the primary treatment is surgical. If the symptoms are caused by a hypermobile odontoid, surgical stabilization in extension at the occipitocervical junction is needed [►2.18]. Anterior excision of the odontoid is needed, if it cannot be reduced (41), but this should be preceded by posterior stabilization and fusion. If the symptoms are from posterior impingement, suboccipital decompression and often, upper cervical laminectomy are needed. The dura often needs to be opened to look for a tight posterior band (32,42). Posterior stabilization also should be performed. These are general statements, and each case should be considered individually.

Atlantooccipital Anomalies. Children with congenital bony anomalies of the atlantooccipital junction present with a wide spectrum of deformities. The anterior arch of C1 is commonly assimilated to the occiput, usually in association with a hypoplastic ring posteriorly (Fig. 21-6), as well as condylar hypoplasia. The height of C1 is variably decreased, allowing the odontoid to project upward into the foramen magnum (i.e., the primary basilar impression). More distal cervical anomalies can also occur in association with the atlantooccipital anomaly. The odontoid may be misshapen, or directed posteriorly more than normal. Up to 70% of children with this condition have a congenital fusion of C2-C3 (Fig. 21-6). (Posterior congenital fusion of C2-C3 is a clue that occiput-C1 anomalies, or other more distal cervi-

cal fusions, may be present. These may be cartilaginous initially, and not appear on plain radiographs until the child becomes more mature.)

Clinically, these children resemble those with Klippel-Feil syndrome: short, broad necks; restricted neck motion; low hairline; high scapula; and torticollis (42,43). The skull may be deformed and shaped like a "tower skull." They also may have other associated anomalies, including dwarfism, funnel chest, jaw anomalies, cleft palate, congenital ear deformities, hypospadias, genitourinary tract defects, and syndactyly. They can present with neurologic symptoms during childhood, but more symptoms appear between 40 and 50 years of age. These symptoms can be initiated by traumatic or inflammatory processes, and they progress slowly and relentlessly. Rarely do they present suddenly or dramatically, although they have been reported as a cause of sudden death. The most common signs and symptoms, in decreasing order of frequency, are neck and occipital pain, vertigo, ataxia, limb paresis, paresthesias, speech disturbances, hoarseness, diplopia, syncope, auditory malfunction, and dysphagia (44,45).

Standard radiographs are difficult to obtain, because of fixed bony deformities and overlapping shadows from the mandible, occiput, and foramen magnum. An x-ray beam, directed 90 degrees perpendicular to the skull (rather than to the cervical spine), usually gives a satisfactory view of the occipitocervical junction. The anomaly usually is studied further with CT. In young children, the head-wag automography technique can be quite useful (46). This technique involves side-to-side rotation of the child's head, while a slow anteroposterior radiographic exposure of the upper cervical spine is performed. This rotation blurs the overlying head and mandibular structures, allowing for improved visualization of the occiput-C1-2 complex.

The position of the odontoid, relative to the opening of the foramen magnum, has been described by measuring the distance from the posterior aspect of the odontoid to the posterior ring of C1 or the posterior lip of the foramen magnum, whichever is closer (43,47). This should be determined in flexion, because this position maximizes the reduction in the SAC. If this distance is less than 19 mm, a neurologic deficit is usually present. Lateral flexion and extension views of the upper cervical spine often show up to 12 mm of space between the odontoid and the C1 ring anteriorly (43); associated C1-C2 instability has been reported to develop eventually in 50% of these patients.

MRI is used to visualize the neural structures. Flexion-extension MRI is often necessary to fully evaluate the pathology (48). Compression of the brainstem or upper cervical cord anteriorly occurs from the backward-projecting odontoid. This produces a range of findings and symptoms, depending on the location and degree of compression. Pyramidal tract signs and symptoms (e.g., spasticity, hyperreflexia, muscle weakness, gait disturbances) are most common, although signs of cranial nerve involvement (e.g., di-

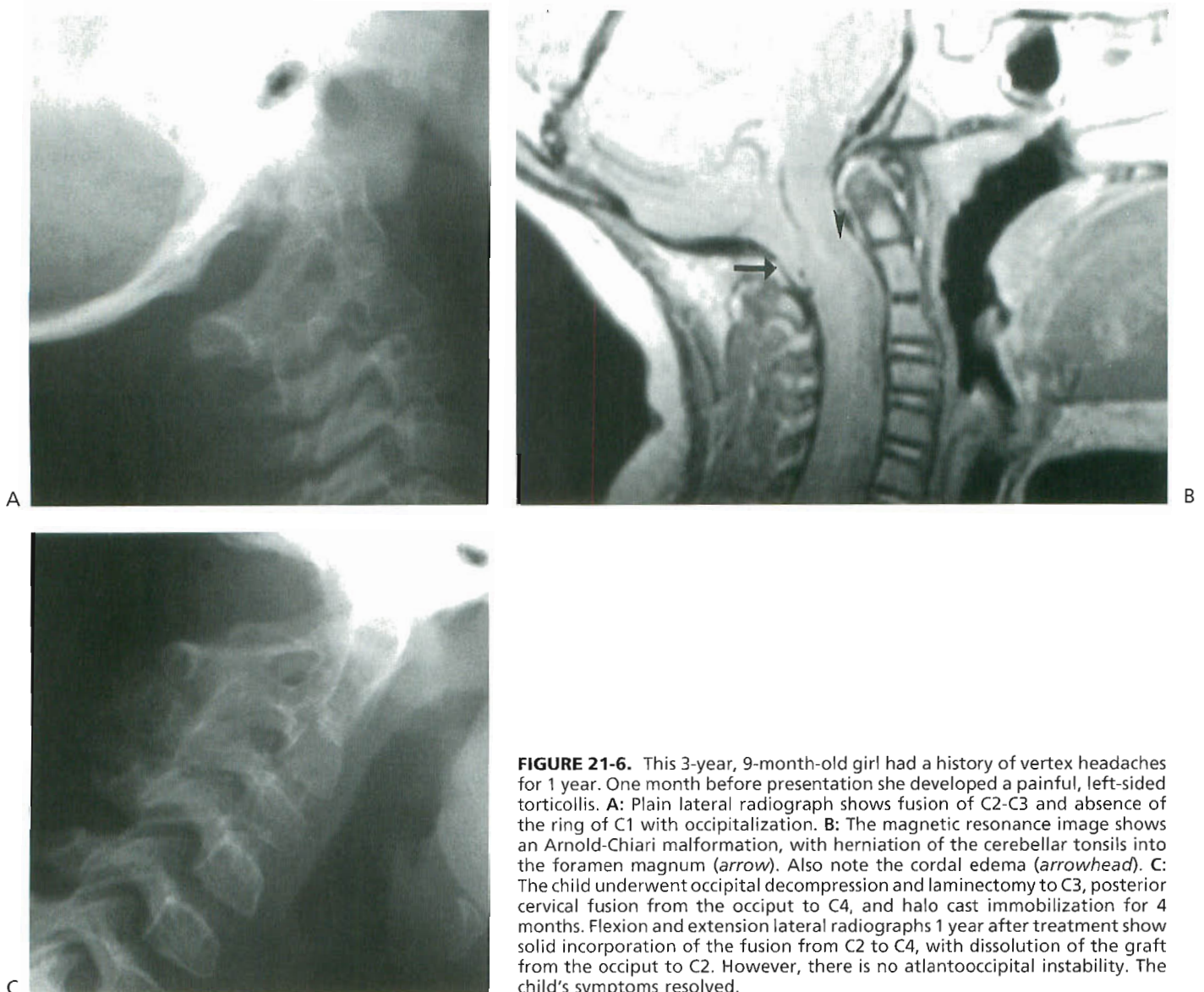


FIGURE 21-6. This 3-year, 9-month-old girl had a history of vertex headaches for 1 year. One month before presentation she developed a painful, left-sided torticollis. **A:** Plain lateral radiograph shows fusion of C2-C3 and absence of the ring of C1 with occipitalization. **B:** The magnetic resonance image shows an Arnold-Chiari malformation, with herniation of the cerebellar tonsils into the foramen magnum (arrow). Also note the cordal edema (arrowhead). **C:** The child underwent occipital decompression and laminectomy to C3, posterior cervical fusion from the occiput to C4, and halo cast immobilization for 4 months. Flexion and extension lateral radiographs 1 year after treatment show solid incorporation of the fusion from C2 to C4, with dissolution of the graft from the occiput to C2. However, there is no atlantooccipital instability. The child's symptoms resolved.

plopia, tinnitus, dysphagia, auditory disturbances) can be seen. Compression from the posterior lip of the foramen magnum or dural constricting band can disturb the posterior columns, with a loss of proprioception, vibration, and tactile senses. Nystagmus also occurs frequently as a result of posterior cerebellar compression. Vascular disturbances from vertebral artery involvement can result in brainstem ischemia, manifested by syncope, seizures, vertigo, and unsteady gait. Cerebellar tonsil herniation can occur. The altered mechanics of the cervical spine may result in a dull, aching pain in the posterior occiput and neck, with intermittent stiffness and torticollis. Irritation of the greater occipital nerve may cause tenderness in the posterior scalp.

The natural history of atlantooccipital anomalies is unknown. The neurologic symptoms may develop so late, and progress so slowly, because the frequently associated C1-C2

instability progresses with age, and the increased demands placed on the C1-C2 interval produce gradual spinal cord or vertebral artery compromise.

Treatment is difficult. Surgery for atlantooccipital anomalies is more risky than with isolated anomalies of the odontoid (42,45). For this reason, nonoperative methods should be attempted, initially. Cervical collars, braces, and traction often help for persistent complaints of head and neck pain, especially after minor trauma or infection. Immobilization may achieve only temporary relief if neurologic deficits are present. Patients with evidence of a compromised upper cervical area should take precautions not to expose themselves to undue trauma.

When symptoms and signs of C1-C2 instability are present, a posterior C1-C2 fusion is indicated [2.17]. Preliminary traction to attempt reduction is used if necessary. If

reduction is possible and there are no neurologic signs, surgery has an improved prognosis (42,44,45). Posterior signs and symptoms may be an indication for posterior decompression, depending on the evidence of dural or osseous compression. Results vary from complete resolution to increased deficits and death (42,49). In the instance of no instability but only compressive pathology, the role of concomitant posterior fusion has not yet been determined. However, if decompression (whether anterior or posterior) can destabilize the spine, concomitant posterior fusion should be considered.

Unilateral Absence of C1. This congenital malformation of the first cervical vertebra is, in essence, a hemiatlas or a congenital scoliosis of C1. Doubousset (50) has described 17 patients with this absence. No definite population incidence is known. The problem often is associated with other anomalies common to children with congenital spine deformities (e.g., tracheoesophageal fistula).

Two-thirds of the children present at birth; the others develop torticollis and are noticed later. A lateral translation of the head on the trunk, with variable degrees of lateral tilt and rotation (best appreciated from the back) is the typical finding. There also may be severe tilting of the eye line. The sternocleidomastoid muscle is not tight, although regional aplasia of the muscles in the nuchal concavity of the tilted side is noted. Neck flexibility is variable and decreases with age. The condition is not painful. Plagiocephaly can occur, and increases as the deformity increases. Neurologic signs (e.g., headache, vertigo, myelopathy) are present in about one-fourth of the patients. The natural history is unknown.

Standard anteroposterior and lateral radiographs rarely give the diagnosis, although the open-mouth odontoid view may suggest it. Tomograms or CT scans usually are needed to visualize the anomaly (Fig. 21-7). The defect can range from a hypoplasia of the lateral mass to a complete hemiatlas with rotational instability and basilar impression. Occasionally the atlas is occipitalized. There are three types of this disorder. Type I is an isolated hemiatlas. Type II is a partial or complete aplasia of one hemiatlas, with other associated anomalies of the cervical spine (e.g., fusion of C3-C4, congenital bars in the lower cervical vertebrae). Type III is a partial or complete atlantooccipital fusion and symmetric or asymmetric hemiatlas aplasia, with or without anomalies of the odontoid and the lower cervical vertebrae.

Once this malformation is diagnosed entire spinal radiographs should be taken to rule out other congenital vertebral anomalies. Other imaging studies that may be needed are vertebral angiography and MRI. Angiography should be performed if operative intervention is undertaken, because arterial anomalies (e.g., multiple loops, vessels smaller than normal, abnormal routes between C1 and C2) often are found on the aplastic side. MRI also should be performed if operative intervention is undertaken, because many of

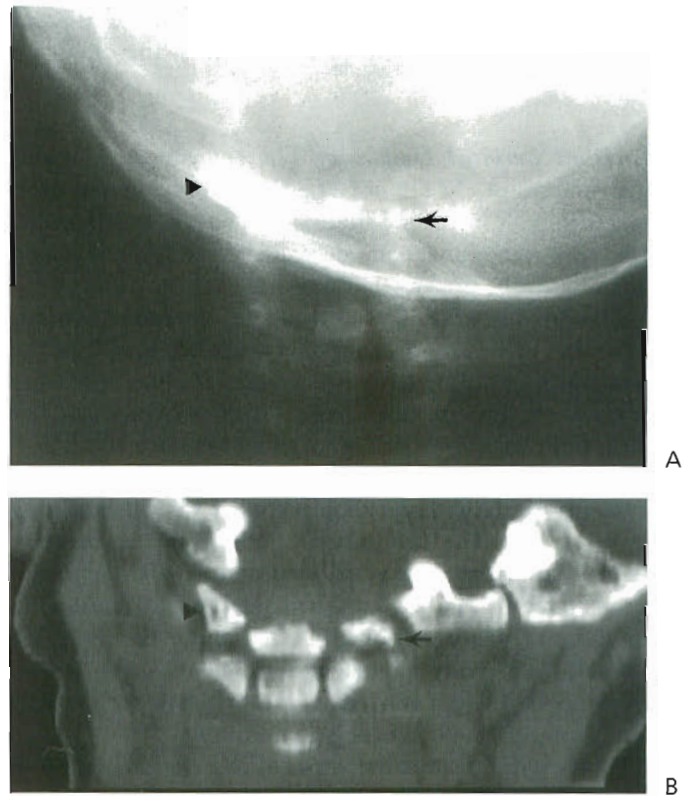


FIGURE 21-7. This 2-month-old girl presented with left-sided torticollis. Physical examination revealed no tightness in the sternocleidomastoid muscle, but reduced right lateral extension was present. **A:** An anteroposterior radiograph of the cervical spine demonstrates the head tilt and suggests a hypoplastic lateral mass on the patient's left at C1 (arrow) compared with that on the patient's right (arrowhead). **B:** A computed tomography scan with frontal reconstruction clearly demonstrates the left hypoplastic lateral mass of C1 (arrow), with a normal right lateral mass (arrowhead). Further workup of this child demonstrated nearly complete tracheal stenosis, which required reconstructive surgery. The lateral tilt of the neck has been slowly resolving with gentle physiotherapy and improvement of normal cervical muscle motor tone.

these children will have stenosis of the foramen magnum, and occasionally an Arnold-Chiari malformation.

The deformity should be observed to document the presence or absence of progression. This observation is primarily clinical (e.g., photographic), because radiographic measurements are difficult if not impossible to obtain. Bracing does not halt the progression of the deformity. Surgical intervention is recommended in those patients with severe deformities. A preoperative halo cast is used for gradual traction correction over 6 to 8 days. An ambulatory method of gradual cervical spine deformity correction has been described using the halo-Ilizarov technique (51). A posterior fusion from the occiput-C2 or occiput-C3 is then performed, [➤2.18] depending on the extent of the anomaly. Decompression of the spinal canal is necessary when the canal size is not ample, either at that time or if it is projected not to be able to fully accommodate the developed spinal

cord. The ideal age for posterior fusion is between 5 and 8 years, corresponding to the age at which the canal size reaches adult proportions.

Familial Cervical Dysplasia. The epidemiology of this atlas deformity (52) is not known. Clinical presentation varies from an incidental finding to a passively correctable head tilt, suboccipital pain, decreased cervical motion, or a clunking of the upper cervical spine.

Plain radiographs are difficult to interpret. Various anomalies of C1, most commonly a partial absence of the posterior ring of C1, typically are seen. Various anomalies of C2 also commonly exist, e.g., a shallow hypoplastic left facet. Other dysplasias of the lateral masses, facets, and posterior elements, and occasionally spondylolisthesis, are seen. Occiput–C1 instability is frequently seen; C1–C2 instability rarely is seen. The delineation of this complex anatomy often is seen best with a CT scan and three-dimensional reconstruction (Fig. 21-8). When symptoms of instability are present, MRI in flexion and extension is recommended to assess the presence and magnitude of neural compression. Occipitocervical junction instability attributable to the malformation may lead to neural compromise.

Nonsurgical treatment consists of observation every 6 to 12 months to ensure that instability does not develop, either clinically (e.g., progressive weakness and fatigue or objective signs of myelopathy) or radiographically, with lateral flexion and extension radiographs. Surgical intervention is recommended for persistent pain, torticollis, and neurologic symptoms. A posterior fusion from the occiput to C2 usually is required [➔2.18], with gradual preoperative reduction using an adjustable halo cast (51).

Atlantoaxial Rotary Displacement. Atlantoaxial rotary displacement is one of the most common causes of childhood torticollis. Rotary displacements are characteristically

a pediatric problem, but they may occur in adults. There are several causes. Because the resultant radiographic findings and treatment regimens are the same for all pediatric causes, they are discussed as a unit, and individual exceptions are noted where necessary.

The confusing terminology includes rotary dislocation, rotary deformity, rotational subluxation, rotary fixation, and spontaneous hyperemic dislocation (53,54). “Atlantoaxial rotary subluxation” is probably the most accepted term used in describing the common childhood torticollis. “Subluxation” is misleading, however, because cases of subluxation usually present within the normal range of motion of the atlantoaxial joint. “Rotary displacement” is a more appropriate and descriptive term because it includes the entire range of pathology, from mild subluxation to complete dislocation. If the deformity persists, the child presents with a resistant and unresolving torticollis that is best termed “atlantoaxial rotary fixation or fixed atlantoaxial displacement.” Gradations exist between the very mild, easily correctable rotary displacement and the rigid fixation. Complete atlantoaxial rotary dislocation rarely has been reported in surviving patients.

The radiographic findings of rotary displacement are difficult to demonstrate (55). With rotary torticollis the lateral mass of C1 that has rotated anteriorly appears wider and closer to the midline (medial offset), whereas the opposite lateral mass is narrower and away from the midline (lateral offset). The facet joints may be obscured because of apparent overlapping. The lateral view shows the wedge-shaped lateral mass of the atlas lying anteriorly where the oval arch of the atlas normally lies, and the posterior arches fail to superimpose because of the head tilt (Fig. 21-9). These findings may suggest occipitalization of C1 because with the neck tilt the skull may obscure C1. The normal relation between the occiput and C1 is believed to be maintained in children with atlantoaxial rotary displacement. A lateral radiograph of the skull may demonstrate the relative positions of C1 and C2 more clearly than a lateral radiograph of the cervical spine. This is because tilting of the head also tilts C1, which creates overlapping shadows and makes interpretation of a lateral spinal radiograph difficult.

The difficulty with plain radiographs is differentiating the position of C1–C2 in a child with subluxation from that in a normal child whose head is rotated, because both give the same picture. Open-mouth views are difficult to obtain and interpret, and the lack of cooperation and diminished motion on the part of the child often make it impossible to obtain these special views. Cineradiography has been recommended, but the radiation dose is high and patient cooperation may be difficult because of muscle spasms (55,56). CT is helpful in this situation if it is done properly (57). A CT scan, when taken with the head in the torticollis position, may be interpreted by the casual observer as showing rotation of C1 on C2. If the rotation of C1 on C2 is within the normal range, as it usually is early in this condi-

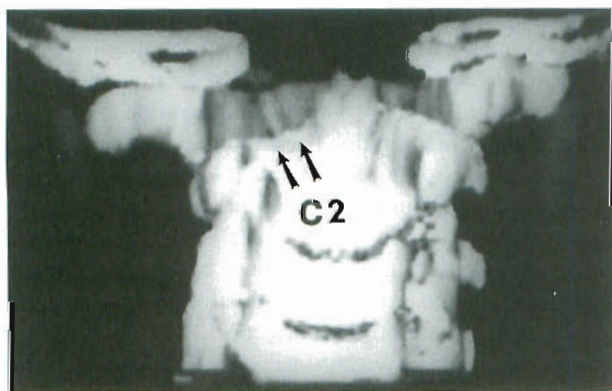


FIGURE 21-8. A three-dimensional computed tomography scan of the upper cervical spine in a child with familial cervical dysplasia. The left superior facet of C2 is shallow and hypoplastic (arrows). (From ref. 52, with permission.)

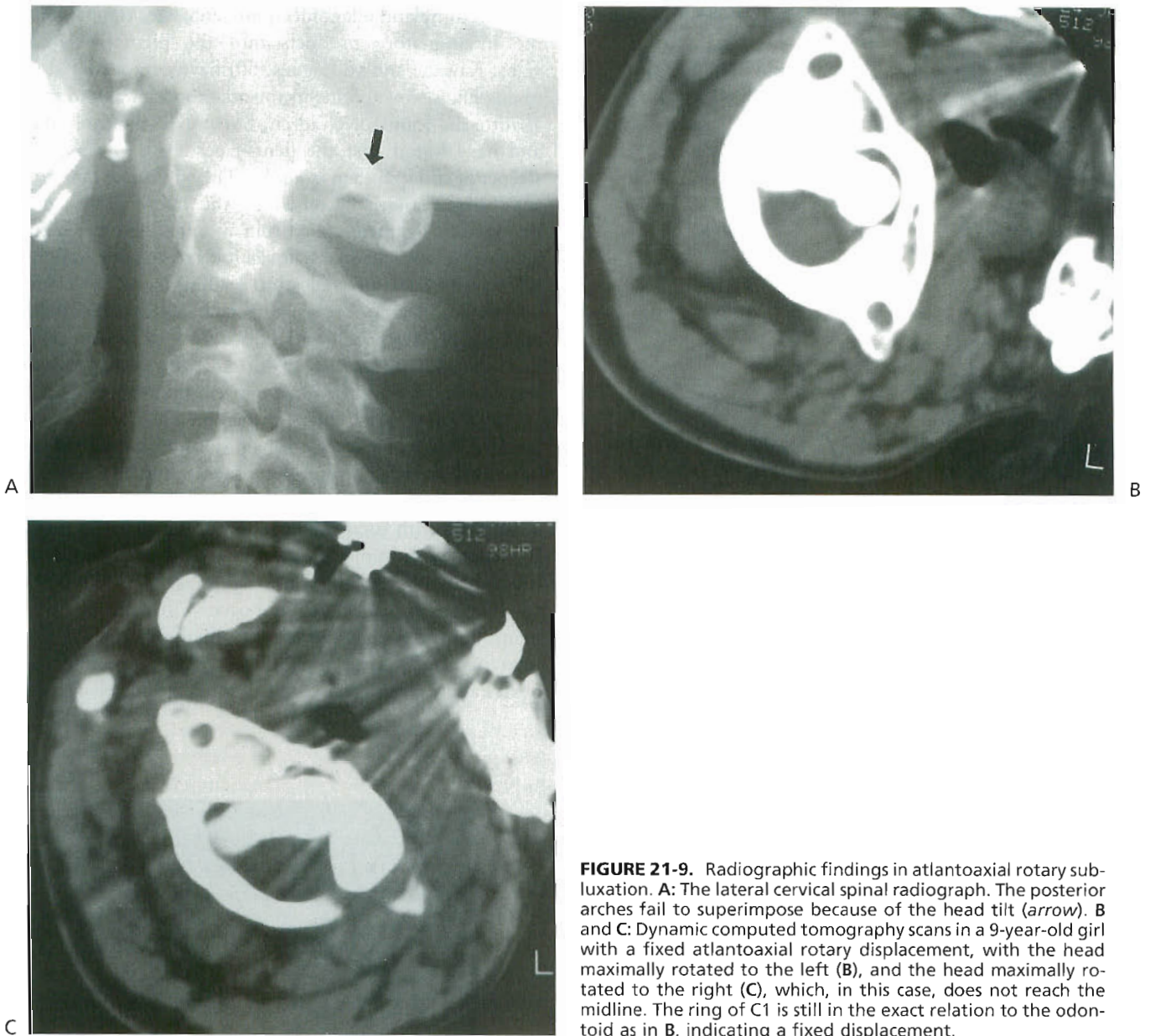


FIGURE 21-9. Radiographic findings in atlantoaxial rotary subluxation. **A:** The lateral cervical spinal radiograph. The posterior arches fail to superimpose because of the head tilt (*arrow*). **B** and **C:** Dynamic computed tomography scans in a 9-year-old girl with a fixed atlantoaxial rotary displacement, with the head maximally rotated to the left (**B**), and the head maximally rotated to the right (**C**), which, in this case, does not reach the midline. The ring of C1 is still in the exact relation to the odontoid as in **B**, indicating a fixed displacement.

tion, the observer may attribute this rotation to patient positioning. A dynamic-rotation CT scan is helpful here. Views with the head maximally rotated to the right, then to the left, will demonstrate atlantoaxial rotary fixation when there is a loss of normal rotation (Fig. 21-9).

Rotary displacement can be classified into four types (53) (Fig. 21-10): type I is a simple rotary displacement without an anterior shift; type II is rotary displacement with an anterior shift of 5 mm or less; type III is rotary displacement with an anterior shift greater than 5 mm; and type IV is rotary displacement with a posterior shift. The amount of anterior displacement considered to be pathologic is greater than 3 mm in older children and adults, and greater than

4 mm in younger children (7). Flexion and extension lateral-stress radiographs are suggested to rule out the possibility of anterior displacement.

Type I is the most common pediatric type. It is usually benign and frequently resolves by itself. Type II deformity is potentially more dangerous. Types III and IV are very rare, but because of the potential for neurologic involvement and even instant death, management must be approached with great caution.

The cause and pathoanatomy are not known completely (58). Several etiologic mechanisms are possible. Fracture is a rare cause. More commonly, atlantoaxial rotary displacement occurs after minor trauma, after head and neck sur-

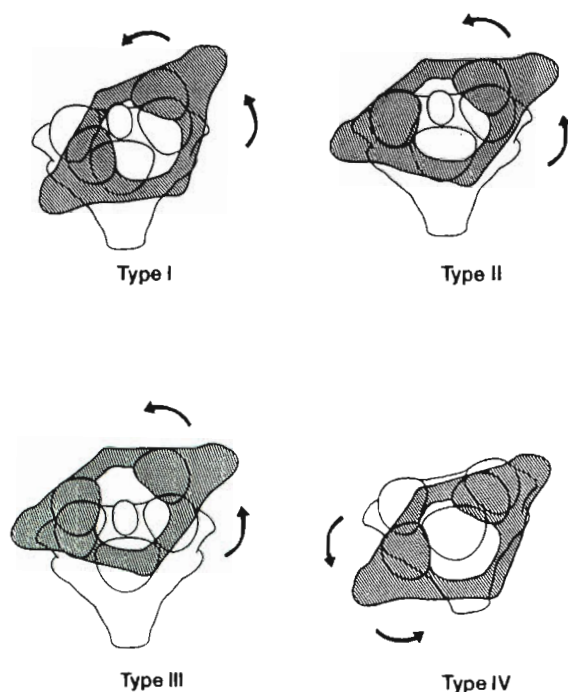


FIGURE 21-10. The four types of atlantoaxial rotary displacement. (From ref. 53, with permission.)

gery, or after an upper respiratory infection. The child presents with a “cocked-robin” torticollis, and resists any attempt to move the head because of pain. The associated muscle spasm is noted on the side of the long sternocleidomastoid muscle because the muscle is attempting to correct the deformity, unlike congenital muscular torticollis, in which the muscle causes the torticollis. If the deformity becomes fixed, the pain subsides but the torticollis persists, along with decreased neck motion. In long-standing cases, plagiocephaly and facial flattening may develop on the side of the tilt.

Spontaneous atlantoaxial subluxation with inflammation of adjacent neck tissues, also known as Grisel syndrome, is commonly seen in children after upper respiratory infections (Fig. 21-11). A direct connection exists between the pharyngovertebral veins and the periodontal venous plexus and suboccipital epidural sinuses (59). This may provide a route for hematogenous transport of peripharyngeal septic exudates to the upper cervical spine and an anatomic explanation for the atlantoaxial hyperemia of Grisel syndrome. Regional lymphadenitis is known to cause spastic contracture of the cervical muscles. This muscular spasm, in the presence of abnormally loose ligaments (hypothetically caused by the hyperemia of the pharyngovertebral vein drainage), could produce locking of the overlapping lateral joint edges of the articular facets. This prevents easy repositioning, resulting in atlantoaxial rotary displacement. The hyperemia after surgery of the oral pharynx, most frequently

tonsillectomy and adenoidectomy, enhances the passage of the inflammatory products into the pharyngovertebral veins. Kawabe and colleagues (60) have demonstrated meniscus-like synovial folds in the atlantooccipital and lateral atlantoaxial joints of children, but not in those of adults, and have found that the dens–facet angle of the axis is steeper in children than in adults. They postulate that excessive C1-C2 rotation, caused by the steeper angle, compounded by ligament laxity from an underlying hyperemia, allows the meniscus-like synovial folds to become impinged in the lateral atlantoaxial joint, leading to rotary fixation. The predominance of this syndrome in childhood correlates with the predilection for the adenoids to be maximally hypertrophied and inflamed at this same time, and located in the area drained by the pharyngovertebral veins.

Most atlantoaxial rotary displacements resolve spontaneously. Rarely, however, the pain subsides and the torticollis becomes fixed. The duration of symptoms and deformity dictates the recommended treatment (61).

Patients with rotary subluxation of less than 1 week can be treated with immobilization in a soft cervical collar and rest for about 1 week. Close follow-up is mandatory. If spontaneous reduction does not occur with this initial treatment, hospitalization and the use of halter traction, muscle relaxants (e.g., diazepam), and analgesics are recommended next. Patients with rotary subluxation of greater than 1 week

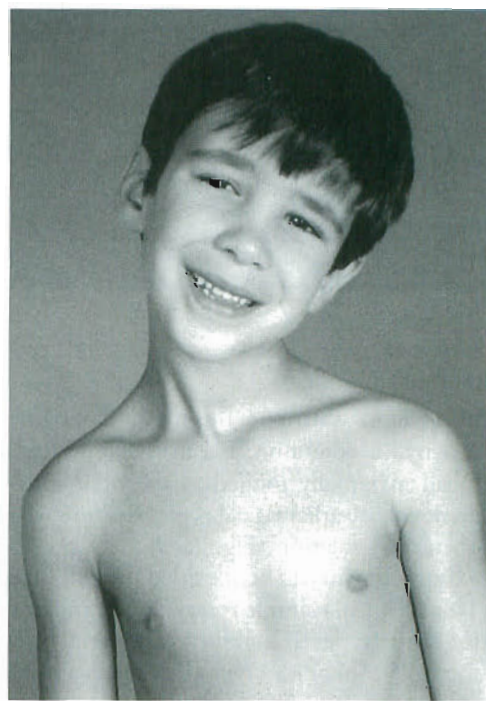


FIGURE 21-11. A 5-year-old boy developed an atlantoaxial rotary subluxation after an upper respiratory viral infection (Grisel syndrome). It rapidly resolved after treatment with a soft collar and mild doses of diazepam.

but less than 1 month should be hospitalized immediately for cervical traction, relaxants, and analgesics. A halo cast occasionally is needed to achieve reduction. The reduction is noted clinically and confirmed with a dynamic CT scan. If no anterior displacement is noted after reduction, cervical support should be continued only as long as symptoms persist. If there is anterior displacement, immobilization should be continued for 6 weeks to allow ligamentous healing to occur. In patients with rotary subluxation for more than 1 month cervical traction (usually halo skeletal) can be tried for up to 3 weeks, but the prognosis is guarded. These children usually fall into two groups: those whose rotary subluxation can be reduced with halo traction but, despite a prolonged period of immobilization, resubluxate when the immobilization is stopped, and those whose subluxation cannot be reduced, and is fixed.

When the deformity is fixed, especially when anterior C1 displacement is present the transverse atlantal ligament is compromised, with a potential for catastrophe. In this situation, posterior C1-C2 fusion should be performed. The indications for fusion are neurologic involvement, anterior displacement, failure to achieve and maintain correction, a deformity that has been present for more than 3 months, and recurrence of deformity after an adequate trial of conservative management (at least 6 weeks of immobilization after reduction). Before surgical fusion halo traction for several days is used to obtain as much straightening of the head and neck as possible; a forceful or manipulative reduction should not be performed. Postoperatively, the child is simply positioned in a halo cast or vest in the straightened position obtained preoperatively; this usually results in satisfactory alignment. A Gallie-type fusion, with sublaminar wiring at the ring of C1 and through the spinous process of C2, is preferred to a Brooks-type fusion in which the wire is sublaminar at both C1 and C2. This is because of the decreased SAC at C2 with a higher risk of neurologic injury. This wiring does not reduce the displacement, but simply provides some internal stability for the arthrodesis. The overall results with a Gallie fusion are very good (62) (Fig. 21-12).

Nonosseous Types

Congenital Muscular Torticollis. Congenital muscular torticollis, or congenital wry neck, is the most common cause of torticollis in the infant and young child. The deformity is caused by contracture of the sternocleidomastoid muscle, with the head tilted toward the involved side and the chin rotated toward the opposite shoulder. A disproportionate number of children with this deformity have a history of a primiparous birth or a breech or difficult delivery. However, it has been reported in children with normal births and in children born by cesarean section (63,64).

The exact cause is not known, and there are several theories. Because of the birth history, one theory is that of a

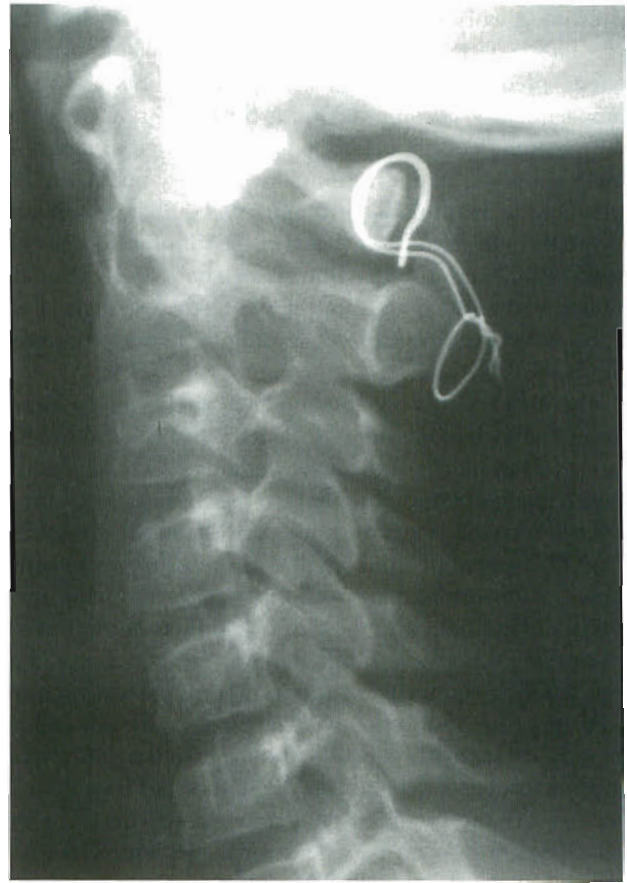

FIGURE 21-12. The child in Figure 21-9 had a fixed deformity that occurred 6 months earlier, immediately after reconstructive maxillofacial surgery for Goldenhar syndrome. It did not respond to traction, including halo traction. She underwent posterior C1-C2 (Gallie-type) fusion. A solid fusion was present 9 months later; clinically, the patient achieved 80 degrees of rotation to the left and 45 degrees of rotation to the right.

compartment syndrome occurring from soft tissue compression of the neck at the time of delivery (65). Surgical histopathologic sections suggest venous occlusion of the sternocleidomastoid muscle (66). This occlusion may result in a compartment syndrome, as manifested by edema, degeneration of muscle fibers, and muscle fibrosis. This fibrosis is variable, ranging from small amounts to the entire muscle. It has been suggested that the clinical deformity is related to the ratio of fibrosis to remaining functional muscle. If ample muscle remains the sternocleidomastoid will probably stretch with growth and the child will not develop torticollis; if fibrosis predominates there is little elastic potential and torticollis will develop. Another theory is *in utero* crowding, because three of four children have the lesion on the right side (67) and up to 20% have developmental hip dysplasia (68). The fact that this condition can occur in children with normal birth histories or in children born by cesarean section challenges the perinatal compartment

syndrome theory, and supports the *in utero* crowding theory. The fact that it can occur in families (supporting a genetic predisposition) (69) also raises doubts about the compartment syndrome theory. A third theory is primarily neurogenic (70), supported by histopathologic evidence of denervation and reinnervation. The primary myopathy initially may be attributable to trauma, ischemia, or both, and unequally involves the two heads of the sternocleidomastoid muscle. With continuing fibrosis of the sternal head the branch of the spinal accessory nerve to the clavicular head of the muscle can be trapped, leading to a later progressive deformity (70).

The final theory concerns mesenchymal cells remaining in the sternocleidomastoid from fetal embryogenesis. Recent histopathologic studies have demonstrated the presence of both myoblasts and fibroblasts in the sternocleidomastoid tumor in varying stages of differentiation and degeneration (71). The source of these myoblasts and fibroblasts is unknown. After birth environmental changes stimulate these cells to differentiate, and the sternocleidomastoid tumor develops. Hemorrhagic and inflammatory reactions would be expected if the tumor was a result of perinatal birth trauma or intrauterine positioning, yet these cells were not seen in the sternocleidomastoid histopathologic studies. The occurrence of torticollis depends on the fate of the myoblasts in the mass. If the myoblasts undergo normal development and differentiation no persistent torticollis will occur, and conservative treatment will likely succeed. If the myoblasts mainly undergo degeneration, the remaining fibroblasts produce large amounts of collagen, with a scar-like contraction of the sternocleidomastoid muscle and the typical torticollis.

The clinical features of congenital muscular torticollis depend on the age of the child. It is often discovered in the first 6 to 8 weeks of life. If the child is examined during the first 4 weeks of life a mass or "tumor" may be palpable in the neck (63). Although the mass may be palpable, it is unrecognized up to 80% of the time (72). Characteristically, it is a nontender, soft enlargement beneath the skin, and is located within the sternocleidomastoid muscle belly. This tumor reaches its maximum size within the first 4 weeks of life then gradually regresses. After 4 to 6 months of life the contracture and the torticollis are the only clinical findings. In some children the deformity is not noticed until after 1 year of life, which raises questions about both the congenital nature of this entity and the perinatal compartment syndrome theory. Recent studies (73) indicate that the rate of associated hip dysplasia in children with congenital muscular torticollis is 8%, lower than the previously cited 20% (68).

If the deformity is progressive, skull and face deformities can develop (plagiocephaly), often within the first year of life. The facial flattening occurs on the side of the contracted muscle, and is probably caused by the sleeping position of the child (74). In the United States children usually sleep

prone, and in this position, it is more comfortable for them to lie with the affected side down. The face, therefore, remodels to conform to the bed. If the child sleeps supine reverse modeling of the contralateral skull occurs. In the child who is untreated for many years the level of the eyes and ears becomes unequal and can result in considerable cosmetic deformity.

Radiographs of the cervical spine should be obtained to rule out associated congenital anomalies. Plain radiographs of the cervical spine in children with muscular torticollis are always normal, aside from the head tilt and rotation. If any suspicion exists about the status of the hips appropriate imaging (e.g., ultrasonography, radiography) should be performed, depending on the age of the child and the expertise of the sonographer.

Research MRI studies demonstrate abnormal signals in the sternocleidomastoid muscle but no discrete masses within the muscle (65). The muscle diameter is increased to two to four times that of the contralateral muscle. In older patients the signals are consistent with atrophy and fibrosis, similar to those encountered in compartment syndromes of the leg and forearm.

As the deficit in cervical rotation increases the incidence of a previous sternocleidomastoid tumor and hip dysplasia, and the likelihood of needing surgery, increase (75). Treatment initially consists of conservative measures (63,64, 72,76,77). Good results can be expected with stretching exercises alone, with one series reporting 90% success (76). These results also may reflect, in part, the favorable natural history of many of these children. The exercises are performed by the caregivers and guided by the physiotherapist. The ear opposite the contracted muscle should be positioned to the shoulder, and the chin should be positioned to touch the shoulder on the same side as the contracted muscle. When adequate stretching has occurred in the neutral position, the exercises should be graduated up to the extended position, which achieves maximum stretching and prevents residual contractures. Treatment measures to be used along with stretching consist of modifying the child's toys and crib so that the neck is stretched when the infant is reaching for or looking at objects of interest. The exact role of the efficacy of these stretching measures, versus a natural history of spontaneous resolution, is not known; there are many anecdotal cases of spontaneous resolution.

Stretching measures are usually unsuccessful after 1 year of age (77,78), and surgery is recommended. The child's neck and anatomic structures are larger, making surgery easier. Established facial deformity or a limitation of more than 30 degrees of motion usually precludes a good result, and surgery is required to prevent further facial flattening and cosmetic deterioration (77). Asymmetry of the face and skull can improve as long as adequate growth potential remains after the deforming pull of the sternocleidomastoid is removed; good but not perfect results can be obtained as

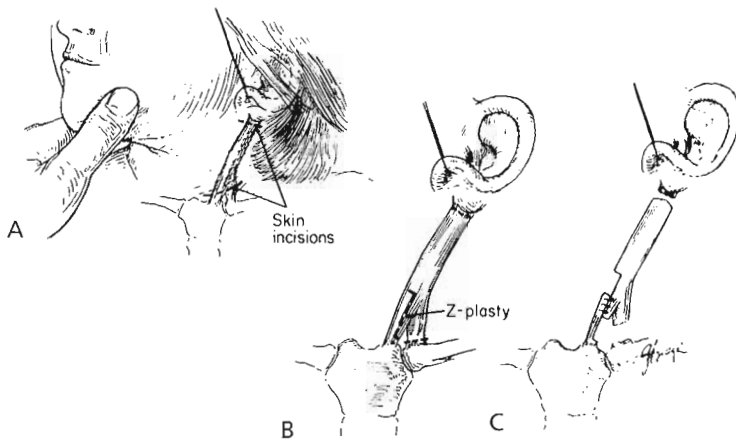


FIGURE 21-13. The Z-plasty procedure for torticollis. **A:** The location of the skin incisions. **B:** The clavicular and mastoid attachments of the sternocleidomastoid muscle are cut, and a Z-plasty is performed. Note that the medial aspect of the sternal attachment is preserved. **C:** The completed procedure after release of the proximal muscle insertion. (From ref. 78, with permission.)

late as 12 years of life (72). The best time for surgical release is between the ages of 1 and 4 years (63,79).

Surgical treatments include unipolar release at either the sternoclavicular or the mastoid pole, bipolar release, middle-third transection, and even complete resection. Bipolar release, combined with Z-plasty of the sternal attachment (Fig. 21-13), yielded 92% satisfactory results in one series, whereas only 15% satisfactory results were obtained with other procedures (78). Middle-third transection has also been reported to give 90% satisfactory results (80). Z-plasty lengthening maintains the V contour of the neck and cosmesis, which middle-third transection does not. Structures that can be injured during surgery are the spinal accessory nerve, the anterior and external jugular veins, the carotid vessels and sheath, and the facial nerve. Skin incisions should never be located directly over the clavicle because of cosmetically unacceptable scar spreading; rather, they should be made one finger-breadth proximal to the medial end of the clavicle and sternal notch, and in line with the cervical skin creases. The postoperative protocol can vary from simple stretching exercises to cast immobilization. Some type of bracing device to maintain alignment of the head and neck is probably desirable as part of the postoperative protocol.

Neurogenic Types

Although rare, these causes should be considered in the differential diagnosis of any atypical torticollis, especially when the condition is unresponsive or progressive in the face of therapy believed to be appropriate. The major neurogenic causes are central nervous system tumors (i.e., of the posterior fossa or spinal cord), syringomyelia with or without cord tumor, Arnold-Chiari malformation, ocular dysfunction, and paroxysmal torticollis of infancy.

Posterior fossa tumors can present with torticollis (81). The ophthalmologic literature (82) has described three children with torticollis, photophobia, and epiphora (tearing).

In all three children the diagnosis was delayed, with an initial diagnosis of a local ocular inflammatory condition. The age at presentation ranged from 1 to 23 months. The delay in diagnosis ranged from 5 months to 4 years. The neoplastic diagnosis was not considered initially by the ophthalmologists because the primary signs of posterior fossa tumors are extraocular muscle paresis, nystagmus, and papilledema.

Cervical cord tumors can present with torticollis, often early in their course (83,84). Frequently, the initial diagnosis is congenital torticollis, obstetric birth palsy, muscular dystrophy, or cerebral palsy (83). The peculiar, often overlooked signs of the tumor are spinal rigidity, early spinal deformity, and spontaneous or induced vertebral pain. In young children pain may be expressed as irritability and restlessness.

Imaging of a child with a potential central nervous system tumor should consist of plain radiographs of the skull and cervical spine, followed by CT and MRI scans. Vertebral angiography also may be needed, both diagnostically and in neurosurgical planning.

The Arnold-Chiari malformation (Fig. 21-6) is caudal displacement of the hindbrain, often with other congenital deformities of the brainstem and cerebellum (85,86). It may be associated with myelomeningocele (i.e., type II malformation). The Chiari type I malformation is a downward displacement of the medulla oblongata with extrusion of the cerebellar tonsils through the foramen magnum, and is encountered in older children. Dure and colleagues (85) described 11 children with Chiari type I malformations; torticollis was the presenting complaint at 5 years of age in 1 of the 11 children. It also was associated with headaches and paracervical muscle spasm; the torticollis was left-sided. As with tumors, the workup of a child with the potential for a Chiari malformation consists of plain radiographs of the skull and cervical spine, followed by an MRI scan (85). The treatment is neurosurgical.

Ocular pathology accounts for up to one-third of chil-

dren with no obvious orthopaedic cause of torticollis (87). The torticollis is usually atypical (88). These children typically present around 1 year of age. The face can be turned about a vertical axis, the head can be tilted to one shoulder with the frontal plane of the face remaining coronal, the chin can be elevated or depressed, or a combination of any of these positions can occur. These abnormal head positions optimize visual acuity and maintain binocularity. An ocular cause is likely if the head is tilted but not rotated, or if the tilt changes when the child is lying versus sitting or standing. Children with ocular torticollis have a full range of cervical motion without the fibrotic sternocleidomastoid muscle seen in congenital muscular torticollis. Ophthalmologic evaluation is usually positive for paralytic squint or nystagmus. Detailed tests conducted by an experienced ophthalmologist are diagnostic. Treatment of ocular torticollis is usually surgical.

Paroxysmal torticollis of infancy is a rare episodic torticollis lasting for minutes to days with spontaneous recovery (89,90). The attacks usually occur in the morning, with a frequency from less than one episode per month to three to four episodes per month. The attacks can be associated with lateral trunk curvature, eye movements or deviations, and alternating sides of torticollis. The children are usually girls (71%), the average age of onset is 3 months (range, 1 week to 30 months), and the recovery period is 24 months (range, 6 months to 5 years). It has been suggested that paroxysmal torticollis of infancy is equivalent to migraine headache because of positive family histories for migraines in 29% of patients, or that it is a forerunner of benign paroxysmal vertigo of childhood (90). Whatever the cause, it is usually self-limiting and does not require therapy.

Sandifer Syndrome

This is a syndrome of gastroesophageal reflux, often from a hiatal hernia, and abnormal posturing of the neck and trunk, usually torticollis (91,92). The torticollis is likely an attempt by the child to decrease esophageal discomfort resulting from the reflux. The abnormal posturing also may present as opisthotonos or neural tics and often mimics central nervous system disorders. The majority of patients present in infancy. The incidence of gastroesophageal reflux is high (up to 40% of infants) (93), with the principal symptoms being vomiting, failure to thrive, recurrent respiratory disease, dysphagia, various neural signs, torticollis, and respiratory arrest. The diagnosis of symptom-causing gastroesophageal reflux frequently is overlooked. On careful examination of these infants the tight and short sternocleidomastoid muscle or its tumor is not seen, eliminating congenital muscular torticollis. Further workup excludes dysplasias and congenital anomalies of the cervical spine and central nervous system disorders. In these situations, the physician should consider Sandifer syndrome in the differential diagnosis.

Plain radiographs of the cervical spine eliminate congenital anomalies or dysplasias; contrast studies of the upper gastrointestinal tract usually demonstrate the hiatal hernia and gastroesophageal reflux (94). Esophageal pH studies may be necessary; many children, both asymptomatic and symptomatic, show evidence of gastroesophageal reflux (95). Treatment begins with medical therapy. When this fails, fundoplication can be considered, which is usually curative (96).

Klippel-Feil Syndrome

Klippel-Feil syndrome consists of congenital fusions of the cervical vertebrae clinically exhibited by the triad of a low posterior hairline, a short neck, and variably limited neck motion (97). Its incidence is approximately 0.7% (98). Other associated anomalies are often present in both the musculoskeletal and other organ systems. The congenital fusions result from abnormal embryologic formation of the cervical vertebral mesenchymal anlagen. This unknown embryologic insult is not limited to the cervical vertebrae, and explains the other anomalies associated with Klippel-Feil syndrome.

Approximately one-third of these children have an associated Sprengel deformity. Other anomalies associated with the syndrome are scoliosis (both congenital and idiopathic like) (97), renal anomalies (99), deafness (100), synkinesis (mirror movements) (101), pulmonary dysfunction (102), and congenital heart disease (103). Radiographs demonstrate a wide range of deformity, ranging from simple block vertebrae to multiple and bizarre anomalies. Associated scoliosis makes interpretation of the radiographs even more difficult. Flexion and extension lateral radiographs are used to assess for instability, and should always be made before any general anesthetic is administered. Any segment adjacent to unfused segments may develop hypermobility and neurologic symptoms (104). A common pattern is fusion of C1-C2 and C3-C4, leading to a high risk of instability at the unfused C2-C3 level (105). If the flexion and extension radiographs are difficult to interpret, flexion and extension CT or MRI scans can be useful. CT is especially helpful at the C1-C2 level in assessing the SAC; sagittal MRI is more helpful at other levels.

All children with Klippel-Feil syndrome should be further evaluated for other organ system problems. A general pediatric evaluation should be undertaken by a qualified pediatrician to ensure that no congenital cardiac or other neurologic abnormalities exist. Renal imaging should be performed in all children; simple renal ultrasonography is usually adequate for the initial evaluation (106). MRI should be performed whenever any concern for neurologic involvement exists on a clinical basis, and before any orthopaedic spinal procedure (107).

The natural history depends on the presence of renal or cardiac problems with the potential for organ system failure

and death. Cervical spine instability (108) can develop with neurologic involvement, especially in the upper segments or in segments with iniencephaly (108,109). Degenerative joint and disc disease develops in patients with lower-segment instabilities. In adulthood, many patients with Klippel-Feil syndrome will complain of headaches, upper-extremity weakness, or numbness and tingling. Subtle findings on neurologic examination can be seen in up to half of these adults. Degenerative disc disease, as seen on MRI scans, occurs in nearly 100% of these patients (110).

Because children with large fusion areas are at high risk for developing instabilities, strenuous activities should be avoided, especially contact sports. Other nonsurgical methods of treatment are the use of cervical traction, collars, and analgesics when mechanical symptoms appear, usually in the adolescent or adult patient. Arthrodesis is needed for neurologic symptoms because of instability. Asymptomatic hypermobile segments pose a dilemma with regard to stabilization. Unfortunately, no guidelines exist for this problem. The need for decompression at the time of stabilization depends on the exact anatomic circumstance, as will the need for combined anterior and posterior fusions versus simple posterior fusion alone. Surgery for cosmesis alone is usually unwarranted and risky.

Os Odontoideum

Os odontoideum is a rare anomaly in which the tip of the odontoid process is divided by a wide transverse gap, leaving the apical segment without its basilar support (111). The exact incidence is not known. It most likely represents an unrecognized fracture at the base of the odontoid, or damage to the epiphyseal plate during the first few years of life, although a congenital cause has also been proposed. Either of these conditions can compromise the blood supply to the developing odontoid, resulting in the os odontoideum. MRI scans have further documented the presence of nuchal cord changes consistent with trauma (112).

Local neck pain is the usual presentation; transitory episodes of paresis, myelopathy, or cerebral brainstem ischemia, attributable to vertebral artery compression from the upper cervical instability, is less common. Sudden death rarely occurs.

Radiographs demonstrate an oval or round ossicle with a smooth sclerotic border of variable size, located in the position of the normal odontoid tip. It is occasionally located near the basioccipital bone in the foramen magnum area. The base of the dens is usually hypoplastic. The gap between the os and the hypoplastic dens is wider than in a fracture, usually well above the level of the facets. However, it may be difficult to differentiate an os odontoideum from nonunion after a fracture. Tomograms and CT scans are useful to further delineate the bony anatomy, and flexion and extension lateral radiographs are useful to assess instability. The instability index and the sagittal plane rotation

angle can be measured (113). The presence of myelopathy is highly correlated with a sagittal plane rotation angle of greater than 20 degrees and an instability index of greater than 40%.

The neurologic symptoms are caused by cord compression from posterior translation of the os into the cord in extension or from translation of the odontoid into the cord in flexion. Hypermobility at the C1-C2 level may cause vertebral artery occlusion with ischemia of the brainstem and posterior fossa structures; this will result in seizures, syncope, vertigo, and visual disturbances.

Patients with local pain or transient myelopathies often recover with immobilization. Subsequently, only nonstrenuous activities should be allowed, but the curtailment of activities in the pediatric age group can be difficult. The risk of a small insult leading to catastrophic quadriplegia and death must be weighed. The long-term natural history is unknown.

Surgery is indicated when there is 10 mm or more of ADI, an SAC of 13 mm or less (11), neurologic involvement, progressive instability, or persistent neck pain. Surgery should also be strongly considered in asymptomatic patients with an instability index of greater than 40% and/or a sagittal plane rotation angle of greater than 20 degrees. A Gallie fusion is recommended. The surgeon must be careful when tightening the wire so that the os is not pulled back posteriorly into the canal and cord with disastrous consequences. In small children the wire may be eliminated. In all children a Minerva or halo cast or vest also is used for at least 6 weeks, and often for 12 weeks.

Developmental and Acquired Stenoses and Instabilities

Down Syndrome

Because of underlying collagen defects in these children, cervical instabilities can develop at both the occiput-C1 and C1-C2 levels. The instability may occur at more than one level, and in more than one plane (e.g., sagittal and rotary planes). With the advent of the Special Olympics, there has been much concern regarding the participation of children with Down syndrome, and much confusion regarding the appropriate approach to the problem of upper cervical instability in these children. Outlined below are the most recent recommendations regarding this problem.

Atlantooccipital hypermobility recently has been described in Down syndrome children. The incidence of occiput-C1 instability has been reported to be as high as 60% in children (15) and 69% in adults (114). The vast majority are asymptomatic (115,116). Measurement reproducibility is poor (117), but a Powers ratio of less than 0.55 is more likely to be associated with neurologic symptoms (118). No guidelines exist regarding the frequency of periodic screening or the indications for surgery, with the exception of

those for atlantooccipital fusion in the symptomatic child. Tredwell and colleagues (15) believe that treatment plans for these children should depend on the amount of room available for the cord, rather than on absolute values of displacement for both atlantoaxial and atlantooccipital instability. This area requires further investigation.

Atlantoaxial instability in children with Down syndrome was first reported by Spitzer and colleagues (114) in 1961. Subsequently, there have been many reports on this instability. Despite these reports, there is no documentation of the true incidence of atlantoaxial dislocation (in contrast to instability), and there are no long-term studies regarding the natural history of this problem.

The incidence of atlantoaxial instability in children with Down syndrome has been estimated to range from 9 to 22% (15,119–121). The incidence of symptomatic atlantoaxial instability is much less; it was reported to be 2.6% (119) in a series of 236 Down syndrome patients. Progressive instability and neurologic deficits are more likely to develop in male patients older than 10 years (121). Children with Down syndrome have a significantly greater incidence of cervical skeletal anomalies, especially persistent synchondrosis and spina bifida occulta of C1, than do normal children (122). Also, children with both Down syndrome and atlantoaxial instability have an increased frequency of cervical spine anomalies, compared with other Down syndrome children without atlantoaxial instability (122). These spinal anomalies may be a contributing factor in the cause of atlantoaxial instability in these children.

The majority of children with atlantoaxial or occipitoatlantal hypermobility are asymptomatic. When symptoms occur they are usually pyramidal tract symptoms, such as gait abnormalities, hyperreflexia, easy fatigability, and quadripareisis. Occasionally, local symptoms exist, such as head tilt, torticollis, neck pain, or limited neck mobility. The neurologic deficits are not necessarily attributable to hypermobility of the atlantoaxial or occipitoatlantal joints. Neurologic symptoms in one series of adult Down syndrome patients were equally as common in those with an increased ADI as in those with a normal ADI (123). Further evaluation with flexion/extension CT or MRI scans to assess for cord compression is needed in this situation.

Rarely does sudden catastrophic death occur. Nearly all of the individuals who have experienced catastrophic injury to the spinal cord have had weeks to years of preceding, less severe neurologic abnormalities. In a recent review by the American Academy of Pediatrics, 41 cases of symptomatic atlantoaxial instability were compiled. In only 3 of these 41 children did the initiation or worsening of symptoms of atlantoaxial instability occur after trauma during organized sports activities (120).

In the past, screening of Down syndrome patients with lateral flexion/extension radiographs was recommended (124). However, symptomatic atlantoaxial instability is very rare, and the chances of a sports-related catastrophic injury

are even rarer. The reproducibility of radiographic screening for atlantoaxial and occipitoatlantal mobility is poor (116,117). Furthermore, the radiologic picture can change over time, most frequently from abnormal to normal (121). Because of all these factors, and the absence of any evidence that a screening program is effective in preventing symptomatic atlantoaxial and occipitoatlantal mobility, lateral cervical radiographs are of unproven value, and the previous recommendations for screening radiographs by the American Academy of Pediatrics have been retired (120).

The identification of patients with symptoms or signs consistent with symptomatic spinal cord injury is thus more important than radiographs. Neurologic examination is often difficult to perform and interpret in these children (15). Parental education regarding the early signs of myelopathy is extremely important (e.g., increasing clumsiness and falling, worsening of upper-extremity function). A thorough history and neurologic examination are more important before participation in sports than are screening radiographs. However, further research is needed in this confusing matter, and because of persistent concerns, the Special Olympics does not plan to remove its requirement that all Down syndrome athletes have radiographs of the cervical spine before athletic participation.

Because of this requirement, spinal radiographs are often obtained without neurologic symptoms. When these are available, they should be reviewed to determine if there are any other associated anomalies, such as persistent synchondrosis of C2, spina bifida occulta of C1, ossiculum terminale, os odontoideum, or other less common anomalies. When the plain radiographs indicate atlantoaxial or atlantooccipital instability of 6 mm or more in an asymptomatic patient, CT and MRI scans in flexion and extension can determine the extent of neural encroachment and cord compression.

Once a Down syndrome patient presents with radiographic instability, what treatment should be instituted? Those with asymptomatic atlantoaxial or occipitoatlantal hypermobility should probably be followed up with repeat neurologic examinations; the role of repeat radiographs is more clouded, as noted in the previous discussion. Because the risk of a catastrophic spinal cord injury is extremely low with organized sports in Down syndrome children without any neurologic findings, the avoidance of high-risk activities must be individualized. For those children with sudden onset or recent progression of neurologic symptoms, immediate fusion should be undertaken if appropriate imaging confirms cord compromise. The most difficult question concerns the patient with upper cervical hypermobility with minimal or nonprogressive chronic symptoms. Before embarking on arthrodesis, imaging with flexion/extension MRI (48) or CT should be undertaken to confirm cord compression from the hypermobility, and to eliminate other central nervous system causes of neurologic symptoms. CT is faster, reducing the need for sedation, which is potentially danger-

ous in these children. CT also easily visualizes the C1-C2 relationships necessary to measure the SAC. MRI is more useful for evaluating other central nervous system lesions. Even if successfully stabilized, patients with chronic symptoms often show little symptomatic improvement after arthrodesis (125).

Posterior cervical fusion at the levels involved is the recommended surgical treatment. The classic technique for posterior C1-C2 fusion uses autogenous iliac crest bone grafting, with wiring and postoperative halo cast immobilization. Internal fixation with wiring provides protection against displacement, shortens the time of postoperative immobilization, permits the consideration of using less-rigid forms of external immobilization, and is reported to aid in obtaining fusion. However, internal fixation with sublaminar wiring poses added risk. If the instability does not reduce on routine extension films the patient is at high risk for development of iatrogenic quadriplegia with sublaminar wiring and acute manipulative reduction (126,127). For this reason, it has been recommended that preoperative traction be used to effect the reduction. If reduction does not occur with traction, then only onlay bone grafting should be performed without sublaminar wiring (126). Sublaminar wiring at C2 is not recommended, regardless of the success of reduction, because it was associated with the only death in a recent series at the author's institution (128). If wiring is to be performed, pliable, smaller-caliber wires should be used. Satisfactory results can be obtained with onlay bone grafting and rigid external immobilization without internal fixation (129).

The Down syndrome patient is at higher risk for postoperative complications (neurologic and other) after fusion (130-132). Neurologic complications can range from complete quadriplegia and death to Brown-Séquard syndrome (128). Another potential cause of neurologic impairment is overreduction, if an unstable os odontoideum is present (128). A posterior translation of the ring of C1 and the os fragment into the SAC can occur from this overreduction. In a study of the results of surgical fusion in 35 symptomatic Down syndrome children, 8 made a complete recovery, 14 showed improvement, 7 did not improve, 4 died, and the outcome for 2 is unknown (119). Patients with long-standing symptoms and marked neural damage showed no or little postoperative improvement, whereas patients with more recent onset of symptoms usually made an excellent recovery. Other complications are loss of reduction despite halo cast immobilization, and resorption of the bone graft with a stable fibrous union or unstable nonunion (129,130) (Fig. 21-14).

The long-term results after cervical fusion are not yet known. Individuals with Down syndrome who undergo short cervical fusions are at risk for developing instability above the level of fusion, such as occiput-C1 after a C1-C2 fusion, or C1-C2 after lower-level fusions (133). This later instability occurred in four of five children between 6 months and 7 years after surgery.

Nontraumatic Occipitoatlantal Instability

Nontraumatic occipitoatlantal instability is rare in the absence of any underlying syndrome (e.g., Down syndrome). Georgopoulos and colleagues (134) have described pediatric nontraumatic atlantooccipital instability. Congenital enlargement of the occipital condyles may have been the cause by increasing motion at this joint. The presenting symptoms were severe vertigo in one 14-year-old boy and nausea with projectile vomiting in one 6-year-old girl. These symptoms are postulated to be a result of vertebrobasilar arterial insufficiency resulting from the hypermobility at the occiput-C1 junction. The diagnosis of instability was suggested by plain radiographs initially, and confirmed by cineradiography. Both children were treated with a posterior occiput-C1 fusion with resolution of symptoms.

Cerebral Palsy

Cervical radiculopathy and myelopathy in cerebral palsy (135-138) were first described in the athetoid types, and subsequently in the spastic types. Athetoid cerebral palsy patients, compared with the normal population, develop cervical disc degeneration at a younger age. This degeneration progresses more rapidly and involves more levels. Angular and listhetic instabilities also are more frequent and appear at a younger age (139). The combination of disc degeneration and listhetic instability predisposes these patients to a relatively rapid, progressive neurologic deficit.

The symptoms are brachialgia and weakness of the upper extremity, with decreased functional use or increased paraparesis or tetraparesis (136-138). In ambulatory patients, a loss of ambulatory ability is often a sign of presentation. Occasional loss of bowel and bladder control also occurs.

Radiographic findings (Fig. 21-15) are narrowing of the spinal canal and premature development of cervical spondylosis; malalignment of the cervical spine with localized kyphosis, increased lordosis, or both; and instability of the cervical spine manifested as spondylolisthesis. Flattening of the anterosuperior margins of the vertebral bodies and beak-like projections of the anteroinferior margins are radiographic findings of the spondylosis. Myelography demonstrates stenosis, disc protrusion, osteophyte projection, and blocks in dye flow, most commonly at the C3-C4 and C4-C5 levels.

The kyphosis, herniated discs, and osteophytes result in nerve root and cord compression. It is believed that the exaggerated flexion and extension of the neck in these young adults with cerebral palsy cause accelerated cervical degeneration and cervical stenosis earlier than in unaffected people, who develop stenosis in the late fourth and fifth decades of life. Exaggerated flexion and extension occur in patients with athetosis and writhing movements. Difficulty with head control also can cause exaggerated flexion and extension in the spastic cerebral palsy patient.

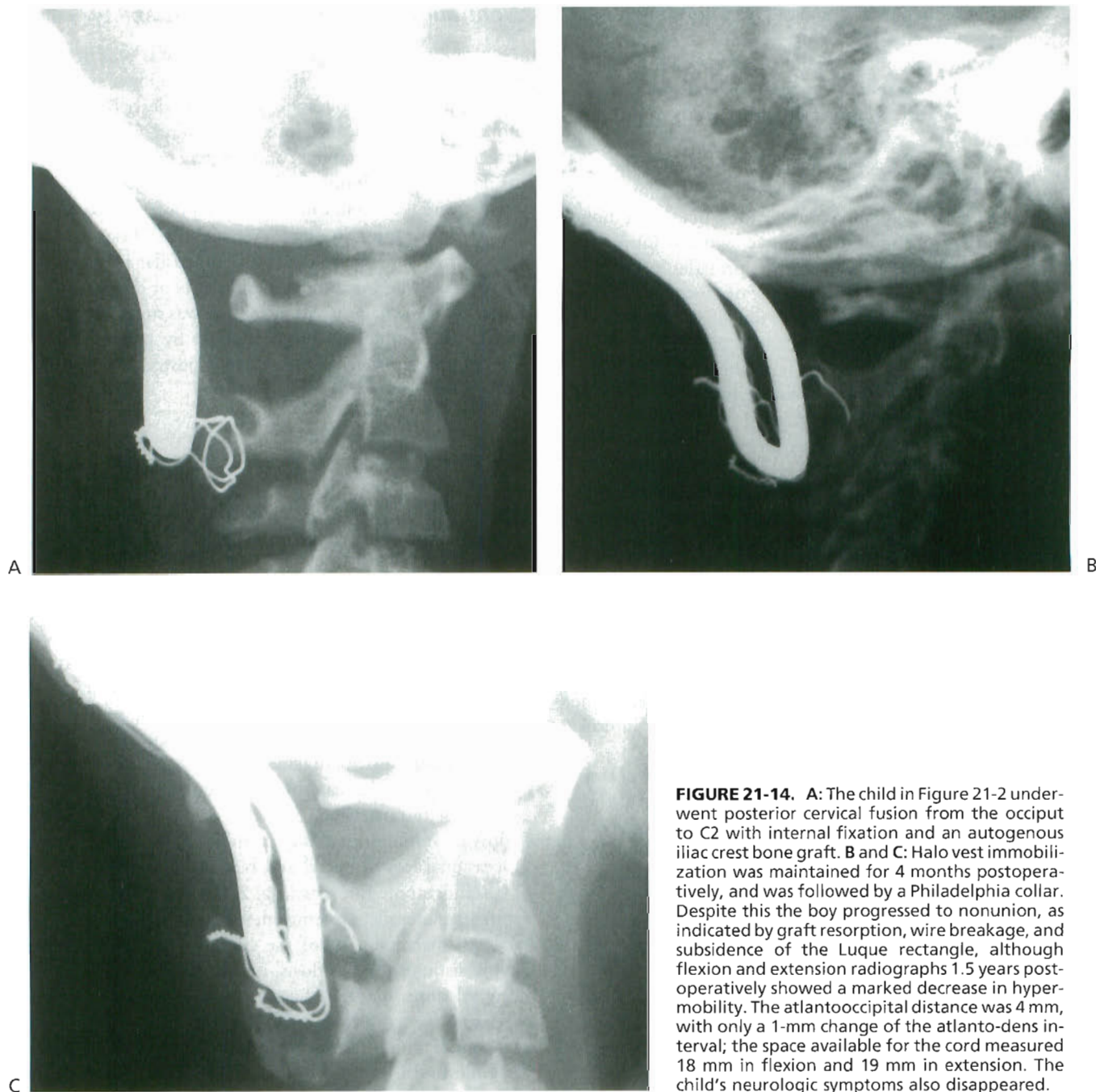


FIGURE 21-14. A: The child in Figure 21-2 underwent posterior cervical fusion from the occiput to C2 with internal fixation and an autogenous iliac crest bone graft. B and C: Halo vest immobilization was maintained for 4 months postoperatively, and was followed by a Philadelphia collar. Despite this the boy progressed to nonunion, as indicated by graft resorption, wire breakage, and subsidence of the Luque rectangle, although flexion and extension radiographs 1.5 years postoperatively showed a marked decrease in hypermobility. The atlantooccipital distance was 4 mm, with only a 1-mm change of the atlanto-dens interval; the space available for the cord measured 18 mm in flexion and 19 mm in extension. The child's neurologic symptoms also disappeared.

Treatment is primarily surgical. Anterior discectomy, resection of osteophytes, and interbody fusion have been the most effective methods. A halo cast is best and is well tolerated in some patients with athetosis (137). However, postoperative immobilization can be a problem for some patients, and thus some authors also recommend posterior wiring of the facets to minimize the amount of time that postoperative immobilization is needed (136). Posterior laminectomy alone (137) is contraindicated in cerebral palsy

patients with developmental cervical stenosis because this increases the instability.

Postlaminectomy Deformity

Cervical kyphosis is common after cervical laminectomy in children (140–146). This phenomenon is more likely in immature, growing children. It has been duplicated in animal models; a C3–C6 laminectomy in growing cats uni-

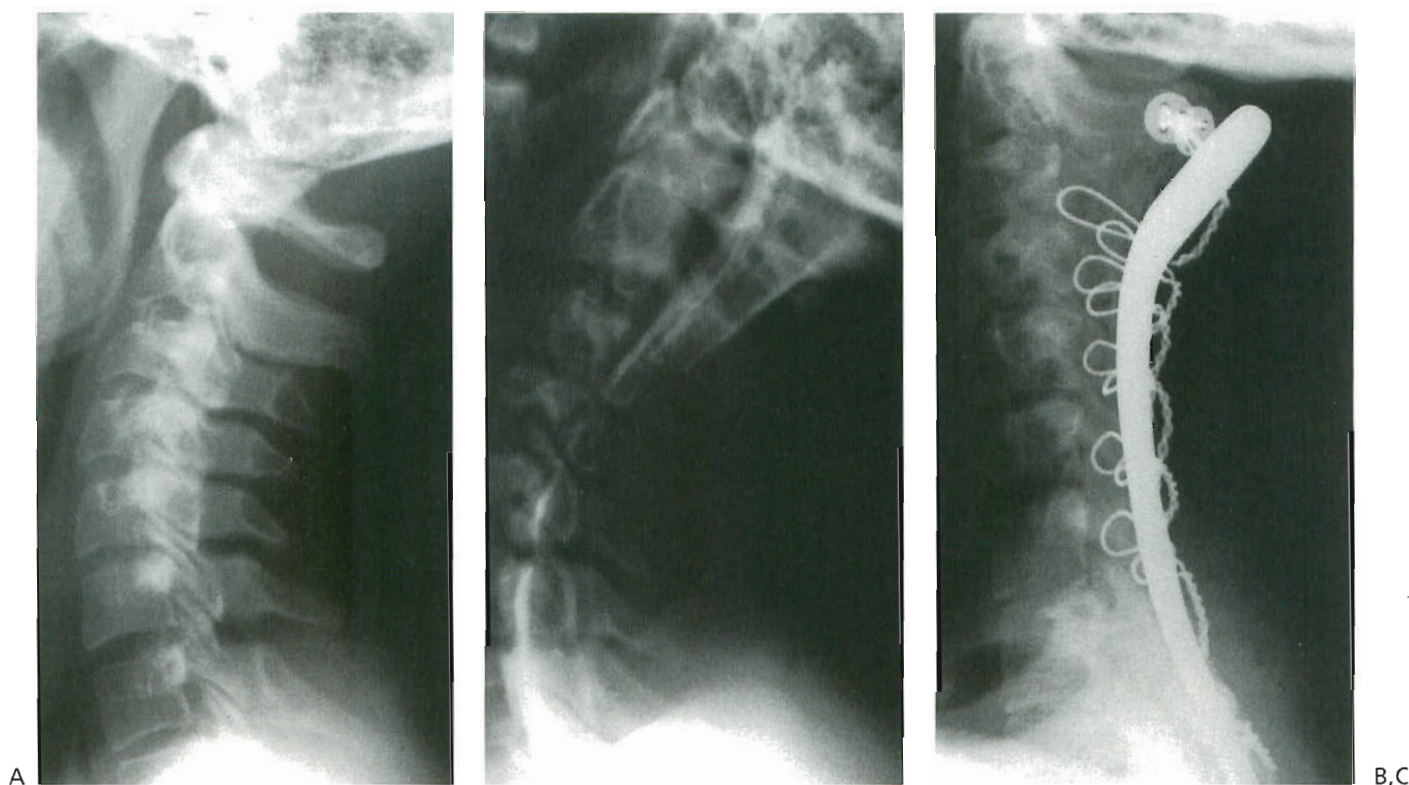


FIGURE 21-15. A 14-year-old girl with spastic quadriplegia showed progressive loss of upper-extremity function, with loss of the ability to control her wheelchair and feed herself. She also complained of some mild neck pain. **A:** The lateral radiograph shows marked stenosis from C3 to C6, as indicated by a spinal canal-to-vertebral body ratio (Torg ratio) of less than 0.8. **B:** The myelogram shows nearly complete block of the dye column from C3 to C5. This stenosis was treated by posterior laminectomy from C3 to C7, and posterior cervical fusion from C2 to T1, using Luque rectangle fixation with spinous process and facet wiring. **C:** Eight months postoperatively there is stable fixation and solid facet joint fusion. The girl's upper-extremity strength is improved, and she is able to feed herself. (From ref. 19, with permission.)

formly resulted in kyphosis, whereas normal cervical curves were maintained in adult cats (147). The natural history of postlaminectomy kyphosis is unknown; however, the incidence of kyphosis when extensive cervical laminectomies are performed in childhood varies from 33 to 100%, with an overall average of 70% (145).

Postlaminectomy kyphosis is weakly age-dependent (mean age at laminectomy of 10.5 years), and is not dependent on the total number of levels decompressed or the location of these levels (145). Postlaminectomy lordosis is less common and is strongly correlated with a peak age at decompression of 4 years (145). In one study, 12 of 15 children who had undergone cervical or cervicothoracic laminectomy before 15 years of age, developed kyphosis (144). The normal posterior muscular attachments to the spinous processes and laminae, as well as facet capsules, the ligamentum nuchae, and the ligamentum flavum, are violated by the laminectomy. This loss of posterior supporting structures allows for a progressive deformity, which, if

kyphotic in nature, can eventually result in neurologic symptoms and deficits. The early radiographic appearance is of a simple kyphosis; later, vertebral body wedging and anterior translations of one vertebral body on another can develop. A late, severe deformity is the swan-neck deformity (143). Neurologic problems result from cord stretching and compression from the anterior kyphotic vertebral bodies. MRI is useful to delineate the extent of cord attenuation and compression.

Nonsurgical treatment starts with frequent radiographic follow-up studies after laminectomy; the role of prophylactic bracing is not yet known. When kyphotic deformities develop, anterior vertebral body fusion with a halo cast or vest, or Minerva cast immobilization is recommended (142) (Figs. 21-16 and 21-17). The role of prophylactic posterior fusion at the time of laminectomy is not yet known (140), nor is the role of osteoplastic laminotomy, instead of laminectomy (148), although this approach might not always be amenable to the primary pathology.

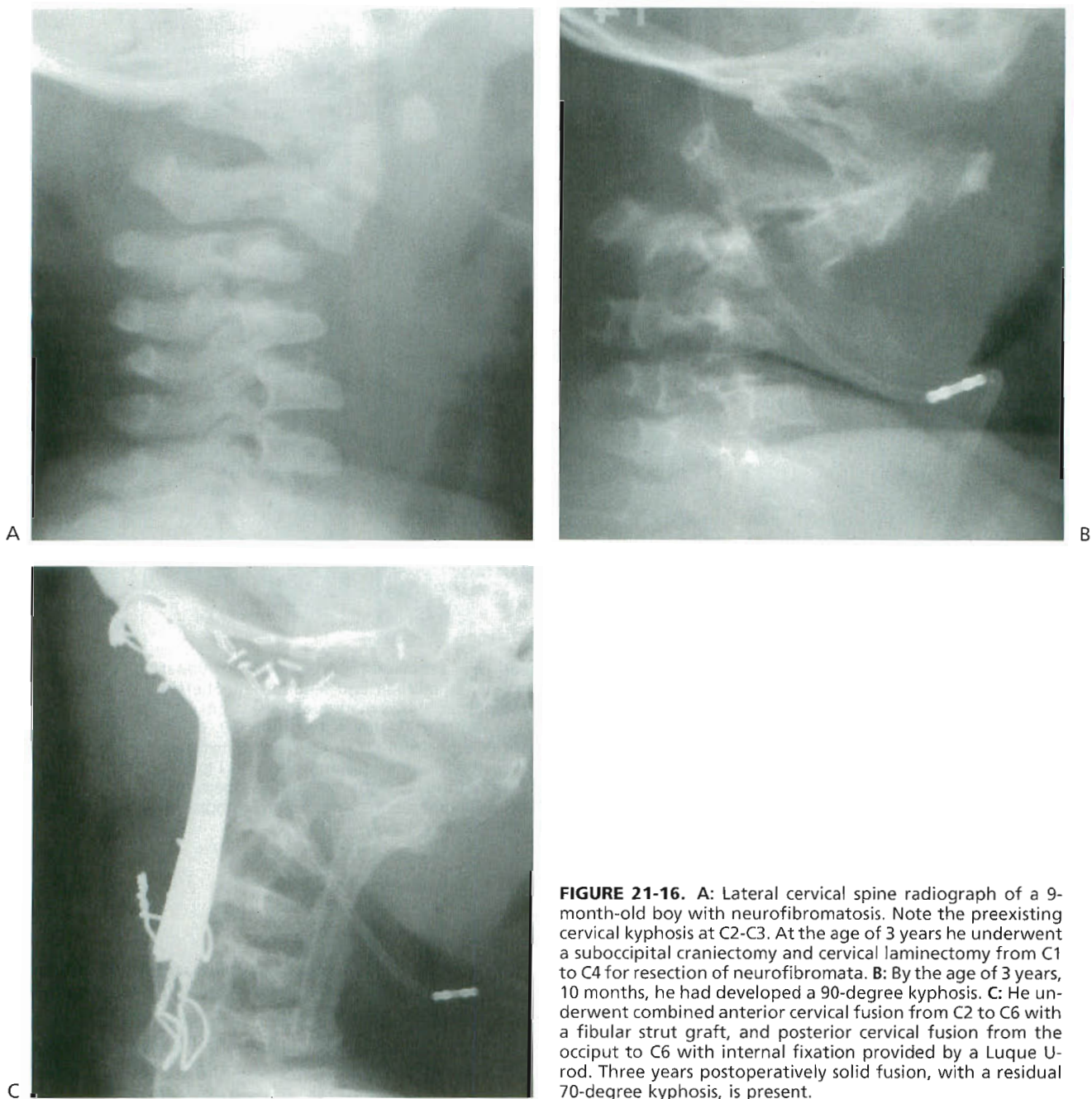


FIGURE 21-16. A: Lateral cervical spine radiograph of a 9-month-old boy with neurofibromatosis. Note the preexisting cervical kyphosis at C2-C3. At the age of 3 years he underwent a suboccipital craniectomy and cervical laminectomy from C1 to C4 for resection of neurofibromata. B: By the age of 3 years, 10 months, he had developed a 90-degree kyphosis. C: He underwent combined anterior cervical fusion from C2 to C6 with a fibular strut graft, and posterior cervical fusion from the occiput to C6 with internal fixation provided by a Luque U-rod. Three years postoperatively solid fusion, with a residual 70-degree kyphosis, is present.

Other Syndromes

Fetal Alcohol Syndrome

Central nervous system dysfunctions, growth deficiencies, facial anomalies, and variable major and minor malformations are the characteristics of fetal alcohol syndrome. The children present with developmental delay, especially in motor milestones, failure to thrive, mild to moderate retardation, mild microcephaly, distinct facies (hypoplasia of the facial bones and circumoral tissues), and congenital cardio-

vascular anomalies. The cervical findings are similar to those of Klippel-Feil syndrome. Radiographically, congenital fusion of two or more cervical vertebrae occurs in approximately one-half of these children, resembling Klippel-Feil syndrome (149). The major visceral anomaly in Klippel-Feil syndrome is in the genitourinary system, whereas in fetal alcohol syndrome, it is in the cardiovascular system (149).

The natural history is not known. Radiographic imaging and treatment recommendations regarding the cervical spine are the same as those for Klippel-Feil syndrome.

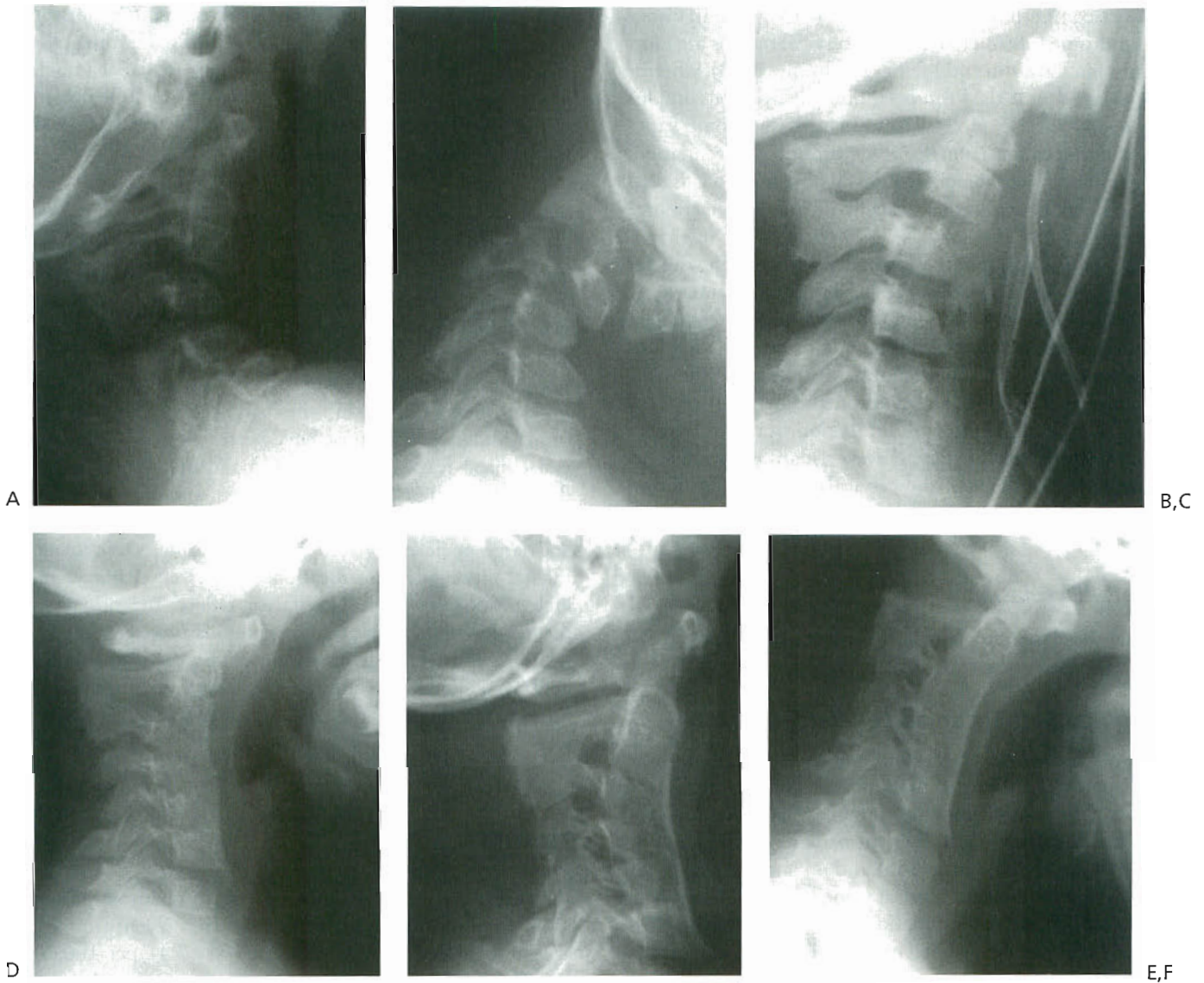


FIGURE 21-17. This girl underwent a cervical laminectomy from C2 to C6 for a low-grade astrocytoma of the cervical cord. At 1 year, 7 months of age, she had a postlaminectomy kyphosis that was 45 degrees in extension (**A**) and 82 degrees in flexion (**B**). **C:** An anterior cervical discectomy and fusion from C2 to C6 was performed with an autogenous iliac crest strut graft. Immediately after the operation the kyphosis was corrected to 20 degrees. Halo vest immobilization was used for 3 months. **D:** Solid incorporation of the fusion occurred by 6 months postoperatively. At 4 years, 7 months of age, flexion (**E**) and extension (**F**) lateral radiographs show maintenance of the correction, solid fusion, and no instability at the remaining levels.

Craniofacial Syndromes

Cleft lip and palate is the most common craniofacial anomaly. It can be a solitary finding, but more often it is associated with other syndromes and anomalies. Children with cleft anomalies have a 13% incidence of cervical spinal anomalies, compared with the 0.8% incidence of children undergoing orthodontia care for other reasons (150). This incidence is highest in patients with soft palate and submucous clefts (45%). These anomalies, usually spina bifida and vertebral body hypoplasia, are predominantly in the upper

cervical spine. The potential for instability is unknown, as is the natural history. No documented information regarding treatment is available; however, the clinician should be aware of this association and make sound clinical judgments as needed.

Craniosynostosis Syndromes

The craniosynostosis syndromes—Crouzon, Pfeiffer, Apert, and Goldenhar—exhibit cervical spine fusions, atlantooccipital fusions, and butterfly vertebrae (151–153). Fusions

are more common in Apert syndrome (71%) than in Crouzon syndrome (38%) (151). Upper cervical fusions are most common in Crouzon and Pfeiffer syndromes (153), whereas in Apert syndrome the fusions are more likely to be complex and involve C5-C6 (151). However, this syndrome variation is not accurate enough for syndromic differentiation. Congenital cervicothoracic scoliosis with rib fusions is seen in Goldenhar syndrome, usually from hemivertebrae (153,154).

The cervical fusions are progressive with age; in younger children the vertebrae appear to be separated by intervertebral discs, but as the children grow older the vertebrae fuse together. There are no specific, standard recommendations for treatment. The author recommends following the same principles as in Klippel-Feil syndrome. The main concern is the potential difficulty with intubation in these children. Odontoid anomalies are rare; however, if any question exists regarding the stability of the cervical spine, lateral flexion and extension radiographs should be obtained.

Skeletal Dysplasias

Skeletal dysplasias are discussed in detail in Chapter 8.

Combined Soft Tissue and Skeletal Dysplasias

Neurofibromatosis. Neurofibromatosis is the most common single-gene disorder in humans. The proportion of patients with neurofibromatosis and cervical spine involvement is difficult to assess: 30% of patients in the series of Yong-Hing and colleagues (155) and 44% of patients with scoliosis or kyphosis had cervical spine lesions. The cervical lesions are often asymptomatic (155). Symptoms, when they do occur, are diminished or painful neck motion, torticollis, dysphagia, deformity, and neurologic signs ranging from mild pain and weakness to paraparesis and quadriplegia (31,156). Neck masses constituted 20% of presenting symptoms in one study of neurofibromatosis patients (157).

Radiographic features of neurofibromatosis in the cervical spine are vertebral body deficiencies and dysplasia or scalloping (155). This condition often is associated with kyphosis and foraminal enlargement. Lateral flexion and extension radiographs are recommended for all neurofibromatosis patients before general anesthesia or surgery (155). MRI is helpful for assessing the involvement of neural structures and dural ectasia. CT is useful for evaluating the upper cervical spine complex and the bony definition of the neural foramen. The natural history of neurofibromatosis in the cervical spine is unknown, but patients with severe kyphosis often develop neurologic deterioration.

Surgical indications are cord or nerve root compression, C1-C2 rotary subluxation, pain, and neurofibroma removal (155,156). A halo cast or vest is usually needed after fusion with or without internal fixation, and is usually achieved

with simple interspinous wiring. Kyphosis requires both anterior and posterior fusion (Fig. 21-16). Pseudarthroses are frequent with isolated posterior fusions. Vascularized fibular grafts may be necessary to effect fusion in difficult cases (158,159). If there are no indications for surgical treatment the patient should be followed closely.

Fibrodysplasia Ossificans Progressiva. Fibrodysplasia ossificans progressiva is an inherited, autosomal dominant disorder (160) of connective tissue with progressive soft tissue ossification. The disorder itself is rare; most cases represent new spontaneous mutations. Eventually all patients with this disorder develop cervical spine changes (161), often starting in childhood. These patients usually present with neck stiffness (162) within the first 5 years of life. No cases of neurologic compromise have been reported. Other general clinical features are big-toe malformations, reduction defects of all digits, deafness, baldness, and mental retardation. Early in the course of the disease small vertebral bodies and large pedicles are seen radiographically. Occasionally, nuchal musculature ossification also is seen. Later, neural arch fusions are seen. This factor reflects the progressive ossification of the cervical spinal musculature, ligament ossification, and spontaneous fusion of the cervical discs and apophyseal joints. No effective medical treatment is known. Surgical treatment of the cervical spine has not been necessary.

TRAUMA

Injuries to the cervical spine are rare in children, and are more common in boys than in girls. In a recent study the age- and gender-adjusted incidence was 7.41 per 100,000 population per year (163); this incidence was much less in children (younger than 11 years of age, 1.19 per 100,000) than in adolescents (older than 11 years of age, 13.24 per 100,000). The cause of the injury in children is frequently a fall, whereas in adolescents it is frequently sports, recreational activities, or motor vehicle crashes. In general, children (younger than 11 years of age) are more likely to sustain ligamentous injuries and injuries to the upper cervical spine, whereas adolescents are more likely to sustain fractures and injuries to the lower cervical spine (163). By the age of 10 years the bony cervical spine has reached adult configurations, and the injuries it sustains are essentially those of the adult. Therefore, the author concentrates on those injuries sustained in the first decade of life.

Most children with potential cervical spine injuries have sustained polytrauma, and frequently arrive immobilized on backboards and wearing cervical collars. If the child is comatose or semiconscious, if there are external signs of head injury, or if the child complains of neck pain, cervical spine radiographs are needed. All children involved in motor vehi-

cle crashes with head trauma and neck pain, or who have neurologic signs or symptoms, should have cervical spine radiographs (164,165). The views recommended for this initial screening are the cross-table lateral, open-mouth odontoid, and anteroposterior views. If the child is too critically ill to be positioned for all views, the cross-table lateral view is adequate until a complete evaluation can be performed. Cervical spine precautions must be maintained until a complete evaluation has demonstrated no injury. Once a cervical injury has been identified, close scrutiny must be undertaken to ensure that there are no other injuries in the remainder of the axial skeleton.

The child arriving in the emergency suite is often on a standard backboard. Young children have a disproportionately large head, and positioning them on a standard backboard leads to a flexed posture of the neck (166) (Fig. 21-18A). This flexion can lead to further anterior angulation or translation of an unstable cervical spine injury, and can also cause pseudosubluxation, which, in an injured child, can be difficult to interpret. To prevent this undesirable cervical flexion in young children during emergency transport and radiography, modifications must be made by either creating a recess for the occiput of the larger head or using a double mattress to raise the chest (Fig. 21-18B). A simple clinical guideline is to align the external auditory meatus with the shoulder.

Flexion and extension lateral radiographs may be necessary to determine the stability of the cervical spine; hyperflexion ligamentous injuries may not be seen immediately, and flexion and extension views a few weeks after the spasm has subsided may document instability. In one series of children with ligamentous injuries of the cervical spine 8 of 11 children with lower cervical instability were diagnosed between 2 weeks and 4 months after the trauma (167).

Secondary signs of spinal injury in children often are

seen before the actual injury or fracture itself. Malalignment of the spinous processes on the anteroposterior radiograph should be regarded as highly suspicious for a jumped facet. Widening of the posterior interspinous distances should be regarded as highly suspicious for a posterior ligamentous injury. In adults, an increase in the retropharyngeal soft tissue space can indicate a hematoma in the setting of trauma, and increase the suspicion on the part of the clinician that an upper cervical fracture exists. In children, however, the pharyngeal wall is close to the spine in inspiration, whereas there may be a large increase in this space with forced expiration, as in a crying child (168). This should be remembered when considering the significance of prevertebral pharyngeal soft tissue in the cervical spine radiographs of a frightened, crying child.

CT is useful to further assess the upper cervical spine, especially the ring of the atlas, and occasionally the odontoid. As a rule, CT is not recommended for screening, but to further study suspicious areas on plain radiographs or for treatment planning. It should be used to study all fractures of C1. MRI is useful to assess the spinal cord and discs.

Fractures and Ligamentous Injuries of the Occipital Complex to the C1-C2 Complex

Atlantooccipital Dislocation

Atlantooccipital dislocation is rare (169), and most of the children do not survive (170). Deployment of air bags has been associated recently with this injury in children (171). With the present rapid response to trauma victims and more aggressive field care more of these children now survive. These children are usually polytrauma victims with severe head injuries, and present with a range of clinical neurologic pictures (169,170). In the past, those who survived had incomplete lesions, often demonstrating cranial nerve dysfunctions and varying degrees of quadriplegia. Many of the children have complete loss of neurologic function below the brainstem, and survive only because of outpatient ventilatory support. Other presentations may include a responsive child with hypotension or tachycardia, or a child in complete cardiac arrest. Occasionally, some patients present with normal neurologic examinations.

In severe cases the diagnosis is evident; however, some of the cases do not demonstrate marked radiographic displacement. In the past, a Powers ratio greater than 1.0 (Fig. 21-19A) was used to indicate the presence of atlantooccipital dislocation (172). This criterion can cause the practitioner to miss isolated distraction injuries, anterior atlantooccipital dislocations that have spontaneously reduced after injury, and posterior atlantooccipital injuries (169). For this reason, the distance between the tip of the dens and the basion (Fig. 21-19B) has been used, in which a

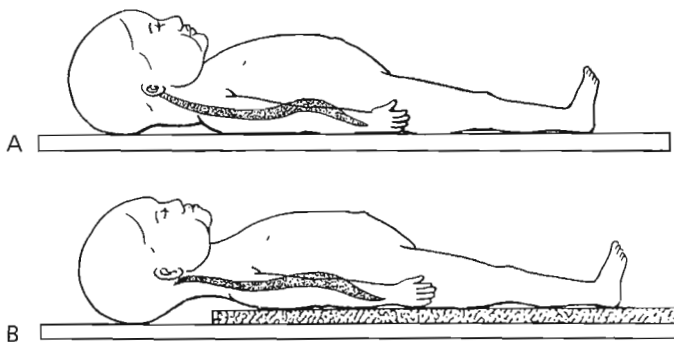


FIGURE 21-18. A: Positioning a young child on a standard backboard forces the neck into a kyphotic position because of the relatively large head. B: Positioning a young child on a double mattress, which raises the chest and torso and allows the head to translate posteriorly, compensates for the relatively large head. This creates a normal alignment of the cervical spine. (From ref. 166, with permission.)

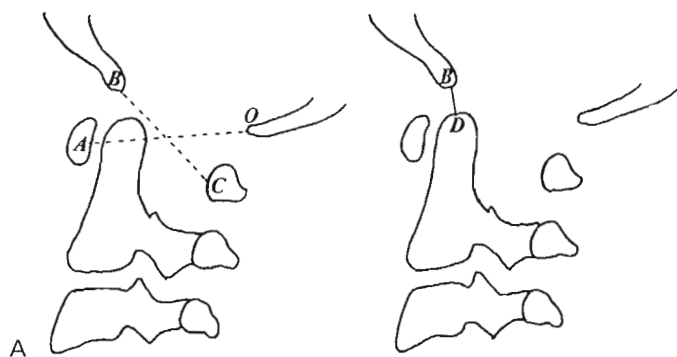


FIGURE 21-19. The BC:OA ratio (A) and the DB distance (B) are used to assess for traumatic atlantooccipital dislocation. (From ref. 169, with permission.)

distance of more than 12.5 mm indicates the potential for atlantooccipital dislocation.

The first obstacle in the treatment of this injury is its diagnosis. If the suspicion for craniocervical trauma is still present after inconclusive plain radiography, CT or MRI can be quite useful (Fig. 21-20). Subarachnoid hemorrhage at the craniocervical junction will be seen after atlantooccipital dislocation (173); CT can also assist in assessing osseous alignment (174). Once atlantooccipital dislocation is diagnosed, standard respiratory and other supporting measures are given. Early definitive immobilization of the dislocation should be undertaken. The immobilization can be with a halo cast alone, or with supplemental internal fixation and posterior fusion (173,175). Traction should be avoided because it can distract the joint and cause further neurologic injury. These children must be moved rapidly into an upright position to maximize pulmonary care. Late neurologic deterioration may indicate progressive hydrocephalus or retropharyngeal pseudomeningocele (176).

Fractures of the Atlas

The Jefferson fracture is rare in children (177,178). It is caused by an axial load from the head into the lateral masses. Unlike in adults, a single fracture through the ring in children may be isolated, hinging on the synchondrosis (178), instead of being a double break in the ring. A transverse atlantal ligament rupture may occur as the lateral masses separate, resulting in C1-C2 instability.

CT scans are useful in both the diagnosis of this injury and the assessment of healing. This injury in children is not commonly seen on plain radiographs, which usually show only an asymmetry between the odontoid and the lateral masses. If it is clearly seen on plain radiographs CT should also be performed to confirm the diagnosis and to rule out a transverse alar ligament rupture. Treatment is usually simple immobilization with a Minerva or halo cast. Rarely is surgery necessary unless rupture of the transverse alar ligament occurs, which renders the spine unstable. The timing of surgery needs to be individualized.

Transverse Atlantoaxial Ligament Ruptures

Transverse atlantoaxial ligament ruptures may occur from either severe or mild trauma (167). Radiographically the ADI is increased, usually well beyond the normal 5 mm. Adequate ligamentous healing and stability do not occur from simple immobilization. The recommended treatment is reduction in extension, posterior cervical C1-C2 fusion with autogenous bone graft [→2.17], and immobilization with a halo or Minerva cast. A solid arthrodesis is documented on flexion and extension lateral radiographs after 2 to 3 months of immobilization.

Odontoid Fractures

Odontoid fractures are a common pediatric cervical spine injury (179). They are usually physeal fractures of the dens, usually Salter-Harris type I fractures. These may occur after major or minor trauma. Neurologic deficits are rare. These fractures usually displace anteriorly, with the dens posteriorly angulated (Fig. 21-21). This fracture usually is seen only on the lateral view. If there is confusion between the mild posterior angulation of the dens and a dens fracture with posterior angulation, which occurs in up to 4% of normal children (180), dynamic flexion and extension CT, with sagittal reconstruction, can be performed to evaluate for any motion or instability.

Displaced odontoid fractures in children reduce easily with mild extension and posterior translation. In most circumstances the simple double-mattress technique is all that is needed to obtain a reduction. After a few days of recumbency and early healing the fracture can be immobilized easily with the use of a Minerva or halo cast. As with all physeal fractures, healing is rapid, and immobilization usually can be stopped in 6 to 10 weeks. Flexion and extension lateral radiographs should be taken to confirm union with stability. These fractures, unlike those in adults, do not have a significant nonunion rate requiring subsequent C1-C2 fusion. The intact hinge of the anterior periosteum most

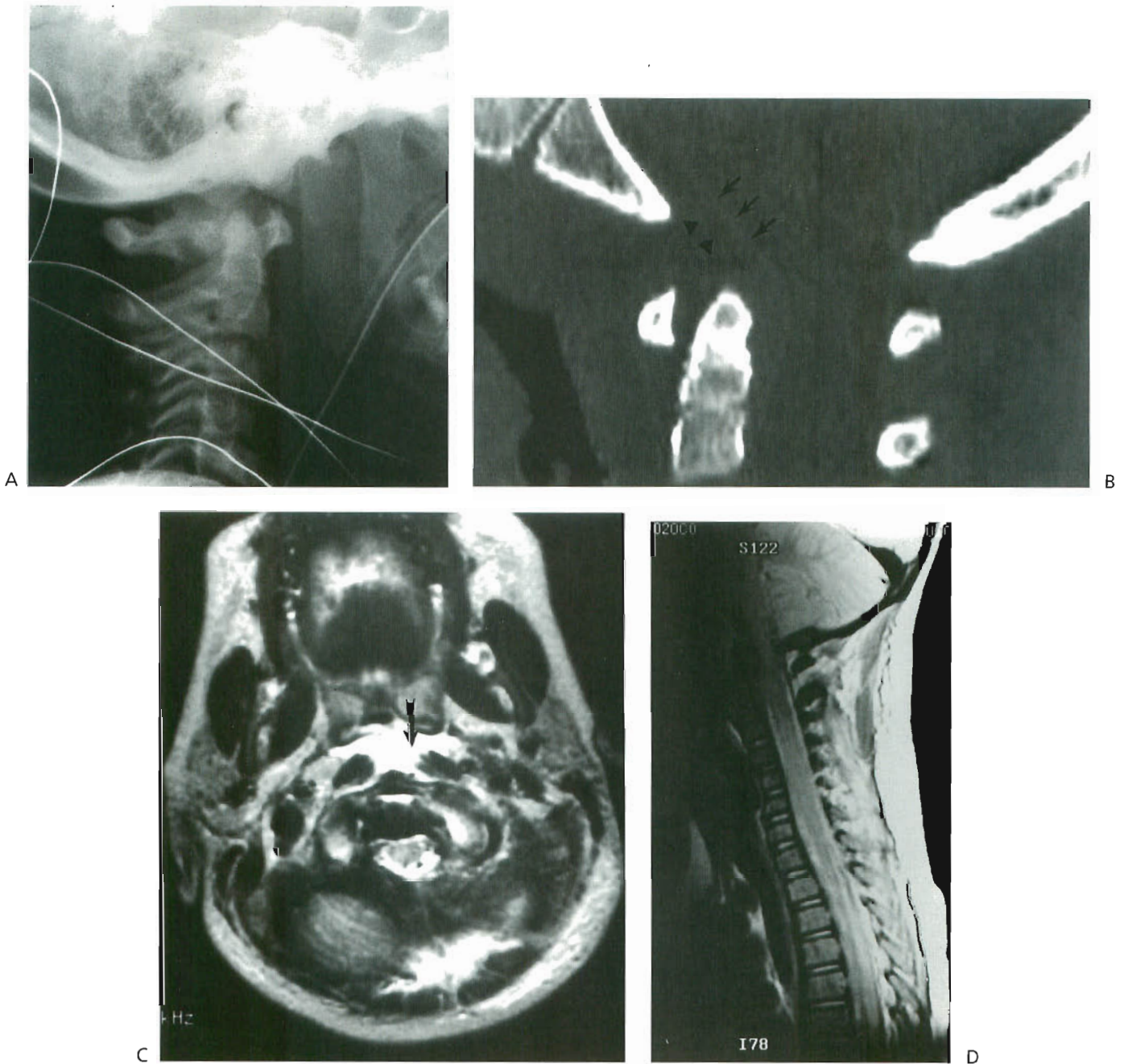


FIGURE 21-20. This 5-year, 6-month-old girl was hit by a van from behind, and presented with bilateral palsies of cranial nerve VI. **A:** The lateral radiograph of the upper cervical spine demonstrates a rotational malalignment. The basion hemishadows fail to overlap, whereas the C1 arches nearly superimpose on each other, raising the concern for atlantooccipital dislocation. **B:** A computed tomography scan with sagittal reconstruction demonstrates elevation of the periosteum at the caudal level of the clivus level (*arrows*) and hemorrhage (*arrowheads*). **C:** An axial image from the magnetic resonance imaging scan demonstrates abnormal fluid accumulation immediately anterior to the atlantooccipital junction (*arrow*). **D:** The magnetic resonance imaging scan sagittal view demonstrates subarachnoid space narrowing at the level of the foramen magnum and the atlantooccipital joint.

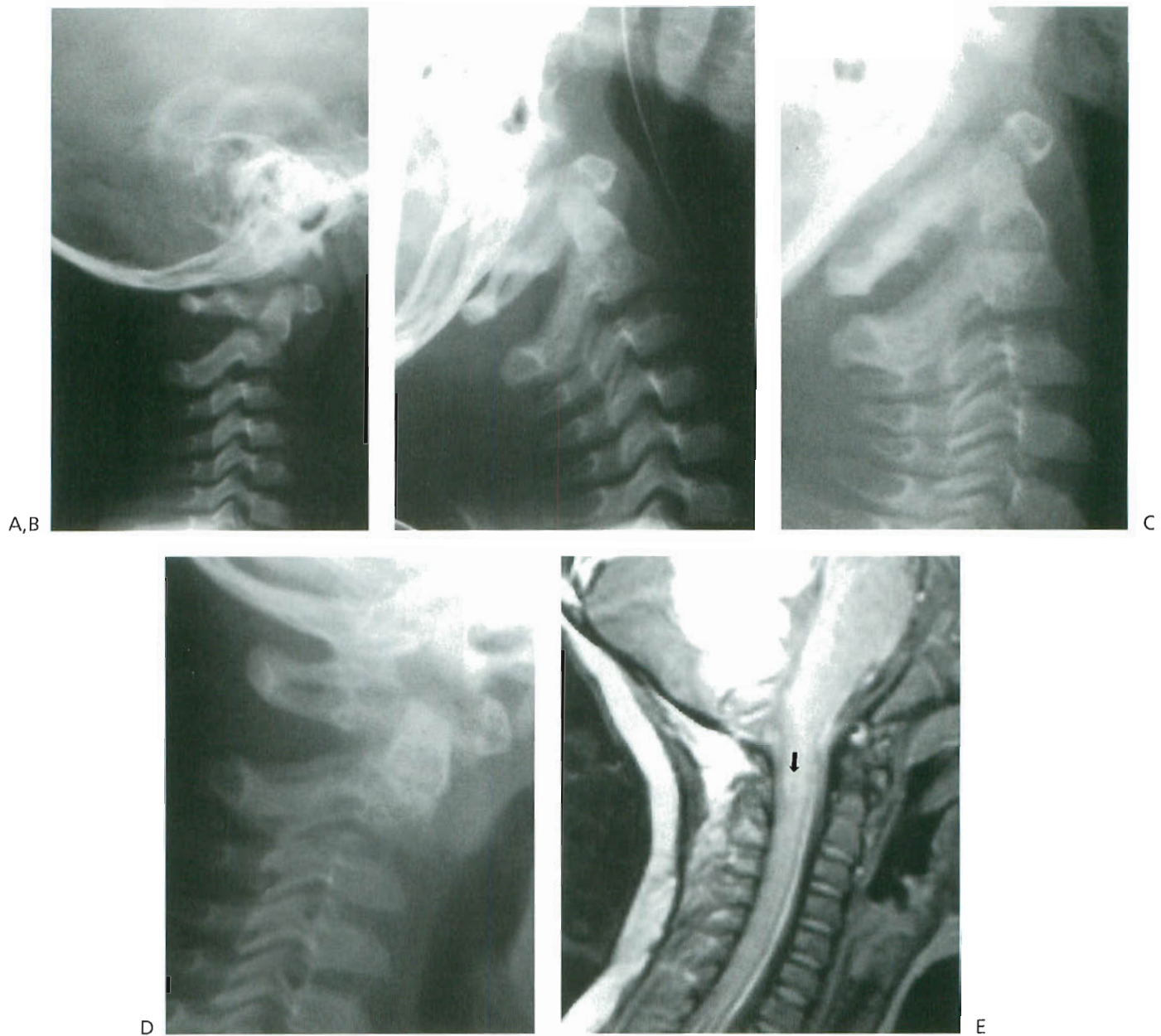


FIGURE 21-21. This 2-year, 9-month-old boy was brought to the emergency department unable to move his upper extremities, and withdrew his lower extremities only in response to noxious stimuli. He had a history of falling off a couch. On investigation it became clear that the child had been battered. **A:** A lateral radiograph demonstrates the odontoid fracture through the dentocentral synchondrosis, with anterior angulation and translation. A magnetic resonance imaging scan did not reveal any abnormalities in the cord. **B:** Simple positioning with a double mattress allowed for reduction of the fracture; the child was maintained on a double mattress for several days to allow for subsidence of cord edema and early healing. He was then placed into a Minerva cast 10 days after injury. The cast was removed 6 weeks after injury, followed by immobilization with a soft collar. Flexion (**C**) and extension (**D**) radiographs demonstrated no instability with the healed fracture. **E:** The child improved remarkably. By 2 months after injury he was running and walking without difficulty. There were some subtle upper-extremity changes, indicated by a change in hand dominance from right to left. Magnetic resonance imaging showed signal changes in the cord (*arrow*), which were interpreted as development of an early posttraumatic syrinx.

likely aids in the ease of reduction and accounts for the stability of reduction and rapid healing.

Spondylolisthesis of C2

Spondylolisthesis of C2, also known as hangman fracture in adults, is rare in children. It most likely arises from hyperextension. Pizzutillo and colleagues (181) reported on a series of five cases in children. Care must be taken to not confuse this fracture with congenital anomalies that may mimic hangman fracture and lead to overtreatment. These fractures readily heal with immobilization in either a Minerva or halo cast after gentle positioning to obtain reduction. Traction alone, as with most cervical injuries in children, should be avoided because it overdistracts the spine with an increased potential for nonunion and more serious neurologic injury. Posterior cervical fusion of C1-C3 is indicated for the rare case of nonunion or instability.

Fractures and Ligamentous Injuries of C3-C7

These injuries are more common in older children and adolescents than in young children (163,182). The typical patterns of fracture usually are compression fractures of the vertebral body, or facet fractures and dislocations caused by hyperflexion. These injuries are adult patterns, and standard adult treatment should be used. Physeal fractures, usually of the inferior end plates, also can occur (183); these are caused by hyperextension. In older children they are usually ring apophyseal fractures with minimal instability or neurologic damage. In younger children they usually involve the entire end plate. Physeal fractures frequently are not recognized in severely injured children, or they may be noted for the first time at autopsy (183). They have a high incidence of neurologic damage (Fig. 21-22). In these children, simple positioning (e.g., double mattresses and rarely, traction followed by immobilization) is all that is needed for treatment. Because these are physeal injuries, healing is rapid.

Traumatic ligamentous instability in children also can occur (167). The pivot point for younger children is in the upper cervical spine because of their large head size, weak cervical musculature, incompletely ossified wedge-shaped vertebrae, physiologic ligamentous laxity, and horizontal facet joints in this region. The upper cervical spine offers little resistance to traumatic shear forces, which often result in ligamentous instability. The goal is to differentiate this traumatic ligamentous instability from pseudosubluxation, using the posterior cervical line. In one study of ligamentous injuries of the cervical spine in children, 7 of 11 injuries occurred at the C2-C3 level (167). When instability exists, treatment should consist of posterior cervical fusion with Minerva or halo immobilization [➔2.17] (Fig. 21-23). Children undergoing cervical arthrodesis for cervical spine injury demonstrate decreased mobility and increased osteo-

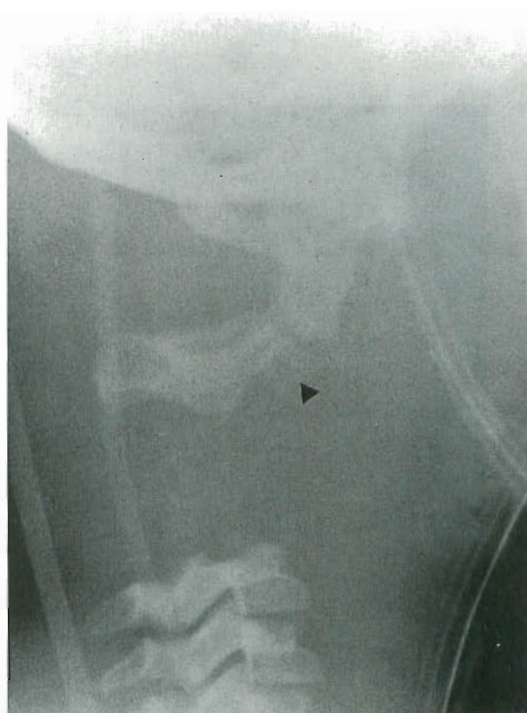


FIGURE 21-22. This 7-year, 2-month-old girl sustained polytrauma and presented in an agonal state. A lateral radiograph demonstrates complete separation at the C2-C3 level, along with an associated C2 hangman fracture. Also note the small fleck of bone (arrowhead) attached to the base of the C2 body; this likely represents an avulsion of the superior aspect of the body of C3 with the C2-C3 disc.

arthritis at long-term follow-up (184). Treatment for a mild sprain is immobilization for comfort followed by flexion and extension radiographs several weeks to a few months later to ensure that late instability does not occur.

Spinal Cord Injury without Radiographic Abnormality

Spinal cord injury without radiographic abnormality (SCIWORA) occurs in 5 to 55% of all pediatric spinal cord injuries (185). By definition, no disruption, malalignment, or other abnormalities are seen on plain radiographs. The immature and elastic pediatric spine is more easily deformed than that of an adult. Momentary displacement from external forces endangers the spinal cord without disrupting bones or ligaments. The four major factors involved in this injury are hyperextension, flexion, distraction, and spinal cord ischemia. Ischemia may arise from cord contusion or direct vascular insult (186).

The neurologic deficit may range from complete cord transection to partial cord deficits. The physiologic disruption of the spinal cord is not necessarily associated with anatomic disruption. The majority of deficits (78%) are

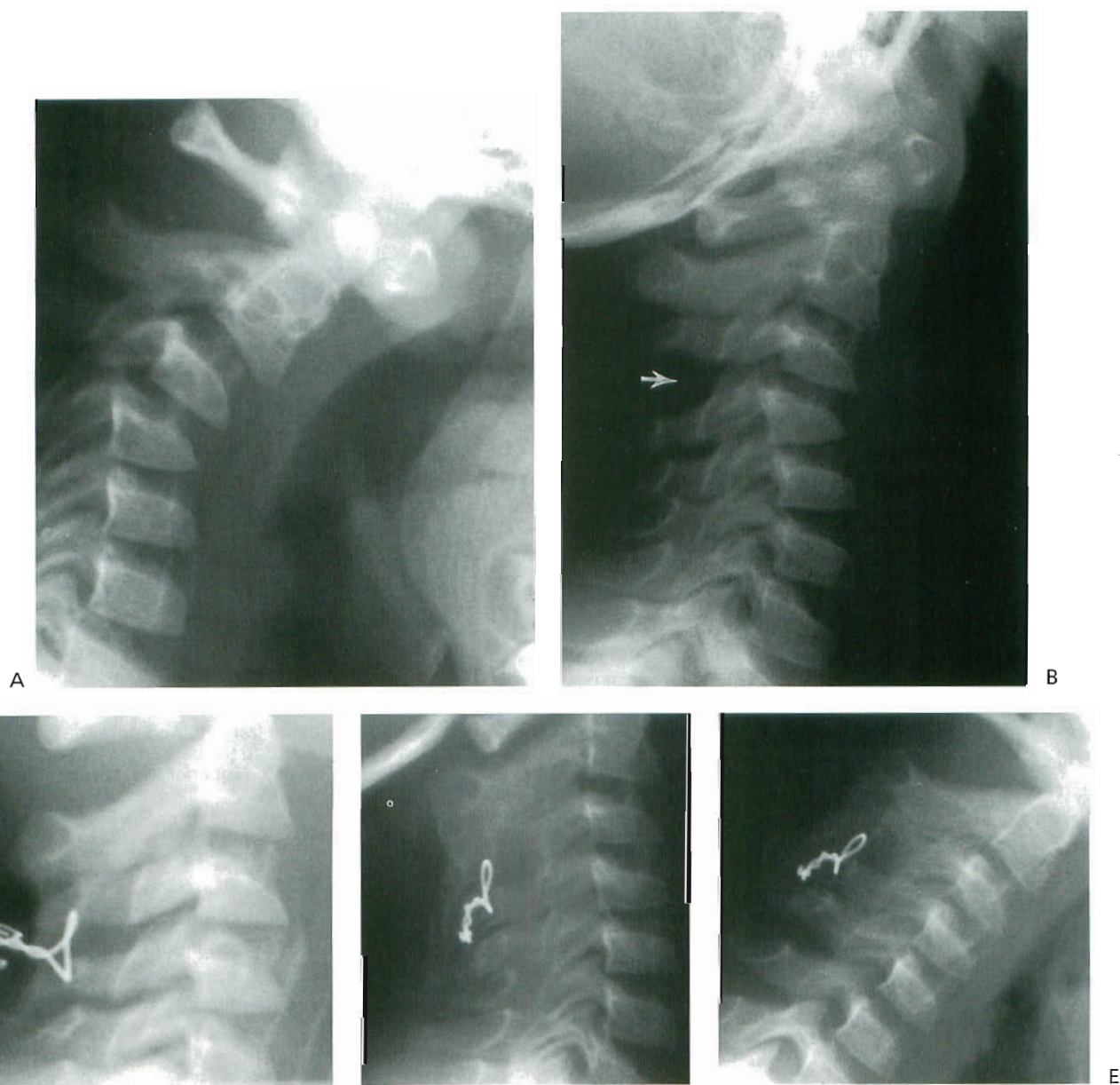


FIGURE 21-23. This 4-year, 9-month-old boy was run over by a snowmobile trailer 2 weeks before these radiographs were taken. He had complained of some neck pain and had been treated by chiropractic manipulation during these 2 weeks. The flexion (A) and extension (B) radiographs demonstrate marked instability at the C3-C4 interspace, which does not completely reduce, even with extension (arrow). C: He was treated by posterior fusion with an iliac crest bone graft and interspinous wiring at C3-C4, as shown in this intraoperative radiograph. Halo vest immobilization was used for 3 months. D and E: One year postoperatively, there was no instability at the C3-C4 level, and there was solid fusion that had extended to C2 and C5, despite meticulous care not to expose the laminae of C2 and C5 or the interspinous ligaments of C2-C3 and C4-C5.

cervical; patients with upper cervical SCIWORA are more likely to have severe neurologic lesions than patients with lower cervical SCIWORA. An MRI is most useful to study the cord and disc/ligament complexes, and correlates with clinical outcome (187). The outcome usually is determined by the presenting neurologic status. Approximately one-

fourth of these children have late deterioration in neurologic function.

Treatment is controversial. Immobilization in a Guilford brace for 3 months has been recommended by Pang and Pollack (185), with complete avoidance of all sports. However, in that series no instability was noted in any of the

children at initial evaluation, and only one child later developed instability on flexion and extension radiographs. Without documented radiographic instability the biomechanical usefulness of brace immobilization is questionable. Pang and Pollack, however, denote this as treating "incipient instability" (185). Most ligamentous spine injuries, when allowed to heal with simple immobilization, do not return to the stability seen in the preinjury state; fusion usually is needed. It is atypical for SCIWORA to behave differently with regard to instability, incipient or otherwise. Regardless of whether the child is braced, close follow-up of neurologic function is needed. Flexion and extension radiographs should be taken after 3 months of bracing; any late development of instability requires surgical stabilization.

Transient Quadripareisis

Transient quadripareisis is a neuropraxia of the cervical cord with transient quadriplegia. It is seen most often in collegiate and professional athletes (188,189), although several cases in younger athletes have been reported (190). The incidence in the National Collegiate Athletic Association is 1.3 per 10,000 athletes per season (189).

The anteroposterior diameter of the spinal canal is decreased in these athletes. The spinal cord is compressed on forced hyperextension or hyperflexion, causing the transient quadripareisis. Sensory changes, such as burning pain, numbness, tingling, and loss of sensation, and motor changes, ranging from weakness to complete paralysis, are seen. These episodes are transient, and recovery occurs in 10 to 15 minutes; neck pain is not present at the time of injury. Transient quadripareisis needs to be differentiated from a brachial plexus stretch, or "burner." Brachial plexus stretch presents with monoparesis of the upper extremity and often with neck pain.

No fractures or dislocations are present. The ratio of the spinal canal to the vertebral body is decreased, with a value of 0.8 used to indicate significant developmental cervical stenosis. Congenital fusions, cervical instability, and intervertebral disc disease also may exist. In children, this spinal canal-to-vertebral body ratio is not as accurate, and is inconsistent in predicting spinal cord concussion (190). An MRI may be necessary to assess the presence or absence of a herniated nucleus pulposus.

Symptom resolution is universal. The only nonsurgical treatments that are needed are the use of collars, analgesics, and antispasmodics. The role of fusions for coexistent instability, discectomy for herniated nucleus pulposus, or decompression for congenital cervical stenosis is not known.

The major concern is whether or not athletic participation should continue, and if so, what is the risk of permanent quadriplegia developing with a later episode. Torg and colleagues (191) believe that athletes with pure developmental spinal stenosis are not predisposed to more severe injuries if they return to sports, and that only those with

instability or degenerative changes should be precluded from participation in contact sports. Odor and colleagues (192) found that one-third of professional and rookie football players have a spinal canal ratio of less than 0.8, and that it is difficult to make continued play decisions based on this ratio alone. Eismont and colleagues (193), however, have shown that smaller cervical canals are correlated with significant neurologic injury in routine trauma. Considering this finding, and the fact that narrowing of the spinal canal correlates even more poorly with spinal cord concussion in children (190), it is prudent to preclude any child who has had a cervical cord concussion from further contact sports until further epidemiologic data have been established.

Special Injury Mechanisms

Birth Injuries and Battered Children

Birth trauma is a common cause of pediatric spinal cord injury, and usually involves the cervical cord (194,195). As in SCIWORA, the vertebral column is more elastic than the cord, and during delivery with prolonged distraction it may be tethered by nerve ends and blood vessels, injuring the cord but not the chondroosseous structures. Damage to the vertebral artery with resultant ischemia of the cord also can occur (196). In battered children, the large head, poorly supported by the cervical musculature, makes the upper cervical spine vulnerable to repeated shaking, with either SCIWORA or fracture.

The diagnosis is difficult, especially with incomplete neurologic injury. Pure transection of the cord itself is rare (197). Temperature regulation dysfunction can cause fevers, reflex movements may be mistaken for voluntary movements, and respiratory distress can occur from paralyzed intercostal muscles. These children also may present with a cerebral palsy-like picture (198) or as victims of sudden infant death syndrome (199). In one study, the diagnosis was delayed in three of four children, and the delay averaged 4.4 years from birth (200). Typically, no fractures are seen radiographically; MRI is often helpful in assessing cord damage.

Some children without complete transection can improve neurologically. Treatment is usually nonsurgical because these are very young infants. Bed rest, respiratory support, and physical therapy, to prevent paralytic contractures, should be instituted. Older children with bony injuries may need Minerva casts (Fig. 21-21). Surgical fusion and stabilization rarely are needed.

Car Seat Injuries

Cervical fractures are described with the increased and recent use of infant car seats (201). When these devices, which clearly make automobile travel safer for children, are not adequately tightened serious and potentially fatal injuries

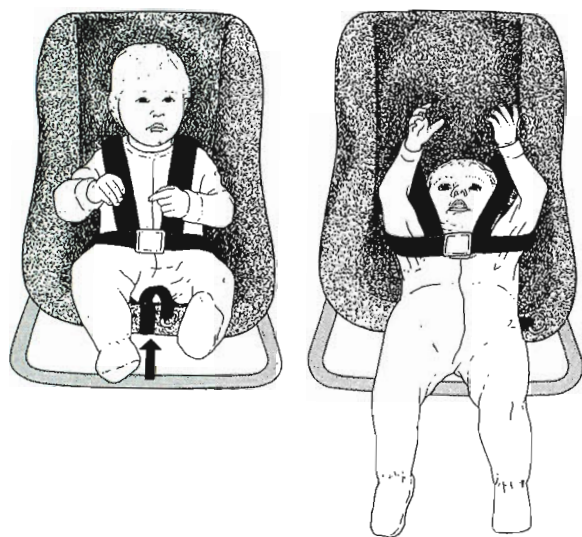


FIGURE 21-24. Placing a child in a car seat without locking the crotch strap (arrow) is a dangerous situation, and can allow serious injury in a collision. (From ref. 201, with permission.)

can occur. The harness must be adjusted periodically to account for normal growth and seasonal changes in clothing thickness. Car seat styles that allow the main lock to be attached to the crotch strap (Fig. 21-24) prevent forward sliding movements which can apply hyperextension forces to the head, the neck, and the upper chest.

Gunshot Wounds

Spinal injuries from gunshot wounds (202) are increasing, and currently account for half of all adolescent spinal cord injuries (203). One-third of these injuries involve the cervical spine. Various degrees of neurologic loss are noted, with complete lesions in 75% in one series (202). Other body areas can be injured as well, which may cause more morbidity than the trauma to the neck itself.

Various degrees of fracture and intracanal bullets are seen radiographically. Other imaging studies, such as arteriography and esophagography, often are needed to look for other injuries. Panendoscopy is useful to assess injury to the trachea and esophagus. Spinal decompression is not indicated in either complete or incomplete lesions. For patients with complete injuries removal of retained bullet fragments from the canal does not improve neurologic outcome. Patients who undergo decompression have a higher risk of meningitis and spinal instability without any added benefit. Spinal instability is rare unless laminectomy is performed. Indications for neck exploration are a positive arteriogram, impending airway obstruction, tracheal deviation, widened mediastinum, expanding hematoma, and appropriate pathology on panendoscopy. Routine exploration of the neck and wound is not advised.

INFLAMMATORY AND SEPTIC CONDITIONS

Juvenile Rheumatoid Arthritis

Juvenile rheumatoid arthritis is a chronic synovitis that can affect the joints of the cervical spine as well. The subtypes that usually involve the cervical spine are the polyarticular and systemic onset types; only rarely does the pauciarticular type affect the cervical spine (204).

Cervical spine involvement usually occurs in the first 1 to 2 years from disease onset and presents with stiffness. Pain and torticollis are rare, and when they occur in a patient with juvenile rheumatoid arthritis other causes should be examined, such as fracture, infection, or tumor. Torticollis was present in only 4 of 92 children in the series of Fried and colleagues (205), and in only 1 of 121 children in the series of Hensinger and colleagues (204). Neurologic findings are also infrequent in these children.

The radiographic features consist of seven types (204):

1. Anterior erosion of the odontoid process
2. Anteroposterior erosion of the odontoid process (apple-core odontoid) (Fig. 21-25)
3. Subluxation of C1 on C2
4. Focal soft tissue calcification appearing adjacent to the ring of C1 anteriorly
5. Ankylosis of the apophyseal joints
6. Growth abnormalities
7. Subluxations between C2 and C7

The most common radiographic features in children with neck stiffness are soft tissue calcification at the leading edge of C1, anterior erosion of the odontoid process, and apophyseal joint ankylosis. Although there may be mild hypermobility at C1-C2 with flexion and extension, true instability or myelopathy is rare. Basilar invagination, which often occurs in adult rheumatoid arthritis, also is rare in juvenile rheumatoid arthritis (205). The radiographic findings of juvenile rheumatoid arthritis that differ most from those of adult rheumatoid arthritis are late destruction of articular cartilage and bone, growth disturbances, spondylitis with associated vertebral subluxation and apophyseal joint ankylosis, and micrognathia (206). In five patients who had long-standing disease (average age, 19 years), Hallah and colleagues (207) described a nonreducible head tilt attributable to collapse of an atlantoaxial lateral mass.

Other imaging studies are needed in the child with juvenile rheumatoid arthritis and neck pain. A bone scan is used to pinpoint the exact anatomic location of activity, and the anatomy is further studied by CT. These studies can be helpful in looking for occult fractures, infections, and bony tumors.

Odontoid erosion results from the inflammatory synovitis and the pannus of the synovial ring surrounding the odontoid process. The pannus erodes the odontoid anteriorly and posteriorly, but leaves the apical and alar ligament

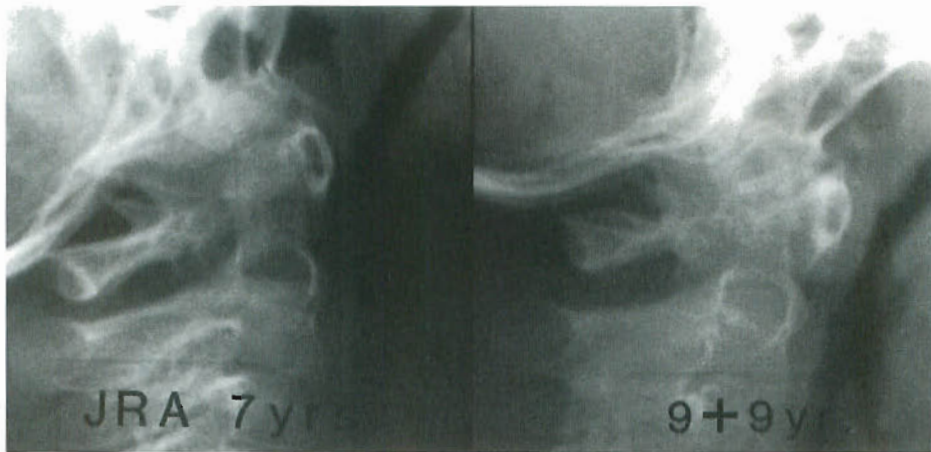


FIGURE 21-25. A boy with polyarticular juvenile rheumatoid arthritis. At 7 years of age there was only slight erosion of the anterior part of the odontoid but by 9 years of age there was an apple-core lesion exhibited by both marked anterior and posterior erosion of the odontoid. (From ref. 204, with permission.)

attachments free, creating the apple-core lesion. This lesion is more susceptible to fracture, both from erosions and from vascular compromise to the odontoid, because the blood supply to the odontoid courses along its side (208), and may be disturbed by the invading pannus. Ankylosis of the apophyseal joints is most common in the systemic-onset subtype. In these young children posterior ankylosis of the immature spine creates a tether, preventing further anterior growth. Decreased disc-space height and smaller vertebral bodies, both longitudinally and circumferentially, result.

The treatment is generally nonsurgical, in conjunction with good rheumatologic care. Patients rarely develop flexion deformities; early in the course of the disease, a cervical collar may prevent this deformity (205). A cervical collar is recommended for patients with involvement of the odontoid process or subaxial subluxation whenever they are in an automobile or other mode of travel. If these patients need surgery for any reason intubation can be difficult because of the micrognathia, flexion deformity, and neck stiffness. Cervical fusion rarely is needed, and should be reserved for children with documented instability or progressive neurologic deterioration.

Intervertebral Disc Calcification

The first description of pediatric disc calcification appeared in 1924, and there are now more than 100 cases reported in the literature (209). It is slightly more common in boys than in girls (7:5 ratio), with an average age at presentation of 8 years (range, 8 days to 13 years). It occurs most often in the cervical spine, and is especially symptomatic when located there. The cause is unclear. Theories proposed are antecedent trauma (present in 30% of patients) and recent upper respiratory infections (present in 15% of patients,

which may only reflect the normally high incidence of pediatric upper-respiratory infections). There is no evidence to suggest metabolic disorders.

The most common clinical presentation is neck pain, which occurs in about one-half of the children (209). The onset of symptoms is abrupt: between 12 and 48 h. Twenty-three percent of the children are febrile on presentation. Torticollis occurs in one-fourth of the children. Decreased cervical motion and spinal tenderness also can occur. Radicular signs and symptoms rarely may be seen, and they are never seen without local symptoms. Myelopathy is rare (3 of 127 cases).

Calcified deposits are seen delineating the nucleus pulposus. The number of calcified discs averages 1.7 per child (Fig. 21-26). No protrusions have been seen in the asymptomatic group; 38% of symptomatic children have detectable protrusions. Recent reports have also shown signal changes in the vertebrae on MRI (210).

Two-thirds of the children are free of symptoms within 3 weeks, and 95% are free of symptoms by 6 months. The radiographs show regression or disappearance of the calcific deposits in 90% of patients; about one-half of the radiographic improvement occurs within 6 months. Children who are asymptomatic may not show radiographic regression, even when followed for long periods. Children with multiple lesions show different rates of regression at the different disc levels. In some cases, persistent flattening of the vertebral bodies is noted into adulthood, and may result in early degenerative changes (211).

Because of this natural history, treatment is symptomatic unless there is spinal cord compression. Analgesics, sedation, and cervical traction can all be used, depending on the severity of symptoms. A short trial of a soft cervical collar also may be helpful. Contact sports probably should be avoided.

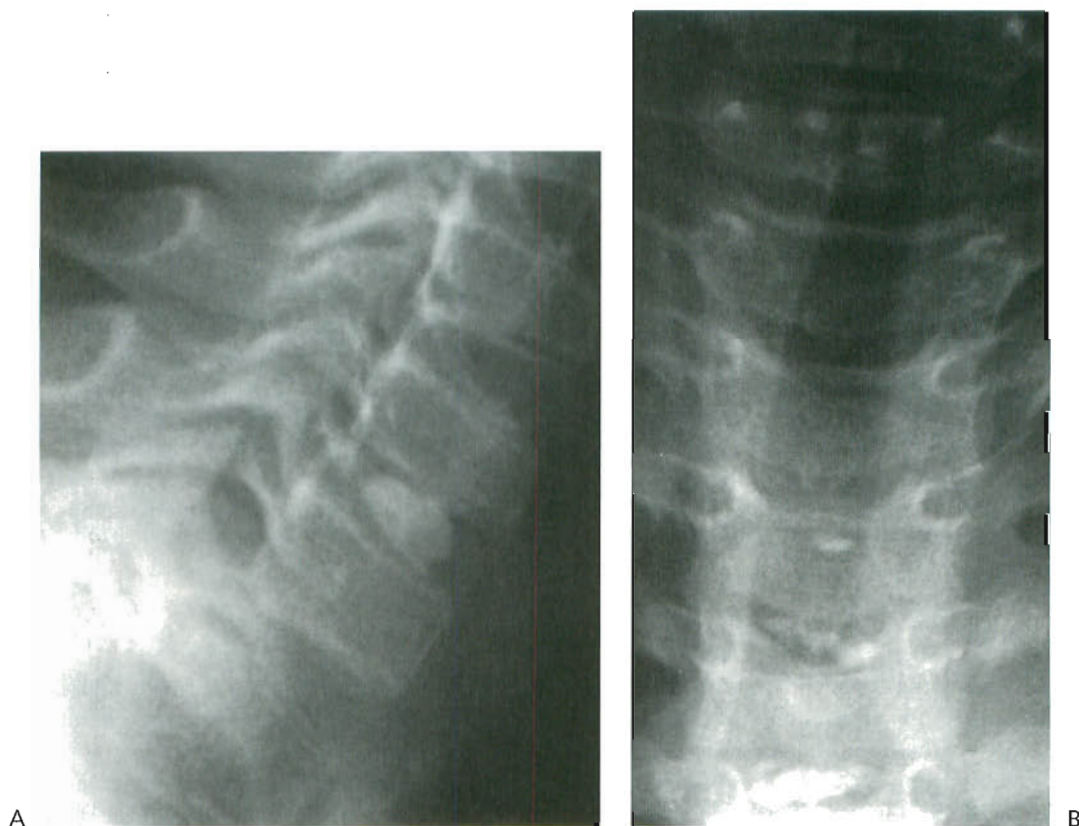


FIGURE 21-26. A: A 7-year-old boy with symptomatic intervertebral disc calcification at the C6-C7 level, as seen on a lateral radiograph. B: He also showed asymptomatic involvement at the T3-T4, T4-T5, and T5-T6 levels, as seen on an anteroposterior radiograph.

Surgical intervention rarely is needed. Two cases have been reported in which anterior discectomy was performed (212,213).

Pyogenic Osteomyelitis and Discitis

Pyogenic osteomyelitis and discitis is a spectrum of disease defined as a symptomatic narrowing of the disc space, often associated with fever and infection-like symptoms and signs. It affects all pediatric age ranges, and is more common in boys than in girls. The cause is most likely infectious in nature; in about one-third of the children an organism can be isolated, usually *Staphylococcus aureus* (214,215).

The children present with pain, difficulty in walking and standing, fever, and malaise. This disorder usually involves the lumbar spine, with cervical involvement being rare. Early on, there is a loss of disc-space height; later, end-plate irregularities on both sides of the disc appear. Bone scans are very useful for identifying the presence of discitis and osteomyelitis in a child with systemic symptoms, when the anatomic location cannot be localized on clinical examination. The MRI findings are consistent with vertebral osteomyelitis (214,216). Other helpful diagnostic studies are de-

termination of erythrocyte sedimentation rate and blood cultures. Disc and bone cultures are necessary only if the child does not respond to an initial course of rest and antibiotic treatment.

Many of these children improve spontaneously without treatment. The intervertebral disc space reconstitutes to varying degrees, but never to the normal height before illness. Sometimes spontaneous vertebral body fusion occurs. Initially nonsurgical treatment is given. This includes rest, immobilization, and intravenous antistaphylococcal antibiotics. Surgery is necessary only when there is no response to nonsurgical management; usually, biopsy and culture to isolate the infectious agent is all that is needed.

Tuberculosis

Mycobacterium tuberculosis infection in the cervical spine is rare compared with other levels of the spine. There will likely be an increase in North America as a result of the increasing number of immigrants from Third World countries, the rise of human immunodeficiency virus infection, and the emergence of drug-resistant strains. There have been two very thorough reviews of this subject (217,218). Four

of 6 patients with upper cervical spine involvement, and 24 of 40 patients with lower cervical spine involvement, were children.

In cases of upper cervical spine involvement the children present with neck pain and stiffness; torticollis, headaches, and constitutional symptoms may also be present. Neurologic symptoms vary from none to severe quadriplegia. In cases of lower cervical spine involvement, the children present with the same symptoms, and also may have dysphagia, asphyxia, inspiratory stridor, and kyphosis. In children younger than 10 years of age, more diffuse and extensive involvement is seen, with large abscesses but with a decreased incidence of paraplegia and quadriplegia. The neurologic symptoms have a gradual onset over a period of 4 to 8 weeks. Sinus formation is not a prominent feature because of the thick cervical prevertebral fascia that contains the abscess. Cord compression occurs from the abscess and the kyphosis. Cultures and biopsies are not always positive. Because the infection is anterior, most cases will progress to spinal cord compression and paralysis if left untreated.

Increased width of the retropharyngeal soft tissue space is seen radiographically, as are osteolytic erosions. Instability at the C1-C2 level can be seen in some children; rarely is there a fixed C1-C2 rotatory subluxation. Kyphosis is present in one-fourth of patients with lower cervical spine involvement. Other useful imaging studies are chest radiography and renal studies.

Treatment involves antituberculous chemotherapy in all children. Surgery also is recommended for the cervical spine because it gives rapid resolution of the pain, upper respiratory obstruction, and spinal cord compression. This is in contrast to the thoracic and lumbar spine, in which chemotherapy alone is an established method of treating tuberculosis (219). Debridement is performed with or without grafting. For children younger than 2 years of age, grafting usually is not needed. For children with upper cervical spine involvement, consideration should be given to anterior transoral drainage and fusion across the lateral facet joints. Most children need halo traction with reduction before drainage, if possible.

HEMATOLOGIC AND ONCOLOGIC CONDITIONS

The primary hematologic condition affecting the cervical spine is hemophilia (220). The involvement is usually asymptomatic, although mild neck discomfort may occur. Diminished lateral rotation can be noted on physical examination. Radiographic findings, which begin to occur in adolescence and early adulthood, consist of cystic changes in the vertebral bodies or end-plate irregularities. Rarely is C1-C2 instability present. These radiographic changes can occur in patients with all degrees of severity of hemophilia.

The pathoanatomy of these changes in the cervical spine is not known.

Many of these degenerative changes occur earlier than in the normal population; the natural history of these premature changes in the hemophilic population is not known. There are no treatment recommendations at present other than standard hemophilic precautions.

Benign Tumors

The common benign tumors that involve the pediatric cervical spine (221,222) are eosinophilic granuloma, osteoid osteoma and osteoblastoma, osteochondroma, and aneurysmal bone cyst. All can be defined as neoplastic disorders without the propensity to metastasize. Although pathologically and physiologically benign, they can be clinically malignant if their surgical accessibility or risk of recurrence places the neural structures at high risk.

The majority of patients with benign cervical vertebral neoplasms are younger than 20 years of age and present with local neck pain (222). Radicular pain may occur in up to one-third of patients (223); gross motor or sensory deficits are much less common. Neoplasms can cause torticollis. Probably the most common neoplasm causing childhood torticollis is osteoid osteoma. In a recent series from the author's institution all four children with cervical osteoid osteomas presented with painful torticollis and decreased neck motion (224). The incidence in the literature of torticollis ranges from 10 to 100% in children with cervical osteoid osteomas (225-227). The pain of osteoid osteoma classically responds to aspirin or other nonsteroidal antiinflammatory medications.

With osteoid osteoma the typical radiographic feature is sclerosis (Fig. 21-27), although it is not always evident. Bone scans are very helpful to locate the lesion; CT is then used to further delineate the anatomy. The osteoid osteoma causes a sclerotic reaction in the surrounding bone, but usually does not invade the epidural space. It is usually located in the laminae, followed by the pedicle and the body. An osteoblastoma is usually a mixture of lytic and blastic elements (228). Bone scans are also positive, but usually are not needed to determine the presence or absence of disease because most tumors are seen on plain radiographs. CT is very helpful to further assess the anatomy, especially the presence or absence of epidural invasion, which is common in osteoblastoma. Typically, it is located in the posterior elements. Osteochondromas of the cervical spine (229,230) have the typical radiographic appearance seen in other parts of the body: expansile lesions with intact cortices and normal trabecular patterns, absence of calcification, and absence of soft tissue masses. Half of patients have multiple osteochondromatosis. The majority of those are in the laminae or spinous processes, and can be mistaken for osteoblastomas. Aneurysmal bone cysts are typically expansile lytic lesions with a thin rim of cortical bone and may involve

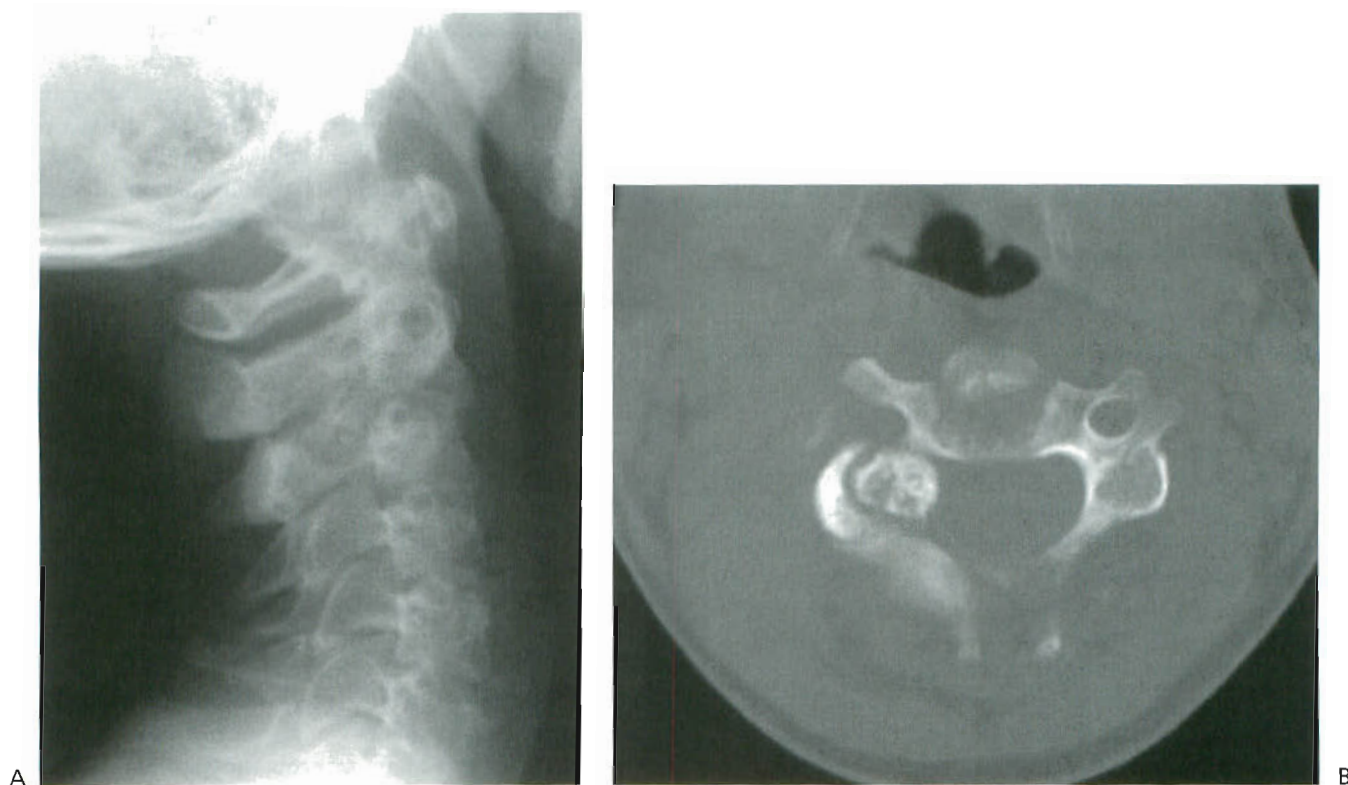


FIGURE 21-27. A 13-year-old boy had a 2-year history of neck pain that did not resolve with long-term chiropractic treatment. **A:** Plain radiographs show a sclerotic nidus with a surrounding lucency at the level of the C3 pedicle and the C2-3 foramen. **B:** Computed tomography scan confirms the typical appearance of an osteoid osteoma; note the proximity of the lesion to both the foramen and the nerve root as well as to the vertebral artery.

contiguous vertebral elements (e.g., the posterior elements, pedicle, and body). CT is useful for determining the exact extent and the potential involvement and proximity of the vertebral artery and neural elements. Angiography may be needed. Aneurysmal bone cysts usually arise in the posterior elements (231). Eosinophilic granuloma usually exhibits vertebra plana radiographically (232). The CT or MRI is useful for determining the potential encroachment on the neural structures. Eosinophilic granuloma usually arises in the vertebral body, with varying degrees of involvement and collapse.

In the cervical spine the main concern is for vertebral artery and neural element involvement, which can lead to neurologic dysfunction. The intense inflammatory nature of osteoid osteoma or osteoblastoma, and its proximity to the neural elements, causes nerve root irritation. This irritation, pain, and muscle spasm may result in torticollis. Compressive myelopathy also can occur, especially in patients with epidural compression, such as that seen with aneurysmal bone cysts (231,233).

The treatment of eosinophilic granuloma in the cervical spine traditionally has been immobilization (e.g., collars, Minerva casts) and low-dose irradiation. Immobilization is

continued until early healing has appeared radiographically. Low-dose irradiation should be reserved for lesions with neurologic deficits that are not surgically accessible. Multiple laminectomies should be avoided. Rarely has immobilization alone been used, and one of these children presented with total collapse of the vertebral body (232). Osteoid osteomas do not undergo malignant transformation. However, continued torticollis and pain may lead to fixed spinal deformities. For this reason, the author advocates surgical resection. Pain relief with complete resection is dramatic. Significant complaints of postoperative pain resembling the preoperative pain indicates either incomplete resection or recurrence. For osteoblastoma and aneurysmal bone cysts the primary treatment is surgical, and nonsurgical treatment is used only as adjunctive therapy. The surgical goal is complete primary excision; however, this is often impossible because of the particular anatomic location of the cysts. In these situations, adjunctive therapy is useful (e.g., radiotherapy for eosinophilic granuloma, or embolization for aneurysmal bone cysts if the nondominant vertebral artery is involved) (234).

Prophylactic fusion should be performed if the resection renders the spine unstable. The amount of resection neces-

sary to render the spine unstable is not known in children; however, in adults, resection of more than 50% of one facet likely leads to segmental instability (235). Because the development of postlaminectomy cervical instability is even more likely in children than in adults, the author recommends an arthrodesis with any degree of facetectomy in children, and strong consideration should be given to an arthrodesis after any degree of laminectomy. Multiple laminectomies should be avoided, if at all possible; if necessary, fusion and stabilization also should be performed. Anterior fusion often is necessary because of insufficient posterior elements after surgical excision; supplemental halo cast or vest or Minerva cast immobilization usually is needed if fusion is required. The overall surgical management is individualized and multidisciplinary (e.g., orthopaedics, neurosurgery, radiotherapy, interventional radiology). Surgical complications include recurrence, pseudarthrosis of the fusion, neurologic deterioration, and vertebral artery injury (236).

Malignant Tumors

The majority of primary and metastatic malignant tumors involving the cervical spine occur in adults; rarely, the cervical spine in children can be involved by chordoma (237), leukemia, Ewing sarcoma (238), or metastatic neuroblastoma.

References

Normal Embryology, Growth, and Development

- O'Rahilly R, Meyer DB. The timing and sequence of events in the development of the human vertebral column during the embryonic period proper. *Anat Embryol* 1979;157:167.
- Sensenig EC. The development of the occipital and cervical segments and their associated structures in human embryos. *Contrib Embryol Carnegie Inst* 1957;36:141.
- O'Rahilly R, Muller F, Meyer DB. The human vertebral column at the end of the embryonic period proper. 1. The column as a whole. *J Anat* 1980;131:565.
- Ogden JA. Radiology of postnatal skeletal development. XI. The first cervical vertebra. *Skeletal Radiol* 1984;12:12.
- Ogden JA. Radiology of postnatal skeletal development. XII. The second cervical vertebra. *Skeletal Radiol* 1984;12:169.
- Ogden JA, Murphy MJ, Southwick WO, et al. Radiology of postnatal skeletal development. XIII. C1-2 interrelationships. *Skeletal Radiol* 1986;15:433.
- Locke GR, Gardner JL, van Epps EF. Atlas-dens interval (ADI) in children: a survey based on 200 normal cervical spines. *Am J Roentgenol* 1966;97:135.
- Pennecot GF, Gouraud D, Hardy JR, et al. Roentgenographical study of the stability of the cervical spine in children. *J Pediatr Orthop* 1984;4:346.
- Catell HS, Filtzer DL. Pseudosubluxation and other normal variations in the cervical spine in children. *J Bone Joint Surg Am* 1965;47:1295.
- Fielding JW, Cochran GVB, Lawsing JF III, et al. Tears of the transverse ligament of the atlas: a clinical and biomechanical study. *J Bone Joint Surg Am* 1974;56:1683.
- Spierings ELH, Braakman R. The management of os odontoides. *J Bone Joint Surg Br* 1982;64:422.
- Steel HH. Anatomical and mechanical considerations of the atlanto-axial articulations. *J Bone Joint Surg Am* 1968;50:1481.
- Jauregui N, Lincoln T, Mubarak S, et al. Surgically related upper cervical spine canal anatomy in children. *Spine* 1993;18:1939.
- El-Khoury GY, Clark CR, Dietz FR, et al. Posterior atlantooccipital subluxation in Down syndrome. *Radiology* 1986;159:507.
- Tredwell SJ, Newman DE, Lockitch G. Instability of the upper cervical spine in Down syndrome. *J Pediatr Orthop* 1990;10:602.
- Wiesel SW, Rothman RH. Occipitoatlantal hypermobility. *Spine* 1979;4:187.
- Gabriel KR, Mason DE, Carango P. Occipito-atlantal translation in Down's syndrome. *Spine* 1990;15:996.
- Swischuk LE. Anterior displacement of C2 in children: physiologic or pathologic. A helpful differentiating line. *Radiology* 1977;122:759.
- Loder RT, Hensinger RN. Developmental abnormalities of the cervical spine. In: Weinstein SL, ed. *The pediatric spine: principles and practice*. New York: Raven, 1994.
- Dolan KD. Developmental abnormalities of the cervical spine below the axis. *Radiol Clin North Am* 1977;25:167.
- Swischuk LE, Swischuk PN, John SD. Wedging of C-3 in infants and children: usually a normal finding and not a fracture. *Radiology* 1993;188:523.
- Ballock RT, Song KM. The prevalence of nonmuscular causes of torticollis in children. *J Pediatr Orthop* 1996;16:500.
- MacAlister A. Notes on the development and variations of the atlas. *J Anat Physiol* 1983;27:519.
- Taylor AR, Chakravorty BC. Clinical syndromes associated with basilar impression. *Arch Neurol* 1964;10:475.
- Burwood RJ, Watt I. Assimilation of the atlas and basilar impression. *Clin Radiol* 1974;25:327.
- Epstein BS, Epstein JA. The association of cerebellar tonsillar herniation with basilar impression incident to Paget's disease. *Am J Roentgenol* 1969;107:535.
- Hurwitz LJ, Shepherd WHT. Basilar impression and disordered metabolism of bone. *Brain* 1966;89:223.
- Harkey HL, Crockard HA, Stevens JM, et al. The operative management of basilar impression in osteogenesis imperfecta. *Neurosurgery* 1990;27:782.
- Yamada H, Nakamura S, Tajima M, et al. Neurological manifestations of pediatric achondroplasia. *J Neurosurg* 1981;54:49.
- Wong VCN, Fung CF. Basilar impression in a child with hypochondroplasia. *Pediatr Neurol* 1991;7:62.
- Isu T, Miyasaka K, Abe H, et al. Atlantoaxial dislocation associated with neurofibromatosis. *J Neurosurg* 1983;58:451.
- de Barros MC, Farias W, Ataide L, et al. Basilar impression and Arnold-Chiari malformation. *J Neurol Neurosurg Psychiatry* 1968;31:596.
- Michie I, Clark M. Neurological syndromes associated with cervical and craniocervical anomalies. *Arch Neurol* 1968;18:241.
- Teodori JB, Painter MJ. Basilar impression in children. *Pediatrics* 1984;74:1097.
- Chamberlain WE. Basilar impression (platybasia): bizarre developmental anomaly of occipital bone and upper cervical spine with striking and misleading neurologic manifestations. *Yale J Biol Med* 1939;11:487.
- McRae DL. Bony abnormalities in the region of the foramen

- magnum: correlation of the anatomic and neurologic findings. *Acta Radiol* 1960;40:335.
37. McGregor M. Significance of certain measurements of skull in diagnosis of basilar impression. *Br J Radiol* 1948;21:171.
 38. Pasztor E, Vajda J, Piffko P, et al. Transoral surgery for basilar impression. *Surg Neurol* 1980;14:473.
 39. Menezes AH, van Gilder JC, Graf CJ, et al. Craniocervical abnormalities: a comprehensive surgical approach. *J Neurosurg* 1980;53:444.
 40. Hunt TE, Dekaban AS. Modified head-neck support for basilar impression with brain-stem compression. *Can Med Assoc J* 1982;126:947.
 41. Menezes AH, van Gilder JC. Transoral-transpharyngeal approach to the anterior craniocervical junction. *J Neurosurg* 1988;69:895.
 42. Bharucha EP, Dastur HM. Craniovertebral anomalies (a report on 40 cases). *Brain* 1964;87:469.
 43. McRae DL, Barnum AS. Occipitalization of the atlas. *Am J Roentgenol* 1953;70:23.
 44. Greenberg AD. Atlantoaxial dislocation. *Brain* 1968;91:655.
 45. Wadia NH. Myelopathy complicating congenital atlantoaxial dislocation (a study of 28 cases). *Brain* 1967;90:449.
 46. Kuhns LR, Loder RT, Rogers E, et al. Head-wag autotomography of the upper cervical spine in infantile torticollis. *Pediatr Radiol* 1998;28:464.
 47. McRae DL. The significance of abnormalities of the cervical spine. *Am J Roentgenol* 1960;84:3.
 48. Weng MS, Haynes RJ. Flexion and extension cervical MRI in a pediatric population. *J Pediatr Orthop* 1996;16:359.
 49. Nicholson JT, Sherik HH. Anomalies of the occipitocervical articulation. *J Bone Joint Surg Am* 1968;50:295.
 50. Doubouset J. Torticollis in children caused by congenital anomalies of the axis. *J Bone Joint Surg Am* 1986;68:178.
 51. Graziano GP, Herzenberg JE, Hensinger RN. The halo-Ilizarov distraction cast for correction of cervical deformity. *J Bone Joint Surg Am* 1993;75:996.
 52. Saltzman CL, Hensinger RN, Blane CE, et al. Familial cervical dysplasia. *J Bone Joint Surg Am* 1991;73:163.
 53. Fielding JW, Hawkins RJ. Atlanto-axial rotatory fixation. *J Bone Joint Surg Am* 1977;59:37.
 54. Jackson G, Adler DC. Examination of the atlantoaxial joint following injury with particular emphasis on rotational subluxation. *Am J Roentgenol* 1956;76:1081.
 55. Fielding JW. Normal and selected abnormal motion of the cervical spine from the second cervical vertebra to the seventh cervical vertebra based on cineroentgenography. *J Bone Joint Surg Am* 1964;46:1779.
 56. Fielding JW. Cineroentgenography of the normal cervical spine. *J Bone Joint Surg Am* 1957;37:1280.
 57. Fielding JW, Stillwell WT, Chynn KY, et al. Use of computed tomography for the diagnosis of atlanto-axial rotatory fixation. *J Bone Joint Surg Am* 1978;60:1102.
 58. Mathern GW, Batzdorf U. Grisel's syndrome: cervical spine clinical, pathologic, and neurologic manifestations. *Clin Orthop* 1989;244:131.
 59. Parke WW, Rothman RH, Brown MD. The pharyngovertebral veins: an anatomical rationale for Grisel's syndrome. *J Bone Joint Surg Am* 1984;66:568.
 60. Kawabe N, Hirotsu H, Tanaka O. Pathomechanism of atlanto-axial rotatory fixation in children. *J Pediatr Orthop* 1989;9:569.
 61. Phillips WA, Hensinger RN. The management of rotatory atlanto-axial subluxation in children. *J Bone Joint Surg Am* 1989;71:664.
 62. Fielding JW, Hawkins RJ, Ratzan SA. Spine fusion for atlanto-axial instability. *J Bone Joint Surg Am* 1976;58:400.
 63. Ling CM. The influence of age on the results of open sternomastoid tenotomy in muscular torticollis. *Clin Orthop* 1976;116:142.
 64. MacDonald D. Sternomastoid tumor and muscular torticollis. *J Bone Joint Surg Br* 1969;51:432.
 65. Davids JR, Wenger DR, Mubarak SJ. Congenital muscular torticollis: sequela of intrauterine or perinatal compartment syndrome. *J Pediatr Orthop* 1993;13:141.
 66. Whyte AM, Lufkin RB, Bredenkamp J, et al. Sternocleidomastoid fibrosis in congenital muscular torticollis: MR appearance. *J Comput Assisted Tomogr* 1989;13:163.
 67. Ling CM, Low YS. Sternomastoid tumor and muscular torticollis. *Clin Orthop* 1972;86:144.
 68. Weiner DS. Congenital dislocation of the hip associated with congenital muscular torticollis. *Clin Orthop* 1976;121:163.
 69. Thompson F, McManus S, Colville J. Familial congenital muscular torticollis. *Clin Orthop* 1986;202:193.
 70. Sarnat HB, Morrissy RT. Idiopathic torticollis: sternocleidomastoid myopathy and accessory neuropathy. *Muscle Nerve* 1981;4:374.
 71. Tang S, Liu Z, Quan X, et al. Sternocleidomastoid pseudotumor of infants and congenital muscular torticollis: fine structure research. *J Pediatr Orthop* 1998;18:214.
 72. Coventry MB, Harris LE. Congenital muscular torticollis in infancy. *J Bone Joint Surg Am* 1959;41:815.
 73. Walsh JJ, Morrissy RT. Torticollis and hip dislocation. *J Pediatr Orthop* 1998;18:219.
 74. Brackbill Y, Douthitt TC, West H. Psychophysiologic effects in the neonate of prone versus supine placement. *J Pediatr* 1973;81:82.
 75. Cheng JCY, Au AWY. Infantile torticollis: a review of 624 cases. *J Pediatr Orthop* 1994;14:802.
 76. Binder H, Eng GD, Gaiser JF, et al. Congenital muscular torticollis: results of conservative management with long-term follow-up in 85 cases. *Arch Phys Med Rehabil* 1987;68:222.
 77. Canale ST, Griffin DW, Hubbard CN. Congenital muscular torticollis: a long-term follow-up. *J Bone Joint Surg Am* 1982;64:810.
 78. Ferkel RD, Westin GW, Dawson EG, et al. Muscular torticollis: a modified surgical approach. *J Bone Joint Surg Am* 1983;65:894.
 79. Tse P, Cheng J, Chow Y, et al. Surgery for neglected congenital torticollis. *Acta Orthop Scand* 1987;58:270.
 80. Gürpınar A, Kristiöglu I, Balkan E, et al. Surgical correction of muscular torticollis in older children with Peter G. Jones technique. *J Pediatr Orthop* 1998;18:598.
 81. Taboas-Perez RA, Rivera-Reyes L. Head tilt: a revisit to an old sign of posterior fossa tumors. *Bol Asoc Med PR* 1984;76:62.
 82. Marmor MA, Beauchamp GR, Maddox SF. Photophobia, epiphora, and torticollis: a masquerade syndrome. *J Pediatr Ophthalmol Strabismus* 1990;27:202.
 83. Giuffrè R, di Lorenzo N, Fortuna A. Cervical tumors of infancy and childhood. *J Neurosurg Sci* 1981;25:259.
 84. Visudhipan P, Chiemchanya S, Somburanasin R, et al. Torticollis as the presenting sign in cervical spine infection and tumor. *Clin Pediatr* 1982;21:71.
 85. Dure LS, Percy AK, Cheek WR, et al. Chiari type I malformation in children. *J Pediatr* 1989;115:573.
 86. Wilkins RH, Brody LA. The Arnold-Chiari malformation: neurological classics XXXVIII. *Arch Neurol* 1971;25:376.
 87. Williams CRP, O'Flynn E, Clarke NMP, et al. Torticollis secondary to ocular pathology. *J Bone Joint Surg Br* 1996;78:620.
 88. Rubin SE, Wagner RS. Ocular torticollis. *Surv Ophthalmol* 1986;30:366.

89. Parker W. Migraine and the vestibular system in childhood and adolescence. *Am J Otol* 1989;10:364.
90. Snyder CH. Paroxysmal torticollis in infancy: a possible form of labyrinthitis. *Am J Dis Child* 1969;117:458.
91. Murphy WJ Jr, Gellis SS. Torticollis with hiatus hernia in infancy. *Am J Dis Child* 1977;131:564.
92. Ramenofsky ML, Buyse M, Goldberg MJ, et al. Gastroesophageal reflux and torticollis. *J Bone Joint Surg Am* 1978;60:1140.
93. Darling DB, Fisher JH, Gellis SS. Hiatal hernia and gastroesophageal reflux in infants and children: analysis of the incidence in North American children. *Pediatrics* 1974;54:450.
94. Darling DB. Hiatal hernia and gastroesophageal reflux in infancy and childhood: analysis of the radiological findings. *Am J Roentgenol* 1975;123:724.
95. Jolley SG, Johnson DG, Herbst JJ, et al. An assessment of gastroesophageal reflux in children by extended pH monitoring of the distal esophagus. *Surgery* 1978;84:16.
96. Johnson DG, Herbst JJ, Oliveros MA, et al. Evaluation of gastroesophageal reflux surgery in children. *Pediatrics* 1977;59:62.
97. Hensinger RN, Lang JE, MacEwen GD. Klippel-Feil syndrome: a constellation of associated anomalies. *J Bone Joint Surg Am* 1974;56:1246.
98. Brown MW, Templeton AW, Hodges FJ III. The incidence of acquired and congenital fusions in the cervical spine. *Am J Roentgenol* 1964;92:1255.
99. Moore WB, Matthews TJ, Rabinowitz R. Genitourinary anomalies associated with Klippel-Feil syndrome. *J Bone Joint Surg Am* 1975;57:355.
100. Stark EW, Borton T. Klippel-Feil syndrome and associated hearing loss. *Arch Otolaryngol* 1973;97:415.
101. Gunderson CH, Solitare GB. Mirror movements in patients with the Klippel-Feil syndrome. *Arch Neurol* 1968;18:675.
102. Baga N, Chusid EL, Miller A. Pulmonary disability in the Klippel-Feil syndrome. *Clin Orthop* 1969;67:105.
103. Nora JJ, Cohen M, Maxwell GM. Klippel-Feil syndrome with congenital heart disease. *Am J Dis Child* 1961;102:110.
104. Hall JE, Simmons ED, Danylichuk K, et al. Instability of the cervical spine and neurological involvement in Klippel-Feil syndrome. *J Bone Joint Surg Am* 1990;72:460.
105. Epstein NE, Epstein JA, Zilkha A. Traumatic myelopathy in a seventeen-year-old child with cervical spinal stenosis (without fracture or dislocation) and a C2-3 Klippel-Feil fusion. *Spine* 1984;9:344.
106. Drvaric DM, Ruderman RJ, Conrad RW, et al. Congenital scoliosis and urinary tract abnormalities: are intravenous pyelograms necessary? *J Pediatr Orthop* 1987;7:441.
107. Ritterbusch JF, McGinty LD, Spar J, et al. Magnetic resonance imaging for stenosis and subluxation in Klippel-Feil syndrome. *Spine* 1991;16(suppl):539.
108. Pizzutillo PD, Woods M, Nicholson L, et al. Risk factors in Klippel-Feil syndrome. *Spine* 1994;19:2110.
109. Sherk HH, Shut L, Chung S. Iniencephalic deformity of the cervical spine with Klippel-Feil anomalies and congenital evaluation of the scapula. *J Bone Joint Surg Am* 1974;56:1254.
110. Guille JT, Miller A, Bowen JR, et al. The natural history of Klippel-Feil syndrome: clinical, roentgenographic, and magnetic resonance imaging findings at adulthood. *J Pediatr Orthop* 1995;15:617.
111. Fielding JW, Hensinger RN, Hawkins RJ. Os odontoideum. *J Bone Joint Surg Am* 1980;62:376.
112. Kuhns LR, Loder RT, Farley FA, et al. Nuchal cord changes in children with os odontoideum: evidence for associated trauma. *J Pediatr Orthop* 1998;18:815.
113. Watanabe M, Toyama Y, Fujimura Y. Atlantoaxial instability in os odontoideum with myelopathy. *Spine* 1996;21:1435.
114. Spitzer R, Rabinowitch JY, Wybor KC. A study of the abnormalities of the skull, teeth, and lenses in mongolism. *Can Med Assoc J* 1961;84:567.
115. Matsuda Y, Sano N, Watanabe S, et al. Atlanto-occipital hypermobility in subjects with Down's syndrome. *Spine* 1995;20:2283.
116. Selby KA, Newton RW, Gupta S, et al. Clinical predictors and radiological reliability in atlantoaxial subluxation in Down's syndrome. *Arch Dis Child* 1991;66:876.
117. Karol LA, Sheffield EG, Crawford K, et al. Reproducibility in the measurement of atlanto-occipital instability in children with Down syndrome. *Spine* 1996;21:2463.
118. Parfenchuck TA, Bertrand SL, Powers MJ, et al. Posterior occipitoatlantal hypermobility in Down syndrome: an analysis of 199 patients. *J Pediatr Orthop* 1994;14:304.
119. Pueschel SM, Herndon JH, Gelch MM, et al. Symptomatic atlantoaxial subluxation in persons with Down syndrome. *J Pediatr Orthop* 1984;4:682.
120. Committee on Sports Medicine and Fitness of the American Academy of Pediatrics. Atlantoaxial instability in Down syndrome: subject review. *Pediatrics* 1995;96:151.
121. Burke SW, French HG, Roberts JM, et al. Chronic atlantoaxial instability in Down syndrome. *J Bone Joint Surg Am* 1985;67:1356.
122. Pueschel SM, Scola FH, Tupper TB, et al. Skeletal anomalies of the upper cervical spine in children with Down syndrome. *J Pediatr Orthop* 1990;10:607.
123. Ferguson RL, Putney ME, Allen BL Jr. Comparison of neurologic deficits with atlanto-dens intervals in patients with Down syndrome. *J Spinal Disord* 1997;10:246.
124. Committee on Sports Medicine and Fitness of the American Academy of Pediatrics. Atlantoaxial instability in Down syndrome. *Pediatrics* 1984;74:152.
125. Pueschel SM, Findley TW, Furia J, et al. Atlantoaxial instability in Down syndrome: roentgenographic, neurologic, and somatosensory evoked potential studies. *J Pediatr* 1987;110:515.
126. Nordt JC, Stauffer ES. Sequelae of atlantoaxial stabilization in two patients with Down's syndrome. *Spine* 1981;6:437.
127. Lundy DW, Murray HH. Neurological deterioration after posterior wiring of the cervical spine. *J Bone Joint Surg Br* 1997;79:948.
128. Smith MD, Phillips WA, Hensinger RN. Fusion of the upper cervical spine in children and adolescents: an analysis of 17 patients. *Spine* 1990;16:695.
129. Rizzolo S, Lemos MJ, Mason DE. Posterior spinal arthrodesis for atlanto-axial instability in Down syndrome. *J Pediatr Orthop* 1995;15:543.
130. Segal LS, Drummond DS, Zanotti RM, et al. Complications of posterior arthrodesis of the cervical spine in patients who have Down syndrome. *J Bone Joint Surg Am* 1991;73:1547.
131. Smith MD, Phillips WA, Hensinger RN. Complications of fusion to the upper cervical spine. *Spine* 1991;16:702.
132. Doyle JS, Lauerman WC, Wood KB, et al. Complications and long-term outcome of upper cervical spine arthrodesis in patients with Down syndrome. *Spine* 1996;21:1223.
133. Msall M, Rogers B, DiGaudio K, et al. Long-term complications of segmental cervical fusion in Down syndrome. *Dev Med Child Neurol* 1991;33(suppl 64):5.
134. Georgopoulos G, Pizzutillo PD, Lee MS. Occipito-atlantal instability in children. *J Bone Joint Surg Am* 1987;69:429.
135. Ebara S, Harada T, Yamazaki Y, et al. Unstable cervical spine in athetoid cerebral palsy. *Spine* 1989;14:1154.
136. Fuji T, Yonenobu K, Fujiwara K, et al. Cervical radiculopathy

- or myelopathy secondary to athetoid cerebral palsy. *J Bone Joint Surg Am* 1987;69:815.
137. Nishihara N, Tnabe G, Nakahara S, et al. Surgical treatment of cervical spondyloric myelopathy complicating athetoid cerebral palsy. *J Bone Joint Surg Br* 1984;66:504.
 138. Reese ME, Msall ME, Owen S, et al. Acquired cervical impairment in young adults with cerebral palsy. *Dev Med Child Neurol* 1991;33:153.
 139. Harada T, Ebara S, Anwar MM, et al. The cervical spine in athetoid cerebral palsy. *J Bone Joint Surg Br* 1996;78:613.
 140. Aronson DD, Kahn RH, Canady A, et al. Instability of the cervical spine after decompression in patients who have Arnold-Chiari malformation. *J Bone Joint Surg Am* 1991;73:898.
 141. Cattel HS, Clark GL Jr. Cervical kyphosis and instability following multiple laminectomies in children. *J Bone Joint Surg Am* 1967;49:713.
 142. Francis WR Jr, Noble DP. Treatment of cervical kyphosis in children. *Spine* 1988;13:883.
 143. Sim FH, Svien HJ, Bickel WH, et al. Swan-neck deformity following extensive cervical laminectomy. *J Bone Joint Surg Am* 1974;56:564.
 144. Yasuoka S, Peterson H, Laws ER Jr, et al. Pathogenesis and prophylaxis of postlaminectomy deformity of the spine after multiple level laminectomy: difference between children and adults. *Neurosurgery* 1981;9:145.
 145. Bell DF, Walker JL, O'Connor B, et al. Spinal deformity after multiple-level cervical laminectomy in children. *Spine* 1994;19:406.
 146. McLaughlin MR, Wahlig JB, Pollack IF. Incidence of postlaminectomy kyphosis after Chiari decompression. *Spine* 1997;22:613.
 147. Lee K-S, Moon M-S. The effect of multilevel laminectomy on the cervical spine of growing cats. *Spine* 1993;18:359.
 148. Hirabayashi K, Satomi K. Operative procedure and results of expansive open-door laminoplasty. *Spine* 1988;13:870.
 149. Tredwell SJ, Smith DF, Macleod PJ, et al. Cervical spine anomalies in fetal alcohol syndrome. *Spine* 1982;7:331.
 150. Sandham A. Cervical vertebral anomalies in cleft lip and palate. *Cleft Palate J* 1986;23:206.
 151. Hemmer KM, McAlister WH, Marsh JL. Cervical spine anomalies in the craniosynostosis syndromes. *Cleft Palate J* 1987;24:328.
 152. Louis DS, Argenta LC. The orthopaedic manifestations of Goldenhar's syndrome. *Surg Rounds Orthop* July 1987;43.
 153. Sherk HH, Whitaker LA, Pasquariello PS. Facial malformations and spinal anomalies: a predictable relationship. *Spine* 1982;7:526.
 154. Gibson JNA, Sillence DO, Taylor TKF. Abnormalities of the spine in Goldenhar's syndrome. *J Pediatr Orthop* 1996;16:344.
 155. Yong-Hing K, Kalamchi A, MacEwen GD. Cervical spine abnormalities in neurofibromatosis. *J Bone Joint Surg Am* 1979;61:695.
 156. Craig JB, Govender S. Neurofibromatosis of the cervical spine. *J Bone Joint Surg Br* 1992;74:575.
 157. Adkins JC, Ravitch MM. The operative management of von Recklinghausen's neurofibromatosis in children, with special reference to lesions of the head and neck. *Surgery* 1977;82:342.
 158. Asazuma T, Yamagishi M, Nemoto K, et al. Spinal fusion using a vascularized fibular bone graft for a patient with cervical kyphosis due to neurofibromatosis. *J Spinal Disord* 1997;10:537.
 159. Nijland EA, van den Berg MP, Wuisman PIJM, et al. Correction of a dystrophic cervicothoracic spine deformity in Recklinghausen's disease. *Clin Orthop* 1998;349:149.
 160. Kaplan FS, McCluskey W, Hahn G, et al. Genetic transmission of fibrodysplasia ossificans progressiva. *J Bone Joint Surg Am* 1993;75:1214.
 161. Hall CM, Sutcliffe J. Fibrodysplasia ossificans progressiva. *Ann Radiol* 1978;22:119.
 162. Connor JM, Smith R. The cervical spine in fibrodysplasia ossificans progressiva. *Br J Radiol* 1982;55:492.

Trauma

163. McGrory BJ, Klassen RA, Chao EYS, et al. Acute fractures and dislocations of the cervical spine in children and adolescents. *J Bone Joint Surg Am* 1993;75:988.
164. Lally KP, Senac M, Hardin WD Jr, et al. Utility of the cervical spine radiograph in pediatric trauma. *Am J Surg* 1989;158:540.
165. Ratchesky I, Boyce WT, Duncan B, et al. Clinical prediction of cervical spine injuries in children: radiographic abnormalities. *Am J Dis Child* 1987;141:199.
166. Herzenberg JE, Hensinger RN, Dedrick DK, et al. Emergency transport and positioning of young children who have an injury of the cervical spine. *J Bone Joint Surg Am* 1989;71:15.
167. Pennecot GF, Leonard P, Gachons SPD, et al. Traumatic ligamentous instability of the cervical spine in children. *J Pediatr Orthop* 1984;4:339.
168. Ardraan GM, Kemp FH. The mechanism of changes in form of the cervical airway in infancy. *Med Radiogr Photogr* 1968;44:26.
169. Bulas DI, Fitz CR, Johnson DL. Traumatic atlanto-occipital dislocation in children. *Radiology* 1993;188:155.
170. Bucholz RW, Burkhead WZ. The pathological anatomy of fatal atlanto-occipital dislocations. *J Bone Joint Surg Am* 1979;61:248.
171. Giguere JF, St-Vil D, Turmel A, et al. Airbags and children: a spectrum of C-spine injuries. *J Pediatr Surg* 1998;33:811.
172. Powers B, Miller MD, Kramer RS, et al. Traumatic anterior atlanto-occipital dislocation. *Neurosurgery* 1979;4:12.
173. Przybylski GJ, Clyde BL, Fitz CR. Craniocervical junction subarachnoid hemorrhage associated with atlanto-occipital dislocation. *Spine* 1996;21:1761.
174. Matava MJ, Whitesides TE Jr, Davis PC. Traumatic atlanto-occipital dislocation with survival. *Spine* 1993;18:1897.
175. Sponseller PD, Cass JR. Atlanto-occipital fusion for dislocation in children with neurologic preservation. *Spine* 1997;22:344.
176. Naso WB, Cure J, Cuddy BG. Retropharyngeal pseudomeningocele after atlanto-occipital dislocation: report of two cases. *Neurosurgery* 1997;40:1288.
177. Marlin AE, Williams GR, Lee JF. Jefferson fractures in children. *J Neurosurg* 1983;58:277.
178. Mikawa Y, Yamano Y, Ishii K. Fracture through a synchondrosis of the anterior arch of the atlas. *J Bone Joint Surg Br* 1987;69:483.
179. Sherk HH, Nicholson JT, Chung SMK. Fractures of the odontoid process in young children. *J Bone Joint Surg Am* 1978;60:921.
180. Swischuk LE, Hayden CK Jr, Sarwar M. The posteriorly tilted dens: a normal variation mimicking a fractured dens. *Pediatr Radiol* 1979;8:27.
181. Pizzutillo PD, Rocha EF, D'Astous J, et al. Bilateral fracture of the pedicle of the second cervical vertebra in the young child. *J Bone Joint Surg Am* 1986;68:892.
182. Evans DL, Bethem D. Cervical spine injuries in children. *J Pediatr Orthop* 1989;9:563.
183. Lawson JP, Ogden JA, Bucholz RW, et al. Physeal injuries of the cervical spine. *J Pediatr Orthop* 1987;7:428.
184. McGrory BJ, Klassen RA. Arthrodesis of the cervical spine for

- fractures and dislocations in children and adolescents. *J Bone Joint Surg Am* 1994;76:1606.
185. Pang D, Pollack IF. Spinal cord injury without radiographic abnormality in children: the SCIWORA syndrome. *J Trauma* 1989;29:654.
 186. Linssen WHJP, Praamstra P, Babreels FJM, et al. Vascular insufficiency of the cervical cord due to hyperextension of the spine. *Pediatr Neurol* 1990;6:123.
 187. Grabb PA, Pang D. Magnetic resonance imaging in the evaluation of spinal cord injury without radiographic abnormality in children. *Neurosurgery* 1994;35:406.
 188. Ladd AL, Scranton PE. Congenital cervical stenosis presenting as transient quadriplegia in athletes. *J Bone Joint Surg Am* 1986;68:1371.
 189. Torg JS, Pavlov H, Genuario SE, et al. Neurapraxia of the cervical spinal cord with transient quadriplegia. *J Bone Joint Surg Am* 1986;68:1354.
 190. Rathbone D, Johnson G, Letts M. Spinal cord concussion in pediatric athletes. *J Pediatr Orthop* 1992;12:616.
 191. Torg JH, Naranja RJ, Pavlov H, et al. The relationship of developmental narrowing of the cervical spinal canal to reversible and irreversible injury of the cervical spinal cord in football players: an epidemiological study. *J Bone Joint Surg Am* 1996;78:1308.
 192. Odor JM, Watkins RG, Dillin WH, et al. Incidence of cervical spinal stenosis in professional and rookie football players. *Am J Sports Med* 1990;18:507.
 193. Eismont FJ, Clifford S, Goldberg M, et al. Cervical sagittal spinal canal size in spine injury. *Spine* 1984;9:663.
 194. Abrams IF, Bresnan MJ, Zuckerman JE, et al. Cervical cord injuries secondary to hyperextension of the head in breech presentations. *Obstet Gynecol* 1973;41:369.
 195. Byers RK. Spinal-cord injuries during birth. *Dev Med Child Neurol* 1975;17:103.
 196. Jones EL, Cameron AH, Smith WT. Birth trauma to the cervical spine and vertebral arteries. *J Pathol* 1970;100:iv.
 197. Shulman ST, Madden JD, Esterly JR, et al. Transection of spinal cord: a rare obstetrical complication of cephalic delivery. *Arch Dis Child* 1971;46:291.
 198. Hillman JW, Sprockin BE, Parrish TF. Birth injury of the cervical spine producing a "cerebral palsy" syndrome. *Am Surg* 1954;20:900.
 199. Towbin A. Central nervous system damage in the human fetus and newborn infant. *Am J Dis Child* 1970;119:529.
 200. Farley FA, Hensinger RN, Herzenberg JE. Cervical spinal cord injury in children. *J Spinal Disord* 1992;5:410.
 201. Conry BG, Hall CM. Cervical spine fractures and rear car seat restraints. *Arch Dis Child* 1987;62:1267.
 202. Kupcha PC, An HS, Cortler JM. Gunshot wounds to the cervical spine. *Spine* 1990;15:1058.
 208. Schiff DCM, Parke WW. The arterial supply of the odontoid process. *J Bone Joint Surg Am* 1973;55:1450.
 209. Sonnabend DH, Taylor TKF, Chapman GK. Intervertebral disc calcification syndromes in children. *J Bone Joint Surg Br* 1982;64:25.
 210. Herring JA, Hensinger RN. Cervical disc calcification: instructional case. *J Pediatr Orthop* 1988;8:613.
 211. Wong CC, Pereira B, Pho RWH. Cervical disc calcification in children: a long term review. *Spine* 1992;17:139.
 212. Smith RA, Vohman MD, Dimon JH III, et al. Calcified cervical intervertebral discs in children. *J Neurosurg* 1977;46:233.
 213. Oga M, Terada K, Kikuchi N, et al. Herniation of calcified cervical intervertebral disc causes dissociated motor loss in a child. *Spine* 1993;18:2347.
 214. Ring D, Johnston CE II, Wenger DR. Pyogenic infectious spondylitis in children: the convergence of discitis and vertebral osteomyelitis. *J Pediatr Orthop* 1995;15:652.
 215. Wenger DR, Bobechko WP, Gilday DL. The spectrum of intervertebral disc-space infection in children. *J Bone Joint Surg Am* 1978;60:100.
 216. Ring D, Wenger DR. Magnetic resonance-imaging scans in discitis. *J Bone Joint Surg Am* 1994;76:596.
 217. Fang D, Leong JCY, Fang HSY. Tuberculosis of the upper cervical spine. *J Bone Joint Surg Br* 1983;65:47.
 218. Hsu LCS, Leong JCY. Tuberculosis of the lower cervical spine (C2-C7). *J Bone Joint Surg Br* 1984;66:1.


Hematologic and Oncologic Conditions

219. Eighth report of the Medical Research Council Working Party on Tuberculosis of the Spine. A 10-year assessment of a controlled trial comparing debridement and anterior spinal fusion in the management of tuberculosis of the spine in patients on standard chemotherapy in Hong Kong. *J Bone Joint Surg Br* 1982;64:393.
220. Romeyn RL, Herkowitz HN. The cervical spine in hemophilia. *Clin Orthop* 1986;210:113.
221. Bohlman HH, Sachs BL, Carter JR, et al. Primary neoplasms of the cervical spine. *J Bone Joint Surg Am* 1986;68:483.
222. Levine AM, Boriani S, Donati D, et al. Benign tumors of the cervical spine. *Spine* 1992;17:S399.
223. Sherk HH, Nolan JP Jr, Moorar PA. Treatment of tumors of the cervical spine. *Clin Orthop* 1988;233:163.
224. Raskas DS, Graziano GP, Herzenberg JE, et al. Osteoid osteoma and osteoblastoma of the spine. *J Spinal Disord* 1992;5:214.
225. Azouzi EM, Kozlowski K, Marron D, et al. Osteoid osteoma and osteoblastoma of the spine in children: report of 22 cases with brief literature review. *Pediatr Radiol* 1986;16:25.
226. Kirwan EOG, Hutton PAN, Pozo JL, et al. Osteoid osteoma and benign osteoblastoma of the spine: clinical presentation and treatment. *J Bone Joint Surg Br* 1984;66:159.
227. Nemoto O, Moser RP, van Dam BE, et al. Osteoblastoma of the spine: a review of 75 cases. *Spine* 1990;15:1272.
228. Schwartz HS, Pinto M. Osteoblastomas of the cervical spine. *J Spinal Disord* 1990;3:179.
229. Cohn RS, Fielding JW. Osteochondroma of the cervical spine. *J Pediatr Surg* 1986;21:997.
230. Novick GS, Pavlov H, Bullough PG. Osteochondroma of the cervical spine: report of two cases in pre-adolescent males. *Skeletal Radiol* 1982;3:13.
231. Capanna R, Albisinni U, Picci P, et al. Aneurysmal bone cyst of the spine. *J Bone Joint Surg Am* 1985;67:527.
232. Sherk HH, Nicholson JT, Nixon JE. Vertebra plana and eosinophilic granuloma of the cervical spine in children. *Spine* 1978;3:116.

Inflammatory and Septic Conditions

203. Haffner DL, Hoffer MM, Wiedbusch R. Etiology of children's spinal injuries at Rancho Los Amigos. *Spine* 1993;18:679.
204. Hensinger RN, DeVito PD, Ragsdale CG. Changes in the cervical spine in juvenile rheumatoid arthritis. *J Bone Joint Surg Am* 1986;68:189.
205. Fried JA, Athreya B, Gregg JR, et al. The cervical spine in juvenile rheumatoid arthritis. *Clin Orthop* 1983;179:102.
206. Martel W, Holt JF, Cassidy JT. Roentgenologic manifestations of juvenile rheumatoid arthritis. *Am J Roentgenol* 1962;88:400.
207. Hallah JT, Fallahi S, Hardin JG. Nonreducible rotational head tilt and atlantoaxial lateral mass collapse: clinical and roentgenographic features in patients with juvenile rheumatoid arthritis and ankylosing spondylitis. *Arch Intern Med* 1983;143:471.

233. Stillwell WT, Fielding JW. Aneurysmal bone cyst of the cervico-dorsal spine. *Clin Orthop* 1984;187:144.
234. Disch SP, Grubb RL Jr, Gado MH, et al. Aneurysmal bone cyst of the cervicothoracic spine: computed tomographic evaluation of the value of preoperative embolization. *Neurosurgery* 1986;19:290.
235. Zdeblick TA, Warden KE, McCabe R, et al. Cervical stability after foraminotomy. *J Bone Joint Surg Am* 1992;74:22.
236. Smith MD, Emery SE, Dudley A, et al. Vertebral artery injury during anterior decompression of the cervical spine. *J Bone Joint Surg Br* 1993;75:410.
237. Sibley RK, Day DL, Dehner LP, et al. Metastasizing chordoma in early childhood: a pathological and immunohistochemical study with review of the literature. *Pediatr Pathol* 1987;7:287.
238. Freiberg AA, Graziano GP, Loder RT, et al. Metastatic vertebral disease in children. *J Pediatr Orthop* 1993;13:148.



22

THE UPPER LIMB

PETER M. WATERS

CONGENITAL DEFORMITIES 842

Pathogenesis 842
Classification 842

ENTIRE LIMB INVOLVEMENT 842

Neuromuscular 842

ELBOW AND FOREARM REGION 853

Congenital Dislocations 853
Congenital Synostoses 855
Musculoskeletal 858

WRIST REGION 861

Congenital 861

HAND REGION 870

Congenital 870

HAND: THUMB 879

Trigger Thumbs/Digits 879
Hypoplasia/Aplasia of the Thumb 880
Thumb Duplication 881
Triphalangeal Thumbs 884

TRAUMATIC INJURIES 885

Overview 885
Distal Phalanx Injuries 886
Phalanx Fractures 887
Metacarpal Fractures 889
Thumb Fractures 890
Wrist Injuries 891
Dislocations 893
Tendon Lacerations 894
Amputations 895

This chapter addresses the evaluation and treatment of the more common upper-limb and hand congenital differences, traumatic and posttraumatic conditions, neuro-pathic problems, and growth deformities. The sections of this chapter examine major diagnostic categories and anatomic regions. To avoid redundancy in the text as a whole, the reader will find more information regarding upper-extremity development (Chapter 2), fractures (Chap-

ter 32), and limb deficiency (Chapter 30) in other chapters of this text.

Treatment of any upper limb or hand problem in a child needs to address the issues of function, growth, cosmetic deformity, and the emotional concerns of the child and family. All are important factors in determining a successful outcome. The means to improve function are to enhance the ability to place the hand in space; to improve deficiencies in grasp, release, or pinch function; and to improve skin mobility and sensibility (1). Treatment of physal abnormalities improves growth-related loss of motion, function, pain, and musculoskeletal deformity. Extensive time and counseling are important to address the concerns of both

the child and parents regarding the alteration in self-image that can occur with any hand deformity.

CONGENITAL DEFORMITIES

Pathogenesis

In utero, the arm bud appears 26 days after fertilization and 24 hours before the appearance of the leg bud. Growth is in a proximal-to-distal manner. Development is guided by the apical ectodermal ridge inducing the mesoderm to condense and differentiate (2). The upper limb anlage is initially continuous and extends to a hand paddle by day 31. The digital rays develop by day 36 with fissuring of the hand paddle, initially in the central rays, followed by the border digits. Mesenchymal differentiation also begins in a proximal-to-distal manner with chondrification, enchondral ossification, joint formation, and muscle and vascular development. Joint formation and digital separation require apoptosis, or programmed cell death. The entire process is complete by 8 weeks after fertilization (3). Other major organ system development is occurring simultaneously, which explains the associated cardiac, craniofacial, musculoskeletal, and renal anomalies that can occur with upper limb malformations.

Homeobox, or *HOX*, genes regulate the development of the limb (4). Their genetic expression controls the timing and extent of growth by regulating mesenchymal cells. At present, understanding of the genetic control of limb development, and therefore the occurrence of congenital differences, is expanding rapidly (5–10). For example, a mutation at the *HOXD13* site has been identified as a cause of poly-syndactyly (11). Further understanding of the genetic control of limb development may revolutionize the treatment of congenital deficiencies.

Congenital differences occur in approximately 6 to 7% of live births, with 1% being multiple anomalies. Between 1 in 531 and 1 in 626 live births have been estimated to involve upper extremity anomalies (12,13). Only 1 to 2% of these congenital differences are the result of chromosomal abnormalities. At present, only a minor portion are known to be secondary to defined genetic causes. In the majority of cases, the cause of the congenital malformation is still unknown.

Classification

There is no perfect classification system for congenital differences of the hand and upper limb. The present accepted classification system for congenital differences was proposed by Swanson (14) and revised by the Congenital Anomalies Committee of the International Federation of Societies for Surgery of the Hand (15). This classification is based on embryologic failure, and defines deficiencies as terminal or

intercalary, with a subclassification into longitudinal or transverse deficiencies. The subcategories are as follows: I, failure of formation of parts; II, failure of differentiation of parts; III, duplication; IV, overgrowth; V, undergrowth; VI, constriction band syndrome; and VII, generalized skeletal abnormalities.

This chapter focuses on the major anomalies in each classification group, but presents them by anatomic region. Care for the child with congenital differences involves more than surgical skill. From the moment of birth, these children may potentially be viewed by their parents, family, society, and, eventually, even themselves as impaired (16,17). It is critical that the treating surgeon help provide the emotional support and caring that allows the parents and child to appropriately grieve the loss of a normal hand (18). It is helpful to provide them with in-depth knowledge of the cause and treatment options (19). This process starts with the initial newborn visit, and continues throughout the growth and development of the child into an independent, self-reliant adult (20). Self-help groups, such as Superkids, are useful for many of these children and their families.

With a normal central nervous system, these children will not be impaired. They will merely develop their skills in a “different” way from their peers. They may need the help of skilled and caring parents, siblings, therapists, teachers, coaches, prosthetists, and surgeons to achieve their goals and dreams. Being part of helping these children grow into unique and independent adults is exciting and rewarding for the surgeon.

ENTIRE LIMB INVOLVEMENT

Neuromuscular

Cerebral Palsy

Cerebral palsy is a nonprogressive disorder of the central nervous system. It occurs in 5 of 1,000 live births, and may be caused by perinatal anoxia, intraventricular hemorrhage, and congenital cerebral vascular accidents. It occurs most commonly in premature infants weighing less than 1,500 g (21,22). The resultant hemiplegia or quadriplegia can lead to significant upper extremity deformities and functional deficits. In hemiplegia, these individuals predominantly use the affected extremity as an assist for the unaffected extremity. In the quadriparetic, both upper limbs will have significant deformity and deficits. The quality of use of an affected extremity is dependent on many factors, including the presence of contractures, voluntary motor control, discriminatory sensibility, learning disabilities, and visual deficits (23–27). This section focuses on the deformities and deficits related to elbow flexion, forearm pronation, wrist palmar flexion and ulnar deviation, finger flexion, and thumb-in-palm deformity in these patients.

Upper-limb Contractures. Nearly three-fourths of patients with hemiplegia develop a forearm pronation contracture (28). The presence of a significant pronation contracture limits the ability to perform bimanual tasks (27,29). Individuals with greater than 60-degree contractures will either perform activities with one hand or use the dorsum of the affected hand or forearm to assist the unaffected hand. These individuals may benefit from surgical correction of their pronation deformity to improve the assistive function of that extremity. This often can be performed with simultaneous procedures to improve thumb-in-palm, wrist palmar flexion, or digital flexion deformities (30).

Elbow flexion contractures are often mild in patients with hemiplegia (28,31). Although nearly 50% of these patients will have a flexion contracture, the vast majority of these contractures are less than 30 degrees and do not limit function (32,33). There may be an associated radial head dislocation in a small number of patients, and this should be assessed radiographically before operative intervention (34). Patients with quadriplegia have greater degrees of elbow flexion contracture. However, these contractures rarely affect their ability to use their motorized wheelchairs, computers, or communication boards. In the care-dependent, nonfunctional quadriplegic, contractures may become severe enough to affect hygiene and care. If skin breakdown develops or is imminent, then surgery may be necessary.

Wrist and hand involvement is common in cerebral palsy. Limited motor function occurs with (i) poor release from wrist and finger flexor spasticity and weak digital extension; (ii) inadequate grasp from wrist palmar flexion spasticity and weak wrist extension; and (iii) minimal pinch from thumb-in-palm deformity. Discriminatory sensibility is deficient in more than 50% of these children. Poor voluntary control of the upper extremity limits functional placement of the hand in space (27,28). In addition, many of these children have visual and cognitive abnormalities that further impair hand function. At best, the majority of patients with spasticity have assistive hand function.

These children generally posture into elbow flexion, forearm pronation, wrist and palmar flexion, thumb-in-palm, and interphalangeal swan-neck deformities. These deformities may be a combination of spasticity and contractures. Pronation deformity and thumb-in-palm contracture seem to affect function the most (28). The combination of neurologic impairment and disuse affect growth in length and girth of the affected arm and hand (28).

Cerebral palsy upper extremity classification systems have been used to assess function (34,35) (Fig. 22-1). The House classification of function has nine levels, extending from 0 (does not use) to 8 (complete spontaneous use) (Table 22-1). In this useful scheme, there are four subgroups of patient function: no use (0), passive assist (1 to 3), active assist (4 to 6), and spontaneous use (7 and 8). Because spasticity changes with stress, growth, and central nervous

system changes, it may be difficult on any one visit to accurately define a patient's level of function. This system is used with the input of the patient, family, and therapist to best define a patient's overall status. It is used to assess the outcome of treatments (30).

Treatment.

Nonoperative Care. In broad terms, the treatment options are to observe the patient's growth and development; use therapy, including splints; consider injections, such as phenol or Botox; and perform surgical reconstruction.

Physical therapy, starting in infancy, is the standard treatment for children with cerebral palsy. The rationale is that although the central nervous system deficit is static, the peripheral manifestations of spasticity and muscle imbalance are progressive with growth. By maintaining range of motion with passive therapy, it is hoped that contractures will not develop (28,36). However, no prospective information is available to validate this rationale. At present, formal therapy is used during the period of infancy. This is most intense in the first year of life, and progresses to a home program with less formal supervision. In many states, early intervention programs end at 3 years of age. Monitoring of function and range of motion is performed less regularly or through the school system, thereafter. During growth spurts that increase spasticity and lessen range of motion, or with specific activities that the patient finds difficult, brief periods of formal therapy are reinitiated (28).

Aside from passive range of motion and active-use programs, splints are often used. These may be daytime or nighttime splints. As Manske has observed, it is unclear whether they are cost-effective and alter long-term outcome (36). No objective study has been performed. However, most caretakers use splints in children with developing contractures. Daytime splints are recommended only if they improve function in patients with dynamic contractures. The success of supplemental electrical stimulation is unclear at present.

Injection may provide useful information about the outcome of surgical procedures. At present, Botox is the most common form of neuromuscular injection (30,38), replacing xylocaine (39,40) and phenol (41,42). It is used at an initial dose of 1 to 2 U/kg of body weight, and should not exceed 6 U/kg per month. Injection into pronator, flexor carpi ulnaris, and thumb adductor are most often performed. Therapy should be performed aggressively to stretch agonistic musculotendinous units and strengthen antagonists. To date, Botox has been most effective for older patients with high levels of function and limiting spasticity. Its role in patients with contractures is limited and less effective, even though these patients may be the most involved. Its effectiveness in young children has not yet been studied critically. There are several ongoing prospective studies of Botox injections in the upper extremity and hand, so more definitive information should soon be available on the indications and effectiveness of its use in all age groups and at

CHILDREN'S HOSPITAL ORTHOPAEDIC HAND SURGERY HEMIPLEGIA EVALUATION				MR No. _____																																																																																																																									
Date / / 				Date _____																																																																																																																									
Evaluation Number 				Pt. Name _____																																																																																																																									
Involved Upper Extremity (circle one) L R				Date of Birth _____																																																																																																																									
<input type="checkbox"/> New Patient <input type="checkbox"/> Return Visit				Sex (circle one) M F																																																																																																																									
Parent History <table style="width: 100%; border-collapse: collapse;"> <tr> <th></th> <th>No</th> <th>Yes</th> <th>dk</th> </tr> <tr><td>Hand splint ever</td><td><input type="checkbox"/></td><td><input type="checkbox"/></td><td><input type="checkbox"/></td></tr> <tr><td>Hand splint now</td><td><input type="checkbox"/></td><td><input type="checkbox"/></td><td><input type="checkbox"/></td></tr> <tr><td> night use</td><td><input type="checkbox"/></td><td><input type="checkbox"/></td><td><input type="checkbox"/></td></tr> <tr><td> day use</td><td><input type="checkbox"/></td><td><input type="checkbox"/></td><td><input type="checkbox"/></td></tr> <tr><td>Hx Upper Ext surgery</td><td><input type="checkbox"/></td><td><input type="checkbox"/></td><td><input type="checkbox"/></td></tr> <tr><td> Green Procedure</td><td><input type="checkbox"/></td><td><input type="checkbox"/></td><td><input type="checkbox"/></td></tr> <tr><td> Web release</td><td><input type="checkbox"/></td><td><input type="checkbox"/></td><td><input type="checkbox"/></td></tr> <tr><td> Elbow release</td><td><input type="checkbox"/></td><td><input type="checkbox"/></td><td><input type="checkbox"/></td></tr> <tr><td> Pronator release</td><td><input type="checkbox"/></td><td><input type="checkbox"/></td><td><input type="checkbox"/></td></tr> <tr><td> Other UE Surg</td><td><input type="checkbox"/></td><td><input type="checkbox"/></td><td><input type="checkbox"/></td></tr> <tr><td> type: _____</td><td></td><td></td><td></td></tr> <tr><td colspan="4" style="font-size: small;">(List date of surgeries, procedure, on back of page)</td></tr> <tr><td>Hx seizures</td><td><input type="checkbox"/></td><td><input type="checkbox"/></td><td><input type="checkbox"/></td></tr> <tr><td> low</td><td><input type="checkbox"/></td><td><input type="checkbox"/></td><td><input type="checkbox"/></td></tr> <tr><td> ave</td><td><input type="checkbox"/></td><td><input type="checkbox"/></td><td><input type="checkbox"/></td></tr> <tr><td> high</td><td><input type="checkbox"/></td><td><input type="checkbox"/></td><td><input type="checkbox"/></td></tr> <tr><td>Intelligence</td><td><input type="checkbox"/></td><td><input type="checkbox"/></td><td><input type="checkbox"/></td></tr> <tr><td>Motivation</td><td><input type="checkbox"/></td><td><input type="checkbox"/></td><td><input type="checkbox"/></td></tr> </table>					No	Yes	dk	Hand splint ever	<input type="checkbox"/>	<input type="checkbox"/>	<input type="checkbox"/>	Hand splint now	<input type="checkbox"/>	<input type="checkbox"/>	<input type="checkbox"/>	night use	<input type="checkbox"/>	<input type="checkbox"/>	<input type="checkbox"/>	day use	<input type="checkbox"/>	<input type="checkbox"/>	<input type="checkbox"/>	Hx Upper Ext surgery	<input type="checkbox"/>	<input type="checkbox"/>	<input type="checkbox"/>	Green Procedure	<input type="checkbox"/>	<input type="checkbox"/>	<input type="checkbox"/>	Web release	<input type="checkbox"/>	<input type="checkbox"/>	<input type="checkbox"/>	Elbow release	<input type="checkbox"/>	<input type="checkbox"/>	<input type="checkbox"/>	Pronator release	<input type="checkbox"/>	<input type="checkbox"/>	<input type="checkbox"/>	Other UE Surg	<input type="checkbox"/>	<input type="checkbox"/>	<input type="checkbox"/>	type: _____				(List date of surgeries, procedure, on back of page)				Hx seizures	<input type="checkbox"/>	<input type="checkbox"/>	<input type="checkbox"/>	low	<input type="checkbox"/>	<input type="checkbox"/>	<input type="checkbox"/>	ave	<input type="checkbox"/>	<input type="checkbox"/>	<input type="checkbox"/>	high	<input type="checkbox"/>	<input type="checkbox"/>	<input type="checkbox"/>	Intelligence	<input type="checkbox"/>	<input type="checkbox"/>	<input type="checkbox"/>	Motivation	<input type="checkbox"/>	<input type="checkbox"/>	<input type="checkbox"/>	Deformities <table style="width: 100%; border-collapse: collapse;"> <tr> <th></th> <th>No</th> <th>Yes</th> <th>nt</th> </tr> <tr><td>Thumb MCP hyperext.</td><td><input type="checkbox"/></td><td><input type="checkbox"/></td><td><input type="checkbox"/></td></tr> <tr><td>Thumb MCP stability</td><td><input type="checkbox"/></td><td><input type="checkbox"/></td><td><input type="checkbox"/></td></tr> <tr><td>First Web Contracture</td><td><input type="checkbox"/></td><td><input type="checkbox"/></td><td><input type="checkbox"/></td></tr> <tr><td>Swan Deformity</td><td><input type="checkbox"/></td><td><input type="checkbox"/></td><td><input type="checkbox"/></td></tr> <tr><td>DIP hyperextension</td><td><input type="checkbox"/></td><td><input type="checkbox"/></td><td><input type="checkbox"/></td></tr> <tr><td>Pronator Deformity</td><td><input type="checkbox"/></td><td><input type="checkbox"/></td><td><input type="checkbox"/></td></tr> <tr><td>Elbow Flex Deformity</td><td><input type="checkbox"/></td><td><input type="checkbox"/></td><td><input type="checkbox"/></td></tr> <tr><td>Thumb in Palm</td><td><input type="checkbox"/></td><td><input type="checkbox"/></td><td><input type="checkbox"/></td></tr> <tr><td>Active Supinator?</td><td><input type="checkbox"/></td><td><input type="checkbox"/></td><td><input type="checkbox"/></td></tr> <tr><td>Web Angle (degrees)</td><td colspan="3"><input style="width: 100px;" type="text"/></td></tr> </table>			No	Yes	nt	Thumb MCP hyperext.	<input type="checkbox"/>	<input type="checkbox"/>	<input type="checkbox"/>	Thumb MCP stability	<input type="checkbox"/>	<input type="checkbox"/>	<input type="checkbox"/>	First Web Contracture	<input type="checkbox"/>	<input type="checkbox"/>	<input type="checkbox"/>	Swan Deformity	<input type="checkbox"/>	<input type="checkbox"/>	<input type="checkbox"/>	DIP hyperextension	<input type="checkbox"/>	<input type="checkbox"/>	<input type="checkbox"/>	Pronator Deformity	<input type="checkbox"/>	<input type="checkbox"/>	<input type="checkbox"/>	Elbow Flex Deformity	<input type="checkbox"/>	<input type="checkbox"/>	<input type="checkbox"/>	Thumb in Palm	<input type="checkbox"/>	<input type="checkbox"/>	<input type="checkbox"/>	Active Supinator?	<input type="checkbox"/>	<input type="checkbox"/>	<input type="checkbox"/>	Web Angle (degrees)	<input style="width: 100px;" type="text"/>		
	No	Yes	dk																																																																																																																										
Hand splint ever	<input type="checkbox"/>	<input type="checkbox"/>	<input type="checkbox"/>																																																																																																																										
Hand splint now	<input type="checkbox"/>	<input type="checkbox"/>	<input type="checkbox"/>																																																																																																																										
night use	<input type="checkbox"/>	<input type="checkbox"/>	<input type="checkbox"/>																																																																																																																										
day use	<input type="checkbox"/>	<input type="checkbox"/>	<input type="checkbox"/>																																																																																																																										
Hx Upper Ext surgery	<input type="checkbox"/>	<input type="checkbox"/>	<input type="checkbox"/>																																																																																																																										
Green Procedure	<input type="checkbox"/>	<input type="checkbox"/>	<input type="checkbox"/>																																																																																																																										
Web release	<input type="checkbox"/>	<input type="checkbox"/>	<input type="checkbox"/>																																																																																																																										
Elbow release	<input type="checkbox"/>	<input type="checkbox"/>	<input type="checkbox"/>																																																																																																																										
Pronator release	<input type="checkbox"/>	<input type="checkbox"/>	<input type="checkbox"/>																																																																																																																										
Other UE Surg	<input type="checkbox"/>	<input type="checkbox"/>	<input type="checkbox"/>																																																																																																																										
type: _____																																																																																																																													
(List date of surgeries, procedure, on back of page)																																																																																																																													
Hx seizures	<input type="checkbox"/>	<input type="checkbox"/>	<input type="checkbox"/>																																																																																																																										
low	<input type="checkbox"/>	<input type="checkbox"/>	<input type="checkbox"/>																																																																																																																										
ave	<input type="checkbox"/>	<input type="checkbox"/>	<input type="checkbox"/>																																																																																																																										
high	<input type="checkbox"/>	<input type="checkbox"/>	<input type="checkbox"/>																																																																																																																										
Intelligence	<input type="checkbox"/>	<input type="checkbox"/>	<input type="checkbox"/>																																																																																																																										
Motivation	<input type="checkbox"/>	<input type="checkbox"/>	<input type="checkbox"/>																																																																																																																										
	No	Yes	nt																																																																																																																										
Thumb MCP hyperext.	<input type="checkbox"/>	<input type="checkbox"/>	<input type="checkbox"/>																																																																																																																										
Thumb MCP stability	<input type="checkbox"/>	<input type="checkbox"/>	<input type="checkbox"/>																																																																																																																										
First Web Contracture	<input type="checkbox"/>	<input type="checkbox"/>	<input type="checkbox"/>																																																																																																																										
Swan Deformity	<input type="checkbox"/>	<input type="checkbox"/>	<input type="checkbox"/>																																																																																																																										
DIP hyperextension	<input type="checkbox"/>	<input type="checkbox"/>	<input type="checkbox"/>																																																																																																																										
Pronator Deformity	<input type="checkbox"/>	<input type="checkbox"/>	<input type="checkbox"/>																																																																																																																										
Elbow Flex Deformity	<input type="checkbox"/>	<input type="checkbox"/>	<input type="checkbox"/>																																																																																																																										
Thumb in Palm	<input type="checkbox"/>	<input type="checkbox"/>	<input type="checkbox"/>																																																																																																																										
Active Supinator?	<input type="checkbox"/>	<input type="checkbox"/>	<input type="checkbox"/>																																																																																																																										
Web Angle (degrees)	<input style="width: 100px;" type="text"/>																																																																																																																												
Sensation Exam <table style="width: 100%; border-collapse: collapse;"> <tr> <th></th> <th>cos</th> <th>asl</th> <th>ind</th> <th>not test</th> </tr> <tr><td>Function</td><td><input type="checkbox"/></td><td><input type="checkbox"/></td><td><input type="checkbox"/></td><td><input type="checkbox"/></td></tr> <tr><td>Two-Point Desc.</td><td><input type="checkbox"/></td><td><input type="checkbox"/></td><td><input type="checkbox"/></td><td><input type="checkbox"/></td></tr> <tr><td> mm: <6 6-10 >10</td><td><input type="checkbox"/></td><td><input type="checkbox"/></td><td><input type="checkbox"/></td><td><input type="checkbox"/></td></tr> <tr><td>Obj. Rec.</td><td><input type="checkbox"/></td><td><input type="checkbox"/></td><td><input type="checkbox"/></td><td><input type="checkbox"/></td></tr> <tr><td> # recog 0 1 2 3</td><td><input type="checkbox"/></td><td><input type="checkbox"/></td><td><input type="checkbox"/></td><td><input type="checkbox"/></td></tr> <tr><td>Palm graphesthesia</td><td><input type="checkbox"/></td><td><input type="checkbox"/></td><td><input type="checkbox"/></td><td><input type="checkbox"/></td></tr> <tr><td> # recog 0 1 2 3</td><td><input type="checkbox"/></td><td><input type="checkbox"/></td><td><input type="checkbox"/></td><td><input type="checkbox"/></td></tr> <tr><td>Rough</td><td><input type="checkbox"/></td><td><input type="checkbox"/></td><td><input type="checkbox"/></td><td><input type="checkbox"/></td></tr> <tr><td> No Yes</td><td><input type="checkbox"/></td><td><input type="checkbox"/></td><td><input type="checkbox"/></td><td><input type="checkbox"/></td></tr> <tr><td>Proprioception</td><td><input type="checkbox"/></td><td><input type="checkbox"/></td><td><input type="checkbox"/></td><td><input type="checkbox"/></td></tr> </table>					cos	asl	ind	not test	Function	<input type="checkbox"/>	<input type="checkbox"/>	<input type="checkbox"/>	<input type="checkbox"/>	Two-Point Desc.	<input type="checkbox"/>	<input type="checkbox"/>	<input type="checkbox"/>	<input type="checkbox"/>	mm: <6 6-10 >10	<input type="checkbox"/>	<input type="checkbox"/>	<input type="checkbox"/>	<input type="checkbox"/>	Obj. Rec.	<input type="checkbox"/>	<input type="checkbox"/>	<input type="checkbox"/>	<input type="checkbox"/>	# recog 0 1 2 3	<input type="checkbox"/>	<input type="checkbox"/>	<input type="checkbox"/>	<input type="checkbox"/>	Palm graphesthesia	<input type="checkbox"/>	<input type="checkbox"/>	<input type="checkbox"/>	<input type="checkbox"/>	# recog 0 1 2 3	<input type="checkbox"/>	<input type="checkbox"/>	<input type="checkbox"/>	<input type="checkbox"/>	Rough	<input type="checkbox"/>	<input type="checkbox"/>	<input type="checkbox"/>	<input type="checkbox"/>	No Yes	<input type="checkbox"/>	<input type="checkbox"/>	<input type="checkbox"/>	<input type="checkbox"/>	Proprioception	<input type="checkbox"/>	<input type="checkbox"/>	<input type="checkbox"/>	<input type="checkbox"/>	Size <table style="width: 100%; border-collapse: collapse;"> <tr> <th></th> <th>AFF</th> <th>UNAFF</th> </tr> <tr><td>Circumference</td><td></td><td></td></tr> <tr><td> arm</td><td><input type="checkbox"/></td><td><input type="checkbox"/></td></tr> <tr><td> forearm</td><td><input type="checkbox"/></td><td><input type="checkbox"/></td></tr> <tr><td>Distance</td><td></td><td></td></tr> <tr><td> O-MF</td><td><input type="checkbox"/></td><td><input type="checkbox"/></td></tr> <tr><td> O-UL</td><td><input type="checkbox"/></td><td><input type="checkbox"/></td></tr> <tr><td>Hand width</td><td><input type="checkbox"/></td><td><input type="checkbox"/></td></tr> </table>			AFF	UNAFF	Circumference			arm	<input type="checkbox"/>	<input type="checkbox"/>	forearm	<input type="checkbox"/>	<input type="checkbox"/>	Distance			O-MF	<input type="checkbox"/>	<input type="checkbox"/>	O-UL	<input type="checkbox"/>	<input type="checkbox"/>	Hand width	<input type="checkbox"/>	<input type="checkbox"/>																																									
	cos	asl	ind	not test																																																																																																																									
Function	<input type="checkbox"/>	<input type="checkbox"/>	<input type="checkbox"/>	<input type="checkbox"/>																																																																																																																									
Two-Point Desc.	<input type="checkbox"/>	<input type="checkbox"/>	<input type="checkbox"/>	<input type="checkbox"/>																																																																																																																									
mm: <6 6-10 >10	<input type="checkbox"/>	<input type="checkbox"/>	<input type="checkbox"/>	<input type="checkbox"/>																																																																																																																									
Obj. Rec.	<input type="checkbox"/>	<input type="checkbox"/>	<input type="checkbox"/>	<input type="checkbox"/>																																																																																																																									
# recog 0 1 2 3	<input type="checkbox"/>	<input type="checkbox"/>	<input type="checkbox"/>	<input type="checkbox"/>																																																																																																																									
Palm graphesthesia	<input type="checkbox"/>	<input type="checkbox"/>	<input type="checkbox"/>	<input type="checkbox"/>																																																																																																																									
# recog 0 1 2 3	<input type="checkbox"/>	<input type="checkbox"/>	<input type="checkbox"/>	<input type="checkbox"/>																																																																																																																									
Rough	<input type="checkbox"/>	<input type="checkbox"/>	<input type="checkbox"/>	<input type="checkbox"/>																																																																																																																									
No Yes	<input type="checkbox"/>	<input type="checkbox"/>	<input type="checkbox"/>	<input type="checkbox"/>																																																																																																																									
Proprioception	<input type="checkbox"/>	<input type="checkbox"/>	<input type="checkbox"/>	<input type="checkbox"/>																																																																																																																									
	AFF	UNAFF																																																																																																																											
Circumference																																																																																																																													
arm	<input type="checkbox"/>	<input type="checkbox"/>																																																																																																																											
forearm	<input type="checkbox"/>	<input type="checkbox"/>																																																																																																																											
Distance																																																																																																																													
O-MF	<input type="checkbox"/>	<input type="checkbox"/>																																																																																																																											
O-UL	<input type="checkbox"/>	<input type="checkbox"/>																																																																																																																											
Hand width	<input type="checkbox"/>	<input type="checkbox"/>																																																																																																																											
Motor Exam <table style="width: 100%; border-collapse: collapse;"> <tr> <th></th> <th>unable</th> <th>min</th> <th>max</th> <th>nt</th> </tr> <tr><td>Grasp</td><td><input type="checkbox"/></td><td><input type="checkbox"/></td><td><input type="checkbox"/></td><td><input type="checkbox"/></td></tr> <tr><td>Release</td><td><input type="checkbox"/></td><td><input type="checkbox"/></td><td><input type="checkbox"/></td><td><input type="checkbox"/></td></tr> <tr><td>Grasp reflex</td><td><input type="checkbox"/></td><td><input type="checkbox"/></td><td><input type="checkbox"/></td><td><input type="checkbox"/></td></tr> <tr><td>Key pinch</td><td><input type="checkbox"/></td><td><input type="checkbox"/></td><td><input type="checkbox"/></td><td><input type="checkbox"/></td></tr> <tr><td>Pulp pinch</td><td><input type="checkbox"/></td><td><input type="checkbox"/></td><td><input type="checkbox"/></td><td><input type="checkbox"/></td></tr> <tr><td>Tip pinch</td><td><input type="checkbox"/></td><td><input type="checkbox"/></td><td><input type="checkbox"/></td><td><input type="checkbox"/></td></tr> <tr><td>Zancolli</td><td><input type="checkbox"/></td><td><input type="checkbox"/></td><td><input type="checkbox"/></td><td><input type="checkbox"/></td></tr> <tr><td> I IIA IIB III</td><td><input type="checkbox"/></td><td><input type="checkbox"/></td><td><input type="checkbox"/></td><td><input type="checkbox"/></td></tr> <tr><td>Bleck</td><td><input type="checkbox"/></td><td><input type="checkbox"/></td><td><input type="checkbox"/></td><td><input type="checkbox"/></td></tr> <tr><td> I II III</td><td><input type="checkbox"/></td><td><input type="checkbox"/></td><td><input type="checkbox"/></td><td><input type="checkbox"/></td></tr> <tr><td>Mowery</td><td><input type="checkbox"/></td><td><input type="checkbox"/></td><td><input type="checkbox"/></td><td><input type="checkbox"/></td></tr> </table>					unable	min	max	nt	Grasp	<input type="checkbox"/>	<input type="checkbox"/>	<input type="checkbox"/>	<input type="checkbox"/>	Release	<input type="checkbox"/>	<input type="checkbox"/>	<input type="checkbox"/>	<input type="checkbox"/>	Grasp reflex	<input type="checkbox"/>	<input type="checkbox"/>	<input type="checkbox"/>	<input type="checkbox"/>	Key pinch	<input type="checkbox"/>	<input type="checkbox"/>	<input type="checkbox"/>	<input type="checkbox"/>	Pulp pinch	<input type="checkbox"/>	<input type="checkbox"/>	<input type="checkbox"/>	<input type="checkbox"/>	Tip pinch	<input type="checkbox"/>	<input type="checkbox"/>	<input type="checkbox"/>	<input type="checkbox"/>	Zancolli	<input type="checkbox"/>	<input type="checkbox"/>	<input type="checkbox"/>	<input type="checkbox"/>	I IIA IIB III	<input type="checkbox"/>	<input type="checkbox"/>	<input type="checkbox"/>	<input type="checkbox"/>	Bleck	<input type="checkbox"/>	<input type="checkbox"/>	<input type="checkbox"/>	<input type="checkbox"/>	I II III	<input type="checkbox"/>	<input type="checkbox"/>	<input type="checkbox"/>	<input type="checkbox"/>	Mowery	<input type="checkbox"/>	<input type="checkbox"/>	<input type="checkbox"/>	<input type="checkbox"/>	ADL (1=NU 2=AST 3=Ind) <table style="width: 100%; border-collapse: collapse;"> <tr><td><input type="checkbox"/> Buttons</td><td><input type="checkbox"/> Hand</td><td><input type="checkbox"/> Screw</td></tr> <tr><td><input type="checkbox"/> Pants/Shirt</td><td><input type="checkbox"/> Groom</td><td><input type="checkbox"/> Knob</td></tr> <tr><td><input type="checkbox"/> Zipper</td><td><input type="checkbox"/> Teacup</td><td><input type="checkbox"/> Bottle</td></tr> <tr><td><input type="checkbox"/> Utencils</td><td><input type="checkbox"/> Knots</td><td><input type="checkbox"/> Purse</td></tr> </table>		<input type="checkbox"/> Buttons	<input type="checkbox"/> Hand	<input type="checkbox"/> Screw	<input type="checkbox"/> Pants/Shirt	<input type="checkbox"/> Groom	<input type="checkbox"/> Knob	<input type="checkbox"/> Zipper	<input type="checkbox"/> Teacup	<input type="checkbox"/> Bottle	<input type="checkbox"/> Utencils	<input type="checkbox"/> Knots	<input type="checkbox"/> Purse																																																
	unable	min	max	nt																																																																																																																									
Grasp	<input type="checkbox"/>	<input type="checkbox"/>	<input type="checkbox"/>	<input type="checkbox"/>																																																																																																																									
Release	<input type="checkbox"/>	<input type="checkbox"/>	<input type="checkbox"/>	<input type="checkbox"/>																																																																																																																									
Grasp reflex	<input type="checkbox"/>	<input type="checkbox"/>	<input type="checkbox"/>	<input type="checkbox"/>																																																																																																																									
Key pinch	<input type="checkbox"/>	<input type="checkbox"/>	<input type="checkbox"/>	<input type="checkbox"/>																																																																																																																									
Pulp pinch	<input type="checkbox"/>	<input type="checkbox"/>	<input type="checkbox"/>	<input type="checkbox"/>																																																																																																																									
Tip pinch	<input type="checkbox"/>	<input type="checkbox"/>	<input type="checkbox"/>	<input type="checkbox"/>																																																																																																																									
Zancolli	<input type="checkbox"/>	<input type="checkbox"/>	<input type="checkbox"/>	<input type="checkbox"/>																																																																																																																									
I IIA IIB III	<input type="checkbox"/>	<input type="checkbox"/>	<input type="checkbox"/>	<input type="checkbox"/>																																																																																																																									
Bleck	<input type="checkbox"/>	<input type="checkbox"/>	<input type="checkbox"/>	<input type="checkbox"/>																																																																																																																									
I II III	<input type="checkbox"/>	<input type="checkbox"/>	<input type="checkbox"/>	<input type="checkbox"/>																																																																																																																									
Mowery	<input type="checkbox"/>	<input type="checkbox"/>	<input type="checkbox"/>	<input type="checkbox"/>																																																																																																																									
<input type="checkbox"/> Buttons	<input type="checkbox"/> Hand	<input type="checkbox"/> Screw																																																																																																																											
<input type="checkbox"/> Pants/Shirt	<input type="checkbox"/> Groom	<input type="checkbox"/> Knob																																																																																																																											
<input type="checkbox"/> Zipper	<input type="checkbox"/> Teacup	<input type="checkbox"/> Bottle																																																																																																																											
<input type="checkbox"/> Utencils	<input type="checkbox"/> Knots	<input type="checkbox"/> Purse																																																																																																																											
THUMB-IN-PALM <ul style="list-style-type: none"> -Type I MC Adduction -Type II MC Ad + MCP flexion -Type III MC Ad + MCP ext/instability -Type IV MC Ad + MCP/IP flexion 				Voluntary Control <table style="width: 100%; border-collapse: collapse;"> <tr> <th>Tendon</th> <th>Good</th> <th>Fair</th> <th>Poor</th> </tr> <tr><td>EPL</td><td></td><td></td><td></td></tr> <tr><td>AbPL</td><td></td><td></td><td></td></tr> <tr><td>EPB</td><td></td><td></td><td></td></tr> <tr><td>FPL</td><td></td><td></td><td></td></tr> <tr><td>FCR</td><td></td><td></td><td></td></tr> <tr><td>FCU</td><td></td><td></td><td></td></tr> <tr><td>BR</td><td></td><td></td><td></td></tr> <tr><td>ECRB/L</td><td></td><td></td><td></td></tr> </table>		Tendon	Good	Fair	Poor	EPL				AbPL				EPB				FPL				FCR				FCU				BR				ECRB/L																																																																																							
Tendon	Good	Fair	Poor																																																																																																																										
EPL																																																																																																																													
AbPL																																																																																																																													
EPB																																																																																																																													
FPL																																																																																																																													
FCR																																																																																																																													
FCU																																																																																																																													
BR																																																																																																																													
ECRB/L																																																																																																																													
Functional Classification <table style="width: 100%; border-collapse: collapse;"> <tr> <th>Class</th> <th>Does not use</th> <th>Does use</th> </tr> <tr><td>0</td><td>Does not use</td><td>Does not use</td></tr> <tr><td>1</td><td>Poor Passive Assist.</td><td>Uses as stabilizing weight only</td></tr> <tr><td>2</td><td>Fair Passive Assist.</td><td>Can hold object placed in hand</td></tr> <tr><td>3</td><td>Good Passive Assist.</td><td>Can hold onto object and stabilize for use in other hand</td></tr> <tr><td>4</td><td>Poor Active Assist.</td><td>Can actively grasp object and hold it weakly</td></tr> <tr><td>5</td><td>Fair Active Assist.</td><td>Can actively grasp object and stabilize it well</td></tr> <tr><td>6</td><td>Good Active Assist.</td><td>Can actively grasp object and manipulate it against other hand</td></tr> <tr><td>7</td><td>Spontaneous use-partial</td><td>Can perform bimanual activities easily and occasionally uses the hand spontaneously</td></tr> <tr><td>8</td><td>Spontaneous use-complete</td><td>Uses the hand completely independently without reference to the other hand</td></tr> </table>				Class	Does not use	Does use	0	Does not use	Does not use	1	Poor Passive Assist.	Uses as stabilizing weight only	2	Fair Passive Assist.	Can hold object placed in hand	3	Good Passive Assist.	Can hold onto object and stabilize for use in other hand	4	Poor Active Assist.	Can actively grasp object and hold it weakly	5	Fair Active Assist.	Can actively grasp object and stabilize it well	6	Good Active Assist.	Can actively grasp object and manipulate it against other hand	7	Spontaneous use-partial	Can perform bimanual activities easily and occasionally uses the hand spontaneously	8	Spontaneous use-complete	Uses the hand completely independently without reference to the other hand																																																																																												
Class	Does not use	Does use																																																																																																																											
0	Does not use	Does not use																																																																																																																											
1	Poor Passive Assist.	Uses as stabilizing weight only																																																																																																																											
2	Fair Passive Assist.	Can hold object placed in hand																																																																																																																											
3	Good Passive Assist.	Can hold onto object and stabilize for use in other hand																																																																																																																											
4	Poor Active Assist.	Can actively grasp object and hold it weakly																																																																																																																											
5	Fair Active Assist.	Can actively grasp object and stabilize it well																																																																																																																											
6	Good Active Assist.	Can actively grasp object and manipulate it against other hand																																																																																																																											
7	Spontaneous use-partial	Can perform bimanual activities easily and occasionally uses the hand spontaneously																																																																																																																											
8	Spontaneous use-complete	Uses the hand completely independently without reference to the other hand																																																																																																																											

FIGURE 22-1. Data sheet for prospective analysis of hemiplegic function used at Children's Hospital, Boston.

all levels of involvement. Complications involve antibody formation to the Botox.

Operative Care. The broad indications for surgery for patients with cerebral palsy include (i) contractures that cause hygiene and care problems not solved by therapy, splints, or casts; (ii) muscle imbalance or contractures that cause functional deficits that may be improved by tendon transfers, musculotendinous lengthening, and/or joint stabilization procedures; and (iii) cosmetic concerns (23–27,43). It

may be difficult to identify the individual who will have improved function through surgical reconstruction. As Smith (22) so aptly pointed out, careful preoperative assessment is necessary to determine and select the appropriate patients and operations. Video recordings of activities of daily living and validated multiple-task assessment scales, such as the Jebsen scale, can be helpful in defining functional limitations. A recently completed, but not yet published, study by the author found video and House classifications reliable and useful for surgical planning.

TABLE 22-1. HOUSE CLASSIFICATION OF UPPER EXTREMITY AND HAND FUNCTION FOR CEREBRAL PALSY PATIENTS

Level	Designation	Activity Level
0	Does not use	Does not use
1	Poor passive assist	Uses as stabilizing weight only
2	Fair passive assist	Can hold onto object placed in hand
3	Good passive assist	Can hold onto object and stabilize it for use by other hand
4	Poor active assist	Can actively grasp object and hold it weakly
5	Fair active assist	Can actively grasp object and stabilize it well
6	Good active assist	Can actively grasp object and manipulate it against other hand
7	Spontaneous use, partial	Can perform bimanual activities easily and occasionally uses the hand spontaneously
8	Spontaneous use, complete	Uses hand completely independently without reference to the other hand

Surgery has been shown to effectively improve the level of function in all forms of cerebral palsy (30). The best candidates are patients with hemiplegia and good voluntary control, sensibility, and motivation. The principle of surgery is to restore muscle imbalance by lengthening or releasing tight, spastic muscles, and augmenting weak, stretched muscles by tendon transfers and tenodesis procedures. Unstable joints need to be stabilized by soft tissue or arthrodesis procedures to maximize the outcome of tendon reconstruction. Multiple upper-extremity rebalancing procedures performed under one anesthesia seem to be best. This can also be performed in conjunction with simultaneous lower-extremity procedures if the patient and surgeons can tolerate it. It cannot be stressed enough to the patient and family that surgery will not achieve a normal hand. Even the best outcome will result in deficiencies of function, cosmesis, and sensibility. Patients, families, and surgeons need to be realistic about the expected results. However, in properly selected patients, surgery will clearly improve function and patient satisfaction (30). This is evident in individuals using the dorsum of the hand or forearm for bimanual tasks. However, it is imperative that both the family and the individual understand that surgery will never create a normal limb. The goal must be well defined and specific to the peripheral manifestation of an incurable, central disorder.

Mital (31) cited excellent results with surgical release of elbow flexion contractures in hemiplegic patients. He recommended release of the lacertus fibrosus, Z-lengthening of the biceps tendon, and musculotendinous lengthening of the brachialis fascia. In mild contractures, release of the lacertus fibrosus and musculotendinous lengthening of the brachialis alone may be sufficient.

More extensive elbow contractures are present in severe quadriparetics. The Z-lengthening of the biceps tendon and release of the brachialis fascia advocated by Mital (31) is not sufficient to obtain adequate release in these patients. In patients with greater than 90-degree contractures and skin breakdown, extensive release of the muscle origins from the medial and lateral epicondyles, biceps and brachialis tendons, and anterior elbow capsule is necessary to solve the hygiene and care-related problems that accompany these conditions.

Forearm hyperpronation significantly limits hand func-

tion (28) in patients with hemiplegia. Patients are forced to use the dorsum of the forearm for two-handed tasks. Wrist and finger flexion deformity is commonplace in patients with hemiplegia. The flexor carpi ulnaris (FCU) is usually the major deforming force at the wrist. Transfer of the FCU to the wrist extensors alleviates the deformity and improves the strength of the antagonist [►1.7]. On occasion, the extensor carpi ulnaris (ECU) is the primary deforming force, as noted by more ulnar deviation than palmar flexion at the wrist. In these situations, the ECU is transferred to the extensor carpi radialis brevis (30). Simultaneous musculotendinous lengthenings of the finger flexors are necessary if the extrinsic finger flexors are tight in the neutral wrist position (26). Otherwise, the patient will develop a disabling clenched fist postoperatively. Z-lengthenings, superficialis to profundus flexor tendon transfers, and bony procedures are reserved for patients with severe contractures and limited function. In the unusual patient with passive digital extension, but no active digital extension, the FCU, ECU, or pronator teres (PT) can be transferred into the extensor digitorum communis. This will improve both wrist and digital extension.

Thumb-in-palm deformity will limit dynamic pinch and grasp function, and make hygiene difficult in severe contractures. Static contractures in the web space are corrected with web-space Z-plasties and adductor releases [►1.8]. Hoffer et al. (32a) have shown by dynamic electromyography that release of the transverse adductor alone may lead to better pinch postoperatively in selected patients. At times, the static contractures include the flexor pollicis longus and brevis, and these need to be appropriately lengthened or released. Dynamic rebalancing is performed with tendon transfers to the weak abductors and extensors of the thumb. The donor muscles used are numerous and include the palmaris longus, flexor carpi radialis, and brachioradialis, among others. The recipient tendons include the extensor pollicis brevis and longus and the abductor pollicis longus. Each patient must be individualized to correct his or her deformity and imbalance. Finally, the metacarpophalangeal (MCP) joint needs to be stable postoperatively. In most patients, this is achieved by muscle rebalancing. On occasion, a capsulodesis or arthrodesis procedure needs to be performed.

Finally, some patients with cerebral palsy have disabling swan-neck deformities of the interphalangeal joints. If the fingers extend at the proximal interphalangeal (PIP) joint beyond 40 degrees and lock, it can both limit grasp and cause pain. Multiple operations have been advised, including flexor digitorum superficialis tenodesis (26), intrinsic muscle slide (26), lateral band rerouting (44), spiral oblique ligament reconstruction, and resection of the motor branch of the ulnar nerve. The lateral band rerouting procedure provides both intrinsic and extrinsic rebalancing, and is effective in correcting the problem.

In summary, patients with cerebral palsy who have disabling dynamic spasticity and fixed contractures of the wrist and hand benefit from surgical reconstruction. Often, the more involved patients (House levels 0 to 2) respond best to musculotendinous lengthenings, tenodesis, and joint stabilization procedures. More functional patients (House levels 3 to 6) improve with dynamic tendon transfers and releases. Both groups of patients tolerate multiple simultaneous procedures (Fig. 22-2). However, surgery will

not create a normal hand. The goals of surgery need to be realistic and obtainable. In properly selected patients, surgery will improve assistive function and cosmesis. For many of these children, especially adolescents, and their families the functional and cosmetic improvement is quite marked and satisfying.

Complications. Recurrence of deformity, or failure to improve function, can occur. Proper preoperative selection to assess functional deficits and patient cooperativeness may lessen the risk of these problems postoperatively (23). Hematoma formation, wound breakdown, and infection can occur after extensive elbow releases (45). The institutionalized quadriparetic patient may be most at risk. If wound dehiscence occurs, and the joint is exposed, coverage with a rotation flap is the treatment of choice.

Brachial Plexopathy

Brachial plexus birth palsy is rare, with an incidence between 0.1 and 0.4% of live births (46,47). Fortunately, many in-

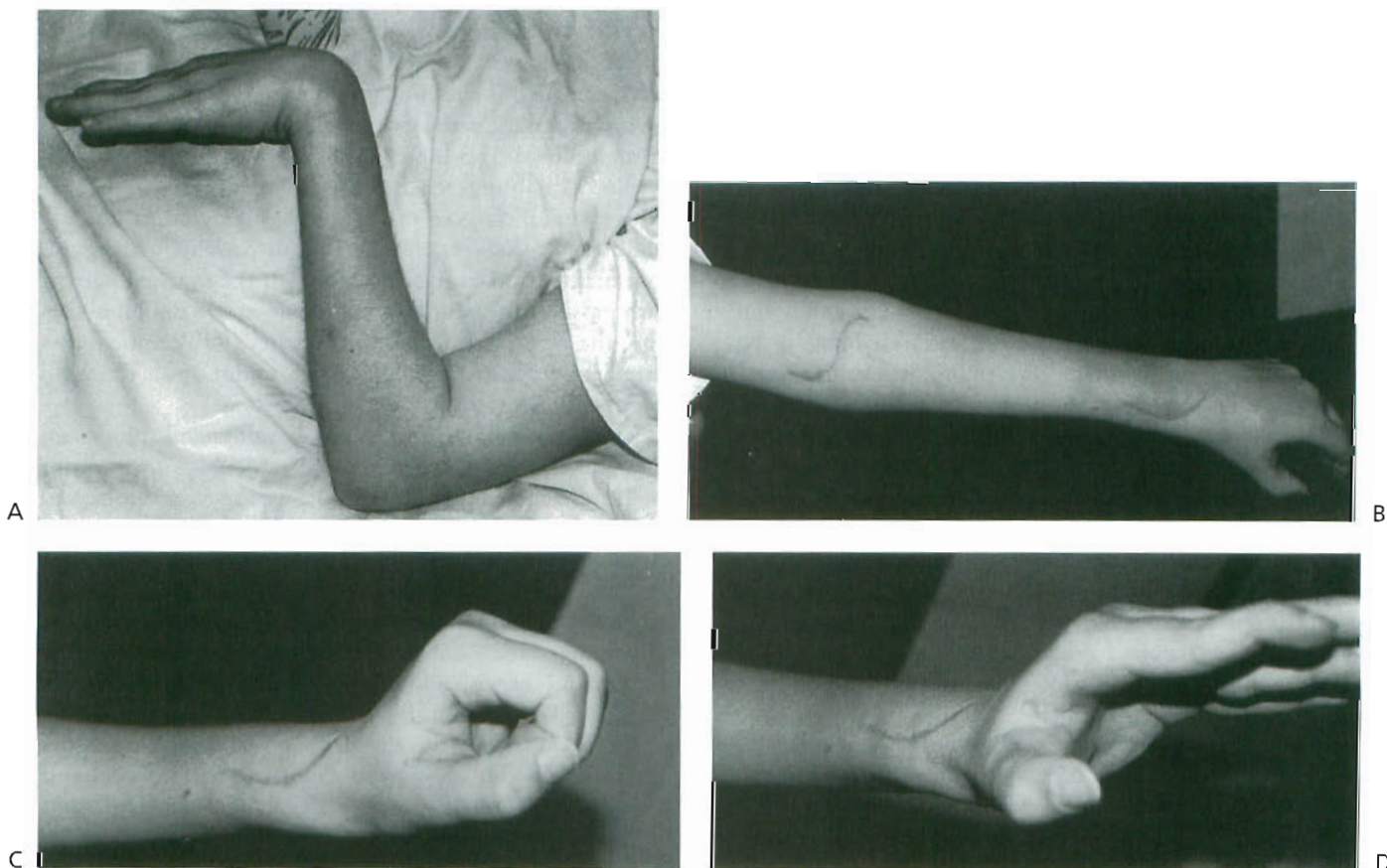


FIGURE 22-2. Clinical photographs of hemiplegic tendon transfers for improving hand and upper limb function. A: Preoperative view of dynamic elbow flexion, forearm pronation, wrist flexion, and ulnar deviation with poor assist function. B: Postoperative active elbow extension with maintenance of active elbow flexion. C: Postoperative active wrist extension with the thumb out of the palm for active pinch. D: Postoperative active grasp function with the thumb abducted and extended actively. (Clinical case courtesy of Ann Van Heest, M.D.)

infants with minor birth palsies recover fully. These are the infants who initiate recovery of all muscle groups in the first 1 to 2 months of life. However, permanent impairment does occur. It is most likely in infants who do not initiate recovery before 6 months of life (48–52). Horner syndrome is also a major risk factor for a poor outcome (52). Most infants have involvement of the upper trunk (C5–C6; Erb palsy), although there can be additional involvement of C7. Less often, the entire plexus (C5 to T1) is affected. Rarely, the lower trunk (C7 to T1; Klumpke palsy) is most affected.

Perinatal risk factors include infants who are large for gestational age; prolonged labor; difficult delivery, including extraction techniques; and fetal distress. Shoulder dystocia is the mechanical factor that leads to an upper-trunk lesion in the difficult vertex delivery. Difficult arm extraction in a breech delivery can result in an avulsion injury (53). The degree of impairment is related to the level and magnitude of injury to the plexus. Neural injury is defined by the type (stretch, rupture, avulsion) and severity (Sunderland grades I to V). Prognosis by natural history has been best defined by the spontaneous rate of recovery of muscle strength in the first 3 to 6 months of infancy. Gilbert and Tassin (51) described the recovery of biceps function in infancy as a predictor of the outcome of spontaneous recovery. This finding was confirmed in a similar study by Waters (52). Their results showed that infants who did not recover biceps function by 3 months of life were not normal after 2 years of age. As a result of the failure of spontaneous recovery, Gilbert and colleagues recommend microsurgical reconstruction of the plexus in the first 3 to 6 months of life for infants who fail to recover biceps function (51,54,55). Michelow et al. (56) noted that return of biceps function alone had a 12% error rate in predicting outcome, as defined by long-term antigravity muscle strength. By using elbow flexion, elbow extension, wrist extension, finger extension, and thumb extension (the Toronto scale), their error rate for predicting poor outcome decreased to 5%. In this system each muscle group is scored as 0 (no motion), 1 (motion present but limited), or 2 (normal motion), for a maximum score of 12. A score of less than 3.5 predicted a poor long-term outcome without microsurgery. In all studies the presence of Horner syndrome, total plexus involvement, and failure of return of function by 3 to 6 months of life indicate a poor long-term outcome.

Clinical examination of an infant for motor-sensory function can be limited. It is important to distinguish true paralysis from the pseudoparalysis that comes with a neonatal clavicle fracture, humeral fracture, or septic shoulder. There can be clinical overlap because fractures also occur in infants with shoulder dystocia and infantile brachial plexopathy. Plain radiographs will identify the infant with clavicle and humeral fractures. In the neonate these fractures heal within 10 to 21 days. If limited motion persists after 1 month there will most likely be a concomitant brachial

plexopathy. In the rare infant with a septic shoulder there will be evidence of systemic illness (altered vital signs, change in appetite, toxicity), marked irritability with glenohumeral range of motion, and abnormal white blood cell count. If there is doubt, ultrasonography will reveal the effusion, and arthrocentesis will be confirmatory.

The pupils should be assessed for Horner syndrome. Motor examination is limited to observation of spontaneous activity and stimulated movement by primitive reflexes in the infant. The Moro startle reflex and the asymmetric tonic neck reflex can elicit upper trunk movement in infants in the first 6 months of life. Classification of nerve injury in the ambulatory child has included physical examination assessment with the Mallet system. The modified Mallet system classifies upper trunk function by grading hand-to-mouth, hand-to-neck, and hand-on-spine activity, global abduction, and global external rotation from 0 (no function) to 5 (normal function). Grades 2, 3, and 4 are illustrated (Fig. 22-3).

Radiography can demonstrate an associated fracture of the clavicle or proximal humerus. Radiographic assessment of the severity of brachial plexus injury has used myelography, combined computed tomography (CT) and myelography, and magnetic resonance imaging (MRI). Kawai et al. (57) compared the results of all three techniques with operative findings. Combined myelography and CT and MRI were more reliable than myelography alone. The presence of large diverticulae and meningoceles was indicative of root avulsion. Small diverticulae were diagnostic only 60% of the time. Electrodiagnostic studies, with electromyography and nerve conduction studies, are diagnostic of avulsion if there is no reinnervation after 3 months of age. However, the presence of reinnervation does not indicate the long-term quality of muscle recovery.

Pathoanatomy. Understanding the normal anatomy of the brachial plexus is critical to assessing and caring for an infant or child with brachial plexus palsy (Fig. 22-4). The brachial plexus supplies every muscle of the upper extremity except the trapezius. It is made up of spinal cord nerve root contributions from C5 to T1. Prefixed cords (22% of specimens) receive a contribution from C4. Postfixed cords are rare (1%) and receive a contribution from T2. The C5 and C6 roots join to form the upper trunk. The C7 root alone becomes the middle trunk. The C8 and T1 roots become the lower trunk. Each trunk has an anterior and a posterior division. The anterior divisions of the upper and middle trunks form the lateral cord. The posterior divisions of all three trunks form the posterior cord. The anterior division of the lower trunk continues as the medial cord. The terminal branches of the cords form the major nerves of the upper extremity. The posterior cord gives off the upper and lower subscapular and thoracodorsal nerves before bifurcating into the radial and axillary nerves. The medial cord branches are the medial pectoral, medial brachial cutaneous, and medial

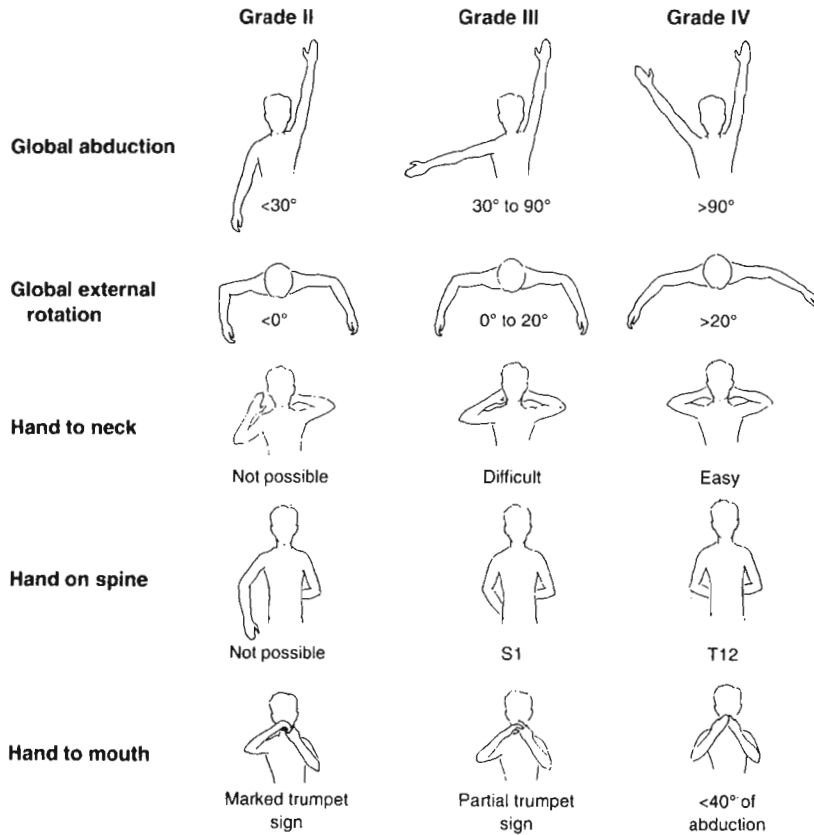


FIGURE 22-3. Mallet classification for brachial plexus birth palsy function about the shoulder. Grade 0 is no function; grade V is normal function; and grades II through IV are depicted for hand-to-mouth, hand-to-neck, external rotation, and hand-to-sacrum activity.

antebrachial cutaneous nerves, terminating in the medial contribution to the median nerve and the ulnar nerve. The lateral cord supplies the lateral pectoral nerve and the lateral branch of the median nerve, and terminates as the musculocutaneous nerve. With infantile brachial plexopathy, any of these nerves can be affected. However, the most severe injuries are avulsions of the nerve roots. The most common injuries are postganglionic ruptures of the upper trunk.

Treatment

Nonsurgical. As mentioned above, all infants with brachial plexus birth palsies should be monitored for spontaneous recovery in the first 3 to 6 months of life. During this time it is important to maintain glenohumeral range of motion, especially passive external rotation. Many infants will initiate recovery in the first 6 to 8 weeks of life, and progress to a normal result. Those infants who do not initiate recovery until after 3 months of life may be microsurgical or reconstructive surgical candidates.

Microsurgery. The timing of microsurgical intervention is still debated. The range used clinically is from 1 month to after 6 months of life (47,51–55). The indications include absence of biceps recovery, Toronto score less than 3.5, and

total plexopathy with Horner syndrome. At present, most centers throughout the world agree that an infant with a flail extremity and Horner syndrome should have microsurgical reconstruction between 1 and 3 months of life. A child with complete absence of upper-trunk function (shoulder abduction, elbow flexion) should have surgery between 3 and 6 months of life. Microsurgery involves resection of the neuroma and bypass nerve grafting or nerve transfer procedures. There is no role for neurolysis alone at any age, especially in the infant older than 6 months of age, based on the information published in peer-reviewed journals. The technique involves exploration of the brachial plexus and reconstruction of avulsion and nonconducting rupture injuries. If the proximal trunk or nerve roots are intact, sural nerve grafting across the neuroma is preferred. In the presence of an avulsion, intercostal and spinal accessory nerve transfers are performed. The results are not normal function, but they are improved over natural history alone (51,52). The controversy regarding the exact timing of intervention (i.e., no upper trunk function at 3 versus 6 months of age) may not be resolved without a prospective, randomized study.

Shoulder Surgery. Children with chronic upper trunk plexopathy may develop external rotation weakness and internal

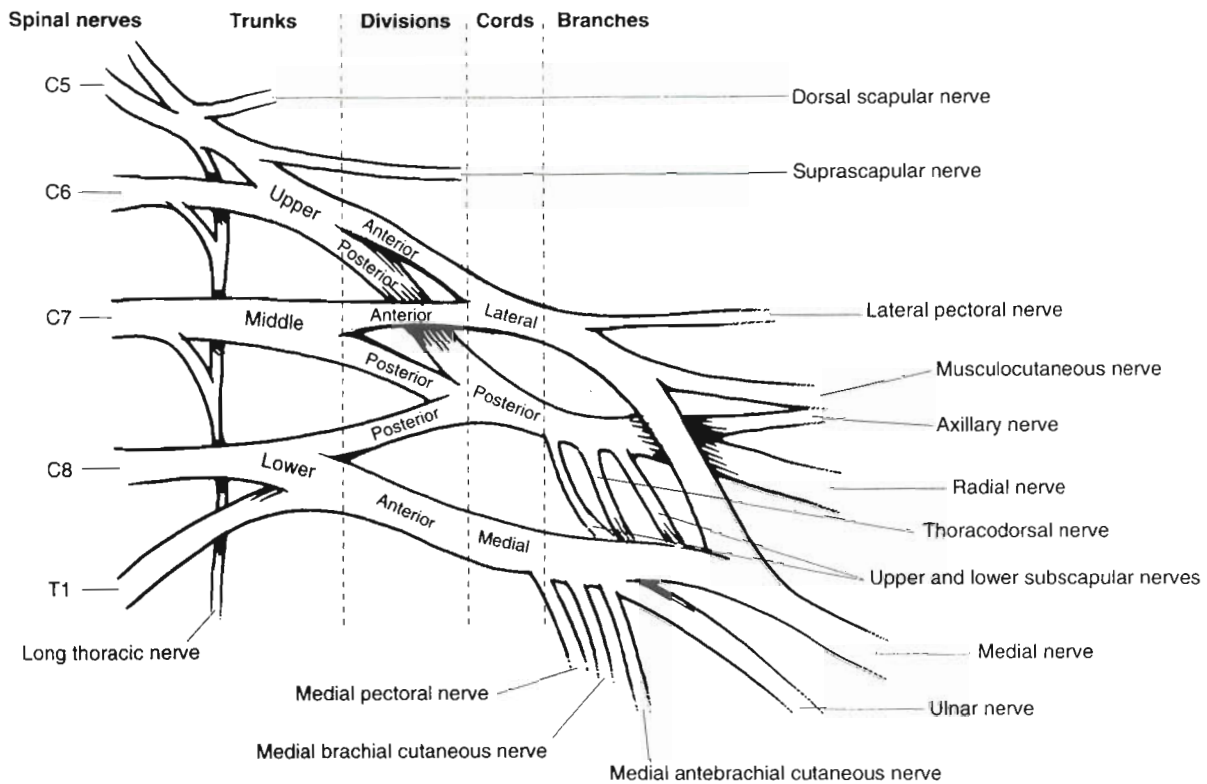


FIGURE 22-4. Anatomic representation of the brachial plexus.

rotation contractures about the shoulder. This muscle imbalance will progressively alter the glenohumeral joint (49,50; Table 22-2). Function, especially with the arm in above-horizontal activities, will be impaired (48,50). These children clearly benefit from surgical intervention (50,56). In the rare situation of an infantile dislocation (58), open reduction and capsulorrhaphy are indicated. More commonly, these children have limited external rotation that affects function.

TABLE 22-2. COMPUTED TOMOGRAPHY/MAGNETIC RESONANCE IMAGING (CT/MRI) CLASSIFICATION OF GLENOHUMERAL DEFORMITY IN CHRONIC BRACHIAL PLEXUS BIRTH PALSIES

Type	CT/MRI Findings
I	Normal glenohumeral joint
II	Minimal glenoid hypoplasia (>5 degrees increased retroversion)
III	Posterior subluxation of the humeral head
IV	Development of a false glenoid
V	Posterior flattening of the humeral head
VI	Infantile dislocation
VII	Proximal humeral growth arrest

Findings are additive, with increasing severity from type I to type V. (From ref. 50, with permission.)

In young children with nearly normal glenohumeral joints (normal or mild increase in glenoid retroversion; grades I and II) or slight posterior subluxation (mild; grade III), anterior musculotendinous lengthening of the pectoralis major and posterior latissimus dorsi and teres major transfer to the rotator cuff (59,60) will improve function (52). In addition, dynamic rebalancing of the muscle forces about the shoulder at a young age has the potential advantages of restoring more normal anatomy, preventing progressive glenohumeral joint deformity, and permitting glenohumeral joint remodeling. In the older child with more established and progressive deformity of the glenohumeral joint (more severe posterior glenoid flattening; advanced grade III), development of a false glenoid (grade IV) (Fig. 22-5), or humeral head dislocation and deformity (grade V), the joint deterioration is too advanced to tolerate a soft tissue procedure. However, humeral derotation osteotomy is indicated and will also improve function (52).

There are rare patients who need both osteotomy and tendon transfer. These patients have been in the middle range of deformity (grade III) and are relatively older (7 to 12 years). To date, it has been difficult to identify this small subset of patients preoperatively. Therefore, the transfer is performed initially, and only if the result is suboptimal more than 1 year later is the secondary-stage osteotomy per-

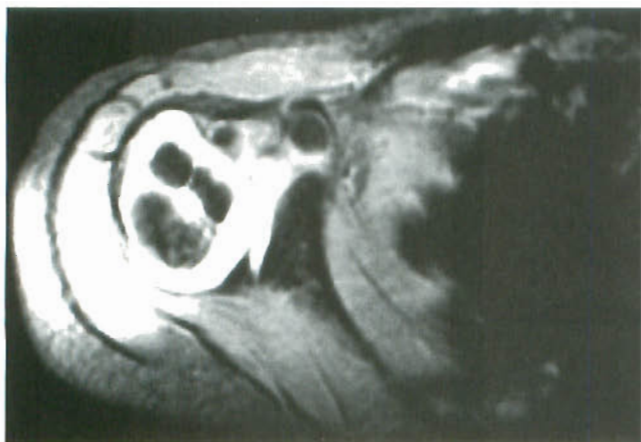


FIGURE 22-5. Magnetic resonance imaging scan of a type IV deformity with posterior humeral head subluxation and development of a false glenoid.

formed. The role of glenoid osteotomy, its risks, and its benefits are still being defined for grade III and mild grade IV patients.

Elbow and Forearm Reconstruction. Elbow flexion and forearm supination deformities can occur with a permanent Klumpke (C8 to T1) or mixed brachial plexus lesion. Contractures, bony deformity, and joint instability are the result of muscle imbalance in a growing child. In the rare patient with residual C8 to T1 neuropathy with recovery of C5–C6 function, the elbow and forearm deformities are secondary to an intact biceps muscle in the presence of weak or absent triceps, pronator teres, and pronator quadratus muscles. Progressively, the biceps creates an elbow flexion and supination deformity from unopposed muscular activity. Soft tissue contractures develop, followed by rotation deformities of the radius and ulna (61). Radial head dislocation may occur (62). The wrist and hand often are in extreme dorsiflexion because of unopposed wrist dorsiflexors. In the position of forearm supination, gravity further exacerbates the dorsiflexion deformity. The patient is left without use of the hand, and performs bimanual activities using the volar and ulnar forearm as an assist. Often, shoulder abduction and internal rotation are required to improve assistive function. Those activities that require simultaneous elbow flexion and forearm pronation, such as dressing, eating, and writing (63), are significantly limited. In addition, the forearm and hand posture is a major cosmetic concern to both the patient and the family (64).

The biceps tendon can be treated by Z-lengthening and rerouting around the radius to convert it from a supinator to a pronator. This will improve elbow extension and forearm pronation. Surgically, the biceps tendon is identified as it inserts into the radial tuberosity. By dissecting lateral to the tendon, the brachial artery and median nerve are protected.

A long Z-plasty of the tendon is performed from the musculotendinous junction to the insertion site. The distal attachment of the tendon is rerouted posteriorly around the radial neck, from medial to lateral. Care must be taken to stay adjacent to the radial neck to avoid injury or compression of the radial nerve. The distal tendon is reattached to its proximal counterpart in a lengthened position. This converts the biceps into a forearm pronator (63–65).

In the presence of a supination contracture, the rerouting procedure alone will fail because of recurrence of the deformity. Zancolli (63) suggested performing simultaneous interosseous membrane release. However, active pronation was maintained in only 50% of patients who underwent this procedure. Bony correction of the forearm deformity can be performed more predictably. Manske et al. (65) proposed staged procedures of tendon rerouting and forearm osteoclasia. Waters and Simmons (64) described simultaneous tendon rerouting and osteotomy, using intramedullary fixation to avoid multiple operations and loss of alignment. In both techniques, the forearm is positioned in approximately 20 to 30 degrees of pronation.

These patients clearly have significant improvement in their functional capabilities. Bimanual tasks, such as lifting, carrying, and transferring, are easier. The affected extremity becomes a better assistive extremity to the unaffected side. The wrist and hand now have greater assisted palmar flexion and resolution of their dorsiflexion deformity. In addition, the patients are usually pleased with their cosmetic results.

Arthrogryposis

Arthrogryposis multiplex congenita is a syndrome of unknown cause that presents at birth with joint contractures and muscle weakness. The incidence is approximately 1 per 3,000 live births (66). The clinical syndrome is variable and includes classic arthrogryposis (amyoplasia), distal arthrogryposis, and syndromic involvement (67). Intelligence is usually average or above average. Sensibility is normal. Upper-extremity involvement is frequent, with 72% of the 114 patients in the Gibson and Urs study affected (68). The wrist was most commonly involved, followed by the hand, elbow, and shoulder. In the classic presentation, the elbow is usually contracted in extension at birth. The shoulder is internally rotated with the forearm pronated. Often, there is wrist palmar flexion and ulnar deviation, and the fingers have flexion deformities (Fig. 22-6). The thumb is usually adducted and flexed in the palm (68–71). These children often have incomplete syndactylies of all web spaces. The first web space contracture is usually the most functionally significant. There usually is marked intrinsic muscle weakness. There may be camptodactyly or symphalangism of the PIP joints. All of this will limit hand function in these children.

Involvement is generally bilateral. The absence of both passive and active elbow flexion is a significant functional liability in these children. The goal of orthopaedic manage-

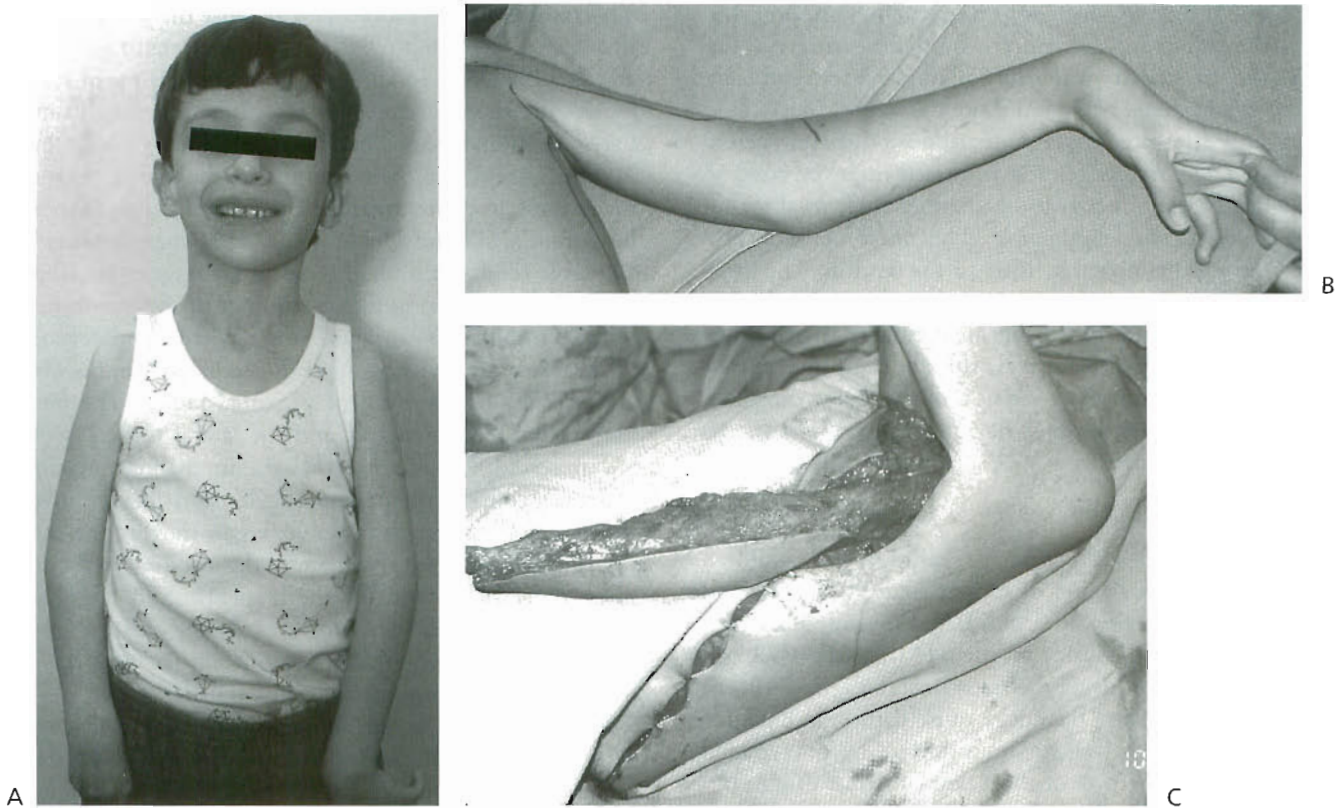

FIGURE 22-6. A: Clinical photograph of an arthrogryptic patient preoperatively, with elbow extension, forearm pronation, and wrist palmar flexion posturing and contractures. B: Intraoperative photograph of the outline of surgical incisions for tendon transfer of the latissimus dorsi to the biceps. C: Intraoperative photograph of the preparation of the latissimus dorsi transfer for active elbow flexion.

ment of the arthrogryptic elbow is to improve self-feeding and independent hygiene skills by achieving both passive and active elbow flexion. The goal of treatment of the hand is to improve pinch, grasp, and release functions.

Treatment

Nonoperative Care. Initial care is with physical therapy to improve passive range of motion. Repetitive, gentle, passive manipulation of the involved joints may progressively lessen the contracture. This process is tedious and requires meticulous, gentle care by both the therapist and the family. Corrective splints and serial casts have been used with varying success. Caution is necessary because of the risk of fractures or dislocations that can occur as a complication of aggressive treatment of resistant contractures. At the elbow, the goal of therapy is to achieve at least 90 degrees of passive elbow flexion by 2 years of age. The majority of patients can achieve the desired passive elbow flexion through therapy (72). However, if this is not obtained, operative elbow release is recommended (72–76). When passive elbow flexion is obtained, therapy should then emphasize the use of adaptive trunk sway, head tilt, and table-assisted passive elbow

flexion to improve feeding and hygiene tasks. Finally, if subsequent active elbow flexion does not develop, active elbow flexion tendon transfer should be considered at approximately 5 years of age (72). The majority of these children will have deficient biceps and brachialis musculature, and will fail to develop active elbow flexion.

Initial treatment of the wrist and hand should involve passive range of motion and nighttime splinting. The goal of therapy in the hand is to improve joint motion and digital strength. Fortunately, in many children their condition improves with growth and therapy during the first several years of life. If passive motion cannot be improved, surgical releases and tendon transfers may be necessary.

Operative Care

Posterior capsulotomy and triceps lengthening. As mentioned above, children who fail to achieve a functional arc of flexion at the elbow with manipulative therapy, splints, and casts, are candidates for operative elbow posterior capsulotomy and triceps lengthening. Surgery can be performed at 2 years of age. If delayed well beyond this age, progressive bony deformity can occur. The goal of operative intervention is

to achieve at least 90 degrees of passive elbow flexion. Initially, the dominant extremity should have surgery. The presence of passive elbow flexion will improve independence in feeding, hygiene, play, and school activities (64,72).

Surgical exposure is by a standard posterior approach to the elbow. The triceps tendon is incised in an inverted V. The angle of the V needs to be acute enough to allow for appropriate triceps lengthening. The ulnar nerve is protected during the medial incision of the tendon. The distal flap of the triceps is elevated from the elbow capsule, but often the triceps and the capsule are confluent distally. The triceps lengthening alone usually does not improve passive elbow flexion. A transverse incision in the elbow capsule is then made. Full passive elbow flexion is gained. The triceps tendon is lengthened in a V-Y manner at 90 degrees of flexion.

Tendon transfers for elbow flexion. Arthrogrypotic children with passive elbow flexion of greater than 90 degrees and no active elbow flexion are candidates for tendon transfer. The transfers to be considered include (i) triceps (72,73); (ii) pectoralis major, using the sternocostal origin (74); (iii) pectoralis major, using the entire musculature on a neurovascular pedicle (74); (iv) latissimus dorsi (72,75); (v) lateral and proximal reinsertion of the flexor-pronator origin; (vi) sternocleidomastoid with a free tendon graft; and (vii) pectoralis minor with a free tendon graft. Each of these transfers has been described in limited series in the arthrogrypotic elbow. Until recently, no objective criteria had been proposed to compare the results of these various transfers (64,72). The muscle considered for transfer must be expendable and of sufficient strength to function actively against gravity after transfer. Each transfer has its inherent negative attributes: triceps transfer may weaken assistive ambulation in patients with lower extremity involvement, and may result in a flexion contracture; pectoralis major transfer may create asymmetric breast appearance in females; Steindler flexorplasty may worsen wrist and finger flexion contractures. Information gained to date indicates that the triceps transfer is most effective at improving strength, active range of motion, and function (64,72).

The triceps muscle is strong in most arthrogrypotic children. With transfer, it is usually successful in providing active elbow flexion in a functional arc. However, the triceps is important for crutch ambulation, rising from a sitting position, and wheelchair transfers in patients with lower-extremity involvement, and should be used cautiously for tendon transfer in these children. This operation involves the transfer of the antagonist to elbow flexion and leaves the patient without an active elbow extensor postoperatively. This can lead to progressive elbow flexion deformity with growth (72).

There are two options for transfer of the pectoralis major muscle for elbow flexion. The first choice is transfer of the sternocostal origin, as originally described by Clark (74a).

This transfer can be problematic because the partial transfer may be too weak to provide antigravity strength for feeding and facial hygiene. In addition, the pectoralis major muscle crosses the shoulder and may lose strength trying to move both the shoulder and the elbow.

The second choice is transfer of the entire pectoralis major muscle on its neurovascular pedicles, as advocated by both Carroll and Doyle (74b). This operation has had favorable results in limited series of arthrogrypotic elbows. It involves transferring the insertion of the pectoralis major to the acromion. The origins of the clavicular and sternocostal heads, with attached anterior rectus abdominis fascia, are inserted distally into the proximal radius. The medial and lateral pectoral nerves and the lateral thoracic vessels are preserved. This transfer has the mechanical advantage of a linear contraction for elbow flexion and does not involve the loss of any strength in stabilizing or moving the shoulder. The proximal advancement of the insertion to the acromion or clavicle improves the lever arm and mechanical advantage of the transfer. However, it may create an asymmetric appearance of the breasts in females, and this has been raised as an argument against transfer (64).

In patients with significant lower extremity involvement, with weak triceps or pectorals, or with failed pectoralis major or triceps transfers, a bipolar latissimus dorsi transfer, as described by Zancolli and Mitre (75), may be the optimal choice (Fig. 22-6). Preoperative assessment of the strength of the latissimus is important before transfer, but at times this is difficult to assess. An experienced pediatric physical therapist with extensive muscle evaluation experience may be helpful. Biopsy of the muscle has been tried, but is not predictive of outcome with transfer.

In summary, physical therapy should be initiated in infancy to obtain and maintain passive range of motion of the elbow. This will frequently result in passive elbow flexion of greater than 90 degrees. If by 24 months of age nearly full passive elbow flexion has not been achieved, elbow capsulotomy and triceps lengthening are recommended. After the age of 4 years, tendon transfer for elbow flexion in the dominant arm is recommended, with consideration given to intelligence, ipsilateral and contralateral upper-limb function, lower-extremity involvement, and available motors for transfer. All transfers have had success, but the triceps-to-biceps transfer gives the most predictably good results (64,72).

Wrist and hand reconstruction. The wrist palmar flexion contracture is addressed with FCU lengthening or transfer to the wrist extensors. Unfortunately, in many of these children the transfer is more of a tenodesis procedure than a dynamic transfer. In addition, there often is bony deformity, even in the very young. Smith (22) had recommended a proximal row carpectomy to correct the wrist flexion contracture. However, there frequently are carpal coalitions

present that preclude that procedure. A dorsal, carpal, closing-wedge osteotomy can correct the deformity in the presence of a carpal coalition. This is an excellent procedure to correct the bone and wrist joint deformity that does not respond to therapy (71). Simultaneous FCU transfer can be performed to rebalance the wrist. An alternative to carpal osteotomy is radius and ulna dorsal osteotomies (67). However, these create an "S" deformity to the distal forearm, and physal remodeling with growth tends to lead to recurrent wrist flexion deformity.

The thumb-in-palm contracture is addressed with a Z-plasty syndactyly release. Care must be taken not to overrelease the adductor. It may be providing the bulk of the pinch strength. Dynamic transfers for thumb abduction and extension are predominantly tenodesis procedures because of the limited strength of the donor muscles. Many of these children will have permanent limited motion and strength of their hands. Fortunately, their high level of intelligence allows them to be very adaptive in their functioning.

ELBOW AND FOREARM REGION

Congenital Dislocations

Congenital Radial Head Dislocations

Congenital dislocation of the radial head is a rare condition that may not be diagnosed until school age. It is usually an isolated condition, but it may be present in association with other congenital malformations and syndromes, including arthrogryposis and Cornelia de Lange, Larsen, and nail-patella syndromes (77–80). It may be associated with radio-ulnar synostosis (81,82) or other musculoskeletal anomalies, such as congenital hip dislocation, club feet, brachydactyly, clinodactyly, tibial fibular synostosis, congenital below-elbow amputation, and radial or ulnar club hand. Dislocations associated with Madelung deformity or familial osteochondromatosis (82) may be acquired, and will be considered elsewhere in this chapter.

Congenital radial head dislocation may be bilateral or unilateral (83). It is defined by the direction of subluxation or dislocation. The majority of congenital dislocations are posterior or posterolateral. It is important to distinguish the congenital dislocation from the posttraumatic dislocation. Because the condition frequently presents late, this distinction can be confusing (78,83). This is especially true for unilateral anterior dislocations in otherwise normal children (84–86). Radiographic criteria have been established to distinguish this lesion from a chronic, traumatic dislocation. These include a small, dome-shaped radial head; a hypoplastic capitellum; ulnar bowing with volar convexity in the anterior dislocation and dorsal convexity in the posterior dislocation; and a longitudinal axis of the radius that does not bisect the capitellum. The presence of these characteristics in the absence of any history of trauma to the affected

elbow has been seen as evidence of a congenital radial head dislocation (64,78,87–92). In addition, bilateral involvement, the presence of other musculoskeletal or systemic malformations, and a positive family history all make a congenital cause more likely.

Clinical and Radiographic Features. These children often present after infancy. The most common reasons for presentation are (i) limited elbow extension; (ii) posterolateral elbow mass/prominence; and (iii) pain with activities, especially athletics (64,93). The elbow extension loss is frequently less than 30 degrees, and not of functional significance. This loss of motion is usually not noted early in life. The mass may be noted in infancy. Radiocapitellar incongruity can be a cause of pain and disability later in life (83,93). Unfortunately, many children present late with pain resulting from radiocapitellar articular changes. There is often chronic discomfort with school and sports activities. On occasion, these children may present with an acute loss of motion attributable to a loose osteochondral fragment. Some individuals remain asymptomatic, and the cosmesis of the deformity is their major concern.

On physical examination, the elbow may have cubitus valgus. A flexion contracture of up to 30 degrees often occurs with a posterior subluxation/dislocation. Hyperextension and/or loss of flexion may occur with an anterior dislocation. The radial head is palpable in its dislocated position. A congenital dislocation is not reducible by forceful manipulation, and should not be misinterpreted as a nursemaid's pulled elbow or a Monteggia lesion. There is usually limited forearm rotation, with supination being affected more than pronation. Clicking and crepitus may be present when there is intraarticular pathology (64).

Radiographs reveal the subluxation/dislocation (Fig. 22-7). The longitudinal axis of the radius does not bisect the capitellum, regardless of the angle of the radiograph. The radius and ulna are of different lengths. The ulna is bowed, with volar convexity in an anterior dislocation and dorsal convexity in the more common posterior dislocation. The capitellum is hypoplastic. The radial head will be dome-shaped, with a long, narrow radial neck.

Natural History. The presence of a congenital dislocated radial head is not an indication for operative intervention. Many patients with this disorder have no functional limitation and no pain. Their mild limitation of motion may not restrict them in any significant way. The degree of cubitus valgus is usually mild, and does not seem to put them at risk for ulnar neuropathy. Therefore, in the majority of cases a definitive diagnosis followed by observation is most appropriate. If the patient develops pain, functional or progressive limitation of motion, or restriction of elbow-related activities, then surgery needs to be considered (64).

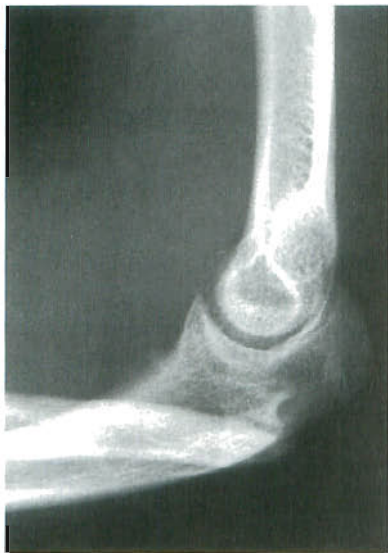

FIGURE 22-7. Lateral radiograph of congenital posterolateral dislocation of the radial head. There is evidence of tapering of the radial head and neck posteriorly, bowing of the ulna posteriorly, and a small dome-shaped radial head. These patients often have limited elbow extension, and develop intraarticular pain at the abnormal radiocapitellar articulation in adolescence.

Treatment

Operative Care. Ideally, the care of a congenital dislocated radial head would involve open reduction and restoration of normal anatomy. This has led many surgeons to consider open reduction of a congenital dislocation if the child presents in infancy (80,81,87,94). The logic is that if the radial head can be reduced early in infancy, the deformity of the capitellum and the forearm may not occur or remodel with growth. This may prevent the long-term complications of pain, loss of motion, and osteochondral loose bodies. However, there have been only a small number of published cases of open reduction of congenital radial head dislocations (81,94,95). Techniques have included ulnar osteotomy and lengthening, radial shortening and osteotomy, annular ligamentous reconstruction, and the use of limb-lengthening devices to reduce the radial head (91,94–96). Sachar and Mih's report of open reduction via an anconeus approach and annular ligament reconstruction is the most promising series to date. They described seven cases of open reduction of a congenitally dislocated radial head with good success (94). Their operative findings included an abnormality of the annular ligament that was surgically correctable. The indications for this procedure, and the age limit, are still being defined in this relatively rare condition. It is reasonable to consider open reduction of the congenitally dislocated radial head in the infant younger than 1 to 2 years of age, provided that the family is well informed of the preliminary nature of the information regarding this procedure.

Most children with congenital radial head dislocation present later than infancy. Therefore, the most common procedures for this problem are excision of loose bodies and excision of the radial head. The indications for excision of a loose osteochondral fragment are the presence of pain, clicking or locking, and loss of motion. Usually, degenerative changes are too advanced for repair of the osteochondral fragment. There is some controversy regarding the indications and timing for excision of the radial head. In the skeletally immature patient the concern is the potential development of postoperative complications (see next section). These concerns have not been supported in the published literature on excision of the congenitally dislocated radial head. Most of these children do not present until adolescence with pain or progressive restriction of motion. In our series, the youngest patient with excision of a symptomatic congenital radial head without complication was 8 years of age (83). However, the presence of an asymptomatic dislocated radial head alone, without painful, progressive restricted range of motion, is not an indication for radial head excision. Indications for radial head excision must include progressive pain, progressive loss of motion, and progressive restriction of activities (64), regardless of age.

Complications. Throughout the twentieth century, standard textbooks and journal articles have condemned the concept of radial head excision in the skeletally immature individual. Postoperative complications of progressive cubitus valgus and potential associated ulnar neuropathy, proximal migration of the radius, with recurrent radiocapitellar impingement, radioulnar synostosis, and reformation of the radial head, have been cited (87,88,97–99). However, most of these problems occurred after radial head excisions to treat trauma. The admonishment to “never excise a radial head in a skeletally immature individual” still holds true in the posttraumatic situation. These complications are rare after excision for congenital radial head dislocations (83).

Reformation of the radial head is the most common problem with excision of a congenital dislocation (98, 100,101). If it leads to recurrent radiocapitellar impingement, limitation of motion, and/or pain, then repeat radial head excision should be performed. Wrist pain does occur in the long term but seems to be mild and nonrestrictive (83). Fortunately, iatrogenic radial nerve injury is rare.

Congenital Humeroulnar Dislocations

Dislocation of the ulnotrochlear joint is exceedingly rare. Mead and Martin described a family with aplasia of the trochlea and humeroulnar dislocations (102). Ulnotrochlear dislocations have also been seen in hyperelasticity syndromes. These situations are rarer than the unusual post-traumatic persistent or recurrent dislocation.

A congenital dislocation will result in limited range of elbow motion that can affect function. The dislocation is

usually palpable on examination. There may be axial malalignment, such as cubitus valgus. If severe, the valgus deformity can result in ulnar neuropathy. In recurrent dislocations secondary to hyperelasticity or associated with syndromes such as Rubinstein-Taybi syndrome (103), the elbow instability is palpable and even audible on examination. On occasion, with recurrent instability osteochondral injury can occur that will cause pain, clicking, or even locking on examination.

Elbow dislocation can also be seen with ulnar dysplasia and ulnar dimelia (104–107). The dysplastic ulnotrochlear joint in ulnar club hand can lead to elbow problems that limit motion and function. Ulnar dimelia, or mirror hand, is exceedingly rare. The forearm and elbow in this condition consist of two ulnae and no radius. This means that there are two olecranon processes articulating with the distal humerus. There are usually two poorly defined trochleae and no capitellum present. The olecranon processes may face one another. There is significant limitation of elbow and forearm rotation (64,108,109).

If the child presents before ossification of the secondary centers, it may be difficult to define the dislocation anatomically by plain radiography. MRI will be diagnostic, but will require sedation or general anesthesia in infancy. Ultrasonography may be diagnostic in skilled hands (64).

Natural History. Children with congenital dislocations will have limited elbow and forearm range of motion and strength that will affect function. They must compensate with shoulder, wrist, or trunk range of motion to perform recreational activities and activities of daily living. If unreduced, there is concern that chronic arthritic pain could develop. However, this is not well documented.

In children with recurrent instability, pain may develop secondary to osteochondral injury. This can lead to osteochondral loose bodies and arthrosis-like pain.

Treatment

Operative Care. The isolated, congenital elbow dislocation has been rarely treated with open reduction (64,103). These cases and operations are rare enough that generalized comment is difficult. The more abnormal the anatomy, the less likely that operative intervention will be successful.

In recurrent instability ligamentous reconstruction, transposition of the biceps tendon insertion to the coronoid process, and an anterior bone-block procedure have all been advocated (103,104). The choice or combination of procedures depends on the pathologic anatomy and the degree of instability.

It is the rare congenital elbow dislocation associated with ulnar dimelia and ulnar club hand that may warrant surgical reconstruction. Although ulnar dysplasia will be described in more detail in the wrist section of this chapter, it is worthwhile to discuss elbow reconstruction in this section. In type II ulnar club hand there is partial absence of the ulna distally

(104–106). The proximal ulna articulates with the humerus but is usually unstable. With growth, the radius migrates proximally, leading to progressive loss of elbow flexion and extension. A supination deformity of the forearm may develop that limits forearm rotation (106). In these circumstances, creation of a single-bone forearm may improve cosmesis, stabilize the forearm, and improve elbow motion (104,108). As described by Bayne (104), with this procedure the ulnar anlage is completely excised and the adjacent ulnar artery and nerve are protected. Radial osteotomy is then performed proximally. The radius is placed distal to the ulna in an end-to-end manner. Intramedullary fixation is performed to connect the proximal ulna to the distal radius. If there is significant bowing of the radius distal to the osteotomy site, a second osteotomy is performed with passage of the intramedullary wire. If it is difficult to attain end-to-end fixation, then side-to-side fusion is acceptable. Resection of the dislocated proximal radius can be performed simultaneously or up to 6 months later. If there is any question of neurovascular compromise it is advisable to delay the proximal radius excision (104). At the time of proximal radius excision, the posterior interosseus radial nerve needs to be exposed and protected.

Wood recommends that reconstruction of the complex elbow deformity associated with ulnar dimelia should begin at the elbow with excision of the lateral olecranon process (108). Reconstruction of ligamentous structures may be necessary after excision to provide elbow stability. Excision of the lateral olecranon reportedly will provide improved passive elbow flexion and extension, but there may be continued limited active elbow flexion as a result of deficiencies in the biceps and brachialis musculature. Tendon transfers for active elbow flexion have reportedly had limited success (108). This condition (and reconstruction) is so rare that in-depth analysis of treatment options is not possible.

Congenital Synostoses

These entities are classified as failure of differentiation of parts with skeletal involvement. In this section, congenital radioulnar and elbow synostoses will be discussed.

Congenital Radioulnar Synostosis

Congenital synostosis of the proximal radius and ulna is a rare malformation of the upper limb. It is caused by a failure of the radius and ulna to separate, usually proximally.

During the embryonic period of fetal development, the humerus, radius, and ulna are conjoined. Longitudinal segmentation begins distally. For a time the proximal ends are united and share a common perichondrium. Abnormal genetic or teratogenic factors can disrupt radioulnar joint development, leading to a bony synostosis. This represents a type I deformity. If rudimentary joint development occurs before developmental arrest, a rudimentary radial head will

develop with a less severe degree of coalition. This is a type II deformity (110).

During this period of intrauterine development, the forearm is anatomically in a position of varying degrees of pronation (111). Failure of formation of the proximal radioulnar joint at this stage of differentiation will leave the forearm in its fetal position of pronation. With rare exceptions (112), the forearm is fixed in pronation with congenital radioulnar synostosis (111).

Congenital radioulnar synostosis is usually an isolated event. There is a three-to-two male predominance. Positive family histories have been reported (77,113,114). It is a bilateral occurrence 80% of the time (115). The condition is also seen in disorders such as acropolysyndactyly (Carpenter syndrome), acrocephalosyndactyly (Apert syndrome), arthrogryposis, acrofacial dysostoses of Najjar and mandibulofacial dystosis, and Klinefelter syndrome and its variants (116,117).

Although radioulnar synostosis is usually an isolated event, there may be associated anomalies of the musculoskeletal, cardiovascular, thoracic, gastrointestinal, renal, and central nervous systems. Cardiac anomalies include tetralogy of Fallot and ventricular septal defects. Thoracic anomalies include hypoplasia of the first and second ribs and the pectoral musculature. Renal anomalies involve anatomic malformations that can be screened by ultrasonography. In the central nervous system associated problems include microcephaly, hydrocephalus, encephalocele, mental retardation, delay in attaining developmental milestones, and hemiplegia. Musculoskeletal problems include clubfeet, dislocated hips, polydactyly, syndactyly, and Madelung deformity (64,81,115,118).

Clinical and Radiographic Features. These children present for evaluation when they have a functional deficit. Generally, the degree of fixed forearm pronation determines the disability and the age of presentation. The presence of bilateral synostosis in marked pronation significantly limits function, and leads to an earlier presentation. Most children will present for evaluation by school age. Radioulnar synostosis is often first noted by a teacher or daycare worker when comparing the affected child with peers performing the same tasks (64).

Functional complaints are variable and include (i) difficulty in holding or using small objects such as spoons or pencils; (ii) inability to dress owing to poor manipulation of belt buckles or buttons; (iii) backhanded positioning when holding objects such as bottles or toys; and (iv) difficulty competing in sports requiring upper-extremity dexterity. Feeding and accepting objects with an open palm are often difficult (64,115).

On physical examination, the elbow often has loss of its normal carrying angle and has a flexion deformity. The flexion contracture is usually minimal. Shortening of the forearm is more apparent in unilateral cases. Rotational hyper-

mobility of the wrist compensates for the lack of forearm rotation (112,114). Despite this ligamentous laxity, patients do not appear to develop symptoms of carpal instability.

Almost all patients present in fixed pronation. In the series by Simmons et al. (115), approximately 40% of patients presented with pronation of less than 30 degrees, 20% had pronation fixed between 30 and 60 degrees, and 40% had more than 60 degrees of pronation. Pronation of greater than 60 degrees appears to be the most limiting.

Radiographs of patients with congenital radioulnar synostosis show anatomic variations from minor radial head deformities in patients with limited forearm rotation, to full synostosis and absence of the radial head in patients with no rotation (81) (Fig. 22-8). The more extensive synostoses are usually fixed in more pronation. Plain radiographic classifications have distinguished partial and complete synostoses. In the partial synostosis there is often a rudimentary radial head present, but it is posteriorly or posterolaterally subluxated. In the complete synostosis the radial head is absent, and the proximal radius and ulna are a single bony mass. There is always an increased anterior bow of the radius. On occasion, the synostosis can extend into the mid-diaphysis of the forearm.

Occasionally, a patient will present with limited forearm rotation and normal radiographs. MRI of the proximal radius and ulna may reveal a cartilaginous synostosis that has yet to ossify or a fibrous tether that limits motion (64).

Natural History. In the absence of functional limitation, children with radioulnar synostosis should be observed. Those children with (i) synostosis in neutral-to-mild pronation (less than 60 degrees), (ii) significantly compensatory radiocarpal and intercarpal wrist rotation, and (iii) unilateral disease often compensate for lack of forearm rotation (64). These children present because they, their parents, and/or their teachers notice them performing home, school, or recreational tasks differently than their peers. However, when questioned extensively, they are without pain or functional disability (114). These children and their families are best served by counseling regarding the diagnosis and genetics of their problem, and reassurance that operative intervention would be unlikely to improve their condition.

Treatment.

Operative Care. The ideal treatment would be to restore normal forearm rotation. Many surgical attempts to do so have been tried. Reported procedures have included division of the bony bridge (111); resection of the synostotic proximal radius to save the bicipital tuberosity with (119–121) and without (122) muscle interposition; division of the interosseous membrane; and muscle, fat, fascia, or silastic interposition after synostosis excision (113,123). All had limited success at restoring motion. Artificial joint replacement, with a metallic swivel in the intramedullary canal of the radius between the supinator and pronator teres, also failed

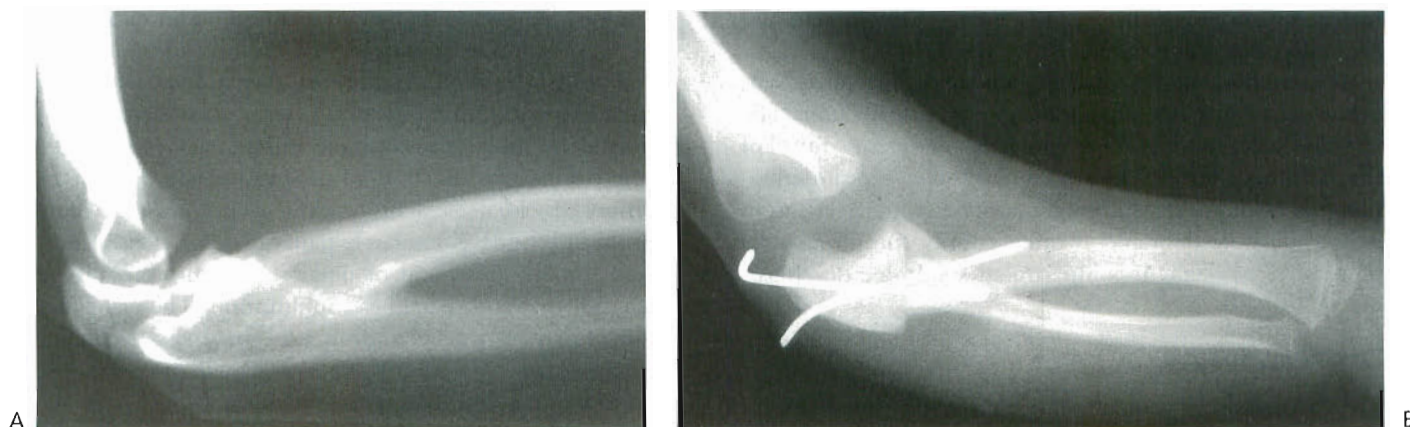


FIGURE 22-8. A: Preoperative radiograph of a congenital radioulnar synostosis. There is complete fusion of the proximal radius and ulna, and posterior dislocation of the radial head. The entire ulna is mildly hypoplastic. B: Postoperative radiograph of a derotation corrective osteotomy for this patient. A longitudinal wire is passed down the medullary canal of the ulna across the synostosis site. This Kirschner wire starts from the proximal ulnar apophysis. The osteotomy cut is performed through the synostosis. The transfixing wire is obliquely placed to secure the corrective derotation to a position of 0 to 20 degrees of pronation.

(121). Tagima et al. (123) reported improved forearm rotation with synostosis takedown, radial osteotomy, and interposition of either a silastic or a free fascial lateral arm flap. Intraoperatively, synostosis takedown procedures can dramatically improve motion, but there is a high incidence of loss of motion in the 6 to 12 months after surgery. At present, the functional gain does not seem to warrant this surgical intervention.

The alternative to synostosis excision is derotation osteotomy. The goal is to place the hyperpronated hand in a more functional position. The dominant extremity is given priority in bilateral cases. It is easiest to perform the osteotomy through the synostosis distal to the coronoid process. Before the procedure, an intramedullary ulnar Kirschner wire is placed to maintain control of the osteotomy. After completion of the osteotomy, the forearm can be rotated into the desired position of correction. Generally, patients undergoing derotation osteotomy have a fixed preoperative position of 60 to 100 degrees of pronation. The final corrected position is often 0 to 20 degrees of pronation (64). Ogino and Hikino advocated measuring the preoperative compensatory wrist supination to define the desired operative osteotomy correction (112). Once this position is achieved a second percutaneous Kirschner wire transfixes the osteotomy site obliquely, from the proximal ulna to the distal radius, across the derotated synostosis (Fig. 22-8). Because there is a high risk of compartment syndrome postoperatively (115,124), it is important to avoid internal fixation that would require a second operation for removal if neurovascular compromise occurs. Resection of bone at the synostosis site (112), or dorsal and volar fasciotomies through the operative incision, lessen the risk of compartment syndrome postoperatively (64) and should be performed routinely.

Patients undergoing derotation osteotomies have been noted to have significant improvement in function and cosmesis (115). Bimanual tasks are easier. Single-handed tasks, such as holding a fork, no longer require backhanding in extreme hyperpronation. Activities of daily living, such as dressing and feeding, are performed more independently and with less adaptive shoulder and trunk motion.

Complications. The most significant complication is postoperative compartment syndrome. It has been reported in one-third of patients undergoing derotation osteotomy. This is attributable to changes in the vascularity and volume of the forearm compartments with derotation osteotomies in the range of 60 to 90 degrees (115). Compartment syndrome is more common in osteotomies with greater than 85 degrees of rotational correction. Prophylactic forearm fasciotomy, or resection of a segment of synostotic bone, reduces the incidence of this complication. If compartment syndrome is developing the compressive dressings should be removed promptly, and the limb should be placed horizontally at the level of the heart. Compartment pressure measurements are routinely performed in the presence of tense compartments in a child with the clinical appearance of compartment syndrome. In pediatric patients an increasing analgesia requirement and a high level of anxiety, are the most diagnostic clinical signs of compartment syndrome (125). Removal of the oblique transfixing Kirschner wire is performed if removal of dressings and proper elevation fail to improve the situation. Removal of the oblique Kirschner wire allows the forearm to rotate to its preoperative position, lessens the tension on the interosseous vessels, and reduces the volume of the forearm compartments. Finally, if these

maneuvers do not resolve the problem, emergent skin and fascia decompression is mandatory (64,115).

With removal of the Kirschner wire in compartment syndrome there is a risk of loss of operative correction. The longitudinal ulnar Kirschner wire helps maintain control of the osteotomy site and allows for controlled, repeat derotation 5 to 10 days later. Although more rigid internal fixation may seem more desirable, it unnecessarily complicates the procedure, especially if compartment syndrome develops.

Elbow Synostosis

Elbow synostosis is very rare. It occurs in isolation or associated with syndromic conditions. Humeroradial is more common than ulnotrochlear synostosis (126–128). This is often in a position of elbow flexion from 60 to 90 degrees. Often, there is also limited or no forearm motion. On examination, there will be no elbow motion.

Elbow synostosis is often associated with other upper limb malformations, such as ulnar clubhand (127). It has been described in siblings with humeroradial synostosis, indicating a potential genetic inheritance pattern. It frequently occurs with phocomelia variants (126). The limitation of elbow motion limits function, particularly if the affected extremity is a dominant extremity. The placement of a functional hand in space is limited by the lack of flexion–extension at the elbow. Compensatory trunk, head, and shoulder motion is difficult to adapt. Associated hand anomalies can further limit function (64).

Treatment. Attempts at synostosis excision and restoration of elbow motion have had minimal success. Techniques have included excision with muscle, fat, silastic interposition, or distraction arthroplasties. Although intraoperatively the motion can be improved, recurrence of the synostosis usually develops postoperatively. The use of continuous passive motion devices, or distraction elbow hinge devices, has not improved results (64). If the ankylosis leads to dysfunctional positioning of the hand in space, such as in the presence of an ulnar clubhand, corrective osteotomy is indicated. Most often, this is a derotation osteotomy at the level of the synostosis (126). Correction of a marked flexion deformity acutely increases the risk of neurovascular compromise. There is no role for total elbow arthroplasty because of early mechanical failure (64).

Musculoskeletal

Osteochondromatosis

Deformity of the forearm is common in multiple hereditary osteochondromatosis, with between 30 and 60% of patients affected in various series (129–131). The most frequent problem seems to be distal ulnar osteochondroma, which selectively slows the growth of the ulna in the presence of

continued radial growth. The resultant ulna shortening can lead to progressive bowing of the radius and/or possible radial head dislocation. At the wrist, there is increased radial angulation of the distal epiphysis, with ulnar deviation of the hand and ulnar translocation of the carpus (131–134). These deformities can lead to progressive loss of forearm rotation. If radial head dislocation occurs, loss of elbow motion and the development of pain can occur. This section focuses on the treatment of ulnar shortening, progressive radial bowing, and radial head subluxation. The principles outlined here for osteochondromatosis have also been used in congenital syndromes with forearm growth discrepancies, such as Conradi and Morquio syndromes (64).

Natural History. There are very limited natural history data on patients with deformity secondary to osteochondromatosis of the upper extremity. There is ample information on the indications for, and the results of, surgical excision of osteochondromas and forearm reconstruction for these patients with deformities (135–137). The Shriners group in St. Louis (138) attempted to obtain natural history data by surveying their patients by telephone. Their data suggest that adults with forearm, wrist, and hand deformities from osteochondromatosis do reasonably well with activities of daily living and occupational tasks. Unfortunately, their data were limited because they could not reach many of their patients, and no patients were examined.

Treatment Indications. The presence of an osteochondroma alone is not an indication for surgical excision. Excision of an osteochondroma will not predictably improve growth or prevent recurrence with growth. However, if the osteochondroma is a source of pain, limitation of motion, or neurovascular or muscular impingement, then excision is indicated. In addition, children with forearm osteochondromatosis may present with progressive deformity, loss of pronation and supination, and wrist or elbow pain related to joint subluxation. The limitations of forearm rotation may be caused by impingement of osteochondromas distally or proximally. When the loss of motion is secondary to impingement alone, rotation will improve with osteochondroma excision (131,132). In the presence of progressive forearm deformity, loss of rotation may also be related to bony malalignment, proximal radial head subluxation, or distal radioulnar joint dislocation. In these situations, rotation and radiocapitellar alignment can be improved by corrective radial osteotomy and ulnar lengthening (135). In the presence of radial head dislocation, reconstruction is very difficult. Attempts at reduction of the radial head by osteotomy or distraction lengthening techniques have had limited long-term success. Radial head excision has been advocated after skeletal maturity (136,137). The creation of a single-bone forearm may be the necessary salvage procedure (131,137,139,140).

Operative Management. Operative intervention is indicated in the presence of either progressive deformity that limits motion or radiocapitellar joint instability. The indications, specifically in terms of deformity, are ulnar-shortening greater than 1.5 cm, increasing distal radial articular angle greater than 30 degrees, ulnar carpal translocation greater than 60%, progressive radial bowing, and radial head subluxation (135). The key to radiocapitellar instability is to treat it before frank dislocation occurs. Once the radial head is dislocated obtaining and maintaining reduction is difficult.

The majority of patients with forearm deformities secondary to osteochondromatosis can be treated with a single-stage operative correction. The ulnar-shortening is addressed by simultaneous excision of the osteochondroma and Z-lengthening of the ulna. After the Z-osteotomy, distraction lengthening is carried out intraoperatively with an external fixator. When the desired lengthening is achieved, a plate is applied to maintain the length until bony healing is complete (64) (Fig. 22-9). This lengthening technique is, in essence, a rebalancing of the forearm skeleton. It realigns the proximal and distal radioulnar joints. In one series, lengthenings of 1 to 2.3 cm, leading to a neutral ulnar variance at the wrist, were obtained in a single stage (135). The majority of patients improved forearm rotation by an average of 40 degrees (64,135). Results indicate improved range of motion and function with minimal risk of complications.

There are rare situations with osteochondromatosis in

which correction cannot be obtained in a single procedure (96,141–143). The choice is to perform serial lengthenings or gradual distraction osteoclasia. Up to 13 cm of length has been obtained by distraction techniques (141,142). However, the rate of complications with distraction osteoclasia in the forearm has been cited as between 60 and 100%. Therefore, forearm lengthenings by distraction techniques should be performed cautiously by skilled surgeons. The options for distraction lengthening include unilateral external fixation frames (144–146), classic Ilizarov technique (145), or hybrid fixation using transverse Ilizarov wires at 90 degrees to half pins (143,147). Most surgeons performing distraction lengthening now use a hybrid technique to lessen the risk of neurovascular and muscle entrapment complications (141–143,147). The fixator is pre-assembled as part of preoperative planning, with a half ring proximally and a full ring distally. In those situations requiring angular correction, appropriate hinges need to be applied to obtain correction. Because each case is unique, the specifics of application are difficult to address in a review such as this. However, certain principles need to be adhered to. The pins need to be placed in the safe zone to lessen the risk of complications. Passive digital flexion and extension need to be full intraoperatively after pin placement to ensure postoperative maintenance of motion. The preferred site for corticotomy is the proximal ulna metaphysis to enhance regenerate bone (143). Lengthening begins 3 to 5 days after surgery and progresses at a rate of 1 mm per day,

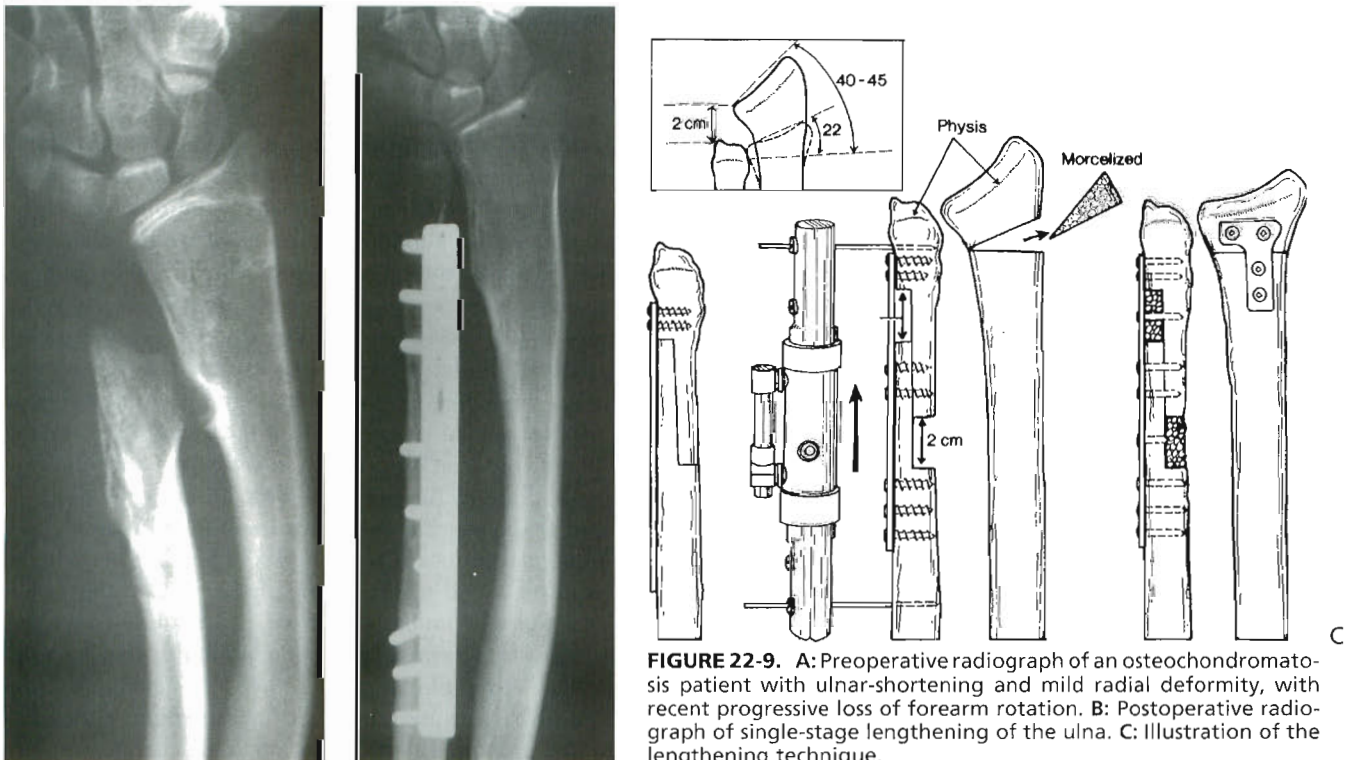


FIGURE 22-9. A: Preoperative radiograph of an osteochondromatosis patient with ulnar-shortening and mild radial deformity, with recent progressive loss of forearm rotation. B: Postoperative radiograph of single-stage lengthening of the ulna. C: Illustration of the lengthening technique.

usually with an advance of 0.25 mm four times per day. Maintenance of passive and active range of motion of the shoulder, elbow, and digits is critical. Clearly, the loss of hand function is not worth the advantage of increased forearm length. Prevention and treatment of expected pin-track infection require meticulous pin care and liberal use of oral antibiotics. After the desired lengthening is achieved, the external fixator is left in place until there is sufficient regenerate bone to allow removal without the risk of fracture. In general, the fixator is left in place at least twice the time necessary to obtain lengthening (64).

In the presence of radial head dislocation, the distraction technique has been used in an attempt to reduce the radial head, before correction of the forearm deformity (96, 143, 147). A separate ring and olive wire are placed in the proximal radius. Progressive distal migration of the radial head has been used for radiocapitellar reduction. Once the radial head is reduced, the forearm correction is performed as described above. However, recurrent subluxation, joint stiffness, and pain have occurred after radial head reduction (64). The limited success of this procedure in this situation does not seem to warrant its use.

The creation of a radioulnar synostosis is indicated for either painful radial head dislocation or radius and ulna instability not salvageable by other means. In these circumstances, it can result in a stable, pain-free extremity (136). Radial head excision is performed to decompress the radiocapitellar joint and improve elbow range of motion. Correction of the deformities of the radius and ulna is performed at the same time as the radioulnar synostosis with internal fixation and bone grafting. Neutral rotation to 20 degrees of pronation is desired. Although this procedure is rarely indicated, these patients have excellent long-term results (136).

Pseudarthrosis

Congenital pseudarthrosis of the forearm is rare and clearly associated with neurofibromatosis. Wood (148) summarized the cases of forearm pseudarthrosis in the medical literature, and noted that 5% of patients with neurofibromatosis have pseudarthrosis of the upper or lower limb, whereas more than 50% of patients with congenital pseudarthrosis of the forearm have definitive neurofibromatosis, multiple café-au-lait spots, or a positive family history of neurofibromatosis. Congenital pseudarthrosis is most often seen in the tibia, but it has been described in all the long bones.

In a survey of the literature, Wood (148) found 46 cases of forearm pseudarthrosis. The ulna was involved in 20 cases (Fig. 22-10), the radius was involved in 15 cases, and both ulna and radius were involved in 11 cases. Twenty-three of these patients had either neurofibromatosis (18 patients) or a positive family history of neurofibromatosis (5 patients). Reports of this disorder range from a single case to up to six patients (149).

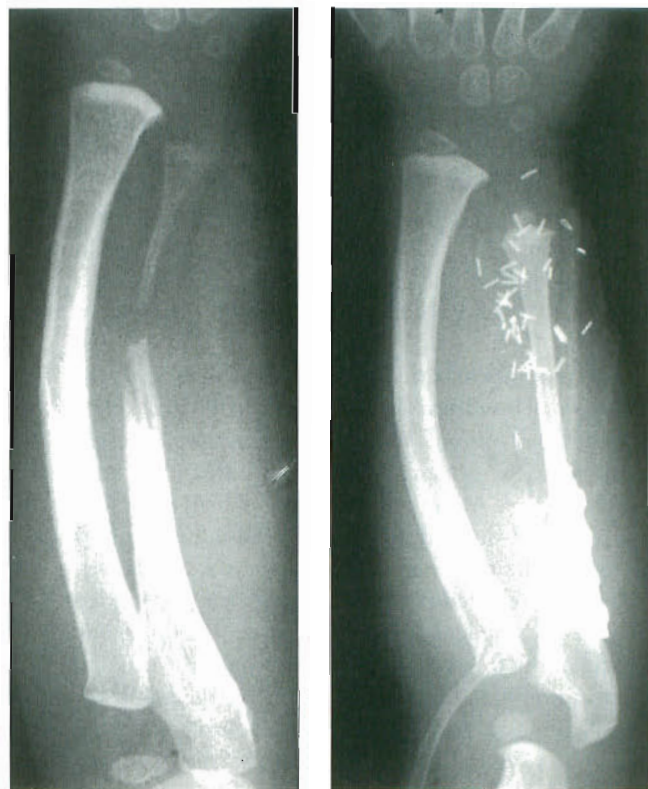


FIGURE 22-10. A: Preoperative radiograph of congenital pseudarthrosis of the ulna. Note the hypoplasia and tapering of the distal ulna. **B:** Postoperative radiograph of vascularized fibular transfer, with proximal epiphyseal and physal transfer, to establish distal ulnar growth. If the patient is very young, the microvascular transfer must include revascularization of both the diaphysis and epiphysis of the fibula to obtain physal growth. The most distal metallic clip indicates the top of the fibular epiphysis in the reconstructed distal radioulnar joint.

Similar to tibial pseudarthrosis, all reports describing treatment options for this problem outline the difficulty of obtaining union with conventional cast immobilization or corticocancellous autografting or allografting, with and without internal fixation techniques. The role of distraction lengthening techniques for congenital pseudarthrosis of the forearm is unclear. There are several reports of the use of vascularized fibular grafts (149, 150) to heal the pseudarthrosis. These reports indicate a high rate of union with vascularized fibular transfer. This is the preferred treatment for this disorder at present. In the forearm the fibula is internally fixed to the proximal ulna. Distally, the fibula is secured to the soft tissues of the distal radioulnar joint and the triangular fibrocartilage complex (TFCC). The vascular anastomosis is end-to-side to the ulna artery. At the donor site of a skeletally immature patient, the distal fibula is fixed to the tibia to prevent valgus ankle instability after harvesting a vascularized fibular graft (148, 151). The proximal fibular epiphysis can be transferred in the young patient to allow for growth. In this situation, the separate vascular

supplies to the fibular diaphysis and epiphysis need to be preserved and maintained with the transfer. The soft tissue support of the lateral knee must be reconstructed.

Creation of a single-bone forearm has been performed successfully as a salvage procedure (149). In the presence of an associated radial head dislocation, this may be the only successful option (64).

WRIST REGION

Congenital

Radial Dysplasia

Radial dysplasia is classified as a longitudinal failure of formation. It occurs in between 1 in 30,000 and 1 in 100,000 live births (152,153). The underdevelopment, or aplasia, of the radius is universally associated with thumb hypoplasia, or absence, and hypoplasia or absence of the radial aspect of the carpus (154). The radial or preaxial deficiency has been classified by Bayne and Klug (152) into four types, ranging from a present but defective distal radial epiphysis (type I), to complete absence of the radius (type IV). The severity of the radial deficiency determines the extent of the associated deficiencies of the thumb, digits, ulna, and elbow (Fig. 22-11). Thus, the spectrum of anatomic deficiency can range from mild radial deviation of the wrist and minimal thumb hypoplasia, to complete absence of the thumb and radius; camptodactyly of the index, long, and ring fingers; foreshortening of the ulna; and a stiff elbow.

Pathogenesis. The pathogenesis of longitudinal deficiency of the radius is unknown. It has been postulated that injury to the apical ectodermal ridge during upper limb development is the cause (6,155). Factors such as intrauterine compression, an inflammatory process, vascular insult, maternal drug exposure (thalidomide, insulin), and irradiation have all been raised as possible etiologic causes (1). There is no known genetic cause except when radial deficiency is associated with other congenital abnormalities. The pattern of inheritance is autosomal dominant or autosomal recessive, depending on the syndrome. There are many associated congenital syndromes, including cardiac, craniofacial, hematopoietic, musculoskeletal, gastrointestinal, and renal organ syndromes. There are associated chromosomal abnormalities, including trisomy 13, 18, and 21. The occurrence is most often sporadic, and at present no definite cause is known.

Associated Anomalies. Although radial longitudinal deficiency can occur in isolation, it is commonly associated with other congenital malformations. Forty percent of patients with unilateral radial club hand, and 27% of patients with bilateral radial club hand, have associated malformations

(156). It is imperative that these problems be assessed by clinical, radiographic, and laboratory evaluations as appropriate. These organ system malformations may present in a nonsyndromic pattern. Congenital cardiac, genitourinary, respiratory, skeletal, and neurologic problems occur in children with radial dysplasia. Similarly, many syndromes have been described in association with longitudinal deficiency of the radius. The most common are VACTERLS, Holt-Oram syndrome, Fanconi anemia, and thrombocytopenia with absent radius. VACTERLS includes the classic VATER of vertebral anomalies, anal atresia, tracheoesophageal fistula, and renal anomalies, as well as cardiac and lower-limb malformations, with a single umbilical artery (157–159). Holt-Oram syndrome is an autosomal dominant disease characterized by upper-limb malformations and major cardiac malformations (160). The gene for Holt-Oram syndrome has been identified. Fanconi anemia is also an autosomal dominant inheritance. In infancy, there are usually characteristic facial features (microphthalmos, strabismus, hearing deficits) (161). Pancytopenia often does not present until later in childhood. Fanconi anemia can now be identified by a mitomycin C test. Thrombocytopenia with absent radius is an autosomal recessive inheritance. The thrombocytopenia is present at birth. The platelet count usually improves with growth, and hand surgery should be delayed until it is safe (162,163).

Clinical Features. The clinical presentation of radial dysplasia depends on the severity of the malformation. Bayne et al. (164) have tried to clarify the spectrum of clinical deformity by classifying radial club hands from type I to type IV. Type IV deficiency is the most common. Type I deformity involves a defective distal radial physis. This leads to a minor foreshortening of the radius and a prominent distal ulna. Although there is mild radial deviation of the wrist throughout life, problems with radioulnar incongruity such as triangular fibrocartilage tears, ulnocarpal impaction syndrome, and distal radioulnar joint pain or loss of motion, usually do not occur. The major clinical issue is the associated thumb hypoplasia with opposition weakness. Type II deficiency involves limited proximal and distal radial physal growth. As a consequence, the wrist is more radially deviated, and the ulna bows. The thumb hypoplasia is usually more significant, with more deficiency of the radial carpus. Type III deficiency is the absence of the distal two-thirds of the radius. The wrist is more severely deviated, and the hand has limited mechanical support. The ulna is thickened and bowed. The associated thumb and finger abnormalities of hypoplasia and camptodactyly are more common and severe. Type IV deficiency involves complete absence of the radius. The ulna bowing is marked. The thumb is usually absent. The index, long, and even ring fingers are often involved. The elbow may have limited range of motion. There is marked limitation of hand, wrist, and forearm function.

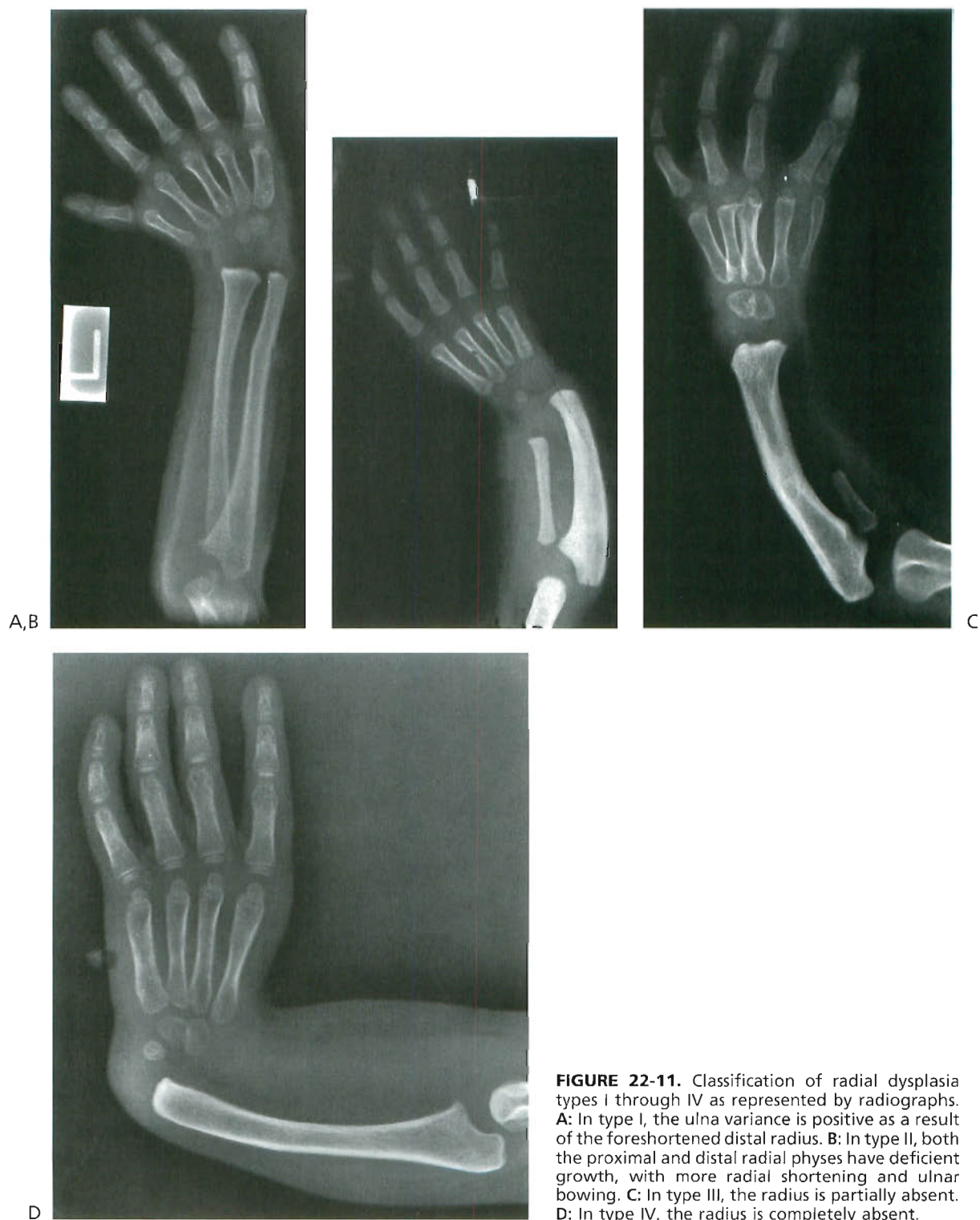


FIGURE 22-11. Classification of radial dysplasia types I through IV as represented by radiographs. A: In type I, the ulna variance is positive as a result of the foreshortened distal radius. B: In type II, both the proximal and distal radial physes have deficient growth, with more radial shortening and ulnar bowing. C: In type III, the radius is partially absent. D: In type IV, the radius is completely absent.

Pathoanatomy. Radial dysplasia involves skeletal malformations and soft tissue deficiencies on the preaxial or radial side of the hand, wrist, and forearm. The severity of the soft tissue loss parallels the skeletal deficiency. The preaxial

muscles arise from the lateral epicondyle, and are normally innervated by the radial nerve. Thus, the radial wrist extensors and brachioradialis are absent or deficient. The pronator–flexor muscle mass is affected when its skeletal insertion

sites are absent or hypoplastic. These structures can be only fibrous tissue (radial anlage) that maintains or worsens wrist and hand deformity with growth. Similarly, the neurovascular structures will be affected. The posterior interosseous and sensory branches of the radial nerve will be absent in a severe deformity. The radial artery is usually absent. The ulnar nerve and artery are usually present and unaffected. The blood supply to the hand comes through the ulnar artery, and possibly the interosseous vessels or a persistent median artery. The median nerve is usually present and serves as a neural supply to the hand with the ulnar nerve. However, the more severe the deformity of the hand and wrist, the more limited the neural and vascular supply will be to the hand.

Natural History. Generally, children with longitudinal deficiency of the radius have an unaffected central nervous system. As with any congenital upper limb malformation, children's creative minds allow them to perform all activities of life. However, they may need to use adaptive mechanisms. These generally include a spherical grip and lateral pinch to compensate for the absence of opposition (165). Fifty to 62% of patients with radial dysplasia have unilateral involvement. Even with severe unilateral radial dysplasia, these children will adapt their skills by increasing their use of the contralateral, normal hand and upper limb. Lamb (166) noted no functional impairment in patients with unilateral involvement. Individuals with bilateral involvement have more difficulty. Activities of daily living, such as hygiene, eating, and dressing, are affected. Adaptive techniques and alteration of clothes are often necessary. Despite these modifications, Bora and colleagues (167,168) noted that patients without surgical correction were more limited than surgically treated patients. Finally, the issue of the cosmetic and psychologic impact of radial dysplasia is difficult to quantify. The social setting is constantly changing, and peer perception plays a major role in an involved individual's self-perception. Parental and family perception and coping must have a profound effect on a developing child's self-image. There is limited objective psychologic information at present.

Treatment. Treatment should address the following problems with radial dysplasia: (i) unstable wrist with lack of support for the hand; (ii) digital weakness secondary to radially deviated wrist; (iii) intrinsic digital weakness and deformity; (iv) thumb hypoplasia or aplasia that results in lack of opposition; and (v) foreshortened ulna. All of these deformities affect function in the patient with radial dysplasia. In addition, there is a significant cosmetic difference in these children that can be improved by intervention.

Nonsurgical Intervention. The options for nonsurgical intervention in these children are corrective casting, bracing, and physical therapy. In infancy, the first goal is to achieve pas-

sive correction of the radial deviation deformity. In mild cases, this involves merely a home exercise program of wrist ulnar deviation, extension, and distraction stretching. In more severe cases, care involves corrective casting or splinting to gradually stretch the contracted soft tissues, then maintain the correction. The splints are used in conjunction with a passive range-of-motion program. If attempts to correct the static radial deviation contracture are not successful by 6 to 12 weeks of vigorous therapy and skilled bracing/casting, the use of distraction external fixation to obtain soft tissue and musculoskeletal alignment should be considered (169).

Once passive motion has been achieved, it is necessary to maintain the correction. Again, for mild cases, this can be done nonsurgically. A nighttime corrective splinting program during infancy and times of rapid growth is useful. This treatment is adequate for the majority of type I and type II malformations. In severe cases, the lack of a stable wrist out of the splint, impairs hand and limb function. These children are candidates for operative correction at 6 to 12 months of age.

Surgical Intervention. There are two indications for surgery: persistent wrist radial deviation contracture (Fig. 22-12) and functionally limiting thumb deficiency. The surgical options for the wrist contracture and lack of support for the hand have included bone graft procedures to the ulna, cen-

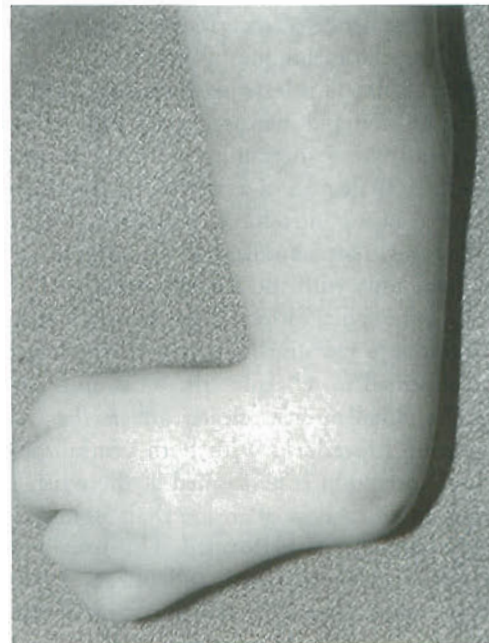

FIGURE 22-12. A patient with complete absence of the radius and thumb aplasia. Note the foreshortening of the forearm, 90-degree radial deviation at the wrist, and dimpling of the skin over the distal ulna, with the proximal and radially subluxated carpus and hand.

tralization, radialization, and wrist fusion (170). Surgical options for thumb aplasia are pollicization and microvascular toe-to-thumb transfer. Thumb hypoplasia can be surgically corrected with first web space deepening, MCP joint stabilization, and opponensplasty tendon transfer. Less clear indications exist for the surgical treatment of digital camptodactyly, ulnar foreshortening, and radial hypoplasia in type II deformities.

Potential contraindications for surgery include (i) lack of elbow flexion, such that the wrist deviation enables the patient to perform hand-to-mouth and hand-to-neck activities; (ii) severe index digital deformity and weakness that will result in failed pollicization; and (iii) severe medical problems that pose a risk to the patient's well-being.

The earliest forms of surgical correction for radial dysplasia involved improving the radial deviation deformity and lack of wrist support for the hand by grafting bone to the ulna. Albee (171), Starr (172), Entin (173), and Riordan (174) described the use of nonvascularized bone grafts from the proximal fibula to the ulna in Y-configuration to support the carpus and hand. These procedures resulted in significant short-term improvement. However, the transplant usually failed to grow, leading to recurrent deformity. Vascularized bone grafting has recently been advocated by Vilkkki (175), in rare circumstances. Centralization of the carpus over the third metacarpal has been a standard treatment (166–168). Soft tissue release of the radial contracture, contouring of the ulna to match the carpus, and capsular reefing are performed. Stabilization is performed with pin fixation until healing. The problem with centralization is a high incidence of recurrence. Lamb (166) advocated modifying the technique by notching the carpus to inset the distal ulna. This lessened recurrence, but also decreased wrist motion and increased early ulnar physal closure postoperatively. Function is clearly impaired when there is less than 30 degrees of wrist motion postoperatively. Buck-Gramcko (176) introduced radialization during the thalidomide crisis. The centralization procedure is modified by aligning the ulna with the second metacarpal. Tendon transfers from the radial aspect of the wrist (extensor carpi radialis, flexor carpi radialis, if present) to the dorsal, ulnar wrist are performed to rebalance the wrist and hand. The quality of the radial muscles clearly affects the success of the radialization procedure. With both centralization and radialization, correction is performed at the wrist. If there is a concomitant ulnar bow of greater than 30 degrees ulnar osteotomy should also be performed. This usually involves a multiple-level open osteotomy and intramedullary fixation. In those rare situations in which passive correction of the wrist is not possible by splinting, casting, or therapy, distraction and correction with an external fixator is performed. As described by Kessler (169), this can be performed in infancy (Fig. 22-13). Often, after 3 to 6 weeks of external fixation an open centralization or radialization

procedure is performed. Wrist fusion is not performed in young patients. This leads to loss of wrist motion and potential loss of ulnar physal growth. However, Catagni et al. (177) performed wrist fusion in conjunction with distraction lengthening in adolescent and young adult patients with recurrent deformity.

Generally, wrist reconstruction is performed before thumb reconstruction. Ideally, thumb reconstruction is performed before 18 months of life. This limits the learning process after central nervous system maturation regarding pinch. In the mild forms of radial dysplasia, the thumb hypoplasia causes functional problems involving decreased first web space, MCP joint instability, and weak thenar muscles. The first web space can be deepened with Z-plasties or rotation flaps (178,179). Release of adductor and first dorsal interosseous fascia is often necessary. The MCP joint can be stabilized with local fascia or use of extra flexor digitorum superficialis tendon length for ligament reconstruction. On occasion, MCP joint chondrodesis (fusion of the proximal phalanx epiphysis to the metacarpal head) or arthrodesis is appropriate. Opponensplasty is performed simultaneously with use of the abductor digiti quinti (180), ring-finger flexor digitorum superficialis (73), or accessory digital extensors. All have had reported success in providing opposition strength. Thumb aplasia is best addressed with pollicization (179,181). Toe-to-thumb microvascular transfers have been reported, but to date the results are less successful than those of index-finger pollicization. The quality of the index-finger donor determines the quality of the subsequent thumb. If there is significant camptodactyly the thumb will be stiff, weak, and poorly used in pinch activities. Compensation will occur by lateral pinch between adjacent digits. In a well-performed pollicization, the results are functionally and cosmetically pleasing to the patient, family, and surgeon.

Complications. Recurrent deformity and premature closure of the distal ulnar physis are the two major complications of wrist reconstruction. The occurrence of these problems depends on the procedure performed (centralization versus radialization) and the quality of the preoperative musculoskeletal and soft tissue anatomy. With radialization, the goal is to dynamically rebalance the wrist and maintain motion. If this fails to occur, radial deviation and flexion deformity will recur with growth. In addition, if there is limited elbow flexion, excessive flexion and radial deviation of the wrist will be used by the patient to compensate for the limited elbow flexion needed for activities of daily living, such as oral hygiene and feeding. This contributes to the recurrence rate.

Physal arrest is more common with centralization procedures. The forearm is already foreshortened, but this is exacerbated by further loss of distal growth. Because 70 to 80% of forearm growth comes from the distal physis, postopera-

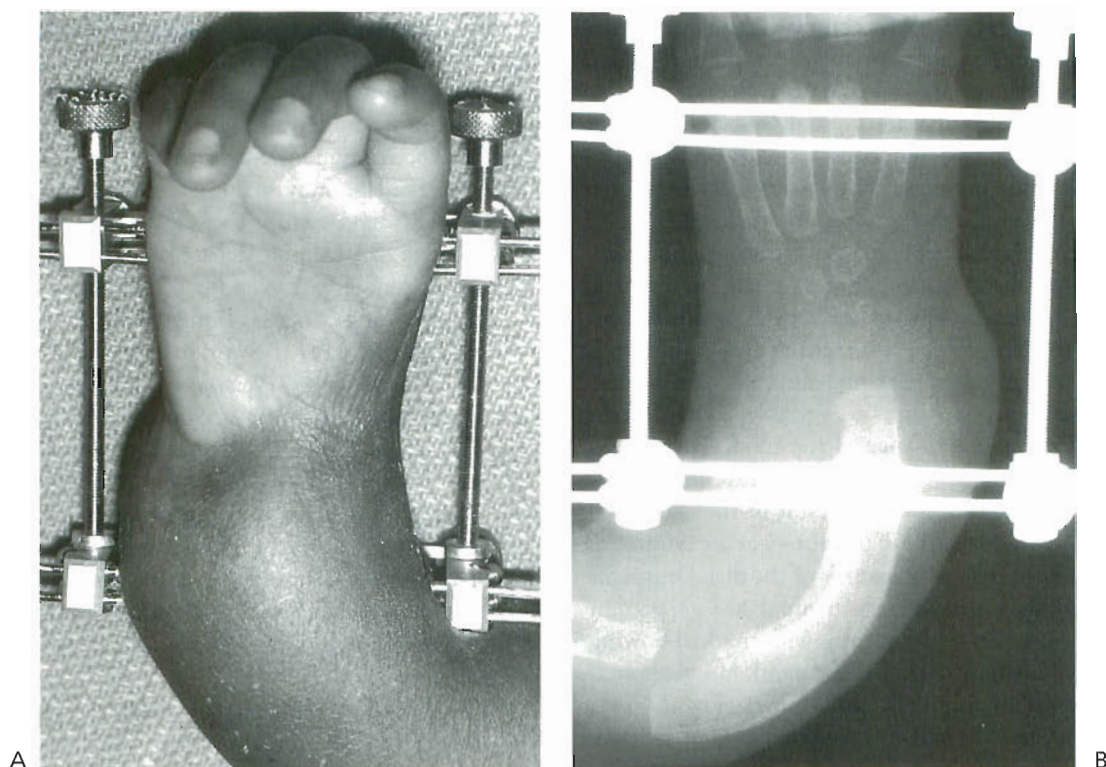


FIGURE 22-13. A: Clinical photograph of a patient undergoing progressive distraction lengthening to stretch the soft tissues, bring the hand out to length, and reduce the wrist over the ulna. This patient has a markedly foreshortened forearm. Preoperatively, there was volar, radial, and proximal subluxation of the carpus and hand that was not correctable with exercises and splinting. B: Radiograph of the same patient with the hand and wrist out to length and centralized. Note the severe proximal ulnar bowing that required osteotomy at the definitive open surgical procedure.

tive growth arrest is a major cosmetic and functional problem.

Finally, in patients with radial dysplasia, pollicization procedures can have poorer results in terms of opposition strength and active range of motion (182). The opposition weakness may be improved by opponensplasty transfer (183,184), but there needs to be a strong donor for this to succeed. Otherwise, the patient will continue to compensate with lateral digital pinch on the ulnar side of the hand.

Ulnar Dysplasia/Ulnar Club Hand

Ulnar, or postaxial, longitudinal deficiency is less common than either radial or central longitudinal deficiency. It is classified as a failure of formation of parts. The incidence was found by Birch-Jensen to be 1 per 100,000 live births (153). Ogden et al. cited a male-to-female ratio of three to two, with only 25% of cases being bilateral (185).

Most cases are sporadic. There are reports of familial occurrence (186–189). It also occurs as a part of rare identified inheritable syndromes, such as ulnar mammary (Schnitzel) syndrome, Klippel-Feil syndrome (190,191), and other

nongenetic syndromes such as Cornelia de Lange syndrome. It is associated with musculoskeletal system malformations in up to 50% of cases. Contralateral upper-extremity deficiencies of phocomelia, transverse arrest, radial deficiency, and aphalangia occur commonly. Similarly, lower-extremity deficiencies, such as proximal focal femoral and fibular deficiencies, occur in almost one-half the cases. Unlike those with radial dysplasia, it is uncommon for patients with ulnar deficiency to have associated major organ system malformations. Ogino and Kato's experimental data may explain this finding (192). They produced major deficiencies in rat fetuses by injecting the mothers with the antimetabolite Myleran. The timing of injection during the gestational period determined the limb malformation produced. For example, ulnar deficiencies were produced by earlier injections than were radial deficiencies. Those fetuses that had ulnar deficiencies had more lethal cardiac malformations. This may explain why there are fewer major organ system malformations and a lower incidence of ulnar deficiency per live births.

Clinical Features. Bayne classified ulnar deficiency into four groups based on the musculoskeletal abnormalities of

the elbow and forearm (193). Most clinicians use this system to define and establish treatment plans for these patients. Type I deficiency is hypoplasia of the ulna. Both distal and proximal physes of the ulna are present, but decreased in growth. There is minimal, nonprogressive bowing of the radius, and a variable presentation of hand malformations. Type II deficiency is the most common type and involves partial absence of the radius. There is a fibrous anlage extending from the distal ulna to the carpus. The hand is ulnarly deviated, with bowing of the radius, and these deformities may be progressive with growth. The elbow is stable if there is sufficient proximal ulna present. Again, digital malformations or absences are variable. Type III deficiency involves complete absence of the ulna. There is no ulnar anlage. The radius, wrist, and hand are usually straight. The elbow is unstable as a result of the lack of an olecranon. Hand malformations and absences are common. Type IV deficiency involves synostosis of the distal humerus to the proximal radius. There is an ulnar anlage present from the distal humerus to the carpus, with marked bowing of the radius and ulnar deviation of the hand. Hand anomalies are common also in type IV deformities (Fig. 22-14).

Cole and Manske (194) further classified ulnar deficiency by the presenting hand malformations. They divided the disorder into four types according to the deficiency of the first web space and thumb. Type A is a normal thumb and first web space. Type B involves a mild web contracture and thumb hypoplasia. Type C involves marked hypoplasia of the thumb with rotation of the thumb into the plane of motion of the other digits. Type D is absence of the thumb. In their series, 73% of the 55 patients had thumb deficiencies. This was similar to Broudy and Smith's findings of 16 hypoplastic thumbs and 5 absent thumbs in 26 patients with ulnar club hand (195).

In addition, in these patients the limb is foreshortened, and usually internally rotated. The glenoid may be dysplastic. The radial head is often dislocated, and range of motion of the elbow is limited in up to 40% of cases (196). These abnormalities make placement of the hand in space difficult. The hand malformations limit pinch, grasp, and release functions. Reconstructive surgery is indicated to improve hand and wrist orientation, thumb opposition, and digital motion and strength.

Treatment. There are few data regarding the natural history of untreated ulnar dysplasia. In 1927, Southwood stated, "From the functional viewpoint, therefore, the deformed limb is much more useful than its anatomical condition would lead one to expect" (197). This malformation is not associated with central nervous system deficiencies. As with all congenital malformations in people with normal brains, the patients will perform activities well, but differently. Treatment has to improve function and cosmesis to be warranted.

Nonsurgical treatment has predominantly involved therapy and corrective casting or splinting. In types I and III deficiencies, the mild ulnar deviation of the wrist and hand may be improved with serial casting, splinting, and passive exercises starting in infancy. In types II and IV deficiencies, the ulnar anlage may make nonsurgical correction of the severe ulnar deviation of the hand and wrist impossible.

There is considerable debate regarding the treatment of the severely ulnarly deviated hand that does not respond to casting/splinting. There is limited information to allow for critical evaluation of the options of (i) leaving the patient alone, (ii) performing excision of the ulnar anlage, or (iii) corrective radial osteotomy. Some of the confusion exists because not all of these deformities are progressive (198). As Flatt (1) makes clear, it is difficult to critically evaluate the literature because of limited objective measurements in previous studies. Finally, Flatt correctly points to the low incidence of this disorder as hampering objective assessment of the therapeutic options. As with many rare conditions, only multicenter, prospective studies can feasibly answer the questions.

The lack of this information allows for subjective interpretation of the treatment options, leading to reluctance to pursue aggressive surgical intervention. Within these limits, an attempt is made to outline treatment options and recommendations for wrist deformity, elbow instability, and digital and thumb deficiencies.

Resection of the ulnar anlage is indicated for progressive ulnar deviation of the wrist and hand of greater than 30 degrees. This can occur in types II and IV deficiencies (1,199). Through an ulna-based incision, the anlage is identified as it inserts into the carpus. The ulnar artery and nerve need to be protected. Resection should be performed until neutral positioning of the wrist can occur intraoperatively. If there is associated marked ulnar deviation of the radius, concomitant radial osteotomy can be performed. However, it is imperative to assess the location of the radial head and the status of forearm rotation before proceeding with anlage excision and consideration of radial osteotomy.

If there is a dislocated radial head and limited forearm rotation preoperatively in the type II deformity, anlage excision, resection of the radial head, and creation of a single-bone forearm should occur simultaneously. If there is acceptable forearm rotation preoperatively, it is best to correct only the wrist deformity and to monitor the status of the forearm and elbow with growth. Resection of the radial head for cosmetic reasons should be performed cautiously, because even the dislocated head may be providing some elbow stability in these patients.

Similarly, creation of a single-bone forearm may result in improved cosmesis, but the loss of forearm rotation may cause an unacceptable loss of function. In patients with type IV deficiency, there may be associated internal rotation posture to the arm that limits placement of the hand in

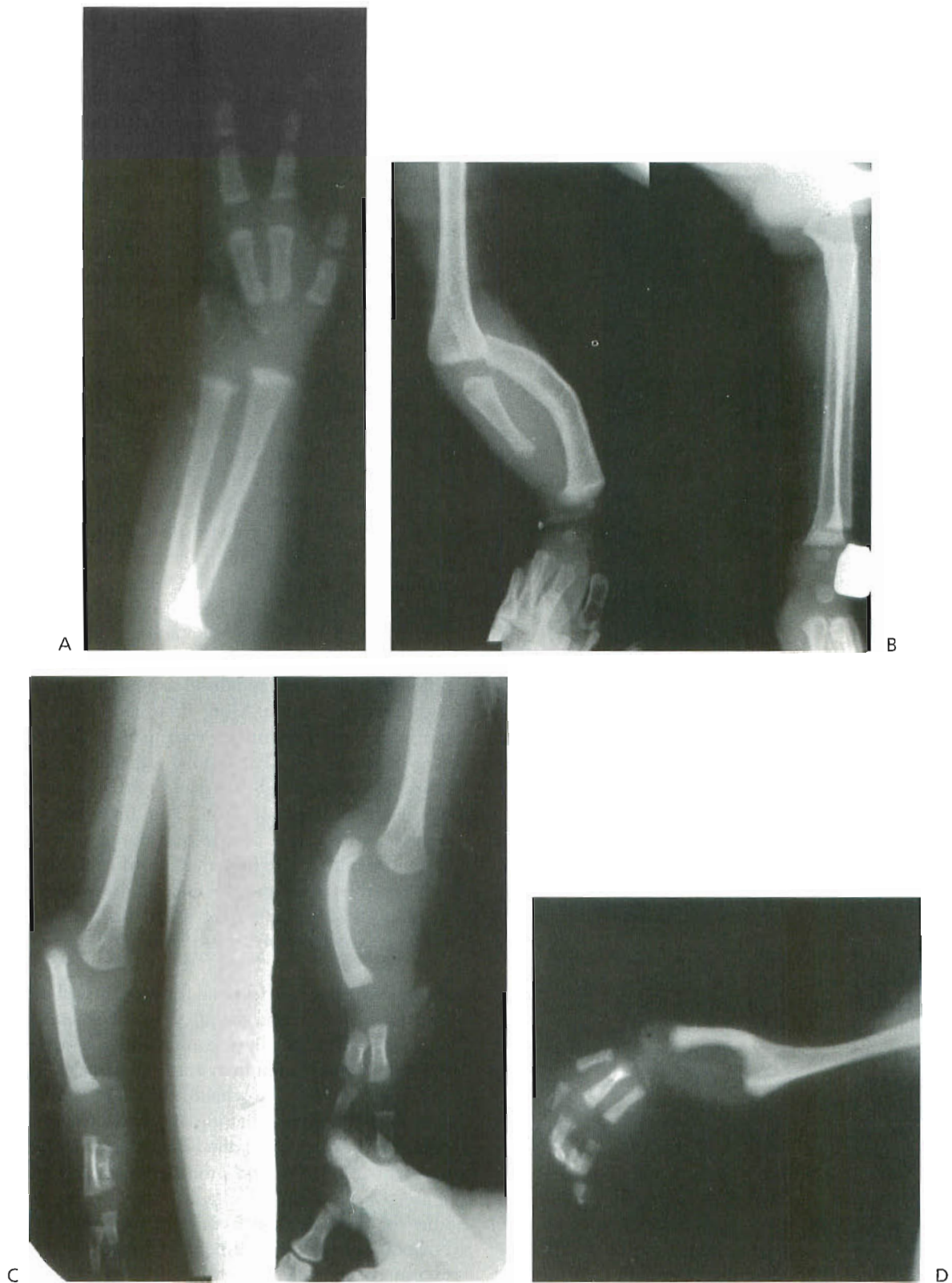

FIGURE 22-14. Classification of ulnar dysplasia types I through IV as represented by radiographs. **A:** Type I dysplasia represents deficiency of both the proximal and distal ulnar physes, with fore-shortening of the ulna and mild bowing of the radius. **B:** Type II is the most common type and represents partial absence of the radius. **C:** Type III involves complete absence of the radius with an unstable elbow joint. **D:** Type IV includes complete absence of the radius and humeroulnar synostosis.

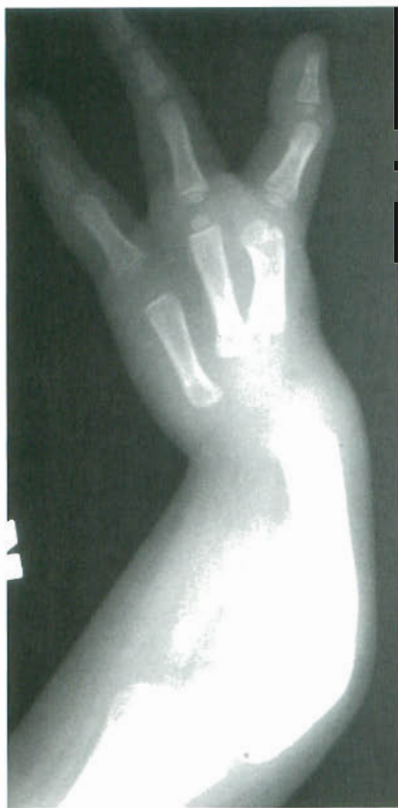

FIGURE 22-15. Radiograph of ulnar dysplasia with complete absence of the ulna, humeroradial synostosis, absence of the ulnar two rays, and thumb deformity.

space. If this is present, simultaneous external rotation osteotomy of the limb and ulnar anlage excision should be performed. This is clearly the case with patients with bilateral deformity who are unable to reach their mouths preoperatively.

Repair of digital and thumb deficiencies is indicated (Fig. 22-15). Syndactyly is common and should be corrected in infancy. Thumb hypoplasia or absence should also be repaired in infancy. Broudy and Smith (195) described a modified pollicization procedure for the malpositioned thumb in the plane of motion of the other fingers. Tendon transfers for intrinsic and extrinsic muscle deficiencies of the thumb and fingers are indicated if there are sufficient adequate donors available.

Madelung Deformity

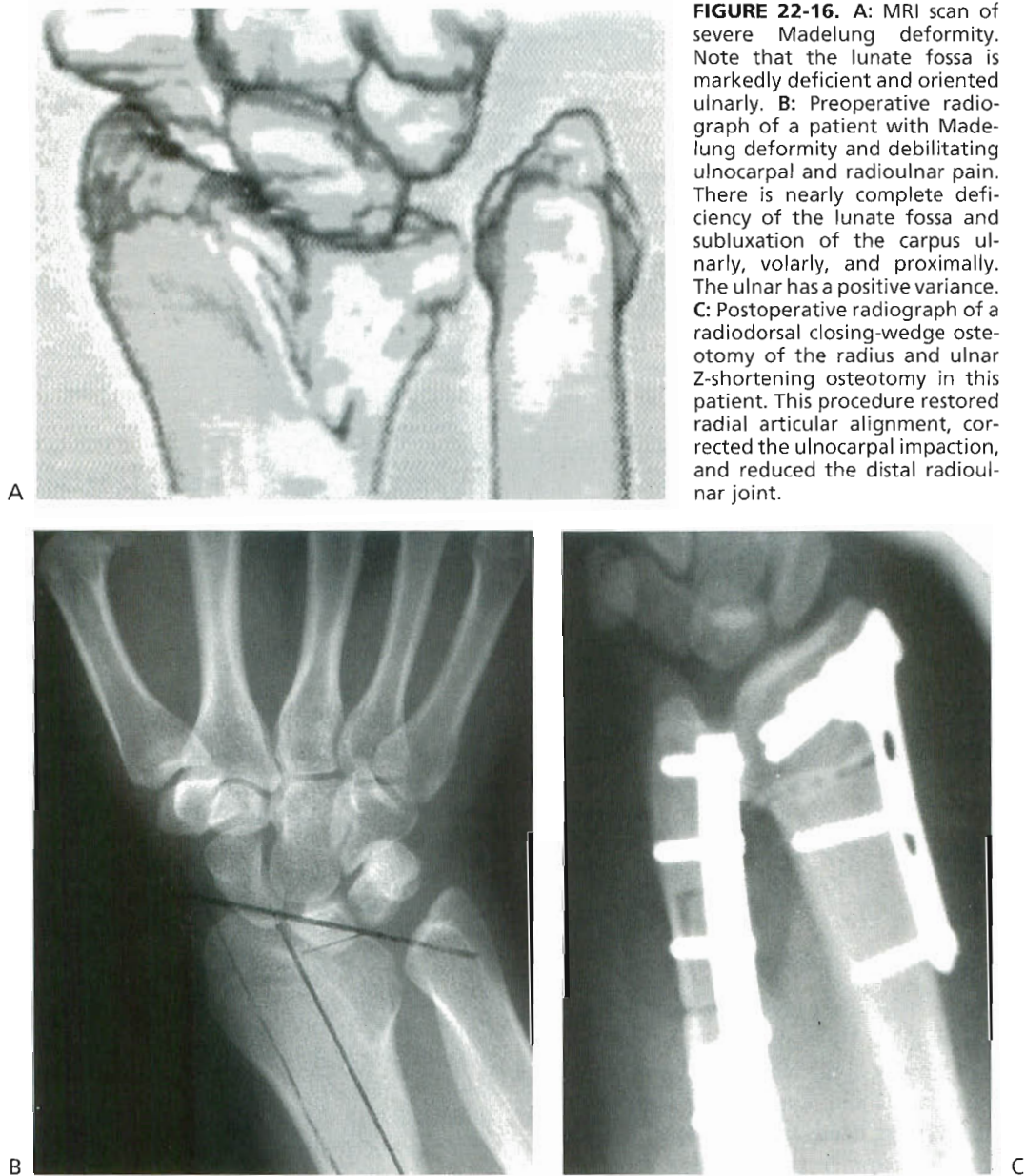
Madelung (200), in 1878, described a growth deformity of the distal radius. For reasons that are still unknown, the volar, ulnar aspect of the distal radial physis slows or stops growth prematurely. The continued normal growth of both the ulnar physis and the remaining dorsal, radial aspect of the radial physis results in ulnar overgrowth, carpal subluxa-

tion, and radial articular deformity (Fig. 22-16). Madelung deformity usually occurs in girls, and is most often bilateral (201). Its clinical appearance may not be present until the adolescent growth spurt, which is when most patients present. It is generally sporadic in presentation. It is also associated with Leri-Weill syndrome, a dyschondrosteosis form of mesomelic dwarfism that is inherited in an autosomal dominant manner (199,202). In addition, Madelung deformity has been associated with Hurler mucopolysaccharidosis, Turner syndrome, osteochondromatosis, achondroplasia, and Ollier disease (203). True Madelung deformity needs to be distinguished from a posttraumatic or postinfectious deformity.

Clinical and Radiographic Features. The clinical and radiographic picture is dependent on the age at presentation and the severity of the growth arrest. Generally, children do not appear until there is marked deformity, limitation of motion, and activity-related pain. Because the condition is usually bilateral, the subtle growth deformity that occurs before the adolescent growth spurt is often ignored. However, with early presentation there is a slight positive ulnar variance and loss of the volar, ulnar aspect of the radial lunate fossa (Fig. 22-16). The carpus subluxates volarly and into the gap between the radius and the ulna. These patients may have mild symptoms of ulnocarpal impaction with power grip activities, and distal radioulnar joint incongruity with forearm rotation. More often, individuals with Madelung deformity present late with marked deformity. There is an increased tilt of the radial articular surface from the dorsal radial corner of the styloid to the volar, ulnar aspect of the depleted lunate fossa. The ulnar variance is more positive, with carpal overlap and dorsal subluxation. The carpus migrates more proximal into the increasing diastasis between the radius and the ulna on anteroposterior radiographs. These patients have more pain and limitation of motion, especially forearm rotation and wrist extension.

Pathoanatomy. The skeletal features are well described. As mentioned previously, the arrest of the volar, radial aspect of the distal radial physis causes subsequent deformity of the radiocarpal, radioulnar, and ulnocarpal joints. Vickers and Nielsen (204), Linscheid (205), and Ezaki (201) have described abnormal tethering of soft tissues from the distal radius to the carpus and ulna. These have included aberrant ligaments (203,204) and pronator quadratus muscle insertions (205). It is unclear whether these structures are responsible for the growth deformity of the radius. Vickers and Nielsen's successful treatment of Madelung deformity by excision of the volar tethering soft tissues and prophylactic physiologic lysis of the volar radial physis indicates that there may be a causal relationship.

Treatment. The early descriptions of the treatment of Madelung deformity advocated treatment only for symptom-



atic patients at skeletal maturity (206). Originally, the mere presence of the deformity was not an indication for operative intervention in the asymptomatic patient, regardless of age. However, the growth discrepancy is easier to treat if it is dealt with early. Young patients become symptomatic and restricted with increasing growth deformity. Vickers and Nielsen advocated early intervention with physiolysis (204). The treatment principle is similar to that of Blount disease, with resection of the abnormal volar, ulnar physeal region of the radius and fat interposition. At the same time, any aberrant tethering anatomic structures are excised. Their case series indicates restoration of radial growth and prevention of progressive deformity. An alternative treatment for

the patient presenting early is to perform ulnar and radial epiphysiodesis to prevent progressive deformity and symptoms. In the patient with bilateral disease, this treatment does not cause upper limb-length discrepancy.

The patient presenting late with marked deformity and symptoms is more problematic. The radial deformity can be addressed by either dorsal, radial closing-wedge osteotomy or volar opening-wedge radial osteotomy and bone grafting. The ulnar overgrowth is treated with an ulnar-shortening procedure (Fig. 22-17). Alternative methods of ulnar-shortening include resection of the distal ulna and a Sauve-Kapandji procedure. However, there may already be significant deterioration of the articular cartilage, wrist liga-

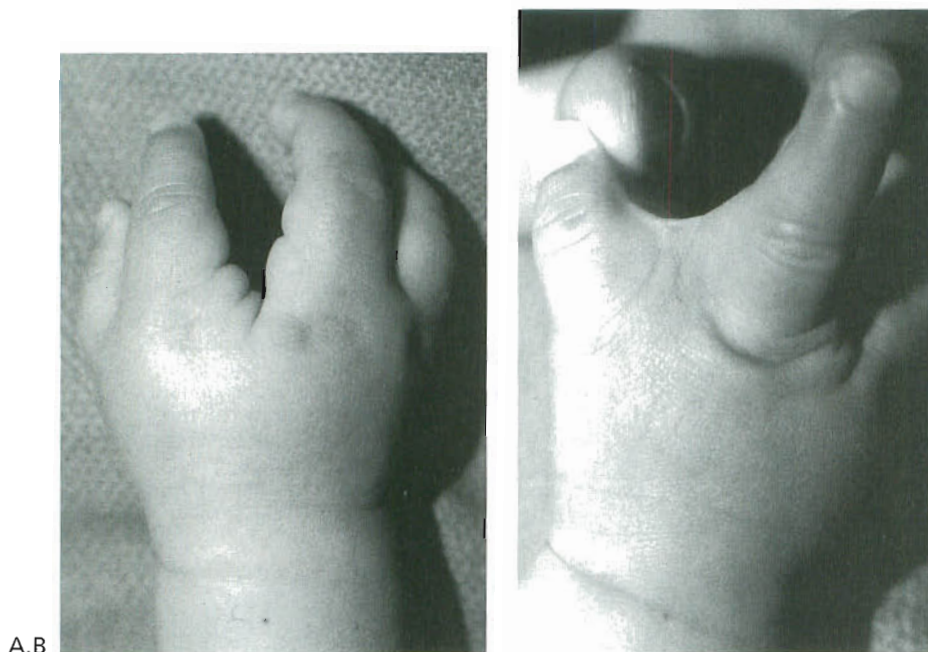

FIGURE 22-17. A: Cleft hand with absent middle ray. B: Incomplete syndactyly of the first web space in the same patient. Closure of the cleft must include deepening of the first web space to maintain maximum hand function.

ments, or triangular fibrocartilage that results in continued pain and limitation of motion postoperatively.

HAND REGION

Congenital

Cleft Hand and Symbrachydactyly

Central defects of the hand have been described in the past as typical or atypical. Since 1992, the International Federation of Societies of Surgery of the Hand has classified typical cleft hands as cleft hands and atypical cleft hands as part of symbrachydactyly. Cleft hands represent a partial or complete longitudinal deficiency in the central portion of the hand. The elbow, forearm, and wrist are usually normal. There are often ulnar and radial-sided syndactylies and digital hypoplasia. Cleft hands often occur in conjunction with cleft feet. In that situation, there is an autosomal dominant inheritance pattern. However, the penetrance is variable, with nearly one-third of the known carriers of the gene having no malformations (207,208). In addition, the phenotypic expression in affected individuals is variable. Cleft hands are also associated with other syndromes and malformations, such as cleft lip/palate (ectrodactyly, ectodermal dysplasia, cleft syndrome), other craniofacial syndromes, Cornelia de Lange syndrome, congenital heart disease, ocular malformations, and imperforate anus (208,209). The incidence is estimated at between 1 per 90,000 and 1 per 100,000 live births (153,210,211). Various classification schemes have been used. Most are based on the deficiencies

centrally (212,213). Manske and Halikis proposed a classification system of cleft hands based on the thumb and first web space (214). This scheme aids the surgeon in surgical reconstruction decisions and thus may be the most useful classification.

Symbrachydactyly is defined by unilateral central digital deficiencies and simple syndactylies. It is a sporadic event without genetic inheritance. There are no associated anomalies. The feet are normal. It is a unilateral process, often with multiple absent digital rays. There are often finger nubbins present, which is a situation not seen with cleft hands. Symbrachydactyly is a transverse deficiency that may or may not be a separate entity from transverse absence of digits (208). These entities are distinct from the amputations associated with constriction band syndrome. Symbrachydactyly should be viewed as a clinical entity distinct from cleft hand, with a very different treatment plan.

Treatment.

Cleft Hands. As Flatt (1) poignantly stated, “The cleft hand is a functional triumph and a social disaster.” The wide central cleft allows for outstanding grasp, release, and pinch functions. Sensibility is normal. The cleft hand, therefore, functions usually without limits.

Treatment of the cleft hand centers on closure of the cleft. However, surgical closure of the cleft must be accompanied by appropriate treatment of the first web space and thumb to avoid limiting the patient. The skin flaps designed for cleft closure, however, must take into account the status of the first web space (Fig. 22-17). If the first web space is normal or mildly narrowed (Manske types I and IIA), simple

cleft closure, such as with a Barsky flap (215), can be performed. If necessary, a simultaneous but separate Z-plasty widening of the first web space can be performed (Manske types IIA and IIB). If the first web space has a marked syndactyly (Manske type III), the flap designs use the redundant skin of the cleft closure to create a first web space. The adduction contracture of the thumb is released, and the index ray is transposed ulnarly at the same time. The Snow-Littler, Miura, and Ueba flaps (216–219) all involve transposition of the cleft skin to the first web space, with simultaneous transposition of the index ray ulnarly. If there is a transverse bone across the cleft, this needs to be removed to prevent progressive deformity. Often there is a conjoint flexor and extensor across the base of the cleft which needs to be released. Sometimes carpal closing-wedge osteotomy is necessary to close the cleft. In addition, the stability of the index- and ring-finger MCP joints needs to be maintained or restored. Associated fourth web space syndactylies are separated with Z-plasties and skin grafts. There may be associated camptodactyly or clinodactyly of the adjacent digits requiring corrective splinting or surgery.

Symbrachydactyly. The treatment of symbrachydactyly in the United States is probably the most individualized of that of any of the congenital malformations. The range of options include (i) leaving the child alone; (ii) nonvascularized transfers to the soft tissue nubbins of the phalanges (219,220); (iii) microvascular toe transfer(s) (221–225); (iv) web space deepening; (v) digital distraction lengthening or bone grafting (226); and (vi) prosthetic use. In addition, families and patients are very interested in the possibilities of transplantation and laboratory cellular growth of digits. There is no correct answer at present. The choice is greatly influenced by the family's desires and the surgeon's experience and biases. There are few peer-reviewed published studies regarding functional and cosmetic outcomes to more objectively guide the decision. However, there are clear principles to help guide all parties to the best choice for them.

The primary goal is to improve pinch. In the presence of a normal thumb and web space, all of the choices listed above will work. In this situation, treatment options focus on the quality of the other digital rays. If the soft tissue pockets of the digits are adequate, nonvascularized transfer of the proximal phalanx of the toes is a very good choice. Although it will not provide normal digital length, it will provide stability for lateral pinch. This must be performed before 18 months of age and include the periosteum and collateral ligaments (219,227). The proximal phalanx is harvested through an extensor tendon-splitting dorsal approach. The proximal phalanx is harvested extraperiosteally, while protecting the neighboring tendons and neurovascular structures. At the metatarsophalangeal joint, the collateral ligaments, dorsal capsule, and volar plate are detached proximally from the metatarsal, while leaving intact their distal attachments to the phalanx. At the PIP joint, those soft

tissues are left attached to the middle phalanx. With transfer to the hand, the proximal soft tissues of the toe phalanx are sutured to the corresponding soft tissues of the recipient site. The best results for phalangeal survival and growth are realized when this procedure is performed before 1 year of age. The quality of the soft tissue pocket clearly affects the outcome. Multiple phalangeal transfers can be performed simultaneously. In the presence of a normal thumb and first web, digital lengthening can be performed. In addition, digital lengthening has been performed successfully after nonvascularized toe phalangeal transfer (226). Finally, prosthetic use has been tried. The major problems with prostheses are that children function as well or better without them because the prostheses are insensate. In the adolescent and adult a cosmetic prosthesis may be used for social reasons (228). It should be noted that the finest cosmetic prostheses are very expensive.

If there is a deficient first web space, deepening of the web with release of the adduction contracture is appropriate. At times, this may require resection or transfer of the index metacarpal (Fig. 22-17) to achieve a useful web for pinch and grasp functions. If there is absence of the thumb digital transposition or microvascular transfer is indicated.

Microvascular toe transfer should be performed only with a child older than 2 years of age; a well-informed family; the presence of proximal nerves, vessels, tendons, and muscles to create a viable and functional transfer; the presence of carpal or metacarpal support for the transfer; and an experienced surgical team (208). Unfortunately, even though this procedure is being performed more commonly, objective data regarding functional, cosmetic, and psychologic outcomes are still minimal in children.

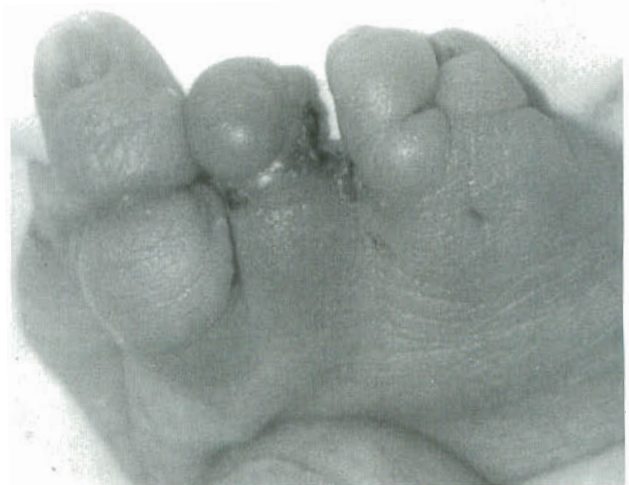

FIGURE 22-18. An amniotic band causing digital ischemia in a neonate in the newborn nursery. Although rare, this condition requires immediate removal of the band to prevent further soft tissue digital loss.

Constriction Band Syndrome

Constriction band syndrome, amnionic band syndrome, or amnion disruption sequence is the result of disruption of the inner placental wall, the amnion. This early amnionic rupture often results in oligohydramnios and amnionic bands. The fibrous bands from the amnionic wall wrap around the digits, causing constricting digital bands, amputations, and syndactylies (229–231). This syndrome is a mechanical deformation rather than a malformation, as originally proposed by Streeter (232).

There is no inheritance pattern. This syndrome occurs in 1 of 15,000 live births (233). It is associated with other musculoskeletal deformations in 50% of cases, the most common being clubfeet. There may be devastating cleft lip and facial deformations as a result of deforming amnionic bands. There are no associated major organ system malformations.

In the hand, the ring finger is most frequently affected. This may be because in a clenched fist, the ring finger is the longest. The band may merely cause an indentation. However, if it is circumferential, the constriction ring may lead to distal edema or cyanosis (Fig. 22-18). Intrauterine amputations are the result of vascular insufficiency caused by the tourniquet-like bands. At times, this can be noted at birth with a necrotic or severely compromised phalanx distal to a constricting band. Syndactyly occurs when the bands attach adjacent digits (Fig. 22-19). There often are skin clefts proximal to the syndactyly, indicating the embryonic formation of a web space before the amnionic rupture and subsequent deformation. The extremity proximal to the band is normal. The development of the underlying tendons, nerves, vessels, and muscles is also normal.

Clinical Treatment. Impending tissue necrosis is an indication for emergent removal of the band to relieve vascular compromise. This is a rare situation, usually seen only in

the neonatal period. Removal of neonatal constricting bands that are causing vascular compromise generally can be performed outside the operating room. The band will literally unravel or debride like an eschar. Improved venous drainage is almost immediate.

Multiple minor band indentations without vascular compromise or functional or cosmetic problems do not require treatment. Constricting rings that cause distal deformity are treated with excision of the constriction ring and staged Z-plasty reconstruction [►1.3]. Complete excision of the ring is necessary to recontour the digit or limb. The depth of excision can extend to the periosteum. Such digits usually have chronic impaired venous outflow with marked distal swelling. In these situations, it is imperative to preserve distal venous drainage and the deep neurovascular structures. Careful dissection of the veins, arteries, and nerves is performed on both sides of the deep constricting band. These structures are then delicately freed from the band to preserve their longitudinal integrity. It is recommended that complete circumferential excision not be performed in one procedure. Rather, excision up to 270 degrees at one time may be safest for preservation of vascular inflow and outflow. Z-plasties are performed after ring excision to prevent recurrence.

Syndactyly release with Z-plasties and skin grafts follows the basic principles outlined in the section on syndactyly. The unique features with amnionic band syndrome are acrosyndactyly secondary to constricting bands and the presence of epithelialized incomplete web space proximal to the syndactyly.

In the rare situation of constricting bands causing progressive deformity in digits of unequal length, early digital separation is necessary. More often, the acrosyndactyly separation can be performed after 6 months of life. There is usually limited skin for coverage, and creative flap design is needed to cover all the web spaces. Abundant skin graft is

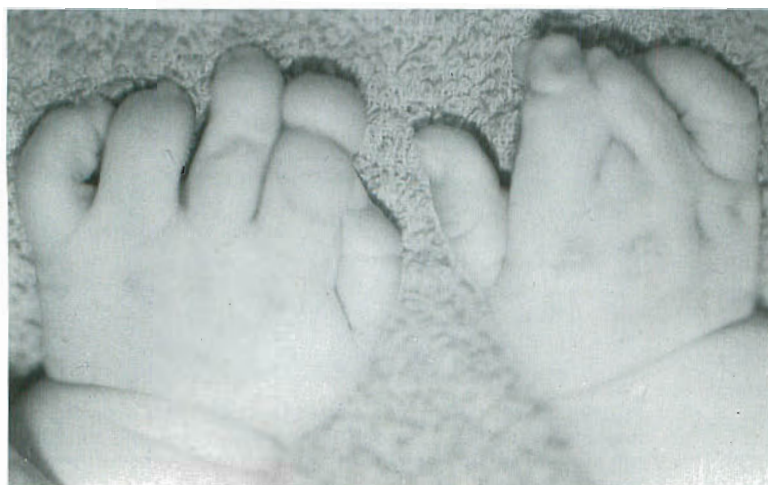

FIGURE 22-19. Bilateral amnionic band syndrome with deep constriction rings on the left hand and partial acrosyndactyly and amputations on the right hand.

necessary. Distal release of complex syndactylies may require excision of osseous or cartilaginous synostoses. The embryologic remnant of the web is usually too distal and small to serve as an acceptable web reconstruction. Excision of that epithelial tract is usually performed. If that primitive web is used, it often needs to be deepened secondarily.

The most severe cases involve absence or deficiency of the thumb. The reconstruction can include metacarpal or phalangeal transposition from the index finger (234,235), nonvascularized toe phalangeal transfer, or vascularized toe transfer. It is imperative to reconstruct the thumb for pinch and proper grasp and release functions in these patients.

Because the underlying tissues are normal, as is the central nervous system, these patients have outstanding hand function after reconstruction. There are clear cosmetic differences, but minimal functional differences between them and their peers.

Syndactyly

Syndactyly is one of the most common congenital differences. It occurs because of a failure of separation of the digital rays *in utero*. Normal differentiation of digits occurs during the fifth to eighth weeks of gestation. Failure of normal programmed cell death results in *syn* (together) *dactylos* (digits). The incidence is between 1 per 2,000 and 1 per 2,500 live births (1). It can occur in isolation or as part of a syndromic condition. It is often an inheritable condition, whether in isolation or as part of a syndrome. It is bilateral and symmetric in up to 50% of patients. It is more common in boys than in girls.

Syndactyly is classified by the extent of, and the tissues involved in, the webbing. Digital separation *in utero* starts

distally and proceeds proximally. Normally, the third web space is the most distal web, followed by the second, fourth, and first web spaces. The normal commissure of the web extends over 30 to 35% of the length of the proximal phalanx (236). The bones, joints, tendons, and neurovascular structures separate before the skin. If separation fails to occur or ends prematurely syndactyly results. If it extends over the entire length of the phalanges then it is complete. Complete syndactyly is when the web is more distal than normal (Fig. 22-20); complex syndactyly is when there is osseous connection between the digits; and simple syndactyly is when the digits are joined by skin only (236). Acro-syndactyly involves webbing of the tips of all the digits. Syndactyly secondary to amniotic band syndrome is not a malformation, but an *in utero* disruption, and will be considered separately. Syndactyly can also be a part of other major developmental problems in the hand that affect hand function, such as brachydactyly, camptodactyly, clinodactyly, symphalangism, and polydactyly. These are the most complicated syndactylies in terms of surgical decisions and care.

Clinical and Radiographic Features. Syndactyly most often affects the third web space of the hand. It is sequentially less common in the fourth, second, and, finally, first web space (1). It may be associated with syndactyly of the toes. In isolated syndactyly, often one of the parents will have an incomplete syndactyly of the fingers and/or toes. As mentioned above, there are many chromosomal, cranio-facial syndromic, and generalized syndromic conditions associated with syndactyly. These all need to be evaluated before treatment of the syndactyly. The most important aspect of the hand evaluation for syndactyly is determination of the quality of the affected digits. In simple syndac-

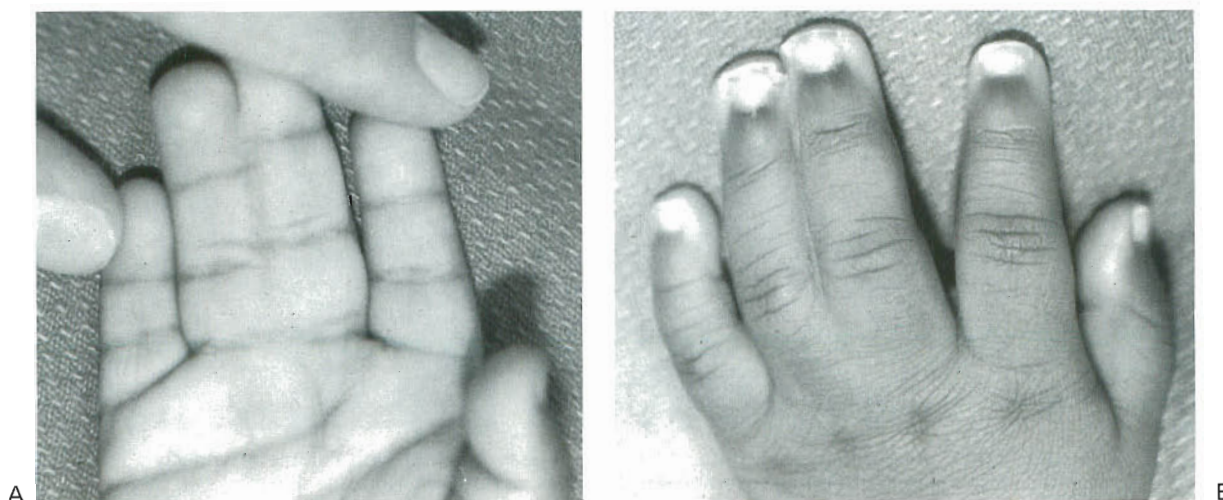


FIGURE 22-20. A and B: A 1-year-old child with complete simple third web space syndactyly. In this patient, the distal eponychial folds and nail plates are already separate. The underlying joints, tendons, nerves, and blood vessels should be separate and normal.

tyly, these digits are usually normal except for their skin union. In more complex situations, the digits may have malalignment, limited motion, and limited strength after surgical separation. Plain radiographs will reveal osseous union and marked joint and bony malalignment. However, in infancy, the areas of chondral abnormalities in the joints, physes, and between digits exhibiting syndactyly will not be visible on plain radiographs. MRI and arteriography are used only in very complex situations to define digital anatomy preoperatively.

Treatment. Patients with incomplete syndactyly may choose not to undergo surgical separation. If the syndactyly does not extend beyond the PIP joint this will not limit function. However, it may affect wedding ring wear in the third web space, and for this reason, some patients request separation.

Most parents and children with complete syndactyly desire separation of the digits for functional and cosmetic reasons. There are rare situations in which a family declines surgery for complete syndactyly. Because of the discrepancy in the lengths of the adjacent digits, this usually results in some degree of bony malalignment and joint contracture. This is most marked in the border digit syndactylies (first and fourth web spaces), and least marked in the third web space. Leaving the digits joined also precludes independent function of the affected digits. There are also syndromic and chromosomal situations in which the overall health or mental capacity of the patient does not warrant the risks of surgical separation. Finally, there are situations of complex

syndactyly in which the affected digits are too hypoplastic, malaligned, or stiff to warrant separation. Otherwise, the standard treatment is surgical separation of the affected digits [➔1.4].

Unfortunately, separation is not as simple as parents wish, i.e., the simple division of the conjoined skin. The uncovered soft tissues result in linear scars with long-term joint contractures, digital malalignment, and loss of motion and function (198,238). Standard treatment now consists of (i) local rotation flap coverage for the commissure; (ii) zig-zag incisions, avoiding the interdigital creases to prevent scar contractures; and (iii) full-thickness skin grafts to cover all areas of the digits not covered by local flaps (Fig. 22-21). In addition, special attention is given to the eponychial reconstruction with either local flaps or composite grafting (239).

Surgery is generally performed in infancy, when anesthesia and surgical handling of the tissues are safe. There is some controversy regarding the best age for surgery (1,240), but in most institutions it is performed at around 12 months of age (241). After 6 months of age, the anesthesia risk is equivalent throughout childhood. With magnification, surgery can be performed safely and skillfully during infancy. The only controversy concerns surgical healing and scarring. Neonatal releases result in more scarring. There is some evidence that surgical release performed at around 18 months of age may result in less scarring and recurrent web contractures than release during infancy (242). However, this is a very difficult developmental age for elective surgical intervention.

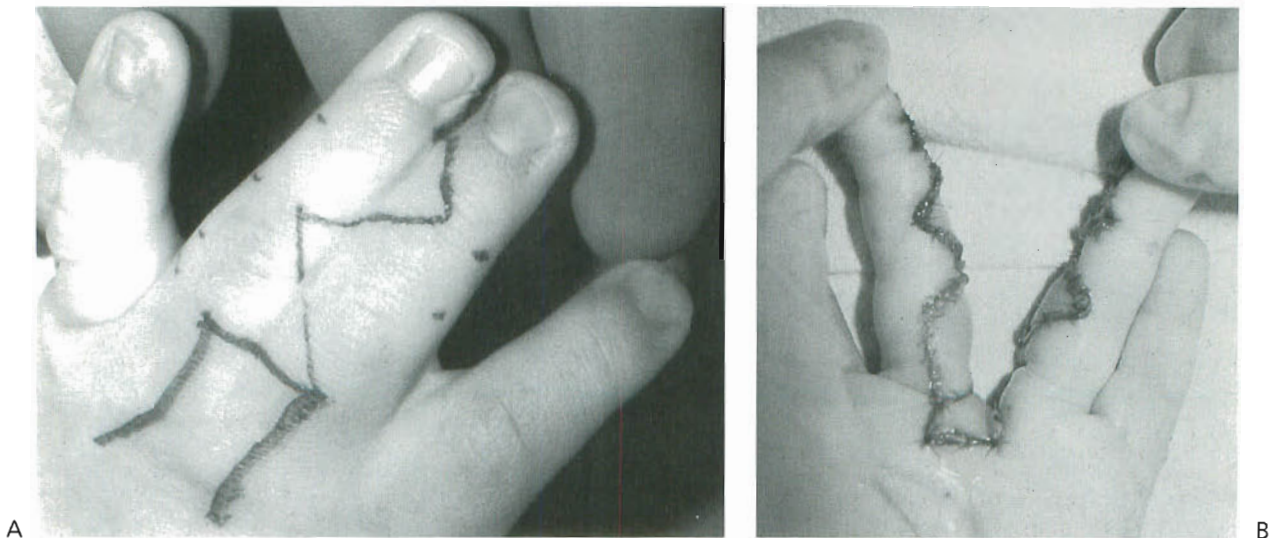


FIGURE 22-21. A: Intraoperative photograph of a 1-year-old child with complete syndactyly treated with dorsal rotation flap coverage and Z-plasties, as outlined. Note the skin marks on the lateral borders of the ring and long fingers to outline the apex and base of each Z-plasty. This allows for precision placement of corresponding volar and dorsal Z-plasties. B: Intraoperative photograph after dorsal-to-volar rotation flap coverage for web space, Z-plasties, and full-thickness skin grafting.

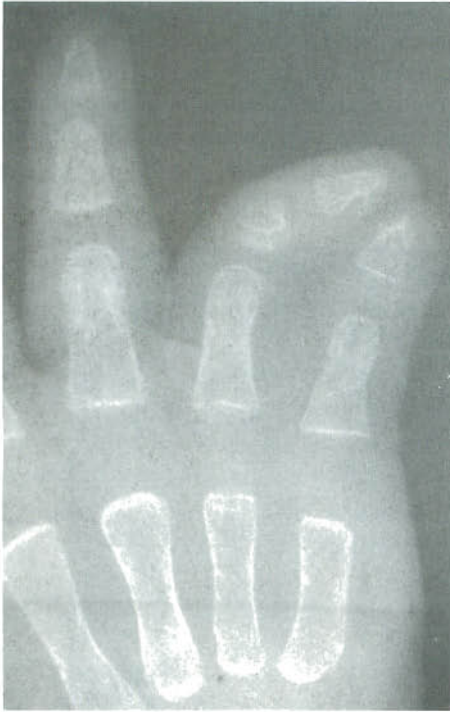

FIGURE 22-22. Radiograph of complex syndactyly of the fourth web space with progressive deformity of the ring finger. This should be released early in infancy to prevent progressive deformity. The abnormal middle phalanx of the ring finger may still require corrective osteotomy.

Complete separation of the digits in the neonatal period has had a higher rate of complications. Border digits of unequal length need to be separated earlier to lessen angular and rotatory deformity in the longer digit (Fig. 22-22).

In incomplete syndactyly that is proximal to the PIP joint, surgery usually involves the use of local flaps such as double-opposing Z-plasties and “stickman” flaps. Separation may not be to normal depth, but patients often prefer avoiding skin grafting. If the incomplete syndactyly extends to the middle phalangeal region, full-thickness skin grafting is necessary.

In simple, complete syndactyly, surgery involves the use of a dorsal rotation flap into the web, Z-plasty flaps the length of the digits, and full-thickness skin grafts to cover the defects. The fascial connections between the digits extending from Grayson’s and Cleland’s ligaments need to be separated. Any synostosis or synchondrosis union of the distal phalanges needs to be divided. Conjoined nails are divided, and the exposed eponychial and paronychia regions are reconstructed with local flaps or composite grafts. If the common digital nerve extends beyond the desired web deepening, epineural separation is performed proximally. If the common digital artery bifurcates distally, ligation of one of the proper digital arteries may be necessary to attain the desired separation. This is one of the major reasons why

surgery is not performed on both sides of a single digit in multiple syndactylies.

Complex syndactylies are more likely to have abnormal underlying joints, bones, neurovascular structures, muscles, or tendons. The separation of skin follows the same principles as in complete syndactyly. With significant digital malalignment, skin incisions may need to be modified to maximize coverage. After separation of the skin, all abnormal connections of fascia, tendons, bones, joints, nerves, and arteries need to be addressed individually. Phalangeal deformity may require osteotomy. Joint instability may require ligamentous reconstruction. Joint stiffness, camptodactyly, or symphalangism may need to be dealt with subsequently. Neural, vascular, and nail problems are managed in a manner similar to that described for complete syndactyly. Tendon reconstruction is performed primarily if possible. Brachydactyly is usually addressed subsequently, if at all.

Acrosyndactyly separation begins early in life, especially if it is bilateral. Adjacent webs are not separated simultaneously. Generally, the first and third webs are separated together, as are the second and fourth webs. Abundant full-thickness skin graft is usually required. Sufficient time between procedures (3 to 6 months) lessens worries about flap necrosis and scar contracture. In syndromic conditions, such as Apert syndrome, the acrosyndactyly is more complex and the end result is never normal.

Complications. Fortunately, the most worrisome complication, an avascular digit, is almost never encountered and should be avoidable. Adhering to the axiom of never operating on both sides of a digit during the same procedure prevents this devastating complication. Careful dissection of the digital vessels in complex situations lessens the risk of avascularity at the initial or subsequent operations. Preoperative vascular studies in complicated situations prepare the surgeon, and allow the surgeon to avoid intraoperative surprises and dangers. Flap necrosis and scar contracture are more common. The flaps should be secured without tension, and their vascularity should be checked with deflation of the tourniquet at the completion of the procedure. If in doubt, lessen the tension and use skin graft. Skin graft failure is usually caused by inadequate immobilization and excessive shear forces applied to the grafts. Secure immobilization with the compressive dressing, long-arm cast, and sling and swathe bandages, is necessary to protect the grafts. Infection is rare but will result in marked scar contractures that require reoperation. Nail deformity and poor eponychial coverage are common when there is an initial conjoined nail. The use of composite grafts seems to lessen the incidence of these complications. Web space creep is common with growth, but often does not require reoperation unless digital contractures develop. Use of local rotation flaps and skin grafts will resolve this problem. Finally, angular deformity may require osteotomy or joint reconstruction.

Polydactyly

Polydactyly is a common congenital malformation. It can occur on the radial (preaxial), central, or ulnar (postaxial) portion of the hand. Preaxial or thumb polydactyly usually

occurs in isolation and will be addressed in the thumb section of this chapter. Central polydactyly is very rare, is usually associated with syndactyly, and the underlying digits are rarely normal. It can be inherited in an autosomal dominant manner. It affects girls more than boys, and it is often bilat-

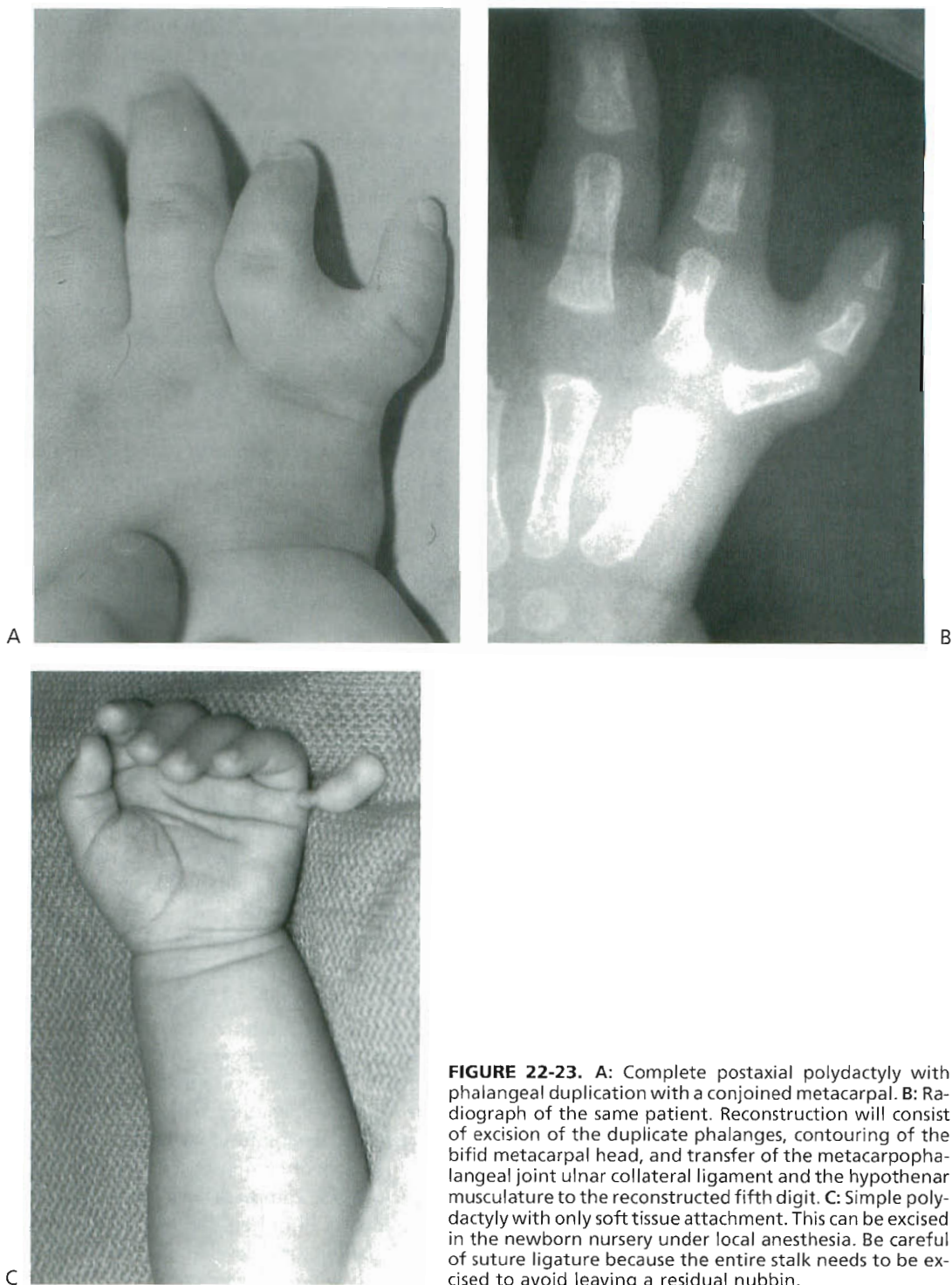


FIGURE 22-23. A: Complete postaxial polydactyly with phalangeal duplication with a conjoined metacarpal. B: Radiograph of the same patient. Reconstruction will consist of excision of the duplicate phalanges, contouring of the bifid metacarpal head, and transfer of the metacarpophalangeal joint ulnar collateral ligament and the hypothenar musculature to the reconstructed fifth digit. C: Simple polydactyly with only soft tissue attachment. This can be excised in the newborn nursery under local anesthesia. Be careful of suture ligature because the entire stalk needs to be excised to avoid leaving a residual nubbin.

eral. Postaxial or small-finger polydactyly has a variable racial incidence, with the occurrence in blacks estimated to be as high as 1 per 300 live births, and that in whites estimated to be 1 per 3,000 live births (243–245). It is often bilateral. Polydactyly has been classified by Stelling (246) and Turek (247) into three types. Type I involves soft tissue alone and is very common in the black population. Type II involves phalangeal duplication articulating with a single or bifid metacarpal head. Type III involves a complete ulnar ray duplication, including the metacarpal. There is also a universal classification of polydactyly proposed by Buck-Gramcko and Behrens (248) that denotes the digit involved by roman numeral (I to V), the extent of bifurcation by abbreviation (DIST [distal], DIP [distal interphalangeal], MID [middle], PIP [proximal interphalangeal], PROX [proximal], MCp [metacarpophalangeal], MET [metacarpal], CMC [carpometacarpal], C [carpal], and IC [intercarpal]), and RUD [rudimentary polydactyly]). The major issue for the surgeon is not the classification of the polydactyly, but whether excision alone, or reconstruction, is warranted. Only postaxial soft tissue polydactyly (type I, or rudimentary) can be treated by excision alone. All other forms require reconstruction. Central polydactyly is usually an isolated malformation. Postaxial polydactyly in blacks is almost always an isolated malformation. Postaxial polydactyly in whites without a positive family history may be associated with chromosomal abnormalities, other syndromes, or other malformations.

Treatment. Soft tissue polydactyly on the ulnar side can be treated with excision during the newborn period (Fig. 22-23). Unfortunately, too often this has been performed with a suture ligature in inexperienced hands. The result is a persistent nubbin caused by incomplete excision of the base of the digit. If a suture ligature is used, it needs to cause necrosis of the entire digit. Otherwise, it may be best to perform an elliptical excision under local anesthesia. Care is taken to ligate the digital vessels with this excision. Other than failure to completely excise the digit, complications are rare, and the hand is normal afterward. The parents should be aware of the future genetic implications for them and their children.

More complex postaxial polydactylies require excision and reconstruction in the operating room (Fig. 22-23). Besides excising the redundant parts, transfer of the hypothenar muscles (abductor digiti quinti, flexor digiti quinti) from the sixth to the fifth digit is necessary. In type II polydactyly, the MCP joint collateral ligaments are also transferred to the reconstructed fifth digit. If the metacarpal head is enlarged or bifid, intraarticular osteotomy is appropriate. With this procedure, the origins of the collateral ligament and the metacarpal physis need to be preserved. In type III polydactyly, the entire ray is resected, and the basilar joint is stabilized. The outcome in both type II and

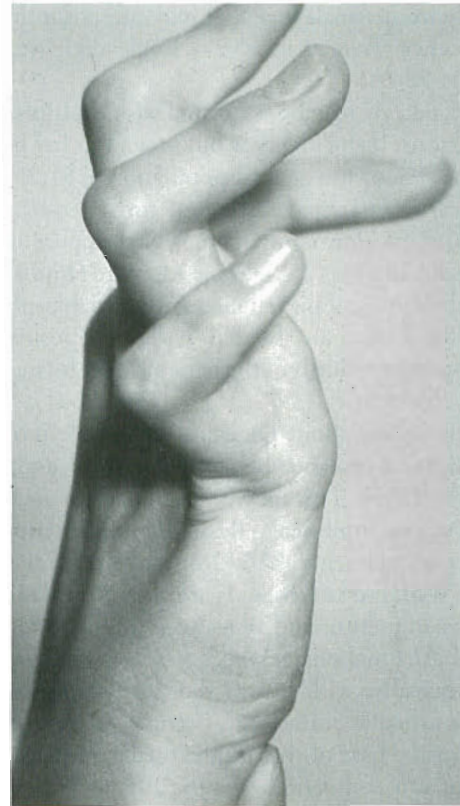

FIGURE 22-24. An adolescent patient with marked camptodactyly of the small, ring, and long fingers. There are proximal interphalangeal joint flexion contractures in each digit, and the patient is actively hyperextending the metacarpophalangeal joints to compensate for those contractures.

type III malformations is usually cosmetically and functionally normal.

Treatment of central synpolydactyly is much more complex (249,250). The major decision is whether independently functioning digits are feasible. The choices are to leave the digits conjoined to attempt reconstruction to a five-digit hand, or to perform ray resections of part or all of the synpolydactyly. Often the involved digits have bone and joint malalignment, hypoplasia, and poor motor, nerve, and vascular supplies. The reconstructed digit is usually smaller, stiffer, weaker, and malaligned. The family needs to be well aware of this from birth, so that their expectations are realistic as far as surgical reconstruction and digital function are concerned. Treatment decisions in this condition are often personal, based on the family's desires and the surgeon's biases.

Camptodactyly

Camptodactyly translates from Greek to mean "bent finger." It involves a flexion deformity of the PIP joint, most

commonly in the small finger. It may present in infancy or in adolescence. It may involve a single digit or multiple digits (Fig. 22-24).

Camptodactyly may be associated with multiple systemic malformations. Its incidence is unknown but has been cited at less than 1% of the general population (251,252). Most cases appear in infancy, and there is equal gender distribution (253). Less commonly, it may first appear in adolescence, usually in girls (254). Some cases are familial with an autosomal dominant inheritance with variable penetrance patterns. Most cases are isolated, without a positive family history. Up to two-thirds of the patients have bilateral small-finger involvement.

There is debate about the cause. In simple terms, there is an anatomic imbalance between the flexor and extensor mechanisms (253). This may be secondary to an abnormal insertion of the lumbricals, flexor digitorum superficialis, or retinacular ligaments (255–260). The volar skin is usually tight. With growth, these anatomic abnormalities cause PIP joint contracture and phalangeal bony abnormalities. The distal proximal phalanx becomes narrowed volarly and flattened dorsally, with loss of the normal contour of the head. The articular surface can become incongruous, with notching of the base of the middle phalanx (261). Initially, the patient can compensate for the PIP joint flexion contracture by MCP and distal interphalangeal joint hyperextension (Fig. 22-25). This keeps the digital pulp of the affected fingers in line with the other digital rays. Thus, the mild contracture in the older child may not need treatment. However, as the contracture progresses beyond 30 degrees and toward 90 degrees, it becomes more difficult for the patient to compensate. Camptodactyly is usually progressive with growth.

Treatment. Treatment should attempt to restore normal flexor–extensor balance. The options for treatment are splinting and surgical reconstruction. Most authors recommend an initial treatment program of progressive extension stretching and splinting with dynamic or progressive static splints. Parents are instructed to perform frequent home exercises for their infants; affected adolescents are similarly instructed to perform a home program for themselves. The goal is to achieve full passive extension. It is hoped that active extension will follow. Many authors (254,262–264) report success with a splinting program in a majority of cases. The best results are in the mild cases in young patients. The patients are followed until the end of growth to treat recurrence.

There is significant debate regarding the indications for surgery. McFarlane and colleagues strongly recommend surgical intervention to reconstruct the aberrant insertion of the lumbrical (259,260). However, the published surgical results are disappointing in terms of outcome (259, 260,263,265). Surgery is reserved for severe contractures not amenable to splinting treatment. Specifically, surgery

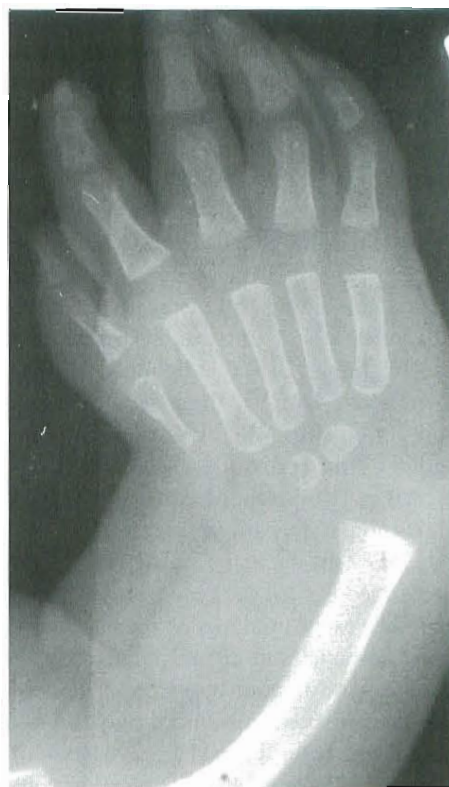

FIGURE 22-25. Radiograph of a thumb with type IIIB hypoplasia without a carpometacarpal joint and proximal thumb metacarpal. This is usually treated with pollicization. Less often, treatment is by reconstruction, potentially including a microvascular toe metatarsophalangeal transfer to form a thumb carpometacarpal joint. Note the radial dysplasia in this patient.

has its best results in patients in whom the finger is flexed into the palm and obstructs use of the hand. The principle of surgical intervention is to correct the abnormal anatomy. This involves release of the aberrant lumbrical (251, 259,260) or flexor digitorum superficialis (256), and insertion in conjunction with volar Z-plasties and PIP joint release (265). Local flaps or full-thickness skin grafts are often necessary for volar skin coverage. Tendon transfer to the extensor mechanism is performed when there is full passive extension of the PIP joint, but no active extension (266). The results of soft tissue reconstruction often merely change the arc of motion rather than normalize it. Preoperatively, patients have significant flexion contracture. Postoperatively, they generally have difficulty achieving full active and passive flexion.

There frequently are bony changes present at the PIP joint that preclude restoration of normal motion or alignment. In the presence of marked radiographic evidence of bone and joint changes, Oldfield (267) and Flatt (1) have stated that corrective extension osteotomy may be most effective at improving alignment and function. This salvage operation has limited published data to objectively evaluate its results (251).

In summary, with treatment of camptodactyly it is unusual to achieve a perfectly aligned and mobile digit. The parents and patients should be aware of this from the outset of care. In addition, deformity can recur with growth and persistent muscle imbalance.

Clinodactyly

Clinodactyly is abnormal angulation (greater than 10 degrees) of the digit in the radioulnar plane. It is usually caused by a misshapen middle phalanx. The middle phalanx is trapezoidal, with less height on the radial side. This results in deviation at the distal interphalangeal joint. Clinodactyly is most often seen in the small finger and is usually bilateral. This form of clinodactyly has an autosomal dominant inheritance (268–271). Clinodactyly is also frequently associated with syndromes (Holt-Oram, Turner, Silver, and Cornelia de Lange syndromes) and chromosomal abnormalities (trisomy 18 and 21), and should alert the primary neonatal examiner to look for associated malformations or problems. For example, clinodactyly of the thumb is seen in Rubinstein-Taybi syndrome (272,273) and diastrophic dwarfism (274,275). In addition, it is common with other congenital differences of the hand. Finally, mild clinodactyly is commonplace in otherwise normal people. In these situations the major issue is cosmesis. Function is affected only when the deformity is severe enough to impinge on the adjacent digit with flexion.

Treatment. Treatment is based on the degree of deformity. Most cases are mild and nonprogressive and, therefore, do not warrant surgical intervention. Progressive, severe clinodactyly may interfere with flexion and grip. In these rare situations the progressive deformity is secondary to altered physeal growth. The middle phalangeal physis may be a bracket delta phalanx. Treatment options are bracket resection and surgical realignment. Physeal bar resection and fat graft interposition have been reported by Vickers (276,277) to restore longitudinal growth and provide correction. Surgical realignment can be in the form of opening-wedge, closing-wedge, and reverse-wedge osteotomies. Osteotomy should be delayed until there is sufficient ossification of the middle phalanx to allow for precise cuts. Generally, this is around school age. The complications of osteotomy are persistent deformity and loss of interphalangeal motion. Loss of motion in a patient whose indication for surgery was cosmetic is unacceptable to most patients, their families, and surgeons.

HAND: THUMB

Congenital differences of the thumb occur in all categories of congenital hand anomalies described by the American Society and the International Federation of Societies for

Surgery of the Hand. Failure of formation occurs with aplasia of the thumb, and this is often associated with other radial-sided longitudinal deficiencies. Failure of separation occurs with thumb–index syndactylies, which are common with other syndactyly syndromes. Duplication is seen with thumb polydactyly. Undergrowth, with thumb hypoplasia, and overgrowth, with macrodactyly and triphalangeal thumbs, occur. Finally, thumb abnormalities with constriction band syndrome and generalized musculoskeletal disorders are common. The list is exhaustive, and this section will cover the more common congenital thumb malformations.

Trigger Thumbs/Digits

Trigger thumb represents an abnormality of the flexor pollicis longus and its tendon sheath at the A1 pulley. There is a palpable mass (Notta nodule), representing the flexor pollicis longus constriction at the A1 pulley. In the past, trigger thumbs were defined as congenital. However, this condition is acquired in the first 2 years of life, as indicated by prospective screening of neonates who failed to yield any trigger thumbs (278,279). The cause appears to be a size mismatch between the flexor pollicis longus and the A1 pulley that leads to progressive constriction. Unlike adult trigger digits, there does not appear to be an inflammatory component (280); 30% of the cases are bilateral. Isolated trigger thumbs have no associated syndromes. However, trigger digits are seen with neurologic syndromes (trisomy 18) and mucopolysaccharidoses (281). There is no familial inheritance pattern. Trigger thumb patients present at ages ranging from infancy to school age. Often, the diagnosis is missed until local trauma brings attention to the thumb. In the emergency setting the flexed interphalangeal joint can be mistaken for an interphalangeal joint dislocation. Radiographs are misleading because of limited phalangeal ossification. A palpable nodule at the A1 pulley is diagnostic. If the trigger is long-standing, compensatory hyperextension of the MCP joint develops to effectively bring the thumb out of the palm. In addition, there may develop mild radial deviation of the interphalangeal joint secondary to eccentric flexor pull.

Treatment

In infants younger than 9 months of age, Dinham and Meggit (282) found that 30% of trigger thumbs may resolve spontaneously. In infants older than 1 year of age, less than 10% of trigger thumbs resolved spontaneously. Ger et al. (283) found lack of resolution with observation for 3 years in their patients. There is limited evidence that splinting will be of benefit (284), and often it is not well tolerated. Surgical release of the constricting A1 pulley and flexor tendon sheath is the treatment of choice [➤1.5]. This is indicated in infants without spontaneous resolution by 1 year of age, and in any toddler or older child presenting with

a locked trigger thumb. Incision is made transversely in the digital crease to lessen scarring. Care must be taken to avoid iatrogenic injury to the superficial digital neurovascular bundles. The oblique pulley needs to be preserved to prevent flexor tendon bowstringing. Recurrence is extraordinarily rare, if at all.

Trigger digits are more often multiple, and can be associated with central nervous system disorders and syndromes (trisomy 18, mucopolysaccharidoses). The pathology appears to predominate at the decussation of the flexor tendons under the A2 pulley, and not at the A1 pulley alone. The triggering appears to occur as the flexor digitorum profundus passes through the chiasm of the flexor digitorum superficialis. Surgical recurrence is high in pediatric trigger digits. This may be because A1 pulley release alone is not sufficient to solve the problem. Further opening of the chiasm or resection of a slip of the flexor digitorum superficialis is often necessary to prevent recurrence (281).

Hypoplasia/Aplasia of the Thumb

Children with thumb hypoplasia or aplasia will have deficient prehension and grasp. Thumb hypoplasia or aplasia can occur in isolation, or be associated with other radial-sided deficiency syndromes (Holt-Oram and Fanconi syndromes). It is seen universally with radial dysplasia. It is common with other congenital malformations (181,285), including those of the cardiac, craniofacial, musculoskeletal, renal, gastrointestinal, and hematopoietic systems. It may involve hypoplasia of the metacarpals (Cornelia de Lange syndrome, diastrophic dwarfism) or phalanges (Rubinstein-Taybi and Apert syndromes). Neonatal examination of a child with thumb deficiency should prompt a thorough multiple-system examination for other malformations.

In general terms, thumb hypoplasia includes a contracted first web space, unstable MCP joint, thenar weakness, and interphalangeal joint stiffness or instability. Buck-Gramcko (286) and Manske et al. (287) have modified the Blauth

(288) classification for thumb hypoplasia. This classification system is useful for treatment considerations. There are five types of thumb hypoplasia in the Buck-Gramcko modification of the Blauth classification (Table 22-3). A type I thumb is essentially a normal thumb, except for diminished size. A type II thumb is even smaller and narrower, with a contracted first web space and thenar atrophy. Type III thumbs have marked atrophy or absence of both the intrinsic and extrinsic musculature. The thumb is globally unstable and underdeveloped. Manske et al. (287) further subdivided type III thumbs into A and B categories. Type IIIA thumbs have a stable carpometacarpal (CMC) joint, whereas type IIIB thumbs have absence of the proximal metacarpal and trapezium. Type IIIB thumbs have no basilar joint stability (Fig. 22-24). Type IV thumbs are the classic *pouce flottant* or “floating thumbs.” A type V thumb demonstrates complete aplasia of the thumb.

The pathoanatomy is dependent on the severity of the thumb hypoplasia. Universally, the thumb ray bones are smaller and narrower. The interphalangeal joint is usually underdeveloped and stiff. The first web space is contracted in all except the rare type I thumb. The MCP joint usually has ulnar collateral ligament insufficiency, but may be globally unstable. The thenar intrinsics are deficient, and may be completely absent in the more severe forms of hypoplasia. The thumb extrinsic musculature is progressively deficient in the classification scheme. The major anatomic determining factor for reconstruction is the status of the CMC joint. Type IIIB and type IV thumbs have no basilar joints. Plain radiographs are helpful in distinguishing the skeletal development, including the carpus and distal radius.

Treatment

The choice in the treatment of children with thumb hypoplasia is surgery or not. If left alone, these children will adapt. They will use lateral pinch between the long and index fingers. However, the deficiencies in pinch, grasp, and fine motor activities will be significant. Surgical reconstruc-

TABLE 22-3. MODIFIED BLAUTH CLASSIFICATION OF CONGENITAL THUMB HYPOPLASIA

Type	Findings
I	Smaller thumb with hypoplasia of abductor pollicis brevis and opponens pollicis
II	Narrow first web space, laxity of the ulnar collateral ligament of the metacarpophalangeal joint, thenar muscle hypoplasia
III	Global thenar weakness and metacarpophalangeal joint collateral ligament instability, partial aplasia of the first metacarpal, extrinsic weakness
IIIA	As above, with present proximal metacarpal and carpometacarpal joint
IIIB	Absent proximal metacarpal, with deficient carpometacarpal joint
IV	<i>Pouce flottant</i> (floating thumb); no bony support
V	Thumb aplasia

Findings are additive with increasing severity.
(Adapted from refs. 286–288, with permission.)

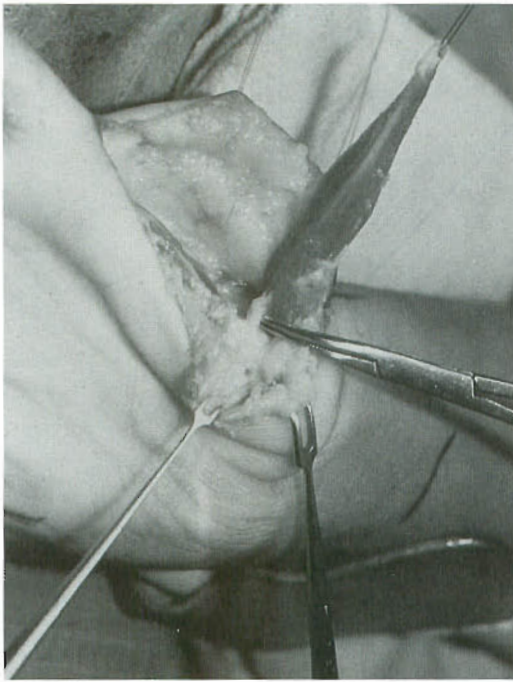


FIGURE 22-26. Intraoperative photograph of a Huber opponensplasty with abductor digiti quinti transfer to the abductor pollicis brevis. The snap identifies the proximal neurovascular pedicle to the muscle that needs to be preserved for successful dynamic transfer.

tion can improve function and cosmesis, and should be advised.

Reconstruction of the hypoplastic thumb, therefore, includes first web space deepening; opponensplasty, with either the abductor digiti quinti or the ring-finger flexor digitorum superficialis tendon; and MCP joint stabilization, with either ligamentous reconstruction or arthrodesis. Blauth types I to IIIA should be reconstructed according to these principles (Fig. 22-26). The choice of first web space deepening procedure includes two-part and four-part Z-plasties or the use of dorsal rotation flaps from the index finger, thumb, or hand. The degree of contracture determines the amount of skin necessary to provide a normal depth and breadth to the web for pinch and grasp activities. The abductor digiti quinti transfer for opposition can be used in the infant with a relatively stable MCP joint. Care must be taken to protect the proximal neurovascular pedicle to the abductor muscle, with dissection near the pisiform (184). In older children or patients with marked instability of the MCP joint, the ring-finger flexor digitorum superficialis is used for opposition. The additional tendon length can be used for ligamentous reconstruction. Besides the flexor digitorum superficialis tendon, local fascia from the adductor can be mobilized for ligamentous augmentation at the MCP joint. If soft tissue procedures fail, or the insta-

bility at the MCP joint is too severe, fusion can be performed. The physis of the proximal phalanx needs to be preserved to maximize growth of the thumb ray. Chondrodesis of the metacarpal head to the epiphysis of the proximal phalanx is desired.

Thumb hypoplasia with the absence of a basal joint (type IIIB), *pouce flottant* (type IV), or aplasia of the thumb (type V) are candidates for pollicization of the index finger. The major area of controversy is still the type IIIB thumb. In the absence of a CMC joint, the results of reconstruction have been disappointing (289). It is a difficult decision for the parents to accept pollicization in these children because of the appearance of the thumb. However, reconstruction without a CMC joint leads to continued lateral pinch of the index and long fingers, rather than use of the reconstructed thumb. CMC joint reconstruction, with microvascular transfer of a toe metatarsophalangeal joint, rarely has been performed in children with type IIIB thumbs (289). This is an alternative to pollicization in these children. Surgery is performed later and is quite extensive. Pollicization involves the conversion of the triphalangeal index finger, without a basilar joint and a narrow web space, to a biphalangeal thumb with a CMC joint and a deep first web space. The removal of the index metacarpal and the use of the index metacarpal epiphysis as the trapezium enable the surgeon to properly position and cover the thumb. The technique described by Buck-Gramcko is used most commonly (178,179) (Fig. 22-27). In congenital absence of the thumb, this is better than microvascular toe transfer. Thumb reconstruction or pollicization is generally performed between 6 and 18 months of age. The quality of the pollicized digit is dependent on the quality of the original index finger, in terms of tendon function and joint motion. Patients with thumb aplasia and radial dysplasia generally do poorer, because the involved index finger has deficient musculature and camptodactyly. Manske and McCarroll performed secondary opposition transfers in children with poor pollicization (183). The best results are seen in children with aplasia alone, and normal index fingers (Fig. 22-28).

Thumb Duplication

Preaxial Polydactyly

Thumb duplication may be a misnomer because it implies that there are two normal thumbs, whereas in fact, both thumbs are hypoplastic. In isolation, thumb duplication is usually a sporadic occurrence. It may be associated with genetic syndromes, such as acrocephalopolysyndactyly (Nock and Carpenter types) and Holt-Oram or Robinow syndromes. If associated with a triphalangeal thumb, it can be autosomal dominant. Preaxial polydactyly is a rare occurrence, with an incidence estimated at 0.08 per 100,000 live births. There are many different classification systems, in-

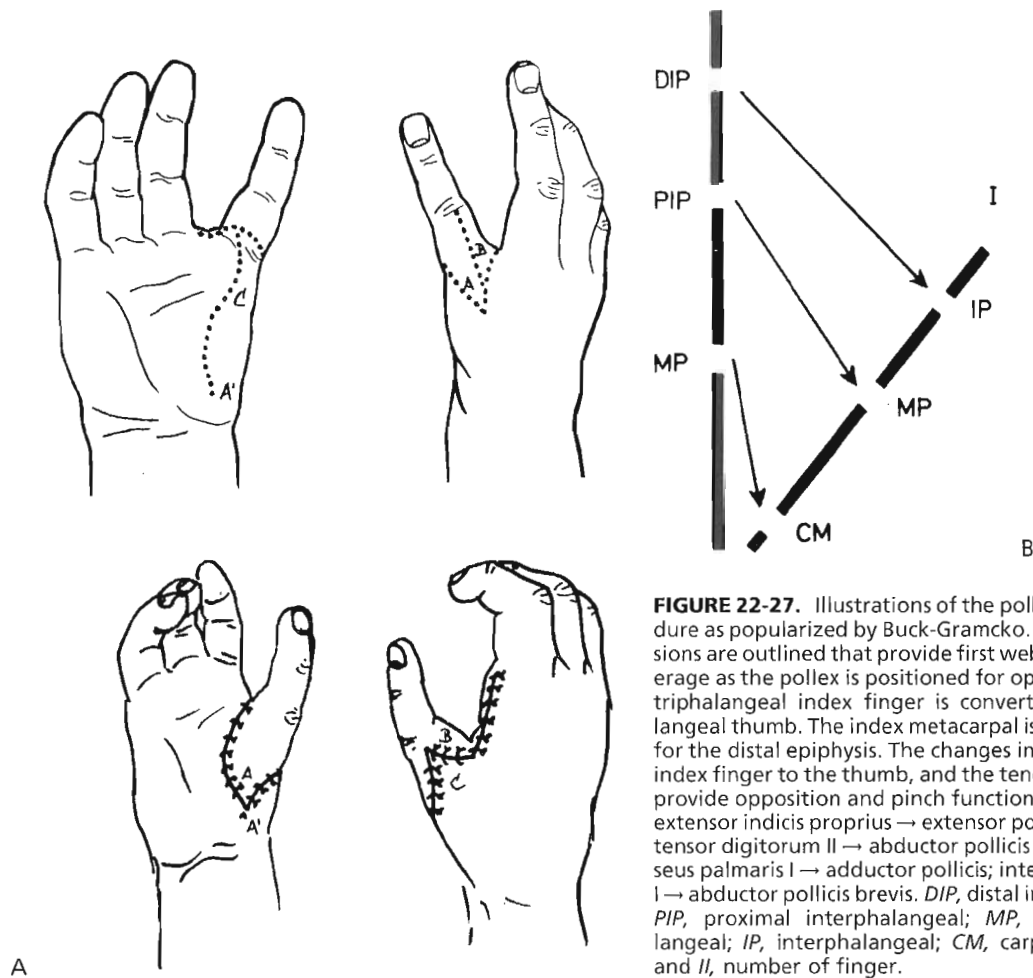


FIGURE 22-27. Illustrations of the pollicization procedure as popularized by Buck-Gramcko. **A:** The skin incisions are outlined that provide first web space flap coverage as the pollex is positioned for opposition. **B:** The triphalangeal index finger is converted to a biphalangeal thumb. The index metacarpal is excised, except for the distal epiphysis. The changes in joints from the index finger to the thumb, and the tendon transfers to provide opposition and pinch function, are as follows: extensor indicis proprius → extensor pollicis longus; extensor digitorum II → abductor pollicis longus; interosseus palmaris I → adductor pollicis; interosseus dorsalis I → abductor pollicis brevis. *DIP*, distal interphalangeal; *PIP*, proximal interphalangeal; *MP*, metacarpophalangeal; *IP*, interphalangeal; *CM*, carpometacarpal; *I* and *II*, number of finger.

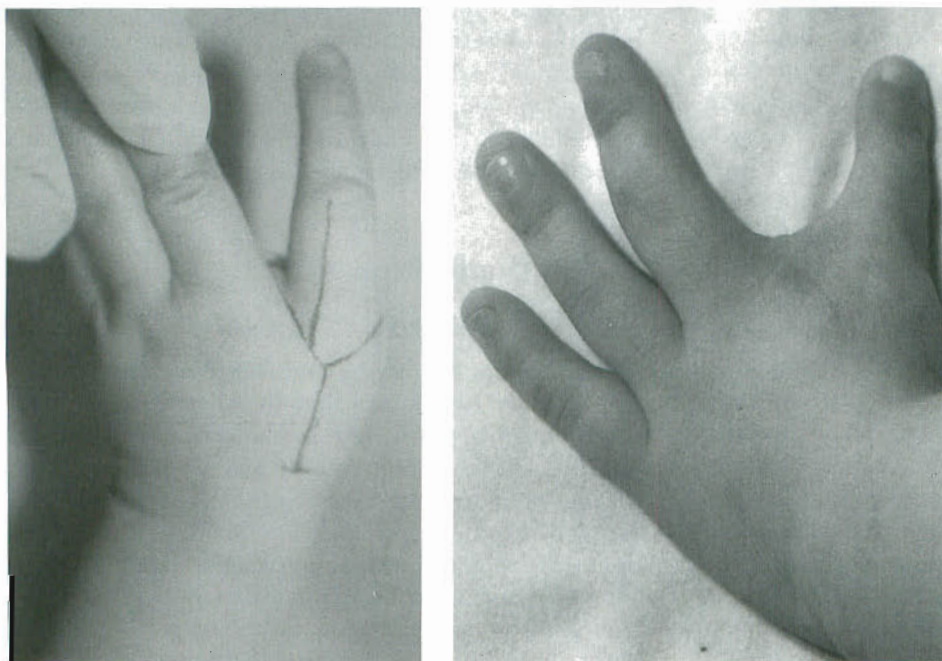


FIGURE 22-28. **A:** A 1-year-old child with thumb aplasia. The surgical incisions for index pollicization are outlined. These flaps provide for deep first web space. **B:** Postoperative long-term follow-up photograph after pollicization. Aesthetically, it is important to set the first web space at the proper depth.

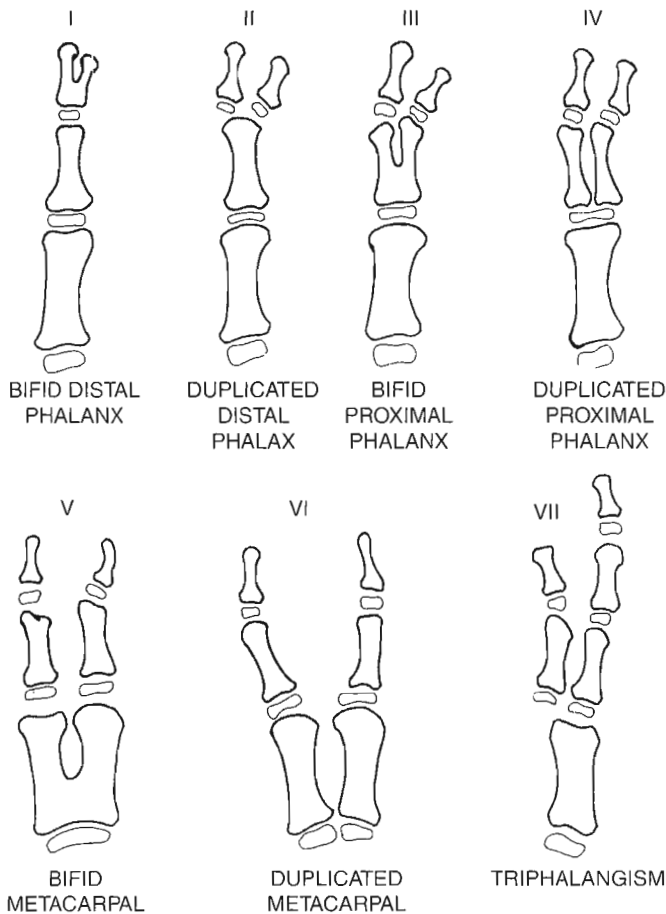


FIGURE 22-29. Wassel classification of thumb duplications. Type IV is the most common, with an incidence of 40%. Types II and VII have an incidence of approximately 20% each.

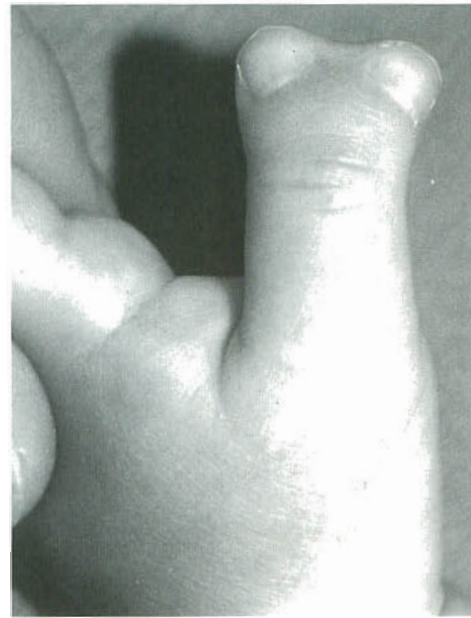

FIGURE 22-30. A 1-year-old patient with Wassel type II thumb duplication. These distal phalanges and nail plates are nearly equivalent. Unfortunately, the Bilhaut-Cloquet recombination procedure has not been rewarding in this circumstance. Surgery should consist of reconstruction of the best thumb.

normal anatomic elements of a thumb. Plain radiographs will generally provide definitive information regarding skeletal pathoanatomy. Careful surgical exploration will define the soft tissue anatomy.

Treatment. Surgical reconstruction is the treatment of choice to improve function and cosmesis. Unlike postaxial polydactyly, ablation in the nursery is not recommended, even for the simplest preaxial polydactyly. Too often, the thenar musculature and collateral ligaments insert on the radius-based digit and can be lost with simple excision (294–296).

Treatment involves excision of the more hypoplastic thumb and reconstruction of the more developed thumb [1.6]. Generally, the radius-based digit is excised. The soft tissue elements usually bifurcate at the level of the skeletal split. Transfers of the shared or aberrant tendons, nerves, and ligaments to the reconstructed thumb are necessary to maximize outcome.

The extensor pollicis longus tendon is usually bifid. The flexor pollicis longus usually inserts on the ulnar thumb, although it can be bifid or insert on the radial thumb. The thenar musculature and the radial collateral ligament to the MCP joint usually insert radially, especially in the common type IV polydactyly (Fig. 22-31). They need to be transposed. The radial digital nerve may be present only in the radial thumb, and should be transposed to the radial aspect

cluding the universal (291), Marks and Bayne (292), and Wassel (293) systems. Classification by the Wassel system is dependent on the number of bifid or duplicated phalanges or metacarpals, starting distally and progressing proximally (Fig. 22-29). A bifid distal phalanx is Wassel type I. A duplicated distal phalanx is type II (Fig. 22-30), which constitutes approximately 20% of all thumb duplications. A duplicated distal phalanx with a bifid proximal phalanx is type III. A thumb with duplicated proximal and distal phalanges is type IV, which is the most common type (approximately 40%) (Fig. 22-31). Duplicated proximal and distal phalanges with a bifid metacarpal is type V. Duplication of all phalanges and metacarpals is type VI. Any duplication with a triphalangeal thumb is type VII, which accounts for approximately 20% of thumb duplications.

The pathoanatomy is dependent on the type of polydactyly. The nails, bones, joints, ligaments, muscles, tendons, nerves, and blood vessels are split among the two digits. In addition, there can be hypoplasia or aplasia of any of the

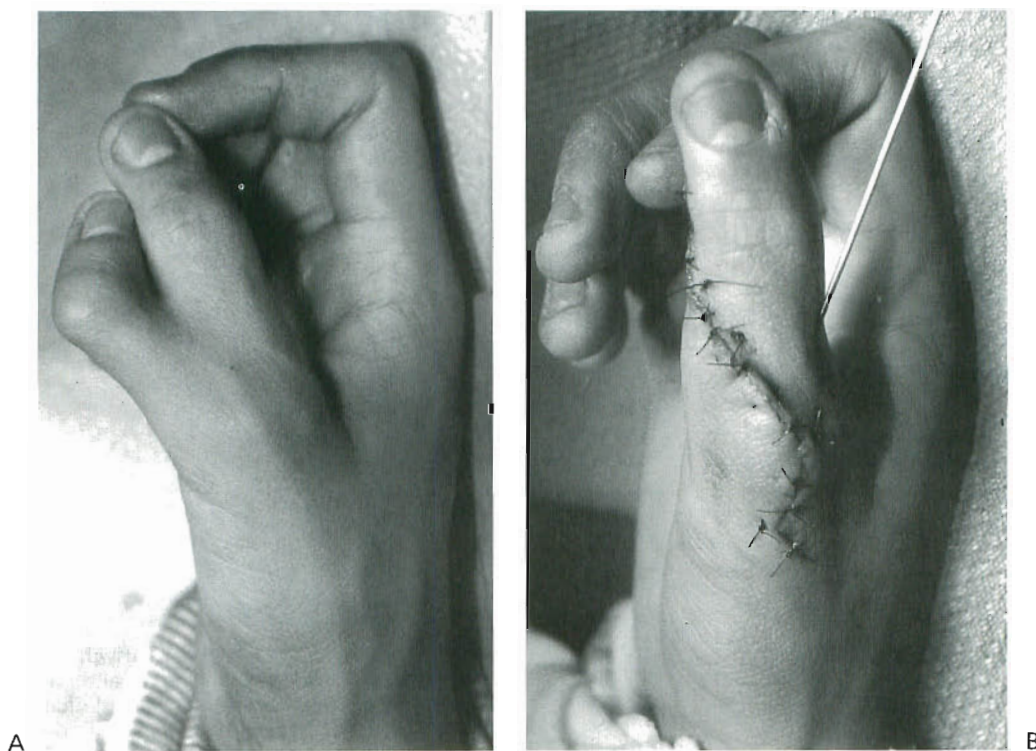

FIGURE 22-31. A: An adolescent with the more common Wassel type IV thumb duplication. B: Results at the conclusion of the surgical reconstruction. Surgery included excision of the radial proximal and distal duplicated digits, transfer of the thenars and metacarpophalangeal joint radial collateral ligament to the reconstructed thumb, and contouring of the skin by excision of redundancy and Z-plasties.

of the reconstructed thumb. The bifid proximal phalanx or metacarpal needs to be excised in type II or IV, respectively. Primary phalangeal or metacarpal osteotomy is indicated with axial malalignment. The more developed thumb often has a larger nail and distal phalanx. However, some Wassel type II malformations have almost equally sized distal phalanges and nails (Fig. 22-30). Surgical recombination of the distal phalanx and nail beds (Bilhaut-Cloquet procedure) in types I and II malformations has been disappointing because of poor nails, loss of joint motion, and physeal closure. It still appears best to accept the more hypoplastic distal phalanx than to consider recombination of the nail and phalanx. Adduction contracture of the first web space should be treated with Z-plasty to deepen the web space. The need for additional surgery with growth may be as high as 40%.

Angular deformity of the proximal and distal phalanges into a zig-zag posture is the most common problem (297–300). Reconstruction with osteotomy, tendon transfers, ligament reconstruction, or arthrodesis may be necessary to improve both function and cosmesis.

Triphalangeal Thumbs

Triphalangeal thumbs are usually inherited in an autosomal dominant manner. This is true whether they are associated

with thumb polydactyly (301) or seen in isolation. The extra phalanx is the middle phalanx. It may be wedge-shaped or rectangular. The thumb may be in a position of opposition, or in the plane of motion of the other fingers. The latter situation may indicate an index finger duplication with an absent thumb. This concept is supported not only by the clinical and radiographic appearance of the most radial digit, but also by the dermatoglyphics (302). The triphalangeal thumbs studied contained the radial loops normally seen in the index finger and not in the thumb.

Triphalangeal thumbs can be associated with musculoskeletal malformations, such as cleft feet and preaxial polydactyly (303); congenital heart disease, including Holt-Oram syndrome (160); hematopoietic abnormalities, such as Fanconi and Blackfan-Diamond syndromes (304,305); and imperforate anus (306).

Classification and pathoanatomy are dependent on the type of triphalangism. Type I involves a delta middle phalanx with radial deviation deformity (Fig. 22-32). Type II involves a normal middle phalanx, but an opposable thumb. Type III is an index-finger duplication with all digits in the same plane. In types I and II triphalangism, the first web space is normal. In the five-fingered hand (type III), there is a contracted first web space that limits prehension. Similarly, usually the thenar musculature is normal in type I and

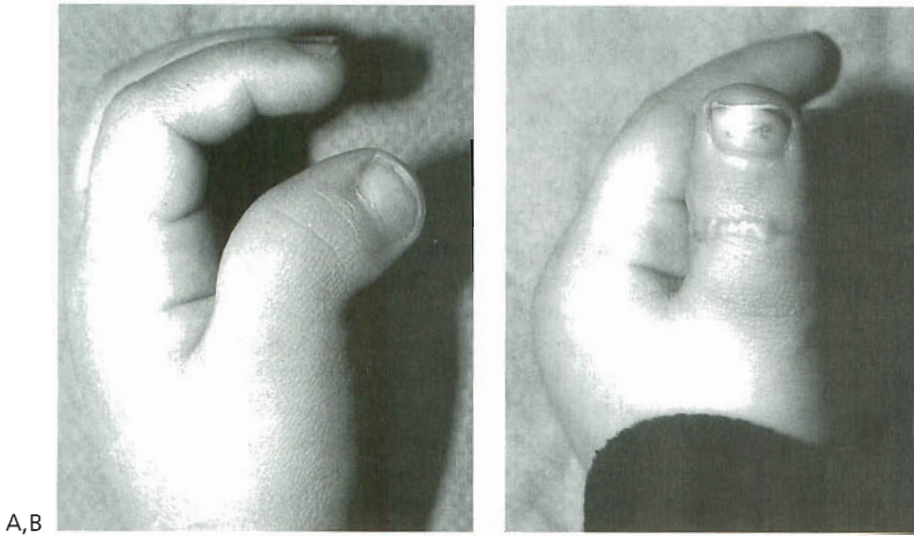


FIGURE 22-32. A: Triphalangeal thumb with a delta phalanx and a marked radial deviation deformity. B: Postoperative photograph after excision of the delta phalanx and rotation flap reconstruction of the soft tissues.

type II triphalangeal thumbs, whereas it is absent in type III triphalangism. In addition, the triphalangeal thumb may be hypoplastic and have associated extrinsic musculature weakness.

Treatment

Rarely, patients with triphalangeal thumbs prefer not to undergo surgical reconstruction. Patients with significant cosmetic differences and limitation of pinch prefer reconstruction for both functional and cosmetic reasons. A malaligned and elongated triphalangeal thumb in the same plane as the other digits is cosmetically different and functionally limited for prehension activities.

Depending on the type of triphalangeal thumb, surgery may involve web space deepening, excision of the extra phalanx (307), opposition transfer (308), or a modified pollicization procedure (308–310). The delta phalanx is usually excised to correct the length and angular deformity of the type I triphalangeal thumb (Fig. 22-32). If this procedure is performed in infancy, usually a stable interphalangeal joint can be reconstructed. In older children, or in children with abnormal phalanges and interphalangeal joints, a combination of shortening osteotomy and arthrodesis is preferred. In these situations, physeal growth of a biphalangeal digit should be preserved. In the five-fingered hand a modified pollicization procedure is necessary to provide a deep first web space and an opposable thumb.

TRAUMATIC INJURIES

Fractures to the pediatric hand are commonplace, accounting for approximately one-fourth of all childhood fractures (311). The two peak ages for these fractures are adolescence (from sport-related activities) and infancy (from crush injuries).

The majority of fractures are nondisplaced, nonphyseal injuries. Physeal injuries, however, can account for up to 40% of finger fractures (312,313), with a Salter-Harris II fracture of the small finger proximal phalanx being the most common. The majority of pediatric hand fractures do well regardless of treatment (314). Malunion and growth disturbance are rare (312,315). However, there is a subset of pediatric hand injuries that will do poorly if not recognized and treated appropriately. The purpose of this section is to review those fractures that are problematic.

Overview

The bones of the digits have only one secondary center of ossification. These appear between birth and 3 to 4 years of age. The epiphyses of the phalanges are proximal. The epiphyses of the metacarpals are distal, except for the thumb, in which the physis is proximal. Distally in the thumb, there can be a second epiphysis or pseudoepiphysis. Ossification of the phalangeal condyles is progressive with growth, but in preschool children the condyles may be predominantly cartilaginous. Radiographic evaluation of injuries in young children may be difficult because of the chondral nature of the epiphysis and the intraarticular portions of the condyles. It is important to obtain true anteroposterior and lateral radiographs of the injured digits. Digital MRI can be performed in the diagnostically confusing situation. Operative exploration may also be appropriate in problematic situations.

To protect the anatomic healing of a traumatized digit in a young child, maximal protection is necessary. It is often necessary to protect the preschool-age child with a long-arm mitten cast. The older child often needs a short-arm mitten cast. Single-finger splinting is difficult to maintain, even in an adolescent. If the fracture is painful, or requires immobilization to maintain reduction, casting of the entire

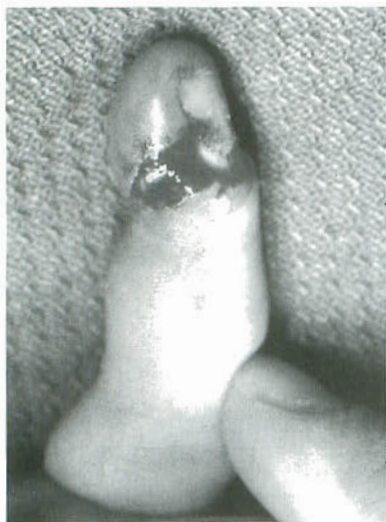

FIGURE 22-33. Typical distal phalangeal crush injury with nail and pulp laceration. Repair requires nail plate removal, absorbable suture repair of the lacerated nail bed, and anatomic closure of the eponychial skin.

hand is appropriate. Fortunately, the majority of pediatric fractures are nondisplaced and stable (316). The outcome will be successful regardless of immobilization technique. In these situations, the patients are changed to simple buddy taping as soon as it is comfortable. However, it is imperative not to mistake a problematic injury for a simple one and treat it with benign neglect. Such a mistake will lead to long-term loss of alignment, motion, and function that may not be salvageable by secondary surgical reconstruction.

Distal Phalanx Injuries

Nail Plate Injuries, Physeal Fractures, Mallet Fingers, and Tip Amputations

The vast majority of injuries to the distal phalangeal region are secondary to crush injury. These injuries are most common in the toddler and preschool-age groups. The mechanism of injury is usually a digit caught in a door. Adults, often parents, are frequently involved in the accident, which makes the situation emotionally charged. The injuries can include partial or complete amputation, nail-bed laceration, and distal phalangeal fracture. All of these sites of trauma need to be addressed in the care of the child. In addition, time and energy need to be spent in helping the family cope with the emotional trauma.

Tip Amputations. A distal phalangeal crush injury in a toddler usually includes a partial amputation with a nail-bed laceration and a distal phalangeal tuft fracture (Fig. 22-33). The fractures are generally minor avulsions that heal without problems. The partial amputation often extends

dorsally through the nail bed, leaving some volar pulp intact. The volar soft tissue attachments maintain the vascularity to the distal tip. Meticulous repair under conscious sedation and/or local anesthesia usually leads to normal long-term outcome. The technique involves initial repair of the eponychial folds to properly align and stabilize the digit. It is imperative to then meticulously repair the nail-bed laceration with fine, absorbable suture (i.e., 6-0 chromic suture) and loupe magnification, to prevent long-term nail deformity. The dorsal roof of the eponychium is preserved by placement of a spacer for several days after repair. Even when there is nearly complete amputation, with apparently nonviable distal tissue, soft tissue repair almost always leads to survival of the tip. Uncomplicated repair of the partial amputation and nail-bed laceration will generally heal without permanent change of the nail or phalanx. However, neglected nail-bed injuries have a high rate of permanent deformity (310,317).

Care of the complete amputation at the level of the nail, or distally, is more controversial. First, this is a much more difficult situation emotionally for the child and family. The injury often occurs while the child is under adult supervision. There usually is significant stress and guilt associated with the amputation. The parents universally want the tissue replaced. However, this injury is beyond the trifurcation of the digital arteries near the level of the distal interphalangeal joint, so the tissue is not replantable. The debate concerns whether to suture the amputated part back on without vascular anastomoses (a composite graft), or to allow healing by secondary intention (318). Replacement of the amputated soft tissue initially makes the family feel better, but usually is not necessary. The amount of soft tissue amputated is small. The physis is proximal and not affected. Subsequent growth will be normal. The overall digital length, therefore, will be nearly normal. The cosmetics of composite grafting and healing by secondary intention are generally equal in the long term. Long-term sensibility and function seem to be equivalent. In addition, in the short term replacement of the amputated part may be more stressful for the family and child, with multiple dressing changes, superficial necrosis of the distal tip, and slow healing. Therefore, if the soft tissue loss is minor, reassurance to the family of the long-term result and treatment with serial dressing changes are best. This is true as well for the situation in which a minimal portion of exposed bone is debrided. However, if the piece includes the eponychium or the entire sterile and germinal matrix of the nail, composite grafting of the amputated part is preferred. There is a chance that this will heal and preclude secondary reconstructive surgery.

Physeal Fractures and Nail-bed Entrapment. Some children will present with distal laceration and flexion, or mallet, posture to the distal phalanx. Radiographs will reveal a displaced physeal fracture with widening dorsally. Too often, these children will be diagnosed with mallet finger

and treated with splinting. This is not an extensor tendon disruption. The extensor mechanism is intact because the terminal tendon inserts into the more proximal epiphysis. The deformity is caused by entrapment of the proximal nail bed (germinal matrix) in the physeal fracture site (319). If not recognized early, the open injury can become secondarily infected. The clinical appearance of the finger and the radiographic physeal changes may be interpreted as distal phalangeal osteomyelitis. However, antibiotic treatment alone or surgical debridement of the distal phalanx is not the proper treatment for this late-presenting fracture. Surgical repair of the nail bed is necessary to prevent long-term nail and distal phalanx growth problems. Under local, regional, or general anesthesia, the nail plate should be removed. By flexing the distal phalanx, the entrapped nail bed can be gently extracted. The germinal matrix needs to be meticulously repaired to avoid long-term nail-plate problems. At times this requires more proximal exposure by raising an eponychial flap. After repair of the nail bed the nail plate can be replaced to preserve the dorsal roof of the eponychium, and to provide an internal splint for the fracture and repair (319,320). Placement of a cautery hole in the nail plate will lessen the risk of subsequent hematoma and paronychia infection.

Mallet Fingers. True mallet fingers are rare in the preadolescent child. In this age group, physeal fracture is more common. In the adolescent, mallet injuries with disruption of the extensor mechanism are more common and adult-like. As long as there is no entrapment of the germinal matrix, as noted above, these injuries can be treated with immobilization. Rarely, the entire epiphysis can be displaced with the extensor mechanism (321,322). If recognized early, this injury should be treated with open reduction of the dislocated epiphysis. The rare, chronic mallet finger in the young child has been treated successfully with tenodesis (323).

Phalanx Fractures

Phalangeal Neck Fractures

Phalangeal neck fractures are problematic. They are usually caused by crush injury. As the child attempts to extract the affected digit, the condyles become entrapped and a fracture occurs in the subcondylar region (316,324,325). The condylar fragment displaces into extension and often malrotates. The fragment is tethered by the collateral ligaments as it rotates dorsally up to 90 degrees. The condylar fragment is small, and has a precarious blood supply through the collateral ligaments. The subcondylar fossa is obliterated, blocking interphalangeal flexion (Fig. 22-34). If not properly recognized and treated, complications of malunion, loss of motion, and avascular necrosis can occur. Too often, the severity of the fracture is underappreciated in the urgent

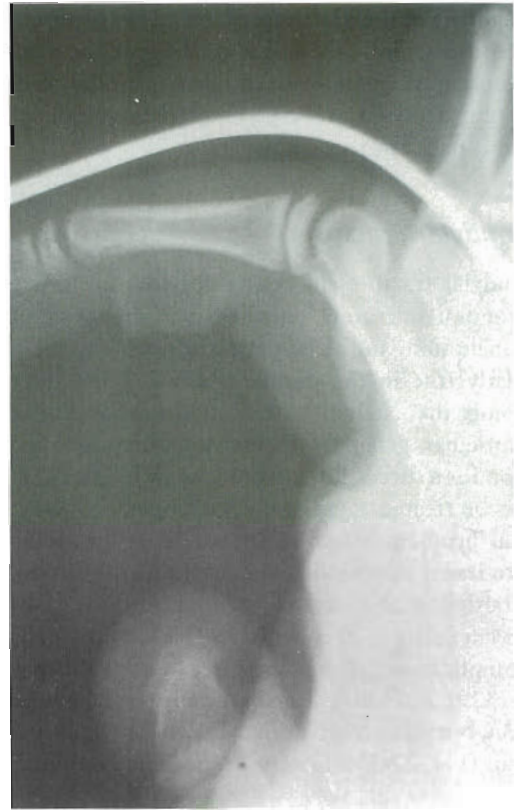

FIGURE 22-34. Phalangeal neck displaced fracture with loss of the subcondylar fossa. This leads to loss of digital flexion. This fracture requires prompt attention, anatomic reduction, and pin stabilization.

care setting. The patient presents late, with inappropriate immobilization and a significantly healed fracture. In addition, the fracture is unstable and often will displace after closed reduction (326). The treatment of choice is closed reduction and percutaneous pinning. In a young child, this can be accomplished with a single oblique pin. In an older child, crossed pins prevent malrotation. Placement of the pins in the distal fragment requires careful localization of the fragment and avoidance of the extensor mechanism. If open reduction is necessary, the collateral ligaments should not be dissected from the distal fragment. Careful dissection lessens the risk of avascular necrosis.

Open reduction, when there is marked callus, may cause avascular necrosis. The fracture is generally too healed for successful closed reduction and percutaneous pinning. If there is still lucency along the fracture line, percutaneous osteoclasis can be performed (327). A pin is placed dorsally in the fracture site under fluoroscopic control, and used to reduce the fracture. The subcondylar fossa can be reconstituted, and the fracture can be pinned percutaneously.

If the fracture is completely healed upon referral, late subcondylar fossa reconstruction can be performed if there is a bony block to flexion (325). An average of 90 degrees

of PIP joint flexion has been obtained with subchondral fossa reconstruction (325). Remodeling of the fracture is rare because of the significant distance from the physis, but it has been described in a case report of a middle phalanx phalangeal neck fracture (328).

Intercondylar Fractures

Intercondylar fractures in young children are often small osteochondral fractures. These carry a high risk of non-union, malunion, and avascular necrosis (310,329). This is particularly true in the middle phalanx if the injury is a crush injury that alters the local blood supply. The fracture is intraarticular, generally displaced, and requires anatomic reduction for a successful outcome. Most often, the fracture needs to be treated aggressively with open reduction. The collateral ligament attachments to the fragment are preserved to lessen the risk of avascular necrosis. On occasion, bone grafting is necessary to maintain articular congruity and prevent collapse. Even with well-performed open reduction, complications of this fracture can occur in the young patient (329). Avascular necrosis usually resolves by revascularization, but often not before collapse. Articular malunion can occur (Fig. 22-35). Loss of motion may not limit function.

In the adolescent, treatment of intercondylar fractures is similar to that in adults. Anatomic reduction and pin fixation

are necessary to restore the joint surface, and to prevent loss of reduction that can occur with this unstable fracture. Generally, the procedure can be performed closed, using distraction and a percutaneous towel clip to obtain reduction (330). Open reduction can be performed with a volar, midaxial, or dorsal approach. This is appropriate for fractures that cannot be reduced closed, or for comminuted fractures. Restoration of an anatomic joint will lessen the risk of loss of motion, malalignment, or long-term arthritis (Fig. 22-35).

Diaphysis-level phalangeal fractures are rare in the young child, and more common in the teenager. The major issue with these fractures is malrotation (312) (Fig. 22-36). Frequently, children will not actively move the finger in the acute setting to allow for accurate assessment of digital alignment. However, close inspection of the nail plates will reveal the digital malalignment. In addition, the examiner can test digital alignment by tenodesis of the wrist. With passive wrist extension, the fingers flex and point toward the volar scaphoid tubercle. Digital alignment is generally symmetric. Children will tolerate this test, even when they are in too much pain or are too frightened to actively move their digits. Tenodesis assessment needs to be performed on all phalangeal and metacarpal fractures, regardless of radiographic appearance. If closed treatment is chosen never immobilize a solitary finger, but secure it to the adjacent digits to prevent subsequent loss of reduction and malrotation.

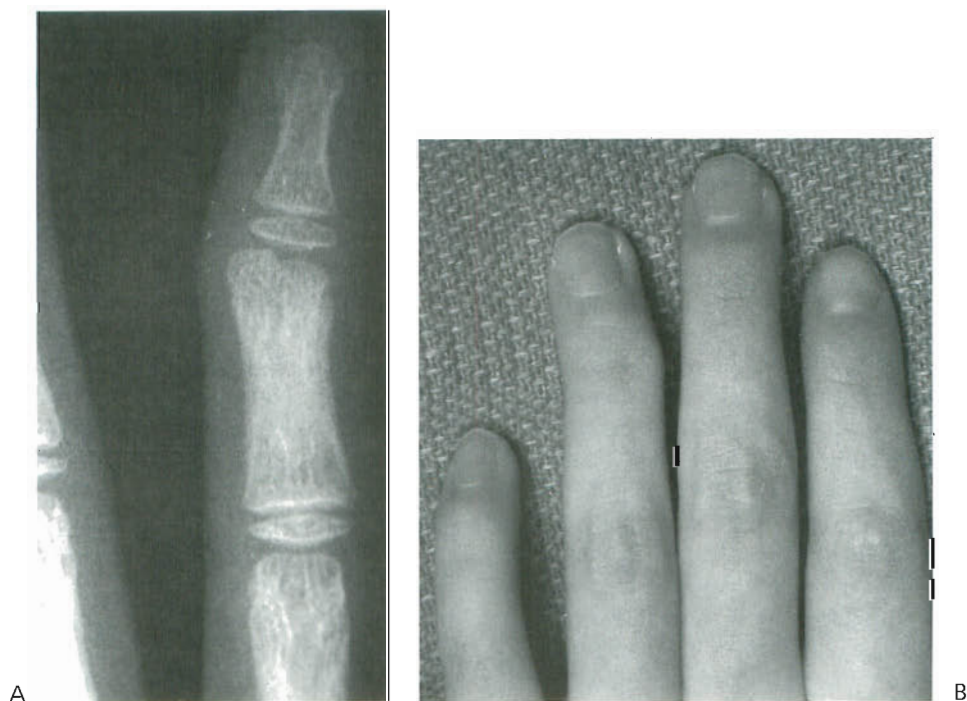


FIGURE 22-35. A: Radiograph of a displaced intercondylar fracture with articular malunion. B: Clinical photograph of a similar patient. This injury requires acute anatomic reduction and pin stabilization to prevent long-term loss of motion, malalignment, and potential pain and arthritis.

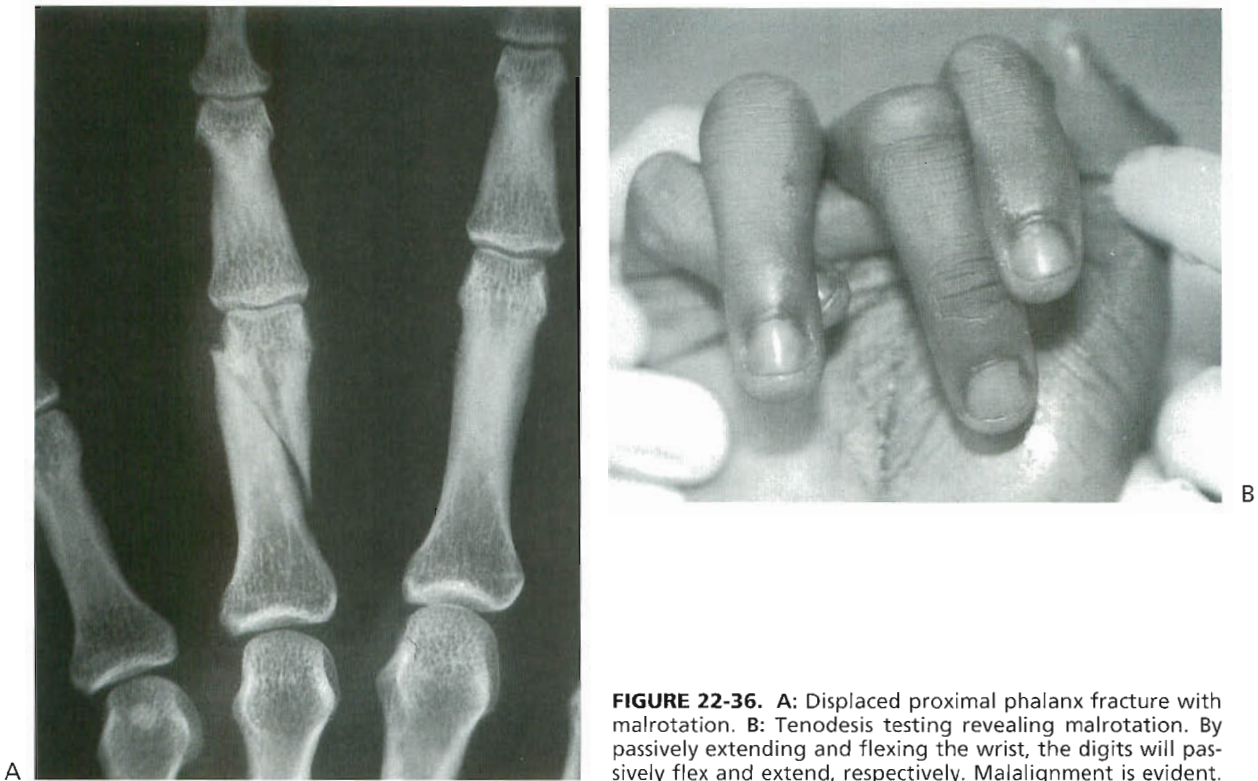


FIGURE 22-36. A: Displaced proximal phalanx fracture with malrotation. B: Tenodesis testing revealing malrotation. By passively extending and flexing the wrist, the digits will passively flex and extend, respectively. Malalignment is evident.

If the fracture is malrotated and unstable, reduction with pin or screw stabilization is necessary (331,332). Although malrotation is uncommon, it is a major problem if missed until after healing. The malrotated digit impairs the function of the adjacent digits because the digits will overlap in flexion. Then, malrotation can be corrected only with osteotomy.

Physeal Fractures

Physeal fractures constitute 30 to 70% of pediatric finger fractures (311–313,315). A Salter-Harris II fracture of the small finger is the most common of these fractures. Closed reduction of the abducted fracture is performed in MCP flexion to lessen the restraint of the more distal web space. The surgeon's thumb or a cylindrical object such as a pencil can be used. Postreduction stability is maintained by taping the digit loosely to the adjacent digit and applying a short-arm mitten cast. Less common type III physeal fractures require open reduction if there is greater than 2 mm of diastasis or articular step-off.

Metacarpal Fractures

Distal metacarpal metaphyseal (boxer) fractures are common in adolescence. The mechanism is a closed fist injury, most often to the small finger metacarpal. These fractures are usually juxtaephyseal and malaligned, with apex dorsal

angulation. In the acute setting, closed reduction and cast immobilization with three-point fixation for 3 weeks is preferred for displaced fractures. This includes volar-to-dorsal pressure on the metacarpal head and dorsal-to-volar pressure on the more proximal shaft. Often, these patients will not seek medical attention until there is significant healing. Fortunately, the fracture is adjacent to the distal metacarpal physis, and the flexion malunion can remodel if there is sufficient growth remaining. This fact has led some clinicians to approach these fractures with neglect to allow for remodeling. Indeed, depending on the age of the patient, remodeling of the flexion deformity can occur. However, malrotation will not remodel. In addition, if remodeling is slow or fails to occur, the prominence of the metacarpal head in the palm can be limiting.

The rare unstable, or multiple, metacarpal fracture(s) should be treated with closed reduction and percutaneous pinning. Two smooth pins are placed under fluoroscopic control, from ulnar to radial, distal to the fracture site(s), from the fifth to the fourth or third metacarpal, as necessary. Late open reduction of the juxtaephyseal fracture carries the risk of physeal injury and should be avoided. Diaphyseal fractures of the fifth metacarpal have a higher risk of malunion that will not remodel. Closed reduction and percutaneous pinning to the adjacent metacarpals is the treatment of choice. Corrective osteotomy may be necessary in the severe, malunited diaphyseal fracture that fails to remodel the flexion deformity with growth.

A,B

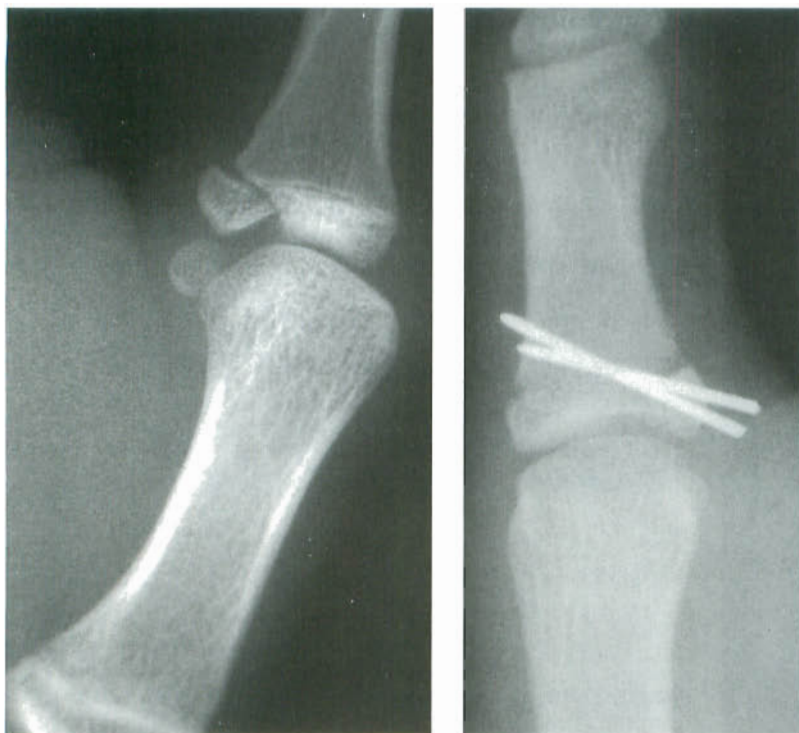

FIGURE 22-37. A: Salter-Harris III displaced proximal phalanx fracture of the thumb. This fracture requires open reduction and internal fixation to restore articular congruity and ligamentous stability. B: Postoperative radiograph of a similar patient with pins in place.

The major issue with other diaphyseal metacarpal fractures, especially if there are multiple metacarpal fractures, is malrotation. Active digital motion or passive tenodesis of the wrist will reveal malrotation. Anatomic reduction and pin, screw, or plate fixation will correct the malrotation.

Thumb Fractures

The unique features of fractures of the thumb are seen in Salter-Harris III fractures of the proximal phalanx, and at the base of metacarpal fractures. The type III physeal fracture of the thumb proximal phalanx is the skeletally immature equivalent of an adult ulnar collateral ligament disruption (333) (Fig. 22-37). These fractures require open reduction and internal fixation to restore joint stability and anatomic alignment of the joint and physis. During surgical exposure, remember that the ligament is intact so that, after adductor takedown, the MCP joint is exposed through the fracture site, rather than through inadvertent incision of the ligament. The long-term results of anatomic open reduction are excellent. Metaphyseal fractures at the base of the thumb metacarpal often displace. Immobilization and observation, even with displaced fractures, are appropriate as long as there are at least 2 years of growth remaining, because the malunited dorsoradial prominence will remodel during the ensuing 6 to 12 months (317) (Fig. 22-38). Most parents would prefer to wait for remodeling rather than have operative reduction and pinning. The presence of a Bennett fracture with articular malalignment requires anatomic align-

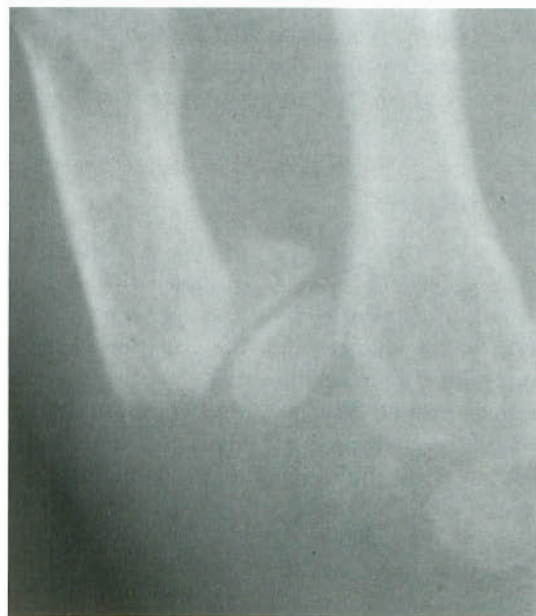

FIGURE 22-38. Displaced base in a metacarpal thumb fracture. Because this fracture is juxta-physeal, adjacent to the carpometacarpal joint with universal motion, its remodeling potential is almost unlimited if the patient is younger than 10 years of age. Treatment choices are closed reduction and pinning, or cast immobilization and biologic remodeling for the ensuing 6 to 12 months of growth. This patient was treated in a cast.

ment of the intraarticular component and pin fixation of the thumb metacarpal to the adjacent second metacarpal and carpus.

Wrist Injuries

Scaphoid Fractures

Scaphoid fractures occur from a fall on an outstretched wrist. The pain is often mild, rather than the severe pain a child or parent expects from an acute fracture. This leads some patients and families to ignore the acute injury and not present until late. When the child presents acutely, there will be tenderness to palpation over the anatomic snuff-box (the region dorsoradially at the wrist between the extensor pollicis longus and the extensor pollicis brevis tendons), the volar scaphoid tubercle, and with axial compression of the thumb carpometacarpal joint. Radiographs may reveal the fracture. The best view is an anteroposterior view in 30 degrees of ulnar deviation (scaphoid view). If the radiographs are diagnostic for the fracture, long-arm immobilization in a thumb spica cast is best. If the radiographs are negative, but the child is tender, as noted above, protected immobilization for 2 weeks is advised. Repeat clinical and radiographic examination should be performed out of cast 2 weeks later if tenderness persists. If there is still doubt about the diagnosis, MRI or CT is advised. The CT scan shows the bony alignment better, but the MRI scan gives added information about the vascularity to the proximal

pole, and better outlines the cartilage surfaces in a young child. CT scans are used for the acute fracture in the adolescent. MRI scans are used for the acute injury in the child younger than 10 years of age.

Previously, it was written that most scaphoid fractures in the skeletally immature patient were distal pole or avulsion fractures (329). Distal pole fractures heal readily with cast immobilization without risk of nonunion or avascular necrosis. However, scaphoid wrist fractures are becoming more common in the adolescent age group. These fractures can displace and carry the same risks of nonunion and avascular necrosis in the child as they do in the adult. Similarly, nonunions are becoming more commonplace (334,335). Treatment of an established nonunion in a child should be with open reduction, bone grafting, and, potentially, internal fixation. Internal fixation screws have been used in children with both acute displaced wrist fractures and established nonunions (328,334,335) (Fig. 22-39). The issue of whether a bipartite scaphoid, even if bilateral, is congenital or posttraumatic, remains unresolved. However, if symptomatic, it should be treated in the same way as a traumatic nonunion. The success of open reduction, bone grafting, and internal fixation for a scaphoid nonunion is high in children (334,335).

Wrist Pain, Triangular Fibrocartilage Complex Tears, and Ligamentous Injuries

Atraumatic Ligamentous Instability. Most adolescents with chronic wrist pain have overuse injuries. These patients

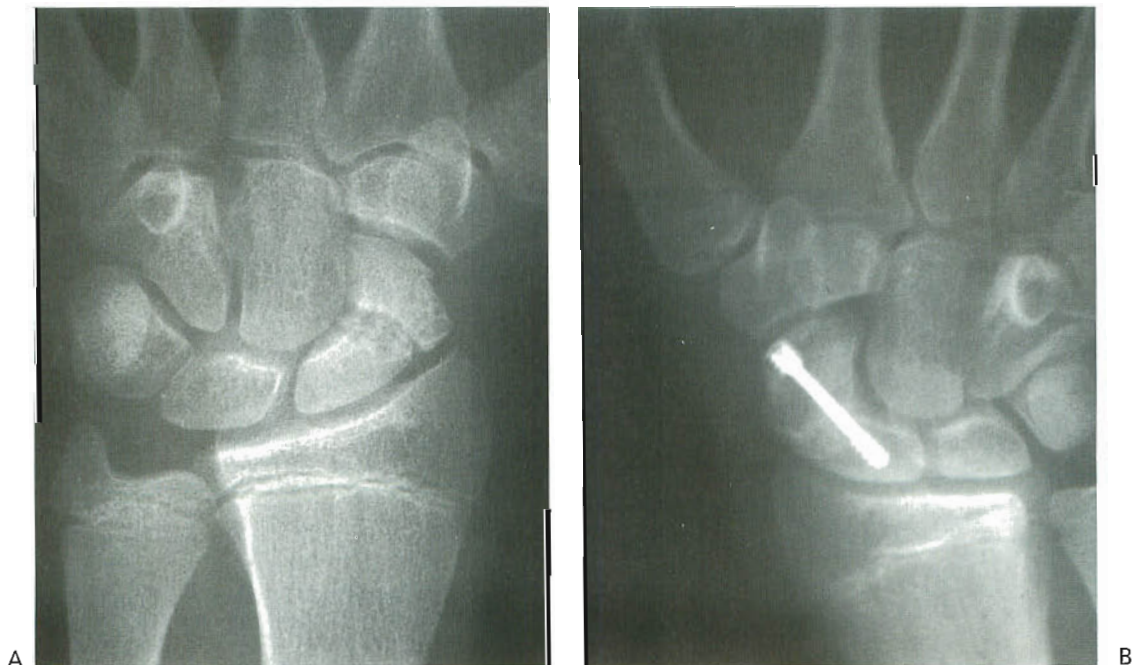


FIGURE 22-39. A: Scaphoid nonunion in an adolescent. B: Postoperative iliac crest bone grafting and internal fixation for a similar scaphoid fracture nonunion.

often have generalized ligamentous laxity or a hyperelasticity syndrome. The wrist pain is similar to the patellofemoral knee pain and multidirectional shoulder instability pain seen in this age group. Overuse, growth, and resultant muscle weakness all contribute to joint instability. On physical examination, there is often systemic evidence of generalized laxity (elbow cubitus valgus, pes planus, knee hyperextension, passive hyperextension of the index finger parallel to the dorsal forearm, and thumb abduction to the volar forearm). At the wrist, there will be increased midcarpal translation to volar and dorsal applied stress. This passive midcarpal instability will be equivalent on both the affected and the unaffected wrist. However, the affected side often will have painful clicking. Plain radiographs may reveal a volar tilt to the lunate on the lateral view. MRI scans and arthrograms appear normal. These children respond to alteration of activities and strengthening, as in other growth-related overuse injuries in the teenager. It is the author's experience that resistive strengthening with therapeutic putty is best.

Traumatic Scapholunate Ligamentous Injuries. Post-traumatic injuries to the scapholunate ligament rarely occur in children. Most descriptions of these injuries have been case reports (336). However, it is the author's experience that these traumatic ligamentous injuries are occurring more frequently with today's higher level of athletic competition in this age group. On physical examination, the tenderness is usually more focal than in atraumatic ligamentous laxity wrist pain. Asymmetric clicking with applied ligamentous stress testing is common. Static injuries are more common in adults, and will show an increased scapholunate distance and a flexed scaphoid on plain radiographs. Most scapholunate injuries in children are dynamic injuries, with normal

plain radiographs. In addition, the scapholunate distance in children has been difficult to interpret because of eccentric ossification and the chondral nature of the carpus in the young. A recent study of pediatric wrist radiographs developed an age standard for scapholunate distances in both sexes (337). This will help in the evaluation of pediatric carpal injuries. MRI scans may reveal the ligamentous injury. Arthroscopic examination of the wrist is diagnostic and often therapeutic. Many of these injuries are partial tears of the ligament, with an associated chondral lesion of the radius. This leads to mechanical impingement that often responds favorably to arthroscopic debridement. It is rare that there will be a complete ligamentous disruption in this age group. However, symptomatic complete scapholunate disruptions need to be treated with ligamentous reconstruction.

Triangular Fibrocartilage Complex Tears (TFCC)

Posttraumatic chronic wrist pain that does not respond to prolonged rest and therapy needs to be evaluated for intra-articular pathology. Similar to scaphoid fractures and intercarpal ligamentous injuries, the epidemiology of TFCC tears may be changing to include the adolescent. Physical examination for TFCC tears includes ulnocarpal compressive testing, lunate-triquetral stress testing, and distal radioulnar joint stress testing. Painful clicking with these maneuvers, especially if asymmetric, may be indicative of a tear. However, many children with nondissociative laxity have similar findings on physical examination. Plain radiographs are normal. The MRI may be diagnostic, but there has been a high incidence of false-negative readings for adolescent TFCC tears. In skilled hands arthroscopy is definitive for diagnosis, and often treatment (Fig. 22-40).

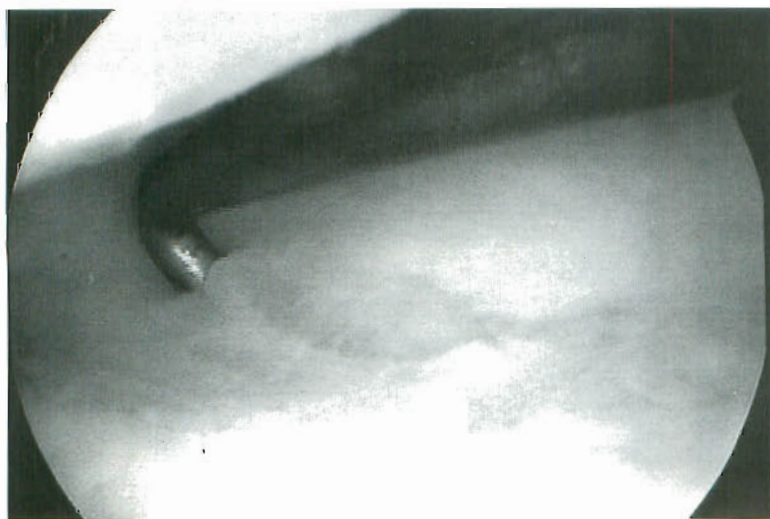

FIGURE 22-40. Arthroscopic photograph of a triangular fibrocartilage complex (TFCC) peripheral tear. The tear is along the peripheral edge of the TFCC, where the blood supply enters and aids in healing. Repair is by arthroscopic suture techniques in this situation.

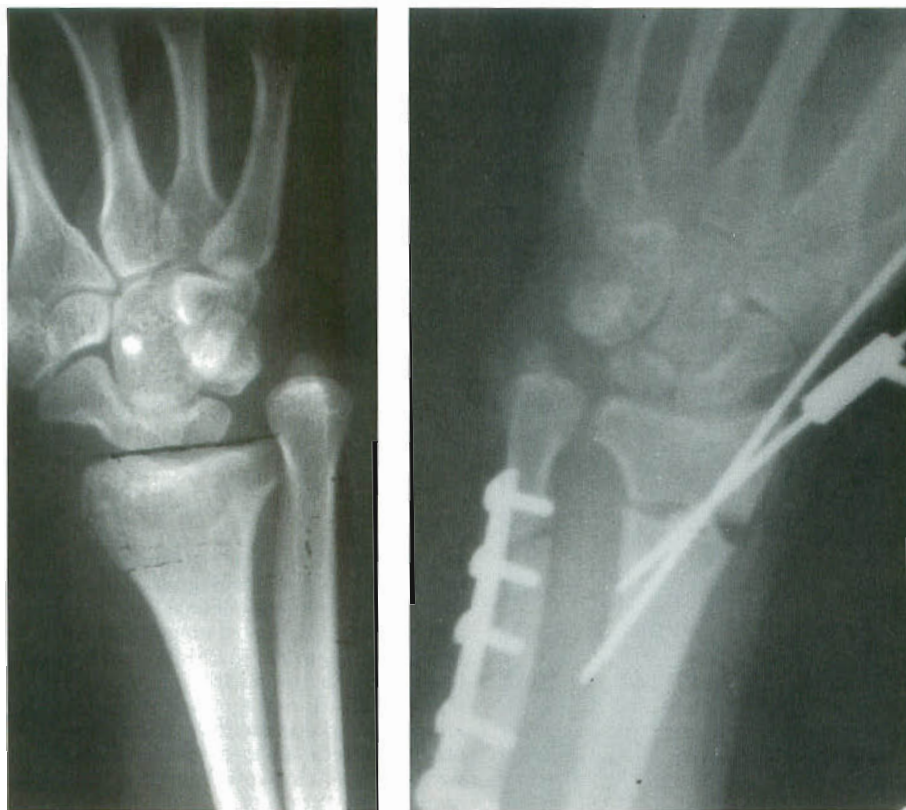

FIGURE 22-41. A: Radiograph of ulnocarpal impaction associated with radial growth arrest, ulnar overgrowth, and a triangular fibrocartilage complex (TFCC) tear. B: Repair of the TFCC, ulnar-shortening, and radial osteotomy with bone grafting were performed.

TFCC tears occur in the skeletally immature. Most tears are associated with ulnar styloid fracture nonunion, radial growth, ulnar overgrowth, and/or ulnocarpal impaction syndrome. Isolated tears also occur. In adolescents and children, these tears are usually peripheral tears that respond well to surgical repair (338). Isolated tears can be repaired arthroscopically. Tears associated with radial and ulnar bony deformities are repaired at the time of corrective osteotomy (Fig. 22-41). Treatment should also include appropriate excision of the ulnar styloid nonunion, shortening of the impacting ulna, osteotomy of the deformed radius, and stabilization of the distal radioulnar joint, if necessary (338).

Dislocations

Most hyperextension injuries to the finger interphalangeal joints in children result in a tear of the volar plate. There may be associated minimal Salter-Harris III physal avulsions of the adjacent phalanx (Fig. 22-42). These injuries are stable. Treatment should be brief immobilization for comfort, followed by buddy taping until the patient is asymptomatic. Prolonged treatment with splints can lead to PIP joint stiffness. True interphalangeal dislocations

occur less often. The dislocation is usually dorsal, and occurs more commonly at the PIP joint than at the distal interphalangeal joint. Closed reduction with distraction and dorsal-to-volar manipulation are generally successful.

Rarely, a displaced epiphysis, flexor tendon, or interposed volar plate can block reduction, and will require open reduction. MCP joint dislocation of the thumb or index finger can be simple or complex (326). Simple dislocations are reducible in the emergency setting. Complex dislocations are irreducible, and have an interposed volar plate blocking closed reduction. Plain radiographic evidence of widening and lateralization of the joint, as well as bayonet apposition of the proximal phalanx and metacarpal, indicate an irreducible situation.

Open reduction of a complex dislocation can be performed by a volar (339,340) or a dorsal (341,342) approach. In the volar approach, the radial neurovascular bundle is tented just beneath the skin by the metacarpal head. It is imperative to be cautious with the skin incision to prevent iatrogenic laceration. By either approach, the volar plate needs to be incised to allow reduction of the joint and anatomic realignment of the flexor tendons, sesamoids, and collateral ligaments. Postoperative treatment is by early protected motion with buddy taping and extension block

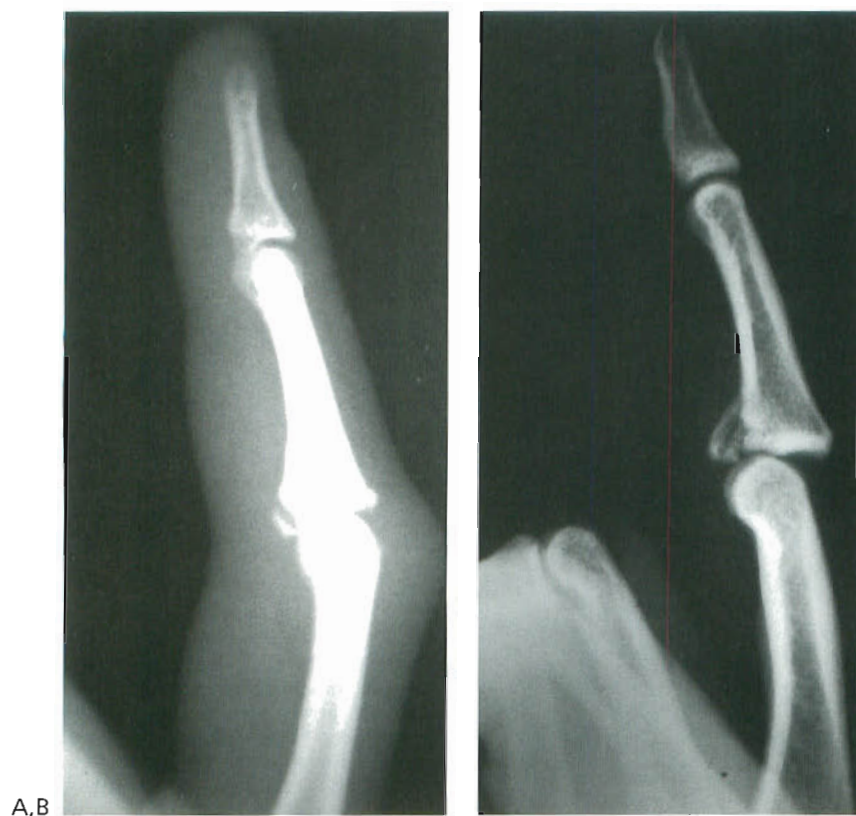

FIGURE 22-42. A: Volar plate injury with non-displaced minor volar and dorsal avulsion injuries. This injury needs minimal immobilization and prompt initiation of range-of-motion exercises to minimize the risk of permanent flexion contracture. B: This injury has a more significant fracture fragment and joint subluxation. This requires anatomic reduction of the proximal interphalangeal joint and an extension block splint to allow for motion within the range of joint stability.

splinting. Chronic instability is rare, but limited MCP motion is not. The digital neuropathia secondary to the dislocation will resolve in this age group.

Tendon Lacerations

The classification system, in terms of zones of injury for flexor tendon lacerations, is the same for the child as it is for the adult. The diagnosis of flexor tendon injury, operative care, and postoperative rehabilitation may be more difficult in the child. This is especially true in the toddler and preschool-age child, in whom patient cooperation is limited. Often, the presenting digital cascade, and digital excursion with wrist tenodesis, serve as the basis for the diagnosis of flexor tendon laceration (Fig. 22-43). If in doubt, explore the wound under anesthesia. Repair of the tendon lacerations in zones I and II requires meticulous technique with fine sutures. Repair can be performed electively in the first 1 to 2 weeks with equivalent results. However, if there is any concern regarding the vascular status of the digit, repair should be emergent, with exploration of the digital neurovascular bundles. In the infant, the core suture may be as fine as 6-0 and the epitendon suture may be 8-0. Postoperative immobilization in a cast for 4 weeks is effective protec-

tion. Subsequent rehabilitation is necessary to regain maximal passive and active motion.

There have been no differences in total active motion (TAM) between early mobilization protocols and cast immobilization for 4 weeks in children younger than 15 years (343). The results of isolated profundus tendon lacerations in zone I averaged 90 to 94% of normal TAM. Isolated profundus lacerations in zone I averaged 71 to 78% TAM. Combined superficialis and profundus lacerations in zone II averaged 72% TAM. However, if cast immobilization continued beyond 4 weeks there was a significant decrease in TAM to 40% by 6 weeks. There was no difference in the results by age groups from birth to 15 years.

Associated nerve or palmar plate injuries diminished the results slightly. Postoperative tendon rupture is rare. Two-stage reconstruction of unrecognized zone II lacerations in children younger than 6 years has had poorer results than in adults, with a higher rate of complications and a mean TAM of approximately 60% of normal. Results were better with supervised rehabilitation (344).

The principles of the treatment of extensor tendon lacerations in the adult apply to the child as well. Direct repair in the emergency room under sedation, or in the operating room under general anesthesia, is preferred. Cast immobilization, in a protected position of wrist

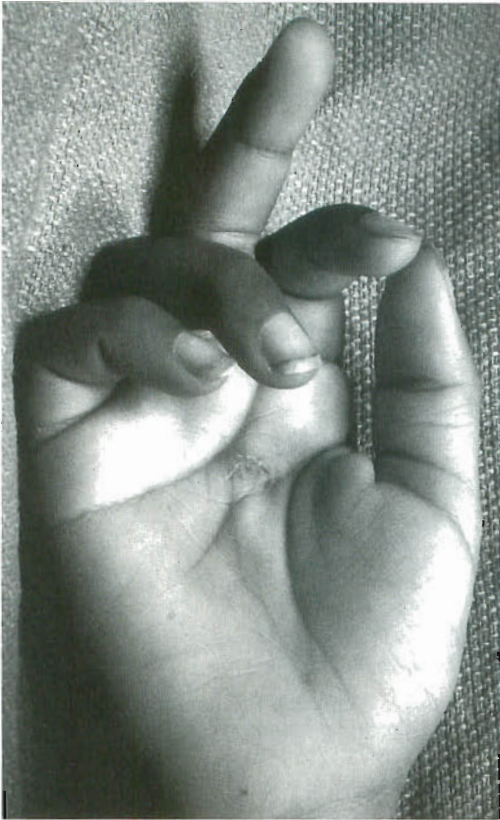

FIGURE 22-43. Photograph of an altered digital flexion cascade with passive wrist extension tenodesis. This is diagnostic of a flexor tendon laceration in the long finger.

dorsiflexion and digital extension, is continued for 4 weeks after repair. Results are excellent with primary repair. Associated fractures, dislocations, and flexor tendon injuries lessen the results.

Amputations

Distal fingertip complete or partial amputations are very common in children, and have been discussed in detail in the section of this chapter on distal phalangeal injuries. Treatment of more proximal, complete digital amputations with replantation in children as young as 1 year of age is now standard. In children, the indications for replantation are more liberal than in adults, and include multiple-digit, thumb, midpalm, hand, and distal forearm amputations as well as single-digit amputations in zones I and II. Crush amputations from doors, heavy objects, or bicycle chains have a peak incidence at 5 years, whereas sharp amputations occur more commonly in adolescence. Digital survival rates from replantation range from 69 to 89% in pediatric series. More favorable digital survival was seen with sharp amputations, body weight greater than 11 kg, more than one vein

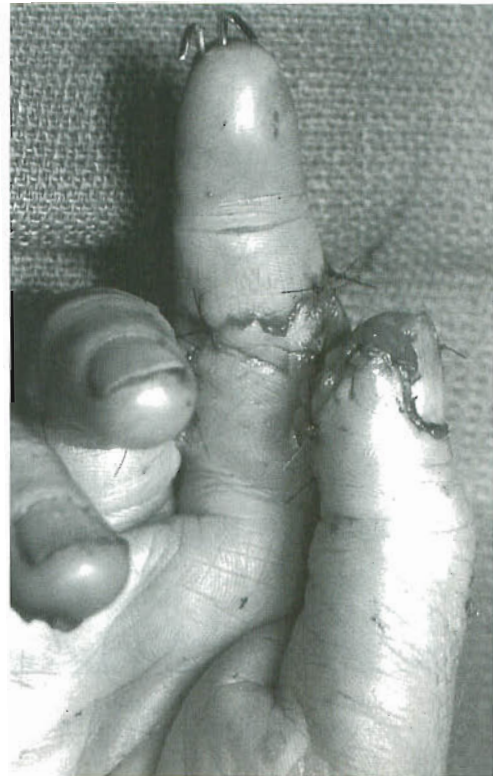

FIGURE 22-44. Postoperative digital replantation in a child at the middle phalangeal level of the index finger. The lacerations and tendon injuries in the adjacent digits were repaired simultaneously. Single-digit replantation procedures are indicated in children.

repaired, bone shortening, interosseous wire fixation, and vein grafting of arteries and veins. Vessel size generally exceeds 0.8 mm in digital replants in children, and is not a technical problem for the skilled microvascular surgeon. Index- and long-finger replants have done better than small finger replants in children. A survival rate of 95% was seen in children if prompt reperfusion occurred after arterial repair with at least one successful venous anastomosis, compared with 0% survival if one or both of these factors were absent (345) (Fig. 22-44). Neural recovery rates far exceed those cited in adults, with return of two-point discrimination less than 5 mm often present (346). Tenolysis may rarely be necessary after tendon repair. Two-stage flexor tendon reconstruction in children has a higher rate of complications than in adults. Growth arrest or deformity is more common if there is a crush component to the amputation. These digits rarely are normal after replanting, and the results in children are better than in adults, in terms of sensibility and recovery of range of motion. Microvascular toe-to-thumb transfer is a very successful alternative to pollicization in the case of a failed replant in a young child (347) (Fig. 22-45).

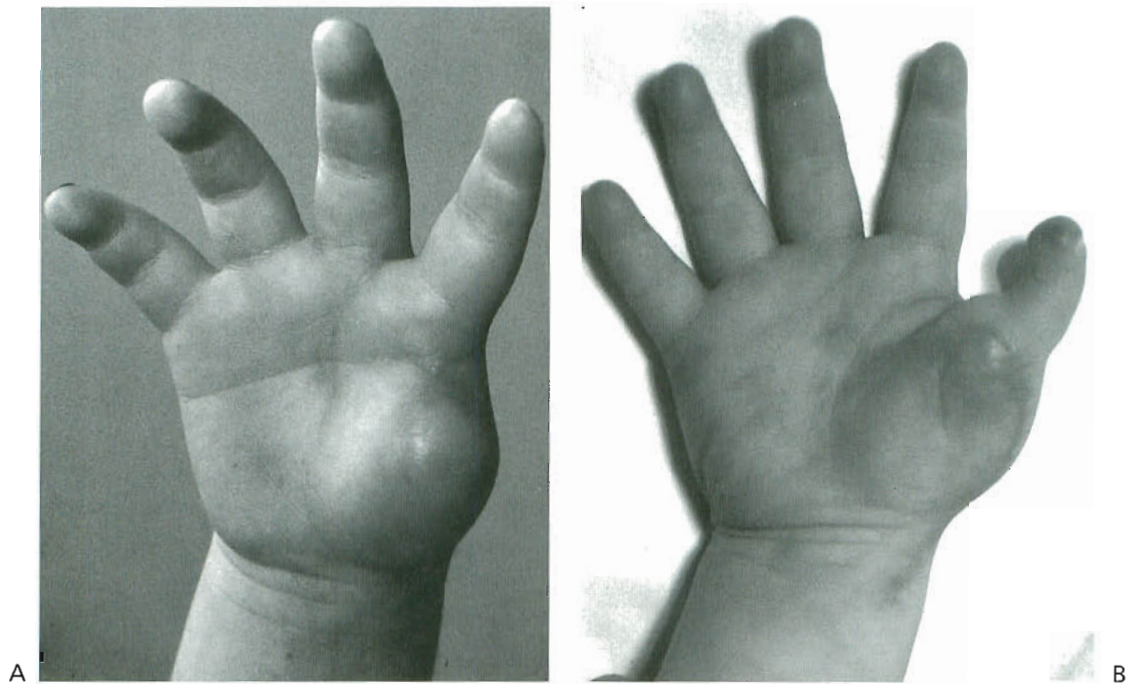


FIGURE 22-45. A: Traumatic amputation of the thumb in a 2-year-old child. B: Postoperative photograph of the same patient after microvascular toe-to-thumb transfer for thumb reconstruction.

References

1. Flatt AE. *The care of congenital hand anomalies*. St. Louis: Quality Medical Publishing, 1994.
2. Saunders JW Jr, Cairns JM, Gasseling MT. The role of the apical ridge of ectoderm in the differentiation of the morphological structure and inductive specificity of limb parts in the chick. *J Morphol* 1957;101:57.
3. Ulthoff HK. *The embryology of the human locomotor system*. Berlin: Springer-Verlag, 1990.
4. Tabin C. The initiation of the limb bud: growth factors, HOX genes, and retinoids. *Cell* 1995;80:671.
5. Omi M, Ude H. Effects of digit tissue on cell death and ectopic cartilage formation in the interdigital zone in chick leg buds. *Dev Growth Differ* 1996;38:419.
6. Saunders JW Jr. The proximo-distal sequence of origin of the parts of the chick wing and the role of ectoderm. *J Exp Zool* 1948;108:363.
7. Solursh M. Ectoderm as a determinant of early tissue pattern in the limb bud. *Cell Differ* 1984;15:17.
8. Summerbell D. A quantitative analysis of the effect of excision of the AER from the chick limb-bud. *J Embryol Exp Morphol* 1974;32:651.
9. Summerbell D. The zone of polarizing activity: evidence for a role in normal chick limb morphogenesis. *J Embryol Exp Morphol* 1979;50:217.
10. Tickle C. Experimental embryology as applied to the upper limb. *J Hand Surg Br* 1987;12:294.
11. Muragaki Y, Mundos S, Upton J, et al. Altered growth and branching patterns in synpolydactyly caused by mutations in HOXD13. *Science* 1996;272:548.
12. Lamb DW, Wynne-Davies R, Soto L. An estimate of the population frequency of congenital malformations of the upper limb. *J Hand Surg Am* 1982;7:557.
13. Conway H, Bowe J. Congenital deformities of hand. *Plast Reconstr Surg* 1956;18:286.
14. Swanson AB. A classification for congenital limb malformation. *J Hand Surg Am* 1976;1:8.
15. Swanson AB, Swanson GD, Tada K. A classification for congenital limb malformation. *J Hand Surg Am* 1983;8:693.
16. Bradbury ET, Hewison J. Early parental adjustment to visible congenital disfigurement. *Child Care Health Dev* 1994;20:251.
17. Bradbury ET, Kay SP, Tighe C, et al. Decision-making by parents and children in paediatric hand surgery. *Br J Plast Surg* 1994;47:324.
18. Gath A. The impact of an abnormal child upon the parents. *Br J Psychol* 1977;3:405.
19. Netscher DT, Scheker LR. Timing and decision making in the treatment of congenital upper extremity deformities. *Clin Plast Surg* 1990;17:113.
20. Varni JW, Setoguchi Y. Effects of parental adjustment on the adaptation of children with congenital or acquired limb deficiencies. *J Dev Behav Pediatr* 1993;14:13.

Entire Limb Involvement

21. Volpe JJ. *Neurology of the newborn*. Philadelphia: WB Saunders, 1987.
22. Smith RJ. *Tendon transfers of the hand and forearm*. Boston: Little, Brown, 1987:177.
23. Zancolli EA, Goldner W, Swanson AB. Surgery of the spastic hand in cerebral palsy: report of the Committee on Spastic Hand Evaluation. *J Hand Surg Am* 1983;8:766.
24. Skoff H, Woodburg DF. Management of the upper extremity in cerebral palsy. *J Bone Joint Surg Am* 1985;67:500.

25. Zancolli EA, Zancolli E Jr. Surgical rehabilitation of the spastic upper limb in cerebral palsy. In: Lamb DW, ed. *The paralyzed hand*. Edinburgh: Churchill Livingstone, 1987:153.
26. Bleck EE. *Orthopaedic management of cerebral palsy*. Philadelphia: WB Saunders, 1979.
27. Waters PM, Van Heest A. Spastic hemiplegia of the upper extremity in children. *Hand Clin* 1998;14:119.
28. Sakelaarides HT, Mital MA, Lenzi WD. Treatment of pronation contractures of the forearm in cerebral palsy by changing the insertion of the pronator radii teres. *J Bone Joint Surg Am* 1981;63:630.
29. Van Heest A, House J, Cariello C. Upper extremity surgical treatment of cerebral palsy. *J Hand Surg Am* 1999;24:323.
30. Koman AL, Gelberman RH, Toby BE, et al. Cerebral palsy: management of the upper extremity. *Clin Orthop Relat Res* 1990; 253:62.
31. Mital MA. Lengthening of the elbow flexors in cerebral palsy. *J Bone Joint Surg Am* 1957;39:553.
32. Pletcher D, Hoffer M, Koffmann D. Non-traumatic dislocation of the radial head in cerebral palsy. *J Bone Joint Surg Am* 1976; 58:104.
- 32a. Hoffer M, Perry J, Garcia M, et al. Adduction contracture of the thumb in cerebral palsy. *J Bone Joint Surg Am* 1983;65:755.
33. House JH, Swathmey FW, Fidler MO. A dynamic approach to the thumb-in-palm deformity in cerebral palsy. *J Bone Joint Surg Am* 1981;63:216.
34. Phelps WM. Long-term results of orthopaedic surgery in cerebral palsy. *J Bone Joint Surg Am* 1957;39:53.
35. Mowery CA, Gelberman RH, Rhoades CE. Upper extremity tendon transfers in cerebral palsy: electromyographic and functional analysis. *J Pediatr Orthop* 1985;5:69.
36. Manske P. Cerebral palsy of the upper extremities. *Hand Clin* 1990;6:697.
37. Koman LA, Mooney JF, Smith BP, et al. Management of spasticity in cerebral palsy with botulinum-A toxin: report of a preliminary randomized double blind trial. *J Pediatr Orthop* 1994; 14:299.
38. Goldner JL, Koman LA, Gelberman R, et al. Arthrodesis of the metacarpophalangeal joint of the thumb in children and adults. *Clin Orthop* 1990;253:75.
39. Botte MJ, Keenan MAE. Percutaneous phenol blocks of the pectoralis major muscle to treat spastic deformities. *J Hand Surg Am* 1988;13:147.
40. Gelberman RH. The upper extremity in cerebral palsy. In Bora W, ed. *The pediatric upper extremity*. Philadelphia: WB Saunders, 1986:323.
41. Braun RM, Hoffer MM, Mooney V, et al. Phenol nerve block in the treatment of acquired spastic hemiplegia in the upper limb. *J Bone Joint Surg Am* 1973;55:580.
42. Keenan MAE, Tomas E, Stone L, et al. Percutaneous phenol block of musculocutaneous nerve to control elbow flexor spasticity. *J Hand Surg Am* 1990;15:340.
43. Tonkin MA, Hughes J, Smith KL. Lateral band translocation for swan neck deformity. *J Hand Surg Am* 1992;17:260.
44. Page CM. An operation for relief of flexion contracture in the forearm. *J Bone Joint Surg Am* 1923;5:233.
45. Manske PR, McCarroll HR, Hale R. Biceps tendon rerouting and percutaneous osteoclasts in the treatment of supination deformity in obstetrical palsy. *J Hand Surg Am* 1980;5:153.
46. Adler J. Erb's palsy: long term results of treatment in 88 cases. *J Bone Joint Surg Am* 1967;49:1052.
47. Hardy AE. Birth injuries of the brachial plexus: incidence and prognosis. *J Bone Joint Surg Br* 1981;63:98.
48. Wickstrom J. Birth injuries of the brachial plexus: treatment of defects in the shoulder. *Clin Orthop* 1962;23:187.
49. Pearl M, Edgerton B. Glenoid deformity secondary to brachial plexus birth palsy. *J Bone Joint Surg Am* 1998;80:659.
50. Waters PM, Smith GR, Jaramillo D. Glenohumeral deformity secondary to brachial plexus birth palsy. *J Bone Joint Surg Am* 1998;80:668.
51. Gilbert A, Tassin JL. Reparation chirurgicale du plexus brachial dans la paralysie obstetricale. *Chirurgie* 1984;110:70.
52. Waters PM. Comparison of the natural history, the outcome of microsurgical repair, and the outcome of operative reconstruction in brachial plexus birth palsy. *J Bone Joint Surg Am* 1999;81:649.
53. Geutjens G, Gilbert A, Helsen K. Obstetric brachial plexus palsy associated with breech delivery: a different pattern of injury. *J Bone Joint Surg Br* 1996;78:303.
54. Gilbert A, Whitaker I. Obstetrical brachial plexus lesions. *J Hand Surg Br* 1991;16:489.
55. Gilbert A, Meyer RD. Treatment of adult and obstetrical brachial plexus injuries. *Orthopedics* 1986;9:899.
56. Michelow BJ, Clarke HM, Curtis CG, et al. The natural history of obstetrical brachial plexus palsy. *Plast Reconstr Surg* 1994;93: 675.
57. Kawai H, Tsuyuguchi Y, Masada K, et al. Identification of the lesion in brachial plexus injuries with root avulsion: a comprehensive assessment by means of preoperative findings, myelography, surgical exploration and intraoperative electrodiagnosis. *Neuro-orthopedics* 1989;7:15.
58. Troum S, Floyd WE, Waters PM. Posterior dislocation of the humeral head in infancy associated with obstetrical paralysis. *J Bone Joint Surg Am* 1993;75:1370.
59. Waters PM, Pelkovich A. Shoulder reconstruction in patients with chronic brachial plexus birth palsy. *Clin Orthop* 1999;364: 144.
60. Hoffer MM, Wickenden R, Roper B. Brachial plexus birth palsies: result of tendon transfers to the rotator cuff. *J Bone Joint Surg Am* 1978;60:691.
61. Leffert RD. Brachial plexus. In: Green DP, ed. *Operative hand surgery*, 3rd ed. New York: Churchill Livingstone, 1993:1509.
62. Aitken J. Deformity of elbow joint as sequel to Erb's obstetrical paralysis. *J Bone Joint Surg Br* 1952;34:352.
63. Zancolli EA. Paralytic supination contracture of the forearm. *J Bone Joint Surg Am* 1967;49:1275.
64. Waters PM, Simmons BP. Congenital abnormalities: elbow region. In: Peimer CA, ed. *Surgery of the hand and upper extremity*. New York: McGraw-Hill, 1996:2049.
65. Manske PR, McCarroll HR Jr, Hale R. Biceps tendon rerouting and percutaneous osteoclasts in the treatment of supination deformity in obstetrical palsy. *J Hand Surg Am* 1980;5:153.
66. Fahy MJ, Hall JG. A retrospective study of pregnancy complications among 828 cases of arthrogryposis. *Genet Coun* 1990; 1:3.
67. Weeks PM. Surgical correction of upper extremity deformities in arthrogryposis. *Plast Reconstr Surg* 1965;36:459.
68. Gibson DA, Urs NDK. Arthrogryposis multiplex congenita. *J Bone Joint Surg Br* 1970;52:483.
69. Bayne LG. Arthrogryposis. In: Green DP, ed. *Operative hand surgery*, 3rd ed. New York: Churchill Livingstone, 1993:363.
70. Lloyd-Roberts GC, Lettin AWF. Arthrogryposis multiplex congenita. *J Bone Joint Surg Br* 1970;52:494.
71. Meyn M, Ruby L. Arthrogryposis of the upper extremity. *Orthop Clin North Am* 1976;7:501.
72. Van Heest A, Waters PM, Simmons BP. Surgical treatment of arthrogryposis of the elbow. *J Hand Surg Am* 1998;23:1063.
73. Bunnell S. Restoring flexion to paralytic elbow. *J Bone Joint Surg Am* 1951;33:566.
74. Carroll RE, Kleinman WB. Pectoralis major transplantation to

restore elbow flexion to the paralytic limb. *J Hand Surg Am* 1979;4:501.

- 74a. Clark J. Reconstruction of biceps brachii by pectoralis major transplantation. *Br J Surg* 1946;34:180.
- 74b. Doyle J, James P, Larsen L, et al. Restoration of elbow flexion in arthrogryposis multiplex congenita. *J Hand Surg* 1980;SA:149.
75. Zancolli E, Mitre H. Latissimus dorsi transfer to restore elbow flexion. *J Bone Joint Surg Am* 1973;55:1265.
76. Williams PF. The elbow in arthrogryposis. *J Bone Joint Surg Br* 1973;55:834.

Elbow and Forearm Region

77. Bergsma D. *Birth defects compendium*, 2d ed. New York: Alan R. Liss (The National Foundation, March of Dimes), 1979.
78. Dobyns JH. Congenital abnormalities of the elbow. In: Morrey BF, ed. *The elbow and its disorders*. Philadelphia: WB Saunders, 1985:161.
79. Fidalgo-Valdúez A. The nail-patella syndrome: a report of three families. *J Bone Joint Surg Br* 1973;55:145.
80. Williams PF. The elbow in arthrogryposis. *J Bone Joint Surg Br* 1973;55:834.
81. Mital MA. Congenital radioulnar synostosis and congenital dislocation of the radial head. *Orthop Clin North Am* 1976;7:375.
82. Wynne-Davies R. *Heritable disorders in orthopedic practice*. Oxford: Blackwell Science, 1973.
83. Campbell C, Waters PM, Emans JB. Excision of the radial head for congenital dislocation. *J Bone Joint Surg Am* 1992;74:726.
84. Bucknill TM. Anterior dislocation of the radial head in children. *Proc R Soc Med* 1977;70:620.
85. Danielson LG, Theander G. Traumatic dislocation of the radial head at birth. *Acta Radiol Diagn* 1981;22(3B):379.
86. Danielisz L. Congenital dislocation of the head of the radius and elbow injury. *Arch Chir Neerl* 1971;23:163.
87. Almquist EE, Gordon LH, Blue AI. Congenital dislocation of the head of the radius. *J Bone Joint Surg Am* 1966;51:1118.
88. Lloyd-Roberts GC, Bucknill TM. Anterior dislocation of the radial head in children: aetiology, natural history and management. *J Bone Joint Surg Br* 1977;59:402.
89. Mardam-Bey T, Ger E. Congenital radial head dislocation. *J Hand Surg Am* 1979;4:316.
90. McFarland B. Congenital dislocation of the head of the radius. *Br J Surg* 1936;24:41.
91. Hirayama T, Takemitsu Y, Yagihara K, et al. Operation for chronic dislocation of the radial head in children: reduction by osteotomy of the ulna. *J Bone Joint Surg Br* 1987;69:639.
92. Exarhou EI, Antoniou NK. Congenital dislocation of the head of the radius. *Acta Orthop Scand* 1970;41:551.
93. Bell SN, Morrey BF, Bianco AJ Jr. Chronic posterior subluxation and dislocation of the radial head. *J Bone Joint Surg Am* 1991;73:392.
94. Sachar K, Mih A. Congenital radial head dislocations. *Hand Clin* 1998;4:39.
95. Brennan JS, Krause ME, Harrey D. Annular ligament construction for congenital anterior dislocation of both radial heads. *Clin Orthop* 1963;29:205.
96. Villa A, Paley D, Catagni MA, et al. Lengthening of the forearm by the Ilizarov technique. *Clin Orthop* 1990;250:125.
97. Lewis RW, Thibodeau AA. Deformity of the wrist following resection of the radial head. *Surg Gynecol Obstet* 1937;64:1079.
98. King BB. Resection of the radial head and neck: an end-result study of thirteen cases. *J Bone Joint Surg Am* 1939;21:839.
99. Sojbjerg JO, Ovesen J, Gundorf CE. The stability of the elbow following excision of the radial head and transection of the annular ligament: an experimental study. *Arch Orthop Trauma Surg* 1987;106:248.
100. Kelly DW. Congenital dislocation of the radial head: spectrum and natural history. *J Pediatr Orthop* 1981;1:295.
101. Sutro CJ. Regrowth of bone at the proximal end of the radius following resection in this region. *J Bone Joint Surg Am* 1935;17:867.
102. Mead C, Martin M. Aplasia of the trochlea: an original mutation. *J Bone Joint Surg Am* 1963;45:379.
103. Wood V. Congenital elbow dislocations. In: Buck-Gramcko D, ed. *Congenital malformations of the hand and forearm*. London: Churchill Livingstone, 1998:487.
104. Bayne LG. Ulnar club hand. In: Green DP, ed. *Operative hand surgery*, 3rd ed. New York: Churchill Livingstone, 1993:298.
105. Ogden JA, Watson HK, Bohne W. Ulnar dimelia. *J Bone Joint Surg Am* 1976;58:467.
106. Riordan DC. Congenital absence of the ulna. In: Lovell WW, Winter RB, eds. *Pediatric orthopaedics*. Philadelphia: JB Lippincott Co, 1978:714.
107. Lloyd-Roberts GC. Treatment of defects of the ulna in children by establishing cross-union with the radius. *J Bone Joint Surg Br* 1973;55:327.
108. Wood VE. Ulnar dimelia. In: Green DP, ed. *Operative hand surgery*, 3rd ed. New York: Churchill Livingstone, 1993:490.
109. Tsuyuguchi Y, Tada K, Yoenobu K. Mirror hand anomaly: reconstruction of the thumb, wrist, forearm, and elbow. *Plast Reconstr Surg* 1982;70:384.
110. Willkie DPD. Congenital radio-ulnar synostosis. *Br J Surg* 1914;1:366.
111. Green WT, Mital M. Congenital radio-ulnar synostosis: surgical treatment. *J Bone Joint Surg Am* 1979;61:738.
112. Ogino T, Hikino K. Congenital radio-ulnar synostosis: compensatory rotation around the wrist and rotation osteotomy. *J Hand Surg Br* 1987;12:173.
113. Henson HO, Anderson ON. Congenital radio-ulnar synostosis. *Acta Orthop Scand* 1970;41:255.
114. Cleary JE, Omer GE. Congenital proximal radio-ulnar synostosis: natural history and functional assessment. *J Bone Joint Surg Am* 1985;67:539.
115. Simmons BP, Southmayd WW, Riseborough EJ. Congenital radio-ulnar synostosis. *J Hand Surg Am* 1983;8:829.
116. Giuffrè L, Corsello G, Giuffrè M, et al. A new syndrome: autosomal dominant microcephaly and radio-ulnar synostosis. *Am J Med Genet* 1994;51:266.
117. Robinson GC, Miller JR, Dill FJ, et al. Klinefelter's syndrome with the XXY sex chromosomes complex. *J Pediatr* 1964;65:266.
118. Sachar K, Akelman E, Ehrlich MG. Radioulnar synostosis. *Hand Clin* 1994;10:399.
119. Morrison J. Congenital radio-ulnar synostosis. *Br J Med* 1892;2:1337.
120. Cross AR. Congenital bilateral radioulnar synostosis. *Am J Dis Child* 1939;58:1259.
121. Kelikian H. *Congenital deformities of the hand and forearm*. Philadelphia: WB Saunders, 1974.
122. Stretton JL. Congenital synostosis of radio-ulnar articulations. *Br Med J* 1905;2:1519.
123. Tagima T, Ogisho N, Kanaya F. Follow-up study of joint mobilization of proximal radio-ulnar synostosis. Presented at the American Society of Surgery of the Hand meeting, Cincinnati, OH, September, 1994.
124. Nieman KM, Gould JS, Simmons BP, et al. Injuries to and developmental deformities of the elbow in children. In: Bora FW, ed. *The pediatric upper extremity: diagnosis and management*. Philadelphia: WB Saunders, 1986:213.
125. Kadiyala K, Waters P. Upper extremity compartment syndromes. *Hand Clin* 1998;14:467.
126. Dobyns J, Wood V, Bayne L. Congenital hand deformities.

- In Green DP, ed. *Operative hand surgery*, 3rd ed. New York: Churchill Livingstone, 1993:251.
127. Leisti J, Lachman RS, Rimoin DL. Humeroradial ankylosis associated with other congenital defects (the boomerang arm sign). *Birth Defects* 1975;11:306.
 128. Murphy HS, Hanson CG. Congenital humero-radial synostosis. *J Bone Joint Surg Am* 1945;27:712.
 129. Solomon L. Hereditary multiple exostosis. *J Bone Joint Surg Br* 1963;45:292.
 130. Jaffe HL. Hereditary multiple exostosis. *Arch Pathol* 1943;36:335.
 131. Shapiro F, Simon S, Glimcher MJ. Hereditary multiple exostoses: anthropometric, roentgenographic, and clinical aspects. *J Bone Joint Surg Am* 1979;61:815.
 132. Bock GW, Reed MH. Forearm deformities in multiple cartilaginous exostoses. *Skeletal Radiol* 1991;20:483.
 133. Fogel GR, McElfresh EC, Peterson HA, et al. Management of deformities of the forearm in multiple hereditary osteochondromas. *J Bone Joint Surg Am* 1984;61:670.
 134. Masada K, Tsuyuguchi Y, Kawai H, et al. Operations for forearm deformity caused by multiple osteochondromas. *J Bone Joint Surg Br* 1989;71:24.
 135. Arms D, Strecker W, Manske P, et al. Management of forearm deformity in multiple hereditary osteochondromatosis. *J Pediatr Orthop* 1997;17:450.
 136. McCornack EB. The surgical management of hereditary multiple exostosis. *Orthop Rev* 1981;10:57.
 137. Rodgers WB, Jall JE. One-bone forearm as a salvage procedure for recalcitrant forearm deformity in hereditary multiple exostosis. *J Pediatr Orthop* 1993;13:587.
 138. Waters PM, van Heest AE, Emans JB. Acute forearm lengthenings. *J Pediatr Orthop* 1997;17: 444.
 139. Lowe HG. Radio-ulnar fusion for defects in the forearm bones. *J Bone Joint Surg Am* 1991;18:316.
 140. Murray RA. The one-bone forearm: a reconstruction procedure. *J Bone Joint Surg Am* 1955;37:366.
 141. Catagni MA, Maurizio A, Szabo RM, et al. Preliminary experience with Ilizarov method in late reconstruction of radial hemimelia. *J Hand Surg Am* 1993;18:316.
 142. Tetsworth K, Krome J, Paley D. Lengthening and deformity correction of the upper extremity by Ilizarov technique. *Orthop Clin North Am* 1991;22:689.
 143. Dahl MT. The gradual correction of forearm deformities in multiple hereditary exostoses. *Hand Clin* 1993;9:707.
 144. Pritchett JW. Lengthening the ulna in patients with hereditary multiple exostoses. *J Bone Joint Surg Br* 1986;68:561.
 145. Cheng JC. Distraction lengthening of forearm. *J Hand Surg Br* 1991;16:441.
 146. Irani RN, Rushen NM, Petrucelli R. Ulnar lengthening for negative ulnar variance in hereditary multiple osteochondromas. *J Pediatr Orthop Part B* 1992;1:143.
 147. Paley D. Lengthening and deformity of the upper arm. Presented at the American Society of Surgery of the Hand Congenital Differences Workshop, Salt Lake City, UT, February, 1994.
 148. Wood VE. Congenital pseudarthrosis of the forearm. In Green DP, Hotchkiss RN, Pederson WC, eds. *Green's operative hand surgery*, 4th ed. New York: Churchill Livingstone, 1999:541.
 149. Bell DF. Congenital forearm pseudoarthrosis: report of six cases and review of the literature. *J Pediatr Orthop* 1989;9:438.
 150. Allieu Y, Gomis R, Yoshimura M, et al. Congenital pseudoarthrosis of the forearm: two cases treated by free vascularized fibular graft. *J Hand Surg Am* 1981;6:475.
 151. Weiland AJ, Weiss APC, Moore JR, et al. Vascularized fibular grafts in the treatment of congenital pseudoarthrosis of the tibia. *J Bone Joint Surg Am* 1990;72:654.
 152. Bayne LG, Klug MS. Long-term review of the surgical treatment of radial deficiencies. *J Hand Surg Am* 1987;12:169.
 153. Birch-Jensen A. *Congenital deformities of the upper extremities*. Copenhagen: Ejnar Munksgaard Forlag, 1950.
 154. Manske PR, McCarroll HR Jr, Swanson K. Centralization of the radial club hand: an ulnar surgical approach. *J Hand Surg Am* 1981;6:423.
 155. Tonkin MA. Congenital hand deformities: ulnar longitudinal deficiency. In: Green DP, Hotchkiss RN, Pederson WC, eds. *Green's operative hand surgery*, 4th ed. New York: Churchill Livingstone, 1999:359.
 156. Goldberg MJ, Bartoszesky LE. Congenital hand anomaly: etiology and associated malformations. *Hand Clin* 1985;1:405.
 157. Barry JE, Auld AW. The VATER association: one end of a spectrum of anomalies. *Am J Dis Child* 1974;128:769.
 158. Beals RK, Rolfe B. VATER association: a unifying concept of multiple anomalies. *J Bone Joint Surg Am* 1987;71:948.
 159. Carroll RE, Louis DS. Anomalies associated with radial dysplasia. *J Pediatr* 1974;84:409.
 160. Newbury-Ecob RA, Leange R, Raeburn JA, et al. Holt-Oram syndrome: a clinical genetic study. *J Med Genet* 1996;33:300.
 161. Goldstein R. Hypoplastic anemia with multiple congenital anomalies (Franconi syndrome). *Am J Dis Child* 1955;89:618.
 162. Hall JG. Thrombocytopenia and absent radius (TAR) syndrome. *J Med Genet* 1987;24:79.
 163. Hedberg VA, Lipton JM. Thrombocytopenia with absent radii: a review of 100 cases. *Am J Pediatr Hematol Oncol* 1988;10:51.
 164. Bayne LG, Costas BL, Lourie GM. The upper limb. In: Morrissey RT, Weinstein SL, eds. *Lovell and Winter's pediatric orthopaedics*, 4th ed. Philadelphia: Lippincott-Raven, 1996:781.
 165. Sherik S, Flatt A. The anatomy of congenital radial dysplasia. *Clin Orthop* 1969;66:125.
 166. Lamb DW. Radial club hand, a continuing study of sixty-eight patients with one hundred seventeen club hands. *J Bone Joint Surg Am* 1977;59:7.
 167. Bora FW Jr, Carniol PJ, Martin E. Congenital anomalies of the upper limb: radial club hand. In: Bora FW Jr, ed. *The pediatric upper extremity: diagnosis and management*. Philadelphia: WB Saunders, 1986:28.
 168. Bora FW Jr, Nicholson JT, Cheema HM. Radial meromelia: the deformity and its treatment. *J Bone Joint Surg Am* 1970;52:966.
 169. Kessler I. Centralization of the radial club hand by gradual distraction. *J Hand Surg Br* 1989;14:37.
 170. Tonkin MA. Radial longitudinal deficiency (radial dysplasia, radial clubhand). In: Green DP, Hotchkiss RN, Pederson WC, eds. *Green's operative hand surgery*, 4th ed. New York: Churchill Livingstone, 1999:344.
 171. Albee FH. Formation of radius congenitally absent, condition seven years after implantation of bone graft. *Ann Surg* 1928;87:105.
 172. Starr DE. Congenital absence of the radius: a method of surgical correction. *J Bone Joint Surg Am* 1945;27:572.
 173. Entin MA. Reconstruction of congenital aplasia of radial component. *Surg Clin North Am* 1964;44:1091.
 174. Riordan CD. Congenital absence of the radius, 15 year follow up. *J Bone Joint Surg Am* 1955;37:1129.
 175. Vilkkki SK. Distraction lengthening and microvascular bone transplantation in the treatment of radial club hand. Presented at American Society for Surgery of the Hand Congenital Differences Workshop, Salt Lake City, UT, February, 1994.
 176. Buck-Gramcko D. Radialization as a new treatment for radial club hand. *J Hand Surg Am* 1985;10:964.
 177. Catagni MA, Szabo RM, Cattaneo R. Preliminary experience

- with Ilizarov method in late reconstruction of radial hemimelia. *J Hand Surg Am* 1993;18:316.
178. Lister G. Reconstruction of the hypoplastic thumb. *Clin Orthop* 1985;195:52.
 179. Buck-Gramcko D. Pollicization of the index finger: methods and results in aplasia and hypoplasia of the thumb. *J Bone Joint Surg Am* 1971;53:1605.
 180. Huber E. Hilfsoperation bei Medianuslahmug. *Dtsch Z Chir* 1921;162:271.
 181. Carroll RE. Pollicization. In: Green DP, ed. *Operative hand surgery*, 2nd ed. New York: Churchill Livingstone, 1988:2263.
 182. Gilbert A. Pollicizations in radial club hand. Presented at the Second International Workshop on Congenital Differences of the Upper Limb, Salt Lake City, UT, February, 1994.
 183. Manske PR, McCarroll HR. Abductor digiti minimi opponens-plasty in congenital radial dysplasia. *J Hand Surg Am* 1978;3:552.
 184. Manske PR, McCarroll HR. Index finger pollicization for a congenitally absent or non-functioning thumb. *J Hand Surg Am* 1985;10:606.
 185. Ogden JA, Watson HK, Bohne W. Ulnar dysmelia. *J Bone Joint Surg Am* 1976;58:467.
 186. Bamshad M, Krakowiak PA, Watkins WS, et al. A gene for ulnar-mammary syndrome maps to 12q23-q24.1. *Hum Mol Genet* 1995;4:1973.
 187. Robert AS. A case of deformity of the forearm and hands with an unusual history of hereditary congenital deficiency. *Ann Surg* 1886;3:135.
 188. Turnpenny PD, Dean JC, Duffty P, et al. Weyers' ulnar ray/oligodactyly syndrome and the association of midline malformations with ulnar ray defects. *J Med Genet* 1992;29:659.
 189. Wulfsberg EA, Mirkinson LJ, Meister SJ. Autosomal dominant retramelic postaxial oligodactyly. *Am J Med Genet* 1993;46:579.
 190. Chemke J, Nisani R, Fischel RE. Absent ulna in the Klippel-Feil syndrome: an unusual associated malformation. *Clin Genet* 1980;17:167.
 191. Franceschini P, Vardeu MP, Dalforno L, et al. Possible relationship between ulnar-mammary syndrome and split hand with aplasia of the ulna syndrome. *Am J Med Genet* 1992;44:807.
 192. Ogino T, Kato H. Clinical and experimental studies on ulnar ray deficiency. *Handchir Mikrochir Plast Chir* 1988;20:330.
 193. Bayne LG. Ulnar club hand (ulnar deficiencies). In: Green DP, ed. *Operative hand surgery*, 3rd ed. New York: Churchill Livingstone, 1993:288.
 194. Cole RJ, Manske PR. Classification of ulnar deficiency according to the thumb and first web. *J Hand Surg Am* 1997;22:479.
 195. Broudy AS, Smith RJ. Deformities of the hand and wrist with ulnar deficiency. *J Hand Surg* 1979;4:304.
 196. Johnson J, Omer GE Jr. Congenital ulnar deficiency: natural history and therapeutic implications. *Hand Clin* 1985;1:499.
 197. Southwood AR. Partial absence of the ulna and associated structures. *J Anat* 1926-1927;61:346.
 198. Raus EE. Repair of simple syndactylism in the healthy newborn. *Orthop Rev* 1984;13:498.
 199. Beals RK, Lovrein EW. Dyschondrosteosis and Madelung's deformity: report of three kindreds and review of the literature. *Clin Orthop* 1976;116:24.
 200. Madelung V. Die Spontane Subluxation der Hand nach vorne. *Verh Dtsch Ges Chir* 1878;7:259; reprinted in *Arch Klin Chir* 1979;23:395.
 201. Ezaki M. Madelung's deformity. In: Green DP, Hotchkiss RN, Pederson WC, eds. *Green's operative hand surgery*, 4th ed. New York: Churchill Livingstone, 1999:528.
 202. Felman AH, Kirkpatrick JA Jr. Dyschondrosteosis: mesomelic dwarfism of Leri and Weill. *Am J Dis Child* 1970;120:329.
 203. Nielsen JB. Madelung's deformity: a follow-up study of 26 cases and a review of the literature. *Acta Orthop Scand* 1977;48:379.
 204. Vickers D, Nielsen G. Madelung's deformity: treatment of osteotomy of the radius and Lauenstein procedure. *J Hand Surg Am* 1987;12:202.
 205. Linscheid RL. Madelung's deformity. *Am Soc Surgery of the Hand Correspondence Newsletter* 1979;24.
 206. Ranawat CS, DeFieore J, Straub LR. Madelung's deformity: an end-result study of surgical treatment. *J Bone Joint Surg Am* 1975;57:772.

Hand Region

207. Scherer SW, et al. Fine mapping of the autosomal dominant split hand/split foot locus on chromosome 7, band q21.3-q22.1. *Am J Hum Genet* 1994;55:12.
208. Kay SPJ. Congenital hand deformities: cleft hand. In: Green DP, Hotchkiss RN, Pederson WC, eds. *Green's operative hand surgery*, 4th ed. New York: Churchill Livingstone, 1999:402.
209. Buss PW. Cleft hand/foot: clinical and developmental aspects. *J Med Genet* 1994;31:726.
210. Calzolari E, Manservigi D, Garani GP, et al. Limb reduction defects in Emilia Romagna, Italy: epidemiological and genetic study in 173,109 consecutive births. *J Med Genet* 1990;27:353.
211. Froster-Iskenius UG, Baird PA. Limb reduction defects in over one million consecutive live births. *Teratology* 1989;39:127.
212. Ogino T. Cleft hand. *Hand Clin* 1990;6:661.
213. Watari S, Tsuge K. A classification of cleft hands, based on clinical findings: theory of development mechanism. *Plast Reconstr Surg* 1979;64:381.
214. Manske PR, Halikis MN. Surgical classification of central deficiency according to the thumb web. *J Hand Surg Am* 1995;20:687.
215. Barsky AJ. Cleft hand: classification incidence and treatment. Review of the literature and report of nineteen cases. *J Bone Joint Surg Am* 1964;46:1707.
216. Snow JW, Littler JW. Surgical treatment of cleft hand. In: *Transactions of the Society of Plastic and Reconstructive Surgery, 4th Congress in Rome*. Amsterdam: Excerpta Medica Foundation, 1967:888.
217. Ueba Y. Plastic surgery for the cleft hand. *J Hand Surg Am* 1981;6:557.
218. Miura T, Komada T. Simple method for reconstruction of the cleft hand with an adducted thumb. *Plast Reconstr Surg* 1979;64:65.
219. Goldberg NH, Watson HK. Composite toe (phalanx and epiphysis) transfer in the reconstruction of the aphalangic hand. *J Hand Surg Am* 1982;7:454.
220. Buck-Gramcko D. The role of nonvascularized toe phalanx transplantation. *Hand Clin* 1990;6:643.
221. Buck-Gramcko D. Symbrachydactylies: classification et traitement chirurgical.
222. Gilbert A, Buck-Gramcko D, Lister GD, eds. *Les malformations congenitales du membre superieur*. Paris: Expansion Scientifique Francaise, 1991:98.
223. Buck-Gramcko D, Pereira JA. Proximal toe phalanx transplantation for bony stabilization and lengthening of partially aplastic digits. *Ann Chir Main Membr Super* 1990;9:107.
224. Cowen NJ, Loftus JM. Distraction augmentation manoplasty: technique of lengthening digits or entire hands. *Orthop Rev* 1978;7:45.
225. Entin MA. Reconstruction of congenital abnormalities of the upper extremities. *J Bone Joint Surg Am* 1975;57:727.
226. Villkki SK. Advances in microsurgical reconstruction of the congenitally adactylous hand. *Clin Orthop* 1995;314:45.
227. Seitz WH Jr, Dobyns JH. Digital lengthening: with emphasis

- on distraction osteogenesis in the upper limb. *Hand Clin* 1993; 9:699.
228. Radocha RF, Netscher D, Kleinert HE. Toe phalangeal grafts in congenital hand anomalies. *J Hand Surg Am* 1993;18:833.
 229. Pilllet J. Esthetic hand prosthesis. *J Hand Surg* 1983;8:778. Torpin R. *Fetal malformations caused by amnion rupture during gestation*. Springfield, IL: Charles C Thomas, 1968.
 230. Kay S. Hypoplastic and absent digits. In Green DP, Hotchkiss RN, Pederson WC, eds. *Green's operative hand surgery*, 4th ed. New York: Churchill Livingstone, 1999:368.
 231. Kino Y. Clinical and experimental studies of the congenital constriction band syndrome with emphasis on its etiology. *J Bone Joint Surg Am* 1975;57:636.
 232. Streeter GL. Focal deficiencies in fetal tissue and their relation to intra-uterine amputation. In: *Contributions to embryology*. Washington, DC: Carnegie Institution, 1930;22:126.
 233. Patterson TJS. Congenital ring-constrictions. *Br J Plast Surg* 1961;14:1.
 234. Dobyns JH. Segmental digital transposition in congenital hand deformities. *Hand Clin* 1985;1:475.
 235. Soiland H. Lengthening a finger with the "on-the-top" method. *Acta Chir Scand* 1961;122:184.
 236. Light TR. Congenital anomalies: syndactyly, polydactyly and cleft hands. In: Peimer CA, ed. *Surgery of the hand and upper extremity*. New York: McGraw-Hill, 1996:2111.
 237. Dobyns JH. Congenital hand deformities. In: Green DP, ed. *Operative hand surgery*, 3rd ed. New York: Churchill Livingstone, 1993:515.
 238. Jones NF, Upton J. Early release of syndactyly within six weeks of birth. *Orthop Trans* 1992;17:360.
 239. Sommerkamp T, Ezaki M, Carter P, et al. The pulp plasty: a composite graft for complete syndactyly fingertip separations. *J Hand Surg Am* 1992;17:15.
 240. Toledo LC, Ger E. Evaluation of the operative treatment of syndactyly. *J Hand Surg Am* 1979;4:556.
 241. Percival NJ, Sykes PJ. Syndactyly: a review of the factors which influence surgical treatment. *J Hand Surg Br* 1989;14:196.
 242. Keret D, Ger E. Evaluation of a uniform operative technique to treat syndactyly. *J Hand Surg Am* 1987;12:727.
 243. Frazier TM. A note on race specific congenital malformation rates. *Am J Obstet Gynecol* 1960;80:184.
 244. Nathan PA, Keniston RC. Crossed polydactyly. *J Hered* 1940; 31:25.
 245. Woolf CM, Myrianthopoulos NC. Polydactyly in American negroes and whites. *Am J Hum Genet* 1973;25:397.
 246. Stelling F. The upper extremity. In: Ferguson AB, ed. *Orthopaedic surgery infancy and childhood*. Baltimore: Williams & Wilkins, 1963:304.
 247. Turek SL. *Orthopaedic principles and their applications*. Philadelphia: JB Lippincott, 1976:23.
 248. Buck-Gramcko D, Behrens P. Klassifikation der polydaktylie fur hand und fuss. *Handchir Mikrochir Plast Chir* 1989;21:195.
 249. Tada K, Kurisaki E, Yonenobu K, et al. Central polydactyly: a review of 12 cases and their surgical treatment. *J Hand Surg Am* 1982;7:460.
 250. Wood VE. Treatment of central polydactyly. *Clin Orthop* 1971; 74:196.
 251. Kay S. Camptodactyly. In: Green DP, Hotchkiss RN, Pederson WC, eds. *Green's operative hand surgery*, 4th ed. New York: Churchill-Livingstone, 1999:510.
 252. Jones KG, Marmor L, Langford LL. An overview on new procedures in surgery of the hand. *Clin Orthop* 1974;12:1061.
 253. Engber WM, Flatt AE. Camptodactyly: an analysis of sixty-six patients in twenty-four operations. *J Hand Surg Am* 1977;2: 216.
 254. Benson LS, Waters PM, Kamil NI, et al. Camptodactyly: classification and results of nonoperative treatment. *J Pediatr Orthop* 1994;14:814.
 255. Millesi H. Camptodactyly. In: Littler JW, Cramer LM, Smith JW, eds. *Symposium on reconstructive surgery*. St. Louis: Mosby, 1974:175.
 256. Smith RJ, Kaplan EB. Camptodactyly in similar atraumatic flexion deformities of the proximal interphalangeal joints of the fingers. *J Bone Joint Surg Am* 1968;50:1187.
 257. Koman LA, Toby EB, Poehling GG. Congenital flexion deformities of the proximal phalangeal joint in children: a subgroup of camptodactyly. *J Hand Surg Am* 1990;15:582.
 258. Courtenmanche AD. Camptodactyly: etiology and management. *Plast Reconstr Surg* 1969;44:451.
 259. McFarlane RM, Classen DA, Porte AM, et al. The anatomy and treatment of camptodactyly of the small finger. *J Hand Surg Am* 1992;17:35.
 260. McFarlane RM, Curry GI, Evans HB. Anomalies of the intrinsic muscles in camptodactyly. *J Hand Surg Am* 1983;8:531.
 261. Buck-Gramcko D. Camptodactyly. In: Bowers WH, ed. *The interphalangeal joints*. Edinburgh: Churchill Livingstone, 1987: 200.
 262. Hori M, Nakamura R, Inoue G, et al. Nonoperative treatment of camptodactyly. *J Hand Surg Am* 1996;30:71.
 263. Ogino T, Kato H. Operative findings in camptodactyly of the little finger. *J Hand Surg Br* 1992;17:661.
 264. Miura T, Nakamura R, Tamura Y. Long-standing extended dynamic splintage and release of an abnormal restraining structure in camptodactyly. *J Hand Surg Br* 1992;17:665.
 265. Siegert JJ, Cooney WP, Dobyns JH. Management of simple camptodactyly. *J Hand Surg Br* 1990;15:181.
 266. Carneiro RS. Congenital attenuation of the extensor tendon central slip. *J Hand Surg Am* 1993;18:1004.
 267. Oldfield MC. Dupuytren's contracture. *Proc R Soc Med* 1954; 47:361.
 268. Hersh AH, DeMarinis F, Stecher RM. On the inheritance and development of clinodactyly. *Am J Dis Child* 1940;60:1319.
 269. McKusick VA, ed. *Mendelian inheritance in man: catalogs of autosomal dominant, autosomal recessive, and X linked phenotypes*, 2nd ed. Baltimore: The Johns Hopkins University Press, 1968.
 270. Poznanski AK, Pratt GB, Manson G, et al. Clinodactyly, camptodactyly, Kirner's deformity, and other crooked fingers. *Radiology* 1969;93:573.
 271. Poznanski AK. *The hand in radiologic diagnosis*. Philadelphia: WB Saunders, 1974;4:112.
 272. Poznanski AK. Rubinstein-Taybi syndrome (broad thumbs syndrome). In: Poznanski AK, ed. *The hand in radiologic diagnosis*. Philadelphia: WB Saunders, 1974:369.
 273. Rubinstein JH. The broad thumbs syndrome: progress report 1968. *Birth Defects* 1969;5:25.
 274. Amuso SJ. Diastrophic dwarfism. *J Bone Joint Surg Am* 1968; 50:113.
 275. Taybi H. Diastrophic dwarfism. *Radiology* 1963;80:1.
 276. Vickers DW. Langenskiold's operation (physolysis) for congenital malformations of bone producing Madelung's deformity and clinodactyly. *J Bone Joint Surg Br* 1984;66:778.
 277. Vickers DW. Clinodactyly of the little finger: a simple operative technique for reversal of the growth abnormality. *J Hand Surg Br* 1987;12:335.

Hand: Thumb

278. Rodgers WB, Waters PM. Incidence of trigger digits in newborns. *J Hand Surg Am* 1994;19:35.
279. Slakey JB, Hennrikus WL. Acquired thumb flexion contracture in children. *J Bone Joint Surg Br* 1996;78:481.
280. Buchman M, Gibson T, McCallum D, et al. Transmission elec-

- tron microscopic pathoanatomy of congenital trigger thumbs. *J Pediatr Orthop* 1999;19:411.
281. Van Heest AE, House J, Krivit W, et al. Surgical treatment of carpal tunnel and trigger digits in children with mucopolysaccharide storage disorders. *J Hand Surg Am* 1998;23:236.
 282. Dinham JM, Meggit DF. Trigger thumbs in children. *J Bone Joint Surg Br* 1974;56:153.
 283. Ger E, Kupcha P, Ger D. The management of trigger thumb in children. *J Hand Surg Am* 1991;16:944.
 284. Tsuyuguchi Y, Toda K, Kawaii H. Splint therapy for trigger fingers in children. *Arch Phys Med Rehabil* 1983;64:75.
 285. Kleinman WB, Strickland JW. Thumb reconstruction. In: Green DP, Hotchkiss RN, Pederson WC, eds. *Green's operative hand surgery*, 4th ed. New York: Churchill Livingstone, 1999: 2068.
 286. Buck-Gramcko D. Congenital absence and hypoplasia of thumb. In Strickland J, ed. *The thumb, the hand, the upper limb*. Edinburgh: Churchill Livingstone, 1971:1605.
 287. Manske P, McCarroll H, James M. Type IIIA hypoplastic thumb. *J Hand Surg Am* 1995;20:246.
 288. Blauth W. Der hypoplastische Daumen. *Arch Orthop Unfall Chir* 1967;62:225.
 289. Shibata M, Yoshizu T, Seki T, et al. Reconstruction of a congenital hypoplastic thumb with use of a free vascularized metatarsophalangeal joint. *J Bone Joint Surg Am* 1998;80:1469.
 290. Light T. Thumb polydactyly. In Green DP, Hotchkiss RN, Pederson WC, eds. *Green's operative hand surgery*, 4th ed. New York: Churchill Livingstone, 1999:432.
 291. Light T, Buck-Gramcko D. Polydactyly: terminology and classification. In Buck-Gramcko D, ed. *Congenital malformations of the hand and forearm*. London: Churchill Livingstone, 1998: 217.
 292. Marks T, Bayne L. Polydactyly of the thumb: abnormal anatomy and treatment. *J Hand Surg Am* 1978;3:107.
 293. Wassel H. The results of surgery for polydactyly of the thumb. *Clin Orthop* 1969;64:175.
 294. Benetar N. Thumb duplication: simple surgery for a common problem? *Curr Trends Hand Surg* 1995;473.
 295. Mih AD. Complications of duplicate thumb reconstruction. *Hand Clin* 1998;14:143.
 296. Seidman GD, Wenner SM. Surgical treatment of the duplicated thumb. *J Pediatr Orthop* 1993;13:660.
 297. Kawabata H, Masatomi T, Shimada K, et al. Treatment of residual instability and extensor lag in polydactyly of the thumb. *J Hand Surg Br* 1993;18:5.
 298. Lourie GM, Consts BL, Bayne LG. The zig-zag deformity in preaxial polydactyly. *J Hand Surg Br* 1995;20:561.
 299. Miura T. An appropriate treatment for postoperative z-formed deformity of the duplicated thumb. *J Hand Surg Am* 1977;2: 380.
 300. Tada K, Yonenobu K, Tsuyuguchi Y, et al. Duplication of the thumb: a retrospective view of two hundred and thirty-seven cases. *J Bone Joint Surg Am* 1983;65:584.
 301. Jaeger M, Refior HJ. The congenital triangular deformity of the tubular bones of the hand and foot. *Clin Orthop* 1971;81: 139.
 302. Shiono H, Ogino T. Triphalangeal thumb and dermatoglyphics. *J Hand Surg Br* 1984;9:151.
 303. Phillips RS. Congenital split foot (lobster claw) and triphalangeal thumbs. *J Bone Joint Surg Br* 1971;53:247.
 304. Aase JM, Smith DW. Congenital anemia and triphalangeal thumb. *J Pediatr* 1969;74:471.
 305. Diamond LR, Allen DM, Magill FB. Congenital (erythroid) hypoplastic anemia: a 25 year study. *Am J Dis Child* 1961;102: 403.
 306. Townes PL, Brocks ER. Hereditary syndrome of imperforate anus with hand, foot and ear anomalies. *J Pediatr* 1972;81:321.
 307. Milch H. Triphalangeal thumb. *J Bone Joint Surg Am* 1951;33: 692.
 308. Buck-Gramcko D. Hand surgery in congenital malformations. In: Jackson IT, ed. *Recent advances in plastic surgery*. New York: Churchill Livingstone, 1981:115.
 309. Barsky AJ. *Congenital anomalies of the hand and their surgical treatment*. Springfield, IL: Charles C Thomas, 1958.
 310. Wood VE. Treatment of the triphalangeal thumb. *Clin Orthop* 1976;120:188.

Traumatic Injuries

311. Landin LA. Fracture patterns in children. *Acta Orthop Scand Suppl* 1983;54:202.
312. Hastings H II, Simmons BP. Hand fractures in children: a statistical analysis. *Clin Orthop* 1984;188:120.
313. Barton NJ. Fractures of the phalanges of the hand in children. *Hand* 1975;11:134.
314. Rang M. *Children's fractures*, 2nd ed. Philadelphia: JB Lippincott, 1983.
315. Fischer MD, McElfresh EC. Physeal and periphyseal injuries of the hand: patterns of injury and results of treatment. *Hand Clin* 1994;10:287.
316. Leonard MH, Dubravick P. Management of fractured fingers in the child. *Clin Orthop* 1970;73:160.
317. DaCruz DJ, Slade RJ, Malone W. Fractures of the distal phalanges. *J Hand Surg Br* 1988;13:350.
318. Louis DS, Jebson PJ, Graham TJ. Amputations. In: Green DP, Hotchkiss RN, Pederson WC, eds. *Green's operative hand surgery*, 4th ed. New York: Churchill Livingstone, 1999:48.
319. Seymour N. Juxta-epiphyseal fracture of the terminal phalanx of the finger. *J Bone Joint Surg Br* 1966;48:347.
320. Wood VE. Fractures of the hand in children. *Orthop Clin North Am* 1976;7:527.
321. Waters PM, Benson LS. Dislocation of the distal phalanx epiphysis in toddlers. *J Hand Surg Am* 1993;18:581.
322. Michelinakis E, Vourexaki H. Displaced epiphyseal plate of the terminal phalanx in a child. *Hand* 1980;12:51.
323. DeBoeck H, Jaeken R. Treatment of chronic mallet finger in children by tenodesis. *J Pediatr Orthop* 1992;12:351.
324. Dixon GL, Moon NF. Rotational supracondylar fractures of the proximal phalanx in children. *Clin Orthop* 1972;81:151.
325. Simmons BP, Peters TT. Subcondylar fossa reconstruction for malunion of fractures of the proximal phalanx in children. *J Hand Surg Am* 1987;12:1079.
326. Green DP. Hand injury in children. *Pediatr Clin North Am* 1977;24:903.
327. Waters PM, Taylor B. Percutaneous osteoclasis and reduction of malangulated phalangeal neck fractures in children. (*Personal communication*).
328. Mintzer CM, Waters OM, Brown DJ. Remodeling of a displaced phalangeal neck fracture. *J Hand Surg Br* 1994;19:594.
329. Light TR. Injury to the immature carpus. *Hand Clin* 1988;4: 415.
330. Weiss AP, Hasting H. Distal unicondylar fractures of the proximal phalanx. *J Hand Surg Am* 1993;18:594.
331. Campbell RM. Operative treatment of fractures and dislocations of the hand and wrist region in children. *Orthop Clin North Am* 1990;21:217.
332. Green DP, Anderson JR. Closed reduction and percutaneous pin fixation of fractured phalanges. *J Bone Joint Surg Am* 1973; 55:1651.
333. Gabuzda G, Mara J. Bony gamekeeper's thumb in a skeletally immature girl. *Orthopedics* 1991;14:792.

334. Mintzer CM, Waters PM, Simmons BP. Non-union of the scaphoid in children treated by Herbert screw fixation and bone grafting. *J Bone Joint Surg Br* 1995;77:98.
335. Mintzer CM, Waters PM. Surgical treatment of pediatric scaphoid fracture non-unions. *J Pediatr Orthop* 1999;19:236.
336. Gerard F. Post-traumatic carpal instability. *J Bone Joint Surg Am* 1980;62:131.
337. Kawaach W, Elkland C, Zurakowski D, et al. Normative values for scapholunate radiographic distance in the skeletally immature. Poster presentation at the American Society of Surgery of the Hand annual meeting, Boston, MA, September, 1999.
338. Terry CL, Waters PM. Triangular fibrocartilage injuries in pediatric and adolescent patients. *J Hand Surg Am* 1998;23:626.
339. Becton JL, Christian JD, Goodwin NH, et al. A simplified technique for treating the complex dislocation of the index metacarpophalangeal joint. *J Bone Joint Surg Am* 1975;57:698.
340. Bohart PG, Gelberman RH, Vandell RF, et al. Complex dislocations of the metacarpophalangeal joint. *Clin Orthop* 1982;164:208.
341. Green DP, Terry GC. Complex dislocations of the metacarpophalangeal joint. *J Bone Joint Surg Am* 1973;55:1480.
342. McLaughlin HL. Complex "locked" dislocation of the metacarpophalangeal joint. *J Trauma* 1965;5:683.
343. O'Connell SJ, Moore MM, Strickland JW, et al. Results of zone I and zone II flexor tendon repairs in children. *J Hand Surg Am* 1994;19:48.
344. Amadio PC. Staged flexor tendon reconstruction in children. *Ann Chir Main Memb Super* 1992;11:194.
345. Baker GL, Kleinert JM. Digit replantation in infants and young children: determinants of survival. *Plast Reconstr Surg* 1994;94:139.
346. Barrios C, de Pablos J. Surgical management of nerve injuries of the upper extremity in children: a 15-year survey. *J Pediatr Orthop* 1991;11:641.
347. Devaraj VS, Kay SP, Batchelor AG, et al. Microvascular surgery in children. *Br J Plast Surg* 1991;44:276.



23

DEVELOPMENTAL HIP DYSPLASIA AND DISLOCATION

STUART L. WEINSTEIN

GROWTH DISTURBANCE OF THE PROXIMAL FEMUR 905

NORMAL GROWTH AND DEVELOPMENT OF THE HIP JOINT 906

Acetabular Growth and Development 906
Growth of the Proximal Femur 907
Determinants of Acetabulum Shape and Depth 909

PATHOANATOMY 909

Dislocations in Newborns 909
Acetabular Development in Developmental Hip
Dysplasia 910

PATHOGENESIS, EPIDEMIOLOGY, AND DIAGNOSIS 912

Causes of Developmental Dysplasia of the Hip 912

Risk Factors and Incidence 912
Diagnosis 913

NATURAL HISTORY 919

Course in Newborns 919
Course in Adults 920
Course of Dysplasia and Subluxation 921

TREATMENT OF HIP DISLOCATION 925

Newborns and Infants Younger Than 6 Months of Age 925
Children 6 Months to 2 Years of Age 928
Children Older Than 2 Years of Age 933

SEQUELAE AND COMPLICATIONS 935

Residual Femoral and Acetabular Dysplasia 935

GROWTH DISTURBANCE OF THE PROXIMAL FEMUR

In the pediatric orthopaedic literature, the long-standing terminology of "congenital dysplasia or dislocation of the hip" (CDH) has been progressively replaced by the use of "developmental dysplasia or dislocation of the hip" (DDH). The former term is attributed to Hippocrates. The term "congenital" implies that a condition existed at birth. The

American Academy of Orthopaedic Surgeons (1), the Pediatric Orthopaedic Society of North America, and the American Academy of Pediatrics have endorsed the name change of this entity from CDH to DDH, because the latter is more representative of the wide range of abnormalities seen in this condition (2).

The term "developmental" is more encompassing and is taken in the literal sense of organ growth and differentiation, which includes the embryonic, fetal, and infantile periods. This terminology includes all cases that are clearly congenital and those that are developmental, and it incorporates subluxation, dislocation, and dysplasia of the hip. Because this change in terminology has not yet been incorporated into the *International Classification of Diseases*, the term

“CDH,” which has existed in the literature for years, will continue to be used in many publications.

One of the most confusing areas in DDH is the terminology used to discuss the condition. What different investigators mean by “instability,” “dysplasia,” “subluxation,” and “dislocation” varies considerably. In this chapter, the term “DDH” denotes developmental dysplasia of the hip and encompasses all the variations of the condition described. Within this spectrum are two entities: subluxation and dislocation. For the newborn, the term “dysplasia” refers to any hip with a positive Ortolani sign, which is a hip that may be provoked to subluxation (i.e., partial contact between the femoral head and acetabulum), provoked to dislocation (i.e., no contact between the femoral head and the acetabulum), or reduced from either of these positions. The distinction between these two entities is often difficult, especially given the subtleties of arthrographic and ultrasonographic classifications. Because further subclassification in the newborn has no influence on treatment, the author prefers to use the term “dysplasia” to encompass these entities and other variations. The term “developmental dislocation” refers here only to complete irreducible dislocations.

NORMAL GROWTH AND DEVELOPMENT OF THE HIP JOINT

For normal hip joint growth and development to occur, there must be a genetically determined balance of growth of the acetabular and triradiate cartilages and a well-located and centered femoral head. Embryologically, the components of the hip joint, the acetabulum, and the femoral head develop from the same primitive mesenchymal cells (3–6) (Fig. 23-1). A cleft develops in the precartilaginous cells at

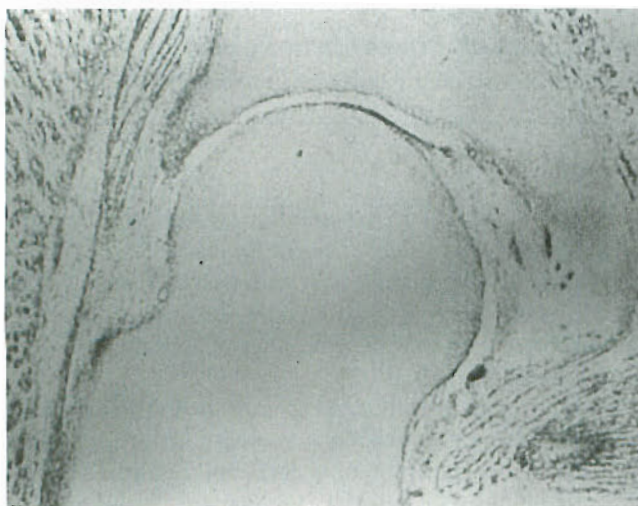


FIGURE 23-1. Embryonic hip. The components of the hip joint, the acetabulum, and the femoral head develop from the same primitive mesenchymal cells. A cleft develops in the precartilaginous cells at about the seventh week of gestation, defining the acetabulum and the femoral head.

about the seventh week of gestation. This cleft defines the acetabulum and the femoral head. By the eleventh week of intrauterine life, the hip joint is fully formed (5–7). Theoretically, the eleventh week is the earliest time at which a dislocation could develop, although this rarely happens (7). Acetabular development continues throughout intrauterine life, particularly by means of growth and development of the labrum (3,6). In the normal hip at birth, the femoral head is deeply seated in the acetabulum and held within the confines of the acetabulum by the surface tension of the synovial fluid. It is extremely difficult to dislocate a normal infant's hip, even after incising the hip joint capsule (8,9). The retaining force is similar to that of a suction cup. Hips in newborns with DDH are not merely normal hips with capsular laxity; they are pathologic entities.

After birth, continued growth of the proximal femur and the acetabular cartilage complex is extremely important to the continuing development of the hip joint (3,7,10,11). The growth of these two members of the hip joint is interdependent.

Acetabular Growth and Development

The acetabular cartilage complex (Fig. 23-2) is a three-dimensional structure, triradiate medially and cup-shaped laterally. The acetabular cartilage complex is interposed between the ilium above, the ischium below, and the pubis anteriorly. Acetabular cartilage forms the outer two-thirds of the acetabular cavity, and the nonarticular medial wall of the acetabulum is formed by a portion of the ilium above, the ischium below, and portions of the triradiate cartilage.

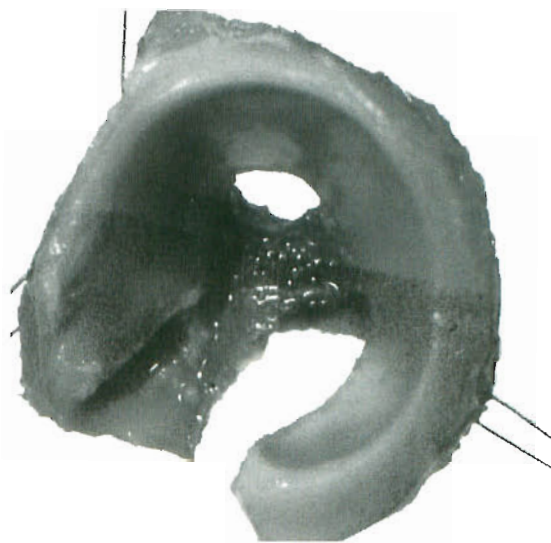

FIGURE 23-2. Normal acetabular cartilage complex of a 1-day-old infant. The ilium, ischium, and pubis have been removed with a curet. The lateral view shows the cup-shaped acetabulum. (From ref. 11, with permission.)

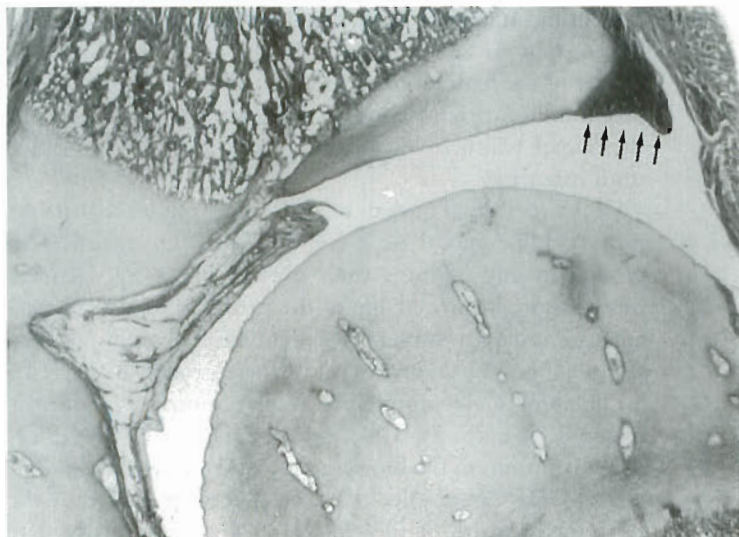


FIGURE 23-3. Coronal section through the center of the acetabulum in a full-term infant. Note the fibrocartilaginous edge of the acetabulum, the labrum (arrows), at the peripheral edge of the acetabular cartilage. The hip capsule inserts just above the labrum.

Thick cartilage, from which a secondary ossification center, the os acetabulum, develops in early adolescence, separates the acetabular cavity from the pubic bone (11). The fibrocartilaginous labrum is at the margin of the acetabular cartilage, and the joint capsule inserts just above its rim (12) (Fig. 23-3).

The triradiate cartilage is a triphalanged structure. One phalange is oriented horizontally between the ilium and the ischium. One phalange is oriented vertically and interposed between the pubis and the ischium. The third phalange is located anteriorly and slanted superiorly between the ilium and the pubis (Fig. 23-4).

The triradiate cartilage is the common physis of these three pelvic bones. The entire acetabular cartilage complex is composed of very cellular hyaline cartilage (Fig. 23-3). The lateral portion of the acetabular cartilage is homologous with other epiphyseal cartilages of the skeleton (13). This is important in understanding normal growth and development and the shape of the acetabulum in skeletal dysplasias and injury. The labrum, or fibrocartilaginous edge of the acetabulum, is at the margin of the acetabular cartilage. The hip joint capsule inserts just above the labrum. The capsule insertion is continuous with the labrum below and the periosteum of the pelvic bones above.

Articular cartilage covers the acetabular cartilage on the side that articulates with the femoral head. On the opposite side is a growth plate, with its degenerating cells facing toward the pelvic bone it opposes. New bone formation occurs in the metaphysis adjacent to the degenerating cartilage cells. Growth of the acetabular cartilage occurs by means of interstitial growth within the cartilage and appositional growth under the perichondrium. This fact is most important when considering various innominate bone osteotomies, because surgical injury to this important area may jeopardize further acetabular growth.

Each phalange of the triradiate cartilage is composed of very cellular hyaline cartilage. This cartilage contains many canals. Each side of each limb of the triradiate cartilage has a growth plate. Interstitial growth within the triradiate cartilage causes the hip joint to expand its diameter during growth.

Growth of the Proximal Femur

In the infant the entire proximal end of the femur, including the greater trochanter, the intertrochanteric zone, and the

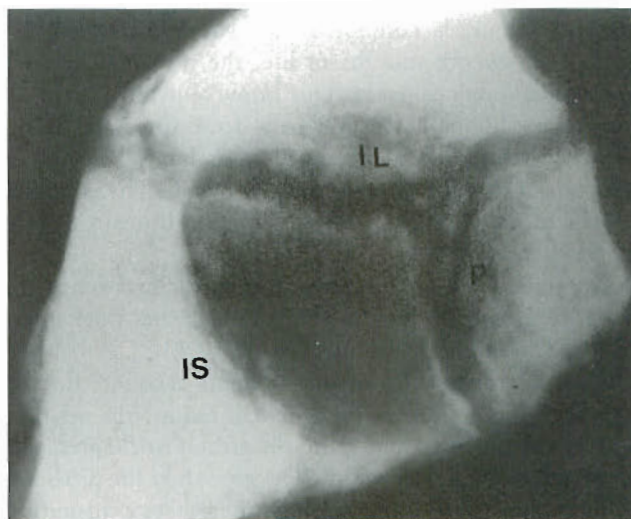


FIGURE 23-4. Lateral roentgenogram of the acetabulum of a 9-year-old girl. Two centers of ossification are seen within the cartilage adjoining the pubis (P) and appear to be developing within the vertical phalange of the triradiate cartilage. The positions of the ischium (IS) and the ilium (IL) are indicated. (From ref. 11, with permission.)

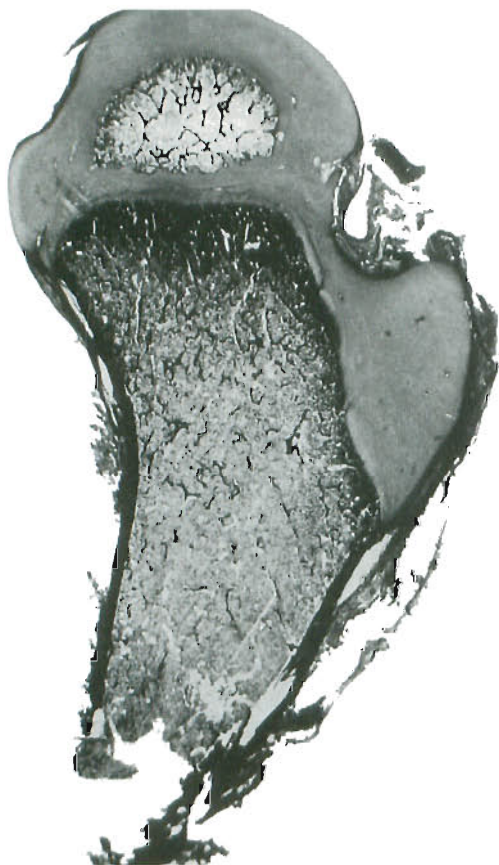


FIGURE 23-5. The infant proximal femur has three physal plates: the growth plate of the greater trochanter, the growth plate of the proximal femoral physal plate, and the growth plate of the femoral neck isthmus connecting the other two plates.

proximal femur, is composed of cartilage. Between the fourth and seventh months of life, the proximal femoral ossification center appears. This bony centrum continues to enlarge, although with a slowly decreasing rate, along with its cartilaginous anlage until adult life, when only a thin layer of articular cartilage remains over it. The proximal femur and the trochanter enlarge by appositional cartilage cell proliferation (14).

The three main growth areas in the proximal femur are the physal plate, the growth plate of the greater trochanter, and the femoral neck isthmus (14) (Fig. 23-5). A balance among the growth rates of these centers accounts for the normal configuration of the proximal femur, the relation between the proximal femur and the greater trochanter, and the overall femoral neck width. The growth of the proximal femur is affected by muscle pull, the forces transmitted across the hip joint by weightbearing, normal joint nutrition, circulation, and muscle tone (15–17). Any alterations in these factors may cause profound changes in development of the proximal femur (18).

During infancy, a small cartilaginous isthmus connects the trochanteric and femoral growth plates along the lateral border of the femoral neck and is a reflection of their previous common origin. This growth cartilage contributes to the lateral width of the femoral neck and remains active until maturity.

It is the normal growth of these three physes that determines adult femoral neck configuration. Disturbances in growth in any of these three growth plates by whatever mechanism alter the shape of the proximal femur. Hyperemia secondary to surgery or inflammatory conditions may stimulate growth in any or all of these growth plates (14).

The proximal femoral physal plate contributes approximately 30% of the growth of the overall length of the femur. Any disruption to the blood supply or damage to the proximal physal plate results in a varus deformity caused by the continued growth of the trochanter and the growth plate along the femoral neck (14,19). Partial physal arrest patterns may be caused by damage to portions of the proximal femoral physal plate. The relation between the growth of the trochanter and the physis of the proximal femur should

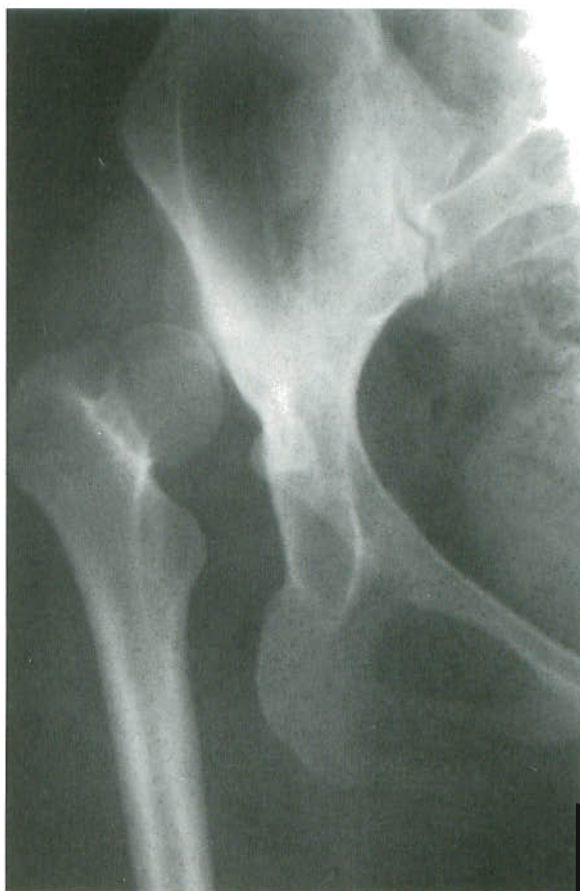

FIGURE 23-6. Untreated dislocation of the hip. Note the lack of the concave shape and the shallowness of the acetabulum.

remain constant; it is measured by the articular trochanteric distance, which is the distance between the tip of the greater trochanter and the superior articular surface of the femoral head. The greater trochanter usually is classified as a traction epiphysis, depending on normal abductor pull for growth stimulation. The trochanter, like the proximal femur, grows by appositional growth.

Determinants of Acetabulum Shape and Depth

Experimental studies and clinical findings in humans with unreduced dislocations suggest that the main stimulus for the concave shape of the acetabulum is the presence of a spherical femoral head (10,13,20–22). Harrison determined that the acetabulum failed to develop in area and depth after femoral head excision in rats (13). He also demonstrated atrophy and degeneration of the acetabular cartilage, although the growth plates of the triradiate cartilage remained histologically normal, as did the length of the innominate bones. These experimental findings are characteristic of humans who have had untreated hip dislocations (Fig. 23-6).

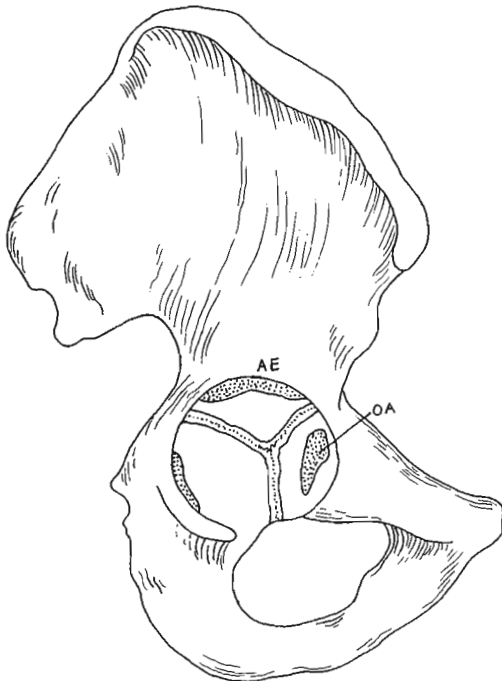


FIGURE 23-7. Diagram of the right innominate bone of an adolescent. The os acetabulum (OA) is shown within the acetabular cartilage adjoining the pubic bone. The acetabular epiphysis (AE) is within the acetabular cartilage adjoining the iliac bone, and another small epiphysis is within the acetabular cartilage adjoining the ischium (left). (Adapted from ref. 11, with permission.)

For the normal depth of the acetabulum to increase during development several factors must act in concert. There must be a reduced spherical femoral head. There also must be normal interstitial and appositional growth within the acetabular cartilage, and periosteal new bone formation must occur in the adjacent pelvic bones (10,11). The depth of the acetabulum is further enhanced at puberty by the development of three secondary centers of ossification (Fig. 23-7). These three secondary centers of ossification are homologous with other epiphyses in the skeleton (11,13). The os acetabulum develops in the thick cartilage that separates the acetabular cavity from the pubis bone. The os acetabulum is the epiphysis of the pubis and forms the anterior wall of the acetabulum. The epiphysis of the ilium, the acetabular epiphysis, forms a major portion of the superior edge of the acetabulum. A third small epiphysis also forms in the ischial region (11,13,23).

Normal acetabular growth and development occur through balanced growth of the proximal femur, the acetabular and triradiate cartilages, and the adjacent bones. This balance, which is probably genetically determined, may be at fault in DDH. There is ample evidence to suggest that an adverse intrauterine environment also plays an important role in the pathogenesis of hip dysplasia (11,24–28).

PATHOANATOMY

Dislocations in Newborns

In the newborn with DDH, the tight fit between the femoral head and the acetabulum is lost. The femoral head can be made to glide in and out of the acetabulum, with a palpable sensation known clinically as the “Ortolani sign” (11,16,29,30). DDH in the newborn refers to a spectrum of anatomic abnormalities, from mild dysplastic changes to the severe pathoanatomic changes that are found in the rare idiopathic teratologic dislocation, and more commonly in teratologic dislocations associated with conditions such as myelomeningocele and arthrogryposis.

The most common pathologic change in the newborn with DDH is a hypertrophied ridge of acetabular cartilage in the superior, posterior, and inferior aspects of the acetabulum. This ridge was referred to by Ortolani as the “neolimbus” (16,30). The neolimbus is composed of hypertrophied acetabular cartilage (9,29) (Fig. 23-8). There often is a trough or groove in the acetabular cartilage caused by secondary pressure of the femoral head or neck. It is over this ridge of acetabular cartilage that the femoral head glides in and out of the acetabulum, with the palpable sensation referred to as the Ortolani sign (9,16,30).

In the typical newborn with DDH, there is empirical evidence that the pathologic changes are reversible, because

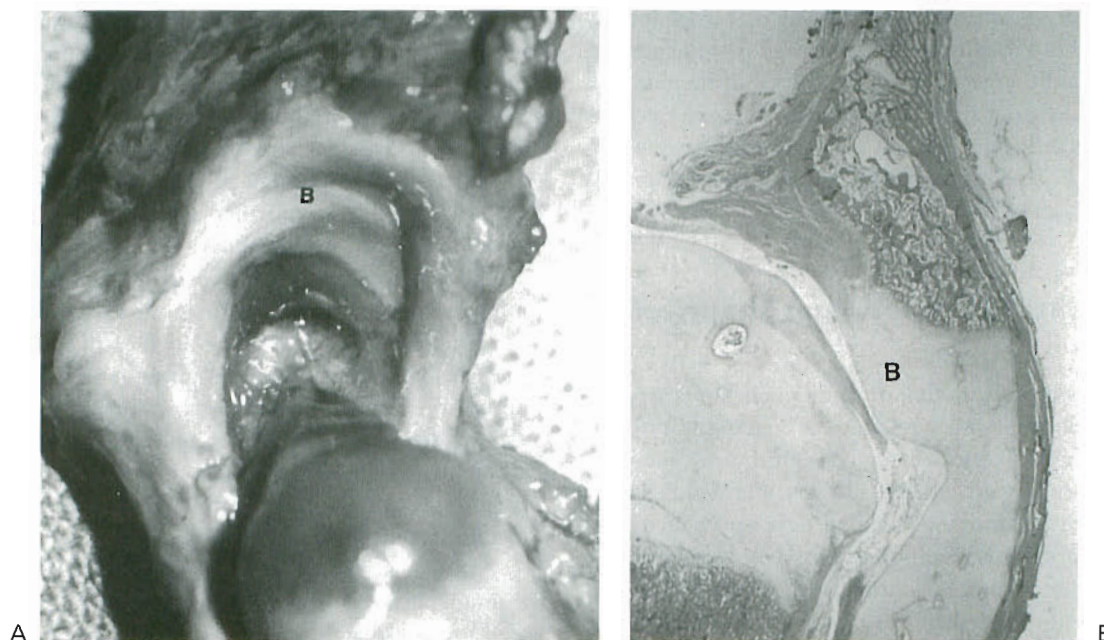

FIGURE 23-8. A: Right acetabular cavity and femoral head of a newborn baby with bilateral congenital hip dysplasia. There is an acetabular bulge (B) or neolimbus along the upper acetabular cartilage, and the acetabular cavity is small. B: Frontal section of the same hip. The femoral head is very large in relation to the acetabular cavity. Note how the labrum is everted and adheres to the joint capsule above. The neolimbus (B) is composed of hypertrophied acetabular cartilage. (From ref. 29, with permission.)

there is a 95% success rate of treatment using simple devices such as the Pavlik harness and the von Rosen splint (31). These changes are typical of 98% of DDH cases that occur at or around birth. However, about 2% of newborns have teratologic (antenatal) dislocations not associated with a syndrome or neuromuscular condition (23,26). In these rare cases, the pathologic and clinical findings are similar to those seen in late-diagnosed DDH, which is described below.

Acetabular Development in Developmental Hip Dysplasia

Acetabular development in treated DDH cases may be different from that described for the normal hip. This is particularly true for the late-diagnosed case. The primary stimulus for normal growth and development comes from the femoral head within the acetabulum (10,21,22). When there is a delay in diagnosis and treatment, some aspects of normal growth and development are lost. The femoral head must be reduced as soon as possible, and the reduction must be maintained to provide the stimulus for acetabular development. If concentric reduction is maintained, the acetabulum has the potential for recovery and resumption of normal growth and development for many years (32–34).

The age at which a dysplastic hip can still return to “normal” after reduction remains controversial (32,

34–42). The resumption and adequacy of acetabular development is a multifactorial problem that depends on the age at which the reduction is obtained and on whether the growth potential of the acetabular cartilage and the proximal femur is normal. The capacity of the acetabular cartilage to resume normal growth depends on its intrinsic growth potential, whether it has been damaged by the subluxated or dislocated femoral head, and whether it has been damaged by various attempts at reduction. In the treated DDH patient, especially in late-diagnosed cases, accessory centers of ossification contribute to acetabular development (Fig. 23-9). Accessory centers of ossification in the acetabulum are seen in only 2 to 3% of normal hips, and they rarely appear before 11 years of age. However, among patients treated for DDH, the centers may be present in as many as 60% of hips, usually appearing from 6 months to 10 years after reduction (32,34,35,43) (Fig. 23-9). In treated DDH cases, these accessory centers of ossification should be sought on every sequential radiograph to determine if acetabular development is progressing. This is an important factor to consider when deciding if surgical intervention is necessary to correct residual acetabular dysplasia. Although the presence of these centers indicates continued growth in the acetabular cartilage, they may be indicative of injury to the cartilage in this area.

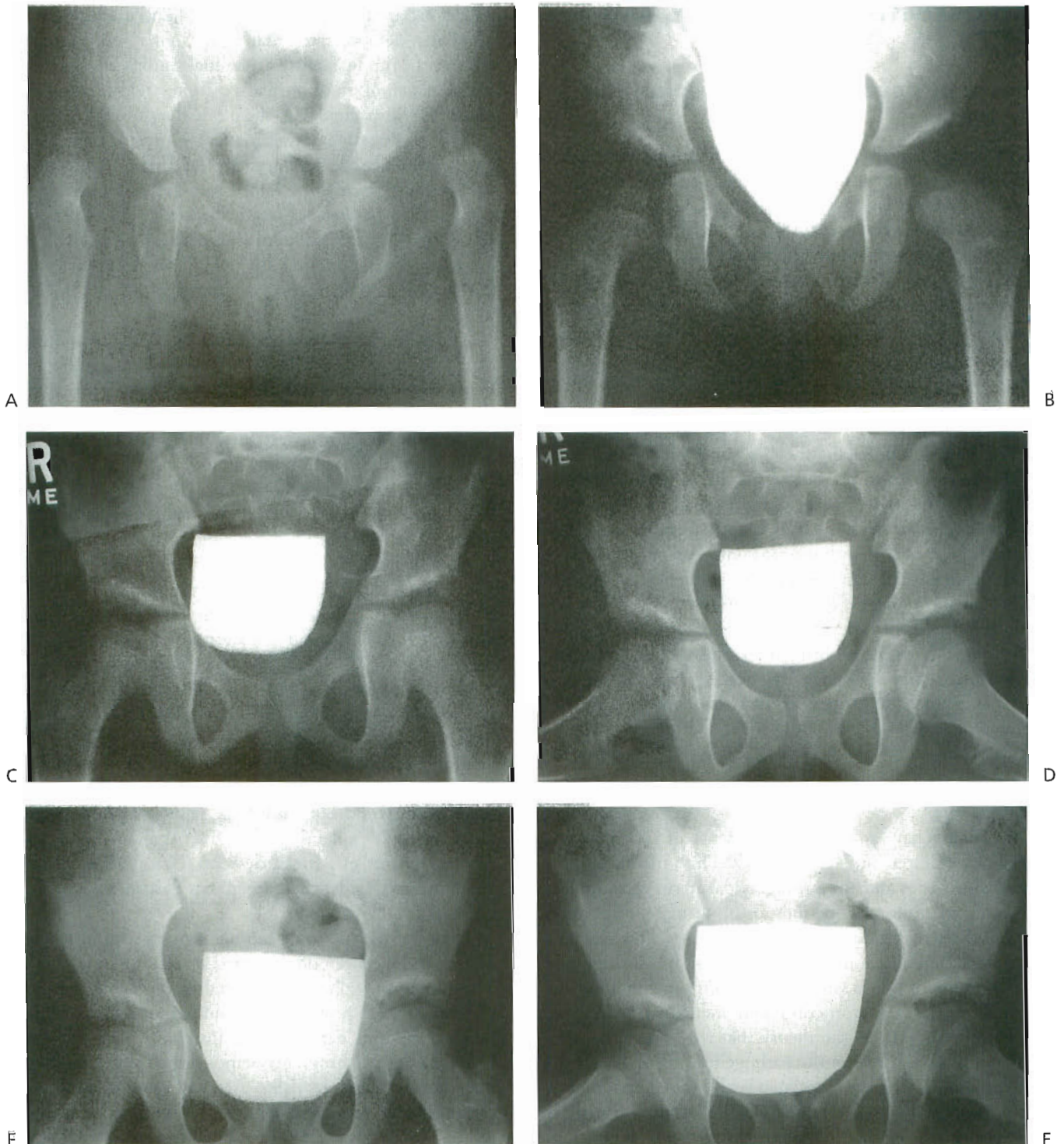


FIGURE 23-9. A: An 18-month-old girl with bilateral high dislocations. Note the poorly developed acetabula with well-developed secondary acetabula. B: At 33 months of age, the irregular ossification centers in the left and right hip have coalesced, with a slight improvement in the acetabular index. C: When the girl is 7 years of age, an anteroposterior (AP) view shows the appearance of the accessory centers of ossification in the periphery of the acetabulum. D: The accessory centers of ossification are somewhat better appreciated in the abduction view at 7 years of age. E: An AP view at 8 years of age shows the coalescence of the accessory centers of ossification, increasing the depth of the acetabulum. Note the excellent *sourcil* formation. F: The accessory centers of ossification are well demonstrated in an abduction view at 8 years of age.

PATHOGENESIS, EPIDEMIOLOGY, AND DIAGNOSIS

Causes of Developmental Dysplasia of the Hip

Many factors contribute to DDH. Genetic and ethnic factors play a key role, with the incidence of DDH as high as 25 to 50 cases per 1,000 live births among Lapps and Native Americans and a very low rate among the southern Chinese population and persons of African descent (27,44–58).

A positive family history for DDH may be found in 12 to 33% of affected patients (28,44,58). One study reported a tenfold increase among the parents of index patients and a sevenfold increase among siblings compared with the general population (44). There is some suggestion that femoral neck or acetabular anteversion may be an etiologic factor (27,29,35,60–62).

The genetic effects on the hip joint in patients with DDH are revealed in primary acetabular dysplasia, various degrees of joint laxity, or a combination of both. Intrauterine mechanical factors, such as breech position or oligohydramnios, and neuromuscular mechanisms, such as myelomeningocele, can profoundly influence genetically determined intrauterine growth (5,6,63,64). The first-born child is more likely to be affected than subsequent children. Any of the factors contributing to an “adverse” intrauterine environment may influence the development of the hip joint, and postnatal influences may also contribute to the development of DDH (5,28,65–67).

Risk Factors and Incidence

White infants have an increased incidence of DDH among first-born children (8,24,25,68–71). The unstretched abdominal muscles and the primigravida uterus may subject the fetus to prolonged periods of abnormal positioning, forcing the fetus against the mother’s spine. This restraint limits fetal mobility, especially hip abduction. The high rate of association of DDH with other intrauterine molding abnormalities, such as torticollis and metatarsus adductus, lends some support to the theory that the “crowding phenomenon” plays a role in the pathogenesis (8,71–73). Oligohydramnios, which is associated with limited fetal mobility, is associated with DDH (8,71). The left hip is the most commonly affected hip; in the most common fetal position, this is the hip that is usually forced into adduction against the mother’s sacrum (8,46,71).

DDH is more common among female patients (80% of cases) and children born breech. In the general population, breech presentations occur in about 2 to 4% of vaginal deliveries; for children with DDH, the reported incidence is higher, with Carter and Wilkinson (24,25) reporting 17% and Salter reporting 23% (80). Twice as many girls as boys are born breech (74). Fifty-nine percent of breech pre-

sentations are first-born children (24,25,74). Ramsey and MacEwen demonstrated that 1 of 15 girls born breech has evidence of hip instability. In animal studies, the prolonged maintenance of an abnormal position, such as the breech position, is associated with the production of DDH (21,22).

The postnatal extrauterine environment may significantly influence the development of DDH. In societies that use swaddling (i.e., hips forced into adduction and extension) in the postnatal period, the incidence of DDH is high, possibly as a result of the forceful positioning of the legs in extension and adduction in the face of normal newborn hip flexion and hamstring contractures (28,46,56,62,67,75–78).

The influence of hip capsular laxity on the development of DDH has been addressed by many investigators. Newborns with DDH may have capsular laxity. Hip capsular laxity has been implicated in the pathogenesis of DDH, because the diagnostic test for DDH, the Ortolani sign, depends on the head gliding in and out of the dysplastic acetabulum over a ridge of abnormal acetabular cartilage. Proponents argue that because reversible dysplasia can be produced in animals by producing ligamentous laxity the acetabular dysplasia seen in DDH is a secondary phenomenon (21,22,28,29,79,80). LeDamany demonstrated that the acetabulum is shallowest at birth (61). Râlis and McKibbin confirmed LeDamany’s anatomic work in a small number of patients (79). They too demonstrated that the acetabulum was shallowest at birth and that this, combined with the normal joint laxity of the infant, makes the time around delivery a high-risk period for dislocation (79,81). These anatomic experiments were repeated by Skirving and Scadden in African neonates (27). In the African neonate, the acetabulum was deeper more frequently and in a narrower range, possibly explaining why DDH is almost nonexistent among persons of African descent. This finding also provided indirect evidence of acetabular dysplasia as a primary cause of DDH.

Laxity of the hip joint capsule is often seen in newborn infants and has been documented by ultrasonography (82). The laxity may allow some instability without a positive Ortolani sign. In postmortem examination of seven stillborn infants, the hips demonstrated instability with a negative Ortolani sign; arthrograms demonstrated slight pooling of the contrast media medially. On gross examination the hip capsules were stretched, and the femoral heads could be pulled slightly away from the acetabula. However, the hips were anatomically and histologically normal, unlike the postmortem findings reported for all infants with positive Ortolani signs (9,11,30,54,59,83). In addition to the normal physiologic capsular laxity expected in the newborn, DDH is not a feature of conditions characterized by hyperlaxity, such as Down, Ehlers-Danlos, and Marfan syndromes (30).

Combining the epidemiologic and etiologic factors, a high-risk group of patients can be identified. This group

TABLE 23-1. HIGH-RISK FACTORS FOR DEVELOPMENTAL DYSPLASIA OR DISLOCATION OF THE HIP

Breech position
Female gender
Positive family history or ethnic background (e.g., Native American, Laplander)
Lower limb deformity
Torticollis
Metatarsus adductus
Oligohydramnios
Significant persistent hip asymmetry (e.g., abducted hip on one side, adducted hip on the other side)
Other significant musculoskeletal abnormalities

includes any patient who has more than one of the factors listed in Table 23-1. For an infant manifesting any combination of these factors, the physician should be alert to the possibility of DDH.

The incidence of DDH is influenced by geographic and ethnic factors and by the diagnostic criteria used by the examining physician. Another important factor is the diagnostic acumen of the examiner. The age of the patient at the time of diagnosis must be taken into account, because the physical findings and manifestations of the condition change with increasing delay in diagnosis (8,9,11,28,30,54,59,71,82–87).

Most DDH cases are detectable at birth (88,89). Despite newborn screening programs, some cases are not detected, and there is some evidence to suggest that a few cases may arise after birth (28,85,90–99). Moreover, the problem of whether acetabular dysplasia is primary or secondary to an unrecognized dislocation or subluxation that has reduced spontaneously remains unanswered. The results of newborn clinical screening programs estimate that 1 of every 100 newborns examined has evidence of some hip instability (i.e., positive Ortolani or Barlow sign), although the true incidence of dislocation is reported to be between 1 and 1.5 cases per 1,000 live births (9,41,84,92–95,100–104).

Diagnosis

The clinical diagnostic test for DDH was originally described by LeDamany in 1912 (61). LeDamany referred to the palpable sensation of the hip gliding in and out of the acetabulum as the *signe de vessant*. In 1936, Ortolani, an Italian pediatrician, described the pathogenesis of this diagnostic sign (30,83). Ortolani called the palpable sensation the *segno dello scotto*. Fellander and colleagues likened this diagnostic sign to the femoral head gliding in and out of the acetabulum over a ridge and referred to this palpable sensation as the “ridge phenomenon” (105). This ridge was named the *neolimbus* by Ortolani. This ridge, over which the femoral head glides in and out of the acetabulum, is

composed of hypertrophied acetabular cartilage (9,29,30,83) (Fig. 23-8).

Unfortunately, inadequate translation of LeDamany’s and Ortolani’s works into English resulted in the use of the term “click” to describe this diagnostic sign. High-pitched soft tissue clicks are often elicited in the hip examination of newborns. These clicks are usually transmitted from the trochanteric region or the knee and have no diagnostic significance (105). This poor understanding of the pathoanatomy of the primary diagnostic sign of DDH in the newborn has no doubt led to overdiagnosis and overtreatment of infants (102,106–108).

Another diagnostic test, the Barlow maneuver, is often referred to as the “click of exit.” The Barlow maneuver is a provocative maneuver in which the hip is flexed and adducted and the femoral head is palpated to exit the acetabulum partially or completely over a ridge of the acetabulum (84). Many physicians refer to the Ortolani sign as the “click of entry,” which is caused when the hip is abducted, the trochanter is elevated, and the femoral head glides back into the acetabulum. Some physicians make treatment decisions on the basis of whether they feel that the hip is Ortolani-positive versus Barlow-positive, feeling that the Barlow-positive hip is more stable. Because Ortolani and LeDamany described the palpable sensation as the femoral head exits or enters the acetabulum, the author prefers to use the Ortolani sign to refer to the palpable sensation of subluxating or dislocating the hip and to reducing a subluxated or dislocated hip. The author also makes no treatment distinction between the Ortolani sign and the Barlow sign.

Complete irreducible dislocations are extremely rare in newborns and are usually associated with other generalized conditions, such as arthrogryposis, myelodysplasia, and other syndromes. These perinatal teratologic dislocations are at the extreme end of the DDH pathologic spectrum and account for only 2% of cases in newborn examination series (9,46,47,109,110). They are usually manifested by the secondary adaptive changes more characteristic of the late-diagnosed case.

Although the clinical examination remains the gold standard (111), ultrasonography has gained popularity worldwide as a screening tool. Its cost effectiveness has yet to be documented for wholesale screening of DDH (see imaging section on page 916).

Late Diagnosis

If the diagnosis of DDH is not made early, preferably in the newborn nursery, secondary adaptive changes develop (45). The most reliable physical finding in late-diagnosed DDH is limitation of abduction (Fig. 23-10). Limited abduction is a clinical manifestation of the various degrees of adductor longus shortening associated with hip subluxation or dislocation (47). Other manifestations of late-diagnosed DDH may include apparent femoral shortening, also called

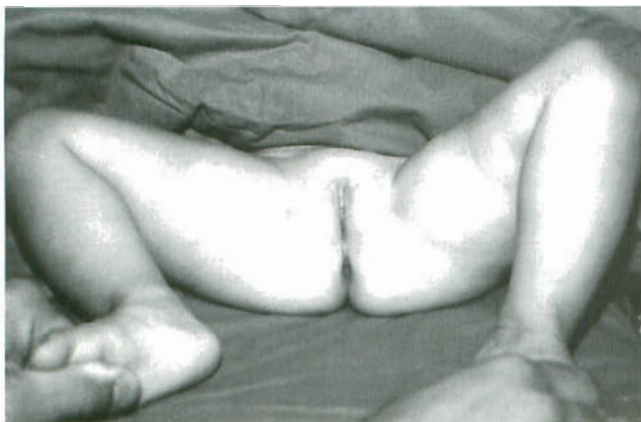

FIGURE 23-10. A 15-month-old child with left hip dislocation. Note the limited abduction of the hip.

the Galeazzi sign (Fig. 23-11); asymmetry of the gluteal (112), thigh, or labial folds (113); and limb-length inequality (Fig. 23-12). In patients with bilateral dislocations, clinical findings include a waddling gait and hyperlordosis of the lumbar spine (Fig. 23-13).

If DDH goes undetected, normal hip joint growth and development are impaired. With increasing age at detection and reduction, particularly for children older than 6 months of age the obstacles (intraarticular and extraarticular) to concentric reduction become increasingly difficult to overcome by simple treatment methods, such as use of the Pavlik harness, and closed or open reduction usually must be performed under general anesthesia. Restoration of normal acetabulum development is less likely as age at detection increases (23,29,41,104,114,115).

In the late-diagnosed case, the extraarticular obstacles to reduction include the contracted adductor longus and the iliopsoas. These muscles are shortened because of the hip

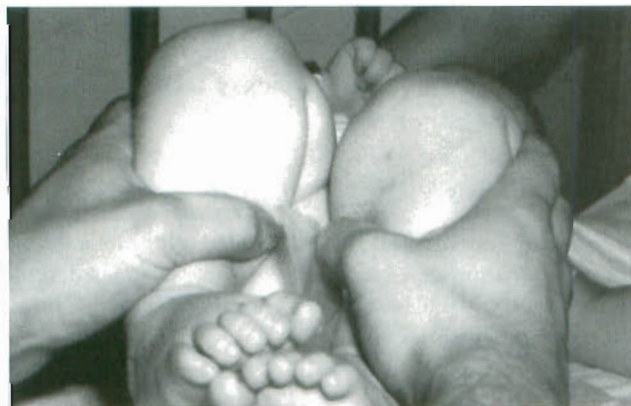

FIGURE 23-11. A 15-month-old girl with developmental dislocation of the left hip. Note the apparent femoral shortening.

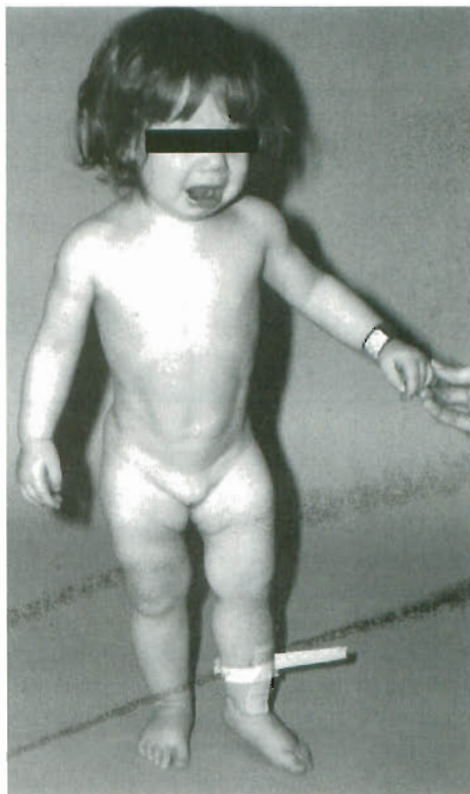

FIGURE 23-12. A 1-year-old white girl with developmental dislocation of the left hip was referred for toe walking. Note the apparent limb-length inequality and the asymmetry of the thigh and labial folds.

being in the subluxated or dislocated position, allowing secondary muscle-shortening.

The intraarticular obstacles to reduction in late-diagnosed DDH include the ligamentum teres, the transverse acetabular ligament, the constricted anteromedial joint capsule, and, rarely, an inverted and hypertrophied labrum (29,116). In the late-diagnosed case, the most significant intraarticular obstacle to reduction is some degree of anteromedial hip capsular constriction (29,117–121). The ligamentum teres may be thickened, and it may become the primary obstacle to reduction in some cases. In children of walking or crawling age, the ligamentum teres may be significantly elongated and enlarged. Its sheer bulk precludes concentric reduction without excision of the ligament. The transverse acetabular ligament may hypertrophy secondary to the constant pull of the ligamentum teres on its attachment at the base of the acetabulum (29,121). This effect decreases the diameter of the acetabulum.

A rare finding in other than teratologic dislocations is a true inverted labrum or limbus (i.e., hypertrophied labrum) (118) (Fig. 23-14). The acetabular labrum may be iatrogenically inverted and may be an obstacle to reduction in patients previously treated with unsuccessful closed reduc-

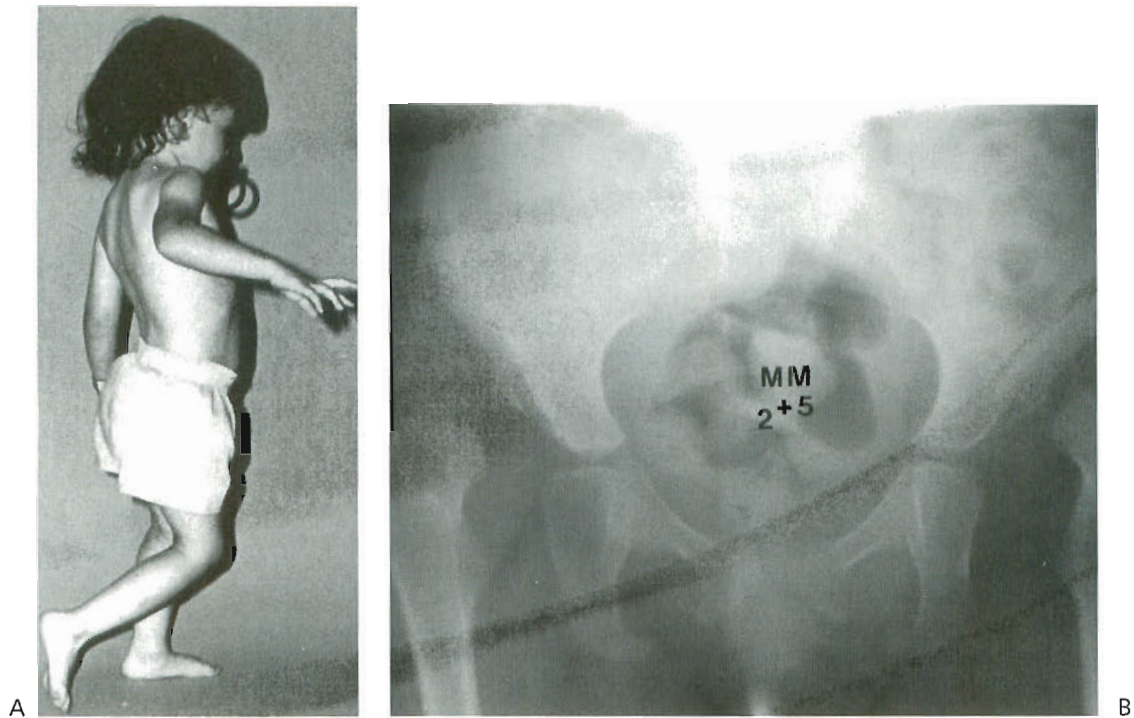


FIGURE 23-13. A 2-year, 5-month-old white girl with bilateral hip dislocations. **A:** Note the waddling gait and hyperlordosis. **B:** Radiograph shows high bilateral dislocations and poorly developed acetabula with well-developed secondary acetabula where the femoral heads articulate with the ilia.

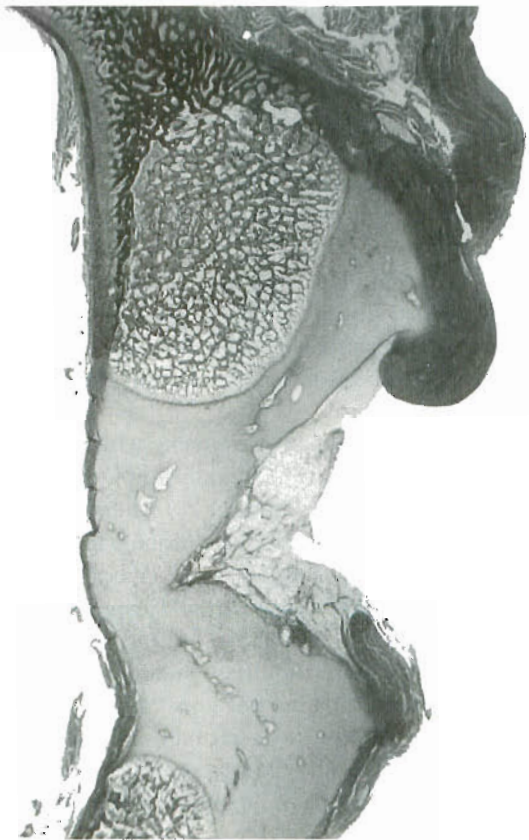

FIGURE 23-14. A coronal section of the acetabulum demonstrates the hypertrophic labrum (limbus) extending over the margin of a slightly thickened acetabular cartilage. The thick capsule extends upward above the inverted labrum, from which it is separated by a shallow groove. In this section through the ilium the growth plate is slanted upward laterally, but endochondral ossification is normal. At the margin of the roof periosteal bone growth is retarded. (From ref. 9, with permission.)

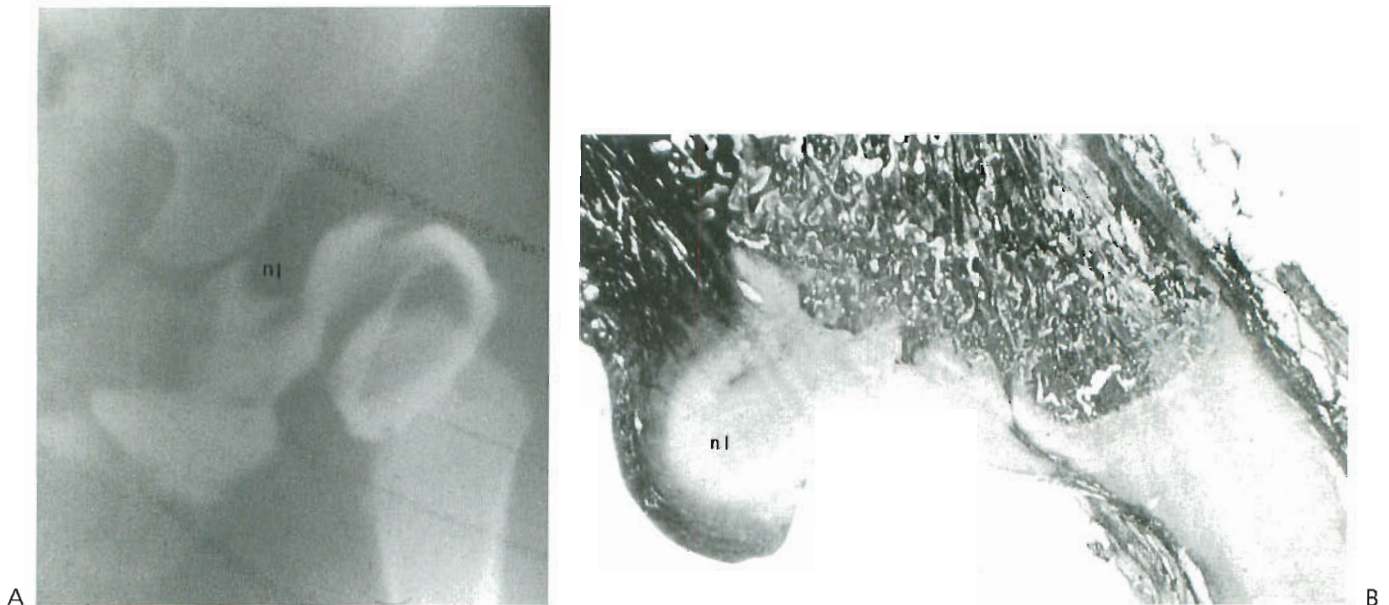


FIGURE 23-15. A: Arthrogram of the left hip in a 15-month-old child with complete dislocation. Note the shadow of the neolimbus (*nl*). B: A histologic specimen demonstrates hypertrophied acetabular cartilage of the neolimbus (*nl*), consistent with the arthrographic appearance in A.

tions. Arthrograms are often misinterpreted as showing an inverted labrum (122); the shadow thought to be the inverted labrum or limbus is instead the neolimbus described by Ortolani (9,29,41,123) (Fig. 23-15). This neolimbus is epiphyseal cartilage and is almost never an obstacle to reduction. It must not be removed, because removal impairs acetabular development (9,124).

The cartilage of the neolimbus may be primarily abnormal or may be damaged by a traumatic open or closed reduction. A response to this damage may be responsible for the appearance of the previously discussed accessory centers of ossification seen in treated cases of DDH (9) (Fig. 23-9).

Diagnostic Imaging and Radiography

The use of ultrasonography in the diagnosis and management of children with DDH remains controversial (125–156). Many proponents strongly recommend that ultrasonography be used as a routine screening tool in the newborn nursery and that it be used extensively in the management of all DDH problems (157–159). The use of ultrasonography in orthopaedic practice was pioneered by Graf in Austria in the 1970s (139,140). Harcke and colleagues in the United States (141–143,160), Terjesen and colleagues in Norway (149–152), and Clarke in Great Britain (131–133) have been the prime motivators in evaluating this tool for the diagnosis of DDH and other hip disorders.

Ultrasonography can be used in two basic ways to evaluate the child with DDH: morphologic assessment and dy-

namic assessment. The morphologic assessment, as pioneered by Graf, focuses primarily on critical evaluation of the anatomic characteristics of the hip joint (Fig. 23-16). This is accomplished by measuring two angles on the ultrasound image: the α angle, which is a measurement of the slope of the superior aspect of the bony acetabulum, and the β angle, which evaluates the cartilaginous component of the acetabulum. The hip is classified into four types and several subtypes according to various factors (139,140) (Fig. 23-17). In the evaluation of Terjesen and colleagues, the percentage of acetabular coverage of the femoral head (i.e., percent coverage) is a key measurement (149,152,161).

The morphologic approach to ultrasonography is widely practiced in Europe. This approach has been criticized because of substantial interobserver and intraobserver variations in the measurement of various angles, particularly the β angle (142).

The availability of equipment with which motion can be observed in real time in multiple planes provides a means of seeing what occurs during the Ortolani or Barlow maneuver. The use of dynamic ultrasonography, as popularized by Harcke and colleagues, has been criticized for being excessively operator-dependent and requiring a subjective assessment of the findings (141–143).

The indications for ultrasonography in the diagnosis and treatment of DDH are not universally established. Because there are many controversies yet to be resolved, ultrasonography cannot be advocated as a routine screening tool (142). Although it is used as such in Europe, prospective longitudi-

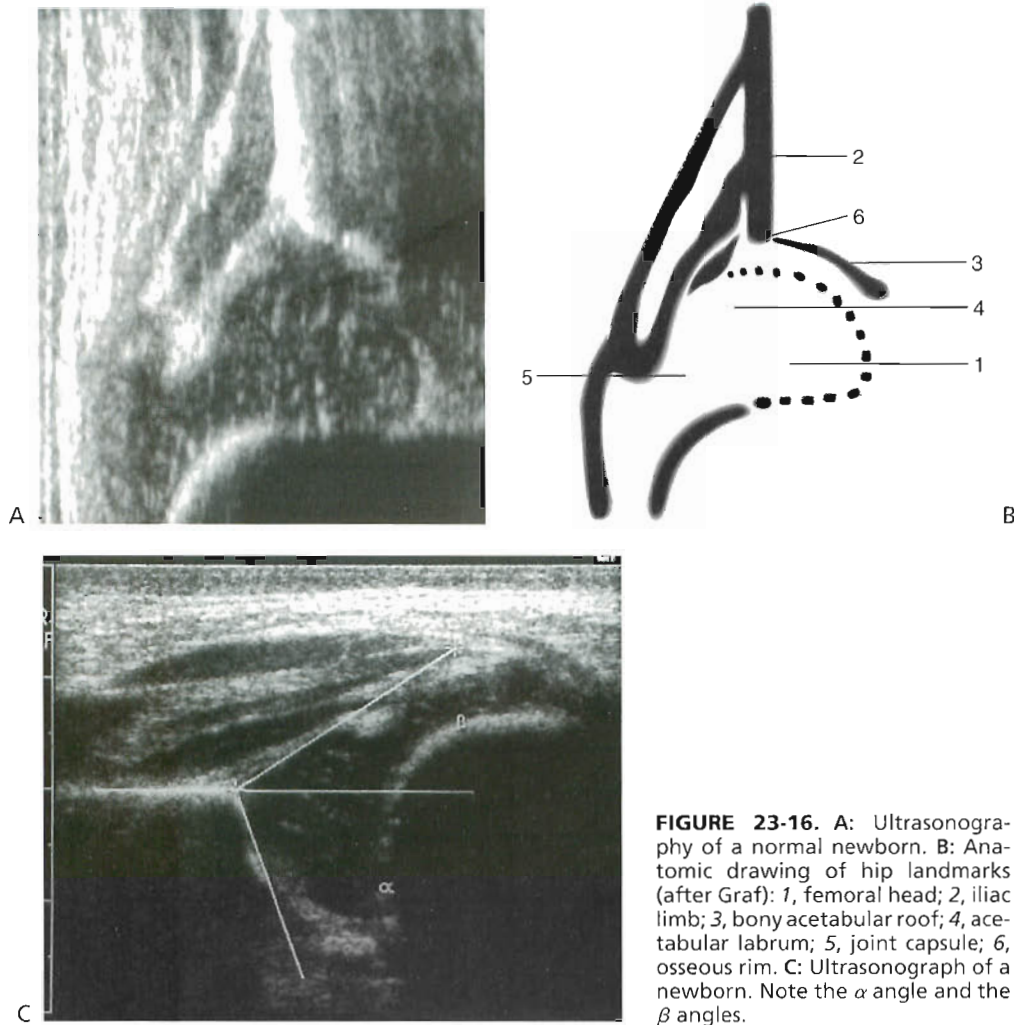


FIGURE 23-16. A: Ultrasonography of a normal newborn. B: Anatomic drawing of hip landmarks (after Graf): 1, femoral head; 2, iliac limb; 3, bony acetabular roof; 4, acetabular labrum; 5, joint capsule; 6, osseous rim. C: Ultrasonograph of a newborn. Note the α angle and the β angles.

nal studies documenting the outcomes of minor anatomic abnormalities found in ultrasonographic examinations need to be completed (162,163). Its routine use in newborn nurseries has resulted in overdiagnosis above the expected incidence of DDH and cannot be considered cost-effective (144,164–166). Its use for only high-risk infants (Table 23-1) may eventually prove cost-effective (166). However, Clarke and colleagues showed that screening all high-risk infants and all infants who had any abnormality on physical examination did not reduce the prevalence of late-diagnosed cases (128,132,133).

Some centers advocate the use of ultrasonography for all Ortolani-positive infants to assess stability at the completion of treatment (142). An ideal indication for ultrasonography is for guided reduction of a dislocated hip in an infant (167). Ultrasonography can be used to check the reduction of the hip and its stability during Pavlik harness treatment at 7- to 10-day intervals. This may temporarily obviate the need for radiographic evaluation. Other uses for ultrasonography

in the treatment of DDH include monitoring of the hip position while the patient is in traction, before attempts at reduction and evaluating closed reductions in the operating room. The distinct advantage of ultrasonography is that it provides some anatomic evaluation of the hip joint without exposing the infant to radiation.

Debate continues regarding the appropriate planes for evaluation and whether an orthopaedic surgeon, the treating physician, or a radiologist with expertise in ultrasonography should perform the evaluation. In the newborn DDH is not a radiographic diagnosis; the diagnosis should be made by clinical evaluation, which may be enhanced by ultrasonography if the examination results are questionable. Some groups have used vibration arthrometry (168–170).

After the newborn period the diagnosis of DDH should be confirmed by radiography. Many radiographic measurements can be made, but there are wide interobserver and intraobserver variations in these measurements (171,172). Because it is difficult to standardize the radiographic posi-




Type according to Graf	Bony roof / bony roof angle α	Superior bony rim (bony promontory)	Cartilaginous roof / cartilage roof angle β	Age	
TYPE I mature hip	good $\alpha \geq 60^\circ$	angular / slightly rounded ("blunt")	covers the femoral head I a $\Rightarrow \beta < 55^\circ$ (extending far distance over the femoral head) I b $\Rightarrow \beta > 55^\circ$ (extending short distance over the femoral head)	any age	
TYPE II a (+) physiological immature \Rightarrow appropriate for age	adequate (satisfactory) $\alpha = 50-59^\circ$ (minimal degree of maturity is attained – look at the "sonometer")	rounded	covers the femoral head	0 to 12 weeks	
TYPE II a (-) physiological immature \Rightarrow maturational deficient	deficient $\alpha = 50-59^\circ$ (minimal degree of maturity is not attained – look at the "sonometer")	rounded	covers the femoral head	> 6 to 12 weeks	
TYPE II b delay of ossification	deficient $\alpha = 50-59^\circ$	rounded	covers the femoral head	> 12 weeks	
EXCEPTION: Type II coming to maturity	deficient	angular (!)	covers the femoral head, (echogenic because of ossification!)	any age	
TYPE II c (critical range) II c stable / II c unstable	severely deficient $\alpha = 43-49^\circ$	rounded to flattened	still covers the femoral head $\beta < 77^\circ$	any age	
TYPE D decentering hip $\Rightarrow \beta > 77^\circ$	severely deficient $\alpha = 43-49^\circ$	rounded to flattened	displaced $\beta > 77^\circ$	any age	
TYPE III a eccentric hip $\Rightarrow \alpha < 43^\circ$	poor $\alpha < 43^\circ$	flattened	pressed upwards - without structural alteration (devoid of echoes) proximal perichondrium goes up to the contour of the iliac wall		
TYPE III b eccentric hip $\Rightarrow \alpha < 43^\circ$	poor $\alpha < 43^\circ$	flattened	pressed upwards - with structural alteration (they are echogenic) proximal perichondrium goes up to the contour of the iliac wall		
TYPE IV eccentric hip $\Rightarrow \alpha < 43^\circ$	poor $\alpha < 43^\circ$	flattened	pressed downwards horizontal or moulded proximal perichondrium		

FIGURE 23-17. Sonographic hip types. (Courtesy of Prof. R. Graf, Stolzalpe, Austria.)

tioning of infants, many centers use positioning frames (173).

When monitoring the treatment of children with DDH, it is essential to notice changes in the radiographic measurements over time and not to make significant decisions based on a single radiograph. The classic radiographic features of late-diagnosed DDH include an increased acetabular index (26,174–179), disruption of the Shenton line, a widened pelvic floor (180), an absent teardrop figure (181–187), delayed appearance of the femoral ossific nucleus on the involved side or dissimilar sizes of the ossific nuclei, abnormality in Smith centering ratios (21,22,34), decreased femoral head coverage, and failure of the medial metaphyseal beak of the proximal femur, and, subsequently, the secondary ossification center to be located in the lower inner quadrant, as defined by the Hilgenreiner and Perkins lines (86,188,189) (Fig. 23-18A). When the triradiate cartilage is closed, the acetabular angle of Sharp (i.e., from the inferior edge of the teardrop figure to the edge of the acetabulum) is a useful measurement of acetabular dysplasia (190).

In children younger than 8 years of age, the acetabular index is a reasonable measure of acetabular development

(171). The center-edge (CE) angle becomes useful only after 5 years of age and is most useful in the adult patient (43) (Fig. 23-18B). Radiographs show only the ossified portion of the pelvic bones and the proximal femur. Excellent acetabular coverage of the femoral head may be found, albeit by unossified cartilage (Fig. 23-19). If this cartilage does not ossify, the residual dysplasia may eventually lead to subluxation and degenerative joint disease.

The Shenton line provides only a qualitative estimate of dysplasia during the first few years of life. After 3 or 4 years of age, the Shenton line should be intact on all views of the hip; thereafter, any disruption of the Shenton line indicates an abnormality in the relation between the proximal femur and the acetabulum. This relation must be restored to prevent degenerative joint disease in later life (23,43,56,62,115).

Magnetic resonance imaging has been used for DDH diagnosis and evaluation, as well as for documentation of femoral head acetabular relationships after closed or open reduction (191,192). With advances in software, this modality will no doubt provide useful information in the future. The need for anesthesia for pediatric patients limits the utility of this modality (193–196).

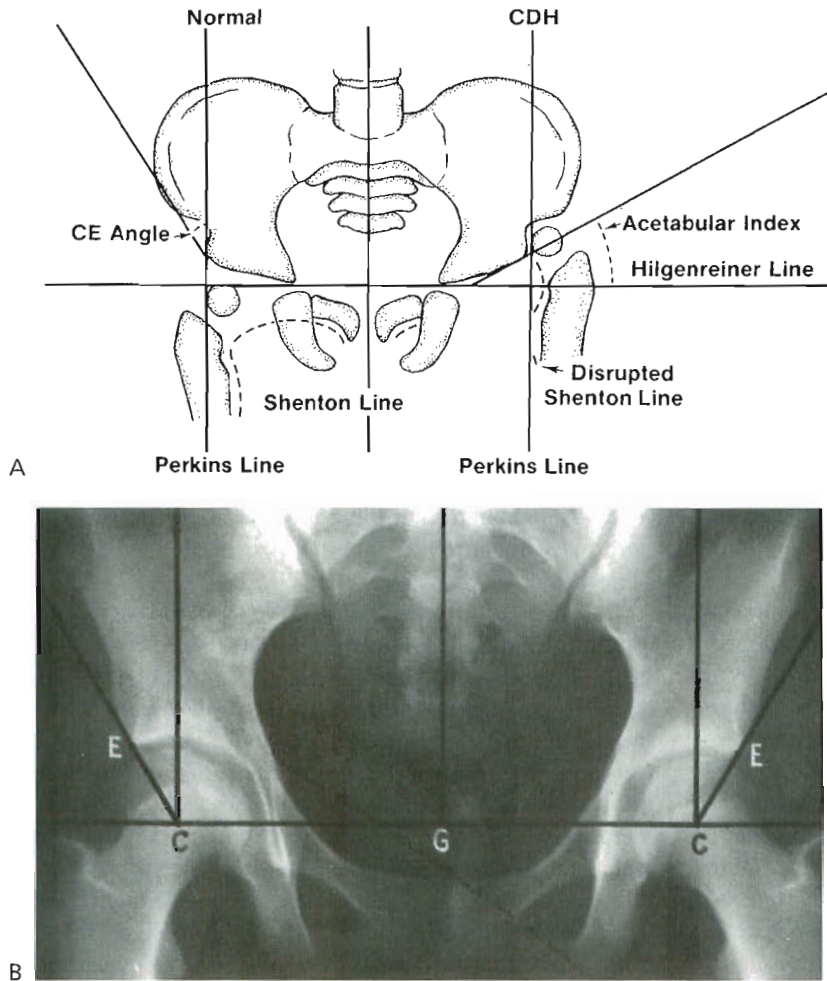


FIGURE 23-18. A: Radiographic parameters. CDH, congenital dysplasia of the hip; CE Angle, center-edge angle. B: Center-edge angle of Wiberg. C, Center of the femoral head; E, bony edge of the acetabulum; G, gravity line.

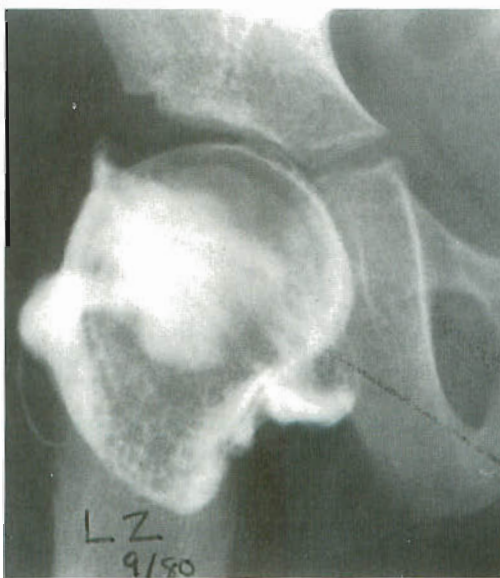

FIGURE 23-19. Arthrogram of a 5-year-old white girl 3 years after open reduction. Note the excellent coverage of the femoral head by unossified acetabular cartilage.

NATURAL HISTORY

Course in Newborns

The natural history of untreated DDH in the newborn is quite variable. Yamamuro and Doi followed 52 hips with positive Ortolani signs for a 2-year period without treatment for the first 5 months. Of the 12 they called “dislocated” hips, 3 (25%) were radiographically normal at 5 months of age. Of the 42 they called “subluxable” hips, 24 (57%) were normal at 5 months (78).

Barlow reported that 1 of every 60 infants born has instability (i.e., positive Barlow sign) of one or both hips (84). More than 60% of these stabilize during the first week of life, and 88% stabilize during the first 2 months, without treatment. The remaining 12% become true congenital dislocations and persist without treatment. Pratt and colleagues followed 18 “dysplastic” hips in patients younger than 3 months of age who were diagnosed based on clinical and radiographic parameters for an average of 11.2 years and found that 15 were roentgenographically normal (77).

Coleman followed 23 untreated DDH patients younger than 3 months of age who were diagnosed based on clinical

and radiographic criteria. He found that 26% of the femoral heads became completely dislocated, 13% had partial contact of the femoral head with the acetabulum, 39% remained located but retained dysplastic features, and 22% were normal (46).

Most unstable hips in newborns stabilize soon after birth, some may go on to subluxation or dislocation, and some may remain located but retain anatomic dysplastic features. Because it is not possible to predict the outcome of unstable hips in newborns, all newborns with clinical hip instability, as manifested by a positive Ortolani or Barlow sign, should be treated.

Course in Adults

In adults, the natural history of untreated complete dislocation varies, and is affected by societal considerations (56,66,197–200). Despite complete dislocation there may be little or no functional disability.

The natural history of complete dislocation depends on two factors: the presence or absence of a well-developed false acetabulum, and bilaterality (23,56,66,114,201,202). Wedge and Wasylenko demonstrated only a 24% chance of a good clinical result with a well-developed false acetabulum, but with a moderately developed or absent false acetabulum, the patients had a 52% chance of a good clinical result (56,66). Of 42 patients with complete dislocations, 13 had roentgenographically confirmed degenerative joint disease, such as loss of joint space, cyst formation, sclerosis, osteophyte formation, and flattening of the femoral head. Of these 13 patients, 10 (76%) had poor clinical results.

Milgram reported the gross and histologic features of a case of bilateral DDH discovered at postmortem examina-

tion (203). This 74-year-old man had no hip or thigh pain and only mild backache for 5 years before his death. His femoral head had no articulation with any portion of the ilium. The femoral head was covered with a thickened, markedly elongated hip joint capsule. The only degenerative changes occurred where the lesser trochanter abutted the overhanging superior acetabular rim. In the absence of a false acetabulum, most patients with complete dislocations do well, maintaining good range of motion with little functional disability (Fig. 23-20). Completely dislocated hips with well-developed false acetabula are more likely to develop roentgenographic degenerative joint disease changes and have poor clinical results (Fig. 23-21). Factors that lead to the formation or lack of formation of a false acetabulum remain unknown (23).

Back pain may occur in patients with bilateral dislocations. It is thought that this pain is secondary to the hyperlordosis of the lumbar spine that is associated with bilateral dislocations (23,56,66,197,198,203,204) (Fig. 23-22).

In unilateral complete dislocations, secondary problems of limb-length inequality, ipsilateral knee deformity and pain, scoliosis, and gait disturbance are common. Limb-length inequalities of as much as 10 cm have been reported in patients with unilateral dislocations. These patients develop flexion adduction deformities of the hip, which may lead to valgus deformities of the knee. The valgus knee deformity is often associated with attenuation of the medial collateral ligament and lateral compartment degenerative joint disease, although some medial compartment disease has been described (23,56,66,115,198,202). The same factors involved in the development of secondary degenerative disease in the false acetabulum and in the associated clinical disability in bilateral cases affect unilateral dislocations.

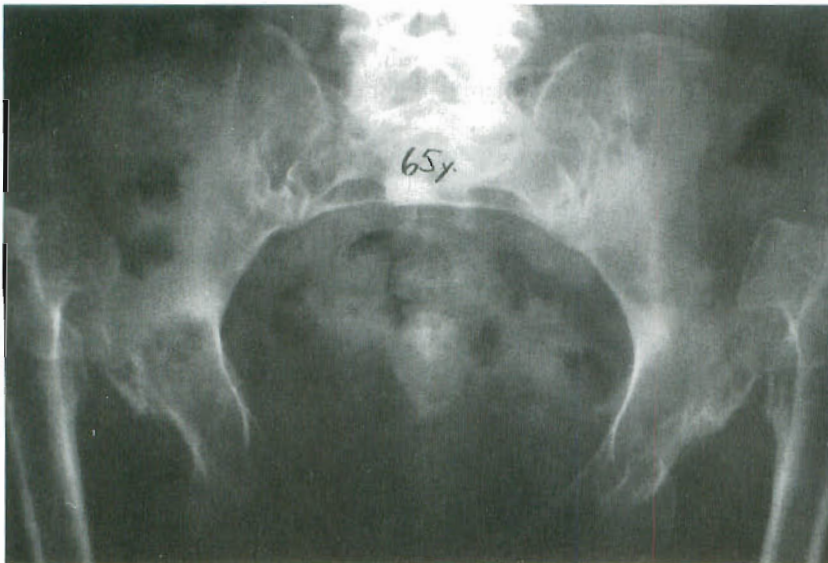


FIGURE 23-20. A 65-year-old white woman with bilateral, untreated developmental dislocations of the hips complained of some low back pain, but had no hip pain. She had a waddling gait and hyperlordosis.

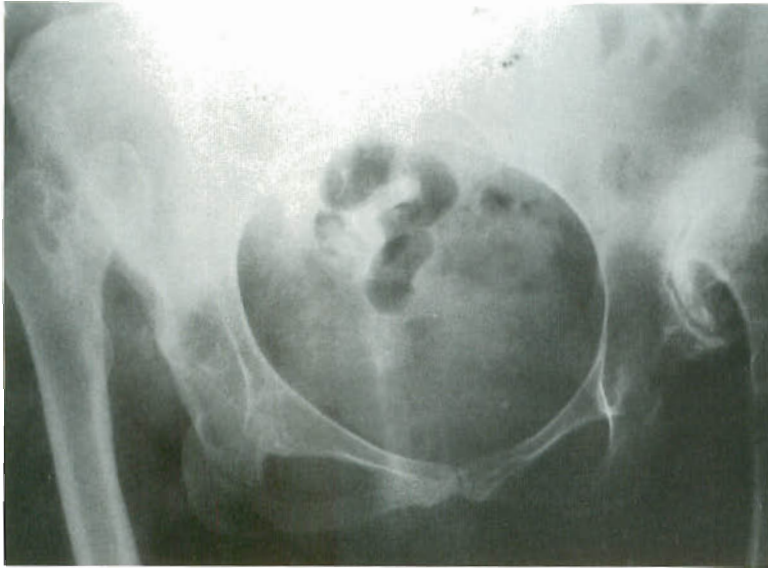


FIGURE 23-21. Roentgenogram of a 43-year-old woman with complete dislocation of both hips. She is asymptomatic on the right, but has disabling symptoms from the left hip. She has no false acetabulum on the right, but has a well-developed false acetabulum on the left with secondary degenerative changes. (From ref. 23, with permission.)

Course of Dysplasia and Subluxation

The natural history of dysplasia and subluxation in untreated patients is important because of the likelihood that these findings can be extrapolated to residual dysplasia and subluxation after treatment (115,127,205–207).

After the neonatal period, the term “dysplasia” has an anatomic and a radiographic definition. Anatomic dysplasia refers to inadequate development of the acetabulum, the femoral head, or both (47). All subluxated hips (i.e., those in which there is some contact between the femoral head and the acetabulum) are by definition anatomic dysplastic. Radiographically, the major difference between dysplasia and subluxation is determined by the integrity of the Shenton line. In hip subluxation, the Shenton line is disrupted and the femoral head is superiorly, laterally, or superolaterally displaced from the medial wall of the acetabulum. In radiographic dysplasia, the normal Shenton line relation is intact (56,66,208,209) (Fig. 23-23). In the literature describing the natural history of DDH, these two roentgenographic and clinical entities often are not separated. Moreover, secondary degenerative changes may convert a radiographically dysplastic hip to a subluxated hip (206,209–211) (Figs. 23-24 and 23-25).

Anatomic abnormalities are seen roentgenographically in subluxation and dysplasia, but the natural histories of these two radiographic entities are different. Residual radiographic subluxation after treatment for DDH invariably leads to degenerative joint disease and clinical disability (23,56,65,115,206,209). The rate of deterioration is directly related to the severity of the subluxation and the age of the patient (206,209).

There is considerable evidence that residual radiographic acetabular dysplasia leads to secondary degenerative joint disease, especially in female patients, although there are no predictive radiographic parameters (206,209,211,212). The



FIGURE 23-22. A 45-year-old white woman with bilateral complete dislocations, hip flexion deformity, and marked hyperlordosis. The patient's only complaints were referable to her back.

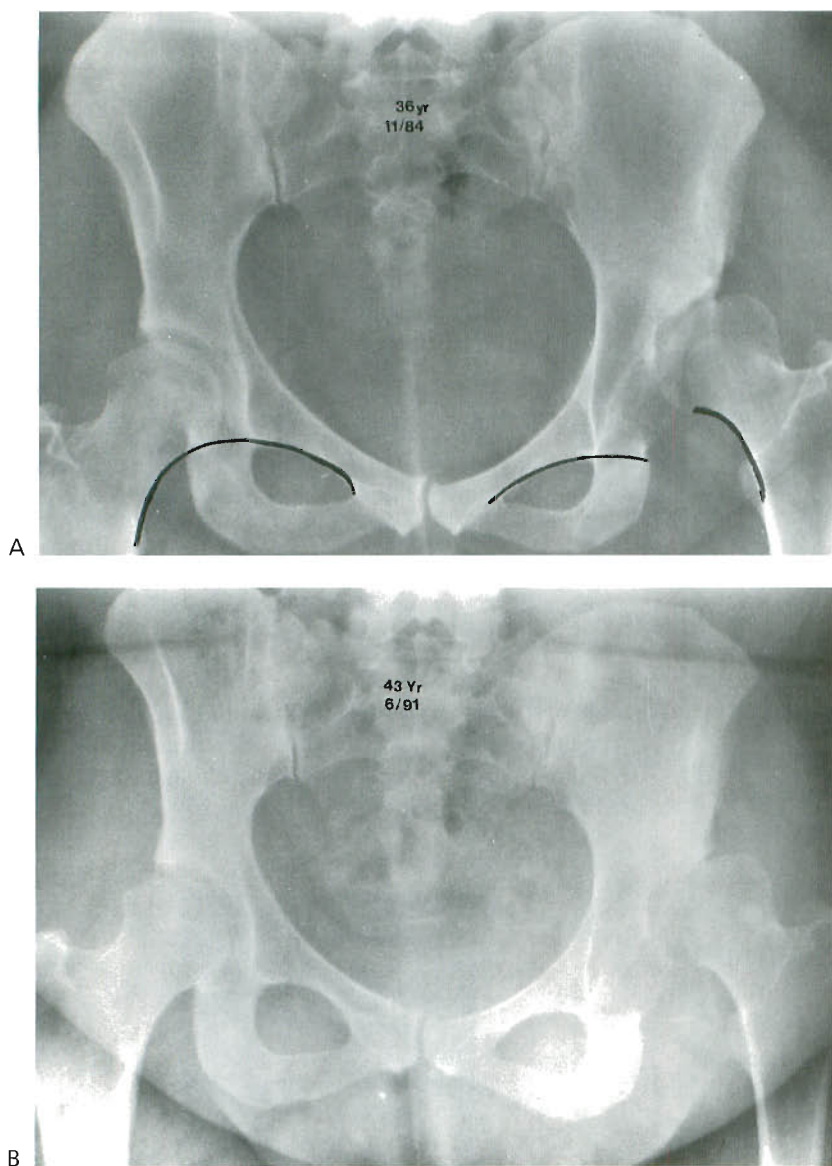


FIGURE 23-23. Radiographic subluxation and dysplasia. **A:** A 36-year-old woman with bilateral anatomically abnormal (dysplastic) hips. The left hip is radiographically subluxated, with the Shenton line disrupted, and the right hip is radiographically dysplastic, with the Shenton line intact. **B:** Seven years later, note the marked loss of joint space in the secondary acetabulum of the left hip and very early disruption of the Shenton line on the right. The right hip is asymptomatic, and the left hip is about to undergo total hip arthroplasty.

reasons for degenerative changes in radiographically dysplastic hips are probably mechanical in nature and related to increased contact stress with time. A certain “overpressure” (213,214) may correlate with long-term outcome. Aspherical femoral heads (e.g., secondary to aseptic necrosis) tend to experience even more severe degrees of overpressure. It appears that radiographic degenerative joint disease correlates with the magnitude of the overpressure and the time of exposure (213).

Because the physical signs of radiographic hip dysplasia are usually lacking, cases are often diagnosed only incidentally on the basis of roentgenograms taken for other reasons or after the patient develops symptoms (24,25,43,74,211). Stulberg and Harris found that 50% of their patients with radiographic dysplasia and degenerative joint disease had radiographic evidence of dysplasia in the opposite hip (211).

Melvin and associates, in their unpublished 30- to 50-year follow-up of DDH, demonstrated that 40% of the patients with DDH had roentgenographic evidence of dysplasia in the opposite hip (198). It has been estimated that 20 to 50% of degenerative joint disease of the hip is secondary to subluxation or residual radiographic acetabular dysplasia (43,56,209,211,212,215–217). Wiberg suggested that there was a direct correlation between the onset of roentgenographic degenerative joint disease and the amount of dysplasia as measured by the decrease in the CE angle (43) (Fig. 23-16).

Cooperman and colleagues, in a roentgenographic study of degenerative joint disease and its relation to the severity of radiographic acetabular dysplasia, reviewed the 17 cases on which Wiberg based his conclusions (209). They concluded that 7 of 17 hips were actually subluxated. These

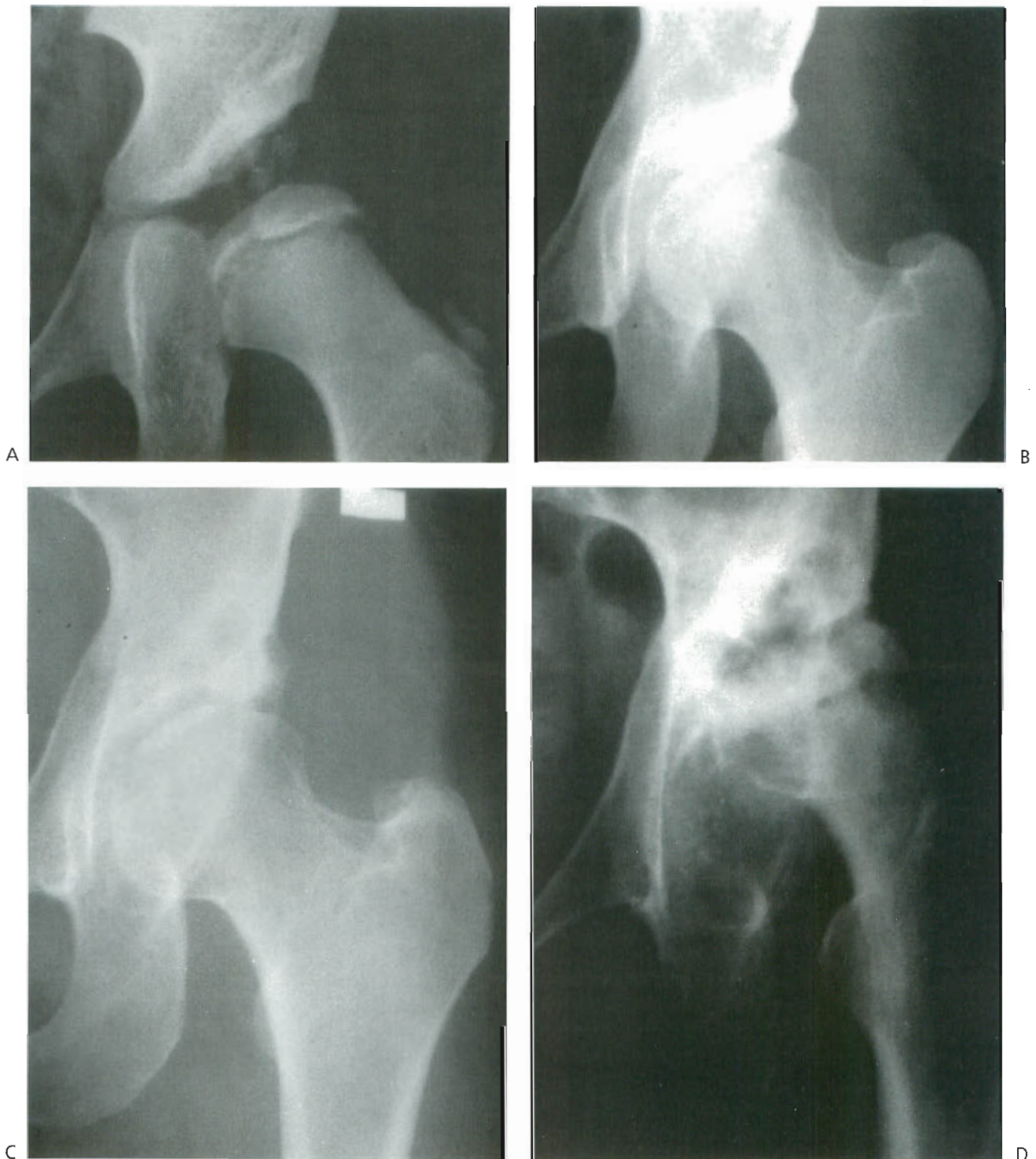


FIGURE 23-24. Anteroposterior radiographs made after closed reduction of developmental dislocation of the hip that had been performed when the patient was 2 years, 4 months of age. **A:** Thirty-nine months after reduction, when the patient was 5 years, 7 months of age, the accessory centers of ossification are visible in the acetabular cartilage. **B:** Fifteen years after reduction, when the patient was 17 years of age, the Shenton line is intact and there is mild, acetabular dysplasia. **C:** Forty-two years after reduction, when the patient was 44 years of age, degenerative changes are present. **D:** Fifty-one years after reduction, when the patient was 53 years of age, the hip is subluxed and has severe degenerative changes (Iowa Hip Rating, 48 of 100 points). The patient subsequently underwent total hip replacement. (From ref. 206, with permission.)

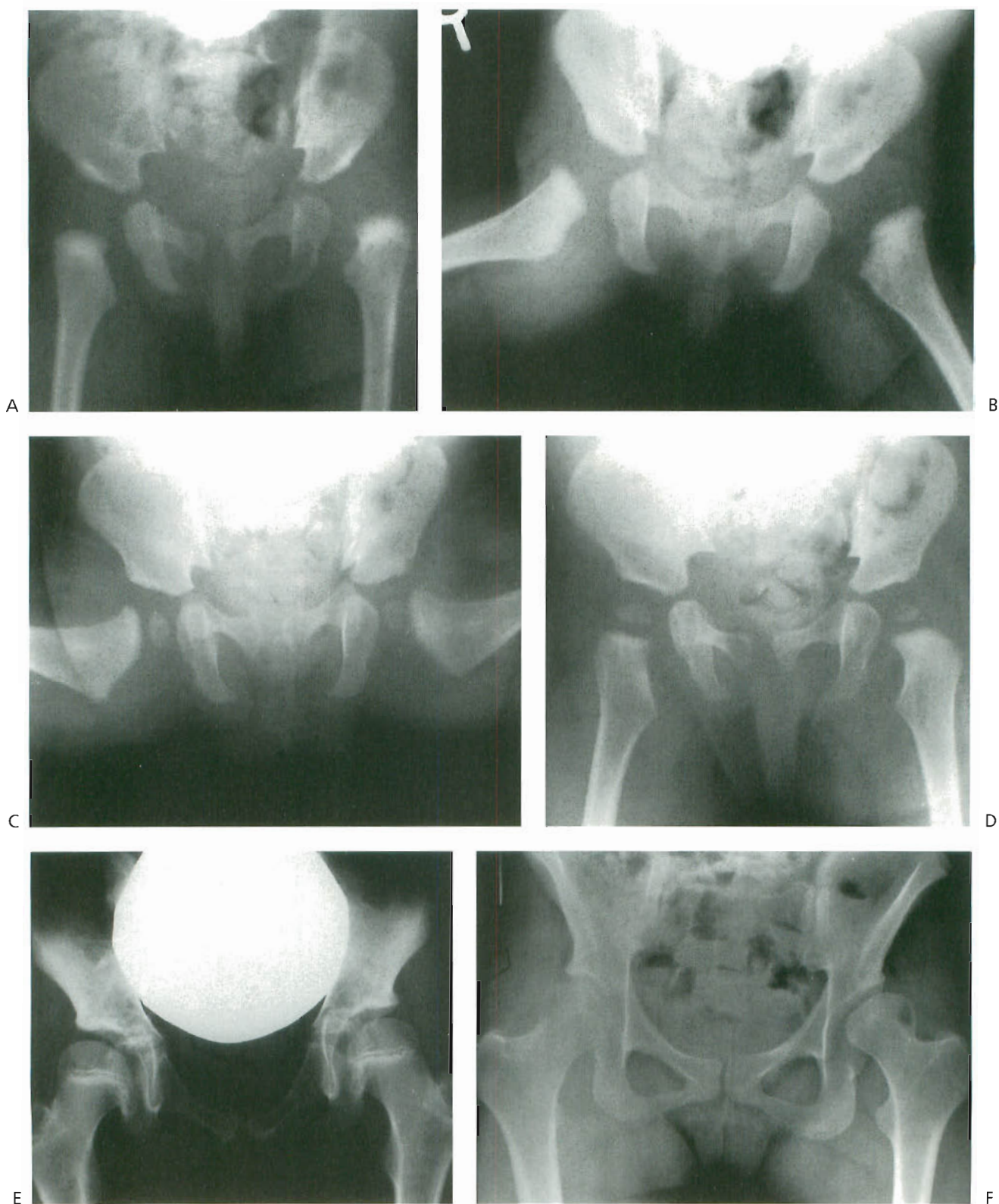

FIGURE 23-25. A 4-month-old white girl with left hip dislocation and right hip subluxation. **A:** Anteroposterior (AP) view. **B:** Abduction view. **C:** Abduction view at 7 months of age, 3 months after closed treatment. **D:** AP view at 7 months of age, 3 months after closed treatment. **E:** AP view at 7 years of age. Note the mild anatomic dysplasia of both hips. **F:** AP view at 15 years of age. Note the bilateral anatomic dysplasia. The right hip is radiographically dysplastic, and the left hip is radiographically subluxated.

subluxated hips were the most anatomically dysplastic; their CE angles averaged 2 degrees, and all 7 had roentgenographic degenerative changes by 42 years of age. The other 10 hips in Wiberg's series were radiographically dysplastic. They had intact Shenton lines and an average CE angle of 10 degrees. None of these patients developed radiographic degenerative joint disease before 39 years of age; however, degenerative changes became apparent roentgenographically by 57 years of age. In this review of Wiberg's series, the decrease in CE angle was associated with an increase in anatomic acetabular dysplasia and an increased likelihood that the hip was subluxated. Subluxation was the primary factor in the development of degenerative joint disease in this group. Subluxation predictably leads to degenerative joint disease and clinical disability over time.

Cooperman and associates described 32 hips (28 patients) with radiographic evidence of acetabular dysplasia (i.e., CE angle less than 20 degrees, but without subluxation, and the Shenton line intact), at an average follow-up of 22 years (209). All patients eventually developed radiographic evidence of degenerative joint disease. However, there was no linear correlation between the CE angle and the rate of development of degenerative joint disease, as had been suggested previously by Wiberg. A decreased CE angle was associated solely with increasing radiographic evidence of acetabular dysplasia and not with subluxation, because patients with subluxation had been excluded in this series. Cooperman and colleagues demonstrated that radiographic evidence of acetabular dysplasia leads to radiographically detectable degenerative joint disease, but the process may take decades. This study also demonstrated that the conventional radiographic parameters used to describe dysplasia (e.g., CE angle, acetabular index of Sharp, percent coverage, depth, inclination) could not predict the rate at which a radiographically confirmed dysplastic hip joint would develop roentgenographic evidence of degenerative joint disease.

Stulberg and Harris demonstrated that there is no roentgenographic picture of degenerative joint disease uniquely associated with preexisting acetabular dysplasia (211). In 80% of patients with dysplasia, the CE angle is usually less than 20 degrees, but acetabular shallowness, as measured by acetabular depth, affects all of these patients. The investigators also demonstrated that the CE angle, the criterion most commonly used to quantitate dysplasia, could be affected by many parameters, including roentgenographic positioning and the changes accompanying the normal development of degenerative joint disease. The secondary degenerative changes in a dysplastic acetabulum may give the hip a normal-appearing CE angle. In their series of 130 patients with primary or idiopathic degenerative joint disease, Stulberg and Harris were able to demonstrate that 48% had evidence of primary acetabular dysplasia, and that acetabular dysplasia frequently occurred in females with degenerative joint disease.

Additional evidence for the association between radio-

graphic evidence of acetabular dysplasia and degenerative joint disease comes from the southern Chinese population. In an epidemiologic study from Hong Kong, where the incidence of childhood hip disease is low, the incidence of adult osteoarthritis (nontraumatic) is also low (52,53).

Wedge and Wasylenko reported three peak periods of pain in subluxation, depending on the severity of the subluxation (56,66). Patients with the most severe subluxation usually had the onset of symptoms during the second decade of life. Those with moderate subluxation presented during their third and fourth decades, and those with minimal subluxation usually experienced the onset of symptoms around menopause.

Patients who present soon after symptom onset rarely have the classic signs of degenerative joint disease, such as decreased joint space, cyst formation, double acetabular floor, and inferomedial femoral head osteophytes. The only radiographic feature present at symptom onset may be increased sclerosis in the weightbearing area. This increased sclerosis is secondary to increasing osteoblastic stimulation in response to the decreased width of the weightbearing surface; the increase of the normal per unit load strains the bone. The mechanism of pain in these instances is purely speculative (Fig. 23-22).

In cases of subluxation, the mean age at symptom onset is 36.6 years for women and 54 years for men. Severe degenerative roentgenographic changes become evident approximately 10 years later, by 46.4 years of age for women and 69.6 years of age for men.

Patients with subluxated hips usually have symptom onset at a younger age than patients with complete dislocations. After pain and radiographically evident degenerative disease starts, the disease progresses rapidly. Harris reported that symptoms of degenerative joint disease associated with radiographic evidence of acetabular dysplasia occurred early in life and that almost 50% of the patients in his series with acetabular dysplasia had their first reconstructive procedure before 60 years of age, with fewer than 5% having their first reconstruction after 60 years of age (212).

TREATMENT OF HIP DISLOCATION

Newborns and Infants Younger Than 6 Months of Age

Based on the understanding of normal growth and development of the hip, the fundamental treatment goals in DDH are the same, regardless of age. The first goal is to obtain reduction and maintain that reduction to provide an optimal environment for femoral head and acetabular development (114). As has been demonstrated by many follow-up studies of treated DDH, the acetabulum has the potential for development for many years after reduction as long as the reduction is maintained (32,34,35). The femoral head and femoral anteversion can remodel if the reduction is

maintained (206,218). Further intervention is necessary only to alter an otherwise adverse natural history, as in the treatment of residual dysplasia and the prevention or treatment of subluxation. The later the diagnosis of DDH is made the more difficult it is to achieve these goals, the less potential there is for acetabular and proximal femoral remodeling, and the more complex are the required treatments. With increasing age and complexity of treatment the risk of complications is greater, and the patient is more likely to develop degenerative joint disease.

The diagnosis of DDH ideally should be made in the newborn nursery (219). If the diagnosis is made in the nursery, treatment should be initiated immediately (220). Triple diapers or abduction diapers have no place in the treatment of DDH in the newborn. They give the family a false sense of security and are generally ineffective. Any success with the use of triple diapers or abduction diapers could be attributed to the natural resolution of the disorder.

The most commonly used device for the treatment of DDH in the newborn is the Pavlik harness (Fig. 23-26). Although other devices are available (e.g., von Rosen splint, Frejka pillow), the Pavlik harness remains the most commonly used device worldwide (33,81,221–231). When appropriately applied, the Pavlik harness prevents hip extension and adduction, which can lead to redislocation, but it allows further flexion and abduction, which lead to reduction and stabilization. By maintaining the Ortolani-positive hip in a Pavlik harness on a full-time basis for 6 weeks, hip instability resolves in 95% of cases.

The Pavlik harness may be used effectively until 6 months of age for any child with residual dysplasia, subluxa-

tion, or complete dislocation. After 6 months of age the failure rate for the Pavlik harness is greater than 50% because it is difficult to maintain the increasingly active and crawling child in the harness. It may also be used to achieve reduction of a dislocated hip in a child in this age group. Ideally, the harness should be applied as soon after birth as the diagnosis is made.

Mubarak and colleagues and others described the disadvantages associated with the use of the Pavlik harness for the treatment of DDH (31,232). They pointed out that failures of treatment most often result from problems related to the physician, the device, or the patient.

Physician-related errors fall into two categories: inappropriate indications and persistence of inadequate treatment. The Pavlik harness is contraindicated in patients with significant muscle imbalance, such as those with myelodysplasia or cerebral palsy. It is also contraindicated for patients who have significant joint stiffness, such as children with arthrogryposis. The harness will fail if it is applied in a child with excessive ligamentous laxity, as seen in Ehlers-Danlos syndrome (31).

The persistence of inadequate treatment is a multifactorial problem. Physicians using the harness must be well versed in its appropriate application and the adjustments that are necessary throughout the course of treatment if treatment is to be successful. It is important that the physician treating the patient understand when a treatment failure has occurred, so as not to prolong treatment with the harness and cause secondary pathologic changes, called "Pavlik harness disease" (233). Persistence of treatment may damage the femoral head, injure the acetabular cartilage, and impair future bone growth. An inappropriately applied harness is a physician failure, not an orthotic failure (232,234).

Another major Pavlik harness problem is related to the specific orthotic device. Not all Pavlik harnesses are the same; the strap attachment sites vary. However, since the article by Mubarak and colleagues, most harnesses on the market meet the requisite standards they outlined (31,232).

Some problems are patient related. Certain family, social, and educational situations make compliance impossible. In these situations, the Pavlik harness would be inappropriate, and closed reduction and casting may be the more judicious approach. The family must be educated about the importance of the harness, its care and maintenance, how the child should be bathed while wearing the harness, and the consequences of failure to achieve success. Family noncompliance can lead to failure, and the use of a visiting nurse may be helpful in these situations.

Application of the harness (Fig. 23-26) should be demonstrated for the family members. The chest halter strap should be positioned at the nipple line, and the shoulder straps are set to hold the cross strap at this level. The leg and foot stirrups must have their anterior and posterior straps oriented anteriorly and posteriorly to the child's

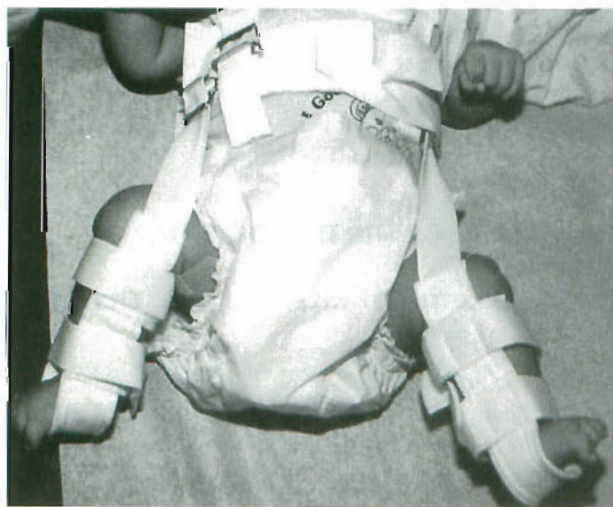

FIGURE 23-26. Newborn with bilateral hip dislocations in a Pavlik harness. Appropriately applied, the harness prevents hip extension and adduction which can lead to redislocation, but allows further flexion and abduction, which lead to reduction and stabilization.

knees. Hip flexion should be set at 100 to 110 degrees. These straps should be in the anterior axillary line. The posterior abduction strap should be at the level of the child's scapula and adjusted to allow comfortable abduction within the *safe zone* (235), which is defined as the arc of abduction and adduction that is between redislocation and comfortable, unforced abduction. The posterior strap acts as a check-rein to prevent the hip from adducting to the point of redislocation. Ultrasonography is a useful means of documenting relocation of the Ortolani-positive hip.

There is great variability in treatment regimens with the Pavlik harness. If the Pavlik harness is used to stabilize an unstable hip (i.e., an Ortolani- or Barlow-positive hip), the harness is used full time for 6 to 12 weeks after clinical stability is achieved. Most hips stabilize in days to weeks. The harness is checked at 7- to 10-day intervals to assess hip stability and to adjust the flexion and abduction straps to allow for growth of the infant. Clinical examination is usually sufficient to check the progress at each visit; ultrasonography may be used, but radiographs are unnecessary.

In a child younger than 6 months of age with a complete dislocation, the Pavlik harness may be used in a trial of guided reduction. In this case, the harness must be applied with enough hyperflexion and abduction to point the femoral head toward the triradiate cartilage. This situation is the ideal indication for the use of ultrasonography to follow the reduction. When the harness is used for guided reduction, the infant should be checked at 7 to 10 days to determine whether the reduction is being accomplished. Clinical examination alone may be adequate, but initial radiographs should be obtained to document adequate flexion and redi-

rection of the femoral neck toward the triradiate cartilage in the harness. After clinical stability is achieved, radiography is not indicated until about 3 months of age to assess acetabular development (Fig. 23-27). Ultrasonography is an excellent means of documenting progress toward and completion of successful reduction (236).

Although the Pavlik harness has provided a 95% overall success rate for the treatment of the Ortolani-positive hip, the success rate for using the harness to guide the reduction of a subluxated or dislocated hip in a child younger than 6 months of age is 85% (31,224,237).

The use of the Pavlik harness can be associated with complications; most of these complications are iatrogenic and can be avoided. Inferior dislocations may occur with prolonged excessive hip flexion (238,239). Hyperflexion may also induce femoral nerve compression neuropathy; this condition generally resolves after the harness is removed. It is important during each examination to make certain that the patient has active quadriceps function. Brachial plexus palsy may occur from compression by the shoulder straps, and knee subluxations may occur from improperly positioned straps.

Skin breakdown may occur in the groin creases and in the popliteal fossa if great care is not taken in keeping these areas clean and dry. Instruction with regard to bathing and skin care is essential.

The most disastrous consequence of Pavlik harness treatment is damage to the cartilaginous femoral head and the proximal femoral physeal plate (240,241). This is usually secondary to forced abduction in the harness or persistent

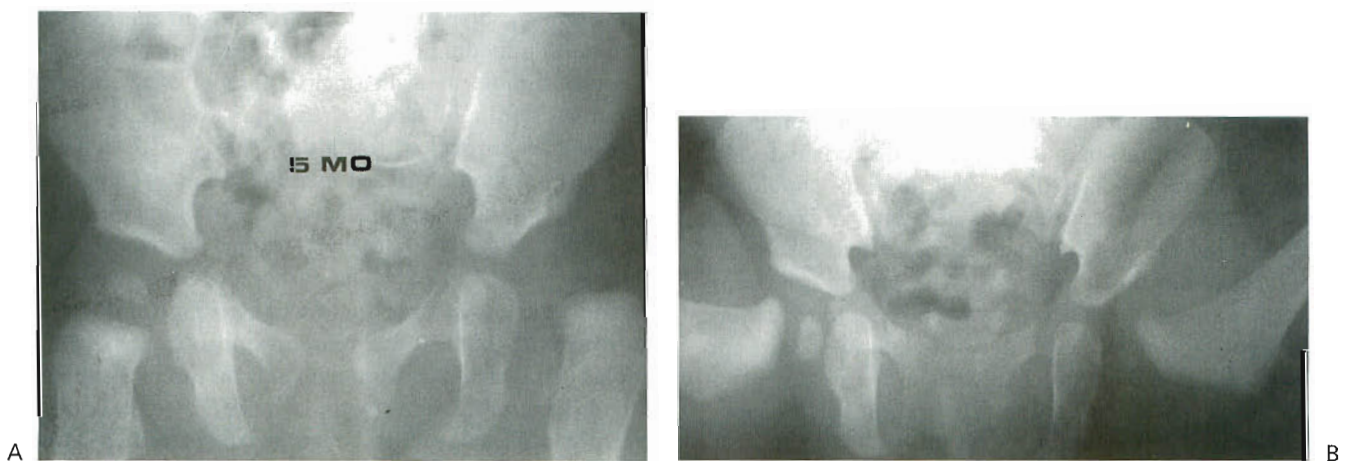


FIGURE 23-27. A 5-month-old child with left developmental dislocation of the hip. **A:** Anteroposterior (AP) view of the pelvis at diagnosis. The acetabular index is increased, the medial floor of the acetabulum is widened, and the acetabular teardrop figure is absent. There is a well-developed secondary acetabulum, the Shenton line is disrupted, and the femoral ossific nucleus is decreased in size. The femoral head is located in the upper outer quadrant, as defined by Hilgenreiner and Perkins lines. **B:** AP view of the pelvis with a hip Pavlik harness in place to demonstrate an excellent reduction. Note the hyperflexed position. (*continued*)

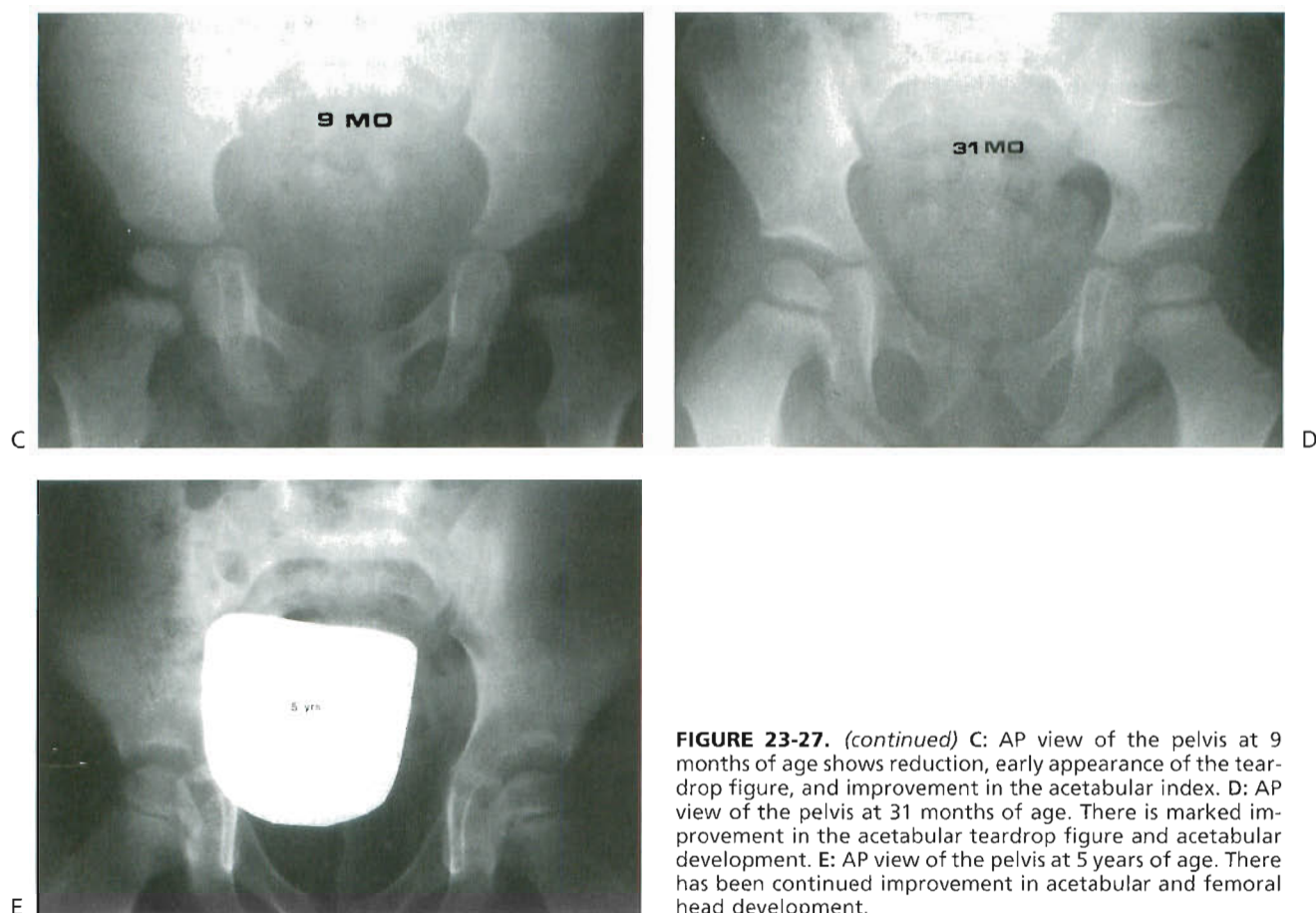


FIGURE 23-27. (continued) C: AP view of the pelvis at 9 months of age shows reduction, early appearance of the teardrop figure, and improvement in the acetabular index. D: AP view of the pelvis at 31 months of age. There is marked improvement in the acetabular teardrop figure and acetabular development. E: AP view of the pelvis at 5 years of age. There has been continued improvement in acetabular and femoral head development.

use of the harness, despite the failure of guided reduction in a complete dislocation.

Children 6 Months to 2 Years of Age

It is difficult to maintain a child older than 6 months of age in a Pavlik harness because of the child's activity levels. In this age group subluxated or dislocated hips should be treated by closed or open means as necessary, because success rates using the Pavlik harness are less than 50%.

In the late-diagnosed patient or the patient who fails treatment with the Pavlik harness, the obstacles to reduction are different, treatment has greater risks, and the results are far less predictable. The principal goals in the treatment of the late-diagnosed patient are similar to those for the newborn. The goal is to obtain reduction, to maintain that reduction to provide an adequate environment for femoral head and acetabular development, and to avoid proximal femoral growth disturbance (Fig. 23-28).

For patients older than 6 months of age at diagnosis and those who have failed a trial of Pavlik harness reduction, closed reduction is indicated. In most centers, closed reduction and spica cast immobilization usually are preceded by

a period of skin or skeletal traction (242–252) (Fig. 23-29). The theoretical purpose of the traction is to facilitate reduction by allowing gradual stretching of the soft tissue structures impeding reduction and stretching of the neurovascular bundle to avoid inciting aseptic necrosis of the proximal femur by sudden reduction. Generally, 1 to 2 weeks of skin or skeletal traction are sufficient. Skin traction is the most commonly used method, although some physicians recommend skeletal traction (242). Skin tapes should be applied above the knee to distribute the traction over a large area (Fig. 23-29). The author prefers to wrap Elastoplast tape loosely over tincture of benzoin from the ankle to the upper thigh. It is important not to stretch the Elastoplast tape at all; it should merely lie on the skin in a circumferential manner, with each edge directly opposing the preceding edge. Buck traction tapes are then applied from above the ankle to the thigh and to the foot plate; weights may be added to both legs, so that the buttocks “lightly” touch the bed. The author has used this method for a number of years without adverse consequences. The direction of application of the traction forces (e.g., overhead, longitudinal, divarication) and the duration of traction (days to months) vary worldwide.

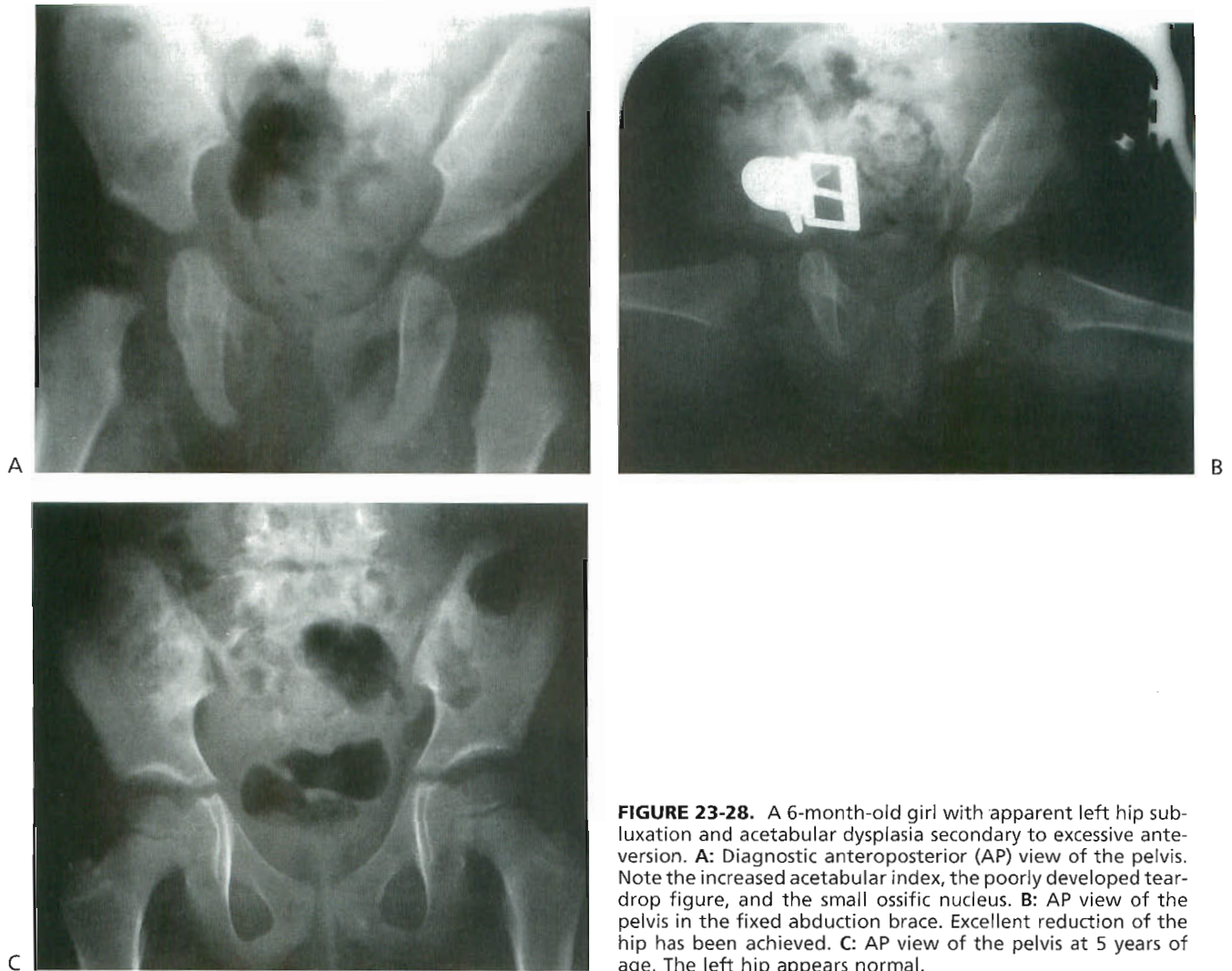


FIGURE 23-28. A 6-month-old girl with apparent left hip subluxation and acetabular dysplasia secondary to excessive anteversion. **A:** Diagnostic anteroposterior (AP) view of the pelvis. Note the increased acetabular index, the poorly developed tear-drop figure, and the small ossific nucleus. **B:** AP view of the pelvis in the fixed abduction brace. Excellent reduction of the hip has been achieved. **C:** AP view of the pelvis at 5 years of age. The left hip appears normal.

Prereduction traction, although still used by most treating physicians, is a somewhat controversial topic (253). Traction theoretically stretches contracted muscles, allows reduction without excessive force, and decreases the need for open reduction. These ideas are lacking the support of scientifically valid studies. The assessment of the adequacy of closed reduction and the need for open reduction varies and is subjective. Fish and colleagues surveyed the members of the Pediatric Orthopaedic Society of North America on this topic (254). Most pediatric orthopaedic surgeons thought that traction did reduce the incidence of necrosis in the treatment of DDH. Only 5% of responders did not use traction in their practice. The purpose of traction is to allow gradual relaxation of secondarily contracted muscles, such as the iliopsoas and adductor longus; theoretically, this allows reduction without creating excessive joint forces. However, the relevant reports on this subject are subjective. Several articles on open and closed reduction without the

use of preliminary traction report incidences of proximal femoral damage comparable to those found in series in which prereduction traction was used (41,255–257). These researchers think that the main obstacles to reduction are intraarticular and therefore would not be affected by the use of traction. Controversy also exists about the amount of weight applied, the direction of the force application, and the duration of applied traction. There are no clinical or experimental studies of the direct effects of traction, and there are no well-controlled studies that analyze the effect of traction as a single variable.

The complications of traction include skin loss and ischemia to the lower extremities attributable to inappropriate application. Neurocirculatory checks must be performed frequently, and traction must be applied in a carefully supervised manner. In appropriate circumstances traction may be used at home (258–260). This markedly decreases the costs associated with hospitalization. Patients usually are

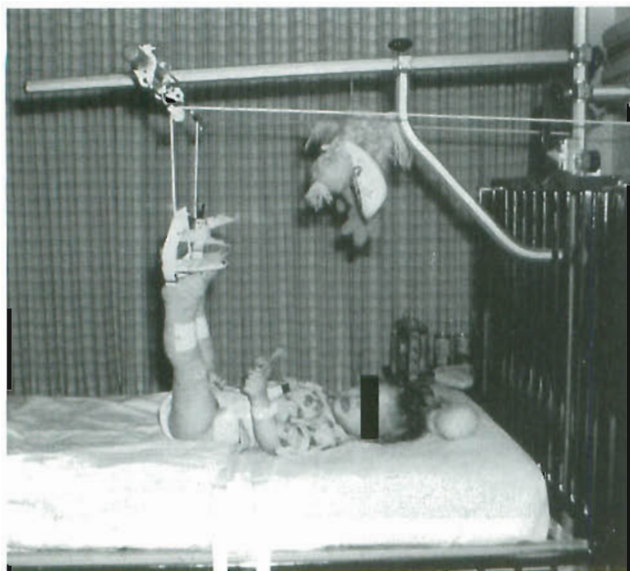

FIGURE 23-29. A 1-year-old child with bilateral hip dislocations in traction. Closed reduction and spica cast immobilization usually are preceded by a period of skin or skeletal traction.

hospitalized for 24 h to allow their parents to become familiar with the traction apparatus, to learn how to monitor neurocirculatory status, and to become totally familiar with the potential risks and danger signs. The patient and family must be cooperative; a visiting nurse is often helpful in instituting this program.

Closed reductions are performed in the operating room. Gentle reduction must be done under general anesthesia. The hip is gently manipulated into the acetabulum by flexion, traction, and abduction. An open or percutaneous adductor tenotomy usually is necessary in these cases because of secondary adduction contracture, and to increase the safe zone, which lessens the incidence of proximal femoral growth disturbance. The reduction must be documented (29,261–265) (Fig. 23-30). Because large portions of the femoral head and acetabulum are cartilaginous, arthrography is a useful tool in assessing the obstacles to and the adequacy of reduction (266–268). Dynamic arthrography using fluoroscopy helps to achieve both of these goals. Intraoperative ultrasonography may also be used.

The reduction is maintained in a well-molded plaster cast. The plaster must be well molded dorsal to the greater trochanters to prevent redislocation (Fig. 23-31). The

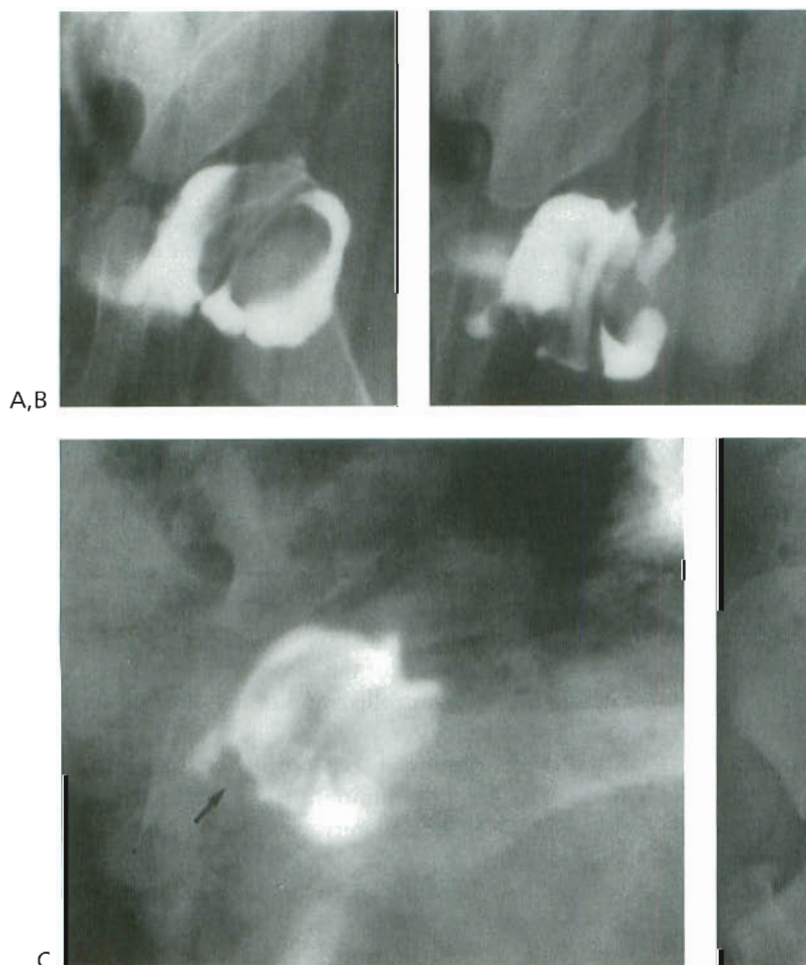


FIGURE 23-30. Arthrograms demonstrate closed reduction of developmental dysplasia of the left hip in an 8-month-old infant. **A:** Untreated. **B:** Reduced. There is no pooling of dye medially. The acetabular cartilage completely covers the femoral head. **C:** Reduction in a plaster cast. Note the arthrographic shadow of the transverse acetabular ligament (arrow). **D:** Nine years after reduction. Note the symmetric acetabular and proximal femoral development.

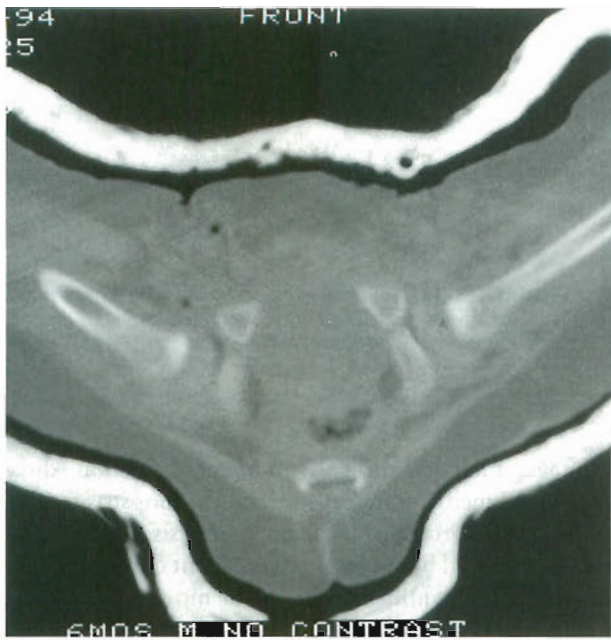
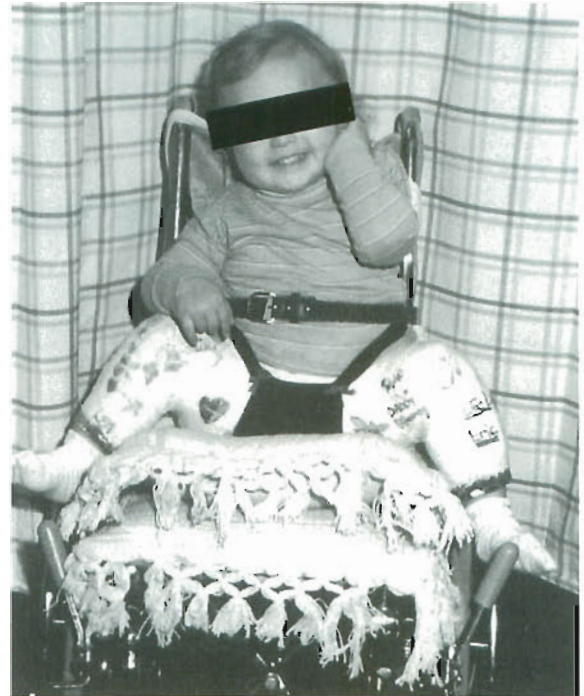
FIGURE 23-31. This computed tomography scan documents a successful closed reduction of a right hip dislocation. The plaster cast is molded dorsal to the greater trochanters to help prevent redislocation.

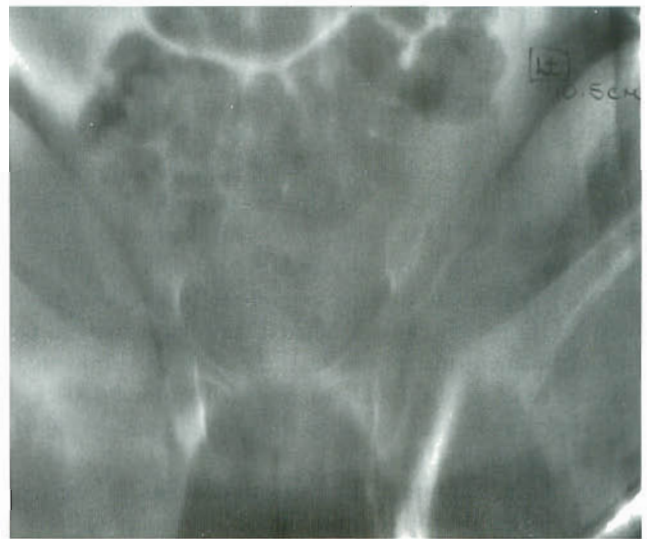
“human position” of hyperflexion and limited abduction is the preferred position (269,270) (Fig. 23-32). The amount of apparent hip flexion during cast application is often greater than the flexion seen on radiographs. Wide, forced abduction or forced abduction with internal rotation should be avoided because these approaches are associated with an increased incidence of proximal femoral growth disturbance (Fig. 23-33).

The author prefers to use plaster of Paris because of its plasticity, but some surgeons prefer to use synthetic materials. The time of maintenance of reduction in the plaster cast varies considerably. The author prefers to maintain the plaster below the knee on the involved side and above the knee on the uninvolved side for approximately 6 weeks, regardless of the patient's age. At that time, the plaster on the involved side (or sides) is cut to above the knee to allow some hip rotation and knee range of motion for an additional 6 weeks.

Twelve weeks after closed reduction, the plaster cast is removed and replaced by an abduction orthotic device to be used on a full-time basis for 2 months, except during bathing, and then at nap time and at night until acetabular development is normal. The use of abduction orthotic devices after reduction of DDH varies widely. The greatest rate of improvement in acetabular development occurs during the first 18 months after reduction. Reduction after casting should be documented by radiography, single-cut tomography, computed tomography, magnetic resonance imaging, or ultrasonography (144,264,265,271) (Fig. 23-



A



B

FIGURE 23-32. A: The “human position” of hyperflexion and limited abduction is the preferred position after closed reduction. The patient shown had bilateral reductions. B: Single-cut tomogram documents the hyperflexed, minimal abduction position.

31). The adequacy of closed reduction is somewhat subjective. In the author's opinion anatomic reduction is the only acceptable reduction (Fig. 23-30C). The use of the femoral head as a “dilating sound” to overcome the intraarticular obstacles to reduction may cause damage to the femoral head and make open reduction more difficult (233, 272,273).

In patients 6 months to 2 years of age, open reduction is indicated if there is failure of closed treatment, persistent

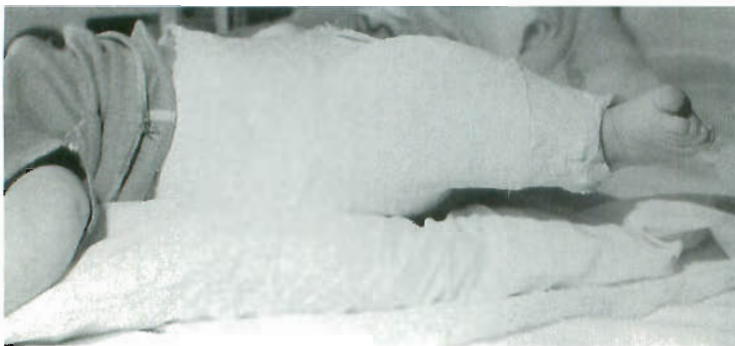

FIGURE 23-33. Wide abduction should be condemned. This position is associated with a high incidence of damage to the proximal femoral epiphysis and the physal plate.

subluxation, soft tissue interposition, and reducible but unstable reductions other than in extreme positions of abduction. There has been some controversy in recent years regarding whether the incidence of damage to the proximal femur is decreased if open reduction is delayed until the femoral ossific nucleus is present. This notion was recently dispelled (274).

The goals of open treatment are to obtain reduction, maintain the reduction, avoid damage to the femoral head, and provide an optimal environment for acetabular and proximal femoral development. Open reduction of a DDH may be accomplished with a variety of surgical approaches (38,41,117,119–121,179,235,275–281).

The most commonly used surgical approach to open reduction is the anterolateral Smith-Petersen approach [➔3.2] with a modified “bikini” incision, as described by Salter and Dubos (280). This is a standard approach to the hip joint and is familiar to most surgeons. In the late-diagnosed DDH patient, any associated capsular laxity can be plicated through this approach. If the surgeon thinks that a secondary procedure, such as pelvic osteotomy, is necessary, it also can be accomplished through the same surgical approach (38,279–281).

One of the advantages of the anterior Smith-Petersen approach is that the hip is immobilized in a functional position, with minimal hip flexion and some degree of abduction. If this approach is used in conjunction with a capsular plication, the postoperative immobilization period is usually 6 to 8 weeks.

The disadvantages may include greater blood loss than with the various medial and anteromedial approaches, possible damage to the iliac crest apophysis and the hip abductors, and postoperative stiffness. If this approach is used in bilateral cases the procedures usually are staged at 2- to 6-week intervals.

The various medial approaches have the advantage of approaching the hip joint directly over the site of the obstacles to reduction (41,117,119–121,277,282–286). The medial approach described by Ferguson [➔3.4] is in the plane between the adductor brevis and the adductor magnus (117,287). Advocates of this approach think that its

advantages include minimal soft tissue dissection, direct access to the medial joint capsule and the iliopsoas tendon, avoidance of damage to the iliac apophysis and abductor muscles, minimal blood loss, and excellent cosmesis. However, it is a less familiar approach to most surgeons, and visualization is somewhat impaired. Capsular repair cannot be accomplished through this approach. The stability of the reduction is maintained only by the postoperative cast. This approach is somewhat difficult to use in older patients, and no concomitant surgical procedures can be performed through the same incision. Questions have been raised about a higher incidence of proximal femoral growth disturbance after use of this approach.

A third approach to open reduction in this age group is the anteromedial approach originally described by Ludloff and modified by Weinstein and Ponseti (41,104,114,119, 288–292). The approach is made in the interval between the femoral neurovascular bundle and the pectineus muscle [➔3.3]. The advocates of this approach cite minimal blood loss (i.e., transfusion is never necessary) and the fact that it is the most direct approach to the obstacles to reduction. There is minimal muscle dissection in this approach; only the iliopsoas and the adductor longus are sectioned. Both hips can be reduced during the same operative procedure, the scar is extremely cosmetic, and there is no damage to the hip abductor muscles or the iliac apophysis. Postoperative stiffness is not a problem.

There are several disadvantages to the anteromedial approach. It is not a familiar approach to most surgeons. Only open reduction can be accomplished; no secondary procedures can be performed through this incision. It is difficult to use in older patients because of the depth of the hip joint and the difficulty with visualization. If the surgeon thinks that capsular plication should be performed it cannot be done through this approach. The medial femoral circumflex vessels (i.e., the primary blood supply to the proximal femur) are in the operative field. Moreover, visualization is claimed by some to be poor, and the approach is associated with a higher incidence of aseptic necrosis (293,294). In the author's experience of more than 200 cases, visualization is excellent (Fig. 23-34) and the incidence of aseptic necrosis

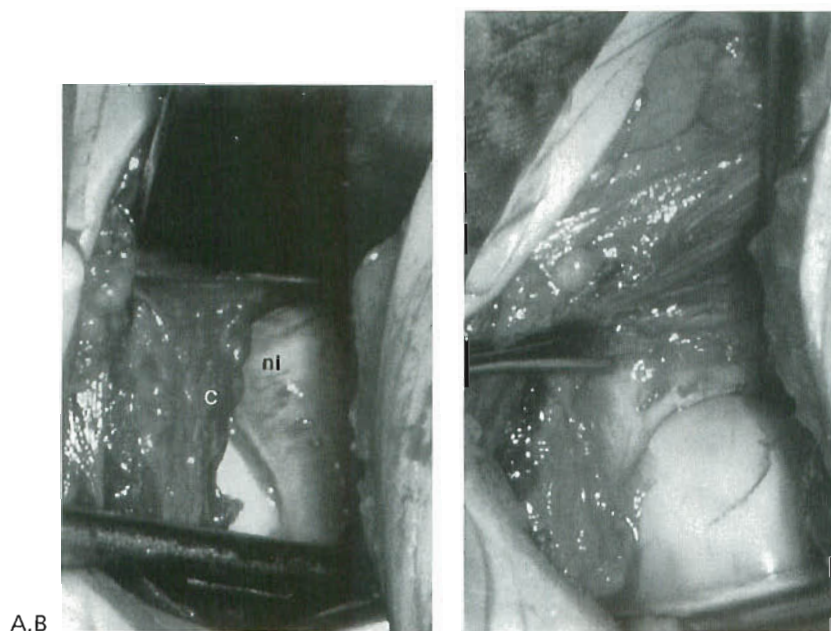


FIGURE 23-34. A: Open reduction through an anteromedial approach in a 14-month-old child. Note the anterior joint capsular edge (c) and the neolimbus (nl). B: The hip is reduced under direct view. The femoral head is well seated in the acetabulum, and the anterior edge of the hip capsule is everted by a hemostat.

with a minimum 4-year follow-up is approximately 14%, which is well in line with the results of other series of open reductions (121,295). Capsular plication appears to be unnecessary in this age group because in a successful closed reduction the capsule tightens and the scar induced by the surgical procedure helps to provide capsular stability. This approach, however, depends on the placement of a well-molded cast. The approach to casting after reduction is the same as that described above for closed reduction. A certain degree of capsular stability is gained through the prolonged postoperative immobilization that is necessary. No residual stiffness has been experienced.

Most physicians use abduction orthotic devices for some period after cast removal. Some use them on a full-time basis for several months, then part-time, usually during the night and napping hours, until acetabular development has caught up to the opposite, normal side. It is important in assessing acetabular development after open or closed reduction to look for accessory ossification centers. These give the treating physician an idea of whether the cartilage in the region of the neolimbus in the periphery of the acetabulum has the potential for ossification.

In patients younger than 2 years of age, a secondary acetabular or femoral procedure is rarely required. The potential for acetabular development after closed or open reduction is excellent and continues for 4 to 8 years after the procedure (34,35,41,296–298). The most rapid improvement in acetabular development—as measured by parameters such as the acetabular index, development of the tear-drop figure, and thinning of the medial floor—occurs in the first 18 months after surgery (32,34,35,41,296,299,300). Femoral anteversion and any coxa valga associated with the

untreated condition have an excellent chance to resolve during this time. However, some surgeons think that every child older than 18 months of age should undergo hip osteotomy accompanying open reduction because of the poor acetabular development potential (38,279,280,301,302).

Children Older Than 2 Years of Age

In a child older than 2 years of age at the time of diagnosis of DDH, open reduction is usually necessary. In this age group the treating surgeon must also consider whether to perform concomitant femoral shortening in conjunction with the open reduction. In children older than 3 years of age, femoral shortening to avoid excessive pressure on the proximal femur gives far lower rates of proximal femoral growth disturbance than does preliminary traction followed by open reduction (303–307) (Fig. 23-35). Schoenecker and Strecker reported a 54% incidence of aseptic necrosis with a 32% incidence of redislocation, with the use of skeletal traction in patients older than 3 years of age (304).

The age range of 2 to 3 years is considered a “gray zone,” with some surgeons advocating preliminary traction before open reduction and others performing concomitant femoral shortening (308–310). In this age range because the potential for acetabular development is markedly diminished, many surgeons recommend a concomitant acetabular procedure in conjunction with the open reduction or 6 to 8 weeks after the open reduction. The decision about whether to perform a secondary acetabular procedure is subjective. The author prefers to judge stability at the time of open reduction. If good stability is evident, the author prefers to observe acetabular development for the next few years, and if

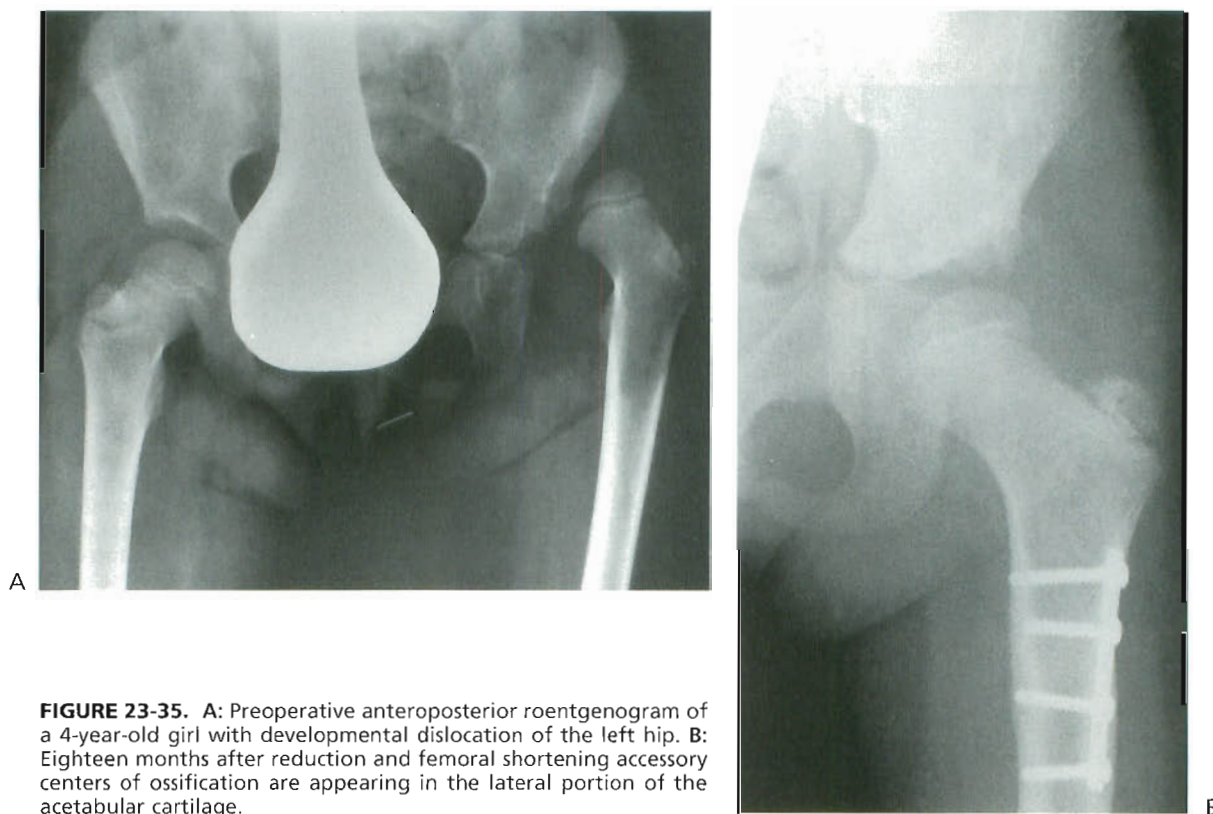


FIGURE 23-35. A: Preoperative anteroposterior roentgenogram of a 4-year-old girl with developmental dislocation of the left hip. B: Eighteen months after reduction and femoral shortening accessory centers of ossification are appearing in the lateral portion of the acetabular cartilage.

acetabular development is not improving by radiographic criteria (e.g., decreasing acetabular index, improvement in teardrop appearance and shape) (186), the author considers secondary acetabular procedures.

The most common accompanying procedure performed in this age group in conjunction with open reduction is innominate osteotomy as described by Salter (38,311) [↗3.5] or by Pemberton (37,312–316) [↗3.7]. Anatomic deficiency of the acetabulum in this age group usually is anterior, and the Salter innominate osteotomy gives anterior coverage, although at the expense of posterior coverage. The Pemberton osteotomy provides coverage anteriorly, and various degrees of lateral coverage, depending on the direction of the osteotomy cuts.

In this age group the standard anterolateral approach described by Smith-Petersen with the Salter modification is the ideal approach, because it enables capsular plication, immobilization of the hip joint in a more functional position, and innominate osteotomy at the same time through the same incision.

A theoretical advantage of open reduction accompanied by femoral shortening is that it can be used to correct any anatomic abnormality, such as excessive femoral anteversion. The disadvantages of femoral shortening include the need for a second incision and internal fixation for the osteotomy, requiring another operation for hardware removal.

After 3 years of age, open reduction of the hip should be accompanied by femoral shortening, and probably by a concomitant acetabular procedure, depending on hip stability at the time of surgery (307,310,317,318). The acetabular procedure may be performed at the time of open reduction, 6 weeks later, or at a later date, depending on acetabular development.

Treatment of Acetabular Dysplasia in Children 6 Months to 2 Years of Age. In children between 6 months and 2 years of age, acetabular dysplasia diagnosed incidentally or as a residual result after Pavlik harnessing, open reduction, or closed reduction is often treated with a fixed abduction orthotic device. The theory behind use of the fixed abduction brace is that dysplasia is associated with mild hip instability and that the device can correct that instability. These devices can be used only if the hip is well reduced, as verified on a radiograph taken with the patient wearing the brace (Fig. 23-28). The abduction device usually is worn full time for several months, then is worn at night and during nap time until acetabular development is normal, as measured by the acetabular index.

The complications of a fixed abduction device include skin breakdown and proximal femoral growth disturbance. It is important in positioning the device that the hip not be placed in extreme positions of abduction to avoid interruption of the vascular supply to the proximal femur.

SEQUELAE AND COMPLICATIONS

Residual Femoral and Acetabular Dysplasia

Based on natural history studies, it is the goal of treatment to have a radiographically normal hip at maturity to prevent degenerative joint disease in the future. Hip subluxations must be corrected. The evidence demonstrates that residual acetabular dysplasia, even in the absence of subluxation, eventually leads to degenerative joint disease, so this also should be corrected. The goal of treatment of DDH is to have a hip as anatomically normal as possible by the end of skeletal growth.

When evaluating the patient with persistent dysplasia, the relation between the acetabulum and the femur must be assessed. Anatomic dysplasia can involve the acetabulum, the proximal femur, or both. In DDH cases, the deficiency is most commonly on the acetabular side or the dysplasia is significantly greater on the acetabular side. If there has been a disturbance of proximal femoral growth secondary to previous treatment the femoral side may be more dysplastic.

Dysplasias of the hip joint can be evaluated with plain radiographs taken in the standing position, when possible, and with standard evaluations of acetabular development, as determined by the acetabular index, the acetabular angle of Sharp, and the CE angle. In young children with DDH most cases of acetabular deficiency are anterior, and in adolescents and adults with DDH, the acetabular deficiencies can be anterior, posterior, or global (38,80,279,319–322). Excessive femoral anteversion can be ascertained clinically, but is most accurately measured by computed tomography (323). There has been an increased interest in evaluating dysplasia by means of three-dimensional computed tomography (207,324,325). However, computed tomography cannot show the cartilaginous component of the proximal femur or the acetabulum; therefore, it is most useful for the patient at or close to maturity.

Deformities of the femoral neck assume significance only if they lead to subluxation of the joint: lateral subluxation with extreme coxa valga or anterior subluxation with excessive anteversion (179). In general, patients with DDH usually have normal neck–shaft angles. They may have persistent anteversion that gives the radiologic appearance of subluxation.

If acetabular dysplasia persists for 2 to 3 years after closed or open reduction and the patient has residual anteversion, proximal femoral rotational osteotomy should be considered [►4.1–4.3]. Excessive anteversion or valgus of the proximal femur may contribute to hip joint instability and failure of normalization of acetabular growth. Varus derotation osteotomies are indicated in children with hip dysplasia, because it is assumed that the femoral head directed toward the center of the acetabulum stimulates normal acetabular development (178,204,326,327). This ap-

proach may also be indicated to correct residual deformity from a partial physeal arrest as a result of aseptic necrosis. Intertrochanteric osteotomies can provide adequate medialization of the femoral shaft and prevent further varus deformity of the proximal femur (328,329).

Before performing varus derotation osteotomy, the surgeon must be certain that the femoral head can be concentrically reduced; if not, this procedure must be accompanied by open reduction. An anteroposterior pelvic film of the hip with apparent coxa valga and anteversion shows lateralization and subluxation of the femoral head (Fig. 23-36). Before surgery, the surgeon must document that the femoral head is concentrically reduced on an anteroposterior pelvic radiograph with the patient's legs abducted 30 degrees and maximally internally rotated (Fig. 23-36). This position allows visualization of the actual femoral neck angle.

When the Shenton line is disrupted, the proper relation of the proximal femur usually can be restored by derotation osteotomy, with or without various degrees of varus. After reduction is obtained in most cases of DDH the femoral neck anteversion, which exists in most patients, corrects spontaneously (330). The varus derotation osteotomy is used alone in such cases by surgeons who think that redirection of the femoral head toward the center of the acetabulum stimulates normal acetabular development (132,326,331–336). The proximal femoral varus derotation osteotomy, if used to “stimulate” more normal acetabular development, must be performed in children younger than 4 years of age (326). After 8 years of age, no improvement in acetabular dysplasia can result from this procedure. These osteotomies must be done in the intertrochanteric region to provide adequate medialization of the femoral shaft. Performing the osteotomy in the intertrochanteric area avoids posterior displacement of the lesser trochanter and prevents excessive varus deformity of the femur, which can lead to mechanical abnormalities at the knee (337).

In small children, any leg-length discrepancy resulting from varus osteotomy should resolve by growth stimulation and restoration of the normal neck–shaft angle (338). In teenagers, however, more than a 15-degree correction of varus deformity may result in limb shortening. The varus osteotomy, if excessive, can cause lateralization of the shaft, shifting the mechanical axis medial to the knee joint. This is an undesirable effect; varus osteotomy should be accompanied by shaft medialization. If the osteotomy is transfixed with smooth wires they can be removed after 6 to 8 weeks. Internal fixation devices are usually removed 12 to 18 months postoperatively; if they are not removed in young children, they become encased within the proximal femur, which could pose problems if future operations become necessary.

In the adolescent or adult patient with residual dysplasia in whom there is no potential for acetabular growth and remodeling, changing the orientation of the proximal femur does not increase the weightbearing area but does shift the weightbearing area to another portion of the femoral head

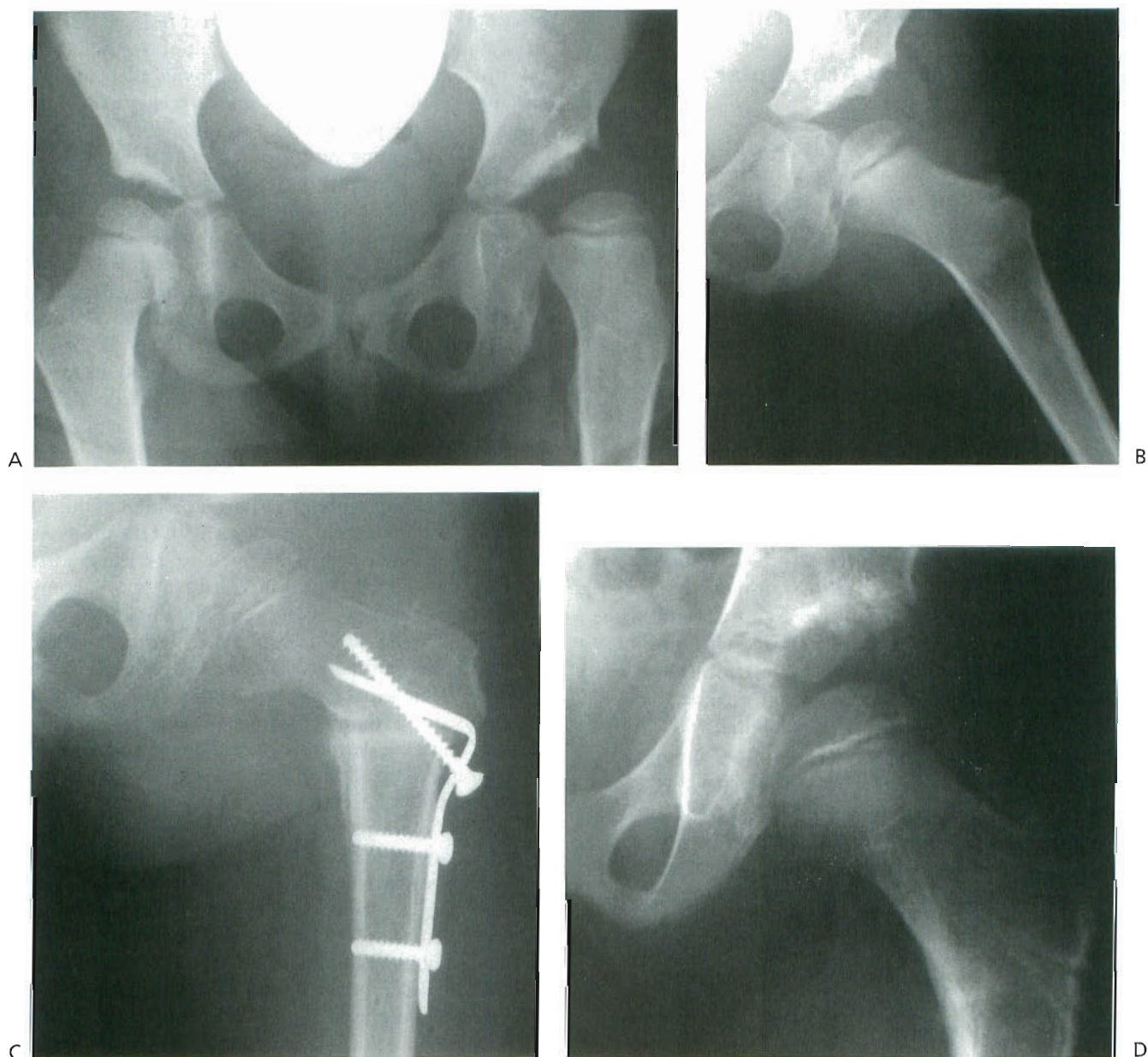


FIGURE 23-36. A 3-year-old white girl 2 years after closed reduction. **A:** Anteroposterior (AP) view of the pelvis. Note the persistent acetabular dysplasia and apparent coxa valga. **B:** The radiograph shows the leg abducted approximately 30 degrees and maximally internally rotated. The femoral head is seated well within the acetabulum, and the Shenton line is restored. **C:** AP view of the left hip 6 weeks after varus derotation osteotomy. **D:** AP view of the left hip 18 months after varus derotation osteotomy, with hardware removal. The Shenton line has been restored, there is improved teardrop figure development, and accessory centers of ossification appear in the periphery of the acetabular cartilage.

(339–341). Proximal femoral osteotomies in the adolescent or adult group are indicated only as adjuncts to pelvic operations and in extreme cases of coxa valga and subluxation (179,340) (Fig. 23-37).

Indications for the treatment of residual radiographic acetabular dysplasia depend on the age of the child and whether or not the patient has symptoms (342). The goal

of treatment is to restore the anatomy to as near normal as possible by skeletal maturity. After concentric reduction is obtained and maintained, the potential for acetabular development continues for many years (32,34,35,41,206). However, after 4 years of age, this potential for restoration of normal anatomy decreases. For minimal residual dysplasias in children younger than 4 years of age observation can be

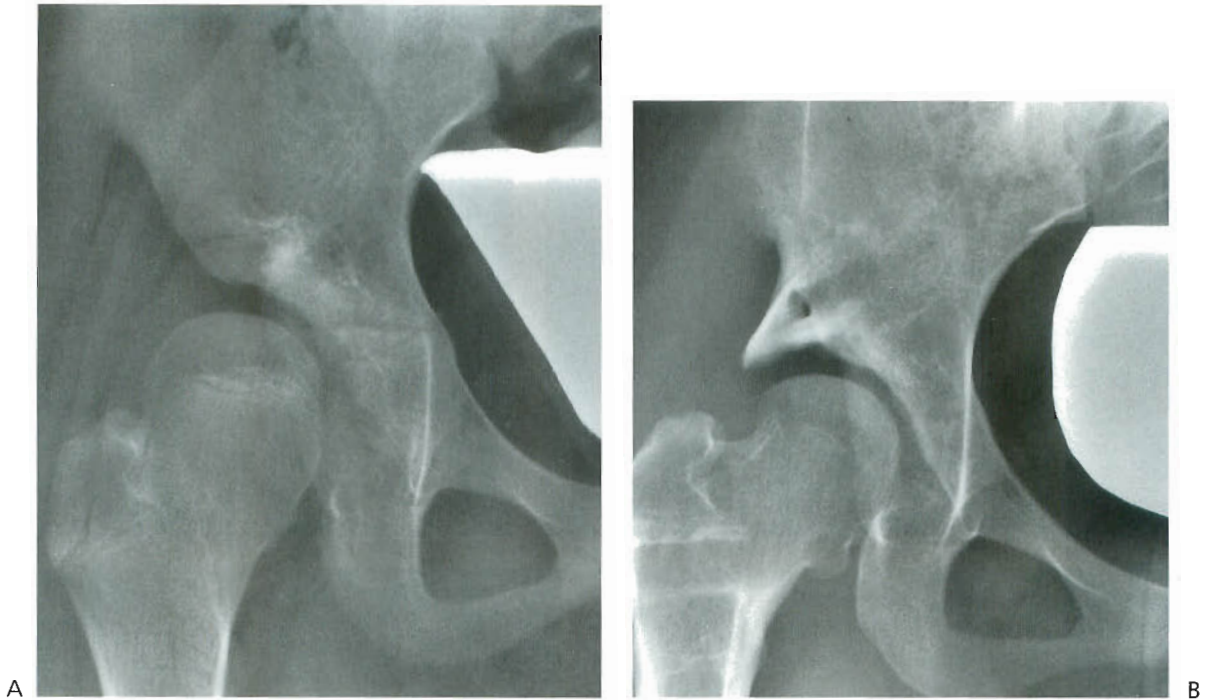


FIGURE 23-37. A 10-year-old girl with the diagnosis of developmental dysplasia of the hip made at 5 years of age. She had previously undergone open reduction, but had residual proximal femoral and acetabular deformities. **A:** Preoperative anteroposterior radiograph of the pelvis. **B:** Three years after varus derotation osteotomy and Staheli slotted acetabular augmentation.

continued, but for significant dysplasia surgical intervention should be entertained.

The treatment options for acetabular dysplasia traditionally are divided into four groups. The first group consists of osteotomies of the pelvis that redirect the entire acetabulum. This redirection of the entire acetabulum provides coverage of the femoral head by acetabular articular cartilage. These osteotomies include the Salter innominate osteotomy (38,80,279–281,343–345) (Fig. 23-38) [↗3.5], the Sutherland double-innominate osteotomy (346), the triple-innominate osteotomies of Tonnis (179,347–352), Steel (353–358), and Ganz (359,360), the spherical osteotomies of Wagner (361–363) [↗3.10] and Epiphry (364), and others (365–368). These procedures involve complete cuts through various pelvic bones and rotation of the acetabulum.

Other acetabuloplasties that involve incomplete cuts and hinge on different aspects of the triradiate cartilage include the acetabular procedures described by Pemberton (37,312,314–316,369) and Dega (370–373) [↗3.7–3.9]. These procedures can theoretically decrease the volume of the acetabulum because they depend on the triradiate cartilage as the fulcrum.

A third group of acetabular reconstructive procedures involves placing bone over the hip joint capsule on the uncovered portion of the femoral head. These procedures provide coverage of the femoral head by capsular fibrous meta-

plasia (374,375). They include the various shelf procedures (376–382) [↗3.12] and the medial displacement osteotomy described by Chiari (383–388) [↗3.11].

Correction of residual dysplasia theoretically provides for a better weightbearing surface for the femoral head, restores the normal biomechanics of the hip, and may increase the longevity of the hip by preventing degenerative joint disease. Unfortunately, only prospective, long-term follow-up studies of these procedures can provide unambiguous answers.

Shelf procedures were described before 1900 and were used widely until the mid-1950s, when Chiari described his medial displacement osteotomy (384). Later, Salter, Pemberton, and others described various pelvic osteotomies used to redirect the acetabulum and cover the femoral head with articular cartilage. In 1981, Staheli and Chew introduced a modification of a previously described shelf arthroplasty, which gained widespread popularity when used alone for significant anatomic dysplasia and in conjunction with various rotational procedures as an augmentation to provide increased femoral head coverage (382) (Fig. 23-37).

Although intuitively it seems better to cover the femoral head with articular cartilage than to rely on fibrous metaplasia, it is impossible to be certain about the long-term results of shelf arthroplasty, because no such results exist.

In the young child, acetabular deficiencies generally are assessed by arthrography and by inspection at the time of open reduction. For reduced hips with residual dysplasia,

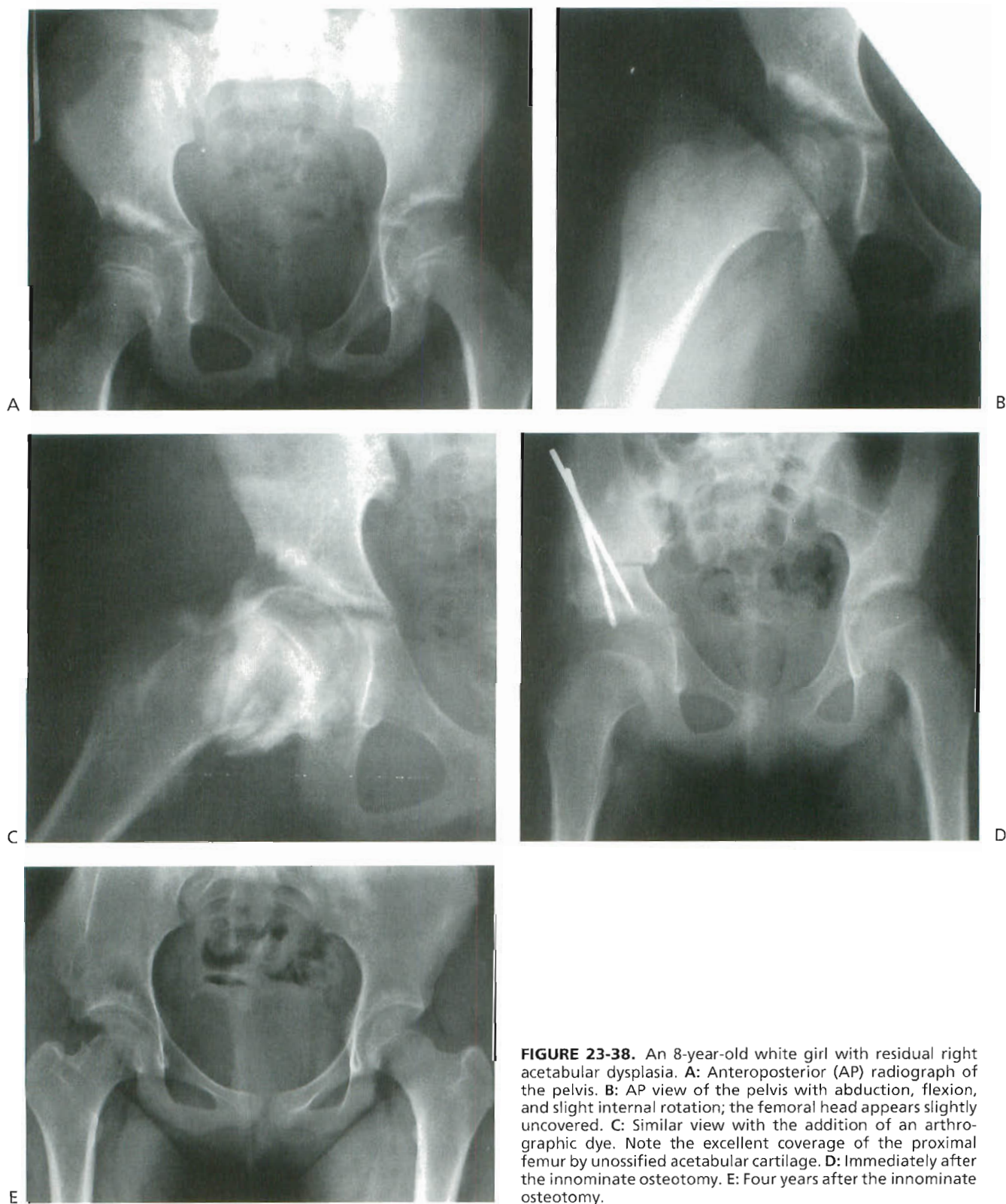


FIGURE 23-38. An 8-year-old white girl with residual right acetabular dysplasia. **A:** Anteroposterior (AP) radiograph of the pelvis. **B:** AP view of the pelvis with abduction, flexion, and slight internal rotation; the femoral head appears slightly uncovered. **C:** Similar view with the addition of an arthrographic dye. Note the excellent coverage of the proximal femur by unossified acetabular cartilage. **D:** Immediately after the innominate osteotomy. **E:** Four years after the innominate osteotomy.

the author has found that the problem is not one of deficiency of the acetabulum, but a failure of the peripheral acetabular cartilage to ossify (Fig. 23-38). In most cases, an arthrogram at the time of surgery shows excellent coverage of the femoral head by the unossified acetabular cartilage. This cartilage fails to undergo normal development because it is intrinsically abnormal or because it was damaged by the femoral head in the unreduced position, causing pressure necrosis. Given enough time, some of this acetabular cartilage may resume normal ossification and correct a large amount of the dysplasia. However, in the author's experience of a large number of patients treated with open and closed reduction, this does not happen in many cases, and intervention should be undertaken after the acetabulum has had a reasonable chance to develop on its own (121,206,389). The osteotomy of the iliac bone and the neovascularity stimulated in healing may increase the ossification of the otherwise unossified acetabular cartilage. In any case, the redirection of the acetabulum restores more normal bony anatomy and normal biomechanics that also may be a factor in stimulating ossification (234).

The best means of evaluating acetabular dysplasia in the mature patient includes three-dimensional computed tomography (123,390–395), the false profile view, and plain radiography (396) (Fig. 23-39). For young, immature patients, computed tomography does not provide adequate assessment of the deficiencies because it does not show the acetabular cartilage.

Concentric reduction is an absolute requirement for all osteotomies other than the shelf or Chiari procedures. Osteotomies that depend on the triradiate cartilage as the fulcrum must be done in patients with open triradiate cartilage. The Salter innominate osteotomy, which hinges on the symphysis pubica, is better performed in the infant, child, and adolescent because of the flexibility of the symphysis pubica. However, this osteotomy can be performed in adults. The procedure is more likely to succeed when the CE angle is greater than 10 degrees.

An important factor to be considered when planning correction of acetabular dysplasia is the amount of dysplasia that needs to be corrected. The amount of coverage obtained by osteotomies such as the Salter procedure is limited, but osteotomies that cut all three pelvic bones provide the ability to obtain greater coverage (397,398). The closer the cuts are placed to the acetabulum the greater the femoral head coverage. The triple-innominate osteotomies described by Tonniss and Ganz provide greater rotational possibilities than that described by Steel. The osteotomies that are closest to the acetabulum (e.g., Eppright, Wagner) provide the greatest potential for redirection, but these require significant technical expertise and have higher rates of complications.

The shelf arthroplasty and the Chiari osteotomy may be performed for well-reduced hips, but they usually are reserved for hips that lack significant femoral head coverage which could not be obtained by means of one of the other procedures that provides coverage with articular cartilage

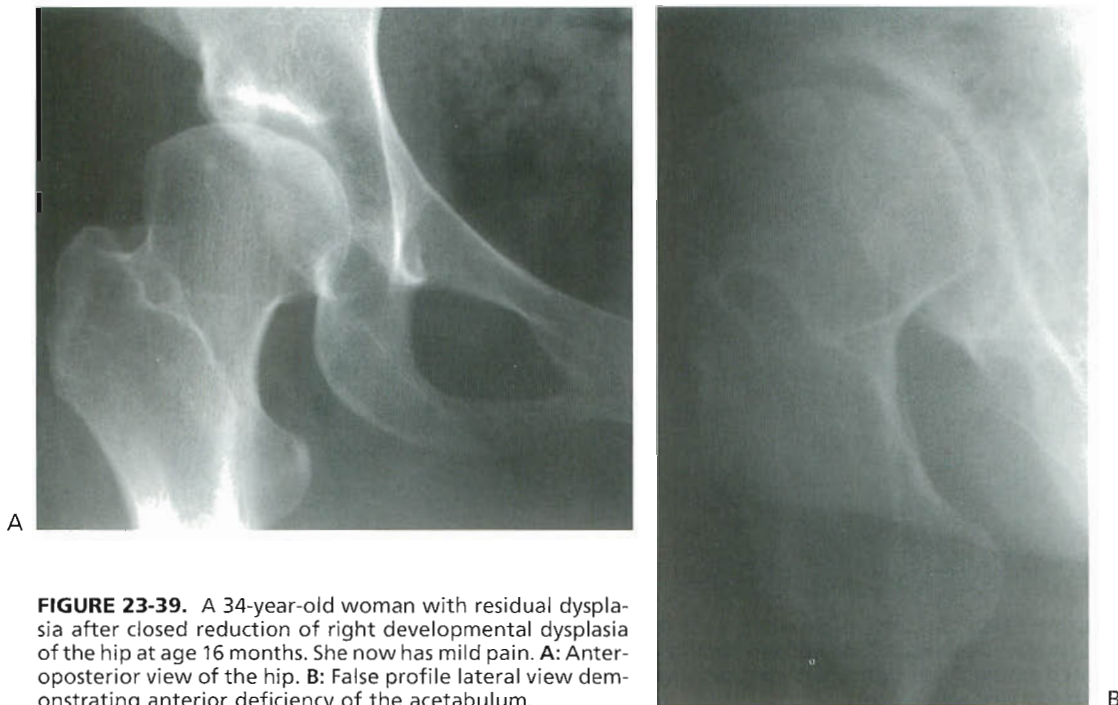


FIGURE 23-39. A 34-year-old woman with residual dysplasia after closed reduction of right developmental dysplasia of the hip at age 16 months. She now has mild pain. **A:** Anteroposterior view of the hip. **B:** False profile lateral view demonstrating anterior deficiency of the acetabulum.

mentioned above (399,400). Many of these procedures can be performed in patients with early degenerative changes in the hope of delaying the onset of arthroplasty or fusion. Further discussion of these issues is beyond the scope of this chapter.

The procedures that involve hinging on the triradiate cartilage, such as the Pemberton osteotomy, have the potential to injure the triradiate cartilage and cause premature closure, but these complications are not common (401). Procedures that must cross the triradiate cartilage, such as the Ganz osteotomy, and induce closure cannot be done in patients with open triradiate cartilage. In shelf arthroplasties performed in immature patients it is important to avoid cutting the ilium in the region of the groove of Ranvier because this may severely impair acetabular development. Acetabular rotational procedures that depend on hinging on the cartilage of the symphysis pubica or various portions of the triradiate cartilage are better performed in younger patients. Rotational pelvic osteotomies in the face of subluxation may lead to severe damage to the femoral head.

The general prerequisites for rotational osteotomies include complete concentric reduction and release of muscle contractures, including the iliopsoas and hip adductors, a congruous joint, and good range of motion. These procedures are best performed before 6 years of age, but the age limits vary considerably, depending on the surgeon.

The double-innominate osteotomy of Sutherland and Moore aims to allow greater rotation of the pelvic fragment by cutting through the pubis, instead of hinging only on the symphysis pubica (346). Complications of this procedure can involve injury to the spermatic cords, bladder, and urethra. The triple-innominate osteotomy allows even greater coverage by means of cuts of all three hip bones.

The Chiari medial displacement osteotomy hinges on the symphysis pubica, with the distal fragment displacing medially and upward (Figs. 23-40 and 23-41). This medialization results in reduction of the lever arm to reduce joint loading. Abductor muscle function is theoretically improved. Patients may limp for as long as 1 year. There is some concern that bilateral Chiari osteotomies may interfere with a woman's ability to deliver children. This is one of the few procedures for which long-term results exist, and these show that, in the absence of subluxation and degenerative joint disease, good long-term results may persist for many years (112,386,402–412).

Decision-making is somewhat difficult for the asymptomatic mature patient. For the asymptomatic adolescent with minimal radiographic dysplasia (because degenerative arthritis is a probability but not a certainty) the author prefers to inform the family about the potential for an adverse natural history and recommend surgery only at the onset of symptoms. There usually is a long interval between

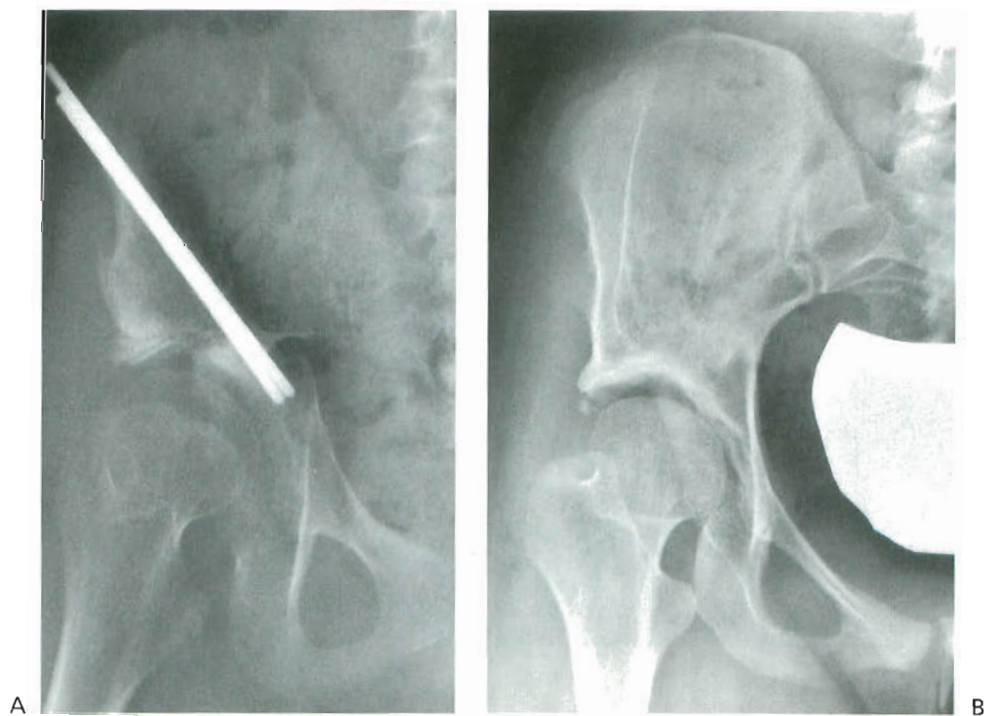


FIGURE 23-40. An 11-year-old white girl with pain and residual right hip subluxation with severe acetabular dysplasia. **A:** Immediately after the right Chiari osteotomy. Note the additional graft placed anteriorly. **B:** Eight years postoperatively there is excellent remodeling of the acetabulum with *sourcil* development.

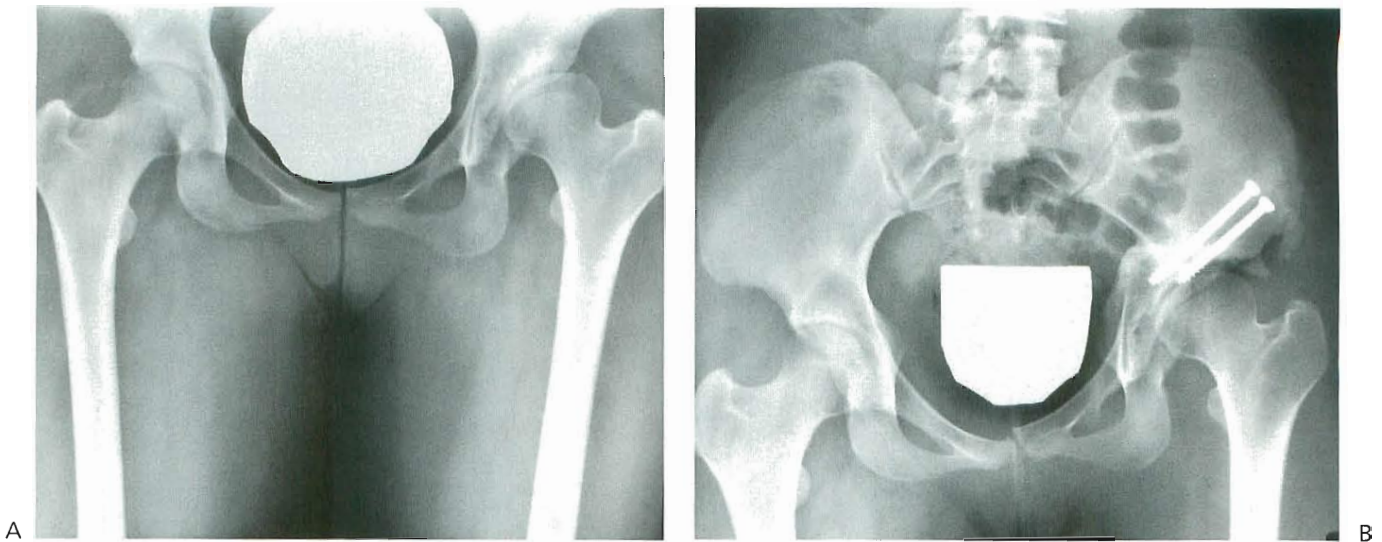


FIGURE 23-41. A white girl underwent open reduction of the left dysplastic hip at 18 months of age. She presented at 17 years of age with subluxation, as seen on the radiograph. **A:** Preoperative anteroposterior view of the pelvis. **B:** Eight weeks after Chiari osteotomy. Note the additional graft placed anteriorly.

symptom onset and radiographic degenerative joint disease (66). The patient can be reassured that if symptoms develop surgical treatment can help to avoid long-term degenerative joint disease. However, faced with an adolescent with radiographic evidence of subluxation, regardless of the symptoms, the author recommends surgical correction, because an adverse natural history is certain without treatment.

Disturbance of Growth of the Proximal Femur

The most disastrous complication associated with the treatment of DDH involves various degrees of growth disturbance of the proximal femur, including the epiphysis and the physal plate. This is commonly referred to by the term “aseptic necrosis.” Because there has never been a study of a pathologic specimen from a patient with what is called aseptic necrosis, the author prefers to use the term “proximal femoral growth disturbance” (206). These growth disturbances can be precipitated by experimental vascular injuries in animals and resemble the growth disturbances seen in humans with treated DDH. The disturbance may be caused by vascular insults to the epiphysis or the physal plate or by pressure injury to the epiphyseal cartilage or the physal plate (272,273,413–428). The blood supply to the proximal femur is described in Chapter 24.

Growth disturbance of the proximal femur in DDH occurs only in patients who have been treated. This may also occur in the opposite normal hip in a patient who has been treated (429,430). The reported incidence of proximal femoral growth disturbance varies from 0 to 73% (206,208, 431,432). Different opinions exist about the reasons for

this variation (433–436). The use of prereduction traction (206,208,242,245,419,431,437), adductor tenotomy (270, 421,438), open or closed reduction (41,117,122,294, 419,439–441), the force of reduction (431,438,442,443), the position of postoperative immobilization (242,245,270, 272,422,424,425,427,444), and the age at reduction (242, 245,250,422) have been implicated as etiologic factors. Others think that the incidence may be much less variable than the means by which it is assessed (206,434).

In an extensive study of the development of ischemic necrosis published by the German Society for Orthopaedic and Traumatology (3,316) conservatively treated hips and 730 operatively treated hips were evaluated to determine the factors associated with the development of ischemic necrosis (179). The factors associated with necrosis included high dislocations and dislocations with inversion of the labrum, narrowing of the introitus between the superior labrum and the transverse ligament in the position of reduction, inadequate depth of reduction of the femoral head (greater than 3 mm from the acetabular floor), older patients (older than 12 months), immobilization in 60 or more degrees of abduction for joint instability, and adductor tenotomy.

Westin and colleagues thought that the marked variation of the reported incidence indicated a lack of definition of terms (437). Thomas and associates concluded that there was some association between the reported incidence in a given series and the rigor with which the diagnosis had been sought (434). Buchanan et al. thought that if signs of growth disturbance were not present within 12 months of reduction they were highly unlikely to appear (242).

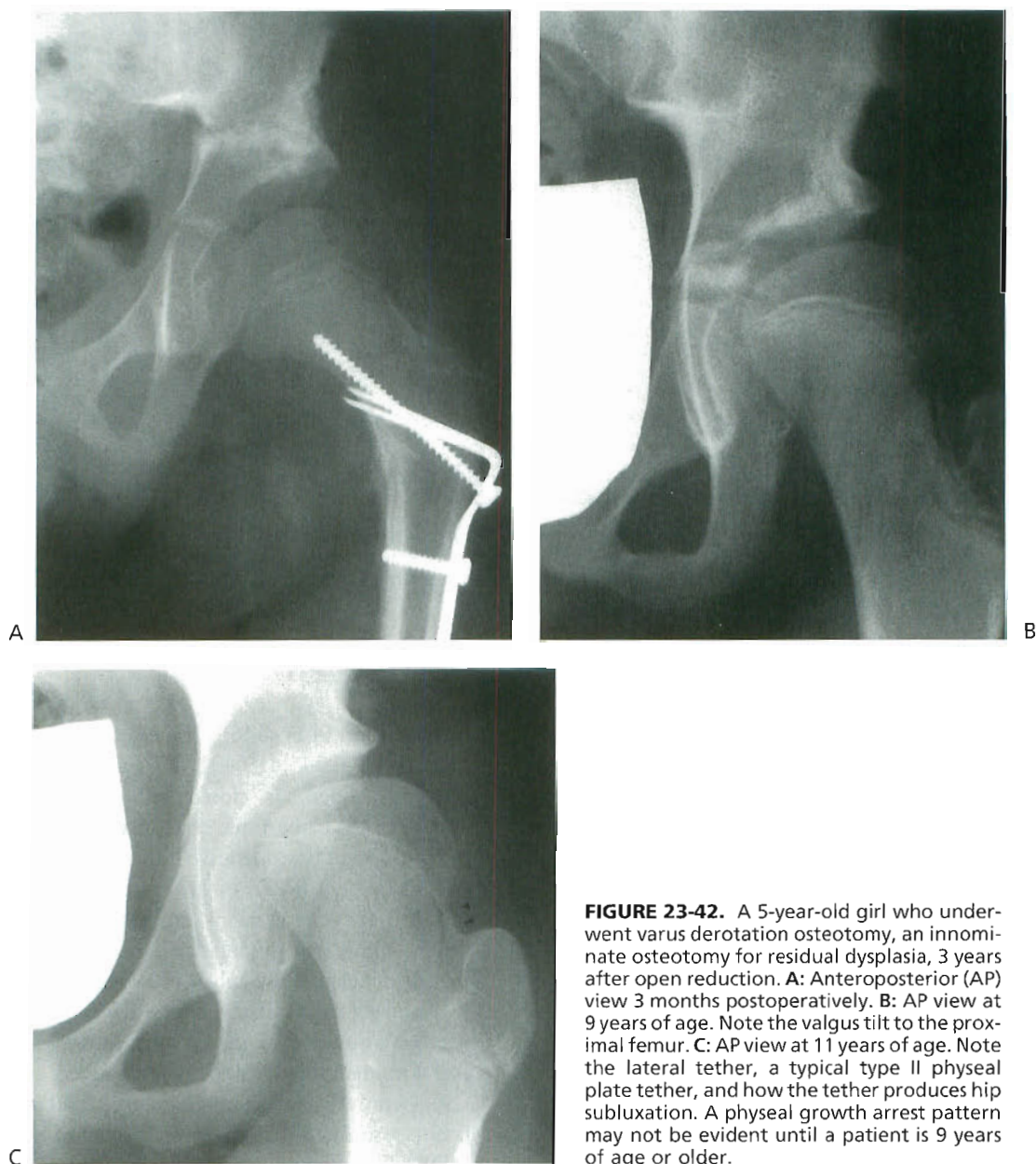


FIGURE 23-42. A 5-year-old girl who underwent varus derotation osteotomy, an innominate osteotomy for residual dysplasia, 3 years after open reduction. **A:** Anteroposterior (AP) view 3 months postoperatively. **B:** AP view at 9 years of age. Note the valgus tilt to the proximal femur. **C:** AP view at 11 years of age. Note the lateral tether, a typical type II physeal plate tether, and how the tether produces hip subluxation. A physeal growth arrest pattern may not be evident until a patient is 9 years of age or older.

Bucholz and Ogden (414) and Kalamchi and MacEwen (419) identified a lateral physeal arrest pattern that may not be evident until a patient is older than 12.5 years of age (mean, 9 years) (Fig. 23-42). This is the most common pattern of growth disturbance reported. Kalamchi and MacEwen stressed that it may be difficult to identify this group early, and studies reporting growth disturbances with follow-up periods of less than 12 years must be regarded as preliminary and may not reflect the actual incidence of proximal growth disturbance (419).

The incidence of proximal femoral growth disturbance increases with delay in reduction (245,250). Younger patients have a lower rate of growth disturbance. Kalamchi

and MacEwen, however, documented an increase in the incidence of the severe form (type IV) in younger patients (419). Salter and colleagues (270) and Ogden (424,425) proposed that the femoral head in DDH is most vulnerable to ischemic changes during the first 12 to 18 months of life, when it is composed mostly of cartilage. According to some orthopaedic specialists the risk of total head involvement becomes somewhat less after the appearance of the femoral ossific nucleus, although, as mentioned above, this concept was recently challenged (250,274).

Prereduction traction to bring the proximal femur epiphysis to the level of the triradiate cartilage is considered essential by many surgeons to decrease the incidence of

proximal femoral growth disturbance. Gage and Winter thought that there was a direct correlation between inadequate traction and the incidence of growth disturbance. They studied a group of patients to quantify prereduction hip positions (245). Weiner et al. found that in patients younger than 1 year of age traction for longer than 21 days substantially reduced the rate of growth disturbance (250). Buchanan and colleagues recommended a minimum of 2 weeks of traction until achievement of a 2+ traction station using the Gage and Winter scale (238). Skeletal traction gradually increased over several weeks, and an average of 39% of body weight usually was required to achieve this position. In contrast, Cooperman et al. studied 30 DDH hips with aseptic necrosis and 30 hips without necrosis and found, at an average 39-year follow-up, that the degree of initial displacement that had to be overcome to obtain reduction was comparable in both groups and that it was not a factor in the development of proximal femoral growth disturbance (416). Some of the worst results were seen in patients with minimal superior dislocation. Schoenecker and Strecker demonstrated that the results of traction were not as good as the results of femoral shortening in older patients with DDH (304). Gibson and Benson thought that although preliminary traction protects against growth disturbance, there was no relation between the original degree of displacement of the proximal femur and the final result (304).

Several factors associated with an increased incidence of proximal femoral growth disturbance have been documented in the clinical setting and in experimental studies. These include extremes in positioning of the proximal femur in abduction and adduction with extreme medial rotation. Extremes in position can cause compression of the medial femoral circumflex vessel as it passes the iliopsoas tendon and compression of the terminal branch between the lateral femoral neck and the acetabular margin (270,424,425). Anatomic and experimental investigations have persistently shown that strong medial rotation with concomitant abduction and extreme abduction alone (i.e., the Lorenz position) can compromise the blood flow to the capital femoral epiphysis. If the hip is maximally abducted against firm resistance, the blood flow can be completely or almost completely arrested. The same is true in forced medial rotation. The blood vessels and blood supply to the proximal femur can be occluded outside the femoral head by compression or as the vessels cross through the epiphyseal cartilage (270,273,428). Schoenecker and colleagues showed a diminution of epiphyseal perfusion by increased pressure, which was relieved after the external fixation device was removed (272,427).

The extreme positions of abduction, frequently called the "frog-leg position" (Fig. 23-33) and used in cases of unrelieved adduction contracture, as seen in dislocations, uniformly result in severe growth disturbances of the epiphysis (269,270,427).

Extreme positions can also cause pressure necrosis of the vulnerable epiphyseal cartilage and the physeal plate. This has been experimentally shown by Law and colleagues (421) and by Schoenecker and associates (427). These studies and others demonstrated the severe effects of cartilage necrosis (179,270,273). These effects can also be precipitated by circumscribed pressure, such as the use of the vulnerable femoral head as a dilating sound to overcome the intraarticular obstacles to reduction.

Severin advocated the use of the femoral head placed in close apposition to the acetabulum to induce regression of the obstacles to reduction (122). The idea is that sustained pressure from the femoral head causes the labrum to adapt itself to the spherical contour of the head. This maneuver can be used to obtain reduction, but the price may be an increased incidence of necrosis (179,438). Although the use of prereduction traction has been implicated as a factor in reducing the incidence of necrosis, the German Orthopaedic Study Group did not find this to be the case (179).

The continued use of closed techniques in an attempt to have the femoral head overcome the intraarticular obstacles to reduction can lead to severe necrosis (179). If closed reduction is attempted, in the author's opinion the only acceptable reduction is an anatomically perfect reduction; otherwise, the hip must be reduced openly to prevent damage to the vulnerable femoral head (179,351,445).

The most widely used classification of proximal femoral growth disturbance is that of Salter and colleagues (270) (Table 23-2). The author disagrees with the inclusion of coxa magna, because coxa magna is often seen after open reduction as a result of the stimulation of blood flow to the proximal femur (446-448). It is also often difficult to ascertain if some of the residual deformities seen after treatment of DDH are alterations in the proximal femur secondary to disturbances that occurred before the reduction or are the result of complications associated with the reduction.

TABLE 23-2. CLASSIFICATION OF THE FEMORAL HEAD

Salter Class	Features
1	Failure of the appearance of the ossific nucleus of the femoral head within 1 year after reduction
2	Failure of growth of an existing ossific nucleus within 1 year after reduction
3	Broadening of the femoral neck within 1 year after reduction
4	Increased radiographic bone density, followed by fragmentation of the femoral head
5	Residual deformity of the femoral head and neck when reossification is complete; these deformities include coxa magna, coxa plana, coxa vara, and a short, broad femoral neck

(From ref. 270, with permission.)

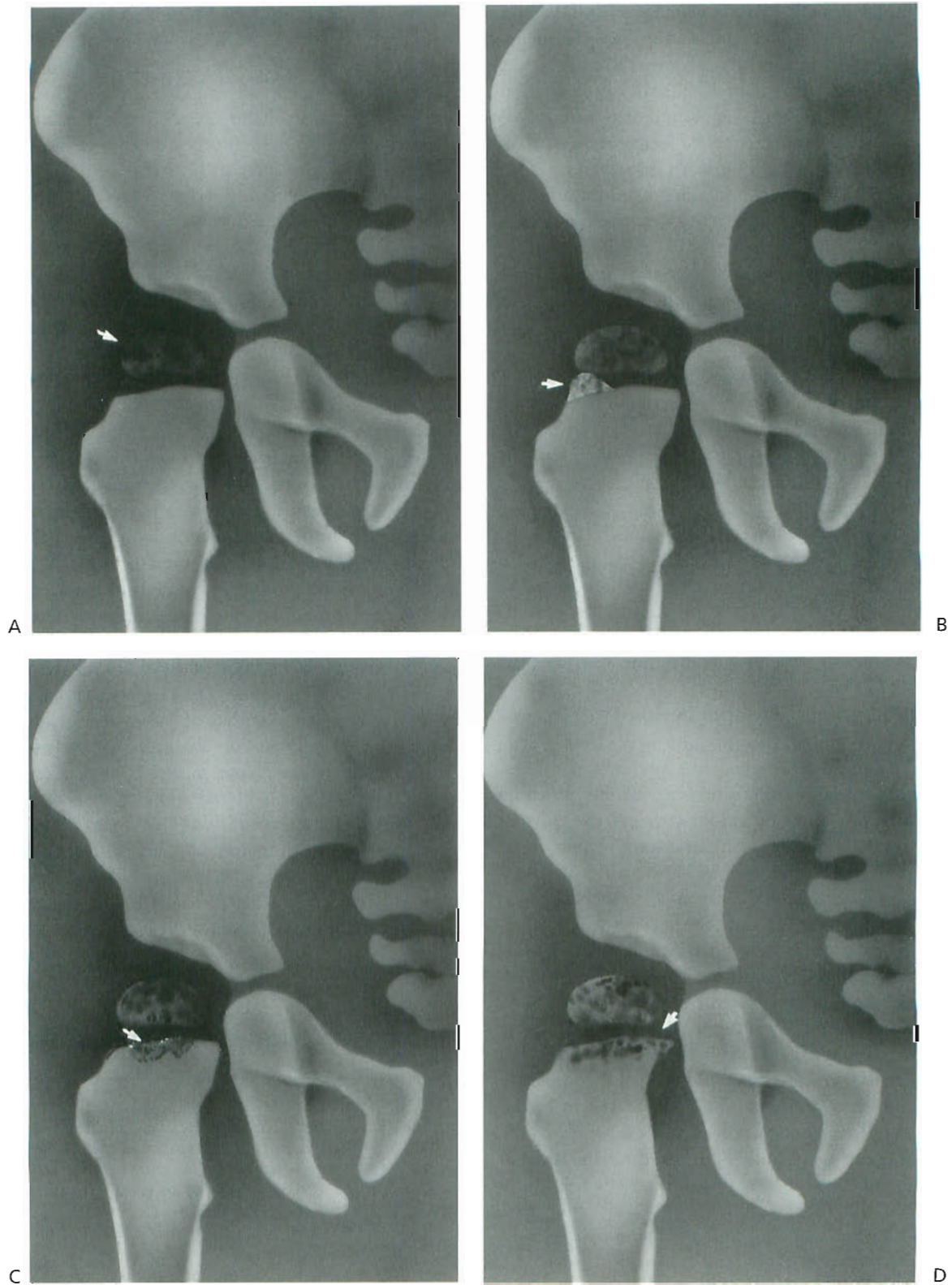


FIGURE 23-43. Classification of proximal femoral growth disturbances. **A:** Group I. **B:** Group II. **C:** Group III. **D:** Group IV. (Adapted from ref. 419, with permission.)

One of the most common deformities seen is flattening of the medial aspect of the proximal femur, which occurs because of pressure of the femoral head lying against the ilium before reduction.

Another area of uncertainty is the issue of temporary irregular ossification of the femoral epiphysis and whether this represents damage to the epiphyseal cartilage or merely multiple ossification centers that eventually coalesce. These areas may be analogous to the accessory centers of ossification seen in the periphery of the acetabulum. This pattern usually does not result in growth disturbance of the proximal femur. Only long-term follow-up studies of this entity can resolve this issue.

Kalamchi and MacEwen developed a classification of necrosis that emphasized the growth disturbances associated with various degrees of physeal arrest (419). This classification (Fig. 23-43) puts all the growth disturbances seen in the ossific nucleus into one category if they are not associated with physeal involvement. Bucholz and Ogden provided an additional classification based on patterns of vascular supply resulting in partial or total ischemia (414). There are few studies documenting the interobserver or intraobserver reliability of these classifications of growth disturbance. As many as 25% of hips may not fit into a particular classification.

O'Brien and associates discussed the importance of identification of growth disturbance lines to predict future deformity of the proximal femur (449,450) (Fig. 23-44). These growth arrest lines may provide the physician with early evidence of a future problem. However, the utility of this approach must await long-term follow-up studies.

Long-term follow-up studies exist of patients suffering from proximal femoral growth disturbance (179,416). The results indicate that any alteration of proximal femoral growth disturbance decreases the longevity of the hip.

In the treatment of the residual effects of necrosis, reduction must be maintained by corrective femoral and/or acetabular procedures (451,452). With arrest of the proximal femoral physeal plate, trochanteric overgrowth ensues producing an abductor lurch (Fig. 23-45). If identified, greater trochanteric physeal plate arrest may maintain articular trochanteric distance if performed in children younger than 8 years of age (19,453,454); otherwise, distal transfer of the greater trochanter may be necessary (371,455–457) [4.9].

The painful hip in the teenager with residual proximal femoral growth disturbance and dysplasia may be caused by a torn labrum (458,459). The diagnosis can be made using contrast-enhanced computed tomography or magnetic resonance imaging, and treatment may require open repair or excision. Another cause of pain includes early degenerative joint disease, which should be treated by the previously described methods to correct residual subluxation and dysplasia. In extreme cases, hip fusion or early total joint arthroplasty may be the only alternatives available. These circumstances are rare among patients younger than 30 years of age.

The key to the diagnosis and management of DDH is early detection. This results in a 95% success rate of treatment with a low risk of complications. It is the initial treating physician who has the greatest chance of successfully achieving a normal hip. Orthopaedic surgeons must educate

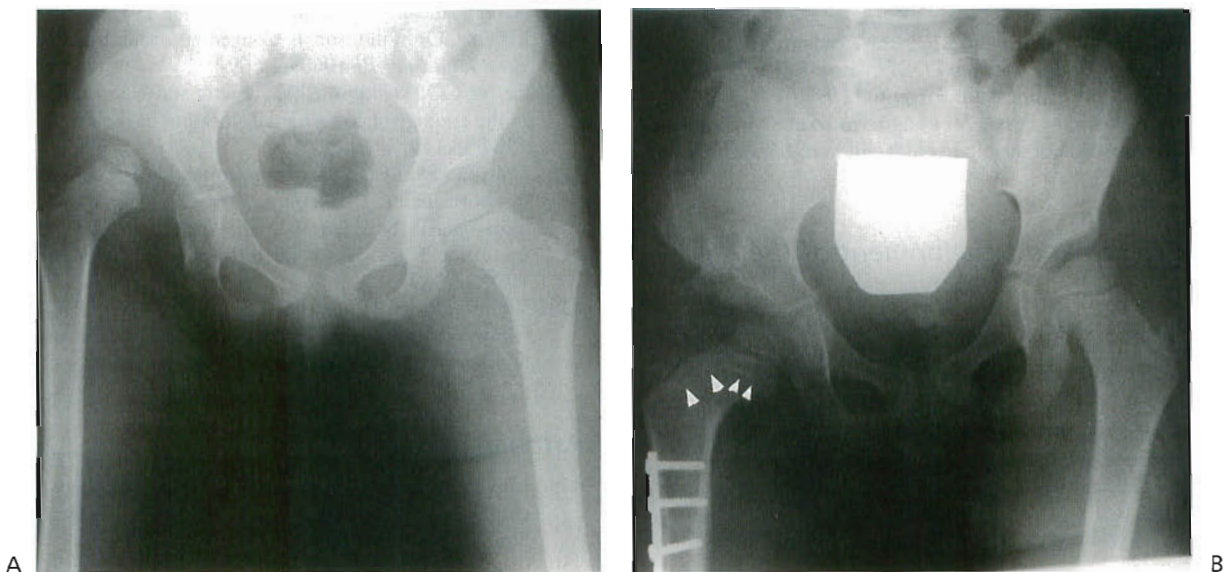


FIGURE 23-44. A 3-year-old girl with right developmental dysplasia of the hip. **A:** Preoperative radiograph. **B:** Ten months after operative open reduction, femoral shortening, and Pemberton osteotomy. Note the presence of growth arrest line at the proximal femur (O'Brien lines; arrows); also note similar lines on the opposite normal hip.

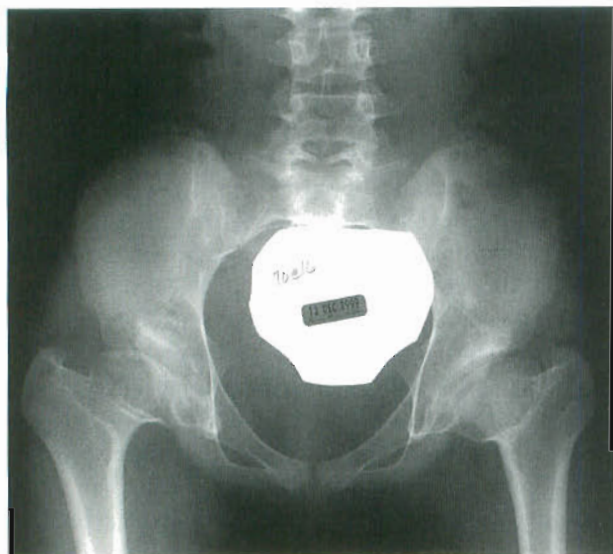


FIGURE 23-45. A 14-year-old girl with residual dysplasia, type III growth arrest, and trochanteric overgrowth. The patient had bilateral open reductions at 14 months of age. She suffered a type III growth arrest of the proximal femur with resultant disturbance of growth of the proximal femur and corresponding acetabular deformity and trochanteric overgrowth. Her Trendelenburg test was negative. Some patients with this deformity have an abductor lurch, necessitating distal transfer of the greater trochanter.

primary care colleagues in making the diagnosis early and initiating prompt referral.

References

Growth Disturbance of the Proximal Femur

1. Surgeons Advisory Statement, American Academy of Orthopaedic Surgeons. "CDH" should be "DDH." Park Ridge, IL: American Academy of Orthopaedic Surgeons, 1991.
2. Klisic P, Jankovic L, Basara V. Long-term results of combined operative reduction of the hip in older children. *J Pediatr Orthop* 1988;8:532.

Normal Growth and Development of the Hip Joint

3. Gardiner HM, Dunn PM. Controlled trial of immediate splinting versus ultrasonographic surveillance in congenitally dislocatable hips. *Lancet* 1990;336:1553.
4. Lee J, Jarvis J, Uhthoff HK, et al. The fetal acetabulum: a histomorphometric study of acetabular anteversion and femoral head coverage. *Clin Orthop* 1992;281:48.
5. Strayer LM. Embryology of the human hip joint. *Yale J Biol Med* 1943;16:13.
6. Strayer LM Jr. Embryology of the human hip joint. *Clin Orthop* 1971;74:221.
7. Watanabe RS. Embryology of the human hip. *Clin Orthop* 1974;98:8.
8. Dunn PM. The anatomy and pathology of congenital dislocation of the hip. *Clin Orthop* 1976;119:23.

9. Ponseti IV. Morphology of the acetabulum in congenital dislocation of the hip: gross, histological and roentgenographic studies. *J Bone Joint Surg Am* 1978;60:586.
10. Harrison TJ. The influence of the femoral head on pelvic growth and acetabular form in the rat. *J Anat* 1961;95:127.
11. Ponseti IV. Growth and development of the acetabulum in the normal child: anatomical, histological and roentgenographic studies. *J Bone Joint Surg Am* 1978;60:575.
12. Walker JM. Histological study of the fetal development of the human acetabulum and labrum: significance in congenital hip disease. *Yale J Biol Med* 1981;54:255.
13. Harrison TJ. The growth of the pelvis in the rat: a mensural and morphological study. *J Anat* 1958;92:236.
14. Siffert RS. Patterns of deformity of the developing hip. *Clin Orthop Relat Res* 1981;160:14.
15. Gage JR, Camy JM. The effects of trochanteric epiphysiodesis on growth of the proximal end of the femur following necrosis of the capital femoral epiphysis. *J Bone Joint Surg Am* 1980;62:785.
16. Osborne D, Effmann E, Broda K, et al. The development of the upper end of the femur with special reference to its internal architecture. *Radiology* 1980;137:71.
17. Schofield CB, Smibert JG. Trochanteric growth disturbance after upper femoral osteotomy for congenital dislocation of the hip. *J Bone Joint Surg Br* 1990;72:32.
18. Sugano NN, Noble PC, Kamaric E, et al. The morphology of the femur in developmental dysplasia of the hip. *J Bone Joint Surg Br* 1998;80:711.
19. Iverson LJ, Kalea V, Eberle C. Relative trochanteric overgrowth after ischemic necrosis in congenital dislocation of the hip. *J Pediatr Orthop* 1989;9:391.
20. Coleman CR, Slager RF, Smith WS. The effect of environmental influence on acetabular development. *Surg Forum* 1958;9:775.
21. Smith WS, Ireton RJ, Coleman CR. Sequelae of experimental dislocation of a weight-bearing ball-and-socket joint in a young growing animal. *J Bone Joint Surg Am* 1958;40:1121.
22. Smith WS, Coleman CR, Olix ML, et al. Etiology of congenital dislocation of the hip. *J Bone Joint Surg Am* 1963;45:491.
23. Weinstein SL. Natural history of congenital hip dislocation [CDH] and hip dysplasia. *Clin Orthop* 1987;225:62.
24. Carter CO, Wilkinson J. Congenital dislocation of the hip. *J Bone Joint Surg Br* 1960;42:669.
25. Carter CO, Wilkinson JA. Genetic and environmental factors in the etiology of congenital dislocation of the hip. *Clin Orthop* 1964;33:119.
26. Coleman SS. Diagnosis of congenital dysplasia of the hip in the newborn infant. *J Bone Joint Surg Am* 1956;162:548.
27. Skirving AP, Scadden WJ. The African neonatal hip and its immunity from congenital dislocation. *J Bone Joint Surg Br* 1979;61:339.
28. Wynne-Davies R. Acetabular dysplasia and familial joint laxity: two etiological factors in congenital dislocations of the hip. *J Med Genet* 1970;7:315.

Pathoanatomy

29. Ishii Y, Weinstein SL, Ponseti IV. Correlation between arthrograms and operative findings in congenital dislocation of the hip. *Clin Orthop* 1980;153:138.
30. Ortolani M. Congenital hip dysplasia in the light of early and very early diagnosis. *Clin Orthop* 1976;119:6.
31. Mubarak S, Garfin S, Vance R, et al. Pitfalls in the use of the Pavlik harness for treatment of congenital dysplasia, subluxation and dislocation of the hip. *J Bone Joint Surg Am* 1981;63:1239.

32. Harris NH, Lloyd-Roberts GC, Gallien R. Acetabular development in congenital dislocation of the hip with special reference to the indications for acetabuloplasty and pelvic or femoral realignment osteotomy. *J Bone Joint Surg Br* 1975;57:46.
33. Harris IE, Dickens R, Menelaus MB. Use of the Pavlik harness for hip displacements. *Clin Orthop* 1992;281:29.
34. Lindstrom JR, Ponseti IV, Wenger DR. Acetabular development after reduction in congenital dislocation of the hip. *J Bone Joint Surg Am* 1979;61:112.
35. Harris NH. Acetabular growth potential in congenital dislocation of the hip and some factors upon which it may depend. *Clin Orthop* 1976;119:99.
36. Mardam-Bey TH, MacEwen GD. Congenital hip dislocation after walking age. *J Pediatr Orthop* 1982;2:478.
37. Pemberton PA. Pericapsular osteotomy of the ilium for treatment of congenital subluxation and dislocation of the hip. *J Bone Joint Surg Am* 1965;87:65.
38. Salter RB. Innominate osteotomy in treatment of congenital dislocation of the hip. *J Bone Joint Surg Br* 1961;43:72.
39. Schwartz D. Acetabular development after reduction of congenital dislocation of the hip: a follow-up study of fifty hips. *J Bone Joint Surg Am* 1965;47:705.
40. Somerville EW. A long-term follow-up of congenital dislocation of the hip. *J Bone Joint Surg Br* 1978;60:25.
41. Weinstein SL, Ponseti IV. Congenital dislocation of the hip. *J Bone Joint Surg Am* 1979;61:119.
42. Weintroub S, Green I, Terdiman R, et al. Growth and development of congenitally dislocated hips reduced in early infancy. *J Bone Joint Surg Am* 1979;61:125.
43. Wiberg G. Studies on dysplastic acetabula and congenital subluxation of the hip joint. *Acta Chir Scand* 1939;83(suppl 58):1.
44. Rabin DL, Barnett CR, Arnold WD, et al. Untreated congenital hip disease: a study of the epidemiology, natural history and social aspects of the disease in a Navajo population. *Am J Public Health* 1965;55:1.
45. Wedge JH, Wasylenko MJ. The natural history of congenital dislocation of the hip: a critical review. *Clin Orthop* 1978;137:154.
46. Albinana JM, Morcuende JA, Delgado E, Weinstein SL. Radiologic pelvic asymmetry in unilateral late diagnosed developmental dysplasia of the hip. *J Pediatr Orthop* 1995;15:753.
47. Haasbeek JF, Wright JG, Hedden DM. Is there a difference between the epidemiologic characteristics of hip dislocation diagnosed early and late? *Can J Surg* 1995;38:437.
48. Palmen K. Preluxation of the hip joint: diagnosis and treatment in the newborn and the diagnosis of congenital dislocation of the hip joint in Sweden during the years 1948–1960. *Acta Paediatr Scand Suppl* 1961;129:1.
49. Fabry G, MacEwen GD, Shands AR Jr. Torsion of the femur: a follow-up study in normal and abnormal conditions. *J Bone Joint Surg Am* 1973;55:1726.
50. LeDamany P. La luxation congenitale de la hanche. In: *Etudes d'anatomie comparee d'anthropogenie normale et pathologique, deductions therapeutique*. Paris: Felix Alcan, 1912.
51. Wedge JH, Munkacsy I, Loback D. Anteversion of the femur and idiopathic osteoarthritis of the hip. *J Bone Joint Surg Am* 1989;71:1040.
52. Walker JM. Morphological variants in the human fetal hip joint: their significance in congenital hip disease. *J Bone Joint Surg Am* 1980;62:1073.
53. Walker JM, Goldsmith CH. Morphometric study of the fetal development of the human hip joint: significance for congenital hip disease. *Yale J Biol Med* 1981;54:411.
54. Palmen K. Prevention of congenital dislocation of the hip: the Swedish experience of neonatal treatment of hip joint instability. *Acta Orthop Scand Suppl* 1984;208:1.
55. Wedge JH, Wasylenko MJ. The natural history of congenital disease of the hip. *J Bone Joint Surg Br* 1979;61:334.
56. Yamamuro T, Ishida K. Recent advances in the prevention, early diagnosis, and treatment of congenital dislocation of the hip in Japan. *Clin Orthop* 1984;184:34.

Pathogenesis, Epidemiology, and Diagnosis

Causes of Developmental Dysplasia of the Hip

44. Bjerkreim I, Arseth PH. Congenital dislocation of the hip in Norway: late diagnosis CDH in the years 1970 to 1974. *Acta Paediatr Scand* 1978;67:329.
45. Bjerkreim I, Johansen J. Late diagnosed congenital dislocation of the hip. *Acta Orthop Scand* 1987;58:504.
46. Coleman SS. Congenital dysplasia of the hip in the Navajo infant. *Clin Orthop* 1968;56:179.
47. Coleman SS. *Congenital dysplasia and dislocation of the hip*. St. Louis: Mosby, 1978.
48. Czeizel A, Szentpetery J, Kellermann M. Incidence of congenital dislocation of the hip in Hungary. *Br J Prev Soc Med* 1974;28:265.
49. Edlestein J. Congenital dislocation of the hip in the Bantu. *J Bone Joint Surg Br* 1966;48:397.
50. Getz B. The hip in Lapps and its bearing on the problem of congenital dislocation. *Acta Orthop Scand Suppl* 1955;22.
51. Heikkila E. Congenital dislocation of the hip in Finland: an epidemiologic analysis of 1035 cases. *Acta Orthop Scand* 1984;55:125.
52. Hoagland FT, Yau AC, Wong WL. Osteoarthritis of the hip and other joints in Southern Chinese in Hong Kong. *J Bone Joint Surg Am* 1973;55:545.
53. Hoaglund FT, Healey JH. Osteoarthritis and congenital dysplasia of the hip in family members of children who have congenital dysplasia of the hip. *J Bone Joint Surg Am* 1990;72:1510; erratum 1991;73:293.
54. Pompe Van Meerdervoort HF. Congenital musculoskeletal disorders in the South African Negro. *J Bone Joint Surg Br* 1977;59:257.

Risk Factors and Incidence

48. Albinana J, Quesada JA, Certucha JA. Children at high risk for congenital dislocation of the hip: late presentation. *J Pediatr Orthop* 1993;13:268.
49. Asher MA. Orthopedic screening: especially congenital dislocation of the hip and spinal deformity. *Pediatr Clin North Am* 1977;24:713.
50. Asher MA. Screening for congenital dislocation of the hip, scoliosis, and other abnormalities affecting the musculoskeletal system. *Pediatr Clin North Am* 1986;33:1335.
51. Dunn PM. Prenatal observation on the etiology of congenital dislocation of the hip. *Clin Orthop* 1976;119:11.
52. Kumar SJ, MacEwen GD. The incidence of hip dysplasia with metatarsus adductus. *Clin Orthop* 1982;164:234.
53. Weiner DS. Congenital dislocation of the hip associated with congenital muscular torticollis. *Clin Orthop* 1976;121:163.
54. Wilkinson JA. A postnatal survey for the congenital displacement of the hip. *J Bone Joint Surg Br* 1972;54:40.
55. Abd-el-Kader-Shaheen M. Mehah: the Saudi tradition of infant wrapping as a possible aetiological factor in congenital dislocation of the hip. *J R Coll Surg Edinb* 1989;34:85.

76. Kutlu A, Memik R, Mutlu M, et al. Congenital dislocation of the hip and its relation to swaddling used in Turkey. *J Pediatr Orthop* 1992;12:598.
77. Pratt WB, Freiburger RH, Arnold WD. Untreated congenital hip dysplasia in the Navajo. *Clin Orthop* 1982;162:69.
78. Yamamuro T, Doi H. Diagnosis and treatment of congenital dislocation of the hip in newborns. *J Jpn Orthop Assoc* 1965;39:492.
79. R  lis A, McKibbin B. Changes in shape of the human hip joint during its development and their relation to its stability. *J Bone Joint Surg Br* 1973;55:780.
80. Salter R. Etiology, pathogenesis, and possible prevention of congenital dislocation of the hip. *Can Med Assoc J* 1968;98:933.
81. McKibbin B. Anatomical factors in the stability of the hip joint in the newborn. *J Bone Joint Surg Br* 1970;63:148.
82. Dunn PM. Congenital dislocation of the hip (CDH): necropsy studies at birth. *J R Soc Med* 1969;62:1035.
83. Ortolani M. *Nuovi criteri diagnostici profilattico correttivi*. Bologna, Italy: Cappelli, 1948.
84. Barlow TG. Early diagnosis and treatment of congenital dislocation of the hip. *J Bone Joint Surg Br* 1962;44:292.
85. Danielsson LG, Nilsson BE. Attitudes to CDH [guest editorial]. *Acta Orthop Scand* 1984;55:244.
86. Hilgenreiner H. Aur Fr  hdiagnose und Fr  hbehandlung der angeborenen Huftgelenkverrenkung. *Med Klin* 1925;21:1385.
87. MacNicol MF. Results of a 25-year screening programme for neonatal hip instability. *J Bone Joint Surg Br* 1990;72:1057.
88. Hadlow V. Neonatal screening for congenital dislocation of the hip: a prospective 21-year survey. *J Bone Joint Surg Br* 1988;70:740.
89. Hansson G, Nachemson A, Palm  n K. Screening of children with congenital dislocation of the hip joint on the maternity wards in Sweden. *J Pediatr Orthop* 1983;3:271.
90. Ilfeld FW, Westin GW. "Missed" or late-diagnosed congenital dislocation of the hip: a clinical entity. *Isr J Med Sci* 1980;16:260.
91. Ilfeld FW, Westin GW, Makin M. Missed or developmental dislocation of the hip. *Clin Orthop* 1986;203:276.
92. Jones D. An assessment of the value of examination of the hip in the newborn. *J Bone Joint Surg Br* 1977;59:318.
93. MacKenzie IG, Wilson JG. Problems encountered in the early diagnosis and management of congenital dislocation of the hip. *J Bone Joint Surg Br* 1981;63:38.
94. Noble TC, Pullan CR, Craft AW, et al. Difficulties in diagnosing and managing congenital dislocation of the hip. *Br Med J* 1978;2:620.
95. Walker G. Problems in the early recognition of congenital hip dislocation. *Br Med J* 1971;3:147.
96. Chan AC, Cundy P, Foster BK, et al. Late diagnosis of congenital dislocation of the hip and presence of a screening programme: South Australia population based study. *Lancet* 1999;354:1514.
97. Darmonov A. Clinical screening for congenital dislocation of the hip. *J Bone Joint Surg Am* 1996;78:383.
98. Godward SDC. Surgery for congenital dislocation of the hip in the UK as a measure of outcome of screening. *Lancet* 1998;351:1149.
99. Robinson R. Effective screening in child health. *Br Med J* 1998;316:1.
100. Churgay CA, Caruthers BS. Diagnosis and treatment of congenital dislocation of the hip. *Am Fam Physician* 1992;45:1217.
101. Frankenburg WK. To screen or not to screen: congenital dislocation of the hip [Editorial]. *Am J Public Health* 1981;71:1311.
102. Fredensborg N, Nilsson BE. Overdiagnosis of congenital dislocation of the hip. *Clin Orthop* 1976;119:89.
103. von Rosen S. Diagnosis and treatment of congenital dislocation of the hip in the newborn. *J Bone Joint Surg Br* 1962;44:284.
104. Weinstein SL. The medial approach in congenital dislocation of the hip. *Isr J Med Sci* 1980;16:272.

Diagnosis

105. Fellander M, Gladnikoff H, Jacobsson E. Instability of the hip in the newborn. *Acta Orthop Scand Suppl* 1970;130:36.
106. Czeizel A, Tusnady G, Vacz   G, et al. The mechanism of genetic predisposition in congenital dislocation of the hip. *J Med Genet* 1975;12:121.
107. Czeizel AE, Intody Z, Modell B. What proportion of congenital abnormalities can be prevented? *Br Med J* 1993;306:499.
108. Jones DA. Neonatal hip stability and the Barlow test: a study in stillborn babies. *J Bone Joint Surg Br* 1991;73:216.
109. Hass J. *Congenital dislocation of the hip*. Springfield, IL: Charles C Thomas, 1951.
110. Stanisavljevic S. *Diagnosis and treatment of congenital hip pathology in the newborn*. Baltimore: Williams & Wilkins, 1964.
111. Benson MKD, Evans JDC. The pelvic osteotomy of Chiari: an anatomical study of the hazards and misleading radiographic appearance. *J Bone Joint Surg Br* 1976;58:163.
112. D'Souza LH, Hynes K, McManus F. Radiological screening for congenital dislocation in the infant at risk. *J Bone Joint Surg Br* 1996;78:319.
113. Ando M, Gotoh E. Significance of inguinal folds for diagnosis of congenital dislocation of the hip in infants aged three to four months. *J Pediatr Orthop* 1990;10:331.
114. Weinstein SL. Closed versus open reduction of congenital hip dislocation in patients under 2 years of age. *Orthopedics* 1990;13:221.
115. Weinstein SL. Congenital hip dislocation: long-range problems, residual signs, and symptoms after successful treatment. *Clin Orthop* 1992;281:69.
116. Hattori T, Ono Y, Kitakoji T, et al. Soft tissue interposition after closed reduction in developmental dysplasia of the hip: the long term effect on acetabular development and aseptic necrosis. *J Bone Joint Surg Br* 1999;81:385.
117. Ferguson AB Jr. Treatment of congenital dislocation of the hip in infancy using the medial approach. In: Tachdjian MO, ed. *Congenital dislocation of the hip*. New York: Churchill Livingstone, 1982:283.
118. Leveuf J. Results of open reduction of "true" congenital luxation of the hip. *J Bone Joint Surg Am* 1948;30:875.
119. Ludloff K. The open reduction of the congenital hip dislocation by an anterior incision. *Am J Orthop Surg* 1913;10:438.
120. Mau H, Dorr WM, Henkel L, et al. Open reduction of congenital dislocation of the hip by Ludloff's method. *J Bone Joint Surg Br* 1971;53:1281.
121. Morcuende JA, Weinstein SL, Dolan L, et al. DDH: results of treatment after reduction by an anteromedial surgical approach at a minimum four year follow-up. *J Bone Joint Surg* 1997;79A:810.
122. Severin E. Contribution to the knowledge of congenital dislocation of the hip. *Acta Scand Chir Suppl* 1941;63:84.
123. Lee DY, Choi IH, Lee CK, et al. Assessment of complex hip deformity using three-dimensional CT image. *J Pediatr Orthop* 1991;11:13.
124. O'Hara JN. Congenital dislocation of the hip: acetabular deficiency in adolescence (absence of the lateral acetabular epiphysis) after limbectomy in infancy. *J Pediatr Orthop* 1989;9:640.
125. Bialik V, Reuveni A, Pery M, et al. Ultrasonography in developmental displacement of the hip: a critical analysis of our results. *J Pediatr Orthop* 1989;9:154.

126. Bialik V, Wiener F. Sonography in suspected developmental dysplasia of the hip. *J Pediatr Orthop B* 1993;2:152.
127. Kerry R, Simonds GW. Long term results of late non operative reduction of developmental dysplasia of the hip. *J Bone Joint Surg Br* 1998;80:78.
128. Boeree NR, Clarke NMP. Ultrasound imaging and secondary screening for congenital dislocation of the hip. *J Bone Joint Surg Br* 1994;76:525.
129. Bradley J, Wetherill M, Benson MK. Splintage for congenital dislocation of the hip: is it safe and reliable? *J Bone Joint Surg Br* 1987;69:257.
130. Catterall A. The early diagnosis of congenital dislocation of the hip [Editorial]. *J Bone Joint Surg Br* 1994;76:515.
131. Clarke NM, Harcke HT, McHugh P, et al. Real-time ultrasound in the diagnosis of congenital dislocation and dysplasia of the hip. *J Bone Joint Surg Br* 1985;67:406.
132. Clarke NMP, Clegg J, Al-Chalabi AN. Ultrasound screening of hips at risk for CDH: failure to reduce the incidence of late cases. *J Bone Joint Surg Br* 1989;71:9.
133. Clarke NM. Diagnosing congenital dislocation of the hip [editorial]. *Br Med J* 1992;305:435.
134. Dahlstrom H, Oberg L, Friberg S. Sonography in congenital dislocation of the hip. *Acta Orthop Scand* 1986;57:402.
135. Dahlstrom H, Friberg S, Oberg L. Current role of sonography in late CDH. *Acta Orthop Scand* 1988;59(suppl 227):94.
136. Engesaeter LB, Wilson DJ, Nag D, et al. Ultrasound and congenital dislocation of the hip: the importance of dynamic assessment. *J Bone Joint Surg Br* 1990;72:197.
137. Gardiner HM, Clarke NM, Dunn PM. A sonographic study of the morphology of the preterm neonatal hip. *J Pediatr Orthop* 1990;10:633.
138. Gardner E, Gray D. Prenatal development of the human hip joint. *Am J Anat* 1950;87:163.
139. Graf R. The diagnosis of congenital hip-joint dislocation by the ultrasonic compound treatment. *Arch Orthop Trauma Surg* 1980;97:117.
140. Graf R. Hip sonography in infancy: procedure and clinical significance. *Fortschr Med* 1985;103:62.
141. Harcke HT, Lee MS, Sinning L, et al. Ossification center of the infant hip: sonographic and radiographic correlation. *Am J Roentgenol* 1986;147:317.
142. Harcke HT, Kumar SJ. The role of ultrasound in the diagnosis and management of congenital dislocation and dysplasia of the hip. *J Bone Joint Surg Am* 1991;73:622.
143. Harcke HT. Imaging in congenital dislocation and dysplasia of the hip. *Clin Orthop* 1992;281:22.
144. Hernandez RJ, Cornell RG, Hensing RN. Ultrasound diagnosis of neonatal congenital dislocation of the hip. *J Bone Joint Surg Br* 1994;76:539.
145. Marks DS, Clegg J, Al-Chalabi AN. Routine ultrasound screening for neonatal hip instability: can it abolish late-presenting congenital dislocation of the hip? *J Bone Joint Surg Br* 1994;76:534.
146. Morin C, Harcke HT, MacEwen GD. The infant hip: real-time US assessment of acetabular development. *Radiology* 1985;157:673.
147. Polanuer PA, Harcke HT, Bowen JR. Effective use of ultrasound in the management of congenital dislocation and/or dysplasia of the hip. *Clin Orthop* 1990;252:176.
148. Stone MH, Clarke NM, Campbell MJ, et al. Comparison of audible sound transmission with ultrasound in screening for congenital dislocation of the hip. *Lancet* 1990;336:421.
149. Terjesen T, Bredland T, Berg V. Ultrasound screening of the hip joints. *Acta Orthop Scand* 1988;59(suppl 227):93.
150. Terjesen T, Runden T, Tangerud A. Ultrasonography and radiography of the hip in infants. *Acta Orthop Scand* 1989;60:651.
151. Terjesen T, Bredland T, Berg V. Ultrasound for hip assessment in the newborn. *J Bone Joint Surg Br* 1989;71:767.
152. Terjesen T. Femoral head coverage evaluated by ultrasonography in infants and children. *Mapfre Med* 1992;3(suppl 1):41.
153. Uden A, Lindberg H, Josefsson PO, et al. Sonography in the diagnosis of neonatal hip instability. *Acta Orthop Scand* 1988;59(suppl 227):94.
154. Feldman DS. How to avoid missing congenital dislocation of the hip. *Lancet* 1999;354:1490.
155. Frank P, Jones D. Neonatal detection of developmental dysplasia of the hip (DDH). *J Bone Joint Surg Br* 1999;81:560.
156. Jones D. Neonatal detection of developmental dysplasia of the hip (DDH). *J Bone Joint Surg Br* 1998;80:943.
157. Bialik VB, Bialik GM, Blazer S, et al. Developmental dysplasia of the hip: a new approach to incidence. *Pediatrics* 1999;103:93.
158. Falliner AH, Hahne HJ, Hassenpflug J. Sonographic hip screening and early management of developmental dysplasia of the hip. *J Pediatr Orthop B* 1999;8:112.
159. Paton RS, Srinivasan MS, Shah B, et al. Ultrasound screening for hips at risk in developmental dysplasia: is it worth it? *J Bone Joint Surg Br* 1999;81:255.
160. Harcke H. The role of ultrasound in diagnosis and management of developmental dysplasia of the hip. *Pediatr Radiol* 1995;25:225.
161. Tumer YW, Ward WT, Grudziak J. Medial open reduction in the treatment of developmental dislocation of the hip. *J Pediatr Orthop* 1997;17:176.
162. Rosendahl K, Markestad T, Lie RT. Congenital dislocation of the hip: a prospective study comparing ultrasound and clinical examination. *Acta Paediatr* 1992;81:177.
163. Terjesen TH, Holen KJ, Tegnander A. Hip abnormalities detected by ultrasound in clinically normal newborn infants. *J Bone Joint Surg Br* 1996;78:636.
164. Rosendahl KM, Markestad T, Lie RT, et al. Cost effectiveness of alternative screening strategies for developmental dysplasia of the hip. *Arch Pediatr Adolesc Med* 1995;149:643.
165. Rosendahl K, Markestad T, Lie RT. Developmental dysplasia of the hip: a population based comparison of ultrasound and clinical findings. *Acta Paediatr* 1996;85:64.
166. Terjesen T. Ultrasound as the primary imaging method in the diagnosis of hip dysplasia in children aged < 2 years. *J Pediatr Orthop B* 1996;5:123.
167. Taylor G, Clarke NMP. Monitoring treatment of developmental dysplasia of the hip with the Pavlik harness: the role of ultrasound. *J Bone Joint Surg Br* 1997;79:719.
168. Kernohan WG, Beverland DE, McCoy GF, et al. Vibration arthrometry: a preview. *Acta Orthop Scand* 1990;61:70.
169. Kernohan WG, Cowie GH, Mollan RA. Vibration arthrometry in congenital dislocation of the hip. *Clin Orthop* 1991;272:167.
170. Kernohan WG, Trainor B, Nugent G, et al. Low-frequency vibration emitted from unstable hip in human neonate. *Clin Orthop* 1993;288:214.
171. Broughton NS, Brougham DI, Cole WG, et al. Reliability of radiological measurements in the assessment of the child's hip. *J Bone Joint Surg Br* 1989;71:6.
172. Weinstein S. Traction in developmental dislocation of the hip: is its use justified? *Clin Orthop* 1997;338:79.
173. O'Brien T, Barry C. The importance of standardised radiographs when assessing hip dysplasia. *Ir Med J* 1990;83:159.
174. Almby B, Lonnerholm T. Hip joint instability after the neonatal period. I. Value of measuring the acetabular angle. *Acta Radiol Diagn* 1979;20:200.
175. Anda S, Terjesen T, Kvistad KA, et al. Acetabular angles and

- femoral anteversion in dysplastic hips in adults: CT investigation. *J Comput Assisted Tomogr* 1991;15:115.
176. Anda S, Terjesen T, Kvistad KA. Computed tomography measurements of the acetabulum in adult dysplastic hips: which level is appropriate? *Skeletal Radiol* 1991;20:267.
 177. Garvey M, Donoghue VB, Gorman WA, et al. Radiographic screening at four months of infants at risk for congenital hip dislocation. *J Bone Joint Surg Br* 1992;74:704.
 178. Tonnis D. Normal values of the hip joint for the evaluation of x-rays in children and adults. *Clin Orthop* 1976;119:39.
 179. Tonnis D, ed. *Congenital dysplasia and dislocation of the hip in children and adults*. New York: Springer-Verlag, 1987.
 180. Papavasiliou VA, Piggott H. Acetabular floor thickening and femoral head enlargement in congenital dislocation of the hip: lateral displacement of femoral head. *J Pediatr Orthop* 1983;3:22.
 181. Albinana J, Morcuende JA, Weinstein SL. Predictive value of the teardrop figure in congenital dislocation of the hip: a quantitative study. POSNA Annual Meeting 1994.
 182. Kohler A. *Roentgenology*. London: Bailliere, Tindall, & Cox, 1935.
 183. Samani DJ, Weinstein SL. The pelvic tear-figure: a three-dimensional analysis of the anatomy and effects of rotation. *J Pediatr Orthop* 1994;14:650.
 184. Smith JT, Matan S, Coleman SS, et al. The predictive value of the development of the acetabular teardrop figure in developmental dysplasia of the hip. Presented at the American Academy of Orthopaedic Surgeons annual meeting, San Francisco, CA, 1993.
 185. Vare VB. The anatomy of the pelvic tear figure. *J Bone Joint Surg Am* 1952;34:167.
 186. Albinana JM, Morevende JA, Weinstein SL. The teardrop in congenital dislocation of the hip diagnosed late: a quantitative study. *J Bone Joint Surg Am* 1996;78:1048.
 187. Smith JM, Matan A, Coleman SS, et al. The predictive value of the development of acetabular teardrop figure in developmental dysplasia of the hip. *J Pediatr Orthop* 1997;17:165.
 188. Bertol P, MacNicol MF, Mitchell GP. Radiographic features of neonatal congenital dislocation of the hip. *J Bone Joint Surg Br* 1982;64:176.
 189. Perkins G. Signs by which to diagnose congenital dislocation of the hip, 1928 [Classical article]. *Clin Orthop* 1992;274:3.
 190. Sharp IK. Acetabular dysplasia: the acetabular angle. *J Bone Joint Surg Br* 1961;43:269.
 191. Bos CF, Bloem JL, Verbout AJ. Magnetic resonance imaging in acetabular residual dysplasia. *Clin Orthop* 1991;265:207.
 192. Kashiwagi NS, Suzuki S, Kasahara Y, et al. Prediction of reduction in developmental dysplasia of the hip by magnetic resonance imaging. *J Pediatr Orthop* 1996;16:254.
 193. Fisher R, O'Brien TS, Davis KM. Magnetic resonance imaging in congenital dysplasia of the hip. *J Pediatr Orthop* 1991;11:617.
 194. Greenhill BJ, Hugosson C, Jacobsson B, et al. Magnetic resonance imaging study of acetabular morphology in developmental dysplasia of the hip. *J Pediatr Orthop* 1993;13:314.
 195. Guidera KJ, Einbecker ME, Berman CG, et al. Magnetic resonance imaging evaluation of congenital dislocation of the hips. *Clin Orthop* 1990;261:96.
 196. Johnson ND, Wood BP, Jackman KV. Complex infantile and congenital hip dislocation: assessment with MR imaging. *Radiology* 1988;168:151.
 198. Melvin P, Johnston R, Ponseti IV. Untreated CDH: long-term follow-up. 1970 (personal communication).
 199. Walker JM. Congenital hip disease in Cree-Ojibwa population: a retrospective study. *Can Med Assoc J* 1977;116:501.
 200. Schwend RP, Pratt WB, Fultz J. Untreated acetabular dysplasia of the hip in the Navajo: a 34 year case series follow up. *Clin Orthop* 1999;36:108.
 201. Henderson RS. Osteotomy for unreduced congenital dislocation of the hip in adults. *J Bone Joint Surg Br* 1970;52:468.
 202. Visser JD. Functional treatment of congenital dislocation of the hip. *Acta Orthop Scand Suppl* 1984;206:1.
 203. Milgram JW. Morphology of untreated bilateral congenital dislocation of the hips in a seventy-four-year-old man. *Clin Orthop* 1976;119:112.
 204. Chapchal GJ. The intertrochanteric osteotomy in the treatment of congenital dysplasia. *Clin Orthop* 1976;119:54.
 205. Fairbank JC, Howell P, Nockler I, et al. Relationship of pain to the radiological anatomy of the hip joint in adults treated for congenital dislocation of the hip as infants: a long-term follow-up of patients treated by three methods. *J Pediatr Orthop* 1986;6:539.
 206. Malvitz TA, Weinstein SL. Closed reduction for congenital dysplasia of the hip: functional and radiographic results after an average of thirty years. *J Bone Joint Surg Am* 1994;76:1777.
 207. Sherlock DA, Gibson PH, Benson MK. Congenital subluxation of the hip: a long-term review. *J Bone Joint Surg Br* 1985;67:390.
 208. Berkeley ME, Dickson JH, Cain TE, et al. Surgical therapy for congenital dislocation of the hip in patients who are twelve to thirty-six months old. *J Bone Joint Surg Am* 1984;66:412.
 209. Cooperman DR, Wallenstein R, Stulberg SD. Acetabular dysplasia in the adult. *Clin Orthop* 1983;175:79.
 210. Bombelli R. *Osteoarthritis of the hip*. Heidelberg, Germany: Springer-Verlag, 1983.
 211. Stulberg SD, Harris WH. Acetabular dysplasia and development of osteoarthritis of the hip. In: *The hip: proceedings of the second open meeting of the Hip Society*. St. Louis: Mosby, 1974:82.
 212. Harris WH. Etiology of osteoarthritis of the hip. *Clin Orthop* 1986;213:20.
 213. Hadley NA, Brown TD, Weinstein SL. The effect of contact pressure elevations and aseptic necrosis on the long-term outcome of congenital hip dislocation. *J Orthop Res* 1990;8:504.
 214. Michaeli DM, Murphy SB, Hipp JA. Comparison of predicted and measured contact pressures in normal and dysplastic hips. *Med Eng Phys* 1997;19:180.
 215. Lloyd-Roberts GC. Osteoarthritis of the hip: a study of the clinical pathology. *J Bone Joint Surg Br* 1955;37:8.
 216. Murray RO. The aetiology of primary osteoarthritis of the hip. *Br J Radiol* 1965;38:810.
 217. Solomon L. Patterns of osteoarthritis of the hip. *J Bone Joint Surg Br* 1976;58:176.

Treatment

218. Dimitriou JK, Cavadias AX. One-stage surgical procedure for congenital dislocation of the hip in older children: long-term results. *Clin Orthop* 1989;246:30.
219. Tredwell SJ. Neonatal screening for hip joint instability: its clinical and economic relevance. *Clin Orthop* 1992;281:63.
220. Dyson PH, Lynskey TG, Catterall A. Congenital hip dysplasia: problems in the diagnosis and management in the first year of life. *J Pediatr Orthop* 1987;7:568.
221. Atar D, Lehman WB, Tenenbaum Y, et al. Pavlik harness versus Frejka splint in treatment of developmental dysplasia of the hip: bicenter study. *J Pediatr Orthop* 1993;13:311.

Natural History

197. Crawford AW, Slovek RW. Fate of the untreated congenitally dislocated hip. *Orthop Trans* 1978;2:73.

222. Burger BJ, Burger JD, Bos CF, et al. Frejka pillow and Becker device for congenital dislocation of the hip: prospective 6-year study of 104 late-diagnosed cases. *Acta Orthop Scand* 1993;64:305.
223. Filipe G, Carlzioz H. Use of the Pavlik harness in treating congenital dislocation of the hip. *J Pediatr Orthop* 1982;2:357.
224. Grill F, Bensahel H, Canadell J, et al. The Pavlik harness in the treatment of congenital dislocating hip: report on a multicenter study of the European Paediatric Orthopaedic Society. *J Pediatr Orthop* 1988;8:1.
225. Heikkilä E. Comparison of the Frejka pillow and the von Rosen splint in treatment of congenital dislocation of the hip. *J Pediatr Orthop* 1988;8:20.
226. Hinderaker T, Rygh M, Uden A. The von Rosen splint compared with Frejka pillow: a study of 408 neonatally unstable hips. *Acta Orthop Scand* 1992;63:389.
227. Ilfeld FW, Makin M. Damage to the capital femoral epiphysis due to Frejka pillow treatment. *J Bone Joint Surg Am* 1977;59:654.
228. Iwasaki K. Treatment of congenital dislocation of the hip by the Pavlik harness: mechanism of reduction and usage. *J Bone Joint Surg Am* 1983;65:760.
229. Lempicki A, Wierusz-Kozłowska M, Kruczyński J. Abduction treatment in late diagnosed congenital dislocation of the hip: follow-up of 1,010 hips treated with the Frejka pillow 1967–76. *Acta Orthop Scand Suppl* 1990;236:1.
230. Pavlik A. Stirrups as an aid in the treatment of congenital dysplasia of the hip in children. *J Pediatr Orthop* 1989;9:157.
231. Pavlik A. The functional method of treatment using a harness with stirrups as the primary method of conservative therapy for infants with congenital dislocation of the hip, 1957 [classical article]. *Clin Orthop* 1992;281:4.
232. Viere RG, Birch JG, Herring JA, et al. Use of the Pavlik harness in congenital dislocation of the hip: an analysis of failures of treatment. *J Bone Joint Surg Am* 1990;72:238.
233. Jones GT, Schoenecker PL, Dias LS. Developmental hip dysplasia potentiated by inappropriate use of the Pavlik harness. *J Pediatr Orthop* 1992;12:722.
234. Moseley CF. The biomechanics of the pediatric hip. *Orthop Clin North Am* 1980;11:3.
235. Ramsey PS, Lasser S, MacEwen GD. Congenital dislocation of the hip: use of the Pavlik harness in the child during the first 6 months of life. *J Bone Joint Surg Am* 1976;58:1000.
236. Suzuki S. Ultrasound and the Pavlik harness in CDH. *J Bone Joint Surg Br* 1993;75:483.
237. Almby B, Hjelmsstedt A, Lonnerholm T. Neonatal hip instability: reason for failure of early abduction treatment. *Acta Orthop Scand* 1979;50:315.
238. Rombouts JJ, Kaelin A. Inferior (obturator) dislocation of the hip in neonates: a complication of treatment by the Pavlik harness. *J Bone Joint Surg Br* 1992;74:708.
239. Fernandez Gonzalez J, Albinana J. Obturator dislocation in developmental dislocation of the hip: a complication during treatment. *J Pediatr Orthop B* 1996;5:129.
240. Suzuki S, Yamamuro T. Avascular necrosis in patients treated with the Pavlik harness for congenital dislocation of the hip. *J Bone Joint Surg Am* 1990;72:1048.
241. Suzuki S, Kashiwagi N, Kasahara Y, et al. Avascular necrosis and the Pavlik harness: the incidence of avascular necrosis in three types of congenital dislocation of the hip as classified by ultrasound. *J Bone Joint Surg Br* 1996;78:631.
242. Buchanan JR, Greer RB III, Cotler JM. Management strategy for prevention of avascular necrosis during treatment of congenital dislocation of the hip. *J Bone Joint Surg Am* 1981;63:140.
243. Danzhou S, Hongzhi I, Weinmin Y, et al. Preoperative intermittent manual traction in congenital dislocation of the hip. *J Pediatr Orthop* 1989;9:205.
244. DeRosa GP, Feller N. Treatment of congenital dislocation of the hip: management before walking age. *Clin Orthop* 1987;225:77.
245. Gage JR, Winter RB. Avascular necrosis of the capital femoral epiphysis as a complication of closed reduction of congenital dislocation of the hip. *J Bone Joint Surg Am* 1972;54:373.
246. Kramer J, Schleberger R, Steffen R. Closed reduction by two-phase skin traction and functional splinting in mitigated abduction for treatment of congenital dislocation of the hip. *Clin Orthop* 1990;258:27.
247. Langenskjöld A, Paavilainen T. The effect of traction treatment on the results of closed or open reduction for congenital dislocation of the hip: a preliminary report. In: Tachdjian MO, ed. *Congenital dislocation of the hip*. New York: Churchill Livingstone, 1982:365.
248. Lehman WB, Grant AD, Nelson J, et al. Hospital for Joint Diseases' traction system for preliminary treatment of congenital dislocation of the hip. *J Pediatr Orthop* 1983;3:104.
249. Morel G. The treatment of congenital dislocation and subluxation of the hip in the older child. *Acta Orthop Scand* 1975;46:364.
250. Weiner DS, Hoyt WA Jr, Odell HW. Congenital dislocation of the hip: the relationship of premanipulation traction and age to avascular necrosis of the femoral head. *J Bone Joint Surg Am* 1977;59:306.
251. Zions LE, MacEwen GD. Treatment of congenital dislocation of the hip in children between the ages of one and three years. *J Bone Joint Surg Am* 1986;68:829.
252. Stucker RH, Nuter T, Haberstroh J. The effect of traction treatment on blood flow in the immature hip: an animal study. *Z Orthop Grenzgeb* 1996;134:332.
253. Wenger DL, Lee CS, Kolman B. Derotational femoral shortening for developmental dislocation of the hip: special indications and results in the child younger than 2 years. *J Pediatr Orthop* 1995;15:768.
254. Fish DN, Herzenberg JE, Hensinger RN. Current practice in use of prereduction traction for congenital dislocation of the hip. *J Pediatr Orthop* 1991;11:149.
255. Coleman S. A critical analysis of the value of preliminary traction in the treatment of CDH. *Orthop Trans* 1987;13:180.
256. Kahle WK, Anderson MB, Alpert J, et al. The value of preliminary traction in the treatment of congenital dislocation of the hip. *J Bone Joint Surg Am* 1990;72:1043.
257. Quinn RH, Renshaw TS, DeLuca PA. Preliminary traction in the treatment of developmental dislocation of the hip. *J Pediatr Orthop* 1994;14:636.
258. Joseph K, MacEwen GD, Boos ML. Home traction in the management of congenital dislocation of the hip. *Clin Orthop* 1982;165:83.
259. Mubarak SJ, Beck LR, Sutherland D. Home traction in the management of congenital dislocation of the hips. *J Pediatr Orthop* 1986;6:721.
260. Voutsinas SA, MacEwen GD, Boos ML. Home traction in the management of congenital dislocation of the hip. *Arch Orthop Trauma Surg* 1984;102:135.
261. Drummond DS, O'Donnell J, Breed A, et al. Arthrography in the evaluation of congenital dislocation of the hip. *Clin Orthop* 1989;243:148.
262. Gabuzda GM, Renshaw TS. Reduction of congenital dislocation of the hip. *J Bone Joint Surg Am* 1992;74:624.
263. Herring JA. Inadequate reduction of congenital dislocation of the hip [letter]. *J Bone Joint Surg Am* 1982;64:153.
264. McNally ET, Tasker A, Benson MK. MRI after operative reduc-

- tion for developmental dysplasia of the hip. *J Bone Joint Surg Br* 1997;79:724.
265. Smith BG, Kasser JR, Hey LA, et al. Post reduction computed tomography in developmental dislocation of the hip. Part I. Analysis of measurement reliability. *J Pediatr Orthop* 1997;7:626.
 266. Ando M, Gotoh E, Matsuura J. Tangential view arthrogram at closed reduction in congenital dislocation of the hip. *J Pediatr Orthop* 1992;12:390.
 267. Forlin E, Choi IH, Guille JT, et al. Prognostic factors in congenital dislocation of the hip treated with closed reduction: the importance of arthrographic evaluation. *J Bone Joint Surg Am* 1992;74:1140.
 268. Renshaw TS. Inadequate reduction of congenital dislocation of the hip. *J Bone Joint Surg Am* 1981;63:1114.
 269. Fogarty EE, Accardo NY. Incidence of avascular necrosis of the femoral head in congenital hip dislocation related of the degree of abduction during preliminary traction. *J Pediatr Orthop* 1981;1:307.
 270. Salter RB, Kostiuik J, Dallas S. Avascular necrosis of the femoral head as a complication of treatment for congenital dislocation of the hip in young children: a clinical and experimental investigation. *Can J Surg* 1969;12:44.
 271. Hernandez RJ. Concentric reduction of the dislocated hip: computed-tomographic evaluation. *Radiology* 1984;150:266.
 272. Schoenecker PL, Lesker PA, Ogata K. A dynamic canine model of experimental hip dysplasia: gross and histological pathology, and the effect of position of immobilization on capital femoral epiphyseal blood flow. *J Bone Joint Surg Am* 1984;66:1281.
 273. Salter RB, Field P. The effects of continuous compression on living articular cartilage. *J Bone Joint Surg Am* 1960;42:31.
 274. Luhmann SS, Schoenecker PL, Anderson AM, et al. The prognostic importance of the ossific nucleus in the treatment of congenital dysplasia of the hip. *J Bone Joint Surg Am* 1998;80:1719.
 275. Akazawa H, Tanabe G, Miyake Y. A new open reduction treatment for congenital hip dislocation: long-term follow-up of the extensive anterolateral approach. *Acta Med Okayama* 1990;44:223.
 276. Dhar S, Taylor JF, Jones WA, et al. Early open reduction for congenital dislocation of the hip. *J Bone Joint Surg Br* 1990;72:175.
 277. Mankey MG, Arntz CT, Staheli LT. Open reduction through a medial approach for congenital dislocation of the hip: a critical review of the Ludloff approach in sixty-six hips. *J Bone Joint Surg Am* 1993;75:1334.
 278. McCluskey WP, Bassett GS, Mora-Garcia G, et al. Treatment of failed open reduction for congenital dislocation of the hip. *J Pediatr Orthop* 1989;9:633.
 279. Salter RB. Role of innominate osteotomy in the treatment of congenital dislocation and subluxation of the hip in the older child. *J Bone Joint Surg Am* 1966;48:1413.
 280. Salter RB, Dubos J-P. The first fifteen years' personal experience with innominate osteotomy in the treatment of congenital dislocation and subluxation of the hip. *Clin Orthop* 1974;98:72.
 281. Salter RB, Hansson G, Thompson GA. Innominate osteotomy in the management of residual congenital subluxation of the hip in young adults. *Clin Orthop* 1984;182:53.
 282. Katz K, Yosipovitch Z. Medial approach open reduction without preliminary traction for congenital dislocation of the hip. *J Pediatr Orthop B* 1994;3:82.
 283. Mergen E, Adyaman S, Omeroglu H, et al. Medial approach open reduction for congenital dislocation of the hip using the Ferguson procedure: a review of 31 hips. *Arch Orthop Trauma Surg* 1991;110:169.
 284. Monticelli G, Milella PP. Indications for treatment of congenital dislocation of the hip by the surgical medial approach. In: Tachdjian MO, ed. *Congenital dislocation of the hip*. New York: Churchill Livingstone, 1982:385.
 285. O'Hara JN, Bernard AA, Dwyer NS. Early results of medial approach open reduction in congenital dislocation of the hip: use before walking age. *J Pediatr Orthop* 1988;8:288.
 286. Roose PE, Chingren GL, Klaaren HE, et al. Open reduction for congenital dislocation of the hip using the Ferguson procedure: a review of twenty-six cases. *J Bone Joint Surg Am* 1979;61:915.
 287. Vedantam RC, Capelli AM, Schoenecker PL. Pemberton osteotomy for the treatment of developmental dysplasia of the hip in older children. *J Pediatr Orthop* 1998;18:254.
 288. Castillo R, Sherman FC. Medial adductor open reduction for congenital dislocation of the hip. *J Pediatr Orthop* 1990;10:335.
 289. Cech O, Sosna A, Vavra J. Indications and surgical technique for open reposition of congenital dislocation of the hip after Ludloff [author's translation]. *Acta Chir Orthop Traumatol Cech* 1976;43:233.
 290. Fabry G. Open reduction by the Ludloff approach to congenital dislocation of the hip under the age of two. *Acta Orthop Belg* 1990;56:233.
 291. Scapinelli R, Ortolani M Jr. Open reduction (Ludloff approach) of congenital dislocation of the hip before the age of two years. *Isr J Med Sci* 1980;16:276.
 292. Sosna A, Rejholec M, Rybka V, et al. Long-term results of Ludloff's repositioning method. *Acta Chir Orthop Traumatol Cech* 1990;57:213.
 293. Fisher EHI, Beck PA, Hoffer MM. Necrosis of the capital femoral epiphysis and medial approaches to the hip in piglets. *J Orthop Res* 1991;9:203.
 294. Simons GW. A comparative evaluation of the current methods for open reduction of the congenitally displaced hip. *Orthop Clin North Am* 1980;11:161.
 295. Morcuende JM, Dolan LA, Weinstein SL, et al. Long term outcome after open reduction through an anteromedial approach for congenital dislocation of the hip. *J Bone Joint Surg Am* 1997;79:810.
 296. Cherney DL, Westin GW. Acetabular development in the infant's dislocated hips. *Clin Orthop* 1989;242:98.
 297. Noritake K, Yoshihashi Y, Hattori TTM. Acetabular development after closed reduction of congenital dislocation of the hip. *J Bone Joint Surg Br* 1993;75:737.
 298. Akagi ST, Tanabe T, Ogawa R. Acetabular development after open reduction for developmental dislocation of the hip: 15 year follow up of 22 hips without additional surgery. *Acta Orthop Scand* 1998;69:17.
 299. Brougham DI, Broughton NS, Cole WG, et al. The predictability of acetabular development after closed reduction for congenital dislocation of the hip. *J Bone Joint Surg Br* 1988;70:733.
 300. Molina-Guerrero JA, Munuera-Martinez L, Esteban-Mugica B. Acetabular development in congenital dislocation on the hip. *Acta Orthop Belg* 1990;56:293.
 301. Gallien R, Bertin D, Lirette R. Salter procedure in congenital dislocation of the hip. *J Pediatr Orthop* 1984;4:427.
 302. Haidar RK, Jones RS, Vergroessen DA, et al. Simultaneous open reduction and Salter innominate osteotomy for developmental dysplasia of the hip. *J Bone Joint Surg Br* 1996;78:471.
 303. Klisic P, Jankovic L. Combined procedure of open reduction and shortening of the femur in treatment of congenital dislocation of the hips in older children. *Clin Orthop* 1976;119:60.
 304. Schoenecker PL, Strecker WB. Congenital dislocation of the hip in children: comparison of the effects of femoral shortening and of skeletal traction in treatment. *J Bone Joint Surg Am* 1984;66:21.
 305. Daoud A, Saighi-Bououina A. Congenital dislocation of the hip

- in the older child: the effectiveness of overhead traction. *J Bone Joint Surg Am* 1996;78:30.
306. Fixen J, Li P. The treatment of subluxation of the hip in children over the age of four years. *J Bone Joint Surg Br* 1996;80:757.
 307. Ryan MJ, Johnson LO, Quanbeck DS, et al. One stage treatment of congenital dislocation of the hip in children three to ten years old: functional and radiographic results. *J Bone Joint Surg Am* 1998;80:336.
 308. Galpin RD, Roach JW, Wenger DR, et al. One-stage treatment of congenital dislocation of the hip in older children, including femoral shortening. *J Bone Joint Surg Am* 1989;71:734.
 309. Heinrich SD, Missinne LH, MacEwen GD. The conservative management of congenital dislocation of the hip after walking age. *Clin Orthop* 1992;281:34.
 310. Klisic PJ. Congenital dislocation of the hip: a misleading term [Brief Report]. *J Bone Joint Surg Br* 1989;71:136.
 311. Waters P, Kurica K, Hall J, et al. Salter innominate osteotomies in congenital dislocation of the hip. *J Pediatr Orthop* 1988;8:650.
 312. Coleman SS. The pericapsular (Pemberton) pelvic osteotomy and the redirection (Salter) pelvic osteotomy. *Mapfre Med* 1992;3(suppl 1):124.
 313. Coleman S. Prevention of developmental dislocation of the hip: practices and problems in the United States. *J Pediatr Orthop B* 1993;2:127.
 314. Faciszewski T, Kiefer GN, Coleman SS. Pemberton osteotomy for residual acetabular dysplasia in children who have congenital dislocation of the hip. *J Bone Joint Surg Am* 1993;75:643.
 315. Coleman S. The subluxating or wandering femoral head in developmental dislocation of the hip. *J Pediatr Orthop* 1995;15:785.
 316. Ward WV, Vogt M, Grudziak J, et al. Severin classification system for evaluation of the results of operative treatment of congenital dislocation of the hip: a study of intraobserver and interobserver reliability. *J Bone Joint Surg Am* 1997;79:656.
 317. Browne RS. The management of late diagnosed congenital dislocation and subluxation of the hip: with special reference to femoral shortening. *J Bone Joint Surg Br* 1979;61:7.
 318. Wenger DR. Congenital hip dislocation: techniques for primary open reduction including femoral shortening. *Instr Course Lect* 1989;38:343.
- ### Sequelae and Complications
319. Barrett WP, Staheli LT, Chew DE. The effectiveness of the Salter innominate osteotomy in the treatment of congenital dislocation of the hip. *J Bone Joint Surg Am* 1986;68:79.
 320. Lloyd-Roberts GC, Harris NH, Chrispin AR. Anteversion of the acetabulum in congenital dislocation of the hip: a preliminary report. *Orthop Clin North Am* 1978;9:89.
 321. Murphy SB, Kijewski PK, Millis MB, et al. Acetabular dysplasia in the adolescent and young adult. *Clin Orthop* 1990;261:214.
 322. Wientroub S, Boyde A, Chrispin AR, et al. The use of stereophotogrammetry to measure acetabular and femoral anteversion. *J Bone Joint Surg Br* 1981;63:209.
 323. Ruwi PA, Gage JR, Ozonoff MB, et al. Clinical determination of femoral anteversion. *J Bone Joint Surg Am* 1992;74:820.
 324. Millis MB, Murphy SB. Use of computed tomographic reconstruction in planning osteotomies of the hip. *Clin Orthop* 1992;274:154.
 325. Kim HW, Wenger DR. The morphology of residual acetabular deficiency in childhood hip dysplasia: a three dimensional computed tomographic analysis. *J Pediatr Orthop* 1997;17:637.
 326. Kasser JR, Bowen JR, MacEwen GD. Varus derotation osteotomy in the treatment of persistent dysplasia in congenital dislocation of the hip. *J Bone Joint Surg Am* 1985;67:195.
 327. Monticelli G. Intertrochanteric femoral osteotomy with concentric reduction of the femoral head in treatment of residual congenital acetabular dysplasia. *Clin Orthop* 1976;119:48.
 328. Niehard FU, Carstens C. Results of intertrochanteric osteotomy in infant and adolescent hip dysplasia. *J Pediatr Orthop B* 1994;3:9.
 329. Williamson DM, Glover SD, Benson MK. Congenital dislocation of the hip presenting after the age of three years: a long-term review. *J Bone Joint Surg Br* 1989;71:745.
 330. Doudoulakis JK, Cavadias A. Open reduction of CDH before one year of age: 69 hips followed for 13 (10–19) years. *Acta Orthop Scand* 1993;64:188.
 331. Blockey NJ. Derotation osteotomy in the management of congenital dislocation of the hip. *J Bone Joint Surg Br* 1984;66:485.
 332. Chuinard EG. Femoral osteotomy in the treatment of congenital dysplasia of the hip. *Orthop Clin North Am* 1972;3:157.
 333. Conforty B. Femoral osteotomy for correction of sequelae of conservative treatment of congenital dislocation of the hip. *Isr J Med Sci* 1980;16:284.
 334. Lloyd-Roberts GC. The role of femoral osteotomy in the treatment of congenital dislocation of the hip. In: Tachdjian MO, ed. *Congenital dislocation of the hip*. New York: Churchill Livingstone, 1982:427.
 335. Rejholec M, Stryhal F. Behavior of the proximal femur during the treatment of congenital dysplasia of the hip: a clinical long-term study. *J Pediatr Orthop* 1991;11:506.
 336. Swenningsen S, Apalset K, Terjesen T. Osteotomy for femoral anteversion: complications in 95 children. *Acta Orthop Scand* 1989;60:401.
 337. Sangavi SS, Szoke G, Murray G, et al. Femoral remodeling after subtrochanteric osteotomy for developmental dysplasia of the hip. *J Bone Joint Surg Br* 1996;78:917.
 338. Karadimas JE, Holloway GM, Waugh W. Growth of the proximal femur after varus-derotation osteotomy in the treatment of congenital dislocation of the hip. *Clin Orthop* 1982;162:61.
 339. Pellicci PM, Hu S, Garvin KL, et al. Varus rotational femoral osteotomies in adults with hip dysplasia. *Clin Orthop* 1991;272:162.
 340. Perlau RW, Wilson MG, Poss R. Isolated proximal femoral osteotomy for treatment of residual of congenital dysplasia or idiopathic osteoarthritis of the hip. *J Bone Joint Surg Am* 1996;78:1462.
 341. Robertson DE, Essinger JR, Imura S, et al. Femoral deformity in adults with developmental hip dysplasia. *Clin Orthop* 1996;327:196.
 342. Marafioti RL, Westin GW. Factors influencing the results of acetabuloplasty in children. *J Bone Joint Surg Am* 1980;62:765.
 343. Kalamchi A. Modified Salter osteotomy. *J Bone Joint Surg Am* 1982;64:183.
 344. Millis MB, Hall JE. Transiliac lengthening of the lower extremity: a modified innominate osteotomy for the treatment of postural imbalance. *J Bone Joint Surg Am* 1979;61:1182.
 345. McCarthy JJ, Fox JS, Gurd AR. Innominate osteotomy in adolescents and adults who have acetabular dysplasia. *J Bone Joint Surg Am* 1996;78:1455.
 346. Sutherland DH, Moore M. Clinical and radiographic outcome of patients treated with double innominate osteotomy for congenital hip dysplasia. *J Pediatr Orthop* 1991;11:143.
 347. Tonniss D. A new technique of triple osteotomy for acetabular dysplasia in older children and adults. In: *Abstracts of the 14th world congress of the Society of International Chirurgiae Orthopaedicae et Traumatologiae*, Kyoto, 1978.
 348. Tonniss D, Behrens K, Tscharni F. A modified technique of the triple pelvic osteotomy: early results. *J Pediatr Orthop* 1981;1:241.

349. Tonnis D. Triple osteotomy close to the hip joint. In: Tachdjian MO, ed. *Congenital dislocation of the hip*. New York: Churchill Livingstone, 1982:555.
350. Tonnis D, Kasperczyk WJ. Acetabuloplasty and acetabular rotation. In: Freeman M, Reynolds D, eds. *Osteoarthritis in the young adult hip*. Edinburgh: Churchill Livingstone, 1988.
351. Tonnis D. Surgical treatment of congenital dislocation of the hip. *Clin Orthop* 1990;258:33.
352. Tonnis D, Arning A, Bloch M, et al. Triple pelvic osteotomy. *J Pediatr Orthop* 1994;3:54.
353. Faciszewski T, Coleman S. Triple innominate osteotomy in the treatment of acetabular dysplasia. *J Pediatr Orthop* 1993;13:426.
354. Guille JT, Forlin E, Kumar SJ, et al. Triple osteotomy of the innominate bone in treatment of developmental dysplasia of the hip. *J Pediatr Orthop* 1992;12:718.
355. Kumar SJ, MacEwen GD, Jaykumar AS. Triple osteotomy of the innominate bone for the treatment of congenital hip dysplasia. *J Pediatr Orthop* 1986;6:393.
356. Steel HH. Triple osteotomy of the innominate bone. *J Bone Joint Surg Am* 1973;55:343.
357. Steel HH. Triple osteotomy of the innominate bone. *Clin Orthop* 1977;122:116.
358. Hsin JS, Saluja R, Eilert RE, et al. Evaluation of the biomechanics of the hip following triple osteotomy of the innominate bone. *J Bone Joint Surg Am* 1996;78:855.
359. Ganz R, Vinh TS, Mast JW. A new periacetabular osteotomy for the treatment of hip dysplasias: technique and preliminary results. *Clin Orthop Relat Res* 1988;232:26.
360. Klaue K, Sherman M, Perren SM, et al. Extra-articular augmentation for residual hip dysplasia. *J Bone Joint Surg Br* 1993;75:750.
361. Wagner H. *The hip: proceedings of the fourth open scientific meeting of the Hip Society*. St. Louis: Mosby, 1976.
362. Wagner H. Spherical acetabular osteotomy: long-term results. In: *Fourth Harvard Medical School course on osteotomy of the hip and knee*. Boston: Harvard University Press, 1992.
363. Millis MB, Kaelin AJ, Schluntz K, et al. Spherical acetabular osteotomy for treatment of acetabular dysplasia in adolescents and young adults. *J Pediatr Orthop B* 1994;3:47.
364. Eppright RH. Dial osteotomy of the acetabulum in the treatment of dysplasia of the hip. *J Bone Joint Surg Am* 1976;58:726.
365. Nakamura T, Yamaura M, Nakamitsu S, et al. The displacement of the femoral head by rotational acetabular osteotomy: a radiographic study of 97 subluxated hips. *Acta Orthop Scand* 1992;63:33.
366. Ninomiya S, Tagawa H. Rotational acetabular osteotomy for the dysplastic hip. *Clin Orthop* 1984;247:127.
367. Ninomiya S. Rotational acetabular osteotomy for the severely dysplastic hip in the adolescent and adult. *Clin Orthop* 1989;247:127.
368. Marsui MM, Masuhara K, Nishii T, et al. Early deterioration after modified rotational acetabular osteotomy for the dysplastic hip. *J Bone Joint Surg Br* 1997;79:220.
369. Eyre-Brook AL, Jones DA, Harris FC. Pemberton's acetabuloplasty for congenital dislocation or subluxation of the hip. *J Bone Joint Surg Br* 1978;60:18.
370. Labaziewicz L, Grudziak JS, Kruczynski J, et al. Combined one stage open reduction femoral osteotomy and Dega pelvic osteotomy for DDH. Presented at the American Academy of Orthopaedic Surgeons annual meeting, San Francisco, CA, 1993.
371. Lloyd-Roberts GC, Wetherill MH, Fraser M. Trochanteric advancement for premature arrest of the femoral capital growth plate. *J Bone Joint Surg Br* 1985;67:21.
372. Synder M, Zwierzchowski H. One-stage hip reconstruction with Dega's transiliacal osteotomy in the treatment of congenital hip dislocation in children. *Beitr Orthop Traumatol* 1990;37:571.
373. Reichel H, Hoin W. Dega acetabuloplasty combined with intertrochanteric osteotomies. *Clin Orthop* 1996;323:234.
374. Albee FH. The bone graft wedge. *NY Med J* 1915;52:433.
375. Hiranuma S, Higuchi F, Inoue A, et al. Changes in the interposed capsule after Chiari osteotomy: an experimental study on rabbits with acetabular dysplasia. *J Bone Joint Surg Br* 1992;74:463.
376. Hamanishi C, Tanaka S, Yamamuro T. The Spitzzy shelf operation for the dysplastic hip: retrospective 10 (5–25) year study of 124 cases. *Acta Orthop Scand* 1992;63:273.
377. Le-Saout J, Kerboul B, Lefevre C, et al. Results of 56 acetabular shelf operations: with a long follow-up. *Acta Orthop Belg* 1985;51:955.
378. Love BR, Stevens PM, Williams PF. A long-term review of shelf arthroplasty. *J Bone Joint Surg Br* 1980;62:321.
379. White RE Jr, Sherman FC. The hip-shelf procedure: a long-term evaluation. *J Bone Joint Surg Am* 1980;62:928.
380. Wiberg G. Shelf operation in congenital dysplasia of the acetabulum and in subluxation and dislocation of the hip. *J Bone Joint Surg Am* 1953;35:65.
381. Staheli LT. Surgical management of acetabular dysplasia. *Clin Orthop Relat Res* 1991;264:111.
382. Staheli LT, Chew DE. Slotted acetabular augmentation in childhood and adolescence. *J Pediatr Orthop* 1992;12:569.
383. Bailey TE Jr, Hall JE. Chiari medial displacement osteotomy. *J Pediatr Orthop* 1985;5:635.
384. Chiari K. Medial displacement osteotomy of the pelvis. *Clin Orthop* 1974;98:55.
385. Colton CL. Chiari osteotomy for acetabular dysplasia in young subjects. *J Bone Joint Surg Br* 1972;54:578.
386. Windhager R, Pongracz N, Schoenecker W, et al. Chiari osteotomy for congenital dislocation and subluxation of the hip: results after 20 to 34 years follow-up. *J Bone Joint Surg Br* 1991;73:890.
387. Winkler W, Weber A. Osteotomy of the pelvis (Chiari) [author's translation]. *Z Orthop* 1977;115:167.
388. Mellerowicz HM, Matussek J, Baum C. Long term results of Salter and Chiari hip osteotomies in developmental hip dysplasia: a survey of over 10 years follow up with a new hip evaluation score. *Arch Orthop Trauma Surg* 1998;117:222.
389. Albinana J, Weinstein SL, Morcuende JA, et al. DDH acetabular remodeling after open or closed reduction: timing for secondary procedures. 1996 *Ortho Trans* 1996;20:298.
390. Atar D, Lehman WB, Grant AD. 2-D and 3-D computed tomography and magnetic resonance imaging in developmental dysplasia of the hip. *Orthop Rev* 1992;21:1189.
391. Azuma H, Taneda H, Igarashi H. Evaluation of acetabular coverage: three-dimensional CT imaging and modified pelvic inlet view. *J Pediatr Orthop* 1991;11:765.
392. Lang P, Genant H, Steiger P, et al. Three-dimensional digital displays in congenital dislocation of the hip: preliminary experience. *J Pediatr Orthop* 1989;9:532.
393. Lafferty CM, Sartoris DJ, Tyson R, et al. Acetabular alterations in untreated congenital dysplasia of the hip: computed tomography with multiplanar re-formation and three-dimensional analysis. *J Comput Assisted Tomogr* 1986;10:84.
394. Mendes DG. The role of computerized tomography scan in preoperative evaluation of the adult dislocated hip. *Clin Orthop* 1981;161:198.
395. O'Sullivan GS, Goodman SB, Jones HH. Computerized tomographic evaluation of acetabular anatomy. *Clin Orthop Relat Res* 1992;277:175.
396. Konishi N, Nagoya MD, Mieno T. Determination of acetabular coverage of the femoral head with use of a single anteroposterior

- radiograph: a new computerized technique. *J Bone Joint Surg Am* 1993;75:1318.
397. Rab GT. Preoperative roentgenographic evaluation for osteotomies about the hip in children. *J Bone Joint Surg Am* 1981;63:306.
 398. Hansson LI, Olsson TH, Selvik G, et al. A roentgen stereophotogrammetric investigation of innominate osteotomy (Salter). *Acta Orthop Scand* 1978;49:68.
 399. Gangloff S, Onimus M. Chiari pelvic osteotomy: technique and indications. *J Pediatr Orthop* 1994;3:68.
 400. Moll FK Jr. Capsular change following Chiari innominate osteotomy. *J Pediatr Orthop* 1982;2:573.
 401. Nishiyama K, Sakamaki T, Okinaga A. Complications of Pemberton's pericapsular osteotomy: a report of two cases. *Clin Orthop Relat Res* 1990;254:205.
 402. Betz RR, Kumar SJ, Palmer CT, et al. Chiari pelvic osteotomy in children and young adults. *J Bone Joint Surg Am* 1988;70:182.
 403. Calvert PT, August AC, Albert JS, et al. The Chiari pelvic osteotomy: a review of the long-term results. *J Bone Joint Surg Br* 1987;69:551.
 404. Dewaal Malefijt MC, Hodgland T, Nielsen HKL. Chiari osteotomy in the treatment of the congenital dislocation and subluxation of the hip. *J Bone Joint Surg Am* 1982;64:996.
 405. Graham S, Westin GW, Dawson E, et al. The Chiari osteotomy: a review of 58 cases. *Clin Orthop* 1986;208:249.
 406. Hogg J, MacNicol MF. The Chiari pelvic osteotomy: a long term review of clinical and radiographic results. *J Bone Joint Surg Br* 1987;69:365.
 407. Lack W, Windhager R, Kutschera H, et al. Chiari pelvic osteotomy for osteoarthritis secondary to hip dysplasia. *J Bone Joint Surg Br* 1991;73:229.
 408. Mitchell GP. Chiari medial displacement osteotomy. *Clin Orthop* 1974;98:146.
 409. Rejcholec M, Stryhal F, Rybka V, et al. Chiari osteotomy of the pelvis: a long-term study. *J Pediatr Orthop* 1990;10:21.
 410. Reynolds DA. Chiari innominate osteotomy in adults: technique, indications and contraindications. *J Bone Joint Surg Br* 1986;68:45.
 411. Rush J. Chiari osteotomy in the adult: a long-term follow-up study. *Aust NZ J Surg* 1991;61:761.
 412. Zlati M, Radojevi B, Lazovi D, et al. Late results of Chiari's pelvic osteotomy: a follow-up of 171 adult hips. *Int Orthop* 1988;12:149.
 413. Brougham DI, Broughton NS, Cole WG, et al. Avascular necrosis following closed reduction of congenital dislocation of the hip: review of influencing factors and long-term follow-up. *J Bone Joint Surg Br* 1990;72:557.
 414. Bucholz R, Ogden J. Patterns of ischemic necrosis of the proximal femur in nonoperatively treated congenital hip disease. In: *The hip: proceedings of the sixth open scientific meeting of the Hip Society*. St. Louis: Mosby, 1978:43.
 415. Campbell P, Tarlow SD. Lateral tethering of the proximal femoral physis complicating the treatment of congenital hip dysplasia. *J Pediatr Orthop* 1990;10:6.
 416. Cooperman DR, Wallensten R, Stulberg SD. Post-reduction avascular necrosis in congenital dislocation of the hip. *J Bone Joint Surg Am* 1980;62:247.
 417. Gotoh E, Ando M. The pathogenesis of femoral head deformity in congenital dislocation of the hip: experimental study of the effects of articular interpositions in pigs. *Clin Orthop* 1993;288:303.
 418. Gregosiewicz A, Wosko I. Risk factors of avascular necrosis in the treatment of congenital dislocation of the hip. *J Pediatr Orthop* 1988;8:17.
 419. Kalamchi A, MacEwen GD. Avascular necrosis following treatment of congenital dislocation of the hip. *J Bone Joint Surg Am* 1980;62:876.
 420. Keret D, MacEwen GD. Growth disturbance of the proximal part of the femur after treatment for congenital dislocation of the hip. *J Bone Joint Surg Am* 1991;73:410.
 421. Law EG, Heistad DD, Marcus ML, et al. Effect of hip position on blood flow to the femur in puppies. *J Pediatr Orthop* 1982;2:133.
 422. Nicholson JT, Kopell HP, Mattei FA. Regional stress angiography of the hip: a preliminary report. *J Bone Joint Surg Am* 1954;36:503.
 423. Ogden JA, Southwick WO. A possible cause of avascular necrosis complicating the treatment of congenital dislocation of the hip. *J Bone Joint Surg Am* 1973;55:1770.
 424. Ogden JA. Anatomic and histologic study of factors affecting development and evolution of avascular necrosis in congenital hip dislocation. In: *The hip: proceedings of the second annual meeting of the Hip Society*. St. Louis: Mosby, 1974:125.
 425. Ogden JA. Changing patterns of proximal femoral vascularity. *J Bone Joint Surg Am* 1974;56:941.
 426. Ogden JA. Normal and abnormal circulation. In: Tachdjian MO, ed. *Congenital dislocation of the hip*. New York: Churchill Livingstone, 1982:59.
 427. Schoenecker PL, Bitz DM, Whiteside LA. The acute effect of position of immobilization on capital femoral epiphyseal blood flow: a quantitative study using the hydrogen washout technique. *J Bone Joint Surg Am* 1978;60:899.
 428. Trueta RJ, ed. *Studies of the development and decay of the human frame*. Philadelphia: WB Saunders, 1988.
 429. Herold HZ. Avascular necrosis of the femoral head in children under the age of three. *Clin Orthop* 1977;126:193.
 430. Herold HZ. Unilateral congenital hip dislocation with contralateral avascular necrosis. *Clin Orthop* 1980;148:196.
 431. Crego CH Jr, Schwartzmann JR. Medial adductor open reduction for congenital dislocation of the hip. *J Bone Joint Surg Am* 1948;30:428.
 432. Kalamchi A, Schmidt TL, MacEwen GD. Congenital dislocation of the hip: open reduction by the medial approach. *Clin Orthop* 1982;169:127.
 433. Pous JG, Camous JY, el-Blidi S. Cause and prevention of osteochondritis in congenital dislocation of the hip. *Clin Orthop* 1992;281:56.
 434. Thomas IH, Dunin AJ, Cole WG, et al. Avascular necrosis after open reduction for congenital dislocation of the hip: analysis of causative factors and natural history. *J Pediatr Orthop* 1989;9:525.
 435. Kruczynski J. Avascular necrosis after non operative treatment of developmental hip dislocation: prognosis in 36 patients followed 17-26 years. *Acta Orthop Scand* 1995;66:239.
 436. Kruczynski J. Avascular necrosis of the proximal femur in developmental dislocation of the hip: incidence, risk factors, sequelae, and MR imaging for diagnosis and prognosis. *Acta Orthop Scand Suppl* 1996;268:1.
 437. Westin GW, Ilfeld FW, Provost J. Total avascular necrosis of the capital femoral epiphysis in congenital dislocated hips. *Clin Orthop* 1976;119:93.
 438. Race C, Herring JA. Congenital dislocation of the hip: an evaluation of closed reduction. *J Pediatr Orthop* 1983;3:166.
 439. Massie WK. Vascular epiphyseal changes in congenital dislocation of the hip: results in adults compared with results in coxa plana and in congenital dislocation without vascular changes. *J Bone Joint Surg Am* 1951;33:284.
 440. Powell EN, Gerratana FJ, Gage JR. Open reduction for congenital hip dislocation: the risk of avascular necrosis with three different approaches. *J Bone Joint Surg Am* 1986;58:1000.
 441. Scaglietti O, Calandriello B. Open reduction of congenital dislocation of the hip. *J Bone Joint Surg Br* 1962;44:257.
 442. Esteve R. Congenital dislocation of the hip: a review and assessment of results of treatment with special reference to frame

- reduction as compared with manipulative reduction. *J Bone Joint Surg Br* 1960;42:253.
443. MacKenzie IG, Seddon HJ, Trevor D. Congenital dislocation of the hip. *J Bone Joint Surg Br* 1960;42:689.
 444. Ponseti IV, Frigerio ER. Results of treatment of congenital dislocation of the hip. *J Bone Joint Surg Am* 1959;41:823.
 445. Tonnis D. An evaluation of conservative and operative methods in the treatment of congenital hip dislocation. *Clin Orthop* 1976;119:76.
 446. Gamble JG, Mochizuki C, Bleck EE, et al. Coxa magna following surgical treatment of congenital hip dislocation. *J Pediatr Orthop* 1985;5:528.
 447. O'Brien T, Salter RB. Femoral head size in congenital dislocation of the hip. *J Pediatr Orthop* 1985;5:299.
 448. Imatani JM, Miyake Y, Nakatsuka Y, et al. Coxa magna after open reduction for developmental dislocation of the hip. *J Pediatr Orthop* 1995;15:337.
 449. O'Brien T. Growth-disturbance lines in congenital dislocation of the hip. *J Bone Joint Surg Am* 1985;67:626.
 450. O'Brien T, Millis MB, Griffin PP. The early identification and classification of growth disturbances of the proximal end of the femur. *J Bone Joint Surg Am* 1986;68:970.
 451. Bar-On EH, Huo MH, DeLuca PA. Early innominate osteotomy as a treatment for avascular necrosis complicating developmental hip dysplasia. *J Pediatr Orthop B* 1997;6:138.
 452. Givon U, Schindler A, Ganel A, et al. Distal transfer of the greater trochanter revisited: long term follow up of nine hips. *J Pediatr Orthop* 1995;15:346.
 453. Andrisano A, Marchiodi L, Preitano M. Epiphysiodesis of the great trochanter. *Ital J Orthop Traumatol* 1986;12:217.
 454. Langenskjold A, Salenius P. Epiphysiodesis of the greater trochanter. *Acta Orthop Scand* 1967;38:199.
 455. Bialik V, Rosenberg N. Transfer of greater trochanter. *J Pediatr Orthop B* 1994;3:30.
 456. Fernbach SK, Poznanski AKK, Kelikian AS, et al. Greater trochanteric overgrowth: development and surgical correction. *Radiology* 1954;3:661.
 457. MacNicol MF, Makris D. Distal transfer of the greater trochanter. *J Bone Joint Surg Br* 1991;73:838.
 458. Harris WH, Bourne RB, Oh I. Intra-articular acetabular labrum: a possible etiological factor in certain cases of osteoarthritis of the hip. *J Bone Joint Surg Am* 1979;61:510.
 459. Nishina T, Saito S, Ohzono K, et al. Chiari pelvic osteotomy for osteoarthritis: the influence of the torn and detached acetabular labrum. *J Bone Joint Surg Br* 1990;72:765.



LEGG-CALVÉ-PERTHES SYNDROME

STUART L. WEINSTEIN

EARLY HISTORY 957

EPIDEMIOLOGY AND ETIOLOGY 958

PATHOGENESIS 962

Radiographic Stages 965
Pathogenesis of Deformity 967
Patterns of Deformity 968

NATURAL HISTORY 972

Long-term Follow-up Results 972
Prognostic Factors 973

CLINICAL PRESENTATION 979

PHYSICAL EXAMINATION 979

IMAGING 979

DIFFERENTIAL DIAGNOSIS 983

TREATMENT 983

Patient Management 984
Nonoperative Treatment 985
Surgical Treatment 986
Treatment Options in the Noncontainable Hip and the
Late-presenting Patient with Deformity 988

FUTURE DEVELOPMENTS 991

EARLY HISTORY

Legg-Calvé-Perthes syndrome is a disorder of the hip in young children. The condition was described independently in 1910 by Legg (1), Calvé (2), Perthes (3), and Waldenström (4,5). In the late 19th century, however, Hugh Owen Thomas (6), Baker (7), and Wright (8) described patients with supposed hip joint infections that resolved without surgery, whose histories were consistent with Legg-Calvé-Perthes syndrome. Maydl (9), in 1897, reported this condition and thought it was a related condition of congenitally dislocated hip (10).

In 1909, Arthur Legg presented a paper on five children

with a limp after injury. This paper was published in 1910. He called this condition an "obscure affection of the hip," and postulated that pressure secondary to injury caused flattening of the femoral head (1). In that same year, Calvé reported 10 cases of a noninflammatory self-limiting condition that healed with flattening of the weight-bearing surface. He postulated that the cause of this condition was an abnormal or delayed osteogenesis. He reported coxa vara and increased femoral head size in these patients, and on physical examination, all of the patients had decreased abduction (2). Perthes simultaneously reported six cases of what he termed "arthritis deformans juveniles." He postulated that this was an inflammatory condition (3). In his description of the condition, Waldenström postulated that the disease was a form of tuberculosis (4,5).

Perthes was the first investigator to describe the pathologic and histologic features of the disorder (11). He reported on a 9-year-old boy with symptoms for 2 years. Ex-

amination of the portion of the excised head revealed numerous cartilage islands throughout and “strings” connecting the joint cartilage and the physal plate. Perthes noted the marrow spaces to be widened, with fatty infiltration; he saw no evidence of inflammation. He believed that the cartilage islands were new, and that this was an osteochondritis, not a tubercular process (11). Schwartz (12), an associate of Perthes, described the pathologic changes in a 7-year-old boy with a 2-year history of symptoms and reported similar findings. Waldenstrom (13) suggested the use of the term *coxa plana* to make the description of the disease consistent with that of other hip deformities, such as coxa vara and coxa valga. Sundt (14,15) published the first monograph on Legg-Calvé-Perthes syndrome, reporting on 66 cases and the pathology of the condition. The essential feature in all of his cases was the cartilaginous islands in the epiphysis. Sundt attributed the disease to an “osteodystrophy due to dysendocrinia of a hereditary disposition.” He believed that people so predisposed would get Legg-Perthes disease after they sustained an injury to the hip (i.e., infection or trauma). Sundt was the first person to introduce the modern concept of the “susceptible child.”

Phemister (16), reporting on the curettage findings of a 10-year-old child with an 8-month history of symptoms, described areas of bone necrosis, granulation tissue, old bone with new bone formation, and osteoclasts. He interpreted these findings as an inflammatory and infectious process. In 1922, Riedel (17) reported on two cases and presented the histology. He described the thickening of the articular cartilage and noted that the junction between the bone and the articular cartilage was filled with blood. He also noted that the physal plate was destroyed and that there were many cartilage rests. Dead bone was surrounded by a rich granulation tissue, and many giant cells were present. He also noted that farther away from the main disease process, the marrow was fibrotic with inflammatory infiltrates. Riedel was the first investigator to notice that there were blastic and clastic changes at the same time working on the same bone trabeculae. In his second specimen he found regeneration of the cartilage in the subchondral area, cell atrophy, and some inflammatory cells. That same year, Waldenstrom (18) proposed the first radiographic classification of the disease process, based on 22 patients followed until the completion of growth. Since then, most of the orthopaedic literature has centered on the etiologic, epidemiologic, and prognostic factors in Legg-Calvé-Perthes syndrome and follow-up of various treatment modalities (19).

EPIDEMIOLOGY AND ETIOLOGY

Legg-Calvé-Perthes syndrome occurs most commonly in the age range of 4 to 8 years (20), but cases have been reported in children from 2 years of age to the late teenage years. It is more common in boys than in girls by a ratio

of 4 or 5 to 1 (21). The incidence of bilaterality has been reported as 10 to 12% (20,22). Although the incidence of a positive family history in patients with Legg-Calvé-Perthes syndrome ranges from 1.6 to 20% (10,20,23–29), there is no evidence that Legg-Calvé-Perthes syndrome is an inherited condition (30).

Wynne-Davies and Gormley (20) reported on a series of 310 index patients with Legg-Calvé-Perthes syndrome. They noted that of the children of affected index patients, only 2% had Legg-Calvé-Perthes syndrome. In this series, all twins were discordant, including one monozygotic pair. Eleven percent had abnormal birth presentations, including breech and transverse, compared with the 2 to 4% incidence that would be expected in the general population. There is an increased incidence of Legg-Calvé-Perthes syndrome in later-born children, particularly the third to the sixth child, and a higher percentage in lower socioeconomic groups (31,32). Parental age of affected patients is higher than in the general population (20,29,33).

Legg-Calvé-Perthes syndrome is more common in certain geographic areas, particularly in urban rather than rural communities, giving rise to the suspicion of a nutritional cause, possibly a trace element deficiency (31–38). There is also a recently reported strong association (33% of affected patients) of Legg-Calvé-Perthes disease with the psychological profile associated with attention deficit hyperactivity disorder (39). Malloy and colleagues (40,41) noted that birth weight was lower in affected children. Harrison and colleagues (42) reported that children with Legg-Calvé-Perthes syndrome lagged behind their chronologic age, and 89% of the involved individuals had delayed bone age. Ralston demonstrated that this delay in skeletal maturation averaged 21 months, but that during the healing stages of the disease there would be recovery of height and weight through increased growth velocity (43–45). There may be certain racial factors in that there is an increased frequency of Legg-Calvé-Perthes syndrome in Japanese people, other Asians, Eskimos, and central Europeans, and a decreased frequency in native Australians, Americans Indians, Polynesians, and blacks (10,36,46,47).

There is considerable evidence of anthropometric abnormalities in children with Legg-Calvé-Perthes syndrome. Cameron and Izatt (48) reported that affected boys were 1 inch shorter and affected girls were 3 inches shorter compared with normal nonaffected children. Burwell and colleagues (49–51) and others (31,52,53) demonstrated that affected children are smaller in all dimensions, except for head circumference, and shorter in the distal portions of the extremities as opposed to the proximal portions. Loder et al. (54), in a more recent study, demonstrated that pelvis bone age in boys was less delayed than hand and wrist bone age. The short stature of the patient affected with the disorder at a young age tends to correct during adolescence, whereas patients affected at an older age tend to be small throughout life (29). Eckerwall et al. (55) followed 110

affected children longitudinally and showed that these children were shorter at birth and remained short during the entire growth period, and that growth velocity never changed. Burwell and colleagues (51) demonstrated an abnormality of growth hormone-dependent somatomedin in boys with Legg-Calvé-Perthes syndrome, whereas Tanaka and colleagues (56), Fisher and associates (23), and Kitsugi and colleagues (57) reported contrary results.

Growth hormone regulates postnatal skeletal development. The effects of growth hormone on postnatal skeletal development are mediated, in part, by the somatomedins (insulin-like growth factors) (58). Somatomedin C (IGF1) is the principal somatomedin responsible for postnatal skeletal bone maturation (58). Plasma IGF1 levels have been reported to be significantly reduced in affected children during the first 2 years after the diagnosis of Perthes disease. These alterations were accompanied by a tendency toward growth arrest and impaired weight gain. This is accompanied by an acceleration in growth and weight gain during the healing stages of the disease.

In plasma nearly all IGF1 is bound to specific binding proteins. However, the major binding protein (IGFBP3) levels are normal during the first 2 years after the diagnosis of Perthes disease (59,60). Low levels of circulating IGF1 and failure of IGF1 to increase normally during the prepubertal years in patients with Perthes disease, in conjunction with reportedly normal growth hormone levels, raise the possibility of decreased responsiveness of growth plate chondrocytes and hepatocytes (58). The combination of moderately reduced IGF1 levels with normal IGFBP3 has been reported in normal-variant short stature children. The skeletal maturation delay and retarded bone age reported in patients with Perthes disease, in conjunction with the findings described above, could be considered a retention of the infantile hormone pattern (60).

Malnutrition is one factor that leads to low IGF levels, and this could be related to the reportedly increased incidence of Perthes disease in low-income families. The disproportionate skeletal development affecting the distal portions of the body reflects a tendency toward infantile body proportions. This correlates with the reduced IGF1 levels in the face of normal binding proteins (61). Controversy still exists in that a recent study by another group of investigators reported results opposite to those reported by Neidel et al. (60), with serum levels of IGF1 being normal, and those of IGFBP3 being lower in children with Perthes disease compared with controls (62). Another recent study, while confirming the skeletal maturation delay in children with Perthes disease, demonstrated no difference in IGF1 measured with IGF2-blocked binding sites and IGFBP3 serum concentrations with respect to bone age (63). This group disputed the claims of disturbance of the hypothalamic-pituitary-somatomedin axis in patients with Perthes disease. The reported differences in the various studies, in some cases, may be attributable in part to the methods used to measure IGF1. There is an increased incidence of hernia in

patients with Legg-Calvé-Perthes syndrome and their first-degree relatives. There is also an increased incidence of minor congenital abnormalities in affected patients (24, 64–66).

The cause of Legg-Calvé-Perthes syndrome remains unknown. Many etiologic theories have been proposed. In the early part of the 20th century most investigators thought that it was a disease of an inflammatory or infectious nature (3–5,67–69). Phemister (16,70) believed that the disease was an infectious process, although cultures were negative. Axhausen (67) believed that it was caused by bacillary embolism in which the infection either was not manifested, or was too weak and healed quickly. As late as 1975, Matsoukas (71) demonstrated an association between Legg-Calvé-Perthes syndrome and prenatal rubella.

Until the 1950s, trauma was considered by many investigators to be the cause, or a significant contributing factor, of Perthes disease (1,72–78). As with most childhood orthopaedic conditions, a significant number of patients may relate an episode of trauma to the onset of symptoms.

Many authors, particularly eastern European investigators, thought that Legg-Calvé-Perthes syndrome was of congenital origin, and that there was a relationship between this disease and congenitally dislocated hips (79–85). Glimcher (86) proposed that cytotoxic agents of external or endogenous origin may be responsible for bone cell death. At one time, Perthes disease was believed to be related to hypothyroidism (87–89); this has since been disproved (90,91). Recent reports demonstrate moderately increased plasma concentrations of free thyroxine and free triiodothyronine in Perthes disease patients compared with controls (61). The causative effects on Perthes disease of the aforementioned findings, and the reduced levels of IGF1 reported in the early disease stages, have yet to be determined. These findings do, however, provide additional evidence that growth-related systemic abnormalities exist in patients with Legg-Calvé-Perthes syndrome (61).

Transient synovitis has been thought by many investigators to be a precursor to the condition. Gershuni (92) reported that 25% of children with benign transient synovitis developed Legg-Calvé-Perthes disease, whereas Jacobs (92a) reported three cases of Legg-Calvé-Perthes disease among 25 patients with acute transient synovitis. Although all hips with Perthes disease have synovitis, especially early in the course of the disease, and many have persistent synovitis for years (93–97), a review of the literature reveals that an average of 1 to 3% of patients with a history of transient synovitis later develop Legg-Calvé-Perthes syndrome (98–103). Chuinard (104) and Craig and colleagues (74,75) have proposed that excessive femoral neck anteversion is a causative factor in the development of Legg-Calvé-Perthes syndrome.

Most current etiologic theories involve vascular embarrassment. The blood supply to the proximal femur has been elucidated by many authors. The terminology used in the literature varies. However, there are three main sources of

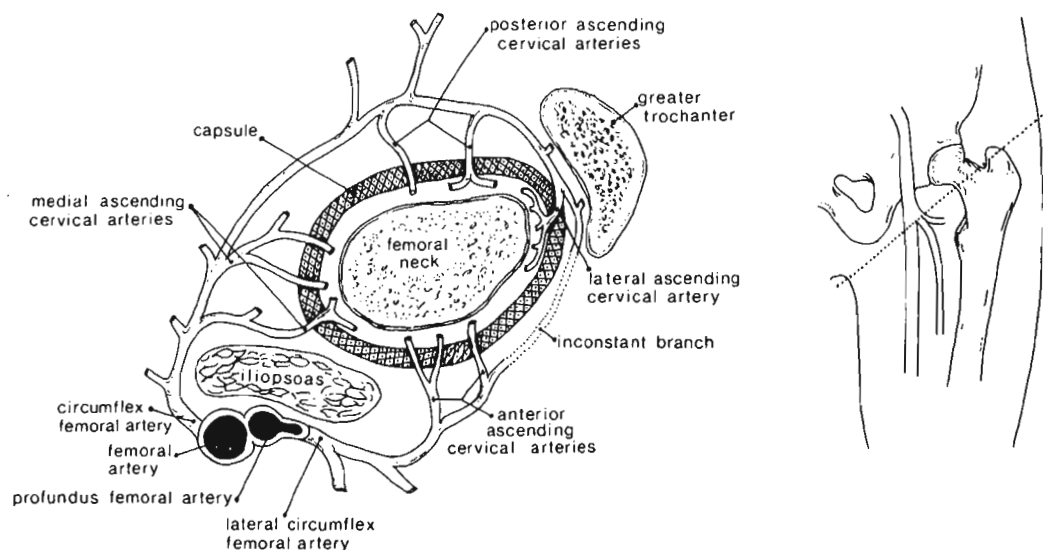


FIGURE 24-1. The blood supply to the normal proximal femur in a child. (Adapted from ref. 105, with permission.)

blood to the proximal femur: an extracapsular arterial ring, the ascending cervical (retinacular branches) vessels, and the artery of the ligamentum teres (105) (Fig. 24-1). The extracapsular ring is formed mostly by the medial and lateral femoral circumflex vessels. This ring gives rise to the ascending cervical branches, which are extracapsular, and these in turn give rise to the metaphyseal and epiphyseal branches. The anterior portion of the extracapsular ring is formed primarily by the lateral femoral circumflex artery. The posterior, lateral, and medial aspects of the ring are formed by the medial femoral circumflex artery. Chung (105) found that the greatest volume of blood flow to the femoral head comes through the lateral ascending cervical vessel (the termination of the medial femoral circumflex artery), which crosses the capsule in the posterior trochanteric fossa. Both Trueta and Pinto de Lima (106,107) and Chung (105) demonstrated that the anterior vascular anastomotic network (Fig. 24-1) is much less extensive than the posterior anastomotic network, particularly in specimens from patients aged 3 to 10 years, which correlates with the age range of Legg-Calvé-Perthes syndrome. Chung also demonstrated that the anterior anastomotic network was incomplete more often in boys, which correlates with male gender predominance in Legg-Calvé-Perthes syndrome. Ogden (108) found vessels crossing the physeal plate in some of his specimens, but Chung disagreed, believing that the vessels did not actually cross the plate, but passed through the peripheral perichondral fibrocartilaginous complex.

Interruption of the blood supply to the femoral head in Perthes disease was first demonstrated in 1926, when Konjetzny (69) showed obliterative vascular thickening in a pathologic specimen. Theron (109) used selective angio-

grams to demonstrate obstruction of the superior retinacular artery in patients with Legg-Calvé-Perthes syndrome. In 1973, Sanchis and colleagues (110) proposed the second infarction theory. They experimentally infarcted the femoral head of animals labeled with tetracycline. They were unable to produce a typical histologic picture of Legg-Calvé-Perthes syndrome with only a single infarction. With a second infarction, however, they were able to show a more characteristic histologic picture of Legg-Calvé-Perthes syndrome. Inoue and colleagues (111) later correlated this double-infarction theory with human histologic material. Clinical correlation for this theory is provided by reports of recurrent Perthes disease (112,113) (Fig. 24-2). Salter and Thompson (114,115) proposed that Legg-Calvé-Perthes syndrome is a complication of aseptic necrosis, and that a fracture manifested radiographically by a subchondral radiolucent zone initiates the resorptive phase. Kleinman and Bleck (116) demonstrated increased blood viscosity in a group of patients with Legg-Calvé-Perthes syndrome, possibly leading to decreased blood flow to the femoral epiphysis. Vascular embarrassment, caused by intraosseous venous hypertension and venous obstruction, has been demonstrated by several authors (30,117,118).

Recent attention has been centered on reports of protein C and S deficiencies in patients with Perthes syndrome (119–122). Thrombophilia induced by low levels of protein C or S, or by resistance to activated protein C, has been associated with the development of osteonecrosis and with arterial thrombosis (120–123). These investigators have suggested routine screening of the levels of protein C, protein S, and lipoprotein(s); plasminogen activator-inhibitor activity; and stimulated tissue-plasminogen activator activ-

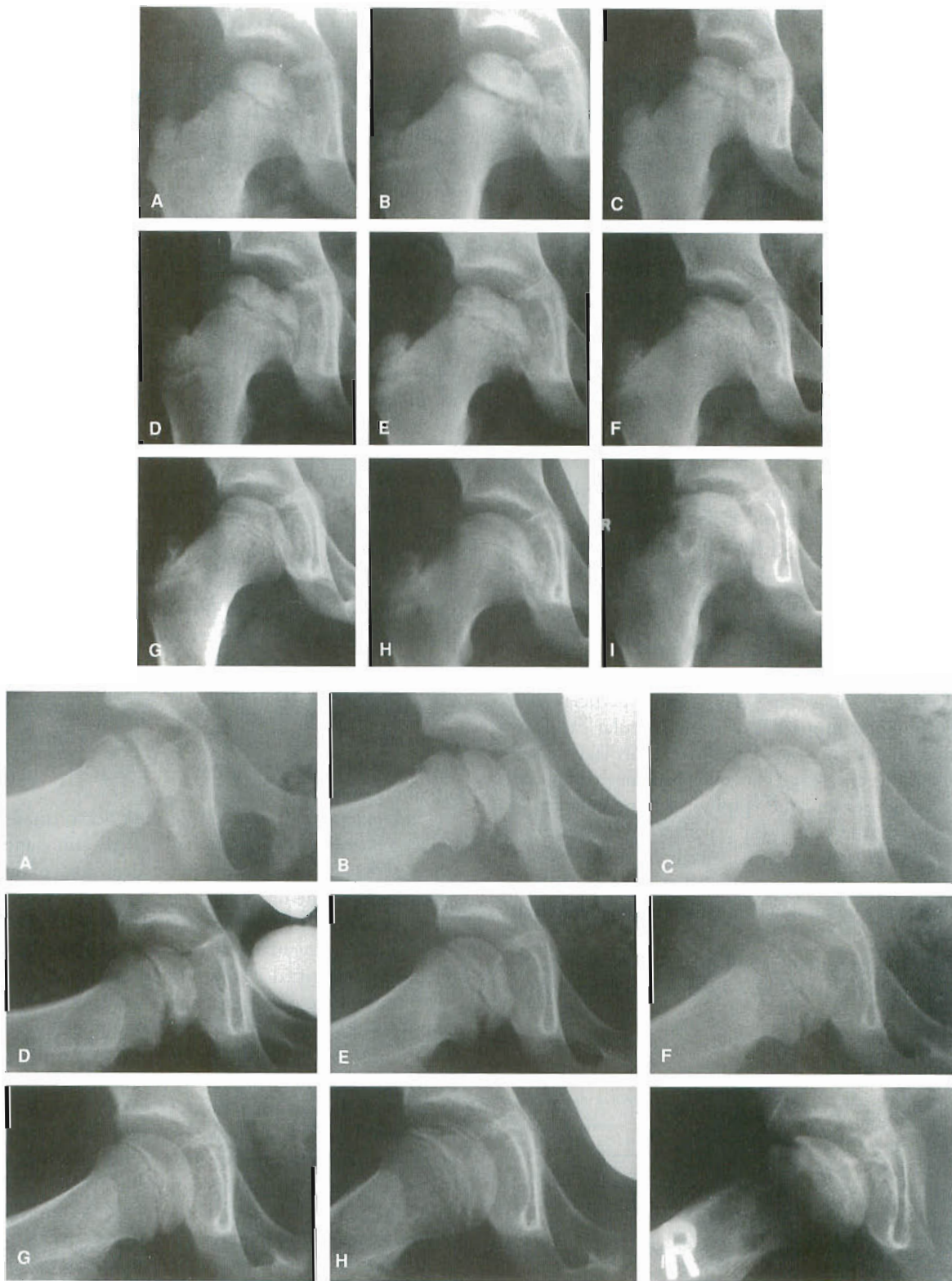


FIGURE 24-2. A 4-year, 8-month-old girl was treated for left hip Perthes disease (late fragmentation phase) beginning in January 1983. Anteroposterior (top) and Lauenstein (bottom) views of the right hip at different stages, January 1983 to December 1987. **A:** View of the right hip at the time of initial presentation, with no signs of involvement (January 1983). **B:** Early involvement, patient still asymptomatic (September 1983). **C to F:** Progressive healing of the right femoral epiphysis in May 1984 (**C**), August 1984 (**D**), May 1985 (**E**), and November 1985 (**F**). **G:** The femoral head was completely healed by December 1986. **H:** Recurrent changes in the density of the femoral head and a subchondral fracture that involves less than 50% of the head (Catterall group 2) were seen in June 1987. **I:** Complete involvement of the ossific nucleus (Catterall group 4) with diffuse metaphyseal reaction and cysts was seen in December 1987. (From ref. 113, with permission.)

ity in patients with Perthes syndrome (120). They believe that another value of routine coagulation screening for children who have Legg-Perthes disease lies in the familial nature of the autosomal dominant coagulopathies. These disorders are associated with thrombotic events in 60% of adult family members. The authors believe that the diagnosis of a coagulation disorder in a child who has Legg-Perthes disease can and should lead to studies in first-degree relatives, with the goal of preventing thrombotic events in families. More recent literature has refuted the role of thrombophilia in the cause of Perthes disease (124,125).

PATHOGENESIS

Histologically, the changes seen in Legg-Calvé-Perthes syndrome must be put in perspective. Few human specimens have been studied, and each specimen studied represents only one stage in the disease process. Most specimens are from curettage or core biopsies, which show only one portion of the involved head at a time.

In the developing normal human femoral head, the secondary center of ossification is covered by cartilage that is composed of three zones (Fig. 24-3). The superficial zone has the morphologic properties of adult articular cartilage. Beneath this zone is the zone of epiphyseal cartilage, which is histochemically different. The zone becomes thinner as the skeleton matures and the epiphyseal bone enlarges in size. Underneath the epiphyseal cartilage is a thin zone formed by small clusters of cartilage cells that hypertrophy and degenerate. Capillaries penetrate this zone from below, and bone forms at a much slower rate than in the metaphysis (126).

Histologic changes of the epiphyseal and physeal cartilage of patients with Legg-Calvé-Perthes syndrome (Figs.

24-4 and 24-5) were described as early as 1913. These and current studies demonstrate that the superficial zone of the epiphyseal cartilage covering the affected femoral head is normal but thickened. In the middle layer of the epiphyseal cartilage, however, two types of abnormalities are seen: areas of extreme hypercellularity, with the cells varying in size and shape and often arranged in clusters, and areas containing a loose fibrocartilage-like matrix. These abnormal areas in the epiphyseal cartilage have histochemical and ultrastructural properties different from normal cartilage and fibrocartilage. Areas of small secondary ossification centers are evident, with bony trabeculae of uneven thickness forming directly on the abnormal cartilage matrix (126-131). The superficial and middle layers of epiphyseal cartilage are nourished by synovial fluid and continue to proliferate, whereas only the deepest layer of the epiphyseal cartilage is dependent on the epiphyseal blood supply, and is affected by the ischemic process (126,129,132-138).

The physeal plate in Legg-Calvé-Perthes syndrome shows evidence of cleft formation with amorphous debris and extravasation of blood. In the metaphyseal region, endochondral ossification is normal in some areas, but in others the proliferating cells are separated by a fibrillated cartilaginous matrix that does not calcify (Fig. 24-5). The cells in these areas do not degenerate but continue to proliferate without endochondral ossification, leading to tongues of cartilage extending into the metaphysis as bone growth proceeds in adjoining areas (126,127,131,139-141).

Catterall and colleagues (139) have demonstrated thickening, abnormal staining, sporadic calcification, and diminished evidence of ossification in the deep zone of the articular cartilage of the unaffected hip. They also demonstrated the physeal plate in these unaffected hips to be thinner than normal, with irregular cell columns and cartilage masses remaining unossified in the primary spongiosa.

Some of these cartilage changes have been seen in other epiphyseal plates, such as the greater trochanter and the acetabulum (142). In the human specimens described by Ponseti (127), the physeal plate lesions were long-standing in view of the fact that there was only necrotic bone in the femoral head and no evidence of repair. Catterall and colleagues reported similar cartilaginous lesions in a patient with Catterall group 1 disease, in which there is no sequestrum formation (129,131) (Fig. 24-6). The various reported physeal plate and epiphyseal plate lesions resemble the lesions produced by Ponseti and Shepard in rats by the administration of aminonitriles (143). These epiphyseal and physeal plate changes, in conjunction with the unusual and precarious blood supply of the proximal femur, make the femoral head vulnerable to the effects of physeal plate disruption.

Skeletal surveys of patients with Legg-Calvé-Perthes syndrome confirm the histologic abnormalities by demonstrating irregularities of ossification in other epiphyses, especially Kohler disease of the navicular (67,127,144). Harrison and

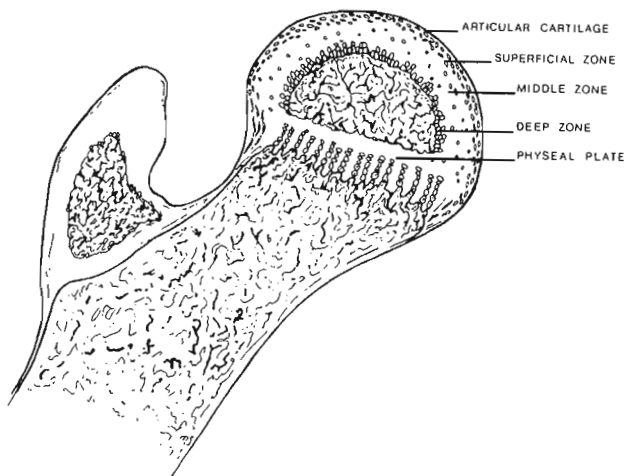


FIGURE 24-3. Proximal femur in a child.




FIGURE 24-4. A: Superficial zone cartilage and epiphyseal cartilage of the femoral head. The superficial zone cartilage is normal and is Alcian blue positive. The epiphyseal cartilage stains with periodic acid–Schiff, but only the perilacunar rims stain with Alcian blue. In the epiphyseal cartilage there is an area of disorganized abnormal Alcian blue–positive cartilage. (Alcian blue with 0.6 mol/L magnesium chloride; original magnification, $\times 25$.) B: Abnormal area of epiphyseal cartilage. The matrix has a fibrillated appearance and is strongly Alcian blue positive. (Alcian blue with 0.6 mol/L magnesium chloride; original magnification, $\times 100$.) C: Junction between the normal and abnormal epiphyseal cartilage. Normal cartilage is periodic acid–Schiff positive, whereas the abnormal cartilage is very cellular, and retains Alcian blue positivity at high concentrations of magnesium chloride. (Alcian blue with 0.7 mol/L magnesium chloride; original magnification, $\times 165$.) D: Extensive area of abnormal epiphyseal cartilage in the femoral head. Bone seems to form directly on the abnormal cartilage. Abnormal cartilage retains intense Alcian blue positivity at a high concentration of magnesium chloride, but loses that positivity and becomes strongly positive to periodic acid–Schiff at the bone–cartilage junction. (Alcian blue with 0.7 mol/L magnesium chloride, periodic acid–Schiff, and Weigert hematoxylin stains; original magnification, $\times 40$.) (From ref. 126, with permission.)

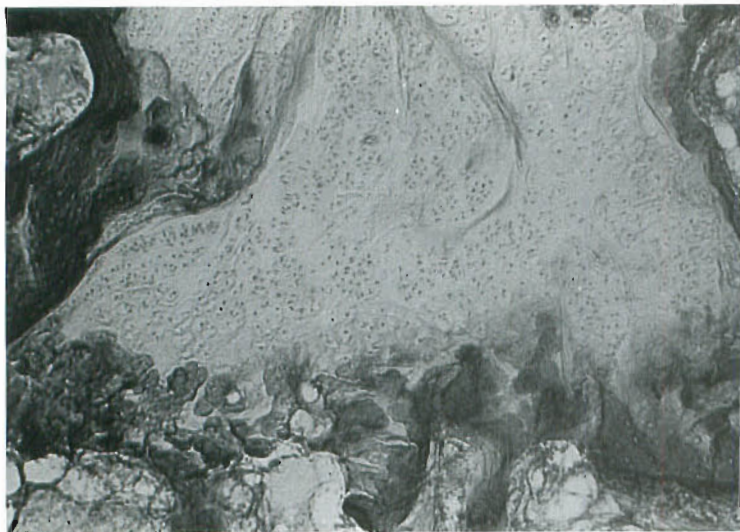


FIGURE 24-5. Photomicrograph showing a large area of cartilage between the bone trabeculae of the femoral neck. (Original magnification, $\times 80$.) (From ref. 127, with permission.)

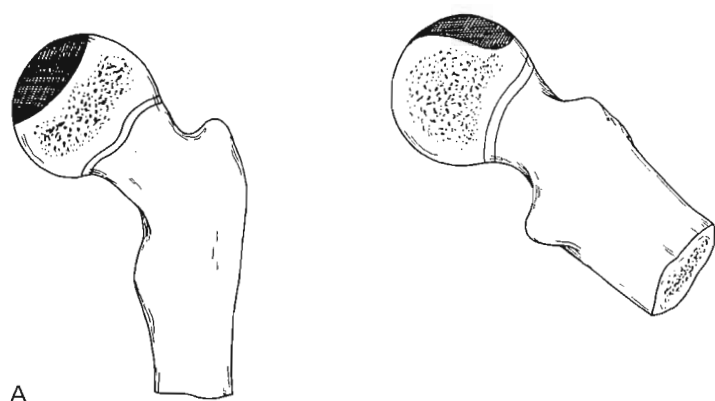
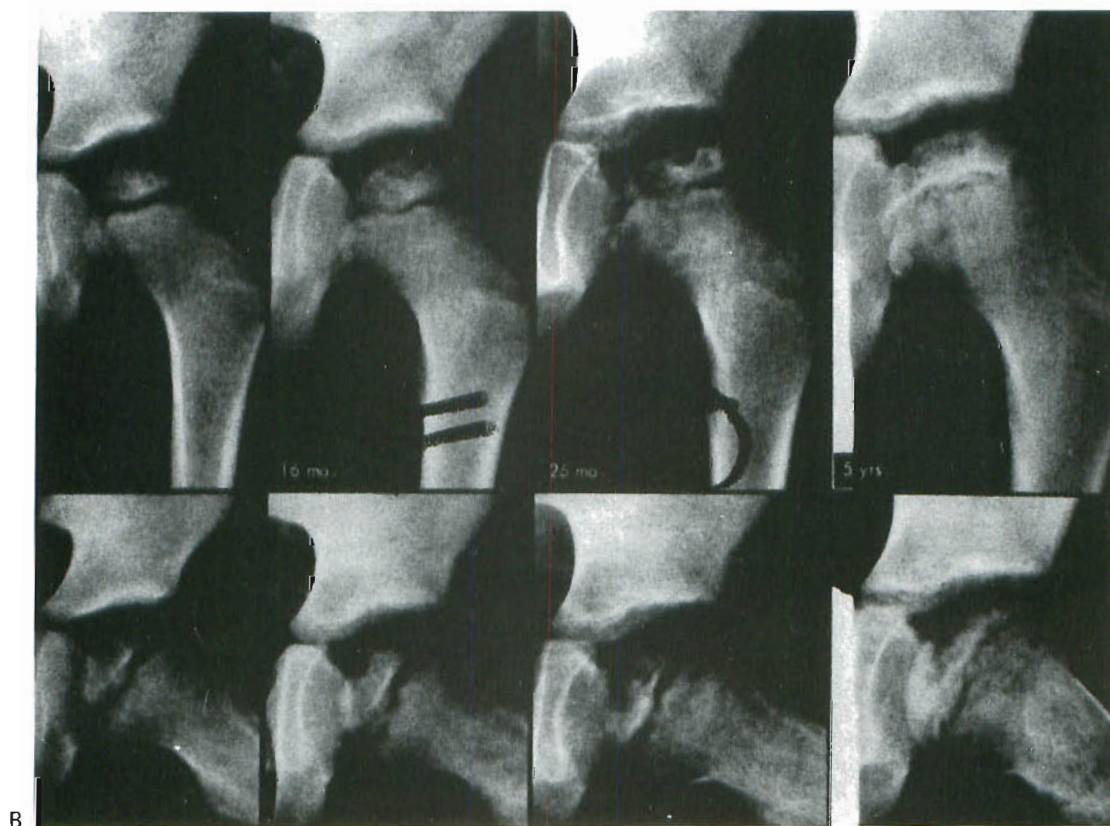


FIGURE 24-6. A: Catterall group 1 disease shows anterior head involvement with no evidence of sequestrum, a subchondral fracture line, or metaphyseal abnormalities. B: Catterall group 1 disease 1 week to 5 years after symptom onset.



Blakemore (145), studying 153 consecutive patients with unilateral Legg-Calvé-Perthes disease, found that 48% had contour irregularities in the contralateral normal capital epiphysis compared with 10% of matched controls. Aire and colleagues (146) demonstrated that the unaffected hip showed anterior and lateral flattening at the time of diagnosis of the affected hip. These data suggest that Legg-Calvé-Perthes disease is a generalized process affecting other epiphyses, and therefore should not be referred to as a disease, but should be called Legg-Calvé-Perthes syndrome.

Disorganization of the physal plate, together with minimal trauma, may interrupt the continuity of retinacular vessels, causing necrosis (126,127). This finding, in conjunction with the aforementioned epidemiologic, histologic, and radiologic data, supports the belief that Legg-Calvé-Perthes syndrome may be a localized manifestation of a generalized disorder of epiphyseal cartilage in the susceptible child (10,30,43,52,65,126,147,148).

Radiographic Stages

Radiographically, Legg-Calvé-Perthes syndrome can be classified into four stages: initial, fragmentation, reossification, and healed. In the initial stage (18,149), one of the first signs of this condition is failure of the femoral ossific nucleus to increase in size because of a lack of blood supply (Fig. 24-7). The affected femoral head appears smaller than the opposite, unaffected ossific nucleus. Widening of the medial joint space, as initially described by Waldenstrom (18,151) (Fig. 24-7), is another early radiographic finding. Widening has been theorized by some researchers to be caused by synovitis. Others have proposed that this finding is secondary to decreased head volume caused by necrosis and collapse and a secondary increase in blood flow to the soft tissue parts, such as the ligamentum teres and pulvinar, causing the head to displace laterally (149,152). Synovitis is present in patients with Perthes disease to varying degrees

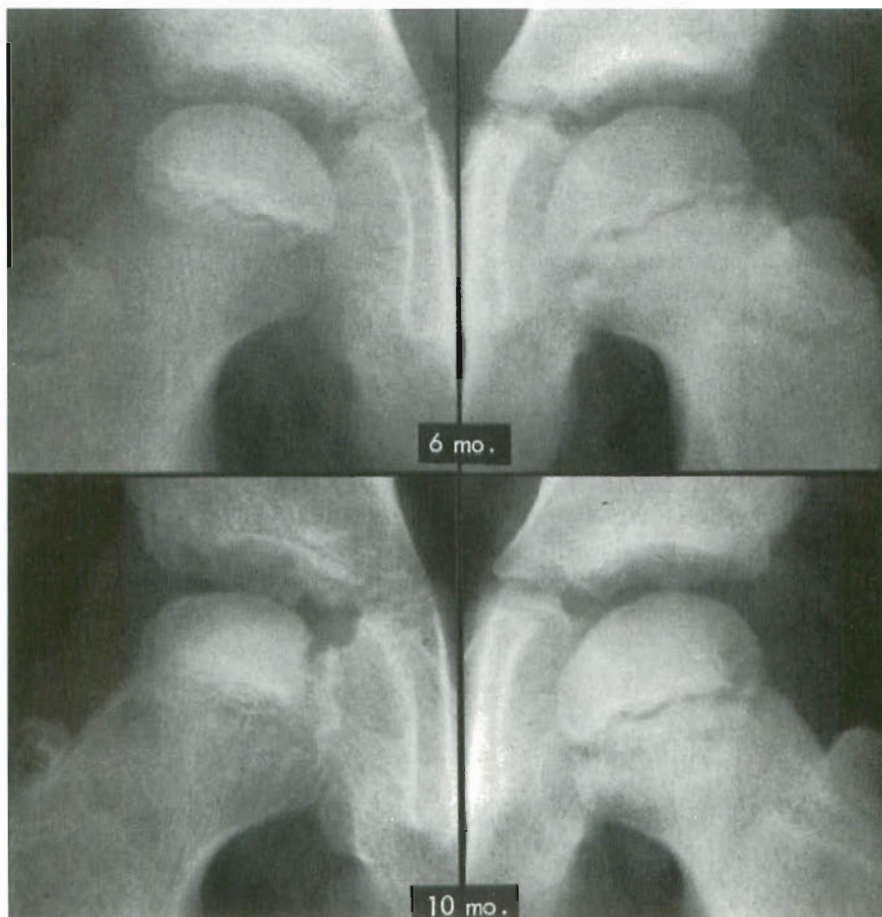


FIGURE 24-7. Anteroposterior roentgenogram of a hip in a patient who developed Legg-Calvé-Perthes disease. On the initial film, taken 6 months after symptom onset, the right ossific nucleus is smaller than the left, and the medial joint space is widened. Note also the retained density of the ossific nucleus compared with the normal hip and the relative osteopenia of the viable bone of the proximal femur and pelvis. Ten months after symptom onset, the evolution of the radiographic changes are seen. (From ref. 150, with permission.)

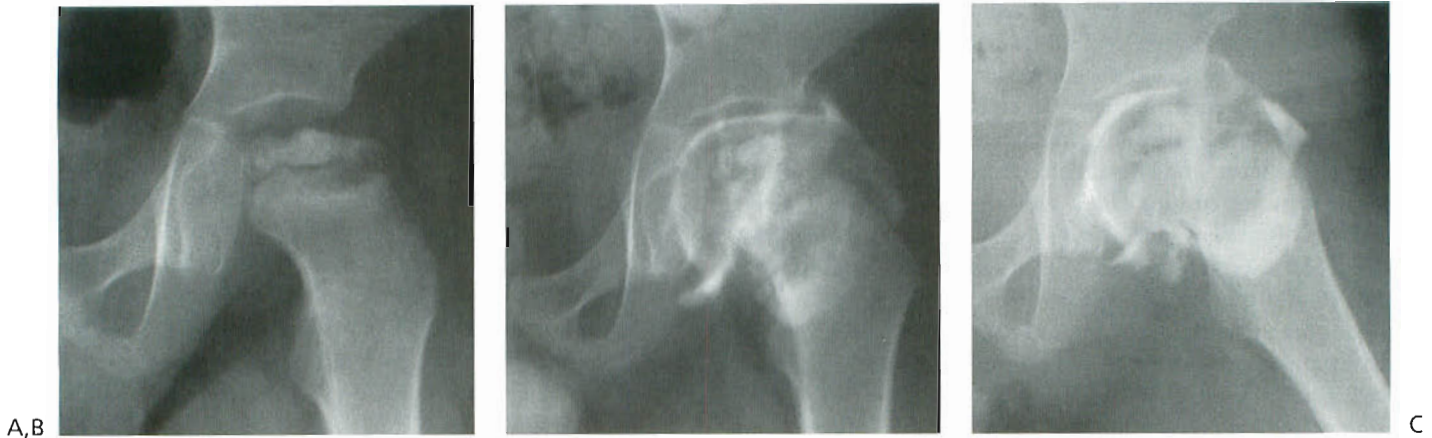

FIGURE 24-8. A 4-year, 9-month-old boy with Catterall group 4 disease and at-risk status. **A:** Plain radiograph. **B:** Arthrogram in neutral abduction, adduction, and rotation. There is enlargement and flattening of the cartilaginous femoral head, and the lateral margin of the acetabulum is deformed by the femoral head. **C:** Arthrogram in abduction and slight external rotation. The femoral head hinges on the lateral edge of the acetabulum, further deforming the lateral acetabulum. Slight pooling of dye is seen medially.

(93,94,96,97,153,154), but the medial joint space widening is probably most often an apparent radiographic phenomenon secondary to epiphyseal cartilage hypertrophy (Fig. 24-8).

In the initial stage, the physal plate is irregular and the metaphysis is blurry and radiolucent (82) (Fig. 24-9B). The femoral ossific nucleus appears radiodense (155). This relative increased radiodensity may be caused by osteopenia of the surrounding bone (156,157), or an increase in the mass of bone in the area.

The second radiographic stage is called the “fragmentation phase” (18,149). Radiographically, the repair aspects of the disease become more prominent (Fig. 24-9B). The bony epiphysis begins to fragment, and there are areas of increased radiolucency and increased radiodensity. Increased radiodensity at this stage may be caused by new bone forming on old bone (158–162) and thickening of existing trabeculae (160). The subchondral radiolucent zone

(i.e., crescent sign) first described by Waldenstrom (151,163), and later popularized by Caffey (164), is one of the very early signs of Legg-Calvé-Perthes syndrome in the fragmentation stage (Fig. 24-2; Fig. 24-10). According to Salter and associates (115,165), this radiographic finding results from a subchondral stress fracture, and the extent of this zone determines the extent of the necrotic fragment.

The third radiographic stage is the reparative or reossification phase (18,149). Radiographically normal bone density returns, with radiodensities appearing in areas that were formerly radiolucent. Alterations in the shape of the femoral head and neck become apparent (Fig. 24-9B).

The final stage is the healed phase. In this stage, the proximal femur is left with any residual deformity from the disease and the repair process (Fig. 24-9B). Legg-Calvé-Perthes syndrome cannot be compared with aseptic necrosis after fracture of the neck of the femur or traumatic dislocations of the hip in the young child. In these situations,

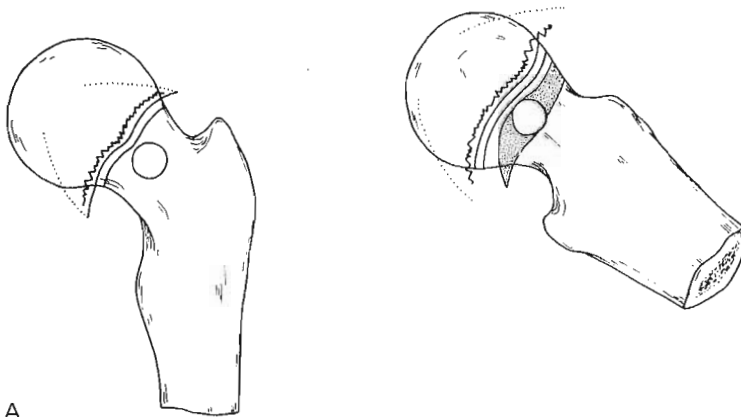


FIGURE 24-9. **A:** Catterall group 4 disease shows whole head movement, with either diffuse or central metaphyseal lesions and posterior remodeling of the epiphysis. (continued)

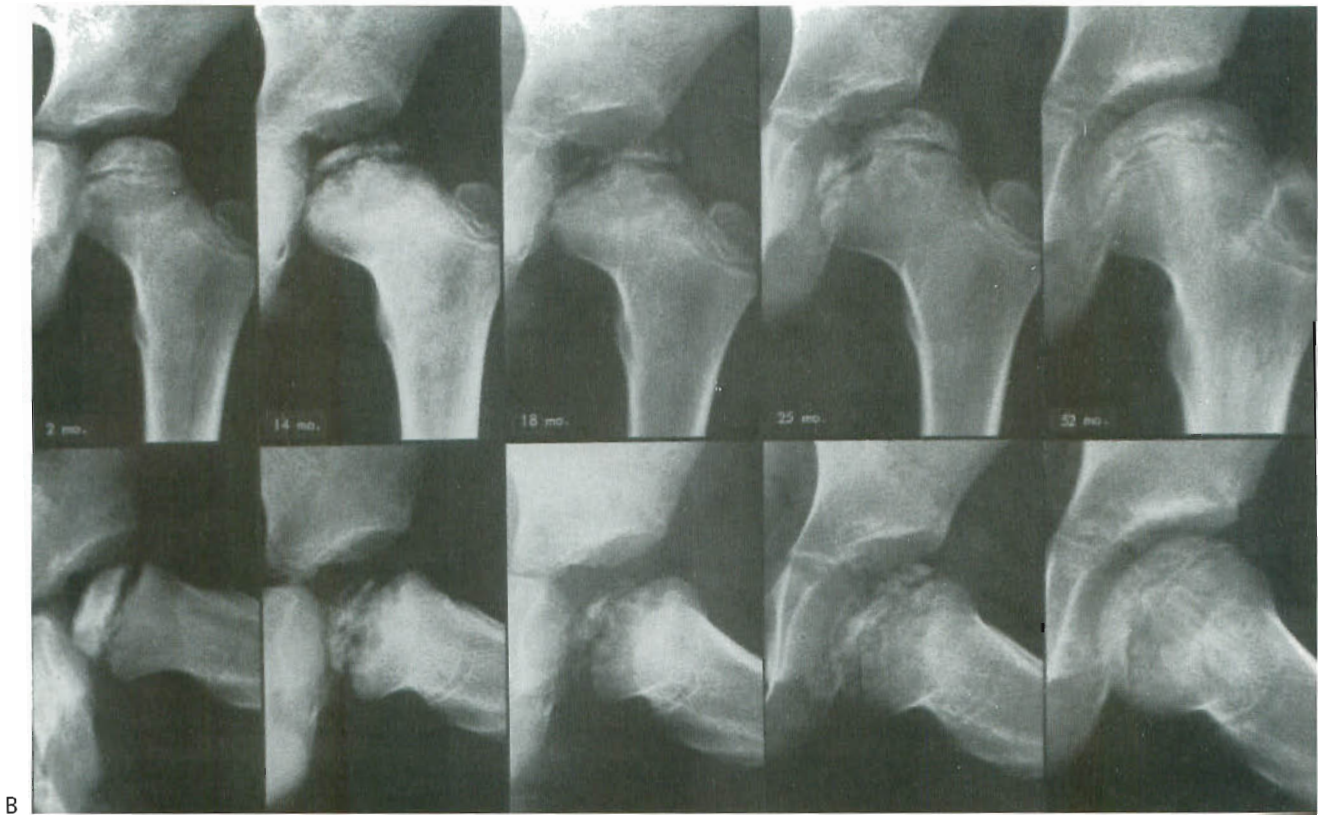


FIGURE 24-9. (continued) B: Catterall group 4 disease 2 months to 52 months after onset of symptoms. Note the stages: 14 months, fragmentation; 18 months, early reossification; 25 months, late reossification; 52 months, healed. Note also the growth-arrest line and evidence of reactivation of the growth plate along the femoral neck.

the vascular insult to the femoral head usually heals rapidly without going through the prolonged stages of fragmentation and repair that are seen in children with Legg-Calvé-Perthes syndrome (126,166,167).

Pathogenesis of Deformity

The head deformities that occur in Legg-Calvé-Perthes syndrome come about in many ways. First, there is growth

disturbance in the epiphyseal and physeal plates. In the physeal plate, this may result in premature closure with resultant deformity, such as central physeal arrest, causing a shortened neck and trochanteric overgrowth (168,169) (Fig. 24-11). The repair process itself may cause physical compaction resulting from structural failure and displacement of tissue elements (86). During the healing process, the femoral head will deform according to the asymmetric repair process and the applied stresses. The molding action of the acetabulum

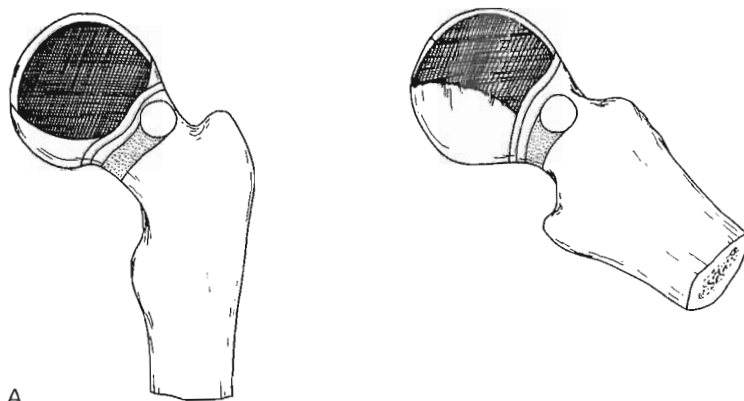


FIGURE 24-10. A: Catterall group 3 disease shows large sequestrum involving three-fourths of the head. The junction between the involved and the uninvolved portions is sclerotic. Metaphyseal lesions are diffuse, particularly anterolaterally, and the subchondral fracture line extends to the posterior half of the epiphysis. The lateral column is involved. (continued)

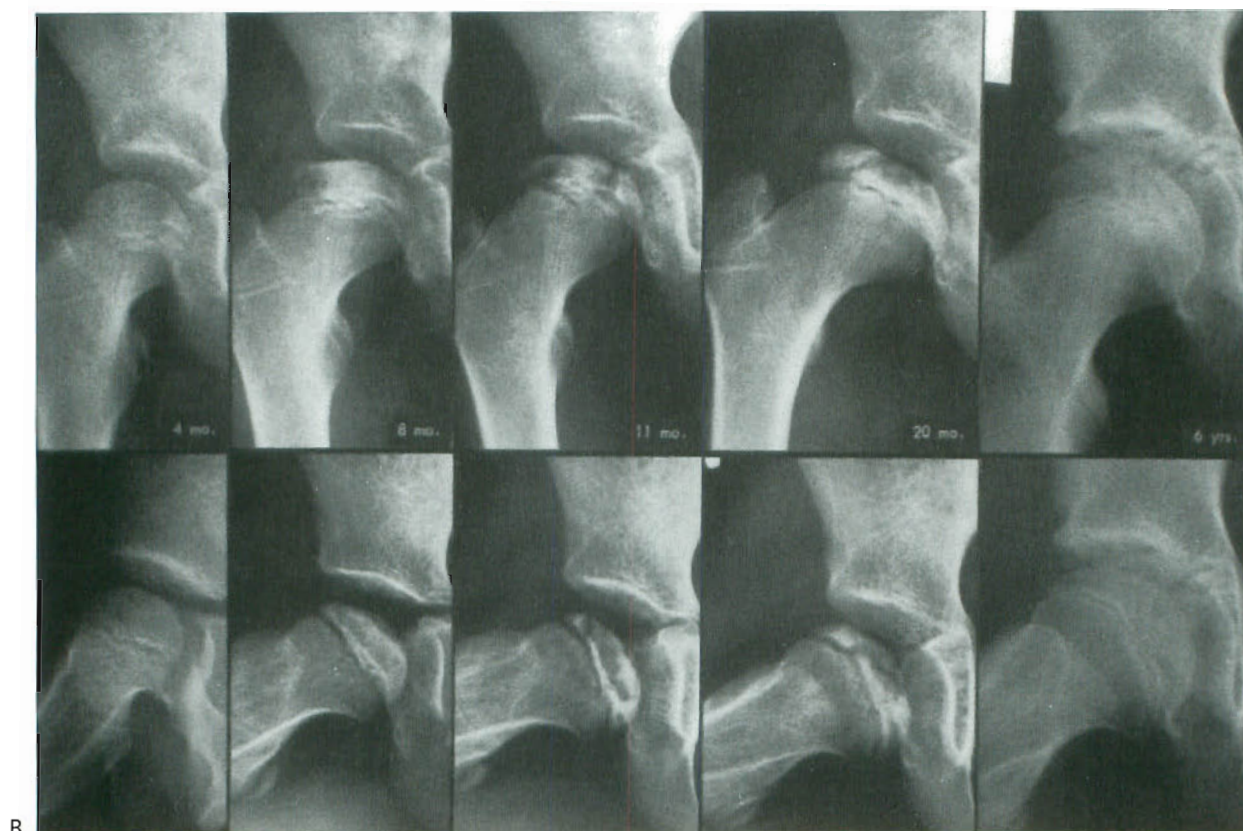


FIGURE 24-10. (continued) B: Catterall group 3 disease 4 months to 6 years after symptom onset. Note the involvement of the lateral pillar, as well as the subchondral radiolucent zone on the radiograph taken 8 months after onset of symptoms.

during new bone formation also may be a factor (170,171). With deformity of the femoral head, the acetabulum, particularly its lateral aspect, is deformed secondarily.

The articular cartilage of the femoral head shows changes in shape secondary to the disease process itself. The deepest layer of the articular cartilage is nourished by the subchondral blood supply. This layer is often devitalized in Legg-Calvé-Perthes syndrome (129,132–135,137). The superficial layers that are nourished by synovial fluid continue to proliferate, causing an increase in the thickness of the articular cartilage. With trabecular collapse and fracture and articular cartilage overgrowth, significant head deformities develop that are manifested clinically by loss of abduction and rotation (Fig. 24-8).

The source of vessel ingrowth is under debate. Many investigators (132,133,172) have demonstrated that the new blood vessels arise from the metaphysis and the metaphyseal periosteum, and penetrate between the epiphysis and the joint cartilage into the epiphysis. Other investigators have shown metaphyseal vessels penetrating the physal plate into the epiphysis (108,173). When the blood supply of the subchondral area is restored, it generally comes from the periphery and moves to the center, restoring endochondral ossification at the periphery first and causing asymmet-

ric growth (93,137) (Fig. 24-12). In addition, there is abnormal ossification of the disorganized matrix of the epiphyseal cartilage. Finally, there is periosteal bone growth and reactivation of the physal plate along the femoral neck, with abnormally long cartilage columns leading to coxa magna and a widened femoral neck (126,127).

The actual deformity that develops is profoundly influenced by the duration of the disease. This, in turn, is proportional to the extent of the epiphyseal involvement, the age of the patient at disease onset, the remodeling potential of the patient, and the stage of disease when treatment is initiated. An additional factor is the type of treatment (174–177).

Patterns of Deformity

Four patterns of residual deformity result from Legg-Calvé-Perthes syndrome: coxa magna, premature physal arrest patterns, irregular head formation, and osteochondritis dissecans (169,178). Coxa magna (Fig. 24-9B) develops with ossification of the hypertrophied articular cartilage, and also from reactivation of the physal plate along the femoral neck. This also occurs in conjunction with periosteal new bone formation along the femoral neck.

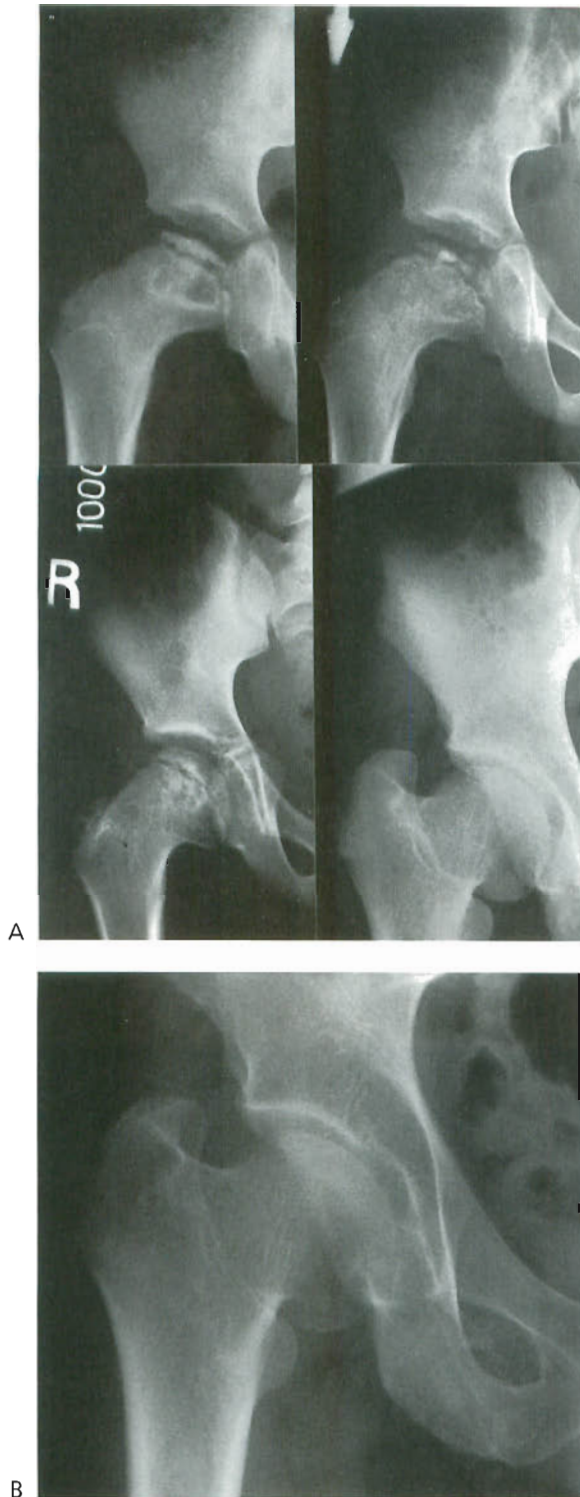


FIGURE 24-11. A: A 6-year-old boy with Catterall group 4 disease. Age 6 years, 2 months, fragmentation stage (upper left). Age 6 years, 9 months, early reossification stage (upper right). Age 8 years, 9 months, healed (lower left). Age 16 years, 2 months, skeletally mature (lower right). Patient healed with a central physal arrest pattern. B: A 51-year-old patient at 45-year follow-up. He was asymptomatic and had a full range of motion (Iowa Hip Rating, 95 of 100 points). At maximal fragmentation the hip is classified as showing Catterall group 4, Salter-Thompson type B, and lateral pillar type C disease.

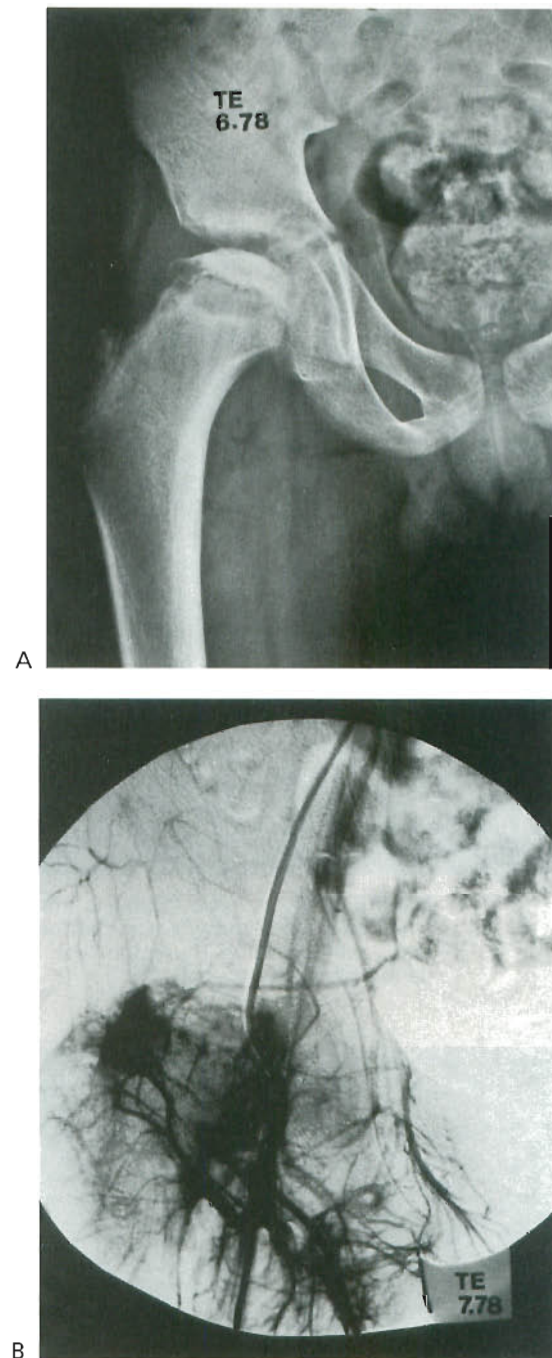


FIGURE 24-12. A: A 12-year-old boy with total head involvement in the early fragmentation stage of the disease. B: Subtraction arteriogram demonstrating the avascularity of the central portion of the head, with increased vascularity at the periphery. (Courtesy of J. G. Pous, M.D., Montpellier, France.)

Premature physal plate closure generally leads to one of two patterns of arrest: central or lateral. In the central arrest pattern, the femoral neck is short and the epiphysis is relatively round (Fig. 24-11). There is trochanteric overgrowth and mild acetabular deformity. In the lateral arrest pattern,

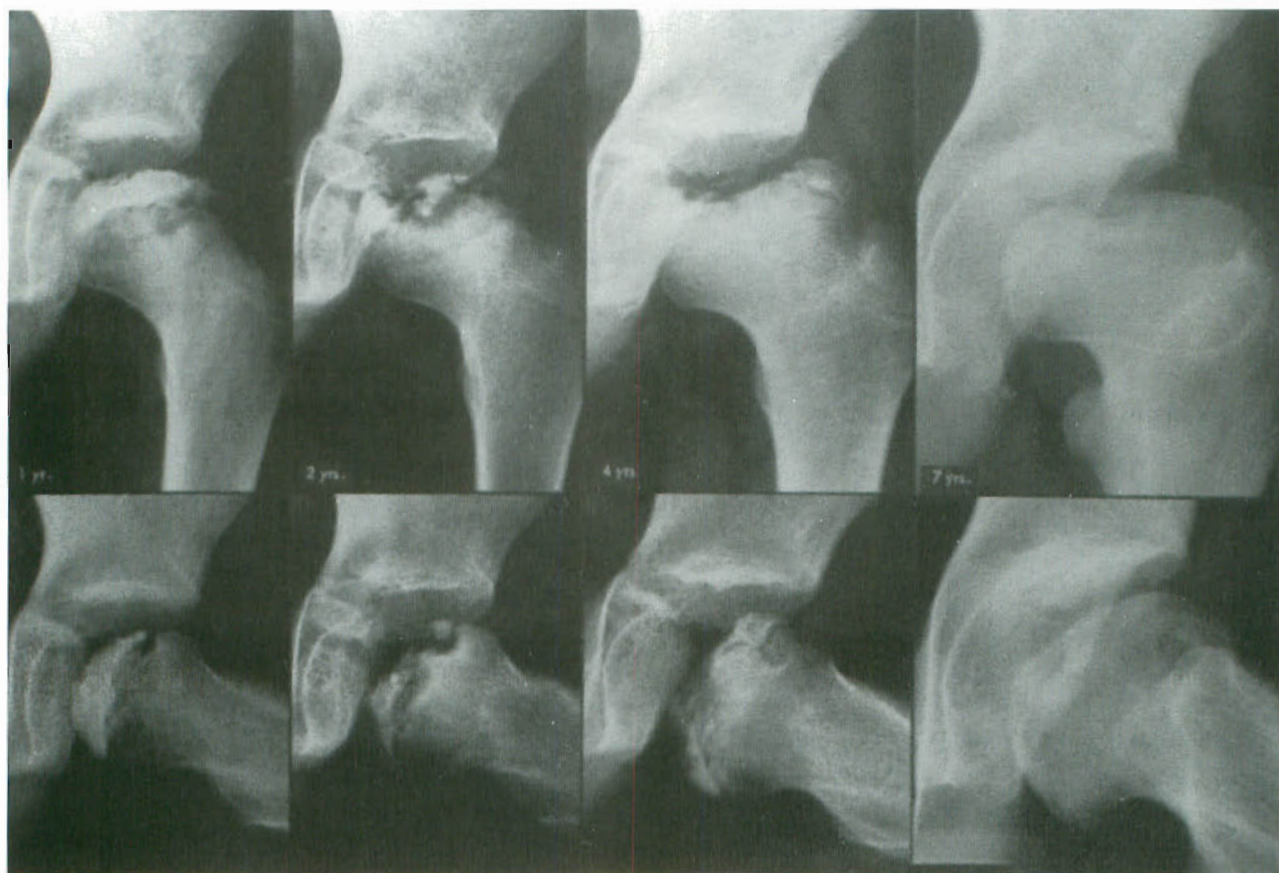

FIGURE 24-13. A 7-year follow-up from presentation in a patient with Catterall group 4 disease, who had a lateral growth-arrest pattern. At maximal fragmentation, the radiographic classification would be Salter-Thompson type B and lateral pillar type C disease. (From ref. 179, with permission.)

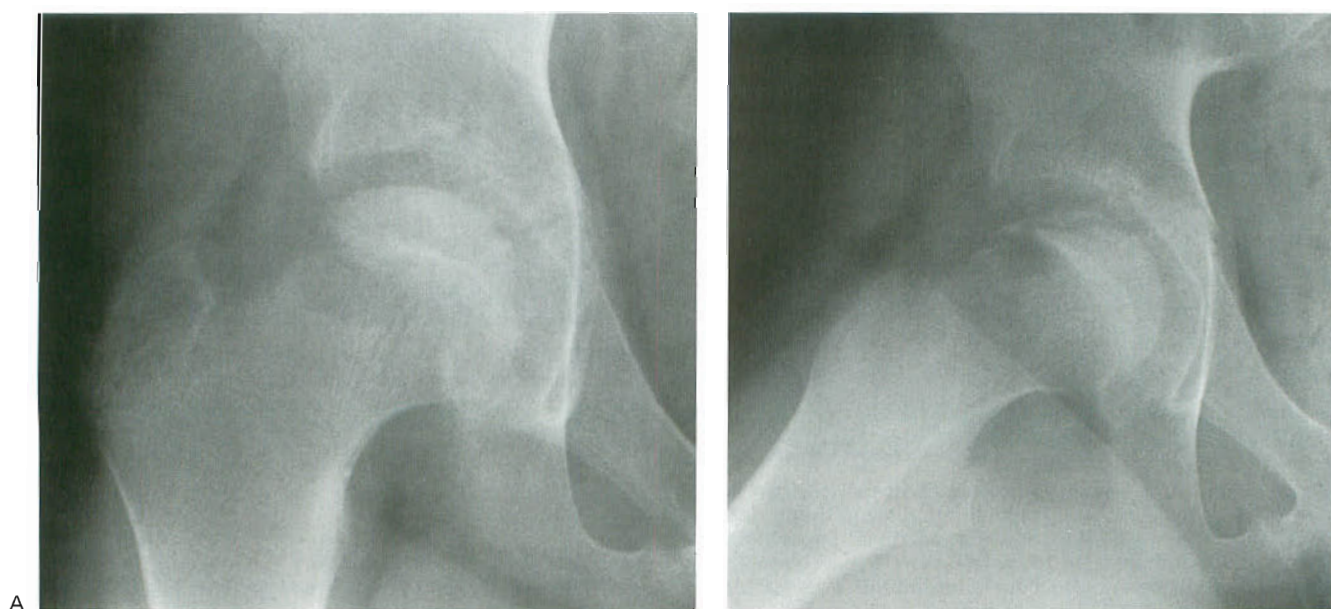


FIGURE 24-14. An 11-year, 3-month-old girl with Catterall group 3 disease had a noncontainable head, yet was treated for a long time in an abduction brace. **A:** Anteroposterior radiograph in the early fragmentation stage (left) and Lauenstein radiograph in the early fragmentation stage (right). (continued)

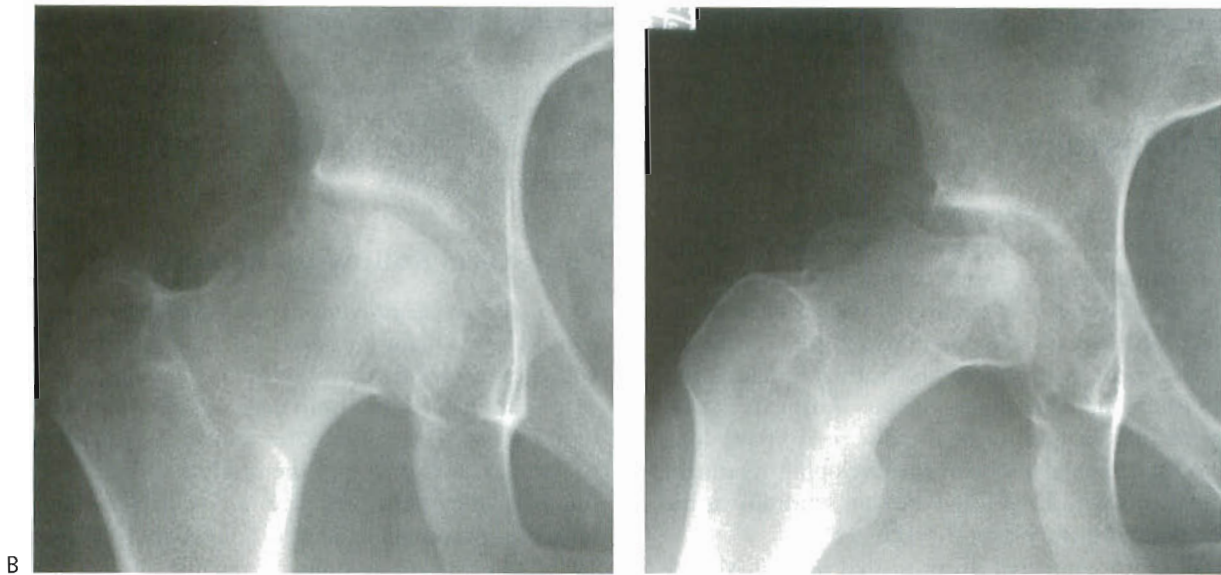


FIGURE 24-14. (continued) **B:** At age 14 years, the patient was skeletally mature, and had an irregular femoral head. Anteroposterior radiograph (left) and Lauenstein radiograph (right). (From ref. 179, with permission.)

the femoral head is tilted externally (Fig. 24-13). There is also trochanteric overgrowth. The epiphysis is oval, with a corresponding acetabular deformity (169,178).

The irregular head may occur secondary to certain patterns of physeal arrest, but it also may be an iatrogenic deformity from attempts at “containment” of a noncontainable head (Fig. 24-14). After the femoral head becomes deformed and is no longer containable within the acetabu-

lum, the only motion that is allowed is in the flexion and extension plane, with abduction leading to hinging on the lateral edge of the acetabulum. This hinge abduction causes acetabular and secondary head deformity (180–182) (Fig. 24-8).

The fourth and least common (3% incidence) residual deformity that occurs in Legg-Calvé-Perthes syndrome is osteochondritis dissecans (Fig. 24-15). This usually occurs

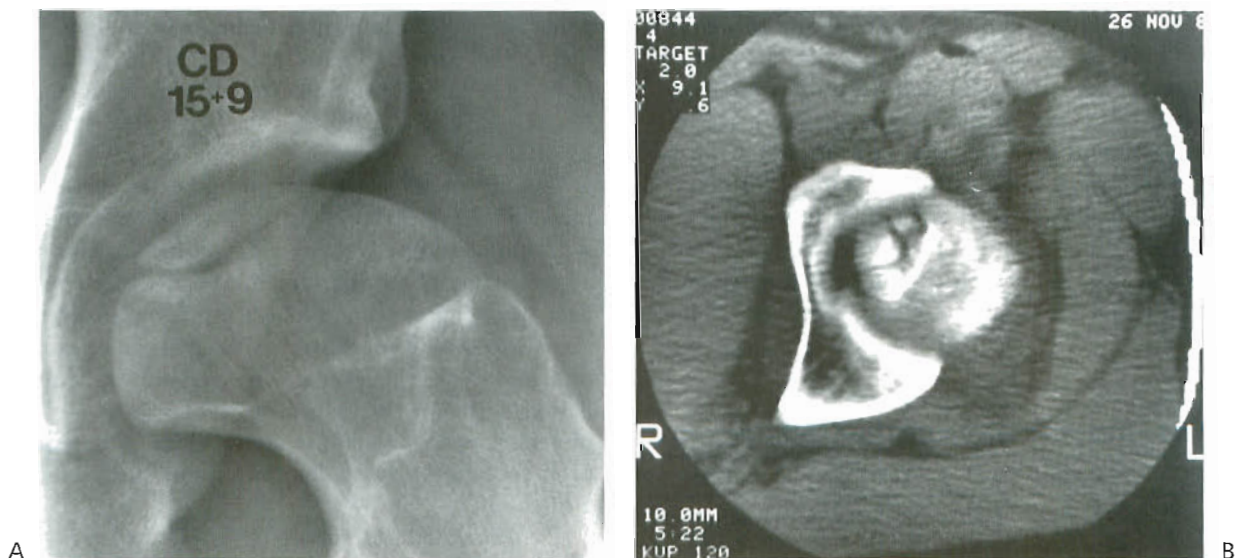


FIGURE 24-15. **A:** A 15-year-old boy, with onset of disease at 8.5 years of age, returned to the physician with pain and synovitis. Anteroposterior radiograph demonstrates osteochondritis of the femoral head. **B:** Computed tomographic scan shows multiple fragments that appear as one on the radiograph.

with the late onset of disease, and with prolonged, ineffectual repair (169,178,183–185).

NATURAL HISTORY

The formulation of disease treatment requires that the treating physician knows what happens to the patient without treatment (natural history), and what prognostic factors lead to an adverse outcome. The treating physician must determine which of these adverse prognostic factors can be affected by treatment. A treatment plan is then initiated, and long-term follow-up determines whether treatment favorably alters the natural history of the disease over the long term. The fundamental problem in developing treatment plans for patients with Legg-Calvé-Perthes syndrome is the paucity of natural history data (65,186–189).

Catterall (186) compared 46 untreated hips of Murley and Lloyd-Roberts with a matched control group of 51 hips treated with a weight-relieving caliper. The average age at diagnosis was 4 years, 6 months, and the average follow-up was 10 years, 5 months, with a range of 4 to 18 years. The patients were evaluated according to the grading system of Sundt, which requires some subjective assessments (190). The 10-year average follow-up in this series is too short to determine the outcomes of patients and thus the natural history of the disease, because most patients with childhood hip disease do well, regardless of the radiographic appearance in their early years (191–194). In addition, no data are presented on the interrater or intrarater reliability of the outcome criteria.

Catterall also reported on 97 untreated patients gathered from around the British Isles. The average follow-up in this series was only 6 years, and the results were graded according to the system of Sundt (190). The outcomes of this group of patients (Table 24-1) are widely quoted in the literature as a comparison for outcomes of various treatment modalities. Unfortunately, very few articles in the literature use the same grading system for outcomes, and the follow-up of this group is too short to be defined as natural history.

The only other article labeled “natural history” in the literature (189) is not a natural history study, but a study of patients treated by different methods, from three centers. This study attempted to establish a relation between residual

deformity and degenerative joint disease, and to identify clinical and radiographic factors in the active phase of disease that would be predictive of hip deformity and degenerative joint disease. Thus, decision-making with reference to treatment is difficult because of the lack of true long-term natural history data.

Long-term Follow-up Results

Although there is little information available on natural history, there are many long-term follow-up studies of patients with Legg-Calvé-Perthes syndrome. The long-term studies that are available suffer from the faults of retrospective long-term reviews, in that most series contain only small numbers of patients, with many of the original patients not traced; original radiographs often are not available. Many of the longer series contain patients diagnosed in the years 1910 to 1940, when little was known about the disease, prognostic factors, and radiographic classifications. In most series, patients are combined, regardless of the extent of epiphyseal involvement, age at disease onset, age at the beginning of treatment, and stage of the disease at treatment initiation. Various treatment modalities are combined in many series, and control groups generally are absent. Because of these inherent problems, different grading systems used to judge clinical and radiographic end results, and lack of interrater and intrarater reliability data, it is difficult to compare and contrast the various reported series. Despite these shortcomings, a great deal has been learned about the prognosis in Legg-Calvé-Perthes syndrome.

In reviewing long-term follow-up studies, it is apparent that results can improve with time, because remodeling potential continues until the end of growth (65,195) (Figs. 24-9 and 24-10). Mose wrote that, “for a precise prognosis, conclusions from any measurements ought not be made before the patient reaches the age of 16, when growth stops,” (194). Reviews of the outcomes of treatment modalities before skeletal maturity must be viewed as preliminary reports.

Twenty to 40 years after the onset of symptoms, the majority (70 to 90%) of patients with Legg-Calvé-Perthes syndrome are active and free of pain. Most patients maintain a good range of motion, despite the fact that few patients have normal-appearing radiographs. Clinical deterioration and symptoms of increasing pain, decreasing range of motion, and loss of function are observed only in patients with flattened irregular heads at the time of primary healing, and in patients with premature physeal closure, as indicated by neck shortening, head deformity, and trochanteric overgrowth (175) (Fig. 24-13).

Danielsson and Hernborg (196) reported a 33-year follow-up of 35 patients. Twenty-eight of the 35 patients were free of pain, with 34 of 35 functioning without restrictions. In a 34-year follow-up, Hall (197) reported 71% satisfactory results in 209 cases. Perpich and colleagues (198) reported

TABLE 24-1. RESULTS OF 97 UNTREATED HIPs

	Good	Fair	Poor
Group 1	27	1	0
Group 2	25	6	2
Group 3	4	7	11
Group 4	0	4	10
Total	56 (57%)	18 (19%)	23 (24%)

(From ref. 65, with permission.)

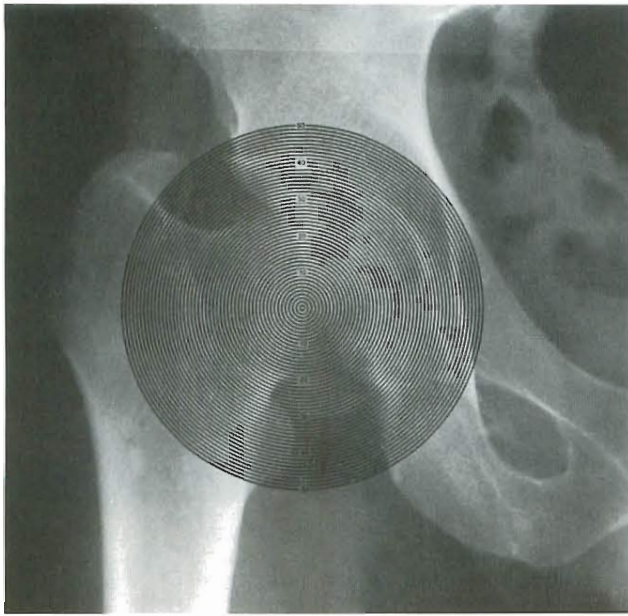


FIGURE 24-16. Mose Sphericity Scale.

a 30-year follow-up of 37 patients. The average Iowa Hip Rating was 93 of a possible 100 points. Eighty-five percent of the patients had good clinical results, despite the fact that only 33% had spherical femoral heads, as rated by the Mose Sphericity Scale (194) (Fig. 24-16). Forty-three percent of the patients had poor Mose ratings; however, of these patients, 76% had good clinical results.

Ratliff (199) followed 34 patients for an average of 30 years, and noted that 80% were fully active and free of pain, whereas only 40% were roentgenographically normal. He followed 16 of these patients for an additional 11 years (200), and noted that, despite the fact that only one-third of them had good anatomic results, "deterioration rarely occurred and many patients had no pain and normal activity."

Yrjonen (191) followed 96 patients (106 hips), all of whom had noncontainment treatment, for an average of 35 years. At maturity, 61% had poor results by the Mose criteria. In a final follow-up, 48% had evidence of degenerative joint disease. However, at an average 35-year follow-up, only 4% had undergone total hip arthroplasty, with an additional 13% having clinical symptoms significant enough to warrant arthroplasty. Ippolito and colleagues (192) reported on 61 patients with an average follow-up of 25 years. Only 19% of their patients had poor results, as measured by the Iowa Hip Rating, at final follow-up. W.J. Cumming (personal communication, 1993) reported on 82 patients with 95 involved hips treated by prolonged frame recumbency, with an average follow-up of 38 years. Only 10% of the patients had required arthroplasty at follow-up, with an additional 10% having symptoms significant enough to warrant arthroplasty.

Gower and Johnston (201) reported on 30 nonoperated hips with an average 36-year follow-up. This series is representative of the 20- to 40-year long-term series reported in the literature. The average Iowa Hip Rating for these 30 patients was 91 points. The typical patient had minimal shortening, absent or mild hip pain, and minimal or no functional impairment, with respect to job and activities of daily living. Ninety-two percent of the patients had Iowa Hip Ratings greater than 80 points, and only 8% of the patients had undergone arthroplasty.

In follow-up studies beyond 40 years, hip function begins to deteriorate. In another study of the Iowa group of patients at 48-year follow-up, McAndrew and Weinstein (193) reported that only 40% of patients maintained an Iowa Hip Rating of greater than 80 points. Forty percent of the patients had undergone arthroplasty, and an additional 10% were suffering from disabling osteoarthritis symptoms, but had not yet undergone arthroplasty (Fig. 24-17). Thus, at 48-year follow-up, 50% of the patients had disabling osteoarthritis and pain, and an additional 10% had Iowa Hip Ratings of less than 80 points. The prevalence of osteoarthritis in this group of patients was ten times that found in the general population in the age range of the studied patients (175). Mose followed a group of patients into the seventh decade of life. All of the patients with irregular femoral heads had degenerative arthritis. Of those patients with femoral heads that Mose classified as "normal, ball shaped," no patient had degenerative joint disease by the middle of the fourth decade, but 67% had severe degenerative arthritis by the middle of the seventh decade (194). Therefore, the follow-up studies beyond 40 years demonstrate marked reduction of function, with the overwhelming majority of patients developing degenerative joint disease by the sixth and seventh decades (175,189,192–194).

Prognostic Factors

In reviews of long-term series of patients with Legg-Calvé-Perthes syndrome, certain clinical and roentgenographic features have been identified that have prognostic value (175,179,180,191,202–205) (Table 24-2). The most important prognostic factor in outcome is the residual deformity of the femoral head, coupled with hip joint incongruity (206–208). Femoral head deformity and joint incongruity are multifactorial problems. They are interrelated with all of the other prognostic factors. It must be kept in mind that Legg-Calvé-Perthes syndrome represents a growth disturbance of the proximal femur; the epiphyseal and physal cartilage is abnormal. Other key factors involved in the development of deformity include the extent of epiphyseal involvement and the varying degrees and patterns of premature physal closure associated with this condition (209).

Stulberg and colleagues (189) established a relation between residual deformity and degenerative joint disease.

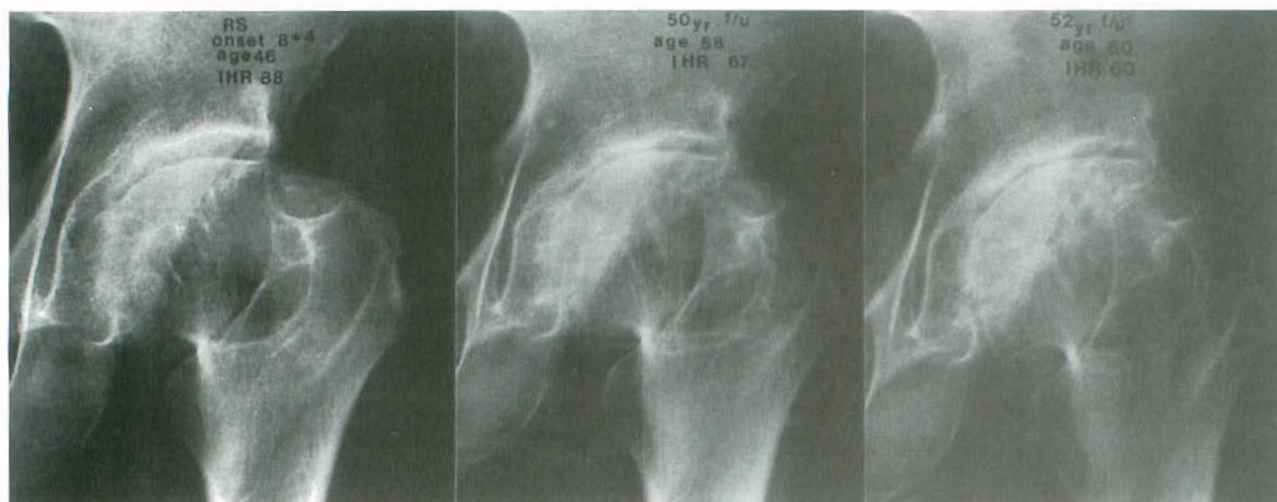


FIGURE 24-17. This patient had disease onset at 8.3 years of age. At 46 years of age (38-year follow-up), the Iowa Hip Rating was 88 points (left). At 58 years of age (50-year follow-up), there was a loss of 21 points on the Iowa Hip Rating, to 67 (center). At 60 years of age, just before arthroplasty, the Iowa Hip Rating was 60 points (right). (From ref. 175, with permission.)

This was accomplished by retrospectively examining the long-term outcomes of patients from three different centers treated by various methods (e.g., bed rest, spica cast, ischial weight bearing, brace, crutches, cork shoe lift on the normal side, combination of methods). They attempted to identify clinical and radiographic factors in the active phase of the disease that were predictive of the development of hip deformity. They proposed a radiographic classification of deformity related to long-term outcome (Table 24-3). The more deformity at maturity (i.e., the higher the Stulberg classification), the worse the long-term outcome. However, as noted from long-term follow-up studies, it is the class 5 hips that deteriorate the earliest; they usually have significant symptoms by the end of the fourth decade (191–194). Patients with aspherical congruency (Stulberg class 3 and 4 disease) may have satisfactory outcomes for many years, with most patients undergoing significant functional deterioration in the fifth and sixth decades of life (191–194). This classification scheme, which attempts to classify a three-dimensional deformity using two-dimensional parameters, has recently

been shown to have poor interrater and intrarater reliability (210). The general principles expressed by Stulberg and colleagues (189), however, have been shown to have validity with reference to long-term outcome studies. That is, the more out of round the femoral head is, and the greater the discrepancy between the shape of the femoral head and the shape of the acetabulum, the greater the chance of development of early degenerative joint disease.

O'Garra (211), Salter and Thompson (114,115), and others (65,91,127,180,186,212) have confirmed Waldenstrom's original finding that partial or anterior head involvement leads to a more favorable prognosis than whole-head involvement. Catterall (65,128,186) demonstrated the importance of the extent of epiphyseal involvement with regard to prognosis, and proposed four groups, based on the presence or absence of seven radiographic signs in 97 untreated hips (Figs. 24-6, 24-9, 24-10 and Fig. 24-18). He compared the final radiograph with the initial radiograph, using the clinical grading of Sundt (190); 90% of the good results in untreated patients were in groups 1 and 2, whereas 90% of the poor results were in groups 3 and 4. This commonly used classification has been criticized as being difficult to use, in that there may be a great deal of interobserver error (202,213). It also has been criticized as being insufficiently prospective, because it may take up to 8 months for the hip to be far enough into the fragmentation phase to determine the extent of epiphyseal involvement (214,215). Furthermore, it also has been noted that the classification may change when radiographs taken during the initial phase are compared with those taken at maximal fragmentation (215,216).

Salter and Thompson (115) described a simplified two-

TABLE 24-2. PROGNOSTIC FACTORS

Deformity of the femoral head
Hip joint incongruity
Age at disease onset
Extent of epiphyseal involvement
Growth disturbance secondary to premature physal closure
Protracted disease course
Remodeling potential
Type of treatment (?)
Stage at treatment initiation

TABLE 24-3. STULBERG CLASSIFICATION

Class	Radiographic Features	Congruency
1	Normal hip	Spherical
2 (Figs. 24-9 and 24-18)	Spherical femoral head, same concentric circle on anteroposterior and frog-leg lateral views, but with one or more of the following: coxa magna, shorter-than-normal neck, abnormally steep acetabulum	Spherical
3 (Figs. 24-11 and 24-17)	Ovoid, mushroom-shaped (but not flat) head, coxa magna, shorter-than-normal neck, abnormally steep acetabulum	Aspherical
4 (Fig. 24-13)	Flat femoral head and abnormalities of the head, neck, and acetabulum	Aspherical
5 (Fig. 24-14)	Flat head, normal neck and acetabulum	Aspherical incongruity

(From ref. 189, with permission.)

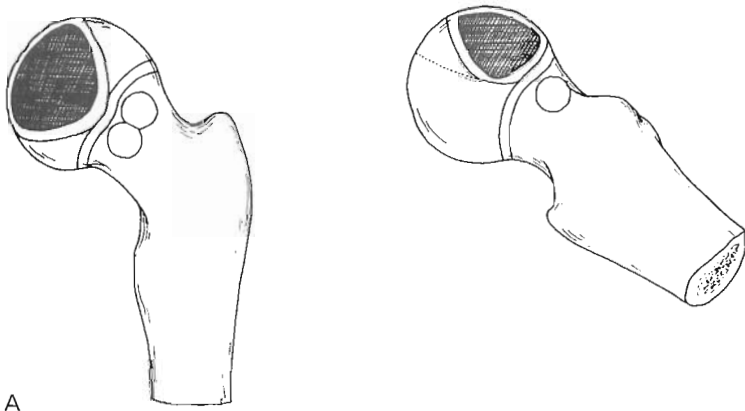
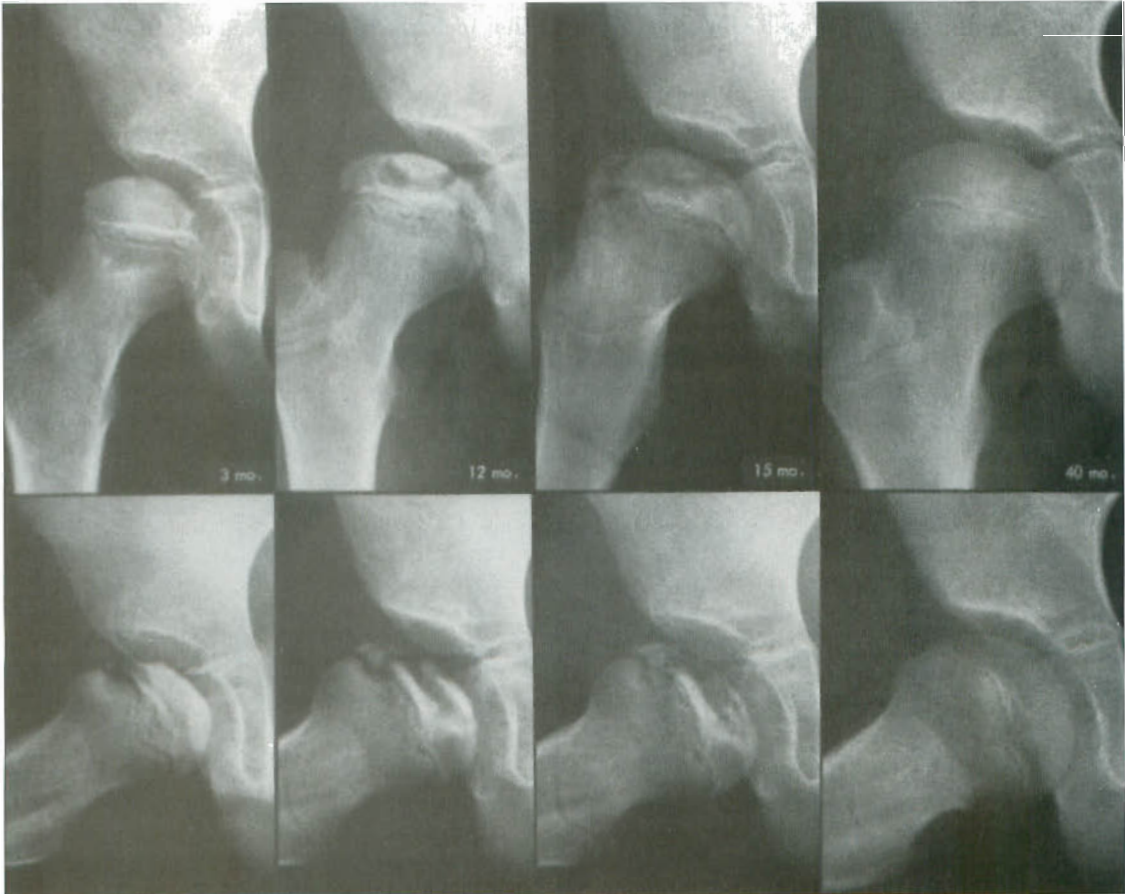

FIGURE 24-18. A: Catterall group 2 disease showing anterolateral involvement, sequestrum formation, and a clear junction between the involved and uninvolved areas. There are anterolateral metaphyseal lesions, and the subchondral fracture line is in the anterior half of the head. The lateral column is intact. B: Catterall group 2 disease. Three to 40 months after symptom onset, the lateral pillar is still intact.



group classification based on prognosis and determined by the extent of the subchondral fracture line, which appears early in the course of the disease: in group A, less than half of the head is involved (Catterall groups 1 and 2), and in group B, more than half of the head is involved (Catterall groups 3 and 4). The major determining factor between groups A and B is the presence or absence of a viable lateral column of the epiphysis. This intact lateral column (i.e., Catterall group 2, Salter-Thompson type A) may shield the epiphysis from collapse and subsequent deformity (Fig. 24-18).

The importance of the maintenance of the integrity of the lateral column and the height of the femoral head has been described by several authors (65,197,202,217,218). Hall (197) reported on the long-term follow-up (34 years) of 209 hips. He considered loss of femoral head height, as seen on the initial radiograph, an important prognostic sign. All of his patients in whom there had been a loss of 2 mm or more of height of the femoral head, compared with the unaffected hip, had unsatisfactory results in adult life. When the height of the head was within 2 mm of that of the unaffected hip on the initial radiograph, all but six hips had done well.

Herring and colleagues (202) proposed a radiographic classification based on the radiolucency of the lateral pillar of the femoral head on anteroposterior films during the fragmentation phase of the disease (Table 24-4) (Figs. 24-11, 24-13 and Fig. 24-19). The lateral pillar occupies the

TABLE 24-4. LATERAL PILLAR CLASSIFICATION

Type A	No involvement of the lateral pillar; lateral pillar is radiographically normal; possible lucency and collapse in the central and medial pillars, but full height of the lateral pillar is maintained
Type B	Greater than 50% of the lateral pillar height is maintained; lateral pillar has some radiolucency, with maintenance of bone density at a height between 50 and 100% of the original height of the lateral head
Type C	Less than 50% of lateral pillar height is maintained; lateral pillar becomes more radiolucent than in type B, and any preserved bone is at a height of <50% of the original height of the lateral pillar

(From ref. 202, with permission.)

lateral 15 to 30% of the femoral head width on an anteroposterior radiograph. The central pillar occupies approximately 50% of the head width, and the medial pillar occupies 20 to 35% of the medial aspect of the head width on an anteroposterior radiograph.

Herring and colleagues reported on the outcomes of 93 hips in 86 patients with radiographic follow-up to maturity (202). Intraobserver reliability was reported to be 0.78, with a good correlation of outcome, as measured by the classification of Stulberg and colleagues (189). The importance of

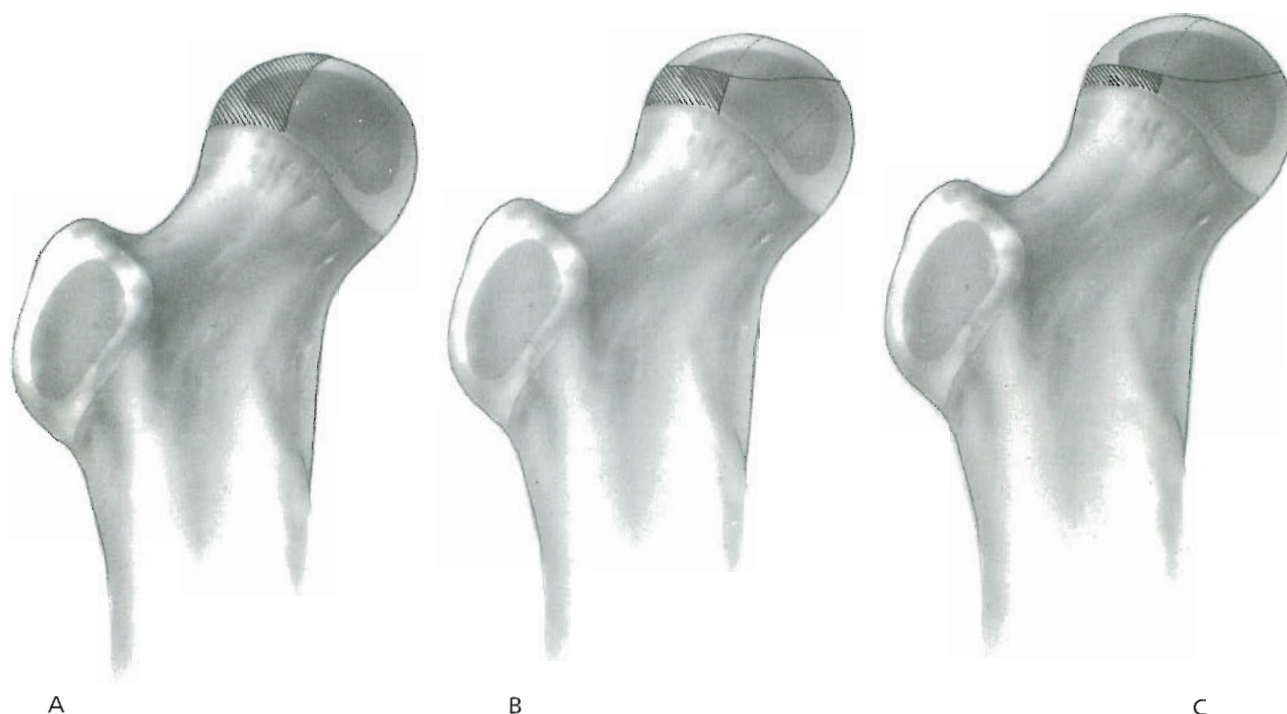


FIGURE 24-19. Lateral pillar classification (See Table 24-4 for a description of A, B, and C).

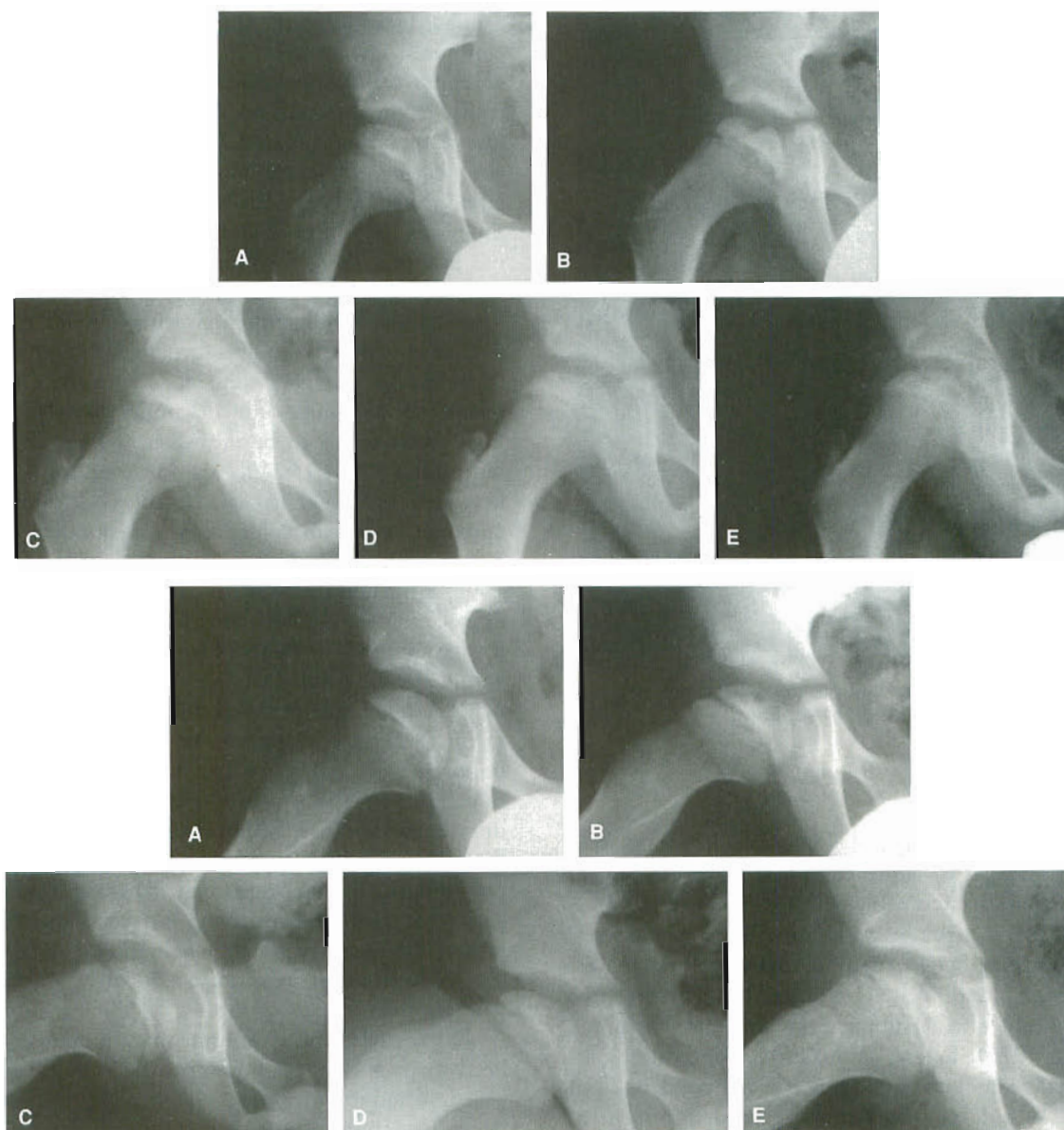


FIGURE 24-20. Anteroposterior (top) and lateral (bottom) views of a 7-year-old boy who presented with hip pain and a limp. **A:** At presentation, the patient was in the initial radiographic stage of the disease; his prognosis was indeterminate. **B:** Six months after presentation, he had minimal loss of height of the lateral pillar and some radiolucency in that region, as well as significant bone resorption centrally. Note how the lateral pillar maintains its height throughout the course of the disease. **C to E:** One year (**C**), 18 months (**D**), and 3 years (**E**) after onset of disease. The patient had only mild symptoms on occasion, and maintained good range of motion throughout the disease course. Only symptomatic treatment was provided.

the integrity of the lateral column is seen in other classifications, with patients in Salter-Thompson type A and Catterall groups 1 and 2 having intact lateral columns. The results of treatment in long-term outcome studies show this to be an important prognostic factor (192,202,216,219,220) (Fig. 24-20).

In analyzing the unexpectedly poor results in each category, Catterall (65,180,186,221,222) identified certain ra-

diographic signs, known as “at-risk signs,” that were associated with poor results (Fig. 24-21). Results in untreated patients show that there were no poor results in patients who did not have two or more of the radiographic at-risk signs during the active stage of the disease. Radiographic at-risk signs include the Gage sign, which is a radiolucency in the lateral epiphysis and metaphysis, and calcification lateral to the epiphysis. These two signs are indicative of

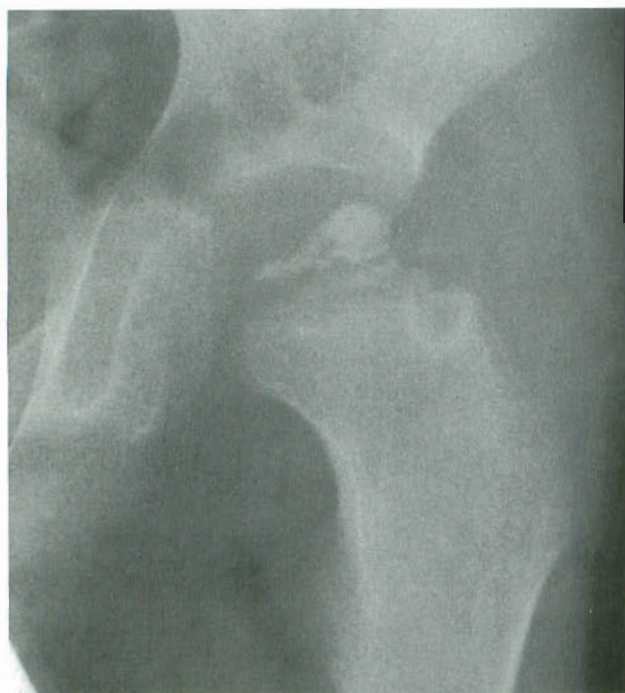

FIGURE 24-21. A 6-year, 5-month-old boy with Catterall group 4 disease demonstrates all of the at-risk signs.

early ossification in the enlarged epiphysis. They are present only when the head is deformed. These signs are present when the changes are reversible with treatment (65,223). A third at-risk sign is metaphyseal lesions. These metaphyseal radiolucencies may herald the potential for a growth disturbance of the physal plate (141,224,225). The final two at-risk signs are lateral subluxation and the horizontal growth plate (226). Lateral subluxation is indicative of a widened head. The horizontal growth plate (adducted hip) is indicative of a developing femoral head deformity that, if left untreated, will lead to fixed deformity, hinge abduction, and subsequent further deformity. These radiographic at-risk signs are manifested clinically by loss of motion and adduction contracture. Catterall reported no poor results in patients not manifesting at-risk signs. The validity of the Catterall classification and the at-risk signs has been confirmed by several series (215,227–234), but questioned by others (192,202,216,235).

Stulberg and colleagues (189) identified lateral and superior subluxation, which are indicative of significant growth disturbance and flattening of the femoral head, as the key factors associated with the development of class 3 and 4 hips and poor long-term outcome (i.e., after 40 years). Disease onset after age 9 years and partial head involvement, particularly anterosuperior quadrant involvement, were associated with the development of a class 5 hip and the early onset of degenerative joint disease (i.e., third to fifth decade of life).

The duration of the disease is related to the extent of epiphyseal involvement. In general, the greater the extent of epiphyseal involvement, the longer the duration and course of the disease. End results are worse with prolonged disease duration (195,202,236,237). The sex of the patient also relates to the extent of epiphyseal involvement, in that girls affected by Legg-Calvé-Perthes syndrome have a poorer prognosis than boys (238,239). This may be explained by the fact that there are more girls (who tend to be more skeletally mature than comparably aged boys, and hence have less remodeling potential) with Catterall groups 3 and 4 disease, which have a less favorable prognosis (147).

Age of disease onset is the second most significant factor related to outcome; only deformity is more significant. Eight years seems to be the watershed age in most long-term series (175,193,240,241); however, some authors believe that the prognosis is markedly worse for long-term outcome in patients older than 6 years of age at disease onset (192). W.J. Cumming (personal communication, 1993) estimated that 45% of patients with onset of Perthes disease after the age of 6 years have undergone arthroplasty by age 60 years. Patients older than 11 or 12 years, even with Catterall group 2 or Salter-Thompson type A disease, may have poor anatomic and clinical results, even with treatment (242). Age at healing, however, is probably a more important factor (Fig. 24-11). The overall skeletal maturation delay (45) in patients with Legg-Calvé-Perthes syndrome, and the usual compensation for this delay during the pubertal growth spurt (43), contribute to the favorable prognosis in the young patient. The more immature the patient at the time of entering the reossification stage, the greater the potential for remodeling. At-risk signs are also less likely to occur in younger patients, particularly those younger than 5 years of age.

The key relationship for outcomes (prognosis) is femoral head shape and its relationships to acetabular shape (congruency) and joint motion. The shape of the acetabulum is dependent on the geometric pattern within it during growth (170,243,244). In addition, the acetabulum continues to have significant potential for development until age 8 or 9 years (78,80,245). If a young patient develops a deformity, the immature acetabulum conforms to the altered femoral head shape. This may lead to the development of an aspherical congruency (Stulberg classes 3 and 4) that may be compatible with normal function for many years. In older patients (whether “older” means older than 6 years or older than 8 years is subject to debate), the acetabulum cannot conform to the shape of a deformed femoral head; hence, there is a greater chance of the development of an incongruous relationship, leading to early degenerative joint disease (189,191–194,244,246).

The importance of premature physal arrest secondary to the disease process cannot be overemphasized. Keret and colleagues (171), in a study of 80 patients with Legg-Calvé-Perthes syndrome, showed that 90% of them had interference with physal growth, with 25% having premature phy-

seal closure. They demonstrated a direct correlation between the severity of physal involvement and deformity of the head. Clarke and Harrison (247) reported that 47% of 31 patients who presented with painful hips after Legg-Calvé-Perthes syndrome, at an average age of 27 years, had evidence of premature physal closure.

Various methods have been used to measure the sphericity of the femoral head and congruency at healing. Goff (10,46,248) used a transparent protractor with concentric circles drawn at 2 mm of radial difference to evaluate femoral head shape. Mose further developed Goff's method and applied it clinically. This is the most commonly used method of measuring sphericity (99,249–251) (Fig. 24-16). It is not clear from the criteria of Mose whether the measurement under consideration is the difference between the outline of the femoral head on the anteroposterior and lateral radiographs or the deviation from a given circle, measured in millimeters, on either the anteroposterior or the lateral radiograph, or a combination of these two parameters. This variability in the application of the method of Mose and colleagues is evident in the literature on Legg-Calvé-Perthes syndrome (90,229,230,252–255).

In general, the template with concentric circles is superimposed on the anteroposterior and lateral roentgenograms. In the author's practice, if the outline of the femoral head is a perfect circle in both projections, it is rated good; less than 2 mm of deviation is rated fair; and more than 2 mm of deviation from a circle, in the anteroposterior or lateral projection, is rated poor. Regardless of measurements used, it is important to realize that, with growth and remodeling of the femoral head and acetabulum, the various parameters used to measure head deformity and congruency may change.

The shape of the head and its congruency, as measured at skeletal maturity, are probably the most reliable indicators of prognosis and the development of degenerative joint disease. Catterall (65) showed, in a follow-up of untreated patients, that 33% of the patients improved in anatomic grade. Twenty percent of these patients improved two anatomic grades; all of these patients were younger than 5 years of age at disease onset. However, it also must be remembered that the various deformities of the femoral head and acetabulum congruency are three-dimensional parameters that cannot be measured adequately by two-dimensional radiographs. Thus far, the only existing radiographic parameter that correlates with good clinical outcome is a perfectly spherical head. Loss of sphericity by itself, however, does not necessarily lead to a poor long-term result (175,193,206).

Thompson and Westin (256) confirmed the work of Ferguson and Howorth (68), which demonstrated that, after the femoral head is in the reossification stage of the disease, it will not deform further. For any treatment to influence head deformity, it must be instituted early in the course of the disease, that is, in the initial or fragmentation stage.

CLINICAL PRESENTATION

Patients with Legg-Calvé-Perthes syndrome most commonly present with a history of the insidious onset of a limp. Most patients do not complain of much discomfort, unless specifically questioned about this aspect. Pain, when present, is usually activity-related and relieved by rest. Because of its mild nature, most patients do not present for medical attention until weeks or months after the clinical onset of disease. The pain the patients experience generally is localized to the groin, or referred to the anteromedial thigh or knee region. Failure to recognize that thigh or knee pain in the child may be secondary to hip pathology may cause further delay in the diagnosis. Some children present with more acute symptom onset. Seventeen percent of patients with Legg-Calvé-Perthes syndrome may give a history of related trauma (20,23,257).

PHYSICAL EXAMINATION

The child with Legg-Calvé-Perthes syndrome usually presents with limited hip motion, particularly abduction and medial rotation. Early in the course of the disease, the limited abduction is secondary to synovitis and muscle spasm in the adductor group; however, with time and the subsequent deformities that may develop, the limitation of abduction may become permanent. Long-standing adductor spasm occasionally leads to adductor contracture. The Trendelenburg test in patients with Legg-Calvé-Perthes syndrome is often positive. These children most commonly have evidence of thigh, calf, and buttock atrophy from disuse secondary to pain. This is additional evidence of the long-standing nature of the condition before detection (1–5,174,248). Limb length should be measured; inequality is indicative of significant head collapse and a poor prognosis. Evaluation of the patient's overall height, weight, and bone age may be helpful to rule out skeletal dysplasias or growth disorders in the differential diagnosis, and may provide confirmatory evidence of the disorder. Laboratory studies generally are not helpful in Legg-Calvé-Perthes syndrome, although they may be necessary to rule out other conditions.

IMAGING

In Legg-Calvé-Perthes syndrome, the diagnosis is made and the clinical course is assessed by plain radiographs taken in the anteroposterior and frog-leg lateral positions. These radiographs are generally sufficient for the assessment of the patient and subsequent follow-up evaluations. From the plain radiographs, the extent of epiphyseal involvement (e.g., Catterall groups 1 to 4; Salter-Thompson type A or B; lateral pillar type A, B, or C) and the stage of the disease

(initial, fragmentation, or reossification) can be determined. According to Salter and Thompson, if appropriate radiographs are taken within 4 months of the clinical onset of the disease, the subchondral radiolucent zone will be detectable (115). Catterall, however, states that this sign is helpful in only 25% of cases, because it is present only transiently in the early phases of the disease (65). It is most important in following the course of the disease that all radiographs be viewed sequentially, and compared with previous, radiographs to assess the stage of the reparative process, and to determine the constancy of the extent of epiphyseal involvement. Additional radiographic or imaging studies are rarely necessary, but may be helpful in the initial assessment and follow-up of the condition (258–260).

Radionuclide bone scanning with technetium and pin-hole collimation (Fig. 24-22) may be helpful in the early stages of the disease, when the diagnosis is in question, particularly if the differential diagnosis is between transient synovitis and Perthes disease. Some investigators consider scintigraphy helpful in determining the extent of epiphyseal involvement and the prognosis (261–270).

Magnetic resonance imaging is widely available in medical centers. It appears to be sensitive in detecting infarction, but cannot yet accurately portray the stages of healing. Its role in the management of Perthes syndrome has yet to be defined. In the future, magnetic resonance imaging may not only help the clinician in the diagnosis, but may shed additional light on the underlying pathology of the condition (93,268,271–274) (Fig. 24-23).

Arthrography is useful primarily in demonstrating any flattening of the femoral head that may not be seen on plain radiographs (Fig. 24-24). It can be used to demonstrate the hinge abduction (Fig. 24-8) phenomenon with abduction of the leg (152,180,181,206,275). Arthrography, in conjunction with plain radiography or computed tomography, also may be useful in the diagnosis of osteochondritis dissecans secondary to Perthes disease. Arthrography is most useful for assessing head shape and the relation to the acetabulum that would be necessary for treatment decisions (Fig. 24-25). With severe flattening of the femoral head, arthrography is helpful in determining containability before any treatment, whether it will be Petrie casts, bracing, or surgery.

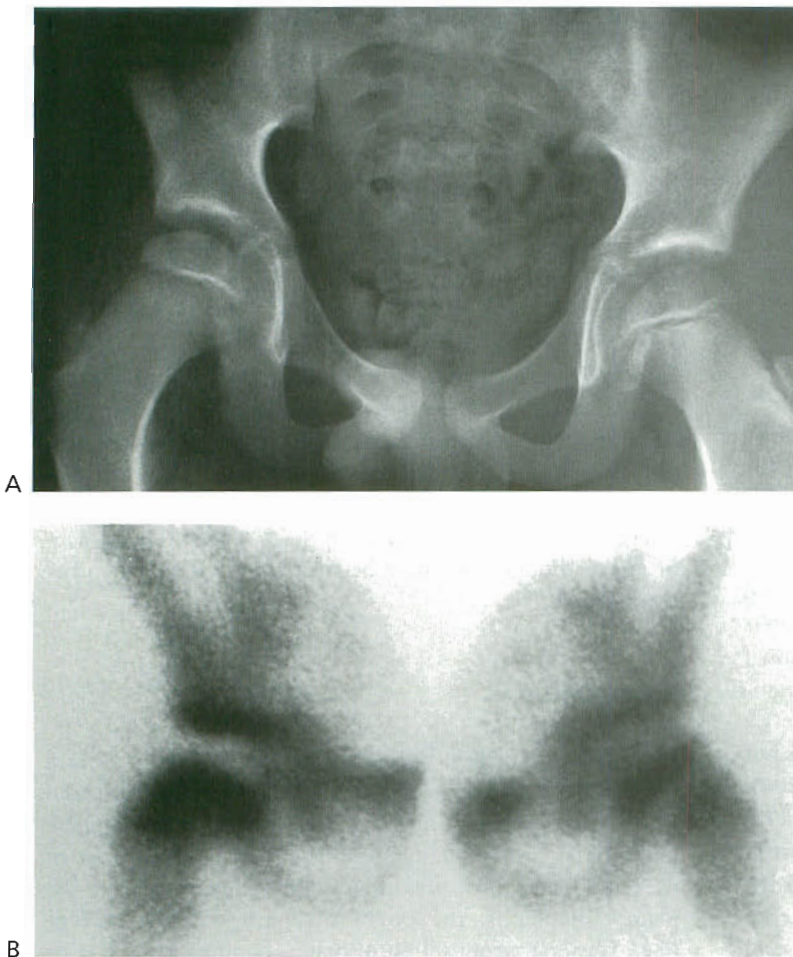

FIGURE 24-22. An 8-year-old boy with right hip pain. **A:** Anteroposterior radiograph demonstrates a slight increase in width and medial joint space; the femoral osseous nucleus is slightly smaller than the opposite side. **B:** Technetium 99 radionuclide scan demonstrates decreased uptake in the entire right femoral head, with increased vascularity in the neck.

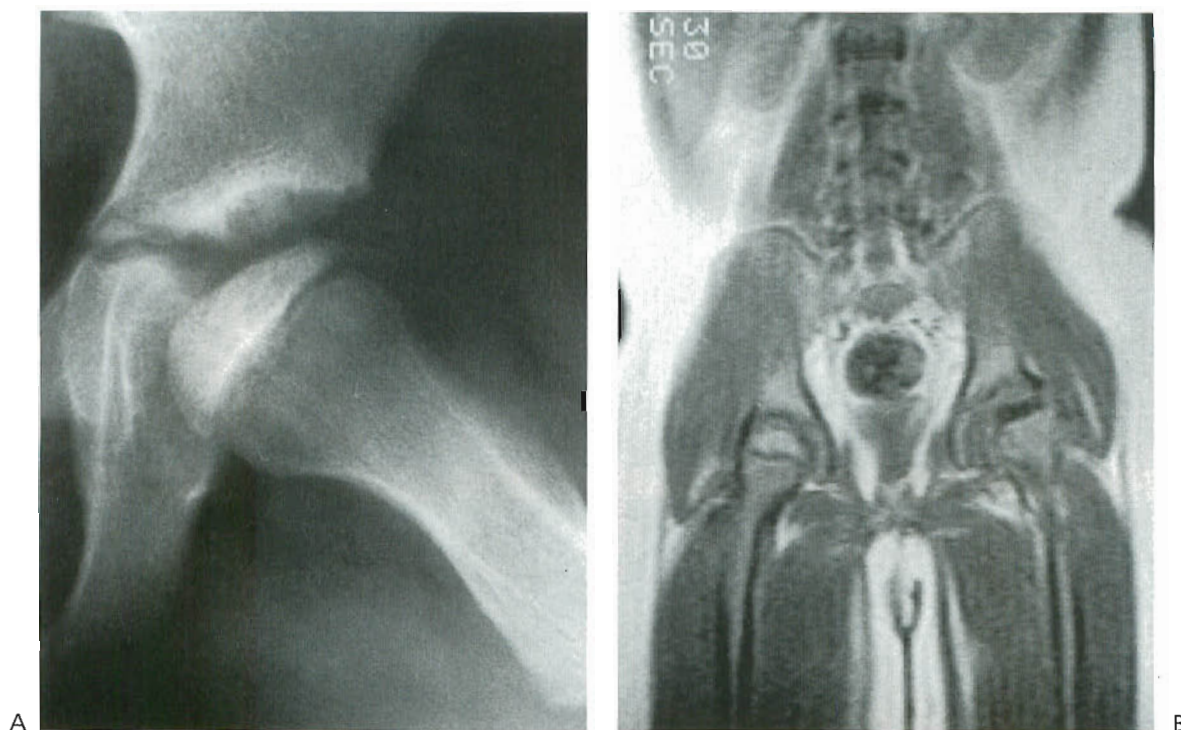


FIGURE 24-23. A 6-year-old boy with Catterall group 3 disease in the early fragmentation stage. **A:** Plain radiograph shows apparent sparing of the posterior head. **B:** Magnetic resonance image demonstrates a complete absence of signal on the affected side. (Courtesy of Peter Scoles, M.D., Case Western Reserve Medical School, Cleveland, Ohio.)

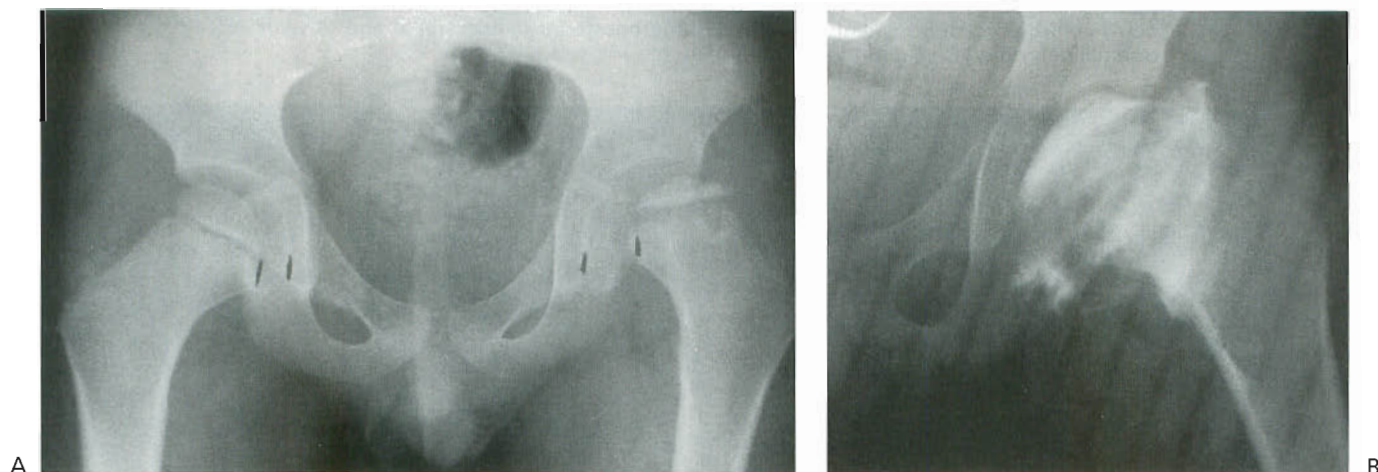


FIGURE 24-24. A 5-year-old boy with Catterall group 4 disease and at-risk status. **A:** Anteroposterior radiograph on presentation. **B:** Anteroposterior arthrogram, in the same position as in **C**, after 10 days of traction. Note the relation between the lateral acetabular margin and the lateral margin of the cartilaginous femoral head, as well as the severe flattening of the femoral head. (continued)

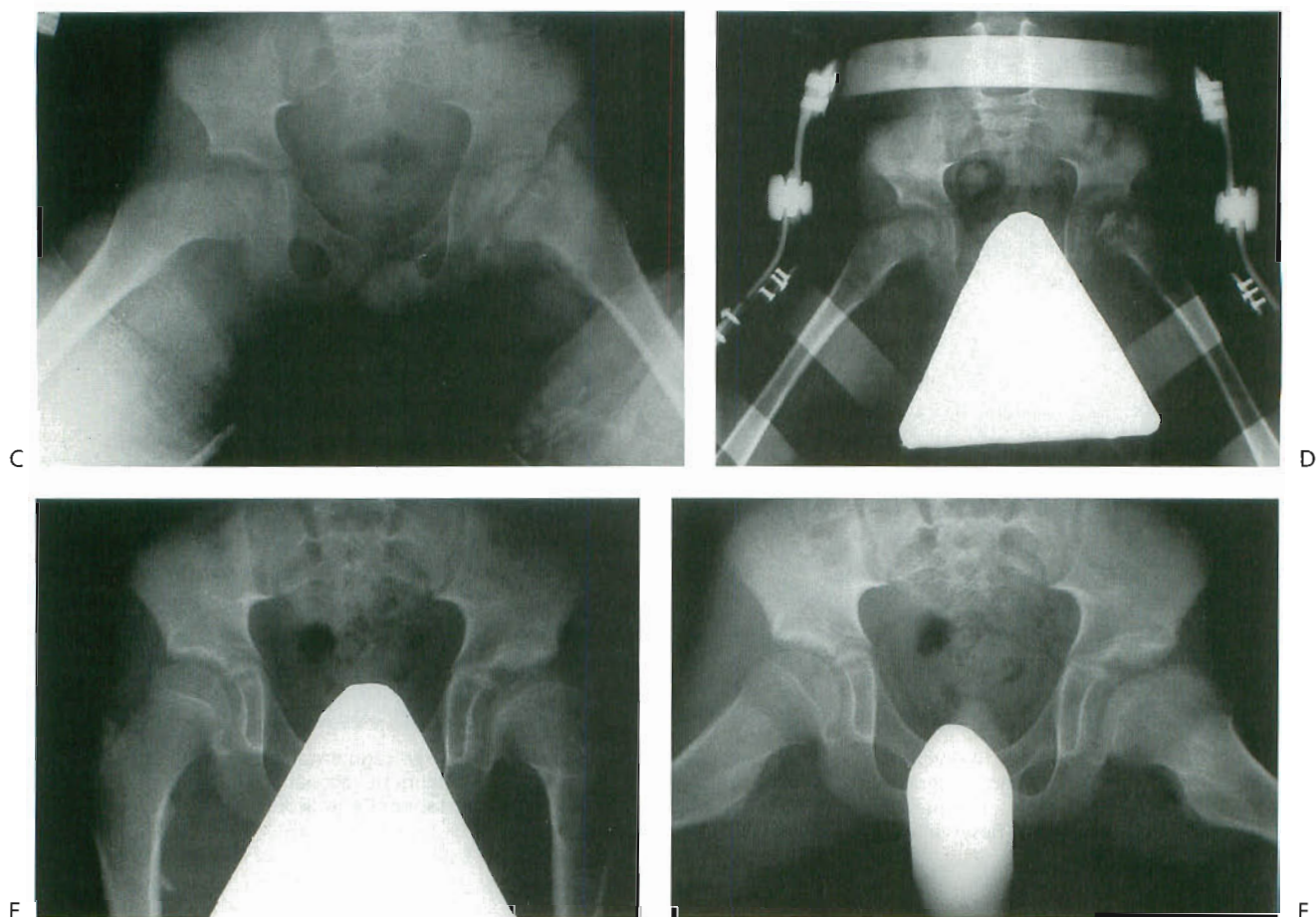


FIGURE 24-24. (continued) C: Anteroposterior roentgenogram in Petrie broomstick abduction plasters. The patient was maintained in casts for 6 weeks. D: Anteroposterior radiograph with pelvis abduction orthosis (weightbearing). E: Anteroposterior radiograph at age 13 years. Note residual deformity. F: Lauenstein radiograph at age 13 years.

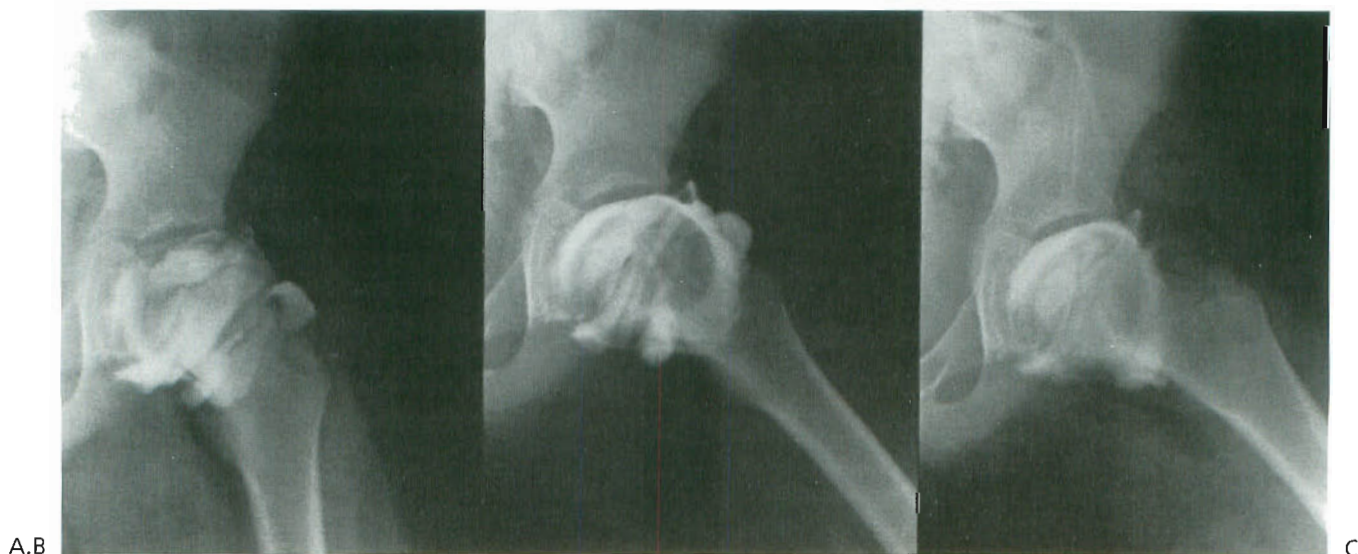


FIGURE 24-25. Arthrogram of a 6-year-old boy with Catterall group 4 disease. A: Neutral position. B: Abduction, external rotation, and slight flexion (the position that would be maintained by an abduction Scottish Rite-type orthosis). C: Abduction and internal rotation (the position that would be maintained by a varus derotation osteotomy). On the basis of the arthrogram, the hip can be contained either by the position that would be maintained by bracing (B) or by surgery (C).

It is also useful in determining the best position of containment, such as internal or external rotation and abduction or adduction, if surgical management is considered.

DIFFERENTIAL DIAGNOSIS

The patient history, physical examination, and plain radiographs are usually sufficient to make a diagnosis of Legg-Calvé-Perthes syndrome (Table 24-5). Diagnosis early in the initial phase of the disease must be differentiated from conditions such as septic arthritis, whether primary or secondary to proximal femoral osteomyelitis, and toxic synovitis (276–278). A complete blood count, including white cell differential, erythrocyte sedimentation rate, C reactive protein, and hip joint aspiration and analysis of the fluid, may be necessary to rule out infection. All laboratory studies of Legg-Calvé-Perthes syndrome generally are normal, although the erythrocyte sedimentation rate may be slightly elevated. In early cases, if all of the laboratory and plain radiographic studies are normal, and doubt regarding the diagnosis persists, radionuclide scanning or magnetic resonance imaging may be helpful.

In patients with bilateral hip involvement, generalized disorders, such as hypothyroidism and multiple epiphyseal dysplasia, must be considered (279,280). Patients with bilateral involvement, particularly those with atypical radiographic features, must have a careful family history obtained, measurements of height and weight, and a bone survey, to rule out a metabolic or a genetic condition (see Chapters 7 and 8). Meyer dysplasia, a benign resolving condition, must be considered in children younger than 4 years of age (281).

TABLE 24-5. DIFFERENTIAL DIAGNOSIS

Chondrolysis
Gaucher disease
Hemophilia
Hypothyroidism
Juvenile rheumatoid arthritis
Lymphoma
Mucopolysaccharidosis
Multiple epiphyseal dysplasia
Meyer dysplasia
Neoplasm
Old congenital dysplasia of the hip residuals
Osteomyelitis of the proximal femur
Septic arthritis
Sickle cell disease
Spondyloepiphyseal dysplasia
Toxic synovitis
Traumatic aseptic necrosis

TREATMENT

For the past 70 years, considerable therapeutic nihilism has been expressed by many authors (14,15,166,189,190,282). Sundt (190) believed that treatment could not prevent degenerative joint disease. Because there is a paucity of long-term natural history data available, the question must be raised whether the outcome of Legg-Calvé-Perthes syndrome can be altered by any particular treatment. As mentioned above, long-term series of treated patients are difficult to evaluate. Long-term series of patients with uniform treatment, and matched for age, gender, stage, and extent of epiphyseal involvement, are necessary to determine the most effective treatment of Perthes syndrome.

Most patients (60%) with Legg-Calvé-Perthes syndrome do not need treatment (65,115,186,214,223,283). Treatment must be considered only for those patients who have an otherwise known poor prognosis based on prognostic factors gleaned from long-term follow-up. It is difficult to formulate specific treatments for patients, because natural history is not well known, and most studies of current treatment methods lack interrater and intrarater reliability of classifications of the extent of epiphyseal involvement and outcome measures, and all lack control groups. These factors, and other variables examined in most series, make it difficult to support a “best” method of treatment.

Standard treatment algorithms are based on radiographic features of the various disease classification schemes. Under these protocols, no treatment is warranted in patients with a good prognosis (i.e., those with Catterall group 1, Salter-Thompson type A, or lateral pillar type A disease) (Table 24-6). Patients with a poor prognosis should be considered for treatment, such as patients with Catterall groups 3 and

TABLE 24-6. TREATMENT OF LEGG-CALVÉ-PERTHES DISEASE

Poor Prognostic Group: Treatment Indicated
Catterall 3 and 4
Salter-Thompson B
Lateral pillar C
At-risk clinically
At-risk radiographically, regardless of the disease extent
Less than age 8 years with deformity
Over age 8 years (Catterall group 2, 3, and 4, with or without at-risk signs; Lateral pillar B and C; Salter-Thompson B), with or without head deformity
Good Prognosis: No Treatment Necessary
Catterall 1 and 2 (generally good prognosis in 90% of cases)
Salter-Thompson A
Lateral pillar A
Indeterminate Prognosis: May Require Treatment
Catterall 2
Lateral pillar B
In Reossification Stage: May Require Treatment

4 disease, Salter-Thompson type B disease, and lateral pillar type C disease. There is another large group of patients whose prognosis is indeterminate; these patients require careful follow-up, because they may need treatment. This group includes patients with Catterall group 2 disease (good prognosis in 90% of cases) and patients with lateral pillar type B disease. Because we have learned that the two major prognostic factors in outcome are deformity and age, these two factors must be taken into account in the decision-making process. Patients with deformity (arthrographically and/or clinically documented), younger than 8 years, should be considered for treatment. Patients older than 8 years, especially females, should be considered for treatment even in the absence of deformity, because of their otherwise poor prognosis (240,241,284). All patients should be treated if they manifest clinical at-risk signs (i.e., if they lose range of motion and have pain), or if they demonstrate several of the radiographic at-risk signs, regardless of their extent of epiphyseal involvement. If the patient is already in the reossification or healing stage of the disease, little deformity ensues, and no treatment is indicated (see "Treatment Options in the Noncontainable Hip and the Late-presenting Patient with Deformity" below).

The earliest treatment methods used weight relief until the head was reossified. These methods were based on the premise that weight relief would prevent the mechanical deformation of the head and early degenerative joint disease (82,285–287). These modalities included prolonged, strict bed rest, often in the hospital, and bed rest with or without various periods of traction on special frames or in spica casts. These methods of treatment were associated with disuse atrophy of muscles, osteopenia, shortening of the involved extremity, loss of thoracic kyphosis, urinary calculi, social and emotional problems, and high hospital costs (148, 199,200,252,288–295).

The concept of weight relief as a treatment for Legg-Calvé-Perthes syndrome was challenged as early as 1927, when Legg stated that, "while the process suggesting weakness of bone structure is going on it is theoretically sound to allow no weight bearing but in practice relief from weight bearing in no way affects the end results" (296). In addition, prolonged immobilization and bed rest do not influence the radiographic course of the disease (214,232,233,297–299). Harrison and Menon (292) pointed out, as had Pauwels and others (148,300,301), that even at rest, significant forces act on the femoral head with minimal activity.

The cornerstone of treatment for Legg-Calvé-Perthes syndrome is referred to as "containment." This concept was originally described by Parker (292) and Eyre-Brook (286). The rationale for this concept has been defined further by Harrison and Menon (292), Petrie and Bitenc (254), Salter (114,302), and others (303–308). The essence of containment is that, to prevent deformities of the diseased epiphysis, the femoral head must be contained within the depths of the acetabulum to equalize the pressure on the

head and subject it to the molding action of the acetabulum. Containment is an attempt to reduce the forces through the hip joint by actual or relative varus positioning (309). Containment may be achieved by nonoperative or operative methods. Considering all the methods of containment, the femoral head represents more than three-fourths of the sphere and the acetabulum only half of the sphere. No method of containment can provide for a totally contained femoral head within the acetabulum during all portions of the gait cycle (137,307,308,310).

Patient Management

The primary goals in the treatment of Legg-Calvé-Perthes syndrome are to prevent deformity (Stulberg classes 3, 4, and 5), alter growth disturbance, and thus to prevent degenerative joint disease. Attainment of these goals requires that each patient be assessed clinically and radiographically. Clinically, the patient is evaluated for clinical at-risk signs of loss of motion, joint contracture, and pain. Radiographically, anteroposterior and frog-leg lateral radiographs are evaluated to determine the radiographic stage of the disease, the extent of epiphyseal involvement, and the presence of radiographic at-risk signs. For treatment to have any effect on subsequent deformity, it must be initiated in the initial or fragmentation phase of the disease (68,256).

Treatment is not indicated if the child demonstrates none of the clinical or radiographic at-risk signs; if he or she has Catterall group 1 or 2, Salter-Thompson type A, or lateral pillar type A disease; or if the disease is already in the reossification stage. A child who demonstrates clinical or radiographic at-risk signs, regardless of the extent of epiphyseal involvement, should receive treatment (174). Even patients with Catterall group 2 disease (or lateral pillar type B disease) who are at risk may have poor results without treatment (65,78) (W.J. Cumming, personal communication, 1993).

The first principle of treatment, regardless of the definitive method of treatment chosen, is restoration of motion. Joint motion enhances synovial nutrition and cartilage nutrition (311,312). This tenet of treatment cannot be overemphasized. The most successful reported series of patients treated for extensively involved femoral heads is that of Brotherton and McKibbin (303). These patients were treated with bed rest and containment. End results in these patients were superior to those in another long-term study (199,200) of patients treated with bed rest and containment on a frame. The only difference between the two treatment regimens was that in the former series motion was always maintained. Restoration of motion can be accomplished by bed rest alone, or with skin traction and progressive abduction to relieve the muscle spasms. Occasionally, surgical release of the contracted adductors may be necessary. Restoration of motion allows abduction of the hip, which reduces the forces on the hip joint, and allows positioning of the

uncovered anterolateral aspect of the femoral head in the acetabulum. Mobilization of the hip joint also can be obtained by rest followed by the use of progressive abduction plasters to stretch the hip adductor muscles while allowing hip flexion and extension. A full or almost full range of motion is usually obtainable within 7 to 10 days of treatment. Because of early deformity, complete abduction and internal rotation may not always be obtainable. Persistence of an adduction contracture is always associated with a serious femoral head deformity and will not respond to traction (313).

Arthrography is a useful adjunct in determining whether the head actually can be contained and, if so, in what position this is best accomplished (314) (Fig. 24-25). Arthrography can reveal any flattening of the femoral head that may not be seen on plain radiographs. More importantly, it can demonstrate the hinge abduction phenomenon (180, 181, 206) (Fig. 24-8). Demonstration of the hinge abduction phenomenon, or the inability to contain the hip, is a contraindication to any type of containment treatment. Serious damage to the femoral head and acetabulum may result from trying to contain a noncontainable head (Fig. 24-14). Arthrography should be performed under general anesthesia. This also provides an opportunity to examine whether muscle spasm, contracture, or mechanical deformity is responsible for any apparent fixed deformities.

The treatment of Legg-Calvé-Perthes syndrome remains controversial, and there is disagreement regarding whether operative or nonoperative treatment is beneficial. The shortage of natural history studies for comparison of the results of different modalities of treatment is another reason why it is difficult to resolve this controversy. In addition, the variability of criteria for inclusion of patients in studies, and the use of different measurements to assess outcomes of treatment, lack of interrater and intrarater reliability data, and lack of untreated control groups, make comparisons difficult. The most widely used methods to maintain containment are abduction orthosis, femoral osteotomy, innominate osteotomy, and lateral shelf acetabuloplasty. Interest has grown in combined femoral and innominate surgical procedures, and in the use of procedures originally regarded as salvage procedures in the primary treatment of Perthes disease.

Nonoperative Treatment

In 1971, Petrie and Bitenc (254) reported excellent results from applying the principles of containment, using broomstick abduction long-leg plasters (Fig. 24-24C). This series proved that weight bearing, with the head contained, was not harmful. This method of treatment allows for weight bearing and maintenance of hip range of motion in the contained position. Successful treatment results using this technique have been reported (315). Pietrie casts are used after muscle-release procedures and capsulotomies to reduce

heads that are deformed and subluxated (316), to maintain containment before bracing or surgical treatment, or as definitive nonsurgical treatment in situations in which bracing compliance is in question.

To avoid the repeated hospitalizations necessary to regain knee and ankle motion, and to avoid the occasional flattening of the femoral condyles seen in patients treated with broomstick plasters, attention turned to the use of removal abduction orthoses, as typified by the Newington abduction brace (252), the Roberts orthosis (317), the Houston A-frame brace (318), and the Toronto Legg-Calvé-Perthes orthosis (160, 319). These devices provide containment in the abducted internal rotation position.

The most widely used abduction orthosis is the Atlanta Scottish Rite orthosis or a modification thereof (Fig. 24-26). These devices were thought to provide for containment solely by abduction without fixed internal rotation (253, 255, 320, 321). These orthotic devices allow free motion of the knee and ankle. Containment is provided by the abduction of the brace and the hip flexion required to walk with the legs in abduction. These devices are less cumbersome than other braces, and are well tolerated by patients. On arthrography, the position of containment that would be demonstrated by abduction, slight flexion, and external rotation (Fig. 24-25). Patients must demonstrate containment on a radiograph in the weight-bearing position while in the brace (Fig. 24-24). At each subsequent visit, the patient must be examined out of the orthosis to be certain that range of motion is maintained. If the range of motion is not adequate, traction should be initiated to restore range of motion, and containability should be reassessed. The brace is worn on a full-time basis until the head is in the reossification stage, when there is no further risk of collapse. Full-time bracing ranges from 6 to 18 months. The negative aspects of bracing include prolonged treatment times and the necessity of having a compliant patient. Some patients may not tolerate the brace for psychological reasons (322). This type of treatment also may be difficult for girls and older patients to accept (323).

Although early radiographic anatomic results were comparable with those of previously used containment weight-bearing methods (255, 321), follow-up reports of patients treated with these orthotic devices question the efficacy of this method of management (216, 324, 325). Martinez and colleagues (216) reported on 31 patients, with 34 hips, who had severe Perthes disease (Catterall groups 3 and 4) that had been treated with a weight-bearing abduction orthosis. The mean age of the patients when first seen was 6 years, and the mean duration of follow-up was 7 years. According to the Mose criteria, at follow-up no hip had a good result, 35% had fair results, and 65% had poor results. On the basis of the classification of Stulberg and colleagues, there were 41% class 2 results, 53% class 3 and 4 results, and 6% class 5 results. With respect to the lateral column, of

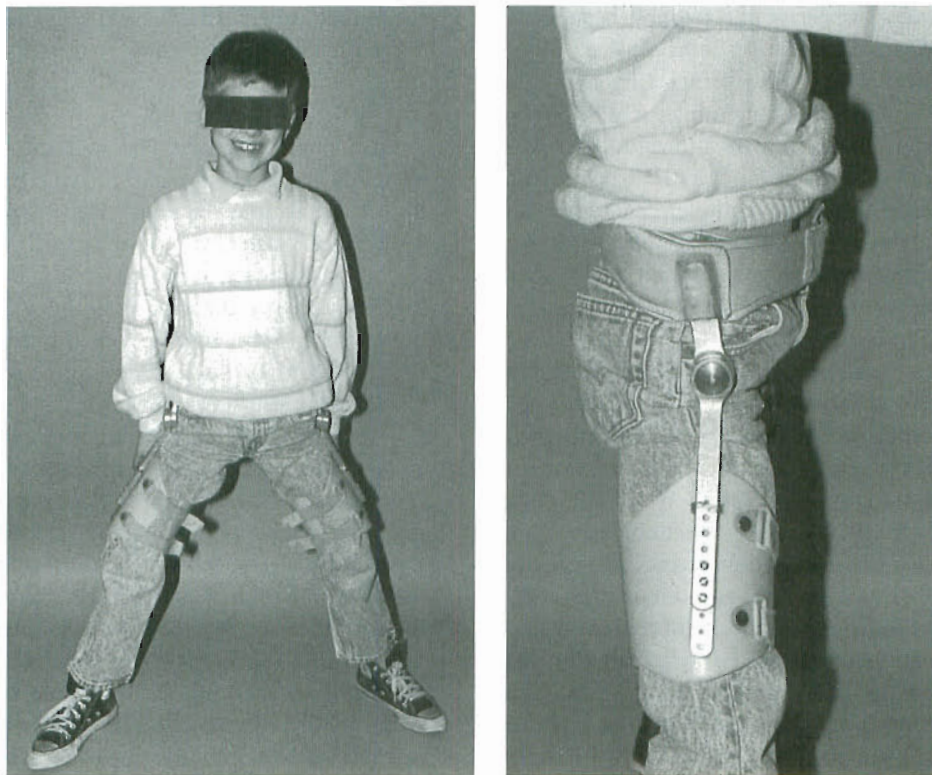


FIGURE 24-26. An abduction orthosis.

the 20 hips in which collapse occurred, only 10% had Stulberg class 2 results, 35% had class 3 results, 45% had class 4 results, and 10% had class 5 results. By comparison, in the 14 hips in which collapse of the lateral column did not occur, 86% had Stulberg class 2 results and only 14% had class 3 results. No hip in which collapse did not occur had a class 4 or 5 result. The authors concluded that although containment is the most widely accepted principle of treatment of Legg-Calvé-Perthes disease, little clinical information supports the contention that bracing in abduction and external rotation, as provided by the Atlanta Scottish Rite orthosis and its modifications, is effective.

Meehan and colleagues (324) reported on 34 patients with Catterall group 3 or 4 disease, with an average age at diagnosis of 8 years. The average follow-up in this series was 6 years, 9 months. At follow-up, there were no Stulberg class 1 results, 3 class 2 results, 24 class 3 results, 6 class 4 results, and 1 class 5 result. These authors also arrived at a similar conclusion concerning the use of this orthotic device in the treatment of Perthes disease. In both of these studies the issue of compliance is not documented, and as with all studies of Perthes disease in the literature, control groups other than historic controls are absent. Because the radiographic outcomes in both of these studies were poor, it is questionable whether the orthosis itself adds anything to the treatment other than maintenance of range of motion.

As expected, the majority of patients in both series were doing well clinically, as do most patients who have Perthes disease over the short term, regardless of the extent of the deformity. The long-term prognosis, for all but the Stulberg class 1 and 2 hips, is guarded.

Because of these results, many physicians have begun treating patients with only maintenance of range-of-motion programs, including stretching exercises, nighttime abduction splinting, home traction, and other combinations. Long-term follow-up studies of these nonoperative range-of-motion regimens are needed to determine their efficacy.

Surgical Treatment

Surgical methods of providing or maintaining containment are advocated by many investigators. Surgical containment methods offer the advantage of early mobilization and the avoidance of prolonged bracing or cast treatment. In addition, no end point for discontinuing treatment is required, and any improved containment is permanent (316). Surgical containment may be approached from the femoral side, the acetabular side, or both sides of the hip joint. Procedures used to obtain or maintain containment in Legg-Calvé-Perthes syndrome are those that originally were used in the treatment of problems associated with developmental hip dysplasia and dislocation.

Varus Osteotomy

Varus osteotomy, [↗4.1,4.2] with or without associated derotation, offers the theoretical advantage of deep seating of the femoral head and positioning of the vulnerable anterolateral portion of the head away from the deforming influences of the acetabular edge (223,313,326–329). The varus position reduces the joint forces on the femoral head (309,326). This procedure also relieves the intraosseous venous hypertension and improves the disturbed intraosseous venous drainage reported in Legg-Calvé-Perthes syndrome, thus speeding the healing process (117,118, 134,326,327,330). This belief, however, has been disproved (331–333).

Prerequisites for varus derotation osteotomy include a full range of motion, congruency between the femoral head and the acetabulum, and the ability to contain the femoral head in the acetabulum in abduction and internal rotation (316,334) (Fig. 24-25). This assessment may require arthrography if the femoral head is well into the fragmentation phase. As with nonoperative treatment, the procedure must be performed early in the initial or fragmentation stage of the disease to have any effect on head deformity (168, 212,326).

The negative aspects of this treatment modality must be considered. Varus osteotomy, with or without derotation, usually requires the use of internal fixation and external mobilization in plaster for 6 weeks. The patient must incur the inherent risks and costs associated with at least one surgical procedure, and most likely a second surgical procedure for hardware removal. The limb is temporarily shortened by the procedure. The varus angle must not exceed a neck–shaft angle of less than 110 degrees. The varus angle generally decreases with growth (180,335,336); however, if there has been physeal plate damage secondary to the disease, this remodeling potential may be lost, and the patient may have permanent shortening and temporary or permanent weakness of the hip abductors (134,336–340). The proponents of varus osteotomy, with or without derotation, report 70 to 90% satisfactory anatomic results using this method (134,212,326,327,337,339,341–345).

Innominate Osteotomy

Innominate osteotomy [↗3.5] provides for containment by redirection of the acetabulum, providing better coverage for the anterolateral portion of the femoral head. The head is placed in relative flexion, abduction, and internal rotation with respect to the acetabulum in the weight-bearing position. Any shortening caused by the disease can be corrected, and the need for bracing is eliminated (114,316, 334,339,346–349). Prerequisites for innominate osteotomy include restoration of a full range of motion, a round or almost round femoral head, and joint congruency demonstrated arthrographically. Treatment must be performed

early in the course of the disease, and the head must be well seated in flexion, abduction, and internal rotation.

Innominate osteotomy is performed in a similar fashion as for residual hip subluxation. The tendinous portion of the iliopsoas muscle is always released at the musculotendinous junction, and any residual contractures of the adductor muscles are released by subcutaneous adductor tenotomy (114,316). The osteotomy is fixed by two or three threaded pins for internal fixation. Partial weight bearing may be resumed in a cooperative child several days after surgery; however, in an uncooperative patient, immobilization in a spica cast for 6 weeks is required.

The disadvantages of innominate osteotomy are the associated risks and cost factors of the surgical procedure and the procedure for pin removal. Additionally, the operation is performed on the normal side of the joint. This procedure may increase the forces on the femoral head by lateralizing the acetabulum and increasing the lever arm of the abductors (326), although this supposition has thus far not been substantiated. Innominate osteotomy also may cause a persistent acetabular configuration change in the face of a previously normal acetabulum, leading to loss of motion, particularly flexion (350). Satisfactory anatomic results from this procedure range from 69 to 94% (316,339,346,347, 351–355).

There is significant biomechanical evidence to show that neither method of surgical containment, innominate or femoral osteotomy, may effectively stress shield an extensively necrotic segment of the femoral head; the same may also apply for patients treated with bracing (307,308, 356,357). Wenger (177) reported a high incidence of complications in surgically treated patients in whom the accepted methods and prerequisites were met.

Varus Osteotomy Plus Innominate Osteotomy

Several short-term results of combined varus osteotomy plus innominate osteotomy have been reported in severely involved Catterall group 3 or 4 disease. This combined procedure has the theoretical advantage of maximizing femoral head containment while avoiding the complications of either procedure alone. The femoral osteotomy directs the femoral head into the acetabulum, while theoretically reducing any increasing joint pressure or stiffness that would result from the pelvic osteotomy. The coverage provided by the innominate osteotomy reduces the degree of correction needed from the femoral osteotomy, thereby minimizing the complications of excessive neck-shaft varus, associated abductor weakness, and limb shortening. Advocates of this procedure also believe that permanent correction of the deformity, early weight bearing, and shortened treatment time are obtained. The disadvantages of the procedure include those mentioned for varus osteotomy and innominate osteotomy alone. Surgical time is increased, potential blood loss is magnified, and the combined procedures are technically

more difficult. Satisfactory anatomic results from this combined procedure are reported in up to 78% of patients. As would be expected in short-term follow-up, the clinical results are excellent (358–362). The prerequisites for this operation include those for the varus and innominate osteotomies alone, in a patient who probably would not achieve satisfactory coverage from either procedure alone.

Shelf Arthroplasty

Shelf arthroplasty [➔3.12] formerly was used only as a salvage procedure. However, recently it has been proposed as a primary method of management in children older than 8 years of age with Catterall groups 2, 3, and 4 disease with or without at-risk signs, lateral pillar types B and C disease, and Salter-Thompson type B disease; if subluxation is present, it must be reducible on a dynamic arthrogram (284,363). Contraindications include hips that do not meet the above criteria and the presence of hinge ab-

duction. Only one intermediate-term follow-up study exists, but proponents believe that containment of the femoral head by shelf arthroplasty, before significant deformity develops, improves femoral head remodeling (284,364). Preliminary risk factors for poor results with this technique are age older than 11 years, female gender, and Catterall group 4 disease. The shelf procedure may cover the antero-lateral portion of the head, preventing subluxation and lateral overgrowth of the epiphysis (Fig 24-27).

Regardless of the method of containment chosen, any episode indicative of loss of containment, such as recurrent pain or loss of range of motion, must be treated aggressively with rest, traction, and reassessment of containment.

Treatment Options in the Noncontainable Hip and the Late-presenting Patient with Deformity

Patients presenting in the later stages (reossification) of the disease with deformity, those with noncontainable deformi-

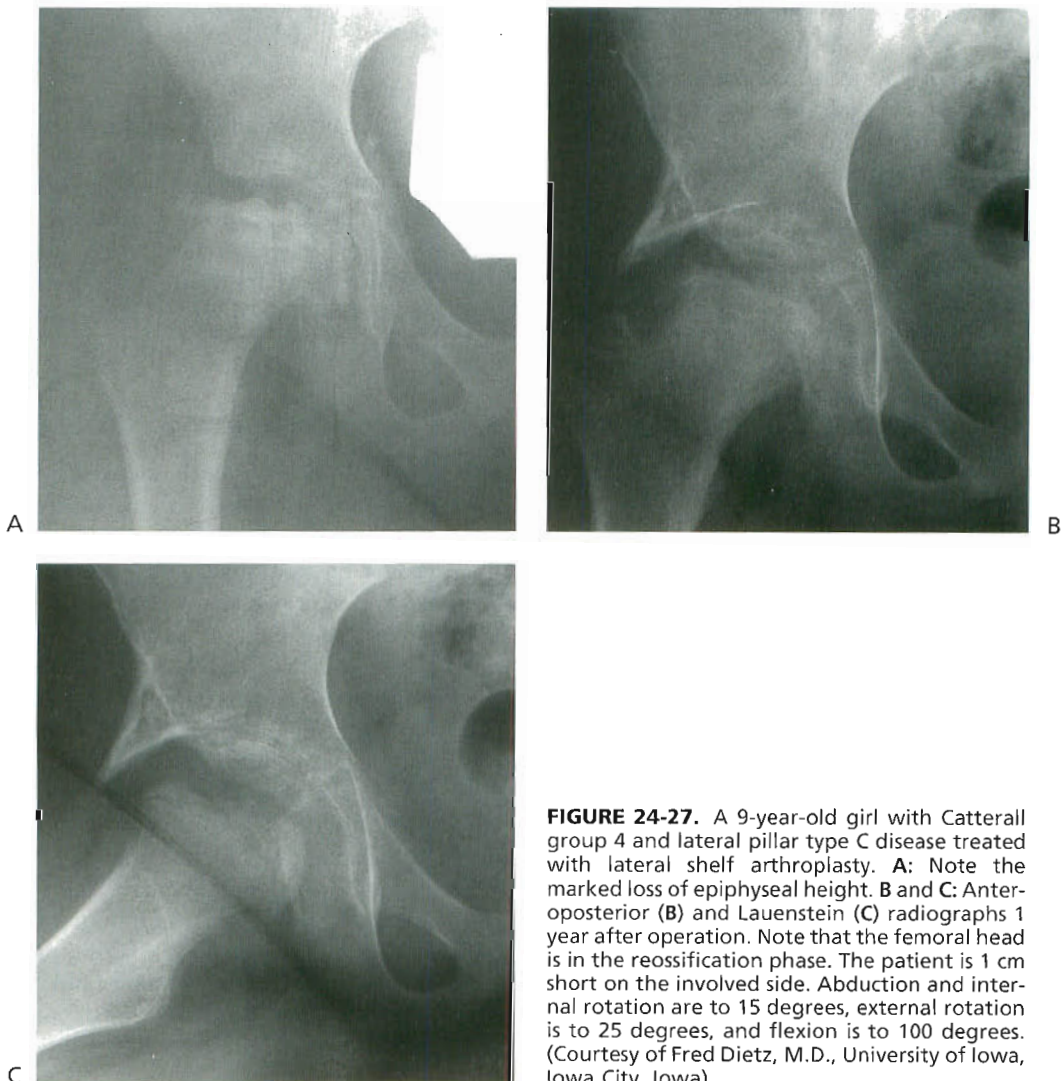


FIGURE 24-27. A 9-year-old girl with Catterall group 4 and lateral pillar type C disease treated with lateral shelf arthroplasty. **A:** Note the marked loss of epiphyseal height. **B and C:** Anteroposterior (**B**) and Lauenstein (**C**) radiographs 1 year after operation. Note that the femoral head is in the reossification phase. The patient is 1 cm short on the involved side. Abduction and internal rotation are to 15 degrees, external rotation is to 25 degrees, and flexion is to 100 degrees. (Courtesy of Fred Dietz, M.D., University of Iowa, Iowa City, Iowa)

ties, and those who have lost containment, after either surgical or nonsurgical containment, present a management problem. These patients usually demonstrate hinge abduction on arthrography, and have an extremely poor prognosis without additional treatment (175,193,222,316,365,366). These patients generally present with persistent pain, shortening of the involved extremity, and a fixed deformity, generally 10 to 15 degrees of fixed flexion and 15 to 20 degrees of fixed adduction (222,366). The salvage procedures to be considered at this point include Chiari osteotomy, lateral shelf arthroplasty, cheilectomy, and abduction extension osteotomy (222,316,366–369). These procedures must be viewed as salvage procedures, with each having specific limited aims, which may include pain relief, correction of limb-length inequality, increasing head coverage, and improvement of movement and abductor weakness (366).

Chiari osteotomy [➔3.11] improves the lateral coverage of the deformed femoral head, but does not reduce the lateral impingement in abduction, and may exacerbate any existing abductor weakness (222,366). Chiari osteotomy may be useful in the enlarged, poorly covered femoral head

that is beginning to develop symptoms of early degenerative joint disease. Although good preliminary results have been reported (368–374), the role of Chiari osteotomy in the treatment of Legg-Calvé-Perthes syndrome has yet to be defined.

In patients in the active stage of the disease with a non-containable hip, or patients with a painful hip after healing, who demonstrate hinge abduction, abduction extension osteotomy [➔4.5] should be considered. Abduction extension osteotomy of the femur is indicated when arthrography demonstrates that joint congruency is improved by the extended adducted position (Fig. 24-28). The preliminary results with this modality of treatment indicate improvement in limb length, decrease in limp, and improvement in function and range of motion (366). This procedure may be applied in either the active or the late stage of the disease, when arthrography demonstrates that joint congruency is improved by the extended adducted position. This modality of treatment allows for realignment of the congruent position of the hip in the neutral weight-bearing position (316,366).

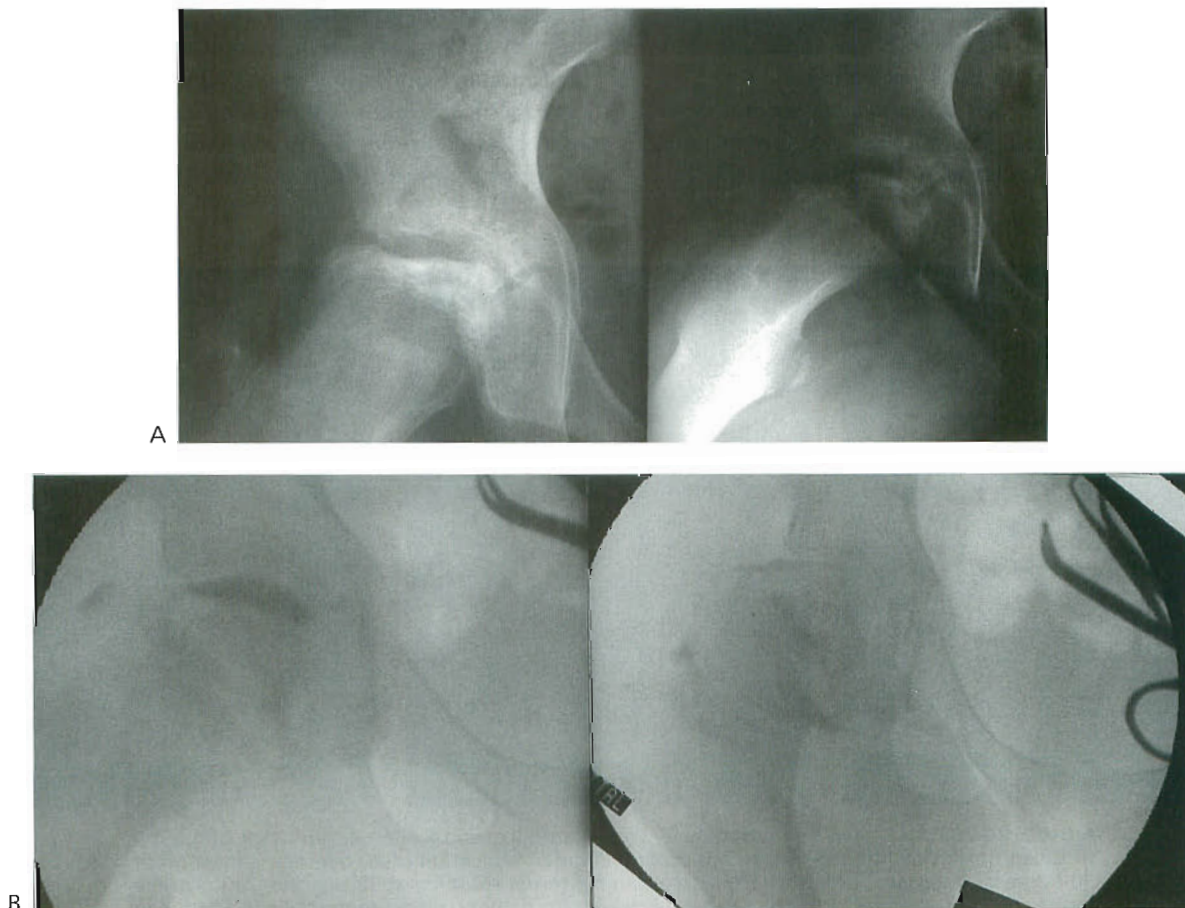


FIGURE 24-28. An 11-year-old girl with Catterall group 4 Perthes disease. Hip range of motion showed marked restriction of abduction (20 degrees) and rotation (10 degrees internal and external). All movement was painful. **A:** Preoperative anteroposterior (left) and Lauenstein (right) views. **B:** Intraoperative arthrograms demonstrating hinging on the lateral aspect of the acetabulum in abduction (left) with good congruency in adduction (right). (continued)

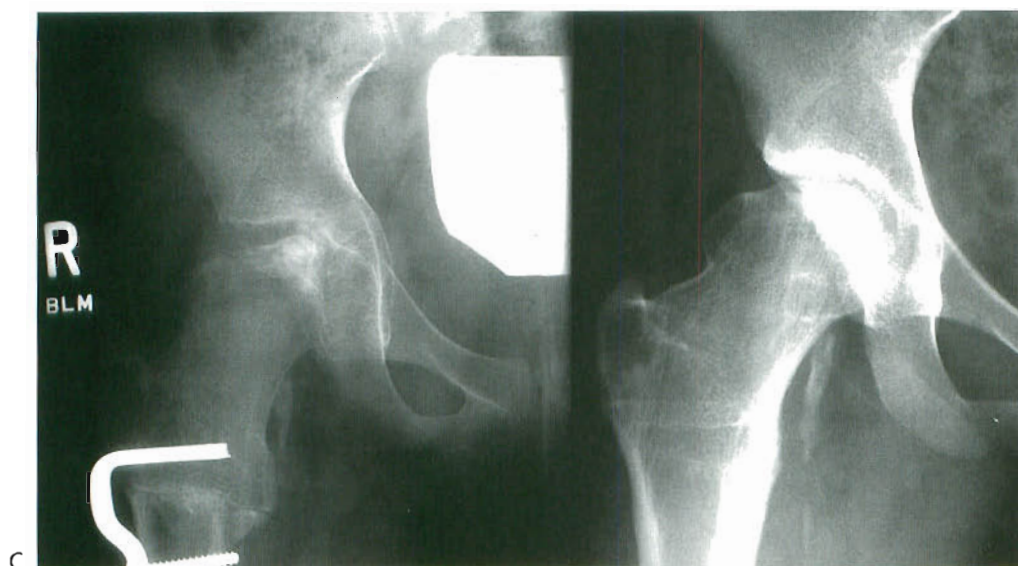


FIGURE 24-28. (continued) C: Six-month (left) and 7-year (right) follow-up after abduction osteotomy. At 7-year follow-up, the patient was free of pain, with 40 degrees of abduction, 20 degrees of adduction, flexion to 130 degrees, and 20 degrees of internal and external rotation. She has been pain free since her surgery.

Lateral shelf acetabuloplasty [➔3.12] may also be used in “salvage” situations, including lateral subluxation of the femoral head, inadequate coverage of the femoral head, and hinge abduction associated with severe Legg-Calvé-Perthes disease (370–375); use in hinge abduction, however, would not be the author’s preference.

Cheilectomy removes the anterolateral portion of the femoral head that is impinging on the acetabulum in abduction (Fig. 24-29). It is indicated only for functionally limit-

ing restricted range of motion. The procedure must be performed only after the physis is closed; otherwise, a slipped capital femoral epiphysis may ensue (367,376). Although cheilectomy may produce gratifying results with regard to improved range of motion, in some cases increasing stiffness may occur secondary to capsular adhesions at the osteotomy site (316). In addition, shortening associated with the femoral head deformity is not corrected.

Osteochondritis dissecans after Perthes syndrome may

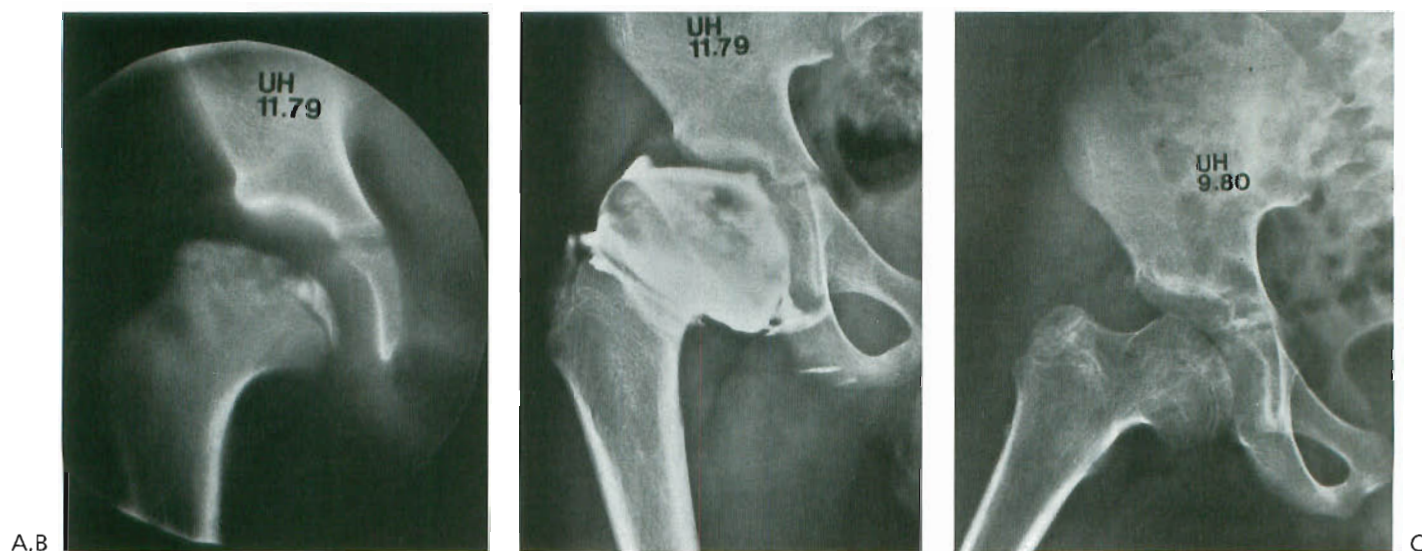


FIGURE 24-29. An 8-year, 6-month-old boy with Catterall group 4 disease. Hip range of motion included flexion of 140 degrees, extension of 0 degrees, abduction of 20 degrees, adduction of 30 degrees, internal rotation of 10 degrees, and external rotation of 30 degrees. **A:** Polytope indicating superolateral growth arrest. **B:** Arthrograph demonstrating femoral head flattening and enlargement, and deformation of the peripheral acetabulum. **C:** Abduction radiograph 7 months after cheilectomy. Range of motion at this time was 130 degrees of flexion, 20 degrees of extension, 50 degrees of abduction, 50 degrees of adduction, 45 degrees of internal rotation, and 40 degrees of external rotation. (Courtesy of J.G. Pous, M.D., Montpellier, France.)

or may not be symptomatic. If it is symptomatic, the pain may be intermittent. In patients with pain, several treatment options are available. Symptomatic treatment with antiinflammatory agents and protective weight bearing may be used to promote healing. Persistent pain may warrant attempts at revascularization. This may include drilling of the fragment via the femoral neck, and internal fixation, either percutaneously with pins or open with devices such as the Herbert screw. If the fragment becomes detached and cannot be reattached, and causes mechanical catching symptoms, it may require removal (181). There is a paucity of information on the natural history of the condition and the results of treatment.

In patients with Legg-Calvé-Perthes syndrome who have premature physal arrest, trochanteric overgrowth may ensue (169,178). Such patients may develop a Trendelenburg gait and pain secondary to muscle fatigue. This rarely has been a significant problem in long-term reviews (175). However, distal and lateral advancement of the greater trochanter may be necessary [4.9] (377,378).

FUTURE DEVELOPMENTS

Long-term series of patients with uniform treatment who are matched for age, gender, degree of epiphyseal involvement, and other diagnostic factors, compared with an untreated control group, will no doubt be required to determine the most effective treatment for Legg-Calvé-Perthes syndrome. As fundamental understanding of Legg-Calvé-Perthes syndrome increases, so does understanding of how various treatment modalities influence this complex growth disturbance.

References

Early History

- Legg AT. An obscure affection of the hip joint. *Boston Med Surg J* 1910;162:202.
- Calvé J. Sur une forme particuliere de coxalgie greffe sur des deformations caracteristiques de l'extremite superieure de femur. *Rev Chir* 1910;42:54.
- Perthes G. Uber arthritis deformans juvenilis. *Dtsch Z Chir* 1910;10:111.
- Waldenstrom H. Der obere Tuberkulose collumnerd. *Z Orthop Chir* 1909;24:487.
- Waldenstrom H. *Die Tuberkulose des Collum Femoris im Kindesalter ihre Beziehungen zur Hufigelenkentzündung*. Stockholm: 1910.
- Thomas HO. *Contributions to surgery and medicine. Part II. Principles of the treatment of diseased joints*. London: HK Lewis, 1883.
- Baker WM. Epiphyseal necrosis and its consequences. *Br Med J* 1883;2:416.
- Wright GA. The value of determining the primary lesion in joint disease as an indication for treatment. *Br Med J* 1883;2:419.
- Maydl K. Coxa vara arthritis deformans coxae. *Wien Klin Wochenschr* 1897;10:153.

- Goff CW. Legg-Calvé-Perthes syndrome (L.C.P.S.). *Clin Orthop* 1962;22:93.
- Perthes G. Osteochondritis deformans juvenilis. *Arch Klin Chir* 1913;101:779.
- Schwartz E. Eine typische Erkrankung der oberen femurepiphyse. *Beitr Klin Chir* 1914;93:127.
- Waldenstrom H. Coxa plana, osteochondritis deformans coxae, Calvé-Perthes'schen krankheit, Legg's disease. *Zentralbl Chir* 1920;17:539.
- Sundt H. Malum coxae: Calvé-Legg-Perthes. *Zentralbl Chir* 1920;22:538.
- Sundt H. Malum coxae Calvé-Legg-Perthes. Kristiania: Monographie, 1920.
- Phemister DB. Perthes' disease. *Surg Gynecol Obstet* 1921;33:87.
- Riedel G. Pathologic anatomy of osteochondritis deformans coxae juvenilis. *Zentralbl Chir* 1922;49:1447.
- Waldenstrom H. The definitive forms of coxa plana. *Acta Radiol* 1922;1:384.
- Wenger DR, Ward WT, Herring JA. Legg-Calvé-Perthes' disease. *J Bone Joint Surg Am* 1991;73:778.

Epidemiology and Etiology

- Wynne-Davies R, Gormley J. The aetiology of Perthes' disease. *J Bone Joint Surg Br* 1978;60:6.
- Barker DJP, Hall AJ. The epidemiology of Perthes' disease. *Clin Orthop* 1986;209:89.
- Van Den Bogaert G, De Rosa E, Moens P. Bilateral Legg Calvé Perthes disease: different from unilateral. *J Pediatr Orthop Part B* 1999;8:165.
- Fisher RI. An epidemiological study of Legg-Perthes' disease. *J Bone Joint Surg Am* 1972;54:769.
- Hall D, Harrison MHM. An association between congenital abnormalities and Perthes' disease of the hip. *J Bone Joint Surg Br* 1978;60:138.
- Hall DJ. Genetic aspects of Perthes' disease: a critical review. *Clin Orthop* 1986;209:100.
- O'Sullivan M, O'Rourke SK, MacAuley P. Legg-Calvé-Perthes' disease in a family: genetic or environmental. *Clin Orthop* 1985;199:179.
- Vasseur PB, Foley P, Stevenson S, et al. Mode of inheritance of Perthes' disease in Manchester terriers. *Clin Orthop* 1989;244:281.
- Wansborough RM, Carrie AW, Walker NF, et al. Coxa plana: its genetic aspects and results of treatment with long Taylor walking caliper. *J Bone Joint Surg Am* 1959;41:1959.
- Wynne-Davies R. Some etiologic factors in Perthes' disease. *Clin Orthop* 1980;150:12.
- Harper PS, Brotherton BJ, Cochlin D. Genetic risks in Perthes' disease. *Clin Genet* 1976;10:178.
- Hall AJ, Barker DJ, Dangerfield PH, et al. Small feet and Perthes' disease: a survey in Liverpool. *J Bone Joint Surg Br* 1988;70:611.
- Hall AJ, Barker DJ. Perthes' disease in Yorkshire. *J Bone Joint Surg Br* 1989;71:229.
- Hall AJ, Barker DJ, Dangerfield PH, et al. Perthes' disease of the hip in Liverpool. *Br Med J* 1983;287:1757.
- Barker DJP, Dixon E, Taylor JF. Perthes' disease of the hip in three regions of England. *J Bone Joint Surg Br* 1978;60:478.
- Catterall A. Legg-Calvé-Perthes' disease. *Instr Course Lect* 1989;38:297.
- Chacko V, Joseph B, Seetharam B. Perthes' disease in South India. *Clin Orthop* 1986;209:95.
- Hall AJ, Margetts BM, Barker DJ, et al. Low blood manganese levels in Liverpool children with Perthes' disease. *Paediatr Perinatol Epidemiol* 1989;3:131.

38. Peic S. Contribution to Perthes' disease. *Z Orthop* 1962;96:276.
39. Loder RT, Schwartz EM, Hensinger RN. Behavioral characteristics of children with Legg-Calvé-Perthes' disease. *J Pediatr Orthop* 1993;13:598.
40. Malloy MK, MacMahon B. Incidence of Legg-Calvé-Perthes' disease (osteochondritis deformans). *N Engl J Med* 1966;275:998.
41. Malloy MK, MacMahon B. Birth weight and Legg-Perthes' disease. *J Bone Joint Surg Am* 1967;49:498.
42. Harrison MHM, Turner MH, Jacobs P. Skeletal immaturity in Perthes' disease. *J Bone Joint Surg Br* 1976;58:37.
43. Cannon SR, Pozo JL, Catterall A. Elevated growth velocity in children with Perthes' disease. *J Pediatr Orthop* 1989;9:285.
44. Exner GU. Elevated growth velocity in children with Perthes' disease [Letter]. *J Pediatr Orthop* 1989;9:732.
45. Ralston EL. Legg-Perthes' disease and physical development. *J Bone Joint Surg Am* 1955;37:647.
46. Goff CW. Recumbency versus nonrecumbency treatment of Legg-Perthes' disease. *Clin Orthop* 1959;14:50.
47. Purry NA. The incidence of Perthes' disease in the population groups in the Eastern Cape region of South Africa. *J Bone Joint Surg Br* 1982;64:286.
48. Cameron J, Izatt MM. Legg-Calvé-Perthes' disease. *Scott Med J* 1960;5:148.
49. Burwell RG, Coates CL, Vernon CL, et al. Anthropometry and Perthes' disease: a preliminary report. *J Bone Joint Surg Br* 1976;58:254.
50. Burwell RG, Dangerfield PH, Hall DJ, et al. Perthes' disease: an anthropometric study revealing impaired and disproportionate growth. *J Bone Joint Surg Br* 1978;60:461.
51. Burwell RG. Perthes' disease: growth and aetiology. *Arch Dis Child* 1988;63:1408.
52. Kristmundsdottir F, Burwell RG, Harrison MHM. Delayed skeletal maturation in Perthes' disease. *Acta Orthop Scand* 1987;58:277.
53. Rao B, Joseph B, Chacko V, et al. Altered skeletal growth in Perthes' disease: an anthropomorphic study of children from rural India. *J Pediatr Orthop Part B* 1995;4:91.
54. Loder R, Farley FA, Herring JA, et al. Bone age determination in children with Legg-Calvé-Perthes disease: a comparison of two methods. *J Pediatr Orthop* 1995;15:90.
55. Eckervall G, Wingstrand H, Hauglund G, et al. Growth in 110 children with Legg-Calvé-Perthes' disease: a longitudinal infancy childhood puberty growth model study. *J Pediatr Orthop Part B* 1996;5:181.
56. Tanaka H, Tamura K, Takano K, et al. Serum somatomedin A in Perthes' disease. *Acta Orthop Scand* 1984;55:135.
57. Kitsugi T, Kasahara Y, Seto Y, et al. Normal somatomedin-C activity measured by radioimmunoassay in Perthes' disease. *Clin Orthop* 1989;244:217.
58. Neidel J, Zander D, Hackenbroch MH. Low plasma levels of insulin-like growth factor I in Perthes' disease: a controlled study of 59 consecutive children. *Acta Orthop Scand* 1992;63:393.
59. Neidel J, Zander D, Hackenbroch MH. No physiologic age-related increase of circulating somatomedin-C during early stage of Perthes' disease: a longitudinal study in 21 boys. *Arch Orthop Trauma Surg* 1992;111:171.
60. Neidel JSE, Zander D, Rutt J, et al. Normal plasma levels of IGF binding protein in Perthes' disease: follow up of a previous report. *Acta Orthop Scand* 1993;64:540.
61. Neidel J, Boddenberg B, Zander D, et al. Thyroid function in Legg-Calvé-Perthes' disease: cross-sectional and longitudinal study. *J Pediatr Orthop* 1993;13:592.
62. Matsumoto T, Enomoto H, Takahashi K, et al. Decreased levels of IGF binding protein 3 in serum from children with Legg Calvé Perthes' disease. *Acta Orthop Scand* 1998;69:125.
63. Grasemann H, Nicolai RD, Hauffa BP, et al. Skeletal immaturity, IGF-I and IGFBP-3 serum concentrations in Legg-Calvé-Perthes' disease. *Klin Pediatr* 1996;208:339.
64. Catterall A, Lloyd-Roberts GC, Wynne-Davies R. Association of Perthes' disease with congenital anomalies of genitourinary tract and inguinal region. *Lancet* 1971;1:996.
65. Catterall A. *Legg-Calvé-Perthes' disease*. Edinburgh: Churchill Livingstone, 1982.
66. Hall DJ, Harrison MHM, Burwell RG. Congenital abnormalities and Perthes' disease: clinical evidence that children with Perthes' disease may have a major congenital defect. *J Bone Joint Surg Br* 1979;61:18.
67. Axhausen G. Kohler's disease and Perthes' disease. *Zentralbl Chir* 1923;50:553.
68. Ferguson AB, Howorth MB. Coxa plana and related conditions at the hip. *J Bone Joint Surg Br* 1934;16:781.
69. Konjetzny GE. Zur Pathologie und pathologischen Anatomie der Perthes-Calvé schen krankheit. *Acta Chir Scand* 1943;74:361.
70. Phemister DB. Operation for epiphysitis of the head of the femur (Perthes' disease). *Arch Surg* 1921;2:221.
71. Matsoukas J. Viral antibody titers to rubella in coxa plana or Perthes' disease. *Acta Scand Orthop* 1975;46:957.
72. Bentzon PGK. Experimental studies on the pathogenesis of coxa plana and other manifestations of "local dyschondroplasia." *Acta Radiol* 1926;6:155.
73. Broder H. The late results in Legg-Perthes' disease and factors influencing them: a study of one hundred and two cases. *Bull Hosp Joint Dis* 1953;14:194.
74. Craig WA, Kramer WG, Watanabe R. Etiology and treatment of Legg-Calvé-Perthes syndrome. *J Bone Joint Surg Am* 1963;45:1325.
75. Craig WA. Course of Legg-Calvé-Perthes: natural history, pathomechanics. *Orthop Rev* 1979;8:29.
76. Helbo S. *Morbus Calvé Perthes*. Odense, Denmark: Fynatidenes Bogtrykkeri, 1954.
77. Leriche R. Recherches experimentales sur le me canisme de formation de l'osteochondrite de la hanche. *Lyon Chir* 1934;31:610.
78. Lindstrom JR, Ponseti IV, Wenger DR. Acetabular development after reduction in congenital dislocation of the hip. *J Bone Joint Surg Am* 1979;61:112.
79. Bunger C, Solund K, Joyce F, et al. Carrageenan-induced coxitis in puppies. *Acta Orthop Scand* 1988;59:249.
80. Calot F. Uber Neuere Anschauungen in der Pathologie der Huft auf Grund der Arbeiten der letzten Jahre. *Z Orthop Chir* 1929;51:134.
81. Canestri G, Monzali GL. Osteochondrite posttridut Lattante iva nella L.C.A.: l'osteochondrite apre reduction de la luxation congenitale de la hanche. *Lattante* 1957;28:537.
82. Gill AB. Legg-Perthes' disease of the hip: its early roentgenographic manifestations and its clinical course. *J Bone Joint Surg Br* 1940;22:1043.
83. Hilgenreiner H. Beitrag zur atiology der osteochondritis coxae juvenilis. *Med Klin* 1933;29:234.
84. Jansen M. Platte huftpfanne und ihre folgen coxa plana: valga, vara and malum coxae. *Z Orthop Chir* 1925;46:234.
85. Slavik J. *Coxa plana: morbus Maydl-Calvé-Legg-Perthes*. Prague: Albertova Sbirka, 1956.
86. Glimcher MJ. Legg-Calvé-Perthes syndrome: biological and mechanical considerations in the genesis of clinical abnormalities. *Orthop Rev* 1979;8:33.
87. Cavanaugh LA, Shelton EK, Sutherland R. Metabolic studies in osteochondritis of the capital femoral epiphysis. *J Bone Joint Surg Br* 1936;18:957.
88. Emerick RW, Corrigan KE, Joistad AH Jr, et al. Thyroid func-

- tion in Legg-Calvé-Perthes' disease: a new approach to an old problem. *Clin Orthop* 1954;4:160.
89. Gill AB. Relationship of Legg-Perthes' disease to the function of the thyroid gland. *J Bone Joint Surg Br* 1943;25:892.
 90. Katz JF. Protein-bound iodine in Legg-Calvé-Perthes' disease. *J Bone Joint Surg Am* 1955;37:842.
 91. Ponseti IV, Cotton RL. Legg-Calvé-Perthes' disease: pathogenesis and evaluation. *J Bone Joint Surg Am* 1961;43:261.
 - 92a. Jacobs BW. Early recognition of osteochondrosis of capital epiphysis of femur. *JAMA* 1960;172:527.
 92. Gershuni DH. Etiology of Legg-Calvé-Perthes syndrome. *Orthop Rev* 1979;8:49.
 93. Hochbergs P. *Magnetic resonance imaging in Legg-Calvé-Perthes' disease* [thesis]. Lund, Sweden: 1998.
 94. Eckerwall G, Lohmander LS, Wingstrand H. Increased levels of proteoglycan fragments and stromelysin in hip joint fluid in Legg-Calvé-Perthes' disease. *J Pediatr Orthop* 1997;17:266.
 95. Eckerwall G, Hochbergs P, Wingstrand H, et al. Sonography and intracapsular pressure in Perthes disease: 39 children examined 2–36 months after onset. *Acta Orthop Scand* 1994;65:575.
 96. Suzuki S, Kasahara Y, Seto Y, et al. Arthroscopy in 19 children with Perthes' disease. *Acta Orthop Scand* 1994;65:581.
 97. Vanpaemel L, Helden P, Kuis W, et al. Destructive synovitis in contralateral Perthes' disease: a report of 2 cases. *Acta Orthop Scand* 1994;65:585.
 98. Hauelsen DC, Weiner DS, Weiner SD. The characterization of transient synovitis of the hip in children. *J Pediatr Orthop* 1986;6:11.
 99. Kallio P, Ryoppy S. Hyperpressure in juvenile hip disease. *Acta Orthop Scand* 1985;56:211.
 100. Kallio P, Ryoppy S, Kunnamo I. Transient synovitis and Perthes: is there an etiologic connection? *J Bone Joint Surg Br* 1986;68:608.
 101. Mukamel M, Litmanovitch M, Yosipovitch Z, et al. Legg Calvé Perthes' disease following transient synovitis: how often? *Clin Pediatr* 1985;24:629.
 102. Wingstrand H, Bauer G, Brimar J, et al. Transient ischemia of the proximal femoral epiphysis in the child: interpretation of bone scintimetry for diagnosis in hip pain. *Acta Orthop Scand* 1985;56:197.
 103. Wingstrand H, Egund N, Carlin NO, et al. Intracapsular pressure in transient synovitis of the hip. *Acta Orthop Scand* 1985;56:204.
 104. Chuinard EG. Femoral osteotomy in treatment of Legg-Calvé-Perthes syndrome. *Orthop Rev* 1979;8:113.
 105. Chung SMK. The arterial supply of the developing proximal end of the human femur. *J Bone Joint Surg Am* 1976;58:961.
 106. Trueta J. The normal vascular anatomy of the human femoral head during growth. *J Bone Joint Surg Br* 1957;39:358.
 107. Trueta J, Pinto de Lima CS. Studies of osteochondritis of the femoral head or Legg-Calvé-Perthes' disease. *Rev Orthop Trauma Latin Am* 1959;4:115.
 108. Ogden JA. Changing patterns of proximal femoral vascularity. *J Bone Joint Surg Am* 1974;56:941.
 109. Theron J. Angiography in Legg-Calvé-Perthes' disease. *Radiology* 1980;135:81.
 110. Sanchis M, Freeman MAR, Zahir A. Experimental stimulation of the blood supply to the capital epiphysis in the puppy. *J Bone Joint Surg Am* 1973;55:335.
 111. Inoue A, Freeman MAR, Vernon-Roberts B, et al. The pathogenesis of Perthes' disease. *J Bone Joint Surg Br* 1976;58:483.
 112. Katz JF. Recurrent Legg-Calvé-Perthes' disease. *J Bone Joint Surg Am* 1973;55:833.
 113. Martinez AG, Weinstein SL. Recurrent Legg-Calvé-Perthes' disease: case report and review of the literature. *J Bone Joint Surg Am* 1991;73:1081.
 114. Salter RB. Legg-Perthes' disease: the scientific basis for the methods of treatment and their indications. *Clin Orthop* 1980;150:8.
 115. Salter RB, Thompson GH. Legg-Calvé-Perthes' disease: the prognostic significance of the subchondral fracture and a two group classification of the femoral head involvement. *J Bone Joint Surg Am* 1984;66:479.
 116. Kleinman RG, Bleck EE. Increased blood viscosity in patients with Legg-Perthes' disease: a preliminary report. *J Pediatr Orthop* 1981;1:131.
 117. Heikkinen E, Lanning P, Suramo J, et al. The venous drainage of the femoral neck as a prognostic sign of Perthes' disease. *Acta Orthop Scand* 1980;51:501.
 118. Sutherland AD, Savage JP, Patterson DC, et al. The nuclide bone scan in the diagnosis and management of Perthes' disease. *J Bone Joint Surg Br* 1980;63:300.
 119. Glueck CJ, Freiberg RA, Crawford A, et al. Secondhand smoke, hypofibrinolysis, and Legg-Perthes disease. *Clin Orthop* 1998;352:159.
 120. Glueck CJ, Crawford A, Roy D, et al. Association of antithrombotic factor deficiencies and hypofibrinolysis with Legg-Perthes disease. *J Bone Joint Surg Am* 1996;78:3.
 121. Glueck C, Glueck HI, Greenfield D, et al. Protein C and S deficiency, thrombophilia, and hypofibrinolysis: pathophysiologic causes of Legg-Perthes disease. *Pediatr Res* 1994;35:383.
 122. Glueck C, Freiberg R, Tracy T, et al. Thrombophilia and hypofibrinolysis: pathophysiologies of osteonecrosis. *Clin Orthop Relat Res* 1997;334:43.
 123. Glueck C, Brandt G, Gruppo R, et al. Resistance to activated protein C and Legg-Perthes disease. *Clin Orthop Relat Res* 1997;338:39.
 124. Hayek S, Kenet G, Lubetsky A, et al. Does thrombophilia play and aetiological role in Legg-Calvé-Perthes' disease? *J Bone Joint Surg Br* 1999;81:686.
 125. Thomas D, Morgan G, Tayton K. Perthes' disease and the relevance of thrombophilia. *J Bone Joint Surg Br* 1999;81:691.

Pathogenesis

126. Ponseti IV, Maynard JA, Weinstein SL, et al. Legg-Calvé-Perthes' disease: histochemical and ultrastructural observations of the epiphyseal cartilage and the physis. *J Bone Joint Surg Am* 1983;65:797.
127. Ponseti IV. Legg-Perthes' disease. *J Bone Joint Surg Am* 1956;38:739.
128. Catterall A. Legg-Calvé-Perthes' disease: classification and pathology. In: Fitzgerald RH Jr, ed. *The hip: proceedings of the thirteenth open scientific meeting of The Hip Society*. St. Louis: Mosby, 1985:24.
129. Catterall A, Pringle J, Byers PD, et al. A review of the morphology of Perthes' disease. *J Bone Joint Surg Br* 1982;64:269.
130. Dolman CL, Bell HM. The pathology of Legg-Calvé-Perthes' disease. *J Bone Joint Surg Am* 1973;55:184.
131. Jensen OM, Lauritzen J. Legg-Calvé-Perthes' disease. *J Bone Joint Surg Br* 1976;58:332.
132. Bernbeck R. Kritischenzum Perthes: Problem der Hufte. *Arch Orthop Unfallchir* 1950;44:445.
133. Bernbeck R. Zur Pathogenese der jugendlichen Hufteknorpelnekrose. *Arch Orthop Unfallchir* 1950;44:164.
134. Bohr H, Baadsgaard K, Sager P. The vascular supply to the femoral head following dislocation of the hip joint: an experimental study in new-born rabbits. *Acta Orthop Scand* 1965;35:264.
135. Larsen FH, Reiman I. Calvé-Perthes' disease. *Acta Orthop Scand* 1973;44:426.
136. McKibbin B, Holdsworth FW. The nutrition of immature joint cartilage in the lamb. *J Bone Joint Surg Br* 1966;48:793.
137. McKibbin B, ed. *Recent advances in Perthes' disease*. Edinburgh: Churchill Livingstone, 1975.
138. Schiller MG, Axer A. Hypertrophy of the femoral head in Legg-

- Calvé-Perthes' syndrome (LCPS). *Acta Orthop Scand* 1972;43:45.
139. Catterall A, Pringle J, Byers PD, et al. Perthes' disease: is the epiphyseal infarction complete? A study of 2 cases. *J Bone Joint Surg Br* 1982;64:276.
 140. Hoffinger SA, Henderson RC, Renner JB, et al. Magnetic resonance evaluation of "metaphyseal" changes in Legg-Calvé-Perthes' disease. *J Pediatr Orthop* 1993;13:602.
 141. Smith RB, Ions GK, Gregg PJ. The radiological features of the metaphysis in Perthes' disease. *J Pediatr Orthop* 1982;2:401.
 142. Gall EA, Bennett GA. Osteochondritis deformans of the hip (Legg-Perthes' disease) and renal osteitis fibrosa cystica: report of a case with anatomic studies. *Arch Pathol* 1942;33:866.
 143. Ponseti IV, Shepard RS. Lesions of the skeleton and of other mesodermal tissues in rats fed sweet-pea (*Lathyrus odoratus*) seeds. *J Bone Joint Surg Am* 1954;36:1031.
 144. Smith RB, Nevelos AB. Osteochondritis occurring at multiple sites. *Acta Orthop Scand* 1980;51:449.
 145. Harrison MHM, Blakemore ME. A study of the "normal" hip in children with unilateral Perthes' disease. *J Bone Joint Surg Br* 1980;62:36.
 146. Aire E, Johnson F, Harrison MHM, et al. Femoral head shape in Perthes' disease: is the contralateral hip abnormal? *Clin Orthop* 1986;209:77.
 147. Catterall A. Thoughts on the etiology of Perthes' disease. *Iowa Orthop J* 1984;4:34.
 148. Harrison MHM, Turner MH, Smith DN. Perthes' disease treatment with the Birmingham splint. *J Bone Joint Surg Br* 1982;64:3.
 149. Jonsater A. Coxa plana, a histopathologic and arthrographic study. *Acta Orthop Scand Suppl* 1953;12:1.
 150. Weinstein SL. Legg-Calvé-Perthes' disease. *Instr Course Lect* 1983;32:272.
 151. Waldenstrom H. The first stages of coxa plana. *Acta Orthop Scand* 1934;5:1.
 152. Kamegaya M, Moriya H, Tsuchiya K, et al. Arthrography of early Perthes' disease: swelling of the ligamentum teres as a cause of subluxation. *J Bone Joint Surg Br* 1989;71:413.
 153. Wingstrand H. Legg-Calvé-Perthes' disease. *Acta Orthop Scand* 1994;65:573.
 154. Wingstrand H. Significance of synovitis in Legg-Calvé-Perthes' disease. *J Pediatr Orthop Part B* 1999;8:156.
 155. Bobechko WP, Harris WR. The radiographic density of avascular bone. *J Bone Joint Surg Br* 1960;42:626.
 156. Ray RD, LaViolette D, Buckley HD, et al. Studies of bone metabolism. I. A comparison of the metabolism of strontium in living and dead bone. *J Bone Joint Surg Am* 1955;37:143.
 157. Watson-Jones R, Roberts RE. Calcifications, decalcification and ossification. *Br J Surg* 1934;21:461.
 158. Bobechko WP, McLaurin CA, Motloch WM. Toronto orthosis for Legg-Perthes' disease. *Artif Limbs* 1968;12:36.
 159. Kemp HBS, Boldero JL. Radiological changes in Perthes' disease. *Br J Radiol* 1966;39:744.
 160. Kenzora JE, Steele RE, Yosipovitch ZH, et al. Experimental osteonecrosis of the femoral head in adult rabbits. *Clin Orthop* 1978;130:8.
 161. McKibbin B, Rails Z. Pathological changes in a case of Perthes' disease. *J Bone Joint Surg Br* 1974;56:438.
 162. Phemister DB. Bone growth and repair. *Ann Surg* 1935;102:261.
 163. Waldenstrom H. The first stages of coxa plana. *J Bone Joint Surg Br* 1938;20:559.
 164. Caffey J. The early roentgenographic changes in essential coxa plana: their significance in pathogenesis. *Am J Roentgenol* 1968;103:620.
 165. Salter RB, Bell M. The pathogenesis of deformity in Legg-Perthes' disease: an experimental investigation. *J Bone Joint Surg Br* 1968;50:436.
 166. Brailsford JF. Avascular necrosis of bone. *J Bone Joint Surg Br* 1943;25:249.
 167. Haliburton RA, Brockenshire FA, Barber JR. Avascular necrosis of the femoral capital epiphysis after traumatic dislocation of the hip in children. *J Bone Joint Surg Br* 1961;43:43.
 168. Barnes JM. Premature epiphyseal closure in Perthes' disease. *J Bone Joint Surg Br* 1980;62:432.
 169. Bowen JR, Foster BK, Hartzell CR. Legg-Calvé-Perthes' disease. *Clin Orthop* 1985;185:97.
 170. Coleman RC, Slager RF, Smith WS. The effect of environmental influences on acetabular development. *Surg Forum* 1958;9:775.
 171. Keret D, Harrison MHM, Clarke NMP, et al. Coxa plana: the fate of the physis. *J Bone Joint Surg Am* 1984;66:870.
 172. Heitzman O. Epiphysenerkrankungen im Wachstumsalter. *Klin Wochenschr* 1923;327.
 173. Bohr HH. On the development and course of Legg-Calvé-Perthes' disease (LCPD). *Clin Orthop* 1980;150:30.
 174. Weinstein SL. *Legg-Calvé-Perthes' disease*. St. Louis: Mosby, 1983.
 175. Weinstein SL. Legg-Calvé-Perthes' disease: results of long-term follow-up. In: Fitzgerald RH Jr, ed. *The hip: proceedings of the thirteenth open scientific meeting of The Hip Society*. St. Louis: Mosby, 1985:28.
 176. Weinstein SL. The pathogenesis of deformity in Legg-Calvé-Perthes' disease. In: Uthoff H, Wiley J, eds. *Behavior of the growth plate*. New York: Raven, 1988:79.
 177. Wenger DR. Selective surgical containment for Legg-Perthes' disease: recognition and management of complications. *J Pediatr Orthop* 1981;1:153.
 178. Bowen JR, Schreiber FC, Foster BK, et al. Premature femoral neck physeal closure in Perthes' disease. *Clin Orthop* 1982;171:24.
 179. Weinstein SL. Perthes' disease: an overview. *Curr Orthop* 1988;2:181.
 180. Catterall A. Legg-Calvé-Perthes syndrome. *Clin Orthop* 1981;158:41.
 181. Grossbard GD. Hip pain in adolescence after Perthes' disease. *J Bone Joint Surg Br* 1981;63:572.
 182. Reinker K. Early diagnosis and treatment of hinge abduction in Legg Perthes' disease. *J Pediatr Orthop* 1996;16:3.
 183. Lecuire F, Rebouillat J. Long-term development of primary osteochondritis of the hip (Legg-Perthes-Calvé): apropos of 60 hips with a follow-up of more than 30 years. *Rev Chir Orthop* 1987;73:561.
 184. Levine B, Kanat IO. Subchondral bone cysts, osteochondritis dissecans, and Legg-Calvé-Perthes' disease: a correlation and proposal of their possible common etiology and pathogenesis. *J Foot Surg* 1988;27:75.
 185. Rowe SM, Kim HS, Yoon TR. Osteochondritis dissecans in Perthes' disease: report of 7 cases. *Acta Orthop Scand* 1989;60:545.

Natural History

186. Catterall A. The natural history of Perthes' disease. *J Bone Joint Surg Br* 1971;53:37.
187. Chigwanda PC. Early natural history of untreated Perthes' disease. *Cent Afr J Med* 1992;38:334.
188. Norlin R, Hammerby S, Tkaczuk H. The natural history of Perthes' disease. *Int Orthop* 1991;15:13.
189. Stulberg SD, Cooperman DR, Wallensten R. The natural history of Legg-Calvé-Perthes' disease. *J Bone Joint Surg Am* 1981;63:1095.
190. Sundt H. Malum coxae Calvé-Legg Perthes. *Acta Chir Scand Suppl* 1949;148:1.

191. Yrjonen T. Prognosis in Perthes' disease after noncontainment treatment: 106 hips followed for 28–47 years. *Acta Orthop Scand* 1992;63:523.
192. Ippolito D, Tudisco C, Farsetti P. The long-term prognosis of unilateral Perthes' disease. *J Bone Joint Surg Br* 1987;69:243.
193. McAndrew MP, Weinstein SL. A long term follow-up of Legg-Calvé-Perthes' disease. *J Bone Joint Surg Am* 1984;66:860.
194. Mose K. Methods of measuring in Legg-Calvé-Perthes' disease with special regard to the prognosis. *Clin Orthop* 1980;150:103.
195. Herring JA, Williams JJ, Neustadt JN, et al. Evolution of femoral head deformity during the healing phase of Legg-Calvé-Perthes' disease. *J Pediatr Orthop* 1993;13:41.
196. Danielsson LG, Hernborg J. Late results in Perthes' disease. *Acta Orthop Scand* 1965;36:70.
197. Hall G. Some long-term observations of Perthes' disease. *J Bone Joint Surg Br* 1981;63:631.
198. Perpich M, McBeath A, Kruse D. Long term follow-up of Perthes' disease treated with spica casts. *J Pediatr Orthop* 1983;3:160.
199. Ratliff AHC. Perthes' disease: a study of 34 hips observed for 30 years. *J Bone Joint Surg Br* 1967;49:108.
200. Ratliff AHC. Perthes' disease: a study of 16 patients followed up for 40 years. *J Bone Joint Surg Br* 1977;59:248.
201. Gower WE, Johnston RC. Legg-Perthes' disease, long-term follow-up of thirty-six patients. *J Bone Joint Surg Am* 1971;53:759.
202. Herring JA, Neustadt JB, Williams JJ, et al. The lateral pillar classification of Legg-Calvé-Perthes' disease. *J Pediatr Orthop* 1992;12:143.
203. Mukherjee A, Fabry G. Evaluation of the prognostic indices in Legg-Calvé-Perthes' disease. *J Pediatr Orthop* 1990;10:153.
204. Weinstein SL. Improving the prognosis in Legg-Calvé-Perthes' disease. *J Musculoskeletal Med* 1984;11:22.
205. Moberg A. *Legg-Calvé-Perthes' disease: an epidemiologic, clinical and radiological study*. Uppsala, Sweden: Uppsala University, 1996.
206. Ismail A, Macnicol JF. Prognosis in Perthes' disease. *J Bone Joint Surg Br* 1998;80:310.
207. Yrjonen T. Long term prognosis in Legg-Calvé-Perthes disease: a meta analysis. *J Pediatr Orthop Part B* 1999;8:169.
208. Sponseller PD, Desai SS, Millis MB. Abnormalities of proximal femoral disease. *J Bone Joint Surg Br* 1989;71:610.
209. Moller PF. The clinical observations after healing of Calvé-Perthes' disease compared with final deformities left by that disease and the bearing of those final deformities on ultimate prognosis. *Acta Radiol* 1926;5:1.
210. Neyt J, Weinstein SL, Spratt K, et al. Stulberg classification system for evaluation of Legg-Calvé-Perthes' disease: intra-rater and inter-rater reliability. *J Bone Joint Surg Am* 1999;81:1209.
211. O'Garra JA. The radiographic changes in Perthes' disease. *J Bone Joint Surg Br* 1959;41:465.
212. Lloyd-Roberts GC, Catterall A, Salamon PB. A controlled study of the indications for the results of femoral osteotomy in Perthes' disease. *J Bone Joint Surg Br* 1976;58:31.
213. Hardcastle PH, Ross R, Hamalainen M, et al. Catterall grouping of Perthes' disease: an assessment of observer error and prognosis using the Catterall classification. *J Bone Joint Surg Br* 1980;62:428.
214. Kelly FP, Canale ST, Jones RR. Legg-Calvé-Perthes' disease: long-term evaluation of noncontainment treatment. *J Bone Joint Surg Am* 1980;62:400.
215. Van Dam BE, Crider RJ, Noyes JD, et al. Determination of the Catterall classification in Legg-Calvé-Perthes' disease. *J Bone Joint Surg Am* 1981;63:906.
216. Martinez AG, Weinstein SL, Dietz FR. The weight-bearing abduction brace for the treatment of Legg-Perthes' disease. *J Bone Joint Surg Am* 1992;74:12.
217. Klisic P, Seferovic O, Blazevic U. Perthes' syndrome, classification and indications for treatment. *Orthop Rev* 1979;8:81.
218. Klisic P, Blazevic U, Seferovic O. Approach to treatment of Legg-Perthes' disease. *Clin Orthop* 1980;150:54.
219. Farsetti P, Tudisco C, Caterini R, et al. The Herring lateral pillar classification for prognosis in Perthes' disease: late results in 49 patients treated conservatively. *J Bone Joint Surg Br* 1995;77:739.
220. Ritterbusch JF, Shantharam SS, Gelinas C. Comparison of lateral pillar classification and Catterall classification of Legg-Calvé-Perthes' disease. *J Pediatr Orthop* 1993;13:200.
221. Catterall A. Coxa plana. In: Apley AP, ed. *Modern trends in orthopaedics*. London: Butterworths, 1972.
222. Catterall A. Adolescent hip pain after Perthes' disease. *Clin Orthop* 1986;209:65.
223. Muirhead-Allwood W, Catterall A. The treatment of Perthes' disease: the results of a trial of management. *J Bone Joint Surg Br* 1982;64:282.
224. Aguirre M, Pellise F, Castellote A. Metaphyseal cysts in Legg-Calvé-Perthes' disease [letter]. *J Pediatr Orthop* 1992;12:404.
225. Carroll NC, Donaldson J. Metaphyseal cysts in Legg-Calvé-Perthes' disease [letter]. *J Pediatr Orthop* 1992;12:405.
226. Gershuni DH. Subluxation of the femoral head in coxa plana [letter]. *J Bone Joint Surg Am* 1988;70:950.
227. Christensen FKS, Ejsted R, Luxiji T. The Catterall classification of Perthes: an assessment of reliability. *J Bone Joint Surg Br* 1978;60:166.
228. Clarke TE, Finnegan TL, Fisher RL, et al. Legg-Perthes' disease in children less than four years old. *J Bone Joint Surg Am* 1978;60:166.
229. Dickens DRV, Menelaus MB. The assessment of the prognosis of Perthes' disease. *J Bone Joint Surg Br* 1978;60:189.
230. Green NE, Beauchamp RD, Griffen PP. Epiphyseal extrusion as a prognostic index in Legg-Calvé-Perthes' disease. *J Bone Joint Surg Am* 1981;63:900.
231. Kamhi E, MacEwen D. Treatment of Legg-Calvé-Perthes' disease. *J Bone Joint Surg Am* 1975;57:651.
232. Mintowt-Czyz WJ, Tayton KJ. The role of weight relief in Catterall group IV Perthes' disease. *J Bone Joint Surg Br* 1982;64:247.
233. Mintowt-Czyz WJ, Tayton KJ. Indication for weight relief and containment in the treatment of Perthes' disease. *Acta Orthop Scand* 1983;54:439.
234. Simmons ED, Graham HK, Szalai JP. Interobserver variability in grading Perthes' disease. *J Bone Joint Surg Br* 1990;72:202.
235. Loder R, Farley FA, Hennsinger RN. Physeal slope in Perthes' disease. *J Bone Joint Surg Br* 1995;77:736.
236. Herring JA. Legg-Calvé-Perthes' disease: a review of current knowledge. *Instr Course Lect* 1989;38:309.
237. Lloyd-Roberts GC. The management of Perthes' disease. *J Bone Joint Surg Br* 1982;64:1.
238. Lovell WW, MacEwen GD, Stewart WR, et al. Legg-Perthes' disease in girls. *J Bone Joint Surg Br* 1982;64:637.
239. Guille J, Lipton GE, Szoke G, et al. Legg Calvé Perthes disease in girls: a comparison of the results with those seen in boys. *J Bone Joint Surg Am* 1998;80:1256.
240. Grasmann H, Nicolai RD, Patsalis T, et al. The treatment of Legg-Calvé-Perthes disease: to contain or not to contain. *Arch Orthop Trauma Surg* 1997;116:50.
241. Yasuda T, Tamura K. Prognostication of proximal femoral growth disturbance after Perthes' disease. *Clin Orthop Relat Res* 1996;329:244.
242. Cooperman DR, Stulberg SD. Ambulatory containment treatment in Legg-Calvé-Perthes' disease. In: Fitzgerald RH Jr, ed. *The hip: proceedings of the thirteenth open scientific meeting of The Hip Society*. St. Louis: Mosby, 1985:38.
243. Bellyei A, Mike G. Acetabular development in Legg-Calvé-Perthes' disease. *Orthopedics* 1988;11:407.

244. Kamegaya M, Shinada Y, Moriya H, et al. Acetabular remodeling in Perthes' disease after primary healing. *J Pediatr Orthop* 1992;12:308.
245. Weinstein SL, Ponseti IV. Congenital dislocation of the hip: open reduction through a medial approach. *J Bone Joint Surg Am* 1979;61:119.
246. Mazda K, Pennecot GF, Zeller R, et al. Perthes' after the age of twelve years: role of the remaining growth. *J Bone Joint Surg Br* 1999;81:696.
247. Clarke NMP, Harrison MHM. Painful sequelae of coxa plana. *J Bone Joint Surg Am* 1983;65:13.
248. Goff CW. *Legg-Calvé-Perthes' syndrome and related osteochondroses of youth*. Springfield, IL: Charles C Thomas, 1954.
249. Joseph B, Chacko V, Rao BS, et al. The epidemiology of Perthes' disease in south India. *Int J Epidemiol* 1988;173:603.
250. Joseph B. Morphological changes in the acetabulum in Perthes' disease. *J Bone Joint Surg Br* 1989;71:756.
251. Kahle WK, Coleman SS. The value of the acetabular teardrop figure in assessing pediatric hip disorders. *J Pediatr Orthop* 1992;12:586.
252. Curtis BH, Gunther SF, Gossling HR, et al. Treatment for Legg-Perthes' disease with the Newington ambulation-abduction brace. *J Bone Joint Surg Am* 1974;56:1135.
253. King EW, Fisher RL, Gage JR, et al. Ambulation-abduction treatment in Legg-Calvé-Perthes' disease (LCPD). *Clin Orthop* 1980;150:43.
254. Petrie JG, Bitenc I. The abduction weight bearing treatment in Legg-Perthes' disease. *J Bone Joint Surg Br* 1971;53:54.
255. Purvis JM, Dimon JH III, Meehan PL, et al. Preliminary experience with the Scottish Rite Hospital abduction orthosis for Legg-Perthes' disease. *Clin Orthop* 1980;150:49.
256. Thompson G, Westin GW. Legg-Calvé-Perthes' disease: results of discontinuing treatment in the early reossification stage. *Clin Orthop* 1979;139:70.
266. Kohler R, Seringe R, Borgi R. *Osteochondrite de la Hanche*. Paris: Expansion Scientific Française, 1981.
267. Suramo I, Puranen J, Heikkinen E, et al. Disturbed patterns of venous drainage of the femoral neck in Perthes' disease. *J Bone Joint Surg Br* 1974;56:448.
268. Kaniklides C. Diagnostic radiology in Legg-Calvé-Perthes disease. *Acta Radiol Suppl* 1996;406:1.
269. Kaniklides C, Sahlstedt B, Lonnerholm T, et al. Conventional radiography and bone scintigraphy in the prognostic evaluation of Legg Calvé Perthes disease. *Acta Radiol* 1996;37:561.
270. Kaniklides C, Lonnerholm T, Moberg A, et al. Legg-Calvé-Perthes' disease: comparison of conventional radiography, MR imaging, bone scintigraphy and arthrography. *Acta Radiol* 1995;36:434.
271. Hosokawa M, Wook-Cheol K, Kubo T. Preliminary report on usefulness of magnetic resonance imaging for outcome prediction in early stage Legg Calvé Perthes disease. *J Pediatr Orthop Part B* 1999;8:161.
272. Jaramillo D, Kasser JR, Villegas-Medina OL, et al. Cartilaginous and growth disturbances in Legg-Calvé-Perthes disease: evaluation with MR imaging. *Radiology* 1995;197:767.
273. Uno A, Hattori T, Noritake K, et al. Legg-Calvé-Perthes disease in the evolutionary period: comparison of magnetic resonance imaging with bone scintigraphy. *J Pediatr Orthop* 1995;15:362.
274. Lahdes-Vasama T, Lamminen A, Merikanto J, et al. The value of MRI in early Perthes' disease: an MRI study with a 2 year follow-up. *Pediatr Radiol* 1997;27:517.
275. Roberts JM, Zink WP. Arthrographic classification of Legg-Perthes' disease. Presented at the annual meeting of the American Academy of Orthopaedic Surgeons, Las Vegas, NV, 1981.

Clinical Presentation

257. Bunnell WP. Legg-Calvé-Perthes' disease. *Pediatr Rev* 1986;7:299.

Imaging

258. Lee DY, Choi IH, Lee CK, et al. Assessment of complex hip deformity using three-dimensional CT image. *J Pediatr Orthop* 1991;11:13.
259. Naumann T, Kollmannsberger A, Fischer M, et al. Ultrasonographic evaluation of Legg-Calvé-Perthes' disease based on sonoanatomic criteria and the application of new measuring techniques. *Eur J Radiol* 1992;15:101.
260. Wirth T, LeQuesne GW, Paterson DC. Ultrasonography in Legg-Calvé-Perthes' disease. *Pediatr Radiol* 1992;22:498.
261. Calvé R, Venugopal V, Dorgan J, et al. Radionuclide scanning in the early diagnosis of Perthes' disease. *J Bone Joint Surg Br* 1981;63:379.
262. Danigelis JA, Fisher RL, Ozonoff MB, et al. 99m Tc-polyphosphate bone imaging in Legg-Perthes' disease. *Radiology* 1975;115:407.
263. Danigelis JA. Pinhole imaging in Legg-Perthes' disease: further observations. *Semin Nucl Med* 1976;6:69.
264. Deutsch SD, Gandsman E, Spraragen SC. Quantitative radio-scintigraphy in the evaluation of hip pain in children. *Trans Orthop Res Soc* 1979;4:187.
265. Fisher RL, Roderique JW, Brown DC, et al. The relationship of isotopic bone imaging findings to prognosis in Legg-Perthes' disease. *Clin Orthop* 1980;150:23.
276. Bickerstaff D, Neill L, Booth A, et al. Ultrasound examination of the irritable hip. *J Bone Joint Surg Br* 1990;7:549.
277. Futami T, Kasahara Y, Suzuki S, et al. Ultrasonography in transient synovitis and early Perthes' disease. *J Bone Joint Surg Br* 1991;73:635.
278. Lucht U, Bunker C, Krebs B, et al. Blood flow in the juvenile hip in relation to changes of the intraarticular pressure: an experimental investigation in dogs. *Acta Orthop Scand* 1983;54:182.
279. Andersen PE Jr, Schantz K, Bollerslev J, et al. Bilateral femoral head dysplasia and osteochondritis: multiple epiphyseal dysplasia tarda, spondylo-epiphyseal dysplasia tarda, and bilateral Legg-Perthes' disease. *Acta Radiol* 1988;29:705.
280. Ikegawa S, Nagano A, Nakamura K. A case of multiple epiphyseal dysplasia complicated by unilateral Perthes' disease. *Acta Orthop Scand* 1991;62:606.
281. Iwasaki K. The role of blood vessels within the ligamentum teres in Perthes' disease. *Clin Orthop* 1981;159:248.

Differential Diagnosis

276. Bickerstaff D, Neill L, Booth A, et al. Ultrasound examination of the irritable hip. *J Bone Joint Surg Br* 1990;7:549.
277. Futami T, Kasahara Y, Suzuki S, et al. Ultrasonography in transient synovitis and early Perthes' disease. *J Bone Joint Surg Br* 1991;73:635.
278. Lucht U, Bunker C, Krebs B, et al. Blood flow in the juvenile hip in relation to changes of the intraarticular pressure: an experimental investigation in dogs. *Acta Orthop Scand* 1983;54:182.
279. Andersen PE Jr, Schantz K, Bollerslev J, et al. Bilateral femoral head dysplasia and osteochondritis: multiple epiphyseal dysplasia tarda, spondylo-epiphyseal dysplasia tarda, and bilateral Legg-Perthes' disease. *Acta Radiol* 1988;29:705.
280. Ikegawa S, Nagano A, Nakamura K. A case of multiple epiphyseal dysplasia complicated by unilateral Perthes' disease. *Acta Orthop Scand* 1991;62:606.
281. Iwasaki K. The role of blood vessels within the ligamentum teres in Perthes' disease. *Clin Orthop* 1981;159:248.

Treatment

282. Allen B. Graphic analysis of femoral growth in young children with Perthes' disease. *J Pediatr Orthop* 1997;17:255.
283. Blakemore ME, Harrison MHM. A prospective study of children with untreated Catterall group I Perthes' disease. *J Bone Joint Surg Br* 1979;61:329.
284. Daly K, Bruce C, Catterall A. Lateral shelf acetabuloplasty in Perthes' disease. *J Bone Joint Surg Br* 1999;81:380.
285. Danforth MS. The treatment of Legg-Calvé-Perthes' disease without weight bearing. *J Bone Joint Surg Br* 1934;16:516.
286. Eyre-Brook AI. Osteochondritis deformans coxae juvenilis, or Perthes' disease: the results of treatment by traction in recumbency. *Br J Surg* 1936;24:166.
287. Howarth B. Coxa plana. *Arch Pediatr* 1959;76:1.

288. Barranco SD, Traver RC, Friedman FM, et al. A comparative study of Legg-Perthes' disease. *Clin Orthop* 1973;96:304.
289. Eaton GO. Long-term results of treatment in coxa plana: a follow-up study of eighty-eight patients. *J Bone Joint Surg Am* 1967;49:1031.
290. Evans DL. Legg-Calvé-Perthes' disease: a study of late results. *J Bone Joint Surg Br* 1958;40:168.
291. Evans DL, Lloyd-Roberts GC. Treatment in Legg-Calvé-Perthes' disease. *J Bone Joint Surg Br* 1958;40:182.
292. Harrison MHM, Menon MPA. Legg-Calvé-Perthes' disease: the value of x-ray measurement in clinical practice with special reference to the broomstick plaster method. *J Bone Joint Surg Am* 1966;48:1301.
293. Heyman CH, Herndon CH. Legg-Perthes' disease: method for measurement of roentgenographic results. *J Bone Joint Surg Am* 1950;32:767.
294. Remvig Q, Mose K. Perthes' disease. *J Bone Joint Surg Br* 1961; 43:855.
295. Siffert RS. Osteochondritis of the proximal femoral epiphysis. *Instr Course Lect* 1973;22:270.
296. Legg AT. The end results of coxa plana. *J Bone Joint Surg Br* 1927;25:26.
297. Bellyei A, Mike G. Weight bearing in Perthes' disease. *Orthopedics* 1991;14:19.
298. Mindell ER, Sherman MS. Late results in Legg-Perthes' disease. *J Bone Joint Surg Am* 1951;33:1.
299. Snyder CF. A sling for use in Legg-Perthes' disease. *J Bone Joint Surg Br* 1947;29:524.
300. Harrison MHM, Turner MH, Nicholson FJ. Coxa plana: results of a new form of splinting. *J Bone Joint Surg Am* 1969; 51:1057.
301. Pauwels F. Des affections de la hanche d'origine mecanique et de leur traitement par l'osteotomie d'adduction. *Rev Chir Orthop* 1951;37:22.
302. Salter RB. Experimental and clinical aspects of Perthes' disease. *J Bone Joint Surg Br* 1966;48:393.
303. Brotherton BJ, McKibbin B. Perthes' disease treated by prolonged recumbency and femoral head containment: a long-term appraisal. *J Bone Joint Surg Br* 1977;59:8.
304. Denton J. Experience with Legg-Calvé-Perthes' disease (LCPD), 1968-1974, at the New York Orthopaedic Hospital. *Clin Orthop* 1980;150:36.
305. Katz JF. Conservative treatment of Legg-Calvé-Perthes' disease. *J Bone Joint Surg Am* 1967;49:1043.
306. Katz JF. Nonoperative therapy in Legg-Calvé-Perthes' disease. *Orthop Rev* 1979;8:69.
307. Rab GT, DeNatale JS, Herrmann LR. Three dimensional finite element analysis of Legg-Calvé-Perthes' disease. *J Pediatr Orthop* 1982;2:39.
308. Rab GT. Determination of femoral head containment during gait. *Biomat Med Devices Artif Organs* 1983;11:31.
309. Bombelli R. *Osteoarthritis of the hip*. Berlin: Springer-Verlag, 1983.
310. Ralis Z, McKibbin B. Changes in shape of the human hip joint during its development and their relation to its stability. *J Bone Joint Surg Br* 1973;55:780.
311. Ekholm R. Nutrition of articular cartilage. *Acta Anat* 1955;24: 329.
312. Maroudas A, Bullough P, Swanson SAV, et al. The permeability of articular cartilage. *J Bone Joint Surg Br* 1968;50:166.
313. Catterall A. The place of femoral osteotomy in the management of Legg-Calvé-Perthes' disease. In: Fitzgerald RH Jr, ed. *The hip: proceedings of the thirteenth open scientific meeting of The Hip Society*. St. Louis: Mosby, 1985:28.
314. Gershuni DH, Axer A, Handel D. Arthrography as an aid to the diagnosis and therapy in Legg-Calvé-Perthes' disease. *Acta Orthop Scand* 1980;51:505.
315. Richards BS, Coleman SS. Subluxation of the femoral head in coxa plana. *J Bone Joint Surg Am* 1987;69:1312.
316. Salter RB. The present status of surgical treatment of Legg-Perthes' disease: current concept review. *J Bone Joint Surg Am* 1984;66:961.
317. Roberts JM, Meehan P, Counts G, et al. Ambulatory abduction brace for Legg-Perthes' disease. Presented at the annual meeting of the American Academy of Orthopaedic Surgeons, Dallas, TX, 1974.
318. Donovan MM, Urquhart BA. Treatment with ambulatory abduction brace. *Orthop Rev* 1979;8:147.
319. Bobechko WP. The Toronto brace for Legg-Perthes' disease. *Clin Orthop* 1974;102:115.
320. Fackler CD. Nonsurgical treatment of Legg-Calvé-Perthes' disease. *Instr Course Lect* 1989;38:305.
321. Lovell WW, Hopper WC, Purvis JM. The Scottish Rite orthosis for Legg-Perthes' disease. Presented at the annual meeting of the American Academy of Orthopaedic Surgeons, Dallas, TX, 1978.
322. Price CT, Day DD, Flynn JC. Behavioral sequelae of bracing versus surgery for Legg-Calvé-Perthes' disease. *J Pediatr Orthop* 1988;8:285.
323. MacEwen GD. Conservative treatment of Legg-Calvé-Perthes condition. In: Fitzgerald RH Jr, ed. *The hip: proceedings of the thirteenth open scientific meeting of The Hip Society*. St. Louis: Mosby, 1985:17.
324. Meehan PL, Angel D, Nelson JM. The Scottish Rite abduction orthosis for the treatment of Legg-Perthes' disease: a radiographic analysis. *J Bone Joint Surg Am* 1992;74:2.
325. Wang L, Bowen JR, Puniak MA, et al. An evaluation of various methods of treatment for Perthes' disease. *Clin Orthop Relat Res* 1995;314:225.
326. Axer A, Gershuni DH, Hendel D, et al. Indications for femoral osteotomy in Legg-Calvé-Perthes' disease. *Clin Orthop* 1980; 150:78.
327. Heikkinen E, Puranen J. Evaluation of femoral osteotomy in the treatment of Legg-Calvé-Perthes' disease. *Clin Orthop* 1980; 150:60.
328. Hoikka V, Poussa M, Yrjonen T, et al. Intertrochanteric varus osteotomy for Perthes' disease: radiographic changes after 2-16-year follow-up of 126 hips. *Acta Orthop Scand* 1991;62:549.
329. Lee DY, Seong SC, Choi IH, et al. Changes of blood flow of the femoral head after subtrochanteric osteotomy in Legg-Perthes' disease: a serial scintigraphic study. *J Pediatr Orthop* 1992;12:731.
330. Green NE, Griffen PP. Intra osseous venous hypertension in Legg-Perthes' disease. *J Bone Joint Surg Am* 1982;64:666.
331. Clancy M, Steel HH. The effect of an incomplete intertrochanteric osteotomy on Legg-Calvé-Perthes' disease. *J Bone Joint Surg Am* 1985;67:213.
332. Kendig RJ, Evans GA. Biologic osteotomy in Perthes' disease. *J Pediatr Orthop* 1986;6:278.
333. Marklund T, Tillberg G. Coxa plana: a radiological comparison of the rate of healing with conservative measures and after osteotomy. *J Bone Joint Surg Br* 1976;58:25.
334. Coleman SS. Observations on proximal femoral osteotomy and pelvic osteotomy. *Orthop Rev* 1979;8:139.
335. Mirovski Y, Axer A, Hendel D. Residual shortening after osteotomy for Perthes' disease. *J Bone Joint Surg Br* 1984;66:184.
336. Somerville EW. Osteotomy in treatment of Perthes' disease of the hip. *Orthop Rev* 1979;8:61.
337. Canario AT, Williams L, Weintraub S, et al. A controlled study of the results of femoral osteotomy in severe Perthes' disease. *J Bone Joint Surg Br* 1980;62:348.

338. Evans IK, Deluca PA, Gage JR. A comparative study of ambulation-abduction bracing and varus derotation osteotomy in the treatment of severe Legg-Calvé-Perthes' disease in children over 6 years of age. *J Pediatr Orthop* 1988;8:676.
339. Sponseller PD, Desai SS, Millis MB. Comparison of femoral and innominate osteotomies for the treatment of Legg-Calvé-Perthes' disease. *J Bone Joint Surg Am* 1988;70:1131.
340. Weiner SD, Weiner DS, Riley PM. Pitfalls in treatment of Legg-Calvé-Perthes' disease using proximal femoral varus osteotomy. *J Pediatr Orthop* 1991;11:20.
341. Coates CJ, Paterson JM, Woods KR, et al. Femoral osteotomy in Perthes' disease: results at maturity. *J Bone Joint Surg Br* 1990;72:581.
342. Cordeiro EN. Femoral osteotomy in Legg-Calvé-Perthes' disease. *Clin Orthop* 1980;150:69.
343. Lahdes-Vasama T, Marttinen EJ, Merikanto JE. Outcome of Perthes disease in unselected patients after femoral varus osteotomy and splintage. *J Pediatr Orthop Part B* 1997;6:229.
344. Hansson G, Wallin J. External rotational positioning of the leg after intertrochanteric combined varus derotational osteotomy in Perthes' disease. *Arch Orthop Trauma Surg* 1997;116:108.
345. Joseph B, Srinivas G, Thomas R. Management of Perthes disease of late onset in southern India: the evaluation of a surgical method. *J Bone Joint Surg Br* 1996;78:625.
346. Canale ST, D'Anca AF, Cotler JM, et al. Innominate osteotomy in Legg-Calvé-Perthes' disease. *J Bone Joint Surg Am* 1972;54:25.
347. Dekker M, VanRens TJG, Sloff TJH. Salter's pelvic osteotomy in the treatment of Perthes' disease. *J Bone Joint Surg Br* 1981;68:282.
348. Salter RB. Perthes' disease: treatment by innominate osteotomy. *Instr Course Lect* 1973;22:309.
349. Salter RB. The scientific basis for innominate osteotomy for Legg-Calvé-Perthes' disease and the results in children with a bad prognosis. *Orthop Trans* 1985;9:203.
350. Coleman S, Kehl D. An evaluation of Perthes' disease: comparison of non-surgical and surgical means. Presented at the annual meeting of the American Academy of Orthopaedic Surgeons, Las Vegas, NV, 1981.
351. Ingman AM, Paterson DC, Sutherland AD. A comparison between innominate osteotomy and hip spica in the treatment of Legg-Perthes' disease. *Clin Orthop* 1982;163:141.
352. Paterson DC, Leitch JM, Foster BK. Results of innominate osteotomy in the treatment of Legg-Calvé-Perthes' disease. *Clin Orthop* 1991;266:96.
353. Robinson HJ Jr, Putter H, Sigmond MB, et al. Innominate osteotomy in Perthes' disease. *J Pediatr Orthop* 1988;8:426.
354. Stevens P, Williams P, Menelaus M. Innominate osteotomy for Perthes' disease. *J Pediatr Orthop* 1981;1:47.
355. Moberg A, Hansson G, Kaniklides C. Results after femoral and innominate osteotomy in Legg-Calvé-Perthes' disease. *Clin Orthop Relat Res* 1997;334:257.
356. Ghaida HI, Hull ML, Rab GT. An instrumented brace for study of Legg-Calvé-Perthes' disease. *Biomater Med Devices Artif Organs* 1987;15:719.
357. Rab GT. Containment of the hip: a theoretical comparison of osteotomies. *Clin Orthop* 1981;154:191.
358. Craig WA, Kramer WG. Combined iliac and femoral osteotomies in Legg-Calvé-Perthes syndrome. *J Bone Joint Surg Am* 1974;56:1314.
359. Crutcher JP, Staheli LT. Combined osteotomy as a salvage procedure for severe Legg-Calvé-Perthes' disease. *J Pediatr Orthop* 1992;12:151.
360. Olney BW, Asher MA. Combined innominate and femoral osteotomy for the treatment of severe Legg-Calvé-Perthes' disease. *J Pediatr Orthop* 1985;5:645.
361. Kim H, Wenger DR. Surgical correction of "functional retroversion" and "functional coxa vara" in Legg-Calvé-Perthes disease and epiphyseal dysplasia: correction of deformity defined by new imaging modalities. *J Pediatr Orthop* 1997;17:247.
362. Kim H, Wenger DR. "Functional retroversion" of the femoral head in Legg-Calvé-Perthes disease and epiphyseal dysplasia: analysis of head-neck deformity and its effect on limb position using three-dimensional computed tomography. *J Pediatr Orthop* 1997;17:240.
363. Willett K, Hudson I, Catterall A. Lateral shelf acetabuloplasty: an operation for older children with Perthes' disease. *J Pediatr Orthop* 1992;12:563.
364. Dimitriou JK, Leonidou O, Pettas N. Acetabulum augmentation for Legg-Calvé-Perthes disease: 12 children (14 hips) followed for 4 years. *Acta Orthop Scand Suppl* 1997;275:103.
365. Mose K, Hjorth J, Ulfeldt M, et al. Legg-Calvé-Perthes' disease: the late occurrence of coxarthrosis. *Acta Orthop Scand Suppl* 1977;169:1.
366. Quain S, Catterall A. Hinge abduction of the hip: diagnosis and treatment. *J Bone Joint Surg Br* 1986;68:61.
367. McKay DW. Cheilectomy of the hip. *Orthop Clin North Am* 1980;11:141.
368. Schepers A, VonBormann PFB, Craig JJG. Coxa magna in Perthes' disease: treatment by Chiari pelvic osteotomy. *J Bone Joint Surg Br* 1978;60:297.
369. Van der Hayden AM, Van Tongerloo RB. Shelf operations in Perthes' disease. *J Bone Joint Surg Br* 1981;63:282.
370. Bennett JT, Mazurek RT, Cash JD. Chiari's osteotomy in the treatment of Perthes' disease. *J Bone Joint Surg Br* 1991;73:225.
371. Cahuzac JP, Onimus M, Trottmann F, et al. Chiari pelvic osteotomy in Perthes' disease. *J Pediatr Orthop* 1990;10:163.
372. Handlesmann JE. The Chiari pelvic shelving osteotomy. *Orthop Clin North Am* 1980;11:105.
373. Schepers A. The Chiari osteotomy in Perthes' disease. *S Afr Bone Joint Surg* 1996;VI(6):3.
374. Koyama K, Higuchi F, Inoue A. Modified Chiari osteotomy for arthrosis after Perthes' disease. *Acta Orthop Scand* 1998;69:129.
375. Kruse RW, Guille JT, Bowen JR. Shelf arthroplasty in patients who have Legg-Calvé-Perthes' disease: a study of long-term results. *J Bone Joint Surg Am* 1991;73:1338.
376. Garceau GJ. Surgical treatment of coxa plana. Presented at the joint meeting of the orthopaedic associations of the English speaking world. *J Bone Joint Surg Br* 1964;46:779.
377. Macnicol MF, Makris D. Distal transfer of the greater trochanter. *J Bone Joint Surg Br* 1991;73:838.
378. Matan A, Stevens P, Smith JT, et al. Combination trochanteric arrest and intertrochanteric osteotomy for Perthes' disease. *J Pediatr Orthop* 1996;16:10.



25

SLIPPED CAPITAL FEMORAL EPIPHYSIS

DOUGLAS K. KEHL

EPIDEMIOLOGY 999

PATHOANATOMY 1000

ETIOLOGY 1001

CLINICAL PRESENTATION 1002

RADIOGRAPHIC FEATURES 1005

NATURAL HISTORY 1008

TREATMENT 1009

Treatment to Prevent Further Slippage 1009

Treatment to Reduce the Degree of Slippage 1018

Salvage Procedures 1024

**PROPHYLACTIC PINNING OF THE CONTRALATERAL
HIP 1026**

COMPLICATIONS 1026

Slipped capital femoral epiphysis (SCFE) remains one of the most common disorders affecting the hip during adolescence. The condition is characterized by a displacement of the femoral neck from the capital femoral epiphysis through the physal plate. The femoral head is held securely in the acetabulum, whereas the femoral neck displaces mainly in an anterior direction, creating an apparent varus deformity at the proximal femur. Rarely, femoral neck displacement can be in a posterior direction, creating a proximal femoral valgus deformity (1,2). The physiolysis in SCFE differs from that seen in traumatic physal fracture. Histologic studies have shown that the separation in SCFE is through a widened zone of hypertrophy, which has become weakened by alterations in chondrocyte maturation and endochondral ossification (3,4).

EPIDEMIOLOGY

The annual incidence of SCFE has been reported to average 2 per 100,000 in the general population. Minomiya and colleagues have reported an incidence as low as 0.2 per 100,000 in the eastern half of Japan (5), whereas Kelsey and colleagues have reported an incidence as high as 10.08 per 100,000 in certain regions of the United States (6). Loder has reported a seasonal predilection for SCFE during the summer months (7).

SCFE is related to puberty, as evidenced by 78% of cases of SCFE occurring during the adolescent growth phase (8). The age range at presentation in boys is most often between 10 and 16 years of age (average, 13.5 years), and in girls it is between 9 and 15 years of age (average, 12.1 years) (6,9,10). When a patient with SCFE presents at an age outside of these ranges the treating physician should strongly consider an underlying endocrine or systemic disorder, to include primary and secondary hypothyroidism, panhypopituitarism, hypogonadal conditions, and renal osteodystrophy (11).

D. K. Kehl: Department of Orthopaedic Surgery, Emory University School of Medicine, Atlanta, Georgia 30303; Department of Orthopaedic Surgery, Children's Healthcare of Atlanta at Scottish Rite, Atlanta, Georgia 30342.

A delay in skeletal maturation commonly is seen in patients with SCFE. In some studies, skeletal age has been found to be as much as 20 months behind chronologic age in up to 70% of affected individuals (8,12). A male predilection for SCFE has been reported at 1.43 to 1, with the left hip being affected twice as often in unilateral SCFE (10,13,14). An increased incidence of SCFE has been reported in the African-American and Polynesian populations (6,14).

Obesity definitely is associated with the development of SCFE. Weight-for-age profiles have been reported by Loder (14) to be over the 90th percentile in 63% of affected individuals. Kelsey and colleagues have also reported weight-for-age profiles over the 95th percentile in 49% of affected individuals (15). Brenkel and colleagues have reported weight-for-height profiles over the 90th percentile in 73% of affected boys and 52% of affected girls (16). Clinically obese patients acquiring SCFE also tend to present at a younger age (14,17).

Bilateral symptomatic involvement with SCFE averages 25% during adolescence (range, 21 to 37%) (13,14,17–20). Approximately 50% of these patients present with bilateral involvement, and the remaining 50% show sequential onset (13,17,18,20). Long-term follow-up studies, however, identify changes of bilateral involvement in as many as 60 to 80% of patients with known unilateral SCFE (19,21,22). This implies that many sequential SCFEs occur asymptotically, prior to the end of growth. When bilateral symptomatic involvement occurs sequentially, Loder and colleagues have shown the second slip to present by 12 months in 77% of patients and 18 months in 88% of patients (14,17). Bilateral involvement also is reported to have a higher incidence in males, African-American patients, and obese patients with younger age at initial presentation (13,14,17,23).

PATHOANATOMY

Historically the femoral head was believed to displace mainly in a medial direction off of the femoral neck in SCFE, creating a radiographic varus deformity at the proximal femur (24). Most recently, Nguyen and Morrissy have demonstrated that the displacement in SCFE occurs mainly in a posterior direction, as the femoral head rotates around the axis of the femoral neck, with the apparent proximal femoral varus deformity being secondary to radiographic parallax (25). Some cephalad displacement of the femoral neck, bringing it into contact with the acetabulum, can occur in chronic SCFE, but only after the femoral head has slipped to the posterior aspect of the femoral neck (Fig. 25-1). This knowledge becomes extremely important when considering surgical stabilization of a slip, as well as reconstructive procedures about the proximal femur.

Histologic examination of the hip joint and physal



FIGURE 25-1. In the early displacement of chronic slipped capital femoral epiphysis, the femoral head is held securely in the acetabulum, whereas the femoral neck initially migrates in an anterior direction (**top left, top right**). The resultant posterior displacement of the femoral head around the axis of the femoral neck continues until the femoral head contacts the posterior aspect of the femoral neck (**bottom left**). In this later stage of displacement, the femoral neck may begin to additionally migrate cephalad in relation to the femoral head (**bottom right**). (From ref. 109, with permission.)

plate, in patients with SCFE, has shown several abnormalities. The synovium demonstrates a hyperplasia with increased vascularity and round cell infiltration, indicative of an inflammatory response (26,27). The physal plate is noted to be widened. Ippolito and colleagues have shown that this increase in physal plate width can be as much as twice normal (4). The majority of the change in the physal plate occurs in the zone of hypertrophy. The hypertrophic zone normally constitutes 15 to 30% of the width of the normal physal plate. In SCFE, this zone can increase to as much as 80% of the width of the physal plate (4,5). Abnormal cartilage maturation and subsequent endochondral ossification are implied by the microscopic identification of disruption of the normal columnar pattern of the cartilage columns into cartilage cell clusters, and the presence of cartilage cell islands extending into the adjacent femoral metaphysis (4,28,29) (Fig. 25-2). The slip cleft is noted to traverse mainly the zone of hypertrophy (4,29,30).

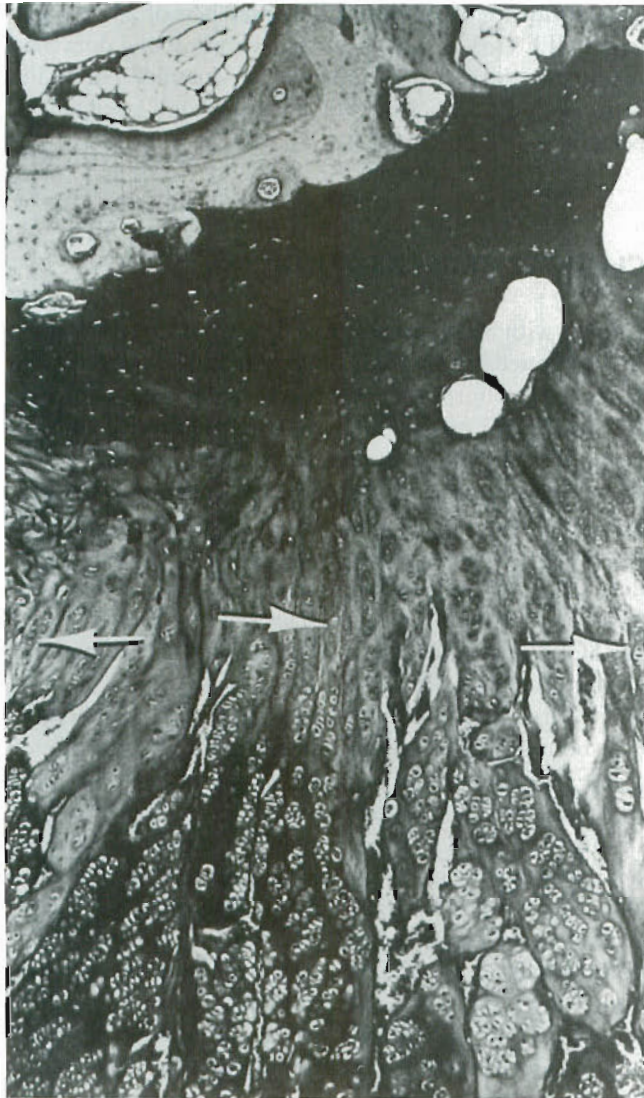


FIGURE 25-2. Photomicrograph of the proximal femoral growth plate of a 13-year-old boy with slipped capital femoral epiphysis. The resting zone is noted to be thinned, and accounts for much less than its normal 60 to 70% of the thickness of the physal plate. The proliferating zone (arrows) demonstrates short columns of chondrocytes enveloped in a compact matrix. The hypertrophic zone is greatly thickened. Large clusters of chondrocytes, separated by deep clefts containing matrix debris, replace the orderly columnar pattern normally seen in this zone. (From ref. 4, with permission.)

Electron microscopic studies demonstrate disorganized collagen fibrils in the physal plate, with abnormal accumulations of proteoglycans and glycoproteins, particularly adjacent to the slip cleft (4,29,31).

Although several abnormalities in the hip joint synovium and proximal femoral physal plate have been documented histologically, it remains undetermined whether these changes are primary abnormalities or, more likely, responses secondary to minimal physal slippage.

ETIOLOGY

The true etiology of SCFE remains unknown. It is unlikely that it is the result of a single factor, but rather is more likely secondary to multiple factors, resulting in a weakened physal plate that is loaded with a higher than normal shear stress, resulting in a failure of the proximal femoral physal plate (32–36).

Local trauma to the proximal femur frequently is reported as a possible contributing etiologic factor in SCFE (13,37). Wilson and colleagues reported 26% of the patients in their review to have had a history of antecedent trauma (13). Trauma was reported much more frequently in slips that presented with an acute onset and a short duration of symptoms. Although traumatic transphysal fracture of the proximal femur and SCFE share a similar gender and age-related peak incidence, the amount of force required to cause physiolsis, and the region of the physis through which the slip cleft traverses differ in the two conditions (3,4). The majority of traumatic transphysal fractures of the proximal femur are the result of high-energy injuries, such as motor vehicle accidents and falls from a height. SCFE presenting with an acute onset, on the other hand, usually follows a minor torsional or low energy injury.

Mechanical factors affecting the proximal femoral physis also have been proposed. Obesity, a decrease in normal femoral anteversion or an actual retroversion of the femoral neck, or a more oblique orientation of the physal plate during adolescence, have all been shown to be associated with increased shear force generation at the proximal femoral physal plate, and could be factors associated with physal plate fatigue (32,36,38). The physal perichondrial ring, which functions as a stabilizer of the physal plate, decreases in strength during the growth years. Chung and colleagues have shown experimentally that physiologic forces at the proximal femur generated by normal activities in obese patients can be of adequate magnitude to cause physal fatigue, if the perichondrial ring is adequately weakened (39).

Inflammatory factors that weaken the physal plate must be considered in any proposed etiology of SCFE, as evidenced by the almost universal association of synovitis of the hip with SCFE (33). It remains unknown, however, whether the synovitis precedes, or is a secondary response to, the physal slippage. Eisenstein and Rothchild proposed the etiology of SCFE to be a systemic immunologic condition with a local manifestation at the hip (40). Their work demonstrated an increase in immunoglobulins and C3 component of complement in the serum, as well as the synovium of the hip joint, in patients with SCFE. Other authors disagree, and propose a local immunologic disorder confined to the hip joint. Morrissy and colleagues have shown no serum abnormalities, but did find increased plasma cells, IgG, and C3 component of complement in the hip joint synovium of patients with SCFE (27). Morrissy and colleagues also have demonstrated the presence of immune

complexes in the synovial fluid of the hip in 10 of 12 patients with SCFE, but not in the synovial fluid of other conditions associated with synovitis (41).

Endocrine imbalance is known to change physal plate physiology, and must therefore be considered as a possible etiologic factor in SCFE (35). An association between endocrine function and SCFE is suggested by the majority of SCFE occurring during the adolescent growth phase. This is a period of significant hormonal change, in which SCFE occurs prior to menarche in girls (8), and is more common in boys, who are known to have a longer, more accelerated growth phase and a frequent association with obesity, which may have an underlying hormonal basis. Additional evidence for an association with endocrine dysfunction is suggested by the frequent association of SCFE with primary and secondary hypothyroidism (42–45), panhypopituitarism (44,46,47), hypogonadal conditions (48), renal osteodystrophy (49,50), and growth hormone therapy (51–53).

Experimental data have confirmed that various hormonal changes affect physal strength by altering physal cartilage collagen and matrix production. Estrogens have been shown to thin the physis and increase physal strength (46), whereas oophorectomy leads to a decrease in physal strength (46,54). Growth hormone therapy is known to be associated with the development of SCFE (51,53). Growth hormone through somatomedin increases the width of the physis by increasing cell activity and matrix production, which in turn decreases the physal strength (46,52). Testosterone in low levels has been shown to weaken the physal plate, whereas high levels for long durations leads to physal plate narrowing (12). In spite of this association between hormonal alternations and physal plate physiology, numerous clinical reports have shown no reproducible laboratory endocrine abnormalities in patients with SCFE (16,40, 55,56). A recent report by Wilcox and colleagues (57) did show significant changes in the levels of thyroid hormone (T3), testosterone, and growth hormone in a group of patients with SCFE. T3 levels were significantly decreased in 25% of 80 patients reviewed. In 64 patients tested, the levels of testosterone and growth hormone were depressed in 76 and 87%, respectively (57).

Loder and associates (58) have identified an association between pelvic and/or proximal femoral radiation therapy for treatment of childhood neoplasms and SCFE. The amount of radiation averaged $4,420 \pm 1,445$ rads. Unlike patients with routine SCFE, patients with SCFE following radiation therapy presented at a younger age (average, 10.4 years) and were usually thin (median weight, 10th percentile). The age at SCFE diagnosis was usually younger when the patient's neoplasm was diagnosed and treatment was initiated at a younger age, or when higher amounts of radiation therapy were given.

Although a definite hereditary pattern in SCFE has never been established, there is some evidence that inheritance can be an etiologic factor. Wilson and colleagues reported

a 5% incidence of SCFE in family members of 240 patients with SCFE (13). Rennie proposed an autosomal dominant inheritance pattern with incomplete penetrance in SCFE, and reported a 7.1% risk of SCFE to a second family member (59).

CLINICAL PRESENTATION

Patients with SCFE usually present with complaints of pain in the affected hip or groin, a change in hip range of motion, and a gait abnormality. A patient can present with pain perceived in the medial thigh and knee region of the affected limb. This phenomenon represents referred pain along the sensory distribution of the obturator and femoral nerves, and commonly is seen in association with hip pathology. If not recognized as referred pain, it can lead to a significantly delayed or even missed diagnosis (60,61). The intensity and duration of symptoms traditionally have been used to classify SCFE into four patterns of presentation: preslip, acute, chronic, and acute-on-chronic.

The true preslip or prodromal stage of SCFE theoretically occurs prior to any actual slippage through the physal plate. Whether preslip is an actual phase in SCFE, or is secondary to a mild synovitis induced by minimal slippage through the physal plate, remains controversial. The patient provides history of an episodic limp and limb weakness associated with intermittent mild pain in the groin, medial thigh, or knee region, particularly with exertion. On physical examination, the patient may show mild pain with rotation of the affected hip, and a minimal decrease in internal rotation. Plain radiographs may show osteopenia and a minor widening and fuzziness of the physal plate; however, the physal plate–femoral neck relation appears normal. The preslip stage in SCFE most likely is not a true prodromal phase, but represents early symptomatology associated with mild physal slippage that cannot be detected on plain radiographs.

The most frequent pattern of presentation is a chronic SCFE. The patient describes intermittent pain in the groin, the medial thigh, or the anterior suprapatellar region of the knee for longer than 3 weeks. The patient remains ambulatory, but does show an antalgic gait with associated limp. The affected limb positions itself in an externally rotated and mildly shortened position. Range of hip motion shows a decrease mainly in internal rotation and abduction with the amount of limitation being dependent on the severity of the slip. Mild to moderate pain is noted with motion of the hip, particularly at the extremes of motion. There may be some thigh and gluteal muscle atrophy secondary to long-standing symptoms and disuse. A frequently seen sign associated with SCFE can be demonstrated during passive flexion of the affected hip. As flexion is increased from an extended position, the thigh of the affected limb abducts and

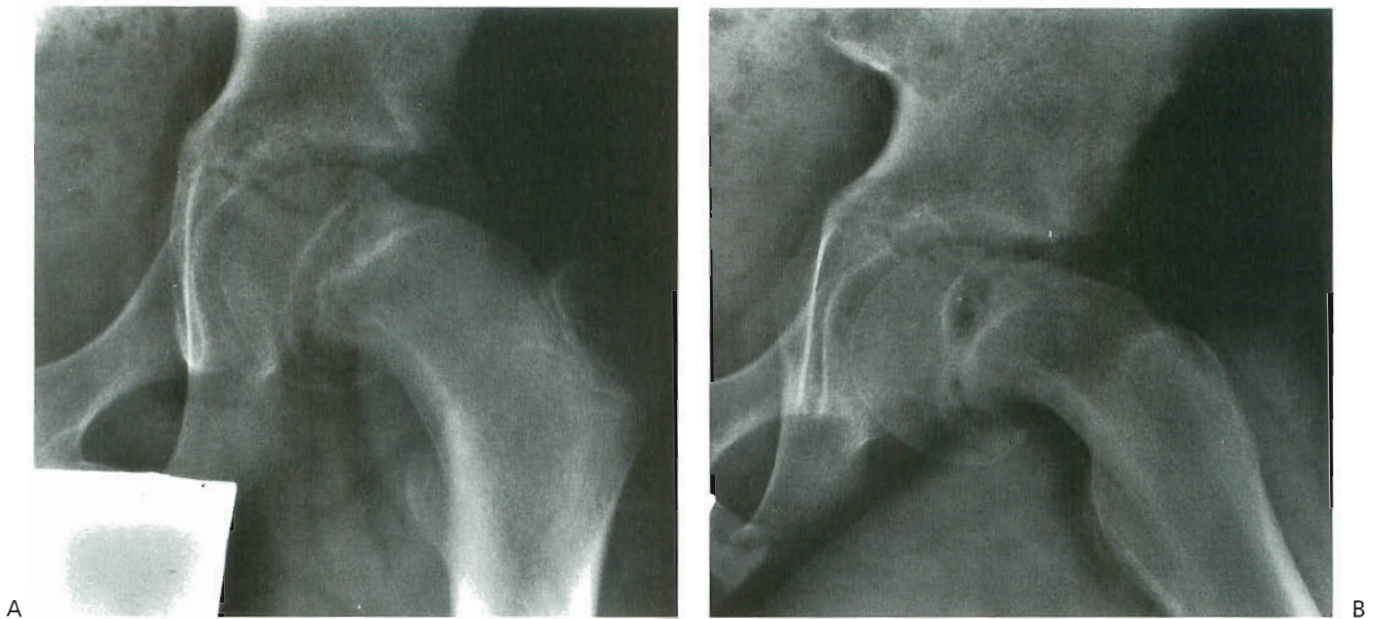


FIGURE 25-3. Anteroposterior (A) and frog-leg lateral (B) hip radiographs of a 13-year, 4-month-old boy demonstrate chronic epiphyseal displacement. The bony resorption on the superior and anterior femoral neck, and the new bone formation on the inferior and posterior femoral neck, indicate a more prolonged process.

externally rotates. Radiographs frequently show attempts at bony healing and remodeling along the posterior and medial femoral neck (Fig. 25-3).

The acute-on-chronic presentation in SCFE occurs when a patient with an extended history of symptoms and signs of chronic SCFE presents with an acute increase in pain and loss of motion at the affected hip. This presentation is associated with an acute increase in slip severity from a previous, more mild chronically displaced pattern (Fig. 25-4).

An acute presentation in SCFE occurs in approximately 10% of patients (18,62). It is manifest by the sudden onset of severe pain and hip dysfunction in a patient who was previously asymptomatic. A few patients may describe prodromal symptoms for a short time preceding the acute onset of pain, which is frequently associated with minimal trauma. Although the literature varies with respect to the duration of painful symptoms prior to presentation, for a SCFE to be classified as acute, most reviews stipulate that the painful symptoms be present for no longer than a 3-week duration (5,62–65). Physical examination demonstrates the affected limb externally rotated and shortened with the patient refusing to bear weight. Active motion of the affected hip is severely limited by muscle spasm, and the patient complains of intense pain with any attempt at passive hip motion. Radiographs document the epiphyseal displacement, and show no evidence of bone healing or remodeling (66,67) (Fig. 25-5).

Classification systems are only useful to the treating phy-

sician if they assist in the planning of treatment or relate to the outcome of a specific disease process. In SCFE, the classification system of acute, chronic, or acute-on-chronic, with respect to patterns of presentation, traditionally has been used. Loder and colleagues have proposed a more simplified classification system in SCFE, based on physeal plate stability at the time of presentation. A slip is classified as unstable if the patient has such severe pain that walking is not possible, even with crutches, regardless of the duration of symptoms. A slip is classified as stable if walking and weightbearing are still possible, with or without crutches (68,69). Other authors include SCFE that shows reduction at the time of surgical stabilization, either intentional or unintentional, as retrospectively unstable (70,71). Both classification systems in SCFE have been shown to be of assistance in the planning of treatment and the projection of outcome. The more simplified system, however, in which slips are classified as stable or unstable, seems to be more objective in its method of classification, and has the potential to be more useful not only in determining treatment, but also predicting outcome. Loder and colleagues (68) have shown that not all slips classified as acute are unstable, and not all slips classified as chronic are stable. They, as well as other authors (70–74), have also shown that slips treated by the same technique and classified as stable have a higher rate of satisfactory results from treatment when compared with unstable slips, which show a lower rate of satisfactory results primarily because of higher rates of osteonecrosis. Loder reported the development of femoral head os-

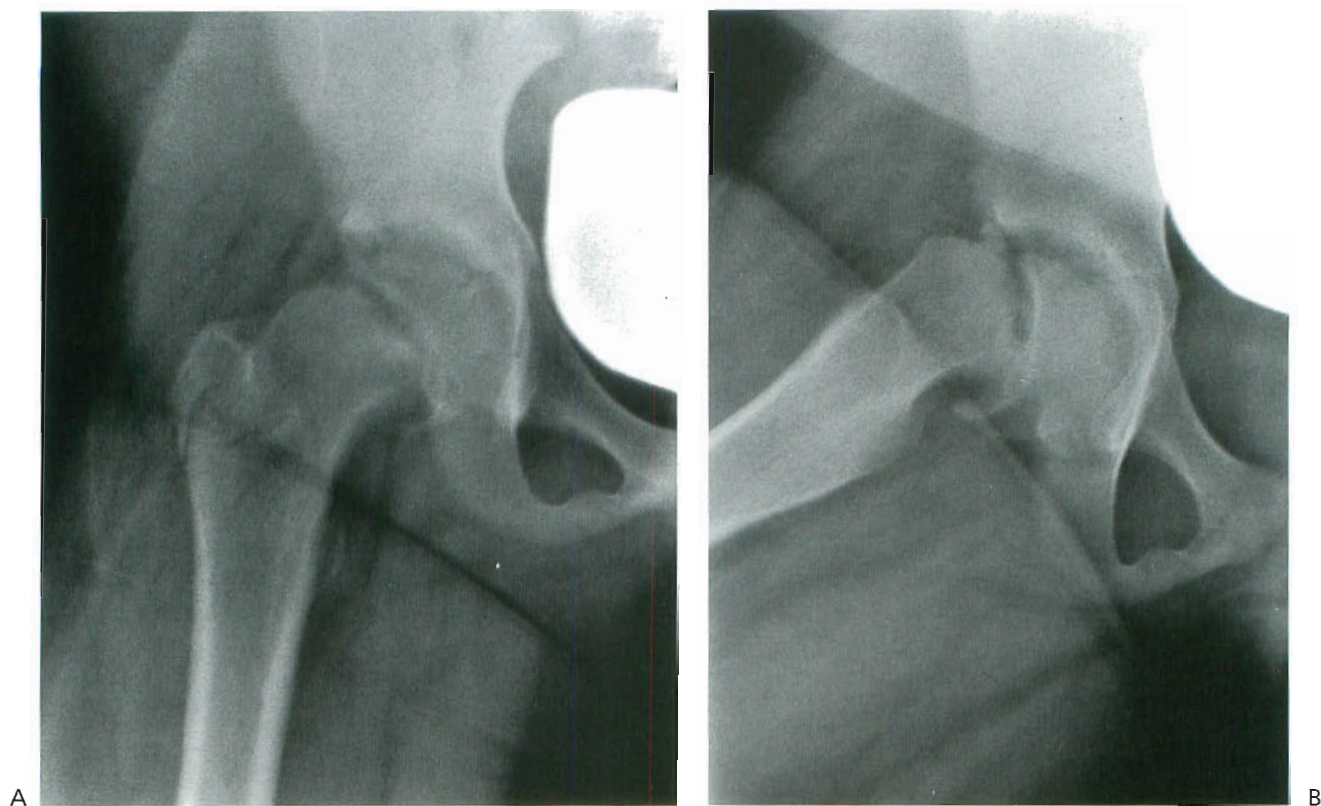


FIGURE 25-4. Anteroposterior (A) and frog-leg lateral (B) hip radiographs of a 12-year, 4-month-old girl demonstrate an acute-on-chronic epiphyseal displacement. The radiographic changes seen on both radiographic views demonstrate an acute increased displacement of the femoral head from a previous more chronic position of displacement, as indicated by the new bone formation on the inferior and posterior femoral neck.

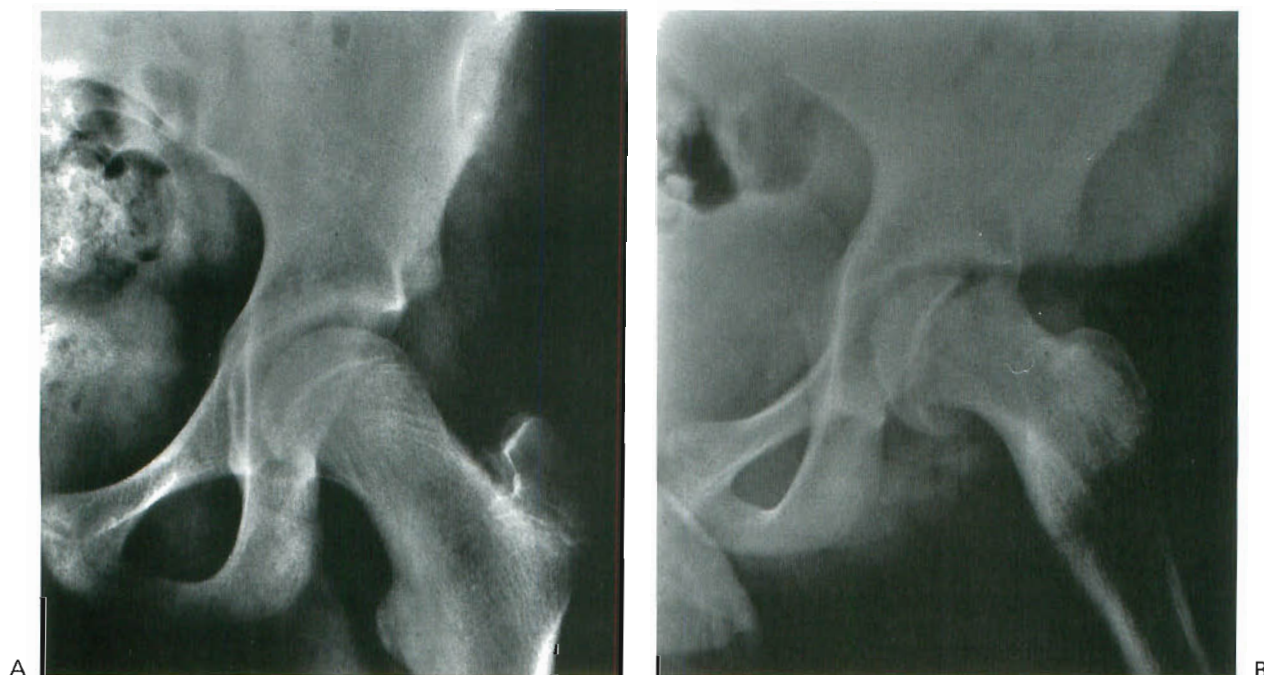


FIGURE 25-5. Anteroposterior (A) and frog-leg lateral (B) hip radiographs of a 12-year, 10-month-old girl demonstrate acute epiphyseal displacement. There is no evidence of bone healing or remodeling at the femoral neck.

teonecrosis in 14 of 30 patients (46.7%) presenting with an unstable SCFE (68). As experience with the more simplified system of classification continues to be reported, it appears that the simplified system (stable versus unstable) is becoming the more useful form of classification in SCFE.

RADIOGRAPHIC FEATURES

The actual diagnosis of SCFE is confirmed by radiographic examination of the affected hip taken in two orthogonal planes. The anteroposterior radiograph usually demonstrates physeal plate widening and irregularity, and a decrease in epiphyseal height in the center of the acetabulum. A crescent-shaped area of increased density frequently can be identified in the proximal portion of the femoral neck, and is known as the blanch sign of Steel (75). This radiographic finding is created by the double density of the posteriorly displaced femoral head on the femoral neck. The femoral metaphysis of the affected hip also appears to be more laterally displaced from the medial acetabular wall, compared with the unaffected hip (Fig. 25-6). A positive Klein

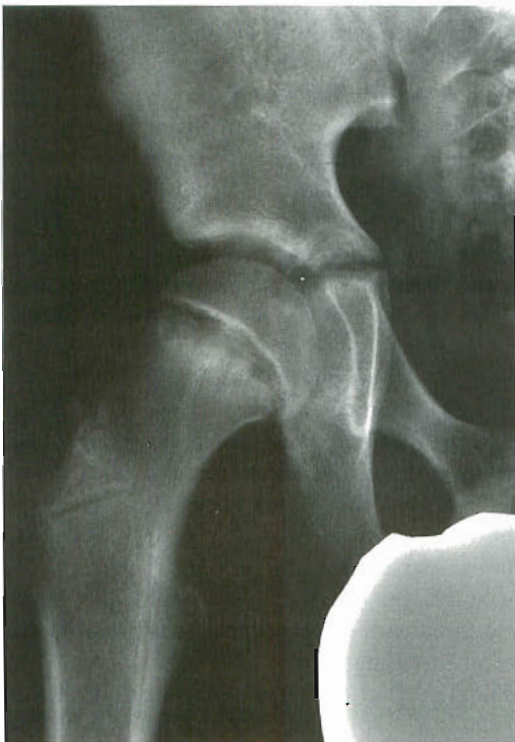

FIGURE 25-6. Anteroposterior hip radiograph demonstrates the classic radiographic findings in slipped capital femoral epiphysis, which include physeal plate widening and irregularity, a decrease in epiphyseal height, and a lateral displacement of the femoral neck from the medial acetabular wall. Also of note is a crescentic area of increased density in the proximal portion of the femoral neck adjacent to the physeal plate, known as the blanch sign of Steel.

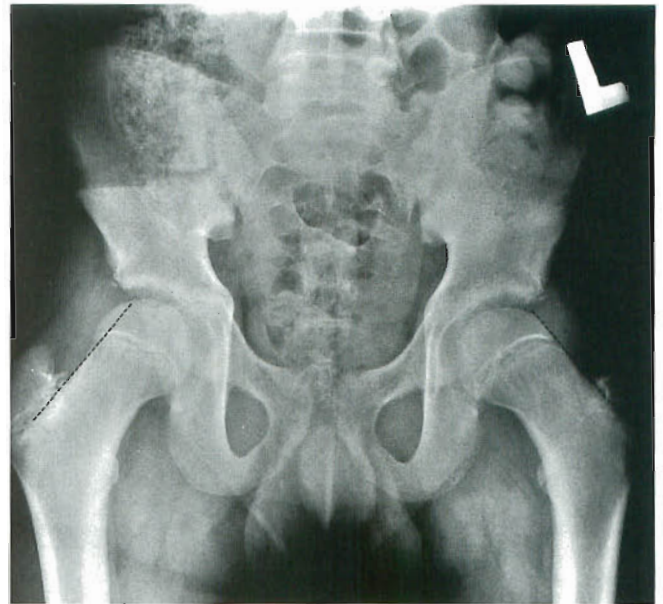

FIGURE 25-7. Anteroposterior pelvic radiograph of a 15-year, 6-month-old boy demonstrates a positive Klein line measurement. A line drawn along the superior basal margin of the femoral neck (i.e., Klein line) intersects the lateral aspect of the right femoral head, but essentially misses intersection with the left femoral head. This finding indicates displacement of the left femoral head-femoral neck relation, and indicates a slipped capital femoral epiphysis at the left hip.

line is identified as the amount of slip increases. Klein line is defined as a straight line drawn along the superior basal margin of the femoral neck on the anteroposterior radiograph (76). Normally this line intersects the lateral aspect of the epiphysis. The amount of femoral head intersected is dependent on the degree of hip rotation, and is greatest when the hip is in maximum internal rotation. As progressive displacement of the epiphysis occurs, the amount of Klein line that intersects the epiphysis decreases, compared with the uninvolved hip. Eventually, the line fully misses intersection with the proximal femoral epiphysis (Fig. 25-7).

A true lateral or cross-table lateral radiographic view of the hip better defines the extent of posterior displacement of the femoral epiphysis (Fig. 25-8). This view can be of assistance in diagnosing minimal slips because it better elucidates the posterior displacement. This view, however, remains difficult to obtain in the extremely obese patient.

A frog-leg lateral radiographic view usually demonstrates the posterior displacement and step-off of the epiphysis on the femoral neck (Fig. 25-9). Although the frog-leg lateral view assists in confirming the diagnosis, it should be avoided in the acute (unstable) presentation, because of the potential of increasing the physeal displacement during positioning for the radiograph.

Two radiographic images of the affected hip in SCFE,

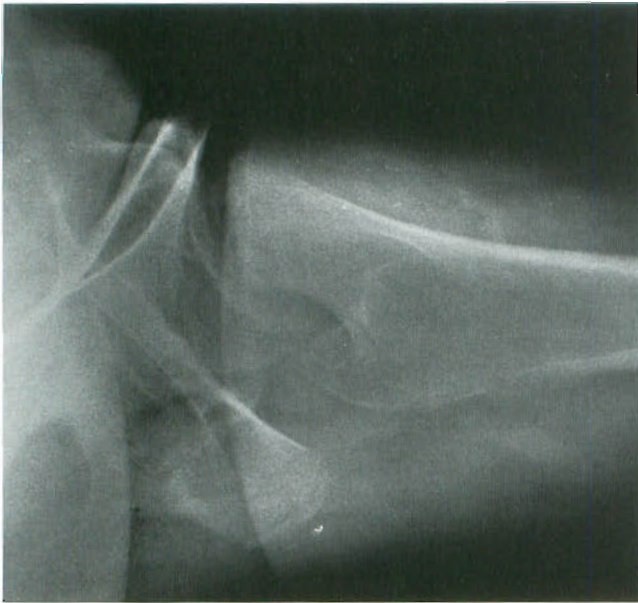


FIGURE 25-8. True lateral hip radiograph of a slipped capital femoral epiphysis demonstrates the posteriorly displaced femoral head remaining in close contact with the femoral neck. Early secondary resorption and rounding of the posterior femoral neck region are noted.

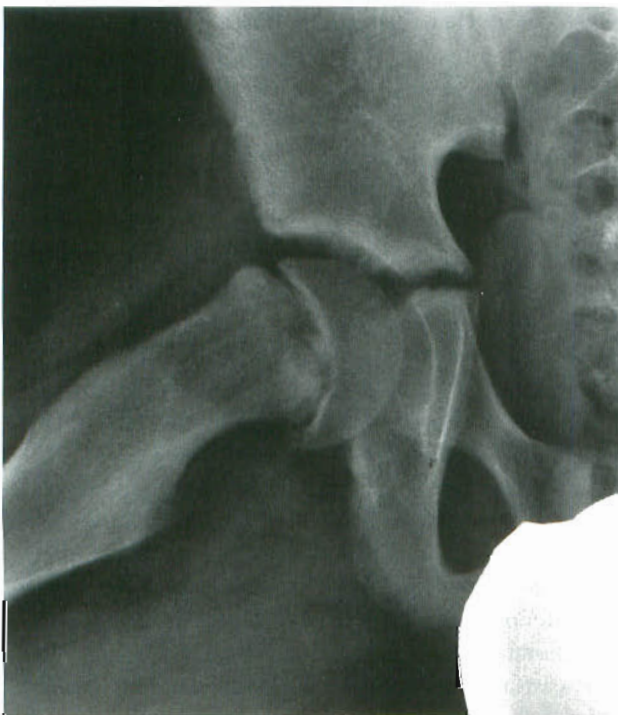

FIGURE 25-9. Frog-leg lateral hip radiograph of a slipped capital femoral epiphysis demonstrates an epiphyseal step-off and posterior displacement of the femoral head on the femoral neck, classically seen in slipped capital femoral epiphysis.

taken in orthogonal planes, should be obtained when possible to assist in diagnosis and planning of treatment. The anteroposterior and true lateral radiographic views of the affected hip are preferred. If a true lateral view of the involved hip is not technically obtainable, a good compromise in most patients is the frog-lateral view.

Ultrasonography recently has been proposed in the diagnosis and evaluation of SCFE (77,78). Kallio and colleagues used ultrasonography in 26 hips of patients with SCFE to confirm diagnosis and degree of slip by evaluating the step-off in the anterior physeal outline, and by measuring the amount of posterior epiphyseal displacement (79). Although ultrasonography can confirm the diagnosis of SCFE, it offers little if any information compared to conventional radiography in SCFE, and has no additional use in treatment.

Computed tomography scan has been shown to be of assistance in both the diagnosis and treatment of SCFE (80). Computed tomography scan can be used to confirm epiphyseal displacement and accurately measure the amount of displacement in patients with symptoms suggestive of a SCFE, but without documentation on plain radiographs (Fig. 25-10). Currently, a computed tomography scan in SCFE is rarely needed in the diagnosis of SCFE, but can be of assistance in assessing the presence of early physeal plate closure in severe slips, in which positioning for standard radiographic views may be difficult.

Reports of the use of magnetic resonance imaging studies in hips affected with SCFE remain rare (81,82). The published reports, however, confirm that magnetic resonance imaging can be of assistance in the early diagnosis of SCFE, by identifying morphologic and signal abnormalities around the affected physeal plate at a time when plain radiographs, and even computed tomograph scans, may appear normal. Umans and colleagues (82) performed magnetic resonance imaging on 15 symptomatic hips secondary to SCFE. They reported T1-weighted images to universally show physeal widening, as well as physeal displacement when present. The T2-weighted images demonstrate synovitis and joint effusion, as well as marrow edema in the juxtaphyseal femoral neck metaphysis and femoral epiphysis of the affected hip (Fig. 25-11). Although magnetic resonance imaging has been shown to assist in the diagnosis of minimal SCFE, it is not to be used as a routine radiologic procedure for diagnosis of SCFE, but may be rarely indicated in cases of hip pain associated with a high clinical suspicion of SCFE but negative plain radiographs.

A radiographic classification system based on the maximum anatomic displacement of the femoral head on the femoral neck, as seen on any of the radiographic views of the hip in a patient with SCFE, has been described (83). In this classification system a "minimal slip" is defined as epiphyseal displacement of less than one-third of the width of the femoral neck (Fig. 25-9); "moderate slip" is defined as displacement of one-third to one-half of the width of the femoral neck (Fig. 25-5); and "severe slip" is defined as

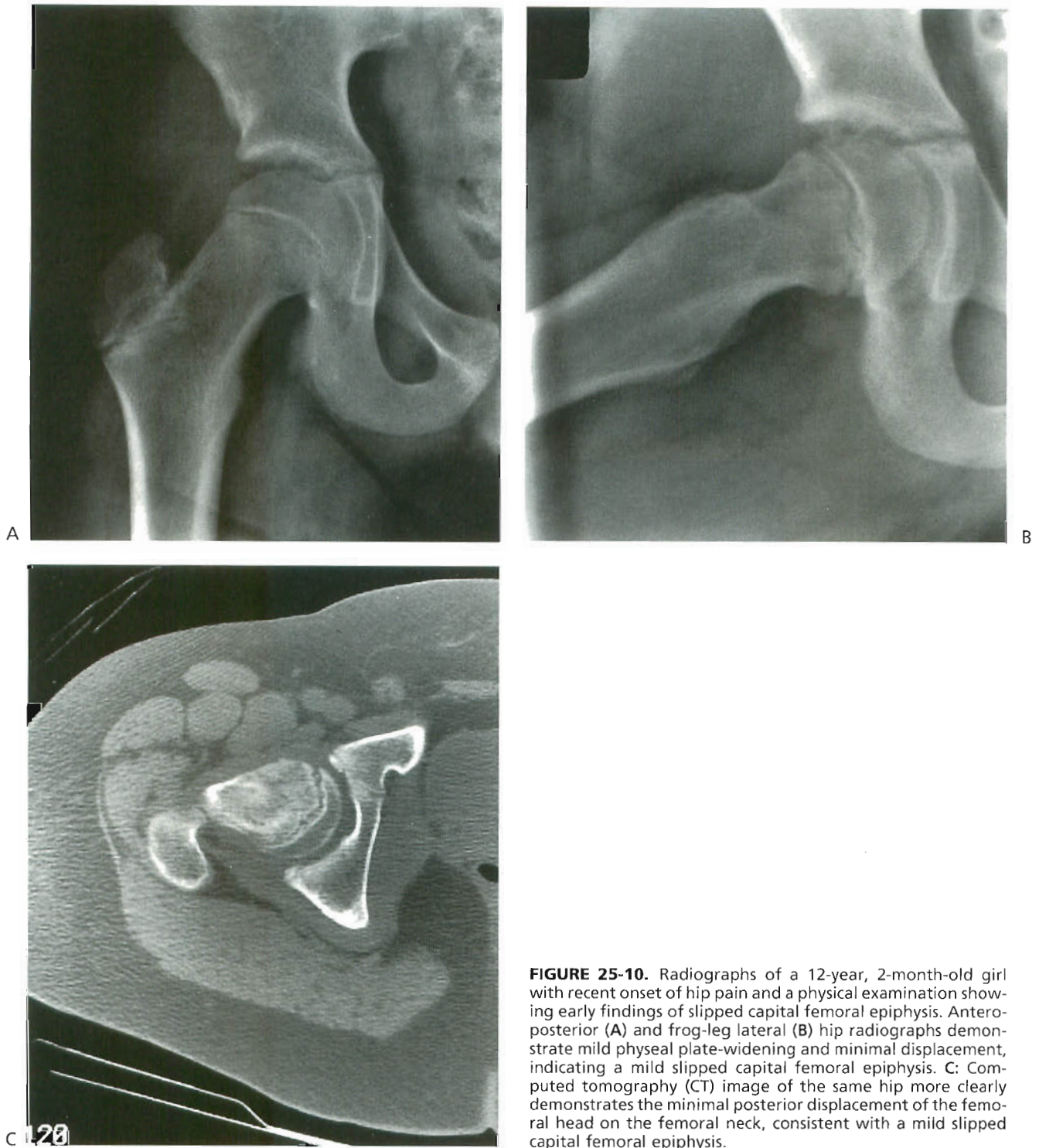


FIGURE 25-10. Radiographs of a 12-year, 2-month-old girl with recent onset of hip pain and a physical examination showing early findings of slipped capital femoral epiphysis. Anteroposterior (A) and frog-leg lateral (B) hip radiographs demonstrate mild physeal plate widening and minimal displacement, indicating a mild slipped capital femoral epiphysis. C: Computed tomography (CT) image of the same hip more clearly demonstrates the minimal posterior displacement of the femoral head on the femoral neck, consistent with a mild slipped capital femoral epiphysis.

displacement greater than one-half of the width of the femoral neck (Fig. 25-8). Southwick has recommended that displacement be measured by the angle subtended between the femoral head and the femoral shaft on the anteroposterior and lateral radiographic views (84). Boyer and colleagues have proposed measurement of the maximum difference in

the Southwick angles, between the involved and uninvolved hip in SCFE, as a radiographic classification system (62). These authors define a mild slip as a head–shaft angle difference of 30 degrees or less, a moderate slip as a 30- to 50-degree difference, and a severe slip as a difference of more than 50 degrees. The reproducibility of these radiographic

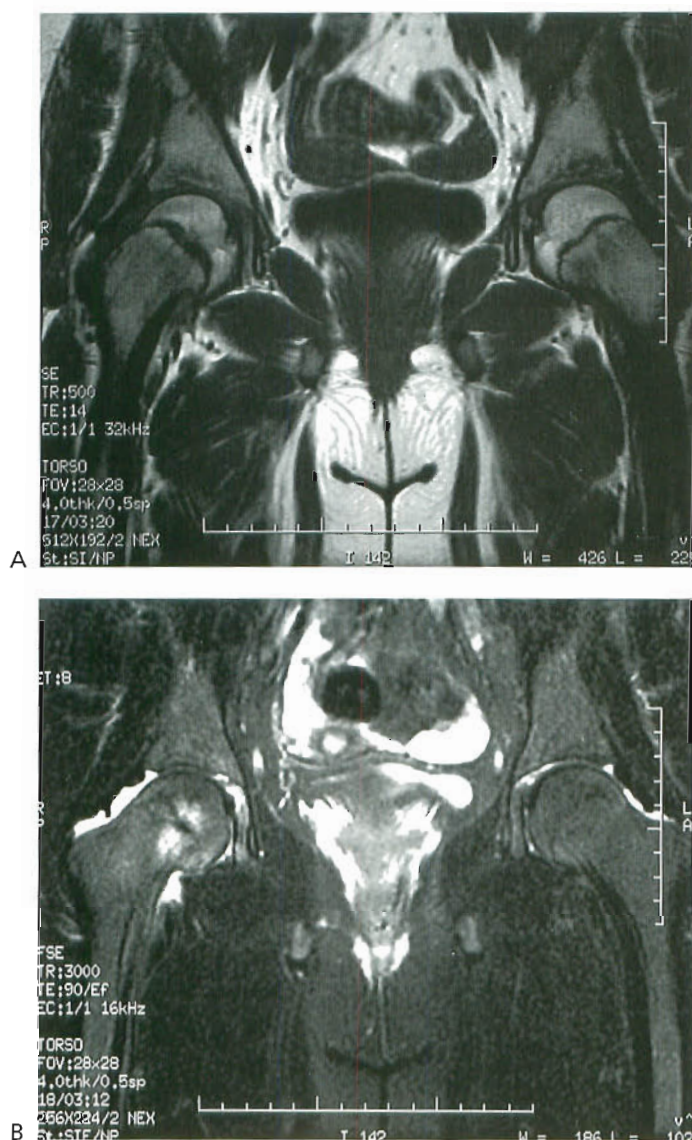


FIGURE 25-11. Magnetic resonance imaging (MRI) of a 12-year, 8-month-old girl with recent onset of right hip pain and a physical examination indicative of a slipped capital femoral epiphysis. **A:** T1-weighted image demonstrates physeal widening and minimal epiphyseal displacement on the right. **B:** T2-weighted image demonstrates marrow edema in the juxtaphyseal femoral neck metaphysis and femoral epiphysis, as well as a joint effusion on the right.

classification systems in SCFE remains unproven, but can be used to assist in planning treatment, and more importantly, aid in determining outcome in SCFE with respect to the severity of slip and the future development of degenerative joint disease.

NATURAL HISTORY

The complete natural history of the hip in SCFE remains unknown. Very few long-term studies with untreated pa-

tients exist in the current literature, and the studies that do exist deal only with small numbers of patients (18,85–89).

The current literature shows that not all hips affected with SCFE are symptomatic during slippage. In fact, the second slip can be asymptomatic in 30 to 40% of patients. In most of these patients the slip shows a very slow minimal progression, with ongoing remodeling during the adolescent growth phase (19,21,22,90). Symptomatic slips, on the other hand, usually show more rapid progressive displacement. Jacobs has shown that the longer the duration of symptoms the more likely the slip will have a greater severity of displacement (83).

Howorth stated that SCFE during adolescence frequently is associated with degenerative joint disease of the hip during middle life (91). Long-term studies of patients with SCFE do indicate a definite relation between SCFE during adolescence and the subsequent development of degenerative joint disease (18,62,89).

The incidence of degenerative joint disease of the hip associated with previous SCFE remains unknown. Murray reported on 200 patients with degenerative joint disease of the hip, and described the tilt deformity, a sign of femoral neck remodeling believed to be associated with previous SCFE, in 40% of the patients (92). Stulberg and colleagues have reported a pistol-grip deformity at the proximal femur, believed to be secondary to previous SCFE or Perthes disease, in 40% of patients with assumed primary osteoarthritis undergoing total hip arthroplasty (93). The presence of this postslip morphology at the proximal femur, and its association with osteoarthritis of the hip, was also reviewed by Goodman and colleagues in 1997 (94). They examined 2,665 adult human skeletons from an osteological collection, and found a prevalence of postslip morphology in 215 skeletons (8%). Severe osteoarthritis of the hip was found to be more prevalent in association with postslip morphology, when compared to the contralateral normal hip. It was therefore concluded that the presence of postslip morphology was a major risk factor for the subsequent development of severe hip degenerative joint disease. Solomon reviewed 327 patients with degenerative joint disease at the hip, and found only six patients with a history of previous SCFE (95). Resnick refuted the association of the radiographic tilt deformity with previous SCFE, by showing that the remodeling process at the femoral neck was not the result of SCFE, but, rather, was solely related to the osteoarthritis (96).

Long-term studies have confirmed that the prognosis for subsequent development of degenerative joint disease and deteriorating function at the hip affected with SCFE are dependent on the severity of the slip and increasing patient age at follow-up (18,86–89). Oram has demonstrated that severe slips develop earlier degenerative joint disease and poorer hip function than do moderate slips (87). Jerre (86) and Ross and colleagues (88) reported an increase in symptoms and a deterioration in hip function associated with increasing patient age at follow-up in patients with SCFE. Jerre also noted that the clinical symptoms do not always correlate with the changes seen radiographically (86). Carney and colleagues recently reported long-term follow-up on 155 hips in 124 patients affected with SCFE, with a mean follow-up of 41 years from symptom onset (18). Their work represents continued follow-up on the patients previously reported by Boyer and colleagues (62). Carney reported a continued deterioration in Iowa Hip Rating scores with increasing time of follow-up. This deterioration in hip-rating scores was shown to occur in all of the grades of slip

severity. An accompanying deterioration in the radiographic grade for degenerative joint disease also was documented.

The current literature suggests that the onset of both symptoms and degenerative joint disease at the hip will be accelerated in most cases of SCFE. This accelerated onset of degenerative joint disease has been shown to be directly related to the severity of the slip. Treatment, therefore, can influence positively the natural history of SCFE, if early recognition and subsequent intervention to prevent progressive deformity are achieved.

TREATMENT

The treatment in SCFE is designed to improve on the natural history of the untreated condition as it is currently understood. The goals of treatment include the prevention of further slipping, by stabilizing the diseased physis and thereby reducing the incidence and onset of osteoarthritis at the affected hip, and the avoidance of iatrogenically induced osteonecrosis of the femoral head and chondrolysis.

Treatment can be divided into three categories: treatment to prevent further slippage, treatment to reduce the degree of slippage, and salvage treatment.

Treatment to Prevent Further Slippage

After slipping of the proximal femoral epiphysis has been documented, treatment should be directed at prevention of further slippage. This can be accomplished by spica cast immobilization, *in situ* metallic pin and screw fixation, and bone-peg epiphysiodesis.

The treatment rationale for the use of spica cast immobilization in SCFE is based on the following assumptions, not all of which have been proven to be true. The slippage in SCFE is short-lived and will heal spontaneously if immobilized for a long-enough period. Further slipping can be prevented by external immobilization. The treatment process is associated with a low complication rate, because there is no violation of the proximal femur or hip joint. Prolonged joint immobilization in adolescence is without increased complications (18,24,97).

Treatment by spica cast immobilization has been reported mainly in chronic and acute-on-chronic SCFE. The use of spica cast immobilization in acute SCFE has been reported in only a limited number of patients (97,98). Previous authors (97,98) have standardized the method of treatment, which includes an initial phase of bed rest with split Russell or Buck skin traction, until joint irritability has lessened. Traction averages 10 days, but has been reported to last as long as 30 days (97). A one-and-a-half or double-spica cast is then applied without any attempt at epiphyseal reduction. The hip is positioned at the midpoint of comfortable internal and external rotation. Radiographs of the hip

are obtained every 4 weeks to document that no additional progression of slip has occurred, and to evaluate healing. Adequate physeal plate healing to allow for discontinuation of the immobilization is determined radiographically, and is present either when physeal plate closure is identified or when the metaphyseal juxtaphyseal lucency (i.e., a radiolucent zone on the metaphyseal side of the physis) (59) is no longer seen on radiographs of the affected hip. The immobilization averages 12 weeks with a range of 8 to 16 weeks. After cast removal, gentle range of motion and muscle-strengthening exercises are initiated.

The results of treatment with spica cast immobilization in SCFE have been reported by several authors (18,97–99). Successful prevention of further slippage by spica cast immobilization is reported at 82 to 97% (97,98). Associated with this high rate of success in preventing further slippage, Betz and colleagues reported 14 of 17 hips (82%) treated by spica cast immobilization to show premature physeal closure at the affected physis, in comparison with the contralateral uninvolved hip (97).

Complications associated with spica cast immobilization include recurrent slip after cast removal in as high as 18% of patients (98). Betz and colleagues reported only a 3% rate of recurrent slip if the spica cast is maintained until full resolution of the metaphyseal juxtaphyseal radiolucent zone has been radiographically documented (97). Osteonecrosis of the femoral head has been reported by Carney and colleagues to be associated with spica cast immobilization, without reduction in 2 of 27 hips (7%) (18). Meier and colleagues reported full-thickness skin pressure ulcers in 2 of 13 patients (16%) (98). The development of psychosocial complications during prolonged treatment with a spica cast in these generally obese patients also must be considered. The most frequent and serious complication associated with spica cast immobilization in SCFE remains chondrolysis. This complication is reported to occur in 19 to 67% of affected hips treated by spica cast immobilization, and has been shown to have a higher occurrence rate, with more severe degrees of slippage at the time of spica cast placement (18,97–99).

Although treatment with spica cast immobilization to prevent further slippage has been considered as an alternative in patients with chronic SCFE, abandoning its use, due to the high rate of associated serious long-term complications, is recommended.

In situ fixation of the displaced femoral head, with metallic pins or screws, historically has been and remains the most commonly used method of stabilization in SCFE [→3.14]. The primary rationale behind the use of metallic fixation is that the fixation device, by crossing the diseased physeal plate, provides mechanical support to prevent further slippage. Historically, *in situ* fixation has been associated with some technical difficulties and higher complication rates, arising from a poor understanding of the three-dimensional characteristics of pin placement, inadequate

radiographic imaging, a lack of knowledge of the intraosseous vascular supply of the femoral head, and inadequate internal fixation. Currently available surgical techniques, fixation devices, and fluoroscopic equipment, as well as a better understanding of the anatomy and the pathoanatomy found in SCFE, have greatly improved and simplified the performance of the procedure, which has led to improved treatment outcomes. When *in situ* fixation is performed percutaneously or through a minimal incision, it has the advantages of minimal blood loss, avoidance of opening of the hip joint, and minimal requirement for postoperative hospitalization and rehabilitation (67). Certain disadvantages, however, are inherent with the technique, and include the possibility of persistent penetration of the hip joint by the fixation device (100) and increased technical difficulty in some severe slips. The need for subsequent hardware removal has historically been proposed as an additional disadvantage; however, several recent reports have questioned the benefit of routine hardware removal (67,101–103). Currently, hardware used for stabilization in SCFE that is causing no symptoms is no longer routinely removed.

Review of the historical literature on metallic fixation in SCFE demonstrates previous complication rates as high as 20 to 40%, with the majority of the complications related to hardware placement and hip joint violation leading to osteonecrosis and chondrolysis (104–106). Proximal femoral fracture, unsuccessful stabilization, and hardware breakage also were reported complications (106,107). The use of multiple pins and screws, improper starting position for the hardware, and inadequate radiography were shown to be associated with this higher incidence of complications (25,108–111). With experience and a better understanding of the actual pathoanatomy of SCFE, the principles of safe and successful *in situ* metallic fixation have been developed, and have been shown to significantly lower the incidence of complications previously associated with metallic fixation.

In situ fixation remains a surgical technique dependent on biplane fluoroscopy to perform properly. With the advent of current fluoroscopic equipment and patient positioning devices, adequate visualization of the femoral head and proximal femur, even in obese patients, is possible, and has greatly improved the simplicity and safety of *in situ* fixation. The proper technique of percutaneous *in situ* fixation in SCFE, to include patient positioning, hardware start-point determination, hardware placement, and postoperative care, has been described by Aronson and Carlson (66) and Morrissy (112).

The principles of successful *in situ* fixation in SCFE warrant reemphasis. It is imperative that the outline of the femoral head be seen on both the anteroposterior and true lateral (not frog-leg lateral) radiographic projections prior to any attempt at fixation placement.

The central axis of the femoral head remains the only safe position for the fixation device. The farther off the central axis the fixation is, the more likely penetration of

the femoral head is to occur. Walters and Simon (104), through the use of mathematical models, have demonstrated what is called the blind spot of the femoral head. In using biplane radiography, it was shown that there is always an area where a pin can violate the femoral head and not be seen radiographically. This blind spot is small in the central axis of the femoral head; however, it increases greatly the

farther the position of the fixation device is from the femoral head central axis (Fig. 25-12). Only by positioning the fixation device centrally, and at least 5 mm from the margin of the femoral head, can avoidance of penetration be assured (Fig. 25-13). Because there is only one central axis in the femoral head, the use of multiple pins and screws must position some of the devices off the central axis and increase

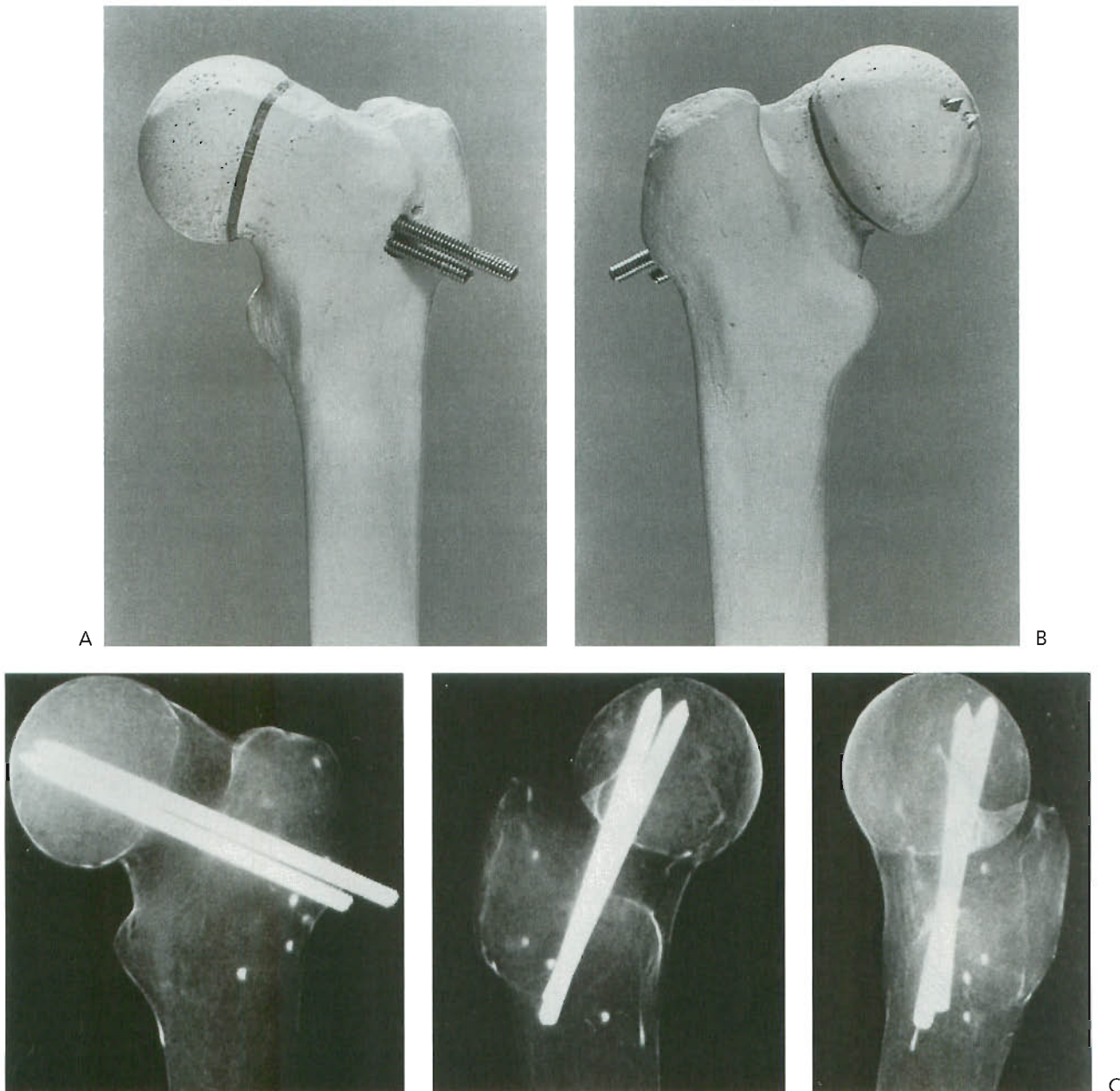
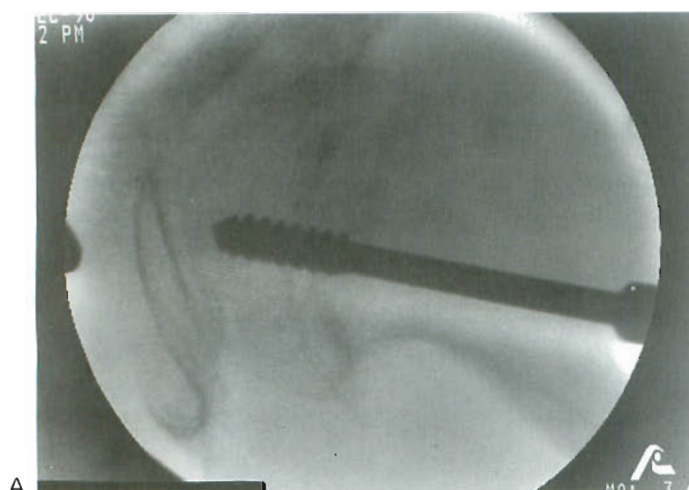
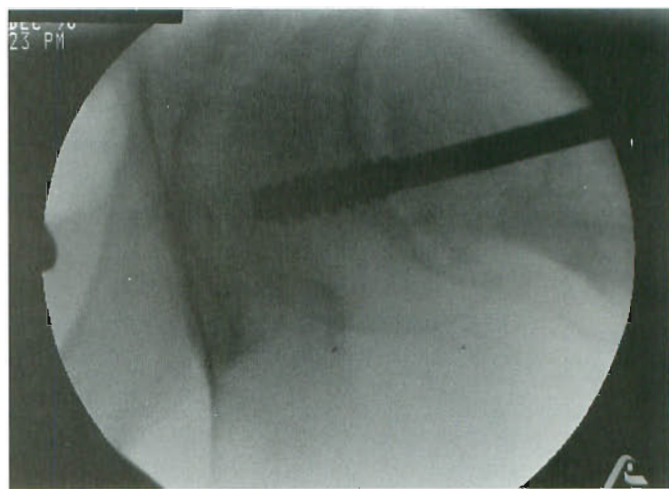


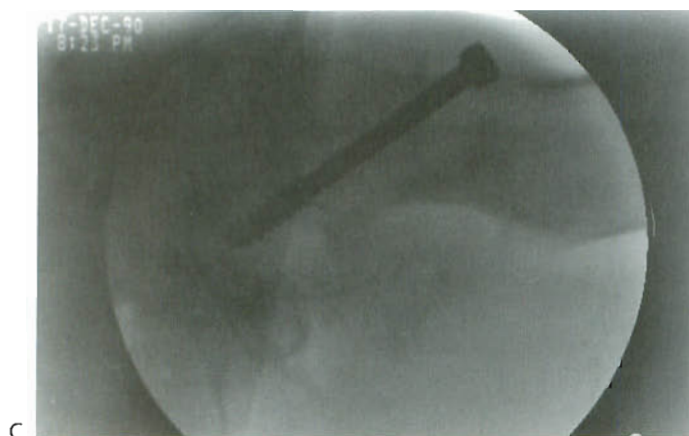
FIGURE 25-12. Models of a moderate slipped capital femoral epiphysis stabilized *in situ* with two threaded pins demonstrate the concept of the radiographic blind spot of the femoral head (A) and (B). This concept proposes that there will always be an area in the femoral head where a pin may violate the head itself, and yet not be seen on plain radiographs (C). The blind spot is smallest in the central axis of the femoral head, and increases greatly the farther the fixation device position is off the central axis. Only by positioning the fixation device centrally, and at least 5 mm from the margin of the femoral head, can avoidance of penetration be assured.



A



B



C

FIGURE 25-13. Anteroposterior (A), frog-leg lateral (B), and true lateral (C) fluoroscopic images of the hip in a 13-year, 6-month-old girl with slipped capital femoral epiphysis taken following *in situ* fixation. All images demonstrate proper hardware placement, with the screw positioned perpendicular to the plane of the femoral head, and centrally within its axis, in all views. The tip of the hardware remains approximately 5 mm from the margin of the femoral head.

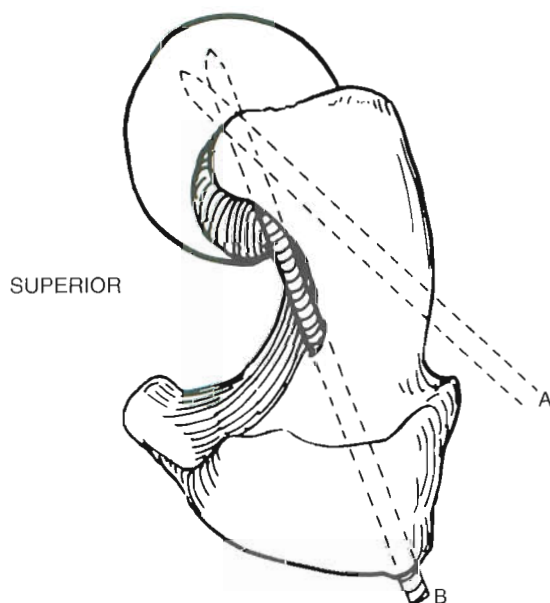


FIGURE 25-14. The metaphysis of the femoral neck displaces anteriorly from the femoral head as the femoral head rotates posteriorly in slipped capital femoral epiphysis. For the fixation device to enter and stay central in the femoral head, it must be placed perpendicular to the plane of the femoral head. This approach necessitates a starting point along the anterior femoral neck (A). The more traditional starting point on the lateral cortex of the femur (B) is associated with penetration of the cortex of the posterior femoral neck before reentering the femoral head. This route can lead to damage of the posterior retinacular vessels, which provide the major blood supply to the femoral head, and direct the hardware into the more vulnerable anterior femoral head quadrant. (From ref. 106, with permission.)

the incidence of potential femoral head penetration. Blanco and colleagues validated this concept in their report of 114 hips in 80 patients treated with single, double, or multiple pins (108). The authors reported a decrease in pin-related complications from 36% in hips stabilized by multiple pins to 4.6% in hips stabilized by a single pin.

The metaphysis of the femoral neck displaces anteriorly from the femoral head, as the femoral head rotates posteriorly around the axis of the femoral neck. For the fixation device to enter and stay central in the femoral head, it must be placed perpendicular to the plane of the proximal femoral

physis. This can only be accomplished if the starting position for the fixation is on the anterior femoral neck and not the lateral cortex of the proximal femur (25,109,113) (Fig. 25-14). The proper starting point on the femoral neck is determined by the severity of displacement of the femoral head. In hips with minimal displacement, the starting point is anterolateral at the base of the femoral neck. In hips with more severe femoral head displacement, the starting point moves progressively more medial on the femoral neck (Fig. 25-15).

The internal fixation device should always avoid the su-

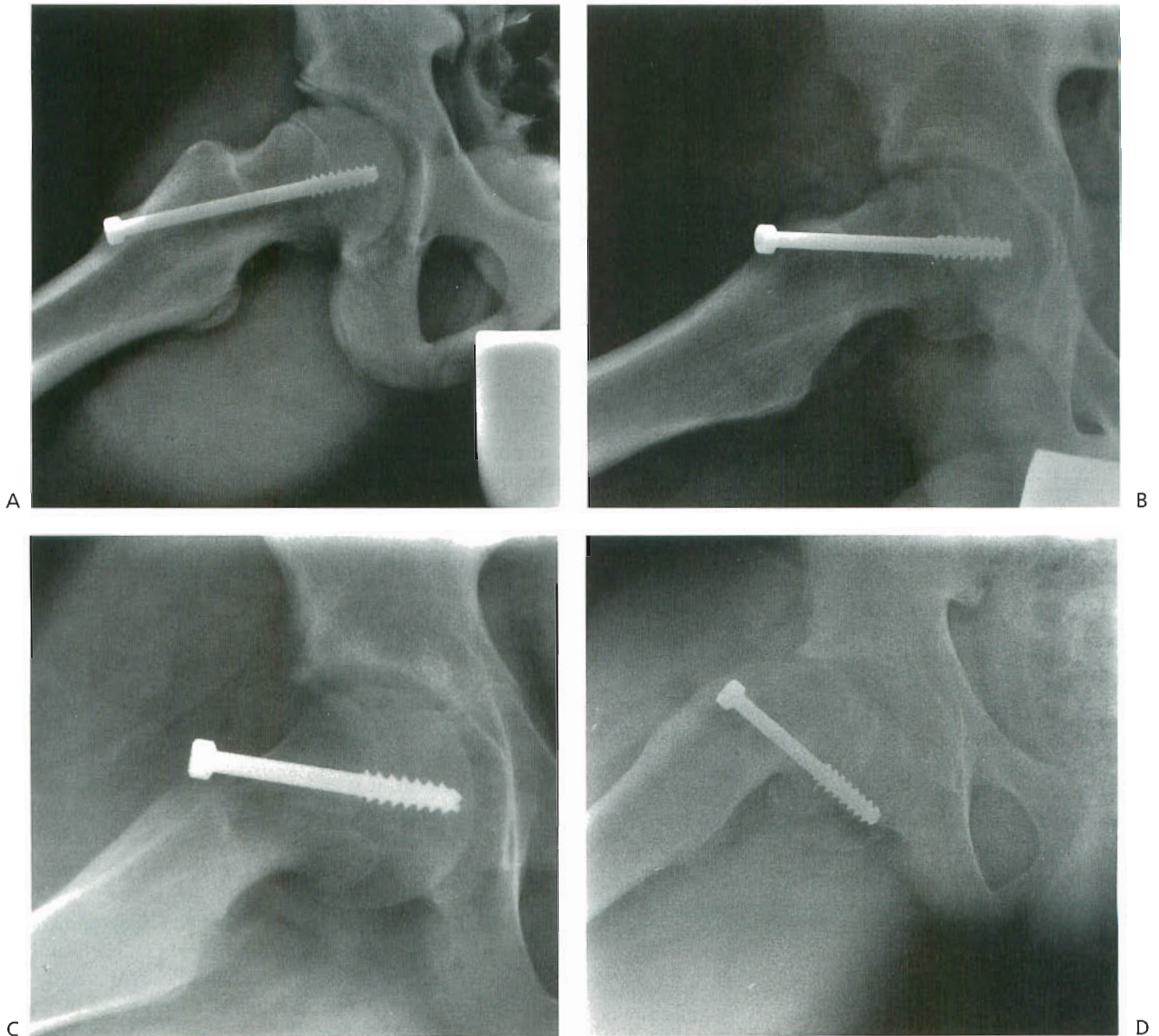


FIGURE 25-15. Series of frog-leg lateral hip radiographs in slipped capital femoral epiphysis following *in situ* fixation. Each radiograph demonstrates progressive posterior displacement of the femoral head. For the fixation device to stay central in the femoral head, its starting position progressively moves more proximal on the anterior femoral neck as the femoral head displacement becomes more severe.

perior and anterior quadrant of the femoral head. The terminal branches of the lateral ascending cervical artery traverse this quadrant (114) (Fig. 25-16). These intraosseous vessels are at high risk for injury leading to segmental osteonecrosis of the femoral head if the fixation device is placed in the superior quadrant of the femoral head, as has been shown by Brodetti (115) and Stambough and colleagues (105) (Fig. 25-17).

Following fixation, radiographic confirmation that the fixation device has not penetrated the joint space is mandatory. This can be accomplished by removing the affected limb from the holding device on the fracture table, and moving the hip through a full range of motion under fluoroscopic examination. The "approach-withdraw" technique of Moseley has been proposed to radiographically confirm avoidance of femoral head penetration (116). This technique employs visualization of the femoral head fluoroscopi-

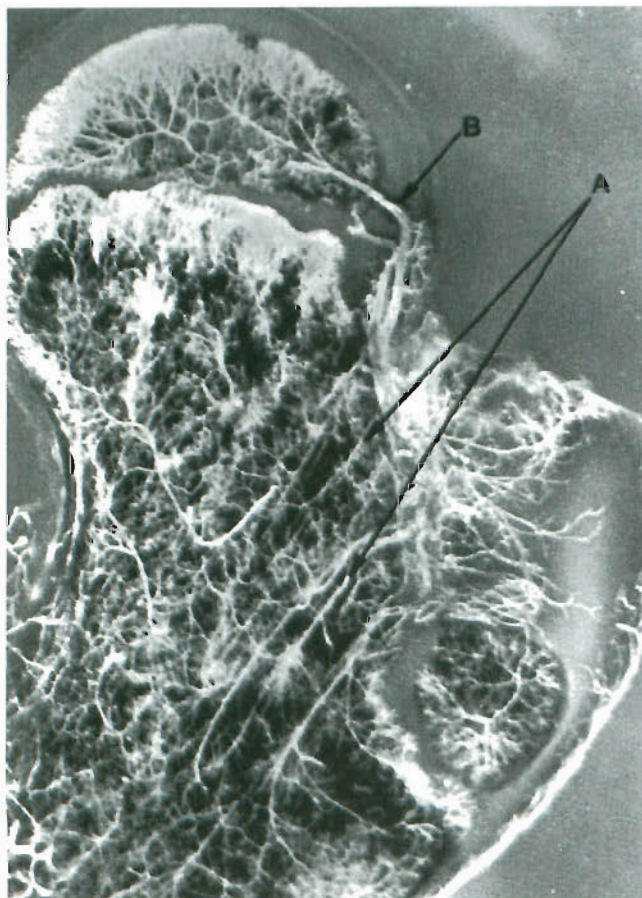


FIGURE 25-16. The blood supply to the femoral neck and proximal femoral epiphysis. The lateral ascending cervical artery gives off metaphyseal branches into the femoral neck (A), then continues on to form epiphyseal branches that provide a segmental blood supply to the superior quadrant of the femoral head (B). Fixation placed into the superior quadrant of the femoral head could damage this blood supply, leading to osteonecrosis. (From ref. 114, with permission.)

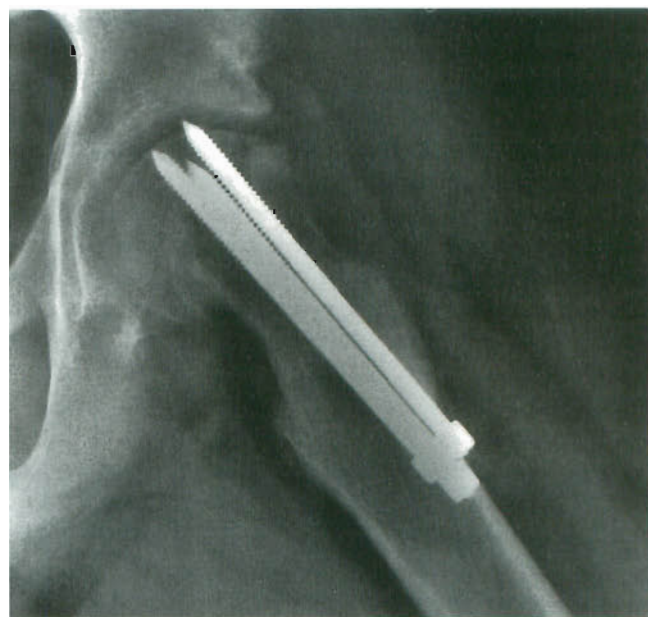

FIGURE 25-17. Frog-leg lateral hip radiograph, in a patient with slipped capital femoral epiphysis, demonstrates multiple pin fixation from a lateral starting position. The hardware is not maintained in the center of the femoral head, but rather is confined to the vulnerable anterosuperior quadrant. Penetration of the femoral head and early segmental osteonecrosis are demonstrated.

cally, while the fully extended limb is rotated from maximum internal rotation to maximum external rotation. As the hip is ranged, the tip of the fixation device in the femoral head is observed to approach the subchondral outline of the femoral head, then withdraw without ever violating the subchondral bone. If violation of the subchondral bone is noted, then femoral head penetration has occurred.

The metallic device used for femoral head stabilization must be of appropriate strength to avoid failure prior to physal plate closure. It should also be of such strength to avoid the need for multiple devices that increase the prevalence of penetration and the volume of metal occupying the femoral head. The device should be of a cannulated design to facilitate placement, and have back-cutting threads for ease of removal, if it should be necessary. Doane and colleagues, through the use of biomechanical analysis of bovine proximal slipped femoral epiphyses, reported that a single 5.5-mm-diameter screw provided approximately the structural stiffness of two 4.5-mm-diameter screws, and that a single centrally placed 7.5-mm-diameter screw approached the stiffness of an unslipped epiphysis (117). Karol and colleagues, using mechanical force analysis in cannulated screw fixation of slipped proximal femoral epiphyses in bovine models, reported only a 33% increase in stiffness to failure in specimens secured with double-screw fixation, compared to single-screw fixation (118). Kibiloski and associates (119) created an acute SCFE in 12 pairs of immature bovine fe-

murs, and pinned one side with a single cannulated screw and the opposite side with two cannulated screws. The specimens were then subjected to physiologic shear loads simulating slow and fast walking. The rates of creep were decreased 23% with double screws compared to a single screw at slow walking and 30% at fast walking. These differences, however, were not statistically significant. These authors concluded that the small gain in fixation stiffness and cyclic creep, seen with a second screw, did not offset the potential increase in complications associated with its placement to warrant its routine use.

By adhering to these treatment guidelines and principles, almost all slipped proximal femoral epiphyses should be able to be stabilized with percutaneous placement of a single 6.5- to 7.5-mm cannulated screw. One possible exception is the acute unstable slip in a very obese and unreliable patient in whom the need for a second screw, to give adequate stabilization and to control possible femoral head rotation, has been proposed by Koval and colleagues (120). The need for a second screw remains controversial, with recent reports implying that it is not needed. Aronson and Carlson (66) reported on single-screw fixation in SCFE in 58 hips. Eight of these 58 hips were classified as acute slips with only 1 of the 8 hips showing loss of fixation. Ward and colleagues (67) reported on fixation with a single screw in SCFE in 53 hips. Five of the 53 hips were acute slips with none of the 5 hips showing loss of fixation. More recently, Goodman and colleagues (121) reported on 21 hips (9 acute and 12 acute-on-chronic) treated with a *single in situ* cannulated screw. At physeal plate closure, no hip showed any significant loss of fixation or change in head-shaft angle.

Reports confirm the safety, reliability, and efficacy of the *in situ* single, centrally positioned, cannulated-screw fixation technique for the stabilization of acute and chronic SCFE (66,67,120,121). If these series are combined, 192 hips of acute, acute-on-chronic, and chronic patterns were stabilized by a single screw, of which 34 hips were classified as acute or acute-on-chronic presentations. Following stabilization, there was only one case of osteonecrosis, which was identified in a patient with an acute slip, and no cases of chondrolysis. Five hips were reported to have had transient femoral head penetration, all of which were recognized and adjusted, and none of which developed any complications related to the penetration. There were no reported cases of hardware breakage. Four hips developed fractures in the proximal femur related to the hardware used to treat SCFE (122,123). Three cases of increased slippage around the fixation were reported. One case occurred in a hip in which the fixation was placed outside of the central quadrant of the femoral head, and the other two cases were following single-screw fixation of an acute slip and an acute-on-chronic slip (124).

Reports suggest that *in situ* pin and screw fixation of SCFE can be associated with an accelerated closure of the

affected physeal plate. Ward and colleagues, in a review of 53 SCFE hips, reported 49 hips (92%) to have undergone closure following single-screw fixation (67). The time to closure was analyzed in 29 of the 49 hips. Physeal plate closure averaged 13 months (range, 2 to 34 months) and showed no correlation to age at the time of fixation, race, or gender. A longer time to physeal closure was noted in hips with more severe displacement and increasingly eccentric screw placement. Premature closure of the physeal plate in the treated hip, compared with the contralateral normal hip, was demonstrated in 19 of 20 patients treated by single-screw fixation. Stanton and Shelton reported on 26 SCFE hips treated with *in situ* fixation, and demonstrated the pinned physes to close an average of 10.2 months earlier than the unpinned physes (125). The average time to closure was 12 months in the pinned physes and 22.2 months in the nonpinned physes. Although accelerated physeal plate closure in SCFE treated with *in situ* metallic fixation has been demonstrated, the reason for the early closure has not been established. Physeal damage from placement of the fixation device, or more likely, physeal damage secondary to the slip itself, could be considered as possible etiologies.

In patients whose age at the onset of SCFE is greater than 1 year earlier than the reported mean for the disorder (boys younger than 12.5 years old and girls younger than 11.1 years old), premature closure of the proximal femoral physis, induced by metallic stabilization, may lead to growth disturbances in the proximal femur, including relative greater trochanteric overgrowth, coxa vara, and coxa breva (126). Segal and colleagues demonstrated radiographic sequelae about the proximal femur in 64% of 33 hips in these younger patients at follow-up, who had been stabilized by metallic fixation for SCFE. The authors concluded that stabilization in younger patients with SCFE should be by fixation devices that will not induce early physeal closure, but rather will allow continued proximal physeal plate growth. Hansson has proposed a similar concept for stabilization in SCFE (127). He has recommended the use of the hook pin as the fixation device of choice, and has shown continued growth of the femoral neck along the pin of as much as 15 mm. Despite the large number of patients showing radiographic changes at the proximal femur (126), only two patients demonstrated limb-length discrepancy, both of which measured 1 cm or less, and only three patients demonstrated a Trendelenburg gait. The true clinical significance of these radiographic findings, seen following premature physeal plate closure in these younger patients, remains in doubt.

In hips in which physeal closure is not induced, femoral head overgrowth off the fixation device is possible. This was reported by Ward and colleagues in 3 of 53 hips treated by single-screw fixation (67). No slip progression or detrimental consequences were noted in these patients.

Carney and colleagues reported long-term follow-up of SCFE patients treated by various techniques, and with a mean follow-up of 41 years after onset of symptoms (18).

They concluded that, regardless of the slip severity in SCFE, pinning *in situ* “provides the best long-term function with a low risk of complications and most effectively delays the development of degenerative arthritis” (18). Other recent studies have also demonstrated that fixation with a single 6.5- to 7.5-mm screw provides safe and reliable epiphyseal stabilization, and promotes premature physeal fusion in patients with SCFE, while decreasing the rate of complications historically associated with multiple-pin fixation (66,67, 108,120,121,128).

The use of open bone-peg epiphysiodesis [➤3.15] for stabilization in SCFE was first described by Ferguson and Howorth in 1931 (26). The rationale behind the use of this technique in the stabilization of SCFE is based on the assumption that open bone grafting of the proximal femoral physis should lead to a more rapid physeal closure as a result of the curetting of a large portion of the physeal plate, with subsequent placement of bone graft bridging the physeal plate, and a lower rate of complications as a result of direct visualization of the femoral neck and head (129–131).

The disadvantages associated with open bone-peg epiphysiodesis include its more demanding and extensive surgical approach, longer operative times, increased blood loss, and the potential for continued femoral head displacement prior to physeal plate closure. Ward and Wood reported operative times averaging 3 h (range, 2 to 5 h), and blood loss averaging 800 mL (range, 250 to 2,400 mL) in association with 17 hips treated by bone-peg epiphysiodesis (132). Irani and colleagues reported an average operative time of 3 h and 40 min, and average blood loss of 750 mL, in 48 hips treated by open bone grafting (133). More recently, Rao and colleagues (134) reported on 64 open bone-peg epiphysiodeses for SCFE. The average operative time was 122 ± 34 minutes, and blood loss was 426 ± 238 mL. Longer hospitalization times—a mean stay of 12.5 days as reported by Rao and colleagues (134)—and the need for more extensive postoperative rehabilitation seen in bone-peg epiphysiodesis, make it a more costly form of treatment. The minimal stability created by the bone graft itself makes the potential for continued femoral head displacement prior to physeal plate closure a definite risk. This potential instability necessitates the additional inconvenience and requirement for spica cast immobilization in most patients, particularly in slips with an acute or unstable presentation. It also necessitates the need for extended limited weightbearing on the affected hip until physeal plate closure has occurred (135).

The recommended surgical technique used in bone-peg epiphysiodesis has been described (132,135) [➤3.15]. Historically, an anterior iliofemoral approach to the hip joint has been used, but Weiner and colleagues have recommended an anterolateral approach, which they report is associated with reduced operative time, less blood loss, and improved wound healing, compared with the anterior iliofemoral approach (136). After the hip capsule is

opened, a tunnel is created between the femoral neck and the central femoral head with drills and curettes. Corticocancellous iliac bone graft is then obtained and packed tightly into the tunnel (Fig. 25-18). Unfortunately, no standardized dimensions or cross-sectional area for the size of the bone graft, needed to avoid graft failure, have been documented. Weiner and colleagues recommended sandwiching multiple corticocancellous slips into the bone tunnel to a width of approximately 1 cm (135). Ward and Wood recommended using a single rectangular bone graft, measuring 5 cm in length and 6 mm in height by 6 mm in width, which is impacted tightly across the physis (132). Postoperatively, a spica cast is placed on all patients with acute slips, as well as any chronic slip demonstrating physeal instability at the time of surgery.

A limited number of reports are available concerning the use of bone-peg epiphysiodesis in SCFE (63,131,132,134, 135). Osteonecrosis and chondrolysis rarely are reported in association with this form of treatment. Weiner and colleagues reviewed 185 hips treated with bone-peg epiphysiodesis, including 26 acute slips and 159 chronic slips (135). A total of only three cases of osteonecrosis and one case of chondrolysis were reported. In the review by Rao and colleagues (134) on 64 open bone-peg epiphysiodeses for SCFE, four hips developed osteonecrosis and three hips developed chondrolysis. Other reported complications associated with bone-peg epiphysiodesis include failure to achieve physeal fusion, bone graft insufficiency with continued slippage, delayed wound healing, heterotopic bone formation, and lateral femoral cutaneous nerve dysesthesia (134).

The time to physeal plate closure following bone-peg epiphysiodesis averaged 2.5 months, as reported by Weiner and colleagues (135); 4.8 months (range, 3 to 15 months), as reported by Irani and colleagues (133); and 17 weeks, as reported by Rao and colleagues (134). Ward and Wood reported physeal closure in 12 of 17 hips treated by bone-peg epiphysiodesis (132). Eight of the 12 hips achieving physeal closure did so by 16 weeks. Two hips, however, required between 24 and 36 weeks for closure.

Bone graft insufficiency, defined as bone graft breakage, displacement, or resorption, was noted in 8 of the 17 hips (47%) reported by Ward and Wood (132). Three of these hips went on to physeal closure, whereas five hips required additional stabilization by metallic pin fixation. Continued radiographic displacement of the femoral head after bone graft epiphysiodesis, but prior to physeal closure, was reported in all patients demonstrating bone graft insufficiency, but also was noted in three of nine hips in which no insufficiency was noted. Rao and colleagues (134) identified one hip with an acute displacement of the bone graft that was then treated by closed reduction and pinning, and 12 hips with continued displacement without bone graft insufficiency, showing greater than or equal to 5 degrees of increase in the lateral head–shaft angle (range, 5 to 36 degrees) at physeal plate healing, in their 64 hips treated by bone-peg epiphysiodesis.

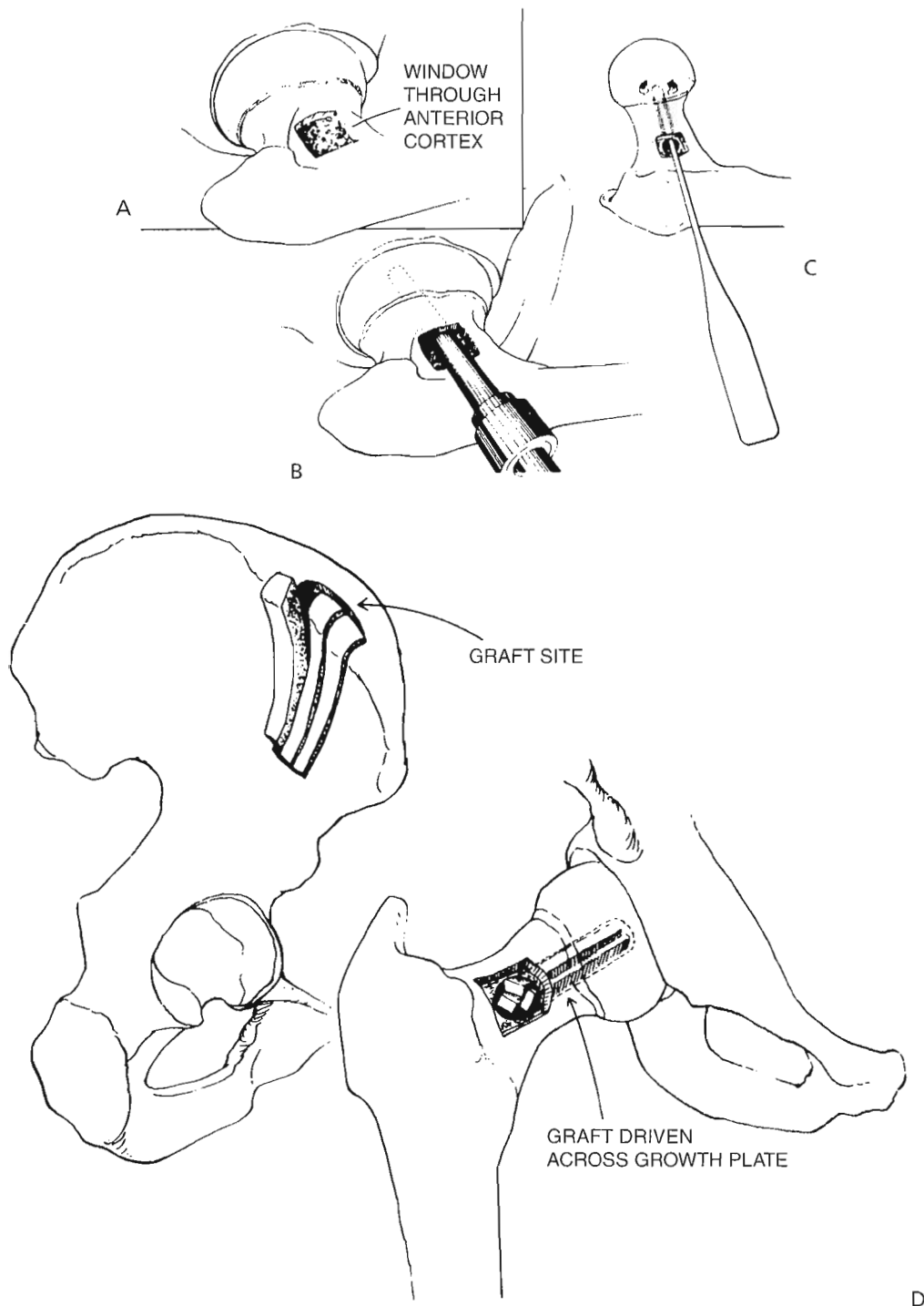


FIGURE 25-18. Technique used in open bone-peg epiphysiodesis in slipped capital femoral epiphysis. **A:** Using an anterolateral approach to the hip, the hip capsule is opened and the proximal femoral physis is identified. A small anterior metaphyseal cortical window is formed in the femoral neck immediately distal to the physis. **B:** A 1-cm hollow mill drill is then passed through the window into the center of the femoral head under fluoroscopic image intensification. **C:** The physeal plate is thoroughly curetted adjacent to the cylindrical bone tunnel. **D:** Cortical cancellous grafts are obtained from the adjacent ilium, and packed tightly into the bone tunnel bridging the physeal plate. The cortical window of bone from the anterior femoral neck is replaced. (From ref. 137, with permission.)

The more extensive surgical approach, greater blood loss, longer hospitalization, and reported problems with bone graft insufficiency, and continued femoral head displacement associated with bone-peg epiphysiodesis, preclude this technique from being recommended for the routine stabilization of the physeal plate in SCFE.

Treatment to Reduce the Degree of Slippage

Natural history studies as well as long-term follow-up studies on *in situ* fixation, have shown a direct relation between the degree of displacement in SCFE and the affected hip's final outcome, including the development of degenerative joint disease (18,87,138). Treatment methods that reduce the degree of slip, and create a more anatomic relation of the femoral head with the remainder of the femur, should lead to improved function and motion, as well as delay the onset of degenerative joint disease. To truly have a beneficial effect on the natural history, however, these treatment methods must not be associated with a significant increase in complications, particularly osteonecrosis and chondrolysis of the femoral head. Techniques to reduce the degree of slip include closed manipulation prior to physeal plate stabilization and osteotomies of the proximal femur, performed either concurrently with physeal stabilization or after physeal closure.

The potential need for closed manipulation of femoral head displacement in SCFE is based on the concept that spontaneous remodeling at the proximal femur, following physeal stabilization, will not be adequate to restore femoral head–femoral neck and femoral head–femoral shaft relations to near-normal alignment. Several authors have implied that remodeling following *in situ* fixation in SCFE has the ability to correct proximal femoral deformity and secondarily to improve hip motion. Key (34), Billing and Severin (21), Bellemans and associates (139), and Wong-Chung and Strong (140) have reported on bony remodeling of the contour of the proximal femur that occurs in SCFE. These authors defined remodeling as the radiographic appearance of new bone formation between the overhanging femoral head and the posteroinferior femoral neck, in association with a rounding off of the prominent anterosuperior margin of the femoral neck. Lacroix and Verbrugge have demonstrated histologically that these radiographic changes are secondary to appositional new bone formation on the inferior margin and osteoclastic resorption on the superior margin of the femoral neck (141). O'Brien and Fahey, in a review of 12 hips of moderate to severe displacement in SCFE treated by *in situ* fixation, suggested that femoral neck remodeling leads to an associated improvement in hip motion to essentially normal values, except for a mild residual loss of internal rotation (142). They reported the probability of sufficient femoral neck remodeling to increase with an open triradiate cartilage, but to decrease with greater severity of slip (142,143).

Siegel and colleagues recently have confirmed that hip motion significantly improves following *in situ* fixation in SCFE, but that remodeling at the proximal femur is insufficient to restore normal hip alignment (20). Their study employed a quantitative evaluation of hip motion and proximal femoral remodeling following *in situ* fixation in 39 patients with SCFE, with 2 or more years follow-up. Hip motion was found to improve most rapidly in the first 6 months after treatment, mainly as a result of resolving muscle spasm, pain, and synovitis. Although hip motion continued to show improvement over the entire period of follow-up related to continued soft tissue stretching and bone resorption from the anterolateral femoral neck, it never approached the motion of the unaffected hip. Plain radiography and computed tomography scans demonstrated femoral neck remodeling, which produced an apparent improvement in the displaced femoral head and femoral neck relation, but did not confirm any significant change in the more critical relation between the displaced femoral head and the femoral shaft. The authors concluded that the improvement in hip motion, seen following *in situ* fixation in SCFE, was not directly related to significant osseous remodeling.

Although motion at the affected hip in SCFE after *in situ* fixation can be expected to improve as synovitis and protective spasm resolve, the bony deformity created by the slip shows little if any true realignment through remodeling. Closed manipulation to reduce the degree of displacement prior to stabilization in SCFE, therefore, has a potentially beneficial effect on the natural history, if it can be performed without increased complications. The major complication seen in association with closed manipulation in SCFE remains osteonecrosis of the femoral head, which leads to rapid deterioration in hip function. Although the incidence of osteonecrosis following closed manipulation in SCFE varies, most studies confirm an increase in the incidence in manipulated hips over nonmanipulated hips (18,21,72,144). Carney and colleagues reported that osteonecrosis developed in 12 of 39 hips (31%) in which reduction of the slippage was attempted, whereas osteonecrosis occurred in only 6 of 116 hips (6%) in which no reduction had been attempted (18). A recent study by Rhoad and colleagues (74), however, implies that the osteonecrosis seen in unstable SCFE treated by gentle manipulation is, more likely, secondary to the initial displacement associated with the unstable slip, and not the reduction maneuver. Vigorous reductions, multiple attempts at reduction, and overreduction continue to be associated with an increased incidence of osteonecrosis (64,145).

Closed manipulation can be considered in patients presenting with acute or acute-on-chronic presentations with severe displacement, in which the risk of significant limitation in range of motion and accelerated degenerative arthritis, associated with fixation *in situ*, outweighs the risk of potential complications from reduction. Closed manipulation is never indicated in patients presenting with chronic

or stable slips, or in slips with displacement of a mild to moderate degree.

If closed manipulation is to be attempted, it can be performed by either slow reduction with skeletal traction through a distal femoral pin over a period of days prior to stabilization, or by a gentle reduction performed at the time of surgical stabilization. Neither method, properly performed, has been statistically proven to be safer or more beneficial than the other (64,69,145).

If traction is employed, it is applied through longitudinal skeletal traction, allowing for slow reduction of the femoral head over a few days. The use of skeletal traction is necessitated by the generally larger body weights of these patients, which require the generation of greater forces than can be safely achieved through skin traction. The addition of an internal rotation force, applied to the lateral aspect of the femoral pin to assist in reduction, also can be used (146).

If reduction under anesthesia is performed, it should be done without force or repeated attempts. The accepted reduction is what is obtained when the patient is placed onto the fracture table and the affected limb is rotated to neutral while the hip is maintained in extension—so-called “unintentional reduction.” No forced internal rotation or flexion should be performed at the affected hip, because of the increased potential for vascular injury associated with these maneuvers (145).

In the treatment of acute and acute-on-chronic SCFE, a question remains as to the urgency of operative stabilization and the avoidance of complications, particularly osteonecrosis. Should operative stabilization, with or without gentle manipulation, be performed as an emergency, or is it safer to employ a more delayed approach, with the affected hip temporarily treated at rest in traction? Loder and associates (68) reviewed acute SCFE in 30 hips, with respect to the time interval between the onset of symptoms and operative stabilization. In eight hips with treatment initiated less than 48 h after the onset of symptoms, osteonecrosis developed in seven hips (87.5%). In 22 hips with treatment initiated after 48 h from onset of symptoms, osteonecrosis was identified in seven hips (31.8%). Although these numbers are small, these data imply that delay in operative stabilization in acute SCFE may decrease the incidence of osteonecrosis. Peterson and colleagues (71), in a similar study of acute unstable SCFE in 91 hips, reviewed the timing of reduction and operative stabilization with respect to the development of osteonecrosis. Gentle manipulative reduction and stabilization were performed in 42 hips less than 24 h from presentation, in which three hips (7.2%) developed osteonecrosis. Reduction and stabilization were performed in 49 hips after 24 h from presentation with 10 hips (20.4%) developing osteonecrosis. The authors concluded that gentle reduction and operative stabilization, performed prior to 24 h from presentation in acute SCFE, does not increase the risk of osteonecrosis, and may actually reduce its risk. Although further prospectively randomized and treatment-standard-

ized research concerning the urgency of reduction and stabilization in acute unstable SCFE will be needed to clarify this issue, the author currently recommends gentle reduction and operative stabilization within 24 h of presentation.

Osteotomies about the proximal femur in SCFE are designed as realignment procedures through which restoration of a more normal relation among the femoral head, the femoral neck and shaft, and the acetabulum, can be achieved. The various osteotomies accomplish this goal by creating a compensatory deformity through which the primary deformity created by the original femoral head/femoral neck displacement is realigned. Realignment of the proximal femur by osteotomy, when indicated, should result in an improved range of hip motion and a delay in the development of degenerative joint disease. The complications of femoral head osteonecrosis and chondrolysis must be avoided. Osteotomies in SCFE can be performed at the time of physeal stabilization, although most are performed as delayed procedures in patients in whom residual hip function remains inadequate.

Several osteotomies, performed at various levels along the femoral neck and proximal femur, have been described in SCFE (84,147–158). In general, as the location of the osteotomy proceeds distally along the proximal femur, the amount of correction achieved at the primary site of deformity decreases. Conversely, as the location of the osteotomy proceeds proximally along the proximal femur, the risk of osteotomy-induced osteonecrosis of the femoral head increases. Procedures performed in the proximal femoral neck can achieve almost anatomic correction of the primary deformity; however, they are associated with a high incidence of osteonecrosis of the femoral head. More distal osteotomies, performed at the intertrochanteric region, have a very low incidence of osteonecrosis of the femoral head, but are limited in the amount of correction of the primary deformity that they can achieve. The use of osteotomies in SCFE is limited to patients with displacement of the femoral head in the severe range, in whom motion at the affected hip after initial treatment remains significantly limited and restricts activities of daily living. In long-term follow-up of hips treated for SCFE using realignment procedures, Jerne and colleagues (159) recognized a high rate of serious complications in 7 of 22 hips (31.8%) treated with subcapital osteotomy, and 3 of 11 hips (27.3%) treated by intertrochanteric osteotomy. At follow-up examination averaging 33.8 years, these hips showed very low rates of excellent and good clinical and radiographic results. The authors concluded that the realignment procedures had not significantly improved on the condition's natural history, and therefore discouraged their use in the routine treatment of chronic SCFE. The needs of the patient must be weighed against the potential complications when realignment osteotomies are considered. The osteotomy that fulfills the patient's needs at the lowest potential risk should always be chosen.

The use of cuneiform osteotomy of the femoral neck in

SCFE has been described by several authors (148, 151–154, 160–162). Cuneiform osteotomy at the level of the proximal femoral physis is the only procedure that has the ability to restore an anatomic relation of the femoral head with the femoral neck, as well as the femoral shaft. The procedure should be performed only in patients with an open proximal femoral physal plate (151, 152, 160). Cuneiform osteotomy performed by the method reported by Fish is preferred (152, 160). The hip capsule is opened anteriorly, and the procedure is performed under direct visualization. The physal plate is removed in conjunction with a wedge resection of bone from the juxtaphyseal femoral neck. The size of the wedge to be removed is determined by the severity of the displacement being corrected. The wedge resection shortens the femoral neck, which allows for reduction of the femoral neck onto the femoral head without excessive tension. Care must be taken throughout the procedure not to damage the periosteum and the vasculature running along the posterior femoral neck (Fig. 25-19). The reduced femoral head is then stabilized with pin or screw fixation.

Although anatomic correction of the deformity is possible, when considering the results reported by a large group of orthopaedic surgeons, a high incidence of femoral head osteonecrosis remains associated with this procedure. Gage and colleagues reviewed the literature and reported the average incidence of femoral head osteonecrosis in association with cuneiform osteotomy to be 21% (153). Other series demonstrate the rate of femoral head osteonecrosis following cuneiform osteotomy to be between 12 and 35% (13, 85, 151, 153, 161, 162). More recently, a lower incidence of osteonecrosis of the femoral head has been reported following cuneiform osteotomy performed by the subcapital wedge-resection technique. Fish reported osteonecrosis of the femoral head in 3 of 66 hips (4.5%) (160), and Nishiyama and colleagues reported osteonecrosis in 1 of 18 hips (5.5%) treated by the technique of cuneiform osteotomy (154). Chondrolysis also has been reported in association with cuneiform osteotomy, but usually is in association with osteonecrosis (153, 162). Fish reported an 11% incidence of pin-related complications due to hardware violation of the hip joint in cuneiform osteotomy (160).

Realignment of the femoral head by cuneiform osteotomy remains a technically demanding procedure, and although a lower incidence of osteonecrosis recently has been reported, the potential for severe complications remains very high.

Osteotomy at the base of the femoral neck has been described by several authors (147, 149, 153, 163). Intracapsular (153, 163) and extracapsular (147, 149) techniques have been reported [➡4.8]. The base of the femoral neck is exposed, and an anterosuperior-based wedge of bone is removed. Care is taken not to place retractors posterior to the femoral neck. The posterior cortex of the femoral neck and its periosteum are not cut, but are “greensticked” during closure of the osteotomy. This avoids injury to the

vasculature running along the posterior femoral neck. The osteotomy is stabilized by pins or screws (Fig. 25-20). The procedure has a lower reported incidence of osteonecrosis of the femoral head than is found in cuneiform osteotomy, but its ability to correct the more proximal femoral deformity is more limited. A maximum correction of 35 to 55 degrees is reported with base-of-neck osteotomies (147, 164). The osteotomy secondarily creates a coxa breva, which can cause the greater trochanter to impinge on the acetabulum during hip motion (163).

Transtrochanteric rotational osteotomy originally was described by Sugioka (157). This osteotomy represents a transtrochanteric osteotomy proximal to the abductor insertion on the greater trochanter. Rotational correction of severe deformities of the proximal femur is possible with this procedure, without disturbing abductor muscle mechanics or limb length. Reports of the use of the procedure in SCFE, however, are limited. Sugioka reported osteonecrosis in one of nine hips (11%) treated with this procedure (157). Masuda and colleagues reported osteonecrosis in one of five hips (20%) treated by transtrochanteric osteotomy (165). The use of transtrochanteric rotational osteotomy has rarely been reported in SCFE, and is not recommended for routine use.

Intertrochanteric osteotomies remain the most frequently used procedures for realignment in SCFE. The surgical technique was originally described by Southwick (84) [➡4.7] and has since been slightly modified by several authors (150, 155, 156, 166–168). Intertrochanteric osteotomy can be performed in a single-plane, biplane, or multiplane technique. A derotational osteotomy of the proximal femur [➡4.6] represents a single-plane intertrochanteric osteotomy, and serves only to adjust internal and external rotation at the affected hip. The biplane and multiplane intertrochanteric osteotomies remove a wedge of bone of varying size from the anterior and lateral cortices of the affected femur at the level of the lesser trochanter. When this osteotomy is reduced and coupled with internal rotation of the femoral shaft, a realignment of the proximal femoral deformity occurs as a secondary deformity in the intertrochanteric region is created (Fig. 25-21). The correction achieved by osteotomy at this level is limited to deformities equal to or less than 45 degrees on the anteroposterior radiograph and 60 degrees on the lateral radiograph, as measured by the Southwick method (84, 155, 156).

Another intertrochanteric osteotomy used for realignment in severe chronic SCFE is the flexion intertrochanteric osteotomy described by Imhauser (158). The justification for this osteotomy is based on the concept that the majority of the deformity in SCFE is a posterior displacement of the femoral head around the axis of the femoral neck, and not a true varus displacement (25, 169). Correction of this deformity would therefore be most efficiently performed by a flexion osteotomy realigning the plane of the proximal physis perpendicular to the femoral shaft. Millis and colleagues

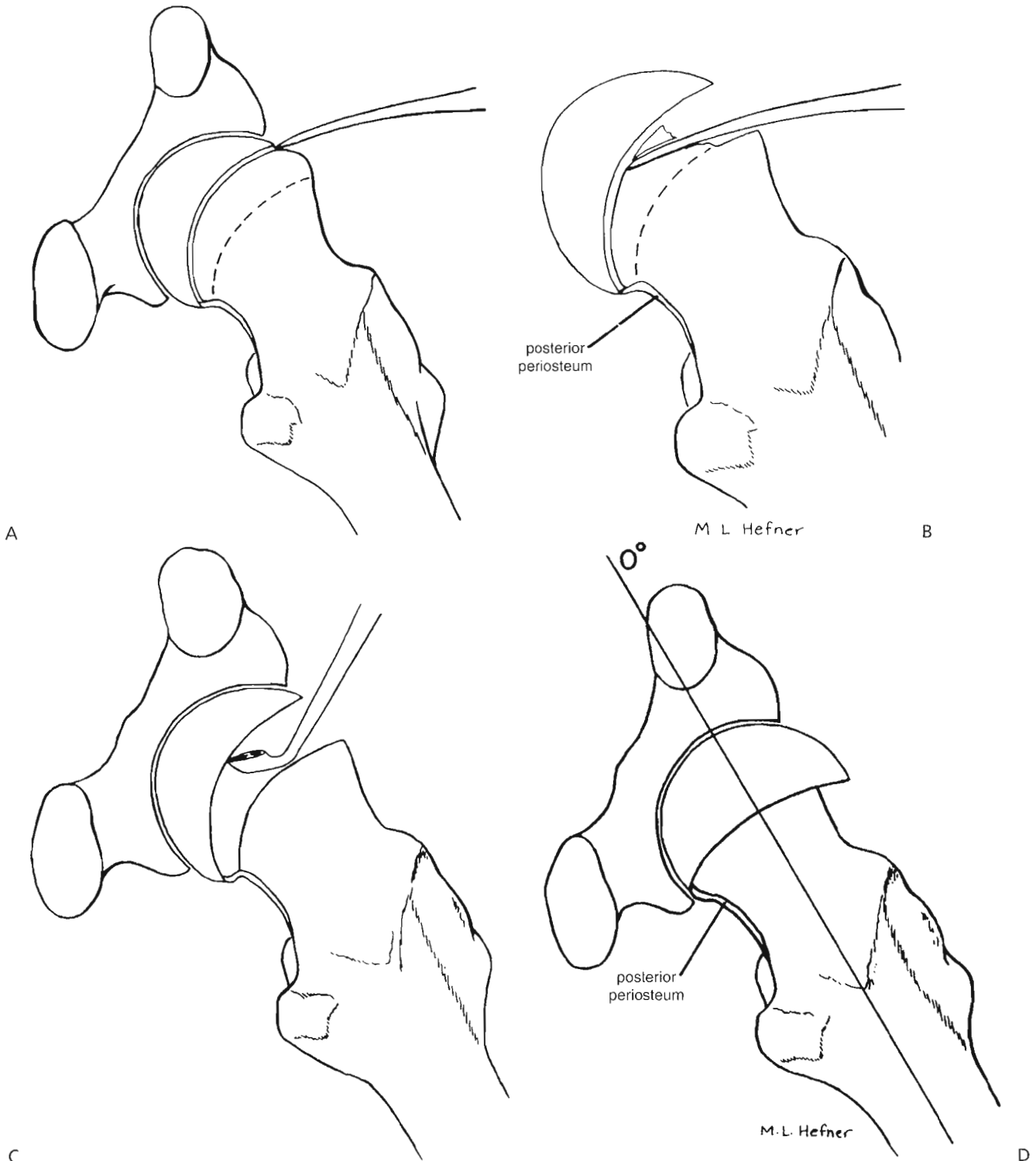


FIGURE 25-19. Technique used in performing a cuneiform osteotomy in slipped capital femoral epiphysis. **A:** The hip capsule is opened anteriorly, and the location of the physeal plate is carefully identified. **B:** A wedge of bone of predetermined size is removed in small pieces from the juxtaphyseal femoral neck. The physeal plate cartilage is identified continuously as the bone wedge is resected. Extreme care is taken not to damage the posterior periosteum. **C:** After the bone wedge has been removed, the physeal plate cartilage is curetted. Adequate bone must be excised from the posterior corner to allow for reduction of the femoral head without tension on the posterior periosteum and vasculature. **D:** The femoral neck is reduced onto the femoral head, recreating more normal proximal femoral alignment. The reduction is stabilized with pin or screw fixation. (From ref. 152, with permission.)

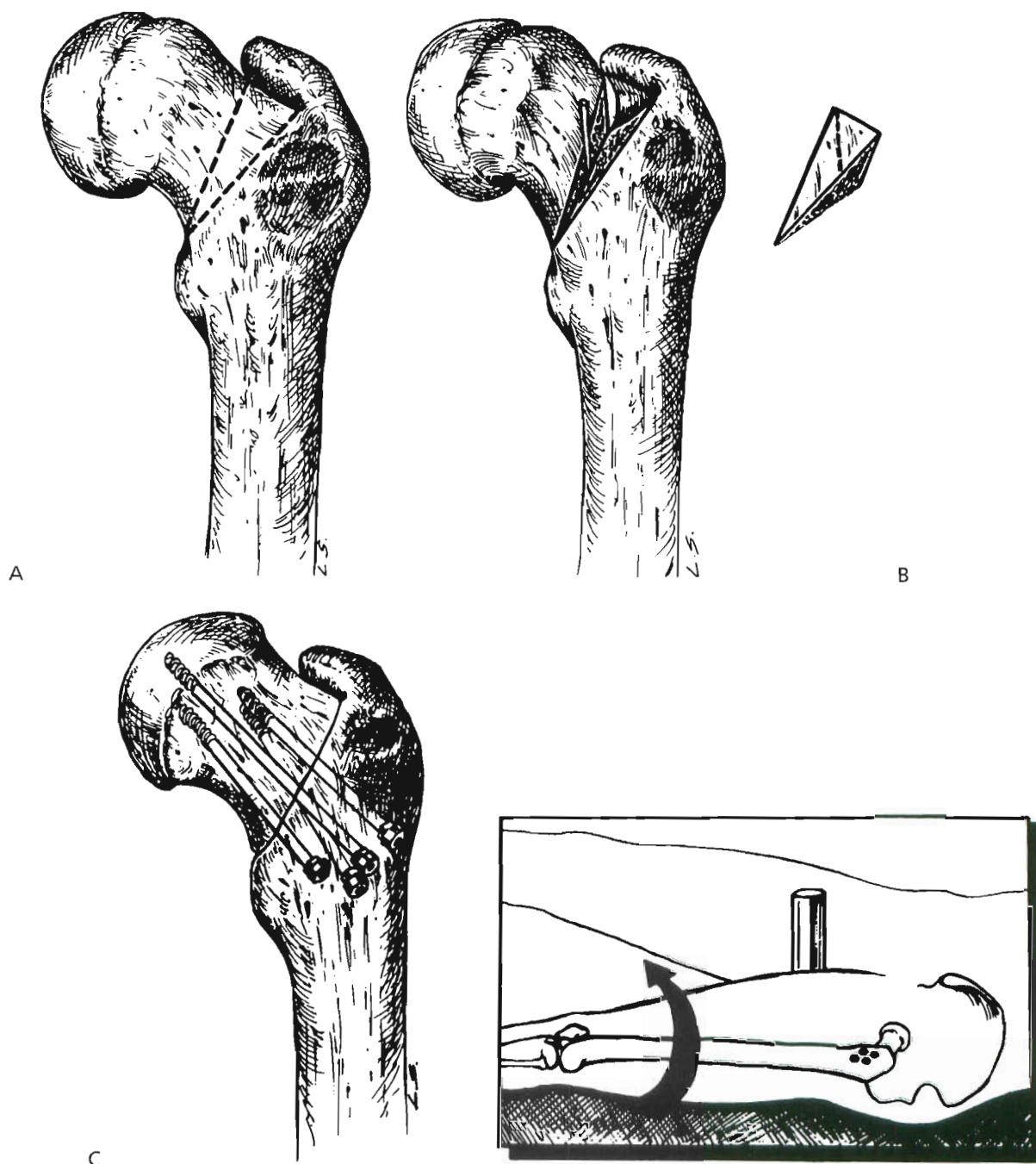


FIGURE 25-20. Technique for performing a base-of-the-neck osteotomy in slipped capital femoral epiphysis. **A:** The base of the femoral neck is exposed through an anterolateral approach to the hip. The outline of an anterosuperior-based wedge of bone of predetermined size is marked on the base of the femoral neck. **B:** The bony wedge is then cut and excised in such a manner that a triangular segment is created that contacts, but does not penetrate, through the posterior cortex. This avoids injury to the vasculature running along the posterior femoral neck. **C:** The gap in the femoral neck is closed by internally rotating the limb while maintaining traction, which "greensticks" the posterior cortex of the femoral neck. The reduction is stabilized by pins or screws. (From ref. 147, with permission.)

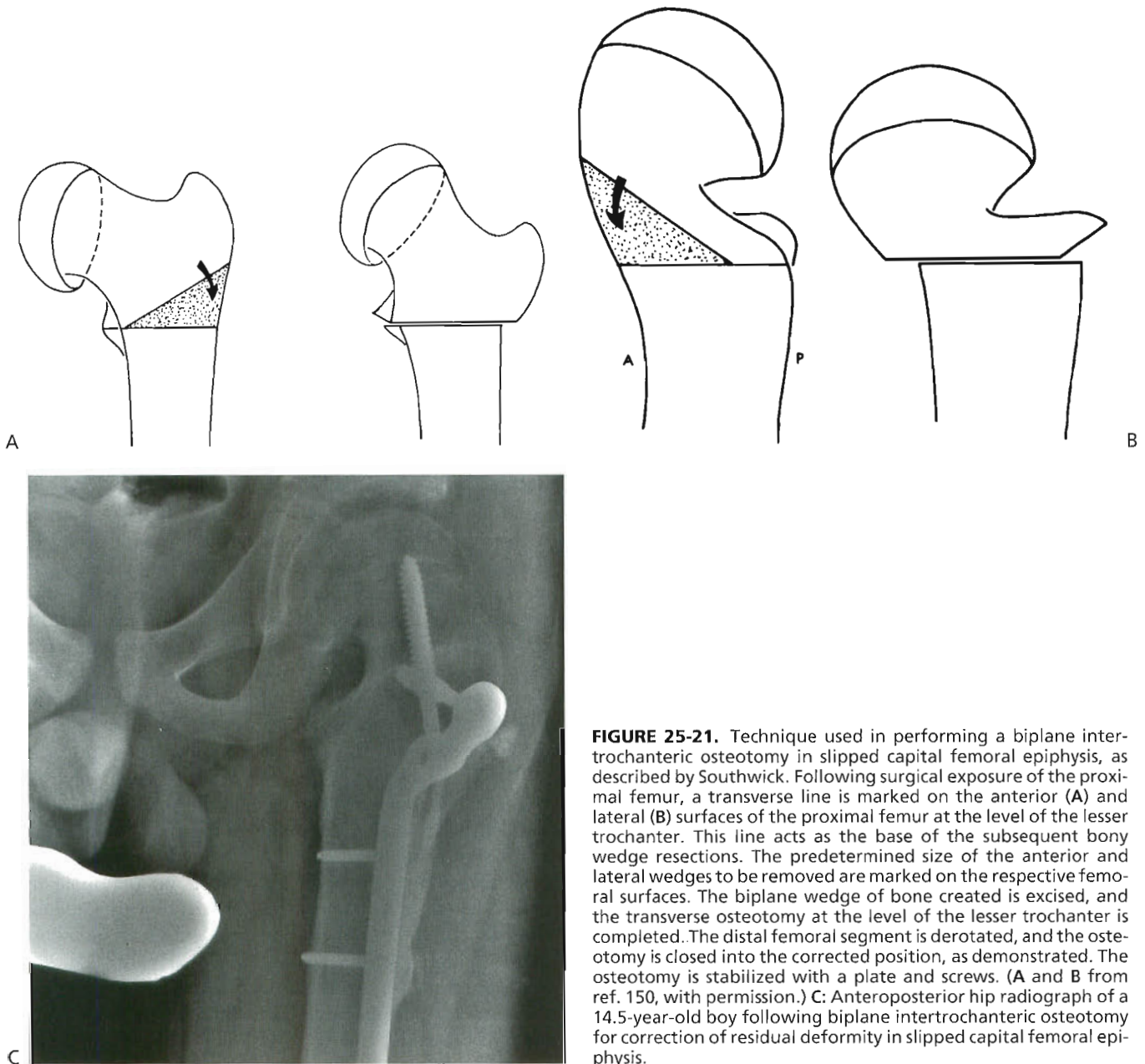


FIGURE 25-21. Technique used in performing a biplane intertrochanteric osteotomy in slipped capital femoral epiphysis, as described by Southwick. Following surgical exposure of the proximal femur, a transverse line is marked on the anterior (A) and lateral (B) surfaces of the proximal femur at the level of the lesser trochanter. This line acts as the base of the subsequent bony wedge resections. The predetermined size of the anterior and lateral wedges to be removed are marked on the respective femoral surfaces. The biplane wedge of bone created is excised, and the transverse osteotomy at the level of the lesser trochanter is completed. The distal femoral segment is derotated, and the osteotomy is closed into the corrected position, as demonstrated. The osteotomy is stabilized with a plate and screws. (A and B from ref. 150, with permission.) C: Anteroposterior hip radiograph of a 14.5-year-old boy following biplane intertrochanteric osteotomy for correction of residual deformity in slipped capital femoral epiphysis.

(170) have recently described their method for flexion intertrochanteric osteotomy of the proximal femur in severe chronic SCFE. Following exposure of the proximal femur, an extensive anterior capsulotomy is performed. This capsulotomy facilitates placement of a cancellous bone screw to stabilize the proximal femoral epiphysis, if the physis remains open, as well as placement of subsequent internal fixation used to stabilize the intertrochanteric osteotomy. It also allows for improved extension of the head/neck fragment following osteotomy, and avoids an unacceptable flexion contracture of the hip. A transverse intertrochanteric osteotomy is performed just proximal to the lesser trochanter. The distal fragment is displaced anteriorly, and flexed

adequately to realign the plane of the proximal femoral physis perpendicular to the femoral shaft. A wedge resection at the osteotomy site to improve bone apposition is usually not needed. When necessary, inward rotation of the distal fragment, to correct rotational malalignment, can also be performed prior to final fixation. Internal fixation is achieved with a blade plate avoiding the need for a spica cast, and allowing for the earlier initiation of hip motion. Correction of up to 90 degrees of posterior displacement of the femoral head is theoretically possible with this osteotomy. If flexion correction is greater than 55–60 degrees, a separate osteotomy of the greater trochanter should be performed, creating a three-part osteotomy prior to fixation.

This is done to avoid excessive anterior displacement of the trochanter, which could potentially impair proper abductor muscle function.

Intertrochanteric osteotomy enjoys a very low incidence of osteonecrosis of the femoral head compared with femoral neck osteotomies. This is secondary to the intertrochanteric osteotomy being performed in an area of the proximal femur that is not in direct proximity to the blood supply of the femoral head. An increased incidence of chondrolysis with joint space narrowing and stiffness, however, has been reported to be associated with intertrochanteric osteotomy. Southwick, in his original description of the procedure, noted 6 of 55 hips (11%) that showed the development of chondrolysis (84). More recent series have reported the development of chondrolysis of the hip in SCFE, following corrective intertrochanteric osteotomy, to range from 6 to 56% (155,156,166). Although Imhauser did not report on osteonecrosis or chondrolysis of the femoral head associated with flexion intertrochanteric osteotomy, Tokarowski and associates (171) reported no cases of osteonecrosis, but reported an 18.2% incidence of chondrolysis in 33 hips treated for moderate or severe SCFE by the Imhauser osteotomy.

The reason for the increase in chondrolysis, seen in association with intertrochanteric osteotomy in SCFE, remains unknown. The author believes that the development of chondrolysis is related to increased pressure at the femoral head, which is created as the osteotomy is closed and the limb is lengthened. A simple femoral shortening, from the distal segment of the femur at the osteotomy site, should relieve femoral head pressure and thereby reduce the incidence of chondrolysis. The deformity created in the intertrochanteric region of the proximal femur by this osteotomy also can have a potentially deleterious effect on later total hip arthroplasty (172). The wedge resections of bone create an angular deformity in the intertrochanteric region that results in a tortuous proximal femoral canal. This could necessitate the need for excessive bone resection from the femoral neck calcar, and make for difficult passage and seating of the femoral component during future total hip arthroplasty.

Salvage Procedures

If the femoral head in SCFE becomes severely deformed and the joint becomes stiff and painful as a result of osteonecrosis or chondrolysis, salvage procedures are indicated to relieve pain and improve function. The procedure of choice in adolescents and young adults remains arthrodesis [3.13]. Sponseller and colleagues reported on 53 patients who had a hip arthrodesis and had been under 35 years of age at the time of the procedure (173). At an average follow-up of 38 years, 78% of the patients remained satisfied with the arthrodesis, and all remained employable. Only 13% who had the arthrodesis converted to a total

hip arthroplasty. Callaghan and colleagues reviewed 28 patients who had a hip arthrodesis as an adolescent or young adult (174). At an average 35-year follow-up, some pain in the ipsilateral knee, the lower back, or the contralateral hip frequently was reported, but had not become symptomatic until an average 20 years or longer following the procedure. Only one patient (4%) was unemployed because of pain, and only six patients (21%) had undergone conversion to a total hip arthroplasty. Hip arthrodesis, therefore, remains a very successful salvage procedure for relief of severe pain in young patients who develop complications in SCFE.

The procedure relieves pain and allows the patient a high level of activity and employment at most occupations. Some pain at the ipsilateral knee, the lower back, or the contralateral hip commonly occurs, but usually only many years following the procedure. Proper positioning of the femur in relation to the pelvis is extremely important to function as well as avoidance of future back and knee pain. The proper position for the hip during arthrodesis is 20 degrees flexion with neutral rotation and neutral to slight adduction. Abduction at the hip is to be avoided secondary to it being associated with accelerated ipsilateral knee pain (174). A take-down of the arthrodesis and conversion to a total hip replacement is possible, if painful back and knee symptoms become too severe (173–176). Also, the abductor muscles should not be injured, in order to facilitate future hip function following total hip arthroplasty. The method of arthrodesis described by Mowery and colleagues is preferred (177). This technique offers many advantages, which include a familiar anterior approach to the hip, a large surface area for fusion, a relatively simple technique of compression arthrodesis using minimal hardware, no disturbance of the greater trochanter and abductor muscles, no additional loss of limb length, and an upper femoral osteotomy that reduces the lever arm force on the fusion area, and allows for adjustment of limb position postoperatively (Fig. 25-22). The main disadvantage associated with this technique remains the need for postoperative immobilization in a spica cast for 6 to 8 weeks.

Schoenecker and colleagues (178) have recently reported on the successful use of hip arthrodesis in 25 patients age 11 to 19 years with severe unilateral osteoarthritis of the hip. The authors describe a two-incision surgical approach utilizing an intraarticular fusion technique with internal fixation with avoidance of dissection of the abductor hip musculature. The technique avoids the need for a proximal femoral osteotomy by precise positioning of the extremity at the time of arthrodesis.

Arthroplasty of the affected hip is not recommended for most adolescents and young adults, with severe unilateral hip osteoarthritis associated with SCFE (179,180). The potential for early component loosening and wear in active young adults remains very high. The need for several revisions over the patient's lifetime, and the subsequent risk of chronic infection, preclude total hip arthroplasty as the

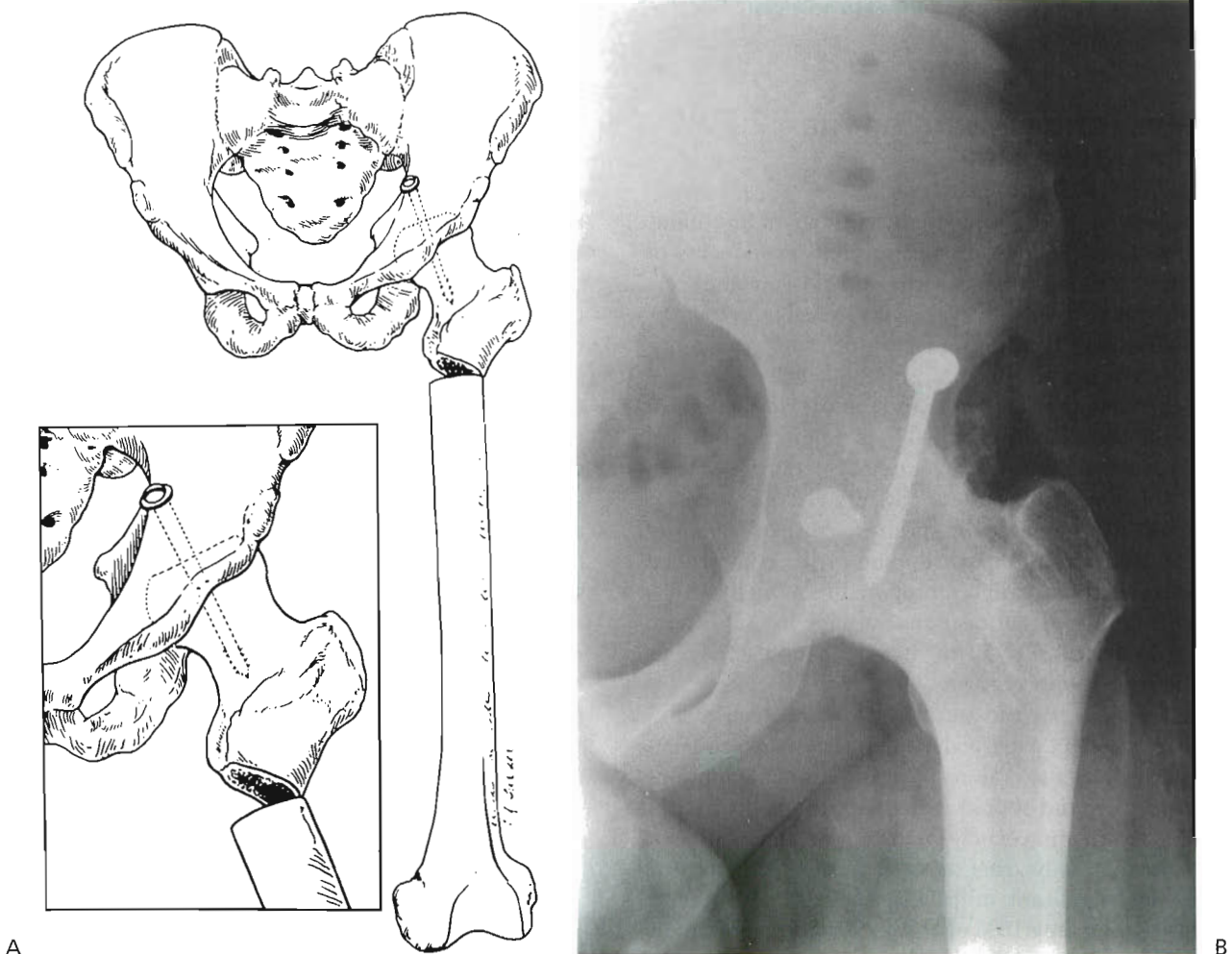


FIGURE 25-22. A: Hip arthrodesis is performed through an anterior approach. The abductor muscles are not disturbed. Compression arthrodesis is achieved with minimal hardware. A proximal femoral osteotomy reduces force on the fusion area, and allows for adjustment in limb position postoperatively. (From ref. 177, with permission.) B: Anteroposterior hip radiograph of a 16-year, 4-month-old boy demonstrates a solid hip arthrodesis performed by the previously described technique. Femoral head osteonecrosis had occurred following treatment for slipped capital femoral epiphysis.

recommended procedure in these younger patients. Chandler and colleagues reported on 29 patients who had been treated with a total hip arthroplasty at an average age of 23 years (range, 14 to 30 years) (180). At 5-year follow-up, 57% of the patients showed evidence of loosening of at least one of the components of the implant. Seven patients (24%) had already undergone revision surgery. The factors of associated osteonecrosis of the femoral head, heavy activity, and excessive weight, all commonly seen in patients with SCFE, were associated with poorer results from arthroplasty. One exception in SCFE is the patient with bilateral disease. Although no universally good method of treatment for bilateral disease has been documented, one option is an arthrodesis of one hip and an arthroplasty of the contralateral hip,

which would provide a better balance of function and durability.

Osteoplasty of the femoral neck has been reported as a means of improving function in hips with severe displacement of the femoral head and secondary deformity (130,181). The prominent bony projection on the superior and anterior segments of the femoral neck can be excised to eliminate the mechanical block to motion between the bony prominence and the acetabulum. Although early improved motion has been documented, mainly in abduction and internal rotation, the long-term results of this procedure remain unpublished. Remodeling of the femoral neck can have a similar result on motion over time. Osteoplasty also leaves a large area of denuded bone surface in the weight-

bearing area of the hip, which can lead to accelerated degenerative joint disease.

PROPHYLACTIC PINNING OF THE CONTRALATERAL HIP

The controversy over prophylactic pinning of the uninjured hip in SCFE remains unanswered. Proponents of prophylactic pinning emphasize the rate of bilateral disease and the higher risk of osteoarthritis associated with increasing slip severity (19,182). Opponents of prophylactic pinning stress the fact that *in situ* pinning can be associated with severe complications that can be more devastating to hip function than the slip itself (109). Symptomatic bilateral SCFE averages 25% (range, 21 to 37%) during growth (13,17–20). One-half of these patients (12.5%) develop the second symptomatic slip prior to skeletal maturity (13,17,18,20). Asymptomatic slipping of the contralateral hip prior to maturity has been proposed in as high as 40% of patients (19,21). If all contralateral hips in SCFE were pinned prophylactically, 50 to 80% of contralateral hips would be treated unnecessarily.

After a patient has had treatment for unilateral SCFE, the patient is under established medical follow-up until maturity. The patient also is aware of the prodromal symptoms of a second slip, and should it develop, the patient is instructed to return immediately for evaluation and treatment. In this situation, only acute unstable slips should have the potential for significant initial displacement. With acute slips representing only 10% of SCFE, 90% of symptomatic slips should be able to be treated prior to the development of more significant displacement.

Observation of the unaffected hip rather than prophylactic pinning remains the most appropriate treatment in patients presenting with unilateral SCFE (90,109). Exceptions to this treatment include patients with an inability to obtain appropriate and timely follow-up, due to personal or family circumstances, and patients who have SCFE associated with known metabolic or endocrine disorders, in which the risk of a contralateral slip is extremely high. In these situations, prophylactic pinning of the contralateral hip is appropriate.

COMPLICATIONS

The two major complications in SCFE, which are associated with the development of accelerated degenerative joint disease and motion loss at the affected hip, are osteonecrosis of the femoral head and chondrolysis.

Osteonecrosis of the femoral head has been reported to occur in 10 to 15% of patients with SCFE (18,62, 71,85,183). More recent reviews of *in situ* fixation in SCFE using cannulated screws, and strict attention to technical detail, report a much lower incidence of os-

teonecrosis: 0 to 5% (67,120,184,185). Osteonecrosis of the femoral head was once believed to be a complication of treatment, because it was reported only rarely in untreated SCFE (18,62). It has recently been shown that osteonecrosis of the femoral head is more frequently associated with acute and unstable slips (18,68), and is most likely secondary to vascular injury associated with the initial femoral head displacement, and not tamponade from joint effusion or injury from gentle repositioning at the time of surgical stabilization (70,73) (Fig. 25-23). Rhoad and associates (74) reviewed 62 consecutive patients with 73 SCFE, who had a pretreatment technetium 99m bone scan with pin hole and single photon emission computed tomography (SPECT) imaging. The patients were followed for a minimum of 12 months following treatment by spica cast or cannulated screw fixation across the physis. None of the 63 stable SCFE hips showed evidence of ischemia by bone scan, and none developed osteonecrosis at follow-up. Ten SCFE hips were unstable at presentation with six of these hips showing ischemia on bone scan. Five of the six hips subsequently developed osteonecrosis at follow-up. Spontaneous reduction of varying degrees in the unstable SCFEs was noted in eight of the ten hips following treatment. Reduction of the unstable SCFE, in patients with normal bone

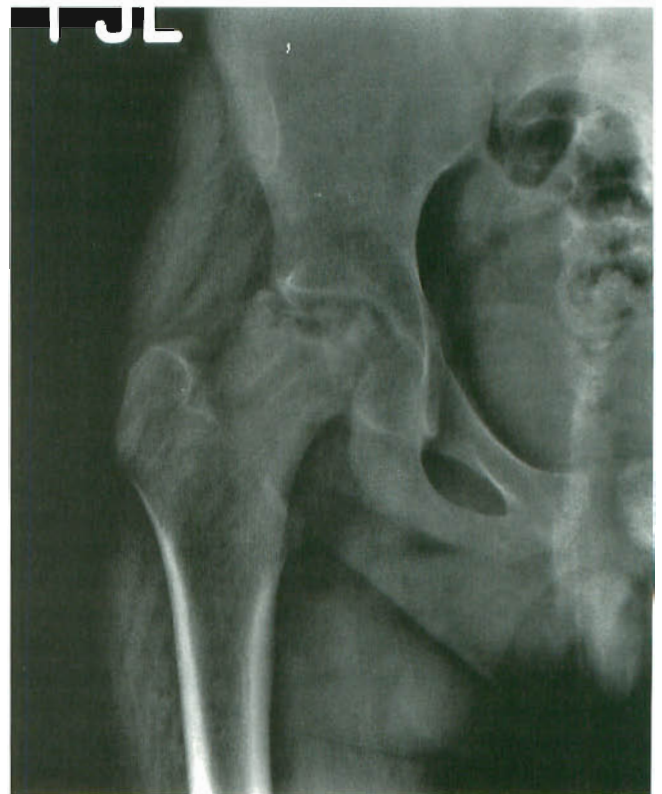

FIGURE 25-23. Anteroposterior hip radiograph of a 14-year, 4-month-old girl with osteonecrosis of the femoral head, following treatment for slipped capital femoral epiphysis.

scan pretreatment, did not result in osteonecrosis. In the five patients with initial ischemia on bone scan and subsequent development of osteonecrosis, the osteonecrosis developed independent of the presence or absence of reduction. Although the author's numbers are small, they do imply that the osteonecrosis seen in acute unstable SCFE more likely occurs at the time of the initial slip, and not during its treatment.

The etiology of osteonecrosis is related to vascular injury to the extraosseous or intraosseous circulation of the femoral head. An increased incidence of osteonecrosis of the femoral head has been reported with increasing severity of the slip (18,62). Carney and colleagues, in a review of 155 hips, reported an incidence of femoral head osteonecrosis of 12% (18). Osteonecrosis was noted in 2% of 65 mild slips, 20% of 50 moderate slips, and 20% of 40 severe slips. Acute slips have a higher incidence of femoral head osteonecrosis, which is secondary to the rapid and excessive stretch of the extraosseous epiphyseal vessels that can occur during the acute displacement (18,62,71). Iatrogenic injury to the extraosseous epiphyseal vessels may occur during aggressive manipulation of the femoral head; stabilization of the femoral head, if the fixation device violates the posterior cortex of the femoral neck; and realignment of the femoral head through osteotomy of the femoral neck (18). Iatrogenic injury to the intraosseous circulation of the femoral head usually is related to hardware placement into the vulnerable superior quadrant of the femoral head, as previously discussed (115).

After osteonecrosis of the femoral head has been established, treatment must be directed at maintaining motion and preventing collapse by decreasing the magnitude of the forces at the affected hip, through relieved weightbearing until healing occurs. Any hardware in the zone of collapse of the femoral head must be withdrawn and replaced, to avoid joint injury. The use of vascularized bone graft and redirection of the intertrochanteric osteotomy, with bone grafting to the femoral head, has been proposed to improve outcome in osteonecrosis of the femoral head (186). No large report directly addressing treatment of osteonecrosis associated with SCFE has been published.

Long-term reviews of SCFE show that hips affected with osteonecrosis have a poorer outcome that continues to deteriorate over time (18,62,187).

Acute cartilage necrosis of the femoral head or chondrolysis was first described by Elmslie, in 1913 (188), and was later reported in association with SCFE by Waldenstrom (189). Chondrolysis is defined as an acute dissolution of articular cartilage in association with rapid progressive joint stiffness and pain.

The etiology of chondrolysis in association with SCFE remains unknown. Historically, the condition was believed to be a result of synovial malnutrition (189), ischemic injury of articular cartilage (85), or excessive cartilage pressure (190). Modern theory suggests an etiology associated with

an immunologic and an autoimmune disorder within the hip joint (27,40,191). A genetic factor is implied by the increased incidence of chondrolysis in female patients in spite of SCFE being more prevalent in males patients.

The incidence of chondrolysis of the hip in SCFE has been reported in the literature to average 16 to 20% (range, 1.8 to 55%) (18,188,192). Recent reviews of the association of chondrolysis with treatment of SCFE by *in situ* stabilization with a single cannulated screw have been reported (67,120). Ward and colleagues reported no chondrolysis in 53 treated hips with at least 24-month follow-up (67). Koval and colleagues reported no cases of chondrolysis to have developed postoperatively in any of 60 hips with at least 2 years follow-up (120). Modern techniques of stabilization and attention to detail during treatment seem to be associated with a lower incidence of chondrolysis than has been previously reported.

Ingram and colleagues have reported on 79 hips in SCFE affected by chondrolysis (192). The authors found the incidence of chondrolysis to be higher in female patients, patients with acute slips, and patients with slips with increased severity of displacement. Similar results have been reported by additional authors (18,99,188). Historically, African-American patients and patients of Hawaiian ancestry have been reported to have a higher incidence of chondrolysis of the hip in association with treatment of SCFE (13,99, 192–194). Recent reports of treatment in SCFE by modern techniques of *in situ* stabilization have shown the incidence of chondrolysis in the African-American population to be no higher than in the general population (111). Kennedy and Weiner reported on *in situ* stabilization of SCFE in 44 African-American children with an incidence of chondrolysis of 2.3% (195). Spero and colleagues reported an incidence of chondrolysis of 6.8% in 44 hips in 29 African-American patients treated by *in situ* pinning (185). Aronson and Loder reviewed *in situ* stabilization of 97 SCFE hips in 74 African-American children, and reported the development of chondrolysis in only 3% (184).

Although chondrolysis of the hip in SCFE can occur in the untreated hip (18,196), the majority of chondrolysis in SCFE has been reported to follow treatment. The treatment modalities shown to be associated with an increased incidence of chondrolysis include manipulative reduction (18), prolonged immobilization (97,98), and realignment osteotomies of the proximal femur (18,153,156). Persistent pin penetration of the femoral head has been shown to be associated with the development of chondrolysis (104,196). Transient penetration of the hip joint in SCFE by stabilizing hardware also was believed to be associated with the induction of chondrolysis. Zionts and colleagues (197), Koval and colleagues (120), and Vrettos and Hoffman (196) have shown that a single episode of transient penetration of the hip joint by a pin or screw, with immediate recognition and removal, is not associated with an increased incidence in the development of chondrolysis.

The diagnosis of chondrolysis is confirmed in a patient

with clinical symptoms of progressive hip stiffness and pain by radiographic confirmation of joint space narrowing at the hip to 3 mm or less (192,198). If chondrolysis does develop, it usually appears within the first year following the SCFE. If chondrolysis follows surgical treatment of SCFE, a

septic process mimicking chondrolysis must always be ruled out by hip aspiration. Mandell and colleagues have reported radiographic premature closure of the greater trochanteric physis to be a predictive sign of chondrolysis (199). The authors demonstrated that decreased activity on bone scin-

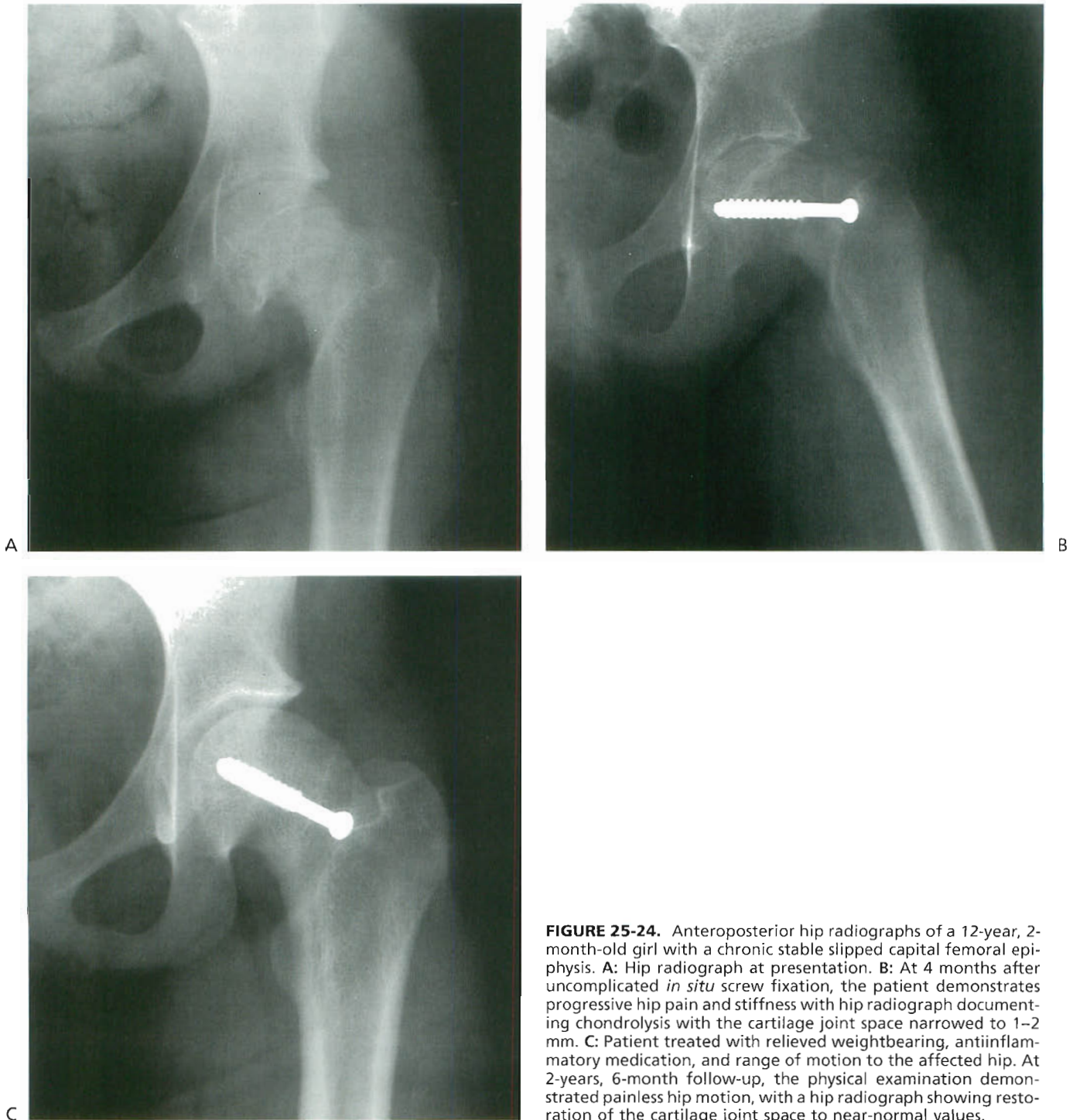

FIGURE 25-24. Anteroposterior hip radiographs of a 12-year, 2-month-old girl with a chronic stable slipped capital femoral epiphysis. **A:** Hip radiograph at presentation. **B:** At 4 months after uncomplicated *in situ* screw fixation, the patient demonstrates progressive hip pain and stiffness with hip radiograph documenting chondrolysis with the cartilage joint space narrowed to 1–2 mm. **C:** Patient treated with relieved weightbearing, antiinflammatory medication, and range of motion to the affected hip. At 2-years, 6-month follow-up, the physical examination demonstrated painless hip motion, with a hip radiograph showing restoration of the cartilage joint space to near-normal values.

tigraphy at the greater trochanteric physis was associated with concurrent or developing chondrolysis in 16 patients with SCFE.

The recommended early treatment of chondrolysis in SCFE has not been standardized, but should include elements of relieved weightbearing, antiinflammatory medication, and passive as well as active hip motion (83,200). In the early stages of chondrolysis, and during recurrent episodes of synovitis and pain, therapeutic doses of nonsteroidal antiinflammatory medications should be initiated and maintained. Periodic hospitalization for enforced bed rest, traction, and frequent physical therapy can be used during episodes of increased pain and motion loss. Physical therapy, consisting of aggressive passive and active motion to the affected hip, should be initiated early. The use of continuous passive motion equipment can be of assistance in maintaining reacquired motion. If pain during physical therapy remains excessive, continuous epidural anesthesia can be of benefit. Ambulation should remain protected, with non-weightbearing and limited-weightbearing crutch use continued until pain has resolved and joint space narrowing radiographically has ceased.

A fibrous ankylosis of the hip joint often can be the final outcome in hips affected by chondrolysis (13,201). However, spontaneous partial cartilage recovery from chondrolysis following SCFE has been reported (190). The prognosis for the hip developing chondrolysis following SCFE is not invariably bad, as had been supposed. Hartman and Gates reported partial restoration of the cartilage space at the hip joint and hip motion in 9 of 28 hips (32%) with chondrolysis (188). At follow-up of 2 to 5 years, 6 of the 9 hips showing recovery were classified as good results. Vretos and Hoffman confirmed partial reconstitution of the joint space to an average of 2.6 mm (range, 1 to 5 mm) in 14 hips with chondrolysis following SCFE (196) (Fig. 25-24). This reconstitution of joint space occurred as late as 3 years after maximum joint involvement. At an average follow-up of 13.3 years, a good functional outcome was reported in 64% of the patients with chondrolysis. Although this information allows for a more optimistic attitude in reference to the early outcome of chondrolysis associated with SCFE, Carney and colleagues, at a mean follow-up of 41 years, have reported that the hip affected by chondrolysis in SCFE eventually shows a continued deterioration in hip function over time (18).

References

1. Segal LS, Weitzel PP, Davidson RS. Valgus slipped capital femoral epiphysis. Fact or fiction? *Clin Orthop* 1966;322:91.
2. Scher MA, Sweet MBE, Jakim I. Acute-on-chronic bilateral slipped capital femoral epiphysis managed by Imhauser-Weber osteotomy. *Arch Orthop Trauma Surg* 1989;108:336.
3. Bright R, Burstein A, Elmore S. Epiphyseal plate cartilage: a

biomechanical and histological analysis of failure modes. *J Bone Joint Surg Am* 1974;56:688.

4. Ippolito E, Mickelson M, Ponseti I. A histochemical study of slipped capital femoral epiphysis. *J Bone Joint Surg Am* 1981; 63:1109.

Epidemiology

5. Weinstein SL. Background on slipped capital femoral epiphysis. *Instr Course Lect* 1984;33:310.
6. Kelsey J, Keggi K, Southwick W. The incidence and distribution of slipped capital femoral epiphysis in Connecticut and the Southwestern United States. *J Bone Joint Surg Am* 1970;52: 1203.
7. Loder RT. A worldwide study on the seasonal variation of slipped capital femoral epiphysis. *Clin Orthop* 1996;322:28.
8. Sorenson K. Slipped upper femoral epiphysis: clinical study on etiology. *Acta Orthop Scand* 1968;39:499.
9. Henrickson B. The incidence of slipped capital femoral epiphysis. *Acta Orthop Scand* 1969;40:365.
10. Jerre R, Karlsson J, Henrikson B. The incidence of physiolyis of the hip: a population-based study of 175 patients. *Acta Orthop Scand* 1996;67:53.
11. Loder RT, Wittenberg B, DeSilva G. Slipped capital femoral epiphysis associated with endocrine disorders. *J Pediatr Orthop* 1995;15:349.
12. Morsher E. Strength and morphology of growth cartilage under hormonal influence of puberty. *Reconstr Surg Traumatol* 1968; 10:3.
13. Wilson P, Jacobs B, Schector L. Slipped upper femoral epiphysis: an end result study. *J Bone Joint Surg Am* 1965;47:1128.
14. Loder RT. The demographics of slipped capital femoral epiphysis. An international multicenter study. *Clin Orthop* 1996; 322:8.
15. Kelsey J, Acheson R, Keggi K. The body builds of patients with slipped capital femoral epiphysis. *Am J Dis Child* 1972;124: 276.
16. Brenkel IJ, Dias JJ, Davies TG, et al. Hormone status in patients with slipped capital femoral epiphysis. *J Bone Joint Surg Br* 1989; 71:33.
17. Loder RT, Aronson DD, Greenfield ML. The epidemiology of bilateral slipped capital femoral epiphysis. *J Bone Joint Surg Am* 1993;75:1141.
18. Carney BT, Weinstein SL, Noble J. Long-term follow-up of slipped capital femoral epiphysis. *J Bone Joint Surg Am* 1991; 73:667.
19. Hagglund G, Hansson LI, Ordeberg G, et al. Bilaterality in slipped upper femoral epiphysis. *J Bone Joint Surg Br* 1988;70: 179.
20. Siegel DB, Kasser JR, Sponseller P, et al. Slipped capital femoral epiphysis. A quantitative analysis of motion, gait and femoral remodeling after *in situ* fixation. *J Bone Joint Surg Am* 1991; 73:659.
21. Billing L, Severin E. Slipping epiphysis of the hip: a roentgenological and clinical study based on a new roentgen technique. *Acta Radiol* 1959;174(suppl):1.
22. Jerre R, Billing L, Hansson G, et al. Bilaterality in slipped capital femoral epiphysis: importance of a reliable radiographic method. *J Pediatr Orthop B* 1996;5:80.
23. Stasikelis PJ, Sullivan CM, Phillips WA, et al. Slipped capital femoral epiphysis. Prediction of contralateral involvement. *J Bone Joint Surg Am* 1996;78:1149.

Pathoanatomy

24. Green WT. Slipping of the upper femoral epiphysis: diagnostic and therapeutic considerations. *Arch Surg* 1945;50:19.

25. Nguyen D, Morrissy RT. Slipped capital femoral epiphysis: rationale for the technique of percutaneous *in situ* fixation. *J Pediatr Orthop* 1990;10:341.
26. Ferguson AB, Howorth MB. Slipping of the upper femoral epiphysis: a study of seventy cases. *JAMA* 1931;97:1867.
27. Morrissy RT, Kalderon AE, Gerdes MH. Synovial immunofluorescence in patients with slipped capital femoral epiphysis. *J Pediatr Orthop* 1981;1:55.
28. Agamanolis DP, Weiner DS, Lloyd JK. Slipped capital femoral epiphysis: a pathological study. I. A light microscopic and histochemical study of 21 cases. *J Pediatr Orthop* 1985;5:40.
29. Mickelson MR, Ponseti IV, Cooper RR, Maynard JA. The ultrastructure of the growth plate in slipped capital femoral epiphysis. *J Bone Joint Surg Am* 1977;59:1076.
30. Ponseti IV, McClintock R. The pathology of slipping of the upper femoral epiphysis. *J Bone Joint Surg Am* 1956;38:71.
31. Agamanolis DP, Weiner DS, Lloyd JK. Slipped capital femoral epiphysis: a pathological study II. An ultrastructural study of 23 cases. *J Pediatr Orthop* 1985;5:47.
48. Primiano GA, Hughston JC. Slipped capital femoral epiphysis in a true hypogonadal male (Klinefelter's mosaic XY/XXY). *J Bone Joint Surg Am* 1971;53:597.
49. Shea D, Mankin HJ. Slipped capital femoral epiphysis in renal rickets: report of three cases. *J Bone Joint Surg Am* 1966;48:349.
50. Loder RT, Hensinger RN. Slipped capital femoral epiphysis associated with renal failure osteodystrophy. *J Pediatr Orthop* 1997;17:205.
51. Fidler M, Brook C. Slipped upper femoral epiphysis following treatment with human growth hormone. *J Bone Joint Surg Am* 1974;56:1719.
52. Rennie W, Mitchell N. Slipped capital femoral epiphysis occurring during growth hormone therapy. Report of a case. *J Bone Joint Surg Br* 1974;56:703.
53. Blethen SL, Rundle AC. Slipped capital femoral epiphysis in children treated with growth hormone. A summary of the National Cooperative Growth Study experience. *Hormone Res* 1996;46:113.
54. Oka M, Miki T, Hama H, et al. The mechanical strength of the growth plate under the influence of sex hormones. *Clin Orthop* 1979;145:264.
55. Mann DC, Weddington J, Richton S. Hormonal studies in patients with slipped capital femoral epiphysis without evidence of endocrinopathy. *J Pediatr Orthop* 1988;8:543.
56. Razzano CD, Nelson C, Eversman J. Growth hormone levels in slipped capital femoral epiphysis. *J Bone Joint Surg Am* 1972;54:1224.
57. Wilcox PG, Weiner DS, Leighley B. Maturation factors in slipped capital femoral epiphysis. *J Pediatr Orthop* 1988;8:196.
58. Loder RT, Hensinger RN, Alburger PD, et al. Slipped capital femoral epiphysis associated with radiation therapy. *J Pediatr Orthop* 1998;18:630.
59. Rennie AM. The inheritance of slipped upper femoral epiphysis. *J Bone Joint Surg Br* 1982;64:180.

Etiology

32. Gelberman R, Cohen M, Shaw B, et al. The association of femoral retroversion with slipped capital femoral epiphysis. *J Bone Joint Surg Am* 1986;68:1000.
33. Howorth MB. Slipping of the upper femoral epiphysis. *J Bone Joint Surg Am* 1949;31:734.
34. Key J. Epiphyseal coxa vara or displacement of the capital epiphysis of the femur in adolescence. *J Bone Joint Surg* 1926;8:53.
35. McAfee P, Cady R. Endocrinologic and metabolic factors in atypical presentations of slipped capital femoral epiphysis. *Clin Orthop* 1983;180:188.
36. Pritchett JW, Perdue KD. Mechanical factors in slipped capital femoral epiphysis. *J Pediatr Orthop* 1988;8:385.
37. Peterson CA, Peterson HA. Analysis of the incidence of injuries to the epiphyseal growth plate. *J Trauma* 1972;12:275.
38. Stanitski CL, Woo R, Stanitski DF. Femoral version in acute slipped capital femoral epiphysis. *J Pediatr Orthop B* 1996;5:74.
39. Chung S, Batterman S, Brighton C. Shear strength of the human femoral capital epiphyseal plate. *J Bone Joint Surg Am* 1976;58:94.
40. Eisenstein A, Rothschild S. Biochemical abnormalities in patients with slipped capital femoral epiphysis and chondrolysis. *J Bone Joint Surg Am* 1976;58:459.
41. Morrissy RT, Steele RW, Gerdes MH. Localized immune complexes and slipped capital femoral epiphysis. *J Bone Joint Surg Br* 1983;65:574.
42. Heyerman W, Weiner D. Slipped epiphysis associated with hypothyroidism. *J Pediatr Orthop* 1984;4:569.
43. Hirano T, Stamelos S, Harris V, et al. Association of primary hypothyroidism and slipped capital femoral epiphysis. *J Pediatr* 1978;93:262.
44. Moorefield WG, Urbaniak JR, Ogden WS, Frank JL. Acquired hypothyroidism and slipped capital femoral epiphysis. *J Bone Joint Surg Am* 1976;58:705.
45. Zubrow A, Lane J, Parks J. Slipped capital femoral epiphysis occurring during treatment for hypothyroidism. *J Bone Joint Surg Am* 1978;60:256.
46. Harris WR. The endocrine basis for slipping of the femoral epiphysis. *J Bone Joint Surg Br* 1950;32:5.
47. Heatley FW, Greenwood RH, Boase DL. Slipping of the upper femoral epiphysis in patients with intracranial tumors causing hypopituitarism and chiasmal compression. *J Bone Joint Surg Br* 1976;58:169.

Clinical Presentation

60. Ledwith CA, Fleisher GR. Slipped capital femoral epiphysis without hip pain leads to missed diagnosis. *Pediatrics* 1992;89:660.
61. Matava MJ, Patton CM, Luhmann S, et al. Knee pain as the initial symptom of slipped capital femoral epiphysis: an analysis of initial presentation and treatment. *J Pediatr Orthop* 1999;19:455.
62. Boyer D, Mickelson M, Ponseti T. Slipped capital femoral epiphysis: long-term follow up and study of one hundred and twenty-one patients. *J Bone Joint Surg Am* 1981;63:85.
63. Aadelen R, Weiner D, Hoyt W, Herndon C. Acute slipped capital femoral epiphysis. *J Bone Joint Surg Am* 1974;56:1473.
64. Casey B, Hamilton H, Bobechko W. Reduction of acutely slipped upper femoral epiphysis. *J Bone Joint Surg Br* 1972;54:607.
65. Fahey J, O'Brien E. Acute slipped capital femoral epiphysis. *J Bone Joint Surg Am* 1965;47:1105.
66. Aronson DD, Carlson WE. Slipped capital femoral epiphysis. A prospective study of fixation with a single screw. *J Bone Joint Surg Am* 1992;74:810.
67. Ward WT, Steffko J, Wood KB, Stanitski CL. Fixation with a single screw for slipped capital femoral epiphysis. *J Bone Joint Surg Am* 1992;74:799.
68. Loder RT, Richards BS, Shapiro PS, et al. Acute slipped capital femoral epiphysis: the importance of physeal stability. *J Bone Joint Surg Am* 1993;75:1134.
69. Aronsson DD, Loder RT. Treatment of the unstable (acute) slipped capital femoral epiphysis. *Clin Orthop* 1996;322:99.

70. Kallio PE, Mah ET, Foster BK, et al. Slipped capital femoral epiphysis. Incidence and clinical assessment of physeal instability. *J Bone Joint Surg Br* 1995;77:752.
71. Peterson MD, Weiner DS, Green NE, et al. Acute slipped capital femoral epiphysis: the value and safety of urgent manipulative reduction. *J Pediatr Orthop* 1997;17:648.
72. Rattey T, Piehl F, Wright JG. Acute slipped capital femoral epiphysis. Review of outcomes and rates of avascular necrosis. *J Bone Joint Surg Am* 1996;78:398.
73. Herman MJ, Dormans JP, Davidson RS, et al. Screw fixation of grade III slipped capital femoral epiphysis. *Clin Orthop* 1996;322:77.
74. Rhoad RC, Davidson RS, Heyman S, et al. Pretreatment bone scan in SCFE: a predictor of ischemia and avascular necrosis. *J Pediatr Orthop* 1999;19:164.

Radiographic Features

75. Steel HH. The metaphyseal blanch sign of slipped capital femoral epiphysis. *J Bone Joint Surg Am* 1986;68:920.
76. Klein A, Joplin RJ, Reidy JA, Hanelin J. Roentgenographic features of slipped capital femoral epiphysis. *AJR Am J Roentgenol* 1951;66:361.
77. Castriota-Scanderbeg A, Orsi E. Slipped capital femoral epiphysis: ultrasonographic findings. *Skeletal Radiol* 1993;22:191.
78. Magnano GM, Lucigrai G, De Filippi C, et al. Diagnostic imaging of the early slipped capital femoral epiphysis. *Radiol Med* 1998;95:16.
79. Kallio P, Lequesne GW, Paterson DC, et al. Ultrasonography in slipped capital femoral epiphysis. Diagnosis and assessment of severity. *J Bone Joint Surg Br* 1991;73:884.
80. Cohen MS, Gelberman RH, Griffin PP, et al. Slipped capital femoral epiphysis: assessment of epiphyseal displacement and angulation. *J Pediatr Orthop* 1986;6:259.
81. Stoller DW. *Magnetic resonance imaging in orthopaedics and sports medicine*. Philadelphia: JB Lippincott, 1993:83.
82. Umans H, Liebling MS, Moy L, et al. Slipped capital femoral epiphysis: a physeal lesion diagnosed by MRI with radiographic and CT correlation. *Skeletal Radiol* 1998;27:139.
83. Jacobs B. Diagnosis and natural history of slipped capital femoral epiphysis. *Instr Course Lect* 1972;21:167.
84. Southwick W. Osteotomy through the lesser trochanter for slipped capital femoral epiphysis. *J Bone Joint Surg Am* 1967;49:807-835.

Natural History

85. Hall JE. The results of treatment of slipped femoral epiphysis. *J Bone Joint Surg Br* 1957;39:659-673.
86. Jerre T. A study in slipped upper femoral epiphysis with special reference to late functional and roentgenological results and the value of closed reduction. *Acta Orthop Scand* 1950;6(suppl):1.
87. Oram V. Epiphysiolysis of the head of the femur. *Acta Orthop Scand* 1953;23:100.
88. Ross P, Lyne E, Morawa L. Slipped capital femoral epiphysis: long-term results after 10-38 years. *Clin Orthop* 1979;141:176.
89. Carney BT, Weinstein SL. Natural history of untreated chronic slipped capital femoral epiphysis. *Clin Orthop* 1996;322:43.
90. Klein A, Joplin RJ, Reidy JA, et al. Management of the contralateral hip in slipped capital femoral epiphysis. *J Bone Joint Surg Am* 1953;35:81.
91. Howorth MB. Treatment and slipping of the upper femoral epiphysis. *Clin Orthop* 1966;48:53.
92. Murray RO. The etiology of primary osteoarthritis of the hip. *Br J Radiol* 1965;38:810.
93. Stulberg SD, Cordell LD, Harris WH, et al. Unrecognized

childhood hip diseases: a major cause of idiopathic osteoarthritis of the hip. In: *The hip: proceedings of the third open scientific meeting of the Hip Society*. St. Louis: CV Mosby, 1975:212.

94. Goodman DA, Feighan JE, Smith AD, et al. Subclinical slipped capital femoral epiphysis. Relationship to osteoarthritis of the hip. *J Bone Joint Surg Am* 1997;79:1489.
95. Solomon L. Patterns of osteoarthritis of the hip. *J Bone Joint Surg Br* 1976;58:176.
96. Resnick D. The "tilt deformity" of the femoral head in osteoarthritis of the hip, a poor indicator of previous epiphysiolysis. *Clin Radiol* 1976;27:355.

Treatment

97. Betz RR, Steel HH, Emper WD, et al. Treatment of slipped capital femoral epiphysis—spica cast immobilization. *J Bone Joint Surg Am* 1990;72:587.
98. Meier MC, Meyer LC, Ferguson RL. Treatment of slipped capital femoral epiphysis with a spica cast. *J Bone Joint Surg Am* 1992;74:1522.
99. Maurer R, Larsen I. Acute necrosis of cartilage in slipped capital femoral epiphysis. *J Bone Joint Surg Am* 1970;52:39.
100. Benner GC, Koreska J, Rang M. Pin placement in slipped capital femoral epiphysis. *J Pediatr Orthop* 1984;4:574.
101. England SP, Morrissy RT. Metal removal following in-situ fixation for slipped capital femoral epiphysis: a cost/benefit analysis. *American Academy of Orthopaedic Surgeons 61st Annual Meeting Final Program* 1994:296.
102. Kahle WK. The case against routine metal removal. *J Pediatr Orthop* 1994;14:229.
103. Crandall DG, Gabriel KR, Alkarnia BA. Second operation for slipped capital femoral epiphysis: pin removal. *J Pediatr Orthop* 1992;12:434.
104. Walters R, Simon S. Joint destruction—a sequel of unrecognized pin penetration in patients with slipped capital femoral epiphysis. In: Riley LH Jr, ed. *The hip: proceedings of the eighth open scientific meeting of the Hip Society*. St. Louis: CV Mosby, 1980:145.
105. Stambough JL, Davidson RS, Ellis RD, et al. Slipped capital femoral epiphysis: an analysis of 80 patients as to pin placement and number. *J Pediatr Orthop* 1986;6:265.
106. Riley PM, Weiner DS, Gillespie R, et al. Hazards of internal fixation in the treatment of slipped capital femoral epiphysis. *J Bone Joint Surg Am* 1990;72:1500.
107. Greenough CG, Bromage JD, Jackson AM. Pinning of the slipped upper femoral epiphysis—a trouble-free procedure? *J Pediatr Orthop* 1985;5:657.
108. Blanco JS, Taylor B, Johnston, CE. Comparison of single pin versus multiple pin fixation in treatment of slipped capital femoral epiphysis. *J Pediatr Orthop* 1992;12:384.
109. Morrissy RT. Principles of *in situ* fixation in chronic slipped capital femoral epiphysis. *Instr Course Lect* 1989;38:257.
110. Stevens DB, Short BA, Burch JM. *In situ* fixation of the slipped capital femoral epiphysis with a single screw. *J Pediatr Orthop B* 1996;5:85.
111. Aronson DD, Peterson DA, Miller DV. Slipped capital femoral epiphysis. The case for internal fixation *in situ*. *Clin Orthop* 1992;281:115.
112. Morrissy RT. Slipped capital femoral epiphysis technique of percutaneous *in situ* fixation. *J Pediatr Orthop* 1990;10:347.
113. Crider RJ, Krell T, McGuire M, et al. Anterolateral approach for moderate to severe slipped capital femoral epiphysis. *J Pediatr Orthop* 1988;8:661.
114. Chung SM. The arterial supply of the developing proximal end of the human femur. *J Bone Joint Surg Am* 1976;58:961.
115. Brodetti A. The blood supply of the femoral neck and head in

- relation to the damaging effects of nails and screws. *J Bone Joint Surg Br* 1960;42:794.
116. Moseley C. The "approach-withdraw" phenomenon in the pinning of slipped capital femoral epiphysis. *Orthop Trans* 1985; 9:497.
 117. Doane RM, Haut RC, Karol L, et al. Biomechanical analysis of the slipped capital femoral epiphysis with single and double screw fixation. *Trans Ortho Res Soc* 1990;15:430.
 118. Karol LA, Doane RM, Cornicelli SF, et al. Single versus double screw fixation for treatment of slipped capital femoral epiphysis: a biomechanical analysis. *J Pediatr Orthop* 1992;12:741.
 119. Kibiloski LJ, Doane RM, Karol LA, et al. Biomechanical analysis of single versus double screw fixation in slipped capital femoral epiphysis at physiological load levels. *J Pediatr Orthop* 1994; 14:627.
 120. Koval KJ, Lehman WB, Rose D, et al. Treatment of slipped capital femoral epiphysis with a cannulated-screw technique. *J Bone Joint Surg Am* 1989;71:1370.
 121. Goodman WW, Johnson JT, Robertson WW Jr. Single screw fixation for acute and acute-on-chronic slipped capital femoral epiphysis. *Clin Orthop* 1996;322:86.
 122. Baynham GC, Lucie RS, Cummings RJ. Femoral neck fracture secondary to *in situ* pinning of slipped capital femoral epiphysis. A previously unreported complication. *J Pediatr Orthop* 1991; 11:187.
 123. Canale ST, Casillas M, Banta JV. Displaced femoral neck fractures at the bone-screw interface after *in situ* fixation of slipped capital femoral epiphysis. *J Pediatr Orthop* 1997;17:212.
 124. Denton JR. Progression of a slipped capital femoral epiphysis after fixation with a single cannulated screw. A case report. *J Bone Joint Surg Am* 1993;75:425.
 125. Stanton RP, Shelton YA. Closure of the physis after pinning of slipped capital femoral epiphysis. *Orthopedics* 1993;16:1099.
 126. Segal LS, Davidson RS, Robertson WW, et al. Growth disturbances of the proximal femur after pinning of juvenile slipped capital femoral epiphysis. *J Pediatr Orthop* 1991;11:631.
 127. Hansson LI. Osteosynthesis with the hook-pin in slipped capital femoral epiphysis. *Acta Orthop Scand* 1982;53:87.
 128. Jerre R, Karlson J, Romanus B, et al. Does a single device prevent further slipping of the epiphysis in children with slipped capital femoral epiphysis? *Arch Orthop Trauma Surg* 1997;116: 348.
 129. Crawford AH. Slipped capital femoral epiphysis. *J Bone Joint Surg Am* 1988;70:1422.
 130. Herndon CH, Heyman CH, Bell DM. Treatment of slipped capital femoral epiphysis by epiphyseodesis and osteoplasty of femoral neck. *J Bone Joint Surg Am* 1963;45:999.
 131. Melby A, Hoyt W, Weiner D. Treatment of chronic slipped capital femoral epiphysis by bone-graft epiphysiodesis. *J Bone Joint Surg Am* 1980;62:119.
 132. Ward WT, Wood K. Open bone graft epiphyseodesis for slipped capital femoral epiphysis. *J Pediatr Orthop* 1990;10:14.
 133. Irani RN, Rosenzweig AH, Cotler HB, et al. Epiphysiodesis in slipped capital femoral epiphysis. A comparison of various surgical modalities. *J Pediatr Orthop* 1985;5:661.
 134. Rao SB, Crawford AH, Burger RR, et al. Open bone peg epiphysiodesis for slipped capital femoral epiphysis. *J Pediatr Orthop* 1996;16:37.
 135. Weiner DS, Weiner SD, Melby A, Hoyt WA. A 30-year experience with bone graft epiphysiodesis in the treatment of slipped capital femoral epiphysis. *J Pediatr Orthop* 1984;4:145.
 136. Weiner DS, Weiner SD, Melby A. Anterolateral approach to the hip for bone graft epiphysiodesis in the treatment of slipped capital femoral epiphysis. *J Pediatr Orthop* 1988;8:349.
 137. Weiner DS. Bone graft epiphysiodesis in the treatment of slipped capital femoral epiphysis. *Instr Course Lect* 1989;38:266.
 138. Hansson G, Billing L, Hogstedt B, et al. Long-term results after nailing *in situ* of slipped upper femoral epiphysis. A 30-year follow-up of 59 hips. *J Bone Joint Surg Br* 1998;80:70.
 139. Bellemans J, Fabry G, Molenaers G, et al. Slipped capital femoral epiphysis: a long-term follow-up, with special emphasis on the capacities for remodeling. *J Pediatr Orthop B* 1996;5: 151-157.
 140. Wong-Chung J, Strong ML. Physeal remodeling after internal fixation of slipped capital femoral epiphysis. *J Pediatr Orthop* 1991;11:2.
 141. Lacroix P, Verbrugge J. Slipping of the upper femoral epiphysis: a pathological study. *J Bone Joint Surg Am* 1951;33:371.
 142. O'Brien E, Fahey J. Remodeling of the femoral neck after *in situ* pinning for slipped capital femoral epiphysis. *J Bone Joint Surg Am* 1977;59:62.
 143. Jones JR, Paterson DC, Hillier TM, et al. Remodelling after pinning for slipped capital femoral epiphysis. *J Bone Joint Surg Br* 1990;72:568.
 144. Lowe HG. Avascular necrosis after slipping of the upper femoral epiphysis. *J Bone Joint Surg Br* 1961;43:688.
 145. Fairbank JT. Manipulative reduction in slipped upper femoral epiphysis. *J Bone Joint Surg Br* 1969;51:252.
 146. Dietz FR. Traction reduction of acute and acute-on-chronic slipped capital femoral epiphysis. *Clin Orthop* 1994;302:101.
 147. Abraham E, Garst J, Barmada R. Treatment of moderate to severe slipped capital femoral epiphysis with extracapsular base-of-neck osteotomy. *J Pediatr Orthop* 1993;13:294.
 148. Badgley E, Isaacson A, Wolgamot J, et al. Operative therapy for slipped capital femoral epiphysis. *J Bone Joint Surg Am* 1948; 30:19.
 149. Barmada R, Bruch RF, Gimbel JS, et al. Base of neck extracapsular osteotomy for correction of deformity in slipped capital femoral epiphysis. *Clin Orthop* 1978;132:98.
 150. Clark CR, Southwick WO, Ogden JA. Anatomic aspects of slipped capital femoral epiphysis and correction by biplane osteotomy. *Instr Course Lect* 1980;29:90.
 151. Dunn DM, Angel JC. Replacement of the femoral head by open operation in severe adolescent slipping of the upper femoral epiphysis. *J Bone Joint Surg Br* 1978;60:394.
 152. Fish JB. Cuneiform osteotomy of the femoral neck in the treatment of slipped capital femoral epiphysis. *J Bone Joint Surg Am* 1984;66:1153.
 153. Gage J, Sundberg A, Nolan D, et al. Complications after cuneiform osteotomy for moderately or severely slipped capital femoral epiphysis. *J Bone Joint Surg Am* 1978;60:157.
 154. Nishiyama K, Sakamaki T, Ishii Y. Follow-up study of the subcapital wedge osteotomy for severe chronic slipped capital femoral epiphysis. *J Pediatr Orthop* 1989;9:412.
 155. Rao J, Francis A, Siwek C. The treatment of chronic slipped capital femoral epiphysis by biplane osteotomy. *J Bone Joint Surg Am* 1984;66:1169.
 156. Salvati E, Robinson H, O'Dowd T. Southwick osteotomy for severe chronic slipped capital femoral epiphysis. Results and complications. *J Bone Joint Surg Am* 1980;62:561.
 157. Sugioka Y. Transtrochanteric rotational osteotomy of the femoral head. In: Riley LH Jr, ed. *The hip: proceedings of the eighth open scientific meeting of the Hip Society*. St. Louis: CV Mosby, 1980:3.
 158. Imhauser G. Late results of Imhauser's osteotomy for slipped capital femoral epiphysis. *Zeitschrift für Orthopädie und Ihre Grenzgebiete* 1997;115:716.
 159. Jerne R, Hansson G, Wallin J, Karlson J. Long-term results after realignment operations for slipped capital femoral epiphysis. *J Bone Joint Surg Br* 1996;78:745.
 160. Fish JB. Cuneiform osteotomy of the femoral neck in the treat-

- ment of slipped capital femoral epiphysis. A follow-up note. *J Bone Joint Surg Am* 1994;76:46.
161. DeRosa GP, Mullins RC, Kling TF Jr. Cuneiform osteotomy of the femoral neck in severe slipped capital femoral epiphysis. *Clin Orthop* 1996;322:48.
 162. Velasco R, Schai PA, Exner GU. Slipped capital femoral epiphysis: a long-term follow-up study after open reduction of the femoral head combined with subcapital wedge resection. *J Pediatr Orthop B* 1998;7:43.
 163. Kramer WG, Craig WA, Noel S. Compensating osteotomy at the base of the femoral neck for slipped capital femoral epiphysis. *J Bone Joint Surg Am* 1976;58:796.
 164. Crawford AH. The role of osteotomy in the treatment of slipped capital femoral epiphysis. *Instr Course Lect* 1989;38:273.
 165. Masuda T, Matsuno T, Hasegawa I, et al. Transtrochanteric anterior rotational osteotomy for slipped capital femoral epiphysis: a report of five cases. *J Pediatr Orthop* 1986;6:18.
 166. Frymover J. Chondrolysis of the hip following Southwick osteotomy for severe slipped capital femoral epiphysis. *Clin Orthop* 1974;99:120.
 167. Merchan EC, Na CM, Munuera L. Intertrochanteric osteotomy for the treatment of chronic slipped capital femoral epiphysis. *Int Orthop* 1992;16:133.
 168. Schai PA, Exner GU, Hansch O. Prevention of secondary coxarthrosis in slipped capital femoral epiphysis: a long-term follow-up study after corrective intertrochanteric osteotomy. *J Pediatr Orthop B* 1996;5:135.
 169. Griffith MJ. Slipping of the capital femoral epiphysis. *Ann R Coll Surg Engl* 1976;58:34.
 170. Millis MB, Murphy SB, Poss R. Osteotomies about the hip for the prevention and treatment of osteoarthritis. *Instr Course Lect* 1996;45:209.
 171. Tokarowski A, Wojciechowski P, Kusz D, et al. Treatment outcome of juvenile slipped capital femoral epiphysis with Imhauser osteotomy. *Chirurgia Narzadow Ruchu i Ortopedia Polska* 1995; 60:307.
 172. Soballe K, Boll KL, Kofod S, et al. Total hip replacement after medial-displacement osteotomy of the proximal part of the femur. *J Bone Joint Surg Am* 1989;71:692.
 173. Sponseller PD, McBeath AA, Perpich M. Hip arthrodesis in young patients. A long-term follow-up study. *J Bone Joint Surg Am* 1984;66:853.
 174. Callaghan JJ, Brand RA, Pedersen DR. Hip arthrodesis. A long-term follow-up. *J Bone Joint Surg Am* 1985;67:1328.
 175. Amstutz HC, Sakai DN. Total joint replacement for ankylosed hips—indications, technique and preliminary results. *J Bone Joint Surg Am* 1975;57:619.
 176. Lubahn JD, Evarts CM, Feltner JB. Conversion of ankylosed hips to total hip arthroplasty. *Clin Orthop* 1980;153:146.
 177. Mowery CA, Houkom JA, Roach JW, et al. A simple method of hip arthrodesis. *J Pediatr Orthop* 1986;6:7.
 178. Schoenecker PL, Johnson LO, Martin RA, et al. Intra-articular hip arthrodesis without subtrochanteric osteotomy in adolescents: technique and short-term follow-up. *Am J Orthop* 1997; 26:257.
 179. Aronson J. Osteoarthritis of the young adult hip: etiology and treatment. *Instr Course Lect* 1986;35:119.
 180. Chandler HP, Reineck FT, Wilson RL, et al. Total hip replacement in patients younger than thirty years old. *J Bone Joint Surg Am* 1981;63:1426.
 181. Whitesides LA, Schoenecker PL. Combined valgus derotation osteotomy and cervical osteoplasty for severely slipped capital femoral epiphysis. *Clin Orthop* 1978;132:88.

Prophylactic Pinning of the Contralateral Hip

182. Hagglund G. The contralateral hip in slipped capital femoral epiphysis. *J Pediatr Orthop B* 1996;5:158.

Complications

183. Canale ST. Problems and complications of slipped capital femoral epiphysis. *Instr Course Lect* 1989;38:281.
184. Aronson DD, Loder RT. Slipped capital femoral epiphysis in black children. *J Pediatr Orthop* 1992;12:74.
185. Spero CR, Masciale JP, Tornetta P, et al. Slipped capital femoral epiphysis in black children: incidence of chondrolysis. *J Pediatr Orthop* 1992;12:444.
186. Scher MA, Jakim I. Intertrochanteric osteotomy and autogenous bone-grafting for avascular necrosis of the femoral head. *J Bone Joint Surg Am* 1993;75:1119.
187. Krahn TH, Canale ST, Beaty JH, et al. Long-term follow-up of patients with avascular necrosis after treatment of slipped capital femoral epiphysis. *J Pediatr Orthop* 1993;13:154.
188. Hartman J, Gates D. Recovery from cartilage necrosis following slipped capital femoral epiphysis. *Orthop Rev* 1972;1:33.
189. Waldenstrom H. On necrosis of the joint cartilage by epiphyseolysis capitis femoris. *Acta Chir Scand* 1930;67:936.
190. Lowe HG. Necrosis of articular cartilage after slipping of the capital femoral epiphysis. Report of six cases with recovery. *J Bone Joint Surg Br* 1970;52:108.
191. Mankin HJ, Sledge CB, Rothschild S, et al. Chondrolysis of the hip. In: *The hip: proceedings of the third open scientific meeting of the Hip Society*. St. Louis: CV Mosby, 1975:127.
192. Ingram AJ, Clarke MS, Clarke CS, Marshall RW. Chondrolysis complicating slipped capital femoral epiphysis. *Clin Orthop* 1982;165:99.
193. Cruess RL. The pathology of acute necrosis of cartilage in slipping of the capital femoral epiphysis. *J Bone Joint Surg Am* 1963; 45:1013.
194. Tillema D, Golding J. Chondrolysis following slipped capital femoral epiphysis in Jamaica. *J Bone Joint Surg Am* 1971;53: 1528.
195. Kennedy JP, Weiner DS. Results of slipped capital femoral epiphysis in the black population. *J Pediatr Orthop* 1990;10:224.
196. Vrettos BC, Hoffman EB. Chondrolysis in slipped upper femoral epiphysis. *J Bone Joint Surg Br* 1993;75:956.
197. Zions LE, Simonian PT, Harvey JP. Transient penetration of the hip joint during *in situ* cannulated-screw fixation of slipped capital femoral epiphysis. *J Bone Joint Surg Am* 1991;73:1054.
198. El-Khoury G, Mickelson M. Chondrolysis following slipped capital femoral epiphysis. *Radiology* 1977;123:327.
199. Mandell GA, Keret D, Harcke HT, et al. Chondrolysis: detection by bone scintigraphy. *J Pediatr Orthop* 1992;12:80.
200. Warner WC Jr, Beaty JH, Canale ST. Chondrolysis after slipped capital femoral epiphysis. *J Pediatr Orthop B* 1996;5:168.
201. Morrissy RT. Slipped capital femoral epiphysis—natural history and etiology in treatment. *Instr Course Lect* 1980;29:81.



DEVELOPMENTAL COXA VARA, TRANSIENT SYNOVITIS, AND IDIOPATHIC CHONDROLYSIS OF THE HIP

DOUGLAS K. KEHL

DEVELOPMENTAL COXA VARA 1035

Historical Review 1037
Incidence 1037
Etiology 1037
Clinical Presentation 1038
Radiographic Findings 1039
Natural History 1040
Treatment 1040
Results 1042

TRANSIENT SYNOVITIS OF THE HIP 1044

Historical Review 1044
Etiology 1045
Incidence 1045

Clinical Presentation 1045
Radiographic Findings 1046
Natural History 1047
Treatment 1048

IDIOPATHIC CHONDROLYSIS OF THE HIP 1048

Historical Review 1048
Etiology 1049
Incidence 1049
Clinical Presentation 1049
Radiographic Findings 1050
Pathology 1052
Natural History 1052
Treatment 1053

This chapter addresses three conditions affecting the juvenile and adolescent hip: developmental coxa vara, transient synovitis, and idiopathic chondrolysis of the hip. Developmental coxa vara and idiopathic chondrolysis of the hip remain relatively uncommon, but continue to present chal-

lenging dilemmas in diagnosis and treatment. Transient synovitis remains the most common condition causing hip pain in childhood. A knowledge of this condition's presentation, diagnosis, and treatment is crucial for any physician treating musculoskeletal problems in pediatric patients.

DEVELOPMENTAL COXA VARA

“Coxa vara” is defined as any decrease below the normal values of the neck–shaft angle of the proximal femur, which is the angle subtended by the femoral neck and shaft in the

D. K. Kehl: Department of Orthopaedic Surgery, Emory University School of Medicine, Atlanta, Georgia 30303; Department of Orthopaedic Surgery, Children's Healthcare of Atlanta at Scottish Rite Children's Medical Center, Atlanta, Georgia 30342.

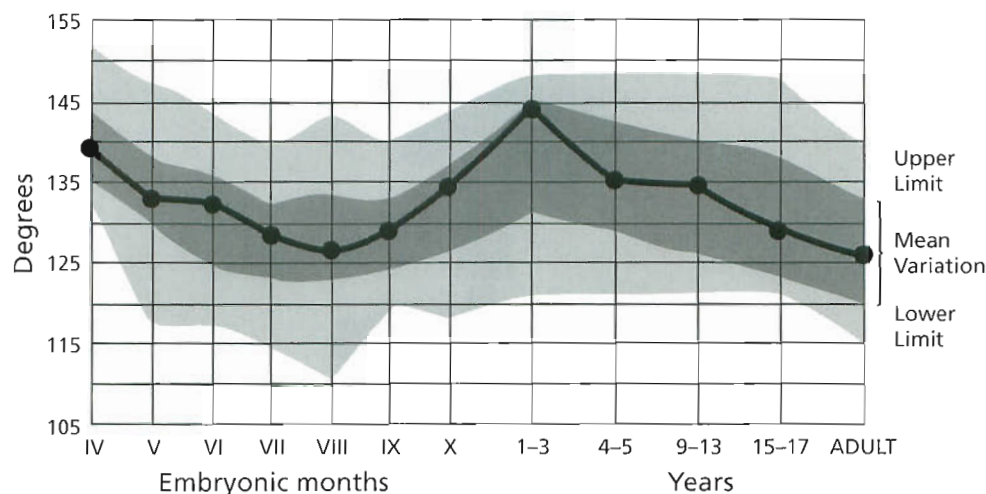


FIGURE 26-1. Variation of the normal neck–shaft angle with age. (From ref. 1, with permission.)

coronal plane (Fig. 26-1). However, instead of referring to a specific clinical disease entity, coxa vara comprises a group of conditions occurring during childhood with different causes and natural histories that ultimately produce a specific deformity in the proximal femur.

Elmslie (2) proposed a classification system for coxa vara that was later expanded by Fairbank (3). This classification system grouped coxa vara on the basis of proposed etiology, and included the congenital, rachitic, infantile or cervical, adolescent (i.e., slipped capital femoral epiphysis), traumatic, inflammatory, and metabolic types. These multiple categories have subsequently been condensed into three: congenital coxa vara, acquired coxa vara, and developmental coxa vara.

Congenital coxa vara is present at birth, and is assumed to be caused by an embryonic limb-bud abnormality. Significant proximal femoral varus is present at birth, but usually shows minimal progression in the degree of varus during growth. Associated congenital musculoskeletal abnormalities and significant limb-length inequality, secondary to femoral segment shortening, are common. This category includes cases of proximal femoral focal deficiency, congenital short femur, and congenital bowed femur (Fig. 26-2).

Acquired coxa vara includes all clinical entities in which the deformity of the proximal femur is secondary to an underlying metabolic, tumorous, or traumatic condition. This classification includes coxa vara secondary to rickets, fibrous dysplasia, and early traumatic proximal femoral epiphyseal plate closure (Fig. 26-3).

Developmental coxa vara, also known as cervical or infantile coxa vara, represents coxa vara not present at birth, but that develops in early childhood and produces progressive deterioration of the proximal femoral neck–shaft angle during growth. Classic radiographic changes accompany the physical findings. There is no significant increase in associ-

ated musculoskeletal anomalies. A minimal limb-length inequality develops secondary to the progressive varus deformity of the proximal femur, but not because of a significant true decrease in the femoral segment length (Fig. 26-4).

More complete discussions on the various forms of congenital and acquired coxa vara are reviewed in chapters 7

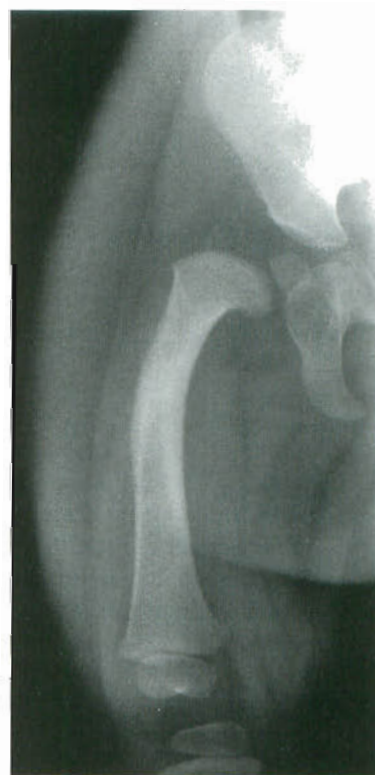

FIGURE 26-2. The radiographic appearance of congenital coxa vara in a 14-month-old girl with a congenital short femur.

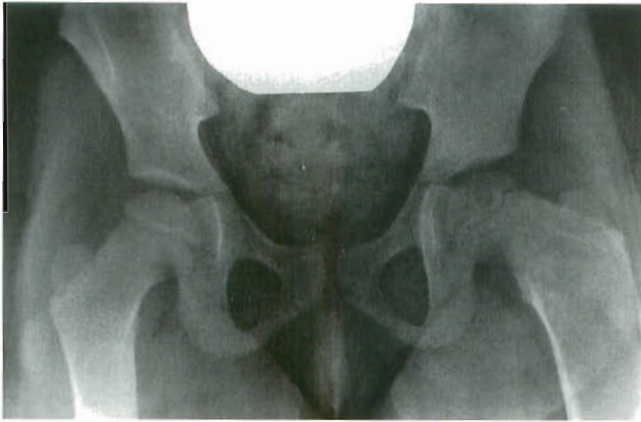

FIGURE 26-3. The radiographic appearance of acquired coxa vara in a girl 7 years, 2 months of age who had fibrous dysplasia and a shepherd-crook deformity of the proximal femur.

and 8 in this textbook. The remainder of this section is devoted to a review of developmental coxa vara.

Developmental coxa vara is a specific deformity of the proximal femur, manifesting in the pediatric patient with characteristic behavior during growth and associated radiographic findings that differentiate it from other forms of childhood coxa vara.

Historical Review

The initial clinical description of coxa vara was presented in 1881 by Fiorani, who described a “bending of the femoral neck” in adult patients (4). In 1888, Muller (5) confirmed Fiorani’s description by anatomic dissection. The first radiographic confirmation of a decreased neck–shaft angle was

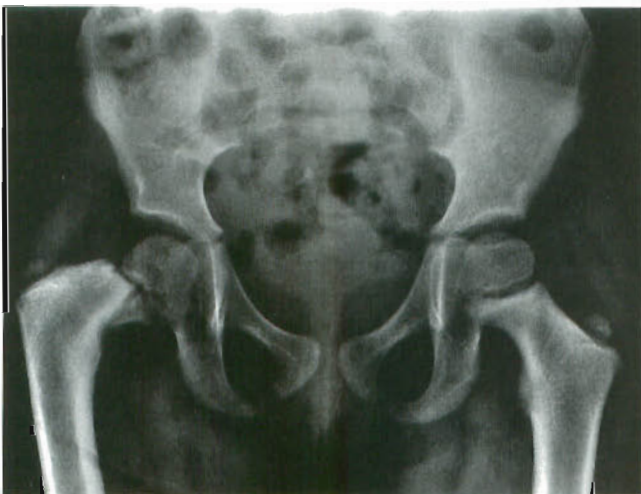

FIGURE 26-4. Radiographic appearance of developmental coxa vara in a girl 3 years, 9 months of age.

described by Hofmeister in 1894 (4). He has also been credited with first using the term “coxa vara” in the clinical description of this entity. In 1905, Hoffa (5) was the first to report the microscopic pathologic findings associated with coxa vara.

Coxa vara occurring during childhood was first described by Kredel in 1896 (4). He proposed that childhood coxa vara had a congenital origin. In 1907, Elmslie (2) proposed the childhood form of coxa vara to be a separate entity from that seen in the adult, and recommended the term “infantile coxa vara.” A progressive tendency to the proximal femoral deformity during growth was described in childhood coxa vara by Fairbank in 1928 (3). In 1938, Duncan (6) disagreed with Kredel’s congenital origin theory, and proposed that progressive childhood coxa vara represented a deformity that appeared during the early years of growth. He coined the term “developmental coxa vara.”

Despite Duncan’s developmental theory for progressive coxa vara of childhood being well documented by his series, his theory was not generally accepted. It was not until 1970 that the confusion about the developmental theory was clarified by Amstutz (7), when he reported two patients with documented normal hip radiographs during the first year of life, who subsequently developed typical clinical and radiographic manifestations of developmental coxa vara by 2 and 3 years of age, respectively. Amstutz documented the presence of a childhood developmental form of coxa vara, and drew attention to the differentiation of this form of coxa vara from the true congenital and acquired varieties.

Incidence

Developmental coxa vara is a rare entity with a reported incidence of 1 in 25,000 live births worldwide (8). Compared with developmental hip dislocation, this represents a ratio of approximately 1 developmental coxa vara case for every 20 developmental hip dislocations. The reported rates of male to female and right to left involvement are essentially equal. Bilateral involvement occurs in 30 to 50% of patients (9–11). Although previous reports have shown developmental coxa vara to occur among white and those of African descent, later reports demonstrated a preference for the latter group (6,9). Although most investigators have not been able to prove a definite hereditary inheritance pattern for developmental coxa vara, reports by Fisher and Waskowitz (12) and Say and colleagues (13) demonstrated a familial pattern in a limited number of cases, which they propose follows an autosomal dominant pattern of genetic transmission.

Etiology

The cause of developmental coxa vara remains unknown. Several investigators have proposed hypotheses about the cause of the varus deformity. A metabolic abnormality caus-

ing a deficient production of, or a delay in, the normal ossification process of the proximal end of the femur has been proposed (4). Hoffa and Alsberg proposed a mechanical abnormality occurring during hip development in which excessive intrauterine pressure on the developing hip results in a depression in the neck of the femur (4). A partial vascular insult, causing an arrest in the early development of the femoral head and neck has been proposed by Nillsone (14). Duncan proposed that the varus deformity occurred secondary to a developmental error, resulting in faulty maturation of the cartilage and metaphyseal bone of the femoral neck (6).

Biopsies of the proximal femoral growth plate and femoral neck, in patients with developmental coxa vara, have been reported by Pylkkanen (11), Chung and Riser (15), and Bos and colleagues (16). Histopathologically confirmed abnormalities exist in cartilage production and secondary metaphyseal bone formation in the inferior portion of the proximal femoral physeal plate and adjacent femoral neck. Biopsies of the involved segment of the femoral neck have shown an increase in the width of the true growth plate, with irregularly distributed germinal cells in the resting zone, an absence of normal orderly progression of the cartilage columns, and a poorly defined or absent zone of provisional calcification. Associated nests of cartilage have been found to extend deeply into the metaphyseal region. The metaphyseal bone is osteoporotic, with an increased vascularized fibrous element between bony spicules (Fig. 26-5). There was no evidence of aseptic necrosis in the reported biopsy specimens. These histopathologic findings are similar to those previously reported from biopsy specimens of the proximal tibias of patients with Blount disease (17,18), and

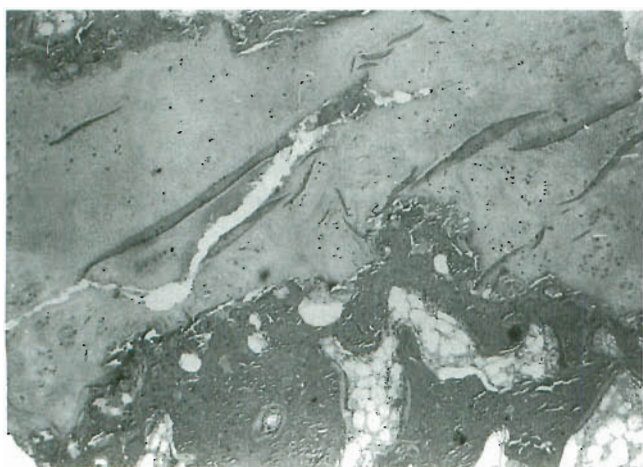


FIGURE 26-5. Photomicrograph of a biopsy specimen of the proximal femoral physeal plate, from a patient with developmental coxa vara, demonstrates irregularly distributed germinal cells in the resting zone; an absence of normal, orderly progression of the cartilage columns; and a poorly defined zone of provisional calcification. Nests of cartilage cells reside at the margin of the metaphyseal bone. (From ref. 16, with permission.)

biopsy specimens of the proximal femoral physeal plates of patients with metaphyseal chondrodysplasia (Schmid type) (16). The significance of these histopathologic similarities, and of any possible association between the cause or pathogenesis of developmental coxa vara and infantile Blount disease or metaphyseal chondrodysplasia, remains undetermined.

In 1960, Pylkkanen (11) proposed what remains as the most widely accepted theory about the cause of developmental coxa vara. He postulated that the deformity in the proximal femur is the result of a primary ossification defect in the inferior femoral neck, on which physiologic shearing stresses, applied during weight bearing, cause fatigue of the local dystrophic bone, resulting in the progressive varus deformity seen clinically. Bos and associates (16), after reviewing biopsy specimens and magnetic resonance imaging studies of hips affected by developmental coxa vara, concurred with Pylkkanen's theory. In particular, their studies found no evidence of slippage of the proximal femoral physeal plate as the cause of the progressive proximal femoral varus deformity.

Clinical Presentation

Most patients affected with developmental coxa vara present sometime between the initiation of ambulation and 6 years of age (9,19). Their most frequent complaint is a progressive gait abnormality; pain is rarely reported. In patients with unilateral involvement, the gait abnormality is caused by combined abductor muscle weakness and limb-length inequality. As the neck–shaft angle of the proximal femur decreases in developmental coxa vara, the articulo-trochanteric distance between the femoral head and greater trochanter also decreases, which affects normal hip joint mechanics. As the articulo-trochanteric distance decreases, the normal length–tension relation of the abductor muscles is lessened, and the ability of the abductor muscles to control the pelvis in one-legged stance is weakened. The functionally weaker abductor muscles produce the gait abnormality seen in patients with developmental coxa vara. Patients with bilateral involvement present with a waddling gait pattern associated with increased lumbar lordosis, similar to that seen in bilateral developmental hip dislocation (3,6,9,20–22).

Physical examination usually reveals a somewhat prominent and elevated greater trochanter, which is often associated with an abductor muscle weakness and positive Trendelenburg testing. An associated limb-length inequality is commonly identified, but this is usually mild and averages only 2.5 cm (9,11). The range of motion of the affected hip is usually restricted in all planes of motion, with the most significant limitations occurring in abduction and internal rotation (9,11). The loss of abduction is associated with a decrease in the neck–shaft angle of the proximal femur. The loss of internal rotation is secondary to the progressive decrease in femoral anteversion seen in develop-

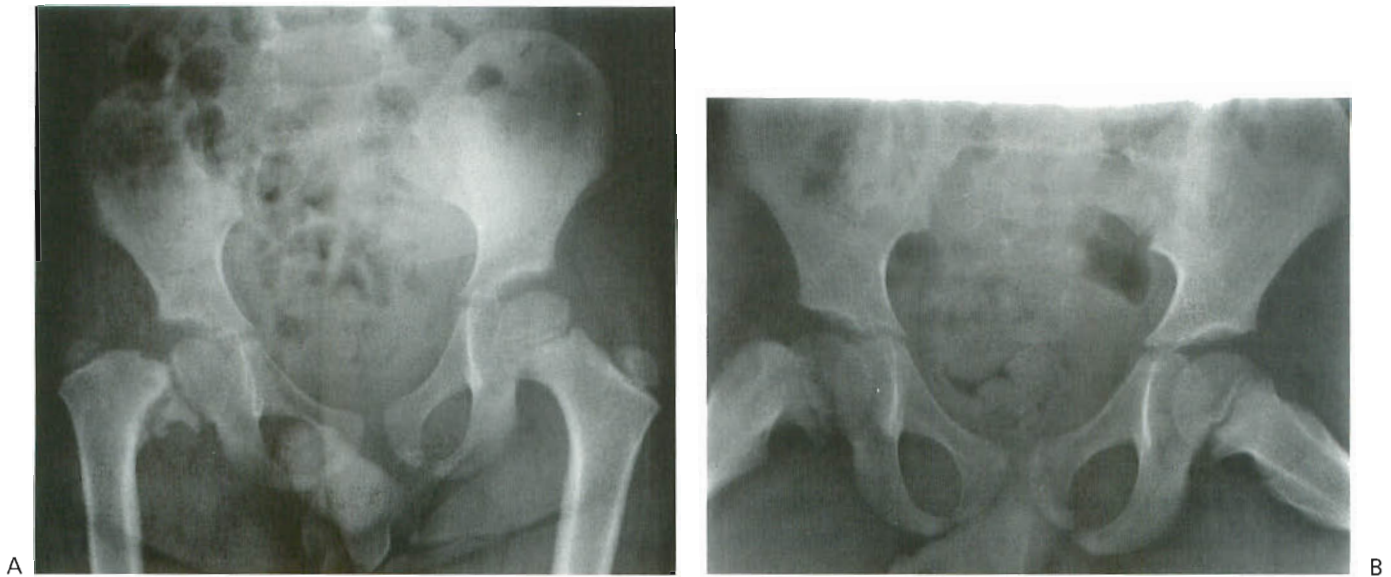


FIGURE 26-6. A: Anteroposterior pelvic radiograph demonstrates the classic radiographic findings in developmental coxa vara, which include a decreased femoral neck–shaft angle, a more vertical physeal plate, an inferior triangular metaphyseal fragment surrounded by an inverted radiolucent Y, and coxa brevia. B: Lateral pelvic radiograph demonstrates changes in the posterior segment of the proximal femoral neck.

mental coxa vara (9,23). An associated hip flexion contracture is often identified. Associated musculoskeletal anomalies are rare (5).

Radiographic Findings

The diagnosis of developmental coxa vara, and its differentiation from other forms of coxa vara, depends on the identification of certain classic radiographic findings. These radiographic features include a decreased femoral neck–shaft angle, often to values below 90 degrees; a more vertical position of the physeal plate; a triangular metaphyseal fragment in the inferior femoral neck, surrounded by an inverted radiolucent Y pattern; a decrease in normal anteversion of the proximal femur, which may become true retroversion; coxa brevia; and, in some patients, mild acetabular dysplasia (3,4,6,19,23,24) (Fig. 26-6).

The more vertical position of the physeal plate is measured by the Hilgenreiner physeal angle, which is defined by the angle subtended by the planes of the physeal plate and the Hilgenreiner line (25) (Fig. 26-7). This angle is normally 25 degrees or less, but in developmental coxa vara, it is usually in the range of 40 to 70 degrees (9).

The inverted Y pattern seen in the inferior femoral neck remains the *sine qua non* of this condition. The inverted Y radiolucency was once postulated to be a true double physeal plate. Biopsy specimens and magnetic resonance imaging studies, however, have shown that the radiolucent area actually represents a zone of widening of the inferior portion of the physeal plate, with associated abnormal ossification

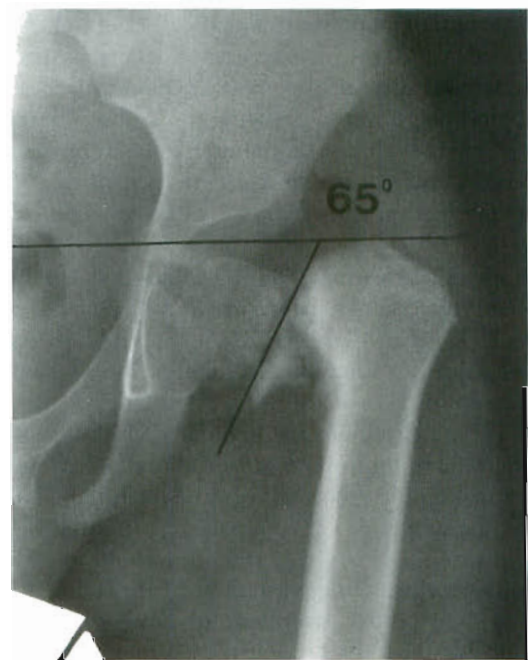

FIGURE 26-7. The anteroposterior view of a hip affected with developmental coxa vara demonstrates the method of measurement of the Hilgenreiner physeal angle. The physeal angle represents the angle subtended between the planes of the Hilgenreiner line and the physeal plate, which measures 65 degrees in this example.

and an interposed triangular segment of dystrophic bone (15,16).

Natural History

Historically, untreated developmental coxa vara was viewed as a condition in which a pattern of progressive varus deformity of the proximal femur ultimately resulted in the development of a stress fracture–related nonunion of the femoral neck and premature degenerative arthritic changes within the hip joint (5). These changes led to progressive pain and disability for the patient, and were thought to occur universally after the condition was established. Weinstein and colleagues (25) and Serafin and Szulc (23) showed that not all patients with developmental coxa vara follow such a progressive course. Their studies demonstrated that the determining factor for progression of the varus deformity was the Hilgenreiner physal angle. Patients demonstrating a physal angle that remained less than 45 degrees more commonly had spontaneous healing of the femoral neck defect and an associated arrest in progression of the varus deformity. Patients with a physal angle greater than this value were found to more commonly manifest the more classic progressive pattern.

Treatment

As long as the actual cause of developmental coxa vara remains unknown, treatment of the condition must continue to concentrate on prevention of the secondary deformities of the proximal femur created by the condition's natural history, instead of on prevention of the disease itself. Borden et al. (26) identified the main objectives of current treatment to include correction of the varus angulation into a more normal physiologic range, changing the loading characteristics seen by the abnormal femoral neck from shear to compression, correction of limb-length inequality, and reestablishment of a proper abductor muscle length–tension relation.

Nonoperative treatment during childhood has historically been unsuccessful in achieving the objectives of proper treatment. Jones and Lovett (3) and Barr (27) previously proposed spica cast immobilization, with the affected limb in abduction for 6 to 12 months. Although Barr was able to demonstrate closure of the femoral neck defect, neither group found any improvement in the neck–shaft angle of the proximal femur with this form of treatment. Nillsone (14) and Le Mesurier (22) investigated the use of heavy skeletal traction and bed rest, but they could not identify any beneficial effects from such treatment. Zadek (4), in a review of conservative treatment of developmental coxa vara, concluded that the previously attempted nonoperative methods had universally poor or no value.

Surgical derotational valgus-producing proximal femoral osteotomy has been shown to be the most effective form of treatment in the restoration of more normal hip joint

mechanics in developmental coxa vara (3,9,11,22,26,28–30) [→4.4]. Historically, femoral osteotomies at the level of the neck and intertrochanteric and subtrochanteric regions have been proposed. Brackett and New (31) recommended a femoral neck procedure in which the dysplastic neck was resected, with the remaining proximal shaft inserted into the femoral head, coupled with advancement of the greater trochanter. In general, this and other femoral neck procedures have higher morbidity rates and poorer clinical results than the intertrochanteric–subtrochanteric osteotomies, which remain the treatments of choice (10). Pauwels' Y-shaped osteotomy (32,33) and Langenskiöld's valgus-producing osteotomy (11) are examples of intertrochanteric corrective osteotomies that have produced good results. Unfortunately, Pauwels' Y-shaped osteotomy does not allow rotational correction of the upper femur. Subtrochanteric valgus-producing osteotomies, as described by Fairbanks (3), Borden et al. (26), and Amstutz and Wilson (28), also remain well-proven forms of successful therapy in achieving the goals of surgical treatment (Fig. 26-8).

Additional principles of proper surgical treatment include a concomitantly performed adductor tenotomy that allows less-forceful correction of the bony deformity and improved stability at the osteotomy site, when the femur is put into valgus (30). A proximal femoral shortening procedure at the level of the osteotomy can be employed to facilitate correction of the varus deformity and unload the femoral head, in situations in which difficulty in reduction of the osteotomy and excessive femoral head pressure are realized as proximal femoral valgus is recreated (34). To prevent loss of the surgical correction achieved before healing of the osteotomy, firm internal fixation, by a tension band technique, blade plate, or nail-plate system, is recommended. Violation of the physal plate by the internal fixation device should be avoided, if possible. A spica cast may or may not be applied, depending on the stability of the internal fixation and patient compliance.

It is important to include internal rotation of the distal segment at the time of osteotomy, to correct the loss of internal rotation seen in developmental coxa vara and reestablish more normal rotational arcs at the hip, postoperatively. The goal of surgical treatment is to produce a valgus overcorrection of the neck–shaft angle of the proximal femur, regardless of the patient's age. Several researchers have demonstrated that the neck–shaft angle of the proximal femur should be corrected to a value of 160 degrees or greater, and that the Hilgenreiner physal angle should be corrected to 30 to 40 degrees, or less at the time of osteotomy, to significantly decrease the potential for varus deformity recurrence (9,25,32,35) (Fig. 26-9). In 1997, Carroll and colleagues (36) reemphasized the importance of adequate correction of the Hilgenreiner physal angle in the prevention of recurrent varus during treatment of coxa vara. Ninety-five percent of their operative hips, with a postoperative correction of the physal angle to less than 38 degrees,

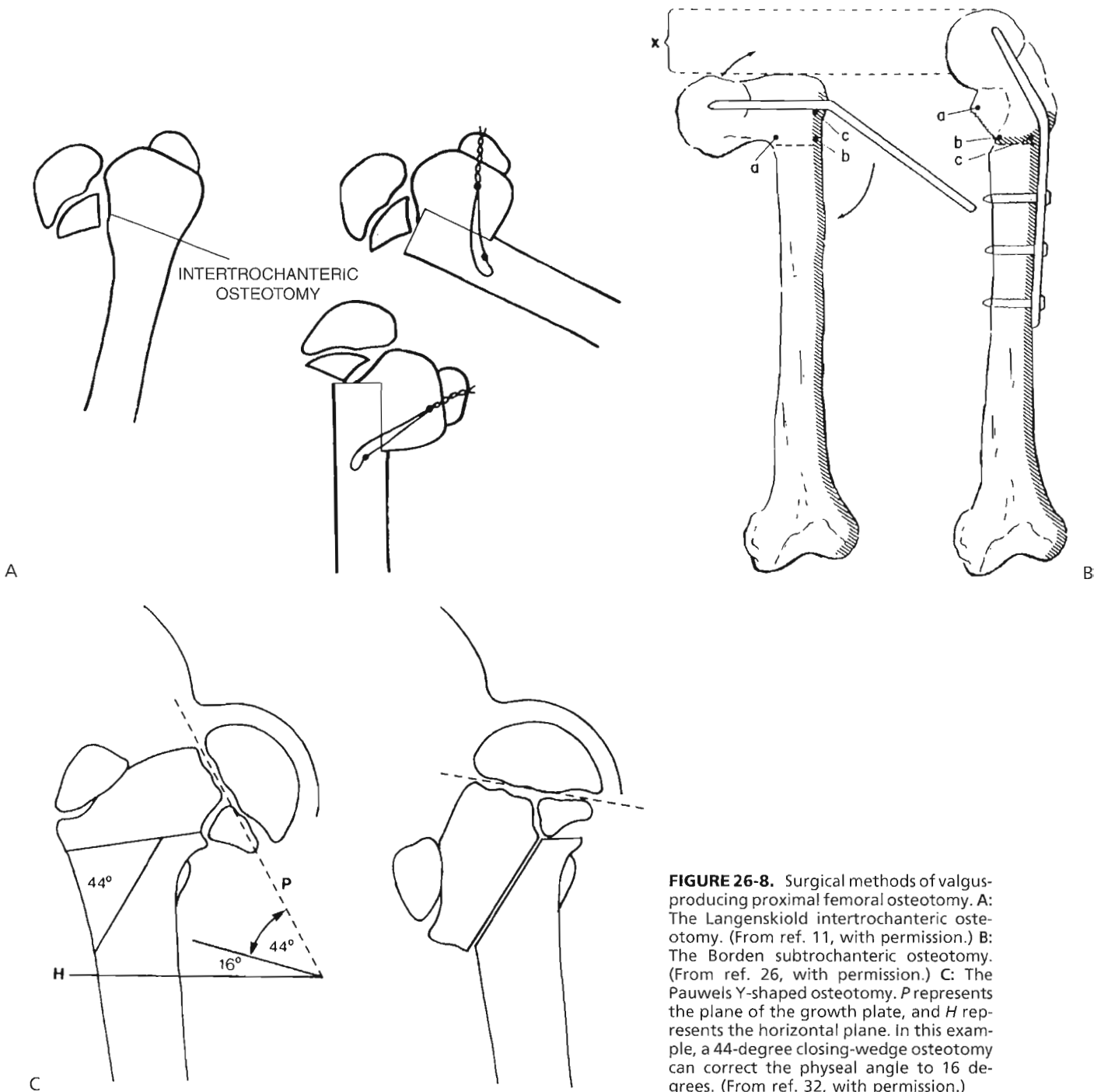


FIGURE 26-8. Surgical methods of valgus-producing proximal femoral osteotomy. **A:** The Langenskiöld intertrochanteric osteotomy. (From ref. 11, with permission.) **B:** The Borden subtrochanteric osteotomy. (From ref. 26, with permission.) **C:** The Pauwels Y-shaped osteotomy. *P* represents the plane of the growth plate, and *H* represents the horizontal plane. In this example, a 44-degree closing-wedge osteotomy can correct the physal angle to 16 degrees. (From ref. 32, with permission.)

had no recurrence of the coxa vara during growth. In contrast, 93% of the osteotomies that retained a physal angle greater than 40 degrees required revision for recurrent varus.

Zadek (4) and Le Mesurier (22) proposed drilling and supplemental bone grafting of the femoral neck at the time of osteotomy, to facilitate healing of the femoral neck defect and restrain recurrent deformity. The need for these addi-

tional procedures at the time of osteotomy has subsequently been shown to be unnecessary.

The criteria for surgical intervention, in a patient with developmental coxa vara, include one or more of the following clinical and radiographic findings: the proximal femoral Hilgenreiner physal angle is greater than 45 to 60 degrees, the proximal femoral neck-shaft angle is progressively de-

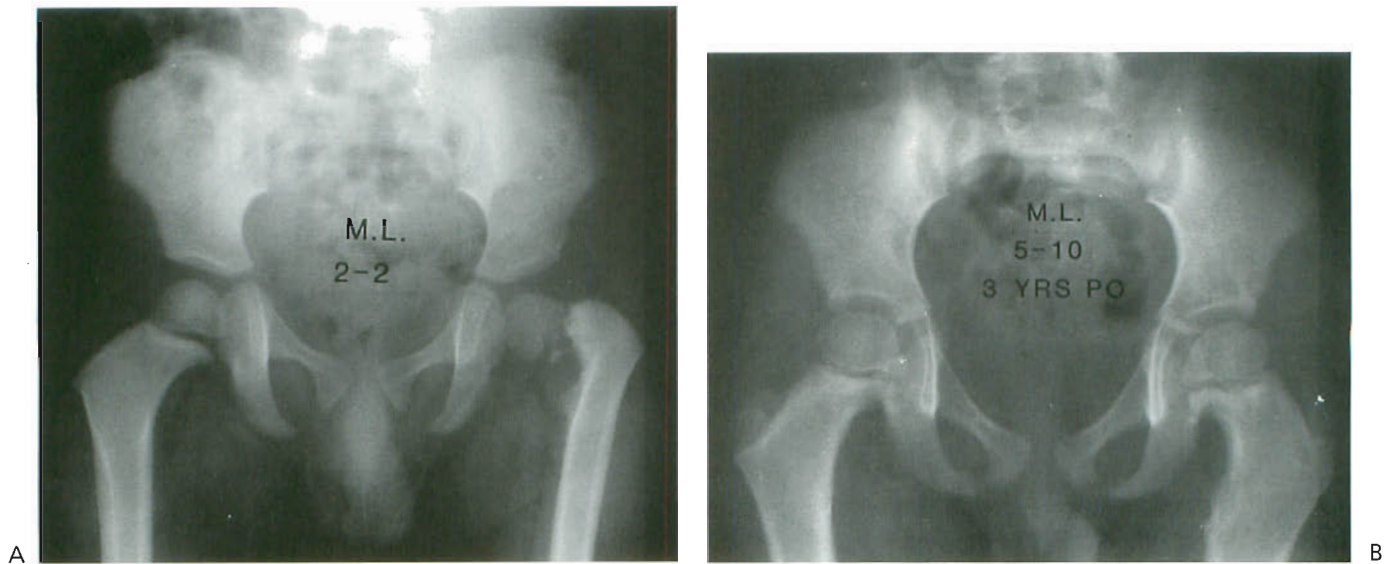


FIGURE 26-9. Anteroposterior pelvic radiographs of a boy 2 years, 2 months of age, with developmental coxa vara. **A:** Preoperative radiograph. **B:** Postoperative radiograph. A subtrochanteric derotational proximal femoral osteotomy successfully achieved the objectives of surgical correction, including correction of the varus angulation into a physiologic range, changing the loading characteristics of the femoral neck from shear to compression by achieving a physeal angle of 30 degrees or less, and reestablishing a proper abductor muscle length-tension relation.

creasing or measures less than or equal to 90 to 100 degrees, or the patient with developmental coxa vara develops a Trendelenburg gait (9,25,28).

Duncan (6) and Weinstein and colleagues (25) recommended delaying surgical intervention until after the patient is 5 to 6 years of age. Weighill (30) proposed performing surgery on all patients after 18 months of age, as soon as the proper diagnosis has been made. Pylkkanen (11) and Serafin and Szulc (23) demonstrated improved results from surgery in younger patients. Corrective osteotomy is best performed, not at a particular age, but as soon as the criteria for surgical intervention are apparent. If the proper indications are unambiguous, a delay in surgical intervention until an older age, in hopes of achieving better internal fixation, is not justified. The progressive proximal femoral deformity and dysplastic changes at the femoral head, neck, and acetabulum, which occur with time, make complete and lasting correction much more difficult or impossible to achieve.

Results

The triangular metaphyseal defect in the femoral neck spontaneously closes by 3 to 6 months postoperatively, in the majority of cases of developmental coxa vara, if adequate valgus has been created (9) (Fig. 26-10). Between 50 and 89% of operated hips demonstrate a premature closure of the proximal femoral physeal plate. This usually occurs within 12 to 24 months after surgery (9,24) (Fig. 26-11). This premature physeal plate closure is not related to surgical trauma, patient age, or degree of valgus correction. It

more likely represents a possible surgically induced acceleration of natural physeal plate closure. Premature physeal plate closure may also be a manifestation of an inherently abnormal proximal femoral physis in developmental coxa vara, which is stimulated to undergo closure as the stresses across the plate change from shear to compression after surgical realignment of the proximal femur.

If premature closure of the proximal femoral physeal plate occurs, the patient must be monitored closely for the development of a growth-related recurrent varus deformity of the proximal femur, and for development of a significant limb-length inequality secondary to closure of the proximal femoral physis, which accounts for approximately 13% of the growth of the lower limb.

Historically, recurrence of the proximal femoral varus after surgical correction was a frequent complication as patient growth continued. This recurrence of the varus deformity was thought to be secondary to the underlying pathologic process associated with developmental coxa vara. However, Weighill (30), Weinstein and colleagues (25), Kehl and associates (9), Desai and Johnson (35), and Cordes' group (32) have all demonstrated that true varus recurrence, secondary to the underlying pathologic process, is rare if adequate proximal femoral valgus is reestablished and maintained by stable internal fixation.

The proximal femoral physeal angle must be corrected to 30 to 40 degrees or less, to facilitate the conversion of shear to compression forces on the proximal femoral growth plate. It is equally important that stable internal fixation be used to maintain the valgus correction until full osseous

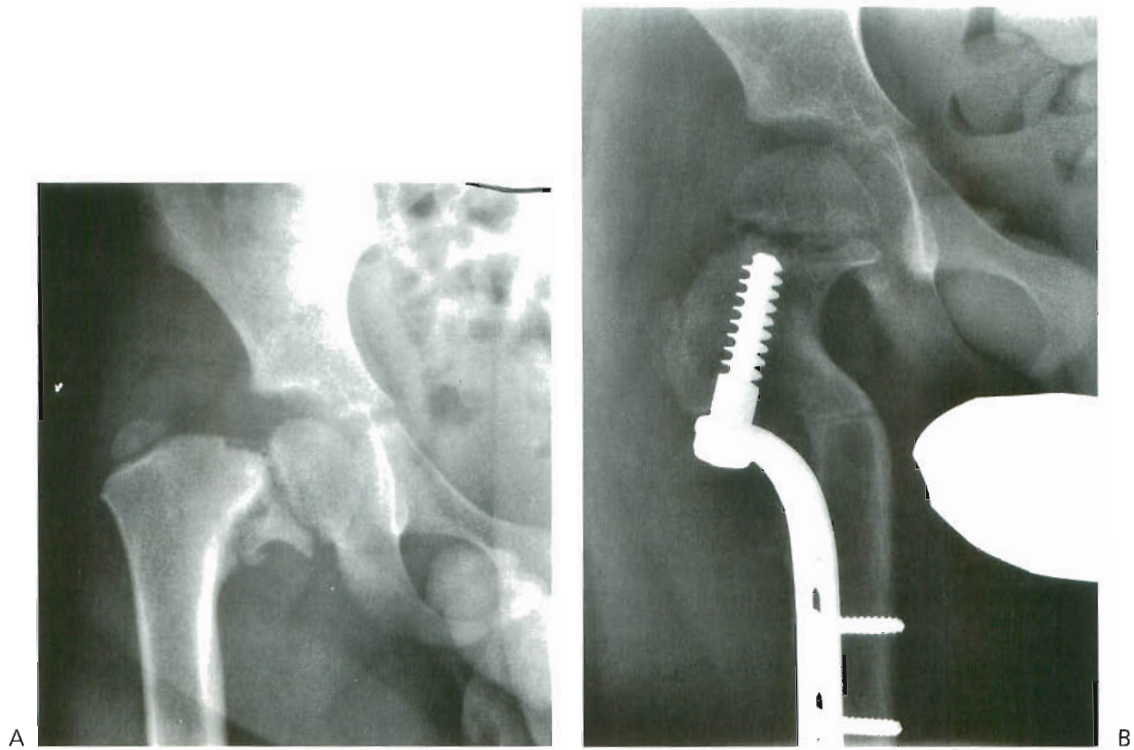


FIGURE 26-10. Anteroposterior radiographs of a hip affected with developmental coxa vara. A: The preoperative radiograph demonstrates a classic inferior femoral neck triangular fragment. B: Three months postoperatively, the radiograph demonstrates correction of the physeal angle, with spontaneous closure of the femoral neck triangular metaphyseal fragment.

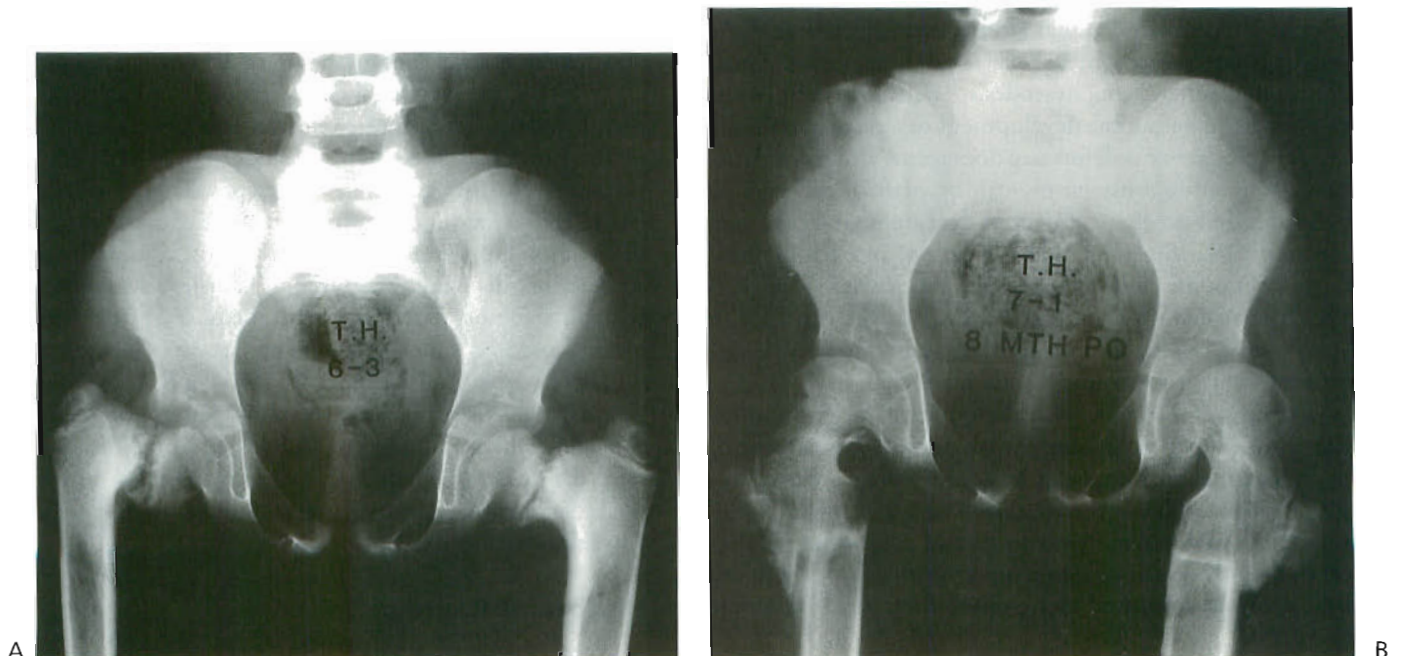


FIGURE 26-11. The anteroposterior pelvic radiographs of a boy 6 years, 3 months of age demonstrates bilateral developmental coxa vara. A: Preoperative radiograph. B: The postoperative radiograph, 8 months after the subtrochanteric proximal femoral derotational osteotomies, demonstrates bilateral spontaneous closure of the proximal femoral epiphyseal plates, and the greater trochanteric apophyses remain open. (From ref. 34, with permission.)

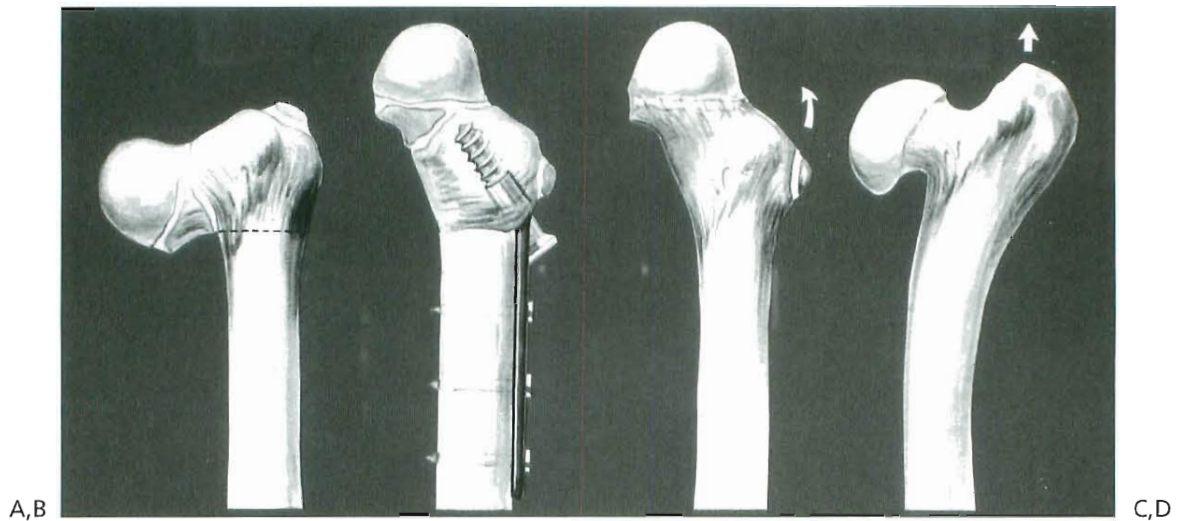


FIGURE 26-12. Illustration of recurrent coxa vara secondary to premature proximal femoral epiphyseal plate closure and secondary greater trochanteric overgrowth. **A:** Preoperatively, the proximal femoral epiphyseal plate is open. **B:** Postoperatively, adequate surgical correction has been achieved. **C:** Premature closure of the proximal femoral epiphyseal plate, with the greater trochanteric apophyseal plate remaining open. **D:** Recurrent coxa vara secondary to unbalanced growth about the proximal femur. Arrows in **C** and **D** indicate the direction of subsequent growth. (From ref. 34, with permission.)

healing has occurred, and that the internal fixation device does not violate the physeal plate. If premature proximal femoral epiphyseal plate closure occurs, it creates a situation of unbalanced growth about the proximal femur, with secondary trochanteric overgrowth and recurrent coxa vara and coxa brevia (Fig. 26-12). To prevent this recurrent deformity, it is recommended that after premature closure of the proximal femoral epiphyseal plate has been documented, greater trochanteric apophyseodesis, or advancement [➔4.9] be performed before the development of a recurrent deformity (9). If the varus deformity does recur, a repeat valgus-producing femoral osteotomy can be performed.

Proper and timely treatment of developmental coxa vara can result in a hip joint that is painless, has a functional range of motion, and demonstrates a negative Trendelenburg gait at maturity. Although most patients continue to show a mild residual limb-length inequality, it rarely is significant enough to require a shoe lift (9,11).

Through compliance with the outlined surgical indications and proper technique, the objectives of treatment of developmental coxa vara can be accomplished, with a predictable conversion of the condition's natural history—development of degenerative arthritis and pain in late adolescence or early maturity—to a hip joint that is painless and has a much-improved long-term functional outcome (9,32,35).

TRANSIENT SYNOVITIS OF THE HIP

Transient synovitis of the hip represents the most common cause of hip pain in childhood (37,38). Although the condi-

tion's true cause remains unknown, the associated signs and symptoms, natural history, and ultimate patient outcome have been well documented. Transient synovitis is usually characterized by the acute onset of monarticular hip pain, limp, and restricted hip motion, in a patient who is otherwise not systemically ill. The symptoms generally show a gradual but complete resolution over several days to weeks, and are rarely associated with recurrences or late sequelae.

This clinical entity has been previously described by numerous names because of confusion about its cause. Some of the previously used terms include transitory synovitis, transitory coxitis, acute transient epiphysitis, coxitis fugax, coxitis serosa seu simplex, phantom hip, toxic synovitis, and observation hip. Transient synovitis is most commonly used to describe this clinical condition. Transient synovitis also remains the most descriptive term, because of its reference to the condition's short duration and associated pathology.

There remains no diagnostic test to confirm the disease transient synovitis. The several variable patterns of presentation and courses of illness associated with transient synovitis raise the question whether this disease has many different phases and features, or represents a number of diseases that appear clinically alike.

Historical Review

In 1892, Lovett and Morse (39) first described transient synovitis of the hip, and differentiated it from tuberculous synovitis, when they referred to the condition as "a short-lived and ephemeral form of hip disease that presents at first the characteristics of common hip disease, but the symptoms of which disappear within a few weeks or months

instead of continuing for years" (39). Bradford and Lovett (40), Todd (41), Fairbank (42), and Belmonte (43) subsequently described a similar painful condition of the hip that was characterized by a transient course of symptoms with rapid resolution and permanent recovery. In 1933, Butler (44) described children admitted to the hospital with painful hip symptoms but normal radiographs, who subsequently demonstrated a self-limiting and rapidly resolving clinical course. He coined the term "observation hip" for this condition. In 1936, Finder (45) confirmed, through biopsy specimens, that the condition was characterized by a nonpyogenic inflammatory response of the synovium of the hip joint.

Etiology

Although the cause of transient synovitis of the hip remains undefined, the more popular hypotheses proposed imply an association between transient synovitis and one or more of the following: active or recent infection, trauma, or allergic hypersensitivity (38,41,42,44,46–50).

The concept of a possible infectious cause is given credence by the frequent association of transient synovitis with current or antecedent illness. A nonspecific upper respiratory infection, pharyngitis, and otitis media have been associated with the occurrence of transient synovitis in as many as 70% of cases (38,47,51). Fairbank (42), Miller (48), Butler (44), and Spock (38) have proposed a definite causal association between transient synovitis and a concomitant viral or bacterial infection. Spock reported isolating an increased incidence of β -hemolytic streptococci from the nose and throat of patients with transient synovitis, compared with asymptomatic pediatric patients. He also found elevated viral titers in 50% of the patients tested (38). Harding (52), however, could find no definite correlation between infectious sources and transient synovitis, when comparing parameters of infection found in involved patients with age-matched controls. Tolat and associates (53) demonstrated elevated interferon levels in the systemic circulation, normally negligible in healthy individuals, in 43% of 65 patients with acute transient synovitis. Fifteen of 16 of these patients, with fluid aspirated from the involved hip, also showed elevated interferon levels in the synovial fluid. Although viral cultures of the same synovial fluid were all negative, the authors concluded that elevated interferon levels in the joint and blood of several patients with acute transient synovitis indicated an activated interferon system, possibly secondary to a viral etiology. Blockey and Porter (54) and Lockhart and colleagues (51), however, were unable to confirm any correlation with viral infections through detailed virologic studies of patients with transient synovitis.

A history of preceding local trauma to the involved hip in transient synovitis has been reported in 17 to 30% of patients (38,43). In 1925, Todd (41) proposed that trauma was a frequent factor associated with transient synovitis of the hip, and thought that the condition was nothing more than a simple "contusion of the hip." Rauch (49) proposed

injury to be the leading cause of transient synovitis, and Gledhill and McIntyre (47) also found trauma frequently was associated with the condition.

An association between an allergic predisposition and the development of transient synovitis of the hip has been reported for 16 to 25% of symptomatic patients (38,43). Edwards thought the condition represented an allergic hypersensitivity response manifesting itself within the hip joint, as evidenced by the dramatic clinical improvement seen in symptomatic patients given antihistamines (46). Rothschild, Russ, and Wasserman (50) supported an allergic cause, based on the rapid clinical improvement seen in their patients with transient synovitis, when given intramuscular steroid injections. Nachemson and Scheller (55) reported on 12 patients (16.4%) of a 73-patient study group with transient synovitis of the hip, who demonstrated an association between a hyperallergic state and a history of transient synovitis of the hip. This association, however, was also discredited when the investigators demonstrated that the percentage of patients in the general population reporting allergic hypersensitivity was essentially equal to that found in patients with previous transient synovitis.

Spock (38) proposed that body size in the child may predispose to the development of transient synovitis. He demonstrated a three times greater incidence of the condition in patients of a stocky and obese physique than in a randomly selected group of children with similar ages. Biopsy specimens from hip joints of patients with transient synovitis have universally demonstrated synovial hypertrophy secondary to a nonspecific nonpyogenic inflammatory reaction (45,56,57). Hip joint aspiration has shown an associated culture-negative synovial effusion, usually measuring 1 to 5 mL (58–60).

Incidence

Transient synovitis has been reported to be the most common cause of hip pain in children. The diagnosis of transient synovitis has historically accounted for 0.4 to 0.9% of annual pediatric hospital admissions (37,38). The actual incidence of the condition, however, is likely to be higher than that reported, because many patients with the condition never seek medical attention, and few patients are hospitalized once the diagnosis has been established. Landin and colleagues (37) reported that the risk for a child to have at least one episode of transient synovitis of the hip is 3%. A seasonal preference for the condition has not been demonstrated other than by Landin and associates (37), who showed a slightly higher rate of occurrence during the autumn months.

Right and left involvement is essentially equal, with simultaneous bilateral involvement never having been reported. There is an approximately 2:1 male to female ratio, and a much lower incidence among African-Americans (58).

Clinical Presentation

The condition has been reported in patients as young as 9 months of age through adolescence. The average age of

symptom onset is 6 years, with most cases occurring between 3 and 8 years of age (43,47,58,61). The most frequent presenting complaint is the acute onset of unilateral hip pain in an otherwise healthy patient. The pain is usually confined to the ipsilateral groin and hip area; however, it may present as anterior thigh or knee pain. An associated limp and antalgic gait are usually seen, with some patients refusing to bear weight on the involved extremity. The involved extremity is held in a flexed and externally rotated position, and has a restricted range of hip motion, especially abduction and internal rotation. Protective muscle spasm and an associated flexion contracture are frequently identified. The patient may have a low-grade temperature that is rarely greater than 38°C (38,43,58). Ipsilateral muscle atrophy is rarely seen, but when present, it usually implies a long-standing duration of symptoms, and a diagnosis other than transient synovitis should be considered.

Laboratory values are nonspecific and are usually within normal limits, despite the wide range of values that have been reported. The peripheral blood smear includes a white blood cell count averaging 10,000 to 14,000 cells/mm³ (range, 3,000 to 28,000 cells/mm³) and a Westergren erythrocyte sedimentation rate averaging 20 mm/h (range, 1 to 63 mm/h) (58). Urinalysis, blood culture, febrile agglutinins, serum electrophoresis, rheumatoid factor, and tuberculin skin test results are usually within normal limits.

The diagnosis of transient synovitis of the hip remains a diagnosis of exclusion. Although routine laboratory and radiographic studies have not been of specific value in making the diagnosis, they do assist in eliminating other conditions of the hip that may have features similar to those of transient synovitis. The differential diagnosis of transient synovitis includes pyogenic arthritis, osteomyelitis in the adjacent femoral neck or pelvis, tuberculous arthritis, juvenile rheumatoid arthritis, acute rheumatic fever, Perthes disease, tumor, and slipped capital femoral epiphysis.

Pyogenic arthritis of the hip, with or without associated osteomyelitis of the femoral neck, differs from transient synovitis of the hip, in that the patient is usually systemically ill with a high fever. Pain at the affected hip is usually more intense than is seen in transient synovitis, with voluntary guarding allowing little or no hip motion. Unlike transient synovitis, the symptoms of pyogenic arthritis do not improve significantly with rest, and are progressive. Laboratory studies of pyogenic arthritis show a higher elevation in the white blood cell count, usually with a left shift; a higher elevation of the erythrocyte sedimentation rate; and purulent fluid on aspiration of the hip joint (62).

The synovitis associated with acute rheumatic fever and poststreptococcal reactive arthritis usually occurs 2 to 4 weeks after a group A streptococcal infection. The affected joint is warm, erythematous, and exquisitely tender to any attempt at motion. Unlike transient synovitis, the joint symptoms in these two conditions may be migratory and can be associated with a transient rash (63).

The pain and synovitis associated with juvenile rheumatoid arthritis (64), tuberculous arthritis (65), and Perthes disease (66) usually are more insidious in onset, and more protracted in duration, than is seen in transient synovitis. Hip motion at the onset of symptoms tends to be limited to a lesser degree than is seen in transient synovitis. Skin testing results are positive in tuberculous arthritis, and radiographic changes subsequently develop in Perthes disease and tuberculous arthritis.

Radiographic Findings

Radiographs of the pelvis and hip of a patient with transient synovitis are usually normal. Their main purpose is to exclude other diseases that may involve the hip joint. Drey (67) and Hermel and Sklaroff (68) previously proposed the use of plain radiographs in diagnosing hip joint effusion in transient synovitis. They proposed that capsular distension resulted in measurable displacement of the muscle shadows of the iliopsoas, obturator internus, and gluteus minimus. They also proposed that local inflammation could lead to the loss of the intermuscular fat planes lateral to the hip joint. Subsequent investigators have reported demonstrating these soft tissue changes in as many as 60% of patients with transient synovitis (47). In 1975, Brown (69) refuted this finding, by showing that the previously reported soft tissue changes lateral to the hip on plain radiographs were unreliable in determining true hip joint effusion. He demonstrated that the displacement of the muscle planes was related to positioning of the limb, and was not the result of true capsular distension.

Wingstrand (70), Bickerstaff and colleagues (71), Futami and associates (72), and Terjesen and Osthus (73) have used ultrasound for patients with transient synovitis, to document the presence of a hip joint effusion and determine its natural history (Fig. 26-13). Bickerstaff and colleagues documented joint effusions with ultrasound in 71% of 111 patients presenting with an acutely irritable hip. Serial ultrasound studies showed the effusions to decrease steadily in size, with resolution in a mean time of 9 days. Symptoms resolved in these same patients in a mean period of 5 days. Larger effusions at presentation were associated with a longer duration of symptoms and a longer time to effusion resolution. Thirty-two (29%) symptomatic patients had no documented joint effusion at presentation or at follow-up, implying that the joint effusion in transient synovitis may not always be the source of symptoms. Although ultrasound can be useful in documenting and following a hip joint effusion in transient synovitis, it is not in and of itself diagnostic of the condition, and is not routinely required in making the diagnosis.

Wingstrand and colleagues (74), Kloiber and associates (75), and Hasegawa et al. (76) evaluated pin-hole collimation scintigraphy of the hip involved with transient synovitis, and showed a variety of possible patterns of isotope

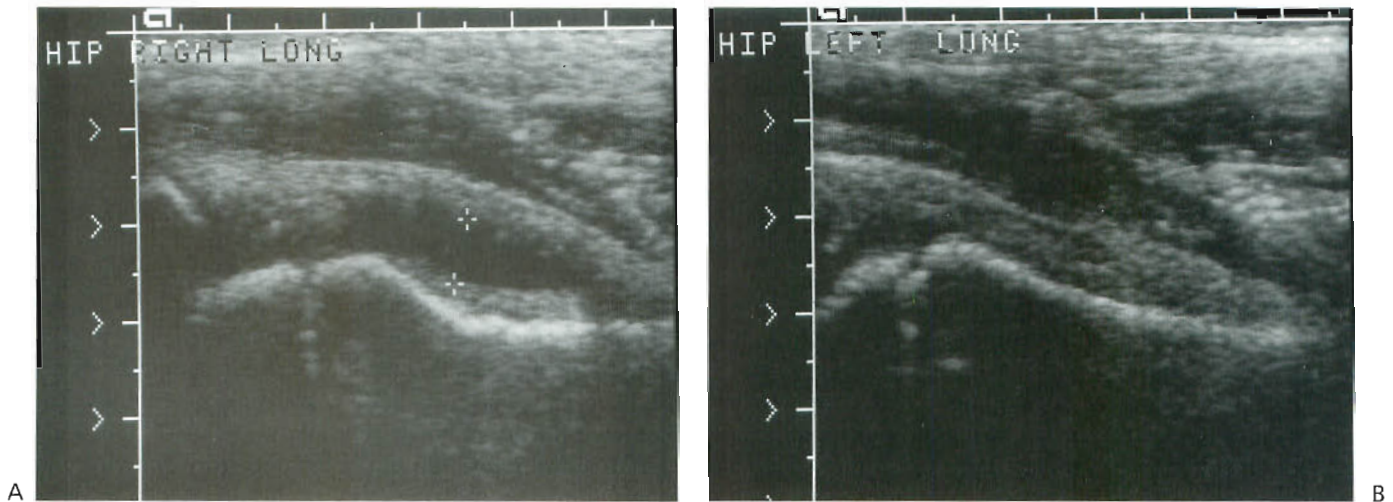


FIGURE 26-13. Longitudinal linear ultrasonographic view of the hips in a boy 5 years, 4 months of age, who had transient synovitis of the right hip. **A:** Ultrasound scan of the symptomatic right hip demonstrates a large joint effusion, as indicated between the cursor markings. **B:** Ultrasound scan of the asymptomatic left hip, for comparison, demonstrates no joint effusion.

uptake. Hasegawa and colleagues demonstrated that 49% of femoral heads of 55 patients involved with transient synovitis appeared normal on the scan. Twenty-four percent of femoral heads demonstrated decreased activity, and increased regional activity about the femoral head was found in 27%. It was observed that the patients with decreased femoral head activity on scintigraphy had an average of 5 days from the onset of symptoms, and the patients with increased femoral head activity averaged 23 days. When follow-up scintigraphy was performed on five of the patients initially demonstrating decreased uptake in the femoral head, all five patients demonstrated normalization or increased isotope activity in the femoral head.

These findings demonstrate that there can be a transient decrease in vascular perfusion of the femoral head during the early stages of transient synovitis. The decrease in perfusion, however, was never severe, and seemed to resolve spontaneously, with femoral head perfusion subsequently returning to a normal or increased pattern (48,76). The role of bone scanning in transient synovitis remains undetermined, and until the proposed therapeutic benefits afforded by early bone scintigraphy in the patient with transient synovitis have been documented, its routine use is not recommended.

Natural History

As its name implies, transient synovitis usually demonstrates a limited duration of symptoms. The average duration of symptoms is 10 days, but some patients have remained symptomatic for as long as 8 weeks (47,58). Hauelsen and colleagues (58), in reviewing a large number of cases, reported the duration of symptoms to be less than 1 week for 67% of patients, and less than 4 weeks for 88% of patients.

Although most episodes of transient synovitis are isolated to a single event, recurrence of the symptoms in the same or contralateral hip has been reported for approximately 4 to 17% of patients (58,77). Illingworth has shown that recurrences can develop at any time, but are most likely to occur within the first 6 months after the initial episode (77).

Most short-term retrospective reviews on transient synovitis report complete resolution of all signs and symptoms in the affected hip, with no immediate residual clinical or radiographic abnormalities (38,42,43). Although most patients remain asymptomatic, long-term studies have demonstrated mild radiographic changes in the involved hip.

Kallio reported asymptomatic coxa magna of 2 mm or more in 32% of 109 patients with transient synovitis of the hip, after a follow-up period of 1 year (59). He questioned if this high frequency of coxa magna seen after transient synovitis could play a role in the development of degenerative joint disease in adulthood. De Valderrama (78) reported 23 patients who had had transient synovitis and were reviewed at an average of 21 years later. He reported a 50% incidence of radiographic changes in the involved hip, consisting of various degrees of coxa magna, degenerative joint disease, and femoral neck widening. He thought these changes were secondary to the local hypervascularization of the hip that had been associated with the initial inflammatory synovitis. Nachemson and Scheller (55) described 73 patients with 20- to 22-year follow-up periods. When the clinical and radiographic sequelae of transient synovitis occurred, they were described as "few and mild." Although the researchers described a few patients with mild decreases in hip motion, the change was not associated with any functional disability. Coxa magna and femoral neck density changes were increased over normal values, but these

changes were unassociated with functional limitations. Nachemson and Scheller (55) found no radiographic changes of degenerative joint disease in their patients at follow-up.

The full importance of these radiographic changes occurring about the hip previously involved with transient synovitis remains unknown. Although very few of the patients whose radiographs showed mild changes have been found to be symptomatic, with longer follow-up, it is possible that the incidence of symptoms may change.

Several investigators have reported cases of Legg-Calvé-Perthes disease developing several months after an episode of transient synovitis (37,38,47,71,73,79). Jacobs (57) and Bickerstaff and colleagues (71) thought that there was a definite correlation between the two conditions, and that patients with transient synovitis who had a more slowly resolving or recurrent clinical pattern were much more likely to develop Legg-Calvé-Perthes disease. Spock's survey of the modern literature demonstrates an association of the two conditions in an average of 1.5% of patients (range, 0 to 17%) (38,57,80). Gledhill and McIntyre (47) reported an association in 0.9% of patients with transient synovitis. A direct causative correlation, however, between transient synovitis and the subsequent development of Legg-Calvé-Perthes disease, secondary to an induced vascular insult to the femoral head, has never been documented. It is more reasonable to conclude that the small percentage of patients demonstrating this association were patients with Legg-Calvé-Perthes disease who manifested an early synovitis that was indistinguishable from that seen in transient synovitis.

Treatment

Treatment of transient synovitis of the hip is directed at rapidly resolving the underlying inflammatory synovitis with its associated symptomatology. Bed rest and full relief of weight bearing on the involved joint, until pain resolves and full motion returns, is the initial treatment of choice (38,43,47,58). This is followed by a period of continued cessation of all strenuous activities involving the hip. If an asymptomatic limp persists, continued bed rest for younger patients, or partially relieved weight bearing for patients capable of crutch ambulation, should be used until a normal gait pattern has returned. Failure to enforce joint rest, and a too-early return to activities, were shown by Hermel and Albert to result in a doubling of the time required for initial symptomatic relief, and an increased rate of symptom recurrence (43).

During the initial treatment of transient synovitis, the routine use of skin traction on the involved limb is no longer recommended. Skin traction is mainly used in patients with recalcitrant or recurrent symptoms. It can also be of assistance for the younger child in whom enforcement of bed rest cannot otherwise be easily achieved. If traction is to be employed, the position of the involved limb and hip during traction has potential significance. Wingstrand and associ-

ates (81), Kallio and Ryoppy (82), and Kesteris and colleagues (60), through the use of ultrasound scanning and intraarticular pressure measurements of patients with transient synovitis and an associated joint effusion, demonstrated that hip joint pressure measurements are at a maximum when the hip is positioned in extension, and can reach potentially critical values with respect to capillary blood flow. Minimum pressure measurements are recorded when the hip is placed in 30 to 45 degrees of flexion. To avoid potential vascular complications, the involved limb and hip should not be positioned in extension when skin traction is used during bed rest; the limb and hip should be placed in 30 to 45 degrees of flexion, and subsequently lowered, as determined by patient comfort.

To aid in resolution of the inflammatory synovitis, oral nonsteroidal antiinflammatory medication, given in therapeutic doses, can be used. The use of aspirin is avoided in the child with an active viral infection, because of the association of aspirin and Reye syndrome in children with acute viral illnesses. The routine use of antibiotics and systemic steroid preparations is not indicated.

Routine aspiration of the hip joint is of no proven short-term or long-term therapeutic value in transient synovitis, and is recommended only to assist in diagnosis (79,80). Wingstrand and associates (81), Terjesen and Osthus (73), and Kesteris and colleagues (60) demonstrated by ultrasound scans that intracapsular hip joint effusions and secondary hip capsular distension in this condition are only minimally reduced by aspiration, and that they recur rapidly after aspiration.

IDIOPATHIC CHONDROLYSIS OF THE HIP

Chondrolysis represents a process characterized by progressive destruction of the articular cartilage from both surfaces of the involved joint, resulting in secondary joint space narrowing and stiffness. Chondrolysis involving the hip joint has followed infection, trauma, prolonged immobilization (83), and severe burns about the lower extremities (84). It is most frequently reported as a complication associated with the treatment of slipped capital femoral epiphysis (83,85,86). An acute form of rapidly progressive chondrolysis, occurring most frequently during adolescence, with isolated involvement of the hip joint, but without a demonstrable cause, has also been reported. This condition is referred to as "idiopathic chondrolysis of the hip." The rapid loss of articular cartilage from the femoral head and the acetabulum in this condition is unique, and differs from that usually seen in other noninfectious inflammatory conditions affecting the hip joint in this same age group.

Historical Review

Chondrolysis involving the hip joint was originally referred to by Elmslie (86) in 1913 as a potential complication after

the treatment of slipped capital femoral epiphysis. The association between chondrolysis and slipped capital femoral epiphysis was documented by Waldenstrom in 1930 (87). In 1971, Jones (88) reported a series of nine adolescent black African girls who had no clinical or radiographic evidence of slipped capital femoral epiphysis or hip joint infection, who spontaneously developed the symptoms and signs of classic chondrolysis of the hip. Jones' series represents the first clinical description of idiopathic chondrolysis of the hip joint. Several articles since that time have documented the condition's existence, clinical presentation, suggested treatment, and prognosis (83,89–95).

Etiology

As the name implies, the cause of idiopathic chondrolysis of the hip remains unknown. Previously proposed theories about the cause of idiopathic chondrolysis of the hip include nutritional abnormalities (85,87), mechanical injury (96), ischemia (97), abnormal intracapsular pressure (97), and an inherent abnormal chondrocyte metabolism within the articular cartilage (98). Waldenstrom (87) proposed that an alteration in the normal synovial supply of nutrition to the articular cartilage led to chondrolysis. Cruess (85) agreed with this theory, and proposed that a fibrosis of the synovial membrane led to a decrease in synovial fluid production within the hip joint that resulted in inadequate nutritional support of the articular cartilage, with subsequent chondrocyte death and secondary cartilage resorption. Jacobs (96) proposed that chondrolysis was the result of a mechanical insult to the articular cartilage or synovium that resulted in a release of lysosomal chondrolytic enzymes that led to cartilage destruction. Kozlowski and Scougall (98) proposed that idiopathic chondrolysis represents a form of articular cartilage dysplasia in which the chondrocytes of articular cartilage have an inherent abnormality in metabolism that can be triggered into a disease state by an unknown environmental event in susceptible individuals.

The most plausible theory concerning the cause of chondrolysis remains that proposed by Golding in 1973 (93), Mankin et al. in 1975 (99), and Eisenstein and Rothchild in 1976 (97), in which they postulated articular cartilage resorption to be secondary to an autoimmune response within the hip joint in genetically susceptible individuals. Microscopic evaluation of the synovial tissue from hip joints involved with idiopathic chondrolysis give credence to the autoimmune theory by routinely demonstrating an increase in chronic inflammatory cells consisting of lymphocytes, plasma cells, and monocytes concentrated in a perivascular pattern (88,92,100,101).

Eisenstein and Rothchild (97) demonstrated significant elevations of serum and synovial fluid immunoglobulins, and of the C3 component of complement, in patients with slipped capital femoral epiphysis and associated chondrolysis. In particular, the levels of the IgM fraction of the

serum immunoglobulins showed the greatest elevations in patients with associated chondrolysis. Morrissy et al. (101) evaluated 16 patients with slipped capital femoral epiphysis. Although they did not demonstrate an increase in the serum immunoglobulin levels above normal values, they did document 3 of the 16 patients to have positive immunofluorescence for immunoglobulin G (IgG) and the C3 component of complement in the synovial tissue of the hip, with two of these patients subsequently developing chondrolysis. Van der Hoeven and colleagues (102) demonstrated immunocomplex deposition of IgM and the C3 component of complement in the synovium of 3 of 4 patients with idiopathic chondrolysis.

Minimal information has been reported concerning similar evaluations of the serum or synovial factors of the autoimmune system in patients with idiopathic chondrolysis of the hip. Bleck reviewed nine patients with idiopathic chondrolysis of the hip, and reported normal levels of serum immunoglobulins in all (89). In 1983, a case report by Smith et al. (103) demonstrated normal immunofluorescence studies of the synovium and cartilage in a single patient with idiopathic chondrolysis of the hip.

Incidence

The incidence of idiopathic chondrolysis of the hip remains unreported. The condition, however, is relatively uncommon, with only 42 patients having been recorded in the literature through 1989 (90).

Clinical Presentation

Idiopathic chondrolysis of the hip occurs five times more frequently in female patients than in male patients. The reported age at the onset of symptoms averages 12.5 years for girls (range, 9 to 18 years) and 14.8 years for boys (range, 13 to 20 years). The right hip is involved at a slightly higher frequency than the left (104). Bilateral hip involvement has been reported for seven patients (89–91,95,105). Following Jones' original description of idiopathic chondrolysis of the hip in nine adolescent black African females, the condition was regarded as an affliction primarily of persons of African descent. Since that time, idiopathic chondrolysis has been recorded in white, Hispanic, and American Indian patients. As of 1989, 52% of the recorded patients were of African descent and 38% were white (90).

The most frequent presenting complaint is the insidious onset of pain in the anterior or medial side of the affected hip in an afebrile patient. The pain is associated with progressive joint stiffness and a limp. Patients often complain of the development of a limb-length inequality secondary to contractures about the affected hip with secondary pelvic obliquity. Examination of the involved hip demonstrates significant restriction of motion in all planes, and associated muscle spasm. Variable patterns of contracture about the

affected joint, in idiopathic chondrolysis of the hip, have been reported; the most common presenting pattern is that of a fixed flexion, abduction, and externally rotated position (88–90,93,95,104).

Laboratory values for complete blood count, urinalysis, rheumatoid factor, antinuclear antibody, HLA-B27 marker, blood culture, and tuberculin skin testing are usually within normal limits. The Westergren erythrocyte sedimentation rate is also usually within normal limits. It can be slightly elevated, but rarely exceeds 30 mm/h (102,104).

The differential diagnosis for idiopathic chondrolysis of the hip includes such entities as pyogenic arthritis, tuberculous arthritis, juvenile rheumatoid arthritis, seronegative spondyloarthropathy, and pigmented villonodular synovitis. Pyogenic arthritis of the hip differs from idiopathic chondrolysis in that the patient is systemically ill with high fever. Hip pain is usually of a more acute onset, and is associated with intense guarding against hip motion. Laboratory studies in pyogenic arthritis show a significant elevation in the white blood cell count and erythrocyte sedimentation rate, which are usually not seen in idiopathic chondrolysis (62).

The chondrolysis associated with juvenile rheumatoid arthritis (64) and tuberculous arthritis (65) occurs only after an extended period of symptoms. Although hip motion is limited in these conditions, it rarely reaches the degree of restriction seen in idiopathic chondrolysis. Skin testing is positive in tuberculous arthritis.

Seronegative spondyloarthropathy can present as isolated involvement at the hip, but usually has additional joint involvement later in the course of the disease. Unlike idiopathic chondrolysis of the hip, seronegative spondyloarthropathy has a male predominance, and is frequently seen in patients who are positive for the HLA-B27 marker (106).

Pigmented villonodular synovitis of the hip has an insidious onset, with progressive motion loss as in idiopathic chondrolysis. The course of the disease leading to chondrolysis in pigmented villonodular synovitis tends to be more chronic and prolonged than in idiopathic chondrolysis. Radiographs of the hip in pigmented villonodular synovitis show more cystic erosions in the subchondral bone on both sides of the joint. Aspiration of the hip of a patient with pigmented villonodular synovitis usually produces a moderate amount of bloody fluid (107).

Radiographic Findings

The recognition of certain abnormalities on the plain radiographs of the affected hip, in conjunction with the presence of appropriate clinical findings, establishes the correct diagnosis of idiopathic chondrolysis. The radiographic hallmark of the condition remains a narrowing of the joint space of the involved hip from its normal 3 to 5 mm to a value less than 3 mm (89,90). Complete obliteration of the joint space rarely or never occurs. There is usually associated osteopenia

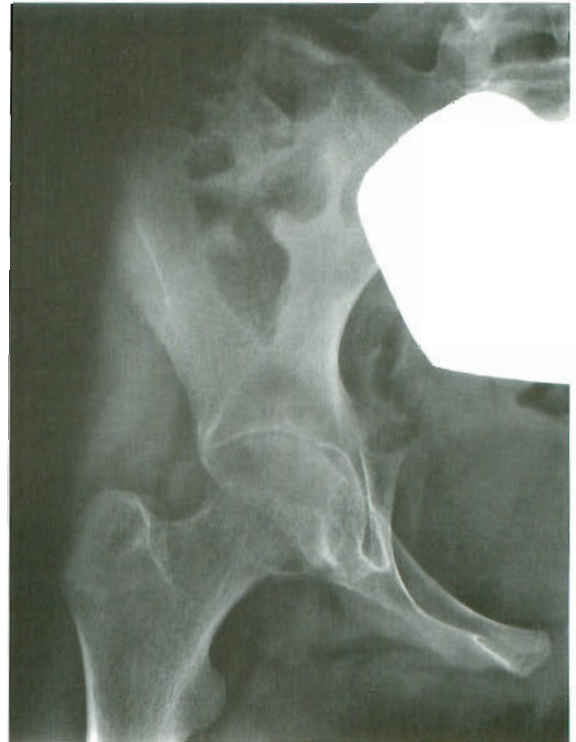

FIGURE 26-14. Anteroposterior hip radiograph of a girl 14 years, 2 months of age. The classic radiographic findings in this case of idiopathic chondrolysis of the hip include a narrowing of the joint space to less than 3 mm, diffuse osteopenia, blurring of the subchondral sclerotic lines on both sides of the joint, and an enlargement of the fovea capitis femori. The hip is also in a position of abduction, which is commonly seen in this condition.

of the periarticular osseous structures, an irregular blurring of the subchondral sclerotic lines at the femoral and acetabular joint surfaces, and an enlargement of the fovea capitis femori. With time, the involved femoral head develops a mild coxa magna, and the femoral neck widens slightly (88–90,93,104,105,108) (Fig. 26-14). Moule and Golding reported that the femoral neck may occasionally demonstrate a limited area of periosteal new bone formation (108) (Fig. 26-15).

With time, the hip involved with idiopathic chondrolysis frequently demonstrates a premature closure of the proximal femoral physis and the trochanteric apophysis. This rarely results in any major growth abnormality or significant architectural change at the proximal femur, because of the limited growth remaining at these growth centers. A mild protrusio acetabuli, assumed secondary to hyperemic softening of the bony acetabular floor, associated with a buttressing osteophyte at the lateral margin of the acetabulum, has been reported in up to 50% of cases (89,90,95,104,105,109).

Arthrography of the hip of a patient with idiopathic chondrolysis can be used to document articular cartilage loss and secondary joint space narrowing (Fig. 26-16). Moule and Golding (108) have described a “dappled” pat-

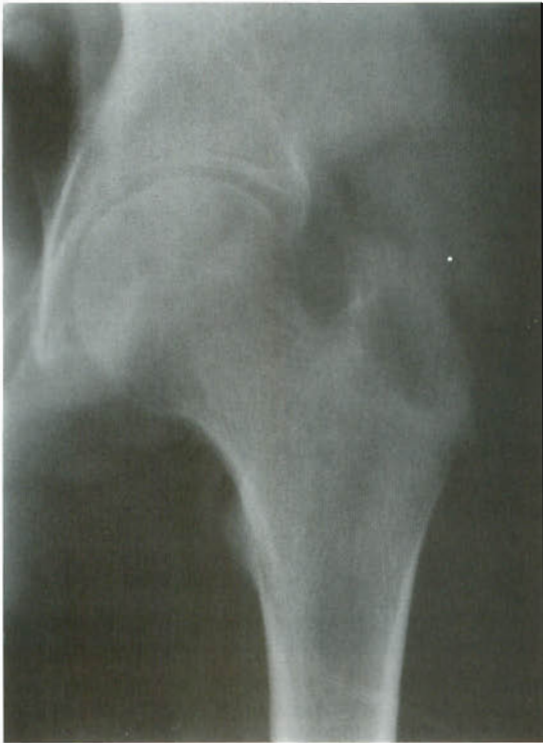

FIGURE 26-15. Anteroposterior tomographic view of the hip in a girl 12 years, 3 months of age with idiopathic chondrolysis demonstrates a limited area of periosteal new bone formation along the inferior femoral neck.

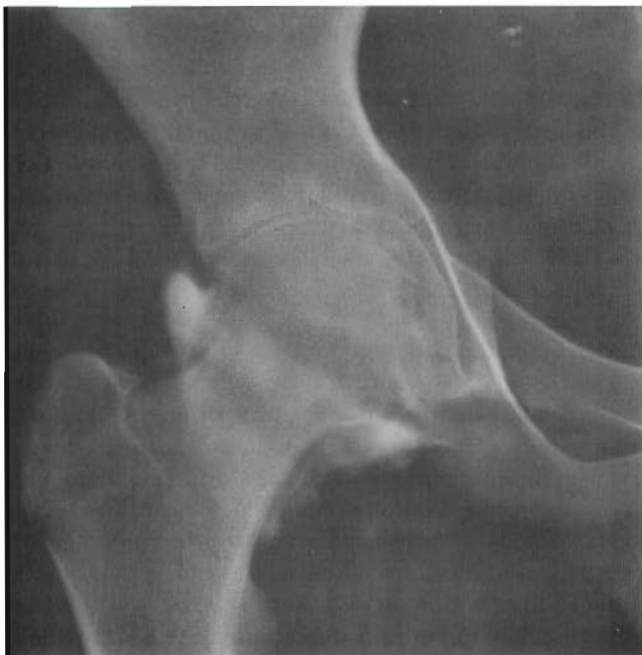

FIGURE 26-16. Arthrographic appearance of a hip involved with idiopathic chondrolysis, demonstrating articular cartilage loss on the femoral head and acetabulum.

tern of contrast outlining the femoral head and acetabulum in idiopathic chondrolysis, secondary to the patchy loss of articular cartilage that is associated with the condition. Although not routinely required, arthrography allows for aspiration of the hip to rule out an infectious etiology.

Scintigraphic evaluation of the hip in the active stage of idiopathic chondrolysis demonstrates a generalized increase in uptake on both sides of the affected joint. This is secondary to the local inflammatory and hyperemic response associated with the early stage of the condition (Fig. 26-17). Mandell and colleagues (110) have shown that decreased activity on bone scintigraphy around the physis of the greater trochanter, in patients with slipped capital femoral epiphysis, is frequently associated with concurrent or developing chondrolysis. Whether this scintigraphic finding is of prognostic value in idiopathic chondrolysis has not yet been determined.

Axial computed tomography scans of the pelvis can be used to document local changes in the subchondral bone, cartilage loss, and secondary narrowing of the joint space at the involved hip (Fig. 26-18). The use of magnetic resonance imaging as a method of assessing the local bone and cartilage changes at the hip may also be of benefit, but no large volume of experience has been recorded.

In the majority of cases, the diagnosis of idiopathic chondrolysis of the hip can be made by the patient's clinical presentation and plain radiographs. The routine use of arthrography, scintigraphy, axial computed tomography, and magnetic resonance imaging in this condition is not recommended. Selected use of these modalities, however, can be of assistance in making a proper diagnosis, when the

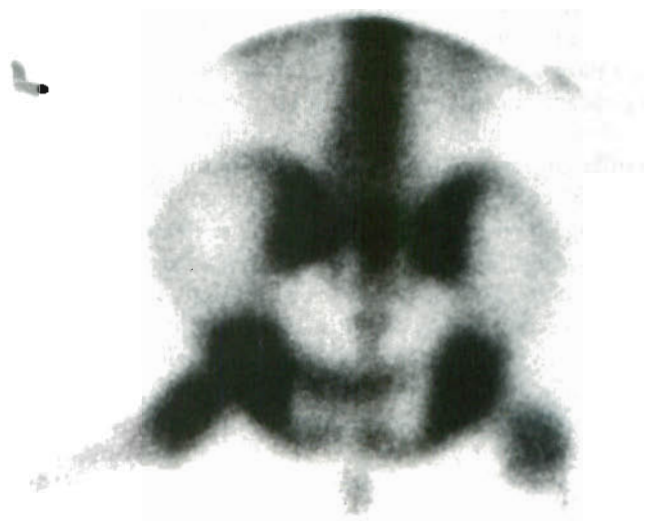

FIGURE 26-17. The scintigraphic appearance of a technetium 99m bone scan of a hip with idiopathic chondrolysis demonstrates a diffuse increased uptake of the isotope by both sides of the affected hip.

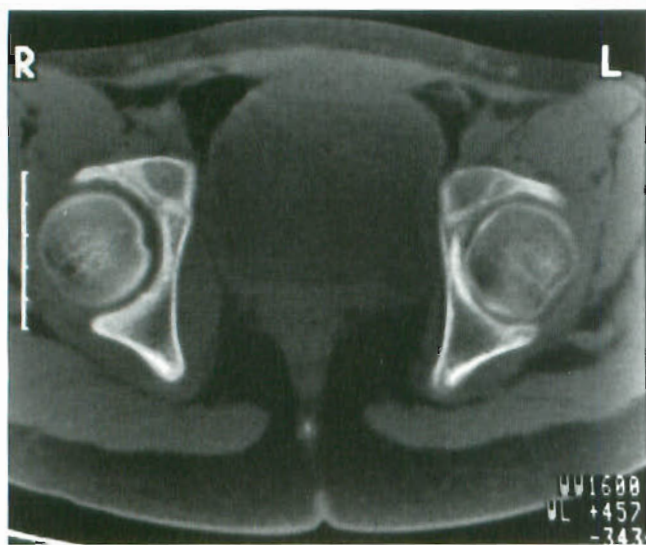


FIGURE 26-18. Axial computed tomographic view of the pelvis and hips in a patient with idiopathic chondrolysis demonstrates osteopenia and narrowing of the involved joint space of the affected hip.

diagnosis is clinically suspected, but cannot be confirmed by plain radiographs alone.

Pathology

Exploration of the hip joint involved with idiopathic chondrolysis demonstrates numerous abnormalities. The capsule is routinely thickened. The quantity of synovial fluid is decreased, producing a “dry joint” (103). The synovial tissue can be edematous and hypertrophic in the early stages of the disease, but with more prolonged involvement, the synovium becomes thinned and fibrotic. The articular cartilage shows changes on both sides of the joint, with the more significant alterations occurring on the femoral head. The cartilage has a lusterless appearance, with irregular thinning, fibrillation, and fragmentation seen in the surface layers. Areas of erosion in the articular cartilage of various sizes tapering down to subchondral bone, are identified mainly in the weightbearing region of the femoral head and acetabulum (88,92,97,100,103,104,108) (Fig. 26-19).

Microscopic review of biopsy specimens of the synovium consistently demonstrates a nonspecific chronic inflammation. An increased infiltration of plasma cells, lymphocytes, and monocytes is interspersed throughout a stroma, exhibiting an increased vascular and fibrotic pattern. Specimens of the involved articular cartilage demonstrate frayed and fragmented superficial layers with areas of necrotic chondrocytes. The more basal layers of chondrocytes are usually viable, which may be important in the subsequent regeneration of articular cartilage. The subchondral bone is histologically normal, and often demonstrates a mild increase in

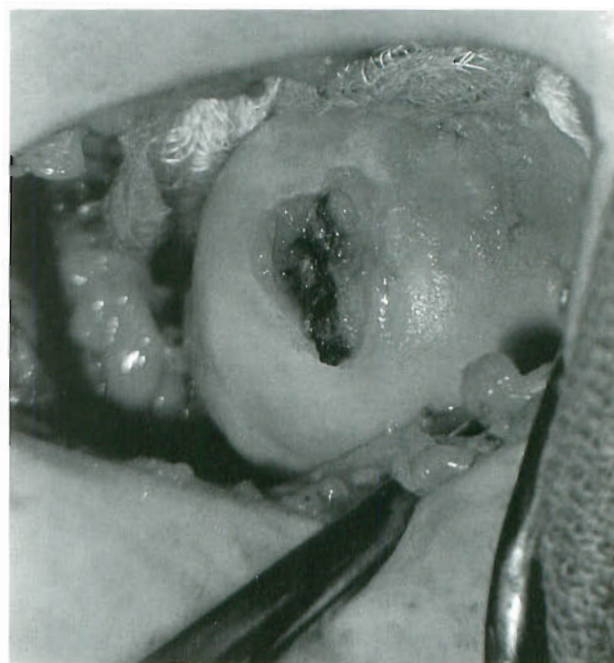

FIGURE 26-19. The clinical photograph of the femoral head of a girl 12 years, 3 months of age with idiopathic chondrolysis demonstrates the lusterless appearance of the articular cartilage, and areas of irregular erosion, fibrillation, and fragmentation.

vascularity. No evidence of bone necrosis has been identified (86,88,90–92,100,102,104) (Fig. 26-20).

Ippolito and associates (111) reported the electron microscopic ultrastructural findings in the articular cartilage from the femoral head of a patient with idiopathic chondrolysis. The superficial zone I of normal articular cartilage was found to be missing (112). The normally deeper zone II had become the most superficial layer. The collagen fibrils of this zone showed abnormalities in alignment and architecture. Degenerated chondrocytes and debris were found to be interspersed among viable chondrocytes within the extracellular matrix of this layer.

Natural History

At one time, idiopathic chondrolysis of the hip was viewed as a universally progressive disorder with an inevitable outcome of joint destruction, pain, and stiffness. Additional information concerning the condition's natural history changed this pessimistic point of view. In 1971, Jones (88), in his original description of idiopathic chondrolysis of the hip, recorded a very poor prognosis for the condition. All nine patients he described ultimately developed significantly stiffened hips, with most also showing significant dysfunction secondary to hip pain and joint malposition. In 1982, Sparks and Dall (113) reexamined six of Jones' original nine patients and found no significant change in their conditions. They concluded that idiopathic chondrolysis inevitably re-

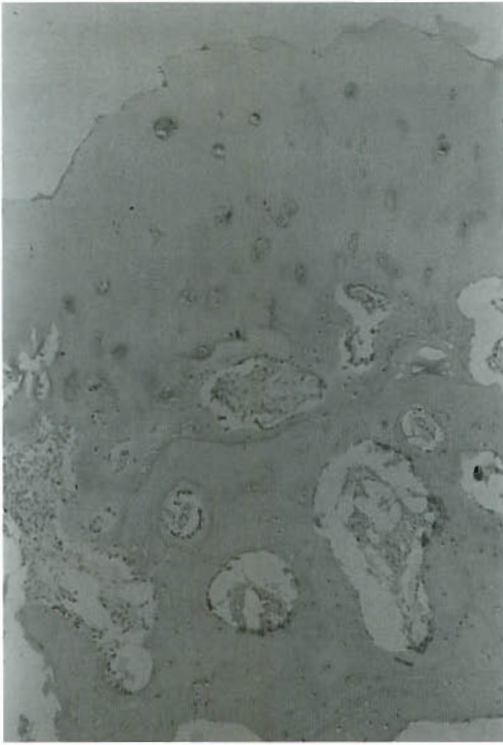


FIGURE 26-20. The photomicrograph of a biopsy specimen of the femoral head from a patient with idiopathic chondrolysis demonstrates a frayed and fragmented superficial layer of articular cartilage, with viable chondrocytes remaining in the more basal layers. The subchondral bone appears histologically normal.

sults in the development of a malpositioned fibrous ankylosis of the involved hip joint.

In 1970, Lowe (86) reported six cases of chondrolysis complicating slipped capital femoral epiphysis. Before his review, the prognosis for this form of chondrolysis was also poor. Lowe demonstrated that after 2 to 9 years all six patients showed improved function, range of motion, and radiographic widening of the involved joint space. He therefore concluded that, at least in some cases of chondrolysis of the hip, the articular cartilage has the ability to recover partially with time. In 1983, Bleck (89) demonstrated a similar favorable outcome for patients affected with idiopathic chondrolysis of the hip. At a mean follow-up of 6.2 years, 6 of the 9 patients had become essentially asymptomatic, with an improved range of hip motion and a partial restoration of joint space width. In 1989, Daluga and Millar (90) reported 14 patients (16 hips) with idiopathic chondrolysis of the hip, after a mean follow-up period of 84 months. Although no patient showed full restoration of the joint space, eight hips showed partial joint space restoration up to 2 mm. Nine hips demonstrated improved range of motion, and five of these hips had a full return of motion.

Idiopathic chondrolysis of the hip appears to have two separate stages. The acute stage is initiated at the condition's

onset, and lasts for 6 to 16 months. This stage is characterized by an inflammatory response within the affected hip joint, leading to a painful hip with a decreasing range of motion and loss of articular cartilage. During the latter portion of this stage, the degree of synovial inflammation decreases, with the synovium showing an increase in fibrous tissue deposition. The acute stage is followed by the chronic stage, which may last for 3 to 5 years. During this stage, the hip joint manifests one of three possible outcomes. The involved hip may continue to deteriorate to an ultimately painful and malpositioned ankylosis. The involved hip may become painlessly ankylosed in a position that causes some limitation of hip function for the patient. Alternatively, the involved hip may have a resolution of pain, with a partial or complete return of motion and improved joint space width shown on radiographs (Fig. 26-21).

Although this new information concerning idiopathic chondrolysis of the hip allows a more optimistic prognosis, the full understanding of the condition's natural history and outcomes awaits further investigation. Questions about the condition's cause, variable severity of involvement, and inherent factors, such as race, age, and gender and how they may influence outcome need to be answered before the optimum recommendations for treatment can be determined.

Treatment

As knowledge about the natural history of idiopathic chondrolysis is gained, a change in philosophy concerning the condition's treatment will follow. Previously, the prognosis of idiopathic chondrolysis was viewed as universally poor, with ultimate hip joint function rapidly declining and symptoms rapidly increasing. Recommended treatment included early definitive intervention with corrective osteotomy, bony fusion, or joint arthroplasty for the involved hip. As knowledge has been gained, a less pessimistic treatment approach was developed. As many as 50 to 60% of involved hip joints have the potential to achieve satisfactory function and motion (89,90,104).

In 1979, Duncan et al. (91) reviewed eight patients with idiopathic chondrolysis of the hip. Assuming that the hip involved with idiopathic chondrolysis would inevitably undergo ankylosis, and that many previously reported patients who had been treated with range of motion had undergone ankylosis of the hip in a nonfunctional position, the investigators proposed early and prolonged spica cast treatment, with the affected hip held in a functional position until fibrous ankylosis was achieved. They reported that all patients so treated were functioning well, with an ankylosed pain-free hip and satisfactory gait at last evaluation. Treatment to attempt to maintain motion was only recommended for patients with hip involvement of a "milder degree" (91).

In the 1980s, Bleck (89) and Daluga and Millar (90) reported a much more favorable prognosis for idiopathic

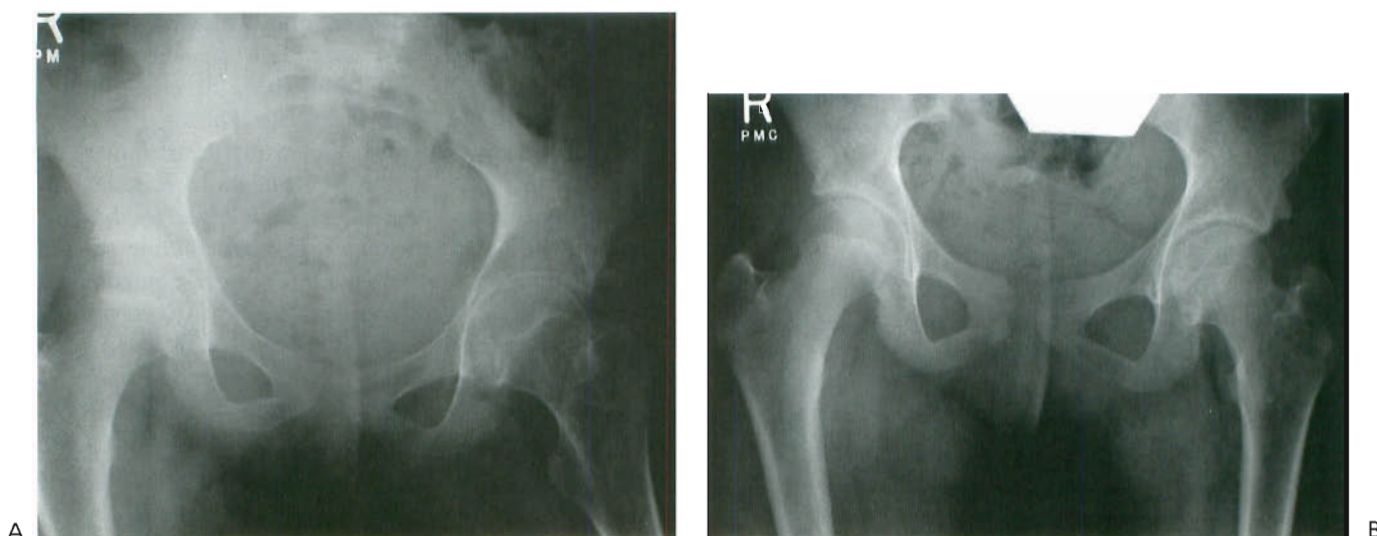


FIGURE 26-21. Anteroposterior pelvic radiograph of a girl 12 years, 3 months of age, with idiopathic chondrolysis of the hip. **A:** A radiograph made at the time of diagnosis demonstrates significant joint space narrowing at the involved hip. **B:** A radiograph of the same patient 2 years after diagnosis demonstrates partial regeneration of the joint space width at the affected hip.

chondrolysis of the hip, with respect to ultimate function, persistent joint pain, partial restoration of the radiographic joint space, and range of motion of the involved joint. The researchers employed a treatment protocol that included therapeutic doses of nonsteroidal antiinflammatory medications, aggressive physical therapy, periodic traction and bed rest, and prolonged non-weight-bearing or limited weight-bearing crutch activities for the involved hip.

In 1985, Hughes (104) reported the use of continuous passive motion in the acute stage of idiopathic chondrolysis of the hip for one patient, who demonstrated the maintenance of an improved range of hip motion throughout early treatment. In 1993, Canadell and associates (114) proposed joint distraction (arthrodiastasis) with a hinged unilateral external fixator as treatment for residual hip stiffness in adolescent patients resulting from various etiologies of hip disease. Although at 39-month follow-up most hips demonstrated significantly less pain, improved motion, and radiographic articular space widening averaging 2.8 mm, only one patient in the study had the diagnosis of idiopathic chondrolysis, and that patient demonstrated a much less favorable result in comparison to the results reported for patients with other etiologies of hip disease.

The potential benefit of aggressive surgical treatment, within the first year after the onset of symptoms of idiopathic chondrolysis of the hip, has only recently been investigated. Bleck reported one patient who underwent surgical release of tendon contractures and a limited anterior capsulotomy. This patient at follow-up was asymptomatic, with a functional range of motion and an improved radiographic joint space width. In 1988, Roy and Crawford (115) reported three patients with idiopathic chondrolysis of the

hip, who were treated with a subtotal circumferential capsulectomy and release of tendons at the involved hip. The surgical procedure was followed by a period of traction, continuous passive motion, and an aggressive program of physical therapy. The patients were subsequently allowed crutch ambulation with partial weight relief for a prolonged period. At an average follow-up time of 3 years, the investigators reported all patients to be asymptomatic, with a full return of hip motion and an improved joint space width on radiograph. In 1999, Del Couz Garcia and colleagues (95) reported on eight hips with idiopathic chondrolysis treated by capsulectomy and tendon release with an average 13.2 year follow-up. Although the initial surgical outcome appeared to be more favorable, long-term follow-up showed no significant difference in pain, range of motion, or radiographic appearance, when comparing surgically treated hips to nonsurgically treated hips.

Although some limited reports demonstrate favorable outcomes for aggressive surgical release, many questions remain unanswered. What are the specific clinical indications for an aggressive surgical release to be considered for an individual patient? Does the degree of radiographically demonstrated involvement affect outcome? Is the procedure best performed early or late within the actively evolving pathophysiology of the disease process? Were the favorable results attributable to the surgical intervention or to the aggressive joint motion and prolonged joint unloading after surgery? Will the favorable results from surgical intervention be lasting or will they deteriorate in long-term follow-up? The answers to these questions can only be obtained through further investigations.

The current recommendations for treatment of idio-

pathic chondrolysis of the hip embrace the philosophy of a more favorable long-term prognosis for improved motion and function in most patients. The principles of early treatment include control of synovial inflammation, maintenance of hip motion, and prolonged relief of weight bearing on the involved joint. For most patients, these principles are achieved through the administration of nonsteroidal antiinflammatory medications at therapeutic doses, the periodic use of skin traction and bed rest during periods of acute exacerbation of joint pain and motion loss, surgical release of unresolving contractures, and an aggressive program of passive and active physical therapy for the involved joint. The patient is also maintained on non-weight-bearing or limited-weight-bearing crutch ambulation for the involved hip, until all pain has resolved and progressive loss of joint space radiographically has ceased. The use of prolonged spica casting, with the involved hip in a position of function in an attempt to achieve fibrous ankylosis, is mainly of historical interest, and should only be considered for patients who do not respond to the described protocol. Hip arthrodesis is the more appropriate treatment for relief of pain and malalignment in young patients recalcitrant to nonoperative treatment. Although the early reports on the use of aggressive subtotal capsulectomy and tendon release indicated very favorable initial results, more recent long-term follow-up indicates the favorable results may be only temporary. For this reason, the routine use of this procedure cannot yet be recommended in the treatment of idiopathic chondrolysis of the hip.

References

Developmental Coxa Vara

1. von Lanz T, Mayet A. Die gelenkorper des menschlichen Hufgelenkes in der progredienten Phase ihrer umwegigen Ausformung. *Z Anat* 1953;117:317.
2. Elmslie RC. Injury and deformity of the epiphysis of the head of the femur—coxa vara. *Lancet* 1907;1:410.
3. Fairbank HAT. Infantile or cervical coxa vara. In: Milford H. ed. *The Robert Jones birthday volume, a collection of surgical essays*. London: Oxford University Press, 1928;225.
4. Zadek I. Congenital coxa vara. *Arch Surg* 1935;30:62.
5. Babb FS, Ghormley RK, Chatterton CC. Congenital coxa vara. *J Bone Joint Surg Am* 1949;31:115.
6. Duncan GA. Congenital and developmental coxa vara. *Surgery* 1938;3:741.
7. Amstutz HC. Developmental (infantile) coxa vara—a distinct entity. *Clin Orthop* 1970;72:242.
8. Johanning K. Coxa vara infantum—clinical appearance and aetiological problem. *Acta Orthop Scand* 1951;21:273.
9. Kehl DK, LaGrone M, Lovell WW. Developmental coxa vara. *Orthop Trans* 1983;7:475.
10. Magnusson R. Coxa vara infantum. *Acta Orthop Scand* 1954;23:284.
11. Pyllkanen PV. Coxa vara infantum. *Acta Orthop Scand* 1960;48(suppl):1.
12. Fisher RL, Waskowitz WJ. Familial developmental coxa vara. *Clin Orthop* 1972;86:2.
13. Say B, Taysi K, Pirnar T, et al. Dominant congenital coxa vara. *J Bone Joint Surg Br* 1974;56:78.
14. Nillsone H. On congenital coxa vara. *Acta Chir Scand* 1929;64:217.
15. Chung SMK, Riser WH. The histological characteristics of congenital coxa vara. *Clin Orthop* 1978;132:71.
16. Bos CFA, Sakkers RJB, Bloem JL, et al. Histological, biochemical and MRI studies of the growth plate in congenital coxa vara. *J Pediatr Orthop* 1989;9:660.
17. Langenskiöld A, Riska EB. Tibia vara (osteochondrosis deformans tibiae). *J Bone Joint Surg Am* 1964;46:1405.
18. Wenger DR, Mickelson M, Maynard JA. The evolution and histopathology of adolescent tibia vara. *J Pediatr Orthop* 1984;4:78.
19. Pavlov H, Goldman B, Freiburger RH. Infantile coxa vara. *Pediatr Radiol* 1980;135:631.
20. Blockley NJ. Observations on infantile coxa vara. *J Bone Joint Surg Br* 1969;51:106.
21. Langenskiöld F. On pseudarthrosis of the femoral neck in congenital coxa vara. *Acta Chir Scand* 1949;98:568.
22. Le Mesurier AB. Developmental coxa vara. *J Bone Joint Surg Br* 1948;30:595.
23. Serafin J, Szulc W. Coxa vara infantum, hip growth disturbances, etiopathogenesis and long-term results of treatment. *Clin Orthop* 1991;272:103.
24. Schmidt TL, Kalamchi A. The fate of the capital femoral physis and acetabular development in developmental coxa vara. *J Pediatr Orthop* 1982;2:534.
25. Weinstein JN, Kuo KN, Millar EA. Congenital coxa vara. A retrospective review. *J Pediatr Orthop* 1984;4:70.
26. Borden J, Spencer GE, Herndon CH. Treatment of coxa vara in children by means of a modified osteotomy. *J Bone Joint Surg Am* 1966;48:1106.
27. Barr JS. Congenital coxa vara. *Arch Surg* 1929;18:1909.
28. Amstutz HC, Wilson PD Jr. Dysgenesis of the proximal femur (coxa vara) and its surgical management. *J Bone Joint Surg Am* 1962;44:1.
29. Horwitz T. The treatment of congenital (or developmental) coxa vara. *Surg Gynecol Obstet* 1948;87:71.
30. Weighill FJ. The treatment of developmental coxa vara by abduction subtrochanteric and intertrochanteric femoral osteotomy with special reference to the role of adductor tenotomy. *Clin Orthop*, 1976;116:116.
31. Brackett EG, New MS. Treatment of old ununited fracture of the neck of the femur by transplantation of the head of the femur to the trochanter. *Boston Med Surg* 1917;177:351.
32. Cordes S, Dickens DRV, Cole WG. Correction of coxa vara in childhood. The use of Pauwels' Y-shaped osteotomy. *J Bone Joint Surg Br* 1991;73:3.
33. Von Bormann PFB, Erken EHW. Pauwels' osteotomy for coxa vara in childhood. *J Bone Joint Surg Br* 1982;64:144.
34. Kehl DK. Developmental coxa vara. Lesson 36. *Orthop Surg Update Series* 1983;2:1.
35. Desai S, Johnson L. Long-term results of valgus osteotomy for congenital coxa vara. *Clin Orthop* 1993;294:204.
36. Carroll K, Coleman S, Stevens PM. Coxa vara: surgical outcomes of valgus osteotomies. *J Pediatr Orthop* 1997;17:220.

Transient Synovitis of the Hip

37. Landin LA, Danielsson LG, Wattsgard C. Transient synovitis of the hip. Its incidence, epidemiology and relation to Perthes disease. *J Bone Joint Surg Br* 1987;69:238.
38. Spock A. Transient synovitis of the hip joint in children. *Pediatrics* 1959;24:1042.

39. Lovett RW, Morse JL. A transient or ephemeral form of hip disease. *Boston Med Surg J* 1892;127:161.
40. Bradford EH, Lovett RW. Treatment of hip disease. *Am J Orthop Surg* 1911;9:354.
41. Todd AH. Discussion on the differential diagnosis of nontuberculous coxitis in children and adolescents. *Proc R Soc Med* 1925; 18:31.
42. Fairbank HAT. Discussion on non-tuberculous coxitis in the young. *Br Med J* 1926;2:828.
43. Hermel MB, Albert SM. Transient synovitis of the hip. *Clin Orthop*, 1962;20:21.
44. Butler RW. Transitory arthritis of the hip joint in childhood. *Br Med J* 1933;1:951.
45. Finner JG. Transitory synovitis of the hip joint in children. *JAMA* 1936;107:3.
46. Edwards EG. Transient synovitis of hip joint in children. *JAMA* 1952;148:30.
47. Gledhill RB, McIntyre JM. Transient synovitis and Legg-Calvé-Perthes disease. A comparative study. *Can Med Assoc J* 1969; 100:311.
48. Miller OL. Acute transient synovitis of the hip joint. *JAMA* 1931;96:575.
49. Rauch S. Transitory synovitis of the hip joint in children. *Am J Dis Child* 1940;59:1245.
50. Rothschild HB, Russ JD, Wasserman CF. Corticotropins in treatment of transient synovitis of the hip in children. *J Pediatr* 1956;49:33.
51. Lockhart GR, Longobardi YL, Ehrlich M. Transient synovitis: lack of serologic evidence for acute parvovirus B-19 or human herpesvirus-6 infection. *J Pediatr Orthop* 1999;19:185.
52. Hardinge K. The etiology of transient synovitis of the hip in childhood. *J Bone Joint Surg Br* 1970;52:100.
53. Tolar V, Carty H, Klennerman L, et al. Evidence for a viral aetiology of transient synovitis of the hip. *J Bone Joint Surg Br* 1993;75:973.
54. Blockley NJ, Porter BB. Transient synovitis of hip. A virological investigation. *Br Med J* 1968;4:557.
55. Nachemson A, Scheller S. A clinical and radiological follow-up study of transient synovitis of the hip. *Acta Orthop Scand* 1969; 40:479.
56. Adams AJ. Transient synovitis of the hip joint in children. *J Bone Joint Surg Br* 1963;45:471.
57. Jacobs BW. Synovitis of the hip in children and its significance. *Pediatrics* 1971;47:558.
58. Hauelsen DC, Weiner DS, Weiner SD. The characterization of "transient synovitis of the hip" in children. *J Pediatr Orthop* 1986;6:11.
59. Kallio P. Coxa magna following transient synovitis of the hip. *Clin Orthop* 1988;228:49.
60. Kesteris U, Wingstrand H, Forsberg L, et al. The effect of arthrocentesis in transient synovitis of the hip in the child: a longitudinal sonographic study. *J Pediatr Orthop* 1996;16:24.
61. Sharwood PF. The irritable hip syndrome in children. *Acta Orthop Scand* 1981;52:633.
62. Green NE, Edward K. Bone and joint infections in children. *Orthop Clin North Am* 1987;18:555.
63. De Cunto CL, Giannini EH, Fink CW, et. al. Prognosis of children with poststreptococcal reactive arthritis. *Pediatr Infect Dis J* 1988;7:683.
64. Schaller JG. Chronic arthritis in children—juvenile rheumatoid arthritis. *Clin Orthop* 1984;182:79.
65. Versfield GA, Solomon A. A diagnostic approach to tuberculosis of bones and joints. *J Bone Joint Surg Br* 1982;64:446.
66. Catterall A. Legg-Calvé-Perthes disease. *Instr Course Lect* 1989; 38:297.
67. Drey L. A radiographic study of transient synovitis of the hip joint. *Radiology* 1953;60:588.
68. Hermel MB, Sklaroff DM. Roentgen changes in transient synovitis of the hip joint. *Arch Surg* 1954;68:364.
69. Brown I. A study of the "capsular" shadow in disorders of the hip in children. *J Bone Joint Surg Br* 1975;57:175.
70. Wingstrand H. Transient synovitis of the hip in the child. *Acta Orthop Scand* 1986;57(suppl):1.
71. Bickerstaff DR, Neal LM, Booth AJ, et al. Ultrasound examination of the irritable hip. *J Bone Joint Surg Br* 1990;72:549.
72. Futami T, Kasahara Y, Suzuki S, et al. Ultrasonography in transient synovitis and early Perthes' disease. *J Bone Joint Surg Br* 1991;73:635.
73. Terjesen T, Osthus P. Ultrasound in the diagnosis and follow-up of transient synovitis of the hip. *J Pediatr Orthop* 1991;11: 608.
74. Wingstrand H, Bauer G, Brismar J, et al. Transient ischaemia of the proximal femoral epiphysis in the child. *Acta Orthop Scand* 1985;56:197.
75. Kloiber R, Pavlosky W, Portner O, et al. Bone scintigraphy of hip joint effusions in children. *AJR Am J Roentgenol* 1983;140: 995.
76. Hasegawa Y, Wingstrand H, Gustafson T. Scintimetry in transient synovitis of the hip. *Acta Orthop Scand* 1988;59:520.
77. Illingworth CM. Recurrences of transient synovitis of the hip. *Arch Dis Child* 1983;58:620.
78. De Valderrama JAF. The "observation hip" syndrome and its late sequelae. *J Bone Joint Surg Br* 1963;45:462.
79. Erken EHW, Katz K. Irritable hip and Perthes' disease. *J Pediatr Orthop* 1990;10:322.
80. Kallio P, Ryoppy S, Kunnamo I. Transient synovitis and Perthes disease. *J Bone Joint Surg Br* 1986;68:80.
81. Wingstrand H, Egund N, Carlin NO, et al. Intracapsular pressure in transient synovitis of the hip. *Acta Orthop Scand* 1985; 56:204.
82. Kallio P, Ryoppy S. Hyperpressure in juvenile hip disease. *Acta Orthop Scand* 1985;56:211.

Idiopathic Chondrolysis of the Hip

83. Heppenstall RB, Marvel JP, Chung SMK, et al. Chondrolysis of the hip joint—usual and unusual presentations. *J Bone Joint Surg Am* 1973;55:1308.
84. Pellicci PM, Wilson PD. Chondrolysis of the hips associated with severe burns. *J Bone Joint Surg Am* 1979;61:592.
85. Cruess RL. The pathology of acute necrosis of cartilage in slipping of the capital femoral epiphysis. *J Bone Joint Surg Am* 1963; 45:1013.
86. Lowe HG. Necrosis of articular cartilage after slipping of the capital femoral epiphysis. *J Bone Joint Surg Br* 1970;52:108.
87. Waldenstrom H. On necrosis of the joint cartilage by epiphyseolysis capitis femoris. *Acta Chir Scand* 1930;67:936.
88. Jones BS. Adolescent chondrolysis of the hip joint. *S Afr Med J* 1971;45:196.
89. Bleck EE. Idiopathic chondrolysis of the hip. *J Bone Joint Surg Am* 1983;65:1266.
90. Daluga DJ, Millar EA. Idiopathic chondrolysis of the hip. *J Pediatr Orthop* 1989;9:405.
91. Duncan JW, Nasca R, Schrantz J. Idiopathic chondrolysis of the hip. *J Bone Joint Surg Am* 1979;61:1024.
92. Duncan JW, Schrantz JL, Nasca RJ. The bizarre stiff hip—possible idiopathic chondrolysis. *JAMA* 1975;231:382.
93. Golding JSR. Chondrolysis of the hip. *J Bone Joint Surg Br* 1973;55:214.
94. Wenger DR, Mickelson MR, Ponseti IV. Idiopathic chondrolysis of the hip. *J Bone Joint Surg Am* 1975;57:268.

95. Del Couz Garcia A, Lopez Fernandez P, Cimadevilla Gonzalez MP, et al. Idiopathic chondrolysis of the hip: Long-term evolution. *J Pediatr Orthop* 1999;19:449.
96. Jacobs B. Chondrolysis after epiphyseolysis. *Instr Course Lect* 1972;21:224.
97. Eisenstein A, Rothschild S. Biochemical abnormalities in patients with slipped capital femoral epiphysis and chondrolysis. *J Bone Joint Surg Am* 1976;58:459.
98. Kozlowski K, Scougall J. Idiopathic chondrolysis—diagnostic difficulties. *Pediatr Radiol* 1984;14:314.
99. Mankin HJ, Sledge CB, Rothschild S, et al. Chondrolysis of the hip. In: *The Hip. Proceedings of the third open scientific meeting of the Hip Society*. St. Louis: CV Mosby, 1975;127.
100. Ippolito E, Ricciardi-Pollini PT. Chondrolysis of the hip—idiopathic and secondary forms. *Ital J Orthop Traumatol* 1981;7:335.
101. Morrissy RT, Kalderon AE, Gerdes MH. Synovial immunofluorescence in patients with slipped capital femoral epiphysis. *J Pediatr Orthop* 1981;1:55.
102. Van der Hoeven H, Keessen W, Kuis W. Idiopathic chondrolysis of the hip. *Acta Orthop Scand* 1989;60:661.
103. Smith EJ, Ninin DT, Keays AC. Idiopathic chondrolysis of the hip. *S Afr Med J* 1983;63:88.
104. Hughes AW. Idiopathic chondrolysis of the hip. A case report and review of the literature. *Ann Rheum Dis* 1985;44:268.
105. Rowe LJ, Ho EK. Idiopathic chondrolysis of the hip. *Skeletal Radiol* 1996;25:178.
106. Cabral DA, Malleson PN, Petty RE. Spondyloarthropathies of childhood. *Pediatr Clin North Am* 1995;42:1051.
107. Docken WP. Pigmented villonodular synovitis. A review with illustrative case reports. *Semin Arthritis Rheum* 1979;9:1.
108. Moule NJ, Golding JSR. Idiopathic chondrolysis of the hip. *Clin Radiol* 1974;25:247.
109. Sherlock DA. Acute idiopathic chondrolysis and primary acetabular protrusion may be the same disease. *J Bone Joint Surg Br* 1995;77:392.
110. Mandell GA, Keret D, Harcke HT, et al. Chondrolysis: detection by bone scintigraphy. *J Pediatr Orthop* 1992;12:80.
111. Ippolito E, Bellocchi M, Santori FS, et al. Idiopathic chondrolysis of the hip. An ultrastructural study of the articular cartilage of the femoral head. *Orthopedics* 1986;9:1383.
112. Weiss C, Rosenberg L, Helfet AJ. An ultrastructural study of normal young adult human articular cartilage. *J Bone Joint Surg Am* 1968;50:663.
113. Sparks LT, Dall G. Idiopathic chondrolysis of the hip joint in adolescents. *S Afr Med J* 1982;61:883.
114. Canadell J, Gonzales F, Barrios RH, et al. Arthrodiastasis for stiff hips in young patients. *Int Orthop* 1993; 17:254.
115. Roy DR, Crawford AH. Idiopathic chondrolysis of the hip. Management by subtotal capsulectomy and aggressive rehabilitation. *J Pediatr Orthop* 1988;8:203.



THE LOWER EXTREMITY

PERRY L. SCHOENECKER
MARGARET M. RICH

ROTATIONAL VARIATION 1059

Definition 1059
Assessment 1060
Differential Diagnosis 1060
Radiographic Evaluation 1062
Natural History 1062
Treatment 1063
Complications 1064

GENU VARUM 1065

Physiologic Bowing 1065
Infantile Blount Disease 1068
Adolescent Blount Disease 1075
Treatment 1077
Preoperative Evaluation 1078
Hemiepiphyodesis 1079
Osteotomy 1079

KNOCK-KNEES (GENU VALGUM) 1081

Definition 1081
Differential Diagnosis 1081
Natural History 1081
Assessment 1082

Treatment 1082
Complications 1084

BOWING OF THE TIBIA 1084

Anterolateral Bowing 1084
Congenital Pseudarthrosis of the Fibula 1091
Posterior Medial Bowing of the Tibia 1092

CONGENITAL DISLOCATION OF THE KNEE 1095

Definition 1095
Etiology 1095
Clinical Presentation 1096
Nonoperative Treatment 1096
Surgical Treatment 1097

IDIOPATHIC TOE-WALKING 1098

Definition 1098
Etiology 1098
Natural History 1098
Clinical Features 1098
Other Diagnostic Studies 1098
Treatment Recommendations 1099

ROTATIONAL VARIATION

Definition

Rotational profiles vary widely among normal children (1–3). Differences in appearance during walking or running are most often just that—differences—not pathologic con-

ditions. Foot position is described by the direction of the foot, relative to the body's line of progression during the gait cycle. This is referred to as torsion. It is produced by the summation of factors that include version of the bones, capsular laxity or tightness, and muscle control (3,4). Parents are more often concerned about a relatively intoed position than an out-toed position.

Rotational variations, although a frequent concern, are most often variations of a normal exam. The foot's line of progression relative to the body during walking describes rotational alignment, internal, external, or neutral. It is a result of rotational forces applied relative to the axis of the lower limb. These torsional forces include the effects of version, soft tissue flexibility, and muscular control (1,3–5). "Version" is tilt or inclination within a bone, such as the relationship of the femoral head/neck to the shaft of the femur. Contracture of a joint capsule may restrict rotation. Similarly, capsular laxity may allow a greater than normal arc of motion. Arthrosis or incongruity may also restrict motion. Balance between opposing muscle groups is also a determinant of foot position, and may introduce a significant dynamic component to the rotational profile. Age is another important variable since version, soft tissue pliability, and muscle coordination change as the child matures (1–8).

Assessment

Assessment of rotational alignment includes static and dynamic components. The static exam describes the available range of rotational motion. The dynamic exam displays the effect of various torsional forces at play during the walking cycle (Fig. 27-1). The static exam is best performed on a firm examining table, with the child in comfortable, loose clothing, such as shorts or a diaper. Rotation is best assessed with the child in the prone position, keeping the pelvis flat and level on the exam table (3–5). Flexion of the knee to 90 degrees allows the leg to be used like a goniometer relative to the thigh. Some children will not allow examination other than on a parent's lap. This is usually adequate, although not as controlled as in the prone position. The arc of rotation may be more generous if measured with the hip flexed (sitting position) (5).

Rotation of the foot laterally or medially is used to assess the degree of available hip rotation. When there is a greater degree of internal or medial rotation (outward movement of the foot) than external or lateral rotation, a toed-in gait is more likely to be observed. Similarly, if there is greater external rotation than internal rotation, the gait pattern is usually toed-out. A greater ability to internally rotate than externally rotate the thigh is frequently referred to as "*anteversion*." It should correctly be called "*antetorsion*" because hip rotation is the combined effect of version of the femur, joint mobility, and muscular contracture (1,3,5).

Medial hip rotation is generally greater in girls than boys. Variability is greater in younger children. Static medial hip

rotation averages 40 degrees (range 10 to 60) in infants and 40 degrees (range 15 to 60) by age 10 years in girls and 50 degrees (range 25 to 65) by age 10 years in boys (1–3,5,7,9,10). Lateral hip rotation is greater in infants: an average of 70 degrees (range 45 to 90), compared to children over age 10 years, who average 45 degrees (range 25 to 65) (1–3,5,9,10).

Observation of the alignment of the sole of the foot, relative to the thigh, which is held in neutral rotation, determines the thigh–foot angle. This relationship also describes the contribution of the leg segment or the degree of tibial torsion. Foot deformity, which may contribute to rotational abnormalities, can easily be assessed in this position. Forefoot adduction/abduction and hindfoot varus or valgus should be noted. Many young children have significant internal/external rotation laxity through the knee. Rotation of the tibia, internal and external, demonstrates the degree of knee joint laxity, which may contribute to variation in foot position. Average thigh–foot angle is 5 degrees internal in infants (range –30 to +20) and 10 degrees external by age 8 years (range –5 to +30) (1–5). Thigh–foot angle changes very little after age 8 years.

Correlation of the static exam with the dynamic exam is important. The child's walking pattern should be observed in an area large enough to allow comfortable, safe walking and running. The child should be able to walk alone (not holding someone's hand). It is often helpful to observe the child in shoes, as well as barefoot. Variations are common with change in speed or direction of walking. Foot and knee position should be observed over several cycles of gait. The relationship of foot position to an imaginary line along the path being walked describes the *foot-progression angle*. Variability is tremendous in children up to age 5 years. Out-toed position predominates. Once a mature gait pattern is established, foot-progression angle changes very little (1–6,9,10).

The child's rotational profile includes the contribution of each of these components to the gait pattern. The position of the foot relative to the line of walking progression (foot-progression angle), alignment of the foot relative to the body (thigh–foot angle), and knee relative to the body (femoral torsion), all contribute to the sum of rotational factors. Each area needs to be assessed along with its contribution, either positive (internal rotation) or negative (external rotation), to the overall gait pattern. Those children whose rotational profiles are beyond two standard deviations of the mean, are considered to be abnormal according to Staheli et al.'s criteria (3,4).

Differential Diagnosis

Infrequently, pathologic conditions will cause a rotational abnormality. Residual foot deformity, disorders of the hip, and neuromuscular disease are the most common causes of pathologic intoeing or out-toeing. Intoeing may be caused by residual foot deformity from metatarsus adductus, club-

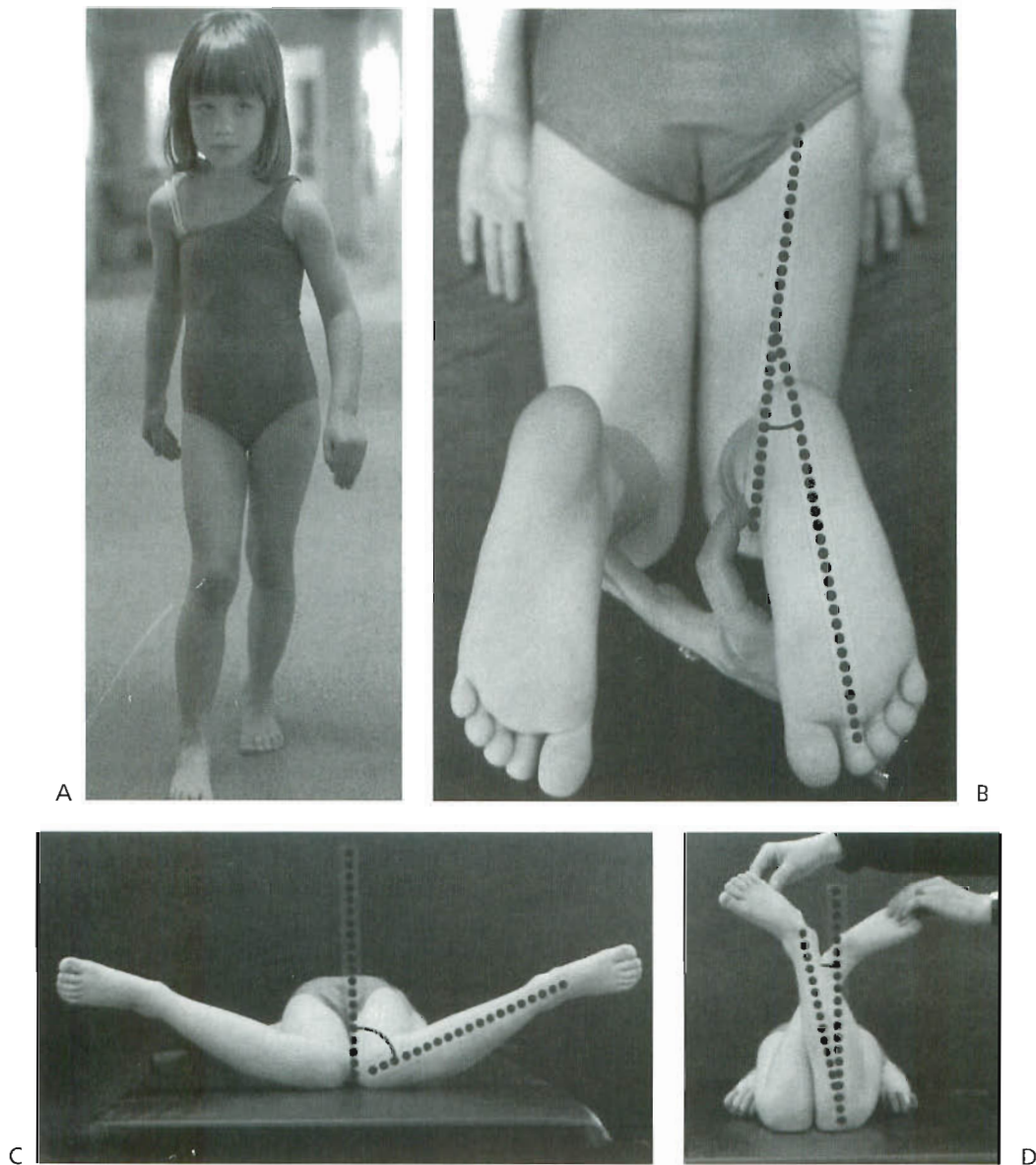


FIGURE 27-1. How the rotational profile measurements are made. **A:** The foot-progression angle (FPA) is estimated by observing the child's gait. It is defined as the angular difference between the axis of the foot and the line of progression. This child's FPA is 0 degrees. **B:** The thigh-foot angle (TFA) is the angular difference between the axis of the foot and thigh, as viewed from above. The TFA in this child is 18 degrees. From this view the shape of the foot is apparent. **C:** Medial hip rotation is the maximum angular difference between the vertical and the axis of the tibia. In these hips, this measurement is 70 degrees. **D:** Lateral hip rotation is the corresponding measurement. On this patient the angle is 10 degrees.

foot and/or skew foot (1,4,5). These conditions are discussed in greater detail in Chapter 29 of this text. Intoeing, which is only apparent during swing phase, may be the result of over pull of the posterior tibial tendon, often seen in spastic hemiplegia (11).

Femoral anteversion may be seen in spastic diplegia or quadriplegia. This may be a combination of excess femoral anteversion with contracture of the adductor and medial

hamstring muscles (4,5,12). Excess valgus and pronation of the foot, which contribute to an out-toed foot progression, may also be seen (12). For some children with spasticity, extremes in rotational posture are a compensatory mechanism for limited hip, knee, and/or ankle motion. The combination of excess internal femoral rotation and external tibial rotation is often observed in children with spasticity, who also have lower-extremity weakness. As the foot is con-

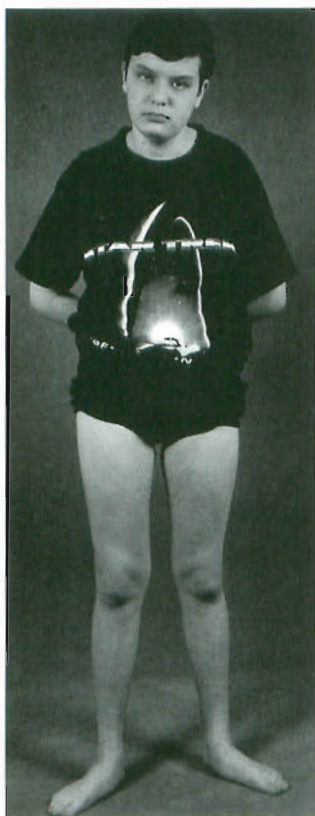

FIGURE 27-2. Excess external rotational deformity may not resolve. It may be associated with symptomatic flat foot, with or without tarsal coalition. The use of medial support orthotics may reduce symptoms, but will not alter rotation.

stantly dragged along the floor rather than swinging through, external torsional force is applied to the foot, pushing it out, leaving the knee internally rotated.

Pathologic out-toeing may result from severe pes planovalgus often associated with external tibial torsion (13) (Fig. 27-2). This may be secondary to tarsal coalition. It can also be seen in adolescents with rigid flat feet, without tarsal coalition. It is unclear whether the external tibial rotation is an adaptation to a rigid flat foot, or whether the lack of foot flexibility encourages external rotation. Slipped capital femoral epiphysis should be considered in the differential diagnosis of out-toeing, particularly when the gait deviation is asymmetric or of recent onset (4,14).

Developmental hip dysplasia can alter rotation, but is highly variable (7). An asymmetric hip exam may be apparent, but is not always reliable in detecting hip dysplasia. In such instances, further evaluation with radiographic hip examination is warranted (3,4). Coxa vara may also present as an out-toed gait.

Radiographic Evaluation

It is recommended that any child who presents to an orthopaedic surgeon with concerns of a gait abnormality should

have a single anteroposterior (AP) pelvis radiograph. Although the incidence of otherwise occult pathology is low, the consequence of a missed diagnosis, such as developmental dysplasia of the hip (DDH) or a slipped capital femoral epiphysis, may be significant for the child. Radiographs should also be obtained if there has been a significant change in the gait pattern, particularly if there is asymmetry or if pain is present (3,4,14). Cross-table lateral films are essential for the diagnosis of a minimally displaced slipped capital femoral epiphysis.

It is not necessary to obtain serial radiographs of the hips or lower extremities to follow the course of normal rotational development (4,5). Special views to quantify version of the femur or tibia are not indicated in the routine evaluation of rotation (3–5). Three-dimensional imaging studies (CT or MRI) are rarely indicated in the assessment or follow-up of rotational variations, but are more accurate than clinical exam or bi-plane radiography (15).

Natural History

Most children brought in for concerns of intoeing or out-toeing are normal. Rotational profiles are highly variable, particularly in toddlers who have not mastered the basic skills needed for normal walking, which is just about every child under 2 years of age, and many of those 2 to 5 years of age (1,2,6,10). Internal and external rotation variations should be considered just that; these are variations of normal, not pathologic disease or disorder. The natural history of rotational variations is gradual normalization, usually accomplished by 5 to 6 years of age. There are no compelling studies to show that any nonsurgical intervention speeds or assures the normalization of gait (4,5,16).

Internal tibial torsion is more common than external tibial torsion in toddlers (4,5). It is often associated with physiologic genu varum, and decreases 1 to 2 years after resolution of the bowing. Occasionally, it will persist into preadolescence. External tibial torsion is less common, and more likely to persist through adolescence (4,5). Neither has been shown to be a risk factor for degenerative joint disease.

The assessment of hip range of motion in newborns and infants is highly variable (2,3,5,7). Most normal infants have an external rotation contracture about the hip, likely a result of intrauterine positioning. This may not fully resolve until they become established walkers at 18 to 24 months. An intoed gait may then be more apparent. Lateral hip rotation gradually decreases as medial rotation increases. Paradoxically, anteversion in the femoral neck typically decreases from 30 degrees (range 15 to 50) at birth, to 20 degrees (range 10 to 35) by age 10 years (1–5,7,8). A decrease in anteversion of the femoral neck would be expected to produce greater external rotation of the hip. A child who toes-in while walking, but has at least 20 degrees of hip external rotation, is within normal limits. Similarly, a child who toes-out while walking, but has at least 20 degrees of hip internal rotation, has motion within a normal range (4,5,10).

Internal rotation variations have not been shown to cause degenerative joint disease (9,10,17–20). Hip pain is rarely a complaint (17,19). Anterior knee pain may be associated with increased medial rotation of the femur, but not generally with patellofemoral changes (19,21). Although the presence of hip external rotation may augment posterior shear loads, an increased incidence of slipped epiphysis has not been found in patients with femoral retroversion without other contributory factors being present (14). Athletic ability does not correlate with the position assumed during normal walking, although some activities may be hindered by rotational variations (22–24). High-performance sprinters do, however, tend to adopt a toed-in position during running, regardless of their walking style (24). Functional impairment, such as tripping, clumsiness, or lack of running ability, although often attributed to rotational differences, has not been shown to correlate with rotational profile (22).

There are some children with such extreme variation in rotation that their appearance is unacceptable to the child, the parents, and/or families (usually grandparents). The natural history of rotational variations, the lack of evidence for musculoskeletal sequelae, and absence of objective functional disability must be kept in mind, and these individuals educated in this regard (1,3–5). The natural history of rotational variations should be clearly communicated and understood prior to any recommendation for active treatment.

Treatment

The natural history of rotational variations is gradual normalization, which cannot be altered by nonsurgical means. The use of shoe modifications, orthotics, or positioning devices is ineffective (5,16). Although not harmful, there is little to show any positive effect. Their use reinforces the errant notion that intoeing or out-toeing is an abnormal condition or disorder that requires treatment. The cost of orthopaedic shoes and orthotics can be considerable.

For those otherwise normal children, who have persistent rotational abnormality into adolescence and find the appearance of their gait unacceptable, corrective osteotomy may be considered (4,5,25,26). An awkward gait may appear less so following rotational osteotomy. However, it should be clearly understood that function may change little, if at all. Pain, while rarely a complaint, may be improved following surgical treatment (21). Treatment options for foot and ankle abnormalities are covered in Chapter 29.

Supramalleolar rotational osteotomy of the tibia and fibula [↗4.6.8] has less potential for serious neurovascular complication than proximal tibial osteotomy (25,27). The author's preferred technique uses fixation with crossed K-wires, supplemented with a long leg cast for 6 weeks. The tibia should be cut 2 to 3 cm above the physis and parallel to the ankle. Rotation through an oblique cut can tilt the articular surface of the tibia. Sectioning of the fibula also allows easier rotation of the tibia without displacement. The degree of correction is determined by aligning the foot and ankle, such that the second toe is in line with

the tibial tubercle and the center of the patella. As the foot is dorsiflexed and the knee bent, the foot should remain in line with the lateral thigh. Two or three stainless steel wires (0.062 is sufficient) are inserted, one from proximal medial to distal lateral, and the second from distal medial to proximal lateral. A long-leg bent-knee cast is used for 6 weeks. Healing is usually sufficient at that time for pin removal and application of a short-leg weight-bearing cast for 4 to 6 weeks more.

Correction of excess femoral internal or external rotation is obtained by equalizing the degree of internal versus external rotation. The amount to be rotated can be estimated from the prone exam, comparing internal and external hip rotation, preoperatively (5). Femoral osteotomy may be proximal [↗4.6] or distal, [↗4.18] depending on the surgeon's preference and the type of fixation to be used (26,28). Proximal femoral osteotomy may be considered if there is also proximal femoral varus or valgus deformity. A standard lateral approach to the proximal femur is used. A pediatric or adolescent blade plate is used for fixation. If a distal femoral osteotomy is performed, a lateral approach is preferred. In skeletally immature patients, a small compression plate is used. Blade plate fixation may be used in skeletally mature individuals. Use of additional cast or brace immobilization is at the discretion of the surgeon. Alternatively, a medial approach can be used along with K-wire fixation (26). This latter technique should be reserved for smaller children, and must be supplemented with a spica cast. The amount of rotational correction sought is an equal amount of internal and external rotation.

Intramedullary fixation can be used for either the tibia or the femur. Supplemental fixation is generally not necessary. Locking screws or similar mechanisms are needed proximal and distal to the osteotomy, because the osteotomy has no intrinsic stability. In the skeletally immature, and for those with a relatively narrow medullary canal, the osteotomy is generally performed by open technique. The proximal femoral entry site is made lateral and distal to the tip of the greater trochanter. Great care is taken in avoiding any dissection (including penetration) on the medial side of the trochanter. Recent modification in femoral nail design (proximally angulated 15 degrees) enhances nail placement with this approach. In skeletally mature patients with relatively larger bony anatomy, the femur can be sectioned using an intramedullary saw. Because of the technical demands of this technique, it is recommended only for those with considerable experience with intramedullary fixation in children.

External fixation can be used, but effective rotation may be hindered by pull of the soft tissues (30,31). Acute correction with unilateral frame can be used. Pins should be inserted, taking into account the rotation to be accomplished. This can be a difficult technique, particularly in large adolescents. The amount of change in rotation can be reassessed in the early postoperative period, and adjusted if needed. Gradual rotation is not necessary in these normal children.

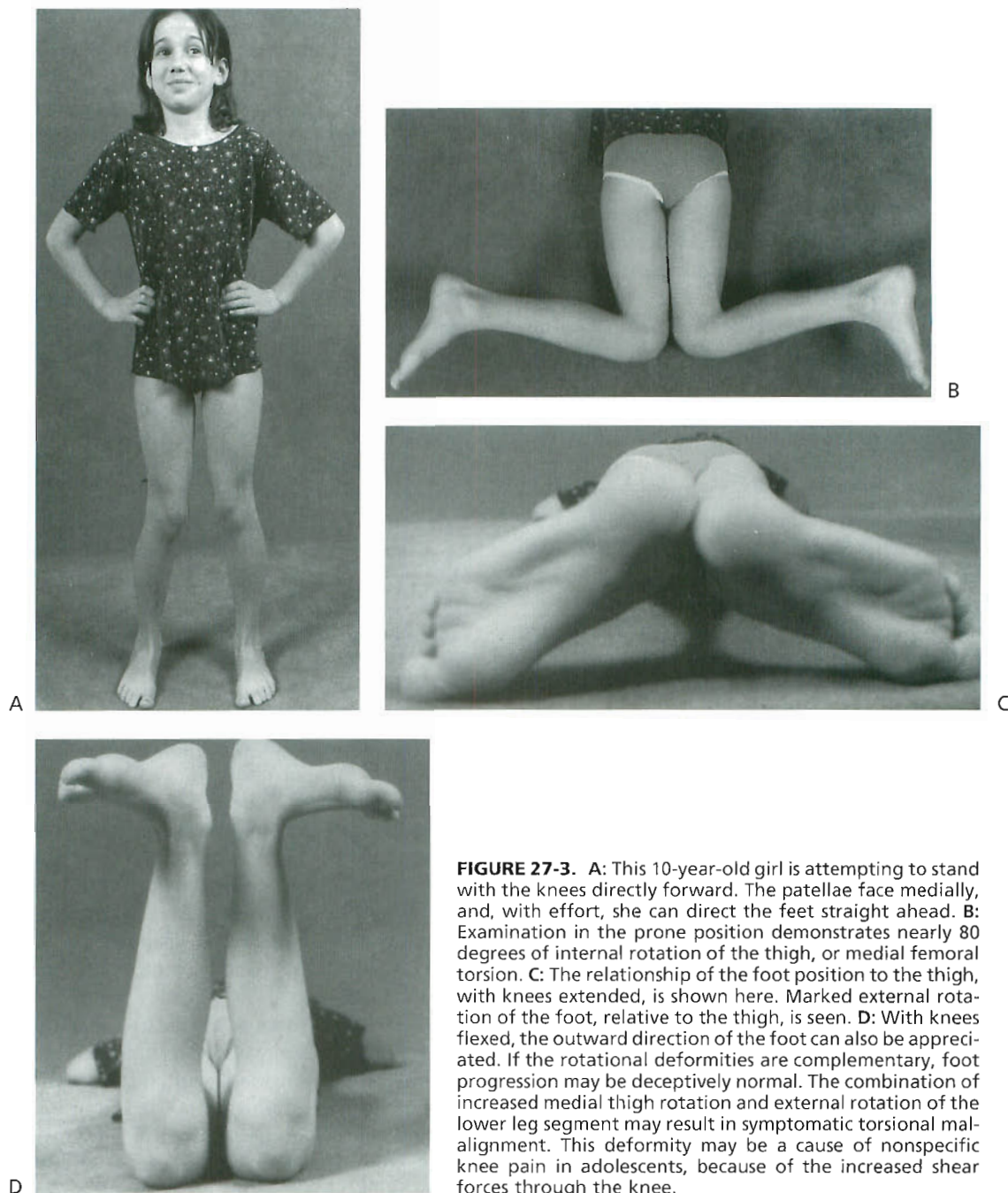


FIGURE 27-3. A: This 10-year-old girl is attempting to stand with the knees directly forward. The patellae face medially, and, with effort, she can direct the feet straight ahead. B: Examination in the prone position demonstrates nearly 80 degrees of internal rotation of the thigh, or medial femoral torsion. C: The relationship of the foot position to the thigh, with knees extended, is shown here. Marked external rotation of the foot, relative to the thigh, is seen. D: With knees flexed, the outward direction of the foot can also be appreciated. If the rotational deformities are complementary, foot progression may be deceptively normal. The combination of increased medial thigh rotation and external rotation of the lower leg segment may result in symptomatic torsional malalignment. This deformity may be a cause of nonspecific knee pain in adolescents, because of the increased shear forces through the knee.

Increased femoral internal rotation and tibial external rotation may coexist, producing a rotational malalignment (21) (Fig. 27-3). Knee pain, which is usually diffuse, may be present. Patellar maltracking usually is not present. Because the deformities are complementary, foot progression may be normal, but the static exam will demonstrate the abnormality. Combined osteotomy of the femur and tibia may be necessary to correct symptomatic malrotation (4,21). Femoral rotation is corrected as the first step of the

procedure. The foot is aligned with a tibial osteotomy to complete the correction.

Complications

Any of these techniques can be used to alter rotation. Choosing a technique with which the surgeon is most familiar can reduce technical errors and complications. Proximal femoral osteotomy is preferred over distal osteotomy by

some, because proximal osteotomy is more forgiving of any inadvertent varus or valgus angulation resulting from an oblique osteotomy (26,28). Scars may be less apparent with proximal osteotomy. Asymmetric growth arrest can occur from periosteal stripping and injury to the lateral distal femoral physis. Injury to the greater trochanteric apophysis can produce valgus deformity in the proximal femur. These risks may be minimized by choice of a technique with which the surgeon is familiar, appropriately sized internal fixation devices, and consideration of the patient's level of skeletal maturity. Osteotomy performed in adolescence has less potential for serious growth disturbance than that performed in young children.

The risks and complications of intoeing and out-toeing are related to its treatment, not its presence (3–5,15,17,18,22). Therefore any recommendation for surgical treatment carries greater risk than no treatment. Because most patients who have surgical alteration of their rotation do so for a change in the appearance of their gait, the surgical procedure should accomplish the desired change in rotation. Function may not be altered.

Complications of rotational osteotomy are the same as for other osteotomies. Problems related to nonunion, infection, blood loss, joint stiffness, scarring, and anesthesia are the most serious (21,25–27). Distal tibial osteotomy has less risk of compartment syndrome and peroneal nerve injury than proximal osteotomy.

Use of intramedullary fixation of the femur carries with

it the risk of avascular necrosis of the femoral head, which is not a concern with other types of fixation (29,32,33). Recent changes in pediatric intramedullary nail design permit safer entry through the greater trochanter. The availability of appropriately sized locked nails for the femur may limit the feasibility of this technique in small femurs.

GENU VARUM

Physiologic Bowing

Definition

Infants and children frequently present to the orthopaedic surgeon for evaluation of bowleg deformity (34). Typically, these children are early walkers, achieving independent ambulation before the first year of life (35–37). The normal knee alignment at birth is 10 to 15 degrees of varus, which remodels to a neutral femoral–tibial alignment at approximately 14 months of age (38–40) (Fig. 27-4). Levine and Drennan (41) have defined physiologic bowing as more than 10 degrees of bilateral varus noted after the age of 18 months.

Clinical Features

Parents are concerned with both the cosmetic appearance of the bowing deformity and the seemingly associated problems of excessive tripping. A family history of bowing is common (34,42). Examination typically reveals bowing of

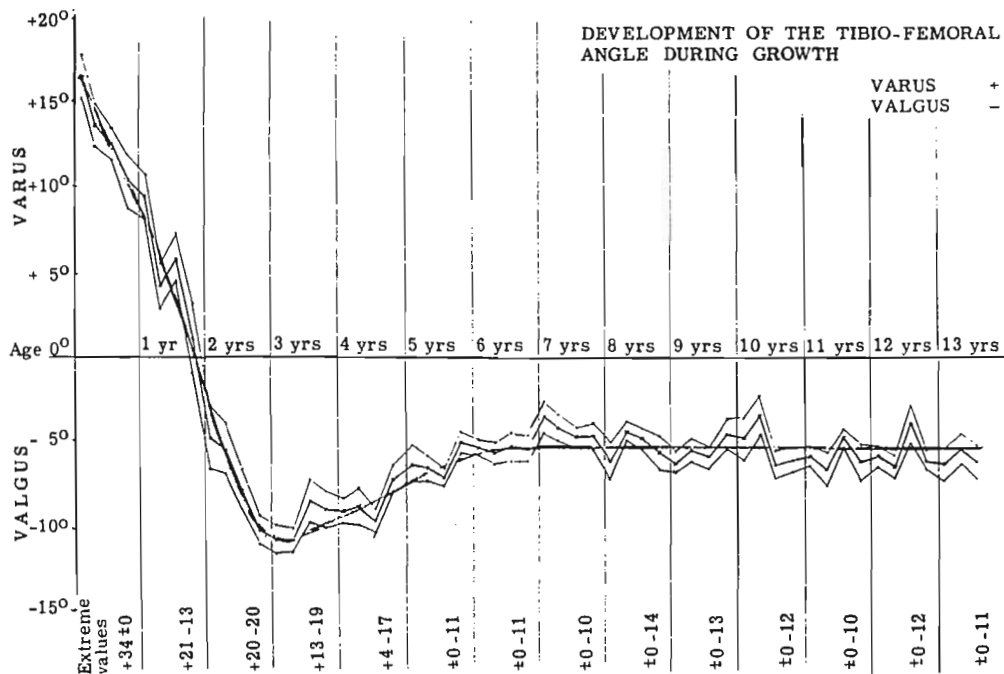


FIGURE 27-4. The graph depicts the expected change in genu varum and genu valgum with age. Children with bowlegs after 2 years of age are outside the normal range, and should be thoroughly evaluated. (From ref. 38, with permission.)

both lower extremities with intoeing. Although the bowing deformity is bilateral, it can vary in relative severity of left versus right. Despite their bowlegged, toed-in gait deformity, these infants characteristically are very agile walkers. The child should be observed walking, both coming and going, to assess the severity of the dynamic varus and associated internal rotation deformity. Internal rotation of the extremity seemingly permits maintaining the foot contact point along the body-centered line of progression with the child standing. It should be noted whether or not there is a lateral thrust, a characteristic brief dynamic lateral knee joint protrusion that occurs in stance.

The degree of varus deformity of lower extremity is measured with a goniometer. Standing photographs are helpful in documenting the deformity noted on initial clinical exam. Subsequent photos can be compared with the originals to determine the degree of resolution or progression of the bowing deformity. The "bench exam" is performed with smaller children on the parent's lap and older children on the examining room table.

Angulatory and rotational alignment and joint range of motion for the entire lower extremity is assessed. Knee joint laxity typically is not present. More than likely, the clinical diagnosis will be physiologic bowing and, because the children present at a slightly older age, possibly infantile tibia vara (Blount disease). In the child less than 15 months of age, radiographs document the degree and location of the varus deformity, but usually will not distinguish between physiologic bowing and early Blount disease. Radiographs become a more essential part of the evaluation as the child grows older (>15 months of age), for more relatively pronounced deformities (>20 degrees), if a lateral thrust is observed, if the child is relatively short in stature (<20 percentile), or a metabolic bone disease is suspected (Fig. 27-5). Preferably, the x-ray is taken with the patient standing and the patella pointed straight ahead. The relative degree of varus deformity is noted, observing the shaft-shaft angle of the femur and tibia (41,42). More importantly (43), the distribution of bowing deformity is noted. In physiologic bowing, it occurs diffusely at the distal femur, proximal tibia, and distal tibia, and, in early Blount disease, more focally at the proximal tibia.

Differential Diagnosis

The differential diagnosis of bowing in the young child includes physiologic bowing and pathologic bowing. Pathologic bowing occurs in infantile tibia vara (Blount disease), metabolic bone disease, and skeletal dysplasias. The clinical and radiologic features associated with metabolic bone disease or skeletal dysplasia can be readily differentiated from physiologic bowing. Most often, the differentiation is between physiologic bowing and infantile Blount disease. If the bowing is physiologic, the entire lower extremity will appear to be bowed. If the varus alignment results in relative

greater deformity of the proximal tibia, infantile tibia vara, or Blount disease, may be present. Children with either physiologic bowing or Blount disease usually are early walkers, and typically present for evaluation at 15 to 18 months of age. It is not uncommon for siblings to be affected with either physiologic bowing or Blount deformity (34,35, 42,43). No doubt, physiologic bowing and Blount disease ought to be perceived as two different points on the same spectrum, as the end results of the persistence of infantile bowing (35,41,44). Radiographic distinction between physiologic bowing and Blount disease may not be initially obvious, because Langenskiöld changes diagnostic of Blount disease typically are not distinctive until 2 to 3 years of age (36,39,41,43,45) (Fig. 27-6). Measuring the metaphyseal-diaphyseal (M-D) angle of both the proximal tibia and distal femur further helps to identify the specific location and relative severity of varus deformity (41,45,46) (Fig. 27-5A and B). Although an absolute M-D angle is not diagnostic, it does serve as a more specific guide in differentiating Langenskiöld stage I infantile Blount disease from physiologic bowing (39,43) (Fig. 27-6). The authors' study of the proximal tibial M-D angle, in patients with physiologic bowing and Blount disease, identifies two distinct bell curves with considerable overlap (45) (Fig. 27-7). From this one concludes that if the M-D angle is less than 10 degrees, chances are (95% probability) that the diagnosis is physiologic bowing. Conversely, if the M-D angle is >16 degrees, then chances are (95% probability) that the diagnosis is Blount disease. The initial indeterminate patient, those between 10 and 16 degrees, often need follow-up for at least 1 to 2 years to note whether progressive remodeling or the occurrence of Blount disease occurs. The ratio of the M-D angle of the distal femur, relative to the same angle of the proximal tibia, can be helpful in attempting to differentiate physiologic bowing from early Blount disease. A ratio of greater than 1 suggests the bowing is physiologically proportioned to the femur and tibia, and remodeling will typically occur (46). If, however, this ratio is <1, the bowing probably will evolve into Blount disease.

Less often, physiologic bowing must also be differentiated from the pathologic bowing associated with metabolic bone disease or skeletal dysplasia. Rickets is the most likely metabolic bone disease presenting in the toddler with bowed-leg deformity (47,48) (Fig. 27-5C). In this age group, rickets (most likely X-linked hypophosphatemic rickets, or XLH) is the most likely metabolic bone disease to initially present with a lower-extremity bowing deformity. Infants presenting with rickets are very short, the measured height being less than the tenth percentile. Radiographs of infants with bowing deformity secondary to rickets should not be mistaken for physiologic bowing (43). In patients with XLH, the physis will appear abnormally wide, with the metaphysis flared out and around the physis in a trumpet shape. Similar changes will be noted at all metaphyseal/physeal areas. Overall, bone density will be dimin-

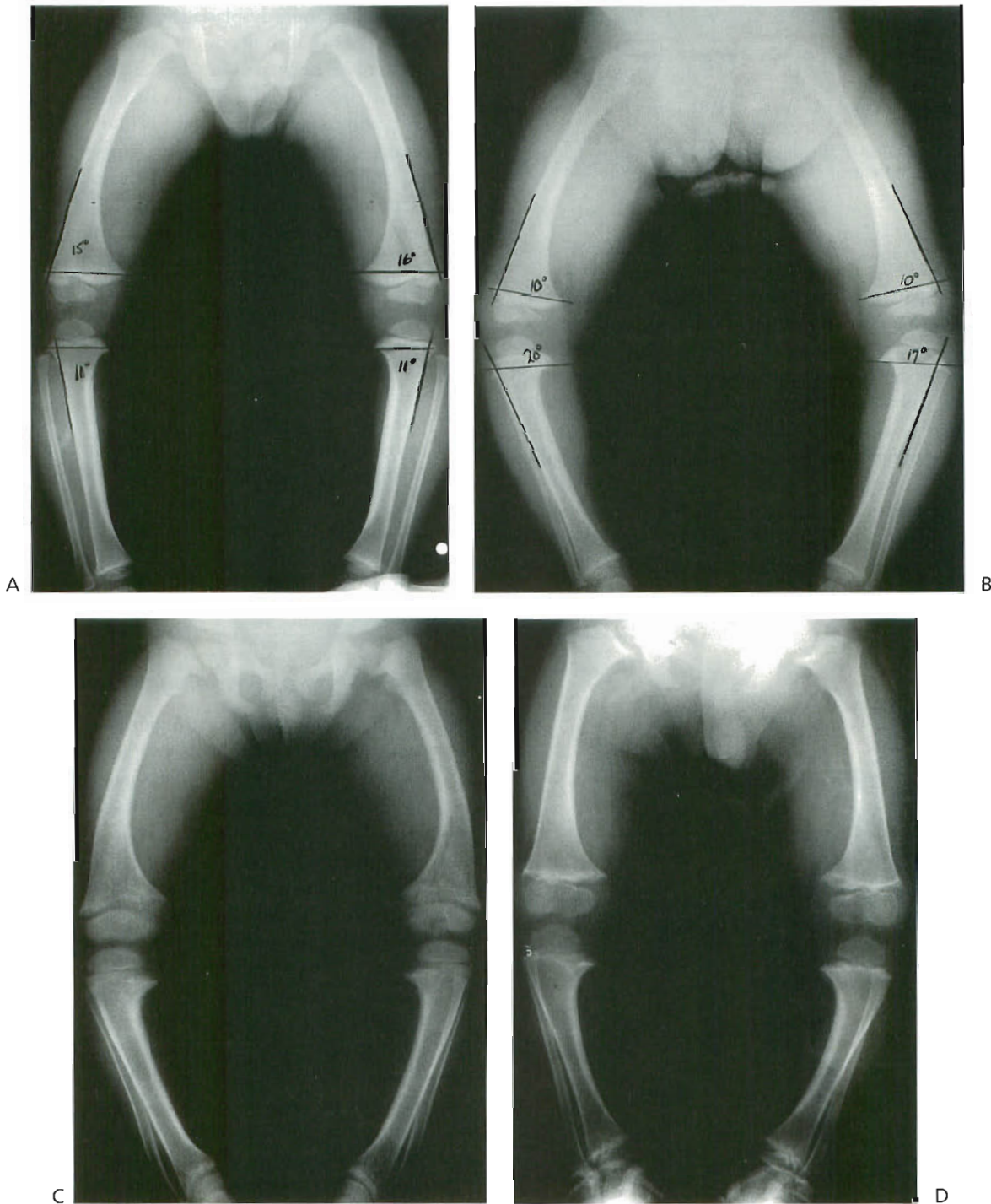


FIGURE 27-5. Standing AP films of both lower extremities help distinguish physiologic bowing from pathologic causes. **A:** Tibial metaphyseal–diaphyseal (M-D) angles are typically 11 degrees or less. A similar angle constructed in the distal femur is the same or greater, indicating that the femur and tibia contribute similarly to the bowing. The ratio of femoral to tibial M-D angle is ≥ 1 . **B:** Early Blount disease may be difficult to distinguish from severe physiologic bowing. The M-D angle in Blount disease is usually greater than 16 degrees, and the ratio of femur to tibia is ≤ 1 . Fragmentation of the medial tibial metaphysis may not be evident. **C:** This patient with X-linked hypophosphatemic rickets (XLH) has multiple widened physes. Osteopenia is evident in the adjacent metaphysis, which is also flared. Bowing tends to be more diffuse throughout the bone, rather than focal in the proximal tibia. **D:** Skeletal dysplasia, such as chondrometaphyseal dysplasia, may cause genu varum. These children are usually of short stature. Skeletal abnormalities are multifocal, as in this example of Schmid-type metaphyseal chondrodysplasia. The proximal and distal metaphyses of the femur and tibia are all abnormal. The epiphyses, physes, and bone density are normal.

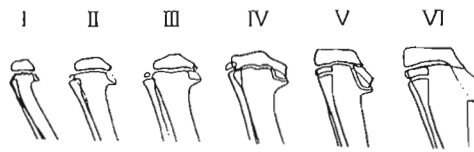


FIGURE 27-6. Depiction of the six stages of radiographic changes seen in Langenskiöld classification of tibia vara. (From ref. 56, with permission.)

ished, with particularly poorly defined diaphyseal/metaphyseal cortices. The severity of both bone morphological and osteomalacia changes varies considerably. The diagnosis of XLH is definitively made by analyzing serum calcium and phosphate and urine calcium and phosphate (47,48). Patients suspected of having rickets should be referred to an endocrinologist for a definitive metabolic workup.

Skeletal dysplasias can initially present as a bowing deformity of the lower extremity (see chapter 8 in this text).

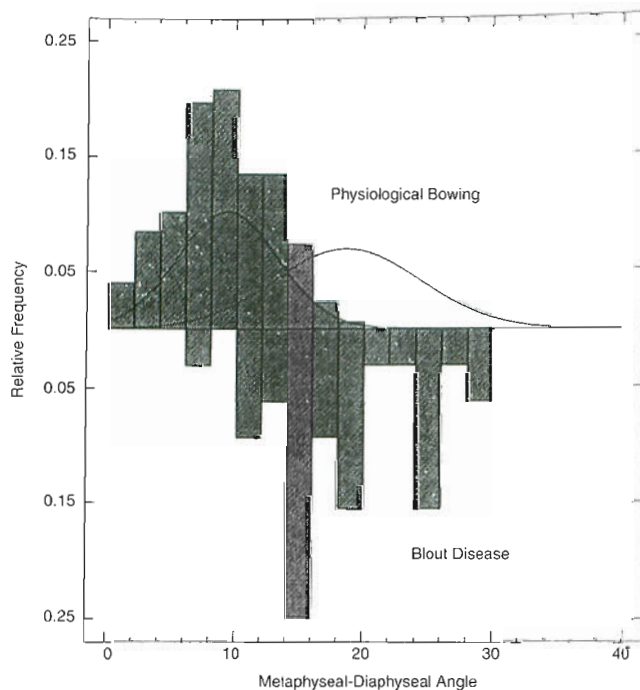


FIGURE 27-7. The relative frequency of metaphyseal–diaphyseal (M–D) angle, measured in children with physiologic and Blount disease, is presented. The M–D angle in physiologic bowing is graphed above the horizontal line; similar measurements in Blount disease are graphed below. The bell curve to the left shows the distribution in physiologic bowing. The bell curve to the right is the distribution in Blount disease. Although peak distributions are clearly separate, there is significant overlap between M–D angles of 10 and 16. Below 10, there is a 95% probability that the bowing is physiologic. Above 16, there is a 95% probability that the bowing observed is in fact Blount disease. Angles in between are indeterminate. Additional risk factors, such as obesity, instability (lateral thrust), and family history, must be considered.

Metaphyseal chondrodysplasia (Schmid or McKusick type) typically presents with persistent bowing and short stature, in an otherwise normal child (Fig. 27-5D). The child presenting with bowing deformity, in association with a skeletal dysplasia, will be very short, typically in the <5th percentile. Morphologically, the radiographic changes about the physis and metaphysis will not appear pathologically flared, the physes are not abnormally widened, and bone density will appear to be normal. Achondroplasia often presents with bowing. The distinctive physical findings of achondroplasia should allow for differentiation. Patients with pseudoachondroplasia may initially present with a varus or valgus deformity, in association with ligamentous laxity. Again, these patients can present with very short stature and distinctive physical findings.

Focal fibrocartilaginous dysplasia is a very uncommonly occurring, progressive, unilateral focal dysplasia of the proximal medial tibial metaphysis (49–52). The clinical presentation is very similar to unilateral infantile Blount disease. The diagnosis is made radiographically. A characteristic focal indentation is noted into the medial metaphyseal–diaphyseal cortex, with associated varus of the tibia (Fig. 27-8). The epiphysis will appear normal.

Natural History of Physiologic Bowing

Physiologic bowing in the vast majority of patients will resolve with growth, as predicted by the Salenius plot (Fig. 27-4) of the natural changing frontal plane alignment of the lower extremities (38,40). Parents should be properly informed that spontaneous correction of this physiologic varus is anticipated to occur within 1 to 2 years. Additional effort should be made to explain the futility of nonoperative treatment (be it orthotic shoe insert, shoe modification, or nighttime orthoptic splinting, etc.), in attempting to expedite the anticipated remodeling. Follow-up visits may not be necessary in milder physiology deformities, because the bowing and associated internal torsion predictably resolve. For the relatively more pronounced or persistent deformities, follow-up visits are scheduled at 4 to 6 month intervals. Correction or progression of varus that occurs with growth can be documented with subsequent physical examination and both radiography and photography. Occasionally, physiologic varus may persist into late childhood, warranting longer follow-up.

Infantile Blount Disease

Definition

In 1937, Walter Blount published his classic review of tibia vara or osteochondrosis deformans of the proximal tibia, noting its progressive course of both clinical deformity and correlative radiographic pathology (53). The radiographic and pathologic changes described by Blount, and histopath-

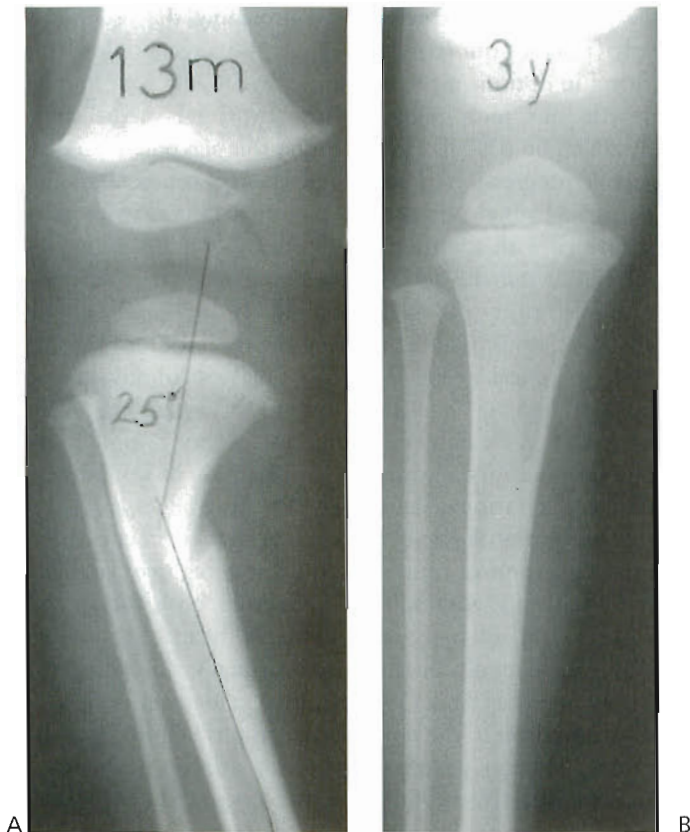


FIGURE 27-8. Focal fibrocartilaginous dysplasia. **A:** Initial radiograph of the patient at 6 months of age shows anterior and lateral bowing of the tibia, but is more proximal than in congenital pseudarthrosis **B:** The deformity resolved spontaneously, as seen in a radiograph made at 3 years of age.

ologic changes by Langenskiöld (36,54–56), were felt to be secondary to a disruption of normal growth of cartilage and bone from excessive abnormal weight-bearing pressure on the growth plate and adjacent bone. Avascular necrosis of bone has not been observed (56). The inherent progression of this developmental, pathologic tibia vara can be definitively corrected with treatment (53,55,57–59).

Etiology

Like physiologic bowing, infantile Blount disease is usually bilateral (35,37,42). In the early presentation of the infant bowed-leg deformity, there is no clear distinction between Blount disease and physiologic bowing (35,37,42,44, 60–62). Rather, physiologic bowing is a continuum with Blount disease. When unilateral infantile Blount deformity is noted, it is not uncommon for the contralateral extremity to be physiologically bowed and often indistinguishable from early infantile Blount disease (Fig. 27-9A and B). They share the common etiologic factor of early weight-bearing by a child who may or may not be overweight (34,35,

37,39,41,43,44,53,54). Early walking results in a variable increase in physeal shear stress and eventual disruption in medial physeal and bony growth (35,36,63). Obesity increases the potential for chronic growth plate injury.

Cook et al., using finite-element stress analysis, calculated that the compressive force resultant from weight-bearing on a bowed leg was sufficient to cause progressive growth disturbance (64). In some extremities, by chance, physiologic bowing remodels (35,39), and in others the varus focally worsens at the proximal tibia, and Blount disease develops. The resulting osteochondrosis is a consequence of increased pressure on the medial proximal tibial physis and adjacent epiphysis and metaphysis (35,42,44,62,65). A prediction for developing an osteochondrosis has been postulated (34–36,44,66). There is a variably occurring familial history of infantile tibia vara (34,37,42,67).

Pathoanatomy

In 1952, Langenskiöld identified six distinct radiographic stages of infantile Blount disease that can be seen during skeletal maturation (54) (Fig. 27-6). The ages at which each stage occurs varies, as does the observed prognostic significance (39,42,43,54,56). In stages I–II, irregular and reversible early metaphyseal ossification changes are often indistinguishable from physiologic bowing. Stage IV lesions can be associated with early, though often difficult-to-detect, bar formation across the deformed vertical physis (39,43). Profound disruption of normal physeal cartilage and adjacent bony growth is noted in stage V (more than age 8 years) with resultant severe joint depression deformity in stage VI (36). Langenskiöld and Riska (36) felt that the evolution from stages II–IV does not necessarily predict outcome or response to treatment (56). However, recent reports (37,39,42) note that in stage IV an osseous bar is often detectable. The severity of the secondary tibial varus deformity varies directly with the extent of the bony changes involving the proximal medial tibia. In some cases, a compensating secondary valgus deformity of the distal femur develops (35,68).

Treatment

Nonsurgical Treatment. Brace treatment should be considered in all patients less than 2½ years of age with early Blount disease changes (Langenskiöld stages I–II), and in other patients with persistent bowing and at-risk signs for Blount disease. A M-D angle of >16 degrees is a radiographic sign at risk (39,43,45). A relative radiographic sign at risk is a M-D angle of 10 to 16 degrees and a clinically noted persistent or progressive varus deformity. Obesity and ligamentous instability (evidenced by the presence of a lateral thrust [43]) potentiate the severity of varus deformity

from any cause, and are added risk factors (4,9,45). The authors have previously noted successful definitive brace treatment of six patients with infantile Blount disease. Recent reports (37–39) demonstrate that brace treatment can be definitive in correcting both the varus deformity and the pathologic proximal medial tibial growth disturbance. Brace treatment should be initiated early. A modified knee-ankle-foot orthosis (KAFO) that prevents knee flexion is worn 23 of 24 h (39,57–59,69). The locked KAFO unloads the pathologic medial compression forces, allowing resumption of the growth and correction of the genu varum.

The bowleg deformity typically improves over the ensuing months. The pathologic radiographic changes at the proximal medial tibial metaphysis, physis, and epiphysis are much slower to remodel. The authors maintain the brace treatment until the bony changes in the proximal medial tibia resolves; typically, this takes 1½ to 2 years of brace treatment (57–59). To be predictably successful, definitive correction must be achieved before 4 years of age (37–39,43). In combining the results of the three recent reports of brace treatment for infantile Blount disease, a total of 79 extremities were treated. The best results were obtained with unilateral deformity, with brace treatment being reported as successful in 22 of 23 patients. Contrastingly, brace treatment was relatively unsuccessful in treating bilateral deformities, with only 18 of 28 patients noted to be successfully treated with bracing (57,58). Understandably, brace-wearing compliance was much more difficult to achieve for the child with bilateral deformity. Bracing should not be initiated after 3 years of age, nor should brace treatment be continued if Langenskiöld stage III changes develop (57–59).

Surgical Treatment. The goal of surgical treatment of early infantile Blount disease (Langenskiöld stage < IV) is to correct the abnormal limb alignment that indirectly restores more normal proximal-medial growth. Early corrective surgery (≤ 4 years of age) is critical in predictably achieving restoration of normal growth (39,42,43,56,61). In older children with more advanced pathologic changes (Langenskiöld stage > IV), the goal is to directly correct both abnormal lower-limb alignment and pathologic bony changes, either at the proximal medial tibial physis or the articular surface of the proximal tibial. Comprehensive correction of all aspects of the often complex deformity is essential in achieving a satisfactory outcome.

Moderate Varus. A corrective proximal tibial osteotomy is indicated if, following brace treatment, the varus deformity and abnormal proximal medial tibial growth have not resolved (39,43) by age 4 years (Fig. 27-9A and B). Children 2 to 3 years old, who are either noncompliant or anticipatedly not good brace-treatment candidates (39,57) (relatively large thigh confluence and/or bilateral involvement, or ≥ 3 years) at initial presentation, should be treated with

a vagus correcting osteotomy. Performing the osteotomy early (at least prior to 4 years of age, < Langenskiöld III) is critical in optimizing restoration of eventually near-normal growth and morphology of the proximal medial tibia (39,42,43,56,61,70). Delay beyond this age potentiates inevitable progression of pathologic changes centered around the medial tibial physis. The proximal tibia osteotomy is performed with attention to both the known inherent risks (39,71,72) and the need for obtaining adequate correction of the deformity (39,43). The fibula is osteotomized with great care, so as to avoid injuring the deep motor branches of the peroneal nerve (27). The tibial osteotomy can be accomplished in a variety of ways (39,43,56,73–75) [→6.2–6.5]. A straight transverse osteotomy optimally allows for necessary adjustment in correction of frontal, sagittal, and rotational deformity. The fragments are stabilized with smooth Kirschner wires. A slight over correction into valgus, and/or translating the distal fragment laterally, is desirable (39,42,43,76). This allows both for frontal plane alignment correction and places the mechanical axis of the leg laterally in the knee, optimally unloading the medial proximal tibia (39). In unilateral deformities, clinical comparison to the normal extremity is helpful in determining whether adequate correction has been obtained. An intraoperative anteroposterior x-ray of the entire lower extremity can be taken to assess the correction obtained.

Alternatively, the authors trace the mechanical axis of the leg from the hip to the ankle with the metallic Bovie cord and the C-arm (Fig. 27-9C). This simple technique provides for a reproducible method to verify that the mechanical axis has truly been transferred lateral to the center of the knee joint (77). Neurovascular complications are associated with a proximal tibia osteotomy (42,71,78–81). Subperiosteal exposure minimizes direct nerve and/or vessel trauma. Prophylactic limited fasciotomy (43) and utilizing drains help to prevent a build-up of compartment pressure. If a compartment syndrome is suspected postoperatively, immediate treatment with fasciotomies should be performed. In fact, in recent clinical experience, the authors have been more likely to observe an acute traction or impingement injury to the peroneal nerve (27). Again, prompt surgical release of the peroneal nerve compression has typically resulted in a satisfactory outcome.

Postoperatively, the extremity is immobilized in a long-leg, bent-knee cast or, alternatively, a spica cast, for the child with relatively short, fat extremities. It is essential to radiographically document that valgus alignment has been obtained and maintained. Alternatively, Price et al. have effectively utilized monolateral external fixation to stabilize the osteotomy(ies) (77). On occasion, short-term postoperative long-leg bracing (KAFOs) is utilized if the preoperative deformity was severe and associated with ligamentous laxity. Following corrective osteotomy, the bony medial pathologic changes must be carefully monitored because further pro-

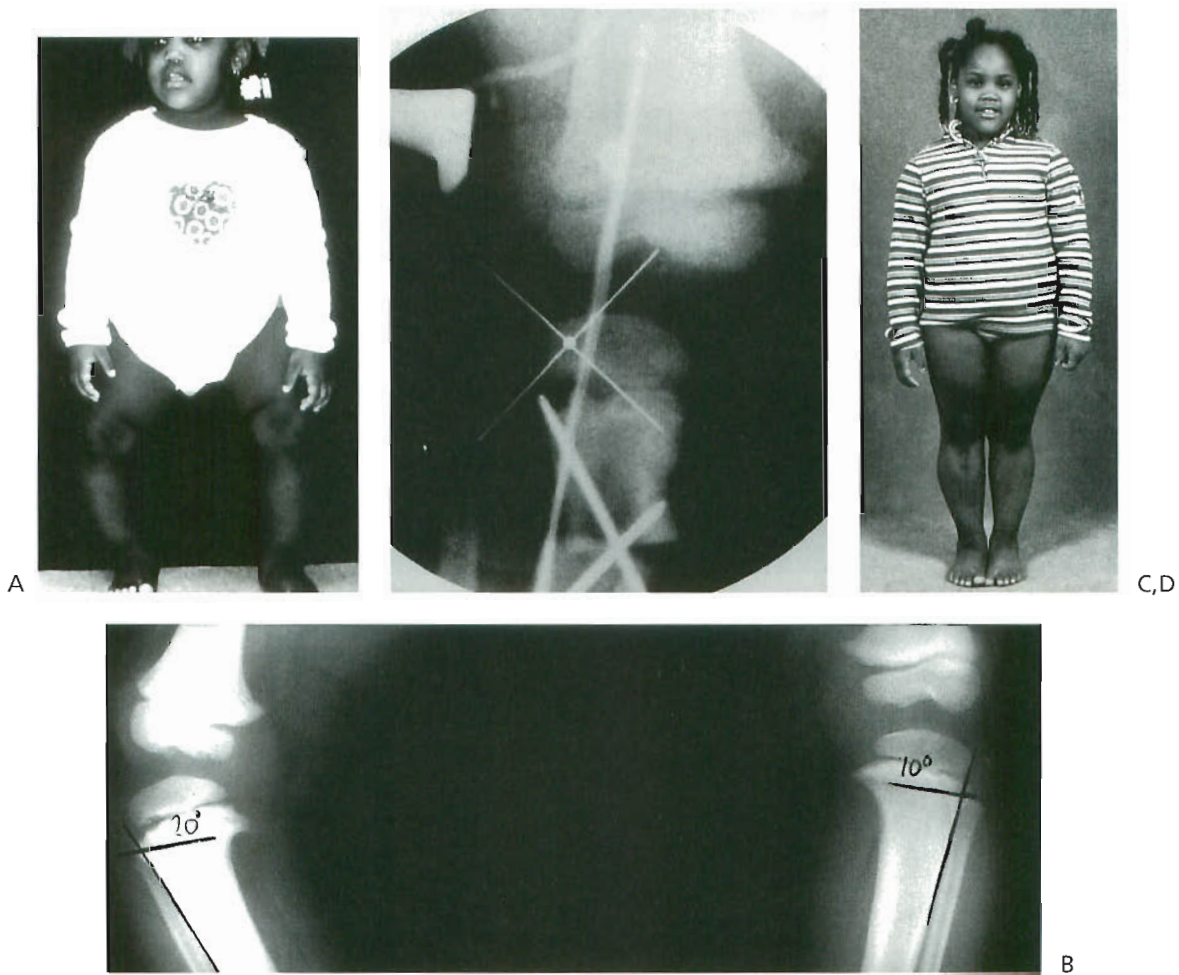


FIGURE 27-9. A: This 30-month old girl shows clinically asymmetric bowing. She is large for her age (>95% weight). B: The M-D angle on the right is 20 degrees, compared to 10 degrees on the left. This is consistent with stage II changes of Blount disease on the right and physiologic bowing on the left. C: Intraoperative films of a right proximal tibial osteotomy show slight over correction to valgus. A Bovie cord, centered over the hip and ankle, is an easy method to assess mechanical axis intraoperatively. Crossed K-wires are used for fixation. D: A clinical photo taken 2 years later shows maintenance of correction on the right. Spontaneous correction of physiologic bowing has occurred on the left.

gression in their development may or may not be associated with a recurrent of deformity (36,39,43) (Fig. 27-9D).

Worsening Varus Deformity

Recurrence of varus deformity and/or persistent pathologic tibia vara radiographic changes can occur despite restorative osteotomies done prior to 4 or 5 years of age. The recent clinical experience in North America (39,42,43,61) cites a recurrence rate of varus deformity much higher than observed by Langenskiöld, whose clinical experience with Blount disease has been in a very homogeneous Finnish population. In North America, the population is more heterogeneous, many children are obese, and a high percentage are black (35). Blount disease may be a more rapidly pro-

gressing disease in North America than it is in Finland (39,43,56). The authors have observed advanced changes in Langenskiöld stages (IV–V) in patients 4 to 5 years of age, both obese and nonobese, and of variable race. Risk factors that have been identified for recurrence include Langenskiöld stages III–IV, marked obesity (>95 percentile), ligamentous laxity, and black females (39,42,43,61). Alternatively, patients may initially present with more advanced pathology (\geq Langenskiöld stage IV) (Fig. 27-10A). If patients present initially or with recurrent deformity, MRI, CT, or conventional tomography should be utilized to search for the presence or absence of bony tether traversing the distorted proximal medial tibial physis. Identification of a bar through the serpentine, vertically sloped medial tibial physis can be difficult. Early bridging typically occurs

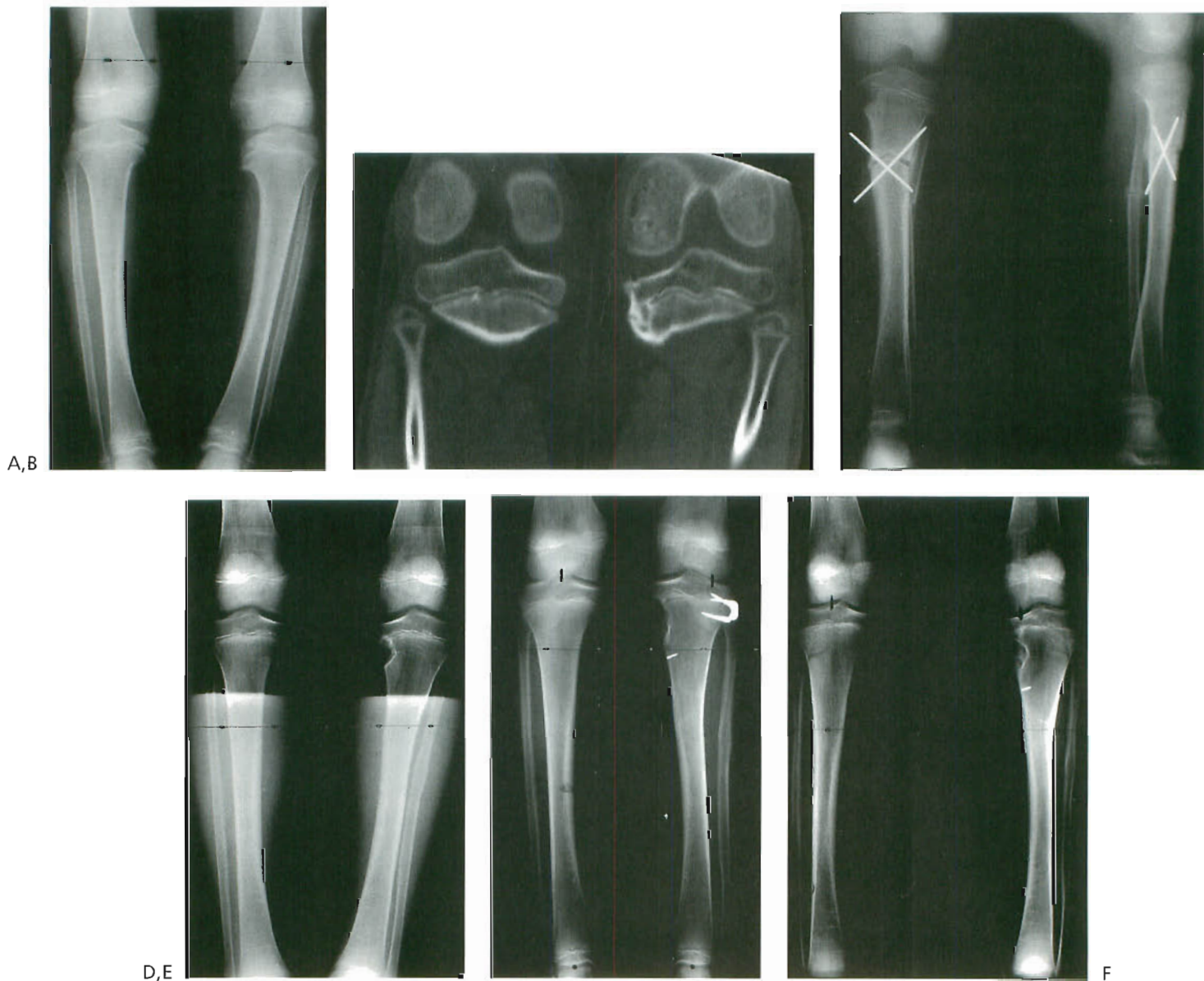


FIGURE 27-10. A: These anteroposterior radiographs show focal changes of unilateral stage IV Blount disease. The medial tibial physis is indistinct. These changes are suggestive of physeal bar formation. B: A CT scan shows the deformity in the medial physis. The growth plate has a vertical, rather than horizontal, orientation. A bridge of bone is clearly evident here. Varus will rapidly recur following osteotomy if the physeal bar is not recognized or treated. C: These postoperative films show correction of the varus and resection of the bar. The defect created by excision is filled with radiolucent methylmethacrylate (Cranioplast). D: Subsequent films show recurrent bar formation, with gradual loss of correction over 2 years. E: A second excision of the physeal bar, along with lateral physeal stapling, has resulted in improved alignment. F: Following removal of the staples, varus has gradually recurred. The abnormal medial physis tends to close prematurely.

at the most inferior aspect of the vertical limb of the distorted medial physis (Fig. 27-10B).

On occasion, the varus recurs without an obvious bony bar (Langenskiöld III or early IV) (39). This occurs rather subtly, as a result of a relatively decreased growth rate of

the proximal medial tibial physis. This can occur early or late, until the time of maturity. In this setting, the varus deformity can be controlled with temporary staple epiphysiodesis (39,82,83). The staples are removed after a slight over correction is obtained. Again, the growth of the in-

volved tibia must be closely monitored for a tendency for recurrence and/or early physal closure.

If recurrent progressive varus occurs with an identifiable osseous bar, appropriate restorative surgery is indicated. Progression of initial bar formation eventually results in complete arrest of the entire medial physis (Langenskiöld stage VI). Physal bar resection [►4.22] in conjunction with a second varus correcting osteotomy (39,43,56,61,84,85), will most likely be effective if the patient is relatively young (<10 years), the bar is relatively small, and the patient is not excessively overweight (39,43,86). A similar approach might be indicated for the unusual patient who presents for primary treatment with Langenskiöld late stage IV or stage V radiographic changes (Fig. 27-10C). The proximal tibia is approached through an anteromedial longitudinal incision, and the physal bar is resected first. There may or may not be a discrete bar; often, there are several small punctate foci of bone that appear to coalesce and function as a tether. The medial edge of the normal physis is often difficult to locate. Excision of the bony bridges is done cautiously, so that as much normal physal tissue as possible is preserved. However, resection must be complete, such that an intact physal line, coursing 180 degrees from the posteromedial to the anteromedial cortical edge of the tibia, is defined. The C-arm can be helpful in monitoring the procedure. Cranioplast is used to fill the void, inhibiting growth of another osseous tether.

The varus-correcting osteotomies of the tibia and fibula are then performed (Fig. 27-10C). Alternatively, in combination with the medial epiphysiodesis, a temporary lateral staple epiphysiodesis [►6.14] may be very effective in correcting the varus deformity (Fig. 27-10E). This is most applicable if the varus deformity is not too severe, the patient is not obese, and there is no lateral knee-joint thrust. The majority of patients experience resumption of medial physal growth (84,87). The remaining potential growth of the proximal medial physis is invariably limited. Long-term follow-up is essential to monitor the longitudinal growth and development of the proximal medial tibia. The physal bony tether may reform, with resulting recurrence of varus deformity. A second bar resection and varus corrective osteotomy is indicated for smaller recurrent bars in younger patients (Fig. 27-10D). If a lateral temporary hemiepiphysiodesis has been done, timing of staple removal is critical to prevent secondary deformity (Fig. 27-10E and F). Alternatively, and more appropriately for relatively larger osseous bars, obese patients, and/or older patients, a permanent lateral epiphysiodesis of the tibia and fibula may be indicated, with a varus corrective osteotomy (39,43,56). With this approach, it may later be necessary to surgically address problematic residual proximal medial joint depression. The potential for leg-length inequality exists with any of the above approaches. If anticipated, it

often can be corrected early with an epiphysiodesis, or conceivably later with leg lengthening.

Severe Varus Deformity

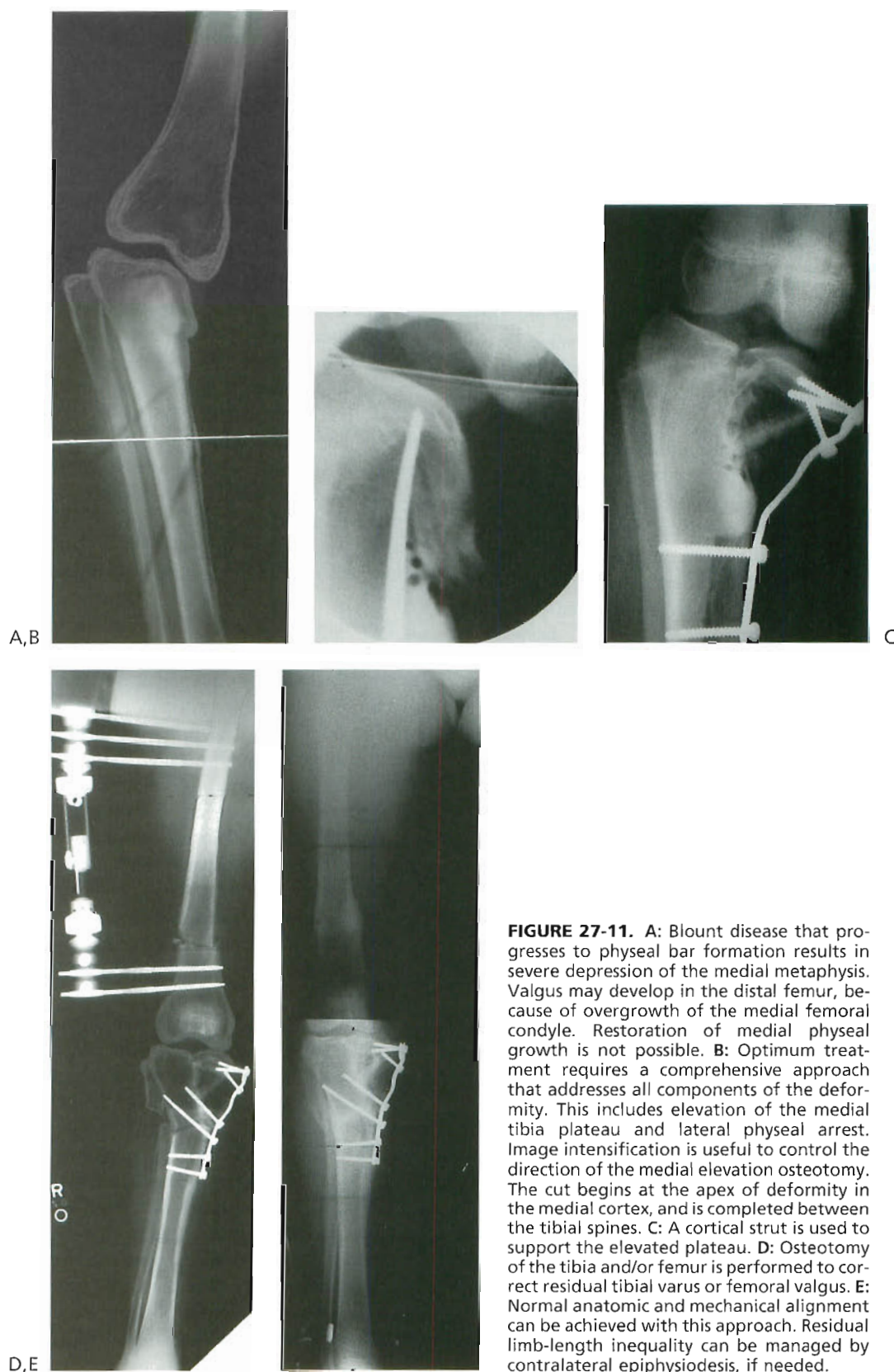
In some patients with untreated or recurrent infantile Blount disease, the proximal medial tibia bony architecture can become very deformed. These patients have irreversible Langenskiöld advanced stage V and VI radiographic pathologic changes (Fig. 27-11A). Typically, they are older (>10 years of age) yet these changes have been seen as early as 6 years of age. The proximal tibial varus deformity (with limb-length discrepancy in unilateral cases) is characterized by severe depression of the medial tibial plateau and variable ligamentous laxity. A secondary distal femoral compensatory valgus deformity may develop (68). In severe cases, the tibia will be subluxed medially on the femur. Left untreated, degenerative arthritis is likely to occur early in life (70,88).

For a lasting satisfactory outcome, the surgical goal is to restore all aspects of this extensive deformity. The physis will be completely closed medially. In this setting, epiphysiodesis will not predictably restore proximal tibial growth (56).

Alternatively, the authors' preferred approach in attempting to restore this extensive deformity is a combination of tibial plateau elevation and realignment osteotomies of the proximal tibia, and occasionally the distal femur (36,56,76,89–91). The proximal medial tibia should not be approached subperiosteally. Rather, soft tissue attachments to the proximal medial tibia are preserved so as to minimize medial tibial circulatory changes, following the subsequent plateau-elevating osteotomy. A medial peripatellar arthrotomy is often performed to visualize the articular surface of the tibia. The posterior neurovascular structures are at risk, and are protected by placing either a curved subperiosteal retractor or the surgeon's finger between the structures and the potentially penetrating drill bit and/or osteotomes.

Intraoperative radiography or fluoroscopy is used to assure that the plane of the proximal osteotomy is directed superolaterally, with the apex of the osteotomy bisecting the tibia intercondylar eminence (Fig. 27-11B). The depressed tibial condyle must be sufficiently elevated and fixated without disturbance of the articular surface of the tibial condyle (Fig. 27-11C). The correction obtained following plateau elevation typically restores the tibial condylar angle to a near-normal value (89). A concomitant epiphysiodesis of the lateral proximal tibia and proximal fibula is always done.

Tibial plateau elevation alone will produce a marked correction of much of the preoperative varus deformity. However, concomitantly or staged, a proximal tibial varus-correcting osteotomy, and often, a distal femoral valgus osteotomy, are essential for restoration of normal axial alignment. The distal femoral osteotomy may be necessary to



correct valgus deformity, which occurs secondary to relative overgrowth of the medial femoral condyle. The surgical goal of this comprehensive approach is to achieve correction of all components of the deformity, i.e., medial tibial plateau depression, asymmetric proximal tibial growth, varus of the tibia, and valgus of the distal femur (Fig. 27-11D). As noted above, precise intraoperative assessment of correction obtained is critical. The mechanical axis of the limb should bisect the center of the knee joint, and should be relatively perpendicular to the anatomically restored joint surface (Fig. 27-11E). After correction of the angulatory deformity, significant limb-length equality may remain. This may be managed by epiphysiodesis of the contralateral limb, or, in more severe discrepancies, a combination of lengthening and shortening may be required to equalize limb length. Davidson (76) has similarly utilized the circular external fixator to stabilize the elevated plateau fragment, and to concomitantly perform a gradual correcting osteotomy of the proximal tibia. By utilizing the external fixator there is also the option for lengthening of the proximal tibia.

Complications

Extensive soft tissue and bony dissection is necessary to concomitantly elevate the medial tibial plateau and perform a varus-correcting proximal tibial osteotomy. The medial proximal tibial becomes relatively more protuberant and longer, following a concomitant plateau-elevating and varus-correcting osteotomy. Wound closure may be relatively compromised, and possibly delayed. Three of the authors' 20 patients experienced wound healing complications. In two patients, eventual wound healing occurred with local care. One required operative repair, with subsequently satisfactory secondary wound healing. The extensive soft tissue and bony dissection necessary to perform a tibial plateau elevation potentiates the occurrence of avascular necrosis of the medial tibial condyle. This has occurred in 1 of 20 tibial plateau elevations the authors have performed. Satisfactory revascularization and reossification occurred following a 1-year period of non-weight-bearing for this morbidly obese 8-year-old child.

Adolescent Blount Disease

Definition

Blount also described a second group of patients with the onset of varus deformity in later childhood or early adolescence, which he described as adolescent tibia vara (53) (Fig. 27-12).

These children typically present for evaluation of a bowed-leg deformity later in childhood. They may or may not have a history of persistent physiologic bowing persisting through early childhood (92–95). However, there should be no confusion in differentiating patients with adolescent Blount disease from patients with persistent infantile tibia vara, which by later childhood will typically have ad-

vanced pathologic changes involving the proximal medial tibia.

Etiology

Adolescent Blount disease usually, but not always, occurs in obese patients with characteristically wide thighs (62,63,92–94,96). If biopsied, growth plate histologic aberrations are present throughout the entire physis. Medial, more than lateral, physal growth is adversely affected (94). The histologic changes are very similar to histologic changes noted in infantile Blount and slipped capital femoral epiphysis (SCFE) (94,95). The resulting radiographic changes in adolescent Blount are less extensive, because of the well-formed secondary ossification center (94,95). Relative obesity potentiates the occurrence of adolescent Blount (92,93,96,97). Adolescent tibia vara and SCFE do occur in association with each other (94,98,99).

Dauids et al. (92) examined the dynamic gait deviations that compensate for the increased thigh girth associated with obesity. During ambulation, individuals presumably attempt to keep foot placement close to the midline of foot progression in order to minimize weight transfer, thereby minimizing energy expenditure during ambulation. The obese individual with large thighs has a very difficult time adducting the hip adequately to place the foot in the midline progression. Davids et al. (92) speculated that this "fat thigh syndrome" produces a varus moment on the knee that leads to increased pressure on the medial proximal tibial physis (and presumably the medial distal femoral physis), and inhibits growth in accordance with the Hueter-Volkmann law (62). Davids and colleagues' work supports the observation that static varus of the knee is not a prerequisite in the pathomechanics of adolescent tibia vara. Seemingly, the incidence of adolescent Blount has markedly increased in the past 15 years, paralleling the increased preadolescence of adolescent obesity (93,100).

Pathoanatomy

The posteromedial growth inhibition of the proximal tibia initially produces varus, then progressive procurvatum of the proximal tibia (39,68,94). Although the name of the disorder would suggest that varus of the proximal tibia is the only deformity present, a similar associated varus deformity of the distal medial femur also occurs (68,94,100). This is in contradistinction to infantile tibia vara, in which the most common finding is a compensatory distal femoral valgus deformity. The intoeing in adolescent Blount disease is relatively less severe than it is in infantile Blount. The combined varus, procurvatum, and internal rotation results in a complex three-dimensional deformity of the proximal tibial. As the proximal tibial and distal femoral varus deformities increase, there is a significant strain placed on the lateral collateral ligament of the knee, which leads to laxity

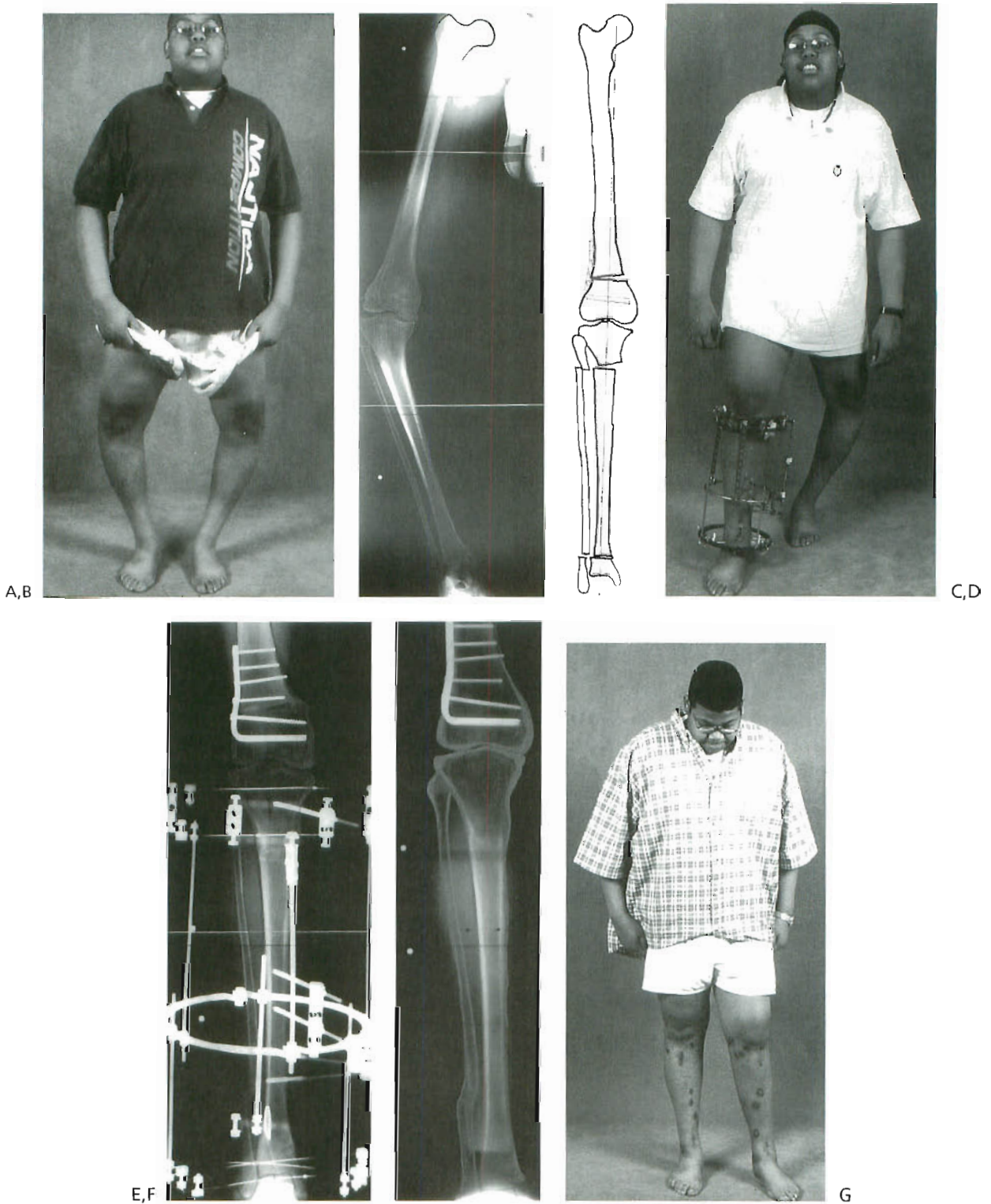


FIGURE 27-12. A: Adolescent Blount disease frequently occurs in very large teens. The deformity is often bilateral. B: Long cassette films are used to assess mechanical alignment, as well as the anatomic axes of the femur and tibia. Distal femoral and distal tibial valgus may be present, in addition to the obvious proximal tibial varus deformity. C: Restoration of normal alignment may include multilevel osteotomies. Preoperative templates are useful for planning operative strategies. D: In this example, the plan included immediate correction of distal femoral varus, using a blade plate, with gradual correction of proximal tibial varus and distal tibial valgus, using a circular small wire frame. Multiplane correction is facilitated with this technique. E: Radiographs confirm the restoration of alignment. Adjustments can also be made to correct the procurvatum that may be present. F: This film shows limb alignment following removal of the circular frame. Correction is generally well maintained. G: Clinical photo after bilateral treatment shows satisfactory clinical correction, compared to the preoperative photo. (Courtesy of J. Eric Gordon, M.D., St. Louis, MO.)

and varus deformity within the knee joint itself. Finally, in some very severe cases, compensatory distal tibial valgus can occur allowing the patient to place the foot flat on the floor. The natural progression of advanced infantile Blount disease is the formation of a medial proximal tibial physal bar. Conversely, although overt bar formation in adolescent Blount disease does not occur, early closure of all lower extremity physis is frequently noted, perhaps as a consequence of the associated obesity.

Clinical Features

The typical patient with adolescent tibia vara is an obese, black male who typically presents for complaints of bowing and knee pain and/or instability (93,94,96,101,102). The patient should be observed during gait, walking both toward and away from the examiner, for overall gait mechanics, and specifically the presence of a limp or lateral thrust to one or both knees. Though unilateral complaints are more common (96,101), attention should be paid to the contralateral limb, because the patient's obesity can mask mild bowing on the contralateral limb (92). The knee stability is assessed; lateral collateral ligament laxity can occur. Proximal tibia procurvatum deformity variably occurs, effecting a relative knee-flexion contracture. Patients complain of medial knee pain secondary to medial knee-joint stress. They also experience anterior knee pain, no doubt secondary to holding the knee in a flexed position during gait. The magnitude of internal tibial torsion should be assessed with the patient prone on the examining table, looking at both the thigh-foot angle and the bimalleolar axis (Fig. 27-1). The hips should also be examined for evidence of SCFE. Morbidly obese patients presenting with adolescent Blount may have varying amounts of respiratory distress. The walk from the waiting room to the examination area can be quite taxing to these patients.

Radiologic Features

A standing long-cassette radiograph of both lower extremities is essential for evaluating the patient with adolescent tibia vara (Fig. 27-12B). Although some younger or smaller patients can be evaluated on a 36-in. cassette, most patients require a 51-in. cassette. Simultaneous satisfactory radiographic visualization of the hips through an abundance of soft tissue, as well as the ankles through a relative paucity of soft tissue, can be difficult. Care should be taken when positioning the patient to ensure that the knees are straight ahead, with the patellae centered. This is particularly difficult in large patients in whom the palpation of bony landmarks is uncertain. Radiology technicians who are not experienced in obtaining these radiographs frequently can compensate for the inability to visualize the patella by turning the feet straight ahead. However, internal tibial torsion produces external rotation of the knees and an inadequate

radiograph for accurate assessment of bony deformity. Occasionally, because of the width of the patient or the patient's inability to sufficiently internally rotate the hip, it may be necessary to obtain separate standing radiographs of each lower extremity. A true lateral supine radiograph of the proximal tibia is obtained to evaluate the magnitude of the procurvatum deformity. The radiograph should be centered on the knee and the film positioned so that a significant portion of the tibial diaphysis can be visualized. Finally, with the feet positioned straight ahead, a standing AP radiograph of both ankles should be obtained to accurately assess distal tibial valgus.

The radiographs should be assessed according to the method described by Paley and Tetsworth (103). Initially, the mechanical axis deviation should be measured, using a line drawn from the center of the femoral head to the center of the ankle. The surgeon should also look for a limb-length discrepancy at this point. Both the lateral distal femoral angle and the medial proximal tibial angle should be measured, to evaluate the frontal plane deformity of both the distal femur and the proximal tibia. Beware of assuming that the distal femur is normal because the knee joint appears to be parallel to the floor. The genu varum produces relative abduction at the hip, and can mask a significant femoral deformity. Finally, the center of rotation of angulation (CORA—the intersection point of the proximal and distal mechanical or anatomic axes) (Fig. 27-13A) for both the femur and the tibia should be located, and the magnitude of the deformity measured (103,104). This is typically at a level close to the physis in both the femur and the tibia, but may lie anywhere between the joint and the metaphysis, and in some cases, may even be located beyond the joint surface. The knee must be examined in the weight-bearing film to assess the presence of significant lateral collateral laxity and an increased joint line congruency angle (the angle formed by an intersect of two lines, one drawn parallel to the distal articular surface of the femur and one parallel to the proximal articular surface of the tibia). Likewise, the lateral knee should be evaluated to assess the size and location of the procurvatum deformity (Fig. 27-13B). A standing radiograph of the ankles is examined for the presence and location of any distal valgus deformity.

Treatment

Goals

The problems that must be addressed are a varus deformity of the proximal tibia and distal femur, and often a secondary deformity of the distal tibia. The goal of surgery is to restore normal anatomic alignment of the knee and ankle joint, and also a normal mechanical axis of the leg (77,80, 96,100,101,103). For a unilateral deformity, leg-length inequality is also to be addressed. Nonoperative approaches are ineffective in adolescent tibia vara. When the diagnosis of

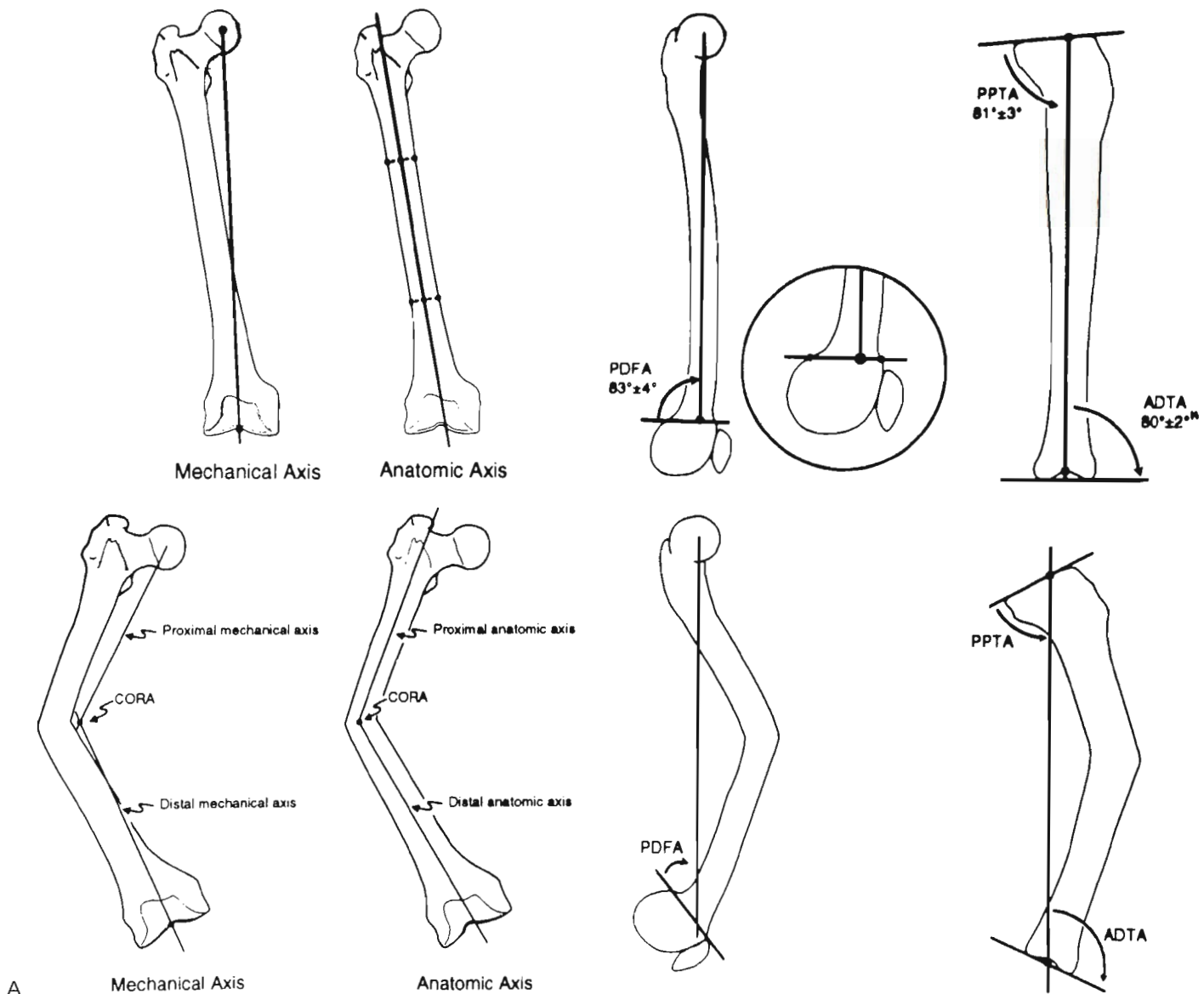


FIGURE 27-13. A: The anatomic and mechanical axes of the femur are different. The anatomic axis of the femur is its middiaphyseal line. The mechanical axis of the femur is the line from the center of the knee joint to the center of the ankle joint. When the femur is angulated, the mechanical and anatomic axes are also angulated. Just as there is a segment of femur proximal and distal to the break, there is a proximal and distal segment of the mechanical and anatomic axes. Where the two intersect is the center of rotation of angulation (CORA). The mechanical and anatomic CORAs lie on the same bleactor line. B: Sagittal plane malalignment test. Femur: line from the center of the femoral head to the junction of the anterior and middle third of the distal femoral joint line. The posterior distal femoral angle (PDFA) should be 83 ± 4 degrees. Tibia: line from the midpoint of the distal tibial joint line to the junction of the anterior and middle third of the proximal tibial joint line. The posterior proximal tibial angle (PPTA) should be 81 ± 3 degrees. The anterior distal tibial angle (ADTA) should be 80 ± 2 degrees. (From ref. 104, with permission.)

adolescent tibia vara is made, surgical treatment is indicated. Osteotomy is the mainstay of treatment for adolescent Blount disease. However, depending on the patient's age, on occasion definitive treatment can be attained by staple hemiepiphysiodesis, or more likely by a combination of hemiepiphysiodesis and osteotomy.

Preoperative Evaluation

Because these patients are often obese and, not infrequently, morbidly obese, prior to any consideration of operative treatment a thorough preoperative evaluation of the cardio-pulmonary system should be done. The extreme size of these

patients can lead to nocturnal hypoxia, with significant decreases in sleeping O_2 levels and accompanying hypercardia (105). If these changes are prolonged, significant pulmonary hypertension can result, leading to right heart hypertrophy (105), if symptoms, such as marked snoring or irregular breathing patterns at night, are present. Sleep studies with pulmonary and cardiac evaluation may be indicated prior to a general anesthetic (105). Prior to proceeding with operative intervention, an appropriate, detailed preoperative plan is essential for obtaining a mechanically well-aligned limb (Fig. 27-12C). The magnitude and location of the various bony deformities, the presence of soft tissue laxity at the lateral collateral ligament, and the presence of joint contractures and leg-length discrepancy should all be assessed and incorporated into a global plan for addressing the deformity.

Hemiepiphysiodesis

Hemiepiphysiodesis, by a variety of techniques [➤6.12–6.14] is indicated if the growth plates are still open (82,101,106) and the varus deformity is relatively not too severe. The authors prefer staple hemiepiphysiodesis. Two to three reinforced “Blount staples” (Zimmer) may be placed extra-epiosteally at the lateral distal femoral physis [➤4.21], the lateral proximal tibial physis [➤6.14], or the medial distal tibial physis, as needed (39,82). Once hemiepiphyseal stapling is performed, it is critical to follow the patient closely with clinical and radiographic examinations to monitor correction obtained, and possible staple displacement and/or breakage. If complete deformity correction is obtained, staple removal is necessary to prevent over correction.

Relative rebound (82) varus growth is unpredictable in this clinical setting. Accordingly, concomitant with staple removal, a permanent epiphysiodesis of the growth plate(s) previously stapled is preferred. The authors have successfully used stapling in obtaining either complete or partial correction or arrest progression of proximal tibial or distal femoral deformities in some of the patients with, typically, at least 15 to 18 months of growth remaining. Often, hemiepiphysiodesis obviates the subsequent need for a femoral, and on occasion, a tibial varus-correcting osteotomy. The exceptional patient, who is not a candidate for staple hemiepiphysiodesis, typically presents with a history of progressive varus deformity and knee-joint pain. A dynamic lateral thrust is often noted during walking. This severe, dynamically unstable deformity will predictably not be significantly improved by the slow correction obtained with staple hemiepiphysiodesis.

Osteotomy

The majority of patients with moderate to severe adolescent Blount disease will require a varus-correcting osteotomy of the proximal tibia, and perhaps also the distal femur, to obtain definitive correction of the varus deformity. To definitively determine the need for osteotomy correction of

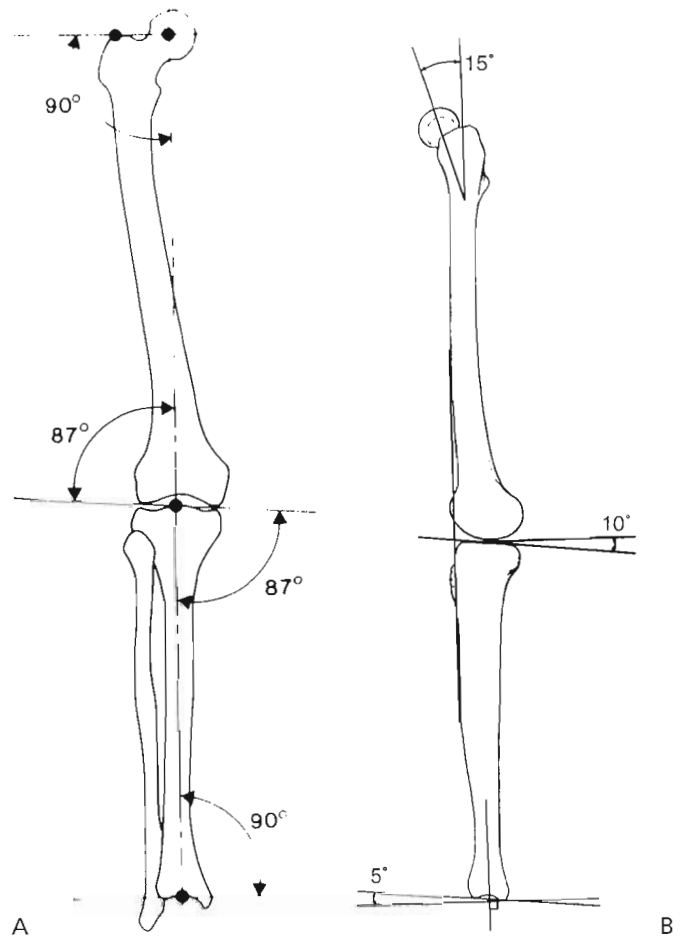


FIGURE 27-14. A: Frontal plane mechanical axis of the lower extremity consists of two components: (i) colinear centers (of the femoral head, knee joint, and ankle joint), and (ii) an almost perpendicular relationship of the hip, knee, and ankle joint orientation lines to the mechanical axis. B: Normal sagittal plane mechanical axis and joint orientation lines.

the varus deformity, the mechanical axes of the lower extremity, and also individually for the femur and the tibia, are determined (107) (Figs. 27-13A and 27-14A). In skeletally near-mature or mature patients, osteotomy(ies) is/are indicated if the mechanical axis of the lower extremity is deviated medial to the center third of the knee joint. The deformity in both the medial proximal tibial angle (MPTA) and lateral distal femoral angle (LDFA) is determined. In addition, the sagittal plane alignment is assessed (Figs. 27-13B and 27-14B), and procurvatum deformity noted. All patients will require a proximal tibial varus-correcting osteotomy, ideally restoring a normal anatomic alignment of the proximal tibia. The tibial osteotomy should be performed distal to the tibial tubercle. Regardless of the method chosen, the proximal tibial deformity should be completely corrected by the redirective osteotomy, including internal rotation (if present), procurvatum, and varus. Similarly, anatomic restoration of the distal femur with a concomitant

femoral varus-correcting osteotomy is indicated if the DFLA measures >5 degrees varus (normal DFLA is 87 degrees). The distal femoral osteotomy is performed through a lateral approach. The preoperative deformity analysis should also include more assessment of the distal tibia. If the distal tibia growth plate is open, the authors correct distal valgus of ≥ 5 degrees with a staple hemiepiphyodesis. If closed, the authors will perform a valgus-correcting osteotomy for deformity ≥ 8 degrees. The distal valgus-correcting osteotomy is performed through a medial approach.

Limited Internal Fixation

Osteotomy with limited internal fixation, the mainstay of treatment of infantile Blount disease, has limited application in adolescent Blount disease. A supplemental long-leg cast often adds minimal additional protection for these extraordinarily large patients. The difficulties associated with non-weight bearing on the affected extremity make ambulation difficult in these patients. Outcome of treatment with this approach has far too often been unsatisfactory (96).

Inherently Stable Internal Fixator

Osteotomy, with acute correction and relatively stable internal fixation, can be effectively utilized in patients with mild to moderate varus and procurvatum deformity (39,108,109). Because the true location of the deformity is very close to the level of the physis, a transverse osteotomy of the tibia at the metaphysis distal to the tubercle must be translated laterally, sometimes as much as the entire diameter of the tibia, in order to prevent creating a translational deformity. To circumvent creating this deformity, Millis and Jakob and Murphy (108,110) have effectively utilized an oblique, laterally based closing-wedge osteotomy that hinges at the intact cortex, just distal to the proximal tibial physis [►6.4]. Fixation is achieved using a laterally placed compression plate, which serves as a tension band and permits weight bearing without external immobilization. Because the hinge point is nearly at the level of the physis, the correction is achieved at the level of the deformity, and a translational deformity is not created. The distal femoral deformity may be addressed by supracondylar osteotomy and stable fixation of the distal femur, using a blade plate to maintain alignment. This may be performed through a medial or lateral approach, with an opening- or closing-wedge osteotomy technique. The authors prefer to use a lateral approach to perform an opening-wedge osteotomy of the distal femur, [►4.17] fixing the fragments with an adult 95-degree condylar blade plate. The femoral osteotomy is done concomitant to the tibial osteotomy.

Monolateral External Fixation

External fixation of the tibia can be used for correction in the most severe deformities. The dynamic axial monolateral

fixator has the advantages of ease of performing an acute correction, adjustability after the initial surgical correction has been achieved, and relative patient acceptance (77). Price et al. obtained satisfactory stability of the osteotomy fragments, even on heavier patients. In applying a monolateral fixator of any type, pin placement parallel to the adjacent knee and/or ankle joint enhances obtaining a satisfactory acute correction of deformity (77). Similarly, Gaudinez and Adar (111) and Stanitski et al. (112) have effectively incorporated the Garsche clamp, when utilizing a monolateral fixation in the treatment of adolescent Blount. The Garsche external fixator optimizes fixation, and allows for postoperative frontal plain adjustment and lengthening. It is, however, not conducive to postoperative adjustments in the sagittal plane, or in rotation (112).

Circular External Fixation

Circular external fixation, with a gradual correction of the proximal tibia, allows for the maximal adjustability of the alignment in all planes, and is most applicable in the most severe deformities and relatively more obese patients. This is the authors' preferred approach (80,113,114). Advantages include stable fixation with improved patient mobility; the ability to evaluate alignment in a functional, standing position; and the ability to accurately correct all of the tibial deformities, including proximal tibial varus and procurvatum, internal tibial torsion, and distal tibial valgus (112,113,115).

Ideally, all of the deformities are addressed in a single surgical procedure. First, if indicated, distal femoral varus is corrected acutely by a supracondylar distal femoral opening-wedge osteotomy, performed after a lateral approach, and fixed with a 95-degree condylar blade plate. The fibula osteotomy is then performed through a posterolateral incision made over the midshaft area of the fibula, at least 10 cm distal to the proximal fibula. Great care should be taken in obtaining subperiosteal exposure of the fibula, so that no injury occurs to the branches of the deep peroneal nerve, to the extensor hallucis longus, or the peroneal artery and vein, which lie just medial to the fibula. A section of the fibula is removed in performing the fibular osteotomy. The preconstructed circular fixator is suspended from the leg, and fixed with an appropriate combination of transfixing wires and half-pins. Ring strategy and transfixing wire placement vary with the presence or absence of growth plates, need for fibular transfer for ligamentaxis, and need for distal tibial valgus-correcting osteotomy (112,113). The proximal tibial osteotomy is performed with a drill and osteotomes. If indicated, a distal tibial osteotomy is created in a identical fashion.

Gradual correction is begun on postoperative day 2 or 3 and serial radiographs are obtained to monitor the correction and bone formation. The patient is encouraged to be

fully weight bearing as early as possible, and vigorous physical therapy is instituted to maintain mobility and joint range of motion (Fig. 27-12D). Circular frame adjustments in all planes are made, as necessary, to correct all aspects of the deformity. The fixator is left in place and progressively dynamized, until complete consolidation and cortication of the osteotomy site is completed. Bilateral deformities are corrected one at a time, the second extremity correction usually staged within 6 months of obtaining correction of the opposite extremity. Generally, very satisfactory results have been achieved in this most difficult group of patients (112,115) (Fig. 27-12F and G). The results are a marked improvement in outcome over traditional methods (96). Despite the procedure being done on often extremely large extremities, there have been notably very few surgical complications (112,113). All osteotomies, including those that also required lengthening, have healed without delay. The knee and ankle joints have been restored to relatively normal anatomic relationships. A near-normal mechanical axis of the leg has been reestablished. Knee pain has resolved. Patients have been satisfied with the more normal lower-extremity alignment.

KNOCK KNEES (GENU VALGUM)

Definition

Parental concerns regarding knock-knees are far less common than those regarding bowed legs (5,116,117). Genu valgum generally becomes a concern between 3 and 5 years of age, when the normal femoral–tibial angle is at its maximum valgus angle (5,116,117) (Fig. 27-15). Parents often notice the flat appearance of the foot before the valgus knee position is noted. There may be occasional complaints of medial foot or medial knee pain.

Typically, valgus knee position becomes apparent after 2 years of age, reaching a maximum femoral–tibial angle of 8 to 10 degrees at approximately 3 to 4 years of age, a time when it is most noticeable (2,5,38). As demonstrated by Salenius and Vankka (Fig. 27-4), valgus gradually decreases to a stable “adult” level of 5 to 7 degrees of femoral–tibial valgus by age 6 to 7 years. There is, however, wide variation among normal children. Normals are those children who fall within two standard deviations of the mean. This includes measurements of ± 8 to 10 degrees, which means that normal femoral–tibial angles may range from 2 degrees varus to 20 degrees valgus at 3 to 4 years of age, and 0 to 12 degrees valgus after age 7 years (38, 116,117).

Physiologic knock-knees are typically symmetric (5,116). The severity of the deformity can easily be assessed and documented by standing photographs. Radiographic evaluation is indicated in those children with clinically excessive femoral–tibial angles, those who present outside of typical



FIGURE 27-15. Physiologic genu valgus peaks between 3 and 4 years of age. It may be associated with asymptomatic flat feet. It is typically symmetric, and shows gradual resolution by age 8 years.

age range for physiologic valgus, those with asymmetric deformity, or those who fall below the tenth percentile of height.

Differential Diagnosis

Most children who present with knock-knees will have physiologic genu valgum. The differential diagnosis includes metabolic bone disease, such as rickets, posttraumatic valgus, or skeletal dysplasia (118–121). Osteomalacia, which has its onset when physiologic valgus is present, is more likely to progress as a knock-knee deformity. Valgus may result from overgrowth of the proximal medial tibia, following a proximal tibia fracture (Cozen fracture), or from distal lateral femoral physeal injury (121–123). Skeletal dysplasias most commonly associated with genu valgum are chondroectodermal dysplasia (Ellis-van Creveld), mucopolysaccharidosis type IV, and spondyloepiphyseal dysplasia tarda (120).

Natural History

Genu valgum in normal children typically decreases to a stable, slightly valgus position by age 7 years (2,5,38,

116,117). Minimal, if any, change in femoral–tibial angle should occur through adolescent growth. Rarely, valgus continues to increase, and may be associated with an out-toed gait. Lateral patellar subluxation may develop with increasing valgus deformity. The deformity apparent on clinical exam is often more striking than the radiographic appearance. Walking may become awkward because of the knees rubbing or hitting together as the child tries to narrow the base of support.

Assessment

Anteroposterior standing long-cassette radiographs of both lower extremities, which include the hips, knees, and ankles, are used to quantify mechanical axis deviation from normal. The lower extremities should be placed such that the kneecaps are facing directly forward. This must be done without regard to foot position. This technique produces the truest AP of the knees, and minimizes errors when serial examinations are compared. A normal mechanical axis, drawn from the center of the hip through the center of the ankle (Fig. 27-14A), should pass through the center of the knee, roughly in the zone determined by the tibial spines (124).

Lateral deviation of the mechanical axis, beyond the midportion of the lateral tibial plateau, can result in relative overload of the lateral compartment (124). The severity of deformity, which will produce premature degenerative changes in the lateral compartment of the knee, is not known. Genu valgum, severe enough to produce mechanical axis deviation beyond the lateral margin of the tibia, is pathologic, and should be corrected. In addition to improving the appearance of lower-limb alignment, normal mechanical axis can be restored (122,125).

Treatment

Conservative treatment of genu valgum includes education of the parents regarding the natural history of physiologic knock-knees (117). If medial foot, knee, or leg pain is a significant concern, foot orthotics may provide some relief of symptoms, but do not alter lower-limb alignment (116,117). Lower-extremity bracing is not indicated for the treatment of physiologic genu valgum (117). Bracing with a single upright, valgus-correcting KAFO might be considered in a child less than 4 years of age, who is also being treated for metabolic disease, such as rickets.

Surgical treatment can usually be deferred until 10 to 11 years of age. Correction of valgus in the skeletally immature child, with 1 to 2 years of growth remaining, can be accomplished with hemiepiphyodesis, preferably by hemiepiphyseal stapling (82,83,106,125–129) (Fig. 27-16). Hemiepiphyseal stapling in younger children often results in rapid correction (within 4–6 months), but uncertain resumption of a normal growth pattern once the staples are removed

(82,83,125). Once valgus resolves the staples may need to be removed to avoid over-correction to varus. Injury to the underlying physis can cause partial growth arrest. Premature physeal closure is less problematic near the end of growth than with several years' growth remaining.

Whether medial physeal stapling is performed in the distal femur, proximal tibia, or both, will depend on the site of deformity, and growth remaining (106,122,129). Most often, valgus deformity arises primarily from the femur. However, it is not correct to assume that this is always the case with valgus deformity. The anatomic alignment of the femur and tibia should each be evaluated. Although deformity may be present only in one bone, combined stapling of the femur and tibia may be considered, if bone age estimates that there are less than 18 months growth remaining, to afford maximum correction (122,125).

The technique of stapling, although simple, requires attention to a few important details. Placement technique, type and size of staple, and follow-up are three key areas (82,83,122,126,127). The staples are generally placed extra-periosteally. They should span the physis, but should not be excessively large. These staples should be placed so that the prongs of the staple are parallel to the physis. This may require a slightly oblique orientation to the cortex. Use of C-arm image intensification facilitates placement, and avoids errors. Two staples per location are generally sufficient. Three may be used if the bone is unusually large. The staples, made of cobalt-chrome alloy, should have reinforced corners (125,126). Patients must have reliable follow-up. Over-correction to a varus position can occur, and is not desirable. Long-cassette radiographs of the lower extremities should be obtained at 3-month intervals. Some correction of the valgus should be apparent 3 to 6 months after stapling. Once a normal mechanical axis is restored, the staples should be removed (if there is significant growth remaining), or the epiphysodesis should be completed (83,125). Rebound growth in the previously stapled physis may occur (82,125–127). It is more likely to occur when stapling is performed in younger children, those under 10 years of age, or in children who show rapid (within 6 months) correction of the valgus deformity. Resumption of growth following staple removal may not occur if the staples have been in place for more than 24 months, or if they are placed subperiosteally (126,127). Children should be followed to skeletal maturity to document satisfactory correction and maintenance of normal alignment.

Alternatively, osteotomy can be used to correct deformity (48–50). The site of deformity correction is dependent on the anatomic deviations present in the tibia and/or femur (107,132–134). The femur is more often the primary site of valgus deformity. Immediate correction of femoral valgus, using internal fixation with a blade plate, is preferred for most adolescents. A lateral approach to the distal femur allows exploration and release of the peroneal nerve, which

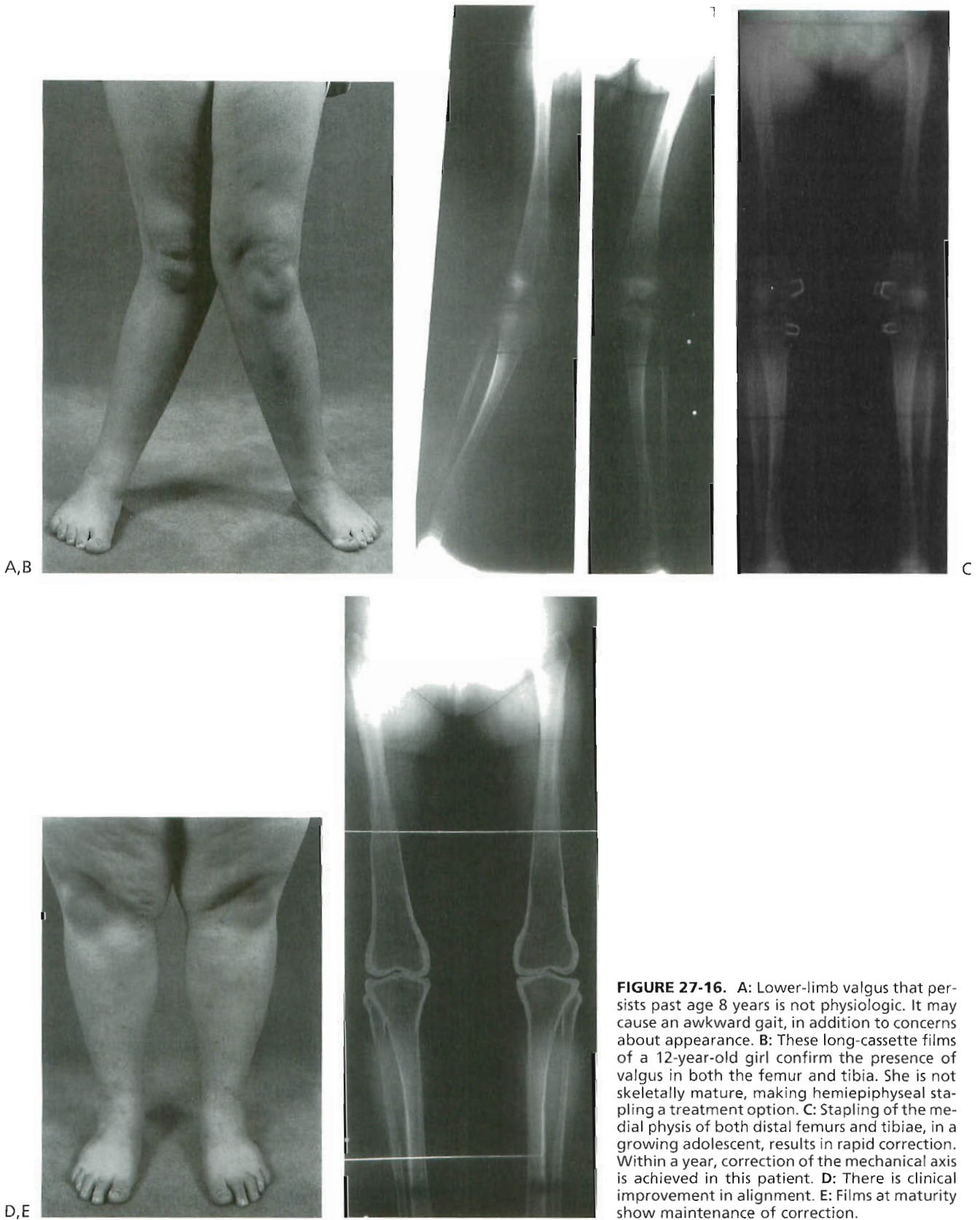


FIGURE 27-16. A: Lower-limb valgus that persists past age 8 years is not physiologic. It may cause an awkward gait, in addition to concerns about appearance. B: These long-cassette films of a 12-year-old girl confirm the presence of valgus in both the femur and tibia. She is not skeletally mature, making hemiepiphysal stapling a treatment option. C: Stapling of the medial physis of both distal femurs and tibiae, in a growing adolescent, results in rapid correction. Within a year, correction of the mechanical axis is achieved in this patient. D: There is clinical improvement in alignment. E: Films at maturity show maintenance of correction.

may be considered in severe deformities. Alternatively, an anterior midline incision can be used for medial and lateral exposure of the distal femur (134). Compression can be applied along the medial cortex by placing the blade plate along the medial cortex (132–134).

External fixation with immediate correction can also be used (130). Gradual correction, using external fixation, may also be considered (31,107,131). This technique is recommended when lengthening is also necessary, or when there is increased risk of peroneal neurapraxia, as in children with severe deformity. Circular frame fixation may facilitate angulatory correction combined with lengthening (31, 108,130). A unilateral frame may be considered when external fixation is used with immediate correction.

Similar techniques can be used for correction of tibial valgus deformity in adolescents. Valgus correction in younger children can be accomplished by a simple closing-wedge technique, using two or three crossed stainless steel wires (130). Alignment can also be restored with removal of a medial wedge and controlled fracture of the lateral cortex. A compression plate is placed along the medial cortex, following removal of the wedge. Compression is slowly applied through an outrigger, gradually closing the osteotomy.

Complications

Errors in technique can lead to failure with hemiepiphyseal stapling. Poor fixation, inadequate design, or number of staples will compromise results (82,83,126). Timing of placement, follow-up, and removal are sources of error (106,125). Stapling performed too late will not adequately correct deformity. Overcorrection can occur because of unrecognized premature physeal closure. Lack of appropriate, timely evaluation poststapling can result in overcorrection. This is a significant complication. Varus alignment results in greater mechanical loads across the medial compartment of the knee than the same degree of valgus would produce over the lateral compartment (39). Increased medial compartment load can accelerate degenerative changes. If reliable long-term follow-up cannot be assured, osteotomy may be preferred over hemiepiphyseal closure.

Complications related to osteotomy include failures of union and/or fixation, infection, blood loss, knee stiffness, and scar formation. None of these are unique to distal femoral or tibial osteotomy for valgus correction.

Peroneal nerve injury is a serious concern in the process of valgus correction. The nerve is tethered above and below the knee, as it passes around the distal femur and proximal fibula (27). Release of these tethers can reduce the risk of permanent injury. Closing-wedge technique for immediate correction is less likely to stretch the peroneal nerve than opening wedge. Gradual correction of severe deformities may allow the nerve to accommodate to these changes more

safely than acute correction. Injury to the nerve must be avoided during pin placement, however.

BOWING OF THE TIBIA

Anterolateral Bowing

Definition

Bowing of the tibia that presents at birth typically occurs anteriorly, anterolaterally, or posteromedially. Anterior tibial bowing, occurring in association with a deficient or absent fibula, is diagnostic of fibula hemimelia. Posteromedial bowing occurs in association with calcaneal valgus foot deformity, and has a relatively excellent prognosis. In contrast, anterolateral bowing, which usually presents soon after birth, is typically a progressive deformity with resultant pseudarthrosis. Anterolateral bowing, associated with congenital pseudarthrosis of the tibia, is rare (1:140,000), yet it is the most common type of pseudarthrosis (135,136). Neurofibromatosis occurs in approximately 50% of patients with anterolateral bowing, with or without pseudoarthrosis of the tibia (135,138,139). This bowing may be the first clinical manifestation of neurofibromatosis (137,138).

Natural History

Spontaneous resolution is uncommon (140). Rather, the anterolateral bowed tibia appears variably dysplastic with failure of tubulation, cystic prefracture, and/or frank pseudarthrosis, with narrowing of the fragments (135,137). Fracture, with resultant pseudarthrosis, typically occurs in the first 4 to 5 years of life (Fig. 27-17). Once established, the natural history of congenital pseudarthrosis of the tibia is that of persistent instability and progressive deformity. Numerous classification systems have been proposed in attempting to prognosticate the natural history and outcome of treatment. In reality, in the past there has been very little correlation with initial radiograph classification and eventual outcome of treatment (137,141–144).

The most widely used classification system is Boyd's (135), who described six distinct radiographic types of anterolateral bowing deformity, noting the variable natural history and/or prognosis of each type (Table 27-1). Consolidation was most difficult to obtain in the dysplastic type II (Fig. 27-18). When anterolateral bowing occurs in association with neurofibromatosis, both progression of deformity and treatment failure are more likely to occur (137,138).

Nonoperative Treatment

Once the diagnosis of anterolateral bowing is made, full-time brace treatment is indicated. An AFO is appropriate protection prior to walking, and a KAFO is fit as the infant

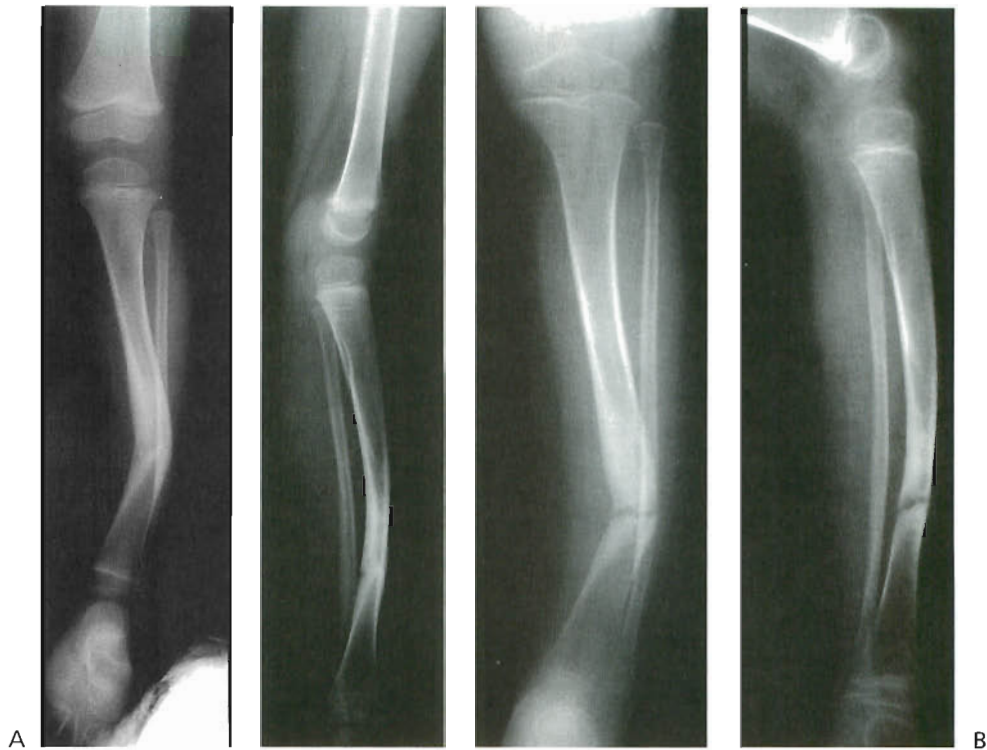


FIGURE 27-17. A: Anterolateral bowing of the tibia may be apparent at birth, or may progress with weight-bearing. Bowing usually occurs between the middle and distal thirds of the tibia. The adjacent bone may appear sclerotic, with increased density, or it may be atrophic and spindle-shaped. Once the deformity is recognized, the leg should be protected with a total-contact orthosis. Although fracture is not likely to be avoided, it may be delayed until the child is bigger. B: Fracture occurs at the apex of the bow, usually without prodromal symptoms, and with minimal or no trauma. Once fracture occurs, surgical management begins.

begins walking. Orthotic support is continued indefinitely during the growing years with or without surgical reconstruction of a pseudarthrosis. Although very uncommon, anterolateral bowing occasionally does not progress (140). These unusual patients present with an anteriorly bowed

tibia, with or without a previous fracture (Boyd type IV), which actually consolidates with immobilization (140). Supplemental onlay bone grafting may be beneficial (145). Patients seemingly carry less chance of further progression and fracture following this procedure.

Operative Treatment

Despite a gradual improvement in overall outcome of treatment in the past 100 years, congenital pseudarthrosis of the tibia has been, and still is, one of the most challenging problems in pediatric orthopaedics. Even with a consolidation, the tenuous status of the atrophic bone often markedly limits functional potential (146–148). A major improvement in outcome can be traced to Boyd and Fox's (149) use of dual onlay grafts, Moore's (150) use of staged bone graft and external fixation, McFarland's (151) bypass graft, and Sofield and Millar's (152) innovative use of intramedullary rod stabilization. Less-invasive technical innovations were developed by both Brighton and Bassett and their colleagues utilizing, respectively, implanted cathode leads and pulsed electromagnetic fields alone or in combination with surgical stabilization (153,154). Currently, there are three

TABLE 27-1. CLASSIFICATION OF TREATMENT OF CONGENITAL PSEUDARTHROSIS OF THE TIBIA

Boyd System	Anderson System
I Fracture present at birth	
II Hourglass constriction of tibia often associated with neurofibromatosis	Dysplastic type
III Bone cysts	Cystic type
IV Sclerotic segment of tibia without constriction, stress fracture results	Sclerotic type
V Dysplastic fibula	Fibular type
VI Intraosseous neurofibroma	Clubfoot or congenital band type

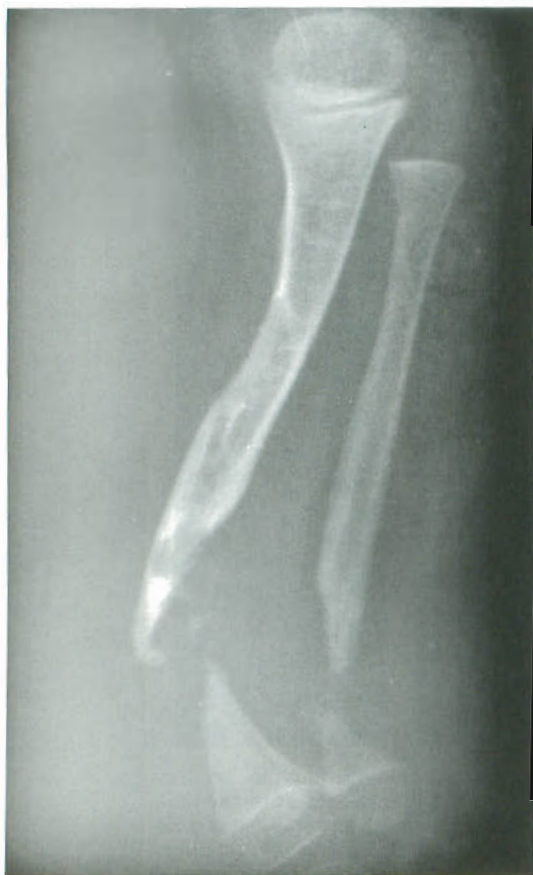

FIGURE 27-18. Early (Boyd type II) congenital pseudarthrosis of the tibia and fibula in a patient with neurofibromatosis.

different surgical approaches that are being successfully used in the surgical treatment of pseudarthrosis of the tibia (Table 27-2) (Fig. 27-19). After obtaining consolidation with any of these techniques long-term follow-up is critical to properly address predictably occurring associated deformities. Vascularized composite donor tissue transfers have been utilized for the past 100 years in the surgical treatment of

congenital pseudarthrosis of the tibia (155–157). In the last 25 years, refinements in microsurgical techniques have been developed that allow for a predictable successful transplantation of vascularized bone from a variety of donor sites to bony defects elsewhere in the body (158). Early reports (158,159) clearly demonstrated that a free vascularized fibular graft could successfully be used to biologically bridge a congenital pseudarthrosis of the tibia. The current technique of implanting a free vascularized fibular graft for a congenital pseudarthrosis of the tibia includes the following essential steps, as outlined by Tolo (160,161). Preoperative arteriography of both legs is obtained. A two-team approach is helpful in simultaneously harvesting the contralateral fibula and internally stabilizing the involved remaining distal fibula of the donor extremity to the tibia with a screw and autologous bone graft. The pseudarthrosis is resected extra-periosteally back to “good” bone. Next, the harvested fibula is dowel-fit into the host tibia, and fixed with a plate or an external fixator. Vessels are anastomized, and a skin paddle is used to monitor blood flow. A spica cast is used for 2 to 3 months, and a clamshell brace for several years.

Using a similar protocol, Weiland et al. (162) reported 18 of 19 pseudarthroses to have ultimately healed at an average follow-up of 6.3 years. In a review of recent publications (163–167) reporting on treatment of congenital pseudarthrosis of tibia by a vascularized fibular graft, 65 cases were available for review, with sufficient follow-up to assess early outcome. Fifty-six cases eventually healed. Often, a secondary bone graft (162) was necessary to achieve the same. Subsequent to obtaining consolidation, several problems may have to be addressed. Following consolidation refracture, and resulting recurrence of a nonunion at one end of the graft site (162,163) or in the graft itself (166), variably occurred. Subsequent additional surgical treatment was often necessary with variable success in achieving a functional consolidation.

A second long-term problem is the occurrence of malalignment, either anterior bowing or valgus deformity (162). The angulatory deformity does not remodel, and often is progressive (162,165). Fourteen of Weiland et al.’s patients were noted to have residual angular deformity.

TABLE 27-2. OPTIONS FOR TREATMENT OF CONGENITAL PSEUDARTHROSIS OF THE TIBIA

Method	Rate of Union	Advantages	Disadvantages
Electrical stimulation	55–80%	Noninvasive, may be combined with other techniques	Limited ability to correct deformity, long time in cast
Intramedullary rod with bone graft (Williams, Coleman)	90–100%	Corrects deformity, provides long-term internal splint	May cause ankle stiffness; does not correct severe, established shortening
Free vascularized bone graft	90–95% eventual	Provides excellent bone stock, may add slight length	Requires specialized skill, relatively long operation, distal angulation hard to correct
External fixator (circular or monolateral frame)	90–100%	Corrects nonunion length, angulation	High risk of refracture, bowing; long-term follow-up not available

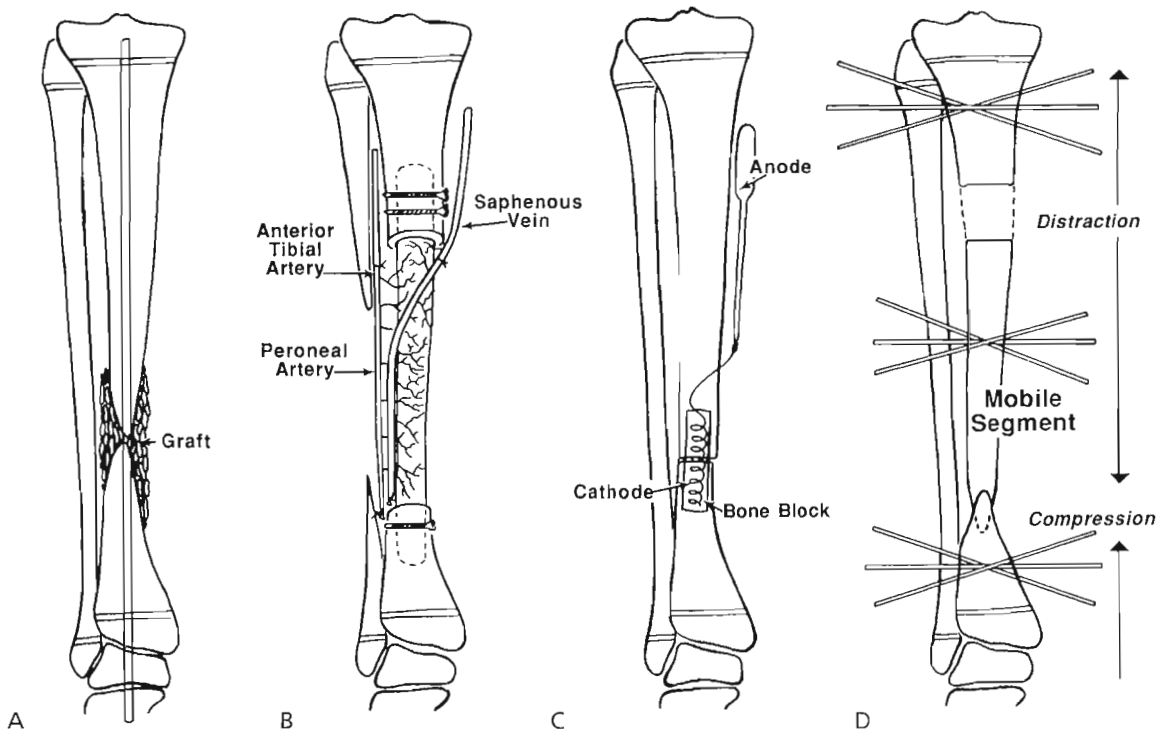


FIGURE 27-19. Operative options for pseudarthrosis of the tibia: **A:** Coleman osteosynthesis. **B:** Vascularized fibular graft from the opposite leg. **C:** Electrical stimulation. **D:** Ilizarov technique of lengthening above and compression of the pseudarthrosis to achieve union.

Donor site morbidity (progressive valgus with proximal migration of the distal fibula) can potentially occur following harvesting the fibula (166). The occurrence of this most-concerning deformity is not consistently addressed (162–168). Prophylactic stabilization of the donor site distal fibula tibia syndesmosis was done by Weiland et al. (162) and Kanaya et al. (165), and was not done by Dormans et al. (163) or Simonis et al. (167). In follow-up, the above authors noted minimal donor site morbidity, such as progressive valgus deformity. Tolo's (160) current indications for the use of a vascularized graft in the treatment of pseudarthrosis of the tibia is specifically for those lesions with marked bony atrophy and/or measurable gap at the pseudarthrosis site (Fig. 27-20). For less-severe deformities, he prefers intramedullary (IM) rod stabilization of the tibia, without transfixing the ankle joint.

Charnley (169) is credited with the first reported innovative use of an IM rod that both stabilized the pseudarthrosis site and transfixed the ankle joint. In a similar technique, Umber et al. (170) popularized in North America the two-part Peter Williams (171) IM solid rod. This IM rod technique, [6.11] in conjunction with pseudarthrosis excision and iliac crest bone grafting, has been further refined in dealing with all aspects of the deformity (156). It is the authors' approach of choice in treating congenital pseudarthrosis of the tibia (Fig. 27-21).

A posterior iliac bone graft is always obtained, consisting of adequate corticocancellous strips and bits. The pseudarthrosis is excised, and the bone fragments stabilized with a Williams rod (171). The entire rod assembly is inserted at the pseudarthrosis site into the medullary canal of the distal fragment, and advanced antegrade across the distal tibia, the ankle joint, the calcaneus, and out through the heel pad. During the passage of the rod across the ankle joint, it is imperative that the foot be positioned to maximally correct the typical calcaneus and valgus deformity of the ankle and foot. The desired foot position is neutral dorsiflexion/plantar flexion, verified clinically and with the C-arm. The tibial fragments are anatomically reduced at the pseudarthrosis site, and the rod is driven retrograde into the proximal fragment. Occasionally, because of extensive deformity, an additional osteotomy in the proximal fragment is necessary to assure both intramedullary passage of the rod and a near-anatomic bony alignment. On occasion, it may be possible to stabilize the fibular fragments with an intramedullary rod. This is typically done with an appropriately sized Kirschner wire, which is placed into the distal fragment through an open incision. The rod is directed antegrade, out through the distal tip of the fibula, then retrograde into the proximal fragment. Fixating the fibula adds additional stability to the construct.

For planning purposes, the portion of the Williams (171)

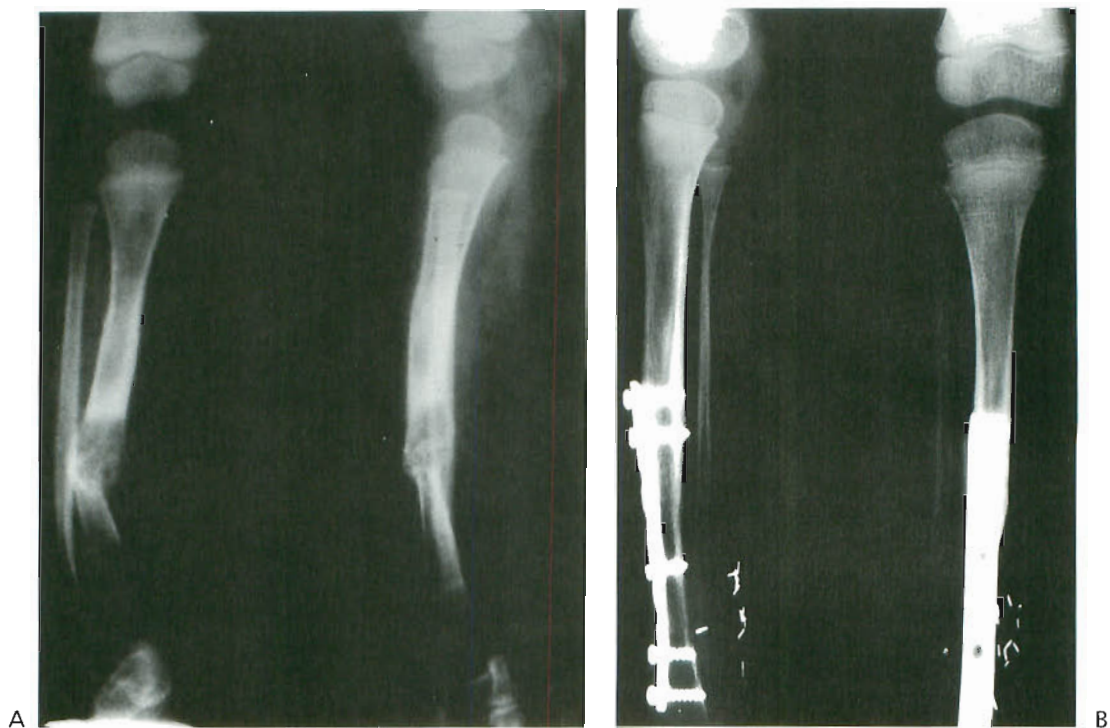


FIGURE 27-20. A: This film shows another fracture resulting from anterolateral bowing. Note the quality of the bone at the pseudarthrosis site. B: A contralateral vascularized fibular graft has been used to bridge the pseudarthrosis. Healing proximally and distally has occurred. (Courtesy of Vern Tolo, MD., Los Angeles, CA.)

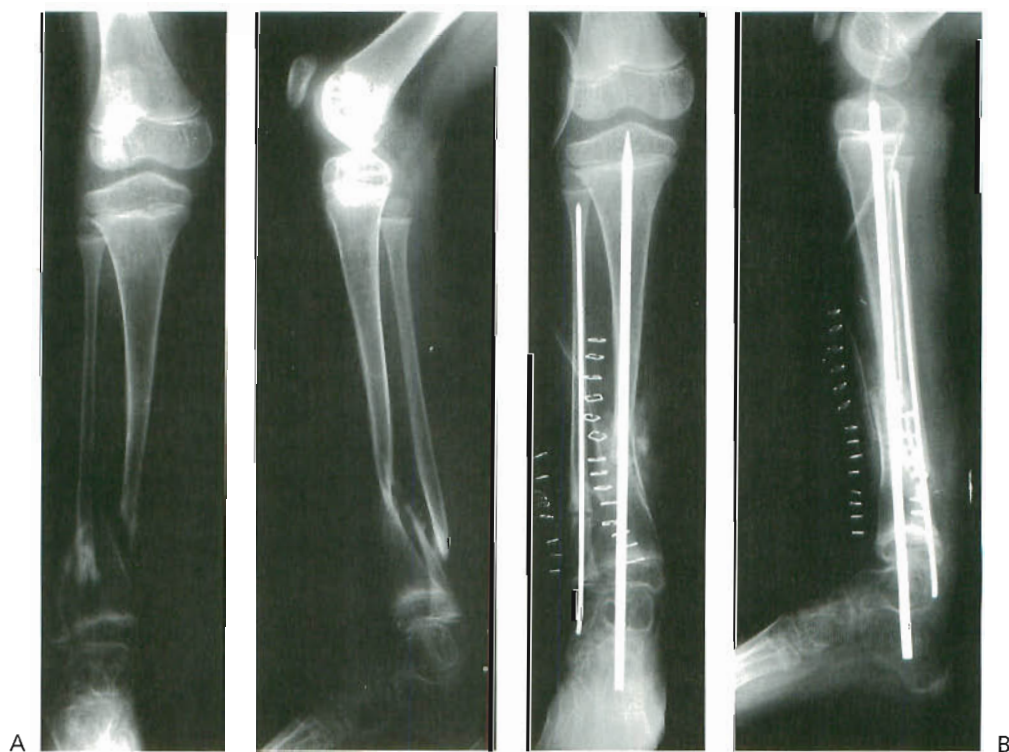


FIGURE 27-21. A: This is another example of a tibial pseudarthrosis. Treatment includes stabilization of the fracture, establishment of a source of healthy bone, and maintenance of alignment. B: Among the options for treatment is intramedullary stabilization and autologous bone graft. The pathologic bone was resected, and a Williams rod was used in the tibia with a Steinmann pin in the fibula. Iliac crest graft was packed around the pseudarthrosis. (*continued*)

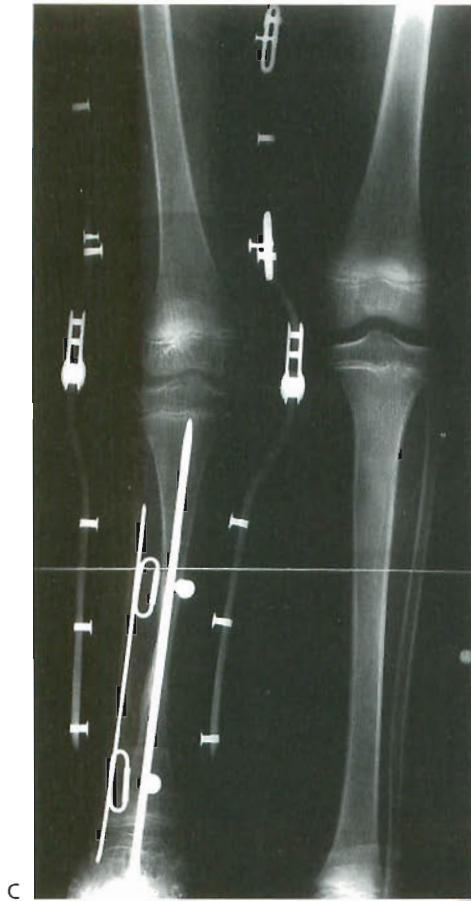

FIGURE 27-21. (continued) C: A spica cast is applied postoperatively, and a total contact orthosis used once union is established. Ankle motion is prohibited, as long as the rod remains across the subtalar and ankle joints. A knee-ankle-foot orthosis (KAFO) is used in smaller children. A PTB orthosis can be used in most children over 7 years of age.

rod to be left in place should proximally be abutting the tibial physis, and distally extending to the hindfoot. With longitudinal growth of the distal tibia, the distal end of the rod “migrates” proximally. Therefore, the anticipated remaining growth determines the appropriate placement of the distal end of the rod at the time of surgery. The previously harvested iliac bone graft strips are then placed around the pseudarthrosis site. The composite is further secured with circumferentially placed absorbable heavy suture material, establishing a stabilizing, barrel-stave construct.

By protocol, for children 6 years and younger, a $1\frac{1}{2}$ spica cast is applied to assure minimal rotatory stress at the pseudarthrosis site. The spica cast is replaced with a long-leg cast at 6 to 8 weeks, and cast immobilization is discontinued at approximately 4 months. Older children are treated with long-leg casts for the entire 4 months.

Once cast protection is discontinued, the involved extremity is protected with a custom-fabricated KAFO with a locked ankle joint and free knee joint. The presence of the rod across the ankle joint and in the hindfoot has a considerable advantage in providing optimal immobilization and protection of the consolidating pseudarthrosis. Refracture may occur, and spontaneous healing with plaster immobilization may occur. However, such is not always

assured, and regrafting and/or rerodding may be required. With longitudinal growth of the tibia, the distal end of the rod migrates more proximally, and eventually will be positioned in the distal tibia (Fig. 27-22). As the tip of the rod crosses the ankle joint, the potential for disruption of articular cartilage exists. To minimize such, the rod can be surgically pushed across the ankle joint as the tip approaches the articular surface of the talus. This adjustment is easily accomplished with a slightly larger diameter, concave-tipped IM pusher rod inserted through the calcaneus, as monitored with a C-arm.

On occasion, despite consolidation of the pseudarthrosis and growth of the tibia, the rod does not migrate. If such occurs, the rod should be replaced. This has always been done with the intraoperative perceived need for additional bone grafting. In the case of failure of rod migration, the replacement rod should probably be proximally secured with methylmethacrylate (172).

Valgus deformity of the involved tibia of the ankle is a potential deformity that can compromise the functional result. The authors feel that the valgus deformity is more of a natural outcome of the initial deformity (deficient fibula and lateral support), and less of an iatrogenic complication of traversing the physis with the rod. Long-term bracing is

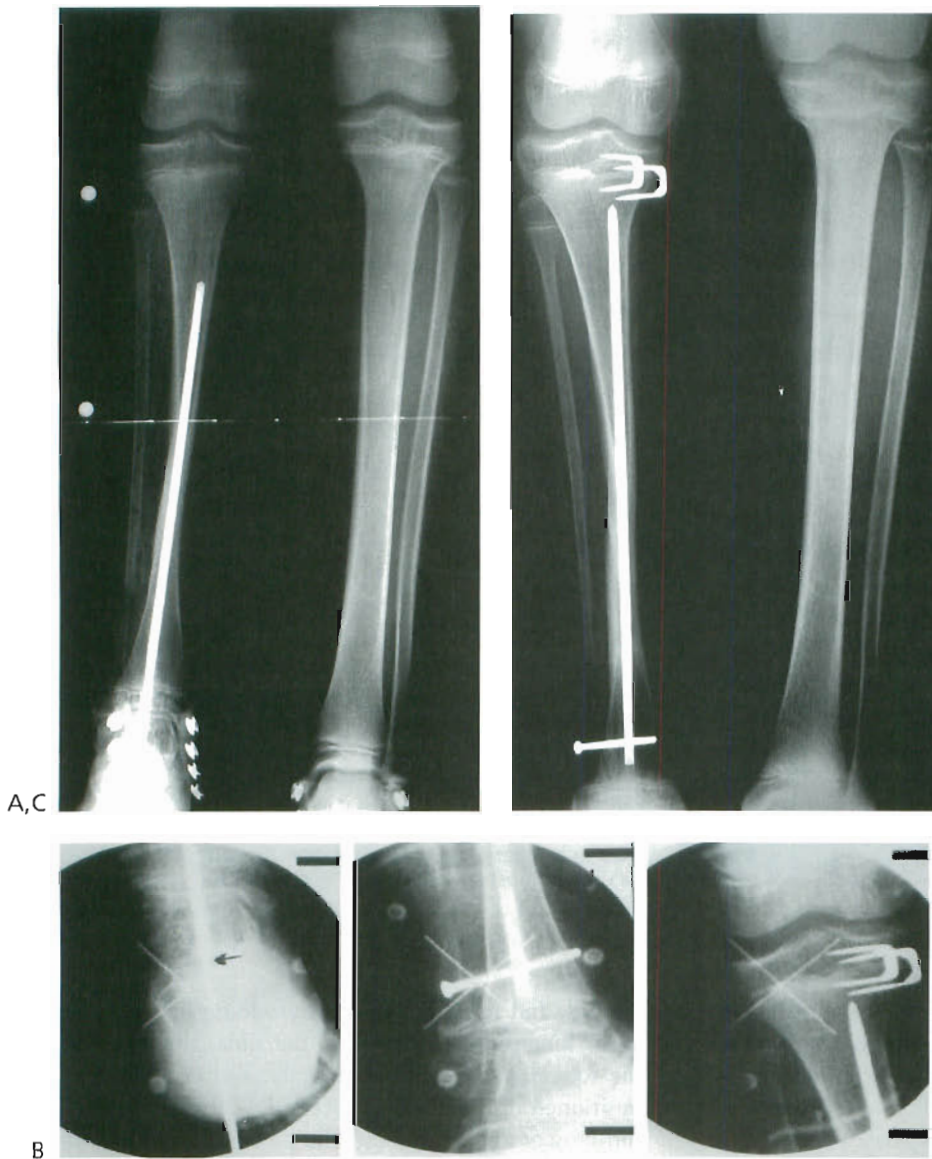

FIGURE 27-22. A: As the child grows, the rod remains in the tibia. Growth in the tibia, proximally and distally, makes the rod appear to migrate. As the distal tibia grows off the rod, the child may complain of pain, with stress of the ankle. B: The rod can be advanced into the tibia under image intensification guidance. A smaller rod, or Steinmann pin, can be positioned in line with the Williams rod, and used to push the rod across the ankle into the tibia. A syndesmosis screw was placed at the same time, to aid in valgus stabilization at the ankle, due to the fibular pseudarthrosis. Proximal medial stapling of the tibia was also performed to correct the mild valgus deformity. C: Tibial growth has continued. The pseudarthrosis remains healed with satisfactory alignment of the tibia. Limb-length inequality can be managed with contralateral epiphysiodesis. Lengthening of the affected leg may be complicated by delayed bone formation and healing.

mandatory during the growth years to minimize progressive valgus. This is particularly true once the rod no longer traverses the growth plate. Valgus has been satisfactorily treated by either proximal or distal medial tibial physeal stapling and/or insertion of a fibula/tibia transverse stabilizing screw. Following medial physeal stapling, the valgus deformity predictably improves over approximately a 1- to 2-year period. If complete correction occurs, the staples are then removed. At the time of staple placement or removal, a fibula/tibia transverse syndesmosis stabilizing screw may be placed. This is indicated for persistent valgus and/or a relative proximal position of, typically, an ununited distal fibular fragment. With this approach symmetric growth of the distal tibia has generally continued, and the valgus deformity has not recurred.

Leg-length inequality is often significant secondary to pseudarthrosis of the tibia. Fourteen of the authors' 20 patients had a noted leg-length discrepancy (LLD), which was greater than 2 cm in 10 patients. Six of these patients were treated with epiphysiodesis, for an average predicted LLD at maturity of 4 cm. Two patients underwent a proximal tibial leg-lengthening. One patient underwent an amputation at age 15 years, with a 9-cm leg-length inequality and other musculoskeletal abnormalities.

A relatively satisfactory functional outcome has been achieved in 16 of the 20 patients followed to an average age of 14 ± 8 years with an average length of follow-up of 9 ± 9 years. The remaining five patients have gone to amputation at various stages of treatment. The quality of ankle function and gait have varied considerably. The best

results have been noted in those patients in whom the tibia is anatomically aligned and the foot is not in dorsiflexion. A recent gait analysis assessment of the outcome of treatments of CPT (173) cited relatively poor push-off following IM rod treatment. Although this potential exists for all techniques of treatment, it is more potentially problematic following long-term IM splinting of the ankle joint. To date, gait analysis of the authors' most recently treated patients has shown a more favorable outcome regarding demonstrable push-off activity. The authors now are utilizing a more active strengthening program about the ankle, once the rod has migrated or is surgically advanced proximal to the ankle.

Ilizarov pioneered the innovative use of a circular external fixator, utilizing combinations of compression, distraction, resection, and bone transfer via means of a circular external fixator. Subsequently, numerous authors have made further refinements in the technique (174–179). Notably the initial reports of Paley et al. (177), citing the early combined multicenter experience with this technique, cited a very impressive initial union rate in 16 CPTs (94% after one treatment and 100% with two treatments). The mean age at treatment was 8 years. Five refractures occurred, and were successfully treated with a variety of additional procedures. In a more recent multiauthor study, Boero et al. (179) reported 7 of 21 failures in treating CPT with Ilizarov's technique. In their study, all 21 patients had neurofibromatosis. The best results were obtained with sclerotic and/or normotrophic bone (6 of 6 consolidated early at an average of 10 to 12 months), and did not refracture, whereas only 5 of 11 hour-glass CPTs eventually healed. In the same series, consolidation was obtained in 86% of those patients operated on who were older than 5 years of age, and on only 14% of those younger than age 5 years.

Dahl's report on work in progress is indicative of the state of the art in treatment of CPT with external fixation (180,181). He reported on 21 patients, treated by a single surgeon, followed to maturity. To date, Dahl (180) has reported a satisfactory outcome of treatment (consolidation sustained, independent ambulation, with a score of at least 87, according to the Musculoskeletal Tumor Society rating scale), in 20 of 21 patients. One patient had an amputation. The average age was 11 years (range 8 months to 29 years), and 18 of 21 patients had been treated with multiple prior surgeries. Dahl noted refractures in 33% of the first 12 patients he treated. Refinements in his techniques have led to fewer fractures. His protocol in achieving prompt and lasting union includes resection of the pseudarthrosis and pathologic periosteum, creating a stable intrinsic fit of the bone end, bone grafting the site of pseudarthrosis to maximize the cross-sectional area, ideal axial alignment eliminating bending forces, judicious length, and deformity correction through the proximal tibia. To deal with the inherent problem of refracture, he has chosen to prophylactically place an IM pin 8 weeks postfixator removal (181) (Fig. 27-23).

Congenital pseudarthrosis of the tibia has and will continue to be a very challenging problem. A stable consolidation is essential for a long-term satisfactory functional outcome. Each case is unique, and, as such, the treatment plan must often be modified. The newer techniques (vascularized bone graft, IM stabilization, external fixator) have been refined and successfully used by a few. All of these authors have had considerable experience in learning how to apply and adapt their particular surgical technique to the variables of each individual case. The overall good early results, with these newer and/or refined surgical techniques, are encouraging. However, as Boyd and Sage (182) suggested years ago, the true success of treatment of CPT in the growing child can only be known by following these patients until maturity.

Amputation

Amputation can be a viable and prudent alternative. Amputation should be considered following failure to obtain consolidation with the above-described surgical techniques and/or an unsatisfactory outcome, despite having obtained consolidation. Crawford and Jacobsen et al. prefers preserving the hind foot with a Boyd-Syme procedure (137,183), which preserves the distal leg and hindfoot length, potentiating optimal prosthetic fitting. Having done such, the authors subsequently have observed problematic stump instability. Eventually, more proximal stump revision was necessary to improve the prosthetic fit.

Congenital Pseudarthrosis of the Fibula

Definition

Congenital pseudarthrosis of the fibula almost always occurs in association with congenital pseudarthrosis of the tibia. It rarely occurs as an isolated entity, with only 21 cases reported to date in the literature (184–190). Congenital pseudarthrosis of the fibula presents later in life than congenital tibial pseudarthrosis. It occurs typically with a gait abnormality and/or a valgus deformity of the leg with a prominent fibula (184,185,188,189). The condition is frequently linked to neurofibromatosis. The tibia is involved by a prepseudarthrotic process with variable deformity (184).

Pathology

As with congenital pseudarthrosis of the tibia, congenital pseudarthrosis of the fibula may occur after a fracture through pathologic bone, or through an area of mesodermal maldevelopment (185). Dooley et al. (185) outlined a gradation in the severity of the condition: (i) fibular bowing

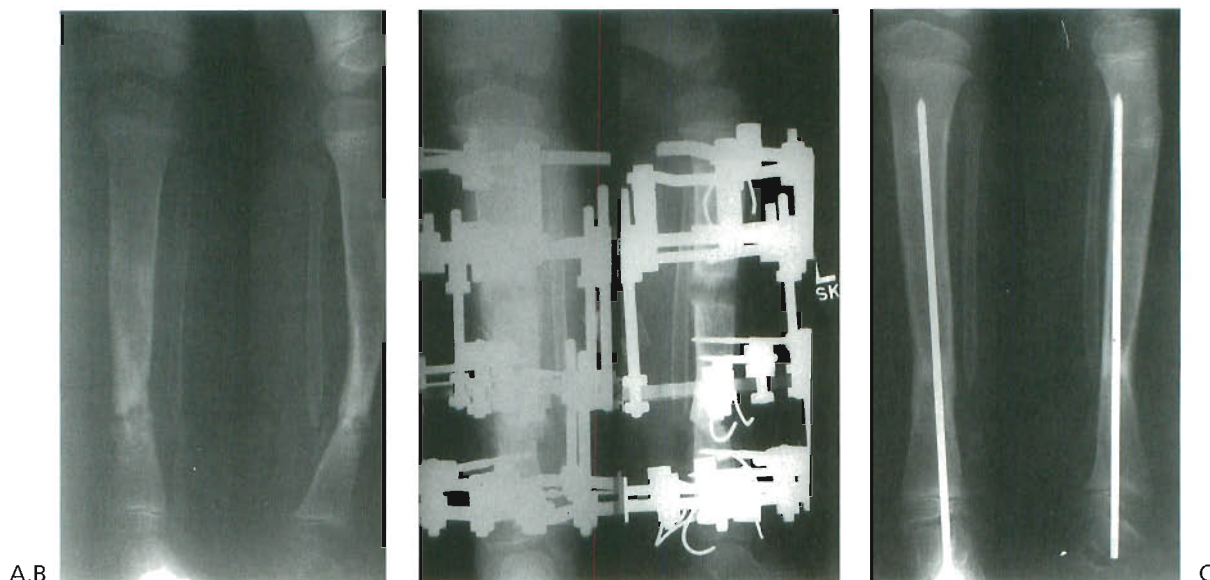


FIGURE 27-23. A: These anteroposterior and lateral films are of a 6-year-old with neurofibromatosis, whose tibial pseudarthrosis recurred following multiple bone graft procedures and intramedullary pinning. B: The pseudarthrosis was resected. The circular frame was used to apply compression across the distal site, and to lengthen proximally. C: Subsequent to this, an intramedullary rod was placed across both osteotomy sites in the tibia and the ankle. A solid AFO has also been used. Alignment and bone union have been maintained, as shown in these films 2 years later. (Courtesy of Mark Dahl, M.D., Minneapolis, MN.)

without pseudoarthrosis, (ii) fibular pseudoarthrosis without ankle deformity, (iii) fibular pseudoarthrosis with ankle deformity, and (iv) fibular pseudoarthrosis with late development of tibial pseudoarthrosis.

Treatment

Bowing of a congenitally abnormal fibula needs no treatment, if no ankle deformity or tibial pseudoarthrosis exists (184,185). Isolated pseudoarthrosis of the fibula in a growing child may (186) or may not (185) potentiate ankle valgus deformity. Dooley et al. (185) suggest observation if no ankle deformity is noted. Hsu et al. (186) suggest the potential for ankle valgus is too significant without an intact fibula, and suggest interpositional bony reconstitution of the fibula. If pseudoarthrosis of the fibula is associated with an ankle valgus deformity it should be treated. Langenskiöld (187) has successfully synostosed the fibula to the tibia, correcting progressive deformity in the growing child (184,185).

If there is associated significant distal tibial valgus deformity it should be surgically addressed. In less-severe deformities, and in skeletally immature patients, this can be accomplished with medial distal or tibial staple hemiepiphyodesis. In severe deformities and/or skeletally mature patients, this is best done with a supramalleolar valgus-correcting osteotomy.

Posterior Medial Bowing of the Tibia

Definition

Posteromedial bowing of the tibia is a congenital anomaly, associated with calcaneovalgus foot deformity (191). Unlike its counterpart, anterolateral bowing, posteromedial bowing is not associated with pathologic fracture or pseudoarthrosis of the tibia, and has generally been considered a relatively benign condition. Although the severity of the bow does diminish, significant leg-length discrepancy develops (191). It is this sequela that presents the greatest need for orthopaedic management.

Etiology

The pathogenesis of posteromedial bowing is unclear. Mechanical forces (the dorsiflexed foot against the tibia) and embryologic vagaries of tibial development (circulatory or limb bud anomaly) have been suggested as causes, but remain unproven. The rapid decrease of bow in the tibia in the first 6 to 12 months supports mechanical factors as a cause of bowing (191,192). It cannot, however, account for the growth inhibition.

Assessment

What is most evident at birth is the extreme dorsiflexed position of the foot against the tibia (Fig. 27-24). Plantar

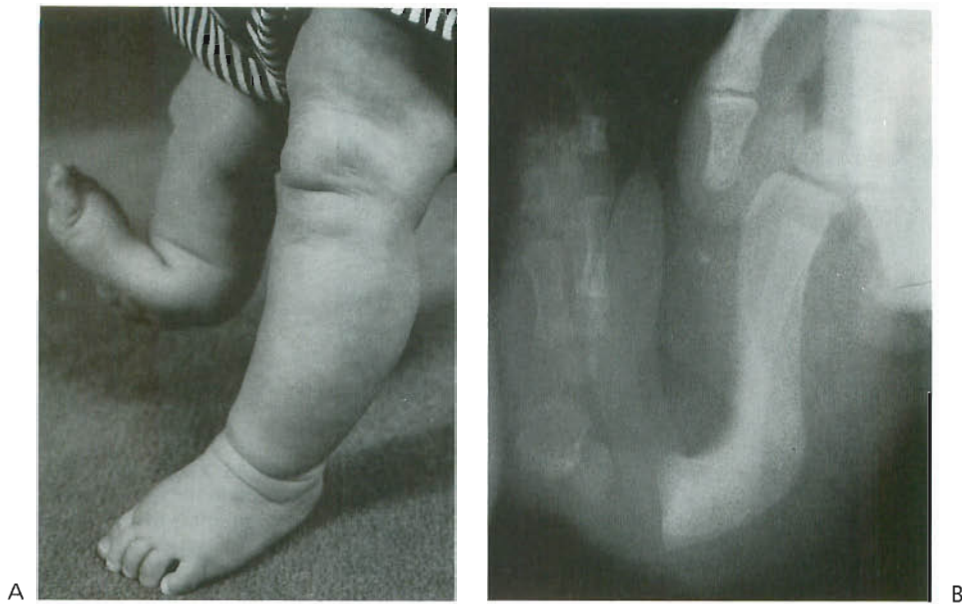


FIGURE 27-24. **A:** Infants with posteromedial bowing usually present because the foot is in an abnormal, severely dorsiflexed, position. The bow can be palpated along the subcutaneous border of the tibia. A skin dimple is usually present over the apex of the bow. Shortening of the leg may not be as obvious as the bowing deformity. **B:** This infant's lateral radiograph shows how the foot seems to nestle against the curve of the tibia. The bone appears normal, or may show signs of remodeling with thickening of the anterior cortex, and smoothing posteriorly.

flexion of the foot may be limited. Bowing of the tibia may be overlooked by parents, and upon initial newborn examination. The bow is most easily felt by palpation of the anterior tibia. A normal infant has an anterior bow, which is distinct from the posterior defect palpated in infants with posteromedial bow. A skin dimple is usually present over the posterior apex of the bow. Shortening of the affected tibia may not be readily apparent clinically in newborns, but is expected to increase in these children. Evaluation should include AP and lateral radiographs of both tibias. The severity of the posterior and medial deformity can be measured and a percent inhibition of tibial growth can be calculated. The lateral tibial films provide more accurate tibial length measurements in infants. Orthoroentgenograms or similar radiographic techniques can be used for serial assessments of limb-length inequality. The posterior angulation rarely persists, often producing a mild S-shaped tibia. The medial angulation is less likely to resolve completely, and residual valgus in the tibia may be clinically significant (Fig. 27-25). Growth inhibition is fairly constant, as the absolute leg-length difference increases with growth.

Differential Diagnosis

There is little to consider in the differential diagnosis of posteromedial bowing. Its direction is clearly different from the more serious pathology of anterolateral bowing. Postero-

medial bowing may be overlooked in the presence of severe calcaneovalgus foot deformity. Occasionally, adolescents will present with limb inequality and mild valgus, the result of previously unrecognized posteromedial bowing. Metabolic bone disease, such as osteogenesis imperfecta, rarely results in this type of bowing deformity.

Treatment

Initial treatment of infants is primarily passive stretching of the foot. Serial cast application may be used for severe deformities. The bowing generally corrects rapidly in the first year (191,192). Rarely, extreme dorsiflexion and valgus persist, such that plantigrade weight-bearing cannot be accomplished. Use of a solid AFO or SMO may be facilitate weight-bearing for walking (193,194). As tibial length inequality increases, a shoe lift may be needed to balance the pelvis. Gradual contracture of the plantar flexors is not uncommon. Passive stretching is usually adequate treatment in young children.

Recently, 35 patients with posteromedial bowing of the tibia were reviewed at the Shriners Hospitals for Children in St. Louis. All had some degree of limb-length inequality. The minimum discrepancy was 1.4 cm at 1 month of age, and the projected difference at maturity ranged from 3 to 8 cm. Pes planovalgus, which was seen in some children, resulted in decreased foot height as well. This degree of

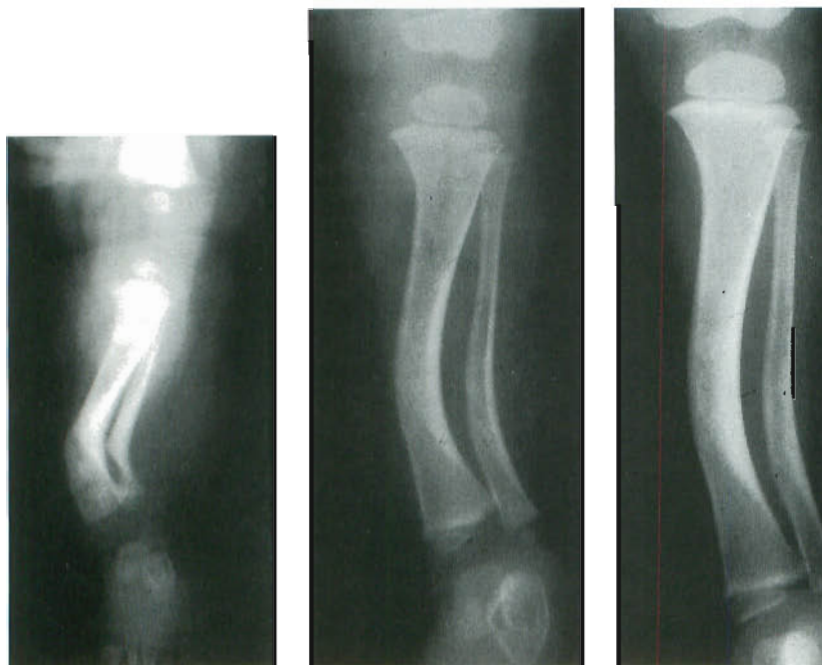


FIGURE 27-25. Both the posterior and medial components show spontaneous resolution. Improvement is often very dramatic within the first year. This series of AP films show the typical course of resolution from 1 month to 6 months and 12 months of age. Medial bowing may not fully resolve, resulting in residual valgus. Posteromedial bowing is not associated with risk of pathologic fracture.

inequality is best managed by surgical equalization, either by shortening the long tibia or lengthening the short tibia.

Appropriately timed epiphysiodesis has been most widely used for differences up to 4 to 5 cm. Shortening is almost always confined to the tibia. Epiphysiodesis of

the proximal tibia is usually sufficient. There are several techniques that can be employed [➔6.12, 6.13] (see Chapter 28). A staged hemiepiphysiodesis may be used to correct residual angulation prior to completion of the epiphysiodesis. Lengthening techniques [➔6.9, 6.10] are recom-

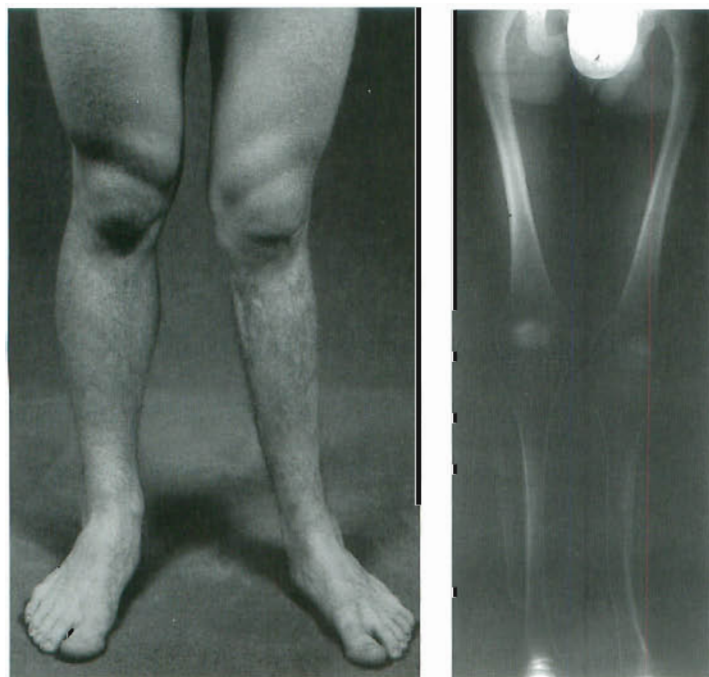


FIGURE 27-26. A: This 17-year-old male has a history of posteromedial bowing of the left tibia. At age 14 years, he had lengthening of his tibia, for a 4.8-cm discrepancy. B: The residual valgus was not corrected. Lengthening exaggerated the valgus appearance. There was also residual shortening, in part, from decreased foot height secondary to the valgus position. (continued)

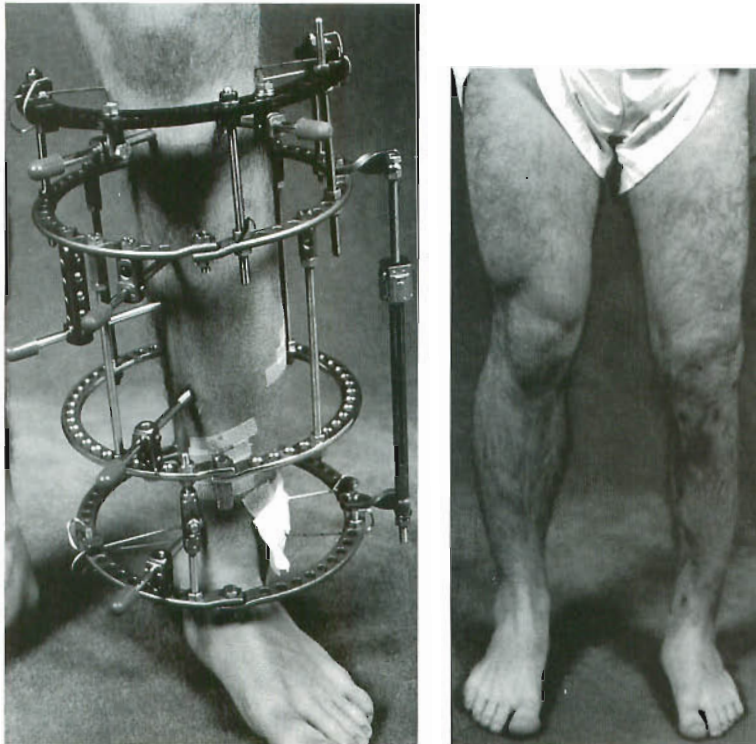


FIGURE 27-26. (continued) C: Subsequently, a bilevel tibial osteotomy was performed. Residual valgus was corrected through the distal tibia, and limb-length equalization accomplished with proximal lengthening. D: Valgus has been corrected, as well as balancing the pelvis.

mended for those children with projected discrepancies greater than 3 to 4 cm, and for those with residual valgus angulation (Fig. 27-26). Lengthening alone in this latter group can add to existing valgus, particularly when unilateral frames are used. Circular frame fixation allows better control of valgus (31,108). Bi-level osteotomies in the tibia (lengthening proximally, deformity correction distally) provide optimum management of length and angulation. The foot may assume a varus position to compensate for residual tibial valgus, and require modification of the frame, if it is rigid. Stability of the knee and ankle is normal with posteromedial bow, making these relatively less complicated corrections than other congenitally short tibiae.

CONGENITAL DISLOCATION OF THE KNEE

Definition

Congenital dislocation of the knee (CDK) is a relatively rare deformity that varies from simple hyperextension to anterior dislocation of the tibia on the femur. The variable spectrum of deformity in the clinical presentation of CDK has been classified as recurvatum, subluxation, and dislocation (195,196). The incidence of CDK is estimated at 1 per 100,000 live births, nearly one-tenth the incidence of developmental hip dysplasia (197–199). Although there are

some reports of occurrence within families, most cases are sporadic occurrences (200–202). The deformity may be unilateral or bilateral.

Etiology

Several etiologic factors have been proposed for CDK. The abovementioned familial occurrence suggests a possible genetic basis. There is also a strong relationship of CDK with both hip dysplasia and congenital foot deformities (195,197,203). Both congenital deformities (clubfoot and vertical talus) have polygenic modes of inheritance, again suggesting a genetic link with CDK (195,197,204).

Milder forms of CDK occur in association with breech position *in utero*. In one study, 41% of otherwise normal newborns with CDK were breech position. These are generally believed to be positional, not pathologic deformities (197). Severe CDK often occurs in the presence of muscle imbalance and/or ligamentous laxity, as occurs in myelodysplasia, arthrogryposis, Larsen syndrome and maternal oligohydramnios (195,197,203,205).

Imbalance about the knee created by a relatively strong or contracted quadriceps muscle, along with deficient hamstrings, can lead to anterior dislocation of the knee. These infants typically have severe hyperextension *in utero*, and presumably decreased fetal mobility. The chronic knee hyperextension allows anterior subluxation of the hamstrings,

making them “perverted” knee extensors (206). The quadriceps muscle is short and contracted. Uthoff and Ogata were able to study a 19.5-week-old fetus with such a deformity (207). They found early fibrosis of the quadriceps, absence of the suprapatellar pouch, and incomplete patellofemoral cavitation. The authors suggest that these abnormalities, intrinsic to the extensor mechanism, were the primary cause of knee subluxation, rather than being secondary to some other extrinsic cause. The pathologic findings in this fetus are the same as those found in patients treated surgically.

Clinical Presentation

The hyperextended knee(s) deformity is obvious, but of variable severity. There is inability to actively or passively flex the knee (Fig. 27-27). The quadriceps tendon is often severely contracted. A dimple or deep crease may be present over the anterior aspect of the knee. The patella is difficult to palpate, and often laterally displaced. In the more severe forms, hip dysplasia and congenital foot deformities are present. Milder forms, such as hyperextension or recurvatum, are usually isolated abnormalities. Radiographs (Fig. 27-28) help to differentiate anterior dislocation of the tibia from the less complex hyperextension deformity. CDK, occurring in association with a neuromuscular or genetic syn-

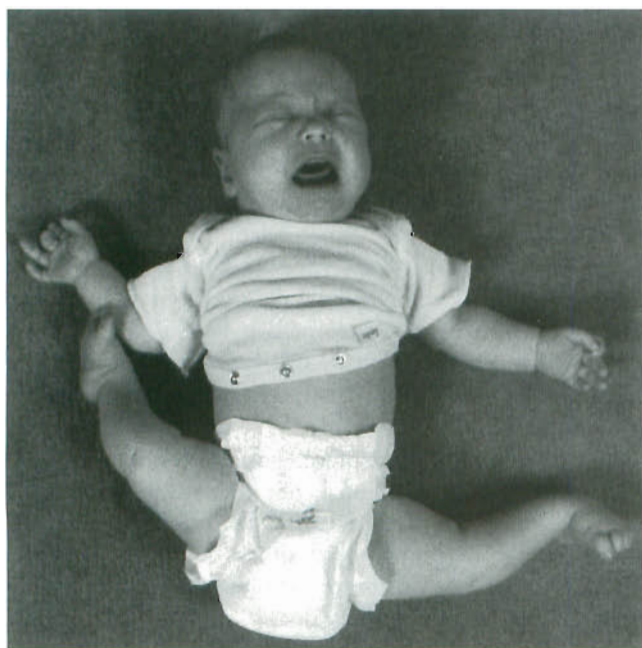

FIGURE 27-27. This infant has bilateral anterior knee subluxation and club foot deformities. These deformities are often associated with intrauterine breech position. Deep skin creases are often found across the front of the knee. The skin may be dimpled posteriorly. See Fig. 27-29 for follow-up of this patient.

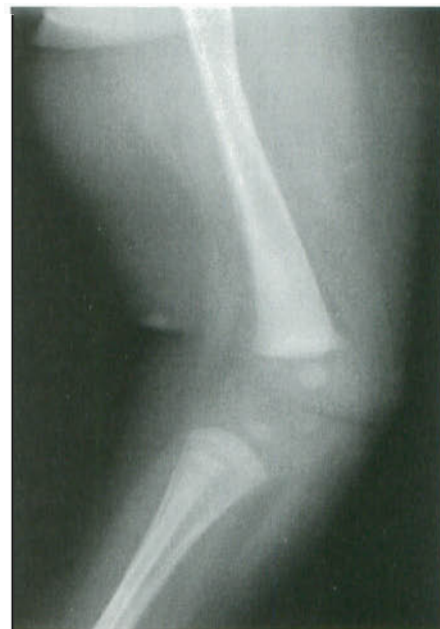

FIGURE 27-28. A lateral radiograph differentiates between simple hyperextension, subluxation, and anterior dislocation. The anterior aspect of the knee is to the left. Note the deep skin crease anteriorly. The ossification center of the proximal tibial epiphysis is anterior to that of the distal femur. Serial lateral radiographs should be used to document anatomic reduction of the knee. Failure to achieve anatomic reduction by closed manipulation, or inability to flex the knee more than 60 degrees, are indications for surgical treatment.

drome, is typically very severe and the most difficult to manage (195,208,209).

Nonoperative Treatment

Treatment begins with gentle stretching. The use initially of serial casts changed weekly, and subsequently, removable splints changed every 2 to 3 weeks, is often helpful, particularly in the milder forms. These knees often show rapid improvement in flexion. A Pavlik harness is useful for maintaining knee flexion (210–212). Once flexion beyond 90 degrees is obtained it is unlikely that additional treatment will be needed. It is important to document the restoration of a normal relationship of the femur to the tibia. A lateral plane radiograph of the knee is usually sufficient. Ultrasound can also be used. Knees with more severe subluxation or dislocation may not respond to passive stretching or splinting. Traction has been suggested as a means to achieve gradual reduction (195,209,213). During attempted closed treatment, it is particularly important to radiologically document the restoration of a normal relationship of the tibia on the femur. A lateral plane radiograph of the knee joint is usually sufficient. Ultrasound can also be used. It is possible to create an iatrogenic separation through the distal fem-

oral physis, or plastically deform the proximal tibia. Rather, flexion obtained must occur at the knee joint as the tibia translates on the femur.

Surgical Treatment

Those infants who do not respond to nonoperative treatment (failure to achieve knee flexion beyond ≥ 60 degrees) should be considered for surgical treatment [►5.3] (199). Early surgery (<4 to 6 months of age) is desirable. However, extensive and often bilateral releases are required. Often, surgery must be delayed if the child's general health status is compromised by coexisting medical conditions. Alternatively, Roy and Crawford (203) have used a percutaneous release of the quadriceps mechanism, in conjunction with serial casting. This has been performed as early as 1 to 2 months of age.

The extent of the incision and dissection necessary should not be underestimated. The typical incision extends from the proximal thigh, in a serpentine fashion distally, and slightly past the tibial tubercle distally. A serpentine incision, rather than straight, may facilitate wound closure and healing. Subcutaneous flaps are raised to expose the contracted quadriceps mechanism. Fibrosis and scarring of the muscle is usually extensive. It may be adherent to the periosteum of the femur. The patella is usually very small and laterally displaced. The extensor mechanism is usually malrotated, and pulls the tibia into valgus. The quadriceps mechanism must be considerably lengthened, yet remain attached both proximally and distally. This requires extensive dissection through fibrotic tissue. A V-Y advancement, done more proximal to the patella, satisfactorily lengthens moderate contractures (195).

For the relatively more severe quadriceps contractures, the authors have found that greater lengthening can readily be obtained by a Z-plasty of the entire distal portion of the quadriceps mechanism (195). The anterior knee joint is transversely released to the collateral ligaments, which often must be reflected forward and/or partially released. Typically, the knee can be flexed to 90 degrees. Occasionally, the medial hamstrings, iliotibial band, and the lateral intermuscular spectrum must be released to correct valgus and external rotational deformity (199). The cruciates are typically present, but may be attenuated (195,204,206). The authors have not found it necessary to release the cruciates. The tenuous quadriceps mechanism is repaired with the knee in ≥ 30 degrees of flexion (195,199,206). Postoperatively, the knee is immobilized in a spica cast, in enough flexion (30 to 45 degrees) to prevent recurrent tibial subluxation (197,199). Immobilization in too much flexion both jeopardizes the quadriceps mechanism repair and potentiates necrosis of the rather tense skin and subcutaneous soft tissue (195). It is essential to continue with long-term range of motion and orthotic splinting to maintain maximal flex-

ion and yet minimize loss of extension. Flexion contracture can be more debilitating than lack of full flexion.

Treatment of an ipsilateral hip dislocation is best performed after correction of the knee dislocation. Following release of the contracted quadriceps mechanism, the knee can be flexed, which facilitates treatment of the hip (195,197,199). Mild hip dysplasia, which can be managed by simple closed reduction or limited open reduction with a medial approach [►3.3, 3.4], can be treated in conjunction with the spica cast utilized to immobilize a surgically reduced CDK. For more severe hip dysplasia open reduction should be done later as a staged procedure. If a coexisting foot deformity requires operative treatment, this can be done in conjunction with the knee reconstruction. Knee flexion facilitates cast application necessary for the treatment of associated foot deformities.

The long-term outcome of treatment is variably good. Those who require only stretching, and minimal intervention as infants, anticipatably have the best results. They do not report problems later on. Function is very good and radiographs appear nearly normal (198,208,211,212). Those children who require an open reduction, but do not have any other musculoskeletal problems, generally do well (Fig. 27-29A and B). These patients have knee range of

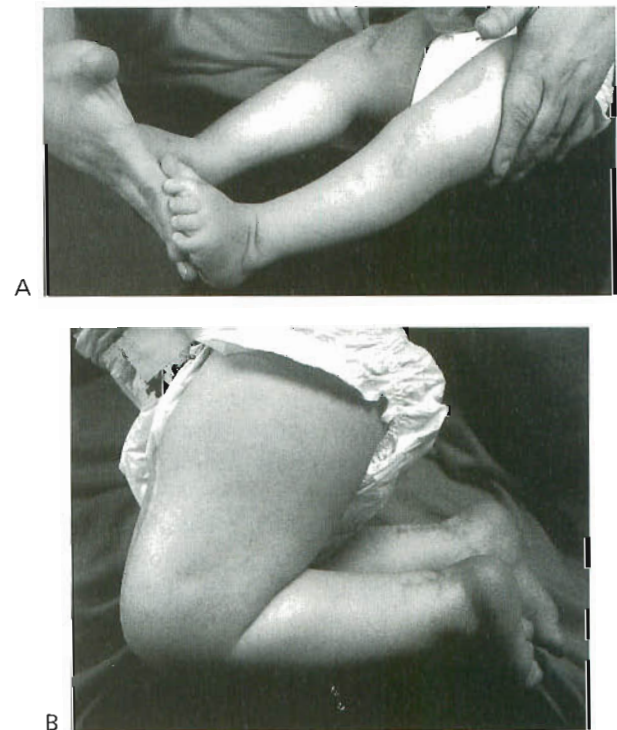


FIGURE 27-29. Follow-up photos of patient seen in Figure 27-27. **A:** The upper photo shows knee extension following open reduction of these bilateral knee deformities. Hyperextension is no longer evident. **B:** Knee flexion greater than 90 degrees has been accomplished. Range of motion exercises and intermittent use of orthotics may be needed to maintain this correction.

motion from near-full to full extension, and flexion, which averages 80 to 120 degrees. This allows very functional independent ambulation. All have some degree of ligamentous laxity of the involved knee. Radiographic abnormalities are found in some, but not all knees. This usually consists of flattening of the femoral and tibial articular contours (195,197).

Those with bilateral deformity do not do as well as those with unilateral deformity. These also tend to be children with neuromuscular disorders. Early repair generally has a more satisfactory functional result than late repair (195,197,203). Recurrent hyperextension deformity is not likely. However, loss of flexion, particularly that gained at surgery, can be a late complication. The development of a flexion contracture can compromise long-term function. This may result from poor quadriceps muscle function or postoperative fibrosis. Release of contracted soft tissues and/or osteotomy may be necessary to place the limb in a functional position.

IDIOPATHIC TOE-WALKING

Definition

Children may present at any age with a history of toe-walking. The habit of doing so is not that uncommon or abnormal in 2- or 3-year-old children. Typically, the habitual toe-walkers, with coaxing, can alternatively walk plantar grade. By the age of 3 years, children should walk with a heel strike (6,214,215). Persistent toe-walking beyond this age is abnormal in the child who is otherwise neurologically normal, and typically is associated with a shortened heel cord of variable severity (216–218).

Etiology

Although originally described as having congenitally short heel cords (217), most children in retrospect did not have a history of recognized heel cord shortening noted at or soon after birth (218). In some idiopathic toe-walkers, there is little evidence of static triceps surae contracture (217). In practice, though, those idiopathic toe-walkers with the greatest degree of heel cord contracture will most likely have a persistence of toe-walking and a need for treatment (218).

Natural History

In actuality, very little is known about the natural history of idiopathic toe-walking (ITW). Stricker and Angulo (218) retrospectively reviewed 80 patients who were evaluated and treated for ITW. Forty-eight of the 80 patients, generally those with the mildest deformity, were observed without treatment for an average of 3 years to 6 years. The degree of minor heel cord contracture remained essentially unchanged

for these patients. Only 25% of parents noted a spontaneous improvement; that is, appreciably less toe-walking occurred. Seemingly, for the children with relatively less severe heel cord contracture (dorsiflexion >5 degrees), persistent toe-walking is not a functional problem resulting in any foot deformities or pain. Toe-walking, for many patients, either diminishes or ceases with time. This perhaps occurs as the body mass becomes too large to be supported by the triceps surae and/or by the secondary development of external tibial torsion (217).

Clinical Features

Patients typically present to the orthopedist for evaluation of ITW at 3 to 4 years of age (218). Males predominate, and the family history (siblings and also generation to generation) is often positive for similar ITW, persisting into adulthood (216,218,219). The suggested inheritance pattern is autosomal dominant with variable penetrance (220,221). Although Stricker and Angulo noted a frequent history of both prematurity and developmental delay, walking age was not delayed (218). On examination, ITW occurs bilaterally, and is best seen when walking barefoot (Fig. 27-30). When the children stand still their feet are flat on the ground. Toeing-out and splaying of the forefoot variably occur. Idiopathic toe-walkers, in contrast to children with spastic dysplasia, do not have any noted tendency to walk with a back-knee thrust.

On bench exam, the range of passive ankle flexion will be normal, and dorsiflexion will be limited, secondary to a variable degree of true shortening of the heel cord (216). The posterior calf muscles are typically very well developed; in fact, they may appear to be enlarged. However, the muscle texture will feel normal on exam, and there will be no evidence of any weakness, proximal or distally in both the upper or lower extremities. Importantly, no spasticity is present. The diagnosis of ITW is a diagnosis of exclusion, and typically can be made from the child's history and physical examination (216,219,222,223).

Other Diagnostic Studies

The differential diagnosis of early-onset toe-walking includes spastic dysplasia and other neurologic etiologies (218,219). Idiopathic toe-walking that develops after the onset of a mature gait pattern must be differentiated from primary muscle disease, tethered cord syndrome, and CNS neoplastic abnormalities (218,219). On occasion, neurologic consultation may be indicated, to assist in the often subtle differentiation of ITW from toe-walking as a manifestation of typically static encephalopathy or remotely secondary to primary muscle disease (dystrophy, myotonia) (218). Diagnostic tests that may be helpful in this setting are MRI of the CNS and/or gait analysis, including dynamic EMG. Usually, the diagnosis of ITW is made without computer-

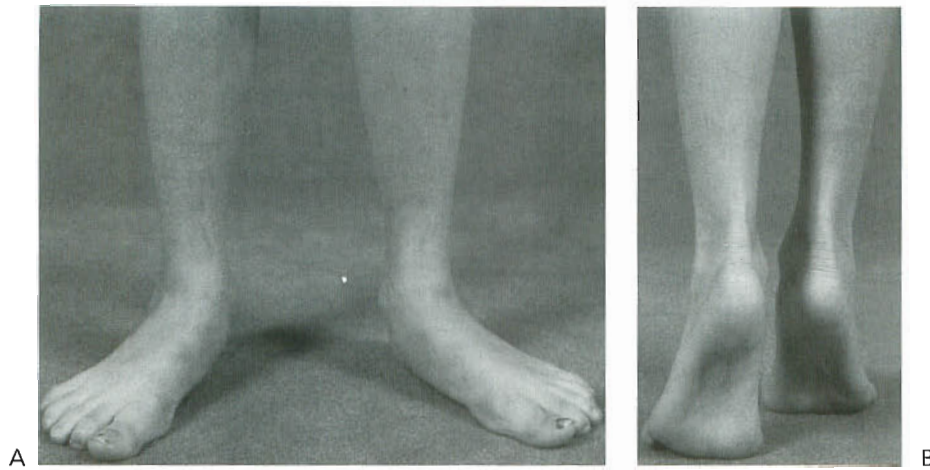

FIGURE 27-30. **A:** Children with idiopathic toe-walking assume an externally rotated posture, to facilitate a foot-flat position. They typically do not hyperextend the knee. **B:** While up on their toes, the heel moves to a varus position. Chronic toe-walking can cause the forefoot to splay, because of the overload of the intermetatarsal ligaments. Forefoot splay and tibial external rotation typically do not resolve after heel-cord-lengthening.

ized gait analysis. However, gait analysis may be helpful if it is essential to differentiate between ITW and spastic diplegia (217,222,224). Children with mild cerebral palsy who walk on their toes may have out-of-phase gastrocnemius soleus muscle activity, whereas the same EMG data for children with ITW will be in phase (224). Kinematic differences include lack of heel strike in both groups, but with greater sustained knee flexion at terminal swing in patients with mild cerebral palsy (217,222,223). Subtle kinematic differentiating patterns exist. Maximal knee extension occurs at ground contact for idiopathic toe-walkers, and at mid- to late-stance for diplegics (222). Maximal swing ankle dorsiflexion occurs early in ITW, followed by plantar flexion; ankle dorsiflexion occurs throughout swing in diplegics (222).

Treatment Recommendations

Nonsurgical Treatment

The treatment of ITW begins with instructions given to the parents regarding the importance of a long-term commitment to assisting the child with heel-cord-stretching exercises. This is particularly true in early childhood, when stretching exercises are more likely to make a difference. A 3- to 4-month course of twice-daily dorsiflexion manipulations, with the hindfoot inverted, may be effective in obtaining increased dorsiflexion. Less toe-walking may be noted. This clinical improvement will be sustained with continued daily heel-cord-stretching exercises and active dorsiflexion-strengthening exercises. There is more often than not a failure to comply with this regimen.

If toe-walking persists, serial stretching casts should be

considered. A series of two or three sets of short-leg casts will often physiologically elongate the heel cord, resulting in greater passive dorsiflexion. Typically, a marked decrease in the tendency to toe-walk is noted. After casting, articulated AFOs with plantar flexion stops are fitted, and the heel-cord-stretching and dorsiflexion-strengthening regimen is resumed. If dorsiflexion can be maintained the children are, over the ensuing months, gradually weaned from daytime and eventually nighttime use of AFOs. This approach will achieve initial correction, particularly in the majority of the younger patients, and even in some of the older patients. However, persistence of relapses are very common, often requiring repeating the casting and orthotic treatment regimen. Although serial casting and subsequent orthotic usage is widely recommended, very little is known of its long-term effectiveness (223).

Surgical Treatment

If the use of serial stretching casts does not realize a satisfactory clinical improvement in the tendency to toe-walk, then heel-cord-lengthening procedures will be necessary to effect a change in gait (216,218). The timing of definitively restoring a more normal gait is of importance. The authors feel that by 6 to 8 years of age, children should have treatment sufficient to realize a more normal heel-toe, rather than toe-heel gait. Persistent toe-walking can potentiate both forefoot splay and an associated permanent, disproportional hindfoot-forefoot size relationship and external tibial torsion. The associated external tibial torsion deformity becomes more obvious once the heel cord has been lengthened. It may be severe enough to warrant corrective osteotomy. In addition, treatment of neglected ITW in early

adolescence necessitates a heel-cord-lengthening at a relatively late age.

The heel-cord-lengthening can be done by a variety of techniques [7.16, 7.17]. The authors prefer performing a fractional lengthening at the junction of the middle and distal thirds of the triceps surae complex. Lengthening is performed sufficient to obtain 10 degrees of dorsiflexion with the knee extended. Short-leg walking casts are used for 5 to 6 weeks, then the child is fitted with AFOs, which are used 22 of 24 h for 4 to 6 weeks, then gradually weaned. Heel-cord-stretching and strengthening and dorsiflexion-strengthening exercises are performed twice daily.

Generally, parents are very satisfied with the improved gait following heel-cord-lengthening; however, they need to be well informed as to the anticipated post-operative course. The child's post-op gait (relatively weak plantar flexor power) will be considerably different from the pre-op gait (relatively strong plantar flexion power). The predominantly equinus gait is replaced with a gait with relatively weak push-off. Quick cadence is replaced by a gait with a slower cadence. It takes time for the push-off power to recover to near-normal parameters (216). Surgical correction predictably has a satisfactory outcome. Hall et al., at an average length of follow-up of 3 years post-heel-cord-lengthening, reported a satisfactory outcome for all 20 patients (216). In a review of all treatment methods, Stricker and Angulo (218) noted that only surgical lengthening of the heel cord permanently improved ankle dorsiflexion. Although 33 of 56 patients still exhibited some degree of toe-walking, most parents were satisfied with the outcome of heel-cord-lengthening (218).

References

- Engel GM, Staheli LT. The natural history of torsion and other factors influencing gait in childhood. *Clin Orthop Rel Res* 1974; 99:12.
- Hensinger RN. *Standards in orthopedics*. New York: Raven, 1986.
- Staheli LT, Corbett M, Wyss C, et al. Lower-extremity rotational problems in children. Normal values to guide management. *J Bone Joint Surg Am* 1985;67:39.
- Staheli LT. Rotational problems in children. In: Schafer M, ed. *AAOS instructional course lecture, vol. 43*. Rosemont: American Academy of Orthopedic Surgery, 1994:199.
- Kling TF, Hensinger RN. Angular and torsional deformities of the lower limbs in children. *Clin Orthop Rel Res* 1983;176:136.
- Sutherland DH, Olshen R, Cooper L, et al. The development of mature gait. *J Bone Joint Surg Am* 1980;62:336.
- Walker JM. Comparison of normal and abnormal human fetal hip joints: A quantitative study with significance to congenital hip disease. *J Pediatr Orthop* 1983;3:173.
- Watanabe RS. Embryology of the human hip. *Clin Orthop Rel Res* 1974;98:8.
- Fabry G, MacEwen GD, Shands AR Jr. Torsion of the femur. A follow-up study in normal and abnormal conditions. *J Bone Joint Surg Am* 1973;55:1726.
- Fabry G, Cheng LX, Molenaers G. Normal and abnormal torsional development in children. *Clin Orthop Rel Res* 1994;302: 22.
- Sutherland DH. Varus foot in cerebral palsy: An overview. In: Heckman JD, ed. *AAOS instructional course lecture, vol. 42*. Rosemont: American Academy of Orthopedic Surgery, 1993: 539.
- Stefko RM, deSwart RJ, Dodgin DA, et al. Kinematic and kinetic analysis of distal derotational osteotomy of the leg in children with cerebral palsy. *J Pediatr Orthop* 1998;18:81.
- Luhman SJ, Schoenecker PL. Painful idiopathic rigid flatfoot in children and adolescents. *Foot Ankle Int* 2000;21:59.
- Pritchett JW, Perdue KD. Mechanical factors in slipped capital femoral epiphysis. *J Pediatr Orthop* 1988;8:385.
- Murphy SB, Simon SR, Kijewski PK, et al. Femoral anteversion. *J Bone Joint Surg Am* 1987;69:1169.
- Staheli LT. Footwear for children. In: Schafer M, ed. *AAOS instructional course lecture, vol. 43*. Rosemont: American Academy of Orthopedic Surgery, 1994:193.
- Hubbard DD, Staheli LT, Chew DE, et al. Medial femoral torsion and osteoarthritis. *J Pediatr Orthop* 1988;8:540.
- Wedge JH, Munkacsy I, Loback D. Anteversion of the femur and idiopathic osteoarthritis of the hip. *J Bone Joint Surg Am* 1989;71:1040.
- Eckhoff DG, Montgomery WK, Kilcoyne RF, et al. Femoral morphometry and anterior knee pain. *Clin Orthop Rel Res* 1994; 302:64.
- Tonnies D, Heinecke A. Diminished femoral antetorsion syndrome: a cause of pain and osteoarthritis. *J Pediatr Orthop* 1991; 11:419.
- Delgado ED, Schoenecker PL, Rich MM, et al. Treatment of severe torsional malalignment syndrome. *J Pediatr Orthop* 1996; 16:484.
- Staheli LT, Lippert F, Denotter P. Femoral anteversion and physical performance in adolescent and adult life. *Clin Orthop Rel Res* 1977;129:213.
- Bauman PA, Singson R, Hamilton WG. Femoral neck anteversion in ballerinas. *Clin Orthop Rel Res* 1994;302:57.
- Fuchs R, Staheli LT. Sprinting and intoeing. *J Pediatr Orthop* 1996;16:489.
- Dodgin DA, deSwart RJ, Stefko RM, et al. Distal tibial/fibular derotation osteotomy for correction of tibial torsion: review of technique and results in 63 cases. *J Pediatr Orthop* 1998;18:95.
- Payne LZ, DeLuca PA. Intertrochanteric versus supracondylar osteotomy for severe femoral anteversion. *J Pediatr Orthop* 1994; 14:39.
- Slawski DP, Schoenecker PL, Rich MM. Peroneal nerve injury as a complication of pediatric tibial osteotomies: a review of 345 osteotomies. *J Pediatr Orthop* 1994;14:166.
- Staheli LT. The lower limb. In: Morrissy RT, ed. *Lovell and Winter's pediatric orthopaedics*, 3rd ed. Philadelphia: Lippincott, 1990:741.
- Winquist RA. Closed intramedullary osteotomies of the femur. *Clin Orthop Rel Res* 1986;212:155.
- Herzenberg JE, Smith JD, Paley D. Correcting torsional deformities with Ilizarov's apparatus. *Clin Orthop Rel Res* 1994; 302:36.
- Catagni MA. Current trends in the treatment of simple and complex bone deformities using the Ilizarov method. In: Eilert RE, ed. *AAOS instructional course lecture, vol. 41*. Rosemont: American Academy of Orthopedic Surgery, 1992:423.
- Green WB. Displaced fractures of the femoral shaft in children. Unique features and therapeutic options. *Clin Orthop Rel Res* 1998;353:86.
- Beatty JH, Austin SM, Warner WC, Canale ST, Nichols L. Interlocking intramedullary nailing of femoral-shaft fractures

in adolescents: Preliminary results and complications. *J Pediatr Orthop* 1994;14:178.

Genu Varum

34. Reinker K. Etiology of Blount's disease. POSNA 28th Annual Meeting, May 16, 1999, Orlando, Florida.
35. Golding JSR, McNeil-Smith JDG. Observations on the etiology of tibia vara. *J Bone Joint Surg Br* 1963;45:320.
36. Langenskiöld A, Riska EB. Tibia vara (osteochondrosis deformans tibiae). A survey of seventy-one cases. *J Bone Joint Surg Am* 1964;46:1405.
37. Barthfield CA, Beighton PH. Blount's disease, a review of etiological factors in 110 patients. *Clin Orthop Rel Res* 1978;135:29.
38. Salenius P, Vankka E. The development of the tibiofemoral angle in children. *J Bone Joint Surg Am* 1975;57:259.
39. Greene WB. Infantile tibia vara. *J Bone Joint Surg Am* 1993;75:130.
40. Engel GM, Staheli LT. The natural history of torsion and other factors influencing gait in childhood. *Clin Orthop Rel Res* 1974;99:12.
41. Levine AM, Drennan JC. Physiological bowing and tibia vara. The metaphyseal-diaphyseal angle in the measurement of bow-leg deformities. *J Bone Joint Surg Am* 1982;64:1158.
42. Schoenecker PL, Meade WC, Pierron RL, et al. Blount's disease: a retrospective review and recommendations for treatment. *J Pediatr Orthop* 1985;5:181.
43. Johnston CE II. Infantile tibia vara. *Clin Orthop Rel Res* 1990;255:13.
44. Bateson EM. The relationship between Blount's disease and bow legs. *Br J Radiol* 1968;41:107.
45. Feldman MD, Schoenecker PL. Use of the metaphyseal-diaphyseal angle in the evaluation of bowed legs. *J Bone Joint Surg Am* 1993;75:1602.
46. Bashner BC, Israelite CL, Betz RR, et al. Reliable early radiographic differentiation of infantile Blount's disease and physiologic bowing: utilizing the ratio of the femoral and tibial metaphyseal-diaphyseal angles. *Orthop Trans* 1991;15:27.
47. Glorieux FH. Hypophosphatemic vitamin D-resistant rickets. In: Favus MJ, ed. *Primer on the metabolic bone disease and disorders of mineral metabolism*, 4th ed. Philadelphia: Lippincott Williams & Wilkins, 1999:328.
48. Petersen DJ, Boniface AM, Schranck FW, et al. X-linked hypophosphatemic rickets: a study (with literature review) of linear growth response to calcitriol and phosphate therapy. *J Bone Miner Res* 1992;7:583.
49. Kugler JL, Schoenecker PL. A 19-month-old female with unilateral bowed leg. *Orthop Rev* 1993;22:108.
50. Bell SN, Campbell PE, Cole WG, et al. Tibia vara caused by focal fibrocartilaginous dysplasia, three case reports. *J Bone Joint Surg Br* 1985;67:780.
51. Bradish CF, Davies SJM, Malone M. Tibia vara due to focal fibrocartilaginous dysplasia, the natural history. *J Bone Joint Surg Br* 1988;70:106.
52. Olney BW, Cole WG, Menelaus MB. Case report, three additional cases of focal fibrocartilaginous dysplasia causing tibia vara. *J Pediatr Orthop* 1990;10:405.
53. Blount WP. Tibia vara, osteochondrosis deformans tibiae. *J Bone Joint Surg*, 1937;19:1.
54. Langenskiöld A. Tibia vara (osteochondrosis deformans tibiae). A survey of 23 cases. *Acta Chir Scand* 1952;103:1.
55. Langenskiöld A. Tibia vara: osteochondrosis deformans tibiae Blount's disease. *Clin Orthop Rel Res* 1981;158:77.
56. Langenskiöld A. Tibia vara, a critical review. *Clin Orthop Rel Res* 1989;246:195.
57. Richards BS, Katz DE, Sims JB. Effectiveness of brace treatment in early infantile Blount's disease. *J Pediatr Orthop* 1998;18:374.
58. Zionts LE, Shean CJ. Brace treatment of early infantile tibia vara. *J Pediatr Orthop* 1998;18:102.
59. Raney EM, Topoleski TA, Yaghoubian R, et al. Orthotic treatment of infantile tibia vara. *J Pediatr Orthop* 1998;18:670.
60. Hansson LI, Zayer M. Physiological genu varum. *Acta Orthop Scand* 1975;46:221.
61. Ferriter P, Shapiro F. Infantile tibia vara: factors affecting outcome following proximal tibial osteotomy. *J Pediatr Orthop* 1987;7:1.
62. Arkin AM, Katz JF. The effects of pressure on epiphyseal growth. The mechanism of plasticity of growing bone. *J Bone Joint Surg Am* 1956;38:1056.
63. Smith CF. Current concepts review tibia vara (Blount's disease). *J Bone Joint Surg Am* 1982;64:630.
64. Cook SD, Lavernia CJ, Burke SW, et al. A biomechanical analysis of the etiology of tibia vara. *J Pediatr Orthop* 1983;3:449.
65. Kessel L. Annotations on the etiology and treatment of tibia vara. *J Bone Joint Surg Br* 1970;52:93.
66. Evensen A, Steffensen J. Tibia vara (osteochondrosis deformans tibiae). *Acta Orthop Scand* 1957;26:200.
67. Sibert JR, Bray PT. Probable dominant inheritance in Blount's disease. *Clinical Genet* 1977;11:394.
68. Kline SC, Bostrum M, Griffin PP. Femoral varus: an important component in late-onset Blount's disease. *J Pediatr Orthop* 1992;12:197.
69. Supant M. Orthotic correction of Blount's. *Clinic Orthot Prosthet* 1985;9:3.
70. Doyle BS, Vok AG, Smith CF. Infantile Blount disease: long-term follow-up of surgically treated patients at skeletal maturity. *J Pediatr Orthop* 1996;16:469.
71. Steel HH, Sandrow RE, Sullivan PD. Complications of tibial osteotomy in children for genu varum or valgum. *J Bone Joint Surg Am* 1971;53:1629.
72. Schrock RD. Peroneal nerve palsy following derotation osteotomies for tibial torsion. *Clin Orthop Rel Res* 1969;62:172.
73. Dietz FR, Weinstein SL. Spike osteotomy for angular deformities of the long bones in children. *J Bone Joint Surg Am* 1988;70:848.
74. Morrissey RT. *Atlas of pediatric orthopaedic surgery*. Philadelphia: JB Lippincott, 1992.
75. Rab GT. Technique, oblique tibial osteotomy for Blount's disease (tibia vara). *J Pediatr Orthop* 1988;8:715.
76. Davidson RS. Epiphyseal deformity of infantile Blount's disease. POSNA 28th Annual Meeting, May 16, 1999, Orlando, Florida.
77. Price CT, Scott DS, Greenberg DA. Dynamic axial external fixation in the surgical treatment of tibia vara. *J Pediatr Orthop* 1995;15:236.
78. Matsen FA, Staheli LT. Neurovascular complication following tibial osteotomy in children, a case report. *Clin Orthop Rel Res* 1975;110:210.
79. Van Olm MJJ, Gillespie R. Proximal tibial osteotomy for angular knee deformities in children. *J Bone Joint Surg Br* 1984;66:301.
80. Stanitski DF, Dahl MT, Louie K, et al. Management of late-onset tibia vara in the obese patient by using circular external fixation. *J Pediatr Orthop* 1997;17:691.
81. Matsen FA, Veith RG. Compartmental syndrome in children. *J Pediatr Orthop* 1981;1:33.
82. Zuege RC, Kempken TJ, Blount WP. Epiphyseal stapling for angular deformity at the knee. *J Bone Joint Surg Am* 1979;61:320.
83. Mielke CH, Stevens PM. Hemiepiphyseal stapling for knee deformities in children less than ten: a preliminary report. *J Pediatr Orthop* 1996;16:423.

84. Birch JG. Surgical technique of physeal bar resection. In: Eilert R, ed. *AAOS instructional course lecture, vol. 41*. Rosemont: American Academy of Orthopaedic Surgery, 1992:445.
85. Birch JG, Lapinsky AS. Results of partial physeal bar resection in patients with Langenskiöld stage VI infantile Blount's disease. POSNA Annual Meeting, paper 84, May 14, 1994, Memphis, Tennessee.
86. Herring JA. Instructional case, Blount disease. *J Pediatr Orthop* 1987;7:601.
87. Beck CL, Burke SW, Roberts JM, et al. Physeal bridge resection in infantile Blount disease. *J Pediatr Orthop* 1987;7:161.
88. Hoffman A, Jones RE, Herring JA. Blount's disease after skeletal maturity. *J Bone Joint Surg Am* 1982;64:1004.
89. Schoenecker PL, Johnston R, Rich MM, et al. Elevation of the medial plateau of the tibia in the treatment of Blount disease. *J Bone Joint Surg Am* 1992;74:351.
90. Gregosiewicz A, Wosko I, Kandzierski G, et al. Double elevating osteotomy of tibia in the treatment of severe cases of Blount's disease. *J Pediatr Orthop* 1989;9:178.
91. Siffert R. Intraepiphyseal osteotomy for progressive tibia vara: case report and rationale of management. *J Pediatr Orthop* 1982;2:81.
92. Davids JR, Huskamp M, Bagley AM. A dynamic biomechanical analysis of the etiology of adolescent tibia vara. *J Pediatr Orthop* 1996;16:461.
93. Henderson RC, Greene WB. Etiology of late-onset tibia vara: is varus alignment a prerequisite? *J Pediatr Orthop* 1994;14:143.
94. Thompson GH, Carter JR. Late-onset tibia vara (Blount's disease). Current concepts. *Clin Orthop Rel Res* 1990;255:24.
95. Wenger DR, Mickelson M, Maynard JA. The evolution and histopathology of adolescent tibia vara. *J Pediatr Orthop* 1984;4:78.
96. Loder RT, Schaffer JJ, Bardenstein MB. Late-onset tibia vara. *J Pediatr Orthop* 1991;11:162.
97. Beskin JL, Burke SW, Johnston II CE, et al. Clinical basis for a mechanical etiology in adolescent Blount's disease. *Orthopedics* 1986;9:365.
98. Carter JR, Leeson MC, Thompson GH, et al. Late-onset tibia vara: a histopathologic analysis. A comparative evaluation with infantile tibia vara and slipped capital femoral epiphysis. *J Pediatr Orthop* 1988;8:187.
99. Lovejoy JF, Lovell WW. Adolescent tibia vara associated with slipped capital femoral epiphysis. *J Bone Joint Surg Am* 1970;52:361.
100. Dietz WH, Gross WL, Kirkpatrick JA Jr. Blount's disease (tibia vara): another skeletal disorder. *J Pediatr Orthop* 1982;101:735.
101. Henderson RC, Kemp GJ, Greene WB. Adolescent tibia vara: alternatives for operative treatment. *J Bone Joint Surg Am* 1992;74:342.
102. Henderson RC, Kemp GJ, Hayes PR. Prevalence of late-onset tibia vara. *J Pediatr Orthop* 1993;13:255.
103. Paley D, Tetsworth K. Mechanical axis deviation of the lower limbs. *Clin Orthop Rel Res* 1992;280:65.
104. Paley D, Herzenberg J, Tetsworth K, et al. Deformity planning for frontal and sagittal plane corrective osteotomies. *Orthop Clin North Am* 1994;25:425.
105. Taussig LM, Landau LI. *Textbook of pediatric medicine*. St. Louis: Mosby, 1999.
106. Bowen JR, Leahey JL, Zhang Z-H, et al. Partial epiphysiodesis at the knee to correct angular deformity. *Clin Orthop Rel Res* 1985;198:184.
107. Paley D, Tetsworth K. Mechanical axis deviation of lower limbs. *Clin Orthop Rel Res* 1992;280:48.
108. Millis MB. Juvenile/adolescent Blount's disease: treatment with osteotomy and internal fixation. POSNA 28th Annual Meeting, May 16, 1999, Orlando, Florida.
109. Martin SD, Moran MC, Martin TL, et al. Proximal tibial osteotomy with compression plate fixation for tibia vara. *J Pediatr Orthop* 1994;14:619.
110. Jakob RP, Murphy SB. Tibial osteotomy for varus gonarthrosis: indication, planning, and operative technique. In: Eilert R, eds. *AAOS instructional course lecture, vol. 41*. Rosemont: American Academy of Orthopaedic Surgery, 1992:87.
111. Gaudinez R, Adar U. Use of Orthofix T-garche fixator in late-onset tibia vara. *J Pediatr Orthop* 1996;16:455.
112. Stanitski DF, Srivastava P, Stanitski CL. Correction of proximal tibial deformities in adolescents with the T-garches external fixator. *J Pediatr Orthop* 1998;18:512.
113. Gordon JE, Schoenecker PL. Results of a comprehensive approach of adolescent Blount's disease utilizing external fixation. POSNA Annual Meeting, Paper No. 55; May 2, 2000, Vancouver, British Columbia, Canada.
114. Gordon JE. Treatment of Blount's disease using the Taylor spatial frame. POSNA 28th Annual Meeting, May 16, 1999, Orlando, Florida.
115. Coogan PG, Fox JA, Fitch RD. Treatment of adolescent Blount disease with the circular external fixation device and distraction osteogenesis. *J Pediatr Orthop* 1996;16:450.

Knock Knees (Genus Valgum)

116. Health CH, Staheli LT. Normal limits of knee angle in white children. *J Pediatr Orthop* 1993;13:259.
117. Green WB. Genu varum and genu valgum in children. In: Schafer M, ed. *AAOS instructional course lectures, vol. 43*. Rosemont: American Academy of Orthopaedic Surgery, 1994:152.
118. White GR, Mencia GA. Genu valgum in children. Diagnostic and therapeutic alternatives. *J Am Acad Orthop Surg* 1995;3:275.
119. Shim JS, Kim HT, Mubarak SJ, et al. Genu valgum in children with coxa vara resulting from hip disease. *J Pediatr Orthop* 1997;17:225.
120. Kopits SE. Orthopedic complications of dwarfism. *Clin Orthop Rel Res* 1976;114:153.
121. Herring JA, Moseley C. Posttraumatic valgus deformity of the tibia. *J Pediatr Orthop* 1981;1:435.
122. Herring JA, Kling TF. Genu valgus. *J Pediatr Orthop* 1985;5:236.
123. McCarthy JJ, Kim DH, Eilert RE. Posttraumatic genu valgum: operative versus nonoperative treatment. *J Pediatr Orthop* 1998;18:518.
124. Bartel DL. Unicompartamental arthritis: biomechanics and treatment alternatives. In: Eilert RE, ed. *AAOS instructional course lecture, vol. 41*. Rosemont: American Academy of Orthopaedic Surgery, 1992:73.
125. Stevens PM, Maguire M, Dales MD, et al. Physeal stapling for idiopathic genu valgum. *J Pediatr Orthop* 1999;19:645.
126. Frantz CH. Epiphyseal stapling: a comprehensive review. *Clin Orthop Rel Res* 1971;77:149.
127. Blount WP, Clarke GR. Control of bone growth by epiphyseal stapling. A preliminary report. *Clin Orthop Rel Res* 1971;77:4.
128. Johnston CE, Beuche MJ, Williamson B, et al. Epiphysiodesis for management of lower limb deformities. In: Eilert RE, ed. *AAOS instructional course lecture, vol. 41*. Rosemont: American Academy of Orthopaedic Surgery, 1992:437.
129. Bowen JR, Torres RR, Forlin E. Partial epiphysiodesis to address genu varum or genu valgum. *J Pediatr Orthop* 1992;12:359.
130. Davis CA, Maranji D, Frederick N, et al. Comparison of crossed pins and external fixation for correction of angular deformities about the knee in children. *J Pediatr Orthop* 1998;18:502.
131. Rajacich N, Bell DF, Armstrong PF. Pediatric applications of the Ilizarov method. *Clin Orthop Rel Res* 1992;280:72.
132. Healy WL, Anglen J, Wasilewski SA, et al. Distal femoral varus osteotomy. *J Bone Joint Surg Am* 1988;70:102.
133. McDermott AGP, Finklestein JA, Farine I, et al. Distal femoral varus osteotomy for valgus deformity of the knee. *J Bone Joint Surg Am* 1988;70:110.

134. Morrey BF, Edgerton BC. Distal femoral osteotomy for lateral gonarthrosis. In: Eilert RE, ed. *AAOS instructional course lecture, vol. 41*. Rosemont: American Academy of Orthopedic Surgery, 1992:77.

Anterolateral Bowing

135. Boyd HB. Pathology and natural history of congenital pseudarthrosis of the tibia. *Clin Orthop Rel Res* 1982;166:5.
136. Anderson KS. Congenital angulation of the lower leg and congenital pseudarthrosis of the tibia in Denmark. *Acta Orthop Scand* 1972;43:539.
137. Crawford AH. Anterolateral bowing. POSNA 28th Annual Meeting, May 16, 1999, Orlando, Florida.
138. Crawford AH. Neurofibromatosis in childhood. In: Murray D, ed. *AAOS instructional course lecture, vol. 30*. St. Louis, MO: Mosby, 1981:56.
139. Morrey RT. Congenital pseudarthrosis of the tibia. *Clin Orthop Rel Res* 1982;166:21.
140. Tuncay IC, Johnston CE II, Birch JG. Spontaneous resolution of congenital anterolateral bowing of the tibia. *J Pediatr Orthop* 1994;14:599.
141. Masserman RL, Peterson HA, Bianco AJ. Congenital pseudarthrosis of the tibia. *Clin Orthop Rel Res* 1974;99:140.
142. Andersen KS. Radiological classification of congenital pseudarthrosis of the tibia. *Acta Orthop Scand* 1973;44:719.
143. Hardinge K. Congenital anterior bowing of the tibia. *Ann Roy College Surg Engl* 1972;51:17.
144. Rathgeb JM, Ramsey PL, Cowell HR. Congenital kyphoscoliosis of the tibia. *Clin Orthop Rel Res* 1974;103:178.
145. Strong ML, Wong-Chung J. Prophylactic bypass grafting of the prepseudarthrotic tibia in neurofibromatosis. *J Pediatr Orthop* 1991;11:757.
146. Leung PC. Congenital pseudarthrosis of the tibia. *Clin Orthop Rel Res* 1983;175:45.
147. Henderson MS. Congenital pseudarthrosis of the tibia. *J Bone Joint Surg* 1928;10:483.
148. Boyd HB. Congenital pseudarthrosis. Treatment by dual bone grafts. *J Bone Joint Surg* 1941;23:497.
149. Boyd HB, Fox KW. Congenital pseudarthrosis. Follow-up study after massive bone grafting. *J Bone Joint Surg Am* 1948;30:274.
150. Moore JR. Delayed autogenous bone graft in the treatment of congenital pseudarthrosis. *J Bone Joint Surg Am* 1949;31:23.
151. McFarland B. Pseudarthrosis of the tibia in childhood. *J Bone Joint Surg Br* 1951;33:36.
152. Sofield HA, Millar EA. Fragmentation, realignment and intramedullary rod fixation of deformities of the long bones in children. *J Bone Joint Surg Am* 1959;41:1371.
153. Brighton CT, Friedenberg ZB, Mitchell EI, et al. Treatment of nonunion with constant direct current. *Clin Orthop Rel Res* 1977;124:106.
154. Bassett CAL, Caulo N, Kort J. Congenital "pseudarthroses" of the tibia: treatment with pulsing electromagnetic fields. *Clin Orthop Rel Res* 1981;154:136.
155. Reichel P. Zur behandlung schwerer formen von pseudarthrosis. *Arch f Klin Chir* 1903;71:639.
156. Anderson DJ, Schoenecker PL, Sheridan JJ, et al. Use of an IM rod in treatment of congenital pseudarthrosis of the tibia. *J Bone Joint Surgery Am* 1992;74:161.
157. Farmer AW. The use of a composite pedicle graft for pseudarthrosis of the tibia. *J Bone Joint Surg Am* 1952;34:591.
158. Hagan KF, Buncke HJ. Treatment of congenital pseudarthrosis of the tibia with free vascularized bone graft. *Clin Orthop Rel Res* 1982;166:34.
159. Gordon L, Weulker N, Jergesen H. Vascularized fibular grafting

- for the treatment of congenital pseudarthrosis of the tibia. *Orthopedics* 1986;9:825.
160. Tolo VT. The role of free vascularized fibular grafts in congenital tibial pseudoarthrosis treatment. POSNA 28th Annual Meeting, May 16, 1999, Orlando, Florida.
161. Tolo VT. Personal communication with P.L. Schoenecker, August, 1999.
162. Weiland AJ, Weiss APC, Moore JR, et al. Vascularized fibular grafts in the treatment of congenital pseudarthrosis of the tibia. *J Bone Joint Surg Am* 1990;72:654.
163. Dormans JP, Krajchich JI, Zucker R, et al. Congenital pseudarthrosis of the tibia: treatment with free vascularized fibular grafts. *J Pediatr Orthop* 1990;10:623.
164. deBoer HH, Verbout AJ, Nielsen HKL, et al. Free vascularized fibular graft for tibial pseudarthrosis in neurofibromatosis. *Acta Orthop Scand* 1988;59:425.
165. Kanaya F, Tsai TM, Harkess J. Vascularized bone grafts for congenital pseudarthrosis of the tibia. *Microsurgery* 1997;17:459.
166. Minami A, Kaneda K, Igota H, et al. Free vascularized fibular grafts. *J Reconstr Micro Surg* 1989;5:37.
167. Simonis RB, Shiralil HR, Mayou B. Free vascularized fibular grafts for congenital pseudarthrosis of the tibia. *J Bone Joint Surg Br* 1991;73:211.
168. Coleman SS, Coleman DA. Congenital pseudarthrosis of the tibia—treatment by transfer of the ipsilateral fibular with vascular pedicle. *J Pediatr Orthop* 1994;14:156.
169. Charnley J. Congenital pseudoarthrosis of the tibia treated by the intramedullary nail. *J Bone Joint Surg Am* 1956;38:283.
170. Umber JS, Moss SW, Coleman SS. Surgical treatment of congenital pseudarthrosis of the tibia. *Clin Orthop Rel Res* 1982;166:28.
171. Williams PF. Fragmentation and rodding in osteogenesis imperfecta. *J Bone Joint Surg Br* 1965;47:23.
172. Schoenecker PLS. Treatment of pseudoarthrosis of tibia with intramedullary rod. POSNA 28th Annual Meeting, May 16, 1999, Orlando, Florida.
173. Karol LA, Haideri NF, Halliday SE, et al. Gait analysis and muscle strength in children with congenital pseudarthrosis of the tibia: the effect of treatment. *J Pediatr Orthop* 1998;18:381.
174. Karlstrom G, Olerud S. External fixation of severe open tibial fractures with the Hoffmann frame. *Clin Orthop Rel Res* 1983;180:68.
175. Fabry G, Lammens J, Melkebeek JV, et al. Treatment of congenital pseudarthrosis with the Ilizarov technique. *J Pediatr Orthop* 1988;8:67.
176. Plawewski S, Carpentier E, Lascombes P, et al. Treatment of congenital pseudarthrosis of the tibia by the Ilizarov method. *J Pediatr Orthop* 1990;10:786.
177. Paley D, Catagni M, Argnani F, et al. Treatment of congenital pseudoarthrosis of the tibia using the Ilizarov technique. *Clin Orthop Rel Res* 1992;280:81.
178. Grill F. Treatment of congenital pseudarthrosis of tibia with the circular frame technique. *J Pediatr Orthop* 1996;5:6.
179. Boero S, Catagni M, Donzelli O, et al. Congenital pseudarthrosis of the tibia associated with neurofibromatosis-1: treatment with Ilizarov's device. *J Pediatr Orthop* 1997;17:675.
180. Dahl MT. Congenital pseudarthrosis of the tibia treated with circular external fixation. POSNA 28th Annual Meeting, May 16, 1999, Orlando, Florida.
181. Dahl MT. Personal communication with P. L. Schoenecker, August 18, 1999.
182. Boyd HB, Sage FP. Congenital pseudarthrosis of the tibia. *J Bone Joint Surg Am* 1958;40:1245.
183. Jacobsen ST, Crawford AH, Millar EA, et al. The Syme amputation in patients with congenital pseudarthrosis of the tibia. *J Bone Joint Surg Am* 1983;65:533.

Congenital Pseudarthrosis of the Fibula

184. DalMonte A, Donzelli O, Sudanese A, et al. Congenital pseudarthrosis of the fibula. *J Pediatr Orthop* 1987;7:14.
185. Dooley BJ, Menelaus MB, Paterson DC. Congenital pseudarthrosis and bowing of the fibula. *J Bone Joint Surg Br* 1974;56:739.
186. Hsu LCS, O'Brien JP, Yau APMC, et al. Valgus deformity of the ankle in children with fibular pseudarthrosis. *J Bone Joint Surg Am* 1974;56:503.
187. Langenskiöld A. Pseudarthrosis of the fibula and progressive valgus deformity of the ankle in children: treatment by fusion of the distal tibial and fibular metaphyses. *J Bone Joint Surg Am* 1967;49:463.
188. Merkel KD, Peterson HA. Isolated congenital pseudarthrosis of the fibula: report of a case and review of the literature. *J Pediatr Orthop* 1984;4:100.
189. Young D, Arford C. Congenital pseudarthrosis of the forearm and fibula. *Clin Orthop Rel Res* 1991;256:277.
190. DiGiovanni CW, Ehrlich MG. Treatment of congenital pseudarthrosis of the fibula with interposition allograft. *Orthopedics* 1998;21:1225.

Posterior Medial Bowing of the Tibia

191. Hofmann A, Wenger DR. Posteromedial bowing of the tibia. Progression in leg lengths. *J Bone Joint Surg Am* 1981;63:384.
192. Pappas AM. Congenital posteromedial bowing of the tibia and fibula. *J Pediatr Orthop* 1984;4:525.
193. Heyman CH, Herdon CH. Congenital posterior angulation of the tibia. *J Bone Joint Surg Am* 1949;31:571.
194. Hey CH, Herdon CH, Heiple KG. Congenital posterior angulation of the tibia with talipes calcaneus. A long-term report of eleven patients. *J Bone Joint Surg Am* 1959;41:476.

Congenital Dislocation of the Knee

195. Curtis BH, Fisher RL. Heritable congenital tibiofemoral subluxation. Clinical features and surgical treatment. *J Bone Joint Surg Am* 1970;52:1104.
196. Leveuf J, Pais C. Les dislocations congénitales du genou (genu recurvatum, subluxation, luxation). *Revue D'Orthopédie* 1946;32:313.
197. Johnson E, Audell R, Oppenheim WL. Congenital dislocation of the knee. *J Pediatr Orthop* 1987;7:194.
198. Ko JY, Shih CH, Wenger DR. Congenital dislocation of the knee. *J Pediatr Orthop* 1999;19:252.
199. Drennan JC. Congenital dislocation of the knee and patella. In: Heckman JD, ed. *AAOS instructional course lecture, vol. 42*. Rosemont: American Academy of Orthopedic Surgery, 1993; 42:517.
200. Curtis BH, Fisher RL. Congenital hyperextension with anterior subluxation of the knee. *J Bone Joint Surg Am* 1969;51:255.
201. McFarland BL. Congenital dislocation of the knee. *J Bone Joint Surg* 1929;11:281.
202. Provenzano RW. Congenital dislocation of the knee. A case report. *New Engl J Med* 1947;236:360.

203. Roy DR, Crawford AH. Percutaneous quadriceps recession: a technique for management of congenital hyperextension deformities of the knee in the neonate. *J Pediatric Orthop* 1989;9:717.
204. Katz MP, Grogono BJS, Soper KC. The etiology and treatment of congenital dislocation of the knee. *J Bone Joint Surg Br* 1967;49:112.
205. Vedantam R, Douglas DL. Congenital dislocation of the knee as a consequence of persistent amniotic fluid leakage. *Br J Clin Pract* 1994;48:342.
206. Bell MJ, Atkins RM, Sharrard WJW. Irreducible congenital dislocation of the knee, aetiology and management. *J Bone Joint Surg Br* 1987;69:403.
207. Uthoff HK, Ogata S. Early intrauterine presence of congenital dislocation of the knee. *J Pediatr Orthop* 1994 14:245.
208. Ferris B, Aicloth P. The treatment of congenital dislocation of the knee. A review of 19 knees. *Clin Orthop Rel Res* 1987;216:135.
209. Laurence M. Genu recurvatum congenitum. *J Bone Joint Surg Br* 1967;49:121.
210. Iwaya T, Sakaguchi R, Tsuyama W. The treatment of congenital dislocation of the knee with the Pavlik harness. *Int Orthop* 1988;7:25.
211. Bensahel H, DalMonte A, Hjelmstedt A, et al. Congenital dislocation of the knee. *J Pediatr Orthop* 1989;9:174.
212. Nogi J, MacEwen GD. Congenital dislocation of the knee. *J Pediatr Orthop* 1982;2:609.
213. Neibauer JJ, King DE. Congenital dislocation of the knee. *J Bone Joint Surg Am* 1960;42:207.

Idiopathic Toe-walking

214. Preis S, Klemms A, Muller K. Gait analysis by measuring ground reaction forces in children: changes to an adaptive gait pattern between the ages of one and five years. *Dev Med Child Neuro* 1997;39:228.
215. Statham L, Murray MP. Early walking patterns of normal children. *Clin Orthop Rel Res* 1971;79:8.
216. Hall, JE, Salter RB, Bhalla SK. Congenital short tendo calcaneus. *J Bone Joint Surg Br* 1967;49:695.
217. Hicks R, Durinick N, Gage JR. Differentiation of idiopathic toe-walking and cerebral palsy. *J Pediatr Orthop* 1988;8:160.
218. Stricker SJ, Angulo JC. Idiopathic toe-walking: a comparison of treatment methods. *J Pediatr Orthop* 1998;18:293.
219. Kalen V, Adler N, Bleck EE. Electromyography of idiopathic toe-walking. *J Pediatr Orthop* 1986;6:31.
220. Katz MM, Mubarak SJ. Hereditary tendo achillis contractures. *J Pediatr Orthop* 1984;4:711.
221. Levine MS. Congenital short tendo calcaneus: report of a family. *Am. J Dis Child* 1973;125:858.
222. Kelly IP, Jenkinson A, Stephens M, et al. The kinematic patterns of toe-walkers. *J Pediatr Orthop* 1997;17:478.
223. Griffin PP, Wheelhouse WW, Shiavi R, et al. Habitual toe-walkers: a clinical and electromyographic gait analysis. *J Bone Joint Surg Am* 1977;59:97.
224. Papariello SG, Skinner SR. Dynamic electromyography analysis of habitual toe-walkers. *J Pediatr Orthop* 1985;5:171.



LEG LENGTH DISCREPANCY

COLIN F. MOSELEY

EFFECTS 1106

Mechanisms of Compensation 1106
Gait 1106
Hip 1107
Knee 1107
Spine 1107

GROWTH 1108

ETIOLOGY 1112

Interference with Length 1114
Inhibition of Growth 1114
Stimulation of Growth 1117

PATIENT ASSESSMENT 1118

History of Discrepancy 1118
Clinical Assessment 1118
Radiologic Assessment 1120

DATA ANALYSIS 1124

Arithmetic Method 1124

Growth-remaining Method 1127
Straight-line Graph Method 1127
Patterns of Inhibition 1129
Inadequate Data 1129

DETERMINATION OF TREATMENT GOALS 1131

Equal Leg Lengths 1131
Unequal Leg Lengths 1131
Level Pelvis 1131
Vertical Lumbar Spine 1131
Equalization by Prosthetic Fitting 1131
Correction of Coexisting Problems 1131

TREATMENT 1131

General Principles 1131
Shoe Lift 1132
Prosthetic Fitting 1132
Epiphysiodesis 1133
Femoral Shortening 1134

CONCLUSION 1145

Cases of leg length discrepancy frequently present challenges to the orthopaedic surgeon. The orthopaedic surgeon must understand the mechanisms and concepts of growth, including the relations among age, maturity, and leg length. Because the patient usually presents during the growing

years, the orthopaedic surgeon must understand the need to correct the discrepancy as it will exist at maturity and not the discrepancy that is present in the growing child. The surgeon must be conversant with the methods used to analyze growth and predict future growth and the effects of surgery. The techniques of leg lengthening evolve rapidly, and the orthopaedic surgeon must consider these new techniques in choosing the most appropriate treatment. As surgeons become more confident in their ability to lengthen legs, discrepancies of greater magnitude for correction are

accepted; surgeons must be confident that the improvements in their abilities outweigh the increased risks. The final challenge facing the orthopaedic surgeon is to maintain perspective on the whole patient, and resist the temptation to direct attention solely toward the lengths of the legs, neglecting the other factors that are important in the patient's overall function and appearance.

The treatment of leg length discrepancy must be preceded by careful and sometimes difficult education of the patient and parents. In the case of epiphysiodesis, parents frequently find it difficult to understand why a problem in one leg requires an operation on the other normal leg, and they are not pleased at the thought that their child will be shorter. In the case of leg lengthening, the parents and the patients must understand that a fairly high morbidity is associated with this procedure, even if things go well, because the child must wear an external device for many months, and be restricted in recreation and athletics. They also must understand that the risk of complications is high, and that these complications can compromise the final result. The orthopaedic surgeon knows that surgery is necessary to correct leg length discrepancy, but parents often are anxious to find some nonsurgical method of stimulating the growth of the short leg. If all other factors were equal, it would be better to correct the leg length discrepancy by lengthening the abnormally short leg than to compensate for the discrepancy by shortening the normal long leg.

EFFECTS

The mechanical and functional effects of leg length discrepancy are immediately apparent. The long-term effects, however, are less understood. Despite a consensus in the orthopaedic and lay communities that leg length discrepancy does

have deleterious effects on the spine and the hips, good documentation to support that consensus is lacking.

Mechanisms of Compensation

The child with leg length discrepancy usually compensates better than the adult, probably because of a greater strength-to-weight ratio. The child may compensate for minor degrees of leg length discrepancy by walking on the toes of the short leg with the heel never touching the ground. This can result in a smooth, symmetric gait that shows no abnormality, except for the lack of heel strike on the short side.

The adult, on the other hand, seldom compensates in that fashion, but tends to walk with a heel-to-toe gait, even on the short side, and to vault over the long leg. This action produces excessive up and down motion of the pelvis and trunk (Fig. 28-1). Although, theoretically, it is possible to compensate for the leg length discrepancy by flexing the knee on the long side, this almost never is done by either adults or children, probably because too much physical effort is required to do so.

Gait

Despite evidence to suggest that discrepancies of less than 2.5 cm are not significant (1), postural sway has been shown to increase as the result of simulated discrepancies of as little as 1 cm (2). Liu et al. proposed the symmetry index (SI) as a measure of the quality of gait, and found that correction of discrepancy by a heel lift significantly improves the SI (3).

It appears that patients are able to compensate extremely well for their discrepancies. The moments about lower limb joints with simulated and real leg length discrepancies have been found to be essentially unchanged with small discrep-

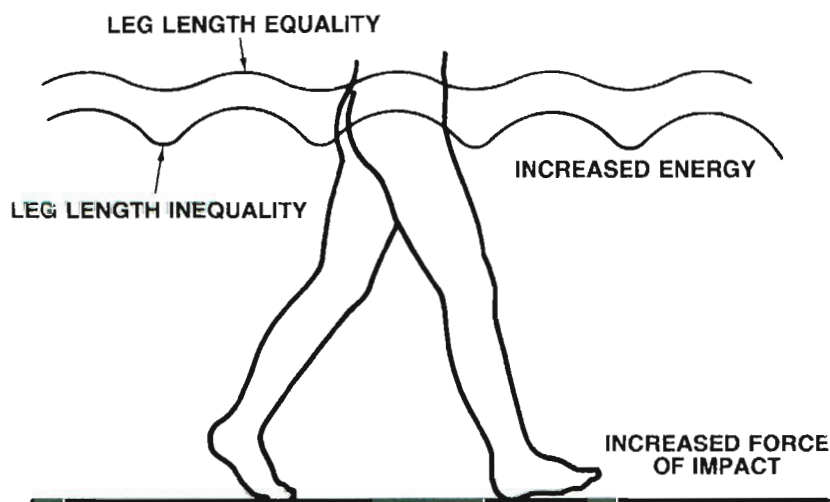


FIGURE 28-1. Motion of pelvis during gait. The amplitude of vertical pelvic motion is increased by leg length discrepancy. The patient vaults over the long leg and descends to plant the heel of the short leg.

ancies (4). Song found that discrepancies greater than 5.5% of the long extremity increased the mechanical work performed by the long limb, and increased the vertical displacement of the center of body mass. Children with lesser discrepancies were able to normalize the work performed by the two extremities.

Hip

Degenerative arthritis of the hip, which is termed “idiopathic” in the elderly patient, may actually be the result of some previously unrecognized minor problem, such as mild dysplasia, slipping of the capital femoral epiphysis, or possibly leg length discrepancy. In two-legged stance with the legs straight, the patient with leg length discrepancy has a pelvic obliquity, with respect to the floor, that relatively uncovers the hip of the long leg and increases coverage of the hip of the short leg (Fig. 28-2).

As the leg length discrepancy increases, so does the un-

covering on the high side with a decrease in the center-edge angle. This relation is illustrated in Figure 28-3. It is reasonable to suspect that the patient with a leg length discrepancy throughout his or her life may be subject to an increased risk of developing degenerative arthritis in the hip of the long leg (6); however, there is no documentation to prove this hypothesis. The effect of the leg length discrepancy in decreasing coverage is present only during two-legged stance, and perhaps during gait if dipping of the pelvis is used as a compensatory mechanism. When one is in one-legged stance, sitting, or lying down, as is the case most of the time, the effect disappears.

Knee

Although the nature of the relation has not been elucidated, there are reports that leg length discrepancy increases the incidence of knee pain in athletes (7).

Spine

The effects of leg length discrepancy on the spine also are not clearly established. The parents of young children with leg length discrepancy worry about their children developing degenerative arthritis of the spine, low back pain, and scoliosis. Contradictory evidence exists concerning the possibility that leg length discrepancy causes low back pain in the long term (8–10). Low back pain is unusual in the younger child and more common in the adolescent, but there is no evidence that low back pain and leg length discrepancy are related in this age group. Froh and colleagues looked for an effect of leg length discrepancy on the orientation of the facet joints in adults, and found none, whereas Giles and Taylor did find changes in the facet joints of cadavers with leg length discrepancy (11). It is not clear that the incidence of back pain is higher in patients with leg length discrepancy than it is in the general population. Radiographs of the spine should be examined carefully to rule out anomalous development of the vertebrae.

Several studies have been performed to determine whether leg length discrepancy leads to scoliosis. Gibson and coworkers assessed 15 patients with leg length discrepancy following femoral fractures, and found that after 10 years none had structural scoliosis (12), but minor structural changes have been reported in such patients (13). Studies have demonstrated an increased incidence of structural scoliosis in patients with leg length discrepancy, when compared with the general population (14), but it has not been established that the leg length discrepancy has caused the scoliosis. If leg length discrepancy were the cause, the scoliosis would be expected to be in the direction that would compensate for the leg length discrepancy, but in up to one-third of the cases in these studies, the scoliosis was in the opposite direction (Fig. 28-4). Because the leg length discrepancy affects the spine only during two-legged stance,

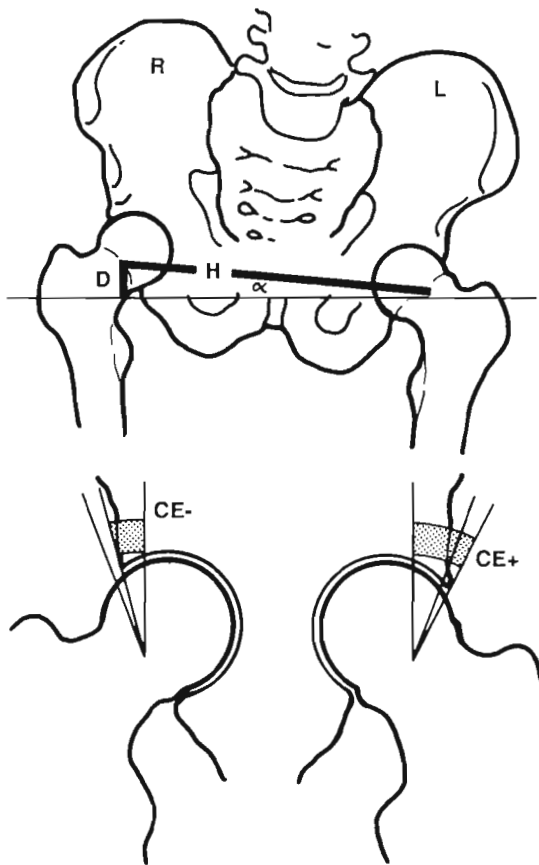


FIGURE 28-2. Decrease in center–edge (CE) angle with pelvic obliquity. The CE angle is decreased on the side of the long leg. Coverage is decreased, and the resulting decrease in the load-bearing area causes an increase in pressure. Such a hip may be susceptible to late degenerative arthritis (L, left; R, right). (From ref. 5, with permission.)

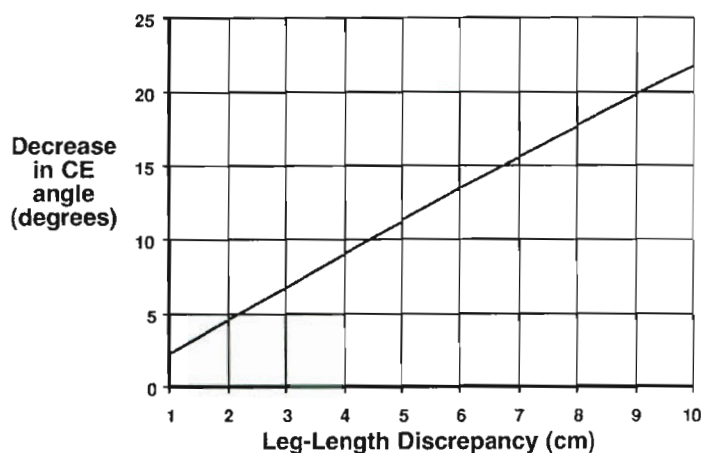


FIGURE 28-3. Relation between leg length discrepancy and center-edge (CE) angle. The CE angle and coverage decrease with increasing leg length discrepancy. For every centimeter of leg length discrepancy, there is a decrease of approximately 2.6 degrees in the CE angle. (From ref. 5, with permission.)

and to some extent while walking, some skepticism toward the cause-and-effect hypothesis seems justified. It has been suggested, however, that scoliosis develops more as the result of the dynamic forces of walking, and not of the static forces of standing (15).

If leg length discrepancy has long-term effects on the spine or hips, it is reasonable to suspect that the severity of the problem is related to the severity of the discrepancy, the

degree to which it remains uncompensated or uncorrected, and the age of the patient at onset.

GROWTH

An understanding of growth is an essential prerequisite to the treatment of patients with leg length discrepancy. The mechanisms of growth are discussed in Chapter 2. In the study of leg length discrepancy, one is concerned with rates and patterns of growth. Growth of the leg is the result of both growth at the four physal plates at the proximal and distal ends of the tibia and femur, and an increase in size of the four adjacent epiphyses. The growth of the epiphyses contributes only 5% to the total growth of the legs, and this usually is ignored in treating patients with leg length discrepancy.

The only good studies relating growth of the legs to age were performed by Anderson and colleagues. Their first study involved populations of girls and boys at various ages from 5 years of age to physal closure (16). Their second study was longitudinal, in that a single group of children was followed until maturity. They published their data in two forms. The first form related the lengths of the femur and the tibia of boys and girls to their ages, from 1 to 18 years (17). These data can be combined to show the total leg lengths rather than the lengths of the individual bones. The total leg length data are shown here in tabular (Table 28-1) and graphic forms (Figs. 28-5 and 28-6). The graph showing leg lengths related to age is a useful tool in the analysis of leg length data. They later published their data in the form of a graph showing the growth remaining at the distal femoral and proximal tibial physes of boys and girls related to skeletal age (18) (Fig. 28-7). Most of the growth of the lower extremity occurs in the physes near the knee, as opposed to the upper extremity, where most growth is contributed by the physes farthest from the elbow. The

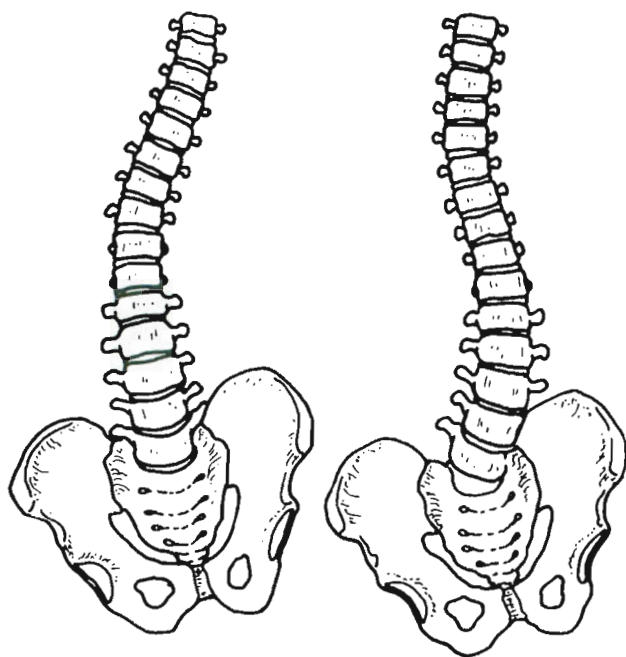


FIGURE 28-4. Oblique pelvis with scoliosis in compensatory and noncompensatory directions. If leg length discrepancy causes scoliosis, the direction of the spinal curvature is expected to be in the direction that is compensatory for the scoliosis. When scoliosis occurs in the other direction, it must be concluded that the leg length discrepancy is not responsible.

TABLE 28-1. LENGTH AS A FUNCTION OF SKELETAL AGE

Age (yr)	Total Leg Length (cm)					Age (yr)	Total Leg Length (cm)				
	+ 2 SD	+ 1 SD	Mean	- 1 SD	- 2 SD		+ 2 SD	+ 1 SD	Mean	- 1 SD	- 2 SD
Boys						Girls					
1	28.58	27.33	26.08	24.83	23.58	1	29.02	27.70	26.38	25.06	23.74
2	36.06	34.37	32.69	31.01	29.32	2	36.00	34.37	32.74	31.11	29.48
3	41.81	39.84	37.88	35.92	33.95	3	42.09	40.09	38.10	36.11	34.11
4	46.89	44.61	42.32	40.03	37.75	4	47.75	45.26	42.78	40.30	37.81
5	51.55	48.97	46.38	43.79	41.21	5	52.56	49.83	47.09	44.35	41.62
6	56.06	53.14	50.21	47.45	44.54	6	57.20	54.04	51.05	47.97	44.90
7	60.63	57.32	54.01	50.70	47.39	7	61.75	58.29	54.82	51.35	47.89
8	64.83	61.25	57.66	54.07	50.49	8	66.05	62.34	58.61	54.88	51.17
9	69.14	65.24	61.35	57.45	53.55	9	70.49	66.38	62.27	58.16	54.05
10	73.16	68.99	64.82	60.65	56.48	10	74.99	70.49	66.00	61.51	57.01
11	77.33	72.80	68.26	63.72	59.19	11	79.52	74.66	69.81	64.96	60.10
12	81.83	76.86	71.87	66.88	61.91	12	85.21	78.28	73.35	68.42	63.49
13	86.86	81.27	75.66	70.06	64.46	13	85.75	80.94	76.14	71.34	66.53
14	90.71	85.03	79.36	73.69	68.01	14	86.57	82.07	77.57	73.07	68.57
15	92.32	87.20	82.07	76.95	71.82	15	86.80	82.43	78.06	73.69	69.32
16	93.01	88.35	83.70	79.05	74.39	16	86.90	82.55	78.21	73.87	69.52
17	93.02	88.66	84.29	79.92	75.56	17	86.95	82.60	78.25	73.90	69.55
18	92.95	88.73	84.52	80.31	76.09	18	86.99	82.63	78.28	73.93	69.57

SD, standard deviation.

(From ref. 17, with permission.)

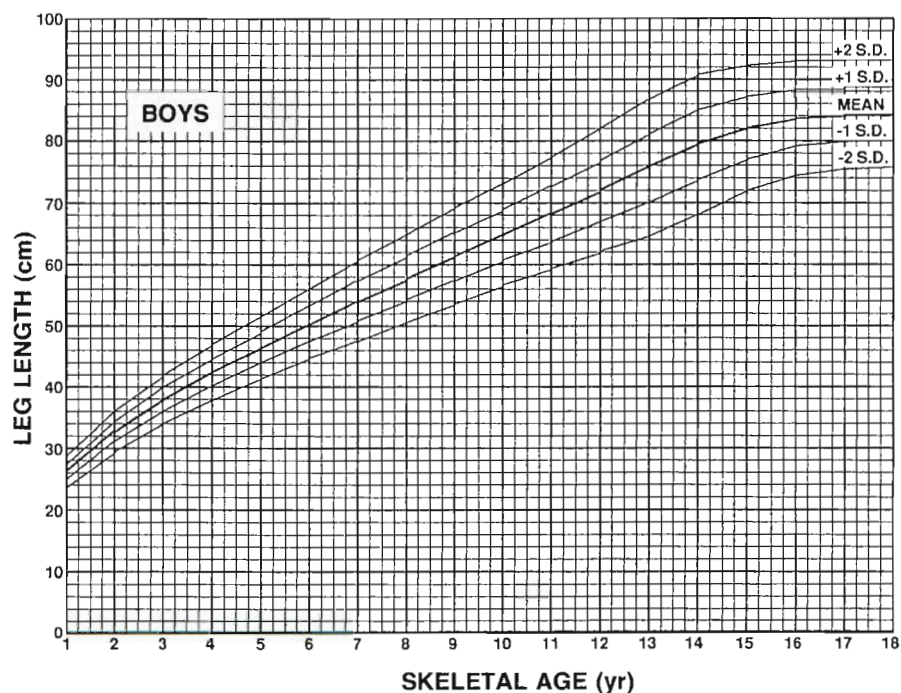


FIGURE 28-5. Total leg length versus skeletal age for boys allows a specific boy to be related to the population by plotting his leg length as a function of his skeletal age. It is useful in the analysis of leg length data because it allows a projection into the future based on the present situation. (From ref. 16, with permission.)

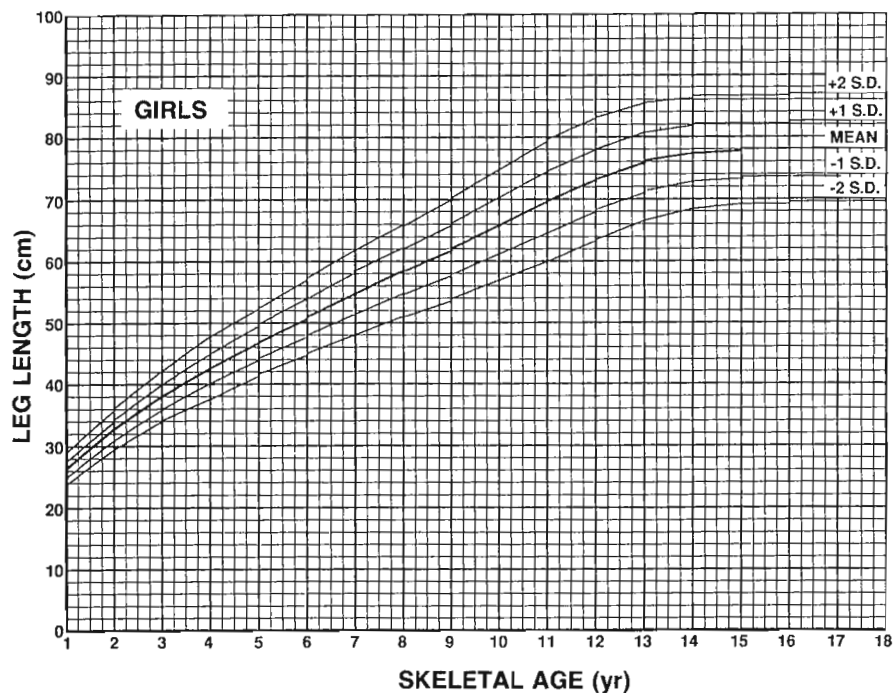


FIGURE 28-6. Total leg length versus skeletal age for girls serves the same purpose for girls as Figure 28-5 serves for boys. (From ref. 16, with permission.)

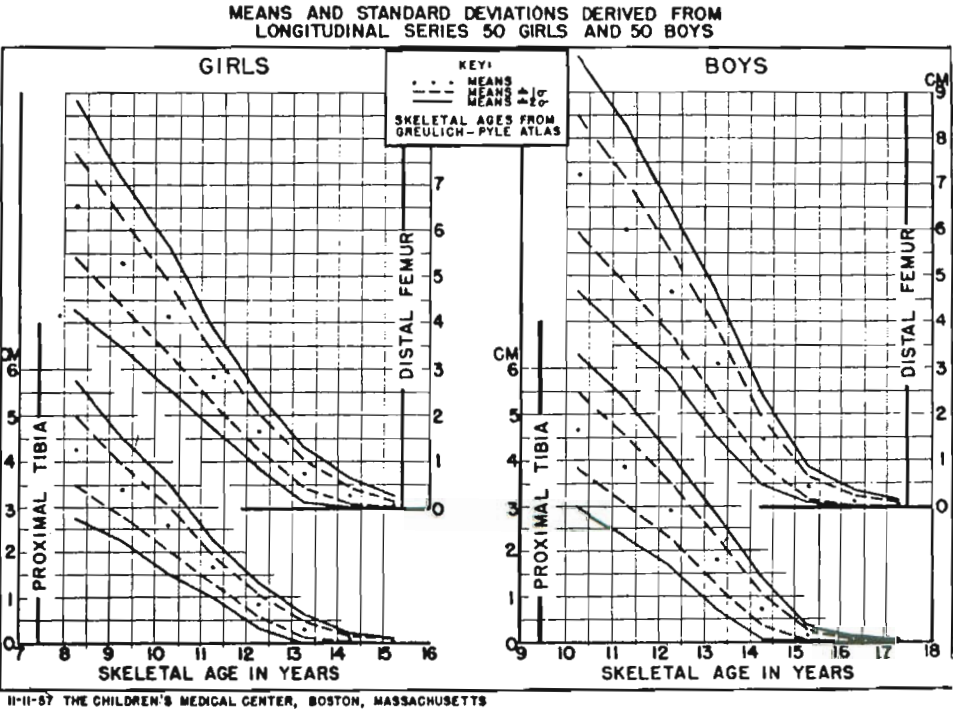


FIGURE 28-7. Green and Anderson growth-remaining graph. This graph shows the amount of growth potential remaining in the growth plates of the distal femur and proximal tibia of boys and girls as functions of skeletal age. It is useful in determining the amount of shortening that will result from epiphysiodesis. (From ref. 17, with permission.)

four growth plates of the lower limb contribute consistent proportions of growth to their individual bones and to the entire extremity (19) (Fig. 28-8). These percentages are worth remembering, because they can be useful in clinical situations. For example, a child with avascular necrosis of the femoral head in infancy cannot lose more than 15% of future growth of the affected leg, and a child whose distal femoral growth plate was destroyed as a result of infection will lose at most 38% of the future growth of the leg. Also noteworthy is that the femur is longer than the tibia, comprising 54% of the total length of the leg.

The study of growth as it pertains to leg length discrepancy involves relationships among three factors: leg length, maturity, and chronologic age (Fig. 28-9). Although these relationships are familiar, some aspects deserve elaboration.

It is evident to all physicians who deal with children that maturation and aging are only loosely related. Some children mature rapidly, and go through their growth spurts early. These children appear tall during the growing years, not because they are of a taller growth percentile, but because they are of advanced maturity. Many of these children, who are tall for their chronologic ages during early adolescence, cease growth early, and are shorter than the mean at maturity. Pediatricians, in their studies of stature, and orthopaedic surgeons, in their studies of leg lengths, need

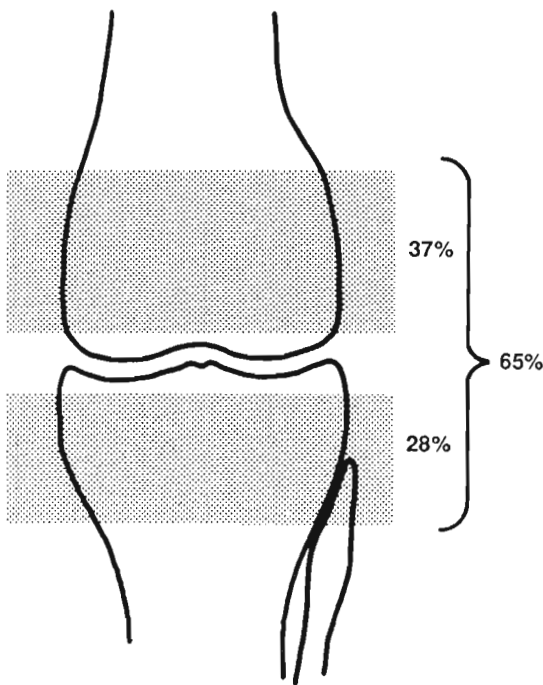


FIGURE 28-8. The growth plates of the lower limb contribute definite and constant proportions to the growth of the long bones of the leg and the total growth of the limb. These contributions determine the slopes of the reference lines of the straight-line graph method, and are thus automatically taken into account by it.

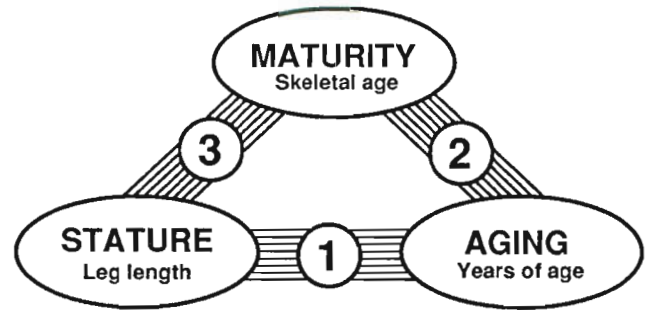


FIGURE 28-9. Leg length, maturity, and age all change with time, and the way they do so is not identical in every child. The three relations among them can be examined individually, and it is important to do so to understand parents' perceptions and to predict future growth. Relation 2 is maturation, whereas relations 1 and 3 are both growth, but from different perspectives.

a measure of maturity, rather than a measure of age. Although leg lengths and chronologic age can be measured accurately and easily, maturity cannot. The best measure of maturity appears to be the development of the bones of the skeleton as seen on radiographs. By comparing the radiographs of a patient with standard radiographs in an atlas (20), it is possible to derive a number known as the "skeletal age." It is used as a measure of maturity, but the skeletal age is actually the most likely age of a person with the given x-ray. It correlates well with menarche and other signs of maturation, such as the appearance of secondary sexual characteristics, and also correlates more closely with the growth of the legs than does chronologic age. Because skeletal age is, in a sense, an average of the general population, it should be apparent that, for a random group of children, the mean skeletal age should be equal to the mean chronologic age.

The three relations seen (Fig. 28-9) among chronologic age, skeletal age, and leg length can be examined individually, and it is instructive to do so. First, consider the relation between growth and chronologic age. This relation is obvious to parents. The parent who is concerned about his or her child being too short or too tall is always comparing the child to classmates and other children of the same age. In this relation, there is steady growth throughout life, with a growth spurt in early adolescence and cessation of growth at the age of 16 to 17 years in boys and 14 to 15 years in girls (21) (Fig. 28-10). Although this relation is the most obvious, it is virtually meaningless without a consideration of maturity, and its variability from child to child presents problems to the treating doctor. A more consistent relation must be used.

Although the relation between chronologic age and skeletal age is extremely variable within the population, children tend to pass the various landmarks of maturity in the same orderly and consistent fashion. The child who develops secondary sexual characteristics early also goes through the

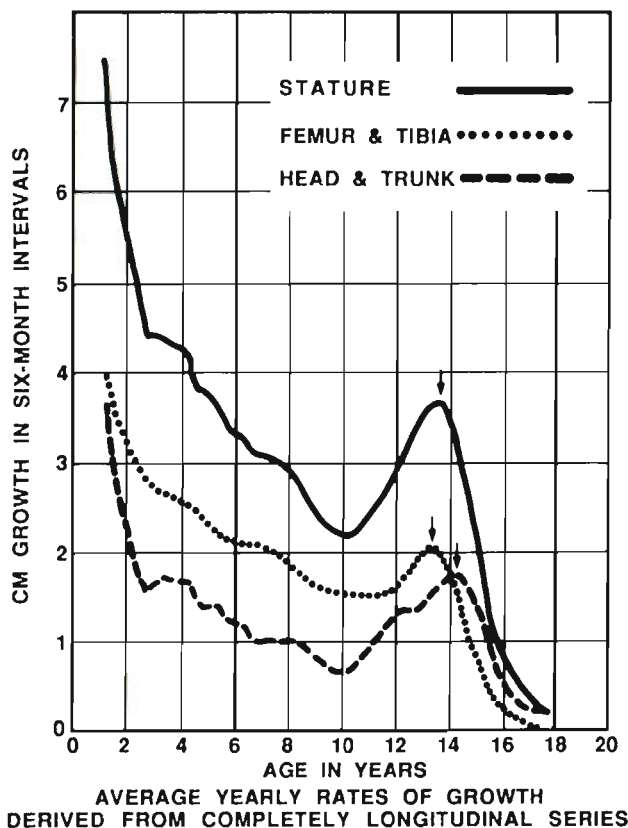


FIGURE 28-10. Green-Anderson growth curve. The examination of growth rate as a function of chronologic age shows a major growth spurt in adolescence. It is of interest to note that no such spurt appears in the growth curve of Figures 28-6 and 28-7. (From ref. 105, with permission.)

growth spurt early, reaches menarche early, and has advanced skeletal age. The implication is that children who mature more quickly or more slowly than average do so throughout their growing years, but this is not necessarily so. Some children appear as if they are going through a maturation spurt, during which they mature faster than they age. This maturity spurt tends to coincide with the growth spurt, and the orthopaedic surgeon who is waiting for just the right time to do an epiphysiodesis can be caught unaware. It is as if these children deal with their rapid growth rate by turning the pages of the skeletal age atlas at a faster rate than normal.

The third relation, that between maturity and growth, correlates more closely than the relation between chronologic age and skeletal age, and is of most interest to the orthopaedic surgeon. This is the relation shown in the data of Green and Anderson (Figs. 28-5 and 28-6), and it has interesting properties. The first property is that growth is never faster, in either absolute or relative terms, than it is in the newborn. The growth rate continually slows down until it stops completely at maturity. There is no inflection point in the curve, meaning that no growth spurt occurs,

as happens when growth is correlated with chronologic age. The absence of the growth spurt has two possible explanations. The first is that these curves are derived from averages of a number of patients, and averaging data tends to dampen individual fluctuations that occur at different times. The second, more interesting, explanation is that the growth spurt may really be a maturation spurt with growth maintaining its customary relation to skeletal age.

The Green and Anderson study provides good documentation of the relation between skeletal age and leg length for the population studied, but there is no guarantee that these data hold for children of other races or of other genetic stocks from within the same race. Indeed, there is one report that shows that Dutch children are taller than those described by Green and Anderson (22). It is not clear, however, that these children actually follow a pattern of growth different from that described by Green and Anderson. They may just behave like children taller than Green and Anderson's mean. These authors modified the straight-line graph to be consistent with their data, but it is not yet clear that it is of benefit, since it has only been tested on the same population from which it was derived. Because the literature contains no reports of consistent errors having been made in the prediction of growth in non-white children, it seems reasonable and practical to assume that the Green and Anderson pattern of growth is followed by children of all races, and that it can be used reliably in predicting future growth.

ETIOLOGY

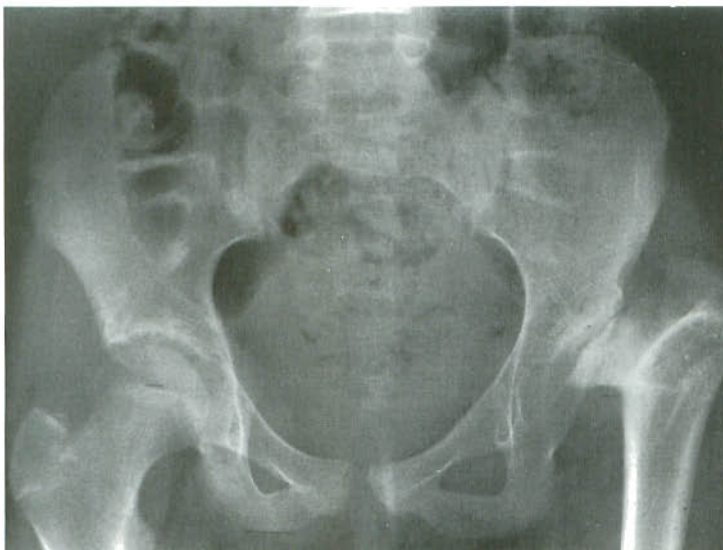Leg length discrepancy can be classified purely by etiology, but the concepts involved in understanding and treating patients suggest a more logical approach. Leg length discrepancy can result from two types of processes: those that change the length of the leg directly, and those that alter its growth. A fracture that heals with overriding is an obvious example of an effect on length with no effect on growth, and injury to the growth plate from osteomyelitis is an example of an alteration in growth rate with no immediate effect on length. These two effects determine whether a discrepancy is static or dynamic, and greatly influence the choice of treatment. The causes of leg length discrepancy can be classified according to their effect on length and growth, but the classification system breaks down because certain causes can affect different patients differently, and some affect both length and growth. A fracture, for example, can cause shortening in one patient and overgrowth in another, and a congenitally short femur can be thought of as being both short and retarded in its growth. Such a classification is shown in Table 28-2.

Some patients with asymmetry above or below the legs present as having leg length discrepancy and are treated as such, even though their legs may be of equal length. One example is the patient with the neglected, high-riding congenital dislocation of the hip (Fig. 28-11).

TABLE 28-2. CLASSIFICATION OF CAUSES OF LEG LENGTH DISCREPANCY

Classification	By Growth Retardation	By Growth Stimulation
I. Congenital	Congenital hemiatrophy with skeletal anomalies (e.g., fibular aplasia, femoral aplasia, coxa vara), dyschondroplasia (Ollier disease), dysplasia epiphysealis punctata, multiple exostoses, congenital dislocated hip, clubfoot	Partial gigantism with vascular abnormalities (Klippel-Trenaunay, Parkes-Weber) Hemarthrosis due to hemophilia
II. Infection	Epiphyseal plate destruction due to osteomyelitis (femur, tibia), tuberculosis (hip, knee joint, foot), septic arthritis	Diaphyseal osteomyelitis of femur or tibia, Brodie abscess Metaphyseal tuberculosis of femur or tibia (tumor albus) Septic arthritis Syphilis of femur or tibia Elephantiasis as a result of soft tissue infections Thrombosis of femoral or iliac veins
III. Paralysis	Poliomyelitis, other paralysis (spastic)	
IV. Tumors	Osteochondroma (solitary exostosis) Giant cell tumors Osteitis fibrosa cystica generalisata Neurofibromatosis (Recklinghausen)	Hemangioma, lymphangioma Giant cell tumors Osteitis fibrosa cystica generalisata Neurofibromatosis (Recklinghausen) Fibrous dysplasia (Jaffe-Lichtenstein)
V. Trauma	Damage of the epiphyseal plate (e.g., dislocation, operation) Diaphyseal fractures with marked overriding of fragments Severe burns	Diaphyseal and metaphyseal fractures of femur or tibia (osteosynthesis) Diaphyseal operations (e.g., stripping of periosteum, bone graft removal osteotomy)
VI. Mechanical	Immobilization of long duration by weight-relieving braces	Traumatic arteriovenous aneurysms
VII. Others	Legg-Calvé-Perthes disease Slipped upper femoral epiphysis Damage to femoral or tibial epiphyseal plates due to radiation therapy	

(From ref. 15, with permission.)

**FIGURE 28-11.** High-riding dislocation of hip. This patient has a functional leg length discrepancy that is greater than the actual discrepancy in the lengths of the legs, because of the adduction of the short leg.

Interference with Length

By definition, the only processes that can acutely affect the length of the leg are fractures and dislocations. Whether or not a congenitally short bone has had a direct interference with its length is a moot point, because it occurred before birth, and it is the inhibition of growth that is the important factor. The terminal deletions and proximal focal femoral deficiency and its variants can be thought of as growth inhibition superimposed on a short limb.

Fractures can result in short bones either by overriding or by angular deformity. In the latter case, the shortening often disappears when the angulation is corrected (23). Sugi and Cole have shown that shortening of up to 10% of the femoral length can be accepted in the treatment of femoral fractures by early spica without causing significant discrepancy (24). Overgrowth frequently accompanies healing of fractures, and can spontaneously correct the shortening (25). Excessive length can result when excessive force is applied in traction.

Dislocations have a direct effect on length only if they are unreduced.

Inhibition of Growth

The growth of the physis can be slowed by three mechanisms. First, congenital short bones grow more slowly than normal bones, as the result of abnormal programming of the genetic mechanism that determines growth rate. Second, the growth plate can be injured in such a way that part or all of it is no longer able to grow, and eventually gets converted to solid bone in the form of a physeal bridge or a prematurely closed plate. Any part of the plate that has retained its ability to grow cannot do so effectively, because of tethering by the fused part. Third, a change in the environment of the plate can influence its growth rate. Unusual vascular malformations can stimulate or inhibit growth (26,27). Children with paralysis usually have shortening of the more severely affected leg, presumably because the growth rate of the plate responds to the decreased compressive forces across it. The concept that pressure might change the direction of the growth of the plate is commonly known as the "Heuter-Volkmann law" (28,29), but the concept was first proposed by Delpech (30,31). He treated an angular deformity of the ankle with casting, to cause the distal tibial plate to change its direction of growth.

Congenital Shortening

When a patient is born with legs of unequal length that are otherwise normal, it is often impossible to know which leg is the abnormal one. Because the more severe cases clearly involve shortening, it is appropriate to think of these cases as hemiatrophy, rather than hemihypertrophy. Beals has stated that the two are separate and distinct clinical syndromes, partly because of associated anomalies (32). The dysplasia usually involves the entire limb, with some shortening of all components, and usually is accompanied by a diminution

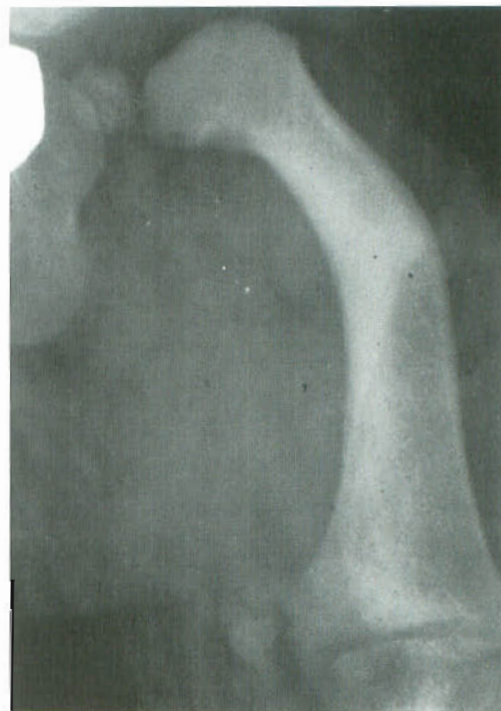


FIGURE 28-12. In proximal focal femoral deficiency, the leg length discrepancy is accompanied by qualitative changes, including coxa vara and bowing.

in girth. Each leg appears to be genetically programmed to be a different size (33).

Congenitally short bones frequently show qualitative as well as quantitative changes (34) (Fig. 28-12). The congenitally short femur also can show coxa vara, bowing, hypoplasia of the lateral condyle (Fig. 28-13), and external torsion (35). It can be associated with anterior cruciate insufficiency (36–38), a short or missing fibula (39,40), and absence of the lateral rays of the foot. Indeed, the congenital short femur is thought by some to be a variant of proximal focal femoral deficiency (41).

Congenitally bowed tibias are frequently accompanied by leg length discrepancy and hypoplastic feet (42–44). Askins and Ger (45) found that 24% of patients with congenital constriction bands have leg length discrepancy; and Garbarino and colleagues (46) reported short tibias in association with congenital diastasis of the inferior tibiofibular joint.

Trauma

Trauma that injures the physeal plate may slow its rate of growth either by direct injury to the cells responsible for growth or by formation of a bony bridge that tethers the epiphysis to the metaphysis. Salter and Harris provided a classification of fractures of the physeal plate that is useful in anticipating the effect of fractures on future growth (47). This classification is shown diagrammatically in Figure 28-14.

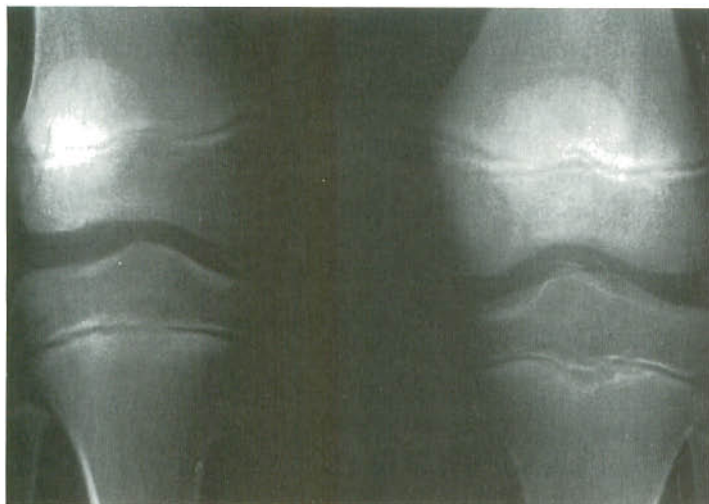

FIGURE 28-13. Hypoplasia of femoral condyle is frequently found in association with congenital shortening of the femur.

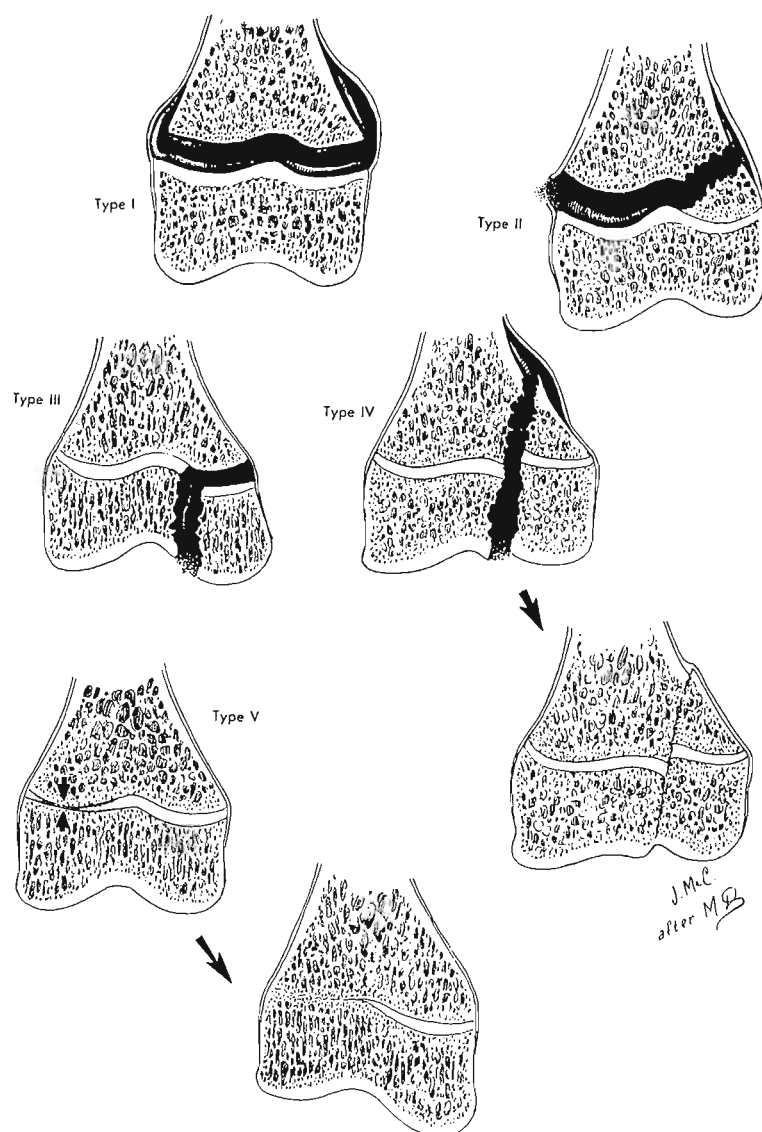


FIGURE 28-14. Salter-Harris classification of epiphyseal fractures. Fractures of types I and II do not cross the part of the growth plate responsible for growth, whereas those of types III and IV do. In the type IV fracture, approximation of epiphyseal bone to metaphyseal bone can result in formation of a bony bridge. (From ref. 46, with permission.)

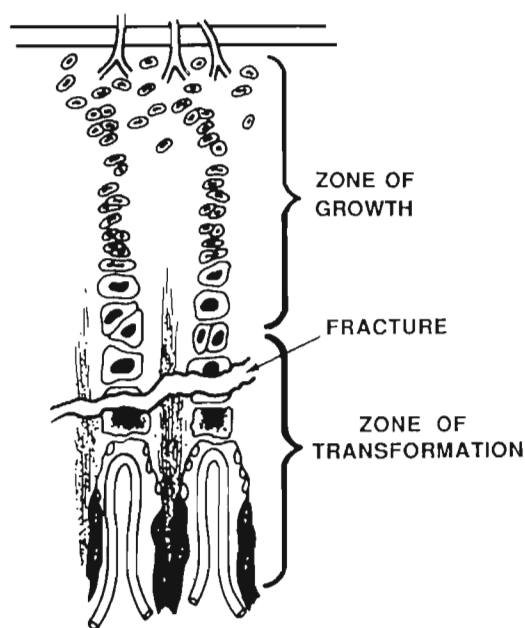


FIGURE 28-15. Location of fractures in the growth plate. Fractures tend to occur through the part of the growth plate where the matrix is least, although individual fractures may wander from zone to zone.

Fractures can wander through all zones of the plate, but tend to pass through the zone of cell hypertrophy where the material is weakest and the amount of material is least. The material in that zone is cartilage that is weaker than bone, and because the cells there are large, the ratio of matrix volume to cell volume is low (Fig. 28-15). It is important to note that this part of the plate is the site of conversion of cartilage to bone, but is not primarily responsible for growth that occurs by virtue of cell multiplication and matrix production in the zones nearer the epiphysis.

Because the type I and type II fractures do not pass through the growth zone, they are less likely than other fractures to interfere with growth. Both types, however, may be associated with a crush injury that injures the cells by compression. This mechanism may account for the higher-than-expected incidence of growth disturbance in type II fractures of the weight-bearing bones, such as the distal femur, where growth arrest is found in more than one-third of patients (48). Type III and IV fractures do, however, cross the growth zone, and therefore are more likely to result in growth arrest. The type IV fracture, in particular, can result in a bony bridge, when the fracture fragment displaces in the diaphyseal direction (Fig. 28-14). This is one reason why these fractures must be anatomically reduced. Type V fractures can occur in isolation, or can accompany any of the other types. They are insidious because they are not initially recognizable on radiographs, and they always demonstrate their presence by a disturbance of growth—either shortening or a combination of shortening and angula-

tion—usually in the first year after the fracture. Although the fracture classifications provide guidelines about the likelihood of growth arrest, the orthopaedic surgeon must be wary of giving a definite prognosis for a given epiphyseal fracture, until enough time has elapsed to rule out a type V injury.

The bony bridge that causes a growth disturbance following physal fractures usually is discrete and well defined, and lends itself to excision if small and peripheral. Bridge resections usually are limited to those that involve less than 50% of the plate, in patients who have at least 2 years of growth remaining. Even more extensive resections can be considered in very young children because, if successful, difficult treatment of severe leg length discrepancy might be avoided. Resection of a bony bridge always should be considered if there is significant growth remaining, even if leg length discrepancy is already present. The angular deformity, which also may be present because of the bridge, can influence treatment of the discrepancy, because both deformities can be corrected at once.

Infection

Osteomyelitis adjacent to the plate can result in destruction of physal cells and disturbance of growth if not treated early (49). The infection is usually hematogenous osteomyelitis of the metaphysis, but can be epiphyseal in infants, and follow or precede septic arthritis of the joint. The bony bridge that results from infection is more difficult to treat than that following trauma, because it is not so amenable to resection. The bridge tends to be larger, more central, and less discrete than that following trauma, and can even consist of multiple small bridges. It is difficult to define by radiograph, is usually more extensive than it appears, and is more difficult to define during resection. There is the danger that minor components of the bridge can be left behind, because the usual end point of resection, a continuous line of physis around the resection tunnel, can be achieved despite incomplete resection of all components of the bridge.

Infection tends to produce more serious leg length discrepancy problems than trauma, because it occurs so commonly in younger children with so much growth ahead of them. As with trauma, angular deformity and leg length discrepancy can coexist.

Paralysis

Inhibition of growth commonly accompanies weakness or paralysis of the leg, but the mechanism is not clear. It may be true that blood flow to the limb is reduced because of the reduced muscle mass, but this does not necessarily mean that flow to the plate also is reduced. Venous return results partly from muscle activity, and therefore, blood flow to the limb and perhaps to the plate could be reduced as a result of reduced muscle activity and decreased pumping effect. Alternately, abnormal vasomotor control, which is

part of the basic neurologic abnormality, could affect blood flow.

The effect of paralysis and reduced muscle activity can have a more direct effect on the growth rate. The Heuter-Volkman law suggests that the growth rate of the physis responds to the compression forces across it, and frequently is invoked to explain how a spontaneous reorientation of the physis occurs in contributing to the remodeling of angular deformities in the immature child. This mechanism also can explain the decrease in the overall growth rate that occurs in children with muscle weakness.

The parents of children with cerebral palsy frequently are concerned about leg length discrepancy, and minor degrees of discrepancy can be seen in this condition. More often, however, the discrepancy is more apparent than real, and results from pelvic obliquity due to hip contractures or asymmetric posturing due to asymmetric spasticity. It is likely that serious discrepancies do not occur more often, because even dysfunctional spasticity can be effective, through the Heuter-Volkman law, in stimulating the physis to grow.

Tumors

Leg length discrepancy can be related to tumors in several ways. The first involves destruction of the plate by direct tumor invasion behaving, in this instance, much like infection.

The second way involves damage to the plate by irradiation used to treat the tumor (50). Irradiation has a particularly harmful effect, because the osteocytes of neighboring bone also are killed, and the bone can take many years to become revascularized and repopulated with healthy osteocytes. The absence of healthy osteoblasts and precursors can complicate the treatment of the ensuing leg length discrepancy, by precluding lengthening procedures through the affected bone. Radiation damage to regional soft tissues also complicates lengthening procedures (51,52).

The third way that leg length discrepancy can be associated with tumors involves those that originate from the cartilage cells of the physis, thereby stealing growth potential from the plate. Examples of this are enchondromatosis and Ollier disease, which can produce growth inhibition of the affected bones (53), and osteochondromatosis, which frequently results in shortening of the ulna with a Madelung deformity. Although unicameral cysts usually do not result in significant leg length discrepancy, some disturbance of growth can result from aggressive attempts to remove the cyst wall, when the cyst is active and immediately adjacent to the plate. Unicameral cysts and fibrous dysplasia cause leg length discrepancy as the result of both growth inhibition and repeated fractures with minimal displacement that produce progressive varus.

Avascular Necrosis

Because the circulation of the physis is derived from the epiphyseal circulation, avascular necrosis of the epiphysis frequently involves the growth plate as well, and these patients can develop leg length discrepancy. This effect may be seen in Legg-Perthes disease, and following treatment of developmental dislocation of the hip. Peterson has reported a case in which a discrepancy resulted from a temporary but significant episode of vascular insufficiency during surgery in an infant (54). This effect, in the case of congenital dislocation of the hip, is maximized by the early age of onset and the years of future growth affected, but is moderated by the fact that the growth plate of the proximal femur contributes only about 15% of the growth of the limb. The likelihood of significant discrepancy has been correlated with the pattern of ischemic damage to the head, and increases with increasing involvement (55). That patients with Legg-Perthes disease do not usually develop significant deformity indicates that the vascular damage to the epiphysis does not always significantly affect the physis (56). Leg length discrepancy also has been reported as a complication of catheterization of the umbilical or femoral artery (57), presumably due to impairment of the arterial supply to the physis.

Stimulation of Growth

Certain conditions are known to stimulate growth, but although the mechanism is popularly thought to be increased circulation, only circumstantial evidence supports this theory. Attempts to stimulate growth in the treatment of leg length discrepancy have been made by numerous means, including sympathectomy to increase blood flow, insertion of foreign materials next to the physis, stripping and elevation of the periosteum (58–60), surgical establishment of an arteriovenous fistula (61), short wave diathermy (62), and electrical stimulation (63). None of these methods has consistently produced sufficient growth stimulation to be clinically useful (64,65), but the fact that the arteriovenous fistula does produce stimulation at all supports the hypothesis that increased circulation can be a final common pathway for the conditions that stimulate growth.

Tumor

Vascular malformations, particularly when they involve large portions of the limb, produce growth stimulation that often involves all growth plates of the limb, and not just the ones in proximity or those of the involved bone. This stimulation is seen with hemangiomatosis and the Klippel-Trenaunay-Weber syndrome (66). Stimulation is also seen with certain nonvascular tumors, such as neurofibromatosis, fibrous dysplasia, and Wilms tumor, although an increase in circulation can be the final common pathway in these cases.

Inflammation

Overgrowth of the involved bone is a common feature of chronic osteomyelitis, presumably because of the increased blood flow to the limb as part of the inflammation. Infection therefore can both inhibit and stimulate growth. Overgrowth of the affected limb can be seen in pauciarticular juvenile rheumatoid arthritis (67), particularly in those cases with onset before the age of 3 years (68), and also has been reported in a hemophiliac with chronic knee synovitis (69).

Fracture

Overgrowth usually is seen following fractures of long bones in children, and also is believed to result from the increased blood flow to the limb that is part of the healing process (70). One particularly pernicious example of this effect is the overgrowth of the tibia and valgus deformity that can follow minimally displaced proximal metaphyseal fractures (71). The mechanism involves overgrowth of the medial side of the tibial growth plate (72), possibly as the result of tethering by the fibula or by release of the torn medial periosteum (73–76).

Overgrowth most commonly occurs following femoral fractures in young children (77,78). Some studies have reported that the stimulatory effect can last for years, but it is believed to occur principally during the healing and remodeling periods in the first 2 years after the fracture (79). The stimulation has been reported variously to be greatest in fractures in the proximal third of the femur, the middle third of the femur (80), and in those fractures with greater degrees of overriding (81) and can be accompanied by overgrowth of the fractured tibia on the same side. Conversely, Meals (82) found that the patient's age and the type and location of the fracture did not influence the extent of overgrowth, although, inexplicably, handedness did.

PATIENT ASSESSMENT

There is a tendency when dealing with patients with leg length discrepancy to concentrate attention on the lengths of the legs and the discrepancy, and to ignore other factors that have some importance with respect to the patient's function and the ultimate outcome of treatment. When choosing treatment goals, as discussed later in this chapter, the importance of a complete and thorough assessment of the patient is emphasized.

History of Discrepancy

A complete history of the patient, the discrepancy, and its previous treatment should be obtained. The cause is important, because knowledge of whether length, growth, or both is affected, is essential to understanding the growth pattern.

Also important is knowledge of the affected physal plates, because this permits an estimation of the future increase in the discrepancy. Parents expect this kind of information on the first visit, and it is important, in establishing a good parent–patient–surgeon relationship, to be as knowledgeable as possible about the condition and its future. The history of surgery, including surgery to correct angular deformity, is needed, because the numeric data concerning leg lengths may be misinterpreted if the examiner is unaware of previous surgery that might have affected the leg lengths.

The history, which delineates the cause, associated deformity, and neuromuscular deficits, is referred to during selection of the treatment goal. That a patient's discrepancy is of congenital origin suggests increased risk, and certain precautionary steps to avoid complications must be taken in conjunction with lengthening. Instability of an adjacent joint can preclude lengthening. Weakness of the leg suggests that the weak leg be left a little short to facilitate floor clearance during swing phase.

Clinical Assessment

The accuracy and ease of obtaining radiologic measurements of the patient should not blind the physician to the necessity of conducting a careful and complete physical examination. There are two reasons for this. First, the radiographic measurements may be wrong because of artifacts caused by angular deformity, positioning, or patient movement. Second, there are important factors not measured by routine radiographs that can be crucial to the outcome of treatment. This latter point is mentioned repeatedly in the section on goal selection. After assessment of the patient is complete, the clinical assessment must be consistent with the radiologic assessment; if it is not, an explanation must be sought. Additional radiographs or reexamination may be necessary to discover the reason for the inconsistency. In the final analysis, it is the functional leg length discrepancy that must be treated, and that cannot be determined by radiographs.

Leg Length

A tape measure is used to measure the real length of each leg from the anterosuperior iliac spine to the tip of the medial malleolus. The apparent length is measured from the umbilicus to the tip of the medial malleolus. The discrepancy determined from these two measurements may be different, because the apparent length is affected by pelvic obliquity and hip position. The leg on the side of the adducted hip appears shorter, but the real length is minimally affected (Fig. 28-16). The patient should be undressed completely for this measurement, to avoid tenting of the tape over the clothes. In any case, the tape often tents over or around the knee, impairing the accuracy of the measurement. Because different landmarks are used, the lengths of

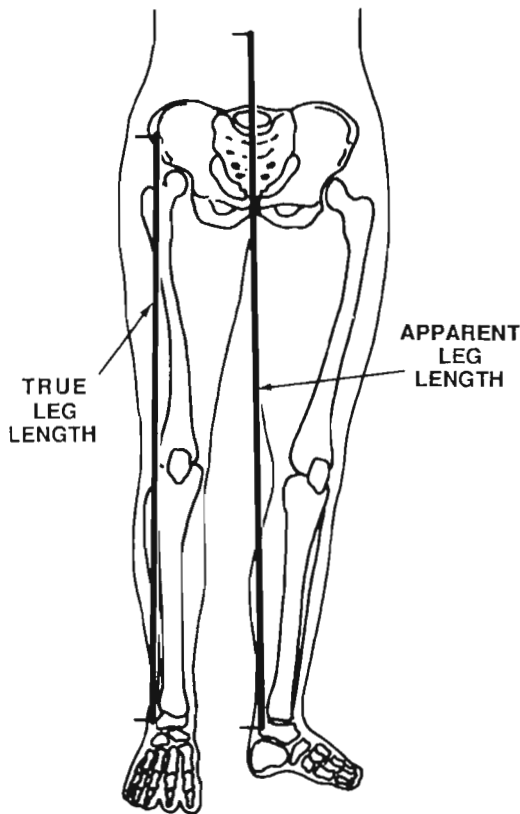


FIGURE 28-16. The measurement of real length is relatively immune from error because of pelvic obliquity. Measurement of apparent length is susceptible to error.

the legs measured in this way are not the same as those measured by radiograph, but the discrepancies should correspond closely.

The medial aspect of the joint line of the knee can be used as a landmark for measuring the segment lengths of the tibia and femur. Although this method is less accurate than the radiologic measurement, it is useful for comparison purposes to avoid errors. If the relative heights of the knees will be a strategy factor, then the lengths of the individual bones can be determined as well.

It is useful to place blocks under the foot on the short side, to lengthen the short leg effectively (Fig. 28-17). The block height required to produce a level pelvis should correspond to the measured discrepancy. Blocks also can be used to estimate the amount of correction that feels best to the patient, and provides him or her with the best correction. This amount may be different from the radiographic measurement, and may indicate that the goal of treatment should be something other than exact correction of leg length. This assessment is most useful in the mature patient whose discrepancy will change further with growth. Even though it only measures the present length and does not indicate the desired amount of correction, it can be helpful with immature patients to indicate that exact correction is

not the best goal. Carrying this idea further, the patient can be provided with a temporary shoe lift, and assessed after a period of ambulation. These techniques are especially useful for patients with complex deformities, because they take into account the combined effects of asymmetric feet, angular deformities, contractures, pelvic obliquity, and spinal balance.

Other Factors

Several factors besides leg length must be assessed, because they affect the measurement of leg length or influence the final outcome of the patient's treatment.

The examiner must remain aware that knee and hip flexion contractures tend to shorten the leg; an equinus contracture of the ankle tends to lengthen it; and apparent length also is affected by pelvic obliquity. The term "pelvic obliquity" has a broader meaning here than when used by spinal surgeons, who use it to refer to the relation of the position of the pelvis to that of the spine (83). In the context of leg length discrepancy, it refers to the relation of the position of the pelvis to that of the legs, and is affected both by adduction and abduction contractures of the hips and by spinal deformity. An adduction contracture of the hip

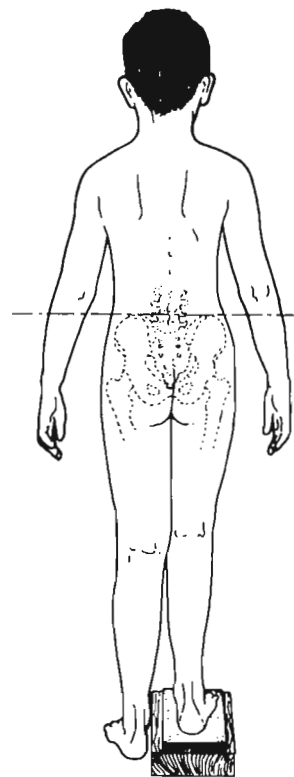


FIGURE 28-17. Placing blocks beneath the heel of the short leg allows assessment of the combined effect of all factors that produce functional leg length discrepancy.

causes the leg on that side to appear short, and to be functionally short, whereas an abduction contracture has the opposite effects (84). This situation is common in patients with cerebral palsy and those with the residuals of poliomyelitis. A difference between the measured real and apparent discrepancies indicates that pelvic obliquity is present.

Hip contractures are particularly important, since adduction contractures produce a functionally short leg, and abduction contractures produce a functionally long leg (85). These effects occur even in the absence of an actual discrepancy, as measured by scanogram. Conversely, in a patient with true shortening, a limitation of ipsilateral hip abduction or contralateral hip abduction will prevent him or her from compensating easily, and exaggerate the effect of the discrepancy.

Angular deformity must be assessed because it affects the measurements of leg length and influences the final outcome if it is to be corrected later. Joint stability must be assessed because it pertains particularly to the risks of lengthening. Femoral lengthening is contraindicated in the presence of hip instability. Congenitally short femurs always are associated with laxity of the anterior cruciate ligament (86) and hypoplasia of the lateral femoral condyle (Fig. 28-13), which predisposes to posterolateral subluxation of the tibial plateau. Lengthening of the tibia can be contraindicated in the presence of an unstable ankle or useless foot, which might be better handled by amputation and prosthetic fitting.

Spinal deformity and balance should be assessed. If there is stiff suprapelvic obliquity, such that the axis of the trunk cannot be brought perpendicular to the transverse axis of the pelvis, an equalization of leg lengths will result in imbalance of the trunk, and some modification of that goal will be necessary. Adduction and abduction contractures of the hips produce infrapelvic obliquity with apparent and functional leg length discrepancy (87).

Weakness and the need for bracing must be assessed, because leg length discrepancy in patients with paralysis or weakness is usually best handled by undercorrection, leaving the weak leg short to facilitate swing-through, particularly if the leg is braced with the knee locked in extension. Patients who require bracing of the short leg to walk can have their leg length discrepancy corrected in the brace and may not require surgical correction at all.

Finally, the concerns, compliance, and emotional state of the parents and patient must be taken into account. This aspect is particularly important when lengthening is being considered, because this is a long and difficult process requiring understanding and cooperation by all. In spite of excellent education and preparation, parents and patients always underestimate the challenge of dealing with duration of lengthening and for later restriction of activities. If there is a lack of understanding or a suggestion of poor compliance, then another approach may be more appropriate. The surgeon constantly must be aware that patients frequently

express concerns about function when they are concerned actually about cosmetic effect, which may be less important when compared with the risks of surgery.

Radiologic Assessment

Leg Lengths

Several methods exist for the radiologic measurement of leg length. These methods are more accurate than clinical methods, but each has its advantages and disadvantages. The nonexistent ideal method allows the hip and ankle to be viewed, minimizes radiation, uses only one exposure, uses a film of convenient size, demonstrates angular deformity, has no magnification, gives true readings from a scale on the film, and is inexpensive.

The bony landmarks used are the top of the femoral head, the medial femoral condyle, and the ankle. The ankle mortise is slightly saddle-shaped, and the midpoint of the saddle can be easily identified. Although these techniques allow the measurement of the femur and tibia individually, these values are not required in analyzing and predicting growth, and the length of the entire leg suffices.

The surgeon cannot rely on measurements recorded in the patient's record, but must review all films before performing surgery to check their accuracy and reliability. There is the possibility that films taken over the years have been read by different people using different techniques and landmarks. It is also possible that the scales have been misread or that arithmetic errors have been made in determining lengths and discrepancies.

There are four radiologic techniques that measure leg lengths directly, and others that provide useful information. The terminology is confusing, because names used for these techniques are inconsistent in the literature and in use. The term "scanogram," for example, was derived from the technique of split scanography, in which the x-ray beam was tightly collimated to a thin transverse slit that exposed the film, as the x-ray tube was moved from one end of the leg to the other. The principles are more important than the terminology.

The teleoradiograph (Fig. 28-18) is a single exposure of both legs on a long, 35 × 90 cm (14 × 36 in.) film. It is taken from a 2-m (6-ft) distance, usually with the patient standing and a radiopaque ruler placed on the cassette. It has the advantages of showing angular deformities and using a single exposure, but produces a film that is inconvenient to handle and measurements that are subject to magnification, because of parallax of the x-ray beam. There is no significant difference between measurements of the leg taken supine and those taken standing (88).

The orthoradiograph (Fig. 28-19) avoids the magnification factor by taking separate exposures of the hip, knee, and ankle, so that the central x-ray beam passes through the joints, giving true readings from the scale (89). The film

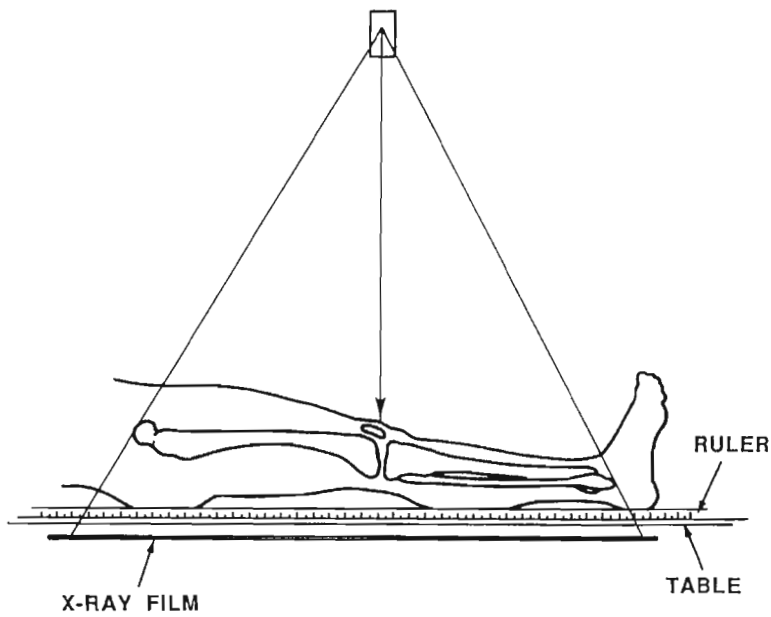


FIGURE 28-18. The diagram of teleoroentgenogram technique reveals angular deformity, but is subject to errors of magnification. It is probably the best technique for children who cannot reliably comply with instructions to remain still for multiple exposures.

is still cumbersome, however, and the need for multiple exposures introduces the risk of error, because of patient movement.

The scanogram (Figs. 28-20 and 28-21) avoids magnification in the same way, but reduces the size of the resulting film by moving the film cassette beneath the patient between exposures (90). This technique is preferred in children over the age of 5 or 6 years who can be compliant with

instructions not to move, because it gives true measurements without magnification, but younger children are better assessed using the teleoradiograph.

Positioning for the scanogram must be modified for patients with contractures of the hip or knee. Patients with hip flexion contractures can have accurate measurements made in the reclining position. In those with only knee contractures, the femur can be measured in either the lateral

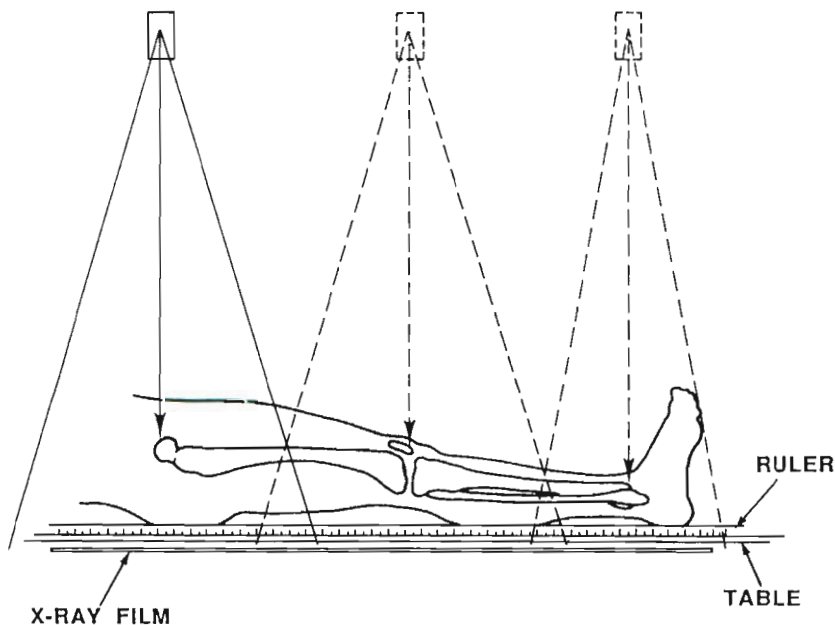


FIGURE 28-19. The orthoroentgenogram technique exposes each joint individually, thereby ensuring that the x-ray beam through each joint is perpendicular to the x-ray film, thereby avoiding errors of magnification.

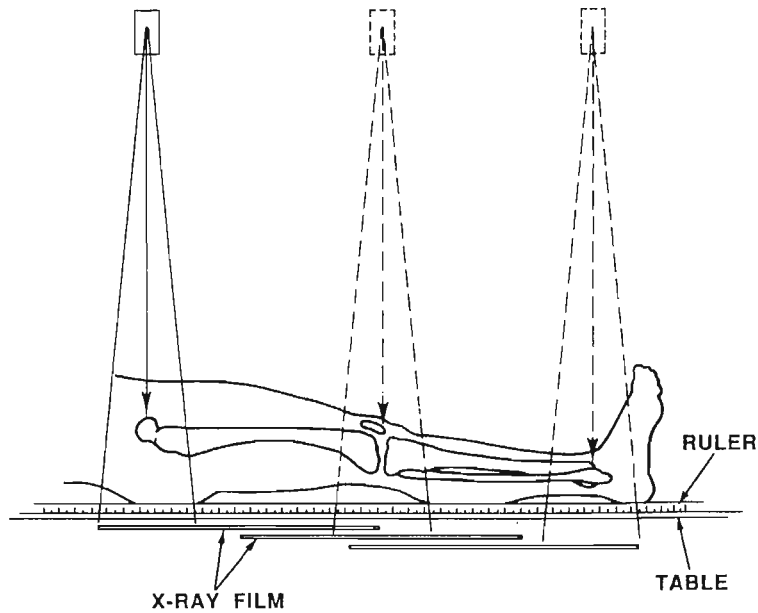


FIGURE 28-20. The scanogram technique avoids magnification error in the same manner as does the orthoroentgenogram, and is the preferred technique for children who can remain still for three exposures.

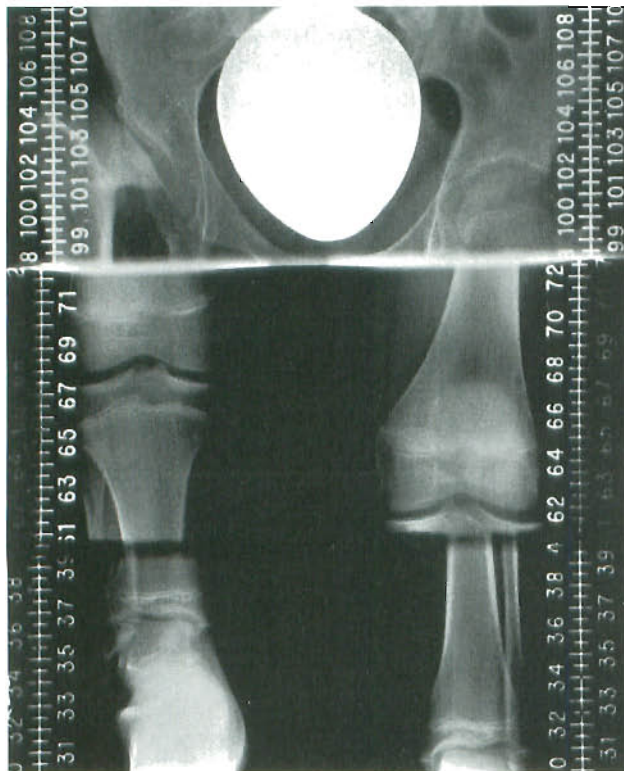


FIGURE 28-21. Scanogram technique allows the images of the three joints to be captured on a film of convenient size by moving the film beneath the patient between exposures.

or prone position, and the tibia in the lateral position. Assessment of both bones can be performed on one x-ray film in the lateral position, if two rulers are used, one parallel to each bone. If a hip contracture is also present, the femur must be assessed in the lateral position. The scanogram of both femur and tibia can be done in the lateral position.

Digital radiography is promising in the measurement of leg length (91,92). Computed tomography can be used to measure the distances between points on the film, and errors from angular deformity are reduced (93). If the examination is done specifically for this purpose, multiple sections are unnecessary, the radiation exposure is less, especially with microdose techniques (94), and the cost is comparable to more traditional techniques (94–96).

Whatever technique is used, it is important to be consistent and, when analyzing data to determine the timing of surgery, not to mix true and magnified measurements. Because errors are possible with all of these techniques, the resulting measurements should be compared with, and should correspond with, the clinical measurements.

An anteroposterior standing film of the pelvis and hips, taken with the legs straight (on blocks if necessary), is occasionally useful in assessing the combined effect of leg length discrepancy, angular deformity, and asymmetry of the foot and pelvis, because it more closely approximates the functional discrepancy. The leg length discrepancy is calculated from the heights of the femoral heads from the floor taking into account the height of the blocks. This assessment can supplement the clinical examination done with blocks.

It is important for the surgeon to integrate all the information from the various methods of measuring leg length in preparing a treatment strategy.

Skeletal Age

All methods of estimating skeletal age involve comparing radiographs of the patient with standards in an atlas. Methods have been described for using the bones of the pelvis and hip, the knee, and the hand and wrist (98,99). The estimation of skeletal age is only moderately accurate, and is the weak link in the techniques of analysis and prediction of growth.

The Greulich and Pyle method is used universally in this context. Their atlas (20) consists of reproductions of radiographs of the left hand and wrist of boys and girls that were considered typical for the stated skeletal age. To estimate the skeletal age of the patient, a radiograph of the left hand and wrist is taken according to the technique described in the atlas, and this film is then compared with the standard radiographs of the appropriate gender, according to qualitative (e.g., the visibility of the hook of the hamate) and quantitative (e.g., the degree of conformity of an epiphysis to its metaphysis) criteria. The standard that most closely matches the patient's radiograph is taken as the skeletal age.

This technique has certain deficiencies. The first is that, in some parts of the atlas, the standards represent skeletal ages that are far apart, with a gap as great as 14 months. There is, therefore, a large standard error built into the technique. With practice, it is possible to interpolate between standards, but this practice is difficult, and studies have shown significant interobserver and intraobserver errors (100). A second problem is that some children do not follow the same orderly succession of maturity indicators shown in the atlas, and an arbitrary choice must be made in assigning a skeletal age. Third, some children with leg

length discrepancy of congenital origin also have congenital anomalies of the hand and wrist, making it impossible to reliably compare their radiographs with the standards. Finally, one of the features of almost all skeletal age atlases is that the mean skeletal age of a sample of similarly aged children is equal to their chronologic age, so that the skeletal age is, in fact, the best possible predictor of chronologic age. That is, of a random sampling of boys or girls of the stated chronologic age, half would be more developed and half would be less developed than the standard radiograph. Greulich and Pyle, however, in selecting standards for their atlas, did not follow this principle exactly, and in some cases, selected radiographs that they believed were more representative. It is important to note that Green and Anderson used the Greulich-Pyle standards in their leg length studies.

The Tanner-Whitehouse method (101) is similar in that it uses radiograph of the hand and wrist, but was developed using modern computerized mathematical procedures. It adds a level of refinement and accuracy to the Greulich-Pyle technique, by defining and showing examples of successive stages of development of 20 specific bony landmarks in the hand and wrist (Fig. 28-22). The same standards are used for boys and girls. The patient's radiograph is compared with the standards, and a letter score is assigned to each of the 20 landmarks. The letter score is then converted to a numeric score by consulting a table for the appropriate gender. The sum of these 20 scores represents the level of skeletal maturity attained by the patient, and can be converted to years and months with a much smaller standard error than with the Greulich-Pyle technique. Of special interest in dealing with leg length discrepancy is that the bony landmarks can be divided into two groups. Tanner and

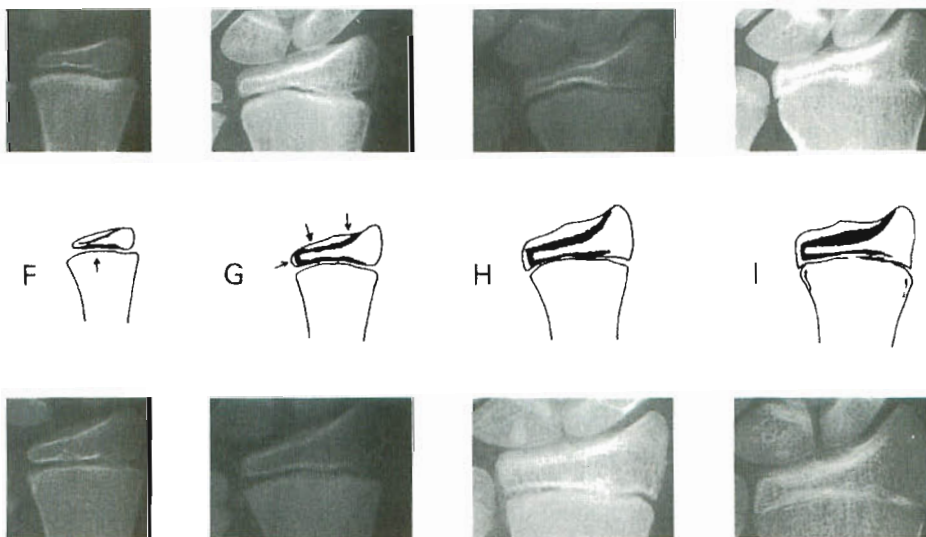


FIGURE 28-22. The Tanner-Whitehouse atlas provides standards like this for twenty different landmarks in the hand and wrist. This technique allows the determination of skeletal age to an accuracy of months, but is not consistent with the Greulich-Pyle atlas. (From ref. 100, with permission.)

Whitehouse provide tables for including either the 12 long-bone standards of the hand or the eight cuboid bone standards of the wrist in the assessment. When these two approaches give different results, it is reasonable to assume that the long-bone standards give a skeletal age that is more pertinent to the growth of the long bones of the leg. The concept that the long bones are more important than the cuboid bones, in the context of leg length discrepancy, can be useful even with the Greulich-Pyle atlas in allowing the resolution of difficulty in selecting the appropriate standard for a given radiograph.

There are two areas of difficulty with this method. The first is that it is more cumbersome and time-consuming than the Greulich-Pyle method, and the second is that it has not been correlated with leg length, and cannot be used by orthopaedic surgeons in the analysis of growth. Tanner-Whitehouse skeletal age cannot be used with the Green and Anderson data derived from the Greulich-Pyle method, because these two methods give different skeletal ages. This is surprising, and probably is related in part to the fact that different populations were used to develop the standards.

The relation between skeletal age and leg length, although reliable, is not as reliable as one would like it to be, and the relative inaccuracy of skeletal age estimation must be accepted. It is still possible to make acceptably accurate predictions.

DATA ANALYSIS

The adult with leg length discrepancy, who has no future growth and no possibility of a changing discrepancy, presents no need to analyze data. The growing child, on the other hand, whose legs may be growing at different rates, and whose discrepancy may be changing, presents another level of difficulty. The treatment goal must be chosen with respect to the discrepancy that would be present at maturity, and not the present discrepancy; therefore, before performing surgery, the orthopaedic surgeon must be able to predict the situation at maturity. The importance of proper data analysis cannot be overemphasized. Blair and associates (102) reviewed 67 epiphysiodeses, and found that correction to within 1 cm had been achieved in only 22 cases, and 35 failures occurred, because of incorrect use of the Green and Anderson data.

Three methods are useful in analyzing leg length data: the growth-remaining method, the arithmetic method, and the straight-line graph method. These methods differ significantly in their convenience, complexity, and accuracy, but the analysis moves through the same stages in all three. The first stage is the analysis of past growth, including the determination of the present discrepancy, and depending on the method, the growth percentile and the growth inhibition. The second stage involves the prediction of future growth, including the lengths of the legs and discrepancy

at maturity. The third stage is the prediction of the effects of corrective surgery.

All three methods have their place in the armamentarium of the orthopaedic surgeon. All require good understanding of the principles of growth and their methodologies, to be used properly without error. The three methods are discussed here in general terms, and step-by-step instructions for their use are shown in Figures 28-23, 28-24, and 28-26. Included in those charts are examples of their use in a specific case. It should be noted that the arithmetic method and the growth-remaining method are designed solely to arrive at the correct timing of epiphysiodesis, whereas the straight-line graph method provides a general description of growth, and also provides for the prediction of future growth.

The accuracy of all methods depends to a degree on the nature of available data. The calculation of growth inhibition, for example, is more accurate with data over longer intervals. It is the interval over which data is collected, and not the number of visits that is important, and data should be gathered for at least 1 or preferably 2 years. Minor errors in measurement over a short time can lead to major errors in estimating the growth inhibition, and consequently, major errors in predicting the discrepancy at maturity. A greater number of visits can be useful in recognizing values that are in error, because they do not fit the pattern established by other visits. For example, one erroneous radiographic reading can be noticed in a group of other, valid, points but can be missed if the patient makes only one or two visits. The straight-line graph is the only one of the three methods that uses all available skeletal ages, and in that method the accumulation of more skeletal age estimates diminishes the errors in single estimates.

Arithmetic Method

The arithmetic method was first described by White, and more recently evaluated by Menelaus and Westh (103,104). It is a method designed solely to manage discrepancy and determine the timing of epiphysiodesis, and not a general method to describe growth. Menelaus intended the method to be based on measurements of discrepancy by blocks, and not on measurements of leg length (105). Although the method uses calendar age and not skeletal age, Menelaus suggests that it only be used in children whose skeletal and chronologic ages are less than a year apart, rendering moot the question of calendar versus skeletal age (105).

It depends on the following statements, all of which are first approximations of the true growth pattern described by Green and Anderson.

Girls stop growing at the age of 14 years.

Boys stop growing at the age of 16 years.

The distal femoral plate grows 10 mm ($\frac{3}{8}$ in.) per year.

The proximal tibial plate grows 6 mm ($\frac{1}{4}$ in.) per year.

The discrepancy increases by 3 mm ($\frac{1}{8}$ in.) per year.

Determining Leg Length Discrepancy: The Arithmetic Method

Leg length data

(for examples for all three methods):

Sex: Female

Age (yr)	Skeletal age (yr)	Right leg length (cm)	Left leg length (cm)
7 + 10	8 + 10	60.0	58.2
8 + 4	9 + 4	64.4	61.9
9 + 3	10 + 3	70.0	66.2

Prerequisite growth information

Distal femoral plate grows 10 mm/yr.
Proximal tibial plate grows 6 mm/yr.

Girls stop growing at 14 years of age.
Boys stop growing at 16 years of age.

A Assessment of past growth

- | | |
|--|--|
| <ol style="list-style-type: none"> Longest time interval for data
= age at last visit - age at first Years of growth remaining
= 14 (16 for boys) - age at last visit Past growth of legs
= present length - first measured length Growth rate of long leg
= $\frac{\text{past growth}}{\text{time interval}}$ Growth inhibition
= $\frac{(\text{growth of long leg} - \text{growth of short leg})}{\text{growth of long leg}}$ | <ol style="list-style-type: none"> Longest time interval for data
= 9 yr 3 mo - 7 yr 10 mo = 1 yr 5 mo
= 1.42 yr Years of growth remaining
= 14 yr - 9 yr 3 mo = 4 yr 9 mo = 4.75 yr Past growth of:
long leg = 70.0 - 60.0 = 10.0 cm
short leg = 66.2 - 58.2 = 8.0 cm Growth rate of long leg
= $\frac{10.0}{1.42} = 7.04 \text{ cm/yr}$ Inhibition
= $\frac{(10.0 - 8.0)}{10.0} = 0.2 \text{ cm}$ |
|--|--|

B Prediction of future growth

- | | |
|---|--|
| <ol style="list-style-type: none"> Future growth of long leg
= years remaining X growth rate Future increase in discrepancy
= future growth of long leg X inhibition Discrepancy at maturity
= present discrepancy + future increase | <ol style="list-style-type: none"> Future growth of long leg
= 4.75 X 7.04 = 33.4 cm Future increase in discrepancy
= 33.4 X 0.2 = 6.7 cm Discrepancy at maturity
= (70.0 - 66.2) + 6.7 = 10.5 cm |
|---|--|

C Prediction of effect of surgery

Effect of epiphysiodesis
= growth rate X years remaining

Effect of epiphysiodesis
Femoral = 1.0 X 4.75 = 4.75 cm
Tibial = 0.6 X 4.75 = 2.85 cm
Both = 1.6 X 4.75 = 7.6 cm

FIGURE 28-23. Step-by-step instructions for use of the arithmetic method. The method presented here is modified from that presented by Menelaus and Westh, in that the future increase in discrepancy is calculated from past growth instead of being assumed to be 0.125 inch per year of growth remaining. An example is shown in the panels in the right column.

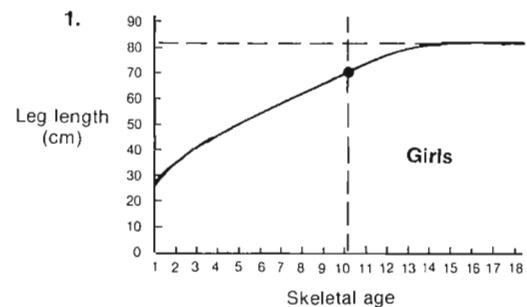
Determining Leg Length Discrepancy: The Growth-Remaining Method

A Assessment of past growth

- | | |
|---|--|
| <ol style="list-style-type: none"> 1. Growth of both legs
= present length - first length 2. Present discrepancy
= length of long leg - length of short leg 3. Growth inhibition
= $\frac{(\text{growth of long leg} - \text{growth of short leg})}{\text{growth of long leg}}$ | <ol style="list-style-type: none"> 1. Growth of long leg
= $70.0 - 60.0 = 10.0$ cm 1. Growth of short leg
= $66.2 - 58.2 = 8.0$ cm 2. Present discrepancy
= $70.0 - 66.2 = 3.8$ cm 3. Growth inhibition
= $\frac{(10.0 - 8.0)}{10.0} = 0.2$ cm |
|---|--|

B Prediction of future growth

1. Plot present length of long leg on Green-Anderson leg length graph for appropriate sex



- | | |
|--|---|
| <ol style="list-style-type: none"> 2. Project to right parallel to standard deviation lines until maturity to determine mature length of long leg 3. Future growth of long leg
= mature length - present length 4. Future increase in discrepancy
= future growth long X inhibition 5. Predicted discrepancy at maturity
= present discrepancy + future increase | <ol style="list-style-type: none"> 2. Length of long leg at maturity = 81.1 cm 3. Future growth of long leg
= $81.1 - 70.0 = 11.1$ cm 4. Future increase in discrepancy
= $11.1 \times 0.2 = 2.2$ cm 5. Discrepancy at maturity
= $3.8 + 2.2 = 6.0$ cm |
|--|---|

C Prediction of effect of surgery

- | | |
|--|---|
| <ol style="list-style-type: none"> 1. The effect of epiphysiodesis of the distal femoral and proximal tibial plates for a given sex and skeletal age can be determined by the Green-Anderson growth = remaining graph. 2. The effect of lengthening is not affected by growth. | <ol style="list-style-type: none"> 1. Correction from proximal tibial arrest
= 2.7 cm
Correction from distal femoral arrest
= 4.1 cm
Correction from combined arrest
= $2.7 + 4.1 = 6.8$ cm |
|--|---|

FIGURE 28-24. Step-by-step instructions for use of the growth-remaining method. An example is shown in the panels in the right column, using the same data as in the example in Figure 28-23.

These approximations are reasonably good during the last years of growth, but are inaccurate in young children. The statement that the discrepancy increases by $\frac{1}{8}$ in. per year is obviously not true in all cases. It is, however, fairly accurate in those children who are in the last few years of growth, whose discrepancies began at birth, whose maturation is not significantly advanced or delayed relative to their chronologic ages, and whose discrepancies are within the clinical range for epiphysiodesis.

Its most significant advantage is its convenience, because no special tools are needed for its use. It is easiest to use with English measure rather than metric. Its disadvantages are that it uses chronologic age rather than skeletal age, and is therefore subject to error in children who grow and mature very early or very late. It uses an approximation of the growth curve rather than the growth curve itself, and is increasingly inaccurate in young children. If, however, its use is restricted to determining the timing of epiphysiodesis, and is applied only to the patients described earlier, then good results can be anticipated, as have been reported by Westh and Menelaus (104). Step-by-step instructions for the use of this method are shown in Figure 28-23.

Fries also has published straight-line approximations to the growth-remaining graph, in which the remaining growth in the epiphyses of boys and girls is determined by first-order equations using skeletal age, but this approach lacks the simplicity of the arithmetic method (64).

Growth-remaining Method

The growth-remaining method is based on the data and tables of growth that Green and Anderson published in their two studies (16,17). These studies are, to the author's knowledge, the only good studies published relating leg lengths to chronologic and skeletal age, and serve as the foundations of the more accurate methods of analyzing growth. Their graphs describing the lengths of the legs of boys and girls, related to age, can be used to determine the growth percentile of the child and the future growth of the long leg. Their graph showing the growth remaining in the distal femur and proximal tibia can be used to predict the effects of epiphysiodesis (106) (Fig. 28-7).

The advantages of this method are that it uses skeletal age, is based on an accurate description of the growth pattern, takes into account the child's growth percentile in predicting future growth, and has been demonstrated to be accurate over decades of use. The disadvantages are that it requires the availability of the two sets of graphs, does not take into account the growth percentile in predicting the effect of epiphysiodesis, and, because it uses only the most recent skeletal age estimation, it will be in error to the extent that the skeletal age estimate is in error. An inherent hazard of this method is that the growth-remaining graph is so familiar and easy to use that the unwary are tempted to

correct the present discrepancy in a growing child, neglecting the steps that involve the prediction of future change. Step-by-step instructions for the use of this method are shown in Figure 28-24.

Straight-line Graph Method

The straight-line graph method initially was devised as a method of presenting the relative growth of the legs in a clear, graphic, fashion (Fig. 28-25). By incorporating the data of Green and Anderson (17), it evolved into a method of recording, analyzing, and predicting growth (107,108). The method is based on two principles: the growth of the legs can be represented graphically by straight lines, and a nomogram can be used to determine the growth percentile from the skeletal age and leg length.

The representation of leg growth by straight lines appears to contradict the Green and Anderson description of growth, in which the growth lines of the legs are clearly curved. It is accomplished by manipulating the scale of the abscissa (x axis), in strict accordance with the Green and Anderson data, so that the curve that disappears from the growth lines reappears as an irregularity of that scale. This curve actually appears on the straight-line graph as a variable distance between the skeletal age lines. The important fact is that the straight line is not an approximation of the Green and Anderson data, but represents the data just as accurately as did their original graphs. In the absence of active disease or treatment, the relative rates of growth of the two legs stay constant, with the result that the growth line of the short leg also follows a straight line on the graph. This means that the length of the leg is represented on the graph by the vertical position of its growth line, and its growth rate by the slope of the growth line. The discrepancy therefore is represented by the vertical distance between the two growth lines, and the inhibition by the difference in slope.

The nomogram for skeletal age allows the plotting of points in a way that relates the length of the patient's long leg to the population and, in a sense, depicts the growth percentile. The nomogram is constructed so that all points, for the child whose growth pattern follows exactly that described by Green and Anderson, lie on a horizontal straight line. In practice, this is rarely the case, partly because of the inaccuracy of estimation of skeletal age, but also in part because of the possibility that children of other races or other genetic stock have different patterns of growth. It is likely that the plotting of every skeletal age point on the nomogram, before drawing the horizontal line representing the growth percentile, "averages out" the inaccuracies of individual determinations of skeletal age. Similarly, the risk of error, due to single estimates of skeletal age, is likely to decrease with an increasing number of estimates.

The straight-line graph facilitates the prediction of the

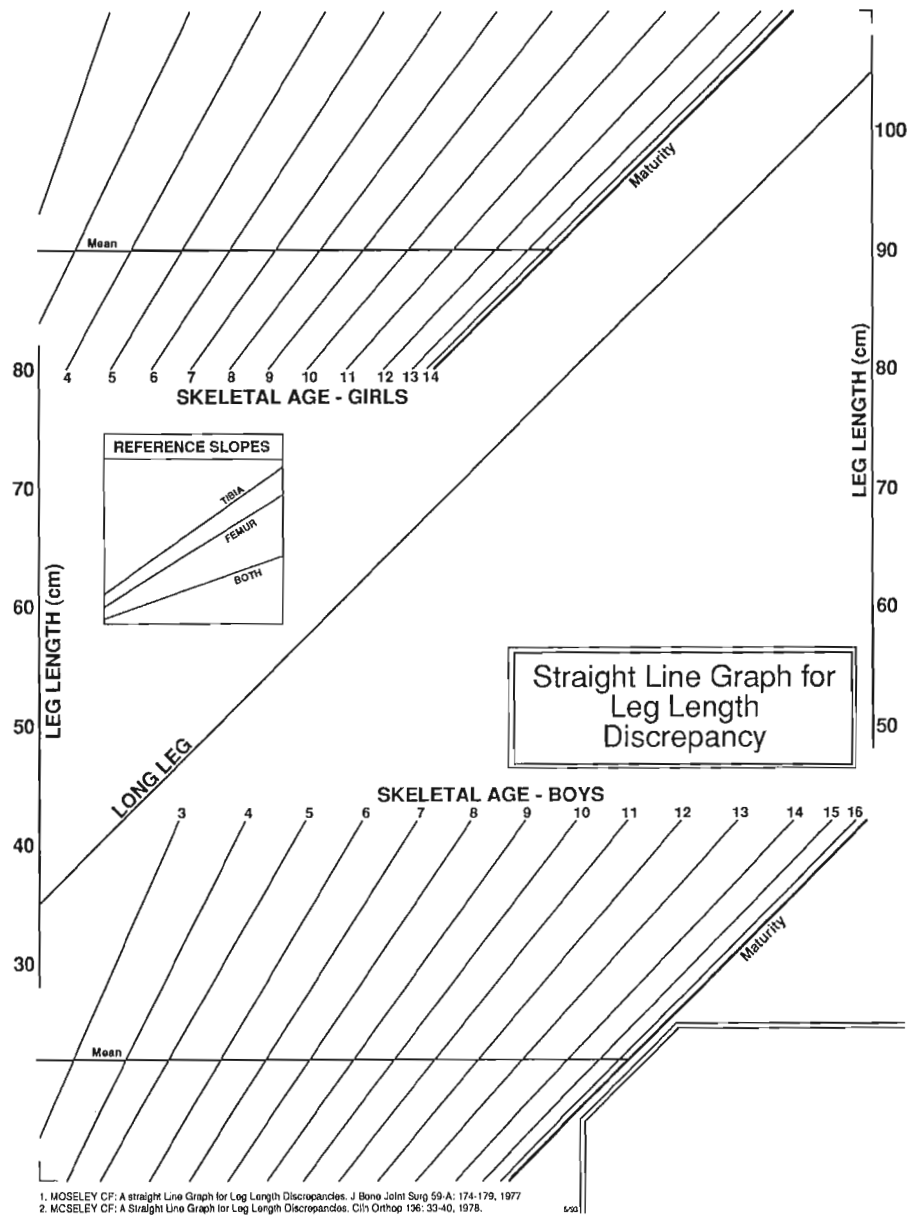


FIGURE 28-25. The straight-line graph comprises three parts: the leg length area with the pre-defined line for the growth of the long leg, the areas of sloping lines for the plotting of skeletal ages, and reference slopes to predict growth following epiphysiodesis.

effect of surgery. Lengthening or shortening will be represented on the graph by a vertical shift of its growth line, either upward or downward by the appropriate amount, without any change in its rate of growth. Conversely, the effect of an epiphysiodesis will be to decrease the slope of the growth line of the long leg. This is a strict mathematical relation, and, because the contributions of the individual growth plates to the overall growth of the leg are known, the future slope of the growth line can be predicted accurately. Reference slopes on the graph depict the slopes to be fol-

lowed after each of the three possible types of epiphysiodeses: distal femoral, proximal tibial, or both. For example, the slope of the growth line of the leg, following a proximal tibial epiphysiodesis, will be reduced to 73%, having lost the 27% normally contributed by that epiphysis. Because the unoperated long leg is defined on the graph as having a slope of 1.0, the slope following that surgery would be 0.73.

The advantages of this method are that it uses skeletal age and the actual growth pattern described by Green and

Anderson, takes into account the growth percentile in predicting future growth and the effect of surgery, minimizes errors due to the inaccuracy of skeletal age estimation, facilitates the flagging of erroneous values, and avoids arithmetic errors (109). It is a general tool for analysis, illustration, and prediction in leg length discrepancy, and can be used in children with large discrepancies and inhibitions, extreme growth percentiles, and marked delay or advancement of maturation. Step-by-step instructions for the use of this method are shown in Figure 28-26.

Patterns of Inhibition

In all three of the preceding methods, the growth inhibition is determined on the basis of past growth, and is then used to predict future growth. Evidence supports the assumption that the growth inhibition will remain constant throughout the growing years (110). Indeed, in the author's study of patients who went on to have epiphysiodeses, the linear correlation coefficient between the lengths of the two legs was greater than 0.955 in every case (107,108). This is an extremely close fit, and suggests that growth inhibition does indeed remain constant. It should be noted, however, that no children in this group had active disease, or were under treatment that could affect growth.

Shapiro reported different patterns, and has also reported that the growth rate of the femur tends to increase, and that of the tibia tends to decrease, following a lengthening procedure (111). This effect is relatively short-lived, and is not of sufficient magnitude to affect clinical decisions. Koman and colleagues have demonstrated constant inhibition in unilateral and bilateral proximal focal femoral deficiency (112), and Hootnick and associates have shown constant inhibition in congenitally short tibias (113).

The important question for the orthopaedic surgeon concerns the possibility of errors in correction because of changing inhibition. Does changing inhibition cause clinically significant errors in clinical judgment? A partial answer can be derived from the author's study, mentioned earlier, in which the inhibition appeared not to change and the straight-line graph predicted the final outcome within 1 cm in all cases. This suggests that, whatever effect changing inhibition has, it is not sufficient to prevent reaching predictions of future growth that are sufficiently accurate for good clinical results.

Inadequate Data

There are certain situations in which patients present late, it is suspected that the time for epiphysiodesis is imminent, and there is insufficient time to accumulate sufficient data for accurate assessment and prediction. In some cases, it is still possible to make reliable assumptions about the growth pattern that allow accurate prediction and confident treatment planning.

Consider the situation in which a child presents without any prior data, and the only information available is from that particular visit. The difficulty here is that it is impossible to calculate the growth inhibition, and to predict the discrepancy at maturity. If, however, the onset of the growth inhibition can be determined, it may be assumed that the legs were of equal length at that time. The length of the long (and therefore the short) leg at that time can be estimated by using either the Green and Anderson growth graph or the straight-line graph, and the growth inhibition can then be calculated in the usual way. Likewise, in the case of a congenital discrepancy, with inhibition beginning before birth, it can be assumed that the legs were of equal length when there was no length or, in other words, that the growth inhibition is equal to the percentage difference in the length of the legs. This assumption is consistent with the conclusion of Herron and associates (114).

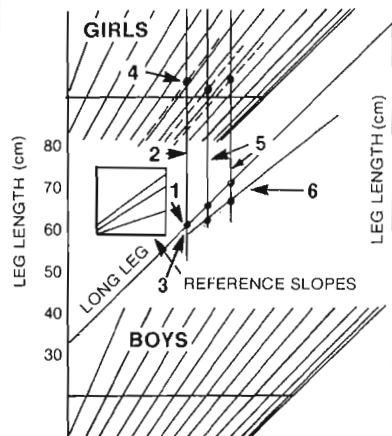
At times, an opinion is sought on the basis of leg length films without skeletal age films, when the patient is not immediately available to obtain them. In this case, the child's chronologic age can be used in place of the skeletal age, and this approach is validated if the development of secondary sexual characteristics and menarche are consistent with the chronologic age. Little et al. have suggested, in fact, that chronologic age is as accurate as skeletal age in determining the timing of epiphysiodesis, but their study eliminated several patients on the basis of skeletal age, and dealt with a select population (115). In the author's view, a surgeon should not base the timing for epiphysiodesis on chronologic age, and should take this approach only as a rough guideline.

In certain patients with remote disease that is no longer active, no continuing growth inhibition or accentuation exists. Patients with leg length discrepancy due to stimulation from fracture healing or osteomyelitis, or with shortening due to fracture malunion that is more than 2 years old, can be confidently assumed to have a static discrepancy. The discrepancy at maturity therefore will be the same as at present, and attention can be directed at correcting the present discrepancy.

Patients with complete destruction of one physis caused by trauma or infection can present with an early minimal discrepancy but significant inhibition that, with growth, will certainly lead to a greater discrepancy requiring treatment. In some cases, these children can be treated with an epiphysiodesis of the corresponding plate of the other limb. This plan does not correct the discrepancy, but ensures equal inhibition in both legs, and an unchanging discrepancy throughout growth.

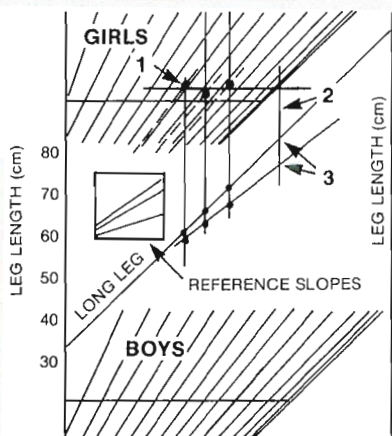
Sometimes no such assumptions are reasonable, and a decision reliable enough to undertake surgery cannot be made. In these cases, it is best to abandon the possibility of epiphysiodesis, and wait until maturity, when the discrepancy can be corrected without error by shortening or lengthening.

Determining Leg Length Discrepancy: The Straight Line Graph Method



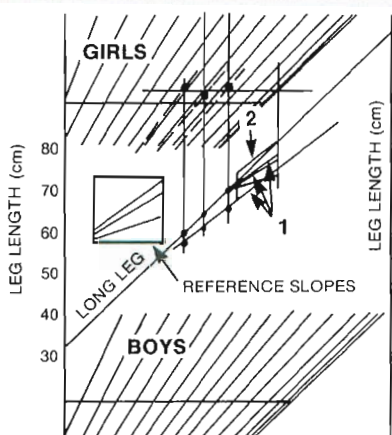
A Assessment of past growth

1. Plot the point for the long leg on the sloping line labeled "LONG LEG" at the appropriate length.
2. Draw a vertical line through that point representing the current assessment.
3. Plot the point for the short leg on the vertical line.
4. Plot the point for skeletal age with reference to the sloping lines in the nomogram.
5. Plot successive visits in the same fashion.
6. Draw a straight line through the short leg points to represent the growth of the short leg.



B Prediction of future growth

1. Draw the horizontal straight line that best fits the points previously plotted for skeletal age. The fit to later points is more important than to earlier points. This is the growth percentile line.
2. From the intersection of the growth percentile line with the maturity skeletal age line, draw a vertical line to intersect the growth lines of the two legs. This line represents the end of growth.
3. The points of intersection of the vertical line with the two growth lines indicate the predicted lengths of the legs at maturity.



C Prediction of effect of surgery

1. To predict the outcome after epiphysiodesis, draw three lines to the right from the last point for the long leg parallel to the three reference slopes. The intersections of these lines with the vertical line representing the end of growth indicates the predicted lengths of the long leg after the three possible types of epiphysiodesis.
2. To predict the outcome after leg lengthening, draw a line parallel to the growth line of the short leg but elevated above it by the amount of length gained.

FIGURE 28-26. Step-by-step instructions for use of the straight-line graph method. The data used are the same as in the example in Figure 28-24.

DETERMINATION OF TREATMENT GOALS

The choice of the goal of treatment and the choice of the treatment method are two different and independent steps in the treatment of patients with leg length discrepancy, and are discussed separately here. The selection of the treatment goal depends heavily on the careful and thorough assessment of the patient, both clinically and radiologically, and the reader is referred to the earlier sections on patient assessment.

Equal Leg Lengths

Many patients who have leg length discrepancy as an isolated problem, such as those with hemiatrophy, present no difficulty in the choice of treatment goal. Leg length equality at maturity is the appropriate goal.

Unequal Leg Lengths

Many patients do best with less than complete correction. Undercorrection of 1 or 2 cm is best for patients with paralysis of the short leg. The residual discrepancy facilitates clearing of the floor by the weak short leg during the swing phase of gait, and this is even more important in patients who wear braces and have the knee locked in extension, in order to ambulate. In patients who cannot walk without braces, the leg length discrepancy usually can be made up in the brace, and corrective surgery may not be indicated.

Level Pelvis

Patients with leg length discrepancy often have asymmetry that extends beyond the legs. Patients with congenital shortening, for example, may have a small foot or hemipelvis, and in these cases, perfectly equal leg lengths result in residual pelvic obliquity and tilting of the lumbosacral joint. A similar situation can arise in patients with leg length discrepancy from avascular necrosis of the femoral head, following treatment of congenital dislocation of the hip, who have also had an innominate osteotomy. These patients should be examined standing with blocks beneath the short leg to relate the desired correction to the leg length discrepancy. The treatment goal can be modified as required.

Vertical Lumbar Spine

Patients with fixed obliquity of the lumbosacral junction cannot achieve a level pelvis and a vertical lumbar spine at the same time. Usually, a vertical lumbar spine and good balance of the spine are more important than a level pelvis, and treatment of the leg length discrepancy should be consistent with the more important goal. It is interesting to

consider the possibility that such a patient could benefit from lengthening of the already long leg, if the pelvic obliquity were greater than the leg length discrepancy.

Equalization by Prosthetic Fitting

Some discrepancies are too great to be considered for correction. The traditional guideline has been that femurs less than half of the length of the other side, and legs that are destined to be more than 15 cm short, are candidates for prosthetic fitting. This is often done in conjunction with other procedures, including knee fusion, Syme amputation, and Van Nes rotationplasty. Modern advances in lengthening have led to the hope that one is more proficient at correcting very large discrepancies, with acceptable morbidity (116,117). It is the author's opinion that some discrepancies, up to 20 cm, are reasonable candidates for correction by a variety of combined simultaneous or staged shortening and lengthening procedures, but there is no reason for wholesale abandonment of the traditional guideline.

Correction of Coexisting Problems

The treatment plan must include those intermediate goals that are prerequisites to surgical treatment of the leg length discrepancy itself. These intermediate goals can include stabilization of unstable joints, release of contractures, correction of angular deformity, correction of spinal deformity, completion of partial growth arrests causing angular deformity, and excision of bony bridges, in an attempt to restore growth.

TREATMENT

General Principles

In general, it is wise to correct coexisting deformities before undertaking correction of the leg length discrepancy. There are two reasons for this. The deformity can adversely affect the outcome of the leg length discrepancy correction, or vice versa. The other reason is that the correction of some deformities affects the treatment goal. The correction of angular deformity of the limb usually increases the length of the leg, and the correction of spinal imbalance often changes pelvic obliquity and the desired amount of correction of leg length.

The choice of treatment method is more dependent on the magnitude of the predicted discrepancy at maturity than it is on its etiology. Fairly straightforward guidelines, expressed in terms of the magnitude of the predicted discrepancy, can be used to choose from among the major treatment categories:

0 to 2 cm:	No treatment
2 to 6 cm:	Shoe lift, epiphysiodesis, shortening
6 to 20 cm:	Lengthening, which may or may not be combined with other procedures
>20 cm:	Prosthetic fitting.

There is some flexibility in these guidelines, to account for factors such as environment, motivation, intelligence, compliance, emotional stability, patient and parent wishes, and associated pathology in the limbs.

There are good reasons for the values of these thresholds. It has been shown that discrepancies of less than 2 cm are of no functional or clinical consequence in adults, and do not require treatment (118). Indeed, Rush and Steiner found leg length discrepancy in 71% of new recruits into the United States Armed Forces (119). Because there is some advantage to being tall (120–123), lengthening procedures are often preferred by parents and patients, but lengthening is not generally done for discrepancies less than 6 cm, because there are other alternatives. The high morbidity and complication rate of lengthening should be avoided, in favor of epiphysiodesis or shortening, whenever possible. Because these alternatives are reasonable for corrections of up to 6 cm, they are the procedures of choice. Shortening procedures are usually not appropriate for correction of greater than 6 cm, because a disproportionate appearance results that is not pleasing to the patient. It should be noted that epiphysiodesis can be performed to correct a discrepancy of any magnitude, in cases in which the long leg is clearly the abnormal leg, because it corrects the abnormally long leg and does not result in abnormal proportions in these patients. It is reasonable to consider patient preference for lengthening over shortening only in the 5 to 6 cm range of correction, because there are overriding considerations outside that range.

The site of correction is chosen to leave the patient as symmetric as possible with knees as level as possible. This involves lengthening the shortest bone or shortening the bone corresponding to the shortest bone on the other side. This principle can be ignored in some cases of correction by epiphysiodesis, in which a single plate is arrested, to reduce the magnitude of surgery and risk of problems, although a combined femoral and tibial epiphysiodesis might produce the most symmetric result. It also can be ignored if more time for data gathering allows a more confident prediction of future growth and a more dependable treatment plan. Symmetry of knee height is a secondary consideration to equality of leg length. Knee height is not a factor in function or comfort, and is not very important in cosmesis.

Shoe Lift

A shoe lift is excellent treatment for discrepancies up to 6 cm. It is believed to be less desirable than surgical correction

of the discrepancy, but is a satisfactory answer for those patients who do not wish, or are not appropriate for, surgery. The shoe lift is only effective when the patient is walking or is in two-legged stance, and is only prescribed for its benefit on gait.

No lift is required for discrepancies less than 2 cm. For larger discrepancies, the height of the lift should be less than the discrepancy. For reasons of cosmesis, up to 2 cm of the lift can be put inside the shoe, with the remainder, if necessary, on the outside. Lifts higher than 5 cm are poorly tolerated, because the muscles controlling the subtalar joint are not strong enough to resist inversion stress, and frequent ankle strains result. If a higher lift is required, an orthotic extension up the posterior calf can be added for stability. The optimum height of the lift can be determined by clinical trials in which the lift height is temporarily modified to suit the patient. Liu et al. found that the benefit provided by a heel lift, insofar as it affects the symmetry index, is unpredictable (3).

Prosthetic Fitting

Prosthetic fitting, often in association with amputation, is a treatment of last resort, but is useful for those patients with very large discrepancies and those with deformed and functionally useless feet (124,125). Discrepancies anticipated to become greater than 15 to 20 cm, and those involving a femoral length less than 50% of the other side, should be treated in this way (35). This approach has the significant advantage of involving one hospitalization and one definitive operation. Patients with fibular hemimelia and an unstable ankle do better with this approach than with multiple hospitalizations and surgical procedures in a futile attempt to conserve the foot; the latter situation usually results in late amputation, which is then more difficult to accept.

Children with below-knee amputations, such as those amputated for fibular hemimelia, do very well functionally. They have an almost normal walking gait and can participate in recreational and sporting activities. Children who are treated for proximal focal femoral deficiency require above-the-knee prostheses, and function well, although not as well as the former group. Some of the latter can function as below-the-knee prosthesis wearers following a Van Nes rotationplasty, in which the reversed ankle functions as a knee, providing active control and motor power to the prosthetic knee (126).

Although the decision to do an amputation is difficult for the parents of a young child, the children who do best are those who have their surgery and prosthetic fitting early in life. The optimum time for the Syme amputation is toward the end of the first year of life, and for the rotationplasty, at about 3 years of age. It is helpful for parents

of children who are candidates for these procedures to see older children who have had the same procedure, and to talk with their parents.

Epiphysiodesis

Epiphysiodesis has very low morbidity and a very low complication rate, and is the treatment of choice for the surgical correction of leg length discrepancy (19,103,127,128). The operation is effective by slowing the growth rate of the long leg and allowing the short leg to catch up. In planning for this procedure, therefore, it is necessary to take into account the ability of the short leg to catch up, by using the growth inhibition to predict the discrepancy at maturity. For all surgical treatments of leg length discrepancy, it is the discrepancy at maturity that should be corrected, and not the present discrepancy in a growing child. Epiphysiodesis is a highly acceptable procedure, because it is straightforward, does not require postoperative immobilization, and disables the child minimally and for short duration. It is only suitable for those children who have sufficient leg length data to enable a confident prediction of the discrepancy at maturity, and who require correction of 2 to 6 cm (129).

Epiphysiodesis is an all-or-nothing procedure that completely and permanently arrests physeal growth. Thereafter, the leg grows at a slower rate, having lost the contribution to growth of the operated physis. The loss is 27% for the proximal tibia plate, 38% for the distal femoral plate, and 65% for combined epiphysiodesis of both plates. The surgeon thus induces a known degree of growth inhibition and has before him or her not a continuous spectrum of shortenings, but only three discrete choices. The exact amount of desired shortening can be achieved only by performing the surgery at exactly the correct time. Performing the operation too late results in undercorrection, and performing it too early results in overcorrection. This is in contrast to shortening and lengthening procedures that can be performed at any time.

The prediction of the effect of surgery can be made accurately within 1 cm in almost all cases (107). Because there is an advantage to being tall (120–123), it is better to err on the side of undercorrection than overcorrection. Because slight discrepancies are well tolerated, it is best to aim for 0.5 to 1.0 cm of undercorrection by doing the epiphysiodesis slightly later than the time for perfect correction. It should be done in the bone that is opposite the shortest on the other side, although this principle may have to be compromised if future growth is insufficient for such an epiphysiodesis to be effective.

The principle of the surgery is to produce a symmetric bony bridge that tethers the physis and prevents future growth. The traditional open techniques involve removing a block of bone from the medial and lateral aspects of the plate, extirpating the plate with a curette, and replacing the block of bone in such a fashion as to produce a bony bridge

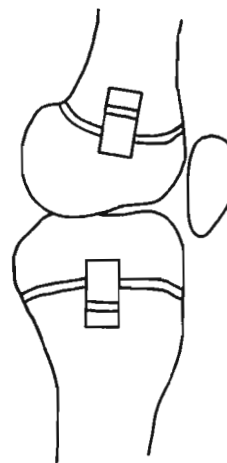


FIGURE 28-27. In epiphysiodesis by the Pnemister technique, a rectangular bone block is replaced in reverse position, to produce a bar across the growth plate.

(130). Pnemister described removal of a rectangular block, two-thirds on the metaphyseal side and one-third on the epiphyseal side of the plate, and its replacement in the reversed position (Fig. 28-27) [4.19, 6.12]. White and Stubbins used a special chisel to remove a square block that later was rotated 90 degrees before replacement (128), and Blount used a circular trephine to remove a cylindrical block that was rotated in the same way. Macnicol and Gupta have reported a percutaneous version of the Blount technique (131). All serve to bridge the physis medially and laterally with solid bone.

Blount produced physeal arrest by placing three staples across the physis both medially and laterally, producing a tethering effect resulting in arrest of growth (132–134) (Fig. 28-28). The rationale was that the arrest was temporary and

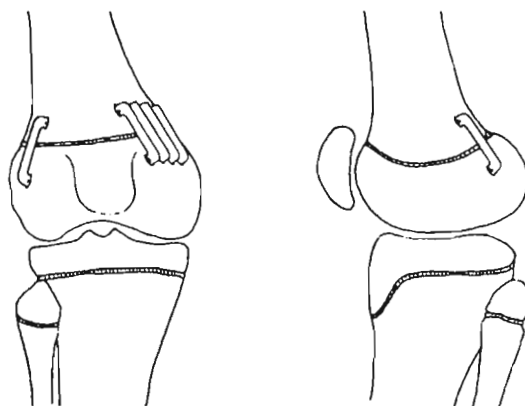


FIGURE 28-28. Epiphysiodesis by stapling. Growth arrest can be accomplished by careful placement of three extraperiosteal staples over the medial and lateral aspects of the plate.

growth would resume following later removal of the staples (135,136). This concept was attractive, because it alleviated the need to make accurate predictions of future growth. Certain patients, however, went on to fuse their physes while the staples were in place, did not resume growth on their removal, and went on to overcorrection of their discrepancies (137,138). Stapling, therefore, lost proponents, and was considered to be a permanent form of growth arrest. Staples caused problems by extruding, entering the adjacent joint, or causing overlying bursitis (139). Growth arrest was occasionally asymmetrical, and a second operation was sometimes necessary to remove the staples.

There have been recent reports that it is possible to perform stapling in such a way that growth confidently resumes when the staples are removed (140). The important technical point is to remain extraperiosteal and not directly expose the growth plate.

Traditional epiphysiodesis requires incisions on both the medial and lateral aspects of the knee, for a total of four incisions if both tibial and femoral epiphysiodeses are performed. Canale and others have reported percutaneous techniques developed to avoid unsightly scarring (131,141,142). It is done with a drill or burr, through small medial and lateral incisions, under image intensifier control. This technique has gained wide acceptance, and is considered by most to be the technique of choice. Great care must be taken to line up the image intensifier beam perfectly to ensure that the tool is in the plate. The percutaneous technique results in a wider excision of the plate, and can be accompanied by excessive bleeding or hematoma formation.

Percutaneous epiphysiodesis [4.20, 6.13] is usually performed through two incisions, one medial and one lateral. Because the growth plates, particularly the distal femoral, are not perfectly flat, there is a significant technical challenge in making sure that the tip of the tool is in the plate, and that it stays there. Scott et al., for example, reported a rate of continued growth of the physis of 12% (143). In the distal femur, the intercondylar notch intrudes into the posterior aspect of the plate, and the surgeon must be careful not to inadvertently enter the notch by being sensitive to the feel of the tool touching cortical bone. Entering the notch can escape the notice of the operator, because it is not obvious on the anteroposterior view of the image intensifier.

Approximately 50% of the area of the plate should be removed in the pattern shown (Fig. 28-29). This is sufficient to ensure arrest of the physis, and maintains enough bone strength through residual plate and surrounding periosteum and perichondral ring to make postoperative immobilization unnecessary. Tibial epiphysiodesis should be accompanied by arrest of the proximal fibular physis, if the tibial shortening is greater than 2.5 cm (144).

Epiphysiodesis has significant advantages over other approaches, because of its low morbidity and low complication rate, but there are minor disadvantages (115,146). It is a

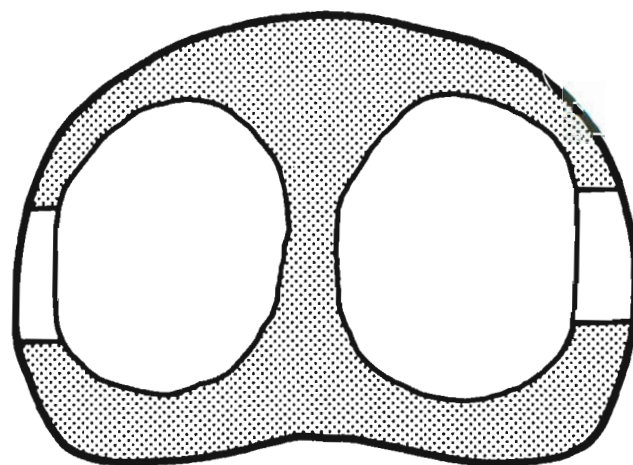


FIGURE 28-29. Area of plate to be removed in epiphysiodesis. Obliteration of medial and lateral circular segments of the plate, leaving the central part and the strong periphery, successfully stops growth, yet the bone retains sufficient strength to forego immobilization.

compensatory, and not a corrective operation, in that it makes the normal leg abnormal. Compared to lengthening, it results in a decrease in the patient's stature that may be undesirable.

Femoral Shortening

Shortening of the femur has the same indications as epiphysiodesis, but is offered to patients who do not meet the prerequisites for epiphysiodesis, either because they are too old or their conditions are such that confident prediction of the discrepancy at maturity cannot be made. It has the advantage over epiphysiodesis that it can be done in the mature patient when the discrepancy is known and unchanging, and the desired degree of correction can be obtained precisely.

Shortening of the tibia also has been performed, but is very rarely done, except in cases in which the femur does not lend itself to shortening. Although shortening of 7.5 cm in the femur and 5 cm in the tibia have been reported with no loss of function (147), it is believed that no more than 3 cm of shortening can safely be achieved in the tibia, and it is unusual to perform shortenings of more than 5 cm in the femur. The risk of neurovascular complications is higher in the tibia, because of the proximity and tethering of neurovascular structures, as is the risk of delayed and nonunion. Fasciotomy is advisable to reduce the risk of compartment syndrome. Internal fixation is more difficult in the tibia: closed techniques cannot be used, because the bone is subcutaneous, and the muscles of the leg are slower to recover strength than those of the thigh.

It is interesting to contemplate the reason for this last

factor. The ability of a muscle to adjust to shortening of the underlying bone rests on its ability to remove sarcomeres from the ends of its fibers, until the average length of the remaining sarcomeres regains the normal, which is relatively constant throughout the body. The lengths of the hamstring and quadriceps muscles, crossing two joints, are approximately twice as long as the soleus, but more importantly, there is an even greater difference in the lengths of the fibers within those muscles. The soleus muscle, requiring high strength and short excursion, has a high number of short fibers oriented obliquely, whereas the hamstrings, requiring excursion more than strength, have a smaller number of longer fibers oriented longitudinally. The fiber lengths in any one muscle are relatively equal, and the fiber length in the hamstrings is much longer than the 4-cm length of fibers in the soleus muscle (148). It is not difficult to imagine that a shortening of the tibia of more than 3 cm might completely overwhelm the ability of the fibers of the soleus muscle to accommodate.

The early techniques of shortening involved making step cuts or other complex cuts in the diaphysis of the bone, using interfragmentary screws or intramedullary rods for fixation (149). These techniques are of historical interest only because better techniques with more secure fixation are now available (150). The two principal techniques in use today are proximal shortening with blade plate fixation, and middiaphyseal shortening, open or closed, with intramedullary rod fixation. Both approaches provide secure fixation, and neither requires postoperative immobilization.

Proximal Shortening

Shortening through the proximal femur at the level of the lesser trochanter with blade plate fixation has the advantage of being proximal to most of the quadriceps origin, and therefore does not disadvantage the knee to the same extent as shortening in the midshaft. Patients recover strength and the ability to climb stairs more quickly. This approach leaves a large scar on the lateral thigh, and requires a second later operation of moderate magnitude, to remove the plate.

Closed Femoral Shortening

Winquist and colleagues have pioneered a technique that involves the use of a special set of instruments designed to allow the procedure to be performed entirely from within the medullary cavity [➔4.10] and without any direct approach to the shaft of the femur (151,152). The bone is cut by a special eccentric cam saw, which is passed down the shaft and cuts through the cortex from within. The size of the saw required is determined from the outside diameter of the bone, and the femoral shaft is first reamed to an internal diameter sufficiently large to accept it. The distal cut is made first, and a second cut then is made more proximally, at precisely the correct location to give

the desired amount of correction. The cuts should be placed so that the cylindrical fragment is removed from the isthmus of the femur, where the internal diameter is least, because this provides the best fixation to the rod both proximally and distally. The cylindrical piece of bone can be cut into two sections, using a special hook-shaped reverse-cutting osteotome, and the pieces are pushed aside. The gap can then be closed over an intramedullary rod to provide rigid internal fixation. Locking at both ends maintains shortening and rotation. A second operation is later required to remove the rod.

The technical complications of this procedure usually result from less-than-rigid fixation of the fragments, usually due to inadequate reaming without locking. It is apparent, in using an unlocked nail, that if a 5-cm segment of bone is to be removed and 2.5 cm of fixation is desired both proximally and distally, then the bone has to be reamed until 10 cm of the shaft is reamed to the minimum diameter. This in itself can be a problem, because the cortex can become very thin at the level of the osteotomies, especially because the reaming is usually eccentric, and can lead to fracture of the shaft. Less than rigid fixation can lead to loss of rotational control and opening of the shortening gap, two problems that are difficult to control without locking. Less reaming is necessary for a locked nail, but in that case, the reduced internal diameter of the canal may not allow passage of a cam saw large enough to cut completely through the cortex, and a percutaneous osteotomy may be required to complete the cut. Nevertheless, the benefits of control of position with the locked nail far outweigh this disadvantage, and locking is desirable.

Acute respiratory distress syndrome has been reported during or following closed intramedullary shortening, and has been believed to be the result of fat embolization caused by reaming (153). Possible preventative measures include venting of the distal metaphysis and use of reamers with flutes sufficiently deep to allow the unimpeded egress of reamed material, but the effectiveness of these measures has not been demonstrated. It may be wise not to use this technique until this serious complication can be avoided with certainty.

Although this is an appealing technique, it requires familiarity with the instruments, is technically demanding, and has best results in experienced hands. The major disadvantages are the technical complications and risk of respiratory distress syndrome, as noted above, and the significant quadriceps weakness that results. Patients with greater shortening require 6 to 12 months to regain normal knee control and function (154). It leaves a small cosmetically acceptable scar, and the later procedure to remove the rod is of lesser magnitude than that required to remove a blade plate.

Growth Stimulation

A technique is desired to stimulate the growth of the short leg, so that children discovered early to have growth inhibi-

tion could have their growth stimulated to normal. Many techniques have been used in attempts to accomplish this, but none has been successful enough to be clinically useful. Based on the concept that the periosteum acts as a tether inhibiting growth, circumferential release of the periosteum has been assessed both clinically and experimentally, and found to stimulate growth (155,156). A variety of foreign materials have been implanted next to the growth plate (157), but the stimulation, if it occurred, was too little and too short-lived to be of use. Sympathectomy (158,159) and surgically constructed arteriovenous fistulae (160,161) temporarily stimulate growth, presumably by altering the circulation to the physis, as does stripping and lifting the periosteum by packing bone beneath it (58,59,162). However, these techniques have little or no clinical usefulness. Electrical stimulation inconsistently stimulates physal growth, but even the maximum effect is insufficient to correct clinical discrepancies (63).

As desirable as this approach might appear, there is no method of growth stimulation available at this time that is useful in the treatment of leg length discrepancy.

Leg Lengthening

Lengthening an abnormally short leg would, at first glance, appear to be the preferable method of dealing with leg length discrepancy, because it is a corrective procedure. It involves operating on the abnormal leg to correct its abnormality, as opposed to epiphyseodesis and shortening, which make the normal leg abnormal and only compensate for the discrepancy.

Lengthening was first mentioned in the 18th century, in an account of injuries sustained in battle by Ignatius of Loyola. It was next reported by Codivilla at the beginning of the twentieth century (163). A number of advances have been made involving changes in surgical technique or the lengthening apparatus, or both, and each change has been greeted with hopes that it would solve the problems associated with lengthening (164).

Lengthening is a procedure of last resort, and is reserved for those situations in which other methods of correction are inappropriate. Lengthening is usually not appropriate for patients requiring correction of less than 6 cm, because procedures of lesser risk and morbidity can be used. A reasonable goal of lengthening for most patients is less than 10 cm for the femur and 7 cm for the tibia. Patients requiring large corrections may require simultaneous lengthenings of femur and tibia, repeated staged lengthenings of the same bone (165), or supplementary shortening procedures on the long side. There is a threshold, at about 15 to 20 cm, where the risks outweigh the benefits, and lengthening is abandoned in favor of amputation and prosthetic fitting.

Since Codivilla's report there have been many tech-

niques described for lengthening the leg. These have included step cuts (166), periosteal sleeves (167), onlay cortical grafts (168), slotted plates (169), intramedullary rods (170), and other internal and external devices for gradual controlled lengthening (171–174). Transiliac lengthening has been performed (175), and may be indicated in cases of infrapelvic asymmetry and decompensated scoliosis cases requiring concurrent hip stabilization (176,177). Techniques of instantaneous lengthening of the femur (114,150,178,179) and tibia (180) have been reported, but have not gained widespread support, because the amount of length to be gained is limited. Simultaneous shortening of one femur, and lengthening of the other with the excised bone segment from the other side, has been recommended (181,182). The Anderson device, using large pins and an external fixator with threaded rods for lengthening, became widely used, but confined the patient to bed (Fig. 28-30). Some of the older methods persist in nonindustrialized nations, as, for example, double oblique osteotomy followed by elongation by balanced skeletal traction (183). Many of these methods became obsolete with the introduction of the Wagner device and, later, the Ilizarov and Orthofix devices.

Historically, new lengthening technology has been adopted enthusiastically by the orthopaedic community, and has been used extensively with great optimism. However, the complication rate has remained high and the patient's course difficult, leading to the realization that the human leg has not made similar advances, and lengthening is still a difficult matter for both surgeon and patient.

The surgeon should prepare for an intensive period of education and attention for 2 weeks after the application of the lengthening device, either in or out of the hospital. This allows time for the initial delay, and for the patient and parents to understand and become comfortable with the lengthening mechanism, pin site care, and an exercise program to maintain mobility and attain ambulation with weight bearing. Patients undergoing lengthening as inpatients should be examined daily with respect to blood pressure, neurologic status, and range of motion. The reading from the scale of the lengthener should be recorded daily and checked to be sure that the lengthening is going according to plan. These assessments also should be made at weekly or biweekly visits after discharge. Radiographs are taken at intervals of 2 to 4 weeks to evaluate alignment and the quality of bone in the lengthening gap (i.e., the regenerate). Ultrasonography can be used instead of radiographs to measure the lengthening gap (184,185). The rate of distraction can be modified according to clinical progress or radiologic appearance.

Maintaining motion is extremely important during lengthening. Patients and parents should be instructed in a home exercise program, and range of motion monitored regularly. Stopping the lengthening should be considered,




FIGURE 28-30. The Anderson lengthening device was commonly used, until it was superseded by the Wagner device, then by the Ilizarov and Orthofix devices. It accomplished stable fixation and gradual lengthening, but was not appropriate for application to the femur, and confined the patient to bed.

if limitation of motion develops that is resistant to a more intensive motion program. Wagner recommended that distraction should not be performed on any given day if the patient cannot achieve 60 degrees of flexion (186). The author's personal guidelines are to discontinue lengthening of the femur in the face of a knee flexion contracture greater than 10 degrees, or knee flexion less than 30 degrees. Lengthening can be started again, if those guidelines are later met, before consolidation of the regenerate prevents it. There is evidence in the literature that all patients regain flexion in the first year after lengthening (187), and it appears that maintaining extension is more important. Patients are allowed to ambulate full weight bearing, with aids if necessary. The pin sites are cleaned twice daily, and, if necessary, the stab wounds are elongated weekly under local anesthesia, to prevent tenting and ischemia of the skin, which could lead to pin tract infection. Cutting pins and small wires circumvent the need to release pin sites.

Distraction is discontinued, either when the goal has been achieved or an unresolvable complication (usually loss of motion) supervenes. The device is retained until radiographs show consolidation and suggest adequate strength of the regenerate bone. In the consolidation period, dynamization of the device is considered important, to subject the bone to cyclic longitudinal loading to stimulate bone formation. If the bone in the lengthening gap is slow to consoli-

date, the device can be shortened to put the bone under longitudinal compression, either leaving it somewhat shortened, or lengthening once again, when the regenerate responds. Valid objective guidelines for what constitutes adequate consolidation for removal of the lengthening device have not been established. Findings such as corticalization, with three cortices visible on two radiographs and the appearance of a medullary cavity, are considered to be signs of adequate strength, but the decision to remove the device is still empiric.

It is possible to protect the tibia externally with a cast or brace after device removal, allowing removal from the tibia earlier than the femur. In addition, the mechanical and anatomic axes of the tibia are collinear, and the bone is subject mainly to compressive forces. This is not the case for the femur, in which the regenerate bone, especially for proximal lengthenings, is eccentric and subject to bending loads. Patients should be restricted from violent body-contact sports for a long time, and perhaps until the bone is radiologically normal, because fractures through the lengthening gap have been reported years later.

Wagner Technique

Wagner developed a lengthening device that was first used in North America in 1973 (Fig. 28-31), and appeared to




FIGURE 28-31. The Wagner device can be adjusted in two planes, but not in rotation. It allows correction of angulation that develops during lengthening, but does not allow simultaneous lengthening and gradual correction of angular deformity.

offer several advantages over older devices, such as the Anderson device (51,186,188–190) (Fig. 28-30). It is unilateral, and uses half-pins instead of through-and-through pins, thereby facilitating application to the femur. It is small and light, and was the first device to allow the patient to be ambulatory, whereas older devices required confinement to bed. The patient can do the lengthening simply by turning a knob at one end. It is adjustable in varus–valgus and anteroposterior angulation, but not rotation (Fig. 28-31), so that minor angulation that occurs during lengthening can be corrected without removing the pins.

The Wagner technique involves at least three surgical procedures. The first involves performing an osteotomy, releasing soft tissues, if necessary, and applying the device. At the end of the lengthening phase, a second procedure involves bone-grafting the lengthening gap, plating the bone, and removal of the lengthener. Months or years later, when the bone has achieved sufficient strength, a third procedure is done to remove the plate. There is a prolonged period of restriction of activities to protect the bone and avoid late fracture.

Although the Wagner device retains its simplicity and utility, it has become clear that it is ill-advised to plate the bone in the face of contaminated pin tracts. For that reason, the technique mostly has been replaced by newer methods that involve neither plating nor grafting, and appear to reduce the complication rate. The device, however, remains simple and satisfactory, and can be used with the newer biologic principles.

Orthofix Technique

De Bastiani and colleagues have developed a lengthening device, the Orthofix device (Fig. 28-32), which is applied to the bone with two sets of conical screws (191,192). It has evolved into a lengthener in which pin blocks move along a rail placed beside the pins (Fig. 28-32). This allows the pin sets to start close together and provides long excursion [4.15, 6.10]. It allows the use of up to three screws in each set, which is an advantage, especially in the proximal femur. It is technically similar in operation to the Wagner device, but, although it offers more stable fixation to bone, it has a more cumbersome method of elongation, and is not easily adjustable once in place. Good results have been reported with this method with a complication rate similar to other techniques (193).

Distraction Epiphysiolysis

Distraction epiphysiolysis was pioneered by Ring, and more recently reassessed by Monticelli and Spinelli and others (194–200). It is achieved by applying a distraction force across the physis until it fractures. Lengthening can then be obtained by gradual distraction. This method has the disadvantages that the lysis is sudden, painful, and not well tolerated, and that the physis can be injured, thus compounding the leg length inequality (201,202). The complication rate is high (203) and, if it is to be used at all, it should be reserved for children very near the end of growth, to minimize the consequences of physal damage.




FIGURE 28-32. The Orthofix track lengthening device places the lengthening mechanism beside the pins instead of between them, thereby increasing the excursion and obviating device exchange during lengthening. Like the standard device, it is not adjustable once the pins are in place.

Ilizarov Technique

Ring fixators have been developed (198,200,204–207) (Fig. 28-33 and Fig. 28-35) [4.16, 6.9]. They are more complex than the Wagner and Orthofix devices, but are also more versatile, in that they lend themselves to the correction of complex deformities. They can control more than two segments (209), can extend across joints, and can be used to translate segments of bone in the treatment of congenital pseudoarthrosis and acquired absences (204). Fixation is accomplished by tensioned through-and-through wires attached to complete or partial rings. Unwillingness to use through-and-through wires in the proximal femur has led to the development of half-pins, which are now gaining favor at all levels.

Lengthening over an Intramedullary Rod

In the traditional application of any of the external lengthening devices, the device is responsible for both maintaining

alignment and achieving distraction. Numerous unsightly scars result, because of the multiple percutaneous pins or wires used to achieve sufficient stability, and the fact that they must be left in place for a prolonged period until the bone is strong. It is possible to use an intramedullary rod to maintain alignment during both the distraction and consolidation phases, and the external device only to achieve length (210). In this way, the number of percutaneous tracts can be reduced, the external device can be removed at the conclusion of lengthening, and the complication rate may be reduced (211). Lin et al. reported 2 of 15 cases that required bone grafting (212), so the effect of rodding on osteogenesis remains unclear.

Lengthening over the rod has the disadvantage, compared with other lengthening techniques, that alignment of the anatomic axis of the femur cannot be changed, and that the mechanical axis of the leg cannot be changed. Because the anatomic axes of the femur and tibia are not collinear, elongation in this manner increases valgus of the mechanical axis of the leg. Whether or not this is a problem depends on the initial configuration of the leg. The correction, if necessary, of preexisting angular deformity, or the valgus produced by the lengthening, must be performed at another time, when the rod is no longer in place.

There has been reasonable hesitation in using this ap-

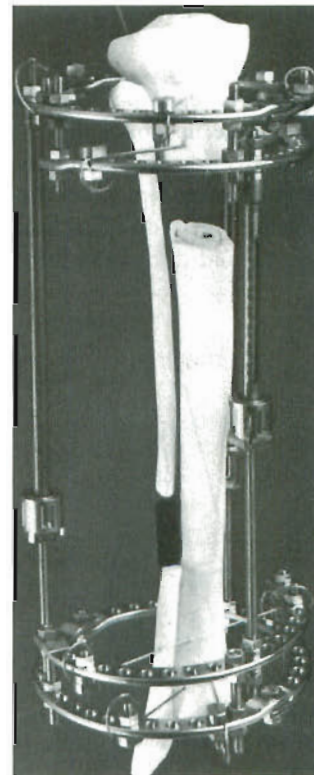


FIGURE 28-33. Ilizarov lengthening device. External fixation is accomplished by tensioned wires fixed to circumferential rings. (From ref. 208, with permission.)

proach, because of the fear of producing a serious intramedullary infection with the intramedullary foreign material in continuity with the exterior through the pin tracts. Although early experience suggests that with care the external device need not contact the rod, and that the risk of intramedullary infection is not as great as feared, widespread use of this technique awaits more definitive reports concerning this and other risks. Fully implantable devices would appear to be the solution, and have been used on a trial basis (213), but reports are preliminary.

The application of this technique is limited to those femurs that are straight enough to accept the rod, and, in the case of the femur, children who are old enough not to be at risk for avascular necrosis of the femoral head.

Wu et al. performed acute lengthenings over a locking rod, but achieved a mean lengthening of only 2.8 cm (214).

Biologic Factors

Several groups have been working in parallel over the past three decades to develop not only improved devices, but also improved concepts and methods of lengthening. In particular, Ilizarov and De Bastiani have contributed new concepts and a new understanding of the biology of lengthening that are more important contributions than the devices themselves (191,192,204–206). Because the biologic principles are not device-specific, they are considered in principle. Then, with that foundation, technologic issues are considered.

Minimal Disturbance of the Bone. Ilizarov recommended corticotomy, a technique in which the cortex is cut, but care is taken not to disturb the medullary contents (Fig. 28-34). He felt it important to preserve the intramedullary blood supply of the bone. It is difficult, however, even with careful technique, to avoid disturbing intramedullary con-

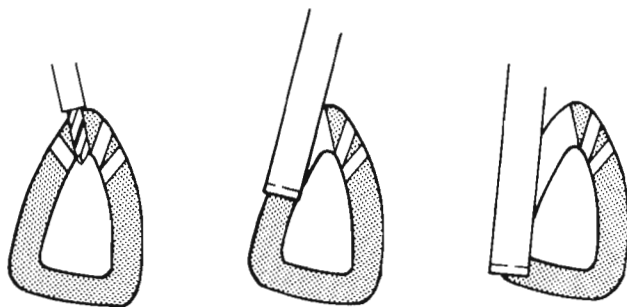


FIGURE 28-34. In the corticotomy technique, care is taken to preserve the contents of the medullary cavity of the bone, so that they may make their greatest contribution to osteogenesis during lengthening. Drill holes of controlled depth are made through the anterior cortex; the lateral cortices are cut with a narrow osteotome to avoid entering the medullary cavity; and the posterior cortex is cracked by bending.

tents, and it has been demonstrated that the intramedullary circulation reconstitutes very quickly, even if interrupted (215). The current consensus is that it is not necessary to perform a corticotomy, but care not to burn the bone with a saw, and care and preservation of the periosteum, are very important.

In contrast to the principle of minimal bone disturbance, massive bone production in the lengthening gap, following peripheral decortication near the osteotomy, has been reported (216).

Location of Lengthening. Whenever appropriate, the lengthening is done in the metaphysis, where the bone is more active, and there are greater numbers of active osteoblasts to participate in the process of regeneration (217) (Fig. 28-35). A second benefit of this location is purely mechanical, and is based on the principle that the strength of a structure in bending varies with the fourth power of its diameter. Because the diameter of the metaphysis is so much greater than that of the diaphysis, the bone is stronger at any stage of healing. This allows earlier removal of the fixator, with decreased risk of fracture when subjected to bending loads.

Number of Lengthening Sites. Devices that lend themselves to fixation of more than two segments of the same bone make it possible to lengthen a single bone both proximally and distally at the same time. Although, theoretically, this doubles the rate of bone elongation, the soft tissues do not easily double their elongation rate, and articular cartilage has been shown experimentally in animals to suffer with rapid elongation (218).

Delay before Distraction. It appears beneficial to delay the onset of distraction after the bone-sectioning procedure, in order to allow the osteogenic process to become established. Osteogenesis can then keep up with the elongating gap. Delays of several days for young children, 1 week for adolescents, and 10 days for adults appear appropriate, without risking premature consolidation that would prevent distraction.

Rate of Distraction. Ilizarov and Deviatov (204) recommend a distraction rate of 1 mm/day, which is slower than the 1.5 mm/day used in the Wagner technique. The rationale is that the separation of the bone ends should proceed in advance of the ability of the regenerating bone in the gap to effect union, and that a rate that is too fast will inhibit bone formation. The rate may have to be slowed, if radiographs show inadequate regeneration and a widening lucency in the regenerating bone. Faster rates induce ischemia and significant slowing of osteogenesis, but some patients, who show excellent regeneration radiologically, can have their distraction rate increased. The rate of 1 mm/day also appears to be appropriate for the soft tissues to grow in length in tandem with the bone (219).

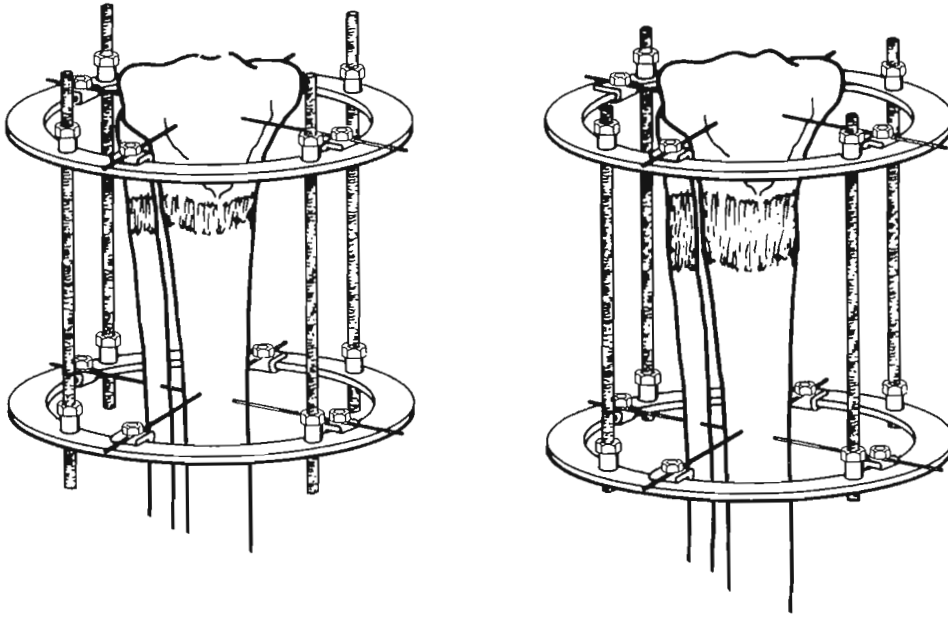


FIGURE 28-35. Metaphyseal lengthening. Elongation through the metaphysis promotes osteogenesis in the lengthening gap because metaphyseal bone is so active, and it promotes strength by the large cross-sectional area.

Rhythm of Distraction. Increasing the frequency of lengthenings, without changing the rate, promotes faster consolidation experimentally, and reduces the tension stress on the regenerating bone. Lengthening by 0.25 mm, four times per day, is better than lengthening by 1 mm, one time per day, and it appears that gradual continuous elongation, perhaps by a motorized device as suggested by Ilizarov, is ideal.

Quality of Regenerate Bone. Osteogenesis in the gap begins first in the medulla, and expands to fill the gap. Multipotential cells become osteoblasts and form bone without a cartilage foundation in a fashion reminiscent of membranous bone formation. Microscopic examination of the regenerating bone, elongated according to modern concepts, shows that it has a longitudinal orientation, probably because its formation is guided so intimately by the architecture of the osteotomy surface (220). The architecture of the regenerate resembles haversian bone, and is said to be stronger than woven bone, and to remodel and calcify faster.

Thin Wires. The ring fixators allow the use of thin (1–2 mm) wires instead of large screws. The wires cause less reaction of surrounding skin and bone, move through the skin more easily, and allow some axial dynamization of the bone fragments.

Amount of Lengthening. It is not known if there is an upper limit to lengthening. Reports on the new techniques

suggest that greater lengthening may be possible than was formerly thought. Carroll et al. have shown that permanent changes occur in muscle and joint cartilage with tibial lengthening greater than 11% (221), and Bell has shown effects on the adjacent joints in animal experiments (218). These effects may be related more to the rate than the magnitude of lengthening, and the degree to which they occur in human patients is uncertain.

Activity Level. Patients can be encouraged to be active and fully weight-bearing from the start, and participate in vigorous calisthenics and physical therapy to maintain normal joint motion and muscle strength. Weight-bearing takes advantage of the flexibility of the devices to apply dynamic compression to the regenerating bone that is believed to stimulate bone formation.

Dynamization. Cyclic loading of the regenerate is thought to promote osteogenesis. The ring fixators have the advantage of allowing dynamic loading of the lengthening gap throughout the period of fixation, while simultaneously controlling length. Their construct of thin wires and circumferential rings provides rigidity against bending in the sagittal and coronal planes, but is not so rigid in the axial direction, allowing slight axial movement in response to applied loads. The Orthofix device can be dynamized by applying an elastic buttress, and when the regenerate bone appears strong enough to resist shortening, the buttress can be removed. The device then maintains alignment, but not length, thus allowing dynamization. The Wagner device

cannot be dynamized, but can be put into compression mode when the regenerate bone is strong enough. All of the devices allow some dynamization by virtue of their elasticity, and can be made less rigid by the removal of wires or pins in a staged fashion.

Lengthening Index. This quantity is the number of months of external fixation required per centimeter of lengthening. It is generally between 1 and 1.5 months per centimeter, and tends to be greater for lesser lengthenings, because one component of this time, the interval from the arrest of elongation to the removal, tends to be constant. This number is a very rough guideline to predict the duration of fixation for patients about to undergo lengthening, but is of little clinical importance (222).

Factors Affecting the Choice of Lengthening Hardware

The biologic factors discussed above are, for the most part, device-independent. The choice of lengthening device is not, however, completely arbitrary. The devices have certain characteristics that affect their ease of use in specific situations. Because deformity correction often goes hand in hand with lengthening, this discussion includes some aspects of device selection and use in the correction of angular deformity.

Gradual versus Acute Correction. Not all deformities need to be corrected gradually. There is a long and successful history of acute correction of deformity by osteotomy, with internal or external fixation or no fixation at all. Although there may be advantages in the use of external fixation, in some cases, there appears to be no advantage to correcting these deformities gradually, as Ilizarov et al. have proposed (220,221).

The question then arises as to the possible advantages or disadvantages of gradual correction, if an external fixator is in place in any case to accomplish lengthening. There is good evidence to suggest that, if an external device is already in place for lengthening, either gradual or acute correction of coexisting deformity can achieve good results (223). Acute correction has the effect of simplifying the lengthening and widens the selection of devices, whereas gradual correction with the Ilizarov or other ring fixator allows the physician to monitor and modify the correction on an ongoing basis.

If the surgeon wishes to perform a gradual deformity correction, then the Ilizarov device or another ring fixator, or the Orthofix device with the Garches clamp, can be used. Using the Ilizarov apparatus to perform gradual angular correction, with or without lengthening, requires attention to the geometric principles of hinge placement, as described by Herzenberg (222). Careful hinge placement can control both translation and angular correction. Placing hinges so

that the axis of rotation is outside the bone can accomplish lengthening and angular correction simultaneously.

Thin Wires versus Half-pins. The Wagner and Orthofix devices require thick half-pins, whereas the Ilizarov device can be used with either thin wires or half-pins. Thin wires appear to pass through the skin more easily, but leave twice as many unsightly scars in the skin, and tether the muscles in twice as many locations, thereby interfering with joint motion (217). Loosening of a wire does not result in a loss of position, as with a screw, because the bone is prevented from sliding on the wire by other oblique wires at the same level.

On the other hand, thin wires have a number of disadvantages. They do not lend themselves to fixation of the proximal femur, and most prefer half pins and partial rings at that level. There is a growing trend to the use of half pins at other levels as well. Wires must be tensioned to close to their elastic limit, and it does not take much additional force to stretch the wires plastically, which compromises the rigidity of the frame.

Conical Screws. The Orthofix device uses 6-mm pins that taper slightly toward the tip. If they loosen, they can be tightened by advancing them slightly. Conversely, if they are inserted too far, they cannot be retracted without loosening. Screws are also manufactured with cutting edges on one side of the shaft, which, when oriented in the proper direction, facilitate passage through the skin.

Excursion. The standard Orthofix lengthener is limited in its excursion. The short model, for example, has an excursion of only 5 cm, meaning that it will have to be replaced with a longer model, if further lengthening is to be attained. The Orthofix rail lengthener is available in several lengths, and can accommodate any desired excursion. The Wagner device has excursion of more than 15 cm, and can accomplish all but the longest lengthenings. The Ilizarov device has the advantage that its external components can be replaced without general anesthesia, and therefore virtually any amount of lengthening or angular correction can be accomplished.

Ease of Replacement of Pins and Wires. Because the Ilizarov device allows pins and wires to be placed at almost any level and angle, there is no problem in removing troublesome wires and inserting new ones. The monolateral fixators, on the other hand, are more limited in that the pin clamps have predesignated locations, and all pins in one cluster are in the same plane. Replacement of one pin may require replacement of all pins of that cluster.

Ability to Place Pin Clusters Close Together. The Ilizarov apparatus and the Wagner device allow the pin clusters in the proximal and distal segments to be placed as close to-

gether as desired. The original Orthofix lengthening device had the body between the pin clamps, so that the pin clusters had to be placed far enough apart to accommodate the length of the device. This is a disadvantage in a short bone, or if other factors govern pin placement. The Orthofix rail lengthener does allow the pin clamps to be placed close to each other.

Number of Pins in Each Segment. The Wagner device permits two pins in each clamp, the Orthofix allows three pins, and the Ilizarov device sets no limits on the number of pins or wires. There may be an advantage to using more than two pins to fix the proximal femur, especially if the lengthening is through the proximal part of the shaft, and the pins must be placed proximally. In that configuration, the loading is eccentric, and three pins provide better fixation with less risk of loosening.

Total Number of Pins and Wires. The Ilizarov apparatus usually requires at least three wires in each segment for a simple lengthening, a total of 12 scars in the skin. The monolateral fixators usually can be applied with only two screws in each segment, producing fewer than half the number of scars, and reducing the operative time for the application.

Ability to Fix More Than One Segment. The Wagner device only allows fixation of two segments, and is incapable of transporting intermediate segments of bone, in cases of bone loss or congenital pseudarthrosis. It is also incapable of traversing joints. The Orthofix rail lengthener can be assembled to fix more than two segments, and, with special clamps and hinges, can traverse joints. The Ilizarov device can easily be extended to provide fixation of as many segments as required, and can be extended across joints, with or without hinges.

Complex Deformities with Multiple Axes of Correction. Only the ring fixators can accomplish gradual correction of deformities in more than one plane. Not only can multiple segments be controlled and multiple hinges incorporated, but the system can be modified, as correction progresses to meet emerging demands.

Ability to Adjust Device while in Place. The Wagner device can be adjusted in two planes, but requires a general anesthetic to do so. With this device, there is a tendency for femoral lengthenings to go into varus, and tibial lengthenings to go into valgus. It is therefore recommended to begin lengthening with the femur in 10 to 15 degrees of valgus or the tibia in 10 to 15 degrees of varus. The Orthofix rail device is adjustable, under general anesthetic and with special pin clamps, only in the plane of the pins. The Ilizarov method is well suited for continual modification of its configuration by differential lengthening of the individual rods.

In addition, its components can be changed and the hinges realigned repeatedly, if required. This can be done without a return to the operating room for anesthesia.

Ease of Adjusting the Lengthening Mechanism. This is of no concern while patients are hospitalized under the care of trained personnel, but it becomes an issue when they are discharged home. A simple mechanism results in less anxiety and fewer errors. The Wagner mechanism is the simplest, requiring only the turn of a single knob. The Orthofix devices require use of a special extender that is advanced with a wrench. The Ilizarov device requires elongation of up to three or four rods individually, perhaps by different amounts.

Conclusion

Simple lengthenings can be accomplished by a number of devices, none of which has a clear advantage over another, except that it might be argued that the simplest device capable of solving the problem is advantageous. Gradual correction of complex deformities may present demands that can only be met by a more versatile device, such as the Ilizarov device.

Complications of Lengthening

All studies of leg lengthening, regardless of technique, have reported high complication rates (160,222,225–233). Most studies report more complications than there are patients, and many patients do not reach their anticipated lengthening goals with uncompromised function. The complication rate, however, is related to the amount of lengthening, and if the goal is modest, the rate is reduced and the proportion of patients reaching their preoperative goals is increased (234). Ghoneem et al. found that all children who had undergone lengthening had a normal psychologic score, 92% had no limitations in daily activities, and 81% were satisfied with the over-all result (116).

Deformity due to soft tissue tension can occur during lengthening, and angular deformity of the tibia has been related to the degree of elongation (235). The Ilizarov technique has been proposed to supplant amputation and prosthetic fitting in fibular hemimelia, but uncontrollable deformity of the tibia and ankle joint has been encountered (236). Ultimate alignment may be improved by using arthrography to delineate the joint surfaces when applying the lengthening device (237).

Hypertension may be seen during lengthening, and may occur suddenly (238–240). The mechanism is not clear, but it resolves dependably, with shortening of the lengthening gap, and may not recur when lengthening is resumed.

Pin tract inflammation is common and of little consequence, in its own right. True pin tract infection usually responds well to local care and systemic antibiotics. It may,

however, be elevated to a serious complication by plating and grafting, as in the Wagner procedure, and that is the main reason this is no longer commonly done.

Mechanical failure can occur in several modes. Pins can break or loosen, and require replacement. Fractures through the lengthening gap or deformation of the bone in the lengthening gap may occur early or late. It may occur soon after removal of the device, indicating that it was removed too soon, or may occur late, while the bone is still remodeling, and has not yet regained its normal strength (240). In the author's series of Wagner lengthenings, there was one fracture 8 years after the lengthening, which suggests that the bone is extremely slow to remodel and regain full strength, and is probably weak, even after it looks normal radiologically. Long-term follow-up is important in assessing the results of leg lengthening, because complications can occur late.

Nakamura and colleagues have examined the diameter of the bone in the lengthening gap, and concluded that axial loading, while the device is in place, may not be enough to increase the diameter, but that the diameter increases dependably after removal of the device (242). This finding has profound implications for the strength of the bone, since strength in bending varies as the fourth power of the diameter. Indeed, there is a report substantiating this conclusion (243).

Subluxation of the knee may occur during femoral lengthening, especially in patients with congenital shortening (244,245). The subluxation appears to be a posterior subluxation of the lateral tibial plateau, and is always preceded by a loss of extension of the knee. Dysplasia, or absence of the anterior cruciate ligament, and hypoplasia of the lateral femoral condyle are usually found in association with congenitally short femurs (246,247), and contribute to this complication. Routine lengthening of the lateral structures, the biceps tendon and iliotibial band, determined maintenance of knee extension, and avoidance of continued distraction in the face of a knee flexion contracture will avoid knee subluxation.

Dislocation of the hip has been reported, may occur even in the early stages of distraction, and tends to be associated with previous hip surgery and residual instability (248).

Delayed union is difficult to define in this context, but there is no doubt that certain cases take significantly longer to consolidate than others. True nonunion occurs, and is similar in appearance and treatment to posttraumatic nonunion, except that it can occur in narrowed and spindle-shaped bone, so that it is fragile even when united.

It appears that the complication rate is affected by the quality of the underlying bone, but inconsistently so. For example, Naudie et al. showed that the complication rate is higher in patients with an underlying bone disorder (249), but patients with achondroplasia seem to have a lower complication rate. Reasonable lengthening expectations in femoral hypoplasia are unclear (250).

Nerve or artery damage from stretching, entrapment by

tense tissues, movement of wires or pins through the tissues, or direct trauma may occur (251). Nerve conduction is affected in one-third or more of patients undergoing lengthening (252).

Karger and colleagues found that femoral lengthenings were more prone to complications than tibias, and that the complication rate increased with lengthenings, exceeding 25% of the initial bone length (253). The author found that the complication rate is significantly higher in children younger than age 8 years, than in older children, and this may reflect the inability of younger children to understand instructions and remain motivated to comply with those of therapists and surgeons (245). Conversely, Noonan found that the complication rate in both femoral and tibial length-

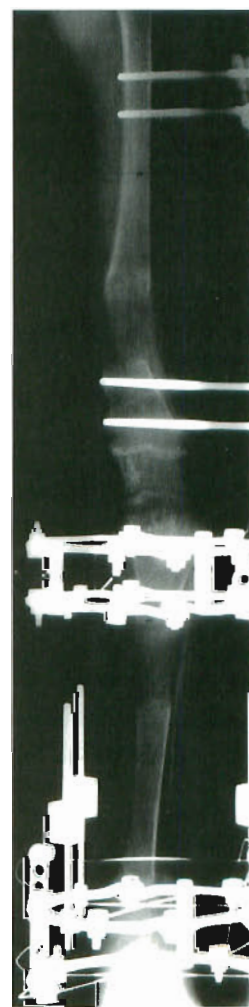


FIGURE 28-36. The course of Ilizarov and Orthofix lengthening. This patient had complex deformities resulting from meningococemia. The femur was managed by an acute correction of the distal femoral varus deformity and subsequent lengthening, using the Orthofix rail lengthener. The distal pins were placed carefully, before the osteotomy was performed. The tibial deformity required valgus osteotomies both distally and proximally. Because fixation of three fragments was required, the more versatile Ilizarov device was used.

ening increased in patients over 14 years of age (222). To some extent, the amount of possible lengthening depends on the length of the bone to start with, and this is another reason to perform lengthening only in older children, whose bones are nearing mature length.

Lengthening affects the subsequent growth of the limb. Price and Carantzas have reported a case of severe growth retardation in the lengthened limb (254). Viehweger has found that lengthening the tibia more than 14% slows its growth, but that this has a negligible effect on the ultimate clinical result, because it is compensated for by femoral overgrowth.

Because of the frequency of concerns, questions, problems, and complications that surround the care of patients undergoing lengthening, it facilitates their management to form a lengthening team in a program with shared responsibilities. A nurse, physical therapist, social worker, and a skilled technician are important members of the team, and should join the surgeon in preparing patients and families for the lengthening. The team can respond to ongoing needs, and offer support during the lengthening. Families never fully appreciate depth and breadth of the hardship they will face, and will require more support than most orthopaedic patients.

There is reason to believe that the complication rate from lengthening is improving with modern techniques and understanding (255) (Figs. 28-36 and 28-37).

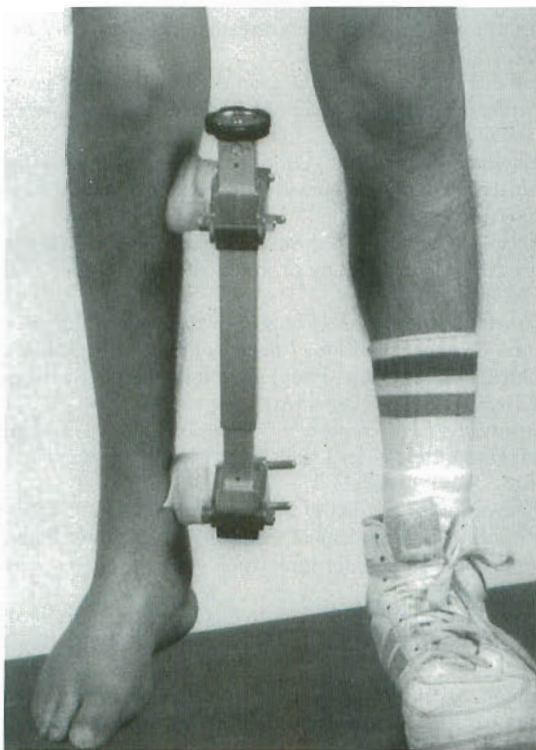


FIGURE 28-37. Patients with the Wagner, Orthofix, and Ilizarov devices can be mobile and undertake partial to full weight-bearing.

CONCLUSION

Excellent care of patients with leg length discrepancy and continuing improvement require comfortable familiarity with the techniques of patient assessment, the methods of prediction of future growth and discrepancy, the factors important in the selection of treatment goals, and the approaches to treatment. Being familiar and up-to-date with respect to the techniques and philosophies of surgical treatment is challenging but the improvement in our capabilities should be an adequate reward.

References

Effects

1. Murrell P, Cornwall M, Doucet S. Leg-length discrepancy: effect on the amplitude of postural sway. *Arch Phys Med Rehabil* 1992;73:401.
2. Mahar R, Kirby R, MacLeod D. Simulated leg-length discrepancy: its effect on mean center-of-pressure position and postural sway. *Arch Phys Med Rehabil* 1985;66:822.
3. Liu X, Fabry G, Molenaers G, et al. Kinematic and kinetic asymmetry in patients with leg-length discrepancy. *J Pediatr Orthop* 1998;18:187.
4. Goel A, Loudon J, Nazare A, et al. Joint moments in minor limb length discrepancy: a pilot study. *Am J Orthop* 1997;26:852.
5. Morscher E. Etiology and pathophysiology of leg length discrepancies. *Prog Orthop Surg* 1977;1:9.
6. Gofton J, Trueman G. Studies in osteoarthritis of the hip. II. Osteoarthritis of the hip and leg length disparity. *Can Med Assoc J* 1971;104:791.
7. Kujala U, Friberg O, Aalto T, et al. Lower limb asymmetry and patellofemoral joint incongruence in the etiology of knee exertion injuries in athletes. *Int J Sports Med* 1987;8:214.
8. Gofton J. Persistent low back pain and leg length disparity. *J Rheumatol* 1985;12:747.
9. Grundy P, Roberts C. Does unequal leg length cause back pain? A case-control study. *Lancet* 1984;2:256.
10. Soukka A, Alaranta H, Tallroth K, et al. Leg-length inequality in people of working age. The association between mild inequality and low-back pain is questionable. *Spine* 1991;16:429.
11. Froh R, Yong-Hing K, Cassidy J, et al. The relationship between leg length discrepancy and lumbar facet orientation. *Spine* 1988;13:325.
12. Gibson P, Papaioannou T, Kenwright J. The influence on the spine of leg-length discrepancy after femoral fracture. *J Bone Joint Surg* 1983;65B:584.
13. Papaioannou T, Stokes I, Kenwright J. Scoliosis associated with limb-length inequality. *J Bone Joint Surg* 1982;64A:59.
14. Scheller M. *Über den Einfluss der Beinverkürzung auf die Wirbelsäule*. Köln: Inaug. Diss, 1964.
15. Taillard W, Morscher E. *Beinlängenunterschiede*. Basel: Karger, 1965.

Growth

16. Anderson M, Green WT. Lengths of the femur and tibia; norms derived from orthoroentgenograms of children from five years of age until epiphyseal closure. *Am J Dis Child* 1948;75:279.
17. Anderson M, Messner M, Green W. Distribution of lengths of

the normal femur and tibia in children from one to eighteen years of age. *J Bone Joint Surg Am* 1964;46:1197.

18. Anderson M, Green W, Messner M. Growth and predictions of growth in the lower extremities. *J Bone Joint Surg Am* 1963;45:1.
19. Green W, Anderson M. Experiences with epiphyseal arrest in correcting discrepancies in length of the lower extremities in infantile paralysis. *J Bone Joint Surg* 1947;29:659.
20. Greulich W, Pyle S. *Radiographic atlas of the skeletal development of the hand and wrist*, 2nd ed. Stanford: Stanford University Press, 1959.
21. Bayley N. Individual patterns of development. *Child Develop* 1956;27:45.
22. Beumer A, Lampe H, Swierstra B, et al. The straight line graph in limb length inequality. A new design based on 182 Dutch children. *Acta Orthop Scand* 1997;68:355.

Etiology

23. Harper M, Canale S. Angulation osteotomy. A trigonometric analysis. *Clin Orthop* 1982;166:173.
24. Sugi M, Cole W. Early plaster treatment for fractures of the femoral shaft in childhood. *J Bone Joint Surg* 1987;69B:743.
25. Shannak A. Tibial fractures in children: follow-up study. *J Pediatr Orthop* 1988;8:306.
26. Beals R, Lovrein E. Diffuse capillary hemangiomas associated with skeletal hypotrophy. *J Pediatr Orthop* 1992;12:401.
27. Dutkowsky J, Kasser J, Kaplan L. Leg length discrepancy associated with vivid cutis marmorata. *J Pediatr Orthop* 1993;13:456.
28. Heuter C. Anatomische studien an den extremitätengelenken neugeborener und erwachsener. *Virchows Arch* 1862;25:572.
29. Volkmann R. Chirurgische erfahrungen über knochenverbiegungen und knochenwachstum. *Arch F Pathol Anat* 1862;24:512.
30. Arkin AM, Katz JF. The effects of pressure on epiphyseal growth. The mechanism of plasticity of growing bone. *J Bone Joint Surg* 1956;38A:1056.
31. Delpech J. *De l'orthomorphie, par rapport à l'espece humaine*. Paris: Gabon, 1829.
32. Beals RK. Hemihypertrophy and hemiatrophy. *Clin Orthop* 1982;166:199.
33. Pappas A, Nehme A. Leg length discrepancy associated with hypertrophy. *Clin Orthop* 1979;144:198.
34. Pappas A. Congenital abnormalities of the femur and related lower extremity malformations: classification and treatment. *J Pediatr Orthop* 1983;3:45.
35. Stanitski D, Kassab S. Rotational deformity in congenital hypoplasia of the femur. *J Pediatr Orthop A* 1997;17:525.
36. Gillespie R, Torode I. Classification and management of congenital abnormalities of the femur. *J Bone Joint Surg* 1983;65B:557.
37. Johansson E, Aparisi T. Missing cruciate ligament in congenital short femur. *J Bone Joint Surg* 1983;65A:1109.
38. Kaelin A, Hulin P, Carliz H. Congenital aplasia of the cruciate ligaments. A report of six cases. *J Bone Joint Surg* 1986;68B:827.
39. Gekeler J, Dietz J, Schuler T. Prognosis of leg length difference in congenital fibula defect. *Z Orthop* 1982;120:729.
40. Westin G, Sakai D, Wood W. Congenital longitudinal deficiency of the fibula: follow-up of treatment by Syme amputation. *J Bone Joint Surg* 1976;58A:492.
41. Kalamchi A, Cowell H, Kim K. Congenital deficiency of the femur. *J Pediatr Orthop* 1985;5:129.
42. Grimes J, Blair V, Gilula L. Roentgen rounds #81. Posteromedial bowing of the tibia. *Orthop Rev* 1986;15:249.
43. Hofmann A, Wenger D. Posteromedial bowing of the tibia. Progression of discrepancy in leg lengths. *J Bone Joint Surg* 1981;63A:384.
44. Pappas A. Congenital posteromedial bowing of the tibia and fibula. *J Pediatr Orthop* 1984;4:525.
45. Askins G, Ger E. Congenital constriction band syndrome. *J Pediatr Orthop* 1988;8:461.
46. Garbarino J, Clancy M, Harcke H, et al. Congenital diastasis of the inferior tibiofibular joint: a review of the literature and report of two cases. *J Pediatr Orthop* 1985;5:225.
47. Salter R, Harris W. Injuries involving the epiphyseal plate. *J Bone Joint Surg* 1963;45A:587.
48. Robert H, Moulies D, Longis B, et al. Traumatic separation of the lower end of the femur. *Rev Chir Orthop* 1988;74:69.
49. Roberts P. Disturbed epiphyseal growth at the knee after osteomyelitis in infancy. *J Bone Joint Surg* 1970;52B:692.
50. Robertson W, Butler M, D'Angio G, et al. Leg length discrepancy following irradiation for childhood tumors. *J Pediatr Orthop* 1991;11:284.
51. Wagner H. Surgical lengthening or shortening of femur and tibia: technique and indications. *Prog Orthop Surg* 1977;1:71.
52. Wagner H. Radiation injuries of the locomotor system. *Langenbecks Arch Chir* 1981;355:181.
53. Shapiro F. Ollier's disease. An assessment of angular deformity, shortening, and pathological fractures in twenty-one patients. *J Bone Joint Surg* 1982;64A:95.
54. Peterson H. Premature physeal arrest of the distal tibia associated with temporary arterial insufficiency. *J Pediatr Orthop* 1993;13:672.
55. Thomas C, Gage J, Ogden J. Treatment concepts for proximal femoral ischemic necrosis complicating congenital hip disease. *J Bone Joint Surg* 1982;64A:817.
56. Shapiro F. Legg-Calve-Perthes disease: a study of lower extremity length discrepancies and skeletal maturation. *Acta Orthop Scand* 1982;53:437.
57. Rosenthal A, Anderson M, Thomson S, et al. Superficial femoral artery catheterization. Effect on extremity length. *Am J Dis Child* 1972;124:240.
58. Jenkins D, Cheng D, Hodgson A. Stimulation of growth by periosteal stripping. A clinical study. *J Bone Joint Surg* 1975;57B:482.
59. Khoury S, Silberman F, Cabrine R. Stimulation of the longitudinal growth of long bones by periosteal stripping. *J Bone Joint Surg* 1963;45A:1679.
60. Sola C, Silberman F, Cabrini R. Stimulation of the longitudinal growth of long bones by periosteal stripping. *J Bone Joint Surg* 1963;45A:1679.
61. Trueta J. Stimulation of bone growth by redistribution of the intra-osseous circulation. *J Bone Joint Surg* 1951;33B:476.
62. Doyle J. Stimulation of bone growth by short-wave diathermy. *J Bone Joint Surg* 1963;45A:15.
63. Armstrong P. Attempts to accelerate longitudinal bone growth. In: Uthoff H, Wiley J, eds. *Behaviour of the growth plate*. New York: Raven, 1988:237.
64. Groves E. Stimulation of bone growth. *J Surg* 1958;95:125.
65. Tupman G. Treatment of inequality of the lower limbs. The results of operations for stimulation of growth. *J Bone Joint Surg* 1960;42B:489.
66. Peixinho M, Arakaki T, Toledo C. Correction of leg inequality in the Klippel-Trenaunay-Weber syndrome. *Int Orthop* 1982;6:45.
67. Simon S, Whiffen J, Shapiro F. Leg-length discrepancies in monoarticular and pauciarticular juvenile rheumatoid arthritis. *J Bone Joint Surg* 1981;63A:209.
68. Vostrejs M, Hollister J. Muscle atrophy and leg length discrepancies in pauciarticular juvenile rheumatoid arthritis. *Am J Dis Child* 1988;142:343.

69. Heim M, Horszowski H, Martinowitz U. Leg length inequality in hemophilia. An interesting case report. *Clin Pediatr* 1985; 24:600.
70. Compere E, Adams C. Studies of the longitudinal growth of long bones: the influence of trauma to the diaphysis. *J Bone Joint Surg* 1937;19:922.
71. Jackson D, Cozen L. Genu valgum as a complication of proximal tibial metaphyseal fractures in children. *J Bone Joint Surg* 1971;53A:1571.
72. Herring J, Moseley C. Posttraumatic valgus deformity of the tibia. *J Pediatr Orthop* 1981;1:435.
73. Rooker G. The effect of division of the periosteum on the rate of longitudinal bone growth: an experimental study in the rabbit. *Orthop Trans* 1980;4:400.
74. Salter R, Best T. Pathogenesis and prevention of valgus deformity following fractures of the proximal metaphyseal region of the tibia in children. *J Bone Joint Surg* 1972;54B:767.
75. Taylor J, Warrell E, Evans R. Response of the growth plates to tibial osteotomy in rats. *J Bone Joint Surg* 1987;69B:664.
76. Taylor S. Tibial overgrowth: a cause of genu valgum. *J Bone Joint Surg* 1963;45A:659.
77. Aitken A, Blackett CW, Ciaccotti JJ. Overgrowth of the femoral shaft following fractures in childhood. *J Bone Joint Surg* 1939; 21:334.
78. Holschneider A, Vogl D, Dietz H. Differences in leg length following femoral shaft fractures in childhood. *Z Kinderchir* 1985;40:341.
79. Parrini L, Paleari M, Biggi F. Growth disturbances following fractures of the femur and tibia in children. *Ital J Orthop Traumatol* 1985;11:139.
80. Lorenzi G, Rossi P, Quaglia F, et al. Growth disturbances following fractures of the femur and tibia in children. *Ital J Orthop Traumatol* 1985;11:133.
81. Kohan L, Cumming W. Femoral shaft fractures in children: the effect of initial shortening on subsequent limb overgrowth. *Aust N Z J Surg* 1982;52:141.
82. Meals R. Overgrowth of the femur following fractures in children: influence of handedness. *J Bone Joint Surg* 1979;61A:381.
92. Helms C, McCarthy S. CT scanograms for measuring leg length discrepancy. *Radiology* 1984;151:802.
93. Glass R, Poznanski A. Leg-length determination with biplanar CT scanograms. *Radiology* 1985;156:833.
94. Altongy J, Harcke H, Bowen J. Measurement of leg length inequalities by micro-dose digital radiographs. *J Pediatr Orthop* 1987;7:311.
95. Huurman W, Jacobsen F, Anderson J, et al. Limb-length discrepancy measured with computerized axial tomographic equipment. *J Bone Joint Surg* 1987;69A:699.
96. O'Connor K, Grady J, Hollander M. CT scanography for limb length determination. *Clin Podiatr Med Surg* 1988;5:267.
97. Temme J, Chu W, Anderson J. CT scanograms compared with conventional orthoroentgenograms in long bone measurement. *Skeletal Radiol* 1987;16:442.
98. Acheson RM. The Oxford method of assessing skeletal maturity. *Clin Orthop* 1957;10:19.
99. Todd T. *Atlas of skeletal maturation*. St. Louis: CV Mosby, 1937.
100. Carpenter C, Lester E. Skeletal age determination in young children: analysis of three regions of the hand/wrist film. *J Pediatr Orthop* 1993;13:76.
101. Tanner J, Whitehouse R, Marshall W, et al. *Assessment of skeletal maturity and prediction of adult height (TW2 method)*. London: Academic, 1975.

Data Analysis

Patient Assessment

83. Winter R, Pinto W. Pelvic obliquity. Its causes and its treatment. *Spine* 1986;11:225.
84. Ireland J, Kessel L. Hip adduction/abduction deformity and apparent leg-length inequality. *Clin Orthop* 1980;153:156.
85. Lee D, Choi I, Chung C, et al. Fixed pelvic obliquity after poliomyelitis: classification and management. *J Bone Joint Surg* 1997;79B:190.
86. Cuervo M, Albinana J, Cebrian J, et al. Congenital hypoplasia of the fibula: clinical manifestations. *J Pediatr Orthop B* 1996; 5:3.
87. Green N, Griffin P. Hip dysplasia associated with abduction contracture of the contralateral hip. *J Bone Joint Surg* 1982; 64A:1273.
88. Cleveland R, Kushner D, Ogden M, et al. Determination of leg length discrepancy. A comparison of weight-bearing and supine imaging. *Invest Radiol* 1988;23:301.
89. Green W, Wyatt G, Anderson M. Orthoroentgenography as a method of measuring the bones of the lower extremity. *J Bone Joint Surg* 1946;28:60.
90. Bell JS, Thompson WAL. Modified spot scanography. *Am J Roentgenol* 1950;63:915.
91. Aaron A, Weinstein D, Thickman D, et al. Comparison of orthoroentgenography and computed tomography in the measurement of limb-length discrepancy. *J Bone Joint Surg* 1992; 74-A:897.
102. Blair V, Walker S, Sheridan J, et al. Epiphysiodesis: a problem of timing. *J Pediatr Orthop* 1982;2:281.
103. Menelaus M. Correction of leg length discrepancy by epiphyseal arrest. *J Bone Joint Surg* 1966;48B:336.
104. Westh R, Menelaus M. A simple calculation for the timing of epiphyseal arrest: a further report. *J Bone Joint Surg* 1981;63B: 117.
105. Menelaus M. Personal communication, 1997.
106. Green W, Anderson M. Skeletal age and the control of bone growth. *Instr Lect Am Acad Orthop Surg* 1960;17:199.
107. Moseley C. A straight-line graph for leg-length discrepancies. *J Bone Joint Surg* 1977;59A(2):174.
108. Moseley C. A straight-line graph for leg length discrepancies. *Clin Orthop Rel Res* 1978;136:33.
109. Porat S, Peyser A, Robin G. Equalization of lower limbs by epiphysiodesis: results of treatment. *J Pediatr Orthop* 1991;11: 442.
110. Bellier G, Carliz H. The prediction of growth in long bones in poliomyelitis. *Rev Chir Orthop* 1979;65:373.
111. Shapiro F. Longitudinal growth of the femur and tibia after diaphyseal lengthening. *J Bone Joint Surg* 1987;69A:684.
112. Koman L, Meyer L, Warren F. Proximal femoral focal deficiency: a 50-year experience. *Dev Med Child Neurol* 1982;24: 344.
113. Hootnick D, Boyd N, Fixsen J, et al. The natural history and management of congenital short tibia with dysplasia or absence of the fibula. *J Bone Joint Surg* 1977;59B:267.
114. Herron L, Amstutz H, Sakai D. One stage femoral lengthening in the adult. *Clin Orthop* 1978;136:74.
115. Little D, Nigo L, Aiona M. Deficiencies of current methods for the timing of epiphysiodesis. *J Pediatr Orthop* 1996;16:173.

Determination of Treatment Goals

116. Ghoneem H, Wright J, Cole W, et al. The Ilizarov method for correction of complex deformities. Psychological and functional outcomes. *J Bone Joint Surg* 1996;78A:1480.

117. Paley D. Current techniques of limb lengthening. *J Pediatr Orthop* 1988;8:73.

Treatment

118. Gross R. Leg length discrepancy—how much is too much? Scientific exhibit. Annual Meeting of the American Academy of Orthopaedic Surgeons. Dallas, Texas, 1978.
119. Rush W, Steiner H. A study of lower extremity length inequality. *AJR Am J Roentgenol* 1946;56:616.
120. Gillis J. *Too tall, too small*. Champagne Ill.: Institute for Personality and Ability Testing, 1982.
121. Grumbach M. Growth hormone therapy and the short end of the stick. *N Eng J Med* 1988;319:238.
122. Mayer-Bahlburg H. Psychosocial management of short stature. In: Shaffer D, Ehrhardt A, Greenhill L, eds. *The clinical guide to child psychiatry*. New York: Free Press, 1985:110.
123. Sandberg D, Brook A, Campos S. Short stature: a psychosocial burden requiring growth hormone therapy? *J Pediatr* 1994;94:832.
124. Anderson L, Westin GW, Oppenheim WL. Syme amputation in children: indications, results, and long-term follow-up. *J Pediatr Orthop* 1984;4:550.
125. Mallet J, Rigault P, Padovani J, et al. Braces for congenital leg length inequality in children. *Rev Chir Orthop* 1986;72:63.
126. Seroguchi Y. Comparison of gait patterns and energy efficiency of unilateral PFFD in patients treated by Symes amputation and by knee fusion and rotational osteotomy. Minneapolis, MN: ACPOC Annual Meeting, 1994.
127. Stephens D, Herrick W, MacEwen G. Epiphysiodesis for limb length inequality: results and indications. *Clin Orthop* 1978;136:41.
128. White J, Stubbs SJ. Growth arrest for equalizing leg lengths. *JAMA* 1944;126:1146.
129. Straub L, Thompson T, Wilson P. The results of epiphysiodesis and femoral shortening in relation to equalization of leg length. *J Bone Joint Surg* 1945;27:254.
130. Phemister D. Operative arrestment of longitudinal growth of bones in the treatment of deformities. *J Bone Joint Surg* 1933;15:1.
131. Macnicol M, Gupta M. Epiphysiodesis using a cannulated tubesaw. *J Bone Joint Surg Br* 1997;79:307.
132. Anders G, Stachon I. Experience with temporary epiphyseodesis after Blount. *Z Orthop* 1979;117:922.
133. Blount WP. A mature look at epiphyseal stapling. *Clin Orthop* 1971;77:149.
134. Blount WP, Clarke GR. Control of bone growth by epiphyseal stapling. A preliminary report. *J Bone Joint Surg* 1949;31:464.
135. Hass S. Mechanical retardation of bone growth. *J Bone Joint Surg* 1948;30A:506.
136. McGibbon K, Deacon A, Raisbeck C. Experiences in growth retardation with heavy Vitallium staples. *J Bone Joint Surg Br* 1962;44:86.
137. Brockway A, Craig WA, Cockrell BRJ. End result of 62 stapling operations. *J Bone Joint Surg Am* 1954;36:1063.
138. Frantz C. Epiphyseal stapling. *Clin Orthop* 1971;77:149.
139. Bylander B, Hansson LI, Selvik G. Pattern of growth retardation after Blount stapling: a roentgen stereophotogrammetric analysis. *J Pediatr Orthop* 1983;3:63.
140. Mielke C, Stevens P. Hemiepiphyseal stapling for knee deformities in children younger than 10 years: a preliminary report. *J Pediatr Orthop A* 1996;16:423.
141. Canale S, Russell T, Holcomb R. Percutaneous epiphysiodesis: experimental study and preliminary clinical results. *J Pediatr Orthop* 1986;6:150.
142. Ogilvie J. Epiphysiodesis: evaluation of a new technique. *J Pediatr Orthop* 1986;6:147.
143. Scott A, Urquhart B, Te C. Percutaneous vs modified Phemister epiphysiodesis of the lower extremity. *Orthopedics* 1996;19:857.
144. Canale S, Christian C. Techniques for epiphysiodesis about the knee. *Clin Orthop Rel Res* 1990;255:81.
145. Atar D, Lehman W, Grant A, et al. Percutaneous epiphysiodesis. *J Bone Joint Surg Br* 1991;73:173.
146. Timperlake R, Bowen J, Guille J, et al. Prospective evaluation of fifty-three consecutive percutaneous epiphysiodeses of the distal femur and proximal tibia and fibula. *J Pediatr Orthop* 1991;11:350.
147. Kenwright J, Albinana J. Problems encountered in leg shortening. *J Bone Joint Surg Br* 1991;73:671.
148. Silver R, de la Garza J, Rang M. The myth of muscle balance. *J Bone Joint Surg Br* 1985;67:432.
149. Merle D'Aubigne R, Dubousset J. Surgical correction of large length discrepancies in the lower extremities of children and adults. *J Bone Joint Surg Am* 1971;53:411.
150. Kempf I, Grosse A, Abalo C. Locked intramedullary nailing. Its application to femoral and tibial axial, rotational, lengthening and shortening osteotomies. *Clin Orthop* 1986;212:165.
151. Winquist R. Closed intramedullary osteotomies of the femur. *Clin Orthop Rel Res* 1986;212:155.
152. Winquist R, Hansen S, Pearson R. Closed intramedullary shortening of the femur. *Clin Orthop Rel Res* 1978;136:54.
153. Edwards K, Cummings R. Fat embolism as a complication of closed femoral shortening. *J Pediatr Orthop* 1992;12:542.
154. Chapman M, Duwelius P, Bray T, et al. Closed intramedullary femoral osteotomy. Shortening and derotation procedures. *Clin Orthop* 1993;287:245.
155. Lynch M, Taylor J. Periosteal division and longitudinal growth in the tibia of the rat. *J Bone Joint Surg Br* 1987;69:812.
156. Wilde G, Baker G. Circumferential periosteal release in the treatment of children with leg length inequality. *J Bone Joint Surg Br* 1987;69:817.
157. Bohlman HR. Experiments with foreign materials in the region of the epiphyseal cartilage plate of growing bones to increase their longitudinal growth. *J Bone Joint Surg* 1929;11:365.
158. Bisgard JD. Longitudinal bone growth, the influence of sympathetic deinnervation. *Ann Surg* 1973;97:374.
159. Harris R, McDonald J. The effect of lumbar sympathectomy upon the growth of legs paralysed by anterior poliomyelitis. *J Bone Joint Surg* 1936;18:35.
160. Manning C. Leg lengthening. *Clin Orthop* 1978;136:105.
161. Petty W, Winter R, Felder D. Arteriovenous fistula for treatment of discrepancy in leg length. *J Bone Joint Surg Am* 1974;56:581.
162. Yabsley R, Harris W. The effect of shaft fractures and periosteal stripping on the vascular supply to epiphyseal plates. *J Bone Joint Surg Am* 1965;47:551.
163. Codivilla A. On the means of lengthening in the lower limbs the muscles and tissues which are shortened through deformity. *Am J Orthop Surg* 1905;2:353.
164. Magnuson P. Lengthening of shortened bones of the leg by operation. Ivory screws with removable heads as a means of holding the two bone fragments. *Surg Gynecol Obstet* 1913;16:63.
165. Coleman S. Simultaneous femoral and tibial lengthening for limb length discrepancies. *Arch Orthop Trauma Surg* 1985;103:359.
166. Agerholm J. The zig-zag osteotomy. *Acta Orthop Scand* 1959;29:63.
167. Westin G. Femoral lengthening using a periosteal sleeve. Report of twenty-six cases. *J Bone Joint Surg Am* 1967;49:836.

168. Compere E. Indications for and against the leg lengthening operation. *J Bone Joint Surg* 1936;18:692.
169. McCarroll H. Trials and tribulations in attempted femoral lengthening. *J Bone Joint Surg* 1950;32A:132.
170. Bost FC, Larson LJ. Experiences with lengthening of the femur over an intramedullary rod. *J Bone Joint Surg Am* 1956;38:567.
171. Gortz J, Schellerman W. Continuous lengthening of the femur with intramedullary stabilisation. *Arch Orthop Unfallchir* 1975; 82:305.
172. Kawamura B. Limb lengthening. *Orthop Clin North Am* 1978; 9:155.
173. Malhis T, Bowen J. Tibial and femoral lengthening. A report of 54 cases. *J Pediatr Orthop* 1982;2:487.
174. Rezaian S. Tibial lengthening using a new external extension device. Report of thirty-two cases. *J Bone Joint Surg Am* 1976; 58:239.
175. Millis M, Hall J. Transiliac lengthening of the lower extremity. A modified innominate osteotomy for the treatment of postural imbalance. *J Bone Joint Surg Am* 1979;61:1182.
176. Barry K, McManus F, O'Brien T. Leg lengthening by the transiliac method. *J Bone Joint Surg Br* 1992;74:275.
177. Lee D, Choi I, Ahn J, et al. Triple innominate osteotomy for hip stabilisation and transiliac leg lengthening after poliomyelitis. *J Bone Joint Surg Br* 1993;75:858.
178. Cauchoix J, Morel G. One stage femoral lengthening. *Clin Orthop Rel Res* 1978;136:66.
179. Morel G, Morin C. Simplified technique of extemporaneous lengthening of the femur in children. *Chir Pediatr* 1986;27: 326.
180. Rezaian S, Abtahi M. A simple and safe technique for tibial lengthening. *Clin Orthop* 1986;207:216.
181. Bianco AJ Jr. Femoral shortening. *Clin Orthop* 1978;136:49.
182. Zanasi R. Surgical equalisation of leg length: shortening of the long femur and lengthening of the short in one operation. *Ital J Orthop Traumatol* 1982;8:265.
183. Yadav S. Double oblique diaphyseal osteotomy. A new technique for lengthening deformed and short lower limbs. *J Bone Joint Surg Br* 1993;75:962.
184. Hughes T, Maffulli N, Fixsen J. Ultrasonographic appearance of regenerate bone in limb lengthening. *J Roy Soc Med* 1993; 86:18.
185. Maffulli N, Hughes T, Fixsen J. Ultrasonographic monitoring of limb lengthening. *J Bone Joint Surg Br* 1992;74:130.
186. Wagner H. Operative lengthening of the femur. *Clin Orthop* 1978;136:125.
187. Anderson WV. Leg lengthening. *J Bone Joint Surg Br* 1952;34: 150.
188. Wagner H. Operative Beinverlängerung. (Surgical leg prolongation.) *Chirurgie* 1971;42:260.
189. Wagner H. Operative correction of leg length discrepancy. *Langenbecks Arch Chir* 1977;345:147.
190. Wagner H. Surgical lengthening of the femur. Report of fifty-eight cases. *Ann Chir* 1980;34:263.
191. De Bastiani G, Aldegheri R, Renzi-Brivio L, et al. Chondrodias-tasis—controlled symmetrical distraction of the epiphyseal plate. Limb lengthening in children. *J Bone Joint Surg Br* 1986; 68:550.
192. De Bastiani G, Aldegheri R, Renzi-Brivio L, et al. Limb lengthening by callus distraction (callostasis). *J Pediatr Orthop* 1987; 7:129.
193. Guidera K, Hess W, Highhouse K, et al. Extremity lengthening: results and complications with the Orthofix system. *J Pediatr Orthop* 1991;11:90.
194. Bensahel H, Huguenin P, Briard JL. Transepiphyseal lengthening of the tibia. *Rev Chir Orthop* 1983;69:245.
195. Monticelli G, Spinelli R. Distraction epiphyseolysis as a method of limb lengthening. II. Morphologic investigations. *Clin Orthop* 1981;154:262.
196. Monticelli G, Spinelli R. Distraction epiphyseolysis as a method of limb lengthening. III. Clinical applications. *Clin Orthop* 1981;154:274.
197. Monticelli G, Spinelli R. Distraction epiphyseolysis as a method of limb lengthening. I. Experimental study. *Clin Orthop* 1981; 154:254.
198. Monticelli G, Spinelli R. Limb lengthening by epiphyseal distraction. *Int Orthop* 1981;5:85.
199. Ring P. Experimental bone lengthening by epiphyseal distraction. *Br J Surg* 1958;46:169.
200. Wasserstein I, Crell J, Niehard F. Closed distraction epiphyseolysis for leg lengthening and axis correction of the leg in children. *Z Orthop* 1986;124:743.
201. Connolly J, Huurman W, Lippiello L, et al. Epiphyseal traction to correct acquired growth deformities. An animal and clinical investigation. *Clin Orthop* 1986;202:258.
202. Hamanishi C, Tanaka S, Tamura K. Early physeal closure after femoral chondrodias-tasis. Loss of length gain in 5 cases. *Acta Orthop Scand* 1992;63:146.
203. Morel G, Servant J, Valle A, et al. Extemporaneous femoral lengthening by the Cauchoix technique in children and adolescents. *Rev Chir Orthop* 1983;69:195.
204. Ilizarov G, Deviatov A. Surgical elongation of the leg. *Ortop Travmatol Protez* 1971;32:20.
205. Ilizarov G, Deviatov A, Trokhova V. Surgical lengthening of the shortened lower extremities. *Vestn Khir* 1972;107:100.
206. Ilizarov G, Trokhova V. Surgical lengthening of the femur. *Ortop Travmatol Protez* 1973;34:73.
207. Monticelli G, Spinelli R. Leg lengthening by closed metaphyseal corticotomy. *Ital J Orthop Traumatol* 1983;9:139.
208. Richards Medical Company. The Ilizarov external fixator, general surgical technique brochure. Memphis, TN: Richards Medical Company, 1988.
209. Ilizarov G, Deviatov A. Surgical lengthening of the shin with simultaneous correction of deformities. *Ortop Travmatol Protez* 1969;30:32.
210. Raschke M, Mann J, Oedekoven G, et al. Segmental transport after unreamed intramedullary nailing. Preliminary report of a monorail system. *Clin Orthop* 1992;282:233.
211. Huang S. Leg lengthening by the Ilizarov technique for patients with sequelae of poliomyelitis. *J Formosa Med Assoc* 1997;96: 258.
212. Lin C, Huang S, Liu T, et al. Limb lengthening over an intramedullary nail. An animal study and clinical report. *Clin Orthop* 1996;Sep(330):208.
213. Baumgart R, Betz A, Schweiberer L. A fully implantable motorized intramedullary nail for limb lengthening and bone transport. *Clin Orthop* 1997;343:135.
214. Wu C, Shih C, Chen W. Nonunion and shortening after femoral fracture treated with one-stage lengthening using locked nailing technique. Good results in 48/51 patients. *Acta Orthop Scand* 1999;70:33.
215. Yasui N, Kojimoto H, Sasaki K, et al. Factors affecting callus distraction in limb lengthening. *Clin Orthop* 1993;293:55.
216. Lokietek W, Legaye J, Lokietek J-C. Contributing factors for osteogenesis in children's limb lengthening. *J Pediatr Orthop* 1991;11:452.
217. Bowen J, Levy E, Donohue M. Comparison of knee motion and callous formation in femoral lengthening with the Wagner or monolateral-ring device. *J Pediatr Orthop* 1993;13:467.
218. Bell D. The effect of limb lengthening on articular cartilage: an experimental study. Newport, RI: Annual Meeting of the Pediatric Orthopaedic Society of North America, 1992.

219. Ilizarov G, Irianov I, Migalkin N, et al. Ultrastructural characteristics of elastogenesis in the major arteries of the canine hind-limb during lengthening. *Arkh Anat Gistol Embriol* 1987;93:94.
220. Ilizarov G, Palienko L, Shreiner A. Bone marrow hematopoietic function and its relationship to osteogenesis activity during reparative regeneration in leg lengthening in the dog. *Ontogenez* 1984;15:146.
221. Carroll N, Grant C, Hudson R, et al. Experimental observations on the effects of leg lengthening by the Wagner method. *Clin Orthop* 1981;160:250.
222. Noonan K, Leyes M, Forriol F, et al. Distraction osteogenesis of the lower extremity with use of monolateral external fixation. A study of two hundred and sixty-one femora and tibiae. *J Bone Joint Surg Am* 1998;80:793.
223. Price C. Unilateral fixators and mechanical axis realignment. *Orthop Clin North Am* 1994;25:499.
224. Herzenberg J, Waanders N. Calculating rate and duration of distraction for deformity correction with the Ilizarov technique. *Orthop Clin North Am* 1991;22:601.
225. Bjerkreim I, Hellum C. Femur lengthening using the Wagner technique. *Acta Orthop Scand* 1983;54:263.
226. Brockway A, Fowler SB. Experience with 105 leg-lengthening operations. *Surg Gynecol Obstet* 1942;75:252.
227. Chandler D, King J, Bernstein S, et al. Results of 21 Wagner limb lengthenings in 20 patients. *Clin Orthop Rel Res* 1988;230:214.
228. Coleman S, Stevens P. Tibial lengthening. *Clin Orthop* 1978;136:92.
229. Hood R, Riseborough E. Lengthening of the lower extremity by the Wagner method. *J Bone Joint Surg Am* 1981;63:1122.
230. Kawamura B, Mosona S, Takahashi T, et al. Limb lengthening by means of subcutaneous osteotomy. *J Bone Joint Surg Am* 1968;50:851.
231. Rigault P, Dolz G, Padovani J, et al. Progressive tibial lengthening in children. *Rev Chir Orthop* 1981;67:461.
232. Seitz D, Yancey H. A review of tibial lengthening procedures. *South Med J* 1976;69:1349.
233. Stephens D. Femoral and tibial lengthening. *J Pediatr Orthop* 1983;3:424.
234. Bassett G, Morris J. The use of the Ilizarov technique in the correction of lower extremity deformities in children. *Orthopaedics* 1997;20:623.
235. Leyes M, Noonan K, Forriol F, et al. Statistical analysis of axial deformity during distraction osteogenesis of the tibia. *J Pediatr Orthop A* 1998;18:190.
236. Cheng J, Cheung K, Ng B. Severe progressive deformities after limb lengthening in type-II fibular hemimelia. *J Bone Joint Surg* 1998;80(5):772.
237. Haddad F, Harper G, Hill R. Intraoperative arthrography and the Ilizarov technique. Role in the correction of paediatric deformity and leg lengthening. *J Bone Joint Surg Br* 1997;79:731.
238. Axer A, Elkon A, Eliahu H. Hypertension as a complication of limb lengthening. *J Bone Joint Surg Am* 1966;48:520.
239. Miller A, Rosman M. Hypertensive encephalopathy as a complication of femoral lengthening. *Can Med Assoc J* 1981;124:296.
240. Yosipovich Z, Palti Y. Alterations in blood pressure during leg-lengthening. A clinical and experimental investigation. *J Bone Joint Surg Am* 1967;49:1352.
241. Luke D, Schoenecker P, Blair V, et al. Fractures after Wagner limb lengthening. *J Pediatr Orthop* 1992;12:20.
242. Nakamura K, Matsushita T, Mamada K, et al. Changes of callus diameter during axial loading and after fixator removal in leg lengthening. *Arch Orthop Trauma Surg* 1998;117:464.
243. Mamada K, Nakamura K, Matsushita T, et al. The diameter of callus in leg lengthening: 28 tibial lengthenings in 14 patients with achondroplasia. *Acta Orthop Scand* 1998;9:306.
244. Jones D, Moseley C. Subluxation of the knee as a complication of femoral lengthening by the Wagner technique. *J Bone Joint Surg Br* 1985;67:33.
245. Mosca V, Moseley C. Results of limb lengthening using the Wagner device. *Ortho Trans* 1987;11:52.
246. Torode I, Gillespie R. Anteroposterior instability of the knee: a sign of congenital limb deficiency. *J Pediatr Orthop* 1983;3:467.
247. Torode I, Gillespie R. The classification and treatment of proximal femoral deficiencies. *Prosthet Orthop Int* 1991;15:117.
248. Salai M, Chechick A, Ganel A, et al. Subluxation of the hip joint during femoral lengthening. *J Pediatr Orthop* 1985;5:642.
249. Naudie D, Hamdy R, Fassier F, et al. Complications of limb lengthening in children who have an underlying bone disorder. *J Bone Joint Surg Am* 1998;80:18.
250. Herzenberg J, Paley D. Leg lengthening in children. *Curr Opin Pediatr* 1998;10:95.
251. Waldhausen J, Mosca V, Johansen K, et al. Delayed presentation of popliteal artery injury during Ilizarov limb lengthening. *Orthopedics* 1998;21:477.
252. Young N, Davis R, Bell D, et al. Electromyographic and nerve conduction changes after tibial lengthening by the Ilizarov method. *J Pediatr Orthop* 1993;13:473.
253. Karger C, Guille J, Bowen J. Lengthening of congenital lower limb deficiencies. *Clin Orthop* 1993;291:236.
254. Price C, Carantzas A. Severe growth retardation following limb lengthening: a case report. *Iowa Orthop J* 1996;16:139.
255. Maffulli N, Lombardi C, Matarazzo L, et al. A review of 240 patients undergoing distraction osteogenesis for congenital, post-traumatic or postinfective lower limb length discrepancy. *J Am Coll Surg* 1996;182:394.



29

THE FOOT

VINCENT S. MOSCA

PRINCIPLES OF MANAGEMENT 1151

CONGENITAL DEFORMITIES 1153

Clubfoot (Congenital Talipes Equinovarus) 1153

Metatarsus Adductus 1161

Skewfoot 1164

Flexible Flatfoot 1168

Congenital Vertical Talus (Congenital Convex Pes Valgus) 1174

Positional Calcaneovalgus 1178

Congenital Overriding Fifth Toe 1178

Curly Toe 1180

CONGENITAL MALFORMATIONS 1181

Accessory Navicular 1181

Tarsal Coalition 1182

Congenital Hallux Varus 1186

Polydactyly/Polysyndactyly 1188

Syndactyly 1190

Macroductyly 1191

Cleft Foot (Ectrodactyly) 1192

DEVELOPMENTAL DEFORMITIES 1194

Cavus 1194

Juvenile Hallux Valgus 1200

ACQUIRED AFFECTIONS 1203

Kohler Disease 1203

Freiberg Infraction 1205

Sever Apophysitis 1206

PRINCIPLES OF MANAGEMENT

The foot is a unique part of the musculoskeletal system. Although it is often discussed as if it was another joint in the body, such as the hip, knee, shoulder, and elbow, it is not a joint. There are 26 bones in the foot with countless articulations. The foot of a child looks different from that of an adult. In fact, there is so much variation in shape that the foot of one child may look quite different from that of another child. This feature of physiologic variation is also seen in the long bones of the child's lower extremities, in conditions such as genu varum, genu valgum, femoral ante-

version, and tibial torsion (1,2). There are average shapes and normal ranges of shapes. The natural history is for spontaneous change from the normal shapes of the child to those of the adult through normal growth and development. Externally applied forces cannot modify these physiologic variations. And the long-term health consequences of persistent physiologic variations of the long bones have yet to be proven. Physiologic variations of the child's foot, such as flexible metatarsus adductus, positional calcaneovalgus, and flexible flatfoot, must be identified as normal, but not average, shapes to avoid inappropriate and potentially harmful interventions. Conversely, congenital and developmental abnormalities of the child's foot must be identified as such, and managed with the nonoperative and operative methods that have been shown to be effective.

An orthopaedist managing congenital and acquired deformities of the child's foot must have:

V. S. Mosca: Department of Orthopaedics, University of Washington School of Medicine, Seattle, Washington 98195; Department of Orthopedics, Children's Hospital and Regional Medical Center, Seattle, Washington 98105.

1. an appreciation of the age-related physiologic variations in the shape of the foot;
2. an understanding of the natural history of each variation and deformity;
3. an appreciation of the effect of a chosen intervention on the growth and development of the foot, as well as the effect of growth and development on a chosen intervention;
4. a thorough and working knowledge of the most unique "joint" in the human body, the subtalar joint complex, which is a combination of the talocalcaneal or subtalar joint plus the talonavicular and calcaneocuboid or transverse tarsal joints (Chopart joint);
5. an understanding of joint positions and motions that supersedes the confusing and inconsistent terminology in the literature;
6. the ability to obtain, and the commitment to evaluate, only weight-bearing or simulated weight-bearing radiographs;
7. a dedication to preserving joint motion by using soft tissue releases and osteotomies, instead of arthrodeses; and
8. a complete understanding of the phrase "the foot is not a joint."

Some of the physiologic variations in the shape of the child's foot include metatarsus adductus, calcaneovalgus, and flexible flatfoot. There are also anatomic variations in the structure of the child's foot, including accessory navicular and tarsal coalition.

An understanding of the natural history of each variation and deformity is of paramount importance. Eighty-five to 95% of feet with metatarsus adductus correct spontaneously, with little if any long-term disability, even with mild to moderate residual deformity (3–5). Essentially all calcaneovalgus "deformities" correct spontaneously (6). Flexible flatfoot is almost ubiquitous at birth, and is present in approximately 23% of adults, most of whom are asymptomatic (7). The height of the longitudinal arch increases spontaneously during the first decade of life in most children (8,9). There is a wide range of normal arch heights at all ages, particularly in young children (8,9). There is no proven benefit from shoe modifications and inserts over spontaneous natural improvement in the development of the longitudinal arch (10,11). Most feet with accessory naviculars (12,13), and approximately 75% of feet with tarsal coalitions (14) are asymptomatic, and do not need treatment. Conversely, congenital clubfoot and congenital vertical talus persist and cause disability, unless treated.

The natural history of the intervention must also be fully appreciated and considered in relation to the natural history of the disease or condition. Unfortunately, although there are few good natural history studies on deformities and variations of the child's foot, there are fewer good long-term follow-up studies on operative interventions for these

conditions. It seems most reasonable that the default should logically go to the natural history of the disease.

A unique challenge facing clinicians who manage foot deformities in children is the consideration of the effect of a chosen intervention on the growth and development of the foot, as well as the effect of growth and development on a chosen intervention. Early reconstruction of pathologic foot deformities in children normalizes the stresses on the bones and joints, to allow more normal development. Delay results in the development or persistence of abnormalities in the shapes of the bones and joints, which makes reconstruction more difficult. Furthermore, procedures that affect, or potentially affect, growth in a positive or an adverse way must be used judiciously. Conversely, one must consider how the early positive results of an intervention may change as the child grows. Cavus foot deformity is most commonly a manifestation of muscle imbalance from an underlying neuromuscular disorder. In some cases, the disorder is static (cerebral palsy) or can be stabilized, but may recur (tethered cord in myelomeningocele). In others, the disorder is progressive, and the rate and extent of neuromuscular deterioration may not be predictable (Charcot-Marie-Tooth disease). It is difficult to establish precise muscle balance in any cavus foot, and it is well known that growth, as well as neurologic deterioration, can undo an excellent early result of intervention. The child and family must be aware that there are no panaceas, and that more surgery may be needed in the future. The surgeon must remember this as well, avoid burning bridges, and keep reasonable options available for future procedures.

Congenital vertical talus and many congenital clubfeet are released operatively in the first year of life, when the foot is 8 to 9 cm in length. The hope is that the correction of these deformities, located at the foundation of the human body, will be maintained through 14 to 16 years of growth and a doubling to tripling in the length of the foot. Problems, including recurrence and overcorrection, as well as plans for their management, should be anticipated.

There is no other "joint" in the human body with the unique anatomy and three-dimensional motion of the subtalar joint complex. This complex consists of two components, the talocalcaneal or subtalar joint, plus the talonavicular and calcaneocuboid or transtarsal joints. The latter is also known as the midtarsal or Chopart joint. Terms that apply to sagittal and coronal plane alignment and motions, such as varus, valgus, abduction, adduction, flexion, extension, supination, and pronation, do not necessarily apply to the subtalar complex, because its axis of motion is in neither the sagittal nor the coronal plane. Inversion and eversion are terms that, in the author's opinion, define the motions of this complex, but they need to be better defined and understood by all who use them. Interestingly, the joint in the body with the most similarity to the subtalar joint complex is the hip. Scarpa (15) identified that similarity almost 200 years ago, when he referred to the talocalcaneo-

navicular joint as the pes acetabulum. The subtalar complex is malaligned in all significant deformities of the child's foot, including clubfoot, vertical talus, cavus foot, and severe flatfoot. It is essential, therefore, that all who manage these deformities have a thorough and working knowledge of this most unique joint complex.

It is important to evaluate deformity, both clinically and radiographically, with the foot in the weight-bearing position. That is the baseline against which the corrected foot will be judged. A flexible flatfoot appears to have an arch and a normal foot may appear to have a cavus or clubfoot deformity when dangling in the air.

Deformities of the child's foot should be corrected by means of soft tissue releases to align the joints and osteotomies to correct residual deformities. Arthrodesis should be reserved for the older child, adolescent, or adult with established degenerative arthrosis of a joint, or with such severe deformity that correction cannot be achieved with releases and osteotomies. Long-term follow-up studies have demonstrated that arthrodesis of even the small joints of the child's foot should be avoided, because of the risk of developing degenerative arthrosis at the adjacent unfused joints (16–18). Arthrodesis of the subtalar joint, particularly triple arthrodesis, leads to stress transfer to the ankle (19–26). The development of degenerative arthrosis at that important joint is a potentially disastrous outcome.

Correction of foot deformity must be combined with balancing of muscle forces to help prevent recurrence. Balancing muscle forces in a mobile foot is much more challenging than in a foot that has undergone arthrodesis. This challenge must be accepted.

Finally, one who chooses to manage deformities of the child's foot must fully understand the phrase "the foot is not a joint." It is extremely unusual for only one portion of the foot or only one joint of the foot or ankle to be congenitally or developmentally deformed. Its many joints are usually deformed in opposite directions, as if the foot was wrung out. As examples, note that there is inversion of the subtalar joint and pronation of the forefoot on the hindfoot in a cavus foot; there is eversion of the subtalar joint and supination of the forefoot on the hindfoot in a flatfoot. And one cannot ignore the ankle joint as a potential site of additional deformity. The child's foot usually has multiple deformities, and the orthopaedist must identify all of them preoperatively, and have a treatment plan that addresses each one. There is no justification for creating a compensating deformity, or incompletely correcting a deformity, to avoid an additional procedure, particularly one that can usually be carried out during the same operative session. Consider the analogy of a child with varus deformities of the distal femur and proximal tibia secondary to rickets. One would never overcorrect the distal femur to a valgus alignment and create valgus orientation of the knee joint, to avoid performing an osteotomy of the proximal tibia. The same principle must apply to the foot.

There is a great need for more natural history studies on deformities and variations of the child's foot, as well as for long-term follow-up studies on the interventions used to treat these conditions. The message must be to exhibit caution with interventions, until it is clear that the treatment is not potentially worse than the condition.

All of these principles apply to the congenital and developmental deformities that are now presented individually. Many of the principles apply as well to the other conditions that are also described in this chapter.

CONGENITAL DEFORMITIES

A congenital deformity is characterized by malalignment of bones at their joints, which is present at birth. Deformations of one or more bones are often present, and may be primary or secondary findings.

Clubfoot (Congenital Talipes Equinovarus)

Definition

"Clubfoot" is the term used to describe a complex, congenital, contractural malalignment of the bones and joints of the foot and ankle. The individual deformities include equinus of the hindfoot, varus (or inversion) of the subtalar joint complex, cavus (plantar flexion of the forefoot on the hindfoot), and adductus of the forefoot on the midfoot (Fig. 29-1). Congenital talipes equinovarus is a more descriptive term, although certainly more cumbersome.

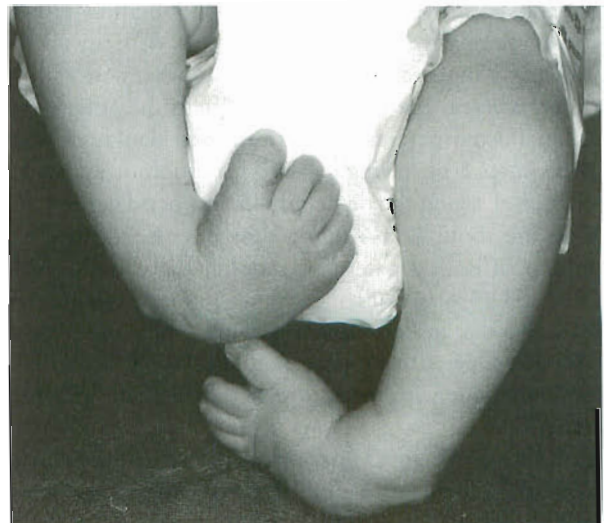

FIGURE 29-1. Infant clubfeet.

TABLE 29-1. SYNDROMES WITH WHICH CLUBFOOT IS COMMONLY ASSOCIATED

Arthrogryposis
Constriction bands (Streeter's dysplasia)
Prune belly
Tibial hemimelia
Möbius syndrome
Freeman-Sheldon syndrome (whistling face) (autosomal dominant)
Diastrophic dwarfism (autosomal recessive)
Larsen syndrome (autosomal recessive)
Opitz syndrome (autosomal recessive)
Pierre Robin syndrome (X-linked recessive)

There are four recognized classes of clubfoot. This section focuses on the idiopathic variety, which is found in otherwise normal children, and does not resolve without intensive treatment. A second class is the postural variety. These resolve completely with manipulation, or with one or two casts. Neurogenic clubfoot refers to clubfoot seen in children with myelomeningocele. Syndromic clubfoot is seen in children with other anomalies (Table 29-1). These tend to be rigid and quite resistant to treatment.

Epidemiology

The incidence of clubfoot is 0.93 to 1.5 per 1,000 live births in whites (27–29), 0.6 per 1,000 in Orientals, and 6.8 per 1,000 in Hawaiians, Polynesians, and Maoris (30). Boys are affected twice as often as girls, and bilateral involvement is seen in approximately 50% of cases (27).

Wynne-Davies (28,29) made several important observations regarding the incidence of clubfoot. The occurrence rate is 17 times higher than in the normal population for first-degree relatives, 6 times higher for second-degree relatives, and approximates the normal population risk for third-degree relatives. Unaffected parents with an affected son have a 1 in 40 chance of having another son with the disorder, whereas the risk to a subsequent daughter is very low. Unaffected parents with an affected daughter have a 1 in 16 chance of having a son with clubfoot and a 1 in 40 chance of seeing the deformity in another daughter. The chances are about 1 in 4 that a subsequent child will have a clubfoot if both a parent and a child have the disorder. There is a 32.5% rate of concordance in monozygotic twins and a 2.9% rate in heterozygotic twins. These observations led Wynne-Davies to propose that clubfoot is inherited as a dominant gene with reduced penetrance or multifactorial inheritance.

Cowell and Wein (31) concluded that the data could be accounted for using a multifactorial inheritance model. Complex segregation analysis, using a regressive logistic model, was used by Rebbeck et al. (32) to conclude that the

probability of having clubfoot was explained by the Mendelian segregation of a single gene with two alleles, plus the effects of some other factors that have yet to be elucidated.

Pathogenesis

Clubfoot is probably etiologically heterogeneous. Genetic factors clearly play a part. Environmental factors may modulate the genetic expression of the disorder. The proximate cause is debated with fervor, based on a small number of personal observations by a large number of investigators. There may be validity in many of the discordant studies if, in fact, clubfoot is a clinical manifestation that can result from multiple causes and mechanisms. Among the proposed theories are *in utero* molding (33), primary muscle lesion (34), primary bone deformity (germ plasm defect) (35), primary vascular lesion (36), intrauterine enteroviral infection (37), developmental arrest (38), primary nerve lesion (39), abnormal tendon insertion, retracting fibrosis (40), and abnormal histology (41).

Clinical Features

The clubfoot is characterized by equinus of the hindfoot, varus (or inversion) of the subtalar joint complex, cavus (plantar flexion of the forefoot on the hindfoot), and adductus of the forefoot on the midfoot. These deformities are not passively correctable. The severity of the deformities and associated findings vary from foot to foot, even in bilateral cases. There is a single (occasionally double) posterior skin crease (Fig. 29-2). The calcaneus is difficult to palpate within the fatty heel pad. A deep transverse skin crease crosses the midfoot and extends under the longitudinal arch. Assessment of tibial torsion in a newborn with a clubfoot is unreliable. The head of the talus can be seen and palpated on the dorsolateral aspect of the midfoot/hindfoot just anterior to the ankle joint. This is attributable to excessive inversion of the subtalar joint complex around the talus. An examiner's thumb can be placed on the dorsolateral aspect of the head of the talus, as a solid fulcrum around which the foot can be externally rotated and everted. In idiopathic clubfoot, the navicular will not fully align with the head of the talus and displace the examiner's thumb.

The foot and calf are smaller than the contralateral side. Little and Aiona (42) noted that leg-length discrepancy of greater than 0.5 cm exists in 18% of children with unilateral clubfoot and in 4% with bilateral deformities. The tibia is short in 89% and the femur is short in 43% of children with unilateral deformity with discrepancy.

A complete physical examination of the child is indicated to rule out a neurogenic or syndromic cause for

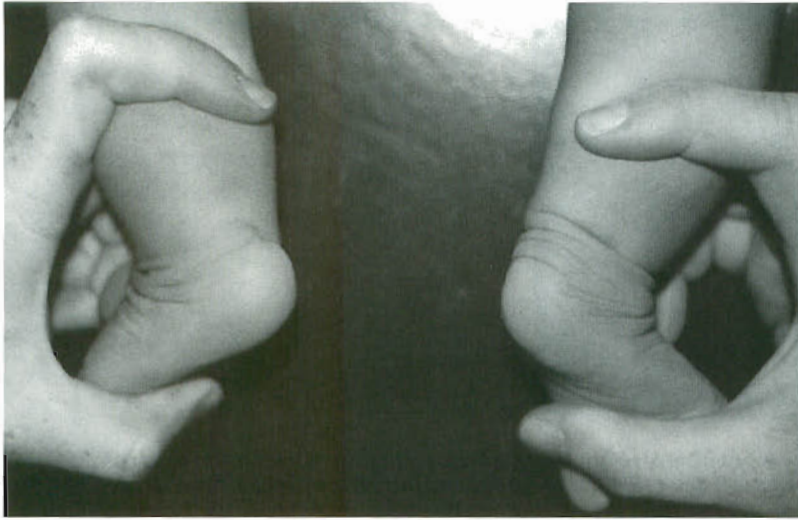


FIGURE 29-2. Clubfoot (left) with single heel crease and normal foot (right) with multiple heel creases.

the deformity. A finding as subtle as adducted and contracted thumbs across the palms will identify a child with clubfeet as having arthrogryposis. Examination of the hips in a newborn is an important part of the musculoskeletal screening examination, but there is no reported increased risk for developmental dysplasia of the hip in children with clubfoot.

Classification of the severity and rigidity of the clubfoot is vital to the assessment of treatment modalities. Several classification systems have been proposed (43–48), but none has been universally accepted. They all suffer from excessive subjectivity and poor reproducibility.

Radiographic Features

There is no consensus on the role of radiography in the diagnosis and management of clubfoot (48,49). However, it should be stated that the diagnosis of clubfoot in the newborn can and should be based solely on clinical findings. The intended role of radiography is to demonstrate the relationships between bones. This is accomplished by first drawing the axis of each bone, and herein lies the limitation of this imaging modality. There is little ossification of the bones of the normal newborn foot, and there is a delay in ossification in the clubfoot (50). The ossific nucleus of the talus is not centrally located in the cartilaginous anlage (51,52). The ossific nucleus of the talus is between the head and neck, and may be spherical in shape for the first several weeks of life. Ossification of the navicular does not begin until the age of 3 to 4 years in children with clubfoot, and even then it is eccentric. Brennan et al. (53) identified an even more fundamental problem when they showed very poor reproducibility in positioning the clubfoot for radiog-

raphy. These factors make it unrealistic to consider radiographs of the newborn and infant clubfoot as containing objective data. The age or point at which radiographs become reliable is unclear.

Despite these limitations, there may be a role for radiography to confirm correction, or to help identify the site(s) of residual deformity in the child who is several months old and has been undergoing serial manipulation and casting. In the latter situation, the information can be helpful for surgical planning, particularly if one subscribes to “a la carte surgery” (54–56). The anteroposterior view is obtained with the foot pressed against the radiograph plate with a dorsiflexion and external rotation force (49,57) (Fig. 29-3A). This will place the subtalar joint in its most everted and corrected position. The lateral radiograph is obtained with the foot dorsiflexed and everted maximally, but also with the leg internally rotated, to ensure a true lateral view of the ankle (manifested by the projection of the fibula within the posterior half of the tibia) (Fig. 29-3B). The talocalcaneal and talus–first metatarsal angles are measured on both views (9). The axes of the talus and the calcaneus normally diverge from each other, and the axes of the talus and the first metatarsal normally form a nearly straight line on both views. The tibiotalar and tibiocalcaneal angles are measured on the lateral view (9). The axis of the talus normally aligns almost perpendicularly to the tibia, and the calcaneus dorsiflexes above a right angle with the tibia. The alignment of the calcaneus and the cuboid is assessed on the anteroposterior view (58).

A second point at which radiography may be helpful is intraoperatively, to confirm the adequacy of correction of the deformities. The low-dose radiation and the convenience of Fluoriscan images make that technology desirable. The third indication for radiography could be, at some sub-

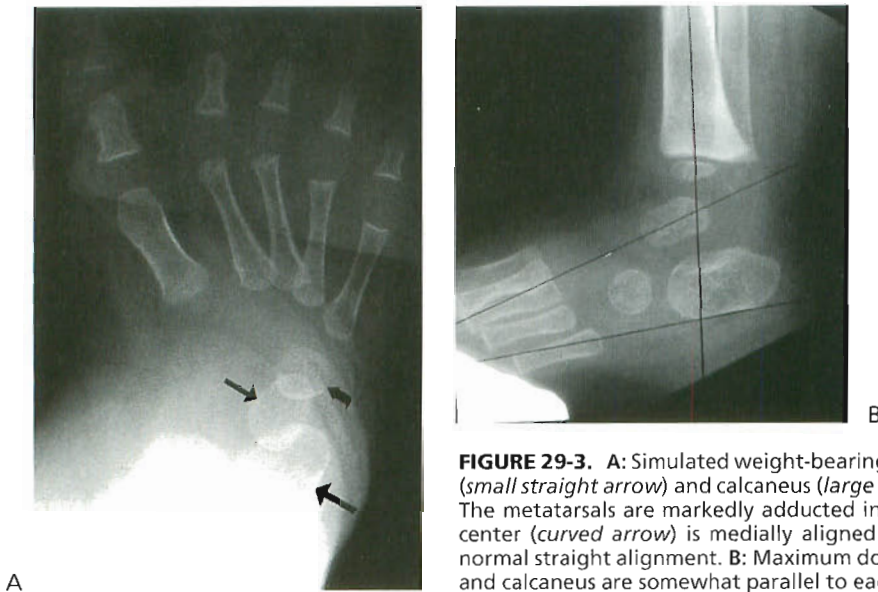


FIGURE 29-3. A: Simulated weight-bearing anteroposterior radiograph of clubfoot. The talus (*small straight arrow*) and calcaneus (*large straight arrow*) are parallel, rather than divergent. The metatarsals are markedly adducted in relationship to the talus. The cuboid ossification center (*curved arrow*) is medially aligned on the end of the calcaneus, rather than in the normal straight alignment. B: Maximum dorsiflexion lateral radiograph of clubfoot. The talus and calcaneus are somewhat parallel to each other and plantar flexed in relation to the tibia.

stantial time after surgery, to confirm maintenance of deformity correction. Alternatively, the third point at which radiographs are obtained is when recurrence or other secondary deformity is clinically identified.

Other Imaging Studies/Diagnostic Studies

The diagnosis of clubfoot is often made prenatally on the maternal abdominal ultrasound examination, which is now being performed fairly routinely at 16 to 20 weeks of gestation (59) (Fig. 29-4). The sensitivity and specificity are very high, but not 100%. Ultrasonographers have recently been more thorough in their evaluation of the limbs of the fetus. Identification is increasing, and accuracy is improving. The outcome of prenatal diagnosis has been the desire on the part of many parents to receive prenatal counseling, a service that cannot be provided by most primary care physicians, radiologists, or obstetricians at the level desired by the parents (60).

In response to the limitations of radiography, ultrasound techniques are evolving for the assessment of the clubfoot during nonoperative and operative treatment (61–64). Early results seem promising; however, the availability of the technology in the orthopaedic outpatient clinic is currently limited. Arthrography, computed tomography (65), and magnetic resonance imaging (51,66,67) may have roles in research or special circumstances, but they do not have roles in the routine management of the idiopathic clubfoot.

Pathoanatomy

The deformities of the clubfoot are created, in part, by malalignment of the bones at the joints, and, in part, by deform-

mation in the shapes of the bones (35,51,65,66,68–76). The neck of the talus is short and deviated plantar-medially on the body of the talus (35,72,73,75,76). This directs the articular cartilage of the head of the talus in the same plantar-medial direction. Anatomic dissections (73) and magnetic resonance images (66,67) confirm that there is a varus deformity of the distal end of the calcaneus, creating a medial tilt of its articular surface at the calcaneocuboid joint.

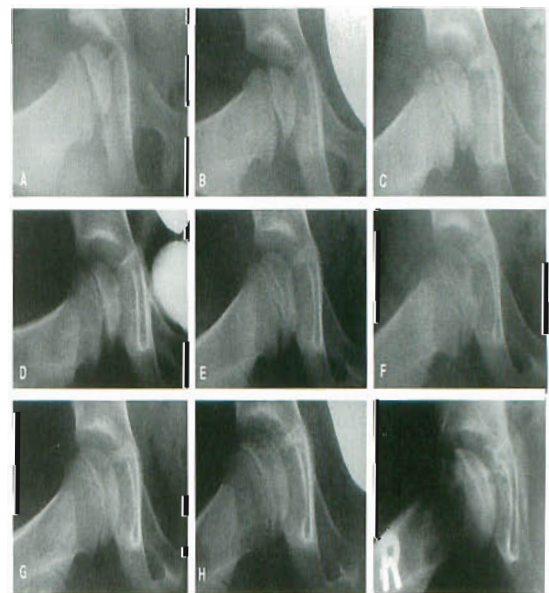

FIGURE 29-4. Maternal abdominal ultrasound image of clubfoot.

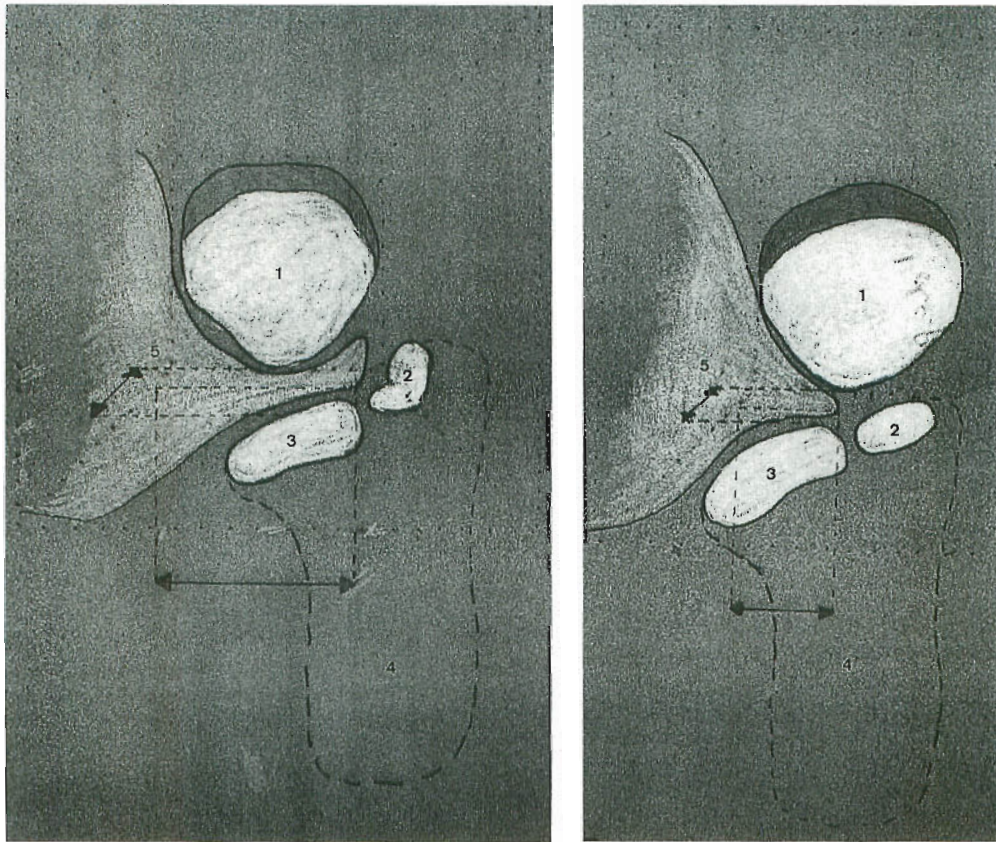


FIGURE 29-5. Navicular. (1) The axis of the anterior facet of the calcaneus (2) is tilted medially in relation to the axis of the middle facet (3) in the clubfoot (left) compared with the normal foot (right). (From ref. 77, with permission.)

Howard and Benson (72) and Epeldegui and Delgado (70,77) found that the anterior facet of the calcaneus is tilted medially, in relation to the middle facet in the clubfoot, indicating that the location of the varus deformity is between the two facets (Fig. 29-5). Epeldegui and Delgado (70) performed elegant microdissections of the feet of 75 stillborn infants, some of whom had clubfoot deformities. They specifically studied the bony and soft tissue anatomy of the talocalcaneonavicular joint, which they, like Sarrafian (77), called the acetabulum pedis (AP) and Scarpa (15) termed the "pes acetabulum." The AP is an ellipsoid articular cavity that holds and rotates around the head of the talus, comparable to the relationship between the pelvic acetabulum and the femoral head at the hip joint. Its bony elements are the posterior articular surface of the navicular and the anterior and middle articular facets of the calcaneus. Epeldegui and Delgado found that the soft tissues of the AP were likewise markedly different in shape and orientation in the clubfoot, compared with the normal foot. The shape of the medial cuneiform has not been studied in the newborn, but it is trapezoid-shaped in the older child with residual forefoot adductus deformity. The subtalar joint complex

is severely inverted, a combination of internal rotation, supination, and plantar flexion. The axis of rotation appears to be in the interosseus talocalcaneal ligament. The AP is inverted around the plantar-medially deviated head and neck of the talus, thereby aligning the navicular at or near the medial malleolus. The calcaneus is rotated downward and inward, resulting in parallel alignment with the talus in the frontal and sagittal planes. The posterior part of the calcaneus is tethered to the fibula by the calcaneofibular ligament. There is a varus deformity of the distal end of the calcaneus, with medial deviation of a congruous calcaneocuboid joint, in many clubfeet (66,67,70–73,75,77,78). There may be medial subluxation of the cuboid on the distal calcaneus in some feet (58,69). The plantar fascia, short plantar muscles, and spring ligament are contracted. The Achilles, tibialis posterior, flexor hallucis longus, and flexor digitorum longus tendons are contracted. The posterior capsules of the ankle and talocalcaneal joints are contracted.

Tibial torsion and the position of the talus in the ankle are debated. McKay (74) believes that the talus is in neutral alignment, Goldner (79) believes that it is internally rotated, and Carroll and associates (68,69,71) believe that it is exter-

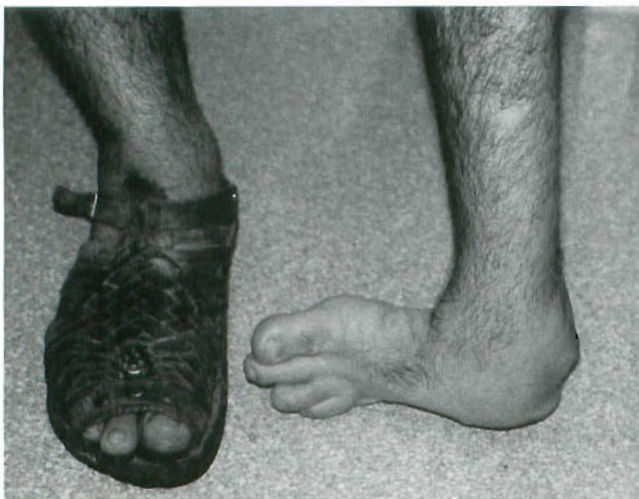

FIGURE 29-6. Untreated clubfoot in an adult migrant farm worker.

nally rotated. A recent three-dimensional magnetic resonance imaging study of clubfoot revealed an externally rotated position of the talus in clubfeet, compared with normal feet (51).

Natural History

The untreated clubfoot persists as a rigid, unsightly deformity. A large, callused bursa develops over the dorsolateral aspect of the hyperflexed midfoot, which functions as the weight-bearing surface of the foot (Fig. 29-6). In the most extreme cases, the toes point backward during ambulation. Specially made footwear is required to accommodate the deformity. Surprisingly, untreated adults in certain cultures and environments have little pain for many years, and can function adequately. Their function is similar to that of individuals with Syme amputations when not wearing their prostheses. City-dwelling adolescents and adults with untreated clubfoot experience pain and disability with ambulation on paved sidewalks and hard floors.

Treatment

The goal of treatment is to achieve a plantigrade, supple, painless foot that looks normal, although it is not normal, and provides adequate function. The initial treatment of clubfoot, regardless of its severity or rigidity, is nonoperative. The goal of nonoperative treatment is to achieve the stated goal of treatment or, at a minimum, to achieve partial correction of the deformity, and thereby decrease the extent of surgery. Modalities include serial manipulation and casting (81–85), taping, physical therapy and splinting (86),

and continuous passive motion with a machine (55). Manipulation and casting (81–85) is the technique used most frequently in the United States, based on experience, practicality, convenience, and cost. The technique is exacting and requires training, experience, and practice. Poor technique can result in an unnecessary failure of nonoperative treatment. It can also create complications that include rocker-bottom deformity, with spurious correction of the deformity and crushing of the cartilage anlage, with resultant joint deformity and stiffness.

Manipulation and casting should begin early. There is no evidence that a delay of several days makes a difference in the rate of success, and it seems a more holistic approach to let the parents hold and bond with an uncasted child for a short period of time. The technique of manipulation and casting, described by Ponseti and colleagues (83–85), is the gold standard, and should be studied in detail and practiced regularly. The first ray is dorsiflexed to stretch the plantar fascia and unlock the talonavicular joint. Next, the forefoot is abducted and the hindfoot is everted through the subtalar complex around the talus. Finally, after all other deformities are corrected, the hindfoot is dorsiflexed, while avoiding excessive dorsiflexion stress on the forefoot. Long-leg plaster of Paris casts are used to ensure that the pressures are maintained where they are applied, that the forces are directed appropriately, and to prevent the short-leg component from slipping down on a fat, conical leg.

Semirigid fiberglass has recently been shown by Coss and Hennrikus (87) to be statistically superior to plaster of Paris in its durability, convenience, performance, and ease of removal. The parents can remove the casts and bathe the child the night before (or the morning of) remanipulation and casting, which should occur weekly until no further improvement is seen. If good correction is not achieved by 3 months, it is unlikely that further nonoperative treatment will be successful.

The efficacy of manipulation and casting is attributable to the viscoelastic, or rate-dependent, behavior of the ligaments and tendons (88). The creep phenomenon occurs during manipulation. A constant stress (force per unit area), or load, is applied. The tissues undergo deformation (strain) relatively quickly at first, then more slowly, until there is little additional elongation possible at that time. The cast is applied with the same load used during manipulation. Stress relaxation takes place in the cast. The tissues undergo a small additional amount of elongation in the cast. As soon as that occurs, the stress on the tissues effectively decreases, and will not increase again until the next manipulation. The ability to correct the clubfoot deformity completely with this technique depends on the unique stiffness of the individual child's foot, the age at which the treatment is initiated, the skill of the practitioner, and the definition of complete. This last point is crucial, and is based on the premise

that it is not possible to make a clubfoot normal by any combination of techniques. Controlling for the child's age and the practitioner's skill, the clinical and radiographic results for any clubfoot depend on the severity, rigidity, or some other unique biologic feature(s) that has yet to be elucidated. The lack of a valid, reliable, universally accepted, and universally applied classification system for clubfeet has resulted in the inability to compare treatment methods. There is no consistency in the indications for abandoning nonoperative treatment for operative treatment, nor for considering a second operative procedure.

Kite (81,82) believed that most clubfeet could be corrected with serial casting, but that has not been the experience of others. Bensahel et al. (86) reported 77% good and fair results with daily physical therapy and splinting, whereas Dimeglio and colleagues (55) reported high success rates with the use of a continuous passive motion machine. These two approaches are difficult to implement in the health care environment.

Surgery is indicated if there is failure to achieve satisfactory clinical and radiographic evidence of deformity correction by nonoperative methods. The definition of satisfactory is debated. Also debated are the timing of surgery, the technique of surgery, the importance and type of short-term and long-term postoperative management, the definition of recurrence or other secondary deformity, and the indications for additional surgery. The definition of satisfactory deformity correction is also debated for clubfeet that are treated operatively. These debates will not be resolved until there are more comparative long-term data on clubfeet that have been treated by the different modalities in use at present. Cooper and Dietz (89) reported the only truly long-term results of a single treatment method for clubfoot. They evaluated 45 patients with 71 clubfeet, at an average age of 34 years (range, 25 to 42 years), who had been treated from infancy by Ponseti's method (83–85). This method is the least invasive of the proposed surgical methods. All feet undergo a total of five to eight manipulations and castings at intervals of 5 to 7 days. More than 90% of clubfeet undergo percutaneous tenotomy of the Achilles tendon in the clinic at between 2 and 3 months of age after the manipulations and castings, initiated at birth, have corrected all but the equinus deformity. Full-time bracing is replaced by nighttime bracing that continues for 2 to 3 years. Somewhat less than 50% of patients undergo transfer of the tibialis anterior to the lateral cuneiform, after walking age. Cooper and Dietz (89) used pedobarographic and electrogoniometric analyses, in addition to clinical and radiographic assessment. With the use of pain and functional limitations as the outcome criteria, 35 of the 45 patients (78%) had excellent or good outcomes, compared with 82 of 97 individuals (85%) who did not have congenital foot deformities. The authors reported that excessive weakening of the triceps

surae might predispose patients to poor results, and that outcomes could not be predicted from the radiographic results.

For reasons that are not clear, most orthopaedic surgeons are unable to achieve the degree of deformity correction with manipulation, casting, and Achilles tenotomy that has been reported by Cooper and Dietz using Ponseti's method. Most authors report the need for a more extensive operative procedure involving multiple tendon lengthenings and capsulotomies in 75 to 100% of clubfeet that have failed nonoperative treatment (30,79). There are no reported long-term studies on any of these procedures that are comparable to the Cooper and Dietz series with regard to length of follow-up, criteria for evaluation, and rate of excellent and good outcomes. It is hoped that such studies are forthcoming. In the short term, one should learn to master Ponseti's method, reserving one's standard operative approach for failures.

The more extensive surgical approaches are each attributed to an individual. Each is based on a slightly different understanding of the pathoanatomy, with an often dramatically different approach to management of the soft tissues, yet the reported short-term results are almost identical [→7.1].

The Turco procedure (90,91) was very popular in the 1970s. A medial incision was used to achieve posteromedial release. The subtalar joint was opened like a book with its binding along the lateral border of the foot. Excessive internal rotation of the foot and valgus deformity of the hindfoot were commonly seen in follow-up.

The Goldner procedure (47,79) is based on the premise that the primary deformity is internal rotation of the talus in the ankle joint. Correction requires lengthening of the deltoid ligament. The subtalar joint is not circumferentially released.

Carroll and colleagues (68,69,92,93) and McKay (94) agreed that circumferential release and rotation through the subtalar joint were necessary to correct the deformity. They believed in the importance of preservation of the talocalcaneal interosseus ligament, if possible. They disagreed with Goldner and with each other on the alignment of the talus in the ankle joint. Carroll and colleagues (68,69,71) believed that it was externally rotated, and McKay (74) believed that it was in neutral alignment.

Simons (95) presented the most extensive release yet described for management of the clubfoot. His was a circumferential release of the subtalar joint, with release of the talocalcaneal interosseus ligament, and often with circumferential release of the calcaneocuboid joint. This release completely destabilizes the bones and joints, risking the creation of gross translational deformities, from which it is extremely difficult to recover. Simons (58) brought attention to the alignment at the calcaneocuboid joint. Debate surrounds the implication of the apparent or real me-

dial subluxation at that joint. His approach is to release the joint circumferentially, and realign it. Others perform a partial plantar-medial release, allowing the joint to open without complete destabilization (69,92). The Hueter-Volkman law may work in this situation to correct the pathoanatomy, which in many cases is a varus deformity of the anterior calcaneus with a medial tilt of the calcaneocuboid joint.

Although some authors have an all-or-none approach to surgery (96,97), many support an a la carte approach (54–56). It makes sense that if there is a spectrum of severity for clubfeet, and some do not require surgery at all, there should be a spectrum of releases that can be performed, regardless of the pathoanatomic approach chosen. Wientroub and Khermouh (98) have written an excellent review and comparison of several of the most popular surgical procedures for clubfoot.

The type of skin incision is debated, but this is certainly less important than the procedures performed under the skin [→7.1]. Most surgeons use the Cincinnati incision, because it is safe, extensile, and cosmetic (99). It can be used for revision surgery, even crossing longitudinal scars from previous operations. Another approach is Carroll's two-incision technique (69,92). It is safe and extensile, but less cosmetic.

In a severe clubfoot that has not responded well to casting, it may not be possible to immediately approximate the edges of the Cincinnati incision with the foot in the fully corrected position without compromising the circulation of the skin. It has been suggested to leave the skin edges separated with the foot in the fully corrected position, and allow for wound closure by secondary intent (100). Alternatively, the skin edges can be approximated, a pin can be inserted across the talonavicular joint, the cast can be applied with the foot in plantar flexion, and the foot can be manipulated safely into further dorsiflexion during a cast change under anesthesia 1 to 2 weeks later (90,91,95,99). Variable success in stretching the soft tissues has been reported with the use of a preoperatively inserted tissue expander (101–103).

Debate also surrounds the need for internal fixation with wires. Procedures that are more extensive, with regard to capsular releases, tend to require fixation. Among the challenges of wire fixation is the determination of the proper alignment of bones that cannot be seen well clinically or radiographically.

Unfortunately, a review of the short-term and intermediate-term follow-up studies on these procedures does little to help one choose the best operative approach. A basic problem created by the lack of a universal classification system for clubfeet is that the studies cannot be compared. The clubfeet in the studies may not be comparable with regard to severity, rigidity, or some other important factor(s). Other variables that may have significant influences on the outcome, such as age at initiation of casting, number of casts, age at surgery, type and duration of postoperative

cast management, type and duration of postcast splinting, and length of follow-up, are not controlled or comparable between studies. Ponseti (84,85), for example, believed that the prolonged splinting that followed Achilles tenotomy was critical to the success of the method. Finally, evaluation rating systems vary from study to study.

These factors force one to choose an operative approach based on one's understanding of the pathoanatomy of the deformity, an impression of the results seen in one's training, and one's own experience. The pathoanatomy is one of severe inversion of the subtalar joint complex around the talocalcaneal interosseous ligament, with equinus, adductus, and cavus deformities. The techniques described by Carroll (69,92) and McKay (94) best address the pathoanatomy. They both stress the importance of preserving the talocalcaneal interosseous ligament which, if released, puts the calcaneus at risk for lateral translation—a disastrous complication. The alignment of the talus in the ankle joint is probably a moot point, because the talus rotates spontaneously during the release and repositioning.

Controversy surrounds the age at which clubfoot surgery should be performed. The argument for early surgery and realignment is that it allows for better remodeling of the cartilage anlage. Neonatal surgery has been reported (104–106). The technique is demanding, the results are variable, and the anesthetic risks are higher than for the older child. This approach obviates the avoidance of surgery that might result from manipulation and casting. Data do not support an optimal age range during which clubfoot surgery should be performed. Most surgeons operate on the child between 3 and 12 months of age (91,92,97,107,108). Anesthetic risks, difficulty with venous access, and the technical challenge related to foot size are greater with children younger than 6 months of age.

General anesthesia, with supplemental caudal epidural anesthesia, has been shown to decrease the postoperative narcotic requirement, provide good pain control for several hours after surgery, and shorten the hospital stay (109).

The need for additional surgery after the first operation is reported to range from 5 to 50% (91,93,110–113). These data are not helpful, because there are no strict indications for additional surgery. Painless recurrent or residual deformity might be an indication for surgery at one center, but not at another. The data are also of limited validity, because of the different lengths of follow-up in these studies.

The complications of nonoperative treatment were discussed above. There are many potential complications of surgical treatment (110,114,115). They include wound problems, neurovascular injury, bone/cartilage damage, avascular necrosis of the talus or navicular, residual deformity, recurrent deformity, dorsal bunion, and overcorrection at the talonavicular, talocalcaneal, and talocalcaneonavicular joints.

The Cincinnati incision is safe if it is placed at least 1 cm proximal to the deep posterior skin crease. Lower

placement may risk slough of the heel pad. The posterior tibial artery is usually the most important and possibly the only blood supply to the clubfoot (36). It should be isolated early and protected throughout the procedure.

Residual and recurrent varus deformity of the hindfoot in the young child is treated with repeat soft tissue release. Painful residual adductus of the forefoot in the older child is treated with opening-wedge osteotomy of the medial cuneiform (116,117), closing-wedge osteotomy of the cuboid, or both (118–121) [↗7.6]. The choice depends on the radiographically determined site(s) of deformity and the age of the child. In residual adductus deformities of the forefoot, the medial cuneiform is usually trapezoid-shaped, with medial deviation of the first metatarsocuneiform joint. Opening-wedge osteotomy will correct this deformity, but it cannot be performed until there is adequate ossification of the cartilaginous anlage, which is often not until after 4 years of age. There is also often a varus deformity of the cuboid, although it is more difficult to document the site of the deformity along the lateral border of the foot. The cuboid ossifies very early, and can undergo closing-wedge osteotomy to improve adductus deformity in the younger child. The ideal situation is to wait until the child is old enough to undergo the combined procedure. There are other techniques for correcting the shape and length of the lateral column of the foot (78). The correction of forefoot adductus can be combined with hindfoot soft tissue release in the older child with residual or recurrent deformity at both sites.

There is imbalance of the tibialis anterior and the peroneus longus and tertius in up to 50% of clubfeet (85). This is manifest as a dynamic, then rigid supination deformity of the forefoot. There may be accompanying adductus of the forefoot and inversion of the hindfoot. This imbalance ultimately leads to the development of a dorsal bunion. Lateral transfer of the tibialis anterior to the lateral cuneiform (85) will improve muscle balance and prevent the development of a dorsal bunion. This transfer can be combined with midfoot osteotomies, as described above, if there is rigid adductus deformity of the forefoot. If a rigid and symptomatic dorsal bunion has already developed in the older child, tendon transfer is indicated, in addition to other procedures (122). These include plantar release of the first metatarsophalangeal joint, transfer of the flexor hallucis longus to the neck of the first metatarsal, and plantar flexion osteotomy of the medial cuneiform or the base of the first metatarsal.

Overcorrection is a worse complication than recurrence, and can occur at different sites. Dorsal subluxation of the navicular on the head of the talus can occur as a result of excessive release of the talonavicular joint, external rotational malalignment of the joint, and residual cavus deformity secondary to failure to release the plantar fascia. The Third Street procedure, described by Barnett (123), is an effective method for realigning the joint in the young child,

but the long-term results have not been reported. This procedure entails capsulotomy of the talonavicular joint, continuing between the cuboid and navicular, the cuboid and lateral cuneiform, and finally between the base of the third and fourth metatarsals. The medial column of the foot is thereby separated from the lateral column, which allows the navicular to align completely and without tension with the head of the talus. Treatment in the older child must be individualized, and includes resection of the prominent dorsal portion of the subluxated navicular, talonavicular arthrodesis, and triple arthrodesis [↗7.9].

Overcorrection of the hindfoot can occur as an excessive eversion of the subtalar joint complex or as a lateral translation of the calcaneus under the talus. The latter is more likely to occur if the talocalcaneal interosseus ligament has been transected. Painful impingement of the calcaneus and lateral malleolus can be treated with posterior calcaneus medial displacement osteotomy (181). The calcaneal lengthening osteotomy described by Evans (124) is effective for management of the overcorrected clubfoot attributable to excessive eversion around an intact interosseus ligament.

Finally, it is important to evaluate the alignment of the ankle joint in cases of apparent overcorrection of a clubfoot. The subtalar joint may be well aligned. Valgus deformity of the ankle joint may account for the deformity seen. Medial malleolus screw hemiepiphysiodesis is a safe, simple, and effective treatment for the skeletally immature individual (125,126). Supramalleolar osteotomy is necessary after closure of growth plates.

Metatarsus Adductus

Definition

Medial deviation of the forefoot on the hindfoot, with neutral or slight valgus alignment of the hindfoot, is the most common congenital foot deformity (Fig. 29-7). The termi-

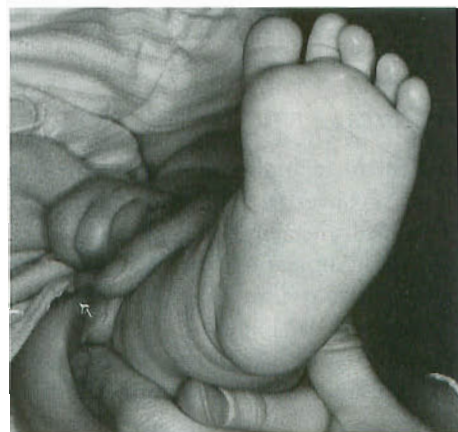


FIGURE 29-7. Metatarsus adductus in an infant. Note convex lateral border and neutral hindfoot alignment.

nology used to describe this deformity has been inconsistent and confusing, and has included metatarsus adductus, metatarsus varus, metatarsus adductovarus, and skewfoot.

Epidemiology

Wynne-Davies (28) reported the incidence of metatarsus varus at 1 per 1,000 live births and 1 per 20 siblings of patients with metatarsus varus. Hunziker et al. (127) documented an overall frequency of 12% in full-term single births, and an even higher frequency for twin births. The actual incidence is unknown, because of the lack of a strict definition of the condition. The increased reported incidence during the past century is probably attributable to an increased awareness of the condition by primary care physicians (4,128–130). Although earlier studies (131,132) indicated an association of metatarsus adductus with hip dysplasia, more recent studies (133,134) have shown no significant association between these two conditions.

Pathogenesis

The cause of metatarsus adductus is unknown. The theory that it is the result of *in utero* positioning is supported by the high rate of spontaneous resolution (5) and the strong association with twin pregnancies (127,135). Variations in anatomy have also been proposed as possible causes. Some authors have proposed the cause to be muscle imbalance resulting from contracture and anomalous insertion of the tibialis anterior (129,136,137) or tibialis posterior (138). Two studies on cadavers with metatarsus adductus have documented an abnormality in the shape of the medial cuneiform (139,140). The bone is trapezoid-shaped, and the first metatarsal–medial cuneiform joint is tilted medially, i.e., in varus alignment (141) (Fig. 29-8). It may be that the position theory applies to those feet that correct spontaneously, and the anatomic theories apply to those that do not.

Clinical Features

Adduction of the metatarsals creates a concave medial border of the foot, a convex lateral border, and prominence at the base of the fifth metatarsal. There may also be varying degrees of forefoot supination. The hindfoot is in neutral or slight valgus alignment, and there is full and free motion at the ankle and subtalar joints.

Bleck (142,143) published two classification systems: one based on the severity and one on the flexibility of the deformity. The severity of metatarsus adductus is determined with the use of the heel bisector method (142) applied to a photocopy of the child's foot in the weight-

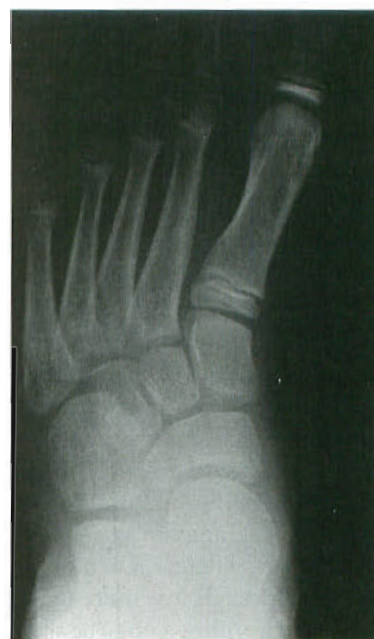

FIGURE 29-8. Metatarsus adductus in an older child with trapezoid-shaped medial cuneiform. (From ref. 141, with permission.)

bearing position (144) (Fig. 29-9). The other classification system (143) defines a foot with metatarsus adductus as flexible if the forefoot can be passively abducted beyond the midline heel bisector while holding the heel (Fig. 29-10). A partly flexible foot can be abducted only to the midline, and an inflexible, or rigid, foot cannot be abducted to the midline.

Radiographic Features

Radiographs are not necessary, nor indicated, to diagnose metatarsus adductus in infants. Berg (145) developed a classification system for metatarsus adductus and skewfoot based on radiographs of the feet of a small group of children between the ages of 2 and 17 months. The system is inherently flawed, because it is strongly dependent on assessment of the relationship between the talus and the navicular. The navicular does not ossify until 4 to 5 years of age. Cook et al. (146) documented poor interobserver and intraobserver agreement using this system, and showed no correlation between classification and response to treatment.

Radiographs are indicated for the older child or adolescent with severe residual deformity, pain, or other disability, when operative intervention is being considered. A standing anteroposterior radiograph will show the trapezoidal shape of the medial cuneiform and the medial deviation, or adductus, of the metatarsals on the tarsal bones. The severity of adductus decreases from the first to the fifth metatarsal.

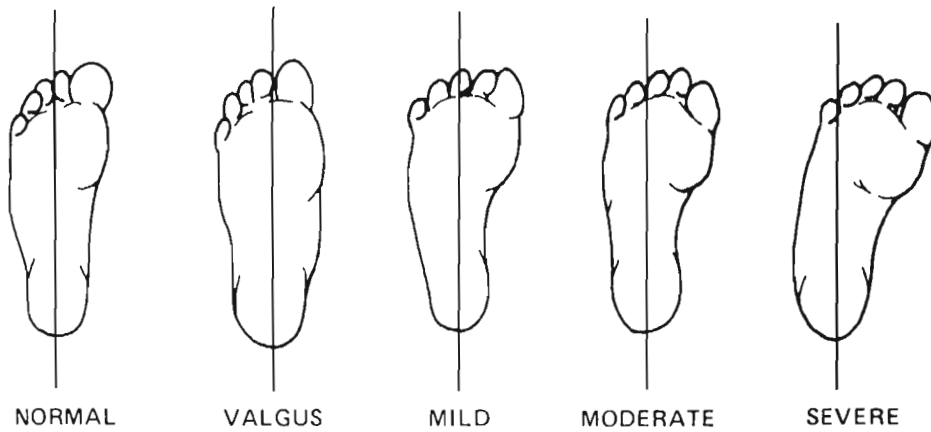


FIGURE 29-9. The heel bisector method. The severity of metatarsus adductus is determined by the relationship between the toes and the distal end of the line bisecting the heel. The severity does not correlate with prognosis. (From ref. 142, with permission.)

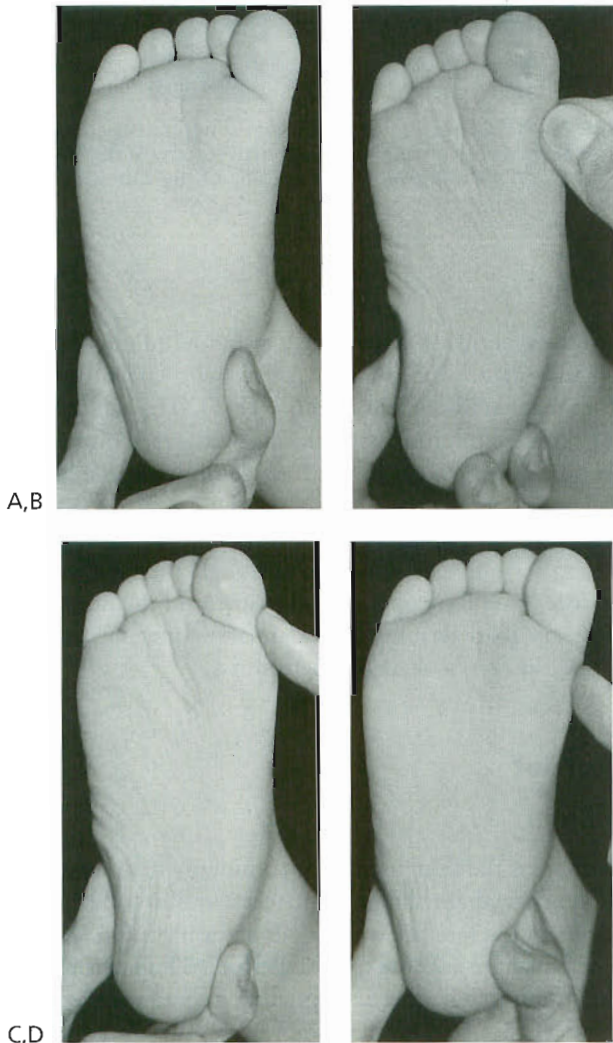


FIGURE 29-10. Bleck's (143) flexibility classification of metatarsus adductus. **A:** Metatarsus adductus in an infant. **B:** A flexible foot can be passively overcorrected into abduction with little effort. **C:** A partly flexible foot can be passively corrected only to the midline. **D:** An inflexible foot cannot be passively corrected to the midline. (From ref. 141, with permission.)

Normal hindfoot alignment is seen on the anteroposterior and lateral views.

Natural History

Rushforth (5) prospectively studied the natural history of metatarsus adductus in 83 children with 130 affected feet who received no treatment. Eighty-six percent were normal, 10% were moderately deformed and asymptomatic, and 4% were deformed and stiff at an average follow-up of 7 years. Rushforth stated that it was not possible to determine prognosis before the age of 3 years.

Ponseti and Becker (4) followed 379 children with metatarsus adductus, and documented improvement by 3 to 4 years of age in 335 patients who had flexible feet, as defined by Bleck (143). Forty-four patients (11%), with partly flexible and inflexible deformities, underwent treatment with corrective plaster casts. Farsetti et al. (3) rated 26 of 29 feet (90%) in this treated group as good, at an average follow-up of 32 years. There were no poor results or long-term functional disabilities in patients with mild or moderate residual deformity. No patient required surgical correction, and hallux valgus was not an identified problem.

The percentage of feet with metatarsus adductus that undergo spontaneous correction without treatment may actually be even higher than reported in these studies, because of the likelihood of underreporting of mild, flexible cases.

Treatment

The proposed nonoperative management for metatarsus adductus includes observation, stretching exercises, splints/braces, corrective shoes, and stretching casts. Many types of operative procedures have been recommended for resistant deformities, including soft tissue releases and osteotomies.

The prognosis for spontaneous correction of flexible deformities without treatment is excellent (3,4,136). The efficacy of passive stretching exercises is not documented. Kite (129) believed that stretching exercises performed by the parents were not effective, and Ponseti and Becker (4) believed that they were potentially harmful.

The efficacy of shoes, braces, and splints in correcting foot deformities in children has never been shown. The Denis-Browne bar has no ability to concentrate corrective forces at the site of deformity, the tarsometatarsal joints. Furthermore, some authors believe that it can do harm by creating valgus deformity of the hindfoot (4,144).

Ponseti and Farsetti and colleagues (3,4), Bleck (143), Berg (145), and others have documented the efficacy of manipulation and serial casting for the correction of partly flexible and inflexible deformities. The upper age limit for this treatment modality is not known, but most authors recommend initiation in children younger than 1 year of age (4,143,145). Anecdotal experience indicates no need to begin this treatment before 6 months of age. The details of the casting technique are important. Care must be exercised to avoid excessive valgus stress on the hindfoot (4,129). Long-leg casts are preferred. Holding casts or postcast splints and shoes have been recommended to decrease the risk of recurrence after casting, which has been reported at 8 to 37% (129,143,147).

Surgery is rarely if ever indicated for metatarsus adductus (3). Spontaneous resolution of the deformity can occur up to 4 years of age (3,4), and minor residual deformity does not necessarily lead to disability (3,5). There are no reported series examining long-term disability from residual deformity. Nevertheless, many different operative procedures have been proposed to correct the deformity. Release of the abductor hallucis has been associated with the development of hallux valgus (148). Medial midfoot capsulotomies have been reported without clearly stated indications or natural history controls (136,149).

Heyman et al. (150) described mobilization of the forefoot by capsulotomy of the tarsometatarsal joints and release of the intermetatarsal ligaments. Long-term follow-up studies (151,152) showed a 41% failure rate, with complications including skin slough, avascular necrosis of the second and third cuneiforms, dorsal prominence of the first metatarsal-cuneiform joint, and early degenerative arthrosis of those joints with pain. Osteotomies at the base of the metatarsals have been used as an extraarticular alternative approach to avoid the complications of capsulotomies (153,154). However, shortening of the first metatarsal from a nonunion or physeal injury, a devastating complication, has been reported in 5 to 30% of patients (153,155,156).

In the rare situation of an older child with disability related to residual deformity, it seems logical to perform the operative correction at the site of the deformity. An opening-wedge osteotomy of the medial cuneiform will

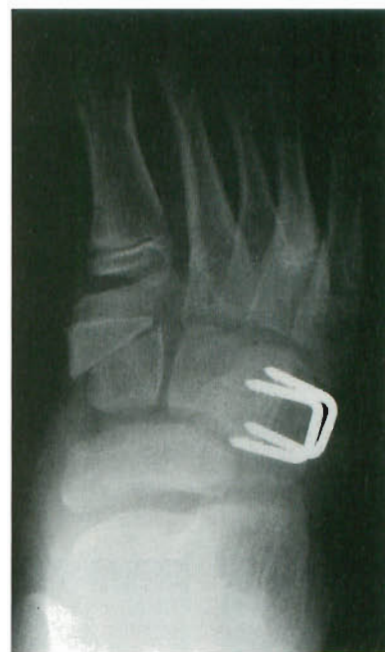

FIGURE 29-11. Correction of symptomatic metatarsus adductus in an older child with an opening-wedge osteotomy of the medial cuneiform and a closing-wedge osteotomy of the cuboid.

change the malformed bone from a trapezoid to the normal rectangular shape, and, thereby, correct the orientation of the first metatarsal-cuneiform joint (116). This procedure [↗7.6] can be combined with closing-wedge osteotomy of the cuboid (Fig. 29-11), or with osteotomies at the bases of metatarsals two through four, in the more severe and resistant case (118–121). These osteotomies have been shown to be safe and effective, although they are rarely indicated. Careful preoperative assessment of the hindfoot is necessary to determine if the apparent metatarsus adductus is, in fact, a skewfoot deformity.

Skewfoot

Definition

“Skewfoot” is the term used most commonly to designate a rare and poorly defined foot shape that combines adduction deformity of the forefoot with valgus deformity of the hindfoot, i.e., metatarsus adductus plus flatfoot. This is a consensus definition that has been adopted recently in the medical literature (157–161), but it has not been officially adopted in medical dictionaries. It is not known how much valgus deformity of the hindfoot is necessary to reclassify a foot with presumed metatarsus adductus as a skewfoot, or how much forefoot adductus is required to reclassify a presumed flatfoot as a skewfoot. Skewfoot is generally discussed in the

literature in relation to metatarsus adductus; however, disability caused by this condition is most often related to the hindfoot deformity (159). Inconsistent terminology was used in the three seminal articles on this deformity in the English literature. Peabody and Muro (137) labeled it "congenital metatarsus varus," McCormick and Blount (130) coined the term "skewfoot," and Kite (128) called it "serpentine metatarsus adductus." Interestingly, McCormick and Blount (130) used the term "skewfoot" to describe a group of deformities of the foot that included the shape that is now called skewfoot. Consistency was found in these articles in the reported rarity of the deformity, and in the difficulty of correcting and maintaining correction of the deformity.

Epidemiology

The lack of a strict definition has contributed to the lack of information on this deformity, including its incidence, pathogenesis, natural history, and treatment. It has been stated, without verification, that the diagnosis cannot be made in the newborn. Some researchers have stated that the deformity occurs as a result of improper cast treatment of metatarsus adductus and clubfoot. There are, however, clearly idiopathic cases.

Pathogenesis

The cause is unknown. Some authors believe that a skewfoot deformity can be created in a foot with metatarsus adductus by applying abduction pressure to the forefoot without stabilizing the hindfoot (4). Most cases, however, are idiopathic. The medial cuneiform in a skewfoot is trapezoid-

shaped, as it is in metatarsus adductus (157,158). A thickened portion of the tibialis anterior courses along an oblique dorsal-to-plantar groove on the concave medial border of the medial cuneiform (157,158). The etiologic significance of these findings is unknown.

Clinical Features

It is challenging to differentiate metatarsus adductus from skewfoot in an infant. The forefoot is adducted on the midfoot, there is frequently the presence of a medial skin crease, and there is normal ankle mobility. Slight valgus and severe valgus are difficult to quantify in a tiny foot with normal baby fat. In some infant feet with forefoot adductus, however, the subtalar joint is sufficiently everted that the head of the talus can be visualized and palpated medially (Fig. 29-12). The author would label such a foot a skewfoot. Valgus deformity of the hindfoot, with adductus of the forefoot, can be better appreciated in older children, adolescents (Fig. 29-13), and adults, although the deformity is often misclassified, even in the orthopaedic literature.

The types of disability associated with skewfoot in the older individual are not well documented. Callusing develops under the head of the talus (Fig. 29-14), as it does in a flatfoot, and at the base of the fifth metatarsal, as it may in severe metatarsus adductus (157-159). Shoes may wear unevenly, as occurs with a severe flatfoot. Pain develops under the callused head of the talus when there is a coexistent contracture of the Achilles tendon. This is identical to the pain and callus experienced in a flexible flatfoot with a short Achilles tendon (157-160).

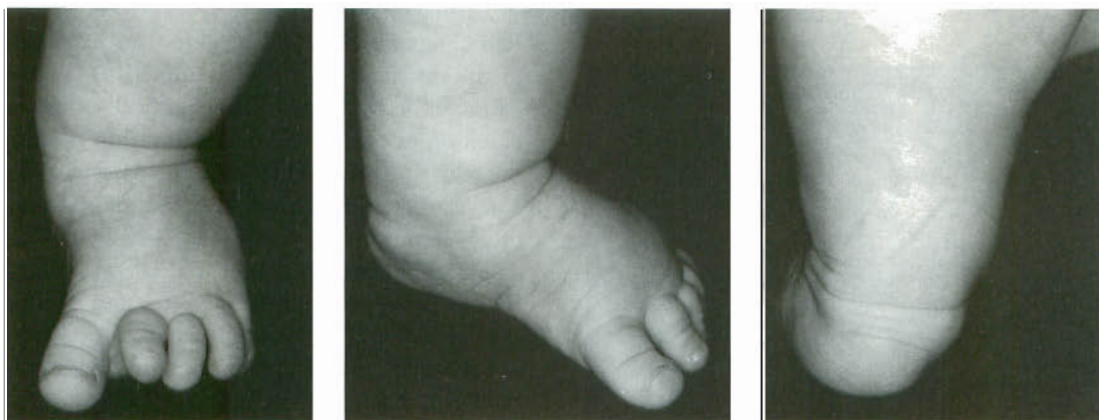


FIGURE 29-12. Probable skewfoot in an infant. Apparent metatarsus adductus, but with the head of the talus visible and palpable medially. This indicates coexistent eversion of the subtalar joint with abduction of the navicular on the head of the talus. (From ref. 157, with permission.)

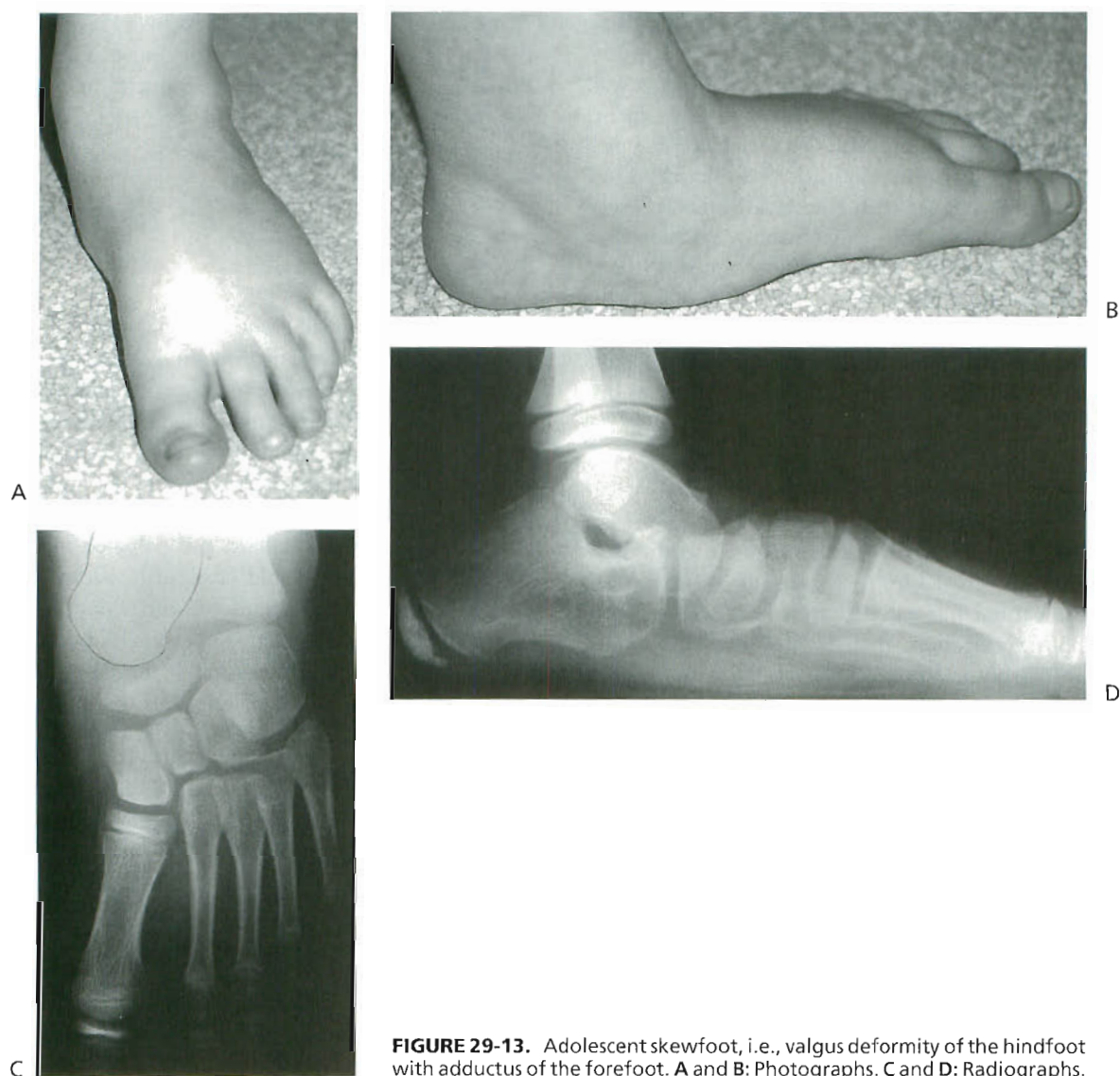


FIGURE 29-13. Adolescent skewfoot, i.e., valgus deformity of the hindfoot with adductus of the forefoot. **A** and **B**: Photographs. **C** and **D**: Radiographs.

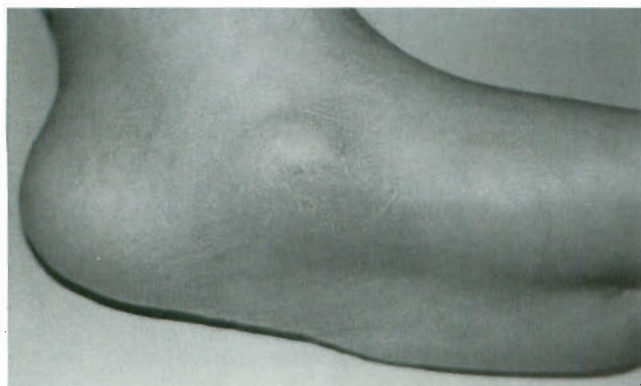

FIGURE 29-14. Painful callus that developed under the head of the talus in a skewfoot with contracted Achilles tendon.

Radiographic Features

Radiographs are not indicated for the diagnosis of skewfoot in the infant. Berg (145) attempted to classify metatarsus adductus and skewfoot radiographically, but his system was based on assessment of the relationship of the navicular to the talus at a time of life when the navicular is not ossified. The classification system was found to have poor interobserver and intraobserver reliability, by Cook et al. (146).

Standing anteroposterior and lateral radiographs of the foot in the older child, adolescent, and adult will confirm the deformities that are appreciated clinically, i.e., adductus of the forefoot on the midfoot and valgus deformity of the hindfoot. Mosca (157) was the first author to stress that the skew, or zigzag, deformity is present in both the frontal and sagittal planes (Fig. 29-15). Previously, only the frontal (anteroposterior) plane deformity was assessed and discussed

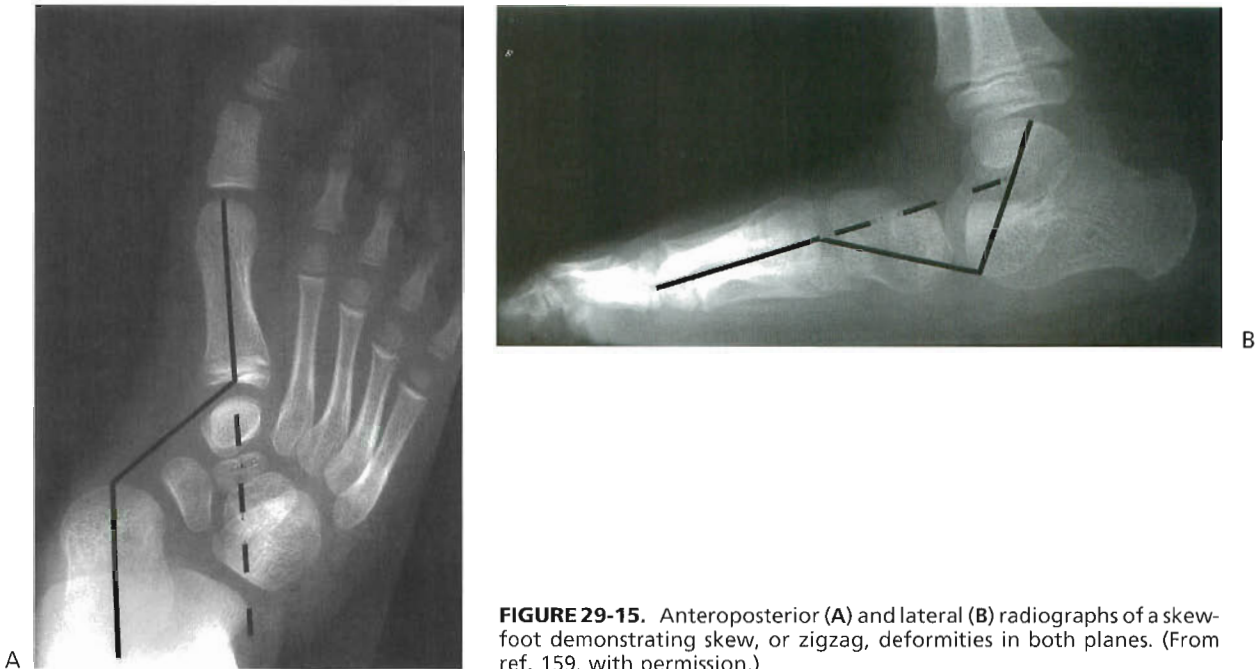


FIGURE 29-15. Anteroposterior (A) and lateral (B) radiographs of a skew-foot demonstrating skew, or zigzag, deformities in both planes. (From ref. 159, with permission.)

in the literature. Mosca (159) also identified the flaw in using the standard talus–first metatarsal angle to assess deformity between the forefoot and the hindfoot. The skew-foot has two deformities, in opposite directions from each other, between the talus and the first metatarsal, in both the frontal and sagittal planes. These angular deformities tend to cancel each other out when the talus–first metatarsal angle is measured. For that reason, a skewfoot with severe valgus deformity of the hindfoot will appear less deformed than a flatfoot with less valgus deformity, when both are assessed clinically and radiographically.

Natural History

The natural history of skewfoot is unknown. One would assume that some children undergo spontaneous correction of their skewfoot deformities with age, as occurs with metatarsus adductus (4,5) and flexible flatfoot (8,9), when each exists as an isolated deformity. The prevalence of long-term disability attributable to residual deformity is unknown, but some children have pain, callosities, and difficulty wearing shoes, as early as the end of the first decade of life (128–130,137,157–161).

Treatment

Despite the inability to definitively differentiate metatarsus adductus from skewfoot in infancy, it is reasonable to treat all feet with partly flexible and inflexible forefoot adductus with serial long-leg casting. Several authors have reported success with this approach, noting that it takes longer to

correct a skewfoot, and that additional care must be exercised to avoid valgus stress on the already deformed hindfoot (4,128–130,143,145). Berg (145) cautioned against the use of reverse last shoes and Denis-Browne bars, for the same reason.

Some older children, adolescents, and adults with skew-foot deformity will report pain and callusing under the prominent head of the plantar-flexed talus (157–160). Invariably, they have contracture of the Achilles tendon, and symptomatically resemble patients with flexible flatfoot with a short Achilles tendon (157–160). Attempts can be made to stretch the Achilles tendon by means of exercises or casts. Rigid orthoses increase the pressure under the head of the rigidly plantar-flexed talus, and should be avoided. Nonoperative management generally holds little hope of relieving symptoms. Less commonly, children with skew-foot will present with isolated or coexisting pain and callosities at the head of the first metatarsal or the base of the fifth metatarsal (160).

Surgery is indicated when nonoperative management fails to relieve the pain and callosities (157–160). Suggestions for operative management can be found in the literature, but most are based on theory, and not on reviews of operative results. Historical recommendations have included tarsometatarsal capsulotomies or osteotomies at the base of the metatarsals to correct the forefoot deformity (137) and subtalar or triple arthrodesis for the hindfoot (152,153,161). Reported complications from these procedures on the forefoot are enumerated in the section of this chapter on metatarsus adductus (151–153,155,156). Reported complications and disability from subtalar and triple

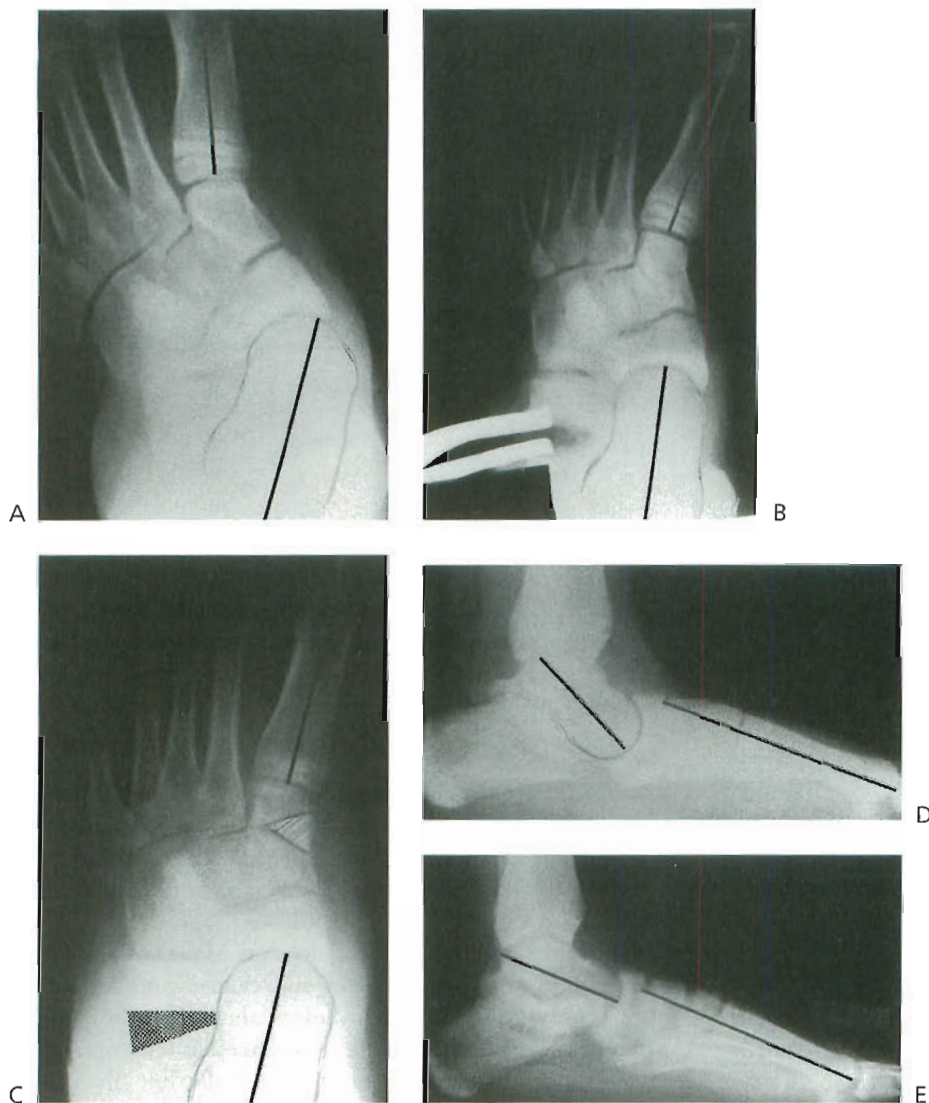


FIGURE 29-16. Preoperative, intraoperative, and postoperative radiographs of a painful skewfoot in a 13-year-old adolescent. **A:** Preop anteroposterior (AP) view. **B:** Intraop distraction of calcaneal osteotomy. **C:** Corrected deformity on AP radiograph with grafts in place. **D:** Preop lateral. **E:** Postop correction. Calcaneal lengthening osteotomy, medial cuneiform opening-wedge osteotomy, and Achilles tendon lengthening were used. (From ref. 157, with permission.)

arthrodesis are enumerated in the section of this chapter on flatfoot (19–26). Mosca (158) proposed correction of symptomatic skewfoot by combining the best and safest methods for correcting the individual deformities of the forefoot and hindfoot. In 1993, he reported the short-term results of the largest series of operatively treated skewfoot deformities using a single technique. The technique consists of calcaneal lengthening osteotomy, modified from the technique of Evans [7.5] (124,159); medial cuneiform opening-wedge osteotomy, according to Fowler et al. (116); and lengthening of the Achilles tendon (Fig. 29-16). Nine of 10 severe skewfoot deformities achieved satisfactory clinical and radiographic outcomes while maintaining joint mobility.

Flexible Flatfoot

Definition

“Flatfoot” is the term used to describe a weight-bearing foot shape in which the hindfoot is in valgus alignment, the

midfoot sags in a plantar direction with reversal of the longitudinal arch, and the forefoot is supinated in relation to the hindfoot. “Flexibility” refers to the mobility of the subtalar joint and the longitudinal arch, and the ability of both to reverse their malalignment.

Epidemiology

The true incidence of flexible flatfoot is unknown, primarily because there is no agreement on strict clinical or radiographic criteria for defining a flatfoot. Nevertheless, it is believed that most children (8,9) and at least 20% of adults (7) have flatfeet, most of which are flexible. Harris and Beath (7) used their own criteria when they identified flatfoot in approximately 23% of the 3,619 adults whom they examined. They classified them into three types and emphasized that the flatness of the arch in weight bearing is less important than the mobility of the joints and tendons. The flexible, or hypermobile, type of flatfoot was characterized

by good mobility of the joints and tendons. It accounted for two-thirds of the flatfeet, and was found to be of little or no clinical concern as a potential cause of disability. Contracture of the Achilles tendon was associated with a flexible, or hypermobile, flatfoot in 25% of the total. This type was found to be a cause of pain and disability (7,162). The least common type was the rigid flatfoot, which was characterized by restricted mobility of the subtalar joint. This type was usually caused by a tarsal coalition, and painful disability was sometimes observed. Flexible flatfeet are said to run in families, although there are, to my knowledge, no data to support this statement. The frequency of flatfeet may be the basis of this observation.

Pathogenesis

There are two main theories explaining the pathogenesis of flexible flatfoot. Duchenne (163) used faradic stimulation of the peroneus longus muscle to produce a longitudinal arch in a child's flatfoot. He felt that subclinical muscle weakness was responsible for the flexible flatfoot, a theory that has been supported by other authors. That theory was fairly decisively refuted by Basmajian and Stecko (164), who demonstrated little or no electromyographic activity in the muscles of the foot and ankle, when physiologic loads were applied to the static plantigrade foot in study subjects. They concluded that the bone–ligament complex determines the height of the longitudinal arch, whereas the muscles maintain balance, accommodate the foot to uneven terrain, protect the ligaments from unusual stresses, and propel the body forward. Mann and Inman (165) confirmed this theory. They also found that the intrinsic muscles are the principal stabilizers of the foot during propulsion, and that greater intrinsic muscle activity is required to stabilize the transverse tarsal and subtalar joints in a flatfooted individual than in an individual with an average height arch.

Harris and Beath (162) and others supported the theory that the shape and function of the foot is dependent on the design, configuration, and relative position of the tarsal bones. They were unable to determine whether the abnormal shape of the bones and joints was primary or secondary to the lax ligaments.

The effects of extrinsic factors on the shape and development of the longitudinal arch is suggested by studies from developing countries. Sim-Fook and Hodgson (166), in China, and Rao and Joseph (167), in India, found a higher prevalence of flatfeet among children who wore shoes compared with children who did not.

Clinical Features

The clinical assessment should consist of a general examination of the musculoskeletal system in addition to the specific foot and ankle examination. The general examination is aimed at assessing ligament laxity, torsional and angular variations of the lower extremities, and the walking pattern.

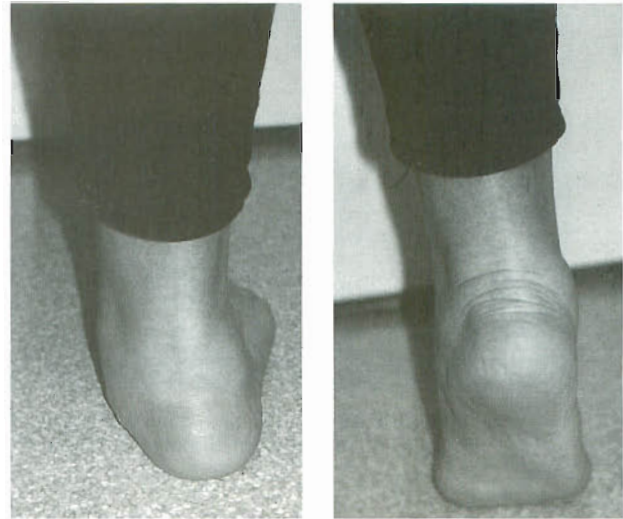

FIGURE 29-17. The arch elevates and the heel corrects from valgus to varus in a flexible flatfoot during toe standing, as a result of the windlass effect of the plantar fascia. (From ref. 157, with permission.)

Assessment of the foot and ankle begins with the recognition that a flatfoot is not a deformity. It is a combination of deformities that includes a valgus deformity of the hindfoot and a supination deformity of the forefoot. There is a lateral rotational deformity as well. The axis of the subtalar joint complex is in an oblique plane, such that eversion creates valgus, external rotation, and dorsiflexion of the so-called pes acetabulum around the talus. The mobility, or flexibility, of the subtalar joint in a flexible flatfoot is revealed by toe standing (Fig. 29-17), and by the Jack toe-raise test (168) (Fig. 29-18). These two maneuvers take advantage of the windlass action (169) of the plantar fascia to mobilize the subtalar joint into inversion and create a longitudinal arch (Fig. 29-19). Supination deformity of the forefoot on the hindfoot is revealed when the hindfoot deformity is passively corrected by inversion. Functional motion of the ankle joint, as assessed by excursion of the Achilles tendon, is important yet difficult to evaluate accurately. A component of eversion of the subtalar joint is dorsiflexion of the calcaneus in relation to the talus. Therefore, the subtalar joint must be held inverted to neutral to isolate and assess the motion of the talus at the ankle. The knee is then flexed, the ankle is dorsiflexed, and the knee is extended while trying to maintain maximum dorsiflexion of the ankle. Dorsiflexion is measured as the angle between the lateral border of the foot and the anterior tibial shaft.

A family history of flatfeet should be ascertained, with particular attention paid to the existence of pain or other disability.

Radiographic Features

Radiographs of the flatfoot are not necessary for diagnosis, but they may be indicated for the assessment of pain or

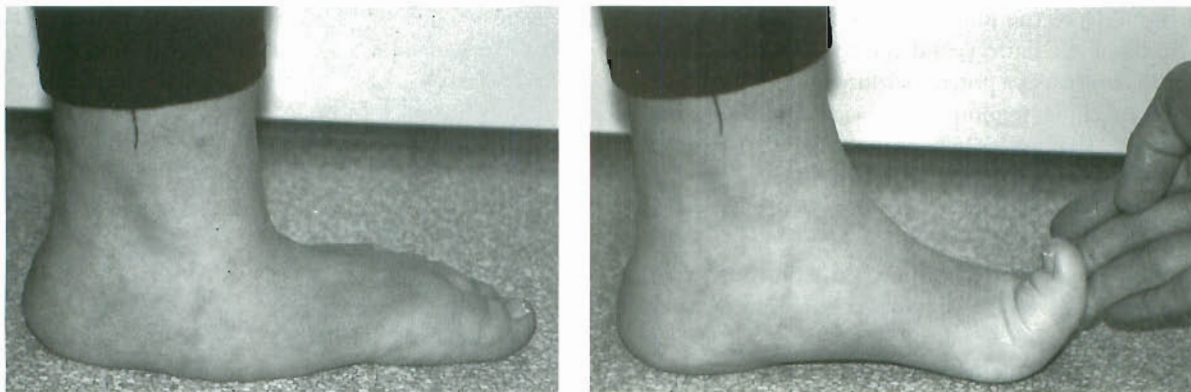

FIGURE 29-18. The arch elevates in a flexible flatfoot with the Jack toe-raise test, as a result of the windlass effect of the plantar fascia. (From ref. 157, with permission.)

decreased flexibility, and for surgical planning. Weight-bearing anteroposterior and lateral views are generally sufficient to evaluate the flexible flatfoot, whereas the addition of the oblique and axial, or Harris, views is necessary to evaluate the rigid flatfoot. Radiographs can define the static relationships between bones, but they cannot provide information on flexibility or function. They should not be used as an indication for treatment. This was the conclusion of the study on radiographs of the adult foot by Steel et al. (170) and the study on radiographs of the child's foot by Vanderwilde et al. (9).

The lateral radiograph of a flatfoot reveals plantar flexion of the calcaneus, measured by the calcaneal pitch, and an even greater degree of plantar flexion of the talus, measured by the talus–horizontal angle (Fig. 29-20). Dorsiflexion of the navicular on the head of the plantar-flexed talus creates a midfoot sag with lowering of the longitudinal arch that can be quantified using the talus–first metatarsal angle. Meary (171) determined that the normal talus–first metatarsal angle is zero degrees, or a straight line, but there is in fact a range of normal values. The lateral view can also be used to identify alternative or additional sites of midfoot sag.

The anteroposterior radiograph is less helpful in quantifying flatfoot deformity in a child. The subtalar complex in a flatfoot is excessively everted, a malalignment that combines external rotation and dorsiflexion of the calcaneus, in

relation to the talus, with abduction and dorsiflexion of the navicular on the head of the talus. The axis of the calcaneus is frequently difficult to assess on the anteroposterior radiograph, because of technical considerations. Therefore, assessment of the relationship at the talonavicular joint is critical. Unfortunately, the child's navicular ossifies eccentrically beginning laterally, making it unreliable for positional assessment. The anteroposterior talus–first metatarsal angle has been used as an alternative means of evaluating that relationship, but it is unreliable as well. As discussed in the skewfoot section of this chapter, abduction or adduction at the tarsometatarsal joint will falsely exaggerate or minimize the apparent deformity at the talonavicular joint if assessed using the talus–first metatarsal angle (159).

Radiographs can also be used to determine if a painful midfoot prominence is the head of the talus or an accessory navicular.

Natural History

Flatfeet are ubiquitous in infants. Footprint (8) and radiographic (9) studies have confirmed that the average arch height is lower in the child than in the adult. The height of the longitudinal arch generally increases spontaneously during the first decade of life in most children. And there is a wide range of normal arch heights at all ages (particularly in young children) (Fig. 29-21).



FIGURE 29-19. The windlass effect of the plantar fascia. The drum of the windlass is the head of the metatarsal. The handle is the proximal phalanx, and the cable wound onto the drum is the plantar aponeurosis, through its attachment to the plantar pad of the metatarsophalangeal joint. Dorsiflexion of the toes creates elevation of the longitudinal arch. (From ref. 169, with permission.)

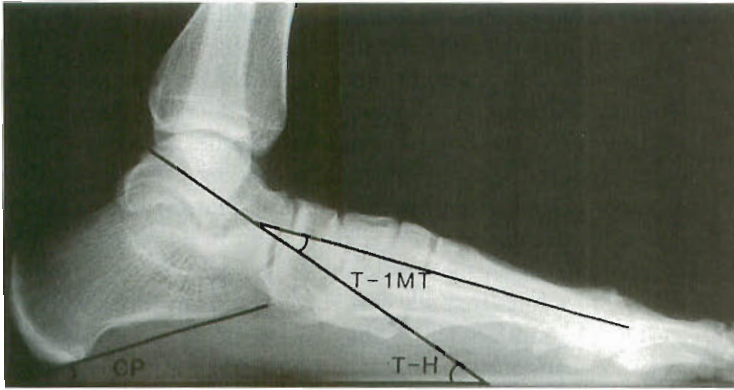


FIGURE 29-20. Weight-bearing lateral radiograph. The calcaneal pitch (CP) and the talus-horizon angle (T-H) are the best measurements to assess valgus deformity of the hindfoot. T-1MT, talus-first metatarsal angle. (From ref. 159, with permission.)

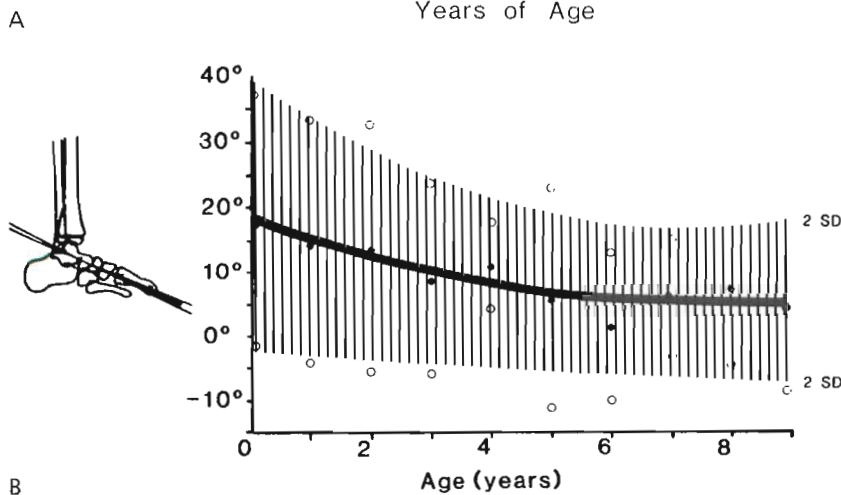
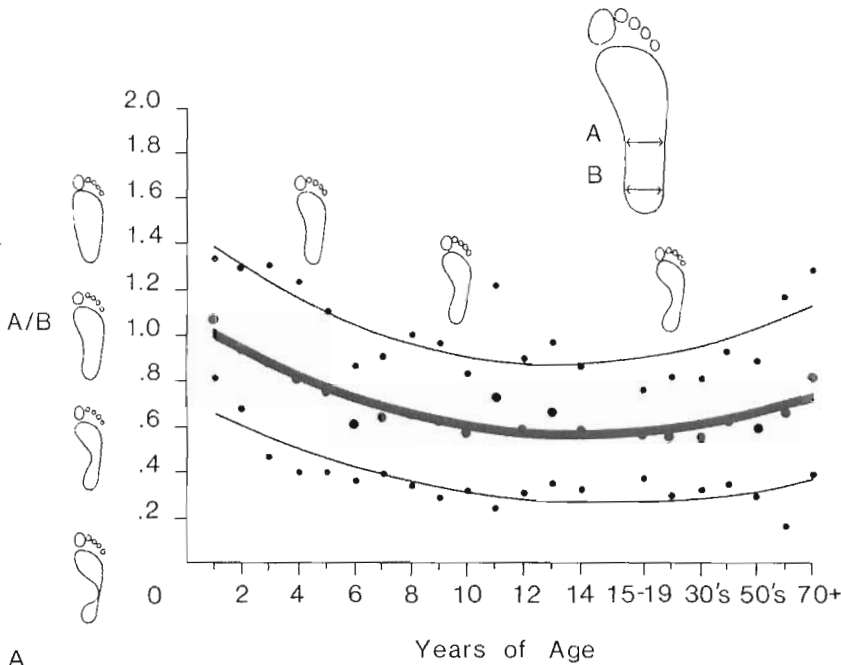


FIGURE 29-21. A: Footprints from individuals of all ages show that children are more flat-footed than adults, that there is a wide range of normal arch heights, and that the arch generally elevates spontaneously during the first decade of life. (From ref. 8, with permission.) B: Radiographs from children of all ages confirm the footprint data. The drawing and graph represent the lateral talus-first metatarsal angle. (From ref. 9, with permission.)

Treatment

There are no long-term, prospective clinical studies on the natural history of flexible flatfoot. The information that has been presented is cross-sectional and inferential. Much of the understanding of the benign nature of flexible flatfoot has only recently been elucidated. Most authorities now agree that the flexible flatfoot is an anatomic variant, and not a potentially disabling deformity (7,157,170). Nevertheless, controversy abounds.

Earlier, uncontrolled studies indicated an efficacy of orthotic devices and shoe modifications in the development of the arch in the child's foot (172). More recent, prospective, randomized, controlled studies revealed no benefit from shoe modifications and inserts, compared to spontaneous development of the longitudinal arch (10,11,173). Driano et al. (174) reported long-term negative psychologic effects on adults who had worn shoe modifications as children compared with controls. Therefore, one must conclude that the management of the asymptomatic flexible flatfoot is education of the child and family.

Some children with flexible flatfoot have activity-related pain in the leg or foot. The pain is usually diffuse and nonlocalized, and it is believed to represent an overuse, or fatigue, syndrome. This is consistent with the findings of Mann and Inman (165) that flatfooted individuals demonstrate greater intrinsic muscle activity than normal. Over-the-counter and custom-molded shoe inserts have been shown to relieve or diminish symptoms, and to increase the useful life of shoes without a simultaneous permanent increase in the height of the arch (175). There is no scientific justification for surgery in these children.

Some children with flexible flatfoot have pain with weight bearing and callosities under the head of the plantar flexed talus. The Achilles tendon is contracted in these children. The contracted Achilles tendon prevents normal dorsiflexion of the ankle joint during the midstance phase of gait, and shifts the dorsiflexion stress to the subtalar joint complex. The talus remains rigidly plantar flexed. The soft tissues under the head of the talus are subjected to excessive direct axial loading and shear stress. Firm or hard arch supports exaggerate these pressures. An aggressive stretching program for the Achilles tendon, performed with the subtalar joint inverted, may relieve the symptoms in this clinical situation. Failure to relieve this localized pain with prolonged attempts at conservative management is an indication for operative reconstruction of the foot (159).

Surgery is rarely, if ever, indicated for flexible flatfoot. Nevertheless, numerous surgical procedures to correct flatfoot have been proposed during the last century. The indications for these procedures, whether for correction of deformity, relief of symptoms, or prophylaxis, are difficult to ascertain from a review of the literature. The procedures can be categorized as soft tissue plications, tendon lengthenings and transfers, osseous excisions, osteotomies, arthrode-

sis of one or more joints, and interposition of bone or synthetic materials into the sinus tarsi. Any procedure should be judged by its ability to achieve and maintain relief of pain and correction of even severe deformity. There have been very few long-term outcome studies on any of these procedures. Nevertheless, those that have been reported have helped to narrow the surgical choices. Mosca (157) recently reviewed the literature, and can be referred to for more detail on these procedures.

Procedures that rely entirely on soft tissue plications and tendon transfers fail in the short term. Osseous excisions were abandoned years ago, because of their obvious destructive nature. Arthrodesis of one or more of the joints in the subtalar complex has been abandoned, because of the detrimental effect of eliminating the shock-absorbing function of that important joint complex. Subtalar and triple arthrodesis shift stress to the ankle and midtarsal joints, leading to premature degenerative arthrosis at those sites (19–26). The most popular procedures used during the last 60 to 70 years are the many modifications of Hoke's limited midtarsal arthrodesis (16–18,168,176–178). These procedures combine arthrodesis of one or more midtarsal joints with soft tissue plication across the talonavicular joint. Favorable short-term results have been reported consistently, but unsatisfactory long-term results were reported in 68 of 138 cases (49%) by Butte (16), 16 of 32 cases (50%) by Seymour (18), and 7 of 9 cases by Crego and Ford (17). The unsatisfactory feet in these series frequently showed degenerative changes at the talonavicular joints, in addition to persistence or recurrence of pain and deformity. Furthermore, the originators of these procedures acknowledged that the procedures were not capable of correcting severe valgus deformities. They recommended triple arthrodesis for those feet.

"Arthroereisis" is the term applied to procedures that limit, but do not eliminate, the motion of a joint with abnormal mobility. Arthroereisis of the subtalar joint in flexible flatfeet has been reported using bone, silicone, and ultra-high-molecular-weight polyethylene pegs in the sinus tarsi (179,180). The bone grafts frequently undergo resorption. Reported complications of the prosthetic implants include pain, malpositioning, breakage, extrusion, infection, and reactive synovitis. Most orthopaedists prefer a biologic approach to deformity in children.

Osteotomy is the last category of procedures. This is a biologic approach that avoids arthrodesis and its known complications. There are two types of osteotomies of the calcaneus that address valgus deformity of the hindfoot. Medial displacement of a posterior calcaneal osteotomy (181) will improve the valgus appearance of the hindfoot by creating a compensating deformity. It does not correct the malalignment of the subtalar joint, which includes external rotation of the foot under the talus and dorsolateral displacement of the navicular on the head of the talus. Rathjen and Mubarak (182) reported good correction of flatfoot

deformities by combining this osteotomy with closing-wedge osteotomy of the medial cuneiform, opening-wedge osteotomy of the cuboid, and medial reefing of the talonavicular joint.

The other osteotomy for correction of valgus deformity of the hindfoot is the calcaneal lengthening osteotomy [7.5] described by Evans (124). It has been shown to correct all components of even severe eversion of the subtalar complex (valgus deformity of the hindfoot) at the site of deformity (124,159,183–185). Additionally, it restores the function of the subtalar complex, relieves symptoms, and, theoretically, protects the ankle and midtarsal joints

from early degenerative arthrosis by avoiding arthrodesis (124,159,183–185). Based on the stated pathology and the indications for treatment, lengthening of the Achilles tendon is always necessary [7.16, 7.17]. Supination of the forefoot is an additional deformity in a flatfoot that is rotationally in the opposite direction from the hindfoot deformity. If it is a structural deformity, it must be treated with an additional procedure on the medial column of the foot, such as a plantar-based closing-wedge osteotomy of the medial cuneiform (159,183). It is only when all three deformities are corrected that the flatfoot has been corrected (159) (Fig. 29-22). There are few indications for

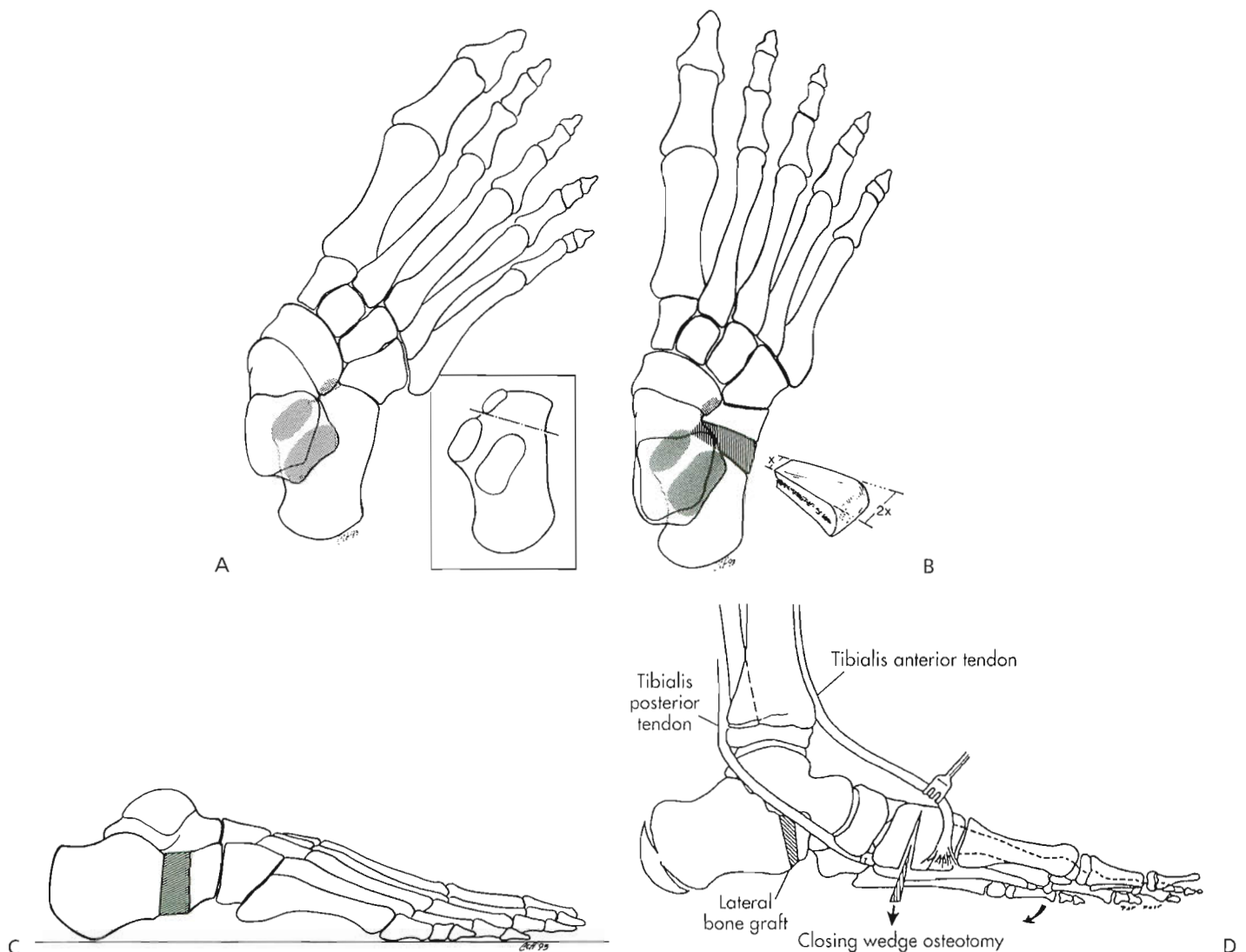


FIGURE 29-22. A: Calcaneal lengthening osteotomy. Dashed line indicates the position of the oblique osteotomy between the anterior and middle facets of the calcaneus. B and C: Insertion of the trapezoid-shaped tricortical iliac crest bone graft corrects all components of the valgus deformity of the hindfoot. D: A plantar-based closing-wedge osteotomy of the medial cuneiform corrects the supination deformity of the forefoot. Lengthening of the gastrocnemius or the Achilles tendon is almost always necessary. (A, B, and C from ref. 159, with permission; D from ref. 183, with permission.)

surgery for flexible flatfeet, except in those with tight Achilles tendons. There are no surgical panaceas, but the combination of procedures just described has the best chance of long-term success, while leaving other surgical options for the future.

Congenital Vertical Talus (Congenital Convex Pes Valgus)

Definition

Congenital vertical talus is a dorsolateral dislocation of the talonavicular joint, and occasionally the calcaneocuboid joint, associated with extreme and rigid plantar flexion of the talus, eversion of the subtalar joint, and fixed dorsiflexion of the midfoot on the hindfoot (186). Other historic terms used to describe this deformity include congenital rocker-bottom foot, congenital convex pes valgus, and congenital flatfoot with talonavicular dislocation.

Epidemiology

The incidence of this deformity is unknown. Several large series have reported that this rare deformity occurs as an isolated congenital abnormality in approximately half of all cases, and is associated with neuromuscular and genetic disorders in the rest (187–190). There is no sex predilection, and approximately 50% of children have bilateral involvement (189).

Pathogenesis

There are probably multiple causes of this deformity. There is evidence that some cases of the isolated deformity are transmitted as an autosomal dominant trait with incomplete penetrance (190,191). Cases associated with neural tube defects, such as myelomeningocele, sacral agenesis, and diastematomyelia, are attributable to muscle imbalance (192). It is a different type of muscle imbalance that creates the deformity in children with arthrogryposis.

Clinical Features

Congenital vertical talus has a rigid, convex plantar surface, giving the foot the appearance of a Persian slipper (Fig. 29-23). Lloyd-Roberts and Spence (193) described the clinical appearance as “a prominence in the sole from which the heel and forefoot rise in a gentle curve.” The Achilles tendon is contracted, and the hindfoot is in a fixed equinovalgus position. There are few posterior heel creases. The head of the talus is palpable on the plantar-medial aspect of the midfoot. The midfoot is dorsiflexed and abducted on the hindfoot, and cannot be plantar flexed. There is a crease overlying the narrow, concave sinus tarsi. The hallmark finding in congenital vertical talus is that none of the deformities is correctable by manipulation. The arch cannot be created, nor can the head of the talus be covered by the navicular.

Oblique talus is a term often mentioned in discussions of congenital vertical talus. To the author’s knowledge, there is no consensus definition of this deformity or any primary literature on the subject. The author’s belief is that oblique talus exists as a milder and more flexible form of congenital vertical talus, but that it is a more severe and rigid deformity than flexible flatfoot with a short Achilles tendon.

It is important to differentiate congenital vertical talus from positional calcaneovalgus, congenital posteromedial bowing of the tibia, and equinovalgus foot deformity associated with fibula hemimelia. The feet in these conditions are flexible, and the arch can be exaggerated by manipulation.

Radiographic Features

Lateral radiographs of the foot, obtained with the foot in maximum plantar flexion and maximum dorsiflexion are recommended to confirm the diagnosis, notwithstanding the limitations of radiographs discussed in the section on clubfoot (192). The talus, calcaneus, and metatarsals are ossified at birth, and the cuboid generally ossifies within the first month of life. These centers of ossification enable one to confirm the diagnosis radiographically soon after

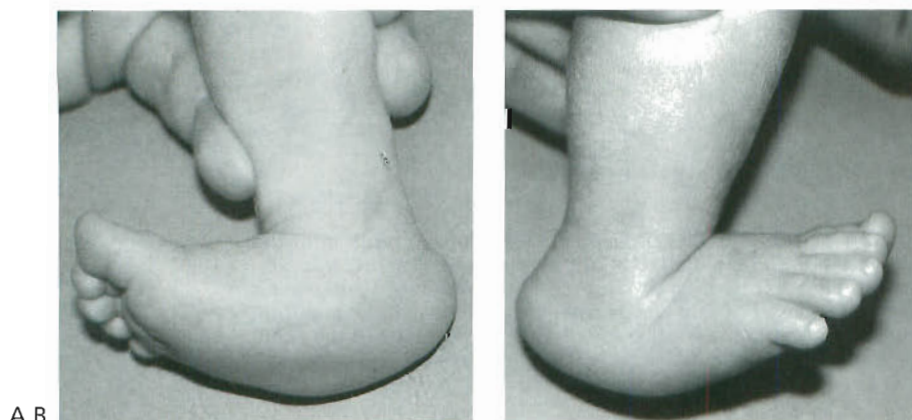


FIGURE 29-23. Congenital vertical talus in an infant. A: Medial. B: Lateral.

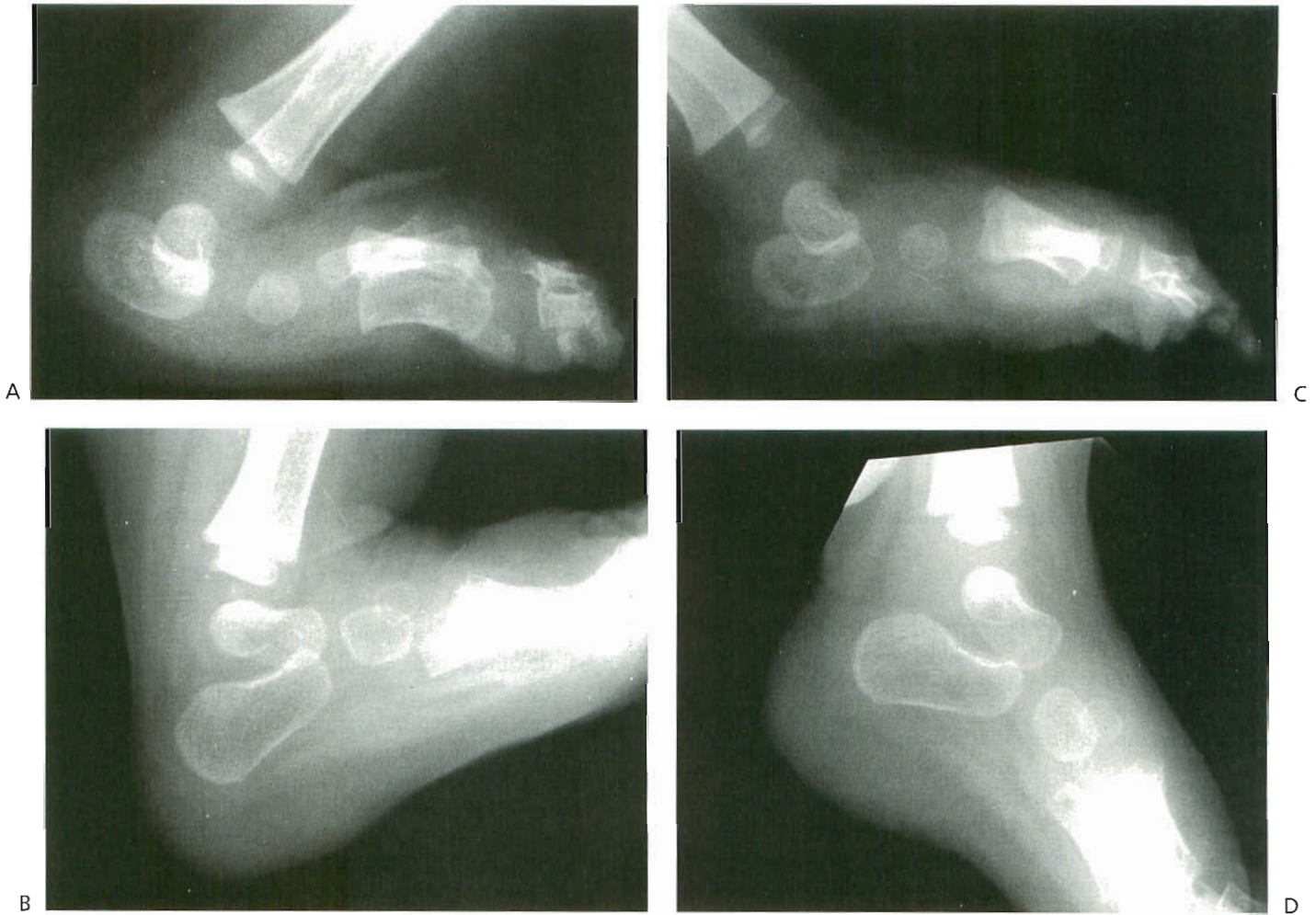


FIGURE 29-24. A: Lateral dorsiflexion radiograph of congenital vertical talus, showing persistent plantar flexion of the talus and calcaneus. B: Lateral dorsiflexion radiograph of a normal foot, showing full dorsiflexion of the talus and calcaneus. C: Lateral plantar flexion radiograph of congenital vertical talus, showing persistent dorsal translation of the forefoot on the hindfoot. D: Lateral plantar flexion radiograph of a normal foot, showing good alignment of the forefoot on the hindfoot.

birth. The maximum dorsiflexion view shows the persistence of plantar flexion of the talus and calcaneus, caused by contracture of the Achilles tendon and posterolateral joint capsules (Fig. 29-24A). In a normal foot, the talus dorsiflexes to a right angle with the tibia and the calcaneus dorsiflexes at least 20 degrees past a right angle with the tibia (Fig. 29-24B). The maximum plantar flexion view shows persistent dorsal translation of the forefoot on the hindfoot, caused by fixed dorsal dislocation of the navicular on the head of the talus (Fig. 29-24C). In a normal, unstressed foot, the axes of the talus and first metatarsal create a nearly straight line. In a normal foot that is maximally plantar flexed, those lines intersect in the midfoot, creating an apex dorsal angle (Fig. 29-24D). The position of the cuboid in relation to the calcaneus should also be noted, because it may be dorsally subluxated to varying degrees in congenital vertical talus.

The author believes that an oblique talus can be characterized radiographically, although there is no literature to confirm or refute this statement. With manipulation of an oblique talus deformity, the talus will partially dorsiflex and the midfoot will plantarflex to an improved, but not complete, alignment at the talonavicular joint.

Pathoanatomy

Postmortem dissections have provided some consistent pathoanatomic findings. Several authors have reported abnormal contractures of the extrinsic muscles, but reached different conclusions on the primary muscle imbalance that leads to the deformity (194–197). Most found contractures of the tibialis anterior, extensor hallucis longus, extensor hallucis brevis, peroneus tertius, peroneus longus, peroneus brevis, and Achilles tendon. The peroneus longus and peroneus

brevis were anteriorly subluxated at the lateral malleolus. The tibialis posterior was noted to be atrophied and anteriorly subluxated at the medial malleolus. There was dorsal extension of the articular cartilage of the talar head, to accommodate the proximal articular surface of the navicular, which was wedge-shaped with a hypoplastic plantar segment. The severe plantar flexion of the talus resulted in minimal contact of only the most posterior aspect of the talar dome with the tibia. The head of the talus was oval-shaped. The calcaneus was severely externally rotated and everted, and in close proximity to the lateral malleolus. The sustentaculum tali was hypoplastic, and the anterior subtalar facet was absent. The posterior facet of the subtalar joint had an increased lateral tilt. The dorsal capsule of the talonavicular joint was thickened and contracted, whereas the plantar calcaneonavicular (spring) ligament was attenuated. The plantar half of the cuboid was hypoplastic, and the entire bone was dorsolaterally subluxated on the calcaneus.

Natural History

Congenital vertical talus persists and causes disability if untreated. The rigidly plantar-flexed head of the talus becomes the predominant weight-bearing surface of the foot, with the development of callosities and pain. The heel does not contact the ground. There is no push-off. The gait simulates that of someone with a Syme amputation, but without the well-cushioned heel pad under the weight-bearing bone. If one accepts the author's definition of oblique talus as existing on a continuum between congenital vertical talus and flexible flatfoot, with a short Achilles tendon (but closer to the vertical talus), the prognosis for the untreated foot is poor.

Treatment

As with clubfoot, treatment for the congenital vertical talus and the oblique talus begins with manipulation and serial casting, but with the forces applied in exactly the opposite direction. The foot is stretched into plantar flexion and inversion, in an attempt to elongate the contracted dorsolateral tendons, joint capsules, and skin. It is not possible to concurrently manipulate the hindfoot into dorsiflexion and inversion, because of its small size and dense capsular contractures. Essentially 100% of vertical talus deformities and an undocumented percentage of oblique talus deformities will fail to achieve deformity correction with casting, and will require surgery. Nevertheless, casting is considered important to stretch the dorsal soft tissues and, thereby, decrease the complexity of the operation (189,190,192,196).

Surgical treatment options include one-stage or two-stage circumferential release, talectomy, naviculectomy, subtalar arthrodesis, triple arthrodesis, and lateral column lengthening. Talectomy was recommended by Lamy and Weissman in 1939 (186), but was soon abandoned. It is a destructive, rather than a reconstructive, procedure that

does not address the pathology. Additionally, it leaves no options for treating future problems that may arise. The primary choices for operative treatment of congenital vertical talus in a child younger than approximately 2 years of age are one-stage and two-stage circumferential release and reduction. The first stage of the two-stage procedure consists of lengthening of the contracted dorsolateral tendons and release of the contracted dorsolateral joint capsules, with reduction of the forefoot on the hindfoot. The second stage consists of posterolateral release of the contracted capsules and lengthening of the Achilles and peroneal tendons. The one-stage procedure simply combines the two steps into one. Ogata et al. (190) found an increased incidence of complications with the two-stage procedure, including avascular necrosis of the talus. Most authors now recommend the one-stage procedure (190,192,198–201), reporting results that are comparable to or better than those reported with the two-stage approach (189,202,203). Several authors have reported the addition of a full or split transfer of the tibialis anterior to the head or neck of the talus (192,198,199,204,205). Although the efficacy of these transfers has not been scientifically proven, the split transfer adds little time and no morbidity, and makes sense theoretically. The peroneus longus, the plantar flexor of the first ray of the foot, is congenitally contracted and strong. Complete transfer of the tibialis anterior, the dorsiflexor of the first ray, could lead to muscle imbalance and the progressive development of a cavus foot deformity. The split transfer leaves some dorsiflexion power on the first ray, while adding supplemental support to the head of the talus.

It is not clear if there is an upper age limit for this reconstructive approach. There is disproportionate growth of the medial and lateral borders of the foot with chronically unreduced vertical talus. Physiologic compression that is normally associated with a reduced talonavicular joint is lacking. Longitudinal overgrowth of the medial border occurs according to the Hueter-Volkman law. Excessive compression along the lateral border of the foot inhibits normal longitudinal growth. This phenomenon may be seen as early as 2 to 3 years of age. It manifests as an inability to fully reduce the deformity, or as residual deformity, despite full reduction of the talonavicular joint. Shortening of the medial column and lengthening of the lateral column of the foot are two approaches to management. Some authors (206,207) have recommended naviculectomy as both a primary and a salvage procedure for congenital vertical talus. It is an effective technique for shortening the medial column of the foot. The proximal articular surfaces of the cuneiform bones have a combined configuration almost identical to that of the proximal articular surface of the navicular. They create a reasonably congruous articulation with the talar head, which is further improved over time according to the Hueter-Volkman law. Posterolateral release is combined with naviculectomy for full deformity correction in this group of slightly older children (Fig. 29-25). The upper

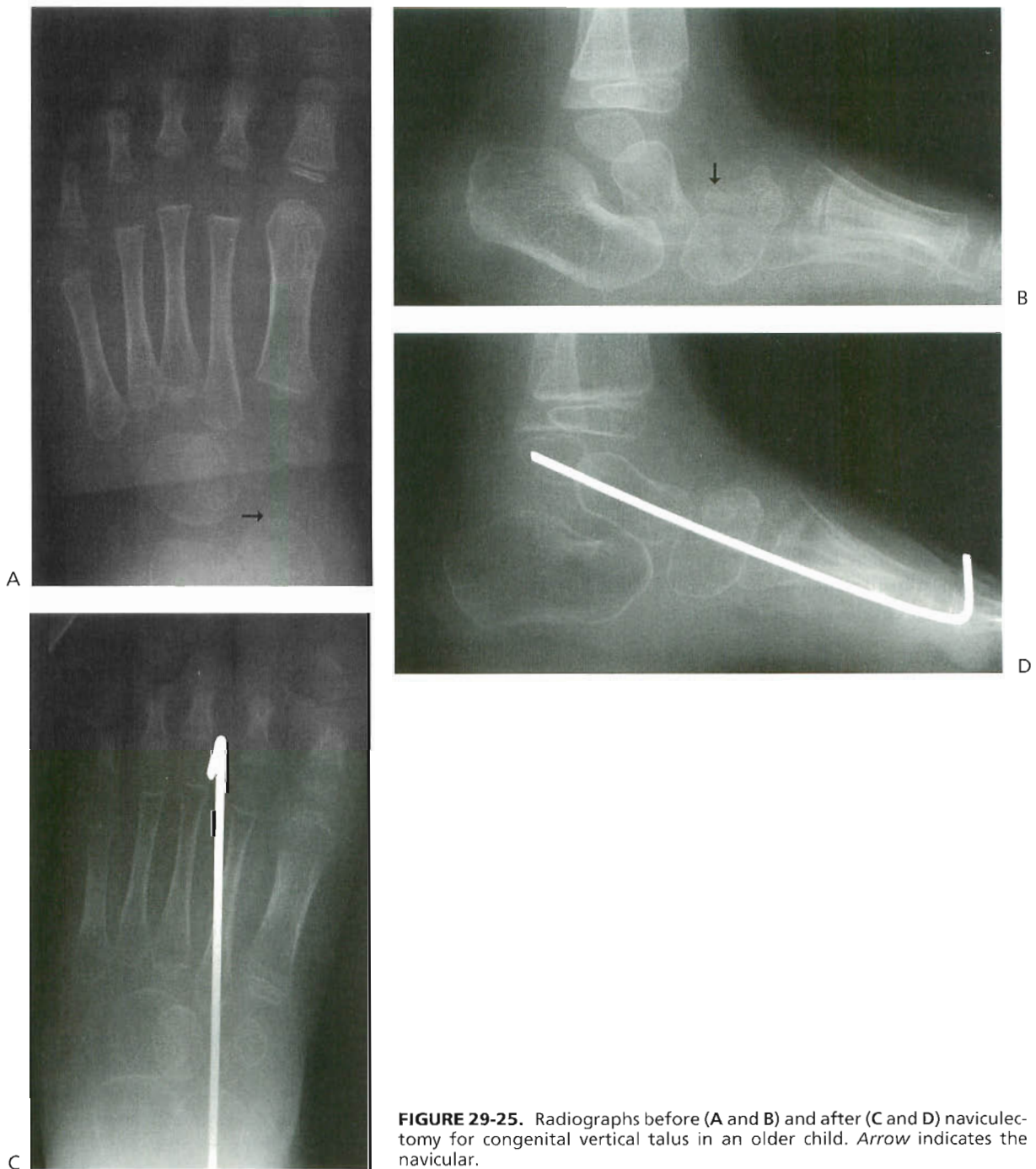


FIGURE 29-25. Radiographs before (A and B) and after (C and D) naviclectomy for congenital vertical talus in an older child. Arrow indicates the navicular.

age limit for this procedure is unknown. The alternative approach of lengthening the lateral column for the older child with residual vertical talus deformity has not been reported. The congenitally contracted skin along the lateral border of the foot limits the applicability of this technique.

Early diagnosis and treatment should eliminate the need for other surgical options in young children. Nevertheless, subtalar (204,205) [➤7.10] and triple arthrodeses [➤7.9]

have been reported for this condition, as they have for almost every major foot deformity in the child. The literature clearly shows that these techniques are associated with a high rate of complications, including the development of degenerative arthritis at the ankle and midtarsal joints (19–26). Napiontek (208) reported overcorrection of the valgus deformity in half of his patients who underwent peritalar reduction combined with subtalar arthrodesis.

Arthrodeses of the joints of the hindfoot, therefore, should be reserved as salvage procedures for the adolescent and adult with painful recurrent deformity or painful degenerative arthritis.

Positional Calcaneovalgus

Definition

Positional calcaneovalgus deformity is characterized by marked dorsiflexion of the entire foot at the ankle joint with mild and flexible eversion of the subtalar joint (Fig. 29-26). The soft tissues of the dorsal and lateral aspects of the foot are contracted and limit, but rarely prevent, plantar flexion and inversion. The dorsum of the foot is often in contact with the anterior shin.

Epidemiology

Wetzenstein (209) reported the incidence at 30 to 50%, and Wynne-Davies (135) reported it at 1 per 1,000 live births. The true incidence figures are not known, but positional calcaneovalgus may be the most common deformity of the foot seen at birth. It is more common in girls, first-born children, and children of young mothers.

Pathogenesis

The probable cause is intrauterine malpositioning.

Clinical Features

The importance of discussing this condition is to differentiate it from other, more serious deformities. Congenital

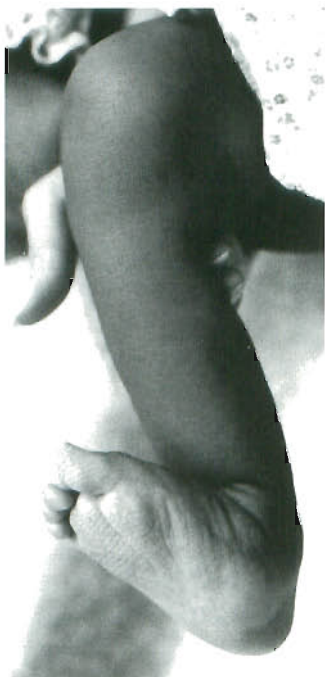

FIGURE 29-26. Positional calcaneovalgus foot deformity.

vertical talus is the most important condition from which to differentiate positional calcaneovalgus. In contrast to the latter condition, congenital vertical talus is characterized by fixed equinus and valgus of the hindfoot, rigid dorsiflexion of the midfoot on the hindfoot, and the inability to create a longitudinal arch by manipulation. Congenital posteromedial bowing of the tibia may also be confused with positional calcaneovalgus, but physical examination and radiography can easily differentiate it. Paralytic calcaneovalgus, due to lack of active plantar flexion, can be seen at birth in children with myelomeningocele. The underlying diagnosis should be apparent.

Radiographic Features

Radiographs of a foot with positional calcaneovalgus deformity show normal interosseus relationships, and are not necessary for diagnosis. They can be used to rule out congenital vertical talus, and to confirm congenital posteromedial bowing of the tibia.

Natural History

The prognosis for spontaneous correction is excellent (6,210).

Treatment

Larsen et al. (6) found no difference between calcaneovalgus feet that underwent manipulation and bandaging versus observation alone, when assessed at 3 to 11 years of follow-up. The majority of the feet were normal. The severity of contractures found at birth appeared to have no influence on the final results. Wetzenstein (209) noted a high degree of correlation between the severity of calcaneovalgus deformity in the newborn and flexible flatfoot in the older child. Flexible flatfoot is a normal foot shape, so there should be no negative implication from this finding. Based on this information, one can conclude that positional calcaneovalgus is a benign deformity with excellent prognosis without treatment. Certainly no treatment is required for a mild deformity in which the foot can be plantar-flexed and inverted beyond the neutral position. In an attempt to hasten correction, passive stretching exercises can be performed by the parents for a moderate deformity in which there is difficulty in manipulating the foot to the neutral position. It is a rare foot that requires serial casting to hasten correction of the contracted tissues. Surgery is never required.

Congenital Overriding Fifth Toe

Definition

Congenital overriding fifth toe is a dorsomedial subluxation of the metatarsophalangeal (MTP) joint of the fifth toe that is present at birth. The entire toe is dorsally and proximally displaced, adducted, and externally rotated, lying across the base of the fourth toe (Fig. 29-27A and B).

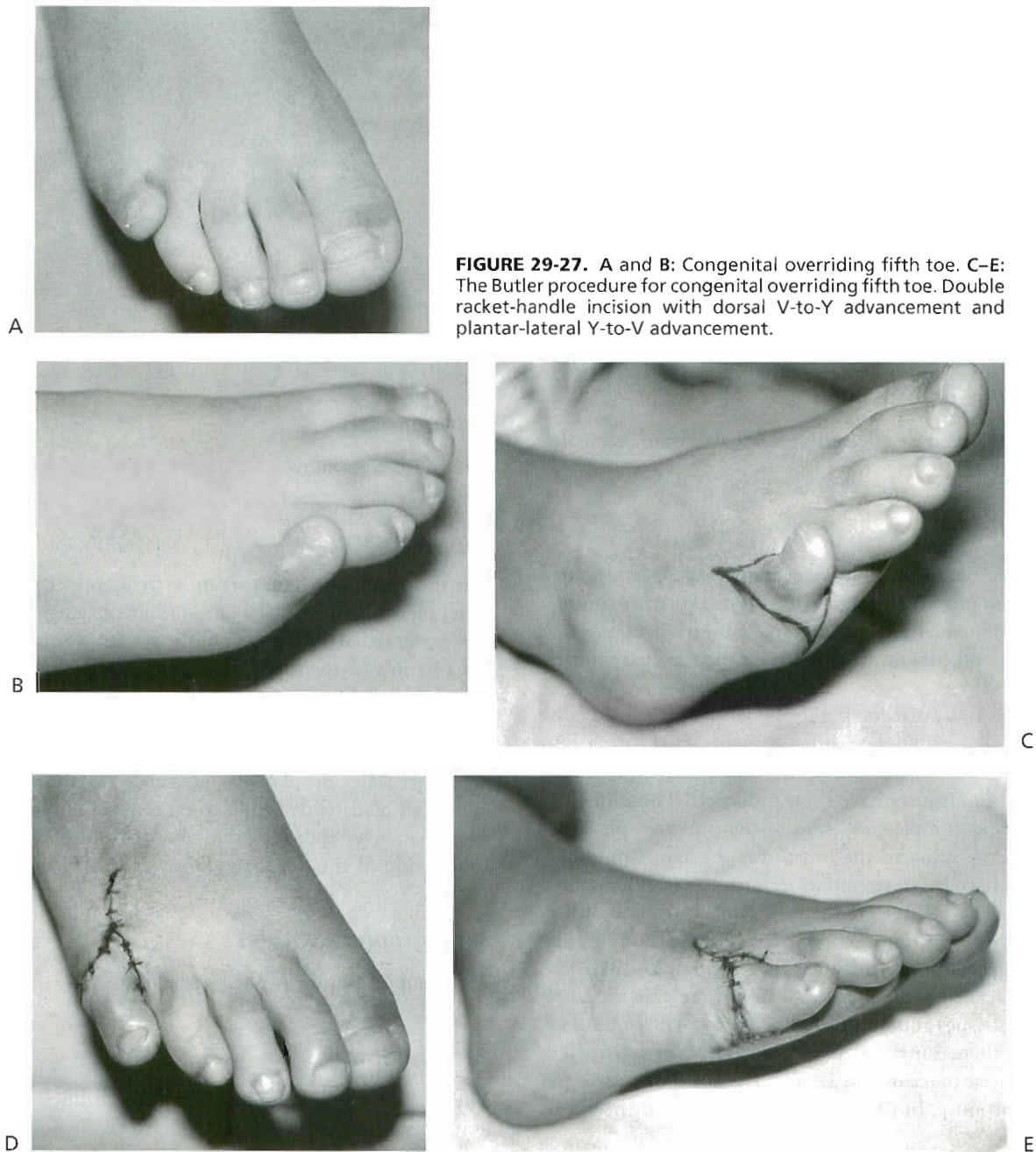


FIGURE 29-27. A and B: Congenital overriding fifth toe. C-E: The Butler procedure for congenital overriding fifth toe. Double racket-handle incision with dorsal V-to-Y advancement and plantar-lateral Y-to-V advancement.

Epidemiology

The incidence is unknown, but congenital overriding of the fifth toe is a common condition. There is no sex predilection. Bilateral involvement is seen in 20 to 33% of cases (211–213).

Pathogenesis

The cause is unknown, but there is a familial tendency (212).

Clinical Features

The toe has a characteristic appearance that is different from that of other congenital and developmental deformities of the toes. The interphalangeal joints are in normal full extension. The skin in the web between the fourth and fifth toes is out of alignment with the other web spaces, yet there is no stress or tension on the skin. The toe was formed in that position, not secondarily contracted. The toenail is normal, and the toe has active flexion and extension. Except for possible bilaterality, this is an isolated deformity.

Radiographic Features

Although difficult to image, radiographs would show dorso-lateral subluxation at the MTP joint.

Pathoanatomy

There is contracture of the dorsomedial capsule of the fifth MTP joint, but the toe is not clawed. There is also shortening of the extensor tendons to the fifth toe that matches the degree of proximal positioning of the toe. The toe seems to have emerged from the end of the foot, translated more proximally and dorsally than the other toes.

Natural History

Approximately half of affected individuals experience pain and disability (212).

Treatment

Conservative measures, such as stretching, taping, and strapping, have no proven efficacy. This is not surprising considering the pathoanatomy. Therefore, education about the reasonably good prognosis is the recommended early treatment.

Surgery is indicated for the roughly 50% of adolescents and adults who experience difficulty with shoe-fitting because of pain over the dorsum of the fifth toe (212). Numerous surgical procedures have been proposed. Those involving partial and complete excision of the proximal phalanx, with syndactylization to the fourth toe, have had only fair results, and have led to secondary deformities (214). Amputation should be considered a salvage procedure. The Butler procedure [➔7.20] originally reported by Cockin (212), is the most successful procedure available (Fig. 29-27C–E). A double-racket-handle incision is used to release the contracted soft tissues and mobilize the neurovascular bundles. The toe is then translated plantar-laterally, which is like “changing gear in a car” (212). There is a risk of neurovascular compromise, but that complication has not been reported.

Curly Toe

Definition

Curly toe is a congenital deformity of one or more of the lesser toes, in which there is flexion, varus, and lateral rotation of the interphalangeal joints, causing the toe to curl under the adjacent more medial toe (Fig. 29-28).

Epidemiology

This is a very common deformity, although the incidence has not been reported. It is usually bilateral and symmetric (215,216). There is a high familial incidence.

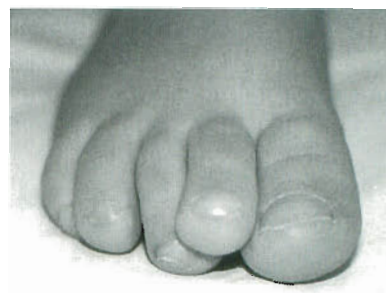

FIGURE 29-28. Curly third toe.

Pathogenesis

The cause is unknown.

Clinical Features

The third and fourth toes are most frequently involved. The distal phalanx or the distal and middle phalanges override the more medial toe, because of the flexion, varus, and external rotation of the distal and/or proximal interphalangeal joints. The nail plate of the affected toe faces laterally. Contrary to the situation seen with congenital overriding fifth toe, the skin in the web spaces is normally aligned. The deformity is flexible in early childhood. The interphalangeal joints can be extended fully when the MTP joint is flexed. This maneuver indicates that the deformity is caused by contracture of the flexor tendon(s).

Radiographic Features

Radiographs are not needed or helpful.

Pathoanatomy

The flexor hallucis longus and/or flexor hallucis brevis tendons to the affected toe are contracted (217). Joint capsules are not contracted.

Natural History

Curly toes are asymptomatic in young children. Many improve in shape spontaneously (216,217). They may become symptomatic in older children, adolescents, and adults, as a result of exaggerated pressure on the skin and nails of the malaligned toes.

Treatment

Stretching, taping, and strapping have no proven efficacy in correcting curly toes (216). The family should be educated

regarding the fact that most affected individuals will have no long-term disability, even with residual deformity.

Surgery is indicated for pain, callosities, and blistering resulting from pressure on the tip of the curly toe or over the interphalangeal joints of the more medial toe that overrides the curly toe. Another indication is an unacceptable problem with growth of the nail on either or both toes. Tenotomy of the flexor hallucis longus [➔7.21], with or without tenotomy of the flexor hallucis brevis, has been successful in 95 to 100% of cases (215,217). A double-blind, randomized, prospective study, comparing simple tenotomy of the flexor hallucis longus with transfer of the flexor hallucis longus to the extensor mechanism (Girdlestone-Taylor procedure), showed no difference in outcome (218). Simple tenotomy of the flexor hallucis longus is the recommended procedure for individuals with symptoms.

CONGENITAL MALFORMATIONS

These are conditions in which the structure(s) was formed improperly. Examples include too large, too small, improperly connected, too many, too few, wrong shape. In some cases, the abnormality does not manifest for several years.

Accessory Navicular

Definition

“Accessory navicular” is the term applied to plantar and medial enlargement of the tarsal navicular bone beyond its normal size. It may consist of a separate ossicle connected to the main body of the navicular by fibrous tissue or cartilage, or it may be a solid bony enlargement of the bone. Other terms for the separate ossicle include os tibiale externum, navicular secundum, and prehallux.

Epidemiology

The accessory tarsal navicular is the most common accessory bone in the foot, occurring in between 4 and 14% of the population (7,12,219). It is frequently bilateral, and occurs more commonly in females.

Pathogenesis

McKusick believed that the accessory navicular was inherited as an autosomal dominant trait (220).

Clinical Features

The accessory navicular produces a firm prominence on the plantar-medial aspect of the midfoot. There may be a coexistent flexible flatfoot (221–224), but there is no con-

clusive evidence of a cause-and-effect relationship between the two conditions, which was historically believed (13). The prominence of an accessory navicular is in close proximity to the head of the talus, which is prominent in a flexible flatfoot. Inverting and everting the subtalar joint, with one's thumb on the prominence, is helpful for differentiating the two. If the prominence moves, it is an accessory navicular. If it remains stationary, it is the head of the talus.

Individuals with an accessory navicular may present for evaluation because of the prominence, but more commonly they present because of pain at the site. The typical patient is an active adolescent girl with a history of minor trauma, who presents with pain, callus formation, tenderness, redness, and, occasionally, swelling over the bony prominence. Because of the frequency of this anatomic variation in the general population, one must be careful not to assume that a radiographically confirmed accessory navicular is the cause of the foot pain, without thorough evaluation (225).

Radiographic Features

An accessory navicular can usually be seen on standing anteroposterior and lateral radiographs, but an internal oblique view may be necessary for identification. There are three types of accessory naviculars (226) (Fig. 29-29). Type I is a rarely symptomatic, pea-sized sesamoid bone located in the center of the most distal portion of the tibialis posterior tendon. Type II, the most frequently symptomatic type, is a bullet-shaped ossicle joined to the tuberosity of the navicular by a syndesmosis or synchondrosis. Type III is a large, horn-shaped navicular that probably results from fusion of a type II accessory navicular with the body of the navicular.

Pathoanatomy

There is proliferating vascular mesenchymal tissue, cartilage proliferation, and osteoblastic and osteoclastic activity in the tissue between the ossicle and the main body of the navicular in painful type II accessory naviculars (226). These histologic findings are consistent with healing microfractures, substantiating the opinion that pain at this site is related to chronic, repetitive stress. There are at least two other possible sources of pain. One is pain from pressure on the skin overlying the bony prominence. The other is tendinitis in the tibialis posterior, the tendon in which the ossicle resides. Any or all of these sources may exist in the same painful foot.

Natural History

Most accessory naviculars are asymptomatic (223).

Treatment

Nonsurgical treatment will often relieve symptoms. Pain is caused by inflammation of the skin, tendon, or cartilage.

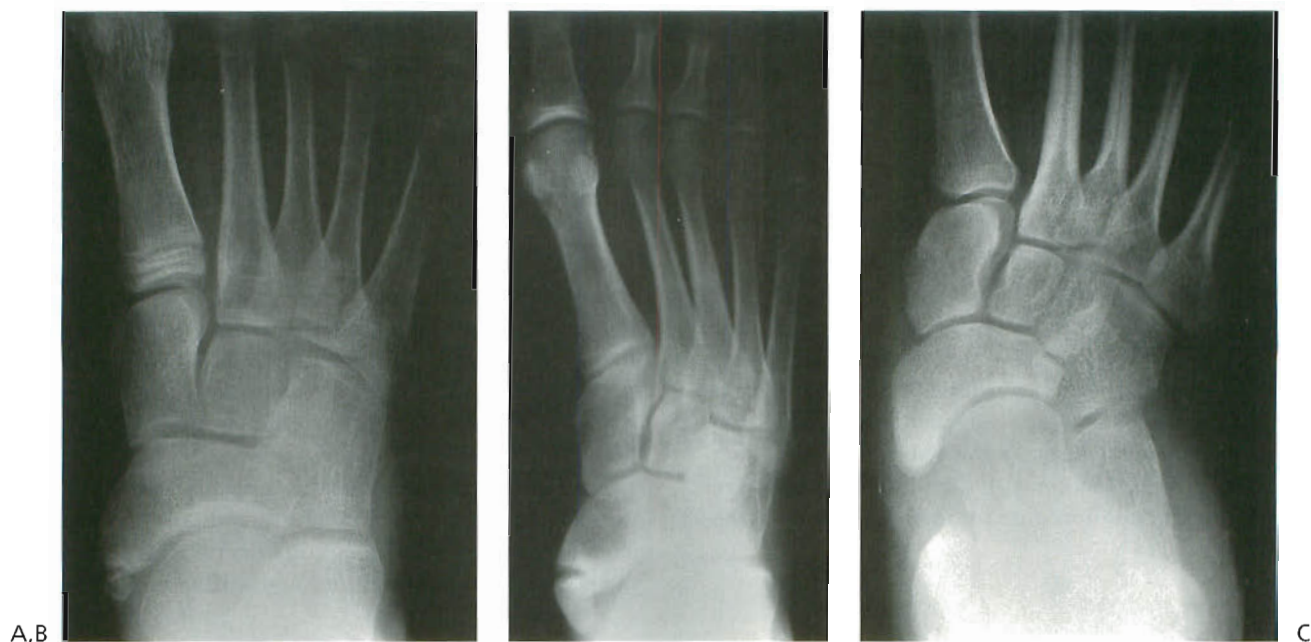

FIGURE 29-29. Accessory navicular. A: Type I. B: Type II. C: Type III.

Strenuous, pain-exacerbating activities should be curtailed. Shoes should be examined to assess the area of contact with the prominence. Shoes can be stretched. Alternatively, shoes that provide softness in that area should be purchased. An over-the-counter orthotic device can be used to elevate the arch and change the site of contact between the prominence and the shoe. This may also decrease the stress on the tibialis posterior, and relieve the tendinitis. If pain is acute and persistent, the foot can be immobilized in a below-knee cast for 4 to 6 weeks.

Surgery is indicated for relief of symptoms after the failure of prolonged attempts at conservative management. The Kidner procedure was developed as a means of removing the ossicle and reestablishing the support of the arch by advancement of the tibialis posterior tendon (221,222). This was based on Kidner's belief that the height of the longitudinal arch was related to its muscular support, a theory that has since been disproved (164,227). Several studies have shown good to excellent results in 90% or more of cases by simple excision of the ossicle and shaving of the medial enlargement of the main body of the navicular through a tendon-splitting approach (13,219,228–231). The incision should be placed slightly dorsomedially to avoid creating a painful scar.

Tarsal Coalition

Definition

Tarsal coalition is a fibrous, cartilaginous, or bony connection between two or more tarsal bones, which results from

a congenital failure of differentiation and segmentation of primitive mesenchyme.

Epidemiology

Tarsal coalition has been described in the archeologic remains of several civilizations since pre-Columbian times (232). The association of the anatomic abnormality with the clinical syndrome of a painful flatfoot occurred 26 years after the introduction of radiographic imaging in 1895. In 1921, Slomann (233) linked the so-called “peroneal spastic flatfoot” with calcaneonavicular coalitions seen on radiographs. Almost three decades later, Harris and Beath (234) linked peroneal spastic flatfoot with talocalcaneal coalition. Tarsal coalition has also been linked, since 1965, with the infrequently occurring tibialis spastic varus, or cavovarus, foot (235,236).

Some tarsal coalitions are associated with other congenital disorders, such as fibular hemimelia (237), clubfoot (238), Apert syndrome, and Nievergelt-Pearlman syndrome. They tend to be quite extensive in terms of the number of tarsal bones involved and the percentage involvement of the subtalar joint. Their natural history and prognosis, although not well studied, seem to be good.

The focus of this section is on the more common types of tarsal coalitions that occur as isolated anomalies in about 1% of the general population (234). The most common sites of coalition are the middle facet of the talocalcaneal joint and between the anterior process of the calcaneus and the navicular. These talocalcaneal and calcaneonavicular coalitions occur with about equal frequency, and together they

account for approximately 90% of all coalitions (239). They coexist in a small percentage of feet (240), and are bilateral in 50 to 60% of cases (241,242). Talonavicular, calcaneocuboid, naviculocuneiform, and cubonavicular coalitions are uncommon (239). The true incidence of tarsal coalition, the relative frequency of affected joints, and the frequency of bilaterality are not known, because most affected individuals are asymptomatic and go uncounted.

Pathogenesis

Wray and Herndon (243) suggested an autosomal dominant pattern of inheritance with variable penetrance, based on a single-family study. Leonard (14) confirmed an autosomal dominant pattern with almost full penetrance in a study of 31 index patients and 98 first-degree relatives.

Clinical Features

Progressive flattening of the longitudinal arch, with valgus deformity of the hindfoot, generally predates symptoms,

but it is rarely the presenting complaint. The insidious onset of vague and aching pain, in the region of the sinus tarsi or the medial aspect of the hindfoot of a child between the ages of 8 and 16 years, is characteristic. The pain is usually aggravated by activity and relieved by rest. Occasionally, children will report recurrent ankle sprains. Pain under the head of the plantar-flexed talus, which is induced by weight bearing, as occurs in flexible flatfoot with a short Achilles tendon, is often reported in feet with the most severe valgus deformities. There is usually tenderness at the site of coalition, and there may be tenderness on the dorsal aspect of the talonavicular joint.

The flatfoot deformity has been variously described as rigid and peroneal spastic. Rigidity refers to restriction of subtalar joint motion, which can be assessed in several ways. It is important to isolate and manipulate the subtalar joint with the ankle joint held in neutral alignment. The subtalar joint will not invert, and the arch will not elevate during toe standing (244) (Fig. 29-30) and with the Jack toe-raise test (168) in a foot with a talocalcaneal coalition. Feet with

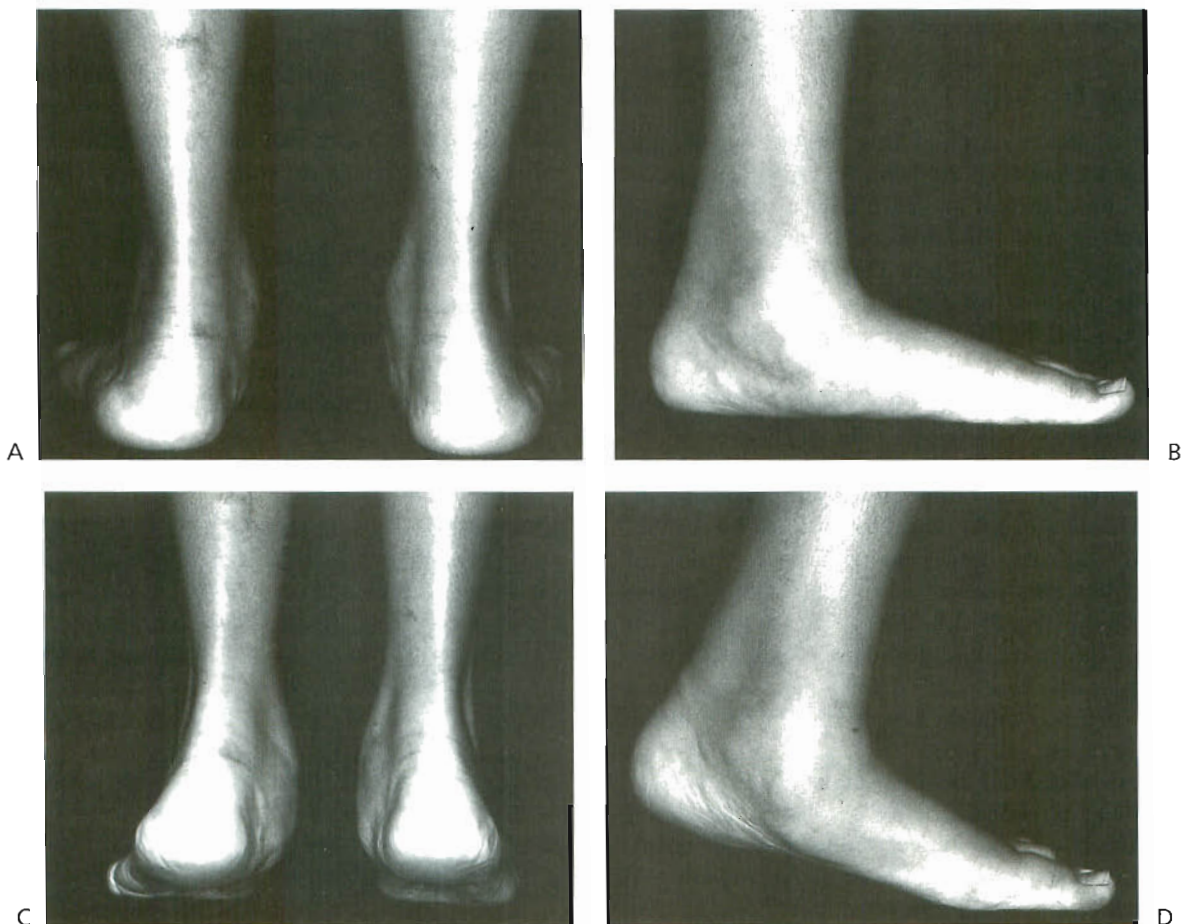


FIGURE 29-30. A,B: Rigid flatfoot. C,D: The arch will not elevate, and the hindfoot valgus will not correct to varus during toe standing, because of immobility of the subtalar joint. (From ref. 244, with permission.)

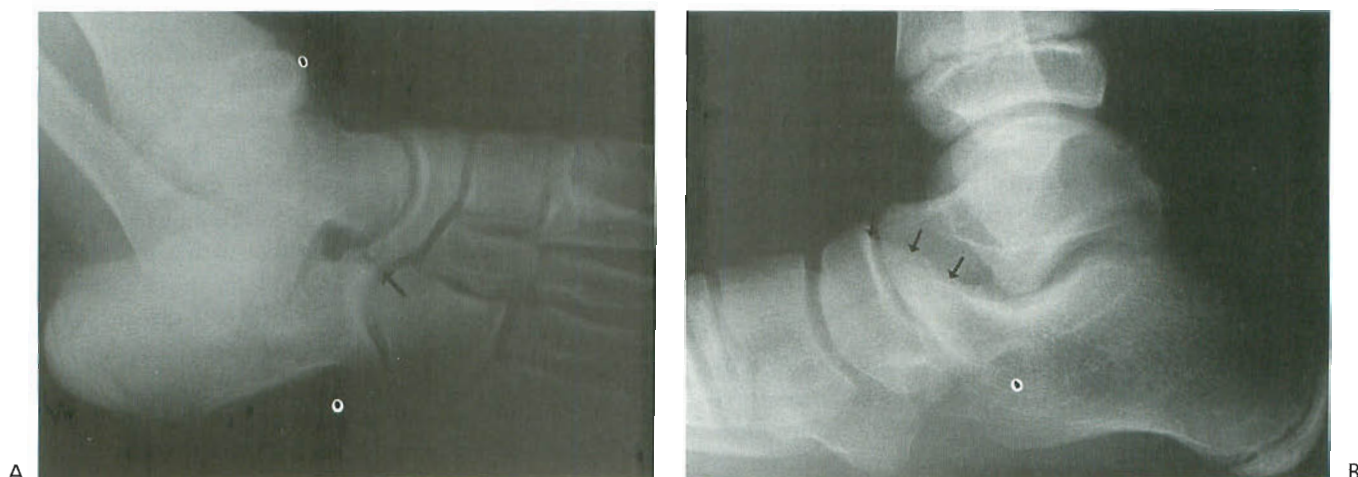


FIGURE 29-31. A: A calcaneonavicular coalition (arrow) is best seen on an oblique radiograph of the foot. (From ref. 244, with permission.) B: Lateral radiograph demonstrating the anteater nose sign (arrows), indicating a calcaneonavicular coalition.

calcaneonavicular coalitions are generally less rigid and less flat than feet with talocalcaneal coalitions, which makes inherent sense, because the former type does not cross the subtalar joint and the latter does.

Radiographic Features

A calcaneonavicular coalition is best seen on an oblique radiograph of the foot (Fig. 29-31A). A cartilaginous coalition has the appearance of an articulation with somewhat undulating subchondral bone surfaces. An osseous coalition is obvious. Its presence is suggested on the standing lateral radiograph by an elongated process of the anterior calcaneus, which is called the “anteater nose sign” (245; Fig. 29-31B).

Other radiographic findings that are best seen on the lateral view may include dorsal beaking on the head of the talus, broadening and rounding of the lateral process of the talus, and narrowing of the posterior talocalcaneal facet joint (242,246). The C sign, a C-shaped line formed by the medial outline of the talar dome and the inferior outline of the sustentaculum tali, is a very reliable indicator of a talocalcaneal coalition (Fig. 29-32) (246A). An anteroposterior radiograph of the ankle should also be obtained. A ball-and-socket ankle may be seen in cases of long-standing tarsal coalition, particularly with the large coalitions seen in the nonidiopathic types (242,246).

A talocalcaneal coalition can be seen on an axial, or Harris (234), radiograph, but the best way to assess a coalition in this location is with computed tomography (247,248). The images must be obtained in the coronal plane using 3- to 5-mm-thick slices (Fig. 29-33). A computed tomography scan should be obtained before resection of a calcaneonavicular coalition, because of the known risk of a coexisting talocalcaneal coalition (240).

Other Imaging Studies

Magnetic resonance imaging can be used to identify a symptomatic tarsal coalition that is still in the fibrous stage of differentiation, if the plain radiograph and computed tomography scan are nondiagnostic (249). It should not be a first-line study. A bone scan can help to identify the true cause of pain in a foot that has radiographic evidence of a tarsal coalition, but an atypical history or pain pattern (247).

Other Diagnostic Studies

Other causes of rigid flatfoot include juvenile rheumatoid arthritis, septic arthritis, and osteomyelitis. A complete blood count, with differential, estimated sedimentation rate, C-reactive protein, antinuclear antibody test, and rheuma-

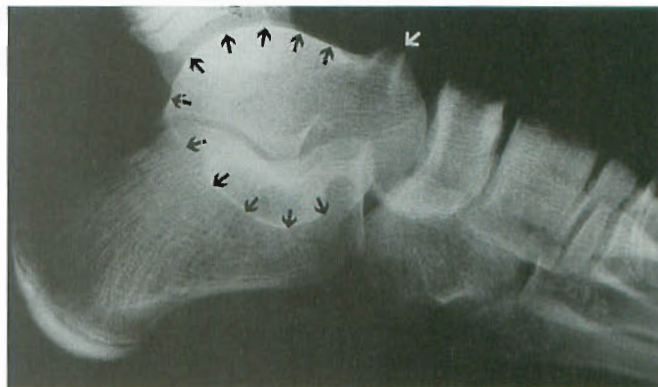


FIGURE 29-32. A dorsal talar beak (white arrow) in a foot with a talocalcaneal coalition. This represents a traction spur, not degenerative arthritis. The C-sign of Lefleur (black arrows) is a very reliable indication of a talocalcaneal coalition.

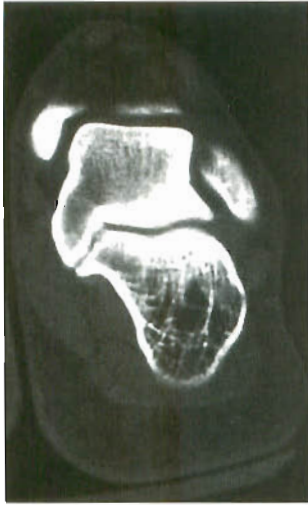

FIGURE 29-33. Talocalcaneal coalitions are best seen on computed tomography scans taken in the coronal plane. The middle facet is narrow, irregular, and down-sloping. (From ref. 244, with permission.)

roid factor may be warranted, if evaluation fails to confirm a suspected tarsal coalition.

Pathoanatomy

In genetically programmed individuals, a tarsal coalition begins as a syndesmosis with fibrous tissue between two bones of the foot that do not join together in 99% of people. The fibrous tissue undergoes metaplasia to cartilage to become a synchondrosis, then to bone, to become a synostosis. This process occurs during late childhood and early to middle adolescence (234,250).

Restriction of subtalar motion caused by a coalition blocks the normal eversion of the subtalar complex that occurs during gait. A component of eversion is dorsiflexion of the pes acetabulum (anterior calcaneus, spring ligament, and navicular), which occurs as it rotates and glides around the head of the talus. When rotation and gliding are eliminated by the coalition, the dorsiflexion force is concentrated at the talonavicular and calcaneocuboid joints (251). They are converted to hinge joints that widen inferiorly and narrow superiorly. The dorsal proximal edge of the navicular impinges on and overrides the head of the talus. This overriding causes elevation of the talonavicular ligament and periosteum on the neck of the talus. The osseous repair of this periosteal elevation leads to the talar beaking that is visible radiographically. The reason for progressive flattening of the longitudinal arch is not established. The author theorizes that this occurs because the eversion forces that are applied during loading in early stance are greater than the inversion forces that exist when the load is eliminated later in the gait cycle. The joint cannot recover its position as it gradually loses motion.

The cause of the pain is unknown (234,239). It has been attributed to ligament sprain, peroneal muscle spasm, sinus tarsi irritation, subtalar joint irritation, fracture through the synchondrosis, stress shift to adjacent mobile joints, and degenerative arthrosis (232). A recent histologic evaluation of nonosseous tarsal coalitions suggested that repetitive stress seemed to induce pain via free nerve endings in the periosteum and the articular capsules surrounding the coalition (251A). There was evidence of microfracture, repair, and remodeling in the boundary between the coalition and the bone.

Natural History

According to Leonard (14), only about 25% of individuals with tarsal coalitions become symptomatic. The onset of pain usually coincides with metaplasia of the coalition from cartilage to bone, but it may occur earlier in its evolution. This generally occurs between 8 and 12 years of age for children with calcaneonavicular coalitions, and between 12 and 16 years of age for children with talocalcaneal coalitions. Metaplasia of the coalition also coincides with the development of progressive valgus deformity of the hindfoot, flattening of the longitudinal arch, and restriction of subtalar motion. All of these findings are more severe in feet with talocalcaneal coalitions (242,250).

Treatment

The goal of treatment is the relief of pain, not the elimination of the coalition or the reestablishment of the longitudinal arch. Treatment is, therefore, indicated only for symptomatic tarsal coalitions (234,241,242). It is not clear what causes some coalitions to become painful, but inflammation underlies the pain. An attempt should be made to relieve symptoms by nonoperative means, including activity modification, nonsteroidal antiinflammatory drugs, over-the-counter shoe inserts, and immobilization in a cast-type walking boot or a below-knee walking cast. Pain is generally relieved completely within 24 to 48 hours of cast application. Approximately 30% of patients remain free of pain after cast removal 6 weeks later (250). An over-the-counter shoe insert may help to maintain pain relief.

Surgery is indicated for patients with recurrent and disabling symptoms. Surgical options include resection of the coalition, osteotomy, and arthrodesis. Resection of calcaneonavicular coalitions [➔7.2] was first reported by Badgley (252) in 1927. Interposition of the extensor digitorum brevis was added to the resection procedure, and reported by Bentzon (253) in 1930. The combined procedure, compared with resection alone, has been shown to decrease the incidence of recurrence, and to increase the incidence of long-term pain relief (254–256). According to one report, resection of a calcaneonavicular coalition with muscle interposition is indicated in a patient younger than 16

years of age who has a cartilaginous bar with no other coalitions present, and no degenerative arthrosis, and who has undergone unsuccessful nonsurgical treatment (255). However, the age limit, the coalition tissue type, and the influence of coexisting coalitions have not been scientifically established. The presence of a talar beak is not indicative of degenerative arthrosis, and is not, by itself, a contraindication for resection (257–260).

The role of surgical resection of a talocalcaneal coalition [➡7.3] is less clear. This coalition is located on the tension side of the valgus deformity of the hindfoot, and additional progressive flattening of the arch may occur after resection. Investigation has only recently focused on a historically frequently quoted, but unproven, statement in the literature, that a talocalcaneal coalition should not be resected if it occupies greater than half of the width of the subtalar joint surface (257). Wilde et al. (260) reported unsatisfactory results of resection in feet in which the ratio of the surface area of the coalition to the surface area of the posterior facet was greater than 50% (as determined by computed tomography mapping of the entire joint). There was excessive valgus deformity of the hindfoot in all of these feet. Many of the feet with poor outcomes also had narrowing of the posterior facet and impingement of the lateral process of the talus on the calcaneus. The independent influence of the size of the coalition was not determined in this or any study to date. These are, however, the most objective criteria for determining the resectability of a talocalcaneal coalition.

Degenerative arthrosis should be considered a contraindication to resection, but that diagnosis is difficult to establish. Historically, the presence of a dorsal talar beak was considered to be evidence of degenerative arthrosis (Fig. 29-32). That theory has been replaced with the belief that the beak represents a traction spur, because it recedes with successful resection of the coalition. Its presence, therefore, is not a contraindication to resection (257–260).

Successful resection and interposition grafting of talocalcaneal coalitions have been reported in up to 89% of cases at 10 years of follow-up (261), although most published and unpublished studies have documented a lower success rate at even shorter follow-up (258,260,262). The poor results have been attributed to poor indications, and indications are evolving. Interposition can be with fat (257,263) or a split portion of the flexor hallucis longus tendon (262).

Documented degenerative arthrosis, particularly in adults, and persistent or recurrent pain after resection of a coalition, represent reasonable indications for triple arthrodesis (232). However, one should establish which joint or joints are arthritic. If the talocalcaneal joint is the only one that is degenerated, it is reasonable to perform a subtalar arthrodesis and avoid arthrodesis of the talonavicular and calcaneocuboid joints (263A). Those joints can help compensate for the loss of subtalar joint mobility and provide

some stress relief for the ankle joint. They can be fused at a later time if they develop painful degeneration.

Osteotomies may have a role in treating symptomatic tarsal coalitions as an alternative to arthrodesis. A medial closing-wedge osteotomy of the posterior portion of the calcaneus has been shown to improve foot shape and relieve symptoms in certain feet with severe valgus deformity for which arthrodesis was being considered (263B).

An additional surgical procedure that has been shown to relieve symptoms in certain feet with tarsal coalitions and to correct even severe valgus deformity of the hindfoot, is the calcaneal lengthening osteotomy [➡7.5] described by Evans (124). It corrects valgus deformity of the hindfoot, even with osseous coalitions in the middle facet of the talocalcaneal joint. It should be considered for the rigid flatfoot with severe valgus deformity and contracture of the Achilles tendon, pain under the head of the talus, and no degenerative arthrosis. It can be performed as an isolated procedure, if the coalition is too large to resect. Or it can be performed with concurrent or staged resection and interposition grafting in a foot with a resectable cartilaginous coalition and severe foot deformity. Long-term studies have not been reported, but short-term anecdotal experience has been good, and must be considered in light of the known poor long-term results of triple arthrodesis (19–21,26).

Congenital Hallux Varus

Definition

Congenital hallux varus is a medial deviation of the hallux on the first metatarsal that is present at birth. It may be an isolated deformity, but very often it is associated with other malformations of the foot. These include a short and thick first metatarsal, longitudinal epiphyseal bracket of the first metatarsal (264), accessory metatarsals and phalanges, duplication of the hallux, and a fibrous band that extends from the medial side of the hallux to the base of the first metatarsal (265,266).

Epidemiology

This is a rare condition, but the incidence has not been reported. Sex predilection, bilaterality, and genetic factors are unknown.

Pathogenesis

Congenital hallux varus is a deformity that has been reported to be associated with multiple malformations. There are probably multiple causes, none of which have been identified.

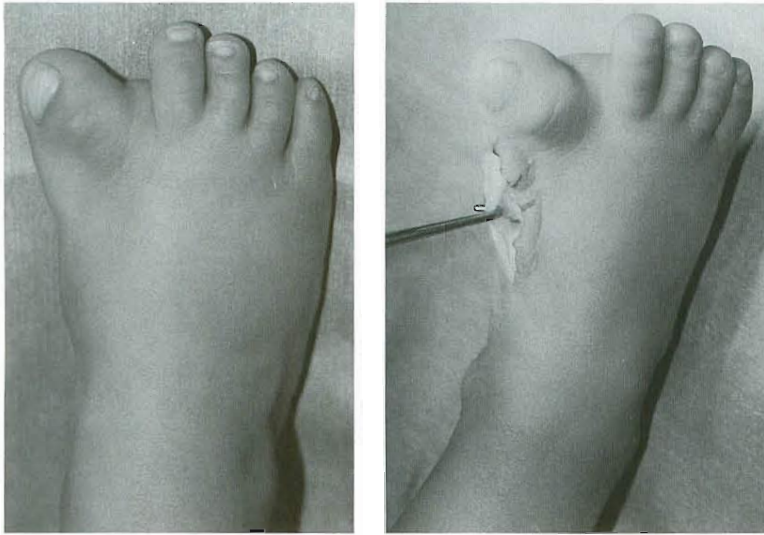


FIGURE 29-34. A: Clinical appearance of congenital hallux varus. B: Fibrous band between the hallux and the cartilaginous duplicate tarsal anlage.

Clinical Features

The hallux is adducted by as much as 90 degrees, and cannot be aligned by passive manipulation (Fig. 29-34A). There is a broad web space between the hallux and the second toe. A firm subcutaneous band of fibrous tissue may be palpable along the medial forefoot. There may be duplication of the hallux as a separate toe, or it may be associated with simple or complex syndactyly. Congenital hallux varus with complex polysyndactyly is commonly seen in Apert syndrome.

Radiographic Features

An anteroposterior radiograph will provide only partial anatomic detail of the abnormalities. The varus alignment will be obvious. Duplication of the phalanges in a hallux associated with polysyndactyly will also be apparent. A rudimentary metatarsal duplication at the base of a fibrous band may not be visible because of the lack of ossification at birth. A longitudinal epiphyseal bracket will be suggested by the "D" shape of the metatarsal, with no cortical differentiation along the convex medial border of the diaphysis (264) (Fig. 29-35A).

Pathoanatomy

A possible explanation for a single toe varus deformity is that two great toes, and perhaps a metatarsal, originate *in utero*, but the medial or accessory one fails to develop. The rudimentary medial structure forms a fibrous band that acts as a taut bowstring and pulls the more fully developed hallux into a varus position, creating an incongruous first MTP joint (267) (Fig. 29-34B).

In the foot with a longitudinal epiphyseal bracket, there is a varus deformity of the metatarsal, creating the varus

alignment of the hallux with the foot. The MTP joint may be congruous, although there have been no published anatomic studies on this aspect of the deformity. The MTP joint congruity is similar to that seen in the opposite direction with juvenile hallux valgus, and, as with the latter condition, it requires an operative approach that preserves joint congruity.

Natural History

Shoe fitting would be difficult or impossible without treatment (266).

Treatment

There is no role for conservative management of this deformity. Surgical management is mandatory, and depends on the individual pathoanatomy. The literature is not particularly helpful in providing direction for operative treatment because of the historical failure to appreciate the frequency with which a longitudinal epiphyseal bracket is associated with the hallux varus.

Soft tissue release and resection procedures with or without syndactylization to the second toe, as described by McElvenny (265) and Farmer (268), are appropriate when the metatarsal is normal. Mills and Menelaus (266) found that unsatisfactory surgical results using these techniques were generally caused by the shortness of the first metatarsal and rarely by symptoms or recurrent deformity. Longitudinal epiphyseal bracket was not recognized at the time of that study, as indicated by the radiographic images in the article.

Mubarak et al. (264) demonstrated that resection and interposition grafting of a longitudinal epiphyseal bracket [7.15] is an effective technique that leads to gradual cor-

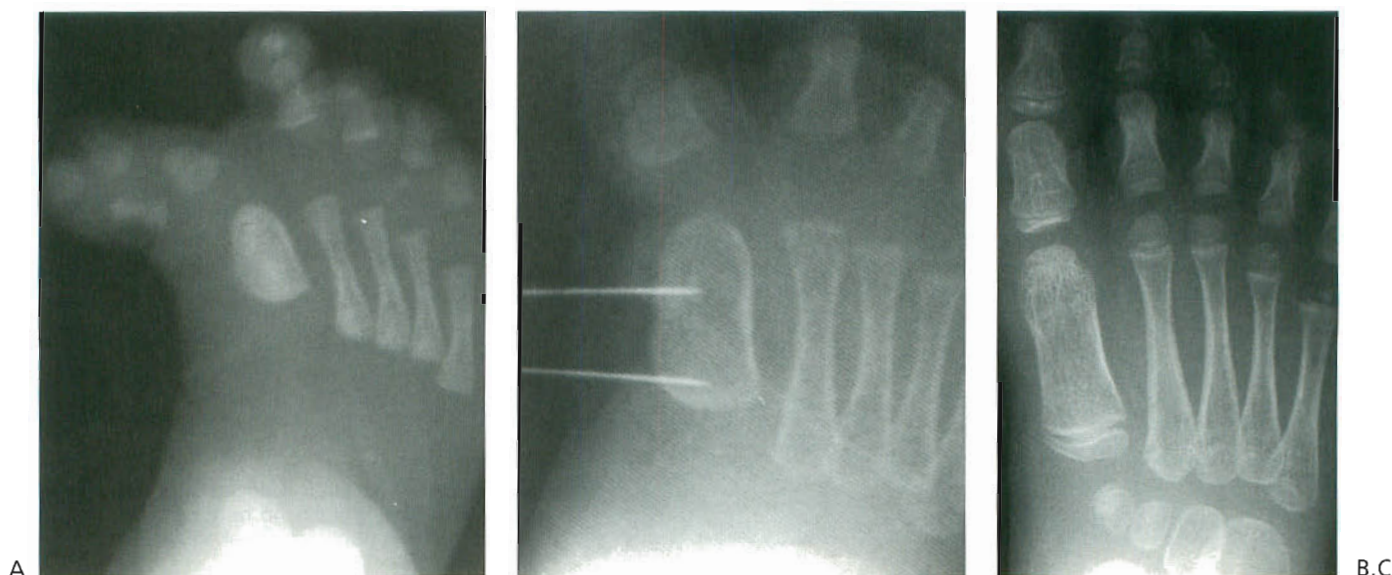


FIGURE 29-35. A: Radiographic appearance of congenital hallux varus with a metatarsal longitudinal epiphyseal bracket. B: Pins mark the extent of the resection of the longitudinal epiphyseal bracket. C: Radiographic appearance 5 years after resection and fat grafting of the longitudinal epiphyseal bracket. The metatarsal has grown normally.

resection of the varus deformity of the first metatarsal, and allows longitudinal growth of the bone (Fig. 29-35B and C). The interposition material can be fat, Silastic, or methyl methacrylate. With adequate resection of the abnormal epiphysis and good anchoring of the graft, fat is an excellent choice, and avoids the risks and potential complications of the foreign materials. This procedure is combined with distal soft tissue release and resection of duplicated parts, as indicated. Hypercorrection of the first MTP joint should be avoided to prevent joint incongruity and progressive hallux valgus.

Late onset of degenerative arthrosis of the first MTP joint can be managed by arthrodesis (266). Residual shortening of the metatarsal, with pain, callosities, or metatarsalgia, can be addressed with metatarsal lengthening or amputation.

Polydactyly/Polysyndactyly

Definitions

Polydactyly is a congenital condition in which one or more toes are duplicated. The metatarsal may be fully or partially duplicated as well. With polysyndactyly, the duplicate toe is joined to the more normal toe by soft tissue (simple) or bone (complex).

Epidemiology

The incidence of polydactyly is 0.3 to 1.3 per 1,000 live births in whites, and 3.6 to 13.9 per 1,000 live births in blacks (269,270). There is no sex predilection. Approximately 50% of cases are bilateral, and 62% of bilateral de-

formities are symmetric (271). There is polydactyly of the hands in 34% of patients (271). Polydactyly is seen in genetic syndromes, but most often it occurs as an isolated trait. It has an autosomal dominant inheritance pattern with variable expressivity (272). Thirty percent of affected individuals have positive family histories (271).

Pathogenesis

The cause is unknown. Polydactyly has been experimentally induced in rats by *in utero* exposure to radiation and cytotoxins, and by folic acid deprivation. The limb bud mesoderm is disturbed, leading to failure of differentiation of the apical ectodermal ridge during the first trimester (271). The implications of this information for humans are not known.

Clinical Features

Temtamy and McKusick (272) classified polydactyly as preaxial, if the hallux was duplicated; postaxial, if the fifth toe was duplicated; and central, if there was duplication of the second, third, or fourth toe. Phelps and Grogan (271), in their review of 194 supernumerary toes in 125 patients, found that 79% were postaxial, 15% were preaxial, and 6% were central. More than one type may exist in a foot (Fig. 29-36). Polydactyly can be further classified as well-formed and articulated (type A) or rudimentary and vestigial (type B). The duplicate toe may be entirely separate, or there may be simple or complex syndactyly. The toenails may be separate or conjoined in cases of polysyndactyly.

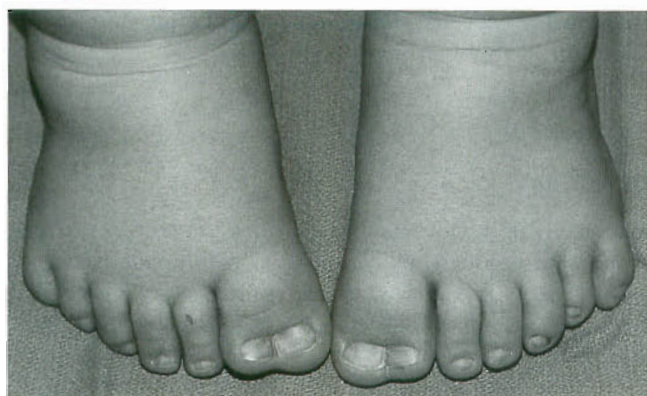

FIGURE 29-36. Preaxial and postaxial bilateral polydactyly.

The central and postaxial duplicate toes are usually well aligned with the other toes. The preaxial duplicate toe is often deviated medially. One must consider the possibility of a longitudinal epiphyseal bracket of the first metatarsal in the presence of preaxial polydactyly and polysyndactyly (see section on congenital hallux varus) (264,273).

Radiographic Features

Venn-Watson (274) proposed a morphologic classification of the abnormalities of the metatarsals and phalanges in

polydactyly of the foot (Fig. 29-37). Unfortunately, there often is not enough ossification of the phalanges, even in the first few years of life, to accurately classify the deformity before surgical treatment. There is clearly no indication for radiography at birth. To help with surgical planning, an anteroposterior radiograph is obtained immediately before surgical ablation. It will reveal a metatarsal abnormality and may suggest the true pathoanatomy of the phalanges.

Natural History

Untreated polydactyly will commonly cause shoe-fitting problems, particularly when the hallux is duplicated.

Treatment

A child and family may choose to retain the duplicate digit if it is well formed, well aligned, and does not extend beyond the border of the foot. Wide shoes may be all that is required.

Surgical treatment, performed at about 1 year of age, is indicated to improve shoe tolerance. Improved cosmesis is a by-product. The most malaligned toe is resected, which is usually the medial duplication in preaxial polydactyly and the lateral duplication in postaxial deformity (271,275). Division of a synchondrosis at the base of the proximal phalanges is quite safe. It is reportedly safe to reduce the size of

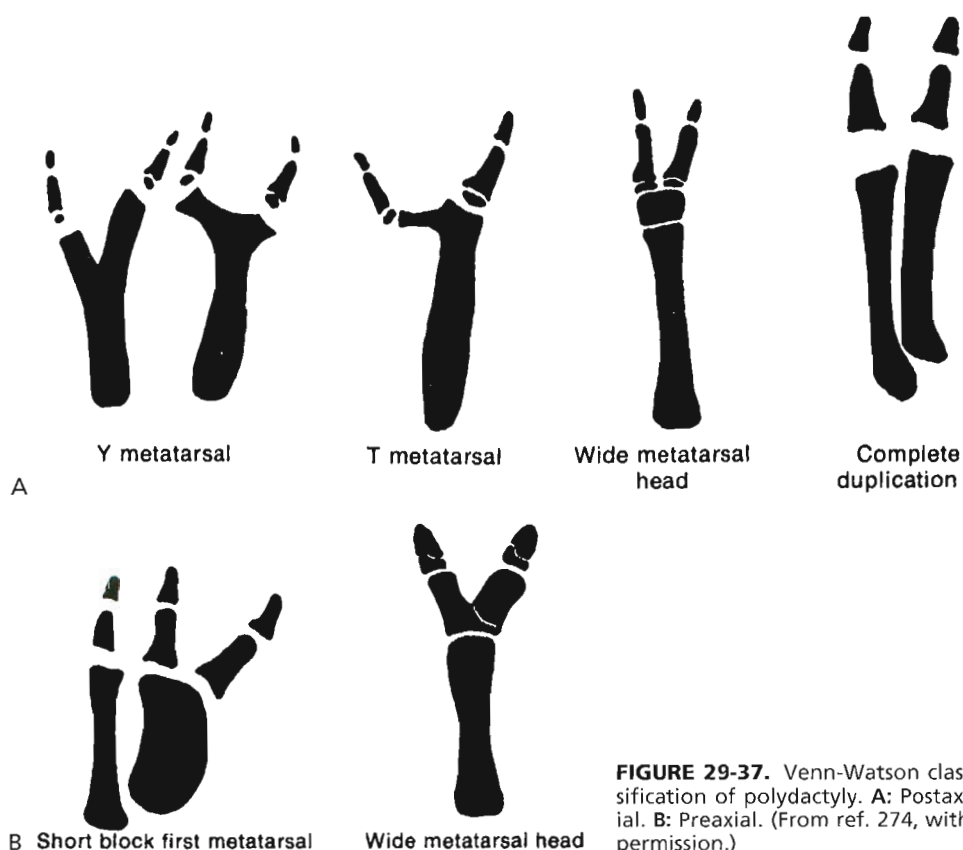


FIGURE 29-37. Venn-Watson classification of polydactyly. A: Postaxial. B: Preaxial. (From ref. 274, with permission.)

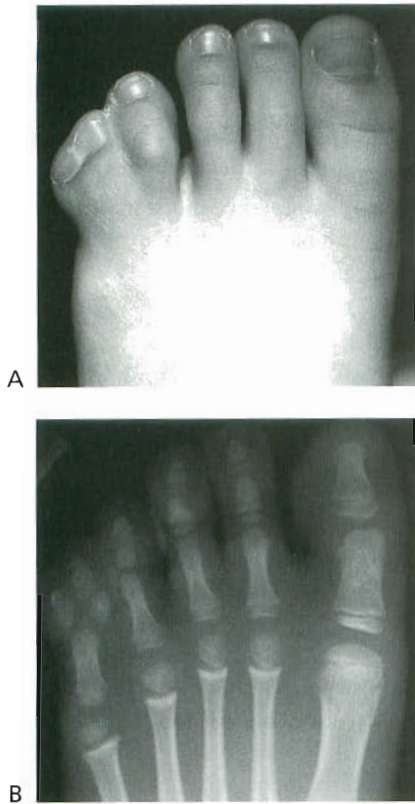


FIGURE 29-38. Postaxial polysyndactyly. Clinical (A) and radiographic (B) appearance.

an enlarged metatarsal head by performing osteotomy perpendicular to the physis (271). However, one may choose a safer approach, and shave down the cartilaginous epiphysis, with care taken to avoid the perichondrial ring. A duplicate metatarsal, as well as the abnormal limb of a Y-shaped metatarsal, should be resected. The MTP joint capsule should be repaired if possible.

In cases of polysyndactyly, the most malaligned phalanges and the associated toenail are enucleated through a dorsal racket-handle incision (271,274,275). The nail fold must be carefully recreated to prevent chronic ingrowth. A common pattern of postaxial polysyndactyly involves medial duplication of the middle and distal phalanges of the fifth toe, wedged into a simple syndactyly that includes the fourth toe (Fig. 29-38). If surgery is elected, the medial duplicate phalanges should be resected without disturbing the syndactyly between the fourth and fifth toes. Otherwise, lateral deviation of the fifth toe might result (275).

One can expect close to 100% good and excellent results with surgical treatment. Most of the reported poor results were in patients with residual hallux varus and a short first metatarsal after resection of a preaxial duplication. Some or all of these patients may have had a longitudinal epiphyseal bracket, which with present knowledge, would have undergone resection and interposition grafting (264), with a bet-

ter outcome expected. Resection of central ray duplication does not reliably narrow the foot (271).

Syndactyly

Definition

Syndactyly of the toes may be classified in two types. Zygosyndactyly is cutaneous complete or incomplete webbing, usually between the second and third toes (Fig. 29-39). Polysyndactyly has been described in the preceding section.

Epidemiology

Zygosyndactyly is a common and often inherited trait that is frequently bilateral.

Pathogenesis

The cause is unknown.

Clinical Features

The webbing may be complete to the ends of the toes or it may be extremely subtle and shallow. There is rarely deviation or deformity of the toes, and there is no widening of the forefoot.

Radiographic Features

Radiographs are not indicated, because there will be no findings.

Natural History

Zygosyndactyly remains asymptomatic throughout life. It does not cause shoe-fitting or functional problems.

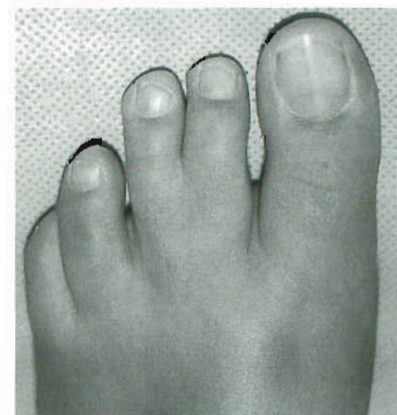


FIGURE 29-39. Clinically benign zygosyndactyly.

Treatment

Surgical treatment is not warranted, because of the excellent prognosis for comfort and function. The surgical scars are less cosmetic than the condition itself.

Macroductyly

Definition

“Macroductyly” is the term used to describe enlargement of the digits of the feet or hands. The term means large digit, but the metatarsal or metacarpal may also be enlarged.

Epidemiology

Macroductyly may occur as an isolated phenomenon or as part of a syndrome, such as neurofibromatosis, Klippel-

Trenaunay-Weber syndrome, lymphangioma, and Proteus syndrome. In 1988, Kalen et al. (276) reported the largest series, and reviewed the English language literature to date on the isolated type that is the focus of this discussion. The incidence is extremely low. There is a slight male predominance. The second digit is most commonly involved (Fig. 29-40A and B), followed by the third digit. Multiple digit involvement is seen in approximately 50% of cases.

Pathogenesis

The cause is unknown. There is no evidence that inheritance plays a role (276). Turra and colleagues (277) and others hypothesized a nerve trunk disease as the cause for macroductyly, but this theory has not been confirmed (276).

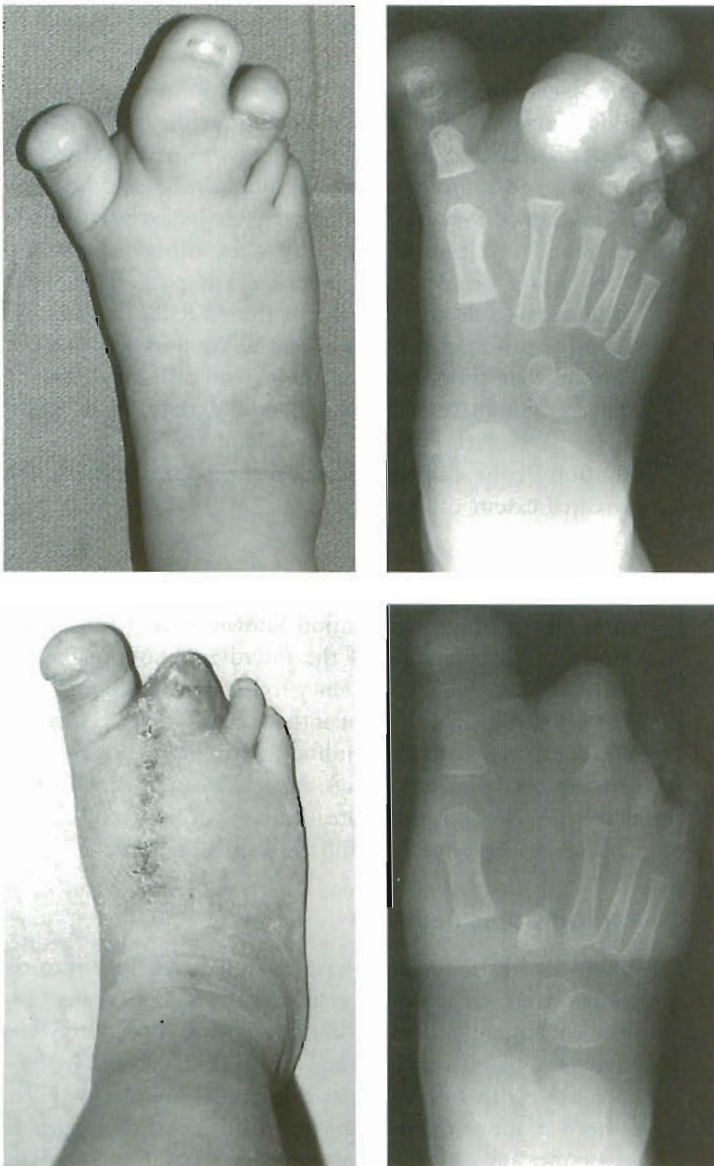


FIGURE 29-40. A: Second ray macroductyly with some enlargement of the hallux and third toe. B: Radiographic appearance. C: Clinical appearance after second ray resection and third toe interphalangeal disarticulation. D: Radiographic appearance 1 year later.

Clinical Features

The enlarged digit is apparent at birth. Features of Klippel-Trenaunay-Weber syndrome and neurofibromatosis should be sought, although features of neurofibromatosis are rarely present at birth. The relative size of the entire extremity should also be assessed to rule out hemihypertrophy as the underlying disorder.

Radiographic Features

Standing anteroposterior and lateral radiographs are useful for monitoring the relative growth rates of the digits, and for surgical planning.

Pathoanatomy

There is enlargement in length and circumference of the involved bones. An overabundance of fibrofatty tissue makes up the bulk of the soft tissue enlargement.

Natural History

Macroductyly may be static, in which the digit is enlarged at birth and growth is proportional to that of the normal digits, or it may be progressive, in which the involved digit grows disproportionately faster than the normal digits (278). The latter type is more common in the foot (276). Although the appearance is often quite grotesque, the main disability is with shoe fitting.

Treatment

Treatment must be individualized. The goal is not cosmesis, *per se*, but the ability to wear shoes of similar size comfortably. Surgical options include soft tissue debulking, osteotomy, epiphysiodesis, complete or partial toe amputation, and ray resection, either as isolated procedures or in combination (276,277,279–282). Ray resection has had the best reported results for decreasing the rate and risk of recurrence and achieving the goal of improved shoe-fitting (276,277,281) (Fig. 29-40C and D). Most patients, even those who undergo ray resection, will need more than one operative procedure, because all of the pathologic soft tissue cannot be removed. An aggressive approach, therefore, is desirable.

A combination of soft tissue debulking and epiphysiodesis of the proximal phalanx, the metatarsal, or both, is recommended for mild, static deformities. Repeated debulking procedures may be necessary.

Cleft Foot (Ectrodactyly)

Definition

Cleft foot, or split foot, is the accepted term for a congenital malformation of the foot in which there are varying degrees

of central longitudinal fissuring and central ray deficiency (283). The term “ectrodactyly,” which means congenital absence of all or part of a digit, is an acceptable synonym. “Lobster-claw foot,” coined by Cruveilhier in 1829 (283), is no longer acceptable.

Epidemiology

Cleft foot is a rare congenital anomaly with an incidence of 1 per 90,000 live births (284). In the typical form, the malformation is bilateral, usually associated with cleft hands, and has an autosomal dominant pattern of inheritance with incomplete penetrance (284–286). In the less common presentation, the cleft foot is unilateral without associated hand malformation, and with no evidence of familial inheritance. The incidence of this form is 1 per 150,000 live births (284). Ten percent of patients have no family history (287). Boys are affected more often than girls.

Pathogenesis

The apical ectodermal ridge (AER) induces the normal development of limb buds by interaction with the underlying mesenchyme (288,289). A defect of the AER, caused by genetic or toxic influence, could induce osseous syndactyly by deficient differentiation, polydactyly by excessive differentiation, or a central defect by some other mechanism. Watson and Bonde (290) proposed a hypothesis for cleft formation as selective damage of the AER localized at the second or third ray, the typical central location of the defect. They further proposed that the extent of damage to the AER in the transverse direction would determine the width at the base of the conical defect, and that the time and duration of the damage to the AER would determine the proximal extent of the defect.

Clinical Features

Variations of the malformation known as cleft foot range from a mere deepening of the interdigital commissure to the typical central ray deficiency to the monodactylous foot (288). The width of the foot at the metatarsal heads is excessive, compared with the hindfoot, particularly in those feet with greater deficiency of rays. Associated anomalies include cleft hand, cleft lip and palate, deafness, urinary tract abnormalities, triphalangeal thumb, and tibial hemimelia.

Radiographic Features

Blauth and Borisch (288) have classified cleft foot into six groups based on the number of metatarsal bones (Fig. 29-41). They identified two additional forms, a polydactylous type and a diastatic type. The latter is characterized by monodactyly with lower-leg diastasis, tibial aplasia, or both. Other variations of morphology in this condition, such as crossbones and synostoses, are well described in their article.

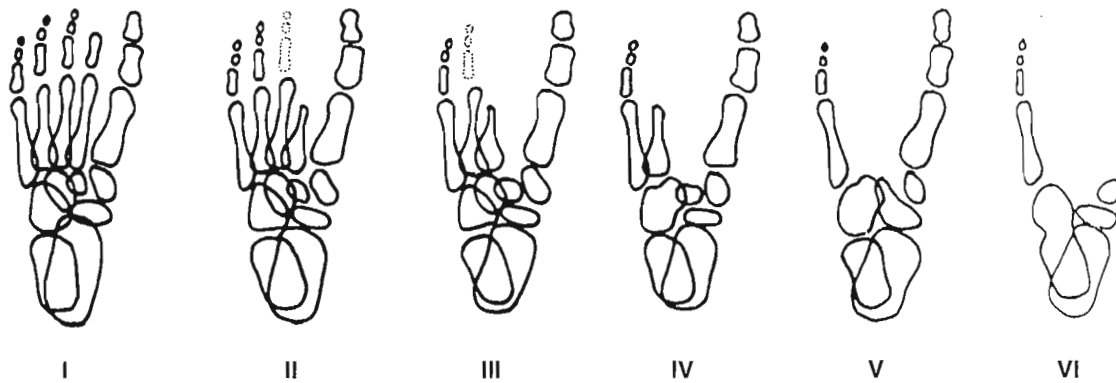


FIGURE 29-41. Cleft foot classification according to Blauth and Borisch. (From ref. 288, with permission.)

Other Diagnostic Studies

Renal ultrasonography is indicated to rule out renal anomalies that are occasionally present in individuals with cleft foot.

Pathoanatomy

The pathoanatomy is one of variable degrees of failure of formation, with occasional duplication and malorientation of bones. Synostoses may be seen at the margins of the cleft and in the tarsals (288).

Natural History

Most patients with cleft foot function well without pain with the use of accommodative shoes. This is certainly the case for feet with shallow clefts and few ray deficiencies. Marked splaying of the forefoot may develop, making it difficult or impossible to find shoes that fit comfortably. Painful callosities develop over the medial and lateral metatarsal heads.

Treatment

Treatment begins with education of the physician on the treatment used in the family member(s) from whom the malformation was inherited (Fig. 29-42). All patterns of cleft foot malformation can be accommodated in shoes during the first few years of life. Thereafter, the width of the forefoot may make it impossible to wear standard shoes without creating painful callosities over the medial and lateral metatarsal heads. At that point, custom-made shoes are an expensive option. The alternative is surgical reconstruction. Interestingly, functional disability is rarely a problem with cleft feet.

Surgical techniques for the symptomatic cleft foot must be individualized. The problem of symptomatic splayfoot can be addressed effectively with an osteotomy or osteotomies at the base of the lateral, and occasionally the medial, ray of the foot (Fig. 29-43). The soft tissues in the cleft can be partially pliated to improve the appearance and help maintain the corrected deformity (291). Hallux valgus and digiti minimi varus deformities are often severe. Soft tissue reconstructions, such as those used to correct hallux valgus,

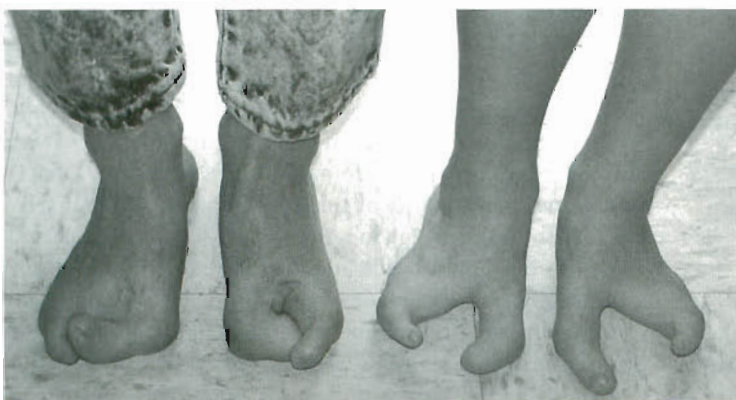

FIGURE 29-42. Father and son with cleft feet.

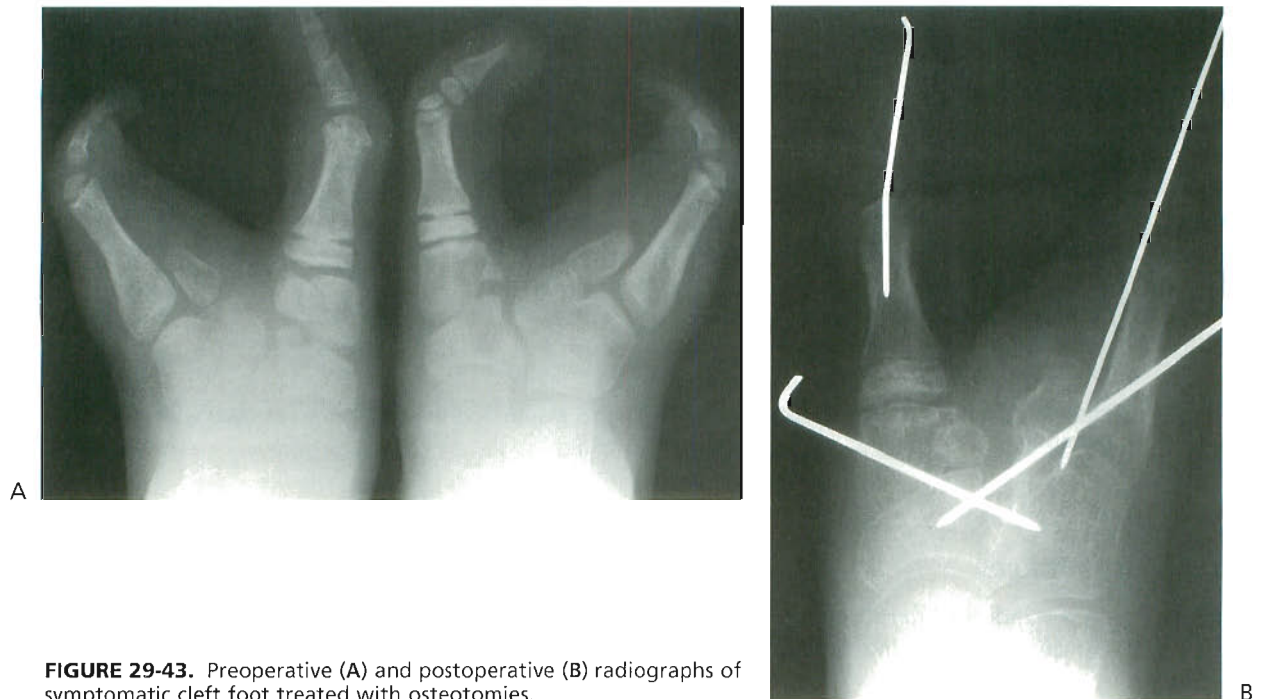


FIGURE 29-43. Preoperative (A) and postoperative (B) radiographs of symptomatic cleft foot treated with osteotomies.

are ineffective. Distal osteotomies of the metatarsals can be used to improve the malalignment, but recurrence of these distal deformities is common, even after osteotomies. Complex plastic surgery procedures that create the appearance of toes have not added sufficient functional benefit or cosmetic improvement to justify their use (292).

DEVELOPMENTAL DEFORMITIES

Developmental deformities consist of malalignment of bones at their joints that develop over time.

Cavus

Definition

Cavus refers to a fixed equinus (plantar flexion) deformity of the forefoot in relation to the hindfoot, resulting in an abnormally high arch. The high arch may be along the medial border of the foot or across the entire midfoot. The heel may be in a neutral, varus, valgus, calcaneus (dorsiflexed), or equinus position. There may be an accompanying clawing of the toes. There are two common patterns of cavus deformity (293). Cavovarus, or anterior cavus, is the most common pattern. Calcaneocavus, or posterior cavus, occurs less frequently.

Pathogenesis

Cavus is a manifestation of a neuromuscular disorder with muscle imbalance, until proven otherwise. At least two-

thirds of patients who seek treatment for a painful high arch will have an underlying neurologic problem, and half of these will have Charcot-Marie-Tooth disease (294). There are many other causes of cavus foot deformity. It is helpful to consider those that cause unilateral versus bilateral deformity when evaluating the patient (Table 29-2).

Calcaneocavus deformity is seen almost exclusively in children with myelomeningocele and poliomyelitis (Fig. 29-44).

Epidemiology

The incidence of cavus is variable, and is related to the prevalence of neuromuscular disorders at any time.

Clinical Features

The clinical features depend on the underlying pathogenesis. Some of the underlying neurologic abnormalities are known at the time of presentation and some are not, some are treatable and some are not, and some are static and some are progressive. The resultant muscle imbalance, however, always leads to progressive foot deformity. The clinical manifestations are instability of gait with frequent falling, a feeling that the ankle is “giving out,” and a history of repeated ankle sprains. Painful callosities develop under the metatarsal heads, lateral to the base of the fifth metatarsal, and over the dorsum of the proximal interphalangeal joints of the progressively clawing toes. In the calcaneocavus foot, callus formation occurs almost exclusively under the calcaneus.

TABLE 29-2. CAUSES OF CAVUS FOOT DEFORMITY

Bilateral	Unilateral
Charcot-Marie-Tooth disease	Traumatic injury of a peripheral nerve or spinal root nerve
Friedreich ataxia	Poliomyelitis
Dejerine-Sottas interstitial hypertrophic neuritis	Syringomyelia
Polyneuritis	Lipomeningocoele
Roussy-Lévy syndrome	Spinal cord tumor
Spinal muscular atrophy	Diastematomyelia
Myelomeningocoele	Spinal dysraphism (tethered cord)
Syringomyelia	Tendon laceration
Spinal cord tumor	Overlengthened Achilles tendon
Diastematomyelia	Cerebral palsy—hemiparesis
Spinal dysraphism (tethered cord)	Clubfoot/recurrent clubfoot
Muscular dystrophy	Compartment syndrome of the leg
Cerebral palsy—paraparesis or quadriparesis (although usually planus deformities)	Severe burn of the leg
Familial (consider Charcot-Marie-Tooth disease)	Crush injury of the leg
Clubfoot/recurrent clubfoot	
Idiopathic cause (diagnosis of exclusion)	

A history of progressive change in foot shape and function must be ascertained, even in situations of a known underlying neurologic abnormality. A sudden increase in cavus deformity in a child with myelomeningocoele or lipomeningocoele could represent evidence of a tethered spinal cord.

A family history of cavus foot deformity should be investigated as an aid to diagnosis. Charcot-Marie-Tooth disease, an autosomal dominant disorder with variable manifestations, is one of the most common causes of cavus foot deformity (294).

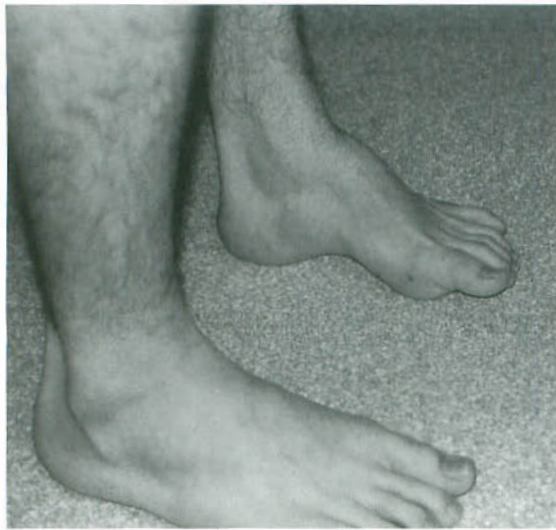
A detailed neurologic examination of the upper and lower extremities, including motor, sensory, and reflex testing, is mandatory. The spine must be examined for midline

defects, hairy patches, dimples, or other evidence of spinal dysraphism.

The foot is examined with the child seated, standing, and walking. The longitudinal arch is excessively elevated along the medial border of a weight-bearing cavovarus foot (Fig. 29-45). The lateral border of the foot is convex and plantigrade, and the base of the fifth metatarsal is prominent and often callused. The hindfoot is in varus alignment. Atrophy of the intrinsic muscles is apparent. There may or may not be contracture of the gastrocnemius or the triceps surae. In many cases, as in most cavovarus deformities secondary to Charcot-Marie-Tooth disease, the forefoot equinus gives the false impression of a hindfoot equinus. The thigh-foot angle is usually neutral, despite the internal rota-

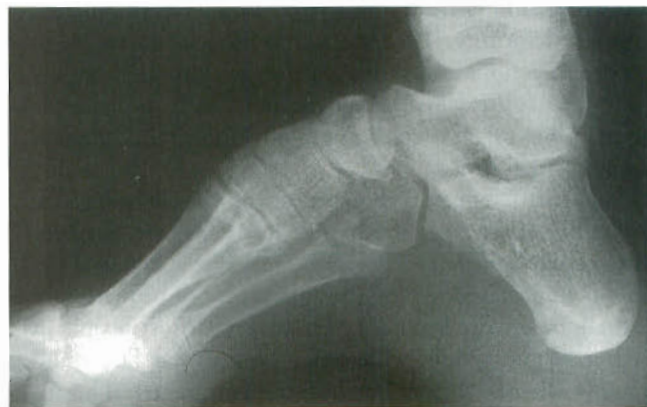
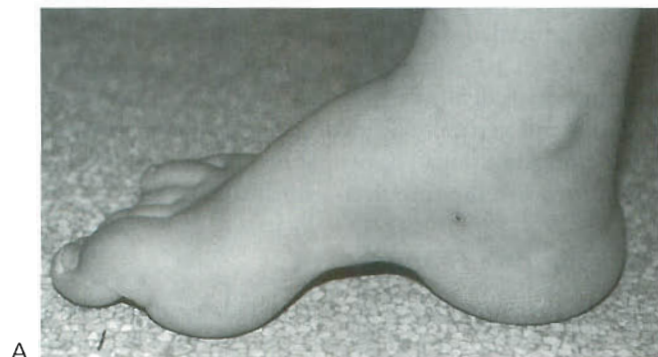
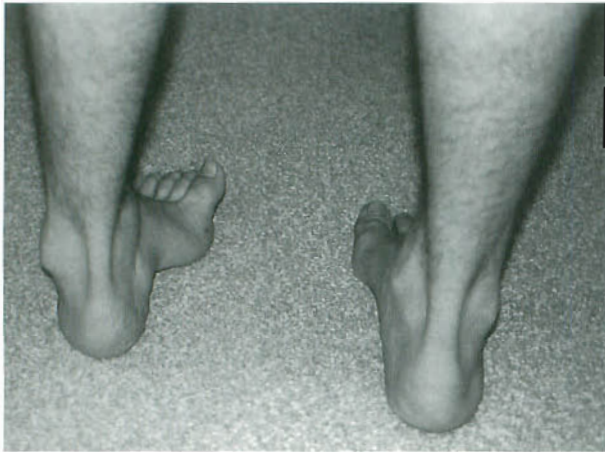FIGURE 29-44. Calcaneocavus deformity in a child with myelomeningocoele. **A:** Transtarsal cavus with thick callosities under the calcaneus and the metatarsal heads. **B:** Radiograph of the calcaneocavus "pistol-grip" deformity.



A



B

FIGURE 29-45. Cavovarus deformity in a child with Charcot-Marie-Tooth disease. **A:** The arch is elevated only along the medial border of the foot. **B:** Varus and adduction can be appreciated.

tion deformity in the subtalar joint. The reason is that external tibial torsion is always associated with a developmental cavovarus deformity. The two rotational deformities are in opposite directions and cancel each other out. It is important to discuss this with the patient and family, because the external tibial torsion will become obvious after correction of the foot deformity.

Despite differences in the patterns of muscle imbalance that lead to cavovarus, the pattern of deformity development is fairly constant (295–297). The first metatarsal becomes plantar flexed, giving the appearance of pronation of the forefoot on the hindfoot. The deformity is flexible at first but becomes rigid with time. The plantar fascia and the other plantar soft tissues become contracted. The incompletely ossified bones change shape as a result of excessive compression on their plantar aspects (Hueter-Volkman law). The normal tripod structure of the foot becomes

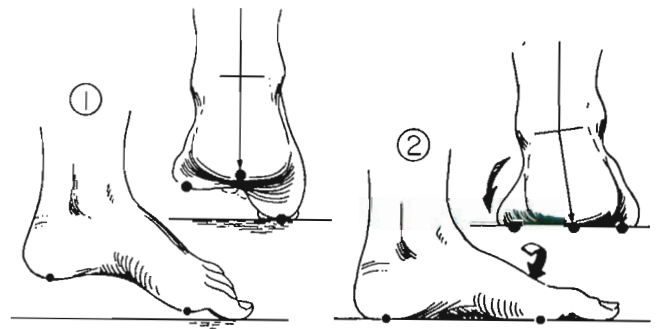


FIGURE 29-46. The tripod effect. The hindfoot must assume a varus position when weight bearing if the first metatarsal is fixed in plantar flexion. (1) Initial contact of plantar-flexed first metatarsal. (2) Fifth metatarsal makes contact through supination of the forefoot (arrow), which also drives the hindfoot into varus. (From ref. 296, with permission.)

unbalanced. Bearing weight on the plantar-flexed first metatarsal causes the forefoot to supinate, thereby driving the subtalar joint into inversion, or varus (296) (Fig. 29-46). The flexible hindfoot varus deformity eventually becomes rigid as the medial soft tissues of the subtalar joint contract. The cavovarus foot, therefore, has two major rotational deformities in opposite directions from each other: pronation of the forefoot, and supination (varus and inversion are other descriptive terms) of the hindfoot. It appears as if the foot is wrung out. Determination of the flexibility or rigidity of each deformity is important when planning an operation. Flexible deformities are treated with tendon transfers, and inflexible deformities are treated with soft tissue releases, osteotomies, and, occasionally, arthrodeses. Coleman and Chesnut (298) devised the block test to help evaluate the flexibility of the hindfoot (Fig. 29-47). The patient stands with a block of wood under the lateral border of the foot to recreate the tripod while allowing the first metatarsal to plantar flex. A flexible varus deformity of the hindfoot will correct to valgus alignment, whereas a varus deformity that is already contracted and rigid, will not. In the first situation, surgery for deformity correction is confined to the forefoot. In the latter case, forefoot and hindfoot procedures are needed.

The arch is elevated across the entire midfoot in the calcaneocavus deformity (Fig. 29-44). The calcaneus is dorsiflexed and vertically aligned, giving it the appearance of posterior truncation. The plantar heel pad is thickly callused from excessive pressure over a small surface area.

Radiographic Features

Standing anteroposterior and lateral radiographs of the foot are indicated on initial evaluation. There is normally a straight-line relationship between the axis of the talus and that of the first metatarsal on the lateral view (171). An apex dorsal angulation between those lines indicates a cavus

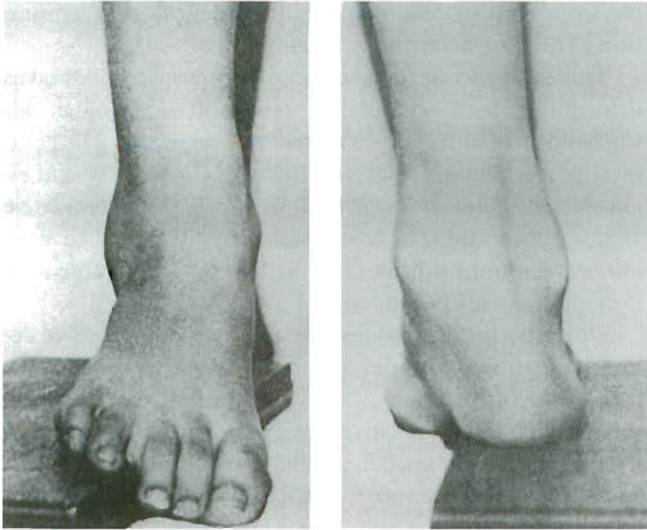

FIGURE 29-47. The Coleman block test for determination of hindfoot flexibility. The flexible varus deformity of the hindfoot will correct to valgus when the plantar-flexed first metatarsal is allowed to drop down off the edge of the block of wood. Failure to correct to valgus indicates the need for surgical correction of the hindfoot, in addition to the procedures on the forefoot. (From ref. 298, with permission.)

deformity. Varus is indicated on the anteroposterior radiograph by parallelism between the talus and the calcaneus, and by adduction between the talus and the first metatarsal.

The author obtains a standing anteroposterior Coleman-type block-test radiograph to document the flexibility of the hindfoot. The author finds that the clinical and radiographic block tests are more reliable if a Plexiglas block is placed under the lateral metatarsal heads alone (Fig. 29-48).

Standing anteroposterior and lateral radiographs of the spine are indicated if any physical examination findings suggest spinal dysraphism, spinal cord tumor, or diastematomyelia.

Other Imaging Studies

Magnetic resonance imaging of the spine may be indicated.

Other Diagnostic Studies

The DNA blood tests for Charcot-Marie-Tooth disease, electromyography with nerve conduction studies, and muscle biopsy are other possible investigations. Consultation with a pediatric neurologist is appropriate.

Pathoanatomy

Several patterns of muscle imbalance can create the covo-varus deformity. A common pattern is that seen in Charcot-Marie-Tooth disease (295,297). Denervation begins in the

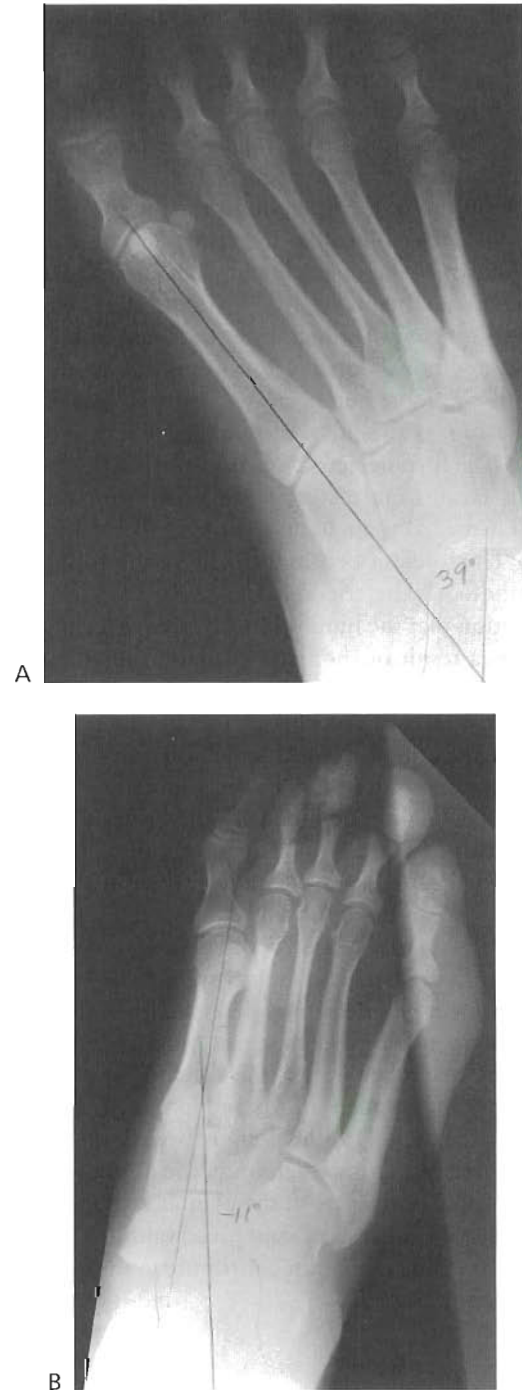


FIGURE 29-48. Standing block test radiograph with Plexiglas under the lateral metatarsal heads. The flexibility or rigidity of the subtalar joint can be documented by assessing alignment at the talonavicular joint using the talus–first metatarsal angle. **A:** Without block. **B:** With block, the hindfoot varus is corrected.

intrinsic muscles of the foot (297). The weakened lumbricals allow the long toe extensors to extend the metatarsophalangeal joints and the long-toe flexors to flex the interphalangeal joints, thereby creating claw toe deformities. These

same forces create elevation of the longitudinal arch during gait, by the windlass effect of the plantar fascia (169) (Fig. 29-19). The intrinsic muscles undergo atrophy, fibrosis, and shortening, which lead to secondary contracture of the plantar fascia. This creates a bowstring between the anterior and posterior pillars of the arch, which draws them closer and produces equinus of the forefoot on the hindfoot. The tibialis anterior, a dorsiflexor of the first metatarsal, becomes weak, whereas the peroneus longus, a plantar flexor of the first metatarsal, remains relatively strong (293). The extensor hallucis longus is automatically recruited in an attempt to provide additional dorsiflexion strength along the medial column of the foot, but it creates a paradoxical effect of plantar flexion, as a result of the windlass effect of the plantar fascia. The first metatarsal starts to plantar flex, and with time, this creates more contracture and shortening along the plantar-medial than along the plantar-lateral border of the foot. The forefoot becomes rigidly pronated in relation to the hindfoot. The tripod effect (296) accounts for the varus position that the hindfoot must assume during weight bearing, as a result of the fixed pronation of the forefoot. Also contributing to the varus deformity of the hindfoot is the muscle imbalance between the tibialis posterior, an inverter of the subtalar joint, which remains strong, and the peroneus brevis, an everter of the subtalar joint, which becomes weak (295). The subtalar joint eventually becomes rigidly deformed in varus, because of contracture of the plantar-medial soft tissues, including those of the subtalar joint complex. Although the triceps surae does not become contracted in Charcot-Marie-Tooth disease, it does in some of the other diseases that cause cavus.

The calcaneocavus deformity develops when there is little or no strength in the triceps surae, but strength exists in the muscles that plantar flex the forefoot and toes. The tibialis posterior, peroneus brevis and longus, flexor hallucis longus, and flexor digitorum longus bypass the calcaneus and plantar flex the entire forefoot on the hindfoot, without creating varus. Contracture of the plantar fascia, elongation of the paralyzed triceps surae, and preservation of functional strength in the tibialis anterior contribute to the dorsiflexion posture of the calcaneus.

Natural History

Muscle imbalance from both static and progressive neurologic disorders leads to progressive cavus foot deformity.

Treatment

Treatment of the underlying neurologic disorder should precede treatment of the foot deformity. Unfortunately, there is no known treatment or cure for many of the neurologic conditions that lead to cavus deformity. Furthermore, established muscle weakness and imbalance are not reversi-

ble, even with successful arrest of the neurologic deterioration. The foot deformity, therefore, progresses.

There is little role for nonoperative management of cavus deformities, because most are progressive and of an advanced degree of severity at the time of diagnosis. The complexity of reconstruction increases with the severity and rigidity of the deformities (296). Inexpensive, accommodative arch supports and shoe modifications may be used to ameliorate symptoms during the time it takes to diagnose and, if possible, treat the underlying cause.

Operative indications include evidence of progressive deformity, painful callosities under the metatarsal heads or the base of the fifth metatarsal, and ankle instability. There are three principles of operative management: correct all of the segmental deformities, balance the remaining muscle forces, and leave reasonable treatment options available for the recurrence of deformity and pain. There is also a principle of patient management: educate the patient and family that there are no treatment panaceas, and that more surgery may be required in the future (19–21,293,296,299–301).

There is a very long list of operative procedures that can be used to correct the individual deformities and balance the muscle forces in the cavus foot (293,296,299,302). No single procedure can accomplish both goals. Although some authors have tried (296,299), no one has yet developed an algorithm to help one choose the combination of procedures that will best address the unique pathology in any particular case.

The cavus foot deformity must be classified based on the flexibility of the segmental deformities. Correction of the deformity begins with soft tissue releases, such as fasciotomies, capsulotomies, and muscle or tendon lengthenings, with the goal of realigning joints. For the cavovarus foot, this means plantar fasciotomy, proximal release of the abductor hallucis, and possibly talonavicular joint capsulotomy and tibialis posterior tendon lengthening (296). Some of the bones in the child's foot will grow abnormally when unbalanced muscle forces are placed on them for a prolonged period of time. Osteotomies are used to correct these bone deformities, which can be identified only after soft tissue release and realignment of the joints. The first ray becomes plantar flexed early in the course of development of the cavovarus foot deformity. The site of that deformity is the medial cuneiform. Treatment with a plantar-based opening-wedge osteotomy of the medial cuneiform is safe, effective, reliable, and inherently stable without the need for internal fixation (116,296,303) (Fig. 29-49). Osteotomy of the first metatarsal (304) [➔7.7] is less desirable because it puts the growth plate at risk for arrest, requires internal fixation, puts the second metatarsal head at risk for a stress transfer lesion, and is not located at the site of deformity. The lateral column of the foot may require shortening if adductus and varus persist after the procedure(s) on the medial column (78). Alternatively, posterior calcaneus lateral displacement (181) or closing-wedge osteotomy

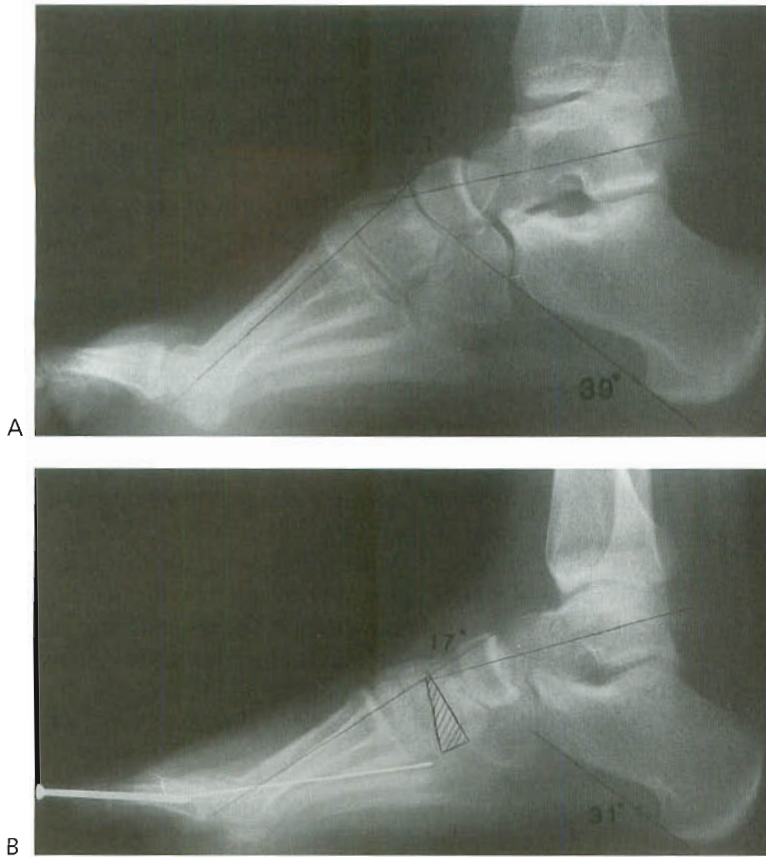

FIGURE 29-49. Lateral radiograph of a cavovarus foot deformity before (A) and after (B) a medial cuneiform planar-based opening-wedge osteotomy. The axis lines of the first metatarsal and the talus cross each other in the body of the medial cuneiform, indicating that as the site of deformity. (From ref. 303, with permission.)

(305,306) can be used. With these techniques, all but the most severe and rigid cavovarus deformities can be corrected with preservation of motion in the subtalar joint.

Midfoot osteotomies [7.8], such as those described by Cole (307), Japas (308), Jahss (309), and Wilcox and Weiner (310), correct the cavus deformity by sacrificing the midtarsal joints to arthrodesis. These procedures, therefore, should be considered second-line treatment for the cavovarus foot. Triple arthrodesis should not be used as a primary, or perhaps even a secondary, reconstructive technique in a child or adolescent with a cavus foot deformity. It causes stress shifting and premature degenerative arthrosis (19–21,26) or Charcot arthropathy (311) in adjacent unfused joints. Furthermore, it cannot by itself correct the coexisting deformities of the forefoot and the hindfoot. Arthrodesis should be reserved as a salvage procedure in cases of existing severe arthritis or recurrent deformity in older individuals. Mild recurrences in younger individuals may be amenable to additional tendon transfers with or without deformity correction.

Deformity correction in the calcaneocavus foot requires radical plantar fasciotomy and release, as well as bony procedures. Dorsal displacement of a posterior calcaneal osteotomy lowers the longitudinal arch by elevating the heel. It is an effective procedure that has the added benefit of pre-

serving joint motion. Alternatively, midfoot wedge resection osteotomies (307–310) can be used. Joint preservation is the goal when treating all deformities in the child's foot. The elimination of midtarsal joint motion has fewer negative long-term consequences than the elimination of subtalar joint motion.

Correction of deformity lends itself more readily to an algorithm than does muscle balancing. And balancing muscles in a mobile foot is more challenging than in a foot that has undergone subtalar or triple arthrodesis. The challenge must be accepted.

There are several principles of tendon transfers. A transfer should eliminate a deforming force and bring strength to a site of weakness. It should not leave behind weakness that could shift the balance of forces in the opposite direction. Phasic transfers are better than transfers that are out of phase. Dynamic tendon transfer cannot correct static bony deformity. The deformity must be corrected concurrently. One must know the present strength of all muscles. A tendon will lose at least one grade of strength when transferred. When choosing tendons to transfer, one must also anticipate the future strength of the muscles if there are underlying neurologic disorders in which there will be progressive deterioration. And always leave treatment options available for the next operation.

Juvenile Hallux Valgus

Definition

Juvenile hallux valgus is defined as greater than 14 degrees of lateral deviation of the hallux on the first metatarsal that has its onset in the preteen or teenage years, when the growth plates of the first metatarsal and proximal phalanx are still open. This age of onset applies regardless of the age at the time of treatment. Other features include minimal bursal thickening over a relatively small medial eminence, and good range of motion and lack of degenerative changes in the first metatarsophalangeal joint.

Epidemiology

The incidence is unknown. It is much more common in girls than in boys, with girls accounting for greater than 80% of operative cases (312).

Pathogenesis

The cause is also unknown. There is maternal inheritance in more than 70% of cases (313,314). Studies and case reports indicate that juvenile hallux valgus may be associated with X-linked dominant, autosomal dominant, or polygenic transmission (312,315).

Controversy surrounds each of the many extrinsic and intrinsic factors purported to influence the development and progression of juvenile hallux valgus deformity. Studies in developing countries have shown an increased risk of hallux valgus in children who wear shoes, compared with children who do not (166,316). However, the majority of evidence supports the conclusion that, in most cases, juvenile hallux valgus deformity does not appear to be influenced by a history of constricting footwear (313,314,317). Poorly fitting shoes play a small role in the cause of this condition.

Pes planus and ligamentous laxity have been reported to be associated with the development of juvenile hallux valgus, based on patient populations that included children with collagen and neuromuscular disorders (318). Studies by Trott (319) and Coughlin and Roger (313) in normal children concluded that pes planus in juveniles had no significant association with the magnitude of the hallux valgus deformity. Coughlin and Roger (313), Kilmartin and Wallace (320), and Canale et al. (321) found no correlation between pes planus and the success rate of surgical correction of juvenile hallux valgus. These data, however, should not be used to completely discount the effect of severe valgus deformity of the hindfoot and significant ligamentous laxity on the development and progression of the juvenile hallux valgus deformity.

The association of juvenile hallux valgus with the length of the first metatarsal is also controversial. An excessively long (313,322,323), as well as an excessively short (80), first

metatarsal has been implicated in the incidence, severity, and recurrence of juvenile hallux valgus deformity. Coughlin and Roger (313) have recently provided data showing that the relative lengths of the first and second metatarsals in children with juvenile hallux valgus are statistically similar to those of the normal population.

The shape of the first metatarsal may be an etiologic factor in the development of juvenile hallux valgus. The articular cartilage on the distal end of the first metatarsal normally aligns almost perpendicularly with the long axis of the bone. Lateral deviation, or orientation, of the articular cartilage can occur, thereby effectively creating a very distal valgus deformity of the metatarsal. The distal metatarsal articular angle (DMAA) quantifies this alignment (312,313,324,325) (Fig. 29-50). A higher angle indicates greater valgus deformity of the metatarsal. Coughlin and Roger (313) reported that 48% of juveniles with hallux valgus had an increased DMAA with a congruous first metatarsophalangeal joint, significantly greater than the percentage of adults with this finding (324). The remainder of his juvenile patients had lateral joint subluxation with a nearly normal DMAA, the usual finding in adults (Fig. 29-51). Coughlin and Roger (313) noted that the DMAA was sig-

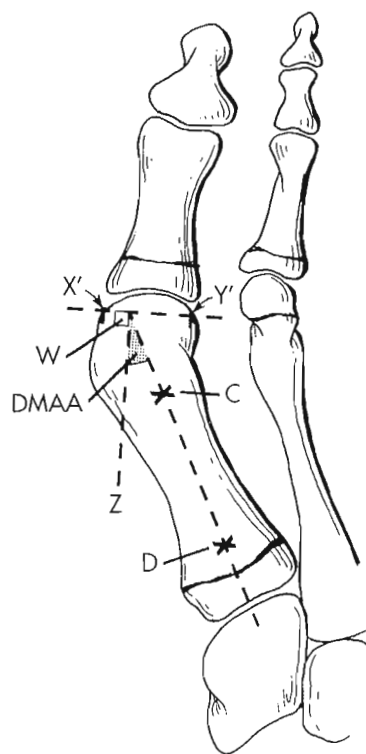


FIGURE 29-50. The distal metatarsal articular angle (DMAA) quantifies the angular relationship between the articular surface and the shaft of the metatarsal. The DMAA is the angle between the metatarsal shaft (C–D) and the line (W–Z) that is perpendicular to the articular surface (X'–Y'). (From ref. 312, with permission.)

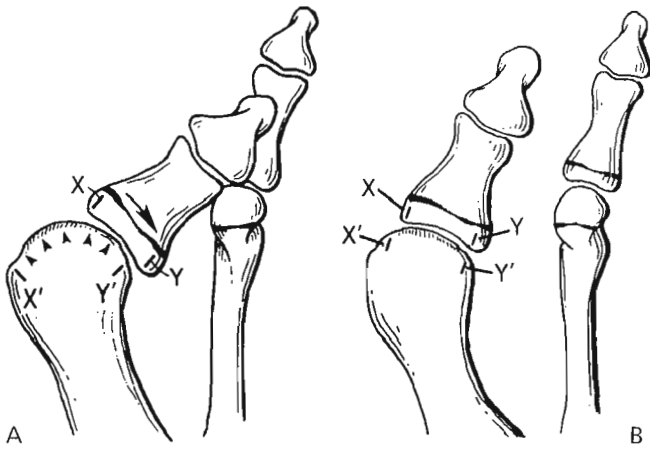


FIGURE 29-51. Subluxated (A) and congruous (B) first metatarsophalangeal joint. X' and Y': extent of metatarsal articular surface; X and Y: extent of proximal phalanx articular surface. (From ref. 312, with permission.)

nificantly higher in patients with positive family histories, in patients with early onset of hallux valgus (younger than 10 years of age), and in patients with long first metatarsals.

The orientation and flexibility of the first metatarsocuneiform (MTC) joint may be etiologic features of juvenile hallux valgus (312,314,322,326,327). Medial deviation of the MTC joint creates metatarsus primus varus. Metatarsus primus varus, or a 1st–2nd intermetatarsal angle (Fig. 29-52) of greater than 8 degrees, is abnormal, and is frequently seen in children with juvenile hallux valgus. The literature is inconsistent in identifying an association between adductus of all of the metatarsals and juvenile hallux valgus (313,328).

Clinical Features

Most adolescents with hallux valgus are asymptomatic and have learned to choose their shoes to avoid pressure and pain on the medial aspect of the first metatarsal head. Some are merely dissatisfied with the appearance of the foot. Others report pain only when wearing certain stylish shoes that fit poorly and are biomechanically inferior. Still others are symptomatic despite attempts to modify their shoe wear. The pain is located in the superficial soft tissues, because of pressure from the shoe on the bony prominence of the first metatarsal head. There may also be pain associated with the overlapping of the second toe on the distal end of the hallux. Intraarticular pain is rare in juvenile hallux valgus. Likewise, it is rare to find restriction of motion of the metatarsophalangeal joint.

Although it is difficult to quantify, the mobility of the MTC joint should be evaluated. The foot should be assessed in weight bearing to determine the alignment of the midfoot and the hindfoot, with particular note being made of

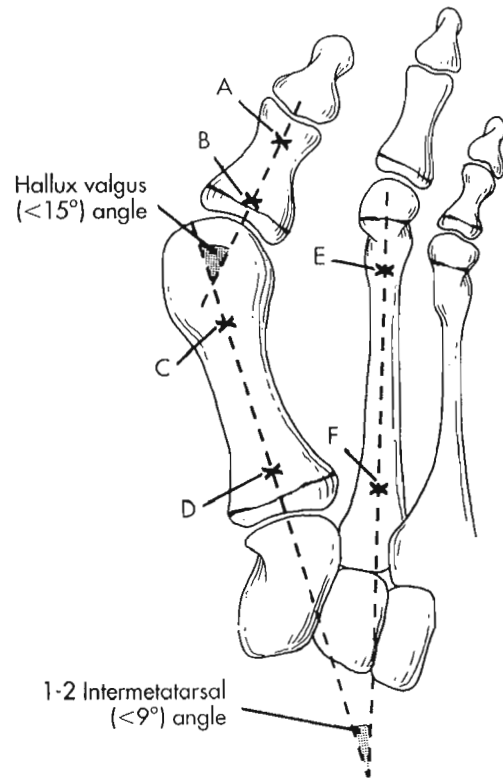


FIGURE 29-52. Hallux valgus and 1st–2nd intermetatarsal angle. A–B: axis of proximal phalanx; C–D: axis of 1st metatarsal; E–F: axis of 2nd metatarsal. (From ref. 312, with permission.)

the presence or absence of valgus deformity. Contracture of the Achilles tendon must be ascertained. A thorough motor and sensory examination is performed. Gait is observed, with a focus on the position of the forefoot during push-off. The shoes are inspected for the pattern of wear. Most importantly, the child's major concerns, symptoms, expectations, and goals must be elicited.

Radiographic Features

Standing anteroposterior and lateral radiographs of the foot are necessary to evaluate juvenile hallux valgus. Assessment of overall foot alignment, including the midfoot and the hindfoot, is important. Forefoot assessment includes measurement of the hallux valgus angle, the 1st–2nd intermetatarsal angle, DMAA, MTP joint congruity, relative lengths of the metatarsals, MTC orientation, proximal phalanx articular angle, and lesser metatarsal orientation (312) (Figs. 29-50–29-52). The importance of determining the DMAA has been stressed. Unfortunately, identification of the extent of the articular cartilage of the metatarsal head is difficult in children and many adolescents. Additionally, a radiographic study on cadavers by Vittetoe et al. (329) showed that, although intraobserver reliability for DMAA measurement

was high, interobserver reliability for this measurement technique was poor.

Pathoanatomy

Valgus alignment of the hallux on the first metatarsal is the final deformity that may result from one or more anatomic variations.

Natural History

The natural history of juvenile hallux valgus is not known. Piggott (324) concluded that congruous joints with juvenile hallux valgus were stable and less likely to progress than those with subluxation. In this situation, the degree of hallux valgus is equal to the DMAA. Nevertheless, a hallux valgus deformity with a congruous first MTP joint may require surgical correction if the severity of the deformity leads to disability. A congruous first MTP joint is found in 9% of adults (324) and 47% of juvenile patients (313) with hallux valgus. Joint incongruity leads to progressive deformity and degenerative arthrosis at an unpredictable rate.

Treatment

The reason for seeking treatment must be ascertained. The natural history of juvenile hallux valgus is not known, and the complication rate from surgery is high. Cosmetic surgery, therefore, is contraindicated. Such treatment could be far worse than the condition itself.

Treatment can be divided into those methods that relieve pain and those that relieve pain through deformity correction. Nonoperative and operative modalities may be successful in relieving pain. Deformity correction can obviously be achieved through operative means. Contrary to expectations, Kilmartin et al. (330) found that hallux valgus deformity increased more in patients who used rigid, thermoplastic, biomechanical foot devices than in patients who did not. There is only one report indicating a possible nonoperative means for correcting deformity. Groiso (331) demonstrated improvement in the hallux valgus and 1st–2nd intermetatarsal angles in approximately 50% of feet that were treated with a moldable thermoplastic night splint, in combination with daytime active and passive stretching exercises. Others have not reproduced this experience.

Conservative measures will relieve symptoms without correcting the deformity in most patients with juvenile hallux valgus. The object is to make the shoe look like the foot, rather than vice versa. Shoes with an adequate toe box, a soft upper, and a low heel are most likely to provide pain relief. A running shoe is the most acceptable shoe that meets these requirements for this age group, although it is not appropriate for all social situations. Bunion stretchers are available where shoes are sold and repaired. When contemplating the purchase of a pair of shoes, the weight-bearing

foot should be traced on a piece of paper, and compared with the outline of the shoe.

Surgery is indicated when prolonged attempts at conservative management have failed to relieve the pain over the first metatarsal head. The age of the patient at the time of surgery is a consideration. Poor results with high complication rates have been reported consistently in 30 to 60% of cases of surgery for juvenile hallux valgus (323,332–335). These results have been attributed to several factors. They include recurrence of deformity as a result of further epiphyseal growth (336), growth arrest secondary to injury of the growth plates at the proximal ends of the first metatarsal and the proximal phalanx, and the application of a single technique that did not take into consideration the unique pathoanatomy of each foot (334). Coughlin and Roger (313) and others (80,335) have performed successful surgical reconstruction with few complications in adolescents with open growth plates with juvenile hallux valgus. These authors have stressed, however, that there is rarely urgency in performing the surgery and that it should be delayed, if possible.

Perhaps the most challenging management decision to be made concerns the adolescent athlete who is performing at a high level, albeit with pain. In this patient, surgery, with its known risks and complications, could have a deleterious effect on future performance.

No single surgical procedure is suitable for all patients with juvenile hallux valgus deformity. All elements and components of the deformity must be analyzed clinically and radiographically. The goal is to correct the deformity to relieve pain and functional disability, while maintaining a flexible first MTP joint and a normal weight-bearing pattern of ambulation. The principle is to correct all components of the deformity at the site(s) of deformity without creating compensating deformities. Knowledge of the DMAA and the congruency of the first MTP joint is central to appropriate surgical planning, for it is this information that determines whether the correction will be intraarticular or extraarticular. The surgeon must have the knowledge and skills to perform the many and varied techniques that may be needed to address the pathoanatomy at all sites.

Surgical treatment for a juvenile hallux valgus deformity with a subluxated MTP joint consists of distal soft tissue realignment. A medial cuneiform or base of the first metatarsal osteotomy should be combined with the soft tissue realignment, if the subluxation is combined with an intermetatarsal angle greater than 8 degrees, i.e., metatarsus primus varus (312,313,333). An opening-wedge osteotomy of the medial cuneiform is a particularly good choice if the MTC joint is medially deviated, the metatarsal growth plate is open, and the first metatarsal is shorter than the second.

The treatment of a juvenile hallux valgus deformity with a congruous MTP joint involves osteotomies to correct the bone deformities and to realign both the joint and the first ray. A distal metatarsal osteotomy is used to correct the

A,B

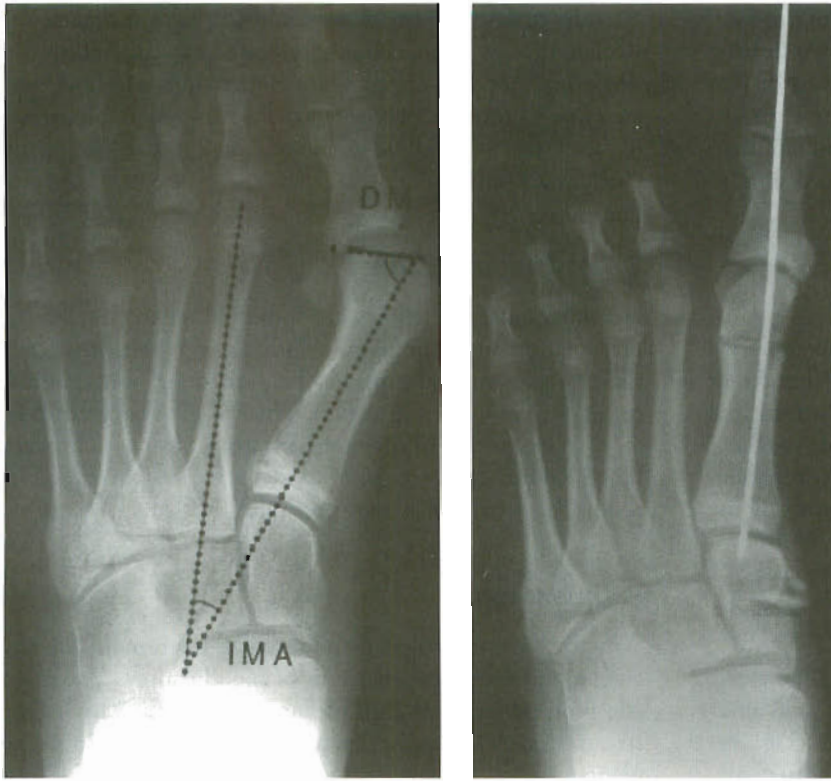


FIGURE 29-53. A: Preoperative radiograph of juvenile hallux valgus. IMA, intermetatarsal angle. (From ref. 303, with permission.) B: Radiograph after medial cuneiform opening-wedge osteotomy and distal first metatarsal closing-wedge osteotomy.

DMAA, whereas a proximal metatarsal osteotomy or a medial cuneiform osteotomy is used to correct the metatarsus primus varus (312,337) [→7.12–7.14] (Fig. 29-53). In some cases, an additional osteotomy at the base of the proximal phalanx is indicated. The distal metatarsal osteotomy can be a simple closing-wedge procedure or a more complex biplanar chevron (312) or Mitchell osteotomy (312,321, 332,334,336,338–341). Standard uniplanar chevron and Mitchell osteotomies do not correct the DMAA. There is a risk of interrupting the blood supply to the metatarsal head, with resultant avascular necrosis, when a lateral soft tissue release is combined with a distal metatarsal osteotomy (342).

Postoperative complications are frequent after surgical correction of juvenile hallux valgus. Recurrence, overcorrection to hallux varus, avascular necrosis of the metatarsal head, metatarsalgia, joint stiffness, and growth arrest are among the most serious complications.

The most reasonable approach to the adolescent with symptomatic hallux valgus is to exhaust all modalities of conservative management to treat the pain before considering surgery. Then, carefully assess the deformity both clinically and radiographically, and choose the combination of techniques that addresses each of the segmental deformities in that individual. Pay particular attention to the DMAA and the congruity of the MTP joint. Have a plan for the potential complications.

ACQUIRED AFFECTIONS

Kohler Disease

Definition

In 1908, Kohler described a self-limited painful condition of the tarsal navicular in young children that was characterized on radiographs by flattening, sclerosis, and irregular rarefaction. Diagnosis is dependent on the clinical and radiographic findings.

Epidemiology

This condition is uncommon. It occurs four times more frequently in boys than in girls (343,344), and it may be bilateral (344,345).

Pathogenesis

Kohler disease is considered an osteochondrosis, an idiopathic condition characterized by disordered endochondral ossification, including both osteogenesis and chondrogenesis, which arises from a previously normal growth mechanism (346). More specifically, it has been classified by Siffert (346) as a secondary articular osteochondrosis, because involvement of the articular and epiphyseal cartilage, if any, is a consequence of avascular necrosis of the subjacent bone.

The navicular is located at the apex of the arch of the foot, and is subjected to compressive forces during weight bearing that could disrupt its blood supply. There is evidence that the disease develops in navicular bones that are constitutionally and biologically inferior and, therefore, vulnerable to damage by mechanical forces that normal bone is able to withstand (347).

Clinical Features

Typically, a child younger than 6 years of age presents with an antalgic limp, bearing weight on the lateral border of the foot. Pain is reported to be located over the dorsomedial aspect of the midfoot. There may be tenderness, swelling, redness, and warmth, signs that might suggest an infection or an inflammatory arthropathy. Range of motion of the joints is normal.

Radiographic Features

Standing anteroposterior and lateral radiographs reveal the characteristic findings of sclerosis, fragmentation, and anterior-to-posterior flattening of the navicular bone (Fig. 29-54). The tarsal navicular is the last bone of the foot to ossify. The average age of appearance of its ossific nucleus is 18 to 24 months in girls and 30 to 36 months in boys (348). Irregularity in the ossification of this bone is common, and may manifest as multiple ossification centers that subse-

quently coalesce (348). This should not be mistaken for Kohler disease if the clinical picture does not correlate. Abnormalities of ossification are more frequent in boys, and are more common in naviculars that ossify late. Radiographs of both feet should be obtained for comparison if the changes are subtle.

Other Imaging Studies

No other imaging studies are indicated when the clinical presentation and radiographic findings are typical, although the use of bone scanning has been reported. The clinical findings may suggest infection, which is extremely unlikely in this location without a penetrating injury. Complete blood count, sedimentation rate, and C-reactive protein should be obtained, if that possibility exists.

Pathoanatomy

Waugh (349) investigated the vascular anatomy of the navicular and found two patterns of blood supply. The most common pattern was a diffuse network supplied by five or six arteries. A less common pattern was a single dorsal or plantar artery. He felt that compressional forces could occlude the vessels and produce avascular necrosis of the bone. Histologic examination of affected bones has disclosed areas of necrosis, resorption of dead bone, formation of new bone, and interference with normal ossification.

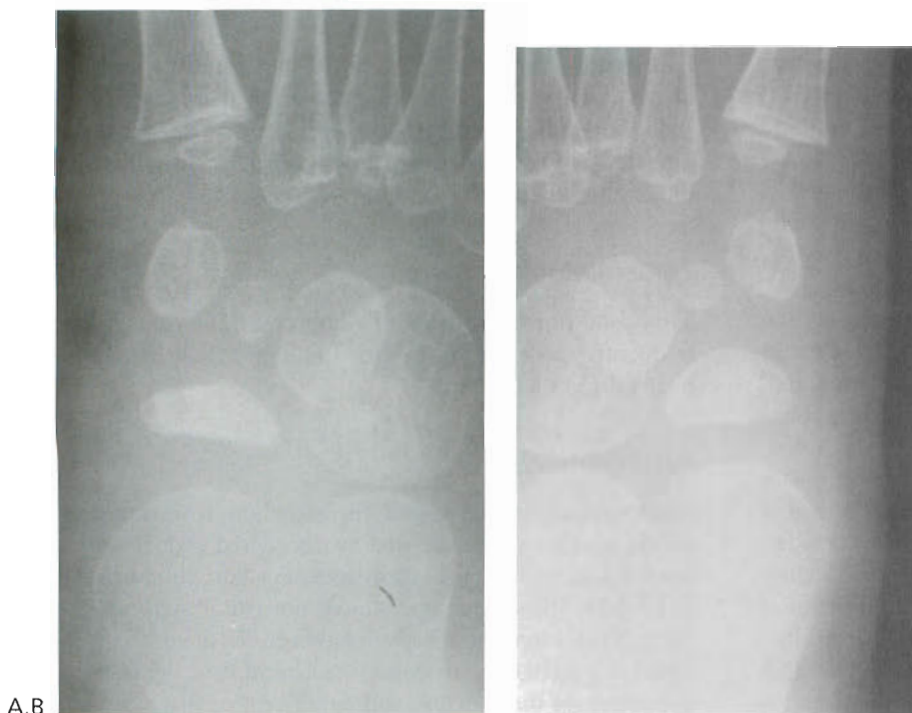


FIGURE 29-54. Kohler disease of the right tarsal navicular. A: Manifest as sclerotic and flattened. B: Normal left navicular.

Natural History

This is a self-limiting condition that never has its onset in later childhood, adolescence, or adulthood. The navicular reconstitutes itself in 4 months to 4 years, and is normal at skeletal maturity (343–345). There is no residual deformity or disability in adults who were affected as children.

Treatment

Treatment is symptomatic. An over-the-counter longitudinal arch support may relieve mild symptoms. More intense pain can be relieved with a below-knee cast. Borges et al. (345), Ippolito et al. (343), and Williams and Cowell (344) found that treatment with a below-knee cast for a minimum of 8 weeks reduced the duration of symptoms to approximately 3 months. The duration of symptoms was 7 to 15 months for patients casted for less than 8 weeks and patients treated with other regimens. A walking cast was as effective as a nonwalking cast. Except for the duration of symptoms, treatment had no effect on the final outcome of the disease (343–345). There is no role for surgery.

Freiberg Infraction

Definition

In 1914, Freiberg (350) reported on a painful condition affecting the second metatarsal head, which was characterized radiographically by flattening of the articular end of the bone. He labeled the condition an infraction, because he postulated a traumatic origin.

Epidemiology

The incidence is unknown, but the condition occurs most commonly in adolescent girls. Freiberg infraction is the only osteochondrosis with a predilection for females. The second metatarsal is most commonly affected, followed by the third; the first, fourth, and fifth metatarsals are rarely involved. Less than 10% of affected individuals have bilateral involvement.

Pathogenesis

The cause is unknown. Like Kohler disease, Freiberg infraction is considered an osteochondrosis, an idiopathic condition characterized by disordered endochondral ossification. However, unlike Kohler disease, it has been classified by Siffert (346) as a primary articular osteochondrosis that may or may not progress to disruption of the subjacent bony epiphysis. These histologic changes occur in constitutionally and biologically susceptible metatarsal heads for unknown reasons. Proposed theories include trauma, repetitive stress, vascular anomalies, and high-heel shoe wear (347,351).

Clinical Features

Typically, a mid- to late adolescent girl presents with forefoot pain that is exacerbated by weight-bearing activities and is relieved by rest. There is soft tissue swelling, tenderness, and restriction of motion of the involved metatarsophalangeal joint. When the pain, swelling, and tenderness are located more proximally on the metatarsal shaft, and there is full motion of the metatarsophalangeal joint, the diagnosis is more likely to be metatarsal stress fracture.

Radiographic Features

Radiographic findings are evident on anteroposterior and oblique radiographs of the forefoot within several weeks of the onset of symptoms. The radiographic findings of Freiberg infraction, like the physical findings, are varied and tend to correlate with the pathologic stage of the disease, but not necessarily with the physical complaints. The prognosis cannot be determined by the extent of involvement seen radiographically. Various authors have proposed different staging schemes (351–353), correlating physical and radiographic findings to various treatment options (Fig. 29-55).

Pathoanatomy

There are three stages of pathologic changes (354). The intraarticular and periarticular soft tissues are thickened and edematous during the first stage. In the second stage, the cells of the epiphysis, which receive nutrition by diffusion from the joint fluid, are deprived as a result of the edematous pressure from chronic synovitis. Blood vessels within the epiphysis are incompetent secondary to thrombosis or microfractures of the trabeculae. The epiphyseal contour becomes deformed because of this disordered osteogenesis and chondrogenesis. Repair takes place during the third stage, with gradual replacement of the necrotic bone. Alternatively, the necrotic bone segment(s) may separate as an intra-articular loose body, leaving a defect in the articular surface.

Natural History

The disease can either progress through the various stages of involvement, or it can be arrested at any level by healing of the subchondral bone. The distribution of cases is unknown. The long-term result depends on the final severity of the deformity and the integrity of the articular cartilage.

Treatment

Nonoperative treatment is indicated to relieve symptoms and to allow healing, as will occur in many cases. Modalities include restriction of activities, avoidance of weight bearing, cast immobilization, use of metatarsal bars and other shoe

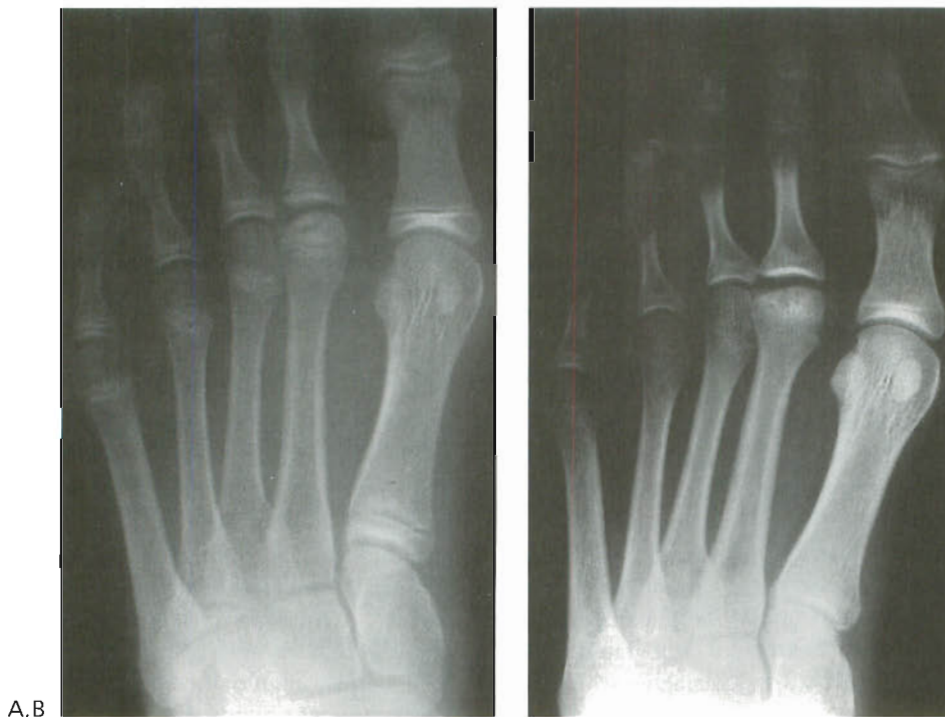

FIGURE 29-55. A: Freiberg infraction of the second metatarsal head. Early stage with crescent sign. B: Later stage with collapse of the metatarsal head. The patient, a young woman, was asymptomatic.

inserts to relieve pressure under the metatarsal head, and modification of shoe wear.

Surgery is indicated when prolonged attempts at nonoperative management have failed to alleviate the symptoms; however, there is no consensus on the best technique. Surgical options include joint debridement with removal of loose bodies (350,352,355), elevation of the collapsed head with bone grafting (353), excision of the metatarsal head, excision of the base of the proximal phalanx, metatarsal shortening (356), metatarsal dorsiflexion osteotomy (351,352,355), and joint replacement. Debridement of the metatarsal head is a minimally morbid procedure that preserves the length and function of the metatarsal, and usually gives satisfactory symptomatic relief (350,352,355). Satisfactory restoration of joint motion has been reported. In more advanced stages of the disease, joint debridement alone might not be sufficient. The addition of a distal metatarsal dorsiflexion osteotomy (351,352,357) has been reported to relieve symptoms and to restore joint motion and patient function at any stage of the disease. Attention to the details of the procedure is important to avoid iatrogenic disruption of the vascularity of the metatarsal head and the creation of transfer lesions to adjacent metatarsal heads (351).

Sever Apophysitis

Definition

In 1912, Sever (358) described an inflammatory disorder of the apophysis of the os calcis, which caused heel pain in the growing child.

Epidemiology

Sever calcaneal apophysitis is the most common cause of heel pain in the immature athlete (359). The average age of clinical presentation is 11.5 years, with the majority of patients presenting between 10 and 12 years of age. It is two to three times more common in boys than in girls. Bilateral involvement occurs about 60% of the time (359).

Pathogenesis

The cause is unknown. Sever apophysitis is considered a nonarticular osteochondrosis (346). Repetitive micro-trauma, or overuse, results in injury to the apophysis in constitutionally susceptible children (359).

Clinical Features

The typical patient with Sever apophysitis is a 10- to 12-year-old avid male soccer player with activity-related heel pain, who has recently undergone a growth spurt. The child continues to play despite the pain. There is no redness, swelling, warmth, or night pain. The classic physical finding is pain on medial-to-lateral compression of the apophysis. Other possible causes of heel pain can usually be diagnosed with careful and specific palpation (360) (Fig. 29-56). The child with calcaneal apophysitis will usually have mild contracture of the Achilles tendon.

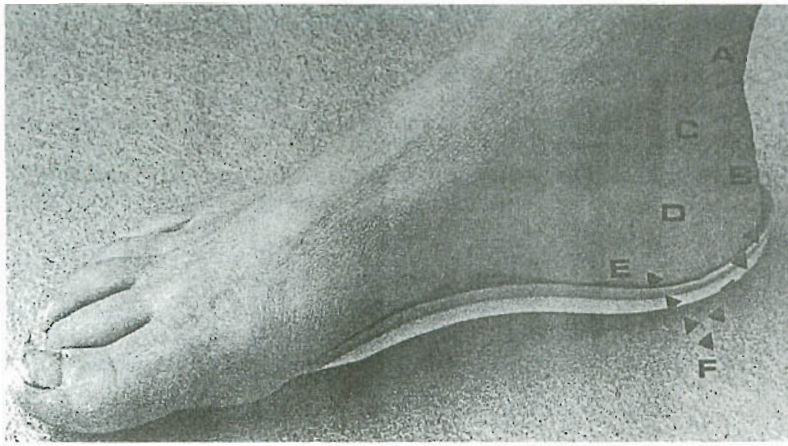


FIGURE 29-56. Sites of heel pain: Achilles tendinitis (A); calcaneal apophysitis (B); retrocalcaneal bursitis (C); calcaneal stress fracture (D); plantar fasciitis/calcaneal bursitis (E); and fat-pad shear syndrome (F). (From ref. 360, with permission.)

Radiographic Features

The diagnosis of Sever apophysitis is a clinical one, because there are no diagnostic or pathognomonic radiographic features. Irregularities of ossification, with sclerosis and fragmentation, represent the normal radiographic appearance of the apophysis of the os calcis in the growing child (361) (Fig. 29-57). Lateral and axial (Harris) radiographs are not necessary in the face of a classic history and physical examination, but they can be used to rule out other causes of heel pain, particularly if there is local swelling, redness, warmth, or a history of night pain.

Other Imaging Studies

A bone scan can be helpful in localizing the site of pathology in cases of heel pain when symptoms, physical findings,

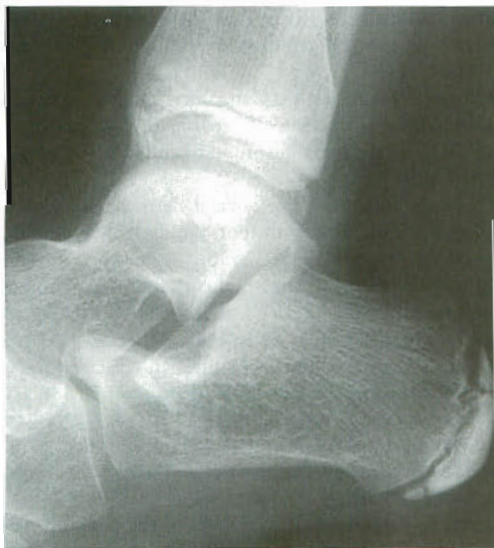

FIGURE 29-57. Lateral radiograph showing the normal irregularities of ossification of the apophysis of the os calcis in the growing child.

and radiographs are nondiagnostic. It is particularly helpful to rule out a stress fracture.

Pathoanatomy

The apophysis of the os calcis experiences opposing traction forces from the Achilles tendon and the plantar fascia during weight bearing (346,362,363). It is also subjected to powerful compressive forces at right angles to the traction forces during heel strike. Siffert (346) believed that, in constitutionally susceptible children, mechanical disruption of the endochondral mechanism might be evident as microfractures that do not heal because of repeated trauma. He felt that the disruption of chondrogenesis and osteogenesis could account for the clinical symptoms and the radiographic changes that, although not diagnostic, are often seen with Sever apophysitis. Liberson et al. (363) had the opportunity to study pathologic specimens of the apophysis of the os calcis in children. Their histologic and computer-aided analyses supported the hypothesis of a stress remodeling process that occurs subclinically in every child at a certain stage of apophyseal development. They determined that it is caused by bending of the apophysis under the repetitive stresses of traction and impact. They concluded that pain, radiographic changes, or both, result when remodeling exceeds certain rates.

Natural History

Sever apophysitis is a self-limited and age-limited condition. It cannot occur after maturation and closure of the apophysis of the os calcis.

Treatment

Treatment is symptomatic. It includes restriction of activities that cause pain, Achilles tendon stretching exercises, strengthening of the anterior compartment muscles, and the

addition of a soft heel pad and lift. Nonsteroidal antiinflammatory medications and/or a short-leg cast can be used for a brief time if the pain is significant. This is the same treatment regimen recommended for most causes of heel pain in the child. The average time to symptomatic relief with this regimen is 2 months, with a range of 1 to 6 months (359). Recurrence of symptoms is possible before skeletal maturation. There is no evidence that continued participation in painful activities has any long-term sequelae. There is no role for surgery in this condition.

References

Principles of Management

- Salenius P, Vankka E. The development of the tibiofemoral angle in children. *J Bone Joint Surg Am* 1975;57:259.
- Staheli LT, Corbett M, Wyss C, et al. Lower-extremity rotational problems in children: normal values to guide management. *J Bone Joint Surg Am* 1985;67:39.
- Farsetti P, Weinstein SL, Ponseti IV. The long-term functional and radiographic outcomes of untreated and non-operatively treated metatarsus adductus. *J Bone Joint Surg Am* 1994;76:257.
- Ponseti IV, Becker JR. Congenital metatarsus adductus: the results of treatment. *J Bone Joint Surg Am* 1966;48:702.
- Rushforth GF. The natural history of hooked forefoot. *J Bone Joint Surg Br* 1978;60:530.
- Larsen B, Reimann I, Becker-Andersen H. Congenital calcaneovalgus: with special reference to treatment and its relation to other congenital foot deformities. *Acta Orthop Scand* 1974;45:145.
- Harris RI, Beath T. *Army foot survey: an investigation of foot ailments in Canadian soldiers*. Ottawa, Ontario, Canada: National Research Council of Canada, 1947.
- Staheli LT, Chew DE, Corbett M. The longitudinal arch: a survey of eight hundred and eighty-two feet in normal children and adults. *J Bone Joint Surg Am* 1987;69:426.
- Vanderwilde R, Staheli LT, Chew DE, et al. Measurements on radiographs of the foot in normal infants and children. *J Bone Joint Surg Am* 1988;70:407.
- Gould N, Moreland M, Alvarez R, et al. Development of the child's arch. *Foot Ankle* 1989;9:241.
- Wenger D, Mauldin D, Speck G, et al. Corrective shoes and inserts as treatment for flexible flatfoot in infants and children. *J Bone Joint Surg Am* 1989;71:800.
- Shands AR Jr, Wentz IJ. Congenital anomalies, accessory bones and osteochondritis in the feet of 850 children. *Surg Clin North Am* 1953;33:1643.
- Sullivan J, Miller W. The relationship of the accessory navicular to the development of the flat foot. *Clin Orthop* 1979;144:233.
- Leonard M. The inheritance of tarsal coalition and its relationship to spastic flat foot. *J Bone Joint Surg Br* 1974;56:520.
- Scarpa A. A memoir on the congenital club feet of children, and of the mode of correcting that deformity. *Clin Orthop* 1994;308:4.
- Butte F. Navicular-cuneiform arthrodesis for flatfoot: an end-result study. *J Bone Joint Surg* 1937;19:496.
- Crego C, Ford L. An end-result of various operative procedures for correcting flat feet in children. *J Bone Joint Surg Am* 1952;34:183.
- Seymour N. The late results of naviculo-cuneiform fusion. *J Bone Joint Surg Br* 1967;49:558.
- Adelaar RS, Dannelly EA, Meunier PA, et al. A long term study

of triple arthrodesis in children. *Orthop Clin North Am* 1976;7:895.

- Angus PD, Cowell HR. Triple arthrodesis: a critical long-term review. *J Bone Joint Surg Am* 1986;68:260.
- Drew AJ. The late results of arthrodesis of the foot. *J Bone Joint Surg Br* 1951;33:496.
- McCall R, Lillich J, Harris J, et al. The Grice extraarticular subtalar arthrodesis: a clinical review. *J Pediatr Orthop* 1985;5:442.
- Ross P, Lyne E. The Grice procedure: indications and evaluation of long-term results. *Clin Orthop* 1980;153:194.
- Scott S, James P, Stevens P. Grice subtalar arthrodesis followed to skeletal maturity. *J Pediatr Orthop* 1988;8:176.
- Smith J, Westin G. Subtalar extra-articular arthrodesis. *J Bone Joint Surg Am* 1968;50:1027.
- Southwell R, Sherman F. Triple arthrodesis: a long-term study with force plate analysis. *Foot Ankle* 1981;2:15.

Clubfoot (Congenital Talipes Equinovarus)

- Danielsson L. Incidence of congenital clubfoot in Sweden: 128 cases in 138,000 infants 1946–1990 in Malmo. *Acta Orthop Scand* 1992;63:424.
- Wynne-Davies R. Family studies and the cause of congenital club foot: talipes equinovarus, talipes calcaneal valgus, and metatarsus varus. *J Bone Joint Surg Br* 1964;46:445.
- Wynne-Davies R. Genetics and environmental factors in the etiology of talipes equinovarus. *Clin Orthop* 1972;84:9.
- Gourineni V, Carroll N. The clubfoot. *Foot Ankle Clin* 1998;3:633.
- Cowell H, Wein B. Genetic aspects of club foot. *J Bone Joint Surg Am* 1980;62:1381.
- Rebbeck T, Dietz F, Murray J, et al. A single-gene explanation for the probability of having idiopathic talipes equinovarus. *Am J Hum Genet* 1993;53:1051.
- Browne D. Congenital deformities of mechanical origin. *Arch Dis Child* 1955;30:37.
- Bechtol C, Mossman H. Clubfoot: an embryological study of associated muscle abnormalities. *J Bone Joint Surg Am* 1950;32:827.
- Irani R, Sherman M. The pathological anatomy of clubfoot. *J Bone Joint Surg Am* 1963;45:45.
- Muir L, Laliotis N, Kutty S, et al. Absence of the dorsalis pedis pulse in the parents of children with club foot. *J Bone Joint Surg Br* 1995;77:114.
- Robertson WJ, Corbett D. Congenital clubfoot: month of conception. *Clin Orthop* 1997;338:14.
- Bohm M. The embryologic origin of clubfoot. *J Bone Joint Surg* 1929;11:229.
- Feldbrin Z, Gilai A, Ezra E, et al. Muscle imbalance in the aetiology of idiopathic club foot: an electromyographic study. *J Bone Joint Surg Br* 1995;77:596.
- Ippolito E, Ponseti I. Congenital club foot in the human fetus: a histological study. *J Bone Joint Surg Am* 1980;62:8.
- Isaacs H, Handelsman J, Badenhorst M, et al. The muscles in club foot: a histological histochemical and electron microscopic study. *J Bone Joint Surg Br* 1977;59:465.
- Little D, Aiona M. Limb length discrepancy in congenital talipes equinovarus. *Aust N Z J Surg* 1995;65:409.
- Bensahel H, Dimeglio A, Souchet P. Final evaluation of clubfoot. *J Pediatr Orthop B* 1995;4:137.
- Catterall A. A method of assessment of the clubfoot deformity. *Clin Orthop* 1991;264:48.
- Dimeglio A, Bensahel H, Souchet P, et al. Classification of clubfoot. *J Pediatr Orthop B* 1995;4:129.
- Flynn J, Donohoe M, Mackenzie W. An independent assess-

- ment of two clubfoot-classification systems. *J Pediatr Orthop* 1998;18:323.
47. Goldner J, Fitch R. Idiopathic congenital talipes equinovarus (clubfoot). In: Jahss M, ed. *Disorders of the foot and ankle: medical and surgical management*, 2nd ed. Philadelphia: WB Saunders, 1991:771.
 48. Laaveg S, Ponseti I. Long-term results of treatment of congenital club foot. *J Bone Joint Surg Am* 1980;62:23.
 49. Simons G. A standardized method for the radiographic evaluation of clubfeet. *Clin Orthop* 1978;135:107.
 50. Miyagi N, Iisaka H, Yasuda K, et al. Onset of ossification of the tarsal bones in congenital clubfoot. *J Pediatr Orthop* 1997;17:36.
 51. Cahuzac J, Baunin C, Luu S, et al. Assessment of hindfoot deformity by three-dimensional MRI in infant club foot. *J Bone Joint Surg Br* 1999;81:97.
 52. Howard C, Benson M. The ossific nuclei and the cartilage anlage of the talus and calcaneum. *J Bone Joint Surg Br* 1992;74:620.
 53. Brennan R, Davidson R, Dormans J, et al. Radiographs of the infant foot: a study of reproducibility of measurement and positioning. *Orthop Trans* 1994;18:996.
 54. Bensahel H, Csukonyi Z, Desgrippes Y, et al. Surgery in residual clubfoot: one-stage medioposterior release "a la carte." *J Pediatr Orthop* 1987;7:145.
 55. Dimeglio A, Bonnet F, Mazeau P, et al. Orthopaedic treatment and passive motion machine: consequences for the surgical treatment of clubfoot. *J Pediatr Orthop B* 1996;5:173.
 56. Hudson I, Catterall A. Posterolateral release for resistant club foot. *J Bone Joint Surg Br* 1994;76:281.
 57. Beatson T, Pearson J. A method of assessing correction in club feet. *J Bone Joint Surg Br* 1966;48:40.
 58. Simons G. Calcaneocuboid joint deformity in talipes equinovarus: an overview and update. *J Pediatr Orthop B* 1995;4:25.
 59. Bar-Hava I, Bronshtein M, Orvieto R, et al. Caution: prenatal clubfoot can be both a transient and a late-onset phenomenon. *Prenatal Diagn* 1997;17:457.
 60. Burgan H, Furness M, Foster B. Prenatal ultrasound diagnosis of clubfoot. *J Pediatr Orthop* 1999;19:11.
 61. Hamel J, Becker W. Sonographic assessment of clubfoot deformity in young children. *J Pediatr Orthop B* 1996;5:279.
 62. Maiza D, Themar-Noel C, Legrand I, et al. Ultrasonographic approach to the neonatal foot: preliminary study. *J Pediatr Orthop B* 1995;4:123.
 63. Napiontek M. Intraoperative ultrasound for evaluation of reduction in congenital talipes equinovarus. *J Pediatr Orthop B* 1995;4:55.
 64. Tolat V, Boothroyd A, Carty H, et al. Ultrasound: a helpful guide in the treatment of congenital talipes equinovarus. *J Pediatr Orthop B* 1995;4:65.
 65. Johnston CE, Hobatho M, Baker K, et al. Three-dimensional analysis of clubfoot deformity by computed tomography. *J Pediatr Orthop B* 1995;4:39.
 66. Downey D, Drennan J, Garcia J. Magnetic resonance image findings in congenital talipes equinovarus. *J Pediatr Orthop* 1992;12:224.
 67. Grayhack J, Zawin J, Shore R, et al. Assessment of calcaneocuboid joint deformity by magnetic resonance imaging in talipes equinovarus. *J Pediatr Orthop B* 1995;4:36.
 68. Carroll N, McMurtry R, Leete S. The pathoanatomy of congenital clubfoot. *Orthop Clin North Am* 1978;9:225.
 69. Carroll N. Pathoanatomy and surgical treatment of the resistant clubfoot. *Instr Course Lect* 1988;37:93.
 70. Epeldegui T, Delgado E. Acetabulum pedis. Part II. Talocalcaneonavicular joint socket in clubfoot. *J Pediatr Orthop B* 1995;4:11.
 71. Herzenberg J, Carroll N, Christofersen M, et al. Clubfoot analysis with three-dimensional computer modeling. *J Pediatr Orthop* 1988;8:257.
 72. Howard C, Benson M. Clubfoot: its pathological anatomy. *J Pediatr Orthop* 1993;13:654.
 73. Ippolito E. Update on pathologic anatomy of clubfoot. *J Pediatr Orthop B* 1995;4:17.
 74. McKay D. New concept of and approach to clubfoot treatment. Section I. Principles and morbid anatomy. *J Pediatr Orthop* 1982;2:347.
 75. Settle G. The anatomy of congenital talipes equinovarus: sixteen dissected specimens. *J Bone Joint Surg Am* 1963;45:1341.
 76. Waisbrod H. Congenital club foot: an anatomical study. *J Bone Joint Surg Br* 1973;55:796.
 77. Epeldegui T, Delgado E. Acetabulum pedis. Part I. Talocalcaneonavicular joint socket in normal foot. *J Pediatr Orthop B* 1995;4:1.
 78. Evans D. Relapsed club foot. *J Bone Joint Surg Br* 1961;43:722.
 79. Goldner J. Congenital talipes equinovarus: fifteen years of surgical treatment. *Curr Pract Orthop Surg* 1969;4:61.
 80. Goldner J, Gaines R. Adult and juvenile hallux valgus: analysis and treatment. *Orthop Clin North Am* 1976;7:863.
 81. Kite J. Principles involved in the treatment of congenital clubfoot. *J Bone Joint Surg* 1939;21:595.
 82. Kite J. *The clubfoot*. New York: Grune & Stratton, 1964.
 83. Morcuende J, Weinstein S, Dietz F, et al. Plaster cast treatment of clubfoot: the Ponseti method of manipulation and casting. *J Pediatr Orthop B* 1994;3:161.
 84. Ponseti I. Treatment of congenital club foot. *J Bone Joint Surg Am* 1992;74:448.
 85. Ponseti I. *Congenital clubfoot*. Oxford, England: Oxford University Press, 1996.
 86. Bensahel H, Guillaume A, Czukonyi Z, et al. Results of physical therapy for idiopathic clubfoot: a long-term follow-up study. *J Pediatr Orthop* 1990;10:189.
 87. Coss H, Hennrikus W. Parent satisfaction comparing two bandage materials used during serial casting in infants. *Foot Ankle Int* 1996;17:483.
 88. Carlstedt C, Nordin M. Biomechanics of tendons and ligaments. In: Nordin M, Frankel V, eds. *Basic biomechanics of the musculoskeletal system*, 2nd ed. Philadelphia: Lea & Febiger, 1989:59.
 89. Cooper D, Dietz F. Treatment of idiopathic clubfoot: a thirty-year follow-up note. *J Bone Joint Surg Am* 1995;77:1477.
 90. Turco VJ. Surgical correction of the resistant clubfoot. *J Bone Joint Surg Am* 1971;53:477.
 91. Turco VJ. Resistant congenital clubfoot: one-stage posteromedial release with internal fixation. *J Bone Joint Surg Am* 1979;61:805.
 92. Carroll N. Surgical technique for talipes equinovarus. *Operative Tech Orthop* 1993;3:115.
 93. Yoneda B, Carroll N. One-stage surgical management of resistant clubfoot. *J Bone Joint Surg Br* 1984;66:302.
 94. McKay D. New concept of and approach to clubfoot treatment. Section II. Correction of the clubfoot. *J Pediatr Orthop* 1983;3:10.
 95. Simons G. Complete subtalar release in club feet. Part I. A preliminary report. *J Bone Joint Surg Am* 1985;67:1044.
 96. Haasbeek J, Wright J. A comparison of the long-term results of posterior and comprehensive release in the treatment of clubfoot. *J Pediatr Orthop* 1997;17:29.
 97. Simons G. Complete subtalar release in club feet. Part II. Comparison with less extensive procedures. *J Bone Joint Surg Am* 1985;67:1056.
 98. Wientroub S, Khermouh O. Comparative evaluation of initial surgical procedures in clubfoot. *J Pediatr Orthop B* 1994;3:171.

99. Crawford AH, Marxen JL, Osterfield DL. The Cincinnati incision: a comprehensive approach for surgical procedures of the foot and ankle in childhood. *J Bone Joint Surg Am* 1982;64:1355.
100. Ferlic RJ, Breed AL, Mann DC, et al. Partial wound closure after surgical correction of equinovarus foot deformity. *J Pediatr Orthop* 1997;17:486.
101. Atar D, Grant AD, Silver L, et al. The use of a tissue expander in clubfoot surgery. *J Bone Joint Surg Br* 1990;72:574.
102. Bassett G, Mazur K, Sloan G. Soft-tissue expander failure in severe equinovarus foot deformity. *J Pediatr Orthop* 1993;13:744.
103. Silver L, Grant A, Atar D, et al. Use of tissue expansion in clubfoot surgery. *Foot Ankle* 1993;14:117.
104. Pous J, Dimeglio A. Neonatal surgery in clubfoot. *Orthop Clin North Am* 1978;9:233.
105. Ryoppy S, Sairanen H. Neonatal operative treatment of club foot: a preliminary report. *J Bone Joint Surg Br* 1983;65:320.
106. Tibrewal S, Benson M, Howard C, et al. The Oxford club-foot programme. *J Bone Joint Surg Br* 1992;74:528.
107. Carroll N. Controversies in the surgical management of clubfoot. *Instr Course Lect* 1996;45:331.
108. DePuy J, Drennan J. Correction of idiopathic clubfoot: a comparison of results of early versus delayed posteromedial release. *J Pediatr Orthop* 1989;9:44.
109. Foulk D, Boakes J, Rab G, et al. The use of caudal epidural anesthesia in clubfoot surgery. *J Pediatr Orthop* 1995;15:604.
110. Atar D, Lehman WB, Grant AD, et al. Revision surgery in clubfeet. *Clin Orthop* 1992;283:223.
111. DeRosa G, Stepro D. Results of posteromedial release for the resistant clubfoot. *J Pediatr Orthop* 1986;6:590.
112. Thompson G, Richardson A, Westin G. Surgical management of resistant congenital talipes equinovarus deformities. *J Bone Joint Surg Am* 1982;64:652.
113. Yngve D, Gross R, Sullivan J. Clubfoot release without wide subtalar release. *J Pediatr Orthop* 1990;10:473.
114. Crawford A, Gupta A. Clubfoot controversies: complications and causes for failure. *Instr Course Lect* 1996;45:339.
115. Lehman W, Atar D, Grant A, et al. Treatment of failed clubfoot surgery. *J Pediatr Orthop B* 1994;3:168.
116. Fowler SB, Brooks AL, Parrish TF. The cavo-varus foot. *J Bone Joint Surg Am* 1959;41:757.
117. Hofmann A, Constine R, McBride G, et al. Osteotomy of the first cuneiform as treatment of residual adduction of the fore part of the foot in club foot. *J Bone Joint Surg Am* 1984;66:985.
118. Anderson DA, Schoenacker PL, Blair VPI. Combined lateral column shortening and medial column lengthening in the treatment of severe forefoot adductus. *Orthop Trans* 1991;15:768.
119. Conklin MJ, Kling TF. Open-wedge osteotomies of the first cuneiform for metatarsus adductus. *Orthop Trans* 1991;15:106.
120. Lincoln C, Wood K, Bugg EJ. Metatarsus varus corrected by open wedge osteotomy of the first cuneiform bone. *Orthop Clin North Am* 1976;7:795.
121. McHale KA, Lenhart MK. Treatment of residual clubfoot deformity—the “bean-shaped” foot—by open wedge medial cuneiform osteotomy and closing wedge cuboid osteotomy: clinical review and cadaver correlations. *J Pediatr Orthop* 1991;11:374.
122. McKay D. Dorsal bunions in children. *J Bone Joint Surg Am* 1983;65:975.
123. Barnett RS. Medial/lateral column separation (Third Street operation) for dorsal talonavicular subluxation. In: Simons G, ed. *The clubfoot: the present and a view of the future*. New York: Springer-Verlag, 1994:268.
124. Evans D. Calcaneo-valgus deformity. *J Bone Joint Surg Br* 1975;57:270.
125. Davids J, Valadie A, Ferguson R, et al. Surgical management of ankle valgus in children: use of a transphyseal medial malleolar screw. *J Pediatr Orthop* 1997;17:3.
126. Stevens P, Belle R. Screw epiphysiodesis for ankle valgus. *J Pediatr Orthop* 1997;17:9.

Metatarsus Adductus

127. Hunziker U, Largo R, Duc G. Neonatal metatarsus adductus, joint mobility, axis and rotation of the lower extremity in pre-term and term children 0–5 years of age. *Eur J Pediatr* 1988;148:19.
128. Kite JH. Congenital metatarsus varus: report of 300 cases. *J Bone Joint Surg Am* 1950;32:500.
129. Kite J. Congenital metatarsus varus. *J Bone Joint Surg Am* 1967;49:388.
130. McCormick DW, Blount WP. Metatarsus adductovarus: “skewfoot”. *JAMA* 1949;141:449.
131. Jacobs JE. Metatarsus varus and hip dysplasia. *Clin Orthop* 1960;16:203.
132. Kumar S, MacEwen G. The incidence of hip dysplasia with metatarsus adductus. *Clin Orthop* 1982;164:234.
133. Gruber MA, Lozano JA. Metatarsus varus and developmental dysplasia of the hip: is there a relationship? *Orthop Trans* 1991;15:336.
134. Kollmer CE, Betz RR, Clancy M, et al. Relationship of congenital hip and foot deformities: a national Shriners’ Hospital survey. *Orthop Trans* 1991;15:96.
135. Wynne-Davies R. Aetiology and interrelationship of some common skeletal deformities. *J Med Genet* 1982;19:321.
136. Ghali N, Abberton M, Silk F. The management of metatarsus adductus et supinatus. *J Bone Joint Surg Br* 1984;66:376.
137. Peabody CW, Muro F. Congenital metatarsus varus. *J Bone Joint Surg Am* 1933;15:171.
138. Browne RS, Paton DF. Anomalous insertion of the tibialis posterior tendon in congenital metatarsus varus. *J Bone Joint Surg Br* 1979;61:74.
139. Reiman I, Werner HH. The pathology of congenital metatarsus varus: a post-mortem study of a newborn infant. *Acta Orthop Scand* 1983;54:847.
140. Morcuende J, Ponseti I. Congenital metatarsus adductus in early human fetal development: a histologic study. *Clin Orthop* 1996;333:261.
141. Cappello T, Mosca VS. Metatarsus adductus and skewfoot. *Foot Ankle Clin* 1998;3:683.
142. Bleck EE. Developmental orthopaedics. III. Toddlers. *Dev Med Child Neurol* 1982;24:533.
143. Bleck E. Metatarsus adductus: classification and relationship to outcomes of treatment. *J Pediatr Orthop* 1983;3:2.
144. Smith J, Bleck E, Gamble J, et al. Simple method of documenting metatarsus adductus. *J Pediatr Orthop* 1991;11:679.
145. Berg E. A reappraisal of metatarsus adductus and skewfoot. *J Bone Joint Surg Am* 1986;68:1185.
146. Cook D, Breed A, Cook T, et al. Observer variability in the radiographic measurement and classification of metatarsus adductus. *J Pediatr Orthop* 1992;12:86.
147. McCauley JJ, Lusskin R, Bromley J. Recurrence in congenital metatarsus varus. *J Bone Joint Surg Am* 1964;46:525.
148. Thompson SA. Hallux varus and metatarsus varus. *Clin Orthop* 1960;16:109.
149. Asirvatham R, Stevens PM. Idiopathic forefoot-adduction deformity: medial capsulotomy and abductor hallucis lengthening

- for resistant and severe deformities. *J Pediatr Orthop* 1997;17:496.
150. Heyman CH, Herndon CH, Strong JM. Mobilization of the tarsometatarsal and intermetatarsal joints for the correction of resistant adduction of the fore part of the foot in congenital club-foot or congenital metatarsus varus. *J Bone Joint Surg Am* 1958;40:299.
 151. Stark J, Johanson J, Winter R. The Heyman-Herndon tarsometatarsal capsulotomy for metatarsus adductus: results in 48 feet. *J Pediatr Orthop* 1987;7:305.
 152. Kendrick R, Sharma N, Hassler W, et al. Tarsometatarsal mobilization for resistant adduction of the fore part of the foot: a follow-up study. *J Bone Joint Surg Am* 1970;52:61.
 153. Berman A, Gartland J. Metatarsal osteotomy for the correction of adduction of the fore part of the foot in children. *J Bone Joint Surg Am* 1971;53:498.
 154. Steytler J, VanderWalt ID. Correction of resistant adduction of the forefoot in congenital club-foot and congenital metatarsus varus by metatarsal osteotomy. *Br J Surg* 1966;53:558.
 155. Gamble J, Decker S, Abrams R. Short first ray as a complication of multiple metatarsal osteotomies. *Clin Orthop* 1982;164:241.
 156. Holden D, Siff S, Butler J, et al. Shortening of the first metatarsal as a complication of metatarsal osteotomies. *J Bone Joint Surg Am* 1984;66:582.
- ### Skewfoot
157. Mosca VS. Flexible flatfoot and skewfoot. In: Drennan JC, ed. *The child's foot and ankle*. New York: Raven, 1992:355.
 158. Mosca VS. Skewfoot deformity in children: correction by calcaneal neck lengthening and medial cuneiform opening wedge osteotomies. *J Pediatr Orthop* 1993;13:807.
 159. Mosca VS. Calcaneal lengthening for valgus deformity of the hindfoot: results in children who had severe, symptomatic flatfoot and skewfoot. *J Bone Joint Surg Am* 1995;77:500.
 160. Mosca VS. Flexible flatfoot and skewfoot. *Instr Course Lect* 1996;45:347.
 161. Peterson H. Skewfoot (forefoot adduction with heel valgus). *J Pediatr Orthop* 1986;6:24.
- ### Flexible Flatfoot
162. Harris R, Beath T. Hypermobile flatfoot with short tendo Achillis. *J Bone Joint Surg Am* 1948;30:116.
 163. Duchenne G. *Physiology of motion*. Philadelphia: WB Saunders, 1959.
 164. Basmajian JV, Stecko G. The role of muscles in arch support of the foot: an electromyographic study. *J Bone Joint Surg Am* 1963;45:1184.
 165. Mann R, Inman V. Phasic activity of intrinsic muscles of the foot. *J Bone Joint Surg Am* 1969;46:469.
 166. Sim-Fook L, Hodgson A. A comparison of foot forms among the non-shoe and shoe-wearing Chinese people. *J Bone Joint Surg Am* 1958;40:1058.
 167. Rao U, Joseph B. The influence of footwear on the prevalence of flat foot: a survey of 2300 children. *J Bone Joint Surg Br* 1992;74:525.
 168. Jack E. Naviculo-cuneiform fusion in the treatment of flat foot. *J Bone Joint Surg Br* 1953;35:75.
 169. Hicks J. The mechanics of the foot. II. The plantar aponeurosis and the arch. *J Anat* 1954;88:25.
 170. Steel MI, Johnson K, DeWitz M, et al. Radiographic measurements of the normal adult foot. *Foot Ankle* 1980;1:151.
 171. Meary R. On the measurement of the angle between the talus and the first metatarsal. Symposium: Le Pied Creux Essential. *Rev Chir Orthop* 1967;53:389.
 172. Bleck E, Berzins U. Conservative management of pes valgus with plantar flexed talus, flexible. *Clin Orthop* 1977;122:85.
 173. Penneau K, Lutter L, Winter R. Pes planus: radiographic changes with foot orthoses and shoes. *Foot Ankle* 1982;2:299.
 174. Driano AN, Staheli L, Staheli LT. Psychosocial development and corrective footwear use in childhood. *J Pediatr Orthop* 1998;18:346.
 175. Theologis T, Gordon C, Benson M. Heel seats and shoe wear. *J Pediatr Orthop* 1994;14:760.
 176. Duncan J, Lovell W. Modified Hoke-Miller flatfoot procedure. *Clin Orthop* 1983;181:24.
 177. Hoke M. An operation for the correction of extremely relaxed flatfeet. *J Bone Joint Surg* 1931;13:773.
 178. Miller O. A plastic flat-foot operation. *J Bone Joint Surg* 1927;9:84.
 179. Miller G. The operative treatment of hypermobile flatfeet in the young child. *Clin Orthop* 1977;122:95.
 180. Smith S, Millar E. Arthrorrhisis by means of a subtalar polyethylene peg implant for correction of hindfoot pronation in children. *Clin Orthop* 1983;181:15.
 181. Koutsogiannis E. Treatment of mobile flat foot by displacement osteotomy of the calcaneus. *J Bone Joint Surg Br* 1971;53:96.
 182. Rathjen K, Mubarak S. Calcaneo-cuboid-cuneiform osteotomy for the correction of valgus foot deformities in children. *J Pediatr Orthop* 1998;18:775.
 183. Anderson A, Fowler S. Anterior calcaneal osteotomy for symptomatic juvenile pes planus. *Foot Ankle* 1984;4:274.
 184. Armstrong G, Carruthers C. Evans elongation of lateral column of the foot for valgus deformity. *J Bone Joint Surg Br* 1975;57:530.
 185. Phillips G. A review of elongation of os calcis for flat feet. *J Bone Joint Surg Br* 1983;65:15.
- ### Congenital Vertical Talus (Congenital Convex Pes Valgus)
186. Lamy L, Weissman L. Congenital convex pes valgus. *J Bone Joint Surg* 1939;21:79.
 187. Dodge L, Ashley R, Gilbert R. Treatment of the congenital vertical talus: a retrospective review of 36 feet with long-term follow-up. *Foot Ankle* 1987;7:326.
 188. Hamanishi C. Congenital vertical talus: classification with 69 cases and new measurement system. *J Pediatr Orthop* 1984;4:318.
 189. Jacobsen S, Crawford A. Congenital vertical talus. *J Pediatr Orthop* 1983;3:306.
 190. Ogata K, Schoenecker P, Sheridan J. Congenital vertical talus and its familial occurrence: an analysis of 36 patients. *Clin Orthop* 1979;139:128.
 191. Stern H, Clark R, Stroberg A, et al. Autosomal dominant transmission of isolated congenital vertical talus. *Clin Genet* 1989;36:427.
 192. Drennan J. Congenital vertical talus. *Instr Course Lect* 1996;45:315.
 193. Lloyd-Roberts G, Spence A. Congenital vertical talus. *J Bone Joint Surg Br* 1958;40:33.
 194. Drennan J, Sharrard W. The pathological anatomy of convex pes valgus. *J Bone Joint Surg Br* 1971;53:445.
 195. Patterson W, Fitz D, Smith W. The pathologic anatomy of congenital convex pes valgus: post mortem study of a newborn infant with bilateral involvement. *J Bone Joint Surg Am* 1968;50:458.

196. Seimon L. Surgical correction of congenital vertical talus under the age of 2 years. *J Pediatr Orthop* 1987;7:405.
197. Specht E. Congenital paralytic vertical talus: an anatomical study. *J Bone Joint Surg Am* 1975;57:842.
198. Duncan R, Fixsen J. Congenital convex pes valgus. *J Bone Joint Surg Br* 1999;81:250.
199. Kodros S, Dias L. Single-stage surgical correction of congenital vertical talus. *J Pediatr Orthop* 1999;19:42.
200. Oppenheim W, Smith C, Christie W. Congenital vertical talus. *Foot Ankle* 1985;5:198.
201. Stricker S, Rosen E. Early one-stage reconstruction of congenital vertical talus. *Foot Ankle Int* 1997;18:535.
202. Coleman S, Stelling F, Jarrett J. Pathomechanics and treatment of congenital vertical talus. *Clin Orthop* 1970;70:62.
203. Walker A, Ghali N, Silk F. Congenital vertical talus: the results of staged operative reduction. *J Bone Joint Surg Br* 1985;67:117.
204. Grice D. An extra-articular arthrodesis of the subastragalar joint for correction of paralytic flat feet in children. *J Bone Joint Surg Am* 1952;34:927.
205. Grice D. Further experience with extra-articular arthrodesis of the subtalar joint. *J Bone Joint Surg Am* 1955;37:246.
206. Clark M, D'Ambrosia R, Ferguson A. Congenital vertical talus: treatment by open reduction and navicular excision. *J Bone Joint Surg Am* 1977;59:816.
207. Colton C. The surgical management of congenital vertical talus. *J Bone Joint Surg Br* 1973;55:566.
208. Napiontek M. Congenital vertical talus: a retrospective and critical review of 32 feet operated on by peritalar reduction. *J Pediatr Orthop B* 1995;4:179.

Positional Calcaneovalgus

209. Werzenstein H. The significance of congenital pes calcaneovalgus in the origin of pes plano-valgus in childhood. *Acta Orthop Scand* 1960;30:64.
210. Widhe T, Aaro S, Elmstedt E. Foot deformities in the newborn: incidence and prognosis. *Acta Orthop Scand* 1988;59:176.

Congenital Overriding Fifth Toe

211. Black G, Grogan D, Bobechko W. Butler arthroplasty for correction of the adducted fifth toe: a retrospective study of 36 operations between 1968 and 1982. *J Pediatr Orthop* 1985;5:438.
212. Cockin J. Butler's operation for an overriding fifth toe. *J Bone Joint Surg Br* 1968;50:78.
213. DeBoeck H. Butler's operation for congenital overriding of the fifth toe: retrospective 1–7-year study of 23 cases. *Acta Orthop Scand* 1993;64:343.
214. Janecki C, Wilde A. Results of phalangectomy of the fifth toe for hammertoe. *J Bone Joint Surg Am* 1976;58:1005.

Curly Toe

215. Pollard J, Morrison P. Flexor tenotomy in the treatment of curly toes. *Proc R Soc Med* 1975;68:480.
216. Sweetnam R. Congenital curly toes: an investigation into the value of treatment. *Lancet* 1958;2:398.
217. Ross E, Menelaus M. Open flexor tenotomy for hammer toes and curly toes in childhood. *J Bone Joint Surg Br* 1984;66:770.
218. Hamer A, Stanley D, Smith T. Surgery for curly toe deformity: a double-blind, randomised, prospective trial. *J Bone Joint Surg Br* 1993;75:662.

Congenital Malformations

219. Geist ES. The accessory scaphoid bone. *J Bone Joint Surg* 1925;7:570.
220. McKusick VA, ed. *Mendelian inheritance in man: catalogs of autosomal dominant, autosomal recessive and X-linked phenotypes*, 2nd ed. Baltimore: The Johns Hopkins University Press, 1968.
221. Kidner FC. The pre-hallux in relation to flatfoot. *JAMA* 1933;101:1539.
222. Kidner FC. The pre-hallux (accessory scaphoid) in its relation to flat-foot. *J Bone Joint Surg* 1929;11:831.
223. Leonard MH, Gonzales S, Breck LW, et al. Lateral transfer of the posterior tibial tendon in certain selected cases of pes plano-valgus (Kidner operation). *Clin Orthop* 1965;40:139.
224. Zadek I, Gold A. The accessory tarsal scaphoid. *J Bone Joint Surg Am* 1948;30:957.
225. Ray S, Goldberg VM. Surgical treatment of the accessory navicular. *Clin Orthop* 1983;177:61.
226. Grogan DP, Gasser SI, Ogden JA. The painful accessory navicular: a clinical and histopathological study. *Foot Ankle* 1989;10:164.
227. Jones RL. The human foot: an experimental study of its muscles and ligaments in the support of the arch. *Am J Anat* 1941;68:1.
228. Bennett GL, Weiner DS, Leighley B. Surgical treatment of symptomatic accessory tarsal navicular. *J Pediatr Orthop* 1990;10:445.
229. Giannestrus NJ. *Foot disorders: medical and surgical management*. Philadelphia: Lea & Febiger, 1973.
230. Macnicol M, Voutsinas S. Surgical treatment of the symptomatic accessory navicular. *J Bone Joint Surg Br* 1984;66:218.
231. Veitch J. Evaluation of the Kidner procedure in treatment of symptomatic accessory tarsal scaphoid. *Clin Orthop* 1978;131:210.
232. Mosier K, Asher M. Tarsal coalitions and peroneal spastic flat foot: a review. *J Bone Joint Surg Am* 1984;66:976.
233. Slomann W. On coalitio calcaneo-navicularis. *J Orthop Surg* 1921;3:586.
234. Harris R, Beath T. Etiology of peroneal spastic flatfoot. *J Bone Joint Surg Br* 1948;30:624.
235. Simmons E. Tibialis spastic varus foot with tarsal coalition. *J Bone Joint Surg Br* 1965;47:533.
236. Stuecker R, Bennett J. Tarsal coalition presenting as a pes cavovarus deformity: report of three cases and review of the literature. *Foot Ankle* 1993;14:540.
237. Grogan D, Holt G, Ogden J. Talocalcaneal coalition in patients who have fibular hemimelia or proximal femoral focal deficiency: a comparison of the radiographic and pathological findings. *J Bone Joint Surg Am* 1994;76:1363.
238. Spero C, Simon G, Tornetta P. Clubfeet and tarsal coalition. *J Pediatr Orthop* 1994;14:372.
239. Stormont D, Peterson H. The relative incidence of tarsal coalition. *Clin Orthop* 1983;181:28.
240. Clarke D. Multiple tarsal coalitions in the same foot. *J Pediatr Orthop* 1997;17:777.
241. Cowell H. Tarsal coalition: review and update. *Instr Course Lect* 1982;31:264.
242. Drennan J. Tarsal coalitions. *Instr Course Lect* 1996;45:323.
243. Wray J, Herndon C. Hereditary transmission of congenital coalition of the calcaneus to the navicular. *J Bone Joint Surg Am* 1963;45:365.
244. Mosca VS. Flexible flatfoot and tarsal coalition. In: Richards B, ed. *Orthopaedic knowledge update: pediatrics*. Rosemont, IL: American Academy of Orthopaedic Surgeons, 1996:211.
245. Oestreich A, Mize W, Crawford A, et al. The "antreater nose":

- a direct sign of calcaneonavicular coalition on the lateral radiograph. *J Pediatr Orthop* 1987;7:709.
246. Conway J, Cowell H. Tarsal coalition: clinical significance and roentgenographic demonstration. *Radiology* 1969;92:799.
 - 246A. Lateur LM, Van Hoe LR, Van Hoe LR, et al. Subtalar coalition: diagnosis with the C sign on lateral radiographs of the ankle. *Radiology* 1994;193:847.
 247. Deutsch A, Resnick D, Campbell G. Computed tomography and bone scintigraphy in the evaluation of tarsal coalition. *Radiology* 1982;144:137.
 248. Herzenberg J, Goldner J, Martinez S, et al. Computerized tomography of talocalcaneal tarsal coalition: a clinical and anatomic study. *Foot Ankle* 1986;6:273.
 249. Wechsler R, Schweitzer M, Deely D, et al. Tarsal coalition: depiction and characterization with CT and MR imaging. *Radiology* 1994;193:447.
 250. Jayakumar S, Cowell H. Rigid flatfoot. *Clin Orthop* 1977;122:77.
 251. Outland T, Murphy I. The pathomechanics of peroneal spastic flatfoot. *Clin Orthop* 1960;16:64.
 - 251A. Kumai T, Takakura Y, Akiyama K, Higashiyama I, Tamai S. Histopathologic study of nonosseous tarsal coalition. *Foot Ankle Int* 1998;19:525.
 252. Badgley C. Coalition of the calcaneus and the navicular. *Arch Surg* 1927;15:75.
 253. Bentzon P. Bilateral congenital deformity of the astragalocalcaneal joint: bony coalescence between os trigonum and the calcaneus? *Acta Orthop Scand* 1930;1:359.
 254. Cowell H. Extensor brevis arthroplasty. *J Bone Joint Surg Am* 1970;52:820.
 255. Gonzalez P, Kumar S. Calcaneonavicular coalition treated by resection and interposition of the extensor digitorum brevis muscle. *J Bone Joint Surg Am* 1990;72:71.
 256. Moyes S, Crawford E, Aichroth P. The interposition of extensor digitorum brevis in the resection of calcaneonavicular bars. *J Pediatr Orthop* 1994;14:387.
 257. Scranton PJ. Treatment of symptomatic talocalcaneal coalition. *J Bone Joint Surg Am* 1987;69:533.
 258. Swiontkowski M, Scranton P, Hansen S. Tarsal coalitions: long-term results of surgical treatment. *J Pediatr Orthop* 1983;3:287.
 259. Takakura Y, Sugimoto K, Tanaka Y, et al. Symptomatic talocalcaneal coalition: its clinical significance and treatment. *Clin Orthop* 1991;269:249.
 260. Wilde P, Torode I, Dickens D, et al. Resection for symptomatic talocalcaneal coalition. *J Bone Joint Surg Br* 1994;76:797.
 261. McCormack T, Olney B, Asher M. Talocalcaneal coalition resection: a 10-year follow-up. *J Pediatr Orthop* 1997;17:13.
 262. Kumar S, Guille J, Lee M, et al. Osseous and non-osseous coalition of the middle facet of the talocalcaneal joint. *J Bone Joint Surg Am* 1992;74:529.
 263. Olney B, Asher M. Excision of symptomatic coalition of the middle facet of the talocalcaneal joint. *J Bone Joint Surg Am* 1987;69:539.
 - 263A. Mann RA, Beaman DN, Horton GA. Isolated subtalar arthrodesis. *Foot Ankle Int* 1998;19:511.
 - 263B. Cain TJ, Hyman S. Peroneal spastic flatfoot. Its treatment by osteotomy of the os calcis. *J Bone Surg* 1978;60B:527.
 264. Mubarak S, O'Brien T, Davids J. Metatarsal epiphyseal bracket: treatment by central physiolysis. *J Pediatr Orthop* 1993;13:5.
 265. McElvenny R. Hallux varus. *Q Bull Northwest Univ Med School* 1941;15:277.
 266. Mills J, Menelaus M. Hallux varus. *J Bone Joint Surg Br* 1989;71:437.
 267. Beatty J. Congenital foot deformities. In: Coughlin M, Mann R, eds. *Surgery of the foot and ankle*, 7th ed. St. Louis: Mosby, 1999:1320.
 268. Farmer A. Congenital hallux varus. *Am J Surg* 1958;95:274.
 269. Frazier T. A note on race-specific congenital malformation rates. *Am J Obstet Gynecol* 1960;80:184.
 270. Woolf C, Myrianthopoulos N. Polydactyly in American Negroes and whites. *Am J Hum Genet* 1973;25:397.
 271. Phelps D, Grogan D. Polydactyly of the foot. *J Pediatr Orthop* 1985;5:446.
 272. Temtamy S, McKusick V. Synopsis of hand malformations with particular emphasis on genetic factors. *Birth Defects* 1969;5:125.
 273. Light T, Ogden J. The longitudinal epiphyseal bracket: implications for surgical correction. *J Pediatr Orthop* 1981;1:299.
 274. Venn-Watson E. Problems in polydactyly of the foot. *Orthop Clin North Am* 1976;7:909.
 275. Nogami H. Polydactyly and polysyndactyly of the fifth toe. *Clin Orthop* 1989;204:261.
 276. Kalen V, Burwell D, Omer G. Macrodactyly of the hands and feet. *J Pediatr Orthop* 1988;8:311.
 277. Turra S, Santini S, Cagnoni G, et al. Gigantism of the foot: our experience in seven cases. *J Pediatr Orthop* 1998;18:337.
 278. Barsky A. Macrodactyly. *J Bone Joint Surg Am* 1967;49:1255.
 279. Dedrick D, Kling D. Ray resection in the treatment of macrodactyly of the foot in children. *Orthop Trans* 1985;9:145.
 280. Dennyson W, Bear J, Bhoola K. Macrodactyly in the foot. *J Bone Joint Surg Br* 1977;59:355.
 281. Grogan D, Bernstein R, Habal M, et al. Congenital lipofibromatosis associated with macrodactyly of the foot. *Foot Ankle* 1991;12:40.
 282. Topoleski T, Ganel A, Grogan D. Effect of proximal phalangeal epiphysiodesis in the treatment of macrodactyly. *Foot Ankle Int* 1997;18:500.
 283. Cruveilhier J. *Anatomie pathologique du corps humaine*. Paris: S Balliere, 1829.
 284. Birch-Jensen A. *Congenital deformities of the upper extremities*. Copenhagen: Ejnar Munksgaard, 1949.
 285. McMullen G, Pearson K. On the inheritance of the deformity known as split foot or lobster claw. *Biometrika* 1913;9:381.
 286. Stiles KA, Pickard JS. Hereditary malformations of the hands and feet. *J Hered* 1943;34:341.
 287. Walker JC, Clodius L. The syndromes of cleft lip, cleft palate and lobster claw deformities of the hands and feet. *Plast Reconstr Surg* 1963;32:627.
 288. Blauth W, Borisch N. Cleft feet: proposals for a new classification based on roentgenographic morphology. *Clin Orthop* 1990;258:41.
 289. O'Rahilly R, Gardner E, Gray DJ. The ectodermal thickening and ridge in the limbs of staged human embryos. *J Embryol Exp Morphol* 1956;4:254.
 290. Watson AG, Bonde RK. Congenital malformations of the flipper in three West Indian manatees, *Tricheus manatus*, and a proposed mechanism for development of ectrodactyly and cleft hand in mammals. *Clin Orthop* 1986;202:294.
 291. Wood VE, Peppers TA, Shook J. Cleft-foot closure: a simplified technique and review of the literature. *J Pediatr Orthop* 1997;17:501.
 292. Sumiya N, Onizuka T. Seven years' survey of our new cleft foot repair. *Plast Reconstr Surg* 1980;65:447.

Developmental Deformities

293. Samilson R, Dillin W. Cavus, cavovarus, and calcaneocavus: an update. *Clin Orthop* 1983;177:125.
294. Brewerton D, Sandifer P, Sweetnam D. "Idiopathic" pes cavus: an investigation into its aetiology. *Br Med J* 1963;2:659.

295. Mann R, Missirian J. Pathophysiology of Charcot-Marie-Tooth disease. *Clin Orthop* 1988;234:221.
296. Paulos L, Coleman S, Samuelson K. Pes cavovarus: review of a surgical approach using selective soft-tissue procedures. *J Bone Joint Surg Am* 1980;62:942.
297. Sabir M, Lyttle D. Pathogenesis of pes cavus in Charcot-Marie-Tooth disease. *Clin Orthop* 1983;175:173.
298. Coleman S, Chesnut W. A simple test for hindfoot flexibility in the cavovarus foot. *Clin Orthop* 1977;123:60.
299. Alexander I, Johnson K. Assessment and management of pes cavus in Charcot-Marie-Tooth disease. *Clin Orthop* 1989;246:273.
300. Levitt R, Canale S, Cooke AJ, et al. The role of foot surgery in progressive neuromuscular disorders in children. *J Bone Joint Surg Am* 1973;55:1396.
301. Sherman F, Westin G. Plantar release in the correction of deformities of the foot in childhood. *J Bone Joint Surg Am* 1981;63:1382.
302. Holmes J, Hansen SJ. Foot and ankle manifestations of Charcot-Marie-Tooth disease. *Foot Ankle* 1993;14:476.
303. Mosca VS. Ankle and foot: pediatric aspects. In: Beaty J, ed. *Orthopaedic knowledge update 6*. Rosemont, IL: American Academy of Orthopaedic Surgeons, 1999:583.
304. Watanabe R. Metatarsal osteotomy for the cavus foot. *Clin Orthop* 1990;252:217.
305. Dekel S, Weissman S. Osteotomy of the calcaneus and concomitant plantar stripping in children with talipes cavo-varus. *J Bone Joint Surg Br* 1973;55:802.
306. Dwyer F. Osteotomy of the calcaneum for pes cavus. *J Bone Joint Surg Br* 1959;41:80.
307. Cole W. The classic. The treatment of claw-foot. By Wallace H. Cole. 1940. *Clin Orthop* 1983;181:3.
308. Japas L. Surgical treatment of pes cavus by tarsal V-osteotomy: preliminary report. *J Bone Joint Surg Am* 1968;50:927.
309. Jahss M. Tarsometatarsal truncated-wedge arthrodesis for pes cavus and equinovarus deformity of the fore part of the foot. *J Bone Joint Surg Am* 1980;62:713.
310. Wilcox P, Weiner D. The Akron midtarsal dome osteotomy in the treatment of rigid pes cavus: a preliminary review. *J Pediatr Orthop* 1985;5:333.
311. Medhat M, Krantz H. Neuropathic ankle joint in Charcot-Marie-Tooth disease after triple arthrodesis of the foot. *Orthop Rev* 1988;17:873.
312. Coughlin M. Juvenile hallux valgus. In: Coughlin M, Mann R, eds. *Surgery of the foot and ankle*, 7th ed. St. Louis: Mosby, 1999:270.
313. Coughlin M, Roger A, Mann Award. Juvenile hallux valgus: etiology and treatment. *Foot Ankle Int* 1995;16:682.
314. Hardy R, Clapham J. Observations on hallux valgus. *J Bone Joint Surg Br* 1951;33:376.
315. Johnston O. Further studies of the inheritance of hand and foot anomalies. *Clin Orthop* 1954;8:146.
316. Shine I. Incidence of hallux valgus in a partially shoe-wearing community. *Br Med J* 1965;1:1648.
317. Jones A. Hallux valgus in the adolescent. *Proc R Soc Med* 1948;41:392.
318. Kalen V, Brecher A. Relationship between adolescent bunions and flatfeet. *Foot Ankle* 1988;8:331.
319. Trott A. Hallux valgus in adolescent. *Instr Course Lect* 1972;21:262.
320. Kilmartin T, Wallace W. The significance of pes planus in juvenile hallux valgus. *Foot Ankle* 1992;13:53.
321. Canale P, Aronsson D, Lamont R, et al. The Mitchell procedure for the treatment of adolescent hallux valgus: a long-term study. *J Bone Joint Surg Am* 1993;75:1610.
322. Price G. Metatarsus primus varus: including various clinicoradiologic features of the female foot. *Clin Orthop* 1979;145:217.
323. Scranton P, Zuckerman J. Bunion surgery in adolescents: results of surgical treatment. *J Pediatr Orthop* 1984;4:39.
324. Piggott H. The natural history of hallux valgus in adolescence and early adult life. *J Bone Joint Surg Br* 1960;42:749.
325. Richardson E, Graves S, McClure J, et al. First metatarsal head-shaft angle: a method of determination. *Foot Ankle* 1993;14:181.
326. Antrobus J. The primary deformity in hallux valgus and metatarsus primus varus. *Clin Orthop* 1984;184:251.
327. Durman D. Metatarsus primus varus and hallux valgus. *Arch Surg* 1957;74:128.
328. Staheli L. Lower positional deformity in infants and children: a review. *J Pediatr Orthop* 1990;10:559.
329. Vittetoe D, Saltzman C, Kreig J, et al. Validity and reliability of the first distal metatarsal articular angle. *Foot Ankle Int* 1994;15:541.
330. Kilmartin T, Barrington R, Wallace W. A controlled prospective trial of a foot orthosis for juvenile hallux valgus. *J Bone Joint Surg Br* 1994;76:210.
331. Groiso J. Juvenile hallux valgus: a conservative approach to treatment. *J Bone Joint Surg Am* 1992;74:1367.
332. Ball J, Sullivan J. Treatment of the juvenile bunion by Mitchell osteotomy. *Orthopedics* 1985;8:1249.
333. Bonney G, MacNab I. Hallux valgus and hallux rigidus: a critical survey of operative results. *J Bone Joint Surg Br* 1952;34:366.
334. Helal B, Gupta S, Gojaseni P. Surgery for adolescent hallux valgus. *Acta Orthop Scand* 1974;45:271.
335. Simmonds F, Menelaus M. Hallux valgus in adolescents. *J Bone Joint Surg Br* 1960;42:761.
336. Luba R, Rosman M. Bunions in children: treatment with a modified Mitchell osteotomy. *J Pediatr Orthop* 1984;4:44.
337. Peterson H, Newman S. Adolescent bunion deformity treated with double osteotomy and longitudinal pin fixation of the first ray. *J Pediatr Orthop* 1993;13:80.
338. Geissele A, Stanton R. Surgical treatment of adolescent hallux valgus. *J Pediatr Orthop* 1990;10:642.
339. Helal B. Surgery for adolescent hallux valgus. *Clin Orthop* 1981;157:50.
340. Wilson J. Oblique displacement osteotomy for hallux valgus. *J Bone Joint Surg Br* 1963;45:552.
341. Zimmer T, Johnson K, Klassen R. Treatment of hallux valgus in adolescents by the chevron osteotomy. *Foot Ankle* 1989;9:190.
342. Jones K, Feiwell L, Freedman E, et al. The effect of chevron osteotomy with lateral capsular release on the blood supply to the first metatarsal head. *J Bone Joint Surg Am* 1995;77:197.

Acquired Affections

343. Ippolito E, Ricciardi PP, Falez F. Kohler's disease of the tarsal navicular: long-term follow-up of 12 cases. *J Pediatr Orthop* 1984;4:416.
344. Williams G, Cowell H. Kohler's disease of the tarsal navicular. *Clin Orthop* 1981;158:53.
345. Borges J, Guille J, Bowen J. Kohler's bone disease of the tarsal navicular. *J Pediatr Orthop* 1995;15:596.
346. Siffert R. Classification of the osteochondroses. *Clin Orthop* 1981;158:10.
347. Duthie R, Houghton G. Constitutional aspects of the osteochondroses. *Clin Orthop* 1981;158:19.

348. Karp M. Kohler's disease of the tarsal scaphoid. *J Bone Joint Surg* 1937;19:84.
349. Waugh W. The ossification and vascularization of the tarsal navicular and their relation to Kohler's disease. *J Bone Joint Surg Br* 1958;40:765.
350. Freiberg A. Infraction of the second metatarsal bone: a typical injury. *Surg Gynecol Obstet* 1914;19:191.
351. Katcherian D. Treatment of Freiberg's disease. *Orthop Clin North Am* 1994;25:69.
352. Gauthier G, Elbaz R. Freiberg's infraction: a subchondral bone fatigue fracture. A new surgical treatment. *Clin Orthop* 1979; 142:93.
353. Smillie I. Freiberg's infraction (Kohler's second disease). *J Bone Joint Surg Br* 1957;39:580.
354. Omer G. Primary articular osteochondroses. *Clin Orthop* 1981; 158:33.
355. Sproul J, Klaaren H, Mannarino F. Surgical treatment of Freiberg's infraction in athletes. *Am J Sports Med* 1993;21:381.
356. Smith T, Stanley D, Rowley D. Treatment of Freiberg's disease: a new operative technique. *J Bone Joint Surg Br* 1991;73:129.
357. Kinnard P, Lirette R. Freiberg's disease and dorsiflexion osteotomy. *J Bone Joint Surg Br* 1991;73:864.
358. Sever J. Apophysitis of the os calcis. *NY Med J* 1912;95: 1025.
359. Micheli L, Ireland M. Prevention and management of calcaneal apophysitis in children: an overuse syndrome. *J Pediatr Orthop* 1987;7:34.
360. Lutter L. Sports-related injuries. In: Drennan J, ed. *The child's foot and ankle*. New York: Raven, 1992:407.
361. Ferguson AJ, Gingrich R. The normal and abnormal calcaneal apophysis and tarsal navicular. *Clin Orthop* 1957;10:87.
362. Katz J. Nonarticular osteochondroses. *Clin Orthop* 1981;158: 70.
363. Liberson A, Lieberman S, Mendes D, et al. Remodeling of the calcaneus apophysis in the growing child. *J Pediatr Orthop B* 1995;4:74.



30

THE LIMB-DEFICIENT CHILD

**RAYMOND T. MORRISSY
BRIAN J. GIAVEDONI
COLLEEN COULTER-O'BERRY**

EPIDEMIOLOGY 1218

CLASSIFICATION 1218

ETIOLOGY 1220

THE CHILD WITH AN AMPUTATION 1220

Psychosocial Development 1220

Differences in Amputees 1221

THE PARENTS 1221

ORGANIZATION OF CARE 1222

GENERAL CONSIDERATIONS 1222

Growth 1222

Timing of Amputation 1223

COMPLICATIONS 1225

Overgrowth 1225

Phantom Sensation/Pain 1225

CONGENITAL DEFICIENCIES OF THE LOWER EXTREMITY 1227

Fibular Deficiency 1227

Tibial Deficiency 1233

Femoral Deficiency 1237

CONGENITAL DEFICIENCIES OF THE UPPER EXTREMITY 1246

Amelia 1248

Phocomelia 1248

Transverse Complete Humeral Deficiency 1250

Transverse Complete Forearm Deficiency (Congenital
Below-elbow Amputation) 1250

Terminal Transverse Transcarpal Deficiency 1250

Prosthetic Management 1251

Multiple Limb Deficiencies 1253

ACQUIRED DEFICIENCIES 1255

Causes 1255

Principles 1255

PROSTHETICS 1256

Role of the Prosthetist 1256

Fitting Techniques 1256

Socket Design and Suspension Systems 1256

Lower Extremity Socket Design 1257

Prosthetic Knees 1261

Prosthetic Feet 1262

Terminal Devices for the Upper Extremity 1264

Endoskeletal versus Exoskeletal Construction 1265

ROLE OF THE PHYSICAL/OCCUPATIONAL THERAPIST 1266

ADAPTATIONS FOR ACTIVITIES AND SPORTS 1267

R. T. Morrissey: Department of Orthopaedics, Children's Healthcare of Atlanta at Scottish Rite; Emory University, Atlanta, Georgia 30342.

B. J. Giavedoni: Department of Orthotics and Prosthetics, Children's Healthcare of Atlanta at Scottish Rite, Atlanta, Georgia 30342.

C. Coulter-O'Berry: Department of Orthotics and Prosthetics, Children's Healthcare of Atlanta at Scottish Rite, Atlanta, Georgia 30342.

EPIDEMIOLOGY

There is little information on the incidence of congenital limb deficiency in the population, and what is reported varies widely from 1 per 4,264 in Canada (1), to 5 per 10,000 in Australia (2), to 310 per 10,000 in Tayside, Scotland (3). This illustrates that caution needs to be used in the interpretation of the information, since the methods of gathering the information vary.

Although such figures, if available, would be of use to health planning agencies, the fact for the orthopaedic surgeon, is that the child with a limb deficiency will not be a common problem. The majority of limb deficiencies seen in childhood are congenital in origin. This is followed at a distant second by trauma, and lastly as a result of tumors; thus, there is a need for these patients to be seen in an organized program where knowledge and experience are available.

Fibular deficiency is the most common long-bone deficiency. The incidence is between 7.4 to 20 per million live births (4,5). The prevalence of tibial deficiencies is far less, and is reported to be approximately 1 per million live births. The incidence of proximal femoral focal deficiency (PFFD) ranges from 1 in 50,000 to 200,000 live births. Although this is a more common anomaly than fibular deficiency, the explanation lies in the difficulty in separating congenital short femur from true PFFD.

The incidence of upper-extremity amputations is not precisely known. However, two general facts are easily accepted. Although upper-extremity amputations of all types are unusual, in children, congenital amputations are far more common than acquired amputations. In one multicenter review, 85% of bilateral deficiencies were congenital (6). Few physicians, other than those working in a limb deficiency program, will have much experience with these amputations.

CLASSIFICATION

The attempt to classify congenital anomalies has taken many paths, and most clinics choose to use some combination of these classification systems to best categorize the child's deficiency. These different classifications are an attempt to more precisely convey the particular anomaly.

The first attempt to devise a classification system for congenital anomalies was that of Frantz and O'Rahilly (7) (Fig. 30-1). This system was widely adopted in the United States and is still widely used by clinicians today to describe longitudinal deficiencies. However, it was not acceptable to European physicians, because of problems created in translating terms, e.g., "hemimelia." This resulted in the classification system devised by the International Standards Orga-

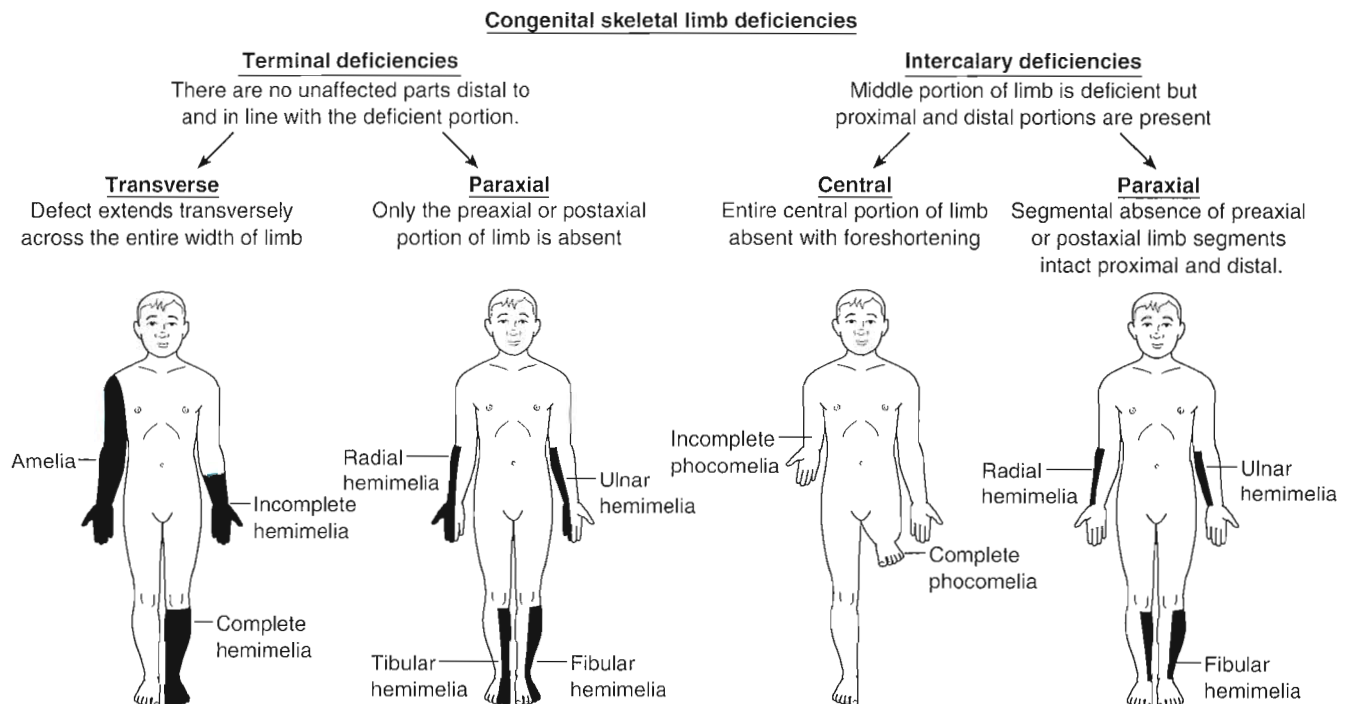


FIGURE 30-1. Diagrammatic representation of the Frantz and O'Rahilly classification of congenital limb deficiencies. (From ref. 7, with permission.)

TABLE 30-1. CLASSIFICATION OF CONGENITAL SKELETAL LIMB DEFICIENCIES

Terminal (T)	
Transverse (—)	Longitudinal (I)
1. Amelia (absence of limb)	1. Complete paraxial hemimelia (complete absence of one of the forearm or leg elements, and of the corresponding portion of the hand or foot) — R, U, TI, or FI ^a
2. Hemimelia (absence of forearm and hand or leg and foot)	2. Incomplete paraxial hemimelia (similar to above, but part of defective element is present) — r, u, ti, or fi ^a
3. Partial hemimelia (part of forearm or leg is present)	3. Partial adactylia (absence of one to four digits and their metacarpals or metatarsals): 1, 2, 3, 4, or 5
4. Acheiria or apodia (absence of hand or foot)	4. Partial aphalangia (absence of one or more phalanges from one to four digits): 1, 2, 3, 4, or 5
5. Complete adactylia (absence of all five digits and their metacarpals or metatarsals)	
6. Complete aphalangia (absence of one or more phalanges from all five digits)	
Intercalary (I)	
Transverse (—)	Longitudinal (I)
1. Complete phocomelia (hand or foot attached directly to trunk)	1. Complete paraxial hemimelia (similar to corresponding terminal defect but hand or foot is more or less complete) — R, U, TI, or FI ^a
2. Proximal phocomelia (hand and forearm, or foot and leg, attached directly to trunk)	2. Incomplete paraxial hemimelia (similar to corresponding terminal defect but hand or foot is more or less complete) — r, u, ti, or fi ^a
3. Distal phocomelia (hand or foot attached directly to arm or thigh)	3. Partial adactylia (absence of all or part of a metacarpal or metatarsal): 1 or 5
	4. Partial aphalangia (absence of proximal or middle phalanx, or both, from one or more digits): 1, 2, 3, 4, or 5

Note: A line below a numeral denotes upper limb involvement, e.g., T-2 represents terminal transverse hemimelia of the upper limb. A line above a numeral denotes lower limb involvement, e.g., I-1 represents intercalary transverse complete phocomelia of the lower limb. —, transverse; I, longitudinal; 1, 2, 3, 4, or 5 denote digital ray involved; FI or fi, fibular; I, intercalary; R or r, radial; T, terminal; TI or ti, tibial; U or u, ulnar.

^a In capital letters when the paraxial hemimelia is complete, in small letters when the defect is incomplete.

(From ref. 7, with permission.)

nization (ISO) and the International Society for Prosthetics and Orthotics (ISPO) (8).

The classification of Frantz and O'Rahilly begins with seven descriptive terms derived from Greek root words. Three of the terms are from the root word *melos*, meaning limb: amelia, absence of a limb; hemimelia, absence of a large part or half of a limb; and phocomelia, or a flipper-like limb (*phoke*; seal). The hemimelias can be divided into complete, partial, and paraxial. The remaining four terms refer to the hands (*cheir*), feet (*pous, podos*) metacarpals (*daktylos*), and phalanges (*phalanx*) (Table 30-1).

The hemimelias can have three additional descriptions: complete, when the entire distal one-half of the limb is missing; partial, when only a portion of the distal half is missing; and paraxial, when either the preaxial or postaxial side of the distal portion of the limb is missing. The hemimelia is named after the missing portion of the limb. Thus, a complete absence of the fibula is a fibular hemimelia.

Next, the deficiencies are either terminal, in which all of the parts of the limb distal to and in line with the defect are affected; or intercalary, in which the parts of the limb proximal and distal to the defect are present. Finally, the terminal and intercalary deficiencies are further divided into transverse, where the defect extends across the entire limb; and longitudinal, where only the pre- or postaxial portion is affected.

The ISO/ISPO system of classification of deficiencies present at birth (ISO 8548-1 Method of Describing Limb Deficiencies Present at Birth) was adopted by the International Organization for Standardization (ISO) and the International Society for Prosthetics and Orthotics (ISPO) (8,9). In this system, the deficiency is first described as transverse, in which all of the limb distal is missing, or longitudinal, in which all or part of one or more bones in a limb is missing. In a longitudinal deficiency ("paraxial" in the Franz and O'Rahilly classification), there may be parts of the limb present distal to the deficiency. In the transverse deficiencies, the part of the segment in which the limb ends is named, and an amount may be stated. A complete loss of the limb distal to the tibial tubercle would be "transverse leg upper third." In a longitudinal deficiency, the bone or bones missing is named and described as "partial" or "total." Thus, a fibular deficiency with part of the distal fibula present would be described as "longitudinal fibula partial." Because this system does not characterize deficiencies, e.g., proximal femoral focal deficiency, phocomelia, and amelia, these terms may still be used.

A second system for describing acquired (traumatic or surgical) amputations (ISO 8549-2.1) uses three adjectives: trans, disarticulation, and partial. Trans is used to describe any amputation across the axis of a long bone. A child who

has an amputation performed through the upper third of the tibia is not a below-knee (B-K) amputation in this classification, but a “transtibial, upper third.” “Disarticulation” is any amputation through a joint. Thus, a Syme amputation is an ankle disarticulation. Partial is any amputation distal to the wrist or ankle joint. Thus, a Boyd amputation is a partial foot amputation, with qualifiers added to distinguish it from a Chopart amputation.

ETIOLOGY

There are at least three ways in which limb deficiencies can be caused: errors in the genetic control of limb development, disruption of the developing arterial supply, such as “the subclavian artery supply disruption sequence” (10), and intrauterine amputation from amniotic bands.

The oldest and most commonly held etiology for congenital amputation in the past was the mechanical amputation of limbs by amniotic bands. Streeter, whose name is attached to this mechanical concept of limb deficiency, actually felt that the bands and constrictions were due to an intrinsic defect in the growth of the fetal limb (11). There is, however, evidence that amniotic bands can form a constriction around the developing limb that interferes with the growth of the limb. The resulting constriction can result in any degree of damage, from a constriction band around a limb that is otherwise normal, to a complete transverse amputation. The previously developed limb has actually been recovered at the time of birth, indicating the mechanism (12). Most children with amniotic band syndrome have either craniofacial abnormalities or other evidence of band formation.

Modern genetics has shown that the development of the limb is a complex phenomenon that requires the precise interaction of a large number of genes and their effects, which are described in Chapter 1 and other review articles (13,14). The opportunity for errors in this system is great, and animal experimentation has identified the probable mechanism in several limb anomalies.

The disruption of the subclavian artery and its supplied tissue explains the overlap of many of the common orthopaedic conditions seen, e.g., Poland syndrome, Klippel-Feil syndrome, Mobius syndrome, Sprengle deformity, and transverse limb deficiencies. There are several possible mechanisms by which this disruption may occur. For more detail, the reader is referred to an excellent review article (15).

This understanding of the various etiologies has importance for the clinician. With genetic control and vascular disruptions playing a large role in the development of the limb and having consequences in other organs and systems, the association of limb deficiencies with other abnormalities creating syndromes is likely. The implications are two: When children present with limb deficiencies, a thorough

examination for other abnormalities is necessary; and any heritable genetic defect should be identified. The possibility of a teratogen always arises in the parent’s mind. Although there may be many suspected agents, to date, thalidomide remains the only drug proven to have caused a large number of congenital limb deficiencies. The role of retinoic acid and low cholesterol on gene expression are discussed in Chapter 1.

Although the vast majority of congenital limb deficiencies are sporadic and not transmissible (transverse below-elbow), a small number are (tibial deficiency and cleft hand and foot). For parents, this is often something they desire to know. Understanding the cause of the deficiency is important to the resolving of the guilt that parents will initially feel. The possibility of a transmissible defect is certainly something their affected offspring will need to know. A recent study from the Medical Birth Registry of Norway showed that children born to a mother with a limb deficiency had a relative risk of 5.6 of having the same defect as the mother (16). This is similar to the relative risk of clubfoot. For the physician, knowing the existence of other problems and the natural history of the syndrome, is necessary for the care of the child.

THE CHILD WITH AN AMPUTATION

Psychosocial Development

The child with an amputation is essentially different—something that no child wants to be. However, almost all children are different in various ways. Some differ in physical appearance, some in physical ways that are not immediately visible, and some in personality and intellectual development. The more the child perceives him- or herself different from peers, the more they understand their disability. Children’s understanding of their disability is general and incomplete at 6 years of age, but within a few years, around the age of 8 or 9 years of age, they come to a much more complete understanding of their handicap (17). Thus, if parents have not discussed this with the child, they can expect the more difficult questions to begin at this age.

All children with disabilities are vulnerable to social isolation. This in turn can have negative effects on the development of self-esteem, body image, and the child’s identity, which are developed through the interaction with parents, teachers, friends, classmates, and others. As children develop these interactions, the issue of “first appearance” becomes important, because it serves as a clue to perceived personal characteristics, and can be an obstacle to further healthy interaction. Children in peer groups tend to devalue those with handicaps, a factor that may greatly interfere with these relationships (18). Parents especially understand this and fear for their child in this regard.

There has been a great deal of study on the nonhandicapped child's reaction to various handicaps, showing that children prefer other children without handicaps, and that they dislike some handicaps more than others (19–21). In addition, it is known that young adults show signs of anxiety when face to face with a handicapped person. However, there is some evidence that young children do not share their parents' values toward various handicaps when young, but between the ages of 6 to 18 years of age, they gradually develop values almost identical to their parents (20). This would suggest that among young children, these values may be subjected to modification, and emphasizes that organized discussions with classmates in school about the child's handicap may be of great value.

Despite the negative "first impression" that physical differences hold for children, there is evidence that demonstrates that the age of the patient, the gender, the degree of limb loss, or socioeconomic status are not predictors of low self-esteem or depressive symptoms. Rather, social factors, e.g., stress and hassle, parental discord, social support from classmates, parents, and teachers, along with the child's own perceptions of competency and adequacy, gained through peer acceptance, scholastic achievement, and athletic accomplishments, play the largest role in the development of self-esteem (22–24).

The importance of this information for parents, physicians, therapists, prosthetists, and teachers is that, while the limb deficiency is the visible problem, and subject to little modification, the important factors in the development of self-esteem are independent of the deficiency, and can be positively affected.

Differences in Amputees

The difference between the juvenile amputee and the adult are as different as are the child and the adult. Acquired amputation in the adult is usually lower extremity and involves only one limb. The child is most often congenital, and more frequently has upper- and multiple-limb involvement.

The more important difference, however, lies in the fact that children are born dependent, and are naturally in the process of becoming independent, whereas adults and older children are independent and far less changeable. The child with a congenital amputation or congenital deformity requiring an amputation will adapt far better to a missing limb than will an older child or adult who suddenly loses a limb. In addition to adaptability in the physical arena, they will have far more adaptability in the psychologic arena.

Similar differences apply to congenital and acquired juvenile amputees. The congenital amputee has a difference; the acquired amputee must adjust to a loss. The difference is dependent on the age and the deficiency. A child born with bilateral amelia will learn to use the feet for all activities of daily living, as will a child with traumatic loss of both upper

limbs at an early age. However, bilateral upper-extremity loss in the older child who has functioned with both hands for years will not be well compensated for by use of the feet.

THE PARENTS

When a child with a congenital deformity or congenital amputation first presents, one of the first concerns has to be the parents. The child does not need a doctor yet, but the parents do. The issues around the child's deficiency, especially if amputation or surgery is required, are not urgent. However, the mental turmoil in the parents' lives is urgent. They did not expect to give birth to anything but a healthy normal child, unless forewarned by ultrasound. They are now there to see a doctor with the certainty that their child is anything but normal and with the unrealistic desire for an expert to make the limb normal.

One of the earliest emotions the parents will have is guilt. What did I take or do during my pregnancy to cause this? Even worse, they may be wondering from which side of the family did this affliction come. It is a time of anticipated joy that has turned into a period of great stress for both the individuals, and often for the marriage. Taking time at the first visit, and again looking for the opportunity later, to explain what is known about the cause of these problems is essential. Obtaining a genetic consultation, even when the deficiency is not known to be hereditary or caused by teratogens, can be therapeutic in this regard. It is usually much more thorough than what one can do, and is done by an expert in that particular area, giving the parents additional reassurance.

Quickly, the feeling of guilt will be mixed with anxiety about the child's future. Will he walk? Can he play sports? Will she have children of her own? The parents probably have never known an amputee, and have no frame of reference to answer these questions. Although one may try to anticipate and answer many of their questions, one is unlikely to have much success in alleviating their fears. The best one can do during the first visit is gain their confidence and give them realistic hope. Fortunately, there are usually no emergent decisions to be made, and there is time to help the parents answer these questions for themselves.

Because "seeing is believing," the next several months are a good time for the parents to meet children with similar deficiencies, and their parents to see what their child might actually be like in the future. This makes known the previously unknown, and the problems become easier to deal with. In addition, the parents can see the various surgical options that might be recommended for their child. Because there is not a need for intervention in the congenital deficiency for a few months to a few years, the parents have time to learn about their child's problem. Introducing the family to other families who have children with similar limitations is one of the most important interventions.

With information from the lay press or the Internet, and encouraged by well-meaning friends, many parents will ask about a miracle cure: sew on a new arm, for example. Carefully listening to and explaining what they have read or heard will usually suffice for most. Seeing other patients and talking to their parents is also of great help, because they are parents who went through the same thing, and they likely asked the same questions.

During this initial period physicians also need to be careful about what they tell the parents. In an effort to help the parents feel better, while not knowing how to deal with this difficult role, physicians may offer false hope and mention treatments that are totally unrealistic. Physicians who do not know, or who do not wish to take on this role should assure the parents that they are referring them to the best possible care.

The relationship between the parents and the physician (as well as all members of the team) is important. In that regard, the first thing the parents must be made to understand is that all of the decisions will be theirs. No one will make them do anything they do not wish to do. In this regard, it becomes the role of the physician to educate the parents. This occurs through repetitive explanation and answering of patient's questions. It is helpful if this occurs, not only with the physician, but also with the therapist and prosthetist, who all should be working together. Again, nothing helps like seeing other patients and parents.

Parents will often refuse a recommendation, e.g., an amputation (25). It is important for the treating physician to recognize the factors that affect their decision and do his or her best to educate the parents. Frequently, the child will have a near normal-appearing foot, and all the parents see is a small amount of shortening. The child may be able to walk in the first few years of life, and the parents may not understand the progressive shortening that will develop. Along with these observations, they share the popular public belief that modern science can cure everything; next year, if not now. They have all heard of miraculous lengthening of limbs in the popular press, and more recently, the "successful" transfer of limbs.

Finally, it may need to be constantly reinforced that the child with a limb deficiency is more normal than abnormal. During this first year, the parents need to resolve their disappointment and loss, accept the child, and see the potential for the future. They need to bond to the child and begin to think of the child as an independent person. Most parents will begin to see their children this way as they grow and develop. Again, this process can be accelerated by seeing other children with similar problems. One recommendation that often needs repeating to the parents is that children tend to acquire the fears of their parents, and that support to participate in any activity the child expresses interest in will allow the child to develop his or her natural abilities to the fullest.

ORGANIZATION OF CARE

The management of pediatric limb deficiency is considered a specialized area of practice. There are several reasons for this. First, these anomalies are rare to any one practitioner outside of a limb deficiency center. The experience of an orthopaedic surgeon, therapist, or prosthetist who has treated several of these different anomalies can be important. Second, all patients and parents benefit by knowing they are not alone. In particular the new parent, and later the children, will benefit immeasurably by seeing other parents and children like themselves. No amount of explanation, pictures, or movies can educate parents like talking to other parents like themselves, and seeing children like their own.

The team should be made up of a physician and surgeon, prosthetist, physical and occupational therapist, and social worker or child psychologist, all of whom are knowledgeable in normal childhood development, and who can anticipate the deviations in development that will occur. The acquired adult amputee knows what he or she had and what he or she wants. The child and parents of a congenital amputee know little, and need education and guidance that usually can not be provided by an orthopaedic surgeon referring the patient to a prosthetist. The parents will be making decisions for their child that the child will live with for the remainder of their life. The professionals caring for the family must provide the necessary education and framework in which the parents can make these decisions.

Family involvement is the essential setting of the treatment program (26). The child has a condition he or she will accommodate to. This is not a disease that will be cured. Hence, the condition should not be "medicalized," but rather treated within the context of family, home, school, play, etc.

GENERAL CONSIDERATIONS

Growth

It has been observed that the percentage of shortening in a congenital limb deficiency remains relatively constant. The principle has been established for congenital short femur (27–29), and fibular hemimelia (30,31). Clinical experience would indicate this to be true for the tibial hemimelias also. It is important for the clinician and the parents to be aware that this percentage difference will translate into significant differences as the limb grows. Thus, in discussing centimeters of shortening and planning treatment, it is important to calculate what the discrepancy will be at maturity.

Because the percentage of shortening remains relatively constant, it is possible to calculate the ultimate discrepancy in centimeters at an early age. Knowing the percentile height of the child, the length of the femoral and tibial segments of the normal limb can be estimated from the Green and Anderson growth charts (32) (Tables 30-2 and 30-3). Then,

TABLE 30-2. GIRLS: LENGTHS OF THE LONG BONES INCLUDING EPIPHYSES
Orthoroentgenographic Measurements from Longitudinal Series of 67 Children

Femur								
No.	Age	Mean	σ_d	σ_m	Distribution			
					+2 σ_d	+1 σ_d	-1 σ_d	-2 σ_d
30	1	14.81	0.673	0.082	16.16	15.48	14.14	13.46
52	2	18.23	0.888	0.109	20.01	19.12	17.34	16.45
63	3	21.29	1.100	0.134	23.49	22.39	20.19	19.09
66	4	23.92	1.339	0.164	26.60	25.26	22.58	21.24
66	5	26.32	1.437	0.176	29.19	27.76	24.88	23.45
66	6	28.52	1.616	0.197	31.75	30.14	26.90	25.29
67	7	30.60	1.827	0.223	34.25	32.43	28.77	26.95
67	8	32.72	1.930	0.236	36.59	34.66	30.78	28.85
67	9	34.71	2.117	0.259	38.94	36.83	32.59	30.48
67	10	36.72	2.300	0.281	41.32	39.02	34.42	32.12
67	11	38.81	2.468	0.302	43.75	41.28	36.34	33.87
67	12	40.74	2.507	0.306	45.75	43.25	38.23	35.73
67	13	42.31	2.428	0.310	47.17	44.74	39.88	37.45
67	14	43.14	2.269	0.277	47.68	45.41	40.87	38.60
67	15	43.47	2.197	0.277	47.86	45.67	41.27	39.08
67	16	43.58	2.193	0.268	47.97	45.77	41.39	39.19
67	17	43.60	2.192	0.268	47.98	45.79	41.41	39.22
67	18	43.63	2.195	0.269	48.02	45.82	41.44	39.24
Tibia								
No.	Age	Mean	σ_d	σ_m	Distribution			
					+2 σ_d	+1 σ_d	-1 σ_d	-2 σ_d
61	1	11.57	0.646	0.082	12.86	12.22	10.92	10.28
67	2	14.51	0.739	0.090	15.99	15.25	13.77	13.03
67	3	16.81	0.893	0.109	18.00	17.70	15.92	15.02
67	4	18.86	1.144	0.140	21.15	20.00	17.72	16.57
67	5	20.77	1.300	0.159	23.37	22.07	19.47	18.17
67	6	22.53	1.458	0.178	25.45	23.99	21.07	19.61
67	7	24.22	1.640	0.200	27.50	25.86	22.58	20.94
67	8	25.89	1.786	0.218	29.46	27.68	24.10	22.32
67	9	27.56	1.993	0.243	31.55	29.55	25.57	23.57
67	10	29.28	2.193	0.259	33.67	31.47	27.09	24.89
67	11	31.00	2.384	0.291	35.77	33.38	28.62	26.23
67	12	32.61	2.424	0.296	37.46	35.03	30.19	27.76
67	13	33.83	2.374	0.290	38.58	36.20	31.46	29.08
67	14	34.43	2.228	0.272	38.89	36.66	32.20	29.97
67	15	34.59	2.173	0.265	38.94	36.76	32.42	30.24
67	16	34.63	2.151	0.263	38.93	36.78	32.48	30.33
67	17	34.65	2.158	0.264	38.97	36.81	32.49	30.33
67	18	34.65	2.161	0.264	38.97	36.81	32.49	30.33

(From ref. 32, with permission.)

knowing the length of the normal segments and the percentage by which the affected segments are short, the length of the affected segments at maturity can be estimated.

Although the above method of calculating the eventual discrepancy at maturity is clinically valid, the clinician should be aware of the effect surgical procedures could have on the growth of the limb. Following amputation, the epiphysis of the bone may not grow at the normal rate. Christiet al. showed that in 20 below-knee amputations in children, only three tibias grew at the expected rate (33). The congenital group grew 36% of what would have been ex-

pected, and the acquired group at 53%. Various reasons for this may be the lack of stress across the growth plate, the decreased blood flow to the bone, or the result of the congenital insult producing the limb deficiency.

Timing of Amputation

The timing of an amputation in a congenital limb-deficient child is best understood in the context of the purpose of the amputation and the development of the child. The amputation is done to provide improved function, compared

TABLE 30-3. BOYS: LENGTHS OF THE LONG BONES INCLUDING EPIPHYSES
Orthoroentgenographic Measurements from Longitudinal Series of 67 Children

Femur								
No.	Age	Mean	σ_d	σ_m	Distribution			
					+2 σ_d	+1 σ_d	-1 σ_d	-2 σ_d
21	1	14.48	0.628	0.077	15.74	15.11	13.85	13.22
57	2	18.15	0.874	0.107	19.90	19.02	17.28	16.40
65	3	21.09	1.031	0.126	23.15	22.12	20.06	19.03
66	4	23.65	1.197	0.146	26.04	24.85	22.45	21.26
66	5	25.92	1.342	0.164	28.60	27.26	24.58	23.24
67	6	28.09	1.506	0.184	31.10	29.60	26.58	25.08
67	7	30.25	1.682	0.205	33.61	31.93	28.57	26.89
67	8	32.28	1.807	0.221	35.89	34.09	30.47	28.67
67	9	34.36	1.933	0.236	38.23	36.29	32.43	30.49
67	10	36.29	2.057	0.251	40.40	38.35	34.23	32.18
67	11	38.16	2.237	0.276	42.63	40.40	35.92	33.69
67	12	40.12	2.447	0.299	45.01	42.57	37.67	35.23
67	13	42.17	2.765	0.338	47.70	44.95	39.40	36.64
67	14	44.18	2.809	0.343	49.80	46.99	41.37	38.56
67	15	45.69	2.512	0.307	50.71	48.20	43.19	40.67
67	16	46.66	2.244	0.274	51.15	48.90	44.42	42.17
67	17	47.07	2.051	0.251	51.17	49.12	45.02	42.97
67	18	47.23	1.958	0.239	51.15	49.19	45.27	48.31
Tibia								
No.	Age	Mean	σ_d	σ_m	Distribution			
					+2 σ_d	+1 σ_d	-1 σ_d	-2 σ_d
61	1	11.60	0.620	0.074	12.84	12.22	10.98	10.36
67	2	14.54	0.809	0.099	16.16	15.35	13.73	12.92
67	3	16.79	0.935	0.114	18.66	17.72	15.86	14.92
67	4	18.67	1.091	0.133	20.85	19.76	17.58	16.49
67	5	20.46	1.247	0.152	22.95	21.71	19.21	17.97
67	6	22.12	1.418	0.173	24.96	23.54	20.87	19.46
67	7	23.76	1.632	0.199	27.02	25.39	22.13	20.50
67	8	25.38	1.778	0.217	28.94	27.16	23.60	21.82
67	9	26.99	1.961	0.240	30.91	28.95	25.02	23.06
67	10	28.53	2.113	0.258	32.76	30.64	26.42	24.30
67	11	30.10	2.301	0.281	34.70	32.40	27.80	25.50
67	12	31.75	2.536	0.310	36.82	34.29	29.21	26.68
67	13	33.49	2.833	0.346	39.16	36.32	30.66	27.82
67	14	35.18	2.865	0.350	40.91	38.04	32.32	29.45
67	15	36.38	2.616	0.320	41.61	39.00	33.76	31.15
67	16	37.04	2.412	0.295	41.86	39.45	34.63	32.22
67	17	37.22	2.316	0.283	41.85	39.54	34.00	32.59
67	18	37.29	2.254	0.275	41.80	39.54	35.04	32.78

(From ref. 32, with permission.)

to what is provided by the deficient limb, correct a severe discrepancy in length, or to facilitate prosthetic fitting, so that the child can keep pace with normal motor milestones.

In general, elective lower-extremity amputations, designed to aid prosthetic fitting of congenital deficiencies, are performed at the time the child is ready to walk as indicated by their pulling to stand. For children with tibial and fibular deficiencies who will be treated with amputation, pulling to stand and cruising are the signals that the child is ready to begin walking. This would be the time for an amputation and prosthetic fitting, so the child can

maintain normal developmental sequence. In some unusual cases in which the deformed extremity is interfering with crawling and other prewalking activities, amputation may be performed earlier. However, prosthetic fitting should wait until it will be of some value. It is very difficult to keep a prosthesis on a crawling child.

In other cases, e.g., proximal femoral focal deficiency, prosthetic fitting will usually be done when the child is ready to walk, but definitive surgical treatment to permit a more functional prosthesis will be done later for technical reasons.

Finally, there will be cases in which leg lengthening is the treatment of choice, but the difference in length must be compensated for prior to lengthening at a later age. Occasionally, it will be necessary to fit such patients with nonconventional prostheses, when shoe lifts are not sufficient.

Although it is poorly documented, there is the impression among both parents and surgeons that with early amputation the child does not suffer the loss in body image that accompanies amputation at a later stage. Also important is that as a general rule, the earlier the amputation, the better the child's neurologic plasticity adapts to the alteration.

COMPLICATIONS

Overgrowth

Bony overgrowth at the end of the residual limb is the most common problem in juvenile amputees. Its occurrence is reported to be between 4 and 35 percent, and depends on the age of the patient at the time of amputation, and of the bone involved (34–36). The condition has not been reported after the completion of growth. Overgrowth occurs most often in below-knee amputations, with the fibula being the problem more often than the tibia, and in transhumeral amputations.

Contraction of the soft tissue and growth of the bone, pushing it through the skin, were the most common reasons given for the problem. Aitken disproved these theories when he demonstrated by implanting metallic markers that the overgrowth took place distal to the end of the bone (34,37). Experimental and clinical work that has demonstrated that plugging of the medullary canal can prevent bony overgrowth is explained by the normal occurrence of wound contracture. This mechanism has been demonstrated by Speer (38).

The patient will often notice pain on weightbearing or prosthetic use. An antalgic gait with decreased stance time may be noticed. Decreased range of motion, to limit pulling of the skin at the end of the limb, is an additional symptom. Clinically, the patient presents with tenderness and pain at the end of the residual limb. There may be inflammation, bursal formation, or the bone end may be protruding through the skin. Commonly, the bony spike can be palpated within a small, tender bursa. Careful medical supervision can often anticipate the problem, which in turn allows the patient to plan for surgical correction.

Various plastic and metallic devices have been used to cap or plug the end of the bone. However, these have been abandoned because the results have not been as good as with biologic material (39,40). Marquardt reported in the mid-1970s, in the German literature, on the capping of the bone end with a cartilage-bone graft. Various reports for both acquired and congenital amputees would indicate generally favorable results, with most revisions being for technical reasons (39–42).

When a patient presents with pain and bursa formation, prosthetic modification and other conservative measures should be used first, unless a bony spike is felt. Once overgrowth occurs in a limb, it is likely to recur during remaining growth, and may possibly result in shortening of the residual limb. If revision surgery is necessary, consideration for a capping procedure should be given. Age is a paramount factor in the decision, since bony overgrowth is very unusual after the age of 12 years. In the case of a primary amputation, it is advisable to use available parts from the amputated portion of the limb to cap the end of the bone, if conditions permit. The most common procedure is the use of the proximal fibula to cap the tibia. As in any revision, adequate resection of bone, to provide a healthy soft tissue envelope, is essential (Fig. 30-2).

Following surgery, the therapist should supervise and educate the child and parents in edema control to hasten return to prosthetic use. In addition, range of motion and strengthening exercises speed, and may even be necessary to regain, full function of the prosthesis. Myoelectric users may need readjustment of their electrodes, and may have difficulty for a while activating the prosthesis. This is because of swelling and reshaping of the limb, which may alter the optimal sites for electrode placement.

Phantom Sensation/Pain

The term "phantom limb" was coined by the neurologist Silas Weir Mitchell in the middle of the 19th century. He described these sensations as replicas of the lost limb, some being painful and some not. Phantom sensation of the limb is often described by the patient as the feeling that they can move the part, tell how the part is positioned, itching, or tingling. Phantom pain, however, is perceived by the patient as just that: painful. It often is the same as the pain before an amputation, or may be cramping, shooting, burning, or of any other characterization.

It has been a general teaching that children born without limbs do not have sensations of them, nor do these children experience phantom pain or phantom sensation as seen in the acquired amputee (43). Recent reports call this commonly accepted truism into question (44,45). Whatever this pain is, it will be recognized by those who care for children with limb deficiencies that these children do not have the same problem as the true chronic phantom pain seen in adult amputees.

Melzak and colleagues reported that phantom limb was present in at least 20% of the congenitally limb-deficient children, and in 50% of those who underwent amputation before age 6 years (45). In addition, 20% of the congenitally deficient group described the sensations as painful, whereas 42% of the acquired amputees described them as painful. To explain the phenomenon of phantom limb in a child who has never had a limb, Melzak et al. have proposed that there is a genetically or innately determined neural network that is distributed in the cortex (not focal), which

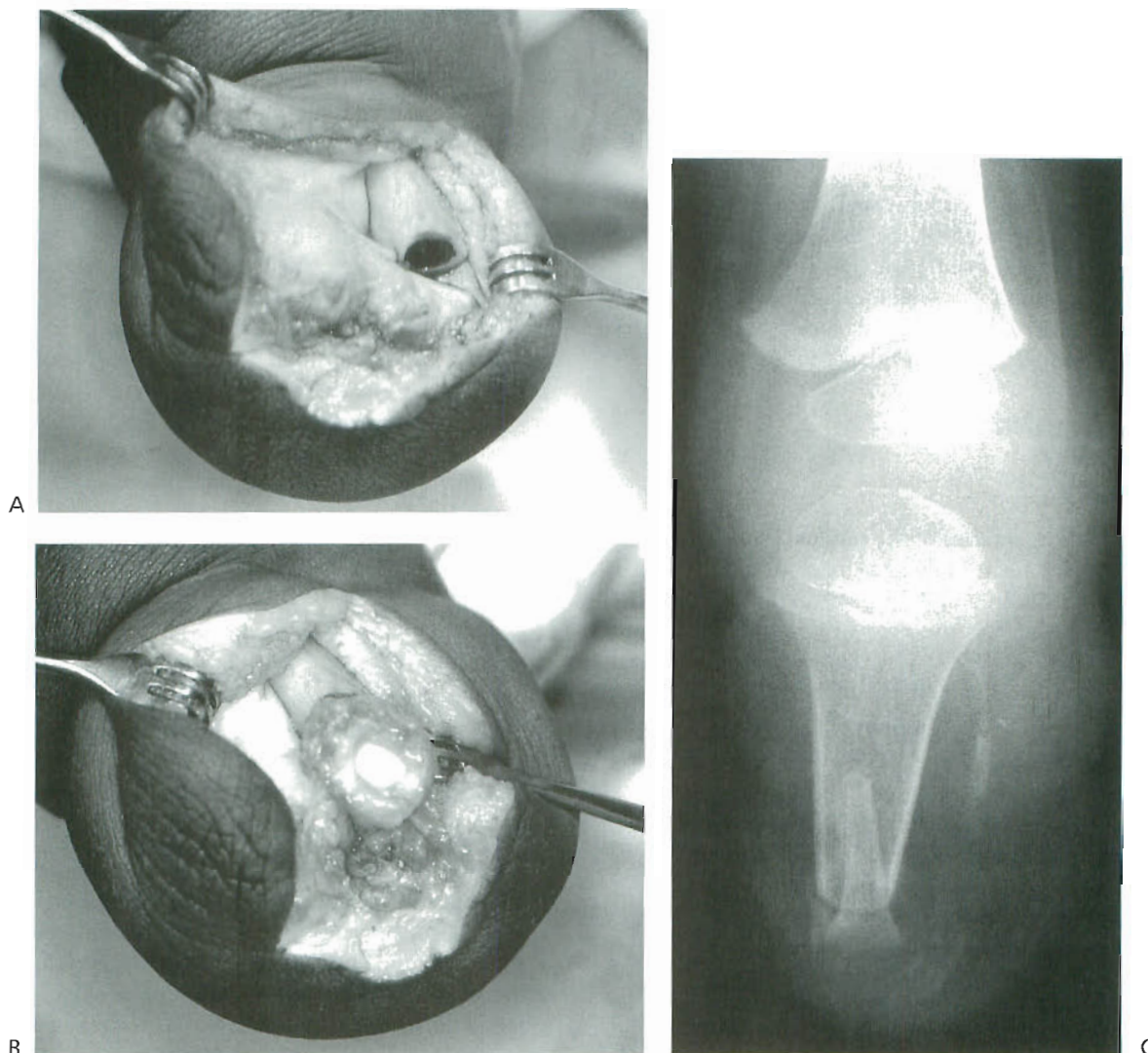


FIGURE 30-2. The end of the tibia with the bony overgrowth removed with the head of the fibula inserted into the medullary canal of the tibia (A) and (B). C: The anteroposterior view of the tibia six weeks after the Marquardt procedure.

is responsible for the representation of the limb, even though the limb bud development was not normal.

Phantom pain and stump pain are also associated, and in general, seen to be associated with other pains, e.g., headache, bone, or joint pain (44,46). The phantom sensations may occur frequently or rarely. They are often triggered by a wide variety of stimuli. Feeling nervous or happy, not wearing a prosthesis, being cold, or being ill are frequent. Fortunately, these sensations do not interfere with the child's usual activity, and most say they just try to ignore the sensations (47).

There is no single highly successful treatment of phantom limb pain, most likely because there is usually not one single cause. Because many of these problems resolve with prosthetic alterations or physical therapy modalities, a mul-

tidisciplinary team approach has proven to be the best intervention in evaluating and properly treating phantom limb phenomenon when it becomes a problem.

A properly fitting socket, with appropriate suspension and sock thickness, is the best and first treatment of choice (47,48). A heavy, tight shrinker, either worn inside the prosthesis or when the prosthesis is off, may give relief. Physical therapy interventions including weightbearing and graduating pressures, such as tapping, rubbing, and massage to the residual limb, have been reported to give temporary or permanent relief. Rubbing and massaging the uninvolved limb at similar points to those in which they are experiencing the phantom limb sensation may provide relief. Various physical modalities have been utilized in the treatment of phantom sensations in children, including transcutaneous

electrical nerve stimulation (TENS), biofeedback, ultrasound, and the physical agents of heat and cold (49).

For the occasional adolescent amputee who has problems with phantom pain following an amputation, gabapentin (Neurontin, Park-Davis) has proven a useful medication.

CONGENITAL DEFICIENCIES OF THE LOWER EXTREMITY

Fibular Deficiency

Classification

According to the ISO terminology, fibular deficiency is longitudinal deficiency that is either partial or complete. But this does little to accurately portray the spectrum of deficiency that is seen.

Numerous classifications specific for fibular deficiency have been proposed (25,30,50–52). To be useful a classification should guide treatment or aid in prognosis. As treat-

ment changes, it may be reasonable to expect that classifications change.

Most classifications are anatomic, and are based on the radiographic appearance. Maffulli and Fixsen describe total aplasia of the fibula and a *forme fruste* of the same condition in which the fibula and tibia are short to varying degrees (53,54). A more specific classification, which is probably the most widely used today, was proposed by Achterman and Kalamchi (30) (Figs. 30-3–30-5). They correlated the classification with the discrepancy in length, and recommended treatment based on the classification.

Recently, Birch et al. have proposed a functional classification based on the functionality of the foot and the limb-length discrepancy as a percent of the opposite side (55). As they point out, however, the problem is picking the correct treatment for the individual patient. Given the large variation in the different aspects of fibular deficiency, including the parents' desire, it remains unlikely that classifications will provide anything more than a rough guide and a method of comparing patients in different reports.

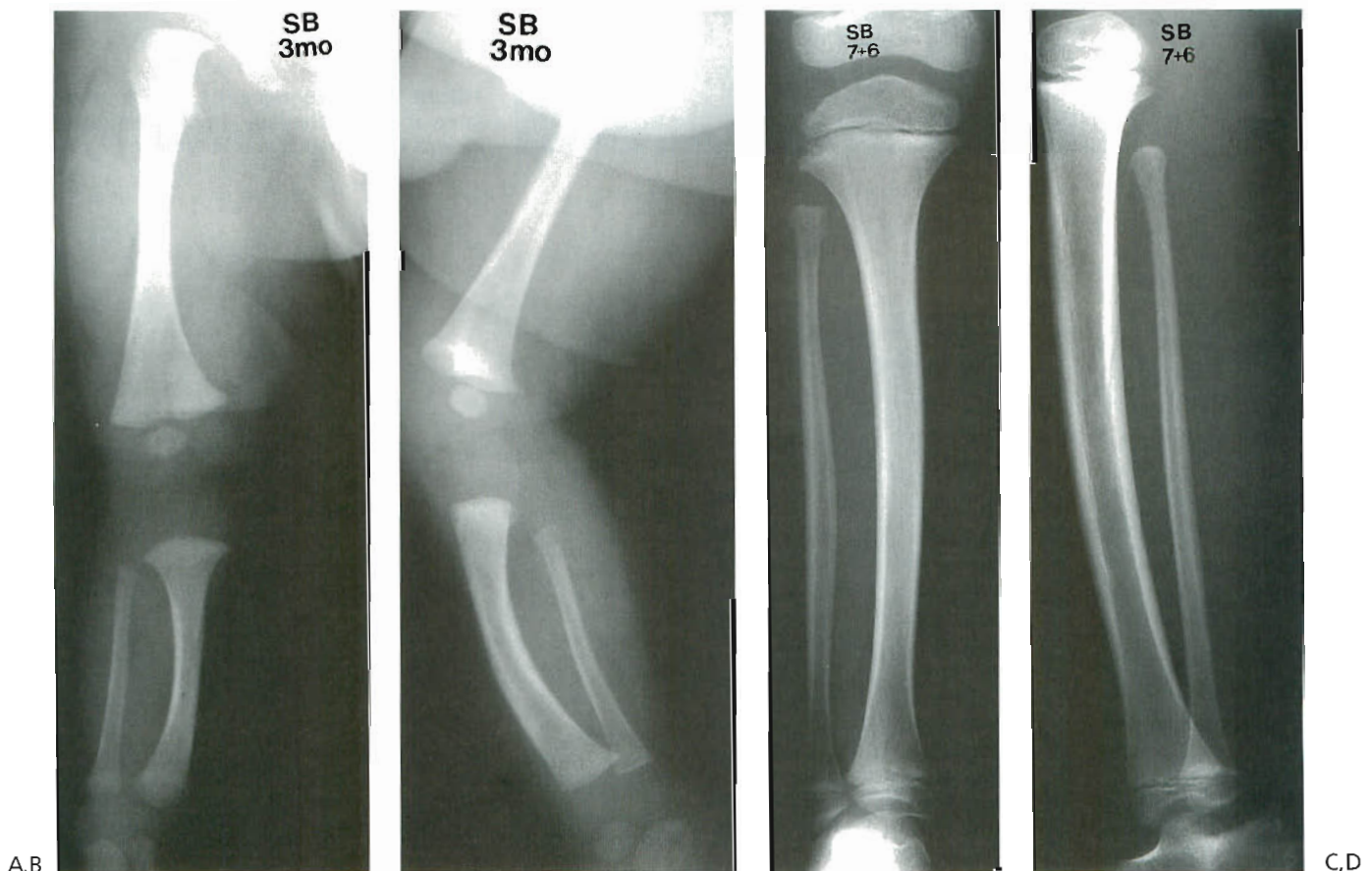


FIGURE 30-3. A, B: The radiographs of a 3-month-old boy with type IA fibular deficiency of Achterman and Kalamchi. Although the bones may seem normal to the casual observer, the proximal fibula is short. C, D: Anteroposterior and lateral radiographs of the same patient at age 7 yr 6 mo. The shortening of the fibula is more apparent and the ball-and-socket ankle joint is easily seen. (continued)

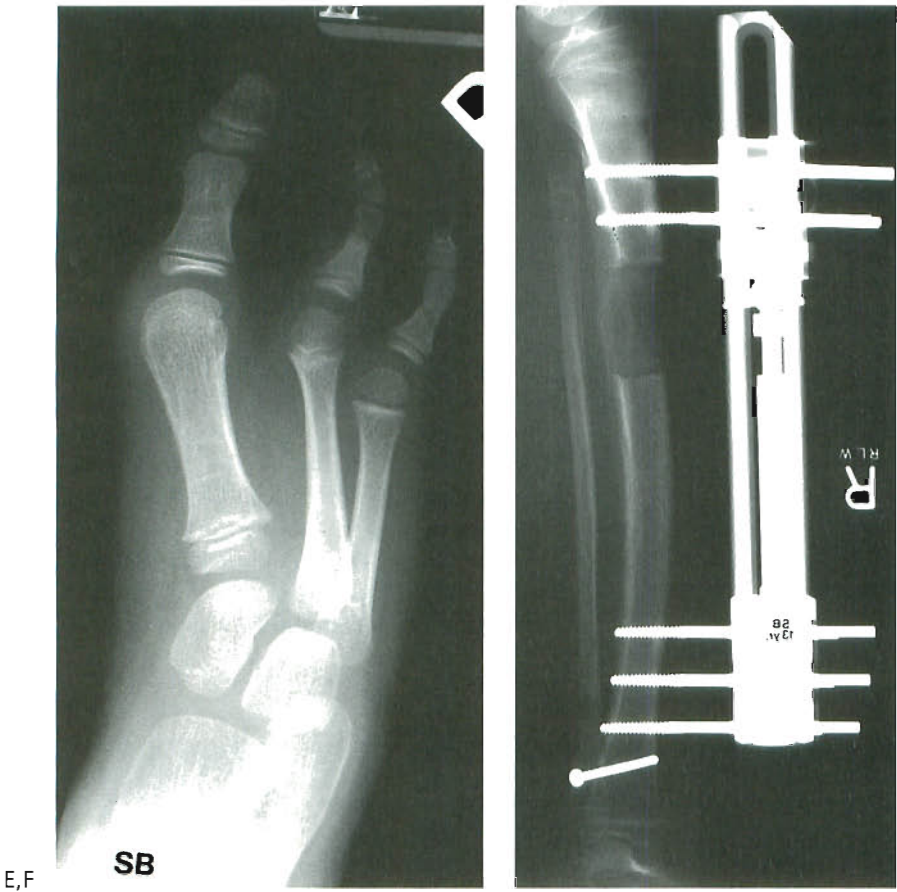


FIGURE 30-3. (continued) E: The foot at the same age, with the lateral two rays missing. F: At age 13 yr, the leg was lengthened 7 cm.

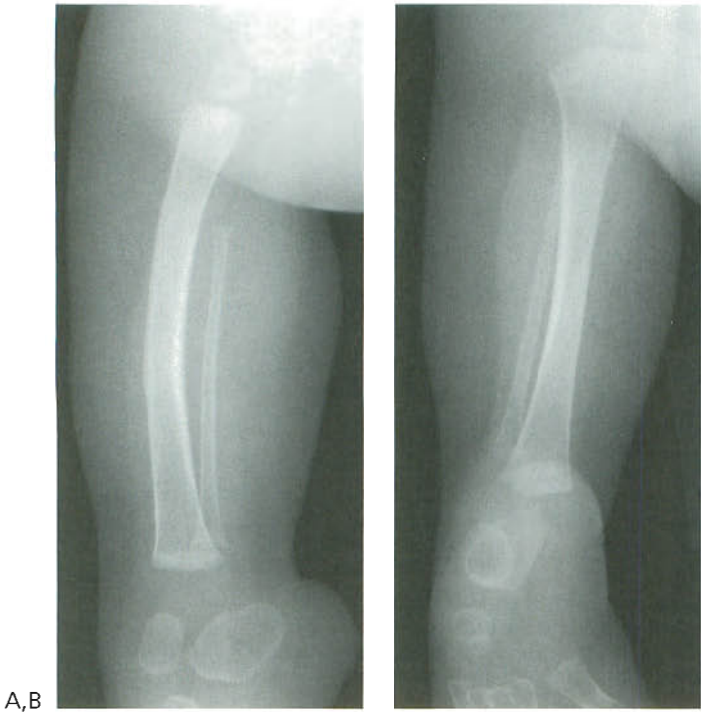


FIGURE 30-4. A, B: Type IB fibular deficiency, in which the proximal fibula is missing. This type is often associated with proximal focal deficiency, as it is in this child.

Clinical Appearance

The appearance of a limb with fibular deficiency can vary from barely detectable to severely deformed. The typical limb is characterized by a valgus foot, shortening of the leg, variable anterior bowing of the tibia with a dimple over the apex, and variable valgus of the knee. The foot is often deformed, missing one to several lateral (post axial) rays (Fig. 30-5E and F).

Examination of the limb will demonstrate anteroposterior instability of the knee, a small patella, variable degree of fixed valgus and equinus of the ankle, and rigidity of the hind foot.

The appearance and physical findings of the leg are indicative of the widespread abnormality that may be present, along with hypoplasia or absence of the fibula, which gives the deficiency its name.

Frequently, the femur is short as well as the tibia. The femoral shortening may be slight to severe, with the associ-

ated diagnosis of proximal femoral focal deficiency. Amstutz (28) reported femoral deficiency in 15% of those with fibular deficiency, whereas Bohne and Root (56) reported femoral deficiencies in almost two-thirds of their patients. Kalamchi noted that 70% of type I and 50% of type II deficiencies were associated with shortening or deformity of the femur (57).

The abnormality extends into the knee joint, where the condylar notch of the femur is shallow, the tibial spines small, and there is laxity in the anteroposterior direction (58).

There is also a valgus deformity of the knee, which is not associated with varus/valgus instability (58), but reflects from a small hypoplastic lateral femoral condyle (59). The natural history of this deformity is that it usually worsens with growth (31,56,60,61). In some cases, the degree of valgus is more severe than can be explained by the smaller lateral femoral condyle alone.

The anterior bow of the tibia is variable, being more

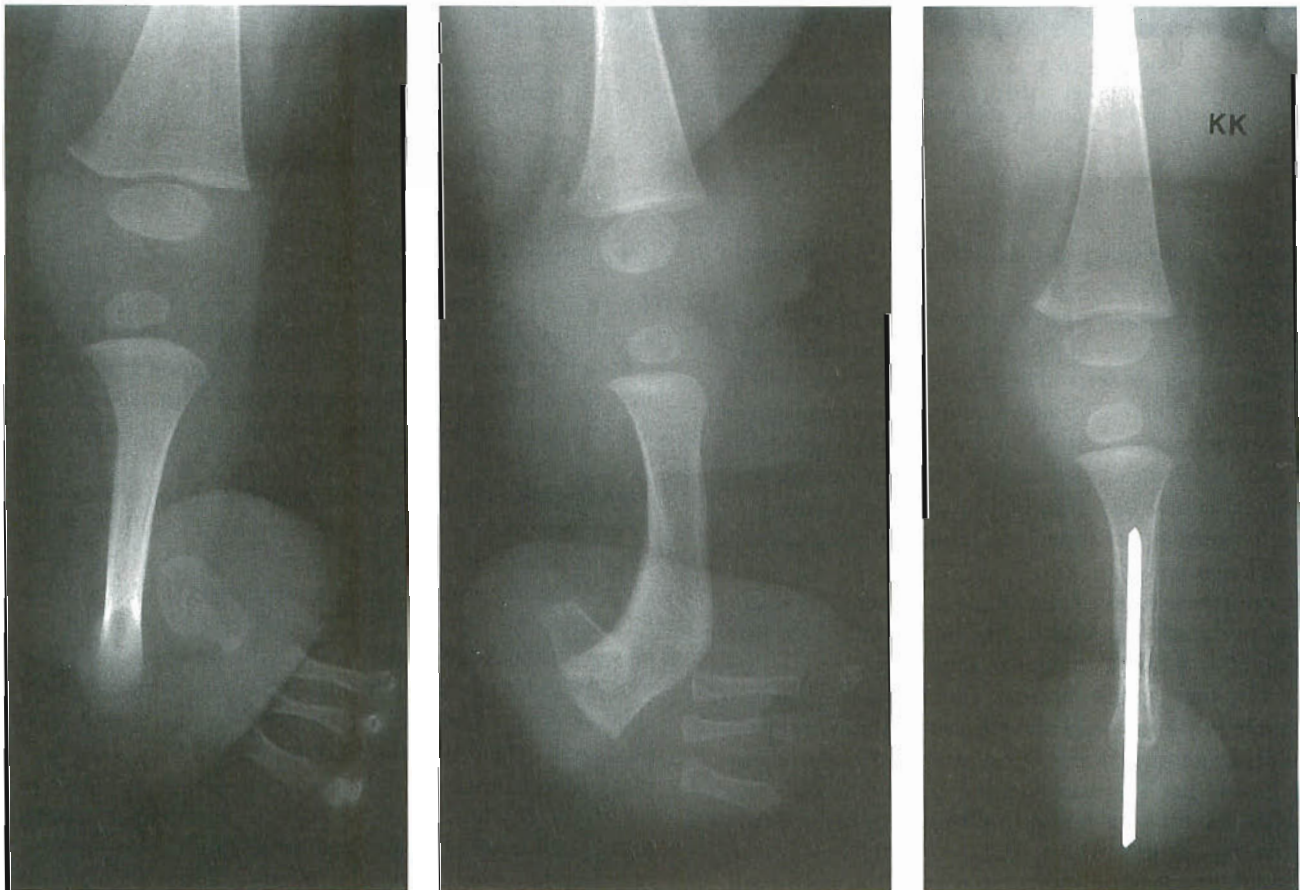


FIGURE 30-5. A, B: Anteroposterior and lateral radiographs of a type II fibular deficiency, in which the entire fibula is missing. Note the missing lateral rays of the foot and the severe angulation of the tibia. C, D: The limb 6 weeks after Syme amputation and an anterior closing-wedge osteotomy of the tibia. Placing the pin through the anterior cortex of the proximal fragment provides rigid fixation, which is not obtained if the pin is simply passed up the medullary canal. The pin was removed in the office at the time of cast removal. (*continued*)

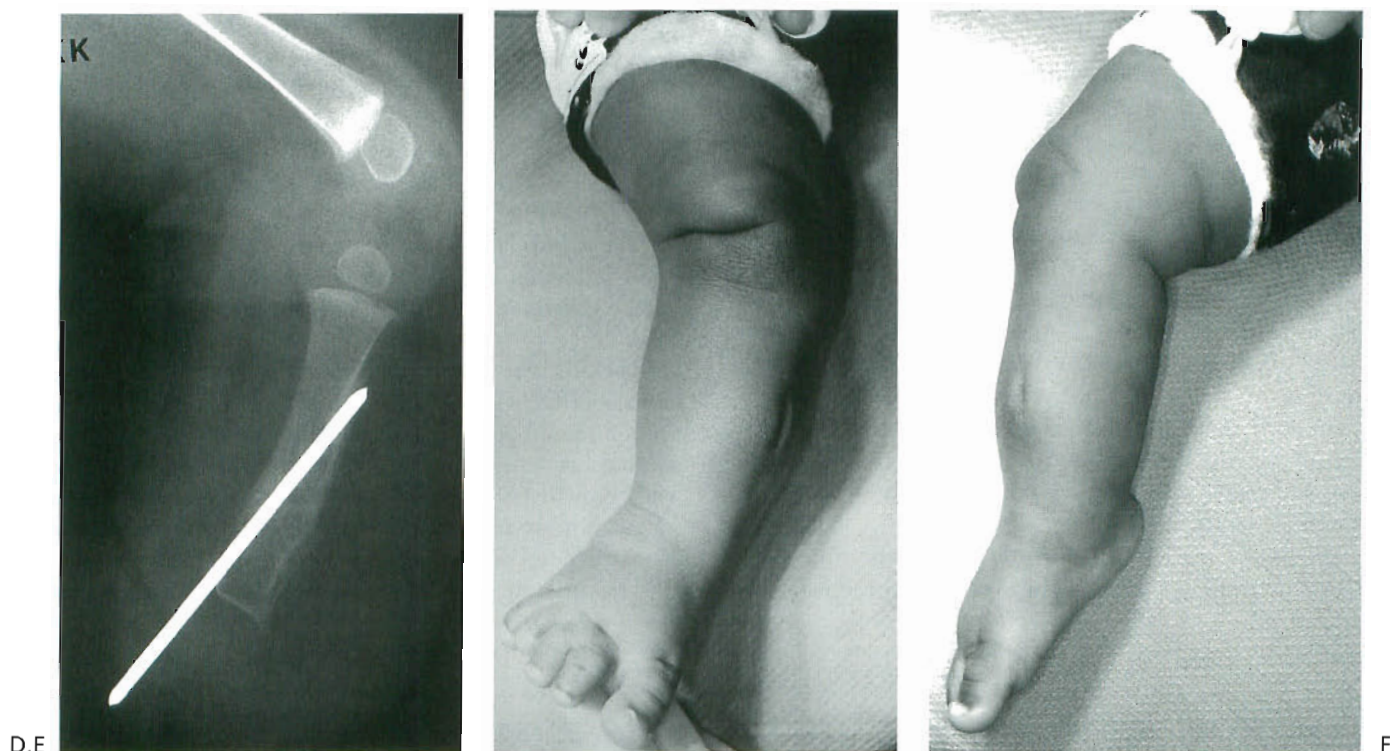


FIGURE 30-5. (continued) The clinical appearance of the same deficiency at the time of surgery in another patient is seen in E and F. Note the short tibial segment, the valgus knee and foot, and the dimple over the tibia.

severe in the more severe deficiencies. It is not always of clinical significance.

The ankle may appear normal in some patients with mild deficiencies. The classic appearance is the ball-and-socket ankle joint, which is seen in less-severe deficiencies (Fig. 30-3C and D). There is disagreement about the origin of this abnormality: some authors feel that it is congenital in nature (62), while others feel that it develops secondary to the tarsal coalitions (63). If caused by the tarsal coalition, it is difficult to explain its absence in tarsal coalitions without fibular deficiency.

In more severe cases, if the fibula is present, it is short and may not reach the level of the ankle joint. The distal tibial epiphysis shows a triangular appearance.

The foot may appear normal, but more frequently is missing one or more lateral rays. It is a common and paradoxical observation that it is the shorter, more severely involved limbs that are usually missing four or five rays, whereas the less involved longer limbs are frequently missing only three rays or less (31).

Although not seen on radiographs at birth, tarsal coalitions are present in the majority of the feet associated with fibular deficiency. Grogan et al. noted such coalitions in 54% of anatomic specimens, although the abnormality could be seen on only 15%, radiographically because of the cartilaginous nature of the coalition (64).

Treatment Options

The main problems in the treatment of fibular deficiency are the limb length discrepancy and the deformity and instability of the foot and ankle. It is very important to realize that the discrepancy will become worse with growth, and it is the ultimate discrepancy at maturity that is important.

Amputation. Until the 1960s, amputation for fibular deficiency was recommended only as a last resort (65). Based on the results of these early attempts to save the limbs, several reports emphasized the advantages of amputation for severe cases (31,66–68). The indications are based primarily on the length difference and the functionality of the foot. Wood et al. recommended amputation for a discrepancy of three inches or more at the time of decision, or if predicted at maturity, for a nonfunctional foot, for a limb that would have severe cosmetic or functional problems, or for children who cannot endure the psychologic trauma of repeated hospitalizations and surgery (68). These recommendations were reaffirmed in a later publication from the same institution, following many of the same patients (31).

More recent recommendations begin to stretch the amount of length that can be restored, reflecting improvements in limb lengthening. Westin et al. suggested amputation for any discrepancy that would be greater than 7.5 cm

at maturity (31). For Letts and Vincent, the number was greater than 10 cm (25), and for Hootnick et al. it was between 8.7 and 15 cm (69).

Although modern prosthetics have made amputation a somewhat more acceptable alternative, the improved ability to lengthen limbs has also made limb salvage a more feasible option. The recommendations of Birch et al. are an effort to account for these changes (55). They would recommend amputation for those with a nonfunctional foot, regardless of length, unless the upper extremities were non-functional. For those with a functional foot, but a length discrepancy of 30% or more, amputation would be recommended. For those with a functional foot and a discrepancy less than 10%, epiphysiodesis or lengthening is reasonable. There is little disagreement about these indications today.

It is between these two groups where the controversy regarding treatment lies today, and the greater the discrepancy in length, the greater the controversy. According to Birch et al., those patients with a functional foot, and a discrepancy between 10 and 30%, are candidates for either amputation or lengthening (55). The parents who are the decision-makers are weighing the hope for their child to retain their limb against what that will entail. They most likely have never seen a child or adult with an amputation; they visualize something horrible. They cannot really know what a lengthened limb will be like at the end of treatment; they see the limb as normal. Although they may understand that they will need two or three lengthening procedures, they cannot know what the impact will be on their child or their family, what complications they will encounter on the way, nor how their child will look or function at the end of treatment.

As yet, there are but a few preliminary reports of lengthening in fibular deficiencies with discrepancies greater than 10 cm. These preliminary reports, using the Ilizarov methods, deal mainly with the amount of length achieved, often before maturity, but with little information on cosmetic and functional result (70–74).

One way to begin to assess the problem is to look at what amount of length is required. The combined femoral and tibial length for a girl of average height at maturity will be approximately 80 cm (32) (Table 30-2). A 10% discrepancy would be approximately 8 cm, a 20% discrepancy would be 16 cm, and a 30% discrepancy would be 24 cm. To achieve greater than 10 cm of length in a congenital limb deficiency with anteroposterior knee instability, ankle instability, foot deformity, and congenitally short soft tissues, is a significant undertaking (75–77).

Reports comparing Syme amputation with lengthening are few and incomplete, but begin to give an appreciation for the problems associated with lengthening severe deficiencies (50,78,79). These authors conclude that lengthening should be reserved for those with more normal feet and less discrepancy in length, while early Syme amputation is the best treatment for the more severe problems. Herring

gives a philosophical perspective on the dilemma (80). Birch et al. reviewed a series of adults who were treated with Syme amputation in childhood. They performed physical examination, prosthetic assessment, psychologic testing, and physical performance testing, and commented that the results of multistaged lengthenings for this condition would have to match these results to be justified (80a). They currently offer lengthening to patients whose limb length discrepancy is 20% or less.

Bilateral. In patients with bilateral fibular deficiency, the three problems are the foot deformity, the discrepancy in length between the two limbs, and the overall shortening in height as a result of two short limbs. Without extenuating circumstances, e.g., nonfunctional upper extremities, disarticulation of the foot and prosthetic fitting is the best solution. For those children with nonfunctional upper extremities who will use their feet for many of the activities of daily living, amputation of the feet is not an option.

In children with bilateral fibular deficiency, there is usually little discrepancy between the two limbs, but rather a discrepancy in their height, compared to what it should be. As they enter into their peer group this becomes an increasing problem. This problem is most easily solved by the prosthetist. If there is a significant difference between the length of the two limbs that cannot be solved by prosthetic adjustment, lengthening of the short limb becomes an attractive option.

It is easy to miss a patient with bilateral deficiency when the deficiency on the opposite side is mild. The focus on the severe deficiency distracts the examiner. The deficiency will become apparent with time, causing disappointment and loss of confidence.

Syme and Boyd Amputation

The amputation described by Syme (81) [→7.22] seems to have been accepted for adults before children, and its use in boys was advocated before its use in girls because it was said that the Syme amputation produced an unsightly bulkiness around the ankle. This resulted in many children receiving a transtibial amputation, rather than a Syme amputation. It was subsequently learned, however, that the ankle does not enlarge following amputation in a young child, and the cosmetic appearance is excellent as the child grows.

Thompson et al. were the first to recommend the Syme amputation, rather than transtibial amputation, although only as a last resort (65). Subsequent reports by Kruger and Talbott (67) and Westin et al. (31) not only confirm the advantages of the Syme amputation in both boys and girls, but also advocated its early use for severe deficiencies. Several studies now confirm the value of Syme amputation (61,67,80,82–86).

One of the major advantages of the Syme amputation is the ability to bear weight on the end of the residual limb.

One of the major complications of the Syme amputation is migration of the heel pad off the end of the residual limb. This is particularly true in congenital limb deficiencies, in which the heel may be on the back of the tibia, making repositioning of the heel pad on the end of the limb difficult or impossible. Although suggestions to remove a piece of the Achilles tendon, suture the extensor tendons into the anterior portion of the heel pad, or fix the heel pad with a Kirschner wire, may each have their place, most authors agree that migration of the heel pad does not produce any insurmountable problem for the patient or the prosthetist (60,82). Most other problems in patients with Syme amputation are caused by the other effects of the underlying disorder (60,61,82,84).

In the most complete study to date on the outcome of Syme amputation in children, Herring et al. examined the functional and psychologic status of 21 patients with a Syme amputation (60). They noted that family stress was the factor that had the greatest influence on the patients' psychologic functioning, and that children who had amputation after several failed attempts at salvage were at considerable risk for emotional disturbance. Functionally, the patients were able to function at the average for their age group, and they did not find that adolescents were less likely to participate in athletics (as Green and Carey also found) (87). In summary, they concluded that Syme amputation may be compatible with the athletic and psychologic function of a nonhandicapped child.

A variation of Syme amputation was described by Boyd (88). In the Boyd amputation [➔7.23], the talus is excised and the retained calcaneus with the heel pad is arthrodesed to the tibia. The operation was initially devised to avoid the complication of posterior migration of the heel pad seen in some children with Syme amputation. However, the main complication of the Boyd amputation is the migration of the calcaneus if arthrodesis is not achieved. This requires an additional operation, which is often conversion to a Syme amputation. A real advantage of the Boyd amputation is that with the retained calcaneus the heel pad tends to grow with the child, rather than remaining small as in the Syme amputation. The Boyd amputation also adds additional length. This can be a problem in children who do not have significant shortening of the limb, when fitting various prosthetic feet, and may require a shoe lift on the normal side.

Eilert and Jayakumar (83) compared the two operations, and found the migration of the heel pad to be the only complication in the Syme amputation, whereas the Boyd amputation had more perioperative wound problems and migration or improper alignment of the calcaneus. In the authors' clinic, all of the children, even bilateral amputees, can and do walk on the ends of their residual limbs, either with or without the heel pad in place. If the heel pad migrates posteriorly, it may alter the weight bearing aspects of prosthetic fitting, especially as the child gets older.

In fitting a Syme amputation, there are two prosthetic

advantages to having the deficient limb shorter. The first is the ability to make a narrower and more cosmetic ankle in the prosthesis. The second is that some shortening, rather than additional lengthening, makes it easier to fit more durable energy-storing feet. In fibular deficiencies, length is never a problem, because these limbs are always short.

Correction of Tibial Bow

The anterior bow in the diaphysis of the tibia varies from nonexistent to severe. Severe bowing is usually seen in the more severe deficiencies with complete absence of the fibula. Westin et al. reported this to be of little consequence (31). However, observations in the authors' center have shown this to be a frequent prosthetic problem, requiring osteotomy during the first decade.

With the tibial bow, the foot is displaced posterior to the weight-bearing axis that passes through the knee. If the foot is placed at the distal end of the tibia (which the parents want for cosmetic reasons), the ground reaction force places a large moment through the toe-break area, leading to premature failure of the foot component and skin problems caused by abnormal pressure. The problem is then blamed on the foot component or the prosthetist.

A reasonable recommendation would be to correct any significant bow at the time of Syme amputation. A small anterior incision, removal of an anterior-based wedge of the tibia, and fixation with a temporary Steinmann pin, placed up through the heel pad, solves the problem, and does not result in any delay in prosthetic fitting (Fig. 30-5). When correction of the bow is necessary in older children who are already in their prosthesis, the authors have preferred the Williams rod technique [➔6.11], because this speeds resumption of prosthetic wearing.

Correction of Valgus

Development of progressive genu valgum has long been known as a complication of fibular deficiency. It is one of the major problems seen in gait in children with this problem. At first, it is merely cosmetic, and can be accommodated with prosthetic alterations. However, if it becomes more severe, it will increase the forces on the lateral compartment and make good alignment impossible.

The cause of the deformity has been controversial. Initially, it was thought to result from tethering by the fibular anlagen; however, release of this lateral band did not prevent or lessen the deformity (28).

Westin et al. noted that the tibia often developed an anterior flexion along with the valgus, and attributed the problem to an abnormality in growth in the lateral and posterior portions of the proximal tibial physis (31). This is separate from anterior bow in the diaphysis of the tibia.

Most recently, Boaks et al. documented a decrease in the height of the lateral femoral condyle that was not present

prior to walking, and correlated with the amount of valgus (59). They suggested that tibial osteotomy [→6.1–6.5], to correct the anteromedial bowing, might prevent the changes in the lateral femoral condyle. If the deformity was present in the lateral femoral condyle, they suggested temporary stapling of the medial femoral condyle [→4.21], since osteotomy had a very high recurrence rate unless performed near the end of growth.

Ankle Reconstruction

Any attempt to save the limb of a child with significant fibular deficiency will require efforts to realign and stabilize the ankle. There is renewed interest in this subject with attempts to lengthen the leg.

The Gruca procedure is designed to provide lateral stability to the foot in the absence of the fibula. Serafin gives the first report of the technique in the English literature, and recounts the various attempts at bone grafting and other procedures that were described before Gruca developed his technique (89).

In the Gruca procedure the tibia is split longitudinally. The medial segment is displaced proximally with the talus, leaving the lateral fragment as a lateral buttress. Thomas and Williams describe the early results in nine patients treated with this procedure. The follow-up is short, and the evaluation of function incomplete (90). The operation has not been widely used, and would seem to have little to recommend it.

Arthrodesis of the talus to the distal tibia is a logical plan in conjunction with leg lengthening, but there are no reports on its outcome. It is likely that this would also require release of all of the tendons crossing the ankle joint to prevent foot deformity.

The ball-and-socket ankle joint, seen in the Kalamchi type IA deficiencies, usually require no treatment. The authors have, however, seen several children with increasing valgus during adolescence or following leg-lengthening, who become symptomatic with normal athletic activity. These have been successfully treated by a Wiltse osteotomy [→6.6] of the distal tibia.

Prosthetic Management

Prosthetic management of the fibular-deficient limb is treated differently than a comparable traumatic adult with a Syme disarticulation. In the child, the prosthesis is designed to accommodate growth, and to help stabilize knee laxity and hyperextension through socket design and alignment. Emphasis is placed on socket alignment and minimizing rotational forces acting on the knee.

The socket fitting for a Syme amputation may be designed to take all of the weight on the end of the residual limb, as intended, all of the weight on the patellar tendon and flare of the proximal tibial condyles, as in a transtibial

amputation, or both. As the child grows, it is a good idea to begin to shift some of the weight bearing to the proximal structures, to prepare the child for the time when full weight bearing on the end may not be possible. Failure to shift weight bearing proximally with age usually results in problem fittings resulting from tolerance issues. This discomfort probably arises from the small distal weight bearing surface seen in many of the congenital limbs. This is an important consideration in the bilateral amputee, in whom disproportionate weight shifting to the sound side is not possible for comfort.

As with most amputations done at a young age, the condyles will be small at the time of amputation, will not grow to normal size, and therefore, do not need to be trimmed as in the adult. The brim of the socket is designed with supracondylar medial and lateral trim lines, in an effort to control any knee valgus instability and/or patellar instability. The type of suspension will depend on the size of the distal end of the residual limb. If very large, an obturator or window may be necessary. With further growth, the distal end may not be sufficient for suspension, and a different design will be necessary. These are discussed later.

To best utilize current prosthetic feet in children who are older and large enough to take advantage of them, it is necessary that at least 4 cm of space be available at the distal end. If the prosthetist is to offer the latest in technologic advances in components, greater residual limb length differences will be required. This need can be anticipated and an arrest of the distal or proximal tibial and fibular physes performed at the appropriate time. This length differential is usually not a problem in children with congenital limb deficiency, because the deficient limb will usually be shorter than the opposite. It is relevant in children with acquired deficiency treated by Syme or, more often, Boyd amputations. Although the longer lever arm of the Syme amputee tends to compensate for the lack of more elaborate components, when fit is possible, they can be an advantage.

Tibial Deficiency

Classification

There are two classifications specific for tibial deficiencies, both based on the radiographic findings. Anatomic studies of available specimens have not proven of value (91,92).

The simplest classification is that of Kalamchi and Dawe (93). Type I is complete absence of the tibia (Fig. 30-6). Type II is absence of the distal tibia, with a proximal portion that forms a relatively normal articulation with the femur (Fig. 30-7). Type III is distal tibiofibular diastasis (Fig. 30-8).

The classification of Jones et al. divides the type I of Kalamchi into 1a and 1b. In neither is the proximal tibia visible radiographically at birth. In type 1a, it is actually absent and without an extensor mechanism, whereas in type

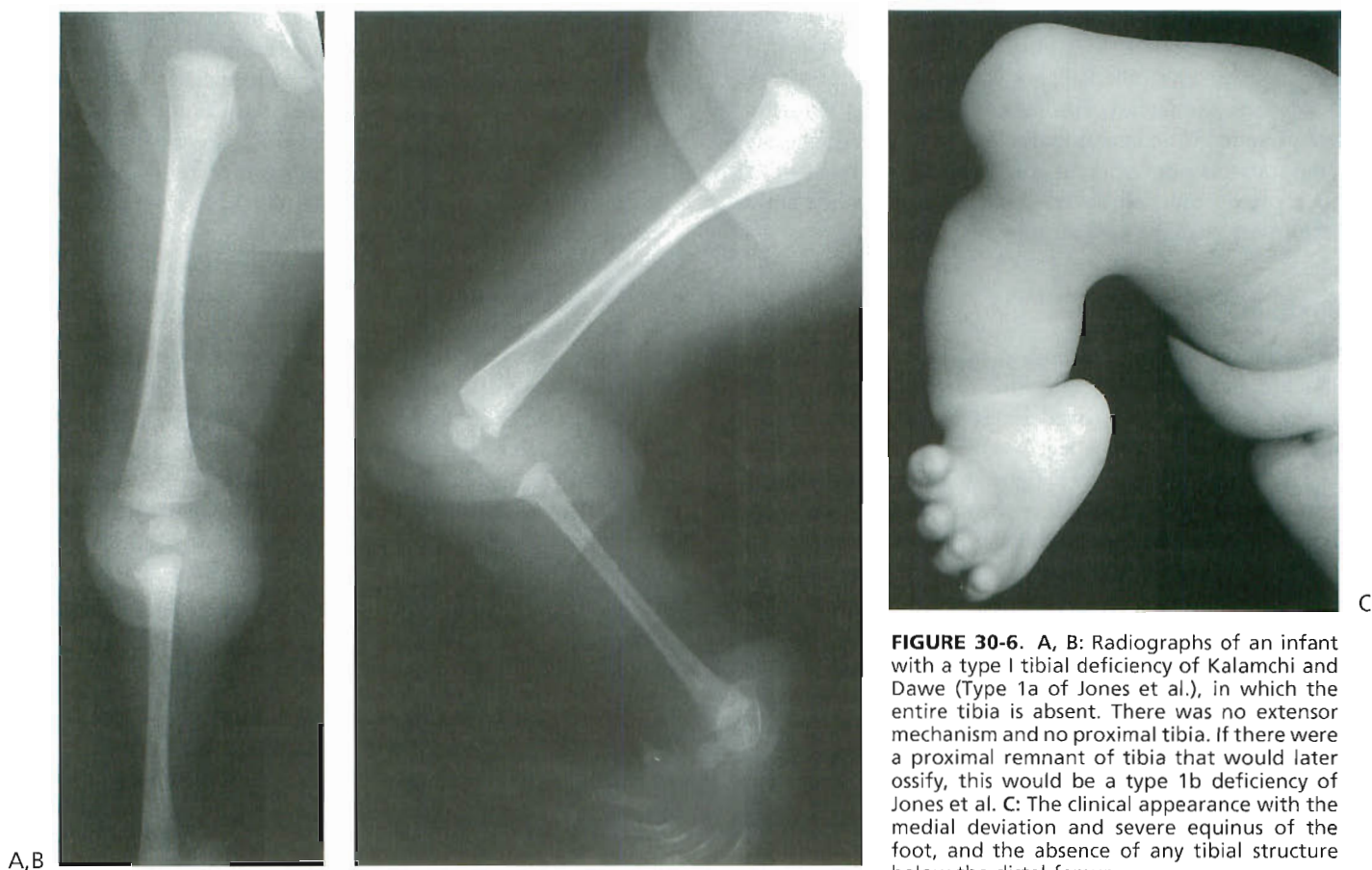


FIGURE 30-6. A, B: Radiographs of an infant with a type I tibial deficiency of Kalamchi and Dawe (Type 1a of Jones et al.), in which the entire tibia is absent. There was no extensor mechanism and no proximal tibia. If there were a proximal remnant of tibia that would later ossify, this would be a type 1b deficiency of Jones et al. C: The clinical appearance with the medial deviation and severe equinus of the foot, and the absence of any tibial structure below the distal femur.

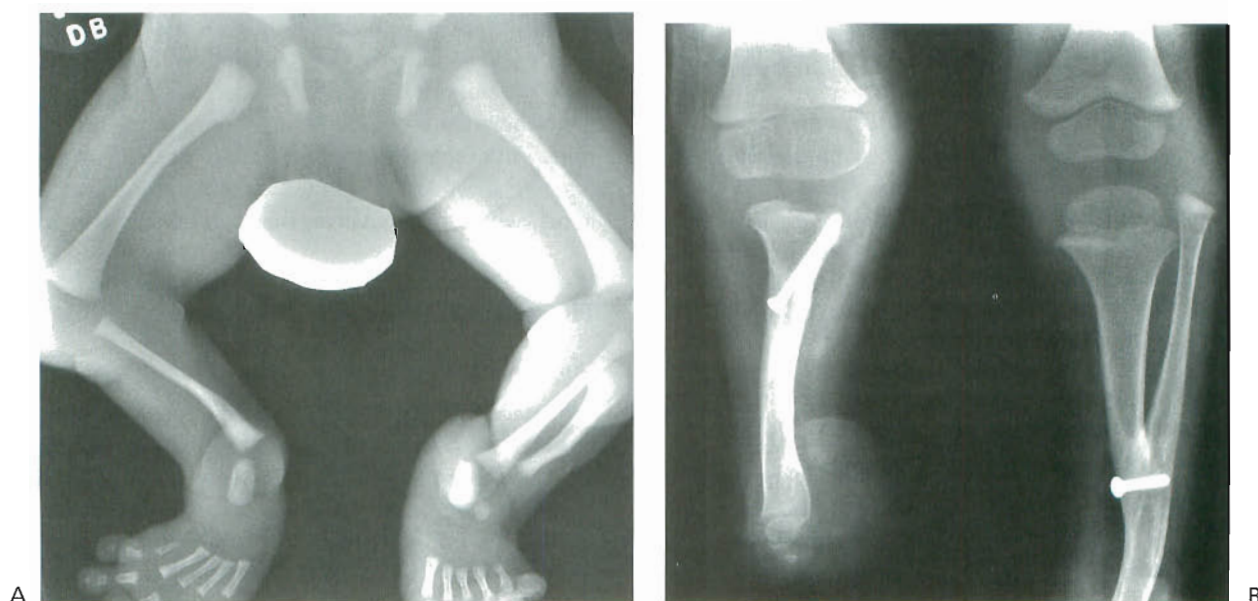


FIGURE 30-7. A: Anteroposterior radiographs of a 4-month-old child with type I tibial deficiency of the right leg and type II deficiency of the left leg. B: On the right leg, he underwent a Brown procedure. Despite the favorable radiographic appearance 4 years after surgery, he developed a severe valgus/flexion deformity, and subsequently had a knee disarticulation on this side. On the left leg, he underwent a synostosis of the fibula to the tibia and a Syme amputation. It is best to excise the proximal remnant of the fibula when performing this procedure, because the continued growth of the proximal fibula produces a large prominence that will interfere with prosthetic fitting. This was resected at the time of his right knee disarticulation.

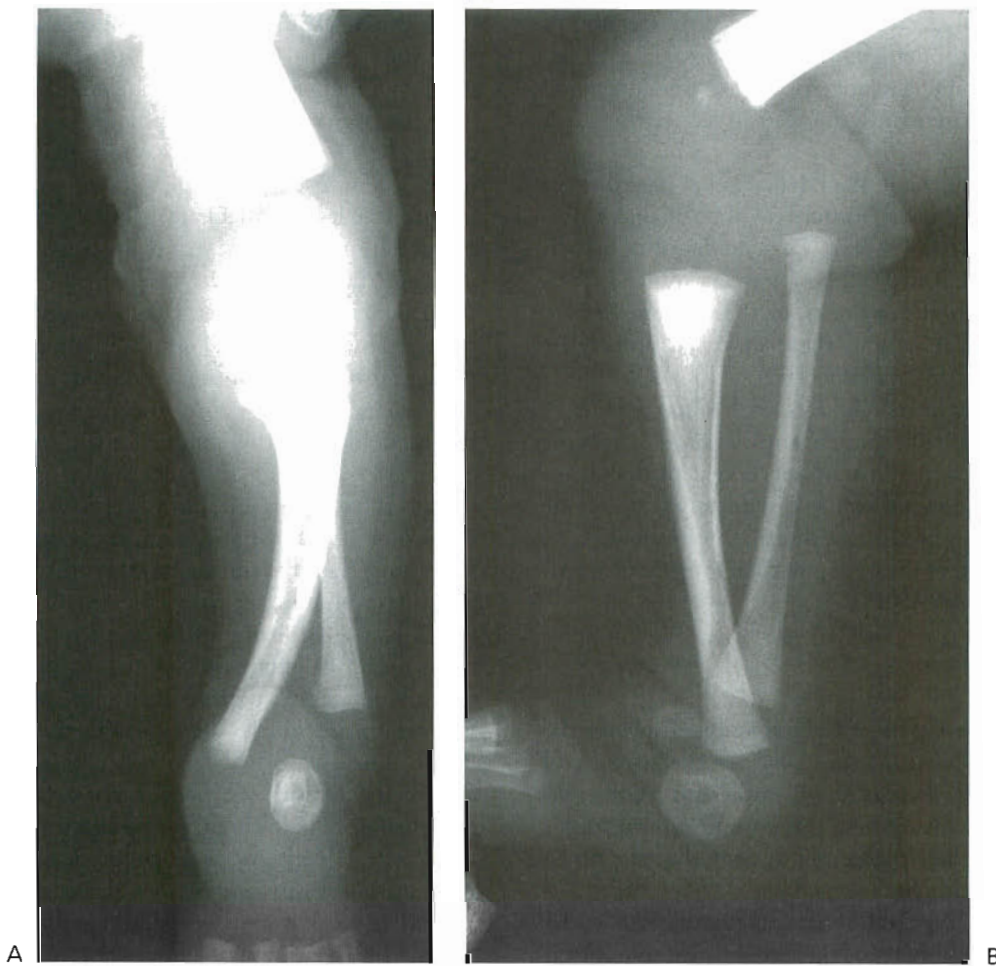


FIGURE 30-8. A, B: Anteroposterior and lateral views of a type III of Kalamchi and Dawe, or type 4 of Jones et al. This is sometimes referred to as a diastasis of the ankle mortise. Notice the shortened tibia and the disruption of the normal relationship between the tibia and the fibula.

1b, it is present as a cartilaginous remnant that will later ossify, and which suggests that the extensor mechanism is intact.

The Jones classification adds an additional type: a very unusual variant, with a diaphyseal and distal remnant of tibia, but no proximal tibia, is type 3. The diastasis of the distal tibiofibular joint is now type 4 in this classification.

The most important point in deciding on the treatment is the presence of active knee extension, which implies an adequate active quadriceps muscle and insertion on the tibia. This usually depends on the presence of a proximal tibial segment. Because this proximal portion of the tibia may be present, but not visible in the Jones Type 1b deficiencies, some authors have recommended direct surgical exploration, sonography (94), or magnetic resonance imaging, to detect its presence. This should seldom be necessary, because it is extension power to the tibial segment that is important, not the presence of a tibial segment. A good radiographic clue is that, in those with the presence of a

proximal portion of the tibia, the distal femoral condyle will be wider, and the ossification of the epiphysis better, than if it is not present.

An unusual type of tibial deficiency is that seen in association with fibular dimelia. Kumar and Kruger summarized the sporadic reports until 1993, and presented the findings, associated anomalies, and treatment in six patients (95). In this deficiency, the tibia is absent and there is a duplication of the fibula. There is a high incidence of other anomalies, including visceral anomalies in these patients. These authors recommended knee disarticulation, if the femur is of normal length, and fusion of the fibula to create a sufficient lever arm, if there is associated PFFD.

Clinical Appearance

The characteristic appearance of an infant with tibial deficiency is a markedly shortened tibia with a rigid equinovarus-supinated foot pointing toward the perineum (Fig.

30-6C). Preaxial polydactyly is relatively characteristic of tibial deficiencies, although absence of the preaxial rays can also be seen. The fibula is relatively long. Other congenital limb anomalies will frequently be seen in association with tibial deficiency.

Children with congenital tibial deficiencies, regardless of type, frequently have other associated abnormalities, frequently musculoskeletal (96,97). The incidence of associated anomalies is reported to be between 60 and 75% (93,98,99). Although the majority of these anomalies are in the musculoskeletal system, there may occasionally be problems in other organ systems (100).

In addition, many of the children with tibial deficiency and other anomalies will represent an inherited syndrome (96,97,101,102). Although it is not necessary for the orthopaedic surgeon to know all of these syndromes, he or she must be aware of the need for a thorough examination of affected children, and of the high potential for genetic transmission of the disorder (102,103).

Treatment

The treatment of the type I of Kalamchi and Dawe or the 1a of Jones is knee disarticulation. Without the presence of active knee extension, there is no possibility for reconstruction of the leg. Notwithstanding this common orthopaedic principle, there have been attempts to centralize the fibula under the femoral condyle.

Adopted from others (104,105), and popularized in the United States by Brown (106), the Brown procedure, as it is commonly known in the United States, is the centralization of the fibula under the femur. It was Brown's recommendation that fibular centralization be done only with active extension. Apparently, there are occasional deficiencies in which some part of the extensor mechanism inserts into the fibula. In reviewing the literature on the results of Brown's procedure, it is not apparent that this is always present before surgery. The operation has now been evaluated in several clinical trials (96,97,107-111). This procedure is distinct from synostosis of the fibula to a tibial remnant, a point that may not always be clear in reports on the subject.

The majority of those reporting on the procedure recommend against it, preferring the early function obtained with knee disarticulation (96,97,108). Loder (112) examined 87 cases from the literature using the minimal requirements for a good result, suggested by Jayakumar and Eilert of acceptable gait, active knee motion of -10 degrees to 80 degrees of flexion, varus/valgus instability less than 5 degrees, and no flexion contracture (113). He found that 53 of the 55 cases of Jones type 1a deficiency treated by Brown's procedure had a poor result because of flexion contracture. This echoes the reported experience of most others, and emphasizes the need for strong, active knee extension, which is usually not present without a remnant of the proximal

tibia (96,107,108,110,111). Simmons et al. were satisfied with their results (109). Their satisfaction was based more on the patients feelings than objective assessment.

It has been said that it is difficult to assess active quadriceps function clinically, prior to surgery (96). However, it might be a wise clinical decision to consider quadriceps function at least inadequate if not absent, if it cannot be observed during the first year of life by an experienced physician and therapist.

In patients with Jones type 1b deficiency, in which a radiographically invisible cartilaginous remnant of tibia is present, it is important to assess it over time for ossification and development, as well as to verify good active extension. It is possible that this remnant will be present, but good active extension will be absent and/or it will not ossify. If there is active extension, but the remnant is not sufficiently ossified by 1 year of age, the surgeon may choose to attempt to transfer the fibula to the unossified segment or perform a Syme amputation, fit with a prosthesis, and wait for ossification before performing the transfer.

In those patients with type I deformities and proximal femoral deficiency, with a very short limb, the best option may be to arthrodesis the fibula to the distal end of the femur. The goal of this procedure is to increase the lever arm of the femoral segment, for the same reasons that a knee fusion is performed in children with PFFD.

In type II deficiencies in either classification, the tibial remnant will ossify and form a satisfactory joint. In these cases it is usually best to create a synostosis between the existing fibula and the tibial remnant, to increase the length of the lever arm. A Syme amputation [►7.22] is performed at the same time, and the patient is fit with a below-knee prosthesis. In performing the synostosis, it is important to achieve good alignment of the fibula in relation to the knee joint. The residual proximal fibula should be removed to avoid problems with prosthetic fit.

Type 3 deficiencies of Jones (not classified by Kalamchi and Dawe) are very unusual, and there is not a lot of published experience. Jones et al. reported one case that was bilateral (114). They described a cartilaginous portion of the tibia proximal to the ossified portion, and that it was "under voluntary muscle control." Their patient was treated with excision of the proximal fibula and Syme amputation. Fernandez-Palazzi et al. had two cases in their report. Both were treated with Syme amputation, implying that there was an active quadriceps mechanism (115).

Type III deficiency of Kalamchi (Type 4 in the Jones classification) presents a unique problem. At birth, the foot is deformed, often appearing like a clubfoot to the inexperienced. In addition, the amount of tibial shortening that will result is not apparent. All of this makes it difficult for the parents to accept amputation. The difficulty for the surgeon is that this deformity is a spectrum of deformity. Garbarino et al. have emphasized the distinction between a short tibia with a varus foot and a true congenital diastasis of the ankle

joint (116). The former is usually amenable to reconstruction according to Schoenecker (99), whereas the true type 4 deficiency with diastasis of the ankle joint usually is treated with amputation (114,117).

There are reports of reconstruction for the type 4 deficiencies, but in general the follow-up is short and the problems of a plantigrade foot and limb length discrepancy just beginning (116,118,119). The only long-term follow-up of a reconstruction is that of a girl followed to age 15 years of age, with what was described as satisfactory ankle function and 6.5 cm of shortening (120).

In their review of tibial deficiencies, Schoenecker et al. reported on ten Jones type 4 deficiencies, of which nine had initial reconstruction of the foot. A Syme amputation was subsequently done in six, usually at the parents' request. Of the four who retained their foot, two had contralateral deficiencies in which the prosthesis accommodated the length discrepancy. One had lengthening of 4.6 cm and one remained 4.8 cm short.

From the available information it would seem reasonable to attempt to retain the foot, if the deformity is at the less severe end of the spectrum, or if there is a significant contralateral deficiency. In most other cases, Syme amputation seems most reasonable.

Prosthetic Management

With various surgical interventions dependent on the severity of the anomaly, there are several prosthetic approaches to management. In those children with type I tibial deficiency who have been treated with knee disarticulation and have a flare at the condyles, the prosthetic socket consists of a nonischial weightbearing design with rotational control achieved through the intimate fit of the distal end of the socket over the femoral condyles and a well-formed gluteal impression. Suspension is usually achieved with the use of a segmented liner or bladder design that allows the wider condyles to pass through, while maintaining pressure over the femur just proximal to the condyles.

In cases in which the condyles are absent, or there is the need to fit with a transfemoral socket, rotational control is achieved through proper contouring of the socket relative to the femur—the musculature surrounding the femur has a slight triangular shape in a cross-sectional view, and the more proximal one moves on the lateral side, the flatter the shape. This allows a locking of the musculature, and with proper socket fit, decreases rotation. In addition, a silicone sleeve suspension may be used in conjunction with a pull-through strap to secure the liner. If all else fails, a standard Silesian belt (around the pelvis) may be utilized. However, this will interfere with toileting and potty training.

In the knee disarticulation (or transfemoral) prosthesis for children, there are differences of opinion as to when young children are able to handle an articulated knee. Current established practice is to first fit with a locked knee,

and allow an articulating knee at approximately 3 to 5 years of age. In contrast, Wilk et al. (121) advocate the use of articulating knees in children as early as 17 months. It is the authors' experience that the very early installation of articulated prosthetic knees, when the children begin to pull-to-stand around 10 to 12 months of age, has proven clinically successful. The children learn how to handle the knee very quickly, and there is very little need for any type of device to temporarily stabilize the knee. The use of a knee joint at this stage permits more normal development, allowing bent-knee sitting, side sitting, crawling and kneeling on hands and knees, and easier pull-to-stand.

In type II cases, in which a tibial segment has been preserved or the fibula has been joined to the tibial remnant, a modified transtibial prosthesis or a Syme prosthesis is utilized. Unlike the standard transtibial design, the socket will incorporate supracondylar and suprapatellar proximal brim lines that will aid in the control and stability of the knee and prevention of a hyperextension moment, respectively. In some instances in which knee stability is less than optimal, outside joints and a thigh cuff or lacer may be required. These are used as a last resort, and often contribute to increased weakening of the musculature as a trade-off for increased control and alignment.

Femoral Deficiency

Classification

There have been numerous classifications of proximal femoral focal deficiency (PFFD) (27,29,52,122–126). These classifications range from attempts to unify all radiographic defects of femoral development to a simple two-part classification based on limb length inequality. Some classifications are radiologic, some functional, and some are designed to suit the authors' preferred treatment. In addition, no classification is able to account for the length, radiographic, and muscle abnormalities, all of which are important in the treatment and outcome.

The most widely used classification is that proposed by Aitken (122). It divides the true PFFD cases into four categories based on the radiographic findings. It is important to keep in mind that in PFFD, as in other congenital deficiencies, the bone may be late in ossifying, and thus may be present but unseen on radiographs. Also, these different groups are not distinct, but rather form a continuous spectrum.

In class A, the femur is short, with its proximal end at or slightly above the acetabulum (Fig. 30-9). There is a defect in the subtrochanteric region. The femoral head may be absent, but will later ossify, and its presence is indicated by a well-developed acetabulum. The subtrochanteric defect will eventually ossify, establishing bony continuity, although usually with considerable varus deformity. The location of this varus deformity in the subtrochanteric region,

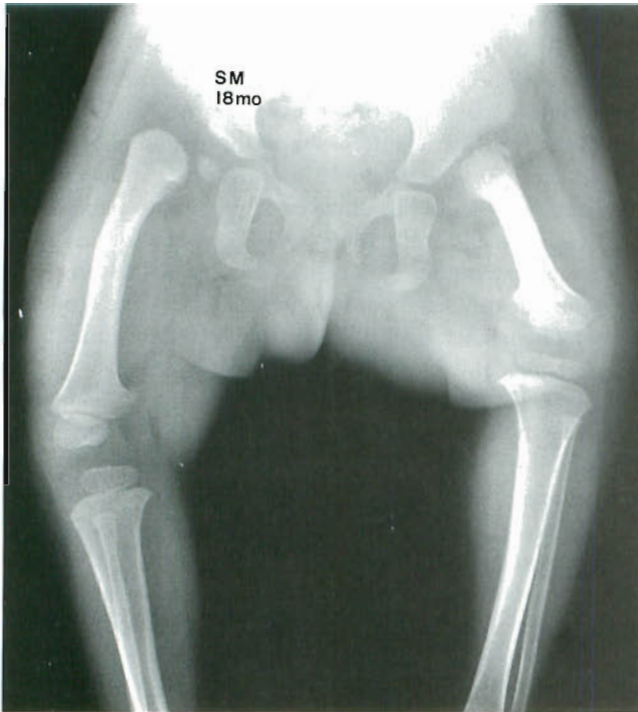


FIGURE 30-9. Anteroposterior pelvis of an 18-month-old child with bilateral proximal focal femoral deficiency. The right hip is an Aitken class A, and demonstrates the presence of the ossific nucleus and a good acetabulum. The femoral metaphysis lies above the level of the ossific nucleus. There is a cartilaginous connection between the metaphysis and the femoral head, which will usually ossify by skeletal maturity, but often with a significant varus deformity. The opposite hip is a class C PFFD. This patient demonstrates the difficulty with limb length difference in some patients with bilateral PFFD.

rather than the femoral neck, is what distinguishes PFFD from congenital coxa vara.

In class B, there is a more extensive defect or absence of the proximal femur (Fig. 30-10). The femoral head is present, although its ossification may be delayed. There is usually a bony tuft on the proximal end of the femoral shaft. The defect will not heal spontaneously, and the proximal end of the femur will be above the acetabulum.

In class C, the femoral head is absent, and will never ossify. The acetabulum is severely dysplastic (Fig. 30-11).

The femoral shaft is shorter than in class B, and the entire proximal portion of the femur, including the trochanters, will not appear.

In class D, the femoral shaft is extremely short, often with only a tuft of irregularly ossified bone proximal to the distal femoral epiphysis (Fig. 30-12). The lateral pelvic wall is flat, without hint of an acetabulum.

Gillespie (124) proposed classifying femoral deficiencies into three groups for purposes of treatment. Group A are those with congenital short femur indicated by clinical hip stability, lack of significant knee flexion contracture, and the foot of the affected extremity lying at or below the mid-point of the opposite tibia. These patients may be candidates for limb-lengthening. His group B patients include those classified as Aitken class A, B, and C, whereas his group C represents the Aitken class D patients. He recommends lengthening for his group A patients, and prosthetic treatment for his group B and C patients.

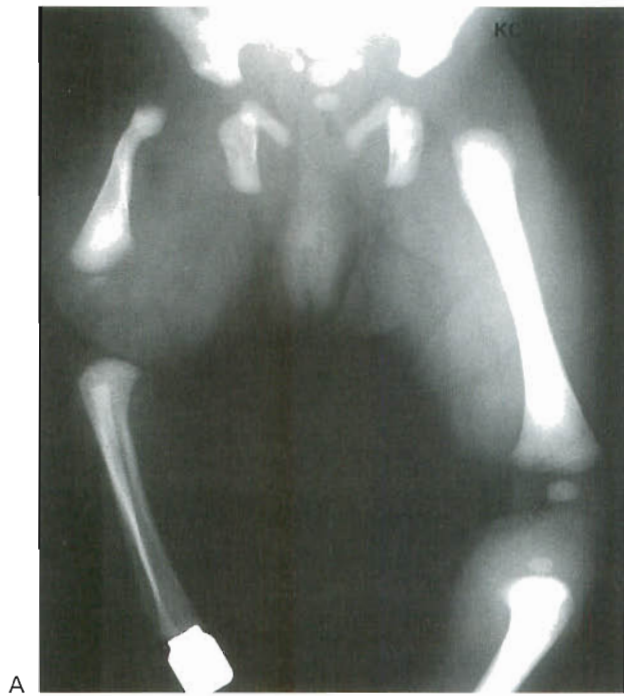An unusual variant of PFFD is that seen with a bifurcated (not duplicated) femur. In this condition, the femur has two distal ends, which form a “Y” (127). There is always an associated type I tibial deficiency without active extension, and treatment is by knee disarticulation and removal of the segment of femur in poorest alignment.

Clinical Appearance

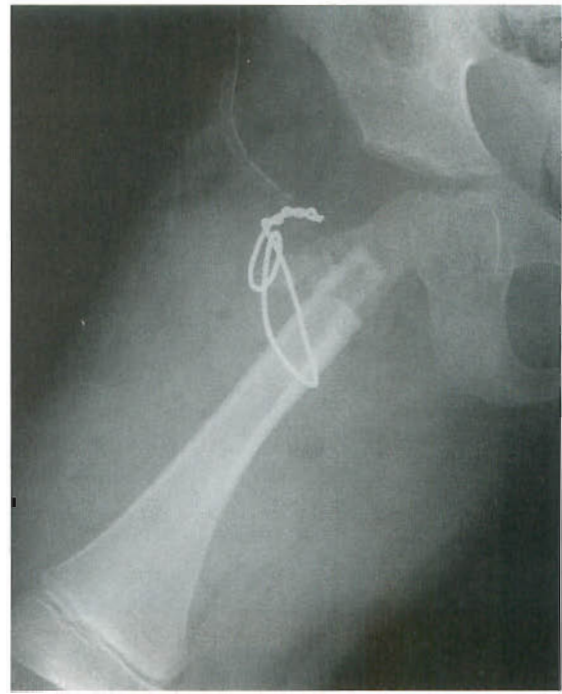The appearance is classic and should be easily recognized. It will be bilateral in 15% of the cases. The femoral segment is short, flexed, abducted, and externally rotated. The hip and knee joint exhibit flexion contractures. The proximal thigh is bulbous and rapidly tapers to the knee joint. Fibular deficiencies are so common in association with PFFD that the valgus foot and other characteristics of fibular deficiency are almost a part of PFFD (Fig. 30-13). PFFD is associated with fibular deficiency in 70 to 80% of cases (128). In addition, about 50% of the patients will have anomalies involving other limbs (122,128).

Examination of the hip joint is difficult because of the bulbous thigh and short femoral segment. Pistoning may be apparent because of associated hip instability. The knee is always unstable in the anteroposterior direction.

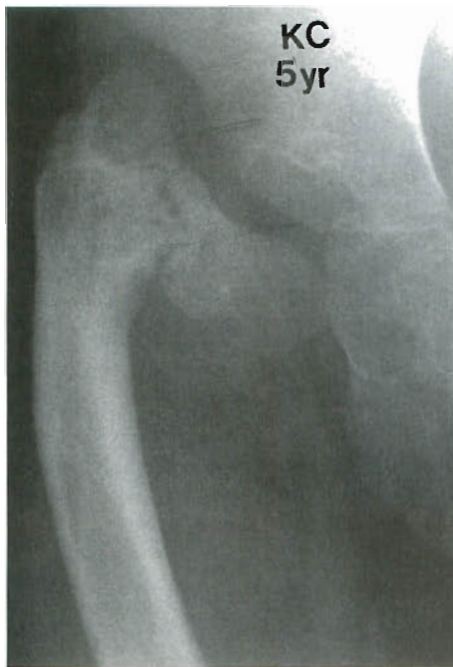FIGURE 30-10. A: Anteroposterior radiograph of the pelvis and limbs of a newborn female with Aitken class B proximal focal femoral deficiency. Note the short femoral segment and the well-developed acetabulum, although the femoral head is not visible. B: By 5 years of age, the femoral head is ossified and the cartilaginous connection between the femoral head and the subtrochanteric region of the femur has undergone considerable ossification. However, a pseudarthrosis persists and a significant varus deformity has developed. C: The femur after correction of the varus with a spike type of osteotomy [→4.4]. The result 1 year later is seen in D. Now faced with a projected discrepancy of 20 cm, the parents elect a van Nes rotationplasty. This was done with part of the rotation through the knee arthrodesis, and the remainder through the tibia. The radiographic result is seen in E. The patient had one additional derotation performed through the midtibia at age 10 years.



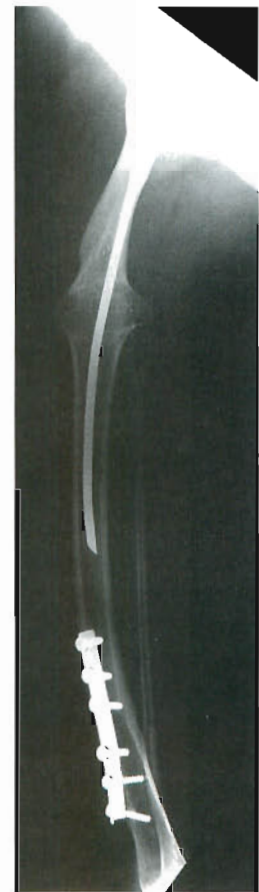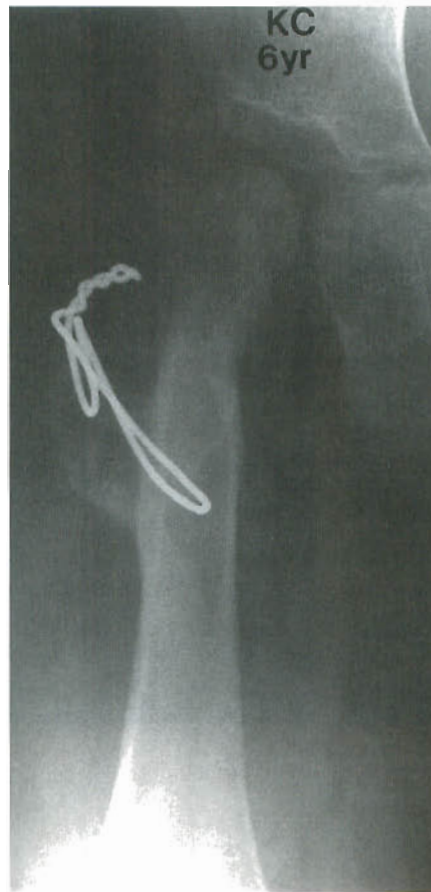A



C



B



D,E

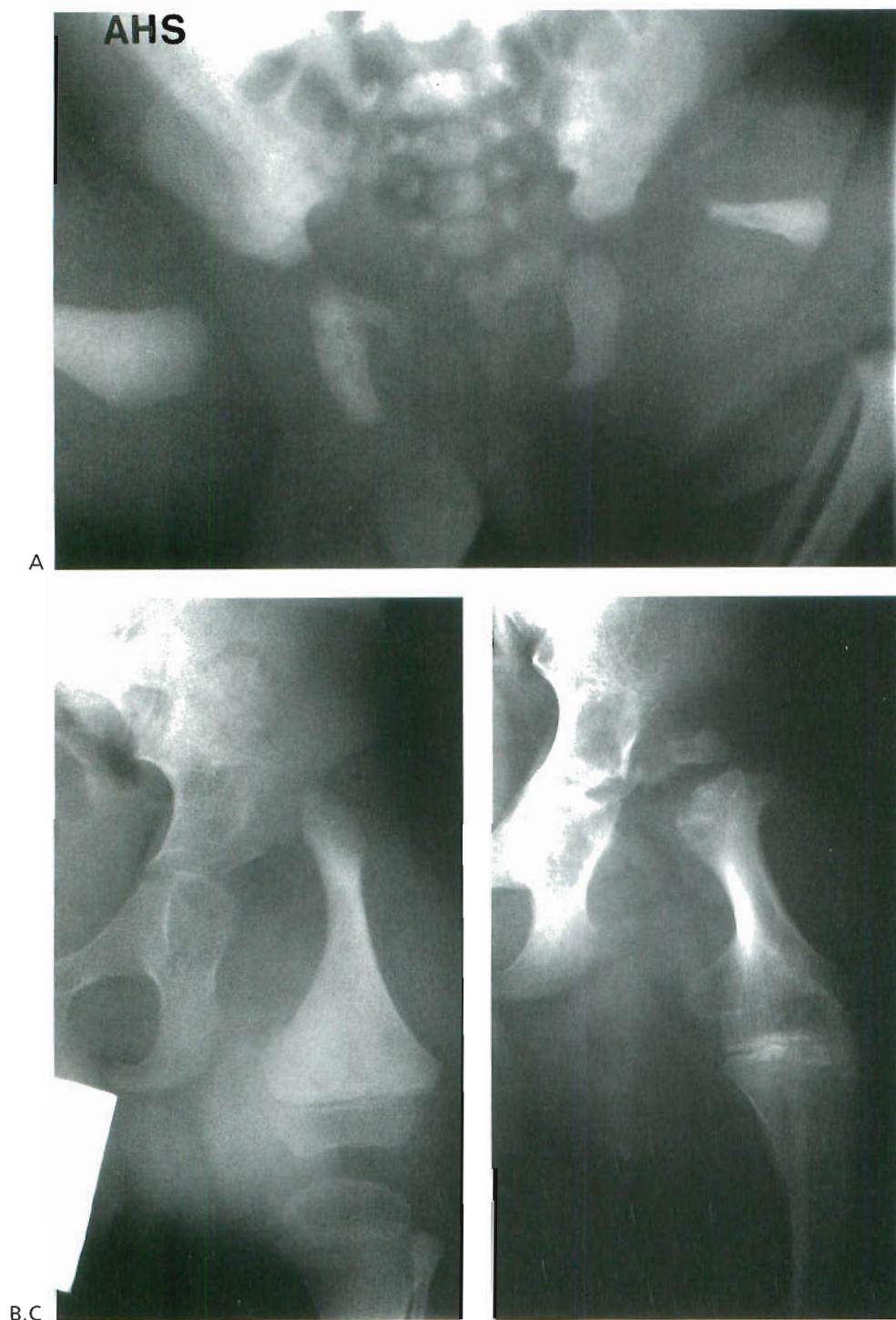

FIGURE 30-11. The anteroposterior pelvis and limbs of a newborn boy (A) and at 3 years of age, just before surgery (B), with Aitken class C proximal femoral focal deficiency. Note the very short femoral segment and the lack of acetabular development. The same patient is seen in C at the age of 12 years, following a Syme amputation and knee arthrodesis with preservation of the proximal tibial physis. There is still no appearance of a proximal femoral ossific nucleus.

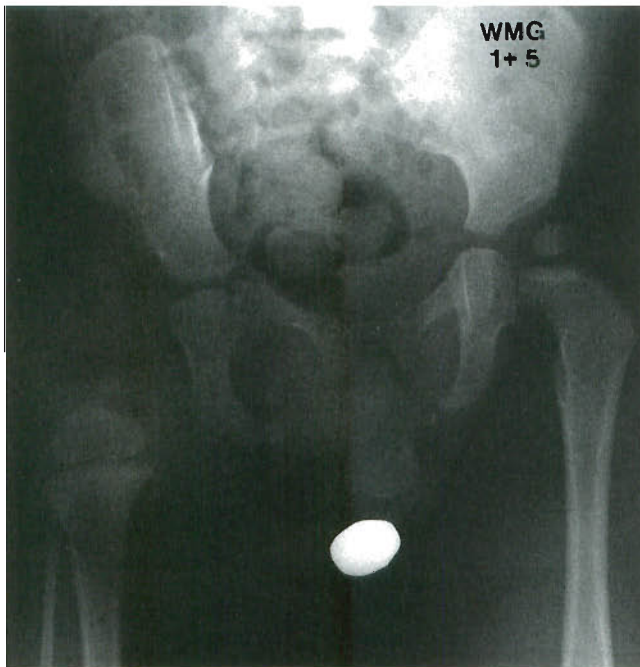

FIGURE 30-12. Anteroposterior radiograph of the pelvis and femur of a 1 yr 5 mo old male with Aitken class D proximal focal deficiency. There is little femur present, and no sign of acetabular development. He underwent knee arthrodesis and Syme amputation at 2½ years of age.

Treatment

The treatment aims to compensate for the functional problems the patient experiences. The most obvious of these is the shortening of the limb. Less obvious is the problem with hip function and its relationship to alignment of the limb. Because of the flexed and externally rotated femoral segment, the knee remains flexed, and the leg and foot are anterior to the axis of the body (Figs. 30-13 and 30-14D). With or without skeletal hip stability, there is deficiency of the muscles around the hip, resulting in significant lurch, to shift the center of gravity in single-leg stance. The knee will have varying degrees of instability. The function of the foot will depend on the severity of any associated deficiencies of the leg, e.g., fibular deficiency.

There are more options and variations in the treatment of PFFD than almost any other congenital limb deficiency. Fortunately, most of these decisions can be postponed until 2½ to 3 years of age, because this is the best age to perform these surgical options. Prior to this time, several important decisions need to be made. The first is whether or not the child is a suitable candidate for limb-lengthening.

According to most literature on this subject, the limb may be judged to be suitable for lengthening if the predicted discrepancy at maturity is not greater than 20 cm, the hip is or can be made stable, and there is a good knee, ankle,

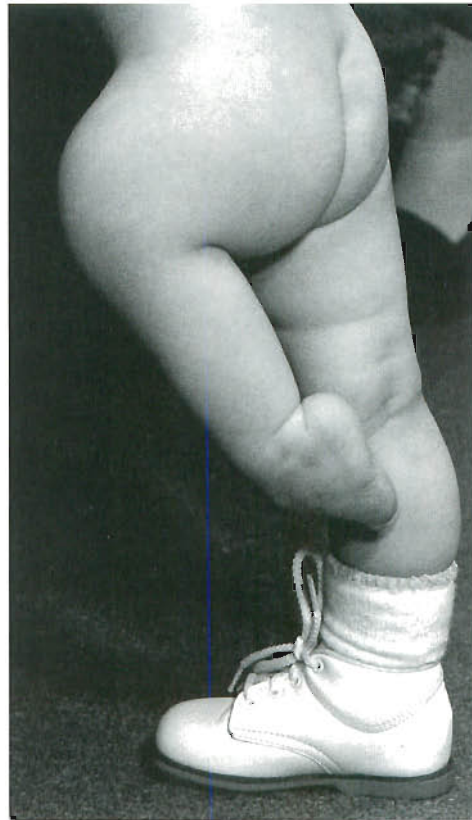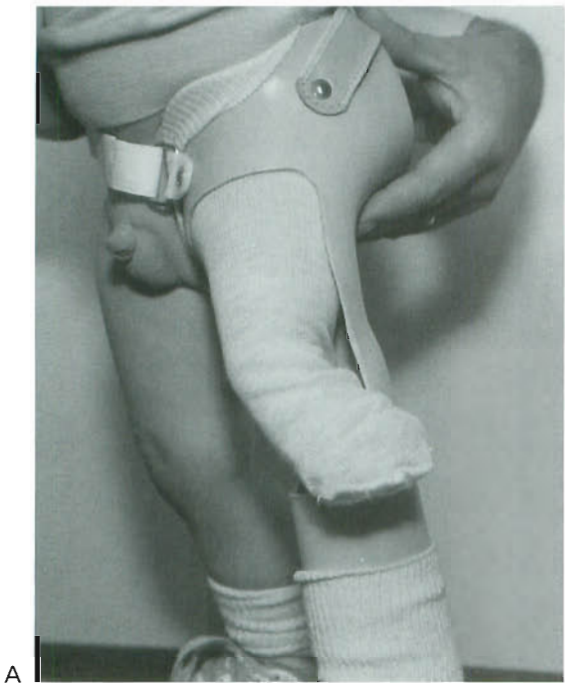


FIGURE 30-13. This photo of a 12-month-old female who is pulling to stand demonstrates the clinical features of proximal focal femoral deficiency: a very short and bulbous femoral segment, which is flexed, abducted, and externally rotated.

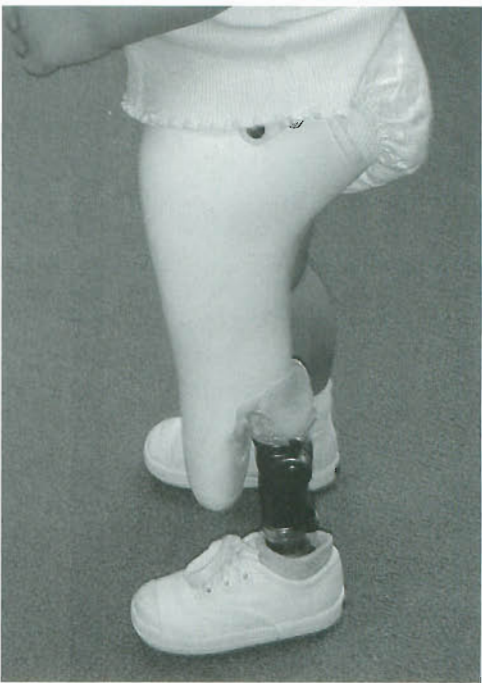and foot. In such cases, multiple staged lengthenings can be planned. The timing and staging of these procedures depends on the choice of the physician, but will usually not start before the age of 3 years. Although it is possible to obtain this much length, there are as yet no good reports on the functional outcome of such lengthenings in patients followed to maturity and into adulthood.

If the discrepancy is predicted to be greater than 20 cm at maturity, or for any other reason lengthening is not chosen as a treatment, a decision should be reached about the best approach to prosthetic fitting.

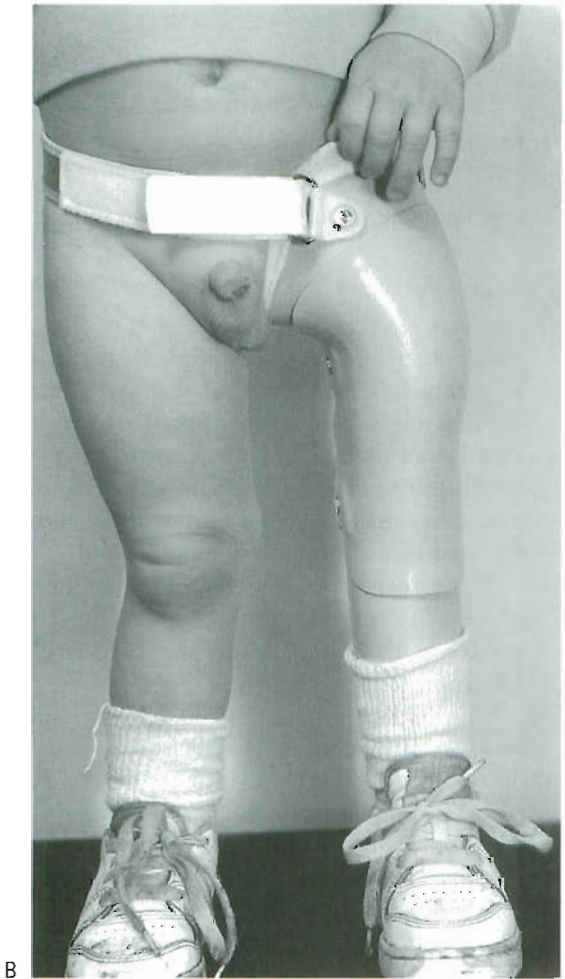
This initial treatment of children with unilateral PFFD is, as in other congenital deficiencies, to parallel normal development. Therefore, when the child is ready to stand, regardless of the treatment planned for the future, he is fitted with a prosthesis to equalize the leg lengths and permit standing and walking. The prosthesis is often called a “non-conventional” or “extension” prosthesis. It is designed to fit the extremity without any surgical modification to the extremity (Fig. 30-14). The flexion, abduction, and external rotation of the proximal segment (the femur) are accommodated in the alignment. Although it is usual to omit a knee



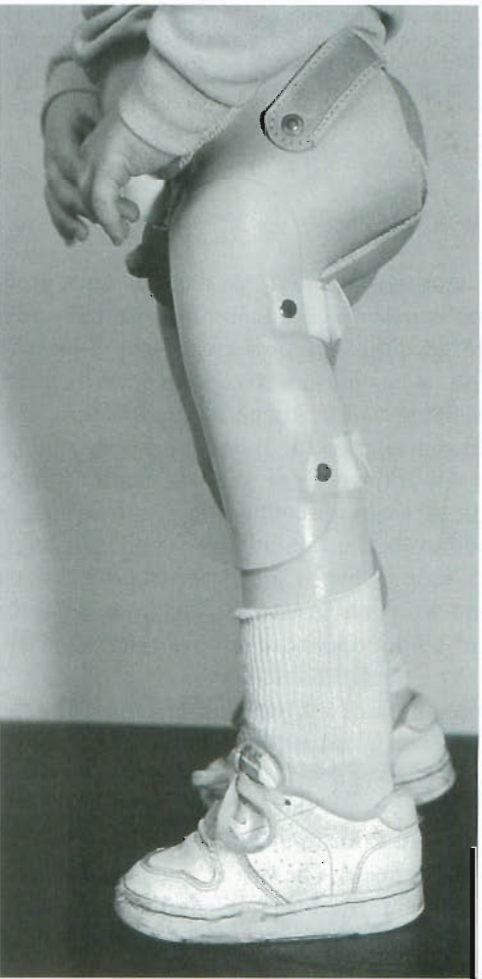
A



C



B



D

joint, the authors have found that if there is sufficient room, a knee joint can be used in the initial prosthesis.

In the authors' clinic knee joints are placed, whenever possible, within limits of the short prosthetic tibial section. This is to allow the infant knee flexion during all developmental functions: one-half kneel, squat, pull-to-stand and climb on toys and furniture. The authors' have found that infants who are fitted with knees learned very rapidly to extend their hips to control knee extension throughout all their movements. Less vaulting and deviations on the non-prosthetic side are also noted if a knee joint is placed within the prosthesis. There is no knee joint in the prosthesis if the length of the limb is too long to fit a prosthetic foot, including a knee.

This nonconventional prosthesis will permit ambulation for the young child. However, as the child grows older, the limitations of this prosthesis soon become apparent (Fig. 30-14D). The continued flexion, abduction, and external rotation of the femoral segment, with limb alignment anterior to the body's axis, along with the hip instability and the flexed knee, which is difficult to contain within the prosthesis, are all factors that make a very poor lever arm to move the prosthesis. The foot frequently lies at the level of the midcalf of the opposite limb, making the placement of the knee joint less than ideal. Surgical correction of these problems is designed to make the limb a more efficient lever arm for the prosthesis. Among the usual surgical choices are knee arthrodesis, amputation of the foot, rotationplasty of the limb, and reconstruction of the hip. Additional possibilities are iliofemoral arthrodesis with or without rotation, and prosthetic fitting without modification to the limb. Thigh reduction by surgical resection and liposuction are of great value in prosthetic fitting as the patient grows older.

The treatment of children with bilateral PFFD is very different. In these children, the feet should be preserved, and knee fusion is not indicated. This is because these children will spend the majority of their lives walking without prostheses. The two biggest problems in these children are foot deformities and unequal limb lengths. Surgical release of the foot and long-term orthotic use can usually provide for a useful foot. Limb length discrepancy when significant is more difficult, because of the problem of shortening the child more, on the one hand, and the difficulty of lengthening these limbs, on the other. No firm recommendation can be made regarding this, and each case should be decided on its own merits.

Knee Arthrodesis

Arthrodesis of the knee joint is a standard procedure in children with PFFD. It creates a single longer and more efficient lever arm, which is easier to contain within the prosthesis. This will greatly enhance prosthetic function and lower energy consumption. Within 6 months of knee fusion and prosthetic fitting, the abduction and flexion deformity at the hip joint will correct, thus aligning the limb under the axis of the body.

Depending on the length of the femoral segment and the limb as a whole, it is usually desirable to remove at least one of the growth plates at the knee at the time of fusion. This is usually the case in Aitken class A, B, and C deformities. If this is not done, the limb will remain too long for fitting of a suitable knee joint at maturity. In some cases, depending on the length, it may be advisable to remove both or neither growth plates (129). Calculation of the anticipated length of both limbs at maturity by means of the Green-Anderson growth charts (Tables 30-2 and 30-3), as described earlier, will help with the answer.

The fusion is usually performed between 2 and 3 years of age. After excision of the epiphysis and physis from one side, usually the femur, and the joint surface from the other, the femur and tibia are fixed with a rigid rod, e.g., a Rush rod placed from proximal to distal. This is supplemented with a spica cast. The patient is usually ready for prosthetic fitting in 6 weeks and ambulation as soon as the prosthesis is ready.

Amputation of the Foot

With the knee fused, ablation of the foot is desirable in most situations. One reason is length: the new lever arm, consisting of the femur and the tibia, needs to be short enough to accommodate an internal knee joint when the child is older. The foot adds unnecessary length. In addition, as the foot grows, it becomes increasingly difficult to accommodate in a cosmetically acceptable socket. The advantages and disadvantages of the Syme and Boyd amputations have been discussed. Amputation is best performed at the time of knee fusion.

van Nes Rotationplasty

In the van Nes rotationplasty, the limb is rotated 180 degrees, either through the knee arthrodesis, the tibia, or a

FIGURE 30-14. The nonconventional or extension prosthesis allows the child to "stand" on the prosthesis, extending his limb to the floor and accommodating the deformity. **A** and **B** show this prosthesis without a knee joint, which is usual. It is possible to add a knee joint to the prosthesis. **C:** The children rapidly learn to control the knee joint. **D:** Lateral view of the patient in the prosthesis, demonstrating why this prosthesis is not a good long-term solution. The knee is at the brim of the socket, is poorly contained, and provides a very poor lever arm. The weightbearing line of the leg remains anterior to the axis of the body; the flexion and external rotation of the hip persist.

combination of both. The goal is to have the ankle of the short limb at the level of the knee on the long limb at maturity. The foot now functions like the residual tibia in a below-knee amputation, thus giving the patient function more like a B-K amputee than a knee disarticulation (Fig. 30.15). An obvious prerequisite is reasonable function of the foot and ankle. Because this procedure is also used in the treatment of both malignant skeletal tumors around the knee and traumatic loss of the knee with its corresponding growth plates, it is important to keep in mind that these patients are very different from those with PFFD. Although some lessons from one group are applicable to the other, care must be taken.

The rotationplasty was first described in 1930 by Borggreve (130) for an acquired limb length discrepancy, and later by van Nes (131) for three cases of congenital deficiency of the femur. Initial reports of rotationplasty for treatment of PFFD by Kostuik et al. (132), and Torode and Gillespie (133) have been followed by more recent reports by Friscia et al. (134) and Alman et al. (135).

The main complication of the procedure is either failure to achieve sufficient rotation at surgery or subsequent derotation with growth. Kostuik et al. (132), in one of the earliest reports on this procedure, recommended waiting until the child was older to perform the operation. However, this delays the procedure many years beyond when the patient can learn to use the prosthesis and benefit from the procedure. Because the complication is easily treated, there seems little reason to wait. Subsequent reports have not found this to be so great a problem.

A potential problem that is of concern to patients, parents, physicians, and prosthetists, when this procedure is considered, is the cosmetic appearance. It appears, however, that the problem is overrated by medical staff, compared to the patients themselves. The procedure has been more widely used and accepted in Canada than the United States, and in large limb deficiency centers. Alman et al. found no difference in the perceived physical appearance of children treated with rotationplasty, compared to knee arthrodesis and Syme amputation (135). In the report of Friscia et al., one patient subsequently had a Syme amputation at the parents' request (134). This emphasizes the importance of proper preparation of the parents, and patient if old enough. This is best accomplished by seeing other patients with a rotationplasty, along with using videos of patients, teaching dolls, etc.

It needs to be emphasized that the ankle must be sufficiently normal to serve as a knee. This is particularly important, because up to 70% of children with PFFD will also have a fibular deficiency on the same side. Although some valgus alignment of the foot and ankle can be compensated for in the prosthetic alignment, the deformity may tend to become greater with age. Severe valgus and equinus deformities, with a deficient foot, is a contraindication to the procedure.

Additional preoperative preparation includes toe and ankle strengthening, in particular, since these are the structures that will power the new knee joint. Equinus position should be emphasized, because this will place the foot in the best mechanical position. Children who have mild equinus contractures of 30 degrees or less will usually stretch these out with prosthetic use, and do not need special attention preoperatively. Crutch training should be done preoperatively, as in all elective surgery that will require crutch use postoperatively.

The improvement in function with the rotationplasty, compared to other procedures, has been documented both for tumor patients (136–138) and for those with PFFD (135,139). These studies demonstrate that those with rotationplasty function better than those with knee arthrodesis and Syme amputation, not quite so well as those with a below-knee amputation, and not as well as those who have rotationplasty for noncongenital conditions, e.g., tumor.

Stabilization of the Hip

Most patients with PFFD who are to be managed with prosthetic fitting will have hip instability. This is not only because of the deficient bony anatomy, but also the deficient musculature. This has resulted in some controversy about the value of surgical procedures to stabilize the hip. Some feel that nothing of functional value is gained and surgical intervention is not warranted (128,129,140), whereas others feel that surgical correction can be of value (27, 141–143). It is the authors' opinion that, in Aitken class A and B patients, who have a femoral head within the acetabulum, surgical correction of the pseudarthrosis, with correction of the varus deformity, is beneficial [►4.4] (Fig. 30-10B–D).

There are two problems to consider: the pseudarthrosis and consequent malalignment, and the bony stability of the femoral–pelvic articulation. In those patients for whom lengthening is planned, it is necessary to obtain good containment of the femoral head, which may require an acetabular procedure. In these patients, retroversion and varus are usually present, and should be corrected prior to lengthening.

In patients with Aitken class B PFFD, there will be a pseudarthrosis of the femoral neck. This can be repaired while, at the same time, restoring more normal alignment. It may not be necessary to wait until complete ossification of the femoral neck to perform this procedure (144). Ossification may accelerate after realignment.

Iliofemoral Arthrodesis

There are two types of iliofemoral arthrodeses described. These procedures are an attempt to address the problem of hip instability.

In 1987, Steel described arthrodesis of the distal femoral segment to the pelvis, in the region of the acetabu-

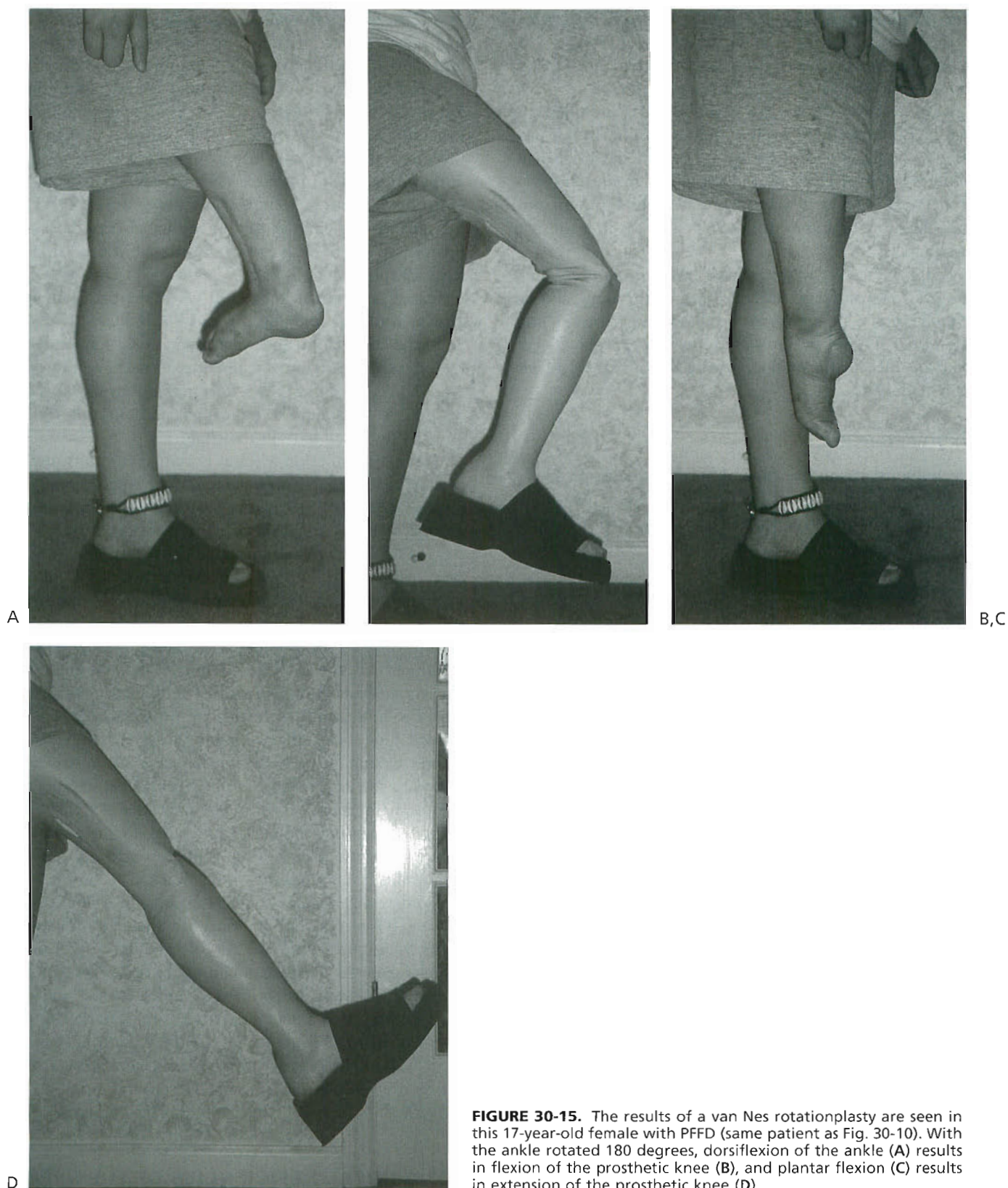

FIGURE 30-15. The results of a van Nes rotationplasty are seen in this 17-year-old female with PFFD (same patient as Fig. 30-10). With the ankle rotated 180 degrees, dorsiflexion of the ankle (A) results in flexion of the prosthetic knee (B), and plantar flexion (C) results in extension of the prosthetic knee (D).

lum in four patients (145). The femur was flexed 90 degrees, so that it was perpendicular to the axis of the body. This results in knee extension being equivalent to hip flexion, and knee flexion equivalent to hip extension.

More recently, Brown has described a rotationplasty in conjunction with iliofemoral arthrodesis (146). In this procedure, the distal end of the femur is rotated 180 degrees, before it is joined to the ilium with its axis in line with that of the body. The knee now functions as the hip joint, and the ankle now functions as the knee joint, as in a van Nes rotationplasty.

Both of these procedures have had limited use. There are significant problems in achieving an arthrodesis, and the distal femoral segment cannot be allowed to grow too long. Additional surgical procedures are to be expected. As yet, there are only very limited reports on the functional advantages (145–147).

Thigh Reduction

The bulbous proximal portion of the thigh makes prosthetic fitting difficult in some patients, and results in discomfort for others. This problem can be resolved by thigh reduction with a combination of surgical excision and liposuction.

Prosthetic Management

Initial prosthetic management of the child presenting with PFFD begins with the extension or nonstandard prosthesis, with or without an activated knee joint (Fig. 30-14). With the foot positioned in plantar flexion, the limb is cast proximal to the hip joint, and the prosthesis fabricated with a prosthetic foot positioned under the shortened limb. The socket was commonly referred to as a “ship’s funnel” design with ischial containment, because of the resemblance to the engine air intake funnels of ocean vessels. This drastic socket design is necessary because of the flexed hip and knee that must be contained within the socket while attempting to gain ischial support.

The purpose of the extension-type prosthesis is to equalize the length between the prosthetic and sound limb, in preparation for early ambulation, while affording time for surgical decisions. There are four indications that have been identified relating to the fitting of nonstandard prostheses (148):

1. While awaiting the proper age for surgical conversion.
2. When the patient or parent refuses surgical intervention, and a prosthesis is necessary for ambulation.
3. In bilateral cases, when extra height or better balance is the goal.
4. When there is lower-extremity involvement, combined with bilateral upper-extremity absence, requiring the feet for ADL.

When a Syme amputation with knee fusion option is chosen, the prosthesis resembles a knee disarticulation pros-

thesis, except for the need for ischial weight bearing and high lateral brim containment to aid in hip stability. Weight bearing is divided between the ischium and the distal heel pad. Full distal weight bearing would severely compromise hip function over a period of time, because of the inherent instability of the hip with possible proximal migration of the femur. Prosthetically, fusion of the knee, with correction of the angular deformities, results in improved gait and ease of fitting, because of a single skeletal lever arm (149). During growth, the child should be evaluated periodically for the relative length of the two limbs so that, if needed, distal femoral epiphysiodesis can be performed. This will allow fitting of an optimal knee joint when the patient is fully grown, while maintaining the knees at the same level.

In the small child, and when the residual limb is longer than the opposite femoral segment, external knee joints may be used. As the child grows, an internal four-bar knee can be used. More about the indications and selection of knee joints is discussed later in the chapter.

A Syme amputation without knee fusion results in difficulty with prosthetic management. Movement within the prosthesis, at the level of the anatomic knee, and the increased need for an intimately fitted socket, fosters a decreased stride length and increased pelvic movement. However, in the child with an Aitken class D PFFD and only a remnant of distal femoral epiphysis in which knee fusion will have little to offer, this may be a suitable choice.

The van Nes rotationplasty requires a nonconventional prosthesis with the ankle functioning as the new knee. This is a very difficult prosthesis to align and fit, although it gives excellent function (134,150). The prosthesis has a lower padded foot socket that contains the rotated foot in full plantar flexion. Lateral and medial external joints are attached to the upper thigh section, to increase stability and to prevent hyperextension of the lower shank (150). The original design incorporated a laminated thigh section with ischial weight bearing. With good hip stability, e.g., in tumor and trauma patients, the laminated section is often replaced with a leather thigh lacer and no ischial weight bearing. It is imperative for proper function that the external joints be aligned with the axis of rotation of the ankle/subtalar complex, while maintaining the line of progression. Failure to ensure this alignment, regardless of the anatomic joint, will result in a poor gait pattern and skin breakdown. The prosthetist should incorporate mechanical joint placement with slight external rotation on a new prosthesis, in anticipation of the mild internal derotation inevitable during growth.

CONGENITAL DEFICIENCIES OF THE UPPER EXTREMITY

Some of the differences between upper- and lower-extremity amputations have been discussed previously. One additional

difference requires emphasis here: upper-extremity amputations are very visible. The hand is one of the most noticed parts of the human body. Thus, unlike the child with a below-knee amputation who walks without a limp and can often match his peers in physical activity, the child with an upper-extremity amputation is more easily seen as different.

This section deals with those congenital deficiencies of the upper extremity that are transverse in nature. The longitudinal deficiencies, e.g., radial club hand and the other classic anomalies that are confined to the hand, are discussed in Chapter 22.

Most transverse deficiencies of the upper extremity will be treated by prosthetic fitting, if they are treated at all. An upper-extremity prosthesis is a way to improve the ability of the deficient limb to assist the intact limb in its activities; it does not replace the function of the missing part as adequately as it does in the lower limb.

The main purpose of the upper extremity, or a prosthetic substitute, lies in the function of the hand, with the rest of the limb used to position the hand. In addition, the upper limb, or a prosthesis also plays a role in support, balance, and trunk stability. In these latter functions, the prosthesis can do well, but in the main function of prehension, it functions poorly when compared to the normal hand. A prosthesis has no sensory feedback, which requires that the child watch the prosthetic hand in use. This, plus the thought and mental practice that goes into making a mechanical device work, makes the upper-extremity prosthesis a far less efficient tool than the lower-extremity prosthesis.

It is important to recognize that many transverse upper-extremity deficiencies will not be well served by prosthetic prescription. If the prosthesis does not afford the child a functional gain or cosmetic benefit, he or she will be quick to reject it. The prosthesis must aid the child in some function he or she wishes to do, i.e., age-appropriate functions that require the use of two hands. The reasons for some children becoming good users of a prosthesis, whereas others with the same characteristics reject it, are not well understood. Although the parent's acceptance and compliance are important, this is not the whole answer. The inability of the prosthesis to substitute for a normal limb, and the hand in particular, is also a partial explanation. These facts, coupled with the incredible ability of the young child to learn to use one hand assisted by the residual limb with so little concession to activities that are assumed to require two hands, must also be a significant factor.

Judging the success of an upper-extremity prosthesis is very specific to the particular patient, and difficult to quantify. The hours of use alone is not a good criterion. Many children will use the prosthesis for specific tasks (riding a bike), and prefer to remove it for others (swimming). Some children will wear it very little during the summer while playing, but will wear and use it every day in school, when bimanual motor tasks are a significant part of the activity.

What the child can do with the prosthesis when asked,

and what they actually do with it in their normal activities, can be very different. Although some children develop an amazing facility with the prosthesis in their everyday activities, many will demonstrate this facility in the medical setting, but continue to use the prosthesis much as they would their residual limb, and not as a prehensile tool, during daily activities. Standardized tests have been developed to measure spontaneous use versus voluntary control as it relates to age-appropriate activities. The University of New Brunswick test of myoelectric control is used by therapists to assess the child's ability to use the prosthesis in a controlled situation. The Prosthetic Upper Extremity Functional Index is a self-reported measure of the child's functional abilities during daily activities.

Although children often will not use a hand for functional purposes, the importance of the hand in appearance must be remembered. Besides the face, it (or its absence) is the most readily noted feature of the body. Good cosmetic hands can be of great help to children, especially adolescents, who desire them, and should not be minimized because of their nonfunctional nature.

The higher the deficiency, the more the disability, the harder it is to replace the function with a prosthesis, and the less will be the patient's acceptance of it. Lack of heat dissipation, weight, energy expenditure, concentration necessary to work it, and lack of functionality are all reasons why children with more proximal deficiencies will be less likely to use a prosthesis.

The main purpose of the upper extremities is grasp and manipulation of objects. Early in infancy the upper extremity reaches and touches objects within the visual fields and provides a rich sensory feedback to the child. This sensory feedback is an essential element of upper-extremity function. For the child with a limb deficiency or high-level amputation, especially if bilateral, sensation seems to be the single most desirable attribute of the extremities. Thus, if the upper extremities meet in the midline, the child will usually reject a prosthesis. If the extremities will not meet, or sometimes, when they meet where they cannot be seen, the patient may prefer a prosthesis for the function it affords.

The fitting of an upper-extremity prosthesis is much more individualized than a lower-extremity prosthesis. For those with a unilateral below-elbow amputation, fitting with a passive hand around 4 to 6 months of age is an easy decision because it is relatively inexpensive, well-tolerated by the patient, and helpful in deciding on later fitting with a more complex prosthesis. However, in cases of high-level amputations, especially bilateral, such a program of routine fitting will frequently result in failure (6).

The age for fitting is based on the normal development of the child. By 4 months of age, the child brings the hands to midline while supine, and props on elbows while prone. Eye-hand coordination develops as the hands are brought into the visual fields. By 6 months, the child is beginning

to prop on the extended arms when sitting, and is rolling in all directions. Early prosthetic fitting between 4 and 6 months allows the infant to incorporate the prosthesis in all gross and fine motor functions that are developing.

Children with bilateral high level amputations will primarily use adaptive performance techniques with their mouth, chin, neck, shoulder, and feet. Therapeutic interventions should focus on promoting these techniques first, and secondarily adapting the environment to assist the child in age-appropriate activities. Attempts should not be made at this point to modify the child with prosthetics. Children with high levels or complete absence of the upper limbs will use their feet to accomplish everyday two-handed activities. The use of the foot in play, and in activities of daily living appropriate for the child's stage of development, should be incorporated in all therapy home programs. It may take considerable persuasion to win the parents to this view.

Children with bilateral high-level amputations should probably be given an opportunity for prosthetic use. In addition to possible functional gains, the families experience a significant benefit in knowing that all has been tried, and the patients gain a valuable experience in having tried prostheses. A multicenter review of bilateral upper-limb deficiencies showed that 50% were still wearing a prosthesis at age 17 years or older (6). Fitting in such children should rarely be attempted before 1 year of age, despite the parent's anxieties. Fitting should be done to help the child perform appropriate tasks for his or her stage of development, or to aid in certain specific activities. It is usually best to fit a child with only one prosthesis at a time, because the problems with two may lead to early rejection.

Amelia

The child with unilateral absence of the arm will be less likely to fully accept a functional prosthesis than those with lower levels of amputation. If body-powered components are used, the patient has difficulty in controlling the devices, because there is no lever arm. Externally powered prostheses are heavy. The weight, and the increased body heat, because of the necessary suspension, make this a difficult prosthesis to wear. When coupled with the problems of function in using an artificial shoulder, elbow joint, and hand, the child will usually choose to function without the prosthesis.

Many children with amelia of the upper extremity are bilateral. The choices for these children are to help them develop their lower extremities to substitute for the upper extremities, to fit them with prostheses, or to attempt a combination of both. There is universal agreement that there is no place for attempting to limit the child's use of their feet and attempting to provide all of their upper extremity function with prostheses. The feet are the best substitute for the hands. Children with bilateral amelia and relatively normal lower extremities can usually master all of the activities of daily living, while leading full lives with

a family, children, and employment. Until the physician becomes acquainted with a child or, preferably, an adult with bilateral amelia, she or he cannot understand the extent to which the legs and feet can substitute for the arms and hands. Most of these children will reject prostheses.

The question of prosthetic fitting most often arises in the child with bilateral amelia and significant lower-extremity anomalies that limit their substitution for upper-extremity function. In such cases, unilateral fitting may be indicated, but is likely to gain limited acceptance, and then only after many years of struggle, coupled with need for the limited function the prosthesis provides.

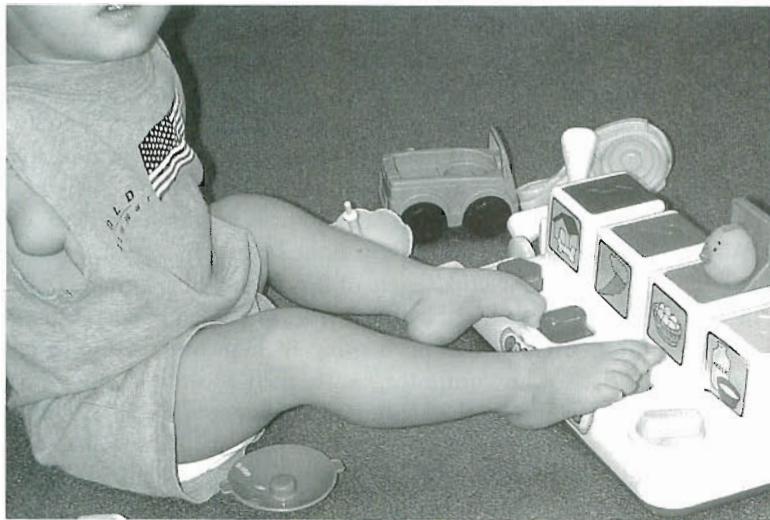
Children with bilateral amelia will often walk late. They will need help in pushing to stand. In addition, the fear of falling, because they cannot protect themselves, comes early. Helmets or some protective head gear are needed until the child is independent in gait. Therapy is directed at trunk control and strength, along with training in the use of their feet for all activities. These children are also prone to develop a progressive scoliosis, often before adolescence. This presents a difficult problem. Bracing restricts the use of their feet in activities of daily living. Surgical fusion does the same. However, often these curves will require fusion, and in such cases, as short a fusion as possible should be done.

Phocomelia

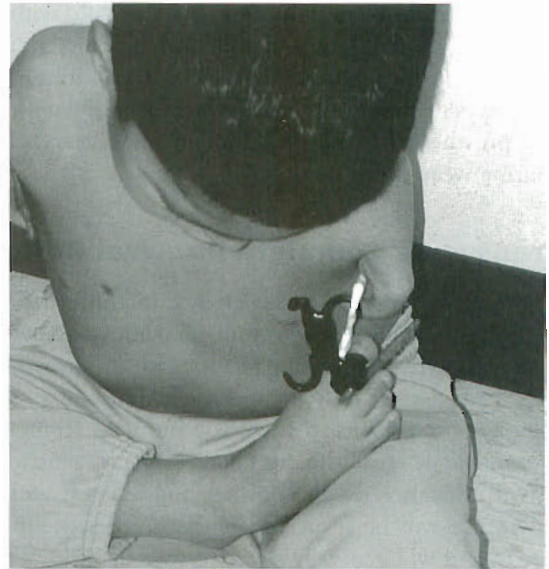
In phocomelia, the distal portion of the extremities appear to attach directly to the body. There are wide variations in this deficiency. In some, the hands may be close to normal, with some remnants of the arm bones, whereas in others the hand may be no more than a single functionless digit with little residual of the arm. Patients with phocomelia usually have some mobility in their residual limbs, and thus differ in one significant way from the child with bilateral amelia: they have a sensate limb often capable of some grasping function. The function of these limbs depends on the function of the hand and the length and function of the arm itself, and the ability to bring the hands together in the midline or to the face.

Those children who cannot bring their hands to the midline or to the mouth will use their feet to substitute in the activities of daily living (Fig. 30-16A–D). They should be encouraged from an early age to develop their foot skills and the body strength that is necessary to use the feet. In those with better function and length, little else than adaptive equipment to aid in dressing, etc. may be necessary (Fig. 30-16E).

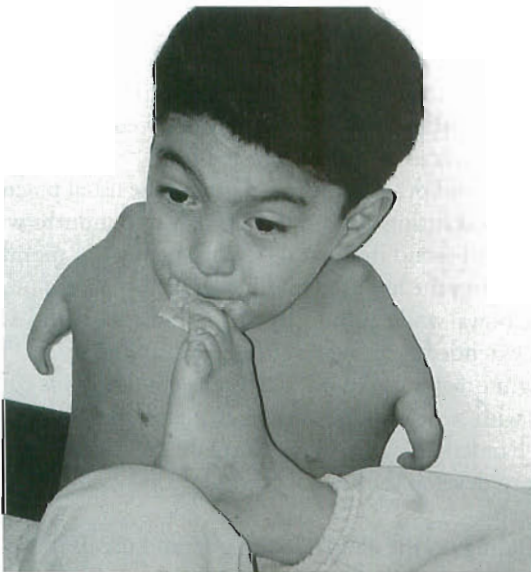Therapy to increase the range of motion of the scapula and limbs, and to strengthen any muscle power in the residual digits, may prove of benefit. Adaptive equipment to aid in the use of their residual limbs can be very useful for some activities, e.g., feeding and dressing as well as other activities. The residual limbs can manipulate switches for powered prostheses, and thus, the temptation for a prosthetic solu-



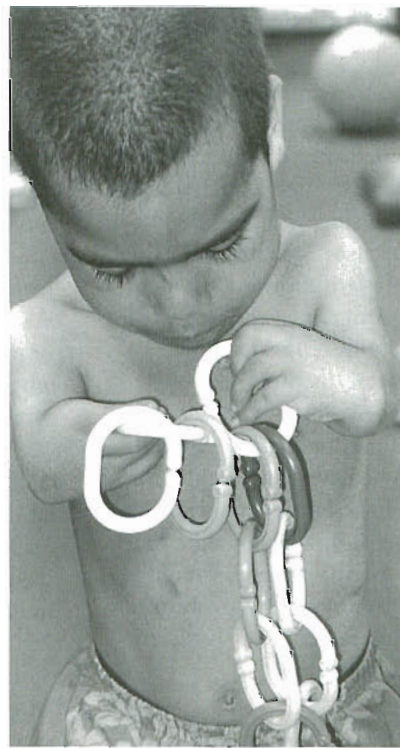
A



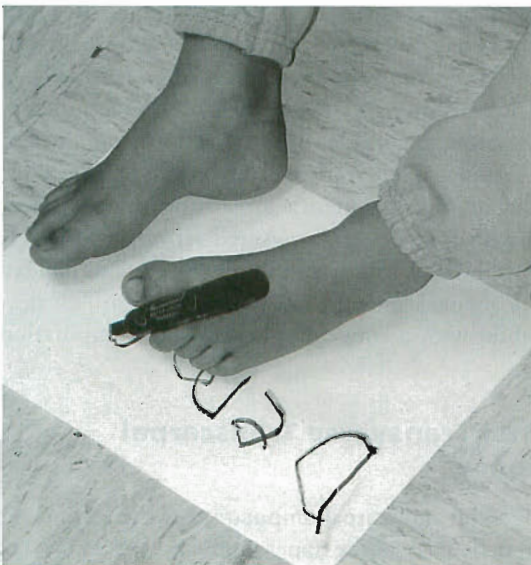D



B



E



C

FIGURE 30-16. A child with bilateral amelia or bilateral phocomelia, when the hands cannot meet in the midline, will use the feet for most activities. In such children, the use of the feet should be encouraged and developed from an early age (A). When older, these children will need the use of their feet to accomplish the activities of daily living (B, C). If there is any motor power in the extremities, they may be capable of useful function assisting the feet (D). When the hands can meet in the midline and have good motor power, excellent function is possible (E).

tion to their problem. However, like the child with bilateral amelia, these children will function in most activities by substituting foot function for what they cannot do with their upper extremities. Fitting the older child with a unilateral prosthesis for specific function may be indicated, but routine wear is not common.

Transverse Complete Humeral Deficiency

There is little published experience in this deficiency. Although some children with unilateral above-elbow amputation will develop surprising facility with this prosthesis, they will often wear it only for specific activities, e.g., sports, or for cosmetic reasons. If there is a humeral segment of any reasonable length, the humeral-thoracic pinch provides useful assistance for the normal opposite extremity. Prosthetic use will be in accord with the patient's functional needs, and will generally relate to specific tasks. These may be as limited as riding a bicycle or as broad as full-time use at school. These patients should be offered the opportunity for prosthetic fitting.

Patients with bilateral congenital transhumeral deficiencies are more inclined to use their own body, rather than a prosthesis. These children may benefit more from assistive devices than prostheses for their needs. Such patients will often prefer prosthetic fitting on one side, utilizing the humeral-thoracic pinch, with intact sensory feedback on the other side, along with their feet. It is important to again make the distinction between the congenital and acquired amputee. The congenital amputee will be less inclined to use prostheses and the traumatic more inclined.

For the patient with bilateral above-elbow transhumeral deficiencies, Marquardt has recommended an angulation osteotomy of the humerus (151). The osteotomy angles the distal 3 to 5 cm of the distal end of the humerus anteriorly 70 to 90 degrees. It allows for suspension without the usual shoulder cap, is easier to put on, permits better shoulder motion, and gives better control of rotation. This procedure should only be performed if the humeral length is sufficient and there is a need for a unilateral prosthesis.

Transverse Complete Forearm Deficiency (Congenital Below-elbow Amputation)

The congenital below-elbow amputation is the most common of all of the upper-extremity deficiencies. It is usually the left arm (Fig. 30-17). It is sporadic and without known cause. Children with this deficiency are the most ideal upper-extremity deficiencies for prosthetic fitting. Children with this deficiency are unlike those with a transverse amputation through the carpal bones, which usually have partial grasping function with sensation. They are also unlike the above-elbow deficiencies, in that they have a normal shoulder and elbow that allows accurate placement of a relatively light prosthetic terminal device.

Despite the fact that congenital below-elbow amputees are ideal candidates for prosthetic use, not all children will remain good prosthetic users during their childhood. Scotland and Galway reviewed the experience at the Ontario Crippled Children's Center, and found that 32% had stopped using their prosthesis, with follow-up of 7 to 17 years (152). How many of these may resume use of the prosthesis in the work environment is unknown. They, like Brooks and Shaperman (153), noted greater acceptance of the prosthesis if fitting was done before the age of 2 years.

In the congenital group of Brooks and Shaperman (153), 22% of those fitted before 2 years of age, and 58% of those fitted after, had stopped using their prosthesis. However, of those who continued to use their prosthesis, there was no difference in the amount of use between the two groups. The most common age at which patients discontinued use was age 13 years, and the most common reasons were cosmetic, and that they could do everything without it. Sorbye (154) reported that, of the patients in their clinic below age 24 years, 87% were using their myoelectric prosthesis, and 65% of these used it all day and for all activities. Hubbard et al. (155), reporting on the Toronto experience, found that 70% of the below-elbow amputees were using their prosthesis, whereas 30% had rejected it.

With this and other evidence, it is now the usual practice to recommend fitting around the age of 4 to 6 months with a passive hand to aid in normal development. At 4 months, the child brings the hands to midline while supine and props on the elbows while prone. By 6 months, the child will prop on extended arms while sitting and rolling over. This lightweight prosthesis is used to have the child become comfortable with a prosthesis, and to acquaint the child with the two-handed activities that a normal child would use, in an effort to develop the central cortical pathways for bimanual dexterity.

Depending on the child's acceptance and use of this passive prosthesis, and the choice of a terminal device, a more functional terminal device is fit between 15 and 18 months (26,156). Today, there are a number of terminal devices available (157). There are two choices to power the device: battery (myoelectric) and body (cables). Although there will be many factors to consider in the selection (cost and funding, clinic philosophy, and parent choice), virtually all centers today in North America are fitting the majority of children with a myoelectric-powered terminal device (Fig. 30-17). Table 30-4 compares the advantages and disadvantages of a myoelectric and body-powered terminal device for the child with a congenital below-elbow amputation.

Terminal Transverse Transcarpal Deficiency

The congenital transcarpal amputation is the second most common deficiency of the upper limb, and occurs in a char-

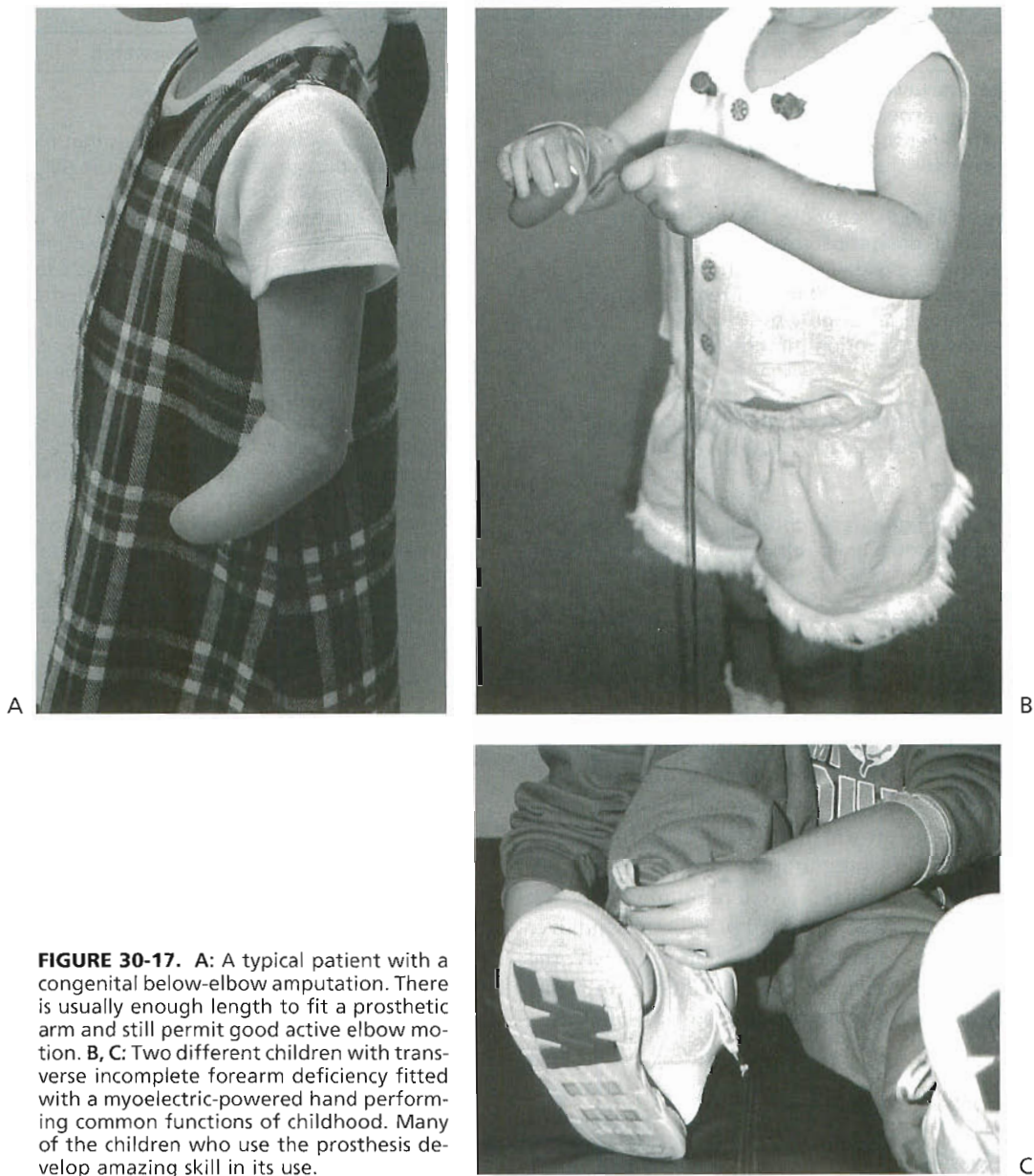


FIGURE 30-17. A: A typical patient with a congenital below-elbow amputation. There is usually enough length to fit a prosthetic arm and still permit good active elbow motion. B, C: Two different children with transverse incomplete forearm deficiency fitted with a myoelectric-powered hand performing common functions of childhood. Many of the children who use the prosthesis develop amazing skill in its use.

acteristic pattern, with some or all of the proximal row of carpal bones preserved. The existing flexion of the carpals on the radius allows for limited grasping function that along with normal sensation, makes this an assistive hand for which no prosthesis can substitute (Fig. 30-18). Occasionally, children will benefit from a volar opposition post for certain tasks. They will usually wear it only for certain tasks, e.g., a guitar pick adapter or to grasp the handle bars on a bicycle.

The authors' experience with such children is that they have much more difficulty with the cosmetic aspect of their deficiency than do those children with transverse amputations at higher levels. In the older child and adolescent, it

may be wise to explore the desire for a cosmetic hand that would be used in certain circumstances or provide a psychosocial benefit. Some cosmetic hands have a passive spring grasp to provide limited function.

Prosthetic Management

Generally, upper extremity prostheses and their control systems can be subdivided into three categories: *passive*, *externally powered*, or *body-powered devices*. The Ballif arm (circa 1400) was the first body powered prosthesis to introduce the use of prosthetic hand operation by transferring shoulder movement to activate the terminal device (158). A harness

TABLE 30-4. COMPARISON OF MYOELECTRIC- TO BODY-POWERED PROSTHESIS

Myoelectric	Body-powered
Weight Heavier—however, passive prostheses are weighted to prepare for the myoelectric system	Weight spread across the shoulders
Grip Strength Stronger than a body-powered, built into the system—less work for the child	Strength is provided by rubber bands that increase or decrease tension and force needed to open the hand—more work needed through scapular control
Cosmesis More accepted—resembles the hand—more self-esteem by the child, greater parental acceptance	Hooklike or clawlike in appearance; usually rejected by the child or parent—object of ridicule by other children
Maintenance Requires gloves—maintenance and electronics—electrodes lose contact and require occasional adjustment—adjustments for growth	Requires gloves; frequently requires repair for broken cables caused by friction; requires gloves if mechanical hand used; adjustments for growth on a regular basis
Harness No harness—suspension through socket—no straps on body	Harness—bulky on a toddler; difficult to keep on without pinning to undergarment; children dislike harness especially in summer months
Muscle Control Uses muscles in limb to control terminal device—prosthetic hand—direct “cause and effect”	Uses muscles distant from the terminal device—biscapular abduction to control hand or hook—very confusing for toddler whose control and balance is developing—easier for older children
Grip Control Maintain grip easier through muscle contraction at the end of the residual limb; is the most successful type of control	Toddlers loose grip very easily, overall gross movements allow the object being grasped to release and fall involuntarily—tension on the cable to the harness does not remain constant—becomes very frustrating for the child

over the contralateral shoulder is connected with a thin cable and housing to a terminal device. Through the use of scapular abduction, the fixed cable is stretched over a greater distance and causes the prosthetic hook or hand to open or close, depending on the configuration of the terminal device. A good analogy is the braking system on most bicycles. Most parents prefer the cable-operated prosthetic hand over the cantered hook for cosmetic reasons. Unfortunately, the hook is far superior in function, but has fallen from favor, because of parental and public pressure to have the pros-

thesis look as natural as possible, at the sacrifice of function. Most hooks are canted in design, and this allows a full field of view, compared to the mechanical hand that obstructs the view and results in an awkward arm positions to grasp objects.

The externally powered prosthesis can be further subdivided into *switch control* or *myoelectric control*. In both systems, a battery, relay switch, electric hand, and electronic control system are present. It should be noted that the electric hand is the only terminal device available for children



FIGURE 30-18. This young boy with a transverse transcarpal deficiency demonstrates the partial grasp at the flexor crease that, when combined with sensation, usually proves superior in function to a prosthesis.




FIGURE 30-19. This example of the myoelectric prosthesis was made with a clear socket for teaching purposes. The proximal portion of the socket, which fits on the residual limb, contains the electrodes that pick up the signals from the muscles. This fits into the prosthesis, which contains the electrical and mechanical working parts of the Otto Bock Electrohand.

using the externally powered prosthesis. In the myoelectric prosthesis (Fig. 30-19), an electrode placed on the surface of the skin acts to pick up the electromyographic signal (EMG), which in turn is amplified with the help of an electronic relay switch, and this, in turn, operates the electric hand (159). The entire system is generally referred to as a one-site or two-site system. This denotes the number of electrodes that are used for signal recognition.

The one-site system can be further categorized as voluntary opening—automatic-closing, rate-sensitive, and level-sensitive. The first fitting of a myoelectric arm occurs at under 2 years of age, and utilizes a voluntary opening—automatic-closing (cookie-cruncher) configuration. The muscle signal opens the electric hand, and relaxing of the signal causes the hand to close automatically. This system is used for children under 4 years of age. The rate-sensitive and level-sensitive control systems use one muscle to control two functions, and are generally fitted to children over 4 years of age, when two sites are not available. The choice of a system depends on the muscle signal strength, muscle control, and prosthetic design factors (26).

In the two-site system, each electrode operates a specific task. Children can often operate this more complex system by 3 to 3½ years of age. The EMG signal of the flexors is used to close the hand, while the EMG signal of the extensors is used to open the hand. This system is used when children have established good control and use of their myoelectric prosthesis, and have demonstrated the ability to control both the flexors and extensors independently of each other.

Patients with a higher level of upper-extremity amputation are generally good candidates for switch-controlled externally powered prosthesis. The electrode is replaced with a miniature switch that can be either a push-pull configuration, a force-sensing resistor, or simple on-off design. The incorporation of these switches into the prosthesis depends primarily on the level of amputation and the design of the prosthetic socket or frame.

Multiple Limb Deficiencies

Management of the patient with multiple limb deficiencies, involving both the upper and lower limbs, is a challenge that requires a team with experience, to achieve the maximum function for the patient. The problem of bilateral upper-extremity amputation has been covered earlier. Children with one upper and one lower extremity pose no problems beyond the management of each individual limb. Children with bilateral knee disarticulation or transtibial amputations will walk without support, and thus a unilateral upper-extremity amputation in association poses no special problem, other than donning and doffing the prostheses. With amputations above the knee disarticulation level, however, walking without support, and thus the need for upper-extremity function, becomes a problem, and may require a wheelchair for long distances and to conserve energy.

A special caution needs to be given in regard to those children with bilateral upper-extremity amputation and lower-extremity anomalies that might ordinarily be treated with amputation and prosthetic fitting. No amputations of the lower extremity should be performed until it is certain that the child will not require the use of the feet for grasping activities.

One of the most common types of patients seen in the pediatric age group with this problem is the quadrimembral amputee as a result of meningococemia. In these patients, it is often necessary to cover the residual extremities with split-thickness skin grafts to maintain length. These grafts, if not adherent to bone, do very well in the prosthesis, and are not a hindrance to fitting. Treatment must be individualized for each patient with certain general guidelines. The first is to help the patient maximize function with his or her residual limbs. This is especially true with the upper extremities, where sensation is so important to function. Although these children will become proficient in the use of bilateral upper-extremity prostheses, if their residual limbs are long enough, they will usually perform many of their daily activities, especially at home, without their prostheses.

A common mistake is to attempt to fit all four extremities of these children with quadramembral loss at the same time. Although the pressure to do so is enormous, it may result in actual delay in functional recovery and rejection of the prostheses. In the vast majority of situations, it is best to first fit the lower extremities and achieve ambulation. After this is accomplished, fitting of the upper extremity is done.

In the child with a congenital quadramembral deficiency, there will usually come a time when the parents, and perhaps the child desire prosthetic fitting. Again, it is best to avoid fitting all four extremities at once, but rather focus on meeting specific needs. Although experience shows that most of these children will use their prosthetic devices in a limited fashion, if at all, they and their parents need and are entitled to the experience at least once (Fig. 30-20).

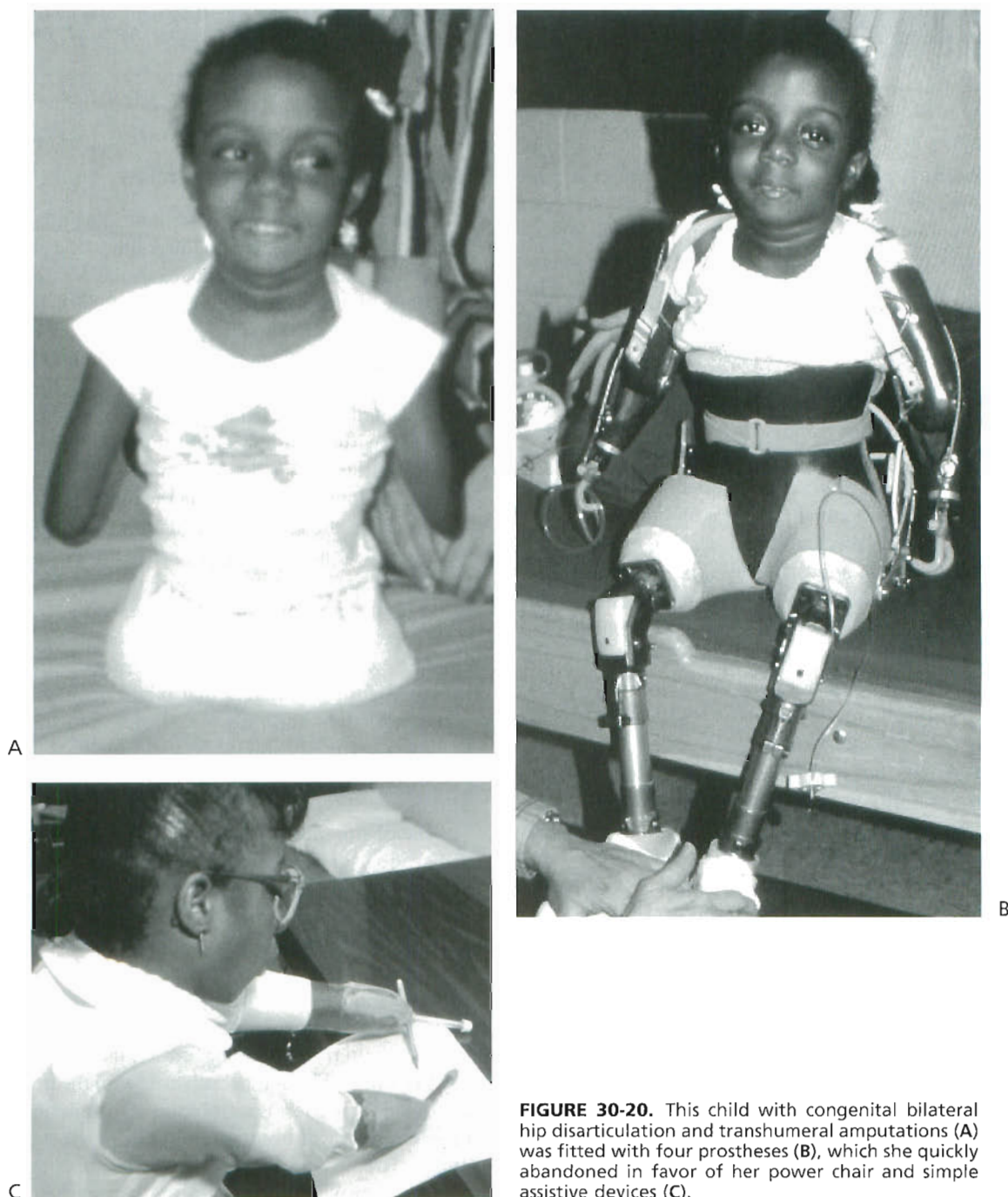

FIGURE 30-20. This child with congenital bilateral hip disarticulation and transhumeral amputations (A) was fitted with four prostheses (B), which she quickly abandoned in favor of her power chair and simple assistive devices (C).

ACQUIRED DEFICIENCIES

Causes

Children may suffer an amputation for a variety of reasons. Although there are no good statistics, trauma is the major cause of amputation in childhood (160). In this group, power lawnmowers lead the list of causes, and most commonly, it is a child riding with a family member. Motor vehicle accidents, farm injuries, and gunshot wounds follow in that order (161). In war-torn countries, land mines may be the leading cause of amputation. Because amputation of the digits is most often caused by machinery, upper extremity amputations are more common than lower extremity. Boys are affected about twice as often as girls.

Tumors, vascular occlusion caused by meningitis or vascular catheterization, and burns are additional causes, and each has its own unique set of circumstances. Indeed, the differences in acquired amputation defy a detailed analysis. Some are semiselective, and allow for some preparation of the patient and the parents, whereas traumatic amputation do not. It is possible, however, to discuss the common principles that are applicable to acquired amputations in children.

Principles

When the surgeon is faced with an acutely mangled extremity, it can be difficult to decide on amputation versus limb salvage. The usual criteria and classifications that are applied to adults are not easily transferred to children. It is often necessary to gain the input of a vascular surgeon and others, to make the best assessment, while always remembering the tremendous healing and adaptive capacity of the child, compared with the adult.

When dealing with feet mangled in a power lawnmower, it is often wise to attempt salvage at the first operation. However, in the case of a mangled leg that will require vascular and nerve repair, along with bone reconstruction and free tissue transfer, the decision needs to be made more realistically. The more energy expended in saving the limb, the higher the parents' expectations of the result.

The surgeon rarely will have options regarding the level of amputation in trauma. The lack of preparation, coupled with the parents' expectations, usually dictates saving as much of the limb as possible. This often results in less functional level of amputation than one more proximal. The most obvious example is preservation of the talus and calcaneus, which the parents and child may see as having at least part of the foot, whereas the result will may be a worse gait, worse cosmesis, and more prosthetic problems than a Syme amputation.

In the child, it is usually advisable to save as much length as possible in amputations of the long bones. This is especially true in the femur, where 70% of the growth of the

bone occurs from the distal physis. A 5-year-old child with a midhigh amputation will have less than ideal length as an adult. In the leg, however, little is lost, so long as an adequate portion of proximal tibia, where the majority of the growth occurs, is preserved, and in fact, shortening the bone to achieve good soft tissue coverage may be the best course.

The common teaching that skin grafts do not make suitable coverage for a residual limb that will bear weight in a prosthesis, is not applicable to children, especially very young children. In children, skin grafts do make good coverage so long as they are not adherent to bone. Split-thickness skin grafts are frequently needed to preserve length in meningococcemia, burns, and some cases of trauma. In older children with traumatic amputations, free vascularized flaps can provide excellent coverage.

Where possible, disarticulations will avoid the problem of bony overgrowth. It is not necessary, or perhaps even advisable, to remove the cartilage from the bone end. Tapering of the bone ends, e.g., at the distal tibia, is not necessary, unless the child is approaching adulthood. The bony prominences will not develop to adult proportions, and thus do not represent a prosthetic fitting problem. If a young child has a through-bone amputation, it may be possible to salvage a portion of bone and cartilage from the amputated part for capping the bone. This is similar to performing a Marquardt procedure, and has the potential to substantially reduce problems of overgrowth.

It is important not to forget the child during the acute phase of the amputation. Often the surgeon has enough problems dealing with the parents' emotions, and can easily forget that the child also needs emotional as well as physical attention.

In many circumstances, the amputation will be elective. Such is the case with children who have posttraumatic injuries, and are electing surgical modification for better function and prosthetic fitting. Children with gigantism, Klippel-Trenauney-Weber syndrome, and malignant tumors not suitable for limb salvage, also are in this category. In many cases the need is obvious, and the child and parents have come to their decision after careful consideration.

In the case of tumors, however, it is not so easy, and there is generally not complete acceptance for what is a life-saving procedure. In all cases, the more preparation by the professionals, and the parents and patient talking with other patients the better. It needs to be emphasized that the challenge is to live, and that the operation is necessary for that. The options revolve around the functional and cosmetic aspects of the different procedures.

There remains a difference of opinion as to whether or not it is worthwhile to fit the acquired juvenile amputee in the immediate postoperative period. In the young child with a congenital deficiency, there seems little to be gained. However, in the older child, especially when the amputation is

caused by trauma, there can be large psychologic benefits to placing the child in an immediate postoperative prosthesis. This also aids in control of edema and phantom pain.

PROSTHETICS

In the prosthetic fitting of the pediatric amputee, the single most important guiding principle is that function should never be sacrificed for cosmesis. When dealing with the adult population, overall biomechanical forces resulting from prosthetic alignment can do relatively little damage to skeletal integrity. This is not the case for the pediatric patient, in whom skeletal development is ongoing. Incorrect alignment can have far-reaching and often pronounced negative results.

Role of the Prosthetist

The role of the prosthetist is to ensure that the highest level of functional need of the patient is achieved through prosthetic intervention, or the wisdom for no intervention at all. The skilled prosthetist is able to assess anatomic and functional deficiencies, and recommend socket design and component selection. In addition, he or she must possess the clinical skills, medical knowledge, and ability to communicate that will enable timely and appropriate flow of knowledge to the other team members and parents, so that realistic expectations can be identified and achieved. Routine servicing of the prosthesis is extremely important to minimize extensive repairs and anticipate the need for a new prosthesis. Children are generally not happy to be without their prosthesis.

Fitting Techniques

Technique will vary, based on the experience of the prosthetist, team approach, integration of ever-changing technology, and the severity of the deficiency. Physiologically, the child is in a constant state of growth and the prosthetic device must be designed to permit weight bearing, and allow for the greatest amount of growth without compromising fit and function. Most congenital lower-extremity amputees are able to bear some weight on the distal end of the residual limb, and the prosthetist is able to allow for a slightly less intimate fit of the prosthetic socket than might be the case for the acquired amputee. Unlike the adult, the child's skin has greater tolerance for skin breakdown. The increased activity levels of the child amputee place tremendous expectations on the prosthetic devices and the components. All of these factors are constant challenges to the prosthetic prescription, and emphasize the need for a nonstructured approach to fitting. What may be suitable for one child may be unsuitable for a different child with the same anomaly. Rigid time schedules are discouraged, and developmental

levels should be used only as a guideline to aid the practitioner.

Fitting the pediatric amputee leads to unique issues not normally seen in the adult population. Disarticulations lead to long residual limbs with knee centers lower than the sound side. Ischial containment sockets are not normally recommended (unless needed because of hip instability) because of problems with soft tissue containment and diapers in infants. Location of bony landmarks is obscured by fatty baby tissue, and casting is difficult and nonexact.

The various stages involved prior to receiving a prosthesis are generally standard within the profession. Upon referral to a clinic, the child is assessed by the team, and a treatment protocol is established. The stages involved in prosthetic fitting include:

1. CASTING of the residual limb.
2. TEST fitting of the modified interfacing socket.
3. DYNAMIC alignment and gait training.
4. DELIVERY of the completed prosthesis.

Socket Design and Suspension Systems

The cast or impression forms the foundation for the prosthetic design (162). It is only after a well-fitting and comfortable socket-skin interface is achieved that the additional componentry can be added and expected to function as designed. Casting usually involves the placing of a casting sock on the residual limb, marking all landmarks and wrapping circumferentially with plaster or synthetic bandage. This becomes the negative impression. It is then filled with molding plaster and stripped, forming the positive cast ready for modification. This positive cast is then modified to distribute forces and relieve pressure in the socket for proper hydrostatic control of the residual limb.

Through the use of a clear test or diagnostic socket, fabricated over the positive mold, the practitioner is able to ascertain the areas of high and low pressure, and to ensure that they are directed over the appropriate areas. Common fitting problems can be flagged and corrected before final socket design.

Computer-aided design-computer-aided manufacture (CAD/CAM) has been used as an alternative tool to plaster casting and modification of the prosthetic socket. In its most simplified form, a residual limb is scanned with an optical laser. The information is relayed to a computer, where modifications can be made to the scanned shape, to allow for increased or decreased weight bearing areas. The finished design is transferred to a computerized milling machine to form a positive model. This, in turn, is used to fabricate the finished device. Slowly, CAD/CAM is becoming more widely used within the profession, because of advantages of design reproducibility, record keeping, and flexibility in remote locations (163). Its advantages in the pediatric setting have yet to be proven. All current CAD/CAM systems

rely on surface topography of the residual limb, therefore disregarding crucial data, such as tissue density, tissue mobility, and underlying skeletal structures (164).

During dynamic alignment in the crawling infant, the prosthetist initially focuses on creating a prosthesis that will aid the infant in preparation for ambulation, transitioning from crawling to standing, with little consideration at this point to gait. Sutherland concluded that mature gait patterns were established by 3 years of age (165), whereas others place the time frame closer to 6 years of age. Early infant gait patterns are, in fact, the processes of suppression of primitive reflexes and the acquisition of postural responses (166). Dynamic alignment is the manipulation of relative position of the socket to the foot and knee, while the prosthesis is moving through the various stages of gait. Through the use of alignment mechanisms in the components, the prosthetist is able to shift, tilt, and rotate the knee and foot in relation to the socket. Once independent gait is established in the infant, further refinement to gait can be achieved through prosthetic alignment.

Lower-extremity Socket Design

The design and fitting of lower-extremity prostheses encompasses numerous biomechanical principles and their application to the residual limb–socket interface, and it is the successful manipulation of these forces that ensures a patient's comfort and function. The accommodation for differences in tissue compressibility, pressure tolerance, underlying bony structures, and vascular integrity are factors taken into account prior to socket design. Dynamic forces exerted through ground reaction forces and resulting moments, including torque and shear forces, increase the vulnerability of the skin–socket interface.

Hip Disarticulation

Amputees at the hip disarticulation level require extensive prosthetic intervention. The socket encompasses the amputated pelvic remnant, and encloses the contralateral side for suspension. The traditional socket design rises proximally to the waist, and fits similar to a Boston spinal orthosis. The Diagonal socket is a modified version of the standard design, and it affords a more comfortable fit and increased flexibility. Prosthetic hips are single axis, and are mounted on the outside anterior distal aspect of the affected side. Hip and knee flexion are easy to activate, if the prosthesis is perfectly aligned. The hip is anterior to the weightline and the knee is posterior. This allows for a stable stance and a smooth gait. The endoskeletal system is used exclusively for this level of amputation because of an increased level of cosmesis and decreased weight. Children at this level can achieve remarkable gains, when fitting begins while the child is pulling to stand, and when therapy intervention and parental training are incorporated. It is recommended that the knee be locked, initially, so that hip control can first be learned. Once the child is walking independently, the knee can be activated.

Transfemoral Prosthesis

Transfemoral socket design has evolved significantly over the last 10 years. The quadrilateral socket was the socket design of choice until 1987, when the International Society for Prosthetics and Orthotics (ISPO) formulated recommendations on the narrow medial lateral (ML) socket design (167). Variants of this design (ischial containment socket) continue as the CAT-CAM (contoured adducted trochanteric/controlled alignment method), NSNA (normal shape, normal alignment), and the modified quad design, to name a few (Fig. 30-21). The underlying principle is to

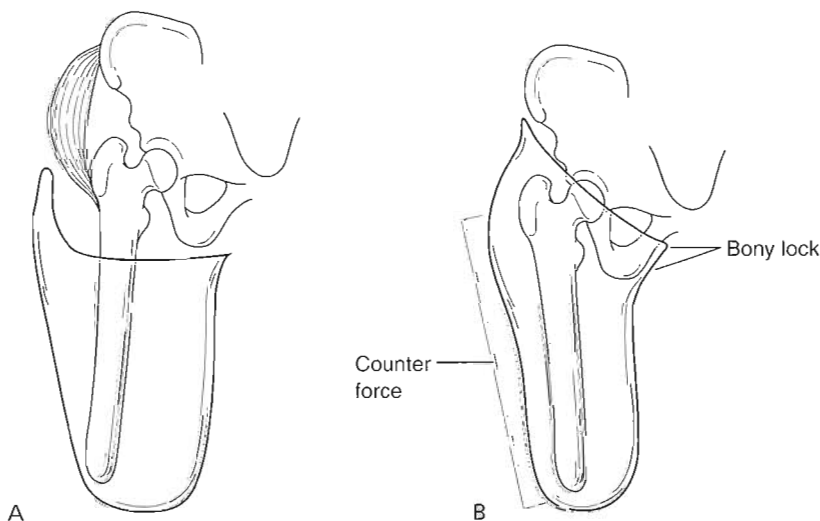


FIGURE 30-21. A: The quadrilateral socket is useful for the young child, especially if end-bearing is possible. However, it fails to stabilize the femoral segment in a transfemoral amputation. B: This has led to the popularity of the narrow medial lateral socket design, e.g., the ischial containment socket shown here. This design can prove impossible in small infants, because of the fatty thigh and buttocks as well as diapers.

adduct the femur, while locking the ischial tuberosity within the socket, thus providing a more anatomically correct alignment during all phases of gait (168). The controversy over these designs has been increasingly dispelled, with further clinical experience.

There are various suspension mechanisms that may be utilized for the secure attachment of the socket to the residual limb. These devices may be auxillary suspension, which is attached to the socket to suspend or enhance suspension. The suspension may be incorporated in the socket itself, e.g., suction sockets, supracondylar sockets, etc.

Pediatric amputees are usually fitted with a *Silesian belt* system of suspension (Fig. 30-14A and B; Fig. 30-22A), until adequate development of the residual limb allows for silicone suspension, at approximately 2 to 3 years of age. The Silesian belt attaches to the anterior/medial aspect and the lateral aspect of the transfemoral socket, and lays across the pelvis at the waist. Tightening the Silesian belt prevents the socket from slipping distally. The total elastic suspension (TES) belt may be used instead of the Silesian belt. The TES belt is a neoprene suspension system that is applied over the proximal portion of the transfemoral socket, then secures around the waist.

Suction sockets are not typically used for the pediatric population because of tight tolerances in fitting that cannot be maintained by a growing child. With the suction socket, the residual limb is pulled into a socket that incorporates a one-way valve in its design (Fig. 30-22B). Once the valve is in place, the amputee expels air every time the prosthesis is in contact with the ground. During swing phase, the negative pressure within the socket holds the prosthesis in place. Air that leaks into the socket is quickly expelled through the one-way valve, and a constant negative pressure is maintained. Total contact suction sockets are generally used for the transfemoral amputee with a mature residual

limb, and at the completion of skeletal growth. Short limbs, volumetric changes, and severe scarring are contraindications for the suction suspended socket.

Transtibial Prosthesis

The transtibial prosthesis is used the least in the pediatric population. Although most amputations in children are disarticulations, growth changes in the fibular deficiency often result in a transtibial-level residual limb that is distal end weight bearing. The true transtibial socket is most often required for the traumatic amputee. Total contact design allows for increased pressure-bearing over the patellar tendon, medial flare of the tibia, medial shaft of the tibia, and lateral shaft of the fibula, and the anterior and posterior compartments. Similarly, weight-sensitive areas most affected include the tibial crest, fibular head, distal tibia and fibula, peroneal nerve, and the patella. The socket design is comprised of an outer shell, inner soft liner, and a cosmetic cover.

The patellar-tendon-bearing (PTB) socket is the standard socket (Fig. 30-23A). It provides the least suspension, and for that reason, is not often suitable for young children. The supracondylar/suprapatellar (SCSP) transtibial socket design (Fig. 30-23B) allows for suspension without the need for belts or cuffs. The medial, lateral, and anterior walls extend proximally, to fully enclose the patella and femoral condyles. The supracondylar (SC) transtibial socket (Fig. 30-23C) is almost identical to the SCSP design, except the anterior proximal brim does not enclose the patella, and therefore allows greater freedom and range of motion. Contraindications for both the SCSP and SC design include obese or muscular limbs, patients with severe ligamentous laxity, and patients with heavy scarring around the knee.

Supracondylar cuff suspension is a common form of sus-

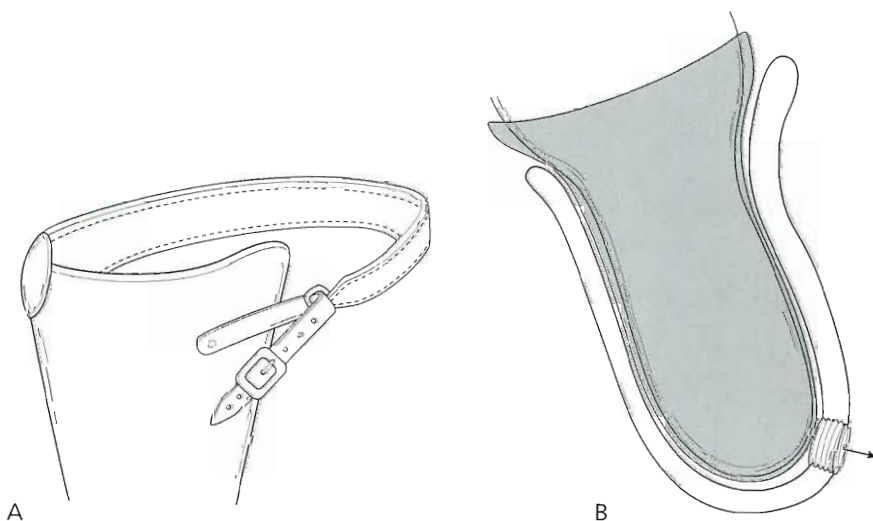


FIGURE 30-22. Methods of suspension for transfemoral prostheses. **A:** The Silesian belt is almost universally used in the young pediatric patient, to suspend a transfemoral prosthesis, and occasionally a knee disarticulation or transtibial prosthesis (see also Fig. 30-15B). **B:** The suction socket is a tight-fitting socket design with a one-way valve that allows air to be expelled with weight bearing to maintain a suction fit on the residual limb. It is best suited for the older child or adolescent, who has a mature limb that is not changing in size.

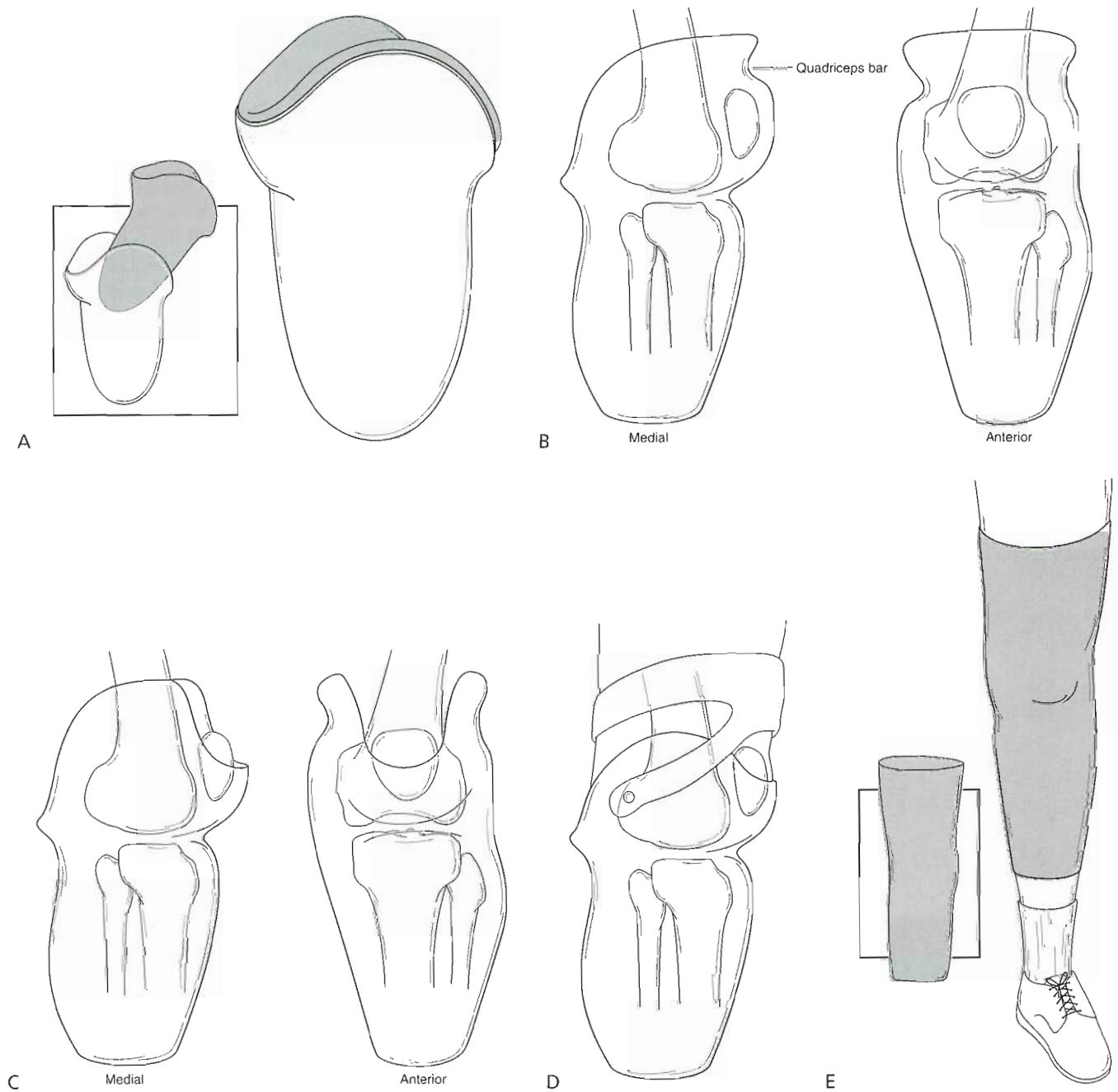


FIGURE 30-23. Common sockets and suspensions for transtibial pediatric amputees. **A:** Patellar-tendon-bearing (PTB) socket is most useful for the mature patient. It gives the most freedom of motion, but the least secure suspension. **B:** The supracondylar suprapatellar (PTB-SCSP) design gives the most secure suspension and best knee control of any of the sockets that incorporate the suspension in the socket. **C:** The supracondylar (PTB-SC) socket eliminates the suprapatellar portion of the socket anteriorly, for better range of motion with less control of hyperextension. **D:** The supracondylar cuff suspension is a common suspension used in the pediatric age range. **E:** The neoprene sleeve suspension provides very secure suspension for the very active amputee. This can also be used for the transfemoral amputee.

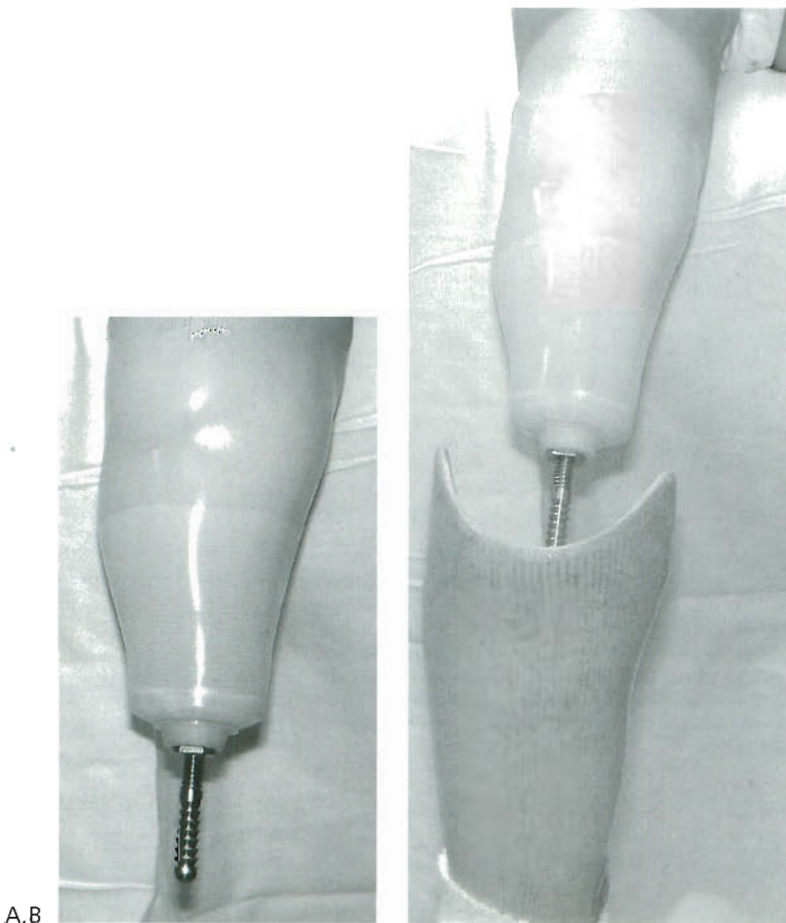
pension for the pediatric transtibial amputee (Fig. 30-23D). The cuff is fabricated from leather, and encompasses the femoral condyles and patella. It is attached to the medial and lateral aspects of the socket. The neoprene sleeve suspension is another useful suspension in the pediatric amputee (Fig. 30-23E). It can also be used for the transfemoral amputee. It tends to be hot, and is poorly tolerated by some children for this reason, but for the very active child, it provides a great level of security that the prosthesis will not come off.

Silicone suspension liners have become increasingly popular as a method of suspension without the need for belts or cuffs (Fig. 30-24). The liner is rolled onto the residual limb. At the distal end of the liner is a serrated pin. Inside the distal end of the socket is a shuttle or receptacle mechanism. Once the liner is donned, the amputee places the limb in the socket, and the pin and shuttle engage and lock into place. Pressing of a button hidden on the medial distal aspect of the prosthesis releases the pin and the residual limb can be removed from the socket. Because of the physical characteristics of the liner, the greater the distracting forces

placed on the prosthesis, the tighter the liner grips the residual limb. This system is used extensively in young children.

Ankle Disarticulation Prosthesis (Syme)

The obturator (medial opening) design is most often used when the distal bulbous end is large and the medial malleolus is prominent (Fig. 30-25A). The removable or segmented liner socket incorporates a full foam liner that has been built up to the same circumference as the distal bulbous end. A laminated shell is then formed over this insert. The patient dons the liner first, then slips this into the laminated receptacle (Fig. 30-25B). An atrophied residual limb with a small heel pad is best suited for this design, and the degree of cosmetic restoration will be very good. The silicone or bladder prosthesis utilizes an inner elastic area that stretches to permit passage of the bulbous end of the residuum through the narrower circumference of the tibia and fibula, then constricts once the distal end has passed through (Fig. 30-25C). All of the above designs maintain total contact, and the proximal brim is at the level



A,B

FIGURE 30-24. The silicone suspension liners (Triple S socket) have become very popular. The soft silicone liner has a serrated pin incorporated into the bottom of the liner. The patient rolls the liner on the residual limb (A), then inserts the limb into the prosthesis (B). At the bottom of the prosthesis is a socket where the pin locks. It is released by pushing the button on the medial side of the prosthesis.

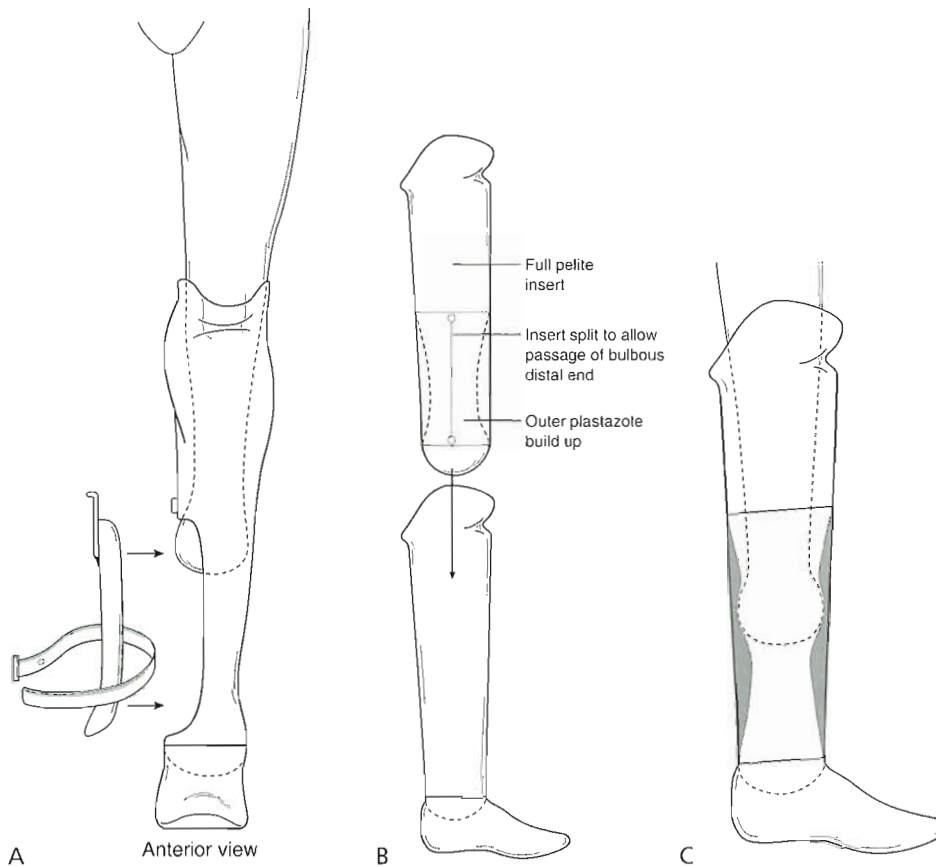


FIGURE 30-25. Common socket designs for Syme amputation. **A:** Obturator design is often needed if the distal end of the residual limb is large and bulbous or the medial malleolus is prominent. It is the least cosmetic. **B:** The removable or segmented liner consists of a complete separate foam liner, which has a split in the side to allow the distal end of the limb to pass. Once the patient applies the liner, they slide the limb covered by the liner into the prosthesis. The patient must have the manual dexterity and strength to use this suspension, which will eliminate some patients with hand anomalies. Limbs with a small heel do best with this system. **C:** The bladder design has a built-up silicone sleeve, which the patient slides the limb past. This socket fits more loosely, and does not stabilize the heel pad as well as the other designs.

of the patellar tendon. This ensures that the biomechanical forces are adequately spread up to a load bearing landmark to increase comfort and function.

Prosthetic Knees

It has been estimated that more than 100 prosthetic knees are commercially available, and the number is growing each year (169). Although the majority of these are for adults, recently there are a number of new knees available for children. The prosthetic knee is comprised of the knee mechanism or frame, and may contain a control unit. The control unit consists of either a pneumatic, hydraulic, or mechanical system, or some combination of these three. The control unit responds to changes in cadence and dampens sudden abrupt changes. The faster a hydraulic or pneumatic unit is compressed, the faster the energy is released, and this helps to regulate the lower shank of the prosthesis. The prosthetic knee unit can be further subdivided into single axis and polycentric.

The maturation of gait from infant to adult carries with it the need for sound practice in selecting the appropriate

knee, based on amputation level, functional level, and body size. In general, the single-axis internal knee without any control unit is the first knee to be used on the child, because of its light weight, short lever arm, and simplicity. In the single-axis knee joint, the lower shank rotates around a single point in relation to the socket.

A polycentric knee was introduced in 1998 for the infant and toddler, and may also be used if space permits. Internal polycentric knees move around a center of rotation that varies with the flexion angle of the lower shank (169). The four-bar linkage knee is the most common polycentric knee and the most widely used by prosthetists (170) (Fig. 30-26). The inherent stability during stance, the fluid knee flexion movement, and the mechanical design, to give more ground clearance during flexion, increases patient and practitioner confidence in the unit (170).

Changes in design and technology have now widened the boundaries and age distinctions for the prescribing of specific knees. Traditionally, an articulating knee would be introduced in a congenital amputee around 3½ to 4 years of age. This age was used, in part, because of limitation in size and function of the components. In the experience at

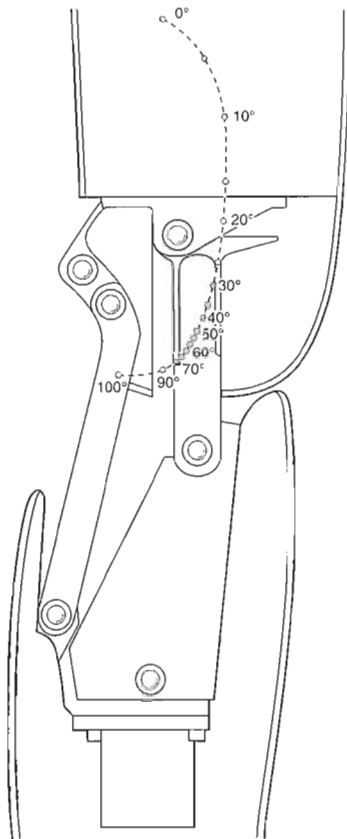


FIGURE 30-26. Four-bar-linkage is an internal polycentric knee that provides many advantages to the patient, e.g., increased stability and better ground clearance during swing phase. As indicated in this illustration, the point of rotation varies with the degree of flexion. With the knee flexed, the leg folds under the thigh segment, and thus is very useful for longer residual limbs. There is also a hydraulic version of the four-bar linkage for children.

the authors' center, as well as others, introduction of a prosthetic knee without a locking feature can be used in the first prosthesis when the child first pulls to stand. A recent report demonstrated the benefits of early fitting with articulated knees in children as young as 17 months. All children learned to walk with an articulated knee, despite their age differences (121).

As the child develops and grows, more sophisticated control systems (e.g., hydraulic knees) can be incorporated into the prosthesis. Most components carry specific weight guidelines, and many children reach these ranges well before adulthood. For example, an adult hydraulic polycentric knee is routinely used on 8-year-old boys whose weight has surpassed 100 lb. This does not mean that every child of a certain age and weight should have a particular knee. Placing a sophisticated knee and control system on an individual who has neither the hip range, muscle strength, nor residual limb length to activate the knee, often results in contralateral hip and lower back pain, and patient frustration.

Prosthetic Feet

Variations in the materials, design, and alignment of the foot can have profound effects on the performance of the prosthesis. Functionally, prosthetic feet can be categorized into five main groups (171):

- Solid ankle cushion heel
- Single axis
- Multi axis
- Elastic keel
- Dynamic response

The solid ankle cushion heel (SACH) foot contains no articulating parts, and foot motion depends on the various compressive properties of the materials used between heel-strike and toe off (Fig. 30-27A). It is generally considered when amputees require maximum late-stance stability because of weak knee extensors, knee-flexion contractures, or poor mid- to late-stance balance (172). The SACH foot is used in pediatrics when the foot size is below 12 cm, but has mostly been replaced by the dynamic response or energy-storing feet.

The single-axis foot usually contains rubber bumpers that allow passive dorsi- and plantar flexion. By changing the hardness of the bumper, the prosthetist is able to effectively change the properties of the foot. This foot is best suited for the transfemoral amputee, in whom full-foot contact with the ground is necessary to increase stability. The multi-axis foot allows passive dorsi- and plantar flexion, inversion and eversion. The multi-axis foot is best suited for the amputee who requires flexibility in foot position because of uneven terrain, or when lifestyle, such as golfing or various sports, require some rotational control. These feet do not find much use in the pediatric age group.

Once the child's foot size exceeds 12 cm, the prosthetist can move the child into a dynamic-response foot. This group of feet is distinguished by a spring mechanism in the keel that deflects during gait (Fig 30-27B). Originally called an "energy-storing foot," this class of foot is ideally suited to the child amputee. Although the variety of componentry for children is still much less than for adults, there is a wide variety of feet with different performance characteristics available. It is important to use components that will maximize performance, and at the same time be appropriate for the patient (173).

At slower walking velocities, there is little difference between the dynamic-response foot and the SACH foot (174). Generally, children are not fitted with highest performance dynamic-response feet, because of constant growth and weight changes, and high costs associated with foot replacement. The involvement in competitive sports is usually a good benchmark to initiate fitting adolescents with highest-performance dynamic-response feet.

In the transfemoral amputee, it is crucial to properly choose a foot that will enhance gait, but, also to choose the complementary knee that will aid in controlling the foot

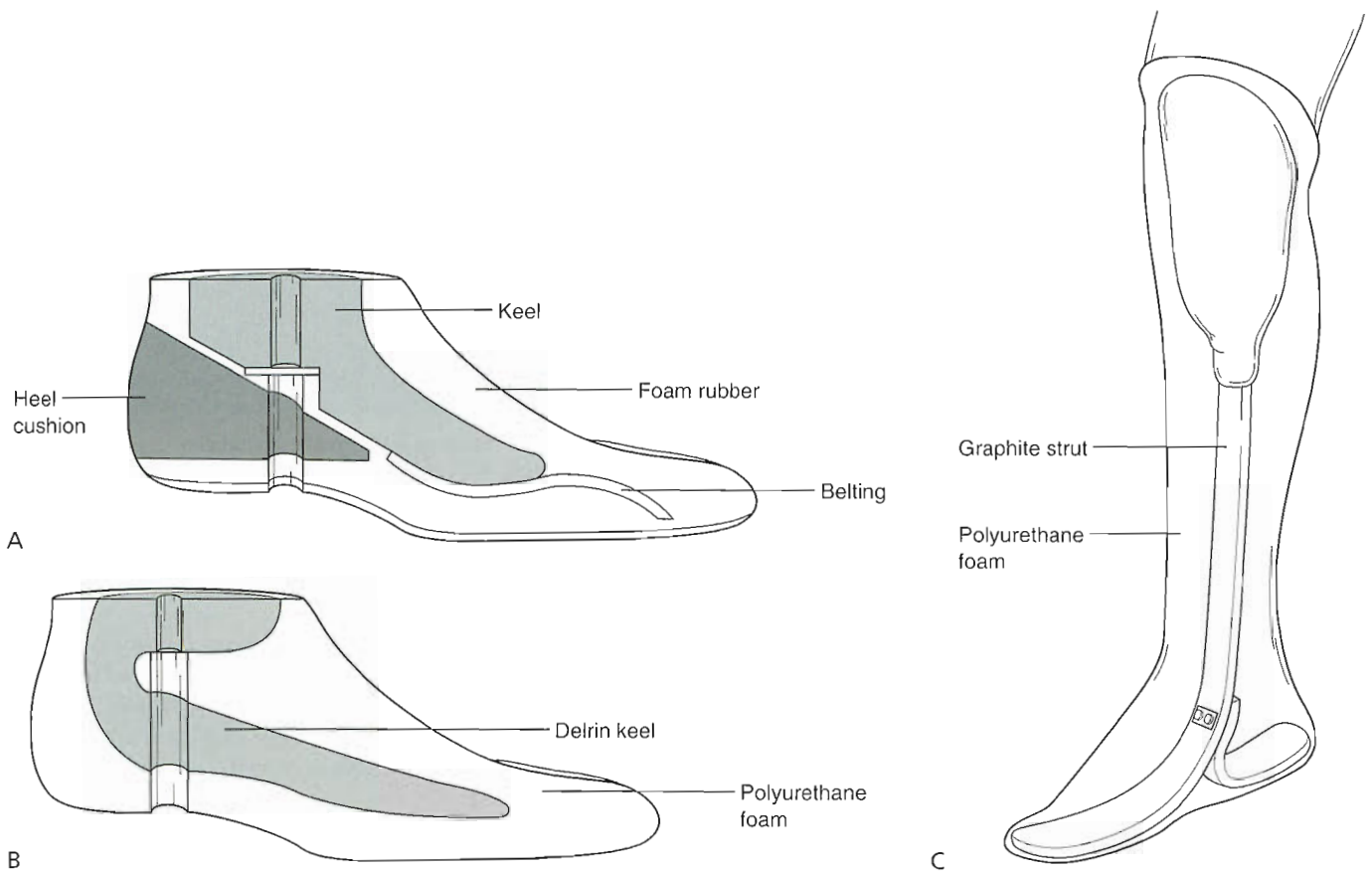


FIGURE 30-27. A: The solid ankle cushion heel (SACH) foot. The length of the keel controls the toe lever arm, and thus the hyperextension moment at the knee, while the compression of the material at the heel absorbs the forces at heel strike. B: The Seattle foot is one of the many varieties of energy-storing feet. It incorporates a flexible keel in the foam foot. This is one of the most common feet used in the pediatric amputee. C: The Flex-foot is another energy-storing foot, but with much different performance characteristics than the Seattle foot. It is used for the older, stronger, and physically active child who has the physical ability to use such a foot.

during all aspects of the gait cycle. A common mistake is to prescribe a dynamic-response foot with a simple, friction-controlled knee that is incapable of preventing uncontrolled heel rise. The same is true of the transtibial amputee, who lacks muscle strength to control the foot, often resulting in premature muscle fatigue. In the selection of multiple components, the prosthetist must marry the characteristics of all components, so that maximum benefit can be available to the amputee.

Partial Foot Prosthesis

The most important consideration in the fitting of the partial foot amputee is to ensure that adequate load-bearing is designed into the prosthesis of choice. As a general rule, the more proximal the level of amputation, the higher the prosthesis must fit over the ankle complex and proximal on the tibia/fibula. Tissue condition, function of the remaining

foot complex, and activity of the child, all play a role in determining the prescription and design of the prosthesis.

Complete or partial absence of the toes usually requires little more than a shoe filler. A carbon fiber insert, to better control forces from heel to toe-off, may be incorporated in the shoe filler. In the case of the very young child, no intervention may be required until a need has been demonstrated, e.g., the inability to keep the shoe on, especially when the child becomes more active in sports.

The prosthesis most commonly used for the moderate/short partial-foot amputee is the Lange silicone partial-foot prosthesis (Fig. 30-28). This incorporates a cosmetic foot shell, silicone laminated socket with modified foot sole, and a posterior zipper for ease of donning and doffing. The prosthesis is fabricated over a modified model of the patient's partial foot. The socket trim line is proximal to the malleoli, and is fitted intimately, to ensure adequate control. The design of a partial foot prosthesis may also include a

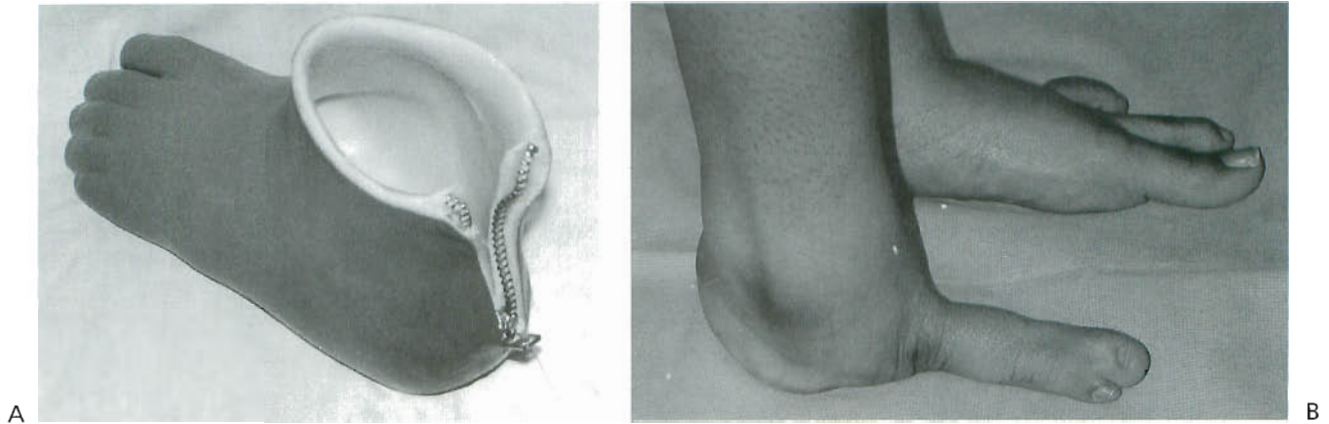


FIGURE 30-28. A: The Lange silicone partial-foot prosthesis is a custom-made prosthesis that can incorporate a keel to aid in foot stability and push-off in gait. B: It is useful for children with partial amputations of the foot or congenital longitudinal deficiencies of the foot, shown here. It is not useful in feet with insufficient length, e.g., the Chopart amputation.

removable insert, to accommodate the need for corrective alignment of the residual foot. The prosthesis is then cosmetically finished to resemble the contralateral limb. Overall, this type of prosthesis is perfectly suited for the child amputee, and resists premature wear and tear. If needed, a partial-foot prosthesis should be prescribed once the child is pulling to furniture, so that foot control will begin at an early age. It should be noted that a low-profile insert (distal to the malleoli), used in conjunction with a high-top boot, will offer adequate function and cosmesis until a lower-cut shoe is requested by the parent.

The Chopart, or midtarsal amputation is rarely used, except in special instances (175). In the Chopart partial-foot amputation level, the prosthesis is modified to encompass the calcaneus and talus, and this results in a prosthesis that is often longer than the contralateral limb. The prosthesis must encompass the ankle joint, and often rises proximally to the patellar tendon in an effort to reduce forces on the tibial crest-socket interface. Selection of prosthetic feet is compromised, because of the lack of space distally, and commercially available carbon foot plates require permanent attachment with vulcanizing rubber cement. This negates any changes caused by growth, and realignment to compensate for gait changes is virtually impossible.

Terminal Devices for the Upper Extremity

The choices left open to the prosthetist are numerous and, at times, controversial. Where some clinics maintain rigid protocols for terminal device selection, other clinics rely more on patient and parent input, combined with historic success rates for device types. Clinics that maintain very high myoelectric caseloads, for example, will most likely have far more experience in fitting externally powered prostheses, compared to a clinic that may only see a handful of potential myoelectric candidates.

In simple terms, the terminal devices can be divided into hands and hooks, and they can be body-powered (cable and harness) or externally powered (electric). Hands and hooks can be either voluntary opening or closing. Patton lists the functional and prescription criteria for the various terminal devices (175a).

The initial fitting of a child with upper-extremity limb deficiency begins at 4 months of age in a passive prosthesis with a clenched fist passive terminal device (Fig. 30-29A). This allows for equal arm lengths for the development of propping up on the amputated side and greater acceptance by the parents. Following initial sitting balance, the clenched-fist terminal device is exchanged for a small infant passive hand. When the infant begins to reach (at approximately 15 to 18 months of age), the clinic team begins to assess the need for either body-powered or externally powered prostheses. If body-powered is recommended, a cable-operated Hosmer 12P plastic-covered hook (Fig. 30-29B) or an ADEPT infant hand (Fig. 30-29C) will be prescribed. The canted design of the 12P hook allows for greater visual feedback to the wearer. In the event that a myoelectric device is warranted, the Variety Village 0-3 (VV 0-3) electric hand (Fig. 30-29D) or the Otto Bock Electrohand (Fig. 30-19) is used. In the pediatric VV 0-3 hand, the thumb and opposing two fingers operate to form a three-point chuck grip. In the OB 2000 hand, the same principle is applied, except that from the open to close position, the thumb sweeps from a lateral position to meet the two opposing fingers upon close.

Progression from this starting point through the various component sizes and versions allows for a relatively smooth transition into adulthood. Prescription criteria are reviewed during each clinic visit, and changes are made based on the child's changing needs. In today's environment of active children and sports activities, the use of sports or other adaptive terminal devices is essential for the amputee. Therapeutic Recreation Systems Inc. (TRS) has developed nu-

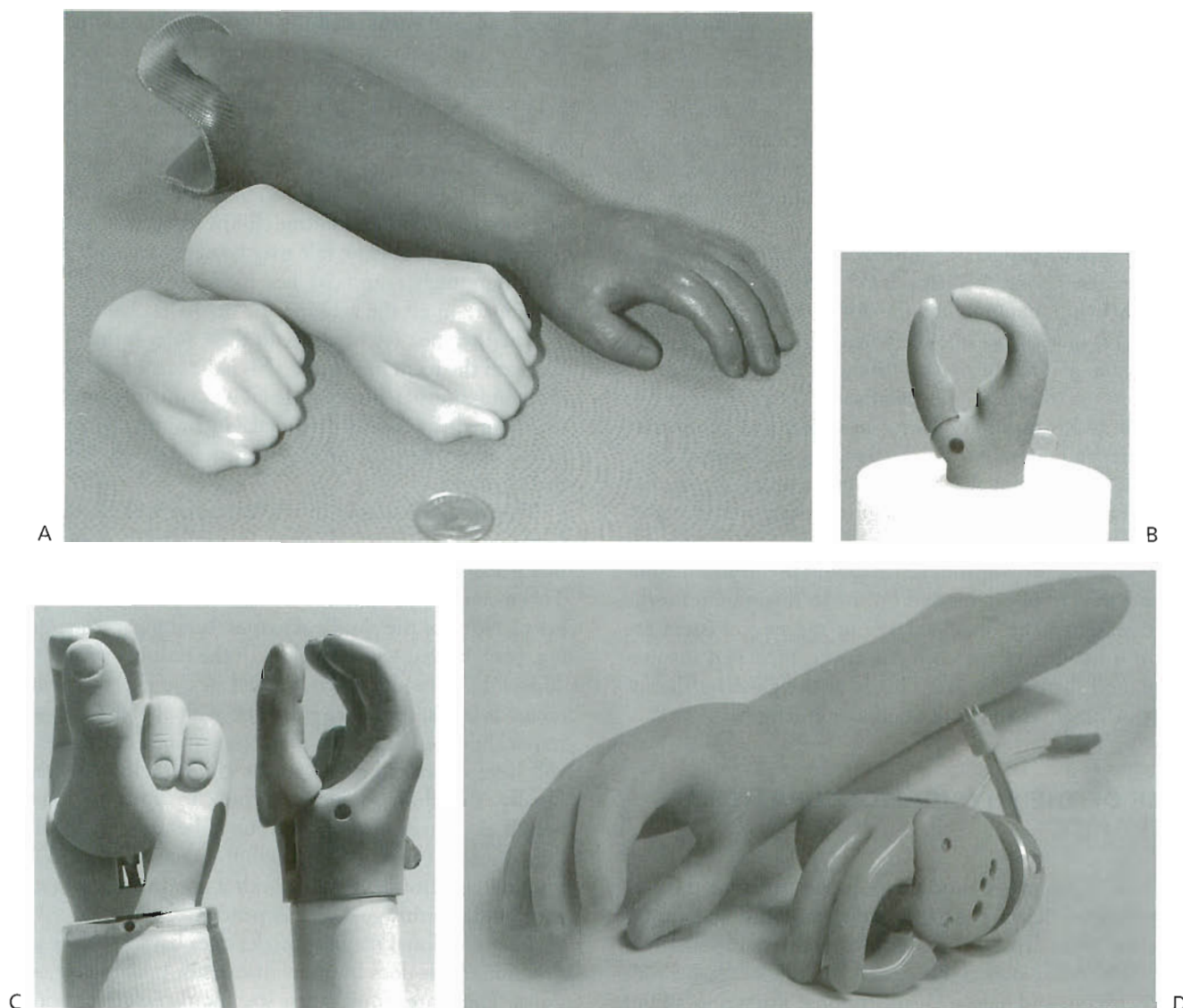


FIGURE 30-29. A: The passive fist or hand, which is used as the first hand for a child. This would commonly be fitted between 4 and 6 months of age. The fist has proven more useful than the open spoon-shaped passive hand since it allows the child to prop on the hand. Active hands are divided into two categories: body-powered and externally (electric) powered. B: The ADEPT is a voluntary closing body-powered hook that would be fitted around 15 months of age, if the child were ready and a body-powered device was desired. C: The Lite-Touch is a voluntary closing hand that would find the same indication as the ADEPT hook. It looks a bit more like a hand, which often makes this the parents' choice. D: The Variety Village hand is one of the most commonly used myoelectric hands in the pediatric age group. The Otto Bock Electrohand is shown in Figure 30-19. Both of these electric hands are covered with a cosmetic glove.

merous devices for use in sports and recreational activities. These can be interchanged on the prosthesis, so that only one socket is required.

Endoskeletal versus Exoskeletal Construction

The structure or construction of a prosthesis is referred to as an endoskeletal (internal structure) or exoskeletal (external structure) prosthesis. Generally, transtibial, partial foot, and

transradial prostheses are constructed exoskeletally, and transfemoral, knee disarticulation, hip disarticulation and transhumeral, and shoulder disarticulation levels are constructed endoskeletally.

Exoskeletally finished prostheses are more durable and better suited to the growing child. There are various techniques and materials used in the construction of the exoskeletal prosthesis. Generally, following the completion of dynamic alignment, the ready-to-be-finished prosthesis is placed within a transfer jig that allows the socket to be

separated from the foot, while maintaining alignment. A rigid polyurethane foam is added, and the prosthesis is cosmetically shaped to equal the sound limb. The structure is then laminated with acrylic resin forming the outer "shell." The advantages of this construction are increased durability, easy to clean, and structurally stronger. The major disadvantages are lack of further alignment capabilities, and they are less cosmetically acceptable.

Endoskeletal design was initially used in the immediate postoperative period as a temporary method to initiate ambulation, while maintaining the ability to alter the alignment. This quickly became the norm for fitting in the adult population, and has been used primarily for the knee disarticulation or transfemoral prosthesis. The prosthesis is modular and comprised of a pylon (tube) and connecting hardware, and allows for quick changing of damaged components. In the event that realignment is necessary, the endoskeletal design incorporates alignment jigs within the attachment couplings, and only the cosmetic soft cover needs to be removed for adjustment. In children, advanced components tend to be engineered for use in this system for the above reasons. The disadvantages of the endo system are lack of durability of the cosmetic cover, increased maintenance, and increased costs. This is outweighed by the increase in function and ease of adjusting length.

ROLE OF THE PHYSICAL/OCCUPATIONAL THERAPIST

The role of the physical/occupational therapist in the care of the limb-deficient child is mostly nontraditional, but at the same time, central. In addition to the traditional role of physical/occupational therapist is the role of teacher, advocate, friend, and liaison (176). In some situations, all but the traditional role of therapist may be filled by a nurse. In some cases, the role may be shared. What is important is to recognize the need for all of these activities.

The first role of the therapist will usually be that of educator. In this role, it is important that the therapist, physician, and prosthetist all be of one mind regarding the patient's treatment. First is the education of the parents. Like nurse practitioners, the therapists will usually have more time and be better heard than the doctor when relaying information to the parents about their child. The therapist will be able to reinforce with the parents the options that have been discussed at the initial meeting with the physician. Most importantly, they can arrange for the family and child to meet others with similar deficiencies during routine sessions. Throughout the child's life, the experienced therapist can be of immense value to the child and young adult, in anticipating problems and helping with solutions.

The therapist's first role as advocate will start with the first meeting with the parents. The importance in this role is to bring the parents to see the normal, as well as the

abnormal, and ensure that the initial bonding to the parents occurs. The therapist will frequently need to advocate for the patient to insurance companies and other agencies, to help provide for the patient's needs. When the child starts into day care, then school, the therapist will assist in the child's transition into a new world by educating the teachers and the child's peers about the child's differences. This can be extremely important for the child's acceptance and socialization. Later, the same role may be necessary with physical education teachers and coaches, to ensure that the child can participate in all the activities he or she is able to.

The therapist (or nurse) with these roles is the ideal liaison with the team members. This close teamwork can spare the child and parents countless visits to clinics and delays in treatment: a very important goal in avoiding the medicalization of a condition for which there is no cure, only good management.

The traditional role of the therapist will be far more home/community-based than hospital/office-based, for many reasons. First, the child's condition will be permanent. This means adapting to the environment in which the child exists. None of the child's activities (toileting, eating, dressing, play, sports) will take place in the hospital or an office. Therefore, they should be learned in the normal environment. Second, the parents will be with the child, and are responsible for the child's development and learning. They will have unlimited access to the child for this "therapy." Finally, the child should not come to think of him- or herself as a medical problem, but rather as a child with a difference that they will successfully adapt to. Unnecessary hospital/clinic/office visits are not a good way in which to communicate this goal of independence.

The traditional medical model does have a role in acute situations, as it does in many diseases or postsurgical situations. These are times when specific therapeutic exercises or the use of new prostheses must be performed, supervised, and taught. During the first months of life in a congenital amputee, the parents are seen by the therapist every 6 to 8 weeks. The child's development is monitored, and the parents are taught activities appropriate for the stage of development, e.g., rolling over and coming to stand from sitting. These visits are used to monitor the parents' coping, to listen and answer questions, review treatment options, and arrange for the meeting with other parents and children.

Following surgical intervention and prosthetic fitting, the medical model is more appropriate, and the frequency of the visits increase briefly, while the child and parent are taught the use of the prosthesis. In addition to the usual goals of increasing or maintaining motion and strength following surgery, the therapist plays a critical role in edema control. This is very important if the patient is to resume prosthetic wear quickly. Teaching and supervising elastic wrapping obtaining shrinkers are important postsurgical issues.

Older children need to be taught ways to become inde-

pendent in donning and doffing the prosthesis, toileting, and other activities with the prosthesis. Fitting of a new prosthetic component, e.g., a hydraulic knee joint, will usually require specific training to maximize the benefits of the new components.

As the child grows out of infancy, the therapist can be helpful in designing and modifying age-appropriate play activities. With the approach of school age, emphasis switches to independence in the activities of daily living, and later, fine motor skills that may be needed for classroom activities. Adaptations for sports, e.g., special terminal devices, if desired, or a swimming leg, are important, as is the advocacy role to allow the children to participate in all possible activities.

In adolescence the need for specific therapeutic interventions is usually minimal. The child has now become fully aware of his or her differences and their significance. The child will usually dictate the needs. Appearance being important, more cosmetic prostheses and improved gait become important issues.

At this time, driving becomes one of the major issues defining independence. The therapist can play a critical role in directing the child and parents to the appropriate agency for the rules of the state, and to a source for evaluation and modifications to the vehicle. As with any adolescent, the amputee should attend driver education training, using modifications if needed. Modifications can range from simple to complex. Switching the brake and gas pedals to accommodate unilateral lower-limb loss is one of the most common examples. Many amputees, even with bilateral lower-extremity loss, drive without adaptations. This must be closely monitored and evaluated by the state's examiners. Hand controls are used most commonly in bilateral lower-extremity loss. A ring adaptation can be used to modify the steering wheel for upper-extremity amputees. A handicap license is appropriate for individuals whose mobility is limited. The higher-level amputee, and those with multilevel limb loss, may benefit from a handicap parking license. All modifications are listed on the amputee's driver's license.

College is often the patient's first test of complete independence, and the needs may be greater than the child anticipates. The therapist can be of great value in assessing the situation, counseling the patient, and helping with the transition.

ADAPTATIONS FOR ACTIVITIES AND SPORTS

Children of all ages with limb deficiencies or amputations should be encouraged to participate in sports and recreational activities with their peers. The psychologic impact of sports cannot be underestimated. Improving self-esteem and confidence, gaining independence, learning to win and lose, developing decision-making and problem-solving

skills, and cooperating as a team member are a few of the benefits that a child carries throughout his/her life. Improving physical fitness, developing balance, strength, coordination and motor skills, increasing endurance, and weight control are benefits of physical activity.

Over the years, there has been an increased awareness of adapted sports and recreation for individuals with physical and mental impairments. The Paralympic and Special Olympics initiatives have been the most obvious, and have sparked an increase in availability of programs for special-needs children. Laws also have been passed for children to receive education in the least-restrictive environments. PL 94-142 provides free and appropriate education for all children with disabilities (Campbell S, *Physical Therapy For Children*, 1994). Physical therapy and recreation are related services included in this legislation. This allows for adapted physical education to be included in a child's everyday school activities. Physical therapists need to be aware of the resources and adaptations that provide accessibility of a sport to a child within limits of his/her physical abilities in the school and community settings. Gross motor achievements are a measure of a child's development. Learning to toss a ball, jump, run, hop, and ride a bicycle are activities included on standardized developmental screenings and tests. It is important that these activities be included in the child's plan of treatment, so that a child can be offered the same age-appropriate physical challenges as his/her peers.

Special adaptations and specific sports-related prostheses are available, depending on the degree and level of the disability. All of the adaptations are too numerous to mention. Recreational and sports-related terminal devices are available for the upper-extremity amputee (177,178). Adaptations can be as simple as raising the handlebars on a bicycle and adding a toe strap to highly sophisticated prosthetic components specific to each sport (179). Information and resources for sports and adaptive recreation for the amputee can be obtained through the Amputee Coalition of America (e-mail: www.amputee-coalition.org; phone 1-888-267-5669). The Association of Children's Prosthetic and Orthotics Clinics is an excellent resource for services in geographical regions (e-mail: www.acpoc.org; phone 847-698-1637).

References

Epidemiology

1. McDonnell P. Developmental response to limb deficiency and limb replacement. *Can J Psychol* 1988;42:120.
2. Jones L, Lipson A. The care of the limb deficient child in Australia. *Prosthet Orthot Int* 1991;15:140.
3. Stewart CP, Jain AS. Congenital limb anomalies and amputees Tayside, Scotland 1965-1994. *Prosthet Orthot Int* 1995;19:148.
4. Rogala EJ, Wynne-Davies R, Littlejohn A, et al. Congenital limb anomalies: frequency and aetiological factors. *J Med Genetics* 1974;11:221.
5. Froster UG, Baird PA. Congenital defects of lower limbs and

associated malformations: a population base study. *Am J Med Genetics* 1993;45:60.

6. Clark M, Atkins D, Hubbard S, et al. Prosthetic devices for children with bilateral upper limb deficiencies: when and if, pros and cons. In: Herring JA, Birch JG, eds. *The child with a limb deficiency*. Rosemont, IL: American Academy of Orthopaedic Surgeons, 1998:397.

Classification

7. Frantz C, O'Rahilly R. Congenital skeletal limb deficiencies. *J Bone Joint Surg Am* 1961;43:1202.
8. Schuch CM. International standards organization terminology: application to prosthetics and orthotics. *J Prosthet Orthot* 1993; 6:29.
9. Day HJB. The ISO/ISPO classification of congenital limb deficiency. In: Bowker JH, Michael JW, eds. *Atlas of limb prosthetics: surgical, prosthetic, and rehabilitation principles*. 2nd ed. St. Louis, MO: Mosby, 1992:743.

Etiology

10. Bavinck JN, Weaver DD. Subclavian artery supply disruption sequence: hypothesis of a vascular etiology for Poland, Klippel-Feil, and Mobius anomalies. *Am J Med Genet* 1986;23:903.
11. Streeter GL. Focal deficiencies in fetal tissues and their relation to intra-uterine amputation. *Contrib Embryol* 1930;22:1.
12. Glessner JR. Spontaneous intra-uterine amputation. *J Bone Joint Surg Am* 1963;45:351.
13. Sadler TW. Embryology and gene regulation of limb development. In: Herring JA, Birch JG, eds. *The child with a limb deficiency*. Rosemont, IL: American Academy of Orthopaedic Surgeons, 1998:3.
14. Lovett M, Clines G, Wise CA. Genetic control of limb development. In: Herring JA, Birch JG, eds. *The child with a limb deficiency*. Rosemont, IL: American Academy of Orthopaedic Surgeons, 1998:13.
15. Weaver DD. Vascular etiology of limb defects: the subclavian artery supply disruption sequence. In: Herring JA, Birch JG, eds. *The child with a limb deficiency*. Rosemont, IL: American Academy of Orthopaedic Surgeons, 1998:25.
16. Skjaerven R, Wilcos AJ, Lie TR. A population-based study of survival and childbearing among female subjects with birth defects and the risk of recurrence in their children. *N Engl J Med* 1999;340:1057.

The Child with an Amputation

17. Dunn NL, McCartan KW, Fuqua RW. Young children with orthopedic handicaps: self-knowledge about their disability. *Except Child* 1998;55:249.
18. Vaughn BE, Langolis JH. Physical attractiveness as a correlate of peer status and social competence in preschool children. *Dev Psychol* 1983;19:561.
19. Harper D, Wacker D, Cobb L. Children's social preferences toward peers with visible physical differences. *J Pediatr Psychol* 1986;11:323.
20. Richardson S. Age and sex differences in values toward physical handicaps. *J Health Soc Behav* 1970;11:207.
21. Richardson S. Handicap, appearance and stigma. *Soc Sci Med* 1971;5:621.
22. Varni J, Setoguchi Y, Rappaport L, et al. Effects of stress, social

support, and self-esteem on depression in children with limb deficiencies. *Arch Phys Med Rehabil* 1991;72:1053.

23. Varni J, Setoguchi Y. Correlates of perceived physical appearance in children with congenital/acquired limb deficiencies. *Dev Behav Pediatr* 1991;12:171.
24. Varni JW, Setoguchi Y. Effects of parental adjustment on the adaptation of children with congenital or acquired limb deficiencies. *J Dev Behav Pediatr* 1993;14:13.

The Parents

25. Letts M, Vincent N. Congenital longitudinal deficiency of the fibula (fibular hemimelia). Parental refusal of amputation. *Clin Orthop* 1993;287:160.

Organization of Care

26. Hubbard S, Heim W, Giavedone B. Paediatric prosthetic management. *Curr Orthop* 1997;11:114.

General Considerations

27. Amstutz HC. The morphology, natural history, and treatment of proximal femoral focal deficiency—a congenital anomaly. Washington, DC: National Academy of Sciences, 1969:50.
28. Amstutz HC. Natural history and treatment of congenital absence of the fibula. *J Bone Joint Surg Am* 1972;54:1349.
29. Hamanishi C. Congenital short femur: clinical, genetic and epidemiological comparison of the naturally occurring condition with that caused by thalidomide. *J Bone Joint Surg Br* 1980;62: 307.
30. Achterman C, Kalamchi A. Congenital deficiency of the fibula. *J Bone Joint Surg Br* 1979;61:133.
31. Westin GW, Sakai DN, Wood WL. Congenital longitudinal deficiency of the fibula: follow-up of treatment by Syme amputation. *J Bone Joint Surg Am* 1976;58:492.
32. Anderson M, Messner MB, Green WT. Distribution of lengths of the normal femur and tibia in children from one to eighteen years of age. *J Bone Joint Surg Am* 1964;46:1197.
33. Christie J, Lamb DW, McDonald JM, et al. A study of stump growth in children with below-knee amputations. *J Bone Joint Surg Br* 1979;61:464.

Complications

34. Aitken GT. Overgrowth of the amputation stump. *Int Clin Info Bull* 1962;1:1.
35. Jorring K. Amputation in children: a follow-up of 74 children whose lower extremities were amputated. *Acta Orthop Scand* 1971;42:178.
36. Pellicore RJ, Lambert CN, Hamilton RC. Incidence of bone overgrowth in the juvenile amputee population. *Int Clin Info Bull* 1974;8:1.
37. Aitken GT. Surgical amputation in children. *J Bone Joint Surg Am* 1963;45:1735.
38. Speer DP. The pathogenesis of amputation stump overgrowth. *Clin Orthop* 1981;159:294.
39. Abraham E. Operative treatment of bone overgrowth in children who have an acquired or congenital amputation [letter; comment]. *J Bone Joint Surg Am* 1996;78:1287.
40. Davids JR, Meyer LC, Blackhurst DW. Operative treatment of bone overgrowth in children who have an acquired or congenital

- amputation [see comments]. *J Bone Joint Surg Am* 1995;77:1490.
41. Benevina J, Makley JT, Leeson MC, et al. Primary epiphyseal transplants and bone overgrowth in childhood amputations. *J Pediatr Orthop* 1992;12:467.
 42. Bernd L, Blasius K, Lukoschek M, et al. The autologous stump plasty: treatment for bony overgrowth in the juvenile amputees. *J Bone Joint Surg Br* 1991;73:203.
 43. Tooms R. Acquired amputations in children. In: Bowker J, Michael J, eds. *Atlas of limb prosthetics: surgical, prosthetic, and rehabilitation principles*. St. Louis, MO: Mosby, 1992:738.
 44. Wilkins K, McGrath P, Finley G, et al. Phantom limb sensations and phantom limb pain in child and adolescent amputees. *Pain* 1998;78:7.
 45. Melzack R, Israel R, Lacroix R, et al. Phantom limbs in people with congenital limb deficiency or amputation in early childhood. *Brain* 1997;120:1603.
 46. Lindsay J. Multiple pain complaints in amputees. *J Roy Soc Med* 1985;78:452.
 47. Davis RW. Phantom sensation, phantom pain and stump pain. *Arch Phys Med Rehabil* 1993;74:79.
 48. Sherman RA. A survey of current phantom limb treatments in the United States. *Pain* 1980;8:85.
- ### Congenital Deficiencies of the Lower Extremity
49. Carabelli R, Kellerman WC. Phantom pain: relief by application of TENS to the contralateral extremity. *Arch Phys Med Rehabil* 1985;66:466.
 50. Choi IH, Kumar SJ, Bowen JR. Amputation or limb-lengthening for partial or total absence of the fibula. *J Bone Joint Surg Am* 1990;72:1391.
 51. Coventry MB, Johnson EWJ. Congenital absence of the fibula. *J Bone Joint Surg Am* 1952;34:941.
 52. Pappas AM. Congenital abnormalities of the femur and related lower extremity malformations: classification and treatment. *J Pediatr Orthop* 1983;3:45.
 53. Maffulli N, Fixsen JA. Fibular hypoplasia with absent lateral rays of the foot. *J Bone Joint Surg Br* 1991;73:1002.
 54. Maffulli N, Fixsen JA. Management of forme fruste fibular hemimelia. *J Pediatr Orthop B* 1996;5:17.
 55. Birch JG, Lincoln TL, Mack PW. Functional classification of fibular deficiency. In: Herring JA, Birch JG, eds. *The child with a limb deficiency*. Rosemont, IL: American Academy of Orthopaedic Surgeons, 1998:161.
 56. Bohne WH, Root L. Hypoplasia of the fibula. *Clin Orthop* 1977;107.
 57. Kalamchi A. *Congenital lower limb deficiencies*. New York: Springer-Verlag, 1989.
 58. Torode IP, Gillespie R. Anteroposterior instability of the knee: a sign of congenital limb deficiency. *J Pediatr Orthop* 1983;3:467.
 59. Boakes JL, Stevens PM, Moseley RF. Treatment of genu valgus deformity in congenital absence of the fibula. *J Pediatr Orthop* 1991;11:721.
 60. Herring JA, Barnhill B, Gaffney C. Symes amputation; an evaluation of the physical and psychological function in young patients. *J Bone Joint Surg Am* 1986;68:573.
 61. Davidson WH, Bohne WH. The Syme amputation in children. *J Bone Joint Surg Am* 1975;57:905.
 62. Pappas AM, Miller JT. Congenital ball-and-socket ankle joints and related lower-extremity malformations. *J Bone Joint Surg Am* 1982;64:672.
 63. Takakura Y, Tamai S, Masuhara K. Genesis of the ball-and-socket ankle. *J Bone Joint Surg Br* 1986;68:834.
 64. Grogan DP, Holt GR, Ogden JA. Talocalcaneal coalition in patients who have fibular hemimelia or proximal femoral focal deficiency. A comparison of the radiographic and pathological findings. *J Bone Joint Surg Am* 1994;76:1363.
 65. Thompson TC, Straub LR, Arnold WD. Congenital absence of the fibula. *J Bone Joint Surg Am* 1957;39:1229.
 66. Farmer AW, Laurin CA. Congenital absence of the fibula. *J Bone Joint Surg Am* 1960;42:1.
 67. Kruger LM, Talbot RD. Amputation and prosthesis as definitive treatment in congenital absence of the fibula. *J Bone Joint Surg Am* 1961;43:625.
 68. Wood WL, Zlotsky N, Westin GW. Congenital absence of the fibula: treatment by Syme amputation—indications and technique. *J Bone Joint Surg Am* 1965;47:1159.
 69. Hootnick D, Boyd NA, Fixsen JA, et al. The natural history and management of congenital short tibia with dysplasia or absence of the fibula. *J Bone Joint Surg Br* 1977;59:267.
 70. Miller LS, Bell DF. Management of congenital fibular deficiency by Ilizarov technique. *J Pediatr Orthop* 1992;12:651.
 71. Stanitski DF, Shahcheraghi H, Nicker DA, et al. Results of tibial lengthening with the Ilizarov technique. *J Pediatr Orthop* 1996;16:168.
 72. Catagni MA, Guerreschi F. Management of fibular hemimelia using the Ilizarov method. In: Herring JA and Birch JG, eds. *The child with a limb deficiency*. Rosemont, IL: American Academy of Orthopaedic Surgeons, 1998:179.
 73. Catagni MA. Management of fibular hemimelia using the Ilizarov method. *Instr Course Lect* 1992;41:431.
 74. Gibbons PJ, Bradish CF. Fibular hemimelia: a preliminary report on management of the severe abnormality. *J Pediatr Orthop B* 1996;5:20.
 75. Ghoneem HG, Wright JG, Cole WG, et al. The Ilizarov method for correction of complex deformities: psychological and functional outcomes. *J Bone Joint Surg Am* 1996;78:1480.
 76. Gibbons PJ, Bradish CF. Fibular hemimelia: a preliminary report on management of the severe abnormality. *J Pediatr Orthop B* 1996;5:20.
 77. Price CT. Editorial: are we there yet? Management of limb-length inequality. *J Pediatr Orthop* 1996;16:141.
 78. Naudie D, Hamdy RC, Fassier F, et al. Management of fibular hemimelia: amputation or limb lengthening [see comments]. *J Bone Joint Surg Br* 1997;79:58.
 79. Correll J. Management of fibular hemimelia [letter; comment]. *J Bone Joint Surg Br* 1997;79:1040.
 80. Herring JA. Symes amputation for fibular hemimelia: a second look in the Ilizarov era. *Instr Course Lect* 1992;41:435.
 - 80a. Birch JG, Walsh SJ, Small JM, et al. Syme amputation for the treatment of fibular deficiency. *J Bone Joint Surg Am* 1999;81:1511.
 81. Syme J. Amputation at the ankle joint. *London Edinburgh Monthly J Med Sci* 1843;3:93.
 82. Anderson L, Westin GW, Oppenheim WL. Syme amputation in children: indications, results, and long-term follow-up. *J Pediatr Orthop* 1984;4:550.
 83. Eilert RE, Jayakumar SS. Boyd and Syme ankle amputations in children. *J Bone Joint Surg Am* 1976;58:1139.
 84. Fergusson CM, Morrison JD, Kenwright J. Leg-length inequality in children treated by Syme's amputation. *J Bone Joint Surg Br* 1987;69:433.
 85. Mazer R Jr. Syme's amputation. A follow-up study of fifty-one adults and thirty-two children. *J Bone Joint Surg Am* 1968;50:1549.
 86. Gaine WJ, McCreath SW. Syme's amputation revisited: a review of 46 cases. *J Bone Joint Surg Br* 1996;78:461.
 87. Green WB, Cary JM. Partial foot amputations in children. *J Bone Joint Surg Am* 1982;64:438.

88. Boyd HB. Amputation of the foot with calcaneotibial arthrodesis. *J Bone Joint Surg* 1939;21:997.
89. Serafin J. A new operation for congenital absence of the fibula: preliminary report. *J Bone Joint Surg Br* 1967;49:59.
90. Thomas IH, Williams PF. The Gruca operation for congenital absence of the fibula. *J Bone Joint Surg Br* 1987;69:587.
91. Turker R, Mendelson S, Ackman J, et al. Anatomic considerations of the foot and leg in tibial hemimelia. *J Pediatr Orthop* 1996;16:445.
92. Williams L, Wientroub S, Getty CJM, et al. Tibial dysplasia. A study of the anatomy. *J Bone Joint Surg Br* 1983;65:157.
93. Kalamchi A, Dawe RV. Congenital deficiency of the tibia. *J Bone Joint Surg Br* 1985;67:581.
94. Grissom LE, Harcke HT, Kumar SJ. Sonography in the management of tibial hemimelia. *Clin Orthop* 1990;251:266.
95. Kumar A, Kruger LM. Fibular dimelia with deficiency of the tibia. *J Pediatr Orthop* 1993;13:203.
96. Loder RT, Herring JA. Fibular transfer for congenital absence of the tibia: a reassessment. *J Pediatr Orthop* 1987;7:8.
97. Schoenecker PL, Capelli AM, Millar EA, et al. Congenital longitudinal deficiency of the tibia. *J Bone Joint Surg Am* 1989;71:278.
98. Aitken GW. Tibial hemimelia. In: Aitken GW, ed. *Selected lower limb anomalies: surgical and prosthetic management*. Washington, DC: National Academy of Sciences, 1971:1.
99. Schoenecker PL. Tibial deficiency. In: Herring JA, Birch JG, eds. *The child with a limb deficiency*. Rosemont, IL: American Academy of Orthopaedic Surgeons, 1998:209.
100. Setoguchi Y. Medical conditions associated with congenital limb deficiencies. In: Herring JA, Birch JG, eds. *The child with a limb deficiency*. Rosemont, IL: American Academy of Orthopaedic Surgeons, 1998:51.
101. Clark MW. Autosomal dominant inheritance of tibial meromelia. Report of a kindred. *J Bone Joint Surg Am* 1975;57:262.
102. Wilson GN. Heritable limb deficiencies. In: Herring JA, Birch JG, eds. *The child with a limb deficiency*. Rosemont, IL: American Academy of Orthopaedic Surgeons, 1998:39.
103. Goldberg MJ. *The dysmorphic child: an orthopaedic perspective*. New York: Raven, 1987.
104. Meyers TH. Congenital absence of the tibia: transplantation of head of fibula: arthrodesis at the ankle joint. *Am J Orthop Surg* 1910;3:72.
105. Sulamaa M, Ryoppy S. Congenital absence of the tibia. *Acta Orthop Scand* 1963;33:262.
106. Brown FW. Construction of a knee joint in congenital total absence of the tibia (paraxial hemimelia tibia). *J Bone Joint Surg Am* 1965;47:695.
107. Christini D, Levy EJ, Facanha FA, et al. Fibular transfer for congenital absence of the tibia. *J Pediatr Orthop* 1993;13:378.
108. Epps CH Jr, Tooms RE, Edholm CD, et al. Failure of centralization of the fibula for congenital longitudinal deficiency of the tibia. *J Bone Joint Surg Am* 1991;73:858.
109. Simmons ED Jr, Ginsburg GM, Hall JE. Brown's procedure for congenital absence of the tibia revisited. *J Pediatr Orthop* 1996;16:85.
110. Wehbe MA, Weinstein SL, Ponseti IV. Tibial agenesis. *J Pediatr Orthop* 1981;1:395.
111. Jayakumar SS, Eilert RE. Fibular transfer for congenital absence of the tibia. *Clin Orthop Rel Res* 1979;139:97.
112. Loder RT. Fibular transfer for congenital absence of the tibia (Brown procedure). In: Herring JA, Birch JG, eds. *The child with a limb deficiency*. Rosemont, IL: American Academy of Orthopaedic Surgeons, 1998:223.
113. Jayakumar SS, Eilert RE. Fibular transfer for congenital absence of the tibia. *Clin Orthop* 1979:97.
114. Jones D, Barnes J, Lloyd-Roberts GC. Congenital aplasia and dysplasia of the tibia with intact fibula. Classification and management. *J Bone Joint Surg Br* 1978;60:31.
115. Fernandez-Palazzi F, Bendahan J, Rivas S. Congenital deficiency of the tibia: a report on 22 cases [in process citation]. *J Pediatr Orthop B* 1998;7:298.
116. Garbarino JL, Clancy M, Harcke HT, et al. Congenital diastasis of the inferior tibiofibular joint: a review of the literature and report of two cases. *J Pediatr Orthop* 1985;5:225.
117. Pattinson RC, Fixsen JA. Management and outcome in tibial dysplasia [see comments]. *J Bone Joint Surg Br* 1992;74:893.
118. Bose K. Congenital diastasis of the inferior tibiofibular joint. *J Bone Joint Surg Am* 1976;58:886.
119. Tuli SM, Varma BP. Congenital diastasis of the tibio-fibular mortise. *J Bone Joint Surg Br* 1972;54:346.
120. Sedgwick WG, Schoenecker PL. Congenital diastasis of the ankle joint. *J Bone Joint Surg Am* 1982;64:450.
121. Wilk B, Karol L, Halliday S. Characterizing gait in young children with a prosthetic knee joint. *Phys Ther Products* 1999;10:20.
122. Aitken GT. Proximal femoral deficiency. In: *A symposium on proximal femoral focal deficiency—a congenital anomaly*. Washington, DC: National Academy of Sciences, 1969:1.
123. Gillespie R, Torode IP. Classification and management of congenital abnormalities of the femur. *J Bone Joint Surg Br* 1983;65:557.
124. Gillespie R. Classification of congenital abnormalities of the femur. In: Herring JA, Birch JG, eds. *The child with a limb deficiency*. Rosemont, IL: American Academy of Orthopaedic Surgeons, 1998:63.
125. Kalamchi A, Cowell HR, Kim KI. Congenital deficiency of the femur. *J Pediatr Orthop* 1985;5:129.
126. Fixsen JA, Lloyd-Roberts GC. The natural history and early treatment of proximal femoral focal dysplasia. *J Bone Joint Surg Br* 1974;56:86.
127. Wolfgang GL. Complex congenital anomalies of the lower extremities: femoral bifurcation, tibial hemimelia, and diastasis of the ankle. Case report and review of the literature. *J Bone Joint Surg Am* 1984;66:453.
128. Bevan-Thomas WH, Millar EA. A review of proximal focal deficiencies. *J Bone Joint Surg Am* 1967;49.
129. Epps, CH Jr. Proximal femoral focal deficiency. *J Bone Joint Surg Am* 1983;65:867.
130. Borggreve J. Kniegelenkersatz durch das in der Beinlängsachse um 1800 gedreht Fussgelenk. *Arch Orthop Unfall Chir* 1930;28:175.
131. van Nes CP. Rotation-plasty for congenital defects of the femur: making use of the ankle of the shortened limb to control the knee joint of a prosthesis. *J Bone Joint Surg Br* 1950;32:12.
132. Kostuik JP, Gillespie R, Hall JE, et al. Van Nes rotational osteotomy for treatment of proximal femoral focal deficiency and congenital short femur. *J Bone Joint Surg Am* 1975;57:1039.
133. Torode IP, Gillespie R. Rotationplasty of the lower limb for congenital defect of the femur. *J Bone Joint Surg Br* 1983;65:569.
134. Friscia DA, Moseley CF, Oppenheim WL. Rotational osteotomy for proximal femoral focal deficiency. *J Bone Joint Surg Am* 1989;71:1386.
135. Alman BA, Krajchich JI, Hubbard S. Proximal femoral focal deficiency: results of rotationplasty and Syme amputation. *J Bone Joint Surg Am* 1995;77:1876.
136. Hillmann A, Hoffmann C, Goshager G, et al. Malignant tumor of the distal part of the femur of the proximal part of the tibia: endoprosthetic replacement of rotationplasty. *J Bone Joint Surg Am* 1999;81:462.
137. Murray PM, Jacobs PA, Gore DR, et al. Functional performance after tibial rotationplasty. *J Bone Joint Surg Am* 1985;67:392.
138. Steenhoff RM, Daanen HAM, Taminiau HM. Functional analysis of patients who have had a modified van Nes Rotationplasty. *J Bone Joint Surg Am* 1993;75:1451.

139. Fowler E, Zernicke R, Setoguchi Y, et al. Energy expenditure during walking by children who have proximal femoral focal deficiency. *J Bone Joint Surg Am* 1996;78:1857.
140. Westin GW, Gunderson FO. Proximal femoral focal deficiency—a review of treatment experiences. In: Aitken GT, ed. *Proximal femoral focal deficiency. A congenital anomaly*. Washington, DC: American Academy of Sciences, 1969:100.
141. Koman LA, Meyer LC, Warren FH. Proximal femoral focal deficiency: a 50-year experience. *Dev Med Child Neurol* 1982;24:344.
142. Goddard NJ, Hashemi-Nejad A, Fixsen JA. Natural history and treatment of instability of the hip in proximal femoral focal deficiency. *J Pediatr Orthop B* 1995;4:145.
143. Panting AL, Williams PF. Proximal femoral focal deficiency. *J Bone Joint Surg Br* 1978;60:46.
144. Tonnis D, Stanitski DF. Early conservative and operative treatment to gain early normal growth in proximal femoral focal deficiency. *J Pediatr Orthop B* 1997;6:59.
145. Steel HH. Iliofemoral fusion for proximal femoral focal deficiency. In: Herring JA, Birch JG, eds. *The child with a limb deficiency*. Rosemont, IL: American Academy of Orthopaedic Surgeons, 1998:99.
146. Brown KLB. Rotationplasty with hip stabilization in congenital femoral deficiency. In: Herring JA, Birch JG, eds. *The child with a limb deficiency*. Rosemont, IL: American Academy of Orthopaedic Surgeons, 1998:103.
147. Steel HH. Iliofemoral fusion for proximal femoral focal deficiency. In: Herring JA, Birch JG, eds. *The child with a limb deficiency*. Rosemont, IL: American Academy of Orthopaedic Surgeons, 1998:99.
148. McCollough NC. Non-standard prosthetic applications for juvenile amputees. *Inter-Clinic Information Bulletin* 1963;2:7.
149. Kruger L. Lower limb deficiencies/surgical management. In: Bowker JH, Michael JW, eds. *Atlas of limb prosthetics: surgical, prosthetic, and rehabilitation principles*. St. Louis, MO: Mosby, 1992:759.
150. Bochmann D. Prostheses for the limb-deficient child. In: Kostuik J, Gillespie R, eds. *Amputation surgery and rehabilitation: the Toronto experience*. New York: Churchill Livingstone, 1981:293.

Congenital Deficiencies of the Upper Extremity

151. Marquardt E. The multiple limb deficient child. In: Bowker JH, Michael JW, eds. *Atlas of limb prosthetics: surgical, prosthetic, and rehabilitation principles*. St Louis, MO: Mosby, 1992:839.
152. Scotland T, Galway H. A long-term review of children with congenital and acquired upper limb deficiency. *J Bone Joint Surg Br* 1983;65:346.
153. Brooks M, Shaperman J. Infant prosthetic fitting: a study of results. *Am J Occup Ther* 1965;19:329.
154. Sorbye R. Upper extremity amputees: Swedish experiences concerning children. In: Atkins DJ, Meier RHI, eds. *Comprehensive management of the upper-limb amputee*. Berlin: Springer-Verlag, 1989:235.
155. Hubbard SA, Kurtz I, Heim W, et al. Powered prosthetic intervention in upper extremity deficiency. In: Herring JA, Birch JG, eds. *The child with a limb deficiency*. Rosemont, IL: American Academy of Orthopaedic Surgeons, 1998:426.
156. Patton JG. Developmental approach to pediatric prosthetic evaluation and training. In: Atkins DJ, Meier RHI, eds. *Comprehensive management of the upper limb amputee*. Berlin: Springer-Verlag, 1991:137.
157. Patton JG. Upper-limb prosthetic components for children and teenagers. In: Atkins DJ, Meier RHI, eds. *Comprehensive man-*

agement of the upper limb amputee. Berlin: Springer-Verlag, 1991:99.

158. Muilenburg A, LeBlanc M. Body-powered upper-limb components. In: Atkins K, Meier RHI, eds. *Comprehensive management of the upper-limb amputee*. Berlin: Springer-Verlag, 1988:28.
159. Scott RN. Biomedical engineering in upper-limb prosthetics. In: Atkins DJ, Meier RHI, eds. *Comprehensive management of the upper-limb amputee*. Berlin: Springer-Verlag, 1988:173.

Acquired Deficiency

160. Letts M, Davidson D. Epidemiology and prevention of traumatic amputations in children. In: Herring JA, Birch JG, eds. *The child with a limb deficiency*. Rosemont, IL: American Academy of Orthopaedic Surgeons, 1989:235.
161. Trautwein LC, Smith DG, Rivara FP. Pediatric amputation injuries: etiology, cost, and outcome. *J Trauma* 1996;41:831.

Prosthetics

162. Quigley MJ. Prosthetic management: overview, methods, and materials. In: Bowker JH, Michael JW, eds. *Atlas of limb prosthetics: surgical, prosthetic, and rehabilitation principles*. St. Louis: Mosby, 1992:67.
163. Steele A. A survey of clinical CAD/CAM use. *J Prosthet Orthot* 1994;6:42.
164. Michael JW. Reflections on CAD/CAM in prosthetics and orthotics. *J Prosthet Orthot* 1989;1:116.
165. Sutherland DH. The development of mature walking. Oxford: MacKeith Press, 1988.
166. Keen M. Early development and attainment of normal mature gait. *J Prosthet Orthot* 1993;5:34.
167. Pritham C. Workshop on teaching material for above-knee variants. *J Prosthet Orthot* 1989;1:50.
168. Gortschalk F, Stills S, McClellan B, et al. Does socket configuration influence the position of the femur in above-knee amputation? *J Prosthet Orthot* 1990;2:94.
169. Michael JW. Prosthetic knee mechanisms. *Phys Med Rehabil State Art Rev* 1994;8:147.
170. Gard S, Childress D, Uellendahl J. The influence of four-bar linkage knees on prosthetic swing-phase floor clearance. *J Prosthet Orthot* 1996;8:34.
171. Michael JW. Options meet varying needs. *Motion* 1997;7:34.
172. Barth D, Schumacher L, Thomas S. Gait analysis and energy cost of below knee amputees wearing six different prosthetic feet. *J Prosthet Orthot* 1991;4:63.
173. Cummings K, Kapp S. Lower limb pediatric prosthetics: general considerations and philosophy. *J Prosthet Orthot* 1991;4:196.
174. Neilson DH, Shurr DG, Golden JC, et al. Comparison of energy cost and gait efficiency during ambulation in below-knee amputees using different prosthetic feet—a preliminary report. *J Prosthet Orthot* 1988;1:24.
175. Letts M, Pyper A. The modified Chopart's amputation. *Clin Orthop* 1990;256:44.
- 175a. Patton JG. Upper-limb prosthetic components for children and teenagers. In: Atkins DJ, Meier RHI, eds. *Comprehensive management of the upper limb amputee*. Berlin: Springer Verlag, 1991:99.

The Role of the Physical/Occupational Therapist

176. Coutler-O'Berry C. Physical therapy management in children with lower extremity limb deficiencies. In: Herring JA, Birch

JG, eds. *The child with a limb deficiency*. Rosemont, IL: American Academy of Orthopaedic Surgeons, 1998:319.

Adaptations for Activities and Sports

177. Radocy B. Upper-limb prosthetic adaptations for sports and recreation. In: Bowker JH, Michael JW, eds. *Atlas of limb pros-*

thetics: surgical, prosthetic, and rehabilitation principles. St. Louis, MO: Mosby-Year Book, 1992:325.

178. Michael JW, Gailey RS, Bowker JH. New developments in recreational prostheses and adaptive devices for the amputee. *Clin Orthop* 1990;256:64.
179. Anderson TF. Aspects of sports and recreation for the child with a limb deficiency. In: Herring JA, Birch JG, eds. *The child with a limb deficiency*. Rosemont, IL: American Academy of Orthopaedic Surgeons, 1998:345.



31

SPORTS MEDICINE IN CHILDREN AND ADOLESCENTS

MICHAEL T. BUSCH

CARE OF THE YOUNG ATHLETE 1273

Nutrition 1274
Heat Illness and Fluids 1275
Strength Training 1276
Performance-enhancing Substances 1276
Antiinflammatory Drugs 1276

OVERUSE SYNDROMES 1277

Classic Stress Fractures 1277
Repetitive Physeal Injuries 1279
Apophyseal Conditions 1280
Tendinosis 1283
Shin Pain 1284
Iliotibial Band Friction Syndrome 1286
Breaststroker's Knee 1286
Valgus Overload Injuries of the Elbow 1287

SPORTS TRAUMA 1289

Epidemiology 1289
Prevention 1289
Athletic Trainers 1290

Ankle Injuries 1290
Knee Injuries 1293
Quadriceps Contusion 1297
Avulsion Fractures of the Pelvis 1298
Spinal Injuries 1298

OTHER COMMON KNEE PROBLEMS 1299

Patellofemoral Disorders 1299
Anterior Knee Pain 1300
Chondromalacia 1304
Saphenous Nerve Entrapment 1304
Bipartite Patella 1304
Dorsal Defects of the Patella 1304
Fat Pad Impingement 1305
Plica Syndrome 1305
Acute Patellar Dislocation 1306
Recurrent Patellar Dislocations 1308
Popliteal Cyst 1309
Discoid Lateral Meniscus 1309

CONCLUSION 1311

CARE OF THE YOUNG ATHLETE

Young athletes sustain musculoskeletal injuries that are different from those of their adult counterparts. Although

many of these are the torus fractures, greenstick fractures, and physeal injuries that are common to children, the proliferation of youth athletics has increased the incidence of overuse syndromes and other injuries (1). The role of rehabilitation in the treatment of sports-related injuries is recognized, and there is a growing emphasis on prevention of these injuries (2).

The volume of organized sports activities and levels of

M. T. Busch: Department of Orthopaedics, Children's Healthcare of Atlanta at Scottish Rite, Atlanta, Georgia 30342.

intensity for youth training and competition have grown tremendously in recent years. The United States Consumer Product Safety Commission reported that approximately 2 million medically attended sporting injuries occur annually to youths between the ages of 5 and 14 years (3). In response to this problem, preparticipation physical examinations, heat illness education, safety reviews, school athletic trainers, team physicians, and health education programs for grade school and high school sports participants have evolved (4).

Sports have important effects on strength, speed, and stamina. If appropriately organized, sports can be a positive social experience, with opportunity for character growth and development. Competition is often emphasized, but the lifelong values of health, exercise, and recreation should not be overlooked. Particularly during the elementary school years, programs should be available that emphasize the participation by all children, not just the physically advantaged (5). Involving younger children in elite-level sports training and competition should be done with caution, because there is a risk of exploiting the child and producing long-term emotional consequences (6). However, many important behavioral needs of youths can be satisfied by athletic participation and competition (7).

Approximately 2% of children suffer from chronic medical problems that restrict their activity (8). Besides having to live with the inherent aspects of these conditions, these children are often excessively restricted from physical activities. Most children with asthma, cystic fibrosis, congenital heart disease, or juvenile rheumatoid arthritis can benefit from an appropriately structured exercise and sports recreation program (8,9). Recommendations are available from the American Academy of Pediatrics for sports participation by youths with special health conditions, although a physician's assessment of the individual situation should always be considered (10,11).

Programs such as the Special Olympics have grown from the recognition that children with physical impediments can benefit from the personal, social, and physical aspects of sports participation. Children with a variety of chronic illnesses, including asthma, can benefit from exercise conditioning (12); however, this should be done with the advice and direction of their physicians.

Nutrition

Everyone seriously involved with youth sports should be familiar with the facts and myths concerning nutrition. This area has received much attention in the medical and lay literature. Inaccurate nutritional information leaves the impressionable and naive young athlete easy prey for food faddists and nutrition charlatans.

Vigorous training increases the consumption of calories, but does not significantly alter the athlete's need for essential

nutrients (13). Minerals and electrolytes are replaced by a normal diet, unless the athlete is experiencing daily fluid losses of 4 to 6% of body weight because of excessive sweating. Nutritional supplements, such as vitamins and protein powder, are unnecessary if the youth eats a basic mixed daily diet consisting of four fruit or vegetable servings, four grain servings, two dairy products, and two high-protein foods (13,14). As many as 15 to 20% of menstruating female athletes may require an iron supplement. Children from low socioeconomic backgrounds may also lack adequate iron in their diet (15).

Young athletes have increased energy requirements related to rapid growth and exercise expenditure. The increased need for food energy is best met through complex carbohydrates. A high-carbohydrate and protein diet provides the needed calories, while increasing muscle and liver glycogen stores, which are important for athletic performance (16). Simple sugars provide a readily available source of carbohydrate calories. They may be a needed component of an active athlete's diet to meet total caloric requirements. The disadvantage of simple sugars is that they are absorbed quickly. This induces an insulin response that can lower serum glucose and result in fatigue.

The recommended caloric intake is 50 to 60% carbohydrate, 10 to 15% protein, and 30 to 35% lipids (17). The ratio of complex carbohydrates to these other components can be achieved with fruits, leafy vegetables, and starches such as potatoes, rice, pasta, and breads. Greasy and salty foods should be discouraged.

Carbohydrate loading during the days before competition can enhance glycogen stores to optimize energy availability for prolonged muscle performance (18–20). The pre-game meal should consist primarily of light carbohydrate foods consumed approximately 3 h before the activity (19). Foods high in fats and salt slow gastric emptying and increase water retention in the gut (13).

Fats are a rich source of energy, but they are poorly mobilized for a short-term energy expenditure. A diet high in fat fails to enhance the body's glycogen stores, which are important for athletic performance. Excessive consumption of fats also carries the associated risks of elevating serum cholesterol and triglycerides (17).

Proteins are complex amino acids. They are necessary components for building new muscle tissue. Proteins should account for approximately 15% of total caloric intake, and any surplus is metabolized for energy or excreted in urine (17). Most protein supplement preparations are solely expensive sources of calories. Gains in muscle strength and mass are made by training, and have not been proven to result only from providing a high-protein diet (20).

A variety of minerals and vitamins are important. Because potassium is primarily an intracellular ion, losses associated with sports are slow and gradual. Potassium does not need to be replenished acutely, but it is needed over the

prolonged course of serial competition and training (17). Magnesium is a key component in the adenosine triphosphate (ATP) cycle. Bananas are an excellent source of magnesium and potassium. Iron deficiency is still a problem in teens, especially females, vegetarians, and individuals from lower socioeconomic groups (14). Adolescents should be encouraged to eat iron-fortified foods, such as whole grain breads and lean red meats. When combined with citrus fruits, the bioavailability of iron increases. Athletic activity theoretically depends on all vitamins, but emphasis has been placed on vitamin C and B complex vitamins, because of their roles in the metabolism of proteins, fats, and carbohydrates for energy (17). However, there is no evidence to suggest that an intake in excess of normal requirements improves performance (17).

Heat Illness and Fluids

Heat illness is almost entirely preventable through awareness and education (21) (Table 31-1). Between 70 and 80% of the energy consumed in muscle contraction is transformed to heat (22). Heat loss is promoted by increased blood flow to the skin, and by increased sweating. Cooling is provided by thermal conduction, convection, radiation, and evaporation. Extrinsic factors affecting heat exchange include ambient temperature, humidity, clothing, sunlight, and wind.

The spectrum of heat illness can be divided into four clinical entities: heat cramps, heat syncope, heat exhaustion, and heat stroke (23). Heat cramps are painful muscle spasms that typically occur in the gastrocnemius and soleus, hamstrings, quadriceps, and spine extensors. Because the spasms are primarily caused by fluid depletion, the key elements of treatment are fluid replacement, stretching, and cooling. Heat syncope usually involves a feeling of fatigue and resolves with cooling, fluids, and rest. Heat exhaustion is characterized by extreme weakness, exhaustion, headache, al-

tered consciousness, and profuse sweating. This is a much more advanced stage of the heat illness continuum, and should be treated aggressively with fluid replacement, cooling, and restriction of further participation in sports for the day. Occasionally, intravenous fluids and hospitalization are necessary.

Heat stroke is a true medical emergency resulting from dehydration with severe hyperthermia. There can be severe abnormalities affecting the brain, heart, clotting system, kidneys, and liver. Edema of the brain and meninges, as well as petechial hemorrhage, can lead to loss of consciousness, dysphoria, headache, dizziness, weakness, confusion, euphoria, coma, and seizures. Myocardial injury and increased pulmonary vascular resistance can lead to tachycardia, hypotension, and shock. Systemic petechial, gross tissue hemorrhage, and consumptive coagulopathy are thought to be triggered by thermal injury to the vascular endothelium. Renal tubular dysfunction and acute tubular necrosis can result in severe dehydration and marked hypokalemia and hyponatremia. Occasionally, there is liver damage, including centrilobular necrosis and cholestasis resulting in hyperbilirubinemia and jaundice (24). Maximal cooling efforts should be made at the site, and the victim should be rapidly transported for emergency medical care (23).

Children are less efficient thermal regulators than adults and acclimatize more slowly than adults. They have a lower sweating capacity, especially before puberty. Children also produce more metabolic heat per mass, and have a decreased ability to conduct heat to the skin (25). They have a greater ratio of surface area to mass, which increases heat transfer from the environment on hot days. Additional risk factors for children can include obesity, fever, recent gastroenteritis with dehydration, and cystic fibrosis (26).

Sweat is hypotonic to body fluids, containing 40 to 80 mEq/L of sodium and less than 5 mEq/L of potassium. Sweating increases serum electrolyte concentrations. Electrolyte solutions for replacement are recommended only after 1 or 2 h of rigorous activity (27). Initially, plain water adequately replace these losses. The water should be cooled to stimulate thirst. Cool liquids do not significantly slow gastrointestinal emptying, but delayed motility can be a side effect of electrolyte solutions with high osmolalities. Salt tablets, once popular, are dangerous, because they can produce intracellular dehydration by their osmotic effect in the serum (22).

Situations that increase heat gain include rigorous exercise, bright direct sunlight, and dark clothing. Cooling is inhibited by dehydration, high humidity, high air temperature, a lack of wind, and equipment or clothing that act as insulation. Acclimatization is also important, because it reflects the body's capacity to transfer heat to the skin for convection and the body's ability to produce sweat for evaporation. With this as background, the guidelines in Table

TABLE 31-1. GUIDELINES FOR PREVENTING HEAT ILLNESS

Proper acclimatization at the beginning of the workout season
Evaluate weather conditions for temperature, humidity, and sunlight
Schedule rest in the shade
Identify participants at particular risk
Hydrate before practice and competition
Have chilled fluids readily available at the practice site
Enforce periodic drinking
Never use water restriction as discipline
Discourage deliberate dehydration for weight loss
Make appropriate clothing adjustments
Schedule events to avoid peak hours of heat and sun
Educate the players and parents
Record daily weights to ensure adequate rehydration between practices

31-1 outline most of the key components for avoiding heat illness.

Strength Training

Weight lifting should be differentiated from weight training. Olympic lifting and power lifting are the two categories of weight lifting. The Olympic lifts consist of snatch and clean-and-jerk lifts. The dead lift, squat lift, and bench press are the three power lifts. In both categories of weight lifting, the object is to perform a one-repetition maximum lift.

Weight training refers to the use of free weights and machines to enhance strength and endurance. Submaximal weights are lifted repeatedly with a large variety of exercises typically intended to enhance performance for other sports, rather than for a specific contest (28).

Children can increase strength by 20 to 40% in a well-supervised program, with a relatively low risk of injury (29,30). Females and prepubescent males do not produce significant hypertrophy of their muscles in response to weight training because of insufficient circulating androgens. The strength gains that occur result from enhanced recruitment of motor units and synchronization rather than significant muscular hypertrophy.

Common injuries associated with weight lifting include patellofemoral pain, meniscal tears, pelvic apophyseal avulsion fractures, and clavicular osteolysis (31,32). Lumbosacral injuries, including disc herniation and spondylolysis, are the most common problems in adolescent weight lifters (33). The most common injuries from weight lifting are muscle pulls, tendinitis, sprains, and other minor injuries (33). Stress fractures and a variety of acute physeal, metaphyseal, and diaphyseal fractures have been reported in weight lifters (28,34–36). Despite concerns, there does not seem to be any substantial evidence that weight training using submaximal loads harms the physeal plates. However, power lifting or Olympic weight lifting is generally not recommended for skeletally immature youths (37).

Many high schools run successful and safe weight-training programs. A proper strength-conditioning program should be a prerequisite to participation in contact sports. For safe participation, there should be a structured program supervised by an educated and attentive staff. Proper technique should be emphasized, using repetition without maximal weight lifts. Equipment must be in good repair. An attentive partner (i.e., spotter) is important when free weights are used. A conscientious, concurrent stretching program is also important (29,34). Although the scientific documentation is just evolving for warm-up and stretching, they appear to be important for preventing injuries (38,39). Stretching and warm-up exercises apparently enhance muscle, tendon, and ligament elasticity, and may improve performance by nervous system recruitment and psychologic effects (38,39).

Performance-enhancing Substances

The use of drugs with which athletes hope to enhance performance has become common (40). Frequently involved substances include amphetamines, analgesics, tranquilizers, diuretics, anabolic steroids, and creatine. The evidence for actual performance enhancement is questionable, but the potential complications are well known. Most widely abused are the anabolic steroids used in conjunction with weight training and weight lifting. The use of anabolic steroids, for example, has been reported to be as high as 5 to 11% of high school males and 2.5% of females (41–43). Up to two-thirds of the users start before 16 years of age (41,43).

Creatine supplements are legal, readily available, and increasingly popular with adolescents. Muscles convert creatine to phosphocreatine, which serves as a reservoir for the high-energy phosphate bonds of ATP. The idea behind the supplements is that excess phosphocreatine will lead to a higher rate of ATP synthesis, so the supplements are thought to delay the fatigue that results from ATP depletion. This may have some benefit in activities requiring short bursts of high-intensity muscle contraction; however, there is little evidence that it is helpful in endurance sports (44,45). Some argue that it allows athletes to train more intensely. Because the long-term effects are unknown, the use of creatine is generally not endorsed.

Anabolic steroid use appears to be spreading, despite the known side effects, which include premature epiphyseal closure, jaundice, acne, behavioral changes such as aggressiveness and mood swings, fluid retention, hematoma, hepatocellular carcinoma, testicular atrophy, and female hirsutism (42,46–48). Physicians dealing with adolescent athletes should be aware and suspicious of these problems. Unfortunately, physicians are occasionally the source for these drugs (41,43,47).

Young athletes are easily influenced, so the health aspects of reputed performance-enhancing substances must be addressed frankly. The efficacy of most of these substances is questionable. Those trying to offer easy alternatives to better conditioning and training rarely explain the risks. Rather than concentrating solely on competition or achievement, sports programs should stress the overall importance of health and activity.

Antiinflammatory Drugs

Nonsteroidal Antiinflammatory Drugs

The principles for using nonsteroidal antiinflammatory drugs (NSAIDs) in sports-produced inflammation include decreasing the pain of inflammation to allow compliance of rehabilitation and to avoid pain-induced atrophy, reducing inflammation in freshly healed and relatively vascular tissues during retraining, and limiting the zone of edema-induced tissue necrosis after acute injury. Although their effects, effi-

cacy, and roles are still being clarified, it is important to be familiar with these medications, because they are commonly used by young athletes.

NSAIDs work primarily through inhibition of cyclooxygenase in the pathway of prostaglandin synthesis (49). The three main clinical features are analgesic, antipyretic, and antiinflammatory effects. In inflammatory conditions, the response may take time. In rheumatoid arthritis, only one-half of the patients have an adequate response to the NSAID within 2 weeks, and an additional 30% respond by 10 weeks (50). Fifty percent of patients who experience no relief from the first type of NSAID improve after another is tried, and a trial of several drugs may be needed before a satisfactory response is achieved. In cases of prolonged use, a drug may become ineffective with time, requiring substitution of another NSAID (50).

The principal metabolic pathway of NSAIDs is hepatic, with renal excretion of the conjugated metabolites. All NSAIDs are extensively bound to proteins, giving them the potential to displace other drugs, but this seldom produces significant potentiation of other drug effects. The potentiation of anticoagulants is therapeutically significant, but these agents are seldom used in children and adolescents. Occasionally, two NSAIDs are used concomitantly, but this should be done under careful scrutiny for toxic side effects.

Aspirin, ibuprofen, naproxen, and tolmetin sodium are the only NSAIDs approved by the U.S. Food and Drug Administration for children younger than 13 years of age. Among the NSAIDs, aspirin is the least expensive, but has the highest rate of minor side effects. Most parents are reluctant to administer aspirin because of the well-publicized association with Reye syndrome. Naproxen has the advantage of twice-daily dosing, and is available in liquid suspension form. Ibuprofen is used widely, because it is relatively inexpensive and available without prescription.

Most of the information available about the use of these agents in younger patients derives from experience in treating juvenile rheumatoid arthritis. Their use in musculoskeletal inflammation secondary to trauma and overuse syndromes is less well documented, particularly in youths. Although these drugs are widely used, their efficacy in sports-related disorders is largely empiric and not well documented in placebo-controlled studies (49).

Occurring in as many as 10% of patients, the most common side effects of NSAIDs are gastrointestinal: gastritis, abdominal pain, nausea, diarrhea, and, occasionally, constipation. Hematuria, proteinuria, and marrow suppression also can occur. Most NSAIDs inhibit platelet function, and can lead to bleeding-related complications. Newly released cyclooxygenase-2 inhibitors avoid these problems, although safety in children is still being studied. Rarely, tinnitus, blurred vision, exacerbation of asthma, mood changes, drowsiness, and mouth ulcers are seen. These side effects usually resolve after discontinuance of the medication. Patients on prolonged NSAID therapy should have a hemo-

gram, urinalysis, and liver function profile at 2 weeks, 6 weeks, then every 6 months after therapy is begun. Rarely, NSAIDs can cause peptic ulcer, severe liver or renal toxicity, or severe allergic reactions (50). The use of NSAIDs in young children, or for prolonged periods in older children and teens, is probably best supervised by a rheumatologist or an experienced pediatrician.

Corticosteroids

Oral and parenterally administered steroids have multiple inhibitory effects on inflammation. Their action is more potent, but they may produce harmful side effects, including the retardation of healing (51).

There are concerns that intraarticular injection of steroids can damage articular cartilage, possibly by inhibiting the synthesis of chondral matrix (52). In adults, there are several reports of adults undergoing rapid radiographically-evident degeneration after intraarticular injections, but these are probably anecdotal. The risk of adult tendon rupture after steroid injection appears to be substantially more founded (51). Intraarticular triamcinolone hexacetonide, in the management of children with juvenile rheumatoid arthritis, has been effective with relatively few side effects (53). Because there is no definitive evidence regarding the safety and efficacy of oral or parenteral steroids for sports-related maladies in children, these treatment options should probably be avoided or used sparingly (54).

OVERUSE SYNDROMES

The term "overuse syndrome" categorizes several musculoskeletal maladies that are characterized by connective tissue failure in response to repetitive submaximal loading. In the course of normal activities, a small amount of tissue breakdown usually occurs. With repetition, musculoskeletal tissue hypertrophies and this is the essence of athletic training. If the rate of tissue fatigue exceeds the reparative response, failure occurs. Inflammation ensues and leads to clinical symptoms (55) (Fig. 31-1).

Classic Stress Fractures

Stress fractures are partial or complete disruptions of the bone secondary to an inability to withstand repetitive, non-violent loads. Normally, the bone remodels itself in response to microtrauma. However, with excessive use, the mechanical fatigue and bone resorption can outpace the osteoblastic response. Although the classic example of stress fractures are the "march fractures" of young adult military recruits (56,57), stress fractures do occur in younger athletes, including adolescents and occasionally children (58-61). In a series of 200 stress fractures occurring in all ages, 36.5% oc-

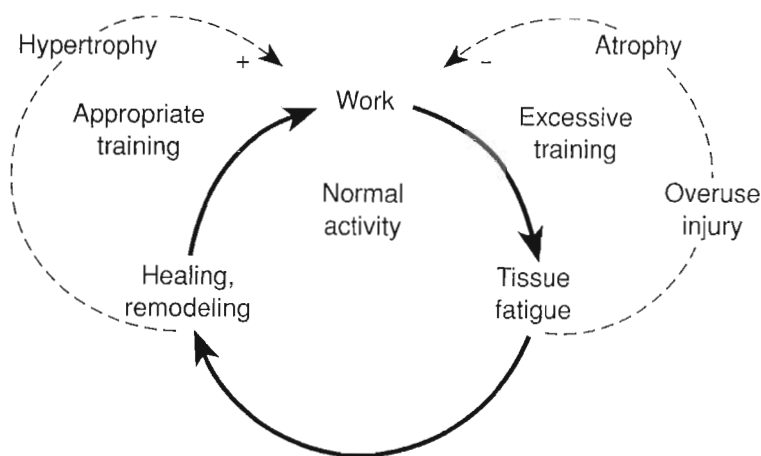


FIGURE 31-1. Cyclic loading of all tissues leads to tissue fatigue. Normally, these tissues heal and remodel, permitting continued activities. Athletic training involves increasing activity and converting the healing and remodeling process into hypertrophy of the tissues. This strengthens tissue, allowing increased tissue loading and greater performance. Excessive training leads to tissue fatigue by exceeding the rate of healing or remodeling.

curred in 16- to 19-year-old adolescents, and 6% occurred in youths 15 years of age or younger (60).

Adolescents with stress fractures closely parallel their adult counterparts, with a few exceptions (60,61). The proximal third of the tibia is the most commonly affected site; metatarsal fractures are rare in youngsters (60). There is equal distribution among male and female patients. Although most stress fractures in adolescents are associated with endurance running, the average training distance is typically not excessive (60).

Engl reported stress fractures of the proximal tibia in a series of nine children younger than 12 years of age, with the youngest diagnosed at 21 months of age (59). In many of these cases, there was no clear history of athletic overuse, so these cases likely represent an entity distinct from sports-related stress fractures.

Stress fractures about the knee can involve the distal femoral physis, the proximal tibial physis, and the patella (62–64). Although the lower extremities are most commonly affected, cases of adolescent athletes with stress fractures of the metacarpal, radius, ulna, humerus, and olecranon have been reported (65–68). Spondylolysis is often the result of a stress fracture of the pars interarticularis, and is most commonly seen in young gymnasts and football linemen (69,70) (see Chapter 20).

The typical history of a stress fracture is one of insidious onset of pain in the area of fracture that is initially relieved by rest. The pain eventually increases. It persists after activity, and affects normal walking. On examination, the tenderness can be localized to the site of fracture in about two-thirds of cases, and swelling occurs in about one-fourth (71).

Approximately 10% of initial radiographs are abnormal (71). With time, the osteoclastic process may lead to cortical disruption, and even to a displaced fracture. Bone scintigraphy is helpful for establishing the diagnosis, especially during early stages. As many as 50% of adolescents with stress fractures show multiple asymptomatic areas of stress re-

sponse on bone scan (61). If clinically asymptomatic, these other areas of bone scan uptake do not warrant treatment.

Osteoid osteoma, malignancies, and infection can have presentations and radiographic appearances similar to stress fractures. The differential diagnosis of tibial stress fracture includes all of the causes of shin splints. Occasionally, a biopsy is indicated, but this should be avoided if possible, because the surgical defect may delay healing or precipitate a complete fracture. If a biopsy is performed, an adequate sample must be obtained and the interpretation reviewed carefully. A healing fracture can have many features similar to a malignancy.

Stress fractures of the proximal femur can have serious complications, including avascular necrosis if displacement occurs. These occur in young adults, with a few cases reported as young as 16 years of age (56,72). Only rarely has stress fracture of the femoral neck been reported in skeletally immature children (73,74). Other diagnoses, particularly slipped capital femoral epiphysis, should be considered in the young athlete complaining of vague hip, thigh, or groin pain related to activity.

The treatment of most stress fractures involves breaking the cycle of repetitive trauma. This usually can be done by eliminating running, while permitting normal walking. Crutches or a cast can be used for fractures that seem to be at particular risk for displacement or for the uncooperative adolescent (71). Alternative training, such as swimming, cycling, or pool jogging, can be used for maintaining aerobic conditioning in the serious athlete. Compliance is critical in ensuring that a complete fracture does not occur (75). Healing takes 2 weeks to 3 months. Recommending when to return to sports is a complex judgment, and prevention of reinjury by modifying the athlete's training program is essential. Distal fibular stress fractures have little risk of residual complications. For these, the use of a pneumatic leg brace is useful for the early return to sports (76). Tibial stress fractures deserve special attention, because nonunion

occasionally occurs, even after 4 to 6 months of conservative care (77). Femoral neck stress fractures should be treated aggressively and may require internal stabilization.

Repetitive Physeal Injuries

Epiphysiolysis of the Proximal Humerus

Adolescents may develop widening of the proximal humeral physeal plate associated with shoulder pain during rigorous upper-extremity activities, such as baseball pitching. Coined by Dotter, the descriptive term "Little League shoulder" is not precise because other overhead sports may be involved (78). The pathology has not been delineated, because biopsy is not indicated for this self-limiting disorder. The pathomechanics are presumed to be repetitive traction or torsional forces at the physis (79). The exact incidence of Little League shoulder is unknown (80).

The typical patient with epiphysiolysis of the proximal humerus is a male baseball player between the ages of 12 and 15 years. Typically, the pain begins during throwing, without an inciting event. Initially, the youth may continue to play despite the pain, with the discomfort resolving between games. Playing ability diminishes as the pain becomes more constant.

Tenderness is primarily in the proximal humerus or shoulder. Pain is elicited with active internal rotation against resistance (80). The shoulder has a full range of motion.

Plain radiographs demonstrate widening and irregularity of the physeal plate (Fig. 31-2A), and a comparison view of the unaffected shoulder is helpful (Fig. 31-2B). Bone scans do not demonstrate greater than normal activity (80).

The primary differential diagnoses include rotator cuff tendinitis, acromioclavicular joint injury, shoulder instability, and bony lesions of the proximal humerus, such as a solitary bone cyst.

Initially, a sling may be indicated if the shoulder is extremely sore, although treatment primarily involves modification of activity. Gradual return to activity can begin within 1 or 2 months. Radiographic resolution may take up to 6 months (80). Callus or periosteal new bone may develop (81). The physeal plate gradually returns to normal.

Initially, the athlete should avoid or minimize the precipitating activity, and symptoms should be monitored as sports are resumed. Baseball pitchers and catchers can usually tolerate infield positions. Permanent restriction of pitching until skeletal maturity is reached probably is not necessary, because there are no known sequelae to this condition (81,82).

Epiphysiolysis of the Distal Radius

Physeal abnormalities of the distal radius have been reported in young female gymnasts (83). These are stress injuries of the physis. Radiographs demonstrate widening of the growth plate, and there are often lucent defects of the adjacent metaphysis and irregularities of the metaphyseal margin (83,84) (Fig. 31-3). Bone scans may be normal (84). This process resolves with rest, although it may take 3 months or longer for resolution of the radiographic abnormality (83) (Fig. 31-4). Mild cases become asymptomatic in as little as 4 weeks, and result in no growth inhibition or residual deformity (83,84). However, more severe cases are slow to resolve, and can lead to premature physeal closure of the distal radius (85). Premature closure can lead to relative

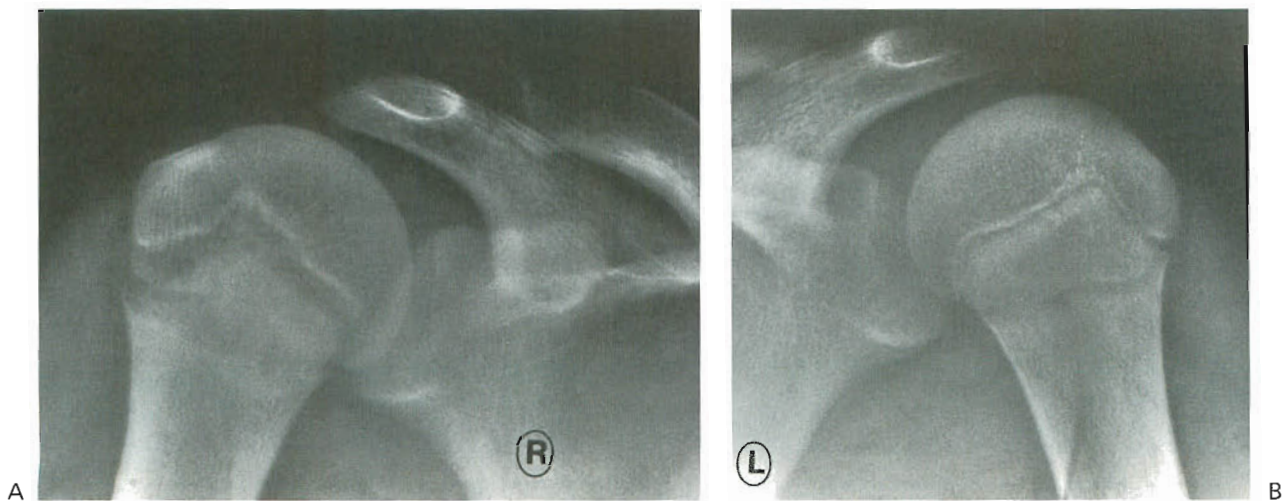


FIGURE 31-2. Radiographs of the proximal humerus in a 14-year-old, right-handed baseball pitcher with shoulder pain that progressed over the final few weeks of the season. **A:** Widening and irregularity of the physeal plate are present in the right shoulder. **B:** Radiograph of the left shoulder is provided for comparison.

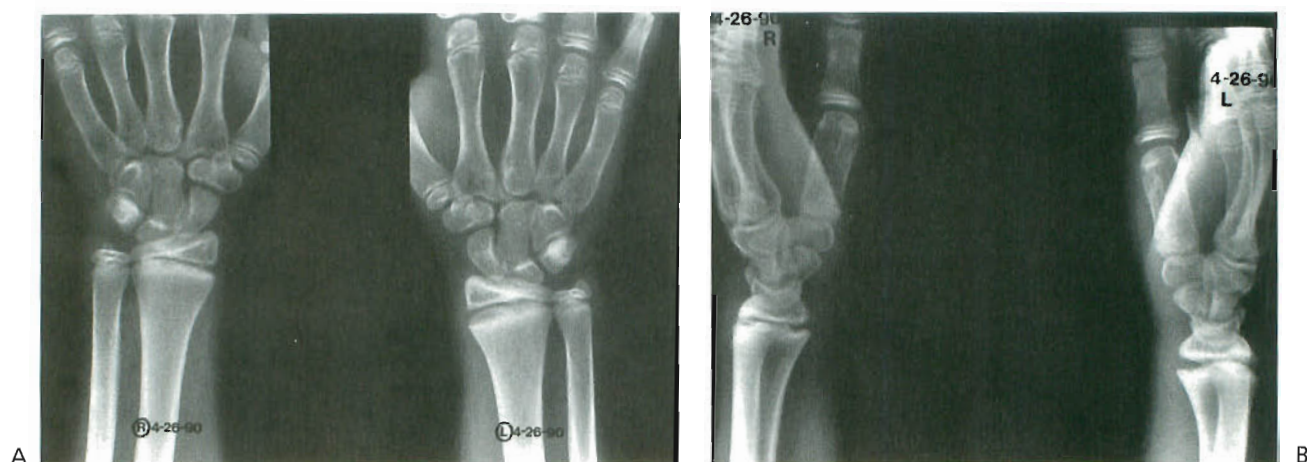


FIGURE 31-3. Bilateral epiphysiolysis of the distal radii in a highly competitive, 11-year-old gymnast. The left is more symptomatic than the right. **A:** The anteroposterior view shows widening of the left distal radial physis, compared with the right. The metaphyseal margins are irregular. **B:** The lateral view of the wrists shows definite cupping of the distal metaphyses, which is greater on the left than the right.

overgrowth of the ulna and subsequent carpal impingement. Rest and training modification sufficient for resolution appears warranted.

Apophyseal Conditions

Osgood-Schlatter Disease

In 1903, Osgood and Schlatter separately described the tibial tuberosity disturbance that commonly affects active adolescents. Through membranous ossification, the apophysis

of the tibial tubercle is formed anterior to the tibial metaphysis. In Osgood-Schlatter disease, there appears to be a partial avulsion of the developing ossification center and overlying hyaline cartilage from the anterior surface of the apophysis (86).

Patients are usually 10 to 15 years of age at the onset of the disorder, with the lesion typically occurring in girls about 2 years earlier than boys (87,88). Boys are more commonly affected than are girls. Approximately 15% of teenage boys and 10% of teenage girls develop pain in their tibial tubercles (88). The incidence may be as high as 20%

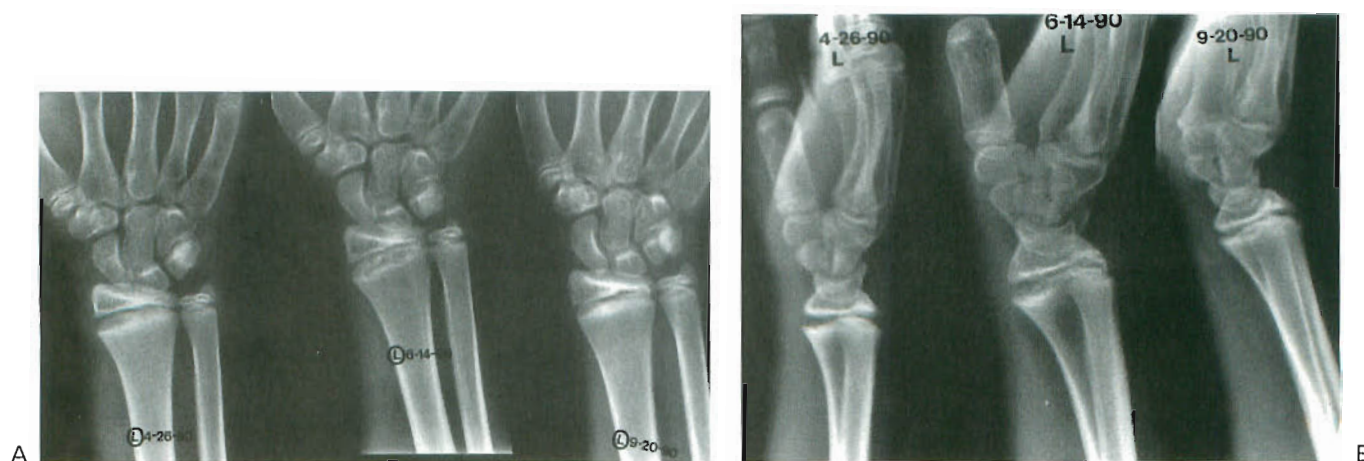

FIGURE 31-4. Sequential radiographs of the patient shown in Figure 31-3. She was asymptomatic 6 weeks after the initial presentation, and gradually returned to activities. She remained asymptomatic. The radiographs demonstrate progressive, but incomplete resolution. **A:** Anteroposterior radiographs were taken at the time of presentation, 6 weeks later and 5 months after initial presentation. **B:** Lateral radiographs show gradual resolution of the physeal widening and metaphyseal cupping.

in athletic youngsters, compared with 5% in nonathletes (88). The incidence of bilaterality is 35 to 55% in boys and as low as 18% in girls (88,89). There may be a familial component as well, with an incidence of 20 to 30% among youngsters whose siblings had Osgood-Schlatter disease (88). Biomechanical malalignment of the lower extremity, including increased quadriceps angle, genu valgum, femoral anteversion, and forefoot pronation, may be a contributing factor (90). Youths with one of the osteochondroses are likely to develop others; as many as two-thirds of athletes with Sever disease later develop symptoms of Osgood-Schlatter disease (88).

The pain is localized to the tibial tubercle, which is often prominent, and may have some local swelling. Abnormal findings of the joint itself are absent.

In unilateral cases, radiographs are indicated, unless the history is typical of Osgood-Schlatter disease and the findings are directly localized to the tubercle. Radiographs are not usually necessary in bilateral cases. The radiographic findings include prominence and irregular ossification of the tibial tubercle (Fig. 31-5A). One or more ossicles may exist. The diagnosis should not rely solely on the x-ray film, because fragmentation of the tibial tubercle may be an asymptomatic normal variant. Radiographic blurring of the infrapatellar fat pad has been described, and probably results from the associated inflammatory response (87). Tumor and infection involving the tibial tubercle are rare occurrences, but should be considered in the unilateral case. If there is a history of an acute injury, a tibial tubercle fracture may

have occurred, and there is the potential of this becoming displaced (91).

Most symptoms spontaneously resolve with closure of the physal plate, although as many as 20% of patients have some residual tenderness with kneeling (89). The treatment is primarily reassurance, symptomatic treatment, and occasional activity modifications. After being assured of the benign nature and self-limited course of this problem, most parents and youngsters are satisfied with tolerating some discomfort during certain activities; occasionally, restriction from sports may be necessary to control symptoms. Avulsion of the tibial tubercle associated with Osgood-Schlatter disease has been described in a young athlete (91). This appears to be an uncommon complication, and probably does not dictate that all young athletes must be curtailed from sports in an attempt to eliminate this risk.

Additional measures that may be helpful for young athletes include intermittent NSAIDs and hamstring stretching. Pads or braces may reduce local trauma, and commercially available straps and knee sleeves appear to help. In view of the risks and unsubstantiated efficacy, steroid injection is not recommended. If a significant biomechanical abnormality exists, such as excessive foot pronation, foot orthoses may be helpful (90). Casts are seldom used because immobilization weakens ligament insertions (92).

Occasionally, an ossicle and painful bursa forms deep in the tendon, and this remains symptomatic (Fig. 31-5B). If symptoms persist after physal closure, excision of the ossicle offers simple and successful treatment (93).

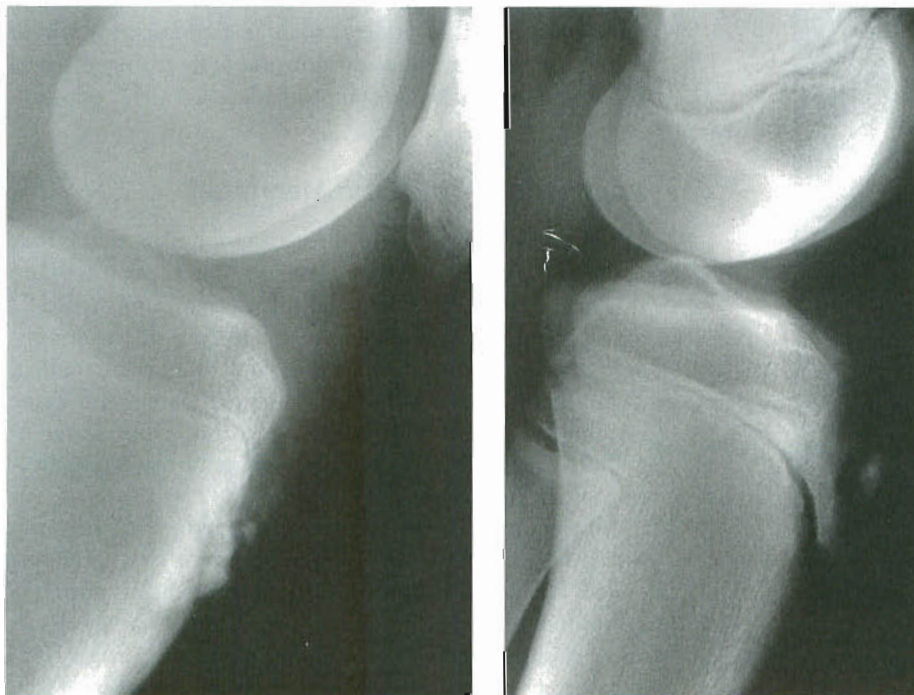


FIGURE 31-5. Osgood-Schlatter disease. **A:** Typical radiographic findings include a prominence of the tibial tubercle with irregularity of the bone at the insertion of the patellar tendon. **B:** In some cases, a separate ossicle may form and not unite. If persistently symptomatic, this ossicle may require excision.

Sinding-Larsen-Johansson Disease

Sinding-Larsen and Johansson independently described a condition in adolescents consisting of painful fragmentation of the patella's inferior pole (Fig. 31-6). Although associated with conditions involving spasticity of the lower extremities, this is more commonly seen in healthy, active, and athletic youngsters (94–96). Many analogies are made between this entity and the Osgood-Schlatter lesion, and both processes may occur in the same patient (96). In the early stages, there may not be radiographically detectable changes in the inferior pole of the patella, and some youngsters with similar clinical findings never develop abnormal calcification. This latter group is often diagnosed with “jumper’s knee,” or patellar tendinitis, and Sinding-Larsen-Johansson disease may represent a specific variant of this disorder. Calcification and ossification at the inferior pole of the patella presumably occur in response to persistent traction in a growing individual.

The presenting complaints are typically pain in the knee associated with rigorous activities, especially running, climbing stairs, and kneeling. Tenderness is confined to the inferior pole of the patella, with no other significant knee findings. Other conditions that cause inflammation of the fat pad or anterior knee synovium can produce similar findings when the patient is examined with the knee in extension. With 90 degrees of knee flexion, the finding of tenderness at the inferior pole of the patella is more precisely

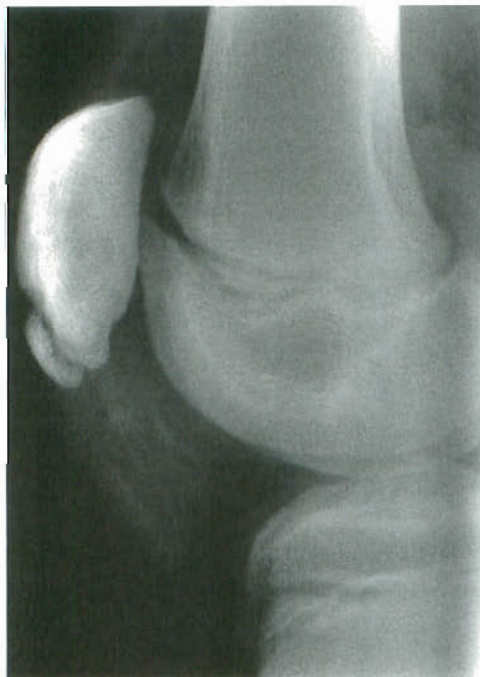

FIGURE 31-6. Sinding-Larsen-Johansson disease. The lateral radiograph best demonstrates the irregularity at the inferior pole of the patella.

indicative of Sinding-Larsen-Johansson disease or patellar tendinitis. A lateral radiograph of the knee should be able to confirm the presence of a calcified area separated from the patella. An MRI is rarely indicated, but does show edema and irregular calcification at the inferior pole of the patella.

This entity is self-limited. Typically lasting 3 to 12 months, it is shorter in duration than the Osgood-Schlatter condition. Management focuses on reassurance, and for discussion with parents, the term “condition” may be more appropriate than “disease.” Activity modification, ice, and NSAIDs may be helpful. Immobilization is seldom needed, and surgery is not indicated (96). While activity modifications may reduce symptoms, restriction from athletics is not absolutely indicated.

Calcaneal Apophysitis

Heel pain in the area of the calcaneal apophysis is a common complaint in young athletes. The age of onset is typically 9 to 14 years of age (97). The condition is bilateral in 60 to 80% of cases (98).

This was first described by James Sever in 1912, and is often referred to as Sever disease. Although histologic analysis is lacking, the clinical condition is that of an inflammation of the apophyseal growth plate of the calcaneus. It is a self-limited disorder, without documented complications or residual problems. The symptoms resolve after fusion of the apophysis, and treatment is therefore symptomatic. Like the other apophyseal overuse conditions, ice, oral NSAIDs, and activity modification can be helpful. Heel pads or lifts seem to improve symptoms. Cast immobilization may be indicated for the unusual case with severe, unremitting symptoms (98). For athletes such as gymnasts, for whom shoe wear modifications are not practical, taping the heel and arches may provide symptomatic relief (97).

Apophysitis of the Fifth Metatarsal

Often referred to as Iselin disease, apophysitis at the base of the fifth metatarsal is much less common than an apophysitis of the tibial tubercle or calcaneus. Symptoms typically occur in adolescents who have tenderness of the prominence of the proximal fifth metatarsal without acute trauma. Typically, there is a prominence of the tubercle, soft tissue swelling, and pain with resisted eversion. Oblique radiographic views may show enlargement and irregular ossification of the apophysis (99,100).

The natural history is apparently benign. Like the unresolved Osgood-Schlatter lesion, a persistently symptomatic ossicle has been described (99). Treatment is primarily symptomatic, consisting of ice, oral NSAIDs, and reassurance. Arch supports or foot taping may have a role (100). A cast may be indicated if the symptoms are severe (99).

Olecranon Apophysitis

Pain at the tip of the olecranon can occur in young athletes, and may be associated with ossification irregularity (101). This is thought to result from repetitive traction forces (102), or may result from hyperextension impingement, particularly in young gymnasts. Olecranon apophysitis is relatively uncommon (101). It appears to have a benign natural history, and should respond to conservative measures.

Apophysitis of the Hip and Pelvis

There are six major apophyses in the hip and pelvis: iliac crest, anterosuperior iliac spine, anteroinferior iliac spine, ischial apophysis, greater trochanter, and lesser trochanter. Each of these can be affected by an apophysitis.

The iliac crest is a common site for apophysitis, and it can be troublesome, particularly for young runners (103,104). Tenderness is localized to the iliac apophysis, and it is often bilateral (105). Resisted trunk rotation produces pull by the abdominal oblique muscles, and reproduces the athlete's pain. This is different from an iliac contusion or hip pointer, because there is no history of direct injury. The differential diagnosis should include avulsion of one of the iliac spines, Perthes disease, slipped capital femoral epiphysis, tumor, and infection. Radiographs are negative in iliac apophysitis. It is a self-limited disorder that improves with rest and training modifications (103–105). Likewise, apophysitis of the other growth centers about the pelvis are usually innocent problems.

Tendinosis

Overuse injuries of tendons and their surrounding sheaths have been classified into three groups by Puddu et al. (106). Group I tenosynovitis or tenovaginitis is an inflammation of only the paratenon, whether lined by synovium or not. Tendinitis and tenosynovitis often occur together, and it is difficult to differentiate the two clinically. Group II tendinitis is an injury or symptomatic degeneration of the tendon from a resulting inflammatory reaction of the surrounding paratenon. Group III tendinosis involves degeneration of the tendon, caused by aging, accumulated microtrauma, or both. Although tendinitis is much more common in adults, it is seen in younger athletes. Typically, young athletes have tenosynovitis, and occasionally have tendinitis; degeneration and tendon rupture is rare.

Achilles Tendinitis

Inflammation of the Achilles tendon is typically localized 2 to 6 cm above the insertion of the tendon into the calcaneus (107). Contributing factors include overtraining, sudden changes in training, extreme forefoot pronation, poor gas-

trocnemius-soleus flexibility, and inappropriate training surfaces or shoes (108,109). Tenderness should be localized to the tendon itself.

The differential diagnosis includes calcaneal apophysitis, retrocalcaneal bursitis, symptomatic pump bumps, and symptomatic os trigonum. Radiographs are usually unnecessary, but they may show minor soft tissue changes.

Treatment in young athletes is almost exclusively nonoperative. Training modification, heel lifts, custom foot orthotics, ice, stretching, and oral NSAIDs are used in combination, depending on the individual circumstances. If an underlying training error is identified, educating the patient and parent about the principles of overuse syndromes is helpful for treatment and prevention of recurrence. Immobilization and surgery are rarely indicated in young individuals.

Popliteus Tendinitis

The popliteus resists internal rotation of the tibia during gait (110). Popliteus tendinitis likely results from overuse of the muscle tendon unit, usually caused by excessive forefoot pronation (111). This is exacerbated by running on banked surfaces and down hills (112). There may be additional irritation of the tendon caused by friction as the popliteus tendon courses beneath the fibular collateral ligament.

Young athletes are particularly prone to tendinitis at the beginning of a sport season, when they are often out of shape, inexperienced, and impatient with proper stretching and warm-up exercises. The lateral joint line pain of popliteus tendinitis is typically brought on by activity. Pain may subside during the workout, only to return after practice. Sitting cross-legged exacerbates the pain.

On physical examination, the course of the popliteus tendon along the lateral femoral condyle and beneath the fibular collateral ligament is tender (Fig. 31-7). Joint effusion or ligamentous instability usually is not present (112). Popliteus tendinitis is occasionally associated with clicking, and may simulate a discoid meniscus or iliotibial band friction syndrome. Although typically negative, radiographs should be obtained to exclude any osseous pathology. Occasionally, a small site of ossification is adjacent to the origin of the tendon (112). Magnetic resonance imaging (MRI) may have a role in excluding other sources of symptoms.

Treatment of popliteus tendinitis consists of "relative rest." This involves diminishing the running component of training and, for the serious athlete, substituting other activities, such as swimming, cycling, pool running, and weight training (112). NSAIDs and ice massage are helpful. The runner's shoes should be checked for any obvious imbalance related to uneven wear. A foot orthosis may be helpful to control excessive pronation (113). A graduated, progressive running program with proper warm-up and stretching exercises is begun as symptoms resolve. Steroid injection usually is ineffective for this condition, and not

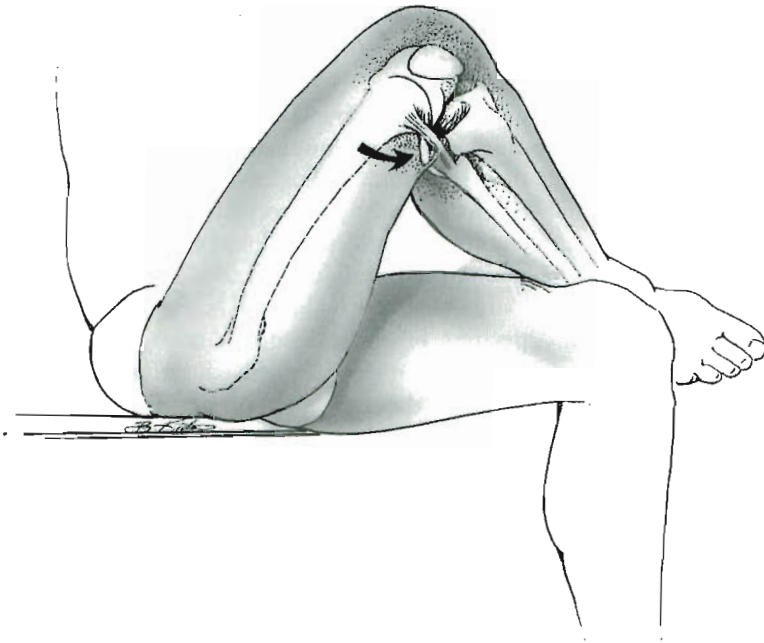


FIGURE 31-7. Popliteus tendinitis is most easily detected with the leg in a figure-four position. The popliteus tendon courses from the proximal tibia to the distal femur, passing beneath the fibular collateral ligament. In this position, the lateral collateral ligament is prominent; tenderness is elicited along its anterior and posterior margins, where the tendon passes.

recommended in young athletes; steroids are never injected into the tendon itself.

Shin Pain

Shin pain in young athletes accounts for as many as 10% of all athletic complaints (114,115). These problems can significantly interfere with training and performance, but most forms of shin pain have no long-term sequelae. The term “shin splints” has been applied to a variety of symptom complexes characterized by exercise-induced pain in the middle part of the leg (116). Although there may be multiple factors involved in the etiology of this problem, periostitis is the most common source of the pain. Other common sources of shin pain include chronic compartment syndrome, muscle herniation through the fascia, and superficial nerve entrapment.

The differential diagnosis of shin pain should also include stress fractures, sciatica, deep venous thrombosis, popliteal artery entrapment, varicose veins, muscle strain, tumor, and infection (116). Shin pain in youths should be evaluated for a specific diagnosis, because shin splints are uncommon in patients younger than 15 years of age (117). Radiographs are likely to be positive if the nonacute symptoms are caused by a tumor or infection. If the radiographs are negative, a bone scan may be needed to rule out subtler pathology or stress fractures (118).

Regardless of the cause of pain, patients with shin splints, and most of those with more specific diagnoses for shin pain, often respond to the same fundamental empiric treatment. The first stage of treatment is to diminish inflamma-

tion by relative rest, NSAIDs, and the application of ice after activity (119). An isometric strengthening program can be started early, and the athlete advances to progressive resistance exercises as pain permits. Therapeutic modalities such as ultrasound may help. Crutches may be indicated. Casts are seldom used, but a foot orthosis may be appropriate for the patient with an obvious biomechanical abnormality (120). The issues of good shoe wear, training surface, and exercise program should be addressed before running is resumed. Rest and shoe modifications may be the most effective components of this program (121). After the patient is pain-free during walking and strengthening exercises, a graduated running program is begun and monitored closely.

Periostitis

Medial tibial stress syndrome, also called the “soleus syndrome,” is the most common form of periostitis in athletes, and is characterized by localized tenderness over the posterior medial edge of the distal third of the tibia (122,123). About 75% of running athletes with shin pain have posteromedial tenderness (121). The pain probably results from periostitis, which has been documented histologically and by bone scan (118,122,123). The soleus muscle and its investing fascia originate in this area, and are also implicated in causing the syndrome (122).

The pain is bilateral in as many as one-half of the cases (117). Both sexes are equally affected (123). Predisposing factors include muscle weakness, running shoes with a lack of heel cushion, inadequate arch support, and hard running

surfaces. Training errors, such as sudden increases in intensity or mileage, are common factors (120). Contributing biomechanical abnormalities include varus hindfoot alignment, excessive forefoot pronation, genu valgum, excessive femoral anteversion, and external tibial torsion (120).

Initially, the pain is related to activity; later, it persists after the activity is stopped. There is no associated numbness. The history should include the intensity of sports participation, training and competition schedule, any recent change in regimen or shoes, and surface training conditions. The localization of pain, intensity, onset, duration, and any associated numbness are important in the differential diagnosis.

The physical examination should include evaluation of gait, leg lengths, sagittal-plane alignment, rotational abnormalities, muscle laxity or tightness, joint motion, and muscle strength (113,120). An attempt should be made to localize the painful site. The only significant physical finding is tenderness localized to the margin of the bone. The discovery of a fascial defect, for example, may indicate that the pain is secondary to muscle herniation. A positive Tinel sign indicates sensory nerve compression. Tenderness transverse across the subcutaneous margin of the bone may indicate stress fracture, whereas tenderness over the muscle compartments during exercise is suggestive of chronic compartment syndrome.

Radiographs occasionally show periosteal new bone. When positive, bone scans demonstrate a diffuse longitudinal area of uptake along the bone, rather than the transverse pattern characteristic of a stress fracture (122). Radiographs and bone scans are indicated when there is a clinical suspicion that symptoms and findings are not typical of periostitis.

If the patient is unresponsive to the usual treatments for shin splints, release of the periosteum localized to the area of pain may provide relief (115,122,124). Surgery should be undertaken only after a substantial attempt at nonoperative treatment has failed (123).

Chronic Compartment Syndromes

In contrast to the acute compartment syndrome, which results from trauma or arterial insufficiency, chronic compartment syndromes are induced by exertion, relieved by rest, and seldom result in tissue necrosis or residual disability (125). The elevated interstitial pressure of chronic compartment syndromes is secondary to inadequacy of the osseofascial compartments to accommodate exercise-induced volume and pressure changes. When compartment pressures exceed capillary filling pressure, the muscle becomes ischemic and produces pain. The anterior compartment is the most commonly involved, although any of the four compartments in the lower leg may be affected (126).

Typically, the patient complains of aching pain, tightness, or a squeezing sensation brought on by and interfering

with athletics (126). A history of bilateral symptoms should be specifically sought. After unilateral surgical release, patients frequently increase their activity levels, only to develop pain on the side that had been asymptomatic (126). The pain usually lasts only a short time after exercise. The athlete may experience transient footdrop. Typically, there are paresthesias across the dorsum of the foot, with an anterior compartment involvement or plantar paresthesias with chronic posterior compartment syndrome. Fascial defects with muscle herniation may be discernible over the anterior and lateral compartments (127).

Mubarak et al. pointed out that the symptoms attributed to a chronic deep compartment syndrome frequently are clinically indistinguishable from periostitis (123). Because the physical findings are nonspecific, the diagnosis is made by measuring compartment pressures (128). In chronic compartment syndrome, resting pressures typically are not elevated. With exercise, the pressures rise to 70 to 100 mm Hg, whereas normal compartments rise to less than 30 mm Hg. The degree of compartment pressure elevation correlates with the level of symptoms (124). All compartments should be assessed, because symptoms may not be adequate to identify all involved compartments.

As in any other form of shin pain, initial treatment includes activity modification, orthoses, physical therapy, and time. About one-third of patients find these efforts to be helpful. Definitive treatment involves fasciotomy, which can be performed by a variety of techniques. All involved compartments should be released. This can be done through limited skin incisions, rather than through the extensive releases suggested for adequate management of the acute traumatic compartment syndrome (125,126,129,130). Care must be taken to protect the saphenous vein, saphenous nerve, and the superficial branch of the peroneal nerve (130).

A success rate of at least 90% can be expected with surgery. Failure can result from not recognizing, preoperatively, that multiple compartments can be involved; from inadequate decompression, especially of the deep posterior compartments; and from excessive scar tissue response (126, 130). Few patients require repeat compartment releases (126,130). Recurrence secondary to excessive scarring is best treated by fasciectomy, although this is not recommended as the primary procedure, because it may reduce strength (126).

Muscle Herniation and Superficial Peroneal Nerve Compression

Styf's series of 90 patients with exercise-induced anterior leg pain included 13 patients with documented compression of the superficial peroneal nerve (117). Compression of this nerve can be caused by increased muscle pressure within the compartment during exercise. Muscle herniation through a fascial defect, entrapping the nerve, may also produce these

symptoms. Patients typically experience diminished sensation over the dorsum of the foot with exertion, and they have point tenderness where the nerve exits the compartment. Nerve conduction velocities can help confirm the diagnosis, but one-half are normal at rest and require exercise testing for documentation of this problem (117).

Ischemia of the entrapped tissue in cases of muscle herniation has been theorized to cause shin pain during activity. This may occur in as many as 60% of chronic compartment syndromes (127).

Limited fasciotomy is performed for persistently symptomatic peroneal nerve compression or muscle herniation. Specific attention should be directed to the exit point of the superficial peroneal nerve to ensure it is free (125).

Iliotibial Band Friction Syndrome

Iliotibial band friction syndrome is an overuse phenomenon caused by the iliotibial tract rubbing over the lateral epicondylar prominence during repetitive knee motion (131,132). Although most commonly seen in adult distance runners, adolescents involved in recreational and team sports also can be affected (133). Iliotibial band friction syndrome is more common in males.

Symptoms typically commence at the beginning of sports training session. Two-thirds of cases are associated with a recent increase in running intensity or distance (134). The athlete complains of pain over the lateral aspect of the knee, especially during running or cycling, and the pain occurs with every knee flexion (135). Usually, there is no history of injury or mechanical symptoms, such as locking or catching.

Typical physical findings include genu varum, external

tibial torsion, pes planovalgus, and pes cavus (133–135). Slight swelling may occur if a bursitis develops, but there usually is no joint effusion. Tenderness extends from the lateral epicondyle to the joint line from the anterior to posterior margins of the condyle. Frequently, there is a contraction of the iliotibial band that can be detected by the Ober test (Fig. 31-8). This maneuver reproduces pain and demonstrates restricted adduction.

Radiographs are normal. The differential diagnosis includes lateral meniscus tear, discoid lateral meniscus, stress fracture, popliteus tendinitis, biceps femoris tendinitis, and patellofemoral pain syndrome (136). These usually can be differentiated by careful history and physical examination.

Initial treatment involves relative rest or a change in training habits, ice massage, NSAIDs, and a rigorous iliotibial band–stretching program (135–137). This condition may take 6 weeks or more to resolve (132,133). Foot orthoses are often helpful, particularly if an alignment abnormality exists. Extraarticular steroid injection may help recalcitrant cases (134). In young athletes, surgical release of the distal iliotibial band and excision of the bursa rarely are required (135,136).

Breaststroker's Knee

Competitive breaststroke swimmers are prone to develop medial knee pain along the course of medial collateral ligament, medial facet of the patella, and the plica (138,139). The whip-kick technique, which is a more powerful modification of the frog kick, has certain variations that are strongly implicated in the cause (138). This condition may begin in the first few years of competitive swimming, and

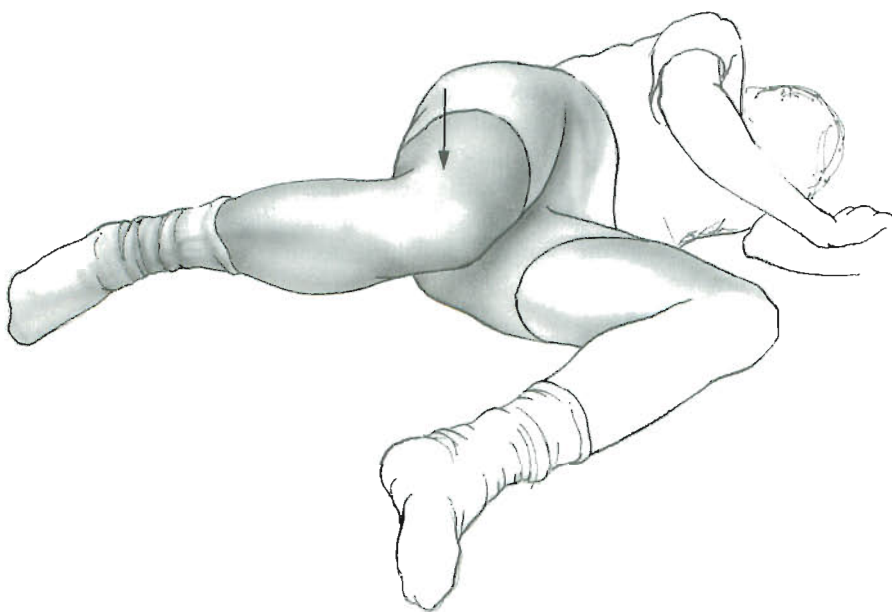

FIGURE 31-8. The Ober test is used to detect tightness of the iliotibial band. With a patient lying on his or her side, the hip is first abducted and extended, with the knee held flexed. The test is then performed by attempting to adduct the knee to the midline. Palpation along the lateral femoral epicondyle typically elicits tenderness at this site, if iliotibial band friction exists.

may occur in swimmers as young as 6 years of age (138), although the frequency is related to increasing age of the swimmer, increasing years of competitive swimming, increasing breaststroke training distance, and decreasing warm-up time (140,141). Other than medial knee tenderness, there are no other consistently associated physical or radiographic findings.

Initially, the symptoms are reversible with rest or training alterations, although with time, chondromalacia and medial facet patellar arthritis may occur (138–141). Measures to quiet inflammation of the medial plica, such as ice, NSAIDs, and phonophoresis, may help (141). Most important is altering the swimmer's whip-kick technique, particularly by keeping the legs together during the recovery and rapid extension phase of kicking (138). Arthroscopy is only occasionally indicated, because it typically shows medial synovitis without other significant derangements; it is only occasionally indicated (142).

Valgus Overload Injuries of the Elbow

The most commonly affected athletes are baseball players (particularly pitchers), gymnasts, American football quarterbacks, and potentially, other throwing and racquet sport athletes (143,144). Such activities can lead to a variety of abnormalities of the capitellum, radial head, and medial epicondyle (145).

During the throwing and racquet motions, a significant valgus moment is generated at the elbow (Fig. 31-9). The result is excessive and repetitive compression forces through the radiocapitellar joint, and tension across the medial epicondyle and collateral ligaments. Collectively, these are referred to as Little League elbow.

Osteochondral Lesions of the Capitellum

Primarily based on age, repetitive use lesions of the capitellum can be divided into Panner disease and osteochondrosis of the capitellum.

Panner described a lesion of a young boy's capitellum that he compared with Legg-Calvé-Perthes disease (146). In children younger than 10 years of age who have Panner disease, the course is usually benign (147,148). The entire ossific nucleus of the capitellum may demonstrate irregular ossification, but an osteochondral loose body does not form. The lesion completely resolves with reconstitution of the capitellum.

Adolescent baseball pitchers and gymnasts can develop fragmentation of the capitellum's subchondral bone and dislodgment of the articular surface. Based on the belief that a low-grade inflammatory process was responsible, Franz König called this condition "osteochondritis dissecans." Histologically, there are no inflammatory cells present, so the term "osteochondrosis" is more appropriate (143,149).

The causes of Panner disease and osteochondrosis of the

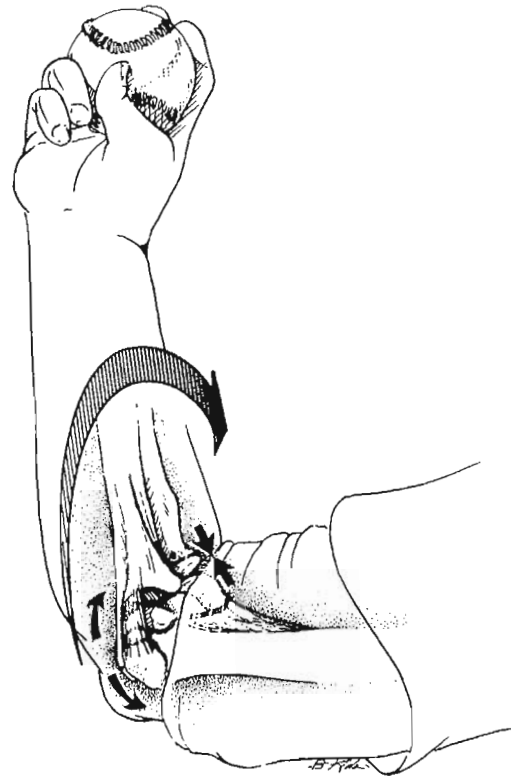


FIGURE 31-9. Pitching produces a valgus moment (*large curved arrow*) at the elbow. There are compressive forces (*straight arrows*) across the radiocapitellar joint, and tension (*curved arrows*) across the medial epicondyle and medial collateral ligament.

capitellum are unknown. The two entities may represent the same process in persons of different ages, but the course and prognosis contrast sufficiently to consider the disorders separately. Heredity may be a factor (143). Repetitive microtrauma frequently occurs in throwing athletes, and disturbance of the blood supply has also been implicated. By 8 years of age, the capitellum's vascularity is solely from a group of end vessels (150). These vessels traverse the chondroepiphysis posteriorly, with no significant collateral contribution. Upon closure of the physis, the blood supply of the epiphysis and metaphysis becomes interconnected (143).

Patients with Panner disease and osteochondrosis of the capitellum typically complain of pain with throwing. Tenderness is maximal over the radiocapitellar joint, and there may be crepitus. The elbow typically lacks 10 to 20 degrees of full extension, and flexion is mildly limited (147,149).

Initial assessment should include bone detail radiographs with anteroposterior, lateral, and oblique views. There is irregular ossification of the capitellum and rarefaction within a crater (79,147) (Fig. 31-10A). Tomograms or computed tomography (CT) scans are occasionally helpful to better define bony pathology (Fig. 31-10B). Loose bodies may be present. Arthrograms are unreliable for cartilaginous

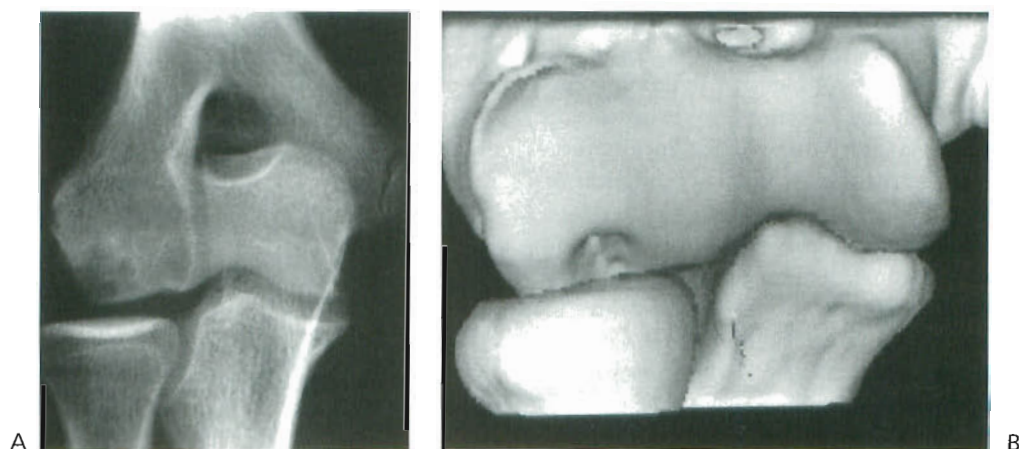


FIGURE 31-10. Osteochondral lesion of the capitellum in a 15-year-old baseball player with a painful elbow. **A:** The subchondral plate of the capitellum appears intact. Subchondral cysts are present. **B:** The computed tomography scan with three-dimensional reconstruction demonstrates the bony defect of the capitellum, including loss of the subchondral plate in that area.

loose bodies, because filling defects related to synovial convolutions can lead to false-positive studies. False-negative results can occur if the loose bodies are completely enveloped by synovium or hidden in joint space recesses (149).

Initial treatment should include restriction of forceful upper-extremity activities, application of ice, and NSAIDs. A sling or splint is occasionally needed (144). It may take 6 or more weeks for the pain to subside, at which time range of motion and strengthening exercises are begun.

After almost full and pain-free range of motion with good strength is achieved, a graduated and well-supervised program for returning to upper-extremity activity is initiated. Throwing technique should be reviewed to minimize unnecessary valgus load to the elbow. The prognosis for return to competitive pitching, however, is guarded (144,147). Baseball players should be switched to a position, such as the infield, that requires less throwing. For gymnasts, particularly stressful maneuvers or “tricks” are modified from their workout, and most can continue to participate.

The athlete is monitored for recurrent symptoms. Radiographs may remain abnormal, and symptoms are followed closely. Activities are gradually advanced, and readjusted if pain recurs (143). Persistent difficulty should prompt further investigation for a loose body or a chondral flap in the articular cartilage. In this situation, given the indeterminate reliability of CT and MRI, arthroscopy may be the most prudent next diagnostic step, and offers the advantage of being potentially therapeutic.

Indications for surgery include a locked elbow, a symptomatic intraarticular loose body, or failure of nonoperative program to adequately diminish pain and restore motion (144,149). Whether open or arthroscopic surgery is performed, loose bodies should be searched for carefully (151).

Flaps of articular cartilage from the surface are debrided, because loose chondral fragments produce synovial inflammation (152). Bone grafting and internal fixation of the fragment are rarely indicated, because most procedures other than simple excision have been unfavorable in the elbow (144,147). Drilling of the base of the defects may stimulate a fibrocartilaginous response; however, the advantage of drilling over simple debridement of the lesion is not well documented (144).

The prognosis for the more advanced lesions is less favorable. After surgery, many athletes are unable to resume their prior levels of competitive throwing (144,149).

The most important lesson about this condition is the opportunity for prevention. Junior baseball programs should all have rules limiting the duration that a youngster pitches. Typically, this is a maximum of three innings per game and up to six innings per week. Training and practice are difficult to regulate, making it essential to educate parents, coaches, and physicians about this condition.

Osteochondral Lesions of the Radial Head

Osteochondral lesions of the radial head are much less common than those of the capitellum (153,154). Most patients are boys between 8 and 15 years of age (153). Because repetitive valgus loading occurs, the mechanical stress of throwing is implicated as the cause. Because osteochondrosis of the radial head is an uncommon problem, a more generalized disorder should be considered (153). Radiographs should be obtained of the other elbow, and if abnormal, a radiographic survey should be done of the other major joints. The treatment principles are similar to those for symptomatic lesions of the capitellum.

Injuries of the Medial Epicondyle

Traction on the medial elbow structures is the counterpart to radiocapitellar compression during valgus stress. With excessive throwing, the medial epicondyle may become prominent and intermittently painful. Active adolescent baseball players frequently develop accelerated growth, and widening of the medial epicondylar apophysis and fragmentation of the medial apophysis (154). The prognosis is excellent, with the pain usually resolving after rest (148).

Avulsion of the medial epicondyle can occur with forceful throwing. This results from the tension forces exerted by the ulnar collateral ligament and the pull of the forearm flexor muscles. If the elbow is stable and the fragment is minimally displaced, the elbow is immobilized for 3 weeks, after which range of motion is begun, and the athlete is gradually returned to activity.

Significantly displaced fractures probably should be repaired. Elbow instability can be disabling to throwing athletes, wrestlers, and gymnasts (155). If there is question of valgus instability, a stress radiograph should be obtained (156). Other standard indications for internal fixation include intraarticular incarceration of the fragment and ulnar nerve dysfunction (156).

SPORTS TRAUMA

Epidemiology

The number of youth sports participants, the amount of coaching, the intensity of training, and the level of competition are increasing. Injuries are inevitable, and parents often seek advice regarding the risk of injury from sports participation, particularly contact sports. Most trauma in children occurs from activities such as running, tree climbing, and skate boarding (157). Organized sports account for only about one-third of sports injuries, with the remainder occurring in physical education classes and nonorganized sports (11,158).

In youths 5 to 14 years of age, the sports related to the most total injuries, in order of frequency, are football, baseball, basketball, gymnastics, other ball sports, soccer, wrestling, volleyball, and ice hockey (3,159). When injury data are adjusted for the number of participant hours, the general trend is for American football to be the highest-risk sport, followed by basketball, gymnastics, soccer, and baseball (157). Injuries occur most frequently in contact sports. Each year, as many as 20 to 40% of high school football players are injured; however, about 75% of these injuries are minor, resulting in a loss of fewer than 7 days of participation (160–162). The risk of injury in sports must also be weighed against the risk in normal activities. As many as one-third of junior sports participants are sidelined by injuries they sustained outside of their sports program.

Although it may intuitively seem that the younger child is at greater risk in contact sports, the converse is true, with fewer injuries occurring among younger athletes. Soccer, for instance, results in injuries to about 3% of players in elementary school, 7% in junior high school, and 11% in high school (7,163).

In junior American football programs (9 and 15 years of age), the incidence of injury is only 2%. Of an estimated 463,000 football-related injuries treated in 1980, 37% occurred in 5- to 14-year-old children, and 63% occurred in athletes 15 years of age and older (3). Most injuries are mild, with about 10% resulting in hospitalization, 15% requiring minor procedures, and 2% needing reconstructive surgery (164,165).

Contusions, sprains, and simple fractures of the upper extremity account for most injuries in younger athletes (164,165). Teenagers have more lower-extremity trauma, with the knee injuries being common and the knee reinjury rate being as high as 25 to 60% (160,161,166,167).

Tragic injuries do occur occasionally in youth sports. The U.S. Consumer Product Safety Commission reported that almost 1.8 million sports-related, medically attended injuries occurred in 5- to 14-year-old children from 1973 through 1980. Of these, 93 were fatalities. Baseball accounted for 40 deaths, with most related to bat or ball blows to the chest or head. Football resulted in 19 fatalities, almost all secondary to head and neck injuries. Surprisingly, golf was related to 13 deaths, with 11 children being struck by clubs and 2 with balls. Many of these children were not actually participating in golf at the time; they were struck by an adult who was playing or by a playmate. Eight children were killed by equipment falling on them, including four soccer goals, two football goal posts, one baseball backstop, and one trampoline (3).

Prevention

Although the prevention of all injuries related to sports participation is not realistic, the rate and severity of injuries can be reduced significantly. Many sports injuries can be avoided or ameliorated with conscientious supervision, appropriate rules, safe equipment, and adequate rehabilitation of injuries (2,158). Stretching and warm-up exercises are key components of injury prevention, although the scientific basis of these standard training techniques are just starting to be understood (39,168). Because there is significant individual variation in body types, accurate and specific advice is still evolving (169–171). A preseason conditioning program, consisting of warm-up, stretching, running, weight training, and skill development, appears to have a positive impact on preventing injuries, especially in collision and contact sports (172).

Medical evaluations are commonly required before young athletes are allowed to participate in sporting pro-

grams, particularly on the interscholastic level. This is often done through a preparticipation screening evaluation. The principle is to identify young athletes at high risk for sports-related injuries or illness. Unfortunately, there is no consensus of opinion regarding the components of an optimal screening program (173). The yield of identifying disqualifying conditions is low on initial sports screening examinations, and becomes even lower on repeated examination (4,174). Although the cost of doing such screening may appear minimal at first look, unnecessary exclusions and referrals can result in a significant health care cost (175).

To produce a favorable cost-benefit ratio, the screening process must focus on the relevant history and pertinent physical examination. Medical history is the most sensitive and specific component. The history should include prior musculoskeletal injury, neurologic injury, infectious disease, and cardiopulmonary problems. Questions related to general health, immunization status, hospitalizations, and limitations of function are helpful. Athletes should be specifically asked about prior history of concussion, unconsciousness, paresthesias, and prior musculoskeletal treatment or rehabilitation (173). Syncope can be an important clue to undetected heart disease, specifically, idiopathic hypertrophic subaortic stenosis, which is one of the most common causes of sudden death in young athletes (176). Despite conscientious screening, this uncommon but tragic event is not completely preventable. Athletes and parents should always be informed that screening cannot ensure detection and prevention of all problems.

The general medical examination should include blood pressure measurement, cardiopulmonary examination, and review for any contagious skin lesions (177). Ideally, a dynamic evaluation of recovery after exercise should be performed, but this is usually impractical (178).

Since inadequate rehabilitation probably accounts for almost one-fourth of sports-related injuries in children, the musculoskeletal examination should focus on prior injuries and any residual problems from them (4). A screening examination of the ankles, knees, and neck range of motion should be included for all athletes, and other areas of the musculoskeletal system should be examined, based on the individual's prior history.

Evaluation of athletic performance, joint laxity, and visual acuity are optional components. Otoscopy, ophthalmoscopy, and hernia evaluations are probably unnecessary. Routine laboratory testing does not appear to be cost-effective (4,173,174).

Athletic Trainers

Athletic trainers have been caring for sports injuries since ancient times. The education, ability, and role of athletic trainers have evolved considerably since the founding of the National Athletic Trainers' Association in 1950. These allied health professionals have rigorous credentialing requirements. They can provide valuable help in recognition,

initial management, triage, prevention, and rehabilitation of athletic injuries. Used effectively, athletic trainers are liaisons between physicians and athletes, and provide important educational information for athletes, partners, and coaches.

Although they are widely used for college and professional sports programs, it is estimated that only about 10% of the U.S. high schools have certified athletic trainers (160). An estimated 636,000 injuries occur annually among American high school football players. Half of these occur during practice, when physician medical coverage is seldom available (160). Many injuries can be prevented through safe equipment, proper supervision, appropriate instruction, training, and injury rehabilitation (2,3,158). To take advantage of this opportunity, the involvement of certified athletic trainers in high school and other youth sports programs should be strongly encouraged.

Ankle Injuries

Ankle Sprains

Ankle sprains are among the most common injuries in sports. They occur in approximately 6% of all high school sports participants, and in as many as 70% of all high school basketball players over the course of 4 years of participation (179). Most ankle sprains involve the lateral ligaments. Approximately 3% of sprains are medial, with wrestling being the only sport that is associated with a significant number of these (179,180). Inversion and supination injuries sequentially tear the anterior ankle capsule, the anterior talofibular ligament, and the calcaneofibular ligament (181, 182). Although most ankle sprains are minor, one-third of these injuries lead to more than 2 weeks of disability (183). For severe ankle sprains, a minimal intervention approach is not universally favorable, and treatment does have a positive impact (184,185).

For the purpose of this discussion, the following classification is used:

Grade I: mild sprains involve stretching and minimal interstitial tearing of the ligament, with little swelling, limp, and disability.

Grade II: moderate sprains involve partial disruption of the ligaments, with modest swelling, diffuse tenderness, and difficulty with weightbearing.

Grade III: severe sprains result in complete ligament disruption, often with extensive bleeding swelling, instability, and disability.

Knowing the mechanism of injury may be helpful. The common lateral ligament complex sprain usually results from an inversion injury, whereas anterior tibiofibular sprains (high ankle sprains) typically result from a dorsiflexion injury. Recollection of a popping sensation varies, but a history of prior ankle injuries is important for the assessment of acute or chronic instability.

If the patient is first seen after considerable swelling has developed, it may be difficult to localize the tenderness. Examination of the acute injury should be directed toward pinpointing the maximally tender structures. The entire length of the tibia and fibula should be inspected, with specific attention to the area of the physal plates. Gentle percussion of the physis and epiphysis by the examiner's fingertip is a useful technique for differentiating physal fractures from ankle sprains. A more reliable assessment of tenderness and stability can often be achieved after several days of rest, ice, elevation, and compression.

The anterior drawer maneuver primarily tests the stability of the anterior talofibular ligament complex. This can

be performed by securing the distal leg with one hand and applying an anterior pull on the heel, with the foot held in gentle plantar flexion (Fig. 31-11A). Alternatively, with the patient supine on a table, and with the knees flexed about 90 degrees, a posterior force is applied to the lower leg while the foot is held flat on the table top (Fig. 31-11B).

Routine views of the ankle should include anteroposterior, lateral, and "mortise" views. Clinical judgment ultimately dictates the decision to obtain radiographs. For adults, tenderness along the posterior edge of malleoli, or inability to bear weight, are reliable indicators to prompt ankle radiography. Although not as well studied in youths, similar criteria probably apply. Tenderness over the navicu-

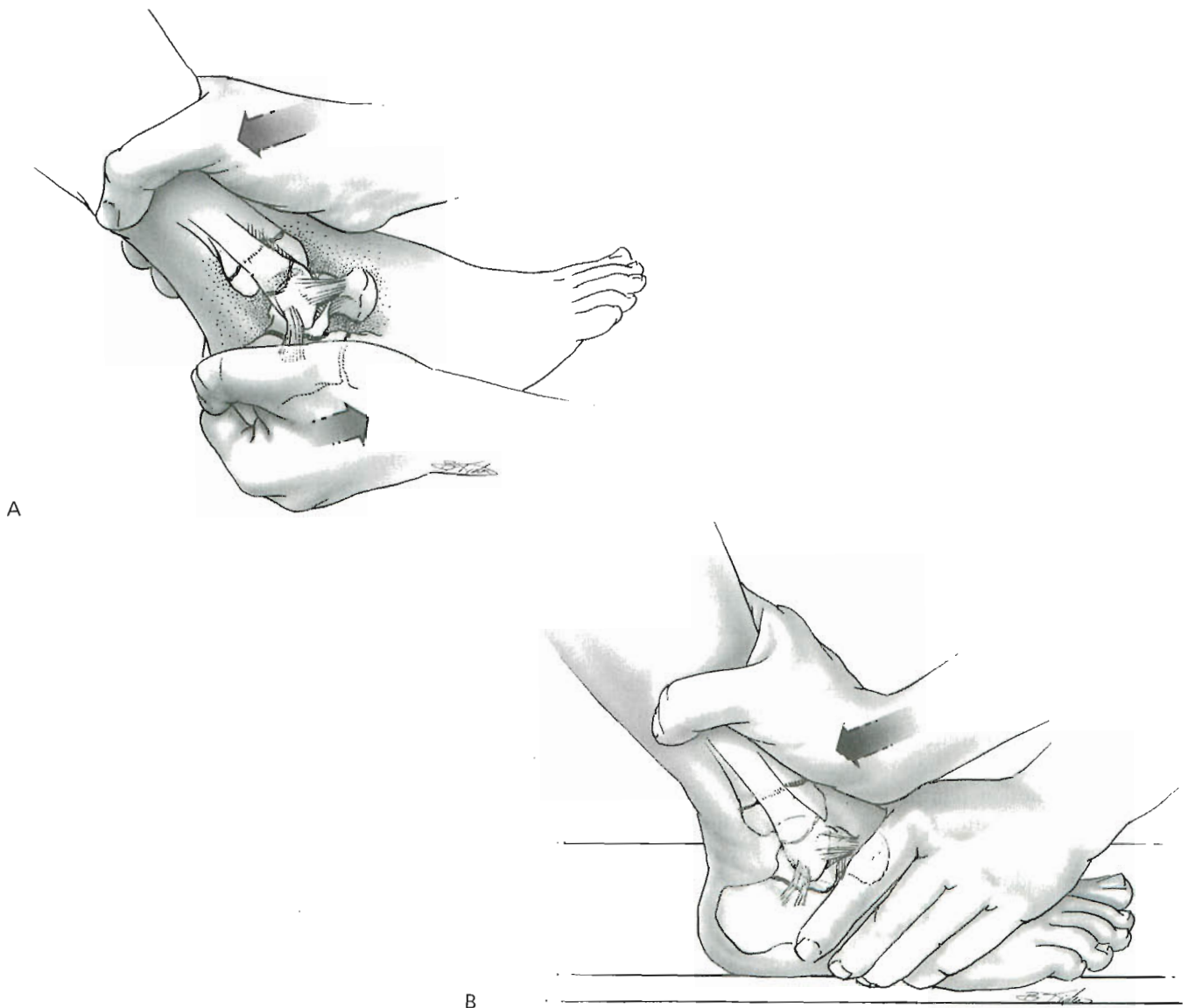


FIGURE 31-11. The anterior drawer test of the ankle is used to evaluate stability of the anterior talofibular ligament. **A:** The heel is pulled anteriorly, with the foot held in gentle plantar flexion. Counter force is applied at the tibia. **B:** Alternatively, the foot is held firmly on a table top, with the hip and knee flexed at 90 degrees, and posterior force is applied to the lower leg.

lar, cuboid, and base of the fifth metatarsal should prompt additional views of the foot (186).

The indication for other studies depends on the index of suspicion for injury, and treatment philosophy. Anteroposterior or lateral view stress radiographs are intended to demonstrate ligamentous laxity (187). Unfortunately, the reliability is affected by individual variation, timing, muscle spasm, the patient's pain tolerance, foot position, and variability of manual technique (188). Even with an apparatus and local anesthesia, the overlap between normal and abnormal is considerable (189). Ankle arthrography can reliably detect anterior talofibular and calcaneal fibular injuries, although the clinical relevance is unproven (190).

If subtalar motion is limited after resolution of the acute injury, radiographs of the foot should be obtained to look for tarsal coalitions. The athlete's risk for recurrent ankle sprain is increased by the presence of a coalition (191).

The primary differential diagnoses include physeal fracture of the distal fibula, triplane fracture, osteochondral fracture of the talus, subluxation of the peroneal tendons, fracture of the base of the fifth metatarsal, sprains of the midfoot ligaments, and Maisonneuve fracture (181). Accessory ossification centers, at the tip of the medial and lateral malleoli in youths, should not be confused with avulsion fractures (192). Localization of maximal tenderness and radiographs can differentiate most of these.

Nondisplaced Salter-Harris type I physeal fracture of the distal fibula is the most commonly occurring problem that closely imitates an ankle sprain. Fingertip percussion over the physeal plate usually differentiates the two; in cases of fracture it is distinctly positive. If doubt remains, immobilizing the ankle in a cast for 3 weeks adequately treats the fracture, without being overtreatment of a sprain.

Although treatment of ankle sprains varies considerably, a few sound principles have evolved (193). Sprains are initially treated with rest, ice, compression, and elevation (R.I.C.E.). The goal of the initial treatment is to limit bleeding, edema, and any further soft tissue injury. Ideally, these occur at the time and site of injury. After the degree of injury is determined, an appropriate course is planned. Each progressive step of the rehabilitation is based on functional goals, rather than an arbitrary calendar (194).

A grade I sprain is a minor injury. The pain usually resolves, and motion returns in less than 1 week (195). In some cases, the athlete may be able to return almost immediately to sports competition. The athlete must have minimal pain and be able to run, cut, and perform specific tasks relevant to the activity to which he or she is about to return.

Supporting the ankle by taping, a laced stabilizer, or a semirigid orthosis facilitates early return and diminishes the risk of recurrent injury (196,197). Taping restricts extremes of ankle motion and shortens reaction time of the peroneal muscles, probably by affecting the proprioceptive function of the ankle (198). The lace stabilizers and semirigid ortho-

tics may offer an advantage over tape, which loosens after a short period of exercise (197,199,200).

Grade II sprains involve more extensive tissue injury and result in an average of 2 weeks of disability (195). Crutches are often helpful for several days, as weight bearing is progressively increased. For the athlete concerned about an early return to sports, early phases of a supervised rehabilitation program should be directed toward diminishing the swelling and regaining motion. Initially, ice pack and intermittent compression boots are useful modalities (201). Isometric exercises are started immediately, and progressive resistance exercises are subsequently introduced. Satisfactory strength of all muscle groups, particularly the peroneals, must be restored to ensure dynamic protection from a repeat injury. Proprioceptive training may be helpful as well (202).

For the serious athlete, aerobic conditioning is continued during rehabilitation by swimming, using an upper body ergometer, running in a pool, or cycling. Upper body conditioning is continued. The use of ankle supports in grade II sprains is the same as that for a grade I sprain.

Treatment of grade III sprains remains the most controversial. Options include taping, casting, and surgical repair. Tape and immediate motion theoretically minimize stiffness. Treatment with a dorsiflexion cast reduces the talus in the mortise, and theoretically reapproximates the torn ligament fibers to their premorbid location (183). Advocates of surgical treatment feel that other soft tissues may prevent anatomic reduction of the torn ligament fibers, especially if there is an associated bony fragment. Most series reporting surgical outcomes report no difference over immobilization and therapy protocols, or they fail to have an adequate control group to demonstrate a clear superiority of one treatment approach over another (184,203,204).

The author prefers to treat grade III sprains initially with a posterior plaster mold and compression dressing. This controls the initial hemorrhage and swelling. In 7 to 10 days, as swelling starts to resolve, the patient is placed in an articulated ankle orthosis (164). This permits plantar flexion and dorsiflexion but protects against inversion and eversion. An intermittent compression boot device and other physical therapy modalities are used to reduce swelling. Weight bearing progresses as tolerated. The rehabilitation program is advanced in the same fashion as outlined for grades I and II sprains. The orthosis is used continuously for 8 weeks. The athlete may return to competition wearing the device, if pain-free motion and adequate strength have been regained. This typically occurs 4 weeks after injury (205).

Recurrent severe sprains occasionally lead to chronic ligamentous laxity. A variety of reconstructive procedures are available, but are uncommonly needed in youths (206,207). Results of delayed reconstruction are comparable to primary surgical repair, further supporting the approach of nonoperative treatment of most ankle sprains, particularly in young athletes (208).

Anterolateral Ankle Impingement

After ankle sprains, chronic anterolateral ankle pain occasionally develops, because of impingement of the anterior inferior tibiofibular ligament or the synovium in that area (209,210). Tenderness is localized along the anterolateral corner of the joint. Some patients experience popping with dorsiflexion of the ankle. Radiographs are normal. MRI may be helpful to rule out other sources of pain, such as osteochondral injuries and subtalar pathology. Occult instability of the ankle and subtalar should also be considered.

Rest, immobilization, NSAIDs, and physical therapy modalities may be tried to reduce the symptoms (211). Injection of local anesthetic and a steroid can be both diagnostic and therapeutic. If pain persists, arthroscopic inspection debridement of the reactive synovium and resection of the inferior fibers of the tibiofibular ligament should resolve the problem, unless significant instability exists (209,210).

Distal Tibiofibular Sprains

Isolated injuries of the distal tibiofibular syndesmosis are uncommon, but need to be recognized (212). These may be associated with injury of the deltoid ligament. Pain and tenderness are located principally at the anterior aspect of the syndesmosis and interosseous membrane. Tenderness is elicited by squeezing the tibia and fibula together, and by dorsiflexing and externally rotating the foot at the ankle (186,213). Radiographs occasionally demonstrate an osseous avulsion. The CT scan and bone scan are occasionally helpful in demonstrating occult degrees of injury to the tibiofibular ligament complex (214).

Sprains of the distal tibiofibular ligament and syndesmosis are usually treated nonoperatively, with rehabilitation principles similar to those for lateral complex sprains (215). The athlete should be aware that the recovery process is typically twice as long as for a severe ankle sprain (213). Impingement of the ankle joint created by disrupted fibers can cause chronic pain (210). Occasionally, immediate surgical repair or reconstruction of the syndesmosis becomes necessary if there is significant diastasis (215).

Knee Injuries

Collateral Ligament Injuries of the Knee

Ligaments of the knee originate from the distal femoral epiphysis, and insert into the proximal tibial epiphysis, with the exception of the superficial portion of the medial collateral ligament, which inserts into the proximal tibial metaphysis distal to the physal plate (216) (Fig. 31-12). The ligaments are generally stronger than the physal plates, so significant bending injuries usually produce physal fractures, although pure ligament disruption can occur in children. Complete rupture of the medial collateral ligament has been reported in children as young as 4 years of age

(217–219). The results after these injuries are favorable in children and adults.

The grading of collateral ligament sprains requires comparison of the injured with the uninjured knee, because the normal degree of laxity varies considerably. A mild sprain (grade I) has little or no disruption of the ligament's mechanical integrity and no increased laxity on examination. Moderate sprains (grade II) result in plastic deformation of the ligament without complete disruption; the examination demonstrates increased laxity, but there is a distinct end point. Severe sprains (grade III) are complete ligament disruptions, resulting in significant laxity, and do not have distinct end points (220).

The history of injury obtained from youngsters is often poor, so the examination must be relied on heavily. Often, tenderness can be localized to the physal plate or to the path of the collateral ligaments themselves. The collateral ligaments are tested with the knee flexed 20 to 30 degrees, to relax the posterior capsule and posterior cruciate ligament (221). The joint line should be palpated while varus and valgus stresses are applied. Standard radiographs are obtained to look for physal fractures or bony avulsions.

If there is instability, a stress radiograph must be obtained to differentiate opening of the joint space, because of severe sprain, from motion through the bone, because of an unstable physal fracture. If an effusion is present in the knee, it can be aspirated, and the area can be infused with a local anesthetic to facilitate the examination.

If a hemarthrosis is detected, a cruciate ligament injury should be suspected. MRI is very useful for defining the injury.

Isolated collateral ligament sprains in the knee are treated according to the degree of injury, and by the same principles that are established for adults. Definitive studies of collateral ligament sprains in children are not available. All partial tears are treated nonoperatively. Most sprains are immobilized only until pain subsides (222). Sports are resumed when there is full motion, good muscle strength, and ability to run, cut, and perform necessary sport-specific activities (220,223,224). The use of these functional criteria is particularly helpful for the adolescent athlete who is anxious to return to sports. Grade I sprains result in an average of 10 days lost from activities, and grade II sprains average 20 days (225). For grade III collateral ligament sprains to the knee, the same rehab principles are applied. The recovery is slower than more mild sprains. Residual laxity is generally well tolerated. Double-upright, hinged functional braces provide medial stability, and therefore have a logical role in the protection of more severe medial collateral ligament sprains as they heal (226).

Although a few studies have suggested operative treatment for grade III collateral ligament sprains of the knee, isolated injuries in adults appear to have good clinical results without surgery (227–229). Successful nonoperative treatment is predicated on establishing that the grade III sprain is

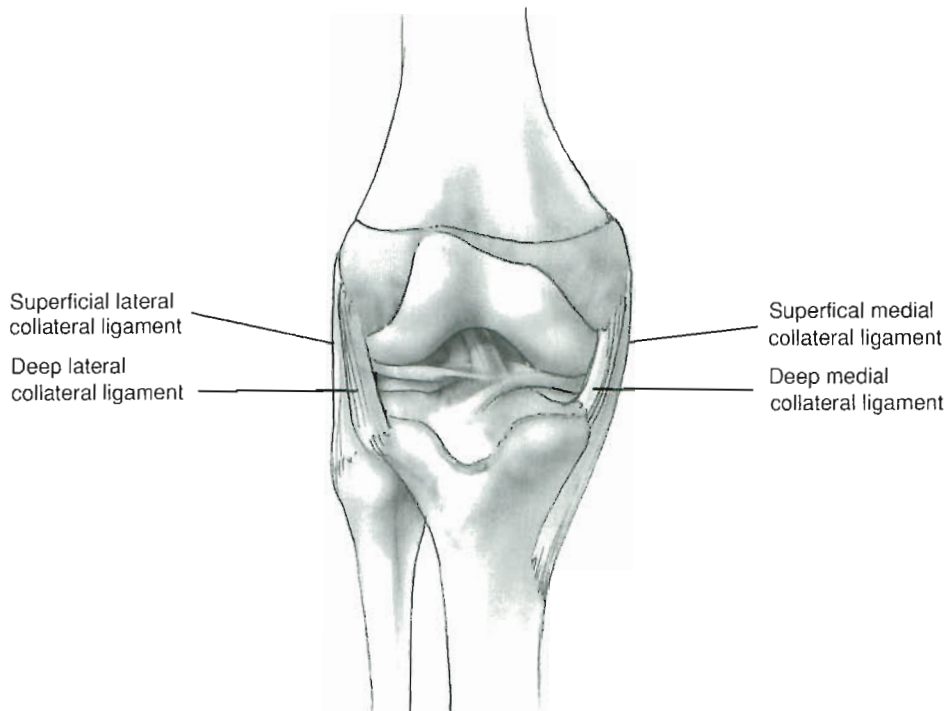


FIGURE 31-12. The collateral ligaments of the knee insert into the epiphyses, with the important exception of the distal insertion of the superficial medial collateral ligament. Bending injuries of the immature knee typically disrupt the physal plates, which are usually the “weak link in the chain.”

isolated. Concomitant meniscal tears or an anterior cruciate disruption must be considered.

Bony avulsions of the collateral ligaments are best managed operatively (218).

Anterior Cruciate Ligament Injuries

Anterior cruciate ligament (ACL) injuries occur far less commonly in children than in adults. Throughout adolescence and young adulthood, these injuries become more frequent. The principles of evaluation and treatment are very similar to those used for adults, although the specifics must take into account the open physes and high activity level of youngsters.

In children, the collagen fibers of the ACL blend from ligament to perichondrium to epiphyseal cartilage. Adult ligaments insert directly into bone by means of the Sharpey fibers (230). This difference probably accounts for the childhood tibial eminence avulsion fracture, which usually spares the ligament itself, although interstitial tears of the ACL can occur in children. Midsubstance disruption has been reported in a 3-year-old child (231). Avulsion of a bony fragment from the femoral attachments occurs less often, and rarely from both ends of the ligament (232,233). Avul-

sion from the distal insertion through the chondral–bony interface also may occur.

Fractures of the distal femoral and proximal tibial physes have a significant incidence of associated ligament injuries (234). The presence of a physal fracture of the knee does not preclude ligament damage, so ACL injury can easily be overlooked.

Meniscal tears are commonly associated with ACL sprains (235,236). Evaluation of the menisci by MRI may be useful, particularly if nonoperative treatment is being considered (237).

The history of injury in the adolescent is usually one of hyperextension, direct blow, or sudden twisting in the open field or court. Occasionally, a pop is heard, and the early onset of swelling caused by hemarthrosis is common (236). The **younger** child is typically a poor historian of the event. As in tibial eminence fractures, bicycle accidents commonly cause ACL injuries in children (238,239). The amount of initial pain is variable, with discomfort lasting over the ensuing days. Instability may be noticed if the youngster attempts to return to play.

The physical examination typically reveals effusion, diffuse tenderness, and limited motion. Although the anterior drawer test has been the classic test of anterior cruciate stability, the Lachman test and pivot–shift signs are felt to be

more sensitive and specific (221,240,241). Instrumented knee laxity testing is useful, if the physical examination is equivocal (242). The degree of inherent or congenital laxity must be considered in grading these tests, particularly for children. The other knee can usually provide a control against which the injured extremity is compared.

Routine anteroposterior and lateral radiographs of the knee are obtained, to look for osteochondral fractures and physeal fractures. A tunnel view may show bony fragments avulsed from the femoral origins of the cruciate ligament. A hypoplastic intercondylar notch, with a diminished tibial spine, is a sign of congenital absence of the cruciate ligaments (243,244).

MRI is fairly reliable for identifying injuries of the ligaments, menisci, and cancellous bone. Most clinically significant ACL injuries are adequately diagnosed by history and manual examination, so the indications for MRI must be weighed against its cost (245–247). Imaging studies are most valuable if management decisions will be influenced by the results. MRI is particularly useful if the presence of an associated injury, such as a meniscal tear, is going to influence the decision to operate. If a reconstruction is already decided on, the menisci can be evaluated at the time of arthroscopy.

The natural history of ACL tears in adults depends on patient age, activity level, expectations, degree of instability, ability to rehabilitate muscle strength, and the patient's resolve to modify activities as needed (248–250). Similarly, the decision to stabilize a young person's knee must be individualized, and the risk of reinjury, leading to subsequent damage of the menisci should be given strong consideration (251). Most should be reconstructed.

Left unstabilized, complete ACL disruption and instability generally have unfavorable results. Of McCarroll et al.'s 16 patients treated without reconstruction, nine gave up their sport because of instability. Each of the remaining seven had episodes of instability; four of them had multiple reinjuries, recurrent effusions, and pain (252).

Young athletes with partial tears (grade II, using the system previously defined for collateral ligament sprains of the knee) of the ACL can be treated without surgery, if there is no significant meniscal pathology. This usually is successful, if the knee does not demonstrate significant instability on examination. The examination is most accurately done under anesthesia with arthroscopy, to document the instability, degree of ACL disruption, and associated meniscal tears. The knee should be soundly rehabilitated before returning to sports. A functional brace is probably indicated. If instability with episodes of subluxation and pain develop, or if there is a subsequent injury, steps need to be taken to prevent further injury, especially to menisci. The activities must be substantially modified or the knee surgically stabilized.

For complete ACL tears, nonoperative treatment is an option, particularly if the physeal plates are open and the

patient is relatively inactive. However, children and adolescents tend to be active, rambunctious, and poorly attentive to rehabilitation. Despite the guarded prognosis, nonoperative treatment is occasionally selected in very young patients with substantial growth ahead. Healing of complete mid-substance ACL disruptions is apparently no more favorable in youths than in adults, and primary suturing, as an isolated procedure, is minimally effective (217,253–255).

Numerous braces have been developed with the intent of protecting the ligaments of the knee. The first were functional braces that had double-upright knee hinges. Although the hinges, strapping, brace fitting, and materials have evolved considerably, the stability imparted by these braces is marginal. Braces may prevent hyperextension injury, but rotational control is poor, and therefore raises doubt about the overall efficacy. A simple upright "prophylactic" brace was developed as a less cumbersome measure to protect uninjured athletes. Most well-designed studies have failed to demonstrate any statistically significant effect of these lateral stabilizing knee braces (256,257).

For the skeletally mature adolescent, the indications for standard reconstructive techniques used for adults apply.

The remaining growth is best evaluated in adolescents by bone age (258,259). Because little growth occurs during the last year that the physes are open, the risk of growth arrest complications are minimal.

Several techniques for reconstruction of the ACL can be considered in patients with open physes. Although extra-articular procedures avoid the physeal plates (252,260,261), they are probably not adequate to prevent a significant pivot shift and thereby protect the menisci (252,260–262). Intra-articular procedures more accurately reproduce the anatomic and biomechanical properties of the ACL, and prevent subsequent loosening (263). Most intraarticular ACL reconstructions involve crossing the physeal plates. The potential complications of shortening or angular deformity are particularly worrisome in the knee region, because approximately 65% of the leg's growth occurs from the combined distal femoral and proximal tibial physeal plates (264). Complications are uncommon in reported series of intraarticular reconstructions of patients with open physeal plates; however, caution must be used in extrapolating these data to significantly younger patients (252,265).

For the active adolescent with open physeal plates and more than 1 year of growth remaining, the author thinks a semitendinosus and gracilis graft makes the most sense. Drilling a hole across the physis, and filling it with a soft tissue graft is analogous to resecting a physeal bar. If a central bridge does occur in the proximal tibia of an adolescent, it is unlikely to produce an angular deformity or functionally significant shortening. The primary concern rests with the femoral tunnel, because the distal femoral physis has the most rapid growth in the lower limb, and the eccentric location of the resulting physeal bar could lead to a signifi-

cant angular (valgus) deformity. This is still a controversial area.

Posterior Cruciate Ligament Injuries

Posterior cruciate ligament (PCL) sprains are much less common in children than ACL injuries (266,267). They are significant, because of the serious potential morbidity. The mechanism of injury can be hyperextension or a fall onto a flexed knee. The patient typically has popliteal fossa tenderness, and recurvatum may be present, if the injury was caused by hypertension. The results of the posterior drawer and reverse pivot-shift tests are usually positive, although examination under anesthesia may be necessary to demonstrate this resultant laxity. Although midsubstance injuries may occur, avulsion of the femoral origin of the ligament should be suspected, even if a bony fragment is not seen on radiographs. MRI should be obtained to look for avulsion of the PCL, as well as concomitant injury to the articular and meniscal cartilages.

Primary repair of osteochondral avulsions appears superior to nonoperative treatment. Repair of a femoral end avulsion can be done through an anterior approach, with sutures passed through the epiphysis without crossing the physal plate (266,267). Tibial end avulsions are better handled through a posterior approach. If a midsubstance PCL tear is encountered in an adolescent, the principles of adult PCL injury treatment should be applied (268–271).

Meniscal Tears

The menisci serve several important functions in the knee, and are no longer considered expendable. The menisci provide stability for the joint, and apparently nourish the articular cartilage by distributing synovial fluid (272). They transmit and distribute load between the articular surfaces (273).

Most tears in young individuals are sports-related, with some injuries resulting from falls and automobile accidents (274). The exact incidence of meniscal tears in youths is unknown. Large series of meniscectomy cases typically include about 5% of cases involving youths younger than 15 years of age. Less than one-third of these cases are acute traumatic tears. Most meniscal tears in children are related to discoid menisci, or occur with concomitant injury to the cruciate ligaments (275,276). These younger children typically have a more vague history of injury (277).

Adolescent meniscal tears usually result from a significant injury, and typically involve a twisting mechanism. Often a pop is heard or felt. After injury, complaints of popping, intermittent swelling, limping, and giving way are common (276,278,279). Concomitant ligament injuries are common. The diagnosis may be delayed as long as 12 months (274). Rarely, the onset is atraumatic, as is so often the case in the middle-aged patient (276).

Joint line tenderness and effusion are the most common signs (278). The McMurray test, Apley grind test, and quadriceps atrophy may be helpful in the diagnosis of a chronic lesion, but typically, the acutely injured knee is too painful for these maneuvers to be performed effectively (280). With a bucket-handle tear, the knee may become locked. Ligamentous laxity, common in children, results in hypermobility that can produce a false-positive McMurray test (277).

The differential diagnosis includes collateral ligament sprain, synovial contusion, acute plica syndrome, osteochondritis dissecans, chondral fracture, patellar subluxation, discoid meniscus, and popliteus tendinitis (281).

Routine radiographs of the injured knee should be obtained. Further investigation must be tailored to the degree of suspicion for a tear and the perceived urgency for definitive diagnosis and treatment. Imaging is particularly useful in diagnosing the patient with a known medial collateral ligament sprain, for whom joint line pain from the sprain cannot be separated from that potentially caused by a concomitant meniscal tear (220). Imaging can help determine whether early arthroscopy or trial rehabilitation should be recommended (282).

Although arthrography is minimally invasive and relatively inexpensive, it is rarely used for the diagnosis of meniscal injuries, because MRI has become so readily available. MRI scanning for meniscal tears has a reported accuracy as high as 98% (245,247,283).

Several series of total meniscectomy in youths have shown that well over one-half of the patients are symptomatic within 5 to 8 years of surgery. Most of these have significant degenerative changes demonstrated on radiography (274,278,279,284). While patients undergoing arthroscopic partial meniscectomy generally do better than total meniscectomy, the long-term outcome studies are still pending. Meniscal injuries in youths should not be neglected, because of the predictable consequences.

The key issue to meniscal healing appears to be vascularity. Although the embryonic human meniscus has vessels throughout its substance, with age and development, the inner portion becomes completely avascular (285,286). Microangiographic studies have shown that about 30% of the capsular margin of the adult meniscus receives its blood supply from a plexus of circumferential vessels arising from the medial, lateral, and middle geniculate arteries (287) (Fig. 31-13). A proliferation from the interstitial vessels and the adjacent synovium had been experimentally shown in dogs, in response to injury. Mesenchymal cells fill the gap with a cellular fibrovascular scar tissue. With time, the lesion remodels to reflect the contours of the normal meniscus (287,288).

Children and adolescents seem to have a high percentage of peripheral detachments and vertical longitudinal tears near the capsular margin, which are good candidates for repair (277,289). Repair yields an 80 to 90% success rate and minor deterioration over time (254,289). Several open and arthroscopic techniques for meniscal repair have been

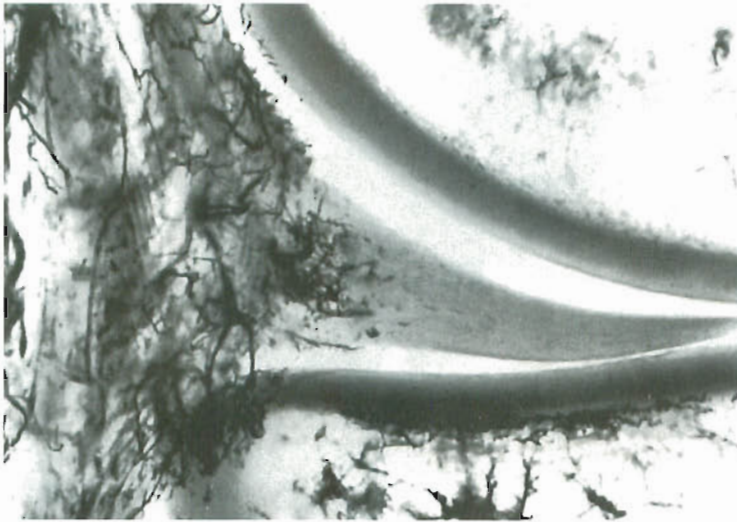


FIGURE 31-13. Vascularity of the human meniscus, as seen in a frontal section of the medial compartment of the knee. Branching vessels from the perimeniscal capillary plexus penetrate the capsular third of the adult meniscus. (From ref. 286, with permission.)

developed, and each has its merits. There are several key principles. The meniscus should be reduced anatomically and secured by multiple closely placed sutures (291). Since healing is slow, the sutures should be a nonabsorbable or a slowly resorbable material. They must be passed carefully to avoid neurovascular structures, and should be tied down directly on the knee capsule (289,291).

A variety of bioabsorbable fasteners have been developed recently. Most of these offer the advantage of being inserted with arthroscopy alone. The efficacy of these is still being evaluated. Currently, vertical suturing is the standard against which these newer devices are being compared.

Rasping the synovium to stimulate a vascularized tissue response, much like a pannus formation, seems to augment healing (289,291). Puncturing the capsular margin of the meniscus may create channels for vascular ingrowth, and the addition of fibrin clot into the repair may augment healing (287).

Because of the slow healing of the meniscus, the aim of rehabilitation after surgery is to shield the repair from the mechanical stresses of extreme motion and weightbearing. The knee is placed in a brace, to limit motion for 6 weeks, and weight bearing is restricted. Rigorous strengthening is started after 6 weeks. Cycling is started at 3 months postoperatively. Straight-ahead jogging is started at 4 months, with full-speed running and sports at 6 months (292).

Quadriceps Contusion

Blunt trauma to the anterior thigh musculature is a common sports injury, occurring most often in soccer, American football, lacrosse, and rugby (293). Although simple contusions may be a daily event for young athletes, severe quadriceps hematomas can result in marked disability. Because continued participation, despite injury, can significantly

worsen the prognosis, players and coaches should be educated to recognize this injury (294).

Bleeding typically occurs in the fascial compartment, and a variable amount of thigh swelling results. Swelling and muscle spasm then limit knee flexion.

The differential diagnosis should include fracture of the femoral shaft, physeal fracture, stress fracture, myositis ossificans, osteomyelitis, and sarcomas of the bone or soft tissues. The keys to the correct diagnosis are a careful history, detailed review of the radiographs, and timely follow-up. The radiographs must be of good quality and checked for subtle evidence of bone resorption and periosteal new bone, which may indicate the problem to be an infection, tumor, or stress fracture that has come to attention because of incidental trauma.

Initial treatment consists of rest, ice, compression, elevation, immobilization, and crutches. After pain and spasm subside, gentle active range of motion exercise is begun. After good motion is achieved, progressive strengthening and conditioning are pursued. Athletes with greater than 90 degrees of knee flexion, within 48 h of injury, have an average of 1 week of disability. Severe contusions of the quadriceps may take several months to resolve (293).

Premature return to activity can result in recurrent hemorrhage. The athlete is returned to sports based on the functional parameters of pain, motion, strength, and agility. A padded guard should be fashioned to protect the area from reinjury. Aspiration of the hematoma and injection of proteolytic enzymes or steroids have not been proved efficacious. These may create complications and are not recommended.

Ossification may be an incidental finding after minor trauma. Myositis ossificans traumatica can occur after severe contusions, particularly if reinjury occurs during the healing phase (295). Ossification of the soft tissue typically appears

on radiographs 2 to 4 weeks after injury (294,295). After localized trauma, the course of myositis ossificans is much more benign than after head trauma. Ossification in the midportion of the muscle belly rarely produces significant limitation of motion (293). The patient is cautiously rehabilitated until normal function is regained. Excision of the lesion is rarely indicated (294,295).

Avulsion Fractures of the Pelvis

Avulsion fractures of the apophysis about the hip and pelvis are most commonly related to athletic injuries during adolescence (296–298). The usual mechanism is a sudden forceful concentric or eccentric muscle contraction. This occurs with rapid acceleration or deceleration. Excessive passive lengthening or stretch, such as a cheerleading split, and a variety of gymnastic maneuvers may also be responsible. Rarely, a direct blow produces these injuries.

The amount of displacement is related to the degree of injury to the associated soft tissue attachments (Fig. 31-14). The anterior inferior iliac spine is avulsed by the direct head of the rectus femoris, but migration is limited by the reflected head. The iliac crest apophysis is avulsed by the abdominal muscles, and tethered by the attachment of the gluteus medius, iliacus, and tensor fascia lata muscles. The pull of the iliopsoas on the lesser trochanter, the sartorius on the anterior superior iliac spine, and the hamstrings on the ischium are relatively unopposed, resulting in greater potential for displacement.

Typically, the athlete experiences an acute onset of pain that may be accompanied by a popping sensation. Tenderness is usually confined to the area of avulsion. The patient is most comfortable in a posture with the attached muscle-tendon unit relaxed. Pain is reproduced by active or passive stretch. Anteroinferior iliac spine avulsions may be particularly hard to localize, because of their location, and the inciting event may not be recalled (296). The avulsed fragment usually is seen on routine radiographs. Occasionally, special views are needed, but for most cases, MRI and radionuclide scans are unnecessary (296).

A history of antecedent apophysitis is common. Persistent tenderness of the anterior iliac crest can result from an apophysitis, which may be associated with radiographic discontinuity of the apophysis. Neoplasm and infection should be considered, especially if the history is atypical (299,300).

Initially, the patient rests, with the injured region in a relaxed position. Generally, crutches are recommended for the first 2 weeks, then a phased rehabilitation program should be guided by functional improvement. The goal should be to restore motion, strength, and sports-specific functioning. Premature return to play may delay recovery or further displace the apophysis. The decision for early or safe return to competition is not easily made and must weigh the clinical findings and radiographic evidence of healing. Complete healing may take 6 weeks to several months.

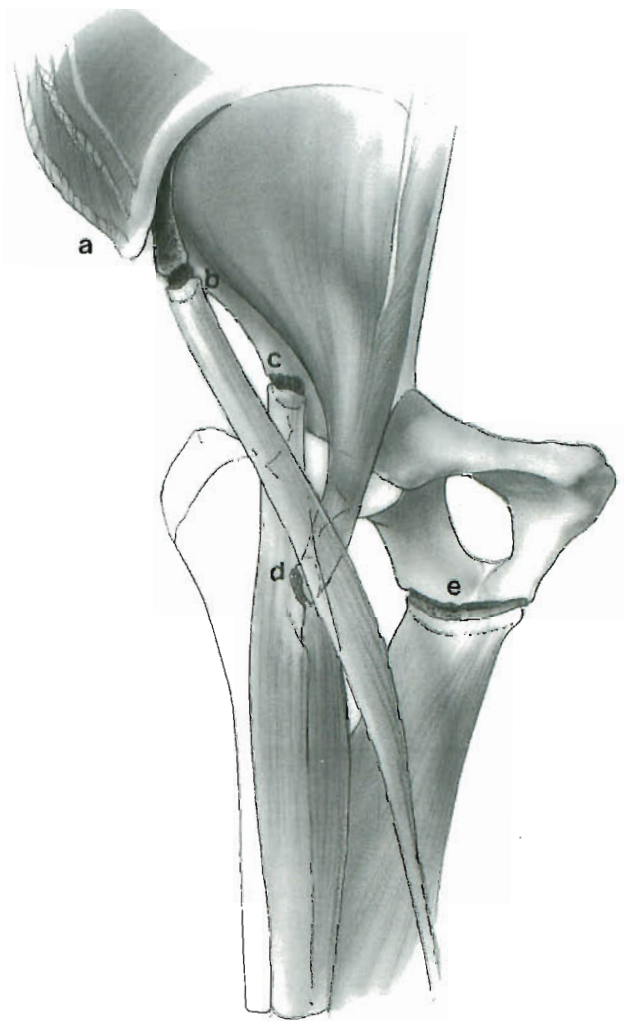


FIGURE 31-14. Avulsion fractures of the growing pelvis result from traction injuries where major muscle groups insert into or originate from apophyses about the pelvis. **A:** The abdominal and trunk muscles insert into the iliac apophysis. **B:** The sartorius originates from the anterior superior iliac apophysis. **C:** The direct head of the rectus femoris originates from the anterior inferior iliac apophysis. **D:** The iliopsoas inserts into the lesser trochanteric apophysis. **E:** The hamstrings originate from the ischial apophysis.

With time, bone is laid down in response to the injury. Relative shortening of the muscle, prominence of the bony mass, and potential interference of the sciatic nerve have been sighted as causes of residual disability. Limitation of athletic ability rarely occurs, and is apparently only related to severely displaced ischial avulsions (301). In rare cases, troublesome bony fragments should be resected (302). Surgical reduction and fixation are seldom indicated (297,298).

Spinal Injuries

Serious injuries to the head and neck are infrequent, but often devastating. Football, trampoline, ice hockey, rugby, and diving are the most common activities associated with these injuries to younger athletes (303–305).

American football remains a serious risk to the young athlete, despite improved equipment and changes in tackling techniques; 72% of high school athletes suffering quadriplegia were attempting to make tackles. Defensive backs are the most commonly injured players. Ironically, the improved protective capabilities of the helmet and face mask during the 1960s and 1970s resulted in the use of the head as a primary point of contact in blocking and tackling (305). Fifty-two percent of quadriplegics between 1971 and 1975 were injured by "spearing," which is the use of the head to ram an opponent. In 1975, the National Collegiate Athletic Association and the National Federation of State High School Associations adopted football rule changes that prohibit spearing. Since then, there has been a downward turn in the incidence of serious cervical spine injuries, and a dramatic decline in quadriplegia (305). Although the incidence of spine injuries is approximately 5 per 100,000 players (1 quadriplegic per 100,000), this remains a serious problem because of the tragic nature of the injury.

In the United States, trampolines and gymnastics are second to football in causing sports-related spinal cord injuries (306). At least 114 cervical spine injuries resulting in quadriplegia are known to have resulted from the trampoline and minitrampoline (307). In 1977, the American Academy of Pediatrics issued a policy statement that prompted most schools to eliminate trampolines. Since then, the estimated frequency of head and neck injuries associated with trampolines has declined by almost two-thirds. The trampoline is a dangerous apparatus, and spine injuries can occur even in experienced athletes taking reasonable precautions (307).

Cineradiography has shown that most cervical spine injuries from sports are caused by axial loading, with the neck in a slightly flexed position (307,308). Improper tackling (American football), checking into the boards (ice hockey), diving into shallow water, and trampolines are clearly causes of spine fractures and paralysis.

Recognizing that these injuries are not just freak accidents provides the opportunity to diminish their occurrence by research, education, rule changes, technique modifications, and equipment improvements. Players should be informed of the hazards, and programs for strengthening neck muscle are essential (308,309). Management of these injuries is beyond the scope of this text, but prevention should be a primary interest of everyone dealing with young athletes.

OTHER COMMON KNEE PROBLEMS

Patellofemoral Disorders

Disorders of the patellofemoral joint include a variety of overuse syndromes, congenital and developmental abnormalities, and instabilities. In adolescents, patellofemoral problems account for almost 10% of all sports injuries (216).

Anatomy and Biomechanics

Evolving in upper-level primates, the patella is a sesamoid bone of the quadriceps mechanism (310). The patella furnishes a site of convergence for the four components of the quadriceps muscle, to provide an extension moment arm through the entire knee range of motion (311,312). Phylogenically, the vastus medialis was the last of the quadriceps group to develop (313). The trochlear shape of the distal femur stabilizes the patella's tracking.

The hyaline cartilage of the patella is the thickest in the body. It provides a low-friction surface that is able to bear high compressive loads, and the patella protects the distal femoral surface from direct blows during a fall (311).

The inferior pole of the patella first contacts the trochlea at 20 degrees of flexion with a relatively low-contact surface area (313). With further flexion, the contact site moves more superiorly, and the surface area increases. The most medial facet or "odd facet" only comes into contact with the trochlea between 90 and 130 degrees of knee flexion.

The patellofemoral articulation is subject to extremely high compressive loads, particularly with progressive knee flexion (314). With the knee flexed 9 degrees during walking, the patellofemoral joint reactive force is approximately one-half of the body weight. This increases to 3.3 times body weight at 60 degrees of flexion, during activities such as stair climbing. The contact forces reach 7.8 times body weight with full knee flexion during a deep knee bend (311).

The alignment of the quadriceps relative to the patellar tendon has a valgus relation, much like that of the tibia and femur. This angle is influenced by the patient's height and pelvis width. The quadriceps vector is approximated by a line from the anterosuperior iliac spine to the center of the patella. The line of pull through the patellar tendon runs from the center of the patella to the tibial tubercle. The relation between these two lines is referred to as the quadriceps angle, or Q angle. As this angle increases, the vector created by the extensor mechanism tends to translate the patella laterally (Fig. 31-15A). As the Q angle increases, so does the degree of that laterally directed force (315). The Q angle increases even further with external rotation of the tibia, which occurs dynamically as the tibia externally rotates during terminal extension. There may be a developmental degree of outward rotation of the tibia (external tibial torsion) as well.

The lateral retinaculum, including the lateral patellofemoral and lateral meniscopatellar ligaments, add to the laterally directed moment of the extensor mechanism (316). The sum of these forces is resisted by the medial parapatellar-stabilizing soft tissues, and the pull of the vastus medialis (Fig. 31-15B). The lateral patellotrochlear articulation is the other key component balancing these forces, and any deficiency of any of these components can exacerbate lateral maltracking or instability of the patellofemoral joint (314,315,317) (Fig. 31-15C).

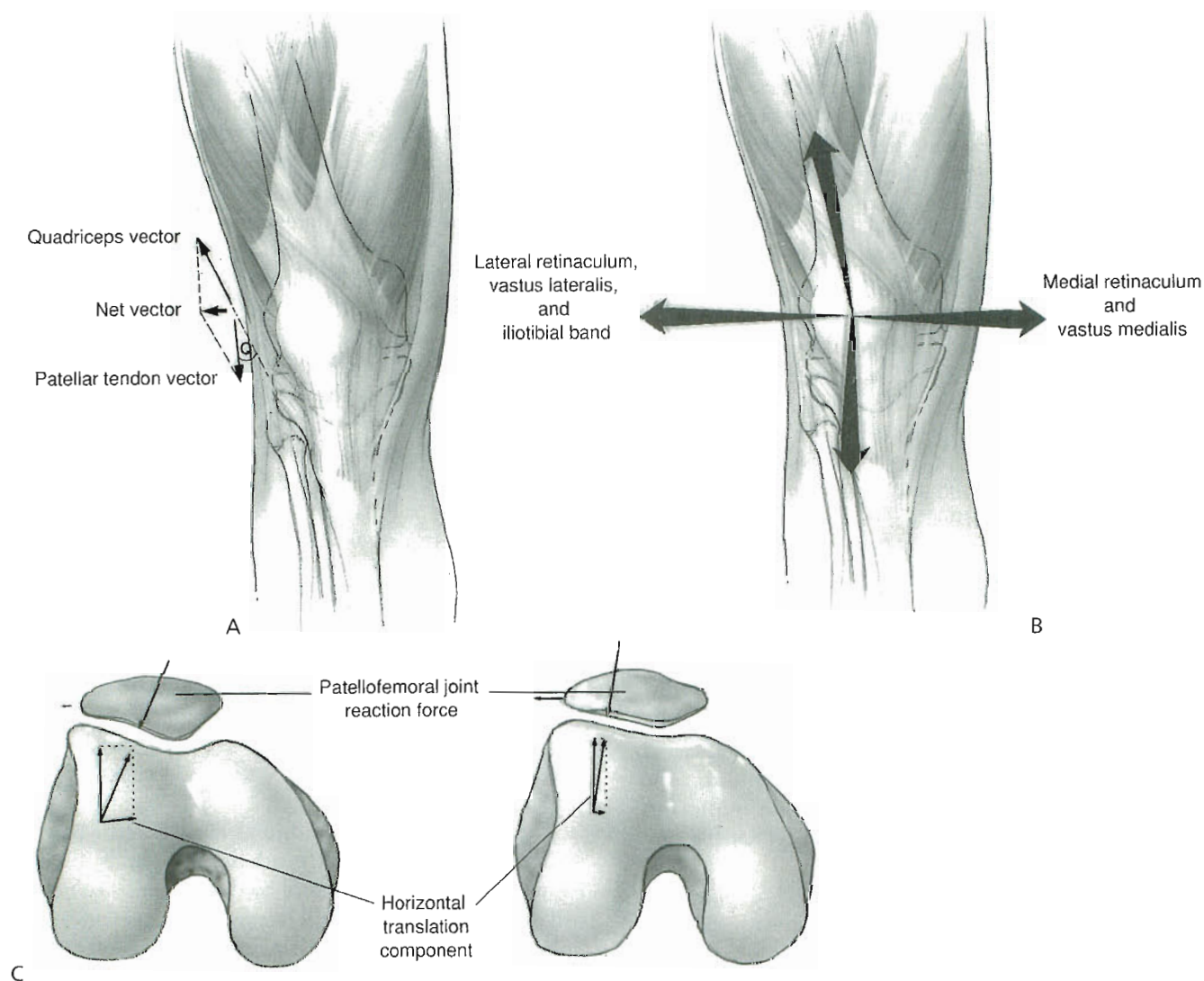


FIGURE 31-15. Patellofemoral biomechanics. **A:** The Q angle relates the direction of pull of the quadriceps mechanism to that of the patellar tendon. These are the two most powerful forces exerted on the patella. Their vector sum is directed laterally. **B:** There are additional soft tissue forces applied to the patella. **C:** The laterally directed net vector is opposed by the patellofemoral articulation. If the groove is shallow, there is less potential resistance to horizontal translation than for knees with a deeper femoral groove. The dysplastic patellofemoral articulation results in less resistance to lateral translation, and therefore greater articular surface shear forces.

Anterior Knee Pain

Mechanics and Diagnosis

“Patellofemoral pain syndrome” is a descriptive term applied to patients with nonspecific anterior knee pain. Malalignment or maltracking appears to be a significant predisposing factor. Lateral tracking or subluxation of the patella, demonstrated arthroscopically, is highly correlated with the patellofemoral pain syndrome. In some people, lateral tracking is associated with pain and instability. Other patients complain primarily of instability, and have relatively little

pain. For the purpose of this discussion, patellofemoral pain syndrome is separated from patellofemoral instability, although some patients have components of both.

Chondromalacia patella is not typically found in these younger patients. Several hypotheses have been proposed for the mechanism of pain production. Ficat and associates have proposed that excessive pressure from the lateral facet is transmitted to the sensate subchondral bone, leading to the perception of pain (318). Hejgaard and Diemer found increased interosseous pressure of the patella in many patients with patellofemoral pain (319). James proposes that

the cause in many patients is an underlying overuse syndrome, resulting in excessive rotational forces in the peripatellar soft tissues (320).

Factors predisposing to patellofemoral pain syndrome include habitual overloading related to overuse, a variety of lower-extremity malalignments, poorly developed quadriceps muscles, and various dysplastic changes about the patellofemoral articulation. One particularly common aggregate of these abnormalities is commonly seen in adolescent girls, and has been called the "miserable malalignment syndrome." These patients have increased femoral anteversion, external tibial torsion, genu valgum, excessive Q angles, heel cord contracture, and pronated feet (320,321).

The pain in most patellofemoral disorders is generalized to the anterior part of the knee. The pain is typically related to activity, and patients feel more comfortable at rest. Climbing stairs is particularly troublesome, because of the excessive patellofemoral loads. Prolonged sitting may produce discomfort and the need to move the knees. Patients may complain of stiffness after prolonged sitting. Erythema and effusion are uncommon. The patient may experience catching or giving way, but true locking is unusual. Training errors usually related to the change in intensity, duration, or training surface are common factors in patellofemoral disorders (320). The complaints are frequently bilateral, although not necessarily concurrent.

The physical findings include diffuse medial and lateral peripatellar tenderness. The combination of increased femoral anteversion and external tibial torsion causes the patellae to face toward each other to some degree when the feet are directed forward; this has been called "squinting patellae." Frequently, the lateral retinaculum is contracted; this can be demonstrated by the inability to elevate the lateral margin of the patella during the tilt test. Crepitus may signal significant articular irregularity, although this must be tested in at least 20 degrees of flexion, to ensure that the patella is articulating with the trochlea, rather than with the femoral metaphysis. Perhaps the most important finding is the lack of other specific abnormalities, because patellofemoral pain syndrome is primarily a diagnosis of exclusion.

Because underlying biomechanical abnormalities are common, the evaluation must include a thorough inspection of the entire lower extremities and the athlete's shoes, which may demonstrate asymmetric wear patterns, a finding that can be particularly helpful if the problem is unilateral (320,322). Even if wear is symmetric, breakdown of the medial counter of the shoe indicates excessive pronation. A wedged pattern of heel wear suggests a valgus heel strike, which is typical of runners with excessive pronation. As the foot rolls during pronation, the tibia rotates inward, and the extensor mechanism experiences greater stresses to resist this (113). If the shoes demonstrate wear on the lateral edge of the heel, this suggests a hindfoot varus strike, possibly caused by a cavus foot. The more rigid cavus foot pattern can result in less shock absorption at the foot and relatively

greater ground reaction forces being translated to the knee (120).

The Q angle, patellar tilt, and lateral glide should be considered (315,323). Medial and lateral peripatellar tenderness most often is related to inflammation of the soft tissues, rather than a painful articular surface. Thigh circumference and vastus medialis atrophy are signs of long-standing dysfunction, and may even be contributing factors (323). Tightness of the hamstrings and iliotibial band should be checked, because they can lead to increased patellofemoral contact forces (324–326). Anterolateral or anteromedial joint line tenderness may overlap the symptoms and findings associated with meniscal problems (327,328).

Radiographic evaluation should include anteroposterior, lateral, and tangential views of the patella. The anteroposterior and lateral views may identify bipartite patella, Sinding-Larsen-Johansson disease, osteochondritis dissecans, and dorsal defects of the patella. The lateral view can be used to identify patients with patella alta or patella infera. Insall et al. described a ratio of the maximal patella length to the patellar tendon length; normal was defined as a ratio of $1:1 \pm 20\%$ (329). Lancourt and Cristini have correlated patellar instability and chondromalacia to a decrease in this ratio (330).

Various tangential views have been developed to evaluate the patella's anatomic relation to the trochlear groove and to the femur (318,331,332). Merchant's technique is performed with the knee minimally flexed over the edge of the table and supported by an apparatus (332) (Fig. 31-16). Supine positioning relaxes the quadriceps and avoids direct pressure to the patella. This allows a maltracking patella to rest in a subluxated position, probably making the Merchant's view the most sensitive plain radiographic technique. Patellar views done with the knee simply flexed, often called "sunrise views," pull the patella into the distal femoral sulcus, and can lead to a false impression that the patella is tracking centrally. CT and MRI can also demonstrate patellar subluxation, but are probably not indicated for the routine case (333,334). A variety of lines, angles, and ratios have been developed to quantitate static patellar tilt and subluxation as an indicator of tracking (332,333,335). However, the usefulness of this information in determining treatment has not been definitively demonstrated (327,336).

Bone scans may demonstrate increased radionuclide activity in the patella, suggesting increased metabolic activity of the bone, but for patellofemoral pain, the sensitivity, specificity, and predictive values of bone scans in younger patients have not been proved (337–340).

Treatment

Many patients only need reassurance that the problem is not more serious. The intermittent use of NSAIDs, a knee sleeve, and other isolated modalities may be adequate to control the symptoms. If the symptoms are persistent and

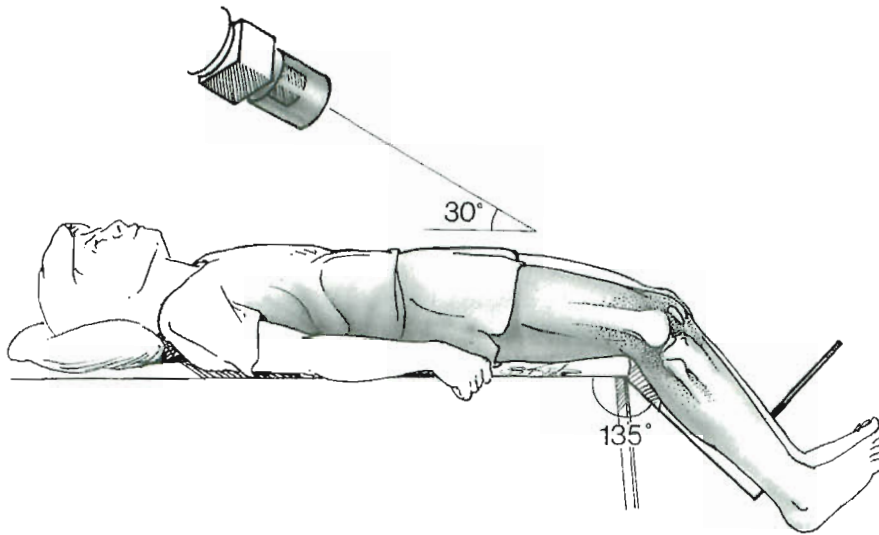


FIGURE 31-16. Tangential x-ray view for evaluating the patellofemoral joint. Merchant's view allows the quadriceps mechanism to relax. The patella is not artificially held reduced in the distal femoral groove.

troublesome, a more formalized program is helpful. The importance of genuine and concerted efforts at nonoperative management of the patellofemoral pain syndrome should be emphasized. Most patients should be successfully managed without surgery (324,325,341,342).

The treatment program can be divided into four phases, which blend together, rather than being separate steps (343).

Phase 1 concentrates on symptom reduction. The initial management of symptoms includes modification of activities, ranging from elimination of activities, such as stair-climbing or hill-running, to complete cessation of sports. For the serious athlete, modification of training or substitution of an alternative, such as swimming, is critical. NSAIDs may be helpful. Many patients find that use of a knee sleeve with a patella cutout reduces pain, especially when they have pain with daily activities (344). Isometric quadriceps-strengthening exercises and hamstring stretching should be started in this initial phase. Ice is used in conjunction with exercise. Occasionally, the knee may require a brief period of splinting. Crutches are rarely needed. Several bracing and strapping techniques have been advocated to improve patellar tracking. The McConnell taping technique appears to be the most successful of these. An experienced therapist can work with this technique and, if successful, teach it to the patient.

Phase 2 concentrates on reconditioning. When the patient is able to tolerate isometrics comfortably, a quadriceps-strengthening program is advanced. Straight-leg raising and terminal extension quad arc-strengthening exercises are begun. Weights are later added. Isometrically loading the quadriceps, or the use of terminal range of motion strengthening exercises, minimizes the excessive patellofemoral contact forces generated in flexion past 20 degrees (311). DeHaven et al. achieved excellent results with the use of a

simple knee extension exercise apparatus or the use of a weight boot (343). Specific instructions are necessary, and most adolescents require some supervision to ensure compliance.

Isokinetic exercise has been shown to be an excellent method of strengthening muscles; however, there can be disadvantages to its use in the early phases of rehabilitation. Isokinetics may result in excessive patellofemoral contact forces being generated by a rigorous contraction. With appropriate precautions, eccentric strengthening can be used effectively, although this is usually unnecessary until the advanced stages of reconditioning (345).

A general lower-extremity strengthening program, including hamstring stretching and strengthening, is included in phase II. Physical therapy modalities, such as high-voltage galvanic stimulation (i.e., Highvolt) or transcutaneous electrical nerve stimulation may be helpful, particularly for the athlete who has limited exercise capacity because of pain. A patellar "stabilizing" sleeve may also be helpful in controlling pain and facilitating weight lifting (346).

In phase 3, activities are gradually resumed. After a patient demonstrates consistent progress in quadriceps strengthening, a graduated running program is instituted. This can commence when the patient is performing quadriceps strengthening at about one-half of projected goal. DeHaven et al. outlined recommendations for this in terms of a young adult male eventually progressing to 60 lbs, using a weight-added isometric technique (343). If using a weight boot or ankle weights, the goal should be 10 pounds for straight-leg raises and terminal extensions, before initiating a running program.

The running program is based on prior training experience and ability, but it should include a period of stretching and warm-up exercises, gradually increased duration and speed, initial avoidance of hills, ice after running, good shoe wear, and a foot orthosis, if there appears to be a significant

biomechanical anomaly. Running should initially be done every other day, with the phase 2 weight program on the alternate days.

In phase 4, a maintenance level is reached. Stretching and warm-up exercises before all activities are continued. In addition to the athlete's usual training program, weight training is continued two or three times each week. The athlete is advised that minor setbacks can be expected; the program is backed up to the prior comfortable step and progressed more gradually as symptoms permit.

Although the results of surgical treatment for patellofemoral pain are generally good, failure can result in significant disability. This emphasizes the importance of a sincere effort to have patients persevere with a conservative rehabilitation program, until all reasonable attempts have been made. Patellofemoral pain syndrome typically does not resolve until adequate strength gains are made. Often, the stumbling block is that adequate strength gains cannot be made, because of the pain encountered with each attempt to progress the exercise program. Surgery is not a substitute for exercise therapy; instead, it should be viewed as an aid to improve the patellar tracking, and thereby facilitate strengthening (347).

Lateral Retinacular Release

Contracture of the lateral retinaculum is a common finding in patellofemoral pain syndrome. The contracture may be the underlying cause of the problem or a manifestation of it. The principle is to release the tight structures, and thereby improve tracking. The role of retinacular release in the treatment of the patellofemoral pain in adolescents is controversial. Most patients will respond to conservative means.

The indications for lateral release then include intractable patellofemoral pain, findings such as tenderness over the lateral retinaculum with a tight lateral retinaculum, and no other explanation for the problem (348). The prerequisites include failure of substantial conservative measures, a tight lateral retinaculum with evidence of lateral tracking, and peripatellar pain (349,350). Evidence of lateral tracking or subluxation should be confirmed arthroscopically (328, 351,352). The relative contraindications include reflex sympathetic dystrophy, poor cooperation with rehabilitative exercises, psychosomatic illness, and ulterior motives, such as a desire to establish a compensation-related disability (353–355).

Arthroscopy should be performed at the time of lateral release to thoroughly assess the knee, identifying concurrent pathologic processes or other problems with symptoms that could lead to misdiagnosis (328). The incidental finding of lateral tracking in an otherwise asymptomatic knee should not be an indication for lateral retinacular release (328,347).

Lateral retinacular release can be performed through an open incision, or percutaneously (326–328,336,350, 356–362). The release should transect the lateral menisco-

patellar fibers inferiorly, and extend just above the superior pole of the patella. Adequacy of the release should be demonstrated by an intraoperative manual tilt test. The vastus lateralis should not be detached from the superolateral pole of the patella, because this can be associated with significant atrophy of the vastus lateralis and postoperative medial subluxation of the patella (363).

Hemarthrosis is a relatively common complication, and can be associated with delayed rehabilitation, persistent synovitis, and poor overall results. Specific attention is paid to the superolateral branch of the geniculate artery, which is typically transected. Although cautery is theoretically an advantage of the open technique, the arthroscopic use of electric cautery has also been proven effective (364).

Postoperatively, the use of a sleeve that fills with ice water, such as the Cryocuff (Aircast Corporation, Summit, NJ), seems to greatly reduce pain, swelling, and hemarthrosis. Therapy is begun a few days later, to restore the range of motion and prevent adhesions from forming. Within a short time, strengthening should be better tolerated than before surgery (347).

The overall results of most studies of lateral retinacular release are 75 to 85% favorable (327,328,347,350, 359,361,362,365). Complications include persistent pain, painful hemarthrosis, synovitis, reflex sympathetic dystrophy, recurrent medial subluxation, patellofemoral osteoarthritis, saphenous neuritis, and thrombophlebitis. Factors associated with poor results include reflex sympathetic dystrophy, ligamentous instability, and high-grade chondromalacia (331,353,354,362,365).

Chondral Shaving

Cartilaginous debris in a joint produces synovitis. This is the rationale for debriding or shaving articular cartilage in the treatment of patellofemoral pain with advanced grades of chondromalacia patella (152). Ogilvie-Harris and Jackson demonstrated reasonable results from chondral debridement in cases of trauma in which there is no underlying maltracking (365). In these cases, a lateral retinacular release is only indicated if there is demonstrated concurrent maltracking. In cases of patellofemoral pain with concurrent grade II or III chondromalacia, cartilage debridement should be viewed as an adjuvant procedure only.

Other Procedures

Advancement of the vastus medialis and distal realignment procedures may be indicated for specific cases with medial soft tissue defects or excessive Q angles (348). For patellofemoral pain without overt symptoms of instability, lateral retinacular release is usually the first line of treatment. If the lateral retinacular release fails, secondary procedures should be approached cautiously, first confirming that there is no other diagnosis to explain the symptoms.

Chondromalacia

The term “chondromalacia” refers to softening and degeneration of the articular cartilage (313). Adults with maltracking frequently have these cartilage changes, but it is probably incidental in many cases. Significant cartilage fibrillation or fissuring is not typically present in younger patients with signs of patellofemoral pain syndrome. Occasionally, these cartilage changes are seen in larger adolescents, and sometimes result from direct trauma to the patella or occur after patellar dislocations. Symptomatic chondromalacia is much less responsive to rehabilitation efforts than patellofemoral pain. These patients occasionally respond to arthroscopy and chondral shaving, but the physician must beware of other concurrent or underlying processes that have led to the chondromalacia.

Saphenous Nerve Entrapment

Anterior thigh pain extending to the superomedial pole of the patella can be produced by an entrapment syndrome of the saphenous nerve. This branch of the femoral nerve enters the adductor canal alongside the superficial femoral artery. It then penetrates anteriorly through the dense fascia connecting the adductor magnus to the vastus medialis 10 cm proximal to the medial femoral condyle.

Although most reported cases have involved patients past their teens, this condition can be seen in adolescents (366). Medial thigh and knee pain is typically produced with walking or running. It is often aggravated by quadriceps exercises. The most reliable finding is point tenderness, where the nerve exits Hunter’s canal. Saphenous nerve entrapment should be considered in the differential diagnosis of anterior knee pain, and not mistaken for patellofemoral maltracking or plica syndrome.

Injection of a local anesthetic into the affected site relieves the pain and produces an area of numbness in the distribution of the saphenous nerve. If the condition is unresponsive to rest and NSAIDs, a steroid can be injected. This may need to be repeated, and the pain may not completely resolve (367).

The results of surgical release and neurolysis are mixed, with failures apparently secondary to scar tissue entrapping the nerve. Neurectomy may be necessary, but the patient must be warned of the resultant numbness (366).

Bipartite Patella

Ossification of the patella begins between 4 and 6 years of age, and is completed by adolescence. Secondary ossification centers often occur, beginning around 12 years of age, and are usually located in the superolateral portion of the patella. In about 2% of the population, the secondary ossification centers failed to fuse completely with the primary ossification center.

Most bipartite patellae are asymptomatic. In some, pain apparently stems from the motion at the interface between the patella and its secondary ossification center. This is analogous to a symptomatic accessory tarsal navicular or a fracture nonunion. In some cases, the articular portion of the bipartite patella is incongruous with the rest of the joint. Typically, these are sloped posterolaterally. The surrounding synovium becomes inflamed, often because of chondromalacia of the surface beneath the secondary ossification center.

Most bipartite patellae are asymptomatic, with the diagnosis being made as a coincidental finding on a radiograph obtained for other reasons. In some youngsters, the secondary ossification center becomes symptomatic after a direct load blow to the patella, typically from a fall. The rigors of training for competition can also precipitate symptoms.

Often, the patient will have localized pain at the superolateral pole of the patella. A prominence and/or cleft may be palpable, along with tenderness of the surrounding joint capsule and synovium. Effusion, instability, or other findings should suggest that the bipartite patella is coincidental, rather than the primary source of the patient’s complaint.

Most bipartite patellae can be adequately visualized on plain radiographs of the knee with the Merchant’s view demonstrating this the best. Occasionally, CT and MRI aid in evaluation.

The initial treatment includes reassurance, ice, NSAIDs, and a knee sleeve. Occasionally, rest, activity modifications, and a few weeks of immobilization are helpful.

For persistently troublesome symptoms, excision of the smaller bipartite fragments may become necessary. For these, sports can be resumed at 1 to 2 months postoperatively. If the bipartite segment is large, internal fixation may be preferable to excision, depending on the quality and contour of the articular surface.

Dorsal Defects of the Patella

Haswell and associates first described a lesion, now called “dorsal defect of the patella” (368). Radiographically, there is a round radiolucency surrounded by a zone of sclerosis. This is typically located in the superolateral aspect of the patella (Fig. 31-17). It occurs in persons as young as 10 years of age, and rarely persists past 30 years (368–370). Histologically, it is composed of a vascular fibrous connective tissue surrounded by sclerotic bone without inflammation (371). Some necrotic bone may be present (370,372). The cause is unknown, but the evidence suggests that dorsal defects of the patella result from irregular ossification. This may result from stress exerted by the vastus lateralis insertion. Bipartite patella may have a similar etiology (370).

Although a rare occurrence, almost any benign or malignant tumor can appear as a radiolucent lesion in the patella (373). Osteomyelitis, Brodie abscess, and osteochondritis dissecans of the patella should be considered in the differential diagnosis (374,375).

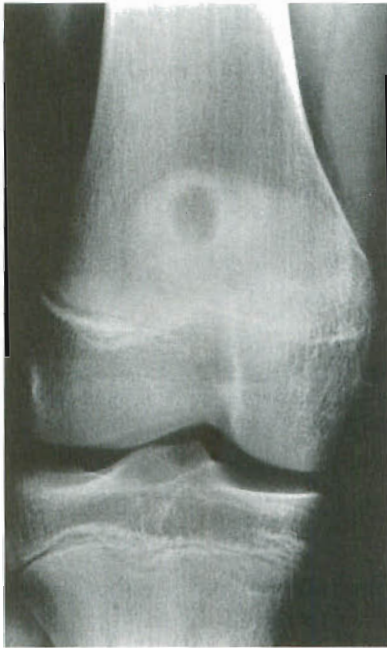

FIGURE 31-17. Dorsal defect of the patella. The typical lesion is a round, radiolucent area in the superolateral pole of the patella. The margins of the lesion are well circumscribed. This is best seen on the anteroposterior radiograph. Typically, the lateral radiograph is normal.

Dorsal defect of the patella is usually an asymptomatic, incidental radiographic finding. It undergoes spontaneous regression in most cases and requires no treatment (368, 372). In the adolescent, however, it may become symptomatic, and can be associated with an underlying articular cartilage defect (371,372,376). Most patients with this lesion respond to rest, but surgical excision and grafting occasionally may be necessary (371,372,376).

Fat Pad Impingement

Impingement of the anterior fat pad and its associated synovium was described in 1904 by Hoffa. Most patients are females in their teens and early twenties (377,378).

The cause is unknown, although it is postulated that hypertrophy or trauma initiates repetitive impingement, inflammation, and fibrosis. The fat pad may be hypertrophic. The characteristic histopathologic findings include the presence of mononuclear inflammatory cells and some degree of fibrosis. In chronic cases, the adipose tissue becomes replaced by fibrocartilage (377).

Typically, the pain is related to activity, and is localized to the anterior knee joint. There may be a history of trauma. Prominence of the fat pad on each side of the patellar tendon is by no means diagnostic. Hoffa described a test performed by applying fingertip pressure to the fat pad while the knee is passively extended (377). If pain is elicited near terminal extension, the test result is considered positive.

At times, this condition appears to be a distinct entity, causing anterior knee pain. Other problems, including patellofemoral pain syndrome, chondromalacia, and inflammatory arthritis can inflame the fat pads. Differential diagnosis also includes meniscal cyst, meniscal tear, soft tissue trauma, patellofemoral pain, patellar tendinitis, and patellar instability (378).

Hyperextension injuries to the knee can lead to acute edema of the fat pads, as well as edema and bruising in the bone. For these acute injuries, MRI can detect the edema in the fat pads, and shows the changes in the subcortical bone as well. For chronic or subacute cases, radiographs are typically negative, and the value of the other imaging studies has not been proven.

Nonoperative treatment includes rest, ice, NSAIDs, and a sequential exercise program. Because terminal quadriceps extension often produces impingement, the exercise range of motion is modified to avoid terminal extension. Physical therapy modalities including high-voltage galvanic stimulation and phonophoresis, or conophoresis with hydrocortisone may be helpful.

Nonoperative therapy is usually effective. Occasionally, arthroscopy becomes indicated for recalcitrant cases. The difficulty in differentiating pathologic changes from normal anatomy fuels the controversy in diagnosing this entity. A normal fat pad should not be resected, so a knowledge of the anatomy, including the normal basal prominences of fat and the variability of fat pad size, is essential (377). Generally, the texture and contour of the fibrotic fat pad differs appreciably from the soft texture and yellow color of normal fat. This can be used as a guide during arthroscopic resection, but unfortunately, no proven guidelines are available. Postoperatively, range of motion exercise is resumed early, to minimize scarring. A standard patellofemoral rehabilitation protocol is used, and the patient should demonstrate full return of function before participating in sports activities.

Plica Syndrome

The symptomatic medial patellar plica can be considered “the great imitator” of knee disorders. The challenge is to recognize this disorder without diagnosing plica syndrome for every case of knee pain associated with a tender synovial fold.

Embryologically, the synovial cavity of the knee begins as three separate compartments that fuse during the fourth fetal month. The remaining membranes give rise to the three commonly encountered plicae (Fig. 31-18).

The suprapatellar plica usually is a crescent-shaped fold originating beneath the quadriceps tendon. It extends to the medial or lateral walls of the joint (379). The suprapatellar plica may result in complete separation of the suprapatellar bursa from the knee. There may be a small opening in

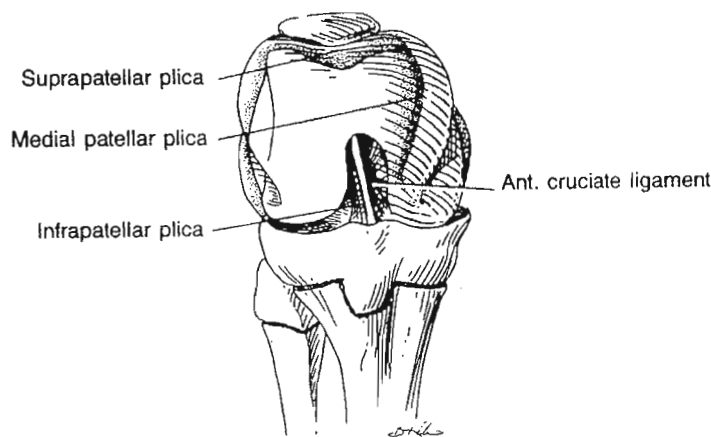


FIGURE 31-18. Plicae of the knee. Superior plica. Medial plica, the one most commonly symptomatic. Inferior plica (ligamentum mucosum) overlying the anterior cruciate ligament.

the suprapatellar plica, called the “porta.” The suprapatellar plica is also rarely symptomatic.

The medial parapatellar plica lies along the medial wall of the joint, originating near the suprapatellar plica, and coursing obliquely downward to attach near the infrapatellar fat pad (141,380,381). This is the plica that potentially becomes symptomatic.

The incidence of plica varies, depending on the examiner’s criteria for how large a fold must be to constitute a plica. The lesions range from a small cord to a large shelf. The plica may completely cover the surface of the medial femoral condyle, and it may be fenestrated (382).

Inflammation or direct trauma can produce thickening and fibrosis of the plica. This can lead to further impingement of the plica in the patellofemoral joint, with the potential for becoming a self-propagating problem. Pain may be secondary to mechanical compression of the plica, or to the plica applying traction to the fat pad (380). In advanced cases, the articular surface may become eroded (379).

The presenting symptoms of plica syndrome include anteromedial knee pain, popping, snapping, and giving way. The pain may be referred to the medial or lateral joint line. Symptoms often begin after repetitive activities, such as running, jumping, and climbing stairs (379,380). Occasionally, the plica becomes acutely inflamed after a twisting injury or direct blow, and the patient may present with pseudolocking of the knee (380,381).

The plica can usually be palpated along the medial surface of the femoral condyle in symptomatic and asymptomatic patients. Tenderness is invariably present, but it is not a pathognomonic finding. Many abnormalities produce localized or generalized synovitis that secondarily affects the plica. To further confuse the examiner, the patient with an inflamed plica may also have a false-positive Apley test, McMurray test, or a patellar compression test. The medial joint line may be tender anteriorly, and rarely, an effusion may be present (380).

Radiographs usually should be normal, and other studies have not proven to be efficacious (379). The diagnosis is based on compilation of all available data and the exclusion of other lesions. Even at arthroscopy, the determination of a pathologic plica from an incidental finding is not always clear, thus the potential for underdiagnosis and overdiagnosis (380).

It is imperative to search for other pathologic processes of the knees, such as a meniscus tear, loose body, chondromalacia, significant patellofemoral maltracking, or instability (379). Initial treatment should include rest, ice, NSAIDs, and a gradual patellofemoral exercise program. Because terminal extension may impinge the plica, exercises are modified to avoid that range. McConnell taping may be helpful. Intraplasmic steroid injection has been used with mixed results (141).

If persistently symptomatic, the synovial band is easily resected arthroscopically, and the rest of the joint is carefully inspected. Good and excellent results of more than 90% have been achieved, with appropriate patient selection (379–381). Because scarring may occur from simple division of the plica, complete resection is recommended. The surgeon must keep in mind that the symptomatic plica may be the early signs of patellofemoral maltracking, and this is a common cause of surgical failure.

Acute Patellar Dislocation

Dislocation of the patella is often related to an underlying dysplasia or a malalignment of the patellofemoral articulation (383). The depth of the patellofemoral articular groove, patella alta, excessive Q angle, and ligamentous laxity have been cited as predisposing factors (384). In as many as 75% of patients with patellofemoral instability, at least one element of deficiency can be identified (352). There is a positive family history for one-fourth of these patients (383). A direct blow to the medial aspect of the patella accounts for only 10% of cases (384). Most patellofemoral disloca-

tions are lateral, although medial dislocations are a recognized complication of an overzealous lateral retinacular release (363).

Most patellar dislocations first occur in patients from 14 to 20 years of age (352,383–385). Although football, baseball, and basketball commonly are involved, significant numbers of patellar dislocations occur from simple falls, gymnastics, dancing, cheerleading, and a wide variety of other activities (386). The mechanism usually involves a twisting event. Although affecting more girls than boys, patellar dislocations must be considered in the differential diagnosis of acute knee injuries in young male athletes (331, 352,386,387). A history of prior episodes of subluxation, anterior knee pain, and a family history may help to support the diagnosis.

Most patellar dislocations reduce spontaneously or shortly after they occur, especially if the episodes are recurrent. A patient with an unreduced patellar dislocation presents with the knee flexed and the hamstrings being tight. With the patella displaced laterally, the femoral condyles become prominent medially, often leading the patient or lay observer to report that the dislocation was medial, rather than lateral. A wide array of activities can precipitate the episode.

After reduction, the residual findings include diffuse parapatellar tenderness, and a positive apprehension test. The medial capsule and retinaculum may have been stretched or torn, and the tenderness may extend to the medial femoral epicondyle. Medially, there may be a palpable defect of the patella from avulsion of the vastus medialis insertion.

Hemarthrosis results from a capsular tear or a concurrent osteochondral fracture. The ligaments should be examined carefully, because the mechanism of injury and findings with patellar dislocation are similar to those of a cruciate sprain.

Postreduction radiographs should be inspected for evidence of osteochondral fragments. Bony fragments seen along the medial patellar margin often are not free in the joint, but rather result from avulsion of the vastus medialis insertion. A Merchant's view, showing both patellae, may demonstrate significant residual maltracking.

The natural history of acute patellar dislocation in children is such that approximately 1 of 6 will develop recurrent dislocations, 2 of 6 will have some minor residual symptoms, and 3 of 6 will remain asymptomatic (388). The incidence of redislocation after nonoperative treatment diminishes considerably with advancing age. Cash and Hughston found a 60% incidence among patients between 11 and 14 years of age, 30% incidence among patients between 19 and 28 years of age, and few older than 28 years of age (352).

Acutely, the extensor mechanism holds the patella trapped over the margin of the distal femoral condyles. With the patella posterior to the axis of the knee, and the hamstrings contracted in response to pain, the knee is firmly held in

flexion. The reduction is performed without forceful manipulation. Reduction is facilitated by turning the patient into a prone position, so that the hip is extended and the hamstrings become relaxed. The knee is gradually and steadily extended, usually leading to reduction. Afterward, the knee can be aspirated if a tense hemarthrosis develops. The surface of the bloody fluid should be inspected for fat droplets, which would suggest an osteochondral fracture.

Rehabilitation begins as soon as practical, particularly after a repeat dislocation from which there may be little acute damage to the medial stabilizers. The knee is placed in an immobilizer for comfort and support during gait. It is unnecessary to continue immobilization arbitrarily for 6 weeks, as some have suggested (384,388).

Straight-leg-raising exercises are begun immediately, to minimize quadriceps atrophy. The knee is periodically reexamined (for up to 6 weeks), and when comfortable, a formal patellar rehabilitation program is begun. Once range of motion is restored and the extensor mechanism is working adequately to support the knee, the immobilization is discontinued. The patient should be able to do straight-leg raises with 5 lb (2.25 kg) of ankle weights. A flexible knee sleeve, with the patellar cutout, is then used. As strengthening is gained, activities progress, starting with biking and straight-ahead running. Cutting and twisting activities are then reintroduced. The patient is encouraged to continue with quadriceps exercises, particularly emphasizing the vastus medialis.

After an acute patellar dislocation treated with an adequate rehabilitation program, most patients do not require surgical stabilization. Cash and Hughston had acceptable results, after nonoperative care, for 75% of appropriately selected patients. Rather than surgically stabilizing all patients, a group at high risk can be identified (352).

Younger patients are at high risk for recurrent dislocation, with those less than 14 years of age having the highest incidence of recurrent dislocation (352) (Table 31-2). Highly active and competitive athletes may also benefit from immediate stabilization. Those with congenital dysplasia may be at higher risk for recurrence. The signs of this dysplasia include hypermobility of the patella, radiographic

TABLE 31-2. RISK FACTORS FOR RECURRENT PATELLAR DISLOCATION

Osteochondral fracture
Child younger than 14 years of age
Highly active or competitive youth
Mechanism other than direct blow
Palpable medial defect
Contralateral evidence of dysplasia
Hypermobility of the patella
Multiple prior dislocations
Positive family history
Patella alta

evidence of a shallow intercondylar groove, contralateral subluxation, a positive family history, patella alta, and a mechanism of injury other than a direct blow (352, 383, 389).

If there is an associated osteochondral fracture from the lateral femoral condyle or patellar surface, removal of the fragment or internal fixation is required, depending on the size and location of the injury. Small pieces avulsed from the medial edge of the patella usually are attached, and may not require removal. Small loose bodies can be removed arthroscopically. There are preliminary reports of successful arthroscopic repair of a torn medial retinaculum and capsule (352, 390).

Early repair or advancement of the vastus medialis and distal realignment procedures are sometimes indicated. If there is an underlying malalignment or dysplasia accompanying a significant osteochondral fracture, both problems should be addressed. Occasionally, there is significant avulsion of the vastus medialis that requires primary repair (391).

Recurrent Patellar Dislocations

Although the risk of ongoing patellofemoral instability increases with each subsequent dislocation, many patients are successfully managed without surgery. In most cases, even young, active youths with other risk factors deserve a thorough trial of rehabilitation after a first patellar dislocation. Knee sleeves and foot orthoses, for those with severe pronation and tibial torsion, may be helpful. Activity modifications are another option.

The decision to treat recurrent patellar instability surgically must be individualized [5.1–5.2]. The degree of instability and disability should be weighed against the risks and benefits. Age is another factor to be considered. Compliance with rehabilitation is important, and tibial tubercle transfers are generally contraindicated, if the physes are open.

A lateral retinacular release is routinely combined with medial advancements and distal realignments. The lateral retinacular release procedure is discussed earlier in this chapter. Most studies of lateral retinacular release mix patients with patellofemoral pain among those with patellofemoral instability. Metcalf analyzed the 14 cases of recurrent patellar dislocation in his series of 79 patients, and found that none dislocated subsequent to lateral retinacular release alone (328). Nine were rated good and three rated excellent, and there were no instances of medial instability. Although it appears that lateral retinacular release has a role in the treatment of patellofemoral instability, the degree of instability that responds to this as an isolated procedure is still being defined (334).

Patients with an obvious defect of the vastus medialis insertion are probably best served with advancement of the medial retinaculum and muscle. A variety of techniques have been described, but the fundamental elements include

lateral release and plication of the vastus medialis (391–393). The vastus medialis is advanced one-third to one-half of the width of the patella. The suture repair needs to be protected for at least 4 weeks after surgery.

Patients with an excessive Q angle can benefit from a distal realignment to medialize the pull of the patellar tendon. This can be accomplished by moving part of the patellar tendon itself, by moving the tibial tubercle or by transferring another tendon to the patella.

The Roux-Goldthwait operation involves splitting the patellar tendon, and transferring the lateral half beneath the medial side (Fig. 31-19). For recurrent patellar dislocations, Chrisman et al. reported 93% acceptable results with this procedure, when combined with lateral retinacular release and medial reefing (394). How much of the effect is the result of the distal transfer is unknown.

The Galleazzi procedure transfers the proximal end of the semitendinosus to the inferomedial pole of the patella, leaving the distal end of the semitendinosus attached to the tibia (395) (Fig. 31-20). This effectively redirects the vector of force of the extensor mechanism. The next most common complication is necrosis of the skin flap, so undermining should be minimized. Baker and colleagues had 81% successful results with this procedure (387). Patients with excessive ligamentous laxity have the highest risk of persistent instability.

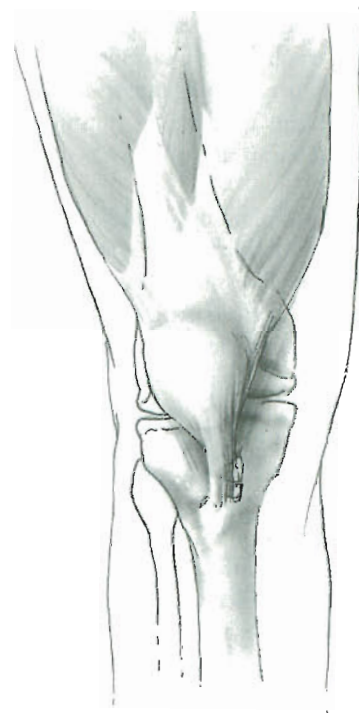

FIGURE 31-19. The Roux-Goldthwait procedure splits the patellar tendon. The lateral half is transferred beneath the medial side and sutured to the periosteum along the metaphysis. This redirects the patellar tendon vector more medially.

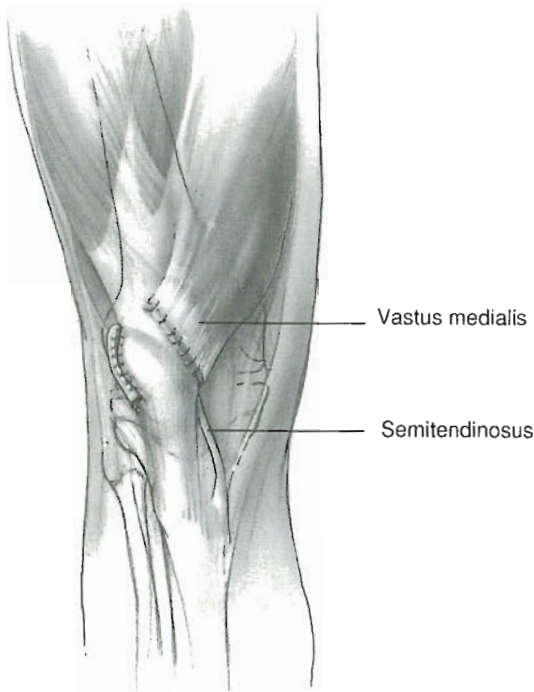


FIGURE 31-20. The Galeazzi procedure transfers the semitendinosus to the inferior pole of the patella. From there, it courses through a drill hole placed obliquely through the patella, exiting the superior lateral aspect. The tendon is then sutured to the soft tissues. This provides a medial tether and effectively alters the net vector of the patellar tendon toward the medial side. Typically, the vastus medialis is advanced approximately one-third the width of the patella.

For adolescents with closed physal plates, the tibial tubercle can be transferred medially. This must be done in a manner that does not move the insertion of the tibial tubercle posteriorly along the face of the upper tibia, as did the Hauser procedure (396,397). The Elmslie-Trillat technique avoids this problem by shifting a long segment of bone, including the tubercle (Fig. 31-21A,B). If there is significant growth remaining for the patient, tibial tubercle transfers can lead to distal migration of the tubercle or genu recurvatum secondary to growth arrest (337,386).

Tibial tubercle transfers are routinely combined with a lateral retinacular release. A vastus medialis obliquus advancement should be added, if the patella drifts laterally when the knee reaches full extension and the quadriceps relaxes (329). For patellofemoral instability, good results can be expected in 80% of cases (398).

If there is a significant component of patellofemoral pain or marked chondral injury of the patella, the Fulkerson modification of the Elmslie-Trillat procedure can reduce patellofemoral contact forces (399). Instead of the osteotomy being in the coronal plane, it is tilted toward the sagittal plane, such that the tubercle migrates anteriorly as it shifts medially (Fig. 31-21C).

The Maquet procedure reduces the patellofemoral contact forces by elevating the tubercle through the use of a bone block (Fig. 31-21D). This does not medialize the pull of the tendon, but it may be useful in cases of isolated patellofemoral chondromalacia.

All of these procedures require adequate rehabilitation to restore knee motion and maximize dynamic stability from the quadriceps.

Popliteal Cyst

Often termed “Baker cysts,” popliteal cysts are common findings in youngsters. Typically, they are located subcutaneously along the medial side of the popliteal fossa. They are simple, synovial-lined ganglion cysts that arise from the semimembranous sheath in youths; they are rarely associated with any other pathologic processes of the knee. Occasionally, they are associated with meniscal tears, inflammatory arthritis, pigmented villonodular synovitis, and others. Popliteal masses deep to the fascia are often sarcomas.

The ordinary popliteal cyst is asymptomatic and is discovered coincidentally. These may wax and wane in size, but should not cause limp or disability. On examination, these are superficial, firm or rubbery, smooth, nontender, mobile and nonpulsatile. Most will transilluminate with a simple handheld light, which should adequately confirm that the mass is fluid-filled, rather than a solid tissue tumor. Most often, history and physical examination are adequate for making this diagnosis. Radiographs are not necessary, unless associated articular pathology is suspected, for other reasons. Aspiration can confirm the diagnosis. However, other tests should be undertaken, if there is a clinical suspicion of sarcoma or vascular anomaly. Ultrasound, CT, or MRI each offer advantages, depending on the situation.

A simple popliteal cyst, arising from the medial hamstring sheath, rarely requires treatment. Typically, they do not interfere with function, cause pain, or produce other problems. They may wax and wane in size for a while, but almost all resolve.

Discoid Lateral Meniscus

The discoid lateral meniscus is a congenital abnormality affecting approximately 1% of all lateral menisci. Occasionally, the medial meniscus is involved (approximately 3% of all discoid menisci), and rarely, both are affected. There may be a familial factor (400). The discoid meniscus was once thought to be an arrest in the resorption of the central portion of the mesenchymal layer between the ends of the tibia and femur. However, a disc-like plate of fibrocartilage is never seen in normal development. This anomaly is apparently caused by the abnormal formation of fibrocartilage in the mesenchyme.

The most widely used classification system for categorizing the varied features of the discoid lateral meniscus is

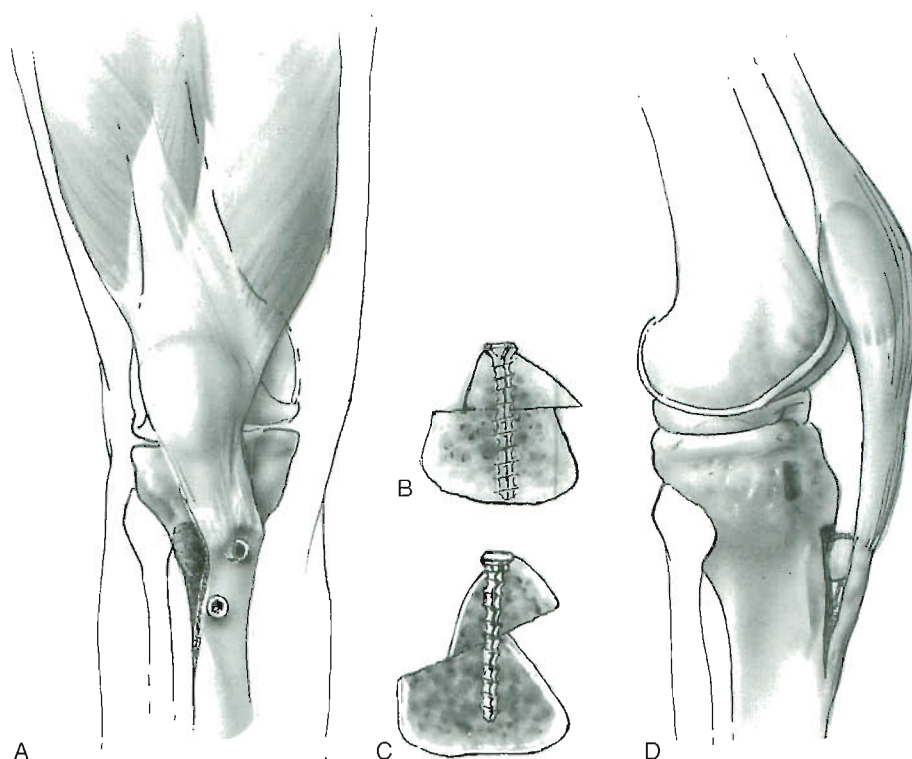


FIGURE 31-21. A, B: The Elmslie-Trillat technique shifts the tibial tubercle medially. The tubercle stays in the same plane. C: The Fulkerson modification involves an oblique cut that results in anterior translation as the tubercle is moved medially. This reduces the patellofemoral contact forces while shifting the pull of the patella medially. D: The Maquet procedure moves the tibial tubercle anteriorly by inserting a block of bone. This diminishes the patellofemoral contact forces but does not medialize the pull of the patellar tendon.

that proposed by Watanabe and coauthors (Watanabe). The Wrisberg ligament-type is the most anomalous. In this variety, the lateral meniscotibial ligaments are absent, so the meniscus is not attached to the tibial plateau. There are meniscomfemoral fibers present and the ligament of Wrisberg attaches to the PCL. In addition to the hypermobility of the lateral meniscus, the peripheral portion is quite thickened, and contributes to the symptoms, as well as to the treatment dilemma. The complete-type discoid lateral meniscus covers essentially the entire lateral tibial plateau. The peripheral attachments are intact, so it is stable, although the capsular margin may still be thickened. Finally, the incomplete-type is similar to the complete-type, but covers less of the plateau.

The discoid lateral menisci present in several ways. The Wrisberg ligament-type often presents with the classic picture of a “snapping knee.” Usually, by 8 years of age, the child demonstrates remarkable snap and shift of the tibial plateau, as the knee moves. A visible and palpable mass becomes prominent anterolaterally as the flexed knee extends. Suddenly, the discoid meniscus reduces and disappears, as the knee stutters, then moves freely into full extension. With repetition, the knee may become sore. The

repetitive snapping may later be associated with an osteochondritis dissecans lesion of the lateral femoral condyle.

The complete-type and the incomplete-type usually present with signs and symptoms more typical of a meniscal tear. The patient complains of a sudden onset of unilateral joint pain, catching, and swelling. Often, they are younger than typical for meniscal tear (less than 14 to 16 years of age). The onset is often spontaneous or related to a minor injury.

The differential diagnosis includes snapping popliteus tendon, snapping hamstring tendons, loose body, subluxating proximal tibiofibular joint, osteochondritis dissecans, iliotibial band tendinitis, ACL laxity, and a conventional meniscal tear. Routine radiographs are done to rule out a bony anomaly; if the discoid lateral meniscus is particularly thick, there may be some widening of the lateral joint space. MRI is indicated in most cases, because it should be diagnostic, and should delineate the type of anomaly, including any concurrent pathology, such as a tear.

If a partial or complete discoid lateral meniscus is an asymptomatic, incidental finding, excision of the discoid meniscus is not recommended. A study of total meniscectomy for discoid lateral meniscus showed a 75% rate of

degenerative articular changes, although 70% of cases were clinically acceptable 20 years after surgery (401). The results of partial discoid meniscectomy, to contour or sculpt the remaining meniscal tissue, are hopeful, but await long-term follow-up data (402). Minor tears of the discoid meniscus may heal or become asymptomatic with nonoperative treatment. Some tears require a combination of partial meniscectomy and meniscal repair, to optimize the size and shape of the remaining meniscus.

The Wrisberg ligament-type remains the most challenging to convert to a nearly normal cartilage. Although reattachment of a Wrisberg ligament type discoid lateral meniscus has been described (403), the thickness of the remaining rim can lead to recurrent snapping. With time, this can lead to articular cartilage degeneration and osteochondritis dissecans formation. Ideally, the meniscus is contoured and thinned to approximate the anatomy and hopefully, the biomechanics of a normal meniscus. The techniques for doing this are still evolving. Ultimately, meniscal transplantation during adolescence may be the best solution.

Some lesions are amenable to partial meniscectomy, and others can be sutured (404). A symptomatic Wrisberg ligament-type discoid lateral meniscus has been reattached successfully, but long-term success depends on adequate vascularity and collagen healing (403).

CONCLUSION

The care of young athletes presents many challenges. Many of the principles of adult sports medicine and sports orthopaedics apply to youths, but there are many unique problems related to the growing musculoskeletal system. The maturing musculoskeletal systems and psychology of young athletes makes working with them a challenge and a pleasure.

References

Care of the Young Athlete

1. Wilkins KE. The uniqueness of the young athlete: musculoskeletal injuries. *Am J Sports Med* 1980;8:377.
2. Goldberg B, Witman PA, Gleim GW, Nicholas JA. Children's sports injuries: are they avoidable? *Physician Sports Med* 1979;7:93.
3. Rutherford GW, Miles R. Overview of sports related injuries to persons 5 to 14 years of age, 1981, U.S. Consumer Product Safety Commission.
4. Goldberg B, Saraniti A, Witman P, et al. Pre-participation sports assessment—an objective evaluation. *Pediatrics* 1980;66:736.
5. American Academy of Pediatrics. Committee on Pediatric Aspects of Physical Fitness, Recreation, and Sports. Competitive sports for children of elementary school age. *Pediatrics* 1981;67:927.

6. Rutenfranz J. Ethical considerations: the participation of children in elite sports. *Pediatrician* 1986;13:14.
7. Smith NJ. Is that child ready for competitive sports? *Contemp Pediatr* 1986;3:30.
8. Goldberg B. Children, sports, and chronic disease. *Physician Sports Med* 1990;18:45.
9. Beekman R. Exercise recommendations for adolescents after surgery for congenital heart disease. *Pediatrician* 1986;13:210.
10. Committee on Sports Medicine. American Academy of Pediatrics, recommendations for participation in competitive sports. *Pediatrics* 1988;81:737.
11. Lambert GP. Children and sports medicine in the 1990's. *N Engl J Med* 1991;38:635.
12. Orenstein DM, et al. Exercise conditioning in children with asthma. *J Pediatr* 1985;106:556.
13. Smith NJ. Nutrition and the athlete. *Orthop Clin North Am* 1983;14:387.
14. Meredith CN, Dwyer JT. Nutrition and exercise: effects on adolescent health. *Ann Rev Public Health* 1991;12:309.
15. Committee on Sports Medicine. American Academy of Pediatrics: Nutrition and sports performance. In: Smith N, ed. *Sports medicine health care for young athletes*. Evanston, IL: American Academy of Pediatrics, 1983:161.
16. Bergstrom J, Hultman E. Nutrition for maximal sports performance. *JAMA* 1972;221:999.
17. Klepping J, Boggio V, Guillard JC, et al. The nutritional requirements of young athletes. *Ann Nestle* 1986;44:1.
18. Costill DL. Carbohydrate for athletic training and performance. *Bol Assoc Med P R* 1991;83:350.
19. Costill DL, Hargreaves M. Carbohydrate nutrition and fatigue. *Sports Med* 1992;13:86.
20. Karlsson J, Saltin B. Diet, muscle glycogen, and endurance performance. *J Applied Phys* 1971;31:203.
21. Knochel JP. Dog days and siriasis. *JAMA* 1975;233:513.
22. Smith NJ. The prevention of heat disorders in sports. *AJDC* 1984;138:786.
23. Murphy RJ. Heat illness in the athlete. *Am J Sports Med* 1984;12:258.
24. Clowes GH, O'Donnell TF. Heat stroke. *N Engl J Med* 1974;291:564.
25. Committee on Sports Medicine. American Academy of Pediatrics: Climactic heat stress and the exercising child. *Pediatrics* 1982;69:808.
26. Bar-Or O. Climate and the exercising child—a review. *Int J Sports Med* 1980;1:53.
27. Committee on Sports Medicine. American Academy of Pediatrics, Thermoregulation and fluid and electrolyte needs. In: Smith N, ed. *Sports medicine health care for young athletes*. Evanston, IL: American Academy of Pediatrics, 1983:142.
28. Brown EW, Abani K. Kinematics and kinetics of the dead lift in adolescent power lifters. *Med Sci Sports Exerc* 1985;17:554.
29. Sewall L, Micheli LJ. Strength training for children. *J Pediatr Orthop* 1986;6:143.
30. Weltman A, Janney C, Rians C. The effect of hydraulic resistant strength training in pre-pubertal males. *Med Sci Sports Exerc* 1986;18:629.
31. Brady TA, Cahill BR, Bodnar LM. Weight training-related injuries in the high school athlete. *Am J Sports Med* 1982;10:1.
32. Scavenuis M, Iversen BF. Nontraumatic clavicular osteolysis in weight lifters. *Am J Sports Med* 1992;20:463.
33. Brown EW, Kimball RG. Medical history associated with adolescent powerlifting. *Pediatrics* 1983;72:636.
34. Gumbs VL, Segal D, Halligan JB, Lower G. Bilateral distal radius and ulnar fractures in adolescent weight lifters. *Am J Sports Med* 1982;10:375.

35. Hamilton H. Stress fracture of the diaphysis of the ulna in a body builder. *Am J Sports Med* 1984;12:405.
36. Ryan JR, Saliccioli GG. Fractures of the distal radial epiphysis in adolescent weight lifters. *Am J Sports Med* 1976;4:26.
37. Committee on Sports Medicine. American Academy of Pediatrics, weight training and weight lifting: information for the pediatrician. *Physician Sports Med* 1983;11:157.
38. Shellock FG, Prentice WE. Warming-up and stretching for improved physical performance and prevention of sports-related injuries. *Sports Med* 1985;2:267.
39. Taylor DC, Dalton JD Jr, Seaber BV, Garrett WE Jr. Viscoelastic properties of muscle-tendon units. *Am J Sports Med* 1990;18:300.
40. Dymant PG. The adolescent athlete and ergogenic aids. *J Adolesc Health Care* 1987;8:68.
41. Windsor RE, Dumitru D. Prevalence of anabolic steroid use by male and female adolescents. *Med Sci Sports Exerc* 1989;21:494.
42. Johnson MD, Jay MS, Shoup B, Rickert VI. Anabolic steroid use by male adolescents. *Pediatrics* 1989;83:921.
43. Buckley WE, Yesalis CE, Friedl K, et al. Estimated prevalence of anabolic steroid use among male high school seniors. *JAMA* 1988;260:3441.
44. Grindstaff PD. Effects of creatine supplements on the repetitive sprint performance and body composition in competitive swimmers. *Int J Sports Nutr* 1997;7:330.
45. Kreider RB. Effect of creatine supplementation on the body composition, strength, and sprint performance. *Med Sci Sports Exerc* 1998;30:73.
46. Cararasco D, Prieto M, Pallardo L. Multiple adenomas after long-term therapy with testosterone enanthate. *J Hepatol* 1985;1:573.
47. Terney R, McLain LG. The use of anabolic steroids in high school students. *Am J Dis Child* 1990;144:99.
48. Whitehead R, Chillag S, Elliott D. Anabolic steroid use among adolescents in a rural state. *J Fam Pract* 1992;35:401.
49. Abramson SB. Nonsteroidal anti-inflammatory drugs: mechanism of action and therapeutic considerations. In: Leadbetter WB, Buckwalter JA, Gordon SL, eds. *Sports-induced inflammation*. Park Ridge, IL: American Academy of Orthopaedic Surgeons, 1990:421.
50. Brewer EJ, Arroyo I. Use of nonsteroidal anti-inflammatory drugs in children. *Pediatr Ann* 1986;15:575.
51. Leadbetter WB. Corticosteroid injection therapy in sports injuries. In: Leadbetter WB, Buckwalter JA, Gordon SL, eds. *Sports-induced inflammation*. Park Ridge, IL: American Academy of Orthopaedic Surgeons, 1990:527.
52. Mankin HJ, Conger KA. The acute effects of intraarticular hydrocortisone on articular cartilage in rabbits. *J Bone Joint Surg Am* 1966;48:1383.
53. Allen RC, Gross KR, Laxer RM, et al. Intraarticular triamcinolone hexacetonide in the management of chronic arthritis in children. *Arthritis Rheum* 1986;29:997.
54. Behrens TW, Goodwin TW. Oral corticosteroids. In: Leadbetter WB, Buckwalter JA, Gordon SL, eds. *Sports-induced inflammation*. Park Ridge, IL: American Academy of Orthopaedic Surgeons, 1990:405.
55. Milgrom C, Giladi M, Stein M. Stress fractures in military recruits. *J Bone Joint Surg Am* 1985;67:732.
56. Devas MB. Stress fractures in children. *J Bone Joint Surg Br* 1963;45:528.
57. Engh CA, Robinson RA, Milgram J. Stress fractures in children. *J Trauma* 1970;10:532.
58. Orava S, Jormakka E, Hulkko A. Stress fractures in young athletes. *Arch Orthop Trauma Surg* 1981;98:271.
59. Rosen CPR, Micheli LJ, Treves S. Early scintigraphic diagnosis of bone stress and fractures in athletic adolescents. *Pediatrics* 1982;70:11.
60. Caine D, Roy S, Singer KM, Broekhoff J. Stress changes of the distal radial growth plate. *Am J Sports Med* 1992;20:290.
61. Dickson JM, Fox JM. Fracture of the patella due to overuse syndrome in a child: a case report. *Am J Sports Med* 1982;10:248.
62. Weber PC. Salter-Harris type II stress fracture in a young athlete. *Orthopedics* 1988;11:309.
63. Murakami Y. Stress fracture of the metacarpal in an adolescent tennis player. *Am J Sports Med* 1988;6:419.
64. Read MT. Stress fractures of the distal radius in adolescent gymnasts. *Br J Sports Med* 1981;15:252.
65. Rettig AC. Stress fracture of the ulna in an adolescent tournament tennis player. *Am J Sports Med* 1983;11:103.
66. Rettig AC, Beltz HF. Stress fracture in the humerus in an adolescent tennis tournament player. *Am J Sports Med* 1985;13:55.
67. Jackson D, Wiltse L, Cirincione R. Spondylolysis in the female gymnast. *Clin Orthop* 1976;68:117.
68. Ferguson RJ, McMasters MC, Stanitski CL. Low back pain in college lineman. *J Bone Joint Surg Am* 1974;58:1300.
69. Matheson GO, et al. Stress fractures in athletes. *Am J Sports Med* 1987;15:46.
70. Fullerton LR, Snowdy HA. Femoral neck stress fractures. *Am J Sports Med* 1988;16:365.
71. Hajek MR, Noble HB. Stress fractures of the femoral neck in joggers. *Am J Sports Med* 1982;10:112.
72. Wolfgang GL. Stress fracture of the femoral neck in a patient with open capital femoral epiphyses. *J Bone Joint Surg Am* 1977;59:680.
73. Dickson JM, Fox JM. Fracture of the patella due to overuse syndrome in a child. *Am J Sports Med* 1982;10:248.
74. Dickson JM, Kichline PD. Functional management of stress fractures in female athletes using a pneumatic leg brace. *Am J Sports Med* 1987;15:86.
75. Green NE, Rogers RA, Lipscomb AB. Nonunions of stress fractures of the tibia. *Am J Sports Med* 1985;13:171.
76. Dotter WE. Little leaguer's shoulder. *Guthrie Clinic Bull* 1953;23:68.
77. Tullos HS, King JW. Lesions of the pitching arm in adolescents. *JAMA* 1972;220:264.
78. Hansen NM. Epiphyseal changes in the proximal humerus of an adolescent baseball pitcher. *Am J Sports Med* 1982;10:380.
79. Cahill BR, Tullos HS, Fain RH. Little league shoulder. *Am J Sports Med* 1974;2:150.
80. Barnett LS. Little league shoulder syndrome: proximal humeral epiphyseolysis in adolescent baseball pitchers. *J Bone Joint Surg Am* 1985;67:495.
81. Roy S, Caine D, Singer KM. Stress changes of the distal radial epiphysis in young gymnasts. *Am J Sports Med* 1985;13:301.
82. Yong-Hing K, Wedge JH, Bowen CV. Chronic injury to the distal ulna and radial growth plate in an adolescent gymnast. *J Bone Joint Surg Am* 1988;70:1087.
83. Albanese S, Palmer A, Kerr D. Wrist pain and growth plate closure of the radius in gymnasts. *J Pediatric Orthop* 1989;9:23.

Overuse Syndromes

55. Kibler WB. Concepts in exercise rehabilitation of athletic injury. In: Leadbetter WB, Buckwalter JA, Gordon SL, eds. *Sports-induced inflammation*. Park Ridge, IL: American Academy of Orthopaedic Surgeons, 1990:759.
56. Kaltsas D-S. Stress fractures of the femoral neck in young adults. *J Bone Joint Surg Br* 1981;63:33.

86. Ogden JA, Southwick WO. Osgood-Schlatter's disease and tibial tuberosity development. *Clin Orthop Rel Res* 1976;116:180.
87. Crigler NW, Riddervold HO. Soft tissue changes in x-ray diagnosis of the Osgood-Schlatter lesion. *VA Med* 1982;109:176.
88. Kujala UM, Kvist M, Heinenen O. Osgood-Schlatter's disease in adolescent athletes. *Am J Sports Med* 1985;13:236.
89. Krause BL, Williams JPR, Catterall A. Natural history of Osgood-Schlatter's disease. *J Pediatr Orthop* 1990;10:65.
90. Willner P. Osgood-Schlatter's disease: etiology and treatment. *Clin Orthop Rel Res* 1969;62:178.
91. Bowers KD Jr. Patellar tendon avulsion as a complication of Osgood-Schlatter's disease. *Am J Sports Med* 1981;9:356.
92. Noyes FR. Functional properties of knee ligaments and alterations induced by immobilization. *Clin Orthop Rel Res* 1977;123:210.
93. Mital MA, Matza RA, Cohen J. The so-called unresolved Osgood-Schlatter lesion. *J Bone Joint Surg Am* 1980;62:732.
94. Kay JJ, Freiburger RH. Fragmentation of the lower pole of the patella in spastic lower extremities. *Radiology* 1991;101:97.
95. Rosenthal RK, Levine DB. Fragmentation of the distal pole of the patella in spastic cerebral palsy. *J Bone Joint Surg Am* 1979;59:934.
96. Medlar RC, Lyne ED, Sinding-Larsen-Johansson disease. *J Bone Joint Surg Am* 1978;60:1113.
97. McKenzie DC, et al. Calcaneal epiphysis in adolescent athletes. *Can J Applied Sports Sci* 1981;6:123.
98. Micheli LJ, Ireland ML. Prevention and management of calcaneal apophysitis in children: an overuse syndrome. *J Pediatr Orthop* 1987;7:34.
99. Canale ST, Williams KD. Iselin's disease. *J Pediatr Orthop* 1992;12:90.
100. Lehman RC, Gregg JR, Torg E. Iselin's disease. *Am J Sports Med* 1986;14:494.
101. Danielsson LG, Hedlund ST, Henricson AS. Apophysitis of the olecranon. A report of four cases. *Acta Orthop Scand* 1983;54:777.
102. Hunter LY, O'Connor GA. Traction apophysitis of the olecranon. A case report. *Am J Sports Med* 1980;8:51.
103. Clancy W, Folotz AS. Iliac apophysitis and stress fractures in adolescent runners. *Am J Sports Med* 1976;4:214.
104. Fox IM. Iliac apophysitis in teenage distance runners. *J Am Podiatr Med Assoc* 1986;76:294.
105. Julsrud ME. Iliac apophysitis and a review of the osteochondroses. *J Am Podiatr Med Assoc* 1985;75:586.
106. Puddu G, Ippolito E, Postacchini F. A classification of Achilles tendon disease. *Am J Sports Med* 1976;4:214.
107. Leach RE, James S, Wasilewski S. Achilles tendinitis. *Am J Sports Med* 1981;9:93.
108. Nelen G, Martens M, Burssens A. Surgical treatment of chronic Achilles tendinitis. *Am J Sports Med* 1989;17:754.
109. Clement DB, Tauton JE, Smart GW. Achilles tendinitis and paratinitis: etiology and treatment. *Am J Sports Med* 1984;12:179.
110. Basmajian JV, Lovejoy JF. Functions of the popliteus muscle in man. *J Bone Joint Surg Am* 1971;53:557.
111. Olson WR, Reckemmer L. Popliteus tendinitis. *J Am Podiatr Med Assoc* 1993;83:537.
112. Mayfield GW. Popliteus tendon tenosynovitis. *Am J Sports Med* 1977;5:31.
113. Mann RA, Baxter DE, Lutter DL. Running symposium. *Foot Ankle* 1981;1:190.
114. Harvey JS. Overuse syndromes in young athletes. *Pediatr Clin North Am* 1982;29:1369.
115. Puranen J. The medial tibial syndrome. *J Bone Joint Surg Br* 1974;56:712.
116. Slocum DB. The shin splint syndrome. *Am J Surg* 1967;114:875.
117. Styf J. Diagnosis of exercise-induced pain in the anterior aspect of the lower leg. *Am J Sports Med* 1988;16:165.
118. Holder LE, Michael RH. The specific scintigraphic pattern of "shin splints in the lower leg" [inside communication]. *J Nuc Med* 1984;25:869.
119. Clement DB. Tibial stress syndrome in athletes. *J Sports Med* 1975;2:81.
120. Lutter LD. Runner's knee injuries. *Instr Course Lect* 1984;33:258.
121. Andrich JT, Bergfeld JA, Walheim J. A prospective study on the management of shin splints. *J Bone Joint Surg Am* 1974;56:1697.
122. Michael RH, Holder LE. The soleus syndrome. *Am J Sports Med* 1985;13:87.
123. Mubarak SJ, et al. The medial tibial stress syndrome. *Am J Sports Med* 1982;10:201.
124. Puranen J, Alavaikko A. Intracompartmental pressure increase on exertion in patients with chronic compartment syndrome in the leg. *J Bone Joint Surg Am* 1981;63:1304.
125. Mubarak SJ, Owens, CA. Double incision fasciotomy of the leg for decompression in compartment syndromes. *J Bone Joint Surg Am* 1977;59:184.
126. Detmer DE, et al. Chronic compartment syndrome: diagnosis, management, and outcomes. *Am J Sports Med* 1985;13:162.
127. Reneman RS. The anterior and lateral compartment syndrome of the leg due to intensive use of muscles. *Clin Orthop Rel Res* 1975;113:69.
128. Mubarak SJ, Hargens AR, Owen CA, et al. The Wick catheter technique for measurement of intramuscular pressure. *J Bone Joint Surg Am* 1976;58:1016.
129. Matsen FA, Winkquist RA, Krugmire RB. Diagnosis and management of compartment syndromes. *J Bone Joint Surg* 1980;62:286.
130. Rorabeck CH, Bourne RB, Fowler PJ. The surgical treatment of exertional compartment syndrome in athletes. *J Bone Joint Surg Am* 1983;65:1245.
131. Kaplan EB. The iliotibial tract—clinical and more physiological significance. *J Bone Joint Surg Am* 1958;40:817.
132. Renne JW. The iliotibial band friction syndrome. *J Bone Joint Surg Am* 1975;57:110.
133. Sutker AN, Jackson DW, Pagliano JW. Iliotibial band syndrome in distance runners. *Physician Sports Med* 1981;9:69.
134. Noble CA. Iliotibial band friction syndrome in runners. *Am J Sports Med* 1980;8:232.
135. Holmes JC, Pruitt AL, Whalen NJ. Iliotibial band syndrome in cyclists. *Am J Sports Med* 1993;21:419.
136. Martens M, Libbrecht, Burssens A. Surgical treatment of the iliotibial band friction syndrome. *Am J Sports Med* 1989;17:651.
137. Orava S. Iliotibial tract friction syndrome in athletes. *Br J Sports Med* 1978;12:69.
138. Stulberg SD, et al. Breaststroker's knee: pathology, etiology, and treatment. *Am J Sports Med* 1980;8:164.
139. Vizsolyi P, et al. Breaststroker's knee: an analysis of epidemiological and biomechanical factors. *Am J Sports Med* 1987;15:63.
140. Rovere GD, Nichols AW. Frequency, associated factors, and treatment of breaststroker's knee in competitive swimmers. *Am J Sports Med* 1985;13:99.
141. Rovere GD, Adair DM. Medial synovial shelf plica syndrome. *Am J Sports Med* 1985;13:382.
142. Keskinen K, Eriksson E, Komi P. Breaststroke swimmer's knee: a biomechanical and arthroscopic study. *Am J Sports Med* 1980;8:228.

143. Singer KM, Roy SP. Osteochondrosis of the humeral capitellum. *Am J Sports Med* 1984;12:351.
144. Tivnon MC, Anzel SH, Waugh TR. Surgical management of osteochondritis dissecans of the capitellum. *Am J Sports Med* 1976;4:121.
145. Brogdon BG, Crow NE. Little leaguer's elbow. *AJR Am J Roentgenol* 1960;83:671.
146. Panner HJ. An affection of the capitellum humeri resubling Calvé-Perthes disease of the hip. *Acta Radiol* 1927;10:234.
147. Woodward AH, Bianco AJ Jr. Osteochondritis dissecans of the elbow. *Clin Orthop Rel Res* 1975;110:35.
148. Smith MG. Osteochondritis of the humeral capitellum. *J Bone Joint Surg Br* 1964;46:50.
149. McManama GB Jr, et al. The surgical treatment of osteochondritis of the capitellum. *Am J Sports Med* 1985;13:11.
150. Haraldsson S. On osteochondrosis deformans juveniles capituli humeri including investigation of intra-osseous vasculature in distal humerus. *Acta Orthop Scand* 1959;38:1.
151. Guhl JF. Arthroscopy and arthroscopic surgery of the elbow. *Orthopedics* 1985;8:1290.
152. Chrisman OD, Fessel JM, Southwick WO. Experimental production of synovitis and marginal articular exostoses in the knee joints of dogs. *Yale J Biol Med* 1965;37:409.
153. Trias A, Ray RD. Juvenile osteochondritis of the radial head. *J Bone Joint Surg Am* 1963;45:576.
154. Adams JE. Injury to the throwing arm. *California Med* 1964;102:127.
155. Woods GM, Tullos HG. Elbow instability and medial epicondyle fracture. *Am J Sports Med* 1977;5:23.
156. Wilkins DE. Fractures and dislocations of the elbow region in fractures in children. In: Wilkins KE, King RE, eds. Philadelphia: JB Lippincott, 1984.
157. Chambers RB. Orthopaedic injuries in athletes (ages 6 to 17). *Am J Sports Med* 1979;7:195.
158. Zaricznyj B, et al. Sports-related injuries in school-aged children. *Am J Sports Med* 1980;8:318.
159. Grana WA. Injury registry for Oklahoma secondary schools. *Okla State Med Assoc J* 1979;72:369.
160. Powell J. 636,000 injuries annually in high school football. *Athletic Training* 1987;22:19.
161. Pritchett JW. A statistical study of knee injuries due to football in high-school athletes. *J Bone Joint Surg Am* 1982;64:240.
162. Thompson N, Halpern B, Curl WW. High school football injuries: evaluation. *Am J Sports Med* 1987;15:117.
163. Sullivan JA. Evaluation of injuries in youth soccer. *Am J Sports Med* 1980;8:325.
164. Kvist M, et al. Sports-related injuries in children. *Int J Sports Med* 1989;10:81.
165. McLain LG, Reynolds S. Sports injuries in a high school. *Pediatrics* 1989;84:446.
166. DeHaven KE. Athletic injuries in adolescents. *Pediatr Ann* 1978;7:96.
167. Pitman MI. Sports injuries in children. *Resident Staff Physician* 1986;32:47.
168. Stanish WD, Curwin SL, Bryson G. The use of flexibility exercises in preventing and treating sports injuries. In: Leadbetter WB, Buckwalter JA, Gordon SL, eds. *Sports-induced inflammation*. Park Ridge, IL: American Academy of Orthopaedic Surgeons, 1990:731.
169. Grana WA, Moretz JA. Ligamentous laxity in secondary school athletes. *JAMA* 1978;240:1975.
170. Munnings F. Does stretching really help performance and prevent injuries? *Your Patient Fitness* 1990;3:10.
171. van Mechelen W, Hlobil H, Kemper HC, et al. Prevention of running injuries by warm-up, cool-down, and stretching exercises. *Am J Sports Med* 1993;21:711.
172. Cahill BR, Griffith EH. Effect of preseason conditioning on the incidence and severity of high school football knee injuries. *Am J Sports Med* 1978;6:180.
173. Runyan DK. The pre-participation examination of the young athlete. *Clin Pediatr* 1983;22:674.
174. Linder CW, et al. Preparticipation health screening of young athletes. *Am J Sports Med* 1981;9:187.
175. Risser WL, et al. A cost-benefit analysis of preparticipation sports examinations of adolescent athletes. *J School Health* 1985;55:270.
176. Maron BJ, Roberts WC, McAllister HA, et al. Sudden death in young athletes. *Circulation* 1980;62:218.
177. Blum RW. Preparticipation evaluation of the adolescent athlete. *Adolesc Athlete* 1985;78:52.
178. Strong WB, Steed D. Cardiovascular evaluation of young athletes. *Pediatr Clin North Am* 1982;29:1325.
179. Garrick JG. The frequency of injury, mechanism of injury, and the epidemiology of ankle sprains. *Am J Sports Med* 1985;9:241.
180. Brastrum. Sprained ankles anatomic lesions in recent sprains. *Acta Orthop Scand* 1964;188:483.
181. Cox JS. Surgical and nonsurgical treatment of acute ankle sprains. *Clin Orthop Rel Res* 1985;198:118.
182. Dias LS. Lateral ankle sprain: an experimental study. *J Trauma* 1979;4:266.
183. Smith RW, Reischl SF. Treatment of ankle sprains in young athletes. *Am J Sports Med* 1986;14:465.
184. Staples OS. Result study of ruptures of lateral ligaments of the ankle. *Clin Orthop Rel Res* 1972;85:50.
185. Staples OS. Ruptures of the fibular collateral ligaments of the ankle. *J Bone Joint Surg Am* 1975;57:101.
186. Stiell IG, Greenberg GH, McKnight RD, et al. Decision rules for the use of radiography in acute ankle injuries. *JAMA* 1993;269:1127.
187. Sauser DD, et al. Acute injuries of the lateral ligaments of the ankle: comparison of stress radiography and arthrography. *Radiology* 1983;148:653.
188. Fordyce AJW, Horn CV. Arthrography in recent injuries in the ligaments of the ankle. *J Bone Joint Surg Br* 1972;54:116.
189. Hackenbruch W, Noesberger B, Debrunner HU. Differential diagnosis of ruptures of the lateral ligaments of the ankle joint. *Arch Orthop Trauma Surg* 1979;93:293.
190. Raatikainen T, Putkonen M, Puranen J. Arthrography, clinical examination, and stress radiograph in the diagnosis of acute injury to the lateral ligaments of the ankle. *Am J Sports Med* 1992;20:2.
191. Snyder RB, Lipscomb AB, Johnston RK. The relationship of tarsal coalitions to ankle sprains in athletes. *Am J Sports Med* 1981;9:313.
192. Ogden JA, Lee J. Accessory ossification patterns in injuries of the malleoli. *J Pediatr Orthop* 1990;10:306.
193. Kay DB. The sprained ankle: current therapy. *J Foot Ankle* 1985;6:22.
194. Garrick JG. "When Can I . . . ?" *Am J Sports Med* 1981;9:67.
195. Jackson DW, Ashley RL, Powell JW. Ankle sprains in young athletes. *Clin Orthop Rel Res* 1974;101:201.
196. Gross MT, et al. Comparison of support provided by ankle taping and semi-rigid orthosis. *J Orthop Sports Phys Ther* 1987;9:33.
197. Rovere GD, et al. Retrospective comparison of taping and ankle stabilizers in preventing ankle injuries. *Am J Sports Med* 1988;16:228.
198. Karlsson J, Andreasson GO. The effect of external ankle support

Sports Trauma

- in chronic lateral ankle joint instability. *Am J Sports Med* 1992; 20:257.
199. Larsen E. Taping the ankle for chronic instability. *Acta Orthop Scand* 1984;55:551.
 200. Rarick GL, et al. The measurable support of the ankle joint by conventional methods of taping. *J Bone Joint Surg Am* 1962; 44:1183.
 201. Hocutt JE, et al. Cryotherapy in ankle sprains. *Am J Sports Med* 1982;10:316.
 202. Tropp H, Askling C, Gillquist J. Prevention of ankle sprains. *Am J Sports Med* 1985;13:259.
 203. Brand RL, Collins MDF, Templeton T. Surgical repair of ruptured lateral ankle ligaments. *Am J Sports Med* 1981;9:40.
 204. Evans GA, Hardcastle A, Frenyo D. Acute rupture of the lateral ligament of the ankle. *J Bone Joint Surg Br* 1984;66:209.
 205. Henning CE, Egge LN. Cast brace treatment of acute unstable lateral ankle sprain. *Am J Sports Med* 1977;5:252.
 206. Chrisman OD, Snook GA. Reconstruction of lateral ligament tears of the ankle. *J Bone Joint Surg Am* 1969;51:904.
 207. St. Pierre R, et al. A review of lateral ankle ligamentous reconstructions. *Foot Ankle* 1982;3:114.
 208. Cass JR, et al. Ankle instability: comparison of primary repair and delayed reconstruction after long-term follow-up study. *Clin Orthop Rel Res* 1985;198:110.
 209. Meislin RJ, Rose DJ, Parisien JS, Springer S. Arthroscopic treatment of synovial impingement of the ankle. *Am J Sports Med* 1993;21:186.
 210. Bassett FH, Gates HS 3d, Billys JB, et al. Talus impingement of the anterior inferior tibiofibular ligament: a cause of chronic pain in the ankle after inversion sprain. *J Bone Joint Surg Am* 1990;72:55.
 211. McCarroll JR, Schrader JW, Shelbourne KD. Meniscoid lesions of the ankle in soccer players. *Am J Sports Med* 1987;15:225.
 212. Fritschy D. An unusual ankle injury in top skiers. *Am J Sports Med* 1989;17:282.
 213. Hopkinson WJ, St. Pierre P, Ryan JB, Wheeler JH. Syndesmosis sprains of the ankle. *Foot Ankle* 1990;10:325.
 214. Marymont JV, Lynch MA, Henning CE. Acute ligamentous diastasis of the ankle without fracture: evaluation by radionuclide imaging. *Am J Sports Med* 1986;14:407.
 215. Edwards GSL, DeLee JC. Ankle diastasis without fracture. *Foot Ankle* 1984;4:306.
 216. DeHaven KE, Lintner DM. Athletic injuries: comparison by age, sport, gender. *Am J Sports Med* 1986;14:218.
 217. Bradley GW, Shives TC, Samuelson KM. Ligament injuries in the knees of children. *J Bone Joint Surg Am* 1979;61:588.
 218. Clanton TO, DeLee JC, Sanders B, et al. Knee ligament injuries in children. *J Bone Joint Surg Am* 1979;61:1195.
 219. Joseph KN, Pogrand H. Traumatic rupture of the medial ligament of the knee in a four-year-old boy. *J Bone Joint Surg Am* 1978;60:402.
 220. Bergfield J. First-, second-, third-degree sprains. *Am J Sports Med* 1979;7:207.
 221. Hughston JC, Andrews JR, Cross MJ. Classification of knee ligament instabilities. Part I: the medial compartment and cruciate ligaments. *J Bone Joint Surg Am* 1976;58:159.
 222. Noyes FR, Butler DL, Grood ES, et al. Biomechanical analysis of human ligament grafts used in knee-ligament repairs and reconstructions. *J Bone Joint Surg Am* 1984;66:344.
 223. O'Connor GA. Collateral ligament injuries of the joint. *Am J Sports Med* 1979;7:209.
 224. Steadman JR. Rehabilitation of first and second degree sprains of the medial collateral ligament. *Am J Sports Med* 1979;7:300.
 225. Derscheid GL, Garrick JG. Medial collateral ligament injuries in football. *Am J Sports Med* 1981;9:365.
 226. Baker BE, Van Hanswyk E, Bogosian S, et al. A biomechanical study of the static stabilizing effect of knee braces on medial stability. *Am J Sports Med* 1987;15:566.
 227. Indelicato PA. Nonoperative treatment of complete tears of the medial collateral ligament of the knee. *J Bone Joint Surg Am* 1983;65:323.
 228. Frank C, Woo SL, Amiel D. Medial collateral ligament healing: a multidisciplinary assessment in rabbits. *Am J Sports Med* 1983; 11:379.
 229. Fetto JF, Marshall JL. Medial collateral ligament injuries of the knee: a rationale for treatment. *Clin Orthop Rel Res* 1978;147: 29.
 230. Matz SO, Jackson DW. Anterior cruciate ligament injury in children. *Am J Knee Surg* 1988;1:59.
 231. Waldrop JL, Broussard TS. Disruption of the anterior cruciate ligament in a three-year-old child. *J Bone Joint Surg Am* 1984; 66:1113.
 232. Eady JL, Cardenas CD, Sopa D. Avulsion of the femoral attachment of the anterior cruciate ligament in a seven-year-old child. *J Bone Joint Surg Am* 1982;64:1376.
 233. Robinson SC, Driscoll SE. Simultaneous osteochondral avulsion of the femoral and tibial insertions of the anterior cruciate ligament. *J Bone Joint Surg Am* 1981;63:1342.
 234. Bertin KC, Goble EM. Ligament injuries associated with physical fractures about the knee. *Clin Orthop Rel Res* 1983;177: 188.
 235. DeHaven KE. Diagnosis of acute knee injuries with hemarthrosis. *Am J Sports Med* 1980;8:9.
 236. Noyes FR, Bassett RW, Grood ES, et al. Arthroscopy in acute traumatic hemarthrosis of the knee. *J Bone Joint Surg Am* 1980; 62:687.
 237. Odensten M, Lysholm J, Gillquist J. The course of partial anterior cruciate ligament ruptures. *Am J Sports Med* 1985;13:183.
 238. Nichols JN, Tehranzadeh J. A review of the tibial spine fractures in bicycle injury. *Am J Sports Med* 1987;15:172.
 239. Roberts JM, Lovell WW. Fractures of the intercondylar eminence of the tibia. *J Bone Joint Surg Am* 1970;52:827.
 240. Marshall JL, et al. The anterior drawer sign: what is it? *Am J Sports Med* 1975;3:152.
 241. Marshall JL, Baugher WH. Stability examination of the knee: a simple anatomic approach. *Clin Orthop Rel Res* 1980;146:78.
 242. Oliver JH, Coughlin LP. Objective knee evaluation using the Genucom knee analysis system. *Am J Sports Med* 1987;15:571.
 243. Johansson E, Aparisi T. Congenital absence of cruciate ligaments. *Clin Orthop Rel Res* 1982;162:108.
 244. Thomas NP, Jackson AM, Aichroth PM. Congenital absence of the anterior cruciate ligament. *J Bone Joint Surg Br* 1985;67: 572.
 245. Jackson, DW, Jennings LD, Maywood RM. Magnetic resonance imaging of the knee. *Am J Sports Med* 1988;16:29.
 246. Boger DC, Kingston S. Magnetic resonance imaging of the normal knee. *Am J Knee Surg* 1988;1:99.
 247. Polly DW, Callaghan JJ, Sikes RA. The accuracy of selective magnetic resonance imaging compared to the findings of arthroscopy of the knee. *J Bone Joint Surg Am* 1988;70:192.
 248. Fetto JF, Marshall JL. The natural history and diagnosis of anterior cruciate ligament insufficiency. *Clin Orthop Rel Res* 1980;147:29.
 249. Hawkins RJ, Misamore GW, Merritt TR. Follow-up of the acute nonoperated isolated anterior cruciate ligament tear. *Am J Sports Med* 1986;14:205.
 250. McDaniel WJ Jr, Dameron TJ Jr. Untreated ruptures of the anterior cruciate ligament. *J Bone Joint Surg Am* 1980;62:696.
 251. Holden DL, Jackson DW. Treatment selection in acute anterior cruciate ligament tears. *Orthop Clin North Am* 1985;16:99.
 252. McCarroll JR, Rettig AC, Shelbourne KD. Anterior cruciate

- ligament injuries in the young athlete with open physes. *Am J Sports Med* 1988;16:44.
253. Arnoczky SP, Rubin RM, Marshall JL. Microvasculatures of the cruciate ligament and its response to injury. *J Bone Joint Surg Am* 1979;61:1221.
 254. DeLee JC, Curtis R. Anterior cruciate ligament insufficiency in children. *Clin Orthop Rel Res* 1983;172:112.
 255. Marshall SC. Combined arthroscopic/open repair of meniscal injuries. *Contemp Orthop* 1987;14:15.
 256. Hewson GF Jr, Mendini RA, Wang JB. Prophylactic knee bracing in college football. *Am J Sports Med* 1986;14:262.
 257. Teitz CC, et al. Evaluation of the use of braces to prevent injury to the knee in collegiate football players. *J Bone Joint Surg Am* 1987;69:2.
 258. Anderson M, Green WT, Messner MB. Growth and predictions of growth in the lower extremities. *J Bone Joint Surg Am* 1963;45:1.
 259. Green WT, Anderson M. Skeletal age and the control of bone growth. *Instr Course Lect* 1960;XVII:199.
 260. Andrews JR, Sanders R. A "mini reconstruction" technique in treating anterior lateral rotatory instability. *Clin Orthop Rel Res* 1983;172:93.
 261. Snyder RW, Andrews JR. Combined arthroscopy and "mini-reconstruction" techniques in the acutely torn anterior cruciate ligament. *Orthop Clin North Am* 1958;16:171.
 262. Carson WG Jr. Extra-articular reconstruction of the anterior cruciate ligament: lateral procedures. *Orthop Clin North Am* 1985;16:191.
 263. Penner DA, Daniel DM, Wood PFL. An in vitro study of anterior cruciate ligament graft placement and isometry. *Am J Sports Med* 1988;16:238.
 264. Digby KH. The measurement of diaphyseal growth in proximal and distal directions. *J Anat Physiol* 1915;50:187.
 265. Lipscomb AB, Anderson AF. Tears of the anterior cruciate ligament in adolescents. *J Bone Joint Surg Am* 1986;68:19.
 266. Mayer PJ, Micheli LJ. Avulsion of the femoral attachment of the posterior cruciate ligament in an eleven year old boy. *J Bone Joint Surg Am* 1979;61:431.
 267. Sanders WE, Wilkins KE, Neidre A. Acute insufficiency of the posterior cruciate ligament in children. *J Bone Joint Surg Am* 1980;62:129.
 268. Clancy WG, Shelbourne KD, Zoellner GB, et al. Treatment of knee joint instability secondary to rupture of the posterior cruciate ligament. *J Bone Joint Surg Am* 1983;65:310.
 269. Dandy DJ, Pusey RJ. The long-term results of unrepaired tears of the posterior cruciate ligament. *J Bone Joint Surg Am* 1982;64:92.
 270. Hughston JC, Bowden JA, Andrews JR, et al. Acute tears of the posterior cruciate ligament. *J Bone Joint Surg Am* 1980;62:438.
 271. Meyers MH. Isolated avulsion of the tibial attachment of the posterior cruciate ligament of the knee. *J Bone Joint Surg Am* 1975;57:669.
 272. Orethorp N, Anders A, Ekstrom H. Immediate effects of meniscectomy in the knee joint: the effect of tensile load on knee joint ligaments in dogs. *Acta Orthop Scand* 1978;49:407.
 273. Walker PS, Erkman MJ. The role of the menisci in force transmission across the knee. *Clin Orthop Rel Res* 1975;109:184.
 274. Manzione M, Pizzutillo PD, Peoples AB, et al. Meniscectomy in children: a long-term follow-up study. *Am J Sports Med* 1983;11:111.
 275. Helfert AJ. Mechanism of derangements of the medial semilunar cartilage and their management. *J Bone Joint Surg Br* 1956;41:319.
 276. Ritchie DM. Meniscectomy in children. *Aust N Z J Surg* 1965;35:239.
 277. King AG. Meniscal lesions in children and adolescents: a review of the pathology and clinical presentation. *Injury* 1983;15:105.
 278. Medlar RC, Mandiberg JJ, Lyne ED. Meniscectomies in children. *Am J Sports Med* 1980;8:87.
 279. Vahvanen V, Aalto K. Meniscectomy in children. *Acta Orthop Scand* 1979;50:791.
 280. Hoppenfeld S. Physical examination of the spine and extremities. New York: Appleton-Century-Croft, 1976.
 281. Busch MT. Meniscal injuries in children and adolescents. *Clin Sports Med* 1990;9:661.
 282. Ireland J, Trickey EL, Stoker DJ. Arthroscopy and arthrography of the knee. *J Bone Joint Surg Am* 1980;62:3.
 283. Silva I, Silver DM. Tears of the meniscus as revealed by magnetic resonance imaging. *J Bone Joint Surg Am* 1988;70:199.
 284. Zaman M, Leonard MA. Meniscectomy in children: results in 59 knees. *Br J Accident Surg* 1981;12:425.
 285. Clark CR, Ogden JA. Development of the menisci of the human knee joint. *J Bone Joint Surg Am* 1983;65:538.
 286. Kaplan EB. Discoid lateral meniscus of the knee joint. *J Bone Joint Surg Am* 1957;39:77.
 287. Arnoczky SP, Warren RF. Microvasculature of the human meniscus. *Am J Sports Med* 1982;10:90.
 288. Ghadially FN, Wedge JH, LaLonde J. Experimental methods of repairing injured menisci. *J Bone Joint Surg Am* 1986;68:106.
 289. Cassidy RE, Shaffer AJ. Repair of peripheral meniscus tear: a preliminary report. *Am J Sports Med* 1981;9:209.
 290. Sommerlath K. Meniscus repair: 6- to 10-year follow-up. *Am J Knee Surg* 1988;1:169.
 291. Scott GA, Jolly BL, Henning CE. Combined posterior incision and arthroscopic intra-articular repair of the meniscus. *J Bone Joint Surg Am* 1986;68:847.
 292. DeHaven KE. Meniscus repair in the athlete. *Clin Orthop Rel Res* 1985;198:31.
 293. Jackson MDW, Feagin LCJA. Quadriceps contusions in young athletes. *J Bone Joint Surg Am* 1973;55:95.
 294. Rothwell AG. Quadriceps hematoma. *Clin Orthop Rel Res* 1982;171:97.
 295. Lipscomb AB, Thomas ED, Johnston RK. Treatment of myositis ossificans traumatica in athletes. *Am J Sports Med* 1976;4:111.
 296. Fernbach SK, Wilkinson RH. Avulsion injuries of the pelvis and proximal femur. *Am J Radiol* 1981;137:581.
 297. Howard FM, Piha RJ. Fractures of the apophysis in adolescent athletes. *JAMA* 1965;192:150.
 298. Metzmaker JN, Pappas AM. Avulsion fractures of the pelvis. *Am J Sports Med* 1985;13:349.
 299. Hedstrom SA, Lidgren L. Acute hematomogenous pelvic osteomyelitis in athletes. *Am J Sports Med* 1982;10:44.
 300. Highland TR, Lamont RL. Osteomyelitis of the pelvis in children. *J Bone Joint Surg Am* 1983;65:230.
 301. Schlonsky J, Olix ML. Functional disability following avulsion fracture of the ischial epiphysis. *J Bone Joint Surg Am* 1972;54:641.
 302. Winkler H, Rapp IH. Ununited epiphysis of the ischium: report of a case. *J Bone Joint Surg Am* 1947;29:234.
 303. McCoy GF, Piggot J, Macafee AL, Adair IV. Injuries of the cervical spine in schoolboy rugby football. *J Bone Joint Surg Br* 1984;66:500.
 304. Torg JS, Das M. Trampoline-related quadriplegia: review of the literature and reflections on the American Academy of Pediatrics' position statement. *Pediatrics* 1984;74:804.
 305. Torg JS, Vesgo JJ, Sennett B, Das M. The National Football Head and Neck Injury Registry. *JAMA* 1985;254:3439.
 306. Clarke KS. A survey of sports-related spinal cord injuries in schools and colleges. *J Safety* 1977;9:140.

307. Torg JS. Epidemiology, pathomechanics, prevention of athletic injuries to the cervical spine. *Med Sci Sports Exerc* 1985;17:295.
308. Tator CH, Edmonds VE. National survey of spinal injuries in hockey players. *Can J Neurol Sci* 1984;130:875.
309. Tator CH, Ekong CE, Rowed DW, et al. Spinal injuries due to hockey. *Can J Neurol Sci* 1984;11:34.

Other Common Knee Problems

310. Herzmark MH. The evolution of the knee joint. *J Bone Joint Surg Am* 1938;20:77.
311. Hungerford DS, Barry M. Biomechanics of the patellofemoral joint. *Clin Orthop Rel Res* 1979;144:9.
312. Kaufer H. Mechanical function of the patella. *J Bone Joint Surg Am* 1971;53:1551.
313. Goodfellow J, Hungerford DS, Woods C. Patello-femoral joint mechanics and pathology. *J Bone Joint Surg Br* 1976;58:291.
314. Maquet P. Mechanics and osteoarthritis of the patellofemoral joint. *Clin Orthop Rel Res* 1979;144:70.
315. Paulos L, Rusche K, Johnson C, Noyes FR. Patellar malalignment. *Phys Ther* 1980;60:1624.
316. Fulkerson JP, Gossling HR. Anatomy of the knee joint lateral retinaculum. *Clin Orthop Rel Res* 1980;153:183.
317. Fox TA. Dysplasia of the quadriceps mechanism. *Surg Clin North Am* 1975;55:199.
318. Ficat RP, Philippe J, Hungerford DS. Chondromalacia of the patella: a system of classification. *Clin Orthop Rel Res* 1979;144:55.
319. Hejgaard N, Diemer H. Bone scan in the patellofemoral pain syndrome. *Int Orthop* 1987;11:29.
320. James SL. Chondromalacia of the patella in the adolescent. In: Kennedy, JC ed. *The Injured Adolescent Knee*. Baltimore: Williams & Wilkins, 1979:205.
321. Boucher JP, King MA, Lefebvre R, Pepin A. Quadriceps femoris muscle activity in patellofemoral pain syndrome. *Am J Sports Med* 1992;20:527.
322. James SL, Bates BT, Osternig LR. Injuries to runners. *Am J Sports Med* 1978;6:41.
323. Paulos L, Noyes FR, Malek M. A practical guide to the initial evaluation and treatment of knee ligament injuries. *J Trauma* 1980;20:498.
324. Yates CK, Grana WA. Patellofemoral pain in children. *Clin Orthop Rel Res* 1990;255:36.
325. Yates C, Grana WA. Patellofemoral pain: a prospective study. *Orthopedics* 1986;9:663.
326. Harwin SF, Stern RE. Subcutaneous lateral retinacular release for chondromalacia patellae: a preliminary report. *Clin Orthop Rel Res* 1981;156:207.
327. Grana WA, Hinkley B, Hollingsworth S. Arthroscopic evaluation and treatment of patellar malalignment. *Clin Orthop Rel Res* 1984;186:122.
328. Mercalf RW. An arthroscopic method for lateral release of the subluxating or dislocating patella. *Clin Orthop Rel Res* 1982;167:9.
329. Insall J, Goldberg V, Salvati E. Recurrent dislocation and the high-riding patella. *Clin Orthop Rel Res* 1972;88:67.
330. Lancourt JE, Cristini JA. Patella alta and patella infera: their etiological role in patellar dislocation, chondromalacia and apophysitis of the tibial tubercle. *J Bone Joint Surg Am* 1975;57:1112.
331. Hughston JC. Subluxation of the patella. *J Bone Joint Surg Am* 1968;50:1003.
332. Merchant AC, Mercer RL, Jacobsen RH, Cool CR. Roentgenographic analysis of patellofemoral congruence. *J Bone Joint Surg Am* 1974;56:1391.
333. Fulkerson JP, Schutzer SF, Ramsby GR, et al. Computerized tomography of the patellofemoral joint before and after lateral release or realignment. *J Arthroscopic Rel Surg* 1987;3:19.
334. Schonholtz GJ, Zahn MG, Magee CM. Lateral retinacular release of the patella. *J Arthroscopic Rel Surg* 1987;3:269.
335. Laurin CA, Dussault R, Levesque HP. The tangential x-ray investigation of the patellofemoral joint. *Clin Orthop Rel Res* 1979;144:16.
336. Larson RL, Cabaud HE, Slocum DB. The patellar compression syndrome: surgical treatment by lateral retinacular release. *Clin Orthop Rel Res* 1978;134:158.
337. Hejgaard N, Skive L, Perrild C. Recurrent dislocation of the patella. *Acta Orthop Scand* 1980;51:673.
338. Fogelman I, McKillop JH, Gray HW. The "hot patella" sign: is it of any clinical significance? Concise communication. *J Nucl Med* 1983;24:312.
339. Dye SF, Boll DA. Radionuclide imaging of the patellofemoral joint in young athletes. *Orthop Clin North Am* 1986;17:249.
340. Kohn HS, Newton GN, Collier BD. Chondromalacia of the patella: bone imaging correlated with arthroscopic findings. *Clin J Nucl Med* 1988;13:96.
341. Doucette SA, Goble EM. The effect of exercise on patellar tracking in lateral patellar compression syndrome. *Am J Sports Med* 1992;20:434.
342. O'Neill DB, Micheli LJ, Warner JP. Patellofemoral stress: a prospective analysis of exercise treatment in adolescents and adults. *Am J Sports Med* 1992;20:151.
343. Dehaven KE, Dolan WA, Mayer PJ. Chondromalacia patellae in athletes. *Am J Sports Med* 1979;7:5.
344. Palumbo RM. Dynamic patellar brace: A new orthosis in the management of patellofemoral disorders. *Am J Sports Med* 1981;9:45.
345. Bennett JG, Stauber WT. Evaluation and treatment of anterior knee pain using eccentric exercise. *Med Sci Sports Exerc* 1986;18:526.
346. Lysholm J, Nordin M, Ekstrand J. The effect of a patella brace on performance in a knee extension strength test in patients with patellar pain. *Am J Sports Med* 1984;12:110.
347. Bigos SJ, McBride GG. The isolated lateral retinacular release in the treatment of patellofemoral disorders. *Clin Orthop Rel Res* 1984;186:75.
348. Fulkerson JP, Schutzer SF. After failure of conservative treatment for painful patellofemoral malalignment: lateral release or realignment? *Orthop Clin North Am* 1986;17:283.
349. Fulkerson JP, Shea KP. Disorders of patellofemoral alignment. *J Bone Joint Surg Am* 1990;72:1424.
350. Merchant AC, Mercer RL. Lateral release of the patella: a preliminary report. *Clin Orthop Rel Res* 1974;103:40.
351. Casscells SW. The arthroscope in the diagnosis of disorders of the patellofemoral joint. *Clin Orthop Rel Res* 1979;144:45.
352. Cash JD, Hughston JC. Treatment of acute patellar dislocation. *Am J Sports Med* 1988;16:244.
353. Bray RC, Roth JH, Jacobsen RP. Arthroscopic lateral release for anterior knee pain. *Arthroscopy* 1987;3:237.
354. Busch MT, DeHaven KE, Panni AS. Two- to ten-year results of lateral retinacular release for patellofemoral pain. In: American Academy of Orthopaedic Surgeons, 56th Annual Meeting. Las Vegas, Nevada, 1989.
355. Poehling GG, Pollock FE, Koman LA. Reflex sympathetic dystrophy of the knee after sensory nerve injury. *Arthroscopy* 1988;4:31.
356. Berz RR, Lonergan R, Patterson R. The percutaneous lateral retinacular release. *Orthopedics* 1982;5:57.
357. Ceder LC, Larson RL. Z-plasty lateral retinacular release for the treatment of patellar compression syndrome. *Clin Orthop Rel Res* 1979;144:110.
358. Dzioba RB, Strokon A, Mulbry L. Diagnostic arthroscopy and

- longitudinal open lateral release: a safe and effective treatment for "chondromalacia patella." *Arthroscopy* 1985;1:131.
359. Krompinger WJ, Fulkerson JP. Lateral retinacular release for intractable lateral retinacular pain. *Clin Orthop Rel Res* 1983;179:191.
 360. Lankner PA, Micheli LJ, Clancy R, Gerbino PG. Arthroscopic percutaneous lateral patellar retinacular release. *Am J Sports Med* 1986;14:267.
 361. McGinty JB, McCarthy JC. Endoscopic lateral retinacular release. *Clin Orthop Rel Res* 1981;158:120.
 362. Simpson LA, Barrett JP Jr. Factors associated with poor results following arthroscopic subcutaneous lateral retinacular release. *Clin Orthop Rel Res* 1984;186:165.
 363. Hughston JC, Deese M. Medial subluxation of the patella as a complication of lateral retinacular release. *Am J Sports Med* 1988;16:383.
 364. Miller GK, Dickason JM, Fox JM. The use of electrosurgery for arthroscopic subcutaneous lateral retinacular release. *Orthopedics* 1982;5:309.
 365. Ogilvie-Harris DJ, Jackson RW. The arthroscopic treatment of chondromalacia patellae. *J Bone Joint Surg Br* 1984;66:660.
 366. Worth RM, Kettelkamp DB, Defalque RJ, Duane KV. Saphenous nerve entrapment. *Am J Sports Med* 1984;12:80.
 367. Romanoff M, Cory T, Kalenak A. Saphenous nerve entrapment at the adductor canal. In: Annual Meeting of the American Academy of Orthopaedic Surgeons. Atlanta, GA, 1988.
 368. Haswell DM, Berne AS, Graham CB. The dorsal defect of the patella. *Pediatr Radiology* 1976;4:238.
 369. Goergen TG, Resnick D, Greenway G. Dorsal defect of the patella (DDP). *Radiology* 1979;130:333.
 370. Holsbeek MV, Vandamme B, Marchal G, et al. Dorsal defect of the patella: concept of its origin and relationship with bipartite and multipartite patella. *Skeletal Radiol* 1987;16:304.
 371. Hunter LY, Hensinger RN. Dorsal defect of the patella with cartilaginous involvement. *Clin Orthop Rel Res* 1979;143:131.
 372. Denham RH. Dorsal defect of the patella. *J Bone Joint Surg Am* 1984;66:116.
 373. Alexander JE, Seibert JJ, Aronson J. Dorsal defect of the patella and infection. *Pediatr Radiol* 1987;30:325.
 374. Edwards DH, Bentley G. Osteochondritis dissecans patellae. *J Bone Joint Surg Am* 1977;59:58.
 375. Miller WB, Murphy WA, Gilula LA, Kantor OS. Brodie's abscess of the patella. *JAMA* 1977;238:1179.
 376. Gamble JG. Symptomatic dorsal defect of the patella in a runner. *Am J Sports Med* 1986;14:425.
 377. Metheny JA, Mayor MB. Hoffa disease: chronic impingement of the infrapatellar fat pad. *Am J Knee Surg* 1988;1:134.
 378. Smillie IS. *Diseases of the knee joint*. New York: Churchill Livingstone, 1974.
 379. Hardaker WT, Whipple TL, Bassett FH. Diagnosis and treatment of the plica syndrome of the knee. *J Bone Joint Surg Am* 1980;62:221.
 380. Nottage WM, Sprague NF, Auerbach BJ, Shahriaree H. The medial patellar plica syndrome. *Am J Sports Med* 1983;11:211.
 381. Parel D. Arthroscopy of the plicae—synovial folds and their significance. *Am J Sports Med* 1978;6:217.
 382. Barber FA. Fenestrated medial patella plica. *J Arthroscopic Rel Surg* 1987;3:253.
 383. Brattstrom H. Shape of the intercondylar groove normally and in recurrent dislocation of patella. *Acta Orthop Scand* 1964;68:1.
 384. Larsen E, Lauridsen F. Conservative treatment of patellar dislocations. *Clin Orthop Rel Res* 1982;171:131.
 385. Henry JH, Craven PR. Surgical treatment of patellar instability: indications and results. *Am J Sports Med* 1981;9:82.
 386. MacNab I. Recurrent dislocation of the patella. *J Bone Joint Surg Am* 1952;34:957.
 387. Baker RH, Carroll N, Dewar FP, Hall JE. The semitendinosus tenodesis for recurrent dislocation of the patella. *J Bone Joint Surg Br* 1972;54:103.
 388. McManus F, Rang M, Heslin DJ. Acute dislocation of the patella in children. *Clin Orthop Rel Res* 1979;139:88.
 389. Brattstrom H. Patella alta in non-dislocating knee joints. *Acta Orthop Scand* 1970;41:578.
 390. Yamamoto RK. Arthroscopic repair of the medial retinaculum and capsule in acute patellar dislocations. *J Arthroscopic Rel Surg* 1986;2:125.
 391. Madigan R, Wissinger HA, Donaldson WF. Preliminary experience with a method of quadricepsplasty in recurrent subluxation of the patella. *J Bone Joint Surg Am* 1975;57:600.
 392. Baksi DP. Restoration of dynamic stability of the patella by pes anserinus transposition. *J Bone Joint Surg Br* 1981;63:399.
 393. Insall J, Falvo KA, Wise DW. Chondromalacia patellae. *J Bone Joint Surg Am* 1976;58:1.
 394. Chrisman OD, Snook GA, Wilson TC. A long-term prospective study of the Hauser and Roux Goldthwait procedures for recurrent patellar dislocation. *Clin Orthop* 1979;144:27.
 395. Woo R, Busch M. Management of patellar instability in children. *Operative Techniques Sports Med* 1998;6:247.
 396. Crosby EB, Insall J. Recurrent dislocation of the patella. *J Bone Joint Surg Am* 1976;58:9.
 397. Hauser ED. Total tendon transplant for slipping patella. *Surg Gynecol Obstet* 1938;66:199.
 398. Brown DE, Alexander AH, Lichtman DM. The Elmslie-Trillat procedure: evaluation in patellar dislocation and subluxation. *Am J Sports Med* 1984;12:104.
 399. Fulkerson JP. Anteromedialization of the tibial tubercle for patellofemoral malalignment. *Clin Orthop* 1983;177:176.
 400. Dashefsky JH. Discoid lateral meniscus in three members of a family: case reports. *J Bone Joint Surg Am* 1971;53:1208.
 401. Kurosaka M, Yoshiya S, Ohno O. Lateral discoid meniscectomy: a 20-year follow-up. In: Annual Meeting of the American Academy of Orthopaedic Surgeons. San Francisco, 1987.
 402. Fujikawa K, Iseki F, Mikura Y. Partial resection of the discoid meniscus in the child's knee. *J Bone Joint Surg Am* 1981;63:391.
 403. Rosenberg TD, Paulos LE, Parker RD. Discoid lateral meniscus: case report of arthroscopic attachment of a symptomatic Wrisberg-ligament type. *Arthroscopy* 1987;3:277.
 404. Dickhaut SC, DeLee JC. The discoid lateral-meniscus syndrome. *J Bone Joint Surg Am* 1982;64:1068.



32

MANAGEMENT OF FRACTURES

**CHARLES T. PRICE
JONATHAN H. PHILLIPS
DENNIS P. DEVITO**

GENERAL FEATURES OF FRACTURES IN CHILDREN 1320

Biomechanical Considerations 1320
Anatomic Considerations 1321
Physiologic Considerations 1321

INJURY TO THE PHYSIS 1322

Anatomy and Physiology of the Physis 1322
Physeal Fractures 1323
Physeal Arrest 1324

INITIAL MANAGEMENT CONSIDERATIONS 1327

Multiple Trauma Evaluation and Management 1327
Open Fractures 1327
Compartment Syndromes 1328
Anesthesia and Analgesia for Emergency Department Management 1329

INJURIES OF THE SHOULDER AND HUMERUS 1332

Shoulder Injuries in Infants 1332
Clavicle Fractures 1332
Acromioclavicular Separation 1334
Scapular Fracture 1334
Shoulder Dislocation 1335
Proximal Humerus Fractures 1335
Humeral Shaft Fracture 1335

FRACTURES AND DISLOCATIONS ABOUT THE ELBOW 1338

Supracondylar Fracture 1339
T-condylar Fracture 1344
Lateral Condyle Fracture 1344
Lateral Epicondyle Fracture 1348
Medial Epicondyle Fracture 1348
Medial Condyle Fracture 1349
Fracture-separation of the Distal Humeral Physis 1349
Radial Neck Fracture 1350
Olecranon Fractures 1352
Elbow Dislocation 1352
Radial Head Dislocation and Nursemaid's Elbow 1354

FOREARM AND WRIST FRACTURES 1355

Forearm Fracture-dislocations 1356
Midshaft Fractures 1357
Distal Metaphyseal Fractures of the Radius and Ulna 1364
Distal Radius Physeal Fracture 1365

FRACTURES OF THE THORACIC AND LUMBAR SPINE 1366

Clinical Features 1366
Anatomy and Classification 1367
Treatment of Thoracolumbar Fractures 1367
Complications 1368

PELVIC FRACTURES 1369

Clinical Features 1369
Anatomy and Classifications of Pelvic Fractures 1370
Treatment of Pelvic Fractures 1370
Complications 1371

C. T. Price: Chief, Department of Orthopaedics, Nemours Children's Clinic, Orlando, FL 32806.

J. H. Phillips: Department of Orthopaedics, Nemours Children's Clinic, Orlando, FL 32806.

D. P. Devito: Department of Orthopaedics, Children's Healthcare of Atlanta at Scottish Rite, 5455 Meridian Mark Road, Atlanta, Georgia 30342.

FRACTURES AND DISLOCATIONS OF THE HIP 1372

Hip Dislocation 1372

Proximal Femur Fractures 1373

FEMORAL SHAFT FRACTURES 1379

Treatment of Femoral Shaft Fractures 1379

Complex Femoral Fractures 1387

Complications of Femur Fractures 1388

FRACTURES AND DISLOCATIONS ABOUT THE KNEE 1389

Distal Femoral Physeal Separations 1389

Tibial Spine Fracture 1390

Tibial Tubercle Fracture 1393

Patellar Fractures 1394

TIBIAL FRACTURES 1396

Proximal Tibial Epiphyseal Fracture 1396

Proximal Tibial Metaphyseal Fracture (Cozen Fracture) 1397

Tibial Diaphysis 1398

FRACTURES OF THE ANKLE 1401

Classifications 1402

Treatment 1402

Complications 1406

FRACTURES OF THE FOOT 1408

Anatomy 1409

Talus Fractures and Dislocations 1409

Calcaneus Fracture 1411

Midfoot Fractures and Tarsometatarsal Injuries 1411

Fractures of the Metatarsals 1411

Fractures of the Phalanges 1412

Injuries of all types are the second leading cause of hospitalization among children younger than 15 years (1), and account for 80% of deaths among teenagers and young adults (2). Properly instituted injury prevention programs can be effective in reducing the number and severity of pediatric trauma events (3). Musculoskeletal trauma, although rarely fatal, accounts for 10 to 25% of all childhood injuries (3).

Boys have a 40% risk and girls a 25% risk of incurring a fracture before the age of 16 years (3). The most common sites of fracture are the distal forearm and hand, which account for 50% of pediatric fractures. The fracture rate increases as children grow, with the incidence peaking in early adolescence. Fortunately, most fractures are minor. Only 20% require reduction, whereas greenstick and torus fractures constitute approximately 50% of all fractures in children (3–5). Thus, the management of pediatric fractures is often straightforward, but one must know when to intervene and when to allow nature to take its course. The skeleton of a young child behaves differently than the skeleton of an older child. There are also musculoskeletal differences in biomechanics, anatomy, and physiology between children and adults. It is the purpose of this chapter to highlight the unique aspects of managing fractures in children, and to delineate age-appropriate treatment guidelines.

GENERAL FEATURES OF FRACTURES IN CHILDREN**Biomechanical Considerations**

The bones of children are less mineralized and have more vascular channels than adult bones. This results in a lower modulus of elasticity (6). Thus, for a given stress applied to the same area of pediatric bone, more strain results com-

pared with adult bone. Bending strength is lower than in adult bone, but the low modulus of elasticity allows for greater energy absorption before failure. Pediatric bone also has the capacity for plastic deformation, in which the bone does not return to its original shape. Microscopic mechanical failure, not evident on routine radiographs, occurs through oblique slip lines or microfractures on the compression side of the bone. This produces no fracture hematoma and minimal periosteal reaction during healing. Plastic deformation results from an applied load after the yield point is reached, but before the breaking point is reached. This partly explains why greenstick fractures can occur when a bending load is applied. Much of the strain energy is dissipated through plastic deformation of the concave cortex, while tension failure occurs on the convex side. This prevents larger, more catastrophic failure from occurring.

In addition to greenstick fractures, children can have torus or “buckle” fractures from compression failure. This usually occurs at the metaphyseal–diaphyseal junction, where the more rigid diaphyseal cortex meets the thinner metaphyseal cortex. The less-rigid metaphyseal cortex buckles and deforms without complete failure, creating a relatively stable injury. The rate at which the force is applied also influences the fracture type. Higher load rates more often result in complete fracture (6). Complete fractures display transverse, oblique, or spiral configurations, depending on how the injury force was applied. Comminuted fractures are less common in children than in adults, because pediatric bone can dissipate energy before failure and porosity inhibits fracture line propagation. The smaller diameter of pediatric bone also affects its strength compared with adult bone. The polar moment of inertia of a structure, which measures resistance to torque, is proportional to the fourth power of the radius of the structure. Thus, a relatively

small increase in the cortical diameter results in a large increase in a bone's ability to resist torsional load.

The epiphysis also affects the mechanical properties of bone. In young children, the epiphysis is largely cartilaginous, and transmits injury forces to the metaphysis. Increasing ossification in the epiphysis occurs with age and imparts more rigidity to the epiphysis. This increased rigidity partially explains why epiphyseal fractures and separations are more commonly seen in older children.

Anatomic Considerations

Growth plates and their surrounding growth centers are major anatomic features that distinguish children's bones from those of adults. The physis, also called the growth plate or the epiphyseal plate, is the area of growing cartilage that contributes length to the growing bone. The epiphysis is the region at the end of the bone. The epiphysis forms a secondary center of ossification and determines the shape and size of the articular surface. An apophysis is a secondary growth center at a site of tendon attachment. Apophyses are extraarticular and do not contribute to longitudinal growth. Each of these structures ossifies at predictable times during growth and provides information regarding skeletal maturity. Lack of ossification in young children, and variable patterns of ossification during growth, make the diagnosis of injury an even greater challenge in children than in adults.

Another anatomic characteristic of growing bone is the thick, vascular, and highly osteogenic periosteum. The cambium or osteogenic layer lies directly on the cortex of bone. The outer fibrous layer provides attachment for muscles and ligaments. Between these two layers lie elastic fibers that allow the fibrous layer to be stripped from the bone, leaving the osteogenic layer intact (7). Muscle and periosteum are firmly attached to bone in only a few places, such as the linea aspera. The periosteum is also firmly attached to the growth plate at the perichondrial ring of LaCroix, which helps stabilize the physis. The thick periosteum in children is rarely torn circumferentially after a fracture, and often remains intact on the compression side of the injured bone. This intact periosteal sleeve may then be used as a tension band for fracture reduction and stabilization. Intact periosteum may also prevent soft tissue interposition and facilitate reduction. Conversely, the periosteum itself may become interposed between the fracture fragments, and the longitudinally torn periosteum may interfere with reduction, by allowing the bone to "button-hole" through the periosteal defect.

Physiologic Considerations

Children experience considerably more rapid fracture healing than adults. Children also have the potential for bone remodeling and overgrowth after fracture. Nonunion is rare in pediatric fractures. This is explained in part by the osteogenic potential of the periosteum and the magnitude of the vascular response in children (7). The periosteum is vital

to fracture healing, and should be preserved as much as possible. Large segments of bone may regenerate and remodel as long as the periosteal tube is intact.

The majority of pediatric fractures unite by secondary fracture healing, which occurs without rigid immobilization, and involves a combination of intramembranous and endochondral ossification. Trauma that results in fracture causes cellular injury and hematoma formation. Blood, marrow, and necrotic cells release cytokines that stimulate inflammation and the proliferation of stem cells (8). The clot gives rise to platelet-derived growth factor and transforming growth factor beta. This leads to general cellular proliferation. Stem cells produce bone morphogenetic proteins, which lead to cellular differentiation. The exact relationship between these factors and other factors involved in the coordination of fracture healing is the subject of ongoing research (9). During the second stage of fracture healing, angiogenesis occurs. This stage of bone healing is facilitated in children by the highly vascular periosteum and preservation of a viable muscle envelope. The periosteum also contributes bone formation by membranous ossification within 10 to 14 days of injury. Angiogenesis is followed by the formation of soft callus. Low oxygen tension and fracture motion promote cartilage formation as the initial stage of endochondral ossification. This cartilage is subsequently removed and replaced by hard callus with woven bone (7,9). Ultimately, the ossification phase gives way to a more prolonged phase of fracture remodeling.

Remodeling of angulated fractures in children is a well-recognized phenomenon (Fig. 32-1). The site of correction and the mechanism by which remodeling occurs are poorly understood. Remodeling at the fracture site occurs by bone resorption on the convexity and deposition on the concavity of the fracture. This phenomenon of "bone drift" is well recognized clinically, and has been quantified in the rabbit model (10). However, the majority of remodeling occurs by reorientation of the growth plates, with improvement in the overall alignment of the limb. Asymmetric and longitudinal growth of the physis contribute to this remodeling. Therefore, measurement of angular remodeling at the fracture site alone gives an inadequate picture of the overall limb alignment as remodeling occurs (10,11). Remodeling capacity depends on the number of years of growth remaining, the proximity of the fracture to a rapidly growing physis, the magnitude of angular deformity, and the plane of angulation relative to adjacent joints. Remodeling may continue for 5 to 6 years after fracture, as long as growth occurs during the period of remodeling (11). The rate of remodeling is minimally influenced by age, but the completeness of remodeling may be limited by the number of years of growth remaining (11–14). Fractures in the plane of joint motion and near a rapidly growing physis have the greatest capacity to remodel. Fractures with smaller degrees of malunion are more likely to remodel completely (15). Remodeling of rotational deformity has also been noted in children, but this is less predictable than angular remodeling (16,17).

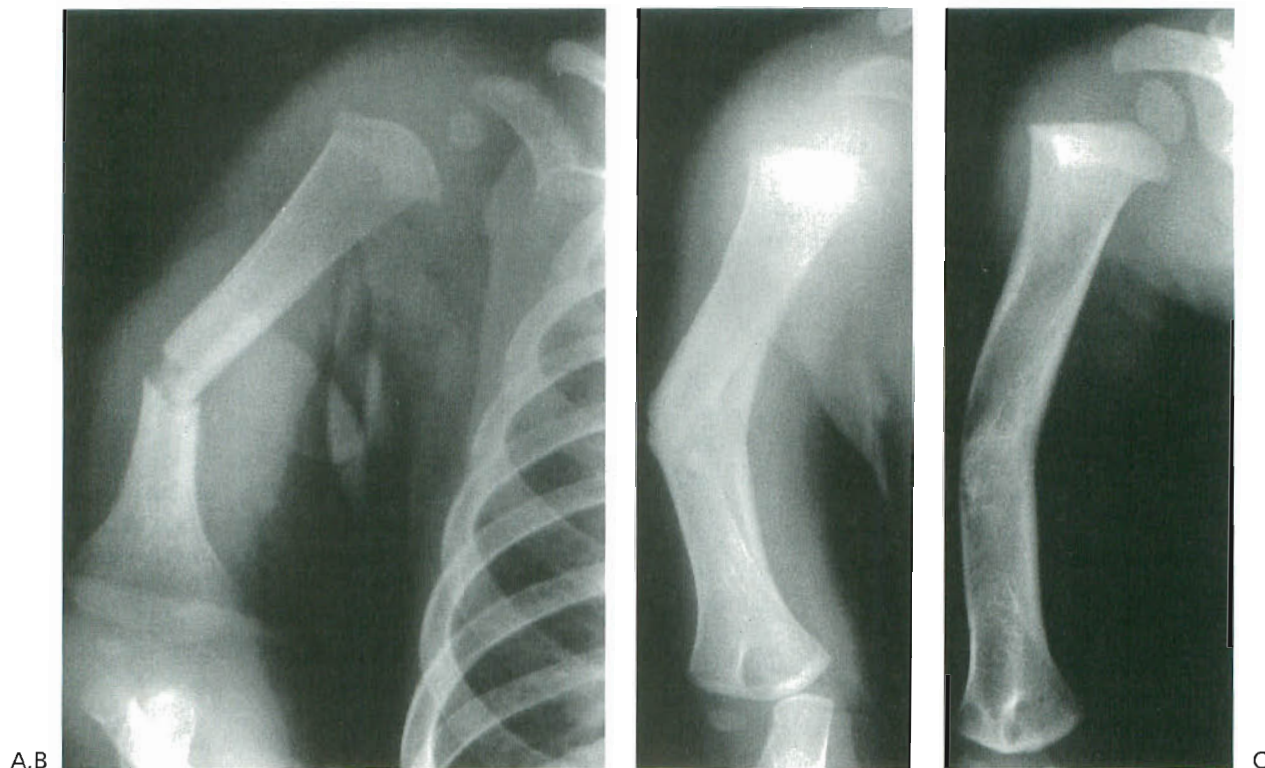


FIGURE 32-1. Periosteal bone formation. **A:** Complete fracture of the humeral diaphysis in a 6-month-old child. The periosteum is presumed to be intact on the compression (concave) side. **B:** Four weeks later, the periosteum has formed a complete column of new bone. **C:** Six months after injury, there has been significant remodeling, with a 50% correction of the angular deformity.

It has been postulated that torsional remodeling occurs by helical growth of the physis (10).

Another distinguishing physiologic response to bone healing in children is the potential for growth stimulation after fracture. The age of the patient and the amount of periosteal stripping influence the amount of growth stimulation (7). This phenomenon is most commonly reported after femoral fractures in children between the ages of 3 and 9 years, but it also occurs after other fractures (18–21). The exact mechanism for growth acceleration is unknown, but increased blood flow to the growth plate and release of periosteal tension after fracture are potential causes. Hyperemia as a cause of overgrowth is supported by the observation that growth acceleration may occur with conditions that cause increased vascularity, such as congenital vascular anomalies, inflammatory conditions, and tumoral disorders (19). Transverse sectioning of the periosteum also produces overgrowth. Periosteal stripping or division close to the growth plate increases the effect of transverse periosteal release, but longitudinal incision of the periosteum does not cause growth acceleration (7,22). Hemicircumferential release of the periosteum causes asymmetric growth and subsequent angular deformity (23). This phenomenon is most often seen clinically after fracture of the proximal tibial metaphysis in children, when the medial periosteum is torn

transversely, while the lateral periosteum remains intact. These findings support the observation that the periosteum acts as a mechanical restraint on epiphyseal growth through its attachments to the perichondrial ring (24). In older children, premature physal closure has been noted after diaphyseal fracture (25,26). Perhaps the variable growth responses after fracture can be partially explained by differences in periosteal damage or asymmetric hyperemic responses after fracture.

INJURY TO THE PHYSIS

Anatomy and Physiology of the Physis

Growth plates are located at the ends of all long bones and contain the cells responsible for bone growth. Longitudinal growth occurs as columns of cartilage form and undergo endochondral ossification. Fracture of the growth plate generally heals within 3 to 4 weeks, because this is a well-vascularized region that is growing rapidly and forming bone at the time of injury.

The development, histology, and physiology of the growth plate are described in greater detail in Chapter 1. Several anatomic features are essential to the understanding

of trauma to the growth plate. The germinal zone of cartilage formation is located on the articular side of the physis. This zone consists of resting cells that initiate the process of long-bone growth, by dividing to form the zone of proliferating cartilage. The hypertrophic zone is next. This is a zone of maturation where the chondrocytes begin to enlarge. On the metaphyseal side of this zone, vascular buds grow into the degenerating columns of cartilage and initiate provisional calcification as the chondrocytes degenerate. Remodeling into lamellar bone in the metaphysis rapidly follows provisional calcification.

Fractures through the physis are usually the result of tension or shearing forces. Compressive forces tend to cause fracture through bone. Bright and colleagues (27), using rapid loading techniques to simulate *in vivo* forces, demonstrated that the weakest zone is the zone of provisional calcification. However, fracture failure was rarely limited to one zone, and propagating cracks traversed, at least partially, the upper germinal zones in 85% of the animals tested. In younger animals, the fracture was more likely to traverse only the zone between the hypertrophic cells and metaphyseal bone, avoiding the germinal zones. This is clinically relevant, because injury to the germinal zone may be more likely in older children, and can cause arrest of bone growth.

The perichondrial groove of Ranvier and the perichondrial ring of LaCroix surround each physis circumferentially at the periphery. These structures constitute a separate growth center that provides growth of the physis in width. The groove of Ranvier consists of resting and proliferating cells, whereas the ring of LaCroix consists of cartilage cells that extend toward the metaphysis and become continuous with the metaphyseal periosteum. The groove and ring provide support to the physis and resistance to physeal separation. Additional stability is provided by large and small undulations of the growth plate. The smaller projections are called mamillary processes. Larger contours include the lappet formation, which is the overlapping shape of the physis as it cups the metaphysis. The lappet formation is readily appreciated where the anterior portion of the proximal tibial growth plate extends distally as the tibial tuberosity. Muscular, capsular, and ligamentous attachments to the epiphysis may provide additional stability. However, these structures can also transmit force to the growth plate, resulting in characteristic fracture patterns that vary with the specific anatomy of a joint.

The vascularity of the growth plate is essential to its development. There is strict separation of the epiphyseal and metaphyseal circulation, because blood vessels do not cross the growth plate. There are two patterns of blood supply to epiphyses (28). Some epiphyses are completely intracapsular (e.g., the proximal femur and the proximal radius). Blood vessels for these epiphyses must enter the epiphysis around the periphery of the growth plate, and through a narrow region between the articular cartilage and the physis. This type of blood supply is very susceptible to damage during

physeal separation or occlusion of supporting vessels. The second pattern of epiphyseal blood supply is more common, and is seen in epiphyses that are extracapsular (e.g., the proximal tibia and the distal radius). Vessels that supply circulation to the epiphysis and the growth plate penetrate directly through the side of the epiphysis where it is covered with periosteum and capsular attachments. Extracapsular epiphyses are less vulnerable to devascularization when physeal separation occurs.

Physeal Fractures

Physeal fractures constitute 15 to 30% of all childhood fractures (29). The peak age for injury to the growth plate is early adolescence (11 to 12 years), and physeal fracture is uncommon in children younger than 5 years of age. Boys are affected twice as often as girls (29,30). Several classification systems have been proposed since Foucher first described different types of physeal fractures in 1863 (31). The most widely used classification of physeal fractures is that described by Salter and Harris (32). There are five types of fractures in this classification. Rang has added a sixth that is commonly recognized (33) (Fig. 32-2).

Type I injury involves a transverse fracture through the entire growth plate without evidence of a metaphyseal fragment. This type of fracture is most commonly seen in infants and young children. The epiphyseal fragment may be nondisplaced or minimally displaced, making diagnosis difficult. Localized swelling and point tenderness may confirm the diagnosis. The prognosis for resumption of growth is excellent with a few notable exceptions, such as physeal separation of the proximal or distal femur. Partial growth arrest may occur after severely displaced fractures, when reduction is difficult, or when the growth plate is impaled on the corner of the metaphysis.

Type II fractures represent 75% of all physeal fractures. The fracture line passes through a portion of the growth plate and exits through a triangular segment of the metaphysis that remains attached to the intact portion of the growth plate. The metaphyseal fragment (Thurston-Holland fragment) is on the compression side of the fracture. The prognosis for resumption of growth is good, but growth disturbance occurs in 10 to 30% of patients, depending on the location of the fracture.

Type III injury results when the fracture line traverses a portion of the growth plate, then crosses the epiphysis and the articular surface. The prognosis for resumption of growth is more guarded with this injury, and depends on the vascularity of the physis and damage to the germinal zone. These fractures are more common in older children in whom growth arrest may not be problematic (29). Anatomic reduction is recommended to reduce the risk of growth arrest, and to restore the congruity of the articular surface.

Type IV fractures vertically cross all zones of the physis.

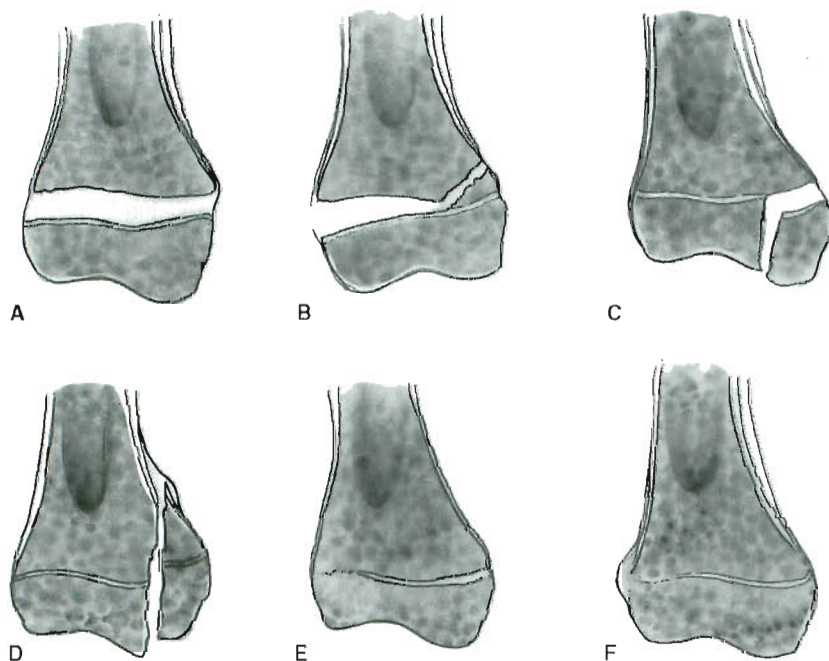


FIGURE 32-2. Salter-Harris classification. **A:** Type I is a transepiphyseal separation without evidence of a metaphyseal fragment. **B:** In type II, the fracture line is through the physis, exiting into the metaphysis, leaving a small triangular portion attached to the physal plate (i.e., Thurston-Holland fragment). **C:** The type III fracture is an intraarticular fracture, with the fracture traversing the physis and exiting through the epiphysis. **D:** Type IV describes a vertical fracture line that is intraarticular. It passes through the epiphysis, physis, and metaphysis. **E:** Type V fracture describes a crush injury to the physis that usually is not apparent on initial injury films. **F:** Type VI fracture is a localized injury to a portion of the perichondrial ring. Subsequent healing produces bone formation across the perimeter of the physis, connecting the metaphysis to the epiphysis.

These fractures are intraarticular and traverse the epiphysis, physis, and metaphysis. The prognosis for resumption of growth is poor (32). Precise anatomic reduction is recommended to realign the physis and restore the articular surface.

Type V injury results from a crushing force applied to the growth plate. This injury may not be apparent on radiographs, because it does not always involve fracture fragment displacement. Growth arrest is common. Crush injury to the germinal physal cells can occur in combination with other Salter-Harris fracture patterns.

Type VI injury is a peripheral physal injury at the level of the perichondrial ring. This may result from ligamentous avulsion, direct trauma, burn, or other forces. Localized growth arrest may occur, and lead to asymmetric growth with angular deformity.

Physal Arrest

Growth arrest after fracture of the growth plate can result from compromised vascularity of the physis, damage to the germinal cells, and bone bridge formation between epiphysal and metaphysal bone (34). Destruction of the epiphysal vasculature leads to central growth arrest followed by complete epiphysodesis. In contrast, destruction of the metaphysal vasculature may temporarily interfere with ossification, but does not result in growth arrest (35). Direct injury to germinal cells of the growth plate can also lead to physal arrest, but small areas of physal damage, i.e., less than 7% of the total area, do not usually cause permanent growth disturbance (36,37). Bone bridge formation can also

develop after a Salter-Harris type IV fracture when displacement allows the epiphysal bone to remain in contact with the metaphysal bone. Peripheral defects result in greater deformities than central defects of the same size, because of their location. Also, small central defects may yield to the force of growth in the remaining viable growth plate (34).

The size and location of physal arrest determine the kind of deformity that eventually develops. Complete growth arrest may produce limb-length discrepancy without angular deformity. The amount of discrepancy depends on the growth rate of the affected physis and the age of the child. Contralateral epiphysodesis should be considered as a treatment option, as soon as complete arrest is diagnosed. No treatment is required when there is minimal growth remaining or the resultant lower-extremity discrepancy will be less than 2 cm at maturity. Limb-lengthening is a treatment option, instead of contralateral epiphysodesis, when the projected discrepancy will be greater than 5 cm.

Partial growth arrest is often a more serious problem than complete arrest, because partial arrest may result in length discrepancy combined with angular deformity and/or joint incongruity. Early recognition is desirable to minimize complications. Partial growth arrest can be recognized as early as a few months after fracture, or may take up to 2 years to become evident. A sclerotic bridge of bone or blurring and narrowing of the growth plate is often visible on plain radiographs if the x-ray beam is tangential to the physis. Another early sign of growth disturbance is the development of an oblique growth arrest line (38) (Fig. 32-3). Magnetic resonance imaging (MRI) may also be useful to detect early physal arrest (39,40).

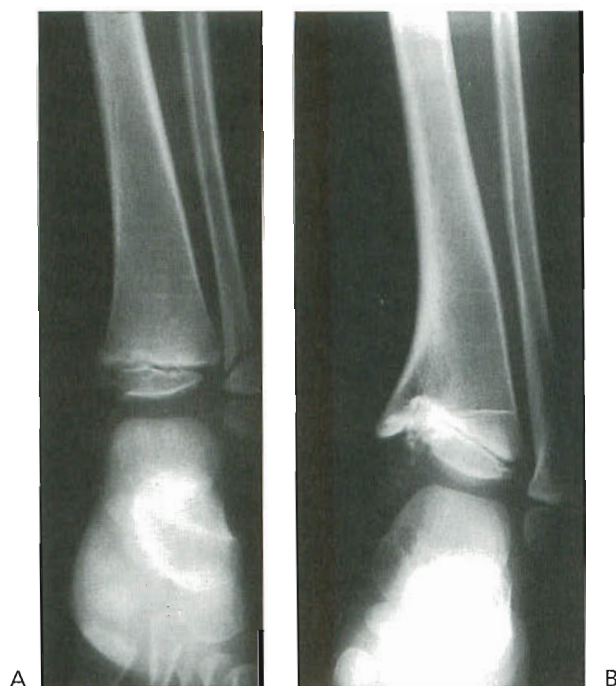

FIGURE 32-3. Distal tibial growth arrest. **A:** Distal tibial physal Salter-Harris type IV injury treated with cast immobilization without reduction. **B:** Two years later, there is varus angulation to the distal tibia from a medial physal bar. The Harris growth arrest line is not parallel to the distal physis, and does not extend across the entire width of the metaphysis.

Treatment of Partial Growth Arrest

There are many treatment options for partial growth plate damage, depending on the location of the bone bridge, the size of the bar, and the amount of growth remaining. Once identified, partial arrest can be surgically converted to complete arrest to prevent further angulation. This approach may be combined with contralateral epiphysiodesis, when the resulting discrepancy would be greater than 2 cm, but less than 4 to 5 cm. This method can also be combined with osteotomy when angular deformity has already developed. Epiphysiodesis with or without osteotomy is particularly appropriate for growth disturbances of slowly growing physes such as the distal tibia. An alternative treatment plan involves epiphysiodesis with or without angular correction and lengthening (41). This may be appropriate when the predicted discrepancy is greater than 4 to 5 cm, or when osteotomy for deformity correction is necessary. On rare occasions, resection of the physal bar, with interposition of fat, cranioplast, or other materials, may be appropriate.

Physal bar resection may be indicated when less than 50% of the physis is damaged, and more than 2 cm of growth remains in the affected growth plate. Corrective osteotomy is often unnecessary if the angular deformity is less than 20 degrees. Before surgical excision, it is necessary to clearly delineate the extent and location of the bar. Plain

radiography should be performed with the beam centered on the growth plate and tilted in the same plane as the growth plate. Conventional multiplanar tomography with thin sections has been used in the past to obtain radiographs in the sagittal and coronal planes to detail the bony bar. These radiographs are then used to construct a map of the physis that demonstrates the exact extent and location of the bar (42). Helical computed tomographic scanning and MRI have largely replaced traditional tomography (43,44). Three-dimensional reconstruction using these techniques allows accurate identification of the size and location of the bar.

Three patterns of partial growth arrest have been identified (Fig. 32-4). The most common type is a peripheral bar, which produces an angular deformity. The second type is a central bar, which acts as a central tether, and results in tenting of the physis with eventual articular surface distortion. The third pattern of bar formation is referred to as a "linear bar" and involves portions of the central and peripheral physis. This last type is often the result of a Salter-Harris type IV fracture that has healed in a displaced position.

Peripheral bone bridges are approached directly, with excision of the overlying periosteum and removal of the abnormal bone, until normal physal cartilage is uncovered. A high-speed bur, small curettes, and a dental pick facilitate the removal of unwanted bone without damaging the normal physis. Loupe magnification, a headlight, and a dental mirror can facilitate visualization of the normal growth plate. Alternatively, an arthroscope can be used to verify complete excision. Interposition material is inserted to prevent the bone bridge from recurring. Fat and cranioplast are the two most commonly used materials for interposition, but cultured chondrocytes or other biologic tissue may be useful in the future (45). The material must remain in contact with the physis during further growth. This is accomplished by securing the interposed substance to the epiphysis. Radio-dense markers are usually inserted in the bone to facilitate the measurement of subsequent growth (Fig. 32-5). Central bars are approached through a metaphyseal window, or through an osteotomy when angular correction is necessary. [4.22] An alternative approach is to remove a wedge of metaphyseal bone and replace it after the bar resection has been completed (46). The peripheral margins of the physis are carefully preserved. Intraoperative fluoroscopy may help guide the approach to the bone bridge. A linear bar is approached directly where it contacts the periphery of the growth plate. The bone bridge is then resected from one side to the other, creating a tunnel that follows the original fracture line.

Results of excision of partial growth arrest are difficult to evaluate, because long-term results reported in peer-reviewed journals are generally lacking. Some excellent results have been noted, and partial growth has been restored in many cases (47). Williamson and Staheli (48) noted excellent results in 50% of cases with an average follow-up of 2

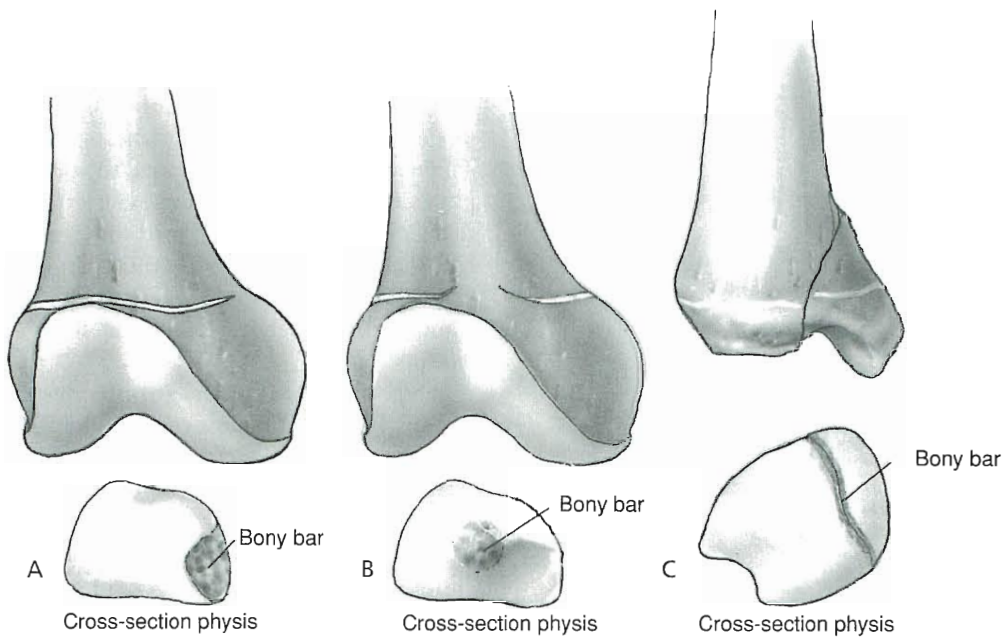


FIGURE 32-4. Growth arrest patterns. **A:** Type I is peripheral growth arrest with a peripheral bony bar. **B:** Type II is central growth arrest with central physeal tethering. The peripheral physis and perichondrial ring are intact. **C:** Type III is combined growth arrest, demonstrating a linear bar involving the peripheral and central portions of the physeal plate. This type of growth arrest is more typical after a Salter-Harris type III or IV fracture.

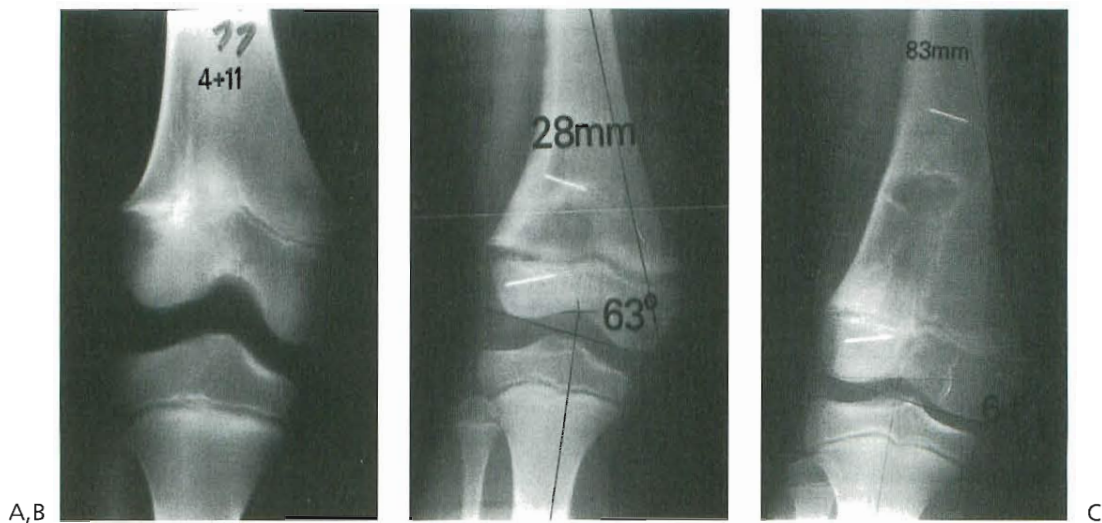


FIGURE 32-5. Physal bar resection. **A:** A distal physal bar is depicted in this anteroposterior hypocyloid tomogram. **B:** This condition was treated with bar excision and insertion of cranioplast. Five months later, the physis remains open, and the two metal markers inserted at the time of surgery are 28 mm apart. There is residual femoral tibial valgus deformity. **C:** Four years later, there has been some improvement in the femoral tibial alignment, and growth of the distal femur has resumed. The markers are 83 mm apart.

years. However, others have reported resumption of growth in only 33% of cases (49). Recurrences and additional surgical procedures are common. The resected growth plate may also close prematurely. Therefore, parents should be advised that the results of physal bar excision are unpredictable.

INITIAL MANAGEMENT CONSIDERATIONS

Multiple Trauma Evaluation and Management

Accidents and injuries are the leading cause of death in children, adolescents, and young adults after the age of 1 year (50). Death from trauma is most often attributable to head injury, but preventable deaths still occur. These are most often caused by airway obstruction, pneumothorax, and hemorrhage (51,52). Children respond differently to trauma than adults. The child's vascular system can maintain systolic blood pressure for a prolonged period of time in the presence of significant hypovolemia. Tachycardia may be the only sign of impending hypovolemic shock, which can occur precipitously. Hypothermia poses a greater problem for children, because they have a higher ratio of surface area to body weight than adults. The child also has greater capacity to recover from neurologic injury and hypoxia. For these reasons, all children should be treated aggressively, with the expectation of survival and recovery of function. Several scoring systems have been developed to predict outcome and assess the need for transport to major trauma centers. The Glasgow Coma Scale is helpful in assessing cortical brain function (53) (Table 32-1). Sequential

assessment can help detect worsening or recovery from brain injury. A child with a Glasgow Coma Scale score of less than 8 has a significantly worse prognosis for survival. The score obtained at 72 h after injury is more predictive of permanent impairment (54). The Pediatric Trauma Score is an effective triage tool and a reliable predictor of injury severity (55) (Table 32-2).

Initial treatment consists of airway management, fluid resuscitation, and blood replacement. Systematic, multidisciplinary management of all organ systems is essential. Musculoskeletal injuries are common in the severely traumatized child, and may be obscure. Children with multiple injuries should be treated as though they have a cervical spine injury, until this can be ruled out clinically or radiographically. Regional examination of the spine, pelvis, shoulders, and extremities should be complete, especially if the child cannot communicate.

Management of fractures may need to be altered from conventional methods to meet the general needs of the patient. Armstrong and Smith (56) have recommended the following principles for children with major trauma:

1. Make sure that any child with a major long-bone fracture does not have any other significant injuries.
2. Early treatment of the fractures should be compatible with the general care of the patient.
3. Fracture care should consider the need for early mobilization of the child.
4. Care of fractures should facilitate the management of associated soft tissue injuries.
5. The initial method of fracture management should be the definitive method, whenever possible.
6. Fracture care must be carefully individualized.
7. Treat all children as though they are going to survive.

TABLE 32-1. GLASGOW COMA SCALE

Variable	Score
Opening of the eyes	
Spontaneously	4
To speech	3
To pain	2
None	1
Best verbal response	
Oriented	5
Confused	4
Inappropriate words	3
Incomprehensible sounds	2
None	1
Best motor response	
Spontaneous (obedience to commands)	6
Localization of pain	5
Withdrawal	4
Abnormal flexion to pain	3
Abnormal extension to pain	2
None	1

The Glasgow Coma Scale is used to measure level of consciousness. A score of less than 8 carries a worse prognosis for survival. (From ref. 55, with permission.)

Open Fractures

Open fractures result from high-energy trauma or penetrating wounds. The tibia is the most commonly involved site in children and adults. Open tibial fractures are discussed in the section on tibial fractures. The femur, forearm, humerus, and other bones may also sustain open injuries.

The traditional classification system of Gustillo (modified by Mendoza) (57) is illustrated in Table 32-3. This classification system is appropriate for children as well as adults, and provides a method of assessment for purposes of management and prognosis.

Management of open fractures requires prompt initiation of antibiotic and tetanus prophylaxis (58). Operative irrigation and debridement should be performed as soon as possible, to minimize the subsequent risk of infection (59). All necrotic or devitalized material is removed. Bone devoid of soft tissue attachments is removed, especially if it is grossly contaminated. However, children frequently have less comminution than adults, and periosteum is often attached to

TABLE 32-2. PEDIATRIC TRAUMA SCORE

Variable	+2	+1	-1
Weight (kg)	>20	10–20	<10
Airway patency	Normal	Maintained	Unmaintained
Systolic blood pressure (mm Hg)	>90	50–90	<50
Neurologic	Awake	Obtunded	Comatose
Open wound	None	Minor	Major
Skeletal trauma	None	Closed	Open or multiple

The Pediatric Trauma Score is a reliable predictor of injury severity. Each variable is given one of the three scores. The scores are totaled (range, –6 to +12). A total of 8 or less indicates potentially important trauma.

(From ref. 55, with permission.)

most segments. Avascular segments of bone that are clean may be preserved, if needed, to provide fracture stability. Bone should be stabilized to create optimal conditions for soft tissue recovery. Cultures can be obtained, but their value for subsequent management is questionable. Partial wound closure over a drain is acceptable for clean grade I and grade II injuries (58,60). Early soft tissue coverage is advantageous, and may require local or free-flap reconstruction (61). Patients with open wounds are returned to the operating room in 48 to 72 h for repeat irrigation, debridement, and possible delayed primary closure or flap coverage. Antibiotics are generally used for 72 h. Cephalosporins are used for grade I injury, and an aminoglycoside is added for grade II or grade III injury. Specific antibiotic selection is made after the culture results become available.

Open fractures in children take longer to heal, and have more complications than closed injuries (16,62,63). Open fractures in children share many of the same complications reported in the adult literature. However, the overall complication rates in children are less than in adults with similar injuries (64–66). This is especially true for children younger than 12 years of age (64,66).

Compartment Syndromes

Compartment syndrome develops when there is an increase of interstitial pressure in a closed osteofascial compartment,

resulting in inadequate circulation to the nerves and muscles of that compartment. There is little documentation of the incidence of compartment syndrome, but it has been reported in numerous anatomic regions, including the abdomen. Increased intracompartmental pressure may develop after athletic exertion, relatively minor injuries, and major trauma (67–69).

Increased tissue pressure in a confined space leads to obstruction of venous outflow from the compartment. This contributes to further swelling and increased pressure. When the pressure increases above the arteriolar circulatory pressure to muscle and nerve, ischemia will occur, leading to irreversible damage to the contents of the compartment. Muscle and nerve damage commences as soon as 4 to 6 h after the onset of abnormal pressures.

Pain out of proportion to the injury should alert the clinician to the possibility of impending or established compartment syndrome. Excessive pain is often the earliest symptom. This is followed rapidly by clinical findings that include sensory changes associated with nerve ischemia within the compartment, excessive pain with passive movement of the muscles within the compartment, and loss of active movement of those muscles. Distal pulses and peripheral capillary refill are unreliable indicators of compartment syndrome. Peripheral circulation may be normal, because major arterial blood flow through the compartment is preserved in the presence of increased pressures, which elimi-

TABLE 32-3. CLASSIFICATION OF OPEN FRACTURES

Wound Type	External Wound Size	Fracture Pattern	Soft Tissue Damage
Type I	<2 cm	Simple	Minimal muscle contusion
Type II	2–10 cm	Simple; minimal comminution	Mild muscle damage; no crush
Type IIIA	Extensive or gunshot wound	Comminuted or segmental fracture	Adequate local soft tissue coverage
Type IIIB	Extensive or crush injury	Extensive periosteal stripping; bone loss	Incomplete coverage; exposed bone
Type IIIC	Same as above	Same as above	Neurovascular injury

(From ref. 57, with permission.)

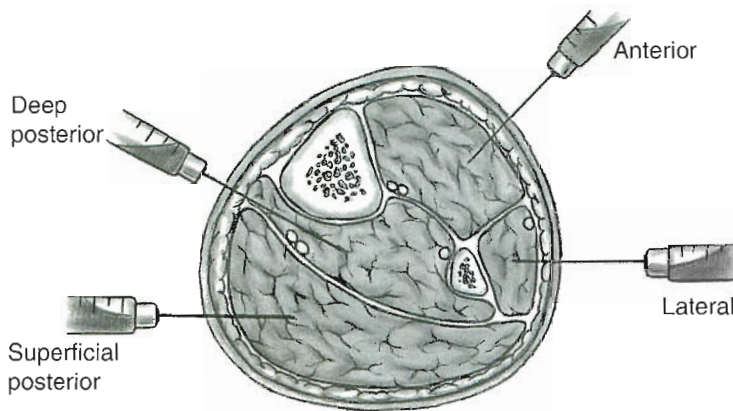


FIGURE 32-6. Orientation and entry points for measurement of compartment pressures. (From ref. 70, with permission.)

nate microvascular perfusion to the muscles and nerves within the compartment. The injured extremity should not be elevated when compartment syndrome is suspected, because this maneuver reduces mean arterial pressure, causing a reduction in perfusion that leads to further ischemia.

The diagnosis of acute compartment syndrome is based on signs and symptoms. Tissue pressure measurements should be obtained whenever the diagnosis is in doubt (70) (Fig. 32-6). The pressure threshold for fasciotomy is not clearly established. Mubarak and Owen (71) recommend fasciotomy if compartment pressure exceeds 30 mm Hg. Others recommend fasciotomy if the pressure is greater than 35 to 40 mm Hg or within 30 mm Hg of the patient's diastolic pressure (70).

Fasciotomy of the forearm can be accomplished by the volar Henry approach or the volar ulnar approach (69). It is essential to decompress the deep flexor compartment, in addition to the superficial flexor compartment muscles (Figs. 32-7 and 32-8). Fasciotomy of the leg can be per-

formed by single-incision or double-incision technique (70) (Fig. 32-9). The two-incision technique facilitates decompression of the deep posterior compartment. The fibula should be left intact. Devitalized muscle is debrided when necessary, but extensive debridement is usually performed 36 to 72 h later, when muscle viability is more readily determined. Approaches for foot compartment syndromes are discussed in the section on metatarsal fractures.

Anesthesia and Analgesia for Emergency Department Management

Numerous techniques have been used to provide sedation and pain relief for outpatient fracture management (72–78). These can be categorized into three groups: blocks, sedation, and dissociative anesthesia (75). When sedation or dissociative anesthesia is used, it is advisable to follow guidelines for monitoring and management that have been established by the American Academy of Pediatrics (79).

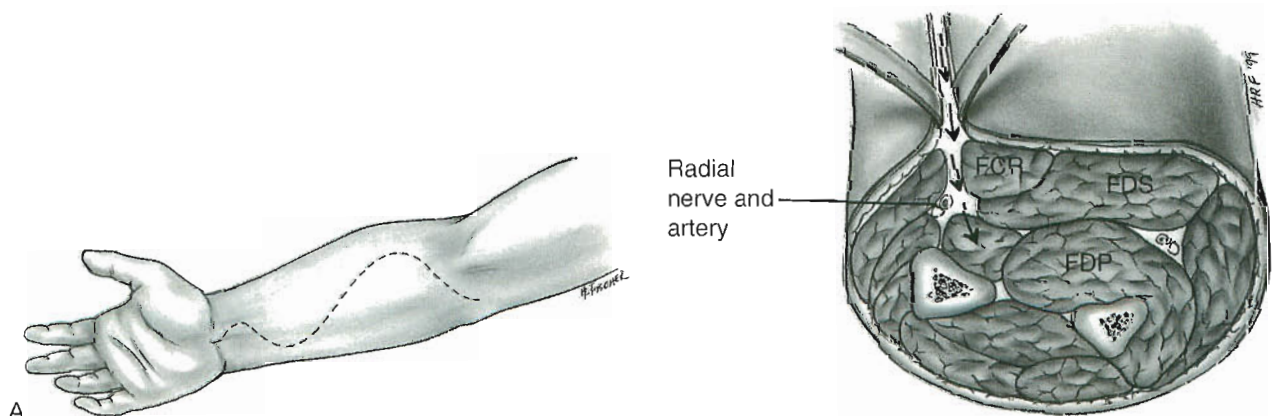


FIGURE 32-7. A: Skin incision crosses the elbow crease and enters the palm along the thenar eminence. B: The superficial fascia is divided. The deep compartment is approached by retracting the flexor carpi radialis (FCR) to the ulnar side. The superficial radial nerve and brachioradialis are retracted radially. The Henry approach is used for decompression of the volar forearm compartments. FDP, flexor digitorum profundus; FDS, flexor digitorum sublimis.

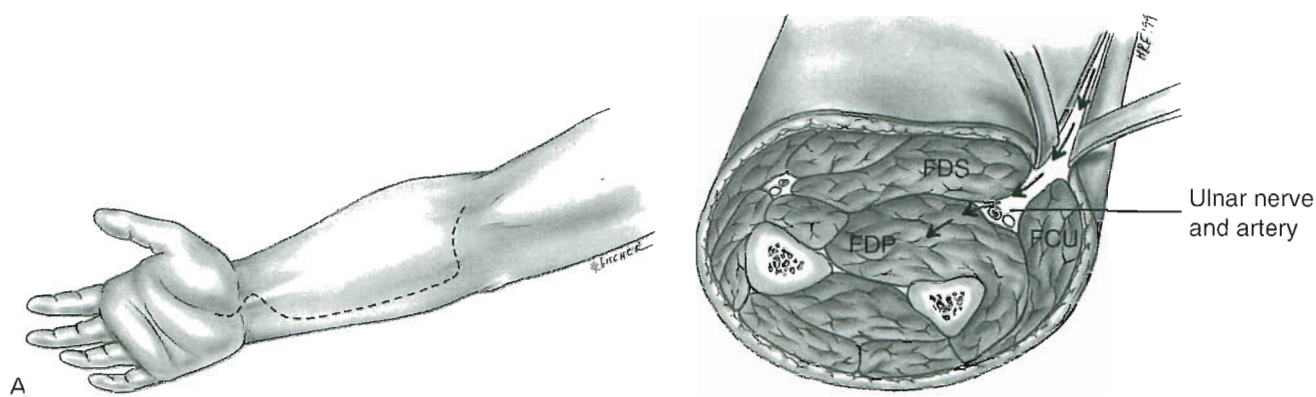


FIGURE 32-8. The volar ulnar approach (modified McConnell exposure) is more direct for decompressing the forearm compartments. **A:** Skin incision extends along the ulnar side of the forearm. **B:** The ulnar nerve and artery are retracted to expose the deep flexor compartment. *FDP*, flexor digitorum profundus; *FDS*, flexor digitorum sublimis; *FCU*, flexor carpi ulnaris.

Blocks

Local and regional blocks include hematoma blocks, nerve blocks, and intravenous regional anesthesia. Hematoma block is particularly useful for distal radius fractures. After appropriate skin preparation, a needle is inserted into the fracture hematoma. The hematoma is aspirated, and 3 to 10 mL of 1 or 2% lidocaine (maximum dose is 3 to 5 mg/kg of body weight) is injected into the fracture site. This technique has been shown to be safe and effective in adults, without any reports of infection (72). Excessive volume of injection should be avoided, because hematoma block can increase carpal tunnel pressure and increase the risk of neurologic complications (80). A randomized prospective study compared hematoma block with intravenous regional block, and found that hematoma block required less time to administer and provided adequate pain relief for reduction

(81). The technique of hematoma block may be difficult when the hematoma is small, as in greenstick fractures, or when the fracture hematoma has already coagulated.

Intravenous regional anesthesia, or Bier block, has been reported to be successful by several authors (74,82). The primary site of nerve block is thought to be small, peripheral nerve branches. For this reason, it is suggested that nerve blockade is better achieved with a larger volume of dilute anesthetic (8,74). Intravenous access is obtained in a vein of the dorsum of the hand of the injured extremity. It is not necessary to have additional intravenous access to the opposite extremity. The arm is then exsanguinated by elevation, or by gentle application of an elastic bandage. A single blood pressure cuff is then rapidly inflated above the elbow to 100 mm Hg greater than systolic blood pressure. The cuff may be taped to avoid Velcro failure, and the inflation tube may be cross-clamped to prevent premature cuff deflation.

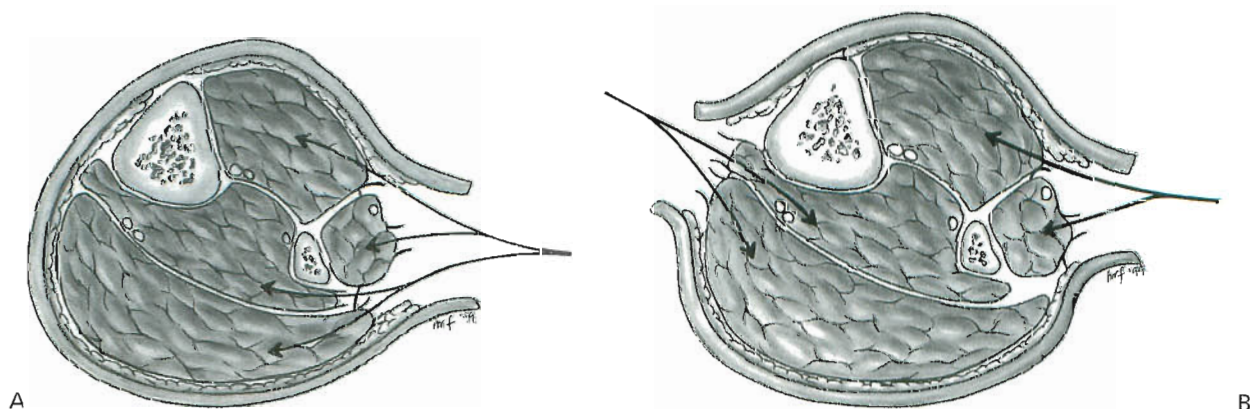


FIGURE 32-9. **A:** Single-incision fasciotomy may be used to decompress all four compartments of the leg. Excision of the fibula is not necessary. **B:** Double-incision fasciotomy allows a more direct approach to the deep posterior compartment of the leg. (From ref. 70, with permission.)

tion. Two cuffs may be used to minimize tourniquet discomfort, but this is not usually necessary for fracture reductions. Lidocaine, diluted with normal saline to a 0.125% solution, is then administered in a dose of 1 to 1.5 mg/kg of body weight (74). The tourniquet should be kept inflated for at least 20 minutes to permit the lidocaine to become fixed to the tissue, thus minimizing the risk of lidocaine toxicity when the cuff is deflated. This method has proven most effective for forearm fractures and less effective for supracondylar, finger, and hand fractures (8).

Ulnar nerve block at the elbow, median nerve block at the wrist, or digital blocks can be useful for reduction of certain hand and finger fractures and dislocations. Axillary block has proved to be a safe technique for a variety of upper-extremity fractures in children (83). In most children, the axillary sheath is superficial, and the pulse is easily identified, compared with adults, who generally have more subcutaneous fat. Intravenous access in the uninjured extremity is recommended, and can be used to administer low-level sedation before axillary block. The arm is abducted and externally rotated to a 90–90 position (i.e., hip and knee flexed 90 degrees); 1% plain lidocaine is used at a dose of 3 to 5 mg/kg of body weight. Cramer et al. (83) recommend the transarterial method of administration. A 23-gauge butterfly needle is inserted through the axillary artery during continuous aspiration. Approximately two-thirds of the lidocaine is slowly injected into the sheath on the opposite side of the artery. Periodic aspiration is performed to minimize the risk of intraarterial injection. The needle is withdrawn just to the superficial side of the sheath, and the remaining lidocaine is injected. This anesthetic technique provides prolonged pain relief for complex manipulations, but requires considerable cooperation from the patient.

Sedation

Conscious sedation is defined as a level of consciousness that maintains protective reflexes and retains the patient's ability to maintain an airway independently. During conscious sedation, the patient can respond appropriately to verbal commands or physical stimulation. Deep sedation is defined as a more profound state of unconsciousness, accompanied by partial or complete loss of protective reflexes and inability to respond purposefully to verbal or physical stimuli. The American Academy of Pediatrics has developed specific guidelines for monitoring and managing pediatric sedation (79). These guidelines state that the risks of deep sedation may be indistinguishable from those of general anesthesia.

Narcotics and benzodiazepines are widely available agents for intravenous sedation. Narcotics provide analgesia, whereas benzodiazepines are primarily sedatives. These drugs act synergistically to induce controlled sedation and analgesia. Intravenous access and continuous monitoring of pulse and oxygen saturation are advised. Respiratory rate and blood pressure should be monitored periodically. An emergency cart with resuscitation equipment should be immediately available. Nasal oxygen and personnel skilled in airway management increase the level of safety.

Numerous medications and combinations of medications have been used (75) (Table 32-4). Varela and associates (77) reported satisfactory pain relief in 98% of patients who were sedated by titrating meperidine (Demerol) and midazolam (Versed). The target doses were 2 and 0.1 mg/kg of body weight for meperidine and midazolam, respectively. Meperidine is less potent than morphine, but it has a slightly faster onset and some euphoric properties (75). Fentanyl, a potent narcotic, is sometimes used as a substitute for me-

TABLE 32-4. MEDICATIONS MOST COMMONLY USED FOR SEDATION IN PEDIATRIC FRACTURE REDUCTION

Medication	Dosage	Comments
Midazolam (Versed)	0.05–0.2 mg/kg IV	Benzodiazepine
Meperidine (Demerol)	1.0–2.0 mg/kg IV	Narcotic
Fentanyl	1.0–5.0 μ g/kg IV	Potent, rapid-onset narcotic
Ketamine	1.0–2.0 mg/kg IV; 3.0–4.0 mg/kg IM	Manage emergence reactions with small doses of midazolam
Naloxone (Narcan)	1.0–2.0 μ g/kg IV	Narcotic-reversal agent
Flumazenil (Romazicon)	5.0–10.0 μ g/kg IV (maximum, 0.2 mg)	Benzodiazepine-reversal agent
Atropine	0.01 mg/kg IV or IM (maximum, 0.5 mg)	Antisialagogue
Glycopyrrolate	4.0–10.0 μ g/kg IV or IM (maximum, 0.25 mg)	Antisialagogue

IM, intramuscular; IV, intravenous.
(Adapted from ref. 75, with permission.)

peridine, because it reaches peak analgesia within 2 to 3 minutes, and has a shorter duration of action than meperidine. Hypoxemia and apnea are not uncommon after sedation with midazolam and fentanyl. Monitoring of oxygen saturation is essential, because hypoxemia can occur in the absence of apnea. If respiratory depression occurs, reversal agents should be administered. Naloxone is used to reverse the narcotic effect, and the benzodiazepine is reversed with flumazenil (75).

Dissociative Anesthesia

Ketamine has gained popularity as a useful drug for emergency department use (84,85). It induces a trance-like state that combines sedation, analgesia, and amnesia, with little cardiovascular depression. It has been suggested that protective orotracheal reflexes are preserved, but respiratory depression is dose-related (84,85). The intramuscular or intravenous route may be used to administer ketamine. The intravenous route permits titration and more rapid onset of action, with quicker recovery. The target intravenous dose is 1 to 2 mg/kg of body weight. The intramuscular dose is 4 mg/kg, and a repeat dose may be given after 10 to 15 minutes, if necessary. Ketamine increases upper-airway secretions, so atropine or glycopyrrolate are recommended before sedation. Emergence hallucinations are more common in children older than 10 years of age. Therefore, ketamine may be a less desirable choice in older children. When ketamine is used in older children, low-dose midazolam (0.05 mg/kg) can reduce the risk of emergence reactions (76).

INJURIES OF THE SHOULDER AND HUMERUS

The clavicle, scapula, and humerus articulate to form the shoulder. The clavicle is flat laterally, triangular medially, and has a double curve that is convex anteriorly in the medial third and convex posteriorly in the lateral third. The scapula is a large, flat, triangular bone that is connected to the trunk by muscles only. The spine arises from the dorsal surface and forms the acromion laterally, and the coracoid process arises from the anterior surface. The clavicle and scapula are attached at the acromioclavicular joint, and held in place by the coracoclavicular ligaments. The clavicle connects the shoulder girdle to the axial skeleton at the sternoclavicular joint. This joint is very mobile and allows the clavicle to move through an arc of 60 degrees and accommodate a wide range of scapular rotation. The shoulder girdle articulates with the humerus through the glenohumeral joint. This joint is a ball-and-socket joint that is supported primarily by the articular capsule and surrounding muscle. Thus, the shoulder mechanism functions as a universal joint, allowing freedom of motion in all planes.

Fractures around the shoulder are generally easy to treat, and rarely require reduction or surgical stabilization. The wide range of motion in this region contributes to rapid remodeling and accommodates modest residual deformity.

Shoulder Injuries in Infants

Difficult birth can result in injury to the infant's shoulder (86). The most common injuries are fracture of the clavicle and brachial plexus palsy. The differential diagnosis should also include proximal humeral physeal separation, septic arthritis of the shoulder, osteomyelitis, and nonaccidental injuries. Lack of arm movement in the neonatal period is the most common clinical finding for each of these problems. Pain, swelling, and crepitus may be noted when fracture has occurred. Often, birth fracture of the clavicle is undetected until swelling subsides and the firm mass of healing callus is noticed in the midshaft of the clavicle. Parental reassurance and gentle handling are all that are required for managing birth fracture of the clavicle. Clavicle fracture is occasionally confused with congenital pseudarthrosis of the clavicle. Pseudarthrosis can be distinguished from birth fracture of the clavicle by the absence of pain, and by radiographic features of established pseudarthrosis.

Neonatal trauma may also result in Salter-Harris type I physeal separation of the proximal humerus. This injury may be difficult to diagnose radiographically, because the proximal humeral epiphysis does not ossify until 3 to 6 months of age. Ultrasonography, MRI, or joint aspiration may facilitate diagnosis in questionable cases. Closed reduction is not indicated because healing is rapid and remodeling is certain. Immobilization for 2 to 3 weeks provides comfort and allows union to occur.

Clavicle Fractures

Clavicle Diaphysis Fracture

The clavicle is frequently fractured in children, and the most common portion injured is the shaft. The mechanism of injury is usually a fall on the shoulder or excessive lateral compression of the shoulder girdle. The subclavian vessels, brachial plexus, and apex of the lung lie beneath the clavicle, but are rarely injured at the time of fracture.

Treatment of clavicle shaft fractures in children and adolescents is supportive; reduction is not attempted, except for fractures with extreme displacement. Both a figure-eight harness and a sling are used initially to provide comfort. After a few days, the sling may be discontinued. The figure-eight harness is worn for 3 to 4 weeks, and sports are avoided for an additional 2 to 3 weeks. Uneventful, rapid healing is the rule, although many fractures heal in a malunited position with palpable subcutaneous callus. Parents should be advised that, regardless of alignment, healing will produce a bump that will remodel over the course of several

months. Operative indications are rare, but include open fractures, severe displacement with the bone end impaled through the trapezius, and irreducible tenting of the skin by the bone fragments. Even in these severe cases, internal fixation is rarely required. Nonunion after clavicle fracture has been reported in adolescents, but it responds to bone grafting and plating (87).

Medial Clavicle Fracture

The medial clavicular ossification center appears at approximately 17 years of age, but the physis does not close until the person is 20 to 25 years of age (88). Thus, fractures of the medial end of the clavicle consist of physeal separations, mimicking sternoclavicular dislocation (89). These are Salter-Harris type I or II injuries, although the epiphyseal fragment is not visualized well on radiographs. The direction

of displacement can be anterior or posterior. Posterior displacement can cause dysphagia or respiratory compromise, especially when the child's head and neck are extended. Apical lordotic radiographs are helpful, but computed tomography (CT) scans best visualize the deformity (Fig. 32-10).

Treatment of posteriorly displaced fractures consists of closed reduction. This is performed under general anesthesia for complete relaxation. The reduction maneuver entails hyperextension of the clavicle combined with longitudinal arm traction. It may also be necessary to capture the medial clavicle with a percutaneous towel clip, and pull in an anterolateral direction. Posteriorly displaced fractures are usually stable after reduction. A shoulder immobilizer or figure-eight harness provides sufficient immobilization. Anteriorly displaced epiphyseal separations are less stable, and partial redisplacement may occur. However, remanipulation or op-

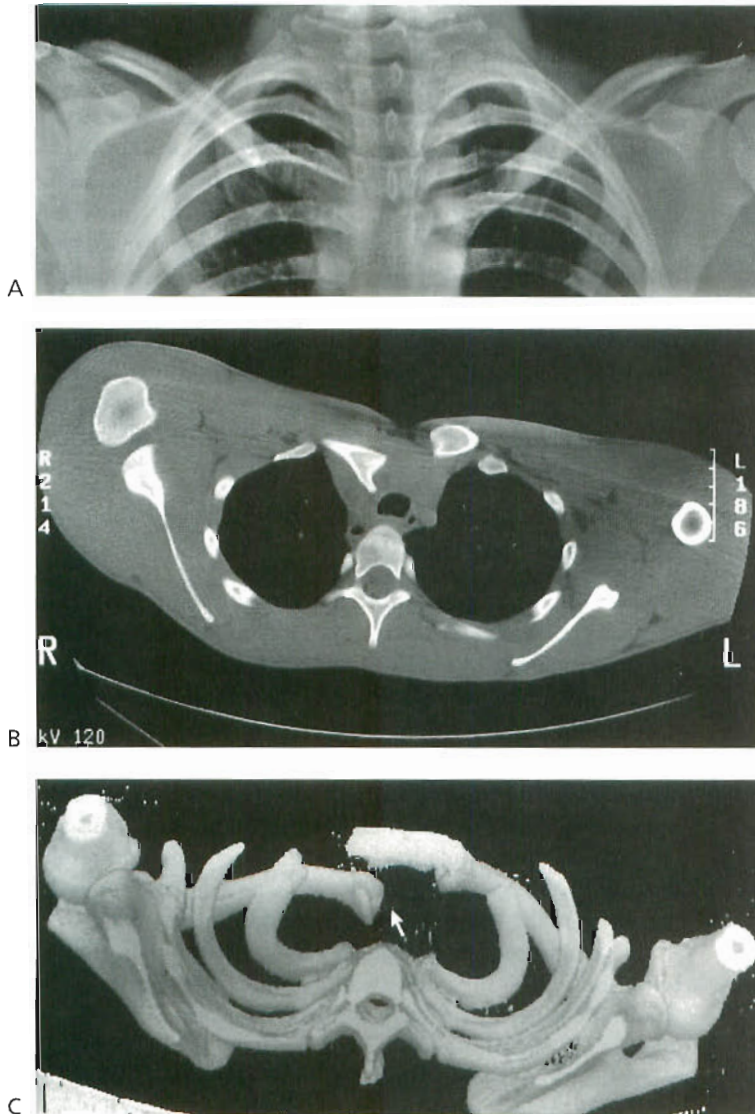


FIGURE 32-10. Sternoclavicular separation. This 14-year-old boy sustained an injury to the right clavicle during a wrestling match when his shoulder was compressed against his chest wall. He complained of shortness of breath, especially when he extended his neck. **A:** The anteroposterior radiograph demonstrates asymmetry of the sternal position of the clavicle. **B:** The computed tomographic scan demonstrates posterior displacement of the medial end of the right clavicle, which is in close proximity to the trachea. **C:** A three-dimensional reconstruction, with a cephalic projection, demonstrates the posterior and midline displacement of the clavicle.

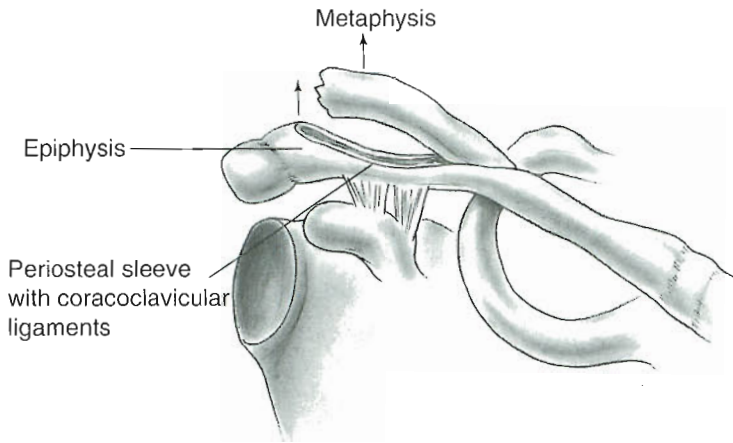


FIGURE 32-11. Lateral clavicle fracture-separation. The swelling and dorsal prominence of the clavicle may suggest an acromioclavicular separation. However, the distal epiphysis of the clavicle and acromioclavicular joint remain reduced. New bone forms from periosteum, with subsequent remodeling of the prominence. (From ref. 90, with permission.)

erative treatment is unnecessary, because fracture remodeling will occur.

Lateral Clavicle Fracture

The mechanism of injury to the distal clavicle is similar to adult acromioclavicular separation. A fall onto the point of the shoulder drives the acromion and scapula distally. This results in distal clavicular physeal separation. The distal epiphysis of the clavicle remains a cartilaginous cap into the mid-20s (88), whereas the acromioclavicular and coracoclavicular ligaments are firmly attached to the thick periosteum of the clavicle. Typically, the lateral metaphysis displaces through the injured dorsal periosteum, leaving the ligaments intact and the epiphyseal end of the clavicle reduced in the acromioclavicular joint (90) (Fig. 32-11). Because these injuries represent physeal disruption with herniation of bone from the periosteal tube, tremendous potential for healing and remodeling exists.

Treatment of most distal clavicle fractures consists of support with a sling or shoulder immobilizer for 3 weeks. Reduction and fixation are unnecessary, except for the rare instance in which the clavicle is severely displaced in an older adolescent (91).

Acromioclavicular Separation

True acromioclavicular separation is very rare before the age of 16 years. Fracture or physeal separation of the distal clavicle is more common, and has been called “pseudodislocation of the acromioclavicular joint” (92). Tenderness over the acromioclavicular joint and prominence of the lateral end of the clavicle are present with fracture, physeal separation, and joint separation. Radiographs demonstrate increased distance between the coracoid process and the clavicle, compared with the opposite side. The MRI can distinguish between these three similar injuries, but it is

rarely necessary, because the treatments are similar. When true joint separation occurs, the injury may be a sprain, subluxation, or dislocation. These have been classified as grades I to III, depending on the severity of injury to the acromioclavicular and coracoclavicular ligaments (93).

Treatment of all grades of separation is usually conservative without attempting reduction. Therefore, it is unnecessary to determine the degree of separation by stress radiography with handheld weights. A sling or shoulder immobilizer is used for 3 weeks followed by a graduated exercise program. Even in competitive athletes, shoulder strength and range of motion are not impaired after rehabilitation (94–97). In complete separations (type III), the clavicle remains prominent, but is usually asymptomatic. The occasional patient who develops late symptoms of pain and stiffness may be relieved by resection of the distal clavicle (95).

Scapular Fracture

Fracture of the scapula, although rare in children, should be suspected whenever there is shoulder tenderness or swelling after trauma. These fractures are usually the result of a severe, direct blow of high energy. Therefore, initial evaluation should include a diligent search for more serious chest injuries, such as rib fractures, pulmonary or cardiac contusion, and injury to the mediastinum. Fractures of the scapula can involve the body, glenoid, or acromion. Avulsion fractures of the scapula have also been reported, and result from indirect trauma (98). The CT is quite helpful for evaluating scapular fractures and associated injuries.

Treatment for most scapular fractures consists of immobilization with a sling and swathe, followed by early shoulder motion after pain has subsided. The scapular body is encased in thick muscles, so displacement is rare and well tolerated after healing (91). Fractures of the acromion or coracoid require surgery only when severely displaced. Gle-

noid fractures are the most likely to require reduction and internal fixation. Intraarticular fractures with more than 3 mm of displacement should be restored to anatomic positions. Large glenoid rim fractures can be associated with traumatic dislocations. An anterior approach is recommended for anterior glenoid fractures, and a posterior approach is used for scapular neck and glenoid fossa fractures (99).

Shoulder Dislocation

Less than 2% of glenohumeral dislocations occur in patients younger than 10 years of age (100). These may be traumatic or atraumatic. Atraumatic shoulder dislocations and chronic shoulder instability are discussed in Chapter 4 of this text. Traumatic shoulder dislocation in the adolescent age group is more common. Approximately 20% of all shoulder dislocations occur in persons between the ages of 10 and 20 years. Most displace anteriorly, and produce a detachment of the anteroinferior capsule from the glenoid neck (i.e., Bankart lesion).

Treatment of traumatic shoulder dislocation in children and adolescents is nonoperative, with gentle closed reduction. This is accomplished by providing adequate pain relief, muscle relaxation, and arm traction that is gravity-assisted in the prone position. An alternative method is the modified Hippocratic method, in which traction is applied to the arm, while countertraction is applied using a folded sheet around the torso. After reduction, a shoulder immobilizer or sling is used for 2 to 3 weeks before initiating shoulder muscle strengthening. The most frequent complication is recurrent dislocation, which has an incidence between 60 and 85%, usually within 2 years of the primary dislocation (101,102). Posterior dislocations of the shoulder may also recur, and require surgical stabilization in children (103).

Proximal Humerus Fractures

Proximal humeral growth accounts for 80% of the length of the humerus. The proximal humeral physis is an undulating structure that forms a tent-like peak in the posteromedial humerus quadrant, near the center of the humeral head. The glenohumeral joint capsule extends to the metaphysis medially. Thus, a portion of the metaphysis is intracapsular. The proximal humeral physis remains open in girls until age 14 to 17 years and in boys until age 16 to 18 years.

Mechanisms of injury that would produce a shoulder dislocation in adults usually result in a proximal humeral fracture in children and adolescents. These are usually Salter-Harris type II epiphyseal separations or metaphyseal fractures. Metaphyseal fractures are more common before the age of 10 years, and epiphyseal separations are more common in adolescents. The distal fragment usually displaces in the anterior direction, because the periosteum is thinner and weaker in this region. Posteriorly, the periosteal

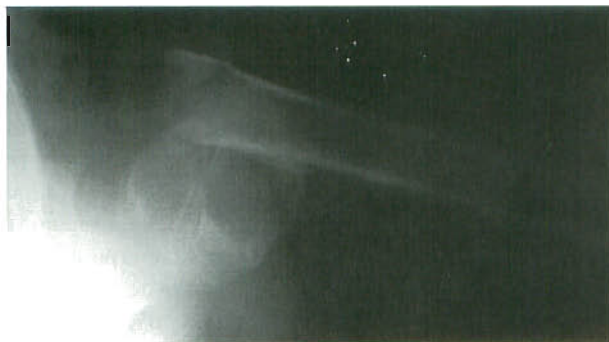sleeve is thicker and remains intact. The proximal fragment is flexed and externally rotated, because of the pull of the rotator cuff, whereas the distal fragment is displaced proximally as a result of the pull of the deltoid muscle. Adduction of the distal fragment is caused by the pectoralis major muscle. The long head of the biceps may be interposed between the fracture fragments, and further impede reduction. Remarkably, this is a relatively benign injury, because of the rapid rate of remodeling with growth and the wide range of shoulder motion (104,105).

The majority of these fractures are minimally displaced or minimally angulated. These are managed in a shoulder immobilizer for 3 to 4 weeks, followed by range of motion exercises and gradually increased activity.

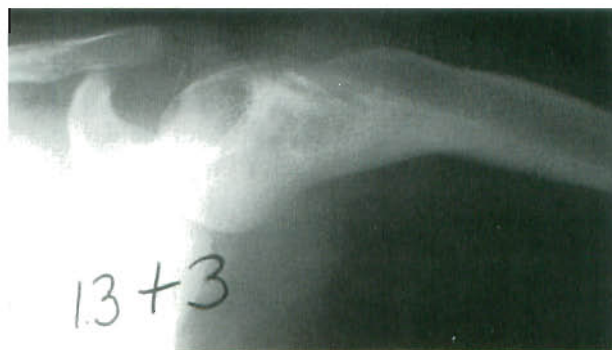Severely displaced fractures pose a greater dilemma for the treating physician. The alarming radiographic appearance invites overtreatment. These fractures are difficult to reduce and almost impossible to maintain in a reduced position by closed methods. Traction and cast immobilization have mostly been abandoned, because these techniques are inconvenient, cumbersome, and have not been shown to improve results. Current options for management include immobilization without attempting reduction and reduction under anesthesia with percutaneous pinning. Authors who have studied these options have concluded that the majority of severely displaced fractures should be treated by sling and swathe immobilization (104–106). Complete displacement, 3 cm overriding, and 60 degrees of angulation may be accepted in all children and adolescents with open physes (Fig. 32-12). Closed or open reduction under anesthesia with percutaneous pinning may be indicated for fractures with deformity greater than this, or in situations in which tenting could lead to skin breakdown, such as open fractures, vascular injuries, and severe displacement (91) (Fig. 32-13).

Humeral Shaft Fracture

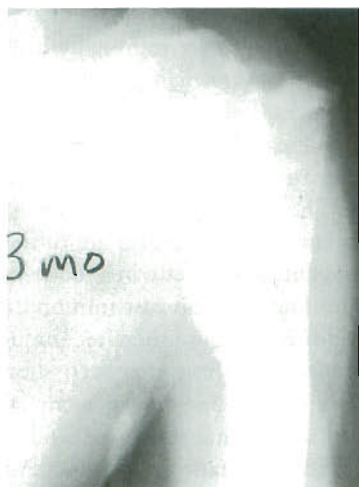
Humeral shaft fractures are less common in children than adults. Birth fractures of the humeral shaft may occur as a result of difficult delivery. Humeral fractures in children younger than 3 years of age are often the result of nonaccidental injury (107). Any time there is a delay in seeking medical attention, inconsistent history of injury, or evidence of concurrent injuries, there is an increased likelihood of inflicted trauma. However, no particular fracture pattern is diagnostic of child abuse. Fractures seen in older children are usually the result of blunt trauma. The radial nerve is susceptible to injury, because it is fixed by the intramuscular septum as it passes lateral to the humerus at the junction of the middle and distal thirds. The prognosis for radial nerve recovery is excellent. Nerve injury with closed fractures of the humerus should be observed for 3 months before considering intervention.



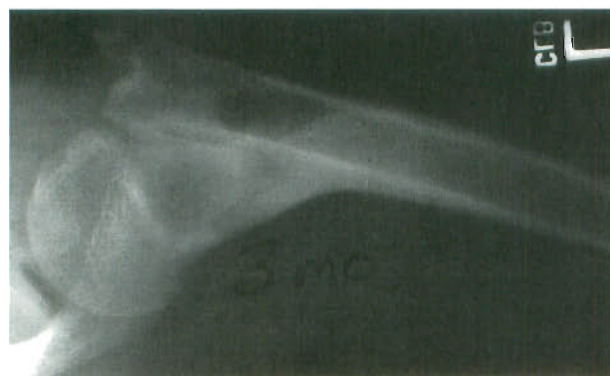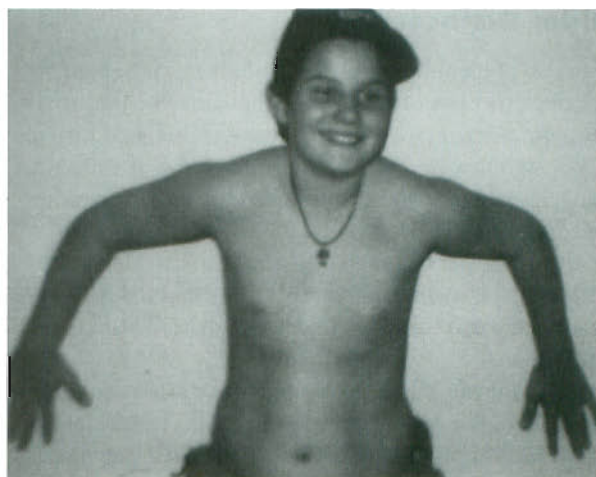A



E



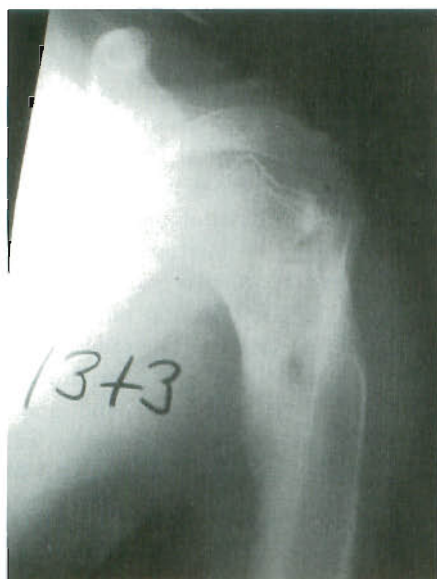B



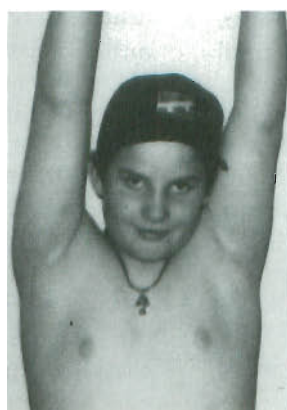C



F



D



G

FIGURE 32-12. Proximal humeral fracture separation in a 12-year, 3-month-old boy. **A:** The initial fracture displacement was treated with sling and swathe. **B and C:** Three months after injury, healing and early remodeling are evident. **D and E:** Twelve months after injury, anteroposterior and lateral radiographs demonstrate continued remodeling. **F and G:** The patient recovered full range of motion with a 2-cm length discrepancy.

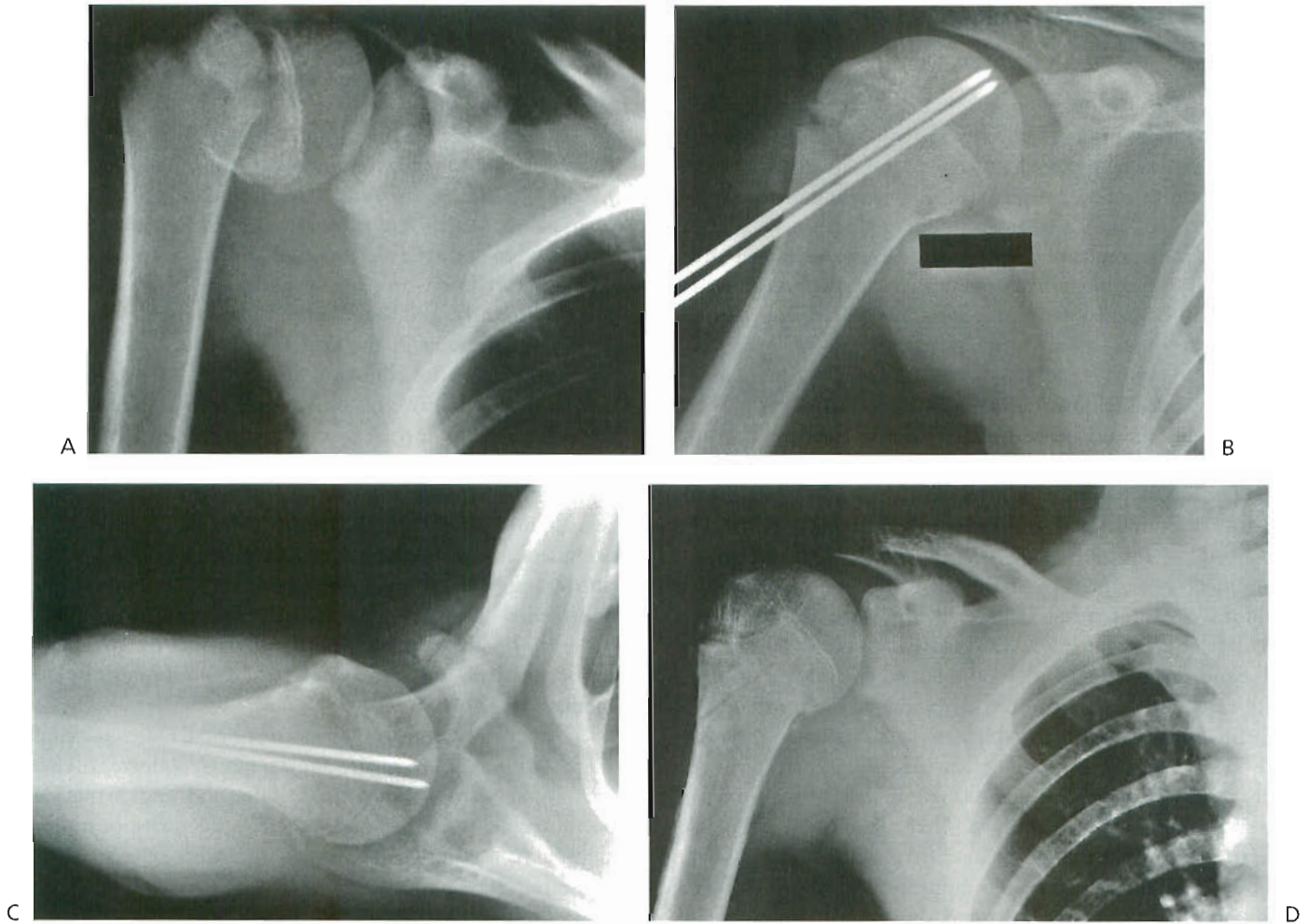


FIGURE 32-13. Salter-Harris type II fracture of the proximal humerus in a 15-year-old adolescent. **A:** Displaced fracture with 70 degrees of angulation. The proximal fragment is abducted and externally rotated, because of the rotator cuff attachments. The shaft is displaced proximally by the pull of the deltoid muscle, and is generally adducted by the action of the pectoralis muscle. The distal fragment is also internally rotated if the arm is placed in a sling. **B and C:** Anteroposterior and lateral radiographs after closed reduction and percutaneous pinning. The arm is externally rotated and abducted with longitudinal traction to achieve this position. **D:** Final alignment after removal of the pins 4 weeks later.

Treatment of humeral shaft fractures consists of closed management. Infants may be treated with gentle positioning, a small coaptation splint, or the arm may be splinted in extension, using a tongue blade and tape. Healing is prompt in infants and young children. It is the authors' opinion that up to 45 degrees of angulation can be accepted before 3 years of age. Older children may be treated with a coaptation splint and a sling to maintain alignment of the arm. A hanging arm cast or collar and cuff may also be used, but a U-slab coaptation splint allows better control of the fracture. Occasionally, an abduction splint or pillow is necessary to control varus alignment. In older children and adolescents, complete displacement and 2 cm of shortening are acceptable. In the proximal shaft, one can accept

25 to 30 degrees of angulation. Fracture deformity closer to the elbow is more visible. Only 20 degrees of angulation is acceptable in the middle third and 15 degrees in the distal third of the humeral shaft (106,108). Greater degrees of deformity are usually unacceptable cosmetically, even though they may remodel without causing functional problems. Operative indications include open fractures, multiple injuries, and ipsilateral forearm fractures in adolescents (i.e., "floating elbow"). Fixation techniques include the use of flexible intramedullary nails [1-1.9], antegrade insertion of a Rush rod, and compression plating. Severe open fractures can be stabilized with an external fixator, until union is complete or until fracture stability and wound healing permit converting to splint immobilization.

FRACTURES AND DISLOCATIONS ABOUT THE ELBOW

It is best to assume the worst when evaluating the child with an elbow injury. Only full range of motion, complete absence of swelling, and normal radiographs warrant the diagnosis of sprain or contusion. Any swelling or restriction of movement necessitates thorough evaluation with comparison radiographs of the opposite elbow, whenever there is doubt regarding normal anatomy. Small fractures that appear to be avulsions should be accurately diagnosed, because they may indicate major pathology. Arthrography, ultrasonography, and MRI have been used to successfully diagnose occult elbow trauma in children (109–111). These techniques should be considered whenever there is doubt regarding the diagnosis.

The elbow region is injured frequently and accounts for 8 to 12% of all fractures in children and adolescents. The majority of injuries occur in the 5- to 10-year age group. Supracondylar fracture of the distal humerus is the most common, representing 75% of all elbow fractures, followed by lateral condylar (17%) and medial epicondylar injuries. T-condylar, medial condyle, and lateral epicondyle fractures are rare, and have a combined incidence of less than 1%. Delineating exact fracture patterns is a challenge in young children, because of the large cartilage composition of the distal humerus; at birth, the distal epiphysis of the humerus is still completely cartilaginous. There are also multiple ossification centers that appear at different ages (Fig. 32-14). The capitellum is the first to appear, at 6 months of age, followed by the radial head and the medial epicondyle at 5 years of age. The trochlea ossifies at 7 years, and the lateral

epicondyle and olecranon appear at 9 and 11 years of age, respectively. The lateral epicondyle, trochlea, and capitellum coalesce to form a single epiphysis by 12 years of age.

The elbow is a complex joint, and has three major articulations: radiohumeral, ulnohumeral, and radioulnar joints. Except for the medial and lateral epicondyles, the other ossification centers are intraarticular. Other intraarticular structures include the olecranon fossa and the coronoid fossa and process. There are two fat pads: one in the olecranon fossa posteriorly, and the other in the coronoid fossa anteriorly. Displacement of the posterior fat pad may be visible on radiographs after elbow trauma. This is a reliable indication of intraarticular effusion. The anterior fat pad is sometimes seen under normal conditions, and does not necessarily indicate joint effusion. Most of the distal humerus has good collateral circulation, with the majority of the intraosseous blood supply entering posteriorly. Caution should be exercised to avoid disrupting this posterior blood supply during surgical exposure of fractures (112). The trochlea and medial condyle are particularly vulnerable to avascular necrosis, because they are perfused by sets of nonanastomotic nutrient vessels that enter the bone posteriorly and medially (113).

The clinical carrying angle of the normal elbow is a slight valgus alignment, averaging approximately 7 degrees. There are several helpful radiographic lines and angles that can be measured to determine if there is adequate postinjury alignment; a comparison view of the other elbow often is needed as a reference (Fig. 32-15). All measurements are subject to the inaccuracies caused by elbow positioning, and this should be kept in mind when making clinical decisions.

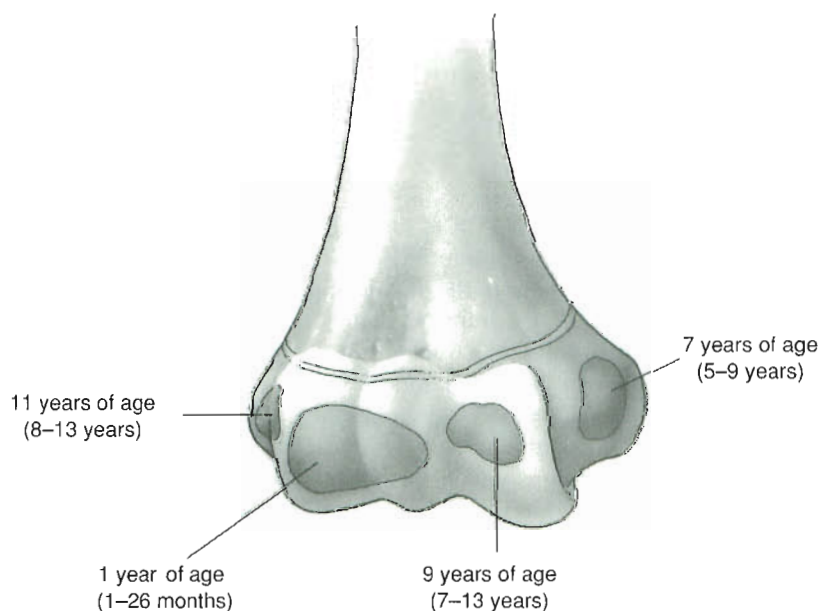


FIGURE 32-14. Ossification of the secondary centers of the distal humerus. The average ages are specified, and the age ranges are indicated. The ossification ranges are earlier for girls than for boys. The lateral epicondyle, capitellum, and trochlea coalesce between 10 and 12 years of age, subsequently fusing to the distal humerus between 13 and 16 years of age. This is about the time that the medial epicondyle fuses to the proximal humerus.

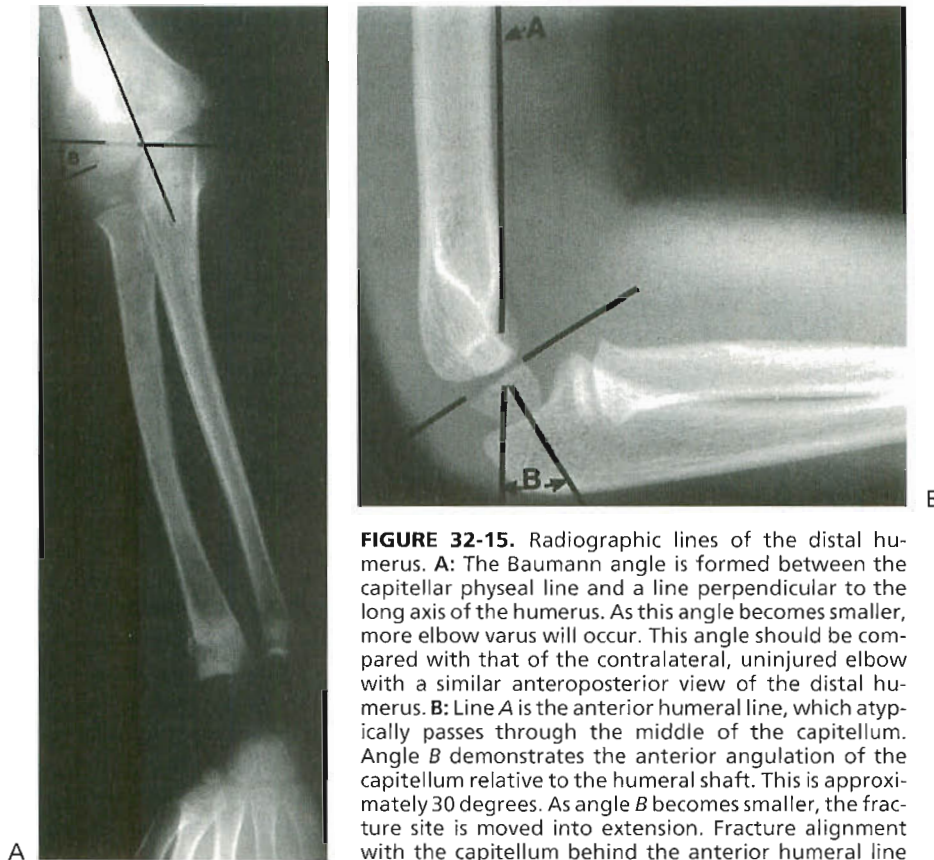


FIGURE 32-15. Radiographic lines of the distal humerus. **A:** The Baumann angle is formed between the capitellar physal line and a line perpendicular to the long axis of the humerus. As this angle becomes smaller, more elbow varus will occur. This angle should be compared with that of the contralateral, uninjured elbow with a similar anteroposterior view of the distal humerus. **B:** Line A is the anterior humeral line, which atypically passes through the middle of the capitellum. Angle B demonstrates the anterior angulation of the capitellum relative to the humeral shaft. This is approximately 30 degrees. As angle B becomes smaller, the fracture site is moved into extension. Fracture alignment with the capitellum behind the anterior humeral line produces a hyperextension deformity and a loss of elbow flexion.

The Baumann angle is used to assess the varus attitude of the distal humerus, usually after a supracondylar elbow fracture. It is the angle formed between the capitellar physal line and a line perpendicular to the long axis of the humerus. This angle normally should be within 5 to 8 degrees of the contralateral elbow. An anteroposterior view of the distal humerus, positioned parallel to the radiographic plate, is necessary to reduce the variation of the Baumann angle that occurs by rotating the arm. Ten degrees of rotation produces a 6-degree change in the angle (114). Another measure of coronal alignment is the medial epicondylar epiphyseal angle. This angle is measured between the long axis of the humerus and a line through the medial epicondylar physis (115). It has the advantage of being reliably measured while the elbow is held in flexion (i.e., Jones view), such as during the reduction process. The medial epicondylar epiphyseal line ranges from 25 to 46 degrees. This angle is not reliable for children younger than 3 years or older than 10 years of age (115). Sagittal alignment may be determined by the lateral capitellar angle, which indicates the normal forward-flexed position of the capitellum. This angle averages 30 to 40 degrees. The anterior humeral line offers a similar means to assess the position of the capitellum, and is measured on a

true lateral radiographic projection. A line along the anterior humeral cortex should pass through the center of the capitellum (Fig. 32-15).

Supracondylar Fracture

This is the most common elbow fracture. The mechanism of injury is an acute hyperextension load on the elbow from falling on the outstretched arm. The distal fragment displaces posteriorly (i.e., extension) in more than 95% of fractures. The medial and lateral columns of the distal humerus are connected by a very thin area of bone between the olecranon fossa posteriorly and the coronoid fossa anteriorly. The central thinning and the surrounding narrow columns predispose this area to fracture. As the elbow is forced into hyperextension, the olecranon impinges in the fossa, serving as the fulcrum for the fracture. The collateral ligaments and the anterior joint capsule also resist hyperextension, transmitting the stress to the distal humerus and initiating the fracture (116) (Fig. 32-16).

The classification system most commonly used is that of Gartland, who described three stages of displacement (117): type I, nondisplaced or minimally displaced; type II, angu-

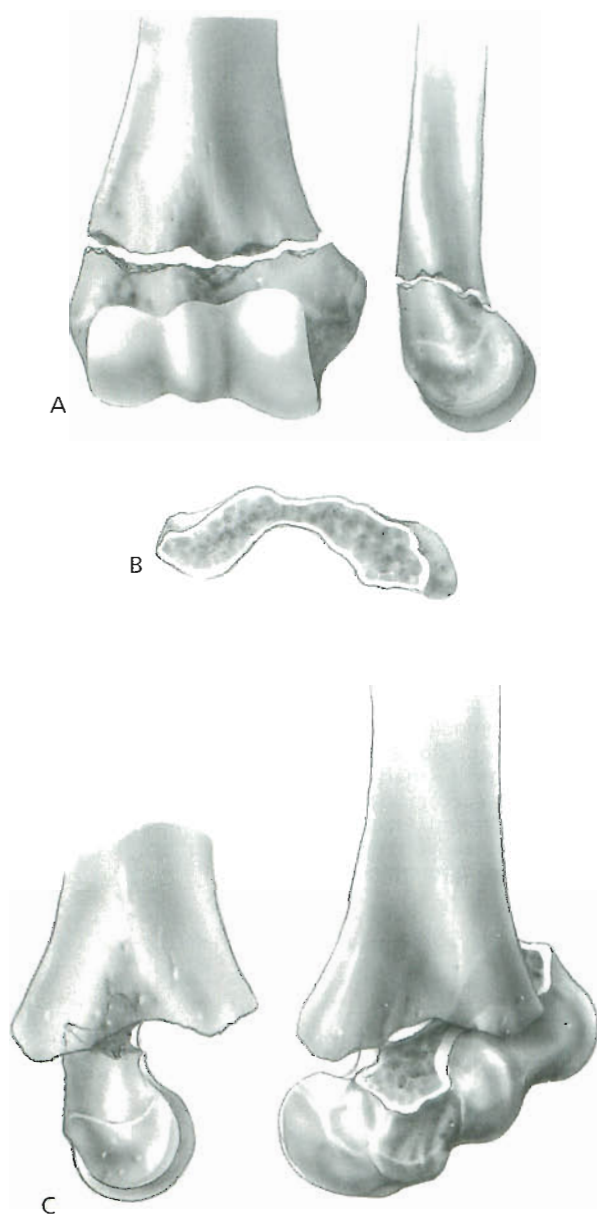


FIGURE 32-16. A: The typical orientation of the fracture line in the supracondylar fracture. Sagittal rotation of the distal fragment generally results in posterior angulation, although, less commonly, it can be flexed. B: The cross-sectional area through the fracture demonstrates the thin cross-sectional area of the supracondylar region. C: Any horizontal rotation tilts the distal fragment. Typically, medial tilting occurs, producing cubitus varus. The lateral projection readily demonstrates this horizontal rotation, producing a fishtail deformity. In this instance, the distal portion of the proximal fragment is obliquely profiled, although there is a true lateral view of the distal humeral fragment.

lated with moderate disruption, but with a portion of the cortex maintaining end-to-end contact; and type III, completely displaced. Supracondylar fractures with medial impaction may appear to be nondisplaced, but may result in

cubitus varus attributable to unacceptable angulation (118) (Fig. 32-17). After complete fracture, a small amount of rotational malalignment allows tilting of the fragments, because of the thin cross-sectional area in the supracondylar region. This may also lead to malunion with cubitus varus or, less commonly, cubitus valgus.

Associated injuries include nerve injuries, vascular injuries, and other fractures of the upper extremity, including the ipsilateral forearm. The incidence of nerve injury is approximately 15%; most often, nerve injury is a neuropraxia that resolves spontaneously within 4 months. The nerve injured is related to the position of the displaced fragment (119). Median nerve injuries, including injury to the anterior interosseous nerve, are more common with posteromedial displacement of the distal fragment. Radial nerve injuries are seen more often with posterolateral displacement.

Treatment

Nondisplaced or minimally displaced fractures may be treated with an above-elbow cast for 3 weeks. Any medial buckling or impaction of the medial metaphysis may indicate a fracture that requires reduction. This fracture is a diagnostic trap, because the collapse of the medial wall may be very subtle. The Baumann angle, or the medial epicondylar epiphyseal angle, should be carefully measured bilaterally. Greater than 10 degrees of varus impaction warrants closed reduction and percutaneous pinning. It is difficult to maintain the reduction by cast immobilization alone, and residual deformity will not remodel (118,120).

Type II supracondylar fractures are usually extension injuries, with an intact or nondisplaced posterior cortex. Type II fractures, in which the capitellum is posterior to the anterior humeral line, have an unacceptable amount of extension. Many of these are stable after closed reduction. However, elbow flexion to 120 degrees is often required to hold the reduction (121). This degree of flexion, in the presence of excessive swelling, can result in decreased vascular perfusion to the forearm. This may prevent positioning with adequate flexion to maintain reduction. In such cases, percutaneous pinning is recommended to avoid extreme flexion with possible vascular embarrassment. Follow-up radiographs are made at weekly intervals until there is sufficient healing, usually 3 to 4 weeks.

Type III supracondylar fractures are completely displaced. Treatment begins with a diligent examination for ischemia and nerve palsies. Neurovascular problems are frequent, and management may be altered, if compromise occurred as a result of injury or as a result of treatment. Primary closed reduction and percutaneous pinning is the preferred treatment for type III injuries (122–124) (Fig. 32-18; see also Fig. 32-42) [↗1.10]. Displaced fractures treated with closed reduction and casting have a higher incidence of residual deformity, usually cubitus varus, than those treated with closed or open reduction and percutane-

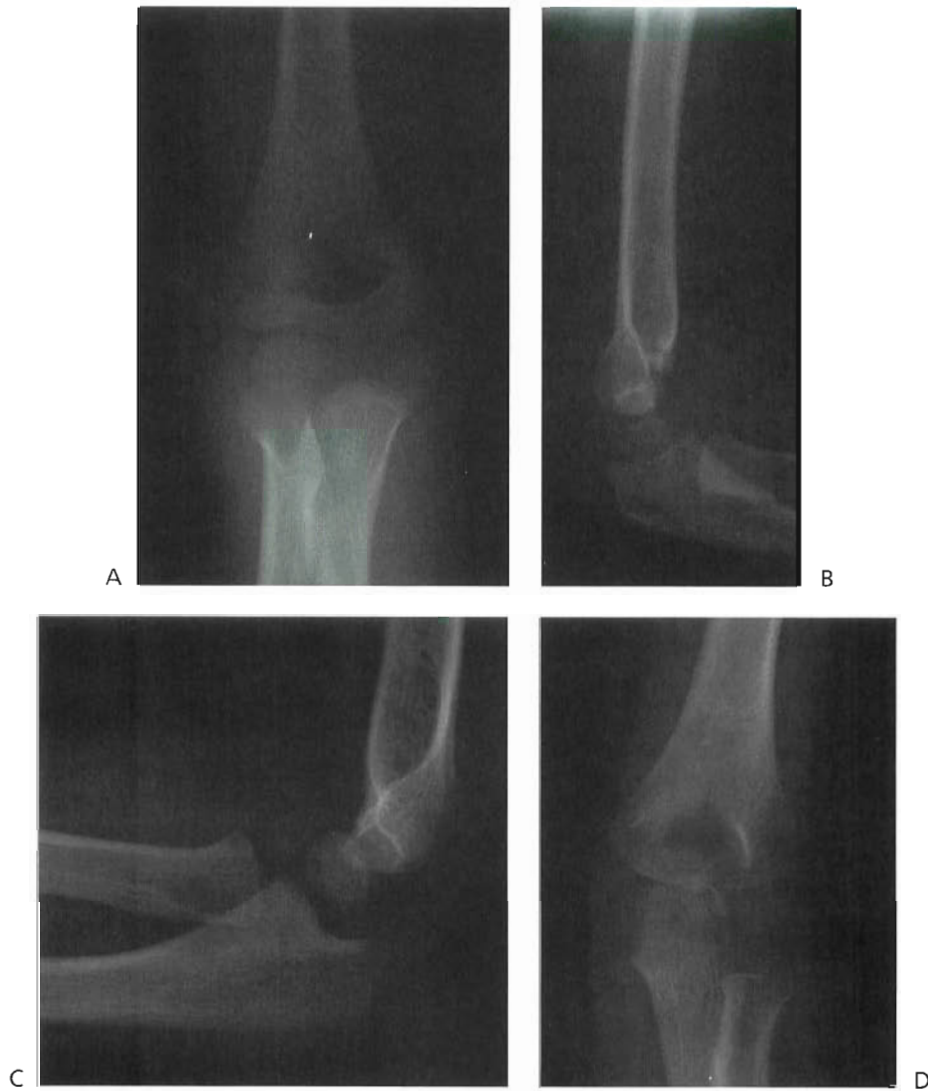

FIGURE 32-17. Impacted type II supracondylar fracture. **A** and **B**: Anteroposterior and lateral projections show medial impaction with hyperextension of the fracture. **C**: The Baumann angle measures 6 degrees. **D**: Comparison radiograph of the opposite elbow demonstrates a Baumann angle of 25 degrees, indicating a 19-degree varus deformity of the fractured humerus.

ous pinning (123–126). Closed reduction and casting also has a higher risk of Volkmann ischemic contracture than treatment with early pinning (124). This is probably because elbow flexion of more than 90 degrees is often required to maintain reduction without pinning, whereas elbow flexion is not required to maintain reduction when the fracture has been pinned.

Skin or skeletal traction has been used in the management of supracondylar fractures. However, this technique requires longer hospitalization, and may not provide any advantage over immediate reduction (127). The idea that the arm is too swollen for reduction is not valid, because the appropriate bony landmarks are usually palpable. After closed reduction and pinning, the edema lessens.

The technique for closed reduction involves extension of the elbow to 15 to 30 degrees, followed by correction of the medial and lateral translation. Traction is applied, and the elbow is flexed, using digital pressure over the olecranon to bring the distal fragment forward. The elbow is then held in hyperflexion to lock in the position of the distal fragment. If the fracture is medially displaced, the lateral periosteum is torn. For this condition, the forearm is pronated, tightening the reduction against the intact medial periosteum, while helping to maintain closure of the lateral column (128). Pronating the forearm is ineffective in holding some type III fractures, if the periosteal sleeve is completely disrupted. Occasionally, the proximal fragment is in a subcutaneous position, producing the “pucker” sign, and this frac-

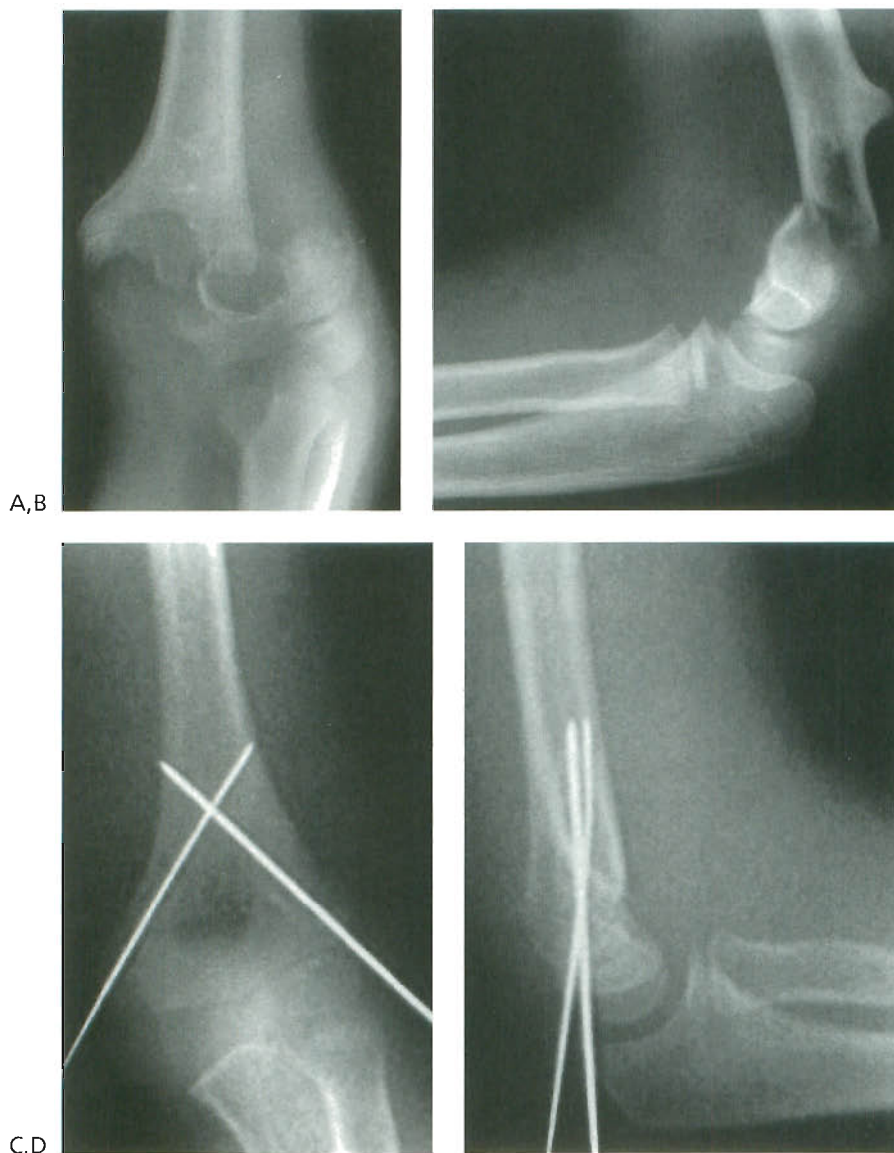

FIGURE 32-18. Type III supracondylar elbow fracture. **A:** This type III fracture demonstrates lateral displacement. **B:** The lateral projection also shows flexion of the distal fragment. The treatment of this less common position is the same as that for extension fractures. The posterior periosteum is torn, and hyperflexion of the elbow will excessively forward-flex the distal fragment. The elbow is best pinned at slightly less than 90 degrees of flexion, because it is technically difficult to pin the elbow in extension. **C** and **D:** Anteroposterior and lateral postreduction and pinning films.

ture is unreducible unless the muscles can be manipulated back over the end of the bone. The elbow must be flexed while this is attempted.

After reduction, and with the elbow in maximal flexion, anteroposterior radiographic images are obtained with the arm slightly internally and externally rotated to evaluate the quality of the reduction. The shoulder can be gently externally rotated to yield a true lateral view of the elbow. Percutaneous pinning is performed once reduction has been achieved. Pins should be of adequate diameter to control the fracture. The author prefers 2.5-mm diameter pins, except for in very small children, in whom 1.5-mm diameter pins are used. *In vitro* biomechanical studies have concluded that crossed-pin fixation is more stable than lateral pin configurations (129). However, clinical experience has demonstrated that two laterally placed pins, supplemented with

plaster immobilization, are often sufficient for stabilization (130,131). When a medial pin is used, one should be aware that extreme flexion can sublux the ulnar nerve from its groove and increase the risk of damage during pinning. When possible, it is advisable to place the medial pin with the elbow in less than full flexion, so that the ulnar nerve is farther posterior. It is also advisable to make a small incision over the medial epicondyle and dissect with a hemostat, so that the medial pin can be placed directly on bone. Confirmation of satisfactory alignment after pinning is documented with anteroposterior and lateral radiographs of the distal humerus. Anatomic alignment is preferred, but this may be difficult to achieve in some cases. The Baumann angle should be within 10 degrees of the opposite side. It is the author's opinion that one may accept up to one-third translation of the distal fragment, 30 to 45 degrees of

malrotation, and 20 degrees of extension after pinning, as long as fixation is secure. Follow-up radiographs of the distal humerus are obtained 7 to 10 days after reduction, to confirm acceptable alignment. Immobilization is maintained for 3 to 5 weeks, after which the pins are removed and active range of motion exercises are instituted.

The rare irreducible fracture can be managed with open reduction through a medial approach, adding a lateral incision, if necessary [1.11]. An anterior surgical interval (i.e., S-curved incision over the antecubital fossa) can also be used, and is recommended if the neurovascular structures need to be exposed. The posterior approach should be used cautiously, because it disrupts any remaining intact soft tissue, and may disrupt the primary vascular supply to the distal humeral fragment (11).

Complications

In the event of a pulseless extremity, prompt reduction of the supracondylar fracture usually restores arterial flow (132,133) (Fig. 32-19). Complete vascular disruption is uncommon, because the thick local muscle envelope protects the artery. Vascular evaluation after reduction requires differentiation of the pulseless, but pink and viable, extremity from one that is cold and pale with vascular insufficiency. The child who has a well-perfused hand, but an absent radial pulse after satisfactory closed reduction, does not necessarily require routine exploration of the brachial artery (119,122,132,134). The pulse usually returns within 48 h, indicating resolution of arterial spasm. The absence of a Doppler-detected pulse at the wrist is not an absolute indication for arterial exploration. The collateral circulation is vast and often provides enough distal perfusion, despite brachial artery occlusion. The hand may be warm and normal-colored, with brisk capillary refill and 100% oxygen saturation. There is no clear evidence of a clinical problem with cold intolerance or exercise-induced muscle fatigue for the hand

surviving on collateral vascularity, but long-term studies addressing the problem are lacking (134).

For persistent true vascular insufficiency (e.g., avascular, cold, pale hand), especially if there is nerve palsy or inadequate reduction, anterior open reduction is recommended. Frequently, the neurovascular bundle is found kinked at the fracture site, and liberation of the artery restores the pulse. There may also be evidence of brachial artery injury. Vascular reconstruction should be performed if the vessel does not respond to local measures (e.g., release of tether, adventitia stripping, lidocaine, papaverine) and the hand remains avascular. The fracture should be stabilized before vascular repair. After reconstruction, there is a significant rate of asymptomatic reocclusion and residual stenosis, even though the hand remains well perfused (134).

Nerve injury associated with supracondylar fracture rarely requires exploration (Fig. 32-20). Patients with preoperative nerve injury should undergo reduction and fixation as described. Exploration of the nerve is not necessary when the reduction is anatomic. However, failure to obtain anatomical reduction may indicate that the nerve is interposed at the fracture site, and exploration may be indicated.

Postoperative neurologic deficit that was not present preoperatively may represent a preexisting nerve deficit that was undetected at the time of the initial examination, or an iatrogenic injury sustained during reduction. Median and radial nerve injuries are more frequently seen as a result of the initial trauma, and may be observed when the reduction is anatomic. Postoperative ulnar nerve deficits are more often iatrogenic, and result from placement of the medial pin (119,130,135). Recommendations for management of this complication vary from observation to exploration. It is the author's opinion that the medial pin should be removed and the patient should be observed without early exploration of the ulnar nerve. Spontaneous recovery is expected within 2 to 6 months.

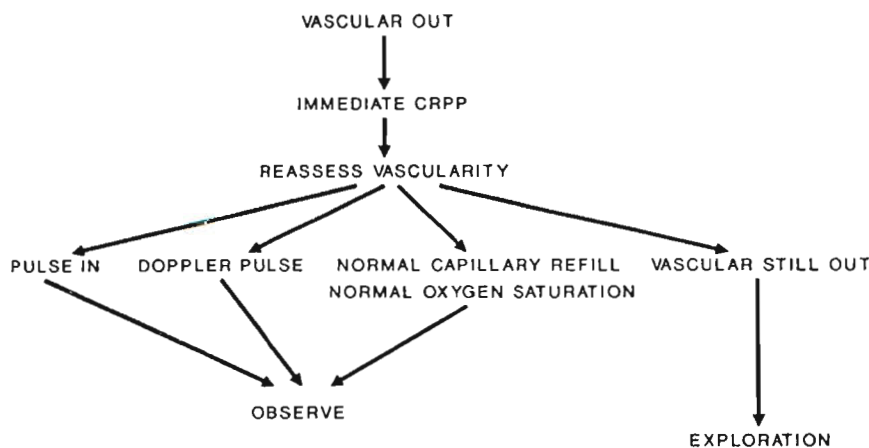


FIGURE 32-19. Vascular compromise flow sheet. CRPP, closed reduction percutaneous pinning. (From ref. 119, with permission.)

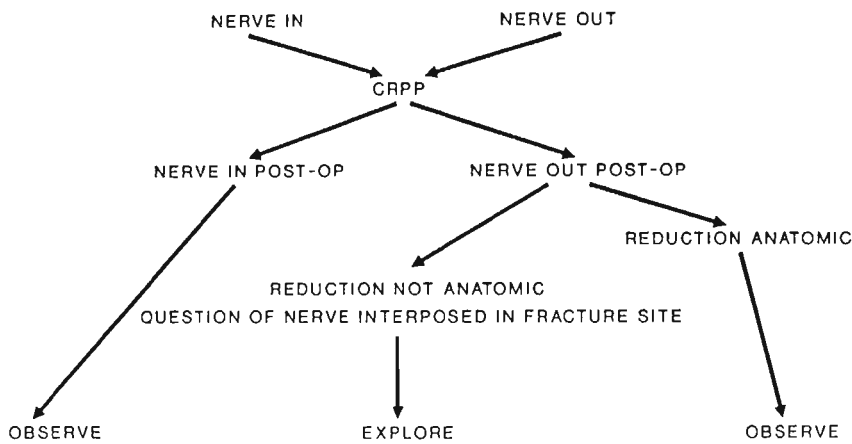


FIGURE 32-20. Nerve compromise flow sheet. CRPP, closed reduction percutaneous pinning. (From ref. 119, with permission.)

Cubitus varus is the most common late complication of supracondylar fracture. This deformity represents fracture malunion and rarely results from partial growth arrest of the medial condylar growth plate (120). Malunion may be avoided by careful attention to the Baumann angle at the time of initial management. Cubitus varus is principally a cosmetic deformity, but increased risk of subsequent lateral condyle fracture and tardy ulnar palsy have also been reported (136,137). Osteotomy to correct deformity may be performed at any age, but complications are not uncommon (138). Full-length radiographs of both arms are recommended preoperatively for accurate planning. Torsional deformity does not require correction. Simple uniplanar closing-wedge osteotomies have the lowest complication rates (139).

T-condylar Fracture

The T-condylar fracture is a variation of the supracondylar fracture. The mechanism of injury is axial impaction with resultant intraarticular fracture. This injury occurs predominantly in adolescents, around the time of physeal closure, but it can also occur in younger children. The capitellum and trochlea usually are separated from each other, and the two are separated from the proximal humerus.

Treatment of displaced fractures usually requires open reduction, with the primary goal of anatomic alignment of the articular surface. A posterior approach is recommended, by splitting the triceps, reflecting a distally based tongue of triceps, or olecranon osteotomy. Re and colleagues (140) observed that the olecranon osteotomy approach resulted in better recovery of extension than the triceps-splitting approach. Extensive dissection of the fragments should be avoided to minimize the risk of avascular necrosis of the trochlea. Transverse fixation of the trochlea to the capitellum is performed first, and this unit is secured to the distal humerus with sufficiently strong crossed pins or cancellous screws. Alternatively, 2.5-mm reconstruction plates are ap-

plied to the medial and lateral columns of the distal humerus. Internal fixation should be stable, to allow early motion and preferably continuous passive motion during the early postoperative period (140,141).

Lateral Condyle Fracture

Fracture of the lateral condyle is the second most common elbow fracture in children. This injury is usually the result of a varus force on the supinated forearm, in which the extensor longus and brevis muscles avulse the condylar fragment. The peak age range for this injury is 5 to 10 years, but it is often seen in older or younger children.

This is a complex fracture, because it involves the physis and the articular surface. It is a Salter-Harris type IV injury in the majority of cases, but growth disturbance is rarely seen, because the distal humerus contributes little to the longitudinal growth of the humerus. A significant portion of the fragment is unossified, especially in children younger than 5 years of age. The injury is identified by a thin lateral metaphyseal rim of bone, but the fracture line continues across the physis and into the elbow joint, through unossified cartilage. An internal oblique radiograph of the distal humerus usually provides the best view of this fracture.

The fracture line may take several paths through the unossified cartilage of the distal humerus. Milch suggested two fracture types: the first exits lateral to the capitellar-trochlear groove (Fig. 32-21), and the second exits medial to this groove, with resultant elbow instability (Fig. 32-22). The Milch classification system has been shown to have poor correlation between preoperative radiographs and intraoperative findings (142). However, it is important to have an understanding of the possible fracture configurations before initiating treatment. The fracture may stop before passing completely through the cartilaginous epiphysis. This leaves an intact hinge with inherent stability. The fracture line may pass completely through the cartilaginous epiphysis, including the articular surface, and exit into the elbow joint

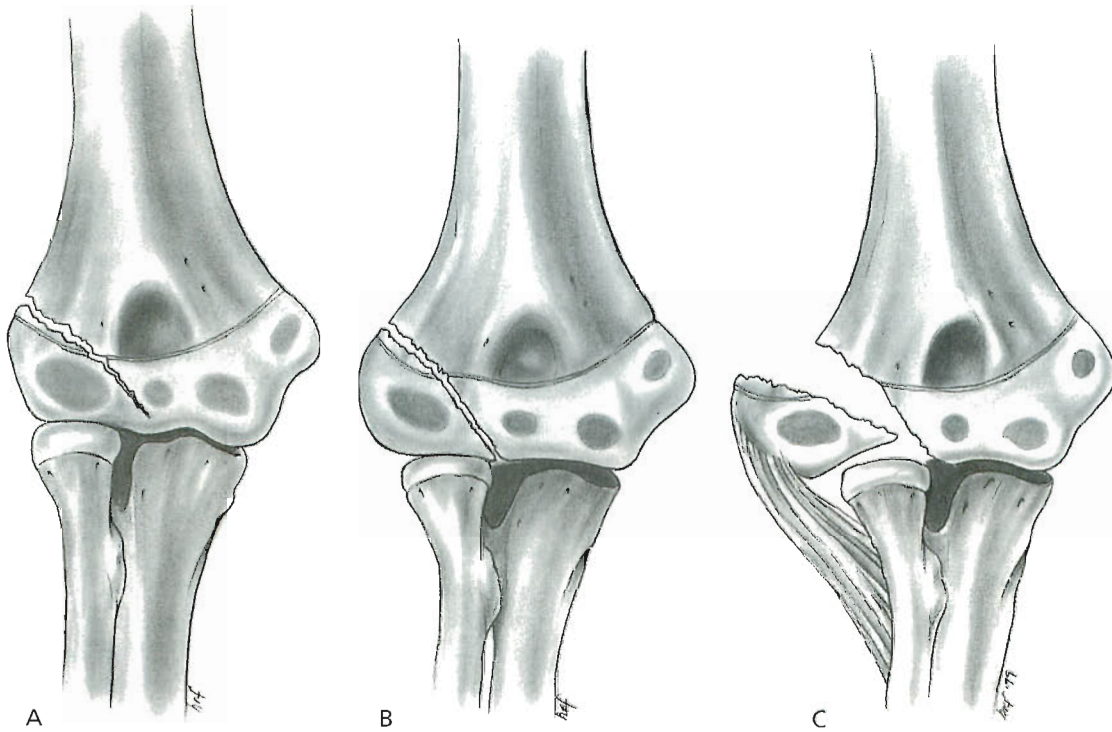


FIGURE 32-21. Milch type I lateral condyle fracture. **A:** The fracture line may stop before passing completely through the cartilaginous epiphysis. **B:** The fracture may pass completely through the articular cartilage lateral to the capitellar trochlear groove. **C:** Displaced Milch type I fracture requires reduction, but does not lead to ulnar instability.

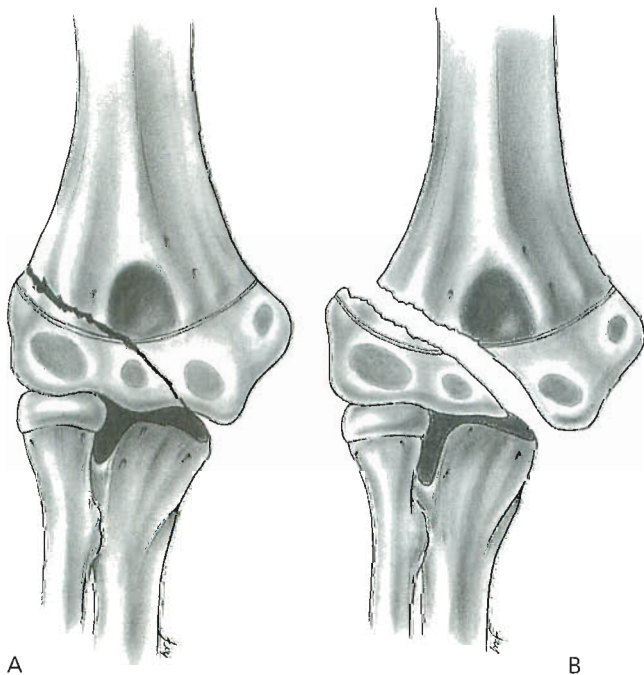


FIGURE 32-22. Milch type II lateral condyle fracture. **A:** The fracture line passes medial to the capitellar trochlear groove. **B:** Displacement leads to lateral displacement of the ulna.

lateral or medial to the trochlear groove, as described by Milch. When the fracture exits into or medial to the trochlear groove, the ulna may displace laterally with the radius and lateral condylar fragment. In young children, this may be confused with fracture-separation of the entire distal humeral epiphysis. Determining the exact location and extent of the fracture line is difficult by plain radiography. Arthrography may be helpful intraoperatively, to define the fracture (Fig. 32-23).

Treatment depends on the degree of displacement and the assessment of fragment stability, rather than the exact classification. Fractures displaced 2 mm or less without obvious rotational deformity can be treated with cast immobilization (143,144) (Fig. 32-24). Follow-up radiographs should be obtained 7 to 10 days later, to detect any additional displacement of the fragment. It is often necessary to remove the cast to obtain adequate anteroposterior and lateral radiographs of the distal humerus. The internal rotation, oblique view is also helpful to determine fracture alignment. Gentle cast removal and radiography will not cause displacement if the fracture is incomplete and inherently stable. Radiographs out of the cast will allow detection of instability that has progressed in spite of immobilization. Healing for minimally displaced fractures is complete when bridging callus is identified, usually by the fourth week of immobilization.

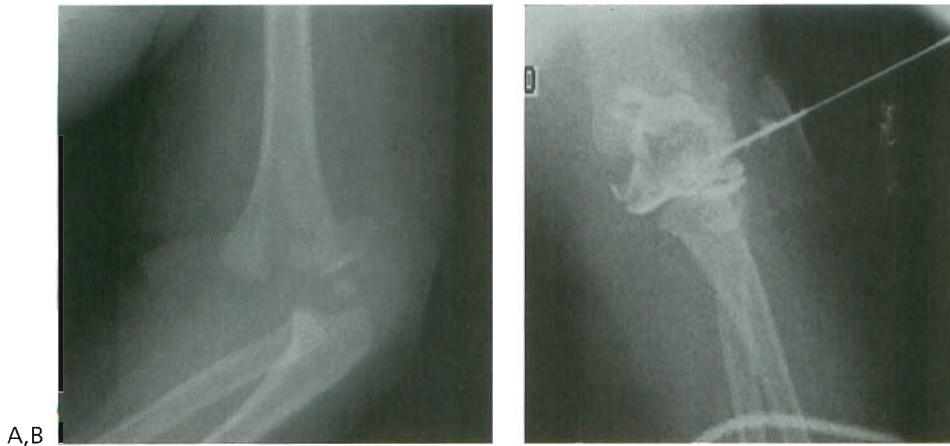


FIGURE 32-23. Fracture separation of the distal humeral epiphysis in a young child may include a small metaphyseal fragment. This can be easily confused with a Milch type II fracture-dislocation of the lateral condyle, when the distal fragment displaces laterally. **A:** A 14-month-old child with apparent lateral condyle fracture-dislocation. **B:** Arthrogram confirms complete distal humeral separation (Salter-Harris type II) with intact joint.

Operative intervention with pin fixation is indicated when displacement is 3 mm or greater. Some good results have been reported when greater degrees of displacement have been treated nonoperatively (145,146). However, non-union, delayed union, and further displacement are more frequent complications of fractures displaced 3 mm or more. Closed reduction and percutaneous fixation have been re-

ported for fractures separated 3 to 4 mm (147). An arthrogram may provide confirmation of joint surface congruity. However, many of these fractures display rotation of the condylar fragment, which is difficult to correct accurately by closed reduction. Primary open reduction, with restoration of articular congruity, is preferred in the majority of cases requiring surgery (Fig. 32-25). In severe cases, the

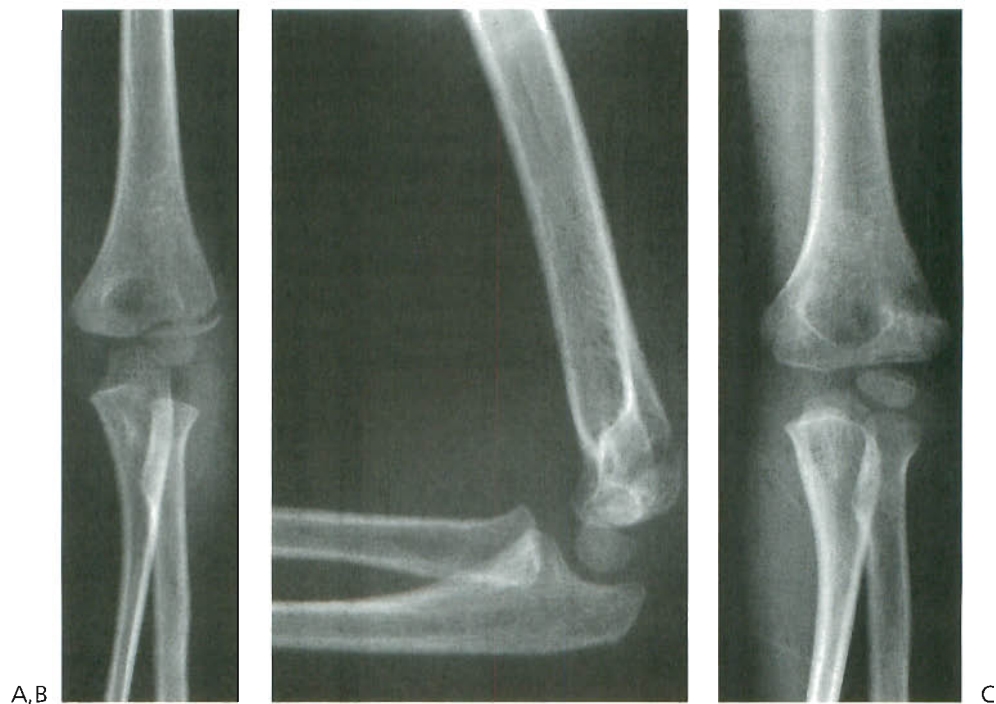


FIGURE 32-24. Lateral condyle fracture. **A:** The anteroposterior projection shows a 3-mm gap. The fracture is wider radially than it is medially, probably representing a stage II fracture, although the articular cartilage could be intact. The stability of this fragment is not easily determined radiographically, and must be closely followed for displacement. **B:** Lateral projection demonstrates minimal sagittal rotation of the lateral condylar fragment. **C:** Six weeks later, there is complete fracture healing after closed treatment in an above-elbow cast.

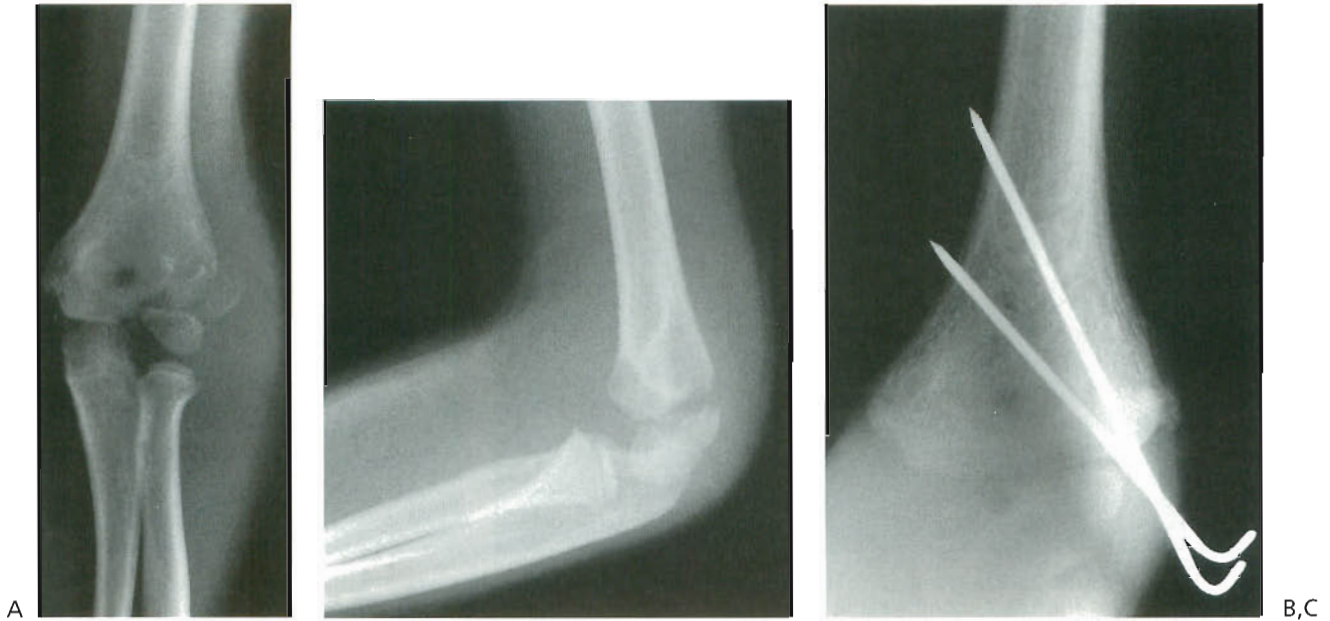


FIGURE 32-25. Lateral condylar fracture. A: The anteroposterior projection shows more than 3 mm of separation, with significant rotation of the condylar fragment. B: The lateral projection shows some sagittal rotation of the fragments. C: Treatment consisted of open reduction and fixation, with Kirschner wires crossing in the condylar fragment for greater stability.

condylar fragment may be rotated 180 degrees (Fig. 32-26). A standard lateral approach is used, but excessive soft tissue stripping posteriorly should be avoided, to reduce the risk of avascular necrosis of the capitellum and trochlea. Stabili-

zation is achieved with two smooth pins crossing the fracture site and exiting the opposite cortex. These pins will traverse the physis, but growth disturbance is rarely a concern.

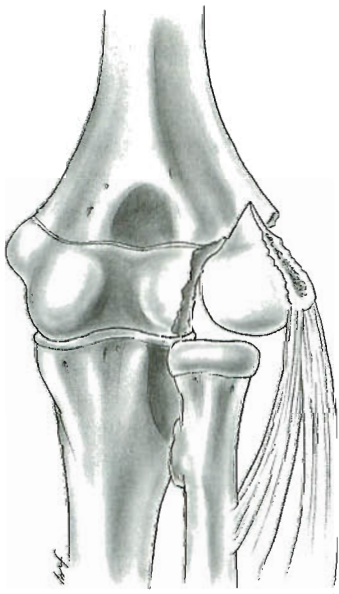

FIGURE 32-26. Lateral condyle fracture may rotate laterally 180 degrees. Reduction requires medial rotation of the displaced fragment.

Complications

Management of the late-presenting lateral condyle malunion is an area of controversy. Displacement greater than 4 to 5 mm can be anatomically reduced and pinned, with good results, for as long as 6 weeks after the injury (148,149). After this time, the ability to reduce the fragment precisely is lessened, because of remodeling of the fracture surfaces and soft tissue contracture. Excessive stripping of the condyle to facilitate reduction may result in avascular necrosis and greater joint stiffness. Two surgical approaches are described in the literature for management of symptomatic patients with malunion. Supracondylar osteotomy, combined with ulnar nerve transposition, has been performed with satisfactory improvement in function (143). Intraarticular osteotomies, with partial reduction, have also achieved satisfactory results in some patients (149).

Nonunion after lateral condyle fracture is seen most often in untreated patients. Long-term sequelae include ulnar neuritis, progressive valgus deformity, and elbow instability with decreased strength. In established nonunions, the lateral condyle fragment should be pinned in a position that preserves the best functional range of motion, realizing that anatomic restoration is not possible. Bone grafting is neces-

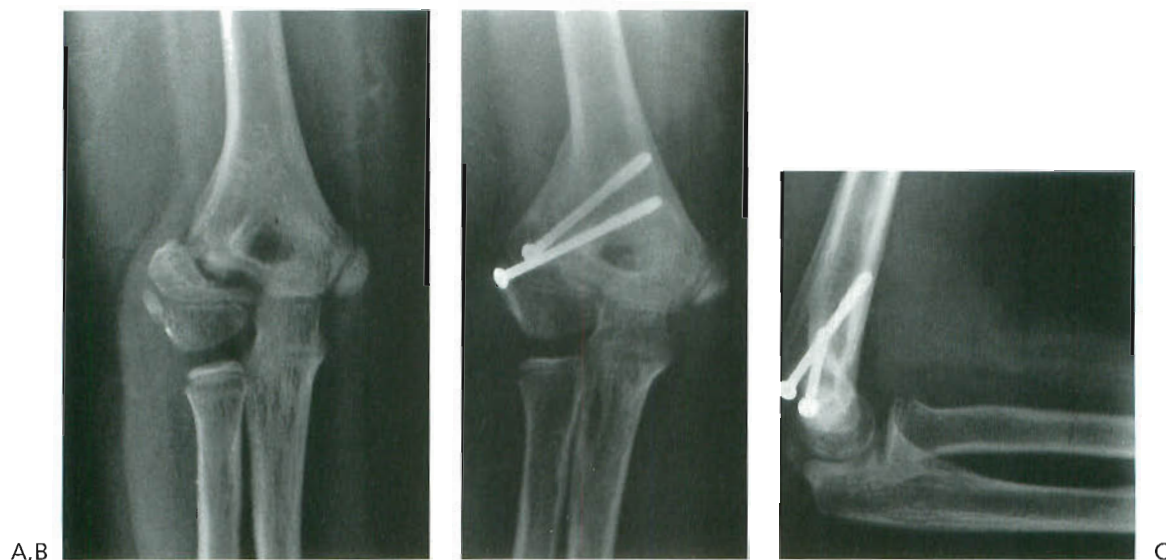

FIGURE 32-27. Nonunion of the lateral condyle. **A:** Anteroposterior view of a child who sustained this fracture 4 months earlier. Symptoms consisted of pain and decreased range of motion. **B:** Anteroposterior projection after stabilization of the condylar fragment with bone screws and bone grafting of the nonunion. **C:** Lateral projection.

sary to achieve union (149–151) (Fig. 32-27). Any residual valgus deformity can be corrected with a supracondylar osteotomy. Ulnar nerve transposition may be needed, especially if there are preoperative symptoms.

Lateral Epicondyle Fracture

Lateral epicondyle fracture is a rare elbow injury that does not involve the articular surface. This ossification center does not appear until the second decade. This injury is often misdiagnosed as an avulsion fracture of the lateral condyle. Treatment is usually immobilization followed by early motion, when comfortable. Displacement greater than 5 mm may lead to joint stiffness. If this occurs, early excision of the displaced epicondyle should be considered.

Medial Epicondyle Fracture

The medial epicondylar apophysis is fractured when a valgus load is applied to the extended elbow. The displacement is encouraged by the pull of the forearm flexor wad, which is attached in this region. The medial collateral ligament also originates from this apophysis, and may play a role in the initial fracture displacement, especially when there is an initial elbow dislocation. This injury typically occurs in children between the ages of 9 and 14 years, later than the peak age for most other elbow fractures. Almost 50% of these fractures occur concomitantly with posterolateral elbow dislocation, and the medial epicondyle may be trapped in the joint after reduction. When this occurs, the ulnar nerve

may also be in the joint, and vigorous attempts at closed manipulation should be avoided.

Treatment

There is general agreement that operative intervention is indicated when the epicondyle is trapped in the joint. Otherwise, management is controversial. There are advocates for the closed treatment of this injury, regardless of the magnitude of displacement (152,153). Nonunion is a frequent result of closed management; however, many patients with nonunion are asymptomatic, and those who are symptomatic can be treated with excision of the fragment. Valgus instability to stress testing has been suggested as an indication for operative stabilization (154). However, the majority of medial epicondyle avulsion injuries will demonstrate instability when stressed acutely, so most patients will require surgery if this test is used. The magnitude of displacement probably provides the best indicator for management. Fractures with less than 5 mm displacement have a lower risk of nonunion and subsequent intervention than fractures with more than 5 mm displacement. Excellent results have been reported after operative stabilization of displaced fractures (155,156). Therefore, the authors recommend consideration of open reduction and fixation for medial epicondyle fractures when displacement is greater than 5 mm (Fig. 32-28) [1.14]. Surgical intervention should be considered in highly competitive gymnasts or throwing athletes with lesser degrees of displacement. The goal is to restore the integrity of the medial collateral ligament, and to retension the forearm flexors for optimal elbow function (154).

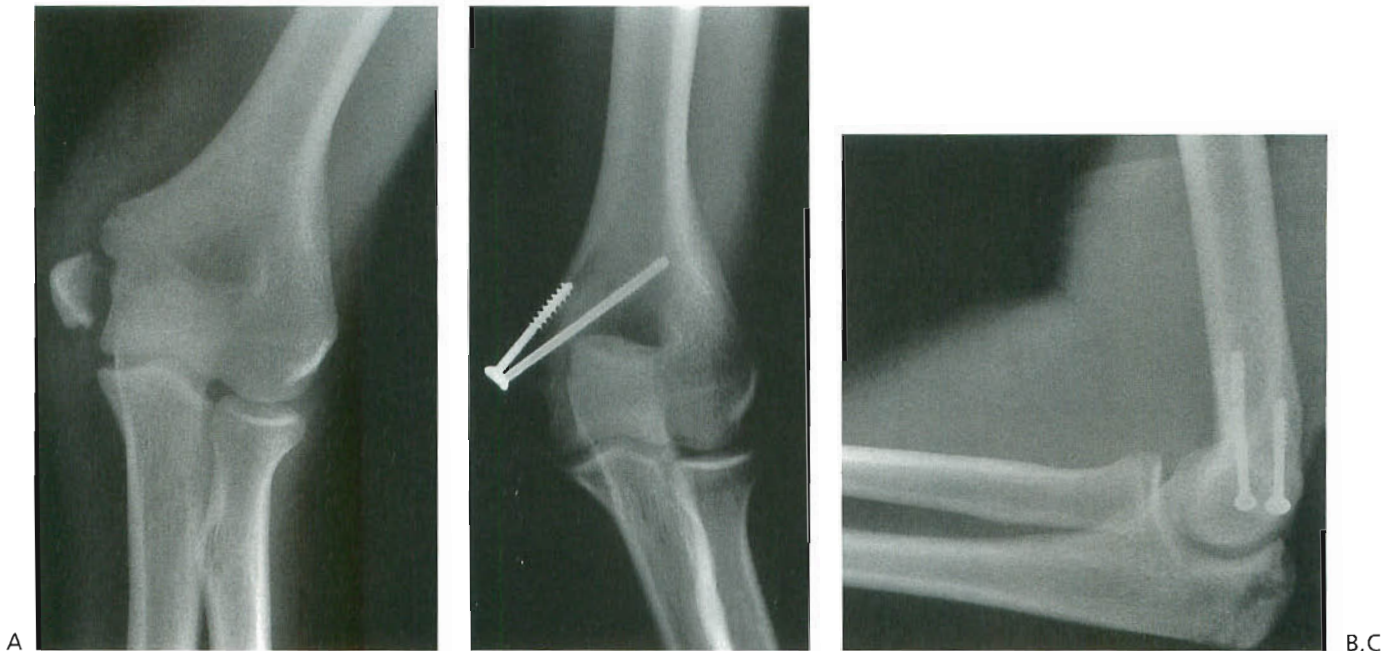


FIGURE 32-28. A: Displaced medial epicondyle fracture in an adolescent. It is difficult to quantify the amount of displacement based on the anteroposterior projection because the fragment has also moved anteriorly. It also may be malrotated. B: Treatment with bone screws and early motion. C: Lateral projection. A single screw is sufficient, if it is placed in a posterior-to-anterior direction, capturing the anterior cortex of the distal humerus.

In adolescents, fragment fixation can be accomplished with a cannulated bone screw. It is important to understand that the fragment tends to rotate forward from its postero-medial origin, and fixation should be directed from a posterior position to engage the anterior humeral cortex. Stable fixation allows early postoperative range of motion exercises, as soon as the patient is comfortable. Preadolescents may require fixation with smooth Kirschner wires and cast immobilization for 3 weeks, to minimize the risk of growth arrest of the apophysis.

Medial Condyle Fracture

Fracture of the medial condyle of the humerus is an unusual injury, and may be difficult to diagnose. Before ossification of the trochlea, it is important to examine the radiographs for a chip or flake of bone from the metaphysis (99,157). Medial condyle fracture may be misdiagnosed as medial epicondyle avulsion in children between the ages of 5 and 7 years, because the epicondylar ossification center is visible on radiographs approximately 2 years before the trochlea ossifies. The mechanism of injury is similar to that for medial epicondylar fracture, but medial condyle fracture is a much more serious injury, because it involves the articular surface. Thus, the radiographic appearance of a displaced medial epicondyle fracture in a 5- to 7-year-old child should arouse suspicion of a more serious injury, because the ossified epicondyle may still be attached to the cartilaginous

condyle. If the condyle is displaced more than 2 mm, it needs open reduction and internal fixation (158).

Fracture-separation of the Distal Humeral Physis

Fracture-separation of the distal humeral physis is seen primarily in infants and young children. The mechanism of injury involves rotatory shear forces, resulting in a Salter-Harris type I or type II fracture pattern. Abuse should be suspected (159). This injury may present a diagnostic challenge, because of the lack of ossification of the distal humerus in young children (Fig. 32-23). Diagnosis of this fracture should be considered in any young child with significant soft tissue swelling and crepitus on elbow motion. This fracture is most often confused with elbow dislocation and lateral condyle fracture (Fig. 32-29). Elbow dislocation is rare in young children; the forearm is displaced laterally and the long axis of the radius is lateral to the capitellum. A lateral condyle fracture in a 2- to 3-year-old child may be confused with transphyseal separation, especially if there is joint subluxation. However, the subluxation associated with lateral condyle fracture is in the lateral direction, whereas distal humeral physeal separations usually displace in a medial direction. Arthrography, MRI, or ultrasonography can help confirm the diagnosis of separation of the entire distal hu-

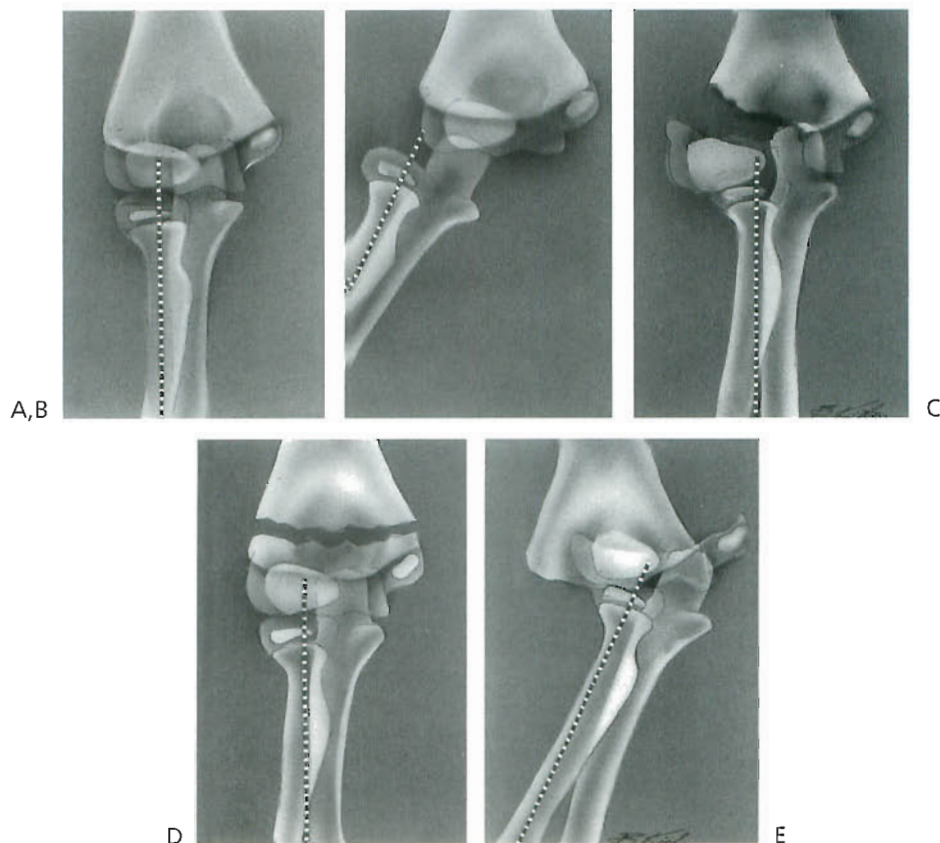


FIGURE 32-29. A: Normal elbow demonstrating the alignment of the radius with the capitellum. B: In a dislocation of the elbow, there is disruption of the radiocapitellar alignment. Most dislocations are posterolateral. C: In a displaced lateral condyle fracture, there is again disruption of the radial capitellar alignment. D: Supracondylar elbow fracture, in which the radius and capitellum remain aligned, despite displacement of the distal humeral fragment. E: Fracture-separation of the distal humeral physis. The radiocapitellar relation is preserved, and typically, the distal segment is posteromedially displaced. (Adapted from ref. 159, with permission.)

meral physis. Arthrography is a helpful adjunct at the time of definitive treatment to confirm the quality of fracture reduction.

Treatment and complications are similar to those for supracondylar fractures. Closed reduction and plaster immobilization frequently lead to cubitus varus that does not resolve (159–161). Therefore, fixation with two small-diameter, laterally placed pins is recommended after reduction. Fractures diagnosed after 7 to 10 days should not be manipulated, because healing is rapid and growth arrest may result from vigorous attempts at reduction. It is better to wait and perform supracondylar osteotomy for residual deformity.

Radial Neck Fracture

Fractures of the proximal radius in children usually involve the radial neck. Associated injuries are found in 50% of cases, and include fractures of the medial epicondyle and olecranon or dislocation of the elbow. Associated injuries should be treated independently, according to accepted

guidelines. Radial neck fractures are predominantly Salter-Harris type I or II injuries. The radial head is largely cartilaginous, and is rarely injured. Proximal radius fractures occur most commonly in the 9- to 12-year age group, but may occur at any age. The mechanism of injury is usually valgus stress, with compression of the radial neck from a fall on the extended elbow. Fracture displacement can result in angulation, translation, or both, or complete separation of the radial head from the radius. Angulation after union may remodel, especially in younger children. Translation is more worrisome, and may limit motion as a result of a cam effect, because the congruity of the proximal radioulnar joint is disrupted, and the radial head can no longer rotate in a circle. Approximately one-half of children who sustain fractures of the radial neck will have some permanent limitation of forearm rotation. Results are poorer in children older than 10 years of age, when treatment is delayed, when the elbow has associated injuries, after open reduction, and when the initial angulation was greater than 30 degrees or the displacement was greater than 3 mm (162–164).

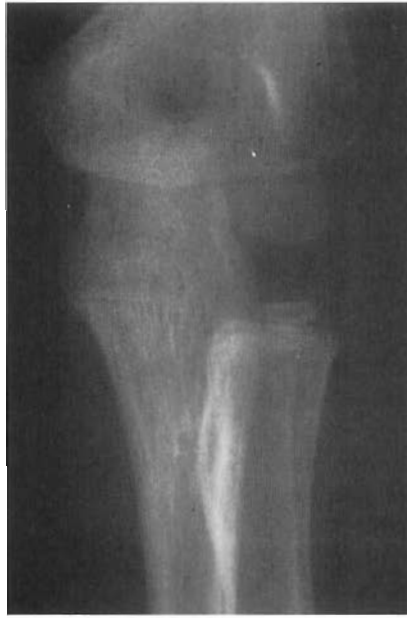
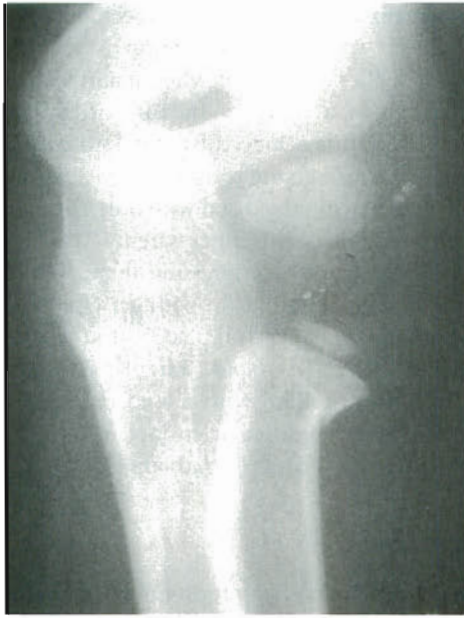
FIGURE 32-30. Impacted radial neck fracture in a 6-year, 5-month-old boy. **A:** Angulation measures 30 degrees. **B:** Nine months later, alignment is normal without treatment. The child regained full range of motion.

Treatment depends on the age of the child and the amount of angulation and translation (163). When angulation is greater than 30 degrees, or translation is greater than 3 mm, closed reduction usually should be attempted, because anatomic alignment is associated with better outcome (Fig. 32-30). However, closed reduction may fail, and one must decide whether to accept suboptimal alignment or to resort to open reduction, with increased risks in each case. Age is important in this situation. For a child younger than 10 years of age, the author will accept up to 45 degrees of angulation and 33% translation, before resorting to open reduction. In a child older than 10 years of age, up to 30 degrees of angulation and 3 mm of translation may be accepted.

The manipulation technique for closed reduction consists of traction and varus stress, combined with digital pressure over the radial head [1.15]. If this is unsuccessful, the forearm should be pronated and supinated, as pressure over the radial head or metaphysis is maintained. Wrapping the arm firmly in an Esmarch bandage produces compression and elongation forces that may also reduce the fracture. Alternatively, a percutaneous pin proximally, or a flexible intramedullary wire introduced distally, can be used to manipulate and stabilize the proximal fragment (165,166) (Fig. 32-31) [1.15]. Open reduction is performed when these methods fail to produce an acceptable reduction. Another indication for open reduction is a displaced Salter-Harris type IV fracture involving more than one-third of the articular surface. Fixation is best accomplished with Kirschner wires placed obliquely across the fracture, avoiding the use of a transhumeral pin [1.15]. These wires are removed in 3 to 4 weeks to begin elbow range of motion. If the metaphyseal fragment is large

enough, a minifragment screw can be used instead of the Kirschner wires.

Complications

Complications of this fracture and its treatment include loss of forearm rotation, radioulnar synostosis, injury to the posterior interosseous nerve, nonunion, premature physal

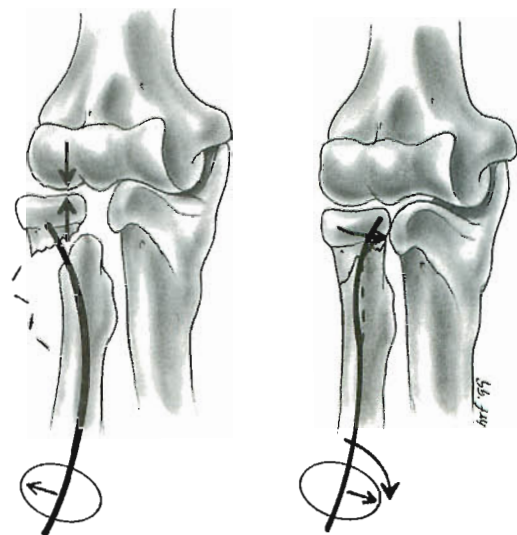


FIGURE 32-31. Radial neck fractures may be reduced by introduction of a percutaneous wire from the distal metaphysis. The wire is rotated after it engages the proximal fragment. (From ref. 166, with permission.)

arrest, and avascular necrosis of the radial head (167). These complications are usually observed, unless they are progressive or disabling. Radial head excision may be performed in growing children when symptoms warrant this procedure (168).

Olecranon Fractures

Olecranon fractures are uncommon in children. In young children, the spongy bone and thick surrounding cartilage often prevent significant displacement. Older children and adolescents are more likely to have displaced fractures and associated injuries. The most common mechanism of injury is an avulsion or flexion injury that disrupts the posterior periosteum and fractures the cortex. Extension injuries leave the posterior periosteum intact, but often result in angulated fractures and associated fractures attributable to varus or valgus forces acting on the extended elbow. Olecranon fractures may also result from a direct blow that causes comminution, but minimal displacement, because the periosteum remains intact (Fig. 32-32).

Treatment consists of splint or cast immobilization for 2 to 3 weeks, if displacement is minimal. When displacement is greater than 4 mm in metaphyseal bone, or there is a joint step-off in the coronoid fossa of greater than 2 mm,

closed reduction is attempted by reversing the mechanism of injury. Open reduction with internal fixation is recommended when closed reduction fails, or when maintenance of reduction is difficult as a result of fracture instability (169,170). Internal fixation is achieved by standard osteosynthesis, using the AO tension band technique or its modification, which involves placing the distal wire hole anterior to the axis of the intramedullary Kirschner wires (171) (Fig. 32-33). This provides additional compression forces across the articular surface of the olecranon. In younger children, heavy absorbable suture may be used in place of the figure-of-eight wire, because healing is rapid. Angulated metaphyseal fractures that do not align with closed reduction, and which do not involve the articular surface, often can be straightened with insertion of an intramedullary pin.

Elbow Dislocation

Elbow dislocation is a relatively uncommon injury in young children; the peak incidence is in the second decade of life. Often, there is an associated fracture, most commonly of the medial epicondyle, but occasionally of the coronoid process or the radial neck. Elbow dislocation is predominantly a male injury (70%) involving the nondominant arm (60%). The most common pattern is posterolateral displace-

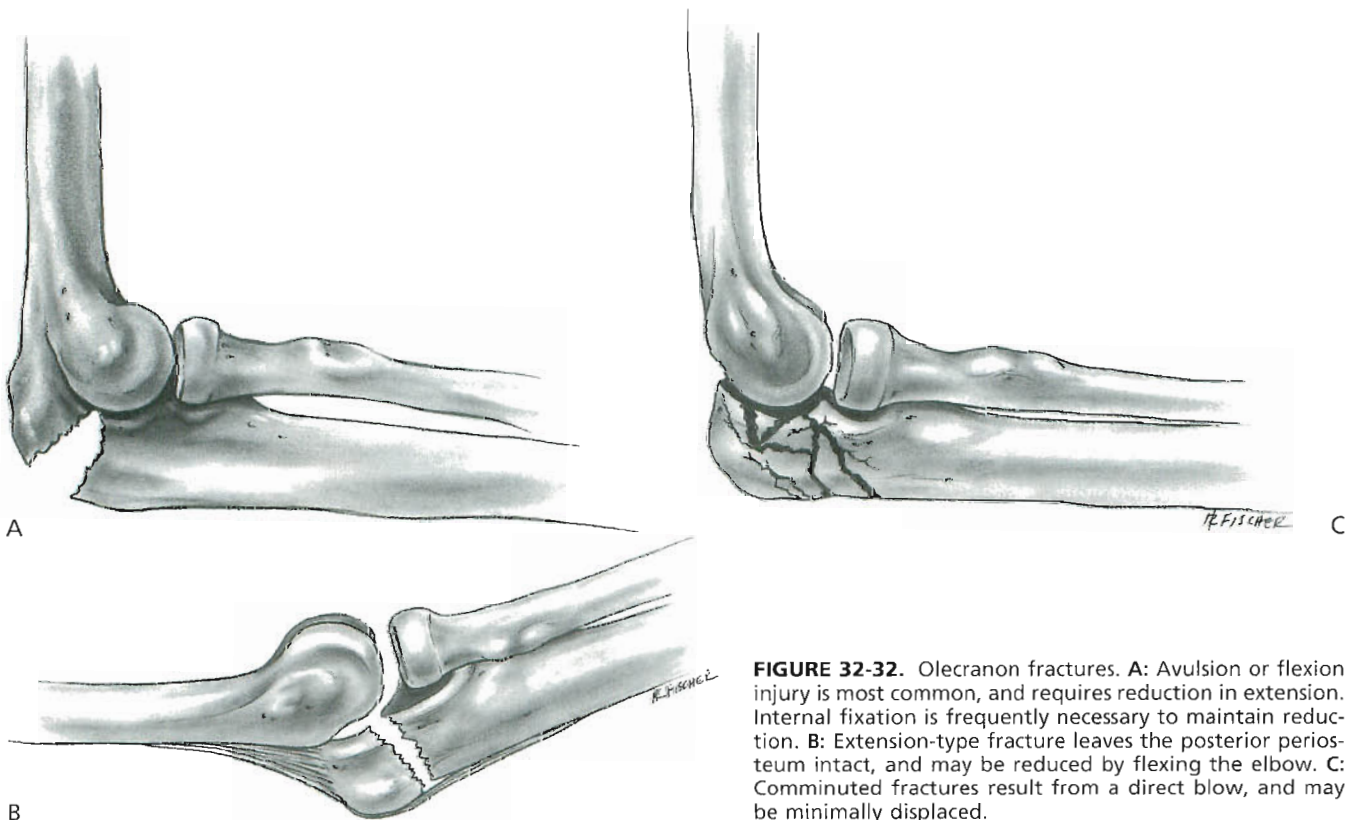


FIGURE 32-32. Olecranon fractures. **A:** Avulsion or flexion injury is most common, and requires reduction in extension. Internal fixation is frequently necessary to maintain reduction. **B:** Extension-type fracture leaves the posterior periosteum intact, and may be reduced by flexing the elbow. **C:** Comminuted fractures result from a direct blow, and may be minimally displaced.

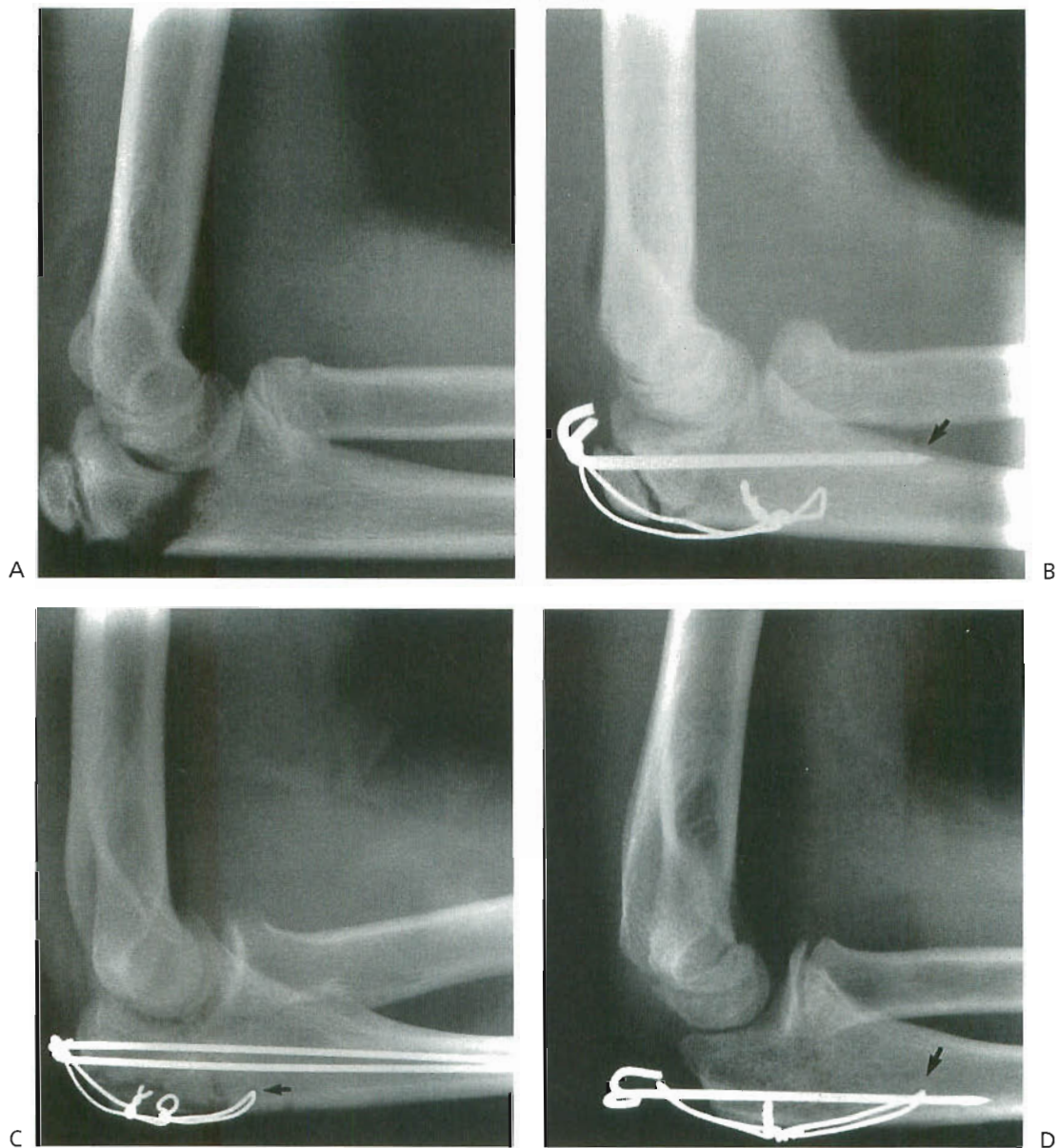


FIGURE 32-33. Olecranon fracture. **A:** Lateral projection showing displaced intraarticular olecranon fracture. There is also an impacted radial neck fracture. **B:** Treatment with standard tension band technique. The slight variation from standard fixation is to capture the anterior cortex of the ulna with the Kirschner wires (*arrow*). **C:** Standard AO technique, used in a similar case, with parallel intramedullary Kirschner wires with the tension band transverse hole inferior (*arrow*). **D:** Modified AO technique performed by placing the transverse hole anterior to the Kirschner wires (*arrow*). The compressive force is anterior to the pin, which prevents the articular surface of the semilunar notch from gapping. Ideal joint compressive forces are obtained with placement of the Kirschner wires down the middle axis of the ulna and the transverse hole anterior to this axis.

ment of the proximal radius and ulna articulation from the humerus, without disruption of the radioulnar articulation (172).

Treatment is accomplished by prompt closed reduction, usually in the emergency department, after establishing pain control and muscle relaxation. The surgeon should

be aware of possible interposed fragments, such as from the medial epicondyle, or unsatisfactory postreduction alignment, suggesting soft tissue or cartilaginous interposition. A posterior splint is applied for 2 weeks; thereafter, elbow range of motion is initiated to minimize the risk of fixed contracture.

Complications

The most common complication is loss of motion. This can be minimized for stable reductions by initiating early mobilization 2 weeks after injury (172). Stiffness, in the absence of fracture, usually resolves within 6 to 8 months. The author recommends avoiding the use of passive stretching devices for at least 4 months, because recovery is expected in children. Occult avulsion fractures should be excised if range of motion has not returned by 6 months. Rarely, operative release of contracture may be required in older adolescents, when range of motion is less than functional (30 to 100 degrees) 8 months or more after injury (173,174). Neurapraxia involving the median or ulnar nerves occurs in approximately 10% of dislocations, and usually resolves within 3 months. Arterial injury is rare.

Radial Head Dislocation and Nursemaid's Elbow

Traumatic isolated dislocation of the radial head is a rare injury (Fig. 32-34). The radial head dislocates anteriorly.

The majority of these injuries actually represent occult Monteggia injuries, with plastic deformation of the ulna and anterior dislocation of the radial head. Treatment consists of closed reduction and immobilization, with the elbow in flexion and supination.

Occasionally, a child with a previously undiagnosed congenital radial head dislocation falls and injures the elbow. Congenital dislocation of the radial head is distinguished from traumatic dislocation by the fact that congenital dislocation is almost always in a posterior direction and the articular surface of the radial head is convex or flat, rather than having the normal concave contour.

Nursemaid's elbow, or pulled elbow, is a very common injury in children between 1 and 4 years of age. Typically, the child is being held by the hand and suddenly falls, or is pulled upward. Pain is variable. The child will not move the arm and will hold it in a slightly flexed and pronated position. Radiographs are not indicated initially, and are normal, because the injury consists of subluxation of the annular ligament, rather than true joint subluxation (175) (Fig. 32-35). When longitudinal traction is applied to the

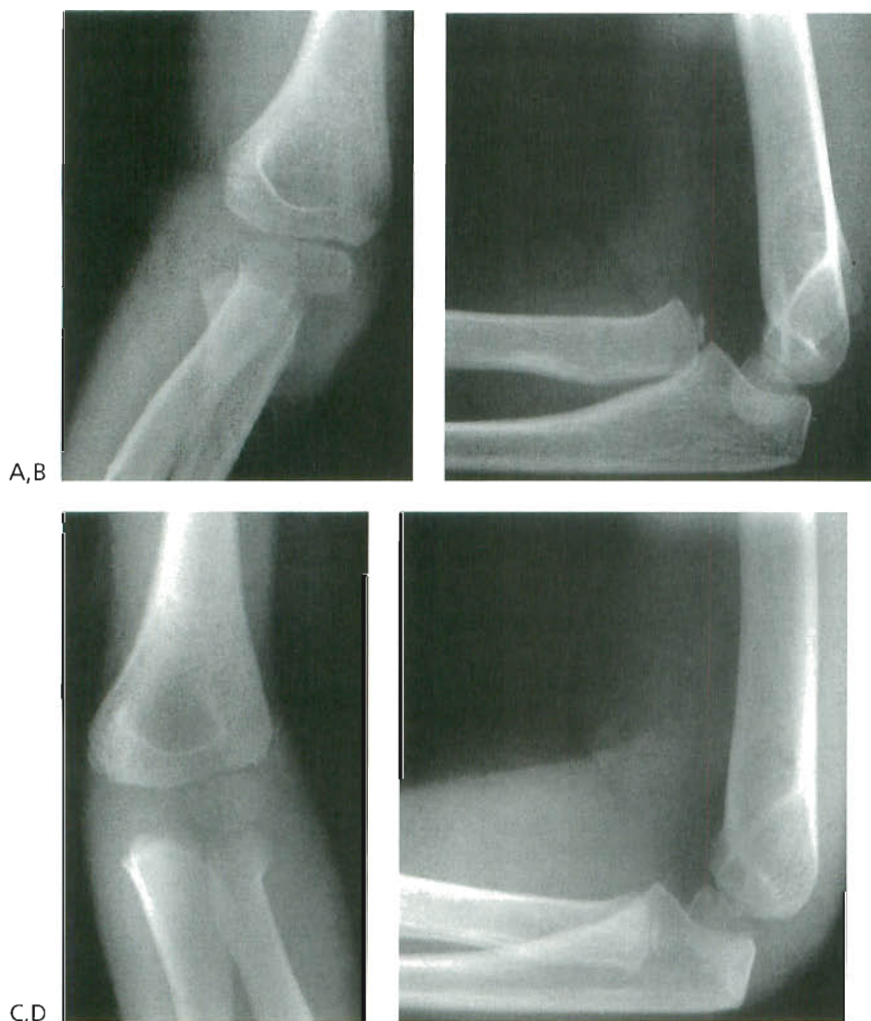

FIGURE 32-34. Anterior radial head dislocation. **A:** Anteroposterior projection demonstrating an overlap of the radial metaphysis with the capitellum, suggesting disruption of this articulation. **B:** Lateral projection indicating anterior dislocation of the radial head. There were no other fractures of the forearm or elbow. **C:** Anteroposterior projection after closed reduction, showing more normal radial capitellar alignment. **D:** Lateral projection showing a reduced radius. A line drawn down the long axis of the radius should bisect the capitellum of the humerus, regardless of the degree of extension of the elbow.

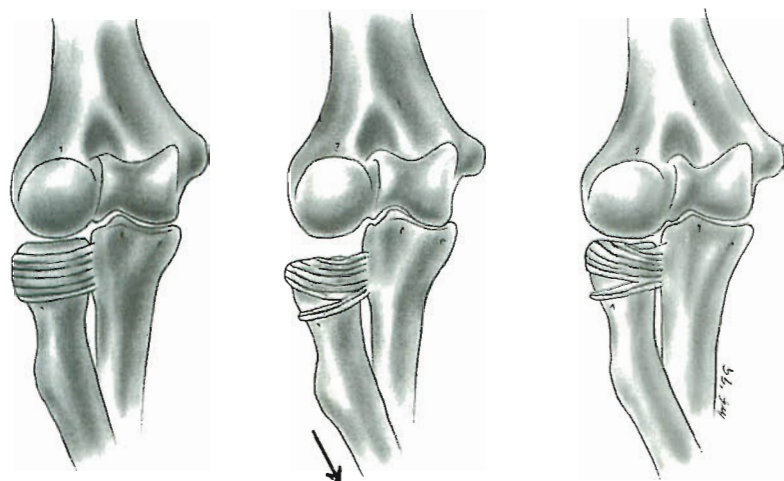


FIGURE 32-35. Pulled elbow, or “nursemaid’s elbow,” occurs as the radial head moves distally. The annular ligament is partially torn and displaced onto the radial head. (From ref. 106, with permission.)

child’s pronated arm, the annular ligament slips off the radius and rides up onto the broader radial head, like a rope that has jumped out of the groove in a pulley wheel. The child is unwilling to move the elbow until the stretched annular ligament is reduced.

Treatment consists of flexing the elbow to 90 degrees, then fully and firmly supinating the forearm. A click or snap is often felt as the ligament snaps back into place. Occasionally, it is necessary to quickly and fully pronate, then supinate the forearm, to achieve reduction. This is especially true for delayed cases. The child should begin to move the arm within a few minutes after reduction. If this is not the case, then radiographs should be obtained to rule out occult fracture, and the arm may be immobilized in a splint for 2 to 3 days, followed by repeat examination. Recurrences are not uncommon, but are treated in the same manner as the initial injury. Eventually, children outgrow this condition, and long-term sequelae have not been reported.

FOREARM AND WRIST FRACTURES

Fractures of the forearm and wrist are common in children, accounting for 30 to 50% of all children’s fractures (4,5,176). Most forearm fractures occur in children older than 5 years of age. The location of the fracture advances distally with increasing age of the child, probably because of the anatomic changes in the metaphyseal–diaphyseal junction that occur with maturity (177). The younger child’s radius is more elastic, and has a gradual transition of the diameter of the radius from shaft to metaphysis, whereas the transition in diameter is more abrupt at the metaphyseal–diaphyseal junction in the older child (177). The distal forearm is the site of 70 to 80% of fractures of the radius and ulna. Most of these are nonphyseal. Physeal

separations are more likely in early adolescence, because of the more adult shape of the radius, which concentrates stress closer to the epiphysis. In 10 to 15% of patients, forearm fractures are associated with elbow fractures. This highlights the importance of a thorough clinical and radiographic examination of the injured extremity.

Anatomically, the forearm is unique. The ulna is a straight bone with a triangular cross section. The radius has a more complex, curved shape, with a cylindrical proximal portion, a triangular middle portion, and a flattened distal third. The radius rotates around the ulna during forearm supination and pronation. There are three areas of soft tissue interconnection between the radius and ulna. Proximally, there is the radioulnar articulation, which is stabilized by the annular ligament. Centrally, the shafts of the two bones are connected by the interosseous membrane, which is wider distally. The fibers run obliquely from the ulna distally to the radius proximally. This helps transmit force to the ulna during load-bearing activities. Distally, the triangular fibrocartilage complex stabilizes the radioulnar joint by means of the ulnar collateral ligament and the volar and dorsal radiocarpal ligaments. The proximal and distal radioulnar joints are most stable in supination, and the interosseous membrane is widest with the forearm in a position of 30 degrees of supination. Because of these interconnections, both bones are usually injured at the time of fracture. When only one bone is broken, there is frequently damage to the proximal or distal radioulnar articulation.

Forearm and wrist fractures are usually classified into three major categories: fracture-dislocations, fractures of the midshaft, and distal fractures. Fracture-dislocations include the Monteggia and Galeazzi lesions. Midshaft fractures of the radius and ulna tend to follow three injury patterns: plastic deformation, greenstick fracture, and complete fracture. Distal fractures are either metaphyseal fractures or physeal separations. Each type of injury presents unique features

with regard to mechanism of injury, recognition, and management.

Forearm Fracture-dislocations

The combination of forearm fracture with joint dislocation is less common than other types of forearm fractures. Misdiagnosis may result if radiographs of forearm fractures fail to clearly demonstrate the elbow and wrist joints. The peak incidence occurs between 4 and 10 years of age. The Monteggia lesion is more common, and involves dislocation of the radial head. The usual mechanism of injury is a fall on the hyperextended arm. The Galeazzi lesion involves dislocation of the distal radioulnar joint, and is usually associated with a distal radius fracture.

Monteggia Fracture-dislocation

The Monteggia lesion should be suspected with any pediatric forearm fracture, including minimally displaced greenstick fractures of the ulna. A true lateral radiograph of the elbow provides the best assessment of the radiocapitellar joint. In the normal elbow, a line drawn down the long axis of the radial shaft will bisect the capitellum, regardless of the position of flexion or extension of the elbow (178) (Fig. 32-36). Congenital dislocation of the radial head is distinguished from traumatic dislocation by the fact that congenital dislocation is usually posterior and the articular surface of the radial head is convex. In contrast, anterior dislocation

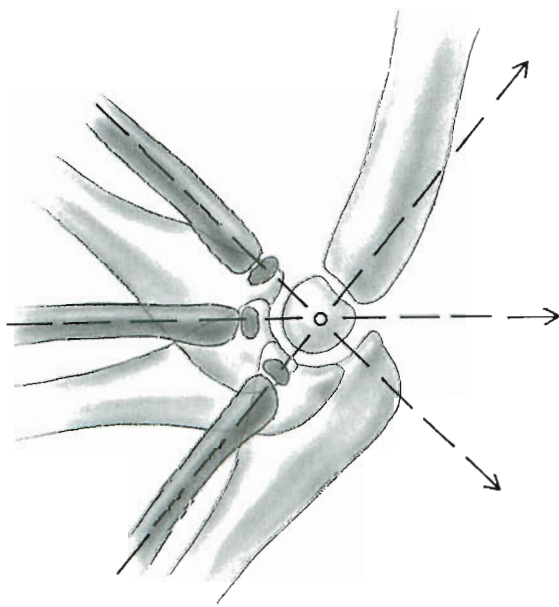


FIGURE 32-36. A true lateral radiograph of the elbow joint allows assessment of the integrity of the radiocapitellar joint. A line drawn down the long axis of the shaft of the radius will bisect the capitellum in all positions of flexion and extension. (From ref. 178, with permission.)

of the radial head is common with Monteggia fracture-dislocation (179,180).

Bado (179) devised a classification system of four basic types of injury and several equivalent lesions. Type I involves anterior radial head dislocation (i.e., ulnar apex deformity anterior), which accounts for the majority of childhood Monteggia injuries (179,180) (Fig. 32-37). Type II fracture is the least common, and entails posterior or posterolateral radial head dislocation. In Type III lesions, the radial head is dislocated laterally, and the ulna fracture is usually in the proximal metaphyseal region. Type III injury accounts for 25 to 30% of pediatric Monteggia injuries. Type IV fracture-dislocations involve anterior dislocation of the radial head, in combination with fracture of the radius and ulna. This may be considered a variant of the type I lesion. There are numerous Monteggia equivalents that represent a multitude of variations. For example, the ulna fracture may be combined with a radial neck fracture, rather than a simple radial head dislocation (Fig. 32-38). Segmental fractures and plastic deformation of the ulna are other forms of Monteggia equivalent injury.

Treatment depends on the character of the ulnar fracture, more than the direction of the radial head dislocation, because stable, anatomic reduction of the ulnar fracture maintains anatomic reduction of the radial head. Most Monteggia injuries in children younger than 12 years of age can be managed successfully by closed reduction and above-elbow casting, with the elbow in full supination and 90 to 110 degrees of flexion. Weekly follow-up is suggested for 2 to 3 weeks, to detect recurrent radial head subluxation. Transient nerve palsies, most commonly of the posterior interosseous nerve, occur in approximately 10% of patients.

Operative intervention is indicated when there is a radial neck fracture, instead of a simple dislocation. Another indication is ulnar angulation that cannot be controlled, which may be the case with oblique or segmental ulnar fracture (181). The percutaneous insertion of an ulnar intramedullary pin is a simple and effective way to manage this problem. Alternatively, the ulnar shaft can be plated. On rare occasions, when the radial head is not reduced after correction of ulnar length and alignment, open examination of the joint is indicated. Interposition of the annular ligament or an intraarticular osteochondral fragment may be found. Transcapitellar pinning of the reduced radial head is usually unnecessary and inadvisable.

Complications. Delayed diagnosis is the most frequent complication associated with Monteggia fracture-dislocations. Patients presenting less than 3 weeks after injury with persistent dislocation should be treated by attempting closed reduction. If the ulna can be reduced and held, the radial head will usually reduce and remain stable. Open reduction, with reconstruction of the annular ligament, is indicated if closed reduction fails, or when the injury is more than 4 weeks old. Ulnar osteotomy to restore length and alignment may be necessary (182–184).

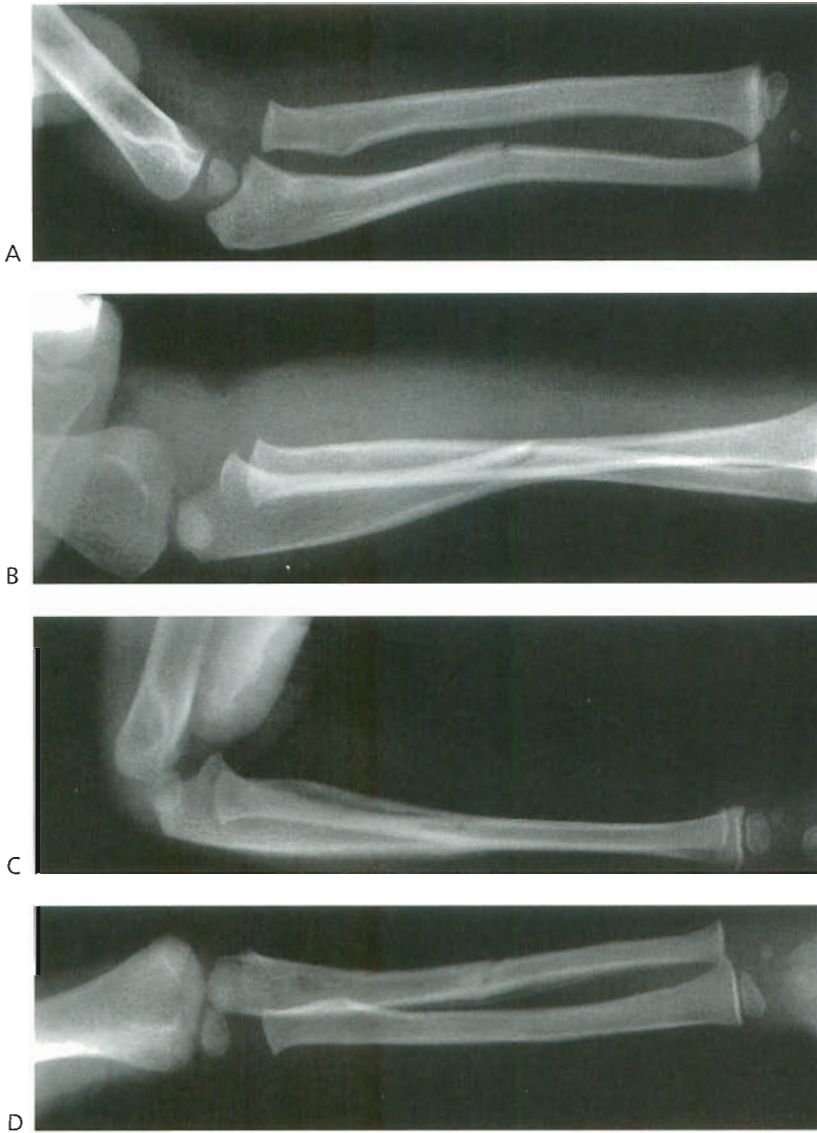

FIGURE 32-37. Type I Monteggia lesion. **A:** The lateral projection shows an ulnar fracture angulated anteriorly, with dislocation of the radial head in the same direction. **B:** The anteroposterior projection shows malalignment of the radiocapitellar joint. **C:** Alignment after closed reduction and correction of the ulnar angulation. A line through the central axis of the radius points to the capitellum. This fracture must be followed closely for recurrent angulation. **D:** The anteroposterior projection shows early healing of the ulna and normal alignment of the radiocapitellar joint.

Galeazzi Fracture-dislocation

The classic Galeazzi lesion is a fracture of the distal third of the radius, without fracture of the ulna, and is associated with dislocation of the distal radioulnar joint. This is an uncommon injury in children. The triangular fibrocartilage complex is disrupted, and the distal ulna is dorsally displaced, as viewed on a lateral radiograph. Injury to the distal radioulnar joint is frequently overlooked, and persistent joint subluxation is responsible for poor long-term results (185). The Galeazzi equivalent injury is represented by physeal separation of the distal ulna, instead of a triangular fibrocartilage tear (186,187). Long-term problems with this injury include premature physeal arrest and loss of supination.

Treatment consists of closed reduction and above-elbow casting with the forearm in full supination. It is rarely necessary to place a smooth Kirschner wire across the joint or the fracture to maintain reduction.

Midshaft Fractures

Plastic Deformation

Plastic deformation or traumatic bowing of the forearm is possible, because of the elastic properties of young children's bones. This injury represents a series of microfractures that are not seen on radiographs. Bowing of both bones may occur, but plastic deformation of one bone is often associated with complete or incomplete fracture of the other forearm bone. Reduction is recommended, if deformity was immediately obvious at the time of injury, or when angulation is greater than 20 degrees (188,189).

Treatment of plastic deformation usually requires general anesthesia, because a prolonged corrective force must be applied to permanently straighten the bone. The position of immobilization follows the principles outlined in the discussion of greenstick fractures.

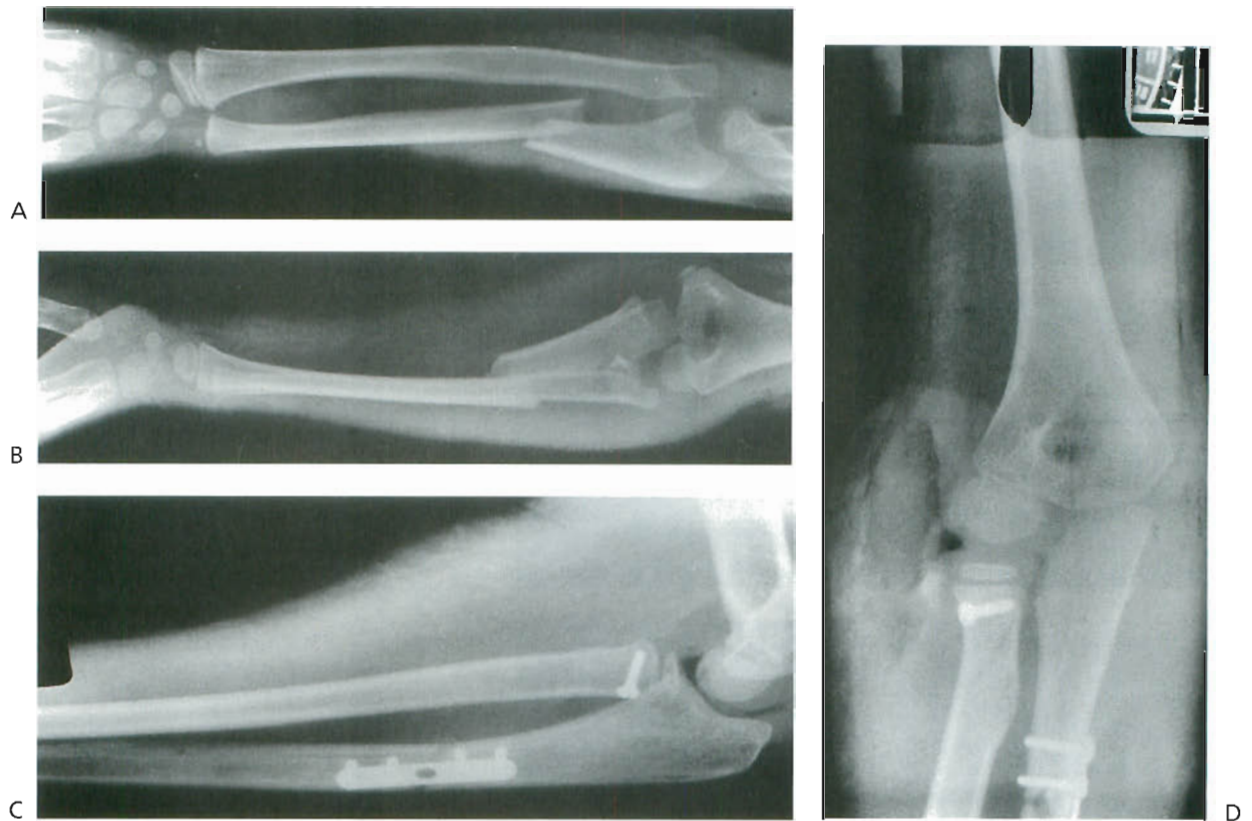


FIGURE 32-38. Monteggia equivalent lesion. **A:** There is an anteriorly angulated proximal ulnar fracture with an anterior displaced radial shaft. There is also a fracture of the radial neck with malalignment of the radiocapitellar joint. **B:** Anteroposterior projection. **C:** This fracture configuration usually requires open reduction. In this instance, a small plate was used on the ulnar shaft. An alternative would have been an intramedullary rod. The radial neck fracture was treated with a minifragment compression screw. **D:** The anteroposterior projection shows restoration of alignment.

Greenstick Fractures

A complete fracture of one cortex and plastic deformation of the opposite cortex characterize greenstick fractures. Most greenstick fractures represent a rotational malalignment, in addition to angular deformity. Apex-volar greenstick fracture is the most common type, and results from excessive supination forces applied to the distal segment, combined with axial load. The child presents with the palm facing the apex of the fracture deformity (Fig. 32-39). Apex-dorsal deformity results from excessive pronation force applied to

the distal segment; the child presents with the palm facing down, relative to the apex of the fracture deformity (Fig. 32-40). Occasionally, greenstick fractures of the radius and ulna are caused by direct force, producing mostly angular deformity, without much malrotation. Reduction is indicated if deformity was immediately obvious at the time of injury, or when shaft angulation exceeds 20 degrees in a child younger than 8 years or 15 degrees in an older child.

Treatment of greenstick fractures requires adequate pain relief for one quick reduction attempt that is usually successful. Reduction is accomplished by simply reversing the in-

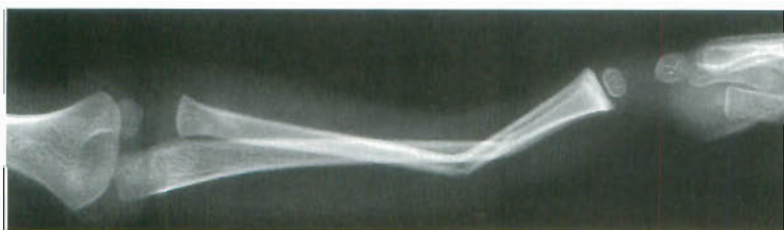

FIGURE 32-39. Coupled relation of rotation and angulation. This fracture demonstrates volar angulation. The mechanism of injury was falling on the outstretched hand. When the fractures of the radius and ulna are at different levels, angulation cannot occur without rotation. Note the anteroposterior appearance of the elbow and the lateral projection of the wrist. This deformity is corrected with pronation of the distal fragment.

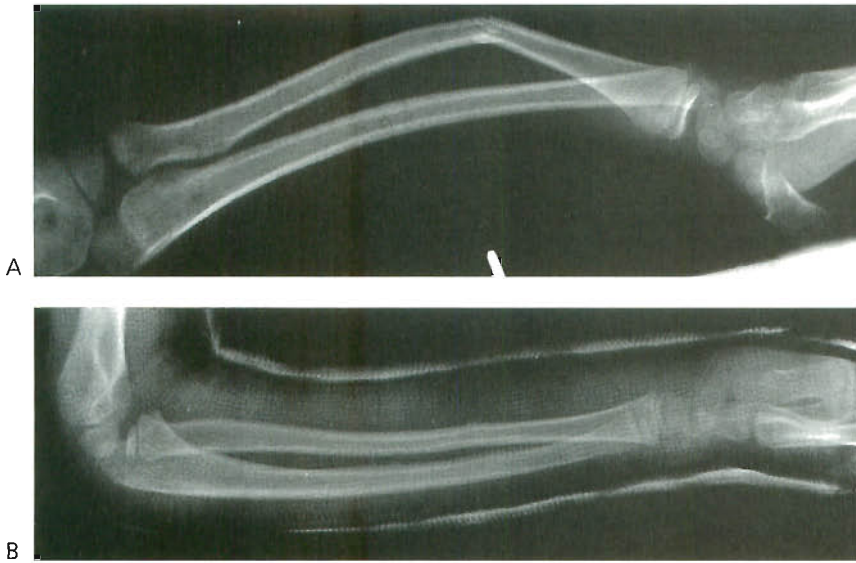


FIGURE 32-40. Coupled relation of rotation and angulation. **A:** The radiograph shows deformity with pronation of the distal fragment and dorsal angulation of the radius. The ulna has undergone plastic deformation. When a single bone angulates, it must rotate around the other. **B:** Alignment is restored with supination of the distal fragment. The lateral projections of the elbow and the wrist are now matched.

jury mechanism. Apex-volar deformity (apex of fracture in the direction of the palm of the hand) is reduced by pronating the wrist, while applying pressure to the volar surface of the forearm. Apex-dorsal deformity (apex of fracture in the direction of the dorsum of the hand) is reduced by supinating the wrist, while applying pressure to the dorsal surface of the forearm. Completing the fracture of the opposite cortex is unnecessary, although this occurs frequently during the reduction maneuver. After reduction, the arm is immobilized in a well-molded sugar-tong splint or a bivalved long-arm cast. Three-point pressure is essential for the maintenance of reduction. Weekly follow-up is recommended for 2 to 3 weeks after reduction. It is generally necessary to change the cast for remolding as swelling subsides during this period. Six weeks of immobilization are usually adequate, but refracture is a risk when immobilization is discontinued too soon.

Complications. Refracture is seen more often after greenstick fractures than after complete forearm fractures (190,191). This is possibly attributable to resorption on the fractured side, with the intact cortex preventing gap closure, and leading to delayed union. One method to reduce the risk of refracture is to complete the fracture of the intact cortex at the time of reduction. Another option is to use a longer period of immobilization in a cast or removable splint, until union of both cortices is complete.

Complete Shaft Fractures

Complete fractures of the forearm result from higher-energy trauma than greenstick fractures. The proximal segments usually assume a position dictated by muscle forces, because the muscle actions are unrestrained by an intact cortex. Most

proximal fragments are in a position of supination, as a result of the actions of the biceps and supinator muscles. When the fracture is more distal, the pronator teres has a neutralizing effect on the proximal fragment. Evans (192) plotted the rotational position of 50 complete shaft fractures and determined that the proximal radial fragment was in neutral to slight supination, when the fracture was in the distal third. The proximal fragment was more frequently in supination, when the fracture was in the proximal third. None of the shaft fractures reviewed by Evans resulted in pronation of the proximal fragment.

Managing these fractures can be difficult, but nonunions and serious complications are rare after closed treatment. The principal concerns are the possibility of residual deformity and loss of forearm rotation. Guidelines for the management of complete forearm fractures are based on the following observations:

1. Younger children with more distal fractures have the best prognosis (12–14,193,194).
2. Children within 1 year of skeletal maturity should be treated as adults (195).
3. Residual loss of supination (pronation deformity) is more difficult to accommodate than loss of pronation. When in doubt, immobilize the forearm in neutral or moderate supination (196,197).
4. Cosmetic appearance is principally influenced by the alignment of the ulna. A straight ulna usually produces a straight-appearing forearm (192).
5. Rotational function is determined primarily by the position of the radius (192,198).
6. The interosseous membrane is wider and more accommodating distal to midshaft. Mild loss of radial bow and interosseous encroachment are acceptable distally (198).

7. Bayonet apposition is acceptable for all pediatric shaft fractures, if rotation is correct and there is no angulation (199,200).
8. Consider immobilization with the elbow extended for children younger than 4 years, and for proximal third fractures in all age groups. Incorporate the thumb to avoid cast slippage (201).
9. Improvements in alignment can be made by gentle molding in a new cast, or by remanipulation for 1 to 3 weeks after injury (202,203).
10. In children younger than 8 years of age, 15 degrees of midshaft angulation is acceptable. For a more proximal fracture, less deformity should be the goal (200,204).
11. Children older than 8 years should not be allowed to develop more than 10 degrees of angulation of middle or proximal shaft fractures, and should be held to less than 15 degrees for fractures distal to the midshaft (196,200,205).
12. Malrotation of 20 to 30 degrees is acceptable for a good outcome (200,206).
13. Loss of forearm rotation of less than 30 degrees does not result in significant functional limitations (207,208).

Treatment is usually by closed reduction and plaster immobilization. Adequate pain relief and muscle relaxation are required, because more than one attempt may be necessary. Regional (i.e., Bier or axillary block) or general anesthesia is often preferred. The reduction technique typically involves

increasing the angular deformity, applying longitudinal traction to lock in place and straighten the fracture, then correcting any malrotation by supinating or pronating the forearm. If this is unsuccessful, it is often helpful to apply traction, using finger traps for a period of 10 minutes, before another attempt is made. Rotational alignment is assessed by observing the bone widths and matching their contours on radiographs. Comparison radiographs of the opposite extremity, in various degrees of rotation, may be helpful in determining rotational alignment (206). Alternatively, the position of the bicipital tuberosity may serve as a guide to rotation, because it is approximately on the side of the radius opposite the radial styloid and thumb (192). Postreduction casting entails a flat interosseous mold along the volar forearm, creating an oval shape, while keeping a straight lateral border along the ulnar side. An above-elbow cast or splint should be used. Fracture stability is improved with at least 50% bone apposition. If one bone disengages, shortening may occur, followed by increasing angulation. This may respond to remanipulation or require surgical stabilization. Weekly reevaluation is recommended for the first 3 weeks (Fig. 32-41). Union is usually complete in 6 to 8 weeks. Nonunion is rare, and closed treatment produces excellent results in greater than 95% of patients, when the physician is able to observe the management guidelines (196,200,204,209).

Operative intervention with internal fixation is indicated for 7 to 10% of all complete shaft fractures (210). Indica-

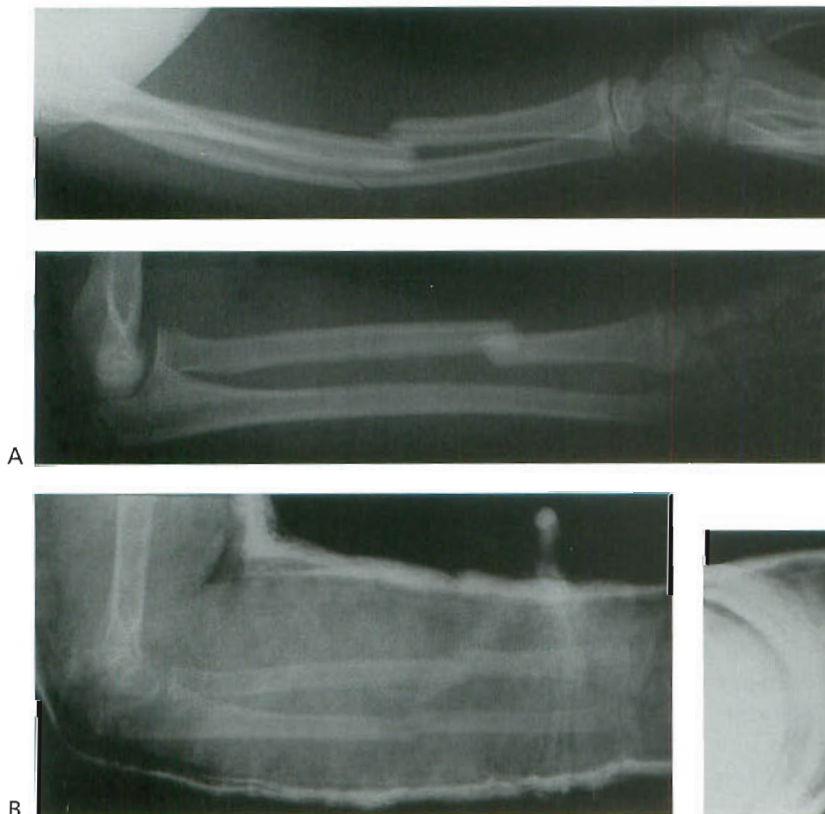


FIGURE 32-41. Forearm with subsequent malunion fracture in a 10-year-old boy. **A:** Radiographs demonstrate displaced fracture of the radius with greenstick fracture of the ulna. **B:** Acceptable reduction is achieved with completion of the ulnar fracture. The cast is poorly molded along the ulnar border. The patient did not return for follow-up as instructed. (*continued*)

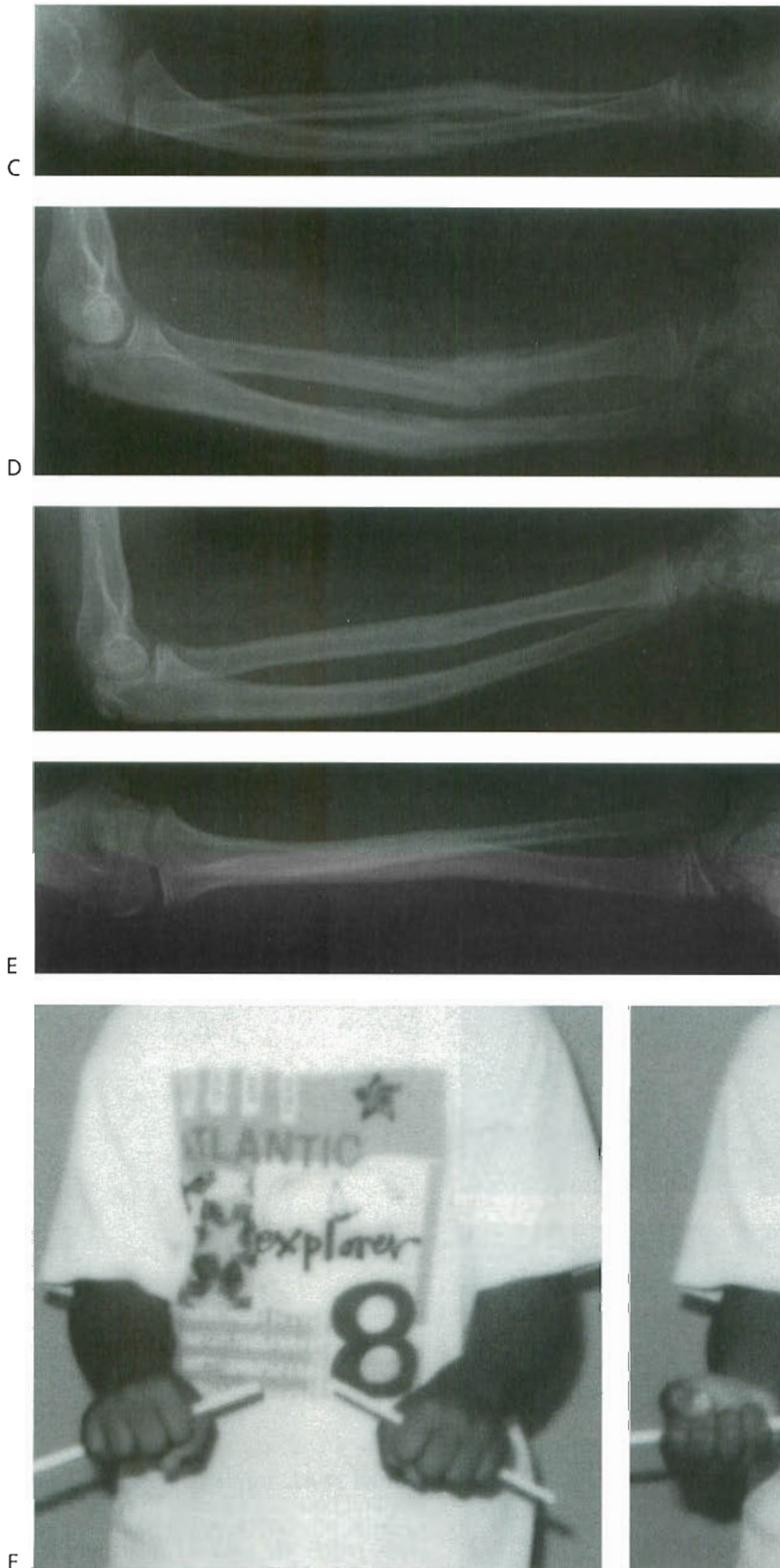


FIGURE 32-41. (continued) C and D: Anteroposterior and lateral radiographs demonstrate midshaft malunion. E: Radiographs and clinical photographs 10 months later demonstrate remodeling. F: Range of motion and function are normal. The patient is not aware of any cosmetic deformity.

tions include open fractures, soft tissue interposition blocking reduction, refracture with displacement, and failed closed management (211–213). Segmental fractures, multiple trauma, and high-energy injuries constitute relative indications for operative stabilization (Fig. 32-42). Intramedullary fixation is usually preferred for children and adolescents, because healing is rapid and supplemental casting does not lead to loss of motion (210,214,215) [1.16]. Fixation is usually achieved by insertion of a small, flexible pin of 1.5 mm or 2.5 mm in diameter (211) (Fig. 32-43). The tip is dulled, and a 30-degree bend is made at the very tip, to facilitate passage across the fracture site. The ulnar pin can be inserted proximally just lateral to the tip of the olecranon, or distally in the flare of the ulna. The radial pin is inserted in the distal metaphysis, avoiding penetration of the growth plate. An oblique drill hole is made in the metaphyseal cortex, and the wire is introduced into the medullary canal. It is tapped or gently rotated into the medullary canal, until it passes the fracture site. Occasionally, it is necessary to perform a limited open reduction at the fracture site to facilitate passage of the wire. Both bones are usually stabilized, but one is suf-

ficient in some cases (216). It is usually best to bend the pins and leave them under the skin, because they should be left in place for 3 months to reduce the risk of early refracture. Supplemental casting is used for approximately 6 weeks after fixation.

Plating is rarely used in younger children, but it is indicated for comminuted fractures, or for adolescents within 1 year of skeletal maturity. This provides anatomic fracture alignment, and allows early unprotected range of motion. Plating requires more dissection, and has the disadvantage of possible later hardware removal, which entails the added risk of neurovascular injury and refracture (217,218).

Complications. Complications of forearm fractures include refracture, malunion, decreased forearm rotation, synostosis, nerve injuries, and, rarely, nonunion or other problems. Malunion is the most common complication, but remodeling may be surprising, and function may return to normal, despite malunion (200,204,205,209,219).

A 3- to 6-month period of observation is recommended when deformity is less than 20 degrees. Shaft deformities

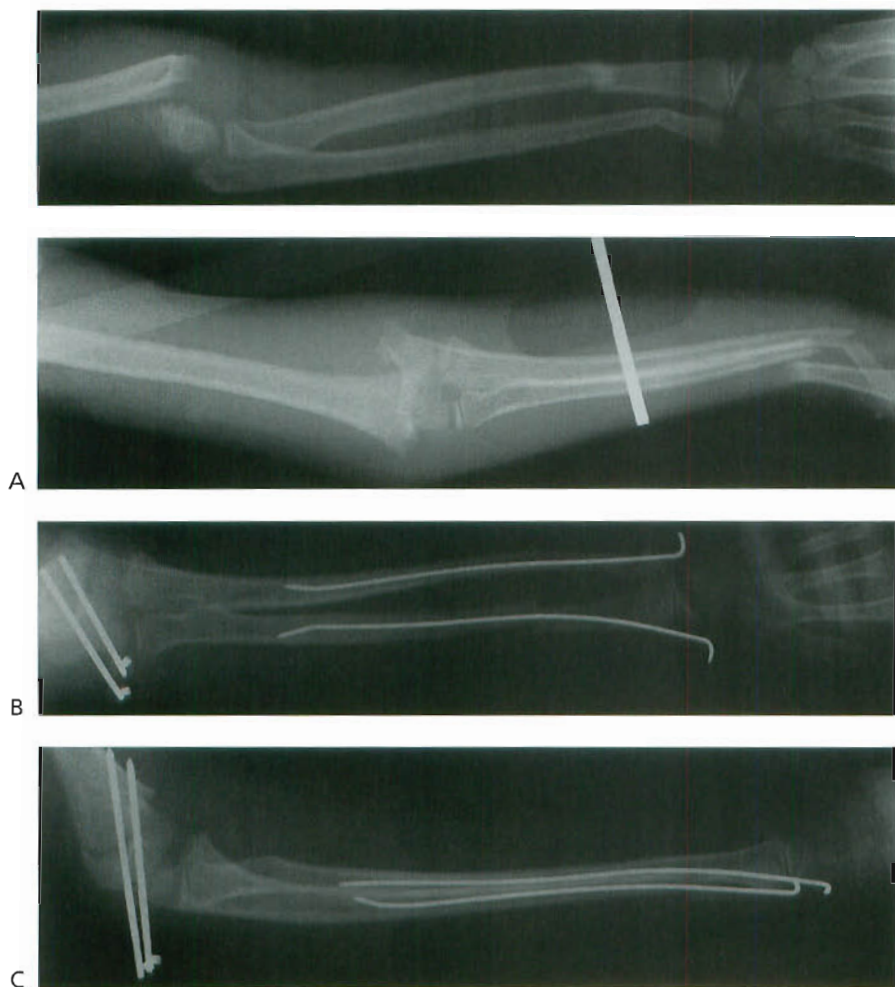

FIGURE 32-42. Displaced fractures of the radius and ulna associated with type III supracondylar fracture. **A:** Radiograph at time of presentation. No neurovascular deficits are noted. **B and C:** Flexible intramedullary wires were used to stabilize the forearm, with percutaneous pins to stabilize the humerus. This facilitates postoperative management during cast changes.

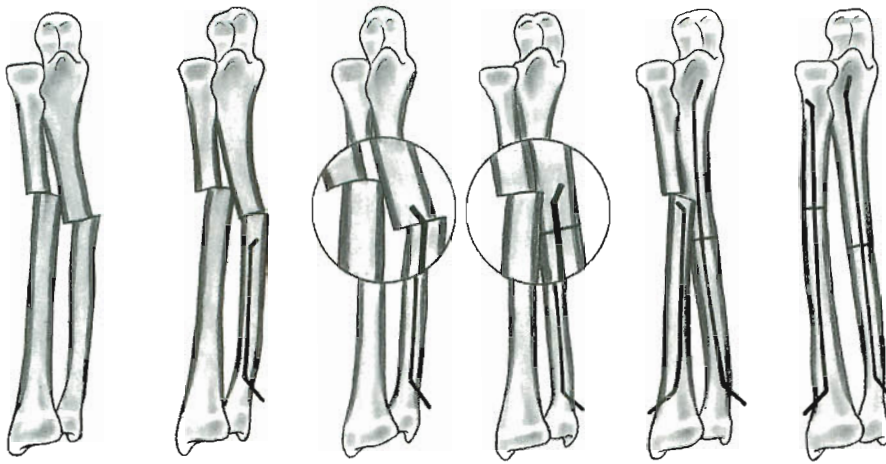


FIGURE 32-43. Surgical nailing procedure for flexible intramedullary nails. The ulnar wire can be introduced digitally, as shown, or through the olecranon. (From ref. 210, with permission.)

greater than 30 degrees should be corrected as soon as some strength and motion have been regained, usually 3 months after the initial injury. Deformities between 20 and 30 degrees may require early correction at 3 months, depending on the clinical appearance, the age of the child, and the location

of the malunion. Results are better when deformity is corrected within 1 year of the initial injury (220). Intramedullary fixation is usually sufficient for younger children (221). Older children benefit from plate fixation, to begin early motion after osteotomy to correct malunion (Fig. 32-44).

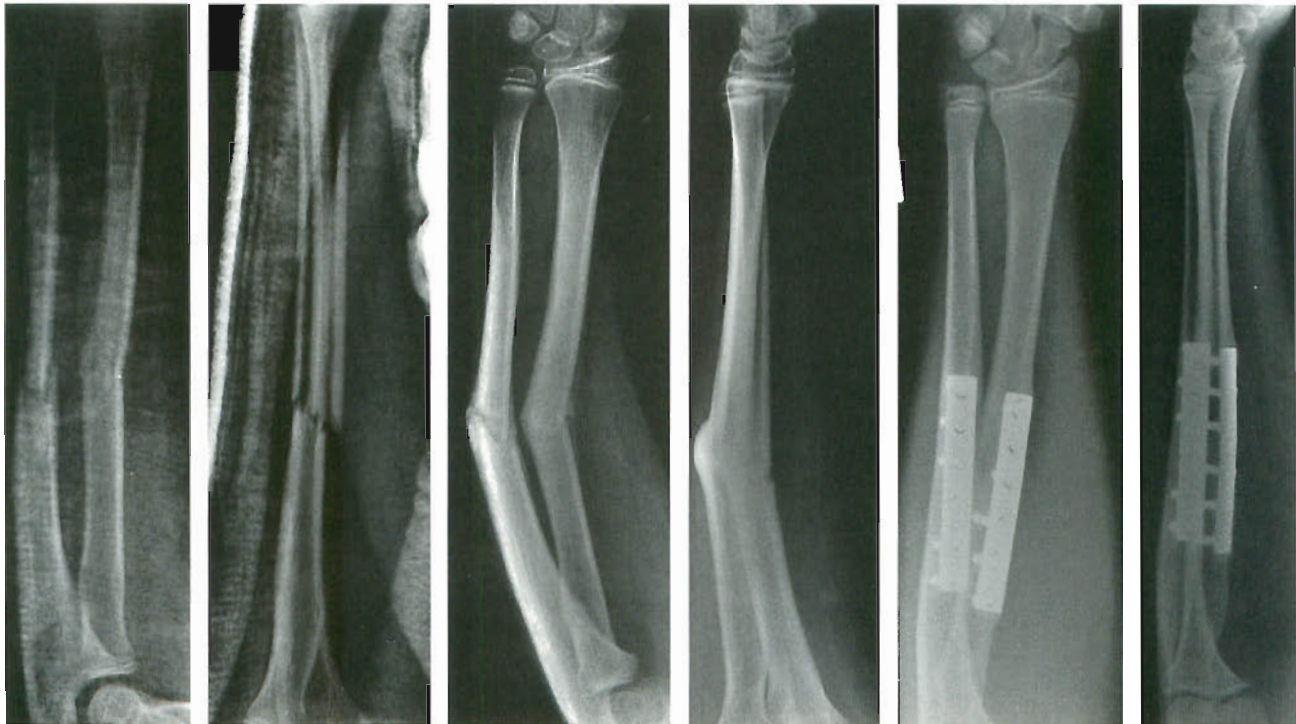

FIGURE 32-44. Malunion of the forearm in a 14-year-old child. **A:** Anteroposterior view of the alignment after closed reduction and casting. **B:** The lateral projection shows acceptable alignment. **C:** The anteroposterior projection 12 weeks after treatment shows malunion of the radius and ulna. **D:** A lateral projection shows dorsal angulation. Clinical evaluation demonstrated only 15 degrees of rotation of the forearm. **E:** An anteroposterior projection after osteotomy and internal fixation with 3.5-mm compression plates. **F:** The lateral projection shows restoration of anatomic alignment. The range of motion was improved significantly, with full supination but a loss of the last 20 degrees of pronation.

A-C

D-F

Distal Metaphyseal Fractures of the Radius and Ulna

Distal metaphyseal fractures of the radius and ulna are common, and are usually caused by a fall onto the hand with the wrist in a pronated, extended position. Unicortical fractures (i.e., torus or buckle fractures) are frequently encountered, and are stable injuries. Treatment is directed toward patient comfort and protection of the forearm from further injury. Immobilization with a below-elbow cast or splint for 2 to 3 weeks is sufficient. Torus or unicortical fractures should be differentiated from the minimally displaced bicortical fracture that has a propensity for secondary angulation (222) (Fig. 32-45). A well-molded cast is recommended for complete fracture, and should extend above the elbow, if there is pain with forearm rotation. Follow-up radiographs are recommended 1 week after complete bicortical fractures.

Fractures of the distal radial metaphysis have great potential for remodeling, because of their proximity to the distal growth plate. Bayonet apposition may be accepted until

early adolescence (223) (Fig. 32-46). Friberg (12–14) observed that dorsal tilt up to 20 degrees remodels 50% of these fractures in the first 6 months, and the remaining 50% in an additional 18 months, as long as the growth plate remains open. Deformity greater than 20 degrees may also remodel, but this is less predictable, especially in older children. The guidelines for acceptable residual angulation are age-dependent, and serve only as a general indicator of expected results. Dorsal tilt (apex-volar angulation), up to 35 degrees, can be accepted in children younger than 5 years of age. This decreases to 25 degrees for children between 5 and 12 years of age. In older children, the dorsal tilt should be controlled at less than 15 degrees, to ensure a good outcome. Radial deviation remodels less than angulation in the plane of flexion and extension. Therefore, radial deviation should be kept to less than 15 degrees in children younger than 12 years of age and to less than 10 degrees in older children (223–225).

Treatment of displaced or angulated fractures consists of closed reduction and plaster immobilization. In complete fractures, the distal fragment is usually dorsally displaced, but the dorsal periosteum is intact. Reduction is accomplished by increasing the deformity, which relaxes the intact periosteal hinge. Longitudinal traction is then applied with digital pressure at the fracture site until length is restored. The angular deformity is then corrected (Fig. 32-47). More reduction force is required if the ulna is intact, and pronating the distal segment during the reduction maneuver assists in fragment realignment. After reduction, the wrist should be placed in slight palmar flexion and ulnar deviation. The cast is molded with three-point pressure dorsally over the distal fragment, centrally on the volar surface of the forearm, and proximally on the dorsal surface of the forearm. The cast molding technique is designed to counter the tendency for later radial and dorsal fracture displacement. Most often, an above-elbow cast or splint is used for immobilization, but it has been demonstrated that a well-molded below-elbow cast can also effectively control these fractures (226). Fracture alignment should be monitored closely for the first few weeks after injury, when the potential for redisplacement is greatest.

Occasionally, a distal third metaphyseal fracture is irreducible by closed manipulation. This may be accepted, except in patients approaching skeletal maturity, as long as alignment is within the described guidelines. However, redisplacement is more common when bayonet apposition is accepted. The reported incidence of fracture redisplacement varies considerably (226,227). Supination of the forearm has been recommended to reduce the pull of the brachioradialis, and thereby reduce the incidence of delayed dorsal angulation (228). Fractures that do not maintain their positions can be remanipulated. Percutaneous pinning has been recommended to avoid repeated manipulation (228), but physeal closure has been reported with this technique (229).

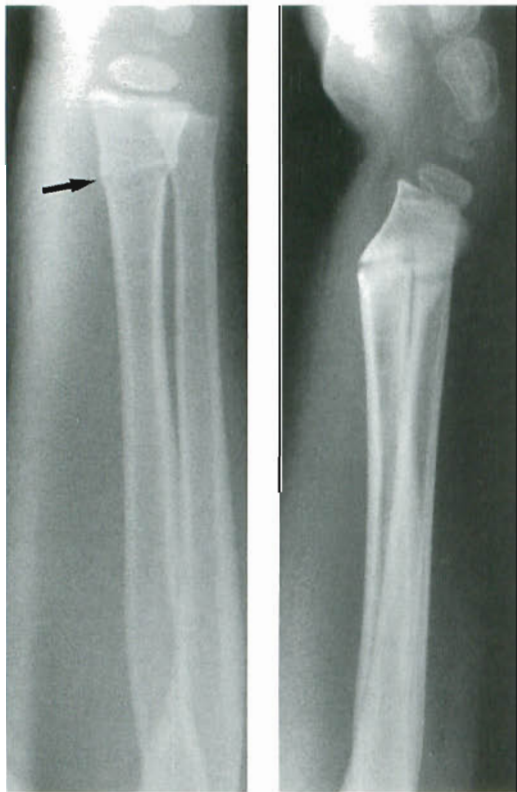

FIGURE 32-45. Bicortical fracture. **A:** This minimally displaced bicortical fracture (arrow) of the distal radius can easily be mistaken for a simple dorsal buckle fracture. **B:** Three weeks later, after cast removal, 35 degrees of dorsal angulation is seen. Although this probably will remodel during the next year, there is considerable clinical deformity and loss of rotation until this angulation resolves. This problem can be avoided through the use of a well-molded below-elbow cast or a cast placed above the elbow to control rotation.

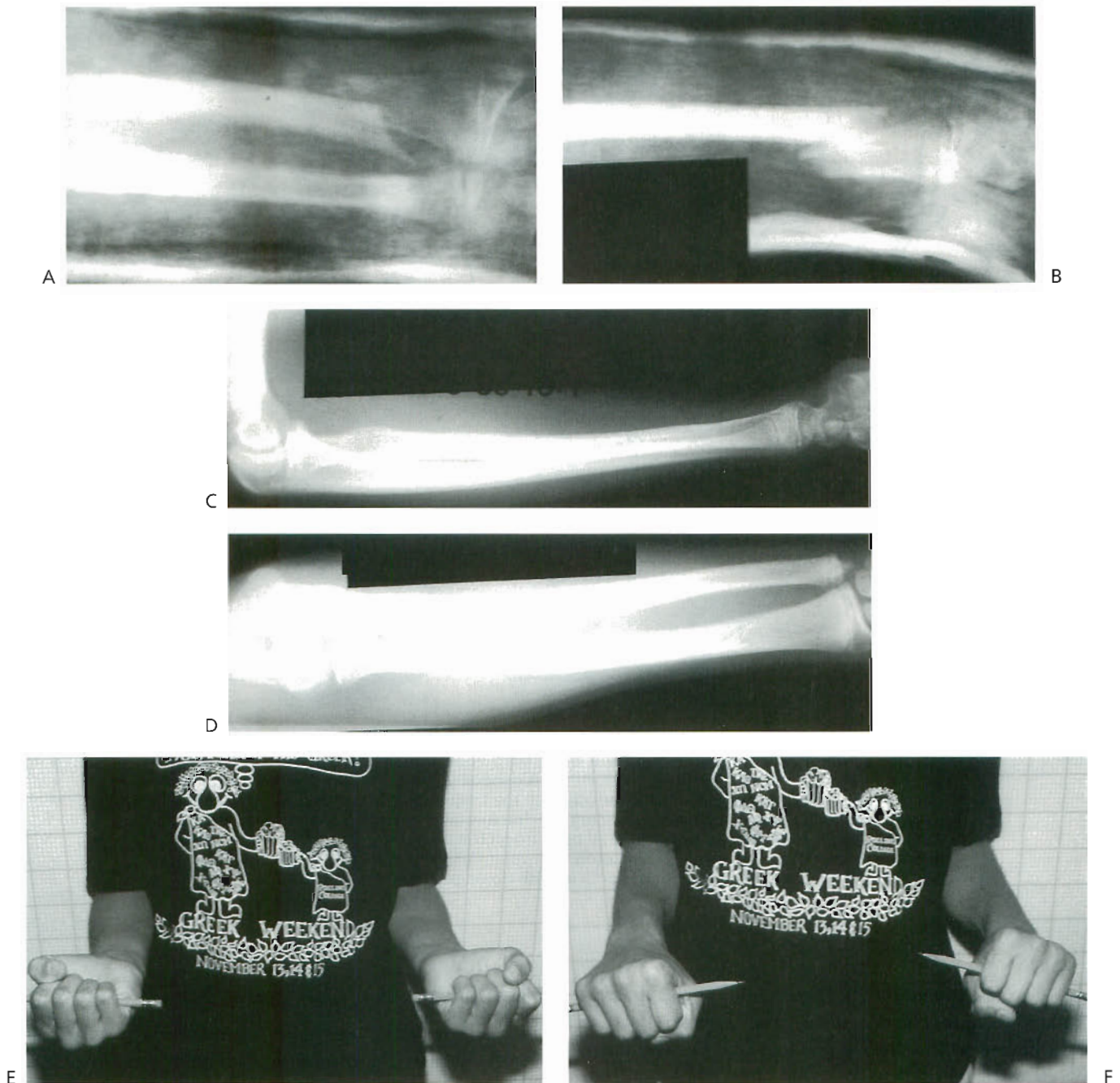


FIGURE 32-46. Distal radius and ulna fractures in a 14-year, 6-month-old boy. **A** and **B**: Bayonet opposition was accepted in cast. **C** and **D**: Eighteen months after injury, radiographs demonstrate satisfactory remodeling. **E** and **F**: Range of motion and function are symmetric.

Complications

Complications are rare. Significant residual deformity can remodel. Dorsal tilt of 35 degrees and radial tilt of 15 degrees should be given a chance to remodel before considering osteotomy. Misdiagnosis of a Galeazzi-type fracture can also occur. Galeazzi-type fracture-dislocation should be suspected when an isolated radius fracture is associated with

fracture of the ulnar styloid (186). Distal physeal separation of the ulna is uncommon, but often leads to premature physeal closure (187).

Distal Radius Physeal Fracture

Fracture of the growth plate of the distal radius is the second most common physeal injury, with phalangeal fractures

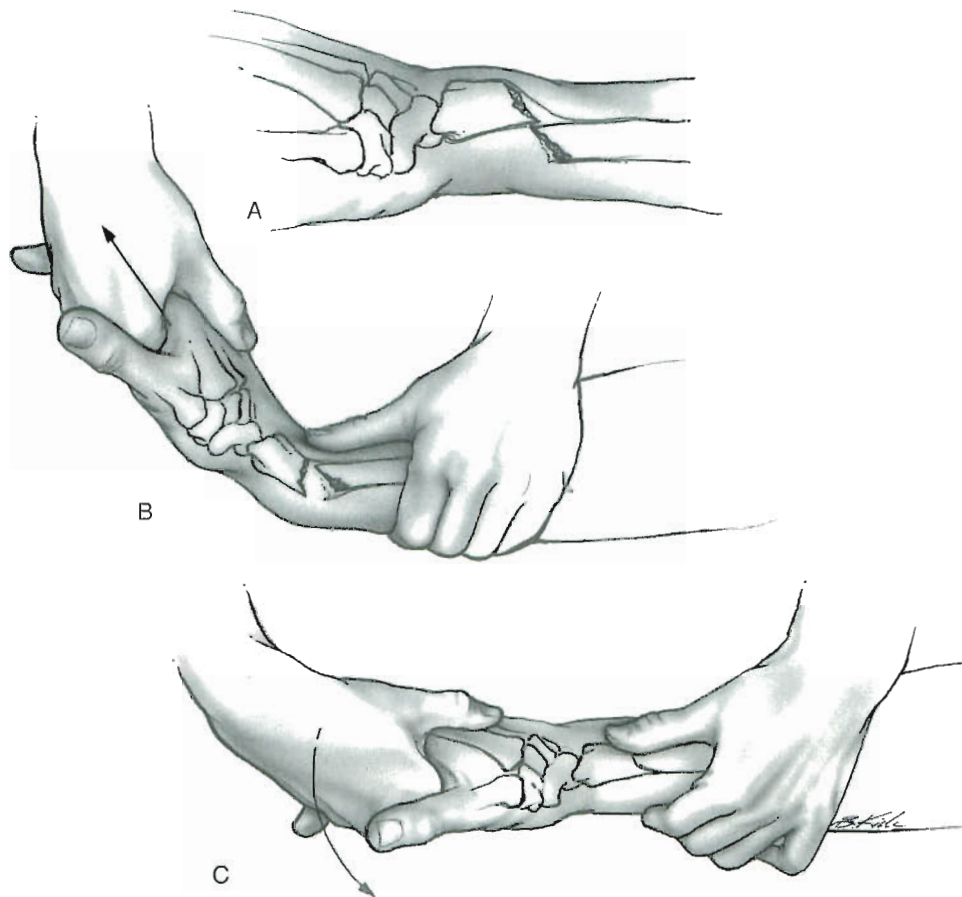


FIGURE 32-47. Reduction technique for a distal both-bone fracture. **A:** The fracture is 100% translated and shortened. The dorsal periosteum is generally intact. Longitudinal traction alone can tighten the soft tissues, preventing reduction of the fragment. **B:** The dorsal soft tissues need to be completely relaxed, by hyperextending the fracture and providing longitudinal traction, restoring length to the dorsal cortex. Digital pressure on the distal fragment generally helps with this maneuver. **C:** The reduction is completed with volar flexion of the distal fragment. The goal is at least 50% apposition of the bony surfaces with no angulation.

being the most common (29). Distal radius physal fracture accounts for approximately 15% of all forearm fractures (177). Eighty percent are Salter-Harris type I or II injuries. The germinal cells remain with the distal epiphyseal fragment, and anatomic reduction is unnecessary for continued normal growth. Occasionally, more complex injuries occur, with higher rates of premature growth arrest, and anatomic reduction may be required.

Treatment for the type I and II fractures is similar to the treatment of distal radius metaphyseal fracture described previously. Multiple reduction attempts may lead to growth plate damage. Two or more attempts have produced growth arrest in slightly more than 25% of these patients (230). Repeat manipulation should not be attempted more than 10 days after injury, because physal healing has already commenced, and further growth plate trauma may result. Cast immobilization can usually be discontinued 4 weeks after injury.

Complications

Growth arrest has been reported after nondisplaced or minimally displaced fracture. If growth arrest occurs, corrective lengthening osteotomy using iliac crest graft has been successful in restoring alignment and function (231,232).

FRACTURES OF THE THORACIC AND LUMBAR SPINE

Clinical Features

Spine fractures in children represent 1 to 2% of all pediatric fractures (3). Most of these injuries involve the cervical spine, and are discussed in Chapter 21. Thoracolumbar spine injuries are less common in children than in adults, but the incidence is difficult to determine. The reported incidence may be artificially low, because some children

with injuries severe enough to cause spinal fracture may die from associated injuries (233). Causes of spine injury include falls, athletic activities, battering, and motor vehicle trauma (234,235).

There is a 50% incidence of associated injuries in children who sustain spine trauma from motor vehicle crashes (234). Complete examination is essential when evaluating a child with multiple injuries, because spine fractures are occasionally overlooked (236,237). Examination may reveal tenderness, swelling, ecchymosis, or a palpable defect posteriorly along the spinous processes. A seatbelt mark across the abdomen or injury of an abdominal organ should increase the index of suspicion. Any loss of sensory or motor function should be accurately documented.

Spinal cord injury is less frequent in children than in adults. Perhaps this is attributable to the fact that the pediatric spine is much more flexible than the adult spine, and allows greater deformation without fracture. This increased musculoskeletal elasticity is not shared by the spinal cord, and may lead to the occurrence of spinal cord injury without radiographic abnormality. The disproportionately large head size and other structural features in children place the cervical and upper thoracic region at greatest risk for spinal cord injury. Trauma to the lower thoracic or lumbar spine in children is rarely associated with spinal cord injury. The prognosis for recovery from incomplete neurologic injury is better in children than in adults, but complete lesions rarely improve (234).

Plain radiographs should be obtained when spine trauma is suspected, but these may be difficult to interpret. A CT and/or MRI are indicated for evaluation of the majority of patients, when thoracolumbar injuries are suspected or known to be present (237). A CT is especially helpful to evaluate the bony structures. Sagittal and coronal reconstruction can be used to evaluate alignment and spinal canal encroachment. MRI is more useful than CT to evaluate the spinal cord, intervertebral discs, and other soft tissue structures (237). An MRI is indicated in all cases with neurologic deficit.

Anatomy and Classification

The thoracic and lumbar vertebrae form three main ossification centers, one for the left and right sides of the neural arch and one for the body. The junction of the arches with the body occurs at the neurocentral synchondrosis. This junction is visible radiographically until the age of 3 to 6 years. It lies just anterior to the base of the pedicle, and can be misinterpreted as a congenital anomaly or fracture in younger children. Secondary centers of ossification occur in flattened, disc-shaped epiphyses superior and inferior to each vertebral body. These centers provide longitudinal growth, but do not cover the entire vertebral body (238). Ossification of these growth plates at the age of 7 to 8 years creates the radiographic impression of a groove at the corner of each vertebral body. This groove is circumferential around the upper and lower end plates of each vertebra.

The ligaments and discs attach to this groove, which is therefore an apophyseal ring. The ring apophysis develops its own ossification center by the age of 12 to 15 years, and fuses with the remainder of the vertebra at skeletal maturity (239).

Classification systems for thoracolumbar spine fractures in children have not been proposed. The three-column theory of Denis (240) allows classification of adult fractures, and also has relevance for the pediatric population. According to this theory, the thoracolumbar spine consists of anterior, middle, and posterior columns. The anterior column includes the anterior longitudinal ligament, the anterior half of the vertebral body, and the anterior portion of the annular ligament. Middle column structures are the posterior half of the vertebral body, the posterior annulus, and the posterior longitudinal ligament. The posterior column includes the neural arch, the ligamentum flavum, the facet joint capsules, and the interspinous ligament. Spinal stability is primarily dependent on the status of the middle column (241).

Denis (240) applied this three-column theory, to classify minor or major thoracolumbar fractures. Minor injuries include isolated fractures of the posterior elements. Major fractures are subdivided into compression fractures, burst fractures, seatbelt-type injuries, and fracture-dislocations. Compression of the anterior column is usually stable, and results from axial loading in flexion. Lateral compression fractures of the vertebral body may also occur. Further compression results in a burst fracture that is unstable, because the middle column becomes involved. Lapbelt injuries (Chance fractures) are unstable, because they disrupt the posterior and middle columns by flexion and distraction forces. Fracture-dislocations usually involve all three columns, and result from various combinations of forces.

Certain types of thoracolumbar injuries are unique to children. These include most cases of spinal cord injury without radiographic abnormality, posterior limb or apophyseal fractures, and fractures associated with child abuse.

Treatment of Thoracolumbar Fractures

Older adolescents sustain injuries similar to those seen in adults, and should be managed accordingly (242). The majority of thoracolumbar spine fractures in children and younger adolescents are minor, stable, and without neurologic deficit. Simple bed rest and gradual resumption of activities are generally sufficient for management of these injuries. In the active athlete with an acute fracture of the pars intraarticularis, a thoracolumbar-sacral orthosis (TLSO) is recommended for 6 to 8 weeks in an attempt to obtain union.

Compression Fractures

The majority of compression fractures in children occur in the thoracic spine (Fig. 32-48). Multiple compression

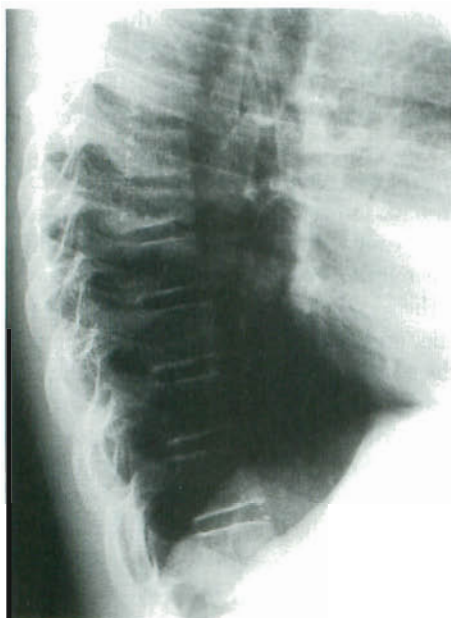

FIGURE 32-48. An 11-year-old girl fell from a horse and sustained a compression fracture at T6, which is seen on this lateral spine radiograph.

injuries are not uncommon. When wedging of the thoracic or lumbar vertebra is less than 10 degrees, treatment consists of bed rest with gradual resumption of activities, as tolerated. When wedging is greater than 10 degrees and the Risser sign is less than 3, immobilization in hyperextension is recommended for a period of 2 months, followed by bracing for 1 year or more (235). Surgical stabilization is recommended when compression is greater than 50%, for lateral compression greater than 15 degrees, or in adolescents near skeletal maturity (235,243).

Burst Fractures

These injuries can be managed nonoperatively when the posterior column is intact and there is no neurologic injury (235,243,244). Treatment usually consists of hyperextension casting for 2 to 3 months and bracing for an additional 6 to 12 months. Surgical decompression and instrumentation are recommended for patients with neurologic compromise (243,244). Posterior distraction and instrumentation may achieve decompression by ligamentotaxis with reduction of the retropulsed fragments (245). Anterior decompression has been recommended in the presence of multiple nerve root paralysis, but the role of anterior decompression and instrumentation remains controversial (246).

Lapbelt Fractures (Chance-type Fracture)

This flexion-distraction injury has been associated with the use of lapbelt restraints, when the lapbelt slides up the torso

and rests over the abdomen, instead of the proximal thighs and hips (246). The incidence of Chance fractures in children has increased since the introduction of mandatory seat-belt laws. Fortunately, this injury has a better prognosis in children than in adults (247). Neurologic deficits are infrequent, but intraabdominal injury is common and obscures the diagnosis of spine trauma (Fig. 32-49).

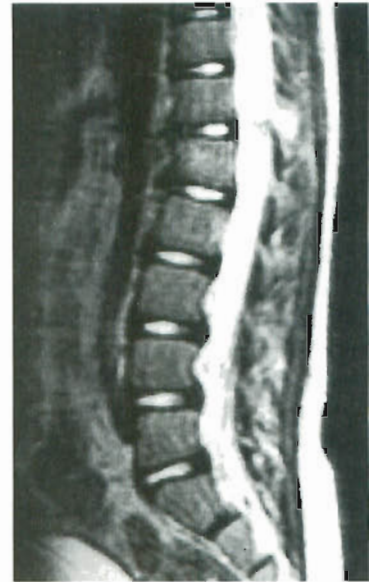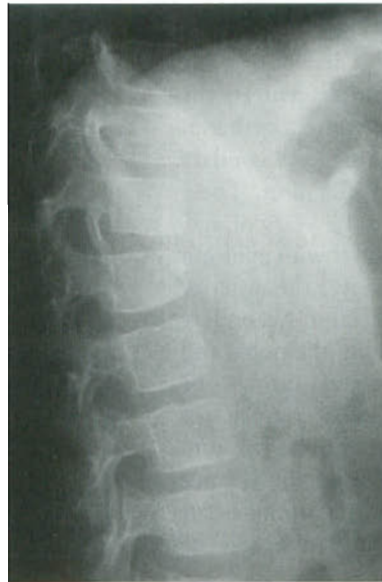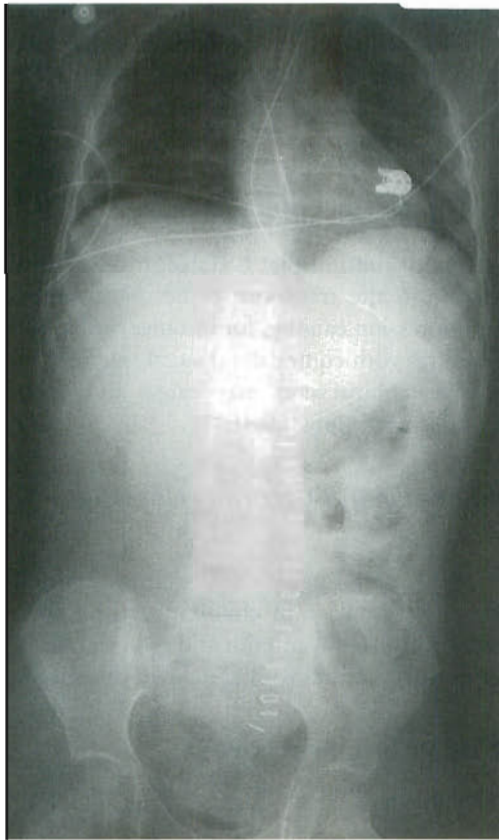This is an unstable injury in most cases. Treatment consists of cast immobilization for 8 to 10 weeks, when there is minimal displacement and the fracture line goes through bone. Posterior surgical stabilization is indicated in the presence of displacement or neurologic deficits, or when there is a significant ligamentous component, instead of fracture through bone. One-level posterior fusion is generally sufficient (139,236). This can be achieved by spinous process wiring and cast immobilization, or by hook/rod and pedicle screw fixation in older children.

Limbus Fracture (Apophyseal Fracture)

This fracture is typically seen in the adolescent or young adult, and presents clinically like a herniated nucleus pulposus. It often results from lifting a heavy object, but may occur from falls or twisting injuries. The patient may describe a “pop” at the time of injury, followed by radiculopathy. Delayed diagnosis is common (248). Takata et al. (249) described four types of growth plate injuries to the spine. However, nonoperative management is rarely successful, regardless of the type (243,248). Once the diagnosis is confirmed, MRI and/or CT should be used to determine the exact location and configuration of the lesion. Surgical excision is then performed by piecemeal excision of the limbus fragment.

Complications

Complications of thoracolumbar fractures in children are uncommon, unless there is an accompanying neurologic deficit. Major fractures in children can be unpredictable. They may remodel or develop late deformity with spontaneous progression (234,235). Late deformity is common when there is an associated neurologic deficit, or after wide laminectomy (250). Remodeling is more likely in younger children without spinal cord injury, particularly when the iliac apophysis is incompletely ossified (Risser sign less than 3) (235). However, remodeling can occur in older children. Spontaneous remodeling and redevelopment of the spinal canal has been observed in adults after burst fractures with canal encroachment (251). Long-term back pain is uncommon after spine fractures in children. Perhaps the juvenile discs and facet joints are relatively resistant to permanent damage (234).



B,C

FIGURE 32-49. Lapbelt fracture (Chance fracture). **A:** Anteroposterior abdominal and chest radiograph of a 10-year-old girl involved in a motor vehicle crash. She was restrained with a lapbelt only. This radiograph was taken after laparotomy for a mesenteric tear. **B:** Several days after laparotomy, the patient complained of back pain. This lateral radiograph shows a flexion/distraction injury through the body of L1, and posteriorly through the cephalad portion of L1 and the spinous process of T12. **C:** Magnetic resonance image. Note the injuries to the body of L1, and to the interspinous and supraspinous ligaments at T12 and L1. The posterior column failed in tension. The patient was managed successfully with an extension cast for 8 weeks.

PELVIC FRACTURES

Clinical Features

Fractures of the pelvis in children are uncommon. The annual incidence has been estimated to be 1 per 100,000 children per year (3). Avulsion fractures often result from athletic injuries in adolescent athletes. Avulsion injuries are discussed elsewhere in this textbook. Other types of pelvic fractures in children are usually the result of high-energy trauma. However, pediatric pelvic fractures are often stable and minimally displaced. The immature pelvis is more malleable than that of an adult, largely because of a greater component of cartilage and the greater flexibility of adjacent joints. This allows greater energy absorption before fracture. The flexibility of the pediatric pelvis also permits single breaks in the pelvic ring to occur. High-energy, unstable pelvic fractures are rare. The majority of unstable pelvic fractures are caused by a pedestrian being struck by a motor vehicle (252,253).

Approximately 20% of polytraumatized children have pelvic fractures (52), and children with pelvic fractures have associated injuries in approximately 75% of cases (254–256). These associated injuries include head injuries, intraabdominal trauma, urologic disruptions, and addi-

tional fractures. Mortality rates are lower in children than in adults, but death occurs in 3 to 15% of juvenile pelvic trauma cases (51,253–255,257). Death is most frequently related to head injury, but exsanguination from fractures or visceral injuries can occur. The risks of hemorrhage and associated visceral injuries correlate with fracture patterns (254,258). Patients with bilateral anterior and posterior fractures are at greatest risk, whereas isolated pubic ramus fractures have the lowest risk of hemorrhage and intraabdominal injury.

Evaluation includes a careful physical examination for associated injuries, including neurologic deficits. Any laceration should be inspected to determine whether an open fracture has occurred. Rectal examination is indicated to look for hemorrhage signifying bone penetration into the rectum, and to verify intact perineal sensation (i.e., sacral plexus function). Pelvic stability should be tested with anterior and lateral compression of the pelvis. Peripheral arterial circulation should also be noted. Plain radiographs are useful for screening, but may be difficult to interpret. Pelvic inlet (40 degrees caudal), outlet (40 degrees cephalad), and Judet (45 degrees oblique) views can help define the fracture pattern and the potential involvement of the acetabulum. However, these views have largely been replaced with CT with or without three-dimensional reconstruction.

Anatomy and Classifications of Pelvic Fractures

The pelvis is formed from three ossification centers: the ischium, the pubis, and the ilium. These come together at the acetabulum to form the triradiate cartilage. Secondary ossification centers can be confused with fractures. These appear at the apophyses between 13 and 16 years of age. The apophyses that are principally associated with avulsion injuries are located on the ischial tuberosity, the anterior inferior iliac spine, and the anterior iliac crest. Secondary centers of ossification can also develop along the pubis and the ischial spine. Several other normal variants can also be confused with fractures. An area of particular confusion is at the junction of the inferior pubic ramus and the ischium. Before ossification, this junction can have the appearance of a fracture, especially when ossification is asymmetric. A swelling may also occur in this area, and can simply be observed when asymptomatic.

Several classifications have been proposed for pelvic fractures (253). The author prefers the classification proposed by Watts (259):

1. Avulsions.
2. Fractures of the pelvic ring (stable and unstable).
3. Fractures of the acetabulum.

Fractures of the pelvic ring can be subclassified using the AO/ASIF classification of adult pelvic fractures (257). This classification is based on both the mode of injury and the resulting stability characteristics of the fracture.

Type A: Stable Injury

Stable injuries include isolated fractures of the pubic ramus or iliac wing (Fig. 32-50). It should be noted that diastasis

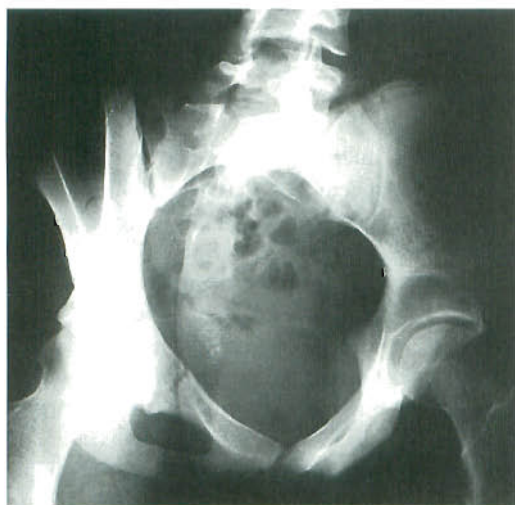

FIGURE 32-50. A 16-year-old girl with an isolated right pubic ramus fracture best visualized on this oblique radiographic view.

of the pubic symphysis can occur in children, without instability of the sacroiliac joint posteriorly, because of the elasticity of the child's pelvis. In young children, this fracture usually represents separation at the bone–cartilage junction rather than joint disruption.

Type B: Rotationally Unstable Fractures

This is a pelvic ring disruption that is stable in the vertical plane, but unstable in the transverse plane. Mechanisms include lateral compression causing, for instance, pubic and ischial ramus fractures with contralateral sacral fracture. Alternatively, anterior compression may cause an “open-book” type of injury with pubic diastasis.

Type C: Rotationally and Vertically Unstable Fractures

This group includes bilateral pubic rami fractures (straddle injuries), which rarely displace in children; vertical shear fractures through the ipsilateral anterior and posterior pelvic rings, and anterior ring fractures with acetabular disruption.

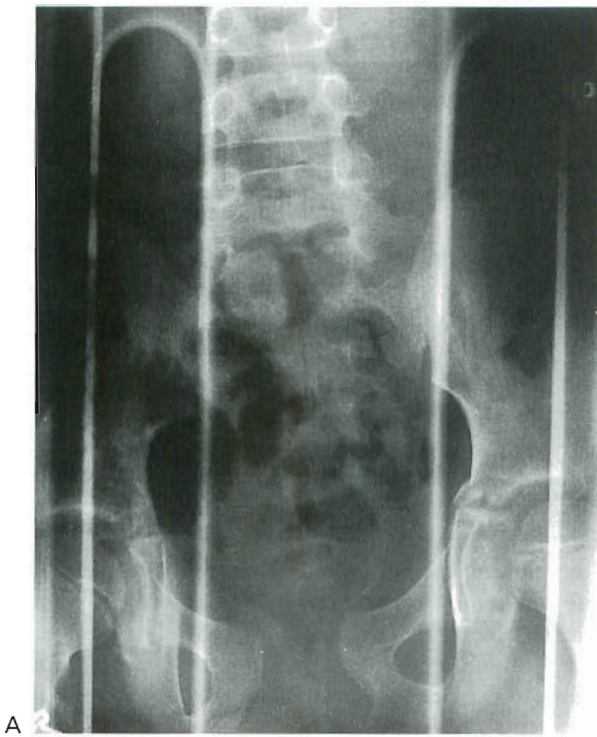Treatment of Pelvic Fractures

Pelvic Ring Fractures

Most pelvic fractures in children have a favorable result with a minimum of treatment. Stable fractures are managed by bed rest followed by gradual resumption of weight bearing, as tolerated. Unstable pelvic fractures that do not involve the acetabulum can be managed with more prolonged bed rest (1 to 2 months), when displacement is minimal (less than 1 cm, in the author's opinion). Careful observation with frequent radiographs is recommended to recognize and treat any additional displacement. Union and remodeling occur reliably, in spite of mild displacement (252,255,260). Unstable pelvic fractures with greater amounts of displacement (more than 1 cm) should be reduced with traction or open reduction. The author recommends reduction of pubic diastasis (open-book) fractures, when the diastasis exceeds 3 cm, or when stability is required for urologic reconstruction. Stabilization after reduction can be achieved with pelvic sling and/or cast immobilization. Usually, external and/or internal fixation are preferred for unstable open-book or other type B fractures (253,257) (Fig. 32-51). Type C fractures may require internal fixation of posterior injury, in addition to anterior stabilization with external fixation or other means. Surgical stabilization is also appropriate to reduce retroperitoneal blood loss, and to facilitate mobilization of the child with multiple injuries.

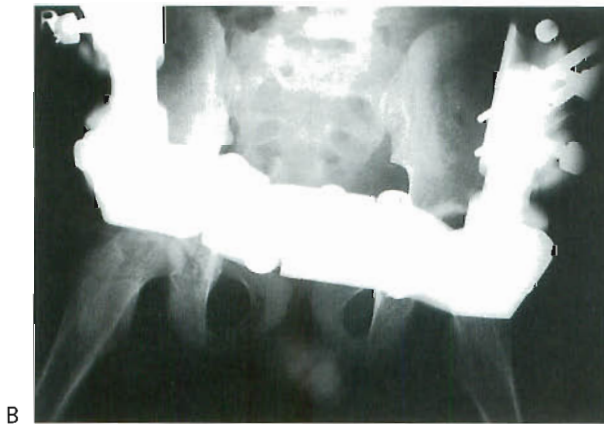Acetabular Fractures

Acetabular fractures, except for stable posterior fracture-dislocations, require precise restoration of joint congruity.

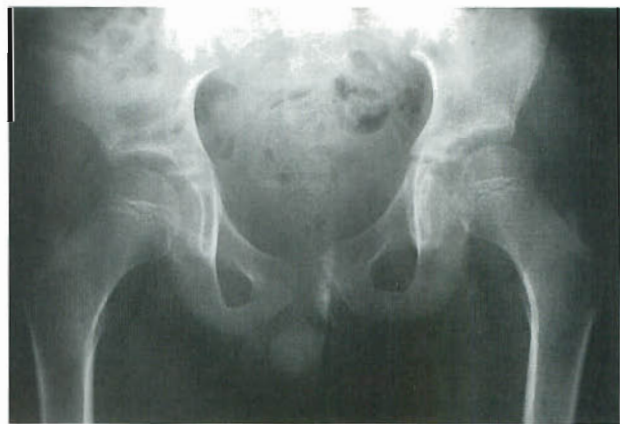

A

FIGURE 32-51. A 10-year-old boy run over by a bus. **A:** Rotationally unstable pelvic fracture with bilateral acetabular fracture. Note the pubic diastasis. **B:** Open removal of a loose fragment in the left acetabulum and anterior external fixation for pubic diastasis were performed. **C:** Three months after surgery, the pubic diastasis has healed. The patient was fully weight bearing with no pain.



B



C

Nondisplaced acetabular fractures are managed closed. When displacement is present, open reduction with stable internal fixation and early motion is recommended (257). Communion is often less severe in children than in adults, and the results of surgical management are generally satisfactory. Poor results after anatomic reduction may still occur, because of the magnitude of the initial trauma (261).

Premature closure of the triradiate cartilage is a potential complication that is unique to the immature skeleton (262). Fractures that cause premature closure are usually nondisplaced, and do not require open reduction. Children younger than 10 years of age are at the greatest risk for this complication. Disturbance in growth leads to the development of a shallow acetabulum, because the triradiate cartilage is responsible for growth in the height and width of

the acetabulum. Hip subluxation may follow, necessitating redirection pelvic osteotomy.

Complications

Acute management of pelvic fractures and associated injuries can be challenging, but long-term complications are rarely attributable to the bony structures. Untreated, severely displaced fractures can result in a limp, rotational deformity, or limb-length discrepancy. Acetabular injuries are at risk for developing traumatic arthritis, in spite of anatomic reduction. Premature closure of the triradiate cartilage can be problematic in younger children. However, residual morbidity is usually attributed to associated injuries, especially traumatic brain injury.

FRACTURES AND DISLOCATIONS OF THE HIP

Hip Dislocation

Dislocation of the hip in children is uncommon, representing only 5% of all pediatric dislocations. Most hip dislocations are posterior, but anterior and obturator dislocations can occur (263,264). This injury may result from minor trauma, such as tripping or falling; from moderate force, as in football or soccer; or from high-energy impact, as in motor vehicle crashes. The mechanism of injury depends somewhat on the age of the child. Hip dislocations in children younger than 10 years of age are frequently the result of mild trauma, because joint laxity is common, and the acetabulum is largely cartilaginous (263,264). Dislocations in children older than 10 years of age are likely the result of moderate or severe trauma. Dislocation from moderate trauma may result in spontaneous incongruous reduction and capsular interposition (265). This is rare, but easily misdiagnosed in children and adolescents. Any suggestion of joint space widening after reduction should be investigated with CT (Fig. 32-52).

Treatment

Treatment consists of closed reduction with adequate muscle relaxation and analgesia. Early closed reduction within 6 h of injury is recommended. Reduction is rarely difficult in children, but gentle reduction is especially important in the adolescent age group. Occult epiphyseal injury may be present in this older age group, and epiphyseal separation can occur during attempted reduction. The reduction technique for posterior dislocation requires hip and knee flexion, usually with adduction of the hip. Longitudinal traction is then applied, while an assistant stabilizes the pelvis. The limb is then extended, internally rotated, and abducted. After the hip is reduced, the stable arc or motion should be assessed. Postreduction radiographs should include the opposite hip to confirm a concentric reduction with symmetric joint spaces. A CT is recommended for any joint space widening, when instability is noted, and after reduction in older children. A CT is not necessary in younger children with stable concentric reduction and no evidence of acetabular fracture on plain radiographs. The child younger than 8 years should be immobilized in a spica cast or abduction pillow, with strict bed rest for 4 to 6 weeks, to reduce the risk

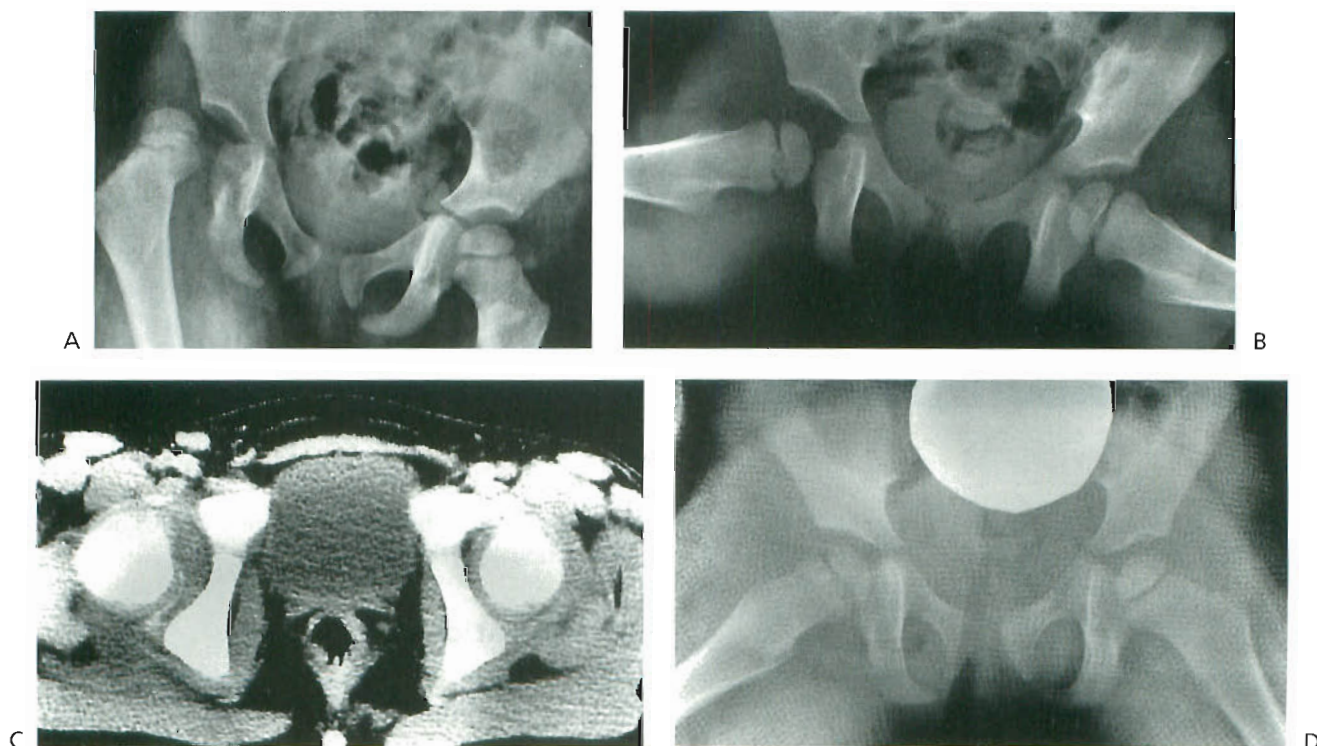


FIGURE 32-52. Traumatic hip dislocation. **A:** Anteroposterior projection of a 3-year, 6-month-old child with a low-energy injury producing a posterior hip dislocation. **B:** An anteroposterior view of the pelvis after closed reduction of the hip, taken in an emergency department. Clinically, a stable reduction was obtained, but there is significant joint space widening, suggesting an intraarticular obstruction. **C:** The computed tomography scan confirms incomplete reduction. There is some radiodense material in the posterior acetabulum. **D:** Posterior open reduction of the hip was performed, and the interposed soft tissue was removed. There was no osteochondral fracture. An anteroposterior radiograph of the pelvis confirms the concentric symmetric reduction of the hip. A spica cast was applied for 4 weeks.

of recurrent dislocation. Stable closed reductions in older children can be managed with activity restriction and decreased weight bearing for 6 weeks, to allow capsular healing and reduction of posttraumatic inflammatory response.

The indications for open reduction include unstable closed reduction, nonconcentric reduction, or a large acetabular rim fragment with displacement of more than 2 mm. Open reduction is approached in the direction of the dislocation, such as the posterior interval (i.e., Kocher-Langenbeck approach) for posterior dislocations. Postoperative management after open reduction is the same as that after closed reduction.

Complications

The reported incidence of avascular necrosis in children is 3 to 10%, approximately one-half that of adults. The risk of avascular necrosis is diminished when reduction is achieved within 12 h, and preferably within 6 h, of injury (263,264). Traumatic arthritis is infrequent. The long-term prognosis for arthritis is related to the severity of the trauma, associated fractures, and treatment delays beyond 24 h. Coxa magna in the absence of avascular necrosis has been observed in many children after traumatic hip dislocation. The cause is probably reactive hyperemia secondary to extensive soft tissue injury.

Coxa magna does not seem to influence clinical outcome.

Proximal Femur Fractures

Proximal femur fractures represent approximately 1% of all pediatric fractures, and are usually the result of high-energy trauma, typically a motor vehicle crash or a fall from a substantial height. In 30% of cases, there is another significant associated injury to the chest, head, or abdomen. The exceptions to this mechanism of injury are children younger than 2 years of age who have been subjected to child abuse and fracture through a pathologic lesion of the femoral neck (e.g., bone cyst). Fortunately, proximal femur fractures are rare. The consequences of this injury are significant, including femoral head avascular necrosis, physeal damage with growth arrest, malunion, and nonunion. Long-term studies indicate an overall 47% avascular necrosis rate for proximal femur fractures, with a 30% malunion rate (266,267). Most patients who develop avascular necrosis need later reconstructive hip surgery, with almost one-half requiring total hip arthroplasty (267).

Anatomy and Classification

In the infant, the proximal femur is composed of a single, large cartilaginous growth plate (268) (Fig. 32-53). The

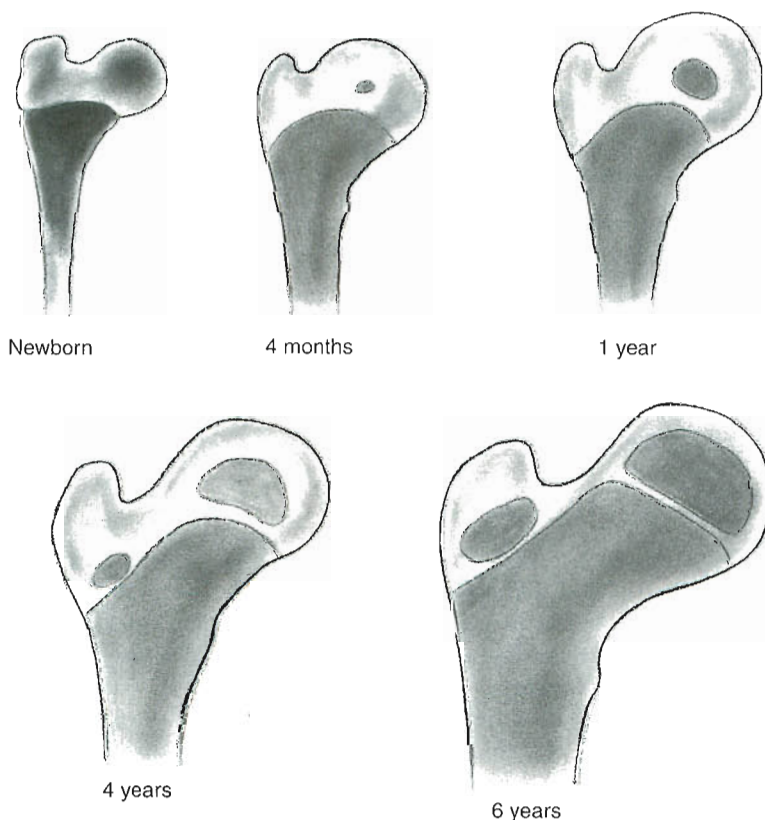


FIGURE 32-53. Development of the growth centers in the proximal femur. (From ref. 268, with permission.)

medial portion becomes the epiphyseal center of the femoral head (ossifying around 4 months of age), forming the proximal femoral physis. The lateral portion of the proximal femur forms the greater trochanter physis, and this epiphysis ossifies by 4 years of age. Injury to the proximal femur can affect one or both centers of growth. The proximal femoral physis is responsible for the metaphyseal growth of the femoral neck, and provides 13% of the total length of the femur. The greater trochanter helps shape the proximal femur, and damage to this apophysis, in children younger than 10 to 12 years of age, produces an elongated, valgus femoral neck (269).

The vascular supply of the growing child's proximal femur is jeopardized by these fractures, and the extent of damage greatly affects the final outcome. The dominant arterial source for the femoral head is the lateral epiphyseal vessels, which are the terminal extension of the medial femoral circumflex artery. These posterosuperior and posteroinferior vessels are found at the level of the intertrochanteric groove, where they penetrate the capsule and course along the femoral neck toward the head, supported by the retinacular and periosteal tissue in the region (270,271) (Fig. 32-54). The lateral circumflex system can supply a portion of the anterior femoral head until 2 to 3 years of age, after which it primarily supplies the metaphysis. In children older than 14 to 18 months of age, the proximal femoral physeal plate becomes an absolute barrier to the metaphyseal blood supply, preventing direct vascular penetration of the femoral head (270,271). Subsequently, the metaphyseal and epiphyseal vascular networks remain separate in children, until complete physeal closure occurs. This may account in part for the higher incidence of avascular necrosis among children than adults. The vessels of the ligamentum teres do not contribute a significant portion of the blood supply to the femoral head, especially in children younger than 8 years of age.

It is postulated that displaced fractures may leave the vascular leash intact, but occluded until realignment is established (272). Nondisplaced fractures do not have the same incidence of avascular necrosis as displaced fractures. This fact further supports the concept that the magnitude of initial fragment separation is a major determinant of vascular damage (273). It has also been suggested that prompt decompression of the intracapsular hematoma contributes to the restoration of normal vascular flow, and reduces the incidence of femoral head avascular necrosis (272,274,275).

Delbet's classification (Fig. 32-55) offers a simple yet useful system for the treatment and prognosis of proximal femur fractures (277). Type I fractures are transphyseal separations. Although this physeal separation is occasionally seen as a birth fracture, it is usually the result of high-energy trauma, and it may also be the result of intentionally inflicted injury. Obstetric fracture-separations uniformly have excellent clinical results without avascular necrosis, despite

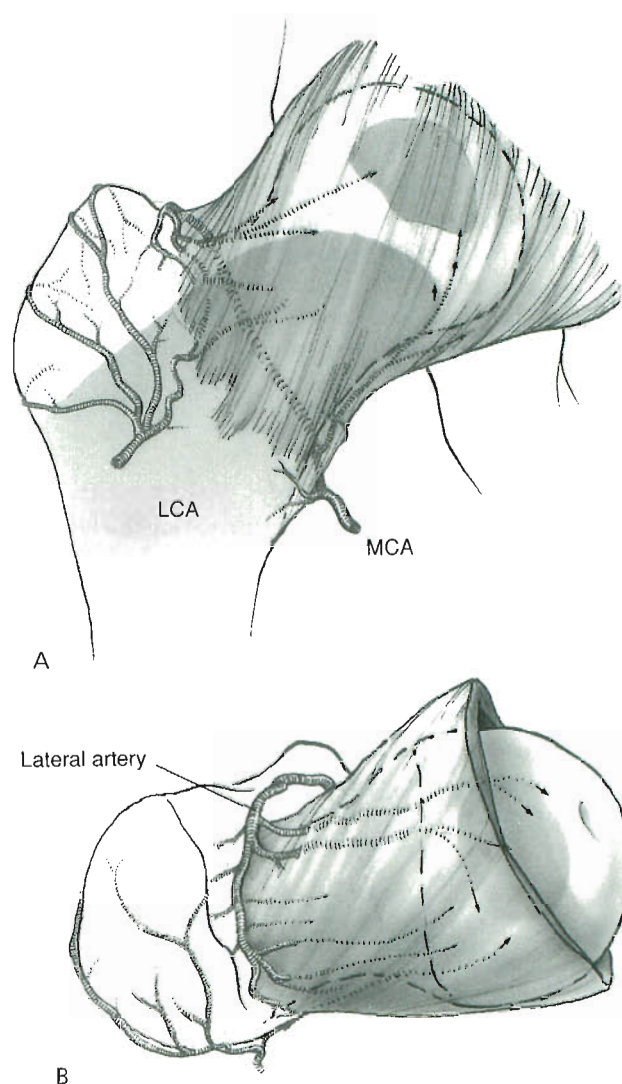


FIGURE 32-54. Arterial supply of the developing proximal femur. **A:** The anterior view demonstrates the lateral circumflex artery (LCA), which supplies the metaphysis and greater trochanter. The medial circumflex femoral artery (MCA) is the dominant vessel to the femoral head. **B:** The superior view shows the lateral ascending artery, which sends numerous epiphyseal and metaphyseal branches (arrows) that supply the greatest volume to the femoral head and neck. These ascending cervical branches traverse the articular capsule as the retinacular arteries. The interval between the greater trochanter and the hip capsule is extremely narrow, and is the area where the lateral ascending cervical artery passes. This may be a site of vascular compression or injury.

frequent delayed diagnosis and no apparent treatment (276). Children who are younger than 2 years of age, with type I fractures, have a better prognosis than older children. Older children experience an 80% avascular necrosis rate, and the rate of osteonecrosis is much lower in younger children. This difference is mainly the result of the mechanism of injury, which involves less force in younger children. More rapid healing and the reestablishment of transphyseal

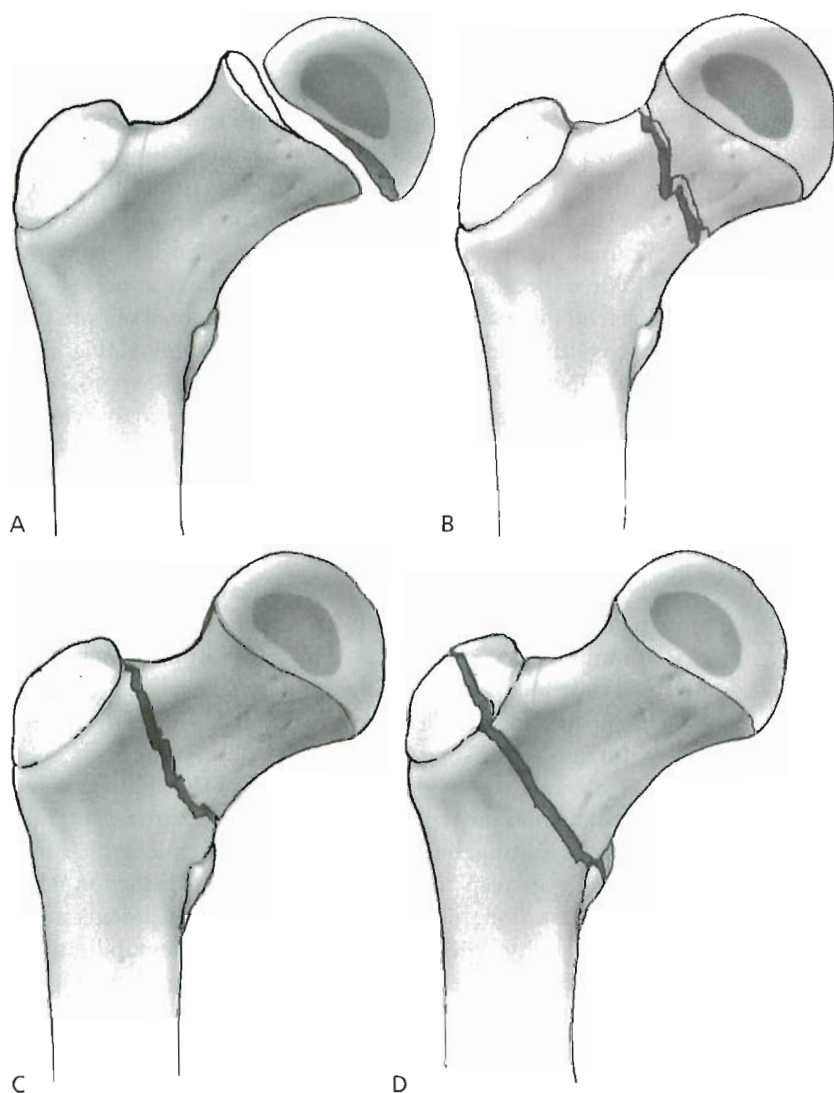


FIGURE 32-55. Delbet's classification for proximal femur fractures. A: Type I is a transepiphyseal fracture. B: Type II is a transcervical fracture. C: Type III is a cervicotrochanteric fracture (basicervical). D: Type IV is an intertrochanteric fracture.

vascularity are unique to children younger than 18 months of age, and may help to prevent clinical avascular necrosis. Transphyseal fracture is associated with dislocation of the epiphyseal fragment from the acetabulum in 50% of cases involving high-energy trauma (277). This combined injury has an especially poor prognosis, with certain avascular necrosis and frequent proximal femoral growth arrest.

Type II fractures occur in the neck of the femur, between the epiphyseal plate and the base of the neck, and are called "transcervical fractures." They constitute approximately one-half of all fractures of the proximal femur (267). Complications are frequent with type II fractures. The incidence of avascular necrosis and physeal growth arrest approaches 50 to 60%. The nonunion rate is 15%. The proximal femoral physis is responsible for 0.125 inch (0.3 cm) of femoral length per year, and a significant limb-length discrepancy is only a potential problem for the preadolescent.

Type III fractures occur in the cervicotrochanteric or basal neck region of the femoral neck. This is the second most common location of proximal femoral fractures in children. Avascular necrosis occurs in 30% of displaced fractures, and the malunion (i.e., varus) rate is 20%. Because the fracture line is vertically oriented, shear forces can inhibit bone union. Nonunion occurs in 10% of these patients. This problem may be lessened by precise fracture reduction, combined with compression across the fracture site by means of cancellous bone screws (i.e., lag technique) (278,279).

Type IV fractures occur in the intertrochanteric region. This proximal femur fracture has the least risk of damage to the femoral head vascular supply. The incidence of avascular necrosis is between 0 and 10%. Varus deformity is the most likely complication, but this often corrects with growth in younger children (280). The malunion rate is approximately

30%, and malunion is more common in fractures treated with closed methods (267,277).

Treatment

Proximal femur fractures should be treated as urgent cases, preferably within 12 h of injury. Delay in treatment may be necessary because of associated life-threatening injuries. The author recommends joint aspiration for delayed cases, to potentially reduce intracapsular tamponade of femoral head circulation. Initial fragment displacement and delay in fracture reduction may be the most significant factors affecting the incidence of avascular necrosis.

Type I Fractures. Treatment with closed reduction and casting is appropriate for minimally displaced fractures, and for children younger than 2 years of age (281). In children 2 to 12 years of age, stabilization of the reduced fracture may be accomplished with two smooth pins supplemented with spica casting. In older children, the author prefers to place the screws across the physis, when better stability is required. Open reduction is often necessary if the epiphysis is dislocated.

Type II Fractures. Nondisplaced fractures in patients younger than 6 years of age can be treated with spica cast alone with good results (267). Displaced fractures can usually be reduced by closed methods, but a small incision to open the hip capsule is recommended, because it might reduce the risk of avascular necrosis (274,275). Fixation is achieved by the percutaneous insertion of two or three cannulated bone screws into the metaphyseal portion of the proximal fragment (Fig. 32-56). If the proximal metaphyseal fragment is too small for secure fixation, smooth pins can be placed across the physis, to allow subsequent growth. Stable fixation of the fracture should be given priority over preservation of the proximal femoral physis (279). After the age of 12 years, threaded screws may be placed across the physis for better fixation. Spica casting is used to augment fixation in children, especially when smooth pins have been used. Open reduction is occasionally required if suitable alignment is not obtained by closed means. An anterolateral (Watson-Jones) approach is recommended, with opening of the anterior capsule to avoid damaging the posterior vascular network.

Type III Fractures. Nondisplaced fractures in young children can be treated with a spica cast, if there is anatomic alignment, especially of the medial cortex. Serial radiographs are necessary to monitor possible fracture migration that would lead to varus malalignment. Nondisplaced fractures in the older child or adolescent should be treated with internal fixation to prevent late displacement. Displaced

fractures are reduced by gently flexing the hip while traction is applied. The limb is then internally rotated and abducted. Biplanar radiographs are obtained to confirm reduction. Two cannulated bone screws provide compression across the fracture site, and are sufficient fixation if supplemented with a spica cast. Larger-diameter compression hip screws may be used in larger children or for comminuted fractures. Caution is advised when using compression hip screws in children, because dense bone may generate heat necrosis of the femoral neck during reaming. An additional smooth pin is recommended to improve rotational stability (Fig. 32-57). Open reduction through an anterolateral approach is indicated when reduction cannot be achieved by closed means.

Type IV Fractures. This fracture does not demand the urgency of the types I, II, and III fractures, but in polytrauma, the prompt stabilization of this injury improves general management. Nondisplaced fractures in this region are uncommon, but can be managed by spica cast immobilization and close follow-up in younger children. Displaced fractures in infants and toddlers may be treated with early closed reduction and casting, as long as the neck-shaft angle does not decrease to less than 115 degrees. Displaced fractures in older children can be managed by skeletal traction, followed by casting, but hospitalization is often lengthy. After the age of 6 years, the author prefers open reduction with internal fixation. Interfragmentary screws may provide sufficient stability when combined with cast immobilization, but a pediatric-size hip screw with side plate, or an angled blade plate, is recommended. The physis should be avoided. The femoral neck should be stabilized before reaming, and reaming should be performed slowly to avoid heat necrosis of the femoral neck. Adolescents are treated in the same manner as adults, with stable fixation across the physis, if necessary, using a sliding hip screw or angled blade plate. This avoids the need for a supplemental body cast for older adolescent patients.

Complications

The most frequent complications after fracture of the proximal femur in children are osteonecrosis of the femoral head, malunion, and nonunion. Other complications include infections, premature closure of the proximal femoral growth plate, and chondrolysis. Exact complication rates are difficult to determine, because of changing patterns of treatment. Prompt, accurate reduction, joint decompression, and appropriate internal fixation and immobilization reduce all of these complications (275,278).

Avascular necrosis in children may involve a portion of the femoral head, just the portion of the femoral neck between the fracture and the physis, or the entire femoral neck

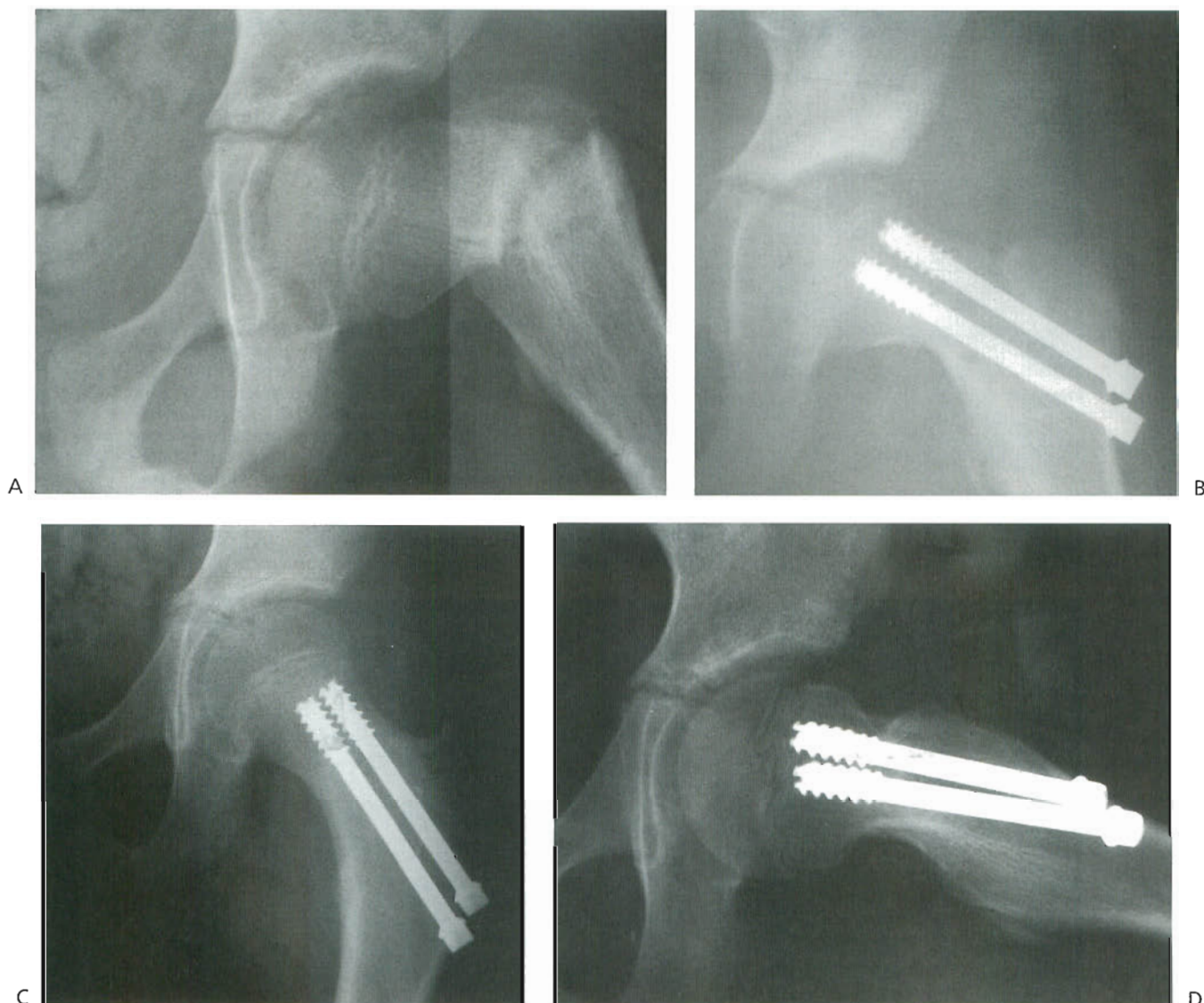


FIGURE 32-56. Femoral neck fracture in an 11-year-old child. **A:** Anteroposterior radiograph demonstrates a type II transcervical fracture. **B:** Stability was achieved with two screws and a spica cast. The capsule was opened for decompression. A smooth pin across the growth plate may be substituted for the second screw. **C** and **D:** Twelve months after injury, there is no evidence of osteonecrosis.

and physis. Recovery is expected when only the neck is involved, but delayed physeal instability can result in subsequent slipped capital femoral epiphysis. Necrosis of the femoral head occurs in approximately 30% of all hip fractures in children, and often leads to poor results (279). Early recognition is helpful, and can be obtained by MRI or isotope bone scanning. Children with osteonecrosis who are younger than 12 years of age can be treated with containment and/or prolonged non weight bearing. These patients have a possibility of recovering satisfactory function (266,282). The outcome for older children with os-

teonecrosis of the femoral head is poor. The author recommends treating these adolescents in a manner similar to adults, because the consequences of femoral head collapse are much more severe than the consequences of premature closure of the proximal femoral physis.

Nonunion occurs in 6 to 10% of pediatric fractures of the proximal femur (279). Treatment is recommended as soon as the diagnosis is established. Subtrochanteric valgus osteotomy is preferred, with bone grafting, internal fixation, and application of a spica cast for 3 months (279,283). Supplemental vascularized bone grafting, with

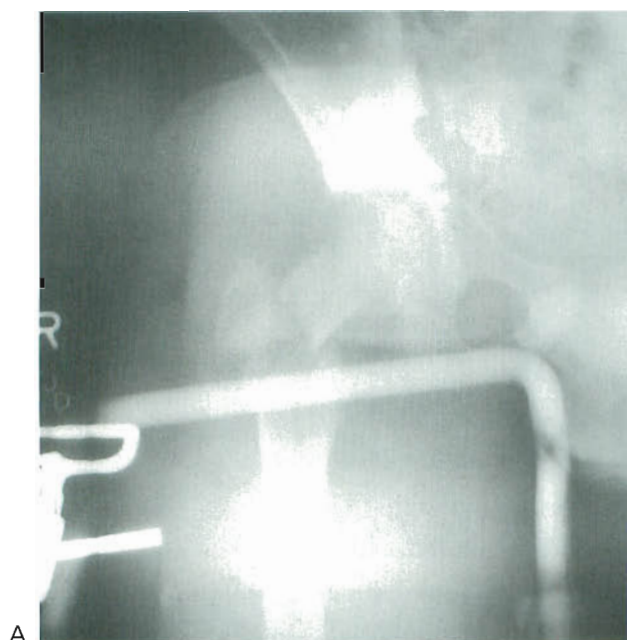
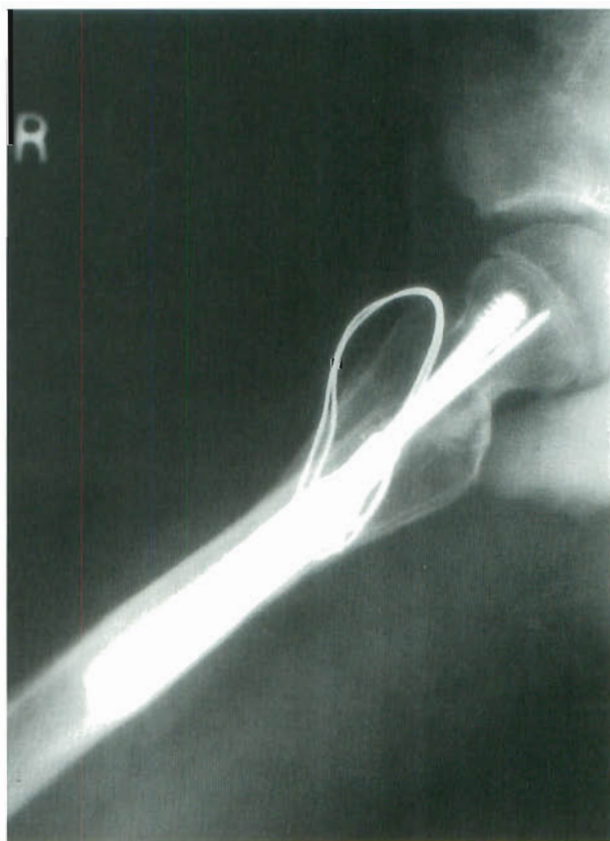
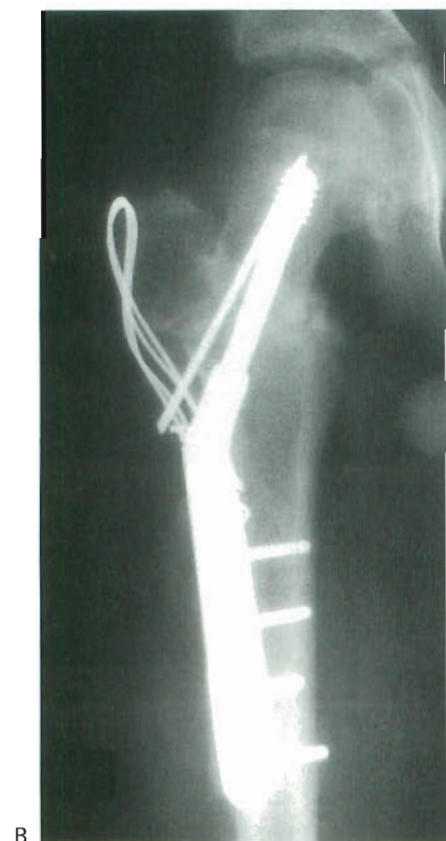
FIGURE 32-57. Comminuted type III femoral neck fracture. **A:** The anteroposterior projection shows a cervicotrochanteric fracture with an associated fracture of the greater trochanter. **B and C:** Open reduction with internal fixation was necessary. Adolescent-sized lag screw fixation was supplemented with a smooth pin for rotational stability. The trochanter may be stabilized with Kirschner wires instead of a tension band. Spica cast immobilization is indicated when fixation does not cross the growth plate.



a vascular-pedicle graft from the iliac crest, should be considered when there is a large defect in the femoral head or neck (284).

Malunion and coxa vara occur in approximately 20% of reported patients, but this complication has a lower incidence when internal fixation is used (279). Remodeling may occur in younger patients (280). Subtrochanteric osteotomy is recommended for persistent deformity.

FEMORAL SHAFT FRACTURES

Femoral shaft fractures account for 1 to 2% of all childhood fractures (3,5,285). Boys sustain this injury 2.5 times more often than girls. There is a bimodal age distribution, with a peak incidence at 2 to 3 years of age and another peak in adolescence. The cortical thickness of the femur increases rapidly after the age of 5 years, and this may explain the decreasing incidence of femur fracture in late childhood. When obvious causes of fracture, such as motor vehicle crashes are excluded, 65% of femur fractures in infants younger than 1 year old may be attributable to abuse (286). In children 1 to 5 years of age, the incidence of abuse decreases. Children in this toddler age group may sustain fractures with relatively minor trauma, such as falling from a low height or tripping while running. Intentional abuse should always be considered in young children, but there are no distinguishing clinical parameters or fracture patterns to help determine which injuries are inflicted and which are accidental (286). Approximately one-half of femoral shaft fractures caused by bicycle crashes occur in the 4- to 7-year age group. In the adolescent age group, motor vehicle crashes account for the large majority of femur fractures.

As stated by Mercer Rang (106), "It does not require a physician to diagnose a fractured femur." However, the physician must carefully evaluate the entire patient. Children and adolescents with femur fracture have a 35 to 40% incidence of associated injuries. Some of these injuries are occult, and include femoral neck fracture, hip dislocation, ligamentous instability of the knee, and visceral injuries (287,288). Hemodynamic instability or steadily declining hematocrit does not occur as a result of isolated closed femur fracture. Other sources of blood loss must be evaluated in these patients (288).

Treatment of Femoral Shaft Fractures

Principles of Management

The age of the child and the severity of the trauma are the principal determinants of management. Younger children are less likely to require prolonged traction or surgical stabilization. Higher-energy trauma is more likely to benefit

from operative intervention. At one end of the spectrum, there are low-energy injuries in young children, which are managed with closed reduction and immediate spica casting. At the other end of the spectrum, high-velocity injuries in adolescents are managed with early operative stabilization. Occasionally, however, infants with life-threatening trauma require surgical stabilization of femoral fractures to facilitate life support. There are many treatment methods, and fortunately, they all work well when applied properly.

Proximal fractures in all age groups are more difficult to control, but residual deformity is better-tolerated, because of multidirectional hip motion. Deformity is also less obvious proximally, because thick thigh muscles hide residual angulation. Proximal fragments tend to flex, abduct, and externally rotate as a result of the unopposed action of the hip abductor, external rotator, and iliopsoas muscles. The proximal fragment of a midshaft fracture also tends to flex, abduct, and externally rotate, but the deformity is less extreme, because of adductor and hamstring attachments proximal to the fracture. Fractures closer to the knee are easier to control, and produce little proximal fragment angulation, except for supracondylar fractures, which tend to hyperextend as a result of the posterior pull of the gastrocnemius muscle on the short distal fragment. Fractures of the distal femur require more precise alignment, because deformity is more visible closer to the knee, and remodeling in the coronal plane is limited.

The potential for remodeling determines the guidelines for acceptable alignment. Children younger than 1 year of age have considerable remodeling potential, because their femurs will more than double in size before skeletal maturity. Remodeling potential between 2 and 12 years of age is also excellent. Long-term studies have demonstrated that up to 20 degrees of midshaft angulation in any plane can be expected to correct satisfactorily (11,289,290) (Fig. 32-58). Slightly greater deformity may correct in the sagittal plane. Remodeling continues for up to 5 years, and results from fracture site remodeling, as well as reorientation of the growth plate. Rotational remodeling may also occur, but the precise amount is unpredictable (17,291). Clinically significant rotational deformity is uncommon, even when failure of remodeling has been documented (16,292).

Stimulation of growth after femoral fracture occurs routinely in the 3- to 9-year age group (18,20). Unfortunately, most authors reporting the overgrowth phenomenon do not distinguish between "catch-up growth," which compensates for fracture overriding, and true overgrowth, which results in the fractured femur being longer than normal. Growth stimulation is greater when overriding is greater, and may continue for 5 years after fracture. Average growth stimulation is approximately 1 cm, and ranges from 0.5 to 2.5 cm. Therefore, any femoral fracture that heals in a shortened position should be observed for several years to determine the final outcome (Fig. 32-59). Overgrowth has also been

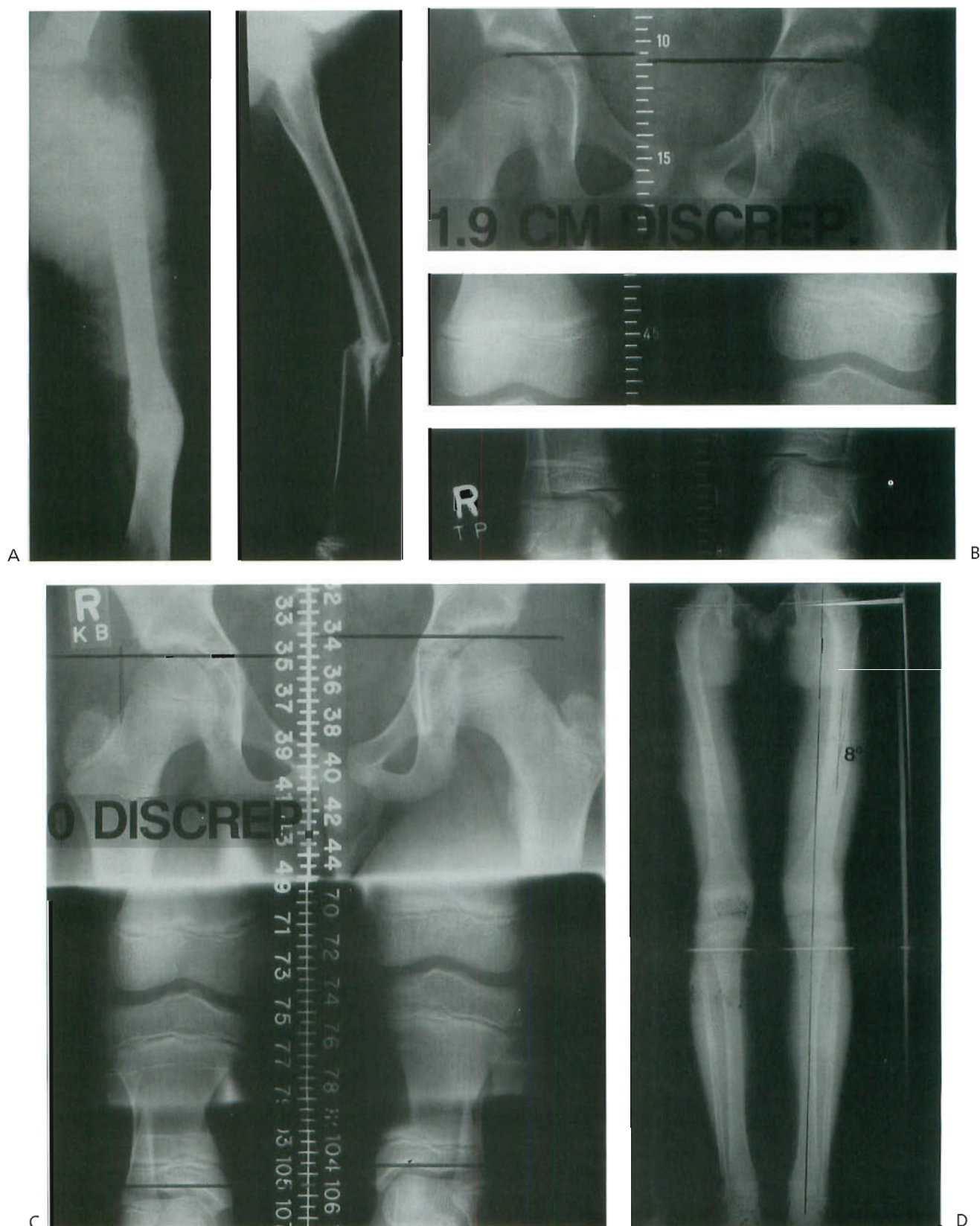

FIGURE 32-58. A: Femoral shaft fracture in a 10-year, 7-month-old boy, healed with 15 degrees of varus and 19 degrees of anterior angulation. B: Discrepancy measures 1.9 cm. C: Eighteen months later, the discrepancy has resolved, and there is no significant anterior bowing. D: The varus deformity has corrected to 8 degrees with reorientation of the growth plate to produce a normal mechanical axis.

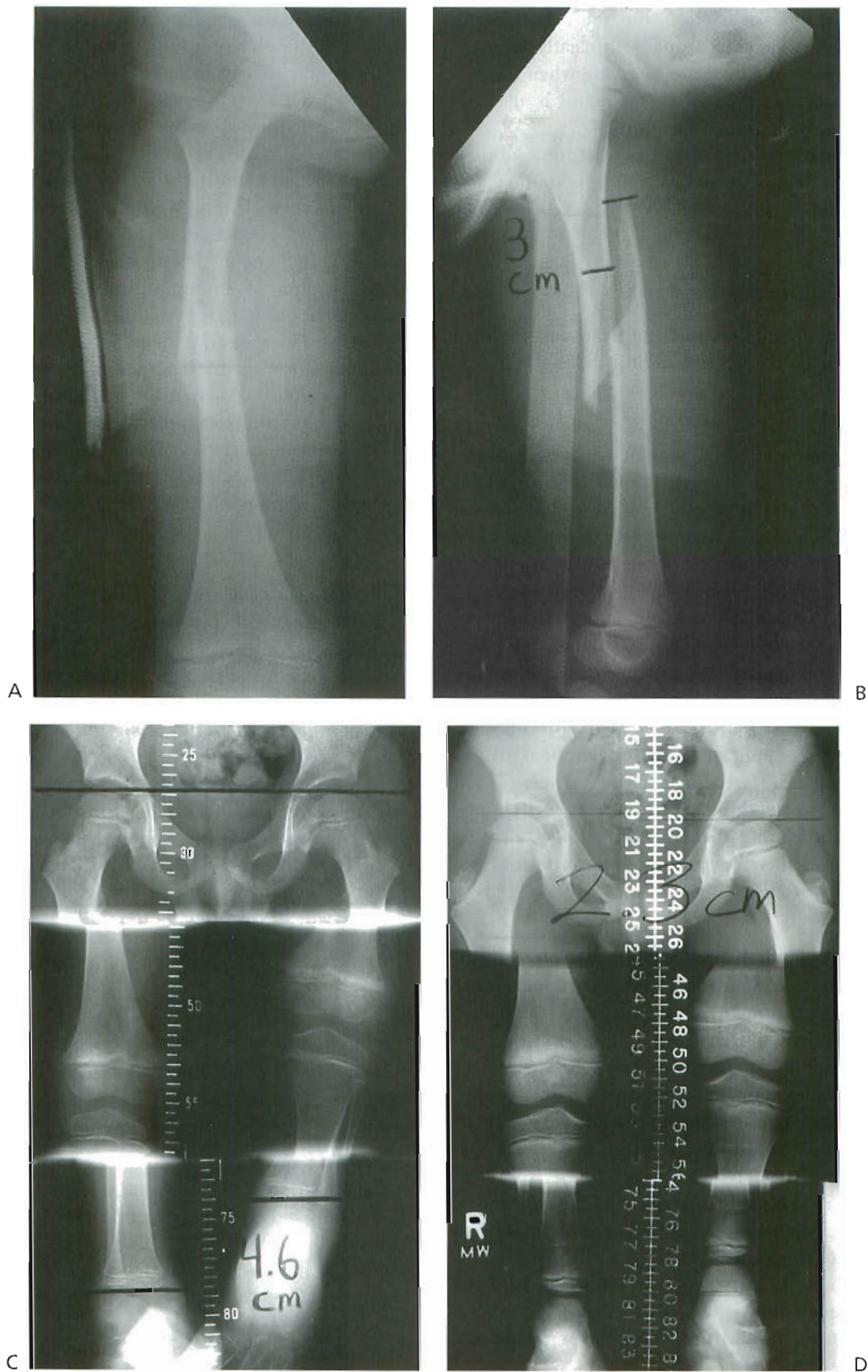


FIGURE 32-59. A 5-year-old boy with a femur fracture. **A** and **B**: Early spica cast application. Alignment is good, but overriding is 3 cm in the initial cast. **C**: Four weeks after cast removal, the leg-length discrepancy measures 4.6 cm. **D**: Two years later, the discrepancy measures 2.6 cm. Equalization of length may continue for 3 more years.

reported after rigid internal fixation, but the risk of overgrowth in this circumstance has not been clearly defined (293,294). Parents are usually more forgiving when the injured femur grows longer than when the femur is allowed to heal in a markedly shortened position.

Special circumstances, such as open fractures, subtrochanteric fractures, floating knee, and multiple trauma, are discussed at the end of this section.

Management Guidelines by Age

Age or weight is the first determinant of treatment choices. Age is used here with the understanding that age reflects children of average weight and maturity.

Infants. Infants younger than 1 year of age often sustain femur fractures as a result of birth trauma or abuse. Osteogenesis imperfecta and other metabolic disorders should also be suspected. Thick periosteum and rapid hematoma consolidation usually prevent worrisome shortening or angulation. Healing is rapid, and remodeling potential is great. One can accept 2 to 3 cm of shortening and 30 degrees of angulation in both the coronal and sagittal planes. Immobilization may not be necessary for infants with stable fractures, such as nondisplaced spiral fractures or impacted metaphyseal fractures. Unstable fractures in infants may be treated with immediate application of a conventional plaster spica cast, a Webril spica cast, or a Pavlik harness (295). Modified Bryant skin traction, which consists of straight-leg traction at an angle of 45 to 60 degrees, can also be used as definitive treatment (296). Immobilization for 2 to 3 weeks is usually sufficient.

Age 1 to 6 Years. Children between the ages of 1 and 6 years are usually treated with early spica cast application. All aspects of spica cast treatment are easier for preschool children than for older children (297). Children in this age group also heal rapidly, so immobilization time is brief. Closed reduction and casting may be performed under sedation in the emergency department, but overnight observation is recommended in most cases. More frequently, the child is placed in skin traction for 1 or 2 days, to allow swelling and pain to subside before applying the cast under general anesthesia. Alignment should be as close to normal as possible, but full functional recovery can be expected in this age group if shortening at the time of union is no greater than 3 cm and angulation is less than 20 degrees in any plane. Fractures in the distal third should be angulated no more than 15 degrees.

Age 6 to 10 Years. Children between the ages of 6 and 10 years may be managed by a wide variety of methods,

depending on the severity of the fracture and social circumstances. Low-velocity injuries without severe displacement or shortening may be managed by early spica cast immobilization (298,299). However, children in the 6- to 10-year age group require a longer period of immobilization than younger children. This immobilization and dependency may pose a problem if both parents are working, or when the child lives with a single working parent. Operative stabilization may be beneficial in these and similar social circumstances. High-energy fractures, with severe displacement, comminution, or shortening greater than 3 cm require maintenance of length in addition to alignment. This may be achieved by skeletal traction for 2 to 3 weeks, before cast immobilization, or by incorporating a traction pin in the spica cast (300). Alternatively, surgical stabilization with internal or external fixation achieves the same objectives and allows early mobilization. Guidelines for acceptable alignment in this age group are the same as for the 1- to 6-year age group, although remodeling and recovery may be more prolonged in this older age group.

Age 10 Years to Maturity. Children older than 10 years of age are frequently best managed by operative stabilization with internal or external fixation (138,301). Accurate restoration of length and alignment is desirable in older children, because of limited remodeling potential. Operative stabilization permits early mobilization and return to school and social activities. Various techniques for stabilization are discussed below. It is generally agreed that rigid reamed intramedullary nailing through a piriformis fossa entry point should be avoided, because of the risk of iatrogenic avascular necrosis of the femoral head (302). The risk of this complication is present as long as the proximal femoral physis remains open.

Management Techniques

Techniques for management are selected according to the principles and guidelines discussed in the preceding paragraphs.

Early-fit Spica Cast. The typical candidate for early cast immobilization is a child younger than age 10 years with a low-energy closed femur fracture that has less than 2 cm overriding at rest (298,299,303). The spica cast may be applied in the emergency department under conscious sedation. More commonly, 1 or 2 days of traction are followed by closed reduction and casting under general anesthesia. Four to 5 lb of skin traction is sufficient for most children younger than 7 years old. Skeletal traction is preferred for older, heavier children, or when delay in cast application may exceed 72 h. Several methods of cast application have been reported (298,299,304) [►4.12]. The author's pref-



FIGURE 32-60. Early-fit spica cast. In children younger than 6 years of age, the usual position of reduction is 70 to 90 degrees of hip flexion, 30 to 45 degrees of abduction, and slight external rotation. Anterior and lateral molding of the cast helps prevent varus deformity and anterior angulation.

erence is to use the image intensifier to assess alignment and overriding. If the fracture fragments shorten more than 3 cm with gentle longitudinal compression, then traction, pins and plaster, or surgical stabilization may be more appropriate than early spica casting (telescope test) (298). After fracture alignment is obtained, a bent-knee, long-leg cast is applied and molded anteriorly and laterally, to prevent the tendency for later angulation into flexion or varus. The foot may be left free. The popliteal area and all bony prominences should be well padded. The hip is held at 70 to 90 degrees of flexion, 30 to 45 degrees of abduction, and slight external rotation (sitting position), while the remainder of the cast is applied (304) (Fig. 32-60). Slight traction may be applied to the cylinder cast, while the cast is being completed, but this should not be excessive to prevent skin breakdown, calf compartment syndrome, or peroneal nerve palsy (305). After casting, patients are usually discharged within 24 h. Two or three weekly follow-up visits are necessary to monitor alignment (Fig. 32-61). It is often helpful to tape a paper clip or other small metallic object to the outside of the cast before radiographic examination. This can be used to identify the fracture site, if wedging of the cast is required.

Skeletal Traction. Skeletal traction is a safe, reliable, and easily instituted form of management for almost any femur fracture in any age group. There are several ways in which balanced traction can be constructed (306–308). The simplest is the 90–90 position for preadolescents, and for proxi-

mal femur fractures. Adolescents are usually placed in balanced traction with a thigh sling and adjustable knee support to allow 45 degrees of knee flexion (Fig. 32-62). The technique entails insertion of a smooth or threaded traction pin in a lateral to medial direction, into the metaphyseal region of the distal femur, under local anesthesia and intravenous sedation. Proximal tibial pins are avoided, although they may not be responsible for some cases of growth arrest (26,309,310). The pin should be approximately 2 cm proximal to the distal femoral growth plate and aligned parallel to the knee joint to reduce the risk of malalignment (311). A traction bow is attached to the pin, and traction is applied. Periodic radiographs are obtained to guide the weight and direction of traction vectors needed to restore alignment. After relative fracture stability has been obtained (17 to 21 days) and callus formation is confirmed on radiographs, a cast is applied for an additional 4 to 8 weeks.

Cast Brace and Home Traction. Cast brace management of femoral shaft fractures in children has been reported by several authors (312–314). A functional cast is applied from groin to toe, using a quadrilateral mold or socket for the proximal thigh. Polypropylene or metal hinges cross the knee, to allow knee movement. Cast application usually follows a period of traction, to allow early healing and increased stability. A distal femoral traction pin may be used in the cast to help control alignment and permit earlier cast brace application (312,313). Cast brace management of pediatric femur fractures requires experience and close follow-up. Potential problems include poor control of proximal fractures and patient discomfort attributable to increased levels of activity in the cast, compared with bed rest activities in a spica cast (314,315).

Skeletal traction at home has been used successfully to decrease length of hospitalization (316,317). These methods require special beds or frames and close attention by trained nursing staff (318). Readers are referred to the original articles for technical details.

External Fixation. The prime indication for external fixation is a fracture with significant comminution or soft tissue damage, as in open fractures or burns (319). Other relative indications include polytrauma, in which multiple fractures and the child's general medical condition favor the rapid and bloodless stabilization that is possible with this technique (Fig. 32-63). It may be considered as a form of ambulatory traction, enabling the child to be partially weight bearing and independent several days after sustaining the injury.

The technique involves the sequential insertion of two pins above and below the fracture site and attaching them to a unilateral frame [→4.14]. Preferred pin location should be far enough away from the fracture site that pins avoid the fracture hematoma. However, pins should avoid penetrating the femoral neck calcar or the distal femoral physis. Under fluoroscopic guidance, final align-

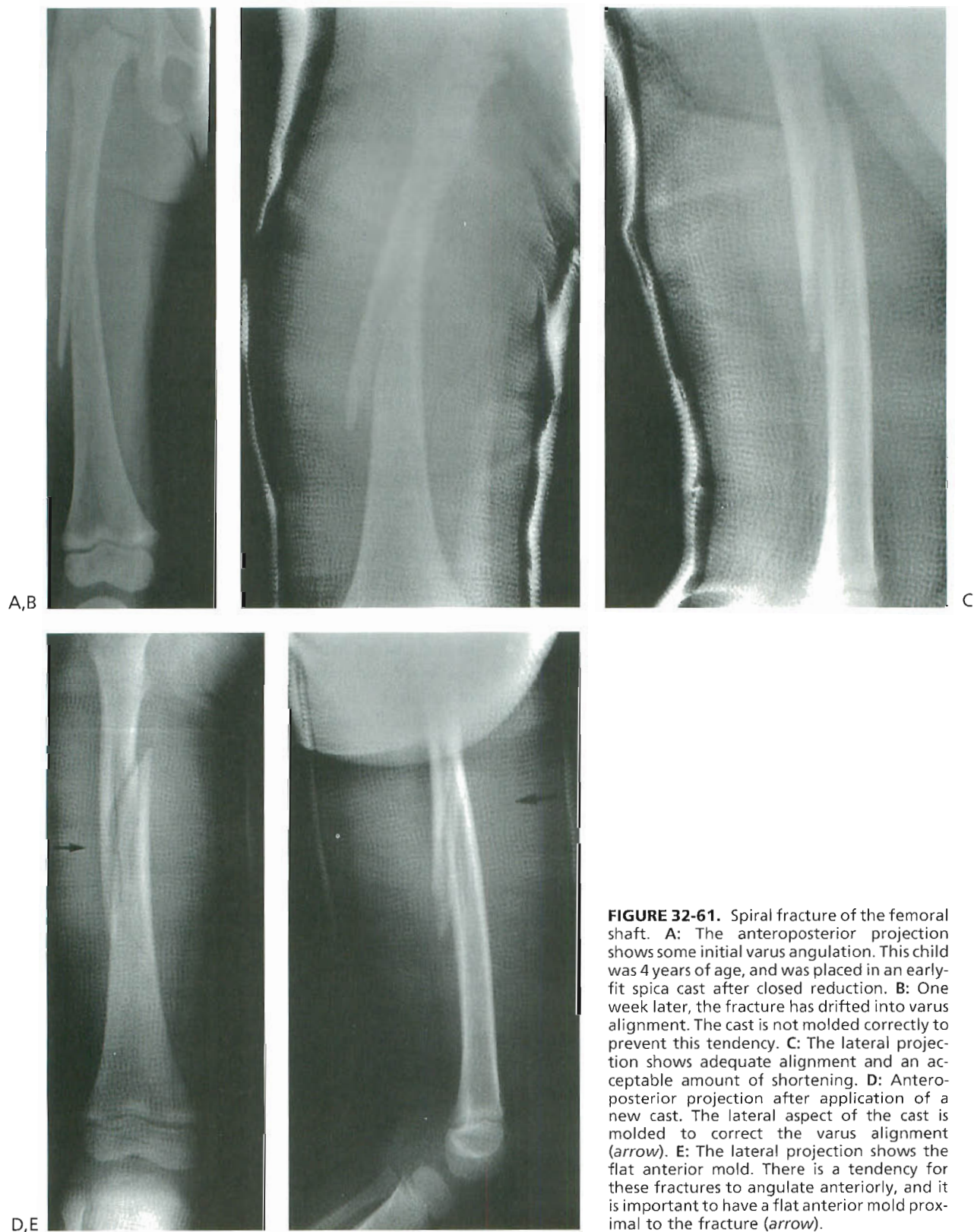


FIGURE 32-61. Spiral fracture of the femoral shaft. **A:** The anteroposterior projection shows some initial varus angulation. This child was 4 years of age, and was placed in an early-fit spica cast after closed reduction. **B:** One week later, the fracture has drifted into varus alignment. The cast is not molded correctly to prevent this tendency. **C:** The lateral projection shows adequate alignment and an acceptable amount of shortening. **D:** Anteroposterior projection after application of a new cast. The lateral aspect of the cast is molded to correct the varus alignment (arrow). **E:** The lateral projection shows the flat anterior mold. There is a tendency for these fractures to angulate anteriorly, and it is important to have a flat anterior mold proximal to the fracture (arrow).

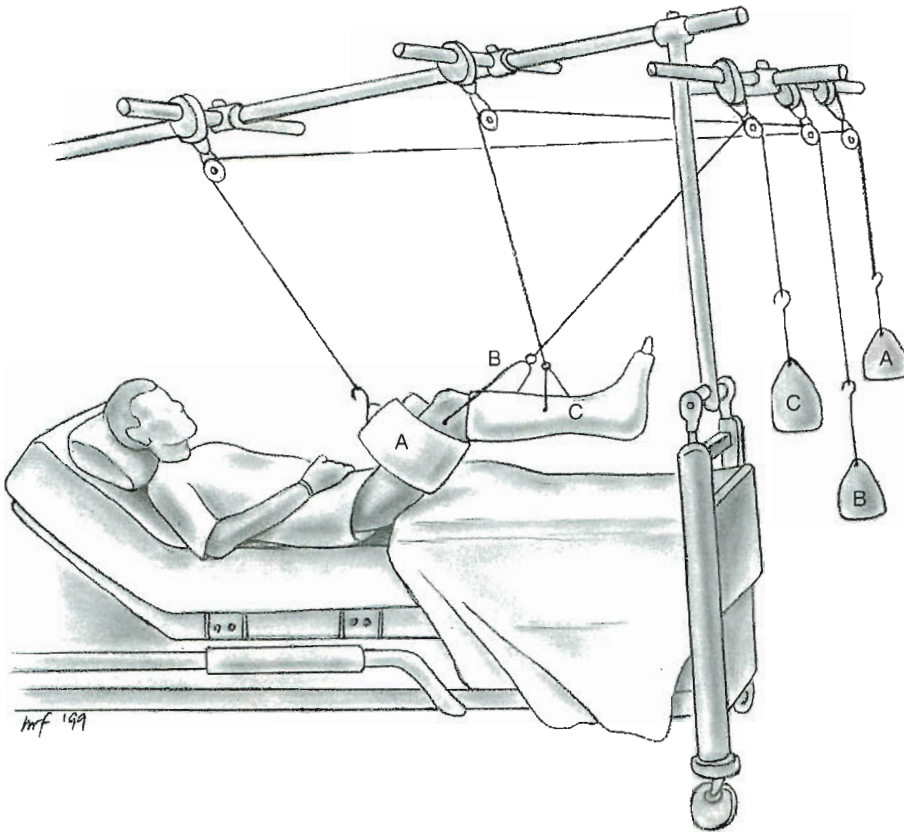


FIGURE 32-62. Balanced traction with a distal femoral pin, a thigh sling, and cast suspension of the leg. This is easily converted to 90–90 traction for more proximal fractures. Weight *A* supports the thigh, weight *B* provides traction, and weight *C* supports the leg in a cast.

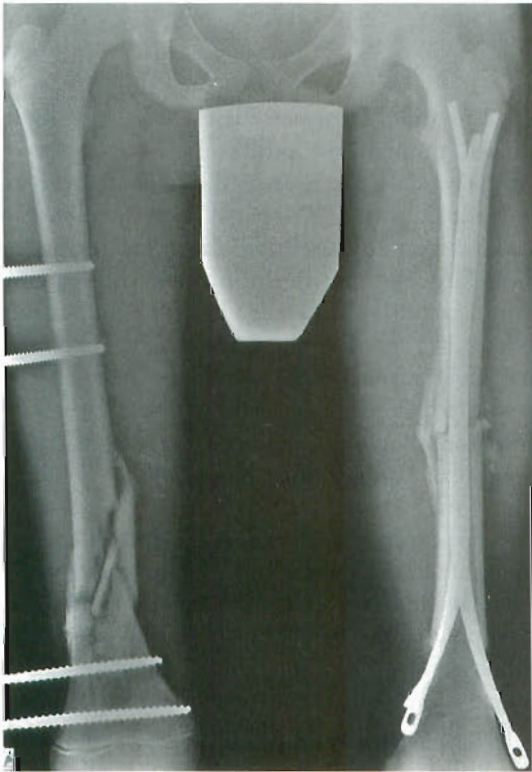


FIGURE 32-63. Bilateral femur fractures. The distal location, proximity to the growth plate, and marked comminution of the right femur fracture are best managed through the application of an external fixator. Although external fixation could have been applied to the contralateral fracture, intramedullary fixation was chosen because of the transverse pattern of the fracture.

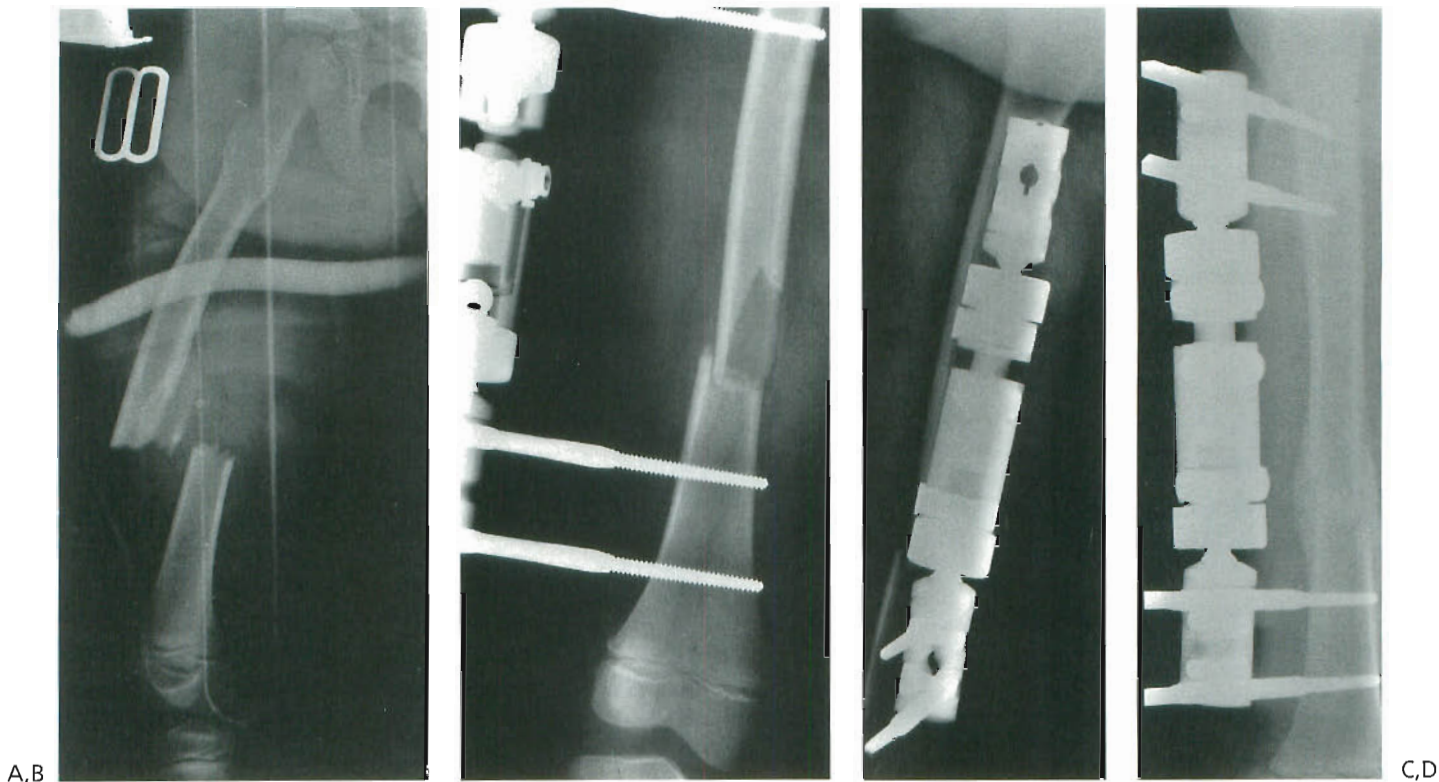


FIGURE 32-64. External fixation for open fracture. **A:** Injury film of grade III open femur fracture in a 7-year-old child. **B:** Alignment and stabilization with external fixation after irrigation of the wound and removal of the devitalized segment of the femoral shaft. **C:** The lateral projection shows anatomic alignment. **D:** Twelve weeks later there is good callus formation and new bone formation in the area of segmental bone loss. The child was ambulatory with full weightbearing without assistance. The fixator was removed at this time.

ment can be adjusted as the pins are secured to the body of the fixator (Fig. 32-64).

The most frequent problems encountered with the use of external fixation are pin-track infections, delayed union, and refracture after device removal. Pin-track inflammation and superficial infection requiring oral antibiotics are common (320,321). Rarely, deep infection may require intravenous antibiotics or pin removal. In this instance, fixator removal before complete union can be managed by application of a cast. Delayed union and refracture are more frequent with transverse and short oblique midshaft fractures that are anatomicallly reduced (322). Delayed healing has also been associated with excessively rigid constructs and lack of dynamization (321,323). Careful attention must be paid to operative technique and postoperative management to reduce the risk of complications.

Intramedullary Fixation. Two devices used for intramedullary fixation are rigid nails and flexible unreamed nails (293,315,324). Rigid nails are ideally suited for adults, because they can be locked proximally and distally, to control

shortening and rotation. However, the use of reamed rigid nails introduced through the piriformis fossa has been associated with avascular necrosis of the femoral head in children and adolescents (302). Rigid nails in children younger than 13 years of age have also been associated with a high incidence of growth disturbance with femoral neck deformity, including coxa valga and thinning of the femoral neck (325,326). For these reasons, it is recommended that rigid reamed nails should be reserved for adolescents who are closer to skeletal maturity. The technique of insertion should be modified, so that entry is through the tip of the greater trochanter, carefully avoiding the piriformis fossa.

Flexible or elastic intramedullary nails have the advantage of being applicable to the smaller and younger child, without risking damage to the trochanter, the femoral neck, or the vascular supply to the femoral head. Flexible rods are commonly inserted from the distal femoral metaphysis, retrograde, toward the proximal end of the femur, avoiding the physes. Two C-shaped nails, one inserted medially and one laterally, usually provide sufficient stability, if three-

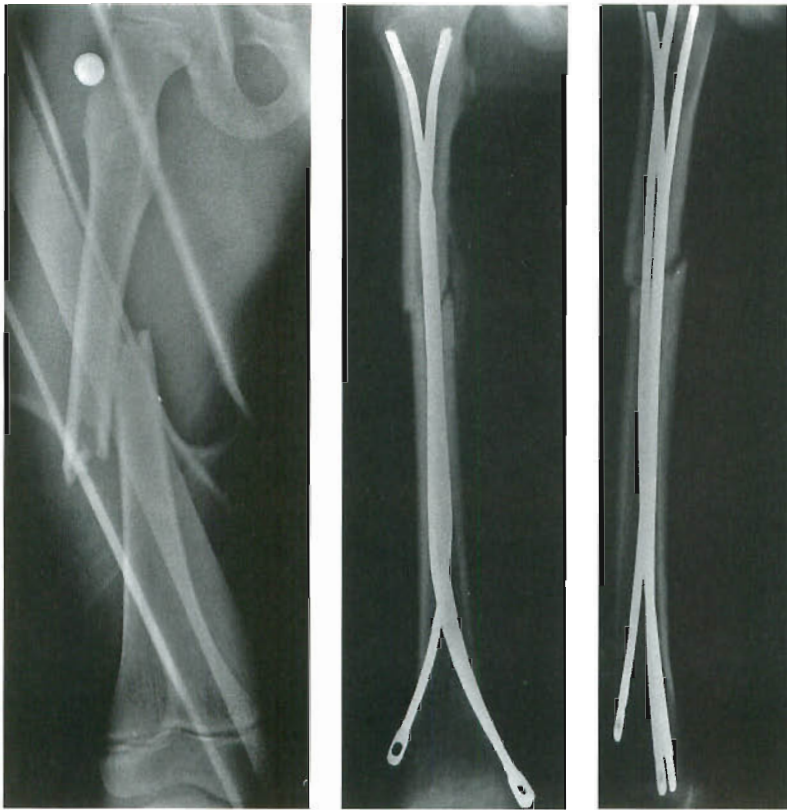

FIGURE 32-65. Flexible intramedullary fixation. **A:** Short, oblique midshaft femur fracture in a skeletally immature child. **B:** Flexible nails placed distal to proximal. The starting point is in the metaphyseal flare of the distal femur, and three-point fixation is obtained by using curved nails. **C:** The lateral projection shows that three nails were used to stack the femoral canal. A cast is unnecessary.

point intramedullary contact is obtained (327,328) (Fig. 32-65) [►4.13]. Another option is to use a unilateral approach distally, and insert one C-shaped nail and one S-shaped nail. Alternatively, nails may be introduced proximally in the region of the greater trochanter when the fracture is very distal. Additional nails may be added, if needed. A transverse or stable fracture pattern is best for this method of internal fixation. Comminuted, spiral, or segmental fractures are unstable, and are not well suited for this kind of fixation. The addition of a cast can supplement unstable internal fixation, but this partially defeats the advantages of operative stabilization.

Plate Fixation. Femoral plate fixation has not been widely used for pediatric femur fractures (329). Ziv and Rang (330) reported a high rate of deep infection when this method was used in children with head injury, but Ward et al. (329) reported satisfactory results without any infections in 25 cases. This method of fixation may be suitable for fractures that are located in an area difficult to secure with an intramedullary nail or external fixation (Fig. 32-66). The advantages of plate fixation of femoral fractures are anatomic reduction and early mobilization. Disadvantages include extensive dissection with additional blood loss, possible

plate breakage or delayed union, and the risks of plate removal, in some cases.

Complex Femoral Fractures

Femur fracture management may be altered in complex circumstances, as seen in children with head injuries, multiple trauma, open fractures, floating knee, or high subtrochanteric fractures. Children with head injuries or multiple trauma benefit from more aggressive fracture stabilization so that they can be transported and mobilized (52). The general management of open fractures is discussed earlier in this chapter. External fixation is recommended for open fractures with severe soft tissue injury, but grade I and many grade II open femur fractures can be managed in standard fashion after appropriate wound care.

Floating Knee

Simultaneous ipsilateral fracture of the femur and tibia has been termed the “floating knee” (331,332). This injury pattern has been classified by Letts and colleagues (332) (Fig. 32-67). The fracture usually is the result of high-energy trauma, such as a pedestrian–motor vehicle collision. Knee ligament damage occurs in approximately 10% of these pa-

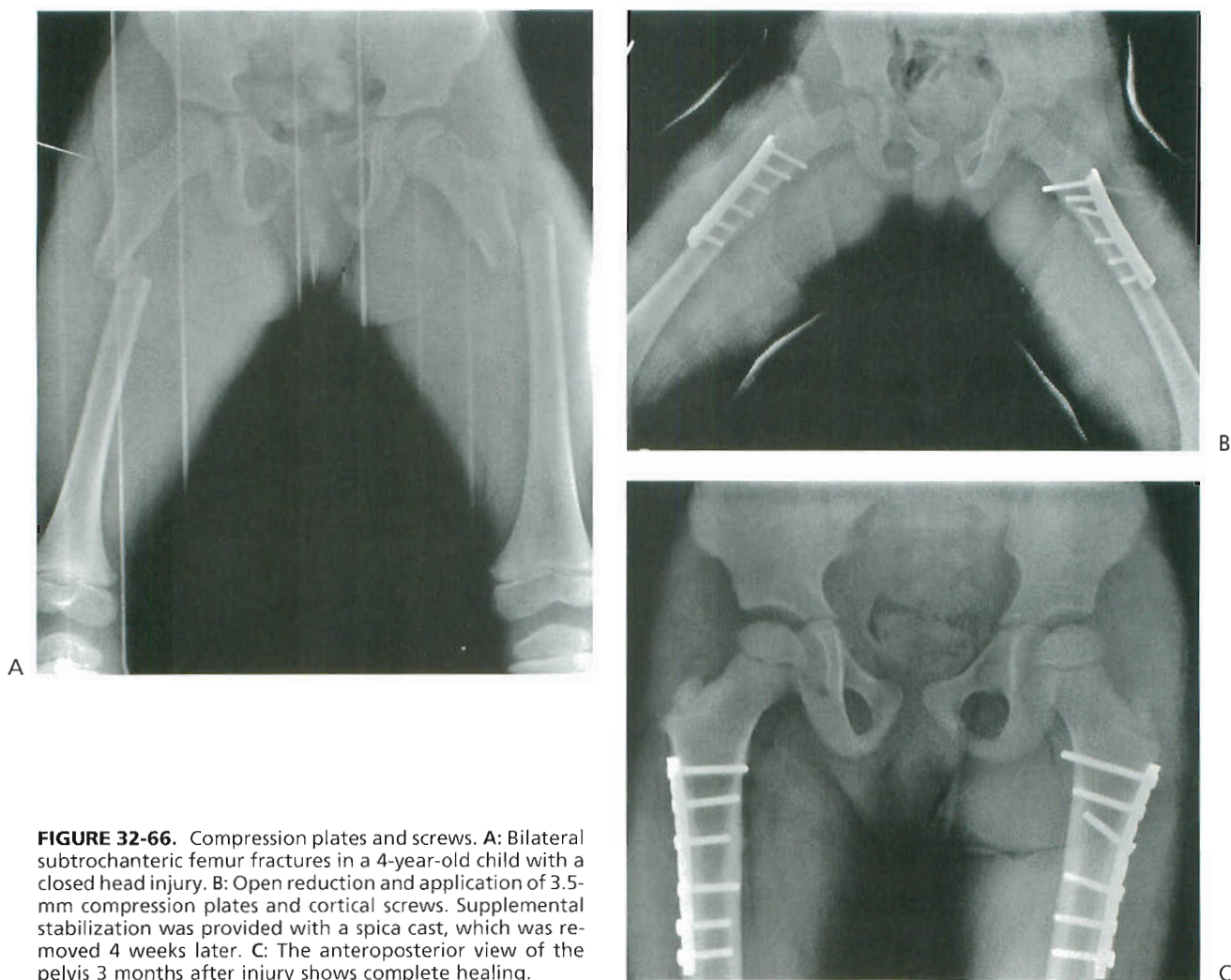


FIGURE 32-66. Compression plates and screws. **A:** Bilateral subtrochanteric femur fractures in a 4-year-old child with a closed head injury. **B:** Open reduction and application of 3.5-mm compression plates and cortical screws. Supplemental stabilization was provided with a spica cast, which was removed 4 weeks later. **C:** The anteroposterior view of the pelvis 3 months after injury shows complete healing.

tients, and is better assessed after fractures are stabilized. The juxtaarticular fracture pattern, and fractures in children older than 10 years of age, have worse prognoses for early and late problems (331). Operative stabilization of at least one bone is recommended in most cases, especially in older children (331,332).

Subtrochanteric Fractures

Subtrochanteric fractures usually result from high-energy trauma and are difficult to treat closed, because of flexion, abduction, and external rotation of the proximal fragment. Union in the anatomic position is rarely achieved with closed treatment, but remodeling potential is great in this anatomic region. Fractures that are closer to the greater trochanter, and fractures in children older than 8 years, have poorer prognoses for malunion (333,334). Early spica cast application in the “sitting” position may suffice in very young children, but traction in the 90–90 position is fre-

quently necessary until callus formation has occurred (334,335). Alternatively, children older than 8 years of age, or younger children with very unstable fractures, may be considered for surgical stabilization.

Complications of Femur Fractures

Malunion with or without limb-length discrepancy is the most frequent complication of pediatric femur fractures. Compartment syndrome, neurovascular injuries, nonunion, and infections may also occur. These latter complications are more frequent after open injuries, and are discussed elsewhere. Management principles are similar to those in adults. Malunion and limb-length discrepancy may resolve with remodeling, as long as the deformities are within management guidelines. Osteotomy is performed to correct persistent deformity in older children, or when remodeling is incomplete in younger children after a period of observation. Persistent limb-length discrepancy is rarely severe, and

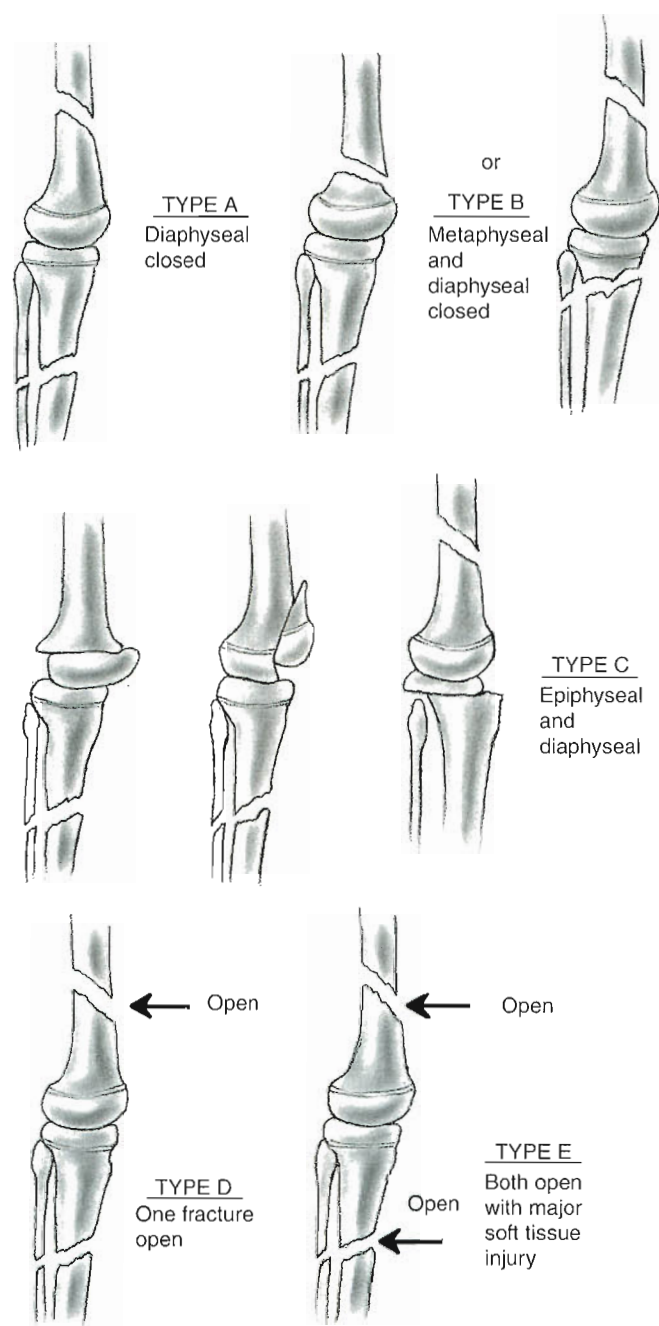


FIGURE 32-67. Classification of the "floating knee" in children. (From ref. 332, with permission.)

is usually managed by epiphysiodesis of the contralateral extremity at an appropriate age.

FRACTURES AND DISLOCATIONS ABOUT THE KNEE

Significant trauma to the knee in children usually results in a fracture, instead of a ligamentous injury. The attach-

ments of the joint capsule and the surrounding ligaments expose the pediatric knee to certain characteristic avulsions and physeal injuries. However, isolated ligamentous damage can occur, especially in the maturing adolescent (336). Soft tissue injuries of the juvenile knee and acute patellar dislocations are discussed in Chapter 31. The child presenting with an acute hemarthrosis of the knee may have a soft tissue injury, a fracture, or both. Physical examination may determine the site of the injury; the clinician should note the precise location of tenderness, and test for ligamentous integrity. Plain radiographs can usually confirm the diagnosis of a fracture. Stress views are sometimes useful, if there is any remaining question about the nature of the injury. The MRI has been used to provide additional information, but this modality is much less accurate in children than in adults (337,338). Arthroscopic evaluation is warranted when the cause of hemarthrosis remains obscure. Radiographically silent osteochondral fractures have been noted in 7 to 67% of juvenile patients undergoing arthroscopy for acute hemarthrosis (339,340).

Distal Femoral Physeal Separations

Distal femoral physeal fractures constitute approximately 5% of all long-bone physeal fractures and 1 to 2% of all fractures (29,176). The distal femoral growth plate has a complex geometric configuration, and is securely anchored to the metaphysis. Any fracture, whether displaced or not, represents considerable trauma. The diagnosis is easily made, except in cases of nondisplaced fractures. These injuries may mimic ligamentous instability on clinical examination. However, careful inspection will reveal that the area of tenderness and swelling is proximal to the joint line. Stress radiographs, with the patient sedated, can be used to reveal the fracture. When the epiphysis is displaced, the direction of displacement reflects the direction of the injuring force. Hyperextension of the knee produces anterior epiphyseal displacement, and valgus or varus stress produces medial or lateral displacement. Direct impact in the knee-flexed position causes posterior displacement of the femoral epiphysis.

The Salter-Harris type III fracture of the medial femoral condyle usually results from valgus force on the knee. The medial collateral ligament and joint capsule transmit this force to the condyle producing the fracture. Spontaneous reduction is frequent, and may obscure the diagnosis. The Salter-Harris type III injury to the medial condyle may appear innocuous, but is often associated with cruciate ligament damage and intraarticular osteochondral fragments (341).

Salter-Harris type I and II fractures account for the majority of distal femoral epiphyseal separations, but there is poor correlation between the type of fracture and the likelihood of growth arrest (342,343). It has been observed that growth arrest is more closely related to the severity of dis-

placement (343,344). Fractures in the 2- to 11-year age group are frequently caused by severe trauma, and have the poorest prognosis for physeal arrest (80%) (344). Fractures in the adolescent age group are often the result of less-severe trauma, but still, they have a 50% risk of growth disturbance. Close follow-up is recommended to detect partial or complete growth arrest during the early stages of deformity development. In contrast to these fractures in the juvenile and adolescent age groups, distal femoral separations in infants and toddlers rarely lead to growth problems, and have excellent remodeling potential.

Treatment

Nondisplaced fractures can be immobilized in a long-leg or cylinder cast for 3 to 4 weeks, until the fracture site is nontender. Close follow-up is warranted to detect any tendency toward displacement. Displaced distal femoral physeal separations are probably best treated with prompt, gentle, closed reduction under general anesthesia (343). After reduction, fixation is recommended, using crossed percutaneous pins to avoid redisplacement while in a cast. Pins may be placed from proximal to distal, to avoid traversing the synovium of the knee joint (Fig. 32-68). If the metaphyseal portion of the Salter-Harris type II metaphyseal fragment is large enough, fixation can be accomplished with percutaneous insertion of one or two cancellous bone screws through this fragment (Fig. 32-69).

Open reduction is indicated when periosteum or muscle

blocks closed reduction, for Salter-Harris type III and IV injuries, for open injuries, and for fractures associated with neurovascular disruption. Salter-Harris type III and IV injuries require precise alignment to restore the articular surface and reduce the risk of growth arrest. At least two cannulated 6.5-mm-diameter screws are recommended to ensure stability (Fig. 32-70).

After reduction and fixation, the patient is immobilized in a long-leg or cylinder cast for 3 to 6 weeks. Pins can be removed in the clinic, and gentle range of motion is initiated. Progressive weightbearing and strengthening are permitted as tolerated. Follow-up consists of repeat evaluation for ligamentous laxity and observation for early growth disturbances.

Complications

Growth arrest is frequent after distal femoral epiphyseal separations. Early diagnosis is helpful, and can be determined by plain radiography or MRI 3 to 6 months after injury (39,40). Management of physeal arrest has been discussed in a previous section of this chapter.

Tibial Spine Fracture

The terms “tibial eminence fracture” and “tibial spine fracture” have been used interchangeably to describe avulsion of the tibial attachment of the anterior cruciate ligament.

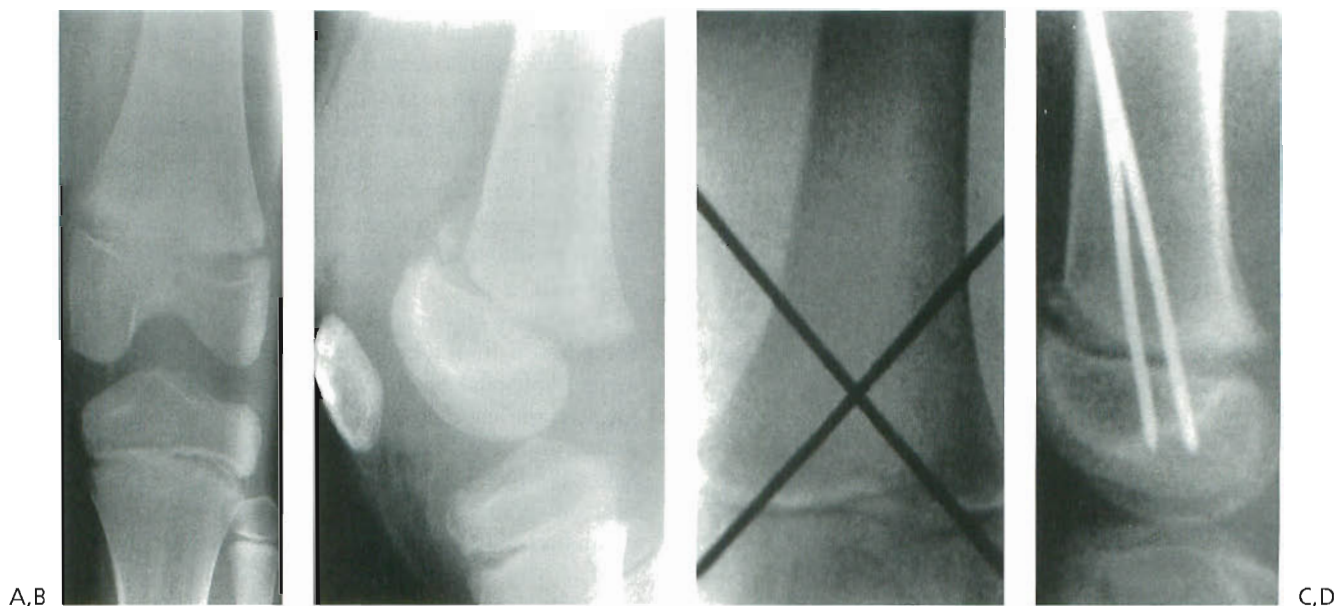


FIGURE 32-68. Distal femoral physeal fracture. **A:** An anteroposterior radiograph shows a widening of the distal femoral physis. **B:** The lateral view shows an anteriorly displaced Salter-Harris type II fracture. **C:** Intraoperative anteroposterior view after closed reduction and crossed Kirschner wire fixation. The pins are placed from a proximal to a distal direction. Smooth pins are used when crossing the physis. **D:** The lateral projection shows the pins in the midaxis of the femur.

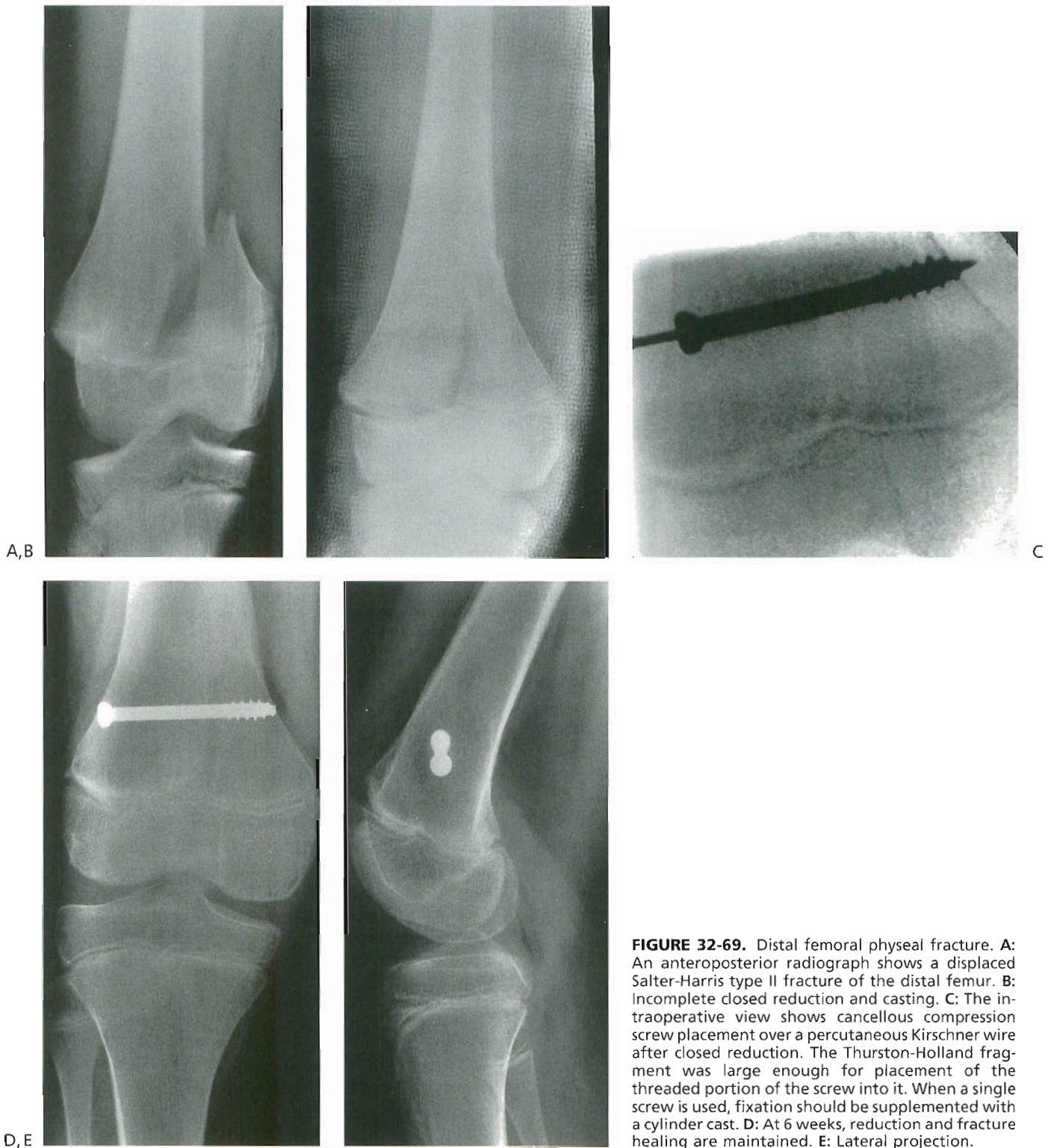


FIGURE 32-69. Distal femoral physal fracture. **A:** An anteroposterior radiograph shows a displaced Salter-Harris type II fracture of the distal femur. **B:** Incomplete closed reduction and casting. **C:** The intraoperative view shows cancellous compression screw placement over a percutaneous Kirschner wire after closed reduction. The Thurston-Holland fragment was large enough for placement of the threaded portion of the screw into it. When a single screw is used, fixation should be supplemented with a cylinder cast. **D:** At 6 weeks, reduction and fracture healing are maintained. **E:** Lateral projection.

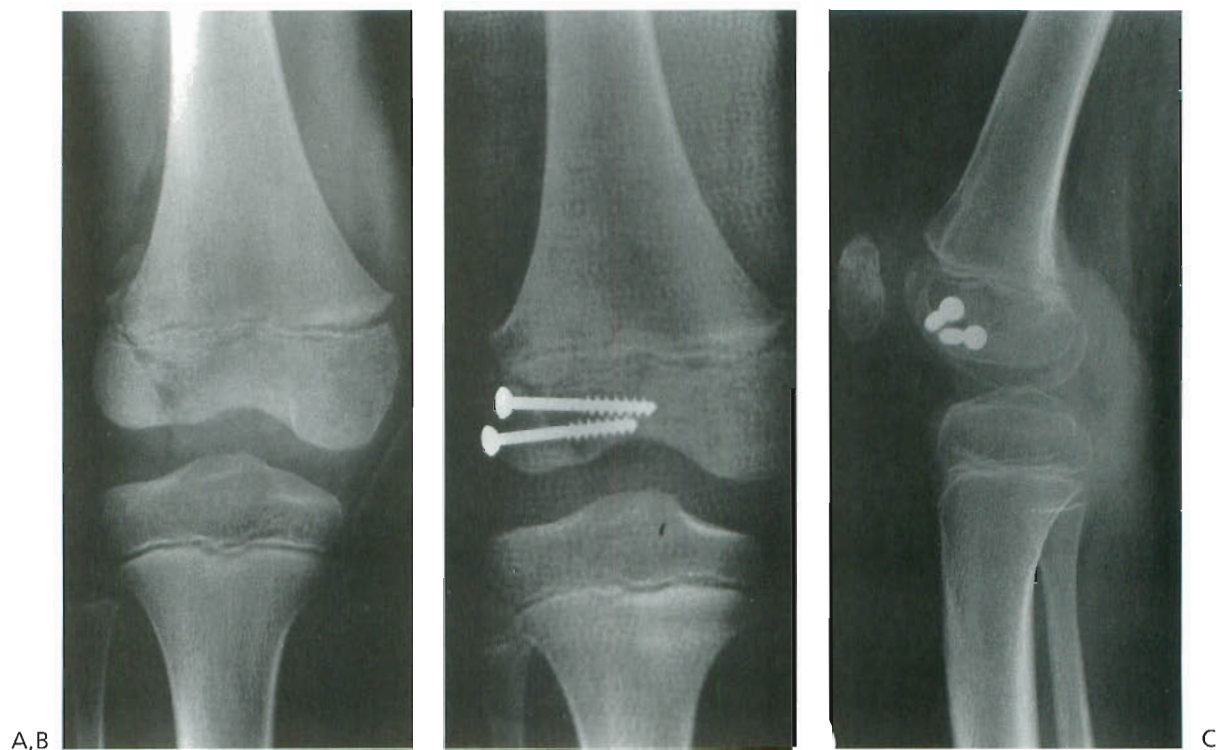


FIGURE 32-70. Distal femoral physal fracture. **A:** Salter-Harris type IV fracture involving the lateral condyle of the distal femur. Although the injury film does not show significant displacement, fragment stabilization is recommended to maintain this alignment. **B:** Anteroposterior projection after placement of cancellous bone screws. **C:** Lateral projection.

The tibial eminence consists of two bony spines, and is located between the medial and lateral plateaus of the tibia. The anterior cruciate ligament attaches to the medial spine, but nothing attaches to the apex of the lateral spine. Between these spines are the attachments of the menisci. Avulsion of the tibial eminence in children is usually caused by a fall from a bicycle, a sporting injury, or some other indirect trauma to the knee. The typical age range for this injury is 6 to 15 years.

Myers and McKeever (345) classified this avulsion fracture by degree of displacement:

type I: minimally displaced, with only slight elevation of the anterior margin;

type II: hinged posteriorly, producing a beak-like appearance on the lateral radiograph;

type III: completely displaced and elevated from its bed.

With displacement, the meniscus may become trapped underneath the fragment and interfere with reduction. Long-term studies have reported some residual knee laxity, regardless of anatomic reduction with internal fixation (346, 347). This would suggest that the fibers of the anterior cruciate ligament are stretched before bone failure. After closed treatment of type I and II fractures, any residual instability is mild, with a firm end point, and has not led

to functional deficits or subjective feelings of knee instability. A more troublesome problem has been failure to regain full knee extension. Wiley and Baxter (347) carefully evaluated knee range of motion, and determined that 60% of all patients lost more than 10 degrees of extension. This loss of motion was noted in all type III injuries that were treated closed, and in approximately one-half of the type III injuries treated with open reduction. Long-term functional results are generally excellent, except for those for displaced type III fractures (346–348).

Treatment

Type I injuries do not require reduction, and can be immobilized in a cylinder cast for 4 to 6 weeks. This is followed by range of motion exercises, strengthening, and gradual resumption of activities.

Type II fractures may be difficult to distinguish from completely displaced fractures. Aspiration of the joint and injection of local anesthetic facilitate reduction. Reduction is then attempted by fully extending the knee and applying a cylinder cast (Fig. 32-71). If radiographs after reduction are inconclusive or demonstrate inadequate reduction, MRI or arthroscopic evaluation may be necessary to determine whether the posterior attachment is disrupted, and whether

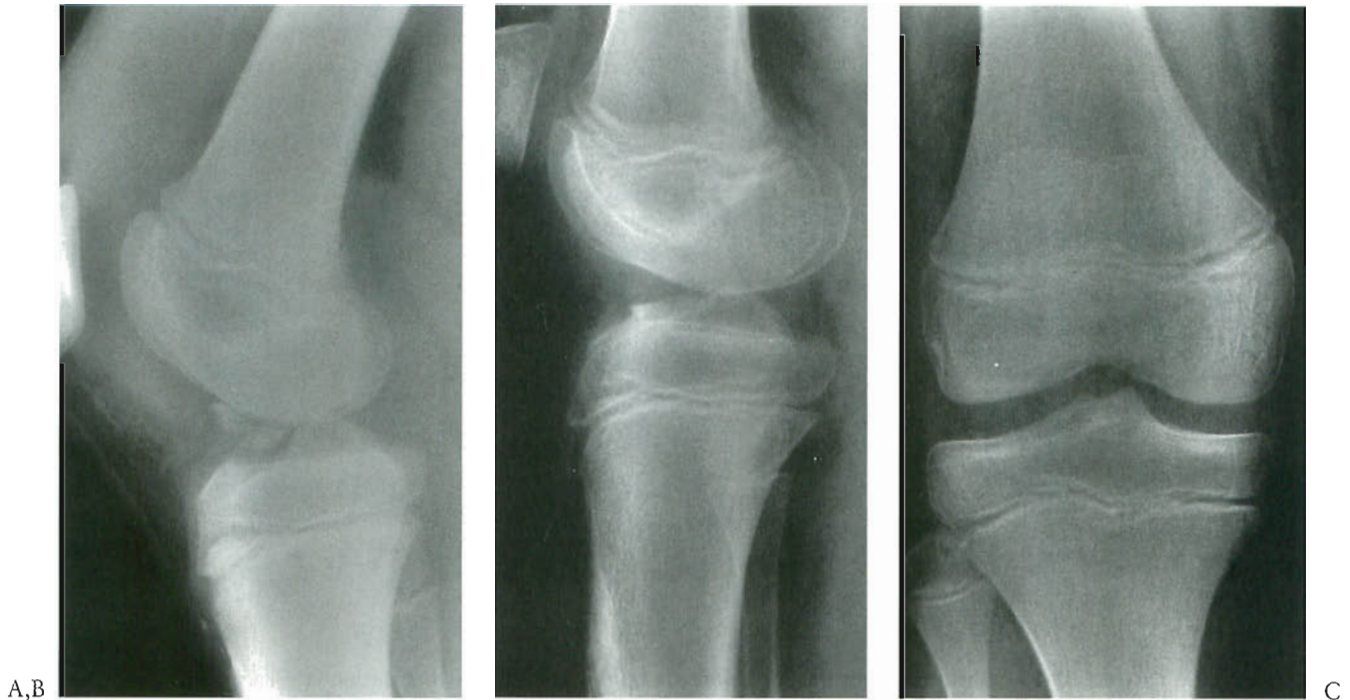


FIGURE 32-71. Tibial eminence fracture. **A:** Lateral projection of a type II avulsion fracture. This fracture is probably in transition between type II and type III displacement. However, when the knee was placed in full extension, the fragments were reduced to an acceptable degree. Treatment was in a cylinder cast. **B:** Six weeks after injury reduction has been maintained, and there is evidence of healing. **C:** The anteroposterior projection shows no significant elevation of the tibial spine.

there is meniscal entrapment. The preferred position of immobilization after reduction is controversial. Some authors recommend immobilization in extension (349), whereas others recommend immobilization with 20 to 30 degrees of knee flexion to relieve tension on the anterior cruciate ligament (349). The authors recommend immobilization in extension, because loss of extension after union is more problematic than joint instability when adequate reduction has been achieved. Hyperextension should be avoided, because this position becomes uncomfortable.

Type III fractures are best treated with open or arthroscopic reduction and stable internal fixation (350). This can be achieved by using a small intraepiphyseal cancellous screw. Alternatively, sutures or wires can be passed that enter the osteochondral fragment and exit through the periphery of the epiphysis (351). Consideration should be given to countersinking the fragment to achieve retention of the anterior cruciate ligament. When fixation is secure, early mobilization can be initiated to avoid loss of motion.

Complications

Some loss of motion and ligamentous instability are common after tibial eminence fracture, even when management has been appropriate. These problems are usually mild and

rarely interfere with function. Occasionally, patients will present late with malunion that limits knee extension. This can be treated with anterior closing-wedge osteotomy with internal fixation (349).

Tibial Tubercle Fracture

The tibial tubercle is the anterior and distal extension of the proximal tibial epiphysis. It develops a secondary ossification center and serves as the insertion site of the patellar tendon. Fracture of the tibial tubercle is an injury of the adolescent knee joint, usually occurring in boys between 13 and 16 years of age. During this period of growth, the proximal tibial physis is usually in the process of physiologic closure. Tibial growth plate closure begins centrally, proceeds centrifugally, and finally proceeds distally to include the tubercle. The mechanism of injury for avulsion of the tubercle is forceful quadriceps contraction against resistance (e.g., jumping). There may be a preceding history of Osgood-Schlatter disease (352,353).

Examination reveals swelling, deformity, and tenderness. The ability to perform a straight-leg raise should also be tested. The diagnosis is confirmed on a lateral radiograph by identifying the displaced fragment and a high-riding patella. A classification was proposed by Watson-Jones, and

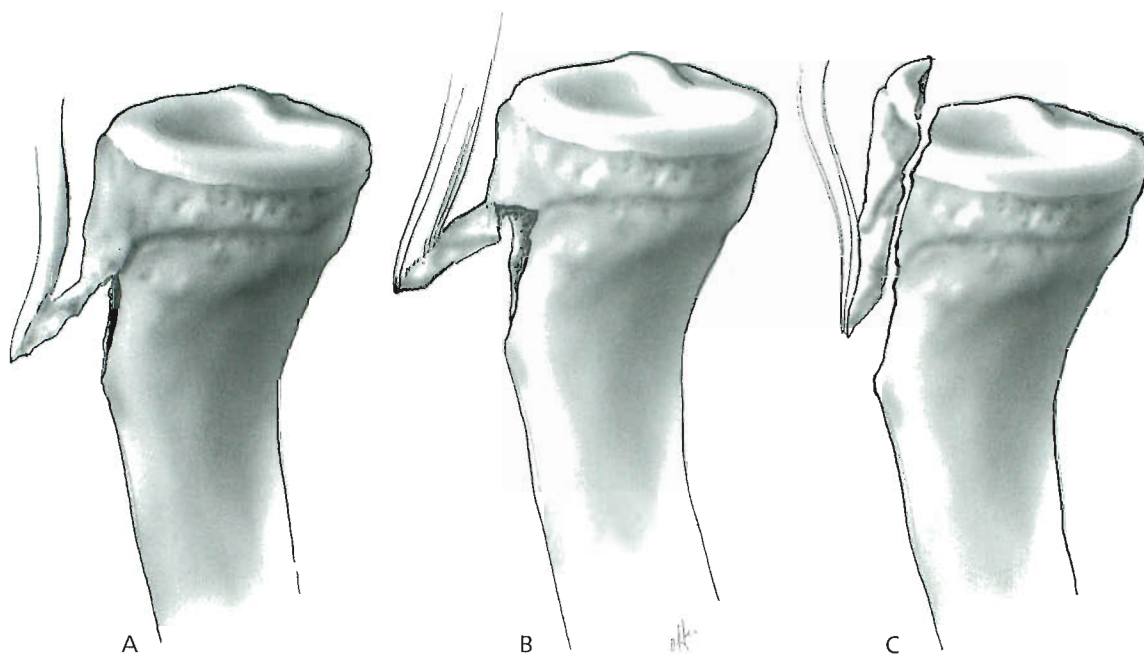


FIGURE 32-72. Classification of tibial tuberosity fractures. **A:** Type I fracture through the secondary ossification center. **B:** Type II fracture located at the junction of the primary and secondary ossification centers. Sometimes this fragment is in two pieces. **C:** Type III fracture, which is an intraarticular fracture (Salter-Harris type III). This can also be a two-part fracture.

modified by Ogden and colleagues (353) (Fig. 32-72). Type I fracture is through the distal ossification center; type II is at the junction of the tubercle and the tibial ossification centers; and type III involves the articular surface of the tibia.

Treatment

Treatment for all but minimally displaced type I fractures consists of anatomic reduction and internal fixation. This can be accomplished by open reduction and insertion of cancellous bone screws (Fig. 32-73). In younger children with significant growth remaining, smooth pins, placed obliquely across the fracture, can be substituted for screws. This can be supplemented with a tension band suture or wire to the tibial metaphysis, if pin fixation is insecure. Knee immobilization is used for 3 to 4 weeks, before beginning active range of motion.

Complications

Avulsion fractures of the tibial tubercle have few associated long-term problems. However, several authors have reported acute compartment syndrome of the leg after this injury (354). This may be attributable to the fact that the tubercle is in close proximity to the anterior compartment fascia, and bleeding from the fracture enters this compartment. Pape and colleagues (354) observed that compartment syndrome may be more frequent in patients who are

managed closed or by percutaneous methods. Bolesta and Fitch (352) recognized this potential complication, and performed prophylactic fasciotomy on selected patients.

Posttraumatic genu recurvatum can occur in younger patients after tibial tubercle avulsion fracture. This is caused by premature arrest of the anterior aspect of the growth plate. Patients with more than 1 year of growth remaining should be observed for development of this deformity. Bilateral proximal tibial epiphysiodesis is generally the preferred procedure when deformity is mild. Greater degrees of deformity may necessitate proximal tibial flexion osteotomy to restore normal alignment.

Patellar Fractures

Patellar fractures are much less common in children than in adults. This may be attributable to the fact that the patella is largely cartilaginous until adolescence. The child's patella is also more mobile than the adult's, and is subjected to less tensile force during quadriceps contraction. In adolescents, the patellar anatomy approaches that of the adult, and is more likely to be damaged by direct trauma. Osteochondral fractures have also been reported in 40% of children and adolescents sustaining acute patellar dislocations (355). The patellar sleeve fracture is a type of patellar fracture that is unique to younger children. The age range for patellar sleeve fracture is 8 to 12 years. This injury consists of an avulsion of the cartilaginous portion of the distal patella from the ossification center (356,357) (Fig. 32-74).

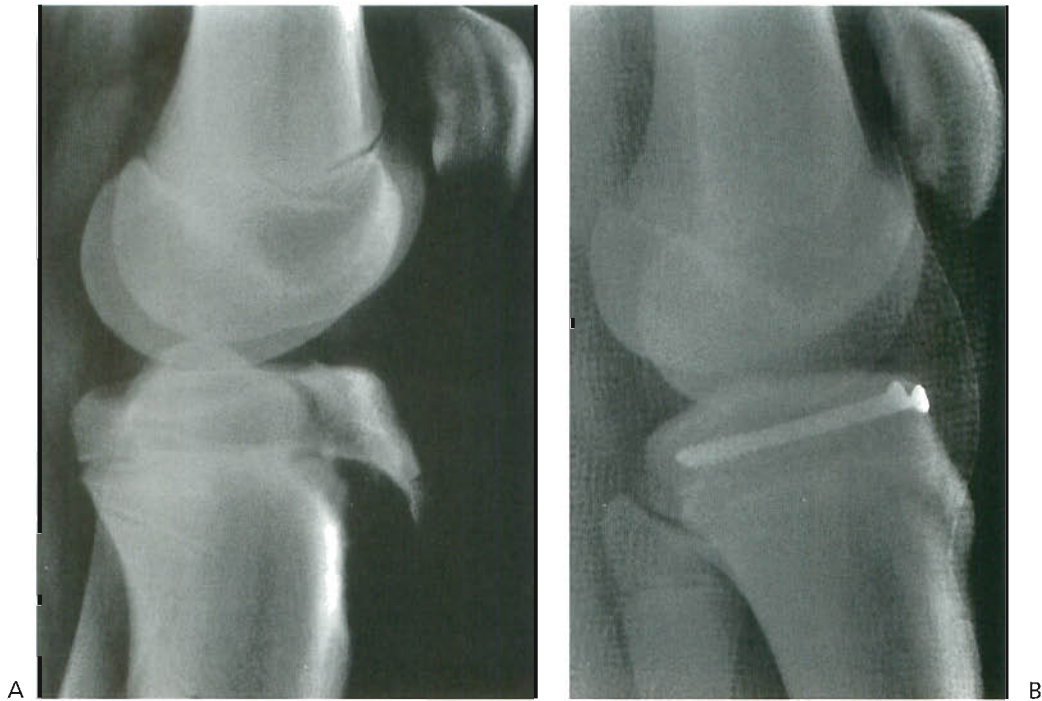


FIGURE 32-73. Tibial tubercle fracture. **A:** The lateral radiograph shows a type III tibial tubercle avulsion. This is a Salter-Harris type III fracture. Open reduction and internal fixation are indicated. **B:** The postoperative lateral radiograph demonstrates reduction of the fracture with intraepiphyseal cancellous screw placement. This type of fixation was chosen, because the patient was a 13-year-old boy who had significant growth remaining. In the older adolescent with less than 2 years of growth remaining, the screws can cross the physis.

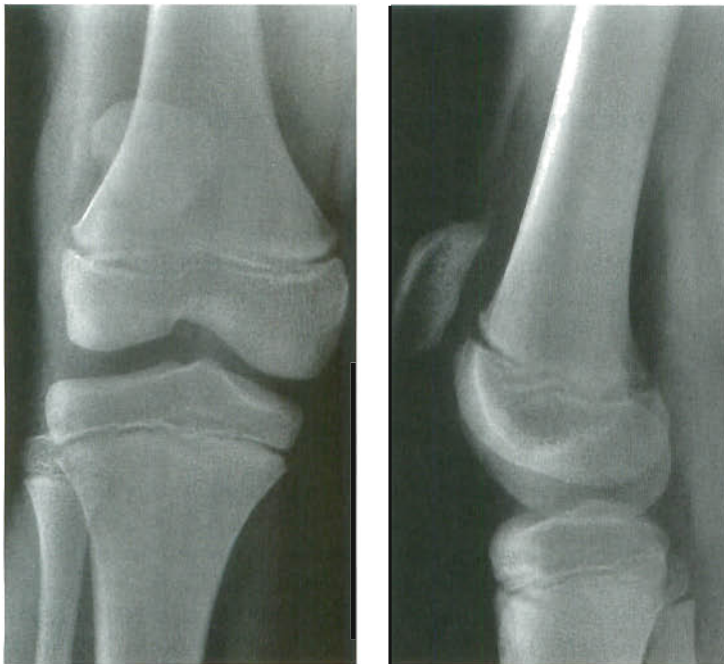

FIGURE 32-74. Patella injury. **A:** An anteroposterior radiograph of the knee suggests proximal displacement of the patella. **B:** The lateral view demonstrates patella alta, and a faint calcification is seen 1 cm distal to the inferior pole of the patella. These findings are consistent with patellar sleeve fracture. (*continued*)

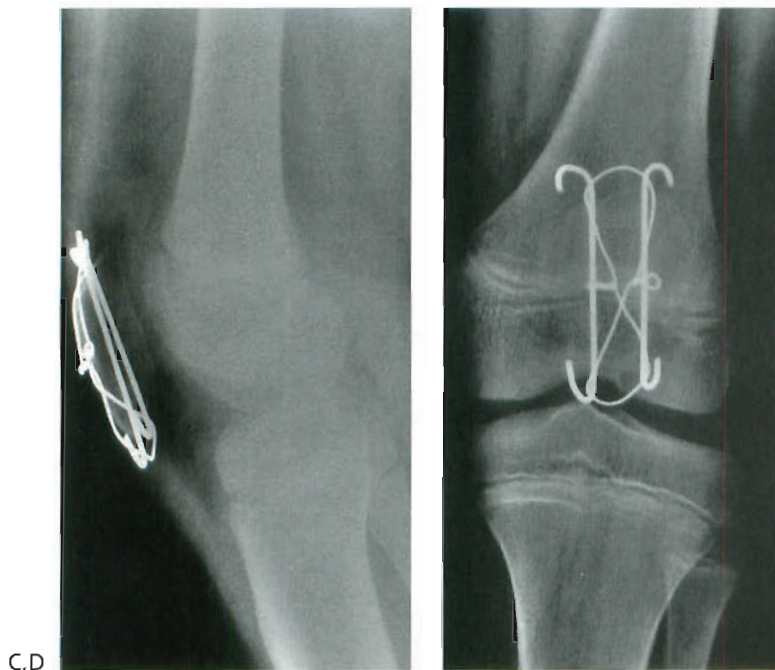


FIGURE 32-74. (continued) C: Lateral view after open reduction and fixation with AO tension band technique. The patella has returned to its normal position. D: The anteroposterior projection shows the configuration of the internal fixation devices.

The diagnosis of patellar fracture may be more difficult in children than in adults. Palpation may reveal a defect, but can be difficult to perform, because of pain and tense hemarthrosis. Lack of function and abnormal movement of the extensor mechanism on physical examination are generally useful indicators of patellar injury. Radiographs can be difficult to interpret. Bipartite patella (i.e., secondary ossification center) may be painful, and can be confused with nondisplaced fracture. A fractured patella may be difficult to diagnose accurately, as a result of incomplete ossification. This is particularly true for patellar sleeve fractures, in which the lateral radiographs may demonstrate only patella alta and a very small fragment of bone attached to the distal unossified cartilage. The MRI can be diagnostic when there is doubt regarding the nature of the injury.

Treatment

Treatment of patellar fractures in children is generally the same as for adults (358). The patella is a sesamoid bone that grows by apposition, so growth disturbances are uncommon. Nondisplaced fractures with intact extensor mechanisms may be treated by immobilization in extension for 4 to 6 weeks. Open reduction with internal fixation is indicated for displaced fractures. Stability may be achieved by means of the AO tension band technique or by cerclage wiring.

TIBIAL FRACTURES

Tibial fractures are the most common lower extremity fracture in children, and make up 10 to 15% of all pediatric

fractures (5,176). Many of these are toddler fractures or low-energy nondisplaced fractures occurring from minor falls, twisting injuries, or sports. Motor vehicle crashes and high-energy injuries are more common in older children, resulting in displaced tibia and fibula fractures. Soft tissue injury is more severe in displaced fractures, and adds to the complexity of fracture management. The location of the fracture, its severity, and the child's age influence treatment.

Proximal Tibial Epiphyseal Fracture

Separation of the proximal tibial epiphysis is uncommon (Fig. 32-75). This is probably attributable to the supporting ligamentous structures and the shape of the physis. The fibula buttresses the tibia laterally, and the physis slopes downward anteriorly in the region of the tibial tubercle. The medial collateral ligament inserts on the metaphysis, in addition to the epiphysis. Many of the musculotendinous units that span the knee do not insert on the proximal tibial epiphysis. Thus, varus and valgus stresses are not propagated to the tibial epiphysis.

The mechanism of injury to this epiphysis is usually direct force to the knee, as in a fall from a height, lawn mower injuries, or motor vehicle crashes. Hyperextension injuries from sports may also injure this region. Lawn mower injuries are seen in younger children, but the majority of patients are older than 12 years at the time of injury (359,360). Most proximal epiphyseal injuries are Salter-Harris type II fractures, demonstrating posterolateral or posteromedial displacement. These are followed in frequency by type I separations, which tend to displace posteriorly. This threat-

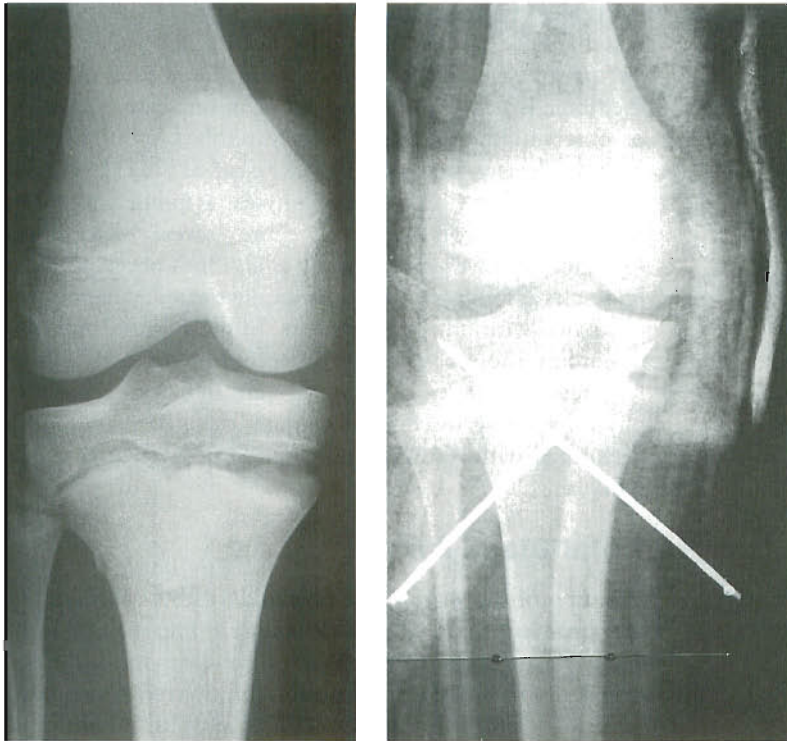


FIGURE 32-75. A: Salter-Harris type II fracture of the proximal tibia. Compartment syndrome accompanied this injury. B: Fasciotomies were performed for compartment syndrome, and the fracture was treated with closed reduction and percutaneous pin fixation.

ens the popliteal artery, because the artery is tethered to the posterior aspect of the tibia by its branches. The posterior branch passes under the arch of the fibers of the soleus muscle, whereas the anterior branch passes into the anterior compartment just distal to the growth plate (Fig. 32-76).

Treatment

Management consists of closed reduction in most cases, but percutaneous pinning or cannulated screw fixation is performed if the fracture is unstable, if vascular repair is necessary, or if early motion is required. Precise reduction is recommended, because future growth may be impaired or insufficient to spontaneously correct residual deformity. Displaced type III and IV fractures are intraarticular injuries, and require precise reduction and internal fixation to preserve joint function and reduce the risk of premature physeal closure. These fractures should be followed closely for growth arrest, which occurs in 25 to 33% of patients, regardless of the type of physeal separation (359,360).

Complications

Vascular compromise requires prompt reduction and stable fixation. After reduction, blood pressures by Doppler pulse are compared with those in the opposite limb. Any significant difference is an indication for arteriography. It is recommended that this be performed in the operating room

to avoid delay in vascular exploration and repair. If vascular repair is necessary or if ischemia has exceeded 4 h, prophylactic fasciotomy is recommended (68). This prevents reperfusion compartment syndrome from developing.

Proximal Tibial Metaphyseal Fracture (Cozen Fracture)

Metaphyseal fractures of the proximal tibia occur most commonly in children between the ages of 2 and 8 years. The usual mechanism of injury is a valgus force applied to the extended knee, producing an incomplete fracture of the tibia, with or without fracture of the fibula. The lateral cortex of the tibia may be buckled or impacted, or may undergo plastic deformation. Pronounced displacement is uncommon, except in instances of high-energy trauma. This innocuous-appearing fracture is often in more valgus than one readily appreciates from the initial radiographs. A comparison radiograph of the opposite tibia is helpful to determine the true deformity of the injured leg.

Treatment

Management consists of closed reduction with the knee in extension. This position allows effective three-point cast molding to generate a varus force. The extension position also facilitates subsequent radiographic interpretation. After reduction, the author recommends that an angle formed by

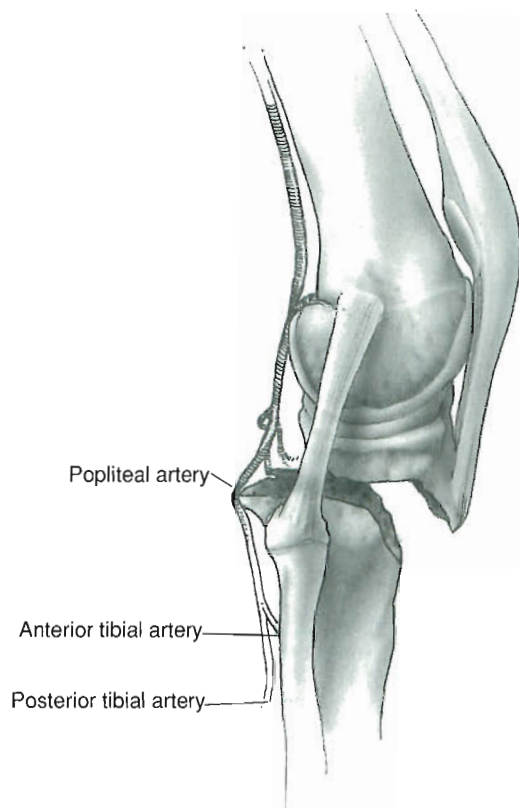


FIGURE 32-76. Proximal epiphyseal fracture. The distal tibial segment is displaced posteriorly, producing vascular occlusion of the popliteal artery.

a line through the physis and a line down the tibial shaft should be within 5 degrees of the opposite intact tibia. The cast is maintained until healing is complete, usually 6 weeks. Displaced proximal tibial fractures in adolescents sometimes require operative stabilization to control alignment and expedite mobilization. During the 48 h after closed reduction and casting, the extremity should be closely monitored for signs of excessive compartment swelling.

Complications

Progressive valgus deformity of the leg frequently develops in children younger than 10 years of age who sustain this fracture (361–363) (Fig. 32-77). Close review of the initial postreduction radiographs occasionally reveals that an imprecise reduction was responsible for at least part of the deformity. However, nondisplaced and anatomically aligned fractures can also develop progressive valgus deformity (362). Angulation increase begins several weeks after fracture and usually ceases by 12 months after fracture. The cause of this problem remains somewhat obscure, but it probably results from selective overgrowth of the medial tibial physis, in response to asymmetric vascular stimulation

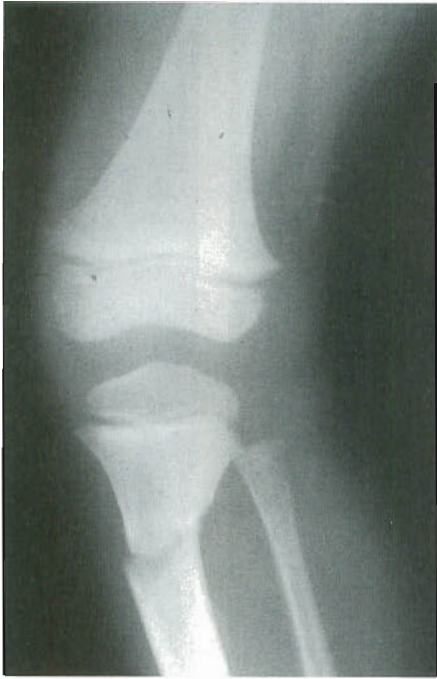(361,362). Overgrowth of the tibia, with tethering by the intact fibula, has also been postulated as a possible cause, but progressive valgus deformity can develop, even when the fibula is fractured. Treatment of this deformity consists of observation, because it usually resolves spontaneously with the development of a slightly S-shaped tibia (364,365). Tibial osteotomy and hemiepiphyseal stapling have been reported for correction of more severe deformities (358,366). However, McCarthy et al. (364) observed similar results at follow-up, when surgically treated patients were compared with untreated patients. In the authors' opinion, osteotomy should be avoided, because of the high risk of recurrent deformity. Although rarely indicated, hemiepiphyseal stapling in children younger than 10 years can be performed with resumption of normal growth after staple removal.

Tibial Diaphysis

Fractures of the shaft of the tibia and/or fibula account for approximately 4 to 5% of all pediatric fractures (5,176). These fractures generally fall into three categories: (i) non-displaced, (ii) oblique or spiral, and (iii) transverse and comminuted displaced fractures (367,368). In infants and young children, the tibial shaft is relatively porous, and is more likely to bend or buckle than to comminute. The surrounding periosteum is strong and imparts stability to the fracture site, limiting displacement and shortening. In contrast, the adolescent tibial shaft is composed of more dense cortical bone and a thinner, weaker periosteum. Fractures in the adolescent age group are more often the result of high-energy trauma, and are associated with greater fracture displacement, comminution, and slower healing rates than in younger children.

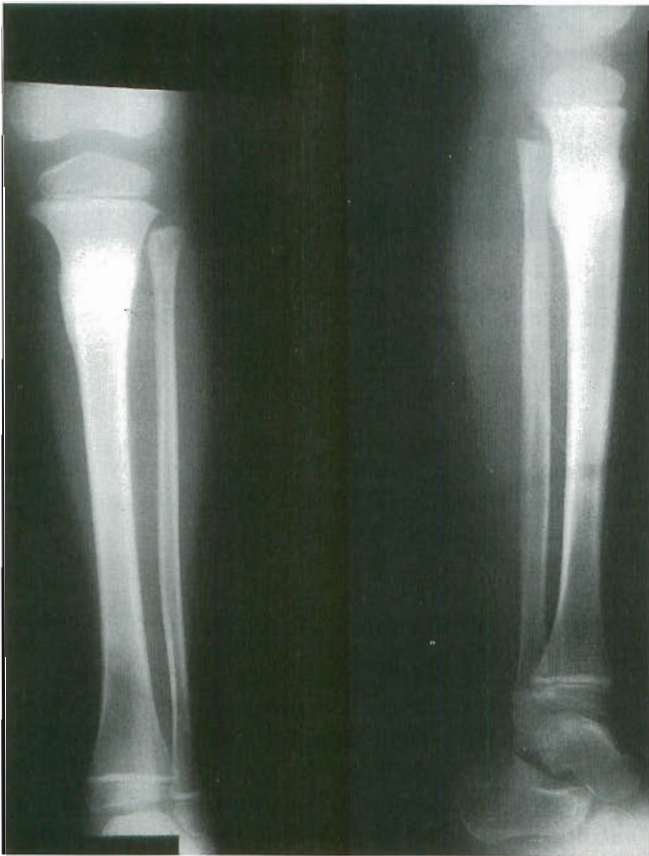The remodeling potential of the tibia is limited. Rotational deformity does not remodel, although external rotation deformity is better tolerated than internal rotation deformity (368). Final alignment should be within 10 degrees of angulation in any direction (367–370). Infants and young children can correct approximately 50% of residual angulation with growth. In children older than 10 years of age, only 25% of the axial malalignment improves. Hansen and Grief (367) reported only 13.5% correction of angular deformity with subsequent growth, but Shannak (368) demonstrated that one-third of children with more than 10 degrees of angulation at healing had persistence of the malunion at final follow-up assessment. In general, varus malalignment seems to remodel more completely than valgus deformity.

The ability to compensate for shortening decreases with age. Children younger than 5 years of age show the greatest capacity. Unlike the fractured femur, this increase in tibial growth rate is less dramatic, and growth acceleration greater than 5 to 7 mm is unusual (371). In a review of 142 tibial fractures, Shannak (368) reported an average of only 4.35 mm of growth acceleration. Comminuted and long spiral

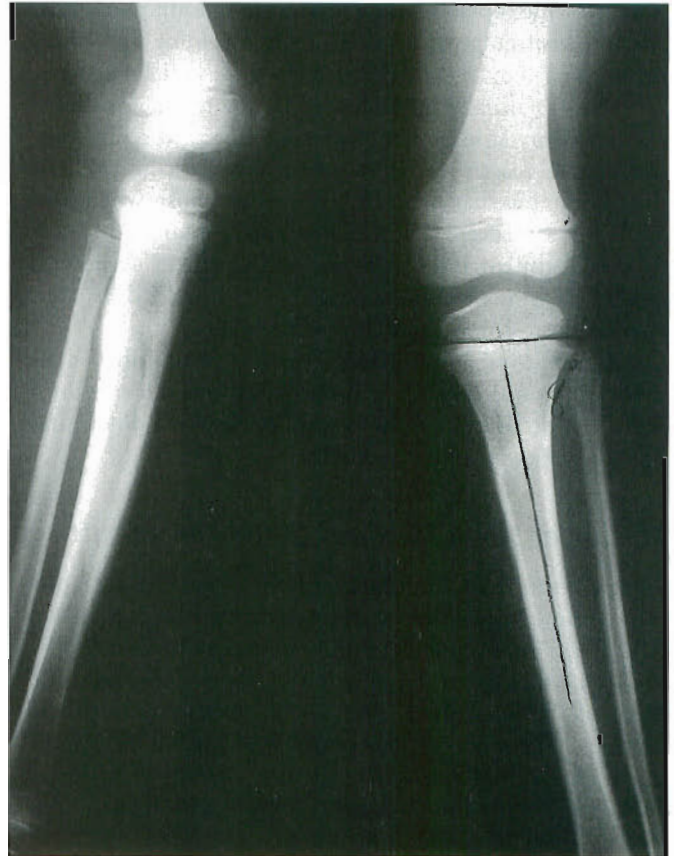

A

FIGURE 32-77. A: Radiograph of a proximal metaphyseal fracture of the tibia with valgus deformity. Closed reduction was performed. B: Radiographic appearance at the time of union demonstrates satisfactory alignment. C: Radiographs 8 months later demonstrate valgus alignment attributable to asymmetrical growth stimulation.



B



C

fractures displayed the greatest amount of overgrowth, including those that were treated with anatomic reduction and internal or external fixation. Overgrowth is not routinely seen in girls older than 8 years or boys older than 10 years of age.

Nondisplaced Fractures of the Tibial Shaft

Nondisplaced tibial fractures are more common in younger children. So-called “toddler’s fracture” is seen in the 1- to 4-year age group. A mildly traumatic event may have been observed, but often the child presents with an acute limp of unknown cause. Approximately 20% of these acutely limping toddlers have sustained occult fractures, and one-half of these fractures are in the tibia (372). Low-energy torsional forces, as when the child twists a leg, usually cause these fractures. The child limps or refuses to walk on the affected lower limb. Examination may reveal a point of tenderness or subtle swelling in the distal third of the leg, but often the examination is unremarkable. Radiographs may show a fracture, but frequently the fracture line is not initially evident. Toddler’s fracture is differentiated from pathology of the hip and femur by the child’s ability to crawl and a normal range of motion of the hip joint. Infectious processes need to be considered in the differential diagnosis, but these can usually be diagnosed by the presence of fever and laboratory studies demonstrating increased sedimentation rate, C-reactive protein, and leukocyte count. A tri-phase bone scan may help establish the diagnosis when pain and limp are severe and the workup remains equivocal (373). Treatment is initiated when fracture is suspected, and the diagnosis is usually confirmed 10 to 14 days later, when periosteal new bone has formed.

Treatment for nondisplaced fractures of the tibial shaft in all age groups consists of immobilization in a cast until union has occurred, usually 3 to 4 weeks for toddlers and 6 to 10 weeks for older children.

Oblique or Spiral Fractures of the Tibial Shaft

Isolated fracture of the tibia, with an intact fibula, is the most common tibial shaft fracture in the pediatric age group (370,374). A rotational or twisting force, resulting in a spiral or oblique fracture at the junction of the middle and distal thirds of the tibial shaft (Fig. 32-78), usually causes these fractures. The most common mechanism of injury is indirect trauma, such as sports accidents or falls. The intact fibula imparts stability, but may interfere with reduction of displaced fractures and contribute to the development of varus angulation.

Treatment consists of reduction and immobilization in an above-knee cast, with the knee flexed to 30 degrees and the ankle in 15 degrees of plantar flexion, to minimize varus muscle forces (370,374). Unstable displaced fractures may require fibular osteotomy and surgical stabilization (Fig. 32-

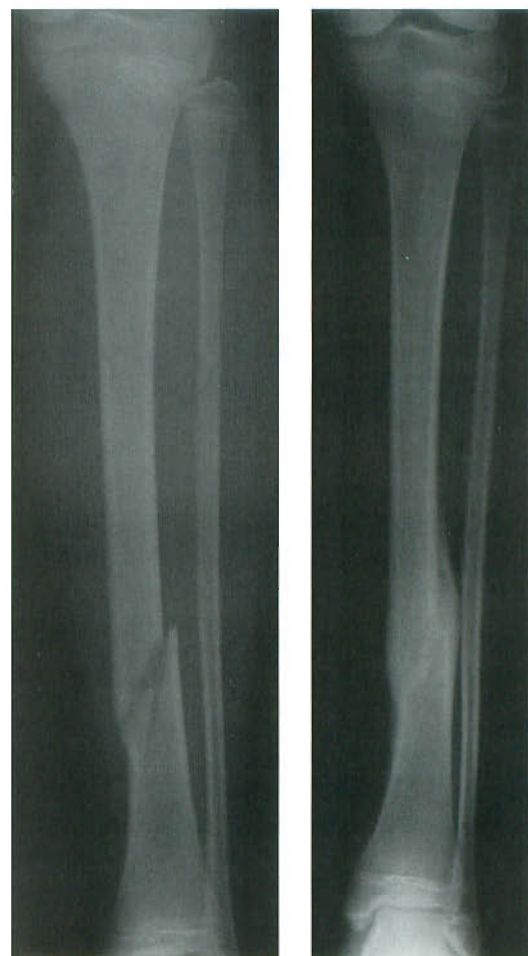


FIGURE 32-78. A: Spiral or oblique fracture of the tibia, without fibula fracture, is common in children. B: Radiograph at the time of union demonstrates satisfactory alignment with acceptable varus deformity.

79). Angulation greater than 10 degrees in any direction should be corrected, except in very young children, in whom 15 degrees may be accepted (367–370).

Transverse and Comminuted Displaced Fractures of the Tibia and Fibula

Complete fractures of the tibia and fibula are more common in older children. These fractures result from high-energy trauma, and are frequently unstable. Open fractures of the tibia are not uncommon, and account for 4% of all tibial fractures in children and adolescents (375). Soft tissue damage and periosteal stripping predispose to more severe complications, such as compartment syndrome, delayed union, and infection. Inherent fracture stability after reduction is variable.

Treatment of closed injuries is similar to that for oblique and spiral fractures. Closed reduction may be easier to

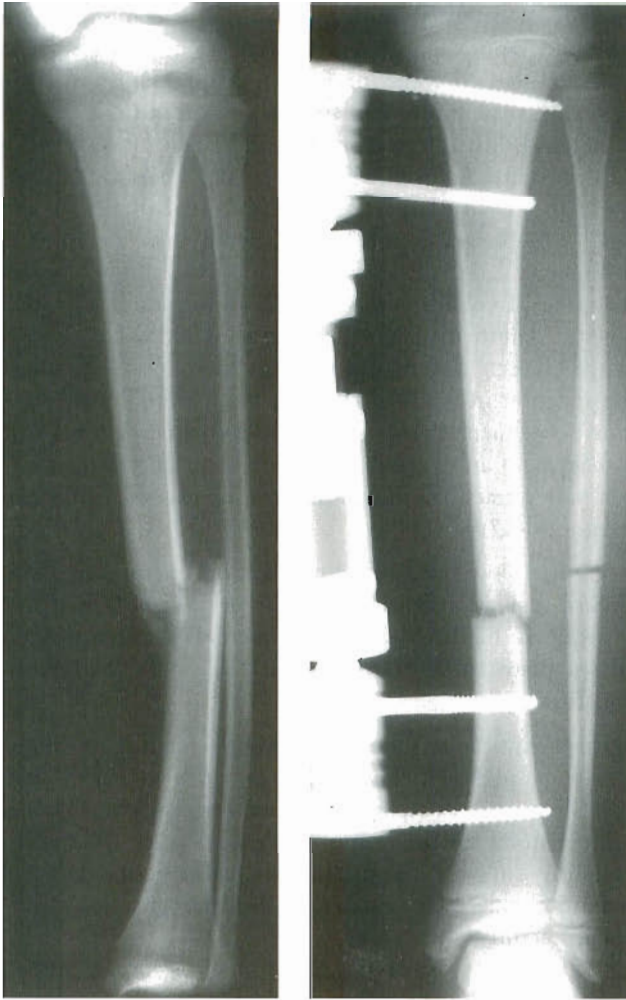


FIGURE 32-79. A: Transverse fracture of the tibia, with an intact fibula. B: Osteotomy of the fibula was necessary to obtain reduction. After this, the fracture was very unstable and required fixation. Flexible intramedullary nails, introduced through the metaphysis, also would have provided stabilization.

achieve than when the fibula is fractured, but there is a tendency for the fracture to drift into valgus and procurvatum, because of the greater muscle bulk posterolaterally in the leg. An above-knee cast is used for 4 to 8 weeks, until initial stability has been achieved. Immobilization may then be continued with a patella-tendon-bearing cast, until healing is complete. Final axial alignment should be within 10 degrees in any direction.

Unstable fractures may require surgical stabilization to maintain alignment or facilitate rehabilitation. The techniques for surgical stabilization are similar to the techniques discussed with regard to femur fractures, and include the use of pins and plaster, flexible intramedullary nails introduced through the metaphysis, plates and screws, and external fixation. Additional indications for surgical stabilization of tibial fractures include associated head injuries, multiple

trauma, floating knee, vascular injury, and open fractures requiring wound access.

Open Fractures of the Tibia

The general management of open fractures has been discussed earlier in this chapter. Open fractures of the tibia in children are the result of high-energy trauma, and are associated with other injuries in 25 to 50% of cases (59,375).

Treatment. Initial management consists of administration of intravenous antibiotics and tetanus prophylaxis, followed by aggressive wound irrigation and debridement (59,60,66,375). Clean, grade I open wounds may be loosely closed over a drain after adequate debridement, but the majority of wounds should be left open, with repeated debridement, before soft tissue coverage (60). Surgical stabilization facilitates wound management. External fixation is generally preferred, but satisfactory results have been reported with pins and plaster, plates and screws, and flexible intramedullary fixation (59,60,66,375).

Complications. Open fractures in children share many of the same complications reported in the adult literature (62,63). Kreder and Armstrong (59) noted that a delay of more than 6 h correlated with a 25% infection rate, compared with a 12% rate for patients operated on within 6 h. Others have noted that age is the most significant prognostic indicator (64,66). Children younger than 12 years of age require less aggressive surgical management, heal faster, have lower infection rates, and have fewer complications than older children. Children older than 12 years of age have fracture patterns and complications that are similar to those in the adult population.

FRACTURES OF THE ANKLE

Ankle fractures in children constitute approximately 5% of all pediatric fractures and one of six physeal fractures (17%) (3,29). The same mechanisms that produce spiral fractures of the tibial shaft in younger children may produce epiphyseal fractures of the ankle in older children. Tillaux and triplane fractures, referred to as transitional fractures because they occur in adolescents during the transition to skeletal maturity, are specific injuries that occur as the distal tibial growth plate is beginning to close (376).

The ossification centers of the distal tibial and fibular epiphyses appear between the ages of 6 months and 2 years. The medial malleolar extension forms around 7 to 8 years of age, and is complete by age 10 years. Closure of the distal tibial growth plate begins centrally, proceeds medially, and ends on the lateral side. This sequence of closure is responsible for transitional fracture patterns. The fibular physis lies

at the level of the talar dome, and closes 1 to 2 years later than the distal tibia.

Ankle motion consists essentially of plantar flexion and dorsiflexion only, rendering this region susceptible to injury with twisting or bending forces. Medial stability is provided by the deep fibers of the deltoid ligament that attach the medial malleolus to the body of the talus. The lateral ligament complex consists of anterior and posterior talofibular ligaments and the calcaneofibular ligament. Strong ligamentous structures also bind the distal tibia to the fibula at the level of the joint. The anterior tibiofibular ligament is important in the pathomechanics of transitional fractures. All of these ligaments, and others around the ankle, principally attach to the epiphyses distal to the level of the growth plate. This anatomic arrangement transmits injury forces to bone, and results in physeal fractures in older children and adolescents.

Diagnosis can be difficult in patients with nondisplaced or minimally displaced fractures. This is particularly true for distal fibular physeal separations and Tillaux fractures. Swelling may be minimal. Careful palpation usually reveals that the most tender area is the growth plate rather than the joint or ligaments. Displaced fractures are painful, with visible deformity attributable to the subcutaneous nature of the ankle joint. The position of the foot relative to the tibia provides evidence of the mechanism of injury, and indicates the direction of manipulation required for reduction. Motor, sensory, and vascular assessments should be performed before reduction. Plain radiographs usually confirm the diagnosis and define the fracture pattern. Ultrasound assessment has been used to diagnose nondisplaced Salter-Harris type I separations of the distal fibula, but this has not altered treatment (377). CT scanning, with or without three-dimensional reconstruction, is invaluable for the evaluation and management of transitional fractures. An MRI does not offer great advantage over plain radiography, except to evaluate complications such as growth arrest (378).

Malleolar avulsion fractures are more common in younger children, whereas a variety of epiphyseal injuries may be seen in older children. Fractures with syndesmosis disruption are uncommon in children until late adolescence. The most common injury is avulsion of the tip of the lateral malleolus, followed by separation of the distal fibular physis (376,377,379).

Classifications

Ankle injuries in children have been classified by mechanism of injury, by type of growth plate injury, and by combinations of both systems (380,381). Classifications based on mechanism of injury have been proposed to help guide reduction, but these classifications have been formulated independent of the clinical examination. Also, children rarely have comminution or syndesmosis disruption, which have poor prognoses in adult classification schemes. In children, the steps necessary for reduction are usually evident when

the clinical examination of foot position is combined with the radiographic appearance. Classifications have also been proposed that combine mechanism of injury with the type of growth plate injury, but these classifications can be confusing and difficult to remember. The authors agree with Vahvanen and Aalto (379), who stated: "The simultaneous use of the classifications based on both type of trauma and type of epiphyseal lesion for classifying ankle fractures in children has led to unsatisfactory and unnecessarily complex groupings. In children the mechanism of trauma can often not be identified, and experimental work, such as what Lauge-Hansen did to support the mechanism-of-trauma classification in adults, is lacking in children." Those authors subsequently proposed a simple classification to guide management and predict outcome. According to their system, ankle fractures in children can be classified into two categories (379):

group I: low-risk, including avulsion fractures and epiphyseal separations (Salter-Harris types I and II); and

group II: high-risk, including fractures through the epiphyseal plate (Salter-Harris types III, IV, and V) and transitional fractures.

In this classification scheme, transitional fractures would be considered high risk. The authors prefer to consider transitional fractures as a separate category, because of the distinct pathoanatomy of these injuries. Spiegel et al. (382) used a slightly different classification of high-risk and low-risk pediatric ankle fractures, with a third category for transitional fractures.

Treatment

Low-risk Fractures

This category includes avulsion fractures that do not involve the growth plate, and all Salter-Harris type I and II physeal separations. Nondisplaced fractures are treated with cast immobilization for 3 to 6 weeks. Close follow-up with frequent early radiographs is recommended to detect any displacement in the cast.

Displaced low-risk fractures are usually managed by closed reduction (Fig. 32-80). This can be attempted in the emergency room, but complete muscle relaxation may be required for successful manipulation. Interposed soft tissue may interfere with reduction and necessitate surgical exploration. A flap of periosteum is usually found, but tendons or neurovascular structures can also become interposed. Internal fixation with smooth pins or metaphyseal screws can be used after open reduction, but this is not required if the fracture is stable clinically. Minor amounts of displacement and angulation can be accepted, especially in younger children, because these injuries are usually extraarticular and have good prognoses for resumption of growth. Immobilization in an above-knee cast is recommended for the first 3 weeks after closed reduction. A below-knee cast, for an additional 2 to 3 weeks, follows this.

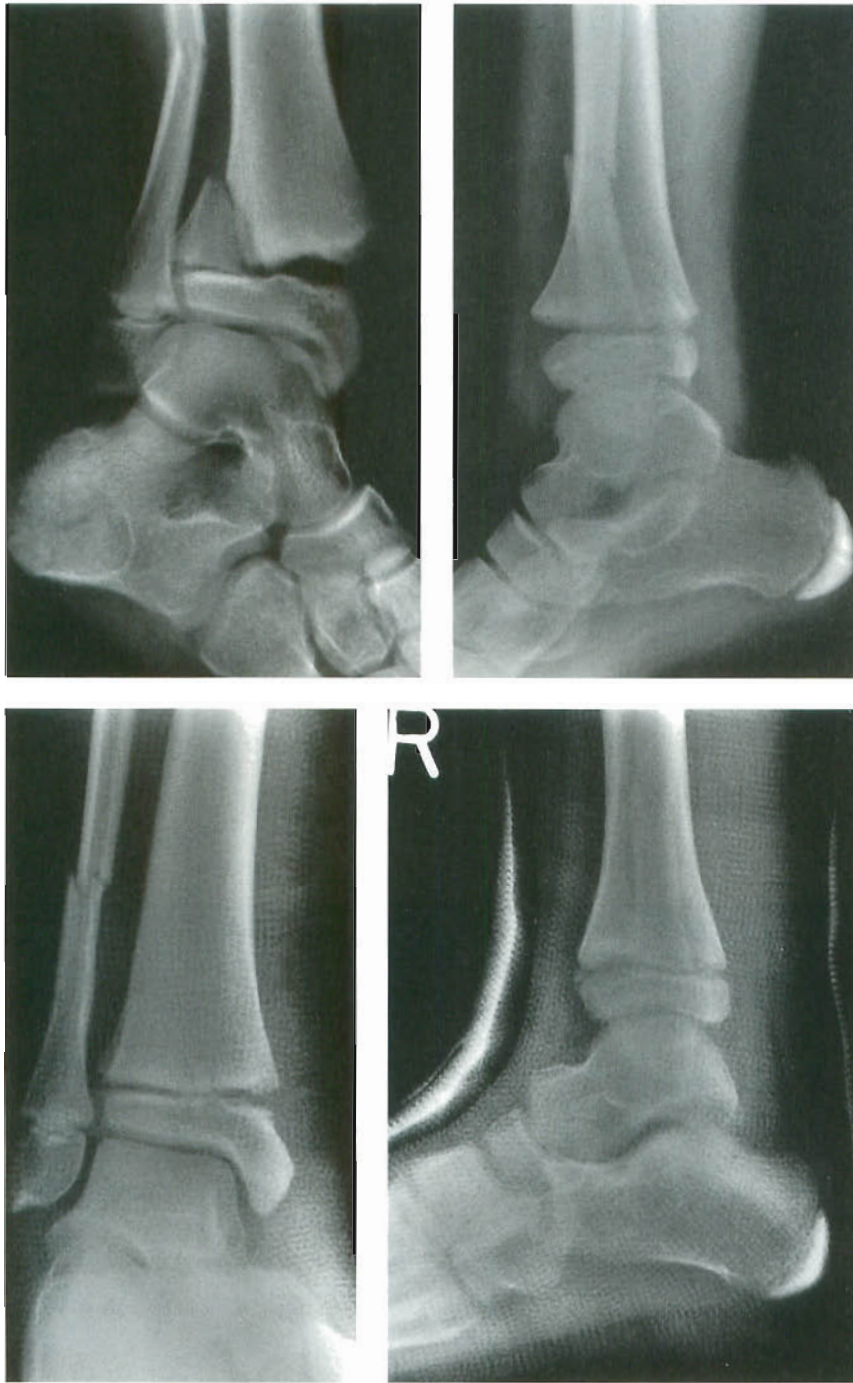


FIGURE 32-80. Pronation and external rotation ankle fracture. **A:** The anteroposterior radiograph demonstrates a Salter-Harris type II fracture of the distal tibia. The Thurston-Holland fragment is lateral. The fibular fracture is transverse and located well above the fibular physis. **B:** Lateral projection of the same injury. **C:** This fracture was treated with closed reduction and application of an above-knee cast. **D:** A lateral radiograph demonstrates acceptable alignment. This fracture was managed successfully with closed reduction.

High-risk Fractures

These fractures include Salter-Harris type III and IV fractures. They are usually intraarticular, with joint instability. Hairline fractures, in which the fracture line is 1 mm or less on all views, can be managed by immobilization in a long-leg cast (Fig. 32-81). Greater degrees of displacement require accurate reduction. Salter and others (383–385) have noted that reduction of these fractures must be “per-

fect,” to restore the articular surface and minimize the risk of growth arrest. Closed reduction may be attempted for displaced fractures, but is rarely successful. Open reduction is usually performed with fixation, using intraepiphyseal smooth Kirschner wires or small, cannulated screws (Fig. 32-82). Lintecum and Blasier (386) described a technique of direct visualization and reduction through an anterior arthrotomy incision. This was accompanied by percutaneous fixation with cannulated screws inserted medially or

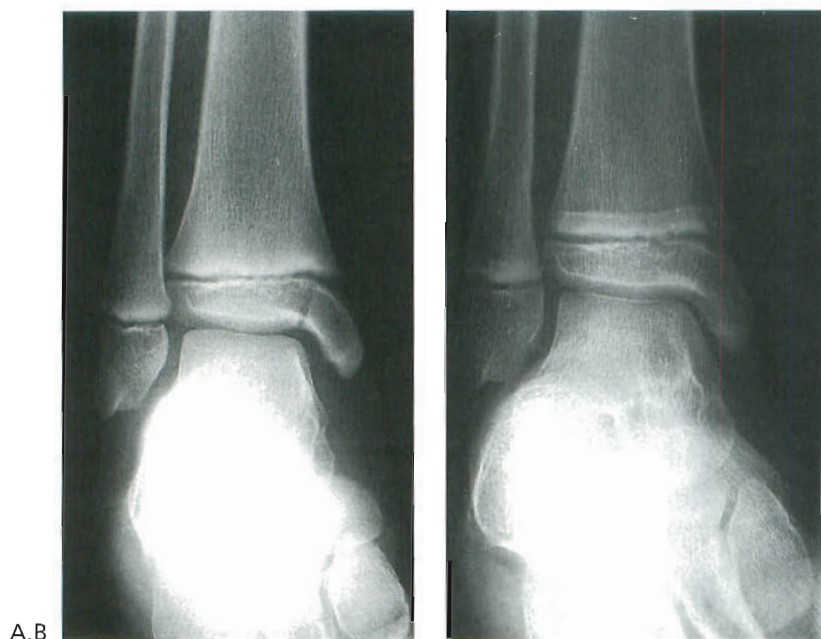

FIGURE 32-81. A: A 9-year-old girl sustained an undisplaced Salter-Harris type III fracture of the distal tibial epiphysis, as seen in this anteroposterior radiograph. B: Management in a cast resulted in healing by 6 weeks. This anteroposterior radiograph shows the result at 3 months. There is symmetrical growth of the physis at the tibia and fibula.

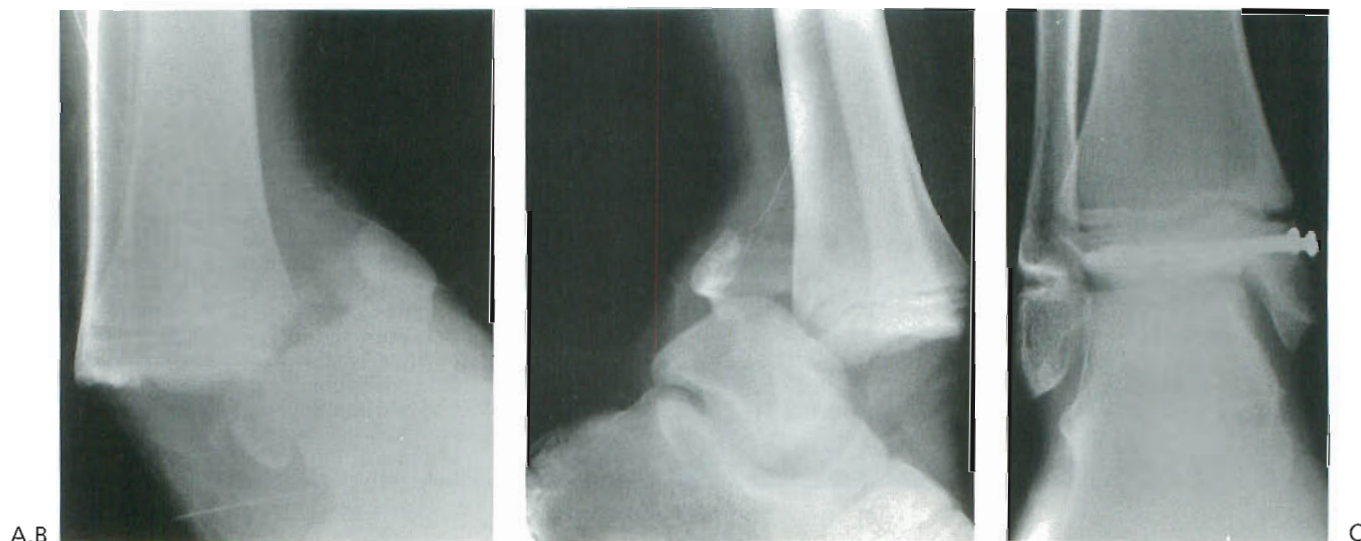


FIGURE 32-82. Supination-inversion ankle fracture. A: The anteroposterior radiograph demonstrates a bimalleolar ankle fracture with ankle dislocation. There is a Salter-Harris type I fracture of the distal fibula and a Salter-Harris type III fracture of the medial tibial epiphysis. B: Lateral projection. C: Anteroposterior radiograph after open reduction and internal fixation. Transepiphyseal screws are used to avoid fixation crossing the growth plate. The joint surface is restored to anatomical alignment. No fixation was required for the fibula fracture. A smooth Kirschner wire can be placed across this physis, if needed, for ankle stability.

laterally. Every effort should be made to avoid crossing the growth plate with internal fixation devices. However, restoration of articular integrity is more important than preserving growth at the ankle. The distal tibia and fibular epiphyses contribute only 3 to 4 mm of longitudinal growth per year. In older patients with unstable fractures, it is occasionally advisable to place internal fixation devices across the physis and perform epiphysiodesis to avoid subsequent angular deformity.

Transitional Fractures

These fractures are also high-risk, and include the Tillaux and triplane injuries. These fractures occur as the growth

plate is in the process of closing, so growth disturbance is not a concern. Restoration of articular congruity is the objective of treatment.

Tillaux fracture results from an external rotational force, and consists of avulsion of the anterolateral portion of the distal tibial epiphysis by the anterior tibiofibular ligament. This is a biplane Salter-Harris type III injury that can be difficult to detect on plain radiographs. Closed reduction is performed, followed by internal rotation and immobilization in an above-knee cast. The quality of reduction should be accurately documented. CT scans are helpful if plain radiographs are inconclusive. Open reduction with internal fixation is indicated when displacement after closed reduction is greater than 2 mm (376,387) (Fig. 32-83). An anter-

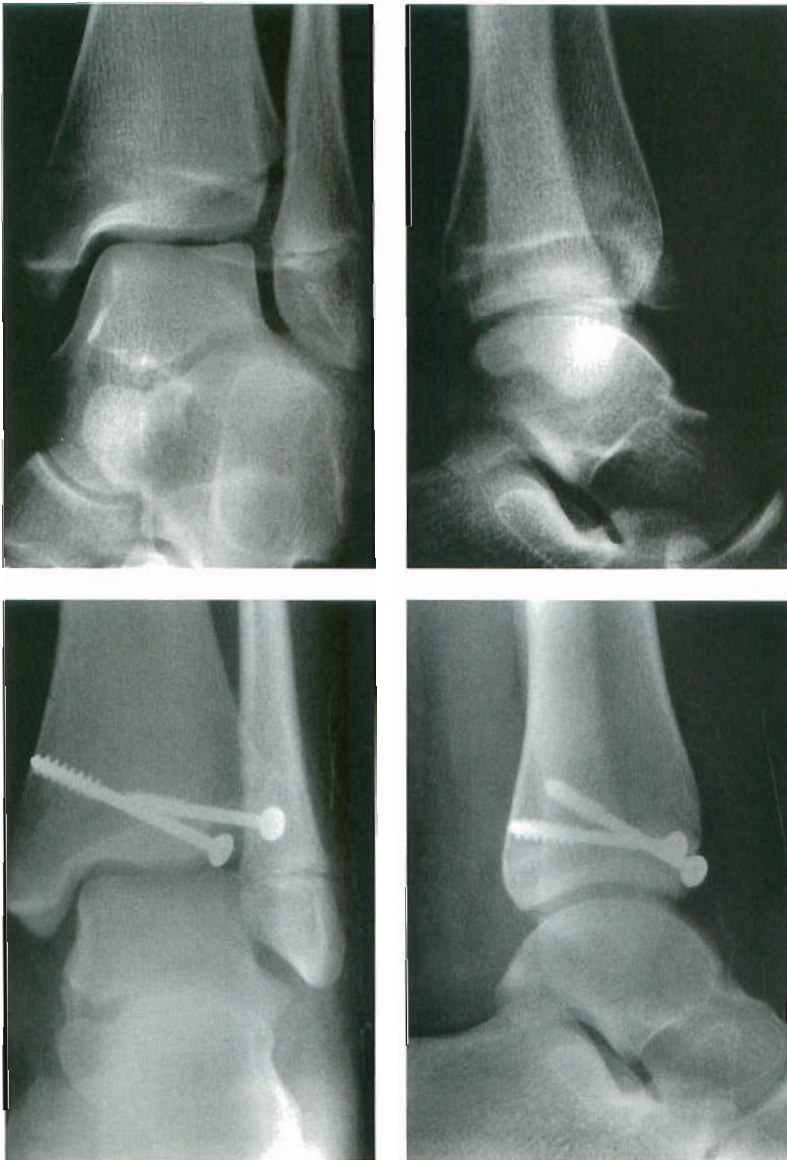


FIGURE 32-83. Transitional fracture. **A:** The anteroposterior radiograph shows displacement of the anterolateral distal epiphysis (Tillaux fracture). **B:** The lateral radiograph demonstrates anterior displacement and rotation of the fragment. **C:** Postoperative radiograph after open reduction and internal fixation with cancellous bone screws. **D:** Lateral radiograph. In this instance, the screws can cross the physal line, because this injury occurred in an adolescent after the growth plate had begun physiological closure.

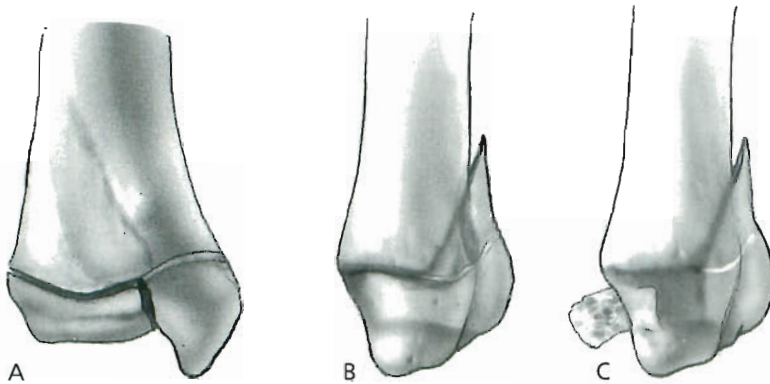


FIGURE 32-84. Triplane fracture. **A:** On the anteroposterior radiograph, the fracture appears as a Salter-Harris type III fracture of the distal tibial epiphysis. **B:** On the lateral view, the fracture appears as a Salter-Harris type II fracture of the distal tibia. **C:** In the three-part triplane fracture, the anterolateral epiphyseal fragment is displaced as a separate fragment.

olateral approach is used, and the fracture is repaired with cancellous screws crossing the physis.

Triplane fracture is also caused by external rotation of the foot (Fig. 32-84). On anteroposterior radiographs, it appears as a Salter-Harris type III fracture, but on the lateral projection, it appears to be a type II fracture (Fig. 32-85). The triplane fracture may be a two-part fracture or a three-part fracture, but greater comminution can occur. The CT scans of two-part fractures reveal a single fracture line on the horizontal section through the epiphysis. Three-part fractures demonstrate three radiating fracture lines (“Mercedes sign”) on the transverse section through the epiphysis. An extraarticular type of triplane fracture can also occur when the fracture line exits through the medial malleolus, past the articular surface (376) (Fig. 32-86). Initial

management consists of closed reduction with internal rotation and application of a long-leg cast. CT is recommended to confirm reduction. Open reduction with internal fixation is indicated when displacement exceeds 2 mm after attempted closed reduction (376,387,388). The anterolateral approach is satisfactory for reduction and fixation of two-part fractures. Three- and four-part fractures generally require anterolateral and posteromedial exposures. Arthroscopic assisted reduction can also be performed.

Complications

Complications of pediatric ankle fractures are related to joint incongruity and growth disturbance. Both of these are

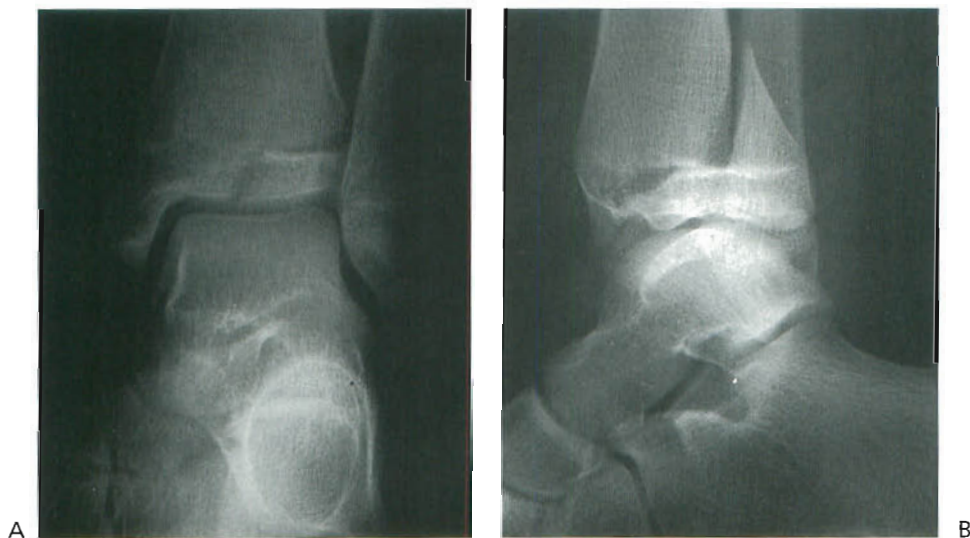

FIGURE 32-85. Triplane fracture of the distal tibia in a 12-year-old girl. **A:** The anteroposterior radiograph shows a Salter-Harris type III fracture. **B:** The lateral radiograph shows an apparent Salter-Harris type II fracture. This indicates a triplane injury. (*continued*)

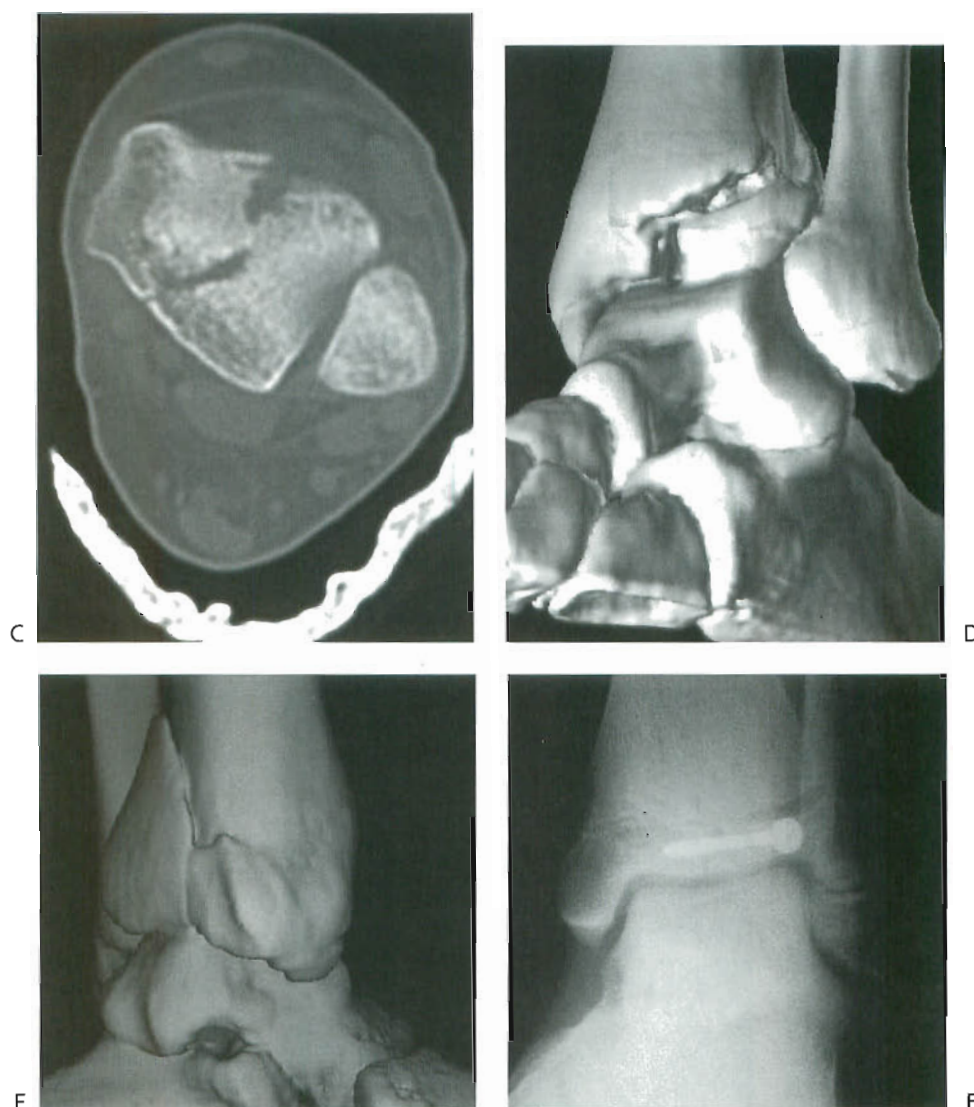

FIGURE 32-85. (continued) C: Computed tomography through the epiphysis confirms a two-part fracture. D and E: Three-dimensional reconstruction demonstrates the fracture from the anterolateral and posteromedial views. F: Closed reduction was unsuccessful. Arthroscopically assisted open reduction was performed. The fracture was stabilized with a single anterolateral cannulated screw inserted percutaneously.

influenced by the adequacy of reduction. Kling et al. (384) reported that 19 of 20 Salter-Harris type III and IV fractures, which were treated with accurate open reduction and internal fixation, healed without growth disturbance. In contrast, 5 of 9 similar fractures, which were treated by closed means, developed bone bridges. Growth arrest leads to angular deformity. The distal tibia and fibula grow 3 to 4 mm in length per year. Therefore, leg-length discrepancy is rarely a major problem, except in younger children. Complete epiphyseodesis, with or without contralateral epiphyseodesis, should be considered as soon as growth

disturbance is recognized. Other alternatives for management of growth arrest are discussed in the physeal injuries section of this chapter.

Restoration of joint congruity is essential to prevent long-term disability (387,388). More than 2 mm of displacement at the articular surface is poorly tolerated. Every attempt should be made to restore articular surfaces without interfering with growth. However, it is the authors' opinion that maintenance of articular integrity is a higher priority than preservation of growth around the ankle.

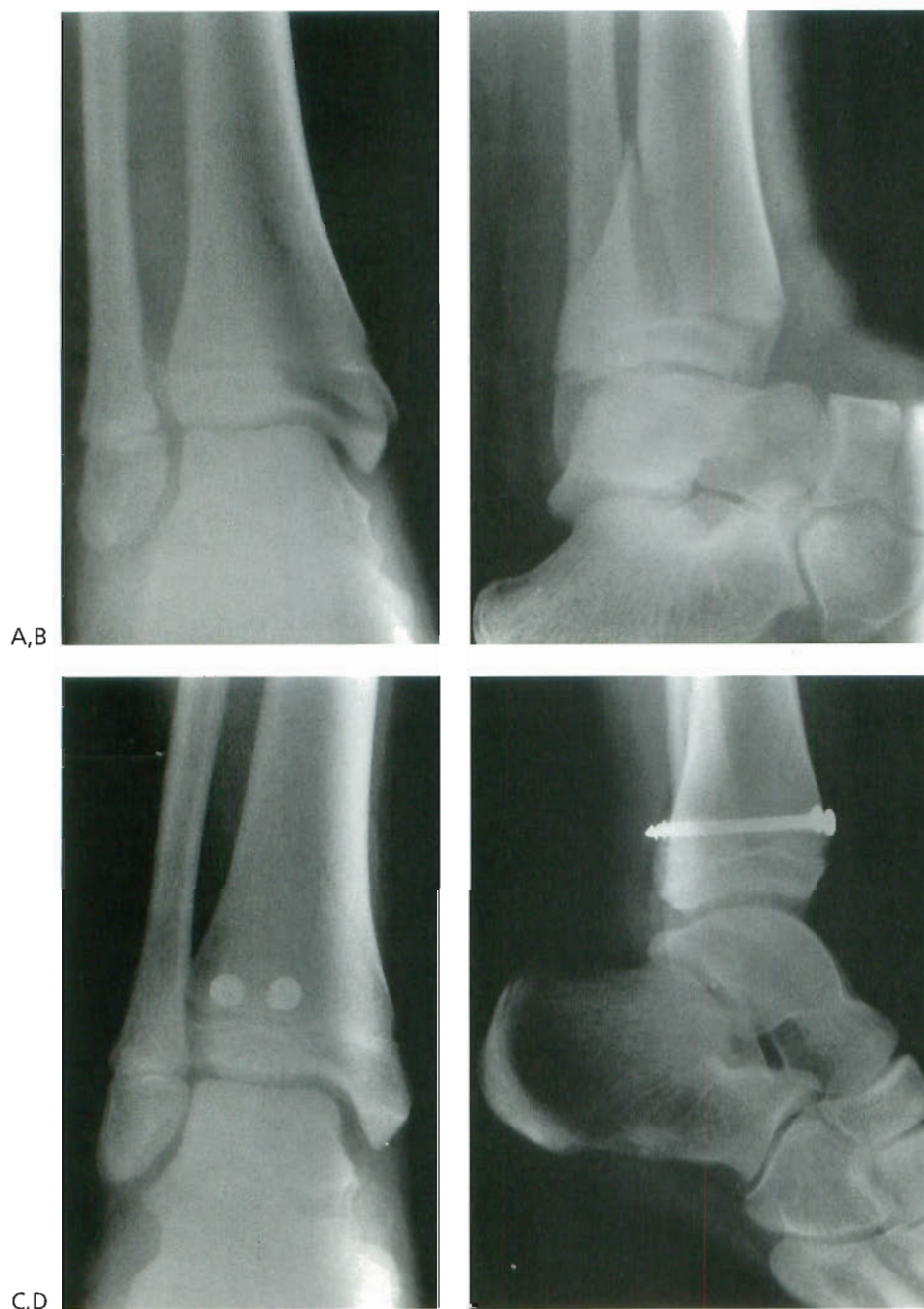


FIGURE 32-86. Two-part triplane fracture. **A:** The anteroposterior radiograph shows a Salter-Harris type III fracture. In this instance, the fracture line does not come out in the intraarticular portion, but exits in the medial distal epiphysis. **B:** The lateral radiograph shows what appears to be a Salter-Harris type II fracture of the distal tibia. Despite closed manipulation, improvement in alignment could not be obtained, and open reduction and internal fixation were performed. **C:** The anteroposterior radiograph shows anatomical alignment and the placement of distal metaphyseal screws. **D:** The lateral view shows reduction of the displaced fracture.

FRACTURES OF THE FOOT

Fractures of the metatarsals and phalanges of the toes are common, accounting for 7 to 9% of all pediatric fractures (3,5,29). However, fractures of the tarsal bones are uncommon in children, and account for less than 1% of all childhood fractures. The majority of these are nondisplaced, and may be an underreported cause of limping in toddlers (389,390). The rarity of midfoot and hindfoot fractures is

attributable to the fact that the juvenile foot is very flexible, with a large component of cartilage until late adolescence. The ossification center of the medial cuneiform does not appear until 4 years of age. Some of the secondary ossification centers do not appear until 10 years of age or later. Thus, there are numerous ossification centers in various stages of development. This can make radiographic interpretation difficult. Comparison radiographs of the opposite foot should be obtained when the diagnosis of a

fracture is in question. A CT is often helpful to evaluate complex fractures.

Anatomy

The calcaneus functions posteriorly with the distal first and fifth metatarsals to form a tripod for weight bearing and shock absorption. Ligamentous structures, joint capsules, bone geometry, and dynamic muscular forces maintain longitudinal and transverse arches. The talus is a complex bone that links the tibia to the foot, and bears all the forces of body weight. It is composed of three parts: head, neck, and body. The talus is supported by the calcaneus, and the head of the talus articulates with the tarsal navicular bone. The cuboid laterally and the three cuneiforms medially constitute the distal row of tarsal bones.

The talus allows plantar flexion and dorsiflexion through the ankle joint, and accommodates pronation-supination motion through the obliquely oriented subtalar joint. This articular function determines the fact that the talus is largely covered with articular cartilage, leaving few avenues of entry for nutrient vessels. Thus, the talus is particularly susceptible to osteonecrosis after fracture. The navicular is also susceptible to osteonecrosis, and lies between the head of the talus and the cuneiforms. Idiopathic or posttraumatic necrosis of the navicular is a self-limited condition without long-term sequelae. However, this condition, also known as Kohler disease, can cause pain and have the radiographic appearance of a fracture.

The calcaneus supports the talus with a bony architecture that is much more cancellous, and has a thin cortical wall with less articular covering. It has a direct weight-bearing function through the complex subcutaneous septae and the thick skin of the heel pad. Anteriorly, transmission of longitudinal forces is achieved at the calcaneocuboid joint. The calcaneus is susceptible to compression failure and collapse of the outer cortical shell when subjected to direct impact, such as the force sustained in a fall from a height. In addition, the wedge-like lateral process of the talus may be driven into the superior region of the calcaneus between the posterior and middle or anterior surfaces of the subtalar joint. This intraarticular mechanism of injury is seen more often in adults and older adolescents. It results in division of the calcaneus into anterior and posterior fracture fragments.

Talus Fractures and Dislocations

Talar Neck Fractures

Fractures of the talar neck are thought to result from forced dorsiflexion. However, there is a 25 to 30% incidence of associated medial malleolar fractures, which suggests a supination component to the deforming force (391). Most talar neck fractures in children are nondisplaced. The majority of displaced fractures are from high-energy trauma. Dis-

placement jeopardizes the tenuous blood supply of the talus, because the neck region is the primary site of vascular penetration into the talus. Fortunately, there are numerous vascular anastomoses within the body of the talus. The principal blood supply penetrates the neck from within the tarsal canal that is formed by the sulcus of the calcaneus and the sulcus of the talus at the base of the neck. The other major blood supply is a deltoid branch from the posterior tibial artery that enters the medial body of the talus along the deltoid ligament (392).

Letts and Gibeault (393) proposed a classification for pediatric fractures of the talus, which is helpful to determine prognosis:

type I: minimally displaced fracture of the distal talar neck (the incidence of osteonecrosis is low);

type II: minimally displaced fracture of the proximal neck or body (the risk of osteonecrosis is also low with this type);

type III: displaced talar neck or body fracture (osteonecrosis is more likely);

type IV: talar neck fracture with dislocation of the body fragment (osteonecrosis is expected in all of these fracture-dislocations).

Treatment. Fractures that are minimally angulated (less than 5 degrees on the anteroposterior view), and displaced less than 2 mm, can be managed closed (394). The foot is placed in slight plantar flexion to reverse the mechanism of injury. Immobilization in a non-weight-bearing below-knee cast is continued until union is evident, usually 6 weeks. Then a full-weight-bearing cast is used for an additional 4 to 6 weeks. Displaced fractures require open reduction with internal fixation. The anteromedial approach is preferred for fragment reduction. Kirschner wires or cannulated screws can be placed anterior to posterior or retrograde, depending on the location of the fracture (Fig. 32-87). Lag screws are recommended, because they may eliminate displacement better than smooth wires (391). Cast immobilization with non-weight bearing is maintained until union is achieved.

Osteonecrosis in children does not usually prevent healing of the fracture, and the long-term outcome may be satisfactory. Prolonged non-weight bearing in a cast yields the best results when osteonecrosis has developed (394). Subchondral lucency may become visible in the body of the talus 6 to 8 weeks after fracture (Hawkins sign). This sign results from disuse osteopenia, and indicates that the body of the talus is vascularized.

Osteochondral Fractures of the Talar Dome

Forced supination of the foot, as in a sprained ankle, may produce osteochondral fracture of the medial or lateral margin of the talar body. This lesion should be suspected when

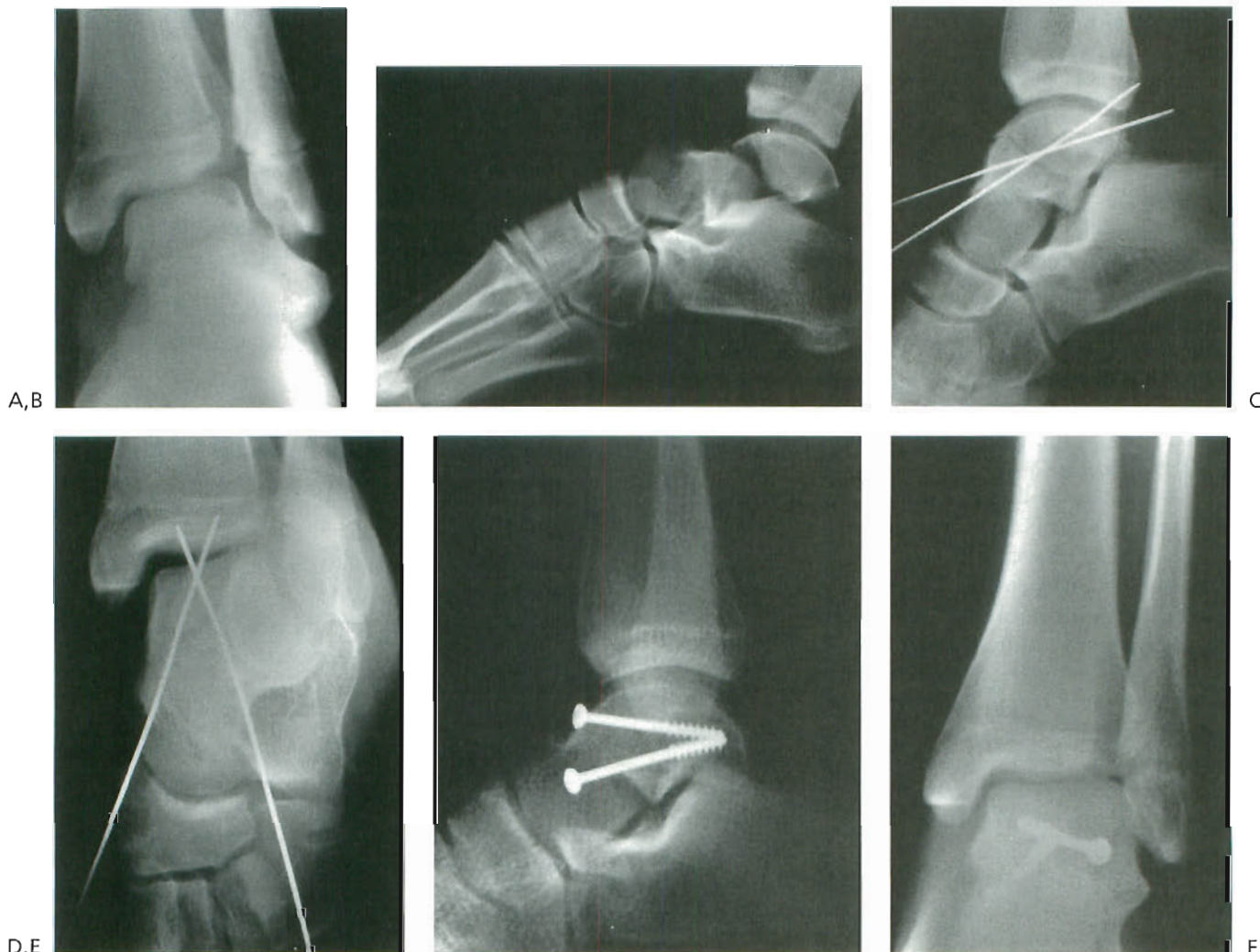


FIGURE 32-87. Talus fracture. **A:** Anteroposterior radiograph of the ankle of a 13-year-old gymnast who injured her foot during a dismount. It appears that the head and neck of the talus are displaced laterally toward the fibula. **B:** The lateral projection shows a type III talus fracture with subluxation of the talonavicular joint. **C:** The intraoperative film shows provisional fixation with Kirschner wires. The fracture is reduced with plantar flexion of the foot. **D:** Another intraoperative anteroposterior view shows anatomical alignment of the talar neck with the body. The entry sites for the screws are in the nonarticular portion of the talar neck. **E:** The postoperative film shows cancellous screw placement. **F:** An anteroposterior radiograph shows restoration of the normal alignment of the ankle. Compared with the injury radiograph, there is no longer a prominence of the talar neck laterally.

a “sprained ankle” does not improve as expected. Medial lesions tend to be posteromedial, and result from inversion, plantar flexion, and external rotation. Lateral lesions tend to be anterolateral, and result from inversion and dorsiflexion. Plain radiographs of the ankle mortise in plantar flexion and dorsiflexion may be necessary to visualize the fracture. A CT is useful in problematic cases.

Initial treatment after diagnosis is non-weight-bearing immobilization for 6 to 8 weeks. Many patients become asymptomatic in spite of persistent defects (395). Drilling and pinning, or removal of the loose fragment, is indicated,

if symptoms persist after a period of immobilization. This frequently can be accomplished arthroscopically.

Lateral Process Fracture

Lateral process fractures of the talus may occur in an inversion or twisting injury to the foot. The initial symptoms are similar to those of an ankle sprain, but these fractures are easily missed, unless there is a high index of suspicion and good-quality anteroposterior radiographs of the talus are obtained. More commonly, the patient presents with

persistent symptoms after an “ankle sprain” (396). The diagnosis can be made with stress radiographs or CT scanning. Displaced fractures are often associated with other fractures.

Treatment consists of cast immobilization for nondisplaced injuries. When the patient presents late or an acute fracture is displaced, small fragments can be excised, but large fragments should be treated with reduction and internal fixation.

Calcaneus Fracture

Fractures of the calcaneus may be extraarticular, sparing the subtalar joint, or intraarticular. Extraarticular fractures are more frequent in younger children (75% of cases), whereas intraarticular fractures account for the majority of calcaneus fractures in adolescents and adults. Fracture of the calcaneus may be minimally displaced, and can be easily overlooked in children. Delay in diagnosis occurs in 30 to 50% of cases (397–399). Swelling, pain, or localized tenderness after a fall should alert the clinician to the possibility of calcaneus fracture. Multiple radiographic views are recommended for diagnosis. However, CT has evolved as the best method for imaging calcaneal fractures for the complete assessment of displaced fractures.

Schmidt and Weiner (399) classified calcaneal fractures in children as extraarticular, intraarticular, or those with loss of the insertion of the Achilles tendon and significant soft tissue injury (e.g., lawnmower injury). Intraarticular fractures in adults have been further classified by Sanders et al. (400), to help plan operative management and predict outcome.

Treatment

Nondisplaced and extraarticular fractures have good prognoses. Closed injuries are usually treated with 4 to 6 weeks of cast immobilization and progressive ambulation as tolerated. Displaced avulsion fracture of the tuberosity of the calcaneus is an extraarticular fracture that requires reduction (401). This may be accomplished by closed reduction, using direct pressure over the Achilles insertion, while the knee is flexed and the ankle is plantar-flexed to relax the posterior calf muscles. Open reduction with internal fixation is recommended, if closed reduction is unsuccessful.

Open reduction and internal fixation are recommended for displaced intraarticular fractures. The preferred approach is lateral, through a long, L-shaped incision, lifting the peroneal tendons within their sheath, and protecting the sural nerve. The lateral wall of the calcaneus is folded down to reveal the medial side, allowing elevation of depressed central fragments. Internal fixation of the posterior facet is achieved by placing subchondral cancellous screws into the medial sustentaculum, then buttressing the lateral

wall with an H-shaped or Y-shaped plate (Fig. 32-88). Excessive comminution of the articular surface precludes this type of surgery (400). Long-term results in children are usually good. Satisfactory long-term results have also been reported after closed management of intraarticular calcaneal fractures in children (402).

Midfoot Fractures and Tarsometatarsal Injuries

Injuries to the tarsometatarsal joints and fractures of the cuboid or cuneiform bones are rare in children, but can have long-term sequelae (403,404). Fracture of the base of the second metatarsal is usually an indication of associated tarsometatarsal joint injury. These injuries are often misdiagnosed and easily overlooked, and may occur more commonly than recognized. The mechanism of injury may be direct impact, but is more commonly forced plantar flexion of the forefoot, combined with a rotational force (405). Heel-to-toe compression of the foot can also produce these injuries. Dislocations or displaced fractures require closed reduction. Percutaneous pinning and cast immobilization are usually necessary to maintain reduction (Fig. 32-89).

Fractures of the Metatarsals

Metatarsal fractures are common in children, accounting for 5 to 7% of all pediatric fractures (3,5). The second through fourth metatarsals are most commonly injured. The mechanism of injury producing metatarsal fracture is usually direct trauma or crush to the foot. Associated swelling can be significant, and may cause compartment syndrome.

Fractures of the base of the fifth metatarsal are usually avulsion injuries, and can cause diagnostic confusion. Transverse fracture at the junction of the metaphysis and diaphysis is called a “Jones” fracture. This fracture has a high incidence of nonunion. An oblique avulsion fracture through the tuberosity of the fifth metatarsal may be confused with the normal secondary ossification center of the apophysis or avulsion of the apophysis. The apophysis does not extend into the joint. Stress fractures may also occur at this location. Prolonged casting is frequently required for fractures at the base of the fifth metatarsal, and healing should be verified before resumption of activities.

Nondisplaced and minimally displaced metatarsal fractures can be immobilized in a below-knee cast for 4 to 6 weeks, with weight bearing as tolerated. Operative treatment is indicated for open fractures, displaced fractures of the metatarsal heads, and displaced intraarticular fractures (Fig. 32-90). Kirschner wire fixation is usually adequate, but the pinning technique requires securing the metatarsophalangeal joint in a reduced position. If this is not done, extension contracture of the metatarsophalangeal joint can result, with development of a prominent and painful metatarsal head. The wires are left in place for 3 to 4 weeks,

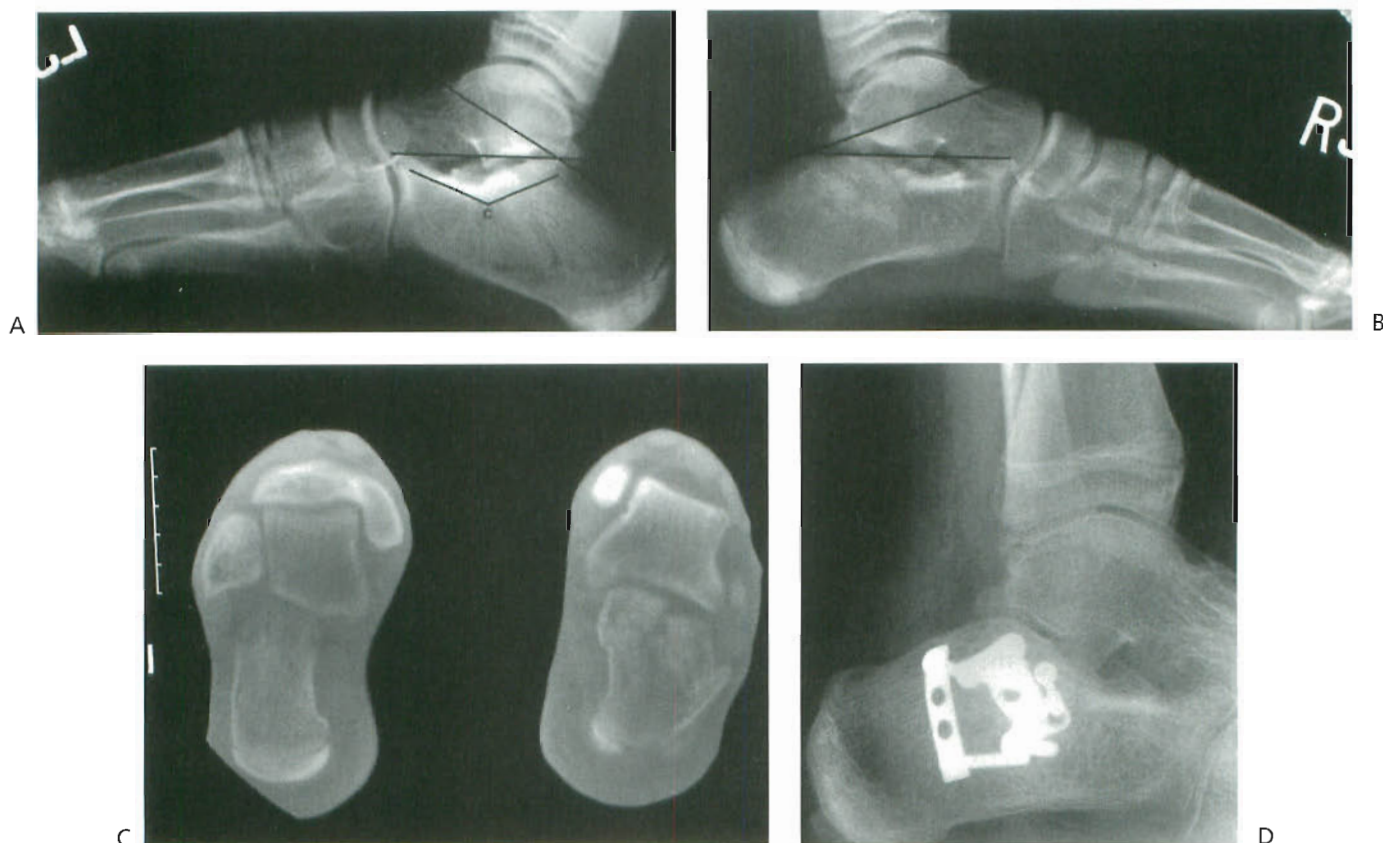


FIGURE 32-88. Calcaneus fracture. This 12-year-old boy injured both feet after jumping off a second-story deck. **A:** The lateral radiograph of his left foot reveals a minimal fracture of the body of the calcaneus. The Bohler angle is subtended by a line connecting the anterior process of the calcaneus to the highest part of the posterior articular surface, intersecting a line along the most superior point of the calcaneal tuberosity. This angle normally is 25 to 40 degrees, and usually is compared with the contralateral side. The crucial angle (c) is directly related to the shape of the overlying lateral process of the talus. In axial compression fractures, the lateral process is driven into the calcaneus, and the crucial angle is distorted. **B:** The radiograph of the more significantly injured right calcaneus shows flattening of the calcaneus, reduction in the Bohler angle, and flattening of the crucial angle. **C:** The computed tomography scan demonstrates displacement of the posterior facet of the calcaneus, with impaction of the lateral fragment and widening of the body of the calcaneus. The lateral wall is fractured. This injury should be treated with open reduction and internal fixation. **D:** After reduction of the posterior facet, a cancellous bone screw is placed through the lateral joint fragment into the sustentacular fragment, securing the subtalar reduction. The lateral wall can be buttressed with a contoured Y-shaped plate or a small H-shaped plate. The Bohler angle and the height of the calcaneus are restored.

with non-weight-bearing immobilization, followed by weight bearing in a cast until union is complete.

Significant swelling, associated with unusually severe pain, should be evaluated to exclude compartment syndrome. Fasciotomy is indicated if compartment syndrome is confirmed. Compartment syndrome of the foot can involve any of the four compartments: medial (i.e., abductor hallucis), central (i.e., flexor brevis, lumbricals, quadratus), lateral, and interosseous (406). Fasciotomy may be performed through a medial approach, with incision from the medial malleolus to the first metatarsal head. The neurovascular bundle is identified and released, including the tarsal tunnel. This releases the medial compartment, and allows

retraction for exposure of the central, lateral, and interosseous compartments from the plantar side. Alternatively, two longitudinal dorsal incisions are centered over the second and fourth metatarsals. Blunt and sharp dissection is performed through each interspace to release all compartments. The dorsal approach can also be combined with a medial incision to release the medial compartment.

Fractures of the Phalanges

A direct blow usually causes these common injuries. Fractures of the phalanges can be treated with closed management, such as buddy taping and use of a hard-soled shoe.

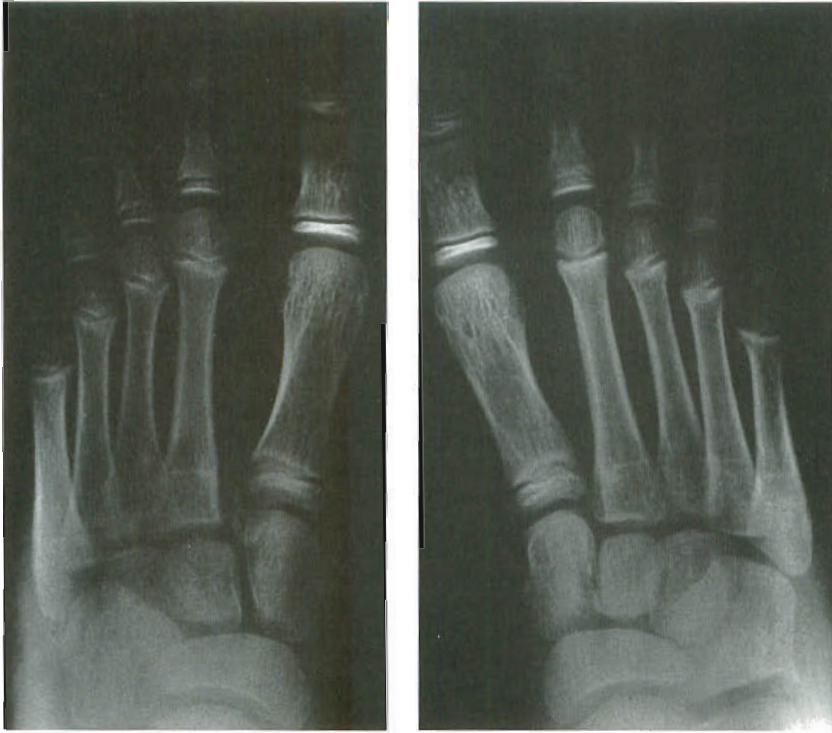

FIGURE 32-89. Tarsometatarsal joint injury. This 4-year-old girl had a file cabinet land on the dorsum of her foot. **A:** There is widening between the first and second metatarsals, and a small fragment of bone is seen in the space. This suggests a partial incongruity, with lateral subluxation of the metatarsals. **B:** The contralateral foot shows a normal relation of the tarsometatarsal joint.

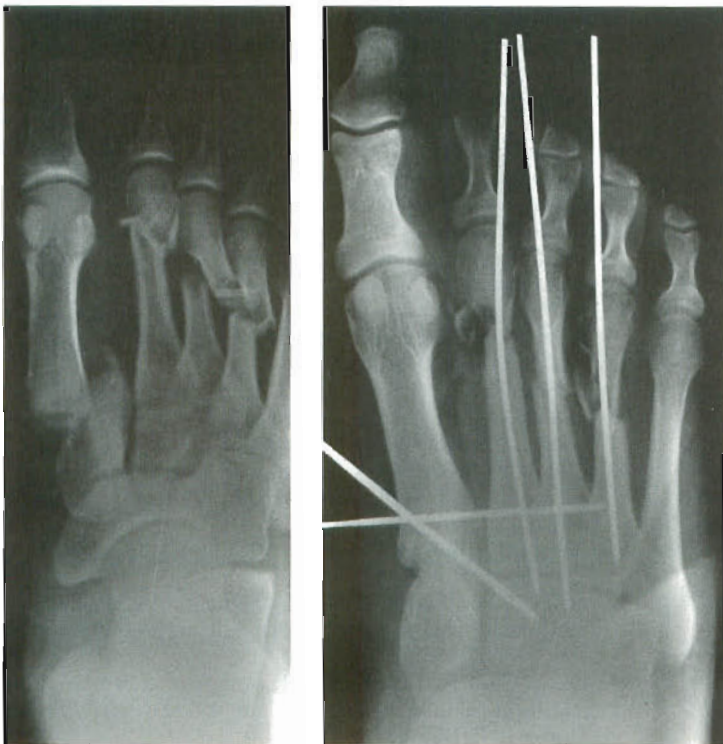

FIGURE 32-90. Tarsometatarsal displacement. **A:** Anteroposterior projection of the foot of a 14-year-old boy who sustained a plantar flexion injury in a motor vehicle crash. There is complete dislocation of the first metatarsal-cuneiform joint and medial displacement. There are fractures of the second, third, and fourth metatarsal shafts. The ipsilateral tibial fracture was treated with intramedullary fixation. The swelling in the foot was attributed to the tibial shaft injury, and diagnosis of the foot injury was delayed. **B:** The postoperative anteroposterior radiograph demonstrates reduction and pinning of the fracture-dislocation.

The exception to this is an open fracture, which most often occurs to the proximal phalanx of the great toe, and may require open debridement and stabilization with Kirschner wires. The physis of the great toe's proximal phalanx underlies the nail bed, and may be injured in the same fashion as a nail bed avulsion of the hand. Antibiotics should be prescribed, if there is concern about a communicating skin breach, and obvious contamination requires debridement.

References

1. Irwin C Jr, Cataldo M, Matheny A Jr, et al. Health consequences of behaviors: injury as a model. *Pediatrics* 1992;90:798.
2. Baker S. Injuries: the neglected epidemic. Stone Lecture, 1985 America Trauma Society meeting. *J Trauma* 1987;27:343.
3. Landin L. Epidemiology of children's fractures. *J Pediatr Orthop Br* 1997;6:79.
4. Reed M. Fractures and dislocations of the extremities in children. *J Trauma* 1977;17:351.
5. Worlock P, Stower M. Fracture patterns in Nottingham children. *J Pediatr Orthop* 1986;6:656.
6. Currey J, Butler G. The mechanical properties of bone tissue in children. *J Bone Joint Surg Am* 1975;57:811.
7. Jacobsen J. Periosteum: its relation to pediatric fractures. *J Pediatr Orthop Br* 1997;6:84.
8. Lane J. Breakout session 2: fracture repair process. *Clin Orthop* 1998;355S:S354.
9. Einhorn T. The cell and molecular biology of fracture healing. *Clin Orthop* 1998;355S:S7.
10. Murray D, Wilson-MacDonald J, Morscher E, et al. Bone growth and remodelling after fracture. *J Bone Joint Surg Br* 1996;78:42.
11. Wallace M, Hoffman E. Remodelling of angular deformity after femoral shaft fractures in children. *J Bone Joint Surg Br* 1992;74:765.
12. Friberg K. Remodelling after distal forearm fractures in children. I. The effect of residual angulation on the spatial orientation of the epiphyseal plates. *Acta Orthop Scand* 1979;50:537.
13. Friberg K. Remodelling after distal forearm fractures in children. II. The final orientation of the distal and proximal epiphyseal plates of the radius. *Acta Orthop Scand* 1979;50:731.
14. Friberg K. Remodelling after distal forearm fractures in children. III. Correction of residual angulation in fractures of the radius. *Acta Orthop Scand* 1979;50:741.
15. Perona P, Light T. Remodeling of the skeletally immature distal radius. *J Orthop Trauma* 1990;4:356.
16. Benum P, Ertesvag K, Hoisetii K. Torsion deformities after traction treatment of femoral fractures in children. *Acta Orthop Scand* 1979;50:87.
17. Hagglund G, Hansson L, Norman O. Correction by growth of rotational deformity after femoral fracture in children. *Acta Orthop Scand* 1983;54:858.
18. Corry I, Nicol R. Limb length after fracture of the femoral shaft in children. *J Pediatr Orthop* 1995;15:217.
19. Gasco J, dePablos J. Bone remodeling in malunited fractures in children: is it reliable? *J Pediatr Orthop Br* 1997;6:126.
20. Hougaard K. Femoral shaft fractures in children: a prospective study of the overgrowth phenomenon. *Injury* 1989;20:170.
21. Shapiro F. Fractures of the femoral shaft in children: the overgrowth phenomenon. *Acta Orthop Scand* 1981;52:649.
22. Wilde G, Baker G. Circumferential periosteal release in the treatment of children with leg-length inequality. *J Bone Joint Surg Br* 1987;69:817.
23. Carvell J. The relationship of the periosteum to angular deformities of long bones. *Clin Orthop* 1983;173:262.
24. Houghton G, Rooker G. The role of the periosteum in the growth of long bones. *J Bone Joint Surg Br* 1979;61:218.
25. Beals R. Premature closure of the physis following diaphyseal fractures. *J Pediatr Orthop* 1990;10:717.
26. Hresko M, Kasser J. Physical arrest about the knee associated with non-physal fractures in the lower extremity. *J Bone Joint Surg Am* 1989;71:698.
27. Bright R, Burstein A, Elmore S. Epiphyseal-plate cartilage: a biomechanical and histological analysis of failure modes. *J Bone Joint Surg Am* 1974;56:688.
28. Dale G, Harris W. Prognosis of epiphyseal separation. *J Bone Joint Surg Br* 1958;40:116.
29. Peterson H, Madhok R, Benson J, et al. Physal fractures. Part 1. Epidemiology in Olmsted County, Minnesota, 1979–1988. *J Pediatr Orthop* 1994;14:423.
31. Peterson H. Physal fractures. Part 3. Classification. *J Pediatr Orthop* 1994;14:439.
30. Mizuta T, Benson W, Foster B. Statistical analysis of the incidence of physal injuries. *J Pediatr Orthop* 1987;7:518.
32. Salter H, Harris W. Injuries involving the epiphyseal plate. *J Bone Joint Surg Am* 1963;45:587.
33. Rang M. *The growth plate and its disorders*. Baltimore: Williams & Wilkins, 1969.
34. Shapiro F. Epiphyseal growth plate fracture-separations: a pathophysiologic approach. *Orthopedics* 1982;5:720.
35. Trueta J, Amato V. The vascular contribution to osteogenesis. *J Bone Joint Surg Br* 1960;42:571.
36. Janarv P, Wikstrom B, Hirsch G. The influence of transphysal drilling and tendon grafting on bone growth: an experimental study in the rabbit. *J Pediatr Orthop* 1998;18:149.
37. Makela E, Vainionpaa S, Vihtonen K, et al. The effect of trauma to the lower femoral epiphyseal plate: an experimental study in rabbits. *J Bone Joint Surg Br* 1988;70:187.
38. Hynes D, O'Brien T. Growth disturbance lines after injury of the distal tibial physis: their significance in prognosis. *J Bone Joint Surg Br* 1988;70:231.
39. Gabel G, Peterson H, Berquist T. Premature partial physal arrest: diagnosis by magnetic resonance imaging in two cases. *Clin Orthop* 1991;272:242.
40. Smith B, Rand F, Jaramillo D, et al. Early MR imaging of lower-extremity physal fracture-separations: a preliminary report. *J Pediatr Orthop* 1994;14:526.
41. Noonan K, Price C, Sproul J, et al. Acute correction and distraction osteogenesis for the malaligned and shortened lower extremity. *J Pediatr Orthop* 1998;18:178.
42. Carlson W, Wenger D. A mapping method to prepare for surgical excision of a partial physal arrest. *J Pediatr Orthop* 1984;4:232.
43. Borsa J, Peterson H, Ehman R. MR imaging of physal bars. *Radiology* 1996;199:683.
44. Loder R, Swinford A, Luhns L. The use of helical computed tomographic scan to assess bony physal bridges. *J Pediatr Orthop* 1977;17:356.
45. Lee E, Chen F, Chan J, et al. Treatment of growth arrest by transfer of cultured chondrocytes into physal defects. *J Pediatr Orthop* 1998;18:155.
46. Jackson A. Excision of central physal bar: a modification of Langenskiold's procedure. *J Bone Joint Surg Br* 1993;75:664.

Injury to the Physis

47. Peterson H. Partial growth plate arrest and its treatment: review. *J Pediatr Orthop* 1984;4:246.
48. Williamson R, Staheli L. Partial physal growth arrest: treatment by bridge resection and fat interposition. *J Pediatr Orthop* 1990; 10:769.
49. Birch J. Surgical technique of physal bar resection. *Instr Course Lect* 1992;41:445.

Initial Management Considerations

50. National Center for Injury Prevention and Control. *10 leading causes of death, United States, 1997, all races, all sexes*. Atlanta: Centers for Disease Control and Prevention, National Center for Health Statistics, 1997.
51. Ismail N, Bellemare J, Mollitt D, et al. Death from pelvic fracture: children are different. *J Pediatr Surg* 1996;31:82.
52. Loder R. Pediatric polytrauma: orthopaedic care and hospital course. *J Orthop Trauma* 1987;1:48.
53. Teasdale G, Jennet B. Assessment of coma and impaired consciousness. *Lancet* 1974;2:81.
54. Michaud L, Rivara F, Grady M, et al. Predictors of survival and severity of severe disability after severe brain injury in children. *Neurosurgery* 1992;31:254.
55. Tepas J, Mollitt D, Talbert J, et al. The Pediatric Trauma Score as a predictor of injury severity in the injured child. *J Pediatr Surg* 1987;22:14.
56. Armstrong P, Smith J. Initial management of the multiply injured child. In: Letts RM, ed. *Management of pediatric fractures*. New York: Churchill Livingstone, 1994:27.
57. Gustillo R, Mendoza R, Williams D. Problems in the management of type III (severe) open fractures: a new classification. *J Trauma* 1984;24:742.
58. Patzakis M, Wilkins J. Factors influencing infection rate in open fracture wounds. *Clin Orthop* 1989;243:36.
59. Kreder H, Armstrong P. A review of open tibia fractures in children. *J Pediatr Orthop* 1995;15:482.
60. Cullen M, Roy D, Crawford A, et al. Open fracture of the tibia in children. *J Bone Joint Surg Am* 1996;78:1039.
61. Fischer M, Gustilo R, Varecka T. The timing of flap coverage, bone-grafting, and intramedullary nailing in patients who have a fracture of the tibial shaft with extensive soft-tissue injury. *J Bone Joint Surg Am* 1991;73:1316.
62. Buckley S, Smith G, Sponseller P, et al. Open fracture of the tibia in children. *J Bone Joint Surg Am* 1990;72:1462.
63. Hope P, Cole W. Open fractures of the tibia in children. *J Bone Joint Surg Br* 1992;74:546.
64. Blasier R, Barnes C. Age as a prognostic factor in open tibial fractures in children. *Clin Orthop* 1996;331:261.
65. Buckley S, Smith G, Sponseller P, et al. Severe (type III) open fractures of the tibia in children. *J Pediatr Orthop* 1996;16:627.
66. Song K, Sangeorzan B, Benirschke S, et al. Open fractures of the tibia in children. *J Pediatr Orthop* 1996;16:635.
67. Kadiyala R, Waters P. Upper extremity pediatric compartment syndromes. *Hand Clinics* 1998;14:467.
68. Mubarak S, Carroll N. Volkmann's contracture in children: etiology and prevention. *J Bone Joint Surg Br* 1979;61:285.
69. Willis R, Rorabeck C. Treatment of compartment syndrome in children. *Orthop Clin North Am* 1990;21:401.
70. Gulli B, Templeman D. Compartment syndrome of the lower extremity. *Orthop Clin North Am* 1994;25:677.
71. Mubarak S, Owen C. Double-incision fasciotomy of the leg for decompression in compartment syndromes. *J Bone Joint Surg Am* 1977;59:184.
72. Case R. Haematoma block: a safe method of reducing Colles' fractures. *Injury* 1985;16:469.
73. Evans J, Buckley S, Alexander A, et al. Analgesia for the reduction of fractures in children: a comparison of nitrous oxide with intramuscular sedation. *J Pediatr Orthop* 1995;15:73.
74. Juliano P, Mazur J, Cummings R, et al. Low-dose lidocaine intravenous regional anesthesia for forearm fractures in children. *J Pediatr Orthop* 1992;12:633.
75. McCarty E, Mencia G, Green N. Anesthesia and analgesia for the ambulatory management of fractures in children. *J Am Acad Orthop Surg* 1999;7:81.
76. Proudfoot J. Analgesia, anesthesia, and conscious sedation. *Emerg Med Clin North Am* 1995;13:357.
77. Varela C, Lorfing K, Schmidt T. Intravenous sedation for the closed reduction of fractures in children. *J Bone Joint Surg Am* 1995;77:340.
78. Wattenmaker J, Kasser J, McGrahey A. Self-administered nitrous oxide for fracture reduction in children in an emergency room setting. *J Orthop Trauma* 1990;4:35.
79. American Academy of Pediatrics Committee on Drugs. Guidelines for monitoring and management of pediatric patients during and after sedation for diagnostic and therapeutic procedures. *Pediatrics* 1992;89:1110.
80. Kongsholm J, Olerud C. Neurological complications of dynamic reduction of Colles' fractures without anesthesia compared with traditional manipulation after local infiltration anesthesia. *J Orthop Trauma* 1987;1:43.
81. Cobb A, Houghton G. Local anesthetic infiltration versus Bier's block for Colles' fracture. *Br Med J Clin Res* 1985;291:1683.
82. Bolte R, Stevens P, Scott S, et al. Mini-dose Bier block intravenous regional anesthesia in the emergency department treatment of pediatric upper-extremity injuries. *J Pediatr Orthop* 1994;14: 534.
83. Cramer K, Glasson S, Mencia G, et al. Reduction of forearm fractures in children using axillary block anesthesia. *J Orthop Trauma* 1995;9:407.
84. Green S, Johnson N. Ketamine sedation for pediatric procedures. Part 2. Review and implications. *Ann Emerg Med* 1990; 19:1033.
85. Green S, Nakamura R, Johnson N. Ketamine sedation for pediatric procedures. Part 1. A prospective series. *Ann Emerg Med* 1990;19:1024.

Injuries of the Shoulder and Humerus

86. McBride M, Hennrikus W, Mologne T. Brief report: newborn clavicle fractures. *Orthopedics* 1998;21:317.
87. Manske D, Szabo R. The operative treatment of mid-shaft clavicular non-unions. *J Bone Joint Surg Am* 1985;67:1367.
88. Ogden J, Conlogue G, Bronson M. Radiology of postnatal skeletal development. III. The clavicle. *Skeletal Radiol* 1979;4:196.
89. Denham R, Dingley A. Epiphyseal separation of the medial end of the clavicle. *J Bone Joint Surg Am* 1967;49:1179.
90. Ogden J. Distal clavicular physal injury. *Clin Orthop* 1984; 188:68.
91. Curtis R. Operative management of children's fractures of the shoulder region. *Orthop Clin North Am* 1990;21:315.
92. Black G, McPherson J, Reed M. Traumatic pseudodislocation of the acromioclavicular joint in children. *Am J Sports Med* 1991;19:644.
93. Allman F. Fractures and ligamentous injuries of the clavicle and its articulation. *J Bone Joint Surg Am* 1967;49:774.
94. MacDonald P, Alexander M, Frejuk J, et al. Comprehensive functional analysis of shoulders following complete acromioclavicular separation. *Am J Sports Med* 1988;16:475.
95. Taft T, Wilson F, Oglesby J. Dislocation of the acromioclavicular joint: an end result study. *J Bone Joint Surg Am* 1987;69: 1045.
96. Tibone J, Sellers R, Tonino P. Strength testing after third-

- degree acromioclavicular dislocations. *Am J Sports Med* 1992; 20:328.
97. Walsh WM, Peterson DA, Shelton G, et al. Shoulder strength following acromioclavicular injury. *Am J Sports Med* 1985;13: 153.
 98. Goss T. The scapula: coracoid, acromial, and avulsion fractures. *Am J Orthop* 1996;25:106.
 99. Hardegger F, Simpson L, Weber B. The operative treatment of scapular fractures. *J Bone Joint Surg Br* 1984;66:725.
 100. Rowe C. Prognosis in dislocation of the shoulder. *J Bone Joint Surg Am* 1956;38:957.
 101. Hoelen M, Burgers A, Rozing P. Prognosis of primary anterior shoulder dislocation in young adults. *Arch Orthop Trauma Surg* 1990;110:51.
 102. Hovelius L. Anterior dislocation of the shoulder in teen-agers and young adults. *J Bone Joint Surg Am* 1987;69:393.
 103. Kawam M, Sinclair J, Letts M. Recurrent posterior dislocation of the shoulder in children: the results of surgical management. *J Pediatr Orthop* 1997;17:533.
 104. Baxter M, Wiley J. Fractures of the proximal humeral epiphysis: their influence on humeral growth. *J Bone Joint Surg Br* 1986; 68:570.
 105. Beringer D, Weiner D, Noble J, et al. Severely displaced proximal humeral epiphyseal fractures: a follow-up study. *J Pediatr Orthop* 1998;18:31.
 106. Rang M. *Children's fractures*, 2nd ed. Philadelphia: Lippincott, 1983.
 107. Shaw B, Murphy K, Shaw A, et al. Humerus shaft fractures in young children: accident or abuse? *J Pediatr Orthop* 1997;17: 293.
 108. Beatty J. Fractures of the proximal humerus and shaft in children. *Instr Course Lect* 1992;41:369.
 109. Akbarnia B, Silberstein M, Rende R, et al. Arthrography in the diagnosis of fractures of the distal end of the humerus in children. *J Bone Joint Surg Am* 1986;68:559.
 110. Davidson R, Markowitz R, Dormans J, et al. Ultrasonographic evaluation of the elbow in infants and young children after suspected trauma. *J Bone Joint Surg Am* 1994;76:1804.
 111. Greenberg D, Jones J, Zink W, et al. Anatomy and pathology of the pediatric elbow using magnetic resonance imaging. *Contemp Orthop* 1989;19:345.
 112. Gennari JM, Merrot T, Piclet B, et al. Anterior approach versus posterior approach to surgical treatment of children's supracondylar fractures: comparative study of thirty cases in each series. *J Pediatr Orthop Br* 1998;7:307.
 113. Morrissey R, Wilkins K. Deformity following distal humeral fracture in childhood. *J Bone Joint Surg Am* 1984;66:557.
 114. Camp J, Ishizue K, Gomez M, et al. Alteration of Baumann's angle by humeral position: implication for treatment of supracondylar humerus fractures. *J Pediatr Orthop* 1993;13:521.
 115. Biyani A, Gupta S, Sharma J. Determination of medial epicondylar epiphyseal angle for supracondylar humeral fractures in children. *J Pediatr Orthop* 1993;13:94.
 116. Abraham E, Powers T, Whit P, et al. Experimental hyperextension supracondylar fractures in monkeys. *Clin Orthop* 1982; 171:309.
 117. Gartland J. Management of supracondylar fractures in children. *Surg Gynecol Obstet* 1959;109:145.
 118. DeBoeck H, De Smet P, Penders W, et al. Supracondylar elbow fractures with impaction of the medial condyle in children. *J Pediatr Orthop* 1995;15:444.
 119. Campbell C, Waters P, Emans J, et al. Neurovascular injury and displacement in type III supracondylar humerus fractures. *J Pediatr Orthop* 1995;15:47.
 120. Flynn J, Price C. Impacted nondisplaced supracondylar fractures of the humerus in children and resultant varus deformity. *Orthop Trans* 1987;11:44.
 121. Millis M, Singer I, Hall J. Supracondylar fracture of the humerus in children: further experience with a study in orthopedic decision making. *Clin Orthop* 1984;188:90.
 122. Flynn J, Matthews J, Benoit R. Blind pinning of displaced supracondylar fractures of the humerus in children. *J Bone Joint Surg Am* 1974;56:263.
 123. Kurer M, Regan M. Completely displaced supracondylar fracture of the humerus in children: a review of 1708 cases. *Clin Orthop* 1990;256:205.
 124. Pirone A, Graham H, Krajchich J. Management of displaced extension-type supracondylar fractures of the humerus in children. *J Bone Joint Surg Am* 1988;70:641.
 125. Cramer K, Devito D, Green N. Comparison of closed reduction and percutaneous pinning versus open reduction and percutaneous pinning in displaced supracondylar fractures of the humerus in children. *J Orthop Trauma* 1992;6:407.
 126. Hadlow A, Devane P, Nicol R. A selective treatment approach to supracondylar fracture of the humerus in children. *J Pediatr Orthop* 1996;16:104.
 127. Palmer E, Niemann K, Vesely D, et al. Supracondylar fracture of the humerus in children. *J Bone Joint Surg Am* 1978;60:653.
 128. Arnold J, Nasca R, Nelson C. Supracondylar fractures of the humerus: the role of dynamic factors in prevention of deformity. *J Bone Joint Surg Am* 1977;59:589.
 129. Zions L, McKellop H, Hathaway R. Torsional strength of pin configurations used to fix supracondylar fractures of the humerus in children. *J Bone Joint Surg Am* 1994;76:253.
 130. Royce R, Dutkowsky J, Kasser J, et al. Neurologic complications after K-wire fixation of supracondylar humerus fractures in children. *J Pediatr Orthop* 1991;11:191.
 131. Topping R, Blanco J, Davis T. Clinical evaluation of crossed-pin versus lateral-pin fixation in displaced supracondylar humerus fractures. *J Pediatr Orthop* 1995;15:435.
 132. Garbuz D, Leitch K, Wright J. The treatment of supracondylar fractures in children with an absent radial pulse. *J Pediatr Orthop* 1996;16:594.
 133. Shaw B, Kasser J, Emans J, et al. Management of vascular injuries in displaced supracondylar humerus fractures without arteriography. *J Orthop Trauma* 1990;4:25.
 134. Sabharwal S, Tredwell S, Beauchamp R, et al. Management of pulseless pink hand in pediatric supracondylar fractures of humerus. *J Pediatr Orthop* 1997;17:303.
 135. Rasool M. Ulnar nerve injury after K-wire fixation of supracondylar humerus fractures in children. *J Pediatr Orthop* 1998;18: 686.
 136. Abe M, Ishizu T, Shirai H, et al. Tardy ulnar nerve palsy caused by cubitus varus deformity. *J Hand Surg* 1995;20:5.
 137. Davids J, Maguire M, Mubarak S, et al. Lateral condylar fracture of the humerus following posttraumatic cubitus varus. *J Pediatr Orthop* 1994;14:466.
 138. Herndon W, Mahnken R, Yngve D, et al. Management of femoral shaft fractures in the adolescent. *J Pediatr Orthop* 1989; 9:29.
 139. Voss F, Kasser J, Trepman E, et al. Uniplanar supracondylar humeral osteotomy with preset Kirschner wires for posttraumatic cubitus varus. *J Pediatr Orthop* 1994;14:471.
 140. Re P, Waters P, Hresko T. T-condylar fractures of the distal humerus in children and adolescents. *J Pediatr Orthop* 1999; 19:313.
 141. Jarvis J, D'Astous J. The pediatric T-supracondylar fracture. *J Pediatr Orthop* 1984;4:697.
 142. Mirsky E, Karas E, Weiner L. Lateral condyle fractures in chil-

- dren: evaluation of classification and treatment. *J Orthop Trauma* 1997;11:117.
143. Badelon O, Bensahel H, Mazda K, et al. Lateral humeral condylar fractures in children: a report of 47 cases. *J Pediatr Orthop* 1988;8:31.
 144. Finnbogason T, Karlsson G, Lindberg L, et al. Nondisplaced and minimally displaced fractures of the lateral humeral condyle in children: a prospective radiographic investigation of fracture stability. *J Pediatr Orthop* 1995;15:422.
 145. Flynn J, Richards J, Salzman R. Prevention and treatment of non-union of slightly displaced fractures of the lateral humeral condyle in children. *J Bone Joint Surg Am* 1975;57:1087.
 146. Ippolito E, Tudisco C, Farsetti P, et al. Fracture of the humeral condyles in children. *Acta Orthop Scand* 1996;67:173.
 147. Mintzer C, Waters P, Brown D, et al. Percutaneous pinning in the treatment of displaced lateral condyle fractures. *J Pediatr Orthop* 1994;14:462.
 148. Dhillon K, Sengupta S, Singh B. Delayed management of fracture of the lateral humeral condyle in children. *Acta Orthop Scand* 1988;59:419.
 149. Roye D, Bini S, Infosino A. Late surgical treatment of lateral condylar fractures in children. *J Pediatr Orthop* 1991;11:195.
 150. Flynn J, Richards J. Non-union of minimally displaced fractures of the lateral condyle of the humerus in children. *J Bone Joint Surg Am* 1971;53:1096.
 151. Flynn J. Nonunion of slightly displaced fractures of the lateral humeral condyle in children: an update. *J Pediatr Orthop* 1989;9:691.
 152. Bede W, Lefebvre A, Rosman M. Fractures of the medial humeral epicondyle in children. *Can J Surg* 1975;18:137.
 153. Josefsson P, Danielsson J. Epicondylar elbow fracture in children: 35 year follow-up of 56 unreduced cases. *Acta Orthop Scand* 1986;57:313.
 154. Woods G, Tullos H. Elbow instability and medial epicondyle fractures. *Am J Sports Med* 1977;5:23.
 155. Dunn P, Ravn P, Hansen L, et al. Osteosynthesis of medial humeral epicondyle fractures in children: 8-year follow-up of 33 cases. *Acta Orthop Scand* 1994;65:439.
 156. Hines R, Herndon W, Evans J. Operative treatment of medial epicondyle fractures in children. *Clin Orthop* 1987;223:170.
 157. Dangles C, Tyllowski C, Pankovich A. Epicondylorochlear fracture of the humerus before appearance of the ossification center: a case report. *Clin Orthop* 1982;171:161.
 158. Papavasiliou V, Nenopoulos S, Venturis T. Fractures of the medial condyle of the humerus in childhood. *J Pediatr Orthop* 1987;7:42.
 159. DeLee J, Wilkins K, Rogers L, et al. Fracture separation of the distal humeral epiphysis. *J Bone Joint Surg Am* 1980;62:46.
 160. Abe M, Ishizu T, Nagaoka T, et al. Epiphyseal separation of the distal end of the humeral epiphysis: a follow-up note. *J Pediatr Orthop* 1995;15:426.
 161. Holda M, Manoli A, Lamont R. Epiphyseal separation of the distal end of the humerus with medial displacement. *J Bone Joint Surg Am* 1980;62:52.
 162. Evans M, Graham H. Radial neck fracture in children: a management algorithm. *J Pediatr Orthop Br* 1999;8:93.
 163. Fowles J, Kassab M. Observations concerning radial neck fractures in children. *J Pediatr Orthop* 1986;6:51.
 164. Tibone J, Stoltz M. Fractures of the radial head and neck in children. *J Bone Joint Surg Am* 1981;63:100.
 165. Bernstein S, McKeever P, Bernstein L. Percutaneous reduction of displaced radial neck fractures in children. *J Pediatr Orthop* 1993;13:85.
 166. González-Herranz P, Alvarez-Romera A, Burgos J, et al. Displaced radial neck fractures in children treated by closed intramedullary pinning (Metaizeau technique). *J Pediatr Orthop* 1997;17:325.
 167. D'Souza S, Vaishya R, Klenerman L. Management of radial neck fractures in children: a retrospective analysis of 100 patients. *J Pediatr Orthop* 1993;13:232.
 168. Campbell C, Waters P, Emans J. Excision of the radial head for congenital dislocation. *J Bone Joint Surg Am* 1992;74:726.
 169. Gaddy B, Strecker W, Schoenecker P. Surgical treatment of displaced olecranon fractures in children. *J Pediatr Orthop* 1997;17:321.
 170. Matthews J. Fractures of the olecranon in children. *Injury* 1980;12:207.
 171. Rowland S, Burkhart S. Tension band wiring of olecranon fractures. *Clin Orthop* 1992;227:238.
 172. Carlouz H, Abols Y. Posterior dislocation of the elbow in children. *J Pediatr Orthop* 1984;4:8.
 173. Cohen M, Hastings H. Post-traumatic contracture of the elbow: operative release using a lateral collateral ligament sparing approach. *J Bone Joint Surg Br* 1998;80:805.
 174. Mansat P, Morrey B. The column procedure: a limited lateral approach for extrinsic contracture of the elbow. *J Bone Joint Surg Am* 1998;80:1603.
 175. Salter R, Zaltz C. Anatomic investigations of the mechanism of injury and pathologic anatomy of "pulled elbow" in young children. *Clin Orthop* 1971;77:134.

Forearm and Wrist Fractures

176. Mann D, Rajmaira S. Distribution of physeal and nonphyseal fractures in 2,650 long-bone fractures in children aged 0–16 years. *J Pediatr Orthop* 1990;10:713.
177. Tredwell SJ, Van Peteghem K, Clough M. Pattern of forearm fractures in children. *J Pediatr Orthop* 1984;4:604.
178. Smith F. Children's elbow injuries: fractures and dislocations. *Clin Orthop Relat Res* 1967;50:25.
179. Bado J. The Monteggia lesion. *Clin Orthop* 1967;50:71.
180. Letts M, Loch R, Wilens J. Monteggia fracture-dislocations in children. *J Bone Joint Surg Br* 1985;67:724.
181. Ring D, Waters P. Operative fixation of Monteggia fractures in children. *J Bone Joint Surg Br* 1996;78:734.
182. Tawse B. The treatment of malunited anterior Monteggia fractures in children. *J Bone Joint Surg Br* 1965;47:718.
183. Rodgers W, Waters P, Hall J. Chronic Monteggia lesions in children: complications and results of reconstruction. *J Bone Joint Surg Am* 1996;78:1322.
184. Seel M, Peterson H. Management of chronic posttraumatic radial head dislocation in children. *J Pediatr Orthop* 1999;19:306.
185. Walsh H, McLaren C. Galeazzi fractures in children. *J Bone Joint Surg Br* 1987;69:730.
186. Letts M, Rowhani N. Galeazzi-equivalent injuries of the wrist in children. *J Pediatr Orthop* 1993;13:561.
187. Ray T, Tessler R, Dell P. Traumatic ulnar physeal arrest after distal forearm fractures in children. *J Pediatr Orthop* 1996;16:195.
188. Borden S. Traumatic bowing of the forearm in children. *J Bone Joint Surg Am* 1974;56:611.
189. Sanders W, Heckman J. Traumatic plastic deformation of the radius and ulna: a closed method of correction of deformity. *Clin Orthop* 1984;188:58.
190. Gruber R. The problem of the relapse fracture of the forearm in children. In: Chapchal G, ed. *Fractures in children: ninth international symposium on topical problems in orthopaedic surgery*. Stuttgart: Verlag, 1981:154.
191. Schwarz N, Pienaar S, Schwarz A, et al. Refracture of the forearm in children. *J Bone Joint Surg Br* 1996;78:740.
192. Evans E. Fractures of the radius and ulna. *J Bone Joint Surg Br* 1951;33:548.

193. Vittas D, Larsen E, Torp-Pedersen S. Angular remodeling of midshaft forearm fractures in children. *Clin Orthop* 1991;265:261.
194. Younger A, Tredwell S, Mackenzie W. Accurate prediction of outcome after pediatric forearm fracture. *J Pediatr Orthop* 1994;14:200.
195. Ortega R, Loder R, Louis D. Open reduction and internal fixation of forearm fractures in children. *J Pediatr Orthop* 1996;16:651.
196. Carey P, Alburger P, Betz R, et al. Both-bone forearm fractures in children. *Orthopedics* 1992;15:1015.
197. Thomas E, Tuson K, Browne P. Fractures of the radius and ulna in children. *Injury* 1975;7:120.
198. Tarr R, Garfinkel A, Sarmiento A. The effects of angular and rotational deformities of both bones of the forearm: an *in vitro* study. *J Bone Joint Surg Am* 1984;66:65.
199. Blount W. Fractures of the wrist and forearm. In: *Fractures in children*. Huntington, NY: Krieger, 1977:76.
200. Price CT, Scott DS, Kurzner ME, et al. Malunited forearm fractures in children. *J Pediatr Orthop* 1990;10:705.
201. Walker J, Rang M. Forearm fractures in children. *J Bone Joint Surg Br* 1991;73:299.
202. Chan C, Meads B, Nicol R. Remanipulation of forearm fractures in children. *N Z Med J* 1977;110:249.
203. Voro S, Weiner D, Leighley B. Redispacement after closed reduction of forearm fractures in children. *J Pediatr Orthop* 1990;10:79.
204. Fuller D, McCullough C. Malunited fractures of the forearm in children. *J Bone Joint Surg Br* 1982;64:364.
205. Daruwalla J. A study of radioulnar movements following fractures of the forearm in children. *Clin Orthop* 1979;139:114.
206. Creasman C, Zaleske D, Ehrlich M. Analyzing forearm fractures in children: the more subtle signs of impending problems. *Clin Orthop* 1984;188:40.
207. Morrey G, Askew L, An K, et al. A biomechanical study of normal functional elbow motion. *J Bone Joint Surg Am* 1981;63:872.
208. Sarmiento A, Ebramzadeh E, Brys D, et al. Angular deformities and forearm function. *J Orthop Res* 1992;10:121.
209. Holdsworth B, Sloan J. Proximal forearm fractures in children: residual disability. *Injury* 1982;14:174.
210. Verstrecken L, Delronge G, Lamoureux J. Shaft forearm fractures in children: intramedullary nailing with immediate motion. A preliminary report. *J Pediatr Orthop* 1988;8:450.
211. Arunachalam V, Griffiths J. Fracture recurrence in children. *Injury* 1975;7:37.
212. Haasbeek J, Cole W. Open fractures of the arm in children. *J Bone Joint Surg Br* 1995;77:576.
213. Thompson G, Wilber J, Marcus R. Internal fixation of fractures in children and adolescents: a comparative analysis. *Clin Orthop* 1984;188:10.
214. Amit Y, Salai M, Chechik A, et al. Closing intramedullary nailing for the treatment of diaphyseal forearm fractures in adolescence: a preliminary report. *J Pediatr Orthop* 1985;5:143.
215. Lascombes P, Prevot J, Ligier J, et al. Elastic stable intramedullary nailing in forearm shaft fractures in children: 85 cases. *J Pediatr Orthop* 1990;10:167.
216. Flynn J, Waters P. Single-bone fixation of both-bone forearm fractures. *J Pediatr Orthop* 1996;16:655.
217. Bednar D, Grandwilewski W. Complications of forearm plate removal. *Can J Surg* 1996;36:16.
218. Deluca P, Lindsey R, Ruwe P. Refracture of bones of the forearm after the removal of compression plates. *J Bone Joint Surg Am* 1988;70:1372.
219. Högström H, Nilsson B, Willner S. Correction with growth following diaphyseal forearm fracture. *Acta Orthop Scand* 1976;47:299.
220. Trousdale R, Linscheid R. Operative treatment of malunited fractures of the forearm. *J Bone Joint Surg Am* 1995;77:894.
221. Blackburn N, Ziv I, Rang M. Correction of the malunited forearm fracture. *Clin Orthop* 1984;188:54.
222. Schranz P, Fagg P. Undisplaced fractures of the distal third of the radius in children: an innocent fracture? *Injury* 1992;23:165.
223. Roy D. Completely displaced distal radius fractures with intact ulnas in children. *Orthopedics* 1989;12:1089.
224. Mani G, Hui P, Cheng J. Translation of the radius as a predictor of outcome in distal radial fractures of children. *J Bone Joint Surg Br* 1993;75:808.
225. Roberts J. Angulation of the radius in children's fractures. *J Bone Joint Surg Br* 1986;68:751.
226. Chess D, Hyndman J, Leahey J, et al. Short arm plaster cast for distal pediatric forearm fractures. *J Pediatr Orthop* 1994;14:211.
227. Gibbons C, Woods D, Pailthorpe C, et al. The management of isolated distal radius fractures in children. *J Pediatr Orthop* 1994;14:207.
228. Gupta R, Danielson L. Dorsally angulated solitary metaphyseal greenstick fractures in the distal radius. *J Pediatr Orthop* 1990;10:90.
229. Boyden E, Peterson H. Case reports: partial premature closure of the distal radial physis associated with Kirschner wire fixation. *Orthopaedics* 1991;14:585.
230. Lee B, Esterbai J, Das M. Fracture of the distal radial epiphysis. *Clin Orthop* 1984;185:90.
231. Hove L, Engesæter L. Corrective osteotomies after injuries of the distal radial physis in children. *J Hand Surg Br* 1997;22:699.
232. Zehntner M, Jakob R, McGinty P. Case report: growth disturbance of the distal radial epiphysis after trauma. Operative treatment by corrective radial osteotomy. *J Pediatr Orthop* 1990;10:441.

Fractures of the Thoracic and Lumbar Spine

233. Aufdermaur M. Spinal injuries in juveniles: necropsy findings in twelve cases. *J Bone Joint Surg Br* 1974;56:513.
234. McPhee I. Spinal fractures and dislocations in children and adolescents. *Spine* 1981;6:533.
235. Pouliquen J, Kassis B, Glorion C, et al. Vertebral growth after thoracic or lumbar fracture of the spine in children. *J Pediatr Orthop* 1997;17:115.
236. Gumley G, Taylor T, Ryan M. Distraction fractures of the lumbar spine. *J Bone Joint Surg Br* 1982;64:520.
237. Spivak J, Vaccaro A, Cotler J. Thoracolumbar spine trauma. I. Evaluation and classification. *J Am Acad Orthop Surg* 1995;3:345.
238. Bick E, Copel J. Longitudinal growth of the human vertebra. *J Bone Joint Surg Am* 1950;32:803.
239. Bick E, Copel J. The ring apophysis of the human vertebra. *J Bone Joint Surg Am* 1951;33:783.
240. Denis F. The three column spine and its significance in the classification of acute thoracolumbar spinal injuries. *Spine* 1983;8:817.
241. Bucholz R, Gill K. Classification of injuries to the thoracolumbar spine. *Orthop Clin North Am* 1986;17:67.
242. Spivak J, Vaccaro A, Cotler J. Thoracolumbar spine trauma. II. Principles of management. *J Am Acad Orthop Surg* 1995;3:353.
243. Crawford A. Operative treatment of spine fractures in children. *Orthop Clin North Am* 1990;21:325.
244. Andreychik D, Alandar D, Senica K, et al. Burst fractures of

- the second through fifth lumbar vertebrae. *J Bone Joint Surg Am* 1996;78:1156.
245. Kim N, Lee H, Chun I. Neurologic injury and recovery in patients with burst fracture of the thoracolumbar spine. *Spine* 1999;24:290.
 246. Voss L, Cole P, D'Amato C. Pediatric Chance fractures from lapbelts: unique case report of three in one accident. *J Orthop Trauma* 1996;10:421.
 247. Glassman S, Johnson J, Holt R. Seatbelt injuries in children. *J Trauma* 1992;33:882.
 248. Epstein N, Epstein J. Limbus lumbar vertebral fractures in 27 adolescents and adults. *Spine* 1991;16:962.
 249. Takata K, Inoue S, Takahashi K, et al. Fractures of the posterior margin of the lumbar vertebral body. *J Bone Joint Surg Am* 1988;70:589.
 250. Mayfield J, Erkkila J, Winter R. Spine deformity subsequent to acquired childhood spinal cord injury. *J Bone Joint Surg Am* 1981;63:1401.
 251. DeKlerk L, Fontijne Q, Stijnen T, et al. Spontaneous remodeling of the spinal canal after conservative management of thoracolumbar burst fractures. *Spine* 1998;23:1057.

Pelvic Fractures

252. Garvin K, McCarthy R, Barnes C, et al. Pediatric pelvic ring fractures. *J Pediatr Orthop* 1990;10:577.
253. Torode I, Zieg D. Pelvic fractures in children. *J Pediatr Orthop* 1985;5:76.
254. McIntyre R, Bensard D, Moore E, et al. Pelvic fracture geometry predicts risk of life-threatening hemorrhage in children. *J Trauma* 1993;35:423.
255. Musemeche C, Fischer R, Cotler H, et al. Selective management of pediatric pelvic fractures: a conservative approach. *J Pediatr Surg* 1987;22:538.
256. Reichard S, Helikson M, Shorter N, et al. Pelvic fractures in children: review of 120 patients with a new look at general management. *J Pediatr Surg* 1980;15:727.
257. Rieger H, Brug E. Fractures of the pelvis in children. *Clin Orthop* 1997;336:226.
258. Bond S, Gorschall C, Eichelberger M. Predictors of abdominal injury in children with pelvic fracture. *J Trauma* 1991;31:1169.
259. Watts H. Fractures of the pelvis in children. *Orthop Clin North Am* 1976;7:615.
260. Lane-O'Kelly A, Fogarty D, Dowling F. The pelvic fracture in childhood: a report supporting nonoperative management. *Injury* 1995;26:327.
261. Heeg M, Klassen H, Visser J. Acetabular fractures in children and adolescents. *J Bone Joint Surg Br* 1989;71:418.
262. Bucholz R, Ezaki M, Ogden J. Injury to the acetabular triradiate physal cartilage. *J Bone Joint Surg Am* 1982;64:600.

Fractures and Dislocations of the Hip

263. Hamilton P, Broughton N. Traumatic hip dislocation in childhood. *J Pediatr Orthop* 1998;18:691.
264. Offierski C. Traumatic dislocation of the hip in children. *J Bone Joint Surg Br* 1981;63:194.
265. Olsson O, Landin L, Johansson A. Traumatic hip dislocation with spontaneous reduction and capsular interposition. *Acta Orthop Scand* 1994;654:476.
266. Canale S, Bourland W. Fracture of the neck and intertrochanteric region of the femur in children. *J Bone Joint Surg Am* 1977;59:431.
267. Davison B, Weinstein S. Hip fractures in children: a long-term follow-up study. *J Pediatr Orthop* 1992;12:335.
268. Edgren W. Coxa plana: a clinical and radiological investigation

- with particular reference to the importance of the metaphyseal changes for the final shape of the proximal part of the femur. *Acta Orthop Scand* 1965;84:24.
269. Raney E, Ogden J, Grogan D. Premature greater trochanteric epiphysiodesis secondary to intramedullary femoral rodding. *J Pediatr Orthop* 1993;13:516.
270. Chung S. The arterial supply of the developing proximal end of the human femur. *J Bone Joint Surg Am* 1976;58:961.
271. Ogden J. Changing patterns of proximal femoral vascularity. *J Bone Joint Surg Am* 1974;56:941.
272. Swiontkowski M, Winkquist R. Displaced hip fractures in children and adolescents. *J Trauma* 1986;26:384.
273. Lam S. Fractures of the neck of the femur in children. *J Bone Joint Surg Am* 1971;53:1165.
274. Cheng J, Tang N. Decompression and stable internal fixation of femoral neck fractures in children can affect the outcome. *J Pediatr Orthop* 1999;19:338.
275. Ng G, Cole W. Effect of early hip decompression on the frequency of avascular necrosis in children with fractures of the neck and femur. *Injury* 1996;27:419.
276. Theodorou S, Ierodiconou M, Mitsou A. Obstetrical fracture-separation of the upper femoral epiphysis. *Acta Orthop Scand* 1982;53:239.
277. Morrissy R. Hip fractures in children. *Clin Orthop* 1980;152:202.
278. Azouz E, Karamitsos C, Reed M, et al. Types and complications of femoral neck fractures in children. *Pediatr Radiol* 1993;23:415.
279. Hughes L, Beaty J. Current concepts review: fractures of the head and neck of the femur in children. *J Bone Joint Surg Am* 1994;76:283.
280. DeLuca F, Keck C. Traumatic coxa vara: a case report of spontaneous correction in a child. *Clin Orthop* 1976;116:125.
281. Forlin E, Guille J, Kumar S, et al. Transepiphyseal fractures of the neck of the femur in very young children. *J Pediatr Orthop* 1992;12:164.
282. Ovesen O, Arreskov J, Bellstrom T. Hip fractures in children: a long-term follow-up of 17 cases. *Orthopedics* 1989;12:361.
283. Huang C. Treatment of neglected femoral neck fractures in young adults. *Clin Orthop* 1986;206:117.
284. Leung P, Chow Y. Reconstruction of proximal femoral defects with a vascular-pedicled graft. *J Bone Joint Surg Br* 1984;66:32.

Femoral Shaft Fractures

285. Hedlund R, Lindgren U. The incidence of femoral shaft fractures in children and adolescents. *J Pediatr Orthop* 1986;6:47.
286. Gross R, Stranger M. Causative factors responsible for femoral fractures in infants and young children. *J Pediatr Orthop* 1983;3:572.
287. Buckley S, Sturm P, Tosi L, et al. Ligamentous instability of the knee in children sustaining fractures of the femur: a prospective study with knee examination under anesthesia. *J Pediatr Orthop* 1996;16:206.
288. Lynch J, Gardner M, Gains B. Hemodynamic significance of pediatric femur fractures. *J Pediatr Surg* 1996;31:1358.
289. Malkawi H, Shannak A, Hadidi S. Remodeling after femoral shaft fractures in children treated by the modified Blount method. *J Pediatr Orthop* 1986;6:421.
290. Viljanto J, Kiviluoto H, Paananen M. Remodelling after femoral shaft fracture in children. *Acta Chir Scand* 1975;141:360.
291. Brouwer J, Molenaar C, Van Linge B. Rotational deformities after femoral shaft fractures in childhood: a retrospective study 27-32 years after the accident. *Acta Orthop Scand* 1981;52:81.
292. Davids J. Rotational deformity and remodeling after fracture of the femur in children. *Clin Orthop* 1994;302:27.

293. Beatty J, Austin S, Warner W, et al. Interlocking intramedullary nailing of femoral shaft fractures in adolescents: preliminary results and complications. *J Pediatr Orthop* 1994;14:178.
294. Kregor P, Song K, Routt C, et al. Plate fixation of femoral shaft fractures in multiply injured children. *J Bone Joint Surg Am* 1993;75:1774.
295. Stannard J, Christensen K, Wilkins K. Femur fractures in infants: a new therapeutic approach. *J Pediatr Orthop* 1995;15:461.
296. Ferry A, Edgar M. Modified Bryant's traction. *J Bone Joint Surg Am* 1966;48:533.
297. Hughes B, Sponseller P, Thompson D. Pediatric femur fractures: effects of spica cast treatment on family and community. *J Pediatr Orthop* 1995;15:457.
298. Buehler K, Thompson D, Sponseller P, et al. A prospective study of early spica casting outcomes in the treatment of femoral shaft fractures in children. *J Pediatr Orthop* 1995;15:30.
299. Irani R, Nicholson J, Chung S. Long-term results in the treatment of femoral shaft fractures in young children by immediate fit spica immobilization. *J Bone Joint Surg Am* 1976;58:945.
300. Curtis J, Killian J, Alonso J. Improved treatment of femoral shaft fractures in children utilizing the pontoon spica cast: a long-term follow-up. *J Pediatr Orthop* 1995;15:36.
301. Reeves R, Ballard R, Hughes J. Internal fixation versus traction and casting of adolescent femoral shaft fractures. *J Pediatr Orthop* 1990;10:592.
302. Mileski R, Garvin K, Huurman W. Avascular necrosis of the femoral head after closed intramedullary shortening in an adolescent. *J Pediatr Orthop* 1995;15:24.
303. Henderson O, Morrissy R, Gerdes M, et al. Early casting of femoral shaft fractures in children. *J Pediatr Orthop* 1984;4:16.
304. Illgen R, Rodgers W, Hresko M, et al. Femur fractures in children: treatment with early sitting spica casting. *J Pediatr Orthop* 1998;18:481.
305. Weiss A, Schenck R, Sponseller P, et al. Peroneal nerve palsy after early cast application for femoral fractures in children. *J Pediatr Orthop* 1992;12:25.
306. Buxton R. The use of Perkins' traction in the treatment of femoral shaft fractures. *J Bone Joint Surg Br* 1981;63:362.
307. Ryan J. 90-90 skeletal femoral traction for femoral shaft fractures in children. *J Trauma* 1981;21:46.
308. Woolson S, Meeks L. A method of balanced skeletal traction for femoral fractures. *J Bone Joint Surg Am* 1974;56:1288.
309. Bowler J, Mubarak S, Wenger D. Tibial physal closure and genu recurvatum after femoral fracture: occurrence without a tibial traction pin. *J Pediatr Orthop* 1990;10:653.
310. Miller P, Welch M. The hazards of tibial pin replacement in 90-90 skeletal traction. *Clin Orthop* 1978;135:97.
311. Aronson D, Singer R, Higgins R. Skeletal traction for fractures of the femoral shaft in children: a long term study. *J Bone Joint Surg Am* 1987;69:1435.
312. Cheng J, Cheung S. Modified functional bracing in the ambulatory treatment of femoral shaft fractures in children. *J Pediatr Orthop* 1989;9:457.
313. Gross R, Davidson R, Sullivan A, et al. Cast brace management of the femoral shaft fracture in children and young adults. *J Pediatr Orthop* 1983;3:572.
314. McCollough N, Vinsant J, Sarmiento A. Functional fracture-bracing of long-bone fractures of the lower extremity in children. *J Bone Joint Surg Am* 1976;60:314.
315. Levy J, Ward W. Pediatric femur fractures: an overview of treatment. *Orthopedics* 1993;16:183.
316. Boman A, Gardell C, Janarv P. Home traction of femoral shaft fractures in younger children. *J Pediatr Orthop* 1998;18:478.
317. Newton P, Mubarak S. The use of modified Neufeld's skeletal traction in children and adolescents. *J Pediatr Orthop* 1994;15:467.
318. Walsh C, McBryde A. A joint protocol for home skeletal traction. *Orthop Nurs* 1997;16:28.
319. Bar-on E, Sagiv S, Porat S. External fixation or flexible intramedullary nailing for femoral shaft fractures in children. *J Bone Joint Surg Br* 1997;79:975.
320. Blasler R, Aronson J, Tursky E. External fixation of pediatric femur fractures. *J Pediatr Orthop* 1997;17:342.
321. Gregory P, Pevny T, Teague D. Early complications with external fixation of pediatric femoral shaft fractures. *J Orthop Trauma* 1996;10:191.
322. Mendelow M, Kanellopoulos A, Mencia G, et al. External fixation of pediatric femur fractures. *Orthop Trans* 1997;21:185.
323. Green S. Failure to obtain union. In: Green S, ed. *Complications of external skeletal fixation*. Springfield, IL: Charles C Thomas, 1981:84.
324. Gregory P, Sullivan J, Herndon W. Adolescent femoral shaft fractures: rigid versus flexible nails. *Orthopedics* 1995;18:645.
325. González-Herranz P, Burgos-Flores J, Rapariz J, et al. Intramedullary nailing of the femur in children. *J Bone Joint Surg Br* 1995;77:262.
326. Skak S, Overgaard S, Nielsen J, et al. Internal fixation of femoral shaft fractures in children and adolescents: a ten- to twenty-one-year follow-up of 52 fractures. *J Pediatr Orthop Br* 1996;5:195.
327. Heinrich S, Drvaric D, Darr K, et al. Stabilization of pediatric diaphyseal femur fractures with flexible intramedullary nails (a technique paper). *J Orthop Trauma* 1992;6:452.
328. Mazda K, Khairouni A, Pennecot G, et al. Closed flexible intramedullary nailing of the femoral shaft fractures in children. *J Pediatr Orthop Br* 1997;6:198.
329. Ward W, Levy J, Kaye A. Compression plating for child and adolescent femur fractures. *J Pediatr Orthop* 1992;12:626.
330. Ziv J, Rang M. Treatment of femoral fracture in the child with head injury. *J Bone Joint Surg Br* 1983;65:276.
331. Bohn W, Durbin R. Ipsilateral fractures of the femur and tibia in children and adolescents. *J Bone Joint Surg Am* 1991;73:429.
332. Letts M, Vincent N, Gouw G. The "floating knee" in children. *J Bone Joint Surg Br* 1986;68:442.
333. Lane J, Hensinger R, Graham T, et al. Evaluation and management of pediatric subtrochanteric femur fractures. *Orthop Trans* 1990;14:688.
334. Theologis T, Cole W. Management of subtrochanteric fractures of the femur in children. *J Pediatr Orthop* 1998;18:22.
335. Ireland D, Fisher R. Subtrochanteric fractures of the femur in children. *Clin Orthop* 1975;110:157.

Fractures and Dislocations about the Knee

336. Clanton T, DeLee J, Sanders B, et al. Knee ligament injuries in children. *J Bone Joint Surg Am* 1979;61:1195.
337. McDermott M, Bathgate B, Gillingham B, et al. Correlation of MRI and arthroscopic diagnosis of knee pathology in children and adolescents. *J Pediatr Orthop* 1998;18:675.
338. Stanitski C. Correlation of arthroscopic and clinical examinations with magnetic resonance imaging findings of the injured knees in children and adolescents. *Am J Sports Med* 1998;26:2.
339. Marelic T, Aronsson D, Boyd D, et al. Acute hemarthrosis of the knee in children. *Am J Sports Med* 1995;23:668.
340. Stanitski C, Harvell J, Fu F. Observations on acute knee hemarthrosis in children and adolescents. *J Pediatr Orthop* 1993;13:506.
341. Torg J, Pavlov H, Morris V. Salter-Harris type-III fracture of

- the medial femoral condyle occurring in the adolescent athlete. *J Bone Joint Surg Am* 1981;63:586.
342. Lombardo SJ, Harvey JP Jr. Fractures of the distal femoral epiphyses. *J Bone Joint Surg Am* 1977;59:742.
 343. Thomson JD, Stricker S, Williams M. Fractures of the distal femoral epiphyseal plate. *J Pediatr Orthop* 1995;15:474.
 344. Riseborough E, Barrett I, Shapiro F. Growth disturbances following distal femoral physal fracture-separations. *J Bone Joint Surg Am* 1983;65:885.
 345. Meyers M, McKeever F. Fracture of the intercondylar eminence of the tibia. *J Bone Joint Surg Am* 1959;41:209.
 346. Janarv P, Westblad P, Johansson C, et al. Long-term follow-up of anterior tibial spine fractures in children. *J Pediatr Orthop* 1995;15:63.
 347. Wiley J, Baxter M. Tibial spine fractures in children. *Clin Orthop* 1990;255:54.
 348. Willis R, Blokker C, Stoll T, et al. Long-term follow-up of anterior tibial eminence fractures. *J Pediatr Orthop* 1993;13:361.
 349. Fyfe I, Jackson J. Tibial intercondylar fractures in children: a review of the classification and the treatment of mal-union. *Injury* 1981;13:165.
 350. McLennan J. Lessons learned after second-look arthroscopy in type III fractures of the tibial spine. *J Pediatr Orthop* 1995;15:59.
 351. Mah J, Otsuka N, McLean J. An arthroscopic technique for the reduction and fixation of tibial-eminence fractures. *J Pediatr Orthop* 1996;16:119.
 352. Bolesta M, Fitch R. Tibial tubercle avulsions. *J Pediatr Orthop* 1986;6:186.
 353. Ogden J, Tross R, Murphy M. Fractures of the tibial tuberosity in adolescents. *J Bone Joint Surg Am* 1980;62:205.
 354. Pape J, Goulet J, Hensinger R. Compartment syndrome complicating tibial tubercle avulsion. *Clin Orthop* 1993;295:201.
 355. Nietosvaara Y, Aalto K, Kallio PE. Acute patellar dislocation in children: incidence and associated osteochondral fractures. *J Pediatr Orthop* 1994;14:513.
 356. Grogan D, Carey T, Leffers D, et al. Avulsion fractures of the patella. *J Pediatr Orthop* 1990;10:721.
 357. Houghton G, Acroyd C. Sleeve fractures of the patella in children. *J Bone Joint Surg Br* 1979;61:165.
 358. Maguire J, Canale S. Fractures of the patella in children and adolescents. *J Pediatr Orthop* 1993;13:567.
- ### Tibial Fractures
359. Burkhart S, Peterson H. Fractures of the proximal tibial epiphysis. *J Bone Joint Surg Am* 1979;61:996.
 360. Shelton W, Canale S. Fractures of the tibia through the proximal tibial epiphyseal cartilage. *J Bone Joint Surg Am* 1979;61:167.
 361. Jordan S, Alonso J, Cook F. The etiology of valgus angulation after metaphyseal fracture of the tibia in children. *J Pediatr Orthop* 1987;7:450.
 362. Ogden J, Ogden D, Pugh L, et al. Tibia valga after proximal metaphyseal fractures in childhood: a normal biologic response. *J Pediatr Orthop* 1995;15:489.
 363. Salter R, Best T. The pathogenesis and prevention of valgus deformity following fractures of the proximal metaphyseal region of the tibia in children. *J Bone Joint Surg Am* 1973;55:1324.
 364. McCarthy J, Kim D, Eilert R. Posttraumatic genu valgum: operative versus nonoperative treatment. *J Pediatr Orthop* 1998;18:518.
 365. Tuten H, Keeler K, Gabos P, et al. Posttraumatic tibia valga in children: a long-term follow-up. *J Bone Joint Surg Am* 1999;81:799.
 366. Mielke C, Stevens P. Hemiepiphyseal stapling for knee deformities in children younger than 10 years: a preliminary report. *J Pediatr Orthop* 1996;16:423.
 367. Hansen B, Grieff J. Fractures of the tibia in children. *Acta Orthop Scand* 1976;47:448.
 368. Shannak A. Tibial fractures in children: follow-up study. *J Pediatr Orthop* 1988;8:306.
 369. Dietz F, Merchant T. Indications for osteotomy of the tibia in children. *J Pediatr Orthop* 1990;10:486.
 370. Yang J, Letts R. Isolated fractures of the tibia with intact fibula in children: a review of 95 patients. *J Pediatr Orthop* 1997;17:347.
 371. Grieff J, Bergmann F. Growth disturbance following fracture of the tibia in children. *Acta Orthop Scand* 1980;51:315.
 372. Oudjane K, Newman B, Oh K, et al. Occult fractures in pre-school children. *J Trauma* 1988;28:858.
 373. Aronson J, Garvin K, Seibert J, et al. Efficiency of the bone scan for occult limping toddlers. *J Pediatr Orthop* 1992;12:38.
 374. Briggs T, Orr M, Lightower C. Isolated tibial fractures in children. *Injury* 1992;23:308.
 375. Irwin A, Gibson P, Ashcroft P. Open fractures of the tibia in children. *Injury* 1995;26:21.
- ### Fractures of the Ankle
376. Von Laer L. Classification, diagnosis, and treatment of transitional fractures of the distal part of the tibia. *J Bone Joint Surg Am* 1985;67:687.
 377. Gleeson A, Stuart M, Wilson B, et al. Ultrasound assessment and conservative management of inversion injuries of the ankle in children: plaster of Paris versus Tubigrip. *J Bone Joint Surg Br* 1996;78:484.
 378. Petit P, Panuel M, Faure F, et al. Acute fracture of the distal tibial physis: role of gradient-echo MR imaging versus plain film examination. *Am J Roentgenol* 1996;166:1203.
 379. Vahvanen V, Aalto K. Classification of ankle fractures in children. *Arch Orthop Trauma Surg* 1980;97:1.
 380. Dias L, Tachdjian M. Physeal injuries of the ankle in children. *Clin Orthop* 1978;136:230.
 381. Karrholm J, Hansson L, Laurin S. Pronation injuries of the ankle in children. *Acta Orthop Scand* 1983;54:1.
 382. Spiegel P, Cooperman D, Laros G. Epiphyseal fractures of the distal ends of the tibia and fibula. *J Bone Joint Surg Am* 1978;60:1046.
 383. Cass J, Peterson H. Salter-Harris type IV injuries of the distal tibial epiphyseal growth plate, with emphasis on those involving the medial malleolus. *J Bone Joint Surg Am* 1983;65:1059.
 384. Kling T, Bright R, Hensinger R. Distal tibial physeal fractures in children that may require open reduction. *J Bone Joint Surg Am* 1984;66:647.
 385. Salter R. Injuries of the ankle in children. *Orthop Clin North Am* 1974;5:147.
 386. Lintecum N, Blasier R. Direct reduction with indirect fixation of distal tibial physeal fractures: a report of a technique. *J Pediatr Orthop* 1996;16:107.
 387. Rapariz J, Ocete G, Gonzalez-Herranz P, et al. Distal tibial triplane fractures: long term follow-up. *J Pediatr Orthop* 1996;16:113.
 388. Ertl J, Barrack R, Alexander A, et al. Triplane fracture of the distal tibial epiphysis. *J Bone Joint Surg Am* 1988;70:967.
- ### Fractures of the Foot
389. Schindler A, Mason D, Allington N. Occult fracture of the calcaneus in toddlers. *J Pediatr Orthop* 1996;16:201.

390. Simonian P, Vahey J, Rosenbaum D, et al. Fracture of the cuboid in children: a source of leg symptoms. *J Bone Joint Surg Br* 1995;77:104.
391. Jensen I, Wester J, Rasmussen F, et al. Prognosis of fracture of the talus in children. *Acta Orthop Scand* 1994;65:398.
392. Mulfinger G, Trueta J. The blood supply of the talus. *J Bone Joint Surg Am* 1970;52:160.
393. Letts R, Gibeault D. Fractures of the neck of the talus in children. *Foot Ankle* 1980;1:74.
394. Canale S, Kelly F. Fractures of the neck of the talus. *J Bone Joint Surg Am* 1978;60:143.
395. Wester J, Jensen I, Rasmussen F, et al. Osteochondral lesions of the talar dome in children: a 24 (7–36) year follow-up of 13 cases. *Acta Orthop Scand* 1994;65:110.
396. Heckman J, McLean M. Fractures of the lateral process of the talus. *Clin Orthop* 1985;199:108.
397. Inokuchi S, Usami N, Hiraishi E, et al. Calcaneal fractures in children. *J Pediatr Orthop* 1998;18:469.
398. Schantz K, Rasmussen F. Calcaneus fracture in the child. *Acta Orthop Scand* 1987;58:507.
399. Schmidt T, Weiner D. Calcaneal fractures in children: an evaluation of the nature of the injury in 56 children. *Clin Orthop* 1982;171:150.
400. Sanders R, Fortin P, DiPasquale T, et al. Operative treatment in 120 displaced intraarticular calcaneal fractures: results using a prognostic computed tomography scan classification. *Clin Orthop* 1993;290:87.
401. Cole R, Brown H, Stein R, et al. Avulsion fracture of the tuberosity of the calcaneus in children. *J Bone Joint Surg Am* 1995;77:1568.
402. Schantz K, Rasmussen F. Good prognosis after calcaneal fracture in childhood. *Acta Orthop Scand* 1988;59:560.
403. Holbein O, Bauer G, Kinzl L. Fracture of the cuboid in children: case report and review of the literature. *J Pediatr Orthop* 1998;18:466.
404. Wiley J. Tarso-metatarsal joint injuries in children. *J Pediatr Orthop* 1981;1:255.
405. Johnson G. Pediatric Lisfranc injury: “bunk bed” fracture. *Am J Radiol* 1981;137:1041.
406. Silas S, Herzenberg J, Myerson M, et al. Compartment syndrome of the foot in children. *J Bone Joint Surg Am* 1995;77:356.



THE ROLE OF THE ORTHOPAEDIC SURGEON IN CHILD ABUSE

BEHROOZ A. AKBARNIA
ROBERT M. CAMPBELL, JR.

DEFINITION 1424

PREVALENCE 1424

DIAGNOSIS 1424

THE INVESTIGATIVE INTERVIEW 1425

At-risk Profiles 1425

CLINICAL MANIFESTATIONS 1426

Soft Tissue Injuries 1426

Head Injuries 1428

Internal Injuries 1428

ORTHOPAEDIC MANIFESTATIONS 1428

Physeal Fractures 1428

Metaphyseal Fractures 1429

Diaphyseal Fractures 1430

Miscellaneous Fractures 1432

Spinal Injuries 1432

DECISION-MAKING 1435

Dating Fractures 1436

MANAGEMENT 1437

Limitations of Imaging Techniques 1438

Differential Diagnosis 1438

The Team Approach 1440

Medical Neglect 1441

THE ORTHOPAEDIC SURGEON, CHILD ABUSE, AND THE LAW 1441

Preparation for Court Testimony in Child Abuse Cases 1442

APPENDIX: GUIDELINES FOR EXPERT WITNESSES 1443

ACKNOWLEDGMENTS 1443

Few of us can tolerate with equanimity the concept of small and defenseless children, the weakest members of our species, deliberately and cruelly being harmed by those who care for them. Inflicted trauma is not a new occurrence.

B. A. Akbarnia: Department of Orthopaedics, University of California—San Diego, La Jolla, California 92093; San Diego Center for Spinal Disorders, San Diego, California 92123.

R. M. Campbell, Jr.: Department of Orthopaedics, University of Texas Health Sciences Center at San Antonio, San Antonio, Texas 78229; Department of Pediatric Orthopaedics, Christus Santa Rosa Children's Hospital, San Antonio, Texas 78207.

Over the centuries, parents have reacted to the stress and frustration of everyday life by striking out at their children, causing soft tissue and bone injuries. As for children, there never has been a golden age. Throughout the history of various societies, children have been killed, abandoned, beaten, and sexually abused. However, only for the past three decades has the attention of the medical community been focused on child abuse and neglect.

In 1946, Dr. John Caffey (1), a pediatrician and pediatric radiologist in New York City, reported, for the first time in the United States, the association of multiple fractures in long bones with chronic subdural hematoma in six infants who had no recorded history of trauma. He recommended

investigation for subdural hematoma in infants with long-bone fractures as well as investigation for long-bone fractures in patients with subdural hematoma. In 1953, Silverman (2) clearly implicated parents and guardians as the cause of these traumatic lesions, and described, as part of the syndrome, irregular fragmentation of one or more metaphyses in the tubular bones associated with new bone formation external to the shaft. In 1960, Altman and Smith (3) became the first authors to report cases of unrecognized trauma in infants and children in the orthopaedic literature, and concluded that removing the child from the home environment could be lifesaving.

Although many physicians contributed to the recognition and understanding of child abuse, medicine as a profession did not officially acknowledge child abuse until a paper describing the battered-child syndrome was published by C. Henry Kempe and associates (4) in 1962. The introduction of the term "battered-child syndrome" was helpful in attracting attention to this neglected medical and social problem. Within a few years of the publication of this article, reporting laws were passed in all states, mandating that health professionals report suspected cases of abuse. Increased public awareness finally resulted in the passage of the Child Abuse Prevention Act of 1974. The first large study of patients with orthopaedic manifestations of this syndrome was published in 1974 (5). In 1990, Schmitt and Clemmens (6) reported that 35% of abused children will be reinjured and 5% will die if they return to the original environment without any intervention. Great strides have been made, not only in the passage of child abuse legislation, but also in the diagnosis, management, and understanding of the social, psychologic, and epidemiologic aspects of this problem. Unfortunately, the syndrome remains a major cause of death and physical and mental disability among our children.

DEFINITION

In 1968, Helfer and Kempe (7) defined child abuse as physical injury inflicted on children by persons caring for them. Since then, the concept of child abuse has been broadened to include physical and emotional neglect, physical abuse, and psychologic and sexual abuse. In addition, the list of professionals required to report such abuse has been increased to include virtually all those who are responsible for the care of children. Thus, the definition can vary, depending on the professionals involved. This chapter deals mainly with the diagnosis and management of physical abuse.

PREVALENCE

The prevalence of child abuse is difficult to determine. It has been estimated that 1 to 1.5% of all children are abused

each year. The number ranges from 70,000 to 3 million (8,9). In 1997, 45 states reported that nearly 3 million children were alleged victims of maltreatment (for a national rate of 42 children per 1,000 children in the population). One-third of investigations resulted in a disposition of either substantiated or indicated child maltreatment (the rate of victimization was 13.9 per 1,000 children). More than one-half of all victims suffered neglect, and almost one-fourth suffered physical abuse. The number of childhood deaths attributable to abuse is difficult to estimate. This is particularly true in infancy, when many cases of homicide are likely to remain undetected (4). In 1997, 41 states reported 967 child maltreatment fatalities, which were extrapolated to a national estimate of 1,197 (for a rate of 1.7 per 100,000 children, or 123 child fatalities per 100,000 victims of maltreatment). However, many states have indicated that the actual number may be significantly higher. The number of children who were victims of maltreatment peaked in 1993, and has since decreased from 15.3 victims per 1,000 children to 13.9 per 1,000, and it is now only slightly higher than the rate in 1990 (8). For every case that is reported, many others are not. The case reports and statistics are heavily biased toward poor and minority children. Children of the affluent may receive different diagnostic labels for their problems (i.e., "accidents" rather than "abuse"), and practitioners may feel an obligation to protect more affluent families from the stigma of reporting to public agencies (5). About 30% of fractures in children younger than 3 years of age are nonaccidental (10,11). In a study of children younger than 1 year of age, 56% of fractures were found to be nonaccidental (12,13). The gender ratio is about equal, but premature babies and stepchildren are at greater risk. Besides parents, who are the perpetrators in three-fourths of cases, boyfriends and stepparents are also frequent abusers. Younger children, in general, are at greater risk, because they are demanding, defenseless, and nonverbal. In a study of 231 abused children, 50% were younger than 1 year of age, and 78% were younger than 3 years of age (5). Although a larger percentage of maltreated children are between birth and 4 years of age, the number of victims is distributed across most age ranges between birth and 16 years. However, fatalities from physical abuse are seen most often in children younger than 3 years of age (75%) (8).

DIAGNOSIS

In the spectrum of child abuse and maltreatment, orthopaedic surgeons are involved more often in cases of physical injury, and less often in cases of physical and emotional neglect. Physical abuse and chronic neglect of young children tend to be recurrent, and often result in permanent sequelae, such as skeletal deformities, brain injury, and even death. The orthopaedic surgeon must be satisfied that each injury seen in a child is adequately explained, and that the injury is consistent with the history provided. The role of

the orthopaedic surgeon extends beyond simple treatment of the child's fracture.

To differentiate those lesions resulting from inflicted trauma from those caused by accidents, physicians should have a high index of suspicion, as well as diagnostic skill. Furthermore, they should be knowledgeable regarding the patterns of normal growth and development, and the common injuries of children (14,15). The diagnosis of child abuse seldom is made without difficulty. A combination of the history given, the age of the child, the behavior of the parent, and certain clinical manifestations serves as a practical guideline for differentiating nonaccidental injury from injury associated with pathologic conditions. Child abuse should be viewed in the same manner as any other medical condition in which facts are gathered and evaluated and a medical judgment, based on knowledge and expertise, is formulated (16).

Because all cases of suspected inflicted injuries are possible forensic cases, the diagnosis should include an expression regarding the level of certainty to which the physician is willing to commit. This might be a phrase such as "reasonable degree of medical certainty," "more likely than not," or "suspicious." All interventions other than voluntary ones in child abuse cases require that the existence of the abuse be proven at some specific level of certainty (17).

THE INVESTIGATIVE INTERVIEW

The child abuse interview is usually taken in the chaotic environment of a busy emergency room, and it is important to find a quiet area for the interaction, where tempers can cool and distractions can be minimized. The interview goes beyond the usual history in many ways. Documenting the symptoms (or the absence of symptoms) of the injury is only the beginning; what is equally important is to discover enough details about the child's life, so that plausible scenarios can be created to explain the injury. The orthopaedist must become both social worker and detective in the interview, calmly and methodically establishing how the child lives, seeking information about everyone, friends and family, with access to the child, and determining how likely it is that they might have contributed to the injuries.

At-risk Profiles

The Parents

Although any parent could be capable of child abuse, during the interview specific "at-risk" profiles are developed for the parents or other caregivers, to determine if they are more likely to abuse a child. Substance abuse, whether by alcohol or other drugs, makes a parent more likely to abuse a child. With maternal cocaine use, the risk of physical abuse of a

child is increased fivefold (18). Households in crisis from job loss, marital separation, divorce, a family death, housing difficulties, or money problems are more prone to abuse situations (19). Boyfriends and stepparents are frequent abusers, as are relatives, baby-sitters, and even older siblings (20,21). Young, unmarried mothers are more likely to have their infants die from intentional injury, with one Colorado study (22) showing a peak incidence of 10.5 intentional deaths per 10,000 live births for mothers 16 years of age. Parents of abused children often, themselves, were abused in childhood (23). Typically, the adult who abuses a child is young, poor, and socially isolated (24), but any adult from any social or economic level may be guilty of abusing a child (13).

The Children

Certain groups of children are more likely to experience abuse. Age is an important risk factor, because most abuse involves children younger than 3 years of age, with infants 1 year or younger especially at risk. Stepchildren, premature infants, and first-born children are at greater risk for abuse (13). Children of families with two unplanned births have a threefold higher risk of abuse than children from families with no unplanned births (25). Handicapped children have a 4.6% incidence of abuse, with severely disabled children somewhat less likely to be abused, and marginally functioning children at greatest risk (26). The incidence of sexual abuse in handicapped children has been estimated between 25% and 83%, with boys more likely to be abused (27). Children who are repeatedly brought in for medical assessment by their parents for vague illness, with a history of multiple diagnostic or therapeutic procedures without definitive diagnosis, may be at risk for Munchausen syndrome by proxy (28). In this condition, the parents, through a misguided sense of purpose, invent symptoms of illness for the child, and induce signs of disease, provoking needless workup and treatment, which can lead to an 8% risk of long-term sequelae from induced illness and a 9% risk of death. Acute signs and symptoms cease only when the child is separated from the parent.

A careful, detailed history of each adult family member should be obtained individually in a quiet, private setting. If the patient and siblings can communicate, they should be interviewed separately from the parents. The crucial questions to be answered are not only whether the history of trauma given is sufficient to explain the severity of injury, but also what possible scenarios could explain the injury if the volunteered explanation is not plausible. This involves establishing a working knowledge of how the family operates: Who has access to the child? Which of those individuals are unsupervised by family members when they are with the child? What are the living conditions for the family? Which adult is working and which is not? Who is the pri-

mary caregiver for the child? Who is responsible for feeding the child, as well as for toilet training and discipline? What are the sleeping arrangements for members of the household? What is the marital status of the parents? Does the single parent have a boyfriend or a girlfriend? Is there any history of substance abuse in the adults who have contact with the child? Is there any past history of child abuse in the family?

The interview is begun by asking the primary caregiver in a nonjudgmental manner how the presentation injury occurred. If the answer is vague or implausible, or if risk factors are present for child abuse, other undocumented injuries must first be searched for by careful physical examination and radiographic skeletal survey, before proceeding with the full interview. Once a full injury assessment of the child is complete, then the full interview can resume. To avoid provoking emotions, any additional soft tissue or skeletal trauma discovered should be brought up *at the end of the interview* for explanation, once the presentation injury has been thoroughly discussed. Each investigative interview should follow a systematic review of symptoms: What happened? Who was there? When was the injury recognized? How long before medical treatment was sought? Inconsistencies between accounts are not contested, and the orthopaedist should avoid volunteering more plausible explanations for the injury. The location where the incident occurred and the individuals who were actually present are determined. Leading questions are to be avoided. Do not ask *who* caused the injury; rather, ask each person *what* he or she saw or *what* he or she thinks happened. Establish who discovered the injury, how soon the child received medical attention, and where the child was taken for care (19). Delays in treatment should raise the index of suspicion for an abuse situation. Be as gentle as possible in questioning the injured child, asking *how* he or she got hurt, rather than *who* hurt him or her. Ask the child what he or she was doing at the time of the injury, and compare that account with what the adult witnesses state. If possible, also interview the siblings of the injured child, because they too are at risk for child abuse.

Nonvisual clues during the interview may help to define an abuse situation. Parents who are abusive can be evasive, and may not readily volunteer information. They may be self-contradictory, and may display irritation at inquiries regarding their children's symptoms. They may show overreaction, such as hostility, or underreaction, such as casualness or little evident concern. They may be unavailable or refuse to give information or to consent to different tests. Often, they have inappropriately delayed seeking medical care. When they interact with their children, they may seldom touch or look at them, seeming indifferent to the child's distress, or they may be critical and angry with the child, and not mention any positive or good qualities. The abused child may be sobbing hysterically or may be quiet and withdrawn. These children may not look to the parents

for reassurance, may avoid physical contact with adults, may be overly compliant, and may appear wary of danger (13,23).

Careful documentation is critical. Chart notes may be needed later in court as evidence in custodial hearings. Record each account as faithfully as possible, using *italics* for exact quotes, and specify who is giving the history. Not infrequently, the family will wish later to change their story. No changes should be made to the earlier record, but an addendum should be added detailing the new account. The record should be as detailed as possible, noting all accounts of the mechanism of injury, family social history, past medical history, any family history of diseases such as osteogenesis imperfecta, physical examination findings, and radiographic and laboratory results. Photographs of soft tissue injuries should also be added to the record. The results from any consultations are also placed in the chart note. Along with the diagnosis of any injuries, the orthopaedist must specifically include the diagnosis of *probable* or *possible* child abuse, if the evidence supports such a conclusion. Treatment recommendations should include a care plan for the acute injuries, and a status report for child protective services involvement in the case. If child protective services recommends emergency transfer of the child to a foster home or shelter, the orthopaedist should summarize all chart documentation in a separate notarized narrative, which is preferred by the court system.

CLINICAL MANIFESTATIONS

When confronted with a traumatic lesion, the physician must examine the whole child and look for other possible clues. If there is any question regarding the general medical examination, help should be sought from medical colleagues. Often, it is the nonorthopaedic manifestations of child abuse that lead to the diagnosis.

Failure to thrive, or growth retardation secondary to physical and emotional deprivation, is common in children who have been subjected to repeated abuse. This should be differentiated from the usual causes of growth retardation.

Soft Tissue Injuries

Soft tissue injuries are strong indications of abuse. Soft tissue injuries were found in up to 92% of children suspected of being victims of child abuse (29). A variety of skin lesions, including ecchymosis, abrasions, burns, welts, lacerations, and scars, are by far the most common finding in cases of child abuse (30). Typical toddlers have bruises over the shins, knees, elbows, and brow. They may have a few old cuts or scars around the eyes or cheekbones as a result of normal collisions. However, bruising of the buttocks, perineum, trunk, back of the legs, and especially the head or neck, suggests inflicted trauma. These lesions may have the

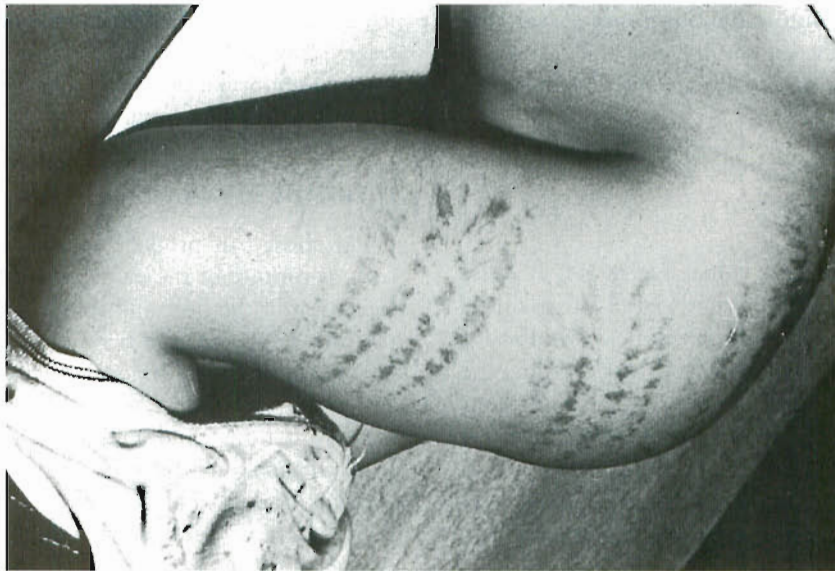

FIGURE 33-1. Rope marks on an infant who was a victim of repeated physical abuse.

same shapes or configurations as the implements used to create them (Fig. 33-1). Loop marks or scars on the skin are inflicted by a doubled-over cord or rope. Human bite marks are distinctive, paired, crescent-shaped bruises that face each other. McMahon et al. (29), however, found that these pathologic patterns occurred in only 8% of their patients. The skin lesions may be in various stages of healing (Fig. 33-2). Wilson (31) has suggested some guidelines for estimating the age of a bruise from its color. From 0 to 3 days after injury, a bruise usually is red, blue, or purple; from 3 to 7 days, it is green or green-yellow; and from 8 to 28 days, it is yellow or yellow-brown. These guidelines can be helpful in determining whether bruises are the result of one or more traumatic episodes. When bruises are present, diseases such as leukemia, idiopathic thrombocytopenia purpura, and hemophilia should be ruled out. Other cutaneous manifestations of child abuse include bruises in the shape of a hand print, alopecia or subgaleal hematoma from pulling of the hair, and areas of abraded skin from bindings or restraints. Impetigo in its various forms can be confused with burns or inflicted injuries.

It is essential that photographs of skin lesions be taken for the purpose of documentation and possible future use in the courts. Informed consent should be obtained, and the photographs can be taken by a member of the child abuse team or by a social worker.

Cao-gio, or "scratch the wind," is a Vietnamese folk medicine practice. It consists of using a boiled egg covered with hair, a coin, or a similar object to scratch skin previously massaged with hot oil. This leaves broad bruises or ecchymosis. It is believed that these scratching maneuvers help rid the body of "bad wind." These lesions should not be confused with nonaccidental lesions (32).

Burn injuries are common and are seen in 10% of abused children (13). These lesions can be scalding injuries, cigarette burns, or burns caused by flames. Burns are most common among children between birth and 2 years of age (29).

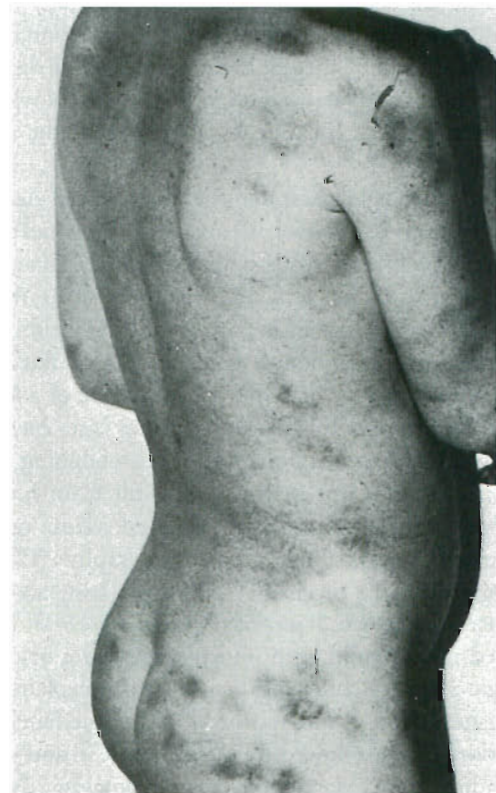

FIGURE 33-2. Bruising of the back and buttocks, typical of physical abuse. Bruises may be found in different stages of healing.

The pattern of deliberate immersion burns often is symmetric, with sharp lines between the burned and unburned skin. Accidental scald burns usually are distributed asymmetrically (30).

Head Injuries

The head is a convenient and vulnerable target. Because “the face represents the person,” it is logical to strike the face to assail the person. The most convenient weapon for striking a child is the human hand. An open palm, the knuckles, or a closed fist is sufficient to produce severe damage to the brain, skull, or scalp, when used forcefully. Of 110 physically abused children seen by O’Neill and associates (21), 32 had evidence of cerebral trauma. More than 50% of all cases of permanent disability occur among children younger than 2 years of age, and result, in large part, from inflicted head injuries. The scalp may be swollen. Extension of the swelling and ecchymosis to the eyelids and face is a telltale sign of cranial trauma. Head injuries may be severe and result in immediate death, or they may be less severe and cause various subtle neurologic impairments. Subdural hematoma can occur with or without skull fractures. Many children with brain injuries have no external evidence of trauma. Caffey (33) suggested that violent shaking may cause stretching and tearing of the veins, creating subdural hematoma. If the insult is repeated, causing minor brain injury each time, it may result in additional brain damage manifested by mental retardation, seizure disorders, and other motor and learning disabilities, some of which do not become apparent for months or years after the abusive behavior has ended.

Careful neurologic assessment of all suspected victims of abuse or neglect is essential. Conversely, the unexplained appearance of central nervous system symptoms in an infant should trigger suspicion of abuse. Fractures of the skull are not easy to produce in infants, because of the yielding elasticity of the thin cranial bones, which are not yet fixed at the sutures. When present, they may be indicative of a forceful nonaccidental impact to the skull. Several cases have been reported of children with inappropriate widening of the cranial sutures, which is believed to result from increased intracranial pressure secondary to cerebral edema or subdural hematoma (5). Computed tomography (CT) has greatly improved the precision in differentiating accidental and nonaccidental head injuries, and this test should be performed in any child with unexplained acute or chronic neurologic signs. A child with acute and unexplained unconsciousness should undergo head CT immediately after stabilization, often followed by abdominal CT and skeletal survey radiography. Magnetic resonance imaging (MRI) is not recommended as the primary imaging study, because

it can fail to reveal subarachnoid hemorrhage in the early stages. After a few days, MRI can be helpful in detecting cerebral abnormalities. MRI also is useful in patients with chronic neurologic findings.

Internal Injuries

Child abuse can produce injuries to the internal organs, such as rupture of the pancreas and pseudocyst formation, laceration of the liver and spleen, intramural hematoma of the bowel, hemorrhage behind the peritoneum, laceration or contusion of the kidneys, perforation of the intestine, and rupture of the ureter or bladder (34). Of the deaths that result from child abuse, many are caused by internal hemorrhage from the rupture of abdominal organs after punches or kicks. Most such deaths occur in children 3 years of age or younger. The high death rate from these injuries is attributable not only to the severity of the trauma, but also to the delay of the abuser in seeking medical attention. Unfortunately, the lack of a history of trauma and the failure of the physician to notice other signs of abuse often result in a delay of diagnosis as well.

ORTHOPAEDIC MANIFESTATIONS

About one-third of all physically abused children require orthopaedic treatment (5). The incidence of fractures in child abuse cases varies from 11 to 55%. Skeletal injuries are significantly more common in the younger age groups. Factors that influence the reported incidence of fractures relate to the age of the patient, the type of abuse, and the type and quality of the imaging techniques used to detect skeletal injuries. Fractures can occur in almost any bone of the body. However, the long bones, ribs, and skull are common locations. Fractures can be categorized as epiphyseal, metaphyseal, diaphyseal, or miscellaneous (5).

Physeal Fractures

Physeal fractures, although rare, are seen most often in the femur, tibia, and humerus, and are being recognized in more cases of child abuse (35–37). A fracture through a growth plate, especially when the epiphysis is not visible, can cause difficulty in diagnosis. Metaphyseal lucency or irregularity and soft tissue swelling may be the only findings on radiographic examination. Arthrographic examination of the joint, as well as MRI, can be helpful in certain cases, such as fractures around the elbow (35) (Fig. 33-3).

Fractures of the proximal femur involving the epiphyseal–metaphyseal region are much less common than those involving the shaft and distal femur. They are identical to fractures caused by birth trauma. These fractures not only are difficult to detect, especially before the ossific nucleus

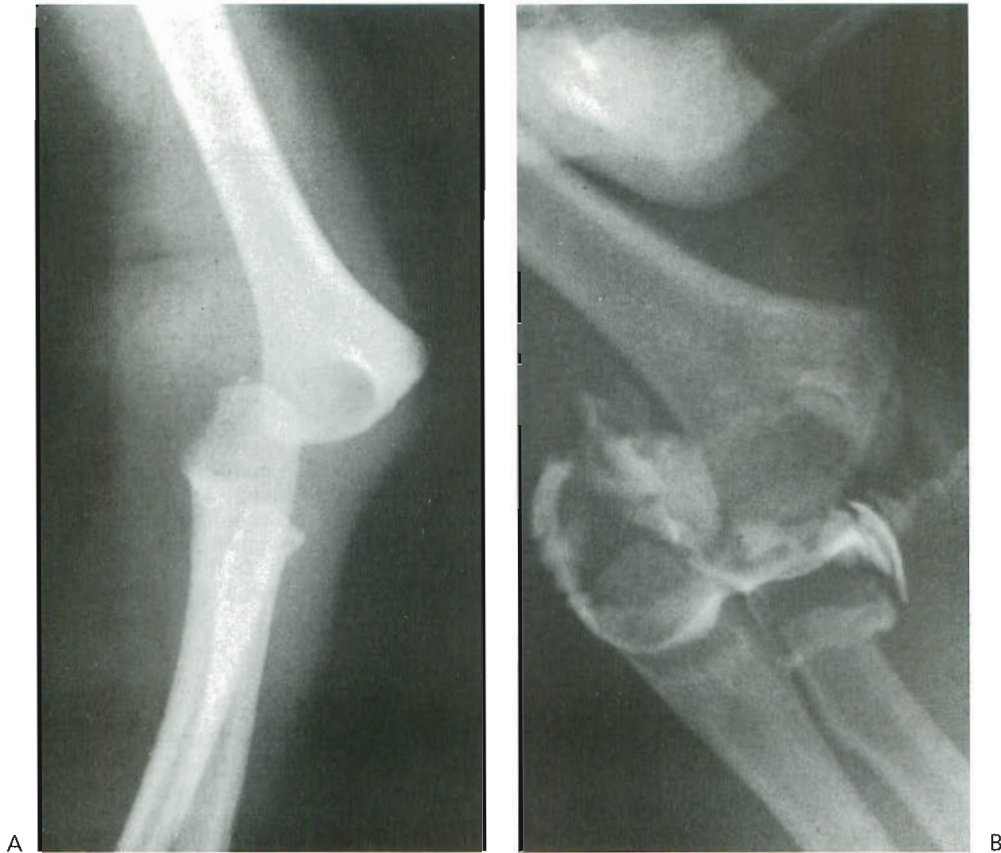


FIGURE 33-3. A 15-month-old infant was seen in the emergency department because she was not able to move her right elbow. **A:** The exact location and severity of the fracture of the distal humerus cannot be identified. **B:** An arthrogram of the elbow shows the outline of the distal humeral epiphysis, which is separated.

has appeared, but they may result in the most severe deformities of the lower extremities caused by child abuse.

Metaphyseal Fractures

Metaphyseal fractures are classified as corner fractures, impaction injuries, buckle fractures, or irregular metaphyseal deformities. Corner fractures are caused by forceful downward pulling on the extremity, and often are bilateral. They may not be visible on the initial radiograph, but they can result in periosteal separation and subperiosteal hemorrhage, with subsequent new bone formation external to the cortex. The periosteal new bone formation becomes visible in about 7 to 10 days. These patients often have swollen and painful extremities that cannot be moved. If the lesion is already 7 to 10 days old, the swollen and warm extremity with periosteal new bone formation, often associated with fever, can be confused with osteomyelitis.

Metaphyseal injuries, especially corner fractures as opposed to shaft fractures, are highly specific. However, detection of these lesions often requires high-quality radiographic

images. Kleinman and colleagues (38) believe that these lesions are the most diagnostic fractures indicating nonaccidental trauma. They presented an extensive radiologic–histopathologic study, and indicated that the fundamental histologic lesion is a series of microfractures occurring in a planar fashion through the most immature portion of the metaphyseal primary spongiosa. The most subtle indication of injury is a transverse lucency within the subepiphyseal region of the metaphysis. These lucent lines occasionally are indistinguishable from those found in patients with chronic diseases, such as leukemia. The fracture fragment is made up of epiphysis, physis, and a thin portion of metaphysis (Fig. 33-4). In the peripheral margin, the disc-like fragment is relatively thick, and can show evidence of different degrees of density. It is this peripheral margin that has been called a “metaphyseal corner fracture.” A similar fragment often is seen in the lateral and anteroposterior projections, indicating that these apparently separate triangular fragments actually are portions of the same larger disc-like fragment (Figs. 33-5 and 33-6).

In an impaction injury that is severe, the epiphysis is

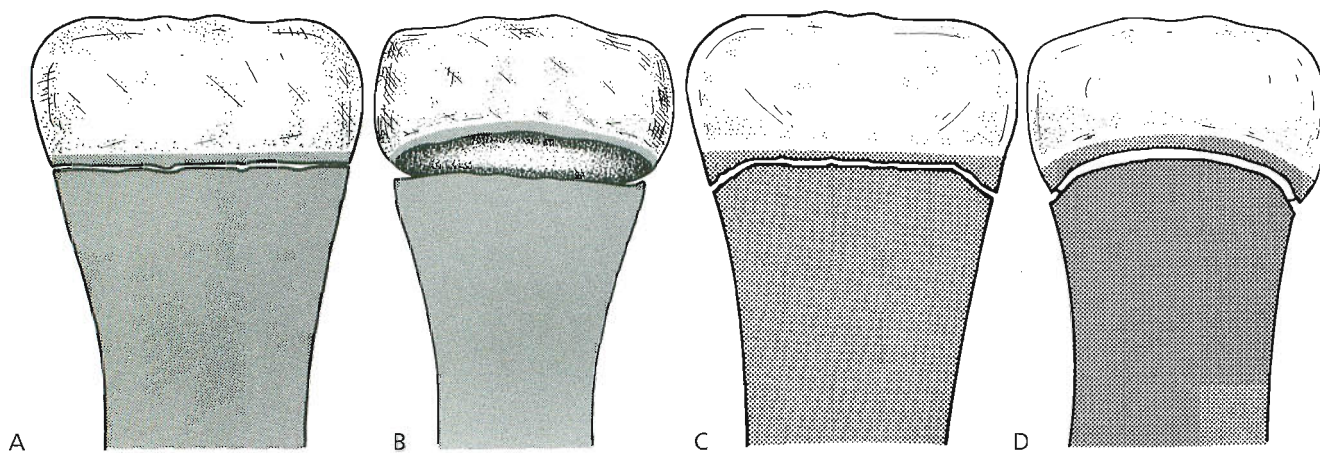


FIGURE 33-4. Metaphyseal lesions. **A:** A planar fracture through the primary spongiosa produces metaphyseal lucency. **B:** If the metaphysis is tipped, or simply projected at an obliquity to the x-ray beam, the margin of the resultant fragment is projected with a bucket-handle appearance. **C:** If the peripheral fragment is substantially thicker than the central fragment, and the plane of injury is viewed tangentially, a corner fracture appearance will result. **D:** If the metaphysis is displaced or projected at an obliquity, as in **B**, a thicker bucket handle will be apparent. (From ref. 16, with permission.)

impacted into an expanded metaphysis, and exuberant periosteal new bone formation occurs subsequently (Fig. 33-7). Simple buckle fractures are common in the metaphysis, and often are multiple. Unlike other metaphyseal lesions, they do not produce a significant amount of callus (Fig. 33-8). Gross irregularity of the metaphysis is seen after repeated injuries, and frequently is associated with deformity of the joint and limitation of motion (39).

Diaphyseal Fractures

Diaphyseal lesions are grouped into three categories:

1. Transverse, spiral, or oblique fractures of the shaft, sometimes associated with exuberant callus, because of delay in seeking medical help and lack of proper immobilization.
2. Multiple lesions in various stages of healing.
3. Gross bony deformities.

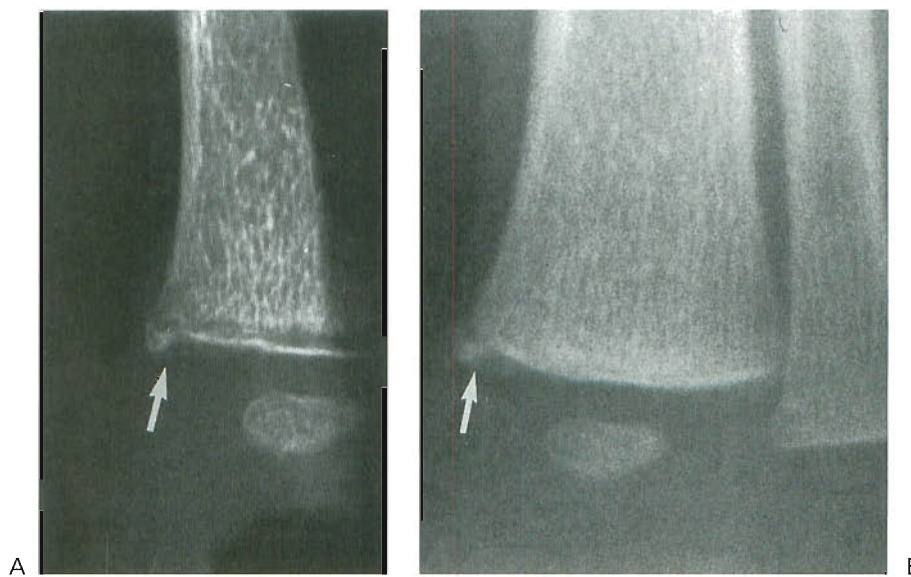


FIGURE 33-5. Distal tibia of a 3-month-old abused infant. **A:** Specimen radiograph reveals a corner fracture medially (arrow), in addition to a conspicuous metaphyseal radiolucency. **B:** Antemortem radiograph tangential to the metaphyseal margin also demonstrates the corner fracture (arrow), with the suggestion of a radiolucent band. (From ref. 16, with permission.)

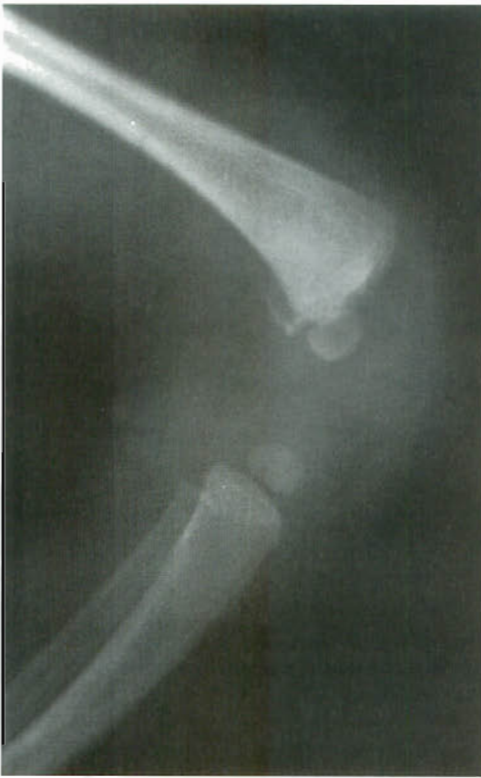

FIGURE 33-6. Metaphyseal corner fracture or bucket-handle fracture in the lateral view.

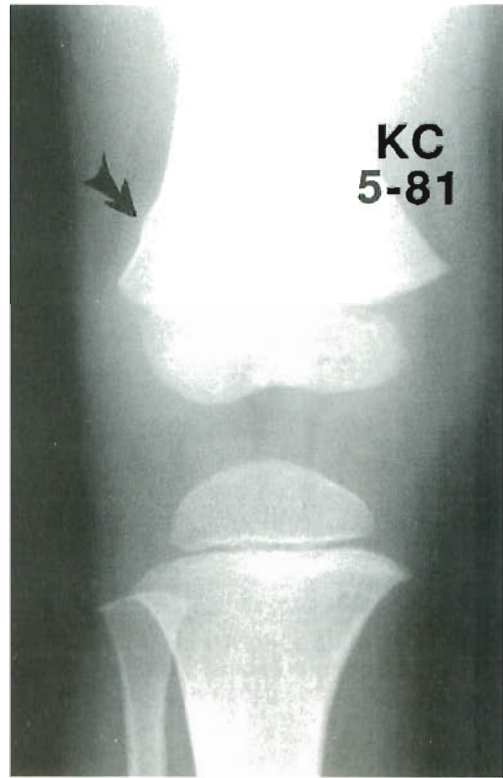


FIGURE 33-8. Metaphyseal buckle fractures involving the distal end of the femur. These fractures often are bilateral.

The femur and humerus are the two long bones most frequently fractured in abused children. The overall incidence of femoral fractures is 20% (5,21,37). In a series of 80 femoral fractures in children younger than 4 years of

age, 30% were caused by child abuse (40). Anderson (41) described 117 patients with 122 femoral fractures. Of 24 children younger than 2 years of age, 19 (79%) were abused. Of 18 children younger than 13 months of age, 15 (83%)

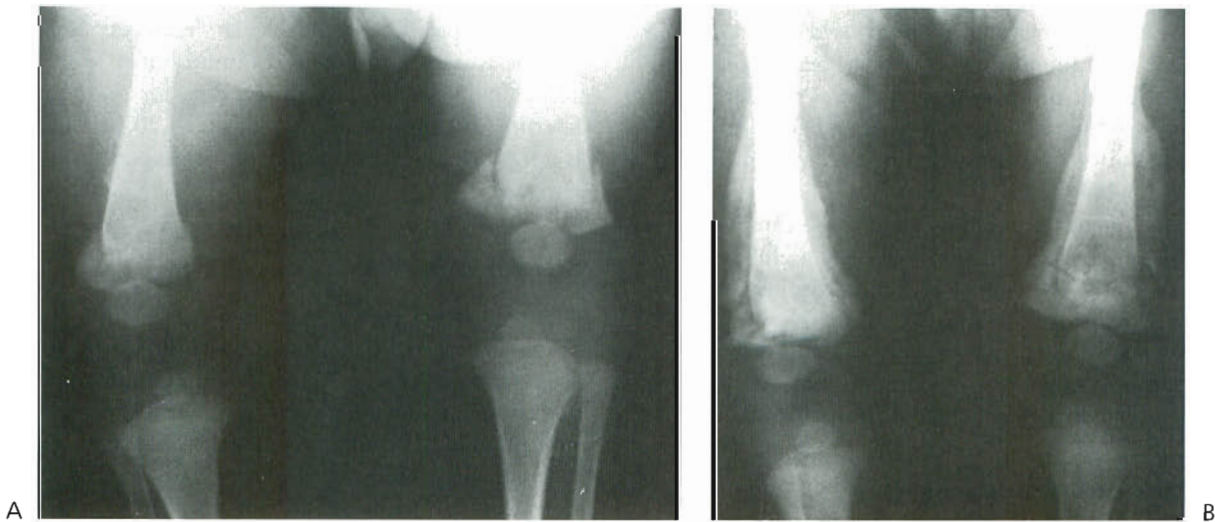


FIGURE 33-7. Bilateral impact fracture of the distal end of the femur (A), with subsequent exuberant periosteal new bone formation (B). (From ref. 5, with permission.)

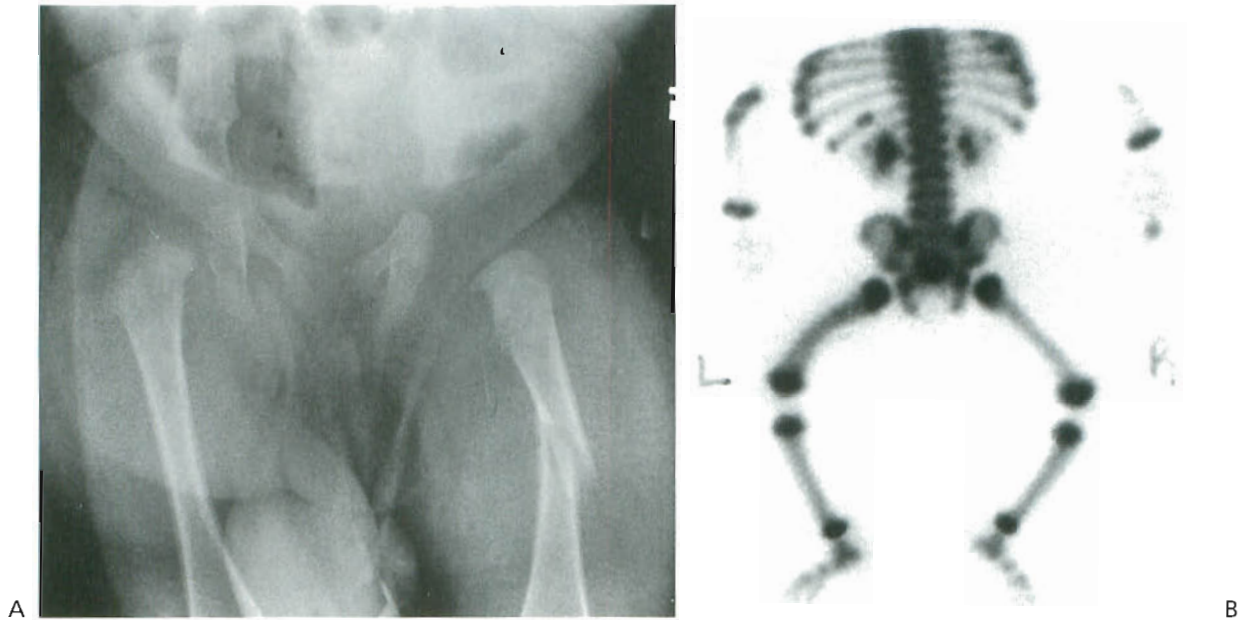


FIGURE 33-9. A 2-month-old boy reportedly fell from a sofa. **A:** Femur fracture was not very specific. **B:** Because of the patient's age and vague history, a bone scan was obtained. The bone scan showed increased uptake in the rib that was not seen on the plain radiographs.

were abused. In older children, there are more accidental injuries causing femoral fractures.

Some authors have emphasized the frequency of spiral and oblique fractures of the long bones caused by physical abuse (42). However, it is increasingly evident that the usual types of diaphyseal fractures (e.g., transverse fractures) are common in cases of nonaccidental trauma. Therefore, in long-bone fractures, especially in the femur, no specific type of fracture (e.g., transverse, oblique) should be considered pathognomonic of child abuse. Other criteria, such as history and patient age, are more helpful in making the diagnosis (43) (Fig. 33-9).

In a review of 429 fractures in 189 abused children, King and associates (34) found the humerus to be the long bone most often affected, and transverse fractures to be the most common type. About 50% of their patients had only a single long-bone fracture, 35% in the femur and 29% in the humerus (Fig. 33-10).

Long-bone fractures caused by child abuse can be similar to those resulting from accidental trauma. Careful attention to the history and the age of the child could reveal the nonaccidental nature of the injury. Because the risk for accidents begins with mobility, especially walking, when these injuries occur in young, nonambulatory infants, they almost always are inflicted in the absence of bone disease.

Miscellaneous Fractures

Rib fractures account for 5 to 27% of all fractures occurring in abused children (16). Fractures involving the ribs usually

are posterior or posterolateral, and can be in various stages of healing (Fig. 33-11). They rarely are caused by cardiopulmonary resuscitation. In the absence of radiographic evidence of intrinsic bone disease or obvious major trauma, unexplained rib fractures are specific for abuse. Rib fractures usually are not suspected clinically. Radionuclide bone scanning has been shown to be extremely useful in the detection of rib fractures in abused infants and children, and should be used if nonaccidental injury is suspected and the skeletal survey is negative.

Other miscellaneous fractures include spinal, clavicular, scapular, and sternal fractures. Spinal and sternal fractures are more specific than clavicular fractures. Although the clavicle is one of the most common bones to be fractured accidentally in children, it accounts for only 2 to 6% of fractures associated with child abuse (5,20,44). Therefore, it is not specific for child abuse. Spinal fractures are described separately.

Spinal Injuries

The true incidence of spinal injuries is difficult to determine. The reported incidence has varied from 0 to 3% in large series (5,37,41). Abused children with spinal injuries occasionally show mild kyphosis, but most do not have significant clinical symptoms referable to the spine. Therefore, many of these injuries go unrecognized. Because spinal injuries are likely to be silent, but associated with extremely violent assaults, routine evaluation of the spine in cases of suspected child abuse is mandatory. Spinal radiographs, es-

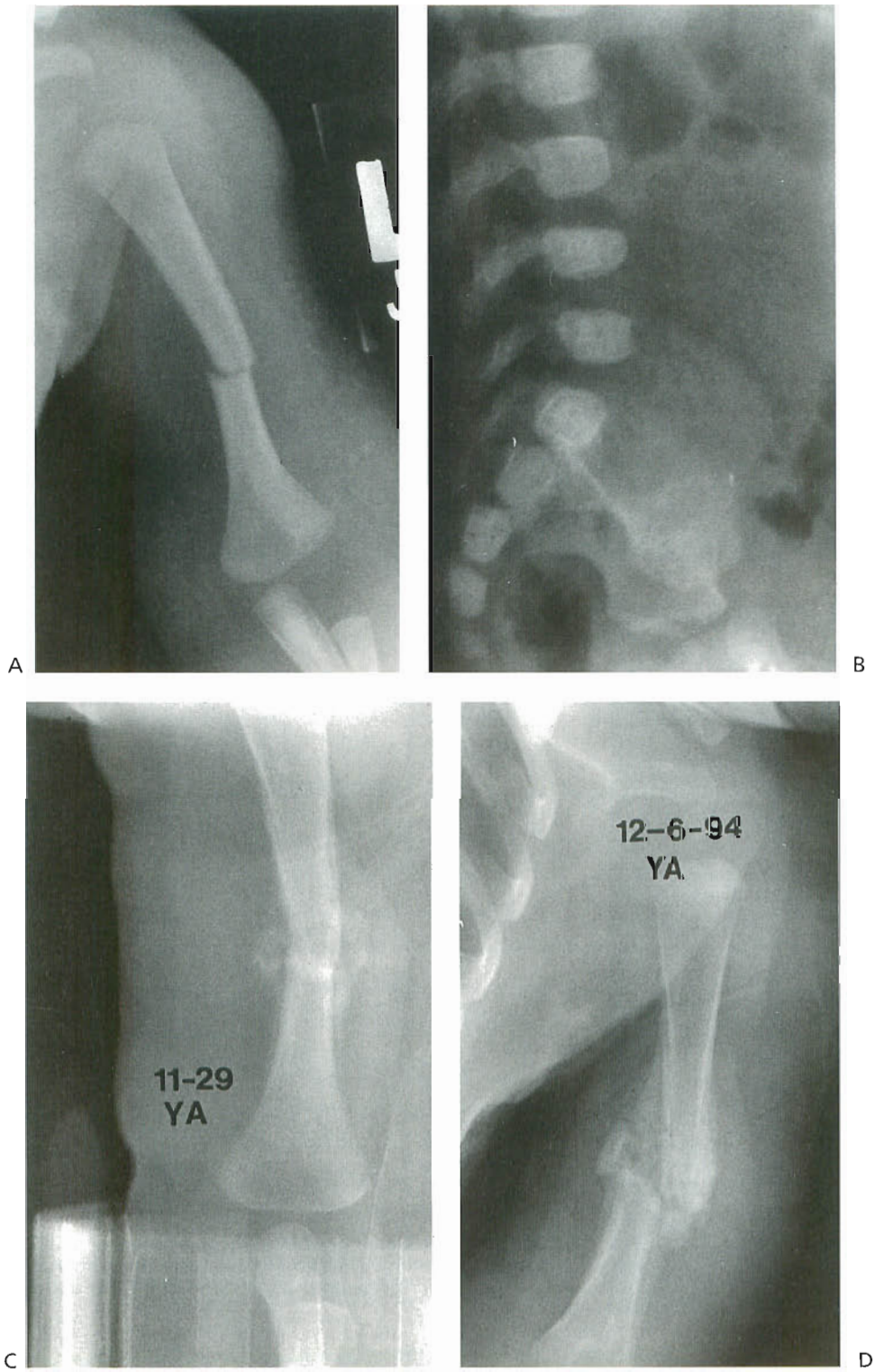


FIGURE 33-10. A 2-month-old infant with a nonaccidental transverse humeral fracture, a spinal fracture, and cerebral hemorrhage. **A:** Transverse humeral fracture. **B:** L4 compression fracture and anterior wedging. **C and D:** Humeral fracture at 2 and 3 weeks after injury, showing progressive healing and new bone formation.

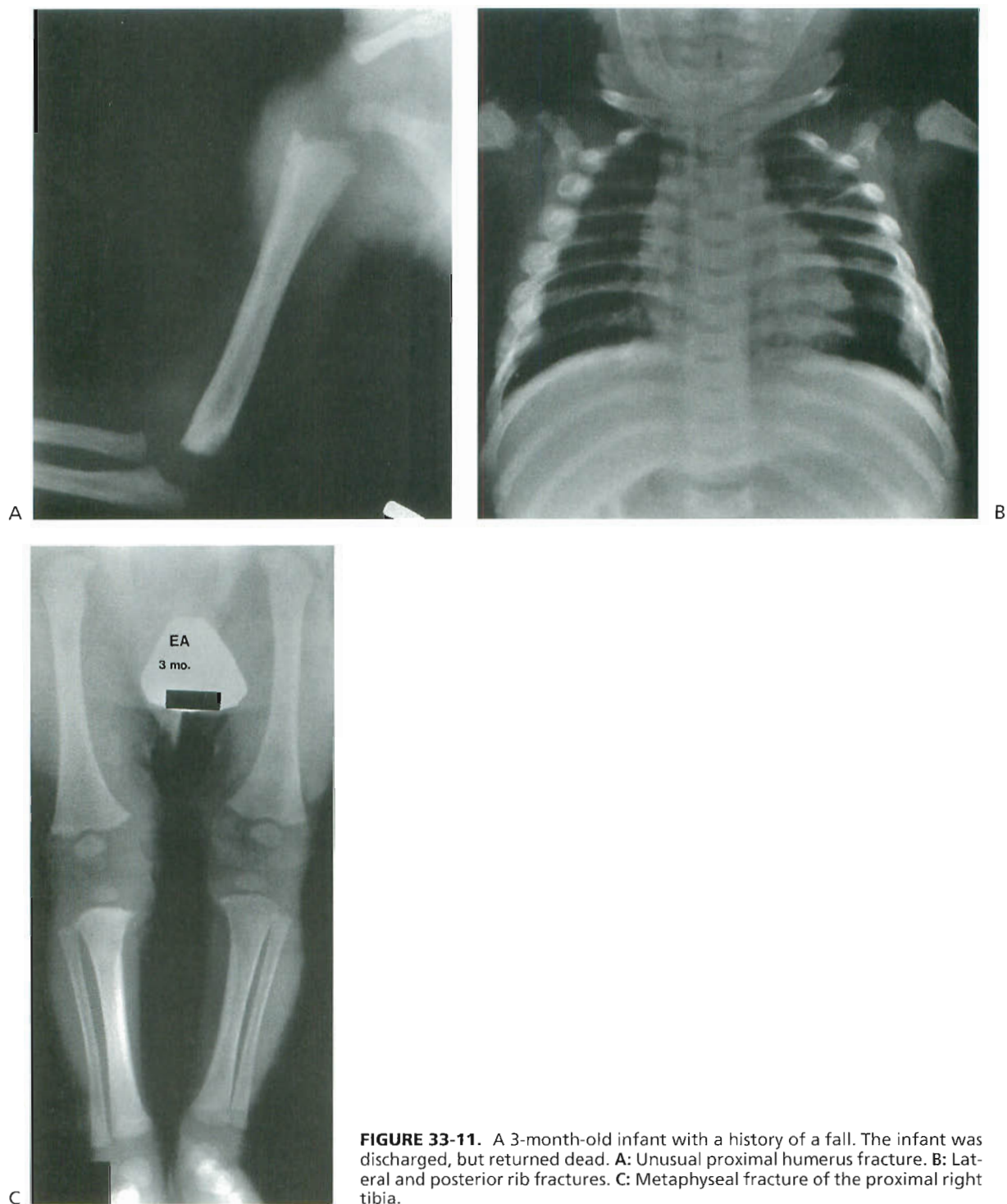


FIGURE 33-11. A 3-month-old infant with a history of a fall. The infant was discharged, but returned dead. **A:** Unusual proximal humerus fracture. **B:** Lateral and posterior rib fractures. **C:** Metaphyseal fracture of the proximal right tibia.

pecially a lateral projection of the entire spine, should be part of the routine skeletal survey.

In a report of 85 spinal fractures in 41 children, Kleinman (16) found the average patient age to be 22 months. Most of the fractures involved the vertebral bodies. Occasionally, fractures of the posterior arch, without in-

volvement of the vertebral bodies, are described. Vertebral bodies can show varying degrees of anterior compression. There can be anterior notching, which usually is superior (45). In cases of disc herniation, intervertebral disc narrowing can be present (Figs. 33-10 and 33-12). Fracture dislocations, with or without neurologic deficits, have been re-

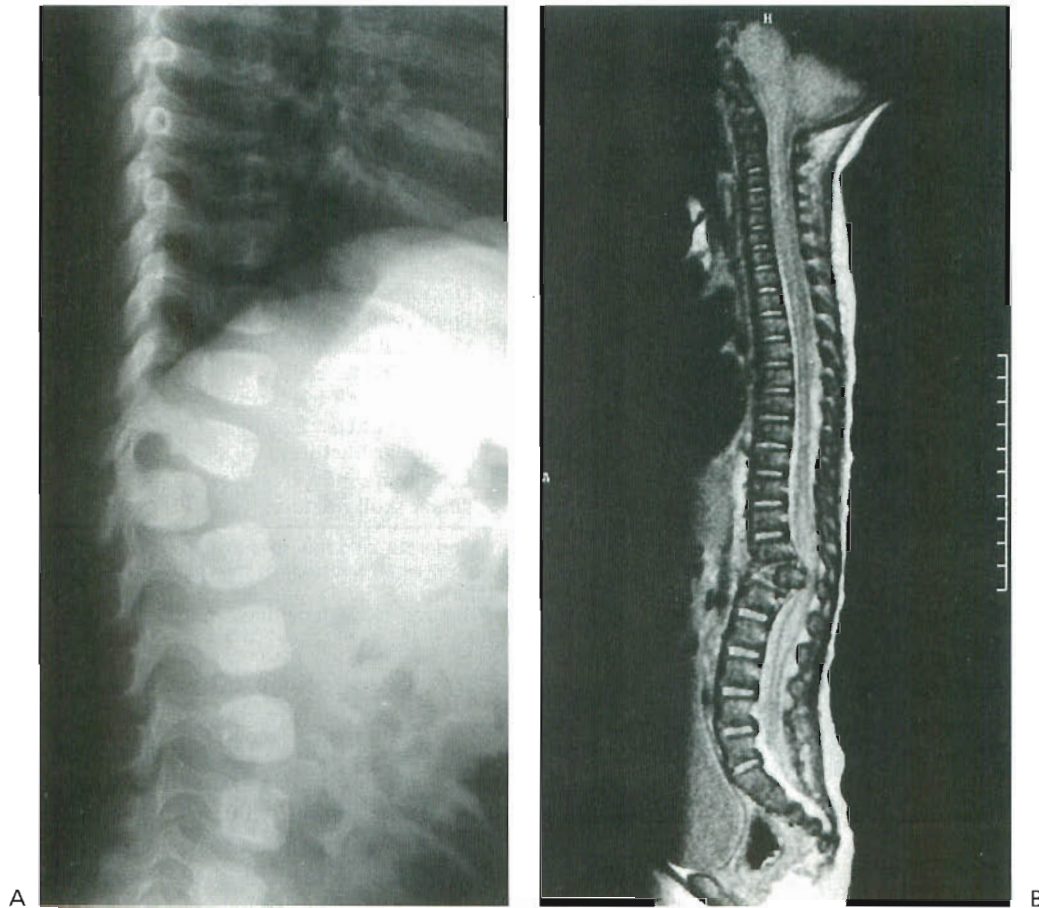


FIGURE 33-12. Fracture-dislocation of the spine in a 10-month-old infant, a victim of abuse, who had incomplete paraplegia. **A:** Lateral radiograph of the spine. **B:** Magnetic resonance image showing cord compression. (Courtesy of Keith Gabriel, M.D., Cardinal Glennan Children's Hospital, St. Louis, Missouri.)

ported. Spinal cord injuries or hematomas also can be seen without bony involvement. Significant fracture-dislocations, especially those that are not associated with neurologic deficits, may go unrecognized, and can result in significant spinal deformity later in life.

The mechanism of injury in most cases is hyperflexion, extension, or both. Therefore, multiple compression fractures in a single patient are common. Occasionally, fractures of the upper extremities are associated with these compression fractures, when the child is held above a table or kitchen counter and the buttocks are slammed against the surface. The child uses outstretched arms to break the impact, causing fractures of the upper extremities. Most compression fractures are in the region of the thoracolumbar and lumbar spine. However, fractures and fracture dislocations of the cervical and sacral regions also are seen.

The changes in vertebral bodies and discs that accompany normal development or infection can cause confusion. Notching of traumatic origin generally involves a large portion of the anterior margin. Disc space narrowing caused

by infection usually is more severe than that caused by trauma and disc herniation. The value of bone scanning in detecting spinal injuries is not clear. Standard radiography generally is regarded as the primary method of investigation. In the presence of any neurologic findings, MRI is useful for evaluation of the spinal canal.

DECISION-MAKING

Orthopaedic surgeons often are asked to give an opinion regarding the cause of certain fractures (i.e., accidental versus nonaccidental). The presence of fractures alone may not provide a sufficient basis for making such a determination. However, a major part of the recognition of child abuse still depends on radiologic diagnosis. Certain fractures are more specific than others in these cases. Again, the history and the age of the patient should be considered in making the determination.

In a study of 89 fractures in 36 children with docu-

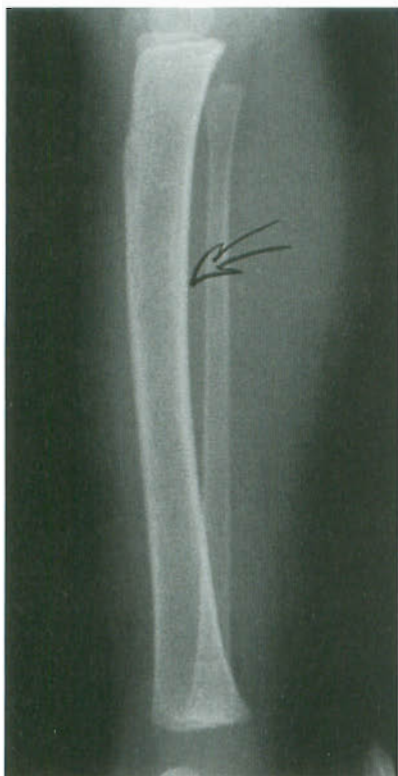

FIGURE 33-13. Undisplaced oblique fracture of the tibia (toddler's fracture).

mented histories of child abuse, the pattern of fractures was found to be more helpful than the presence of multiple fractures in various stages of healing in making the diagnosis of child abuse (37). Suspicious fracture patterns included metaphyseal corner fractures; lower-extremity fractures in nonambulatory children; bilateral acute fractures; fractures in special locations, such as the ribs and spine; and physeal fractures in young children (46). As infants begin walking, they may sustain a classic fracture known as the toddler's fracture (47,48), which appears as an oblique lucent line in the tibia (Fig. 33-13). Although there can be a good explanation for this fracture, the history and any other available clues should be evaluated carefully before the diagnosis is made. In a very young patient of the right age without a convincing history, even a fracture of the clavicle should be considered suspicious.

Kleinman (16) suggests that relative specificities can be applied to these fractures, based on their nature, location, and chronicity (Table 33-1).

Dating Fractures

The relation between the alleged cause and the timing of an injury is one of the critical elements in the decision-making process. The literature contains little information

TABLE 33-1. SPECIFICITY OF RADIOLOGIC FINDINGS

High Specificity
Metaphyseal lesions
Posterior rib fractures
Scapular fractures
Spinous process fractures
Sternal fractures
Moderate Specificity ^a
Multiple fractures, especially bilateral
Fractures of different ages
Epiphyseal separations
Vertebral body fractures and subluxations
Digital fractures
Complex skull fractures
Common but Low Specificity ^a
Clavicular fractures
Long-bone shaft fractures
Linear skull fractures

^a Moderate- and low-specificity lesions become high-specificity lesions when a history of trauma is absent or inconsistent with injuries.

(From ref. 16, with permission.)

regarding the dating of fractures based on their radiographic appearance (49,50). Obliteration of soft tissue planes is the earliest sign of injury. Edema of the soft tissues is associated clinically with pain and swelling that are accentuated by any attempt to move the extremity. When fractures are not displaced, the duration of acute inflammation can be only a few days. Infants and children can be free of pain as early as 1 to 2 days after the original injury. Generally, new bone formation occurs between 10 and 14 days after injury. In young infants, this interval is shorter, probably between 7 and 14 days (50). In addition, solidification and remodeling are more rapid in infants than in older children (Fig. 33-14). The age of the child should be considered in dating a fracture, along with the history, the presence of repetitive injuries, and the degree of immobilization.

Although the actual date of a fracture can only be approximated, a few guidelines have been developed. A fracture without periosteal new bone formation usually is less than 7 to 10 days old, and seldom is 20 days old. Slight but definite periosteal new bone formation can be as recent as 4 to 7 days old. A 20-day-old fracture almost always has well-defined periosteal new bone and typically has early (soft) callus. A large amount of callus always indicates a fracture more than 14 days old (Fig. 33-10). Loss of marginal sharpness of the fracture line can be delayed for 7 to 14 days. Corner fractures may not cause significant periosteal new bone formation, and can only be dated based on their loss of marginal definition. Chronic repetitive trauma and lack of immobilization can lead to loss of fracture line definition as the earliest finding.

The results of radionuclide bone scanning become positive a few hours after injury, and remain positive for a long

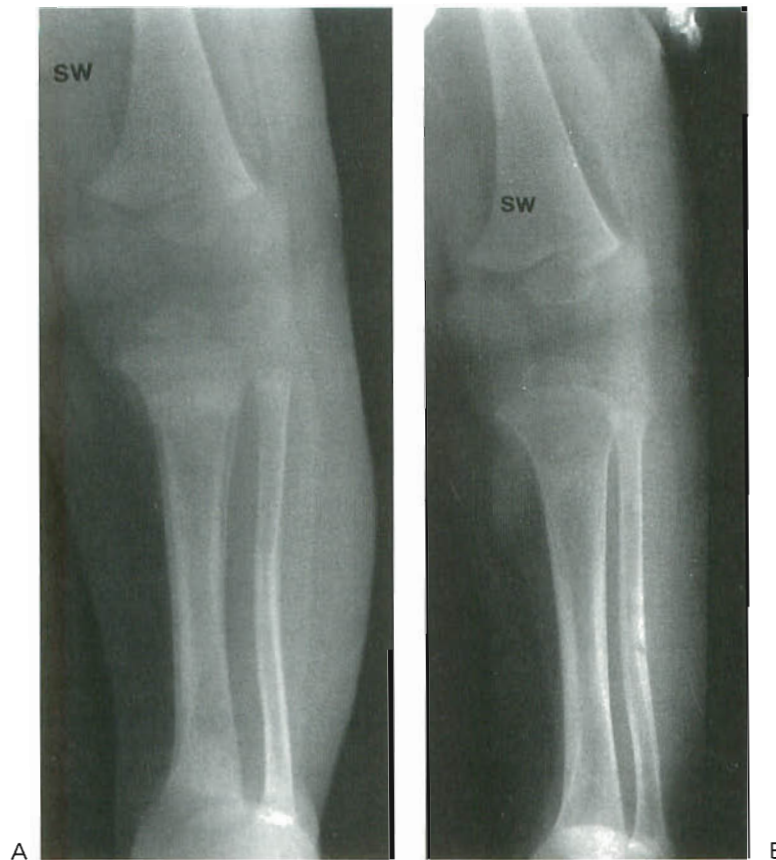


FIGURE 33-14. A 6-month-old infant abused by his baby-sitter. **A:** Ten-day-old proximal tibial fracture and periosteal new bone formation. **B:** Significant remodeling has occurred 2 months later.

time (1 to 2 years). They are not helpful in establishing the age of fractures. The role of MRI in the dating of fractures has not been established. O'Connor and Cohen (50) have outlined a timetable of radiographic changes in children's fractures (Table 33-2).

MANAGEMENT

The management of child abuse is divided into two phases: diagnosis and documentation, and treatment. When physical abuse is suspected, documentation is the first step. Skeletal radiography, bone scanning, and CT are the usual imaging modalities. However, the indiscriminate use of these tests in all cases of suspected child abuse contributes to unnecessary radiation exposure and increasing health care costs. Radiographic skeletal surveys are more helpful in children younger than 5 years of age who have clinical evidence of physical abuse (51). The yield from skeletal surveys in neglected and sexually abused children is extremely low, and does not justify the investigation. The skeletal survey should include anteroposterior and lateral views of the skull and

thoracolumbar spine, as well as anteroposterior views of the thoracic cage and extremities. The radiographs of the extremities should include the shoulders, pelvis, hands, and feet. Other imaging studies can add more information to

TABLE 33-2. TIMETABLE OF RADIOGRAPHIC CHANGES IN CHILDREN'S FRACTURES

Category	Early	Peak	Late
1. Resolution of soft tissues	2 to 5 d	4 to 10 d	10 to 21 d
2. Periosteal new bone	4 to 10 d	10 to 14 d	14 to 21 d
3. Loss of fracture line definition	10 to 14 d	14 to 21 d	—
4. Soft callus ^a	10 to 14 d	14 to 21 d	—
5. Hard callus	14 to 21 d	21 to 42 d	42 to 90 d
6. Remodeling ^b	3 mo	1 yr	2 yr to epiphyseal closure

Repetitive injuries may prolong categories 1, 2, 5, and 6.

^a The stage of soft callus usually lasts 3 to 4 weeks, or until the bony fragments are bridged by lamellar bone, and ends clinically when fragments no longer can be easily moved.

^b In this stage, both periosteal and endosteal bone begin to be converted to lamellar bone and remodeling of the callus begins. (From ref. 50, with permission.)

that gained by the full skeletal survey, but the orthopaedist should be knowledgeable in the limitations of each technique.

Limitations of Imaging Techniques

A single film of the entire infant (i.e., the so-called baby-gram) usually is not helpful, because it lacks detail, is a single anteroposterior view without an accompanying lateral view, and subtle findings, such as metaphyseal corner fractures, may be obscured by the oblique projection of the x-ray beam at the margins of the film. A full skeletal survey is much more accurate, and a follow-up survey 2 weeks later will detect additional fractures and aid in dating the fractures in a majority of cases (52).

The use of radionuclide bone scanning as a screening procedure for skeletal trauma is controversial. Some authors have suggested that this is a more sensitive screening test in cases of physical abuse, and are using it as part of the initial evaluation (53,54). In a study of 261 cases of suspected child abuse, radiographic skeletal surveys and bone scanning were performed, with meticulous attention paid to technique (54). Abnormalities were found at one or more sites on bone scans in 120 patients and on radiographs in 105 patients. False-negative results were obtained in 32 patients with radiography, but in only 2 patients with bone scanning. This report demonstrates the superior sensitivity of bone scanning to radiography under the conditions described by those authors. However, this view is not shared by most pediatric radiologists, who still prefer the skeletal survey as the primary radiologic screening test in cases of suspected child abuse. Bone scanning is more sensitive in assessing rib fractures, particularly those involving the costovertebral junction (55); acute, undisplaced long-bone fractures; and subperiosteal hemorrhage (38). Skeletal surveys are more sensitive in detecting spinal fractures, bilateral metaphyseal injuries, skull fractures, and scapular fractures.

Other factors also influence the use of these methods in the initial evaluation. Bone-seeking radionuclides concentrate in areas of increased blood flow and bone formation, so that fractures appear as hot spots. However, these findings are not specific for fractures, and can be seen in other conditions of rapid bone turnover, such as osteomyelitis and neoplasia. In addition, radionuclide uptake and activity normally are increased near the growth plate, making it more difficult to identify epiphyseal–metaphyseal fractures, especially when they are bilateral.

Other disadvantages of bone scanning as the initial skeletal imaging procedure include the limited availability of nuclear medicine services at all hours in many hospitals, the inexperience of many general radiology departments in taking and interpreting pediatric bone scans, and the relatively high radiation dose delivered to the patient's growth plates (51). In addition, bone scans not only are more costly, but they lack the ability to identify the age and mechanism of the injury, often necessitating additional radiologic exami-

nation of suspicious areas for confirmation. Skeletal surveys, on the other hand, are more specific, rarely require patient sedation, and are less subject to interpretive error. Thus, radiographic skeletal surveys should be used first in the evaluation of suspected child abuse cases. If these radiographs do not show any evidence of trauma, despite clinical suspicion, a bone scan may prove valuable in identifying subtle or occult injuries to the ribs, the diaphyses, and, occasionally, the epiphyses. Some of these occult fractures are not visible on plain radiographs until 7 to 10 days after injury. In these situations, a second radiograph 1 to 2 weeks later usually is helpful. Bone scanning should be performed as well, if the results of plain radiography are negative or questionable (Fig. 33-9). Children older than 5 years of age usually can provide a more reliable history. Radiographic studies, in these cases, are selected based on the clinical findings and the index of suspicion. CT often is helpful when head or abdominal trauma is suspected, especially if liver function test results show elevation of aspartate aminotransferase, alanine aminotransferase, and lactate dehydrogenase.

Differential Diagnosis

Coagulation disorders, both hereditary and acquired, can produce bruises that can be confused with bruises caused by physical abuse. Hereditary coagulation disorders include hemophilia and von Willebrand disease. Acquired coagulation disorders, such as idiopathic thrombocytopenia purpura and leukemia, also have been confused with physical abuse (56). In cases of suspicious or unexplained bruising, blood tests, such as complete blood count, partial thromboplastin time, prothrombin time, platelet count, and bleeding time, should be performed. A prolonged partial thromboplastin time is seen in both hemophilia and von Willebrand disease.

Many conditions can cause fractures, periosteal new bone formation, and bone irregularities, and these should be considered in the differential diagnosis of physical abuse. Errors in diagnosis can result from suboptimal radiographic techniques or errors in interpretation.

The most common difficulty in diagnosis involves the differentiation of accidental from nonaccidental trauma, especially in isolated, nonspecific fractures. An example of this was discussed in the section on diaphyseal femur fractures. Normal variants, such as periosteal new bone formation and cupping of the metaphysis, can be seen in healthy infants. These findings are observed first at 1 to 3 months of age, and usually resolve by 8 months of age (57).

Conditions to be considered in the differential diagnosis are syphilis, osteogenesis imperfecta, scurvy, Caffey disease, osteomyelitis, septic arthritis, fatigue fractures, osteoid osteoma and other tumors, rickets, hypophosphatasia, leukemia, metastatic neuroblastoma, fractures in neurogenic disorders, congenital indifference to pain, and osteopetrosis and the so-called "temporally brittle-bone disease" (58). These con-

ditions usually have additional signs of the primary disorder and a history of previous disease, to distinguish them from nonaccidental trauma.

Osteogenesis imperfecta (OI) may be easy to diagnose when there is easy bruising, the presence of family history of the disease, blue sclerae, thin cortices, osteopenia, and the tendency to bowing and angulation, but some forms of OI are difficult to identify and could lead to a mistaken diagnosis of child abuse. Easy bruising is not unique to OI, and could be caused by any condition associated with coagulopathy or capillary fragility. There is no family history when OI is caused by spontaneous mutation.

OI has been classified into types based on inheritance and clinical features (52,59). Type I patients have blue sclerae and normal stature, and most have hearing loss, little extremity deformity, and autosomal dominant inheritance. Type II patients have severe disease with marked deformity, and may die soon after birth; their inheritance is usually autosomal dominant, although, rarely it may be autosomal recessive. Type III patients have gradual progression of deformity and blue sclerae that may lighten with time; dentinogenesis imperfecta, a central core darkening of the teeth, is often present; stature is short, hearing loss is common, and inheritance is autosomal dominant, although it is autosomal recessive in some cases. Type IV patients have mild deformity and dentinogenesis imperfecta, some have short stature, and inheritance is autosomal dominant.

Intensely blue sclerae is consistently present only in patients with type I OI; it may be present at birth in type II or III patients, but the sclerae may become normal by adolescence; and blue sclerae may be completely absent in type IV patients (52,58,60). On the other hand, blue sclerae can be found in normal children. Long bones may have normal density in types I and IV OI, whereas type II patients frequently have osteopenic long bones. Type III OI, which is usually associated with early death, has both long-bone bowing and osteopenia. Wormian bones of the skull are usually seen only in type III disease, whereas they are often absent in types I and IV. In cases in which the diagnosis of OI cannot be made clinically, fibroblasts obtained by skin biopsy can be assayed for the abnormal procollagen found in OI (59,61,62). Although the presence of OI could explain the fractures and bruising of a child with a history of minimal trauma, the orthopaedist should always remember that children with OI can also be victims of child abuse (63).

A controversial temporary brittle-bone disease was described by Patterson and co-workers (58) in 1993, as a variant of OI. They reported 39 patients with fractures observed only within the first year of life with later spontaneous improvement. Clinically, these children also had vomiting, diarrhea, anemia, hepatomegaly, episodes of apnea, edema, and neutropenia. On radiographs, there were metaphyseal corner fractures, diaphyseal fractures, rib fractures, periosteal reaction of the long bones, lucency at the

costochondral junction, and delayed bone age. Osteopenia was seen in only 31% of patients. A transient period of copper deficiency was suggested as the cause of the disease, but copper levels in selected patients were inconclusive. Other medical authors (64,65) doubt the existence of temporary brittle-bone disease, because of the rarity of fractures associated with proven copper deficiency. Judicial authorities (66,67) have commented that, although one patient in the series by Patterson et al. had injuries attributable to child abuse, this fact was not included in the study. They had concerns that assumptions by medical experts that injuries are caused solely by disease may inhibit full investigation of such injuries by civil authorities and place abused children at risk.

Congenital indifference to pain has an autosomal recessive inheritance. These children have normal intelligence, and the only abnormal neurologic finding is insensitivity to painful stimuli. Repeated trauma to the growing skeleton can go unrecognized and result in major changes and deformities of the metaphysis, as well as the epiphysis. A careful sensory neurologic examination and history helps in making the diagnosis.

Congenital syphilis involves multiple bones of the body, most commonly the tibia, femur, and humerus. Destructive changes are seen in the metaphysis and diaphysis between the first and sixth months of life. Pathologic fractures of the metaphysis and periosteal new bone formation can mimic the skeletal findings of child abuse. The serologic test for syphilis is most helpful in making the diagnosis.

In most conditions, radiologic features are helpful in differentiating the injuries of child abuse. In other conditions, clinical findings of the disease provide diagnostic clues.

Fractures in the neonatal period often involve the humerus, clavicle, and femur. In these injuries, callus usually appears on radiographs within 2 weeks of life. In this age group, an unusual site or the absence of callus after 2 weeks should alert the physician to the possibility of nonaccidental trauma (42). Pathologic fractures caused by rickets also are seen in neonates, especially premature infants.

Falling out of bed is a common history frequently related when parents bring the child to the care of a physician. Helfer and associates (68) studied 246 children younger than 5 years of age who fell out of bed. There were only three cranial fractures, three clavicular fractures, and one humeral fracture. None of the children had neurologic impairment from skull fractures. In another prospective study of 436 infants from birth to 1 year of age, 101 (30%) sustained falls (69). There were no limb fractures, and only two skull fractures. Based on these statistics, falling out of bed is rarely the cause of fractures in young infants. A large body of literature exists on the incidence of fractures in children after accidents such as falls (68–72). The orthopaedic surgeon must be familiar with this literature to interpret properly the history of the accident.

If child abuse is suspected, every effort should be made to protect the child. Although the statistics regarding the

incidence of child abuse and the resulting mortality are admittedly inaccurate, it is recognized that many children may eventually die of these or subsequent injuries. The home environment in which child abuse occurs is unquestionably pathologic. Returning the child to this home in most cases poses the risk of repeated abuse, additional complications, and possible death.

The Team Approach

Because child abuse is believed to be a symptom of family distress, and a problem with multiple complex origins, it should be managed by an interdisciplinary team that can include a pediatrician, a social worker, a nurse, a psychiatrist, and an attorney. When such a diagnostic unit is not available, the physician must work with a social worker and the protective agencies to which mandated reports are sent in the management of these cases. A social worker should be contacted at the time of the family's presentation, to facilitate the social assessment and to form a helping relationship. It is helpful to avoid confrontation. The parents should be informed of the physician's responsibility, and the fact that other professionals, such as a social worker, will be talking to them. The child should be admitted to the hospital only for medical reasons. In view of the cost of hospitalization, most of the workup and referral should be accomplished in the emergency department or an outpatient facility. If this is not possible, the child should be admitted to the hospital (73). In most cases, this is acceptable to the parents, if the need is clearly explained to them. If the parents refuse admission of the child, the law in most states allows the hospital or the physician to assume custody of the child for a limited period until a court order can be obtained. A report should be made to the local protective services agency immediately. This usually is an oral report followed by a written report within 24 h. Under the Child Abuse Prevention and Treatment Act, a central registry of child abuse is required in all states. Laws mandate reporting in all states.

Abuse and neglect must be identified before child protective agencies can deal with them. An increase in public awareness has led to an increase in the number of reported incidents of abuse and neglect. Professionals who work with children are in a unique position to observe child abuse and neglect, and are required by law to report suspected cases to the authorities. Among these individuals are nurses, social workers, physicians, daycare providers, teachers, and school personnel. A reporter does not have to be certain that abuse or neglect has occurred. All that is required is a reasonable suspicion of maltreatment (74). However, some professionals are hesitant to report suspected cases, for a variety of reasons. Some of the reasons they hesitate to file reports are lack of knowledge of the responsibility to report; lack of knowledge regarding the type of cases to report, and to whom to report them; concern about confidentiality con-

flicts; pressure by others not to report, and the threat of lawsuits or other reprisals by parents; reluctance to get involved; and the belief that reporting would not really help and may aggravate the situation.

The amount of time and effort required in these cases also can make orthopaedic surgeons reluctant to get involved. Each case can place a significant demand on a physician's schedule for depositions, testimony, and court appearances. To avoid such involvement, the responsibility can be delegated to a child abuse team in the hospital. In most hospitals, procedures are in place for reporting and subsequent follow-up. All that may be required is that the physician start the process when suspicion of maltreatment exists. When formal teams or other professionals are not available, the orthopaedic surgeon may have no choice but to get involved. However, the legal system is cooperative and understanding. Physicians' schedules usually are accommodated, and compensation for their time is provided. Physicians should submit their hourly fees as they do for any other legal work.

Education is the most effective way to overcome the problem of underreporting. Since the creation of a nationwide toll-free telephone hotline for 24-h reporting, the number of reported cases has increased sharply. A physician or any other reporter has immunity against any civil or criminal liability (30). This means that a parent or caretaker cannot bring a successful lawsuit against a physician for defamation or for invasion of the family's right to privacy. However, in many states, failure to report subjects the physician to civil or criminal liability.

The most important phase in the management of child abuse cases is the follow-up and rehabilitation of the child and the family. In many cases, failure to provide such follow-up, because of lack of funding or personnel, has resulted in a higher rate of reinjury or death.

The following seven axioms of child abuse management appear in the literature on child abuse (75).

1. Once diagnosed, an abused child (especially an infant younger than 1 year of age) is at great risk of reinjury or continued neglect.
2. In the event that the child is reinjured, it is likely that the parents will seek care at a different medical facility.
3. There rarely is any need to establish precisely who injured the child and whether the injury was intentional. The symptoms themselves should open the door to a helping alliance and the development of a comprehensive service plan for the child and the family.
4. If there is evidence that the child is at significant risk, hospitalization may be appropriate to allow time for interdisciplinary assessment. The complex origins of the child's injuries seldom are revealed in the crisis atmosphere at the time of presentation.
5. Protection of the child must be the principal goal of

intervention, but protection must go hand in hand with the development of a family-oriented service plan.

6. Traditional social casework alone may not adequately protect the abused child in the environment in which the injuries were received. Multidisciplinary follow-up is necessary, and frequent contact by all those involved in the service plan may be needed to encourage the child's healthy development.
7. Problems of public social service agencies in both urban and rural areas, especially in the number of adequately trained personnel and the quality of administrative and supervisory functions, mitigate against their effective operation in isolation from other care-providing agencies. Simply reporting a case to the public agency mandated to receive child abuse case reports may not be sufficient to protect an abused child or to help the family.

There is no doubt that prevention is the primary goal. This goal can be achieved by identifying high-risk children and helping families in distress. Orthopaedic surgeons can play an important role in breaking the cycle of child abuse and neglect by remaining aware, facilitating early detection, and helping to initiate therapeutic and rehabilitative measures for both the child and the family.

Medical Neglect

During the usual course of therapy for an orthopaedic condition, parents or caregivers may not follow the instructions provided by their treating physicians, and may not adhere to the treatment protocols. For example, the family of a child with developmental dysplasia of the hip who is being treated in a Pavlik harness may fail to bring the child for follow-up appointments, or the family of a child with a positive Ortolani sign who is being treated with a harness may remove the device after returning home, and fail to keep follow-up appointments. The family of a child with idiopathic scoliosis may refuse to use a brace, when orthotic treatment is likely to be effective. They may allow the curve to progress to 55 to 60 degrees, then refuse surgical intervention. Situations such as these are considered instances of medical neglect.

If the treatment is clearly advantageous, and the child is harmed by the lack of treatment, intervention through the proper authorities is indicated. There are situations in which a chronic condition requires more complex treatment, and the type and length of the treatment clearly present a hardship for the family. In these cases, help should be provided to the family through appropriate social workers and social service agencies. In some cases, the presence of medical neglect is uncertain. In these instances, the amount of harm caused by the lack of treatment should be compared with the benefits of treatment and an appropriate decision should be made. In more complex cases, it often is helpful for both a physician and a social worker to explain fully the nature

of the treatment and the responsibility of the family before treatment is initiated. In this way, any necessary arrangements can be made before treatment is begun, to maximize compliance.

THE ORTHOPAEDIC SURGEON, CHILD ABUSE, AND THE LAW

Orthopaedic surgeons should be familiar with the law regarding child abuse. Questions about obtaining informed consent for testing, maintaining medical confidentiality, filing mandated child abuse reports, understanding court actions, and testifying in a courtroom are common. Although the law varies from state to state, the principal issues are the same. Orthopaedic surgeons should obtain appropriate legal counsel whenever necessary. The sensitive management of cases of family violence requires both medical and legal expertise (76). In many hospitals, this is facilitated by the use of a team approach, and by the maintenance of continuous contact between the department of social services, protective agencies, and the police department.

Legal consent is required for any action taken to treat an abused child. Parents or legal guardians can give this consent. A minor child cannot give consent except in an emergency or other exceptional situation. When there is a conflict with the parent or guardian, it is advisable to consult a hospital lawyer. Consent also is necessary for the release of any information from the medical record, and for testifying in court, unless a court-ordered subpoena has been issued.

The physician's findings should be recorded as soon as the patient is seen. The record in the chart should be legible, and any errors should be corrected by adding follow-up entries rather than removing previous statements.

For the purpose of identifying and protecting abused children, all 50 states have mandatory reporting statutes. The basis of notification is "reasonable suspicion or belief." Legally, it always is better for a mandated reporter to file an abuse or neglect report, even if the allegation later proves erroneous, than to fail to file. All states have immunity provisions protecting mandated reporters. The question of privacy statutes often arises, but abuse reporting requirements override this privilege (76). After the child is examined, the report should be filed by the professional who knows the child best. This usually is the family physician, the pediatrician, or a social worker; however, the orthopaedic surgeon is responsible for reporting if he or she is suspicious, and no other report has been filed. Reports should be filed, based on the reasonable cause of the injury, and not on the characteristics of the family. Many people complain that even if a case is reported, the state does not provide appropriate protection. Again, a report should be filed, regardless of whether the state's response is helpful.

Preparation for Court Testimony in Child Abuse Cases

The number of physicians who are being required to testify in court is increasing because of the rapid increase in the volume of child abuse reports, as well as a continuing trend toward the use of litigation (77). The orthopaedist should be well prepared before appearing as a witness, and should determine the degree of certainty to which he or she is willing to testify. Although most child abuse reporting laws require reporting at the level of suspicion, actions of any sort require proof at some higher level of certainty. The process of substantiation or verification is always a medical one in cases of physical abuse.

If a physician is not willing to carry out these examinations and to testify in court as an expert witness, no legal action of any kind is possible in most child abuse cases (77). In court, the burden of proof is on the plaintiff. In the courtroom, for better or worse, it is evidence or proof that matters, not reality or fact. Most judges feel that children should remain with their parents whenever possible. The testimony of the physician as an expert witness is an important part of the process. Often, court action is the result of a "war between experts." Of greatest concern is what the orthopaedic surgeon does not say on the witness stand or in a deposition that he or she should say, and most physicians are reluctant to become actively involved in such cases. Brent (78) has called attention to the problem of irresponsible medical experts, and has provided guidelines for responsible conduct in court. These have been adopted by the Committee on Medical Liability of the American Academy of Pediatrics in a policy statement (79) (see Appendix).

The orthopaedist will usually serve as a material witness in the courtroom. Testimony will be confined to his or her personal involvement in the care of the child, although it may include clarification of the information in progress notes or other past documentation. The expertise of the orthopaedist is also defined by the attorneys before testimony, and if this includes special knowledge of or experience with child abuse, then he or she may be sworn in as an expert witness who can render opinions about certain facts in the courtroom (80).

Preparation is of paramount importance before a deposition or trial (A. Brodeur, personal communication, July 1988). The American law system is adversarial, and the courtroom is an unfamiliar, hostile environment for most orthopaedists, where the perception of truth is just as important as the truth itself. The testimony of a witness is a response to a series of questions asked to develop a logical and progressive line of thought leading to a conclusion. In child abuse cases, the testimony concentrates on the fact that abuse has occurred, and that it has been appropriately diagnosed. Questions about medical findings may be prefaced by the legal term "is there reasonable medical certainty," which is a concept that is poorly understood by most physicians. Reasonable medical certainty is defined by

Chadwick (77) as "certain as a physician should be in order to recommend and carry out treatment for a given medical condition." Cross-examination will search for inconsistencies in the testimony or unfamiliarity with the record to discredit the orthopaedist's testimony. To avoid being a poor witness, the orthopaedist should thoroughly review the child's medical records and the recent literature on child abuse (80).

Physicians should dress appropriately for the courtroom, appear attentive, poised, and competent, and be at ease with the testimony given (77). If they want to show radiographs, they should make sure that the necessary equipment is available.

Physicians should be objective and act as neutral experts. When a question is asked, they should pause before answering to consider the form and content of their response and to give their attorneys a chance to object. Physicians should listen carefully to each question, and answer only the question asked. They should not expand on the question or open up new issues. Answers should be framed in clear terms, understandable by anyone in the courtroom. It also is a mistake for physicians to assume that they are credible and effective just because they have a medical degree. If they do not know the answer to a question, they should say so.

Physicians should be prepared for their testimony; however, they may review a patient chart to refresh their memory on the witness stand, if necessary. Physicians should not argue with the attorney, because invariably they will appear foolish; rather, they should look to the judge for help. Attorneys may ask confusing yes-or-no questions that could place misleading words in the mouth of the orthopaedist; when neither answer is appropriate, these may be answered in a full sentence with the permission of the judge.

Another tactic in the courtroom is for the attorney to frame a complex question that contains both elements that the physician agrees with and others that the physician cannot agree with, then ending the question with the statement, "Isn't that so, doctor?" This is a way for the opposing attorney to insert facts supportive of his or her case into the testimony of the orthopaedist in a misleading manner. The orthopaedist should clearly split such questions into parts that can be agreed with and parts that cannot be agreed with (77). Attorneys may also offer hypotheses in their questions that are extremely unlikely; in their answers, physicians should point out the improbability of such theories. In making conclusions, physicians should provide supportive facts, and ensure that the link between the facts and the conclusion is clear.

Orthopaedists should become accustomed to dating fractures based on the amount of bone repair and the criteria described above. More than anyone else, orthopaedists are in a position to testify when children sustain broken bones. This type of evidence is helpful in cases in which the evidence is cumulative, rather than direct and explicit. Chadwick (77) has published an excellent article regarding prepa-

ration for court testimony (D. L. Chadwick, personal communication, March 1999).

Finally, if physicians have any doubt or uncertainty, they should consult with colleagues before testifying to formulate clear and reasonable opinions regarding the degree of certainty to which they are willing to testify. Even when the evidence is almost overwhelming, defense attorneys will attempt to prove that injuries resulted from diseases or accidents rather than abuse, and physicians must be prepared to defend their diagnoses. Although physicians should never present opinions that are not justified by the data, they should not exercise excessive caution when a child has characteristic patterns of abusive injury, and abuse is the only reasonable explanation.

APPENDIX: GUIDELINES FOR EXPERT WITNESSES

1. The physician should have current experience and ongoing knowledge about the areas of clinical medicine in which he or she is testifying and familiarity with practices during the time and place of the episode being considered as well as the circumstances surrounding the occurrence.
2. The physician's review of medical facts should be thorough, fair, and impartial and should not exclude any relevant information to create a view favoring either the plaintiff or the defendant. The ultimate test for accuracy and impartiality is a willingness to prepare testimony that could be presented unchanged for use by either the plaintiff or the defendant.
3. The physician's testimony should reflect an evaluation of performance in light of generally accepted standards, neither condemning performance that clearly falls within generally accepted practice standards nor endorsing or condoning performance that clearly falls outside accepted practice standards.
4. The physician should make a clear distinction between medical malpractice and medical maloccurrence when analyzing any case. The practice of medicine remains a mixture of art and science; the scientific component is a dynamic and changing one based to a large extent on concepts of probability rather than absolute certainty.
5. The physician should make every effort to assess the relationship of the alleged substandard practice to the patient's outcome, because deviation from a practice standard is not always causally related to a less-than-ideal outcome.
6. The physician should be willing to submit transcripts of depositions and/or courtroom testimony for peer review.
7. The physician expert should cooperate with any reasonable efforts undertaken by the courts or by the plaintiffs' or defendants' carriers and attorneys to provide a better understanding of the expert witness issue.

These principles have been adopted as guidelines by the American Academy of Pediatrics for its members who assume the role of expert witness. (From ref. 79, with permission.)

ACKNOWLEDGMENTS

The authors thank David L. Chadwick, M.D., for his review and comments on this chapter, and Mel Senac, M.D., for providing selected radiographs.

References

1. Caffey J. Multiple fractures in the long bones of infants suffering from chronic subdural hematoma. *Am J Radiol* 1946;56:163.
2. Silverman FN. The roentgen manifestations of unrecognized skeletal trauma in infants. *Am J Radiol* 1953;69:413.
3. Altman DH, Smith RL. Unrecognized trauma in infants and children. *J Bone Joint Surg Am* 1960;42:407.
4. Kempe CH, Silverman FN, Steele BF, et al. The battered child syndrome. *JAMA* 1962;181:17.
5. Akbarnia BA, Torg JS, Kirkpatrick J, et al. Manifestations of the battered-child syndrome. *J Bone Joint Surg Am* 1974;56:1159.
6. Schmitt B, Clemmens M. Battered child syndrome. In: Touloukian R, ed. *Pediatric trauma*. St. Louis: Mosby-Year Book, 1990: 161.

Definition

7. Helfer RE, Kempe CH, eds. *The battered child*. Chicago: University of Chicago Press, 1968.

Prevalence

8. US Department of Health and Human Services, Administration on Children, Youth and Families. Child maltreatment 1997: reports from the states to the National Child Abuse and Neglect Data System. Washington: US Government Printing Office, 1999.
9. US Senate, 93rd Congress, First Session, Senate Bill 1191, Child Abuse Prevention Act. Hearing before the Subcommittee on Children and Youth of the Committee on Labor and Public Welfare. Washington: US Government Printing Office, 1973.
10. Holter JC, Friedman SB. Child abuse: early case finding in the emergency department. *Pediatrics* 1968;42:128.
11. Kowal-Vern A, Paxton TP, Ros SF, et al. Fractures in the under-3-year-old cohort. *Clin Pediatr* 1992;31:653.
12. McClelland CO, Heiple KG. Fractures in the first year of life: a diagnostic dilemma? *Am J Dis Child* 1982;136:26.
13. Akbarnia BA, Akbarnia NO. The role of orthopaedist in child abuse and neglect. *Orthop Clin North Am* 1976;7:773.

Diagnosis

14. Levinthal JM, Thomas SA, Rosenfield NS, et al. Fractures in young children: distinguishing child abuse from unintentional injuries. *Am J Dis Child* 1993;147:87.
15. Thomas SA, Rosenfield NS, Leventhal JM, et al. Long-bone fractures in young children: distinguishing accidental injuries from child abuse. *Pediatrics* 1991;88:471.
16. Kleinman PK. *Diagnostic imaging of child abuse*. Baltimore: Williams & Wilkins, 1987.

17. Chadwick DL. The diagnosis of inflicted injury in infants and young children [review]. *Pediatr Ann* 1992;21:477.

Investigative Interview

18. Wasserman DR, Leventhal JM. Maltreatment of children born to cocaine-dependent mothers. *Am J Dis Child* 1993;147:1324.
19. Dubowitz H, Bross DC. The pediatrician's documentation of child maltreatment. *Am J Dis Child* 1992;146:596.
20. Herndon WA. Child abuse in a military population. *J Pediatr Orthop* 1983;3:73.
21. O'Neill JA Jr, Meacham WF, Griffin PP, et al. Patterns of injury in the battered child syndrome. *J Trauma* 1973;13:332.
22. Siegel CD, Graves P, Maloney K, et al. Mortality from intentional and unintentional injury among infants of young mothers in Colorado, 1986 to 1992. *Arch Pediatr Adolesc Med* 1996;150:1077.
23. Green FC. Child abuse and neglect: a priority problem for the private physician. *Pediatr Clin North Am* 1975;22:329.
24. Wolfner GD, Gelles RJ. A profile of violence toward children: a national study. *Child Abuse Neglect* 1993;17:197.
25. Zuravin SJ. Unplanned childbearing and family size: their relationship to child neglect and abuse. *Fam Plann Perspect* 1993;23:155.
26. Benedict RB, Wulff LM, Hall BJ. Reported maltreatment in children with multiple disabilities. *Child Abuse Neglect* 1990;14:207.
27. Sullivan PM, Brookhouser PE, Scalan JM, et al. Patterns of physical and sexual abuse of communicatively handicapped children. *Ann Otolaryngol Rhinol Laryngol* 1991;100:188.
28. Rosenberg DA. Web of deceit: a literature review of Munchausen syndrome by proxy. *Child Abuse Neglect* 1987;11:547.

Clinical Manifestations

29. McMahon P, Grossman W, Gaffney M, et al. Soft-tissue injury as an indication of child abuse. *J Bone Joint Surg Am* 1995;77:1179.
30. Newberger EH. *Child abuse*. Boston: Little, Brown, 1982.
31. Wilson EF. Estimation of the age of cutaneous contusions in child abuse. *Pediatrics* 1977;60:750.
32. Anh NT. "Pseudo-battered child" syndrome. *JAMA* 1976;236:2288.
33. Caffey J. The whiplash shaken infant syndrome: manual shaking by the extremities with whiplash-induced intracranial and intra-ocular bleedings, linked with residual permanent brain damage and mental retardation. *Pediatrics* 1974;54:396.

Orthopaedic Manifestations

34. King J, Diefendor FD, Apthrop J, et al. Analysis of 429 fractures in 189 battered children. *J Pediatr Orthop* 1988;8:585.
35. Akbarnia BA, Silberstein MJ, Rende RJ, et al. Arthrography in the diagnosis of fractures of the distal end of the humerus in infants. *J Bone Joint Surg Am* 1986;68:599.
36. DeLee JC, Wilkins KE, Rogers LF, et al. Fracture separation of the distal humeral epiphysis. *J Bone Joint Surg Am* 1980;62:46.
37. Galleno H, Oppenheim WL. The battered-child syndrome revisited. *Clin Orthop* 1982;162:11.
38. Kleinman PK, Marks SC, Blackbourne B. The metaphyseal lesion in abused infants: a radiologic-histopathologic study. *Am J Radiol* 1986;146:895.
39. Gabriel KR, Akbarnia BA. Complications of child abuse. In: Epps C, Bowen J, eds. *Complications in pediatric orthopaedic surgery*. Philadelphia: JB Lippincott, 1995.

40. Beals RK, Tufts E. Fractured femur in infancy: the role of child abuse. *J Pediatr Orthop* 1983;3:583.
41. Anderson WA. The significance of femoral fractures in children. *Ann Emerg Med* 1982;11:174.
42. Cumming WA. Neonatal skeletal fractures: birth trauma or child abuse? *J Can Assoc Radiol* 1979;30:30.
43. Dalton HJ, Slovis T, Helfer RE, et al. Undiagnosed abuse in children younger than 3 years with femoral fracture. *Am J Dis Child* 1990;144:875.
44. Merten DF, Radkowski MA, Leonidas JC. The abused child, a radiological reappraisal. *Radiology* 1983;146:377.
45. Swischuk LE. Spine and spinal cord trauma in the battered-child syndrome. *Radiology* 1969;92:733.

Decision-making

46. Loder RT, Bookout C. Fracture patterns in battered children. *J Orthop Trauma* 1991;5:428.
47. Mellick LB, Reesor K. Spiral tibial fractures of children: a commonly accidental spiral long bone fracture. *Am J Emerg Med* 1990;8:234.
48. Tenenbein M, Reed MH, Black GB. The toddler's fracture revisited. *Am J Emerg Med* 1990;8:208.
49. Kleinman PK, Marks SC Jr, Spevak MR, et al. Extension of growth-plate cartilage into the metaphysis: a sign of healing fracture in abused infants. *Am J Radiol* 1991;156:775.
50. O'Connor JF, Cohen J. Dating fractures. In: Kleinman PK, ed. *Diagnostic imaging of child abuse*. Baltimore: Williams & Wilkins, 1987:103.

Management

51. Leonidas JC. Skeletal trauma in the child abuse syndrome. *Pediatr Ann* 1983;12:875.
52. Sillence D. Osteogenesis imperfecta: an expanding panorama of variants. *Clin Orthop* 1981;159:11.
53. Hasse GM, Ortiz VN, Sfakianakis GN, et al. The value of radio-nuclide bone scanning in the early recognition of deliberate child abuse. *J Trauma* 1980;20:873.
54. Sty JR, Starsha RJ. The role of scintigraphy in the evaluation of the suspected abused child. *Radiology* 1983;146:369.
55. Kleinman PK, Marks SC, Spevak MR, et al. Fractures of the rib head in abused infants. *Radiology* 1992;185:119.
56. Bays J. Conditions mistaken for child abuse. In: Reece RM, ed. *Child abuse: medical diagnosis and management*. Malvern, PA: Lea & Febiger, 1994:358.
57. Brill PW, Winchester P. Differential diagnosis of child abuse. In: Kleinman PK, ed. *Diagnostic imaging of child abuse*. Baltimore: Williams & Wilkins, 1987:221.
58. Patterson CR, Burns J, McAllion SJ. Osteogenesis imperfecta: the distinction from child abuse and the recognition of a variant form. *Am J Med Genet* 1993;45:187.
59. Steiner RD, Pepin M, Beyers PH. Studies of collagen synthesis and structure in the differentiation of child abuse from osteogenesis imperfecta. *J Pediatr* 1996;128:542.
60. Sillence D, Butler B, Latham M, et al. Natural history of blue sclerae in osteogenesis imperfecta. *Am J Med Genet* 1993;45:183.
61. Byers PH. Disorders of collagen biosynthesis and structure. In: Scriver CR, Beaudet AL, Sly WS, et al., eds. *The metabolic basis of inherited disease*. New York: McGraw-Hill, 1989:2814.
62. Gahagan S, Rimza ME. Child abuse or osteogenesis imperfecta: how can we tell? *Pediatrics* 1991;88:987.
63. Knight DJ, Benner GC. Nonaccidental injury in osteogenesis imperfecta: a case report. *J Pediatr Orthop* 1990;10:542.
64. Ablin DS, Sane SM. Non-accidental injury: confusion with tem-

- porary brittle bone disease and mild osteogenesis imperfecta. *Pediatr Radiol* 1997;27:111.
65. Chapman S, Hall CM. Non-accidental injury or brittle bones. *Pediatr Radiol* 1997;27:106.
 66. Cazalet J. Note re: R (a minor) (expert evidence) 1 FLR 291, 1991.
 67. Wall J. Re: AB (child abuse: expert witnesses) 1 FLR 181–200, 1995.
 68. Helfer RE, Slovis TL, Black M. Injuries resulting when small children fall out of bed. *Pediatrics* 1977;60:533.
 69. Kravitz H, Driessen G, Gomberg R, et al. Accidental falls from elevated surfaces in infants from birth to 1 year of age. *Pediatrics* 1969;44(suppl):869.
 70. Barlow B, Niemirska M, Gandhi RP, et al. Ten years of experience with falls from a height in children. *J Pediatr Surg* 1983; 18:509.
 71. Nimityongskul P, Anderson L. The likelihood of injuries when children fall out of bed. *J Pediatr Orthop* 1987;7:184.
 72. Smith MD, Burrington JD, Woolf AD. Injuries in children sustained in free falls: an analysis of 66 cases. *J Trauma* 1975;15: 987.
 73. Gross RH. Child abuse: are you recognizing it when you see it? *Contemp Orthop* 1980;2:676.
 74. Myers JEB. Medicolegal aspects of child abuse. In: Kleinman PK, ed. *Diagnostic imaging of child abuse*. Baltimore: Williams & Wilkins, 1987.
 75. Bittner S, Newberger EH. Pediatric understanding of child abuse and neglect. *Pediatr Rev* 1981;2:197.

The Orthopaedic Surgeon, Child Abuse, and the Law

76. Bourne R. Child abuse and the law. In: Kleinman PK, ed. *Diagnostic imaging of child abuse*. Baltimore: Williams & Wilkins, 1987:243.
77. Chadwick DL. Preparation for court testimony in child abuse cases. *Pediatr Clin North Am* 1990;37:955.
78. Brent RL. The irresponsible expert witness: a failure of biomedical graduate education and professional accountability. *Pediatrics* 1982;70:754.
79. American Academy of Pediatrics, Committee on Medical Liability. Guidelines for expert witness testimony. *Pediatrics* 1989;83: 312.
80. Halverson KC, Elliott BA, Rubin MS, et al. Legal considerations in cases of child abuse. *Primary Care* 1993;20:407.

SUBJECT INDEX

Page numbers in *italics* denote figures; page numbers followed by “t” denote tables.

A

- Abduction orthoses, for Legg-Calvé-Perthes syndrome, 985–986, 986
- Abscess
Brodie, 492, 511
“cold,” in tuberculosis, 498
talar, 79
- Accessory navicular, 1181–1182
clinical features of, 1181
definition of, 1181
epidemiology of, 1181
pathoanatomy of, 1181
pathogenesis of, 1181
radiographic features of, 1181, 1182
treatment of, 1181–1182
- Accidents. *See* Trauma
- Acetabular index, 916–919, 918, 919
- Acetabulum
on arthrography, 70
in cerebral palsy, 574–575
in chondroectodermal dysplasia, 257
in chondrolysis of hip, 1050
determinants of shape and depth of, 908, 909, 909
in developmental dysplasia of hip, 70, 910, 911
hypertrophic labrum, 914–915, 915, 916, 917
residual dysplasia after reduction, 935–941, 936–941
treatment of acetabular dysplasia in children 6 months to 2 years of age, 934
fractures of, 1370–1371
in Legg-Calvé-Perthes disease, 70–71
in metatropic dysplasia, 256, 256
normal growth and development of, 906, 906–907, 907
on sonography, 75, 75–77
- Acetabulum pedis, 1152, 1157, 1169
- Acheiropodia (Brazil type), 17
- Achilles tendon
inflammation of, 1283
stretching of, for flexible flatfoot, 1172
- Achondrogenesis, 279
prenatal diagnosis of, 245
- Achondroplasia, 246–253
clinical features of, 247, 247
FGFR3 gene mutation and, 161, 166–167, 247
growth and development in, 247–248, 248
incidence of, 247
Madelung deformity and, 868
medical treatment of, 250
orthopaedic treatment of, 250–253
for genu varum, 250–251, 1068
for kyphosis, 251–252, 252, 253, 763, 764
limb lengthening, 251
for spinal stenosis, 253
prenatal diagnosis of, 246
radiographic features of, 248–250, 249
rhizomelic, 247
- ACL injuries. *See* Anterior cruciate ligament injuries
- Acquired immunodeficiency syndrome (AIDS), 394–395
- Acromioclavicular separation, 1334, 1334
- Acrosyndactyly, 353–355
- ACTH (adrenocorticotropin), 225
- Actinomycin D, 528
- Acute lymphoblastic leukemia, 416–419
diagnosis of, 417–418
differentiation from juvenile rheumatoid arthritis, 418
signs and symptoms of, 417, 417t
treatment of, 418
- Adamantinoma, 537
- Adams forward-bending test, 114, 120, 120–121, 685, 686
- Adams sign, 678
- Adapted activities, for limb-deficient child, 1267
- Addison disease, 228
- ADI. *See* Atlantodens interval
- Adolescent Blount disease, 1075–1081
clinical features of, 1076, 1077
definition of, 1075
etiology of, 1075
pathoanatomy of, 1075–1076
radiologic features of, 1076, 1077
treatment of, 1077–1081
circular external fixation, 1080–1081
goals of, 1077–1078
hemiepiphyseodesis, 1079
inherently stable internal fixator, 1080
limited internal fixation, 1080
monolateral external fixation, 1080
osteotomy, 1079–1080
preoperative evaluation, 1078, 1078–1079, 1079
- Adolescent idiopathic scoliosis, 53, 120–121, 681, 682, 695
- Adolescents
examination of, 101, 120–129
Osgood-Schlatter disease in, 1280–1281, 1281
puberty, 41–43
stress fractures in, 1277–1279
- Adrenal hyperplasia, 227
- Adrenocorticotropin (ACTH), 225
- Adriamycin. *See* Doxorubicin
- Adverse reactions to radiographic contrast materials, 64
- AER (apical ectodermal ridge), 10–11, 11, 13–14, 14, 15, 17, 27, 1192
- AFOs. *See* Ankle-foot orthoses
- Agammaglobulinemia, X-linked, 394
- Age
average developmental achievement by, 104t, 567t
changes and variants related to, 65–67
in cervical spine, 800–804
epiphyseal and apophyseal, 65, 65
on magnetic resonance imaging, 82
metaphyseal, 66–67, 66–67
physeal, 65–66, 66
round bone variant, 67
growth related to, 39–43
at onset of genetic disorders, 164
orthopedic examination related to, 99–129
- Ainhum, 354
- Alar ligament, 801
- Alar plate, 22
- Albers-Schonberg disease, 212
- Albright hereditary osteodystrophy, 201, 201–202, 229, 535–536
- Alcohol, teratogenicity of, 17, 172
- Alkaline phosphatase, 204
conditions associated with elevation of, 513
hyperparathyroidism and, 200
hypophosphatasia and, 199
osteosarcoma and, 513
- Allergic hypersensitivity
to radiographic contrast materials, 64
transient synovitis of hip and, 1045
- Aluminum hydroxide, for tumoral calcinosis, 218
- Ambulation. *See* Gait; Walking
- Amelia, 1219. *See also* Limb deficiencies
upper limb, 1248, 1249
- Amniocentesis, 174
- Amniotic band syndrome, 17, 18, 352–355
affecting hands, 872, 872–873
clinical features of, 352–353, 353
differential diagnosis of, 354
etiology of, 354
leg length discrepancy and, 1114
limb deficiencies due to, 352–355, 353, 355, 872, 1220
treatment of, 354–355, 355
- Amoxicillin, 479t
- Ampicillin, 479t
- Amputation
congenital, 1227–1254 (*See also* Limb deficiencies)
due to amniotic bands, 352–355, 353, 355, 872, 1220
lower extremity, 1227–1246
multiple, 1253–1254, 1254
upper extremity, 1246–1253
prosthetic fitting for, 1256–1266 (*See also* Prosthetics)
surgical
for Gorham disease, 347
for Klippel-Trenaunay syndrome, 345
for leg length discrepancy, 1132
for limb-deficient child, 1223–1225
acquired deficiencies, 1255
fibular deficiency, 1230–1232
foot amputation for proximal focal femoral deficiency, 1243
tibial deficiency, 1236–1237
for osteosarcoma, 523–524, 526
for tibial bowing, 1091
traumatic, 1255–1256
digital, 895, 895, 896
fingertip, 887
- Amyloidosis, 443
- Analgesics, for fracture management, 1331, 1331t

- Anatomy, developmental, 1–29
 early embryogenesis and organogenesis, 2–8, 2–9
 of hip, 906–909, 906–909
 intrauterine growth, 39
 of limbs, 9–18, 10–16
 upper limb, 842
 of nervous system, 5–7, 5–7, 22–23
 brain, 563–564
 terms related to, 27–29
 of vertebral column, 18–22
 cervical spine, 799–800
- Anderson leg lengthening device, 1136, 1137
- Androgens
 bone formation and, 180
 for Fanconi anemia, 380
 growth and, 227
- Anemia
 of chronic inflammation, 391–392
 Diamond-Blackfan, 380
 Fanconi, 380, 861, 880
 iron-deficiency, 383
 sickle cell (*See* Sickle cell disease)
 thalassemia, 389–391
- Anencephaly, 6
- Anesthesia
 conditions associated with complications of
 Cornelia de Lange syndrome, 314
 Goldenhar syndrome, 323
 Larsen syndrome, 301
 Rett syndrome, 329
 Rubinstein-Taybi syndrome, 316
 skeletal dysplasias, 246
 for fracture management, 1329–1332
 blocks, 1330–1331
 dissociative anesthesia, 1332
 sedation, 1331–1332, 1331t
- Aneuploidy, 162, 163
- Aneurysmal bone cyst, 540–542, 541, 542
 histology of, 541, 542
 radiographic features of, 541, 541
 of spine, 541–542
 cervical, 833–834
 treatment of, 541
- Angelman syndrome, 171, 319
- Angiography
 Klippel-Trenaunay syndrome on, 345
 vascular malformations on, 341
- Angle(s)
 1–2 intermetatarsal, 1201, 1201
 alpha and beta, of hip joint, 77
 Baumann, 1339, 1339
 carrying, of elbow, 1338
 center-edge angle of Wiberg, 916, 918, 919
 leg length discrepancy and, 1107, 1108
 Cobb, 689–691, 690, 698, 701
 distal metatarsal articular, 1200, 1200–1201
 femoral neck-shaft, 1035, 1036
 femoral or tibial metaphyseal-diaphyseal, 1066, 1067, 1068
 foot-progression, 105, 105, 114, 1060
 Hilgenreiner physal, 1039, 1039–1041
 popliteal, 114, 115
 Q, 122–123, 123, 1299, 1300, 1301
 rib-vertebral angle difference, 694–695, 695
 slip, in spondylolisthesis, 783
 thigh-foot, 1060
 tibio-femoral, 1065
- Ankle
 in gait cycle, 139–140, 140
 gait deviations associated with, 146
 due to excessive dorsiflexion, 146
 due to excessive plantar flexion, 146
 ligaments of, 1402
 motions of, 1402
 in specific conditions
 Achilles tendinitis, 1283
 Becker muscular dystrophy, 644
 Duchenne muscular dystrophy, 640–641
 fibular deficiency, 1227, 1230, 1233
 hemophilia, 410, 413
 multiple epiphyseal dysplasia, 270
 poliomyelitis, 666
 spastic diplegia, 584–587
- Ankle disarticulation prosthesis, 1260–1261, 1261
- Ankle-foot orthoses (AFOs)
 for Duchenne muscular dystrophy, 640
 for Friedreich ataxia, 656
 for idiopathic toe walking, 1099
 myelomeningocele and, 628–629, 629
 for posterior medial bowing of tibia, 1093
 for spastic diplegia, 583
 for spastic hemiplegia, 589–590
 for tibial pseudarthrosis, 1084
- Ankle trauma, 1290–1293, 1401–1407
 anterolateral ankle impingement, 1293
 fractures, 1401–1407
 classification of, 1402
 complications of, 1406–1407
 diagnosis of, 1402
 high-risk, 1403–1405, 1404
 low-risk, 1402, 1403
 mechanism of injury, 1401
 transitional, 1401, 1405–1406
 Tillaux fracture, 71, 1401, 1405, 1405–1406
 triplane fracture, 1401, 1406, 1406–1408
 sprains, 128, 128–129, 1290–1293
 classification of, 1290
 differential diagnosis of, 1292
 examination of, 1291, 1291
 radiographic evaluation of, 1291–1292
 recurrent, 1292
 treatment of, 1292
- Ankylosing spondylitis, juvenile, 441, 447–448, 448
 radiographic features of, 450, 450
- Anterior cruciate ligament (ACL) injuries, 1294–1296
 clinical features of, 1294
 meniscal tears and, 1294
 natural history of, 1295
 nonoperative management of, 1295
 radiographic evaluation of, 1295
 surgical treatment of, 1295–1296
 tests for, 124, 1294–1295
- Anterior drawer test, 1291, 1291, 1294
- Anteroposterior axis determination, 5, 10–11, 14–16
- Antibiotics, for bone and joint sepsis, 476–480, 479t
- Anticipation, generic, 164
- Anticonvulsant rickets, 181, 193
- Antidiuretic hormone, 225
- Antigens, human leukocyte (HLA)
 juvenile idiopathic arthritis and, 441
 enthesitis-related arthritis, 446–447
 inflammatory bowel disease-associated arthritis, 448
 juvenile ankylosing spondylitis, 447
 polyarthritis, 445
 psoriatic arthritis, 445
 Lyme disease and, 435
 post-streptococcal arthritis and, 436
 reactive arthritis and, 433, 435
- Antinuclear antibodies, 433
- Apert syndrome, 821–822
- Apical ectodermal ridge (AER), 10–11, 11, 13–14, 14, 15, 17, 27, 1192
- Apley test, 123, 1296
- Apophyseal conditions, 1280–1283
 apophysitis of fifth metatarsal, 1282
 apophysitis of hip and pelvis, 1283
 calcaneal apophysitis, 119–120, 1206–1208, 1207, 1282
 fracture, 1368
 normal age-related variants, 65
 olecranon apophysitis, 1283
 Osgood-Schlatter disease, 1280–1281, 1281
 Sinding-Larsen-Johansson disease, 1281, 1281
- Apoptosis, 27
 p53 and, 509
 synostoses due to failure of, 17
 synovial joint development and, 12
- Apprehension tests
 patellar, 123, 123
 shoulder, 126, 126, 127
- Arachnodactyly
 in Marfan syndrome, 218–219, 219
 in type I homocystinuria, 221
- Archenteron, 18
- Areflexic dystaxia, 657t. *See also* Hereditary motor sensory neuropathies
- Arithmetic method for determining leg length discrepancy, 1124–1127, 1125
- Arm span, 38
- Arnold-Chiari malformation, 806
 basilar impression and, 804
 definition of, 813
 myelomeningocele and, 602, 603, 605
 torticollis and, 813
- Arteries
 embryology of, 12
 epiphyseal, 27

- nutrient, of diaphysis, 27
 perichondral, 27
 transverse intersegmental, 20
 Arteriovenous malformations, 340. *See also*
 Vascular malformations
- Arthritis
 conditions associated with, 434–435
 acute lymphoblastic leukemia, 417, 438
 acute rheumatic fever, 435–436
 benign tumors, 438
 cystic fibrosis, 437
 foreign body synovitis, 437
 inflammatory bowel disease, 448
 Lyme disease, 435
 serum sickness, 437
 sickle cell disease, 388, 490
 systemic autoimmune diseases, 437
 transient synovitis of hip, 435
 X-linked agammaglobulinemia, 394
 definition of, 433
 enthesitis-related, 446–447, 447
 gonococcal, 496–497
 gouty, 437
 idiopathic (*See* Juvenile idiopathic arthritis)
 juvenile ankylosing spondylitis, 441, 447–448, 448
 oligoarthritis, 429–430, 444, 444
 polyarthritis, 430, 444–445
 postinfectious (reactive), 388, 435
 poststreptococcal
 differentiation from juvenile idiopathic arthritis, 436
 differentiation from transient synovitis of hip, 1046
 psoriatic, 430, 445–446, 446
 septic (*See* Septic arthritis)
 systemic, 430, 442, 442–444, 443
- Arthrochalis multiplex congenita, 221
- Arthrodontosteodysplasia, 327, 328
- Arthrodesis
 for foot deformities, 1153
 congenital vertical talus, 1177–1178
 flexible flatfoot, 1172
 hip, for slipped capital femoral epiphysis, 1024, 1025
 iliofemoral, for proximal femoral focal deficiency, 1244–1246
 for juvenile idiopathic arthritis, 452
 knee, for proximal femoral focal deficiency, 1243
 for poliomyelitis, 665
 for spondylolisthesis, 787
 for spondylolysis, 783–785, 785
 triple, 1153
 for pes cavovarus, 660–661, 661
- Arthroereisis of subtalar joint, for flexible flatfoot, 1172
- Arthrography
 in chondrolysis of hip, 1050–1051, 1051
 contrast materials for, 64–65
 in developmental dysplasia of hip, 70
 indications for, 69
 in Legg-Calvé-Perthes syndrome, 70, 70–71, 980–983, 982, 985
 normal anatomy on, 70
 technique for, 69–70
- Arthrogryposis, 295–296
 distal, 301, 301–302
 Freeman-Sheldon syndrome and, 302, 303
 prerygia syndrome and, 303–305, 303–305
- Arthrogryposis multiplex congenita, 296–299
 clinical features of, 296, 296–297, 850
 congenital radial head dislocation and, 853
 developmental dysplasia of hip and, 102, 297, 297–298
 etiology of, 296
 radiographic features of, 297, 297
 treatment of, 297–299
 upper limb involvement in, 298–299, 850–853, 851
 incidence of, 850
 nonoperative management of, 851
 posterior capsulotomy and triceps lengthening for, 851–852
 tendon transfers for elbow flexion, 852
 wrist and hand reconstruction for, 852–853
- Arthropathy
 Charcot, myelomeningocele and, 627–628, 628
 in Down syndrome, 309–310
 hemophilic, 409–412, 410, 411, 438
- Arthroscopy, for bone and joint sepsis, 481–482
- Arthrotomy, for septic arthritis, 481, 481
- Ascorbic acid, 217
- Askin tumor. *See* Peripheral neuroectodermal tumor
- Aspartylglucosaminosis, 398t
- Aspiration
 for bone and joint sepsis, 468, 473–474, 481
 for hemarthrosis, 412
- Aspirin, 1277
- Ataxia, Friedreich, 656–657
 clinical features of, 656
 genetics and molecular biology of, 656
 treatment of, 656–657
 painful muscle spasms, 657
 pes cavovarus, 656
 spinal deformity, 121, 656–657
- Ataxia-telangiectasia, 340t, 341
- Ataxic cerebral palsy, 565
- Atheroid cerebral palsy, 565
 cervical spine problems in, 817
 management of, 590
- Athletic participation. *See* Sports medicine
- Athletic trainers, 1290
- Atlanta Scottish Rite orthosis, for Legg-Calvé-Perthes syndrome, 985, 986
- Atlantoaxial instability, 802
 Down syndrome and, 305, 306, 802, 802, 815–817, 818
 juvenile idiopathic arthritis and, 448–449
- McKusick-type metaphyseal chondrodysplasia and, 272
 measurement of, 802, 803
 posterior C1–2 fusion for, 807
 Schmid-type metaphyseal chondrodysplasia and, 273
 spondyloepiphyseal dysplasia congenita and, 264, 265
- Atlantoaxial motion, 801–802
- Atlantoaxial rotary displacement, 808–811
 classification of, 809, 810
 etiology of, 809–810
 in Grisel syndrome, 810, 810
 radiographic features of, 808–809, 809
 spontaneous resolution of, 810
 terminology for, 808
 treatment of, 810–811
- Atlantodens interval (ADI), 801, 801
 transverse atlantoaxial ligament rupture and, 824
- Atlantooccipital anomalies, 805–807, 806
 clinical presentation of, 805–806
 natural history of, 806
 radiographic features of, 805, 806
 treatment of, 806–807
- Atlantooccipital dislocation, 823–824, 824, 825
- Atlas (C1)
 anomalies of, 805
 atlantoaxial motion, 801–802 (*See also* Atlantoaxial instability)
 atlantoaxial rotary displacement, 808–811, 809, 810
 components of, 800
 embryology of, 800
 in familial cervical dysplasia, 808
 fracture of, 824
 growth and development of, 800
 nontraumatic occipitoatlantal instability, 817
 unilateral absence of, 807, 807–808
- Atropine, 1331t
- Autoimmune diseases, arthritis and, 437
- Autosomal chromosomes, 158, 158–159
 abnormalities of, 162–163, 163
- Autosomal dominant disorders, 164, 164–167
- Autosomal recessive disorders, 167, 167–168
- Avascular necrosis
 familial dysautonomia and, 314
 hip dislocation and, 1373
 leg length discrepancy and, 1117
 multiple epiphyseal dysplasia and, 270
 proximal femoral fractures and, 1374–1377
- Axis (C2)
 anomalies of, 805
 atlantoaxial motion, 801–802 (*See also* Atlantoaxial instability)
 atlantoaxial rotary displacement, 808–811, 809, 810
 components of, 800
 embryology of, 800
 in familial cervical dysplasia, 808, 808
 growth and development of, 800
 spondylolisthesis of, 827

- B**
- Babinski sign, 634
in spastic cerebral palsy, 116
- Babygram, 1438
- Back pain. *See also* Pain
acute lymphoblastic leukemia and, 417, 417
Gaucher disease and, 401
osteopetrosis and, 214
- Backboard, positioning child on, 823, 823
- Baclofen, intrathecal, for spastic diplegia, 580
- Bailey-Dubow rods, 209, 210
- Baker cyst, 123
- Banayan-Zonana syndrome, 344
- Bankart lesion, 128
- Barlow provocative test, 103, 103, 913, 919
- Basilar impression, 804–805
clinical presentation of, 804
cranial nerve involvement and, 804
primary vs. secondary, 804
radiographic assessment of, 804, 805
treatment of, 805
- Battered child syndrome, 111, 1424. *See also* Child abuse
- Baumann angle, 1339, 1339
- Bean syndrome, 340t, 341
- Becker muscular dystrophy, 637, 644, 644, 645
clinical features of, 644
treatment of, 644
- Beckwith-Wiedemann syndrome, 320–321, 321, 344
genetics of, 170–171, 320
hemihypertrophy in, 320–321, 321, 348t, 350
- Benzodiazepines, 1331, 1331t
- Bier block, 1330–1331
- Bilhaut-Cloquet procedure, 884
- Biomechanics
of bone, 1320–1321
of patellofemoral joint, 1299, 1300
- Biopsy of bone or soft tissue tumor, 517–518
- Bipartite patella, 1304
- Birth injuries
brachial plexus palsy, 109–110, 846–850, 1332
cervical spine, 829
clavicular fracture, 1332
humeral shaft fracture, 1335
physcal separation of proximal humerus, 1332
- Bisphosphonates
for fibrous dysplasia, 230
for osteogenesis imperfecta, 209
- Blanch sign of Steel, 1005, 1005
- Blastocyst, 3, 3, 4, 27
- Blastula, 2, 28
- Bleomycin, 528
- Blount disease, 110, 369
adolescent, 1075–1081
clinical features of, 1076, 1077
definition of, 1075
etiology of, 1075
pathoanatomy of, 1075–1076
radiologic features of, 1076, 1077
treatment of, 1077–1081
circular external fixation, 1080–1081
goals of, 1077–1078
hemiepiphyodesis, 1079
inherently stable internal fixator, 1080
limited internal fixation, 1080
monolateral external fixation, 1080
osteotomy, 1079–1080
preoperative evaluation, 1078, 1078–1079, 1079
developmental coxa vara and, 1038
infantile, 1068–1075
definition of, 1068–1069
differential diagnosis of, 1066
etiology of, 1069
Langenskiöld's radiographic stages of, 1066, 1068, 1069, 1070, 1072
nonoperative management of, 1069–1070
pathoanatomy of, 1069
surgical treatment of, 1070–1075
complications of, 1075
goal of, 1070
moderate varus deformity, 1070, 1070–1071
severe varus deformity, 1073–1075, 1074
worsening varus deformity, 1071–1073, 1072
- Blue rubber bleb nevus syndrome, 340t, 341
- BMPs. *See* Bone morphogenetic proteins
- Body cast, for spondylolysis, 783, 785
- Body mass index, 39
- Body plan, 9, 28
- Bone
anatomy of, 1321
biomechanical properties of, 1320–1321
composition of, 204
cylinderization of, 27, 27
elongation of, 27, 27
embryology of, 11
fractures of, 1319–1414 (*See also* Fractures)
funnelization of, 27, 27
healing of, 204, 1321–1322, 1322
normal age-related changes and variants of, 65–67, 65–67
on magnetic resonance imaging, 82
physiology of, 204–205, 1321–1322, 1322
radiographic appearance in newborn, 64, 64
remodeling of, 27, 27, 204, 1321
tumors of (*See* Tumors)
turnover of, 178–180
woven, 64
- Bone age
delayed, conditions associated with, 43
determination of, 34, 43–45, 44–50, 68–69, 224, 1123, 1123–1124
Greulich and Pyle atlas, 42, 43, 1123
in paralytic child, 59
Sauvegrain method, 43, 44
in scoliosis, 53, 691, 691
Tanner-Whitehouse method, 1123, 1123–1124
leg length and, 1108–1112, 1109–1112, 1109t
puberty and, 41–43
- Bone and joint sepsis, 459–500. *See also* Osteomyelitis; Septic arthritis
chronic recurrent multifocal osteomyelitis, 490–492, 491
definitions of, 460
diagnosis of, 466–474
aspiration, 468, 473–474
history, 466–467
imaging, 469–473
laboratory testing, 467–469, 468t
physical examination, 467
differential diagnosis of, 474–476
epidemiology of, 460
etiology of, 460–461
gonococcal arthritis, 496–497
in neonate, 486–488
pathophysiology of, 461–466
of pelvis and sacroiliac joint, 484–486, 486
puncture wounds of foot and, 494–496, 495
radiographic features of, 469–473
bone scan, 470–472, 471, 472
computed tomography, 472
magnetic resonance imaging, 470, 472–473, 473
plain radiographs, 469, 469–470, 470, 472
ultrasound, 473
results of, 482
sickle cell disease and, 386, 386–387, 387, 488–490, 489
skeletal tuberculosis, 497–500, 498, 499
of spine, 482–484, 483
subacute osteomyelitis, 492–494, 493, 494
treatment of, 476–482
antibiotic delivery for, 478
antibiotic efficacy and, 479–480
antibiotic penetration and, 479
antibiotics for, 479t
duration of antibiotic therapy, 480
organism identification for, 476–478
route of drug administration for, 478–479
surgical, 480–482, 481
- Bone bridge formation
infantile Blount disease and, 1072, 1072–1073
physcal fracture and, 1324–1325, 1326
- Bone cyst, 538–542
aneurysmal, 540–542, 541, 542
histology of, 541, 542
radiographic features of, 541, 541
of spine, 541–542
cervical, 833–834
treatment of, 541
lower extremity, 117
unicameral, 538–540, 540

- Bone densitometry, 89–90
 applications of, 90
 dual-energy x-ray absorptiometry, 90
 quantitative computed tomography, 90
 radiation exposure from, 90
 risks and limitations of, 90
 trends in utilization of, 90
 “Bone drift,” 1321
- Bone formation, 23–27, 64, 177–181, 204
 calcium and phosphorus homeostasis and, 181–186
 cartilage formation and, 179–180
 collagen and, 178, 179t, 204
 embryonic, 23–27, 178
 endochondral bone, 24, 178
 genetic factors and, 180–181
 growth plate structure and development, 24–27, 25, 26
 hormonal regulation of, 180
 intramembranous ossification, 24
 mechanical force and, 180, 204
 mineralization, 204
 in acute lymphoblastic leukemia, 417
 noncollagenous proteins and, 178, 204
 osteoblasts, osteocytes, and osteoclasts, 178
 in osteopetrosis, 213
 periosteal, 214–217, 215t, 1321
- Bone grafting
 for aneurysmal bone cyst, 541
 for fibrous dysplasia, 229–230
 for unicameral bone cyst, 540
- Bone infarction, 475
- Bone marrow
 detection of tumor cells in, 508
 Gaucher cells in, 399
 hematopoiesis in, 379
 leukemic cells in, 417
 normal age-related variants of, 84
- Bone marrow failure syndromes, 379–383
 cartilage-hair hypoplasia, 381
 Diamond-Blackfan anemia, 380
 Fanconi anemia, 380
 Schwachman-Diamond syndrome, 380–381
 thrombocytopenia with absent radius syndrome, 381–383, 382, 382t
- Bone marrow transplantation
 for acute lymphoblastic leukemia, 419
 for cartilage-hair hypoplasia, 381
 for chronic granulomatous disease, 393
 for Fanconi anemia, 380
 for Gaucher disease, 402
 for genetic diseases, 174–175
 for Hurler syndrome, 325
 for osteogenesis imperfecta, 209
 for osteopetrosis, 213–214
 for sickle cell disease, 389
 for thalassemia, 391
- Bone morphogenetic proteins (BMPs), 9, 178t
 fibrodysplasia ossificans and, 218
 in fibrodysplasia ossificans progressiva, 363–364
 in neurulation, 6
 role in limb development, 15, 15–16
- Bone scan. *See* Scintigraphy
- Bony overgrowth, 1225, 1226
- Boston brace, 699, 699
- Botulinum-A toxin (BTX), for spastic cerebral palsy, 579–580, 584, 843–844
- Bowleg deformity. *See* Genu varum
- Boxer fracture, 889
- Boyd amputation, for fibular deficiency, 1231–1232
- Boys
 development of secondary sexual characteristics in, 41
 leg length related to skeletal age of, 1109, 1110
 lengths of long bones including epiphyses, 1224t
 normal growth chart for, 222
 pubertal growth curve for, 42
 remaining growth in lower limbs between ages 5 and 17 years for, 57
 sitting heights of, 37, 37t
 standing heights of, 36t, 37t, 40–41, 43
 subischial limb length of, 37, 40
 weight of, 38, 43
- Braces. *See* Orthotic devices
- Brachial plexus birth palsy, 846–850, 1332
 classification of nerve injury in, 847, 848
 Erb type, 109
 fractures and, 847
 Horner syndrome and, 847
 imaging evaluation of, 847
 incidence of, 846
 Klumpke type, 109, 850
 pathoanatomy of, 847–848, 849
 perinatal risk factors for, 847
 physical examination for, 847
 prognosis for, 847
 total, 109
 traumatic, 109
 treatment of, 848–850
 microsurgery, 848
 nonoperative, 848
 shoulder surgery, 848–850, 849t, 850
- Brachial plexus development, 12
- Brachydactyly, 17
 in Albright hereditary osteodystrophy, 201
- Brain
 development of, 563–564
 injuries of, due to child abuse, 1428
 torticollis and tumors of, 813
- Brain stem
 atlantooccipital anomalies and compression of, 805
 myelomeningocele and displacement of, 602, 605
- Breaststroker's knee, 1286–1287
- Breech birth, developmental dysplasia of hip and, 102
- Brittle-bone disease. *See* Osteogenesis imperfecta
- Brodie abscess, 492, 511
- Brown procedure, for fibular centralization, 1234, 1236
- Bruises
 due to child abuse, 1426–1427, 1427
 due to coagulation disorders, 1438
- BTX (botulinum-A toxin), for spastic cerebral palsy, 579–580, 584, 843–844
- Bunions
 Down syndrome and, 309
 spastic diplegia and, 584
- Burns
 due to child abuse, 1427–1428
 periosteal reaction and, 214, 215t
- Burst fractures, of thoracolumbar spine, 1368
- Buschke-Ollendorf syndrome, 358
- Butler-Albright syndrome, 192
- Buttiens distal limb deficiencies syndrome, 17
- C**
- C1. *See* Atlas
- C2. *See* Axis
- Café-au-lait spots
 in fibrous dysplasia, 229, 535–536
 in neurofibromatosis, 289, 289, 685
- Caffey disease, 214–216, 215t, 216
- Calcaneal apophysitis, 1206–1208, 1282
 clinical features of, 1206, 1207
 definition of, 1206
 epidemiology of, 1206
 examination for, 119–120
 natural history of, 1207
 Osgood-Schlatter disease and, 1281
 pathoanatomy of, 1207
 pathogenesis of, 1206
 radiographic features of, 1206–1207, 1207
 treatment of, 1207–1208
- Calcaneal osteotomy
 for flexible clubfoot, 1172–1173, 1173
 for pes cavovarus, 659–660
 for tarsal coalition, 1186
- Calcaneocuboid joint, 1152
- Calcaneonavicular coalition, 74
- Calcaneovalgus, positional, 1152, 1178, 1178
 clinical features of, 1178, 1178
 definition of, 1178
 epidemiology of, 1178
 natural history of, 1178
 pathogenesis of, 1178
 radiographic features of, 1178, 1178
 spontaneous correction of, 1152
 treatment of, 1178
- Calcaneus, 1409
 in clubfoot, 1156–1157, 1157
 in flexible flatfoot, 1170
 fractures of, 1411, 1412
 myelomeningocele and deformity of, 625–626, 626
 normal sclerosis of, 65, 65
 ossification of, 65
 in Larsen syndrome, 278, 279
- Calceiferol, 183, 183

- Calcifications
 in chondrodysplasia punctata, 270–271, 271
 intervertebral disc, 831–832, 832
 soft tissue, 217–218
 fibrodysplasia ossificans, 218
 hypoparathyroidism and, 201
 renal osteodystrophy and, 195, 195
 tumoral calcinosis, 217–218
 Calcitonin, 180
 for hypercalcemia, 186
 for Paget disease, 186
 Calcitriol, 182
 Calcium. *See also* Hypercalcemia;
 Hypocalcemia
 bone storage of, 181
 dietary requirement for, 184
 factors affecting absorption of, 185
 homeostasis, 181–186
 idiopathic juvenile osteoporosis and, 211
 kinetics in normocalcemic,
 hypocalcemic, and hypercalcemic
 states, 184, 185–186, 186
 osteopetrosis and, 213
 phosphate and transport of, 182
 to prevent corticosteroid-induced bone
 loss, 228
 provitamins D and, 182–183, 183
 sites of cell-mediated transport of, 181,
 184
 transport across gut cell, 181–182, 182
 Calcium channel blockers, 22
 Camptodactyly, 877–879, 878
 cleft hand and, 871
 definition of, 877–878
 etiology of, 878
 incidence of, 878
 treatment of, 878–879
 goals of, 878
 indications for surgery, 878
 Camurati-Engelmann syndrome, 355–357,
 356
 Cancer. *See* Tumors
 Candidate genes, 161
 Cao-gio, 1427
 Capillary hemangioma, 340, 544
 Capitellum, osteochondral lesions of,
 1287–1288, 1288
 Caput quadratum, 187
 Car seat injuries, 829–830, 830
 Cardiac defects
 chondroectodermal dysplasia and, 257
 cleft hand and, 870
 Down syndrome and, 305
 Duchenne muscular dystrophy and,
 637–638, 643
 Emergy-Driefuss muscular dystrophy
 and, 645–646
 fibrodysplasia ossificans progressiva and,
 364
 Hadju-Cheney syndrome and, 327
 Holt-Oram syndrome and, 861
 Larsen syndrome and, 278, 301
 radial dysplasia and, 861
 Rubinstein-Taybi syndrome and, 316
 skeletal dysplasias and, 246
 thrombocytopenia with absent radius
 syndrome and, 382
 VACTERLS and, 321
 Carditis, in acute rheumatic fever, 436
 Carpal bones. *See also* Wrist
 in chondroectodermal dysplasia, 257
 in pseudoachondroplasia, 268
 terminal transverse transcarpal deficiency,
 1250–1251, 1251
 Carrying angle of elbow, 1338
 Cartilage, 179–180
 articular, 179
 composition of, 179
 effects of known mutations on
 development of, 244, 245
 in Kniest dysplasia, 261
 physeal, 25–26, 178–179 (*See also*
 Physis)
 sensitivity to somatomedins, 180
 triradiate, closure of, 42
 types of, 179
 Cartilage-hair hypoplasia, 271–273, 272,
 273, 381
 Cartilaginous tumors, 528–534
 chondroblastoma, 531–532, 532, 533
 chondromyxofibroma, 531, 531
 enchondroma, 528–529, 529
 exostosis, 529–531, 530
 periosteal chondroma, 532–534, 534
 Casting
 for Kohler disease, 1205
 for kyphosis, 755
 manipulation and
 for clubfoot, 1158–1159
 for metatarsus adductus, 1163
 for spastic diplegia, 583
 for skewfoot, 1167
 Cauda equina, 22
 Cauda equina syndrome, 794
 “Cauliflower ear,” 258
 Cavernous hemangioma, 340, 544–545
 Cavus foot deformity, 1152, 1194–1199
 calcaneocavus, 1194, 1195
 myelomeningocele and, 627, 1152,
 1194, 1195
 cavovarus, 1194
 hereditary motor sensory neuropathies
 and, 658–661, 659, 1152
 clinical features of, 1194–1196, 1195,
 1196
 conditions associated with, 1195t
 definition of, 1194
 epidemiology of, 1194
 examination for, 1195
 Coleman block test, 116, 116, 1196,
 1197, 1197
 natural history of, 1198
 pathoanatomy of, 1197–1198
 pathogenesis of, 1194
 radiographic features of, 1195,
 1196–1197, 1197
 surgical treatment of, 1198–1199, 1199
 CD44s, 16
 Cefazolin, 479t
 Cefotaxime, 479t
 Cefprozil, 479t
 Ceftazidime, 479t
 Ceftriaxone, 477, 479t
 Cefuroxime, 478, 479t
 Cell differentiation, 9, 11, 28
 Cell migration, 5
 Cell motility, 28
 Center-edge angle of Wiberg, 916, 918,
 919
 leg length discrepancy and, 1107, 1108
 Central core disease, 649–650
 Central nervous system disorders
 cerebral palsy and, 566
 myelomeningocele, 601–629 (*See also*
 Neural tube defects)
 Centronuclear myopathy, 650
 Cephalixin, 479t
 Cephalopolysyndactyly, Grieg-type, 17
 Cerebral palsy, 43, 563–593
 anatomic patterns of, 565–566
 assessing results of treatment for,
 568–569
 ataxic, 565
 athetoid, 565
 management of, 590
 brain development and, 563–564
 central nervous system problems in, 566
 cervical spine problems in, 817–818,
 819
 classification of, 565–566
 diagnosis of, 566–567
 history, 567, 567t
 imaging studies, 567, 568
 other tests, 567
 physical examination, 567
 etiology of, 564, 842
 gastrointestinal system problems in, 566
 genitourinary system problems in, 566
 growth in child with, 58–59
 handedness and, 105
 hypotonic, 565
 incidence of, 564–565, 842
 leg length discrepancy and, 1117
 mixed-type, 565
 neuropathic types of, 565
 prematurity and, 104
 reflex testing in, 116
 spastic, 565
 Beckwith-Weidemann syndrome and,
 320
 management of spastic diplegia,
 577–589 (*See also* Spastic diplegia)
 management of spastic hemiplegia,
 589–590 (*See also* Spastic
 hemiplegia)
 management of spastic quadriplegia,
 569–577 (*See also* Spastic
 quadriplegia)
 toe walking due to, 113–116, 114–116
 upper extremity involvement in,
 590–593, 842–846
 classification of, 843, 844, 845t
 complications of surgery for, 846
 contractures of, 843
 elbow surgery for, 591–592, 845

- hand surgery for, 592–593, 593, 845–846, 846
- nonoperative management of, 843–844
- nonsurgical treatment for, 591
- shoulder surgery for, 591
- surgical indications for, 844
- surgical principles for, 844–845
- wrist surgery for, 592, 592, 845
- Cervical spine, 799–835
 - congenital and developmental problems of, 804–815
 - Klippel-Feil syndrome, 814–815
 - os odontoideum, 815
 - torticollis, 804–814
 - developmental and acquired stenoses and instabilities of, 815–819
 - cerebral palsy and, 817–818, 819
 - Down syndrome and, 305–307, 306–307, 802, 802, 815–817, 818
 - nontraumatic occipitoatlantal instability, 817
 - postlaminectomy deformity, 818–819, 820, 821
 - embryology of, 799–800
 - C3–7, 800
 - occipitoaxioatlas compound, 799–800
 - growth and development of, 50–51, 800
 - hematologic and oncologic conditions of, 833–835
 - benign tumors, 833–835, 834
 - malignant tumors, 835
 - inflammatory and septic conditions of, 830–833
 - intervertebral disc calcification, 831–832, 832
 - juvenile rheumatoid arthritis, 830–831, 831
 - pyogenic osteomyelitis and discitis, 832
 - tuberculosis, 832–833
 - normal radiographic parameters of, 800–804
 - atlantodens interval, 801, 801
 - atlantooccipital motion, 801–802, 802, 803
 - normal lower cervical spine motion, 804
 - pseudosubluxation, 802–803, 803
 - variations that may resemble injury, 803–804
 - ossification centers of, 800
 - in other conditions, 820–822
 - chondrodysplasia punctata, 271
 - craniofacial syndromes, 821
 - craniosynostosis syndromes, 821–822
 - diastrophic dysplasia, 258, 259, 260
 - fetal alcohol syndrome, 311, 820
 - fibrodysplasia ossificans progressiva, 364, 822
 - hemophilia, 833
 - juvenile idiopathic arthritis, 448–449, 449
 - Larsen syndrome, 278, 278, 301
 - Morquio syndrome, 326, 327
 - mucopolysaccharidosis type I, 325
 - neurofibromatosis, 822
 - pseudoachondroplasia, 267–269
 - spondyloepiphyseal dysplasia congenita, 263, 264, 265
- Cervical spine trauma, 822–830
 - backboard positioning for, 823, 823
 - in battered children, 829
 - birth injuries, 829
 - car seat injuries, 829–830, 830
 - causes of, 822
 - differentiation from anatomic variants, 803
 - fractures and ligamentous injuries, 823–827
 - C3–7, 827, 827, 828
 - occipital complex to C1–2 complex, 823–827
 - atlantooccipital dislocation, 823–824, 824, 825
 - fractures of atlas, 824
 - odontoid fractures, 824–827, 826
 - spondylolisthesis of C2, 827
 - transverse atlantoaxial ligament rupture, 824
 - gunshot wounds, 830
 - incidence of, 822
 - radiographic evaluation for, 822–823
 - spinal cord injury without radiographic abnormality, 827–829
 - transient quadriplegia, 829
- CFBA1 gene, in cleidocranial dysplasia, 276
- Chamberlain's line, 804, 805
- Chance fractures, 1368, 1369
- Charcot arthropathy, myelomeningocele and, 627–628, 628
- Charcot-Marie-Tooth disease, 657–662, 657r, 659–661, 1152. *See also* Hereditary motor sensory neuropathies
- Charleston brace, 699, 700
- Cheilectomy, for Legg-Calvé-Perthes syndrome, 990, 990
- Chemotherapy, cancer, 527–528
 - drugs used for, 528
 - multidrug resistance and, 510
 - for osteosarcoma, 523
- “Cherub dwarf,” 258
- Chiari osteotomy, for Legg-Calvé-Perthes syndrome, 989
- Chief complaint, 100
- Child abuse, 111, 1423–1443
 - decision making regarding, 1435–1437
 - dating fractures, 1436–1437, 1437, 1437r
 - suspicious fracture patterns, 1436
 - definition of, 1424
 - diagnosis of, 1424–1425
 - differential diagnosis of, 1438–1440
 - osteogenesis imperfecta, 205–206, 1439
 - fractures due to, 1428–1435
 - diaphyseal, 1430–1432, 1432–1434
 - metaphyseal, 1429–1430, 1430, 1431, 1434
 - physeal, 1428–1429, 1429
 - rib, 1432, 1434
 - spinal, 829, 1432–1435, 1433, 1435
- head injuries due to, 1428
- historical recognition of, 1423–1424
- imaging evaluation for, 1437–1438
 - limitations of, 1438
 - plain films, 69
 - scintigraphy, 88–89
 - specificity of radiologic findings, 1436r
- internal injuries due to, 1428
- investigative interview for, 1425–1426
 - at-risk profiles of parents and children, 1425
 - documentation of, 1426, 1437
 - history taking, 1425–1426
- legal issues related to, 1441–1443
 - guidelines for expert witnesses, 1443
 - informed consent, 1441
 - mandatory reporting statutes, 1441
 - preparation of court testimony, 1442–1443
- management of, 1437–1441
 - team approach to, 1440–1441
- medical neglect and, 1441
- prevalence of, 1424
- prevention of, 1441
- soft tissue injuries due to, 1426–1428
 - bruises, 1426–1427, 1427
 - burns, 1427–1428
 - underreporting of, 1440
- Child protective services, 1440
- CHILD syndrome, 17
- Chimera, 3, 28
- Chloral hydrate, 93
- Chondroblastoma, 531–532, 532, 533
- Chondrocytes, 25
 - in hemophilia, 409, 410
- Chondrodysplasia punctata, 244, 270–271
 - clinical features of, 270–271
 - radiographic features of, 271, 271
 - treatment of, 271
- Chondrodystrophy, 43
- Chondroectodermal dysplasia, 257–258
 - clinical features of, 257
 - radiographic features of, 257, 257
 - treatment of, 257–258
- Chondrogenic core, 11
- Chondrolysis of hip, 1048–1055
 - age at onset of, 1049
 - clinical presentation of, 1049–1050
 - definition of, 1048
 - differential diagnosis of, 1050
 - epidemiology of, 1049
 - etiology of, 1049
 - historical descriptions of, 1048–1049
 - incidence of, 1049
 - laboratory findings in, 1050
 - natural history of, 1052–1053
 - pathology of, 1052, 1052, 1053

- Chondrolysis of hip (*contd.*)
 radiographic features of, 1050–1051, 1050–1052, 1054
 arthrography, 1050–1051, 1051
 computed tomography, 1051, 1052
 scintigraphy, 1051, 1051
 slipped capital femoral epiphysis and, 1027–1029, 1028, 1049, 1053
 treatment of, 1053–1055
- Chondroma, periosteal, 532–534, 534
- Chondromalacia patella, 1300, 1304
- Chondromatosis, synovial, 549–551, 550
- Chondromyxofibroma, 531, 531
- Chondrosarcoma, 531
- Chopart joint, 1152
- Chordoma, 22
 in cervical spine, 835
- Chorea, in acute rheumatic fever, 436
- Chorionic villus sampling, 174
- Chromosome abnormalities, 9, 162–163
 of autosomal chromosome number, 162
 Down's syndrome, 162, 163, 305
 of autosomal chromosome structure, 162–163
 limb defects due to, 17
 in sarcomas, 508, 508t
 of sex chromosomes, 163
- Chromosomes, 158, 159, 158–159
- Chronic granulomatous disease, 392–394, 393
 genetics of, 392–393
 infections in, 393
 management of, 393–394
 osteomyelitis in, 392, 393
- Chvostek sign, 201
- Chylothorax, Gorham disease and, 346, 347, 347
- Ciprofloxacin, 479t
- Cisplatin, 528
 for osteosarcoma, 523
- Clavicle
 in cleidocranial dysplasia, 276, 277
 congenital pseudarthrosis of, 359–361, 1332
 clinical features of, 360
 etiology of, 360
 histopathology of, 361
 radiographic features of, 361, 361
 treatment of, 361
 fractures of, 1332–1334
 due to birth injury, 1332
 lateral, 1334, 1334
 medial, 1333, 1333–1334
 shaft, 1332–1333
 in renal osteodystrophy, 196
- Cleavage, 2, 2–3, 3, 28
- Cleft foot, 17, 1192–1194
 classification of, 1192, 1193
 cleft hand and, 870, 1192
 clinical features of, 1192, 1193
 definition of, 1192
 epidemiology of, 1192
 natural history of, 1193
 pathoanatomy of, 1193
 pathogenesis of, 1192
 radiographic features of, 1192, 1194
 treatment of, 1193–1194, 1194
- Cleft hand, 17, 870–871, 871
 classification of, 870
 cleft foot and, 870, 1192
 conditions associated with, 870
 incidence of, 870
 treatment of, 870–871
- Cleft lip/palate
 cervical spine problems and, 821
 cleft hand and, 870
 cleidocranial dysplasia and, 276
 congenital constriction band syndrome and, 354
 diastrophic dysplasia and, 258
 distal arthrogryposis and, 302
 Kneist dysplasia and, 262
 Larsen syndrome and, 278
- Cleidocranial dysplasia, 276–277
 clinical features of, 276
 genetics of, 276
 orthopaedic implications of, 277
 radiographic features of, 276–277, 277
- Clindamycin, 479t
- Clinodactyly, 879
 cleft hand and, 871
 conditions associated with, 871
 definition of, 879
 treatment of, 879
- Club hand
 due to constriction rings, 18
 radial, 861–865, 862, 863, 865 (*See also* Radial dysplasia)
 ulnar, 865–868, 867, 868 (*See also* Ulnar dysplasia)
 in VACTERLS, 321
- Clubfoot, 1153–1161
 classes of, 1154
 classification of severity and rigidity of, 1155
 clinical features of, 1153, 1154–1155, 1155, 1158
 conditions associated with, 1154t
 arthrogryposis multiplex congenita, 298
 chondrodysplasia punctata, 271
 congenital constriction band syndrome, 18, 353–354
 congenital myotonic dystrophy, 649
 diastrophic dysplasia, 259, 261
 distal arthrogryposis, 302
 fetal alcohol syndrome, 311
 Freeman-Sheldon syndrome, 302, 303
 Larsen syndrome, 278, 279, 299, 301
 myelomeningocele, 623–625
 nail-patella syndrome, 312
 spondyloepiphyseal dysplasia congenita, 263
 definition of, 1153
 epidemiology of, 1154
 examination for, 1154–1155
 incidence of, 1154
 inheritance of, 1154
 intoeing and, 1060–1061
 leg length discrepancy and, 1154
 natural history of, 1158, 1158
 nonoperative treatment of, 1158–1159
 manipulation and casting, 1158–1159
- pathoanatomy of, 1153, 1154, 1156–1158
 pathogenesis of, 1154
 prenatal diagnosis of, 1156, 1156
 radiographic features of, 1155, 1155–1156, 1156
 surgical correction of, 624–625, 625, 1159–1161
 anesthesia for, 1160
 Carroll procedure, 1159
 choice of procedure for, 1160
 Cincinnati incision for, 1160–1161
 complications of, 1160
 Goldner procedure, 1159
 outcome of, 1159
 overcorrection, 1161
 repeat procedures, 1160, 1161
 Simons procedure, 1159–1160
 timing of, 1160
 Turco procedure, 1159
- Coagulation disorders, 408, 1438. *See also* Hemophilia
- Cobb angle
 in kyphosis, 753
 in scoliosis, 689–691, 690, 698, 701
 “Coccygeal tail,” 255, 255
- Codman tumor. *See* Chondroblastoma
- Cog-wheel rigidity, in spastic cerebral palsy, 116
- COL1A1 gene, 158, 159
 in osteogenesis imperfecta, 165, 245t
- COL1A2 gene, in osteogenesis imperfecta, 165, 245t
- COL2A1 gene
 in Kneist dysplasia, 261
 in spondyloepiphyseal dysplasia, 166, 245t, 265
- COL7A1 gene, in Larsen syndrome, 278
- COL9A2 gene, in multiple epiphyseal dysplasia, 269
- COL11A1 gene, in Stickler syndrome, 166
- COL11A2 gene, in Stickler syndrome, 166
- Coleman block test, 116, 116, 1196, 1197, 1197
- Collagen, 178–179, 204
 ascorbic acid in synthesis of, 217
 in Ehlers-Danlos syndrome, 220–221
 structure of, 204
 type I
 gene locus for, 158, 159
 in osteogenesis imperfecta, 205, 206, 208
 types of, 178, 179t, 204
- Collateral ligament injuries of knee, 1293–1294, 1294
- COMP gene
 in multiple epiphyseal dysplasia, 269
 in pseudoachondroplasia, 267
- Compaction of blastomere, 3, 28
- Compartment syndromes
 chronic, shin pain due to, 1285
 clinical features of, 1328–1329
 due to muscle hemorrhage in hemophilia, 414, 414
 after elbow injury, 119

- fasciotomy for, 1329, 1329, 1330
 after fracture, 1328–1329
 pathogenesis of, 1328
 tissue pressure measurements for, 1329, 1329
- Compression fractures of thoracic spine, 1367–1368, 1368
- Computed radiography, 69
- Computed tomography (CT), 71–74
 advantages of, 71
 contrast materials for, 64
 cost of, 85t
 helical (spiral), 71
 indications for, 71–74
 quantitative, 89–90
 radiation exposure from, 92
 risks and limitations of, 74
 in specific conditions
 achondroplasia, 248–249, 249
 aneurysmal bone cyst, 541
 atlantoaxial rotary displacement, 808–809, 809
 atlantooccipital dislocation, 825
 bone and joint sepsis, 472
 brachial plexopathy, 847, 849t
 calcaneus fracture, 1412
 chondrolysis of hip, 1051, 1052
 closed reduction of hip dislocation, 931
 congenital kyphosis, 747
 developmental dysplasia of hip, 72, 72
 hip dislocation, 1372, 1372
 infantile Blount disease, 1072
 Jefferson fracture, 824
 juvenile ankylosing spondylitis, 450
 myositis ossificans, 368
 osteoid osteoma, 515, 518, 520
 scoliosis, 680, 691–693, 692
 slipped capital femoral epiphysis, 71–72, 72, 1006, 1007
 spondylolysis and spondylolisthesis, 782
 sternoclavicular separation, 1333
 tarsal coalition, 74, 1184, 1184
 thoracolumbar spine trauma, 1367
 tripplane fracture of distal tibia, 1407
 tumors, 514, 515
 unilateral absence of C1, 807
 techniques for, 71
 trends in utilization of, 74
- Condylar fracture
 lateral, 1344–1348
 complications of, 1347–1348
 differentiation from fracture-separation of distal humeral epiphysis, 1345, 1346
 mechanism of injury, 1344
 Milch types I and II, 1344, 1345
 nonunion of, 1347–1348, 1348
 treatment of, 1345–1347, 1346, 1347
 medial, 1349
- Congenital abnormalities
 causes of, 9
 of foot, 1153–1194
 genetic causes of, 16–18 (*See also* Genetics)
- infant mortality due to, 9
 limb deficiencies, 16–17, 1217–1254
 myelomeningocele, 601–629
 prevalence of, 9
 vertebral, 21–22
- Congenital coxa vara, 1036, 1036
- Congenital dislocation of knee, 1095–1098
 clinical presentation of, 1096, 1096
 definition of, 1095
 etiology of, 1095–1096
 nonoperative management of, 1096–1097
 radiographic features of, 1096, 1096
 surgical treatment of, 1097, 1097–1098
- Congenital dislocation of radial head, 853–854, 854
- Congenital fiber-type disproportion, 650
- Congenital hallux varus, 1186–1188, 1187
 clinical features of, 1187, 1187
 definition of, 1186
 epidemiology of, 1186
 natural history of, 1187
 pathoanatomy of, 1187
 pathogenesis of, 1186
 radiographic features of, 1187, 1188
 surgical treatment of, 1187, 1187–1188
- Congenital humeroulnar dislocation, 854–855
- Congenital kyphosis, 744–749. *See also* Kyphosis
 anomalies associated with, 746
 classification of, 744–745, 745t
 clinical presentation of, 746
 complications of treatment for, 749
 etiology of, 745–746
 imaging evaluation of, 746, 746–747
 inheritance of, 746
 natural history of, 746
 treatment, 747–749, 748
 type I deformities, 747–749
 vertebral abnormalities and, 744–745, 745, 745t
- Congenital muscular dystrophy, 651, 651–652, 652
- Congenital muscular torticollis, 811–813, 813
- Congenital myopathies, 649–651
 central core disease, 649–650
 centronuclear myopathy, 650
 congenital fiber-type disproportion, 650
 metabolic myopathies, 650–651
 nemaline myopathy, 650
- Congenital myotonic dystrophy, 649
- Congenital radioulnar synostosis, 855–858, 857
 anomalies associated with, 856
 clinical features of, 856
 embryogenesis of, 855–856
 natural history of, 856
 radiographic features of, 856, 857
 surgical treatment of, 856–857
 complications of, 857–858
- Congenital scoliosis, 53, 724–733. *See also* Scoliosis
 classification of, 725, 725–727, 726
 definition of, 724–725
- myelomeningocele and, 614
 natural history of, 727, 727, 728
 nonoperative treatment of, 727–728
 surgical treatment of, 728–733
 anterior fusion, 729–731
 goals of, 729
 hemivertebra excision, 732, 733
 partial fusion, growth modulation, hemiepiphyodesis, 731, 731–733
 posterior fusion, 729
 posterior instrumentation, 729
 preoperative assessment, 728–729, 730
- Congenital spondylolisthesis, 777, 778, 779
- Congenital stippled epiphysis. *See* Chondrodysplasia punctata
- Connective tissue syndromes, 218–221
 Ehlers-Danlos syndrome, 220, 220–221
 homocystinuria, 221
 Marfan syndrome, 218–220, 219
- Conradi-Hünermann syndrome, 270–271
- Conscious sedation, 1331
- Constriction band syndrome, 17, 18, 352–355
 affecting hands, 872, 872–873
 clinical features of, 352–353, 353
 differential diagnosis of, 354
 etiology of, 354
 leg length discrepancy and, 1114
 limb deficiencies due to, 352–355, 353, 355, 872, 1220
 treatment of, 354–355, 355
- Contractures
 abduction, of hip, 115
 chondrolysis and, 1050, 1050
 Duchenne muscular dystrophy and, 641
 with extension contracture, in cerebral palsy, 577
 leg length discrepancy and, 1120
 adduction, of hip, 115
 cerebral palsy and, 115
 developmental dysplasia of hip and, 103–104, 104
 leg length discrepancy and, 1119–1120
 spastic diplegia and, 588
 in arthrogryposis multiplex congenita, 296–299, 850–853
 in cerebral palsy, 115, 576–577, 584–588, 592–593, 843
 in distal arthrogryposis, 301–302
 in Duchenne muscular dystrophy, 640–641
 in Emery-Dreifuss muscular dystrophy, 645–646
 equinovagis, of ankle and foot, in spastic diplegia, 586, 586–587
 equinovarus, of ankle and foot
 in Duchenne muscular dystrophy, 640
 in spastic diplegia, 585–586
 equinus, of ankle and foot
 in Duchenne muscular dystrophy, 640
 in spastic diplegia, 584–585

- Contractures (*contd.*)
 extension, of hip, in cerebral palsy, 576–577
 in fetal alcohol syndrome, 311
 finger, in cerebral palsy, 592–593
 flexion, of hip
 chondrolysis and, 1050
 developmental coxa vara and, 1039
 diastrophic dysplasia and, 259, 261
 Duchenne muscular dystrophy and, 641
 proximal femoral focal deficiency and, 1238
 spastic diplegia and, 588
 spondyloepiphyseal dysplasia congenita and, 263
 tests for, 114–115, 115
 transient synovitis and, 1046
 flexion, of knee
 Duchenne muscular dystrophy and, 641
 hemophilia and, 415–416, 416
 myelomeningocele and, 622
 proximal femoral focal deficiency and, 1238
 in Freeman-Sheldon syndrome, 303
 in hemophilia, 414–415, 414–416
 leg length discrepancy and, 1119–1120
 in melorheostosis, 357
 in metatropic dysplasia, 255–256
 in multiple epiphyseal dysplasia, 269
 in nail-patella syndrome, 312
 in poliomyelitis, 664
 in pterygia syndrome, 303–305
 in Rett syndrome, 329
 Volkmann ischemic, 119, 414, 414
- Contrast materials
 adverse reactions to, 64
 epinephrine and, 65
 for magnetic resonance imaging, 80
 for radiographic procedures, 64–65
- Convex pes valgus, congenital. *See* Vertical talus, congenital
- Cooley anemia, 390
- Cornelia de Lange syndrome, 313, 313–314, 314
 cleft hand and, 870
 clinodactyly and, 871
 congenital radial head dislocation and, 853
 ulnar dysplasia and, 865
- Cortical hyperostosis, infantile, 214–216, 215t, 216
- Cortical irregularity, normal metaphyseal, 67, 67
- Corticosteroids
 for athletes, 1277
 for Diamond-Blackfan anemia, 380
 for Fanconi anemia, 380
 for hemangiomas, 340
 intraarticular injection of, 1277
 for juvenile idiopathic arthritis, 451
 for progressive diaphyseal dysplasia, 357
 skeletal abnormalities associated with, 228
 for systemic arthritis, 443–444
 for unicameral bone cysts, 540
- Cotrel-Duboussier instrumentation system
 for kyphosis, 755
 for scoliosis, 703
- Court testimony in child abuse cases, 1442–1443
- COX (cyclooxygenase) inhibitors, 450
- Coxa magna
 Legg-Calvé-Perthes syndrome and, 967, 968
 spondyloepiphyseal dysplasia tarda and, 266
 transient synovitis of hip and, 1047
- Coxa valga
 progeria and, 317, 317
 after reduction of developmental dysplasia of hip, 935–936, 936
 Rett syndrome and, 329
- Coxa vara
 acquired, 1036, 1037
 classification of, 1036
 conditions associated with
 chondrodysplasia punctata, 271
 cleidocranial dysplasia, 276, 277
 fibrous dysplasia, 229
 multiple epiphyseal dysplasia, 270
 osteopetrosis, 212, 214
 proximal femoral fracture, 1379
 proximal focal femoral deficiency, 1114, 1114
 spondyloepiphyseal dysplasia congenita, 263–265, 264
 congenital, 1036, 1036
 definition of, 1035–1036, 1036
 developmental, 1035–1044
 clinical presentation of, 1038–1039
 epidemiology of, 1037
 etiology of, 1037–1038
 gait in, 1038
 histopathology of, 1038, 1038
 historical descriptions of, 1037
 incidence of, 1037
 leg length discrepancy and, 1036, 1044
 natural history of, 1040
 nonoperative treatment of, 1040
 physical examination for, 1038–1039
 postoperative recurrence of, 1042–1044, 1044
 radiographic features of, 1037, 1039, 1039–1040, 1042
 surgical treatment of, 1040–1042, 1041–1044
- Cozen fracture, 1397–1398, 1399
- Cranial nerves, basilar impression and, 804
- Craniosynostosis, cervical spine problems and, 821–822
- Crank test, 126
- Crankshaft phenomenon, 54, 705, 705
- Crescent sign, 270
- Cretinism, 226
- Crohn disease, rickets and, 192
- Crouzon syndrome, cervical spine problems and, 821–822
- Cruciate ligament injuries
 anterior, 124, 1294–1296
 clinical features of, 1294
- meniscal tears and, 1294
 natural history of, 1295
 nonoperative management of, 1295
 radiographic evaluation of, 1295
 surgical treatment of, 1295–1296
 tests for, 124, 1294–1295
 posterior, 124, 124, 1296
- CT. *See* Computed tomography
- Cubitus valgus
 congenital humeroulnar dislocation and, 855
 lateral condylar fracture and, 1347–1348
 Noonan syndrome and, 318–319
 Turner syndrome and, 318
- Cubitus varus, supracondylar fracture and, 1344
- Cuneiform osteotomy, for slipped capital femoral epiphysis, 1019–1020, 1021
- Curly toe, 1180–1181
 clinical features of, 1180, 1180
 definition of, 1180
 epidemiology of, 1180
 natural history of, 1180
 pathoanatomy of, 1180
 treatment of, 1180–1181
- Cushing syndrome, 228, 228
 systemic arthritis and, 443, 443
- Cutaneous hemangiomas, 340
- Cutaneous osteomatosis, 217
- Cutis marmorata telangiectatica congenita, 341
- Cyclooxygenase (COX) inhibitors, 450
- Cyclophosphamide, 528
- Cylinderization, 27, 27
- Cyst
 Baker, 123
 bone, 538–542
 aneurysmal, 540–542, 541, 542
 lower extremity, 117
 unicameral, 538–540, 540
 hemophilic, 415, 416
 popliteal, 1309
- Cystathione synthetase deficiency, 221
- Cystic fibrosis, 168
 arthritis and, 437
 uniparental disomy and, 171
- Cytosin. *See* Cyclophosphamide
- D**
- Dactinomycin, 528
- Dactylitis
 sickle cell disease and, 385–386
 tuberculous, 498
- DDH. *See* Developmental dysplasia of hip
- de Lange syndrome, 313, 313–314, 314
 cleft hand and, 870
 clinodactyly and, 871
 congenital radial head dislocation and, 853
 ulnar dysplasia and, 865
- Debridement, surgical, for bone and joint sepsis, 480–481, 481
- Dejerine-Sofia disease, 657t, 658. *See also* Hereditary motor sensory neuropathies

- Demerol. *See* Meperidine
- Denis-Browne bar, for metatarsus adductus, 1163
- Dental abnormalities
osteogenesis imperfecta and, 204
renal osteodystrophy and, 196
rickets and, 187
- Dermatome, 18, 19, 28
- Dermatomes, 12, 12
- Dermomyotome, 18, 19, 28
- Determination (cellular), 9, 28
- Development
in achondroplasia, 247–248, 248
average developmental achievement by age, 104t
maturation of gait, 144–145
myelomeningocele and, 606–607
- Developmental anatomy, 1–29
early embryogenesis and organogenesis, 2–8, 2–9
of hip, 906–909, 906–909
intrauterine growth, 39
of limbs, 9–18, 10–16
upper limb, 842
of nervous system, 5–7, 5–7, 22–23
brain, 563–564
terms related to, 27–29
of vertebral column, 18–22
cervical spine, 799–800
- Developmental coxa vara, 1035–1044
clinical presentation of, 1038–1039
epidemiology of, 1037
etiology of, 1037–1038
gait in, 1038
histopathology of, 1038, 1038
historical descriptions of, 1037
incidence of, 1037
leg length discrepancy and, 1036, 1044
natural history of, 1040
nonoperative treatment of, 1040
physical examination for, 1038–1039
postoperative recurrence of, 1042–1044, 1044
radiographic features of, 1037, 1039, 1039–1040, 1042
surgical treatment of, 1040–1042, 1041, 1042
indications for, 1041
premature physal plate closure after, 1042, 1043
results of, 1042–1044, 1043, 1044
timing of, 1041–1042
- Developmental dysplasia of hip (DDH), 905–946
causes of, 912
conditions associated with
arthrogryposis multiplex congenita, 102, 297, 297–298
fetal alcohol syndrome, 311
metatarsus adductus, 102, 1162
diagnosis of, 913–918
Barlow test, 103, 103, 913, 919
imaging, 915–919
computed tomography, 72, 73
magnetic resonance imaging, 919
radiographic measurements, 916–919, 918, 919
ultrasound, 75, 76, 77, 915–916, 917, 918
late, 913–915, 914–917
Ortolani maneuver, 103, 103, 906, 909, 913
etiology of, 102
incidence of, 913
natural history of, 919–925
course in adults, 920, 920, 921
course in newborns, 919–920
course of dysplasia and subluxation, 921–925, 922–924
normal growth and development of hip, 906–909, 906–909
pathoanatomy of, 909–910
acetabular development and, 910, 911
dislocations in newborns, 909–910, 910
physical examination for, 102–104, 103, 104
risk factors for, 912–913, 913t
sequelae and complications of treatment for, 935–946
disturbance of growth of proximal femur, 941–946, 942, 944–946
residual femoral and acetabular dysplasia, 935–941, 936–941
terminology for, 905–906
treatment of acetabular dysplasia in children 6 months to 2 years of age, 934
treatment of hip dislocation, 925–935
arthrography during, 70, 930
in children 6 months to 2 years of age, 928–933, 929–933
closed reduction, 930–931, 930–931
open reduction, 931–933, 933
prereduction traction, 928–930, 930
in children older than 2 years of age, 933–934, 934
intraarticular obstacles in late-diagnosed cases, 914
in newborns and infants younger than 6 months of age, 925–928, 926–928
- Developmental history, 100
- Developmental milestones, 104t, 567t
- DEXA (dual energy x-ray absorptiometry), 89–90
- Diabetes insipidus, Langerhans cell histiocytosis and, 403
- Diabetes mellitus
fibrous dysplasia and, 535
maternal, 173
- Diamond-Blackfan anemia, 380
- Diaphyseal aclasia, 274–275
clinical features of, 274
genetics of, 274
orthopaedic implications of, 275
radiographic features of, 274, 274–275, 275
- Diaphyseal dysplasia, progressive, 355–357, 356
clinical features of, 355
differential diagnosis of, 356
etiology of, 356
pathology of, 356
radiographic features of, 355–356, 356
treatment of, 356
- Diastematomyelia, 22
myelomeningocele and, 608
- Diastrophic dysplasia, 244, 258–261
classification of, 245t
clinical features of, 258, 258–260
clinodactyly and, 879
genetics of, 258
kyphosis and, 258, 259, 260, 765
prenatal diagnosis of, 260
radiographic features of, 259, 260, 260
treatment of, 260–261
- Dicloxacillin, 479t
- Digital Imaging and Communications in Medicine (DICOM), 69
- Digital radiography, 69
- 1,25-Dihydroxyvitamin D, 182–184, 183–184
idiopathic juvenile osteoporosis and, 211
for osteopetrosis, 213
to prevent corticosteroid-induced bone loss, 228
renal osteodystrophy and, 194, 196
vitamin D-resistant rickets and, 192–193
- Diplegia. *See also* Spastic diplegia
cerebral palsy and, 565
- Disappearing bone disease. *See* Gorham disease
- Disclitis, 482, 483
cervical, 832
- Discoid lateral meniscus, 1309–1311
classification of, 1309–1310
clinical presentation of, 1310
differential diagnosis of, 1310
treatment of, 1310–1311
Wrisberg ligament-type, 1310, 1311
- Dislocation
atlantooccipital, 823–824, 824, 825
elbow, 1352–1354
complications of, 1354
congenital humeral, 854–855
examination for, 119
finger, 893–894
hip, 1372, 1372–1373
CT evaluation after reduction of, 72, 73
Down syndrome and, 308, 308–309
high-riding, 1112, 1113
Larsen syndrome and, 279, 300–301
McKusick-type metaphyseal chondrodysplasia and, 273
mechanism of injury, 1372
spastic quadriplegia and, 575–576, 576
spinal muscular atrophy and, 654
treatment of, 1372–1373
knee, congenital, 1095–1098
patellar
acute, 1306–1308
recurrent, 1308–1309, 1308–1310
radial head, 1354, 1354–1355, 1355
congenital, 853–854, 854
in nail-patella syndrome, 311, 312, 313
shoulder, 1335

- Dissociative anesthesia, 1332
- Distal interphalangeal joints, in
clinodactyly, 879
- Distal metatarsal articular angle, 1200,
1200–1201
- Distal muscular dystrophy, 648
- Distraction epiphyseolysis, 1138
- Disuse atrophy, 211–212, 212
- DMD gene, in Duchenne muscular
dystrophy, 169, 175
- DNA, 2, 7–8
for mutational analysis, 161–162
of sarcomas, 508
structure of, 158, 159
translation of, 159–160
- Dorsal root ganglia, 22
- Dorsal-ventral axis determination, 5, 10,
11, 16, 16
- Dorsalin-1, 23
- Down syndrome, 305–310
atlantoaxial instability in, 305, 306, 802,
802, 815–817, 818
chromosome abnormality in, 162, 163,
305
clinical features of, 305–306, 306, 310
natural history of, 310
orthopaedic disorders in, 308–310
prenatal diagnosis of, 305
radiographic features of, 306–308,
306–308
- Doxorubicin, 528
for osteosarcoma, 523
- Dual energy x-ray absorptiometry (DEXA),
89–90
- Duchenne muscular dystrophy, 637–644
cardiac involvement in, 637, 638
clinical features of, 637–638, 638
diagnosis of, 637–639
clinical, 637–638
electromyography, 638
genetic and molecular biology studies,
639
hematological studies, 638
muscle biopsy, 638
gait in, 146, 637
genetic and psychologic counseling
about, 644
genetics of, 169, 637, 639
progression of, 638
treatment of, 639–643
cardiopulmonary management, 643
fracture management, 640
functional testing, 640
gene therapy, 175, 639
orthoses, 640
physical therapy, 639–640
surgery, 640–643
foot and ankle, 640–641
hip, 641
knee, 641
spinal deformity, 641–643,
642–643
upper extremity, 641
wheelchair use, 643
- Dwarfism, 244. *See also* Short stature
metatropic, 254–257, 255, 256
Russell-Silver, 317, 317–318
- Dynamic electromyography, 149, 151
- Dyschondrosteosis, 275–276
clinical features of, 275
genetics of, 275
orthopaedic implications of, 276
radiographic features of, 275–276, 276
- Dysplasia epiphysealis hemimelica,
361–362
clinical features of, 362
etiology of, 362
histopathology of, 362
radiographic features of, 362, 363
treatment of, 362
- Dystrophin, 639
- E**
- Ear abnormalities
in diastrophic dysplasia, 258
in Goldenhar syndrome, 322, 322
- Ectoderm, 5, 5–7
- Ectrodactyly. *See* Cleft foot
- Ehlers-Danlos syndrome, 220, 220–221
clinical features of, 220
types of, 220–221
- Elbow
assessment for bone age determination,
42, 43, 44–49
carrying angle of, 1338
congenital humeroulnar dislocation,
854–855
conditions associated with, 855
natural history of, 855
surgical treatment of, 855
“floating,” 1337
joints of, 1338
in specific conditions
arthrogryposis multiplex congenita,
850–852
brachial plexopathy, 850
cerebral palsy, 591–592, 843, 845
hemophilia, 410, 413
juvenile idiopathic arthritis, 453
olecranon apophysitis, 1283
poliomyelitis, 665
Turner syndrome, 318
ulnar dysplasia, 866
synostosis, 858
valgus overload injures of, 1287,
1287–1289
injuries of medial epicondyle, 1289
osteochondral lesions of capitellum,
1287–1288, 1288
osteochondral lesions of radial head,
1288
- Elbow replacement, for juvenile idiopathic
arthritis, 453
- Elbow trauma, 1338–1355
compartment syndrome after, 119
dislocation, 1352–1354
evaluation of, 118–119, 1338–1339
fracture-separation of distal humeral
physis, 1349–1350, 1350
- lateral condyle fracture, 1344–1348,
1345–1348
- lateral epicondyle fracture, 1348
- medial condyle fracture, 1349
- medial epicondyle fracture, 1348–1349,
1349
- olecranon fracture, 1352, 1352, 1353
- radial head dislocation and nursemaid’s
elbow, 1354, 1354–1355, 1355
- radial neck fracture, 1350–1352, 1351
- supracondylar fracture, 1339–1344,
1340–1344
- T-condylar fracture, 1344
- Electromyography (EMG), 635
in Duchenne muscular dystrophy, 638
dynamic, 148, 151
myopathic, 635
- Elmslie-Trillat procedure, 1309, 1310
- Ely test, 115–116, 116
- Embryogenesis, 2–9. *See also*
Developmental anatomy
cleavage, 2, 2–3, 3
clinical significance of, 9
conceptual insights of, 7–9
cell differentiation, 9
morphogenesis, 9
pattern formation, 8
early organogenesis, 5–7, 6–8
embryonic and fetal periods of, 2
implantation and gastrulation, 3–5, 4, 5
- Embryonic stem cells, 28, 175
- Emery-Dreifuss muscular dystrophy,
644–646
cardiac involvement in, 645, 646
clinical features of, 644–645
genetics and molecular biology of, 645
treatment of, 645–646
physical therapy, 645
soft tissue contractures, 645–646
spinal stabilization, 646
- EMG. *See* Electromyography
- Encephalocele, Goldenhar syndrome and,
324
- Enchondromas, 528–529, 529
leg length discrepancy and, 1117
Maffucci syndrome and, 341–342, 529
multiple (Ollier disease), 529
- Endochondral bone, 24, 178
- Endocrine disorders, 221–230
fibrous dysplasia, 228–230, 229
glucocorticoid-related abnormalities, 228,
228
gonadal abnormalities and sex steroids,
226–228
growth hormone deficiency and
hypopituitarism, 225, 225–226
growth patterns and, 222–224, 222–224
hypothyroidism, 226, 226–227
normal variant short stature, 224–225
slipped capital femoral epiphysis and,
1002
- Endoderm, 5, 5–6
- Energetics, 149, 151–152
- Energy requirements of athletes,
1274–1275

- Engelmann-Camurati disease, 214, 215r
 Engrailed-1, 13
 Enthesitis-related arthritis, 429t, 430
 screening eye exams in, 445t
 Enzyme deficiency disorders, 167–168
 mucopolysaccharidoses, 324–327, 324t
 Eosinophilic granuloma of bone. *See*
 Langerhans cell histiocytosis
 Epiblast, 28
 Epicondylar fracture
 lateral, 1348
 medial, 1289, 1348–1349
 mechanism of injury, 1348
 treatment of, 1348–1349, 1349
 Epinephrine, use with radiographic contrast
 materials, 65
 Epiphyseal plate. *See* Physis
 Epiphyseodesis
 for adolescent Blount disease, 1079
 for infantile Blount disease, 1073
 for juvenile idiopathic arthritis, 452
 for Klippel-Trenaunay syndrome, 345
 for leg length discrepancy, 56–58, 57,
 1133, 1133–1134, 1134
 open bone peg, for slipped capital
 femoral epiphysis, 1016–1018,
 1017
 physal fracture and, 1324
 for posterior medial bowing of tibia,
 1094
 Epiphyseolysis
 of distal radius, 1279–1280, 1280
 distraction, 1138
 of proximal humerus, 1279, 1279
 Epiphysis, 178, 179, 1321
 age and blood supply to, 462, 463
 in dysplasia epiphysealis hemimelica,
 361–362, 363
 effect on mechanical properties of bone,
 1320–1321
 hemispherization of, 27, 27
 in Kniest dysplasia, 262, 262
 on magnetic resonance imaging, 82, 83
 in metatropic dysplasia, 256
 in multiple epiphyseal dysplasia, 269,
 269–270
 normal age-related variants of, 65, 65,
 82
 in pseudoachondroplasia, 268, 268
 in rickets, 187–190, 188–189
 in trichorhinophalangeal syndrome, 323,
 323, 324
 in type I homocystinuria, 221
 Erlenmeyer-flask deformity, 399, 399
 Erythema marginatum, 436
 Erythrocyte disorders, 383–392
 anemia of chronic inflammation,
 391–392
 iron-deficiency anemia, 383
 sickle cell disease, 383–389, 384t,
 385–387, 388t, 389
 thalassemia, 389–391, 391
 Erythropoietin, 9
Escherichia coli infection, 477
 Escobar syndrome, 303, 303–305, 304
- Estrogens
 bone formation and, 180
 growth and, 227
 Ewing sarcoma, 507, 542–544
 in cervical spine, 835
 clinical features of, 542
 differentiation from osteomyelitis, 474
 histology of, 543, 544
 molecular biology of, 508, 508t
 radiographic features of, 542–544, 543
 treatment of, 544
 Exercise. *See* Sports medicine
 Exostosis, 529–531, 530
 of cervical spine, 833
 fibrodysplasia ossificans progressiva and,
 364
 growth of, 530
 malignant degeneration of, 530
 multiple, 531
 secondary chondrosarcoma and, 531
 multiple osteocartilaginous, 274,
 274–275, 275
 Proteus syndrome and, 345
 radiographic features of, 529–530, 530
 sessile vs. pedunculated, 530
 trichorhinophalangeal syndrome and,
 323
 Expert witnesses, 1443
EXT1 gene, in Langer-Giedion syndrome,
 163, 323
 Extensor carpi ulnaris muscle, in cerebral
 palsy, 845
 Extensor thrust reflex, 107–108, 108
 Eye abnormalities
 arthritis and, 444, 445t
 Goldenhar syndrome and, 323, 323
- F**
 FABER test, 112, 112
 Factor IX deficiency, 408–409, 410
 Factor VIII deficiency, 408–409, 411. *See*
 also Hemophilia
 Fairbanks dysplasia, 269
 Falls, 111, 1439
 Familial cervical dysplasia, 808, 808
 Familial dysautonomia, 314–315, 315
 Fanconi anemia, 380
 radial dysplasia and, 861
 thumb hypoplasia/aplasia and, 880
 Farber disease, 396t
 Fascial-genital-popliteal syndrome, 304,
 305
 Fascioscapulohumeral muscular dystrophy,
 647–648
 infantile, 646–647, 647
 Fascioscapulohumeral muscular dystrophy,
 infantile, 646–647
 Fasciotomy for compartment syndrome,
 1329, 1329, 1330
 Fat
 on magnetic resonance imaging, 78
 on plain radiographs, 64, 67
 Fat pad(s)
 displacement or effacement of, 64, 67
 at elbow, 1338
 impingement at knee, 1305
- Femoral fractures, 1373–1389
 complex, 1387–1388
 “floating knee,” 1387–1388, 1389
 subtrochanteric fractures, 1388
 complications of, 1388–1389
 distal, 80, 1431
 due to child abuse, 1431–1432, 1432
 leg length discrepancy and, 1118,
 1379–1382, 1381, 1388
 myelomeningocele and, 629
 proximal, 1373–1379
 anatomy and classification of,
 1373–1376, 1375
 avascular necrosis and, 1374–1377
 due to child abuse, 1428–1429
 malunion of, 1378
 mechanism of injury, 1373
 nonunion of, 1377–1378
 treatment of, 1376, 1377, 1378
 shaft, 1379–1387, 1380, 1381
 cast brace and home traction for,
 1383
 early-fit spica cast for, 1382–1383,
 1383, 1384
 external fixation of, 1383–1386,
 1385, 1386
 intramedullary fixation of,
 1386–1387, 1387
 management by age, 1382
 management principles for,
 1379–1382
 mechanism of injury, 1379
 plate fixation of, 1387, 1388
 skeletal traction for, 1383, 1385
 stress, 1278
 Femoral nerve palsy, after iliopsoas bleed in
 hemophilia, 414
 Femur
 anatomic and mechanical axes of, 1078
 antetorsion of, 72, 1060, 1061
 congenital shortening of, 1114, 1114,
 1115
 correction of excess internal or external
 rotation of, 1063–1064
 distal
 exostosis of, 530
 hypophosphatasia and, 200
 nonossifying fibroma of, 534
 normal age-related distal epiphyseal
 irregularity, 65, 65
 normal metaphyseal cortical
 irregularity of, 67, 67
 osteosarcoma of, 521, 523, 525,
 526–527
 growth of, 55
 in idiopathic juvenile osteoporosis, 210
 length including epiphyses, 1223t, 1224t
 metaphyseal-diaphyseal angle of, 1066,
 1067, 1068
 neck-shaft angle of, 1035, 1036
 ossification of, 65
 in osteogenesis imperfecta, 207, 207
 osteonecrosis of head of
 in Gaucher disease, 401, 401
 in sickle cell disease, 387, 388, 388t,
 389

Femur (*contd.*)

- proximal (*See also* Hip)
 - anatomy of, 1373–1374
 - in chondrolysis of hip, 1050–1052, 1050–1053
 - deficiency of, 1237–1246 (*See also* Proximal femoral focal deficiency)
 - in developmental coxa vara, 1035–1044 (*See also* Coxa vara)
 - in developmental dysplasia of hip, 905–946 (*See also* Developmental dysplasia of hip)
 - fractures of, 1373–1379
 - growth disturbance after reduction of hip dislocation, 941–946, 942, 943t, 944–946
 - histology of, 962, 962, 963
 - in Legg-Calvé-Perthes syndrome, 957–991 (*See also* Legg-Calvé-Perthes syndrome)
 - normal growth of, 907–909, 908
 - ossification of, 1373, 1373–1374
 - osteoid osteoma of, 117, 518
 - shortening of, for leg length discrepancy, 1134–1135
 - skeletal dysplasias related to fetal length of, 245–246
 - slipped capital femoral epiphysis, 999–1029 (*See also* Slipped capital femoral epiphysis)
 - unicameral bone cyst of, 539, 540
 - vascular supply of, 77, 77, 959–960, 960, 1374, 1374
 - shortening of, for leg length discrepancy, 1135
- “Fencing position,” 107, 107
- Fentanyl, 93, 1331–1332, 1331t
- Fetal alcohol effects, 310
- Fetal alcohol syndrome, 288, 310, 310–311
 - cervical spine and, 311, 820
- α -Fetoprotein, 174
- FGFR3* gene
 - in achondroplasia, 161, 166–167, 245, 245t, 247
 - in hypochondroplasia, 254
- Fibrillin
 - Marfan syndrome and, 161, 680
 - scoliosis and, 680
- Fibroblast growth factor, 13–14, 178t
- Fibrodysplasia ossificans progressiva, 218, 362–366
 - clinical features of, 364, 365–366
 - cervical spine problems, 364, 822
 - etiology of, 363–364
 - histopathology of, 364
 - radiographic features of, 364, 365–366
 - treatment of, 364–366
- Fibrolipomatosis, 350
- Fibroma, nonossifying, 534, 534–535, 535
- Fibroma molluscum, 289
- Fibromatoses, 545–546, 546
- Fibromyalgia, 439
- Fibrous cortical defect, 534–535
- Fibrous dysplasia, 228–230, 229, 535–536, 536

- classification of, 228
 - clinical features of, 228–229
 - cutaneous features of, 229
 - differentiation from Albright hereditary osteodystrophy, 202
 - histology of, 536, 536
 - leg length discrepancy and, 1117
 - management of, 229–230
 - McCune-Albright syndrome, 229
 - monostotic vs. polyostotic, 535
 - radiographic features of, 229
 - rickets and, 193
 - scoliosis and, 680
 - treatment of, 536
- Fibula
- Brown procedure for centralization of, 1234, 1236
 - congenital pseudarthrosis of, 1091–1092
 - definition of, 1091
 - pathology of, 1091–1092
 - treatment of, 1092
 - distal
 - ossification centers of, 1401
 - tibiofibular sprains, 1293
 - fractures of, 1398, 1403
 - stress, 1278
 - transverse and comminuted, 1400–1401
- Fibular deficiency, congenital, 1227–1230, 1227–1233
- bony overgrowth and, 1225
 - classification of, 1227, 1227–1228
 - clinical appearance of, 1229–1230, 1230
 - incidence of, 1218
 - proximal femoral focal deficiency and, 1238
 - radiographic appearance of, 1227–1229, 1229–1230
 - treatment of, 1230–1233
 - amputation, 1230–1231
 - ankle reconstruction, 1233
 - bilateral deficiencies, 1231
 - correction of tibial bow, 1232
 - correction of valgus, 1232–1233
 - limb lengthening and limb salvage, 1231
 - prosthetic management, 1233
 - Syme and Boyd amputation, 1231–1232
- Fingers. *See also* Hand; Thumb
- amputations of, 895, 895, 896
 - finger tip, 887
 - camptodactyly, 877–879, 878
 - clinodactyly, 879
 - contractures in cerebral palsy, 592–593
 - dislocations of, 893–894
 - macroductyly, 350–352, 351
 - mallet fingers, 888
 - polydactyly, 17, 876, 876–877, 877
 - syndactyly, 870–871
 - syndactyly, 17, 873–875, 873–875
- Flatfoot
- examination for, 117–118, 118, 1169
 - flexible, 1152, 1168–1174
 - clinical features of, 1169, 1169, 1170
 - definition of, 1168

- epidemiology of, 1152, 1168–1169
 - natural history of, 1170, 1171
 - nonoperative management of, 1172
 - pathogenesis of, 1169
 - radiographic features of, 1169–1170, 1171
 - spontaneous improvement in, 1152
 - surgical treatment of, 1172–1174, 1173
- juvenile hallux valgus and, 1200
- rigid
- causes of, 1184
 - due to tarsal coalition, 1182–1186
 - out-toeing and, 1062
 - with talonavicular dislocation (*See* Vertical talus, congenital)
- Flexor carpi ulnaris muscle
- in arthrogryposis multiplex congenita, 852–853
 - in cerebral palsy, 845
- Flexor pollicis longus muscle, trigger thumb and, 879
- “Floating knee,” 1387–1388, 1389
- Flumazenil, 1331t, 1332
- FMRI* gene, in fragile X syndrome, 169
- Focal fibrocartilaginous dysplasia, 1068, 1069
- Folate, neural tube defects and, 22, 23, 604
- Follicle-stimulating hormone, 225
- Foot, 1151–1208
- acquired affections of, 1203–1208
 - Freiberg infraction, 1205–1206, 1206
 - Kohler disease, 1203–1205, 1204, 1409
 - Sever apophysitis, 119–120, 1206–1208, 1207, 1282
 - amputation of, for proximal femoral focal deficiency, 1243
 - anatomy of, 1409
 - arthrodesis for deformities of, 1153
 - congenital deformities of, 1153–1181
 - clubfoot, 1153, 1153–1161, 1155–1158
 - curly toe, 1180, 1180–1181
 - flexible flatfoot, 117–118, 118, 1152, 1168–1174, 1169–1171, 1173
 - metatarsus adductus, 1152, 1161–1164, 1161–1164
 - overriding fifth toe, 1178–1180, 1179
 - positional calcaneovalgus, 1152, 1178, 1178
 - skewfoot, 1164–1168, 1165–1168
 - vertical talus, 1152, 1174, 1174–1178, 1175, 1177
 - congenital malformations of, 1181–1194
 - accessory navicular, 1181–1182, 1182
 - cleft foot, 1192–1194, 1193, 1194
 - congenital hallux varus, 1186–1188, 1187
 - macroductyly, 1191–1192, 1191
 - polydactyly/polysyndactyly, 1188–1190, 1189–1190
 - syndactyly, 1190–1191, 1190
 - tarsal coalition, 1182–1186, 1183, 1184, 1185

- developmental deformities of,
1194–1203
cavus foot, 1152, 1194–1199,
1195–1197, 1199
juvenile hallux valgus, 1200,
1200–1203, 1201, 1203
evaluation in weight-bearing position,
1153
fractures of, 1408–1414
calcaneus, 1411, 1412
metatarsals, 1411–1412, 1413
midfoot, 1411
phalanges, 1412–1414
talus, 1409–1411, 1410
growth of, 56
interventions related to growth and
development of, 1152
management principles for, 1151–1153
multiple deformities of, 1153
natural history of conditions of, 1152
normal tripod structure of, 1196, 1196
physiologic variations in shape of,
1151–1152
prosthetic, 1262–1263, 1263
partial foot prosthesis, 1263–1264,
1264
puncture wounds of, 494–496, 495
rotational variation of, 1059–1065 (*See also* Rotational variation of lower
extremity)
in specific conditions
arthrogryposis multiplex congenita,
298
Becker muscular dystrophy, 644, 645
chondrodysplasia punctata, 271
diastrophic dysplasia, 259, 261
distal arthrogryposis, 302
Down syndrome, 309, 310
Duchenne muscular dystrophy,
640–641
fetal alcohol syndrome, 311
fibular deficiency, 1228, 1229, 1230,
1230
Freeman-Sheldon syndrome, 302, 303
Friedreich ataxia, 656
hereditary motor sensory neuropathies,
658–661, 659, 661
Larsen syndrome, 278, 279, 279, 299,
301
multiple pterygium syndrome, 304
myelomeningocele, 622–628, 1194,
1195
nail-patella syndrome, 312
poliomyelitis, 666
popliteal pterygium syndrome, 304
Proteus syndrome, 295, 345, 346
Russell-Silver syndrome, 318
spastic diplegia, 585–587, 586
spondyloepiphyseal dysplasia
congenita, 263, 265
thalassemia, 390
Foot-placement reaction, 107t, 108, 109
Foot-progression angle, 105, 105, 114,
1060
Foramen magnum compression, in
achondroplasia, 248, 248, 250
Forearm, 853–861
brachial plexopathy and, 850
congenital pseudarthrosis of, 860,
860–861
congenital radial head dislocations,
853–854, 854
congenital radioulnar synostosis,
855–858, 857
fasciotomy of, 1329, 1329, 1330
fractures of, 1355–1366
complete shaft fractures, 1359–1363,
1360–1363
complications of, 1362–1363, 1363
distal metaphyseal fractures of radius
and ulna, 1364–1365, 1364–1366
distal radius physeal fracture,
1365–1366
Galeazzi fracture-dislocation, 1357
midshaft green-stick fractures,
1358–1359, 1359
Monteggia fracture-dislocation, 1356,
1356–1358
plastic deformation, 1357
hyperpronation of, in cerebral palsy,
843, 845
osteochondromatosis of, 858–860, 859
poliomyelitis and, 665
radial dysplasia, 861–865, 862, 863, 865
transverse incomplete deficiency of,
1250, 1251
myoelectric vs. body-powered
protheses for, 1250, 1251t
ulnar dysplasia, 865–868, 867, 868
Foreign body synovitis, 437
Forward-bending test, 114, 120, 120–121,
685, 686
Fractures, 1319–1414. *See also* specific
types
ankle, 1401–1407
classification of, 1402
high-risk, 1403–1405, 1404
low-risk, 1402, 1403
Tillaux fracture, 71, 1401, 1405,
1405–1406
transitional, 1401, 1405–1406,
1405–1408
triplane fracture, 1401, 1406,
1406–1408
bone anatomy and, 1321
bone biomechanics and, 1320–1321
bone physiology and, 204–205,
1321–1322, 1322
buckle, 1320
cervical spine, 824–827
atlas, 824
C3–7, 827, 827, 828
odontoid, 824–827, 826
on computed tomography, 71–72
Cozen, 1397–1398, 1399
dating of, 1436–1437, 1437, 1437t
due to child abuse, 1423–1443
due to falls, 111, 1439
elbow, 1338–1352
fracture-separation of distal humeral
physis, 1349–1350, 1350
lateral condyle, 1344–1348,
1345–1348
lateral epicondyle, 1348
medial condyle, 1349
medial epicondyle, 1348–1349, 1349
olecranon, 1352, 1352, 1353
radial neck, 1350–1352, 1351
supracondylar, 1339–1344,
1340–1344
T-condylar, 1344
femur, 1373–1389
complex, 1387–1388
proximal, 1373–1379
shaft, 1379–1387
subtrochanteric, 1388
foot, 1408–1414
calcaneus, 1411, 1412
metatarsals, 1411–1412, 1413
midfoot, 1411
phalanges, 1412–1414
talus, 1409–1411, 1410
forearm and wrist, 1355–1366
complete shaft fractures, 1359–1363,
1360–1363
distal metaphyseal fractures of radius
and ulna, 1364–1365, 1364–1366
distal radius physeal fracture,
1365–1366
Galeazzi fracture-dislocation, 1357
midshaft green-stick fractures,
1358–1359, 1359
Monteggia fracture-dislocation, 1356,
1356–1358
plastic deformation, 1357
green-stick, 1320
growth acceleration after, 1322
hand, 887–891
metacarpal, 889–890
phalangeal, 886, 887–889, 889
thumb, 890, 890–891
hangman, 827
healing of, 204, 1321–1322, 1322
hip, 1373–1379
incidence of, 1320
initial management of, 1327–1332
compartment syndromes, 1328–1329,
1329, 1330
emergency department anesthesia and
analgesia, 1329–1332
blocks, 1330–1331
dissociative anesthesia, 1332
sedation, 1331–1332, 1331t
multiple trauma evaluation and
management, 1327
Glasgow Coma Scale, 1327, 1327t
Pediatric Trauma Score, 1327,
1328t
open fractures, 1327–1328, 1328t
Jefferson, 824
Jones, 1411

Fractures (*contd.*)

- knee, 1389–1396
 - distal femoral physal separations, 1389–1390, 1390–1392
 - patellar fracture, 1394–1396, 1395–1396
 - tibial spine fracture, 1390–1393, 1393
 - tibial tubercle fracture, 1393–1394, 1394, 1395
- leg length discrepancy and, 1114–1116, 1115, 1116, 1118
- “march,” 1277
- nonunion of, 1321
- pelvis, 1369–1371, 1370
 - acetabulum, 1370–1371
 - avulsion, 1298, 1298
 - pelvic ring, 1370, 1371
- phalangeal
 - foot, 1408, 1412–1414
 - hand, 886, 888–889, 889
- physal, 1114–1116, 1115, 1116, 1323–1327
 - growth arrest after, 1324–1327, 1325, 1326
 - Salter-Harris classification of, 1114–1116, 1115, 1323–1324, 1324
- scaphoid, 71, 891, 891
- shoulder and humerus, 1332–1337
 - birth injuries, 1332
 - clavicular fractures, 1332–1334, 1333, 1334
 - humeral shaft fractures, 1335–1337
 - proximal humerus fractures, 1335, 1336, 1337
 - scapular fractures, 1334–1335
- in specific conditions
 - brachial plexus birth palsy, 847, 1332
 - Duchenne muscular dystrophy, 640
 - familial dysautonomia, 314
 - fibrous dysplasia, 229
 - Gaucher disease, 400–401, 401
 - Hadju-Cheney syndrome, 327
 - hemophilia, 415–416
 - hypophosphatasia, 200
 - leukemia, 419
 - myelomeningocele, 629
 - nonossifying fibroma, 535
 - osteogenesis imperfecta, 204–209
 - osteopetrosis, 214
 - osteosarcoma, 524
 - progeria, 317
 - rickets, 198
 - thalassemia, 390
 - tumors, 511
 - Turner syndrome, 318
- stress, 1277–1279
- suspicious patterns of, 1436
- thoracic and lumbar spine, 1366–1368
 - burst fractures, 1368
 - compression fractures, 1367–1368, 1368
 - lapbelt (Chance) fractures, 1368, 1369
 - limbus (apophyseal) fracture, 1368

- tibial, 1396–1401
 - distal, 1401–1407, 1403, 1404
 - proximal epiphysis, 1396–1397, 1397, 1398
 - proximal metaphysis, 1397–1398, 1399
 - shaft, 1398–1401, 1400, 1401
- Tillaux, 71, 1401, 1405, 1405–1406
- “toddler’s,” 1400, 1436, 1436
- triplane, 1401, 1406, 1406–1408
- Fragile X syndrome, 164, 169
- Fragilitas ossium, 205
- Freeman-Sheldon syndrome, 303
- Freiberg infraction, 1205–1206
 - clinical features of, 1205
 - definition of, 1205
 - epidemiology of, 1205
 - natural history of, 1205
 - nonoperative management of, 1205–1206
 - pathogenesis of, 1205
 - pathological stages of, 1205
 - radiographic features of, 1205, 1206
 - surgical treatment of, 1206
- Friedreich ataxia, 656–657
 - clinical features of, 656
 - genetics and molecular biology of, 656
 - treatment of, 656–657
 - painful muscle spasms, 657
 - pes cavovarus, 656
 - spinal deformity, 121, 656–657
- Frontal bossing, rickets and, 187
- Fucosidosis, 398t
- Fukuyama congenital muscular dystrophy, 651
- Fulcrum test, 126
- Fulkerson procedure for patellar dislocation, 1309, 1310
- Funnelization, 27, 27

G

- G proteins
 - Albright hereditary osteodystrophy and, 202
 - McCune-Albright syndrome and, 229
- Gadolinium, 80
- Gait, 131–148
 - antalgic, 145
 - cleidocranial dysplasia and, 276
 - common deviations of, 145–148
 - ankle, 146
 - hip, 147–148
 - knee, 146–147
 - primary vs. secondary, 145
 - developmental coxa vara and, 1038
 - Down syndrome and, 305
 - Duchenne muscular dystrophy and, 146, 637
 - foot-progression angle and, 105, 105, 114, 1060
 - idiopathic toe walking, 113–116, 114–116, 1098–1100, 1099
 - leg length discrepancy and, 1106, 1106–1107
 - Legg-Calvé-Perthes disease and, 117
 - maturation of, 145
 - normal, 133–135, 134
 - pseudoachondroplasia and, 267
 - renal osteodystrophy and, 195
 - rickets and, 187
 - Trendelenburg, 117, 121
- Gait analysis, 148–152
 - in cerebral palsy, 567
 - spastic diplegia, 578, 578, 579
 - clinical and research applications of, 132–133, 152
 - historical studies, 131–132, 132, 133
 - laboratories for, 132, 148
 - in myelomeningocele, 603, 603–604
 - observational, 148, 149
 - quantitative, 132, 148–152
 - dynamic electromyography, 149, 151
 - energetics, 149, 151–152
 - kinematic, 148–149
 - kinetic, 148–151
 - for toe walking, 1099
- Gait cycle, 135–142
 - ankle in, 139–140, 140
 - hip in, 142, 142
 - knee in, 140–142, 141
 - pelvis/trunk/upper extremities in, 143
 - running, 143–145, 144
 - stance phase of, 135, 135, 136, 137t
 - swing phase of, 135, 135, 138, 138, 139t
- Galeazzi fracture-dislocation, 1357
- Galeazzi procedure for patellar dislocation, 1308, 1309
- Galeazzi sign, 104, 104, 914, 914
- Gallant reflex, 108
- Gallium 67 scans, 513
- Gastrointestinal disorders
 - cerebral palsy and, 566
 - nonsteroidal antiinflammatory drug-induced, 566
 - rickets and, 192
- Gastrulation, 3–5, 4, 5, 28
 - vertebral column development and, 18, 19, 21
- Gaucher disease, 168, 396t, 398–402, 399–401
 - clinical features of, 398, 399
 - Erlenmeyer-flask deformity in, 399, 399
 - fractures in, 400–401, 401
 - Gaucher crisis, 399–400, 400
 - genetics of, 398–399
 - management of, 401–402
 - osteonecrosis in, 401, 401
- GDF-5 (growth and differentiation factor 5), 16
- Gene knock-out, 28
- Gene therapy, 175, 509–510
- Genes. *See also* specific genes
 - homeobox, 2, 6, 15–16, 16, 21, 28
 - limb development and, 17, 842
 - vertebral column development and, 21
 - homeotic, 8, 28
 - homologous, 28
 - oncogenes, 508–509
 - tumor suppressor, 508–509
- Genetic counseling, 171, 173–174
 - about burden of genetic disease, 173–174

- about Duchenne muscular dystrophy, 644
- about skeletal dysplasias, 246
- diagnostic precision for, 173
- for estimation of recurrence risk, 173
- indications for, 173
- prenatal, 174
- Genetics, 157–175
 - bone formation and, 180–181
 - chromosome disorders, 162–163, 163
 - developmental anatomy and, 2
 - genetic counseling, 171–172
 - of limb development, 16–18, 842
 - molecular basis of inheritance, 158, 158–160, 159
 - molecular basis of mutations, 160–162
 - multifactorial disorders, 171
 - neonatal and prenatal diagnosis of genetic disorders, 174
 - single-gene disorders, 163–171
 - of specific conditions
 - achondroplasia, 161, 166–167
 - Beckwith-Wiedemann syndrome, 170–171, 320
 - chronic granulomatous disease, 392–393
 - cleidocranial dysplasia, 276
 - clubfoot, 1154
 - congenital kyphosis, 746
 - congenital myotonic dystrophy, 649
 - diaphyseal aclasia, 274
 - diastrophic dysplasia, 258
 - Duchenne muscular dystrophy, 169, 637, 639
 - dyschondrosteosis, 275
 - Emery-Dreifuss muscular dystrophy, 645
 - fragile X syndrome, 164, 169
 - Friedreich ataxia, 656
 - Gaucher disease, 398–399
 - hereditary motor sensory neuropathies, 658
 - Huntington disease, 164, 169, 170
 - hypochondroplasia, 166, 254
 - hypophosphatemic rickets, 169
 - inborn errors of metabolism, 167–168
 - juvenile idiopathic arthritis, 441
 - Kneist dysplasia, 261
 - Larsen syndrome, 278, 299
 - limb deficiencies, 16–18, 842, 1220
 - limb-girdle muscular dystrophy, 646
 - Marfan syndrome, 161, 163–165, 218
 - McCune-Albright syndrome, 170
 - myelomeningocele, 604
 - myotonic dystrophy, 164, 169, 170
 - neural tube defects, 604
 - neurofibromatosis 1, 164, 167, 170, 291
 - osteogenesis imperfecta, 161, 164–166, 206, 206t
 - osteopetrosis, 212
 - polydactyly, 113
 - radial dysplasia, 861
 - retinoblastoma, 170, 509
 - scoliosis, 678–679
 - slipped capital femoral epiphysis, 1002
 - spinal muscular atrophy, 653
 - spondyloepiphyseal dysplasia, 166, 263, 265
 - Strickler syndrome, 166
 - triphalaingeal thumb, 885
 - tumors, 507–510, 508t
 - of syndromes, 288
 - teratologic disorders, 171–173, 288
 - treatment of genetic diseases, 174–175, 175t
 - Web site for current information on, 157
- Genitourinary problems, cerebral palsy and, 566
- Genomic imprinting, 5, 170–171
 - in Beckwith-Wiedemann syndrome, 320
 - in Cornelia de Lange syndrome, 313
 - in Prader-Willi syndrome, 319
- Genotype, 28
- Gentamycin, 479t
- Genu valgum (knock knees), 110, 1081–1084, 1151
 - assessment of, 1081, 1082, 1083
 - conditions associated with, 1081
 - chondroectodermal dysplasia, 257, 257–258
 - Down syndrome, 309, 309
 - dysplasia epiphysealis hemimelica, 363
 - fibular deficiency, 1229, 1230, 1232–1233
 - melorheostosis, 357
 - Morquio syndrome, 326
 - multiple epiphyseal dysplasia, 270
 - progressive diaphyseal dysplasia, 356
 - Proteus syndrome, 295, 345, 346
 - pseudoachondroplasia, 269
 - renal osteodystrophy, 199
 - spondyloepiphyseal dysplasia congenita, 264
 - Turner syndrome, 318
- definition of, 1081
- differential diagnosis of, 1081
- measuring intercondylar distance in, 110, 111
- natural history of, 1081–1082
- nonoperative management of, 1082
- physiologic, 1081, 1081
- surgical treatment of, 1082–1084
- complications of, 1084
- Genu varum (bowleg deformity), 1065–1081, 1151
 - adolescent Blount disease, 1075–1081
 - conditions associated with
 - achondroplasia, 250–251, 1068
 - focal fibrocartilaginous dysplasia, 1068, 1069
 - McKusick-type metaphyseal chondrodysplasia, 272, 272, 1068
 - melorheostosis, 357
 - metatropic dysplasia, 256
 - pseudoachondroplasia, 269, 1068
 - Schmid-type metaphyseal chondrodysplasia, 273, 1067, 1068
 - thrombocytopenia with absent radius syndrome, 382
 - X-linked hypophosphatemic rickets, 1066–1068, 1067
- examination for, 110, 110, 111
- infantile Blount disease, 1068–1075
- measuring intercondylar distance in, 110, 111
- physiologic bowing, 1065–1068
 - age and, 1065, 1065
 - assessment of, 1066
 - clinical features of, 1065–1066
 - definition of, 1065
 - differential diagnosis of, 1066–1068, 1067–1069
 - femoral and tibial metaphyseal-diaphyseal angles and, 1066, 1067, 1069
 - natural history of, 1068
 - radiographic features of, 1067
- Germ layers, 5–7, 28
- Germline mosaicism, 170
- Germline mutations, 509
- Giant cell tumor of bone, 511
- Gigantism
 - localized, 350–352 (*See also* Macroductyly)
 - in neurofibromatosis, 292
 - in Proteus syndrome, 294–295
- Gill procedure, 787
- Gilllette Children's Specialty Healthcare Normalcy Index and Functional Assessment Questionnaire, 569
- Girls
 - age at menarche, 41, 42
 - development of secondary sexual characteristics in, 41
 - leg length related to skeletal age for, 1110
 - lengths of long bones including epiphyses, 1223t
 - normal growth chart for, 223
 - pubertal growth curve for, 42
 - remaining growth in lower limbs
 - between ages 5 and 17 years for, 57
 - sitting heights of, 37, 37t, 40
 - standing heights of, 35t, 37t, 40–41, 43
 - subischial limb length of, 37, 40
 - weight of, 43
- Glasgow Coma Scale, 1327, 1327t
- Glenohumeral joint. *See also* Shoulder
 - brachial plexopathy and, 849, 849t, 850
 - dislocation of, 1335
- Glenoid version, 72
- GLI 3, 17, 23
- Glialization, 564
- Glucocorticoids
 - bone formation and, 180
 - for hypervitaminosis D, 202
 - skeletal abnormalities associated with, 228
- Gluten-sensitive enteropathy, rickets and, 192
- Glycopyrrolate, 1331t
- G_{M1}-gangliosidosis, 396t
- G_{M2}-gangliosidosis, 396t
- Goldenhar syndrome, 322, 322–323
 - cervical spine problems and, 821–822
- Gonadal abnormalities, 226–228
- Gonococcal arthritis, 496–497
- Gordon syndrome, 301–302

- Gorham disease, 346–347
 histopathology of, 347
 radiographic features of, 346–347, 347
 treatment of, 347
- Gout, 437
- Gower sign, 637, 644, 644, 645
- Grasp reflex, 106–107, 107, 107t
 absence in infant with traumatic brachial plexus palsy, 109
- Green-stick fractures, 1320
 of forearm, 1358–1359, 1359
- Greulich and Pyle atlas for bone age determination, 42, 43, 1123
- Grieg cephalopolysyndactyly, 17
- Grisel syndrome, 810, 810
- Groove of Ranvier, perichondrial, 25–27, 27, 1323
- Gross Motor function Measure, 569
- Growing pains, 438
- Growth, 33–59
 achondroplasia and, 247–248
 assessment of, 222–223
 biometric measurements of, 34–39
 arm span, 38
 sitting height, 36–38, 37, 37t, 38
 standing height, 35–36, 35t–37t
 subischial limb length, 37, 38, 39, 40
 weight, 38–39
 bone age determination, 43–45, 44–50, 68–69, 224, 1123, 1123–1124
 changing body proportions during, 38, 39
 chronology of, 39–43
 from 5 to 10 years of age, 39–40
 from birth to 5 years of age, 40–41
 intrauterine development, 39
 puberty, 41–43, 42
 energy requirements for, 34
 fetal alcohol syndrome and, 310
 fractures and, 1322
 physeal arrest, 1324–1327, 1325, 1326
 lessons learned from, 59
 limb deficiencies and, 1222–1223, 1223t, 1224t
 of lower limb, 54–58, 55, 1108–1110, 1109t, 1110–1111
 femur, 55
 foot, 56
 knee, 55–56
 leg length discrepancy, 56–58, 57, 1111, 1111–1112, 1112
 tibia, 55
 microgrowth vs. macrogrowth, 33–34
 myelomeningocele and, 608
 normal growth chart for boys, 222
 normal growth chart for girls, 223
 normal variant short stature, 224–225
 in paralytic child, 58–59
 patterns of, 222–224, 222–224
 progeria and, 317
 ratio of sitting height to total height, 223
 spondylolysis, spondylolisthesis and, 780
 stimulation of, for leg length discrepancy, 1135–1136
 systemic arthritis and, 443, 443
 of trunk and thorax, 50–54
 scoliosis and puberty, 53–54
 spinal column growth, 50–53, 51, 52
 thoracic perimeter, 53
 of upper limb, 58, 58
 velocity of, 223, 224
- Growth and differentiation factor 5 (GDF-5), 16
- Growth disorders. *See also* Short stature
 diagnostic approach to endocrine-related problems, 224
 glucocorticoid-related, 228
 hypopituitarism and, 225, 225–226
 hypothyroidism and, 226, 226–227
 renal osteodystrophy and, 195, 198
 rickets and, 187
 sex steroids and, 226–228
- Growth factors, 178, 178t
 somatomedins, 178t, 179–180, 959
- Growth hormone, 179, 959
 deficiency of, 225–226
 myelomeningocele and, 608
 progeria and, 316
- Growth hormone therapy, 224–226
 for achondroplasia, 250
 for dyschondrosteosis, 275, 276
 for hypochondroplasia, 254
 for normal variant short stature, 224–225
 for Prader-Willi syndrome, 319
 for Russell-Silver syndrome, 318
 slipped capital femoral epiphysis and, 1002
 for Turner syndrome, 318
- Growth plate. *See* Physis
- Growth remaining method for determining leg length discrepancy, 1126, 1127
- Gruca procedure, for ankle reconstruction, 1233
- Gunshot wounds, of cervical spine, 830
- H**
- Hadju-Cheney syndrome, 327, 327–328
- Haemophilus influenzae* type B infection, 460, 477
- Hair
 cartilage-hair hypoplasia, 271–273, 272, 273, 381
 Menkes kinky-hair syndrome, 205, 214, 215t
 trichorhinophalangeal syndrome, 323
- Hair thread constriction, 354
- Hallux valgus
 Down syndrome and, 309, 310
 fibrodysplasia ossificans progressiva and, 364
 juvenile, 1200–1203
 clinical features of, 1201
 definition of, 1200
 epidemiology of, 1200
 inheritance of, 1200
 natural history of, 1202
 pain relief for, 1202
 pathoanatomy of, 1201
 pathogenesis of, 1200, 1200–1201, 1201
 radiographic features of, 1201
 surgical treatment of, 1202–1203, 1203
 spastic diplegia and, 584
- Hallux varus, congenital, 1186–1188, 1187
 clinical features of, 1187, 1187
 definition of, 1186
 epidemiology of, 1186
 natural history of, 1187
 pathoanatomy of, 1187
 pathogenesis of, 1186
 radiographic features of, 1187, 1188
 surgical treatment of, 1187, 1187–1188
- Hand, 870–879
 assessment for bone age determination, 46–49
 camptodactyly, 877–879, 878
 cleft hand, 870–871, 871
 clinodactyly, 879
 constriction band syndrome involving, 872, 872–873
 neurologic examination of, 119
 polydactyly, 876, 876–877, 877
 in specific conditions
 achondroplasia, 250
 arthrogryposis multiplex congenita, 850–853
 cerebral palsy, 592–593, 593, 843, 845–846, 846
 distal arthrogryposis, 301, 301–302
 Down syndrome, 305
 Freeman-Sheldon syndrome, 302, 303
 hereditary motor sensory neuropathies, 662
 hypopituitarism, 225
 Marfan syndrome, 218–219, 219
 poliomyelitis, 665
 progeria, 316, 317
 pseudohypoparathyroidism, 201, 201
 rickets, 189
 Russell-Silver syndrome, 318
 thalassemia, 390, 391
 trichorhinophalangeal syndrome, 323, 323
- VACTERLS, 321
- syndactyly, 873–875, 873–875
 traumatic injuries of, 886–891
 digital amputations, 895, 895, 896
 distal physeal fractures and nail-bed entrapment, 887–888
 finger dislocations, 893–894
 intercondylar fractures, 886, 888–889, 889
 mallet fingers, 888
 phalangeal neck fractures, 888
 physeal fractures, 889
 tendon lacerations, 894–895, 895
 tip amputations, 887
- Hand-foot syndrome, 385–386
- Hand-Schüller-Christian disease, 402, 537, 538. *See also* Langerhans cell histiocytosis
- Handedness, 104–105
- Hangman fracture, 827
- Haploid cells, 28

- Harrington instrumentation system
for kyphosis, 755–756
for scoliosis, 702, 702–703
for spondylolisthesis, 788
- Harris lines, 66, 67
- Harrison's groove, 187
- Hawkins sign, 127, 128
- Head circumference, 40
- Head injuries, due to child abuse, 1428
- Hearing loss
achondroplasia and, 250
fibrodysplasia ossificans and, 218
osteogenesis imperfecta and, 204
spondyloepiphyseal dysplasia congenita and, 264
- Heat illness, 1275–1276
clinical spectrum of, 1275
prevention of, 1275t
risk factors for children, 1275
- Heavy metal poisoning, 66, 203, 203–204
- Heel cord lengthening, for idiopathic toe walking, 1099–1100
- Heel pain, in Sever apophysitis, 119–120, 1206–1208
- Height. *See also* Short stature; Tall stature
sitting, 36–38, 37, 37t, 38, 40, 50
standing, 35–36, 35t–37t, 40–41
- Hemangiomas, 339–340, 544–545, 545
of bone, 545, 545
classification of, 544
conditions associated with, 340t
Klippel-Trenaunay syndrome and, 343–345
Maffucci syndrome and, 341–342
on magnetic resonance imaging, 34
- Hemarthrosis
clinical signs of, 410
in hemophilia, 408–410, 409, 412
joint aspiration for, 412
- Hematoma block, for fracture management, 1330
- Hematopoietic system diseases, 379–419
acute leukemia, 416–419
bone marrow failure syndromes, 379–383
erythrocyte disorders, 383–392
hemostasis disorders, 407–416
lymphocyte and immune system disorders, 394–395
monocyte-macrophage system disorders, 395–407
neutrophil disorders, 392–394
- Hemi-3 syndrome, 348t, 350
- Hemiarlas, 807
- Hemiepiphyseal stapling, for genu valgum, 1082, 1084
- Hemiepiphyseal diaphyseal disease, 1079
for diaphyseal aclasia, 275
for genu valgum, 1082
for infantile Blount disease, 1073
- Hemihypertrophy, 347–350
in Beckwith-Wiedemann syndrome, 320–321, 321, 348t, 350
congenital vs. acquired, 349
differential diagnosis of, 347–349, 348t
in hemi-3 syndrome, 348t, 350
idiopathic, 348t, 349, 349
in Klippel-Trenaunay syndrome, 348t, 350
in neurofibromatosis, 348t, 350
in Proteus syndrome, 345, 348t, 350
- Hemihypotrophy, 347–348
congenital vs. acquired, 349
differential diagnosis of, 347–349, 348t
idiopathic, 348t, 350
neurogenic, 348t, 350
in Russell-Silver syndrome, 317–318, 348t, 350
in Turner syndrome, 348t, 350
- Hemimelia, 1219. *See also* Limb deficiencies
- Hemiplegia. *See also* Spastic hemiplegia
cerebral palsy and, 565–566, 589–590, 842
double, 566
- Hemispherization, 27, 27
- Hemivertebra, 21, 22
in chondrodysplasia punctata, 271
in congenital scoliosis, 725, 725, 726
excision of, 732, 733
in Goldenhar syndrome, 323
myelomeningocele and, 608
- Hemophilia, 408–416
arthropathy and, 409–412, 410, 411, 438
cervical spine and, 833
fractures in, 415–416
hemarthrosis in, 408–410, 409, 412
knee in, 409–411, 410
management of flexion contractures, 415–416, 416
synovectomy and, 412–413
management of contractures in, 414–415, 414–416
muscle hemorrhage in, 413–414, 414
pseudotumors in, 415, 416
radiographic features of, 409–410, 410, 411, 411t
surgery for patients with, 409
synovectomy in, 412–413
transfusion therapy for, 408–412
inhibitor status and, 409
- Hemosiderin, 534, 535
- Hemostasis, 407–408, 408
- Henoch-Schönlein purpura, 437
differentiation from septic arthritis, 475–476
- Hensen node, 5, 5, 28
- Hepatobiliary disease, rickets and, 192
- Hereditary hemorrhagic telangiectasia, 340t, 341
- Hereditary motor sensory neuropathies, 657–662
classification of, 657–658, 657t
diagnosis of, 658
genetics and molecular biology of, 658
treatment of, 658–662
hand and upper extremity dysfunction, 662
hip dysplasia, 661–662, 662
pes cavovarus, 658–661, 659, 1152, 1194–1199, 1196
calcaneal osteotomy, 659–660
midtarsal osteotomy, 660
plantar-medial release, 659
plantar release, 659
tendon transfers, 659
triple arthrodesis, 660–661, 661
spinal deformity, 662
- Hilgenreiner physal angle, 1039, 1039–1041
- Hip
abduction contracture of, 115
chondrolysis and, 1050, 1050
Duchenne muscular dystrophy and, 641
with extension contracture, in cerebral palsy, 577
leg length discrepancy and, 1120
adduction contracture of, 115
developmental dysplasia of hip and, 103–104, 104
leg length discrepancy and, 1119–1120
spastic diplegia and, 588
alpha and beta angles of, 77
apophysitis of, 1283
arthrodesis of, for slipped capital femoral epiphysis, 1024, 1025
chondrolysis of
idiopathic, 1048–1055
slipped capital femoral epiphysis and, 1027–1029, 1028
degenerative disease of, slipped capital femoral epiphysis and, 1009, 1018
developmental coxa vara, 1035–1044
developmental dysplasia of, 905–946
(*See also* Developmental dysplasia of hip)
dislocation of, 1372, 1372–1373
CT evaluation after reduction of, 72, 73
Down syndrome and, 308, 308–309
high-riding, 1112, 1113
Larsen syndrome and, 279, 300–301
McKusick-type metaphyseal chondrodysplasia and, 273
mechanism of injury, 1372
spastic quadriplegia and, 575–576, 576
spinal muscular atrophy and, 654
treatment of, 1372–1373
extension contracture of, cerebral palsy and, 576–577
flexion contracture of
chondrolysis and, 1050
developmental coxa vara and, 1039
diastrophic dysplasia and, 259, 261
Duchenne muscular dystrophy and, 641
iliopsoas bleed in hemophilia and, 414
middle and lower lumbar paraplegia and, 619
proximal femoral focal deficiency and, 1238
spastic diplegia and, 588
spondyloepiphyseal dysplasia congenita and, 263
tests for, 114–115, 115
transient synovitis and, 1046

- Hip (*contd.*)
 in gait cycle, 142, 142
 gait deviations associated with, 147–148
 excessive abduction, 148
 excessive adduction, 147–148
 inadequate extension and excessive flexion, 147
 imaging of
 arthrography, 69–71
 computed tomography, 72, 73
 magnetic resonance arthrography, 81
 scintigraphy, 86–88
 ultrasonography, 74–77, 75–77
 leg length discrepancy and, 1107, 1107, 1108, 1119–1120
 Legg-Calvé-Perthes syndrome, 957–991
 medial and lateral rotation of, 1060, 1062–1063
 assessment in newborns and infants, 1062
 normal growth and development of, 906–909, 906–909
 osteoarthritis of, 576
 septic arthritis of, 111
 differentiation from chondrolysis, 1050
 differentiation from toxic synovitis, 475
 differentiation from transient synovitis, 1046
 shepherd's crook deformity of, 229, 229, 535
 slipped capital femoral epiphysis, 999–1029
 in specific conditions
 cerebral palsy, 567, 568, 572–577
 chondrodysplasia punctata, 271, 271
 cleidocranial dysplasia, 276–277
 diaphyseal aclasia, 274, 275
 familial dysautonomia, 314
 fibrous dysplasia, 229, 229
 hereditary motor sensory neuropathies, 661–662, 662
 Morquio syndrome, 326–327
 multiple epiphyseal dysplasia, 270
 myelomeningocele, 617–621
 osteopetrosis, 212, 214
 poliomyelitis, 665–666, 666
 progeria, 317, 317
 Proreus syndrome, 295
 proximal femoral focal deficiency, 1238, 1244
 pseudoachondroplasia, 269
 Russell-Silver syndrome, 318
 spinal muscular atrophy, 654
 spondyloepiphyseal dysplasia congenita, 263–265, 264
 spondyloepiphyseal dysplasia tarda, 266
 subluxation of
 cerebral palsy and, 574–575, 575
 spinal muscular atrophy and, 654
 synovitis of, 111, 117
 slipped capital femoral epiphysis and, 1001
 transient, 435, 1044–1048
 “Hip click,” 102, 913
 Hip replacement
 for juvenile idiopathic arthritis, 452–453
 for slipped capital femoral epiphysis, 1024–1025
 Histiocytosis X. *See* Langerhans cell histiocytosis
 History taking, 100, 634
 for diagnosis of child abuse, 1425–1426
 Hitchhiker thumb, 258, 259
 HLA. *See* Human leukocyte antigens
 Holt-Oram syndrome
 clinodactyly and, 871
 radial dysplasia and, 861
 thumb hypoplasia/aplasia and, 880
 Homeotic genes, 8, 28
 Homocystinuria, 221
 Homologous genes, 28
 Hormonal regulation of bone formation, 180
 Horner syndrome, 847
 Hot-cross-bun skull, 187
 HOX (homeobox) genes, 2, 6, 15–16, 16, 21, 28
 limb development and, 17, 842
 vertebral column development and, 21
 Hueter-Volkman effect, 180, 198, 678, 680, 681, 1196
 Human Genome Project, 161
 Human immunodeficiency virus infection, 394–395
 Human leukocyte antigens (HLA)
 juvenile idiopathic arthritis and, 441
 enteritis-related arthritis, 446–447
 inflammatory bowel disease-associated arthritis, 448
 juvenile ankylosing spondylitis, 447
 polyarthritis, 445
 psoriatic arthritis, 445
 Lyme disease and, 435
 post-streptococcal arthritis and, 436
 reactive arthritis and, 433, 435
 Humeral fractures, 1335–1337
 birth injury, 109, 1332
 differentiation from pseudofracture due to physeal obliquity, 65–66, 66
 distal
 due to child abuse, 1429
 examination for, 118–119
 physeal fracture-separation, 1345, 1346, 1349–1350, 1350
 supracondylar fracture, 1339–1344, 1340–1344
 due to child abuse, 1431–1432, 1433, 1434
 proximal, 1335, 1336, 1337
 shaft, 1335–1337
 Humeroradial synostosis, 858
 ulnar dysplasia and, 866, 867, 868
 Humeroulnar dislocation, congenital, 854–855
 Humerus
 distal, ossification centers of, 1338, 1338
 head of
 “hatchet-head,” in multiple epiphyseal dysplasia, 270
 sickle cell disease and osteonecrosis of, 387, 388–389, 388t
 proximal
 chondroblastoma of, 532, 532
 epiphysiolysis of, 1279, 1279
 osteosarcoma of, 527
 periosteal chondroma of, 532, 534
 unicameral bone cyst of, 539
 in renal osteodystrophy, 195
 in rickets, 189
 transverse complete deficiency of, 1250
 Hunter syndrome, 324, 324t, 397t
 kyphosis and, 765
 Huntington disease, 164, 169, 170
 Hurler-Scheie syndrome, 397t
 Hurler syndrome, 168, 246, 324, 324t, 325, 396t
 kyphosis and, 765
 Madelung deformity and, 868
 Hutchinson-Gilford syndrome, 316, 316–317, 317
 Hydrocephalus
 achondroplasia and, 248, 250
 Hadju-Cheney syndrome and, 327
 metatropic dysplasia and, 256
 myelomeningocele and, 602–603, 605
 Hydromyelia, scoliosis and, 609
 Hydroxyapatite, 24, 181, 204
 Hydroxyurea, 22
 for sickle cell disease, 389
 25-Hydroxyvitamin D, 182–183, 183
 vitamin D-resistant rickets and, 193
 Hypercalcemia, 202
 associated with immobilization, 202
 calcium kinetics in, 185–186, 186
 hyperparathyroidism and, 200–201
 hypervitaminosis A and, 216
 hypervitaminosis D and, 202
 hypophosphatasia and, 199
 idiopathic, 202
 of malignancy, 193, 202
 Williams syndrome and, 202
 Hypermobility, 438
 Hyperparathyroidism, 200–201
 radiographic features of, 196, 200
 renal osteodystrophy and, 195
 vitamin D-resistant rickets and, 195
 Hyperphosphatasia, 181
 Hyperphosphatemia, 215t
 Hyperthyroidism, 535
 Hypertrophic osteoarthropathy, 215t
 Hypertrophic zone of physeal cartilage, 25
 Hypervitaminosis A, 215t, 216
 Hypervitaminosis D, 202
 Hypocalcemia
 Albright hereditary osteodystrophy and, 201
 calcium kinetics in, 185, 186
 hypoparathyroidism and, 201
 Hypochondroplasia, 254
 clinical features of, 254
 differential diagnosis of, 254
 genetics of, 166, 254
 radiographic features of, 254
 treatment of, 254

- Hypoglycemia, in Beckwith-Weidemann syndrome, 320
- Hypoparathyroidism, 201, 201
- Hypophosphatasia, 181, 199–200
clinical features of, 199
enzyme defect in, 199
laboratory findings in, 199
management of, 199–200
radiographic features of, 199, 200
- Hypopituitarism, 225, 225–226
- Hypothyroidism, 226, 226–227
neonatal screening for, 174
- Hypotonic cerebral palsy, 565
- I**
- I-cell disease, 397t
- Ibuprofen, 1277
- Idiopathic juvenile osteoporosis, 210–212, 210–212, 768
kyphosis and, 768–769, 769
- Ifosfamide, 528
- IGF2* gene, in Beckwith-Weidemann syndrome, 171
- Iliac horns, in nail-patella syndrome, 311, 312
- Iliofemoral arthrodesis, for proximal femoral focal deficiency, 1244–1246
- Iliopsoas bleed, in hemophilia, 414
- Iliotibial band friction syndrome, 1286, 1286
- Ilizarov leg lengthening device, 1139, 1139
- Ilizarov procedure
for melorheostosis, 358
for unilateral absence of C1, 807
- Imaging procedures, 63–93. *See also* specific imaging modalities
bone densitometry, 89–90
magnetic resonance imaging, 78–85
nuclear medicine, 85–89
radiation exposure from, 90–92
radiography, 64–74
relative cost of, 85t
sedation for, 92–93
ultrasonography, 74–78
- Immobilization
hypercalcemia and, 202
osteoporosis and, 211–212, 212
- Immune system disorders, 394–395
acquired immunodeficiency syndrome, 394–395
bone and joint infections and, 461
X-linked agammaglobulinemia, 394
- Implantation, 3
- In situ* pin and screw fixation, for slipped capital femoral epiphysis, 1010–1016, 1011–1014
- In-toeing, 1059–1065. *See also* Rotational variation of lower extremity
conditions associated with, 1060–1061
foot-progression angle and, 105, 105
physical examination of 2-year-old for, 104–106, 105, 106
rotational profile and, 105–106, 105t, 106, 1060
during running, 1063
spastic diplegia and, 588–589
- Inborn errors of metabolism
genetics of, 167–168
metabolic bone diseases, 177–230
metabolic myopathies, 650–651
neonatal screening for, 174
treatment of, 174
- Induction, 28
- Infantile Blount disease, 1068–1075
definition of, 1068–1069
differential diagnosis of, 1066
etiology of, 1069
Langenskiöld's radiographic stages of, 1066, 1068, 1069, 1070, 1072
nonoperative management of, 1069–1070
pathoanatomy of, 1069
surgical treatment of, 1070–1075
complications of, 1075
goal of, 1070
moderate varus deformity, 1070, 1070–1071
severe varus deformity, 1073–1075, 1074
worsening varus deformity, 1071–1073, 1072
- Infantile cortical hyperostosis, 214–216, 215t, 216
- Infantile fascioscapulohumeral muscular dystrophy, 646–647, 647
- Infantile idiopathic scoliosis, 682, 693–695, 694
prediction of curve progression in, 694–695, 695
- Infantile quadriceps fibrosis, 369–370
clinical features of, 369
etiology of, 369
pathology of, 369–370
treatment of, 370
- Infants
bone and joint sepsis in neonates, 486–488
examination of, 100, 102–104, 113
growth of, 40
perinatal lethal skeletal dysplasias, 279–280
primitive reflexes of, 106–108, 107, 107t, 108
pseudoparalysis of upper extremity in, 109
- Infection. *See also* specific types
in acquired immunodeficiency syndrome, 395
bone and joint, 459–500 (*See also* Bone and joint sepsis)
chronic granulomatous disease and, 393
leg length discrepancy and, 1116
myelomeningocele and, 608
teratogenicity of, 173
transient synovitis of hip and, 1045
as trigger for juvenile idiopathic arthritis, 441
X-linked agammaglobulinemia and, 394
- Inflammatory response
anemia of chronic inflammation, 391–392
in bone and joint sepsis, 480
chondrolysis of hip and, 1052
leg length discrepancy and, 1118
slipped capital femoral epiphysis and, 1001–1002
- Informed consent, 1441
- Inheritance. *See also* Genetics
autosomal dominant, 164, 164–167
autosomal recessive, 167, 167–168
genomic imprinting and, 5, 170–171
molecular basis of, 158–160
mosaicism and, 170
of multifactorial disorders, 171
parental disomy and, 171
of single-gene disorders, 163–171
X-linked, 168, 168–169
- Injuries. *See* Trauma
- Inner cell mass, 28
- Innominate osteotomy, for Legg-Calvé-Perthes syndrome, 987–988
- Instrumentation, spinal
for scoliosis
anterior, 706–707
Cotrel-Dubousset and other double rod, multiple hook systems, 703
Harrington instrumentation, 702, 702–703
myelomeningocele and, 612–614
posterior, 702, 729
spinal muscular atrophy and, 654, 655, 656
without fusion, 706, 707
for spondylolisthesis, 788–791, 790
- Insulin, bone formation and, 180
- Insulin-like growth factors, 178t, 179–180, 959
- Integrins, 14, 180
- Interferon- α , for hemangiomas, 340
- Interferon- γ
for chronic granulomatous disease, 393
for osteopetrosis, 214
- Internal injuries, due to child abuse, 1428
- International Classification of Osteochondrodysplasias, 244, 244t
- Intertrochanteric osteotomies, for slipped capital femoral epiphysis, 1020–1024, 1023
- Intervertebral disc
in abused child, 1435
calcification of, 831–832, 832
discitis, 482, 483
cervical, 832
- Intrauterine growth retardation
de Lange syndrome and, 313
fetal alcohol syndrome and, 310
- Invagination, 28
- Investigative interview for child abuse, 1425–1426
documentation of, 1426
history taking, 1425–1426
- Iowa Hip Rating, 973, 974
- Iron-deficiency anemia, 383
- Iron overload, in thalassemia, 390
- Iselin disease, 1282
- Isodisomy, 171

- J**
- J sign, 123
 - Jack toe-raise test, 1169, 1170, 1183
 - Jahnke test, 126, 127
 - Jansen metaphyseal chondrodysplasia, 273
 - Jansen-type chondrodysplasia, 203
 - Jefferson fracture, 824
 - JIA. *See* Juvenile idiopathic arthritis
 - Joint abnormalities
 - differential diagnosis of pain and swelling, 434–439, 434t
 - evaluation of pain and/or swelling, 430–434, 431
 - hypermobility in Ehlers-Danlos syndrome, 220–221
 - juvenile idiopathic arthritis, 427–453
 - on magnetic resonance imaging, 82
 - osteogenesis imperfecta and, 205
 - rickets and, 187
 - Joint aspiration
 - for bone and joint sepsis, 468, 473–474, 481
 - for hemarthrosis, 412
 - Joint development, 12, 15–16
 - Jones fracture, 1411
 - Juvenile ankylosing spondylitis, 441, 447–448, 448
 - radiographic features of, 450, 450
 - Juvenile hallux valgus, 1200–1203
 - clinical features of, 1201
 - definition of, 1200
 - epidemiology of, 1200
 - inheritance of, 1200
 - natural history of, 1202
 - pain relief for, 1202
 - pathoanatomy of, 1202
 - pathogenesis of, 1200, 1200–1201, 1201
 - radiographic features of, 1201–1202
 - surgical treatment of, 1202–1203, 1203
 - Juvenile idiopathic arthritis (JIA), 111, 427–453
 - of cervical spine, 830–831, 831
 - classification and diagnosis of, 428–430, 429t
 - clinical syndromes of, 441–448
 - differential diagnosis of, 434–439, 434t
 - acute rheumatic fever, 435–436, 436t
 - arthritis and limb pain associated with other conditions, 434–435
 - benign pains of childhood, 438–439
 - benign tumors, 438
 - chondrolysis of hip, 1050
 - cystic fibrosis, 437
 - foreign body synovitis, 437
 - gout, 437
 - infectious arthritis, 435
 - Lyme disease, 435
 - malignancies, 418, 438
 - postinfectious arthritis, 435
 - poststreptococcal arthritis, 436
 - septic arthritis, 475
 - serum sickness, 437
 - systemic autoimmune diseases, 437
 - transient synovitis of hip, 435, 1046
 - enthesitis-related arthritis, 430, 446–447, 447
 - epidemiology of, 440–441
 - etiology of, 441
 - evaluation for, 430–434, 431
 - age of child, 432
 - associated symptoms, 432
 - family history, 432
 - imaging studies, 434
 - laboratory tests, 433–434
 - pain duration, 432
 - pain intensity, 432
 - pain location, 432
 - physical examination, 433
 - response to activity or rest and immobilization, 432
 - synovial fluid analysis, 434
 - timing of pain or disability, 431
 - genetics of, 441
 - guidelines for ophthalmologic examination in, 444, 445t
 - incidence of, 428
 - infection as trigger for, 441
 - inflammatory bowel disease-associated, 448
 - juvenile ankylosing spondylitis, 441, 447–448, 448
 - oligoarthritis, 429–430, 444, 444
 - onset diagnosis of, 441–442, 442t
 - other arthritides, 430
 - periosteal reaction in, 215t
 - polyarthritis, 430, 444–445
 - psoriatic arthritis, 430, 445–446, 446
 - radiographic findings in, 448–450, 448–450
 - systemic-onset, 430, 442, 442–444, 443
 - clinical course and complications of, 442–443
 - clinical features of, 442
 - laboratory features of, 442
 - treatment of, 450–453
 - medications, 450–451, 451t
 - physical and occupational therapy, 451–452
 - surgical, 452–453
 - Juvenile idiopathic scoliosis, 682, 695
 - Juvenile osteoporosis, idiopathic, 210–211, 210–211
 - age at onset of, 210–211
 - clinical features of, 211
 - differential diagnosis of, 211
 - management of, 211
 - pathophysiology of, 211
- K**
- KAFOs. *See* Knee-ankle-foot orthoses
 - Kaposiform hemangioendothelioma, 340
 - Karyotype, 158, 158
 - in Down syndrome, 162, 163
 - in tumors, 508
 - Kasabach-Merritt syndrome, 340, 341
 - Ketamine, 1331t, 1332
 - Kinematic gait analysis, 149–150
 - Kinetic gait analysis, 149–151
 - King-Denborough syndrome, 319
 - King-Moe classification of thoracic curves, 703, 707, 707t
 - Kingella kingae* infection, 460, 477
 - Klein line, 1005, 1005
 - Klinefelter syndrome, 163
 - Klippel-Feil syndrome, 17, 22, 805, 814–815, 1220
 - cervical spine in, 814–815
 - congenital kyphosis and, 746
 - Diamond-Blackfan anemia and, 380
 - Fanconi anemia and, 380
 - ulnar dysplasia and, 865
 - Klippel-Trenaunay syndrome, 340, 340t, 341, 343–345, 344
 - clinical features of, 343–344, 344
 - differential diagnosis of, 344
 - etiology of, 343
 - hemihypertrophy in, 348t, 350
 - leg length discrepancy and, 1117
 - macrodactyly and, 1190
 - pathology of, 344
 - radiographic features of, 81, 341, 344–345
 - treatment of, 345
 - Knee. *See also* Patella
 - arthrodesis of, for proximal femoral focal deficiency, 1243
 - breaststroke's, 1286–1287
 - congenital dislocation of, 1095–1098
 - clinical presentation of, 1096, 1096
 - definition of, 1095
 - etiology of, 1095–1096
 - nonoperative management of, 1096–1097
 - radiographic features of, 1096, 1096
 - surgical treatment of, 1097, 1097–1098
 - flexion contracture of, proximal femoral focal deficiency and, 1238
 - “floating,” 1387–1388, 1389
 - in gait cycle, 140–142, 141
 - gait deviations associated with, 146–147
 - excessive flexion and inadequate extension, 146–147
 - excessive varus/valgus, 147
 - inadequate flexion and excessive extension, 146
 - growth of, 55–56
 - leg length discrepancy and, 1107
 - normal alignment at birth, 1065
 - pain in
 - anterior, 122–124, 122–125, 1300–1303
 - in obese adolescent, 121–122
 - prosthetic, 1261–1262, 1262
 - “snapping,” 1310
 - in specific conditions
 - arthrogryposis multiplex congenita, 298
 - chondroectodermal dysplasia, 257, 257–258
 - diaphyseal aclasia, 275
 - diastrophic dysplasia, 259, 259, 261
 - Down syndrome, 309, 309
 - Duchenne muscular dystrophy, 641
 - familial dysautonomia, 314, 315
 - genu valgum, 1081–1084
 - genu varum, 1065–1081

- hemophilia, 409–411, 410
 management of flexion contractures, 415–416, 416
 synovectomy and, 412–413
 juvenile idiopathic arthritis, 453
 Larsen syndrome, 279, 299–300, 300
 McKusick-type metaphyseal chondrodysplasia, 272, 272
 Morquio syndrome, 326
 multiple epiphyseal dysplasia, 270
 myelomeningocele, 621, 621–622
 nail-patella syndrome, 311, 312
 poliomyelitis, 666
 Proteus syndrome, 295
 proximal femoral focal deficiency, 1238, 1243
 pseudoachondroplasia, 268, 268, 269
 pterygia syndrome, 303, 303–305, 305
 Schmid-type metaphyseal chondrodysplasia, 273
 Sinding-Larsen-Johansson disease, 1281, 1281
 spastic diplegia, 587
 spondyloepiphyseal dysplasia congenita, 264
 spondyloepiphyseal dysplasia tarda, 266
 Turner syndrome, 318
 Knee-ankle-foot orthoses (KAFOs)
 for Duchenne muscular dystrophy, 640
 for genu valgum, 1082
 for infantile Blount disease, 1070
 for spastic diplegia, 583
 for tibial bowing, 1084–1085
 Knee replacement, for juvenile idiopathic arthritis, 453
 Knee trauma, 1293–1297, 1389–1396
 anterior cruciate ligament injuries, 124, 1294–1296
 collateral ligament injuries, 1293–1294, 1294
 distal femoral physeal separations, 1389–1390, 1390–1392
 examination for ligamentous injuries, 124, 124–125
 meniscal tears, 1296–1297, 1297
 patellar fracture, 1394–1396, 1395–1396
 posterior cruciate ligament injuries, 124, 124, 1296
 sports-related, 1299–1311
 acute patellar dislocation, 1306–1308
 anterior knee pain, 1300–1303
 bipartite patella, 1304
 chondromalacia, 1304
 discoid lateral meniscus, 1309–1311
 dorsal defects of patella, 1304–1305, 1305
 fat pad impingement, 1305
 patellofemoral disorders, 1299, 1300
 plica syndrome, 1305–1306, 1306
 popliteal cyst, 1309
 recurrent patellar dislocations, 1308–1309, 1308–1310
 saphenous nerve entrapment, 1304
 stress fractures, 1278
 tibial spine fracture, 1390–1393, 1393
 tibial tubercle fracture, 1393–1394, 1394, 1395
 Kneist dysplasia, 261–263
 clinical features of, 262
 genetics of, 261
 radiographic features of, 262, 262
 treatment of, 262–263
 Knock knees. *See* Genu valgum
 Knockout mice, 162
 Koch's postulates, 460
 Kohler disease, 67, 1203–1205, 1409
 clinical features of, 1204
 definition of, 1203
 epidemiology of, 1203
 Legg-Calvé-Perthes syndrome and, 962
 natural history of, 1205
 pathoanatomy of, 1204
 pathogenesis of, 1203–1204
 radiographic features of, 1204, 1204
 treatment of, 1205
 Kozlowski-type metaphyseal chondrodysplasia, 273–274
 Kugelberg-Welander disease, 652–653. *See also* Spinal muscular atrophy
 Kump's bump, 66, 66
 Kyphosis, 22, 741–769
 conditions associated with, 743, 743t–744t
 achondroplasia, 251–252, 252, 253, 763, 764
 cerebral palsy, 570, 817
 diastrophic dysplasia, 258, 259, 260, 765
 familial dysautonomia, 314
 juvenile osteoporosis, 768–769, 769
 Larsen syndrome, 278, 278, 279, 301, 765–766, 767
 Marfan syndrome, 765, 766
 metatropic dysplasia, 256
 mucopolysaccharidosis, 765
 myelomeningocele, 614–616, 615–617
 neurofibromatosis, 767–768
 progressive anterior vertebral fusion, 749–750
 pseudoachondroplasia, 763–765
 rickets, 187
 sacral agenesis, 749
 Scheuermann disease, 121, 750, 750–757, 754
 segmental spinal dysgenesis, 749
 spinal muscular atrophy, 654
 spondyloepiphyseal dysplasia congenita, 263, 263, 264, 765
 tuberculosis, 768
 definition of, 741
 during fetal development, 742
 forces on spine and, 742–743
 length and width of curve in, 743, 743
 normal ranges of, 678, 741–742
 effect of scoliosis on, 678, 680
 postlaminectomy, 758, 758–760, 759
 cervical, 818–819, 820, 821
 posttraumatic, 766–767
 postural, 744, 744
 radiation, 760–763, 762
 Kyphosis, congenital, 744–749
 anomalies associated with, 746
 classification of, 744–745, 745t
 clinical presentation of, 746
 complications of treatment for, 749
 etiology of, 745–746
 imaging evaluation of, 746, 746–747
 inheritance of, 746
 natural history of, 746
 treatment, 747–749, 748
 type I deformities, 747–749
 vertebral abnormalities and, 744–745, 745, 745t
- L**
 Laboratory findings
 in arthritis, 433–434
 in bone and joint sepsis, 467–469, 468t, 475, 476t
 in chondrolysis of hip, 1050
 in Duchenne muscular dystrophy, 638–639
 in neoplasia, 513
 in neuromuscular disorders, 635–636
 in skeletal dysplasia, 246
 in transient synovitis of hip, 1046
 Lachman test, 124, 124, 1294
 Lactic dehydrogenase, tumors and, 513
 Laminectomy
 indications for, 758
 kyphotic deformity after, 758, 758–760, 759
 cervical, 818–819, 820, 821
 Laminoplasty, 760
 Landau reflex, 108
 Langer-Giedion syndrome, 162–163, 323
 Langerhans cell histiocytosis, 402–407, 537–538
 in cervical spine, 833, 834
 clinical presentation of, 404
 criteria of organ dysfunction in, 402–403, 402t
 diabetes insipidus and, 403
 histopathology of, 402
 imaging evaluation of, 404–407
 radiographic features of, 403–407, 404, 537
 bone scan, 513, 537–538, 539
 treatment of, 405
 Lapbelt fractures, 1368, 1369
 Larsen syndrome, 278–279, 299–301
 clinical features of, 278, 299, 299
 congenital radial head dislocation and, 853
 genetics of, 278, 299
 kyphosis and, 278, 278, 279, 301, 765–766, 767
 orthopaedic implications of, 278–279, 299–301
 radiographic features of, 278, 278, 279, 299, 300
 Laryngotracheomalacia, 246

- Lateral condyle fracture, 1344–1348
 complications of, 1347–1348
 differentiation from fracture-separation of distal humeral epiphysis, 1345, 1346
 mechanism of injury, 1344
 Milch types I and II, 1344, 1345
 nonunion of, 1347–1348, 1348
 treatment of, 1345–1347, 1346, 1347
- Lateral epicondyle fracture, 1348
- Lateral plate mesoderm, 28
- Latex hypersensitivity, myelomeningocele and, 606
- Lauenstein projection, 70
- Lead-pipe rigidity, in spastic cerebral palsy, 116
- Lead poisoning, 66, 203, 203–204
- Leg length discrepancy, 43, 1105–1145
 conditions associated with
 cerebral palsy, 1117
 clubfoot, 1154
 congenital constriction band syndrome, 354
 congenital tibial bowing, 1090
 developmental coxa vara, 1036, 1044
 developmental dysplasia of hip, 914, 935
 femoral fracture, 1118, 1379–1382, 1381, 1388
 idiopathic hemihypertrophy, 349, 349, 350
 Klippel-Trenaunay syndrome, 343
 melorheostosis, 357
 poliomyelitis, 665
 posterior medial bowing of tibia, 1093–1094
 Proteus syndrome, 345
 scoliosis, 114, 120, 121, 685–686
 data analysis for, 1124–1129
 arithmetic method, 1124–1127, 1125
 growth remaining method, 1126, 1127
 inadequate data, 1129
 patterns of inhibition, 1129
 straight-line graph method, 1127–1129, 1128, 1130
 effects of, 1106–1108
 gait, 1106, 1106–1107
 hip, 1107, 1107, 1108
 knee, 1107
 mechanisms of compensation, 1106, 1106
 spine, 1107–1108, 1108
 etiology of, 1112–1118
 classification of, 1113t
 inhibition of growth, 1114–1117
 avascular necrosis, 1117
 congenital shortening, 1114, 1114, 1115
 infection, 1116
 paralysis, 1116–1117
 trauma, 1114–1116, 1115, 1116
 tumors, 1117
 interference with length, 1114
 stimulation of growth, 1117–1118
 fracture, 1118
 inflammation, 1118
 tumor, 1117
 growth and, 56–58, 57, 1108–1112, 1109–1112, 1109t
 patient assessment for, 114, 1118–1120
 angular deformity, 1120
 compliance and emotional state, 1120
 contractures, 1119–1120
 history of discrepancy, 1118
 leg length measurements, 1118–1119, 1119
 spinal deformity and balance, 1120
 weakness and need for bracing, 1120
 radiologic assessment of, 1120–1124
 leg lengths, 1120–1122, 1121, 1122
 skeletal age, 1123, 1123–1124
 scoliosis and, 114, 120, 121, 685–686, 1107–1108, 1108
 treatment goals for, 1131
 correction of coexisting problems, 1131
 equal leg lengths, 1131
 equalization by prosthetic fitting, 1131
 level pelvis, 1131
 unequal leg lengths, 1131
 vertical lumbar spine, 1131
 treatment of, 1106, 1131–1145
 epiphysiodesis, 56–58, 1106, 1133, 1133–1134, 1134
 femoral shortening, 1134–1135
 closed, 1135
 proximal, 1135
 growth stimulation, 1135–1136
 leg lengthening, 1106, 1136–1145
 principles of, 1131–1132
 prosthetic fitting, 1132–1133
 shoe lift, 1132
 thresholds for choice of, 1132
 Leg lengthening, 1106, 1136–1145
 for achondroplasia, 251
 Anderson device for, 1136, 1137
 biologic factors and, 1140–1142
 activity level, 1141
 amount of lengthening, 1141
 delay before distraction, 1140
 dynamization, 1141–1142
 lengthening index, 1142
 location of lengthening, 1140, 1141
 minimal disturbance of bone, 1140, 1140
 number of lengthening sites, 1140
 quality of regenerate bone, 1141
 rate of distraction, 1140
 rhythm of distraction, 1141
 thin wires, 1141
 complications of, 1136, 1143–1145, 1144, 1145
 discontinuation of, 1137
 distraction epiphysiodesis, 1138
 factors affecting choice of hardware for, 1142–1143
 ability to adjust device while in place, 1143
 ability to fix more than one segment, 1143
 ability to place pin clusters close together, 1142–1143
 complex deformities with multiple axes of correction, 1143
 conical screws, 1142
 ease of adjusting lengthening mechanism, 1143
 ease of replacement of pins and wires, 1142
 excursion, 1142
 gradual vs. acute correction, 1142
 number of pins in each segment, 1143
 thin wires vs. half-pins, 1142
 total number of pins and wires, 1143
 for fibular deficiency, 1228, 1230–1231
 goal for, 1136
 history of, 1136
 for hypochondroplasia, 254
 Ilizarov technique for, 1139, 1139
 maintaining motion during, 1136–1137
 methods for, 1136
 Orthofix device for, 1138, 1139
 over intramedullary rod, 1139–1140
 patient management for, 1136
 for posterior medial bowing of tibia, 1095
 for proximal femoral focal deficiency, 1241
 Wagner technique for, 1137–1138, 1138
- Legal issues related to child abuse, 1441–1443
 guidelines for expert witnesses, 1443
 informed consent, 1441
 mandatory reporting statutes, 1441
 preparation of court testimony, 1442–1443
- Legg-Calvé-Perthes syndrome, 43, 957–991
 acetabulum in, 70–71
 clinical presentation of, 979
 differential diagnosis of, 983, 983t
 epidemiology of, 958
 etiology of, 959–962
 interruption of proximal femoral blood supply, 959–960, 960
 protein C and S deficiencies, 960–962
 transient synovitis, 959
 gait in, 117
 historical descriptions of, 957–958
 leg length discrepancy and, 1117
 natural history of, 972–973, 972t
 long-term follow-up results, 972–973, 973, 974
 pathogenesis of, 962–972
 histologic abnormalities, 962–964, 963, 964
 pathogenesis of deformity, 967–968, 969
 patterns of deformity, 968–972
 radiographic stages, 965–967, 965–968
 physical examination for, 979

- prognostic factors in, 973–979, 974t
 age at onset, 978
 Catterall's at-risk signs, 977–978, 978
 duration of disease, 978
 femoral head deformity and joint incongruity, 973–974
 lateral pillar classification, 976, 976–977, 976t, 977
 measuring sphericity of femoral head, 978–979
 premature physal arrest, 978–979
 Stulberg classification, 974, 975t
 radiographic features of, 979–983
 arthrography, 70, 70–71, 980–983, 982, 985
 bone scanning, 980, 980
 magnetic resonance imaging, 980, 981
 scintigraphy, 87
 short stature and, 958–959
 transient synovitis of hip and, 959, 1048
 treatment of, 983–991
 abduction orthoses, 985–986, 986
 "containment," 984
 determining need for, 983–984, 983t
 future developments in, 991
 options in noncontainable hip and late-presenting patient with deformity, 988–991, 989, 990
 patient management, 984–985
 principles of, 984–985
 surgical, 986–988
 innominate osteotomy, 987
 shelf arthroplasty, 988, 988
 varus osteotomy, 987
 varus osteotomy plus innominate osteotomy, 987–988
 weight relief, 984
 Lengthening index, 1142. *See also* Leg lengthening
 Leri-Weill syndrome, 275–276, 276
 Madelung deformity and, 868
 Letterer-Siwe disease, 402, 537, 538. *See also* Langerhans cell histiocytosis
 Leucovorin, 528
 Leukemia, 111
 acute lymphoblastic, 416–419, 417, 417t, 418
 arthritis and, 417, 438
 cervical spine involvement in, 835
 Diamond-Blackfan anemia and, 381
 differentiation from osteomyelitis, 474
 metaphyseal sclerosis and, 67
 periosteal reaction and, 214, 215t
 Lidocaine, 1331
 Ligamentous injuries
 ankle sprains, 128, 128–129, 1290–1292
 anterior cruciate ligament, 124, 1294–1296
 collateral ligaments of knee, 1293–1294, 1294
 distal tibiofibular sprains, 1293
 in lower cervical spine, 827, 827, 828
 on magnetic resonance imaging, 83
 posterior cruciate ligament, 124, 124, 1296
 scapholunate ligaments, 892
 transverse atlantoaxial ligament, 801, 824
 Lignac-Fanconi syndrome, 192
 Limb bud, 9–13, 10–13
 Limb deficiencies, 1217–1267
 acquired, 1255–1256
 causes of, 1255
 principles of management for, 1255–1256
 adapted activities and sports for child with, 1267
 classification of, 1218, 1218–1219, 1219t
 complications of, 1225–1227
 bony overgrowth, 1225, 1226
 phantom sensation/pain, 1225–1227
 congenital, 1227–1254
 of lower extremity, 1227–1246
 femoral deficiency, 1237–1246, 1238–1242, 1245
 fibular deficiency, 1227–1230, 1227–1233
 tibial deficiency, 1233–1237, 1234, 1235
 multiple, 1253–1254, 1254
 of upper extremity, 1246–1253
 amelia, 1248, 1249
 phocomelia, 1248–1250, 1249
 prosthetic management for, 1251–1253, 1253
 terminal transverse transcarpal deficiency, 1250–1251, 1251
 transverse complete humeral deficiency, 1250
 transverse incomplete forearm deficiency, 1250, 1251
 differences between children and adults with, 1221
 epidemiology of, 1218
 etiology of, 1220
 congenital constriction band syndrome, 352–355, 353, 355, 1220
 genetic causes, 16–18, 842, 1220
 subclavian artery supply disruption sequence, 1220
 growth and, 1222–1223, 1223t
 intercalary, 17, 842, 1218, 1219, 1219t
 longitudinal, 1218, 1219, 1219t
 organization of care for, 1222
 parents of child with, 1221–1222
 physical/occupational therapy for child with, 1266–1267
 prosthetics for, 1256–1266 (*See also* Prosthetics)
 psychosocial development of child with, 1220–1221
 terminal, 842, 1218, 1219, 1219t
 timing of amputation for, 1223–1225
 transverse, 1218, 1219, 1219t
 upper limb, 842
 Limb development, 9–18, 10–16
 Limb-girdle muscular dystrophy, 646
 Limb hypertrophy, in Klippel-Trenaunay syndrome, 343–345
 Limb salvage procedures, for osteosarcoma, 523–524, 526
 Limbus fracture, 1368
 Limp
 evaluation of child with, 430–434, 431
 after falling, 110–111
 in Legg-Calvé-Perthes disease, 117
 with persistent thigh pain, 116–117
 refusal to walk after, 111–113, 112, 113
 Lines
 Chamberlain's, 804, 805
 Harris, 66, 67
 Klein, 1005, 1005
 Looser, 187, 190, 190
 McGregor's, 804, 805
 McRae's, 804, 805
 Perkins, 918
 posterior cervical, 802, 803, 827
 Shenton, 918, 919, 935
 white lines of Fraenkel, 217, 217
 Linkage analysis, 161
 Lioresal. *See* Baclofen
 Lipomeningocele, 21, 602
 Lisch nodules, 289–291
 Little People of America, 246
 Little's disease, 132
 Lobstein disease, 205
 Lobster claw deformity. *See* Cleft foot; Cleft hand
 Looser lines, 187, 190, 190
 Lordosis
 cervical, development of, 741
 definition of, 741
 lumbar
 myelomeningocele and, 608–614
 normal ranges of, 678, 742
 spastic diplegia and, 588
 spastic quadriplegia and, 570
 normal, 741
 Louis-Bar syndrome, 340t, 341
 Lowe syndrome, 192
 Lower extremity, 1059–1100
 anterolateral bowing of, 1084–1092
 bowing of tibia, 1084–1091
 congenital pseudarthrosis of fibula, 1091–1092
 congenital deficiencies of, 1227–1246
 femoral deficiency, 1237–1246, 1238–1242, 1245
 fibular deficiency, 1227–1230, 1227–1233
 incidence of, 1218
 prostheses for, 1257–1264
 tibial deficiency, 1233–1237, 1234, 1235
 upper extremity deficiencies and, 1253–1254, 1254
 congenital dislocation of knee, 1095–1098
 fasciotomy of, 1329, 1330
 frontal plane mechanical axis of, 1079
 in gait cycle, 135–142
 genu valgum, 1081–1084

- Lower extremity (*contd.*)
 genu varum, 1065–1081
 adolescent Blount disease, 1075–1081
 infantile Blount disease, 1068–1075
 physiologic bowing, 1065–1068
 growth of, 40, 54–58, 55, 1108–1112, 1109t, 1110–1112
 idiopathic toe-walking, 1098–1100
 leg length discrepancy, 1105–1145
 in poliomyelitis, 665–666, 666
 posterior medial bowing of tibia, 1092–1095
 rotational variation of, 1059–1065
 assessment of, 1060, 1061
 complications of, 1064–1065
 definition of, 1059–1060
 differential diagnosis of, 1060–1062, 1062
 natural history of, 1062–1063
 radiographic evaluation of, 1062
 treatment of, 1063–1064, 1064
 in thrombocytopenia with absent radius syndrome, 382, 382t
- Lower extremity trauma, 1372–1414
 ankle, 1290–1293, 1401–1407
 anterolateral ankle impingement, 1293
 distal tibiofibular sprains, 1293
 fractures, 1401–1407
 high-risk, 1403–1405, 1404
 low-risk, 1402, 1403
 Tillaux fracture, 71, 1401, 1405, 1405–1406
 triplane fracture, 1401, 1406, 1406–1408
 sprains, 128, 128–129, 1290–1292, 1291
 femoral shaft fractures, 1379–1389, 1380, 1381, 1383–1389
 foot fractures, 1408–1414
 calcaneus, 1411, 1412
 metatarsals, 1411–1412, 1413
 midfoot, 1411
 phalanges, 1412–1414
 talus, 1409–1411, 1410
 hip, 1372–1379
 dislocation of, 1372, 1372–1373
 proximal femur fractures, 1373–1375, 1373–1379, 1377, 1378
 knee, 1293–1297, 1389–1396
 anterior cruciate ligament injuries, 1294–1296
 collateral ligament injuries, 1293–1294, 1294
 distal femoral physal separations, 1389–1390, 1390–1392
 meniscal tears, 1296–1297, 1297
 patellar fracture, 1394–1396, 1395–1396
 posterior cruciate ligament injuries, 1296
 tibial spine fracture, 1390–1393, 1393
 tibial tubercle fracture, 1393–1394, 1394, 1395
 quadriceps contusion, 1297–1298
 tibial fractures, 1396–1401
 distal, 1401–1407, 1403, 1404
 proximal epiphysis, 1396–1397, 1397, 1398
 proximal metaphysis, 1397–1398, 1399
 shaft, 1398–1401, 1400, 1401
- Lumbar lordosis
 myelomeningocele and, 608–614
 normal, 678
 spastic diplegia and, 588
 spastic quadriplegia and, 570
- Lumbar Scheuermann disease, 752, 753
- Lumbar spine fractures, 1366–1368
- Lumbar spine growth, 52–53
- Lumbosacral plexus, 12
- Luteinizing hormone, 225
- Lyme disease, 435
- Lymphangioma, 1190
- Lymphatic malformations, 340, 342–343
- Lyon hypothesis of X chromosome inactivation, 168
- M**
- Macrocephaly, in achondroplasia, 248, 250
- Macroducty of fingers, 350–352
 clinical features of, 351, 351–352
 conditions associated with, 350
 pathology of, 352
 in Proteus syndrome, 294–295, 345
 treatment of, 352
- Macroducty of toes, 1191–1192
 clinical features of, 1192, 1192
 definition of, 1191
 epidemiology of, 1191
 natural history of, 1192
 pathoanatomy of, 1192
 pathogenesis of, 1191
 radiographic features of, 1192, 1191
 treatment of, 1192
- Macrodystrophia-lipomatosa, 350
- Macrophage activation syndrome, 443
- Macrophages. *See* Monocyte-macrophage system
- Madelung deformity, 868–870
 clinical features of, 868
 conditions associated with, 868
 dyschondrosteosis and, 275, 276
 nail-patella syndrome and, 312
 osteochondromatosis and, 868, 1117
 pathoanatomy of, 868
 radiographic features of, 868, 869
 treatment of, 868–870, 870
- Maffucci syndrome, 340t, 341–342, 344, 529
- Magnetic resonance (MR) angiography, 341
- Magnetic resonance (MR) arthrography, 80, 81
- Magnetic resonance (MR) imaging, 63, 78–85
 applications of, 82–83
 contrast materials for, 80, 81
 cost of, 83, 85t
 mechanisms of contrast for, 78
 flow, 78
 magnetic susceptibility, 78
- normal age-related changes and variants on, 82
- pulse sequences for, 78–80
 gradient recalled echo images, 80, 80
 proton density-weighted images, 78, 80
 short tau inversion recovery images, 80, 81
 T1- and T2-weighted images, 78, 79, 80, 81, 82
- risks and limitations of, 83
- in specific conditions
 achondroplasia, 248, 248
 anterior cruciate ligament injuries, 1295
 Arnold-Chiari malformation, 806
 atlantooccipital anomalies, 805
 atlantooccipital dislocation, 825
 bone and joint sepsis, 79, 82–83, 470, 472–473, 473
 brachial plexopathy, 847, 849t
 chondroblastoma, 532, 533
 congenital kyphosis, 747, 747
 discitis, 482–484, 483
 elbow and forearm reconstruction, 850
 epiphyseal and physal disorders, 83
 Gorham disease, 346, 347
 Klippel-Trenaunay syndrome, 81, 341, 344
 Langerhans cell histiocytosis, 404, 406
 Legg-Calvé-Perthes syndrome, 980, 981
 macroducty, 351
 Madelung deformity, 869
 meniscal injuries, 83
 meniscal tears, 1296
 neuromuscular disorders, 636
 odontoid fracture, 826
 osteochondritis dissecans, 83
 osteogenic sarcoma, 84
 osteoid osteoma, 84, 518, 519, 522
 pelvic osteomyelitis, 485, 486
 posterior cruciate ligament injuries, 1296
 schwannoma, 547
 scoliosis, 684, 691
 sickle cell disease, 389
 slipped capital femoral epiphysis, 1006, 1008
 spinal disorders, 82
 spondylolysis and spondylolisthesis, 782
 tarsal coalition, 1184
 thoracolumbar spine trauma, 1367
 tumors, 83, 84, 514–515
 venous malformations, 341, 342
- Malabsorption syndrome, rickets and, 192
- Malignancies. *See* Tumors
- Mallet fingers, 888
- Mandible, in Caffey disease, 216
- α -Mannosidosis, 398t
- Maquet procedure, for patellar dislocation, 1309, 1310
- Marble bone disease, 212

- Marfan syndrome, 218–220
 asymmetrical, 170
 cardiac abnormalities in, 218, 220
 clinical features of, 218
 diagnosis of, 218–219
 genetics of, 161, 163, 164–165, 218
 kyphosis and, 765, 766
 radiographic features of, 219, 219
 scoliosis and, 120, 219, 219–220, 680
 types of, 218
- Maroteaux-Lamy syndrome, 168, 324t, 397t
 kyphosis and, 765
- Mazicon. *See* Flumazenil
- McCune-Albright syndrome, 170, 229
- McGregor's line, 804, 805
- McKusick-type metaphyseal chondrodysplasia, 271–273
 atlantoaxial instability in, 272
 clinical features of, 272, 272
 genu varum and, 272, 272, 1068
 orthopaedic implications of, 273
 radiographic features of, 272, 273
- McMurray test, 123, 1296
- McRae's line, 804, 805
- mdm-2* gene, in sarcomas, 509
- MDR-1 gene, cancer chemotherapy and, 510
- Medial condyle fracture, 1349
- Medial epicondyle fracture, 1289, 1348–1349
 mechanism of injury, 1348
 treatment of, 1348–1349, 1349
- Medial tibial stress syndrome, 1284–1285
- Median nerve injury, supracondylar fracture and, 1340
- Median nerve testing, 119
- Medical neglect, 1441
- Medications. *See also* specific drugs and classes
 antiinflammatory drugs for athletes, 1276–1277
 for bone and joint sepsis, 476–480, 479t
 for juvenile idiopathic arthritis, 450–451, 451t
 as performance enhancing substances for athletes, 1276
 for spastic diplegia, 579–580
- Medulloblastoma, 761
- Melanocyte-stimulating hormone, 225
- Melatonin, scoliosis and, 681
- Meloreostosis, 357–358
 clinical features of, 357
 differential diagnosis of, 357
 etiology of, 357
 radiographic features of, 357, 358
 treatment of, 357–358
- Menarche, 41, 42
- Meningocele, 21, 23, 601–602
 neurofibromatosis and, 292, 292
- Meningococcemia, multiple limb deficiencies and, 1253
- Meniscus
 discoid lateral, 1309–1311
 classification of, 1309–1310
 clinical presentation of, 1310
 differential diagnosis of, 1310
 treatment of, 1310–1311
 Wrisberg ligament-type, 1310, 1311
- tears of, 1296–1297, 1297
 anterior cruciate ligament injuries and, 1294
 examination for, 123–124, 1296
 on magnetic resonance imaging, 83
 mechanism of injury, 1296
 surgical treatment of, 1296–1297
 rehabilitation after, 1297
- Menkes kinky-hair syndrome, 205, 214, 215t
- Mental retardation
 Albright hereditary osteodystrophy and, 201
 Angelman syndrome and, 171
 chondrodysplasia punctata and, 270
 congenital hypothyroidism and, 226
 Cornelia de Lange syndrome and, 313
 Down syndrome and, 162, 305
 fetal alcohol syndrome and, 311
 fibrodysplasia ossificans and, 218
 fragile X syndrome and, 169
 hypochondroplasia and, 254
 hypoparathyroidism and, 201
 neurofibromatosis and, 294
 Noonan syndrome and, 319
 Prader-Willi syndrome and, 171, 319
 Rett syndrome and, 327
 Rubinstein-Taybi syndrome and, 315
 Williams syndrome and, 202
- Meperidine, 1331, 1331t
- Mesenchyme, 24, 28
- Mesoderm, 5, 5–7, 8, 29
- Metabolic bone diseases, 177–230
 bone formation and, 177–181
 endocrinopathies, 221–230
 fibrous dysplasia, 228–230, 229
 glucocorticoid-related abnormalities, 228, 228
 gonadal abnormalities and sex steroids, 226–228
 growth hormone deficiency and hypopituitarism, 225, 225–226
 growth patterns and, 222–224, 222–224
 hypothyroidism, 226, 226–227
 normal variant short stature, 224–225
- mineral phase, 181–204
 calcium and phosphorus homeostasis and, 181–186, 182–186
 hypercalcemia, 202
 hypophosphatasia, 199–200, 200
 lead poisoning, 203, 203–204
 parathyroid disorders, 200–202
 Albright hereditary osteodystrophy, 201–202
 hyperparathyroidism, 200–201
 hypoparathyroidism, 201, 201
 parathyroid-related protein, 202–203
 renal osteodystrophy, 194–197, 194–199
 rickets and osteomalacia, 186–193, 188–191
- organic phase, 204–221
 bone physiology and, 204–205
 connective tissue syndromes, 218–221
 Ehlers-Danlos syndrome, 220, 220–221
 homocystinuria, 221
 Marfan syndrome, 218–220, 219
 idiopathic juvenile osteoporosis, 210–211, 210–211
 osteogenesis imperfecta, 205–210, 207–208, 210
 osteopetrosis, 212–214, 213
 periosteal reaction and soft tissue calcification, 214–218, 215t
 Caffey disease, 214–216, 216
 hypervitaminosis A, 216
 scurvy, 216–217, 217
 soft tissue calcification, 217–218
- Metabolic myopathies, 650–651
- Metacarpal fractures, 889–890
- Metacarpophalangeal joint
 dislocation of, 893
 thumb hypoplasia/aplasia and, 880–881
- Metaphyseal bands
 in acute lymphoblastic leukemia, 417, 418
 as normal age-related variants, 66, 66–67
- Metaphyseal chondrodysplasias, 271–274
 genu varum and, 272, 272, 273, 1067, 1068
 Jansen, 273
 Kozlowski-type, 273–274
 McKusick-type, 271–273, 272, 273
 Schmid-type, 273
- Metaphyseal fractures
 distal radius and ulna, 1364–1365, 1364–1366
 due to child abuse, 1429–1430, 1430, 1431, 1434
 proximal tibia, 1397–1398, 1399
- Metaphyses, 25–26, 179
 in idiopathic juvenile osteoporosis, 211
 in lead poisoning, 66, 203, 203–204
 lesions in subacute osteomyelitis, 492–494, 493, 494
 in metatropic dysplasia, 255, 255, 256
 normal age-related variants in, 66–67
 avulsive cortical irregularity, 67, 67
 transverse metaphyseal bands, 66, 66–67
 in osteopetrosis, 212
 in type I homocystinuria, 221
- Metatarsals
 apophysis of fifth metatarsal, 1282
 fractures of, 1408, 1411–1412, 1413
- Metatarsus adductus, 1152, 1161–1164
 classification of, 1162
 flexibility, 1162, 1163
 heel bisector method, 1162, 1163
 clinical features of, 1161, 1162
 definition of, 1161–1162
 developmental dysplasia of hip and, 102, 1162
 epidemiology of, 1162

- Metatarsus adductus (*contd.*)
 with flatfoot (*See* Skewfoot)
 intoeing and, 1060
 natural history of, 1163
 nonoperative management of, 1163
 pathogenesis of, 1162
 radiographic features of, 1162,
 1162–1163
 spontaneous correction of, 1152, 1163
 surgical treatment of, 1163–1164, 1164
- Metatropic dysplasia, 254–257
 clinical features of, 255, 255–256
 growth plate histology in, 254–255, 255
 prenatal diagnosis of, 256
 radiographic features of, 256, 256
 treatment of, 256–257
- Methicillin, 479t
- Methotrexate, 528
 for juvenile idiopathic arthritis, 451
 leucovorin and, 528
 for osteosarcoma, 523
- Methotrexate osteopathy, 67
- Meyer dysplasia, 983
- “Michelin tire baby syndrome,” 354
- Midazolam, 1331–1332, 1331t
- Midfoot fractures, 1411
- Midtarsal joint, 1152
- Midtarsal osteotomy, for pes cavovarus,
 660
- Milkman pseudofractures, 187, 190, 190
- Milwaukee brace
 for kyphosis, 754–755, 755, 756, 761
 for scoliosis, 699, 699
- Mineral phase metabolic bone diseases,
 181–204
 calcium and phosphorus homeostasis
 and, 181–186, 182–186
 hypercalcemia, 202
 hypophosphatasia, 199–200, 200
 lead poisoning, 203, 203–204
 parathyroid disorders, 200–202
 Albright hereditary osteodystrophy,
 201–202
 hyperparathyroidism, 200–201
 hypoparathyroidism, 201, 201
 parathyroid-related protein, 202–203
 renal osteodystrophy, 194–197,
 194–199
 rickets and osteomalacia, 186–193,
 188–191
- Mineralization of bone, 204. *See also* Bone
 formation
- “Miserable malalignment syndrome,” 122,
 1301
- Mithramycin, for hypercalcemia of
 malignancy, 202
- Mitochondrial diseases, 169–170
- Mitomycin C, 22
- Mitosis, 158–159
- Mobius syndrome, 17, 1220
- Molecular biology, 2
 of limb development, 13–16
 of nervous system development, 23
 of tumors, 507–510, 508t
 of vertebral column development, 21
- Molecular genetics, 158–160. *See also*
 Genetics
- chromosomes, 158, 158–159
 gene structure, 159, 159
 mutations, 160–162
 posttranslational modification and
 protein assembly, 160
 transcription and RNA processing, 159
 translation, 159–160
- Monocyte-macrophage system, 395–407
 Gaucher disease and, 398–402,
 399–401
 Langerhans cell histiocytosis and,
 402–407, 402t, 403–407
 storage diseases and, 395, 396t–398t
- Monosomy, 162
- Monteggia fracture-dislocation, 1356,
 1356–1358
 classification of, 1356
 complications of, 1356
 treatment of, 1356
- Moro reflex, 106–107, 107, 107t, 109
- Morphogen, 29
- Morphogenesis, 9
- Morquio syndrome, 168, 246, 324, 324t,
 325–327, 326, 397t, 765
- Morula, 3, 3, 29
- Mosaicism, 170
- Mose Sphericity Scale, 973, 973
- Mouse mutant limb deformity, 17
- “Movie sign,” 122
- MR imaging. *See* Magnetic resonance
 imaging
- MSX2 gene, 21
- Mucopolysaccharidoses, 397t–398t
- Mucopolysaccharidoses, 168, 324–327,
 324t, 325, 396t–397t
 kyphosis and, 765
 trigger digits and, 879
 type I, 325
 type IV, 325–327
- Mucopolysaccharidosis, 397t
- Multidrug resistance, cancer chemotherapy
 and, 510
- Multifactorial disorders, 171
- Multiple epiphyseal dysplasia, 269–270
 clinical features of, 269
 radiographic features of, 269, 269–270
 treatment of, 270
- Multiple glomangiomas, 341
- Multiple osteochondilaginous exostosis, 274,
 274–275, 275
- Multiple pterygium syndrome, 303,
 303–305, 304
- Muscle
 biopsy of, 635–636
 in Duchenne muscular dystrophy, 638
 embryology of, 11, 12
 hemorrhages in hemophilia, 413–414,
 414
 rhabdomyosarcoma of, 508, 508t,
 547–548, 549t
 spasms of, in Friedreich ataxia, 657
- Muscle testing, 634
 in Duchenne muscular dystrophy, 640
 strength grading, 125, 125t
- Muscular dystrophies, 636–648
 autosomal dominant, 647–648
 distal muscular dystrophy, 648
 fascioscapulohumeral muscular
 dystrophy, 647–648
 ocular muscular dystrophy, 648
 oculopharyngeal muscular dystrophy,
 648
 autosomal recessive, 646–647
 infantile fascioscapulohumeral
 muscular dystrophy, 646–647, 647
 limb-girdle muscular dystrophy, 646
 classification of, 636t
 congenital, 651, 651–652, 652
 sex-linked, 637–646
 Becker muscular dystrophy, 637, 644,
 644, 645
 Duchenne muscular dystrophy,
 637–644, 638
 Emery-Dreifuss muscular dystrophy,
 644–646
- Muscular torticollis, congenital, 811–813,
 813
 clinical features of, 812
 etiology of, 811–812
 radiographic features of, 812
 stretching exercises for, 812
 surgery for, 812–813, 813
- Mutations, 9, 160–162
 deletions and insertions, 161–162
 detection of, 161
 germline, 509
 missense, 160
 molecular basis of, 160–162
 mosaicism and, 170
 mRNA splicing, 160–161
 nonsense, 160
 point, 160
 promotor, 160
 in tumors, 508–510, 508t
- Myelination in brain, 564
- Myelography
 brachial plexopathy on, 847
 congenital kyphosis on, 747
 contrast materials for, 64
- Myelomeningocele, 601–629
 Arnold-Chiari malformation and, 602,
 603, 605
 cause of, 21–23
 classification and pathology of, 601–603,
 602, 603
 developmental effects of, 606–607
 embryologic development of, 602
 etiology of, 604
 femoral and tibial fractures and, 629
 genetics of, 604
 growth and, 608
 hydrocephaly and, 602–603, 605
 latex hypersensitivity and, 606
 management of foot, 622–628, 623
 calcaneus deformity, 625–626, 626
 cavus deformity, 627, 1152, 1194,
 1195
 Charcot arthropathy, 627–628, 628
 clubfoot, 623–625, 625
 valgus deformity in newborn, 626
 valgus deformity in older child,
 626–627

- management of hip, 617–621, 618
 in middle and lower lumbar paraplegia, 608, 619–621, 620
 in thoracic paraplegia, 608, 617–619
 in upper lumbar paraplegia, 608, 619
 management of knee, 621, 621–622
 management of spinal deformity, 608–616
 kyphosis, 614–616, 615–617
 scoliosis, 608–614, 609, 611, 613
 natural history of, 604–605
 neurologic abnormality in, 603, 603–604
 orthotic devices for child with, 610, 619, 628–629, 629
 prenatal diagnosis of, 604
 recurrent infections and, 608
 rethered cord syndrome and, 602, 605–606, 609
 treatment principles for, 607–608
 walking and, 607–608
 Myeloschisis, 23
MyoD1 gene, 12
 Myopathies, congenital, 649–651
 central core disease, 649–650
 centronuclear myopathy, 650
 congenital fiber-type disproportion, 650
 metabolic myopathies, 650–651
 nemaline myopathy, 650
 Myositis ossificans, 218, 366–368
 clinical features of, 367
 etiology of, 218, 366–367
 histopathology of, 367
 radiographic features of, 367, 367, 368
 treatment of, 367–368
 Myotome, 18, 19, 20, 29
 Myotonia, 648–649
 congenita, 649
 Myotonic dystrophy, 648
 congenital, 649
 genetics of, 164, 169, 170
- N**
 Nafcillin, 479t
 Nail-bed entrapment, 887–888
 Nail-patella syndrome, 311–312, 311–313, 853
 NAIP gene, spinal muscular atrophy and, 653
 Naloxone, 1331t, 1332
 Naproxen, 1277
 Narcotic analgesics, for fracture management, 1331, 1331t
 Navicular fat pad sign, 67
 Naviculectomy, for congenital vertical talus, 1176–1177, 1177
 Neck-righting reflex, 106–107, 107, 107t
 Neer impingement sign, 127, 127
 Nemaline myopathy, 650
 Neonates. *See also* Infants
 bone and joint sepsis in, 486–488
 brachial plexus palsy in, 109–110, 846–850, 1332
 cervical spine injuries in, 829
 fractures in, 1439
 clavicular, 1332
 humeral, 1332, 1335
 metaphyseal sclerosis in, 67
 radiographic appearance of bone in, 64, 64
 Neoplasms. *See* Tumors
 Nerve biopsy, 636
 Nerve blocks, 1330–1331
 Nerve conduction studies, 635
 Nervous system development, 5–7, 5–7, 12, 12, 22–23
 Neural crest, 6, 6–7, 22
 Neural crest cells, 21–23, 29
 Neural tube, 6, 6–7, 7, 20, 22
 Neural tube defects (NTDs), 6, 21–23
 classification and pathology of, 601–602
 folate and, 22–23, 604
 Goldenhar syndrome and, 323–324
 inheritance of, 604
 lipomenigocele, 602
 meningocele, 601–602
 myelomeningocele, 601–629
 prenatal diagnosis of, 174
 rachischisis, 602
 teratogens associated with, 22, 23
 Neurilemmoma, 546–547, 547, 548
 Neuroblastoma, 761
 metastatic to cervical spine, 835
 periosteal reaction and, 214, 215t
 Neurofibrillin, 291
 Neurofibroma, 289, 290, 546, 547
 Neurofibromatosis, 288–294, 344
 cervical spine problems and, 822
 congenital pseudarthrosis and, 860
 fibular, 1086
 tibial, 1084, 1086, 1092
 hemihypertrophy in, 348t, 350
 kyphosis and, 767–768
 leg length discrepancy and, 1117
 macrodactyly and, 1190
 other types of, 288, 291
 type 1, 289–294
 cutaneous markings in, 289, 289
 genetics of, 164, 167, 170, 291
 Lisch nodules in, 289–291
 neurofibromas in, 289, 290, 547
 orthopaedic features of, 291–294, 292–294
 osseous lesions in, 289, 291
 rickets and, 193
 segmental, 170
 Neurofibrosarcoma, 293
 Neurogenic torticollis, 813–814
 Neurologic examination
 of hand, 119
 in neuromuscular disorders, 634–635
 for primitive reflexes, 106–108, 107, 107t, 108
 in Scheuermann disease, 753
 in scoliosis, 121, 686
 in skeletal dysplasia, 246
 Neuromuscular disorders, 633–668
 cerebral palsy, 563–593, 842–846
 congenital myopathies, 649–651
 diagnosis of, 635–636
 electromyography, 635
 hematologic studies, 635
 muscle biopsy, 635–636
 nerve biopsy, 636
 nerve conduction studies, 635
 other studies, 636
 Friedreich ataxia, 656–657
 genetics and molecular biology of, 636
 hereditary motor sensory neuropathies, 657–662, 657t
 history taking for, 634
 muscular dystrophies, 636–648, 636t
 autosomal dominant, 647–648
 autosomal recessive, 646–647
 congenital, 651–652
 sex-linked, 637–646
 myelomeningocele, 601–629
 myotonia, 648–649
 physical examination for, 634–635
 poliomyelitis, 662–668
 postpoliomyelitis syndrome, 668
 spinal muscular atrophy, 652–656
 Neuronal ceroid lipofuscinosis, 398t
 Neurulation, 6, 6–7, 7, 29
 Neutrophils, 392
 defect in chronic granulomatous disease, 392–394, 393
NF1 gene, in neurofibromatosis 1, 167, 291
 Niemann-Pick disease, 396t
 Noggin, 6, 15–16
 Nonossifying fibroma, 534, 534–535, 535
 Nonsteroidal antiinflammatory drugs (NSAIDs)
 for athletes, 1276–1277
 for chondrolysis of hip, 1054
 for juvenile idiopathic arthritis, 450–451, 451t
 mechanism of action of, 1277
 metabolism of, 1277
 side effects of, 1277
 for transient synovitis of hip, 1048
 for tumor pain, 511
 osteoid osteoma, 518, 519
 Noonan syndrome, 318–319
 Normal sagittal balance, 742, 742
 Notochord, 5, 6, 7, 18, 20, 22–23, 29
 Notta nodule, 879
 NSAIDs. *See* Nonsteroidal antiinflammatory drugs
 NTDs. *See* Neural tube defects
 Nuclear medicine. *See* Scintigraphy
 Nursemaid's elbow, 1354–1355, 1355
 Nutrition for athletes, 1274–1275
 Nutritional deficiencies, rickets and, 191–193
- O**
 Ober test, 115, 637, 1286, 1286
 Obesity
 adolescent Blount disease and, 1075, 1076, 1077
 infantile Blount disease and, 1069, 1071
 paralytic disorders and, 58–59
 Prader-Willi syndrome and, 319, 319, 320
 slipped capital femoral epiphysis and, 1000
 transient synovitis of hip and, 1045

- Observational gait analysis, 148, 149
- Obstructive sleep apnea, achondroplasia and, 250
- Occipitoatlantal instability, nontraumatic, 817
- Occipitoaxioatlantal complex development, 799–800
- Occupational therapy
for juvenile idiopathic arthritis, 451–452
for limb-deficient child, 1266–1267
- Ocular-auricular-vertebral dysplasia, 322, 322–323
- Ocular muscular dystrophy, 648
- Ocular pathology, torticollis and, 813–814
- Oculopharyngeal muscular dystrophy, 648
- Odontoid process
embryology of, 800
fractures of, 824–827, 826
hypoplasia or aplasia of
chondrodysplasia punctata and, 271
Morquio syndrome and, 326, 327
mucopolysaccharidosis type I and, 325
pseudoachondroplasia and, 268
spondyloepiphyseal dysplasia and, 263, 264, 266
os odontoidum, 815
chondrodysplasia punctata and, 271
Down syndrome and, 307
spondyloepiphyseal dysplasia and, 263, 264, 266
- Olecranon apophysis, closure of, 42, 43, 44–46, 45
- Olecranon apophysitis, 1283
- Olecranon fracture, 1352, 1352, 1353
- Oligoarthritis, 429–430, 429t, 444. *See also* Juvenile idiopathic arthritis
guidelines for screening eye exams in, 444, 445t
uveitis and, 444, 444
- Ollier disease, 170, 529
leg length discrepancy and, 1117
Madelung deformity and, 868
- Oncogenes, 508–509
- Ontogeny, 29
- Optic atrophy with peroneal muscle atrophy, 657t
- Organic phase metabolic bone diseases, 204–221
bone physiology and, 204–205
connective tissue syndromes, 218–221
Ehlers-Danlos syndrome, 220, 220–221
homocystinuria, 221
Marfan syndrome, 218–220, 219
idiopathic juvenile osteoporosis, 210–211, 210–211
osteogenesis imperfecta, 205–210, 207–208, 210
osteopetrosis, 212–214, 213
periosteal reaction and soft tissue calcification, 214–218, 215t
Caffey disease, 214–216, 216
hypervitaminosis A, 216
scurvy, 216–217, 217
soft tissue calcification, 217–218
- Organizer region, 29
- Organogenesis, 5–9, 6–8, 29
- Orthofix leg lengthening device, 1138, 1139
- Orthopaedic examination, 99–129
from 4 to 10 years of age, 113–120
calcaneal apophysitis, 119–120
elbow trauma, 118–119
limp and persistent thigh pain, 116–117
pes planus deformity, 117–118, 118
toe walking, 113–116, 114–116
from 10 to 18 years of age, 120–129
ankle sprain, 128, 128–129
knee pain aggravated by sports, 122–124, 122–125
persistent knee pain and limp, 121–122
scoliosis, 120, 120–121, 684–686, 685, 686
shoulder pain aggravated by swimming, 125–128, 125–128
from birth to 4 years of age, 102–113
developmental delay and inability to walk, 106–109, 107–109
developmental dysplasia of hip, 102–104, 103, 104
genu varum, 110, 110, 111
infant with paralyzed arm, 109–110
intoeing, 104–106, 105, 106
limp after falling, 110–111
limp then refusal to walk, 111–113, 112, 113
polydactyly, 113
patient profile for, 101–102, 101–102
for specific conditions
bone and joint sepsis, 467
cerebral palsy, 567
clubfoot, 1154–1155
developmental coxa vara, 1–38
juvenile idiopathic arthritis, 430–435, 431
Legg-Calvé-Perthes syndrome, 979
neuromuscular disorders, 634–635
Scheuermann disease, 753
scoliosis, 120, 120–121, 684–686, 685, 686
skeletal dysplasia, 246
spondylolysis and spondylolisthesis, 780–781, 781
tumor, 512
- Orthotic devices. *See also* specific types
for ankle sprains, 1292
for child with myelomeningocele, 610, 619, 628–629, 629
for clubfoot, 1159
for Duchenne muscular dystrophy, 640
for flexible flatfoot, 1172
for genu valgum, 1082
for infantile Blount disease, 1069–1070
for knee in thoracic and upper lumbar paraplegia, 622
for kyphosis, 754–755, 755, 756
radiation kyphosis, 761
for Legg-Calvé-Perthes syndrome, 985–986, 986
- for metatarsus adductus, 1163
for posterior medial bowing of tibia, 1093
after reduction of congenital hip dislocation, 931
for rickets, 197, 198
for rotational variations, 1063
for scoliosis, 698–701, 699, 700
in Friedreich ataxia, 657
in myelomeningocele, 610
in spastic quadriplegia, 570–571
for spastic diplegia, 583
for spastic hemiplegia, 589–590
for spinal muscular atrophy, 654
for spondylolisthesis, 786
for spondylolysis, 783, 784
for thoracic paraplegia, 619
for tibial bowing, 1084–1085
- Ortolani sign, 103, 103, 906, 909, 913, 919
- Os odontoidum, 815
chondrodysplasia punctata and, 271
Down syndrome and, 307
spondyloepiphyseal dysplasia and, 263, 264, 266
- Osgood-Schlatter disease, 123, 1280–1281
differentiation from normal irregularity of tibial tubercle, 65
epidemiology of, 1280–1281
radiographic features of, 1281, 1281
Sever disease and, 1281
treatment of, 1281
- Ossification, 1321
bone age determination and, 68
calcaneal, 65
centers of, 11
primary, 25, 178
secondary, 178
of cervical vertebrae, 800
delayed
in multiple epiphyseal dysplasia, 269–270
in pseudoachondroplasia, 268, 268
in spondyloepiphyseal dysplasia congenita, 263–264
enchondral, 24
femoral, 65
heterotopic
in fibrodysplasia ossificans progressiva, 362–366, 366
in myositis ossificans, 366–368, 367, 368
intramembranous, 24
normal age-related variants of, 65–67, 65–67
Scheuermann disease and, 751
of tarsal navicular, 67
tibial, 65
- Osteitis fibrosa, 196, 210
- Osteoarthritis
in cervical spine, 827
of hip, in cerebral palsy, 576
- Osteoblastoma, 520–521
in cervical spine, 833, 834
- Osteoblasts, 178

- Osteocartilaginous exostosis. *See* Exostosis
- Osteochondritis dissecans of knee, 123
 familial dysautonomia and, 314, 315
 on magnetic resonance imaging, 83
 multiple epiphyseal dysplasia and, 270
 nail-patella syndrome and, 312
 after Legg-Calvé-Perthes syndrome, 971, 971–972
- Osteochondrodysplasias. *See* Skeletal dysplasias
- Osteochondromatosis. *See also* Exostosis
 forearm deformity due to, 858–860
 natural history of, 858
 surgical treatment of, 859, 859–860
 treatment indications for, 858
 leg length discrepancy and, 1117
 Madelung deformity and, 868, 1117
- Osteochondrosis, 368–369
 of capitellum, 1287–1288, 1288
 classification by region, 368r
 clinical features of, 369
 etiology of, 368–369
 histopathology of, 369
 of radial head, 1288
 radiographic features of, 369, 370
 treatment of, 369
- Osteoclast-activating factor, 180
- Osteoclasts, 178
 in osteopetrosis, 212–213
- Osteocytes, 178
- Osteofibrous dysplasia, 536–537, 537
- Osteogenesis. *See* Bone formation
- Osteogenesis imperfecta, 90, 205–210
 classification of, 206–208, 206t, 207–208
 clinical features of, 205
 differential diagnosis of, 205
 child abuse, 205–206, 1439
 eponyms for, 205
 fractures in, 118
 generics of, 161, 164–166, 206, 206t
 histology of, 206
 management of, 209–210
 prenatal diagnosis of, 245–246
 radiographic features of, 206, 207–208
 “temporary brittle-bone disease,” 1439
 type I collagen abnormalities in, 205, 206, 208
 type II, 279–280
- Osteoid bone, 24
- Osteoid osteoma, 518–520
 giant, 520–521
 histology of, 518–519, 520
 locations of, 518
 cervical spine, 833–835, 834
 proximal femur, 117, 518
 spine, 117, 520
 pain of, 518, 519
 radiofrequency ablation of, 520
 radiographic features of, 518, 519, 520
 bone scan, 514
 computed tomography, 515, 518, 520
 magnetic resonance imaging, 518, 519
 surgical treatment of, 519–520
- Osteoid seams, in rickets, 187, 188
- Osteolysis, massive. *See* Gorham disease
- Osteomalacia. *See* Rickets and osteomalacia
- Osteomyelitis, 459–500. *See also* Bone and joint sepsis
 acute hematogenous, 460, 462
 chronic granulomatous disease and, 392, 393
 chronic recurrent multifocal, 490–492, 491
 definition of, 460
 diagnosis of, 466–474
 aspiration, 468, 473–474
 history, 466–467
 imaging, 469–473
 laboratory testing, 467–469, 468t
 physical examination, 467
 differential diagnosis of, 474–475
 epidemiology of, 460
 etiology of, 460–461
 in Gaucher disease, 400
 in infant, 109
 of ischiopubic synchondrosis, 485
 leg length discrepancy and, 1116
 in neonate, 486–488
 osteopetrosis and, 214
 pathophysiology of, 461–465, 462–466
 pelvic, 484–486, 486
 periosteal new bone formation and, 214, 215t, 470, 470
 of proximal femur, 111
 puncture wounds of foot and, 494–496, 495
 pyogenic, of cervical spine, 832
 radiographic features of, 469–473
 bone scan, 470–472, 471
 computed tomography, 472
 magnetic resonance imaging, 82–83, 470, 472–473, 473
 plain radiographs, 469, 469–470, 470
 scintigraphy, 88, 88, 89, 470–472, 471
 ultrasound, 473
 results of, 482
 sickle cell disease and, 386, 386–387, 387, 488–490, 489
 subacute, 492–494, 493, 494
 treatment of, 476–482
 antibiotics, 476–480, 479t
 surgery, 480–482
 vertebral, 482–484
- Osteonecrosis
 acute lymphoblastic leukemia and, 419
 of femoral head, slipped capital femoral epiphysis and, 1019, 1026, 1026–1027
 Gaucher disease and, 401, 401
 sickle cell disease and, 387, 388–389, 388t, 389
- Osteopathia condensans disseminata, 358–359, 359
- Osteopathia striata, 359, 360
- Osteopenia, 90
 acute lymphoblastic leukemia and, 417, 419
- chondrolysis of hip and, 1050
 definition of, 212
 disorders in category of, 212
 Gaucher disease and, 399
 glucocorticoid-induced, 181, 228
 hyperparathyroidism and, 200
 hypophosphatasia and, 199
 juvenile idiopathic arthritis and, 448, 448, 449
 osteogenesis imperfecta and, 207
 tuberculosis and, 497
- Osteopetrosis, 212–214, 213
 clinical forms of, 212
 histology of, 212–213
 inheritance patterns of, 212
 management of, 212–213
- Osteoplasty of femoral neck, for slipped capital femoral epiphysis, 1025–1026
- Osteopoikilosis, 358–359
 clinical features of, 358–359
 pathology of, 359
 radiographic features of, 359, 359
 treatment of, 359
- Osteoporosis, 90
 acute lymphoblastic leukemia and, 419
 corticosteroid-induced, 228
 definition of, 210
 Hadju-Cheney syndrome and, 327, 328
 idiopathic juvenile, 210–212, 210–212, 768
 kyphosis and, 768–769, 769
 Scheuermann disease and, 751
 secondary to immobilization, 211–212, 212
 Turner syndrome and, 318
 type I homocystinuria and, 221
- Osteoporosis fetal, 205
- Osteosarcoma, 507, 521–527
 chemotherapy for, 523
 multidrug resistance and, 510
 classic high-grade, 521–523, 521–524
 definition of, 521
 histologic types of, 522–523, 523
 juxtacortical, 524–526
 parosteal, 524–525, 525
 periosteal, 525–526
 location of, 521
 molecular biology of, 508–510
 pathologic fractures and, 524
 radiographic features of, 521, 522, 523
 bone scan, 89, 522
 magnetic resonance imaging, 84, 522
 retinoblastoma and, 509
 surgical treatment of, 523–524
 limb salvage procedures, 523–524, 526
 local control of extremity sarcomas, 526–527
 metallic prosthesis, 526–527
- Osteosclerosis
 calcaneal, 65, 65
 fragilis generalisata, 212
 metaphyseal, 66, 66–67
 renal osteodystrophy and, 195

- Osteotomies
 for adolescent Blount disease, 1079–1081
 for cavus foot deformity, 1198–1199, 1199
 for cleft foot, 1193, 1194
 for developmental coxa vara, 1040–1041, 1041
 for flexible flatfoot, 1172–1173, 1173
 for Freiberg infraction, 1205–1206
 for genu valgum, 1082–1084
 for infantile Blount disease, 1070, 1070–1075, 1072, 1074
 for juvenile hallux valgus, 1202–1203, 1203
 for juvenile idiopathic arthritis, 452
 for Legg-Calvé-Perthes syndrome, 987–988
 for metatarsus adductus, 1164, 1164
 for pes cavovarus, 659–660
 for poliomyelitis, 664
 for rotational variations, 1063–1065
 for skewfoot, 1167–1168, 1168
 for slipped capital femoral epiphysis, 1019–1024
 complications of, 1019
 cuneiform osteotomy, 1019–1020, 1021
 intertrochanteric osteotomy, 1020–1024, 1023
 osteotomy at base of femoral neck, 1020, 1022
 transtrochanteric rotational osteotomy, 1020
- Out-toeing, 1060–1065, 1062. *See also* Rotational variation of lower extremity
- Overriding fifth toe, congenital, 1178–1180
 clinical features of, 1179, 1179
 definition of, 1178
 epidemiology of, 1179
 natural history of, 1180
 pathoanatomy of, 1180
 pathogenesis of, 1179
 radiographic features of, 1180
 treatment of, 1179, 1180
- Overuse syndromes, 1277–1289
 apophyseal conditions, 1280–1283
 apophysitis of fifth metatarsal, 1282
 apophysitis of hip and pelvis, 1283
 calcaneal apophysitis, 119–120, 1206–1208, 1207, 1282
 olecranon apophysitis, 1283
 Osgood-Schlatter disease, 1280–1281, 1281
 Sinding-Larsen-Johansson disease, 1281, 1281
 breaststroker's knee, 1286–1287
 classic stress fractures, 1277–1279
 iliotibial band friction syndrome, 1286, 1286
 repetitive physal injuries, 1279–1280
 epiphysiolysis of distal radius, 1279–1280, 1280
 epiphysiolysis of proximal humerus, 1279, 1279
 shin pain, 1284–1286
 chronic compartment syndromes, 1285
 muscle herniation and superficial peroneal nerve compression, 1285–1286
 periostitis, 1284–1285
 shoulder pain due to, 125
 tendinosis, 1283–1284
 Achilles tendinitis, 1283
 popliteus tendinitis, 1283–1284, 1284
 tissue fatigue and, 1277, 1278
 valgus overload injuries of elbow, 1287, 1287–1289
 injuries of medial epicondyle, 1289
 osteochondral lesions of capitellum, 1287–1288, 1288
 osteochondral lesions of radial head, 1288
- Oxacillin, 479t
 Oxytocin, 225
- P**
 p53 gene, 509
 locus for, 509
 in osteosarcoma, 509
 as tumor suppressor gene, 509
 P-glycoprotein, cancer chemotherapy and, 510
 PACS (picture archiving and communication systems), 69
 Paget disease, 186
 Pain
 of acute lymphoblastic leukemia, 417
 benign, 438–439
 exaggerated, 438
 chronic, 439
 congenital indifference to, 1439
 evaluation of child with limb or joint pain, 430–434, 431
 fibromyalgia, 439
 of Gaucher crisis, 399–400
 growing pains, 438
 pain amplification syndromes, 438–439
 phantom, 1225–1227
 reflex sympathetic dystrophy, 370–372, 439, 440
 of Scheuermann disease, 752–753
 shin, 1284–1286
 of sickle cell crisis, 385
 of slipped capital femoral epiphysis, 1002–1005
 of spondylolisthesis, 779–781
 of tarsal coalition, 1185
 of transient synovitis of hip, 1044, 1046
 of tumors, 510–511
 osteoid osteoma, 518, 519
 Palmoplantar pustulosis, 490
 Pamidronate, for osteogenesis imperfecta, 209
 Pancreatic insufficiency, in Diamond-Blackfan anemia, 380–381
 Panner disease, 1287–1288
 Parachute reflex, 107t, 108, 108
 Paralysis
 growth in child with, 58–59
 leg length discrepancy and, 1116–1117
 of upper extremity in infant, 109–110
 Paraplegia
 cerebral palsy and, 566
 middle and lower lumbar, 608, 619–621, 620
 sacral level, 608
 spastic, neuropathy with, 657t
 thoracic, 608, 617–619
 upper lumbar, 608, 619
 Parathyroid hormone (PTH)
 Albright hereditary osteodystrophy and, 201–202
 calcium and phosphorus homeostasis and, 180–186
 hyperparathyroidism and, 200–201
 hypoparathyroidism and, 201, 201
 regulation of synthesis and release of, 183–184
 renal osteodystrophy and, 195
 Parathyroid-related protein, 193, 202–203
 Parental disomy, 171
 Parkes-Weber syndrome, 343
 Pars interarticularis defects. *See* Spondylolysis
 Patella. *See also* Knee
 acute dislocation of, 1306–1308
 etiology of, 1306–1307
 natural history of, 1307
 reduction of, 1307
 rehabilitation after, 1307
 surgical treatment of, 1308
 bipartite, 1304
 chondromalacia, 1304
 dorsal defects of, 1304–1305, 1305
 double-layered, in multiple epiphyseal dysplasia, 270
 fractures of, 1394–1396, 1395–1396
 in nail-patella syndrome, 311
 plica syndrome, 1305–1306, 1306
 Q-angle of, 122–123, 123
 recurrent dislocations of, 1308–1309, 1308–1310
 Elmslie-Trillat procedure for, 1309, 1310
 Fulkerson procedure for, 1309, 1310
 Galeazzi procedure for, 1308, 1309
 lateral retinacular release for, 1308
 Maquet procedure for, 1309, 1310
 risk factors for, 1307–1308, 1307t
 Roux-Goldthwait operation for, 1308, 1308
 surgical indications for, 1308
 in Sinding-Larsen-Johansson disease, 1281, 1281
 “squinting,” 122
 stress fracture of, 1278
 Patellar apprehension test, 123, 123
 Patellar inhibition test, 122, 122
 Patelofemoral joint
 anatomy and biomechanics of, 1299, 1300
 anterior knee pain, 1300–1303

- evaluation of, 122–124, 122–125, 1301
 imaging evaluation of, 1301, 1302
 mechanics and diagnosis of, 1300–1301
 physical examination for, 1301
 treatment of, 1301–1303
 chondral shaving, 1303
 lateral retinacular release, 1303
 other procedures, 1303
 instability of, 123
 Patient profile, 101–102, 101–102
 Pattern formation, 8, 29
 PAVF (progressive anterior vertebral fusion), 749–750
 Pavlik harness, 926, 926–928
 complications of, 927–928
 PAX genes, 21–23, 29
 Pectoralis major muscle, absence of, 17
 Pectus carinatum
 McKusick-type metaphyseal chondrodysplasia and, 272
 metatropic dysplasia and, 255
 spondyloepiphyseal dysplasia congenita and, 263, 263
 Pectus excavatum, McKusick-type metaphyseal chondrodysplasia and, 272, 272
 Pediatric Orthopaedic Society of North America's Health Status Questionnaire, 569
 Pediatric Trauma Score, 1327, 1328t
 Pedigree analysis, 163–164
 in autosomal dominant disorders, 164, 164–165
 in autosomal recessive disorders, 167, 167
 in X-linked disorders, 168, 168
 Pelken sign, 217
 Pelvic obliquity, leg length discrepancy and, 1119–1120
 Pelvis
 apophysitis of, 1283
 in cleidocranial dysplasia, 276–277, 277
 in Down syndrome, 305
 fractures of, 1369–1371, 1370
 acetabulum, 1370–1371
 anatomy and classification of, 1370
 avulsion, 1298, 1298
 clinical features of, 1369
 complications of, 1371
 pelvic ring, 1370, 1371
 in gait cycle, 143
 in idiopathic juvenile osteoporosis, 210
 is osteopoikilosis, 359
 in Langerhans cell histiocytosis, 403, 407
 in osteogenesis imperfecta, 204
 osteomyelitis of, 484–486, 486
 in renal osteodystrophy, 196–197
 Penetrance of gene, 164
 Penicillin, 479t
 Performance enhancing substances for athletes, 1276
 Perichondrial groove of Ranvier, 25–27, 27, 1323
 Perichondrial ring of LaCroix, 25–27, 1323
 Perinatal lethal skeletal dysplasias, 279–280
 Periosteal chondroma, 532–534, 534
 Periosteal new bone formation, 214–218, 215t
 acute lymphoblastic leukemia and, 417, 418
 Caffey disease and, 214–216, 216
 dating fractures by, 1436, 1437, 1437t
 fracture and, 1321–1322, 1322
 Gaucher disease and, 400, 400
 hypervitaminosis A and, 216
 osteomyelitis and, 214, 215t, 470, 470
 scurvy and, 216–217, 217
 Periosteum, 1321
 Periostitis, 1284–1285
 Peripheral nerves, 21
 embryology of, 12
 myelination of, 23
 Peripheral neuroectodermal tumor (PNET), 507, 542–544
 clinical features of, 542
 histology of, 544
 molecular biology of, 508, 508t
 radiographic features of, 542–544
 treatment of, 544
 Peroneal nerve compression, 1084, 1285–1286
 Perthes disease, 38
 Pes acetabulum, 1152, 1157, 1169
 Pes cavovarus
 in Friedrich ataxia, 656
 in hereditary motor sensory neuropathies, 658–661, 659
 treatment of, 659–661
 calcaneal osteotomy, 659–660
 midtarsal osteotomy, 660
 plantar-medial release, 659
 plantar release, 659
 tendon transfers, 659
 triple arthrodesis, 660–661, 661
 Pes planus. *See* Flatfoot
 Pes valgus, congenital convex. *See* Vertical talus, congenital
 PET (positron emission tomography), 85, 514
 Pfeiffer syndrome, 821–822
 PFFD. *See* Proximal femoral focal deficiency
 Phalanges of foot, fractures of, 1408, 1412–1414
 Phalanges of hand
 distal phalanx injuries, 887–888
 mallet fingers, 888
 physeal fractures and nail-bed entrapment, 887–888
 tip amputations, 887
 fractures of, 888–889
 intercondylar fractures, 886, 888–889, 889
 phalangeal neck fractures, 888
 physeal fractures, 889
 Phantom sensation/pain, 1225–1227
 Phelps-Baker test, 115
 Phenotype, 7, 21, 29
 chromosome abnormalities and, 162–163
 variable expressivity and, 164
 X-linked, 168–169
 Phenylketonuria, 168, 174
 PHEX gene, in X-linked hypophosphatemic rickets, 169
 Phocomelia, 1219, 1248–1250, 1249. *See also* Limb deficiencies
 Roberts syndrome with, 17
 Phosphate diabetes, 192
 Phosphoethanolamine, in hypophosphatasia, 199
 Phosphorus
 Albright hereditary osteodystrophy and, 201
 factors affecting absorption of, 185, 185
 homeostasis, 181–186
 hyperparathyroidism and, 200
 hypoparathyroidism and, 201
 renal osteodystrophy and, 195
 tumoral calcinosis and, 217–218
 Phylogeny, 29
 Physeal bar resection, 1325, 1326
 in infantile Blount disease, 1073
 Physeal fractures, 1114–1116, 1116, 1323–1324
 distal femur, 1389–1390, 1390–1392
 distal humerus, 1345, 1346, 1349–1350, 1350
 distal radius, 1365–1366
 distal tibia, 1402–1403, 1403, 1404
 due to child abuse, 1428–1429, 1429
 epidemiology of, 1323
 growth arrest after, 1324–1327
 complete, 1324
 etiology of, 1324
 radiographic features of, 1324, 1325
 treatment of partial physeal arrest, 1325–1327, 1326
 mechanism of injury, 1323
 medial clavicle, 1333
 proximal humerus, 1335, 1337
 proximal tibia, 1396–1397, 1397, 1398
 Salter-Harris classification of, 1114–1116, 1115, 1323–1324, 1324
 Physical activity. *See also* Sports medicine
 heel pain aggravated by, 119–120, 1206–1208, 1207, 1282
 knee pain aggravated by, 122–124, 122–125
 shoulder pain aggravated by, 125–128, 125–128
 thigh pain and limp aggravated by, 117
 Physical examination, 100. *See also* Orthopaedic examination
 for sports participation, 1289–1290
 Physical therapy
 for Duchenne muscular dystrophy, 639–640
 for juvenile idiopathic arthritis, 451–452
 for limb-deficient child, 1266–1267
 for spastic diplegia, 581–583
 for upper limb involvement in cerebral palsy, 843

- Physis, 25–26, 178, 179, 1321–1327
 anatomy and physiology of, 1322–1323
 fractures through (*See* Physeal fractures)
 in hypophosphatasia, 199, 200
 on magnetic resonance imaging, 82, 83
 in metatropic dysplasia, 255, 255
 normal age-related variants of, 65–66, 66, 82
 regulation of, 179–180
 remaining growth in lower limbs
 between ages 5 and 17 years, 57
 sports-related injuries of, 83
 structure and development of, 24–27, 25–26
 vascular anatomy of, 27, 179, 1323
 zones of, 25–27, 179
- Picture archiving and communication systems (PACS), 69
- Pigmented villonodular synovitis (PVNS), 438, 551
 differentiation from chondrolysis of hip, 1050
- Pivot-shift test, 124, 1294
- Placental development, 2, 3, 4
- Plantar fascia
 flexible flatfoot and, 1169, 1170
 windlass action of, 1170
- Plantar-medial release, for pes cavovarus, 659
- Plantar release, for pes cavovarus, 659
- Platelet-derived growth factor, 9, 178t, 1321
- Pleiotropy, 164
- Plica syndrome, 1305–1306, 1306
- PNET. *See* Peripheral neuroectodermal tumor
- Poland syndrome, 17, 1220
- Poland's hump, 66, 66
- Polarizing region, 11, 14–16, 15
- Poliomyelitis, 662–668
 etiology of, 662
 growth in child with, 58–59
 lower extremity involvement in, 665–666, 666
 pathology of, 663
 postpoliomyelitis syndrome and, 668
 scoliosis and, 667, 667–668
 stages of, 663–664
 treatment of, 664–665
 arthrodeses, 665
 guidelines for, 665
 osteotomies, 664
 soft tissue contractures, 664
 tendon transfers, 664
 upper extremity involvement in, 665
 vaccine-associated, 663
- Pollicization of index finger, 881
- Polyarthritis, 429t, 430, 444–445. *See also* Juvenile idiopathic arthritis
 guidelines for screening eye exams in, 445t
 radiographic features of, 448, 448–449, 449
- Polycystic kidney disease, 327
- Polydactyly of fingers, 17, 876–877
 bilateral, 877
 central, 876, 877
 classification of, 877
 conditions associated with
 chondroectodermal dysplasia, 257
 Klippel-Trenaunay syndrome, 343, 345
 short rib-polydactyly syndrome, 279
 examination for, 113
 incidence of, 877
 inheritance of, 113, 876
 postaxial, 876, 877
 preaxial, 881–885
 classification of, 883, 883, 884
 pathoanatomy of, 883
 treatment of, 883–885, 884, 885
 treatment of, 877, 877
- Polydactyly of toes, 1188–1190
 classification of, 1188, 1189
 clinical features of, 1188–1189, 1189, 1190
 definition of, 1188
 epidemiology of, 1188
 natural history of, 1189
 pathogenesis of, 1188
 radiographic features of, 1189, 1190
 surgical treatment of, 1189–1190
- Polymerase chain reaction, for mutational analysis, 161–162
- Polysyndactyly, 17, 113
 gene mutation causing, 842
 Greig cephalopolysyndactyly, 17
 of toes, 1188–1190
- Popliteal angle, 114, 115
- Popliteal cyst, 1309
- Popliteal pterygium syndrome, 303–305, 305
- Popliteus tendinitis, 1283–1284, 1284
- Port wine stains, 340–341
- Positional calcaneovalgus, 1152, 1178
 clinical features of, 1178, 1178
 definition of, 1178
 epidemiology of, 1178
 natural history of, 1178
 pathogenesis of, 1178
 radiographic features of, 1178, 1178
 spontaneous correction of, 1152
 treatment of, 1178
- Positron emission tomography (PET), 85, 514
- Posterior cervical line, 802, 803, 827
- Posterior cruciate ligament injuries, 124, 124, 1296
- Posterior fossa tumors, torticollis and, 813
- Postlaminectomy kyphosis, 758, 758–760, 759, 819
 cervical, 818–819, 820, 821
 evaluation of, 759
 locations of, 758–759
 muscle paralysis and, 758
 natural history of, 759
 pathophysiology of, 758
 treatment of, 759
- Postpoliomyelitis syndrome, 668
- Poststreptococcal arthritis
 differentiation from juvenile idiopathic arthritis, 436
 differentiation from transient synovitis of hip, 1046
- Postural kyphosis, 744, 744
- Postural reflexes, 107t, 108, 108
- Prader-Willi syndrome, 171, 228, 319, 319, 320
- Pregnancy. *See also* Teratogens
 folate supplementation during, 22
 genetic counseling during, 174
 iron supplementation during, 383
- Prenatal diagnosis, 174–175
 of chondrodysplasia punctata, 271
 of clubfoot, 1156, 1156
 of Cornelia de Lange syndrome, 313
 of diastrophic dysplasia, 260
 of Down syndrome, 305
 of metatropic dysplasia, 256
 of myelomeningocele, 604
 of skeletal dysplasias, 145–146
- Primitive reflexes, 106–108, 107, 107t, 108
 prognosis for walking related to persistence of, 108–109, 109t
- Progeria, 316, 316–317, 317
- Progress zone, 10, 14, 14, 29
- Progressive anterior vertebral fusion (PAVF), 749–750
- Progressive diaphyseal dysplasia, 355–357
 clinical features of, 355
 differential diagnosis of, 356
 etiology of, 356
 pathology of, 356
 radiographic features of, 355–356, 356
 treatment of, 356
- Prolactin, 225
- Proliferative zone of physeal cartilage, 25
- Pronator quadratus sign, 68
- Prone Staheli test, 114, 115
- Prostaglandin E₂, 180
- Prosthetics, 1256–1266
 endoskeletal vs. exoskeletal construction of, 1265–1266
 fitting techniques for, 1256
 lower extremity
 for femoral deficiency, 1241–1243, 1242, 1246
 for fibular deficiency, 1233
 for leg length discrepancy, 1131–1133
 partial foot prosthesis, 1263–1264, 1264
 prosthetic feet, 1262–1263, 1263
 prosthetic knees, 1261–1262, 1262
 socket design for, 1257–1261
 ankle disarticulation prosthesis, 1260–1261, 1261
 hip disarticulation, 1257
 transfemoral prosthesis, 1257, 1257–1258, 1258
 transtibial prosthesis, 1258–1260, 1259, 1260
 for tibial deficiency, 1237

- for multiple limb deficiencies,
1253–1254, 1254
- role of prosthetist, 1256
- socket design and suspension systems
for, 1256–1257
- upper extremity, 1247, 1251–1253,
1253
- age for fitting of, 1247–1248
- body-powered vs. myoelectric devices,
1251–1253, 1252t
- Prosthetic Upper Extremity
Functional Index, 1247
- terminal devices, 1264–1265, 1265
- for transverse complete humeral
deficiency, 1250
- for transverse incomplete forearm
deficiency, 1250, 1251
- Protein C and S deficiencies, Legg-Calvé-
Perthes syndrome and, 960–962
- Proteus syndrome, 170, 294–295, 295,
345–346, 346
- clinical features of, 294, 345
- etiology of, 294
- hemihypertrophy in, 345, 348t, 350
- macroducty in, 294–295, 345, 1190
- orthopaedic deformities in, 295
- Protooncogenes, 508–509
- Protrusio acetabuli, 204
- Provitamins D, calcium homeostasis and,
182–183, 183
- Proximal-distal axis determination, 10, 11,
14
- Proximal femoral focal deficiency (PFFD),
1237–1246
- bilateral, 1238
- classification of, 1237–1238,
1238–1241
- clinical appearance of, 1238, 1241
- fibular deficiency and, 1229, 1238
- incidence of, 1218
- prosthetic management of, 1241–1243,
1242, 1246
- transfemoral prosthesis, 1257,
1257–1258, 1258
- radiographic appearance of, 1238–1241
- treatment of, 1241–1246, 1246
- foot amputation, 1243
- hip stabilization, 1244
- iliofemoral arthrodesis, 1244–1246
- knee arthrodesis, 1243
- limb lengthening, 1241
- nonconventional prosthesis,
1241–1243, 1242
- thigh reduction, 1246
- van Nes rotationplasty, 1243–1244,
1245
- Proximal interphalangeal joints, in
camptodactyly, 877–878, 878
- Pseudarthrosis
- congenital clavicular, 359–361, 361,
1332
- congenital fibular, 1091–1092
- congenital tibial, 1084–1091, 1085t,
1086–1089
- constriction band syndrome and, 354
- of forearm, 860, 860–861
- in neurofibromatosis, 292–293, 293,
1084, 1086, 1092
- after spinal fusion for postlaminectomy
kyphosis, 760
- Pseudo-osteolysis, in Hadju-Cheney
syndrome, 327, 328
- Pseudoachondroplasia, 266–269
- clinical features of, 267, 267–268
- kyphosis, 763–765
- growth plate histology in, 267, 267
- radiographic features of, 268, 268
- treatment of, 268–269
- Pseudofracture
- due to physeal obliquity, 65–66
- milkman (Looser lines), 187, 190, 190
- Pseudohypoparathyroidism, 181, 201,
201–202
- Pseudomonas aeruginosa* infection from
puncture wounds of foot, 494–496,
495
- Pseudopseudohypoparathyroidism, 201
- Pseudosubluxation, of cervical vertebrae,
802–803, 803
- Pseudotumors, in hemophilia, 415, 416
- Psoriatic arthritis, 429t, 430, 445–446,
446
- radiographic features of, 449, 450
- screening eye exams in, 445t
- Psychosocial development of child with
limb deficiency, 1220–1221
- Pterygia syndrome, 303–305
- PTH. *See* Parathyroid hormone
- Puberty, 41–43
- development of secondary sexual
characteristics at, 41
- precocious, 227
- in neurofibromatosis, 294
- in Russell-Silver syndrome, 317
- pubertal diagram, 41–43, 42
- Risser sign and, 42, 45
- Scheuermann disease and, 752
- scoliosis and, 53–54
- slipped capital femoral epiphysis and,
999
- “Pucker” sign, 1341
- Puncture wounds of foot, 494–496, 495
- PVNS (pigmented villonodular synovitis),
438, 551
- Q**
- Q angle, 122–123, 123, 1299, 1300, 1301
- Quadriceps active test, 124, 124
- Quadriceps contusion, 1297–1298
- Quadriceps fibrosis, infantile, 369–370
- clinical features of, 369
- etiology of, 369
- pathology of, 369–370
- treatment of, 370
- Quadrimebral deficiency, 1253–1254,
1254
- Quadriceps paresis
- diastrophic dysplasia and, 258
- transient, 829
- Quadruplegia. *See also* Spastic quadriplegia
- cerebral palsy and, 565, 842
- Quantitative computed tomography,
89–90
- Quantitative gait analysis, 132, 148–152
- dynamic electromyography, 148, 151
- energetics, 148, 151–152
- kinematic, 148, 150
- kinetic, 148, 150–151
- Quengel cast, 415, 416
- R**
- Rachischisis, 21–22, 602
- Rachitic cat back, 187
- Rachitic rosary, 187
- Radial dysplasia, 861–865
- classification of, 861, 862
- clinical features of, 861
- conditions associated with, 861
- incidence of, 861
- natural history of, 863
- nonoperative management of, 863
- pathoanatomy of, 862–863
- pathogenesis of, 861
- surgical treatment of, 863, 863–864,
865
- complications of, 864–865
- Radial nerve injury
- humeral shaft fracture and, 1335
- supracondylar fracture and, 1340
- Radial nerve testing, 119
- Radiation exposure, 90–92
- from bone densitometry, 90
- diagnostic examinations and, 68t, 91–92
- dosimetry, 91
- effects on vertebral growth, 760–761
- gonadal shielding and, 67, 92
- occupational, 92
- radiation effects, 91
- relationship between radiation dose and
effect, 91
- steps for reduction of, 92
- teratogenicity of, 173
- Radiation kyphosis, 760–763, 762
- incidence of, 761
- monitoring for, 761
- pathophysiology of, 761
- radiographic evaluation of, 761
- treatment of, 761–763, 763
- bracing, 761
- Radiation myelopathy, 763
- Radiation therapy
- for eosinophilic granuloma in cervical
spine, 834
- for Gorham disease, 347
- involving spine, 760–761
- leg length discrepancy and, 1117
- slipped capital femoral epiphysis and,
1002
- Radical fringe, 13
- Radiculopathy, after reduction of
spondylolisthesis, 793–794
- Radioactive synovectomy, hemophilia and,
413
- Radiocapitellar joint, 1356, 1356

- Radiographic findings in specific conditions
 accessory navicular, 1181, 1182
 achondroplasia, 248–250, 249
 aneurysmal bone cyst, 541, 541
 ankle fracture, 1403–1408
 anterior cruciate ligament injuries, 1295
 arthrogryposis multiplex congenita, 297, 297
 atlantoaxial rotary displacement, 808–809, 809
 atlantooccipital anomalies, 805, 806
 Baumann angle of elbow, 1339
 Blount disease
 adolescent, 1076, 1077
 infantile, 1066, 1068, 1069, 1070, 1072
 bone and joint sepsis, 469–473, 469–473
 calcaneus fracture, 1412
 cavus foot deformity, 1195, 1196–1197, 1197
 child abuse, 1429–1437, 1436t, 1437t, 1438
 chondrodysplasia punctata, 271, 271
 chondroectodermal dysplasia, 257, 257
 chondrolysis of hip, 1050–1051, 1050–1052, 1054
 cleft foot, 1192, 1194
 cleidocranial dysplasia, 276–277, 277
 clubfoot, 1155, 1155–1156, 1156
 congenital hallux varus, 1187, 1188
 congenital muscular torticollis, 812
 congenital pseudarthrosis of clavicle, 361, 361
 congenital pseudarthrosis of ulna, 860
 congenital radial head dislocation, 853, 854
 congenital radioulnar synostosis, 856, 857
 congenital vertical talus, 1174–1175, 1175
 developmental coxa vara, 1037, 1039, 1039–1040, 1042
 diaphyseal aclasia, 274, 274–275, 275
 diastrophic dysplasia, 259, 260, 260
 distal femoral physeal fracture, 1390–1392
 distal metaphyseal fractures of radius and ulna, 1364, 1365
 Down syndrome, 306–308, 306–308
 dyschondrosteosis, 275–276, 276
 dysplasia epiphysealis hemimelica, 362, 363
 epiphyseolysis of distal radius, 1279–1280, 1280
 epiphyseolysis of proximal humerus, 1279, 1279
 Ewing sarcoma, 542–544, 543
 exostosis, 529–530, 530
 femoral neck fracture, 1377, 1378
 femoral shaft fracture, 1380, 1381, 1384–1388
 fibrodysplasia ossificans progressiva, 364, 365–366
 fibrous dysplasia, 229
 fibular deficiency, 1227–1229, 1229–1230
 flexible flatfoot, 1169–1170, 1171
 forearm green-stick fractures, 1358, 1359
 forearm shaft fractures, 1360–1363
 fracture-separation of distal humeral epiphysis, 1346
 Freiberg infraction, 1205, 1206
 genu valgum, 1082, 1083
 genu varum, 1066, 1067
 Gorham disease, 346–347, 347
 hemophilia, 409–410, 410, 411, 411t
 hip dislocation, 1372
 hyperparathyroidism, 196, 200
 hypochondroplasia, 254
 hypophosphatasia, 199, 200
 juvenile ankylosing spondylitis, 450, 450
 juvenile hallux valgus, 1201
 juvenile idiopathic arthritis, 448–450, 448–450
 Klippel-Trenaunay syndrome, 81, 341, 344–345
 Kneist dysplasia, 262, 262
 Kohler disease, 1204, 1204
 Langerhans cell histiocytosis, 403–407, 404, 513, 537–538, 539
 lapbelt fracture, 1369
 Larsen syndrome, 278, 278, 279, 299, 300
 lateral condyle fracture, 1346–1348
 leg length discrepancy, 1120–1122, 1121, 1122
 Legg-Calvé-Perthes syndrome, 70, 70–71, 87, 979–983, 980–982
 macrodactyly of toes, 1192, 1191
 Madelung deformity, 868, 869
 Marfan syndrome, 219, 219
 McKusick-type metaphyseal chondrodysplasia, 272, 273
 medial epicondyle fracture, 1349
 melorheostosis, 357, 358
 metatarsal fractures, 1413
 metatarsus adductus, 1162, 1162–1163
 metatropic dysplasia, 256, 256
 Monteggia fracture-dislocation, 1357, 1358
 multiple epiphyseal dysplasia, 269, 269–270
 myositis ossificans, 367, 367, 368
 olecranon fracture, 1353
 Osgood-Schlatter disease, 1281, 1281
 osteochondral lesion of capitellum, 1287–1288, 1288
 osteochondroses, 369, 370
 osteogenesis imperfecta, 206, 207–208
 osteoid osteoma, 514, 515, 518, 519, 520
 osteomyelitis, 82–83, 88, 88, 89, 469–471, 469–473, 470, 473
 osteopoikilosis, 359, 359
 osteosarcoma, 84, 89, 521, 522, 523
 patellar fracture, 1395–1396
 pelvic fracture, 1370, 1371
 periosteal new bone formation, 1322
 peripheral neuroectodermal tumor, 542–544
 physeal arrest, 1324, 1325
 physeal bar resection, 1326
 polyarthritis, 448, 448–449, 449
 polydactyly of fingers, 876
 polydactyly of toes, 1189, 1190
 positional calcaneovalgus, 1178
 posterior medial bowing of tibia, 1093, 1093, 1094
 progressive diaphyseal dysplasia, 355–356, 356
 proximal femoral focal deficiency, 1238–1241
 proximal humeral fracture, 1336, 1337
 pseudoachondroplasia, 268, 268
 psoriatic arthritis, 449, 450
 radial dysplasia, 862
 radial head dislocation, 1354
 radial neck fracture, 1351
 reflex sympathetic dystrophy, 371, 439, 440
 rotational variation, 1062
 scaphoid fracture, 891, 891
 Scheuermann disease, 750, 753–754, 754
 Sever apophysitis, 1207, 1207
 Sinding-Larsen-Johansson disease, 1281, 1281
 skewfoot, 1166, 1166–1167, 1167
 slipped capital femoral epiphysis, 1003–1008, 1005–1008
 spondyloepiphyseal dysplasia congenita, 263–264, 264, 265
 spondyloepiphyseal dysplasia tarda, 266, 266
 sternoclavicular separation, 1333
 stress fractures, 1278
 supracondylar fracture, 1341, 1342
 syndactyly, 874, 875
 talus fracture, 1410
 thoracic spine fracture, 1368
 tibial deficiency, 1234, 1235
 tibial fractures
 distal, 1406–1408
 proximal epiphyseal, 1397
 proximal metaphyseal, 1399
 shaft, 1400, 1401
 tibial eminence, 1393
 tibial tubercle, 1395
 tibial physeal growth arrest, 1325
 transient synovitis of hip, 1046–1047, 1047
 triangular fibrocartilage complex tear, 892, 893
 triphalangeal thumb, 885
 tumors, 512–513
 ulnar dysplasia, 867, 868
 Radiographic techniques, 64–74. *See also*
 specific imaging modalities
 arthrography, 69–71
 basis of radiographic contrast, 64, 64
 computed tomography, 71–74
 contrast materials for, 64–65
 conventional tomography, 71
 gonadal shielding for, 67, 92

- normal age-related changes and variants
on, 65–67
epiphyseal and apophyseal, 65, 65
metaphyseal, 66–67, 66–67
physeal, 65–66, 66
round bone variant, 67
plain films, 67–69
Radiographs, plain, 67–69
for bone age determination, 68–69, 224,
1123–1124
coning for, 67
cost of, 85t
digital radiography, 69
for investigation of child abuse, 69
principles for, 67–68
radiation doses for, 68t
soft tissue on, 67
Radiohumeral joint, 1338
Radionuclide angiography, 86
Radionuclides, 85, 89, 513–514. *See also*
Scintigraphy
Radioulnar joint, 1338
Radioulnar synostosis, congenital, 855–858
anomalies associated with, 856
clinical features of, 856
embryogenesis of, 855–856
natural history of, 856
radiographic features of, 856, 857
surgical treatment of, 856–857
complications of, 857–858
Radius
bowing of, related to ulnar dysplasia,
866, 867
congenital pseudarthrosis of, 860–861
dislocation of head of
congenital, 853–854
clinical features of, 853
complications of surgery for, 854
conditions associated with, 853
nail-patella syndrome and, 311,
312, 313, 853
natural history of, 853
radiographic features of, 853, 854
surgical treatment of, 854
osteochondromatosis and, 858, 860
ulnar dysplasia and, 866
distal, epiphysiolysis of, 1279–1280,
1280
dysplasia of (*See* Radial dysplasia)
fractures of
complete shaft, 1359–1363,
1360–1363
distal, 68
distal metaphyseal, 1364–1365,
1364–1366
distal physeal, 1365–1366
Galeazzi fracture-dislocation, 1357
green-stick, 1358, 1358–1359, 1359
Monteggia fracture-dislocation, 1356,
1356–1358
plastic deformation, 1357
radial neck, 1350–1352, 1351
Madelung deformity of, 868–870, 869,
870
osteochondromatosis of, 858–860, 859,
1288
radial head dislocation and nursemaid's
elbow, 1354, 1354–1355, 1355
thrombocytopenia with absent radius
syndrome, 381–383, 382
RBI gene
locus for, 509
in osteosarcoma, 509
in retinoblastoma, 170
as tumor suppressor gene, 509
Rectus femoris transfer, for spastic diplegia,
587–588
Reflex sympathetic dystrophy, 370–372,
439
clinical features of, 371, 439, 440
diagnostic criteria for, 371
etiology of, 371
radiographic features of, 371, 439, 440
treatment of, 371–372, 439
Reflexes
primitive, 106–108, 107, 107t, 108
prognosis for walking related to
persistence of, 108–109, 109t
in spastic cerebral palsy, 116
testing in patient with scoliosis, 121
Refsum disease, 657t. *See also* Hereditary
motor sensory neuropathies
Regional anesthesia, 1330–1331
Reiter's syndrome, 435
Relocation test, 126
Renal disease
Hadju-Cheney syndrome and, 327
nail-patella syndrome and, 313
Renal osteodystrophy, 118, 187, 194–196
biochemical alterations in, 196
clinical features of, 195–196
management of, 198–199
osteosclerosis and, 195
pathophysiology of, 194, 194–195
radiographic changes in, 195–197, 196
slipped capital femoral epiphysis and,
187, 195, 198
Renal tubular acidosis, 192, 193
Rendu-Osler-Weber syndrome, 340t, 341
Reporting of child abuse, 1440, 1441
Resistance exercise, 1276
Resting zone of physeal cartilage, 25
Retinal detachment, skeletal dysplasia and,
246, 262
Retinitis pigmentosa with distal muscle
weakness and atrophy, 657t
Retinoblastoma
genetics of, 170, 509
osteosarcoma in patients with, 509
periosteal reaction and, 214, 215t
Retinoic acid
role in limb development, 14–15, 15
teratogenicity of, 15, 17, 21–23
Rett syndrome, 169, 328–329
RF (rheumatoid factor), 433, 441
Rhabdomyosarcoma, 507, 548
histologic patterns of, 548
histology of, 548
molecular biology of, 508, 508t, 548
staging of, 548, 549t
treatment of, 548
Rheumatic fever, acute, 435–436
clinical features of, 435–436
differential diagnosis of
septic arthritis, 475
transient synovitis of hip, 1046
Jones criteria for diagnosis of, 436t, 475
treatment of, 436
Rheumatoid factor (RF), 433, 441
Rhizotomy, selective posterior, for spastic
diplegia, 580–581
Rib-vertebral angle difference (RVAD),
694–695, 695
Ribbings dysplasia, 269
Ribs
chondroectodermal dysplasia and, 257
fractures of, 88
due to child abuse, 1432, 1434
Goldenhar syndrome and, 324
metatropic dysplasia and, 256, 256
rickets and, 187, 190
short rib-polydactyly syndrome, 279
Rickets and osteomalacia, 43, 90, 186–199
biochemical alterations in, 190t
causes of, 191–196, 191t
clinical features of, 187
differential diagnosis of, 197
gastrointestinal disorders and, 192
histologic changes in, 187–189, 188
hypophosphatemic (vitamin D-resistant),
192–193
genetics of, 169
genu varum and, 1066–1068, 1067
management of, 196–199
pathogenesis of, 186–187
periosteal reaction and, 215t
radiographic changes in, 189–190,
189–190
renal osteodystrophy, 194–196,
194–197
unusual forms of, 193
anticonvulsant rickets, 181, 193
vitamin D-deficient, 191, 191–193
Rigidity, in spastic cerebral palsy, 116
Riley-Day syndrome, 314–315, 315
Ring of LaCroix, perichondrial, 25–27,
1323
Risser sign for bone age determination, 42,
45, 49, 50
scoliosis and, 53, 691, 691, 695–696
RNA, transcription and, 159
Roberts syndrome, 17
Rocker-bottom foot. *See* Vertical talus,
congenital
Romberg sign, 121, 634
Rooting reflex, 108
"Rose thorn" sign, 70, 70
Rotational variation of lower extremity,
1059–1065
assessment of, 1060, 1061
complications of, 1064–1065
definition of, 1059–1060
differential diagnosis of, 1060–1062,
1062
intoeing and, 105–106, 105, 106, 1060
natural history of, 1062–1063
radiographic evaluation of, 1062
treatment of, 1063–1064, 1064

Rotationplasty, for distal femoral osteosarcoma, 527
 Rotator cuff muscle imbalance, 125
 "Round cell tumors," translocations in, 508
 Roussy-Levy syndrome, 657t, 658. *See also* Hereditary motor sensory neuropathies
 Roux-Goldthwait operation, for patellar dislocation, 1308, 1308
 Rubinstein-Taybi syndrome, 315, 315–316, 316
 clinodactyly and, 871
 congenital humeroulnar dislocation and, 855
 Running cycle, 143–145, 144
 Russell-Silver dwarfism, 317, 317–318
 hemihypotrophy in, 317–318, 348t, 350
 RVAD (rib-vertebral angle difference), 694–695, 695

S

SAC (space available for cord), 801
 SACH (single-axis cushion heel) foot, 1262, 1263
 Sacral agenesis, 749
 Sacrococcygeal teratoma, 22
 Sacroiliac joint sepsis, 484–486
 "Sagging rope" sign, 270
Salmonella osteomyelitis, in sickle cell disease, 387–388, 489–490
 Salter-Harris classification of physeal fractures, 1114–1116, 1115, 1323–1324, 1324
 Sandifer syndrome, 814
 Sanfilippo syndrome, 168, 324t, 397t
 Saphenous nerve entrapment, 1304
 Sarcoidosis, 437
 rickets and, 192
 Sarcoma, 507. *See also* Tumors
 chondrosarcoma, 531
 Ewing, 507, 542–544, 543
 molecular biology of, 507–510, 508t
 neurofibrosarcoma, 293
 osteosarcoma, 507, 521–523, 521–527, 525
 prognosis for, 507–508
 rhabdomyosarcoma, 507, 547–548, 549t
 synovial cell, 548–549, 550
 Sauvegrain method for bone age determination, 43, 44
 Scaphoid fracture, 71, 891, 891
 Scapholunate ligamentous injuries, 892
 Scapula
 fractures of, 1334–1335
 in Langerhans cell histiocytosis, 406, 539
 SCFE. *See* Slipped capital femoral epiphysis
 Scheie syndrome, 168, 324t, 325, 397t
 Scheuermann disease, 121, 180, 750–757
 age at onset of, 750–751
 classification of, 750
 clinical presentation of, 752–753
 conditions associated with, 752
 differentiation from postural kyphosis, 752
 epidemiology of, 750–751
 etiology of, 751–752
 inheritance of, 751
 lumbar, 753
 natural history of, 752
 pain of, 752–753
 physical examination for, 753
 radiographic features of, 750, 753–754, 754
 Schmorl nodes in, 751, 754
 treatment of, 754–756, 755–757
 bracing, 754–755, 755, 756
 electrical stimulation, 754
 nonoperative methods, 754–755
 serial casting, 755
 surgical correction, 755–756
 Schmid-type metaphyseal chondrodysplasia, 203, 273
 atlantoaxial instability in, 273
 genu varum and, 273, 1067, 1068
 Schmorl nodes, 751, 754
 Schnitzel syndrome, 865
 School-age children
 examination of, 101, 116–120
 growth of, 39–40
 School screening for scoliosis, 697–698
 Schwachman-Diamond syndrome, 380–381
 Schwann cells, 21
 Schwannoma, 546–547, 547, 548
 Scintigraphy, skeletal, 85–89
 advantages of, 89
 applications of, 88–89
 collimators for, 86
 cost of, 85t
 interpretation of, 471–472
 lack of specificity of, 89
 magnification for, 87
 mechanism of contrast for, 85
 normal skeletal distribution of Tc-99m-labeled diphosphonates and, 88
 radiation dose from, 68t
 radiopharmaceuticals for, 85, 89, 513–514
 pediatric doses of, 85
 risks of, 89
 significance of "cold scan," 472
 in specific conditions
 bone and joint sepsis, 88, 88, 89, 470–472, 471, 472
 child abuse, 1432
 chondrolysis of hip, 1051, 1051
 Langerhans cell histiocytosis, 513, 537–538, 539
 Legg-Calvé-Perthes syndrome, 980, 980
 osteoid osteoma, 514
 osteosarcoma, 84
 reflex sympathetic dystrophy, 440
 spondylolysis and spondylolisthesis, 781
 stress fractures, 1278
 tarsal coalition, 1184
 transient synovitis of hip, 1046–1047
 tumors, 84, 89, 513–514, 514
 techniques for, 85–88, 86–89
 trends in utilization of, 89

SCIWORA (spinal cord injury without radiographic abnormality), 827–829
 Sclerotomes, 18–21, 19, 20
 cervical, 799–800
 Scoliosis, 677–733
 classification of, 681–682
 age at onset, 682
 curve location, 681–682, 682
 etiologic, 682, 683t
 primary, secondary, structural, nonstructural curves, 682
 conditions associated with, 121, 677, 683t
 arthrogryposis multiplex congenita, 299
 athetoid cerebral palsy, 590
 Becker muscular dystrophy, 644
 Beckwith-Wiedemann syndrome, 321
 cerebral palsy, 570–573, 571, 573
 cleidocranial dysplasia, 276, 277
 congenital myotonic dystrophy, 649
 diastrophic dysplasia, 258–261, 260
 Down syndrome, 307
 Duchenne muscular dystrophy, 641–643, 642–643, 680
 Emery-Dreifuss muscular dystrophy, 646
 familial dysautonomia, 314
 fibrous dysplasia, 680
 Freeman-Sheldon syndrome, 303
 Friedreich ataxia, 656–657
 Goldenhar syndrome, 323
 hereditary motor sensory neuropathies, 662
 Klippel-Trenaunay syndrome, 343
 Kniest dysplasia, 262, 262
 Larsen syndrome, 278
 Marfan syndrome, 120, 219, 219–220, 680
 metatropic dysplasia, 256
 multiple pterygium syndrome, 304, 304
 myelomeningocele, 608–614, 609, 611, 613
 neurofibromatosis, 289, 291, 292
 Noonan syndrome, 319
 osteogenesis imperfecta, 204, 207, 209–210
 poliomyelitis, 667, 667–668
 Prader-Willi syndrome, 319, 320
 Proteus syndrome, 345
 pseudoachondroplasia, 267, 269
 Rett syndrome, 327–329
 rickets, 187
 Scheuermann disease, 752
 spinal muscular atrophy, 654–656, 655
 spondyloepiphyseal dysplasia, 263, 263–264, 264, 266
 spondylolisthesis, 780, 791–792, 791–793
 Turner syndrome, 318
 type 1 homocystinuria, 221
 definitions related to, 678

- etiology of, 678–681
 central nervous system theories, 681
 genetic factors, 678–679
 tissue deficiencies, 680
 vertebral growth abnormality theories, 680–681
 evaluation of, 120, 120–121, 682–693
 forward-bending test, 114, 120, 120–121, 685, 686
 history, 682–684
 limb length, 114, 120, 121, 685–686
 neurologic examination, 121, 686
 physical examination, 684–686, 685
 plain radiography, 686–691, 687–691
 skin inspection, 685
 specialized imaging studies, 691–693, 692
 Hueter-Volkman effect and, 678, 680, 681
 leg length discrepancy and, 114, 120, 121, 685–686, 1107–1108, 1108
 paralytic, 54
 postlaminectomy, 758
 puberty and, 53–54
 pulmonary compromise due to, 677, 678
 Risser sign and curve magnitude in, 53, 691, 691, 695–696
 spasm, 793
 Scoliosis, congenital, 53, 724–733
 classification of, 725, 725–727, 726
 definition of, 724–725
 myelomeningocele and, 614
 natural history of, 727, 727, 728
 nonoperative treatment of, 727–728
 surgical treatment of, 728–733
 anterior fusion, 729–731
 goals of, 729
 hemivertebra excision, 732, 733
 partial fusion, growth modulation, hemiepiphysiodesis, 731, 731–733
 posterior fusion, 729
 posterior instrumentation, 729
 preoperative assessment, 728–729, 730
 Scoliosis, idiopathic, 693–724
 adolescent, 53, 121, 682, 695
 infantile, 682, 693–695, 694, 695
 juvenile, 682, 695
 natural history in adulthood, 697, 697
 nonoperative treatment of, 698–701
 brace efficacy, 700–701
 indications for orthotic treatment, 698
 types of braces, 699, 699, 700
 wearing schedule, 699–700
 prevalence of, 693, 694
 risk factors for progression of, 695–697, 696, 697
 school screening for, 697–698
 surgical complications in, 721–724
 blood loss and transfusion, 723
 early postoperative, 723–724
 late alignment problems, 724, 724
 neurological injury, 721–723
 related to implant hardware, 724
 spinal cord monitoring for, 723
 surgical correction according to curve pattern, 707–715, 707, 708–709
 double thoracic curve pattern, 714
 left lumbar or thoracolumbar curve pattern, 714, 716–718
 right thoracic, left lumbar curve pattern, 709–714, 712–715
 right thoracic curve pattern, 707–709, 710, 711
 triple curve pattern, 714–715, 719
 surgical correction of, 701–707
 anterior release and fusion, 704, 705, 705–706
 anterior spinal instrumentation, 706–707
 cerebral palsy and, 571–572, 573
 Cotrel-Dubousset and other double rod, multiple hook systems, 703
 crankshaft phenomenon and, 54, 705, 705
 Duchenne muscular dystrophy and, 641–643
 effect on final height, 54
 Harrington instrumentation, 702, 702–703
 indications for, 701, 701–702
 instrumentation without fusion, 706, 707
 mechanisms of correction, 703, 703–705
 myelomeningocele and, 610–612, 611, 613
 posterior spinal instrumentation, 702
 spinal muscular atrophy and, 654–656, 655
 surgical outcomes in, 715–721
 anterior surgery, 720–721, 722
 posterior surgery, 715–720, 720–721
 Scurvy, 216–217, 217
 Sedation
 for fracture management, 1331–1332, 1331
 for imaging procedures, 92–93
 Segmental spinal dysgenesis, 749
 Segmentation, 29
 Seizures, cerebral palsy and, 566
 Selective posterior rhizotomy, for spastic diplegia, 580–581
 Septic arthritis, 429, 430, 435, 459–500.
 See also Bone and joint sepsis
 algorithm for probability of, 476
 on bone scan, 471
 definition of, 460
 differential diagnosis of, 475–476
 epidemiology of, 460
 gonococcal, 496–497
 of hip, 111
 differentiation from chondrolysis, 1050
 differentiation from toxic synovitis, 475
 differentiation from transient synovitis, 1046
 in infant, 109
 in neonate, 486–488
 pathophysiology of, 465–466
 puncture wounds of foot and, 494–496
 results of, 482
 of sacroiliac joint, 484–486
 in sickle cell disease, 387–388
 treatment of, 476–482
 antibiotics, 476–480, 479
 surgery, 480–482, 481
 ultrasound examination for, 473
 Serum sickness, 437
 Sever disease, 1206–1208, 1282
 clinical features of, 1206, 1207
 definition of, 1206
 epidemiology of, 1206
 examination for, 119–120
 natural history of, 1207
 Osgood-Schlatter disease and, 1281
 pathoanatomy of, 1207
 pathogenesis of, 1206
 radiographic features of, 1207, 1207
 treatment of, 1207–1208
 Sex chromosomes, 158, 158
 abnormalities of, 163
 uniparental disomy and, 171
 X-linked disorders, 168, 168–169
 Sex steroids, 226–228
 growth and, 226–228
 Sexual characteristics, secondary, 41
 Sexual immaturity
 Noonan syndrome and, 319
 Turner syndrome and, 318
 Shelf arthroplasty, for Legg-Calvé-Perthes syndrome, 988, 988
 Shenton line, 918, 919, 935
 Shepherd's crook deformity, 229, 229, 535
 shh gene, 15–17, 23
 Shin pain, 1284–1286
 chronic compartment syndromes, 1285
 differential diagnosis of, 1284
 muscle herniation and superficial peroneal nerve compression, 1285–1286
 periostitis, 1284–1285
 Shoe modifications
 for cavus foot, 1198
 for flexible flatfoot, 1172
 for leg length discrepancy, 1132
 for posterior medial bowing of tibia, 1093
 for rotational variations, 1063
 Short rib-polydactyly syndrome, 279
 Short stature. *See also* Growth
 achondroplasia and, 247, 247–248
 Albright hereditary osteodystrophy and, 201
 chondroectodermal dysplasia and, 257
 diastrophic dysplasia and, 258, 259
 dwarfing conditions, 244
 dyschondrosteosis and, 275–276
 evaluation of patient with, 246
 Fanconi anemia and, 380
 genu varum and, 110
 growth hormone deficiency and, 225–226

- Short stature (*contd.*)
 hypochondroplasia and, 254
 hypophosphatasia and, 199
 hypothyroidism and, 226
 Legg-Calvé-Perthes syndrome and, 958–959
 Maffucci syndrome and, 342
 metaphyseal chondrodysplasia and, 272, 272–274
 metatropic dysplasia and, 256
 Morquio syndrome and, 325–326
 multiple epiphyseal dysplasia and, 269
 nail-patella syndrome and, 311–312
 Noonan syndrome and, 318–319
 normal variant, 224–225
 osteogenesis imperfecta and, 204
 Prader-Willi syndrome and, 319
 progeria and, 317
 pseudoachondroplasia and, 267, 267
 renal osteodystrophy and, 195
 rickets and, 187
 Russell-Silver syndrome and, 317–318
 skeletal dysplasias and, 244
 spondyloepiphyseal dysplasia congenita and, 263, 263
 Turner syndrome and, 163, 318
- Shoulder
 acromioclavicular separation, 1334
 birth injuries of, 1332
 clavicular fractures, 1332–1334, 1333, 1334
 dislocation of, 1335
 painful, evaluation of, 125–128, 125–128
 posterior subluxation of, 126
 proximal humerus fractures, 1335, 1336, 1337
 scapular fractures, 1334–1335
 in specific conditions
 arthrogryposis multiplex congenita, 299, 850
 brachial plexopathy, 848–850, 849t, 850
 cerebral palsy, 591
 poliomyelitis, 665
- Shoulder “drawer sign,” 125, 125
- Shoulder replacement, for juvenile idiopathic arthritis, 453
- SHOX gene, in dyschondrosteosis, 275
- Sialidosis, 397t
- Sickle cell disease, 383–389
 arthritis in, 490
 clinical features of, 384, 384t
 genotypes for, 383, 488
 osteomyelitis in, 386, 386–387, 387, 488–490, 489
 osteonecrosis of femoral and humeral heads in, 387, 388–389, 388t, 389
 pathophysiology of, 383–384
 sickle cell crisis in, 385
 stroke and, 384–385
 treatment of, 389
- Signs. *See also* Tests
 Adams, 678
 apprehension, 126, 126
 Babinski, 116, 634
 Barlow, 103, 103, 913, 919
 blanch sign of Steel, 1005, 1005
 Chvostek, 201
 crescent, 270
 Galeazzi, 104, 104, 914, 914
 Gower, 637, 644, 644, 645
 Hawkins, 127, 128
 J, 123
 movie, 122
 navicular fat pad, 67
 Neer impingement, 127, 127
 Ortolani, 103, 103, 906, 909, 913, 919
 Pelken, 217
 pucker, 1341
 Risser, for bone age determination, 42, 45, 49, 50
 Romberg, 121, 634
 rose thorn, 70, 70
 sagging rope, 270
 shoulder drawer, 125, 125
 sulcus, 125–126, 126
 Tinel, 547
 Trousseau, 201
 Wimberger, 217
- Sinding-Larsen-Johansson disease, 123, 1281, 1281
- Single-axis cushion heel (SACH) foot, 1262, 1263
- Single-gene disorders, 163–171
 autosomal dominant, 164, 164–167
 autosomal recessive, 167, 167–168
 genomic imprinting in, 170–171
 mosaicism in, 170
 parental disomy and, 171
 variable expressivity of, 164
 X-linked, 168, 168–169
- Single-photon emission computed tomography (SPECT), 87–88
 in scoliosis, 693
- Sitting height, 36–38, 40, 50
 of boys, 37, 37t, 40
 of girls, 37, 37t, 40
 of paralytic child, 58
- Skeletal age
 delayed, conditions associated with, 43
 determination of, 34, 43–45, 44–50, 68–69, 224, 1123, 1123–1124
 Greulich and Pyle atlas, 42, 43, 1123
 in paralytic child, 59
 Sauvegrain method, 43, 44
 in scoliosis, 53, 691, 691
 Tanner-Whitehouse method, 1123, 1123–1124
 leg length and, 1108–1112, 1109–1112, 1109t
 puberty and, 41–43
- Skeletal dysplasias, 243–280
 achondroplasia, 246–253
 chondrodysplasia punctata, 270–271
 chondroectodermal dysplasia, 257–258
 classification of, 244–245, 244t, 245, 245t
 cleidocranial dysplasia, 276–277
 diaphyseal aclasia, 274–275
 diastrophic dysplasia, 258–261
 dyschondrosteosis, 275–276
 evaluation of, 246
 genetic causes of, 17
 hypochondroplasia, 254
 Kniest dysplasia, 261–263
 Larsen syndrome, 278–279
 metaphyseal chondrodysplasias, 271–274
 metatropic dysplasia, 254–257
 multiple epiphyseal dysplasia, 269–270
 perinatal lethal skeletal dysplasias, 279–280
 prenatal diagnosis of, 145–146
 pseudoachondroplasia, 266–269
 spinal deformity and, 245, 246
 spondyloepiphyseal dysplasia congenita, 263–265
 spondyloepiphyseal dysplasia tarda, 265–266
 terminology related to, 244
 treatment of, 246
- Skewfoot, 1164–1168, 1165–1168
 clinical features of, 1165, 1165, 1166
 definition of, 1164–1165
 epidemiology of, 1165
 intoeing and, 1061
 natural history of, 1167
 nonoperative management of, 1167
 pathogenesis of, 1165
 radiographic features of, 1166, 1166–1167, 1167
 surgical treatment of, 1167–1168, 1168
- Skin traction
 for developmental dysplasia of hip, 928, 930
 for supracondylar fracture, 1341
 for transient synovitis of hip, 1048
- Skin webs, in pterygia syndrome, 303–305, 303–305
- Skull abnormalities
 basilar impression, 804–805, 805
 cleidocranial dysplasia and, 276, 277
 Hadju-Cheney syndrome and, 327
 Langerhans cell histiocytosis and, 403, 404, 537, 538
 osteogenesis imperfecta and, 204, 207
 rickets and, 187
 “salt-and-pepper” skull in renal osteodystrophy, 196
 thalassemia and, 390, 391
- Slip angle, in spondylolisthesis, 783
- Slipped capital femoral epiphysis (SCFE), 43, 999–1029
 bilateral involvement in, 1000
 clinical presentation of, 1002–1005
 acute-on-chronic presentation, 1003, 1004
 acute presentation, 1003, 1004
 chronic presentation, 1002–1003, 1003
 classification of, 1003–1004
 prodromal stage, 1002
 complications of, 1026–1029
 chondrolysis of hip, 1027–1029, 1028, 1049, 1053

- osteonecrosis of femoral head, 1019, 1026, 1026–1027
- conditions associated with
 - adolescent Blount disease, 1075, 1077
 - Down syndrome, 309, 309
 - hypothyroidism, 226, 226
 - renal osteodystrophy, 187, 195, 198
- degenerative hip disease and, 1009, 1018
- epidemiology of, 999–1000
- etiology of, 1001–1002
 - endocrine imbalance, 1002
 - inflammatory factors, 1001–1002
 - inheritance, 1002
 - mechanical factors, 1001
 - radiation therapy, 1002
 - trauma, 1001
- examination for, 121–122
- histology of, 1000–1001, 1001
- incidence of, 999
- natural history of, 1008–1009
- obesity and, 1000
- out-toeing and, 1062
- pain of, 1002
- pathoanatomy of, 1000, 1000–1001
- prophylactic pinning of contralateral hip in, 1026
- puberty and, 999
- radiographic features of, 1003–1008, 1005–1008
 - blanch sign of Steel, 1005, 1005
 - classification system based on, 1006–1008
 - computed tomography, 71–72, 72, 1006, 1007
 - magnetic resonance imaging, 1006, 1008
 - ultrasound, 1006
- skeletal age and, 1000
- treatment of, 1009–1026
 - to prevent further slippage, 1009–1018
 - open bone peg epiphysiodesis, 1016–1018, 1017
 - in situ* pin and screw fixation, 1010–1016, 1011–1014
 - spica cast immobilization, 1009–1010
 - to reduce degree of slippage, 1018–1024
 - closed manipulation, 1018–1019
 - femoral remodeling after *in situ* fixation, 1018
 - osteotomies, 1019–1024, 1021–1023
 - salvage procedures, 1024–1026
 - hip arthrodesis, 1024, 1025
 - osteoplasty of femoral neck, 1025–1026
 - total hip arthroplasty, 1024–1025
- Sly syndrome, 168, 324t, 397t
- Smith-Lemli-Opitz syndrome, 17
- SMN gene, spinal muscular atrophy and, 653
- “Snapping knee,” 1310
- Sodium pentobarbital, 93
- Soft tissue
 - calcification of, 217–218
 - injuries due to child abuse, 1426–1428, 1427
 - on plain radiographs, 67–68
 - tumors of, 544–551
 - benign tumors of nerve origin, 546–548, 547
 - fibromatoses, 545–546, 546
 - hemangioma, 339–340, 544–545, 545
 - pigmented villonodular synovitis, 551
 - rhabdomyosarcoma, 548, 549t
 - synovial cell sarcoma, 548–549, 550
 - synovial chondromatosis, 549–551, 550
- Soft tissue release, for juvenile idiopathic arthritis, 452
- Soleus syndrome, 1284–1285
- Somatic mosaicism, 170
- Somatomedins, 178t, 179–180, 959
- Somatosensory evoked potentials, after scoliosis surgery, 723
- Somites, 9, 18–21, 19, 29
- Space available for cord (SAC), 801
- Spastic diplegia, 577–589
 - gait analysis in, 578, 578, 579
 - treating specific problems in, 584–589
 - ankle equinus, 584–585
 - external tibial torsion, 587
 - foot and ankle equinovagis, 586, 586–587
 - foot and ankle equinovarus, 585–586
 - hallux valgus, 584
 - hip adduction contracture, 588
 - hip flexion contracture, 588
 - intoeing, 588–589
 - knee flexion deformity, 587
 - lumbar hyperlordosis, 588
 - rectus femoris transfer, 587–588
 - treatment methods for, 578–584
 - botulinum-A toxin, 579–580
 - intramuscular injections, 579
 - intrathecal injections, 580
 - manipulation and casting, 583
 - oral medications, 579
 - orthopaedic surgery, 583–584
 - orthotics, 583
 - physical therapy, 581–583
 - selective posterior rhizotomy, 580–581
 - walking and, 577–578, 577t
- Spastic hemiplegia, 589–590
- Spastic quadriplegia, 569–577
 - hip management in, 574–577
 - dislocation, 575–576, 576
 - extension contracture, 576–577
 - extension plus abduction contracture, 577
 - hip at risk, 574
 - osteoarthritis, 576
 - subluxation, 574–575, 575
 - hip problems and, 572–574
 - hyperkyphosis and, 570
- hyperlordosis and, 570
- management objectives for, 569
- scoliosis and, 570–572, 571, 573
- spondylolysis and spondylolisthesis and, 572
- wheelchair for child with, 569, 569–570
- Special Olympics, 1274
- SPECT. *See* Single-photon emission computed tomography
- Sphingolipidoses, 396t
- Spina bifida, 6, 21. *See also* Myelomeningocele
 - aperta, 601
 - growth in child with, 58–59
 - Larsen syndrome and, 278
 - occulta, 21, 23, 601
 - cleidocranial dysplasia and, 276
 - of posterior arch of C1, 803
- Spinal cord
 - development of, 22–23, 23
 - injury of, 1367
 - induced by scoliosis surgery, 721–723
 - monitoring for, 723
 - sports-related, 1298–1299
 - thoracolumbar trauma and, 1367
 - transient quadriplegia and, 829
 - without radiographic abnormality, 827–829
 - measuring space available for cord, 801
 - torticollis and cervical cord tumors, 813
- Spinal muscular atrophy, 652–656
 - clinical classification of, 652–653
 - type I: acute Werdnig-Hoffman disease, 652
 - type II: chronic Werdnig-Hoffman disease, 652
 - type III: Kugelberg-Welander disease, 652–653
 - clinical features of, 653
 - diagnosis of, 653
 - functional classification of, 653
 - genetics and molecular biology of, 653
 - radiographic evaluation of, 653
 - treatment of, 653–656
 - hip subluxation and dislocation, 654
 - lower extremity soft tissue contractures, 653–654
 - spinal deformity, 654–656, 655
- Spinal nerves, 20
- Spinal stenosis
 - achondroplasia and, 248, 248, 249, 253
 - diastrophic dysplasia and, 261
 - hypochondroplasia and, 254
- Spindle cell hemangioendothelioma, 342
- Spine. *See also* Vertebral abnormalities
 - aneurysmal bone cyst of, 541–542, 833–834
 - bone and joint sepsis affecting, 482–484, 483
 - cervical (*See* Cervical spine)
 - curvatures of
 - kyphosis, 741–769
 - normal ranges of, 741–742, 742
 - scoliosis, 677–733
 - development of, 18–22, 19–20

Spine (*contd.*)

- fractures of
 - in acute lymphoblastic leukemia, 417, 417
 - cervical, 823–827
 - atlas, 824
 - C3–7, 827, 827, 828
 - odontoid, 824–827, 826
 - due to child abuse, 1432–1435, 1433, 1435
 - thoracolumbar, 1366–1368
 - anatomy and classification of, 1367
 - burst fractures, 1368
 - clinical features of, 1366–1367
 - complications of, 1368
 - compression fractures, 1367–1368, 1368
 - lapbelt (Chance) fractures, 1368, 1369
 - limbus (apophyseal) fracture, 1368
 - growth in, 50–53, 51, 52
 - cervical spine, 50–51, 800
 - lumbar spine, 52–53
 - radiation effects on, 760–761
 - thoracic spine, 51, 51–52, 52
 - leg length discrepancy and, 1107–1108, 1108
 - osteoid osteoma of, 117, 520, 833, 834
- Spinocerebellar degenerative diseases, 656
- Splints. *See also* Orthotic devices
 - for metatarsus adductus, 1163
 - for radial dysplasia, 863
 - for upper limb involvement in cerebral palsy, 843
- Spondylitis, tuberculous, 499–500
- Spondyloepiphyseal dysplasia
 - congenita, 263–265
 - atlantoaxial instability and, 264, 265
 - clinical features of, 263, 263
 - kyphosis and, 765
 - medical problems associated with, 264
 - radiographic features of, 263–264, 264, 265
 - treatment of, 264–265
 - genetics of, 166, 263, 265
 - tarda, 265–266
 - clinical features of, 265–266
 - radiographic features of, 266, 266
 - treatment of, 266
- Spondylolisthesis
 - of C2, 827
 - cerebral palsy and, 572
 - classification of, 777–779, 778
 - complications of surgery for, 793–794
 - increased slippage, 793, 793–794
 - neurologic, 793–794
 - pseudarthrosis, 793
 - definition of, 777
 - Down syndrome and, 307
 - dysplastic (congenital), 777, 778, 779
 - epidemiology of, 779
 - etiology of, 779–780
 - isthmia, 777, 778, 779
 - measurement of, 782, 782–783
 - anatomical changes, 783

- sacral inclination, 783
- sagittal rotation, 783
- slip angle, 783
- slip percentage, 782–783
- natural history of, 779
- pain of, 779–781
- patient evaluation for, 780–781
 - history, 780
 - physical examination, 780–781, 781
- progression of, 779
- radiological evaluation of, 781–782
- scoliosis and, 780, 791–792, 791–793
- treatment of, 785–791
 - anterior fusion, 788
 - arthrodesis, 787
 - bracing, 786
 - decompression, 787
 - instrumentation, 788–791, 790
 - levels to be fused, 787
 - observation, 785–786
 - postoperative immobilization and bed rest, 791
 - reduction, 787–788, 788, 789
 - reduction of activities, 786
 - surgical decision making, 787

Spondylolysis

- cerebral palsy and, 572
- definition of, 777
- epidemiology of, 779
- etiology of, 779–780
- incidence of, 779
- patient evaluation for, 780–781
 - history, 780
 - physical examination, 780–781, 781
- progression of, 779
- radiological evaluation of, 781, 781–782
- treatment of, 783–785
 - arthrodesis, 783–785, 785
 - bracing, 783, 784
 - observation, 783, 784
 - reduction of activities, 783
 - repair of defect, 785, 786

Spondylomegaly, in Proteus syndrome, 345–346

Spondylometaphyseal dysplasia, 273–274

Spondylosis

- cervical, in cerebral palsy, 817
- lumbar, in Scheuermann disease, 752

Sports medicine, 1273–1311

- benefits of sports participation, 1274
- care of young athlete, 1273–1277
 - antiinflammatory medications, 1276–1277
 - corticosteroids, 1277
 - nonsteroidal antiinflammatory drugs, 1276–1277
 - heat illness and fluids, 1275–1276, 1275t
 - nutrition, 1274–1275
 - performance enhancing substances, 1276
 - strength training, 1276
- common knee problems, 1299–1311
 - acute patellar dislocation, 1306–1308

- anterior knee pain, 1300–1303
- bipartite patella, 1304
- chondromalacia, 1304
- discoid lateral meniscus, 1309–1311
- dorsal defects of patella, 1304–1305, 1305
- fat pad impingement, 1305
- patellofemoral disorders, 1299, 1300
- plica syndrome, 1305–1306, 1306
- popliteal cyst, 1309
- recurrent patellar dislocations, 1308–1309, 1308–1310
- saphenous nerve entrapment, 1304
- incidence of athletic injuries, 1274
- overuse syndromes, 1277–1289
 - apophyseal conditions, 1280–1283
 - apophysitis of fifth metatarsal, 1282
 - apophysitis of hip and pelvis, 1283
 - calcaneal apophysitis, 119–120, 1206–1208, 1207, 1282
 - olecranon apophysitis, 1283
 - Osgood-Schlatter disease, 1280–1281, 1281
 - Sinding-Larsen-Johansson disease, 1281, 1281
 - breaststroke's knee, 1286–1287
 - classic stress fractures, 1277–1279
 - iliotibial band friction syndrome, 1286, 1286
 - repetitive physeal injuries, 1279–1280
 - epiphysiolysis of distal radius, 1279–1280, 1280
 - epiphysiolysis of proximal humerus, 1279, 1279
- shin pain, 1284–1286
 - chronic compartment syndromes, 1285
 - muscle herniation and superficial peroneal nerve compression, 1285–1286
 - periostitis, 1284–1285
- tendinitis, 1283–1284
 - Achilles tendinitis, 1283
 - popliteus tendinitis, 1283–1284, 1284
- valgus overload injuries of elbow, 1287, 1287–1289
 - injuries of medial epicondyle, 1289
 - osteochondral lesions of capitellum, 1287–1288, 1288
 - osteochondral lesions of radial head, 1288
- preparticipation screening examinations, 1289–1290
- sports for children with chronic medical conditions, 1274
- traumatic injuries, 1289–1299
 - ankle, 1290–1293
 - anterolateral ankle impingement, 1293
 - distal tibiofibular sprains, 1293
 - sprains, 1290–1292, 1291
 - avulsion fractures of pelvis, 1298, 1298

- epidemiology of, 1289
 knee, 1293–1297
 anterior cruciate ligament injuries, 1294–1296
 collateral ligament injuries, 1293–1294, 1294
 meniscal tears, 1296–1297, 1297
 posterior cruciate ligament injuries, 1296
 on magnetic resonance imaging, 83
 mortality from, 1289
 prevention of, 1289–1290
 quadriceps contusion, 1297–1298
 role of athletic trainers in caring for, 1290
 on scintigraphy, 88
 spinal, 1298–1299
- Sprains
 ankle, 128, 128–129, 1290–1292, 1291
 distal tibiofibular, 1293
 knee, 124–125
- Sprengel deformity, 17, 1220
 Fanconi anemia and, 380
 Goldenhar syndrome and, 324
 Klippel-Feil syndrome and, 814
- Staging of tumors, 515–516, 516t
- Stance phase of gait cycle, 135, 135, 136, 137t
 ankle in, 139–140, 140
 hip in, 142, 143
 knee in, 140–142, 141
- Standing height, 35–36, 39–41
 of boys, 36t, 37t, 40–41, 43
 of girls, 35t, 37t, 40–41, 43
 of paralytic child, 58
 pubertal growth spurt, 42–43
- Staphylococcus aureus* infection, 460–462, 464, 477
- Startle reflex, 108
- Stature. *See* Height; Short stature; Tall stature
- Steel's rule of thirds, 801
- Stem cells, 29
- Stereognosis testing, 114
- Sternoclavicular separation, 1333, 1333
- Strickler syndrome, 166
- Still's disease, 442
- Storage diseases, 168, 395, 396t–398t
 Gaucher disease, 398–402, 399–401
 mucopolysaccharidoses, 168, 324–327, 324t, 325, 396t–397t
- Straight-leg-raising test, 114, 114
- Straight-line graph method for determining leg length discrepancy, 1127–1129, 1128, 1130
- Strawberry hemangiomas, 340
- Strength training, 1276
- Streptococcal infection
 arthritis following, 436
 bone and joint sepsis, 477
- Stress fractures, 1277–1279
 clinical presentation of, 1278
 differential diagnosis of, 1278
 radiographic features of, 1278
 treatment of, 1278
- Sturge-Weber syndrome, 340t, 341
- Subclavian artery supply disruption
 sequence, 17, 1220
- Subdural hematoma, 1423, 1428
- Subischial limb length, 38, 39
 of boys, 37, 40
 of girls, 37, 40
- Subtalar joint, 1152, 1409
 arthrodesis of, 1153
 in cavus foot deformity, 1196, 1198
 in clubfoot, 1153, 1154, 1156–1158
 components of, 1152
 on computed tomography, 74
 in congenital vertical talus, 1174
 in flexible flatfoot, 1168–1170
 malalignment of, 1152–1153
 motions of, 1152
 in tarsal coalition, 1185
- Sulcus sign, 125–126, 126
- Sulfasalazine, for juvenile idiopathic arthritis, 451
- Superficial peroneal nerve compression, 1285–1286
- Superglycine syndrome, 192
- Superior labrum anterior and posterior (SLAP) lesion, 128
- Supernumerary limbs, 10
- Supracondylar fracture, 1339–1344, 1340
 classification of, 1339–1340, 1341
 complications of, 1343–1344
 cubitus varus, 1344
 nerve injury, 1340, 1343, 1344
 vascular compromise, 1340, 1343, 1343
 incidence of, 1338
 mechanism of injury, 1339
 treatment of, 1340–1343, 1342
- Supraspinatus tendonitis, 126–127, 127
- Swan-neck deformities, in cerebral palsy, 593, 843, 846
- Sweating, 1275
- Swimming, shoulder pain due to, 125–128, 125–128
- Swing phase of gait cycle, 135, 135, 138, 138, 139t
 ankle in, 140
 hip in, 143
 knee in, 142
- Symbrachydactyly, 870–871
 clinical features of, 870
 treatment of, 871
 treatment options for, 871
- Syme amputation, for fibular deficiency, 1231–1232
- Syndactyly of fingers, 17, 873–875, 873–875
 classification of, 873
 clinical features of, 873, 873–874
 conditions associated with
 constriction band syndrome, 18, 872, 872–873
 Fanconi anemia, 380
 Griegel-cephealopolysyndactyly, 17
 Klippel-Trenaunay syndrome, 343, 345
 ulnar dysplasia, 868
- embryogenesis of, 873
 radiographic features of, 874, 875
 surgical treatment of, 874, 874–875
 complications of, 875
- Syndactyly of toes, 1190–1191
 clinical features of, 1190, 1190
 definition of, 1190
 epidemiology of, 1190
 natural history of, 1190
 treatment of, 1190
- Syndromes, 287–288
- Synostosis
 congenital radioulnar, 855–858, 857
 definition of, 17
 elbow, 858
 in fetal alcohol syndrome, 311
 humeroradial, 858
 ulnar dysplasia and, 866, 867, 868
 teratogen-induced, 17
- Synovectomy
 hemophilia and, 412–413
 for juvenile idiopathic arthritis, 452
- Synovial cell sarcoma, 548–549, 550
- Synovial chondromatosis, 549–551, 550
- Synovial fluid analysis, 434, 468–469, 468t
- Synovial joint development, 12
- Synovitis
 foreign body, 437
 in hemophilia, 409, 411, 412
 of hip, 111, 117
 slipped capital femoral epiphysis and, 1001
 transient, 435, 1044–1048
 pigmented villonodular, 438, 551
- Syphilis, congenital, 214, 215t, 1439
- Syringomyelia
 cleidocranial dysplasia and, 276, 277
 scoliosis and, 684, 684
- Systemic lupus erythematosus, 437
- T**
- T-condylar fracture, 1344
- Talar beak, dorsal, 1185–1186, 1186
- Talar-tilt test, 128
- Talipes equinovarus. *See* Clubfoot
- Tall stature
 Klinefelter syndrome and, 163
 trisomy X and, 163
- Talocalcaneal joint. *See* Subtalar joint
- Talocalcaneonavicular joint, 1152, 1157
- Talonavicular joint, 1152
 in congenital vertical talus, 1174–1178
- Talus, 1409
 congenital vertical, 1152, 1174–1178
 in flexible flatfoot, 1170
 fractures of, 1409–1411
 lateral process, 1410–1411
 osteochondral, of talar dome, 1409–1410
 talar neck, 1409, 1410
 oblique, 1174
 osteomyelitis of, 79
 position in clubfoot, 1156–1158
- Tanner-Whitehouse method for bone age determination, 1123, 1123–1124

- Tarsal coalition, 74, 1182–1186
 clinical features of, 1183, 1183–1184
 conditions associated with, 1182
 definition of, 1182
 epidemiology of, 1182–1183
 fibular deficiency and, 1230
 natural history of, 1185
 nonoperative management of, 1185
 out-toeing and, 1062
 pain from, 1185
 pathoanatomy of, 1185
 pathogenesis of, 1183
 radiographic features of, 74, 1184, 1184, 1185
 surgical treatment of, 1185–1186
- Tarsal fractures, 1408
- Tarsal navicular
 accessory, 1181–1182, 1182
 fragmentation of, 67
 Kohler disease of, 1203–1205, 1204, 1409
 ossification of, 1204
- Tarsometatarsal joint injuries, 1411, 1413
- Technetium-99m-labeled diphosphonates, 88, 513
- Teeth. *See* Dental abnormalities
- Telangiectasias, 340–341, 340t
- Telangiectatic osteosarcoma, 522
- Tendinitis
 Achilles, 1283
 popliteus, 1283–1284, 1284
 supraspinatus, 126–127, 127
- Tendinosis, 1283
- Tendon lacerations in hand, 894–895, 895
- Tendon transfers
 for brachial plexopathy, 849
 for cavus foot deformity, 1199
 for elbow flexion in arthrogryposis multiplex congenita, 850–852
 for pes cavovarus, 659
 for poliomyelitis, 664
- Tenosynovitis, 1283
- Teratogens, 9, 171–173
 alcohol, 17, 172
 fetal alcohol syndrome and, 288, 310, 310–311
 infections, 173
 maternal diabetes mellitus, 173
 neural tube defects due to, 22, 23
 radiation, 173
 retinoic acid, 15, 17, 21–23, 172
 syndromes caused by, 288
 synostoses due to, 17
 thalidomide, 17, 172
 warfarin, 172
- Teratoma, sacrococcygeal, 22
- Testicular interstitial cell-stimulating hormone, 225
- Testifying in child abuse cases, 1442–1443
- Testosterone
 bone formation and, 180
 growth and, 227
- Tests. *See also* Signs
 Adams forward-bending, 114, 120, 120–121, 685, 686
 anterior drawer, 1291, 1291, 1294
 Apley, 123, 1296
 Barlow, 103, 103, 913, 919
 Coleman block, 116, 116, 1196, 1197, 1197
 crank, 126
 Ely, 115–116, 116
 FABER, 112, 112
 fulcrum, 126
 Jack toe-raise, 1169, 1170, 1183
 Jahnke, 126, 127
 Lachman, 124, 124, 1294
 McMurray, 123, 1296
 Ober, 115, 637, 1286, 1286
 Ortolani, 103, 103, 906, 909, 913, 919
 patellar apprehension, 123, 123
 patellar inhibition, 122, 122
 Phelps-Baker, 115
 pivot-shift, 124, 1294
 prone Staheli, 114, 115
 quadriceps active, 124, 124
 relocation, 126
 shoulder apprehension, 126, 126, 127
 straight-leg-raising, 114, 114
 talar-tilt, 128
 Thomas, 114, 115
 Trendelenburg, 112, 112, 121
 wake-up, 723
 Wilson, 123
- Tethered cord syndrome, 602, 605–606, 609
- TFCC (triangular fibrocartilage complex)
 tears, 892, 892–893, 893
- Thalassemia, 389–391, 391
- Thalidomide, 17, 172
- Thallium scans, 514
- Thanatophoric dysplasia, 245, 279
- Thigh-foot angle, 1060
- Thomas rest, 114, 115
- Thoracic spine
 fractures of, 1366–1368
 growth in, 51, 51–52, 52
- Thorax, growth of, 53
- Thrombin, 408, 408
- Thrombocytopenia with absent radius syndrome, 381–383, 382, 382t, 861
- Thrombocytopenic coagulopathy, 340
- Thromboembolic disorders, type I
 homocystinuria and, 221
- Thumb, 879–886
 duplication of, 881–885
 classification of, 883, 883, 884
 pathoanatomy of, 883
 treatment of, 883–885, 884, 885
 fractures of, 890, 890–891
 hypoplasia/aplasia of, 880–881
 classification of, 880, 880t
 conditions associated with, 880
 in constriction band syndrome, 873
 pathoanatomy of, 880
 treatment of, 880–881, 881
 pollicization of index finger, 881, 882
- in specific conditions
 Diamond-Blackfan anemia, 380–381
 diastrophic dysplasia, 258, 259
 Fanconi anemia, 380
 Larsen syndrome, 278
 radial dysplasia, 861, 864
 Rubinstein-Taybi syndrome, 315–316, 316
 ulnar dysplasia, 866, 868
- thumb-in-palm deformity
 in arthrogryposis multiplex congenita, 853
 in cerebral palsy, 592–593, 593, 843, 845
- trigger thumbs/digits, 879–880
- triphalangeal, 17, 885, 885–886
 classification of, 885
 conditions associated with, 885
 inheritance of, 885
 treatment of, 885–886, 886
- Thyroid hormones
 bone turnover and, 180
 slipped capital femoral epiphysis and, 1002
- Thyroid-stimulating hormone, 225, 226
- Tibia
 congenital anterolateral bowing (pseudarthrosis) of, 1084–1091, 1085, 1114
 amputation for, 1091
 classification of, 1084, 1085t
 in constriction band syndrome, 354
 definition of, 1084
 fibular deficiency and, 1229–1230, 1232
 leg length discrepancy and, 1090
 natural history of, 1084
 nonoperative management of, 1084–1085
 postoperative recurrence of, 1091, 1092
 surgical treatment of, 1085–1091, 1086t, 1087–1090
 congenital deficiency of, 1233–1237, 1234, 1235
 bony overgrowth and, 1225, 1226
 classification of, 1233–1235, 1234, 1235
 clinical appearance of, 1234, 1235–1236
 fibular dimelia and, 1235
 incidence of, 1218
 prosthetic management of, 1237
 transtibial prosthesis, 1258–1260, 1259, 1260
 radiographic appearance of, 1234, 1235
 treatment of, 1236–1237
 Brown procedure, 1234, 1236
 congenital posterior medial bowing of, 1092–1095
 assessment of, 1092–1093, 1093, 1094

- definition of, 1092
 differential diagnosis of, 1093
 etiology of, 1092
 treatment of, 1093–1095, 1094, 1095
- distal
 ossification centers of, 1401
 Poland's hump of, 66, 66
 tibiofibular sprains, 1293
- growth of, 55
- length including epiphyses, 1223t, 1224t
- medial tibial stress syndrome,
 1284–1285
- metaphyseal-diaphyseal angle of, 1066,
 1067, 1068
- normal age-related irregularity of
 tubercle of, 65
- in Osgood-Schlatter disease, 1280–1281,
 1281
- ossification of, 65
- osteofibrous dysplasia of, 536–537, 537
- proximal
 chondromyxofibroma of, 531, 531
 osteosarcoma of, 521, 521, 522, 526
 shortening of, for leg length discrepancy,
 1134
- torsion of, 72–74, 1062, 1062
 correction of excess internal or
 external rotation, 1063–1064
 external, in spastic diplegia, 587
- Tibial fractures, 1396–1401
 distal, 1401–1407, 1403, 1404
 physeal arrest after, 1325
 Tillaux fracture, 71, 1401, 1405,
 1405–1406
 triplane fracture, 1401, 1406,
 1406–1408
 metaphyseal, 1430, 1434
 myelomeningocele and, 629
 overgrowth after, 1118
 proximal epiphysis, 1396–1397, 1397,
 1398
 proximal metaphysis, 1397–1398, 1399
 shaft, 1398–1401
 nondisplaced, 1400
 oblique or spiral, 1400, 1400, 1401
 open, 1401
 “toddler's fracture,” 1400, 1436, 1436
 transverse and comminuted displaced,
 1400–1401
 stress, 1278–1279
 tibial spine, 1390–1393, 1393
 tibial tubercle, 1393–1394, 1394, 1395
- Tibio-femoral angle, 1065
- Tillaux fracture, 71, 1401, 1405,
 1405–1406
- Tinel sign, 547
- Toddlers and preschool children
 examination of, 100–101, 104–116
 growth of, 40–41
 maturation of gait, 144–145
 “Toddler's fracture,” 1400, 1436, 1436
- Toe walking, idiopathic, 1098–1100
 clinical features of, 1098, 1099
 definition of, 1098
 differential diagnosis of, 1098
- etiology of, 1098
 examination for, 113–116, 114–116,
 1098–1099
 inheritance of, 1098
 natural history of, 1098
 nonoperative management of, 1099
 surgical treatment of, 1099–1100
- Toes
 apophysitis of fifth metatarsal, 1282
 congenital hallux varus, 1186–1188,
 1187, 1188
 congenital overriding fifth toe,
 1178–1180, 1179
 curly, 1180, 1180–1181
 Freiberg infraction, 1205–1206, 1206
 juvenile hallux valgus, 1200,
 1200–1203, 1201, 1203
 macrodactyly, 1191–1192, 1191
 metatarsal fractures, 1411–1412, 1413
 phalangeal fractures, 1412–1414
 polydactyly/syndactyly, 1188–1190,
 1189–1190
 in Rubinstein-Taybi syndrome, 315, 316
 syndactyly, 1190–1191, 1190
- Tolmetin, 1277
- Tomography
 computed (*See* Computed tomography)
 conventional, 71
- Tonic neck reflex, 106–107, 107, 107t
- Torticollis, 804–814
 congenital muscular, 811–813
 clinical features of, 812
 etiology of, 811–812
 radiographic features of, 812
 stretching exercises for, 812
 surgery for, 812–813, 813
 developmental dysplasia of hip and, 103
 neurogenic, 813–814
 osseous types of, 804–811
 atlantoaxial rotary displacement,
 808–811, 809–811
 atlantooccipital anomalies, 805–807,
 806
 basilar impression, 804–805, 805
 familial cervical dysplasia, 808, 808
 unilateral absence of C1, 807,
 807–808
 paroxysmal, of infancy, 814
 in Sandifer syndrome, 814
- Total joint arthroplasty
 of hip, for slipped capital femoral
 epiphysis, 1024–1025
 for juvenile idiopathic arthritis, 452–453
- Trabecular bone, in rickets, 187, 188
- Traction
 for congenital knee dislocation, 1096
 for femoral shaft fracture, 1383, 1385
 prereduction, for developmental dysplasia
 of hip, 928–929, 930
 complications of, 929–930
 for supracondylar fracture, 1341
 for transient synovitis of hip, 1048
- Transcription, RNA processing and, 159
- Transcription factors, 8, 29
- p53 protein, 509
- Transforming growth factor- β , 178t
 fracture healing and, 1321
 limb development and, 14
- Transgenic animals, 29, 162
- Transient quadriparesis, 829
- Transient synovitis of hip, 435,
 1044–1048
 age at onset of, 1045–1046
 clinical presentation of, 1045–1046
 coxa magna and, 1047
 differential diagnosis of, 1046
 etiology of, 1045
 allergic hypersensitivity, 1045
 infection, 1045
 obesity, 1045
 trauma, 1045
 historical descriptions of, 1044–1045
 incidence of, 1045
 Legg-Calvé-Perthes syndrome and, 959,
 1048
 natural history of, 1047–1048
 pain of, 1044, 1046
 radiographic features of, 1046–1047
 scintigraphy, 1046–1047
 ultrasound, 1046, 1047
 treatment of, 1048
- Translation of DNA, 159–160
- Translocations, chromosomal, 508
- Transtarsal joints, 1152
- Transtrochanteric rotational osteotomy, for
 slipped capital femoral epiphysis,
 1020
- Transverse atlantoaxial ligament, 801
 atlanroaxial rotary displacement and, 811
 rupture of, 801, 824
- Trauma. *See also* Dislocation; Fractures;
 specific injuries
 amputations due to, 1255
 ankle, 1290–1293, 1401–1407
 anterolateral ankle impingement, 1293
 distal tibiofibular sprains, 1293
 fractures, 1401–1407
 high-risk, 1403–1405, 1404
 low-risk, 1402, 1403
 Tillaux fracture, 71, 1401, 1405,
 1405–1406
 triplane fracture, 1401, 1406,
 1406–1408
 sprains, 128, 128–129, 1290–1292,
 1291
 bone and joint sepsis and, 461
 cervical spine, 822–830
 in battered children, 829
 birth injuries, 829
 of C3–7, 827, 827, 828
 car seat injuries, 829–830, 830
 gunshot wounds, 830
 of occipital complex to C1–2
 complex, 823–827
 spinal cord injury without
 radiographic abnormality, 827–829
 child abuse, 1423–1443
 computed tomography evaluation of, 71
 differentiation from osteomyelitis, 474

Trauma (*contd.*)

elbow, 118–119, 1338–1355
 dislocation, 1352–1354
 fracture-separation of distal humeral physis, 1349–1350, 1350
 lateral condyle fracture, 1344–1348, 1345–1348
 lateral epicondyle fracture, 1348
 medial condyle fracture, 1349
 medial epicondyle fracture, 1348–1349, 1349
 olecranon fracture, 1352, 1352, 1353
 radial head dislocation and nursemaid's elbow, 1354, 1354–1355, 1355
 radial neck fracture, 1350–1352, 1351
 supracondylar fracture, 1339–1344, 1340–1344
 T-condylar fracture, 1344
 femoral fractures, 1373–1389
 complex, 1387–1388
 proximal, 1373–1379
 shaft, 1379–1387
 subtrochanteric, 1388
 foot fractures, 1408–1414
 calcaneus, 1411, 1412
 metatarsals, 1411–1412, 1413
 midfoot, 1411
 phalanges, 1412–1414
 talus, 1409–1411, 1410
 forearm, 1355–1364
 complete shaft fractures, 1359–1363, 1360–1363
 Galeazzi fracture-dislocation, 1357
 green-stick fractures, 1358–1359, 1359
 Monteggia fracture-dislocation, 1356, 1356–1358
 plastic deformation, 1357
 fractures, 1319–1414
 hip fractures, 1373–1379
 humerus fractures, 1335–1337
 birth injury, 109, 1332
 distal, 118–119
 physal fracture-separation, 1345, 1346, 1349–1350, 1350
 supracondylar fracture, 1339–1344, 1340–1344
 proximal, 1335, 1336, 1337
 shaft, 1335–1337
 initial evaluation and management of, 1327
 Glasgow Coma Scale, 1327, 1327t
 Pediatric Trauma Score, 1327, 1328t
 knee, 1293–1297, 1389–1396
 anterior cruciate ligament injuries, 1294–1296
 collateral ligament injuries, 1293–1294, 1294
 distal femoral physal separations, 1389–1390, 1390–1392
 meniscal tears, 1296–1297, 1297
 patellar fracture, 1394–1396, 1395–1396
 posterior cruciate ligament injuries, 1296

tibial spine fracture, 1390–1393, 1393
 tibial tubercle fracture, 1393–1394, 1394, 1395
 kyphosis caused by, 766–767
 leg length discrepancy and, 1114–1116, 1115, 1116, 1118
 limp after falling, 110–111
 myositis ossificans and, 218, 366–368
 pelvic fractures, 1369–1371, 1370
 acetabulum, 1370–1371
 avulsion, 1298, 1298
 pelvic ring, 1370, 1371
 periosteal reaction and, 215t
 puncture wounds of foot, 494–496, 495
 quadriceps contusion, 1297–1298
 reflex sympathetic dystrophy and, 370–372
 shoulder, 1332–1335
 acromioclavicular separation, 1334
 birth injuries of, 1332
 clavicular fractures, 1332–1334, 1333, 1334
 dislocation, 1335
 proximal humerus fractures, 1335, 1336, 1337
 scapular fractures, 1334–1335
 slipped capital femoral epiphysis and, 1001
 spinal, sports-related, 1298–1299
 spondylolysis, spondylolisthesis and, 780
 sports-related, 1289–1299
 thoracic and lumbar spine fractures, 1366–1368
 burst fractures, 1368
 compression fractures, 1367–1368, 1368
 lapbelt (Chance) fractures, 1368, 1369
 limbus (apophyseal) fracture, 1368
 tibial fractures, 1396–1401
 proximal epiphysis, 1396–1397, 1397, 1398
 proximal metaphysis, 1397–1398, 1399
 shaft, 1398–1401, 1400, 1401
 transient synovitis of hip and, 1045
 upper limb, 886–895 (*See also* Upper limb trauma)
 wrist, 891–893, 1364–1366
 differentiation from atraumatic
 ligamentous instability, 891–892
 distal metaphyseal fractures of radius and ulna, 1364–1365, 1364–1366
 distal radius physal fracture, 1365–1366
 scaphoid fracture, 891, 891
 scapholunate ligamentous injuries, 892
 triangular fibrocartilage complex tears, 892, 892–893, 893
 Trendelenburg gait, 121
 cleidocranial dysplasia and, 276
 Legg-Calvé-Perthes disease and, 117
 Trendelenburg test, 112, 112, 121
 Triangular fibrocartilage complex (TFCC) tears, 892, 892–893, 893

Trichorhinophalangeal syndrome, 323, 323–324, 324
 Trigger thumbs/digits, 879–880
 diagnosis of, 879
 etiology of, 879
 treatment of, 879–880
 Trimethoprim-sulfamethoxazole, 479t
 Triphalangeal thumb, 17, 885, 885–886
 classification of, 885
 conditions associated with, 885
 inheritance of, 885
 treatment of, 885–886, 886
 Triplane fracture, 1401, 1406, 1406–1408
 Triple arthrodesis, 1153
 for pes cavovarus, 660–661, 661
 Triplegia, cerebral palsy and, 566
 Trisomies, 162
 Trisomy 21. *See* Down syndrome
 Trisomy X, 163
 Trousseau sign, 201
 TRSP1 gene, trichorhinophalangeal syndrome and, 323
 Trunk, in gait cycle, 142
 Tuberculosis
 in cervical spine, 832–833
 kyphosis and, 768
 rickets and, 192
 skeletal, 497–500, 498, 499
 treatment of, 498–500
 Tumor suppressor genes, 508–509
 Tumoral calcinosis, 217–218
 Tumors, 507–551. *See also* specific types
 arthritis and, 417, 438
 Beckwith-Weidemann syndrome and, 321
 biopsy of, 517–518
 bone cysts, 538–542
 aneurysmal, 540–542, 541, 542
 unicameral, 538–540, 540
 bone-forming, 518–527
 osteoblastoma, 520–521
 osteoid osteoma, 514, 515, 518–520, 519, 520
 osteosarcoma, 84, 89, 521–523, 521–527, 525
 brown, in renal osteodystrophy, 196, 197
 cartilaginous, 528–534
 chondroblastoma, 531–532, 532, 533
 chondromyxofibroma, 531, 531
 enchondroma, 528–529, 529
 exostosis, 529–531, 530
 periosteal chondroma, 532–534, 534
 of cervical spine, 833–835
 chemotherapy for, 527–528
 multidrug resistance and, 510
 differentiation from osteomyelitis, 474
 evaluation for, 510–515
 chief complaint, 510–511
 computed tomography, 514, 515
 laboratory testing, 513
 magnetic resonance imaging, 83, 84, 514–515
 medical history, 511
 physical examination, 512
 plain radiographs, 512–513

- radionuclide scans, 89, 513–514, 514
 - review of systems, 511–512
 - Ewing sarcoma/peripheral neuroectodermal tumor, 542–544, 543
 - Fanconi anemia and, 380
 - hypercalcemia and, 193, 202
 - idiopathic hemihypertrophy and, 349–350
 - Langerhans cell histiocytosis, 402–407, 403–407, 537–538, 538, 539
 - leg length discrepancy and, 1117
 - lesions of fibrous origin, 534–537
 - fibrous dysplasia, 535–536, 536
 - nonossifying fibroma, 534, 534–535, 535
 - osteofibrous dysplasia, 536–537, 537
 - McKusick-type metaphyseal chondrodysplasia and, 272
 - molecular biology of, 170, 507–510, 508t
 - neurofibromatosis and, 293–294
 - pain of, 510–511
 - periosteal reaction and, 214, 215t
 - rickets and, 193
 - soft tissue, 544–551
 - benign tumors of nerve origin, 546–548, 547
 - fibromatoses, 545–546, 546
 - hemangioma, 339–340, 544–545, 545
 - pigmented villonodular synovitis, 438, 551
 - rhabdomyosarcoma, 548, 549t
 - synovial cell sarcoma, 548–549, 550
 - synovial chondromatosis, 549–551, 550
 - staging of, 515–516, 516t
 - vascular, 339–340
 - Turner syndrome, 225, 228, 318
 - chromosome abnormality in, 163, 318
 - clinical features of, 318
 - clinodactyly and, 871
 - Duchenne muscular dystrophy and, 637
 - hemihypertrophy in, 348t, 350
 - Madelung deformity and, 868
 - treatment of, 318
 - Twinning, 3
- U**
- Ulcerative colitis, rickets and, 192
 - Ulna
 - bowing of, related to radial dysplasia, 861, 862
 - Caffey disease and, 216
 - congenital pseudarthrosis of, 860, 860–861
 - congenital radioulnar synostosis, 855–858, 857
 - deficiency of, 868
 - classification of, 865–866, 867
 - clinical features of, 865–866
 - natural history of, 866
 - nonoperative treatment of, 866
 - surgical treatment of, 866–868
 - dysplasia of, 865–868, 867, 868
 - conditions associated with, 865
 - congenital humeroulnar dislocation and, 855
 - fractures of, 1357–1365
 - complete shaft, 1359–1363, 1362, 1363
 - distal metaphyseal, 1364–1365, 1365, 1366
 - green-stick, 1358, 1358–1359, 1360–1361
 - plastic deformation, 1357, 1359
 - osteochondromatosis and, 858–860, 859
 - Ulnar dimelia, 855
 - Ulnar nerve block, 1331
 - Ulnar nerve testing, 119
 - Ulnohumeral joint, 1338
 - Ulnotrochlear joint dislocation, congenital, 854–855
 - Ulnotrochlear synostosis, 858
 - Ultrasonography, 63, 74–78
 - advantages of, 74
 - applications of, 77
 - cost of, 85t
 - Doppler, 74
 - mechanisms of contrast on, 74
 - normal hip anatomy on, 74–75, 75, 77
 - for prenatal diagnosis, 174
 - quantitative, 90
 - in specific conditions
 - bone and joint sepsis, 473
 - clubfoot, 1156, 1156
 - congenital kyphosis, 747
 - developmental dysplasia of hip, 75, 76, 77, 915–916, 917, 918
 - slipped capital femoral epiphysis, 1006
 - transient synovitis of hip, 1046, 1047
 - trends in utilization of, 77
 - Umbauzonnen (Looser lines), 187, 190, 190
 - Unicameral bone cysts, 538–540, 540
 - Uniparental disomy, 171
 - Upper limb, 841–895
 - arm span measurement, 38
 - arthrogryposis multiplex congenita and, 298–299, 850–853
 - brachial plexopathy and, 846–850
 - cerebral palsy and, 590–593, 842–846
 - congenital deficiencies of, 842, 1246–1253
 - amelia, 1248, 1249
 - classification of, 842
 - incidence of, 842, 1218
 - lower limb deficiencies and, 1253–1254, 1254
 - pathogenesis of, 842
 - phocomelia, 1248–1250, 1249
 - prosthetic management for, 1247, 1251–1253, 1253
 - terminal devices, 1264–1265, 1265
 - terminal transverse transcarpal deficiency, 1250–1251, 1251
 - transverse complete humeral deficiency, 1250
 - transverse incomplete forearm deficiency, 1250, 1251
 - elbow and forearm region, 853–861
 - congenital humeroulnar dislocations, 854–855
 - congenital radial head dislocations, 853–854, 854
 - congenital radioulnar synostosis, 855–858, 857
 - elbow synostosis, 858
 - osteochondromatosis, 858–860, 859
 - pseudarthrosis, 860, 860–861
 - embryology of, 842
 - examination for paralysis in infant, 109–110
 - in gait cycle, 142
 - growth of, 58, 58
 - hand region, 870–879
 - camptodactyly, 877–879, 878
 - cleft hand, 870–871, 871
 - clinodactyly, 879
 - constriction band syndrome, 872, 872–873
 - polydactyly, 876, 876–877, 877
 - sybrachydactyly, 870–871
 - syndactyly, 873–875, 873–875
 - in other conditions
 - Cornelia de Lange syndrome, 313, 314
 - Duchenne muscular dystrophy, 641
 - hereditary motor sensory neuropathies, 662
 - poliomyelitis, 665
 - thrombocytopenia with absent radius syndrome, 382, 382t
 - thumb conditions, 879–886
 - hypoplasia/aplasia of thumb, 880–881, 880t, 881, 882
 - thumb duplication, 881–885, 883–885
 - trigger thumbs/digits, 879–880
 - triphalangeal thumbs, 885, 885–886, 886
 - wrist region, 861–870
 - Madelung deformity, 868–870, 869
 - radial dysplasia, 861–865, 862, 863, 865
 - ulnar dysplasia, 865–868, 867, 868
 - Upper limb trauma, 886–895, 1332–1366
 - elbow, 118–119, 1338–1355
 - dislocation, 1352–1354
 - fracture-separation of distal humeral physis, 1349–1350, 1350
 - lateral condyle fracture, 1344–1348, 1345–1348
 - lateral epicondyle fracture, 1348
 - medial condyle fracture, 1349
 - medial epicondyle fracture, 1348–1349, 1349
 - olecranon fracture, 1352, 1352, 1353
 - radial head dislocation and nursemaid's elbow, 1354, 1354–1355, 1355
 - radial neck fracture, 1350–1352, 1351
 - supracondylar fracture, 1339–1344, 1340–1344
 - T-condylar fracture, 1344

- Upper limb trauma (*contd.*)
 forearm, 1355–1364
 complete shaft fractures, 1359–1363, 1360–1363
 Galeazzi fracture-dislocation, 1357
 green-stick fractures, 1358–1359, 1359
 Monteggia fracture-dislocation, 1356, 1356–1358
 plastic deformation, 1357
 hand, 886–891
 digital amputations, 895, 895, 896
 distal phalanx injuries, 887–888
 mallet fingers, 888
 physeal fractures and nail-bed entrapment, 887–888
 tip amputations, 887
 finger dislocations, 893–894
 metacarpal fractures, 889–890
 phalanx fractures, 888–889
 intercondylar fractures, 886, 888–889, 889
 phalangeal neck fractures, 888
 physeal fractures, 889
 randon lacerations, 894–895, 895
 thumb fractures, 890, 890–891
 shoulder and humerus, 1332–1337
 acromioclavicular separation, 1334
 birth injuries, 1332
 clavicle fractures, 1332–1334, 1333, 1334
 glenohumeral dislocation, 1335
 humeral shaft fracture, 1335–1337
 proximal humerus fractures, 1335, 1336, 1337
 scapular fracture, 1334–1335
 wrist, 891–893, 1364–1366
 differentiation from atraumatic
 ligamentous instability, 891–892
 distal metaphyseal fractures of radius and ulna, 1364–1365, 1364–1366
 distal radius physeal fracture, 1365–1366
 scaphoid fracture, 891, 891
 scapholunate ligamentous injuries, 892
 triangular fibrocartilage complex tears, 892, 892–893, 893
 Uveitis, oligoarthritis and, 444, 444
- V**
 VACTERLS, 321–322, 861
 Valproic acid, 23
 van der Hoeve disease, 205
 van Nes rotationplasty, for proximal femoral focal deficiency, 1243–1244, 1245
 Vancomycin, 479t
 Varus osteotomy, for Legg-Calvé-Perthes syndrome, 987–988
 Vascular accident hypothesis, 17–18
 Vascular malformations, 340–343, 342
 complex-combined, 343–355
 congenital constriction band syndrome, 17, 18, 352–355, 353
 Gorham disease, 346–347, 347
 hemihypertrophy and hemihypotrophy, 347–350, 348t, 349
 Klippel-Trenaunay syndrome, 340, 340t, 341, 343–345, 344
 localized gigantism and macrodactyly, 350–352, 351
 Proteus syndrome, 345–346, 346
 Vascular tumors, 339–340, 544–545, 545
 Vasculature
 development of, 11–12
 congenital anomalies associated with abnormalities in, 17–18
 of growth plate, 27, 179, 1323
 of proximal femur, 77, 77, 959–960, 960, 1374, 1374
 Vasculitis, arthritis and, 437
 VATER association, 321–322
 Venous malformations, 340, 341, 342
 Ventriculomegaly
 achondroplasia and, 248
 metatropic dysplasia and, 256
 Versed. *See* Midazolam
 Vertebral abnormalities
 cervical (*See* Cervical spine)
 on computed tomography, 72
 conditions associated with
 chondrodysplasia punctata, 271, 271
 congenital kyphosis, 744–745, 745, 745t
 congenital scoliosis, 725–726, 725–727
 diastrophic dysplasia, 258, 259, 260
 Gaucher disease, 401, 401
 Goldenhar syndrome, 322, 322–323
 hemangioma, 545, 545
 homocystinuria type I, 221
 idiopathic juvenile osteoporosis, 211, 211, 768–769, 769
 Kniest dysplasia, 262
 Langerhans cell histiocytosis, 403–405, 537
 Larsen syndrome, 278, 278, 301
 metatropic dysplasia, 256
 Morquio syndrome, 326, 327
 multiple epiphyseal dysplasia, 270
 multiple pterygium syndrome, 304, 304
 myelomeningocele, 608–616
 neurofibromatosis, 292
 Noonan syndrome, 319
 osteogenesis imperfecta, 205, 207
 osteopetrosis, 213
 progeria, 317
 progressive anterior vertebral fusion, 749–750
 Proteus syndrome, 295
 pseudoachondroplasia, 268, 268
 rickets, 187
 sacral agenesis, 749
 Scheuermann disease, 750, 750
 segmental spinal dysgenesis, 749
 sickle cell disease, 385, 385
 skeletal dysplasia, 245, 246
 spinal osteoid osteoma, 518, 520
 spondyloepiphyseal dysplasia, 263, 264, 266
 tuberculosis, 497, 499
 VACTERLS, 321
 development of, 21–22
 glucocorticoid-related, 228, 228
 on magnetic resonance imaging, 82
 number variations, 21
 spondylolysis and spondylolisthesis, 777–794
 Vertebral bars, 21, 22
 congenital scoliosis and, 725, 726
 myelomeningocele and, 608
 Vertebral column
 development of, 18–22, 19–20
 cervical vertebrae, 799–800
 growth in, 50–53, 51, 52
 cervical spine, 50–51, 800
 lumbar spine, 52–53
 radiation effects on, 760–761
 thoracic spine, 51, 51–52, 52
 Vertebral fractures
 in acute lymphoblastic leukemia, 417, 417
 cervical, 823–827
 atlas, 824
 C3–7, 827, 827, 828
 odontoid, 824–827, 826
 due to child abuse, 1432–1435, 1433, 1435
 thoracolumbar, 1366–1368
 anatomy and classification of, 1367
 burst fractures, 1368
 clinical features of, 1366–1367
 complications of, 1368
 compression fractures, 1367–1368, 1368
 lapbelt (Chance) fractures, 1368, 1368
 limbus (apophyseal) fracture, 1368
 Vertical talus, congenital, 1152, 1174–1178
 clinical features of, 1174, 1174
 definition of, 1174
 epidemiology of, 1174
 in multiple pterygium syndrome, 304
 natural history of, 1176
 nonoperative management of, 1176
 oblique talus and, 1174
 pathoanatomy of, 1175–1176
 pathogenesis of, 1174
 radiographic features of, 1174–1175, 1175
 surgical treatment of, 1176–1178, 1177
 Vinblastine, 22
 Vincristine, 528
 Vitamin A overdose, 215t, 216
 Vitamin C deficiency, 216–217, 217
 Vitamin D, 180–181
 calcium homeostasis and, 182–184, 182–184
 for hypoparathyroidism, 201
 for hypophosphatasia, 200
 overdose of, 202
 Vitamin D-deficient rickets, 191, 191–193
 Volkmann ischemic contracture, 119, 414, 414

von Recklinghausen disease. *See*
Neurofibromatosis, type 1
Von Rosen projection, 70
Voorhoeve disease, 359, 360
Vrolik disease, 205

W

Wagner leg lengthening device,
1137–1138, 1138
Wake-up test, after scoliosis surgery, 723
Walking. *See also* Gait
average age for, 567t
Duchenne muscular dystrophy and, 637
idiopathic toe walking, 113–116,
114–116, 1098–1100, 1099
myelomeningocele and, 607–608
persistence of primitive reflexes and
prognosis for, 108–109, 109t
refusal to walk
in acute lymphoblastic leukemia, 417
evaluation in toddler, 111–113, 112,
113
spastic diplegia and, 577–578, 577t
spastic hemiplegia and, 589
spastic quadriplegia and, 569
Warfarin, 172
WeeFIM, 569
Weight, 38–40, 43
of paralytic child, 58
Weight training, 1276
Werdnig-Hoffman disease, 652. *See also*
Spinal muscular atrophy

Wheelchair use
for Duchenne muscular dystrophy, 643
for spastic quadriplegia, 569, 569–570
“Whistling face,” in Freeman-Sheldon
syndrome, 302, 303
White lines of Fraenkel, 217, 217
Williams syndrome, 202
Wilmington brace, 699
Wilms tumor, 761
Beckwith-Weidemann syndrome and,
321
leg length discrepancy and, 1117
Wilson test, 123
Wimberger sign, 217
Wnt-7a, 16
Wolff’s law, 180, 204
Wolman disease, 398t
Wrist
disuse atrophy of, 212
in specific conditions
arthrogryposis multiplex congenita,
850–853
cerebral palsy, 592, 592, 843, 845
chondroectodermal dysplasia, 257
Madelung deformity, 868–870, 869
radial dysplasia, 861–865, 862, 863,
865
ulnar dysplasia, 865–868, 867, 868
terminal transverse transcarpal deficiency,
1250–1251, 1251
traumatic injuries of, 891–893,
1364–1366

differentiation from atraumatic
ligamentous instability, 891–892
distal metaphyseal fractures of radius
and ulna, 1364–1365, 1364–1366
distal radius physeal fracture,
1365–1366
scaphoid fracture, 891, 891
scapholunate ligamentous injuries, 892
triangular fibrocartilage complex tears,
892, 892–893, 893

Wry neck. *See* Torticollis

X

X chromosome, 158, 158
X-linked disorders, 168, 168–169
agammaglobulinemia, 394
atypical, 169
dominant, 168–169
Lyon hypothesis of, 168
recessive, 169

Y

Y chromosome, 158, 158

Z

Z-foot deformity, in Proteus syndrome,
295
Zonal phenomenon, in myositis ossificans,
367
Zone of polarizing activity, 11, 14–16, 15,
29
Zygosyndactyly, 1190, 1190
Zygote, 2–5

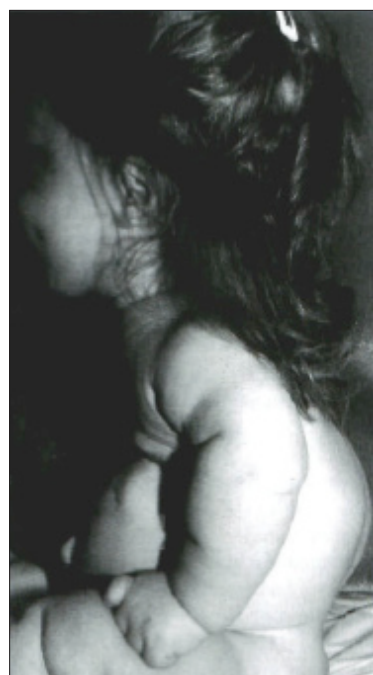The fifth edition of *Lovell & Winter's Pediatric Orthopaedics* is appearing at the beginning of a new millennium and in the same year that the World Health Organization is launching the Bone & Joint Decade, aimed at improving the quality of life for people with musculoskeletal conditions, and at advancing understanding and treatment of these conditions through research, prevention, and education.

In this fifth edition of *Pediatric Orthopaedics*, we have tried to keep pace with the rapid advances in basic research as applied to clinical medicine by presenting discussions of the knowledge about each condition as it currently exists.

The editors realize that some readers of this edition will be among the leaders of the new generations of orthopaedic surgeons who will fill in the gaps in our knowledge and improve the orthopaedics care of children. Patients and parents both expect and deserve their physicians to provide them with the latest evidence regarding their condition and its treatment so they can make informed choices. We hope that this edition will provide the latest and best information for the pediatric surgeon practicing in the new millennium.

This publication is for informational purposes only and is not an appropriate or complete replacement for professional medical diagnosis. Global HELP and the original publishers assume no liability for actions performed as a result of the title.

Please let us know how to make these publications more useful at questions@global-help.org.



Copyright © 2008 Global-HELP Organization
Originally published by Lippincott Williams & Wilkins (Copyright © 2001)
Original ISBN: 0-7817-2582-8
Dimensions: 8.0" x 11.0"

ISBN 978-1-60189-046-7



Children's
Hospital & Regional Medical Center


GLOBAL HELP
HEALTH EDUCATION USING LOW-COST PUBLICATIONS
WWW.GLOBAL-HELP.ORG


**LIPPINCOTT
WILLIAMS & WILKINS**