

# CHAPTER 9

## VASCULAR ACCESS IN CHILDREN

James O. Adeniran  
Hugo A. Heij

### Introduction

Every child presenting to the paediatric surgeon will require vascular access at one time or another during the management of the child's surgical condition. Vascular access becomes critical in patients brought to the hospital as emergencies because many of them may have been on treatment in private hospitals for some time, and the obvious veins have been used already. This common task may be even more daunting with factors such as restlessness due to the clinical pathology, shock, unavailability of appropriate catheters, obese patients, and children with multiple limb injuries.<sup>1</sup> It is therefore important for the paediatric surgeon to be familiar with how to gain access to the vascular tree as and when necessary.

The first part of this chapter considers peripheral vascular access, and the second part considers central vascular access. Indications, techniques of catheter insertion, complications and management of these complications, and the cost-benefit aspect in the African setting are discussed.

### Peripheral Vascular Access

#### Indications for Africa

Virtually all patients presenting to a paediatric surgeon need blood tests for diagnosing their ailments, assessing their fitness for anaesthesia, and use in postoperative management. Accurate figures for Africa are not known, but in the United States an estimated more than 200 million peripheral catheters are placed annually.<sup>2</sup> Vascular access is one of the new tools that enables the neonatologist and paediatric surgeon to provide ongoing therapy for very ill babies, at the same time allowing invasive monitoring of the clinical condition.<sup>3</sup> Many patients present to the paediatric emergency room with intestinal obstruction as neonates with anorectal malformations, Hirschsprung's disease, or bowel atresias.<sup>4</sup> Older patients present with peritonitis, usually due to typhoid or appendix perforation.<sup>5</sup> Some patients also present with multiple trauma, and others may present with sickle cell disease in crises. These patients need urgent vascular access for administration of fluids, blood products, drugs, and nutritional formulas.<sup>3</sup>

#### Venous Access

Venous access is needed for administration of drugs during resuscitation, induction and maintenance of anaesthesia, during cytotoxic therapy, and in haemodialysis. Stem-cell harvest for research and bone marrow transplantation in cases of leukaemias also need venous access. Nutritional support can be given to many patients through peripherally inserted central catheters. Other indications and uses for venous access are shown in Table 9.1.

#### Arterial Access

Arterial access is used much less in developing countries, not because the indications are lacking, but because the necessary equipment is not available. Arterial sampling for O<sub>2</sub> estimation and cardiovascular monitoring in very ill children, especially those who need ventilation, needs arterial access. Various radiological procedures for diagnosis and treatment are becoming popular in children. Children bleeding from

Table 9.1: Indications for peripheral vascular access.

Indications	Uses
Venous blood sampling	For various diagnostic tests
Resuscitation	Fluids, blood and blood products in: Intestinal obstruction Peritonitis Trauma Preoperative work-up
Administration of other products	Drugs during resuscitation Drugs during anaesthesia Correction of anaemia/coagulation defects Parenteral nutrition Cytotoxic drugs
Use as central venous access	

the gastrointestinal tract may need digital subtraction angiography (DSA) for diagnosis and management. Many advanced liver and renal tumours can now be embolised by using the arterial route with excellent palliation.

#### Physiology

The French physiologist Jean Marie Poiseuille<sup>6</sup> in 1839 defined resistance through a vessel as:

$$\text{Resistance} = 8 (\text{viscosity}) (\text{catheter length}) / \pi r^4$$

Resistance through the catheter decreases as the length of the catheter decreases and the radius  $r$  increases. Maximum flow is therefore best when the catheter is short and wide.

#### Sites of Peripheral Vascular Access

##### Venepuncture

##### *Umbilical vein*

The umbilical vein may remain patent for up to two weeks.<sup>7</sup> It is easily cannulated in neonates and is used extensively in third-world countries for venous blood sampling, infusion of crystalloids and colloids, administration of drugs, and exchange blood transfusion. The technique is described below. Portal vein thrombosis can follow prolonged use; therefore, a peripheral vein should be secured as soon as possible. Platelets should not be infused through the umbilical vein.<sup>7</sup>

##### *Upper limb*

The upper limb is the preferred site for cannulation in children. Because the dorsal venous arch starts from the dorsum of the wrist, this site is most commonly attempted first in most children. Two or three veins may be found at the radial and ulna borders. The origin of the cephalic vein may be seen over the snuff box in older children. The cephalic and basilic veins and one or two veins crossing them may be visible at the cubital fossa.

### Lower limb

In the lower limb, two veins are usually visible at the lateral border of the dorsum of the foot, and one at the medial border of the tibia. The long saphenous and femoral veins may not be readily visible in most children unless light-complexioned, but they are anatomically just medial to the femoral artery, which is easily palpable at the groin.

### Scalp

The superficial temporal vein is usually prominent in the crying child, and easy to cannulate by using the butterfly needle.

### Arterial punctures

Although the radial artery at the wrist may be big enough in older children, the femoral artery at the groin is most commonly used in younger children. The superficial temporal artery is small but easily palpable.

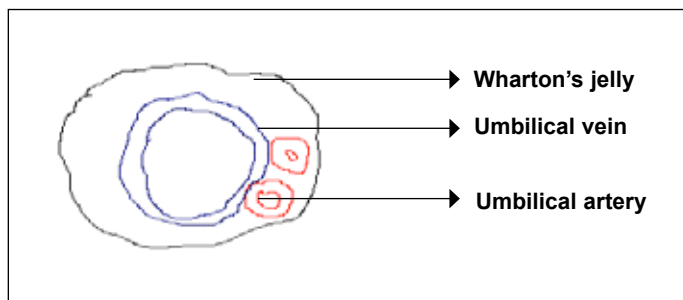
### Bone punctures

The medial border of the tibia is subcutaneous throughout its length. The proximal part of this subcutaneous border just below the tibia tuberosity opens into a wide marrow from which blood could be aspirated for investigations. Fluids, blood, and drugs could also be rapidly infused for resuscitation.

## Technique of Venepuncture

### Umbilical vein

The umbilical stump of a neonate has two small thick-walled umbilical arteries, and a large, thin-walled umbilical vein, enmeshed in Wharton's jelly (Figure 9.1).



Source: Courtesy of Dr. Adeyinka A. Adesiyun, University of Ilorin Teaching Hospital, Ilorin, Nigeria.

Figure 9.1: Transverse section of a neonate's umbilicus.

The baby should be kept warm under a radiant warmer and loosely restrained. The umbilical cord, clamp, and surrounding skin is cleaned with a suitable antiseptic. A size 5 or 6 feeding tube is recommended for cannulation. This tube is primed with normal saline with a 5-ml syringe attached. The base of the umbilicus is tied loosely with a sterile piece of umbilical tape or 2'0 silk suture to control bleeding. The umbilical cord is now transected about 3 cm from the base. The vein is picked with forceps and the catheter inserted and advanced until blood flows back freely into the catheter. Saline in the syringe is injected and should flow without resistance. The catheter is secured by two purse-string silk sutures at the base of the umbilicus, and further taped at several points to the skin of the abdomen.

### Cannulation at the wrist

The first attempt at cannulation at the wrist should be successful in the "virgin" wrist if appropriate steps and precautions are followed. All necessary equipment should be assembled, including tourniquet, sterile swabs, appropriate catheters, infusion fluids, and plaster to anchor the catheter. Adequate illumination is also necessary. The site chosen for cannulation should be cleaned with an antiseptic solution to prevent introduction of organisms ab initio. It is also important for the clinician to wear protective gloves to prevent contacting diseases such as hepatitis or human immunodeficiency virus (HIV). In venepuncture of the wrist in young children, the wrist could be palmar-flexed and the

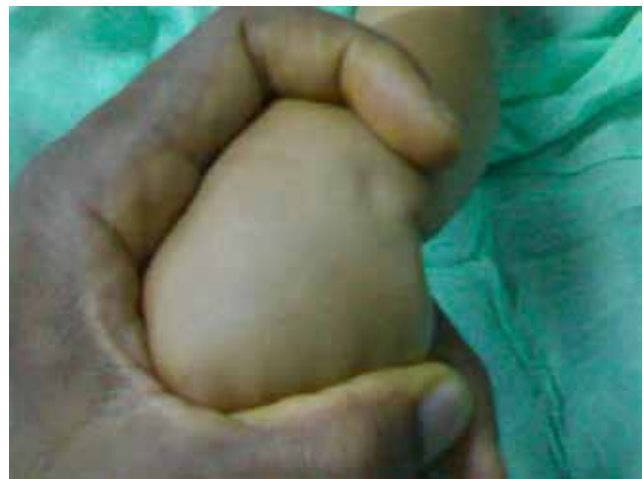

Figure 9.2: Technique of venepuncture at the wrist.

index finger used as a tourniquet while the rest of the hand steadies the child's wrist (Figure 9.2).

If a vein is not immediately visible, the limb can be placed dependent for a couple of minutes before a tourniquet is applied or the wrist can be slapped gently.

An older patient can be asked to grip and relax the fingers for a few minutes. Topical venodilatation may be achieved by topical application of 4% nitroglycerin ointment for 2–4 minutes.<sup>8</sup> Ultrasound, using a handheld Doppler, can be used to locate forearm veins in obese patients.<sup>9</sup> The visible or palpable vein is cleaned with antiseptic fluid. The catheter is then inserted until blood fills the chamber. The hub of the catheter is then withdrawn a little and the rest of the catheter inserted. The infusion fluid is then connected to allow the fluid to open up the rest of the vein. The catheter can then be advanced as far as desirable. Because many children are restless, a small cardboard may be used as a splint. If two or three attempts on one wrist are not successful, the other wrist should be tried by a more experienced person.

### Cannulation at other sites

If attempts at both wrists are not successful, the ante-cubital fossa should be tried next. If a tourniquet is applied just above the ankle and the foot is planter-flexed and turned to equinus position, one or two veins may be visible on the dorsum of the foot. The superficial temporal vein over the temple is easily cannulated in children. As the child cries, the superficial temporal artery is easily palpable and provides a guide to the vein, which is just anterior to it. A scalp vein needle can be used for short periods or a cannula for longer periods.

### Technique of Arterial Punctures

Intraarterial cannulation allows the clinician to continuously monitor the cardiovascular status of patients and to obtain blood samples for blood gases necessary for ventilatory support and acid-base management. The umbilical artery at the umbilical stump can be easily cannulated in neonates.<sup>3</sup> The radial artery at the wrist and the femoral artery at the groin can also be cannulated percutaneously and for radiological procedures. Dorsalis pedis and posterior tibial arteries can also be used. The brachial artery is usually avoided because of poor collateral circulation; similarly, the superficial temporal arteries are avoided to prevent cerebral infarcts.

For arterial cannulation of limbs, an Allen's test is first performed.<sup>7</sup> In this test, both arteries that supply a limb are compressed for a few minutes. One artery is then released. If the collateral circulation is adequate, the extremity should flush in colour within 5 seconds. The artery can be accessed by either a Seldinger technique<sup>10</sup> or by a cutdown. Blood products, pressors, calcium boluses, and sodium bicarbonate should not be infused through arterial catheters.

### Venous Cutdown

A cutdown may be necessary to establish a rapid vascular access, for example, when all visible superficial veins may have been used or the patient comes in shock. The long saphenous vein, either near the ankle or at the groin, the femoral vein at the groin, and the basilic vein at the elbow or the cephalic vein at the delto-pectoral groove are all suitable sites. The area around the chosen vein is cleaned and draped aseptically, then infiltrated with a suitable local anaesthetic. A transverse incision is made only in the skin over the vein. A haemostat is then used to widely open the subcutaneous tissues. The vein is usually then visible. The distal end of the vein is ligated. A small needle is passed transversely across the vein, and the part of the vein superficial to the needle is transected. A suitable catheter is then inserted and anchored with stitches. The transverse skin incision is closed with one or two stitches. The catheter is anchored to skin with both stitches and plaster.

### Intraosseous Infusion

The bone marrow space is a rich, noncollapsible venous network.

Intraosseous infusion is a quick method of resuscitating children in shock when immediate intravenous access fails. Crystalloids, colloids, drugs (including anaesthetic drugs), and blood can be given rapidly through this route.<sup>11</sup> The flat, anteromedial, subcutaneous, upper aspect of the tibia 1–3 cm below the tibia tuberosity is usually used (Figure 9.3). Other sites that could be used are:

- the midline of the distal femur 3 cm proximal to the femoral condyles;
- distal tibia proximal to the medial malleolus;
- anterior superior iliac spine;
- lateral malleolus; or
- proximal humerus distal to deltoid insertion.

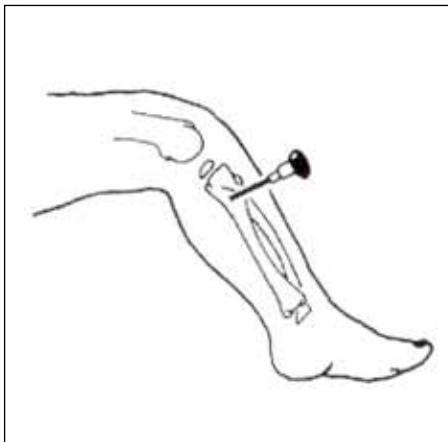


Figure 9.3: Technique of intraosseous infusion.

The chosen site is cleaned and draped, and a little local anaesthetic is given. A Jamshidi needle (which has a trochar), or bone marrow needle, or any size 13–18 butterfly needle can be used. The needle is introduced perpendicular to the skin, then angled away from the growth plate until a “give” is felt. The trochar is then removed. Blood should be aspirated to confirm that the needle is in the marrow. The infusion fluid can then be connected. Sterile gauze and plaster are used to secure the needle. The intraosseous route is for emergency only, and should not be used for more than 2–3 hours. As soon as possible, it should be replaced by a suitable intravenous site.

### Complications of Peripheral Vascular Access

#### Infection/cellulitis

Although our bodies do not normally react to catheters, they are, never-

theless, foreign bodies. Catheters should therefore be retained only for as long as necessary. Feeding and drugs should be changed to the oral route as soon as possible. After 2–3 days, signs of inflammation may appear at the site of cannulation. These include pain, redness, and swelling. If the redness appears other than along the site of cannulation, cellulitis is setting in, and the site of cannulation will need to be changed. If the catheter is being used for parenteral nutrition, intravenous antibiotics may be given in an attempt to salvage the line. If the catheter is planned for long-time use, it may be advisable to give regular antibiotics through the vein from the beginning.<sup>12</sup> The presence of infection elsewhere, prolonged hospital stay, immunosuppression, and poor catheter care all contribute to catheter-related sepsis.

#### Thrombosis/thrombophlebitis

Thrombosis can occur in a catheter, and the thrombus can dislodge to distant parts with grave consequences to the patient. Early signs of thrombosis are inadequate flow in the infusion fluid and extravasation. Use of silicone catheters, parenteral nutrition, and diabetes may predispose the patient to thrombosis. Aortic thrombosis can complicate umbilical artery cannulation, which may lead to leg or bowel gangrene. If persistent blanching of skin of the leg occurs, the catheter may need to be removed. Regular flushing with normal saline, heparin, or urokinase may serve as a preventive. After the catheter has been removed, the vein may become a painful, fibrotic, noncompressible “cord”. This is thrombophlebitis. Only painkillers are necessary, as the condition usually settles with time.

#### Extravasation/skin necrosis

When a new catheter is inserted in a vein, sterile water or saline should be injected first and must be seen to flow freely before the injection of drugs. If this is not done, drugs containing calcium, bicarbonate, or thiopentone, and drugs for chemotherapy can extravasate into subcutaneous tissues, causing necrosis. The dorsum of the hand and foot are common sites. If a toxic drug is given accidentally, application of ice packs to the area, subcutaneous irrigation with water or saline, and injection of hyaluronidase or steroid may reduce the amount of tissue damage.<sup>12</sup> If frank skin necrosis occurs, debridement, sometimes with delayed skin grafting, may be necessary.

#### Cannula dislodgement/fracture/embolisation

Catheters need to be anchored properly with plaster, and cutdowns should be secured with stitches. Brisk bleeding can occur when an arterial catheter inadvertently dislodges. Pressure for a couple of minutes will usually stop the bleeding. Appropriate splints are necessary in restless children. If frequent intravenous injections are necessary in a restless or shocked patient, or if a patient is receiving rapid intravenous infusions, a second line should be considered. Fracture of a cannula with embolism at distant sites has been reported.

#### Complications

Complications of peripheral cannulation include:

- haemorrhage/failed cannulation;
- air embolus during catheter insertion, tube change, or tube removal;
- infection/cellulitis;
- thrombosis/thrombophlebitis;
- extravasation/ skin necrosis;
- cannula dislodgement/fracture/embolisation;
- injury to surrounding structures (artery, nerve, solid organs);
- compartment syndrome/osteomyelitis; and
- ugly scars from subcutaneous extravasation, when debridement and skin grafting have been done.

Care should be taken not to injure the corresponding artery, especially during cutdowns. Once the vein is exposed, the artery should be clearly palpated before any vessel is ligated. Complications from intraosseous infusions are rare, but skin necrosis, compartment syndromes, and osteomyelitis can occur.

### Central Venous Access

This section discusses the purposes of central venous access (CVA), the techniques and devices tailored to the purposes, and the complications (both short- and long-term). For long-term central venous access, an operating theatre and general anaesthesia with fluoroscopy are ideal, and will give the best results. The cost-benefit aspect of CVA in the African setting is addressed in the final paragraph.

#### Incidence/Prevalence in the African Setting

Percutaneously placed short-term central venous catheters (CVCs) have been the primary means of central venous access in critically ill children.<sup>13</sup> Central venous access for administration of drugs or blood products can be required urgently in patients with severe trauma or other life-threatening conditions. A chronic need for CVA will arise in patients with oncological or intestinal conditions and for total parental nutrition.<sup>13</sup> About 5 million CVCs are inserted in the United States annually.<sup>2</sup> The role of the paediatric surgeon in CVA is to offer service to paediatric doctor colleagues, and the need for CVA will depend on the type of paediatric (surgical) practice.

The main patient categories are oncology, congenital intestinal malformations, and short bowel syndrome, with lesser demands from haematology (sick cell disease) and orthopedics (intravenous antibiotics for septic arthritis and osteomyelitis). Devices and facilities for CVA are expensive, so the applicability also depends on financial considerations.

#### Applications and Indications

The indications of central venous access include:

- rapid infusion of intravenous fluids and blood products;
- frequent blood sampling/blood transfusions;
- administration of substances that are likely to damage peripheral veins, such as cytotoxics or hyperosmolar parenteral nutrition (PN);
- long-term administration of drugs (antibiotics) or blood products, obviating the need for repeated venepunctures in children;
- central venous pressure and haemodynamic monitoring of acutely ill patients; and
- haemodialysis.

#### Clinical Considerations

##### Need for emergency central venous access

In patients with life-threatening conditions, the need for CVA is obvious at presentation. Although large-bore peripheral cannulas may be used for initial access in the emergency room, CVA will be required as soon as the patient is admitted to the intensive care unit (ICU). Four routes are available for transcutaneous insertion of a central venous catheter:

1. cephalic or basilic veins in the arm;
2. internal jugular vein;
3. subclavia vein; or
4. femoral vein.

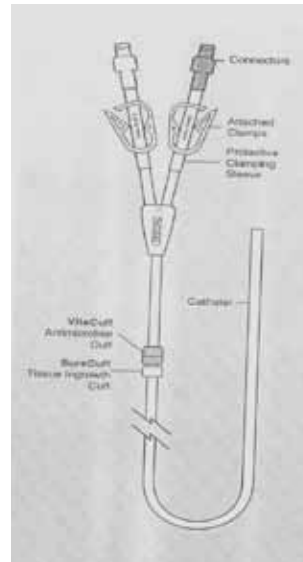
The advantages and disadvantages of these routes are summarised in Table 9.2.

##### Long-term Use of Central Venous Access

Long-term CVA is mainly required for administration of cytotoxics and/or parenteral nutrition. The techniques of insertion and the devices are different from those used in emergency CVA.

Table 9.2: Advantages and disadvantages of different routes for central venous access.

Access	Advantages	Disadvantages
Arm veins	Simple to access, veins visible, and palpable Not close to vital organs Comfortable for patient	Failure to achieve central position High incidence of thrombosis Low maximum infusion rates
Internal jugular	Simple to insert Direct route to central veins High flow-rate Low risk of thrombosis Low risk of pneumothorax	Uncomfortable for patient High rate of long-term complications Tunneling to chest wall more difficult
Subclavian/axillary	Less patient discomfort Lower risk of long-term complications	Curved incision route Difficult to access Higher rate of pneumo/haemothorax
Femoral	High flow rate Good for dialysis Easy insertion	Higher rate of infection/thrombosis More discomfort for patient Difficult in obese patients



Courtesy: Bard Access Systems.

Figure 9.4: A double-lumen Hickman catheter.

#### Types of Catheters

A typical catheter for long-term use (such as seen in Figure 9.4) has the following essential features:

- Is manufactured from soft silicon rubber or polyvinyl chloride (PVC).
- Is chemically inert, nonthrombogenic, flexible, and radio-opaque.
- May have single-, dual-, or triple-lumen, which allows simultaneous infusion or infusion of incompatible solutions.
- Has a Dacron cuff (e.g., SureCuff®), which has a matrix that expands after insertion and into which subcutaneous fibrous tissue grows for good anchorage.
- Is a VitaCuff®, which incorporates an antimicrobial collagen sponge designed to prevent infection.

- Has a plastic area where clamps can be applied.
- Has connectors.
- Costs about US\$135 (100 euros) each.

### **Broviac® catheters**

Long-term, tunneled catheters have been available since 1968. In 1973, Broviac<sup>14</sup> made the first important improvement to the design by producing a catheter with an internal diameter of 1.0 mm, which facilitates repeated blood sampling.

### **Hickman® catheters**

Robert Hickman,<sup>15</sup> a paediatric nephrologist at the Seattle Children's Hospital, modified the Broviac catheter with subcutaneous tunneling and a Dacron cuff that forms an infection barrier. Broviac and Hickman catheters are open-ended and can be cut to the desired length. The major difference between the Broviac and the Hickman is the internal diameter: the Broviac is 1.0 mm, and the Hickman is 1.6 mm.

### **Groshong® catheters**

The Groshong catheter has a design similar to the Hickman but has a formed blunt end with a slit-like orifice just proximal to the distal end. This acts like a valve, which stops back-bleeding, prevents air entry and embolism from negative intrathoracic pressure, and obviates the need for a heparin lock because saline can be used instead. An external clamp, which may damage the catheter, is therefore unnecessary. Groshong catheters cannot be used to monitor central venous pressure due to the valve function. The valves may, however, produce intermittent boluses of fluid or drugs, which may make these catheters unsuitable for inotropic or vasopressor infusion.

The advantages of Groshong catheters are that they are flexible and the insertion site is removed from the exit site. These assist in the prevention of systemic infection. Once the tissue adheres to the Dacron cuff, another barrier to infection is created. The secured cuff also prevents catheter dislodgment.

The main disadvantages of Groshong catheters are that, being outside the body, they provide vehicles for infection. They also require frequent flushes and dressing changes. There are also limitations for swimming and bathing. The catheters are not suitable for dialysis as they are not designed for high-flow blood withdrawals.

### **Port-a-Cath®**

Port-a-Cath<sup>16</sup> catheters are silicon catheters connected to self-sealing injection ports that are completely inserted under the skin. The intravascular segment is similar to the Hickman catheter. The port is a small metal, plastic, or titanium "drum" or reservoir that has a membrane through which the vein can be accessed by using a special Huber-type needle. Suture holes in the base of the port are anchored to fascia layers with nonabsorbable sutures.

The Port-a-Cath catheter has the following features:

- lightweight, durable titanium portal reservoir, which provides gouge resistance and long-term durability;
- contoured shape, designed for patient comfort and ease of portal palpation;
- needle-stop titanium reservoir floor, which creates positive tactile feedback when the accessing needle makes contact;
- distinct rounded septum ring, designed to assist in septum location;
- high compression SECUR SITE® septum captured in titanium, designed for needle retention and stability;
- bevelled suture holes, designed for ease of suturing;
- ULTRA-LOCK® catheter connector integrated with portal, for ease of system assembly; and
- magnetic resonance imaging (MRI)-compatible portal systems.

The two main advantages of Port-a-Cath catheters are that no part of the catheter is exposed, so the infection rate is low, and that catheter displacement and venous occlusion are uncommon. Other advantages are that the catheter requires flushing only every 5–6 weeks, regular dressing is not required after the incision has healed, and the patient can bathe or swim. The Port-a-Cath can be used for brief general anaesthesia (e.g., lumbar puncture).

The two main disadvantages of these catheters are that insertion is time-consuming and that general anaesthesia is necessary for insertion and removal. Another disadvantage is that the assessing needles have fine bores, so blood transfusion is slow. These catheters are very costly, at about US\$675–1350 (500–1000 euros) each.

## **Peripherally Inserted Central Catheters**

Peripherally inserted central catheters (PICC) are fine-bore soft catheters that are passed from cubital veins up the axillary vein into a central vein. They are used as alternatives to Hickman catheters. They generally have higher rates of phlebitis, occlusion, and thrombosis than tunneled catheters.

## **Surgical Techniques**

### **Insertion of central venous catheter in emergency situations**

To be considered a central line, the tip of the catheter must be located in the vena cava, subclavian, brachiocephalic, innominate, or iliac veins.

The safest technique for insertion of a CVC via the transcutaneous route into the internal jugular vein, subclavian, or femoral vein is by the Seldinger<sup>10</sup> method. Complete catheter sets, including aspiration needle, guidewire, dilatator, peel-away sheath, and polyurethane catheter, are available as packs from several companies. In young children, the procedure is best performed under general anaesthesia, but in older or very sick patients, the site can be infiltrated with local anaesthetics. The veins are easier to cannulate by using ultrasound guidance.

Important steps in inserting a central venous line are listed below. These are essentially the steps in the Seldinger technique:

1. Explain the procedure (including possible complications) to the patient.
2. Have the patient or parent sign a consent form.
3. Get all necessary equipment—port, catheter, saline, syringes, heparin solutions, etc.
4. Scrub and don surgical gown and gloves (an assistant may be necessary).
5. Open the port and catheter and flush with heparinised saline. Make sure all connections are working properly.
6. Prep the patient with povidone iodine and drape the required field.
7. Identify the landmarks and infiltrate the required area with local anaesthetic.
8. Place the patient in the Trendelenburg position.
9. Insert an 18-gauge (20G for infants) needle into the chosen vein until blood is freely aspirated (ultrasonic guidance may be helpful).
10. Remove the syringe while retaining the needle.
11. Insert the J-shaped end of the guide wire into the needle (check the position with fluoroscopy, if available).
12. Remove the needle.
13. Advance the dilatator over the guide wire and remove the dilatator.
14. Insert the catheter over the guide wire.
15. Suture the catheter in place.
16. If a port is needed, dissect the subcutaneous tissue with mosquito artery forceps and bluntly with finger to accommodate the port.
17. Flush all ports with heparinised saline.
18. Give the patient intravenous antibiotics.
19. Take a chest x-ray to confirm the final position and rule-out pneumothorax.

### Percutaneous insertion into internal jugular vein

The internal jugular vein (IJV) is the most frequently chosen site for insertion of central venous catheters.<sup>17</sup> The right IJV is commonly used because most practitioners are right handed, and the right vein is wider than the left<sup>18</sup> and has a more direct route to the superior vena cava and the right atrium. The right lung is also lower than the left so that injury to the lung is less, and the thoracic duct is on the left side. The risk of pneumothorax is less with IJV cannulation. If there is carotid artery injury, manual compression can easily control the haemorrhage.

For the cannulation, a sandbag is placed behind the patient's shoulders, and the head is turned to the contralateral side. The patient is placed in the Trendelenburg position, and the field cleaned with antiseptic solution. The carotid artery is palpated and gently pushed away at the level of insertion. The vein is approached at 30° to the sagittal plane at the medial border of the sternomastoid midway between the thyroid cartilage and the hyoid bone in the direction of the ipsilateral nipple. If the syringe is aspirated during insertion, the vein should be entered within 2–4-cm depth. The Seldinger technique is then followed. Easier cannulation is now advisable with ultrasonic guidance by using a handheld Doppler probe.<sup>19–21</sup> This not only reduces the number of needle passes to locate the vein, but also decreases the risk of injury to the carotid artery.<sup>21,22</sup>

### Percutaneous insertion into subclavian vein

The subclavian vein (SCV) may be preferred for central venous access if, for example, the patient has a cervical spine injury, or if the line is for long-term use (e.g., dialysis, feeding) and this site may be more comfortable for the patient.<sup>17</sup> The risk of long-term complications is lowest with SCV cannulations.

The SCV is the continuation of the axillary vein and originates at the lateral border of the first rib. The SCV passes over the first rib anterior to the subclavian artery, to join with the internal jugular vein at the medial end of the clavicle. The external jugular vein joins the SCV at the midpoint of the clavicle.

The patient is placed supine in the Trendelenburg position. The head is turned to the contralateral side (if C-spine injury has been excluded). The Seldinger technique is adopted.

The needle is introduced 1 cm below the junction of the middle and medial thirds of the clavicle. The needle is directed medially, slightly cephalad, and posteriorly behind the clavicle towards the suprasternal notch. The needle is slowly advanced while gently withdrawing the plunger. When a free flow of blood appears, the Seldinger approach is followed, as detailed previously. The catheter tip should lie in the superior vena cava above the pericardial reflection. A chest x-ray is done to confirm position and exclude pneumothorax. A major disadvantage of this route is that if there is injury to the subclavian artery, direct pressure cannot be easily applied to control bleeding.

### Percutaneous insertion into femoral vein

The femoral route is useful in emergency situations or the patient is coagulopathic,<sup>17</sup> but incidences of infection and thrombosis are the highest in this technique.

The long saphenous vein joins the popliteal vein to form the femoral vein, which accompanies the femoral artery in the femoral triangle. To access the vein, the artery is first felt by palpation. Then, keeping a finger on the artery, a needle attached to a 10-ml syringe is introduced at 45 degrees, 1.5 cm medial to the femoral artery pulsation, 2 cm below the inguinal ligament, until blood is aspirated. The Seldinger technique is then continued as described above.

### Insertion of catheter for long-term use

The main difference between long-term and short-term catheters is the application of tunnelled catheters in the former situation, which allows long-term (months or even years) use. The central venous access can either be an external silastic catheter (Broviac or Hickman) or an internal device, where the catheter is connected to a subcutaneous reservoir or port (Port-a-Cath).<sup>23</sup>

For long-term central venous access, either the transcutaneous (Seldinger) route described above or the open approach can be used. The open approach allows the use of smaller veins that can be sacrificed, such as the external jugular vein in the neck, the cephalic vein in the deltopectoral fossa, the great saphenous vein, or the epigastric vein in the groin. The open approach requires an “entrance” site where the catheter is inserted into the vein, and an “exit” site where the catheter exits the chest wall, with a tunnel between the two. If the open approach is used for large veins (internal jugular or femoral), a purse-string suture should be put in the anterior wall of the vein and the catheter inserted in the centre.

### Complications of Central Venous Access

Catheter clotting and other complications cost the health care system in the United States about one billion dollars annually.<sup>2</sup> Prevention of complications such as those described in the following subsections is the best way to “manage” CVCs.

#### Haemorrhage/haematoma

Brisk bleeding may occur with CVA, especially if the adjacent artery is injured. Pressure for a few minutes should control the bleeding. Pressure may be difficult to apply if the subclavian artery is injured.

#### Catheter-related sepsis

In general, CVA has great advantages but requires special facilities, carries significant risks of complications, and is associated with considerable financial costs. The insertion of a foreign body with direct access to the circulation can be considered a cordial invitation to microorganisms to invade the patient. Oncologic patients receiving cytotoxics that depress the bone marrow are particularly at risk of sepsis. Line infection is therefore the most frequent complication leading to early removal of the system. Infection may occur either at the time of insertion or later during changes of connections. Catheter-related infection rates vary from 3% to 60%.<sup>24,25</sup> The infection can be at the exit site, in the tunnel, or catheter-related. Exit-site infections are usually due to *Staphylococcus epidermidis*, and can usually be managed by local wound care. Tunnel or pocket infection relates to suppuration in the subcutaneous tunnel relating to the foreign body. The port will need to be removed with antibiotic treatment. Catheter-related sepsis (especially in patients receiving parenteral nutrition) is the most serious of the catheter-related sepsis.

Depending on the clinical condition of the patient, a trial treatment with broad spectrum antibiotics (e.g., amoxicillin, metronidazole, and gentamicin) should be started in all children with fever and a CVC in situ. Fifty percent or more of the CVC can be salvaged with this policy. If the clinical condition does not improve after 24 hours, removal of the CVC should be considered. A layer of glycoprotein (the glycocalix) forms on the silastic wall of the catheter, which harbours bacteria that are protected from antibiotics. The use of ethanol both as prophylactic and therapeutic modalities in patients with repeated CVC infections has been proposed.

If the catheter is removed due to sepsis, either the tip of the catheter can be rolled on to a plate for culture<sup>26,27</sup> or the lumen of the catheter can be flushed with a nutrient broth (the Cleri technique),<sup>28</sup> which is then cultured. The blood through the catheter can also be sampled and cultured before removal.<sup>29</sup> Kite<sup>30</sup> and others have proposed using a small brush to sample endoluminal organisms without removal of the catheter. Due to the risk of bacterial embolisation, this method has not gained routine use, especially in the intensive-care setting.<sup>31</sup> The risk of infection can be reduced by strict adherence to a protocol and reduction of the number of caretakers that manipulate the line.

#### Thrombosis

The second commonest complication is thrombosis with or without obstruction of the catheter. It is thought that thrombosis starts at the site of the venepuncture and then migrates along the catheter to eventually

occlude the tip. Ultrasound examination of CVCs shows that more than 50% have thrombus at the tip of the line.<sup>31</sup> However, clinically manifest thrombosis is rare and occurs mainly in newborns and infants. So far, no studies support the use of prophylactic anticoagulants. If thrombosis is diagnosed, intravenous heparin should be started and anticoagulant treatment with warfarin continued for 3 months. Increasingly more data have now become available on the long-term sequelae of CVC, particularly in oncologic patients. Significant postthrombotic signs and symptoms occur in less than 10%.

### Malposition

Malposition is any tip position other than in the superior or inferior vena cava. Placement or migration of the catheter tip into the right atrium may cause cardiac arrhythmias or myocardial erosion. Damage to the wall of the superior vena cava and leakage of fluid into the pericardial space resulting in tamponade have been reported. Also, catheters in the right atrium may be associated with thrombus formation and valvular damage. If the tip is not in a large vessel (and blood cannot be aspirated freely), there is a substantial risk of thrombosis and perforation with extravasation into the pericardial or pleural space.

### Obstruction of catheter

Obstruction of the central venous cannula can be caused by administration of incompatible mixtures that form debris. Also, the CVC should be rinsed after withdrawal of blood, and care should be taken to keep the CVC open by continuous flow of infusion. If the CVC is not in use, it should be filled with a heparin solution. If the CVC is blocked, it can sometimes be unblocked by pushing normal saline with a small (2-ml) syringe. Although this manoeuvre can be successful, it may result in rupture of the CVC.

### Pinch-off

The term “pinch-off” refers to entrapment of subclavian catheters between the clavicle and the first rib. Over time, repeated compression causes catheter fracture, resulting in extravasation of fluids, or catheter breakage and embolisation.

### Ethical Issues

The cost-benefit aspect of central venous access in the African setting is addressed in this final paragraph. The use of central venous catheters in the long term is in itself not lifesaving and is potentially dangerous. The advantages are that the caretakers always have CVA, even when the child is asleep. This obviates the need for multiple attempts to set up intravenous lines, allowing normal day-to-day activities and admin-

istration of drugs as prescribed on time. It reduces patient (and parent) anxiety, resulting in a better atmosphere. The price of all these benefits is—apart from the financial burden [Broviac, US\$200 (150 euros); Port-a-Cath, US\$675 (500 euros); use of operating theatre, US\$1350 (1000 euros); plus cost of treatment of complications]—also the risk of potentially life-threatening complications. The balance will have to be found for each individual centre and patient.

## Evidence-Based Research

Table 9.3 presents a prospective Brazilian study of complications of CVC placement in children.

Table 9.3: Evidence-based research.

<b>Title</b>	Central venous catheter placement in children: a prospective study of complications in a Brazilian public hospital
<b>Authors</b>	Cruzeiro PCF, Carmagos PAM, Miranda ME
<b>Institution</b>	Pediatric Surgical Services, Clinics Hospital, Federal University of Minas Gerais, Belo Horizonte, Minas Gerais, Brazil
<b>Reference</b>	Pediatric Surg Intl 2006; 22:536–540
<b>Problem</b>	This study evaluates the complications of percutaneously placed central catheters in a public hospital.
<b>Study design</b>	Prospective study.
<b>Length of study</b>	Eight months.
<b>Results</b>	155 catheters (130 in neck, 25 in groin) were placed in 127 patients. The cannulation success rate was 81.9% at the first attempt and 100% at the second attempt.
<b>Complications</b>	Perioperative complications: haematomas, 6 (3.9%); arterial puncture, 3 (1.9%). Complications with catheter in situ: mechanical, 51(32.9%); infections, 33 (21.3%).
<b>Outcome/ effect</b>	Age, sex, type of catheter, and primary diagnosis were not associated with complications. There was no pneumothorax, hemothorax, or hydrothorax, and no mortality.
<b>Conclusions</b>	Knowledge of anatomy and familiarity with the Seldinger technique improve the success rate. Percutaneously placed central venous catheters produce satisfactory results in paediatric patients.

## Key Summary Points

1. Virtually every child will need vascular access.
2. Maximum flow is achieved with catheters that are wide and short.
3. The umbilical vein can be used for up to 2 weeks in neonates for administration of colloids or crystalloids, and for exchange blood transfusion.
4. The back of the hand is the most commonly used site for venous access in infants.
5. The antecubital fossa, dorsum of the foot, and snuffbox can be accessed in older children.
6. The long saphenous vein at the ankle or at the groin, the femoral vein, antecubital veins, and the cephalic vein are suitable for venous cutdowns.
7. The intraosseous space is a rich, noncollapsible venous network.
8. The upper surface of the tibia, iliac crest, lateral malleolus, and upper femur can be used for bone punctures.
9. The internal jugular vein, subclavian vein, and femoral vein are suitable for central venous access.
10. The Seldinger technique is used for inserting central cannulas.
11. Common complications of vascular access include haemorrhage, line infection, and thrombosis.

## References

1. Mbamalu D, Banerjee A. Methods of obtaining peripheral venous access in difficult situations. *Postgrad Med J* 1999; 75:459–462.
2. Laguna Medical Systems: The Coding Edge Archives. Available at: <http://www.lagunamedsys.com/edgearchive/TOC>.
3. Jona JZ. Vascular access in the newborn. In: Prem Puri, ed., *Newborn Surgery*. Arnold, 2003, Pp 120–129.
4. Adeniran JO, Odebode TO. Congenital malformations in paediatric and neurosurgical practices: problems and pattern (a preliminary report). *Sahel Med J* 2005; 8:4–8.
5. Adeniran JO, Taiwo JO. Typhoid intestinal perforation in children in Ilorin: salmonella versus the surgeon: who is winning the race? *Trop J H Sci* 2007; 15:61–65.
6. Poiseuille. Available at: <http://galileo.phys.virginia.edu/classes/311/notes/>.
7. Hansen AR, Greene A, Puder M. Vascular access. In: Hansen AR and Puder M, eds., *Manual of Neonatal Surgical Intensive Care*. BC Decker Inc, 2003, Pp 117–129.
8. Michael A, Andrew M. The application of emla and glycerine trinitrate ointment prior to venepuncture. *Anaesth Intens Care* 1996; 24:360–364.
9. Whiteley MS, Chang BP, Marsh HP, Williams AR, Marton HC, Horrocks M. Use of hand-held Doppler to identify “difficult” forearm veins for cannulation. *Ann R Coll Surg Engl* 1995; 77:224–226.
10. Seldinger SI. Catheter replacement of the needle in percutaneous arteriography. *Acta Radiol* 1953; 39:368.
11. Intraosseous route. Available at: [http://en.wikipedia.org/wiki/main\\_Page](http://en.wikipedia.org/wiki/main_Page).
12. Barnett AM, Squire R. Vascular access. In: Stringer MD, Oldham KT, Mouriquand PDE, eds. *Pediatric Surgery and Urology. Long-term Outcomes*. Cambridge University Press, 2006, Pp 947–957.
13. Sol J, van Woensel J, van Ommen C, Bos A. Long-term complications of central venous catheters in children. *Paediatrics and Child Health* 2007; 3:89–93.
14. Broviac J, Cole J, Scribner B. A silicon rubber right atrial catheter for prolonged parenteral alimentation. *Surg Gynecol Obstet* 1973; 136:602–606.
15. Hickman R, Buckner C, Clift R, Sanders J, Stewart P, Thomas E. A modified right atrial catheter for access to the venous system in marrow transplant recipients. *Surg Gynecol Obstet* 1979; 148:871–875.
16. Bard Access Systems. Available at: [http://www.bardaccess.com/picc\\_hick\\_buv\\_leon.php](http://www.bardaccess.com/picc_hick_buv_leon.php).
17. Duffy M, Sair M. Cannulation of central veins. *Anaesth Intensive Care Med* 2007; 8:17–20.
18. Lobato EB, Sulec CA, Moody RL. Cross sectional area of the right and left internal jugular veins. *J Cardiothorac Vasc Anesth* 1999; 13:136–138.
19. Denys BG, Uretsky BF, Reddy PS. Ultrasound-assisted cannulation of the internal jugular vein. A prospective comparison to the external landmark-guided technique. *Circulation* 1993; 87:1557–1562.
20. Caridi JG, Hawkins IF Jr, Wiechmann BN. Sonographic guidance when using the right internal jugular vein for central vein access. *Am J Roentgenol* 1998; 171:1259–1263.
21. Keenan SP. Use of ultrasound to place central lines. *J Crit Care* 2002; 17:126–137.
22. Gilbert TB, Seneff MG, Becker RB. Facilitation of internal jugular venous cannulation using an audio-guided Doppler ultrasound vascular access device: results from a prospective, dual-center, randomized, cross-over clinical study. *Crit Care Med* 1995; 23:60–65.
23. Bernacle A, Arthurs AJ, Rowbuck D, Hiofns MP. Malfunctioning central venous catheters in children: a diagnostic approach. *Pediatric Radiology* 2008; 38:363–378.
24. Anderson A, Krasnow S, Boyer M. Thrombosis: the major Hickman catheter complication in patients with solid tumour. *Chest* 1989; 95:71–75.
25. Green F, Moore W, Strickland G, McFarland J. Comparison of a totally implantable access device for chemotherapy (Port-A-Cath) and long-term percutaneous catheterization (Broviac). *South Med J* 1988; 81:580–603.
26. Hartman G, Shochat S. Management of septic complications associated with silastic catheters in childhood malignancy. *Pediatr Infect Dis J* 1987; 6:1042–1047.
27. Maki D, Weise C, Sarafin H. A semiquantitative culture method for identifying intravenous catheter related infection. *N Engl J Med* 1977; 296:1305–1309.
28. Cleri D, Corrado M, Seligman S. Quantitative culture of intravenous catheters and other intravascular inserts. *J Infect Dis* 1980; 141:781–786.
29. Blot F, Nitenberg G, Chachaty E. Diagnosis of catheter-related bacteraemia: a prospective comparison of the time to positivity of hub-blood versus peripheral-blood cultures. *Lancet* 1999; 354:1071–1077.
30. Kite P, Dobbins B, Wilcox M. Evaluation of a novel endoluminal brush method for in-situ diagnosis of catheter-related sepsis. *J Clin Pathol* 1997; 50:278–282.
31. McLure H, Juste R, Thomas M, Soni N, Roberts A, Azadian B. Endoluminal brushing for detection of central venous catheter colonization—a comparison of daily vs single brushing on removal. *J Hosp Infect* 1997; 36:313–316.