

# CHAPTER 114

## HYDROMETROCOLPOS

Bankole S. Rouma  
Jennifer H. Aldrink  
Julia B. Finkelstein  
Howard B. Ginsburg

### Introduction

Hydrocolpos is an uncommon congenital disorder consisting of cystic dilatation of the vagina caused by obstruction of the distal genital tract, resulting in retained fluid. If there is also associated uterine enlargement, the term hydrometrocolpos is applied. Vaginal obstruction may result from a high vaginal septum, varying degrees of vaginal atresia, cloacal malformations, or an imperforate hymen. Hydrocolpos may manifest at birth as a palpable mass or it may present at puberty as progressive accumulation of menstrual blood, causing haematometrocolpos. Hydrocolpos and hydrometrocolpos are the third most common causes of all abdominal masses in the newborn, accounting for 15% of all abdominal masses in female newborns, with an estimated occurrence rate of 1 in 16,000 female deliveries.

The clinical features of hydrometrocolpos in the newborn are dominated by the abdominal mass with regional compression (Figure 114.1). An overly distended vagina can compress the adjacent organs and cause abdominal pain, intestinal obstruction, ureteral obstruction, hydronephrosis, bladder perforation, respiratory distress, and lower extremity venous stasis. Accordingly, presentation of hydrometrocolpos depends on the degree of compression of the surrounding structures by the uterovaginal swelling. Although the rarity and variable presentation of hydrometrocolpos can lead to delayed diagnosis and erroneous management, it should be considered in the differential diagnosis if a female neonate is found to have a large abdominal mass.

Early diagnosis and treatment of hydrocolpos or hydrometrocolpos is important to minimise various complications of mechanical pressure exerted on surrounding structures. The most important step is a comprehensive perineal examination. Cross-sectional imaging and dye studies help in early diagnosis and demarcating the exact anatomy as well as revealing associated renal anomalies.<sup>1</sup> Comprehensive management is necessary, usually involving surgical treatment, to provide normal phenotypic appearance and to preserve reproductive potential.

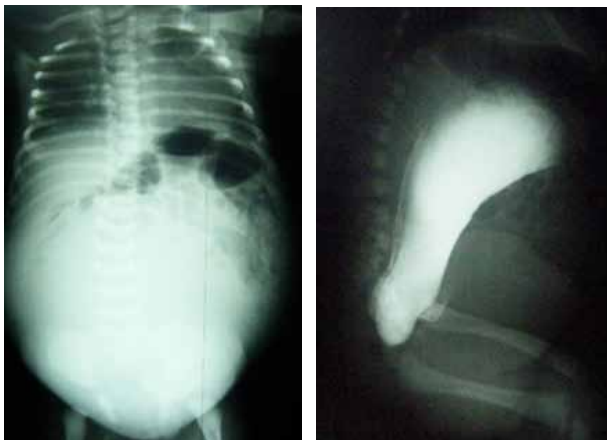

Figure 114.1: Abdominal radiograph showing a mass density in a 3-day-old infant (left); abdominal radiograph on lateral view showing a hydrometrocolpos in a 3-day-old infant (right).

### Demographics

Prevalence data for Africa were not available. In general, the prevalence of hydrocolpos is estimated to be approximately 1 in 16,000 births.<sup>2</sup> Imperforate hymen is the most frequent congenital malformation of the female genital tract.<sup>3</sup> The incidence is estimated to be 0.1%.<sup>4</sup> However, manifestations of imperforate hymen presenting as an abdominal mass in the perinatal or neonatal age are extremely rare, with an estimated incidence of 0.006%.<sup>4</sup> Vaginal atresia is estimated to occur in 1 in 5,000 to 1 in 10,000 live female births; approximately 1 in 70,000 to 1 in 80,000 females are born with a transverse vaginal septum, with septa more frequently occurring in the middle and upper third of the vagina.<sup>5</sup> Persistent cloaca has an incidence of 1 in 250,000 live born infants. Twenty-five percent of patients with persistent cloaca present with associated hydrocolpos.<sup>6</sup>

### Embryology

Both the urinary system and the genital system develop from a common mesodermal ridge along the posterior wall of the abdominal cavity. The excretory ducts of both systems initially enter a common cavity, the cloaca. The cloaca divides into the urogenital sinus anteriorly and the anal canal posteriorly during the 4th to 7th weeks of gestational development. By the 7th week, there is a layer of mesoderm—the urorectal septum—between the primitive anal canal and the urogenital sinus. Three portions of the urogenital sinus can be distinguished:

1. The superior and largest vesicle part becomes the urinary bladder. As the bladder grows, it absorbs the proximal segment of the mesonephric ducts into its posterior wall, forming the trigone of the bladder. Absorption of the mesonephric ducts continues until the ureters open directly into the bladder.
2. The middle segment of the urogenital sinus is a narrow canal, the pelvic portion of the urogenital sinus.
3. The remaining part is the phallic area of the urogenital sinus, which is flattened from side to side.<sup>7</sup>

During the 2nd month of prenatal development, paramesonephric ducts arise as longitudinal invaginations of epithelium on the anterolateral surface of the urogenital ridge, and as tubular invaginations of the coelomic mesothelium parallel to the mesonephric ducts. In the absence of male gene products, the mesonephric ducts disappear. Meanwhile, under the influence of oestrogens, the paramesonephric ducts remain. At first, three different parts can be distinguished in each paramesonephric duct. The first two parts develop into the uterine tube with the descent of the ovary. The caudal part of each contralateral paramesonephric duct is initially separated by a septum, but they later fuse to form the uterine canal. The caudal tip of the combined ducts projects into the posterior wall of the urogenital sinus, where it causes a small swelling, the paramesonephric tubercle. The paramesonephric ducts then fuse in the midline to form a tube with a single lumen, which will form the uterus, cervix, and superior end of the vagina.

Shortly after the tip of the paramesonephric ducts reaches the urogenital sinus, two solid evaginations—the sinovaginal bulbs—grow

out from the pelvic part of the sinus. These evaginations proliferate and form a solid vaginal plate. Proliferation continues at the cranial end of the vaginal plate, increasing the distance between the uterus and the urogenital sinus. The vaginal plate canalises to form the lower two-thirds of the vagina. This is completed by the 20th gestational week. Accordingly, the vagina has a dual origin, from the paramesonephric ducts (mesoderm) and from the urogenital sinus (endoderm). The hymen, a thin tissue plate, separates the lumen of the vagina from the urogenital sinus. The hymen consists of an epithelial lining of the urogenital sinus and a thin layer of vaginal cells. At 5 gestational months, it usually begins to degenerate to establish a connection between the vaginal lumen and perineum. A remnant usually persists postnatally. The tissue superior to the vagina begins to enlarge and extend inferiorly to separate the bladder from the vagina, forming the urovaginal septum.<sup>7,8</sup>

## Pathology

Vaginal outflow obstruction and subsequent hydrocolpos may be secondary to a transverse vaginal septum, atresia of the vagina, imperforate hymen, or a persistent urogenital sinus. Associated anomalies are relatively rare with an imperforate hymen but are common with vaginal atresia, urogenital sinus, or cloacal malformations.

### Vaginal Atresia

If the sinovaginal bulbs fail to develop, vaginal atresia results. Females with vaginal atresia lack the lower portion of the vagina but otherwise have normal external genitalia. Fibrous tissue develops in place of the vagina. In some females, nearly the entire length, beginning at the perineum and extending to the cervix, may be fibrotic. However, as the primary defect is in the sinus contribution to the vagina, the contiguous superior structures, especially the uterus, are well differentiated.<sup>8</sup> Accordingly, a small vaginal pouch originating from the paramesonephric ducts usually surrounds the opening of the cervix. Before hydrocolpos will develop, there must be sufficient oestrogenic stimulation to provoke secretion from the glands in the reproductive tract. For this reason, both oestrogenic stimulation and vaginal obstruction must coexist.

### Transverse Vaginal Septum

A transverse vaginal septum results when there is failure of either fusion of the urogenital sinus and paramesonephric ducts or canalisation of the vaginal plate. There is a well-developed vagina in which a thick intervening septum separates the lower from the upper vagina. The septum may be obstructive, with accumulation of mucus or menstrual blood.<sup>9</sup> In neonates and infants, an obstructive transverse vaginal septum has been associated with fluid and mucus collection in the upper vagina, resulting in a mass that may be large enough to compress abdominal or pelvic organs. The external genitalia appear normal, but internally the vagina is a shortened, blind pouch. A transverse vaginal septum can develop at any level within the vagina but is more common in the upper portion, at the junction between the sinovaginal plate and the caudal end of the fused paramesonephric ducts.<sup>9</sup> The thickness of the septum may be variable. However, thicker septa tend to be located nearer the cervix.

### Imperforate Hymen

Hymenal anomalies are derived from incomplete degeneration of the central portion of the hymen. Imperforate hymen is one of the most common obstructive lesions of the female genital tract. It is almost always an isolated finding. In the presence of vaginal outflow obstruction, there is potential for significant accumulation of cervico-vaginal secretion during foetal life, occurring secondary to circulating maternal oestrogens. In infants, the obstructed vagina may distend from mucus accumulation, with the mucocolpos causing a bulging hydrocele membrane. More commonly, symptoms of cyclic pelvic pain present during adolescence after menarche. Trapped menstrual blood behind the imperforate hymen may create a bluish bulge at the introitus.<sup>9</sup>

### Persistent Urogenital Sinus

Persistent urogenital sinus is an important, but often missed, cause of hydrocolpos. A persistent urogenital sinus represents failure of urethro-vaginal septation at 6 weeks of gestation. This developmental arrest leads to a common channel for the urinary and genital tracts, with drainage of the bladder and the vagina through one orifice. Therefore, there is distal vaginal atresia and a proximal urethrovaginal fistula. The urethrovaginal communication allows urine to empty into the vagina, which subsequently dilates. When the defect occurs at an early stage, the result is a long urogenital sinus with a short vagina and a high urethral opening. A short urogenital sinus with almost normal length of vaginal vestibule and low urethral opening results when the defect occurs later in development. The perineum exhibits two distinctive orifices, a ventral urogenital sinus and a dorsal anus.

### Persistent Cloaca

Persistent cloaca results from partial or total failure of the urorectal septum to descend and divide the cloaca during month 2 of gestation. The anatomic findings in each case may be related to septal differentiation. In the patient for whom the fold develops but fails to make contact with the cloacal membrane, the cloaca will be small and the urinary, genital, and alimentary tracts, which are well separated, will open into the cloaca adjacent to the external orifice. In the case where septal development was incomplete, the cloaca will be larger; separation of urinary, genital, and alimentary tracts will be variable and may be incomplete; and the fistulous communications tend to be remote from the external orifice. Either way, there is junction of the urinary tract, genitalia, and rectum into a single channel, opening onto the perineum in a single orifice.<sup>6</sup>

## Clinical Presentation

### Associated Malformations

The McKusick-Kaufman syndrome is a rare autosomal recessive disorder mapped to 20p12 characterised by hydrometrocolpos, polydactyly, and congenital heart defects.<sup>10,11</sup> The Bardet-Biedl syndrome is a genetic name for a heterogeneous group of autosomal recessive disorders with at least four loci in 16q13q22, 11q13, 3p11-p13, and 15q22.<sup>10</sup> It is characterised by retinal dystrophy or retinitis pigmentosa, postaxial polydactyly, obesity, nephropathy, and mental disturbances or mental retardation. It is also associated with hydrometrocolpos, usually as a consequence of vaginal atresia or transverse vaginal septum. Its diagnosis is typically delayed to the teenage years. Rarely, hydrometrocolpos can be associated with Pallister-Hall syndrome, an autosomal dominant trait with variable expressivity, characterised by postaxial polydactyly, hypothalamic hamartoma, imperforate anus, intrauterine growth retardation, and several visceral anomalies.<sup>12</sup>

Persistent cloaca is the most severe malformation of anorectal anomalies in girls and is associated with complex pelvic malformation and frequent hydrocolpos.<sup>13,14</sup> Hydrometrocolpos due to a urogenital sinus malformation may be associated with ureteral duplication, ectopic ureter, urethral membrane, imperforate anus, hypoplastic or multicystic dysplastic kidney, and bifid clitoris.

### Symptoms

Hydrocolpos or hydrometrocolpos can be asymptomatic if only a small amount of fluid is accumulated, which is the case with most obstructions. Asymptomatic imperforate hymen that does not show a cystic mass can easily be overlooked and undiagnosed until adolescence, when menarche does not appear and the young girl complains of lower abdominal pain.<sup>9</sup>

The condition will be symptomatic if a large cyst is formed, causing urine retention, hydronephrosis and renal impairment, constipation, abdominal mass, ascites, oedema, and even cyanosis of low extremities. The upward pull of the enlarging vagina elongates and makes the urethra angulated, producing dysuria and acute urinary retention. This

may result in infection of the urinary tract or of the fluid retained in the vagina. Moreover, hydronephrosis and hydroureter may result from pressure of the vagina on the ureters crossing the pelvic brim.<sup>15</sup> Foetal urine may drain through the uterine tubes into the peritoneal cavity, giving rise to ascites. In addition, the patient may experience vomiting as a result of intestinal obstruction.

### History

Maternal hormones profoundly affect the reproductive tract of the female infant both in utero and during the early neonatal period. In response to maternal oestrogens, vaginal and cervical epithelium secretes mucus, which pools in the obstructed vagina. Thus, hydrocolpos is usually detected in infancy when there is a high level of maternal hormones. However, uncomplicated hydrocolpos may be initially asymptomatic. The early symptoms associated with hydrocolpos are nonspecific indications of discomfort followed by urinary, venous, or intestinal obstruction, respiratory distress, or superimposed infection of the urinary tract or of the fluid retained in the vagina.<sup>16</sup> Conversely, if there is a low level of maternal hormones, hydrocolpos may not be detected until early puberty, when the female begins to produce oestrogenic hormones. In many of these cases, hydrocolpos is not symptomatic until haematocolpos is superimposed at the time of menarche. Specifically, in the case of vaginal atresia, adolescents often present with primary amenorrhea accompanied by cyclic pelvic pain.<sup>15</sup>

### Physical

Close inspection of the perineum is required in all cases of suspected hydrocolpos or hydrometrocolpos. This may require a general anaesthetic to obtain a thorough evaluation in infants and children. In vaginal atresia, the vaginal orifice may be retraced upward into the pelvis. Hydrocolpos associated with an imperforate hymen presents with a thin translucent membrane bulging between the labia. It may have a bluish color when seen in adolescent females, associated with haematometrocolpos (Figure 114.2). A transverse septum higher in the vagina may protrude through a normally perforated hymen. With this situation, the external genitalia appear normal, but internally the vagina is shortened as a blind pouch.<sup>15</sup> A vaginal dimple may be noted on external examination of a patient with vaginal atresia.

A single perineal orifice may be noted on external examination of a patient with a persistent urogenital sinus or cloaca. In the case of a persistent cloaca, the single perineal orifice will usually be located at the site of the normal urethra and there will also be an imperforate anus as well as partially fused labia.<sup>6</sup> A urine sample will be green and contain meconium due to the admixture of urinary and alimentary products in the cloaca.

Regardless of the pathology, the upper vagina becomes distended in hydrocolpos and, as a result, a tense, round abdominal mass arising from the pelvis may be palpated on abdominal examination.

### Investigations

Current management emphasizes prenatal diagnosis with ultrasonography (US) or magnetic resonance imaging (MRI). US remains the most widely used diagnostic imaging technique for routine evaluation of the foetus.<sup>17</sup> As US becomes increasingly reliable, prenatal diagnosis of hydrocolpos is possible as early as the second trimester.

The most common sonographic finding is a median intraabdominal or pelvic cystic structure. US may demonstrate significant echogenic fluid accumulation in the vagina (Figure 114.3). In addition, targeted foetal US may show the site of obstruction and continuation of the pelvic mass with both the cervical canal and uterine cavity, confirming hydrocolpos.

Diagnosis of transverse vaginal septum is confirmed by either US or MRI. Both investigations help to define the location and thickness of a transverse vaginal septum. However, MRI is most helpful prior to surgery to determine the thickness and depth of the transverse septum. Both US and MRI also facilitate the differentiation between a high septum and

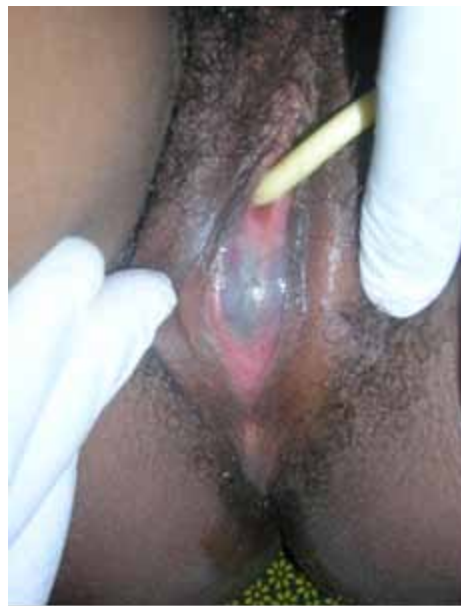

Figure 114.2: Imperforate hymen in a 15-year-old girl.

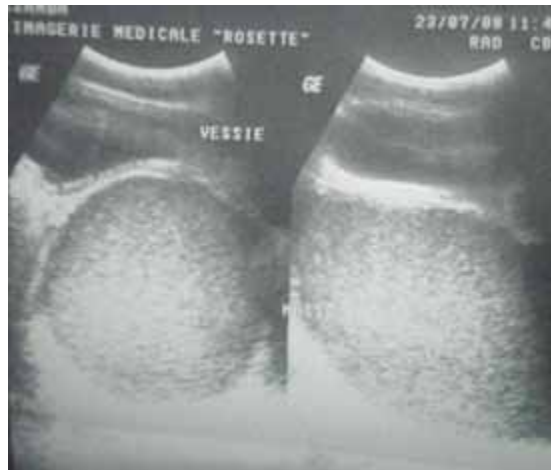


Figure 114.3: A sonographic view of the pelvis showing a hydrometrocolpos in a 15-day-old infant.

congenital absence of the cervix. In particular, for vaginal atresia, MRI is a more accurate diagnostic tool, as the length of the atresia, the amount of upper vaginal dilatation, and the presence or absence of a cervix can be identified. US cannot clearly differentiate between imperforate hymen and transverse vaginal septum. Consequently, foetal MRI is used to assist in the ultimate diagnosis of imperforate hymen. For these reasons, MRI has the capability to provide more accurate anatomical information in hydrocolpos than other diagnostic methods.<sup>17</sup>

A single orifice corresponding to a persistent urogenital sinus can be investigated by cystovaginoscopy. A voiding cystourethrogram (VCUG) is used by many as an initial tool in the evaluation of a single perineal orifice. This radiologic study can demonstrate the entrance of the vagina into the urogenital sinus. It can also evaluate the size and configuration of the vaginal remnant.

In the case of a persistent cloaca, a high-pressure distal colostogram should be performed. A Foley catheter is passed through the mucous fistula (distal stoma), the balloon is inflated with water, and hydrosoluble contrast material is injected under fluoroscopy while applying traction to the balloon to avoid leakage of the contrast material. By doing this, the anatomy of the malformation can be delineated.

## Management

### Temporising Measures

Percutaneous uterostomy or vaginostomy for temporary drainage may be an important temporising measure in neonates. Failure to drain a hydrocolpos exposes the patient to persistent hydronephrosis and/or infection of the hydrocolpos (pyocolpos). Antibiotic prophylaxis may be given to prevent urinary tract infections (UTIs). Pyocolpos and possible subsequent perforation of a hydrocolpos is a serious event that requires emergency laparotomy and may severely and permanently damage the vagina.<sup>6</sup> Percutaneous US-guided drainage of fluid from the hydrocolpos has also been suggested to decompress the distended organs. This may be performed prenatally if needed. Percutaneous nephrostomy may be necessary to salvage renal function. For persistent cloaca, a descending colostomy is indicated.

### Definitive Measures

1. Surgical intervention for isolated hydrocolpos with lower tract obstruction is associated with excellent results. Surgery for persistent urogenital sinus, however, is more complex and uncertain.<sup>18</sup> Commonly utilised treatment options include the following. The treatment goal for most females with vaginal atresia is the creation of a functional vagina. This may be accomplished conservatively or surgically. Each of the several conservative approaches attempts to progressively invaginate the vaginal dimple to create a canal of adequate size. The McIndoe vaginoplasty creates a canal within the connective tissue between the bladder and rectum. A split-thickness skin graft obtained from the patient's buttocks or thigh is then used to line the neovagina. This technique is believed to have a functional success rate >80%.<sup>5</sup> Alternatively, cutaneous or musculocutaneous flaps have been used to line the neovagina. The Williams vaginoplasty creates a vaginal pouch by using labial skin flaps. All surgical methods require a commitment to scheduled postoperative dilatation to avoid significant vaginal stricture.<sup>8</sup> In the case of a very short or small vagina located high in the pelvis, vaginal replacement is necessary. Most often, a length of diverted colon is used to replace the vagina. If the colon cannot be used, the small bowel or a portion of dilated rectum is used.<sup>6</sup>

2. Surgical repair of an imperforate hymen involves an elliptical or cruciate incision in the membrane close to the hymenal ring followed by evacuation of the obstructed material.<sup>9</sup> The vaginal mucosa is then sutured to the hymenal ring to prevent adhesion and recurrence of obstruction. Uncommonly, the hymeneal edges may re-epithelialise, and a repeat procedure may be required. Bleeding, scarring, and stenosis of the vaginal orifice are major complications of this procedure.

3. A thin transverse vaginal septum can be resected, followed by end-to-end anastomosis of the upper to lower vaginal mucosa. As an alternative to end-to-end anastomosis, a Z-plasty technique can be employed that may minimise scar formation. In contrast, a thick septum is more difficult to excise and repair. Preoperative use of vaginal dilators may thin the septum and thereby facilitate reanastomosis. With higher-level septums, diagnostic needle aspiration of the suspected haemato- or hydrocolpos can help to locate the upper vagina to determine the direction of dissection. Once this is complete, the vaginal vault is incised transversely to avoid laceration of the urethra, bladder, or rectum.<sup>9</sup> The septum is transected, and the cervix is then identified. The vaginal mucosa is undermined, and the cephalic mucosal edge is sutured to the opposite caudal edge. A circumferential ring of interrupted sutures is constructed by using absorbable suture. The septum is excised widely to its base to minimise postoperative stricture.

4. If the urogenital sinus is low, with a short common channel, a U-flap vaginoplasty is an effective surgical procedure. If the vagina enters the urogenital sinus higher up, a division of vaginal orifice from the urogenital sinus is required, together with pull-through

vaginoplasty. Some of these cases with a long common channel may require additional manoeuvres, such as creation of a neourethra from the anterior vaginal wall, to complete the reconstruction.

5. In correction of a persistent cloaca, the operation consists of separating the rectum from the genitourinary tract and bringing it down to be placed within the limits of the sphincter. This procedure is beyond the scope of this chapter.

### Postoperative Complications

Successful reconstruction of the vagina is a difficult task. The optimal surgical strategy provides the patient with an adequate vaginal introitus positioned correctly, a vestibule with appropriately innervated skin, and an acceptable external cosmetic appearance.<sup>19</sup> Complications include graft failure, wound infection, haematoma, and fistula formation. In the Williams vaginoplasty, the labia majora are created from hair-bearing skin, which will usually result in an undesirable cosmetic result. Excision of hymenal tissue may occur too close to the vaginal mucosa, causing stenosis of the introitus and dyspareunia. Nevertheless, according to Rock et al., no complaints of dyspareunia were elicited from sexually active women after surgery.<sup>20</sup> In cases of imperforate hymen where retrograde blood flow through the uterus and fallopian tubes occurs, pelvic endometriosis may develop with a subsequent negative impact on fertility.

With correction of a transverse vaginal septum, a common complication of resection of thick septa is scar contracture and vaginal stenosis.<sup>5</sup> Dyspareunia seems to be the most common complaint after surgery for a transverse vaginal septum.<sup>21</sup>

With very high vaginal entrance into the urogenital sinus and/or cloaca, there is a significant incidence of urinary incontinence. When the patient reaches the age of urinary control, she may require a complex urinary reconstruction and diversion.

### Prognosis and Outcomes

Endometriosis and infertility are the most prominent late consequences reported in vaginal obstruction. Early diagnosis and treatment of the vaginal obstruction might enhance pregnancy success by reducing the risk of haematometra and haematosalpinx with the subsequent development of pelvic endometriosis.<sup>21</sup> The general prognosis for hydrocolpos is good, especially in early diagnosed and treated cases. However, late onset of sexual development, ability of the vagina to expand, a normal-appearing vaginal orifice in a mid- and high-transverse vaginal septum, and limited access to expert medical facilities in the developing world can delay the presentation.

The prognosis of isolated imperforate hymen is normally excellent. Although some patients in one particular follow-up suffered from dysmenorrhea and irregular menstruation, most patients progressed well in terms of fertility and sexual function.<sup>22,23</sup> Rock et al. have shown that women with an imperforate hymen had a high success rate in pregnancies, with no infertility.<sup>20</sup> Moreover, obstetric outcome in treated imperforate hymen is no different from that of the general population.<sup>20</sup> When the imperforate hymen occurs with a constellation of other findings, prognosis largely depends on the presence of the associated findings. Associated congenital anomalies involving the urogenital (incidence of 30–50%), gastrointestinal, skeletal, and cardiovascular systems are common in patients with complex anomalies.<sup>24</sup>

Females with imperforate hymen had better pregnancy success than those with complete transverse septum following the surgical correction of obstructive defects.<sup>20</sup> Patients with middle or upper complete transverse septum were less likely to conceive than those with a septum in the lower vagina.<sup>20</sup>

Long-term follow-up after reconstruction is essential because many patients may experience sexual difficulties, menstrual irregularities, infertility, spontaneous abortion, or premature delivery. Infertility is probably due to endometriosis and pelvic adhesion in patients with

outflow obstructions. Rock et al. have reported a pregnancy rate of 47% in cases of lower obstruction, 43% in middle-third obstructions, and only 25% in upper-third obstructions.<sup>20</sup> The rate of spontaneous abortions has been reported to be as high as 50% in cases of transverse vaginal septum and 6% due to imperforate hymen.<sup>21</sup>

### Ethical Issues

Many surgeons in developing countries are constrained by late presentation and lack of facilities. The diagnosis of hydrometrocolpos is often delayed because of its rarity. Moreover, in these countries, neonates

often have prolonged investigations to exclude more common causes of intestinal and urinary obstruction. In the African population, this is complicated by the absence of ultrasound facilities.<sup>10</sup> This may prevent preoperative diagnosis because emergency US is not available at the time of presentation. Consequently, the provision of basic diagnostic services such as US is essential. It is also important to educate health care workers about the need for early referral.

### Key Summary Points

1. Vaginal anomalies range from relatively common to relatively rare.
2. The rarity and variable presentation of congenital obstruction of the vagina can lead to delayed diagnosis and erroneous management.
3. It is important to be aware of the differential diagnoses and associated anomalies, including the consideration of hydrocolpos or hydrometrocolpos, in a female newborn with an abdominal mass and urinary obstruction.
4. A thorough physical genital examination and appropriate imaging can aid in achieving the correct diagnosis.
5. Ultrasonography and magnetic resonance imaging are diagnostic modalities of choice and can reveal associated renal anomalies and the anatomy of complex lesions, although further evaluation may require voiding cystourethrogram.
6. Delayed diagnosis may impair normal functions of urogenital systems and cause compression of surrounding structures.
7. Early surgical intervention will reduce long-term morbidity.

### References

1. Khan RA, Ghani I, Wahab J. Hydrometrocolpos due to persistent urogenital sinus mimicking neonatal ascites. *Iran J Pediatr* 2008; 18(1):67–70.
2. Romero R, et al. *Prenatal Diagnosis of Congenital Anomalies*. Appleton and Lange, 1988, Pp 307–309.
3. Messina M, Severi FM, Bocchi C, et al. Voluminous perinatal mass: a case of congenital hydrometrocolpos. *J Matern Fetal Neonatal Med* 2004; 15:135.
4. Tseng JJ, et al. Prenatal diagnosis of isolated fetal hydrocolpos secondary to congenital imperforate hymen. *J Chin Med Assoc* 2008; 71(6):325–328.
5. Miller RJ, Breech LL. Surgical correction of vaginal anomalies. *Clinical Obstet and Gynecol* 2008; 51(2):223–236.
6. Pena A, et al. Surgical management of cloacal malformations: a review of 339 patients. *J Pediatr Surg* 2004; 39(3): 470–479.
7. Sadler TW. *Langman's Medical Embryology*, 10th ed. Lippincott Williams & Wilkins, 2006, Chap 15, Pp 229–256.
8. DeUgarte CM, et al. Embryology of the urogenital system and congenital anomalies of the female genital tract. In: DeCherney AH, et al. *Current Diagnosis and Treatment: Obstetrics and Gynecology*, 10th ed. McGraw-Hill, 2007, Chap 4. Available at <http://www.accessmedicine.com/content.aspx?aID=2382989>.
9. Schorge JO, et al. *William's Gynecology*. McGraw-Hill, 2008, Chap 18, Anatomic Disorders. Available at <http://www.accessmedicine.com/content.aspx?aID=3157418>. Chap 41, Surgeries for Benign Gynecologic Conditions. Available at <http://www.accessmedicine.com/content.aspx?aID=3166442>.
10. David A, Bitoun P, Lacombe D, Lambert J, Nivelon A, Vigneron J, et al. Hydrometrocolpos and polydactyly: a common neonatal presentation of Bardet-Biedl and McKusick-Kaufman syndromes. *J Med Genet* 1999; 36:599–603.
11. Tekin I, Ok G, Genc A, Tok D. Anaesthetic management in McKusick-Kaufman syndrome. *Pediatr Anes* 2003; 13:167–170.
12. Kos S, Roth K, Korinth D, Zeilinger, G, Eich G. Hydrometrocolpos post axial polydactyly, and hypothalamic hamartoma in a patient with confirmed Pallister-Hall syndrome: a clinical overlap with McKusick-Kaufman syndrome. *Pediatr Radiol* 2008; 38:902–906.
13. Shimada K, Hosokawa S, Matsumoto F, Johnun K, Naitoh Y, Harado Y. Urology management of cloacal anomalies. *Intl J Urol* 2001; 81:282–289.
14. Shono T, Teguchi T, Suita S, Nakanami N, Nekane H. Prenatal ultrasonographic and magnetic resonance imaging findings of congenital cloacal anomalies associated with meconium peritonitis. *J Pediatr Surg* 2007; 42:681–684.
15. Laufer MR. Diagnosis and management of congenital anomalies of the vagina. Available at <http://www.uptodate.com> (accessed 2008).
16. Spencer R, Levy DM. Hydrometrocolpos: report of three cases and review of the literature. *Ann Surg* 1962; 155(4):558–571.
17. Hayashi S, et al. Prenatal diagnosis of fetal hydrometrocolpos secondary to cloacal anomaly by magnetic resonance imaging. *Ultrasound Obstet Gynecol* 2005; 26:577–579.
18. Dhombres F, et al. Contribution of prenatal imaging to the anatomical assessment of fetal hydrocolpos. *Ultrasound Obstet Gynecol* 2007; 30:101–104.
19. Powell DM, Newman KD, Randolph J. A proposed classification of vaginal anomalies and their surgical correction. *J Pediatr Surg* 1995; 30(2):271–275.
20. Rock JA, et al. Pregnancy success following surgical correction of imperforate hymen and complete transverse vaginal septum. *Obstet Gynecol* 1982; 59:448–452.
21. Joki-Erkkila MM, Heinonen PK. Presenting and long-term clinical implications and fecundity in females with obstructing vaginal malformations. *J Pediatr Adolesc Gynecol* 2003; 16:307–312.
22. El-Messidi A, Fleming NA. Congenital imperforate hymen and its life-threatening consequences in the neonatal period. *J Pediatr Adolesc Gyn* 2006; 19(2):99–103.
23. Cunningham FG, Leveno KJ, Bloom SL, et al. *Williams Obstetrics*, 22nd ed. McGraw-Hill, 2005, P 685.
24. Nazir Z, et al. Congenital vaginal obstructions: varied presentation and outcome. *Pediatr Surg Int* 2006; 22:749–753.

### Suggested Reading

Ahment G, et al. Prenatal ultrasonographic features of persistent urogenital sinus with hydrometrocolpos and ascites. *Gynecol Obstet* 2008; 278:493–496.

Arena F, et al. The neonatal management and surgical correction of urinary hydrometrocolpos caused by a persistent urogenital sinus. *BJU Intl* 1999; 84:1063–1068.

Ekenze SO, Ezegwui HU. Hydrometrocolpos from a low vaginal atresia: an uncommon cause of neonatal intestinal and urinary obstruction. *Afr J Paediatr Surg* 2008; 5(1):43–45.

Pena A, Levitt M. Surgical management of cloacal malformations. *Sem Neonatology* 2003; 8:249–257.