

CHAPTER 123

PRENATAL DIAGNOSIS AND FOETAL THERAPY

Kokila Lakhoo

Introduction

Prenatal diagnosis and foetal therapy are rare in Africa except for the presentation of polyhydramnios in foetal bowel obstruction. This chapter therefore covers prenatal diagnosis and therapy as practised in resourced countries.

Expertise in surgical correction of congenital malformations may favourably influence the perinatal management of prenatally diagnosed anomalies, by changing the site of delivery for immediate postnatal treatment; altering the mode of delivery to prevent obstructed labour or haemorrhage; early delivery to prevent ongoing foetal organ damage; or treatment in utero to prevent, minimise or reverse foetal organ injury as a result of a structural defect. The referral base for a paediatric surgeon now includes the perinatal period.

The diagnosis and management of complex foetal anomalies require a team effort by obstetricians, neonatologists, geneticists, paediatricians, and paediatric surgeons to deal with all the maternal and foetal complexities involved in diagnosis of a structural defect. This team should be able to provide information to prospective parents on foetal outcomes; possible interventions; appropriate setting, time, and route of delivery; and expected postnatal outcomes. The role of the surgical consultant in this team is to present information regarding the prenatal and postnatal natural history of an anomaly, its surgical management, and the expected long-term outcome.

Congenital Malformations

Congenital malformations account for one of the major causes of perinatal mortality and morbidity. Single major birth defects affect 3% of newborns, and 0.7% of babies have multiple defects. The prenatal hidden mortality is higher because the majority abort spontaneously. Despite improvements in perinatal care, serious birth defects still account for 20% of all deaths in the newborn period and an even greater percentage of serious morbidity later in infancy and childhood. The major causes of congenital malformation are chromosomal abnormalities, mutant genes, multifactorial disorders, and teratogenic agents.

Prenatal Diagnosis

Prenatal diagnosis has remarkably improved our understanding of surgically correctable congenital malformations. It has allowed us to influence the delivery of the baby, offer prenatal surgical management, and discuss the options of termination of pregnancy for seriously handicapping or lethal conditions. Screening for Down syndrome may now be offered in the first trimester (e.g., nuchal scan combined test) (Figure 123.1) or second trimester (e.g., triple blood test). Better resolution and increased experience with ultrasound (US) scans have led to the recognition of US soft markers, which have increased the detection rate of foetal anomalies albeit at the expense of higher false positive rates.

Routine US screening identifies anomalies and places these pregnancies in the high-risk categories with maternal diabetes, hypertension, genetic disorders, and raised alpha foetoprotein, among others. Parents with high-risk pregnancies may be offered further invasive diagnostic investigations, such as amniocentesis or chorionic villous sampling. Structural abnormalities that are difficult

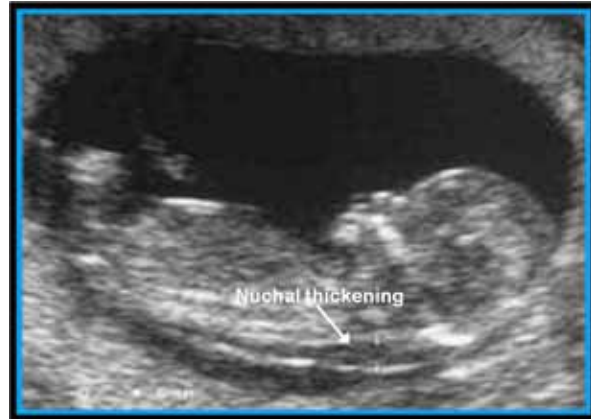

Figure 123.1: Nuchal thickening on scan.

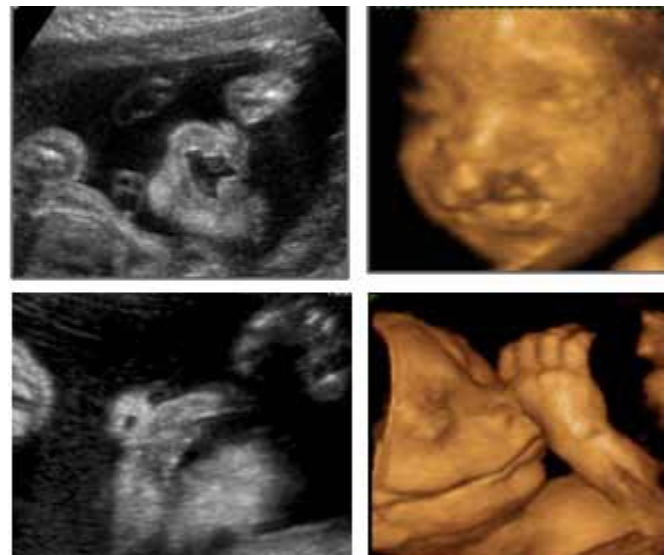

Figure 123.2: Two-dimensional (2D; left panes) and three-dimensional (3D; right panes) scan of facial banding.

to define on US, such as hindbrain lesions or those in the presence of oligohydramnios, are better imaged on ultrafast magnetic resonance imaging (MRI). With the increasing range of options and sophistication of diagnostic methods (Figure 123.2), parents today are faced with more information, choices, and decisions than ever before, which can create as well as help to solve dilemmas.

Specific Surgical Conditions

Congenital Diaphragmatic Hernia

Congenital diaphragmatic hernia (CDH; Figure 123.3) accounts for 1 in 3,000 live births worldwide and challenges the neonatologist and paediatric

atric surgeon in the management of this high-risk condition. Mortality remains high (>60%) when the “hidden” mortality of in utero death and termination of pregnancy are taken into account. Lung hypoplasia and pulmonary hypertension account for most deaths in isolated CDH newborns. Associated anomalies (30–40%) signify a grave prognosis with a survival rate of less than 10%.

In the United Kingdom, most cases of CDH are diagnosed at the 20-week anomaly scan, with a detection rate approaching 60%. MRI has a useful role in accurately differentiating CDH from cystic lung lesions and may be useful in measuring foetal lung volumes as a predictor of outcome. Cardiac anomalies (20%); chromosomal anomalies of trisomy 13 and 18 (20%); and urinary, gastrointestinal, and neurological anomalies (33%) can coexist with CDH. These associated anomalies and, in isolated lesions, early detection, liver in the chest, polyhydramnios, and foetal lung-head ratio (LHR) of less than 1 are implicated as poor predictors of outcome. In these patients with poor prognostic signs, foetal surgery for CDH over the last two decades has been disappointing; however, benefit from foetal endoscopic with tracheal occlusion (FETO) awaits randomised studies. Favourable outcomes in CDH with the use of antenatal steroids has not been resolved in clinical settings. Elective delivery at a specialised centre is recommended with no benefit from caesarean section.

Cystic Lung Lesions

Congenital cystic adenomatous malformations (CCAMs), bronchopulmonary sequestrations (BPSs), or “hybrid” lesions containing features of both are common cystic lung lesions noted on prenatal scans. Less common lung anomalies include bronchogenic cysts, congenital lobar emphysema, and bronchial atresia. Congenital cystic lung lesions (Figure 123.4) are rare anomalies, with an incidence of 1 in 10,000 to 1 in 35,000.

The prenatal detection rate of lung cysts at the routine 18- 20-week scan is almost 100%; this scan may be the most common mode of actual presentation. Most of these lesions are easily distinguished from CDH; however, sonographic features of CCAM or BPS are not sufficiently accurate and correlate poorly with histology. MRI, although not routinely used, may provide better definition for this condition; however, inaccuracies have been reported in 11% of cases.

Bilateral disease and hydrops foetalis are indicators of poor outcome, whereas mediastinal shift, polyhydramnios, and early detection are not poor prognostic signs. In the absence of termination, the natural foetal demise of antenatally diagnosed cystic lung disease is 28%. It is well documented that spontaneous involution of cystic lung lesions can occur, but complete postnatal resolution is rare, and apparent spontaneous “disappearance” of antenatally diagnosed lesions should be interpreted with care because nearly half of these cases subsequently require surgery.

In only 10% of cases does the need for foetal intervention arise. The spectrum of intervention includes simple centesis of amniotic fluid, thoracoamniotic shunt placement, percutaneous laser ablation, and open foetal surgical resection. Maternal steroid administration has also been reported to have a beneficial effect on some CCAMs, although the mechanism is unclear. A large cystic mass and hydrops in isolated cystic lung lesions are the only real indications for foetal intervention.

Normal vaginal delivery is recommended unless the maternal condition indicates otherwise. Large lesions are predicted to become symptomatic shortly after birth; thus, delivery at a specialised centre would be appropriate. Smaller lesions are less likely to be symptomatic at birth, however, and could be delivered at the referring institution with follow-up in a paediatric surgery clinic.

Abdominal Wall Defects

Exomphalos and gastroschisis are both common but distinct abdominal wall defects with an unclear aetiology and a controversial prognosis. Attention may be drawn to their presence during the second trimester because of raised maternal serum alpha foetoprotein level, or abnormal US scan.

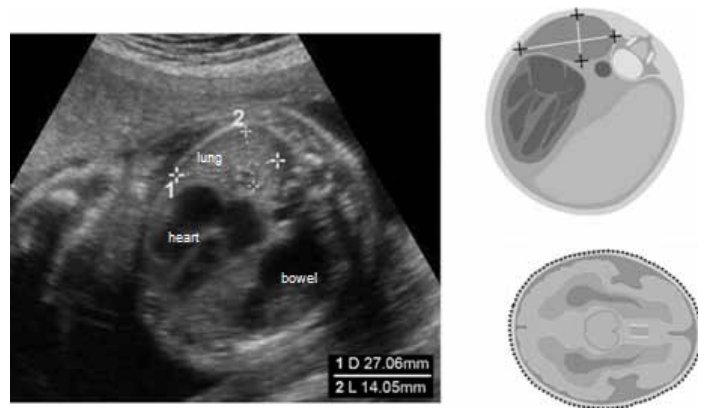


Figure 123.3: Diaphragmatic hernia.

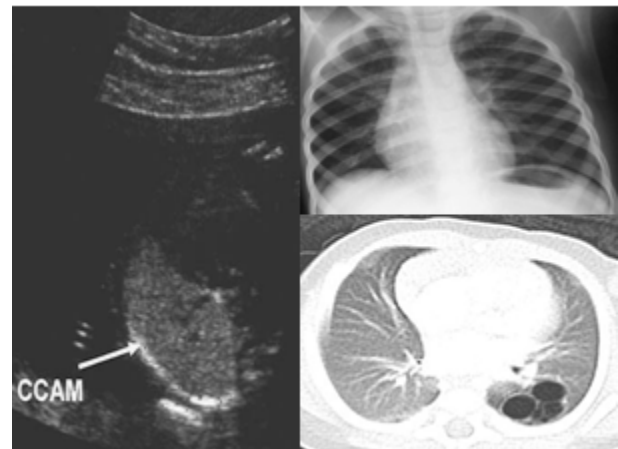


Figure 123.4: Congenital lung cyst.

Exomphalos

Exomphalos (Figure 123.5) is characteristically a midline defect, usually near the insertion point of the umbilical cord, with a viable sac composed of amnion and peritoneum containing herniated abdominal contents. Incidence is known to be 1 in 4,000 live births worldwide. Associated major abnormalities, which include trisomy 13, 18, and 21; Beckwith-Wiedemann syndrome (macroglossia, gigantism, exomphalos); pentalogy of Cantrell (sternal, pericardial, cardiac, abdominal wall, and diaphragmatic defects); and cardiac, gastrointestinal, and renal abnormalities are noted in 60–70% of cases. Thus, karyotyping, in addition to detailed sonographic review and foetal echocardiogram, is essential for complete prenatal screening. Foetal intervention is unlikely in this condition. If termination is not considered, normal vaginal delivery at a centre with neonatal surgical expertise is recommended, and delivery by caesarean section is reserved only for large exomphalos with exteriorised liver, to prevent damage.

Gastroschisis

Gastroschisis (Figure 123.6) is an isolated lesion that usually occurs on the right side of the umbilical defect with evisceration of the abdominal contents directly into the amniotic cavity. The incidence has increased from 1.66 per 10,000 births to 4.6 per 10,000 births worldwide and in the last 10-15 years, affecting mainly mothers younger than 20 years of age. Associated anomalies are noted in only 5–24% of cases, with bowel atresia the most common coexisting abnormality. On prenatal scan, with a detection rate of 100%, the bowel appears to be free floating, and the loops may appear to be thickened due to damage by amniotic fluid exposure, causing a “peel” formation. Dilated loops of bowel (see Figure 123.3) may be seen from obstruction, secondary to protrusion from a defect or atresia due to intestinal ischaemia.

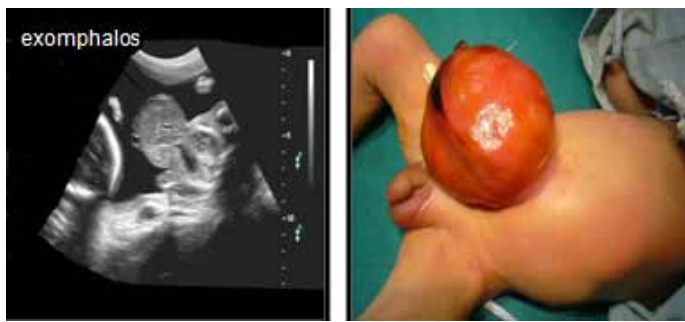

Figure 123.5: Exomphalos.

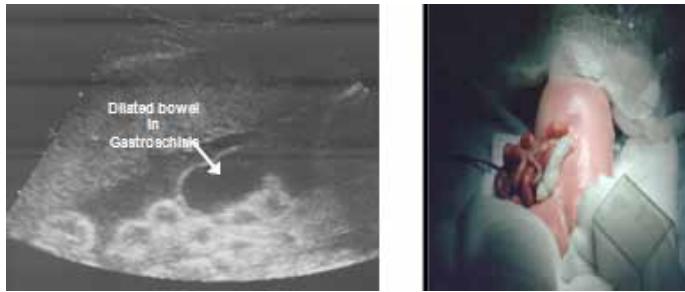

Figure 123.6: Gastroschisis.

Predicting outcomes in foetuses with gastroschisis based on prenatal US findings remains a challenge. There is some evidence that maximum small bowel diameter may be predictive; however, thickened matted bowel and Doppler measurements of the superior mesenteric artery are not accurate predictors of outcome. To reduce the rate of third-trimester foetal loss, serial US scans are performed to monitor the development of bowel obstruction, and delivery at around 37 weeks is recommended, preferably at a centre with neonatal surgical expertise.

Tracheo-Oesophageal Fistula and Oesophageal Atresia

Repair of tracheo-oesophageal fistula and oesophageal atresia (TOF/OA) measures the skill of paediatric surgeons from trainee to independent surgeon. The incidence of TOF/OA is estimated at 1 in 3,000 births worldwide. Prenatally, the condition may be suspected from maternal polyhydramnios and absence of a foetal stomach bubble at the 20-week anomaly scan. Prenatal scan diagnosis of TOF/OA is estimated to be less than 42% sensitive with a positive predicted value of 56%. Additional diagnostic clues are provided by associated anomalies such as trisomy (13, 18, 21), the VACTERAL (vertebral, anorectal, cardiac, tracheo-oesophageal, renal, limbs) sequence, and CHARGE (coloboma, heart defects, atresia choanae, retarded development, genital hypoplasia, ear abnormality) association. These associated anomalies are present in more than 50% of TOF/OA cases and worsen the prognosis; thus, prenatal karyotyping is essential. Duodenal atresia may coexist with TOF/OA. The risk of recurrence in subsequent pregnancies for isolated TOF/OA is less than 1%. Delivery is advised to be at a specialised centre with neonatal surgical input.

Gastrointestinal Lesions

The presence of dilated loops of bowel (>15 mm in length and 7 mm in diameter) on prenatal US scan is indicative of bowel obstruction.

Duodenal atresia has a characteristic “double-bubble” appearance on prenatal scan, resulting from the simultaneous dilatation of the stomach and proximal duodenum. The detection rate on a second-trimester anomaly scan is almost 100% in the presence of polyhydramnios and the double-bubble sign. Associated anomalies are present in approximately 50% of cases, with trisomy 21 most notably in 30% of cases, cardiac anomalies in 20%, and the presence of the VACTERL association.

The incidence of duodenal atresia is 1 in 5,000 live births worldwide. The postnatal survival rate is >95% with associated anomalies, low birth weight, and prematurity contributing to the <5% mortality. Temporary delay in enteral feeding occurs due to dysmotility in the dilated stomach and duodenum.

There are many bowel abnormalities that may be noted on prenatal scanning (dilated bowel, ascites, cystic masses, hyperparistalsis, polyhydramnios, and echogenic bowel); however, none is absolutely predictive of postnatal outcome. Patients with obstruction frequently have findings (especially in the third trimester) of bowel dilatation, polyhydramnios, and hyperparistalsis, but US is much less sensitive in diagnosing large bowel anomalies than those in the small bowel. The large bowel is mostly a reservoir with no physiologic function in utero, so defects in this region, such as anorectal malformations or Hirschsprung’s disease, are very difficult to detect. Bowel dilatation and echogenic bowel may be associated with cystic fibrosis; therefore, all such foetuses should undergo postnatal evaluation for this disease. Prenatally diagnosed small bowel atresia does not select for a group with a worse prognosis, and survival rates are 95–100%.

Sacrococcygeal Teratoma

Sacrococcygeal teratoma (SCT; Figure 123.7) is the most common neonatal tumour, affecting 1 in 35,000 to 40,000 births worldwide. Four types of SCT have been defined:

- Type 1: External tumour with a small presacral component.
- Type 2: External tumour with a large presacral component.
- Type 3: Predominantly presacral with a small external component.
- Type 4: Entirely presacral.

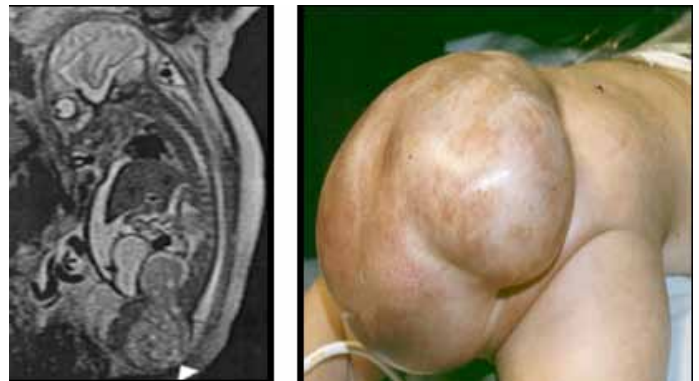


Figure 123.7: Sacrococcygeal teratoma (left: MRI).

Types 3 and 4 carry the worst prognosis due to delay in diagnosis and malignant presentation. Doppler US is the diagnostic tool; however, foetal MRI provides a better definition of the intrapelvic component. SCT is a highly vascular tumour, and the foetus may develop high cardiac output failure, anaemia, and ultimately hydrops, with a mortality of almost 100%. Foetal treatment of tumour resection or ablation of the feeding vessel has been attempted in hydropic patients. Caesarean section may be offered to patients with large tumours to avoid the risk of bleeding during delivery. Postnatal outcomes following surgery in type 1 and 2 lesions are favourable; however, type 3 and 4 tumours may present with urological problems and less favourable outcomes. Long-term follow-up with alpha foetoprotein and serial pelvic US scans are mandatory to exclude recurrence of the disease.

Renal Anomalies

Urogenital abnormalities are among the most common disorders seen in the perinatal period, accounting for almost 20% of all prenatally diagnosed anomalies. The routine use of antenatal US scans has resulted in the early detection of these conditions, and in selected cases this has

led to the development of management strategies including foetal intervention aimed at preservation of renal function. Two major issues are the indications for intervention in bladder outlet obstruction and early pyeloplasty in infancy in cases with hydronephrosis.

Prenatal evaluation of a dilated urinary tract is based on serial US scans as well as measurement of urinary electrolytes. US provides measurements of the renal pelvis, assessment of the renal parenchyma, and the detection of cysts in the cortex. In severe disease, lack of amniotic fluid may make US assessment of the renal tract difficult, and MRI may be helpful. Oligohydramnios is indicative of poor renal function and poor prognosis due to the associated pulmonary hypoplasia. Urogenital anomalies coexist with many other congenital abnormalities, and amniocentesis should be offered in appropriate cases. It is estimated that 3% of infants will have an abnormality of the urogenital system and half of these will require some form of surgical intervention.

Upper Urinary Tract Obstruction

Antenatal hydronephrosis is present in 0.6–0.65% of pregnancies. The most common cause of prenatal hydronephrosis is pelviureteric junction (PUJ) obstruction; others include transient hydronephrosis, physiological hydronephrosis, multicystic kidney, posterior urethral valves, ureterocoele, and ectopic ureter. The prognosis of antenatally diagnosed hydronephrosis in unilateral disease and with renal pelvic diameter of <10 mm is excellent. Spontaneous resolution is noted in 20% of patients at birth and 80% at 3 years of age. Only 17% of prenatally diagnosed hydronephrosis cases need surgical intervention.

Lower Urinary Tract Obstruction

Posterior urethral valves (PUVs; Figure 123.8) are the most common causes for lower urinary tract obstruction in boys, with an incidence

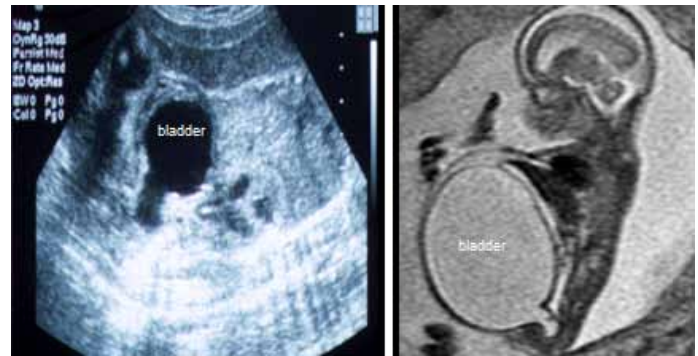


Figure 123.8: US scan (left) and MRI (right) of posterior urethral valves.

of 1 in 2,000 to 4,000 live male births worldwide. The diagnosis of PUV is suspected on a prenatal US finding of bilateral hydronephrosis associated with a thickened bladder and decreased amniotic fluid volume. Serial foetal urine analysis may provide prognostic information on renal function. Prenatal diagnosis for patients with PUV is a poor prognostic sign, with 64% incidence of renal failure and transient pulmonary failure, compared to 33% in postnatally diagnosed patients. Pulmonary hypoplasia secondary to oligohydramnios largely contributes to the morbidity and mortality from foetal urethral obstruction. Outcomes of foetal intervention with vesicicoamniotic shunting or foetal cystoscopic ablation of the urethral valve are still under review and await a multicentre trial.

Key Summary Points

1. The boundaries of paediatric surgical practice have been extended by prenatal diagnosis.
2. The care of patients with surgically correctable defects can now be planned prenatally with the collaborative effort of obstetricians, geneticists, neonatologists, and paediatric surgeons.
3. Understanding the specific surgical condition's prenatal natural history is essential.
4. Prenatal diagnosis has its limitations.
5. Associated anomalies need to be detected.
6. Understanding the risks and indications of foetal intervention programmes and postnatal outcomes is essential.
7. Prenatal counselling is an essential component of paediatric surgical practice and should be ensured in the training programme for future paediatric surgeons.

Suggested Reading

Black R, Boyd P. What's new in prenatal diagnosis? Trends in Urology. Gynaecol Sexual Health 2004; 9:9–11.

Boyd PA, Keeling JW. Congenital abnormalities, prenatal diagnosis and screening. In: Keeling JW, ed. Fetal and Neonatal Pathology. Springer-Verlag, 2007.

Lakhoo K. Fetal counselling for congenital malformations. Pediatr Surg Int 2007; 23:509–519.

Lakhoo K, et al. Best clinical practice: surgical conditions of the fetus and newborn. Early Human Dev 2006; 82:281–324.