

# CHAPTER 37

## LYMPHADENOPATHY IN AFRICAN CHILDREN

S. W. Moore  
N. Tsifularo  
Ralf-Bodo Troebs

### Introduction

Lymphadenopathy is an extremely common clinical finding in children in Africa as well as the rest of the world. It is common in children due to their large lymphoid mass and rapid lymphocytic response to allergens or infections. It is therefore most prevalent in the first decades of life; the majority of children between the ages of 2 and 12 years will have an enlarged lymph node at one stage or another.

In broad terms, lymphadenopathy represents an enlargement of lymph nodes resulting from:

- *Reactive state* – acute lymphadenitis
- *Hyperplasia* – e.g., human immunodeficiency virus (HIV), autoimmune disease
- *Granulomas* – tuberculosis (TB), mycobacteria other than tuberculosis (MOTT), toxoplasmosis, syphilis
- *Neoplastic* – primary (lymphomas) or secondary (metastases)

Lymphadenopathy is important because it may be the first (and sometimes only) indication of underlying disease. The major cause is infection, which may be acute bacterial or viral or chronic due to a host of causes, the majority of which give rise to granulomas. It is therefore understandable that the incidence of lymphadenopathy is reportedly higher in sick children than in those attending well baby clinics.

The obvious therapeutic and prognostic implications of lymphadenopathy necessitate an accurate and prompt diagnosis. Size, location, consistency, and nonresponse to empiric antibiotic therapy are the major criteria for further investigation. More than half the cervical lymph nodes examined in children in a developing country display very significant and clinically important pathology, thereby justifying active management of all paediatric patients with persisting lymphadenopathy.

One of the main concerns is the association between malignancy and lymphadenopathy, which may be primary or secondary but particularly includes the lymphoma group of conditions. Lymphadenopathy therefore needs to be actively investigated should it not respond to simple initial treatment so as not to overlook these important conditions. It is important to institute early treatment.

### Anatomy

Lymph nodes are discrete encapsulated aggregations of lymphoid tissue that are seldom palpable in the normal child. These bean-like ovoid structures are scattered along lymphatic vessels but increase in number where the vessels converge, such as in the neck, axilla, pelvis, mediastinum, and similar situations (Figure 37.1).

Lymph nodes are structurally divided into three zones (the cortex, the paracortex, and the medulla). The architecture of these areas often is important. These sites appear to have separate functions: the cortex is the main site of B-cell activation; the paracortex is the T-cell dependent region; and the medulla, with abundant sinuses lined by macrophages, has a reticulo-endothelial function.

The primary function of the lymph node is to entrap and mount a response against foreign agents as part of the reticulo-endothelial system.

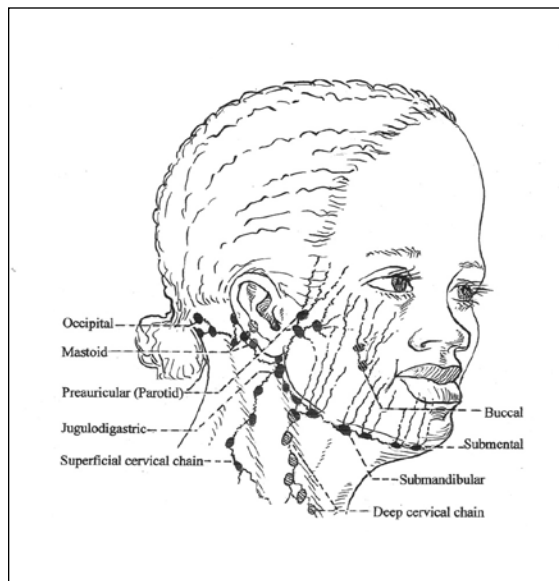


Figure 37.1: Anatomy of lymph nodes.

### Demographics

Well-documented geographical differences exist in the epidemiology of lymphadenopathy in childhood. In general, the pathology usually identifies what is common in that particular environment, which has a special significance for Africa, where tuberculosis remains one of the main causes of lymph node enlargement. For example, in one South African series,<sup>1</sup> the incidence of *Mycobacterium tuberculosis* was 28%, similar to the 24.9% reported in children worldwide, but that incidence is higher than in developed countries such as Australia and countries in Europe and North America, where *M. tuberculosis* is less common, and parallels an increase in infections caused by “atypical mycobacteria” (i.e., MOTT). As a result, chronic granulomatous conditions result mainly from MOTT infections and cat scratch disease in those countries.

### Aetiology

Chronic lymphadenopathy in children of developing countries has a high incidence of infective causes, including pathogenic bacteria, mycobacteria, and fungi, as well as neoplastic, metabolic, and immunological causes, and other causes of lymph node reaction.

Infective causes may be further classified into acute or chronic.

### Acute Suppurative Lymphadenitis

Acute suppurative lymphadenitis is secondary to infections of the upper respiratory tract; ear, nose, and throat (ENT); or scalp. Submandibular lymph nodes are common sites in the 3–6 months age group

Acute lymphadenitis can result from poor dental and mouth hygiene. Involvement of the floor of the mouth is common in developing countries.

Acute lymphadenitis often leads to suppuration and abscess formation (Figure 37.2), and may lead to Ludwig’s angina.

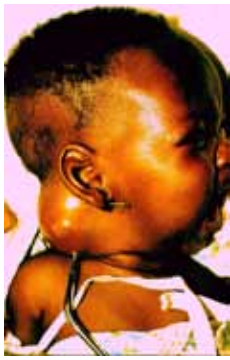

Figure 37.2: Acute suppurative lymphadenitis with abscess.

### Chronic Lymphadenitis

Chronic lymphadenitis may be caused by a reactive hyperplasia virus; defined infections, such as toxoplasmosis or infectious mononucleosis; or chronic granulomas, such as mycobacteria (other than TB), cat scratch disease, or possibly TB; or viruses (e.g., Epstein–Barr, HIV, or cytomegalovirus (CMV)).

### Pathology

Lymphadenopathy represents the response to localised or generalised pathology as a result of antigenic stimulation or infiltration by cellular elements. The larger lymphoid mass as well as a brisk lymphogenic response following exposure to new antigens predisposes to lymph node enlargement in children.

Generalised enlargement of lymph nodes is defined as two or more noncontinuous lymph node regions with enlarged nodes (including intraabdominal lymphadenopathy). It most often occurs as a result of systemic disease due to infectious agents, but malignancies, autoimmune disease, and lipid storage diseases, as well as drug reactions and other miscellaneous pathologies, also contribute to the overall picture. It is often accompanied by other generalised symptoms, such as weight loss, night sweats, and ill health, or symptoms typical of the underlying pathological condition.

In contrast, localised lymphadenopathy occurs mainly as a result of diseases or infections in the node or their drainage areas. It can be cervical, axillary, inguinal, or other (e.g., supratrochlear, occipital, etc.).

### Reactive Hyperplasia

The majority of enlarged lymph nodes in children occur as a result of infective agents; viral infections show only reactive hyperplasia in the majority (in as many as 48% of patients) without a specific cause being identified. This is not entirely unexpected considering the empiric use of antibiotics, which may mask certain aetiological agents, and the difficulty of identifying causative pathogens, particularly in Africa. This high prevalence of reactive hyperplasia does not exclude the need for careful clinicopathological correlation to improve diagnostic capability, however.

The most probable aetiology guides the diagnosis of lymphadenopathy. Despite the myriad causes, lymph nodes enlarge as a result of proliferation of normal lymphoid elements or infiltration by phagocytic cells or malignant cell deposits. Many are caused by viral infections, which result in small, self-limiting lymph nodes. If a bacterial aetiology is anticipated, an empiric course of antibiotics that cover streptococci and staphylococci is appropriate, with re-evaluation. Abscess formation is treated surgically.

### Chronic Granulomas

In our series<sup>1</sup> of 1,877 surgically biopsied lymph nodes, 484 (36.3%) had chronic granulomatous changes. Although *M. tuberculosis* was the causative agent in the majority, in almost 10% the causes of the chronic granulomas were not always clear but included sinus histiocytosis with massive lymphadenopathy (Rosai–Dorfman disease), syphilis, yaws, and toxoplasmosis.

## Acute Bacterial Lymphadenitis

### Aetiology

Unilateral, large, and tender lymph nodes are commonly due to acute bacterial infection. The most common cause of acute lymphadenitis is a bacterial infection arising in the oropharynx. Submandibular and upper cervical nodes are affected in the majority of cases. Axillary, inguinal, and other locations also may be inflamed. Ultrasonography may detect an abscess not already apparent on physical examination.

Typical organisms are penicillin-resistant *Staphylococcus aureus* and *Streptococcus pyogenes*. Group B streptococcal adenitis may occur in the infant with unilateral submandibular swelling, erythema, tenderness, fever, and irritability. In the older child with dental caries or periodontal disease, anaerobic germs (e.g., *Bacteroides* sp., *Peptococcus* sp., *Peptostreptococcus*) play a role. Following animal (dog) bites or animal scratches, *Pasteurella multocida* may cause acute lymphadenitis.

Without treatment, the lymph node usually enlarges and becomes fluctuant. Thinning over the overlying skin and spontaneous perforation may occur. Laboratory findings include an elevation of white blood cell and neutrophil count.

### Treatment

Initial treatment of acute lymphadenitis consists of administration of a beta-lactamase-resistant antibiotic for 2 weeks, at least 5 days beyond resolution of acute signs and symptoms. In older children with dental or periodontal infection, the antibiotic therapy should include an anti-anaerobic antibiotic, such as penicillin V or clindamycin.

If the child appears toxic (high fever, cellulites, respiratory problems) or is quite young, hospitalisation and intravenous (IV) administration of antibiotics are often necessary. In these cases, blood cultures should be obtained. However, the incidence of bacteremia associated with pediatric acute adenitis seems to be low.

Fluctuance of the lesion is a clear indication for surgical evacuation. Needle aspiration and drainage of the purulent material can be both diagnostic and therapeutic. It is particularly attractive when treating in cosmetically important areas. However, repeated aspirations may be necessary, and judicious antibiotic therapy is required.

The aspirated material should be cultured for aerobic and anaerobic germs as well as for mycobacteria. In addition, it is helpful to examine the material by Gram and Ziehl–Neelsen acid-fast stain. In the immunocompromised child, fungal infections have to be taken into account.

An alternative to node aspiration is open drainage under general anaesthesia, which is safe and highly successful. The node can be incised and packed loosely with a Penrose drain or a gauze strip. An attempt should be made to open and drain all localisations. The drain can usually be removed after a period of several days.

### Complications

Major and life-threatening complications reported in children with suppurative cervical lymphadenitis are fasciitis, carotid artery aneurysm, and rupture, thrombosis of the jugular vein, generalised septic embolisation, mediastinal abscess, and purulent pericarditis.

## Mycobacterial-Related Lymphadenitis

### Tuberculosis and Lymphadenopathy

Although the incidence of TB has stabilised or declined in most world regions, it is increasing in Africa, Southeast Asia, and the eastern Mediterranean countries, being fuelled by the HIV pandemic with which it is closely associated. Tuberculous lymphadenitis and malignant nodal spread remain the most frequently encountered reasons for lymph node enlargement. Tuberculosis (TB) is the most frequent form of extrapulmonary tuberculosis and is identified in at least 28% of most series of cervical lymphadenopathy. Given the historical difficulties in diagnosis, the actual figure for Africa is probably somewhat higher.

Cervical lymphadenopathy has been reported to occur in 4–9% of children with pulmonary tuberculosis, with 57% occurring between the ages of 1 and 3 years. Clinical suspicion of cervical TB is high in children with a previous history of TB or close contact with a TB patient from an endemic region. The significance increases in the presence of a markedly positive tuberculin skin test (i.e., Mantoux test). The finding of nontender, painless, unilateral cervical lymph nodes on physical examination further strengthens this suspicion. Objective diagnosis is then fairly difficult and relies on cervical lymph node sampling.

Particular difficulties exist in making a clinical diagnosis in children with HIV disease, who may have atypical presentations. When clinically indicated, screening for pulmonary and laryngeal disease depends heavily on lymph node sampling. Fine needle aspiration (FNA) with culture or polymerase chain reaction (PCR)-based identification are rapidly overtaking the more conventional methods of diagnosis, with the more traditional method of excisional biopsy being reserved for selected cases.

### Nontuberculous Mycobacterial Infections

#### BCG lymphadenitis

A special situation exists in lymphadenopathy related to the Danish strain of bacille Calmette-Guérin (BCG; Figure 37.3), which is estimated to occur at the rate of 36 per 1,000 vaccinations. This may be partly strain specific, and the association of the current Danish-strain BCG and regional lymphadenitis has been recognised especially in HIV-positive children. Similarly, disseminated BCG disease occurs almost exclusively in immunocompromised children and has an extremely high mortality. In HIV-positive children with suspected BCG-regional axillary lymphadenitis, the diagnosis should be confirmed by means of FNA, pus swab, or gastric washout. The investigative protocol in these patients should include a chest radiograph to exclude disseminated mycobacterial disease. If a positive BCG mycobacterium is cultured from the lymph nodes, initial treatment should be by means of tuberculostatics, and surgery should be avoided and reserved for complicated patients and cases where diagnostic doubt exists.

In BCG adenitis, if the lymph nodes are <3 cm in size, the diagnostic FNA should be followed by a “wait and see” policy, which avoids the use of ineffective tuberculostatics, with the inherent problem of acquired drug resistance, as well as affording a lower incidence of surgically related complications. In nodes >3 cm in size with a negative FNA culture, other concerns of underlying disease need to be taken into account in evaluating surgical intervention. This is especially so if the patient is not responding to conventional therapy.

#### Mycobacteria other than tuberculosis

Mycobacteria other than tuberculosis can be a cause of chronic localised cervicofacial lymphadenitis. Due to MOTT's perceived resistance to

antituberculous therapy, surgical excision has become the treatment of choice for nontuberculous mycobacterial lymphadenopathy. Surgical management encompasses total excision or curettage of the affected lymph node(s) and remains the treatment of choice due to the high cure rate with a single procedure. For lesions in proximity to the facial nerve or with extensive skin necrosis, curettage can be performed as an alternative to total excision as the initial procedure. This is usually part of a staged process followed by subsequent excision and wound closure.

Immunocompetent patients with nontuberculous cervical lymphadenitis do, however, appear to show some response to medical therapy alone. A recent study<sup>2</sup> of 92 immunocompetent children with nontuberculous mycobacterial lymphadenopathy (90% *M. avium* complex or *M. hemophilum*) showed a natural history of violaceous skin changes with discharge of pus for 3–8 weeks. The infection then seemed to settle, with 71% achieving total resolution within 6 months and resolution of the remaining 29% within 9–12 months. This raises the question of a possible conservative approach to nontuberculous mycobacterial infestations of the cervicocranial region.

Cervical lymphadenopathy caused by nontuberculous mycobacteria can thus be managed by a variety of therapeutic options in immunoincompetent children, with infection resolution being the eventual outcome regardless of management option selected. The best management option in this group appears to be an individualised approach with excisional biopsy as the recommended option; its feasibility is determined by the length of history, the danger of facial nerve injury (due to position), and the presence of hypertrophic scarring.

In immunocompromised (e.g., HIV-affected) children, the management option may change depending on the CD4 count. The potential for systemic disease in these patients remains (see the preceding section on bacille Calmette-Guérin lymphadenitis).

### Other Causes of Chronic Granulomas in Lymph Nodes

#### Rosai-Dorfman disease

Rosai-Dorfman disease, or sinus histiocytosis with massive lymphadenopathy (SHML), is an uncommon but well-defined cause of chronic lymphadenopathy in childhood. It is a histiocytic proliferative disease. Patients may present with a low-grade fever and cervical lymphadenopathy. It is a benign self-limiting disorder. Histological features include numerous large histiocytes with prominent emperipolesis (a halo observed around the cell), fine vacuoles in the cytoplasm, and lymphocytes and plasma cells in the background.

Diagnosis has successfully been made with a FNA biopsy in a number of reports demonstrating the characteristic SHML features, namely, large histiocytes with abundant pale, eosinophilic cytoplasm containing well-preserved lymphocytes and occasional plasma cells and granulocytes. Additional immunostaining may demonstrate typical positive S-100 protein and alpha-1-antichymotrypsin staining, but no reaction when stained for lysozyme.

#### Cat scratch disease

Cat scratch disease is caused by infection by the *Bartonella henselae* organism. Cat scratch disease occurs in many countries (including some developing ones), but may be difficult to diagnose in children. It is a self-limiting zoonotic condition that may occur at any age, but it is most common among children and adolescents. It usually involves enlargement of only a single node regionally, which is usually the cervical or axillary and very rarely inguinal lymph nodes. It is diagnosed on careful history taking and specific serological test and histopathological examination.

#### Castleman disease

Castleman disease (angiofollicular lymph node hyperplasia) has been reported in Africa both in the cervicofacial area and intraabdominally. Although presentation as an asymptomatic neck mass is not uncommon, it most frequently presents with mediastinal lymphadenopathy.

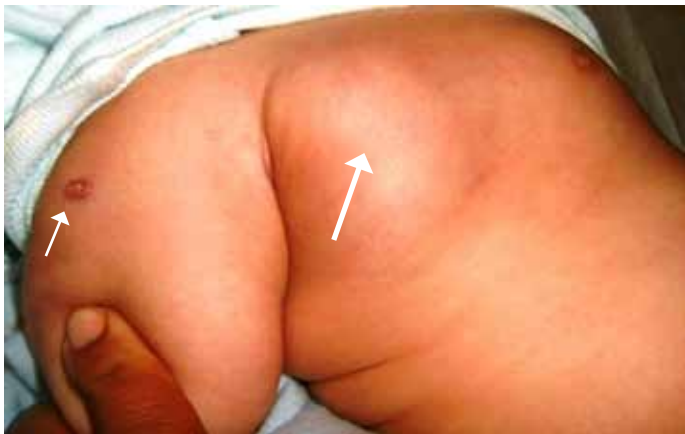

Figure 37.3: BCG ulcer (small arrow) and axillary lymphadenopathy (large arrow) in a neonate.

Other lymph node groups (e.g., cervical, intraabdominal) may occasionally be involved. Castleman disease is not always a benign disorder in children,<sup>3</sup> and associated systemic manifestations may or may not be present. There are two clinical types, localised and multicentric, as well as three histological variants (hyaline-vascular, plasma cell, and mixed type). Of these, the plasma cell and mixed type appear to be more aggressive than the hyaline-vascular type.

Although the aetiology of Castleman disease is uncertain, multicentric Castleman disease (a lymphoproliferative disorder) and Kaposi sarcoma have both been reported to have an increased occurrence in patients with HIV infection. This is as a result of the ability of the human herpes virus (HHV) 8 to persist in B-lymphoid cells and endothelial cells, and the current HIV epidemic has raised a new awareness of this association.

Surgical excision is the treatment of choice for Castleman disease, but it is not always possible to obtain a complete clearance.

### Malignancy and Lymphadenopathy

Problems still exist in excluding malignancy in lymphadenopathy in childhood, which results in difficult clinical management decisions. All efforts should be taken to achieve a definitive diagnosis. Repeated sampling of deeper nodes may be indicated if difficulties persist, and results may be further improved by sampling multiple lymph nodes and taking cultures.

The differential diagnosis of cervical lymphadenopathy includes malignant tumours. The overall risk of malignancy is approximately 12% (1 in every 8 lymph nodes biopsied) in chronic cervical lymphadenopathy. The similar incidence of reactive lymphadenopathy and chronic granulomatous infections (of different kinds) in most series suggests a similar incidence of lymph node malignancy in both developed and developing countries.

In our own series,<sup>1</sup> lymphomas were prominent in 70% of patients. These may be divided into Hodgkin's disease, non-Hodgkin's lymphomas, and Burkitt lymphoma in children. Each of the above groups represented approximately one-third of the total cases.

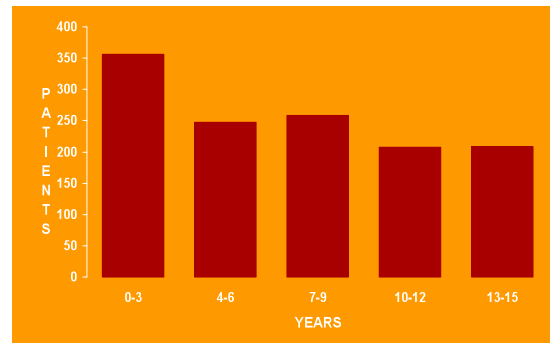
### Age

The mean age of patients with a malignancy was 8.5 years in our own series (Figure 37.4),<sup>1</sup> but some age differences are evident. Burkitt lymphoma, for instance, usually presents almost exclusively in younger children (mean age of 5 years), whereas Hodgkin's and other lymphomas occur predominantly in the older age group. Nonlymphoma-related malignancies in the head and neck region have been reported to occur more frequently at the age of 5 years or less. In our series of 1,877 specimens, these included neuroblastomas (13) and rhabdomyosarcomas (4), as well as local spread from thyroid tumours (3) and nasopharyngeal carcinoma (5). There were also a number of cervical metastases from advanced tumours at distant sites (e.g., Wilm's tumours, hepatocellular carcinomas, sarcomas, malignant melanomas, teratomas, and ovarian tumours).

### Burkitt lymphoma

A special situation occurs with Burkitt lymphoma, a childhood cancer common in sub-Saharan Africa. Burkitt lymphoma has an extremely rapid growth and a 24-hour doubling time. It has a relationship to the Epstein-Barr virus (EBV, an important cause of a variety of viral conditions as well as malignancy) and malaria, but its association with HIV is not clear as yet. The HIV pandemic as well as the increase of malaria in Africa have resulted in an increase of Burkitt lymphoma in HIV-endemic areas, particularly in HIV-infected children. Recent studies<sup>4</sup> suggest that EBV and malaria, and possibly HIV, act jointly in the pathogenesis of Burkitt lymphoma. Malaria prevention may thus potentially decrease the risk of Burkitt lymphoma. As the diagnosis and introduction of chemotherapy is urgent, there is an acute need for improved rapid diagnostic methods as well as early, appropriate oncologic management. In addition, less toxic drug combinations need to be utilised for HIV-infected patients.

### Age for lymph nodes



### Age for neoplastic nodes

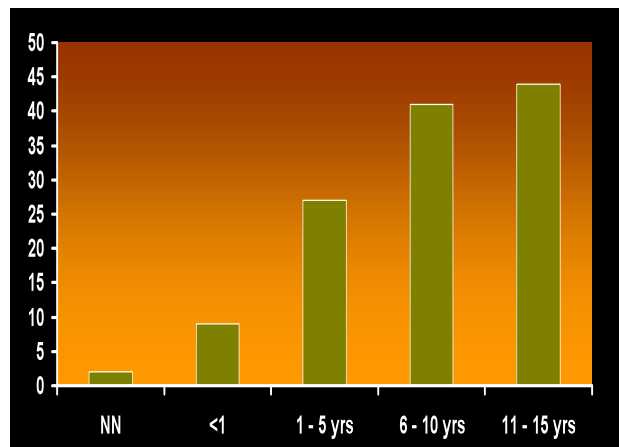


Figure 37.4: Age range of 1,877 patients with biopsy of enlarged lymph nodes. Note the increased incidence of neoplastic nodes with increasing age (right) when compared to the overall decrease in general (left).

### Oncology patients

Oncology patients warrant special consideration as far as tuberculosis is concerned, and active TB should be excluded before commencing chemotherapy in patients at risk. Further identification of latent TB in oncology patients from endemic areas and the early introduction of prophylactic anti-TB treatment during the early stage of chemotherapy might be indicated in these patients. The importance of follow-up of patients with nonspecific reactive nodes is illustrated by the fact that 15 cases (3%) in our series<sup>1</sup> were subsequently diagnosed with lymphoma, and patients identified as having an "atypical hyperplasia" should therefore undergo repeat biopsy.

### Rarer Causes of Lymphadenopathy

Other less obvious causes of lymphadenopathy (e.g., CMV, toxoplasmosis, cat scratch disease) can be identified only with special tests.

### Lymphadenopathy and viruses

Many childhood viral diseases (e.g., measles, rubella, infected chicken pox) are associated with lymphadenopathy but are not the primary presenting feature. CMV, EBV, and HHV, especially types 6, 7, and 8) have been associated with lymphadenopathy.

### Cytomegalovirus and lymphadenopathy

Most CMV infections are subclinical, including those acquired congenitally. The course of CMV mononucleosis infection is generally mild, lasting 2 to 3 weeks. The later stages may have lymphadenopathy as a feature, but that is usually atypical.

It is generally accepted that immunosuppressed or immunocompromised patients (especially those with HIV and bone marrow transplant patients) may experience more severe human CMV (HCMV) infection and disease. Control of HCMV infection and prevention of associated diseases in immunocompetent hosts are ensured mainly by CD8+ T cells.

**Epstein-Barr virus**

The Epstein-Barr virus causes the acute form of infectious mononucleosis, presenting with fatigue, malaise, fever, sore throat, hepatosplenomegaly, and a generalised lymphadenopathy. After the primary infection, EBV (similar to other herpes viruses) gives rise to lifelong latent infection. Because the virus is harboured in the oropharyngeal cells and B lymphocytes in the blood, it is therefore not surprising that both epithelial (e.g., nasopharyngeal Ca) and B lymphocyte activation (Burkitt lymphoma) occur. EBV is associated with up to 98% of cases of endemic Burkitt lymphoma.

Failure to control the EBV infection in immunocompromised patients may have severe consequences. The decrease in T-cell populations allows EBV to escape immune surveillance. It may be associated with conditions such as X-linked lymphoproliferative syndrome and the T/NK-cell lymphoproliferative disorders (LPDs) of children and young adults. These are also sometimes termed severe chronic active EBV (CAEBV) infections, which have an aggressive clinical course.

**Kikuchi-Fujimoto disease**

The cause of Kikuchi-Fujimoto disease (histiocytic necrotising lymphadenitis) is unknown, although viruses such as herpes and EBV have been associated with this condition. This disease appears to represent a common pattern of response to a variety of aetiological factors rather than a single clinicopathological entity.

This relatively newly described condition has sparked recent interest. Although appearing to be largely confined to the Far East, where it was described in young women in Southeast Asia, it has also been described in the Americas and other parts of the world. There are no reports of this condition in Africa as yet, although it is being reported from other developing countries. Reasons for this may be specific to geography or the overwhelming prevalence of tuberculosis in Africa.

**Tropical diseases and lymphadenopathy**

- Lymphadenopathy is a feature of acquired toxoplasmosis (*Toxoplasma gondii*), mainly occurring in cervical nodes. The congenital form of the disease does not show lymphadenopathy as much as hepatosplenomegaly.
- The regional lymphadenopathy that occurs with rickettsial infections such as tick bite fever is often generalised, but if localised, it may indicate the site of the bite and assist in diagnosis. Widespread trematode infections (e.g., schistosomiasis) may also produce generalised lymphadenopathy.
- Dengue fever is transmitted by the *Stegomyia* family mosquitoes and not infrequently presents with lymphadenopathy in addition to the myalgia, gastrointestinal upset, and rash usually associated with this condition.
- Lymphadenopathy may also be present in association with trypanosomiasis and West African sleeping sickness.
- Kala azar is associated with lymphadenopathy in certain areas of northern Africa, the Middle East, and South America. It needs to be differentiated from tuberculosis and malignancies such as leukaemia and lymphoma.
- Lymphadenopathy may also occur with certain zoonotic infections such as toxocariasis (visceral larva migrans).
- *Wuchereria bancrofti* infection affects the lymphatic system, is distributed throughout tropical and subtropical areas of Africa as well as many other parts of the world, and causes filariasis. Lymphatic filariasis can be disabling in the long term, but the problem relates more to lymphangitis than lymphadenopathy per se. Acute infections are characterised by fever, lymphangitis, headaches, and myalgia, mostly in the second decade of life with chronic manifestations occurring later (>30 years).

**Clinical Presentation****History**

Clinical evaluation of a child with enlarged lymph nodes includes careful history and examination. The following questions should be answered:

- When did it arise?
- Is there any association with infections?
- How fast is it growing?
- Is there any other lymphadenopathy?
- Are there any systemic symptoms (e.g., night sweats, loss of weight, bone pain)?

**Physical Examination**

Note the following features:

- position (supraclavicular/posterior triangle neck, etc.);
- size (significant if >1 cm);
- consistency (hard/matted/immobile); and
- presence of other lymphadenopathy/visceromegaly.

**Clinical Evaluation****Age of Patient**

Age plays a role because lymph nodes are usually not palpable in neonates, making neonatal lymphadenopathy suspicious. In our large series of 1,877 biopsied lymph nodes,<sup>1</sup> the mean age was 7 years (for TB, it was 5.8 years, and for neoplastic disease, 8.5 years). A comparison of the ages of all the lymph nodes sampled compared with those with malignancy shows a rather striking difference in those children older than 5 years of age, when malignancy appears to increase in prevalence.

**Size of Significant Lymph Nodes**

The size of lymph nodes should be recorded in the initial evaluation and prior to commencing treatment. Although the majority of studies avoid giving specific measurements for significant lymph nodes, nodes greater than 1 cm were considered abnormal in the cervical region (normal being <3 mm). Lymph nodes in the axilla are not considered to be enlarged unless their diameter exceeds 1 cm for axillary nodes and 1.5 cm for inguinal nodes.

Pathological lymph nodes are abnormal in size and site for the particular age of the child but also include those with an irregular or hard surface as well as lymph nodes that persist for more than 4 to 6 weeks despite adequate antibiotic treatment.

**Position of Enlarged Lymph Nodes**

The main peripheral groups of nodes involved in pathology are the cervical (46%), axillary (23%), inguinal (13%), and submandibular (8%) groups of nodes, as well as deeper areas such as the mediastinum and intraabdominal lymph nodes. The most important area is in the neck, where cervical lymphadenopathy is the most common initial presentation site of the majority of head and neck malignancies and a number of other pathologies (e.g., lymphoma).

A special risk situation exists with mediastinal nodes that may not be clinically obvious but may have exerted pressure on the trachea, thus compromising the airway. A chest x-ray (CXR) on which the mediastinum is broadened in the absence of a thymic shadow is suggestive of mediastinal lymphadenopathy. The outline of the trachea and respiratory tree can be traced on CXR, but if suspect, a computed tomography (CT) scan should be performed prior to any anaesthetic procedures being performed (Figure 37.5).

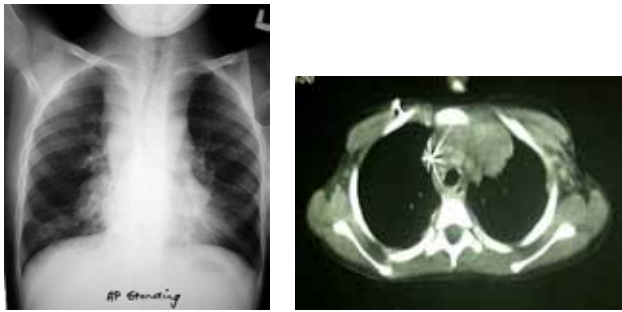


Figure 37.5: Chest x-ray (left) and CT scan (right) showing mediastinal node effect on airway.

## Localised Lymphadenopathy

### Cervical Lymphadenopathy

Cervical lymphadenopathy is a common clinical problem in children; two-thirds of affected patients are older than 5 years of age. Cervical lymphadenopathy is extremely common in developing populations and could therefore be expected to include a higher percentage of patients with acute infection, tuberculosis, neoplasia, and related diseases.

Lymphadenopathy in the posterior triangle of the neck is viewed with suspicion because lymphoma often presents there (Figure 37.6). In addition, the presence of an enlarged post auricular node in children older than 2 years of age is likely to be clinically significant. Lymphadenopathy in the supraclavicular region is highly significant, as up to 60% are caused by malignant tumours.

The clinicopathological spectrum of lymphadenopathy is not always predictable on clinical grounds, and cervical lymph nodes are often asymptomatic. The differential diagnosis largely encompasses reactive hyperplasia, specific infective agents, or malignancy. The obvious therapeutic and prognostic implications necessitate an accurate and prompt diagnosis. Nonresponse to empiric antibiotic therapy is a major criterion for further investigation. Surgical intervention provides material to establish an early diagnosis and is thus a vital part of management.

Although chronic lymphadenopathy in children of developing countries has a high incidence of infective causes, including mycobacteria; it has an approximate 11% risk of malignancy. More than half the cervical lymph nodes examined in children in a developing country displayed very significant and clinically important pathology, thereby justifying active management of all paediatric patients with persistent cervical lymphadenopathy.

The largest safely accessible node is selected for biopsy. Correct handling of a lymph node biopsy is essential. Nodes are divided in half, with half going fresh to histopathology for imprints and histology. The remaining half is further subdivided in two, with one section being sent for tissue culture and the remaining section for TB culture.

The causes of lymphadenopathy may vary from upper respiratory viral infections (e.g., adenovirus, rhinovirus, enterovirus) to the more common childhood diseases (e.g., measles, mumps, rubella, herpes) and other specific viral infections (e.g., cytomegalovirus, EBV, and HIV/AIDS (acquired immune deficiency syndrome) within endemic regions). A number of noninfective causes should also be considered in addition to the viral diseases, such as sarcoidosis, Kawasaki disease, and cat scratch disease in addition to the mycobacterial group of organisms. Axillary lymphadenopathy is mostly associated with malignancy (e.g., Hodgkin's) and cervical lymphadenopathy mostly associated with TB (although a significant number are malignant).

Lymphadenopathy is not an uncommon feature of viral and rickettsial infections and may be a part of infectious diseases such as rubella, infectious mononucleosis, and certain tropical diseases (e.g., dengue fever). In infectious mononucleosis, the lymphadenopathy is mostly cervical and epitrochlear.

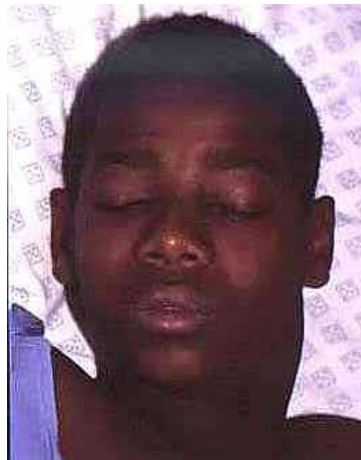

Figure 37.6: Cervical lymphadenopathy as a result of Hodgkin's lymphoma in a 10-year-old boy.

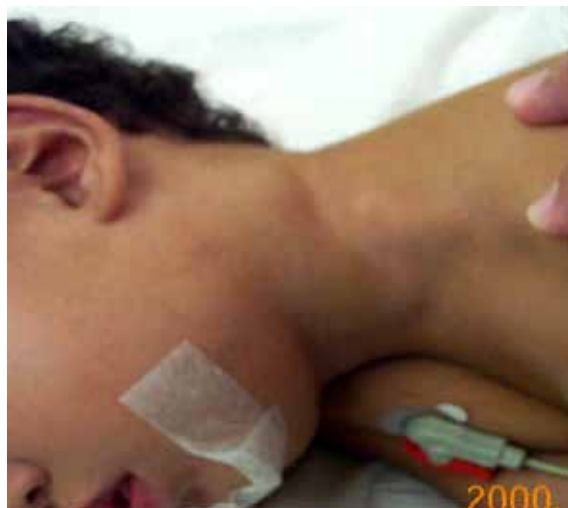

Figure 37.7: Rapidly enlarging lymph nodes in a 4-year-old boy with lymphoma.

Rapidly enlarging lymphadenopathy suggests malignant disease (Figure 37.7). The highest incidence of malignancy occurs in the supraclavicular lymph nodes.

### Axillary and Inguinal Nodes

Enlarged lymph nodes of the axilla and groin are unusual presenting sites for lymphomas, which are the most common forms of malignancy seen involving lymph nodes. Hodgkin's lymphoma may present with enlarged axillary nodes.

The presence of lymphadenopathy in atypical anatomic regions, persistence despite appropriate treatment, absence of previous pyogenic infection, geographical prevalence, history of cat scratch, and a positive TB history are all significant clues for suspecting the diagnosis of lymphoma.

Early tissue sampling may be indicated if the postauricular, epitrochlear, mediastinal, and abdominal lymph nodes are involved in the presence of generalised symptoms of unexplained fever and weight loss. The presence of large mediastinal and hilar nodes may lead to anaesthetic hazards and must be evaluated prior to a surgical procedure (e.g., biopsy) being undertaken.

## Special Investigations

Depending on the clinical presentation, the initial visit may require little or no special investigations if an empiric trial of antibiotics for proven or suspected infection is anticipated. In a subsequent visit, basic special investigations, such as a white cell count, Mantoux test, and a chest x-ray become the initial screening tools. Further investigation depends

on the clinical findings, response to antibiotic therapy, and Mantoux and CXR results. Tuberculosis should be excluded by the Mantoux skin test and chest x-ray in addition to gastric washings and cultures.

The majority of cases of lymphadenopathy are related to infection, so it is logical to rule out acute infection as a possible cause. Many clinicians would thus advocate the use of empiric antibiotics in the initial stages in the absence of other worrying signs. A 7–10 day trial of antibiotics is therefore advocated.

**Biopsy and Sampling**

Fine needle aspiration biopsy (FNAB) and sampling are indicated by any of the following conditions of the lymph nodes:

- no response to antibiotic therapy in 4–6 weeks (>2 cm);
- rapid increase in size;
- hard, matted lymph nodes in the posterior triangle or the supraclavicular region of the neck; and
- difficulty in diagnosis.

Malignancy in lymph nodes may be difficult to assess, particularly in the early stages when they appear as small blue round cells. There is a real risk of malignancy. Specialised tests such as immunostaining and flow cytometry remain useful adjuncts where available.

**Fine Needle Aspiration**

Although excision biopsy remains the gold standard in diagnosis, FNA has changed the practice in adult surgery in the modern era and may provide material to establish an early diagnosis in children.

Technically, FNA makes several passes with a 22-gauge needle from a variety of angles, using suction in the syringe once the capsule of the gland is entered on each occasion before the needle is withdrawn. A small amount of saline may be aspirated, and the obtained cells are expressed onto a glass slide and fixed in the same way as for a Papanicolaou test (Pap smear). It is then submitted to the laboratory for analysis.

FNA is a means of a rapid and definitive diagnosis of tuberculosis in the majority of cases of suspected tuberculous lymphadenitis. Expert care should therefore be expressed in interpreting negative FNA results to exclude a false sense of security. It must be stressed, however, that the interpretation of a FNA in a child is a highly specialized area of expertise, and in most cases cannot be completely sufficient to make the diagnosis of lymphoma. Its major value is probably in establishing metastatic spread from a known tumour and providing material for culture.

The definitive diagnosis is then based on cytomorphology and identification of the organism. FNA is, however, difficult to perform without sedation in the younger child and should be regarded as a diagnostic triage tool, being accurate only as far as its positive findings are concerned. It yields a smaller sample and gives no information on lymph node architecture so it must lead to a more difficult diagnosis in the absence of flow cytometry.

In a recent study,<sup>5</sup> cultures for the TB organism were positive in 79/175 patients (45%) of those subjected to FNA. In these, 61 (77%) were identified as *Mycobacterium tuberculosis* with *M. bovis* (bacille Calmette-Guérin) being identified in the remainder. Where Burkitt lymphoma is a possibility, flow cytometry techniques identify the abundance of B lymphocytes in the specimen.

**Surgical Lymph Node Biopsy**

Lymph node biopsy remains an important and valuable surgical diagnostic tool in the evaluation of lymphadenopathy with very minimal risk to the patient (Figure 37.8). It allows the assessment of gland architecture in addition to the cytological features, thereby allowing for early diagnosis. It should be the endpoint of all cases of lymphadenopathy where a diagnosis is not readily forthcoming.

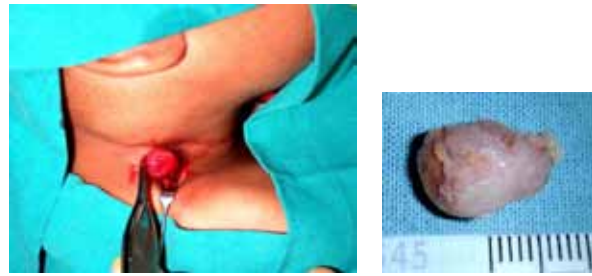


Figure 37.8: Surgical biopsy of cervical lymph node (lymphoma).

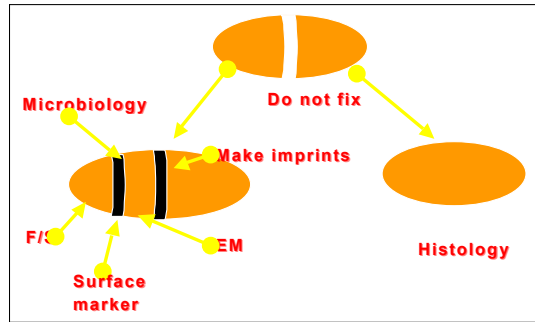


Figure 37.9: Schematic outline for handling lymph node biopsy specimens.

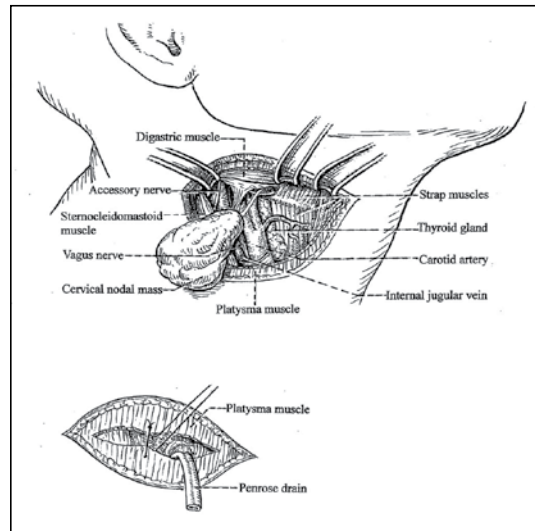
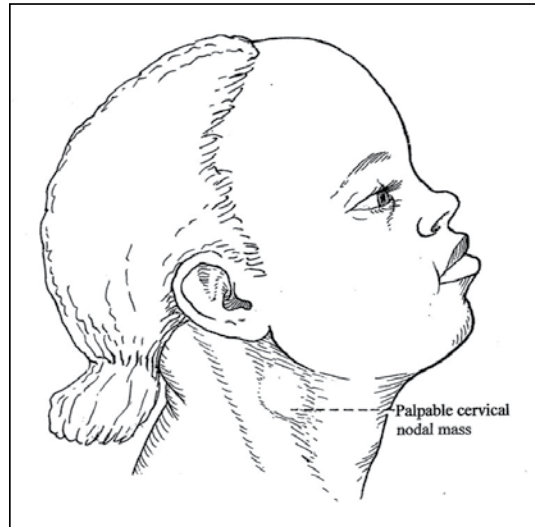


Figure 37.10: Surgical technique to excise lymph nodes.

The node sampled should be a representative node, preferably from a deep site. The node should be divided into specimens for histology and specimens for tissue culture (and TB culture). The specimen for histology should be further divided into a formalin fixed section and a section sent fresh for imprinting. Figure 37.9 outlines the handling of biopsy specimens.

The surgical technique for lymph node excision is shown in Figure 37.10.

### Immunocompromised Patient

Lymphadenopathy may be a much more serious problem in the immunocompromised patient.

Up to 18% of HIV-affected patients in Africa have lymphadenopathy on presentation. A generalised lymphadenopathy (particularly cervical and axillary nodes) has been reported as the most common presentation of children with symptomatic HIV in Zimbabwe, but concomitant tuberculosis needs to be excluded. The histological picture of HIV-affected lymphadenopathy is usually nonspecific with the immunologic reaction to HIV being the most prominent feature. The picture is further complicated by the clinical and multiple HIV virus subtypes in sub-Saharan Africa and Nigeria.

## Key Summary Points

1. Lymphadenopathy is an extremely common clinical finding in the children of Africa as well as the rest of the world.
2. It is most prevalent in the first decades of life and the majority of children between the ages of 2 and 12 will have an enlarged lymph node at one stage or another.
3. A significant lymph node is >2cm.
4. Lymphadenopathy may be the first (and sometimes only) indication of underlying disease.
5. Active management is justified of paediatric patients with persisting lymphadenopathy.
6. Atypical anatomic regions, persistence despite appropriate treatment, absence of previous pyogenic infection, geographical prevalence, history of cat scratch, a positive TB history, are all important in assessment.
7. The aetiology is mostly infective. This may be acute bacterial, viral or chronic inflammation due to many different infective agents.
8. Granulomas suggest chronic infective causes such as mycobacteria (e.g., *M. tuberculosis* and other mycobacteria] organisms.
9. A special situation exists in lymphadenopathy related to the Danish strain of bacille Calmette-Guérin, (BCG) particularly in immunocompromised children.
10. Up to 18% of HIV affected patients in Africa have lymphadenopathy on presentation.
11. Malignancy in enlarged lymph nodes occurs in 12% and 2/3 are lymphomas.
12. Fine needle Aspiration biopsy (FNAB) is a useful triage for the rapid and definitive diagnosis of tuberculosis but may miss malignancy.
13. Early tissue sampling indicated with generalized symptoms of unexplained fever and weight loss and lymphadenopathy (especially mediastinal and abdominal lymph nodes).
14. Where malignancy is suspected biopsy of an entire representative lymph node is required and submitted for appropriate culture and histology.

## References

1. Moore SW, Schneider JW, Schaaf HS. Diagnostic aspects of cervical lymphadenopathy in children in the developing world: a study of 1,877 surgical specimens. *Pediatr Surg Int* 2003; 19:240–244.
2. Zeharia A, Eidlitz-Markus T, Haimi-Cohen Y, Samra Z, Kaufman L, Amir J. Management of nontuberculous mycobacteria-induced cervical lymphadenitis with observation alone. *Pediatr Infect Dis J* 2008; 27:920–922.
3. Foucar E, Rosai J, Dorfman R. Sinus histiocytosis with massive lymphadenopathy (Rosai-Dorfman disease): review of the entity. *Semin Diagn Pathol* 1990; 7:19–73.
4. Mutalima N, Molyneux E, Jaffe H, Kamiza S, Borgstein E, Mkandawire N, et al. Associations between Burkitt lymphoma among children in Malawi and infection with HIV, EBV and malaria: results from a case-control study. *PLoS ONE* 2008; 3(6):e2505.
5. Wright CA, van der BM, Geiger D, Noordzij JG, Burgess SM, Marais BJ. Diagnosing mycobacterial lymphadenitis in children using fine needle aspiration biopsy: cytomorphology, ZN staining and autofluorescence—making more of less. *Diagn Cytopathol* 2008; 36:245–251.