

CHAPTER 49

GASTRO-OESOPHAGEAL REFLUX DISEASE

Merrill McHoney

Introduction

Gastro-oesophageal reflux (GOR) is defined as involuntary (passive) reflux of gastric contents into the oesophagus not caused by noxious stimuli. Gastro-oesophageal reflux disease (GORD) is defined as symptoms and complications arising from gastro-oesophageal reflux. GOR is present in many newborns, in whom it does not necessarily represent a clinical disease, but rather a somewhat delayed physiological development which occurs with time; some GOR can be considered “physiological” up to 3 months of age, and the reflux (without the disease) may also occur in many individuals during certain physiological processes and normal activities during the day. GORD, however, differs from this variant of normal physiological development, with complications and symptoms that lead to presentation and the need for medical or surgical intervention.

Demographics

As discussed further in the next section, GOR is common, but not necessarily pathological, in many newborns. GORD is not common in otherwise healthy children. There is no sex predilection. GORD itself has no age preponderance. The incidence in African countries and blacks is less than that seen in Westernised countries.¹⁻³ In one study, the prevalence was 4–7% of the population.¹

GORD is more common in neurologically impaired children and those with neuromuscular disease. Congenital gastrointestinal anomalies associated with a high incidence are: oesophageal atresia, congenital diaphragmatic hernia, and abdominal wall defects. Populations in which the incidence or survival of premature neonates with neurological impairment is high may also have a higher incidence of GORD.

Aetiology/Pathophysiology

Several anatomical or physiological factors prevent GOR; they can be further broken down into oesophageal factors, diaphragmatic contribution, and stomach contribution.

Oesophageal clearance is thought to act as an antireflux mechanism. The presence of an oesophageal food bolus promotes lower (distal) oesophageal relaxation as a normal enteric reflex to allow swallowing. Therefore, a lack of oesophageal clearance can promote reflux by this effect. Also, if reflux does occur (which is an occasional event in most people; even those without GORD), oesophageal clearance rids the oesophagus of irritant acid (or alkali). Poor oesophageal clearance will increase contact time and promote oesophagitis and GORD.

One of the most important oesophageal contributions is the occurrence of a length of intraabdominal oesophagus. Intraabdominal pressure can reach 10 mm Hg. During times of increased intraabdominal pressure, and with changes during inspiration, there is a positive pressure gradient that can encourage reflux of stomach contents into the lower oesophagus. However, this positive pressure in the abdomen is transmitted to the entire length of intraabdominal oesophagus, which partially closes under this positive pressure and prevents reflux. If the length of oesophagus to which this pressure can be transmitted is decreased, the incidence of reflux is higher.

The importance of the presence of intraabdominal oesophagus is demonstrated by the fact that in patients who have a length of less than 1 cm, the incidence of reflux is high (85%). This is a common situation in the newborn period. This compares to the situation at 3 months of age, when the length of intraabdominal oesophagus reaches 3 cm and the incidence of reflux decreases. With an intraabdominal oesophagus length of 3–4.5 cm, reflux is mostly abolished. This development partially underlies the relatively common finding of reflux in young infants that abates with age.

Another important oesophageal factor is the presence of a high pressure zone (HPZ) in the lower oesophagus, also known as the physiological lower oesophageal sphincter (LOS). This mechanism is thought to contribute between 10 and 30 mm Hg pressure resistance to GOR. This HPZ is identifiable on manometry studies, but not anatomically. This HPZ relaxes in advance of a food bolus to allow swallowing to occur. One major contribution to GORD in children is thought to be inappropriate or excessive relaxation of this HPZ, called transient lower oesophageal sphincter relaxation (TLOSR).

These oesophageal mechanisms are reinforced by an important contribution from the crura of the diaphragm. The right crus of the diaphragm slings around the oesophagus, as the latter enters the abdomen. This provides a pinch-cock effect that contributes to the HPZ, and, more importantly, increases lower oesophageal pressure during inspiration, when thoracic pressure is most negative and would favour reflux.

A physiological mechanism contributed by the stomach is timely and efficient stomach emptying. Some studies have linked the presence of delayed gastric emptying (DGE) to reflux by demonstrating a higher incidence and recurrence rate of reflux in children who have DGE.⁴ Some pharmacological treatments target DGE in an attempt to treat GORD.

Another anatomical contribution to reducing reflux is the presence of the acute angle of His between the oesophagus and the stomach. This acute angle allows a valve-like mechanism to occur. This arrangement is further supplemented by mucosal folds (rosettes) in the stomach. The contribution of this mucosal fold mechanism is minimal, and is thought by some not to contribute at all.

Some pathological causes and consequences of GORD with reference to these mechanisms are outlined in Table 49.1.

In addition to these pathophysiological changes, any process that leads to a significant increase in intraabdominal pressure sufficient enough to overcome these mechanisms may induce reflux and GORD. This may underlie the causation of GORD after tight abdominal closure (e.g., in gastroschisis and congenital diaphragmatic hernia).

Clinical Presentation

History

Infant

Vomiting is the most common symptom of GOR in an infant, and is usually nonbilious and effortless. The presence of bilious vomiting should prompt the search for another diagnosis. GOR should not be

Table 49.1: Possible pathological changes in GORD in relation to physiological factors preventing reflux.

Mechanism preventing reflux	Proposed contribution or pathology in GORD
Oesophageal clearance	Decreased in primary (e.g., oesophageal atresia/tracheo-oesophageal fistule (OA/TOF)) or secondary (e.g., severe oesophagitis) oesophageal motility disorders.
Length of intraabdominal oesophagus	Shortened in some congenital conditions including OA/TOF and sliding hiatus hernia.
Physiological lower oesophageal sphincter	Incriminated in transient lower oesophageal sphincter relaxation. Absent HPZ on manometry.
Diaphragmatic pinch-cock effect of crura	Abnormal anatomical configuration and/or muscular weakness (e.g., in congenital diaphragmatic hernia, muscular dystrophies, scoliosis, and cerebral palsy) may contribute to reflux.
Angle of His	Altered in hiatus hernia and abdominal wall defects. May be altered by gastrostomy placement and other abnormalities of stomach anatomy.
Gastric emptying	Delayed gastric emptying in neurologically impaired and congenital gastrointestinal conditions contribute to, or worsen, reflux.
Mucosal folds (rosettes)	Possibly only a minor contribution.

assumed in these cases, although occasionally a bile vomit may be present in GOR.

Apnoeas and bradycardias are frequent presenting features in neonates and infants.⁵ In some infants, these symptoms may progress to acute life-threatening events (ALTEs). ALTEs are acute respiratory events characterised by apnoeas, bradycardias, and acute respiratory distress, and sometimes respiratory arrest. They are thought to occur during aspiration episodes from GOR. They can lead to the need for ventilation or they can be present in neonates already ventilated on intensive care units.

Excessive vomiting can lead to failure to thrive, leading to presentation with poor or absent weight gain.

Older child

Vomiting and failure to thrive are the main presenting symptoms of GORD in older children. Haematemesis is an uncommon presenting feature, but may be present. Older children may be able to describe the typical heartburn associated with GORD. This retrosternal pain may be associated with a bitter taste in the mouth.

Respiratory symptoms of wheezing and recurrent pneumonias are uncommon but recognised features.⁶ GORD should be suspected in children with these respiratory symptoms that are atypical and resistant to treatment. Patients who have resistant wheezing not typically responding to treatment should be investigated for GORD.

Physical Presentation

No physical findings are specific to GORD. Children who are failing to thrive may have evidence of weight loss and have a weight below the fifth centile or may be crossing down centiles. Children may have features of syndromes associated with GORD. Some children may have dental caries and poor general oral hygiene secondary to their reflux. Neurologically impaired children and those with other syndromes may exhibit features of abnormal posturing suggesting Sandifer's syndrome.

Late and atypical presentations and specific presenting syndromes

Sandifer's syndrome is constellation of abnormal posture (especially back arching) due to muscular spasm involving the back and neck muscles. It may also present as torticollis. The abnormal posturing may be related to feeding or occur soon after a feed, suggesting the associa-

tion. It is usually found in neurologically impaired children, in whom a differential diagnosis is often a neurological illness or fitting.

Regurgitation of undigested food is a sign of late disease with stricture formation. If food has not made it into the stomach, stricture formation should be suspected. This can also present as food bolus obstruction at the level of the stricture. Stricture formation is present at diagnosis in approximately 5% in Western countries. Where patients typically present late, the incidence may be higher. One South African study demonstrated an incidence of 12% in children presenting to the surgical unit.⁷

Iron deficiency anaemia may be a late presenting symptom. In one African study, GOR was present in 44% of patients investigated for refractory iron deficiency anaemia.⁸

Barrett's oesophagus is metaplasia in the lower oesophagus from squamous to specialised intestinal columnar mucosa with goblet cells. It is a precursor of dysplasia and progression to adenocarcinoma. It is present in approximately 5–10% of patients with GORD.⁹ A prevalence of 2.5 per 1000 is quoted in one paediatric population-based study in the United States.¹⁰ The incidence of Barrett's is lower in African compared to Western countries;³ however, these patients tend to present later and have a higher rate of progression to adenocarcinoma.² There are no specific symptoms associated with Barrett's; it is discovered at endoscopy when biopsies are taken.

Differential diagnoses

The main differential diagnoses and the key features to differentiating them are:

- Malrotation and volvulus should be suspected if bilious vomiting is present. All patients with bilious vomiting should have an upper gastrointestinal (GI) contrast meal with follow through looking for malrotation.
- Urinary tract infection, meningitis and sepsis should be ruled out if there are signs of infection (urinary symptoms, fever, lethargy, and signs of meningism). It is important to rule out these out early or to start appropriate treatment if present. If diarrhoea is present, gastroenteritis is the likely diagnosis.
- Intestinal obstruction usually presents with acute symptoms and is associated with distention and decreased passage of stool and flatus. Abdominal x-ray will reveal intestinal distention.

Investigations

The diagnosis of GORD is made by using a combination of three main investigative tools (pH study, contrast study, and upper GI endoscopy). The choice of first-line investigation is based on a combination of availability, expertise, and symptoms. Each has its advantages and disadvantages, and any one or all three may sometimes be necessary. Other extra investigations may be added as necessary.

A 24-hour pH study is considered by most as the gold standard investigation for the diagnosis of GORD. Originally described by Johnson and Demeester in 1974,¹¹ a pH probe placed in the distal oesophagus at the level of T10 is confirmed radiologically. The reflux index (percentage of total time that the oesophageal pH is less than 4) is the main assessment used for diagnosis. If pH is less than 4 for 5% or more of the total time, the study is positive. Twenty-four-hour pH studies have had up to 100% sensitivity and 94% specificity in some studies.¹² The apple juice pH study (using apple juice feeds instead of milk) has been shown to be more sensitive in babies on milk feed,¹³ in whom milk may partially neutralise stomach acid and cause falsely high pH values in the presence of reflux.

An upper GI contrast study can also demonstrate reflux and is used to assess the anatomy of the oesophageal hiatus. It can reveal a sliding or rolling hiatus hernia if present. The contrast study is not mandatory, but it is useful in those not responding to treatment and should be done in those being considered for surgery. It can identify any stricture formation.

It is also useful for delineating the duodenojejunal (DJ) flexure to rule out malrotation.

Oesophagogastrroduodenoscopy (OGD) is performed to assess the severity of oesophagitis, and biopsies are taken. Suspicious areas of Barrett's changes will also be assessed on histology.

Other investigations and their indications include:

- A multichannel impedance study can be combined with the pH study, and may become the "platinum standard" investigation.^{6,14,15} It is thought to increase the sensitivity for reflux by allowing identification of nonacid reflux. Impedance detects changes in fluid contents in the oesophagus, and can determine the direction of flow to identify both acid and nonacid reflux. In patients in whom reflux is strongly suspected, and for whom all investigations have been normal, an impedance study may be warranted. Impedance can also be combined with manometry,¹⁵ and together they can improve the understanding of pathophysiological mechanisms in paediatric GORD.
- A radioisotope gastric emptying scan (milk scan) can be used to assess gastric emptying and identify patients with significant DGE. However, there seems to be little correlation with surgical correction of DGE and outcome (see point 13 in section on Nissen fundoplication later).
- Bronchoscopy and broncho-alveolar lavage are sometimes used to detect lipid-laden macrophages as evidence of aspiration from reflux in those with respiratory symptoms. However more recent evidence has demonstrated a low sensitivity and specificity of this test.¹⁶
- Oesophageal manometry studies may be indicated in those cases of reflux stricture that cannot be distinguished from achalasia.

Management

Medical/Nonsurgical Management

Feed thickening

Feed thickening has been shown to reduce the clinical symptoms associated with GOR,^{17,18} although this has not been proven to be the case in preterm infants in the neonatal intensive care unit (NICU).¹⁹ Several thickening agents are available:

- Alginate (Gaviscon®) and pectin are gelling agents that can be added to milk feeds and result in a thickened feed that remains in the stomach easier than liquid feeds.
- Prethickened milk feeds (e.g., Enfamil® AR) contain an easy-to-digest rice starch that thickens in the stomach and is successful in helping reduce symptoms in some children. Carob-bean gum is another thickener that is added to prethickened feeds.
- Simple common household foods can be used as additives to reduce reflux in children. These can include cereals, breads, fruit purées, corn starch,^{20,21} and other starches.

Overall, feed thickening offers moderate clinical improvement with less vomiting and improved weight gain in many infants and children.²²

Postural changes

Changes in posturing immediately postprandial have been shown to decrease GORD both clinically and experimentally. The upright position is optimal in the postprandial period in infants and children at home or in general wards. Special nursing seats that maintain an upright position are used to reduce reflux. However upright positioning is not possible in all settings (e.g., in the NICU). Nursing infants in the prone position has been shown to reduce the instances of reflux, as demonstrated on dual pH and impedance monitors in the lower oesophagus in infants.²³ Others have shown that the ideal position is determined by the time after feeding, and changes from the right lateral in the early postprandial hour to left lateral later on.²⁴

Feeding regimen

Changes in feeding pattern can be used to achieve a regimen that minimises symptoms. Smaller volumes and more frequent feeds can

accomplish adequate calorific intake and achieve growth with minimal vomiting by reducing stomach distention with each feed. This may be especially useful in infants, most of whom will grow out of their reflux without major intervention.

All three of the above measures can be additive and should be tried together where possible.

Pharmacological treatment

Medical treatment of GORD usually involves therapy with an acid suppressant alongside a prokinetic agent in an attempt to reduce reflux and decrease complications.^{25–28}

Gastrointestinal prokinetics are used to promote gastric emptying, reduce episodes of GOR, and improve symptoms. They may also act by increasing LOS tone. Common therapeutic agents are domperidone and erythromycin. Metoclopramide, an antidopaminergic and cholinomimetic drug, is a prokinetic agent that has also been used for medical management of GORD. However neurologic adverse effects (e.g., tardive dyskinesia) may occur. Cisapride is another very effective drug in this group, but has been taken off the market in most countries due to its cardiac side effects and is now available only in a limited-use protocol.

The H₂-receptor blockers (ranitidine, cimetidine) and proton pump inhibitors (omeprazole, lansoprazole) decrease acid output from the stomach and reduce both the symptoms and complications of GORD.²⁶ Oesophagitis has been shown to significantly improve on antacid therapy (particularly proton pump inhibitors). Proton pump inhibitors have become one of the main arms of maximal medical therapy in treating GORD and reversing the complications associated with the disease. Medical therapy with a thickener (such as Gaviscon), along with a prokinetic (domperidone) and a proton pump inhibitor have been used for 6 months as a maximal medical treatment to treat the disease. Patients who are not responsive to this treatment or need continuing therapy to control disease can be considered for step-up management (surgery).

Nasojejunal feeding is an alternative to operative intervention in those unfit for surgery or when surgery is not available. The incidence of complications and symptom resolution, however, may not be significantly different between operative intervention and jejunal feeding.²⁹ In appropriate clinical settings, the passage of a nasojejunal feeding tube (with radiological control or confirmation) may be enough to allow safe and effective feeding and sufficient time for growth, allowing the infant to "outgrow" GOR. Problems may arise with the presence of a long-term nasal tube (pressure effects, frequent dislodging, and difficulty with feeding regimen) and may push towards either a jejunostomy or definitive surgery.

Surgery

Surgery is usually contemplated only in those who do not improve on maximal medical management or need continuing medical treatment. The main (but not exclusive) indications for surgery include:

- ALTE;³⁰
- presence of a hiatus hernia (GORD will not resolve with medical management);
- recurrent aspiration and pneumonias;²⁹
- failure of, or need for, continued maximum medical management (decreases the need for long-term medical management,³¹ particularly in neurologically normal children);
- stricture; and
- Barrett's oesophagus (relative indication).

Strictures are best treated initially by maximal medical treatment and dilatations. Dilatations may need to be repeated. Oesophageal dilatation can be performed either by bougie or balloon dilatation. There seems to be little difference in the incidence of complications (e.g., perforation) between the two approaches; however, balloon

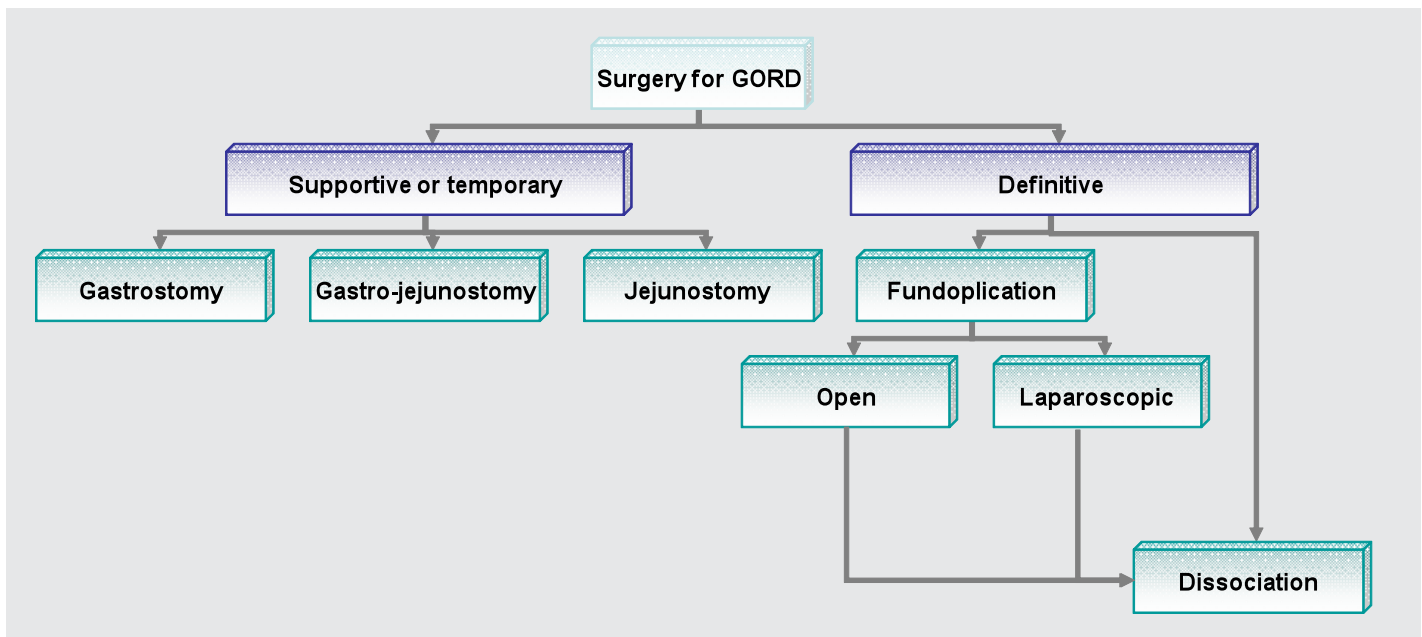


Figure 49.1: Operative intervention for GORD.

dilatation with radiological screening seems to be an inherently safer approach. Most patients then require surgery for their GORD. In one study in Cape Town, only 6 out of 31 patients with strictures secondary to GORD did not require antireflux surgery.³² Overall, the approach of dilatation followed by antireflux surgery cures 75% of strictures. The remainder of patients may require further dilatations or resection of the strictured segment of oesophagus.

Barrett's oesophagus can also be considered a relative indication for antireflux surgery. There is a small incidence of adenocarcinoma secondary to Barrett's metaplasia. The evidence that surgical treatment is more effective than medical management in preventing progression to cancer has not been proven, however.³³ Laser ablation therapy has been shown in adult studies to be highly effective in curing Barrett's metaplasia^{34,35} alongside medical or surgical management of the GORD. No data of its use in children have been published.

Surgery for GORD can be divided into either supportive/temporary or definitive (see Figure 49.1).

Supportive or Temporary Surgery

Gastrostomy for treatment of GORD is occasionally used as a means of establishing feeds and allowing the infant or child to thrive temporarily while maintaining minimal oral intake if possible. There is still some debate in the literature as to whether gastrostomy placement worsens reflux.³⁶ Some surgeons argue that a gastrostomy placed in the lesser curvature of the stomach is associated with less reflux, and may even improve symptoms.^{37,38} Nevertheless, worsening of reflux is a possibility and should be taken into account; this possibility should be mentioned when obtaining consent for surgery. Gastrostomy placement may also be required in patients with severe strictures that need dilatation, both as a means of establishing feeds and a means of accessing the oesophagus for string-guided dilatations.³²

Gastrojejunostomy is one step further along in the management of GORD in children. It offers advantages over gastrostomy in allowing feeding beyond the pylorus, thus significantly reducing reflux. It has the disadvantages of needing more time-consuming feeding regimens due to the inability to bolus feed. There are various methods of achieving gastrojejunostomy tube feeds. A feeding tube can be placed through an existing gastrostomy and confirmed by radiological imaging. Alternatively, custom-made devices, such as the percutaneous endoscopic gastrostomy-jejunostomy (PEG-J) tube, can be used.

This is placed endoscopically with the jejunostomy extension passed through the pylorus at the time of surgery and confirmed to be in the jejunum on x-ray. This tube also has the advantage of having access ports in the stomach to allow gastric feeding or decompression.

Placement of a jejunostomy tube directly into the jejunum is occasionally used. This is usually a tunnelled type (although a Roux-en-Y configuration is possible). Through a mini-laparotomy incision, a loop of jejunum, preferably 15 cm from the DJ flexure, is isolated as the insertion site. The silk jejunostomy tube is then tunnelled along the jejunum by imbricating the serosa around the tube by using sutures. The tube is then inserted into a stab incision in the jejunum and secured with a double purse string suture in a Stamm gastrostomy fashion. The jejunum, from the apex to the insertion site, is then sutured to the abdominal wall to complete the tunnel. The disadvantage of a jejunostomy is the difficulty in re-establishing the tube should it be pulled out. Displacement is possible, and caregivers should be aware of what should be done in the event of this occurrence. Jejunostomies are associated with higher complication rates compared to gastrojejunostomies (e.g., infections, leakage, feeding difficulties).

The options outlined above provide temporary treatment of GOR by allowing enteral intake and growth to be established before embarking on more major surgery. The infant/child can be tried on increasing oral intake while tube-feeding continues. Tube-feeding can then be stopped if full oral intake is achieved. These devices can then be removed on an outpatient basis without the need for surgery. Occasionally, a minor operation is needed if the stoma does not close.

Definitive Surgery

Definitive surgery (fundoplication) for GORD aims to address or augment the main contributing factors preventing reflux and to reverse any pathology present. Table 49.2 shows the key features of definitive surgery to correct GORD as it relates to the antireflux mechanism and pathology discussed earlier.

Nissen Fundoplication to Treat GORD

The operative details of Nissen fundoplication (360° wrap) are presented here because it is the author's operation of choice. Salient points on other operations are briefly presented in the next section.

1. A subcostal incision is appropriate in most cases. (Other options include rooftop, transverse supraumbilical or midline incisions,

Table 49.2: Surgical steps in treating GORD.

Mechanism preventing reflux	Surgical steps in treating GORD
Oesophageal clearance	Secondary effect from treating oesophagitis; however, a tight wrap can delay and cause dysphagia.
Length of intraabdominal oesophagus	Mobilisation of oesophagus and achieving an intraabdominal length of at least 2–3 cm.
Physiological lower oesophageal sphincter	Repairing hiatus hernia. Reinforcing the HPZ with a wrap of stomach around the abdominal oesophagus.
Diaphragmatic pinch-cock effect of crura	Tightening of hiatus with sutures. Repairing hiatus hernia.
Angle of His	Reinforcing acute angle between stomach and oesophagus (e.g., in Boix-Ochoa fundoplication).
Gastric emptying	Increased due to a decrease in stomach size. ± Pyloroplasty increases emptying

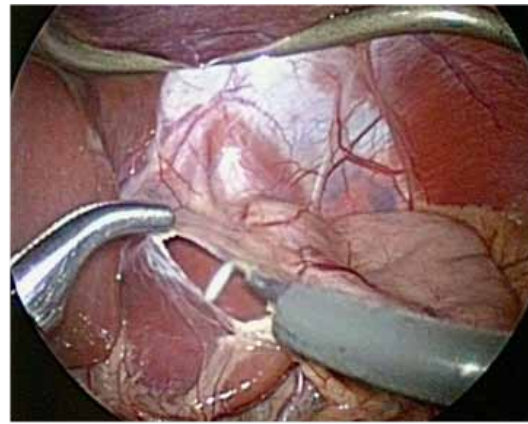


Figure 49.2: Incision in zona pellucida over caudate lobe of liver. The incision is extended towards the crura, seen just superior to the incision.

depending on the body habitus and size of the patient as well as the surgeon's preference.)

2. The upper portion of the gastrohepatic ligament above the left gastric vessels over the caudate lobe of the liver (zona pellucida of the lesser omentum) is incised (Figure 49.2) and extended cranially and medially towards the oesophageal hiatus.

3. The crura of the diaphragm are then identified and dissected free while mobilising the oesophagus (incising the phreno-oesophageal ligament) to ensure an adequate intraabdominal length (usually 2–3 cm, depending on the size of the child).

4. If present, the sac of any hiatal hernia is excised, taking care not to enter the pleural cavity.

5. A window posterior to the oesophagus is created by dissection between it and the crura. The posterior vagus (and anterior, if possible) are identified during the dissection and kept with the oesophagus. The fundus of the stomach should be visible through this window.

6. The fundus of the stomach is freed from adhesions to the abdominal wall and spleen. Small peritoneal adhesions to the spleen are relatively common and need to be divided. Formal division of the short gastric vessels are not mandatory, but should be undertaken if needed to ensure a “floppy” wrap.

7. The oesophageal hiatus is then narrowed by using nonabsorbable sutures to approximate the crura posterior to the oesophagus (Figure 49.3). Usually, two sutures are needed, but this can vary. The crura are approximated enough to leave a small space between them and the oesophagus; this should be just enough for a fingertip.

8. The proximal oesophagus is sutured to the diaphragm by using a nonabsorbable suture to anchor it in place. This is optional, but adds stability to the oesophagus in the abdomen.

9. The fundus is then guided behind the oesophagus, ensuring that it is not under tension when wrapped around the lower oesophagus and that it is not twisted.

10. A floppy wrap is then constructed by using the fundus of the stomach, using three rows of nonabsorbable sutures placed widely on the fundus (Figure 49.4). These sutures can also be passed superficially through the oesophagus between the stomach ends (stomach-oesophagus-stomach).

11. The looseness of the wrap is tested by gently lifting the wrap off the oesophagus (or a gentle shoe-shining manoeuvre).

12. If required, a gastrostomy can be constructed in a Stamm fashion at the junction of the body and antrum.

13. A pyloroplasty is not routinely performed by this author, even in

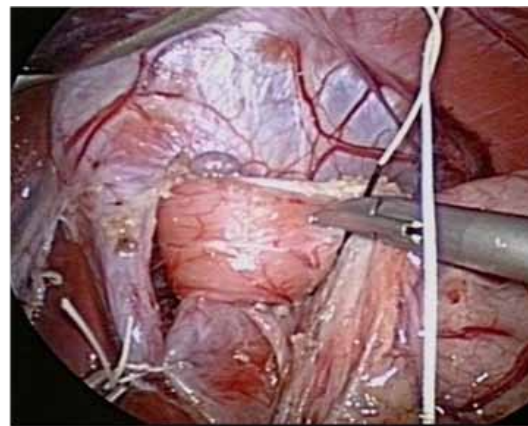


Figure 49.3: Second suture about to be placed to narrow the oesophageal hiatus. The anterior vagus is visible above the oesophagus.

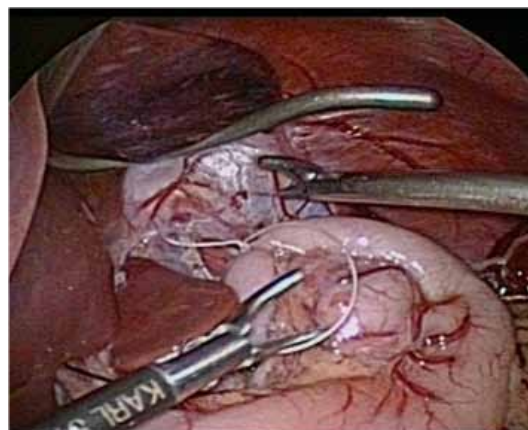


Figure 49.4: Completed floppy Nissen fundoplication.

those that have been shown to have delayed gastric emptying. Brown et al.³⁹ have demonstrated that a gastric outlet operation is not needed in most cases of fundoplication because almost 90% of patients have normalised gastric emptying after surgery. Also, Pacilli et al.⁴⁰ have demonstrated that gastric emptying, measured by using an isotope milk scan, increased following Nissen fundoplication without pyloroplasty. Therefore, a policy of fundoplication without pyloroplasty seems justifiable, leaving this option as a later addition in those that have continuing problems.

14. Pyloroplasty is performed by making a longitudinal incision along the pylorus through all layers. This is then closed transversely using interrupted sutures.

A laparoscopic approach to Nissen fundoplication is justifiable in surgeons with the expertise, with comparable outcomes compared to open surgery in randomised studies (in adults).⁴¹ In a randomised trial, laparoscopic Nissen fundoplication in children was shown to preserve immune function in the postoperative period.⁴² Laparoscopic antireflux surgery has now largely become the preferred approach in children where expertise exists (including our own institution). Day case laparoscopic Nissen fundoplication in South Africa has also been described,⁴³ and is a testament to the advances in recovery that can be achieved with the laparoscopic approach.

The other more common operations used to treat GORD include:

- Thal fundoplication (anterior 180° wrap).
- Toupet fundoplication (posterior 270° wrap).
- Boix-Ochoa fundoplication; additional steps after closing the hiatus involves stitching the fundus to the right crus of the diaphragm to restore the angle of His. The fundus is then plicated over the intraabdominal oesophagus as a partial anterior wrap up to the hiatus. The fundus of the stomach is then sutured to the undersurface of the diaphragm by using three sutures that suspend the fundus.

Many other versions and variations of antireflux surgery exist, with slight variations of the steps for Nissen fundoplication. There is little evidence that any one operation is superior to any other in terms of efficacy and outcome, and the choice of operation is usually up to the surgeon's choice and experience.

Total Oesophago gastric Dissociation

Total oesophago gastric dissociation (Roux-en-Y oesophagojejunal anastomosis and jejunostomy with gastrostomy feeding tube) was initially proposed as a salvage operation for patients who have multiple failed fundoplications^{44,45} (predominantly neurologically impaired children). It has now been proposed to include total oesophago gastric dissociation as a primary procedure in the severely neurologically impaired child or in difficult scenarios.^{46,47} The author has no experience with this operation and further details are therefore not given here.

Complications

Bleeding from trauma to the liver or spleen can occur intraoperatively and should be anticipated with cross-matched blood. Rarely, splenectomy is required due to uncontrollable bleeding.

Perforation of the oesophagus during mobilisation is avoidable if careful dissection is performed. Occasionally, difficult dissection due to severe inflammation may make this complication more likely.

Respiratory complications, including pneumonia and atelectasis, occur mainly in the neurologically impaired or in those with neuromuscular disease. Pneumothorax may be caused during the dissection around the oesophageal hiatus if the pleura is accidentally incised. The consequence is usually mild, and the operation can be continued without intervention. Occasionally, a chest tube may be needed intraoperatively. If suspected and demonstrated on a postoperative x-ray, treatment should be on clinical grounds.

Gastrostomy-related complications include leakage, granuloma formation, infection, and tube dislodgement. Most gastrostomy

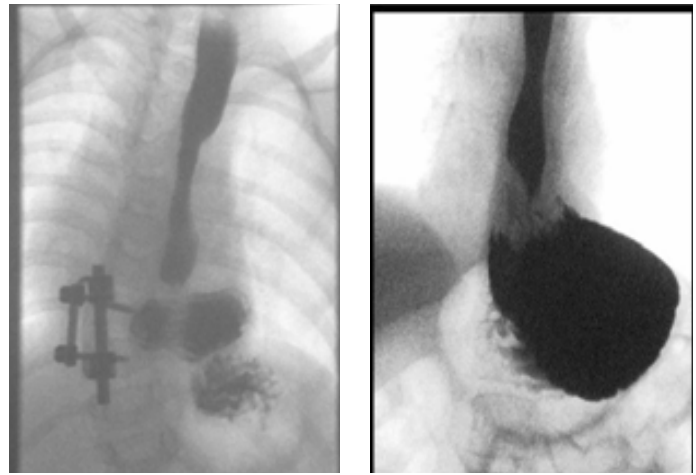


Figure 49.5: Contrast study after a Nissen fundoplication with recurrence of symptoms, demonstrating a sliding hernia. Note the indentation of the oesophagus, indicating the wrap is intact.

complications are treatable by conservative measures. Leakage from the stoma site is best addressed first by changing to a shorter button to achieve a better fit. Occasionally downsizing to a smaller gauge, to allow the stoma to shrink, then replacing with the original size is helpful. Granulomas can be treated with repeated silver nitrate cauterisation, which is effective in most cases. Occasionally, excision is required. Infections are treated with appropriate topical or systemic antibiotics, depending on prevalence and culture results. Parents and caregivers should always be warned of tubes falling out and advised of the action to take to maintain stoma patency. Occasionally, attempts at replacing the tube can lead to separation of the stomach from the abdominal wall, with peritonitis if feeds are then instilled into the abdominal cavity. This can be fatal if not recognised or if recognised too late.

Dysphagia is present in 5–10% of patients in the postoperative period. Most tend to resolve with time. A portion of patients continue to have significant problems and need dilatation; an even smaller portion need redo surgery.

Intestinal obstruction caused by adhesions can occur. This complication can be treated operatively or initially conservatively depending on clinical presentation. The incidence of adhesions may be lower after laparoscopic approach compared to open surgery.⁴⁸

Retching after fundoplication occurs predominantly in the neurologically impaired group. This can resolve with changes in the feeding regimen and type of milk. In some patients, it persists, and a trial of alimemazine, an antihistaminic that has shown to improve this symptom, is sometimes effective.⁴⁹ Most patients with postoperative retching settle with conservative management. In the remainder, alimemazine has variable success. Gas bloat is also common due to the inability to burp up ingested air. Patients with gastrostomies can be vented regularly to avoid bloating.

Recurrence is seen in 5–25% of patients, depending on the series quoted.^{27,31,50,51} The incidence is higher in patients with neurological impairment (20–40%) compared to neurologically normal children (5–10%).^{31,51,52} The incidence is also higher in patients with congenital anomalies. If further surgical intervention is being considered, an upper gastrointestinal contrast study is performed to assess the integrity and position of the wrap. In most series, the cause of the recurrence is equally shared by wrap failure and wrap migration (into the chest). Figure 49.5 shows two contrast studies demonstrating intact wraps that have migrated into the chest. Recurrent herniations are best treated by redo surgery (redo of the wrap itself is not mandatory, however, if it appears sufficient at operation).

Barrett's oesophagus can occur despite surgical or medical treatment. In adults, it seems to be between 4 and 8 per 1,000 patient years, with no

significant difference between those treated medically and those treated surgically.³³ The incidence in children is difficult to establish.

A mortality risk exists for children having Nissen fundoplication. Most of the mortality is late and due to associated conditions. Bradnock et al., in their series of 85 patients, found a late mortality of 7% in children who underwent laparoscopic fundoplication.⁵³ A similar rate of mortality was reported by Tovar et al⁵¹ in their series of 252 children who had either open or laparoscopic fundoplication. In that series, 17 deaths (6.7%) occurred; 3 in the first postoperative month, with only 1 (0.4%) related to the operation.

Prognosis and Outcomes

In patients with mild disease that resolves on conservative management or with pharmacotherapy with no recurrence, the outcome is good. Resolution in infants usually takes 3 to 6 months.⁵⁴ Those with more severe symptoms may have ongoing disease even if improvement is noted.⁵⁵

Table 49.3: Evidence-based research.

Title	The effect of thickened-feed interventions on gastroesophageal reflux in infants: systematic review and meta-analysis of randomised, controlled trials
Authors	Horvath A, Dziechciarz P, Szajewska H
Institution	Department of Paediatrics, Medical University of Warsaw, Warsaw, Poland
Reference	Pediatrics 2008; 122:e1268–e1277
Problem	Currently, thickened feeds are increasingly being used to treat infants with gastro-oesophageal reflux, driven in large part by the baby food industry. Previous meta-analyses have shown that although thickened formulas do not seem to reduce measurable reflux, they may reduce vomiting. However, because data are limited, there is still uncertainty regarding the use of thickening agents.
Intervention	Meta-analysis of randomised controlled trials.
Comparison/control (quality of evidence)	The Cochrane Library, Medline, Embase, and CINAHL databases and proceedings of the European and North American paediatric gastroenterology conferences (from 2000) were searched in May 2008; additional references were obtained from reviewed articles. Only randomised, controlled trials that evaluated thickened feeds used in infants for at least several days for the treatment of gastro-oesophageal reflux were considered for inclusion. Three reviewers independently performed data extraction by using standard data-extraction forms. Discrepancies between reviewers were resolved by discussion among all authors. Only the consensus data were entered.
Outcome effect	Fourteen randomised, controlled trials with a parallel or crossover design, some with methodologic limitations, were included. Use of thickened formulas compared with standard formula significantly increased the percentage of infants with no regurgitation, slightly reduced the number of episodes of regurgitation and vomiting per day (assessed jointly or separately), and increased weight gain per day. It had no effect on the reflux index, number of acid gastro-oesophageal reflux episodes per hour, or number of reflux episodes lasting >5 minutes, but significantly reduced the duration of the longest reflux episode of pH <4. No definitive data showed that one particular thickening agent is more effective than another. No serious adverse effects were noted.
Historical significance/comments	Thickened food is moderately effective in treating gastro-oesophageal reflux in healthy infants.

The main adverse determinants of outcome seem to be the presence of neurological impairment, the presence of associated congenital anomalies, and stricture.

Barrett's oesophagus is a precursor to malignant adenocarcinoma of the oesophagus. Endoscopic surveillance is advocated in older children into adulthood. The incidence of carcinoma in those diagnosed in childhood is not well established.

Prevention

There are no known preventive measures.

Evidence-Based Research

Tables 49.3 and 49.4 present trial studies on thickened-feed interventions in infants and a comparison of laparoscopic and open fundoplication in children, respectively.

Table 49.4: Evidence-based research.

Title	Clinical outcome after open and laparoscopic Nissen fundoplication in children: randomised controlled trial
Authors	McHoney M, Eaton S, Drake DP, Kiely EM, Curry J, Spitz L, Pierro A
Institution	Great Ormond Street Hospital for Children, London, UK
Reference	Abstract Canadian Association of Pediatric Surgery Conference, October 2004
Problem	There have been no randomised controlled studies comparing the outcome between open and laparoscopic fundoplication in children. The aim of this study was to compare the clinical outcome in children undergoing Nissen fundoplication who were randomised to open surgery or laparoscopy.
Intervention	Randomised to open and laparoscopic Nissen fundoplication.
Comparison/control (quality of evidence)	Randomised control trial.
Outcome effect	Twenty patients in the open and 19 patients in the laparoscopic group. Median time to establish full feeds was 2 days in both groups. Median hospital stay was 4.5 days in the open group versus 5 days in the laparoscopic group, with no significant difference between groups. There was no significant difference in morphine requirements, although pain scores fell significantly faster in the laparoscopy group. Incidence of dysphagia, recurrence of reflux, and need for redo fundoplication were not significantly different between groups. At the time of follow-up, the incidence of retching was higher after open surgery (56%) versus laparoscopy (6%; $p = 0.003$).
Historical significance/comments	This randomised trial demonstrated equal efficacy between laparoscopic and open fundoplication in children.

Key Summary Points

1. Gastro-oesophageal reflux is common in newborns and not necessarily related to disease pathology. Gastro-oesophageal reflux disease is more common in neurologically impaired children and those with congenital abnormalities of the upper GI tract.
2. Conservative and medical therapies are the mainstay of management, and surgery is reserved for those with complications and the need for ongoing maximal medical treatment.
3. Laparoscopic or open fundoplication is the operative procedure of choice, with a relatively good outcome, especially in neurologically normal children. There is a higher incidence of complications and recurrences in neurologically impaired children.

References

1. Sonnenberg A, El Serag HB. Clinical epidemiology and natural history of gastroesophageal reflux disease. *Yale J Biol Med* 1999; 72(2-3):81-92.
2. Mason RJ, Bremner CG. The columnar-lined (Barrett's) oesophagus in black patients. *S Afr J Surg* 1998; 36(2):61-62.
3. Segal I. The gastro-oesophageal reflux disease complex in sub-Saharan Africa. *Eur J Cancer Prev* 2001; 10(3):209-212.
4. Di Lorenzo C, Piepsz A, Ham H, Cadranel S. Gastric emptying with gastro-oesophageal reflux. *Arch Dis Child* 1987; 62(5):449-453.
5. Magista AM, Indrio F, Baldassarre M, et al. Multichannel intraluminal impedance to detect relationship between gastroesophageal reflux and apnoea of prematurity. *Dig Liver Dis* 2007; 39(3):216-221.
6. Rosen R, Nurko S. The importance of multichannel intraluminal impedance in the evaluation of children with persistent respiratory symptoms. *Am J Gastroenterol* 2004; 99(12):2452-2458.
7. Rode H, Millar AJ, Brown RA, Cywes S. Reflux strictures of the esophagus in children. *J Pediatr Surg* 1992; 27(4):462-465.
8. Fayed SB, Aref MI, Fathy HM, et al. Prevalence of celiac disease, *Helicobacter pylori* and gastroesophageal reflux in patients with refractory iron deficiency anemia. *J Trop Pediatr* 2008; 54(1):43-53.
9. Ahmed HH, Mudawi HM, Fedail SS. Gastro-oesophageal reflux disease in Sudan: a clinical endoscopic and histopathological study. *Trop Gastroenterol* 2004; 25(3):135-138.
10. El Serag HB, Gilger MA, Shub MD, Richardson P, Bancroft J. The prevalence of suspected Barrett's esophagus in children and adolescents: a multicenter endoscopic study. *Gastrointest Endosc* 2006; 64(5):671-675.
11. Johnson LF, Demeester TR. Twenty-four-hour pH monitoring of the distal esophagus. A quantitative measure of gastroesophageal reflux. *Am J Gastroenterol* 1974; 62(4):325-332.
12. Da Dalt L, Mazzoleni S, Montini G, Donzelli F, Zacchello F. Diagnostic accuracy of pH monitoring in gastro-oesophageal reflux. *Arch Dis Child* 1989; 64(10):1421-1426.
13. Tolia V, Kauffman RE. Comparison of evaluation of gastroesophageal reflux in infants using different feedings during intraesophageal pH monitoring. *J Pediatr Gastroenterol Nutr* 1990; 10(4):426-429.
14. Loots CM, Benninga MA, Davidson GP, Omari TI. Addition of pH-impedance monitoring to standard pH monitoring increases the yield of symptom association analysis in infants and children with gastroesophageal reflux. *J Pediatr* 2009; 154(2):248-252.
15. van Wijk MP, Benninga MA, Omari TI. Role of the multichannel intraluminal impedance technique in infants and children. *J Pediatr Gastroenterol Nutr* 2009; 48(1):2-12.
16. Rosen R, Fritz J, Nurko A, Simon D, Nurko S. Lipid-laden macrophage index is not an indicator of gastroesophageal reflux-related respiratory disease in children. *Pediatrics* 2008; 121(4):e879-e884.
17. Orenstein SR, Magill HL, Brooks P. Thickening of infant feedings for therapy of gastroesophageal reflux. *J Pediatr* 1987; 110(2):181-186.
18. Wenzl TG, Schneider S, Scheele F, et al. Effects of thickened feeding on gastroesophageal reflux in infants: a placebo-controlled crossover study using intraluminal impedance. *Pediatrics* 2003; 111(4 Pt 1):e355-e359.
19. Corvaglia L, Ferlini M, Rotatori R, et al. Starch thickening of human milk is ineffective in reducing the gastroesophageal reflux in preterm infants: a crossover study using intraluminal impedance. *J Pediatr* 2006; 148(2):265-268.
20. Chao HC, Vandenplas Y. Comparison of the effect of a cornstarch thickened formula and strengthened regular formula on regurgitation, gastric emptying and weight gain in infantile regurgitation. *Dis Esophagus* 2007; 20(2):155-160.
21. Chao HC, Vandenplas Y. Effect of cereal-thickened formula and upright positioning on regurgitation, gastric emptying, and weight gain in infants with regurgitation. *Nutrition* 2007; 23(1):23-28.
22. Horvath A, Dziechciarz P, Szajewska H. The effect of thickened-feed interventions on gastroesophageal reflux in infants: systematic review and meta-analysis of randomized, controlled trials. *Pediatrics* 2008; 122(6):e1268-e1277.
23. Corvaglia L, Rotatori R, Ferlini M, et al. The effect of body positioning on gastroesophageal reflux in premature infants: evaluation by combined impedance and pH monitoring. *J Pediatr* 2007; 151(6):591-596.
24. van Wijk MP, Benninga MA, Dent J, et al. Effect of body position changes on postprandial gastroesophageal reflux and gastric emptying in the healthy premature neonate. *J Pediatr* 2007; 151(6):585-590.
25. Cucchiara S, Minella R, Iervolino C, et al. Omeprazole and high dose ranitidine in the treatment of refractory reflux oesophagitis. *Arch Dis Child* 1993; 69(6):655-659.
26. Hassall E, Israel D, Shepherd R, et al. Omeprazole for treatment of chronic erosive esophagitis in children: a multicenter study of efficacy, safety, tolerability and dose requirements. International Pediatric Omeprazole Study Group. *J Pediatr* 2000; 137(6):800-807.
27. Cezard JP. Managing gastro-oesophageal reflux disease in children. *Digestion* 2004; 69 Suppl 1:3-8.
28. Pritchard DS, Baber N, Stephenson T. Should domperidone be used for the treatment of gastro-oesophageal reflux in children? Systematic review of randomized controlled trials in children aged 1 month to 11 years old. *Br J Clin Pharmacol* 2005; 59(6):725-729.

29. Srivastava R, Downey EC, O’Gorman M, et al. Impact of fundoplication versus gastrojejunal feeding tubes on mortality and in preventing aspiration pneumonia in young children with neurologic impairment who have gastroesophageal reflux disease. *Pediatrics* 2009; 123(1):338–345.
30. Valusek PA, St Peter SD, Tsao K, et al. The use of fundoplication for prevention of apparent life-threatening events. *J Pediatr Surg* 2007; 42(6):1022–1024.
31. Lee SL, Sydorak RM, Chiu VY, et al. Long-term antireflux medication use following pediatric Nissen fundoplication. *Arch Surg* 2008; 143(9):873–876.
32. Numanoglu A, Millar AJ, Brown RA, Rode H. Gastroesophageal reflux strictures in children, management and outcome. *Pediatr Surg Int* 2005; 21(8):631–634.
33. Corey KE, Schmitz SM, Shaheen NJ. Does a surgical antireflux procedure decrease the incidence of esophageal adenocarcinoma in Barrett’s esophagus? A meta-analysis. *Am J Gastroenterol* 2003; 98(11):2390–2394.
34. Schulz H, Miehlke S, Antos D, et al. Ablation of Barrett’s epithelium by endoscopic argon plasma coagulation in combination with high-dose omeprazole. *Gastrointest Endosc* 2000; 51(6):659–663.
35. Morino M, Rebecchi F, Giaccone C, et al. Endoscopic ablation of Barrett’s esophagus using argon plasma coagulation (APC) following surgical laparoscopic fundoplication. *Surg Endosc* 2003; 17(4):539–542.
36. Razeghi S, Lang T, Behrens R. Influence of percutaneous endoscopic gastrostomy on gastroesophageal reflux: a prospective study in 68 children. *J Pediatr Gastroenterol Nutr* 2002; 35(1):27–30.
37. Plantin I, Arnbjornsson E, Larsson LT. No increase in gastroesophageal reflux after laparoscopic gastrostomy in children. *Pediatr Surg Int* 2006; 22(7):581–584.
38. Stringel G. Gastrostomy with antireflux properties. *J Pediatr Surg* 1990; 25(10):1019–1021.
39. Brown RA, Wynchank S, Rode H, Millar AJ, Mann MD. Is a gastric drainage procedure necessary at the time of antireflux surgery? *J Pediatr Gastroenterol Nutr* 1997; 25(4):377–380.
40. Pacilli M, Pierro A, Lindley KJ, Curry JI, Eaton S. Gastric emptying is accelerated following laparoscopic Nissen fundoplication. *Eur J Pediatr Surg* 2008; 18(6):395–397.
41. Catarci M, Gentileschi P, Papi C, et al. Evidence-based appraisal of antireflux fundoplication. *Ann Surg* 2004; 239(3):325–337.
42. McHoney M, Eaton S, Wade A, et al. Inflammatory response in children after laparoscopic vs open Nissen fundoplication: randomized controlled trial. *J Pediatr Surg* 2005; 40(6):908–913.
43. Banieghbal B, Beale P. Day-case laparoscopic Nissen fundoplication in children. *J Laparoendosc Adv Surg Tech A* 2007; 17(3):350–352.
44. Bianchi A. Total esophagogastric dissociation: an alternative approach. *J Pediatr Surg* 1997; 32(9):1291–1294.
45. Islam S, Teitelbaum DH, Buntain WL, Hirschl RB. Esophagogastric separation for failed fundoplication in neurologically impaired children. *J Pediatr Surg* 2004; 39(3):287–291.
46. Lall A, Morabito A, Bianchi A. «Total gastric dissociation (TGD)» in difficult clinical situations. *Eur J Pediatr Surg* 2006; 16(6):396–398.
47. Lall A, Morabito A, Dall’Oglio L, et al. Total oesophagogastric dissociation: experience in 2 centres. *J Pediatr Surg* 2006; 41(2):342–346.
48. Gutt CN, Oniu T, Schemmer P, Mehrabi A, Buchler MW. Fewer adhesions induced by laparoscopic surgery? *Surg Endosc* 2004; 18(6):898–906.
49. Antao B, Ooi K, Ade-Ajayi N, Stevens B, Spitz L. Effectiveness of alimemazine in controlling retching after Nissen fundoplication. *J Pediatr Surg* 2005; 40(11):1737–1740.
50. Mattioli G, Esposito C, Lima M, et al. Italian multicenter survey on laparoscopic treatment of gastro-esophageal reflux disease in children. *Surg Endosc* 2002; 16(12):1666–1668.
51. Tovar JA, Luis AL, Encinas JL, et al. Pediatric surgeons and gastroesophageal reflux. *J Pediatr Surg* 2007; 42(2):277–283.
52. Esposito C, Montupet P, van Der ZD, et al. Long-term outcome of laparoscopic Nissen, Toupet, and Thal antireflux procedures for neurologically normal children with gastroesophageal reflux disease. *Surg Endosc* 2006; 20(6):855–858.
53. Bradnock T, Hammond P, Haddock G, Sabharwal A. A roadmap for the establishment of pediatric laparoscopic fundoplication. *J Laparoendosc Adv Surg Tech A* 2009; 19(s1): s41-s45.
54. Tolia V, Wuerth A, Thomas R. Gastroesophageal reflux disease: review of presenting symptoms, evaluation, management, and outcome in infants. *Dig Dis Sci* 2003; 48(9):1723–1729.
55. Gold BD. Is gastroesophageal reflux disease really a life-long disease: do babies who regurgitate grow up to be adults with GERD complications? *Am J Gastroenterol* 2006; 101(3):641–644.