

# CHAPTER 57

## DISORDERS OF THE UMBILICUS

Jean Heuric Rakotomalala  
Dan Poenaru  
Ruth D. Mayforth

### Introduction

Umbilical disorders are frequently encountered by paediatric surgeons. In the newborn, the umbilical cord typically desiccates and separates within three weeks, leaving a dry, “star-like” central abdominal scar that forms the umbilicus. Failure of the umbilical ring to completely close can result in an umbilical hernia, by far the most common umbilical disorder. Discharge or abnormal tissue from the umbilicus is most often due to an umbilical granuloma, but can result from incomplete involution of the urachus or omphalomesenteric duct. Any discharge, mass, or sinus tract is pathological and should be appropriately evaluated and treated. These and other umbilical disorders are discussed in further detail in this chapter.

### Anatomy and Pathology

The umbilical cord is the main portal for entry and exit of blood from the placenta to the foetus during intrauterine life. In addition to the paired umbilical arteries and umbilical vein, the umbilical cord also contains the vitelline or omphalomesenteric duct (which connects the yolk sac to the midgut) and the allantois (the portion connecting the umbilicus to the bladder becomes the urachus). Usually, the vitelline duct obliterates by the 5th to 9th week of gestation, and the urachus obliterates to become the median umbilical ligament by the 4th to 5th month. After birth, the umbilical cord withers and separates, leaving no remnants. Umbilical abnormalities can arise, however, when embryological remnants persist or fail to completely involute.<sup>1,2</sup> Table 57.1 compares the embryological components of the umbilical cord with related disorders.

Like skin anywhere on the body, the umbilicus may also be affected by a variety of dermatological conditions, such as hemangiomas, dermoid cysts, or mechanical irritation. A number of syndromes, such as the Aarskog, Reiger, and Robinow syndromes, are associated with an abnormal umbilical appearance.<sup>3</sup> The umbilicus can also be found in an abnormal position or even absent, as in bladder exstrophy.

### Classification of Umbilical Problems

Umbilical problems can be classified as follows, based on the aetiology of the abnormality:

- *acquired*: delayed umbilical separation, umbilical granuloma;
- *infectious*: omphalitis, umbilical vein phlebitis;
- *congenital*: omphalomesenteric duct remnant, umbilical polyp, patent urachus, umbilical hernia, dermoid cyst, umbilical dysmorphism; or
- *neoplastic*: rhabdomyosarcoma, teratoma.

### Selected Umbilical Pathology

#### Delayed Umbilical Separation

The timing of umbilical cord separation may vary, depending on ethnic background, geographic location, and method of cord care. Cord separation usually occurs 1 week after birth; persistence beyond 3 weeks is generally considered delayed. Various umbilical cord antiseptics can prolong the separation time, however. For example, triple dye may

Table 57.1: Embryology and pathology of umbilical disorders.

Embryological element	Normal remnant	Pathological abnormality
Two arteries	Para-urachal lateral ligaments	Single umbilical artery*
One vein	Round ligament of liver	Phlebitis**
Allantois	Median umbilical ligament	Patent urachus, urachal cyst or sinus
Vitelline duct	None	Omphalomesenteric duct remnant, umbilical polyp, Meckel's diverticulum
Umbilical ring	Physiologic closure; fascia covering defect	Umbilical hernia Omphalocele

Source: Minkes R.K., Disorders of the Umbilicus. EMedicine Specialties. Available at: [emedicine.medscape.com/article/935618-overview](http://emedicine.medscape.com/article/935618-overview); accessed 27 October 2008.

\*Twenty-five percent of umbilical disorders with single umbilical arteries have associated congenital anomalies.

\*\*A possible complication following umbilical vein catheterisation.

prolong separation of the cord for up to 8 weeks. Dry cord care has been found to be effective in developed countries;<sup>4</sup> however, in developing countries, antiseptic cord care continues to be recommended, and has been found to decrease the incidence of and mortality from omphalitis.<sup>5</sup> Agents that have been used include 70% alcohol, silver sulfadiazine, chlorhexidine, neomycin-bacitracin powder, and salicylic sugar powder.<sup>6,7</sup>

Aside from agents used in umbilical cord care, other factors that can delay umbilical cord separation include infection, underlying immune disorders (such as leukocyte adhesion deficiency), or an urachal abnormality.<sup>7-10</sup> On examination, the skin surrounding the umbilical cord remnant should be carefully examined for a urachal remnant or for any evidence of infection; omphalitis (see next section) can be rapidly progressive and life threatening in a neonate.

A complete blood count with a differential may be useful as an initial screen for leukocyte adhesion deficiency. Even in the absence of infection, leukocytosis and neutrophilia may be present in patients with leukocyte adhesion deficiency.<sup>10</sup> Rare neutrophil motility defects may require a more sophisticated immunologic work-up.

If a patient presents with delayed separation of the cord, it may be either gently removed manually or divided just distal to normal skin with scissors or a scalpel. After removal, the stump site should be cleansed with an antiseptic agent and exposed to air.

#### Omphalitis

Omphalitis is an infection of the cord stump or its surrounding tissues. It presents most commonly in the newborn; the mean age at onset is 5–9 days, or earlier in preterm infants. The risk of omphalitis is increased by a number of maternal factors (prolonged rupture of membranes, maternal infection, amnionitis), factors at delivery (nonsterile or home delivery, inappropriate cord care); and neonatal factors (low birth weight, delayed cord separation, leukocyte adhesion deficiency, neonatal alloimmune

neutropaenia). The incidence of omphalitis in developing countries is significantly higher (as high as 6%) than in developed countries (0.7%).<sup>7</sup>

Proper umbilical cord care is important in decreasing the incidence of omphalitis as well as neonatal tetanus (which may or may not be associated with omphalitis). Public health interventions have proven effective in decreasing the incidence and death from these infections. In Nepal, for example, the use of chlorhexidine decreased the incidence of omphalitis by 75% and its mortality by 24% compared to dry cord care.<sup>5</sup>

More than a half million deaths occur yearly in newborn infants from neonatal tetanus. A high rate of neonatal tetanus was seen among the Maasai people in Kenya and Tanzania, who applied cow dung to the umbilical stumps of their infants. In one simple health programme among the Maasai people, the death rate from neonatal tetanus decreased from 82 per 1,000 in control groups to 0.75 per 1,000 in the intervention group.<sup>11</sup> Part of the success was in finding solutions that were culturally applicable and feasible (e.g., if clean water was unavailable, they advocated cleaning the stump with milk), obtaining support from within the community, and maintaining continued health promotion.

Patients with omphalitis present with erythema, oedema, and/or purulent drainage from the umbilical stump. Patients may also have systemic signs of sepsis, including lethargy, irritability, poor feeding, and fever or hypothermia. More extensive disease is seen with necrotising fasciitis or myonecrosis and may also include a rapidly progressive cellulitis, a peau d'orange appearance, violaceous discoloration, bullae, crepitus, and petechiae.

Patients with omphalitis should be admitted to the hospital and blood and wound cultures should be obtained. Omphalitis is usually polymicrobial; intravenous antibiotics covering gram-positive and gram-negative organisms should be initiated and the area of cellulitis marked and closely followed. Some authors also advocate anaerobic coverage, which certainly should be instituted if there is a concern of necrotising fasciitis. Newborns with sepsis should also have a lumbar puncture and supportive care instituted.

Patients with necrotising fasciitis or myonecrosis require emergent and complete surgical debridement of all affected tissue, including preperitoneal tissue, the umbilical vessels, and the urachal remnant. Necrotising fasciitis or myonecrosis can rapidly progress over a few hours; early and aggressive surgical treatment is critical to survival.

Complications of omphalitis include umbilical phlebitis, portal vein thrombosis (which may lead to portal hypertension), liver abscesses, peritonitis, and necrotising fasciitis or myonecrosis. The overall mortality of omphalitis is estimated at 7–15% and is significantly higher (37–87%) if complicated by necrotising fasciitis or myonecrosis.<sup>12</sup>

### Umbilical Granuloma

Umbilical granuloma is the most frequent cause of “wet umbilicus.” It presents as moist, raw, reddish-pink tissue arising from the base of the umbilicus after umbilical cord separation. An umbilical granuloma typically measures 0.1–1 cm in size and may be pedunculated. It is nontender (lacking innervation). Drainage may be clear or have the appearance of a fibrinous exudate. The tissue is friable and may bleed easily. Umbilical granuloma is due to the persistence of capillary and fibroblast cells, markers of an ongoing tissue growth. It may be difficult to distinguish from an umbilical polyp (discussed later in this chapter), which is usually brighter red, slightly larger, and represents remnant omphalomesenteric duct or urachal tissue.<sup>7,8</sup>

Management options for umbilical granuloma include repeated cauterisation with silver nitrate, ligation, use of alcoholic wipes, or, rarely, surgical excision. Care must be taken in applying silver nitrate, as contact with normal skin can cause a chemical burn. If the lesion fails to resolve with silver nitrate, the diagnosis should be questioned because umbilical polyps, which may look similar to umbilical granulomas, do not respond to silver nitrate. If the lesion is excised, histology should be

performed to rule out any retained omphalomesenteric duct or urachal remnants, which require further work-up.<sup>1,7,13</sup>

### Dermoid Cyst of the Umbilicus

Dermoid cyst of the umbilicus is a rare umbilical mass caused by inclusion of skin epithelium below or within the normal skin of the umbilicus. On examination, the umbilicus appears wider and darker in color than normal, and shiny. No inflammation is noted unless the cyst is infected. The diagnosis is made at surgery on finding the characteristic toothpaste-like sebaceous material within the umbilical mass. Surgical excision is curative.

### Omphalomesenteric or Vitelline Remnant

During early foetal development, the omphalomesenteric or vitelline duct serves as a conduit from the yolk sac to the midgut. It normally completely involutes by the 9th week of foetal life. However, a portion or all of the duct may fail to involute and present as one of the following:

- An umbilical polyp, as discussed in the next section.
- Meckel's diverticulum, in which only the diverticulum attached to the ileum has failed to involute. This is the most common vitelline remnant; it most often presents as a lower GI bleed caused by ectopic gastric mucosa, but rarely may present as diverticulitis, or it may function as the lead point for an intussusception.
- A persistent congenital band, which can act as a fixed point around which an intestinal volvulus may occur.
- A complete omphalomesenteric duct remnant with a patent conduit connecting the umbilicus to the ileum; this usually presents with pink mucosa protruding from the umbilicus (Figures 57.1 and 57.2) and usually minimal but persistent discharge of intestinal contents or stool.

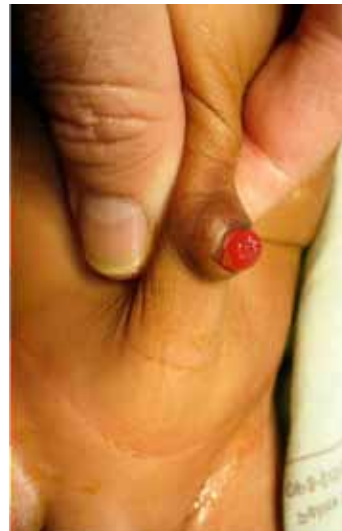

Figure 57.1: Omphalomesenteric fistula.

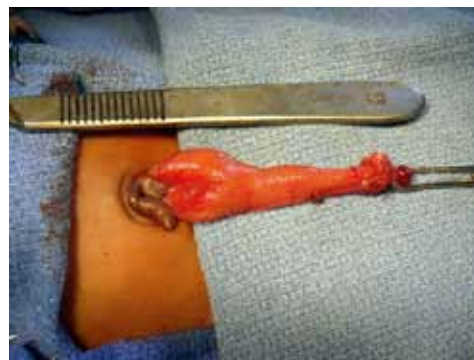

Figure 57.2: Omphalomesenteric fistula (intraoperative).

- An omphalomesenteric duct cyst, in which the proximal and distal ends have obliterated but a remnant persists in between; this may present with an infection or obstruction and is quite rare.

Diagnosis of an omphalomesenteric remnant is generally made on physical exam. An ultrasound may show a loop of bowel present under the umbilicus, but is not diagnostic and usually not necessary. A fistulogram may be helpful in clarifying the diagnosis.

All omphalomesenteric duct remnants should be surgically resected. A Meckel's diverticulum should be amputated at its base, the intestine closed transversely, and the vitelline artery ligated. A broad-based Meckel's diverticulum may require a formal resection with a primary anastomosis. Meckel's diverticula may contain ectopic gastric or pancreatic tissue on histology.<sup>1,2,7</sup>

### Umbilical Polyp

An umbilical polyp (Figure 57.3) is a round, reddish mass at the base of the umbilicus that comprises embryologic remnants of the omphalomesenteric duct or, less commonly, the urachus. It is often brighter red and slightly larger than an umbilical granuloma. Unlike a granuloma, it does not respond to silver nitrate and must therefore be surgically excised and histologically evaluated to confirm the diagnosis. If an umbilical polyp is diagnosed, further work-up for an underlying omphalomesenteric duct or urachal remnant is warranted. One author reported a 30–60% chance of finding an underlying omphalomesenteric duct anomaly if an umbilical polyp was identified.<sup>1,7,10,14</sup>

### Urachal Anomalies

In the foetus, the urachus is the embryonal duct connecting the dome of the urinary bladder to the umbilical ring. It is normally obliterated prior to birth, forming the median umbilical ligament. It forms in the preperitoneal space between the transversalis fascia and the peritoneum. Nonclosure of the entire tract leads to a patent urachus, whereas closure on the bladder side creates an umbilical sinus (Figure 57.4). Closure of both ends but patency of the tract in between may trap fluid in an urachal cyst (Figure 57.5), which is the most common urachal anomaly. A bladder diverticulum results when the distal tract involutes; it is the rarest urachal anomaly.

Both a patent urachus and a urachal sinus may present with clear drainage from the umbilicus, and careful examination demonstrates a sinus at the base of the umbilicus. A patent urachus drains urine and may predispose to cystitis or recurrent urinary tract infections. A urachal cyst most commonly presents once it has become infected. An affected patient will present with infraumbilical swelling, abdominal pain, and erythema. The symptoms may mimic appendicitis. Patients with delayed separation of the umbilical cord may have a urachal anomaly.<sup>9</sup>

Ultrasonography is often useful in diagnosing a urachal cyst, and will show a cystic hypoechoic lesion in the preperitoneal space. The presence of a longitudinal double line from the bladder dome to the umbilicus is indicative of a urachal remnant. A sinogram may be used to identify the presence of a patent urachus or an urachal sinus. For a patent urachus, a voiding cystourethrogram (VCUG) should be obtained to exclude the presence of posterior urethral valves (back-up pressure from the distal obstruction may be keeping the urachus patent).

Treatment involves complete resection of any part of the tract that has failed to completely obliterate. It is important to remove a cuff of bladder when excising the urachus to prevent the risk of developing a urachal adenocarcinoma later in adulthood.<sup>1,2,7</sup>

### Umbilical Hernia

An umbilical hernia is a full-thickness protrusion of the umbilicus with an associated fascial defect; it may contain peritoneal fluid, preperitoneal fat, intestine, or omentum.

In children, umbilical hernias often close spontaneously. Small defects (<1 cm) are much more likely to close than large defects (>2 cm). Meier et al. reported that umbilical hernias continue to close until the age of 14 years in African children.<sup>16</sup> The skin overlying an

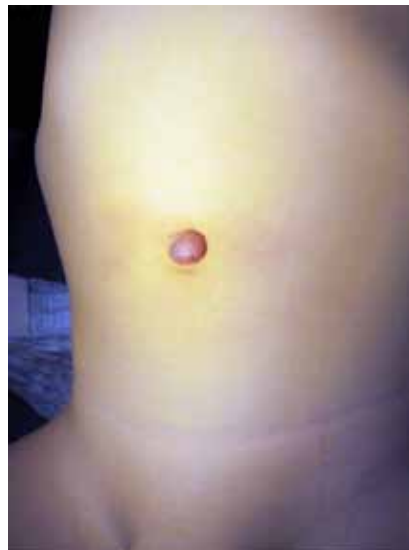

Figure 57.3: Umbilical polyp.

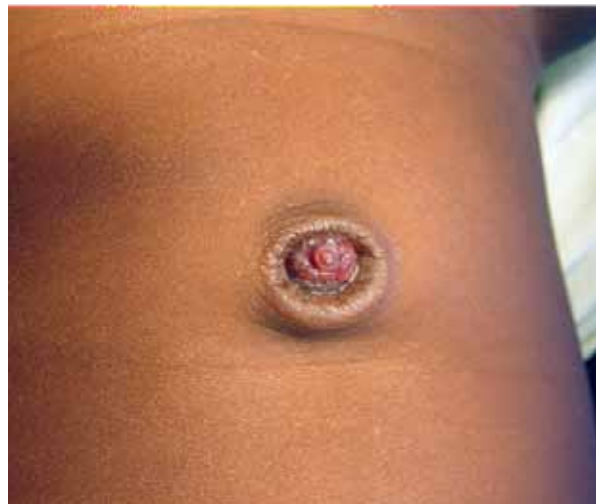

Figure 57.4: Urachal remnant.

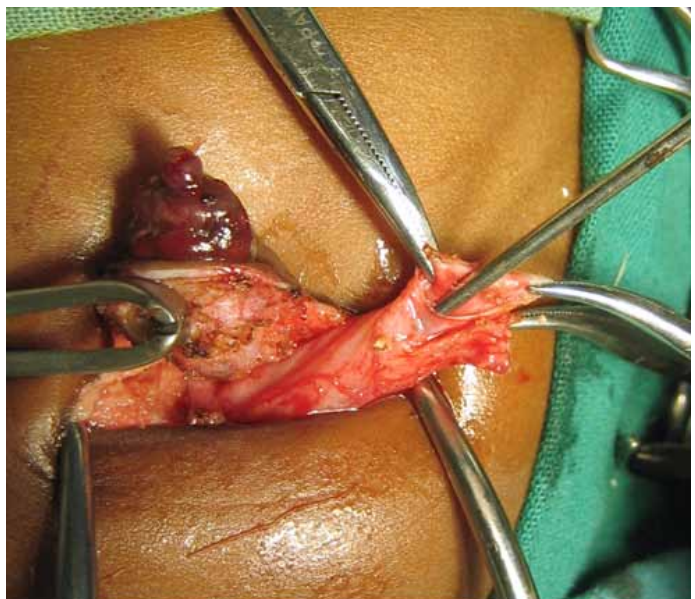


Figure 57.5: Urachal cyst (intraoperative).



umbilical hernia may continue to stretch and result in a proboscoid umbilical hernia. In Africa, most parents are very accepting of its appearance, in contrast to parents from developed countries. Once the umbilical defect has spontaneously closed, the nipple-like umbilical skin may continue to flatten, even during adolescence.

### Aetiology

An umbilical hernia results when the umbilical ring fails to close. Umbilical hernias are more frequent in premature, low birth weight, and black infants. They also occur more often in children with ventriculo-peritoneal shunts, ascites, obesity, and certain syndromes, including Beckwith-Wiedemann, Trisomy 21, and Marfan's syndromes.

### Demographics

Umbilical hernias are common in Africa. In one study from Nigeria, umbilical hernias were found in 91% of under-6-year-olds; 64% of 6- to 9-year-olds, and 46% of 10- to 15-year-olds.<sup>15</sup> Meier found umbilical hernias with a fascial defect >1 cm in 23% of Nigerian children younger than 18 years old.<sup>16</sup> Surprisingly, when 6- to 9-year-old Nigerian children of high socioeconomic class were evaluated for an umbilical hernia, only 1.3% of 7,968 children had an umbilical hernia.<sup>17</sup> It is possible that nutrition may be a factor. Jelliffe found a higher incidence of umbilical hernias in malnourished versus well-nourished adults (27% versus 14%).<sup>15</sup>

### Complications

Complications, including incarceration, strangulation, and rupture of umbilical hernias, may occur. In developed countries, the incidence of incarceration or strangulation is rare—one paper reported an incidence of 1 in 1,500 umbilical hernias.<sup>18</sup> Rupture of umbilical hernias with evisceration is even more rare, but has been reported in infants younger than 6 months of age.<sup>19,20</sup>

Even though the incidence of incarceration and strangulation in children with umbilical hernias in Africa is not known, it appears to be higher than in the West (although this may in part reflect the significantly higher prevalence of umbilical hernias in black children). For instance, at A. Le Dantec Hospital in Senegal, over a five-year period, 41 children had emergency operations for incarcerated or strangulated umbilical hernias.<sup>21</sup> At Jos University Teaching Hospital in Nigeria, over an eight-year period, 23 children underwent surgery for acute or recurrent incarceration.<sup>16,19,22–24</sup>

In contrast, Okada et al. reviewed the literature from 1957 to 1999 and found a total of only 38 cases reported in children worldwide.<sup>25</sup> In King's College Hospital in London, only 3 incarcerated umbilical hernias were treated in children over a 20-year period (and all 3 of these occurred in black children).<sup>26</sup> The fact that most umbilical hernias in the West are repaired by 4–5 years of age does not account for the apparent difference in the frequency of incarceration between the West and Africa. In both Senegal and Nigeria, most of the incarcerations reported occurred in patients younger than 5 years of age; in Senegal, the average age at incarceration was 14 months (range, 8 months–10 years); in Nigeria, the median was 4 years (range, 3 weeks–12 years). Most incarcerated hernias do not have an inciting factor; however, bezoars, digested vegetable matter, parasitic worms, or ascites have been implicated.<sup>21,22,25</sup>

Umbilical hernias can incarcerate regardless of the size of the fascial defect (Figure 57.6). In one report, a majority (52%) of the patients with incarcerated hernias had medium-sized (0.5–1.5 cm) fascial defects, whereas 24% occurred in small defects (<0.5 cm), and 24% in large defects (>1.5 cm).<sup>25</sup> Of the incarcerated hernias in which a measurement was documented in one study in Nigeria, all had defects greater than 1.5 cm in diameter (not all, however, were measured).<sup>22</sup>

### Management

Factors that lead parents to seek medical care for their child in Africa include the age of the child, size of the defect, height of protruding

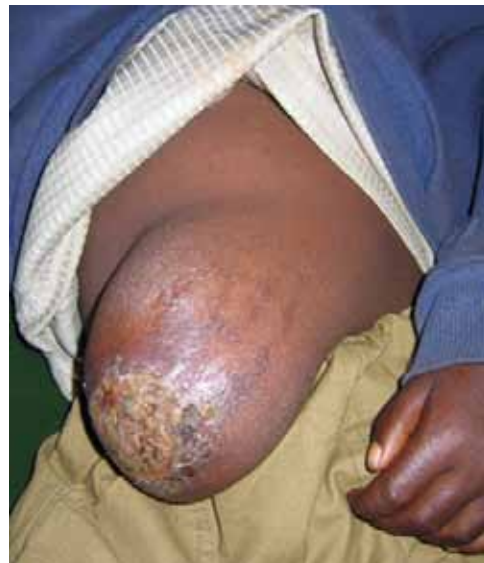

Figure 57.6: Giant ulcerated umbilical hernia.

umbilicus, and pain. On examination, a child with an umbilical hernia usually presents with a protrusion of the umbilicus with contents that are easily reducible. After reduction, the size of the fascial ring can be palpated; it can range from a few millimeters to more than 4 cm in diameter. No other investigations are required for diagnosis.

Umbilical hernia repair is one of the most frequent procedures performed by paediatric surgeons in developed countries.<sup>1</sup> In Africa, however, umbilical hernia repairs are more infrequent because the hernias are usually repaired only if symptomatic or complicated. Generally accepted indications for management in Africa compared to the West are highlighted next.

Due to the high rate of spontaneous closure and the fact that the appearance of a proboscoid umbilical hernia is well tolerated by parents in Africa, conservative management of asymptomatic, easily reducible umbilical hernias is recommended. In the West, conservative treatment is generally recommended for small asymptomatic umbilical hernias (<2 cm fascial defect) in children younger than 4–5 years of age.

In Africa, surgical repair is reserved for symptomatic umbilical hernias. Rarely, parents may request to have a proboscoid hernia repaired. (For further discussion, see the “Ethical Issues” section in this chapter.) In the West, surgical repair is generally recommended for hernias with large fascial defects (>1.5 cm), hernias that have failed to spontaneously close by 4 to 5 years of age, and umbilical hernias with significant proboscoid components.

A classic Mayo “vest-over-pants” procedure or simple approximation with long-lasting absorbable suture are both acceptable for conventional umbilical hernia repairs. For complicated umbilical hernia repairs, the use of mesh may be considered in the closure of a very large uninfected umbilical hernia to prevent excess tension on the fascia. The use of mesh also prevents the development of an abdominal compartment syndrome, which could result with significant fascial tension. Surgical complications are rare after umbilical hernia repairs. The outcome is excellent and the mortality approaches zero for elective repairs. Rare postoperative eviscerations can be prevented by meticulous surgical technique.

### Other Umbilical Problems

#### Absent umbilicus

Malposition or absence of the umbilicus is encountered frequently in patients with bladder exstrophy. When the umbilicus is absent, an omphaloplasty may be performed, as many ethnic groups are culturally sensitive to the absence of the navel. Research has been performed to help the reconstructive surgeon locate the umbilicus in an aesthetically pleasing location.<sup>27</sup>

### Stoma at umbilicus

Some paediatric surgeons in the West have advocated placing intestinal or urinary stomas in the umbilicus primarily for aesthetic considerations. Experience with this in Africa has been limited, and no papers adopting its use have been published in Africa to date.

### Gastroschisis and omphalocele

These problems are discussed in Chapter 56.

## Ethical Issues

As previously discussed, most African surgeons do not use the same indications for umbilical hernia repair as are used in developed countries. Instead, they recommend repairing only those umbilical hernias that are symptomatic in children. However, the incidence of incarceration or strangulation seems to be higher in Africa than in developed countries. Because of this, some African surgeons have recommended repairing all umbilical hernias in children.<sup>21</sup> Others, however, continue to recommend conservative treatment in spite of the risk of incarceration.<sup>16,22</sup> Part of the rationale given is the wide prevalence of umbilical hernias.

Even using selective criteria, Meier et al. have estimated that if all umbilical hernias >1.5 cm were repaired in young children in Africa, about 6–8% of children younger than 4 years of age would require repair;<sup>16</sup> the volume of cases would likely outstrip available surgical resources. The exact criteria for elective repair on which Meier et al. based their estimates were females older than 2 years of age and males older than 4 years of age with a fascial defect  $\geq 1.5$  cm in diameter; they estimated that 6% of 2-year-old females and 8% of 4-year-old males would need repair.<sup>16</sup>

If hernias with large (>1.5 cm) fascial defects are indeed the most likely to incarcerate in Africa, as reported by Chirdan et al.,<sup>22</sup> one could argue that they should be repaired, as they are the most likely to incarcerate and the least likely to spontaneously close. Consideration should also be given to closing umbilical hernias in patients who live more than one hour away from surgical resources. More research is necessary to determine the actual incidence of incarceration or strangulation, and to clearly define which umbilical hernias are at greatest risk.

Perhaps it is time to re-examine how current recommendations for umbilical hernia repair in Africa were developed or became generally accepted. Are the current recommendations truly the best for the patient,

preventing many children with umbilical hernias from unnecessarily undergoing the risk of a surgical procedure and anaesthesia? Or did the current recommendations arise out of necessity, due to the wide prevalence of umbilical hernias, in an effort to strategically utilise surgical resources and time? If the latter is true, and umbilical hernias should be repaired by using the same criteria as those used in developed countries, there may be other creative solutions. For instance, just as health care workers have been specifically trained to suture lacerations or to perform caesarean sections, perhaps consideration should be given to specifically training them to perform simple, straightforward surgical procedures such as umbilical hernia repairs.

## Evidence-Based Research

Table 57.2 presents the results of a trial involving application of chlorhexidine to the umbilical cord to prevent omphalitis and neonatal mortality.

Table 57.2: Evidence-based research.

<b>Title</b>	Topical applications of chlorhexidine to the umbilical cord for prevention of omphalitis and neonatal mortality in southern Nepal: a community-based, cluster-randomised trial
<b>Authors</b>	Mullany LC, Darmstadt GL, Khatry SK, et al.
<b>Institution</b>	DNepal Nutrition Intervention Project, Sarlahi, Kathmandu, Nepal; Institute of Medicine, Tribhuvan University, Kathmandu, Nepal; Department of International Health, Johns Hopkins Bloomberg School of Public Health, Baltimore, Maryland, USA
<b>Reference</b>	Lancet 2006; 365:910–918
<b>Problem</b>	Prevention of omphalitis and neonatal death related to umbilical cord care in southern Nepal.
<b>Intervention</b>	Topical application of chlorhexidine to the umbilical cord.
<b>Comparison/control (quality of evidence)</b>	Prospective, community-based, cluster-randomised trial.
<b>Outcome/effect</b>	Compared to dry cord care, chlorhexidine reduced severe omphalitis by 75% and neonatal mortality by 24%.
<b>Historical significance/comments</b>	Recent recommendations by the World Health Organization for dry umbilical cord care may be inappropriate in developing countries, where the risk of omphalitis and death related to umbilical cord care is higher than in developed countries.

## Key Summary Points

1. Appropriate umbilical cord care is important in preventing omphalitis, which can be a life-threatening infection.
2. The presence of a remnant of the urachus or omphalomesenteric duct should be considered if there is an umbilical sinus, persistent drainage, or remnant tissue.
3. Ultrasonography can be useful in investigating umbilical disorders when the diagnosis is uncertain.
4. Any irreducible umbilical mass or persistent umbilical lesion needs surgical exploration and resection.
5. Umbilical hernias are more common in children in Africa than in the rest of the world, and the incidence of incarceration appears to be higher than in the West.
6. In Africa, proboscoïd umbilical hernias are common, well-accepted, and treated conservatively.
7. Incarceration or strangulation of umbilical hernias is uncommon but has been reported more often in Africa than in developed countries. Complications remain the general indication for umbilical hernia repair in Africa.
8. An omphaloplasty may be indicated for cultural reasons.
9. After umbilical surgery, the prognosis is excellent and complications are rare.

## References

1. Snyder CL. Current management of umbilical abnormalities and related anomalies. *Semin Pediatr Surg* 2007; 16:41–49.
2. O'Donnel KA, Glick PL, Caty MG. Pediatric umbilical problems. *Pediatr Clin N Amer* 1998; 45:791–799.
3. Friedman JM. Umbilical dysmorphism. The importance of contemplating the belly button. *Clin Genet* 1985; 28:343–347.
4. Zupan J, Garner P, Omari AA. Topical umbilical cord care at birth. *Cochrane Database Syst Rev* 2004; CD001075.
5. Mullany LC, Darmstadt GL, Khatri SK, et al. Topical applications of chlorhexidine to the umbilical cord for prevention of omphalitis and neonatal mortality in southern Nepal: a community-based, cluster-randomised trial. *Lancet* 2006; 365:910–918.
6. Pezzati M, Biagioli E, Martelli E, et al. Umbilical cord care: the effect of eight different cord care regimens on cord separation time and other outcomes. *Biol Neonate* 2002; 81:38–44.
7. Palazzi DL, Brandt, ML. Care of the umbilicus and management of umbilical disorders. Available at: [www.uptodate.com](http://www.uptodate.com); accessed 13 August 2008.
8. Minkes RK. Disorders of the umbilicus. *EMedicine Specialities* Available at: [emedicine.medscape.com/article/935618-overview](http://emedicine.medscape.com/article/935618-overview); accessed 13 August 2008.
9. Razvi S, Murphy R, Shalsko E, Cunningham-Rundles C. Delayed separation of the umbilical cord attributable to urachal anomalies. *Pediatr* 2001; 108:493–494.
10. Pomeranz A. Anomalies, abnormalities, and care of the umbilicus. *Paediatr Clin N Amer* 2004; 51:819–827.
11. Meegan ME, Conroy RM, Lengeny SO, et al. Effect on neonatal tetanus mortality after a culturally-based health promotion programme. *Lancet* 2001; 358:640–641.
12. Gallagher PG, Shah SS. Omphalitis. *eMedicine Specialities*. Available at: [emedicine.medscape.com/article/975422](http://emedicine.medscape.com/article/975422); accessed 13 August 2008.
13. Daniels J, Craig F, Wajed R, Meates M. Umbilical granulomas: a randomised controlled trial. *Arch Dis Child Fetal Neonatal Ed* 2003; 88:F257.
14. Kutin ND, Allen JE, Jewett TC. The umbilical polyp. *J Pediatr Surg* 1979; 14:741–744.
15. Jelliffe DB. The origin, fate and significance of the umbilical hernia in Nigerian children (a review of 1,300 cases). *Trans Royal Soc Trop Med Hyg* 1952; 46:428–434.
16. Meier DE, OlaOlorun DA, Omodele RA, et al. Incidence of umbilical hernia in African children: redefinition of "normal" and reevaluation of indications for repair. *World J Surg* 2001; 25:645–648.
17. Uba AF, Igun GO, Kidmas AT, Chirdan LB. Prevalence of umbilical hernia in a private school admission-seeking Nigerian children. *Niger Postgrad Med J* 2004; 11:255–257.
18. Mestel AL, Burns H. Incarcerated and strangulated umbilical hernias in infants and children. *Clin Pediatr* 1963; 2:368–370.
19. Ameh EA, Chirdan LB, Nmadu PT, and Yusufu L. Complicated umbilical hernias in children. *Pediatr Surg Int* 2003; 19:280–282.
20. Weik J, Moores D. An unusual case of umbilical hernia rupture with evisceration. *J Pediatr Surg* 2005; 40:E33–E35.
21. Fall I, Sanou A, Ngom G, et al. Stangulated umbilical hernias in children. *Pediatr Surg Int* 2006; 22:233–235.
22. Chirdan LB, Uba AF, Kidmas AT. Incarcerated umbilical hernia in children. *Eur J Pediatr Surg* 2006; 16:45–48.
23. Mawera G, Muguti GI. Umbilical hernia in Bulawayo: some observations from a hospital based study. *Cent Afr J Med* 1994; 40:319–323.
24. Nmadu PT. Paediatric external abdominal hernias in Zaria, Nigeria. *Ann Trop Paediatr* 1995; 15:85–88.
25. Okada T, Yoshida H, Iwai J, et al. Strangulated umbilical hernia in a child: report of a case. *Surg Today* 2001; 31:546–549.
26. Papagrigoriadis S, Browse DJ, Howard ER. Incarceration of umbilical hernias in children: a rare but important complication. *Pediatr Surg Int* 1998; 14:231–232.
27. Abhyankar SV, Rajguru AG, Patil PA. Anatomical localization of the umbilicus: an Indian study. *Plast Reconstr Surg* 2006; 117:1153–1157.