

# CHAPTER 58

## INGUINAL AND FEMORAL HERNIAS AND HYDROCELES

Francis A. Abantanga  
Kokila Lakhoo

### Introduction

In general, a hernia is defined as a protrusion of a portion of an organ or tissue through an abnormal opening (defect) in the cavity containing it. In children, the abnormal defect, which is congenital, is usually at the internal inguinal ring.

Groin hernias and hydroceles are extremely common conditions in infancy and childhood and form a large part of the general paediatric surgical practice. Inguinal hernias (IHs) and hydroceles in infants and children are overwhelmingly congenital, although a vast majority are noticed after the neonatal period. Most hydroceles in infants and children do not present any urgent problems.

### Demographics

Groin hernias in children are mainly inguinal in nature (Figure 58.1). Inguinal hernias are indirect in nature in more than 99% of cases as a result of the presence of a patent processus vaginalis (PPV). In about 0.5–1% of cases, inguinal hernias in children may be direct and are said to be due to the weakness of the floor of the inguinal canal or occur after surgery to correct indirect inguinal hernias. The direct inguinal hernia bulges through the inguinal floor medial to the inferior epigastric vessels in the Hasselbach's triangle; the indirect hernia arises lateral to the inferior epigastric vessels. About 0.5% of groin hernias constitute femoral hernias (see Figure 58.1).

Incidence data with reference to groin hernias and hydroceles are not available in the literature from Africa; most reports are hospital-based retrospective studies. Such data from Africa on inguinal hernias show a male-to-female ratio ranging from 2.2:1 to 16.6:1. The reported incidence of clinically apparent inguinal hernias in term babies in the world literature ranges from 1% to 5% in large paediatric series, with males outnumbering females by 3–10:1. The incidence is considerably higher in premature babies, ranging from 7% to 35%. Inguinal hernias are found variously on the right side in about 60–70% of cases and on the left side in 25–30%. They are bilateral in about 5–10% of cases.

### Inguinal Hernia

#### Embryology

The gonads develop along the urogenital ridge as retroperitoneal structures by the 6th week of gestation. The gonads are then differentiated into the testes or ovaries by the 7th to 8th week of intrauterine growth under hormonal influence. Retroperitoneal migration of the gonads, under the influence of hormones, results in their being at the internal inguinal ring around the 12th to 14th gestational week. A gubernaculum, which is attached to the lower poles of the testes, is a condensation of mesenchyme that contains cordlike structures within it. It appears to guide the testes into the scrotum. The testes remain quiescent at the internal inguinal ring until about 28 gestational weeks, when there is a rapid descent through the inguinal canal into the scrotum by the 36th to 40th week of intrauterine life.

An outpouching of peritoneum precedes the descent of the gonad (testis) through the inguinal canal at the level of the internal inguinal ring. This outgrowth of peritoneum is referred to as the processus

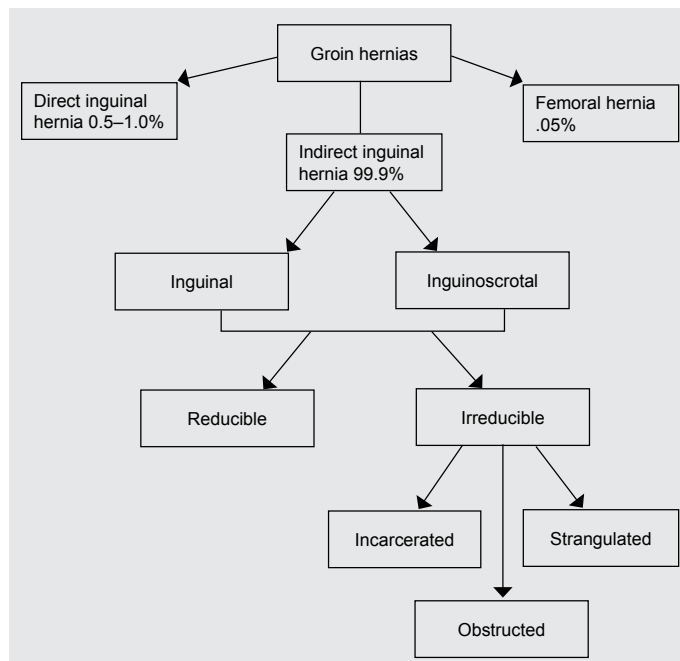


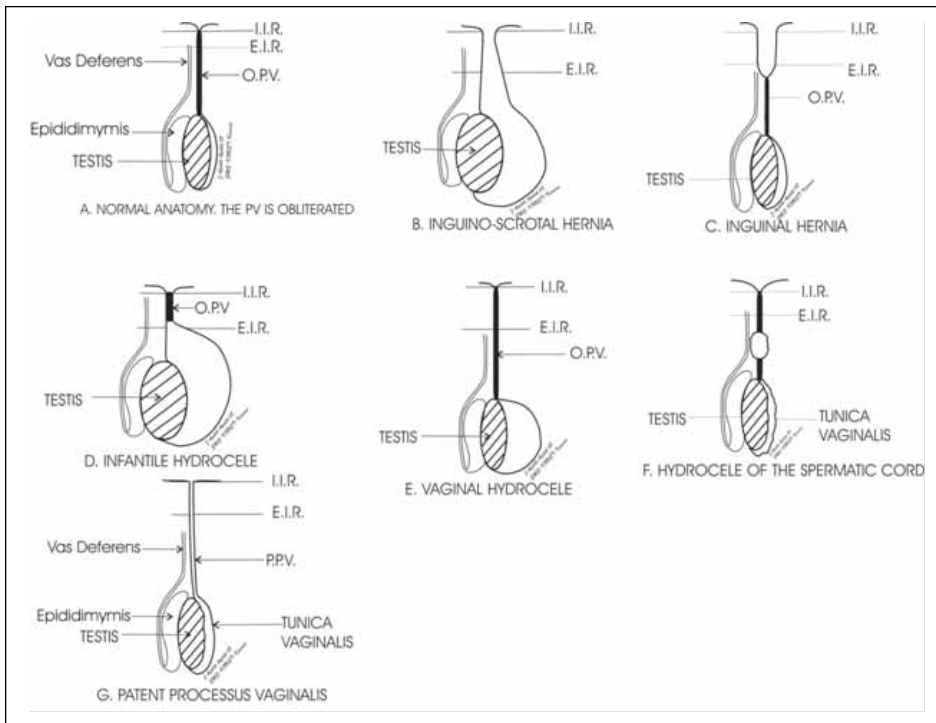
Figure 58.1: Classification of groin hernias.

vaginalis (PV) in the male or canal of Nuck in the female. As the testes descend, the PV is pushed ahead into the scrotum, and when descent is complete, the PV proximal to the testis obliterates either shortly before or just after birth, becoming a fibrous cord. This usually occurs later on the right side than the left, accounting for the greater frequency of hernias on the right. The portion of the PV adjacent to the testes remains patent and is referred to as the tunica vaginalis (which has a visceral and parietal layer) of the testes. In the female, the canal of Nuck ends in the labium majus and is also usually obliterated by the time of delivery of the baby.

As the testis descends into the scrotum, the layers of the anterior abdominal wall contribute to the formation of the layers of the spermatic cord. The transversalis fascia forms the internal spermatic fascia; the internal oblique and the transversus abdominis muscles form the cremasteric muscle; finally, the aponeurosis of the external oblique muscle contributes to the formation of the external spermatic fascia.

#### Pathophysiology

Failure of obliteration of the PV (or canal of Nuck) leads to the occurrence of hernias and hydroceles, the two most common problems of the region of the groin in children. The variety of degrees of patency of the PV account for the various pathologies seen in that region of the groin (Figure 58.2). Obliteration of the distal PV with the proximal portion still patent will lead to intestines herniating into it, resulting in the formation of an indirect inguinal hernia confined to the inguinal region (see Figure 58.2C). In the case of complete failure of obliteration of the



Note: I.I.R. = internal inguinal ring; E.I.R. = external inguinal ring; O.P.V. = obliterated processus vaginalis; P.P.V. = patent processus vaginalis.

Figure 58.2: Diagrammatic representation of different types of inguinal hernias and hydroceles in boys following the descent of the testes into the scrotum.

whole PV and in the presence of a wide neck, an inguinoscrotal (complete, scrotal) hernia will be the outcome (see Figure 58.2B).

Congenital hydroceles formed after the failure of fusion of the PV may be communicating or noncommunicating (see Figure 58.2D–G). Where the opening of the PV that has failed to obliterate completely is narrow and will not allow intestines to herniate but permits peritoneal fluid to trickle into it, a communicating hydrocele will result. Noncommunicating hydroceles can be of three types:

1. *vaginal or scrotal hydrocele*, formed when the proximal portion of the PV obliterates completely, leaving the distal tunica vaginalis to fill with fluid;
2. *infantile hydrocele*, formed when the proximal portion of the PV obliterates as far as the inguinal canal so that part of the PV is patent continuous with the tunica vaginalis; or
3. *encysted hydrocele of the spermatic cord*, or simply *hydrocele of the cord*, formed when there is complete involution of the proximal PV and the part above the tunica vaginalis, leaving an isolated cystic dilatation.

In the case of females in which the canal of Nuck is patent, a hydrocele or a hernia (usually containing intestine or ovary and fallopian tube) will form.

It is important to remember that the mere presence of a PPV does not automatically mean a hernia or a hydrocele necessarily occurs. The PPV may take about a year or two in some instances to obliterate completely, but not all children with a PPV will develop a hernia or a hydrocele.

Conditions associated with an increased risk of development of IH include positive family history, prematurity, low birth weight, undescended testes, hypospadias, epispadias, exstrophy of the bladder, ambiguous genitalia, ascites, gastroschisis, omphalocele, and male gender, among others (e.g., increased intraabdominal pressure).

### Clinical Presentation

Inguinal hernias appear as intermittent, usually reducible, lumps in the groin (Figures 58.3 and 58.4) and are painless.

### History

A careful and accurate history is taken, followed by meticulous examination of the child. There is usually a history (given by the mother or caregiver) of an asymptomatic bulge or mass in the groin or scrotum or labia, which is intermittent and originates from the internal inguinal ring. The mass appears on crying in the infant or younger child; in the older child, it may appear with coughing or walking or playing around (i.e., on increasing the intraabdominal pressure). Also of note in the history is that the bulge varies in size; it may periodically disappear spontaneously (when the contents completely return to the peritoneal cavity) or by application of gentle pressure by the parent. The mass usually does not cause pain or much discomfort to the child. Often the caregiver or the older child can point to the exact location of the bulge. Most hernias are seen in the first year of life, often when the parents are changing the diaper of a crying or straining child or bathing the child.

### Physical examination

The history of a mass should be confirmed by examining the child in various positions, upright or supine. It is important to ascertain that the testes are in the scrotum because a retractile testis will mimic an inguinal hernia by causing a bulge at the external inguinal ring. One of the following procedures will increase the intraabdominal pressure in order to augment the demonstration of a groin mass.

1. Lie the infant supine with the hands held above the head and the lower limbs held straight down. This can be done by an assistant or the parent. This makes the child strain or cry, thus increasing the intraabdominal pressure and causing the bulge to appear if it is actually present. Standing the patient upright may help at times.
2. Ask the older child to jump or bounce up and down, which may allow the mass to appear in the inguinal region.
3. Ask the older child (>6 years of age) to cough or blow up a balloon. This will make the bulge appear. (Often, children <6 years of age just refuse to carry out instructions, even though they very well understand the request to do so.)



Figure 58.3: Bilateral reducible hernias. Both testes are in the scrotum.

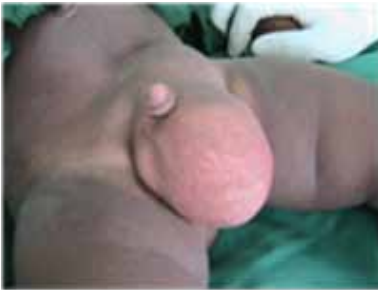

Figure 58.4: Reducible left inguinoscrotal hernia.

In the case where there is no bulge but there is the suspicion that a hernia sac may be present, gently but firmly palpate the cord structures in the male child or the round ligament of the ovary in the female child, sliding the structure over the pubic bone beneath the index finger medially and laterally. This will elicit a palpable thickening of the cord (or ligament of the ovary), usually referred to as the silk glove sign; this is suggestive of the presence of a hernia sac.

An inguinal hernia, if present, may be reducible or irreducible, complicated or uncomplicated. A reducible IH is one in which the contents of the sac return spontaneously to the peritoneal cavity or will do so with gentle manual pressure when the child is recumbent. In such situations, there is usually no pain associated with the mass. For an irreducible IH, the lump will not reduce spontaneously when the child lies supine, but may sometimes be reduced if some amount of pressure is exerted. The contents of the sac are trapped by a narrow neck. An irreducible hernia may or may not be tender.

In the case of an incarcerated IH, an example being the incarceration of the ovary with the fallopian tube in a hernia sac, the mass does not reduce spontaneously when the child lies down, and most often cannot be reduced by the physician examining the child. Note here that the mass is not tender and the contents (ovary and a portion of the fallopian tube) are usually a sliding component of the sac. In children, incarceration of inguinal hernias occurs at the external inguinal ring, whereas in adults, the hernia is normally obstructed at the internal inguinal ring.

The term “incarceration” does not imply obstruction, inflammation, or ischaemia of the herniated mass, although incarceration is necessary for obstruction or strangulation to arise. When an incarcerated hernia becomes painful and the examiner can elicit tenderness, then the IH is either obstructed or strangulated. When it is bowel that is trapped in the sac and the mass becomes tender and irreducible, then signs of intestinal obstruction will eventually occur. In such circumstances, there is usually no interference with the blood supply of the contents of the sac. Rectal examination in infants and small children may be diagnostic if the incarcerated bowel is palpated at the internal inguinal ring.

Strangulation is said to arise when the obstruction progresses to cause compromise to the blood supply of the contents (e.g., bowel or omentum); then bowel infarction leading to severe tenderness of the bulge will occur, and oedema and erythema of the overlying skin will appear. In such a case, the child may pass a bout of one or two bloody stools.

An obstructed or strangulated IH, especially where the contents of the sac are intestines, will lead to abdominal pain, vomiting, and constipation. If the obstruction is not relieved quickly, it may progress to bowel ischaemia, gangrene, perforation, and sepsis. There may also be compression of the spermatic cord, leading to ischaemia, necrosis, and secondary atrophy of the ipsilateral testis with the possibility of subfertility or infertility if, for one reason or another, the contralateral testis is abnormal. As such, incarceration of an IH should be taken seriously and steps initiated to exclude either an obstruction or strangulation. If an obstruction or strangulation is considered present, then the child should be admitted to hospital and managed appropriately to prevent complications.

The differential diagnoses of IH include: hydrocele, inguinal adenitis, femoral hernia, femoral adenitis, undescended testis, retractile testis, varicocele, torsion of the testis, testicular tumour, lipoma, and lymphangioma of the inguinal area.

### Investigations

The diagnosis of IH in an overwhelming majority of cases is clinical (history and examination). In the few cases where the diagnosis cannot be made immediately, the child needs to be re-examined over a period of time to make a definitive diagnosis. Although imaging studies are generally not indicated for the diagnosis of IH, in the literature, ultrasonography has been used to confirm IH in selected patients; however, this is not the gold standard for diagnosing IH in children.

Other laboratory and radiographic investigations to determine the presence of IH in a child are usually not necessary or even indicated. In the African subregion, a full blood count with the determination of the sickling status of the child is usually all that is required to treat a child with a reducible, uncomplicated IH. If the hernia is complicated (obstructed or strangulated) and the child is being prepared for surgery, it is advisable to add blood urea, creatinine, and electrolytes determination to the investigations required before operation, especially if the obstruction or strangulation has been present for 24 hours or more (a frequent occurrence in the subregion).

Complications of an inguinal hernia include incarceration, intestinal obstruction, strangulation, gangrene of bowel, perforation of bowel, peritonitis, septicaemia, intraabdominal abscess formation, infarction of the testis, testicular atrophy, gangrene of the ovary and/or fallopian tube, and infertility.

### Treatment

Inguinal hernias are not known to resolve spontaneously and must therefore be repaired surgically shortly after diagnosis on an elective basis; the definitive treatment for IH is early operation, a herniotomy. This will reduce the risks of incarceration with its attendant complications, such as obstruction and strangulation. A well-administered general anaesthesia is preferable and can be safely done by an anaesthesiologist experienced in the care of infants and children. Ketamine can also be used and is well tolerated by children.

The procedure (Figure 58.5) involves a herniotomy through a transverse or oblique incision made in the lowest inguinal skin crease (Figure 58.5A).

1. The incision is deepened through the Camper's fascia, subcutaneous fat, and Scarpa's fascia (in the process, one will encounter the superficial epigastric and the external pudendal vessels, which may be retracted aside, coagulated, or tied with a suture) until the aponeurosis of the external oblique abdominal muscle (Figure 58.5B) is reached.

After clearing it of overlying fat, the external inguinal ring is identified.

At this stage, depending on the size of the hernia and the age of the child, a decision is made whether to open the aponeurosis. In neonates and infants, the external inguinal ring almost overlies the internal inguinal ring, so there may not be the need to open the aponeurosis of the external oblique muscle to get to the hernia. In large hernias, it is advisable to incise the aponeurosis of the external oblique to open into



the inguinal canal before looking for the hernia sac. Here, too, one may decide to open the external oblique aponeurosis to include the external inguinal ring or not to include it in the incision.

2. The sac is normally found on the anteromedial aspect of the elements of the spermatic cord after bluntly spreading the fibres of the cremasteric muscle; it is picked up with haemostats (Figure 58.5C) and dissected free of the cord, using both blunt and sharp dissection.

3. Once the sac is dissected up to the internal inguinal ring, it is opened (Figure 58.5D), and its content(s) replaced into the peritoneal cavity to make sure it is empty. Figure 58.5E shows the vas deferens.

Where the sac is big and extends into the scrotum, no attempt should be made to dissect it completely into the scrotum. This will lead to unnecessary bleeding and haematoma formation postoperatively. Using sharp dissection and several haemostats (a minimum of 6), a large hernia sac can be circumferentially dissected, clamped, and amputated distally without having to follow it into the scrotum.

4. The dissection is then continued proximally towards the internal inguinal ring until the peritoneum (a white structure; see Figure 58.5F) or preperitoneal fat is visualised.

5. The sac is then twisted several times (Figure 58.5F) on itself to make sure the reduced content(s) stay in the peritoneal cavity out of harm's way, and the neck is then transfixed and ligated high up in the internal inguinal ring with Vicryl 3/0 or 2/0, and excess sac excised.

High ligation of the hernia sac is all that is required. Sometimes, an enlarged internal inguinal ring is narrowed at the medial margin by placing one or two sutures through the transversalis fascia.

6. Haemostasis is secured and, where the aponeurosis was opened, it is re-approximated with Vicryl and the skin closed with a suitable suture material. Usually, one Vicryl 2/0 or 3/0 suture of 90 cm in length is adequate enough to suture-ligate the sac, and close the aponeurosis and the skin, especially if one uses the subcuticular method of closure (Figure 58.5G).

For postoperative pain control, a local anaesthetic such as bupivacaine is injected into the wound during closure. The child can then be given either paracetamol, Tylenol® syrup, or a suppository for use in the house, as herniotomy is considered an outpatient procedure.

A controversial topic concerns the routine exploration of the contralateral side for an inguinal hernia. It is known that more than 50% of children younger than 2 years of age have a PPV, but only about 10% will eventually develop a clinical hernia; most PPV will spontaneously close and not develop into hernias. Many reports in the literature (including those from Africa) show that fewer than 7% of children who had a herniotomy done on one side will eventually develop a hernia on the contralateral side. This is a low incidence rate and does not, therefore, suggest or justify the need for routinely exploring the contralateral groin for a metachronous hernia.

Despite the above-stated argument, some paediatric surgeons will still routinely explore the opposite groin in children younger than 2 years of age, in older boys with a clinical hernia on the left, and in girls younger than 10 years of age because hernias on both sides for these groups are more common. Our experience, though, does not support this fact. Due to the high negative rate in exploration of the contralateral side and possible injury to the vas deferens and testicular vessels, it is strongly recommended to perform a unilateral repair of inguinal hernia if it is on only one side.

Herniotomy should be performed on premature babies before they are discharged home from hospital due to the frequent incarceration of IH in such children.

Findings in a hernia sac may include intestines, ovary with the fallopian tube, uterus (rare), ovotestis, omentum (in older children), appendix (Amyand's hernia; see Figure 58.6), Meckel's diverticulum (Littre's hernia), or Richter's hernia (entrapment of a portion of the antimesenteric wall of the bowel in the hernia sac).

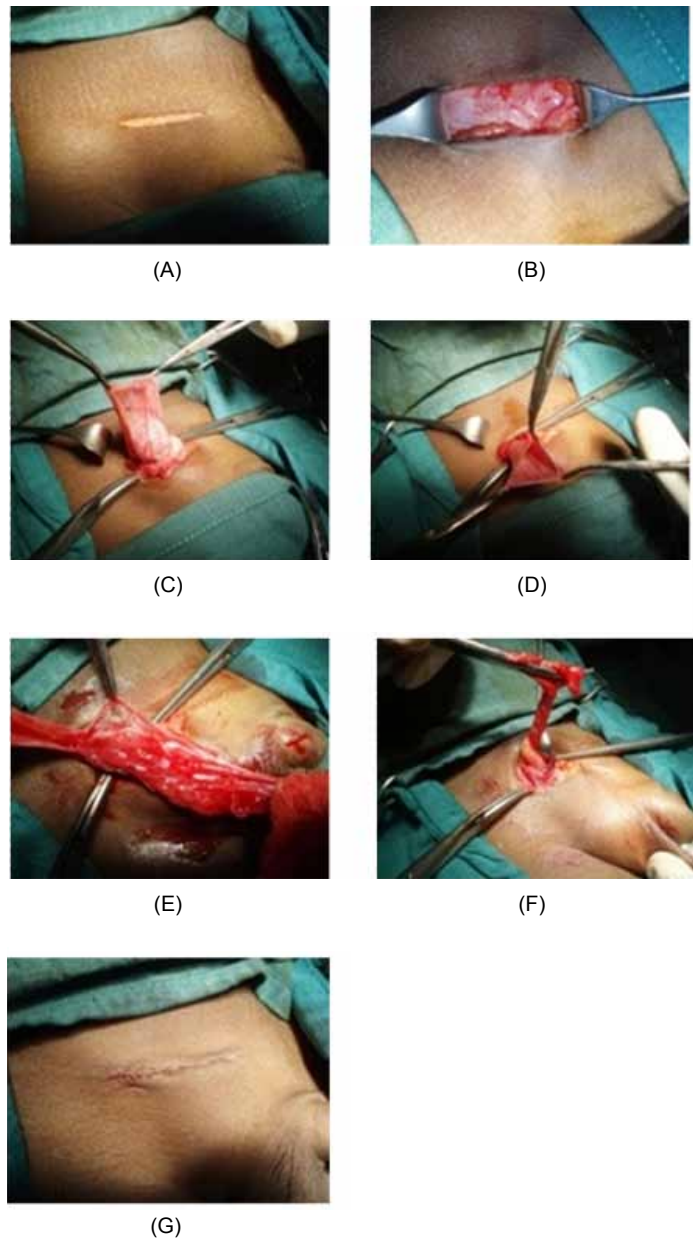


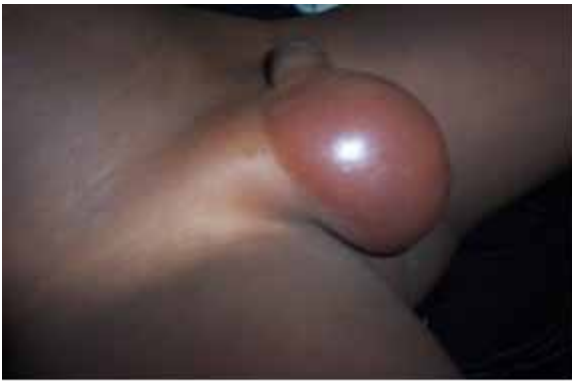Figure 58.5A–G: The various steps of herniotomy of an inguinal hernia in a child.

The child with an irreducible (incarcerated) IH that is tender, making the child irritable, should be admitted to hospital and an attempt made to reduce the mass manually. Even in our subregion, where late presentation is the order of the day, an attempt should first be made to reduce all incarcerated hernias provided there are no signs and symptoms of peritonitis and toxicity. When this fails, surgery can then be performed. Most incarcerated hernias in children have not yet strangulated and can be manually reduced; this will prevent the need for an emergency surgery, with its attendant significantly increased risk to the constituents of the spermatic cord as a result of oedema of the tissues.

When manual reduction of a hernia is attempted on a child with an incarcerated hernia, the child should be given an analgesic (pethidine or tramadol at a dose of 2 mg/kg intramuscularly) and sedated with diazepam (2 mg intramuscularly or intravenously or even rectally), and the foot of the bed should be elevated slightly to allow the intraabdominal organs to fall back and to keep the intraabdominal pressure from being exerted on the inguinal area.

Manual reduction is then attempted as follows:

1. If the incarcerated hernia is on the right side, the thumb and index



Source: By kind permission of the African Journal of Paediatric Surgery.

Figure 58.6: Amyand's hernia in a 5-year-old boy. Note the oedematous and shiny nature of the scrotum. Intraoperatively, an inflamed appendix was found.

finger of the left hand are placed on either side of the external inguinal ring (where the mass is usually obstructed) over the pubic tubercle. The fingers of the right hand compress the fundus of the hernia gently but firmly. The pressure should be gentle, firm, and sustained.

2. Meanwhile, the thumb and the index finger of the left hand attempt to disimpact the neck of the hernia from the narrow external inguinal ring and also prevent the contents of the sac from spreading to the sides and outwards.

3. When reduction is successful, the whole bowel is felt to return to the peritoneal cavity suddenly and with a gurgle or gush.

4. After successfully reducing an incarcerated hernia, the child is kept in hospital for at least 24 hours for observation, and herniotomy is planned for the next available elective list.

Other surgical methods available for repair of inguinal hernias in children consist of the different techniques of laparoscopic surgery. These include percutaneous internal ring suturing, laparoscopic flip-flap technique, and others.

### Postoperative Complications

Complications of herniotomy can be immediate, early, or late. The immediate complications will include anaesthetic complications, such as nausea, vomiting, and laryngeal spasm or oedema. Other immediate complications are haemorrhage (which should be rare if haemostasis is meticulous) and haematoma formation in the wound.

If the vas deferens is transected intraoperatively and this is noticed, then it should be repaired by using fine monofilament sutures.

The early complications comprise

- haematoma formation in the wound or scrotum; such a haematoma will slowly resolve in 3–5 weeks if there is no superimposed infection;
- wound infection, which may occur as a result of anaemia and malnutrition in patients and especially after repair of incarcerated hernias;
- abscess formation in the wound or scrotal haematoma;
- intestinal obstruction; and
- faecal or urinary incontinence as a result of iatrogenic trauma to the bowel or urinary bladder.

Late complications comprise:

- stitch abscess, associated with the use of nonabsorbable sutures;
- undescended testis or high testis due to the fact that the surgeon did not make sure the testis was replaced in the scrotum when closing the inguinal incision;
- recurrence of the inguinal hernia (causes of recurrence include infection and missing the hernia sac during the first operation);
- hydrocele, which may resolve spontaneously or may require surgery;

- testicular atrophy as a result of transection of the vessels during the operation or, in the case of children presenting with incarcerated hernias, with evidence of infarction of the testis at operation;
- infarction of the ovary and fallopian tube (rare because there is usually no obstruction to the blood supply of these organs);
- subfertility or infertility if injury to the vas deferens is bilateral or is to the vas deferens of a solitary testis; and
- numbness of the inguinal region as a result of injury to the ilioinguinal nerve.

### Femoral Hernia

Femoral hernia is an unusual hernia in the paediatric age group. A femoral hernia presents as a mass located lateral to and below the pubic tubercle, inferior and posterior to the inguinal ligament and medial to the femoral pulse. It occurs in about 0.5% of all groin hernias in children. The diagnosis of a femoral hernia is challenging, and the correct preoperative diagnosis is usually not made in many children. Most often, it is misdiagnosed, and only during surgery for a suspected inguinal hernia is the precise diagnosis made. Note that a diagnosis of a missed femoral hernia or a direct inguinal hernia should be considered if any child returns with an early recurrence of a groin bulge after an adequate herniotomy, as recurrent indirect inguinal hernias are rare. In the literature, some femoral hernias are reported to have occurred after an inguinal canal exploration or even as a result of iatrogenic disruption of the femoral canal. Most paediatric surgeons know of the existence of this entity but have not encountered it in their practice due to its rarity.

#### Aetiology

The aetiology of femoral hernias remains elusive. It is suggested that it may be due to either (1) a congenital narrow posterior inguinal wall attachment to Cooper's ligament with a resulting enlarged femoral ring (this is the anatomic aspect accepted by many paediatric surgeons); or (2) an acquired genesis related to increased intraabdominal pressure.

#### Anatomy

The anatomy of the femoral canal, which occupies the most medial compartment of the femoral sheath and extends from the femoral ring above to the saphenous opening below, has the medial border as the lacunar (Gimbernat's) ligament, posterior border as the pectineal (Cooper's) ligament, the lateral border as the femoral vein, and the anterior border as the inguinal ligament. It is usual to have a lymph node (Cloquet) within the canal.

In the available series of childhood femoral hernias, 60–65% are found on the right side, 25–30% on the left, and 10–15% are bilateral.

#### Presentation

The clinical signs and symptoms of a femoral hernia are a bulge below the inguinal ligament and lateral to the pubic tubercle; the mass appears on straining or coughing, and reduces in size or disappears when the patient lies supine; and there may be a cough impulse. A femoral hernia can remain unnoticed for a long period until it incarcerates, drawing the attention of the patient to the problem for the first time. Incarceration of paediatric femoral hernias is a very rare occurrence, however.

#### Diagnosis

The diagnosis of a femoral hernia is mainly clinical or at operation. For the diagnosis to be made preoperatively, the surgeon must consider it in the differentials of groin hernias. There are no known investigations to help confirm the diagnosis of a femoral hernia. The advent of laparoscopic surgery definitely helps with the diagnosis and repair of such hernias.

The differential diagnosis of a femoral hernia include inguinal hernia, ectopic testis, femoral aneurysm, saphena varix, enlarged femoral lymph nodes, lymphadenitis, lipoma, psoas abscess, and lymphangioma.

## Treatment

For uncomplicated femoral hernias, the treatment is surgical repair of the femoral defect as soon as the diagnosis is made. There are three methods of approaching the femoral canal for the repair of a femoral hernia:

1. a high or suprainguinal (transperitoneal or extraperitoneal) approach;
2. an inguinal approach; and
3. a low infrainguinal approach.

Irrespective of the method of approach used, the procedure is as follows:

1. The hernia sac is dissected free and opened to inspect the contents, which are then reduced back to the peritoneal cavity, if present.
2. The sac is then suture-ligated and the inguinal ligament is approximated to the pectineal ligament, thus effectively eliminating the defect.

Caution should be exercised not to strangulate the femoral vein, which will lead to compromised venous return, resulting in the swelling of the lower limb on the affected side. In an incarcerated femoral hernia, the transperitoneal approach may come in handy if there is the need to resect gangrenous bowel.

Femoral hernias can also be repaired laparoscopically.

## Complications

Complications include recurrence of femoral hernia (mainly reported in patients who underwent simple herniotomy without any attempt to close the defect in the femoral canal), trauma to the femoral vessels, oedema of the lower limb, haemorrhage leading to haematoma formation, and wound infection.

## Hydrocele

A hydrocele is an abnormal collection of fluid in the layers of the tunica vaginalis, the persistently patent processus vaginalis surrounding the testis. Hydroceles are common in infants. The PPV is found in about 90% of term babies at birth. This incidence rate will gradually decrease to about 40% at 2 years of age and then to about 10% in adulthood. A clinically apparent hydrocele is present in only 6% of term male children beyond the neonatal period.

## Aetiology

In infants, hydroceles, which are mostly congenital, can be communicating or noncommunicating. A communicating hydrocele (Figure 58.7A) occurs when the proximal portion of the PV remains patent, allowing fluid from the abdominal cavity to trickle down its narrow neck into the scrotal sac, or tunica vaginalis. A communicating hydrocele fluctuates in size and is usually larger in ambulatory patients at the end of the day. It becomes small as the child lies down supine and the fluid trickles back into the peritoneal cavity (Figure 58.7B).

In the case of noncommunicating hydroceles (Figure 58.8), the PV is obliterated proximally with a collection of fluid distally in the tunica vaginalis alone or the tunica vaginalis and part of the PPV proximal to it. Thus, one can have (1) a vaginal (scrotal) hydrocele in which the whole PV is obliterated and there is fluid collection in the tunica vaginalis; (2) an infantile hydrocele, in which part of the PV proximal to the tunica vaginalis is still patent, and can sometimes extend into the inguinal canal as far as the internal inguinal ring; or (3) an encysted hydrocele of the spermatic cord (or, simply, hydrocele of the spermatic cord), in which there is a collection of fluid in a portion of PV somewhere along its length between the external inguinal ring and the testis. Most often, the cyst does not communicate with either the peritoneal cavity above or the tunica vaginalis below, and even may be considered as a third testis by the uninitiated (Figure 58.9). In the case of girls, the inguinal swelling filled with fluid is referred to as a hydrocele of the canal of Nuck.

Acquired hydroceles can be due to viral infection, trauma (called posttraumatic hydroceles), or testicular neoplasia.

Clinically, hydroceles are soft nontender masses within the hemiscrotum. The testis can usually be felt at the posterior aspect of



(A)



(B)

Figure 58.7: A communicating hydrocele in a 6-year-old boy: (A) in a standing position, fluid fills the tunica vaginalis and the hydrocele is apparent; (B) in a lying position, the fluid trickles back into the peritoneal cavity and the hydrocele empties.



Figure 58.8: A vaginal (scrotal) hydrocele in a 10-year-old boy. The PV was completely obliterated above the hydrocele at operation.

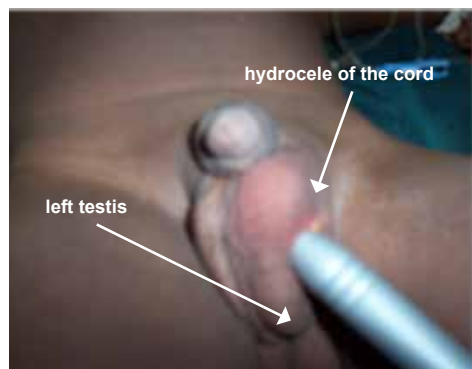


Figure 58.9: Encysted hydrocele of the left spermatic cord. Notice that the mass above the left testis transilluminates light brightly and is separate from the testis below it. Intraoperatively, the PV was found to be completely obliterated above and below the cyst.



fluid collection in the hemiscrotum. To diagnose a mass in the scrotum as a hydrocele, the following should be present:

1. One should be able to get above the mass. This is usually the case, except for the rare infantile hydrocele, which may extend into the internal inguinal ring.
2. The mass must be fluctuant. Always test for fluctuancy in two planes.
3. The mass must brilliantly transilluminate, especially when this test is done in a darkened environment. It must be remembered that hernias in infants can also transilluminate due to the thin walls of the bowel.
4. The mass cannot be emptied on applying pressure; this is very true for the noncommunicating hydroceles (Figure 58.8). For the communicating hydrocele (Figure 58.7A), on applying pressure, the mass empties very slowly; in the case of a reducible inguinoscrotal hernia, the emptying is relatively very fast and intestines are usually palpated in the scrotum.

Hydroceles in infants are often bilateral; like hernias, they are more common on the right than the left. Most hydroceles will resolve spontaneously by the age of 1 to 2 years, on the average by one and a half years of age. Therefore, hydroceles still in existence by this age should be electively repaired.

The diagnosis of a hydrocele in a child is usually clinical. There are no known imaging studies that are used routinely to diagnose the problem. However, ultrasonography may be used as a screening tool if a testicular tumour is considered as being a cause of the hydrocele.

The differential diagnosis of a hydrocele will include: an inguinal hernia, a testicular tumour, and epididymo-orchitis. The last two may have an associated hydrocele, which is usually reactive. For testicular tumours, such as malignant teratomas, measuring serum  $\alpha$ -foetoprotein and human choriongonadotropin levels may help to establish the diagnosis. In the case of epididymitis and orchitis, urinalysis and urine culture and sensitivity may be of help in diagnosis and treatment.

### Treatment

Hydroceles that are asymptomatic should be observed until the child is about 2 years old, at which time the PPV should close spontaneously. If a hydrocele does not resolve spontaneously by then, surgery is advised. The operation is performed through an inguinal approach, as in inguinal hernias, using one of the lowermost skin creases in the groin. Surgery involves, in the case of the communicating hydrocele, high ligation of the PPV within the internal inguinal ring. For encysted hydrocele of the spermatic cord, the hydrocele is usually easily dissected out without much of a problem. Care should be exercised, however, not to traumatise the vas deferens and its vessels. If the hydrocele is infantile or vaginal, then hydrocelectomy is carried out, also through a groin incision, with care not to traumatise the spermatic cord structures. In both cases, the PV proximal to the hydrocele is usually obliterated.

The child should be placed on analgesics after the surgery; Tylenol or a paracetamol suppository three times daily suffices in most cases. No antibiotics are required. Hydroceles in children should not be aspirated as a method of treatment because they have a natural history of resolution and will recollect after aspiration.

### Postoperative Complications

The following complications are possible postoperatively:

- *Injury to the spermatic cord.* Careful surgery and avoidance of rough handling of the spermatic cord structures will prevent trauma to them.
- *Bleeding with possible scrotal haematoma formation.* This can be prevented if bleeding is meticulously controlled at every step during surgery. A diathermy machine (especially a bipolar diathermy), if available, is of great help, with careful avoidance of excessive burning of the tissues in order not to injure the vas deferens and its elements. Haematomas will resolve spontaneously in 3–5 weeks without surgery; if they persist beyond this period, surgical drainage may be necessary.

- *Wound infection.* Antibiotics may be necessary to treat the infection, depending on its severity.
- *Recurrence of the hydrocele.* Recurrence is rare.

### Prognosis and Outcome

The prognosis is excellent for groin hernias and hydroceles if they are diagnosed and repaired early in childhood. Hernia surgery is safe and very effective in eliminating the problem; the outcome is usually good, and recurrence is rare (about 1%). Complications occur mostly in the difficult cases, such as in obstructed or strangulated hernias. An inguinal approach to the repair of hydroceles is extremely successful and should lead to less than a 1% recurrence rate.

### Prevention

Groin hernias and hydroceles are congenital in nature, so prevention is geared towards preventing their complications and not towards preventing the occurrence of these pathologies, per se. Complications of groin hernias can be prevented if they are treated timely, during childhood, on diagnosis. The risk of incarceration of inguinal hernias is high in children, and therefore elective repair is the treatment of choice. Premature babies with hernias should have an elective repair of the hernia done before discharge from hospital or as soon as practicable because their hernias are more prone to incarceration. A well-timed elective operation will prevent incarceration.

During laparoscopic repair of a groin hernia on one side, the contralateral side can be inspected for the presence of a metachronous hernia and a repair carried out as a preventive measure.

### Evidence-Based Research

Table 58.1 presents a retrospective review of the incidence of complications following inguinal herniotomy in newborns weighing 5 kg or less.

Table 58.1: Evidence-based research.

<b>Title</b>	The incidence of complications following primary inguinal herniotomy in babies weighing 5 kg or less
<b>Authors</b>	Nagraj S, Sinha S, Grant H, Lakhoo K, Hitchcock R, Johnson P
<b>Institution</b>	Department of Paediatric Surgery, Children's Hospital Oxford, John Radcliffe Hospital, Oxford, UK
<b>Reference</b>	Pediatr Surg Int 2006; 22(12):1033
<b>Problem</b>	Complications following inguinal hernia surgery in newborns.
<b>Intervention</b>	The aim of this study was to quantify the incidence of complications following inguinal herniotomy in small babies weighing 5 kg or less.
<b>Comparison/control (quality of evidence)</b>	This was a retrospective review of inguinal herniotomies performed between December 1997 and March 2002 on babies weighing 5 kg or less. A total of 154 patients underwent hernia repair, of which 81% (125 patients; 221 hernias) were available for review. The median weight at surgery was 3.6 kg (range, 1.7–5 kg). Eighty-four patients (67%) were classified as premature (<36 weeks gestation). Thirty-three patients presented with an irreducible hernia, in whom all but one were successfully reduced prior to surgery. Patients were reassessed at a clinic following surgery, and follow-up data were obtained from the clinic notes after a median follow-up of three months (range, 1–60 months). Five cases (2.3%) of hernia recurrence occurred in 4 patients, and 6 patients (2.7%) experienced testicular atrophy. In the testicular atrophy group, 4 of the 6 patients presented with an incarcerated hernia, and of these, 3 were noted to have evidence of ischaemia at operation. There were 6 cases (2.7%) of high testes requiring subsequent orchidopexy.
<b>Outcome/effect</b>	Although neonatal inguinal herniotomy is a technically demanding procedure, this series has demonstrated a low complication rate. Testicular atrophy was associated with a history of preoperative incarceration in the majority of cases

## Key Summary Points

1. Hernias and hydroceles in children are considered congenital and are diagnosed clinically (history and examination). Indirect inguinal hernias are overwhelmingly more common than other groin hernias.
2. Open herniotomy is the operation of choice for inguinal hernias in children in our subregion. These hernias can also be repaired laparoscopically.
3. Femoral hernias are very rare in children but should be kept in mind as a differential diagnosis for groin hernias. If there is recurrence after surgery for an indirect inguinal hernia in a child, it is important to exclude a direct inguinal hernia or a femoral hernia.
4. An attempt should be made to manually reduce all incarcerated hernias in children, especially in infants, under sedation and analgesia.
5. If manual reduction is successful, plan to operate on the child on the next available elective list, preferably within the next 72 hours because the oedema would have subsided by then.
6. If manual reduction fails, the child must be operated on immediately after the necessary preoperative preparations.
7. An encysted hydrocele of the spermatic cord may mimic an incarcerated hernia; therefore, careful examination of the child is important.
8. In the case of a dull transillumination of a groin mass, an attempt should be made to exclude an inguinal hernia, which in infants may transilluminate dimly.

## Suggested Reading

- Abantanga FA, Amaning EP. Paediatric elective surgical conditions as seen at a referral hospital in Kumasi, Ghana. *ANZ J Surg* (2002); 72:890–892.
- Abantanga, FA. Groin and scrotal swellings in children aged 5 years and below: a review of 535 cases. *Pediatr Surg Int* 2003; 19:446–450.
- Ameh, EA. Incarcerated and strangulated inguinal hernias in children in Zaria, Nigeria. *East Afr Med J* 1999; 76(9):499–501.
- Calkins CM, St Peter SD, Balcom A, Murphy PJ. Late abscess formation following indirect hernia repair utilizing silk suture. *Pediatr Surg Int* 2007; 23:349–352.
- Chen K-C, Chu C-C, Chou T-Y, Wu C-J. Ultrasonography for inguinal hernias in boys. *J Pediatr Surg* 1998; 33(12):1784–1787.
- Collins, S. Hydrocele and hernia in children. Available at <http://emedicine.medscape.com/article/1015147> (accessed 16 November 2008).
- Davenport, M. ABC of general paediatric surgery: inguinal hernia, hydrocele, and the undescended testis. *BMJ* 1996; 312:564–567.
- De Caluwe D, Chertin B, Puri P. Childhood femoral hernia: a commonly misdiagnosed condition. *Pediatr Surg Int* 2003; 19:608–609.
- De Meulder F, Wojciechowski M, Hubens G, Ramet J. Female hydrocele of the canal of Nuck: a case report. *Eur J Pediatr* 2006; 165:193–194.
- Fresno JCO, Alvarez M, Sanchez M, Rollan V. Femoral hernia in childhood: review of 38 cases. *Pediatr Surg Int* 1997; 12:520–521.
- Hassan, ME. Laparoscopic flip flap technique versus conventional inguinal hernia repair in children. *Ann Pediatr Surg* 2005; 1(1):17–20.
- Hebra, A. Pediatric hernias. Available at <http://emedicine.medscape.com/article/932680> (accessed 14 December 2008).
- Khanna PC, Ponsky T, Zagol B, Lukish JR, Markle BM. Sonographic appearance of canal of Nuck hydrocele. *Pediatr Radiol* 2007; 37:603–606.
- Lau ST, Lee Y-H, Gaty MG. Current management of hernias and hydroceles. *Sem Pediatr Surg* 2007; 16:50–57.
- Lee, S. Hydrocele. Available at <http://emedicine.medscape.com/article/438724> (accessed 12 December 2008).
- Lee SL, DuBois JJ. Laparoscopic diagnosis and repair of pediatric femoral hernia. Initial experience of four cases. *Surg Endosc* 2000; 14:1110–1113.
- Lloyd, DA. Inguinal and femoral hernia. In Azizkhan RG, Weber TR Ziegler MM, eds. *Operative Pediatric Surgery*. McGraw-Hill Professional, 2003.
- Luo C-C, Chan H-C. Prevention of unnecessary contralateral exploration using the silk glove sign (SGS) in pediatric patients with unilateral inguinal hernia. *Eur J Pediatr* 2007; 166:667–669.
- Nmadu, PT. Paediatric external abdominal hernias in Zaria, Nigeria. *Ann Trop Paediatr* 1995; 15(1):85–88.
- Nuss, D. The management of hernias, hydroceles and undescended testes. *SA Med J*, 1976; 548–549.
- Osifo OD, Irowa OO. Indirect inguinal hernia in Nigerian older children and young adults: is herniorrhaphy necessary? *Hernia* 2008; 12:635–639.
- Patkowski D, Czernik J, Chrzan R, Jaworski W, Apoznanski W. Percutaneous internal ring suturing: a simple minimally invasive technique for inguinal hernia repair in children. *J Laparoendoscopic & Advanced Surg Techniques* 2006; 16(5):513–518.
- Rescorla, FJ. Hernias and umbilicus. In Colombani PM, Foglia RP, Skinner MA, Oldham KT, eds. *Surgery of Infants and Children*, Vol. 2. Lippincott Williams & Wilkins, 2005.
- Shabbir J, Moore A, O'Sullivan JB, et al. Contralateral groin exploration is not justified in infants with a unilateral inguinal hernia. *Irish J Med Sc* 2003; 172(1):18–19.
- Sklar C, Cameron BH. Achieving excellent outcomes and avoiding complications in pediatric inguinal hernia surgery. Available at: <http://www.ptolemy.ca/members/archives/2008/hernia.pdf> (accessed 16 November 2008).
- Stephens BJ, Rice WT, KouchyCJ, Gruenberg KC. Optimal timing of elective indirect inguinal hernia repair in healthy children: clinical consideration for improved outcome. *World J Surg* 1992; 16:952–957.
- Usang UE, Sowande OA, Adejuyibe O, Bakare TIB, Ademuyiwa OA. Day case inguinal hernia surger in Nigerian children: prospective study. *Afr J Paediatr Surg* 2008; 5(2):76–78.
- Woolley, MM. Inguinal hernia. In: Welch KJ, Benson CD, Aberdeen E, Randolph JG Ravitch MM. *Pediatric surgery*, Vol. 2. Year Book Medical Publishers, Inc, 1984.
- Zamakhshary M, To T, Guan J, Langer JC. Risk of incarceration of inguinal hernia among infants and young children awaiting elective surgery. *CMAJ* 2008; 179(1):1001–1005.