

CHAPTER 59

INFANTILE HYPERTROPHIC PYLORIC STENOSIS

Lohfa B. Chirdan
Emmanuel A. Ameh
Amy Hughes-Thomas

Introduction

Infantile hypertrophic pyloric stenosis (IHPS) is a common surgical cause of vomiting in infancy in the Western world.^{1,2} Historically, it was described as a disease entity in 1888 by Harald Hirschsprung.³ Gastrojejunostomy was used to treat this disease until 1912, when extramucosal muscle-splitting pyloromyotomy was described by Ramstedt.⁴ This procedure has dramatically changed the outcome of infants with IHPS.

Demographics

The reported incidence of IHPS in the Western world is 1–4 per 1,000 live births.⁵ There is a male-to-female ratio of 4:1, with reported ratios ranging from 2.5:1 to 5.5:1.⁶

Pyloric stenosis appears to be more common in infants of caucasian descent and is less common in India and among black and Asian populations, with a frequency that is one-third to one-fifth that in the white population.⁷

In about 6–33% of infants with IHPS, associated anomalies have been described in the central nervous system (CNS), gastrointestinal tract (GIT), and urinary tract.⁸

Aetiology

Despite the frequency of pyloric stenosis, the aetiology remains unclear. Genetic predisposition acting in conjunction with environmental factors is the most widely accepted explanation; however, debate still continues as to whether it is a congenital or acquired disease.^{9–11} Breast-feeding has been suggested as offering some immunity to the disease.¹²

First-born children have been noted to be more likely affected, and a familial link is seen with a greater than fivefold increase in the risk in first-degree relatives. The genetics explaining this are likely to be polygenic, as no single locus has been identified.⁶ Male and female children of affected mothers carry a 20% and 7% risk, respectively, of developing the condition, whereas male and female children of affected fathers carry a 5% and 2.5% risk, respectively. Furthermore, an association is seen in twins, with concordance among monozygotic twins of 0.25–0.44, and in dizygotic twins of 0.05–0.10.¹³

Pathophysiology

Pyloric stenosis is characterized by hypertrophy of the pyloric musculature, leading to a mechanical obstruction of the gastric outlet in the affected infant. Thus, hypertrophied pyloric antral muscle fibres protrude distally into the duodenal lumen, producing a reflection of duodenal mucosa.

Infants with a diagnosis of pyloric stenosis will show characteristically low chloride and hydrogen ions as measured in the serum. The loss of gastric secretions secondary to protracted vomiting will result in dehydration. As a result, through aldosterone-stimulated absorption, potassium is excreted in the urine in an attempt to conserve sodium. As potassium depletion worsens, sodium resorption across the renal tubule is then achieved in exchange for a hydrogen ion, thereby creating

paradoxical aciduria. Classically, this results in the occurrence of a hypochlorhaemic hypokalaemic metabolic alkalosis. In severe cases with diagnostic delay, hypoglycaemia and hypoalbuminaemia can be observed.

It is known that the pyloric hypertrophy will eventually resolve, but this takes a long period of time; the infant would usually succumb to the electrolyte derangement and dehydration before this happened.

Clinical Presentation

Infants with pyloric stenosis usually present with a gradual onset of worsening nonbilious vomiting, beginning between 3 to 6 weeks of age. The pattern of vomiting can vary, but often it progresses to the characteristic “projectile” vomiting. Infants may present in the early stages of the disease and be treated for reflux disease or undergone numerous formula changes before the diagnosis is made. Delay in diagnosis can result in significant electrolyte imbalance, weight loss, and failure to thrive.

The typical clinical features include the following:

- Nonbilious vomiting is usually forceful and postprandial.
- The infant is hungry after vomiting and eager to feed, only to vomit again.
- Weight loss occurs in severe cases.
- Signs of dehydration present in cases of repeated vomiting.
- Scaphoid abdomen especially noted after recent vomiting.
- Visible peristalsis may be observed in the upper abdomen, usually moving from the left hypochondrium towards the right side.
- A palpable mass is present in the right upper quadrant (90% in experienced hands); this is best appreciated while the infant is being fed with clear fluid.

Differential Diagnosis

The differential diagnosis of pyloric stenosis includes:

- gastro-oesophageal reflux;
- viral enteritis;
- pylorospasm;
- duodenal stenosis/duodenal web; and
- raised intracranial pressure.

Evaluation

Clinical Diagnosis

Depending of the time to presentation, the clinical picture can vary enormously from a well-hydrated baby to an emaciated infant. Weight loss and dehydration coupled with an insatiable appetite lead to a characteristic facies, with a furrowed brow, wrinkled appearance, and prominent sucking pads. In some infants, the distended stomach may be identifiable in the hypochondrium, with active peristaltic activity visible through the

thin abdominal wall. On examination, a mobile, ovoid mass, commonly referred to as an “olive”, is palpable in the epigastrium or the right upper quadrant.

If the pylorus is palpated by an experienced clinician, no further imaging is necessary. In some cases, however, other structures may be confused with hypertrophied pylorus, including the caudate lobe of the liver, the right kidney, the vertebrae, or an orogastric tube in the distal stomach. If there is any doubt, or in the absence of a palpable “olive”, diagnostic imaging can be helpful.

Ultrasonography

In situations where doubt exists, examination by ultrasound (US) should be performed. This would normally confirm the presence of a pyloric “tumour”. The characteristic appearance of pyloric stenosis on ultrasound is that of a “doughnut” or “bull’s eye” on cross section of the pyloric channel. Pyloric dimensions with positive predictive value greater than 90% are muscle thickness greater than 4 mm and a pyloric channel length greater than 17 mm.¹⁴ These limits may be lower in infants younger than 30 days of age (Figure 59.1).

An experienced sonographer will recognize periods of relaxation in infants with pylorospasm, commonly confused with pyloric stenosis at examination. Pylorospasm has been hypothesized to be an early stage of IHPS, but this has not been proven.

Upper Gastrointestinal Contrast Study

In an occasional case where doubt still persists after US examination, an upper gastrointestinal (UGI) series may be done. The UGI series would show a narrow pyloric channel, the so-called “string sign” and the “shoulder sign”, caused by the impression of the pylorus into the stomach (Figure 59.2).

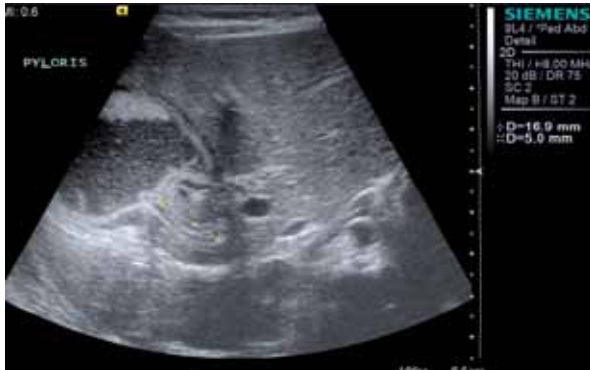

Figure 59.1: Ultrasound features of pyloric stenosis.

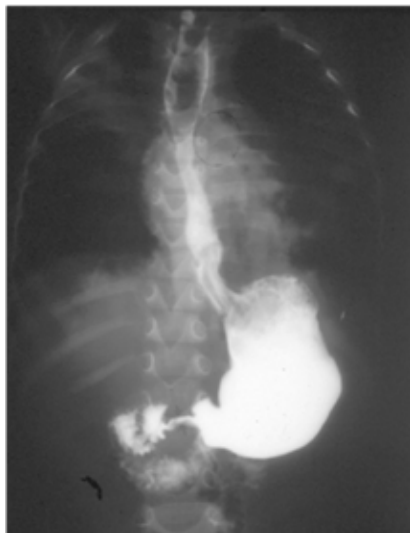


Figure 59.2: UGI contrast showing pyloric stenosis.

Serum Electrolytes

Serum electrolytes should be measured immediately when the patient arrives in hospital. If vomiting has been ongoing for several days, serum electrolytes are frequently deranged. The nature of derangement is a spectrum,^{15,16} ranging from mild to severe hyponatraemia, hypochloraemia, hypokalaemia, and metabolic alkalosis. The degree of elevation of serum urea is directly related to the severity of dehydration.

Haemogram/Full Blood Count

Infants presenting late are often malnourished and may have some degree of anaemia, which may require correction. Therefore, a haemogram and full blood count are warranted.

Treatment

Correction of Electrolyte and Fluid Depletion

Patients with pyloric stenosis may have severe electrolyte disturbances, so the serum electrolytes should always be estimated. Mild electrolyte disturbances can be corrected preoperatively with 0.45% normal saline with 5% dextrose solution. Severe disturbances require correction with 0.9% normal saline bolus of 10 to 20 ml/kg, followed by administration of 0.9% saline in 5% dextrose solution. Potassium can be added if necessary when adequate urine output (1.5–2 ml/kg per hour) is established and under electrocardiogram (ECG) monitor. Fluid should be administered at a rate of 25–50% above maintenance.

Following resuscitation and correction of electrolyte imbalance, maintenance IV with 0.45% saline in 5% dextrose with 20 mmol potassium chloride should be given at 25–50% above the standard rate.

Meticulous care and time should always be taken to correct fluid and electrolyte depletion before any surgical correction. It is important to emphasize that mortalities from pyloric stenosis are attributable to fluid and electrolyte problems.

Nasogastric Decompression

Once diagnosis is made, all feeds are stopped. It is helpful to aspirate all gastric content by nasogastric tube (NGT). Frequently, this content comprises milk curds, which may require lavage with saline to adequately evacuate the stomach. Keeping the stomach empty would help prevent aspiration from vomiting. Once the stomach is emptied, the NGT is either closed off or removed to avoid worsening electrolyte depletion by aspirating gastric content.

In the West, gastric lavage is not routinely performed. An NGT is passed, size 8 Fr or above. Gastric losses are monitored and replaced milliliter for milliliter with 0.9% saline. To avoid iatrogenic hyperkalaemia, no potassium is added to the replacement fluid.

Surgical Correction

Surgical correction of pyloric stenosis is not an emergency, and therefore the electrolyte disturbances can and should be meticulously corrected before operation. Occasionally, children with pyloric stenosis will have jaundice due to a transient impairment of glucuronyl transferase activity. This is self-limited once postoperative feeding is initiated.

Infants undergoing pyloromyotomy are assumed to have a full stomach and the anaesthesiologist should keep this in mind. Both the anaesthesiologist and surgeon should be vigilant during the operation to prevent aspiration of gastric juice. The stomach must be evacuated in the operating room, particularly if NGT had not been inserted earlier.

Preoperative antibiotics are controversial; data supporting their use with the standard right upper quadrant incision are scant. They may be of benefit when performing the operation through the umbilical skinfold.

Operative Details

The standard operation is the Ramstedt pyloromyotomy. Classically, the operation has been approached through a right upper quadrant muscle-splitting approach¹⁷. Alternatively, the approach may be via a supra-umbilical transverse skinfold incision.

1. Once the peritoneum is entered, the omentum is retrieved into

the wound and elevated to lift the transverse colon. This manoeuvre enables the surgeon to identify the antrum of the stomach. The lower third of the stomach is then gently elevated using moist gauze to deliver the pyloric mass into the wound (Figure 59.3).

2. A vertical incision is then made into the mid anterior surface through the serosa and superficial muscularis, beginning about 1–2 mm from the pyloroduodenal junction to a point 0.5 cm into the lower antrum.

3. The underlying firm fibres are then divided using blunt dissection with a clamp, rounded end of a scalpel blade, or special Benson's pyloromyotomy spreader. Special care is taken to prevent mucosal perforation, especially at the lower end of the incision. Upward protrusion of the gastric mucosa indicates relief of the obstruction (Figures 59.4 and 59.5).

Mucosal perforation usually occurs at the duodenal end and is indicated by the appearance of bilious fluid. When this occurs, repair is done by using interrupted fine monofilament long-term absorbable sutures placed transversely and covered with omentum. If the closure of the mucosal perforation compromises the pyloromyotomy, which rarely happens, a fresh pyloromyotomy is done at about 45°–90° of the first incision. Air is then instilled through the NGT to check the integrity of the duodenal mucosa.

Use of a laparoscopic approach is increasing, with evidence supporting its benefits emerging.^{18,19} A recent study has shown a safe alternative with a decreased time to full feeds postoperatively.²⁰

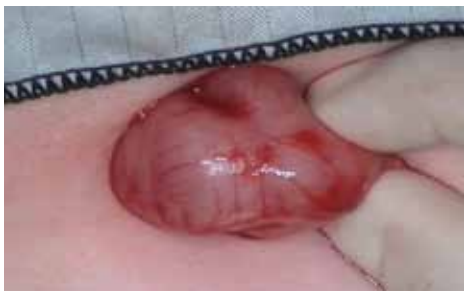

Figure 59.3: Operative view of pyloric mass.

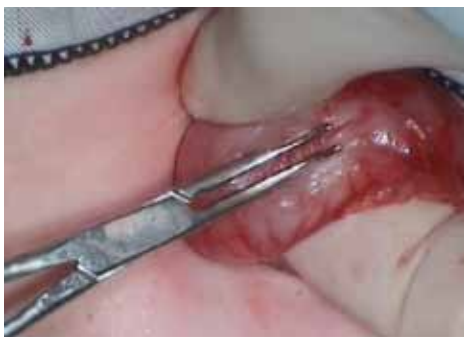

Figure 59.4: Spreading of the divided pyloric muscle.

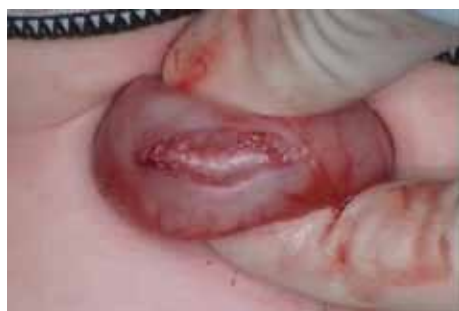

Figure 59.5: Myotomy with mucosal bulge.

Postoperative Management

Postoperative nasogastric decompression is not necessary unless the mucosa has been entered and repaired. Several feeding schedules have been advocated after surgery. Traditional structured feeding regimens as opposed to more rapid initiation and advancing feeding schedules are probably unnecessary. Feedings are begun 4 to 6 hours after operation, normally with low-volume balanced electrolyte or dextrose solution initially, rapidly advanced to full feeds of formula over the next 12- to 24-hour period. If the patient vomits, which is common after this procedure, the same volume feed that caused the emesis can be repeated. The patient is usually discharged the day after operation.

Surgical Complications

Intraoperative risks include bleeding, infection, and mucosal perforation. Postoperative complications include wound infection and dehiscence in about 1%. Persistent vomiting beyond 48 hours, thought to be due to gastric atony, occurs in about 3%. Unrecognized perforation during pyloromyotomy is a serious but rare problem demanding immediate reoperation.

Outcome

The majority of infants go on to make a full recovery postoperatively and need no further medical input. After a surgical pyloromyotomy, the pyloric muscle subsides to a normal size and, when viewed during subsequent operations, is usually visible only as a fine line over the pylorus at the site of the myotomy.

Incomplete pyloromyotomy may occur, but it is difficult to diagnose in the early postoperative phase. Imaging studies done postoperatively are difficult to interpret and usually not helpful. If complete gastric-outlet obstruction is present on a contrast study, repeated pyloromyotomy is necessary.

Mortality is rare, but when it occurs, it is usually from fluid and electrolyte depletion in infants presenting late, and inadequately corrected electrolyte problems before surgery.

Evidence-Based Research

Evidence on the management of pyloric stenosis in African children is rare, so clinicians have to depend on literature from the West, where the disease is more frequent. Table 59.1 presents the results of a survey on the management of IHPS conducted in the United Kingdom and Ireland.

Table 59.1: Evidence-based research.

Title	Surgical practice for infantile hypertrophic pyloric stenosis in the United Kingdom and Ireland—a survey of members of the British Association of Paediatric Surgeons
Authors	Mullassery D, Perry D, Goyal A, Jesudason EC, Losty PD
Institution	Academic Department of Pediatric Surgery, The Royal Liverpool Children's Hospital (Alder Hey), University of Liverpool, United Kingdom
Reference	J Pediatr Surg 2008; 43:1227–1229
Problem	Current practice amongst paediatric surgeons on the management of infantile hypertrophic pyloric stenosis.
Outcome/ effect	More than half of the surgeons surveyed used umbilical incision for pyloromyotomy, whereas only 15% do the pyloromyotomy laparoscopically. Fewer than 10% of surgeons surveyed use the classical right upper quadrant incision for pyloromyotomy. The study also showed that about half of the surgeons do not use antibiotics; however, 70% of those using the umbilical incision use antibiotics. The study concluded that umbilical incision and laparoscopic incisions are benchmarks for surgeons caring for children with infantile hypertrophic pyloric stenosis.
Historical significance/ comments	Acknowledging that IHPS may not be a major workload for the paediatric surgeon practicing in Africa, patients with this condition do come in occasionally, especially in major centres, so paediatric surgeons need to be aware of the current practices amongst paediatric surgeons who care frequently for these patients; hence, the importance of this article. Although there are a lot of variations in the practice, pyloromyotomy through whatever route remains the gold standard for caring for these group of patients.

Key Summary Points

1. Infantile hypertrophic pyloric stenosis affects infants 2–8 weeks of age, often presenting with repeated vomiting.
2. Although the disease may not be common in African children, practitioners may encounter the condition.
3. The aetiology is not clear, but pyloric muscle hypertrophy leading to mechanical obstruction of the pylorus is the endpoint.
4. The disease can be self-limiting, but the infant would succumb to dehydration and electrolyte imbalance if not treated.
5. Care should be taken to correct any fluid and electrolyte depletion before embarking on any surgical correction.
6. Extramucosal pyloromyotomy, introduced about a century ago, still remains the gold standard for surgical management of IHPS.

References

1. Hirschsprung H. Falle von angeborener pyloric stenose. *Jb Kinderheik* 1888; 27:61.
2. Ramstedt C. Zur operation der angeborenen pylorus-stenose. *Med Klin* 1912; 8:1702–1705.
3. Spicer RD. Infantile hypertrophic stenosis: a review. *Br J Surg* 1982; 69:128–135.
4. Stringer MD, Brereton RJ. Current management of infantile hypertrophic pyloric stenosis. *Br J Hosp Med* 1990; 43:266–272.
5. To T, Wajja A, Wales PW, et al. Population demographic indicators associated with incidence of pyloric stenosis. *Arch Pediatr Adolesc Med* 2005; 159:520–525.
6. Michel LE, Risch N. The genetics of infantile hypertrophic pyloric stenosis: a reanalysis. *Am J Dis Child* 1993; 147:1203–1211.
7. Klein A, Cremin BJ. Racial significance in pyloric stenosis. *S Afr Med J* 1970; 44:1130–1134.
8. Bidair M, Kalota SJ, Kaplan GW. Infantile hypertrophic pyloric stenosis and hydronephrosis: is there an association? *J Urol* 1993; 150:153–155.
9. Ohshiro K, Puri P. Pathogenesis of infantile pyloric stenosis: recent progress. *Pediatr Surg Int* 1998; 13:243–252.
10. Abel RM, Bishop AE, Doe CJ, et al. A quantitative study of the morphological and histochemical changes within the nerves and muscle in infantile hypertrophic pyloric stenosis. *J Pediatr Surg* 1998; 33:682–687.
11. Sherwood W, Choudhry M, Lakhoo K. Infantile hypertrophic pyloric stenosis: an infectious cause? *Pediatr Surg Int* 2007; 23:61–63.
12. Osifo DO, Ebuomwan I. Does exclusive breastfeeding confer protection against infantile pyloric stenosis? A 30 year experience in Benin City, Nigeria. *J Trop Pediatr* 2009; 55:132–134.
13. Carter CO, Evans KA. Inheritance of congenital pyloric stenosis. *J Med Genet* 1969; 6:233–254.
14. Hernanz-Schulman M. Infantile hypertrophic pyloric stenosis. *Radiology* 2003; 227(2):319–331.
15. Nmadu PT. Alterations in serum electrolytes in congenital hypertrophic pyloric stenosis: a study in Nigerian children. *Ann Trop Paediatr* 1992; 12:169–172.
16. Touloukian RJ, Higgins E. The spectrum of serum electrolytes in hypertrophic pyloric stenosis. *J Pediatr Surg* 1983; 18(4):394–397.
17. Fonkalsrud EW. Hypertrophic pyloric stenosis. In O'Neil Jr JA, Grosfeld JL, Fonkalsrud EW, Coran AG, Caldamone AA (eds). *Principles of Pediatric Surgery*, 2nd ed. Mosby, 2003, Pp 467–470.
18. van der Bilt JD, Kramer WL, van der Zee DC, Bax NM. Laparoscopic pyloromyotomy for hypertrophic pyloric stenosis: impact of experience on the results in 182 cases. *Surg Endosc* 2004; 18(6):907–909. Epub 27 Apr 2004.
19. Mullassery D, Perry D, Goyal A, Jesudason EC, Losty PD. Surgical practice for infantile hypertrophic pyloric stenosis in the United Kingdom and Ireland—a survey of members of the British Association of Paediatric Surgeons. *J Pediatr Surg* 2008; 43:1227–1229.
20. Hall NJ, Pacilli M, Eaton S, Reblock K, Gaines BA, et al. Recovery after open versus laparoscopic pyloromyotomy for pyloric stenosis: a double blind multi centre randomized controlled trial. *Lancet* 2009; 373:390–398.