

# CHAPTER 69

## MISCELLANEOUS CAUSES OF INTESTINAL OBSTRUCTION

Lohfa B. Chirdan  
Sanjay Krishnaswami

### Introduction

Various causes of mechanical bowel obstruction, such as intestinal atresias, intussusception, meconium ileus, external herniations, and midgut volvulus, have been covered elsewhere in this book. This chapter is concerned with the various other causes of obstruction that could be encountered in children in Africa. These conditions include peritoneal adhesions, parasites, foreign bodies, sigmoid volvulus and ileosigmoid knotting, internal herniations, external compression from abdominal masses, faecal impaction, and paralytic ileus. A summary of the important features and investigations of these conditions is outlined in Table 69.1.

### Peritoneal Adhesions

Adhesions are internal fibrous, band-like scars occurring after injury to the peritoneum and are the result of biochemical and cellular responses attempting to repair the peritoneum. Although this process is beneficial, it could also have detrimental effects, one of which is small bowel obstruction (SBO). The most common cause of adhesions is iatrogenic, secondary to previous abdominal operations. The data on postoperative adhesions in children are sparse, and most of what we know about adhesions is extrapolated from adult series. An estimated 93% of adults undergoing laparotomy eventually develop adhesions, although only a fraction of these will become symptomatic.<sup>1</sup> Grant et al. reported that 1.1% of children younger than 16 years of age undergoing lower abdominal surgery would be admitted as a direct consequence of adhesions and 8.3% would have a readmission that may be related to adhesions four or more years from the time of initial surgery.<sup>2</sup>

In developed countries, strategies to reduce postoperative adhesions, such as the use of talc-free gloves, improved suture and prosthetic materials, and especially minimal access surgery, are commonly utilized. Many of these resources are not available in developing countries, however.<sup>3</sup> Therefore, it appears that the burden of morbidity due to adhesions may gradually shift to developing countries where open laparotomies are still the norm in children.<sup>4-6</sup>

Apart from postoperative adhesions, inflammatory diseases and trauma can cause peritoneal adhesions, leading to bowel obstruction in children. SBO from inflammatory adhesions may sometimes be seen soon after operation for such suppurative conditions of the abdomen as ruptured appendix and typhoid intestinal perforations or in patients with solid organ injury due to trauma who were managed either operatively or nonoperatively.<sup>4-7</sup> Note that other causes of postoperative bowel obstruction, such as intussusception (classically seen after large retroperitoneal operations), can exist, and the treatment of these may differ from adhesion-related SBO.

### Clinical Features

The clinical features of bowel obstruction from peritoneal adhesions could include vomiting, abdominal distention, abdominal pain, constipation, and fever. While the other signs may be seen even early in the disease course, fever usually occurs in children with bowel gangrene or perforated bowel and should therefore be taken seriously if pres-

Table 69.1: Summary of features of intestinal obstruction from various causes.

Aetiology	Important features	Important investigations	Treatment
Peritoneal adhesions	Abdominal scars or history of surgeries, trauma, or acute abdomen in the past	Multiple air-fluid levels on plain x-ray of abdomen; contrast study of GI tract in doubtful cases	Nasogastric decompression, intravenous fluids and antibiotics for 24–48 hours; exploratory laparotomy if child is not improving
Bezoars/foreign bodies	History of ingestion of foreign bodies or psychological condition; vomiting, failure to thrive; abdominal mass that may be palpable	Plain abdominal films and contrast studies; computed tomography (CT) scan if available	Endoscopic removal; use of pancreatic enzymes; laparotomy
Faecal impaction	History of constipation or motility disorder	Plain x-ray of abdomen	Repeated rectal washout; manual evacuation
Parasites	Endemic area, passage of worms per rectum or vomiting of worms	Stool examination, plain x-ray of abdomen	Anthelmintic; laparotomy
Sigmoid volvulus and ileosigmoid knotting	Rapid onset of abdominal distention	Plain x-ray of abdomen; contrast enema, lower endoscopy in doubtful cases	Laparotomy and sigmoidectomy
Pseudo-obstruction (Ogilvie's syndrome)	History of chronic constipation; sickle cell disease	Plain x-ray	Neostigmine
Internal herniation	Recurrent abdominal pains	Plain x-ray; contrast study or CT scan in some cases	Laparotomy
External compression	Abdominal mass	Plain x-ray; CT scan	Laparotomy and removal of mass
Paralytic ileus	Usually postoperative, sepsis or severe hypokalaemia/hypomagnesaemia	Urea and electrolyte estimation; plain x-ray of abdomen, presence of rectal gas	Nasogastric decompression; intravenous fluids; electrolyte replenishment

ent. Other signs of advanced disease, such as rectal bleeding, may be encountered frequently. This was a presenting feature in 10% of children with adhesive bowel obstruction in one series from Nigeria.<sup>4</sup>

### Investigations

The diagnosis of bowel obstruction is usually clinical. In a few patients who have bowel perforation, plain chest x-ray may show gas under the diaphragm. Plain abdominal films may show dilated loops of bowel and multiple air-fluid levels. Prominent valvulae conniventes suggest small bowel obstruction, and marked haustrations may occur in large bowel obstruction. However, although these bowel markings readily appear in adults and older children, they may be absent in infants and younger children. In fact, it may be impossible to distinguish between small and large intestines on plain films in infants.

In patients with previous adhesive SBO who have signs of incomplete obstruction or others in whom the diagnosis is in doubt, a contrast examination of the gastrointestinal tract is useful, although barium contrast may occasionally cause impaction above the obstruction. Failure of the contrast to pass into the distal small bowel suggests intestinal obstruction. The average transit time for oral contrast to reach the colon is 3–4 hours, but this time could be significantly longer when there is obstruction. If the patient's clinical status allows, contrast progression can be followed by plain x-rays up to 12–24 hours later. Contrast enema (typically with water-soluble contrast) may be useful in children with distal obstruction. A complete blood count, grouping and cross matching, and serum chemistry are done in all patients.

### Management

Management involves resuscitation and correction of fluid and electrolyte deficits by administration of intravenous (IV) fluids. Nasogastric decompression is then instituted, and broad spectrum antibiotics may be started. If the condition does not improve on the above management after 48 hours, laparotomy should be considered.<sup>8–11</sup> Early operative intervention is preferred for children, especially infants, because the already nutritionally compromised child has less tolerance compared to adults for the 48-hour starvation period. In children who present with features of bowel strangulation and gangrene, laparotomy should be undertaken immediately after adequate resuscitation (Figure 69.1).

At operation, adhesions can be single, multiple, or dense. Single adhesions are divided (Figure 69.2). In patients with multiple adhesions, it is important to identify all offending bands. Some surgeons believe that it is important to free the entire peritoneal cavity of all adhesions, whereas others believe that only the adhesions that obstruct the intestine should be divided because the other adhesions have fixed the remaining bowel in an unobstructed position. In most instances, it is wiser to remove only the offending bands because trauma may trigger another episode of adhesions. Adhesions are divided sharply, aided by countertraction from the assistant. Bowel gangrene is a common finding, especially in Africa.<sup>4</sup> In this situation, bowel resection with end-to-end bowel anastomosis is done (Figure 69.3).

Repeated adhesions can be a major problem, and therefore many mechanical and chemical approaches have been developed. Internal stenting using long tubes such as the Baker or Leonard tubes can be of help, and intestinal plication may help to fix the bowel in the unobstructed position.<sup>7</sup> Chemical methods have evolved over the years to deal with or reduce the incidence of peritoneal adhesions. These chemical agents include heparin, fibrinolytic compounds, nonsteroidal anti-inflammatory drugs (NSAIDs), low molecular weight dextran solutions, antihistamines, prokinetic agents, calcium channel blockers, and steroids.<sup>3–7</sup> As evidenced by the multiplicity of these methods, none of these techniques has been shown to completely eliminate the problem of adhesions. Meticulous handling of tissues and careful surgery with the use of talc-free gloves as well as minimally invasive abdominal surgery, where possible, may cause less tissue injury and lead to fewer adhesions.

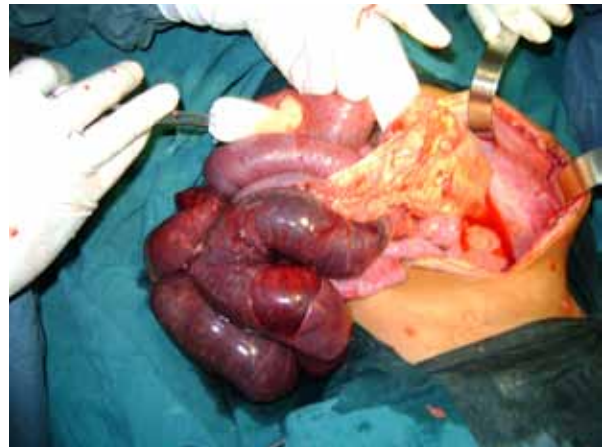


Figure 69.1: Bowel gangrene from postoperative adhesion SBO.

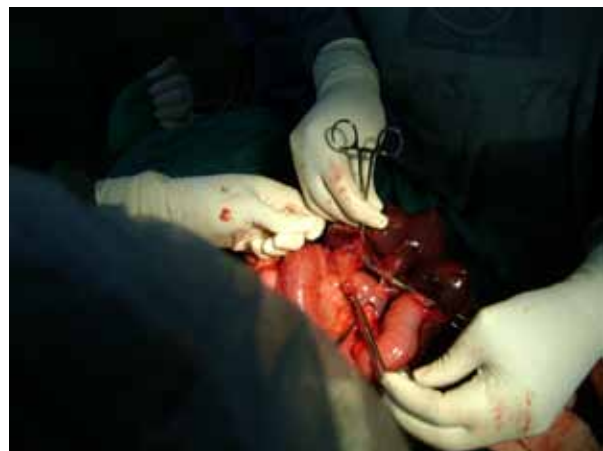

Figure 69.2: Dividing the adhesions.

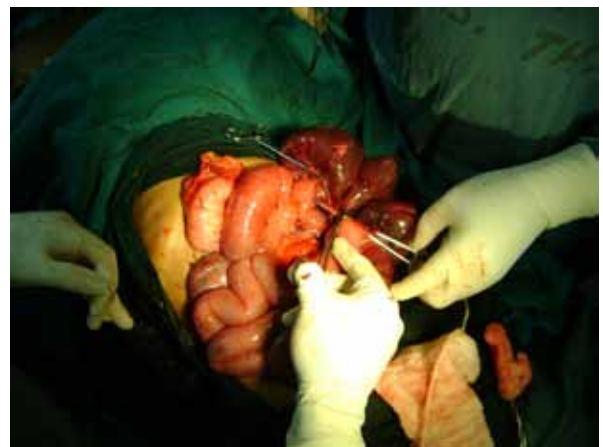

Figure 69.3: Resection of gangrenous bowel.

### Foreign Bodies and Bezoars

Foreign bodies (FBs) of the aerodigestive tract can be involved in causing intestinal obstruction in children of all ages. There is a tendency for children to put everything in their mouths, so ingestion of an FB is a major problem, especially in Africa, where poverty and hunger may be contributory. Below the level of the oesophagus and stomach, ingested FBs may be impacted in the C-loop of the duodenum, at the ligament of Treitz, Meckel's diverticulum, or the ileocaecal valve, causing intestinal obstruction. Perforation with peritonitis may cause secondary obstruction.

Bezoars are masses of solidified ingested materials (organic or inorganic) found in the stomach or small intestines that can cause intestinal obstruction in children.<sup>7,12</sup> They are of many types. Trichobezoars are seen in the mentally retarded as well as in emotionally disturbed children, typically teenage girls, and usually consist of swallowed hair or random ingested objects. Phytobezoars are made of vegetable material and usually obstruct the distal ileum, or stomach, especially postvagotomy. Lactobezoars are usually observed in premature infants receiving early feeding of undiluted milk. They can be caused by powdered formulas mixed inappropriately.

### Presentation and diagnosis

Children usually present with vomiting and failure to thrive. An epigastric mass, often in the shape of the stomach, may be palpable on physical examination. Plain films of the abdomen are often diagnostic, but upper gastrointestinal contrast study may be needed in some cases.

### Management

Bezoars in the stomach may be broken apart by using an endoscope. This may be facilitated by introducing pancreatic enzymes. Laparotomy with gastrostomy or enterostomy may be needed to remove hairs that cause complete obstruction. Care must be taken to remove the entire bezoar because it can fragment on removal and be lodged more distally, causing further problems. In cases of colonic obstruction, colostomy may be needed. The underlying disorder resulting in bezoar formation, such as a psychological problem, must be managed appropriately.

### Parasites

Parasites can cause intestinal obstruction, generally in the mid or distal small bowel, but can even occur in the large bowel. In the tropics, *Ascaris lumbricoides* is the most common parasite involved. These worms usually get entangled in the small intestine, producing a mass that could lead to intestinal obstruction. Although the majority of children present with a subacute course, about a quarter present with features of acute intestinal obstruction, including vomiting, abdominal distention, and constipation.<sup>13–15</sup> Some children may present with vomiting of the round worms or passage of the worms through the rectum. Investigations include plain abdominal x-ray in addition to stool examination for evidence of parasites. The plain roentgenogram of the abdomen may show a typical “whirlpool” pattern that indicates intraluminal worms in most cases. Children with subacute intestinal obstruction usually respond to the administration of an oral antihelminthic such as piperazine and management of pain using antispasmodics such as Buscopan®.<sup>15</sup> Patients with acute intestinal obstruction should be quickly resuscitated by using intravenous fluids and then undergo emergency laparotomy. At laparotomy, the worms should be disimpacted and milked into the distal colon. In cases of bowel gangrene, resection and anastomosis of the bowel is done. However, in the latter situation, note that worms could migrate into the peritoneal cavity through the anastomosis site.

### Sigmoid Volvulus and Ileosigmoid Knotting

Sigmoid volvulus and ileosigmoid knotting are rare in children but can cause intestinal obstruction with lethal consequences.<sup>16</sup> The main predisposing factor to sigmoid volvulus is a large redundant sigmoid colon with a narrow base, which then acts as a fulcrum for the sigmoid colon to twist, usually in a counterclockwise direction. Ileosigmoid knotting involves the twisting of the small bowel and sigmoid mesenteries around each other. The mechanism for ileosigmoid knotting is unclear. An excessively mobile small bowel due to an elongated mesentery, combined with a long sigmoid colon on a narrow mesenteric pedicle, along with the ingestion of a bulky diet in the presence an empty small bowel have been suggested as a possible mechanism.<sup>17,18</sup>

The main presenting feature of either sigmoid volvulus or ileosigmoid knotting is acute onset of abdominal distention and pain followed by obstipation. In ileosigmoid knotting, however, the abdominal distention may not be remarkable. Vomiting may be also be present. Investigations include plain abdominal x-ray, which may show a bent inner-tube sign. The classic features of sigmoid volvulus on plain abdominal films are not as obvious in ileosigmoid knotting. Contrast enema studies occasionally can be helpful in doubtful cases. However, such investigations, as well as small bowel follow-through studies, should be used judiciously because they could precipitate intestinal perforation, especially in ileosigmoid knotting.<sup>16</sup> After the diagnosis is made, laparotomy should not be delayed once fluid and electrolytes status has been corrected and broad spectrum antibiotics administered.<sup>16,17</sup> Bowel gangrene is common, and resection with anastomosis of the bowel should be done in these cases.

### Internal Herniation

Bowel herniation into abnormal or normal peritoneal recesses could lead to acute intestinal obstruction in children.<sup>19</sup> Herniation could occur into normal, anatomic duodenal, or caecal recesses, leading to intestinal obstruction. Postoperative defects in the mesentery can also lead to herniation of the bowel and subsequent obstruction and strangulation.<sup>19</sup> Other abnormal sites for herniation of the bowel leading to obstruction include the falciform ligament, if a defect is present, and the foramen of Winslow.<sup>20,21</sup> A high index of suspicion is needed for prompt diagnosis and subsequent treatment because delay usually leads to bowel gangrene, which increases the mortality rate.

### Other Causes

External abdominal masses such as intraabdominal tumours, faecal impaction, paralytic ileus, and benign bowel tumours can result in intestinal obstruction in children.

### Evidence-Based Research

Articles on adhesive bowel obstruction in children in Africa are scanty. Prospective studies are few, and available guides have to be based on retrospective studies, many of which are from the West. Table 69.2 presents a large series involving postoperative bowel obstruction in newborns and infants.

Table 69.2: Evidence-based research.

<b>Title</b>	High incidence of post-operative adhesions in newborns and infants
<b>Authors</b>	Young JY, Kim DS, Muratore CS, Kurkchubasche A, Tracy TF Jr, Luks FI
<b>Institution</b>	Division of Pediatric Surgery, Brown Medical School, Providence, Rhode Island, USA
<b>Reference</b>	J Pediatr Surg 2007; 42:962–965
<b>Problem</b>	The incidence of, risk factors for, and need for operative intervention in postoperative bowel obstruction in children.
<b>Comparison/control (quality of evidence)</b>	The authors reviewed children who had laparotomy or laparoscopy to determine the incidence of small bowel obstruction due to adhesions. They also compared the incidence in older children to that in infants and neonates.
<b>Outcome/effect</b>	Of 2,187 abdominal operations performed in children, 61 (2.8%) had postoperative bowel obstruction, 70.5% of these requiring reoperation. Postoperative bowel obstruction was more common in children younger than 1 year of age compared to older children (P = 0.01). Infants are significantly more likely to require operative intervention compared with older children (P = 0.01).
<b>Historical significance/Comments</b>	This large series supports previous evidence that nonoperative management of adhesive small bowel obstruction often fails in infants and younger children. A laparotomy is often needed when postoperative obstruction occurs in this age group, and it should be performed with minimum delay.

### Key Summary Points

1. Apart from the classical causes of mechanical bowel obstruction, other pathologic entities may lead to bowel obstruction in children.
2. As techniques to decrease postoperative adhesions, such as minimally invasive surgery, become more widespread in the developed world, the burden of adhesions may begin to shift to Africa.
3. Children with adhesive intestinal obstruction should be meticulously followed; delay in operative intervention should be avoided.
4. A high index of suspicion is needed for the diagnosis of foreign bodies and bezoars in children, and psychiatric evaluation should be part of the postoperative work-up.
5. The mainstay of management of patients with parasitic obstruction is medical (anthelmintic); however, patients with acute symptoms should be explored immediately after adequate resuscitation.
6. Sigmoid volvulus and ileosigmoid knotting, although rare in children, can be fulminant, making early resuscitation and laparotomy the keys to a successful outcome.

### References

1. Menzies D, Ellis H. Intestinal obstruction from adhesions: how big is the problem? *Ann R Coll Surg Engl* 1990; 72:60–63.
2. Grant HW, Parker MC, Wilson MS, Menzies D, Sunderland G, Thompson JN, Clark DN, Knight AD, Crowe AM, Ellis H. Adhesions after abdominal surgery in children. *J Pediatr Surg* 2008; 43:152–157.
3. Attard JP, MacLean AR. Adhesive small bowel obstruction: epidemiology, biology and prevention. *Can J Surg* 2007; 50:291–300.
4. Ameh EA, Nmadu PT. Adhesion obstruction in children in Northern Nigeria. *Trop Doct* 2004; 34:104–106.
5. Olumide F, Adedeji A, Adesola AO. Intestinal obstruction in Nigerian children. *J Pediatr Surg* 1981; 16:225–229.
6. Adejuigbe O, Fashakin EO. Acute intestinal obstruction in Nigerian children. *Trop Gastroenterol* 1989; 10:33–39.
7. Schwartz MZ. Disorders of the peritoneum and peritoneal cavity. In: O'Neil JA, Rowe MI, Grosfeld JA, Fonkalsrud EW, Coran AJ, eds. *Pediatric Surgery*. Mosby St Louis, 1998, Pp 451–455.
8. Young JY, Kim DS, Muratore CS, Kurkchubasche AG, Tracy TF Jr, Luks FI. High incidence of post-operative bowel obstruction in newborns and infants. *J Pediatr Surg* 2007; 42:962–965.
9. Choudhry MS, Grant HW. Small bowel obstruction due to adhesions following neonatal laparotomy. *Pediatr Surg Int* 2006; 22:729–732.
10. Vijay K, Anindya C, Bhanu P, Mohan M, Rao PL. Adhesive small bowel obstruction (ASBO) in children—role of conservative management. *Med J Malaysia* 2005; 60:81–84.
11. Akgur FM, Tanyel FC, Buyukpamukcu HI. Adhesive small bowel obstruction in children: the place and predictors of success for conservative treatment. *J Pediatr Surg* 1991; 26:37–41.
12. Eitan A, Katz IM, Sweed Y, Bickel A. Fecal impaction in children: report of 53 cases of rectal seed bezoars. *J Pediatr Surg* 2007; 42:1114–1117.
13. Villamizar E, Mendez M, Bonilla E, Varon H, de Onatra S. *Ascaris lumbricoides* infestation as a cause of intestinal obstruction in children: experience with 87 cases. *J Pediatr Surg* 1996; 31:201–205.
14. Mukhopadhyay B, Saha S, Maiti S, Mitra D, Banerjee TJ, Jha M, Mukhopadhyay M, Samanta M, Das S. Clinical appraisal of *Ascaris lumbricoides*, with special reference to surgical complications. *Pediatr Surg Int* 2001; 17:403–405.
15. Salman AB. Management of intestinal obstruction caused by ascariasis. *J Pediatr Surg* 1997; 32:585–587.
16. Chirdan LB, Ameh EA. Sigmoid volvulus and ileosigmoid knotting in children. *Pediatr Surg Int* 2001; 17:636–637.
17. Shepherd JJ. Ninety-two cases of ileosigmoid knotting in Uganda. *Br J Surg* 1967; 54:561–566.
18. Akgun Y. Management of ileosigmoid knotting. *Br J Surg* 1997; 84:672–673.
19. Fan HP, Yang AD, Chang YJ, Juan CW, Wu HP. Clinical spectrum of internal hernia: a surgical emergency. *Surg Today* 2008; 38:899–904.
20. Gingalewski C, Lalikos J. An unusual cause of small bowel obstruction: herniation through a defect in the falciform ligament. *J Pediatr Surg* 2008; 43:398–400.
21. Mboyo A, Goura E, Massicot R, Flurin V, Legrand B, Repetto-Germaine M, Caron-Bataille S, Ndie J. An exceptional cause of intestinal obstruction in a 2 year old boy: strangulated hernia of the ileum through Winslow's foramen. *J Pediatr Surg* 2008; 43:e1–e3.