

# CHAPTER 73

## COLONIC ATRESIA

Alastair J. Millar  
Sharon Cox  
Kokila Lakhoo

### Introduction

Atresia of the colon is an uncommon entity distinct from congenital pouch colon, which is a more frequent occurrence in India and Asia, and is associated with anorectal malformations. Although the underlying cause of colonic atresia may be vascular insufficiency, the association with Hirschsprung's disease, in particular, and the gross discrepancy between the proximal and distal bowel diameters militate against management strategies described for small bowel atresias.

### Demographics

Atresia of the colon is a relatively rare form of intestinal atresia with an incidence of 1:40,000–60,000 live births, comprising less than 5% of the total number of gastrointestinal tract atresias. (In the Red Cross War Memorial Children's Hospital series of 316 bowel atresias distal to the duodenum, the incidence was 4.4%.) There is no gender or racial predilection for the abnormality. There is, however, an association with gastroschisis, malrotation/nonfixation of the bowel, a more proximal atresia of the small bowel and Hirschsprung's disease. The association with cloacal exstrophy is well known but will not be described here.

### Aetiology/Pathophysiology

The association with gastroschisis and intestinal atresia is considered a result of a vascular accident in utero. It is not clear why aganglionosis is found in some. It may be that the dilated loop proximal to the transition to aganglionosis undergoes volvulus with bowel ischaemic injury and thus the development of atresia, or it may suggest an early event whereby migrating nerve cells are arrested in their progress to populate the distal gut. This implies an early gestational interruption.

### Clinical Presentation

#### History

In the situation of an isolated atresia, patients present with neonatal intestinal obstruction and gross abdominal distention. A pitfall to be avoided is that with colonic atresia distal to a small bowel atresia, the colon in outward appearance may look normal. It is therefore essential for the colon to be evaluated in any small bowel atresia, preferably preoperatively, by contrast enema. The abdominal x-ray is typical in showing one or two very dilated gas- and fluid-filled loops.

#### Physical

Aspiration of gastric content of a volume >25 ml via orogastric or nasogastric tube, or emesis that is bile stained along with abdominal distention and failure to pass normal meconium are suggestive of a distal bowel obstruction.

### Investigations

Abdominal x-ray is essential (Figure 73.1), and contrast enema (Figure 73.2) prior to surgery is advisable. Rectal suction biopsy to exclude Hirschsprung's disease is mandatory if primary anastomosis is contemplated.

### Management

Management should include full investigation for associated anomalies, exclusion of Hirschsprung's disease and a second atresia or stenosis by biopsy of the bowel distal to the atresia, and contrast enema. The fashioning of a stoma at the level of the atresia is the preferred initial treatment rather than an attempt at primary anastomosis. The gross dilatation of the blind end (Figures 73.1 and 73.3) may need to be tapered or resected to assist in fashioning a manageable stoma.

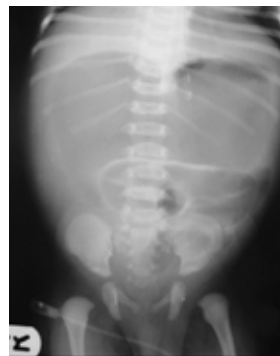


Figure 73.1: Anteroposterior abdominal radiograph showing disproportionately large loops of bowel.

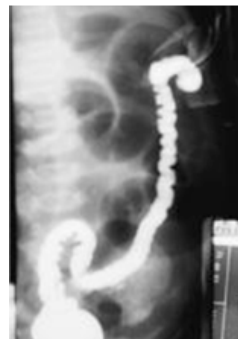

Figure 73.2: Barium enema of patient showing sigmoid atresia and distal microcolon.

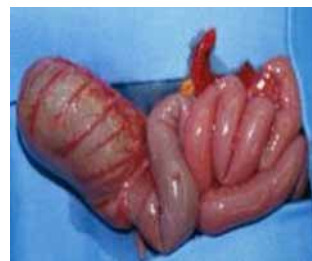

Figure 73.3: Operative photograph of patient with sigmoid atresia, showing dilated transverse colon.

## Postoperative Complications

Missed diagnosis should not occur if the principles stated above are followed. In our series of 14 cases, there was one mortality due to a second colonic atresia, which was missed in a patient presenting with a small bowel atresia, causing a leak from the more proximal anastomosis, peritonitis, and death.

## Prognosis and Outcomes

Outcomes should be good but are limited by associated intestinal atresias with short gut and the extent of other anomalies. Mortality in

Table 73.1: Evidence-based research.

<b>Title</b>	Colonic atresia: spectrum of presentation and pitfalls in management: a review of 14 cases
<b>Authors</b>	Cox SG, Numanoglu A, Millar AJW, Rode H
<b>Institution</b>	Department of Paediatric Surgery, Red Cross War Memorial Children's Hospital, Cape Town, South Africa
<b>Reference</b>	Ped Surg Int, 2005; 10:813–818
<b>Problem</b>	This study describes a case series of 14 patients with colonic atresia.
<b>Intervention</b>	This study seeks to identify predictors of untoward outcomes.
<b>Comparison/control (quality of evidence)</b>	Fourteen cases of colonic atresia seen over a 38-year period are reviewed with particular reference to clinical presentation and pitfalls in management. Seven had Type I atresia, two had Type II and five had Type IIIa. Ten had associated gastrointestinal anomalies. Management varied considerably. Six had primary colonic anastomosis. Two of these developed complications due to unrecognized distal hypoganglionosis, two had associated jejunal atresias resulting in short bowel syndrome, and two had primary anastomosis protected by proximal ileostomies. Seven had a staged repair with initial defunctioning enterostomy, with only one complication, an unfixed mesentery that later resulted in midgut volvulus. The only mortality was a patient in which a jejunal atresia repair leaked as a result of a missed colonic atresia. Operative strategy should depend on the clinical state of the patients, the level of atresia, associated small bowel pathology and exclusion of distal pathology.
<b>Outcome/effect</b>	Primary anastomosis would only rarely be advised with a circumspect approach. Long-term outlook, as in small bowel atresia, is generally excellent.

various series ranges from 7% to 61%. The type of surgery as well as coexistent pathology are major determinants of outcome, with initial primary anastomosis frequently being associated with complications and a poor outcome.

As in any resource-poor environment, the need for parenteral nutrition may be the major determinant for survival.

## Evidence-Based Research

Tables 73.1 and 73.2 present studies on intestinal atresias and atresias of the colon, respectively.

Table 73.2: Evidence-based research.

<b>Title</b>	Atresia of the colon
<b>Authors</b>	Etensef B, Temir G, Karkiner A, Melek M, Edirne Y, Karaca I, Mir E
<b>Institution</b>	Department of Pediatric Surgery, Adnan Menderes University, Aydin, Turkey
<b>Reference</b>	J Pediatr Surg 2005; 40(8):1258–1268
<b>Historical significance/comments</b>	Colonic atresia (CA) is one of the rarest causes of neonatal intestinal obstructions, and no large series can be reported. Therefore, a retrospective clinical trial was performed to delineate our CA cases and carry out a literature survey. We reviewed the charts of CA cases treated in our center between 1992 and 2002. We aimed to collect all reported cases in Medline, and personal communications with the authors of published series were used to reach the missing data.  The chart review revealed 9 newborns with CA treated in our center (6 cases of type III, 2 cases of type II, and 1 case of type IV). These accounted for 3.7% of all gastrointestinal atresias managed in our center. Of the CA cases, 3 were isolated and 6 had at least one or more associated congenital anomalies. The preferred surgical technique at the initial treatment of CA was performing a proximal stoma and distal mucous fistula in an average of 59.4 hours postnatal. The literature survey enabled us to reach 224 cases of CA, including our cases.  Because of the low incidence of CA generally, delay in diagnosis and treatment may occur. The mortality is statistically higher when the surgical management is performed after 72 hours of age. However, the prognosis of CA is satisfactory if diagnosis and surgical management can be made promptly and properly.

## Key Summary Points

1. A very large dilated loop with a fluid level on abdominal x-ray is suspicious.
2. Beware the second atresia in the colon of a patient with a small bowel atresia and perform a preoperative contrast enema to rule this out.
3. Exclude Hirschsprung's disease distal to the atresia.
4. Avoid primary anastomosis.
5. Note the association with nonrotation of the midgut.

## Suggested Reading

Akgur FM, Cahit T. Colonic atresia and Hirschsprung's disease association shows further evidence for migration of the enteric neurons. *J Pediatr Surg* 1993; 26(4):635–636.

Benson CD, Lotf MW, et al. Congenital atresia and stenosis of the colon. *J Pediatr Surg* 1968; 3(2):253–257.

Boles ET, Vassy LE, et al. Atresia of the colon. *J Pediatr Surg* 1976; 11(1): 69–75.

Cox S, Numanoglu A, Millar AJW, Rode H. Colonic atresia: spectrum of presentation and pitfalls in management: a review of 14 cases. *Ped Surg Int* 2005; 10:813–818.

Davenport M, Bianchi A, et al. Colonic atresia: current results of treatment. *J R Coll Surg Edin* 1990; 35(1):25–28.

Erskine JM. Colonic stenosis in the newborn: the possible thromboembolic aetiology of intestinal stenosis and atresia. *J Pediatr Surg* 1970; 5(3):321–333.

Fishman SJ, Islam S, et al. Non-fixation of an atresic colon predicts Hirschsprung's disease. *J Pediatr Surg* 2001; 36(1):202–204.

Harbour MJ, Donald MD, et al. Congenital atresia of the colon. *Radiol* 1965; 84:19–23.

Harris J, Kallen B, et al. Descriptive epidemiology of alimentary tract atresia. *Teratology* 1995; 52:15–29.

Landes A, Schuckett B, et al. Non-fixation of the colon in colonic atresia: a new finding. *Pediatr Radiol* 1994; 24:167–169.

Louw JH, Barnard CN. Congenital intestinal atresia: observations on its origin. *Lancet* 1955; ii:1065–1067.

Millar AJW, Rode H, Cywes S. Intestinal atresia and stenosis, 3rd ed. *Pediatr Surg Ashcraft* 2000; 30:406–424.

Moore SW, Rode H, et al. Intestinal atresia and Hirschsprung's disease. *Pediatr Surg Int* 1990; 5:182–184.

Peter CW, Riccardo A, et al. Colonic atresia combined with Hirschsprung's disease: a diagnostic and therapeutic challenge. *J Pediatr Surg* 1995; 30(8):1216–1217.

Pohlson EC, Hatch EI, et al. Individualized management of colonic atresia. *Amer J Surg* 1988; 155:690–692.