

CHAPTER 78

POLYPS

Behrouz Banieghbal
Kokila Lakhoo

Introduction

Polyps and polypoid disorders in children, unlike those in adults, are relatively rare and are mostly benign. A complete understanding of these conditions is required for correct treatment and follow-up of these children. Polypoid disorder of the gastrointestinal (GI) tract include true polyps (juvenile and adenomatous), a variety of uncommon polyp syndromes, and a number of miscellaneous diseases of the intestinal tract that may present polypoid masses in the lumen of the intestine.

Demographics

Most reports of large series estimate that close to 1% of the population have polyps sometime during their childhood. Juvenile polyps are the most common type of lesion found in the GI tract in children, accounting for more than 80% of juvenile polyps. They are slightly more common in boys than in girls. The reported incidence of juvenile polyposis syndrome is 1:100,000.

Other polyposis syndromes, such as Peutz-Jeghers syndrome and familial adenomatoid polyposis (FAP) with its many variants, are reported to have an incidence of 1:200,000 and 1:35,000, respectively, with no racial variation.¹

Juvenile Polyps

Juvenile polyps are the most common type of polyp in the gastrointestinal tract accounting for more than 80% of polyps in children. The affected age group is between 2 and 5 years. Macroscopically, these lesions appear as beefy red and range from several millimeters to several centimeters in size. Microscopically, they represent benign hamartomas with no malignant potential (Figures 78.1 & 78.2). The most common presentation of these polyps is painless bleeding, which is caused by inflammation and mucosal ulceration of the polyp. They may be asymptomatic and occasionally present with abdominal pain (10%) or prolapse (4%) if located low in the rectum. Diagnosis is made through history, rectal examination, sigmoidoscopy, colonoscopy, and / or air contrast enema. Histological examination of the polyp is vital to the management of the patient.

Many polyps are located in the rectum and lower sigmoid colon and can be snared and removed through a flexible sigmoidoscope. Some of these lesions can be prolapsed through the anus and removed by suture ligation of the pedicle (see Figure 78.1). For higher lesions, a snare and cautery through a colonoscopy may be performed. It is rarely necessary to perform a laparotomy with colostomy for removal of a juvenile polyp. If more than five polyps are identified, a colonoscopic excision of the polyps should be performed. This latter clinical scenario of more than five polyps may indicate juvenile polyposis syndrome (see next section) and would place the child at risk for future colorectal malignancies. Complications after endoscopic removal of juvenile polyps have been rare. Perforation and subsequent bleeding from additional or recurrent juvenile polyps is believed to be approximately 5%. The natural history of juvenile polyps is that they are self-limited and seem to disappear, presumably by auto amputation.

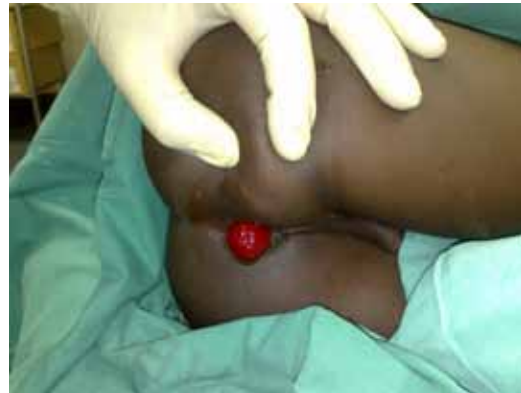

Figure 78.1: A prolapsed juvenile polyp prior to surgical excision in a 3-year-old girl.

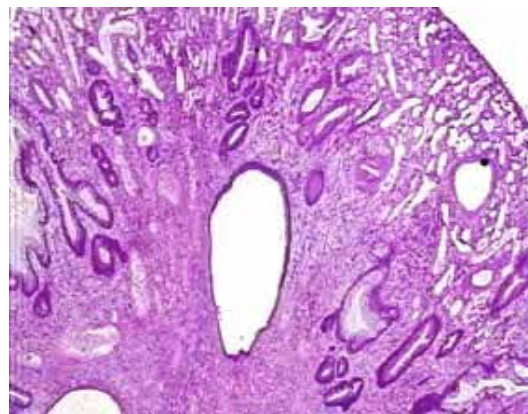


Figure 78.2: Cystic hamartomatous appearance on microscopy of a juvenile polyp.

Juvenile Polyposis Syndrome

Juvenile polyposis syndrome is a dominant inherited disorder that can present as diffuse juvenile polyposis of infancy (age 0–3 months), diffuse juvenile polyposis (age 6 months–5 years) and juvenile polyposis coli (age 5–15 years). Diarrhoea, rectal bleeding, intussusception, anaemia, prolapse, and failure to thrive are common presenting signs. The diagnosis is made as per juvenile polyps (see preceding section), and the presence of more than five polyps in sporadic cases and one polyp in cases with a family history confirms the diagnosis. Although polyps in this disorder are benign, patients have a 17% risk of developing cancer (significantly less than patients with a family history of FAP). The average age for the diagnosis of cancer is 30 years and older. Additionally, gastric duodenal and pancreatic cancers have been reported. In contrast to sporadic juvenile polyps, new polyps almost always form after a polyp is removed, and polyps continue into adulthood. Surveillance colonoscopy every 3 years should begin in the early teens, even in asymptomatic cases. Many surgeons recommend prophylactic colectomy and rectal mucosectomy with endorectal pull-through as the

primary treatment for the disease as soon as the diagnosis is established.

Juvenile polyposis syndrome is a genetic disease linked to a number of mutations on mothers against decapentaplegic homolog 4 gene and SMA protein (collectively called SMAD4 on chromosome 18q21.2), which is a transforming growth factor intracellular protein; bone morphogenetic protein receptor type IA (BMPRI1A on chromosome 10p22.3), an important protein in cell differentiation; and finally phosphatase/tensin homolog (PTEN) oncogene, which is a tumour suppressor gene on chromosome 19q32.²

Peutz-Jeghers Syndrome

Peutz-Jeghers syndrome is characterized by the presence of intestinal polyps with mucocutaneous pigmentation of the mouth, hands, and feet (Figure 78.3). The relationship of mucocutaneous pigmentation to polyposis is unknown; intestinal polyps are not pigmented (Figure 78.4). It is an autosomal dominant disease, and the polyps are classified as hamartomas of the muscularis mucosa. The polyps are mainly located in the small intestine but may be found anywhere from the stomach to the rectum. Patients often present with cramping abdominal pain and bowel obstruction secondary to intussusception of a polyp. These patients have an increased risk of cancer with transformation of hamartomas into carcinomas. Whether the carcinoma develops in these polyps or elsewhere in the mucosa is unknown. Patients are at an increased risk of developing malignancies in epithelial tissues; for example, it has been estimated that there is an 84-, 213-, and 520-fold increased risk of developing colon, gastric, and small intestinal cancers, respectively. A further 10% of patients with Peutz-Jeghers syndrome develop ovarian, cervical, and testicular neoplasms.

Diagnosis is made by family history, pigmented lesions, and cramping abdominal pain. Current recommendations for treatment include annual physical examinations, full blood count, breast and pelvic examinations, testicular examinations with ultrasound, and pancreatic examination with ultrasound. Oesophagogastroduodenoscopy and colonoscopy are recommended annually. Polyps larger than 5 mm are removed.

Peutz-Jeghers polyps arise from mutations in the serine/threonine kinase 11 (STK11/LKB1) tumour suppression gene (chromosome 19p13.3) in 70% of patients.³ This is an important kinase protein that is involved with intracellular growth signals. A different and as yet unrecognized gene is involved in the remaining patients.

Familial Adenomatous Polyposis

Familial adenomatous polyposis is an autosomal dominant syndrome with a 100% risk of developing cancer. It is caused by germ-line mutations in the adenomatous polyposis coli (APC) gene. Presentation includes rectal bleeding, abdominal pain, anaemia, and/or diarrhoea. Diagnosis is usually made during screening of children from affected families and screening for the APC gene. Diagnosis is established by sigmoidoscopy, which reveals a colon carpeted with polyps. Polyps can also occur in other parts of the gastrointestinal tract.

In patients with FAP and its variants, the risk of malignancy in adulthood is so high that prophylactic colectomy is recommended for most cases (Figure 78.5). This is usually delayed until the midteen years.⁴ The surgical options include: total colectomy with mucosal proctectomy and the endorectal ileal-pouch anal anastomosis (IPAA); or subtotal colectomy and ileorectal anastomosis (IRA).

IPAA is a more extensive procedure with a higher complication rate but a lesser incidence of rectal cancer in the follow-up period. It is therefore the recommended procedure for patients with >1,000 polyps or if available in FAP with known genetic mutations at codons 1250–1464. Lesser surgery such as IRA is thus reserved for “attenuated” FAP patients or those who have 50–100 polyps on endoscopy.⁵

Oral use of nonsteroidal anti-inflammatory drugs (NSAIDs, especially sulindac) has remained controversial, but it has been shown to cause regression of polyps in patients, especially if used after rectum-sparing surgery. Lifetime surveillance is still needed, however,

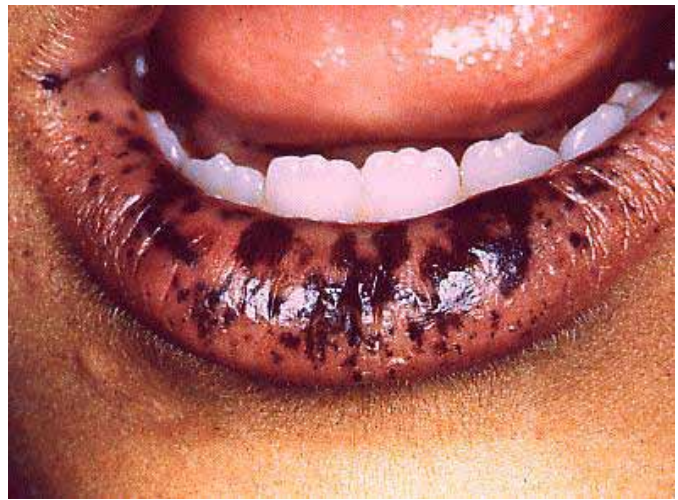

Figure 78.3: Oral pigmentation in an adult with Peutz-Jeghers syndrome.

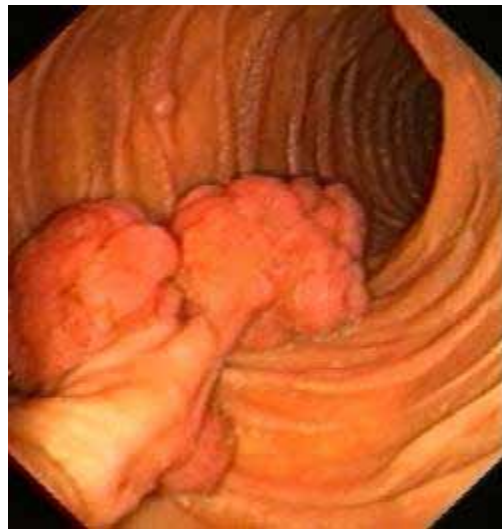

Figure 78.4: Duodenal polyp in a patient with Peutz-Jeghers syndrome.

as rectal carcinoma has been reported in these patients. The rare cases with MAP-type attenuated FAP can be spared surgery and instead have colonoscopic surveillance and regular snare polypectomies.

Mutations within the loci of the tumour suppressor APC gene across the band 5q21–22 result in the multitude of clinical manifestations of this condition. The APC gene encodes a 2843 amino acid protein involved in cell adhesion and signal transduction, the failure of which sets the stage for epithelial tumours. Proximal APC mutations (i.e., proximal to codon 1249) produce a milder FAP syndrome with sparse polyposis, otherwise known as attenuated FAP. However, APC mutations between codons 1250 and 1330 present with tremendous degrees of polyposis (>5,000 adenomas) and intracerebral malignancy (Turcot syndrome), hepatoblastoma, or intraabdominal desmoid tumours (Gardner’s syndrome).

FAP is an autosomal dominant disorder, and registries are in place in most First World countries to monitor families with this disorder, which account for 80% of the cases. Recently, another type of attenuated FAP, termed mutYH-associated-polyposis (MAP), was described in the remaining 20% of the cases; these cases are all attenuated FAPs that—unlike classic FAP—are autosomal recessive in nature and not related to mutation on the APC gene. Rather, mutation is reported to occur on mutY homolog gene on chromosome 1p34.3.⁶

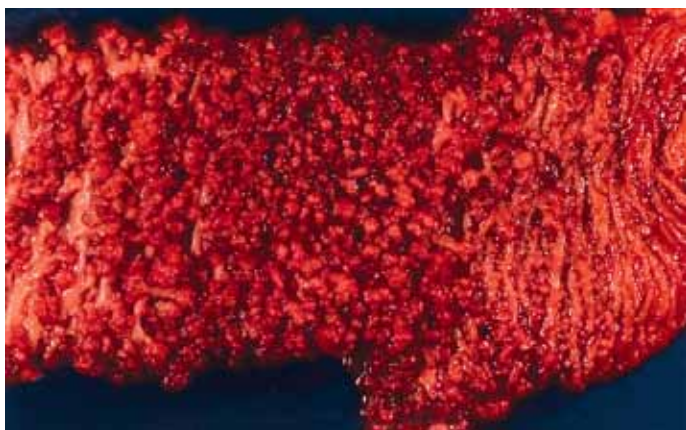


Figure 78.5: Colectomy specimen of a teenager with FAP.

Other Syndromes

Gardner's syndrome is an autosomal dominant disorder described as the association between colonic familial adenomatous polyposis and multiple osteomas, fibromas, and epidermoid cysts. The natural history and treatment of the colonic polyps is the same as for FAP. Turcot syndrome is the association of colonic FAP and brain tumours.

Pseudopolyps

Pseudopolyps consist of submucosal intestinal lymphatic tissue secondary to hyperplasia due to nonspecific infectious causes. Ulceration of these lesions may cause bleeding and anaemia. Diagnosis is confirmed at colonoscopy. Treatment is directed toward eradicating the underlying infectious process.

Differential Diagnosis

The differential diagnosis for rectal bleeding includes the common causes such as anal fissures, which generally can be visualized externally; and acute and chronic inflammatory bowel disease, which usually is accompanied by diarrhoea and blood dyscrasias, such as Henoch-Schönlein purpura. Bleeding from Meckel's diverticulum, duplication cysts of the intestine, and terminal ileal tuberculosis is usually of greater magnitude, dark, and mixed with stool. Bleeding from intussusception is usually accompanied by severe cramping abdominal pain and bilious vomiting.

Prognosis and Outcomes

Polypoid syndromes with known genetic anomalies have significant carcinoma risks; in FAP, surgical strategies as described above minimize these. A close follow-up is needed to detect and deal with other concurrent tumours with these genetic disorders. Counselling of the patients and their immediate relatives should be conducted.⁷

Ethical Issues

All children with polyps must have an expert histological examination of the excised polyp. If this proves to be an adult-type adenomatous polyp, then long-term surveillance with colonoscopies every 2 to 3 years is warranted. All close relatives must also undergo colonoscopies to exclude FAP in the family.

Evidence-Based Research

Table 78.1 presents a review article colonic polyps in children and adolescents.

Table 78.1: Evidence-based research.

Title	Colonic polyps in children and adolescents
Authors	Durno CA
Institution	The Hospital for Sick Children, Division of gastroenterology and Nutrition, University of Toronto, Canada
Reference	Can J Gastroenterol 2007; 21(4):233–239
Problem	The challenge is determining the precise risk of colorectal cancer in polyposis disease of childhood and adolescence.
Intervention	Debate on timing and type of surgery for colonic polyps with malignant potential.
Comparison/control (quality of evidence)	Review article.
Outcome/effect	Juvenile polyps are a common and benign disease. Other polyps require genetic screening and surveillance, and have high degree of malignant transformation.

Key Summary Points

1. Polyps and polypoid disorders in children are mostly benign.
2. Polypoid disorder of the GI tract includes true polyps (juvenile and adenomatous), a variety of uncommon polyp syndromes, and a number of miscellaneous diseases.
3. Juvenile polyps are benign, whereas adenomatous polyps have 100% malignant transformation.
4. Syndromic polyposis diseases also have malignant potential.
5. Presentation may be rectal bleeding, diarrhoea, abdominal pain, intussusceptions, and/or bowel obstruction.
6. Diagnosis is made through history, rectal examination, sigmoidoscopy, colonoscopy, and/or air contrast enema.
7. Treatment is dictated by the histology of the polyp, which includes simple excision or total colectomy.
8. Surveillance is highly recommended for any polyp with malignant potential.

References

1. Tietelbaum DH. Polypoid diseases of the gastrointestinal tract. In: O'Niell JA, Grosfeld JL, Fonkalsrud EW, Coran AG, Caldamone AA (eds). *Principles of Pediatric Surgery*, 2nd ed, Mosby-Year Book Inc. 2004, Pp 547–556.
2. van Hatterm WA, Brosen LA, De Lang WW, Morsink FH, et al. Large genomic deletions of SMAD4, BMPR1A and PTEN in juvenile polyposis. *Gut* 2008; 57(5):623–627.
3. Durno CA. Colonic polyps in children and adolescents. *Can J Gastroenterol* 2007; 21(4):233–239.
4. Vasen HFA, Moslein G, Alonso A, Aretz S, et al. Guidelines for the clinical management for familial adenomatous polyposis. *Gut* 2008; 57(5):704–713.
5. Burt RW, Jacoby RE. Polyposis syndromes. In: Yamada T (ed). *Textbook of Gastroenterology*, 4th ed. Lippincott Williams & Wilkins. 2003, Pp 1914–1939.
6. Al-Tassan N, Chmiel NH, Maynard J. Inherited variants of MYH associated with somatic G:C-T:A: mutations in colorectal tumours. *Nat Genet* 2002; 30(4):227–232.
7. Petersen GM, Boyd PA. Gene testing and counseling for colorectal cancer risk; lessons from familial polyposis. *J Natl Cancer Inst Monogr* 1995; 17:67–71.