

# CHAPTER 92

## BLADDER EXSTROPHY AND EPISPADIAS

William Appeadu-Mensah  
Piet Hoebeke

### Introduction

Exstrophy and epispadias are part of a spectrum of anomalies characterised by exposure of part or all of the mucosa of the lower urinary tract (bladder and urethra) to the external environment through a defect in the anterior abdominal wall. At one end of this spectrum is cloacal exstrophy, which is the most complex of these anomalies. It is characterised by exposure of the bladder mucosa together with the mucosa of the hind gut to the external environment through an anterior abdominal wall defect. At the other end of the spectrum is epispadias, which is characterised by a normal abdominal wall and bladder with a dorsal external urethral meatus, which may be anywhere from the base of the penis to the glans and may or may not be associated with an incompetent bladder neck and sphincter mechanism. Between these two extremes exist variations in pathology, with the most prevalent being classic bladder exstrophy. In most of the anomalies in this spectrum, there is concomitant bone involvement with diastasis of the symphysis pubis.

The most prevalent condition, classic bladder exstrophy, is characterised by exposure of the bladder and posterior urethral mucosa through a defect in the anterior abdominal wall. It is associated with a complete epispadias in boys and bifid clitoris in girls. At neonatal presentation, this anomaly results in the continuous dribbling of urine and exposure of bladder and urethral mucosa to the external environment. It leads to chronic irritation of this mucosa as well as social and emotional complications in Africa due to isolation of the affected person.

The medical literature on treatment of the epispadias-exstrophy complex presents many techniques. There is no ultimate excellent technique. Techniques used depend on various factors, such as extent of the abnormality, surgeon's experience, hospital staff and skills, and possibilities for follow-up, among many others.

This chapter presents examples of how to tackle the problem, specifically in the African situation. This chapter is not intended to be the final state-of-the-art approach to exstrophy; rather, the goal is to inspire those who are confronted with a child presenting with the epispadias exstrophy complex.

### Demographics

The incidence of bladder exstrophy in Africa is not known, but various studies report it to be 3.3 per 100,000, with a male-to-female ratio of 2.3:1. In Africa, most children born with extreme congenital anomalies are neglected and allowed to die. It is therefore difficult to know the exact incidence. The incidence of epispadias is estimated to be 1 in 117,000 in males, with a male-to-female ratio of 3–4:1. The incidence of cloacal exstrophy is estimated to be 1 in 200,000 to 1 in 400,000. The risk of transmission from a patient with exstrophy to a child is about 1 in 70. The risk of recurrence in a particular family is estimated to be about 1 in 100. The worldwide incidence may be affected by antenatal diagnosis, which may increase the abortion rate.

Although rare anomalies, exstrophy and epispadias are challenging conditions. These conditions are not life threatening if left untreated at birth, so the option of no treatment will not lead to death. Therefore, most children born with this devastating condition should be offered treatment

even if they present late. In the African environment, these children sometimes present to hospital at age 6 to 9 years or even older.

### Embryology

Due to the low prevalence of the condition, the exact aetiology of bladder exstrophy is not known. No genetic factors have been identified, but there is an increased risk among siblings, which indicates that a genetic origin is possible. It is also relatively more common among young mothers and multiparous mothers. Exstrophy is believed to result from a failure of incorporation of mesoderm into the cloacal membrane, leading eventually to rupture of this membrane. An overgrowth of the cloacal membrane as well as an abnormal insertion of the body stalk may contribute to this. The pathophysiology depends on the timing of this rupture. In cloacal exstrophy, the rupture occurs very early before the urogenital septum has divided the cloaca into the urogenital sinus and the anorectum. Other studies have shown later rupture of the cloacal membrane in cloacal exstrophy, suggesting that other factors, such as failure of embryogenesis, may contribute to this.

Epispadias is thought to be due to impaired migration of the genital tubercles to the midline.

### Pathology

#### Classic Bladder Exstrophy

In classic bladder exstrophy (Figures 92.1 and 92.2), the pathological process affects the pelvic bones, anterior abdominal wall, pelvic diaphragm, urinary system (ureterovesical junction (UVJ), bladder, and urethra), the genitalia, and the anus.

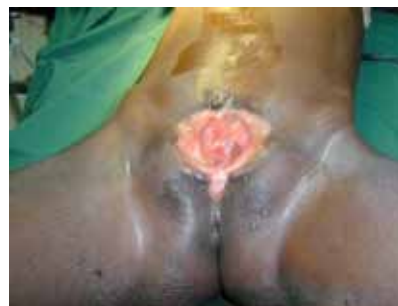

Figure 92.1: Classic bladder exstrophy in the female.

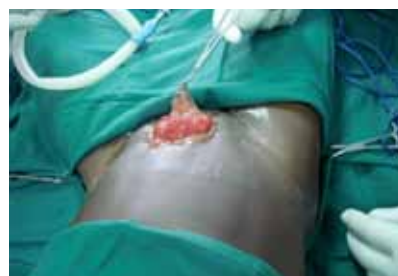

Figure 92.2: Classic bladder exstrophy in the male.

### Boney Anomalies

The pubic bones are widely separated. There is a wider angle between the sacroiliac bones and the sagittal plane as well as between the sacrum and ilium and the ilium and pubis than in normal individuals. This can result in a waddling gait. Over time, however, this gait resolves with no obvious abnormality.

### Muscular Anomalies

The rectus sheath is attached to the separated pubic bones. The pelvic diaphragm also inserts into the widely separated pubic bones and forms an intersymphyseal fibrotic band. The normal sphincteric function is therefore affected, leading to incontinence of urine, sometimes incontinence of stool, prolapse of the uterus, and sometimes prolapse of the rectum.

### Anomalies of the urinary system

The exposed bladder surface is sometimes wide, elastic, and compliant, but may be small, fibrosed, and noncompliant. There exists a wide variation in the size of the bladder plate at birth. Some children have a large bladder plate, which can easily be closed, and others have, from birth, a small fibrotic plate that is difficult to close. If left unclosed, persistent trauma leads to inflammation, fibrosis, metaplasia, and possible carcinoma later in life. Long exposure to the open air can lead to progressive loss in elasticity and compliance. The UVJ is often incompetent, resulting in reflux in nearly all patients with exstrophy of the bladder.

### Anomalies of the genitalia

In male children with classic bladder exstrophy, the penis is completely open dorsally as a complete epispadias. The penis has a dorsal chordee, which, together with the wide attachment of the corpora cavernosa to the separated pubis and short corpora, contributes to a short penis. There are, however, other anatomical variations in exstrophy (Figure 92.3), with the penis sometimes being completely bifid with each corpus attached separately to the pubic bones. The testes and vas deferens are usually normal, although there may be associated inguinal hernias. The prostate gland does not surround the urethra.

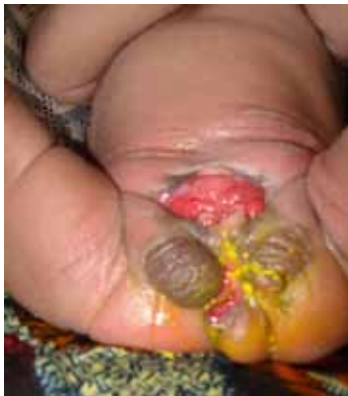

Figure 92.3: Bladder exstrophy, two hemiscrota, and abnormal perineum and anus.

In female children, there is a bifid clitoris and the labia are attached widely to the separated pubic bones. The vagina may be short but is otherwise normal, although it tends to be more anterior in position.

### Anomalies of the anus

In both males and females, the anus tends to be placed more anteriorly; however, it most often functions normally.

### Cloacal Exstrophy

Cloacal exstrophy is characterized by a defect in the anterior abdominal wall, exposing the mucosa of the caecum with bladder mucosa on both sides of it, and resulting in loss of the hindgut and no development of colon. In addition, a short remnant of the hindgut, the appendix, and the

ileum open onto the exposed caecum. There are commonly associated spinal, boney, renal, gastrointestinal, and genital anomalies, such as bicornuate uterus.

### Epispadias

In epispadias in the male, there is a dorsal penile opening of the urethral meatus with a dorsal penile curvature. In this anomaly, the spectrum is between a meatal anomaly alone and an abdominal wall abnormality with wide pubic symphysis and sphincteric incompetence. The exact position of the meatus on the dorsal surface of the penis varies and may be anywhere from the peno-pubic area to the glans. When in the peno-pubic region, the whole urethral mucosa is open dorsally. It is always associated with some degree of dorsal chordee and may or may not be associated with an incompetent sphincter. Vesicoureteric reflux (VUR) may also be present.

In the female, the urethral orifice may be lax and patulous in a normal position or be found anywhere from the bladder neck to the normal position. There may be an associated incompetent sphincter and VUR. There is usually associated diastasis of the pubic symphysis. The clitoris is usually bifid with an open attachment of the labia minora to the separated symphysis, but it may sometimes be normal.

### Clinical Presentation

The presentation of bladder exstrophy can vary, depending on the type of anomaly.

#### Classic Bladder Exstrophy

In classic bladder exstrophy (see Figures 92.1 and 92.2), the newborn child may look well in all respects but for the abdomen, which shows a huge expanse of abdominal wall superiorly with a low-set umbilicus. There is an obvious defect in the lower abdomen, which reveals the bladder mucosa with urine dribbling continuously from the ureteric orifices. This is continuous with the urethral mucosa, which opens dorsally. Sometimes ectopic bowel mucosa is found in association with the bladder mucosa. There is a wide gap between the pubic bones with attached epispadiac penis in the male.

In the female, similar abdominal features are noted, but there is a bifid clitoris attached to the separated pubic bones. The vagina may be short and is relatively anteriorly placed. The labia are also attached widely to the pubic bones.

The anus is seen in the perineum in an anterior position. There may be associated inguinal hernias.

#### Cloacal Exstrophy

In cloacal exstrophy, the abdominal wall defect is occupied by two hemibladders laterally with caecal mucosa in the middle. The hemibladders may be joined together superiorly, laterally, or inferiorly. Three orifices are noted on the caecal mucosa. These open into the ileum, appendix, and short hindgut. Arrangements of bladder and/or bowel mucosa can vary and may not have a classic pattern. Obvious inguinal swellings when the child strains demonstrate bilateral inguinal hernias.

The phallus in the male is obviously short and may have a varied presentation, being bifid, unilateral, or rudimentary. In the female, there is a bifid clitoris with separated labia. The vagina may be double or single.

There may be an imperforate anus with variations in anal pathology. There may be obvious spinal anomalies, such as myelomeningocele, as well as limb anomalies. Associated anomalies are more common in patients with cloacal anomaly and involve practically all systems.

### Epispadias

In males, epispadias presents with a dorsal penile meatus which opens anywhere from the penopubic region to the glans. There is an associated dorsal chordee. The prepuce may be noticed to be ventral and deficient dorsally.

In females, the urethral meatus may be at the normal site but lax and patulous with associated dribbling of urine or may be found anywhere from the bladder neck to the normal site with a dorsal open urethra

distal to the orifice and a bifid clitoris. A definite gap may be palpated between the pubic bones. The labia minora may be seen attached to the separated pubic bones.

In both males and females, there can be associated incontinence of urine due to sphincteric incompetence.

### Age at Presentation

In Africa, age at presentation tends to be late despite the obvious nature of this condition. Reasons for late presentation include cultural beliefs related to a child born with this condition, lack of finances to support the care of the child in a specialised hospital, long distance from specialist hospitals, and lack of available professionals able to manage this condition.

Exstrophy of the bladder may be diagnosed in utero and helps prepare the parents for birth in an appropriate child care centre with relevant expertise and equipment. It may, however, increase the abortion rate and anxiety of parents. Prenatal diagnosis is uncommon in Africa.

### Investigations

The diagnosis is made basically by clinical examination, and investigations are done to rule out other anomalies. An abdominal ultrasound (US) examination helps to exclude associated renal anomalies. An x-ray of the abdomen and pelvis shows pubic diastasis and the wide angle between the pelvic bones.

### Management

#### Exstrophy of the Bladder

Management of exstrophy of the bladder requires the involvement of a team of experts to help manage the various aspects of this complex anomaly. These include a counsellor, a neonatologist, and a team of paediatric surgeons, as well as nurses and anaesthesiologists.

#### Initial Management

Initial management involves counselling the parents to help them understand the pathological process, the management options, and the prognosis. They must be helped to appreciate that, with modern methods, the child will eventually be dry and continent. In addition, they must be helped to recognise the sex of the child in order to appropriately bring up the child. Gender assignment in typical exstrophy is easy. In boys, the scrotum is well developed and the testes are descended. Even in cloacal exstrophy, the scrotum is developed and the testes are descended despite the lack of penile development. In cloacal exstrophy, female gender assignment was readily done based on penile underdevelopment. Recent literature suggests that female-assigned cloacal exstrophy boys tend to have a higher prevalence of gender dysphoria.

In Africa, local beliefs must be taken into consideration and attempts made to diffuse the beliefs of parents that may result in neglecting the child. The financial burden on the parents must be recognised in the initial counselling and suggestions made as to how parents could be supported by available groups. In the absence of a team of experts, the available health attendant must initiate the counselling process.

As part of initial management, it is important that the bladder mucosa be protected from trauma from gauze, clothing, or the clip used on the umbilical cord. The umbilical cord should be ligated with a suture to avoid trauma from the clip. The mucosa may be protected by using plastic material to cover the mucosa. This is then removed and the surface irrigated with saline any time diapers are changed. If saline is not available, clean water may be used. The patient must then be referred to a tertiary centre where this condition can be managed. In most places in Africa, the parents need time to prepare financially and socially to move to a tertiary centre.

At the tertiary centre, the child is examined fully, and necessary investigations are done. The patient is cared for by a team of counsellors or social workers, neonatologists, paediatricians, anaesthetists, and paediatric surgeons, who may include a urologist and an orthopaedic surgeon. In some centres, a full team may not be available, and a

surgeon with interest in managing this condition may be the only one to give all the necessary care. The surgeon helps the parents understand the various stages involved in the management of their child's condition, whereas the counsellor helps the parents accept the child and manage the social implications.

#### Definitive Treatment

Surgery should be done as soon as practicable to give the bladder the best chance of recovery after reconstruction. The timing of surgery depends, however, on the availability of personnel and facilities to manage a newborn undergoing an operation that may take several hours to complete. There must be a competent neonatal anaesthetist with relevant associated equipment, a surgeon or team of surgeons capable of performing an osteotomy and closure of the bladder, a neonatologist or paediatrician to assist with care after surgery, and a neonatal intensive care unit (NICU) with available equipment and personnel to handle the infant. In the absence of a well-equipped NICU, it might be necessary to delay the operation until the child is old enough to withstand a long operation. An appropriate age may be between 1 and 3 months of age in such patients, but surgery can be done from the first day of life. Once surgery is considered safe, initial surgery is done.

#### Surgical Procedures

Surgical options are staged reconstruction, complete primary reconstruction, or urinary diversion.

Indications for reconstruction include a bladder with a wide surface area, good elasticity, and compliance after assessment under anaesthesia. A small, fibrotic, inelastic bladder is not a candidate for reconstruction, and a form of diversion may be necessary. A bladder may be fibrotic at birth, but late presentation with long-term irritation tends to contribute to this. This is quite common in Africa. The procedures for reconstruction include bilateral osteotomies, bladder closure, posterior urethra and abdominal wall repair, epispadias repair, bladder neck reconstruction, and antireflux procedure. These can be done in one stage or as a staged procedure.

In staged repair, bilateral osteotomies, bladder closure, posterior urethra, and abdominal wall repair are done soon after birth. Repair of epispadias is performed between 6 months and 1 year of age. Finally, bladder neck reconstruction with an antireflux procedure is done when the bladder capacity is at least 85 ml.

In complete primary repair, a combination of bilateral osteotomies, bladder closure, posterior urethra, and epispadias repair may be done at any age in one stage. Bladder neck repair with antireflux surgery is then done when the child has an appropriate bladder volume. This approach is particularly useful in children who present at an older age, although it can be used instead of a staged repair in the neonatal period.

#### Osteotomies

Types of osteotomies include posterior iliac osteotomy, anterior pubic ramus osteotomy, anterior oblique innominate osteotomy, and combined transverse innominate and vertical iliac osteotomy. Osteotomies are necessary to ensure adequate repair of the anterior abdominal wall without tension, to place the bladder neck and posterior urethra deep in the pelvis, and to bring the pelvic muscles to the midline to aid eventual continence. In children less than 72 hours postnatal, this may not be necessary but should be done if there is any doubt about the ability to easily repair the abdominal wall without tension.

Combined vertical and transverse innominate osteotomies allow easy approximation of the pubic symphysis without the need to turn the baby during the procedure. Posterior iliac osteotomies are done in the prone position, after which the child is turned supine for the bladder repair. Anterior pubic osteotomy is not very effective. The anterior oblique osteotomy avoids the need to turn the patient. The type of osteotomy performed depends, among other things, on the expertise and training of the available surgeon. Results are usually acceptable in good hands.

After an osteotomy, immobilisation of the pelvis is necessary. The most



popular means are mermaid casts; however, gallows traction and external fixators have been used. The availability of equipment such as external fixators in Africa may influence the type of fixation done postoperatively.

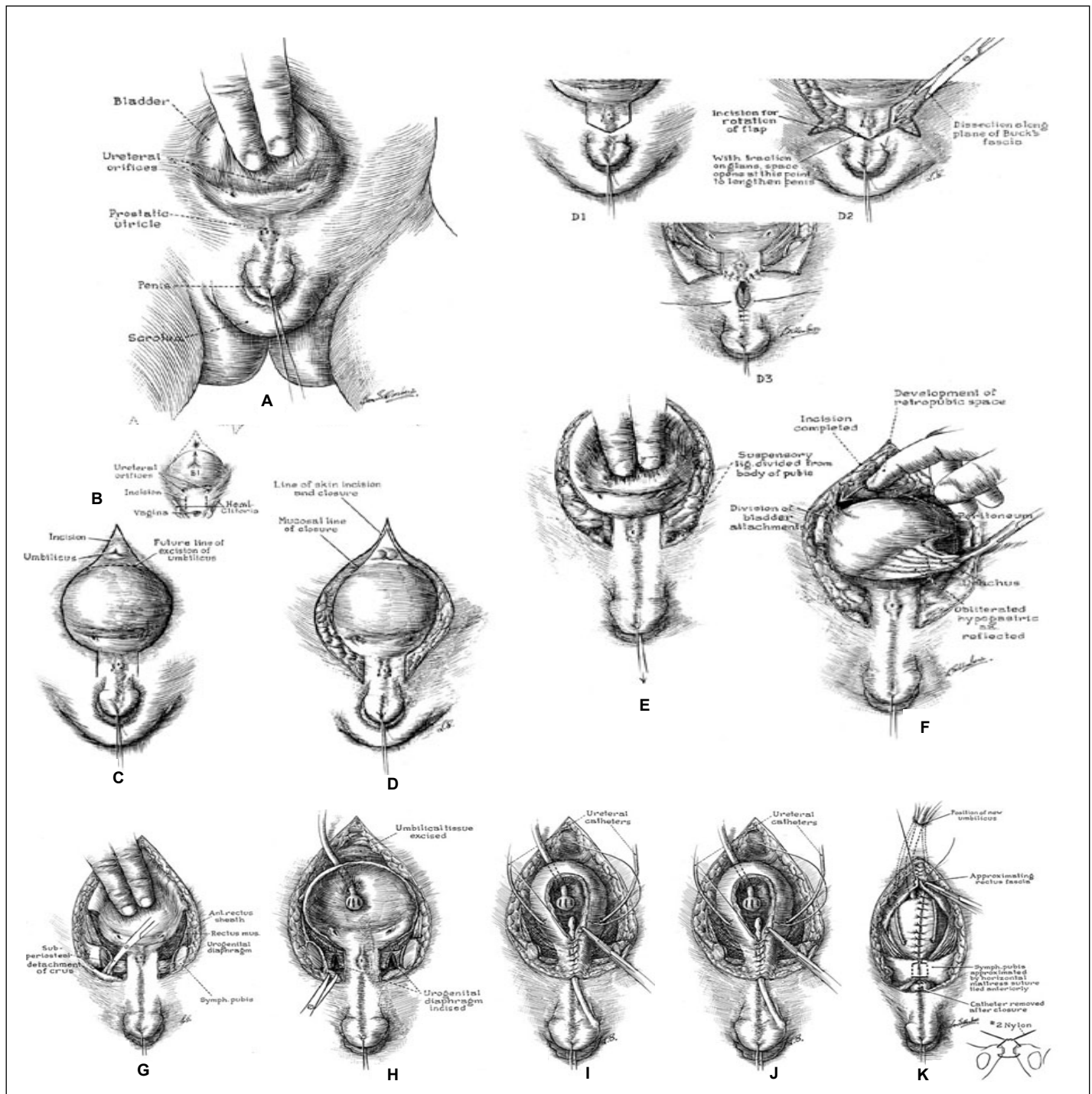
**Technique of Anterior Oblique Osteotomy**

1. After complete preparation of the child from the nipple to the leg, and with the child in a supine position, a skin incision is made along the iliac crest, beginning from the anterior superior iliac spine and extending posteriorly and deepened until the periosteum is reached.
2. An incision is then made in the periosteum along the iliac crest beginning 1 cm posterior to the anterior superior iliac spine.

3. The periosteum is elevated toward the sciatic notch. Both tables of ileum are divided down to the sciatic notch with the aid of an osteotome, reciprocating saw or Gigli saw, including cartilage at the level of the sciatic notch. This results in free movement of the anterior fragment.
4. The surgeon then proceeds to repair the bladder.

**Technique of Repair of Bladder and Posterior Urethra**

1. An incision is made just above the umbilicus and continues around the bladder mucosa to a point 1 cm away from the midline in the distal trigone on both sides (Figure 92.4(A,B)).
2. This incision is then continued in a parallel manner along the



Source: Gearhart JP. Exstrophy, epispadias and other bladder anomalies. In: Walsh PC, Retik AB, Vaughan ED, et al., eds. Campbell's Urology, vol 3, 8th ed. Saunders, 2003, CD ROM version, chapter 61. Reproduced with kind permission of Elsevier Science.  
 Figure 92.4: Technique of repair of bladder and posterior urethra.

urethral plate distally (Figure 92.4(C,D)) to the region lateral to the verumontanum in boys and along the urethral plate in girls. No attempt is made to divide the urethra unless there are compelling reasons to believe the urethra needs to be lengthened

3. The incision is deepened in the region of the umbilicus and a plane developed between the rectus muscle and the bladder wall (Figure 92.4(D,E)).
4. The peritoneum is dissected off the bladder and dissection continued until the area lateral to the trigone is reached, where the urogenital diaphragm will be encountered (Figure 92.4(F)). Ureteric stents must be placed early to avoid inadvertently dividing the ureters.
5. The urogenital diaphragm is sharply dissected off the pubic bone deeply, parallel to the bladder and posterior urethra, until it is completely separated from the pubic bone (Figure 92.4(G,H)). Traction on the pubic bone using skin hooks or a stitch helps to accentuate the fibres and aid complete dissection of these fibres. This is a particularly important step because it ensures that the bladder neck is placed deeply at the end of the procedure and promotes continence later.
6. The bladder mucosa and posterior urethra are then closed in two layers by using long-term absorbable sutures well onto the urethra (Figure 92.4(I,J)). The final urethral orifice must be able to admit a 12 Fr to 14 Fr stent to allow adequate resistance for bladder growth while preventing outlet obstruction.
7. A suprapubic catheter and ureteric stents are left in situ, but no stent is left in the urethra (Figure 92.4(K)). Ideally, nonlatex silastic tubes should be used, but a Foley catheter may be used instead of a malecot catheter for suprapubic drainage, and feeding tubes may be used as ureteric stents in the absence of ideal tubes.
8. Care must be taken not to inflate the balloon of the catheter so much as to cause pressure on the thin mucosal wall; the tip of the Foley catheter beyond the balloon may need to be cut to avoid pressure in the urethra.
9. After bladder closure, the trochanters are brought together by the assistant and the pubic bones approximated with a #2 nylon stitch, ensuring that the knot remains outside the bone to avoid traumatising the urethra. A second stitch may be applied to reinforce the repair.
10. Finally, the abdominal wall is closed in layers. Antibiotics are given at induction to reduce the risk of septic complications.

### Management after Primary Surgery

Postoperatively, gallows traction is applied for 3–6 weeks or an alternative method of fixation is used.

The child is observed to ensure adequate drainage of urine from both ureteric stents. The ureteric stents are left in situ for 10–14 days, and the suprapubic catheter for 4 weeks. The child is discharged, after urine examination has been done, abdominal US shows no upper tract dilatation, and there is no residual urine. If residual urine is observed, the urethral orifice can be calibrated to check for patency. Any infection noted on urine examination is treated and the patient placed on prophylactic antibiotics due to VUR. Abdominal US at 3 months and then at 6-month to yearly intervals is used to observe for any stasis in the urinary system. The presence of stasis may necessitate intervention in the form of dilatation, intermittent catheterisation, urethrotomy, refashioning of the bladder outlet, antireflux surgery, or urinary diversion.

Yearly calibration with the aid of cystoscopy and cystography helps to assess the bladder volume. At the age of about 1 year, epispadias repair is performed because this facilitates a gradual increase in bladder volume.

### Technique of Epispadias Repair

There are various techniques of epispadias repair. These include the Cantwell-Ransley repair, the Modified Cantwell-Ransley repair, and Mitchell's total penile disassembly method. The aim is to obtain a

functional, cosmetic penis by correcting dorsal chordee, urethroplasty, and glanduloplasty, and providing skin cover.

The Modified Cantwell-Ransley procedure, which achieves good results with a low complication rate, is described here (Figure 92.5). Testosterone may be given to increase the size of the penis. Repair may otherwise be done when the penis has an adequate size.

1. A stitch is placed in the glans for traction on the penis, and a longitudinal incision, made at the tip of the urethral mucosa, is closed transversely to widen the urethral mucosa at the distal end (Figure 92.5(A)).
2. The mucosa at the lateral ends of the glans is excised for glanduloplasty later (Figure 92.5(B)).
3. Parallel incisions are made over the urethral plate about 18 mm apart, from the prostatic urethral orifice to the tip of the penis (Figure 92.5(A,B,C)).
4. The skin at the base of the penis is incised with a Z-plasty incision to reduce the risk of later contracture, and all fibrotic tissue is excised.
5. The penile skin is dissected off the corpora ventrally from the corona to the base of the penis while leaving intact the mesentery to the urethral plate, which runs from ventral to dorsal between the corpora at the proximal part of the penis (Figure 92.5(C,D)).
6. The corpora are dissected off the urethral plate from the base to the tip of the penis while leaving intact the distal 1-cm attachment of the urethral mucosa to the glans. It is also dissected partially off the pubic ramus (Figure 92.5(E,F)).
7. The urethra is then tubularised with 6.0 polyglycolic acid sutures over a size 8 Fr stent (Figure 92.5(I)).
8. The corpora are rotated dorsally over the tubularised urethra and sutured together in two layers with 5.0 polyglycolic acid sutures to move the urethra ventrally (Figure 92.5(J,K)).
9. The neurovascular bundle may be dissected off the corpora only if chordee correction cannot easily be achieved and it is necessary to incise the corpora and suture the two defects in the corpora together in the middle to correct dorsal chordee (Figure 92.5(G,H)).
10. Glanduloplasty is done over the urethra with 5.0 and 6.0 polyglycolic acid sutures deeply and superficially.
11. The ventral skin is split in the midline and brought dorsally for skin cover in a bear-hug method (Figure 92.5(L,M)).

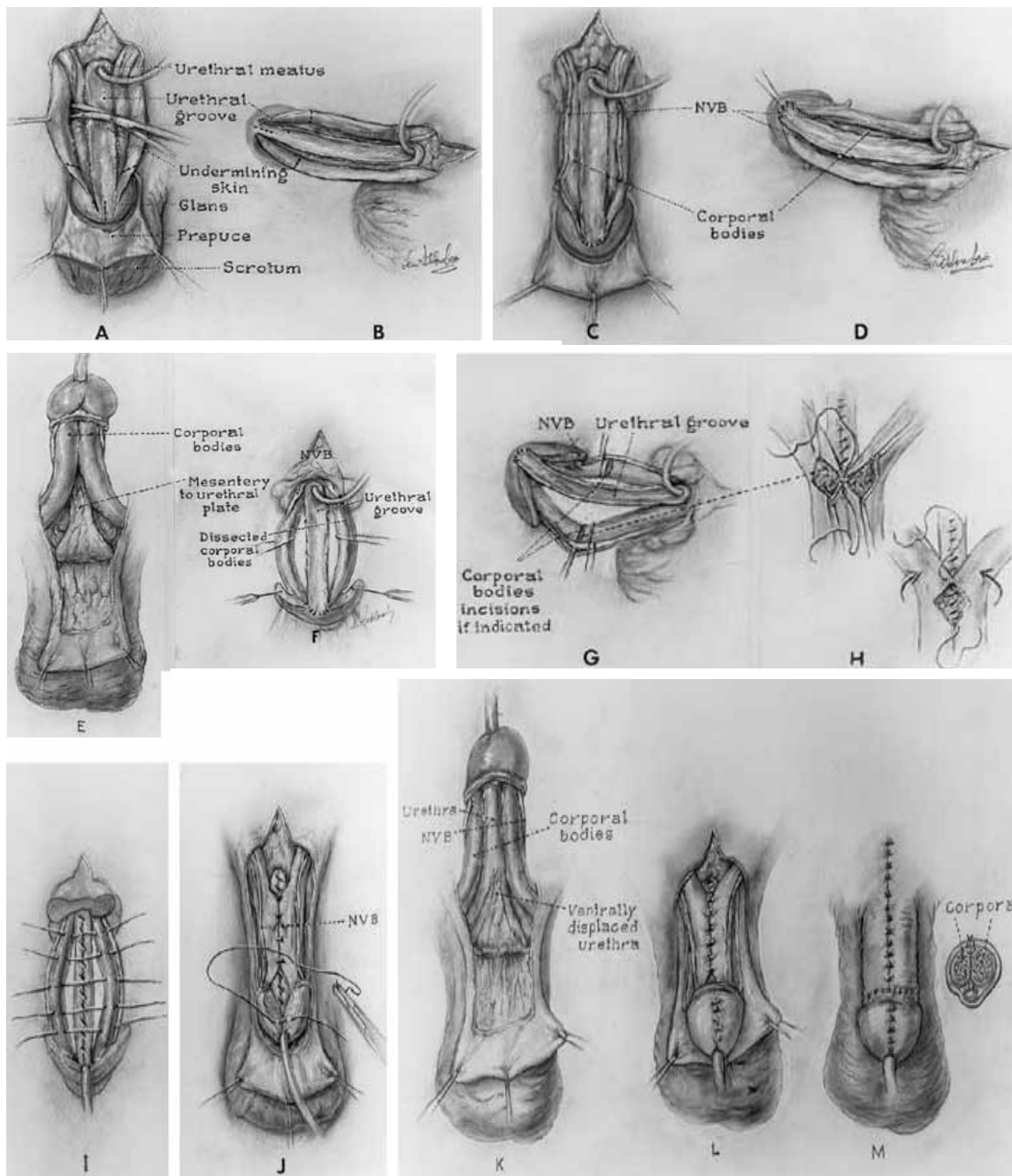
If dorsal chordee is too severe to be corrected this way, the urethra is considered too short, or skin cover is inadequate, skin graft on the dorsum of the corpora after incising the corpora may be used for correction of chordee, while skin flaps or grafts may be used to lengthen the urethra and for skin cover.

Many other techniques have been described, and some authors advocate that ventral rotation of the corpora results in a better bending penis and more penile length.

Whatever technique is used, any surgeon doing this repair must be aware of the lateral course of the neurovascular bundle, and must avoid damage to the neurovascular bundle.

### Management after Epispadias Repair

Postoperatively, a urethral stent is left in place for 10 to 12 days. A Vaseline® gauze dressing may be applied directly to the wound followed by a dry roll of gauze held in place with adhesive plaster. The outer dressing may be changed any time it gets wet. After about a week, the wound may be exposed and allowed to stay dry. Dressings may be removed after 48 hours, and the wound allowed to remain exposed if the child is unlikely to handle the wound. The patient may be discharged soon after surgery if one can ensure a quick return to hospital if the need arises. Otherwise, the patient is kept in hospital until there is adequate healing. Analgesics, antispasmodics, and antibiotics are important adjuncts in the postoperative management to reduce pain, bladder spasm, and infection.



Source: Gearhart JP. Exstrophy, epispadias and other bladder anomalies. In: Walsh PC, Retik AB, Vaughan ED, et al., eds. *Campbell's Urology*, vol 3, 8th ed. Saunders, 2003, CD ROM version, chapter 61.. Reproduced with kind permission of Elsevier Science.

Figure 92.5: Technique of repair of epispadias.

Yearly assessment of bladder volume is done under anaesthesia. Assessment of bladder volume may be done with the aid of US, cystoscopy, cystography, or urodynamic studies. Urodynamic studies, which give added information on pressure in the bladder, are usually not available in most African countries. Once bladder volume is at least 85 ml, bladder neck reconstruction and antireflux surgery is done. This may take up to age of 4 years.

If bladder capacity is adequate for age but incontinence persists, which is usually the case, then bladder neck reconstruction should be considered. Outcome after primary closure tends to be better for girls than for boys.

### Technique of Bladder Neck Repair

There are various techniques for bladder neck repair. The modified

Young-Dees-Leadbetter repair gives good results and is described here (Figure 92.6).

1. A transverse incision is made at the bladder neck and extended vertically in a T-shape. Cohen transtrigonal reimplantation of the ureters is then done (Figure 92.6(A,B,C)).
2. A 15- to 18-mm wide and 30-mm long mucosal strip is chosen between the midtrigone and prostatic urethra. The bladder mucosa lateral to this is excised with the aid of gauze soaked in adrenaline for haemostasis (Figure 92.6(D)).
3. Multiple transverse incisions are made in the muscle edge lateral to this strip without making a transverse incision at the border with the bladder floor to reduce the risk of ischaemia (Figure 92.6(E)).

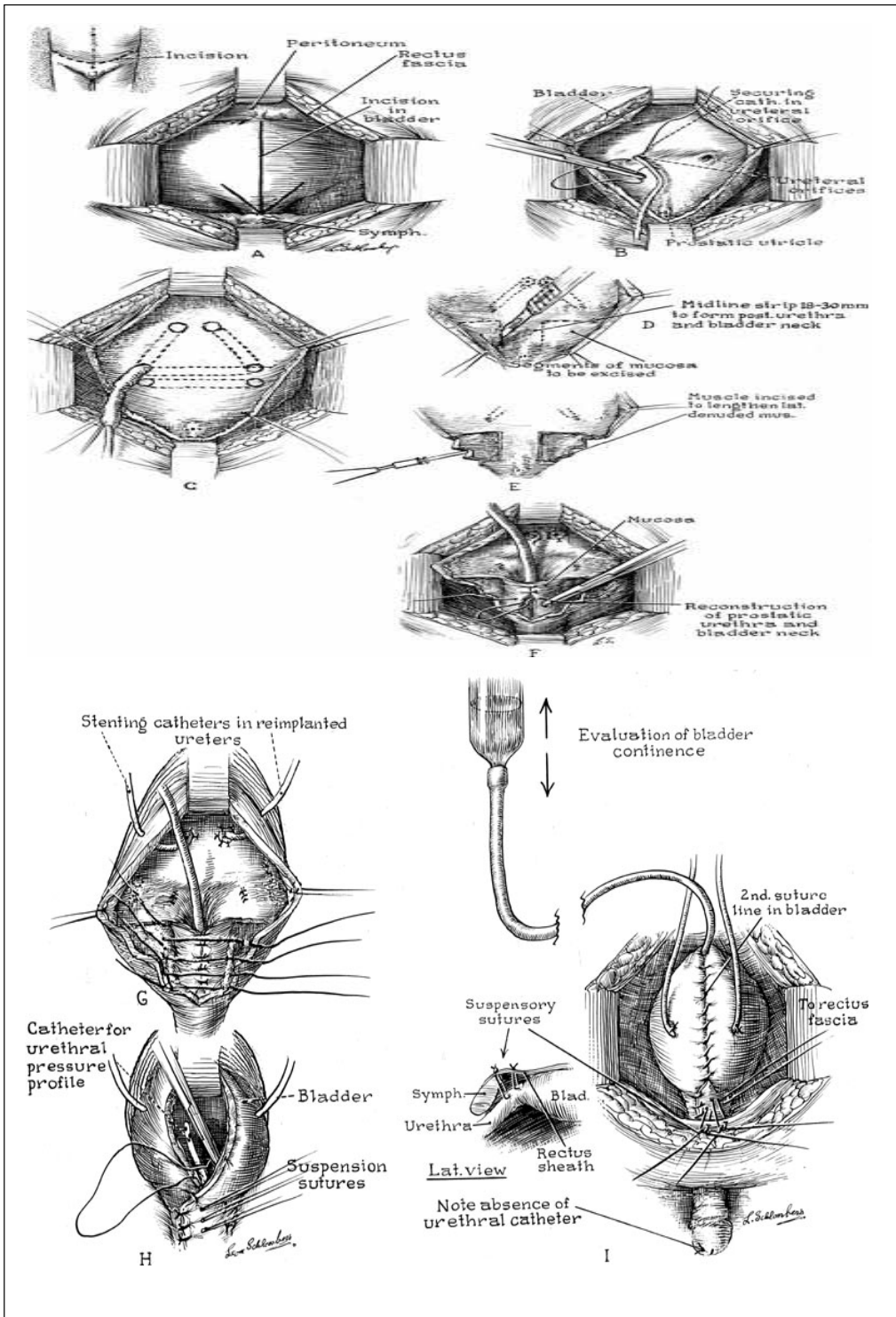


4. The strip of mucosa and underlying muscle is then tubularised with 4.0 polyglycolic acid sutures. The lateral muscle flaps are overlapped over the tubularised mucosa using 3.0 polyglycolic acid sutures (Figure 92.6(F,G)).
5. The bladder neck is then suspended on the anterior rectus muscle (Figure 92.6(H)).
6. The bladder, bladder neck, and posterior urethra are completely dissected to ensure easy mobility and an adequate repair.
7. A size 8 urethral stent may be used to assist closure of the urethra,

but this is not left in situ. Bilateral ureteral stents and a suprapubic catheter are placed for urinary diversion (Figure 92.6(I)).

**Management after Bladder Neck Repair**

The suprapubic tube is left for 3 weeks. Before removal, it is clamped for about 1 hour and then the child is observed for passage of urine. If this fails to occur, a size 8 Foley catheter is passed for 5 days and then another attempt made to void. These attempts are continued until the child is able to void. Some children, however, will be unable to pass urine and should be put on intermittent catheterisation. This can



Source: Gearhart JP. Exstrophy, epispadias and other bladder anomalies. In: Walsh PC, Retik AB, Vaughan ED, et al., eds. Campbell's Urology, vol 3, 8th ed. Saunders, 2003. CD ROM version, chapter 61. Reproduced with kind permission of Elsevier Science.

Figure 92.6: Technique of repair of bladder neck.

be difficult after urethral reconstruction, and some children will need continent diversion (Mitrofanoff's technique) to be able to empty the bladder. The child is then discharged and followed up with regular US examinations to ensure adequate renal function. It is expected that within 1 to 2 years the child should achieve daytime dryness of 3 hours. Failure to achieve this is an indication to consider other methods of urinary control.

### Other Techniques

Various forms of urinary diversion, bladder augmentation, the use of conduits, continent diversion, and artificial sphincters are necessary for various reasons in the management of bladder exstrophy. Indications include small contracted fibrotic bladder incapable of forming a bladder, failed repair of bladder, failure to achieve adequate bladder volume after primary repair, and failed bladder neck repair. Techniques include uretero-sigmoidostomy and modified forms of this, rectal bladders, ileocolonic bladders, ileal bladders, injection of bulking agents to augment sphincteric action, the use of conduits, and continent stomas. These methods may be important in Africa due to the late presentation of patients. However, the method chosen must require minimal follow-up and less cost because follow-up of patients is difficult in Africa.

### Cloacal Exstrophy

Management of cloacal exstrophy is individualised due to the complex and varied nature of the anomalies present. Staged repair is particularly important here, although complete repairs may be done. Procedures that need to be done include repair of spinal defects; stomas for bowel management; osteotomies, and other diversions for urinary anomalies; and repair of genital anomalies.

Spinal and bowel anomalies must be dealt with first after the child is stable. Urinary and genital anomalies may then be managed later.

Gender assignment is another important part of the management of this condition because the male phallus may be so short that gender reassignment may be necessary at the onset.

### Epispadias

Treatment of epispadias in the male follows principles similar to those used for exstrophy of the bladder. In those who are incontinent, which is usual in penopubic and penile epispadias, urethroplasty is done first and then bladder neck repair is done when the bladder volume is 85 ml. In the absence of incontinence, urethroplasty is done. The Modified Cantwell Ransley method and the Young-Dees-Leadbetter repair are adequate for urethroplasty and bladder neck repair, but many other techniques have been described.

Treatment of epispadias in the female follows the same principles as those used in the male with epispadias. Urethroplasty is done first, after which bladder neck repair is done.

1. For urethroplasty, the patient is placed in a lithotomy position, and a vertical skin incision is made on the mons and then extended laterally in a Y-shape from the apex of the urethral orifice distally to the open urethra between the 3 and 9 o'clock positions.
2. Parallel incisions are then made from this position proximally to the bladder neck.
3. The strip of urethra between these incisions is excised.
4. The urethra is tubularised around a size 10 or 12 Fr stent.
5. The mucosa on the medial aspect of the clitoris and labia minora on both sides is excised, and the clitoris and labia minora are repaired in the midline.
6. The skin is then closed in layers, ensuring that fat is brought together over the urethral repair.

Bladder neck repair is done when bladder volume is adequate and the Young-Dees-Leadbetter repair achieves good results. Reimplantation of the ureters is necessary in many of these cases due to reflux and is done in addition.

If bladder volume is adequate at the onset, urethroplasty and bladder neck repair can be done in one stage.

## Postoperative Complications

Table 92.1 outlines possible complications of surgery related to bladder exstrophy and epispadias.

Table 92.1: Complications of surgery.

| Surgical procedure      | Complication  | Management   |
|-------------------------|---|--|
| Primary bladder closure | Partial or complete wound, breakdown with wound dehiscence                                    | Repeat reconstruction, diversion   |
|                         | Bladder prolapse, inadequate bladder volume   | Bladder augmentation   |
|                         | Bladder outlet stenosis, infection, pyelonephritis  | Urethral dilatation, urethrotomy, refashioning of bladder outlet, re-implantation of ureters |
|                         | Vesicoureteric reflux   | Antibiotics  |
| Osteotomies             | Poor healing, nerve injury, osteomyelitis, diastasis  | Good fixation, rest, antibiotics   |
| Epispadias repair       | Urethrocutaneous fistulas, stenosis, short penis, unpleasant scars, difficult catheterisation | Repair, further surgery  |
| Bladder neck repair     | Persistent incontinence   | Diversion, bladder augmentation, artificial sphincters                                       |
| Diversion               | Metabolic acidosis, carcinoma, electrolyte imbalance, infection                               | Monitoring, antibiotics, alkaline drugs  |

## Prognosis and Outcomes

The outcome of staged primary reconstruction and combined reconstruction has improved over the years. Continence, defined as daytime dryness of at least 3 hours, is obtained in 60–90% of patients. Success in becoming continent is related to the number of times surgery is done to close the bladder, the use of osteotomy after the age of 72 hours, and a bladder volume of at least 85 ml prior to bladder neck repair.

Urinary diversion has resulted in continence in up to 90% of patients whenever this has been necessary. This, however, may be associated with the risk of metabolic complications, infection, and carcinoma later in life.

Sexual function has been shown to be normal in most male and female patients with exstrophy. The male genitalia remains short, and further surgery may be needed to achieve better length and to excise unsightly scars later in adult life. Females may require vulvoplasty and/or vaginoplasty in adult life. Libido, erection, and orgasm occur successfully in both males and females.

Fertility is poor in males. It is poorer, however, after primary reconstruction than after urinary diversion due to malejaculation in the former procedure. Assisted reproductive techniques, such as gamete intrafallopian transfer, can be used successfully in these patients.



Females are fertile and have borne children successfully with this condition. Prolapse of the uterus is a common complication for which repair must be done.

For those with cloacal anomalies, modern techniques have made it possible for most to live independent lives. They may have to live with permanent stomas, but they remain socially continent.

Outcomes after surgery for epispadias are better than those for bladder exstrophy.

### Ethical Issues

Exstrophy could be used as an example of the differences in approaches to congenital anomalies, depending on the place of birth. Whereas in most European and North American societies, children with exstrophy are transferred to referral centres within the first 48 hours of life, this is not the case in Africa. With neonatal referral, neonatal staged or complete repair is the first choice and offers the best chance of a final good outcome.

Even prenatal detection has changed the scene. In some European countries, early abortion after prenatal diagnosis is the rule.

Late referral, with children presenting as late as 6 or more years of age, is common in Africa, however. The bladder at this stage may be fibrotic and metaplastic, making urinary diversion a particularly important option for many in Africa. It is still possible, however, to find bladders that are compliant and elastic enough to allow primary reconstruction; combining bladder closure with epispadias repair may be the option of choice in such cases.

Next to late referral, other factors that contribute to prognosis in Africa include the cultural understanding of the condition, availability of experts to help manage this condition, and availability of resources. In a number of African communities, children born with such conditions are considered abnormal and may be neglected, with no attempt made to seek medical attention. The lack of financial resources and distance from a hospital with required expertise may contribute to this problem. Such children may therefore die or grow as social outcasts with possible psychological implications.

In Africa, where resources are scarce, it is important that a few centres be set up in each country or region in which resources and expertise are concentrated to help provide the best care to most of

these children. Education about this condition should be instituted at the community level to help change concepts and make it possible for affected children to receive adequate care on time. Social groups with interest in such conditions need to be established to help provide financial and other social support so that parents do not abandon their children due to inability to bear the burden alone. Such groups may also help influence policy makers to ensure that policies are made to benefit these children.

### Evidence-Based Research

Table 92.2 presents a retrospective study of a large number of patients that showed that bladder volume is an important determinant of continence after bladder neck repair.

Table 92.2: Evidence-based research.

|   |  |
|---|--|
| <b>Title</b>                                    | Modern staged repair of bladder exstrophy: a contemporary series   |
| <b>Authors</b>                                  | Baird AD, Nelson CP, Gearhart JP   |
| <b>Institution</b>                              | Division of Pediatric Urology, Brady Urological Institute, The Johns Hopkins Hospital, Baltimore, Maryland, USA; Department of Urology, Royal Liverpool University Hospital, Merseyside, Liverpool, UK   |
| <b>Reference</b>                                | J Pediatr Urol 2007; 3(4):311–315  |
| <b>Problem</b>                                  | Outcome after modern staged repair.  |
| <b>Intervention</b>                             | Staged repair of exstrophy of the bladder.   |
| <b>Comparison/control (quality of evidence)</b> | Patients with bladder volume of at least 85 ml after repair of the bladder and compared with those who attained less bladder volume.   |
| <b>Outcome/effect</b>                           | Most patients who had a bladder volume of at least 85 ml after repair of the bladder were continent, compared with those who attained less bladder volume.   |
| <b>Historical significance/comments</b>         | This study provides a guideline in decision making as to which patients should undergo bladder neck repair and the best stage at which bladder neck repair is likely to be successful. It also helps in the decision of when to divert urine rather than proceed to do a bladder neck repair that is likely to fail. Before proceeding to bladder neck repair, the patient should have a bladder volume of at least 85 ml. |

### Key Summary Points

1. Exstrophy of the bladder is part of a spectrum of diseases of varying severity.
2. Exstrophy of the bladder may result in carcinoma and social isolation.
3. Use plastic material to protect the bladder mucosa soon after birth.
4. Early surgery gives the best opportunity for reconstruction but must be done at an age when available support facilities can adequately maintain the child postoperatively.
5. Osteotomy is necessary after 72 hours of age.
6. Complete dissection of the urogenital diaphragm from the pubic bone is necessary for adequate closure of the bladder.
7. Bladder neck reconstruction gives the best results when bladder volume is at least 85 ml.
8. With modern reconstructive techniques, 80–90% achieve social continence.
9. Urinary diversion is important in the management of a number of patients and requires long-term follow-up.

### Suggested Reading

Agwu KK. Imaging of the complicated bladder exstrophy presenting with ureteric duplication. *West Afr J Radiol* 2001; 8(1):29–32.

Attah CA, Enabulele UF, Ike CG, Chukwulebe AE. Exstrophy of the bladder—management options. *Ebony Med J* 2006; 5(1):1–6.

Baker LA, Gearhart JP. The staged approach to bladder exstrophy closure and the role of osteotomies. *World J Urol* 1998; 16(3):205–211.

Borzi PA, Thomas DF. Cantwell Ransley epispadias repair in male epispadias and bladder exstrophy. *J Urol* 1994; 151(2):457–459.

- Catti M, Paccalin C, Rudigoz RC, Mouriquand C. Quality of life for adult women born with bladder and cloacal exstrophy: a long term follow-up. *J Pediatr Urol* 2006; 2(1):16–22.
- Fahmy MA, Mansour AZ, Mazy A. Ureterectostomy as continent urinary diversion. *Int J Surg* 2007; 5(6):394–398.
- Gearhart JP. Exstrophy, epispadias and other bladder anomalies. In: Walsh PC, Retik AB, Vaughan ED, et al., eds. *Campbell's Urology*, vol 3, 8th ed. Saunders, 2003, CD ROM version, chapter 61.
- Gearhart JP. Complete repair of bladder exstrophy in the newborn: complications and management. *J Urol* 2001; 165(6, pt 2):2431–2433.
- Grady R, Mitchell ME. Complete repair of exstrophy. *J Urol* 1999; 162:1415.
- Hafez AT, Elsherbiny MT, Ghoneim MT. Complete repair of bladder exstrophy: preliminary experience with neonates and children with failed initial closure. *J Urol* 2001; 165(6, pt 2):2428–2430.
- Hernandez DJ, Purves T, Gearhart JP. Complications of surgical reconstruction of the exstrophy epispadias complex. *J Pediatr Urol* 2008; 4(6):460–466.
- Husmann DA, McLorie GA, Churchill BM. Closure of the exstrophic bladder: an evaluation of the factors leading to its success and its importance on urinary continence. *J Urol* 1989; 142:522.
- Lowentritt BH, Van Zigl PS, Frimberger D, Baird A, Lakshmanan Y, Gearhart JP. Variants of the exstrophy complex: a single institution experience. *J Urol* 2005; 173(5):1732–1737.
- Mteta KA, Mbwambo JS, Eshiemann JL, Aboud MM, Oyieko W. Urinary diversion in children with mainly exstrophy and epispadias: alternative to primary bladder closure. *Cent Afr J Med* 2000; 46(12):318–320.
- Njoku O, Wedderman K. Pregnancies following a treated ectopia vesicae. *Port Harcourt Med J* 2006; 1(1):62–64.
- Schartz RB, King JA, Todd Purves J, Sponseller PD, Gearhart JP. Repeat pelvic osteotomy in cloacal exstrophy: applications and outcomes. *J Pediatr Urol* 2007; 3(5):398–403.
- Sponseller PD, Bisson LJ, Gearhart JP, et al. The anatomy of the pelvis in the exstrophy complex. *J Bone Joint Surg (AM)* 1995; 77:177.
- Youssif M, Badawy H, Saad A, Hanno A, Mokhless I. Single stage repair of bladder exstrophy in older children and children with failed previous repair. *J. Paediatr Urol* 2007; 3(5):391–394.