

CHAPTER 94

HYPOSPADIAS

Ahmed T. Hadidi
Philemon E. Okoro

Introduction

Hypospadias is a wide spectrum of abnormalities involving the inferior surface of the penis and having in common a urethral opening that lies on the inferior surface of the penis, (*hypo* = under; *spadias* = opening or rent).

The spectrum of hypospadias anomalies includes an abnormal urethral opening, chordee (ventral curvature of the penis), an incomplete prepuce, rotation of the penis, abnormal raphe, and disorganised corpus spongiosum and penile fascia.

Worldwide, hypospadias surgery is known to be challenging and technically demanding. In some parts of Africa, this is complicated by unawareness and some deleterious cultural and religious beliefs. Hence, the majority of hypospadias patients in Africa are referred late, already circumcised or with signs of mutilation due to failed repair or cultural practices. In addition, suboptimal theatre conditions, lack of delicate instruments and suture materials, and high infection rates in some parts of Africa make hypospadias repair even more difficult.

Epidemiology

Hypospadias is the most frequent congenital urological anomaly, occurring in 1–3 per 1,000 live births. The incidence varies geographically from 0.26 per 1,000 live births in Mexico to 3.9 per 1,000 live births in the United States.¹

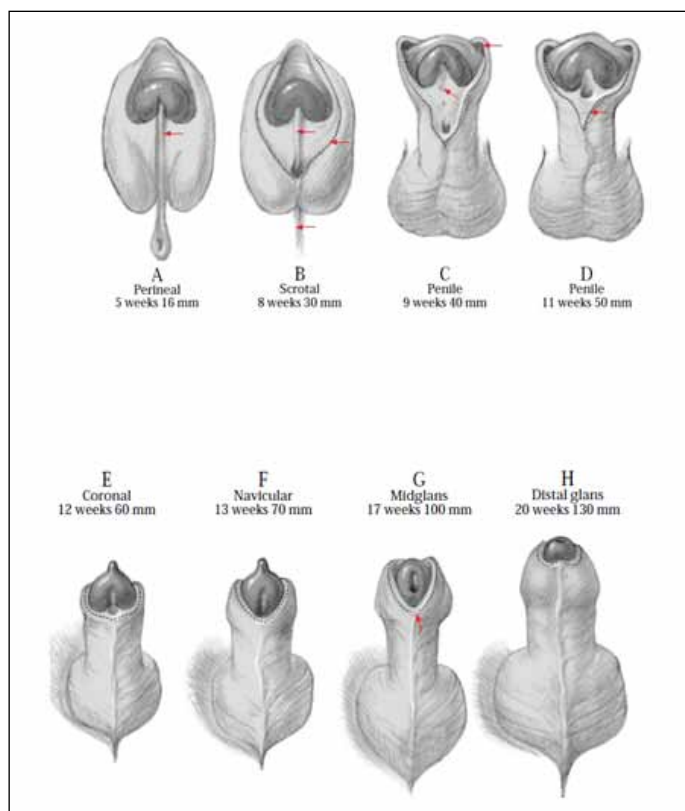
Reports have suggested that the prevalence of hypospadias varies across different races, being highest among caucasians, less in Hispanics, and least in blacks.²

Embryology

During the 3rd week of gestation, mesenchymal cells migrate around the cloacal membrane to form slightly elevated cloacal folds. During the 4th week, the cloaca folds cranially to form the genital tubercle, and caudally to form the urethral folds anteriorly and the anal fold posteriorly. In the meantime, another pair of elevations, the genital swellings, become visible on each side of the urethral folds. These swellings later form the scrotal swellings in the male and the labia majora in the female. Until the end of the 6th week, it is impossible to differentiate between the two sexes.³

Development of the external genitalia in the male is under the influence of androgens secreted by the foetal testis and is characterised by rapid elongation of the genital tubercle, which is now called the phallus. During this elongation, the phallus pulls the urethral folds forward so that they form the urethral plate. This urethral plate extends along the undersurface of the elongated phallus into the glans (Figure 94.1).

The origin of the urethral mucosa has been variously described as endodermal,⁴ ectodermal,⁵ or mixed.⁶ In the 1950s, Glenister proposed that the male urethra develops by fusion of the urethral folds over the urethral groove.⁷ This fusion extends from the proximal to the distal end of the penis. The last part of the formation of the urethra is the canalisation of a cord of ectodermal cells extending from the apex of the glans to the distal end of the developing urethra. Thus,



Source: Hadidi AT, Azmy AF, eds. *Hypospadias Surgery: An Illustrated Guide*, 1st ed. Springer Verlag, 2004. Reproduced with kind permission of Springer Verlag.

Figure 94.1: Normal urethral development. The urethral meatus shifts distally as the embryo gets older to reach the distal glans at about 20 weeks of gestation.

the distal urethra is the last to form and also the most common site of hypospadias.^{8,9} The mesenchyme in the urethral folds subsequently becomes the corpus spongiosum. A ridge just proximal to the corona develops at about the 8th week of intrauterine life. This ridge is carried distally by active mesenchymal growth around the corona to form a cone-shaped prepuce. A defect of the urethra would, therefore, prevent the ventral aspect of the cone from developing. By the 12th week of intrauterine life, the labioscrotal folds fuse completely in the midline to form the scrotum.^{10,11}

The formation of the urethra is still a matter of speculation. The long-accepted assumption that the urethra forms by fusion of the urethral folds in the midline—similar to closing a zipper—has been challenged in recent years. Van der Putte and Kluth failed to find any evidence of midline fusion.^{12–15} Furthermore, the fusion theory cannot explain the wide spectrum of anomalies associated with hypospadias, such as chordee with or without hypospadias, torsion and different glans configuration, and meatus size commonly encountered in hypospadias.

Aetiology

A unifying aetiology for hypospadias remains elusive. Hypospadias probably results from multiple factors—namely, endocrine, genetic, and environmental.

- **Endocrine:** Hypospadias may result from disruption in the synthetic biopathway of androgens, defective local androgen receptors, or a subnormal testosterone response to human chorionic gonadotropin (hCG) stimulation.
- **Genetic:** Hypospadias may have a complex genetic background. The familial incidence of hypospadias is about 7%, which reflects a nonfamilial sporadic finding in most cases.¹⁶
- **Environmental:** The incidence of hypospadias is increasing worldwide. One possible explanation is environmental contamination. Insecticides, pharmaceuticals, plant estrogens—the so-called “endocrine disruptors”—have been incriminated.¹⁷

Morphology

Hypospadias presents in various ways. The abnormality usually affects more than one component of the male organ. It is very important for the surgeon operating on hypospadias to be aware of its different morphological features. Such variations influence dramatically the choice of the most suitable operation for an individual patient.

The task of the hypospadias surgeon is to try to correct all the different components of the hypospadias spectrum and not just bring the urethral meatus to the tip of the glans penis. The surgical technique that is suitable for a child with a cleft glans and wide, well-vascularised urethral plate is totally different from the technique suitable for a patient with flat glans and fibrotic, nonpliable, narrow urethral plate. For this reason, hypospadias surgery differs from surgery for most other anomalies of the human body.

The Meatus

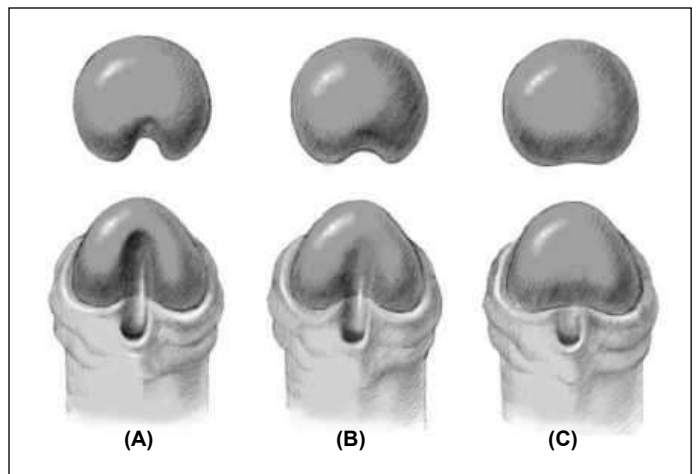
The common shape of meatus in hypospadias is the transverse form. In some patients, the meatus may look like a longitudinal fissure, but in fact it is circular at the proximal end of the fissure. The other common type is the pinpoint type of meatus. The pinpoint opening may be surrounded by a soft yielding tissue that dilates during micturition or may be surrounded by a fibrous ring that may cause difficulty to pass urine. In glanular hypospadias, there may be an elevation (bridge) distal to the meatus. This usually suggests that the urethra is mobile and can be stretched to the tip of the glans. The double-Y glanuloplasty (DYG) or Meatal Advancement and Glanuloplasty Incorporated (MAGPI) technique is suitable for such cases.

There may be several openings, which represent openings of para-urethral canals or lacula of Morgagni. The presence of a distal opening may lead the parents and the inexperienced practitioner to think that the hypospadias is more distal than it really is. As a general rule, *the most proximal orifice is the actual urethral orifice connected to the bladder.*¹⁸

The Glans

Patients with hypospadias have an abnormal-looking globular glans. The glans is classified into three categories based on the degree of clefting and urethral plate projection.¹⁹

1. **Cleft glans** (Figure 94.2(A)): There is a deep groove in the middle of the glans with proper clefting; the urethral plate is narrow and projects to the tip of the glans. An example is the “hidden hypospadias” (megameatus-intact prepuce). Tubularisation of the urethral plate without incision or pyramid repair gives good results.
2. **Incomplete cleft glans** (Figure 94.2(B)): There is a variable degree of glans split, a shallow glanular groove, and a variable degree of urethral plate projection. An inverted-Y tubularised plate (YTP) or inverted-Y meatoglanuloplasty usually gives good results.
3. **Flat glans** (Figure 94.2(C)): The urethral plate ends short of the



Source: Hadidi AT, Azmy AF, eds. *Hypospadias Surgery: An Illustrated Guide*, 1st ed. Springer Verlag, 2004. Reproduced with kind permission of Springer Verlag.

Figure 94.2: Different glans configurations.

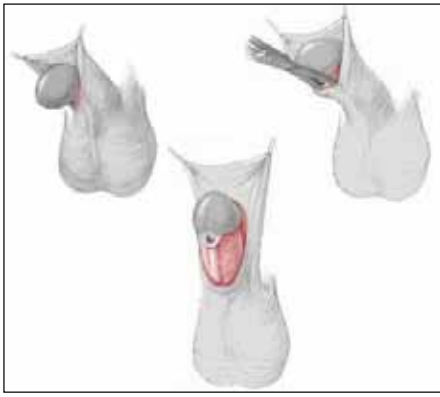glans penis; there is no glanular groove. Generous glans splitting is required to achieve good cosmetic and functional results. The new urethra has to be embedded deep into the glans to have a satisfactory cosmetic appearance and maintain a wide meatus.

Chordee

The term “chordee” was introduced into medical literature in the 17th century from the French in relation to gonorrhoea. It was defined as a “painful downward curvature of the penis due to inflammation”.²⁰ Most hypospadias pioneers in the 19th century used terms such as incurvation, curvature, or bending. Clinton Smith, in the 1930s, was probably the first to use the term chordee to describe congenital curvature associated with hypospadias.²¹ Some publications mention that the word chordee comes from the Greek word *chorde* and means cord²² and define chordee as a congenital defect of the genitourinary tract resulting in a ventral curvature of the penis, caused by presence of a fibrous band of tissue instead of normal skin along the corpus spongiosum.²² This definition is inaccurate and may be misleading.

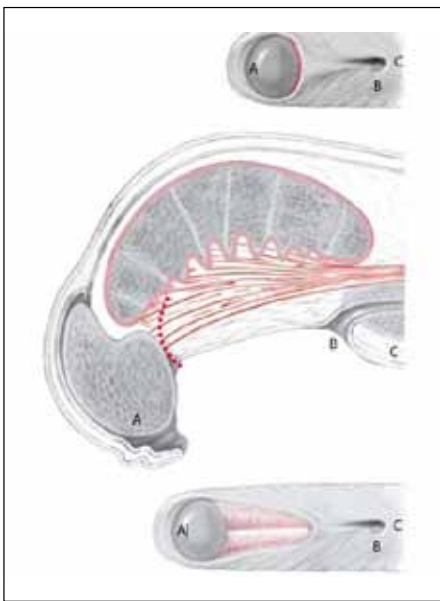
Chordee has a wide spectrum and may be due to disproportionate growth of one of the fascial coverings or skin. It may be classified into one of the following categories:

- **Chordee without hypospadias:** This occurs when there is deficiency or disproportionate growth of skin and/or dartos fascia, Buck’s fascia, or corpus spongiosum. The urethra is normal, although it may be very thin, and it lies directly under the skin when the corpus spongiosum is also deficient.
- **Hypospadias with superficial chordee** (Figure 94.3): This condition is present when there is disproportionate growth of the urethra as well. In this situation, the disproportionate growth involves the fascial structures and skin superficial to the urethra. This may be encountered in some distal forms of hypospadias, and incision proximal to the meatus and mobilisation of the skin from the underlying urethra usually corrects this form of chordee.
- **Hypospadias with deep chordee** (Figure 94.4): This type of hypospadias is encountered when the Buck’s fascia deeper to the urethra is also involved. The disorganised tissue is mainly distal to the meatus. This form of deep chordee is encountered in about 50% of proximal hypospadias. Incision of the urethral plate is needed to correct the curvature of the penis.



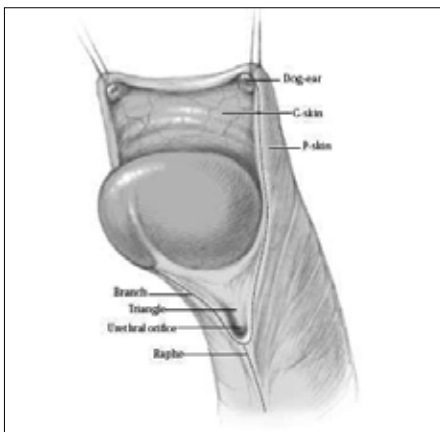
Source: Hadidi AT, Azmy AF, eds. *Hypospadias Surgery: An Illustrated Guide*, 1st ed. Springer Verlag, 2004. Reproduced with kind permission of Springer Verlag.

Figure 94.3: Superficial chordee.



Source: Hadidi AT, Azmy AF, eds. *Hypospadias Surgery: An Illustrated Guide*, 1st ed. Springer Verlag, 2004. Reproduced with kind permission of Springer Verlag.

Figure 94.4: Deep chordee. Deep chordee is usually associated with proximal hypospadias. Incision of the urethral plate at the coronal sulcus will increase the distance between the tip of the penis (A) and the urethral meatus (B). The distance between the urethral meatus (B) and the penoscrotal junction (C) remains constant.



Source: Hadidi AT, Azmy AF, eds. *Hypospadias Surgery: An Illustrated Guide*, 1st ed. Springer Verlag, 2004. Reproduced with kind permission of Springer Verlag.

Figure 94.5: Prepuce in hypospadias.

• *Hypospadias with corporeal disproportion*: This condition is rather rare. The situation is encountered when the ventral tunica albuginea surrounding the corpora cavernosa is also contracted. Excision of the disorganised fascial tissue distal to the meatus is not enough to achieve a straight penis. This condition is thought to be encountered mainly in older children with long-standing uncorrected proximal hypospadias.

The Prepuce

The prepuce presents in several variations in hypospadias. In the majority of patients, the prepuce is longer than normal dorsally but absent ventrally. There are two lateral edges that are fixed at the lateral borders of the ventral aspect of the prepuce. Thus, the prepuce is deficient ventrally. To get an idea about the area of underdevelopment of the urethra and corpus spongiosum, draw two lines along the two lateral edges of the prepuce.

A common finding in many hypospadias patients is two rounded knobs laterally on the dorsum of the prepuce (like two little eyes, whirls, or dog-ears) (Figure 94.5). The significance of these two knobs is still unclear. These two little knobs are visible on the prepuce after preputial reconstruction following hypospadias repair. Attempts to excise the two knobs during the prepuce reconstruction usually results in a very short prepuce, and it is important to inform the parents of this beforehand.

The prepuce itself may accentuate the degree of penile chordee. In many cases, the family doctor reports the presence of penile chordee because of the hooded appearance of the prepuce and the presence of a peculiar line of cleavage.

In less than 5% of hypospadias patients, the prepuce is complete, covers the whole glans and is longer than normal. This may result in late diagnosis of hypospadias and excision of the prepuce wrongly in routine circumcision. This is considered as a separate entity and is called “hidden hypospadias” or mega-meatus intact prepuce (MIP) hypospadias.

The Urethral Plate

The urethral plate is a pink gutter of mucous membrane with a well-defined mucocutaneous line. This gutter may extend from the hypospadiac urethral orifice to the base of the glans penis. Rarely, it may extend well into the glans.

Paul and Kanagasuntheram have described the histological sections of this gutter to be stratified squamous epithelium with pigment in the malpighian layer.²³ These sections show no underlying layer of erectile tissue. In patients with perineal hypospadias, histology of sections within the scrotum showed pseudostratified columnar epithelium rather than transitional epithelium. There is no erectile tissue.

The Penile Raphe

The penile raphe is normally situated in the ventral midline. In hypospadias, it is usually present (85%) and bifurcates proximal to the hypospadiac meatus into two branches that end distally into what is called eyes, whirls, or dog-ears (Figure 94.5). The area between the two branches of the raphe gives an idea of the extent of the developmental defect of the corpus spongiosum and ventral fascia.

Size of the Penis

The size of the penis is normal in the majority of hypospadias patients. Patients with disorders of sex development constitute a different category. Avellán has found penile hypoplasia in 3% of his patients, half of which had associated chromosomal anomalies.²⁴

The Proximal Urethra

The proximal urethra may be very thin for a variable distance down to the perineum. This is probably due to the absence of corpus spongiosum to a variable degree. Incomplete urethral valves may be present and render the introduction of an intraurethral catheter difficult.

In some patients with hypospadias, there may be accessory blind paraurethral tracts that open at the same urethral opening and end blindly after 1–2 cm. Classic posterior urethral valves may be present in about 10% of patients with hypospadias

The Scrotum

In the majority of hypospadias patients (90%), the scrotum is normal. A partially bifid or completely bifid scrotum is occasionally present in proximal forms of hypospadias.

Penoscrotal transposition, a condition in which the scrotal skin surrounds the root of the penis to a variable extent, is also not common. Avellán has reported different degrees of penoscrotal transposition in 20% of his group of patients.²⁴

The Testes

The majority of hypospadias patients have normal testes in the scrotum. Retractable or undescended testes may be encountered in 10% of patients with hypospadias, usually in proximal forms.²⁴

Patients with hypospadias associated with an undescended testis should have chromosomal and hormonal analysis, as well as ultrasound to exclude chromosomal anomalies and disorders of sex differentiation (DSD).

Müllerian Remnants and Enlarged Utricles

Cystoscopy in proximal hypospadias may reveal enlarged verumontanum and utricles. This may explain the occasional difficulty encountered in catheterisation of some patients with severe forms of hypospadias.

Other Urological Malformations

The majority of hypospadias patients have no other urological anomalies. Rarely, there may be vesicoureteric reflux, a double ureter, a double renal pelvis, a single kidney, or an ectopic kidney.

Classification

Consistent classification is necessary to standardise the terminology of hypospadias to enable improved treatment and comparison of results across centres and surgeons. Several classifications have been described for hypospadias. However, the simplest and the most practical classification has been described in 1886 by Kaufmann,²⁵ who classified hypospadias into first degree (glanular), second degree (penile), and third degree (proximal) (Figure 94.6). Duckett classified hypospadias into eight subgroups (glanular, coronal, subcoronal, distal penile, mid-penile, proximal penile, penoscrotal, and perineal).²⁶

Note that the different degrees of hypospadias require different operations, have different complication rates, and have different prognoses. Glanular and penile hypospadias constitute about 85% of patients with hypospadias. There are no specific operations designed for mid-penile hypospadias. Depending on the exact site and presence or absence of chordee, one may use techniques designed for either distal or proximal hypospadias. Children with hypospadias, penile, and gonadal anomalies should be classified under DSD.

It is suggested that preoperative evaluation forms such as those shown in Figure 94.7 be completed at the first operation for proper assessment. However, a two-stage procedure may be necessary in some cases.

Clinical Features

Hypospadias is usually diagnosed early in life because of the peculiar appearance of the hooded prepuce that is deficient ventrally in 95% of patients. The parents may notice that urine comes out from the undersurface of the penis and that it usually splays out rather than exiting in a stream.

Hypospadias is usually asymptomatic. Occasionally, the urethral opening is narrow and the patient may pass a very narrow stream of urine, with difficulty.

Detailed clinical examination is needed with recording of

- meatus site and size;
- presence of chordee and severity;
- glans configuration;
- complete or incomplete prepuce;

Kaufmann 1886	Hadidi 2004	Incidence
1st degree	Glanular	10 %
	Distal	75 %
2nd degree		
3rd degree	Proximal	15 %

Source: Hadidi AT, Azmy AF, eds. Hypospadias Surgery: An Illustrated Guide, 1st ed. Springer Verlag, 2004. Reproduced with kind permission of Springer Verlag.

Figure 94.6: Classification of hypospadias.

Source: Hadidi AT, Azmy AF, eds. Hypospadias Surgery: An Illustrated Guide, 1st ed. Springer Verlag, 2004. Reproduced with kind permission of Springer Verlag.

Figure 94.7: Hypospadias form.

- width of the urethral plate;
- presence of torsion;
- presence of bifid scrotum or penoscrotal transposition; and
- any associated anomalies (e.g., undescended testis).

Investigations

Healthy, asymptomatic patients with glanular and penile hypospadias may require no routine investigations.

Abdominal ultrasound and urinalysis are needed in patients with proximal hypospadias or urinary symptoms. Further investigations (e.g., micturating cystourethrogram) are indicated when the bladder, ureters, or kidneys are dilated. Chromosomal analysis is indicated when DSD is suspected.

Management

Parents Counselling

Once hypospadias is diagnosed, parent counselling is the first step that follows. The doctor should explain the condition in detail, emphasizing that it is not the fault of any of the parents and that familial incidence is about 7%.

It is also important to stress that circumcision is contraindicated in the presence of hypospadias because the preputial fascia and skin may be used to correct hypospadias. Circumcision may be required for medical, ethnic, or religious reasons (for more details on circumcision, see Chapter 95). Parents should be informed that complications can and may occur after surgery, but the majority are correctable.

Parents need assurance that patients with glanular and penile hypospadias have more than a 95% chance of normal functional and sexual life, provided that surgery is done by an experienced surgeon. The first operation has the best chance of success. Patients with penoscrotal hypospadias or intersex have a different prognosis, depending on the size of penis, chordee, and availability of healthy tissue.

Timing of Surgery

The penis grows less than 0.8 cm in the first 3 years of life: the phallus that is small at 3 months of age will still be small at 3 years of age.²⁷ Sexual identity is determined by 3 years of age. In older children, the psychological burden relating to this must not be underestimated (in some cases, this amounts to the sensation of being “different” from one’s peers; in others, repeated operations on genitalia which may have a significant impact on the patient.

Studies²⁸ evaluating emotional, psychosexual, cognitive, and surgical risks have identified that there is an optimal window for surgery at 3–18 months of age (Figure 94.8).

However, anaesthesia in children younger than 6 months of age is technically demanding and requires experience. Hypospadias surgery in small children should be performed only in paediatric centres where experienced anaesthesia and intensive care services are available.

Referral Centres

Hypospadias surgery is a highly specialised surgery. Not every paediatric surgeon or urologist can perform it. Dedication, interest, experience, frequent surgery, and close follow-up of patients are key factors for success. There is no mild form of hypospadias that can be performed by an inexperienced surgeon. The best results of hypospadias surgery are obtained in centres that perform at least 50 hypospadias operations per year.

General Principles of Hypospadias Surgery

Preoperative Hormonal Treatment

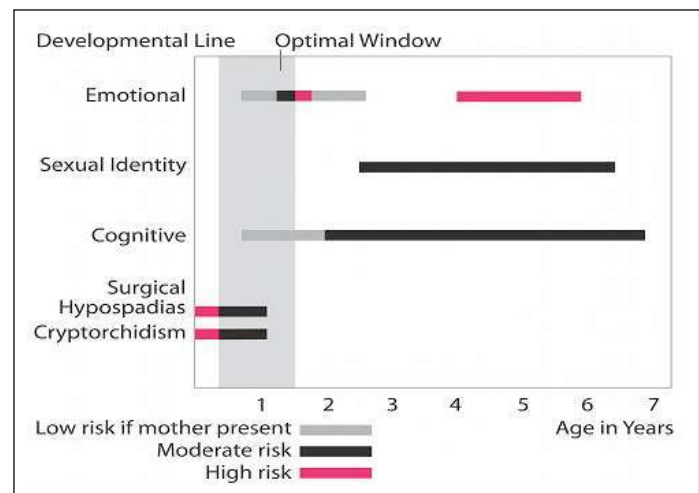
Many surgeons advocate the routine preoperative use of local testosterone cream on the penis or intramuscular injection (1–2 mg/kg monthly for 3 months) up to one month before surgery to increase the size and vascularity of the penis.¹⁷ However, the authors limit the use of preoperative hormones to severe cases of intersex with a very small phallus size. Hormonal therapy never acts locally, has several systemic side effects, makes the tissue oedematous, causes more bleeding, and does not improve the outcome.²⁹

Instruments

A basic plastic surgery set of instruments is sufficient. Essential are 6–12 fine mosquito forceps, two finetooth dissecting forceps, fine sharp scissors, sharp scalpel, and fine needle holder.

Magnification

Urethroplasty is performed by using 6/0 or 7/0 sutures. The surgeon should be able to handle such fine sutures comfortably. Most surgeons



Source: Hadidi AT, Azmy AF, eds. *Hypospadias Surgery: An Illustrated Guide*, 1st ed. Springer Verlag, 2004. Reproduced with kind permission of Springer Verlag.

Figure 94.8: Timing of surgery.

prefer to use 2.5 or 3.5 magnifying loupes.³⁰ Others, including the authors, prefer to use simple reading glasses. There is no evidence that supports the use of operating microscope in hypospadias repair.

Haemostasis

The penis is a very vascular organ. Haemostasis is an integral part of the operation. Some surgeons, including the authors, prefer to use a tourniquet whenever possible in order to reduce bleeding. The tourniquet should be released every 40 minutes. Swabs soaked in adrenaline (1:100,000) are also effective in hypospadias surgery. Bipolar diathermy, where available is useful and may reduce the need for a tourniquet. However, bipolar diathermy is not helpful when cutting through the glans, which is a sponge of blood. Monopolar diathermy is hazardous and is contraindicated because it may lead to thrombosis and sloughing of the penis.

Degloving the Penis

Most surgeons perform degloving the penis as a primary step in hypospadias surgery to release any tethering causing superficial chordee.³¹ The authors do not recommend routine degloving, but rather a 2-cm transverse incision proximal to the meatus to release superficial chordee.³² Routine degloving is not only unnecessary, but may damage the blood supply of skin flaps, necessitate circumcision at the end of the operation, increase incidence of haematoma, and result in severe postoperative oedema of the penis.³²

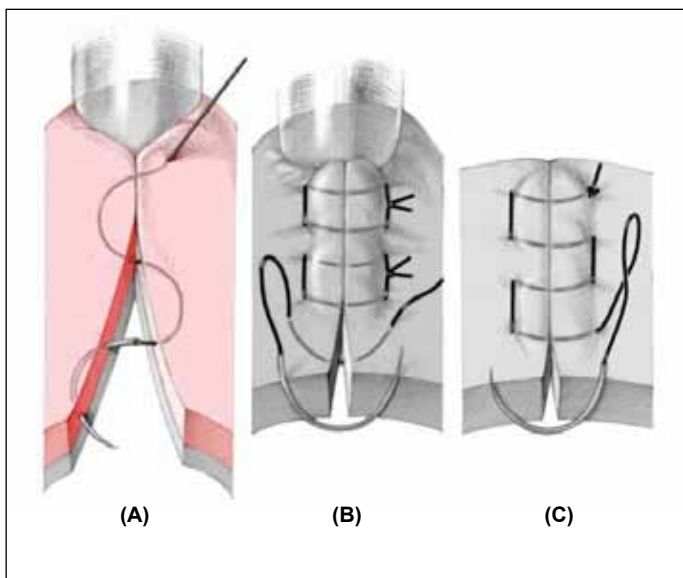
Suture Materials and Techniques

Fine 6/0 and 7/0 polyglactin absorbable suture (vicryl) are the standard sutures used in hypospadias repair. Several studies have shown that polydioxanone (PDS) reacts with urine and causes a chemical reaction that increases the chances of fistula and complications.³³

Different surgeons prefer different techniques, depending on which produces the best results for them. For urethroplasty, the authors prefer to use continuous extramucosal inverting sutures (Figure 94.9(A)). The idea is to reduce as much as possible the number of knots that act as a nidus for reaction and fistula. This technique helps to invert the epithelium into the lumen.³⁴ The surgeon should remember that healing occurs between the sutures. It is more important to have a well-vascularised urethroplasty than a water-tight suture line.

For glans closure, interrupted transverse mattress sutures using 7/0 vicryl help to avoid sutures cutting through the glans due to postoperative swelling and oedema (Figure 94.9(B)).

For skin closure, continuous mattress sutures using vicryl 6/0 or 7/0 usually give good results (Figure 94.9(C)).



Source: Hadidi AT, Azmy AF, eds. *Hypospadias Surgery: An Illustrated Guide*, 1st ed. Springer Verlag, 2004. Reproduced with kind permission of Springer Verlag.

Figure 94.9: Different suturing techniques: (A) continuous subcuticular inverting suturing is suitable for urethroplasty; (B) interrupted transverse mattress is suitable for the glans closure; (C) continuous transverse mattress is suitable for skin closure.

Stents and Catheters

Stents and catheters are foreign bodies that irritate the urethral mucous membrane and may cause inflammation and fistula. The risk is less when silicon catheters or stents are used. In distal hypospadias, the first author does not leave catheters inside the urethra for more than 72 hours. In proximal hypospadias, the author prefers to use a suprapubic catheter for 12 days as a routine. Other surgeons use suprapubic catheters in complicated repair only. A suprapubic catheter leaves the patient symptom-free until the swelling disappears and allows the urethra to heal without having a foreign body (intraurethral stent or catheter) irritating the urethra. If the disposable suprapubic catheters are too expensive or are unavailable, one may use a simple size 10 Fr nelaton catheter introduced through a reusable trocar into the urinary bladder.

Dressings

There are more than 150 methods of dressing to cover the penis after hypospadias operations. Each has its advantages and disadvantages. A prospective randomised study performed in Cairo University showed that applying no dressing results in fewer complications than applying dressing for 5 days or more.³⁵ In places with hot, humid weather, and particularly in Africa, keeping the wound exposed and dry is much better than having a wet dressing on the wound. A dry wound is a clean wound.

The authors prefer to apply a simple dressing of dry gauze and local antibiotic ointment on the ventral aspect of the penis and to fix the penis, dressing, and catheter against the lower abdominal wall with good adhesive plaster for 1 or 2 days, according to the age of the patient. This allows adequate compression of the penis as well as mobilisation of the child who can sit and play a few hours after surgery. After a period ranging from 1 to 7 days, depending on the age of the child and the difficulty of the operation, the penis is left exposed, and local ointment is applied 4 times daily for 1 week.

Postoperative Analgesia

Caudal nerve block is ideal for postoperative pain relief. However, it requires an experienced anaesthetist and complete strict asepsis.

Alternatively, a local penile nerve block could be performed. The dorsal nerves of the penis arise from the pudendal nerves, pass directly under the symphysis pubis, and penetrate the suspensory ligament to

continue under the deep Buck's fascia. Three to four milliliters of 0.5% long-acting bupivacaine mixed with 1% quick-acting lidocaine is used. Palpate the symphysis pubis, insert a 22-gauge needle at 10 o'clock, feel the inferior border of the bone, withdraw slightly and move it so that it is just clear of the bone. Pop it through the Buck's fascia, aspirate, and inject. Repeat the same procedure at 2 o'clock.

Postoperative Antibiotics

A broad-spectrum antibiotic (e.g., cephalosporin) is recommended in hypospadias surgery.³⁶ The authors give the first intravenous (IV) dose after induction of anaesthesia. Oral cephalosporine antibiotics are continued for 1 week after distal hypospadias or until the suprapubic catheter is removed in proximal hypospadias. This protocol may decrease the risk of a complicating urinary tract infections after surgery, and probably reduces meatal stenosis and urethrocutaneous fistula rates.

Objectives of Surgery

The primary goal of hypospadias surgery is to have a good functioning penis. This means ensuring that the penis is straight and that the child can micturate from the tip of the penis in a straight adequately wide stream of urine. The second important goal is for the penis to have a normal or near-normal appearance with a slit-like meatus at the tip of the glans.

An alarming observation in recent literature is that the cosmetic appearance is taking priority over the function of the penis. Many patients with a good-looking penis are referred with recurrent fistula and difficulty to pass urine due to a narrow new urethra.

The steps of hypospadias correction are the following:

1. Assessment;
2. Chordee correction;
3. Urethroplasty;
4. Protective intermediate layer;
5. Meatoglanuloplasty;
6. Scrotoplasty; and
7. Skin cover.

Assessment under Anaesthesia

A thorough examination under anaesthesia and after preparation and cover is a very important step. Based on this assessment, the surgeon should plan the operation and choose the appropriate technique suitable for this particular patient. The surgeon should evaluate the patient under good illumination with magnification, noting the following features:

1. glans configuration (cleft, incomplete cleft, or flat);
2. urethral opening (if narrow, it should be dilated or incised);
3. quality of the skin on the ventral aspect of the penis distal to the urethral meatus;
4. quality of the skin proximal to the urethral opening (sometimes it is very thin and requires incision); and
5. scrotum (ensure that both testes are in the scrotum and exclude bifid scrotum and penoscrotal transposition).

Chordee Assessment and Correction

The different forms of chordee have been discussed earlier in this chapter. There are two methods of assessing chordee. One method is to apply traction on a thread through the glans and check any tethering or limitation. This is considered by many surgeons to be inadequate because it does not detect chordee due to shortening of the tunica albuginea, but it has the advantage of being the least invasive method. The other method is application of the "artificial erection test" (Figure 94.10) described by Gittes and McLaughlin in 1974.³⁷ It is the most common method used. A red rubber catheter is used as a tourniquet at the base of the penis, and normal saline is injected into a corporal body or into the glans through a 23-G butterfly needle. Both corporal bodies are filled and show the extent of curvature. This technique may

be repeated after chordee correction to assess the completion of the correction of chordee before proceeding with urethral reconstruction. Many surgeons, including the authors, consider the artificial erection test invasive because it results in the overuse of tunica albuginea plication and unnecessary shortening of an already short penis.

About 80% of glanular and distal hypospadias have no chordee. Superficial chordee that is released by skin and fascia incision proximal to the urethral meatus can be seen in about 15% of patients with glanular or distal hypospadias.

However, about 50% of proximal hypospadias have deep chordee that requires incision and release distal to the urethral meatus. In such cases, the authors prefer to incise the urethral plate just proximal to the coronal sulcus. Note that the connective tissue tethering may extend proximally and laterally, and mobilisation should be complete.

If the child has proximal hypospadias and presents late, incision of the urethral plate may not be enough, and application of grafts ventrally or dorsal tunica albuginea plication (TAP) may be necessary.

There are different grafts used for correction of severe chordee, including dermal grafts, buccal mucosa, small intestinal submucosa (SIS), or tunica vaginalis (TV).³⁸ Dermal graft is usually harvested from the lower abdominal skin crease after removal of the epithelium. The tunica albuginea is incised at the point of maximum curvature, and the dermal graft is sutured to the edges of the tunica albuginea with continuous sutures.³⁹

The dorsal TAP is advocated by many surgeons due to its simplicity (Figure 94.11). Baskin and Ebbers recommend the application of nonabsorbable sutures dorsally at 12 o'clock position. They suggest that would help to reduce the potential damage of nerves and vessels to the glans.⁴⁰ TAP has two major disadvantages, however: (1) a higher incidence of chordee recurrence, and (2) shortening of an already short penis. Most parents do not approve of shortening the penis.⁴¹

Surgery Options

More than 300 methods are described for hypospadias correction. This is partly because of the wide spectrum of hypospadias presentations and partly because no single method produces 100% satisfactory results.

Surgeons may use one of the following tissues to form the neourethra (Figure 94.12):⁴²

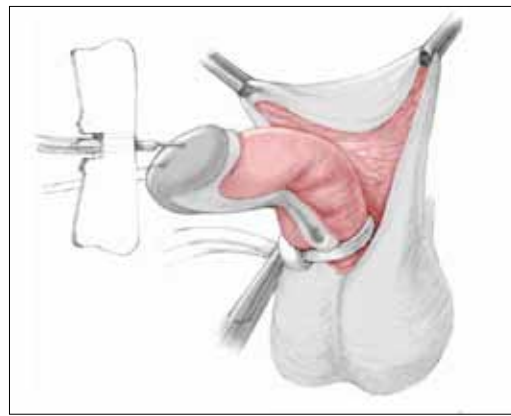
1. mobilisation of the urethra;
2. skin distal to the meatus;
3. skin proximal to the meatus;
4. preputial skin;
5. combined prepuce and skin proximal to the meatus;
6. scrotal skin;
7. dorsal penile skin; and
8. different grafts.

In general, the surgeon should use the technique that is suitable for the patient and with which he is most conversant. The best operation for hypospadias correction is the operation that brings the best results. In addition, the surgeon should not shorten an already short penis. It cannot be overemphasized that the surgeon has to choose the technique that is suitable for each individual patients. In other words, the surgeon needs to master several techniques to use in different situations.

Figure 94.13 summarises the common techniques the authors prefer to use for hypospadias correction.

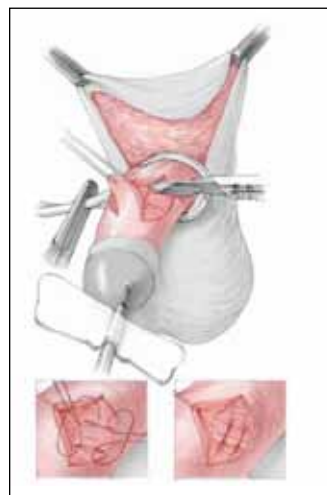
MAGPI Technique

The MAGPI technique⁴³ is suitable in selected patients with glanular hypospadias and a mobile urethral meatus that can be pushed to the tip of the glans. If the technique is used when the urethral meatus is not mobile, the urethra will retract back, in what is known as “retrusive meatus”. If a fixed meatus is forcefully pushed forward, it will always go back to its original position.



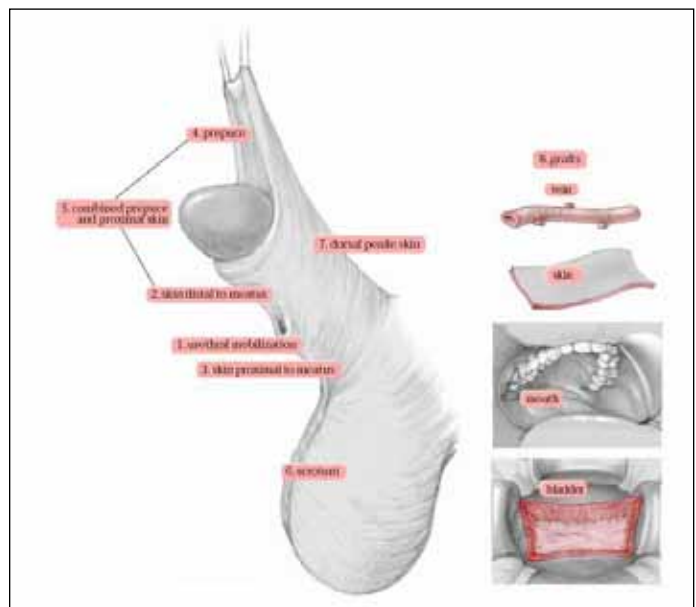
Source: Hadidi AT, Azmy AF, eds. Hypospadias Surgery: An Illustrated Guide, 1st ed. Springer Verlag, 2004. Reproduced with kind permission of Springer Verlag.

Figure 94.10: Artificial erection test.



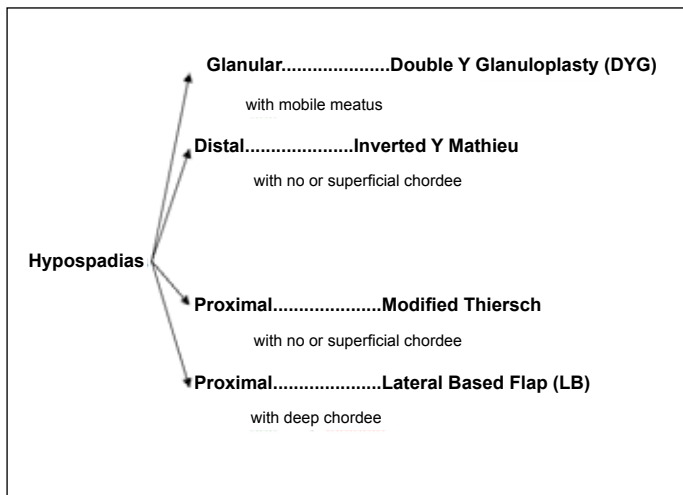
Source: Hadidi AT, Azmy AF, eds. Hypospadias Surgery: An Illustrated Guide, 1st ed. Springer Verlag, 2004. Reproduced with kind permission of Springer Verlag.

Figure 94.11: Tunica albuginea plication.



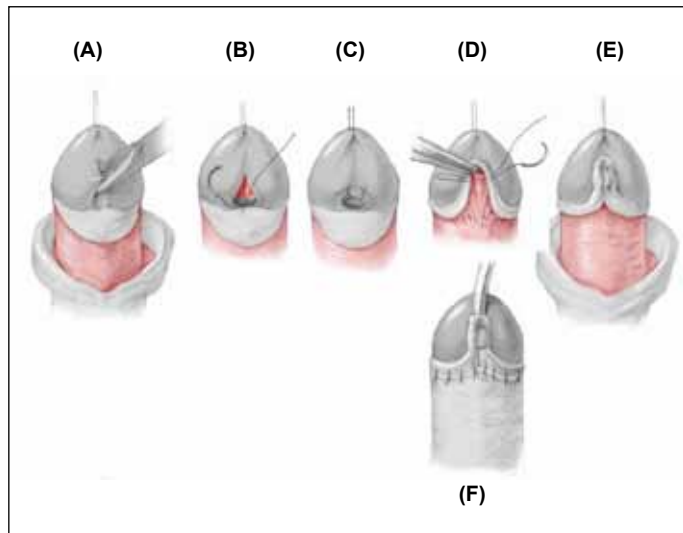
Source: Hadidi AT, Azmy AF, eds. Hypospadias Surgery: An Illustrated Guide, 1st ed. Springer Verlag, 2004. Reproduced with kind permission of Springer Verlag.

Figure 94.12: Tissues used for hypospadias repair.



Source: Hadidi AT, Azmy AF, eds. *Hypospadias Surgery: An Illustrated Guide*, 1st ed. Springer Verlag, 2004. Reproduced with kind permission of Springer Verlag.

Figure 94.13: Authors' personal choice of operations.

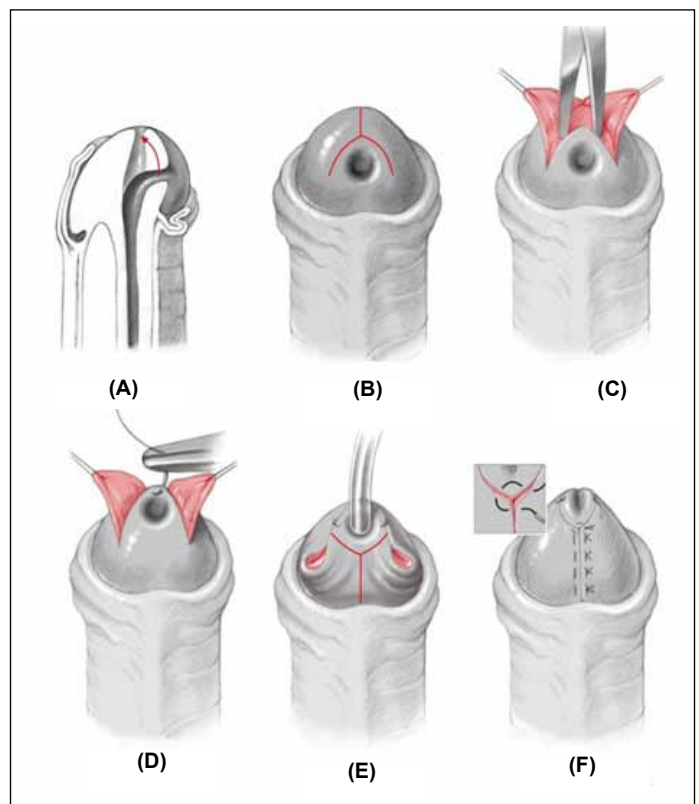


Source: Hadidi AT, Azmy AF, eds. *Hypospadias Surgery: An Illustrated Guide*, 1st ed. Springer Verlag, 2004. Reproduced with kind permission of Springer Verlag.

Figure 94.14: Meatal advancement and glanuloplasty incorporated (MAGPI).

The operative steps illustrated in Figure 94.14 are as follows:

1. A circular incision is made in the prepuce at the level of the coronal sulcus.
2. A longitudinal incision is made at the inner aspect of the meatus as far as the tip of the glans (Figure 94.14(A)).
3. This longitudinal incision is sutured transversely with single stitches (Figure 94.14(B),(C)).
4. The anterior aspect of the newly created meatus is secured with a stay suture and pulled up to the tip of the glans (Figure 94.14(D)).
5. Incisions are made in both glanular wings in an inverted V-shape (Figure 94.14(D)).
6. The glanular wings are sutured in the anteroposterior direction to enclose the urethra within the glans (Figure 94.14(E)).
7. The outer layer of the prepuce is sutured to the coronal sulcus (Figure 94.14(F)).
8. Preputial reconstruction, although possible, is not recommended at this stage.



Source: Hadidi AT, Azmy AF, eds. *Hypospadias Surgery*, 2nd ed. Springer-Verlag, in press. Reproduced with kind permission of Springer Verlag.

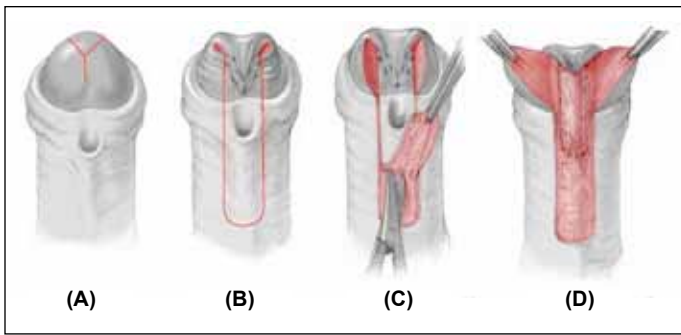
Figure 94.15: Steps of double-Y glanuloplasty: (A) glanular hypospadias with mobile meatus; (B) inverted-Y incision; (C) three flaps elevated; (D) apex of meatus sutured to the tip of the glans; (E) Size Fr 10 catheter introduced inside the urethra and Y incision made that surrounds the meatus and extends down to the coronal sulcus; (F) glanular wings mobilised deep enough to wrap around the urethra and approximated in the midline. The 6 o'clock stitch (see inset) is a 3-point stitch that brings the urethra and the two medial edges of the glanular wings together. It is magnified in the inset.

Double-Y Glanuloplasty Technique

The double-Y glanuloplasty (DYG) technique (Figure 94.15) is suitable for selected patients with glanular hypospadias with mobile meatus in the absence of deep chordee. Those patients usually have a little ridge distal to meatus. This ridge can be pushed with a mosquito or toothed forceps to the tip of the glans.

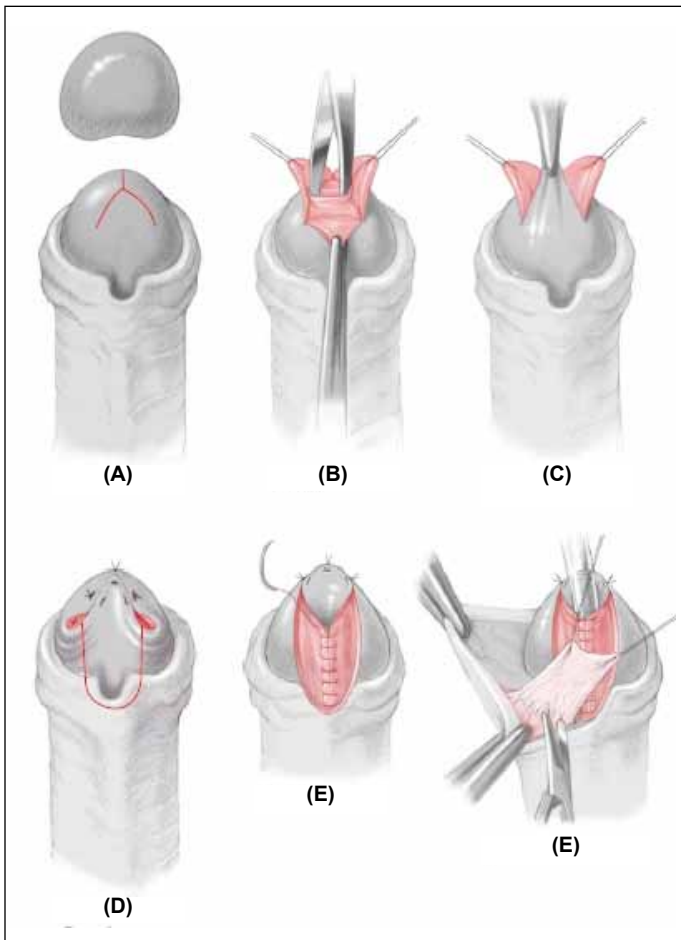
If the distal edge of the urethral meatus is immobile and cannot be pushed to the tip of the glans, the child is not suitable for the DYG technique, and another technique suitable for distal hypospadias is performed (inverted-Y Mathieu technique in patients with flat glans or inverted-Y Thiersch in patients with cleft glans; see following two subsections, respectively).

1. A 5/0 nylon traction suture is placed on the glans, dorsal to the tip of the glans. A tourniquet is placed at the root of the penis and chordee is excluded by using the artificial erection test.
2. An inverted-Y incision is outlined on the glans. The centre of the inverted Y is just above the ridge distal to the meatus. The longitudinal limb extends to the tip of the glans where the tip of the neomeatus will be located. Each oblique limb of the inverted-Y is 0.5 cm long, and the angle between them is 60° (Figure 94.15(A,B)).
3. The incision is deepened and the flaps are mobilised to allow more mobility of the meatus (Figure 94.15(C)).
4. A 6/0 vicryl stitch is approximated and fixes the meatus at the tip of the glans (Figure 94.15(D)).
5. If the meatus is narrow or pinpoint, it is incised to make it wide



Source: Hadidi AT, Azmy AF, eds. *Hypospadias Surgery: An Illustrated Guide*, 1st ed. Springer Verlag, 2004. Reproduced with kind permission of Springer Verlag.

Figure 94.16: Y-V modified Mathieu technique.



Source: Hadidi AT, Azmy AF, eds. *Hypospadias Surgery*, 2nd ed. Springer-Verlag, in press. Reproduced with kind permission of Springer Verlag.

Figure 94.17: Steps of inverted-Y Thiersch technique.

enough to accommodate a catheter size Fr 10 or larger according to the age of the patient and size of the penis. A transurethral Nelaton catheter size Fr 10 or larger is inserted into the bladder.

6. A Y-shaped incision is made proximal to the meatus (Figure 94.15(E)). The longitudinal limb of the Y incision extends from the meatus to the coronal sulcus. Extra care should be taken to avoid injury to the very thin urethra beneath the skin. The use of sharp scissors and traction helps to avoid injury of the distal urethra.
7. Traction is applied on the glanular wings, and the incision is deepened by using sharp scissors starting proximally at the coronal sulcus.
8. The glanular wings are mobilised off the urethra and are opened

like an open book. This is a very important step that helps to wrap the glanular wings around the urethra without any tension.

9. The incision is continued around the meatus to meet the lateral limbs of the inverted-Y incision (Figure 94.15(F)).
10. Local ointment is applied to the wound, a normal gauze is applied, and adhesive tape fixes the gauze, the catheter, and the penis against the lower abdominal wall. This allows free mobility of the patient and secures the catheter and penis against the lower abdominal wall.

The transurethral catheter is left for 1–2 days, depending on the degree of mobilisation and the degree of postoperative oedema of the penis. A caudal block is routinely used to reduce postoperative pain.

Inverted-Y Modified Mathieu Repair

The Mathieu technique is used for distal hypospadias. It is one of the oldest procedures, having withstood the test of time. It has a drawback, however—it results in a circular meatus that is not at the tip of the glans. The inverted-Y-V modification avoids the drawback of the original Mathieu repair and results in a slit-like meatus at the tip of the glans (Figure 94.16).

1. A Y-shaped incision is outlined on the glans (Figure 94.16(A)).
2. A catheter size 10 Fr or larger is inserted into the bladder.
3. The flap is outlined so that the distance between the meatus and the proximal end of the flap is slightly greater than the distance from the meatus to the tip of glans.
4. A U-shaped incision is made, extending from the tip of the V in the glans down to the lower end of the designed flap; this results in two glanular wings (Figure 94.16(B)).
5. The Mathieu flap is mobilised, preserving its fascial blood supply (Figure 94.16(C)).
6. Urethroplasty is performed by using continuous subcuticular polyglactin 6-0 sutures.
7. A protective intermediate layer is fashioned by using the flap fascia or dartos fascia (Figure 94.16(D)).
8. Both granular wings are sutured together around a neourethra by using interrupted mattress sutures.

Inverted-Y Modified Thiersch Technique

The inverted-Y tubularised plate technique⁴⁵ is a modification of the Thiersch technique. It is suitable in hypospadias patients without deep chordee. Thus, incision of the urethral plate is not needed to correct deep chordee. The original Thiersch technique is ideal in patients with cleft glans. However, it is necessary to modify the technique when the glans is flat or incompletely clefted in order to wrap the glanular wings around the new urethra (Figure 94.17).

1. A traction suture of 4/0 nylon is placed through the tip of the glans.
2. An inverted-Y-shaped incision is outlined on the glans. The tip of the longitudinal limb of the inverted-Y is at the tip of the glans, where the tip of the neomeatus will be located. The lower two limbs of the inverted Y are about 0.8 cm long, and the angle between them is 90°. The long vertical limb of the inverted-Y is 0.8 cm long (Figure 94.17(A)).
3. The inverted-Y-shaped incision is deepened to be able to wrap the glanular wings around the new urethra. This results in a median inverted-V flap and two lateral wings. The two lateral wings are elevated and the median flap is mobilised (Figure 94.17(B,C)).
4. A catheter, size 10 Fr or larger, is inserted into the bladder.
5. Using two fine surgical forceps, the adequate diameter of the new urethra is marked around the catheter.
6. A U-shaped skin incision is made by using sharp scissors or scalpel size 15. A transverse incision proximal to the meatus is cut by using sharp scissors (Figure 94.17(D)).

7. If the distal urethra is thin, it is incised until a healthy vascularised urethra is reached.
8. In the glans, the incision is deepened enough to create mobile lateral glanular wings to wrap around the new urethra.
9. Two or three sutures are tied along the length of the new urethra to reduce tension and help orientation.
10. The new urethra is constructed by using 6/0 vicryl on a cutting needle in a continuous subcuticular manner (Figure 94.17(E)).
11. A protective intermediate layer is fashioned from the preputial fascia under the foreskin (Figure 94.17(F)). (In proximal hypospadias without deep chordee, the authors prefer scrotal dartos/tunica vaginalis fascia.)
12. Closure of the glans follows, starting at the tip of the glans to ensure wide meatus.

Lateral-Based Flap Technique

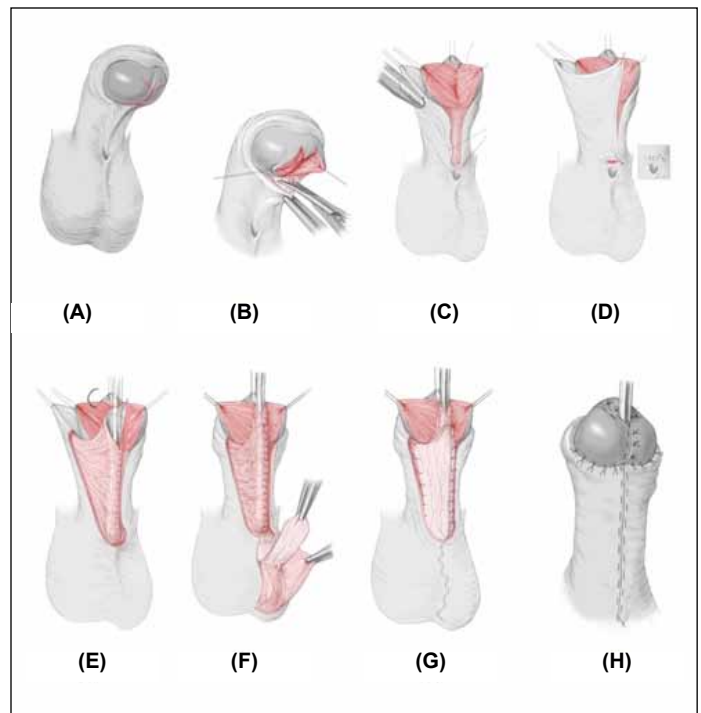
The lateral-based flap technique⁴⁶ may be used in proximal hypospadias with deep chordee that necessitates incision of the urethral plate to straighten the penis. It has a double blood supply and allows extensive excision of ventral chordee. It may offer patients with proximal hypospadias a single-stage urethral reconstruction with a good success rate (91%) and relatively few complications. The operative steps for the lateral-based flap technique listed below are illustrated in Figure 94.18.

1. A deep Y-shaped incision is made on the glans that goes all the way down to the coronal sulcus (Figure 94.18(A)). This permits two deep glanular wings and a wide meatus.
2. The urethral plate is incised at the coronal sulcus and all the tissues that tether the corpora cavernosa and cause the penile curvature are removed (Figure 94.18(B)).
3. The edge of the lateral skin is then sutured at two points. Proximally, it is sutured to the hypospadias meatus (Figure 94.18(C)); distally, it approximates the lateral wall to the tip of the glans (Figure 94.18(D)), thus forming a “new urethral plate”.
4. A 10 Fr catheter (or larger, depending on the size of the penis and the age of the patient) is introduced through the meatus.
5. A rectangular skin strip is outlined, extending proximally from the urethral meatus to the tip of the glans.
6. Several interrupted stitches assist in orientation, and the urethroplasty is carried out from proximal to distal in a subcuticular continuous manner.
7. The adjacent penile skin is elevated (rather than mobilising the flap) to preserve the vascular areolar tissue (Figure 94.18(E)).
8. The neourethra is covered with a protective intermediate layer (dartos or tunica) (Figure 94.18(F)).
9. The neomeatus is constructed by suturing the terminal end of the neourethra to the centre of the glans (Figure 94.18(G)).
10. The glanular wings are sutured around the neourethra by using interrupted mattress sutures (Figure 94.18(H)).
11. A percutaneous suprapubic cystocath is inserted into the bladder for 10–14 days.
12. A compression dressing is applied for 6–24 hours for haemostasis.

TIP Urethroplasty

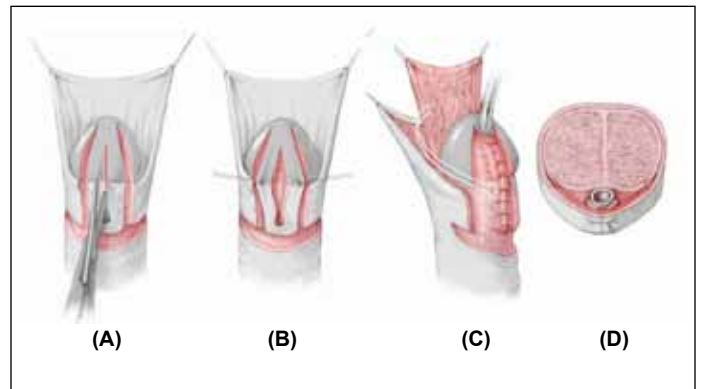
The tubularised incised plate (TIP) is explained in detail by Snodgrass.⁴⁷ Incision of the urethral plate was first described by Reddy in 1975,⁴⁸ then by Orkiszewski⁴⁹ and Rich⁵⁰ in the 1980s, and popularised by Snodgrass in 1994.⁵¹ The operative steps of TIP listed here are illustrated in Figure 94.19.

1. A circumscribing skin incision is made 1–2 mm proximal to the meatus.
2. The urethral plate is separated from the glans wings and distal penile skin by two parallel incisions running from the paramedial skin to the



Source: Hadidi AT, Azmy AF, eds. *Hypospadias Surgery: An Illustrated Guide*, 1st ed. Springer Verlag, 2004. Reproduced with kind permission of Springer Verlag.

Figure 94.18: The lateral-based flap (LB flap) technique for proximal hypospadias: (A) Y-shaped deep incision of the glans; (B) three flaps are elevated and orthoplasty; (C) new urethral plate; (D) design of the LB flap; (E) urethroplasty; (F) mobilisation of dartos/tunica vaginalis fascia; (G) protective intermediate layer; (H) skin closure.



Source: Hadidi AT, Azmy AF, eds. *Hypospadias Surgery: An Illustrated Guide*, 1st ed. Springer Verlag, 2004. Reproduced with kind permission of Springer Verlag.

Figure 94.19: Tubularised incised plate (TIP).

- tip of the glans (Figure 94.19(A)).
3. The penis skin is degloved to the penoscrotal junction.
4. The glans wings are mobilised, avoiding damage to the margins of the urethral plate.
5. A relaxing incision is made by using scissors in the midline from within the meatus to the end of the plate. The depth of this relaxing incision depends on the plate width and depth (Figure 94.19(B)).
6. Using a fine suture, preferably 7-0 polyglactin, the incised urethral plate is tubularised on the inserted catheter, placing the first stitch at approximately the midglans (Figure 94.19(C)).
7. The tubularisation is completed with a two-layer running subepithelial closure.

8. A dartos pedicle is developed from the dorsal shaft skin, button-holed, and transposed to the ventrum as skin cover for the new urethra (Figure 94.19(C)).

9. The skin edges of the tubularised glans are sutured together with the meatus (Figure 94.19(D)).

This method has become popular because of its simplicity. However, the long-term complication rate of the TIP procedure may be up to 35% in distal hypospadias and 66% in proximal hypospadias.^{49,52}

Tubularised Preputial Island Flap

Figure 94.20 illustrates the operative steps of the tubularised preputial island flap procedure (Duckett operation), as outlined below.⁵³

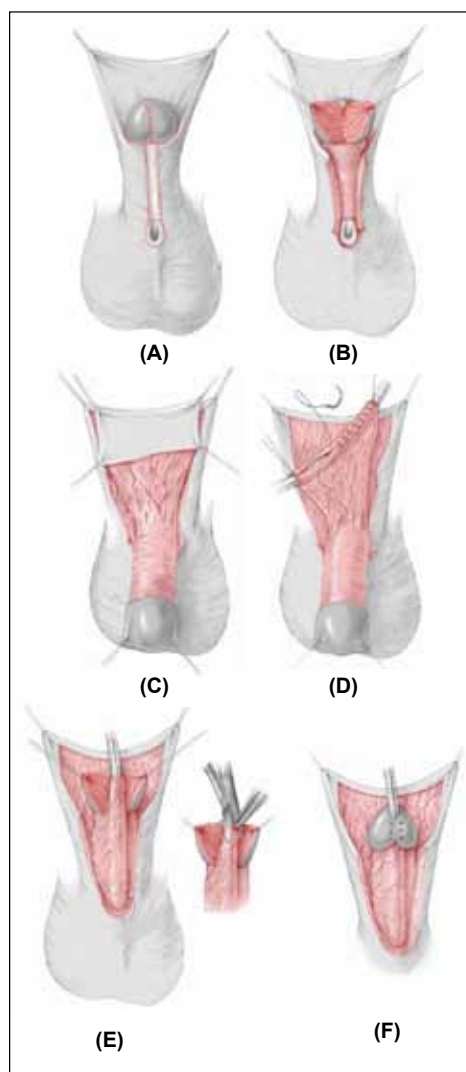
1. A neourethra is created by utilising the inner preputial layer. It is anastomosed proximally with the native urethra and distally with the glans.
2. A circular incision is made just proximal to the meatus and running through the inner preputial layer 0.3 cm behind the coronal sulcus (Figure 94.20(A)).
3. The urethral plate and chordee are excised completely, creating a ventral urethral defect (Figure 94.20(B)).
4. The length of the urethral defect is estimated while the penis is erect.
5. The prepuce is fixed with four holding sutures so that its inner layer is stretched out.
6. A flap is raised from the inner layer of the prepuce with dimensions that match those of the urethral defect. Particular care is taken not to injure its blood supply (Figure 94.20(C)).
7. The dissection of the vascular pedicle is conducted in such a way that rotation of the neourethra is possible in the anteroposterior direction without tension.
8. The neourethra is created by rolling up the inner preputial layer on a catheter as a tube and closing it with a running suture (Figure 94.20(D)).
9. The glans is then incised midline deeply to raise two large glanular wings to wrap around the new urethra (Figure 94.20(E)). A small V-flap is excised from the tip of the new urethra to help in fashioning a slit-like meatus (inset).
10. An oblique anastomosis is made between the neourethra and the native urethra in such a way that the suture line on the neourethra lies on the penile shaft.
11. The neourethra is pulled through the channel previously developed up to the glans tip and fixed to the glans.
12. The skin of the penis is closed on the shaft with a running suture (Figure 94.20(F)).
13. The defect created in the preputial skin is then closed with running sutures.

The recommendation is to avoid reconstruction and removal of the prepuce until a successful result is obtained.

Onlay Island Flap Procedure

Instead of creating a complete neourethra from the inner preputial layer, it is possible to complete the urethral plate with the layer itself. This is the onlay island flap procedure,⁵⁴ illustrated in Figure 94.21 and outlined here.

1. A semicircular skin incision is made along the urethral plate around the meatus.
2. A pedunculated flap is dissected from the inner preputial layer in the same way as for the Duckett's operation (see previous section).
3. The glans is split in line with the urethral plate.
4. The flap is transposed on the ventral aspect of the penile shaft, and both flap borders are sutured with the free borders of the urethral plate.
5. The skin and the glanular wings are then closed.



Source: Hadidi AT, Azmy AF, eds. *Hypospadias Surgery: An Illustrated Guide*, 1st ed. Springer Verlag, 2004. Reproduced with kind permission of Springer Verlag.

Figure 94.20: Duckett tubularised preputial island flap.

Urethral Reconstruction Using Buccal Mucosa

In redo operations, it is possible to resort to buccal mucosa to form a wide urethral plate as a first stage and to reconstruct a neourethra in the second stage. Bladder mucosa and one-stage repair using buccal mucosa are becoming less popular in complicated proximal hypospadias due to the high incidence of complications.

Complications

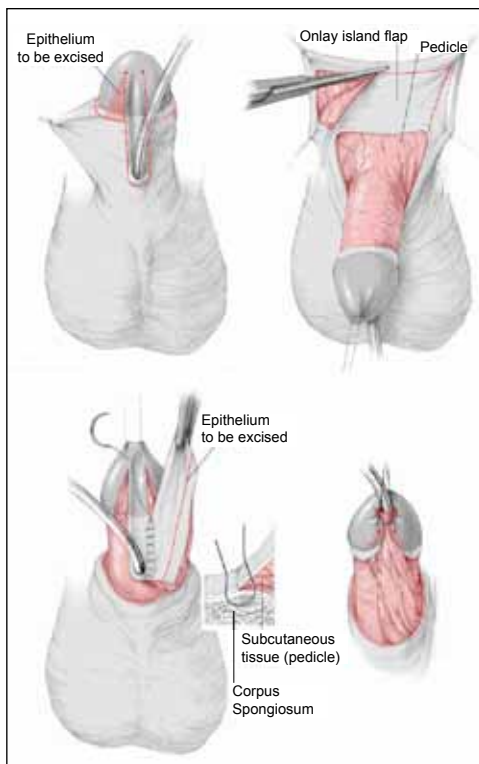
Hypospadias complications are not uncommon. The incidence depends on the experience of the surgeon and the technique employed. Common complications include meatal and urethral stenosis, fistula, diverticulum, and recurrent chordee.

Meatal and Urethral Stenosis

The incidence of meatal and urethral stenosis has increased in recent years due to employment of techniques that may result in narrow new urethra (e.g., the TIP technique).⁵¹ Dilatation may work occasionally. However, if dilatation is needed frequently, a new wide urethra has to be reconstructed to avoid back pressure on the bladder and damage to the kidneys.

Fistula

Fistula used to be the most frequent complication after hypospadias surgery.⁵⁵ Several factors may be responsible for fistula, including distal stenosis, the technique applied, skin damage, tension on the sutures, infection, and overlapping of suture lines.



Source: Hadidi AT, Azmy AF, eds. *Hypospadias Surgery: An Illustrated Guide*, 1st ed. Springer Verlag, 2004. Reproduced with kind permission of Springer Verlag.

Figure 94.21: Onlay island flap procedure.

The four important steps for the correction of urethral fistula are:

1. exclusion and correction of distal stenosis;
2. wide excision of the fistula tract;
3. use of healthy, well-vascularised tissue; and
4. protection of fistula repair with a healthy vascular second protective layer.

Diverticulum

Diverticulum may occur after surgery for distal hypospadias and is probably due to a narrow new urethra. Diverticulum may also occur after proximal hypospadias, however, and is believed to be due to a lack of the supportive corpus spongiosum in patients with proximal hypospadias. This is supported by the finding that diverticulum is often encountered without distal obstruction in proximal hypospadias and may even recur after excision of the redundant urethra.⁵⁶

Persistent or Recurrent Chordee

Persistent or recurrent chordee may occur due to inadequate orthoplasty during hypospadias correction or due to healing by scarring and fibrous tissue formation. In cases of scarring, the urethra is usually healthy, and excision of the fibrous tissue superficial to the urethra is sufficient to correct chordee. Correction of persistent chordee due to inadequate orthoplasty in the first operation is difficult and technically demanding. Some surgeons may opt for repeated tunica albuginea plication. Others, including the authors, would prefer to incise the urethra and correct the curvature from the ventral aspect to avoid shortening the penis.

Key Summary Points

1. Hypospadias is a wide spectrum of anomalies involving all the ventral structures of the penis and not just the urethra.
2. The ideal time to correct hypospadias is before 18 months of age. In fact, many surgeons correct hypospadias starting at age 3 months.
3. Surgeons need to master several techniques to suit the wide range of anomalies encountered.
4. The surgeon should use the technique that is suitable for the patient and not make the patient suitable for the technique he or she prefers.
5. Neourethra should be reconstructed around catheters of size 10 Fr or larger, depending on the age of the patient.
6. Tubularisation of the urethral plate without incision is suitable for more than 60% of hypospadias patients.
7. A second protective layer to cover and protect the new urethra is an essential part of hypospadias surgery.
8. With experience, the success rate in glanular and distal hypospadias has reached more than 95%. In proximal hypospadias, the complication rate is 10–20%.

References

1. Paulozzi L, Erickson D, et al. Hypospadias trends in two US surveillance systems. *Pediatr* 1997; 100:831–834.
2. Duckett JW, Baskin LA. In: Gillenwater J, et al., eds. *Adult and Pediatric Urology*, 3rd ed. Mosby Year Book, 1996.
3. Sadler T. *Langman's Medical Embryology*, 10th ed. Lippincott Williams & Wilkins, 2006, P 248.
4. van der Werff JFA, Nievelstein RAJ, Brands E, et al: Normal development of the male anterior urethra. *Teratology* 2000; 61:172–183.
5. Moore KL, Persaud TVN. *The developing human*, 5th ed. Saunders, 1993.
6. Wood-Jones F: The nature of the malformations of the rectum and urogenital passages. *BMJ* 1904; 2:1630–1634.
7. Glenister TW: The origin and fate of the urethral plate in man. *J Anat* 1954; 88:413–425.
8. Van Bagaert LJ. Surgical repair of hypospadias in women with symptoms of urethral syndrome. *J Urol* 1992; 147(5):1263–1264.
9. Gunn TR, Mora JD, Pease P. Antenatal diagnosis of urinary tract abnormalities by ultrasonography after 28 weeks gestation: incidence and outcome. *Am J Obst Gynecol* 1995; 172:479.
10. Hollowell JG Jr, et al. Embryonic considerations of diphallus and associated anomalies. *J Urol* 1977; 117:728.
11. Hinman FJ. *Penis and male urethra*. In: Hinman FJ, ed. *Urological Anatomy*. WB Saunders, 1993.
12. Van der Putte SCJ, Neeteson FA. The normal development of the anorectum in the pig. *Acta Morphol Neerl Scand* 1983; 21:107–132.

13. Van der Putte SCJ. The development of the perineum in the human. *Adv Anat Embryol Cell Biol* 2005; 177:1e135.
14. van der Putte SCJ. Normal and abnormal development of the anorectum. *J Pediatr Surg* 1986; 21:434–440.
15. Kluth D, Lambrecht W, Reich P: Pathogenesis of hypospadias—more questions than answers. *J Pediatr Surg* 1988; 23:1095–1101.
16. Snodgrass WT, Shukla AR, Canning DA. Hypospadias. In: Docimo SG, ed. *Clinical Pediatric Urology*. Informa Health Care, 2007, P 1206.
17. Baskin LS. Hypospadias and urethral development. *J Urol* 2000; 163:951.
18. Hadidi AT. Morphology of hypospadias. In: Hadidi AT, Azmy AF. *Hypospadias Surgery: An Illustrated Guide*, 2nd ed. Springer Verlag, in press.
19. Hadidi AT. Classification of hypospadias. In: Hadidi AT, Azmy AF. *Hypospadias Surgery: An Illustrated Guide*, 1st ed. Springer Verlag, 2004, P 80.
20. Keating JM, Hamilton H. *A New Pronouncing Dictionary of Medicine*. Young J Pentland, 1892.
21. Smith CK. Surgical procedures for correction of hypospadias. *J Urol* 1938; 40:239.
22. Mosby's Medical Dictionary, 8th ed. Elsevier, 2009.
23. Paul M, Kanagasuntheram R. The congenital anomalies of the lower urinary tract. *Br J Urol* 1956; 28:118–125.
24. Avellán L. Morphology of hypospadias. *Scand J Plast Surg* 1980; 14:239–247.
25. Kaufmann, C. Verletzungen und Krankheiten der männlichen Harnröhre und des Penis. In: Billothe T, Luecke A. *Deutsche Chirurgie*. Lieferung 50a, 1886, Chap 5, Pp 18–39.
26. Duckett JW: Hypospadias. In: Gillenwater JY, Grayhack JT, Howards SS, Duckett JW, eds. *Adult and Pediatric Urology*, 3rd ed. Mosby Year Book, 1996, P 2550.
27. Schonfeld WA, Beebe CW. Normal growth and variation in the male genitalia from birth to maturity. *J Urol* 1942; 48:759.
28. Schulz JR, Klykylo WM, Wacksman J: Timing of elective hypospadias repair in children. *Pediatr* 1983; 71:342–351.
29. Hadidi AT. Editorial overview. In: Hadidi AT, Azmy AF *Hypospadias Surgery: An Illustrated Guide*, 2nd ed. Springer Verlag, in press.
30. Hadidi AT. Principles of hypospadias surgery. In: Hadidi AT, Azmy AF *Hypospadias Surgery: An Illustrated Guide*, 1st ed. Springer Verlag, 2004, P 100.
31. Wacksman J. Results of early hypospadias surgery using optical magnification. *J Urol* 1984; 131:516.
32. Hadidi AT. Principles of hypospadias surgery. In: Hadidi AT, Azmy AF. *Hypospadias Surgery: An Illustrated Guide*, 2nd ed. Springer Verlag, in press.
33. El-Mahrouky A, McElhaney J, Bartone FF, et al. In vitro comparison of the properties of polydioxanone, polyglycolic acid and catgut sutures in sterile and infected urine. *J Urol* 1987; 138:913–915.
34. Hadidi AT. Principles of hypospadias surgery. In: Hadidi AT, Azmy AF. *Hypospadias Surgery: An Illustrated Guide*, 1st ed. Springer Verlag, 2004, P 101.
35. Hadidi A, Abdaal N, Kaddah S. Hypospadias repair: is dressing important. *Kasr El Aini J Surg* 2003; 4(1):37–44.
36. Ben Meir D, Livne PM. Is prophylactic antimicrobial treatment necessary after hypospadias repair? *J Urol* 2004; 171:2621–2622.
37. Gittes R, McLaughlin AI. Injection technique to induce penile erection. *Urol* 1974; 4:473.
38. Leslie JA, Cain MP, Kaefer M, et al. Corporeal grafting for severe hypospadias: a single institution experience with 3 techniques. *J Urol* 2008; 160,1749–1752.
39. Caesar RE, Caldamone AA. The use of free grafts for correcting penile chordee. *J Urol* 2000; 164:1691.
40. Baskin LS, Ebbers MB. Hypospadias: anatomy, etiology, and technique. *J Pediatr Surg* 2006; 41:463.
41. Braga LHP, Lorenzo AJ, Bägli DJ. Ventral penile lengthening versus dorsal placcation for severe ventral curvature in children with proximal hypospadias. *J Urol* 2008; 180:1743–1748.
42. Hadidi AT. Men behind principles and principles behind techniques. In: Hadidi AT, Azmy AF. *Hypospadias Surgery: An Illustrated Guide*, 1st ed. Springer Verlag, 2004, P 23.
43. Duckett JW: MAGPI (meatal advancement and glanuloplasty): a procedure for subcoronal hypospadias. *Urol Clin North Am* 1981; 8:513.
44. Hadidi AT. V modified Mathieu technique. In: Hadidi AT, Azmy AF. *Hypospadias Surgery: An Illustrated Guide*, 1st ed. Springer Verlag, 2004, P 149.
45. Hadidi AT. Inverted Y tubularised plate technique. In: Hadidi AT, Azmy AF. *Hypospadias Surgery: An Illustrated Guide*, 2nd ed. Springer Verlag, in press.
46. Hadidi AT. Lateral based flap with dual blood supply: a single stage repair for proximal hypospadias. In: Hadidi AT, Azmy AF. *Hypospadias Surgery: An Illustrated Guide*, 1st ed. Springer Verlag, 2004, P 209.
47. Snodgrass W. Tubularised incised plate urethroplasty. In: Hadidi AT, Azmy AF. *Hypospadias Surgery: An Illustrated Guide*, 1st ed. Springer Verlag, 2004, P 155.
48. Reddy LN. One-stage repair of hypospadias. *Urol* 1975; 5:475.
49. Orkiszewski M, Ileszniewski J. Morphology and urodynamics after longitudinal urethral plate incision in proximal hypospadias repairs. Long-term results. *Eur J Pediatr Surg* 2004; 14(1):35–38.
50. Rich MA, Keating MA, Snyder HM, Duckett JW. Hinging the urethral plate in hypospadias meatoplasty. *J Urol* 1989; 142:1551.
51. Snodgrass W. Tubularised incised plate urethroplasty for distal hypospadias. *J Urol* 1994; 151:464–465.
52. Chrzan R, Dik P, Klijn A, et al. Quality assessment of hypospadias repair with emphasis on techniques used and experience of pediatric urologic surgeons. *Urol* 2007; 70:148–152.
53. Duckett JW. The island-flap technique for hypospadias repair. *Urol Clin North Am* 1981; 8:503.
54. Elder JS, Duckett JW, Snyder HM. Onlay island flap in the repair of mid-and distal penile hypospadias without chordee. *J Urol* 1987; 138:376.
55. Hadidi AT. Fistula. In Hadidi AT, Azmy AF. *Hypospadias Surgery: An Illustrated Guide*, 1st ed. Springer Verlag, 2004, P 277.
56. Snodgrass WT. Hypospadias. In: Docimo SG, ed. *Clinical Pediatric Urology*. Informa Health Care, 2007, P 1234.