

CHAPTER 98

UNDESCENDED TESTIS

John Lazarus
John R. Gosche

Introduction

Undescended testis (UDT; also known as cryptorchism) can be defined as a failure of the testis to descend normally from the abdominal cavity into the scrotum. UDT is the most common genital problem seen in children. Despite this fact, many conclusions about UDT, its aetiology, and ideal management, remain controversial.

Consequences of UDT

UDT is associated with a variety of potential consequences: neoplasia, testicular carcinoma, infertility, torsion of testis, and inguinal hernia. Treatment of UDT is aimed at minimising these risks.

Neoplasia

UDT is associated with an increased risk of germ cell tumour of the testis. It has been suggested that males with UDT have a 40 times increase in the rate of neoplasia above the general population.¹ Although this number is debatable, these data need to be interpreted with caution because testicular malignancy is very rare in Africa.² The role of orchiopexy in reducing malignancy is controversial, but it makes self-examination easier.

Infertility

Unsurprisingly, reduced fertility and attendant poor-quality semen analysis is seen in men with UDT.¹ Subfertility is observed in 40% of patients with unilateral and 70% of patients with bilateral cryptorchism. There appears to be an advantage to early orchiopexy to improve the fertility potential.³ This guides the timing of surgery, with an ideal window being between 6 and 24 months of age.

Inguinal Hernia and Testicular Torsion

A patent processus vaginalis is found in 90% of UDT.¹ The hernia is routinely repaired at the time of orchiopexy. Torsion of the testis is rarely associated; if it occurs, a tumour is often present.

Demographics

UDT occurs in approximately 30% of premature and 3–5% of full-term males.¹ In 80% of cases, the UDT migrates into the correct position without intervention during the first year, most in the first 3 months. This leaves the incidence from 1 year of age to adulthood at 1%. The condition occurs bilaterally in about 10% of cases. The right side is twice as commonly affected.

The causes of UDT are multifactorial, but risk factors include low birth weight (the most important factor), twins, prematurity, small for gestational age, and maternal exposure to estrogen during the first trimester.¹ Hereditary factors appear to play a role, with fathers and brothers being more commonly affected than the general population. No definite racial differences in incidence are reported.

UDT can be associated with other congenital anomalies, including epididymal cyst (90%), hypospadias, and genital ambiguity. The presence of hypospadias and an undescended testis warrant work-up for intersex.⁴

Aetiology/Pathophysiology

Testicular differentiation occurs during the 7th week of gestation. The testis-determining factor is the *SRY* gene (sex-determining region on

the Y chromosome). Hormones that control male sexual differentiation include testicular androgen from Leydig cells and Müllerian-inhibiting substance (MIS) from the Sertoli cells.

Androgens (testosterone and dihydroxytestosterone) mediate the differentiation of paired wolffian ducts into seminal vesicles, epididymis, vas deferens, and ejaculatory ducts. MIS causes degeneration of the Müllerian structures. The testis lies dormant in the abdomen until the 28th week of gestation; thereafter, it descends into the scrotum.

The multifactorial mechanism of testicular descent involves:

- hormonal factors: the hypothalamus-pituitary-gonadal axis;
- the gubernaculum and genitofemoral nerve;
- increased abdominal pressure; and
- development/maturation of the epididymis.

Heyns et al. of South Africa have helped elucidate the role of the gubernaculum in testicular descent.⁵

There is presently no unified theory of testicular maldescent. Anomalies of the above-mentioned normal mechanism have all been implicated in the development of cryptorchism.

Clinical Presentation

UDTs can be classified into testes that are truly undescended, retractile, ectopic, absent, or ascended.¹ Eighty percent of UDTs are palpable (undescended, retractile, ectopic), and 20% are impalpable (intraabdominal or absent). Those impalpable UDTs that are truly absent at surgical exploration represent an in utero vascular event.

It is critical to identify the retractile testis, which result from an overactive cremasteric reflex and can be manipulated without tension into the scrotum. Retractable testes are regarded as a variant of normal; however, recent suggestions are that ascent may occur, and annual follow-up is now recommended.¹ The acquired ascending testis and the congenital UDT have been shown to share the same histopathology as germ cells.⁶

An ectopic testis follows an abnormal path of descent below the external ring and in this way differs from a typical UDT.

UDT is usually diagnosed during the newborn examination. It is critically important to differentiate between retractile and truly UDT. Warm hands covered in soapy water help reduce skin friction and ease pick-up.

Investigations

Imaging studies looking for an impalpable UDT are of no value.

In the setting of a unilateral UDT with an associated hypospadias, intersex should be considered and a karyotype would be indicated.

Where bilateral impalpable UDTs are present, endocrine work-up is required. Elevated gonadotrophins, especially follicle-stimulating hormones (FSHs), likely represent bilateral anorchia. A human chorionic gonadotropin (HCG)-stimulation test has clinical use where gonadotrophins are normal. However, no matter what the results of the test, surgical exploration remains indicated.¹ Typically, this involves injection of HCG (100 IU/kg or 2940 IU/body surface area) with a post-

testosterone level taken 72 hours after injection.

Management

The ideal timing of intervention is at 6 months of age (Figure 98.1). Few UDTs will descend thereafter, with early management enhancing fertility potential.

Hormonal therapy is used in the management of UDT, yet it achieves success in only 20% of the cases. Surgery remains the gold standard. Typically, HCG (250 IU/dose in young infants, 500 IU/dose for children 6 years or younger, and 1000 IU/dose for individuals older than 6 years) is given intramuscularly twice a week for 5 weeks. The total dose should not exceed 15,000 IU.⁷

Orchiopexy for the palpable UDT is a well-established operation. The following pointers aid in surgical success:

1. After anesthesia is established, it is useful to re-examine the child to establish the site of the UDT. A previously nonpalpable testis may become palpable, thus avoiding abdominal exploration.
2. An incision is made in the groin crease. Careful dissection exposes the external oblique aponeurosis, the inguinal ligament, and the external ring.
3. The latter is opened in line with the fascia. Rolling the cord structures under a finger may help confirm the exact site of the canal. Care inside the canal is taken to identify and preserve the ilioinguinal nerve.
4. The cord is isolated by sweeping the cremasteric fibres off it. The gubernaculum is divided, and the patent processus is dissected off the

vas and vessels.

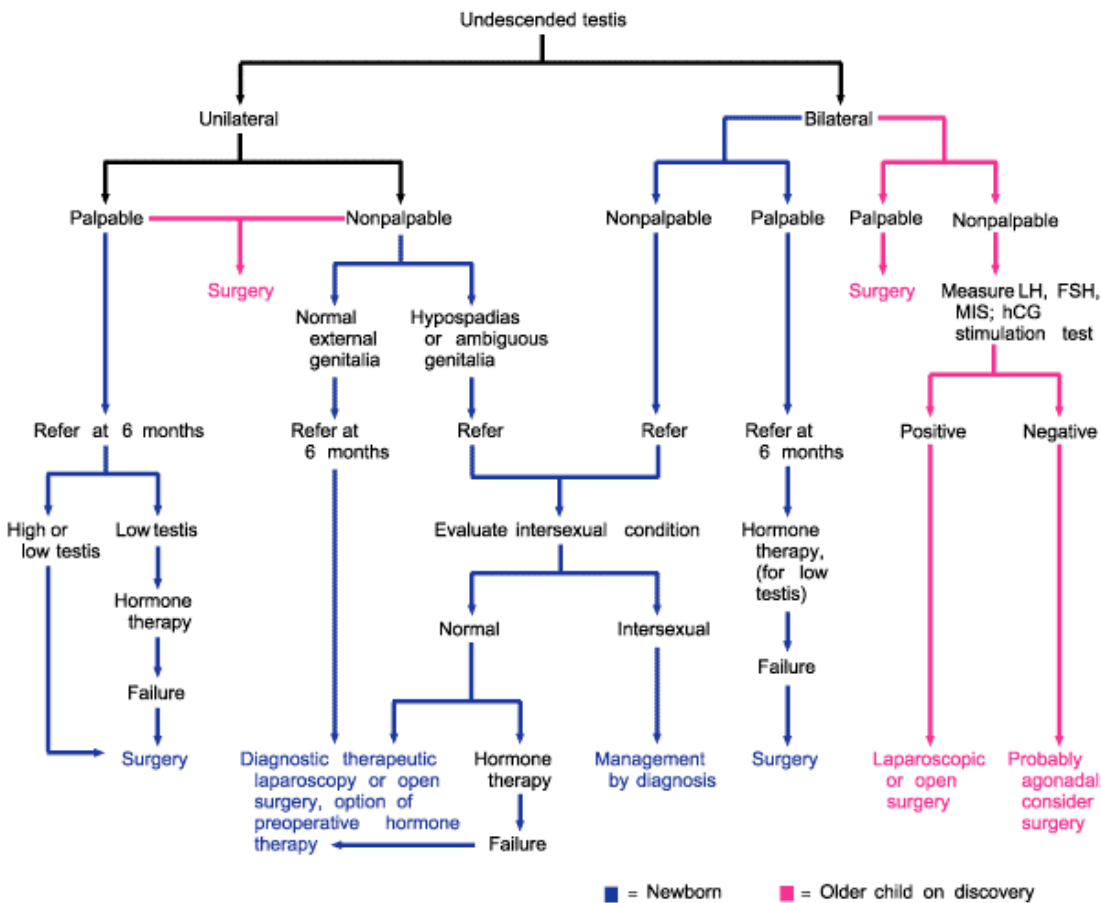
5. A high ligation of the hernia sac is performed, and the remaining structures are skeletonised.

6. Manoeuvres to gain sufficient length include dissection of retroperitoneal attachments of the cord, known as the Prentiss manoeuvre. Divide (or pass the testis under) the inferior epigastric vessels after opening the floor of the canal (transversalis fascia), allowing a more medial and thus direct route to the scrotum.

7. The testis is placed in a superficial dartos pouch. Fixation sutures should be avoided, as they have been demonstrated to cause testicular damage.¹

Impalpable UDTs are explored either via extending the above-mentioned inguinal incision, or an abdominal incision (vertical midline or Pfannenstiel incision), or—preferable if facilities allow—via diagnostic and potentially therapeutic laparoscopy. This exploration will reveal three possible findings:

1. An intraabdominal UDT is seen in roughly 40%.
2. Blind-ending vas and vessels occur in 40%. This implies a vanishing testis syndrome—a foetal vascular event. However, dissection of the retroperitoneum up to the kidney is suggested to confirm absence of a testis where no vessels are seen.
3. Vas and vessels entering the canal occur in 20%. Here inguinal exploration may be warranted to remove the testicular nubbin or remnant and fix the contralateral testis to prevent testicular torsion. This



Note: LH = luteinizing hormone; FSH = follicle-stimulating hormone; MIS = Müllerian inhibiting substance; hCG = human chorionic gonadotropin.

Source: Reprinted from Docimo SG, Silver RI, Cromie W. The undescended testicle: diagnosis and management. Am Fam Physician 2000; 62(9): 2037–2044.

Figure 98.1: Management of the infant with cryptorchism, including suggested times for referral to a paediatric urologist. Older children should be referred on discovery of an undescended testicle.

action is debated because the risk for malignant transformation is low.¹

Options for dealing with the intraabdominal UDT include:

1. A two-stage Fowler-Stephens orchiopexy via either open surgery or laparoscopy. Here the tethering testicular artery is divided at some distance from the testis. The rationale of using Fowler-Stephens orchiopexy is that the testicular arterial supply comes from three sources (testicular, artery to the vas, and cremasteric). At a 2nd stage (after 6 months of age, when collaterals have formed), the testis is brought down on a wide pedicle of peritoneum containing the remaining vessels.
2. The above surgery can also be performed as a one-stage operation where the artery is divided at the same sitting. Temporary occlusion of the testicular artery can give the surgeon confidence to proceed with division and mobilization. A recent multicentre review suggests a significantly higher atrophy rate than with the two-stage repair.⁸
3. Occasionally, the testis can be brought down in a single stage without division of the vessels.
4. Orchiectomy is usually reserved for postpubertal men with a contralateral normally positioned testis.

Postoperative Complications

Standard orchiopexy is associated with the following complications: haematoma, infection, unsatisfactory position (requiring revision), ilioinguinal nerve injury, damage to the vas, testicular atrophy, and torsion testis.

Prognosis and Outcomes

A meta-analysis found an 8% failure rate of orchiopexy, even in the distal UDT. A failure of more than 25% of orchiopexies for intraabdominal testes was seen.⁹

The rate of malignancy has been suggested to be as high as 22 times the incidence of the normal population, yet this represents only 1% of men with UDT. Ten percent of testicular tumours occur in men with a history of UDT.¹

Prevention

Early diagnosis and management of the UDT is needed to preserve fertility and improve detection of potential testicular cancer. In the African context, primary health care standards need to improve to meet these goals and prevent the all too common presentation of an UDT in adulthood.

Evidence-Based Research

Table 98.1 presents a study that compared laparoscopic orchiopexy to other approaches to correct UDT.

Table 98.1: Evidence-based research.

| | |
|---|---|
| Title | A multi-institutional analysis of laparoscopic orchidopexy |
| Authors | Baker LA, et al. |
| Institution | Multicentre |
| Reference | BJU Int 2001; 87(6):484–489 |
| Problem | Multi-institutional review of the outcomes of laparoscopic orchiopexy. |
| Intervention | Laparoscopy. |
| Comparison/control (quality of evidence) | A questionnaire was distributed to participating paediatric urologists. |
| Outcome/effect | Single-stage Fowler-Stephens laparoscopic orchiopexy resulted in a significantly higher atrophy rate than the two-stage repair. |
| Historical significance/comments | First multicentre review of its kind. The laparoscopic approach gave greater success than previously reported for the same open approaches. |

Key Summary Points

1. The retractile testis is important to differentiate on examination from the UDT because no surgery is required for a retractile testis. However, annual follow-up is advised.
2. Eighty percent of UDTs are palpable and 20% are impalpable.
3. Therapy for UDT is motivated by a chance to improve fertility, to ease examination for potential malignancy, and for cosmesis.
4. The ideal time for orchiopexy is at 6 months of age, with an aim to complete staged repairs by 2 years of age.
5. The most significant complication of orchiopexy is testicular atrophy.

References

1. Walsh PC, et al. Campbell-Walsh Urology, 9th ed. Elsevier Health Sciences, 2007.
2. Gajendran V, Nguyen M, Ellison L. Testicular cancer patterns in African-American men. Urology 2005; 66(3): 602–605.
3. McAleer IM, Packer MG, Kaplan GW, Scherz HC, Krous HF, Billman GF. Fertility index analysis in cryptorchidism. J Urol 1995; 153:1255–1258.
4. Rajfer J, Walsh PC. The incidence of intersexuality in patients with hypospadias and cryptorchidism. J Urol 1976; 116:769–770.
5. Heyns CF, Human HJ, Werely CJ, De Klerk DP. The glycosaminoglycans of the gubernaculum during testicular descent in the foetus. J Urol 1990; 143(3):612–617.
6. Rusnack SL, Wu HY, Huff DS, Snyder HM 3rd, Zderic SA, Carr MC, Canning DA. The ascending testis and the testis undescended since birth share the same histopathology. J Urol 2002; 168(6):2590–2591.
7. Docimo SG, Silver RI, Cromie W. The undescended testicle: diagnosis and management. Am Fam Physician 2000; 62(9):2037–2044.
8. Baker LA, Docimo SG, Surer I, Peters C, Cisek L, Diamond DA, Caldame A, Koyle M, Strand W, Moore R, Mevorach R, Brady J, Jordan G, Erhard M, Franco I. A multi-institutional analysis of laparoscopic orchidopexy. BJU Int 2001; 87(6):484–489.
9. Docimo SG. The results of surgical therapy for cryptorchidism: a literature review and analysis. J Urol 1995; 154:1148–1152.