

27 Urology

27.1 Equipment for urology

Disease of the urinary tract can be very distressing, so much so that some sufferer in the Middle Ages is said to have prayed, "O Lord, take me home but *not* through my bladder". Urological cases are often smelly and septic. Because it is usually considered sensible to start making rounds at the 'clean' end, you and your staff are likely to arrive tired at the urological patients, and can easily neglect them.

You should be able to treat acute, chronic, and 'acute on chronic' retention (27.6,19), and urethral strictures, whether they are passable (27.9) or not (27.10). You may be able to remove the prostate (27.20), and take stones from the bladder in adults (27.16) and children (27.17) and from the urethra (27.18) and ureter (27.15), but not so easily from the kidneys. You may alleviate carcinoma of the penis (27.33) and prostate (27.22), but not so readily of the bladder (27.5). You probably cannot do much about the congenital anomalies of the urinary tract, except to remember that the absence of a kidney is most important.

The most useful urological investigations are urinalysis, microscopy and culture, and a blood urea, followed, when necessary, by ultrasound, an intravenous urogram and cystoscopy.

The commonest urological procedure is to pass a catheter to let the urine flow out of the bladder. Catheters are graduated according to the Charrière gauge, which is their circumference in mm. If there are 2 numbers, for example, Ch18/22, the smaller one refers to the circumference of the tip, and the larger one to the circumference of the shaft. Think of catheters in three sizes: Ch8 or 10 for simple drainage, Ch14 or 16 Foley self-retaining catheters for the relief of retention, and large Ch20 or 24 catheters for postoperative drainage or evacuating blood clots. *Do not use the wrong sizes for the wrong indications!* There are many different types of catheter, but in practice the Foley and the Jacques (or Nelaton) type are usually the most readily available. The latter are similar to the Foley, but have no balloon to inflate to keep the catheter in place.

27.2 Catheters & how to pass them

Before you pass a catheter, think for a moment about what you want it to serve. If you are going to drain urine from a healthy patient, who cannot pass urine after a hernia operation, use a soft catheter. If it has only to let out urine, its lumen can be narrow. If you expect bleeding, and want to irrigate a bleeding bladder, so as to dilute the blood in it and prevent it clotting, use a catheter with an additional irrigating channel.

If you need to suck out clots, choose a large catheter made of stiff material which will not collapse. If it is only to monitor urine output, and the patient is able to pass urine, make sure that the amounts passed are correctly recorded, and then ask yourself if the catheter is really necessary.

An indwelling catheter has usually to stay in place for ≥ 10 days, so:

- (1) *Avoid red rubber*, and use latex, plastic, or ideally silicone, because these will be less irritant.
- (2) *Be sure that it does not fit so tightly* that it blocks the mouths of the paraurethral glands: there must be plenty of room beside it for their secretions to ooze out.
- (3) It must be soft, because a stiff tight-fitting catheter can press on the mucosa of the urethra at the external sphincter or the penoscrotal angle, and cause a pressure sore, and finally a stricture. So use the narrowest, softest, catheter which will serve your purpose, and remove it as soon as you can. *Do not use a catheter for incontinence in the male*: use a Paul's tubing (a condom catheter, 27-3). Finally, remember that passing a catheter should be a sterile procedure; *you can so easily infect a patient and cause avoidable misery*.

EQUIPMENT FOR UROLOGY

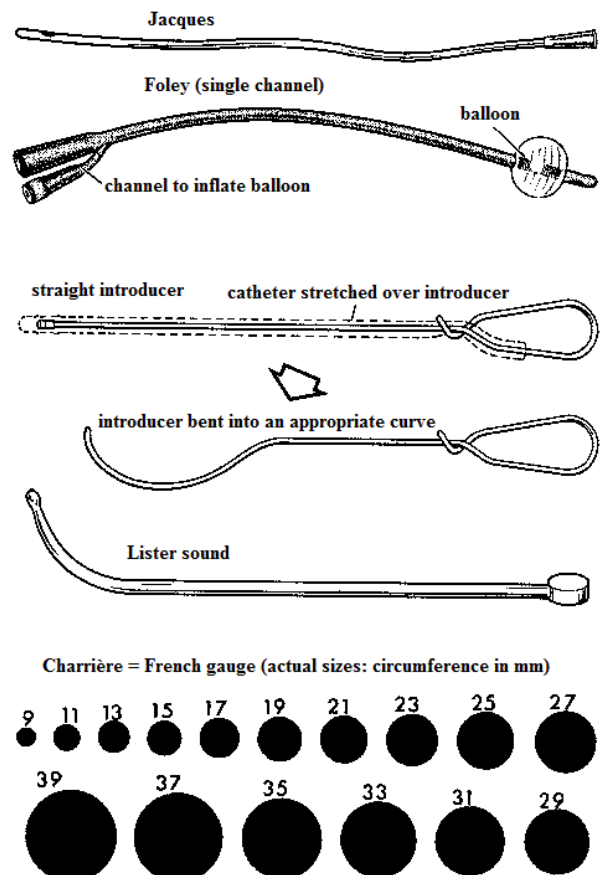


Fig. 27-1 EQUIPMENT FOR UROLOGY. The round black circles show the actual size of each catheter. (Diameter in mm = Ch gauge $\div \pi$)

**USE THE NARROWEST, SOFTEST CATHETER;
AND REMOVE IT AS SOON AS YOU CAN**

CATHETERS, *Foley, latex rubber, self-retaining, double channel, 30ml balloon, (a) Ch14, (b) Ch16, (c) Ch18, (d) Ch20, (e) Ch22*. These have a balloon at the end which you can blow up through the second channel, and so keep the catheter in the bladder.

CATHETERS, *Foley, silicone rubber, self-retaining, double-channel, 30ml balloon, (a) Ch14, (b) Ch22*. Keep these expensive silicone Foley catheters for long-term drainage and stricture management.

CATHETER, *plastic, Foley balloon, three-channel for continuous irrigation, 75ml balloon, straight tip, Ch22*. This catheter holds itself in place and allows you to irrigate the bladder. One channel is for the balloon, one is for irrigating fluid going into the bladder, and one for fluid and urine coming out. Use these for perivesical prostatectomy (27.20).

CATHETER INTRODUCERS. Keep one of these straight for introducing suprapubic catheters, and bend the other one into a smooth curve for introducing urethral catheters. If you use the same introducer for both purposes and keep on bending and unbending it, it will soon become so kinked that you cannot withdraw it. *An introducer can be a dangerous instrument in the urethra, so use it with great care, and only when absolutely necessary.*

SPIGOTS, *plastic, for catheters (a) small. (b) large*. If a patient has a spigot in the indwelling catheter, he can walk about with it in, and remove it to drain the bladder. If you do not have plastic spigots, make wooden ones.

BOUGIES, *neoplex, Porges, filiform, (a) smaller sizes olive-tipped, (b) larger sizes plain, sizes Ch1-20. (c) Follower to fit*. Use these for dilating strictures, for which they have many advantages over metal bougies except that they are much less durable. You can control their passage through the anterior urethra more easily, they follow the curve of the posterior urethra, and you will less easily cause false passages, even with small sizes. Cheatle's forceps can crush plastic bougies when they are hot, so tie them into bundles, and handle them only with tapes. Lift them out of the sterilizer and put them into cold boiled water. They will then be the right consistency for use.

SOUNDS, *metal, large, blunt, straight, plain-end, Powell's, sizes Ch12-20*. Historically, a 'sound' refers to a metal instrument used to locate stones in the bladder by the sound of the instrument hitting the stone. The terms 'sound' and 'bougie' are now used synonymously. If you are going to use a metal sound, Powell's straight sounds are the safest - a large one is much too large to be led down a false passage.

SOUNDS, *metal, Otis-Clutton urethral, curved with olive ends, Ch9/14, Ch11/15, Ch12/17, Ch4/18, Ch15/20, Ch17/21, and Ch18/23*. Use these for dilating a strictured urethra. The set is deliberately incomplete, because small sounds are dangerous, and can too easily cause a false passage.

SYRINGE, *bladder washout 50ml, plastic, boilable*.

RETRACTOR, *Thomson-Walker, with 2 pairs of detachable abdominal wall blades, and a long blade for posterior wall*. Use this for a suprapubic prostatectomy. It is designed to reach into the floor of the bladder.

URINE BAGS, *simple pattern, with drainage outlet at the bottom, plastic, reusable*. Although these bags are intended to be disposable, you can boil them and reuse them many times. Put 20ml of a disinfectant, e.g. cetrimide into the bag to help prevent infection, especially in long-standing cases. If you do not have any urine bags, you can wash blood-giving bags and blood-giving sets, cut them, and adapt them.

CLAMP, *penile with ratchet*. If a patient is incontinent, he may find a penile clamp useful. You can also use one to retain local anaesthetic before you pass a catheter.

BIOPSY NEEDLE, *Travenol 'Tru-cut' (TRAV) code 2N2704*. This is for the operative treatment of priapism (27.32). Several punctures with a large ordinary needle or a sharp trocar may be effective.

PASSING A CATHETER ON A MALE ADULT (GRADE 1.1)

EQUIPMENT. 2% lidocaine gel, preferably with 1% chlorhexidine; an antiseptic suitable for the scrotum; the right catheter; a penile clamp to retain the anaesthetic; receivers, a sterile bottle in which to send urine for culture; a syringe to blow up the Foley balloon; a sterile connecting tube; a bag to receive the urine.

METHOD.

If the patient is in severe pain, administer pethidine. This may help urine pass spontaneously. Explain what you are going to do. Make sure you have help. Arrange the patient sitting or lying comfortably in a good light with the legs apart, hands on the chest (*not behind the head*) and a waterproof sheet under the bottom. Expose the urethral meatus, and clean the glans and surrounding tissues thoroughly with antiseptic solution.

If you cannot expose the urethral meatus, make sure you pull back the foreskin completely, and you remove any sebaceous smegma properly. If the foreskin is very oedematous and you cannot retract it, use a McGill or sponge-holding forceps (4-4) to prise the foreskin apart, and then gently pull the glans forward, whilst at the same time pulling back on the foreskin. You can also reduce the oedema in the foreskin rapidly by injecting hyaluronidase.

Remember you may find the urethral opening in an abnormal position (proximally and ventrally in hypospadias (33.9), or dorsally in epispadias).

When the penis is buried in a large scrotal swelling (hydrocoele or inguino-scrotal hernia), it can be very difficult to grasp: use a proctoscope or vaginal speculum to push against the scrotum around the penis, thus allowing the urethral meatus to emerge.

Using a syringe without a needle, put 10ml of lidocaine gel into the urethra, and keep it there for 4mins with a penile clamp, or with light pressure from your finger and thumb.

CAUTION! Half the trouble in passing a catheter comes from not allowing time for LA to act.

Scrub and put on sterile gloves. Drape the patient with sterile towels. Clean under the foreskin thoroughly. Start with a Ch14 or 16 Foley catheter (smaller latex ones may be too supple). Hold the penis straight upwards to straighten out the urethra (27-2A,B). Take the catheter in your other gloved hand. *Do not touch either your skin, or the patient's skin*. Push the catheter gently into the meatus, and down the urethra, while keeping the penis upright.

If it sticks at the junction of the penis and scrotum, there may be a stricture, because this is the common site.

If it sticks at the external sphincter (27-2C), wait, be gentle, and allow it to relax. If it remains taut, you will never pass the catheter. Force is dangerous. Be slow, gentle, and crafty. Suggest breathing in and out, and pretending to pass urine. If you can catch the sphincter 'off guard', the catheter will slip in.

If it sticks in the posterior urethra, the prostate may be enlarged. Put your non-dominant finger in the rectum, and press on it. You may find that the catheter will now pass onwards.

CAUTION! *Never use force.*

If it still does not pass:

- (1) It may be too large (try a smaller one).
- (2) The sphincter may not be relaxed (27-2C) because the patient is frightened (try sedation).
- (3) The urethra may not be properly anaesthetized (try introducing 5-10ml more lidocaine, with lubricant jelly).
- (4) The catheter may have caught in mucosal pockets in the urethra: you can easily make these into a false passage, if you are not careful.
- (5) There may be a large prostate, which distorts the urethra, and prevents the catheter following it into the bladder. Try passing a small Ch12 catheter folded back on itself (27-2E); if this fails, perform a suprapubic catheterization (27-9)

When the Y-connection of the catheter reaches the urethral meatus and you see urine coming out, then you can inflate the balloon, not before! Do not fill it to its maximum capacity: 10ml is adequate to stop the catheter falling out. Remember to pull back the foreskin over the glans penis to prevent paraphimosis!

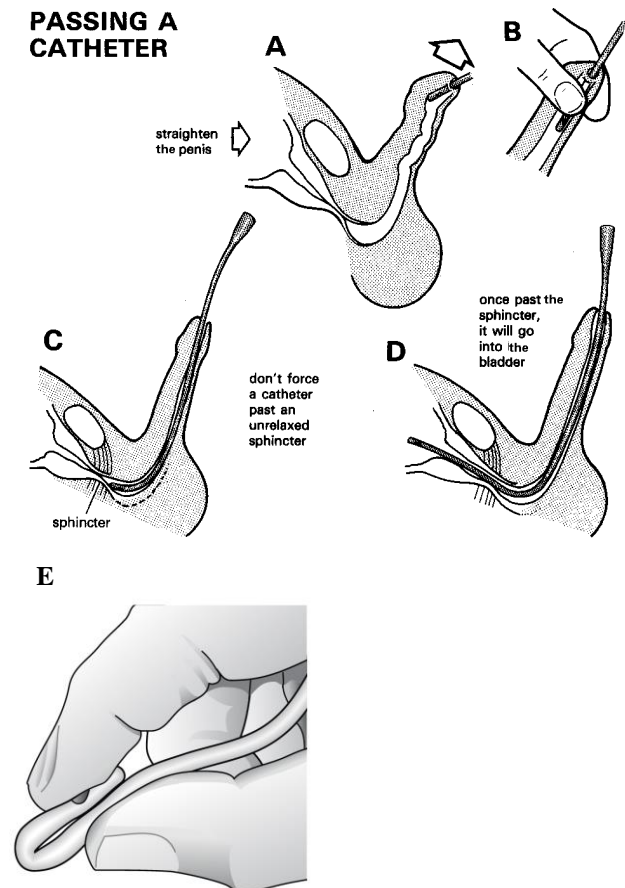


Fig. 27-2 PASSING A CATHETER.

A-B, straighten out the urethra to remove its kinks. C, if the mucosa over the external sphincter is not well anaesthetized, it may go into spasm: *never force a catheter past an unrelaxed sphincter*. D, when it is past the relaxed sphincter, it will find its way into the bladder, provided it is flexible and well-lubricated. E, passing a smaller Ch12 catheter folded back on itself: being more rigid, it may well pass the prostate and once in the bladder open itself out spontaneously.

A-D, after Blandy J. *Operative Urology*, Blackwell 1978 Fig 2.54-6, with kind permission. E, after Buddha S. *Complication of urethral catheterisation*. *Lancet* 2005;365,909.

If the Y-connection does not reach the meatus or urine does not come out, do not inflate the balloon: it may still be in the urethra rather than the bladder, and inflating it may cause urethral damage and ultimately stricture formation. There is no harm in strapping or suturing the catheter in place, if you see no urine but are fairly sure the catheter is in the bladder (e.g. in renal failure), and waiting. If you can, check with ultrasound to see if the bladder is really full. If you are sure the catheter is in the bladder, it might be blocked with debris or blood: try flushing it gently with a little sterile water. *If after an hour, there is still no urine, and the bladder remains full, the catheter cannot be in the correct position.* Use ultrasound to check where it is (38.2H).

CAUTION! Ask your nurses to empty the urine bag *before* it is full and at least every 24hrs, aseptically and without getting urine organisms on their skin. *Do not let a full bag pull on the inflated balloon:* it may cause pressure necrosis of the posterior urethra. Be sure your nurses chart the urine output meticulously.

PASSING A CATHETER ON A FEMALE ADULT (GRADE 1.1)

EQUIPMENT. An antiseptic suitable for the vulva, the right selection of catheters; receivers, a sterile bottle in which to send urine for culture; a syringe to blow up the Foley balloon; a sterile connecting tube; a bag to receive the urine. *Do not use a metal catheter!*

METHOD. If the patient is in severe pain, administer pethidine. This may help urine pass spontaneously. Explain what you are going to do. Make sure you have help. Arrange the patient sitting or lying comfortably in a good light with the legs apart, hands on the chest (*not behind the head*) and a waterproof sheet under the bottom.

CAUTION! Half the trouble in passing a catheter comes from not properly visualizing the urethral orifice, which is situated below the clitoris above the vagina. It may be ectopically placed more posteriorly, especially in elderly women. If you have difficulty locating the orifice, ask the patient to cough, whereupon some drops of urine may come out spontaneously. Make sure you have good lighting, and the thighs are well abducted. Drape the patient with sterile towels. Clean the vulva thoroughly. Start with a Ch14 or 16 Foley catheter (smaller latex ones may be too supple). Take the catheter in your other gloved hand. *Do not touch either your skin, or the patient's skin.* Push the catheter gently into the urethra, until it will go no further. During delivery, in a female, you may have difficulty pushing the catheter inside: insert 2 fingers of your left hand into the vagina between the foetal head and the symphysis pubis. Using one finger on either side of the urethra, gently guide the catheter into the bladder. Remember the female urethra is <4cm long.

In some cases, e.g. VVF repair, it is best to let a catheter drain freely (21.18)

If the urethra is stenosed, this may be due to mutilating surgery or damage from childbirth associated with a vesico-vaginal fistula (21.18). Simple dilation is usually possible (27.9).

If you cannot expose the urethra, especially in an elderly woman with atrophy of the vagina, mount a Ch16 catheter on an introducer, and gently pass this along the anterior wall of the vagina till it drops effortlessly into the bladder. You may need to palpate the urethral orifice with a finger and guide the introducer accordingly.

DIFFICULTIES WITH CATHETERS

If the catheter leaks, it probably has encrustations partially blocking its channel; *do not try to insert a larger size to 'fill' the urethra!* Try irrigating the catheter with sterile water, and if this fails, change the catheter.

If the catheter blocks, especially with clot after prostatectomy, this is usually because of inadequate irrigation. Try to dislodge the clot by instilling heparinised water with a bladder syringe, and sucking out the bloody urine and clots. If this does not work and water can be instilled but not withdrawn, thus making the patient more and more uncomfortable, deflate the catheter balloon and push the catheter in, wriggling it about; this might cause the clot in the eye of the catheter to dislodge. Otherwise, replace the catheter with a larger size. This might be difficult, and require GA; make sure the patient gets a proper bladder wash-out in this case.

If the catheter balloon will not deflate, cut the catheter across, and leave it for 6hrs to empty. It will often deflate by itself. If it does not, inject 10ml mineral oil up the balloon channel, and wait 10mins. Repeat this if necessary and check if the balloon has deflated. Wash out the bladder with 200ml sterile water, to remove the oil and any balloon fragments which may have been left behind. You can also use ether, chloroform or acetone, but these irritate the bladder. Alternatively, palpate the balloon *per rectum*, and direct a needle guided by your finger to burst it: this is potentially hazardous, so wear thick gloves and administer gentamicin! If you have ultrasound, it is easy to guide a needle into the balloon suprapubically to rupture it. If not, you can pass a well-lubricated catheter introducer through the urine drainage channel and thereby push the end of the catheter up against the anterior abdominal wall: when the balloon is palpable or visible, rupture it with a needle.

N.B. This will only work in thin patients.

If you cannot remove an indwelling catheter, even though you have deflated the balloon, you have probably left it in much too long, so that crusts have anchored it to the mucosa. *If you pull it out firmly, you will damage the mucosa and may rupture the urethra.* You may have to open the bladder to remove the catheter; if the reason the patient has a catheter in the first place is prostatic enlargement, use this opportunity to perform a prostatectomy (27.20).

N.B. A latex catheter becomes encrusted in 3-4wks, and a silicone one in 3-4months. Be safe, and change a latex one every 4wks and a silicone one every 12wks.

If you have inflated the balloon in the urethra, deflate it and remove the catheter; *do not attempt re-catheterization via the urethra.* If the patient develops urinary retention, insert a suprapubic catheter (27.7). If the balloon will not deflate, palpate it through the penoscrotal skin, and rupture it with a needle.

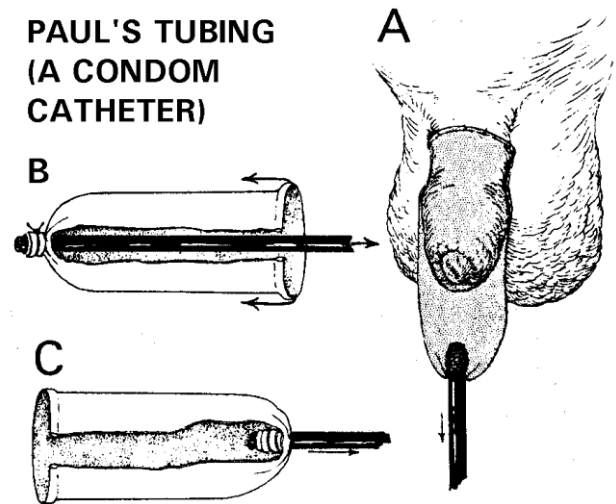


Fig. 27-3 PAUL'S TUBING (CONDOM CATHETER).

If a patient is incontinent, you will find this very useful. You may not have a ready-made catheter, but can fashion one easily like this. Kindly contributed by Jack Lange.

27.3 Cystoscopy

CYSTOSCOPY (GRADE 1.5)

Looking at the bladder with a cystoscope is:

- (1) Often the best way to know what is going on inside.
- (2) Usually more useful than an ultrasound.
- (3) Particularly useful in areas where *schistosoma haematobium* is endemic, because it is the most practical way of diagnosing the cancer of the bladder that commonly complicates this disease, and which also causes haematuria (27.4).

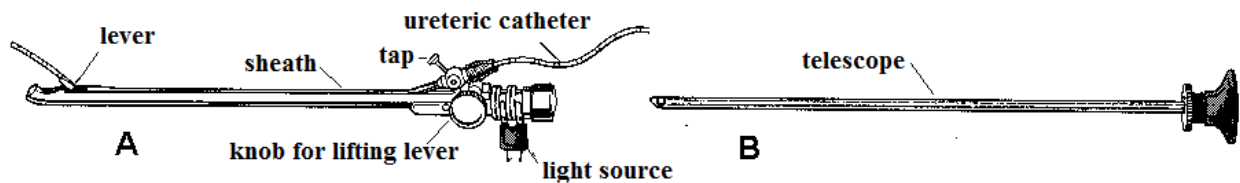
For this you only need the simplest instrument, without provision for catheterizing the ureters.

Cystoscopy is an acquired skill, even with equipment using a fibre-optic light source rather than a solid rod lens system. The problems are:

- (1) to get the instrument in (it is best to do this under direct vision, so as to avoid causing damage),
- (2) to have a good enough instrument to give you a diagnostic view, and
- (3) to know what the normal looks like.

Flexible fibre-optic instruments are not necessarily easier to use.

A SIMPLE CYSTOSCOPE



INTRODUCING THE CYSTOSCOPE

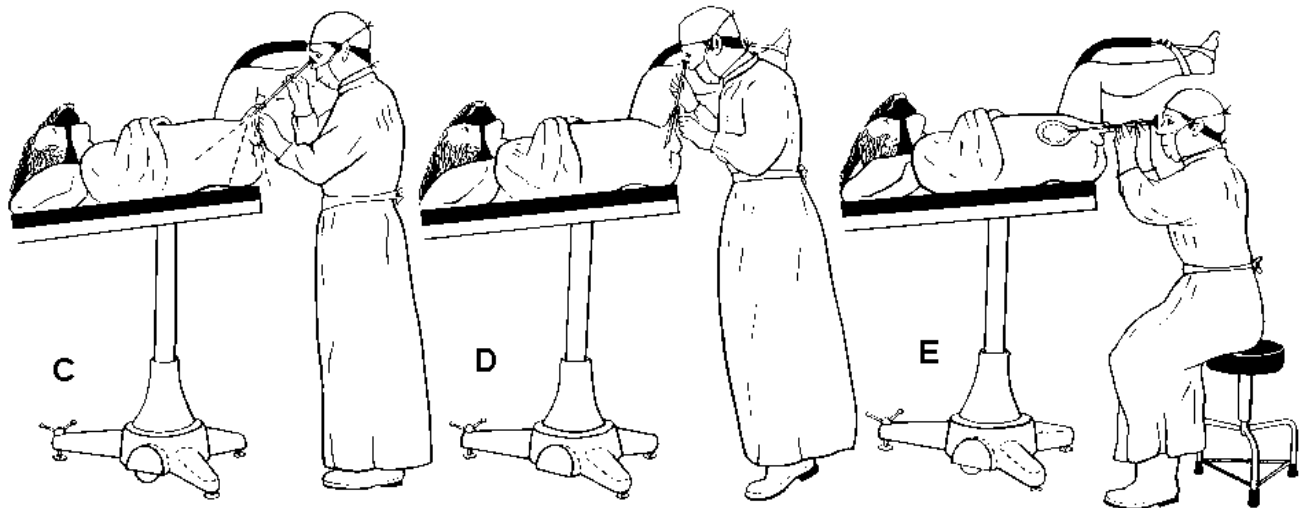


Fig. 27-4 SIMPLE CYSTOSCOPY.

A, sheath. B, telescope. (The Albarran lever is for manipulating the ureteric catheter). C, Introduce the cystoscope under direct vision of the anterior urethra. D, the bulbous urethra, and E, the prostatic urethra. (N.B. The right leg has been removed for clarity.)

CYSTOSCOPE. There are more sophisticated operating, and simple viewing cystoscopes. All need an irrigation channel.

The urethroscope has 0° viewing angle (to look straight ahead), and a viewing cystoscope 30-70° (to look around). Methods of irrigation differ. Some cystoscopes have a tap with two positions, some have two taps, and in others you have to remove the telescope and fix a tap ('the faucet') in the hole where the telescope was.

SYRINGE, bladder, Barrington's metal. Use this to wash out the bladder during cystoscopy.

CAN, douche, metal, 3l, with rubber tubing.

INDICATIONS.

- (1) Urinary retention, or difficult micturition, particularly as a prelude to prostatectomy. If the patient has an enlarged prostate, cystoscopy may precipitate acute retention, so do it as the first stage of a prostatectomy (27.20).
- (2) Haematuria in a patient >30yrs in areas where *schistosoma haematobium* is highly endemic (27.5).
- (3) To diagnose *schistosomiasis* when it is strongly suspected clinically, but you cannot find ova in the urine.
- (4) Recurrent urinary infection.
- (5) Investigation of bladder stones.

CONTRAINDICATIONS.

Acute cystitis, until you have controlled the infection.

TESTING THE CYSTOSCOPE.

Do this before you sterilize it. Look down the telescope; the image should be clear. If it is misty, there is dirt on the lens; clean with spirit-soaked swabs. If it is still misty, water has probably entered the telescope, so return it to the makers or an agent for repair.

If a crescentic part of the visual field is cut off, the telescope has been bent. If this only happens after you have inserted the sheath, it is the sheath which is bent.

STERILIZATION.

Even though you may be able to put your cystoscope (if it is an old-fashioned sort) in an autoclave, it will last longer if you use an antiseptic solution. Keep it in its box until you want to use it.

Remove the compression ring and valve, and immerse it in glutaraldehyde solution, 1% chlorhexidine, $\frac{1}{1000}$ mercury oxycyanide, or $\frac{1}{80}$ phenol for 10mins; immersion will kill all bacteria capable of infecting the bladder. Rinse it thoroughly in sterile water, and place it on a sterile towel. After use, rinse it in water, and dry it with swabs soaked in spirit.

ANAESTHESIA.

You may be able to examine a woman as an outpatient without any anaesthesia if you are gentle and use a lubricated instrument, unless she has a painful stricture of her external meatus, or a very irritable bladder.

GA will be easier in the male and if you are inexperienced, or he has carcinoma of the bladder (27.5) or tuberculosis (16.7).

If you use LA, clean the glans penis with cetrimide, and use the nozzle of a tube of 2% lidocaine jelly to inject 5g down the urethra. Apply a penile clamp proximal to the glans. After 4mins inject a further 5g, and reapply the clamp. Massage the penile urethra, so as to squeeze the jelly into the posterior urethra. Wait a further 10mins before performing a cystoscopy.

PREPARATION.

Use the semi-lithotomy position: flex the hips to only 75° and abduct them 30-45°, so as to leave the buttocks further up the table than the poles. *Do not use the full lithotomy position.* To provide fluid for irrigation, you can use autoclaved water in a receptacle maximally 60cm above the patient.

INTRODUCING THE CYSTOSCOPE.

Introduce the cystoscope into its sheath, and lubricate the outside with petroleum or lidocaine jelly. It is best to start with a 0° urethroscope or 30° cystoscope to visualize the urethra.

In a female, you will have no difficulty, unless her meatus is stenosed. If so, dilate it with sounds.

Clean the glans penis of a man thoroughly under the foreskin and hold the penis vertically with your left hand. Introduce the cystoscope gently into the urethra (27-4C) viewing it directly, and stretch the penis along it, as it descends under its own weight. Look at the bulbar urethra (27-4D), and then the prostatic urethra (27-4E). When the cystoscope tip lies against the triangular ligament, swing the eyepiece down between the thighs with a circular motion, so that the beak of the cystoscope faces downwards, and the telescope will slip directly into the bladder.

If the beak sticks in the external urethra, depress the eyepiece further and it will probably slip in: *never try to push it in by force.* Guide it under direct vision. If it still will not pass, put the index finger of your free hand in the rectum, or on the perineum and guide it in that way: this is seldom necessary. *Remember, though, then to change gloves!* If the beak is in the bladder, the cystoscope will rotate freely.

WASHING OUT THE BLADDER.

Remove the telescope from its sheath and collect the urine which comes out. If it is hazy, send it for microscopy and culture. Crystal clear urine will probably be sterile.

Fill a bladder syringe with water, and expel any air by holding its nozzle upwards, and depressing the plunger. Then squirt some of the water on to your own hand, to make sure that it is not too hot. Wash out the bladder by injecting 50ml at a time, until the washings are clear. Alternatively, use irrigation.

INSPECTION. Distend the bladder with 250ml of water. (A normal bladder holds 250-400ml). You can also use air: this often gives a better view.

VIEWING THE BLADDER

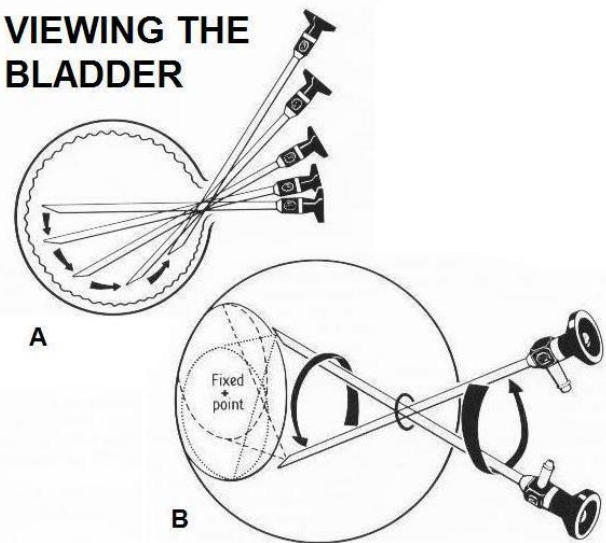


Fig. 27-5 VIEWING THE BLADDER.

A, Swing the cystoscope in an arc to examine the bladder mucosa. B, Rotate the cystoscope to examine the fundus using the air bubble at the top as a reference point. After Clark P. *Operations in Urology* Churchill Livingstone 1985 p.19 Figs1.29,30.

N.B. Advanced carcinoma, severe schistosomiasis or tuberculosis may make a bladder very small, in which case you may cause considerable bleeding if you try to overfill it with >50ml.

Insert the telescope and look around (27-5). Examine the bladder systematically, starting with the fenestra (window), looking downwards towards the base of the bladder. Note the size of the median lobe of the prostate as you enter the bladder (it looks like a 'termite hill', 27-7). Observe the inter-ureteric bar (27-7A). This is a ridge of tissue between the two ureteric orifices (27-19H). It is a useful landmark, but it is sometimes not very conspicuous. Another landmark is the small air bubble which is always present in the dome (top) of the bladder. Return to the inter-ureteric bar, and look all round the side walls and roof of the bladder. Turn the cystoscope through 360°, so as to examine a circular strip of bladder wall. Then push it further into the fundus, withdraw it 2cm and look around 360° again. Find the ureteric orifices by finding the inter-ureteric bar, and tracing it laterally. When you see an orifice, the cystoscope must be in either the 5o'clock, or the 7o'clock position. Now you can thread the ureteric catheter (if you have one) into the orifice, by adjusting the Albarran lever (27-4A). Depress the eyepiece to look at the anterior wall of the bladder. This may be impossible to see in a man, unless he is fully relaxed under GA.

The mucosa of a normal bladder is a yellow sandy colour, and has fine branching vessels under it. If the fluid in the bladder is bloody, the mucosa may look pink: *do not confuse this with cystitis.* A normal trigone, the area between the urethral & ureteric orifices, (27-7C) is pink and vascular.

REMOVING THE CYSTOSCOPE

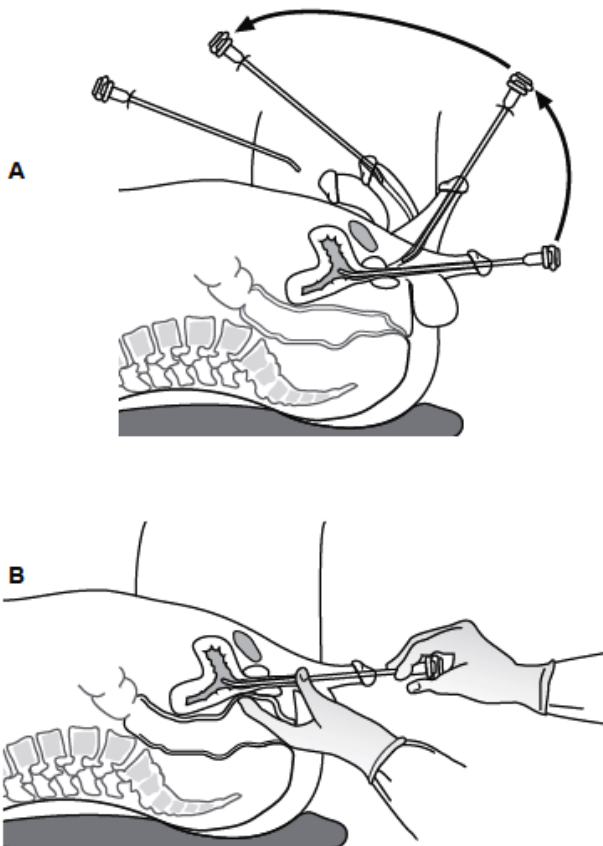


Fig 27-6 REMOVING THE CYSTOSCOPE.

A, Remove the telescope from the urethra over the pubis. B, Examine the prostate rectally against the cystoscope. After Clark P. *Operations in Urology* Churchill Livingstone 1985 p.21 Figs 1.33,34

Finally, partly withdraw the cystoscope (27-6) and examine the trigone and the internal urinary meatus. You should be able to see everything except the base when it is obscured by a very large median lobe. When this is very large you may not see the ureteric orifices either. Palpate the prostate *per rectum* with your finger pressing against the cystoscope.

CYSTOSCOPIC APPEARANCES

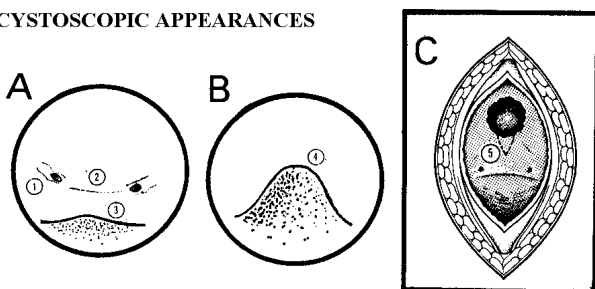


Fig. 27-7 CYSTOSCOPIC APPEARANCES.

A, the base of the bladder, with the ureteric openings (1), interureteric bar (2) and middle lobe as a hardly visible swelling (3). B, in benign prostatic hypertrophy the middle lobe (4) projects into the bladder to obscure the interureteric bar and the ureteric openings. C, position of the wedge (5) excision in bladder neck stenosis (27.21).

If you see nothing to begin with:

- (1) The beak of the cystoscope may still be in the urethra.
- (2) The light may have gone out.
- (3) You may have inserted the telescope incorrectly. The small pin in the eyepiece should fit into the expanded end of the valve collar. Try twisting the compression ring a little.
- (4) There may be blood or clot on the objective.
- (5) If you see nothing but a 'red out', you may have failed to run fluid into the bladder, or your instrument is right up against the bladder wall.
- (6) If the bladder holds <50ml, e.g. because of advanced carcinoma, severe *schistosomiasis*, or tuberculosis: beware there may be bleeding if you fill the bladder too full!

In bladder outflow obstruction, look for:

- (1) Enlargement of the lateral lobes of the prostate (27.19), which will make the prostatic urethra appear as a cleft before you see into the bladder. The median lobe will project from the posterior aspect of the bladder like 'a termite hill', and may make it difficult to see the ureteric orifices (27-3B).
- (2) Thickened criss-cross pattern of the bladder musculature (trabeculation), showing that its outflow is obstructed. In between you may see saccules, which enlarge to form diverticula. These are usually above and lateral to the ureteric orifices, with radiating folds around their openings. You may be able to get the beak of your cystoscope inside one. Diverticula rarely matter; once any outflow obstruction has been relieved, diverticulectomy is seldom necessary.

N.B. Dyskinesia (bladder-neck dysfunction, 27.21) causes retention of urine but cannot be diagnosed cystoscopically. But, suspect **bladder-neck stenosis** if:

- (1) The bladder is obviously obstructed, as shown by muscle hypertrophy, residual urine, and perhaps diverticula.
- (2) The prostate shows no bulging, there is no urethral stricture and no CNS disease.
- (3) The bladder neck is tight and looks like a bar (27-19K) over which you have to pass the cystoscope.

27.4 Haematuria

Blood in the urine can be the result of almost any pathology at any level, but is much more likely to be coming from the bladder than from the upper urinary tract. Bleeding can be the result of injury, bacterial infection, parasitic infestation, stones, or neoplasia.

If *schistosomiasis* is endemic in your district, frank haematuria in someone >30yrs has a 25% chance of being due to a carcinoma of the bladder, so be sure to check this by cystoscopy. Frank (visible, macroscopic) haematuria <30yrs is much more likely to be due to *schistosoma* than carcinoma.

The other important cause is prostatic hypertrophy and HIV-related cystitis. Other rarer causes are renal tuberculosis, renal carcinoma, radiotherapy, ketamine abuse and vascular abnormalities.

Because cystoscopy is so necessary in the diagnosis of malignancy in areas where *S. haematobium* is endemic (27.5), it should be the first investigation after Hb, urea, urine microscopy and culture and ultrasound; *an intravenous urogram is not usually helpful.*

Bladder stones seldom cause macroscopic haematuria. Ureteric stones usually present with renal colic and microscopic haematuria.

Haematuria in a male cannot be simply attributed to a urinary tract infection: there is *always another* underlying cause.

Haematuria in a woman may arise from the urine being contaminated by a menstrual flow.

Confirm that there really is blood in the patient's urine by examining it microscopically.

THE 2 GLASS TEST. Ask the patient to pass the urine into 2 containers, and watch him do it:

- (1) A constant ooze from the urethra, indicating a lesion distal to the external sphincter.
- (2) Initial or terminal haematuria, indicating a local lesion of the bladder or prostate. Terminal haematuria is typical of schistosomiasis.
- (3) Total haematuria which is equal in both glasses, and may contain worm-like clots, indicates bleeding from the upper urinary tract or bladder; it is common in schistosomiasis and carcinoma of the bladder.

CYSTOSCOPY is usually best done after bleeding stops. The exceptions are:

- (1) A bladder full of clot which needs immediate evacuation.
- (2) Recurrent haematuria when you cannot find a cause, and when you would like to know from which kidney blood is coming: this is rare.

ULTRASOUND (38.2H) will show if there is a foreign body or tumour in the bladder.

RADIOGRAPHS. A plain radiograph (in oblique orientation) may show calcifications in the kidney or line of the ureter. You can confirm these with an intravenous urethrogram (38.1)

CAUTION! Occasionally you may see *red urine from eating excessive amounts of beetroot, chewing huge quantities of betel leaf, or in porphyria.* Even more rarely, a patient may have deliberately dripped blood into a urine sample!

27.5 Bladder carcinoma

Histologically, there are two main kinds of carcinoma in the bladder:

(1) Squamous carcinoma, related to exposure to *schistosoma haematobium*. In areas where this is endemic (especially along the Nile), it is often the most common cancer found.

(2) Transitional carcinoma, which has a 75% chance of being papillary, and of such low-grade malignancy that it can be controlled with diathermy. Anaplastic degeneration indicates end-stage disease.

In non-schistosomal areas, most bladder tumours are transitional, papillary, and of low-grade malignancy, and associated with simultaneous tumours of the ureter or renal pelvis.

In areas where *S. haematobium* is endemic, only about 5% are like this, 10% are anaplastic, and 85% are squamous. Of these, most are either sessile or ulcer-cancers, both of which grow rapidly, and penetrate early into the muscle of the bladder or into the paravesical tissues. They may also have obstructed the ureters or the urethra by the time they present.

The patient is usually 35-60yrs and has a 2:1 chance of being male, complaining of:

- (1) haematuria, which is initially painless,
- (2) passage of white sludge, or small pieces of white material (necrotic tumour),
- (3) increased frequency of micturition, as the result of irritability, infection, and a small bladder,
- (4) a suprapubic mass,
- (5) retention of urine (5%), as a result of the tumour obstructing the urethra.

In areas where *S. haematobium* is not endemic, you should cystoscope all patients with haematuria. This is impractical in endemic areas, because so many patients pass bloody urine.

Macroscopic haematuria, due to *S. haematobium* alone, becomes less common as age advances, because of the fibrosis round the ova, so that by the time that someone is 30yrs, there is a 25% chance that, if he sees blood in the urine, it is caused by a bladder tumour, rather than merely by the worms laying their eggs. So, if you are in an endemic area, cystoscope everyone >30yrs who complains of haematuria (27.4). Few cases of carcinoma of the bladder occur in anyone <30yrs.

There is little that you can do for aggressive *schistosoma*-associated carcinoma of the bladder, but do try to confirm the diagnosis.

Patients need to know if they have a serious condition or not. *Do not give repeated treatment for presumed schistosomiasis.*

Stage these tumours (27-8): most patients present in inoperable Stages III or IV. The only useful treatment for squamous tumours in stages I and II is total cystectomy; the recurrence rate after partial cystectomy is high, but even total cystectomy has few 5yr survivors. No effective chemotherapy is affordable, except for those rare patients with high human chorionic gonadotrophin (β -HCG) levels. Ureteric diversion (nephrostomy, 27.14) gives symptomatic relief, but this tends to be short-lived and not without its problems. All you can often do is to palliate the patient (37.1). Death is likely from renal failure, due to obstruction of the ureters by the tumour.

ULTRASOUND (38.2H) will show a thickening or mass in the bladder wall.

RADIOGRAPHS. An intravenous urogram (IVU) is helpful only where low-grade papillary transitional tumours predominate, because there may also be tumours of the ureter and renal pelvis.

STAGING CARCINOMA OF THE BLADDER

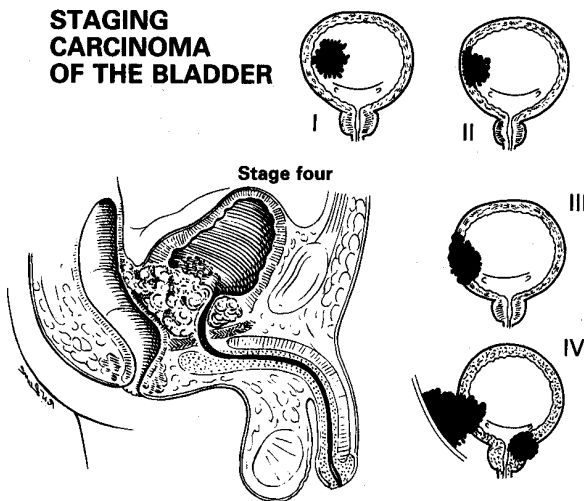


Fig. 27-8 STAGE CARCINOMA OF THE BLADDER by doing a cystoscopy and examining a patient under GA.

Stage I, the tumour is not palpable. Stage II, it is palpable, but is not larger than you would expect from cystoscopy. Stage III, it is mobile, but is larger than you would expect from cystoscopy. Stage IV, it is fixed. Stage V (not shown), it is widespread.

After McNeill Love RJ. Bailey, & Love's Short Practice of Surgery, HK Lewis 15th ed 1971 Fig. 1415 with kind permission.

SPECIAL TESTS.

Measure the Hb, and the blood urea. Examine the urine for microscopy and culture, and if you can, cytology, looking for irregular shed cells, and keratin.

STAGING (27-8). Following cystoscopy, examine the patient bimanually under GA, with the bladder empty and the muscles relaxed. Try to confirm the diagnosis with a biopsy.

Stage I. The tumour is sessile and not palpable. This needs cystodiathermy, or partial cystectomy for a transitional carcinoma. Total cystectomy, for an aggressive squamous carcinoma, is only justified if you explain the situation fully, and the resulting urostomy is manageable at home.

It will spare much suffering, but is unlikely to provide a cure and may be socially unacceptable.

Stage II. The tumour is palpable as a localized, but definite thickening, which is mobile. It is <5cm in diameter, and is not larger than you expect from cystoscopy. Treat as for stage I.

Stage III. The tumour is mobile, >5cm in diameter, and is larger than you expect from cystoscopy. Cystectomy may be possible, but is highly unlikely to provide a cure.

Stage IV. The tumour is fixed to the wall of the pelvis, or to the paravesical glands, or is infiltrating the vagina or rectum. Palliation only is possible.

Stage V. There is widespread disease. Palliation only.

CAUTION!

(1) Confirm the diagnosis histologically, before advising radical surgery. Schistosomal granulomas (common in endemic areas) and tuberculosis, can simulate small tumours.

(2) Avoid a suprapubic cystostomy, because it can cause a distressing, permanent urinary fistula if a malignant tumour is present.

27.6 Retention of urine

Retention of urine can be acute, chronic, or 'acute-on-chronic'. Six kinds of men suffer this way:

- (1) A young man with a history of gonorrhoea, followed by a stricture or prostatitis. Sometimes, acute gonorrhoea alone is enough to cause retention, or he may have both.
- (2) An old man with an enlarged prostate. The acute event causing urinary retention may be a pneumonia, a fractured femur, or just drinking too much beer!
- (3) A man with painless retention caused by an acute neurological lesion, such as HIV transverse myelitis, injury or tumour of the spine, in which case the signs are obvious, but are often overlooked.
- (4) A man with frank haematuria, from previous surgery (e.g. prostatectomy), trauma or a bleeding disorder.
- (5) A man with a urethral injury, often from pelvic disruption.
- (6) An older patient with a bladder tumour.

N.B. Old men may still have urethral strictures, and young men bladder carcinoma.

Retention of urine can happen to women as the result of:

- (1) *detrusor* muscle failure complicating pelvic surgery, especially hysterectomy (23.15),
 - (2) a retroverted gravid uterus,
 - (3) an impacted fibroid in early labour,
- and to both men & women as a result of:
- (4) a neurological lesion particularly HIV neuropathy,
 - (5) an advanced bladder tumour,
 - (6) a rectal mass, which may be a faecal impaction!
 - (7) a horseshoe-type ischiorectal abscess (6.17)

Occasionally drugs may cause urinary retention, especially opioids, and antipsychotics.

Acute retention usually presents in much the same way, whatever its cause, with acute discomfort, often late in the evening when the realization dawns that no urine is going to come out before bedtime. The bladder is usually distended to the umbilicus. No stricture is complete, and the final stage of the obstruction is probably congestion and oedema. This will subside if you drain the bladder suprapubically; then, if you try to pass a urethral catheter after 1-2wks, you will probably succeed. If you are going to perform a prostatectomy, and you can operate during the next few days, you can leave the suprapubic catheter in place until you do so. If there is a stricture, you can dilate this as soon as the acute oedema subsides.

SUPRAPUBIC CATHETERIZATION IS *MUCH* SAFER THAN A DIFFICULT URETHRAL CATHETERIZATION

First make sure that there really is retention of urine, and this is not oliguria or anuria. If you cannot feel or percuss the bladder, the reason for the inability to pass urine must be in the ureters or kidneys, or be pre-renal. In doubt, use an ultrasound to look at the kidneys and the bladder. One glance at the face will usually tell you if the retention is acute or chronic: acute retention is agonizing.

If the bladder is grossly distended, but not painful, the retention is either chronic, or neurological.

HISTORY.

Has there been gonorrhoea, and how was it treated? Is it necessary to strain to pass urine? (suggests a stricture). Frequency, hesitancy, dysuria, nocturia? (prostatism).

EXAMINATION.

Look for heart failure, anaemia, and hypertension, which might be the result of an obstructive uropathy. Look for signs of HIV disease (5.5,6).

Examine the urethra from end to end, using your eyes and your fingers. Start at the glans. Exclude phimosis and stenosis of the meatus. Feel the urethra in the penis, and the perineum, for palpable thickening. Extensive strictures are associated with a large palpable area of scarring in the perineum. You may feel the distended proximal part of the urethra ending in a firm fibrous stricture. Examine the membranous urethra with your finger in the rectum. Look for scars on the scrotum and perineum. If there is a painful tender area in the perineum, it is probably a periurethral abscess complicating a stricture or a horseshoe ischio-rectal abscess. Check for sensation in the ano-perineal area.

Examine the prostate rectally:

(1) The hardness and irregularity of carcinoma are usually easy to distinguish from the softer, smooth consistency of benign hypertrophy, although the gritty feeling of a calcified prostate may be misleading.

(2) A firm mass above the prostate is likely to be carcinoma of the bladder.

(3) Tenderness of the prostate is often difficult to assess, but a genuine prostatic abscess or acute prostatitis is usually exquisitely tender to palpation.

(4) An impacted stone in the prostatic urethra (uncommon, the meatus is the common site of impaction) or tuberculous prostatitis can be readily confused for carcinoma.

CAUTION!

(1) The size of a prostate is no indication as to whether it is causing obstruction or not, but it is useful to know its size when planning surgery.

(2) If the bladder is distended, the upper border of the prostate may be difficult to distinguish from the bladder base, and the prostate may seem enlarged, because it is being pushed downwards by the distended bladder. You may find later, when surgery is scheduled, that the prostate has disappeared! So if you do think it is enlarged, examine it again, after you have relieved the retention: *do not diagnose prostatic enlargement from one examination while in retention.*

Examine if the kidneys are palpably enlarged. Are the nerves to the bladder intact? Is there perianal sensation? Test the anal reflex during rectal examination, and feel for a patulous anal sphincter. If you suspect any neurological abnormality, examine the spine and legs thoroughly.

SPECIAL TESTS.

Later, examine the urine for sugar, protein, and pus. Diabetic and HIV neuropathy can cause retention, and proteinuria may indicate uropathy. Measure the Hb and the blood urea, and repeat this after 7days' relief by catheterization if it was initially abnormally high.

Prostate specific antigen (PSA) is highly specific for prostatic carcinoma; it is very useful (27.22). Acid phosphatase will only tell you crudely about the presence of metastatic deposits: you should do both tests *before doing a rectal examination, or else there may be a false +ve result!*

A PLAIN RADIOGRAPH of the kidney, ureter, and bladder may show stones or evidence of metastatic deposits in the pelvic bones, typical of prostatic carcinoma. *There is no need for a routine IVU:* reserve it for special indications, such as haematuria when the cause is not found on cystoscopy, or if you suspect some abnormality of the kidneys.

ULTRASOUND. Look for the size of the bladder (when it is full), the thickness of its wall, any indentations or diverticula (38.2H) and the size of the prostate (38.2I). Examine the ureters and kidneys, looking especially for pelvi-calyceal dilation (38.2E).

RELIEVING BLADDER OBSTRUCTION

Pass a catheter (27.2). *Do not clamp it*: the pressure in the bladder is reduced by 50% by letting out only 100ml, so serial releasing of the flow is unnecessary and may even promote infection.

It does nothing to prevent haematuria, caused by rupture of compressed bladder wall veins, which usually stops spontaneously.

If you fail to pass a urethral catheter, perform a suprapubic catheterization (27.7). If this is contra-indicated, and *you are* experienced, use pethidine and diazepam, or GA but *not ketamine* (which may cause bladder contraction). With deep relaxation, the sphincter should relax and, a urethral catheter should slip in. If it does not, try a curved metal introducer to 'lift' a catheter into the bladder, *taking great care*. When it is in the bladder, remove the introducer.

CAUTION!

(1) Use an introducer with great care and gentleness: lubricate it generously when you put it into the catheter, and lubricate the catheter when you pass it into the urethra. This will help to prevent it being pulled out with the introducer.

(2) Make sure the introducer has a smooth curve. A kinked introducer will be difficult to extract.

(3) Make sure the introducer tip does not emerge through the catheter hole but sits snugly at its tip when you are introducing the catheter.

(4) *Never use force!*

If the urine comes out murky, turbid or smelly, treat this with the most suitable antibiotic available: viz. nalidixic acid, nitrofurantoin, trimethoprim, gentamicin or a quinolone.

N.B. Ampicillin and tetracycline are not usually very effective.

RECOVERY DIURESIS: DANGER OF RENAL FAILURE

When you have relieved an obstruction to the urinary tract, the bladder and the kidneys may or may not recover. An early sign of recovery is a diuresis, which may amount to >5l/day.

If there is a recovery diuresis, measure the urine output carefully. If this is >200ml/hr, replace this fluid loss by infusing IV fluids at 80% the volume lost in the first 24hrs, then at 50% the volume lost for the subsequent 48hrs. *Do not forget the potassium lost*: this may be as much as 35-40mmol/l urine produced. If possible, measure the serum $[K^+]$, and adjust the dose of potassium accordingly. Be guided also by the pulse and blood pressure chart. If you fail to appreciate the danger of this diuresis, renal failure may recur due to dehydration leading to poor renal perfusion, in spite of an apparently normal fluid intake.

DIFFICULTIES WITH RETENTION

If there are symptoms of prostatic obstruction with acute or chronic retention, but no large prostate, there are 2 possibilities (27.21):

(1) **DYSKINESIA** is a functional rather than a mechanical obstruction. You cannot diagnose it by the size of the prostate or by looking at the bladder neck. The bladder neck is not mechanically tight, but fails to open up during a voiding contraction. It can occur in HIV disease.

You can easily insert a catheter, which drains quantities of urine, and cystoscopy shows trabeculation (hypertrophic submucosal muscle fibres) of the bladder. Medical treatment with prazosin, an α -blocker, 0.5-2mg may help.

(2) **BLADDER-NECK STENOSIS** is a mechanical obstruction due to fibrosis or previous prostatic surgery, or *schistosomiasis*. As with a urethral stricture, passing a catheter is difficult or impossible. Treatment is by incising the bladder neck, if possible endoscopically, deeply enough to divide all its circular fibres.

CYSTOSCOPY (27.3) is necessary to:

(1) exclude a urethral stricture,

(2) examine the size and nature of the prostate,

(3) show if there is bladder neck stenosis,

(4) assess the trabeculation of the bladder (evidence of long-standing obstruction) and presence of diverticula,

(5) demonstrate the presence of stones or carcinoma.

N.B. Never perform a urethral dilation in a woman unless there is a definite urethral stricture! (27.9)

27.7 Emergency (closed/blind) suprapubic cystostomy

If a patient has retention of urine, and you cannot pass a catheter, the alternative is to drain the bladder through the abdomen. As the bladder distends, it rises up above the pubis and strips the peritoneum off the abdominal wall.

This allows you to drain it without passing through the peritoneal cavity. Passing a catheter on an introducer is best if you have to continue drainage for more than a few days. Much less satisfactory is using a plastic tube and trocar or needle puncture, because there is nothing to stop urine leaking internally.

There are special kits to enable you to do this slickly. We describe what to do, if you don't have these.

INDICATIONS

(1) Acute obstruction with a full bladder, such as that from an enlarged prostate, a urethral stone, or a stricture when catheterization has failed.

(2) Urethral rupture.

CONTRAINDICATIONS

(1) An empty bladder. *Do not try closed suprapubic cystostomy if there is extravasation of urine.*

(2) Carcinoma of the bladder causing retention because a fistula track may form, which is very distressing, and carcinoma can spread to the abdominal wall.

So feel for a craggy rectal or suprapubic mass before you make a suprapubic puncture. Get an ultrasound scan if in doubt.

SUPRAPUBIC CATHETERIZATION (SPC)

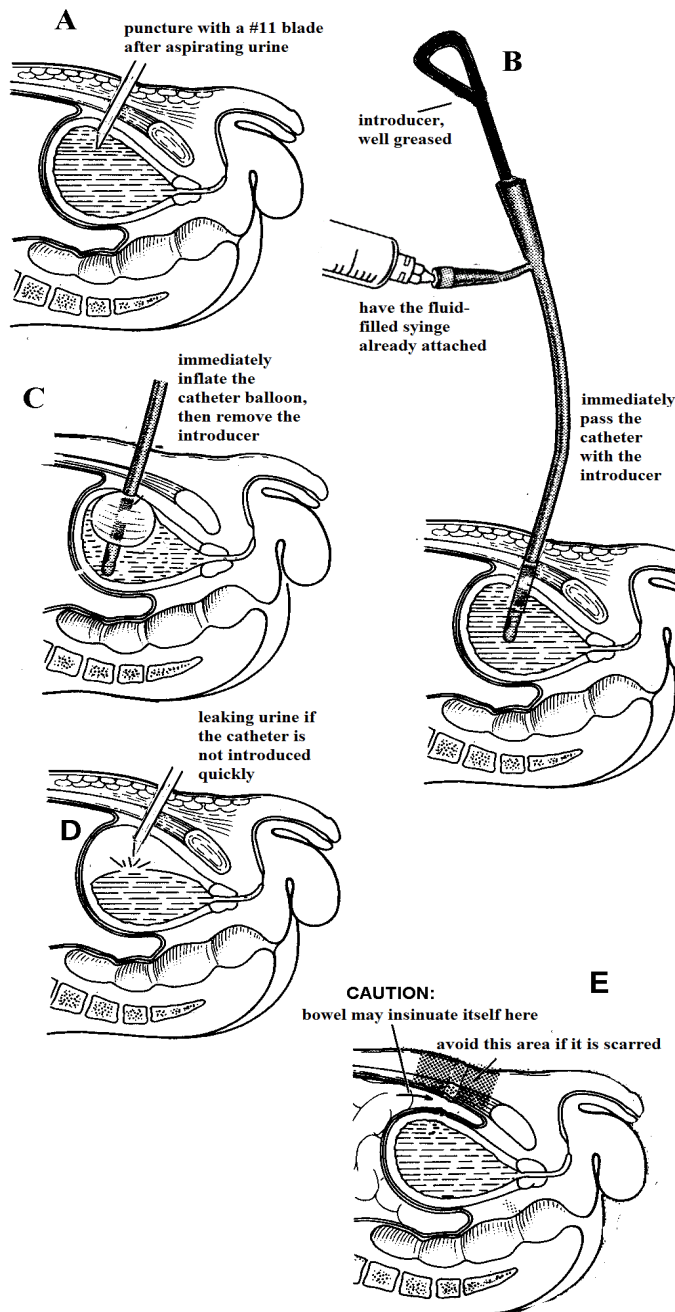


Fig. 27-9 EMERGENCY SUPRAPUBIC CATHETERIZATION (CLOSED/BLIND SUPRAPUBIC CYSTOSTOMY). A, puncture the abdominal wall and bladder with a #11 blade. B, introduce the catheter with introducer inside and syringe attached. C, immediately blow up the balloon when the catheter is inside the bladder. D, urine extravasating if you do not blow up the balloon quickly enough! E, if the peritoneum is tethered by a previous operation scar, you may traverse the peritoneal cavity and damage the bowel.

N.B. Note that in children the distended bladder becomes intra-peritoneal, so closed suprapubic catheterization is dangerous.

CAUTION!

(1) For a closed (blind) suprapubic puncture, the bladder must be distended and palpable. If it is not, wait for it to fill, or perform a formal open cystostomy (27.8).

(2) The classical site for drainage is half-way between the pubis and the upper limit of bladder dullness.

If the patient is to have a prostatectomy later, perform the cystostomy (drainage) as high as you can, so that you can open the abdomen below later, without entering the cystostomy track.

PREPARATION.

Make sure you have all the equipment ready that you need: this is important, because you will otherwise find urine flowing out uncontrolled when you stab open the bladder, and then have to perform an open cystostomy!

Have ready a well-lubricated catheter, already mounted on an introducer, with a filled syringe attached to the balloon channel.

INCISION. (GRADE 2.1)

Scrub up and put on sterile gloves. Check the outline of the bladder by preference using ultrasound. Infiltrate the site of puncture with LA in the midline. Continue to infiltrate down to the bladder; when you get there, confirm it is distended by aspirating urine into the syringe. Keep the bladder steady by placing your left hand on its dome. Make a small cut with a #11 blade (4-1) in the midline half-way between the dome of the bladder and the symphysis pubis. Push this in the same direction as that taken by the needle you used to aspirate urine, till you feel you have punctured the bladder wall (27-9A).

Immediately, when you see urine coming out, pass the catheter with its introducer into the bladder (27-9B) and *blow up the balloon* (27-9C). *Do not delay!*

CAUTION!

(1) *Avoid suprapubic scars:* if the peritoneum is adherent to the abdominal wall, you may injure the bowel. It is quite acceptable to make your puncture wound 2cm lateral to the midline, but *beware the inferior epigastric vessels!* Use ultrasound if possible to check the position of the bladder.

(2) Puncture the abdominal wall in the direction of the lower sacrum. *Do not direct the catheter too caudally you may enter the retropubic space and fail to enter the bladder. Do not direct it too cranially, you may enter the abdomen and possibly injure the bowel.*

Drain the urine into a urine bag. Make sure there is a daily fluid intake of at least 3l/day: a generous fluid intake is the best way of preventing or clearing infection.

If there is a urethral stricture, drain the bladder for 1wk before you attempt to deal with the stricture.

Before removing a suprapubic catheter, clamp it. You can then estimate the residual urine by measuring the volume which drains through the tube, after a good passage of urine *per urethram*. If there is no residual urine you have succeeded.

DIFFICULTIES WITH EMERGENCY SUPRAPUBIC CYSTOTOMY

If urine fails to flow readily, first check that the catheter tube is patent by flushing it with sterile water.

If there is still no urine flow, suspect extravasation of urine into the suprapubic space (27.12), which will result in spreading cellulitis or Fournier's gangrene (6.23); or urinary leak into the peritoneum. Perform an open suprapubic cystostomy (27.8) and leave an extravescical drain.

If there is heavy or prolonged bleeding, suspect a bladder tumour, or damage to the bladder neck or prostate. Abandon the procedure and perform an open suprapubic cystostomy.

If there is bowel content in the catheter, you have punctured small or large bowel! Perform a laparotomy and repair the perforation (14.3) and thoroughly lavage the abdomen; *do not forget to place a catheter formally in the bladder*, through a separate stab incision!

27.8 Open suprapubic cystostomy

If the bladder is not distended, and you should divert the urine flow, you cannot make a closed (blind) suprapubic cystostomy, so you have to use the open method.

INCISION.

CONTRAINDICATIONS.

Carcinoma of the bladder (common in areas where *schistosoma haematobium* is endemic), because it may lead to a permanent and distressing urinary fistula.

Make a midline vertical suprapubic incision. A 5cm incision is adequate unless there is excess fat. Divide the *linea alba*, and retract the rectus muscles. Use your forefinger, covered with a gauze swab, to push the connective tissue and peritoneum upwards, away from the anterior surface of the bladder. Dissect the loose fatty tissue away anterior to it.

The bladder may be empty as the result of extravasation of urine due to trauma or a stricture. A similar operation is needed for the removal of a stone or foreign body from the bladder (27.16).

METHOD (GRADE 2.2)

INDICATIONS.

- (1) Extravasation of urine (27.11).
- (2) Rupture of the bladder.
- (3) Intractable urinary clot retention.
- (4) Extraction of a bladder stone or foreign body.
- (5) An impassable urethral stricture.
- (6) During open prostatectomy (27.20) or laparotomy for another reason.

OPEN SUPRAPUBIC CYSTOTOMY

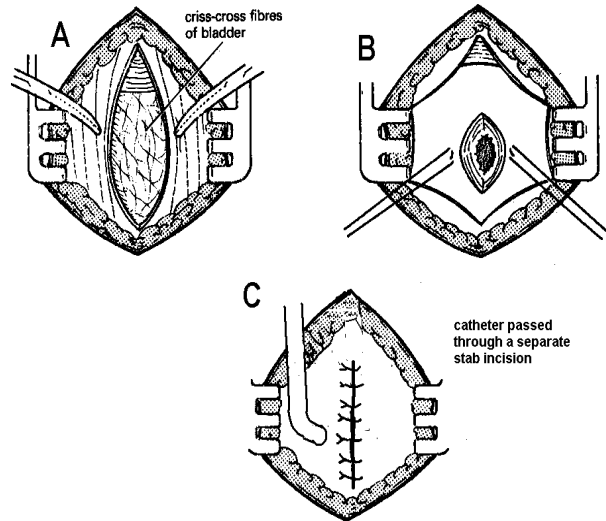


Fig. 27-10 OPEN SUPRAPUBIC CYSTOTOMY.

A, midline incision (avoid using a Pfannenstiel incision). The cystostomy tube should emerge half-way between a patient's umbilicus and the symphysis. Part the rectus muscles to reveal the criss-cross fibres of the bladder. **B**, open the bladder between stay sutures. **C**, close the bladder in 2 layers. Make a separate stab incision for the catheter so that there will be less likelihood of a leak when it is withdrawn.

After Blandy J. *Operative Urology*, Blackwell 1978 Figs. 8.14-24 with kind permission.

Recognize the bladder by its characteristic pale appearance with some tortuous blood vessels on its surface. Aspirate it first, unless it is impalpable (as with trauma causing extravasation). Insert stay sutures, superiorly and inferiorly, at the proposed ends of your vertical bladder incision. They will make useful retractors when it sinks into the pelvis. Open the bladder with a longitudinal 5cm incision, take urine for culture, and explore the bladder with your finger.

If you are going to leave a suprapubic catheter in place, pass a Foley catheter into the bladder through a separate stab incision above or to the side of the main one. Make it a snug fit and hold it in place with a purse-string suture.

Close the main bladder incision with 2 layers of 2/0 or 1/0 absorbable sutures. Close the wound with the catheter emerging through a long, oblique, mid-line track. Extend the wound proximally if necessary. If it is likely to be infected by contaminated urine, as it may be if you are operating for extravasation, insert an extravescical drain.

CAUTION! Make sure the suprapubic catheter emerges through a different incision laterally, so that the track closes easily, and will not interfere with an approach to the bladder later.

Change the catheter monthly or 3-monthly if you have a silicone catheter. Once a track has been established after the first 10-14days, you should have no difficulty replacing the catheter. *Replacing it earlier may be almost impossible*. If the replacement catheter does not pass easily, introduce a guide wire along the track.

Dilate the tract gently and then slide the catheter along the guide wire. To do this, cut a hole *longitudinally* at its end, so it slides along easily. *Do not cut the catheter transversely at its end*, because this creates a sharp edge which does not easily pass along an irregular track.

CAUTION! *Do not leave a persistent urinary fistula without a catheter in place* as this is distressing causing a smell and permanent wetting of clothes. This will mean certain infection, and the probability of an early death.

27.9 Urethral strictures

Gonorrhoea is the most usual cause of urethral stricture in men everywhere. Some strictures are the late results of *schistosomiasis*, prostatectomy, tuberculosis, trauma, or instrumentation of the urinary tract. Whatever its cause, you should try, if possible, to get a urethrogram, urethroscopy, and the release of the stricture with an optical urethrotome.

Strictures can be of any length from 0.5-10cm. The commonest sites for gonococcal stricture are:

- (1) the bulbar urethra (27-18), and rarely
- (2) at the junction of the penis and scrotum,
- (3) in the glans penis. Gonococcal strictures are the result of fibrosis in the corpus spongiosum. Meatal strictures are different (27.31). Traumatic strictures due to instrumentation occur usually in the prostatic urethra, but from external pelvic injury in the anterior urethra.

A urethral stricture increases the resistance to micturition, which causes the detrusor muscle of the bladder to hypertrophy. This may produce an adequate flow initially, but as time passes, sacculations and diverticula form in the bladder; it no longer empties completely, and the high residual urine it contains leads to frequency of micturition, and infection. Sensation is diminished, as its wall is increasingly replaced by fibrous tissue. Finally, the result is 'retention with overflow', and incontinence. Bilateral hydronephrosis develops as high pressure is transmitted to the ureters, and thus secondary renal failure (obstructive uropathy) results.

Apart from acute painful retention, and chronic painless retention with overflow incontinence, the many other complications of urethral stricture include:

- (1) False passages.
- (2) Periurethral abscesses (6.18) causing extravasation of urine, with gross distension of the penis and scrotum (sometimes leading to gangrene), and external fistulae.
- (3) Infection of the urinary tract.
- (4) Infection of the seminal vesicles, epididymes, or testes.
- (5) Chronic non-specific infection ending in elephantiasis.
- (6) Obstructive uropathy ending in renal failure.
- (7) Bladder neck stenosis, and detrusor failure. These are common and may explain why bouginage and external urethroplasty often fail.
- (8) The results of straining, such as hernias or prolapse of the rectum.
- (9) Stones in the urethra and bladder (27.16,17,18).
- (10) Infertility and impotence.

Urethral strictures can be dilated, although they are never cured. *The problem with dilation is that you can very readily traumatize the longer male urethra further and worsen the stricture, or create a false passage by perforating it. This is a disaster.* Try, by all means, to treat strictures under direct vision with an urethrotome.

If this is impossible, and it is not feasible to leave a suprapubic catheter *in situ*, you may be justified in attempting dilation. However, *do not do this with rigid sounds, and do not do this for:*

- (1) *Acute retention of urine,*
- (2) *Prostatic or peri-urethral abscess;*
- (3) *Extravasation of urine.*

Use sedation, but avoid GA as you will then not know how much you are traumatizing the urethra. Administer gentamicin IV pre-operatively. Preferably, only use soft filiform bougies. These are long thin flexible nylon rods which you introduce into the urethra till they reach the point of the stricture. Thread these into the urethra one by one, till one of the bougies passes into the bladder. The bougies have a thread on the distal end, onto which you can screw the follower of greater size. *Dilate the stricture by not more than Ch2 on each occasion!* Full dilation requires many repeated bouginages, until you can easily, and completely atraumatically, pass a metal sound.

The optical urethrotome is a very useful instrument to learn how to use, and useful to obtain.

If you are not experienced, use it with great care.

The aim is to make a cut anteriorly in the stricture (at the 12 o'clock position) and occasionally at the anterolateral (4 & 8 o'clock) positions if the stricture is dense. You can do this under LA if you introduce lidocaine jelly, leave it in the urethra for 5mins using a penile clamp. Generally leave a Ch16 urinary catheter *in situ* 7-10days post-operatively and arrange follow-up dilations (best done with plastic sounds by the patient himself at home). You can do a great deal of harm by enthusiastically dilating urethral strictures blind: leave this for an expert. In the absence of urethrotomy, it is best to divert the urine flow, and allow the expert deal with a simple stricture, than to ask him to deal later with a complicated stricture which may prove impossible to negotiate.

Prostatic obstruction is the main differential diagnosis (27.19). Chronic retention distends the bladder greatly, but is painless, so that decompression is not needed so urgently as it is in acute retention.

Urethral strictures in women occur often in combination with vesico-vaginal fistula (21.18), after mutilating surgery, or in the elderly due to perineal contracture. The urethra is short and usually amenable to simple dilation.

LATE COMPLICATIONS.

If there is a tender painful swelling in the perineum, this is probably a PERI-URETHRAL ABSCESS (6.18), which may or may not be associated with retention of urine. The diagnosis is not difficult, but you can easily overlook it in the presence of retention of urine.

If the testes & epididymes swell, this is an acute epididymo-orchitis. Treat non-operatively with ampicillin or trimethoprim.

If the perineum, lower abdomen or penis swell, this is due to EXTRAVASATION of urine (27.13). Multiple fistulae may develop with gross thickening of the peno-scrotal skin (27-12).

If stones develop, they are the result of infected stagnant urine, and may form in the dilated urethra proximal to the stricture. They will remain until removed by cystotomy or urethrotomy. Treat the infection, and arrange intervention for the stricture.

N.B If there is HAEMATURIA without instrumentation, there may be a bladder tumour (27.5). Get an Ultrasound scan (38.2H).

PERINEAL URETHROSTOMY

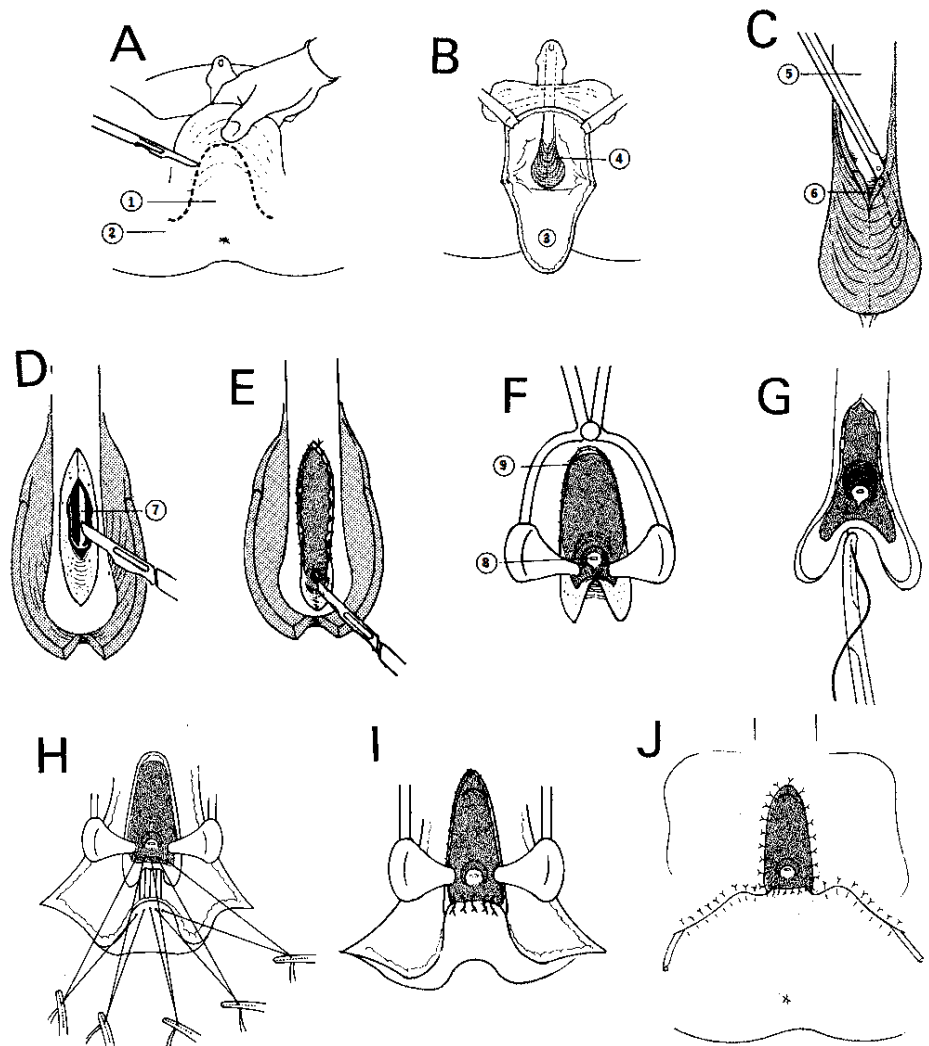


Fig. 27-11 PERINEAL URETHROSTOMY. This is the 1st stage of Blandy's urethroplasty.

A, outline the flap. (1) scrotal flap, (2) ischial tuberosities. B, allow the flap to fall down. (3) flap reflected, (4) bulbospongiosus. C, reflect the bulbospongiosus from the bulbar urethra. (5) urethra. (6) bulbospongiosus incised. D, open the urethra on to a bougie (7) just distal to the stricture. E, oversew the edges of the corpus spongiosum for haemostasis. F, inspect the urethra with a nasal speculum, and continue to incise it, until you emerge into healthy mucosa, and can see the verumontanum (8) proximally. (9) sutured edge of the corpus spongiosum. G, insert sutures at the edge of the divided urethra to evert it. H, lead 5 sutures through the apex of the flap. I, tie the top 5 sutures, bringing the flap to the edge of the opened-out urethra. J, likewise approximate the advancement scrotal skin flap to the opened urethral edge all round. From Blandy J, *Operative Urology*, Blackwell, 1978 Figs 14.43-6, with kind permission.

27.10 Impassable urethral strictures

A stricture which you cannot dilate or open is a difficult problem. If it is short and of traumatic origin, you may be able to excise it, and anastomose the ends of the urethra end-to-end. If however it is the result of inflammation, it is likely to be longer, and needs a formal urethroplasty in at least 2 stages, in which a new urethra is made with scrotal skin. This is a lengthy and difficult procedure and is work for an expert. There are, however, some simpler options:

- (1) A permanent suprapubic cystostomy (27.8),
- (2) A perineal urethrostomy. This is part of the 1st stage of Blandy's posterior urethroplasty.

This will result in a permanent orifice, through which urine is passed 'like a woman'. It will not affect potency, but it may be very embarrassing having semen coming out of 'the wrong place'!

The 1st stage of a posterior urethroplasty is not easy, but is much easier than the 2nd. Even the 1st stage may give much relief, and is much better than a permanent suprapubic catheter, but it is not easy to get a good channel which will not stenose; also bleeding can be a nuisance.

It is feasible for an impassable stricture anywhere in the urethra, even as high as the verumontanum.

PERINEAL URETHROSTOMY (THE 1ST STAGE ONLY OF A POSTERIOR URETHROPLASTY). (GRADE 3.2)

INDICATIONS. Impassable strictures.

PREPARATION. Make sure the perineum is washed and perfectly clean. Put the patient in the lithotomy position. Shave the perineum, and prepare the skin with care.

METHOD. Make an inverted 'U'-shaped scrotal flap with rather a flat apex to end just in front of the ischial tuberosities (27-11A). The key to the operation is access, so the flap must go far back. Cut through the skin and *dartos*, tying and coagulating vessels as you go, and allow the flap to hang down.

CAUTION!

- (1) Allow a generous lining of fat on the flap.
- (2) *Do not disturb the vessels in its base.*
- (3) *Do not use diathermy on the flap, or you may cause flap necrosis.*

Pass a Ch24 bougie down to the tip of the stricture, and ask your assistant to hold it in the midline. Feel for it, and dissect down to it, until you see the *bulbospongiosus* muscle (27-11B). Dissect the muscle from the bulb and reflect it on either side (27-11C). Cut down on to the bougie (27-11D), and immediately insert a 4/0 continuous absorbable suture on either side of the cut *corpus spongiosum*, to prevent bleeding from this spongy tissue. Incise until you have completely opened the stricture and you reach healthy tissue; in a bulbar stricture you may have to cut almost to the bladder within a few mm of the verumontanum. Cut 1cm at a time, and control bleeding by continuing your haemostatic suture down each side of the split *corpus spongiosum* (27-11E). *Do not divide the external sphincter just distal to the verumontanum.*

CAUTION! *Be sure to continue the incision the full length of the stricture.* The only way to be sure about this is to pass your finger past the stricture, to make sure there are no strands of fibrous tissue remaining.

Inspect the stricture and the verumontanum with a nasal speculum (27-11F). Divide all fibrous bands until you see the verumontanum. This is normally a cystoscopic landmark, and is a posterior midline swelling in the urethral mucosa. It is just proximal to the external sphincter and the ejaculatory ducts open onto it. Then pass 5 interrupted 3/0 absorbable sutures through the flap onto the opened urethra (27-11G). Attach each haemostat to the drapes, so that they cannot be muddled up (27-11H). Push the flap towards the bladder. Tie one throw on each knot until it is tight. Reinsert the speculum, and check that the edge of the flap is neatly up against the defect in the urethra, before completing the series of knots. If not, readjust and replace the suture which was at fault. When you are sure the flap is in the right position, put several more throws on each knot, and cut their free ends. Withdraw the speculum and complete the work of suturing in the flap, trimming away surplus skin where necessary (27-11I). Use fine monofilament to bring the edges of the scrotum to the edges of the urethra, previously exposed (27-11J). Leave the catheter *in situ*.

POSTOPERATIVELY, treat with frequent baths or a douche, remove the catheter at 5days, and the sutures, after premedication, at 14days. Make sure that there are no cross-adhesions between the suture lines. If a tissue bridge has formed, separate it, and ask him to keep the passage open by inserting a sound daily in the bath.

DIFFICULTIES WITH A PERINEAL URETHROSTOMY

Curiously, incontinence is uncommon.

If the tip of the scrotal flap necroses, take it down, trim it and resuture it; there is usually plenty of skin left.

If a haematoma forms, return to theatre, take down the wound, evacuate it, and secure haemostasis.

27.11 Urethral fistula

A proximal urethral fistula in the male is usually the consequence of a periurethral abscess, but may arise spontaneously, particularly with HIV disease. Multiple fistulae may involve the perineum, scrotum, penis, perianal region and inner aspects of the thighs (27-12). Sometimes a fistula forms between the urethra and the rectum.

SPECIAL TESTS. Try to delineate the stricture with a urethrogram (38.1) and urethroscopy.

A 'WATERING CAN' PERINEUM

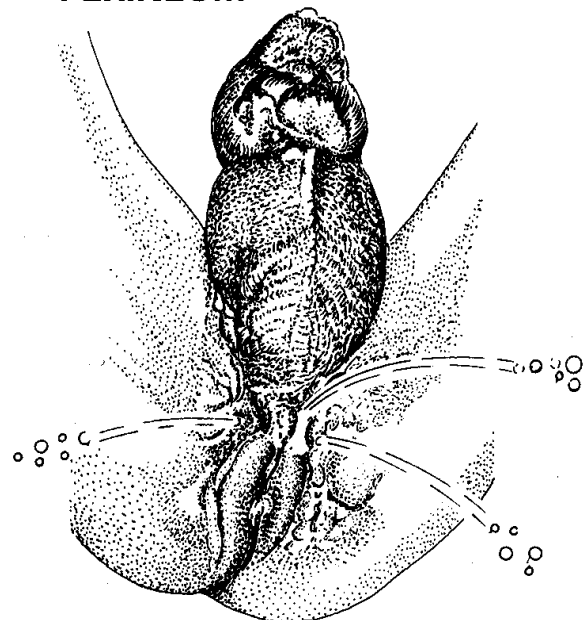


Fig. 27-12 A 'WATERING-CAN PERINEUM' is the late result of a complex gonococcal, or rarely a tuberculous stricture. Multiple chronically infected and epithelialized fistulae have involved the penis, scrotum, perineum and thighs. A slow ooze of purulent discharge is more usual than the shower of urine shown here.

Kindly contributed by Neville Harrison

If the fistula is recent, divert the urine by an open suprapubic cystostomy (27.8), culture the urine from the bladder and use the appropriate antibiotic, and after 6wks clamp the suprapubic catheter to see if urine still leaks. If it does, repeat the process for a further 6wks, and if this fails, the patient needs an optical urethrotomy (27.9).

If the fistula is chronic, divert the urine by an open suprapubic cystostomy and excise the fistula track. If there are many, this may be impossible, forcing you to leave a permanent urinary diversion in place. Consider the possibility of TB or carcinoma, and take a biopsy.

If there is a congenital recto-urethral fistula, it is usually associated with an imperforate anus (33.6).

A distal urethral fistula is usually the result of trauma, either from a crude circumcision, or from penile piercing with rings. Correction requires an operation similar to a hypospadias repair (33.9).

A urethral fistula in women is invariably associated with a vesico-vaginal fistula (21.18)

27.12 Extravasation of urine

The effects of extravasated urine are dramatic. The combination of urine and infection produces severe oedema of the scrotum and abdominal wall. Untreated, the skin over the scrotum, penis, and anterior abdominal wall may slough. This results in Fournier's gangrene (6.23) with consequent severe illness, toxicity, fever, dehydration, anaemia, and uraemia. If renal function is impaired, as it often is after a long-standing stricture, extravasation may be fatal.

Urine can extravasate from a stricture spontaneously especially with HIV disease, through a periurethral abscess, or as the result of bouginage or other types of trauma. The attachments of Camper's & Scarpa's, Buck's and Colles' fascia limit the spread of urine so that from a defect in the bulbous urethra it can track into the scrotum, up over the pubis and into the lower abdominal wall. However, from a defect in the more distal penile urethra the urine leaking is limited to the penis.

PREPARATION

Replace fluids IV, which may be life-saving, and correct electrolyte disorders. Treat with IV chloramphenicol, gentamicin and metronidazole. Counsel the patient that urinary diversion may be long-term. Exclude cardiac, renal, and hepatic causes of oedema.

METHOD

(1) **DIVERT THE URINE FLOW** so that it no longer leaks into the tissues. Perform a formal open suprapubic cystostomy (27.8).

(2) **DRAIN THE URINE OUT OF THE TISSUES.**

Make 5cm incisions on each side of the base of the penis. Insert your index finger, and open up the tissue planes widely towards the abdomen, and down the shaft of the penis. Then make 5cm incisions on the inferolateral aspects of the scrotum, and use your finger to open up the tissue planes as far as possible (27-13).

EXTRAVASATION OF URINE

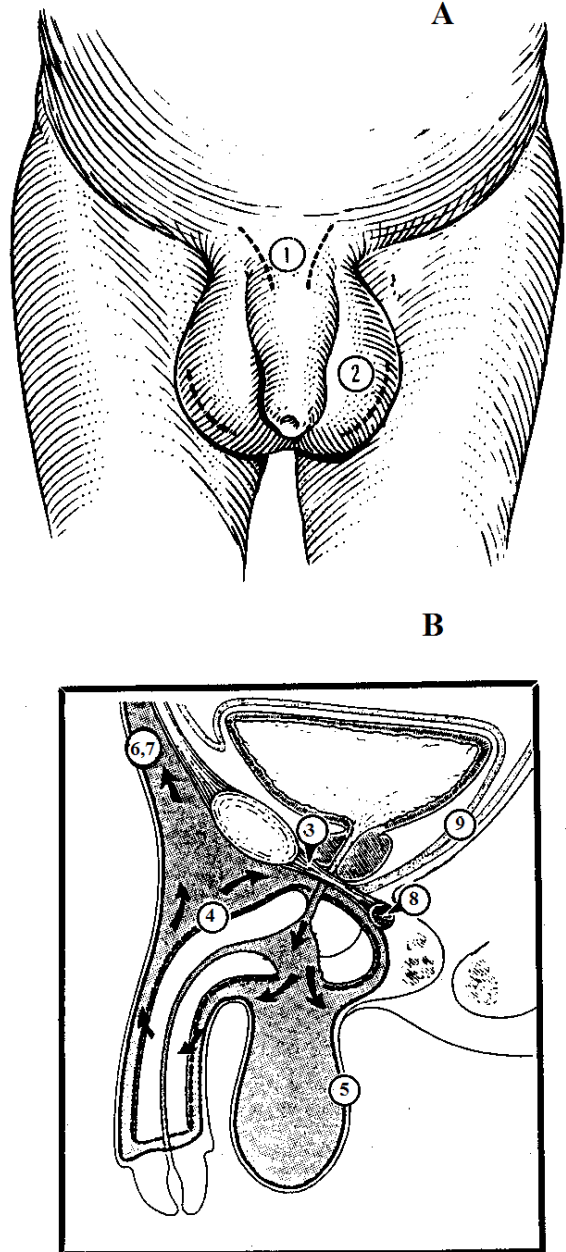


Fig. 27-13 EXTRAVASATION OF URINE.

Subfascial areas where extravasated urine may collect. A, incisions for drainage. B, drawing showing the directions in which urine can track.

(1-2) incisions for drainage. (3) triangular ligament. (4) Buck's fascia. (5) Colles' fascia. (6,7) Camper's (superficial) & Scarpa's (deep) fascia. (8) transversus perinei muscle. (9) Denonvillier's fascia.

A, from Dudley HAF (ed) Hamilton Bailey's Emergency Surgery. Wright 10th ed 1977 Fig 50.11 with kind permission

Place 2 long corrugated rubber drains (4-14B) into the depth of each wound in each direction, and suture them in place. Dress the wounds with gauze and cotton wool. Arrange daily baths. The swelling will usually settle in about 5 days. Shorten the drains 5cm/day.

If you find any areas of necrotic skin and subcutaneous tissue, debride these radically, otherwise Fournier's gangrene (6.23) will result. When infection has subsided, close the skin incisions by secondary suture, and graft the bare areas unless it has healed spontaneously.

(3) **LATER, DEAL WITH THE UNDERLYING STRICTURE.** Allow inflammation to settle for at least 4-6wks; change the suprapubic catheter after 4wks.

27.13 Urinary tract stones

Stones in the urinary tract vary greatly in their prevalence. For example, they are common in North India and the Sudan, but are rare in East and Central Africa. In the 'stone belts' of Southeast Asia and South America, they are very common, even in children. You should be able to:

- (1) Relieve the excruciating pain of renal colic.
 - (2) Make a nephrostomy for calculous anuria: this can be life-saving, but is rarely needed.
 - (3) Remove a ureteric stone (27.15).
 - (4) Remove a bladder stone in an adult (27.16) or child (27.17).
 - (5) Remove a stone impacted in a child's urethra (27.18).
- Removing a stone, however, from the kidney or renal pelvis, is a task for an expert.

Stones are of 2 kinds:

- (1) Primary or metabolic stones.
- (2) Secondary stones resulting from obstruction, or repeated infection. Primary stones are most common in men of 30-50yrs, and usually form in the renal pelvis or else in the lowermost calyx.

The size and position of a stone determines what effect it has. If it is small, and remains in the periphery of the kidney, or in a calyx, it may cause few symptoms; if it enlarges it may obstruct part of the kidney. A small stone <7mm diameter usually passes down the ureter, causes acute ureteric colic as it does so, and later is voided in the urine. If it is too big to pass, it may obstruct the upper end of the ureter, and cause hydronephrosis which will ultimately destroy the kidney.

Stones in the bladder do not usually return when you remove them, but those in the upper urinary tract do so with a 50% chance during the next 10yrs. The most useful preventive measure is a high fluid intake.

Most stones are radio-opaque, so learn where to look for them; an occasional exception is a urate stone in a child's bladder, but even these usually contain enough calcium to let you see them on a radiograph.

SPECIAL TESTS. The presence of microscopic haematuria is the most useful test. If there are pus cells, or a patient's urine is alkaline, it is infected.

RADIOGRAPHS. Take a plain radiograph of the kidneys, ureters and bladder (a slightly oblique abdominal view). You can easily miss a stone if:

- (1) the radiograph is poor,
- (2) the stone is only moderately radio-opaque,
- (3) it is obscured by bone or dilated bowel.

URINARY TRACT STONES

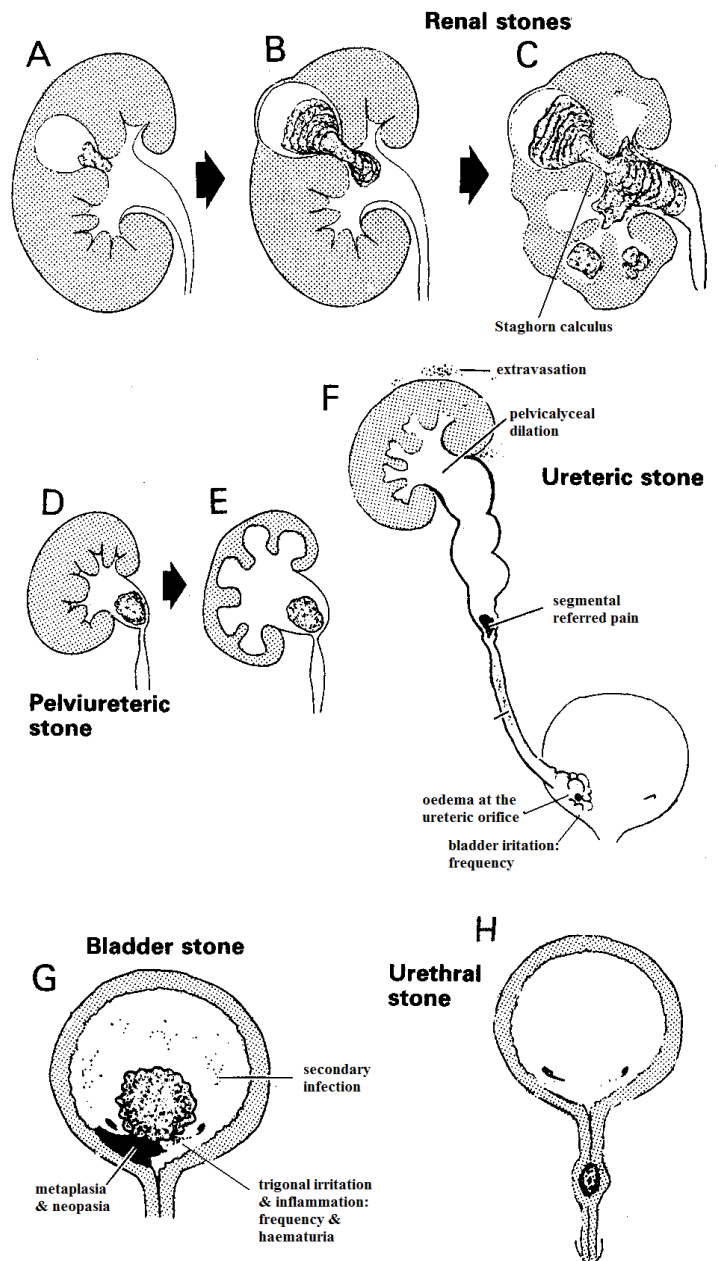


Fig. 27-14 STONES IN THE URINARY TRACT.

A, stone jammed in a calyx causing hydrocalyx. B, atrophied parenchyma over the dilated calyx. C, staghorn calculus formed, with several stones elsewhere in the kidney. D, stone impacted at the pelviureteric junction. E, calyces dilated and renal parenchyma compressed. F, stone in the ureter causing loin pain, segmental referred pain, haematuria, and frequency. G, bladder stone with squamous metaplasia ending in carcinoma. H, stone in the urethra.

After Blandy J. *Operative Urology*, Blackwell 1978 with kind permission.

Look for kidney stones opposite the second lumbar vertebra, and for ureteric stones, as the ureter crosses the tips of the transverse processes of the lumbar vertebrae, runs over the sacroiliac joint, and descends in a gentle arch to a point just medial to the ischial spine, from where it turns medially to enter the bladder.

Do not mistake a gallstone, a phlebolith (calcified thrombus), or a calcified lymph node, for a urinary stone. Most ureteric stones are slightly elongated and *not round*. In a lateral view of the abdomen: gallstones are anterior; renal and ureteric stones overlie the lumbar spine.

AN INTRAVENOUS UROGRAM (IVU: 38.1H) will confirm the diagnosis. If no contrast medium is excreted on one side, that kidney has stopped functioning, or is excreting so slowly that you can be sure function is impaired. You will find the site of an obstructing stone that is not visible on a plain radiograph easily only if there is still some function remaining. Take exposures immediately at 1hr immediately after emptying the bladder, so that contrast medium does not obscure a stone at the lower end of the ureter; then at 3, 12 and even 24hrs. Enough contrast medium may then have accumulated to show up the urinary tract, down to the site of the obstruction.

If contrast medium is concentrated in the kidney (a 'nephrogram'), but does not show up in the renal pelvis, a stone may have blocked the pelvi-ureteric junction (27-14E), and caused the contrast medium to be retained in the kidney tissue. This is a hopeful sign, because it shows that there is still good renal function.

N.B. Clots in the ureter, and small calculi, may cause colic especially if the ureter is narrowed by schistosomiasis or tumour.

ULTRASOUND: will demonstrate most stones easily in the bladder because of their 'acoustic shadow' (38.2H), but not so readily in the ureter or kidney. It may be helpful with the differential diagnosis and follow-up in checking for hydronephrosis. If a ureter is completely blocked, no spurt will be visible on Doppler from the ureteric orifices.

DIFFERENTIAL DIAGNOSIS.

If there is moderate pain in the costovertebral angle, a high fever, chills, an obviously infected urine, and an ultrasound shows that the renal pelvis and calyces are normal, acute pyelonephritis is present.

If there is a palpable tender renal mass, this is probably hydronephrosis. If in addition there is fever, toxæmia, and leucocytosis, it is probably a pyonephrosis.

If there is a dull ache, with occasional fever and pyuria, suspect that there is a stone which is not obstructing the urinary tract.

If there is anuria and renal failure, this can be due to the presence of bilateral stones, but it is more likely to be due to chronic interstitial nephritis or pyelonephritis.

CAUTION! Some stones cause no symptoms, even when they are large.

If there is right iliac fossa pain and fever, this may be appendicitis (14.1) or PID (23.1) in a female, especially with tenderness on rectal or vaginal examination.

TREATMENT FOR URINARY STONES

If there is a small kidney stone (<7mm), which is peripheral in the kidney, and is causing no symptoms and no infection, leave it, but watch it carefully, to see if it gets stuck at the uretero-vesical junction and causes obstruction.

If a stone is obstructing the renal pelvis, try to remove it. The risk of hydro- or pyo-nephrosis is high. If there are stones on both sides, operate on the side with the better function first.

If there is renal colic for a few days, after which oliguria, and then anuria gradually develop, this can arise from bilateral obstruction, or, more commonly, from the obstruction of a solitary functioning kidney. Catheterization of the bladder produces no urine. A plain film may confirm the diagnosis. The blood urea rises. The episode may relieve itself spontaneously as the result of the oedema in the ureter settling, and the infection being brought under control. Observe for 24-48hours.

If you have a cystoscope and can pass a ureteric catheter, it may slide past the stone and produce urine; you can then leave it in place for 2-3days, which will relieve the acute situation. Or the catheter may dislodge the stone back into the renal pelvis. If there is no rapid improvement, urgently fashion a nephrostomy (27.14).

If there is a stone stuck in the ureter, you should remove it extraperitoneally unless you can let the urine drain from above it (27.15).

If there is a uric acid stone, try to raise the pH of the urine. Make it alkaline with sodium bicarbonate tablets tid, or potassium citrate mixture 20ml tid. If possible, measure the serum urate. Treat with allopurinol if there are recurrent uric acid stones, or an elevated urate.

If the serum [Ca²⁺] is consistently high, it suggests a parathyroid adenoma, or some other generalized disease. A raised urinary calcium is more common; advise against taking calcium supplements.

TO PREVENT RECURRENT STONES encourage plenty of fluids and treat any associated infection.

27.14 Nephrostomy for calculous anuria or hydronephrosis

If there is obstruction of the upper urinary tract in the ureters or the pelves of the kidneys, life is only in danger if both sides are obstructed simultaneously, or there is obstruction in a solitary kidney.

When this happens no urine is passed and soon death comes from renal failure, unless something is done quickly. Obstruction can be the result of:

(1) *Schistosoma haematobium* causing strictures at the junctions of the ureters and the bladder, so producing hydronephroses.

(2) Stones obstructing the renal pelves (or a staghorn calculus on one side, and no function on the other).

(3) Mistakenly tying both ureters at a hysterectomy (23.15) or Caesarean Section (21.11).

(4) Bilateral pelvi-ureteric junction obstruction.

A chronically obstructed kidney is usually large, so whenever you diagnose renal failure, always palpate for enlarged kidneys. Permanent relief of the obstruction requires expert surgery. Meanwhile, with luck, you may be able to keep a patient alive long enough, if you put a tube into one of the obstructed kidneys to decompress it. Chronic obstruction of this kind is not uncommon in areas where stones or *schistosomiasis* are endemic.

Open nephrostomy is not an easy operation, because the kidney is deep and difficult to get at. It is easier for schistosomal hydronephrosis of slow onset, than it is for stones, because the kidney is always large.

N.B. If you have ultrasound, it is much easier to drain the kidney by making a percutaneous track and dilating it serially; you may then be able to use this track to remove stones. However, this does require some special instruments.

Having exposed the kidney, you can either push a catheter through a dilated calyx, if you can find one, or you can open the renal pelvis and pull a catheter through the kidney into it. If a stone is the cause, and you can easily remove it, and the patient's condition is good, do so.

NEPHROSTOMY (GRADE 3.2)

If there are bilateral stones, decompress the side on which there has been more recent pain or discomfort, because this is the side which is most likely to regain its function.

POSITION. Use the lateral position with the kidney to be operated on uppermost (27-15B). If your table has a kidney bridge, place this at the 12th rib. Then raise the bridge, so as to open up the space between the rib cage and the pelvis.

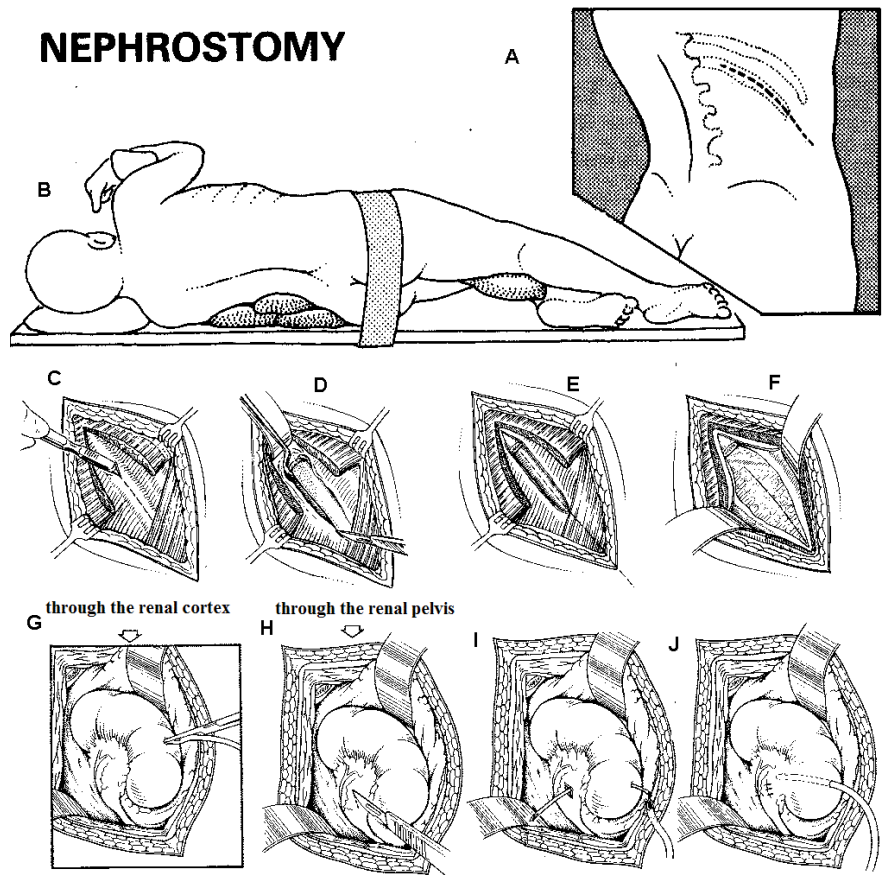


Fig. 27-15 NEPHROSTOMY

A, expose the kidney by an incision over the 12th rib. B, ready for surgery, with sandbags under the loin and the arm supported. C, cut *latissimus dorsi* and strip the periosteum over the 12th rib. D-E, remove the rib. Alternatively, cut just below the 12th rib but *do not* remove it. F, expose the perirenal fat. G, to drain a kidney through its cortex, push a catheter into a tense fluctuant area. H, to drain a kidney through its pelvis, make a short incision in the posterior of the renal pelvis, well away from its junction with the ureter. I, pass a probe through this incision out through the cortex of the kidney, and tie a catheter to it. J, the catheter in place.

If you do not have a kidney bridge, introduce 3 or 4 sandbags or folded pillows into this space.

If you have a table that can be broken (the head or foot end can be lowered separately), use it to give you more room.

Flex the lower knee, straighten the upper knee, and put a pillow between them. Support the upper arm on a cushioned Mayo instrument table, to prevent the trunk rotating. Take a wide strap, or a long piece of wide adhesive strapping, and wrap this round the pelvis and trochanters, so that the pelvis will not rotate. Have the patient leaning forwards a little, rather than strictly on the side.

INCISION.

Here we assume that you are going to remove the 12th rib. You can, if you wish, approach the kidney just below and parallel to it, without excising it, especially when the kidney is large, as with hydronephrosis. If necessary, make a short incision forwards from the last (12th) rib.

Mark the 12th rib with a felt pen (27-15A). Then clean an area about 20cm wide over the 12th rib, from the midline of the back to the umbilicus.

Stand at the back, and make a skin incision starting at the lateral margin of the *sacrospinalis*. Cut along the line you have drawn over the 12th rib. Proceed anteriorly, and stop 5cm short of the umbilicus, at the lateral margin of the rectus sheath. A shorter incision will suffice if there is a marked hydronephrosis.

You will have to cut through much muscle. If possible, use a cutting diathermy, turned down low enough to cut through muscle and coagulate the vessels in it at the same time. Or, use a scalpel, and carefully control the bleeding points as you meet them.

Start by cutting the *latissimus dorsi* over the 12th rib, until you can see the rib clearly (27-15C). Then remove it subperiosteally with a scalpel, or cutting diathermy. Cut the periosteum down the middle of the rib as far as its tip. Using a periosteal elevator, push the periosteum off its raw surface down its entire length. Reflect the flaps of periosteum. Take a curved periosteal stripper, and gently insert it under the distal part of the rib. Slide it up and down, until the rib is completely clear of periosteum (27-15D,E). Cut the narrow strand of *external oblique* attached to the tip of the rib. Use rib shears, or bone cutters, to cut off the rib as close to its neck as is convenient. *Do not push towards the neck of the rib*, it is too close to the pleura! Smooth its stump so that it will not tear your gloves.

Cut the 3 muscles of the anterior abdominal wall in line with the skin incision. Cut the first 2, the *external oblique* and *internal oblique*, boldly. When you get down to the *transversus*, stop temporarily. The peritoneum is under it, and you do not want to risk opening it and flooding it the peritoneal cavity with urine, or having bowel obscure your view.

Return to the bed of the rib, and use the tip of a scalpel to cut its lowermost half. Carry the incision down on to the remaining fibres of the *transversus* muscle. Split this in the direction of its fibres.

You will now see the peritoneum, with the liver and part of the colon under it (27-15F). Using a sponge on a holder, gently push the peritoneum down and away from you forwards and upwards. Use a self-retaining retractor to separate the rib cage above, from the crest of the ilium below, and so open up the whole area.

Feel for the kidney up against the posterior abdominal wall. If you are not sure if it is the kidney, try moving it up and down. Use a scalpel to make a short incision in the fascia over it. Insert your fingers, separate the perirenal fat, which may be extensive in an obese patient; and feel the shape, size, and consistency of the kidney. The tissues around it will probably be engorged and oedematous.

If the kidney is enlarged, soft and feels cystic, it is probably hydronephrotic, but it may be polycystic, in which case nephrostomy does not help. If it is hydronephrotic, it is probably safe to drain a dilated calyx through the cortex (A), without exposing the renal pelvis.

If the kidney looks and feels fairly normal, expose its pelvis, and put the drain there (B).

CAUTION!

(1) *Be careful not to damage the fragile and often flattened renal vein*, which enters the renal hilum anteriorly, and may cover part of the renal pelvis: this is why you should approach it from behind.

(2) The end of the catheter must go into the drainage system, and not into the kidney parenchyma itself.

A. NEPHROSTOMY THROUGH THE CORTEX is easier, but does not provide such good drainage. Choose an area on the convex surface of the kidney, where the renal parenchyma is thinly stretched over a tense fluctuant area, and which feels as if there is probably urine under pressure close below it. To confirm that you have found a dilated calyx or pelvis, aspirate it with a fine needle and syringe. Be sure that you are not dealing with an isolated renal cyst.

Make a ½cm incision into the kidney capsule over its convex border, and then plunge a fine haemostat into the fluctuant area. If urine pours out, you are in the right place. Suck it out. Take a small catheter, hold its tip with a haemostat, and push this far enough into the kidney to get a good flow of urine (27-18G). Remove the haemostat and leave the catheter in. If blood oozes around it, insert a haemostatic fine absorbable suture.

B. NEPHROSTOMY THROUGH THE RENAL PELVIS (PYELOSTOMY) drains a kidney better as it will drain all the calyces, but is more difficult, because you have to find access to the medial side of the kidney.

Turn the kidney forwards and medially, using finger dissection. When the perirenal tissues are oedematous and thickened, separating the kidney from surrounding fat is not difficult. You will see the tense distended renal pelvis as the most posterior of the structures at the hilum. Holding the kidney so as to expose the renal pelvis, confirm that urine is present by aspirating with a syringe and fine needle. Make a short incision in the renal pelvis, well away from its junction with the ureter. Urine should gush out (27-15H).

Pass a curved probe through this incision. With your other hand, feel for an area on the convex surface of the kidney, where its cortex feels thin. Carefully (to minimize bleeding) push the tip of the probe out through this point (27-15I). Tie the probe to a catheter, and draw it back and out through the kidney (27-15J). Close the pyelostomy opening with two fine absorbable sutures. If the kidney bleeds where the catheter emerges, apply a purse-string suture.

Bring the nephrostomy tube to the surface through a separate stab incision where it will not be occluded on lying down. Irrigate the tissues round the kidney, and close all the muscles over it in layers. Close the skin, and fix the nephrostomy tube. Finally, as an extra precaution, tape the nephrostomy tube to the skin. Connect it to a bedside collecting bottle.

If there is no area of thinned cortex, as may happen with a stone, remove the stone through an incision in the renal pelvis, and let the nephrostomy catheter drain from there.

If at any time you open the pleura, close it and put in a chest drain (9.1).

POSTOPERATIVELY, if urine drains freely, you have succeeded, and renal function should improve. Watch for the nephrostomy tube kinking or blocking. If it blocks, try irrigating it. You should replace, or remove, a silicone catheter after 3 months, and an ordinary one after 4 wks. There may develop a massive recovery diuresis, so make sure that you replace the lost fluid IV (27.6). He will need definitive surgery later, when his general condition permits.

27.15 Ureteric stones

The stone that obstructs the ureter originates in the kidney. Once it is free in the renal pelvis, it may pass into the ureter, and cause obstruction most likely:

- (1) at the entry of the ureter into the bladder,
- (2) at the pelvi-ureteric junction,
- (3) in the lower $\frac{1}{3}$ of the ureter, or
- (4) in the upper $\frac{1}{3}$ of the ureter.

A normal-sized stone may obstruct if there is a pre-existing stricture, typically due to schistosomiasis. A stone is usually rough, so that some urine can usually leak past it to begin with. Later, obstruction becomes complete, so that after some weeks or months, hydronephrosis or a hydroureter develop, which may become infected.

As the stone passes down the ureter, it causes severe ureteric colic: even a tiny stone causes agonizing sudden pain in the loin, radiating to the groin, perineum, and testis (or to a woman's labia). The patient vomits, sweats, and rolls about to get relief. If, at the same time, the urine is infected, there are fever and rigors. The urine may be 'smoky', but is seldom grossly blood-stained. There may be slightly tenderness in the area of the referred pain, and there may have been attacks like this before. If the stone impacts, the severe pain of ureteric colic gradually subsides.

There is an 85% chance that the ureteric stone will be passed into the bladder, and then out through the urethra. So administer plenty of fluids, and treat the pain.

DIFFERENTIAL DIAGNOSES include:

- (1) Appendicitis (14.1), especially retrocaecal, but this will only give colicky pain in its early phase.
- (2) Biliary colic (15.2)
- (3) Torsion of an ovarian cyst or uterine fibroid.
- (4) PID (23.1).
- (5) Colic due to the passage of blood clot in the ureters, resulting from trauma, or a neoplasm.

REMOVING A STONE FROM THE MIDDLE AND LOWER THIRDS OF THE URETER

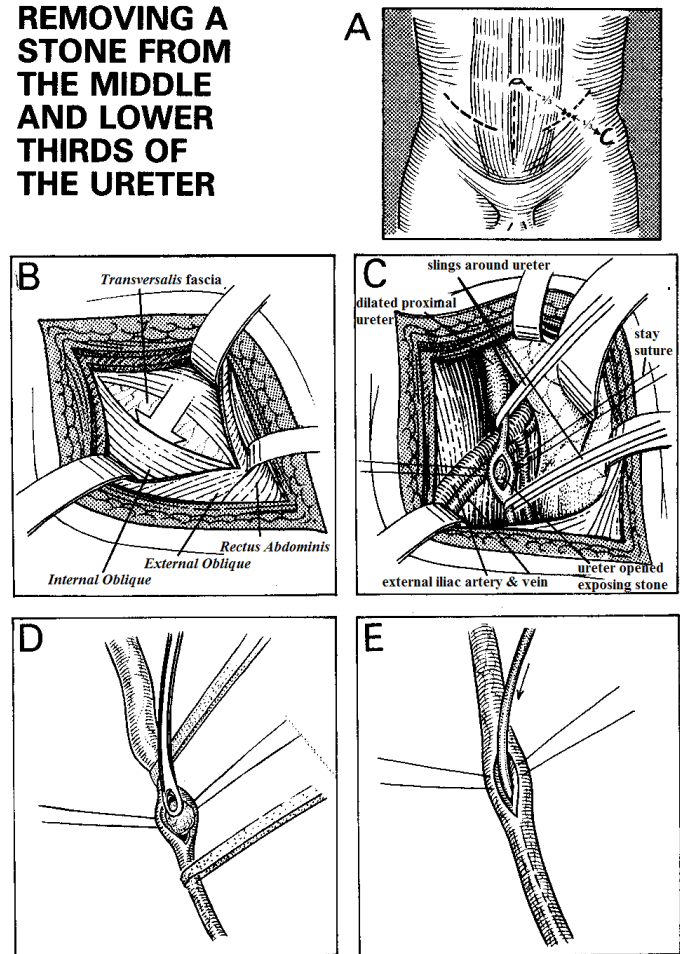


Fig. 27-16 REMOVING A STONE FROM THE MIDDLE & LOWER $\frac{2}{3}$ OF THE URETER.

A, centre the incision on McBurney's point; for the middle $\frac{1}{3}$ carry it laterally in the line of the inguinal ligament, for the lower $\frac{1}{3}$ carry it medially in the line of this ligament. Alternatively, for the lower $\frac{1}{3}$ use a midline incision. B, divide the external oblique in the direction of its fibres. Cut the internal oblique to expose the transversalis fascia. C, sweep the peritoneum medially to the bifurcation of the common iliac artery. Find the ureter and the stone. Pass catheters, or tapes, round the ureter above and below the stone. Cut on to it with a small knife. D, carefully remove it with Desjardin's forceps. E, pass a thin paediatric feeding tube upwards and downwards to check patency. Leave the ureter open and insert a drain.

Kindly contributed by Samiran Nundy.

SPECIAL TESTS (see 27.13)

MANAGEMENT.

Leave a stone of <7mm to pass spontaneously, unless there is some complication. A bigger stone is less likely to pass. An impacted stone may remain in the ureter for weeks or months, without necessarily causing obstruction.

NON-OPERATIVE TREATMENT.

Relieve the pain with opioids and NSAIDs. Repeat these as required. Administer plenty of fluids, and encourage walking about. Filter the urine to look for the stone(s). Repeat the ultrasound or radiographs if pain persists.

INDICATIONS FOR SURGERY.

- (1) Symptoms persist, and serial radiographs taken at 6-8wk intervals show that a stone of >5mm is impacted. (If it is not causing symptoms or obstruction, it does not necessarily have to be removed, but it is desirable to do so.
- (2) Pain comes and goes over days or weeks without any further descent of the stone.
- (3) Ultrasound shows ipsilateral dilation of the kidney.
- (4) An intravenous urogram shows a hydronephrosis or a hydroureter, or no excretion of contrast medium.
- (5) Infection supervenes with fever, chills, rigors, pyuria, and toxæmia.

PREPARATION. Mark the side to be operated upon. Take a plain radiograph of the abdomen just before you operate to make sure that the stone has not moved.

FOR A STONE IN THE RENAL PELVIS OR UPPER $\frac{1}{3}$ OF THE URETER, perform a nephrostomy (27.14) if the kidney is obstructed. *Do not try to remove a stone from the renal pelvis unless it is dilated.* Try to refer the patient.

FOR A STONE IN THE MIDDLE $\frac{1}{3}$ OF THE URETER, perform a MIDDLE $\frac{1}{3}$ URETERO-LITHOTOMY (GRADE 3.2)

Use the supine position.

Start the incision $\frac{2}{3}$ from the umbilicus to the anterior superior iliac spine, and carry it *laterally* for 7cm parallel to the inguinal ligament. Divide the subcutaneous tissues, and the *external oblique* aponeurosis in the direction of its fibres; likewise divide the *internal oblique*.

Divide the *transversalis* fascia, and sweep the peritoneum medially, until you reach the inner margin of the *quadratus lumborum* muscle, and the bifurcation of the common iliac artery into its internal and external iliac branches (24-16). You will see the ureter lifted up by the peritoneum. *Do not injure the spermatic vessels*, which lie lateral to the ureter.

Feel for the stone in the ureter. Carefully pass a long Lahey forceps round the ureter, and pass 2 fine catheters, or cloth tapes, above and below the stone. Exert gentle traction on these. This will prevent the stone slipping upwards or downwards. Cut longitudinally on the ureter onto the stone with a #15 blade. Remove it carefully with Desjardin's forceps. Wash the area free of grit with warm saline. Pass a small paediatric feeding tube up into the kidney, and down into the bladder, to make sure there no other stone, or if you suspect a schistosomal stricture at the vesico-ureteric junction.

Leave the ureteric incision open. *If you try to close it, the sutures may well cut out and a stricture is likely to form.*

Place a #12 catheter near this site, and bring it out through a separate stab incision. Close the abdominal incision in layers, using interrupted absorbable for the muscle, and monofilament for the skin. Connect the catheter to a closed drainage system.

CAUTION! *Make sure you find the stone and place a sling around the ureter above the stone.* If it slips upwards into the kidney, *do not try to remove it by extending the incision, or using a traumatic instrument.* Close the incision and wait. Try to refer the patient, or try again when ureteric colic recurs, after making sure the stone is indeed in the middle $\frac{1}{3}$ of the ureter!

POSTOPERATIVELY, the catheter will drain up to 1l of urine daily, but the volume will gradually diminish. By the 7th day the ureteric incision should close, and the drainage cease.

If the volume draining remains undiminished, there is an obstruction in the ureter distal to the site of the incision, or it is diseased locally. Wait another week, and investigate this with an IVU (38.1H).

FOR A STONE IN THE LOWER $\frac{1}{3}$ OF THE URETER, perform a LOWER $\frac{1}{3}$ URETERO-LITHOTOMY (GRADE 3.3)

Ideally, you can remove a stone at the lower end of the ureter with a cystoscope and a Dormia basket which traps the stone, but this is difficult. Otherwise, empty the bladder by passing a urethral catheter. Use the supine together with a slight Trendelenburg position. There are 3 possible approaches. Remaining outside the peritoneum, which should be your aim, is easier in the first.

(1) Start your incision $\frac{2}{3}$ from the umbilicus to the anterior superior iliac spine and continue *medially* parallel to the inguinal ligament. Incise the *external* and *internal oblique*, and open the *transversalis* fascia. Or,

(2) Make a lower midline incision, starting at the pubis, and ending at the umbilicus. Incise the *transversalis* fascia. Or, (3) use a Pfannenstiel incision.

Carefully strip the peritoneum upwards with a gauze swab. Look for the ureter at the bifurcation of the common iliac vessels (23-16) and follow it downwards to the bladder. It is crossed anteriorly by the vas deferens. You may have to divide the superior vesical artery so as to let you mobilize the bladder medially sufficiently to allow you see the vesico-ureteric junction easily.

Find the stone, and pass a fine sling or cloth tape under the ureter proximally to prevent the stone slipping upwards. Make a longitudinal incision over the stone, and remove it carefully. Leave the ureteric incision open and close as above.

DIFFICULTIES WITH URETERIC STONES

If the ureteric colic resolves, but there is no evidence that the stone has passed, this is not uncommon. It has probably passed without notice, especially if it was small.

If a stone becomes impacted at the pelvi-ureteric junction, and there is only one working kidney, perform a nephrostomy urgently. Try to refer the patient.

If a stone is firmly impacted at the utero-vesical junction deep in the pelvis, it might be that this area is diseased, especially as a result of *schistosomiasis*.

You can try to squeeze the stone upwards into a more accessible part of the ureter where it will be easier to remove, but this does not usually work. Alternatively, make an incision 2cm above the site of impaction, and try to remove the stone carefully with Desjardin's forceps (27-16D): this will, however, not deal with any disease. Take care: you can easily tear off the diseased ureter from the bladder; it may need re-implantation anyway. This is complex surgery.

NEVER CLOSE THE URETER

27.16 Bladder stones in adults

Bladder stones can be primary, or secondary owing to urinary obstruction, or vesico-vaginal fistula (21.18). Primary stones are still common at all ages, mostly, but not only, in the poor, in a 'stone belt' which includes North Africa, Iraq & Iran, the Middle East, Pakistan, India, Burma, Thailand, Vietnam, Laos, Cambodia, southern China, and Indonesia.

If you are not in the stone belt, and you do find a bladder stone in an adult, be sure to exclude distal obstruction. Otherwise, a fistula may form and refuse to heal.

Most bladder stones in adults cause no pain, or slight pain in the perineum, or, if a stone is big, a 'bumping feeling' as the stone moves about. Nonetheless it is likely to cause intermittent infections and grow bigger. Otherwise, on standing up, a stone may fall onto the trigone, produce an intense urge to pass urine, but obstruct the urethral opening, making this impossible.

The operation to remove a bladder stone in an adult is similar to that for the 1st stage of a Freyer's prostatectomy, and open suprapubic cystostomy (27.8). Use absorbable suture to close the bladder.

N.B. For good results, it is important always to:

- (1) Keep the bladder empty with an indwelling suprapubic or urethral catheter.
- (2) Drain the retropubic space, so that blood and urine cannot accumulate.

When you have removed a bladder stone it does not usually recur, but nonetheless encourage a good intake of fluids.

THE SUPRAPUBIC APPROACH TO THE BLADDER

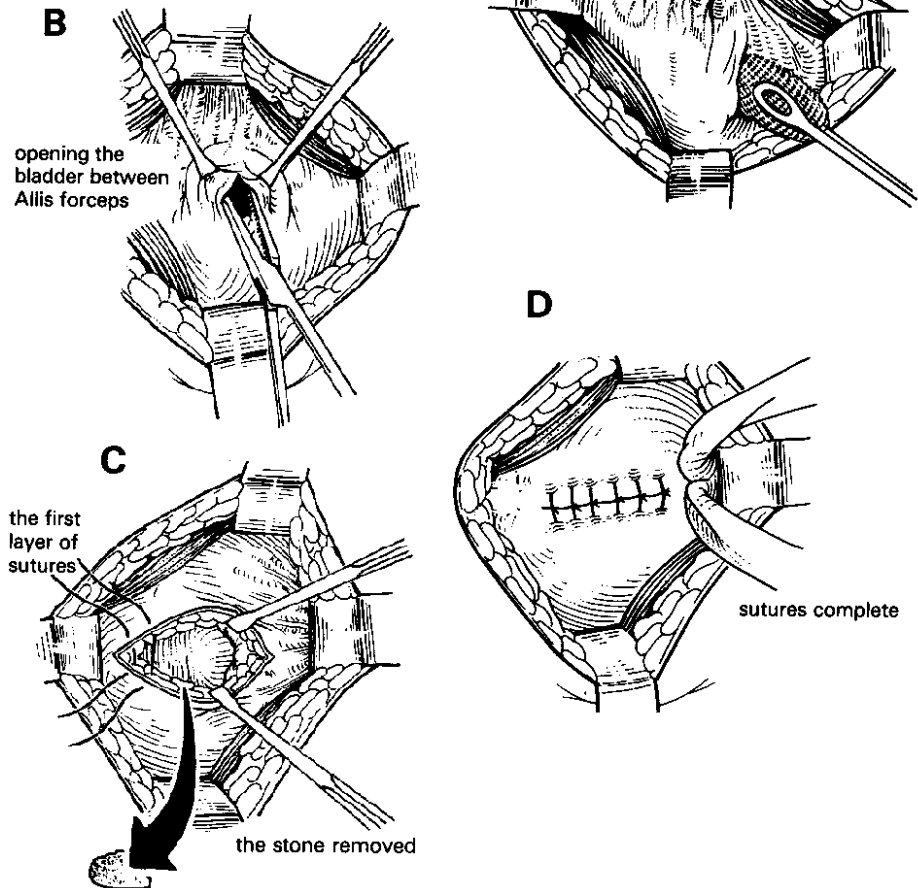


Fig. 27-17 SUPRAPUBIC APPROACH TO THE BLADDER FOR THE REMOVAL OF A STONE. In this view you are standing on the patient's left side, so that the bladder appears upside down.

A, displace the reflection of the peritoneum upwards. B, hold the bladder in Allis forceps and open it. C, the 1st step in closure. D, complete the 2nd layer of sutures. After Flocks RH, Culp DA. *Surgical Urology Yearbook Medical* 4th ed 1975, Plates 69,70.

ULTRASOUND (38.2H) and RADIOGRAPHS confirm the diagnosis, because bladder stones in an adult are usually radio-opaque.

DIFFERENTIAL DIAGNOSIS

- (1) Calcification of the bladder wall due to *schistosomiasis* (very common in endemic areas and gives no trouble). You may be able to confirm this by showing that the shadow is a different size when the bladder is full and empty, if it has not become rigid.
- (2) Calcification in a uterine fibroid.
- (3) A calcified mesenteric lymph node.

CYSTOLITHOTOMY (GRADE 2.5)

PREPARATION.

Insert a urethral catheter and fill the bladder with fluid; you can use the same catheter for postoperative drainage. A steep Trendelenburg position will make exposure easier.

INCISION.

Use a Pfannenstiel incision (11-4) because it is easier then to remain below the peritoneum, and avoid opening it. Incise the skin and subcutaneous tissue transversely. Either part the rectus muscles to expose the peritoneum in the midline, or cut the rectus muscles transversely in line with the skin incision, little by little, until you see the inferior epigastric vessels in the deep surface laterally. This will give you better exposure, and you will be less likely to incise the peritoneal reflection over the bladder in error, which may spread infection into the peritoneum. Find the reflection of the peritoneum and displace this upwards (27-17A).

Grasp the bladder with stay sutures on either side of the midline, or with two Allis forceps, holding the entire thickness of its wall. Make a vertical incision in the bladder. *Avoid a transverse incision:* it will bleed more than a vertical one, and if you are too inferior you may damage the ureters. Suck away the urine as it gushes out.

Put your finger into the bladder to feel if the stone is lying free, or is impacted in a diverticulum. Feel for a tumour or other pathology. Remove any free stones with your fingers, a scoop, or lithotomy forceps.

CAUTION! Repeatedly wash out the bladder before you close it. If you leave any stony fragments, they will act as the nuclei for the formation of more stones.

Close the bladder in two layers with continuous or interrupted 2/0 long-acting absorbable.

Place a suprapubic catheter to provide drainage, and put an extravesical drain as well; bring these out through a separate stab wound.

POSTOPERATIVELY, remove the extravesical drain after 48hrs. Leave the suprapubic catheter in place for 8-10days, to keep the bladder collapsed while it heals. Take a urine specimen for culture before you clamp the suprapubic catheter to see if normal voiding is possible. If so, remove it. An initial leak will stop in 24hrs.

DIFFICULTIES WITH BLADDER STONES IN ADULTS

If there is copious urine coming from the drain, and little in the catheter bag, the bladder closure is probably leaking. Check that the drain fluid is indeed urine by measuring its urea concentration, or by inserting dye *via* the catheter and seeing if it runs out *via* the drain. If the leak continues for 48hrs without diminishing, take the patient back to theatre, open up the wound and close the bladder wall again carefully in layers.

If a fistula develops, it will probably be the result of some obstruction to the urethra. Leave in a urethral catheter in long enough for the fistula to heal. You will probably have to deal with the prostatic enlargement or urethral stricture later, though.

If the wound becomes septic, open it and drain it: *do not rely on antibiotics.*

27.17 Bladder stones in children

In some parts of Asia, smooth stones, mostly ≤ 5 cm in diameter, form in the bladders of underprivileged children (mainly boys). Even an infant may suffer from them. They may be the result of vitamin A deficiency. When you have removed a bladder stone, it is unlikely to recur.

A child's mother will say that he cries every time he passes urine, and pulls at the penis as he tries to relieve the pain. Strangury, *i.e.* slow painful passage of small quantities of urine, makes life unbearable; sometimes he passes blood. Other symptoms include: interruption of the urinary stream, frequency, dysuria, and suprapubic pain.

There are few physical signs: the bladder may be distended, and the foreskin red and swollen from being pulled. You may be able to feel the stone on rectal examination.

It is likely to be made of urates, but it will probably contain enough calcium for you to see it on a radiograph. It will be readily visible on ultrasound (38.2H).

Removing a stone from the bladder of a child is not too difficult. When you have done so, there is no need to drain the bladder with a catheter, either suprapubically or through the urethra, if you have closed it securely.

ASHVIN (3yrs) had repeated urinary infections which had been treated with antibiotics on many occasions, but the symptoms always returned. He then saw another doctor, who remembered that repeated urinary infections in children should always be investigated, so he X-rayed Ashvin's bladder and was surprised to see a large stone. At operation, the stone was difficult to remove, and appeared to be lying in a diverticulum. After it was removed, he had no more urinary infections. **LESSON:** *Do not forget the possibility of stones in children, especially if you are in a high-incidence stone area.*

CYSTOLITHOTOMY IN CHILDREN (GRADE 2.5)

PREPARATION. Distend the bladder with water before you start, so that you can find it more easily. Pass a small plain catheter; then, inject 100-200ml of water into the bladder, depending on its size.

INCISION. Make a lower transverse subumbilical skin incision. Reflect the skin flaps 1cm on either side. Divide the *linea alba* strictly in the midline, without entering the peritoneal cavity.

Keeping the umbilicus in view to help you stay in the midline, make a vertical incision through the whitish aponeurotic fibres of the *linea alba*. Continue the incision down to the symphysis pubis, where you will meet the *pyramidalis* on each side. With a sponge on a holder, gently push the *rectus* muscles laterally, so that you can see the posterior rectus sheath. Insert a small self-retaining retractor to keep the *rectus* muscles apart.

Feel for the distended bladder: it should be easily palpable as it rises out of the pelvis. Using a sponge, or your index finger, gently open the retropubic space. At the same time displace the peritoneum, so that you do not enter the peritoneal cavity. You should now be able to feel and see the distended bladder.

Insert stay sutures, and apply a haemostat on each side of the midline at the most easily accessible part of the bladder. This will prevent it slipping away. Get the sucker ready. Then with a scalpel, or cutting diathermy, make a 2cm incision in the bladder wall, between the 2 stay sutures. Aspirate the urine which squirts out.

With your index finger, feel through the hole in the bladder for the stone. Remove it with stone forceps or a sponge-holder. If the hole is not big enough, enlarge it. Having removed one stone, feel again to make sure that there is no further stone. Wash out the bladder.

Close the bladder carefully with continuous 3/0 long-acting absorbable on an atraumatic needle. Include all layers, and make the bites ≤ 5 mm apart. The longer the incision, the more care you need in closing it.

CAUTION! Make a small stab incision just beside the wound and insert a small soft extravescical drain. *Do not forget to do this.* Even if you think you have closed the bladder securely, it may still leak. If urine extravasates, it may cause serious cellulitis.

Suture up the *linea alba* with 2/0 absorbable. Make sure that you have controlled all bleeding, and then close the skin. If you think that the bladder may leak, or if you have had to make a large incision, insert a Foley urethral catheter for 4-5 days. Otherwise, *do not insert one.* It is, however, helpful to insert a small suprapubic catheter and have it for a trial of voiding.

POSTOPERATIVELY, urine will probably pass without difficulty later that day. If urine leaks through the extravescical drain, insert a urethral catheter, and leave it there for a few days. Otherwise, remove the extravescical drain after 3-4 days. The child is unlikely to get another stone, but his siblings may.

27.18 Urethral stones in children

In some areas, bladder stones are common; these are mostly are passed spontaneously in the urine. Occasionally, one impacts in the urethra, especially in boys. It is usually possible to pass urine around it, but pain, strangury, and dribbling are severe. Suspect this especially if there is a distended bladder, and you can feel a hard mass somewhere along the course of the male urethra. The patient may be able to show you exactly where the stone is stuck.

If ultrasound or radiograph suggests that it might be wedged in the neck of the bladder, try to feel it rectally. You may be able to push it back up into the bladder. If you fail, insert a well-lubricated sound into the urethra, until it strikes the stone. You may be able to push it back into the bladder, *but do not use force!* If this fails, ask your assistant to exert upward pressure on the stone, with the finger in the child's rectum, while you manipulate it with the sound. If you can move the stone back into the bladder, proceed to remove it suprapubically (27.17). Otherwise open the bladder and try to dislodge the stone out of the urethra from above: this may however be difficult.

If it is readily palpable in boys between the bulbous urethra, and the fossa navicularis (27-18A), removal by manipulation under GA may succeed. *Do not use force!*

If it is impacted, remove it by external urethrolithotomy.

If it impacts at the external meatus or the fossa navicularis in boys, you may be able to 'milk' it free, or release it by a meatotomy (27.31).

If it has developed in a diverticulum (rare), you may have to cut down on this, and then close the diverticulum.

URETHROLITHOTOMY (GRADE 3.1)

Use the lithotomy position.

Thoroughly clean the genitalia, the medial surface of the thighs, and the perineum. Feel for the stone in the urethra, and steady it between the thumb and index finger of your left hand. Infiltrate with dilute adrenaline solution: this is a very vascular area. *If you do not control bleeding, everything will be obscured.*

Make a 3cm midline incision over the stone, on the ventral surface of the penis. Cauterize or tie off the bleeding points. Ask an assistant to retract the skin flaps with hooked retractors.

Incise onto the part of the urethra containing the stone. Make the incision just big enough to deliver it. Lift it out with stone forceps or a haemostat. Try not to break it.

Insert a small (Ch10 or 12) Foley catheter into the external urethral meatus, and up past the incision into the bladder. Inflate the balloon. *Do not try to close the urethra:* its edges will fall together and heal naturally. Close the skin. Remove the Foley catheter after 1wk.

URETHRAL STONES

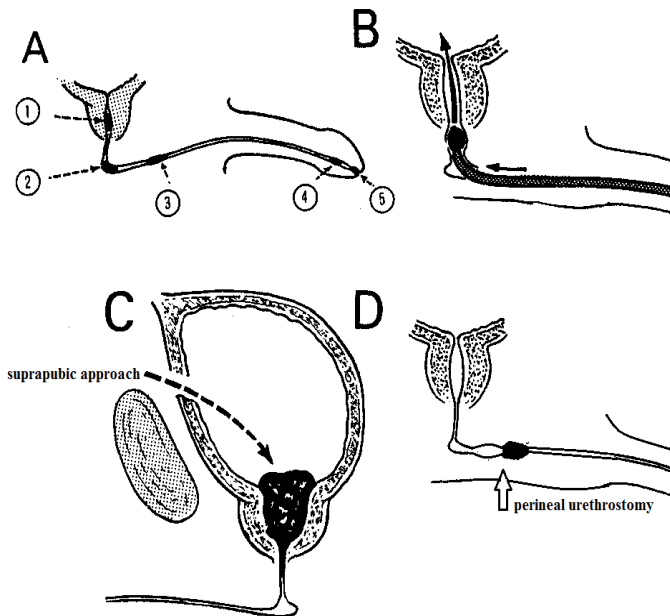


Fig. 27-18 URETHRAL STONES.

A, sites where stones can impact in the urethra. (1) prostatic urethra. (2) membranous (bulbar) urethra. (3) anterior (spongy) urethra. (4) fossa navicularis. (5) external meatus. B, remove a prostatic urethral stone by pushing it up with a sound. C, extract an impacted stone by the suprapubic approach. D, a perineal urethrotomy.

N.B. Urethral stones are very rare in women.

27.19 Prostatic enlargement

Urinary outflow obstruction can occur if the prostate is enlarged through hyperplasia, infection or carcinoma, or from bladder-neck dysfunction or stenosis. The patient presents, before urinary flow is completely obstructed, with:

- (1) Frequency of micturition which interferes seriously with the sleep,
- (2) Hesitancy (difficult voiding),
- (3) Poor urinary stream.

Here you can use selective α -blockers, e.g. prazosin, and 5 α -reductase inhibitors such as finasteride if they are affordable, or available.

Then he may present with various types of complete obstruction:

- (1) Acute retention of urine (27.6), perhaps precipitated by a recent drinking bout. (If you catheterize him, he will usually start to pass urine again, but the retention will probably recur),
- (2) Chronic retention: the bladder remains distended when micturition is over, and he may dribble urine continuously and painlessly (retention with overflow),
- (3) 'Acute on chronic' retention with a poor flow for some time, a large bladder which has recently become painful. This may progress to retention with overflow.

If a patient presents with retention, he may be not be well enough for immediate surgery, because:

(1) the acute retention may be the final episode in a long period of obstructive uropathy; the renal function may be impaired and the urine infected.

(2) the factor that has precipitated retention could be a serious illness, such as pneumonia, or fracture of the neck of the femur.

If you try to do surgery while he is in a poor condition, he may not survive the operation. He is more likely to if you wait, drain the bladder for 1-2wks, and let him recover. Investigate the precipitating factor meanwhile.

If you expect to remove the prostate within 2wks, pass a urethral catheter and drain the urine into a closed sterile system. If you have to delay beyond 2wks, insert a suprapubic catheter (27.7) or change the urethral catheter every month.

It is important to try to distinguish between benign and malignant prostatic enlargement. Rectal examination is not entirely reliable; PSA is very specific (but levels also rise with prostatic TB), but acid phosphatase levels are helpful if metastatic disease is present. *Take blood before a rectal examination or 48hrs after, so as not to get a false +ve result.* Examination under GA gives a good notion of the local extent of prostatic carcinoma, and ultrasound (38.2I) is also very helpful.

INDICATIONS FOR PROSTATECTOMY.

- (1) Difficult voiding and a deteriorating urinary stream.
- (2) Frequency of micturition (especially dribbling, due to outflow obstruction, rather than irritation of the trigone).
- (3) Acute retention of urine.
- (4) Chronic retention with overflow.

N.B. Several medications are now available which can reduce benign prostatic enlargement or improve urinary function; they are expensive and may have significant side-effects.

Conditions which do not by themselves indicate prostatectomy include:

- (1) Frequency and nocturia.
- (2) Haematuria (which is quite common in prostatic hypertrophy).
- (3) An increased residual urine (seen on ultrasound).

CONTRAINDICATIONS.

- (1) A patient whose general condition is very poor especially with minimal renal function, which does not improve after catheterization.
- (2) Severe urinary sepsis.
- (3) Senility with dementia (rather than age alone). A very senile old man is likely to be permanently incontinent anyway, and will be better with permanent urethral or suprapubic drainage through a small Foley catheter.
- (4) Carcinoma of the prostate is a contraindication to open prostatectomy, but is very suitable for transurethral resection if available. You may be able to manage a malignant prostate with oestrogens or anti-androgens and catheter drainage (27.22) and possibly orchidectomy.

27.20 Open pervesical prostatectomy

It is possible to perform a prostatectomy by the trans-vesical route, by the retro-pubic route or endoscopically *via* the urethra. Another method avoids opening the bladder, but is more difficult. It also needs good lighting, more help, and better postoperative care. Endoscopic resection needs much skill and an expensive resectoscope.

The advantages of the trans-vesical method are:

- (1) You can look into the bladder to exclude diverticula, carcinoma, and stones.
- (2) You can control bleeding more easily.
- (3) When well done, mortality is low. One of its disadvantages is that it normally requires large quantities of irrigating fluid, although we describe ways of doing without this.

As age advances, the lateral and median lobes of the prostate enlarge. These lateral lobes are joined anteriorly by a narrow anterior commissure, which is the most anterior part of the prostate. As the lateral lobes enlarge, they compress the normal tissues of the prostate around them to form a false capsule, and compress the prostatic urethra from side to side. Posteriorly the median lobe of the prostate enlarges superiorly and extends upwards into the bladder.

You can enucleate the enlarged parts of the prostate by inserting your finger in the plane between the lateral lobes and the false capsule, and shell them out. The prostatic capsule forms the wall of the urethra, and so *if you damage this capsule, the patient will probably get a stricture*.

However, if you can master this operation, many elderly men in your community will be for ever grateful: you may even find patients come to you from further afield.

N.B. Enucleating the prostate may be impossible if it is malignant, and anyway you do not remove all the prostatic tissue, so this operation is not suitable for carcinoma.

OPEN PERVESICAL PROSTATECTOMY

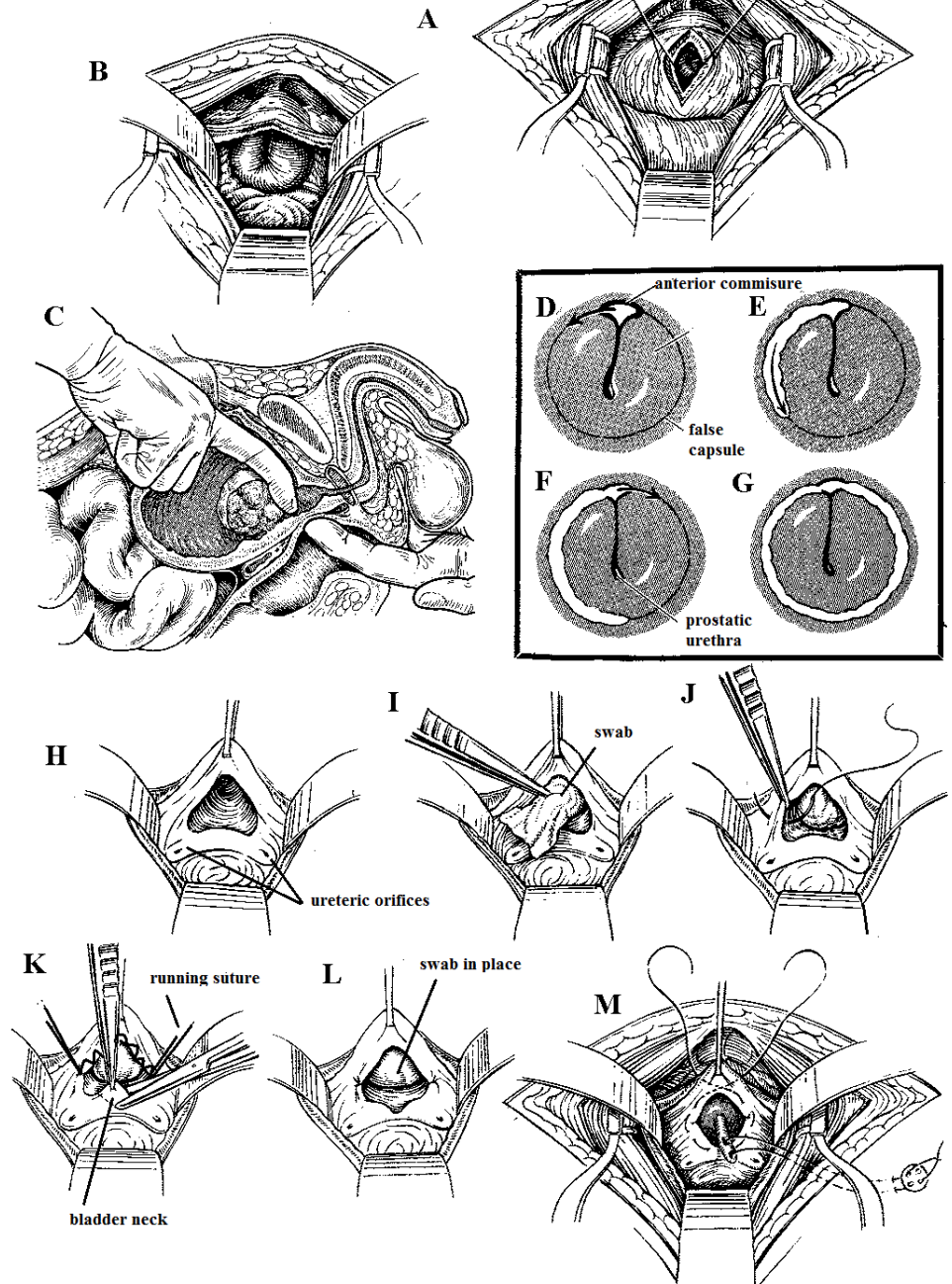


Fig. 27-19 OPEN PROSTATECTOMY.

A, open the bladder between stay sutures. B, inspect the bladder. C, enucleate the prostate by inserting your finger in the internal urethral meatus: (you may need to elevate the prostate by an index finger of the opposite hand *per rectum*). D-G, use your right and then your left index finger to open up the plane between the gland and the false capsule. H, the empty prostatic cavity. I, mop out the prostatic cavity. J, place a running suture from 3 to 9 o'clock positions to control bleeding. K, cut a wedge out of the neck of the bladder. L, the wedge complete. M, remove the swab and suture a Foley catheter in place. A, Adapted from a drawing by Frank Netter, with the kind permission of CIBA-GEIGY Ltd, Basle Switzerland. B-M, After Maxwell Malament, from a publication by Ethicon Ltd, with kind permission.

INDICATIONS.

Benign prostatic enlargement (27.19).

CONTRA-INDICATIONS.

- (1) Prostatic carcinoma (27.22) or fibrosis. If however, you happen to find a carcinoma incidentally, you can open up a sufficient channel to relieve the obstruction. *Avoid a suprapubic catheter*, as this risks spreading tumour along its track.
- (2) Bladder carcinoma.
- (3) Urethral stricture: *deal with this first*.
- (4) Neurological impairment causing bladder or detrusor dysfunction. *There is no point in performing surgery if you end up needing a catheter anyway to drain the bladder!*
- (5) Severe urinary sepsis: *treat this first*.
- (6) Severe renal impairment & debilitation.

EQUIPMENT. Suction and bladder retractors are virtually indispensable. A three-way irrigating Foley balloon catheter is also almost essential. You should hesitate to perform open prostatectomy without these.

PREPARATION.

Make sure you have examined the prostate digitally per rectum. If you suspect carcinoma, measure the acid phosphatase or PSA, check a pelvic radiograph for metastases, and take a biopsy *via the rectum* (27-20).

Try to perform a cystoscopy (27.3) beforehand. If you have difficulties getting past the prostate be gentle: force will make it bleed. Look for:

- (1) carcinoma of the bladder, especially in areas where schistosomiasis is endemic,
- (2) bladder stones,
- (3) fibrosis of the bladder neck,
- (4) diverticula,
- (5) benign enlargement of the prostate. Preferably, have at least two units of blood cross-matched, and an IV infusion running. Treat the patient with prophylactic antibiotics suitable to the sensitivities in your area.

POSITION.

Use the supine position and give the table a mild head-down tilt. If you are right-handed, stand on the left side, so that your right hand is in the most convenient position to enucleate the prostate, and so that you can, if necessary, put your left index finger into the rectum.

SOUNDING.

If there is not already a catheter *in situ*, and you have not done a cystoscopy, pass a sound to make sure that there is no urethral stricture. If all is well, pass a catheter, and leave c.300ml fluid in the bladder to make it easier to find when you operate.

OPERATION (GRADE 3.4)

INCISION: this depends on whether there is already a suprapubic cystostomy scar.

If not, make a Pfannenstiel (11.2), or less satisfactorily, a 7cm midline incision immediately above the pubis longitudinally between the *rectus* muscles.

If there is a suprapubic cystostomy scar, dissection will be easier if you start in an unscarred part of the wound. Make an elliptical incision round the wound, excise the skin edges and the suprapubic track, and split the *rectus* muscles. Dissecting the peritoneum off the bladder will be difficult, so cover your right index with gauze. Keeping the pulp of your finger in contact with the pubic symphysis, push your finger into the retropubic space. When you reach the prostate, rotate your finger through 180° and peel the peritoneum off the anterior surface of the bladder.

Insert stay sutures into the anterior wall of the bladder (27-19B), and then incise it in the sagittal plane.

CAUTION! *Do not enter the peritoneal cavity.* If by mistake you do so, immediately suture it.

Put two fingers of your right hand into the bladder. Feel inside to exclude neoplasms, to feel for stones and the orifices of diverticula. You can easily miss these. Feel the prostate and the internal urinary meatus.

If the prostate is enlarged, and you can easily get your fingers into the internal urinary meatus, enucleate the prostate as described below.

If the prostate is not enlarged, and there is a tight internal meatus which you cannot put your finger into, this is bladder-neck fibrosis (27.21).

If the prostate is fibrous or malignant (27.22), and there is no clear plane of enucleation, *do not try to shell out the prostate* as this causes much bleeding, is difficult and unhelpful. Just remove enough tissue with scissors (or diathermy) to leave an adequate channel for the urine. Send this tissue for histology and screen for carcinoma as above. *You should have done this beforehand!*

ENUCLEATION OF THE PROSTATE: remove the self-retaining retractor and put your index finger into the prostatic urethra. Use your left index finger to split into the recess between the anterior commissure (which should remain *in situ*) and the left lateral lobe of the prostate at the 10o'clock position. Open up the plane between the gland and the false capsule as far distally as you can. Keep in this correct plane to avoid copious venous bleeding. Separate the gland from the false capsule through at least 90°, and preferably 150°. Use your right index finger to repeat the procedure on the right side starting at the 2o'clock position, so as to free the prostate from within its false capsule. There is usually a residual attachment distally. Pull the prostate up into the bladder to make this taut. Divide the attachment with curved dissecting scissors.

CAUTION!

- (1) Divide the attachment *close* to the prostate, or you may damage the internal sphincter which surrounds the membranous urethra, deep and superficial to the perineal membrane.
- (2) Preserve the anterior commissure. Damage to either may lead to incontinence of urine or a stricture.

Remove the lateral lobes and the median lobe, by bringing it into the bladder with your index finger. If it is still lightly attached proximally to the mucosa of the bladder, separate it with scissors. Removing each lateral lobe separately may be easier. One will bring the median lobe with it.

If the patient is very obese, or muscular, you may be unable to reach the lower border of the prostate. You can push it upwards with your opposite index finger in the rectum while you enucleate the prostate from above. If you have to do this, cover your left hand with two gloves, and protect your forearm with a sterile towel under the drapes; otherwise, get an assistant to do this.

When you have removed the lateral lobes, feel the inside of the prostatic cavity, to make sure that no masses have been left behind (27-19H).

CAUTION! You can easily leave a large mass of adenoma behind, so compare one side with the other. Use your fingers, sponge holders, or vulsellum forceps to grasp and twist off any remaining pieces of prostate.

ENLARGE THE BLADDER NECK: first check the position of the ureteric orifices. Cut a wedge out of the bladder neck in the 6 o'clock position level in between the ureteric orifices (27-19K,L). Excess mucosa of the bladder may overhang the prostatic cavity, and if left may produce a valve-like effect leading to retention of urine (27.21).

CONTROL BLEEDING: put a tight gauze pack in the prostatic cavity (27-19I). After 3mins, take it out and assess the amount of bleeding. Insert a running suture inferiorly from the 3 to the 9 o'clock positions (27-19J), taking care to avoid the ureters. Then put a purse string absorbable suture in the floor of the bladder, around what was the internal meatus (27-19M). Blow up the balloon of a 50 or 75ml Foley catheter, until it fits snugly in the prostatic bed (usually 30-50ml is required). This will help to stop bleeding. Then tighten up the purse string round it to hold it in place (27-19M) where it will remain if the balloon is inflated enough.

Alternatively, if bleeding is still brisk, tightly pack the prostatic cavity once more, and leave the pack in place for a full 15mins. Then remove it. If the prostatic cavity is still bleeding, remove the purse string and the catheter, and irrigate the prostatic bed. Then re-insert the balloon of the catheter snugly in the prostatic bed.

Insert a #2 monofilament suture through the abdominal wall and the bladder, and then through the holes in the catheter to hold it in place. Knot it over a button outside the abdominal wall (27-19M). If the patient is confused postoperatively, this will prevent him from pulling out the catheter, even if the balloon bursts.

IRRIGATION: The purpose of irrigation is to remove blood clots, which encourage infection and block the drainage tube. It is, by far, best to use a 3-way irrigating Foley catheter. Introduce fluid down one channel, and let it drain through another.

If you have a shortage of drainable urine collecting bags, or you cannot be sure the bags are surveyed properly, it may be better to let the urine drain freely into a large narrow-necked plastic bottle.

Remove the catheter after 8-10days. Alternatively, you can use 2 large (Ch20-24) ordinary Foley catheters, one urethral and the other suprapubic, passed through a separate stab incision.

Introduce fluid through the suprapubic catheter, and drain it through the urethral one. Remove the suprapubic catheter when the fluid is no longer bloody, usually >3-4days. If you leave it longer it tends to leave a track which leaks. You can improve diuresis by insisting the patient drinks at least 4l water/day, or by using furosemide 40mg bd – but *make sure the patient still drinks plenty of fluids!*

You will need about 10l fluid for irrigation. This can be:

- (1) IV saline, which is expensive and will be needed for other purposes,
 - (2) Sterile 3·8% sodium citrate (which is no better than saline),
 - (3) Mannitol,
 - (4) Sterile tap water or, better, distilled water.
- The disadvantage of this is that it may enter the circulation through the prostatic sinuses and cause water intoxication, and if it is not pyrogen free, it may result in rigors.

Teach your nurses to milk the catheter hourly, until all the clots have gone, usually in 2-4days. Continue irrigation just fast enough for the urine to be pale pink. It is usually necessary for 24-48hrs. You will need about 4l in the first day, and less the next day. You may need to continue irrigation until the 4th day.

CAUTION! *Do not raise the irrigation bottle too high.* If it is >60cm above the bladder, and haemostasis has been poor, the fluid in the bladder may enter the circulation, especially if the outflow catheter is obstructed. Keep the drainage bottle on or near the floor, to make use of gravity.

Deflate the balloon on the 3rd day, unless there is much bleeding; if so, wait until bleeding stops. The prostatic cavity will then become smaller naturally, and there will be less danger of secondary haemorrhage.

CLOSURE. Close the bladder with two layers of continuous absorbable suture. Insert a drain in the retropubic space, through a separate stab incision, below or at the side of the previous one, and secure it to the skin. Close the anterior rectus sheath with continuous absorbable suture. Close the skin.

N.B. Prostatectomy by a suprapubic approach avoids opening the bladder, but access is more difficult. Do this if you can get an expert to teach you.

DIFFICULTIES WITH OPEN PROSTATECTOMY

Besides the normal anaesthetic risks, and those listed below, the postoperative difficulties you will meet include epididymitis, septicaemia, deep vein thrombosis (relatively unusual in low- and middle-income countries), ileus (12.16), uraemia and oliguria, postoperative shock, and bladder tamponade.

If there is bleeding from the prostatic bed after return to the ward, within 48hrs of the operation (reactionary haemorrhage, not uncommon), all that is usually necessary is to keep the catheter clear by milking it hourly. Speed up the irrigation, and wash out the bladder. Start an IV infusion of saline. If the Hb falls <7g/dL, transfuse blood. If copious frank bleeding persists, return to theatre, reopen the wound, and control bleeding from the prostatic bed (27-19J).

If there is a distended painful bladder and no urine drains, this is CLOT RETENTION. This is one of the most feared complications of prostatic surgery, and occurs within the first 72hrs. There has often been severe bleeding, and the blood in the bladder has clotted and obstructed the catheter, usually because the irrigation has been neglected. You may find urine leaking from the extravescical drain or even from the wound. Start transfusion if necessary. Inject 50ml sterile water or saline into the bladder and immediately aspirate it.

CAUTION! *Do not inject more than 50ml*, or you may burst the balloon, and *do not try this method more than once*.

If this fails to dislodge the clot, try using heparinized water; or deflate the catheter balloon, and push it further into the bladder and wriggle it about. *Do not pull the catheter out*: it may be impossible to re-insert without a GA.

If all fails, return to theatre, remove the catheter under GA, and perform a urethro-cystoscopy if possible. Otherwise gently insert a new 3-way Ch24 catheter, using an introducer, and wash out the bladder through this.

If even this fails, re-open the bladder to remove the clots.

If there is bleeding 8-12days post-operatively (secondary haemorrhage, quite common), it usually settles. Many cases are not severe, and will stop on their own. If bleeding does not stop, re-insert a urethral catheter, making sure (by ultrasound if possible) that the balloon is sitting nicely in the prostatic bed and it is inflated maximally. Wash the bladder through this until the fluid is nearly free of blood. Leave the catheter *in situ* some days and repeat bladder wash-outs till the urine stays clear. If bleeding persists, or you cannot re-insert a catheter, take the patient back to theatre and reopen the prostatic bed to control bleeding (27-19J).

If there is incontinence of urine, you can give reassurance that this is almost certain to improve during the next 3months.

The symptoms of urge incontinence are common in patients who had these symptoms preoperatively; they usually resolve spontaneously. *If you have damaged the membranous urethra by enucleating a prostate which did not have a clearly defined capsule (27-19F), incontinence may be permanent*. So, if the prostate feels fibrous or carcinomatous beforehand, *do not proceed*.

If a suprapubic fistula develops, it will close spontaneously unless the outflow is still obstructed. So drain the bladder with a urethral catheter for 10 more days. If the leak persists, go back to close the bladder wall again.

If a recto-urinary fistula develops, drain the bladder with a urethral catheter. If this fails, perform a diverting colostomy (11.6)

If there is a further episode of urinary retention some months or years later, perform a cystoscopy to see what is the cause. It may be a urethral stricture, regrowth of the prostate or bladder neck stenosis. You may have to make a wedge resection of the neck of the bladder. This is very unlikely to happen, if you routinely excise a wedge of tissue from the back of the neck of the bladder when you remove the prostate.

If you find bladder diverticula, leave them: they will become smaller now that you have relieved the obstruction, unless they were very large.

If there is an inguinal hernia present, you may repair this (18.2) at the same time as the prostatectomy, if you are having good results and your complication rates of bleeding and blocked catheters is minimal. Otherwise repair the hernia later.

27.21 Bladder neck problems

There are 2 causes of urinary obstruction in which the prostate feels normal rectally, with no sign that it is enlarged, but in spite of this, urine cannot pass. Between 5-10% of cases of supposed prostatic obstruction are like this. The patient is usually younger than the others. If you can easily pass a sound, you thereby exclude a stricture.

Perform a CYSTOSCOPY: you will find that the bladder is obviously obstructed, as shown by trabeculation, a hypertrophied inter-ureteric bar (27-7A), and perhaps diverticula. But you cannot see any sign of an enlarged prostate. Instead, the posterior lip of the urinary meatus is unduly prominent (difficult to see with an ordinary cystoscope).

The cause is:

- (1) Dyskinesia (which also occurs in HIV disease), or:
- (2) Bladder-neck fibrosis, one cause of which is *schistosomiasis*, affecting the trigonal submucosa.

DYSKINESIA: Try to make this diagnosis before you operate, and use prazosin 0.5-2mg bd. (Beware: this is an α -blocker and may cause postural hypotension)

BLADDER NECK FIBROSIS: you may find, when you open the bladder, that the prostate is not enlarged. Instead, there is a tight internal meatus, which you cannot put your finger into.

BLADDER NECK RESECTION (GRADE 3.4) METHOD.

Get adequate exposure: you cannot expose the internal urinary meatus through a short incision. Approach the inside of the bladder as for open prostatectomy (27.20).

Put a self-retaining retractor into the bladder, open it, and tilt the head of the table downwards slightly. Use a Langenbeck retractor, or a bent copper retractor, to draw the anterior wall of the bladder against the pubis, so that you can see the internal urinary meatus.

Identify the orifices of the ureters. Make deep cuts in the bladder neck in the 5 & 7 o'clock positions, sloping towards one another so as to excise a wedge of the bladder neck (27-7C, 27-19K). The cuts must go deep enough to divide the circular fibres of the neck of the bladder. This will then spring open, and the obstruction will be relieved.

If *schistosomiasis* is the cause, there will be more fibrosis, and you will be cutting fibrous tissue rather than muscle.

CAUTION!

(1) Take great care not to injure the ureters, as they enter the bladder. A wise precaution is to pass a Ch7 catheter (or a feeding tube) into each ureter.

(2) If you find diverticula, leave them alone.

POSTOPERATIVELY, leave a 3-way Foley catheter in place, or insert a urethral and a suprapubic catheter and irrigate the bladder as for a prostatectomy (27.20).

27.22 Prostate carcinoma

Prostate carcinoma is the commonest male cancer >65yrs. It presents commonly with:

- (1) Bone pain, which is not necessarily in the back. 80% of patients have metastases when they present. Perineal pain suggests extensive local disease,
- (2) Difficulty passing urine, acute or chronic urinary retention.
- (3) Weakness in the legs, due to metastases involving the cauda equina.

Because prostate carcinoma is so common, it is fortunate that it can be controlled, for a time, by the cheap hormone therapy, diethylstilbestrol. You may, however, have difficulty persuading patients to continue to take it, because of its oestrogen effects.

Making the diagnosis on the basis of the clinical findings, a raised serum acid phosphatase and X-ray findings, is not be wholly reliable; also microscopic differentiation of carcinoma from benign hyperplasia can be difficult. PSA estimation is, however, highly specific.

RECTAL EXAMINATION. A normal prostate feels smooth, symmetrical, and firm, usually with a median groove and mobile rectal mucosa. A carcinomatous prostate is hard, nodular, and asymmetrical; its median groove is often obliterated, and the rectal mucosa may be fixed to it. Late locally extensive disease may extend to the pelvic wall, form a band round the rectum, and fix the pelvic tissues. Sometimes, you can feel the spread of the tumour in the tissues round the prostate. If possible, confirm these findings by examining the patient bimanually under anaesthesia.

PROSTATIC BIOPSY

1. Lay the biopsy needle, inside its sleeve, over your gloved index finger
2. Put on another glove over the 1st one.
3. Perforate the outside glove with the biopsy needle
4. Now you can use the biopsy needle safely.

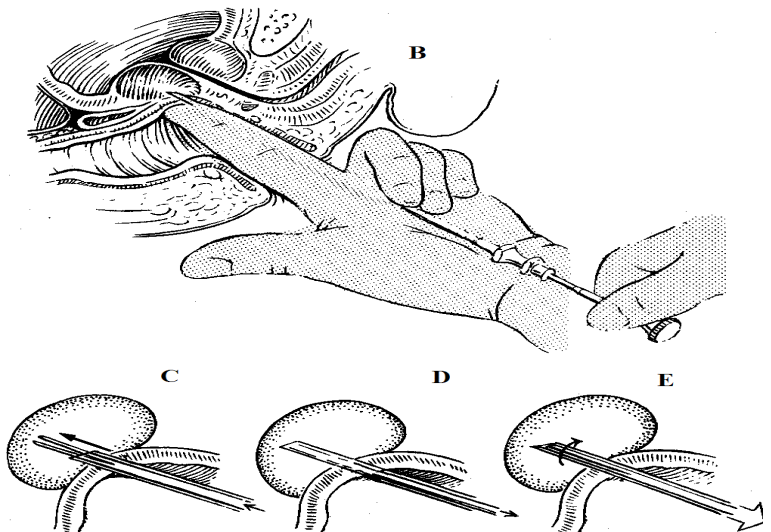
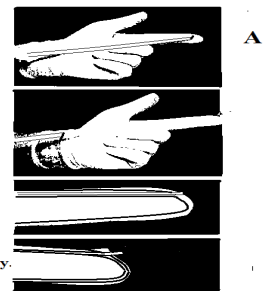


Fig. 27-20 PROSTATIC BIOPSY.

A, holding the sheathed (or Trucut biopsy) needle along the palmar surface of your left index finger, with the tip on the pulp, slip another glove over the biopsy needle and sheath, so that it is sandwiched between the two gloves. Insert your finger into the patient's anus. B, feel each lobe of the prostate, as if you were doing a rectal examination. Using your right hand, push the needle 0.5cm through the rectal mucosa, towards one of the prostatic lobes. Withdraw the stylet, C, insert the biopsy jaws, and push them into the prostate as far as they will go, still keeping the needle along the index finger of your left hand. Remove your finger, D, advance the outer sheath far enough to cover the biopsy jaws. E, Rotate the needle, so as to break off the core of tissue that has been grasped, and withdraw it. Lift the core of tissue from the biopsy needle, with an ordinary injection needle, and put it into formalin. If you fail, repeat the process up to 3 times. Then do the same thing with the other lobe. (Using two gloves makes this procedure very much safer) After Ghei M, Pericleous S, Kumar A et al. Finger-guided transrectal biopsy of the prostate: a modified, safer technique. *Ann Roy Coll Surg Eng* 2005; 87:386

RADIOGRAPHS. Look for lytic and sclerotic (typical but less common) metastases in the pelvis, and lumbar spine. Paget's disease and osteoarthritis produce similar bony symptoms, but show different X-ray changes.

ULTRASOUND (38.2I) will demonstrate an irregular enlarged infiltrating prostate, but cannot detect an early carcinoma, except if you can use a rectal probe.

SPECIAL TESTS. If the carcinoma is present the PSA is $>2\text{U}$; where it has spread beyond the prostatic capsule, the serum acid phosphatase will be >3 King-Armstrong units. A normal level does not exclude it. A persistently raised level supports the diagnosis, and suggests metastasis. It has no prognostic value; its main use is in diagnosis. It falls in response to treatment, and rises when the disease reactivates.

CAUTION! Take blood before you do a rectal examination, or wait for 48hrs. If you take it immediately afterwards, you will get an abnormally high reading.

NEEDLE BIOPSY OF THE PROSTATE. (GRADE 1.3)

To confirm malignancy (or, rarely, TB), biopsy the prostate with a trucut biopsy needle (24-3) through the rectum (27-20). This is not difficult but you may miss the malignancy unless it is quite advanced. Ultrasound will help you guide the needle, but unless you have a rectal ultrasound probe, you will need to use a perineal route. In spite of passing through the rectum, serious infection is rare. You should, though, use a single prophylactic dose of gentamicin beforehand, and make sure the rectum is empty.

CYSTOSCOPY. Examination under GA is necessary with cystoscopy; this is particularly useful in distinguishing carcinoma of the prostate from carcinoma of the trigone of the bladder infiltrating the prostate. You may feel a grating sensation, as you pass the cystoscope through the carcinomatous prostate, or you may see puckering of the apex of the trigone, or submucous nodules in the bladder (late signs).

DIFFERENTIAL DIAGNOSIS includes:

- (1) benign prostatic hyperplasia,
- (2) tuberculous prostatitis,
- (3) bladder carcinoma infiltrating the prostate,
- (4) bladder-neck fibrosis (27.21),
- (5) stricture of the prostatic urethra (27.9).

MANAGEMENT

If the disease is still confined to the prostatic capsule at age $<65\text{yrs}$, there might be benefit from radical radiotherapy if available.

If there is severe bone pain from metastatic disease, localized radiotherapy may give much relief.

If the disease is advanced or you cannot access radiotherapy, treat with hormonal manipulation. The original drug, diethylstilbestrol, an oestrogen analogue, is cheap. Start with 1mg od , and if this fails to control the symptoms increase it to 5mg od .

There is an 80% chance that there will be a good response. However, there are many side-effects: fluid retention, gynaecomastia, impotency, hot flushes, osteoporosis, and itching. You cannot use this drug in the presence of heart failure.

Anti-androgens, such as flutamide 250mg tid , are more acceptable, but are more expensive, and interfere with the action of anti-coagulants and anti-convulsants. Other anti-androgens such as ketoconazole, cyproterone acetate, and spironolactone have too weak actions to be effective.

A good alternative is finasteride, a $5\text{-}\alpha$ -reductase inhibitor, but this is even more expensive.

An alternative hormonal treatment is a subcapsular orchidectomy (27.26), which will avoid the need for life-long drug treatment and its side-effects. Most patients object to castration, but they may accept a reduction in size of their testicles! You must therefore discuss such treatment carefully.

If there is retention of urine, start hormonal treatment and pass an indwelling Foley catheter. Leave it in for at least 3wks, before trying to remove it, and if then there is still urinary retention, consider leaving it in for a further 3wks. Hormonal treatment will usually make the prostate shrink enough to allow micturition. If, unusually, it does not, try to arrange endoscopic resection of the prostate.

If this is quite impossible, retain a urethral or suprapubic catheter. *Do not try to remove the prostate by the open method* (27.20): this is difficult, because it does not shell out properly, leaves tumour behind and risks spreading it, and there will be severe bleeding.

If the urine becomes infected, treat with appropriate antibiotics; in itself infection will not influence the outcome of the carcinoma.

27.23 Epididymo-orchitis

Acute epididymo-orchitis presents with an acute painful swelling of one testis and epididymis. A few cases are viral: the important viral cause is mumps which occurs in adolescents. Occasionally it may be due to brucellosis. The testicle is acutely tender, may be associated with a hydrocoele, lies in its normal position, with pain partially relieved by lifting the testicle in a scrotal support.

Chronic epididymo-orchitis is common in the sexually active and in elderly men with urinary outflow difficulties. It is the result of:

- (1) Previous untreated or imperfectly treated attacks of acute epididymo-orchitis, which is usually gonococcal, or chlamydial.
- (2) Non-specific urinary infection (usually due to *E.Coli*).
- (3) *Schistosomiasis* which is usually confined to the tail of the epididymis, causes little pain, less swelling and only mild tenderness.
- (4) Tuberculosis, which results in a firmer swelling.

ACUTE EPIDIDYMO-ORCHITIS

DIFFERENTIAL DIAGNOSIS & TREATMENT.

Suggesting testicular torsion (27.25): a sudden severe pain in the groin or lower abdomen, associated with an exquisitely tender testis lying horizontally in the scrotum.

Suggesting acute epididymo-orchitis: a history of urethral discharge; either only the epididymis is affected, or the epididymis more than the testis, usually unilaterally. If possible analyze the discharge. Treat with doxycycline 100mg bd for 2wks.

If acquired after anorectal intercourse, use ciprofloxacin 500mg bd for 2wks.

Suggesting epididymo-orchitis secondary to urine infection: there is no urethral discharge, but pain, frequency and burning of micturition. If possible, culture the urine and use an appropriate antibiotic.

Suggesting schistosomiasis: small 3-5mm nodules in the tail of the epididymis. The *vas deferens* is usually palpable. Treat with one dose of praziquantel 40mg/kg.

Suggesting filariasis (34.14): tender swelling of the cord, epididymis and testes, with oedema and inflammation of the scrotal skin. The *vas deferens* is usually *not* palpable. Treat with doxycycline 200mg od for 6wks.

Suggesting mumps orchitis: the testis is affected but the epididymis appears normal. Usually unilateral but occasionally bilateral, not necessarily simultaneously. Ask if others in contact at school have had similar illness. The boy will settle without treatment, but if both testes are affected, he may become infertile, especially if he is a young adult.

CHRONIC EPIDIDYMO-ORCHITIS

DIFFERENTIAL DIAGNOSIS & TREATMENT

Suggesting testicular tumour: painless swelling of the testis (27.28)

Suggesting tuberculous epididymitis: swelling with low-grade pain affecting the epididymis and later the testis, not necessarily but often associated with tuberculosis elsewhere, which does not resolve with the usual antibiotics.

Suggesting bacterial epididymo-orchitis: chronic urinary symptoms predominate: use the appropriate antibiotics related to urine culture.

Suggesting schistosomiasis or filariasis: a globular mass in the spermatic cord, which may extend along its whole course; this suggests fibrosis which may not respond to medical treatment.

If there are severe recurrent attacks of pain which do not settle, even when the urinary infection is controlled and the flow good, consider orchidectomy (27.26) taking the epididymis necessarily with the testis.

27.24 Hydrocoeles in adults

The cause of many hydrocoeles is unknown; they may be one of the manifestations of *filariasis*. A hydrocoele in an adult is different from one in a child, which is almost always a patent *processus vaginalis* (18.5). You must be able to differentiate a hydrocoele from an inguinoscrotal hernia by being able to get above the hydrocoele. Normally a hydrocoele transilluminates (if the skin is not too dark and the light bright).

If a hydrocoele is small, leave it, but if it is so large it makes walking or sex difficult, or is an embarrassment, operate. If it is only a modest size, turn it inside out (*i.e.* evert it out of the *tunica vaginalis*), so that the fluid which it secretes drains into the lymphatics; if it is very large excise its secreting surface. Aspirating smaller hydrocoeles every 3-6months is popular with many patients but is not a cure, and may result in septic complications. As an alternative, sclerotherapy is useful, but may also result in septic complications. To prevent recurrence, insert 1ml 2% phenol with 10ml lidocaine into the hydrocoele cavity for every 200ml aspirated.

The scrotum is famous for its tendency to bleed postoperatively, develop a haematoma and swell up bigger than it ever was before! Complete haemostasis is important. Sharp dissection causes less bleeding than blunt dissection. A continuous locking absorbable suture over the cut edge of the tunica is more reliable than interrupted sutures.

The sac may be tense, enlarged and tender if there is a scrotal abscess (6.21); occasionally it is not tender but contains a necrotic brownish paste associated with an atrophic or absent testis. The cause of this is unclear, but may be related to *filariasis*, and is found in Northern India, known as 'kichad'. In either case, incision and drainage suffice.

Very occasionally in a lax hydrocoele, the testis is abnormal and may contain a tumour: in this case use an inguinal approach (27.26), and be prepared to perform an orchidectomy.

EVERSION OF A HYDROCOELE (JABOULAY OPERATION): (GRADE 2.1)

INDICATIONS. Moderate sized thin-walled hydrocoeles.

METHOD. Hold the scrotum in such a way as to stretch the skin over the hydrocoele. Make a vertical incision (27.29A). Carefully deepen the incision through to the *tunica vaginalis* and pierce this to let out the fluid.

The incision should only be just big enough for you to deliver the testis through the opening. When you have done this, evert the *tunica vaginalis* and suture it behind the testis, in such a way that the testis cannot return into its sac (27-21A).

CAUTION! Make sure you evert the whole sac. If it has an upward prolongation and you fail to evert this, the hydrocoele will recur. To evert it put a haemostat into it, pull it inside out completely, and pass a mattress suture through it. Make sure there is no bleeding from the *tunica vaginalis*; insert another row of sutures if necessary. Stretch the layers of the *dartos* to make a pouch for the testis: this will allow any fluid to get absorbed and not re-collect. Close the wound in 2 layers, taking the *dartos* muscle in the first, and the skin in the second, with continuous short-acting absorbable suture, to secure haemostasis.

EXCISION OF A HYDROCOELE SAC (GRADE 2.2)

INDICATIONS. A large hydrocoele with a greatly thickened wall, perhaps covered with a layer of cholesterol crystals. For enormous hydrocoeles, *e.g.* in *filariasis*, perform a reduction scrotoplasty (27.34).

METHOD. If the hydrocoele is very large, resect the redundant scrotal skin, but leaving enough skin remaining to recreate a scrotum. Excise the entire sac of the hydrocoele, except for a cuff 1cm deep around the testis and epididymis (27-21C). The cut edges will bleed profusely. Pass a simple continuous haemostatic suture along the whole cut edge.

CAUTION!

(1) The cleft between the testis and epididymis may be greatly enlarged by the extension of the hydrocoele, so take care not to injure or remove the epididymis with the *tunica vaginalis*.

(2) Operate gently and control bleeding before you close the skin.

(3) Avoid diathermy because you can overheat the spermatic cord and cause thrombosis of the blood vessels, resulting in testicular infarction.

If mild bleeding persists, insert a drain through the wound. Close it in 2 layers, as above.

If the scrotal sac remains large and floppy, secure it to the anterior abdominal wall between 2 pieces of gauze, for 48hrs.

DIFFICULTIES WITH HYDROCOELES

If the patient is a neonate or child, operate through the groin because this type of hydrocoele is actually usually a hernia with fluid in a patent *processus vaginalis* (18.5).

OPERATION FOR HYDROCOELE

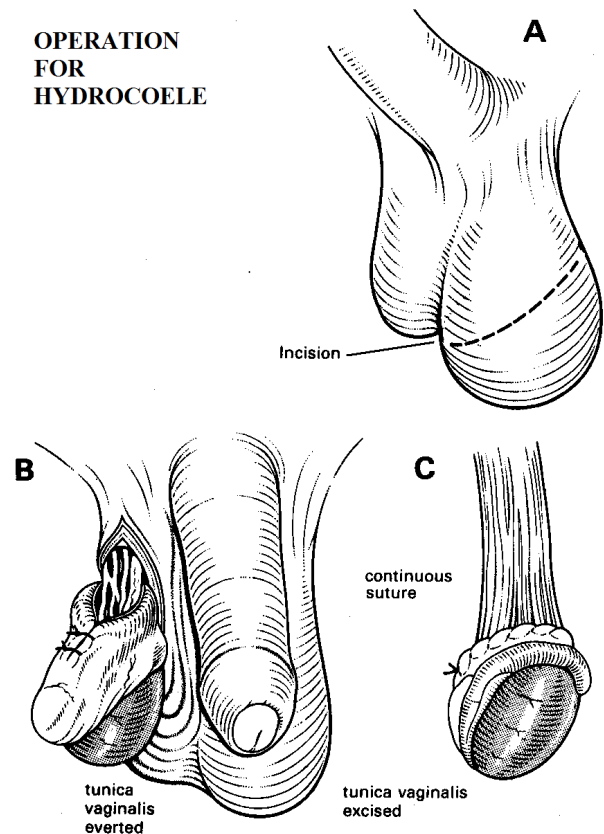


Fig. 27-21 OPERATION FOR HYDROCOELE IN ADULTS.

A, make an elliptical incision, and excise the skin within the ellipse, after which you can turn the *processus vaginalis* inside out (B), or you can excise it (C).

If there appear to be bilateral hydrocoeles, start with the biggest side first; the apparent second hydrocoele may subsequently disappear.

If when you open the sac you find bowel, this is an indirect inguinoscrotal hernia (18.2). Start again through the groin to identify the sac at the internal ring, and proceed as for a hernia repair. Use your scrotal incision as the site for a drain, because of a high risk of bleeding in such cases.

If when you open the sac you find altered blood (an old haematoma), drain it but *do not attempt eversion or excision*. Leave in a corrugated drain (4-14B) and give prophylactic cloxacillin 500mg qid; the scrotum will eventually shrink as it heals by fibrosis.

If you find a malignant-looking testis, start again through the groin and clamp the testicular vessels, and proceed to orchidectomy (27.26). Get histology done.

If the scrotum swells alarmingly postoperatively, suspect a haematoma. Open the wound, evacuate the blood and clots, and leave in a drain. Use prophylactic cloxacillin 500mg qid.

27.25 Testicular torsion

Torsion of the spermatic cord (strictly speaking) is a surgical emergency which needs operation without delay. It is never wrong to operate to exclude torsion.

Occasionally, the *tunica vaginalis* ends abnormally high up the spermatic cord, so that the cord can twist and obstruct the blood supply to the testis and epididymis. When this abnormality (the 'bell-clapper' testis) is present, the testis usually hangs transversely, and does so on both sides.

Unless you can untwist the cord, the testis will necrose, become a purple-black, and fill the *tunica vaginalis* with a blood-tinged fluid. If you do not relieve the torsion before this happens, the testis will atrophy. If you are going to save it, you must operate within 6hrs of the start of symptoms.

PRESENTATION.

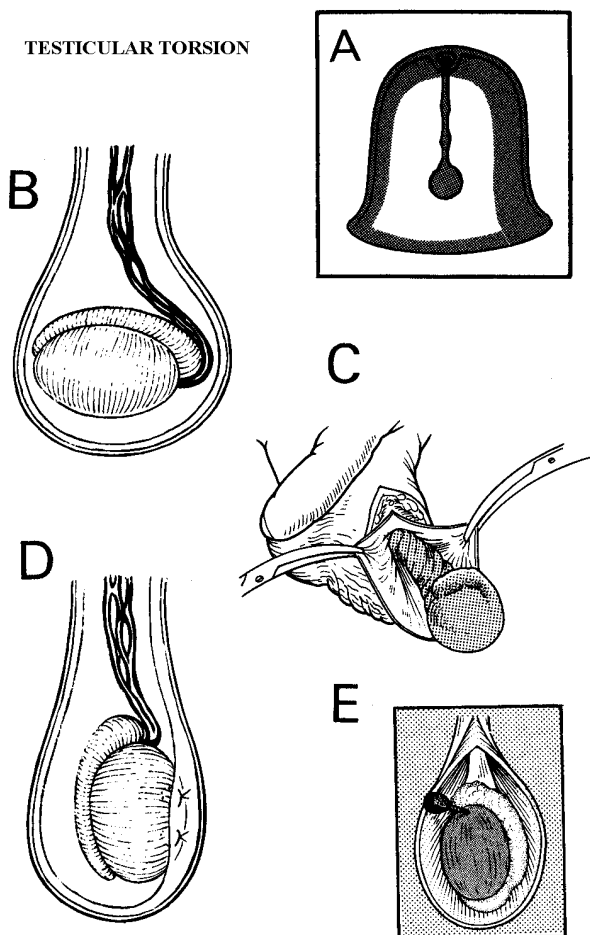


Fig. 27-22 TESTICULAR TORSION (or strictly speaking, the cord). Occasionally, the *tunica vaginalis* ends abnormally high up the spermatic cord, so that it can twist and obstruct the blood supply to the testis and epididymis. This abnormality is the 'bell-clapper' testis. A is a bell with its clapper. B, is such a testis, with a long intravaginal spermatic cord hanging horizontally. C, torsion of the spermatic cord. D, the cord untwisted and the testis anchored to prevent recurrence. E, torsion of the appendix testis, which has no function.

Torsion can occur at any age, but is more common in the first year of life and in adolescence (12-19yrs).

Typically, a teenage boy wakes with sudden severe *pain in the groin or lower abdomen* (owing to the surface neurotome representation of the testis), rather than in the testicle. Often, there is severe nausea and vomiting, and rarely a fever. The testis becomes tender and swollen, and the skin of the scrotum may become red.

DIFFERENTIAL DIAGNOSIS.

Suggesting epididymo-orchitis: the slower onset of pain in an adult with history and signs of past or present sexually-transmitted infection, infected urine, or prostatic symptoms (27.23). Usually a mild fever is present. The testis lies normally but may be quite swollen and tender.

CAUTION!

(1) *Do not diagnose anyone as suffering from epididymo-orchitis under 30yrs* especially if there is no history of sexual contact. If there is any doubt, operate. *You will not do harm by exploring orchitis, but antibiotics will not relieve torsion. Do not rely on a Doppler test:* the presence of blood flow shows the testicle is still viable, but not that it has not twisted!

N.B. Except for the orchitis of mumps, orchitis is very rare in young boys.

(2) Treat painful *testicular* enlargement in an infant or neonate as torsion.

MANIPULATIVE REDUCTION is temporary and is never adequate or definitive treatment. *Do not try it without putting local anaesthetic into the spermatic cord.* It is only appropriate in the 1st 2hrs of symptoms, but may buy you time if you cannot operate within 6hrs. The testis twists medially in 66% of patients and laterally in 33%. Even if it is successful, torsion may recur, so proceed to operation and fixation early.

ORCHIDOPEXY FOR TESTICULAR TORSION (GRADE 2.3)

INCISION

Make a vertical incision in the scrotum, over the area of tenderness. Cut through the subcutaneous tissue and fascial layers down to the *tunica vaginalis*. Open it. You will find it filled with blood-tinged fluid, and you will see the twisted spermatic cord. Untwist it.

If there seems no chance that the testis will survive, check that it is really infarcted by cutting into it: if it does not bleed, transfix the spermatic cord and remove the testis (27.26).

If you are not sure if the testis is viable or not, wrap it in a warm moist swab and inspect it again after 5mins. Bright bleeding when you incise the *tunica albuginea* is a promising sign. If you are in doubt, preserve it, especially if the symptoms have lasted <12hrs, and it has twisted <1½ times.

Once you are confident there is some life in the testis, fix it to the *tunica vaginalis* to prevent recurrence (27.30D). Align the testis with its head placed superiorly. Anchor it laterally with 2 non-absorbable sutures.

CAUTION! Whatever the viability of the twisted testicle, you must *always* anchor the contralateral testis in the same way: the anatomical abnormality is usually bilateral.

Close the *dartos* and skin in 2 layers with continuous short-acting absorbable suture.

DIFFICULTIES WITH TORSION OF THE TESTIS

If you find that the testis is not twisted, but instead there is a small twisted structure attached to it, this is TORSION OF AN APPENDIX TESTIS (27-22E). These are the remains of the *Müllerian duct*. Tie off the twisted structure and excise it.

If in an infant and especially a neonate, you find that the whole *tunica vaginalis* with its contained testis and spermatic cord is twisted (supravaginal torsion), deal with it in the same way.

If a mal descended testis strangulates, you can mistake it for a strangulated hernia (18.6).

If the torsion reduces spontaneously, advise that it can recur and that bilateral orchidopexy is still necessary.

If you find only one testis, the other having been lost to neglected torsion, perform an orchidopexy on the remaining testis.

27.26 Orchidectomy

You may occasionally need to remove the testes, either because of infarction, chronic suppuration or a tumour (a sarcoma, seminoma or teratoma, 27.28). This is much safer than biopsying it, which may spread the tumour. Or, in treatment of prostate carcinoma (27.22), you can perform a bilateral subcapsular orchidectomy. This removes the testicular function whilst retaining the semblance of testicles.

Do not mistake mumps orchitis or epididymo-orchitis for a tumour. This causes rapid enlargement, and some pain (which is minimal in the case of a tumour). Mumps orchitis may cause little pain, so if you are in doubt, wait for a few days rather than remove the testis.

You will have to exert some traction on the cord, but beware of its upper end slipping out of the clamp and retracting out of sight. Take great care to secure haemostasis, before you close the wound. If possible, apply diathermy to the smaller bleeding vessels, and tie off the larger ones. Close the skin with continuous horizontal mattress absorbable sutures.

SUBCAPSULAR ORCHIDECTOMY

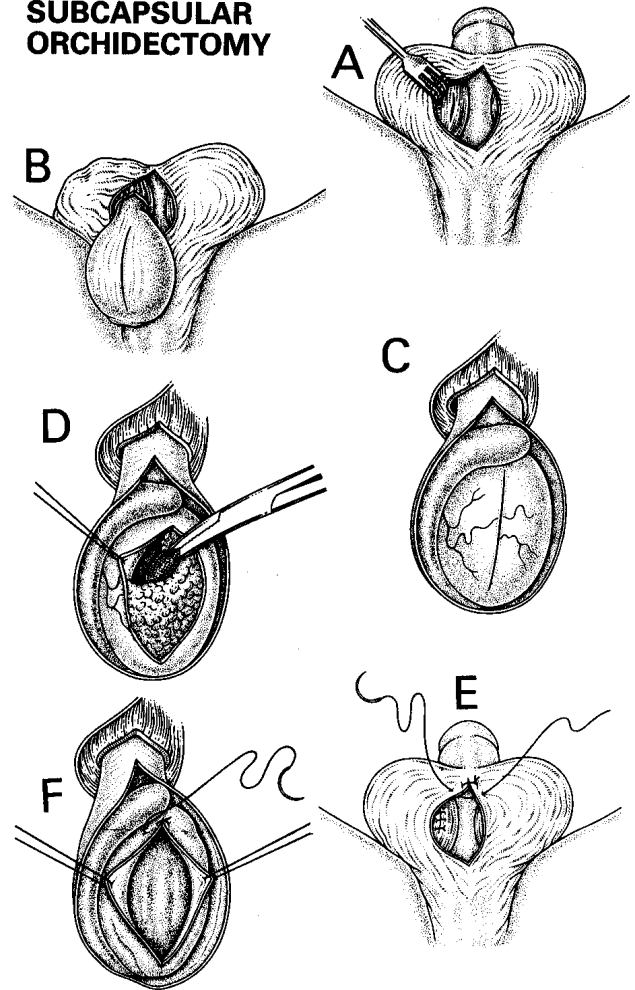


Fig. 27-23 SUBCAPSULAR ORCHIDECTOMY FOR PROSTATE CARCINOMA. A, make a longitudinal incision in the patient's scrotum. B, evaginate the testis. C, incise the tunica albuginea. D, separate the substance of the testis from the inner surface of the tunica albuginea. E, close the tunica. F, close the skin.

After Rob C, Smith R. *Operative Surgery*, Butterworth 1981 p.667-8 with kind permission.

SUBCAPSULAR ORCHIDECTOMY FOR PROSTATIC CARCINOMA (GRADE 2.3)

Raise the scrotum, and incise the stretched skin and *dartos* muscle, to expose both testes (27-23A). Evaginate each testis with its coverings, and incise its *tunica vaginalis* vertically to expose the testis and epididymis (27-23B). Incise the visceral *tunica* vertically over the globe of the testis. Use sharp and blunt dissection, to separate the substance of the testis from the inner surface of the *tunica albuginea* (27-23C). Control bleeding carefully at the upper testicular pole. Remove all testicular tissue, and close the *tunica* with continuous 3/0 absorbable sutures (27-23D). Close the scrotum in 2 layers with continuous 3/0 short-acting absorbable sutures, without inserting a drain. After 2-3wks, blood clot in the *tunica* will become organized to form a small palpable nodule, not unlike a small testis.

ORCHIDECTOMY FOR INFARCTION OR CHRONIC SUPPURATIVE INFECTION (GRADE 2.2)

Expose the testis by incising through the scrotum (27-23A), deliver the testis, clamp the spermatic cord and ligate it with a strong suture. If it is very thick and oedematous, ligate it twice with a fixation suture and divide it. If the area is infected, leave the wound in the scrotum unsutured to drain freely, dress it loosely, and close it by delayed primary suture.

ORCHIDECTOMY FOR TESTICULAR TUMOUR (GRADE 2.5)

You will need to remove the cord with the testis, so open up the inguinal canal as for a hernia with an inguino-scrotal incision (18-7A). Pick up the cord within its covering of *cremaster*. Apply a soft bowel clamp to it (27-24A), before you do anything else. Deliver the testis from the scrotum by pushing it up from below. If the tumour is large, you will have to extend the opening in the external inguinal ring.

If you feel a hard irregular mass, which is not chronic epididymo-orchitis, doubly transfix and tie the cord proximal to the clamp as near the internal ring as you can, and excise the testis.

RADICAL ORCHIDECTOMY

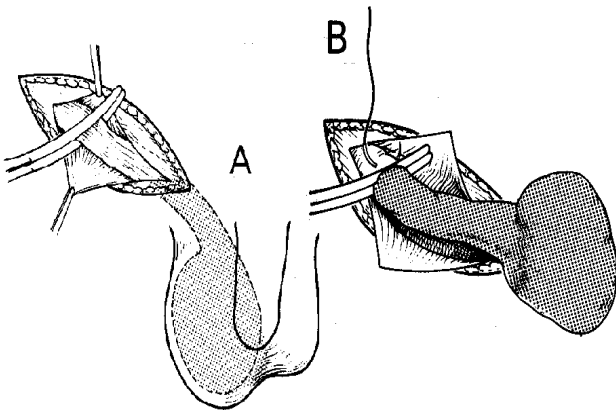


Fig. 27-24 TOTAL ORCHIDECTOMY FOR TUMOUR.
A, apply a soft (non-crushing) bowel or arterial clamp to the cord before you do anything else. B, make an inguino-scrotal incision and remove the cord with the testis through the groin.
After Blandy J. *Operative Urology*, Blackwell 1978 Figs 15.37,40 with kind permission.

N.B. Do not cut through the scrotum as you will then open up a different lymphatic drainage field for the tumour.

You should try to administer adjuvant chemotherapy if testicular malignancy is confirmed (27.28).

27.27 Undescended or maldescended testes

About 3% of neonates and 0.5% of older boys have a testis missing from the scrotum, and in 20% it is missing on both sides. An incompletely descended testis lies along the track of descent of the testis: the common sites for it are in the inguinal canal, or inside the abdomen.

A maldescended testis, however, may lie in the supra-inguinal pouch, just superior to the external ring deep to the membranous part of the superficial fascia, in the perineum, or on the medial aspect of the thigh. The distinction between incomplete descent and maldescent may be difficult. A testis which is absent from the scrotum will produce hormones but not *spermatozoa*. So if neither of the testes is in the scrotum, there will be normal secondary sex characteristics, including potency, but infertility. The less complete the descent, the greater the chance of infertility. If a testis is absent on one side only, there will probably be fertility, but the misplaced testis is more easily injured. Spermatogenesis is normal in an incompletely descended testis and in a maldescended one for up to 2yrs. This is also the age at which nearly all 'retractile testes' will have settled normally into the scrotum. So wait until 2yrs before you advise orchidopexy. If neither of the testes is in the scrotum by this time, orchidopexy may still produce adequate fertility. If one testis descends, fertility may still improve with orchidopexy. Its main effect, however, remains psychological.

Maldescended testes are usually functional, which can be brought down more readily. Unfortunately, the evidence for orchidopexy improving fertility is still inconclusive.

If neither testis is present in a neonate scrotum, the possibilities are commonly,

- (1) Retractable testes;
- (2) A genuine undescended or maldescended testis; or rarely,
- (3) An intersex state. These are complex and include true hermaphroditism and the adrenogenital syndrome.

If the testes tend to lie at the external ring or even a little within it, especially in the cold, but can be manipulated downwards (retractile testes), consider this normal. By puberty they will probably be permanently in the scrotum. Advise the parents to check for this.

If at any stage the testes cannot be manipulated into the correct position in the scrotum, you should perform an orchidopexy, especially above the age of 2yrs.

If there is a hernia and an undescended testis on the same side, perform an orchidopexy at the same time as the herniotomy; it will be much more difficult later.

SPECIAL TESTS.

If you cannot feel the testis in the groin, you might be able to see its position with **ULTRASOUND** (38.2).

ORCHIDOPEXY FOR UNDESCENDED TESTIS (GRADE 2.4)

METHOD

The important part of the operation is getting enough cord length; the method of fixation is less important. Aim to mobilize the spermatic cord to obtain more length, and then to fix the testes in their normal places. Deal with incomplete descent and maldescent in the same way.

To mobilize the spermatic cord, make a 5cm incision from just lateral to the mid inguinal point to the root of the scrotum. Open the inguinal canal from the external to the internal ring. Find the spermatic cord containing the spermatic vessels and vas. Use sharp dissection with fine instruments to mobilize the cord and testis from all surrounding structures, including the *dartos* muscle. If there is a hernia (common) dissect off the sac, divide it and ligate it as in a herniotomy (18.5).

If you now have enough length of cord to bring the testis down into the scrotum, put a stay suture through the lowest point of the testis.

To fix the testis in the scrotum, insert your finger into the scrotal sac to open it up. At the point where the testis will reach easily, incise gently through the scrotal skin but not through the *dartos*. Then insinuate an artery forceps between skin and *dartos* and so make a pouch big enough to accommodate the testis.

Make a small hole in the *dartos* and catch the suture you placed in the testis, and pull this with the testis through into the pouch. The trick is not to make the hole in the *dartos* too big so that the testis pops out again! Make sure that the cord is not twisted. Fix the testis with monofilament in the *dartos* pouch, outside the muscle which prevents it retracting back inside. Close the scrotal skin with chromic catgut.

CAUTION!

- (1) Be sure to discuss with the parents what you can achieve by operation on an incompletely descended testis.
- (2) Take great care not to damage the blood supply of the testis.
- (3) At the end, explain the outcome of the operation.

DIFFICULTIES WITH ORCHIDOPEXY

If, at operation, you cannot bring down the testis fully, and you have mobilized the spermatic cord and vas as much as you can, and have removed any hernia sac present, open the internal inguinal ring further on its medial side and open the peritoneal cavity. Dissect the cord from the peritoneum covering it for about 5cm. This is not easy, so *do not attempt it unless you have had some experience* because you might devascularize the testis.

If you fail to bring down the testis fully, a two-stage procedure will be necessary. Fix the testis as far down as you have been able to bring it. If there is bilateral incompletely descended testes consider carefully whether you wish to tackle this side as well.

There may be a need for further mobilization later at a later stage, but this is unlikely to improve fertility.

27.28 Testicular tumours

Nearly all tumours of the testis are malignant. In Africa, most of them under 16yrs are rhabdomyosarcomas; seminomas are very rare. Elsewhere, most are seminomas or teratomas or a combination of both, and are usually seen between 20-45yrs.

Presentation is with:

- (1) A large, usually painless, testicular swelling.
- (2) An abdominal mass.
- (3) Gynaecomastia and breast tenderness (rare), in which case gonadotrophin production by the tumour may result in a +ve pregnancy test.

DIAGNOSIS.

The testis is large, hard, smooth, heavy, and not tender. It loses its normal sensation early. On standing it usually hangs lower than the normal one, unlike testes with inflammation or torsion, which are usually pulled higher. The vas, prostate and seminal vesicles are normal, and the cord likewise until late, but occasionally (10%) a hydrocoele is present. Early, the epididymis is normal, later it is flattened or hidden in the tumour.

Feel for deposits above the umbilicus on the same side, in the liver, and above the clavicles. X-ray the lungs. Get an ultrasound of the abdomen looking for para-aortic nodes (38.2G) and liver metastases (38.2A).

DIFFERENTIAL DIAGNOSIS:

- (1) epididymo-orchitis (27.23),
- (2) hydrocoele (27.24),
- (3) haematocele following trauma,
- (4) testicular torsion (27.25)
- (5) epididymal cyst,
- (6) tuberculoma (rare),
- (7) syphilitic gumma (rare).

MANAGEMENT.

Do not delay the operation. Under GA, palpate the abdomen for para-aortic masses. Perform a radical orchidectomy through an inguinal incision. (27.26)

If there is a seminoma, arrange postoperative radiotherapy to the upper abdominal para-aortic nodes as soon as possible, even in the absence of demonstrable metastases, though there is an 80% chance of cure by orchidectomy alone. If there is a teratoma, treat with postoperative cyclophosphamide, vincristine, methotrexate and dactinomycin gives a 95% chance of complete cure. Use this even if there are metastases. Get expert advice!

CAUTION!

- (1) If the presentation is with symptoms which might be due to metastases, *do not fail to examine the testes*. A small primary is easily missed.
- (2) *Do not remove the testis through the scrotum.*
- (3) *Do not try to biopsy the lesion.*

27.29 Circumcision

Recommending circumcision to reduce HIV spread in a region where HIV prevalence and incidence of penile carcinoma is high, is controversial. It may be useful before sexual activity starts, because the exposed glans develops, with time, an epithelium supposedly more resistant to spread of the virus. An argument against circumcision is that the foreskin is useful raw material for plastic surgery. *Never do it when there is hypospadias present (33.9).*

ANAESTHESIA FOR CIRCUMCISION

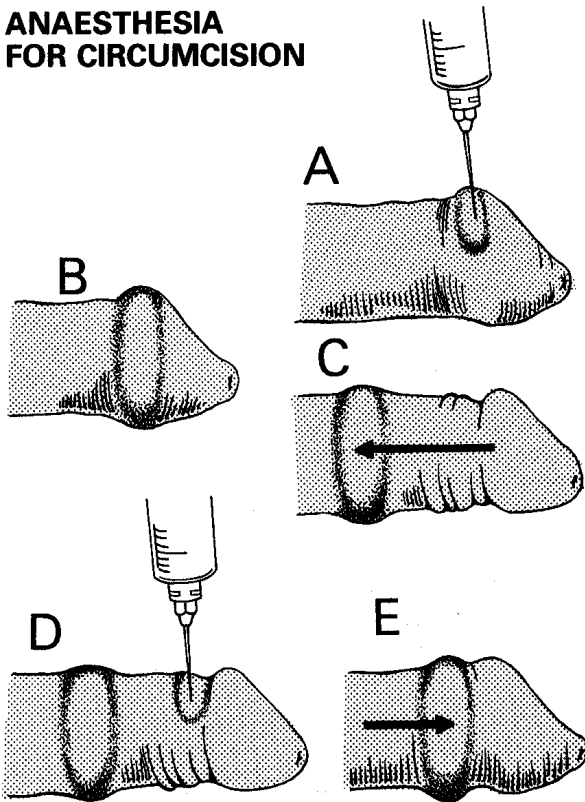


Fig. 27-25 ANAESTHESIA FOR CIRCUMCISION FOR PATIENTS >15YRS.

A,B, with the foreskin forward, infiltrate a ring of LA without adrenaline at the site of section. C, pull back the foreskin. To do this you may have to infiltrate a little more and make a dorsal slit. D,E, infiltrate another ring of solution, at the site of section, just behind the glans. Pull the foreskin forwards again, and all is ready for circumcision to start.

N.B. Under 15yrs and in HIV disease, use a caudal block or ketamine.

A STORY FROM A CITY HOSPITAL.

Horrible shrieks used to be heard from the theatre whenever circumcisions were being done. A caring surgeon put Fig. 27-25 on the wall whereupon they stopped completely, to the gratitude of the staff and the patients! 10yrs later this event was still remembered.

There may be a significant risk, in some cultures, that a child has it done by crudely under non-sterile conditions. You may be able to advertize a course in good surgical technique for traditional practitioners or nurses!

Consider carefully if the risks of surgery are justified. It is usually reasonable to delay the procedure till a child is over 2yrs. Often you can free up an apparently tight foreskin, and mobilize it over the glans with gentle traction.

INDICATIONS FOR INFANTS.

- (1) Phimosis.
- (2) Irreducible paraphimosis.
- (3) Religious requirements.

CONTRA-INDICATIONS FOR INFANTS.

- (1) Child <24hrs old or premature.
- (2) Penile anomaly, including hypospadias.
- (3) Family history of bleeding disorder.

INDICATIONS FOR ADULTS.

- (1) Phimosis; recent balanitis, such as that due to diabetes.
- (2) Paraphimosis.
- (3) A suspected malignant lesion confined to a small area of the foreskin.
- (4) Copious penile condylomata.

N.B. Consider carefully if circumcision is indicated in HIV+ve patients.

ANAESTHESIA.

- (1) In a neonate, sucking on the mother's breast with some sugar on the nipple is usually good preparation. Topical anaesthetic cream is useful if you are performing many circumcisions. Wait for it to take effect!
- (2) If the boy is <15yrs, use ketamine.
- (3) If >15yrs and he is HIV-ve, use LA (27-25). You will have to cut the inner and outer skin of the foreskin, so you will have to infiltrate them both. With the foreskin forward, infiltrate a ring of anaesthetic solution *without adrenaline* at the site of section (27-25A,B). Pull back the foreskin (27-25C). To do this you may have to infiltrate a little more solution and make a dorsal slit in it. Infiltrate another ring of solution at the site of section just behind the glans (27-25D). Pull the foreskin forwards and do the circumcision (27-25E). Or, perform a dorsal nerve block at the base of the penis at 2 & 10 o'clock positions with 1ml of 0.25% bupivacaine or 1% lidocaine, about ½cm below the skin.
- (4) A caudal block is an alternative <5yrs: using a 0.9mm spinal needle, under sterile conditions, introduce up to 4ml 1% lidocaine through the sacral hiatus into the sacral canal to the level of S3.

TIMING.

Neonatal circumcision is best done at day6 of age, and before day10. Check that the child has passed urine, and look carefully for hypospadias or epispadias.

RESOURCES.

Consider carefully if, because of financial incentives from programme donors, the resources for performing circumcisions are being diverted from other essential surgery!

CIRCUMCISION

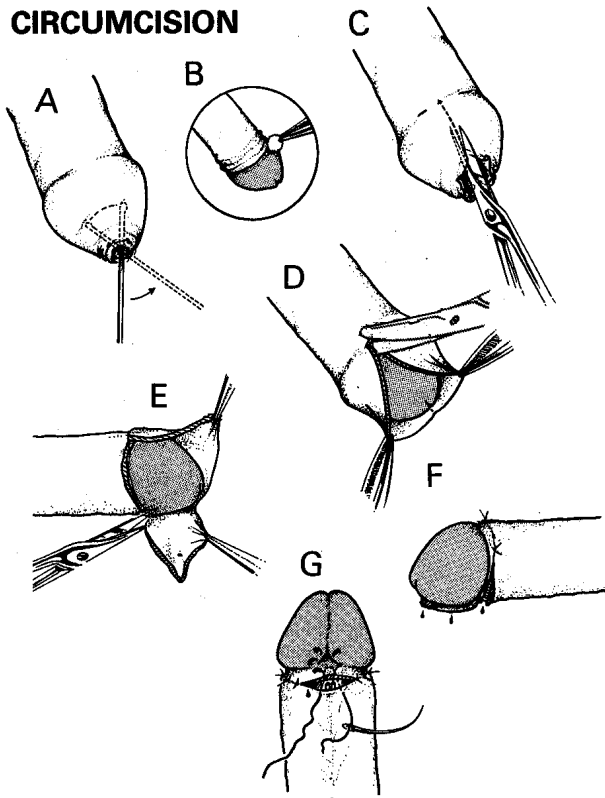


Fig. 27-26 CIRCUMCISION.

A, free up the foreskin. B, retract the foreskin and clean the glans. C, make a dorsal slit. D, cut the outer skin only with scissors. E, cut the inner layer with scissors leaving a 2mm fringe at the corona. F, suture the fringe of foreskin to the skin of the shaft. This will control most of the bleeding. G, control frenal bleeding with this suture.

METHOD. (GRADE 2.1)

Use a warmed room for neonates, and have good lighting available.

Insist on adequate bathing pre-operatively. If adhesions or a tight phimosis prevent you pulling the foreskin back, use a probe to free up the foreskin from adhesions to the glans (27-26A). Retract the foreskin if you can (27-26B), clean thoroughly underneath it and then pull it forwards again. With the penis in its normal relaxed position, feel for the bulge of the corona of the glans. Hold the foreskin laterally on both sides with haemostats, and make sure the space between foreskin and glans is free with the probe.

Use a haemostat to crush a midline portion of the dorsal foreskin and then blunt-ended scissors to cut a slit in exactly this position up to the level of the bulge in the corona (27-26C). If you have been unable to clean underneath the foreskin, do so now.

CAUTION! Make sure that the point of the scissors is not in the meatus.

IN A NEONATE, you can use the Plastibell device, GOMCO or Mogen clamps. Be careful, however, about using any special circumcision clamps and tools which do not allow you to see the glans. Never use diathermy.

CIRCUMCISION DEVICES

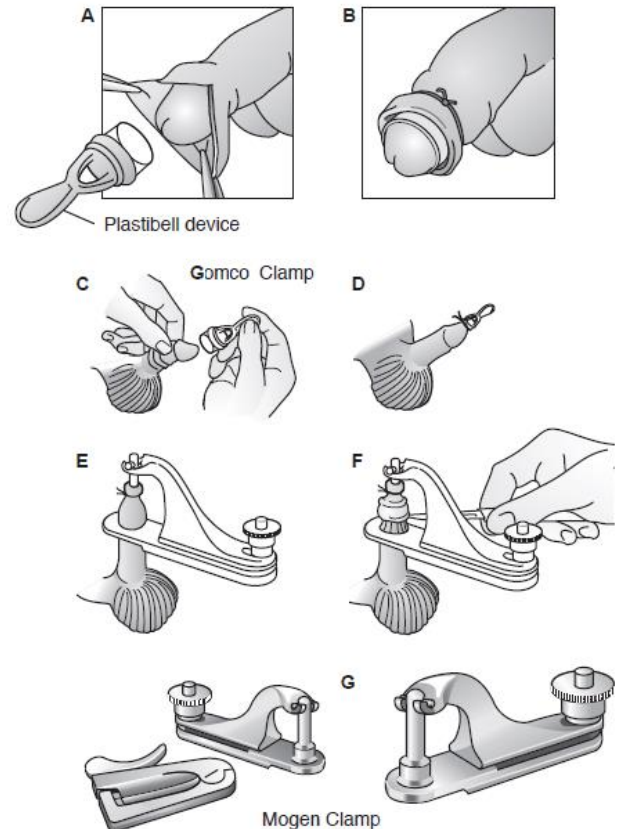


Fig. 27-27 NEONATAL CIRCUMCISION DEVICES.

A, applying the Plastibell device. B, suture tied over the foreskin. C, GOMCO clamp. D, apply the lubricated bell over the glans. E, tie the foreskin to the bell handle. F, fit the bell in the yoke of the clamp. After tightening the thumbscrew, cut off excess foreskin with a scalpel. G, Mogen clamp.

The **Plastibell** is a plastic bell with a groove around its edge. Place it under the foreskin and over the glans, and then tie a suture in the groove. The suture occludes the blood supply to the foreskin, which ultimately drops off along with the bell. It therefore may be more painful.

Make the dorsal slit long enough to accommodate the device (27-27A). Select the Plastibell cap that best fits the glans (6 sizes are available). A cap that is too small will not let you remove sufficient foreskin and a cap that is too big will cause you to remove too much foreskin. A proper fit is a cap that fits halfway down the glans. *The groove must always be distal to the corona.*

Separate the two sides of the dorsal slit incision to expose the glans, put the Plastibell device over the glans, and then close the foreskin over it. *Don't pull the foreskin too tightly*, as this might result in the compressing the urethra. Then tie the string securely around the foreskin in the groove at the ring-shaped base of the bell (27-27B). Some devices have a handle that helps secure the device and you must snap this off once you have secured the device in place. You can cut off any excess foreskin beyond the suture taking care not to cut the suture itself.

The child goes home with the bell part of the device still attached. It will fall off with any foreskin left beyond the suture in 6-12 days.

If the device does not fall off during this interval, you must remove it promptly. Sometimes oedema will trap the plastic ring on the penis, so you will need a guide and ring cutter to cut the ring off.

If the child has difficulty urinating, it may be because the ring has slipped proximally from the glans onto the penile shaft; this can result in venous obstruction and a compartment syndrome leading to necrosis of the glans.

N.B. The advantages of the Plastibell are that you do not cut the frenulum and there is no free incised edge of foreskin that can bleed.

The GOMCO clamp (27-27C) is a 3-part device (base plate, bell, lock). The clamp crushes c.1mm of the foreskin circumferentially, while the bell protects the glans by separating it from the inner preputial mucosa during removal of the foreskin. The bells come in 3 sizes; for a correct fit, the edge of the bell should reach the frenulum and minimally extend over the corona, slightly stretching the preputial skin. (For a newborn, use a clamp with a 1.3cm hole)

A dorsal slit is not always necessary.

Place the bell inside the foreskin and over the glans, lubricated with a little lubricant jelly (27-27D), and remove the two haemostats. Make sure that the apex of the dorsal slit is visible above the rim of the bell.

Too small a bell may injure the glans and fail to protect the corona. Slip the handle of the bell through the circular opening of the base plate, without letting the foreskin slip off. Tie the foreskin in place (27-27E). Check to see that the foreskin is not twisted and remains relaxed proximal to the corona. *If it is taut, you can remove too much foreskin or even cut into the glans; if it is too loose, you will remove too little foreskin!* You may need to adjust the base plate: this is the time to do so. Make sure that the crossbar at the top of the bell sits squarely in the yoke of the clamp so pressure is evenly distributed around the bell (27-27F). Tighten the thumbscrew until snug to crush the foreskin between the bell and base plate; then cut the foreskin at the base plate using a scalpel (27-27F). Carefully remove any remaining tissue in and around the groove that connects the clamp and bell.

Leave the clamp secured for 5mins and then unscrew it to remove it.

N.B. You need care in adjusting the bell and base plate correctly, so not too much or too little foreskin is cut off: don't try repeating the procedure with the clamp. If the clamp is old and worn, it will not give a neat closure!

If too little foreskin is removed, proceed to a formal circumcision.

If too much foreskin is removed, you may need a skin graft to cover the defect.

The **Mogen clamp** (27-27G) technique is the quickest, and therefore least painful. You do not need to make a dorsal slit, although this may help to visualise the glans.

Use your thumb and first finger of the non-dominant hand to grasp the foreskin firmly below the tip of the haemostat and push the tip of the glans out of the way.

Slide the Mogen clamp anteriorly to posteriorly just above your fingers to protect the glans when applying the clamp. Place it at the same angle as the corona with the hollow side facing the glans, so that you remove more foreskin dorsally than ventrally. Before locking the Mogen clamp shut, manipulate the glans to be sure it is free of the clamp. Then close and lock it. Cut off the foreskin distal to the clamp with a scalpel.

N.B. Beware! The glans is not well protected during clamping and cutting. However, since the clamp only opens 3mm, the chance of trapping the glans is minimal.

FORMAL CIRCUMCISION IN OLDER CHILDREN & ADULTS

After performing a dorsal cut of the foreskin, cut the outer skin only round the corona (27-26D). Cut the inner layer with scissors, leaving a 2mm fringe at the corona (27-26E). One of the purposes of the foreskin is to provide enough skin to allow the penis to erect, so when you perform a circumcision, *be careful not to take off too much skin*, or the pubic hair will later be drawn up the root of the erected penis. On the other hand *do not leave too much skin*, or there is the risk of recurrent phimosis.

Use 3/0 absorbable individual ties to control bleeding, and suture the fringe of the foreskin to the skin of the shaft of the penis (27-26F). Finally, control bleeding from the frenal vessels with a special encircling suture (27-26G). Dress the wound with petroleum jelly gauze. No dressing is needed after 24hrs.

CAUTION!

- (1) *Do not cut the glans.*
- (2) *Do not use diathermy on the penis*, it can cause gangrene of the whole organ.
- (3) *Never use adrenaline in a local anaesthetic for the penis*, this too can cause gangrene.
- (4) *Avoid LA in HIV+ve patients*, as postoperative vasculitis and infection may result in gross necrosis (6.21).

DIFFICULTIES WITH CIRCUMCISION

If you cannot separate the foreskin and the glans, because the cleft between them is obliterated, you may find yourself dissecting the glans from the thick adherent foreskin. If necessary, work slowly and carefully with a sharp scalpel. This will leave a raw area. Allow this to granulate on its own, and *do not try to graft it with split skin*.

If an adult has postoperative priapism, sedate him (27.32), but *do not use propofol*.

If there is bleeding post-operatively, find the vessels and insert 1-2 more interrupted absorbable sutures.

If a urethra-cutaneous fistula develops, either from direct injury or because of a periurethral abscess, you can close this if you use a *Dartos* fascia graft.

Measure the fistula, and pass a urethral catheter; decompress the phallus and apply a proximal tourniquet. Insert stay sutures to expose the fistula, and close it using skin flaps (as for hypospadias, 33.9). Then mobilize the *Dartos* fascia to place a graft with suture lines *not* superimposing on each other, using fine 4/0 long-acting absorbable sutures. *Do not use diathermy.*

If a crooked erection develops, there may have been excessive skin removed, or excessive scarring. Excise the contracture and apply a skin-graft.

27.30 Phimosis & paraphimosis

Distinguish three conditions:

- (1) Phimosis, in which the orifice of the foreskin is too small for it to be retracted over the penis.
- (2) Paraphimosis, where the foreskin has retracted, is swollen and stuck behind the glans, so that it cannot be brought forward again.
- (3) A meatal stricture (27.31), in which the external opening (meatus) of the urethra is abnormally constricted.

PHIMOSIS improves with the application of topical steroids (betamethasone 0.1% cream) over 6months; this is successful in 90% of patients in producing an easily retractile foreskin but may fail if there is already scarring present, and especially if there is *balanitis xerotica obliterans*.

PARAPHIMOSIS is the result of forcible retraction of the foreskin. It is common in adolescence, and is fairly common between 8-14yrs. Part of the foreskin is tight, so that it becomes oedematous distally. The oedema may be severe. If it has been present for >6hrs, the base of the penis may be oedematous also. Try to get the foreskin into its normal place over the glans.

REDUCTION OF PARAPHIMOSIS (GRADE 1.2)

METHOD.

Squeeze the swollen foreskin between the thumbs and index fingers of both your hands, so that the fluid which is making it swell, goes up into the tissues of the shaft. If the swelling is severe, wrap layers of gauze coated in sugar over it and squeeze them. When the foreskin is in its normal place, any residual swelling will usually subside in 24-48hrs. This is easier if you can inject hyaluronidase and lidocaine solution (1500U in 10ml water) into the oedematous foreskin. After 2-3mins of firm squeezing, when the swelling is much reduced, push the glans proximally with your thumbs, and draw the foreskin over it with your fingers.

PARAPHIMOSIS

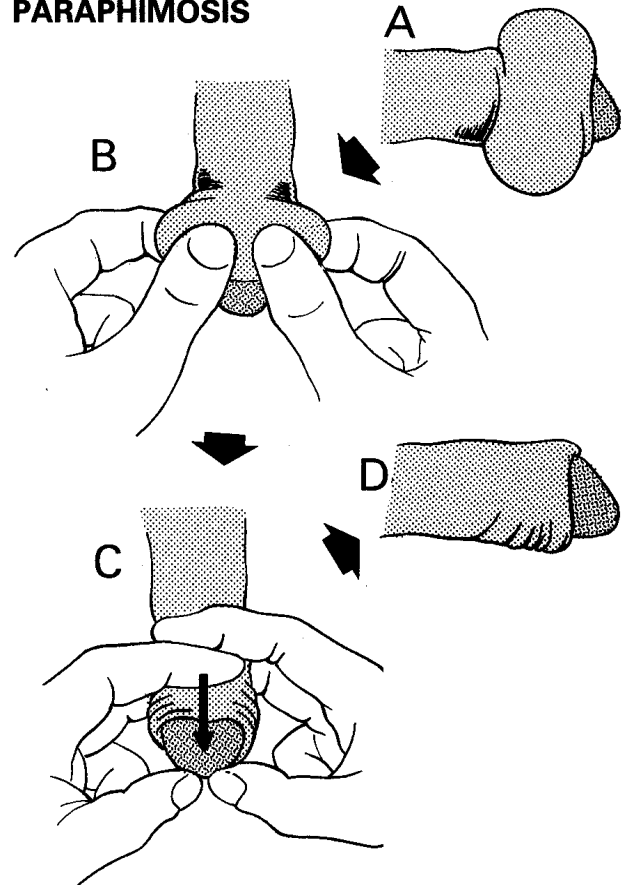


Fig. 27-28 PARAPHIMOSIS.

A, paraphimosis as the patient presents. B, use the thumbs and forefingers of both your hands to squeeze the swollen foreskin. C, slide the roll of foreskin forwards over the now thinner glans. At the same time push the glans back. D, successful reduction.

DIFFICULTIES WITH PARAPHIMOSIS

If you fail to reduce the paraphimosis, the constricting band is too tight, so proceed to circumcision (27.29). Where the paraphimosis is chronic, there develops a fibrous band just distal to the corona: you must excise this to get a good cosmetic result (a straight penis).

27.31 Meatal stricture

Strictures of the meatus have quite a different cause and prognosis from the gonococcal urethral strictures (27.9). You may see them in children, or adults, and they may be congenital, or acquired. The most important acquired cause is infection associated with instrumentation and catheterization.

In adults a meatal stricture may be due to the skin disease called balanitis xerotica obliterans (BXO, *lichen sclerosis atropica*). This also involves the foreskin, so there is usually an associated phimosis also.

Dilation should nearly always precede meatotomy.

If a meatal stricture develops in a child, give the mother a plastic rod to keep it dilated. The rounded plastic containers used for disposable needles are very suitable. Ask her to lubricate it with vegetable oil. If necessary perform a meatotomy.

If a meatal stricture develops in an adult, first try dilatation.

MEATOTOMY

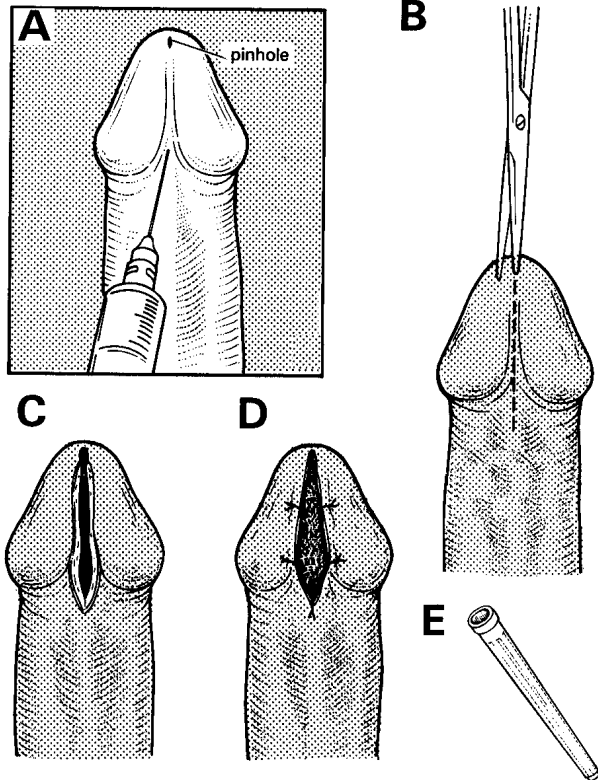


Fig. 27-29 MEATOTOMY.

A, although GA is preferable, you can infiltrate the frenulum and glans with lidocaine. B, introduce one blade of a pair of fine scissors into the urethra. C, cut 1.5 cm beyond the stenosis. D, suture the mucosa to the skin. E, plastic cover of a disposable needle makes a good dilator. Kindly contributed by Neville Harrison

MEATOTOMY (GRADE 1.4)

Either use ketamine, or use LA directly into the frenulum and the glans immediately under it. Alternatively, use a ring block of the base of the penis (27.29).

Put one blade of a pair of fine-pointed scissors into the meatus, and cut its ventral aspect in the midline. To stop the stenosis recurring, cut 1.5cm beyond the meatus, and suture the mucosa to the skin with long-acting absorbable. Use the first 2 sutures on either side as retractors to open the wound, and expose the mucosa of the urethra. Insert a suture at the apex of this incision to control bleeding from the frenal artery. The meatus may re-stenose, so use a dilator regularly.

If there are signs of BXO, hydrocortisone cream will help to prevent recurrence. Apply it into the meatus from the nozzle of a small tube, which will then act as a dilator. You should continue this for 3months.

27.32 Priapism

If there is a sustained painful involuntary penile erection, either rigid, or merely turgid, this is priapism, which is a urological emergency. If this is secondary to sickle-cell disease (in which it is common), leukaemia, use of sildenafil or similar medication, or some neurogenic cause, such as paraplegia, it usually settles with sedation and without impairing subsequent erections. The danger is that if priapism from any cause persists too long, the *corpora cavernosa* may become ischaemic and fibrotic, so that he becomes permanently impotent.

So treat him early by:

- (1) Using sedation (*not propofol*); always try this first.
- (2) Irrigation of the *corpus cavernosum*.
- (3) Injection with an adrenergic drug.
- (4) Creation of a shunt between the *corpus cavernosum* and the *corpus spongiosum* (27-31D).

SEDATION. First try heavy sedation with pethidine and chlorpromazine. This will usually provide a cure, especially if the priapism is due to sickle-cell disease. *Do not persist too long with sedation and anaesthetics.*

IRRIGATION. Infuse lidocaine around the base of the penis to make a ring block. Introduce two 19G needles through the glans penis into each *corpus cavernosum* (27-30A) and use one for aspiration and one for irrigation with saline. Aspirate 5-10ml of blood: if it is bright red, this indicates a high-flow obstruction, which implies a fistula already exists between the *corpora*.

There is no danger of a compartment syndrome and this type of priapism will resolve spontaneously. If the blood is dark and venous, there is a low-flow obstruction and risk of ischaemia. Unless detumescence occurs within 30mins, proceed with injection of adrenergic drugs.

ADRENERGIC DRUGS. Use an adrenergic drug sooner rather than later: through one of the needles already inserted, inject 1ml of 1:10,000 adrenaline diluted in 11 5% Glucose or 0.9% saline every 5min up to 1hr till detumescence occurs. Massage the penis to distribute the drug through both *corpora*.

If this is not effective, especially if priapism has been present >4hrs, proceed to make a fistula.

CAUTION! Monitor the blood pressure every 5mins. *Never use adrenaline in the subcutaneous penile tissues!*

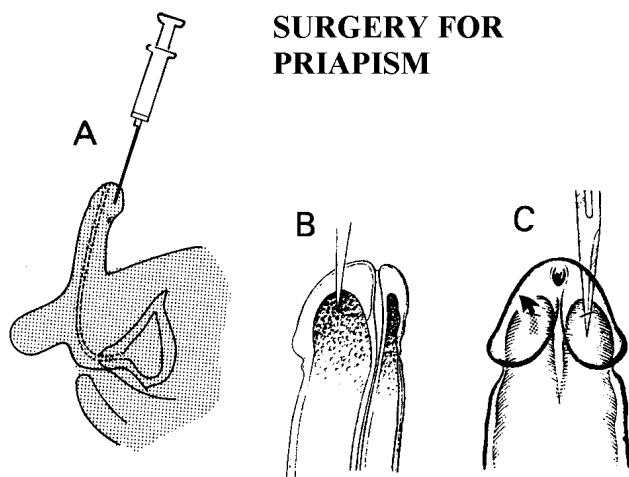


Fig. 27-30 SURGERY FOR PRIAPISM.

Aim to create fistulae, which will allow the corpora cavernosa to drain into the glans penis. In priapism the turgid corpora cavernosa project up under, and into, the glans penis. A, aspirating the corpora cavernosa through the glans. B, and C, use a sharp knife to make an incision on each side between the glans and the corpora. Alternatively, use a needle and syringe, or a trucut biopsy needle. After Rob C. Smith R. *Operative Surgery: Urology*, Butterworth 1981 p.584 with kind permission.

CORPUS-SPONGIOSUM SHUNT. (GRADE 2.4)

Introduce a trucut biopsy needle (24-3) in the closed position through the same skin wound, and push it through the glans to the coronal septum (between the glans and the corpora cavernosa), taking care to avoid the urethra. Note that the ends of the erected corpora cavernosa project well into and under the glans. You may need considerable force.

Open the biopsy needle by extending its obturator blade through the septum, and close it by pushing the sheath over the fenestrated tip, twist it, and remove it. You should withdraw tissue consisting of fibrous septum, and the contents of the corpus cavernosum. Repeat the manoeuvre in another site close by and then do the same thing with the other corpus cavernosum. By doing this you will create 2 fistulae on each side.

The penis should now become flaccid rapidly, and remain so. Control brisk bleeding from the puncture site by pressure or with a figure of 8 absorbable suture. *There is no need for a pressure dressing, nor for an indwelling catheter.*

If you do not have a trucut needle, make cuts (27-30B,C) on each side with a #11 blade, rotate the blade when within the corpus and withdraw it.

27.33 Penile carcinoma

Squamous cell carcinoma of the foreskin is common in India and Africa. The patient is ≥ 40 yrs, and is almost always uncircumcised. Presentation is with a swollen and often infected foreskin, or with phimosis secondary to it. The tumour spreads, until the whole foreskin is involved, after which it invades the *corpus spongiosum*, and later the *corpora cavernosa*. It also spreads to the inguinal lymph nodes, which ultimately ulcerate, so that he dies from sepsis, toxæmia, or sudden haemorrhage from the femoral vessels. The carcinoma does not obstruct the urethra completely, nor is it painful at first, so that commonly presentation is late.

In all but the earliest lesions, which can be treated by radiotherapy if available, you will have to amputate the penis, either partly, or completely. A partial amputation is usually possible; and although it is not easy to do well, it is not nearly as difficult as a complete amputation. This is a difficult, bloody, major operation. Partial amputation is very effective, and the prognosis is good, even if you have to perform a block dissection of affected inguinal nodes (17.8).

After a partial amputation, it is still possible to urinate comfortably. After a complete amputation, it is necessary to squat to pass urine. If you fashion the perineal meatus carefully, it will function well, and is unlikely to stenose. The method of complete amputation described here leaves the *crura* of the corpora cavernosa attached to the bone, which simplifies surgery. Recurrence in the residual *crura* is rare. *There is nothing to be gained by doing a block dissection of unaffected inguinal nodes prophylactically.*

EXAMINATION.

Feel the shaft of the penis carefully to determine the exact extent of the tumour. If necessary, split the foreskin under GA, so that you can examine the glans adequately. Feel the inguinal nodes. They will probably be enlarged by sepsis, so you may find it difficult to know if they have metastases in them or not. Treat with cloxacillin and review if the nodes remain after 2 wks. Fine needle cytology is very useful here.

BIOPSY.

Ulceration alone does not always mean carcinoma is present. So always take a biopsy, and wait for histological proof before you amputate the penis. *Do not amputate until you have received the report.* Surgery is not urgent, because the tumour is very slow-growing.

DIFFERENTIAL DIAGNOSIS: includes condyloma acuminatum and the following:

Suggesting chancroid: an irregular undermined painful ulcer caused by *Haemophilus ducreyi* with a grey base. Enlarged groin nodes. Often associated with HIV disease.

Suggesting primary syphilis: a round or oval painless ulcer, often found under the foreskin, but which does not penetrate or destroy it. Enlarged groin nodes. Serological tests may be -ve early, but are always +ve later.

Suggesting venereal warts: small multiple lumps 1-3mm in diameter, covered by epithelium.

Suggesting donovanosis (*granuloma inguinale*): a slow-growing lesion, which may destroy the foreskin, and parts of the shaft of the penis. The lesion is usually flatter and redder than carcinoma.

MANAGEMENT

The ulcer is almost always infected, so treat with cloxacillin 500mg qid for 1wk pre-operatively.

If the growth is limited to the foreskin and is freely mobile over the glans, make a circumcision and follow up closely.

If it has involved the foreskin and the glans, or the shaft of the penis, take a biopsy, and as soon as the diagnosis is confirmed, perform a partial amputation 2cm proximal to the lesion. If there is a recurrence, it will probably be in the inguinal nodes, not in the stump of the penis.

If the inguinal nodes do not seem to be clinically involved, wait. 'Normal' nodes are palpable, and sepsis may cause some enlargement and tenderness. If they are palpable, and are clinically infected, wait. If they are palpable and clinically cancerous, biopsy the primary and get fine needle cytology on the nodes, if possible. If there is cancer in the nodes, amputate the penis, with a simultaneous bilateral block dissection of the groin (17.8) after allowing any severe sepsis to settle.

PARTIAL AMPUTATION OF THE PENIS (GRADE 3.1)
Aim to fashion the urethral orifice carefully, so that a stricture does not develop. *Remember the anatomical description of the penis assumes it is in the erect position (27-31B).*

Cut a long ventral flap based proximally. Make its width equal to $\frac{1}{2}$ the circumference of the penis. Cut a shorter 2cm dorsal flap. Dissect both flaps back to their bases.

Dissect the *corpus spongiosum* away from the *corpora cavernosa*, until you reach the planned level of section. Divide the *corpus spongiosum* 2cm distal to the level where you intend to section the *corpora cavernosa*.

Pass transfixion sutures of # 1 absorbable through each of the *corpora cavernosa* 0.5cm proximal to the intended level of section. Divide the corpora, dissect proximally for 0.5cm, and then tie the sutures medially and laterally. Cut a small circular slit in the ventral flap, and pull the urethral stump through it. Leave the end of the urethra protruding. It is less likely to stricture if you do this.

Leave adequate spaces between the sutures joining ventral and dorsal flaps to allow blood to drain and prevent a haematoma forming. Split the distal end of the urethra longitudinally.

Evert each half, and suture it carefully so that it everts onto the ventral flap. Leave a narrow self-retaining catheter in place for 5days. Epithelium will grow over the raw surface of the *corpus spongiosum*.

Warn him that, despite your efforts, you may need to perform periodic dilations.

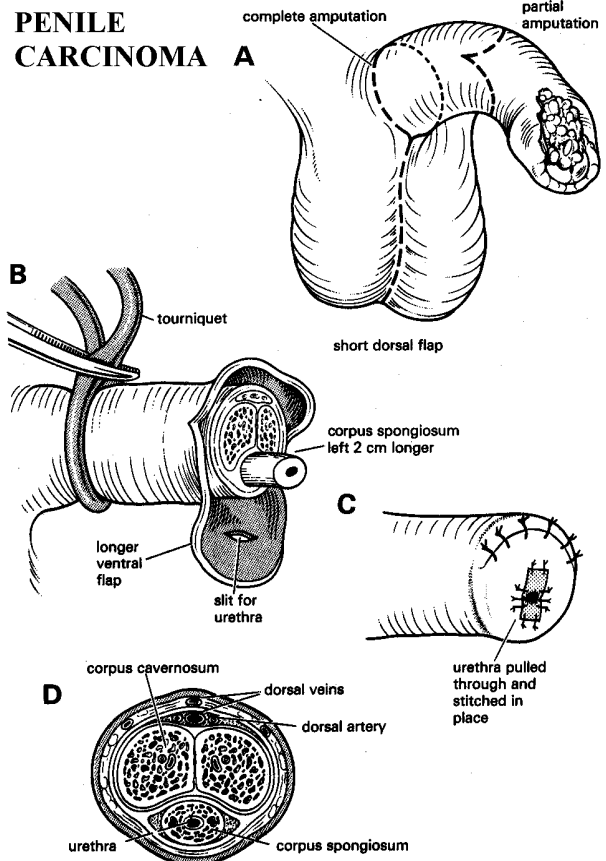


Fig. 27-31 PARTIAL AMPUTATION for penile carcinoma.
A, incisions for partial and complete amputation. B, flaps and the amputation. C, repair. D, cross-section of the penis.

MODIFIED COMPLETE AMPUTATION OF THE PENIS (GRADE 3.5)

INDICATIONS.

Carcinoma of the penis, which you cannot excise with a 2cm proximal margin by partial amputation.

N.B. This is a difficult operation!

METHOD.

The ulcer is almost always infected, so treat with cloxacillin 500mg qid for 1wk pre-operatively.

Use the lithotomy position and pass a Ch20-24 metal dilator to define the urethra. Make a racquet-shaped incision round the base of the penis (27-32B). Extend the arm in the midline posteriorly for about 5cm, between the two sides of the scrotum (27-32A) (extend it further towards the perineum later).

Dissect deeper, clamping all vessels; this area is very vascular. Find, clamp, tie, and divide the large dorsal vein of the penis (27-31D).

Continue dissection until the shaft of the penis is free of subcutaneous tissue. Extend the incision posteriorly to where the scrotum hangs from the perineum, about 4-5cm in front of the anus. Separate the testes with their covering *tunicae vaginales*. Ask your assistant to retract them laterally with tissue forceps placed subcutaneously, first on one side and then on the other.

Dissect the *corpus spongiosum* on its ventral and lateral aspects, as far as the bulb which lies on the perineal membrane. Find it by feeling the expansion round the bougie. Remove the bougie, and cut the *corpus spongiosum* 4cm distal to the bulb. Separate it from the *corpora cavernosa* and retract it.

Now free the *corpora cavernosa* until they diverge as the *crura*, at the inferior border of the *symphysis pubis* (27-32C). Transfix each of them with #1 absorbable and divide them 0-5cm distally. Only some connective tissue will now remain. Divide this and remove the penis.

COMPLETE PENILE AMPUTATION

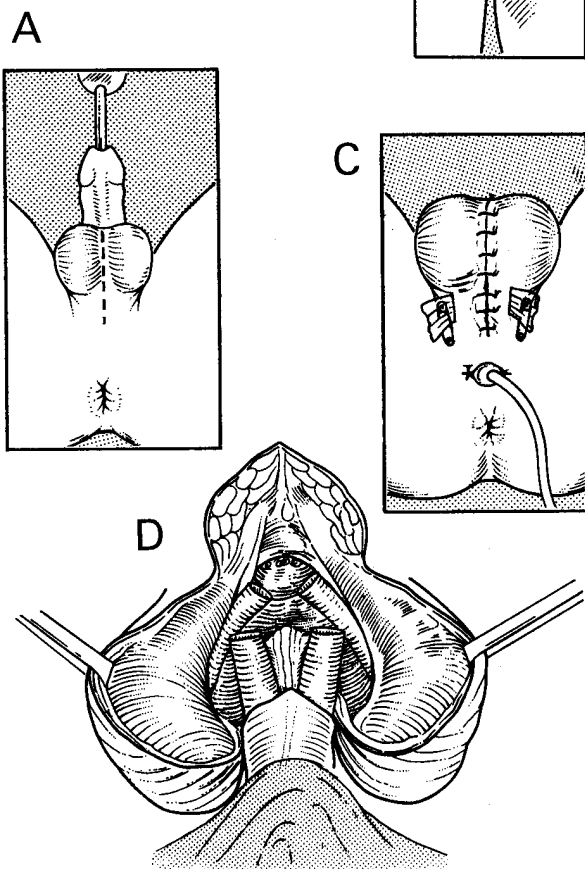


Fig. 27-32 COMPLETE AMPUTATION OF THE PENIS.

A, pass a sound. B, make a racquet-shaped incision round the base of the penis, and carry it vertically downwards in the midline of the scrotum. C, free the *crura* from the pubic bones. D, close the perineum round the stump of the urethra.

Cut a transverse 1cm hole in the perineal skin, 2-3cm anterior to the anal verge. Deliver the stump of the *corpus spongiosum* through it, so that it protrudes about 2cm. Suture the base to the skin, using 2/0 or 3/0 monofilament sutures. *Do not try to evert the stump*, or the urethra may form a stricture. Leave the stump long because it tends to retract. Epithelium from the urethra and skin will grow and cover it.

Insert corrugated rubber drains (4-14B) through 2cm incisions laterally in the scrotum, and suture these to the skin. Or, better, use suction drains.

First close the wound in the midline using 2/0 monofilament. Then suture the anterior part of the wound. If the scrotum would hang down too much, trim off some skin and subcutaneous tissue before you suture it. When you have finished, the scrotum will lie more anteriorly than usual. This allows good skin cover, and is less likely to get in the way when urinating through the perineal urethrostomy.

POSTOPERATIVE CARE. Pass an indwelling catheter, and remove it at 7-10 days.

Apply much cotton wool padding, and a T-bandage pressure dressing. Remove the dressings and the drains >48hrs. Then start baths bd.

27.34 Penoscrotal elephantiasis

Lymphoedema of the penis and/or scrotum may occur as a result of:

- (1) filariasis,
- (2) onchocerciasis,
- (3) donovanosis (granuloma inguinale)
- (4) schistosomiasis.

When chronic this produces the appearance of elephantiasis which may involve:

- (1) the outer skin of the penis (but not its inner layer or its shaft),
- (2) the scrotum,
- (3) the testes which have hydrocoeles, but are otherwise normal; or, often, all three.

If the scrotum is grossly swollen (27-33A) try to excise it. The penis will either be buried in it, or separate, but covered with much thickened skin. This is a very satisfactory operation.

DIFFERENTIAL DIAGNOSIS: giant hydrocoeles (27.24), which may be present with elephantiasis, and hernias (18.4). In elephantiasis the texture of the skin of the scrotum is altered; it pits on pressure, it cannot be moved over the deeper tissues, veins are not visible, and the mass cannot be reduced.

SCROTAL ELEPHANTIASIS

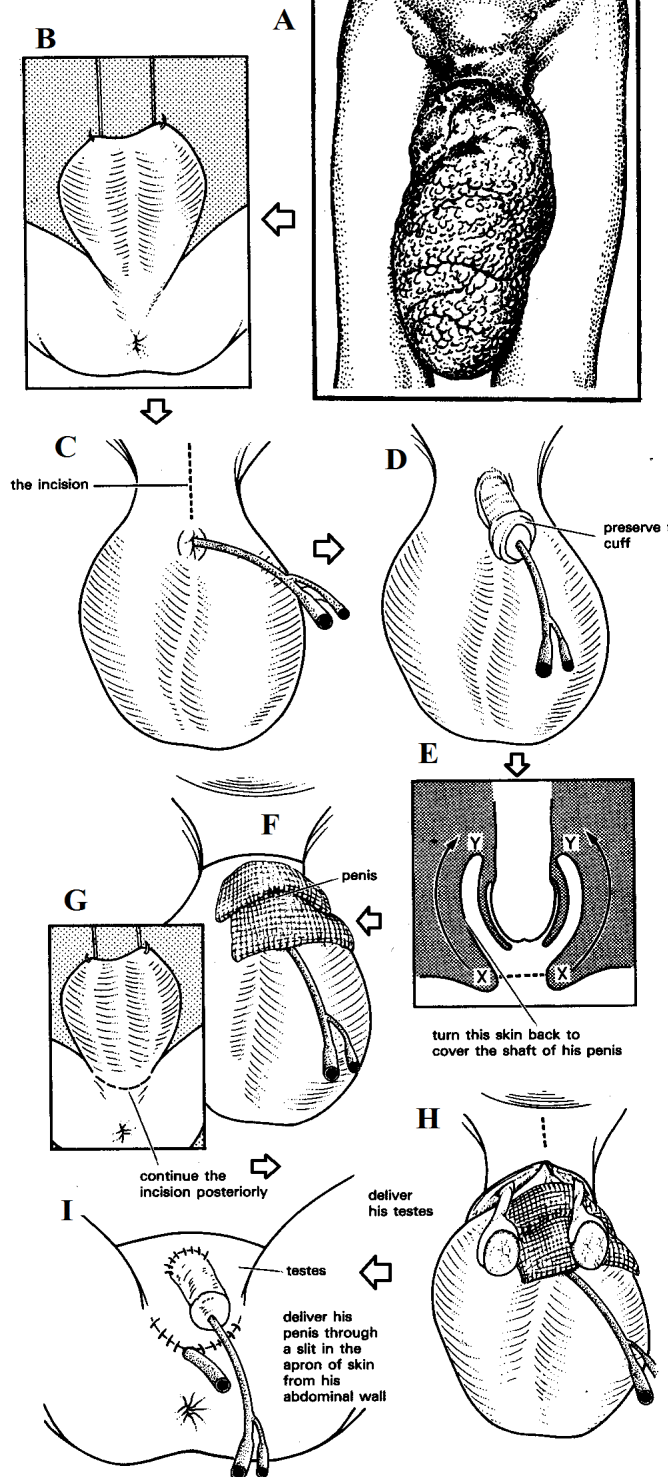


Fig. 27-33 ELEPHANTIASIS OF THE SCROTUM.

A, the appearance at presentation. B, suspend the scrotum (optional). C, catheterize the urethra and make the first incision. D, deliver the penis. E, preserve a cuff of foreskin to cover the penis. F, cover the penis with gauze while the operation continues. G, carry lateral incisions posteriorly. H, find the testes and deliver them. I, deliver the penis through the skin, and remove most or all of the scrotal skin. Partly after Bowesman, C. *Surgery and Pathology in the Tropics*, Livingstone, 1960 with kind permission.

TREATMENT depends on the extent of the elephantiasis.

If there is elephantiasis of the foreskin (27-34), do not make a standard circumcision, or you will remove its inner normal layer. Instead, dissect off the thickened outer layer, and fold the inner one back over the shaft of the penis.

If the elephantiasis is mild and early, a limited operation may be all that is necessary. For example, you may only need to remove a dorsal strip of thickening on the penis, and close the resulting defect.

PREPARATION.

Clean the skin thoroughly. If the scrotum is enormous (27-33A), either operate with the patient sitting and the legs over the edge of the table, or arrange a hook, and a block and pulleys, in the theatre ceiling before the operation starts (27-33B), so that you can raise the scrotum.

Catheterize the urethra (27-33C). If the catheter is difficult to insert, you may have to wait until you have exposed the penis. You will find that a catheter will be useful in locating the urethra, when you come to operate on the perineum.

Bleeding can be a problem. *Do not apply a tourniquet to the base of the scrotum to control bleeding.* Instead, use a long needle, such as a lumbar puncture needle, to inject the tissues with diluted adrenaline solution.

CAUTION! Never use adrenaline on the subcutaneous tissues of the penis; you can if necessary use it in the corpora (27.32).

REDUCTION SCROTOPLASTY (GRADE 3.1)

INCISION.

If there are large hydrocoeles, tap them.

Make a midline incision downwards, from the pubic symphysis, to just above the foreskin (27-33C).

Carefully deepen the incision, until you reach the shaft of the penis (27-33D). Make a circular incision around the external preputial orifice, and preserve the internal layer of the foreskin, or the cuff of skin with which the penis communicates with the exterior (27-33E). Use it later to cover the penis. Clamp the cuff just beyond the glans, and divide the skin distal to it. Cover the raw isolated penis with saline swabs (27-33F), while you deal with the scrotum.

Make 2 lateral incisions round the root of the scrotum, to meet one another posteriorly in the perineum (27-33G). Carefully deepen these lateral incisions, until you reach the spermatic cords on each side. If necessary, find the cords from the external inguinal rings. Follow the cords to the testes, and deliver them (27-33H).

If the testes are of normal size and there are no hydrocoeles, *do not open the tunicae vaginales.*

ELEPHANTIASIS OF THE PENIS

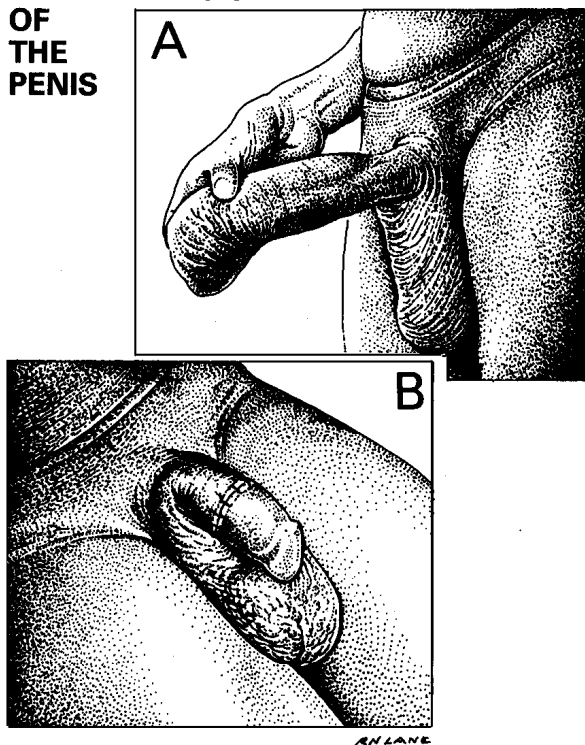


Fig. 27-34 ELEPHANTIASIS OF THE PENIS.

A, appearance at presentation; the scrotum was not involved. B, after a 'basal circumcision'. The skin of the inside of the foreskin has been used to cover the shaft. After Bowesman C. *Surgery and Pathology in the Tropics*, Livingstone, 1960 with kind permission.

If there are large hydrocoeles, you may have to drain them first (if you have not already done so). Open them, and evert their sacs and suture them behind the testis (27-21). **If the sacs are thick**, excise part of them.

Turn the scrotum up on to the abdominal wall. Identify, tie, and divide the many large veins that run from the scrotum. There is one large central one running up from the scrotum under the urethra.

Remove the bulk of the scrotum with a short amputation knife. Excise all thickened oedematous tissue. Either, make a new scrotum from the apron of normal skin that was dragged down by the mass.

Or, bury the testes in pockets, under the skin on the adductor aspects of the thighs. These pockets will be easier to make if you stand on the opposite side of the table. Push a long pair of scissors 15cm into the subcutaneous tissues of the thighs, *not deeper*, and create a pocket with a 5cm mouth. You may meet and need to tie the superficial external pudendal vessels and their 2 companion veins. Control bleeding before you insert the testes. Close the perineal part of the wound loosely, with a drain at its lowest point.

Remove the clamp from the cuff of skin that was the foreskin, trim away the part that was crushed, and roll the rest back to cover the shaft of the penis. Deliver this through a slit in the apron of skin dragged down from the abdominal wall (27-33I). Suture this to the skin of the shaft of the penis, starting with a single central suture, and proceeding laterally on both sides. Graft any remaining raw areas with grafts from the thigh, and dress them with vaseline gauze.

Leave the catheter in place for a few days, to prevent the urine contaminating the wound. Any redundant tissue that you may have left will probably get smaller as time passes.

27.35 Kidney tumours

Renal adenocarcinomas present between 40-70yrs, as haematuria (60%), an enlarged kidney (20%), or with symptoms of secondary spread, such as general ill health and bone pain. Otherwise, pain is not a major feature, unless there is haematuria and clot colic.

If the tumour has not spread outside the renal capsule (<50%), the 5yr survival is 30% and the 10yr survival 7%. If it has, there are few 5yr survivors.

SPECIAL TESTS.

A good quality intravenous urogram will demonstrate most renal masses. Look for displacement, deformity, and destruction of the calyces of the patient's kidney. The tumour is usually in the upper or lower poles.

ULTRASOUND (38.2E) readily distinguishes solid from cystic lesions. If there is haematuria, perform a cystoscopy (27.3). Look for 'cannon ball' metastases on chest radiographs.

DIFFERENTIAL DIAGNOSIS:

- (1) Renal cysts (the commonest cause of a renal mass) and hydronephrosis. The kidney is palpable but haematuria is unusual.
- (2) Polycystic kidney (a mass and haematuria).
- (3) An enlarged spleen.
- (4) Other tumours of the kidney and large bowel.
- (5) In children, a neuroblastoma displacing the kidney downwards

N.B. Not all renal cysts and hydronephrotic kidneys are palpable, and the absence of haematuria does not exclude a carcinoma.

MANAGEMENT.

If there are no obvious metastases, arrange a nephrectomy. It may reverse some of the systemic effects of the tumour (anaemia, myopathies, etc.), even if there are metastases.

If there is a transitional cell tumour of the renal pelvis, it is likely to be associated with similar tumours in the bladder. These tumours usually project into the renal pelvis, so that you can see them on a retrograde urogram. Nephro-ureterectomy is indicated.

If it is a squamous carcinoma (HYPERNEPHROMA), it is likely to be associated with chronic infection, and a curative nephrectomy is seldom possible.

If a child has a nephroblastoma (WILMS TUMOUR), look for other congenital anomalies (eye defects, hemihypertrophy, and urogenital anomalies), which are sometimes associated. After Burkitt's lymphoma, this is the commonest solid tumour of childhood in Africa. The tumour arises from embryonal kidney cells and spreads locally through the capsule of the kidney to neighbouring nodes (often fairly late), as well as to the liver, lungs, and sometimes the bones.

The young child presents with a fairly rapidly growing and usually painless mass on one side of the abdomen. In 70% of cases this is <2yrs, and is seldom >6yrs. In 5% of cases the mass is present at birth, and in 5% it is bilateral. There is rapid weight loss and fever in 50% of cases. Haematuria is late.

STAGING and PROGNOSIS. Nephroblastoma is always fatal without treatment. The survival figures below are for a combination of nephrectomy, radiotherapy, and chemotherapy. Long-term cures for the stages I-III are common.

Stage	Definition	5yr Survival
I	Tumour is confined to the kidney, and can be removed <i>in toto</i> .	95%
II	Tumour penetrates the capsule, but can be entirely excised.	85%
III	Tumour, not completely resectable, but confined to the abdomen.	85%
IV	Tumour widespread, with metastases beyond the abdomen.	5%

N.B. In bilateral disease (6%), palliation only is possible. *Do not try to remove the kidney*, unless you are skilled. Diagnose the condition clinically, and organize investigation, nephrectomy, and chemotherapy, and perhaps radiotherapy. If this is not available, it is acceptable to rely on nephrectomy and chemotherapy. *It is not acceptable to leave the kidney and to treat with chemotherapy only.*

If you are sure of the diagnosis from the IVU or ultrasound, start chemotherapy to reduce the volume of the tumour: this makes surgery easier, and you then know if the tumour is responding to medication.

Treat with vincristine 1.4mg/m² (maximum dose 2mg) IV and repeat after 2days. Arrange surgery 10-12days later if the kidney is of resectable size. Otherwise, continue downstaging chemotherapy with nutritional support, prophylactic anti-TB therapy, antibiotics and antihelmintics also to prepare for surgery. You will need to cross-match blood and prepare the bowel.

CAUTION! Sometimes the tumour spreads into the inferior vena cava.

After nephrectomy, continue the chemotherapy régime monthly for 4-6 months after a gap of 2-3days.

27.36 Schistosomiasis (*Bilharziasis*) in the urinary tract

Schistosomes are trematode blood flukes infecting >2.10⁸ people; there are several types but *S. haematobium* in the Middle East and Africa causes urogenital disease, though other types cause mainly liver and intestinal disease. The adult male fluke encloses the cylindrical female to mate, assuming an elongated shape able to live inside veins by attaching to their walls by suckers. The fertilized female then detaches itself and migrates to narrow veins, preferentially in the vesical plexus, laying >200 eggs daily (27-35). The *S. haematobium* egg has a terminal spine, unlike the *S. mansoni* egg which has a lateral spine.

When these eggs are excreted in the urine, they can hatch in fresh water and attach themselves to certain snails (*Bulinus truncatus*) which lives in slowly flowing shallow water. These snails can then produce 10⁵ free-swimming forked-tailed *cercariae* which have an enzyme that allows them to penetrate human skin, and so continue the life-cycle.

It is the eggs that cause the trouble, initially producing an immune dermatitis ('swimmer's itch') and a Type II serum sickness called Katayama fever; later when they migrate into the tissues eliciting a Type IV immunological response, a granuloma results which depends on its severity on the number of eggs deposited and the host's immune response.

Although the eggs of *S. haematobium* predominantly affect the urinary tract, they can also travel into the lungs, spinal cord and brain. The granuloma is accompanied subsequently by fibrosis and impaired collagen synthesis.

The eggs can survive ≥10yrs and so chronic disease is common. Schistosomiasis affects >200 million people worldwide, and causes up to 200,000 deaths annually.

Schistosomiasis

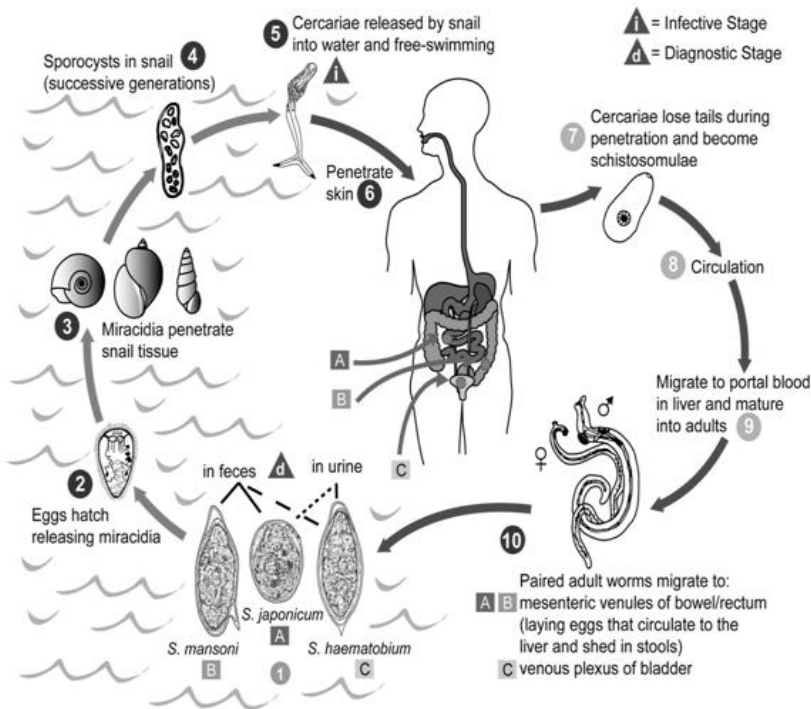


Fig. 27-35 The life-cycle of the schistosomiasis fluke.

After <http://www.cdc.gov/parasites/schistosomiasis/biology.html> & [wikipedia.org](http://www.wikipedia.org).

The results are:

- (1) dilated cystic ureters,
- (2) thickened pipe-stem ureters,
- (3) ureteric strictures all with possible stones (27.15),
- (4) active cystitis,
- (5) chronic cystitis,
- (6) bladder ulcers,
- (7) bladder-neck fibrosis (27.21),
- (8) a contracted low-volume bladder,
- (9) bladder carcinoma (27.5),
- (10) active or chronic prostatitis (27.19),
- (11) epididymitis & chronic spermatic cord inflammation (27.23),
- (12) rarely urethral stricture, dilation and fistula.

Such pathology may obviously lead to renal failure as well as infertility, or death from malignant infiltration. You should feel for an enlarged kidney, a pelvic mass, a hardened prostate or lumpy spermatic cord and epididymis.

Active cystitis usually presents between 5-15yrs with painful micturition, frequency and terminal haematuria. This type of haematuria (27.4) is really the hallmark of *schistosomiasis*.

SPECIAL TESTS.

Examine urine or semen carefully for *schistosoma* eggs, as well as red cells and pus cells (especially in bladder carcinoma where you may find strands of tumour tissue in the urine). You may need a cystoscopic or epididymal biopsy, however, if all the eggs have migrated into the tissues.

The bilharzia fixation antibody test (BFAT) will show if there has been infestation in the past, but *does not necessarily imply the disease is active at the present*. Check the Hb and urea levels.

RADIOGRAPHS. Plain radiographs may show:

- (1) an enlarged kidney;
- (2) linear calcification in a dilated ureter,
- (3) patchy ureteric calcification,
- (4) secondary ureteric stones;
- (5) dense calcification in the cystic wall, sometimes with defects in the calcification where a tumour has developed.

IVU will demonstrate the size, tortuosity and stricture of ureters most clearly. They may have multiple bubble-like filling defects. The ureters can look like small bowel! Also you will be able to see the size of the bladder clearly.

ULTRASOUND will show hydronephrotic kidneys, dilated or tortuous ureters, a contracted bladder possibly with an irregular tumour in its wall.

CYSTOSCOPY. Appearances are striking: you may see in active cystitis:

- (1) reddened congested oedematous patches especially on the posterior wall, as well as raised yellowish tubercles;
- and in chronic cystitis:
- (2) 'sandy' patches,
- (3) nodules, polyps, ulcers, scarring and tumours,
- (4) cystic degeneration in the bladder wall,
- (5) narrowed or patulous ureteric orifices.

TREATMENT.

Praziquantel 60mg/kg stat or 10mg/kg bd for 3days is most effective where fibrotic effects are not yet advanced.

Where the ureter is irreversibly damaged, reconstructive surgery is necessary: this is complicated because excision and spatulated end-to-end anastomosis is rarely feasible. A re-implantation of the ureter into the bladder is usually necessary, and sometimes, if the ureteric stricture is very proximal, with a bladder extension (Boari) flap. Otherwise the whole ureter needs replacing with an ileal segment.

You can treat bladder neck fibrosis with excision (27-19K) but a contracted bladder needs an augmentation cystoplasty and a urethral fistula may need a urethroplasty.

27.37 Other urological problems

If there is a foreign body in the urethra, try to remove it with as little damage as possible. Use GA.

Ideally, identify the foreign body with a cystoscope using the 0° objective to look down the urethra. Failing this, locate it in the penis by palpation and with radiographs.

Try to disimpact its distal end from the wall of the urethra. Use alligator forceps and, perhaps, a large bore cannula. If necessary, perform a urethrotomy (27.12), and cut down on the urethra through the ventral surface of the penis.

If the foreign body is far back in the urethra, try to dislodge it into the bladder, and if you cannot remove it endoscopically, do so through a small suprapubic cystotomy.

If it is a pin, you may have to remove it head first unless you can secure the sharp tip in a biopsy forceps, so put its point through the wall of the urethra, and turn it round.

If the opposing surfaces of the glans and foreskin are acutely inflamed, this is acute BALANITIS. Test the urine for sugar to exclude diabetes. The primary treatment of balanitis is better hygiene. Demonstrate how to retract the foreskin, and do this at least tid, to wash with soap and water and to apply a mild antiseptic, such as chlorhexidine or cetrimide and hexachlorophene. Avoid systemic antibiotics. If there is associated phimosis, arrange for circumcision.

If pain & swelling develop with explosive rapidity in the penis or scrotum, and there is severe illness, suspect that there is severe penoscrotal necrosis and infection (6.21,23: Fournier's gangrene), which needs immediate debridement.

If a painful perineal swelling develops, this is probably a periurethral abscess (6.18).

If milky urine is passed, this is CHYLURIA due to a fistula between the lymphatics and the urinary tract. Sometimes chyle comes out with blood (chylohaematuria).

Where *Wucheria bancrofti* is endemic chyluria is not uncommon and this is the most common cause; elsewhere it is rare, and due to tuberculosis, *schistosomiasis*, ascaris infestation, hydatid disease, malignancy, ureteric stone or trauma. The urine is characteristic; if left to stand it separates into 3 layers: a top layer of fat, a pinkish layer of clots, and a bottom layer of debris in the urine. You can see chylomicrons in the urine under the microscope, and microfilariae in 25% of cases.

Chyluria debilitates, through a persistent loss of fat, protein, electrolytes, vitamins in the urine. Treat with a single dose of diethylcarbamazine 6mg/kg with albendazole 400mg, or ivermectin 150µg/kg.

If this fails, you can lavage 5-10ml of 1:10000 silver nitrate solution into the renal pelvis after passing a ureteric catheter under direct vision by a cystoscope with the patient in a Trendelenburg position. This can be done wkly up to 4 times. It is effective in 70% of cases.

If there is erectile dysfunction, examine the penis for any structural abnormality. Ask if there is ever a sustained erection: although 'wrong time, wrong place, wrong sexual partner' is often the cause, it is not necessarily so.

The underlying problem may well be:

- (1) HIV disease,
- (2) obesity,
- (3) vascular disorders (not only the classical Leriche syndrome caused by aortic bifurcation occlusion),
- (4) medication (especially cimetidine, bendroflumazide, β-blockers and antidepressants).

Sildenafil 25-100mg 1hr prior to sexual activity is most effective; intra-penile injections and prosthesis are very much second best, and can be subject to significant complications, particularly priapism (27.32), and infection.