

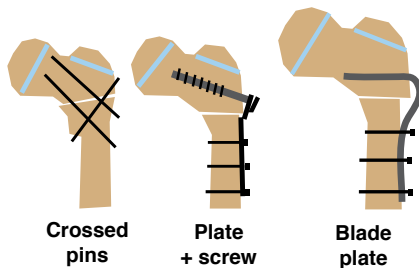


# Proximal Femoral Osteotomy Fixation Inexpensive Fixation Alternative

Lynn Staheli, M.D.  
Professor Emeritus  
University Of Washington  
Children's Hospital, Seattle, WA U.S.

## Introduction

Fixation of osteotomies or fractures may be accomplished by a variety of techniques.



## Indications

Cross pin fixation may be useful for rotational, varus, valgus or combined osteotomies for common conditions such as cerebral palsy, Perthes disease, and DDH.

## Solution

The osteotomy must be performed in the intertrochanteric region with a broad and stable contact surface. The distal fragment should be displaced medially to provide better fixation and promote union.

## Technique

### Setup

The set-up for this technique utilizes tools for the osteotomy and 1/8" Steinman. Power tools are not required.

### Approach

Expose the upper femur through a short later approach. The procedure may be performed through a shorter

incision than is usually required for osteotomies as no plate is applied.

### Osteotomy

Perform the osteotomy in the upper intertrochanteric region. For varus osteotomies remove a medially based wedge of bone.

### Notch bone

Select the site of entry for the distal pin and notch the bone [1].

### Place first pin

Drill the lower pin through the distal fragment and osteotomy site fan into the proximal fragment. This may separate the osteotomy site [2].

### Remove and replace

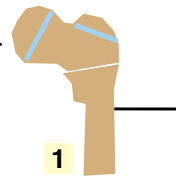
Withdraw pin allowing the osteotomy to close and drive the pin well into the proximal fragment [3].

### Add additional pins

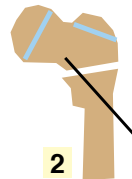
Place two additional pins to secure the fixation [4].

### Cut pins

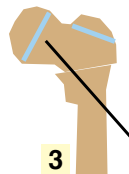
Cut pins subcutaneously. Leave the ends long enough to allow easy removal and yet not too long as to cause skin irritation [5].



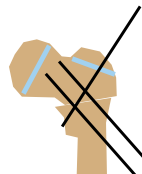
1



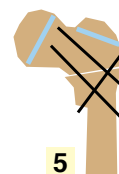2



3



4

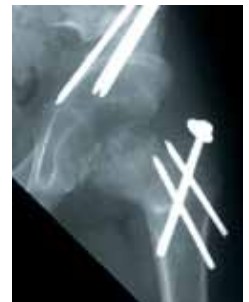

5

## Lesson Learned

### Combined procedures

The use of cross pin fixation is especially useful when multiple procedures are performed at the same sitting, such as a Salter/varus osteotomy for Perthes disease [illustration]. Because the required exposure is small, fixation is rapidly applied additional procedures are more feasible. If the fixation is to be left in place use a screw.



### Pin removal

At about 6 weeks remove the pins through stab incisions. A vice grip tool maybe helpful.

### Experience

The author has performed this method of fixation in over 100 cases. We found that cross pin fixation was comparable to other forms of fixation in terms of union and fixation failure.

ISBN-13 #978-1-60189-099-3  
questions@global-help.org  
www.global-help.org  
www.posna.org