



IMPLANT-RETAINED OVERDENTURE IN EPILEPTIC PATIENT. A CASE REPORT

Dr. Manila Jain*

Director of M-Care Dental Clinic, Delhi.

*Corresponding Author: Dr. Manila Jain

Director of M-Care Dental Clinic, Delhi.

Article Received on 13/02/2023

Article Revised on 05/03/2023

Article Accepted on 25/03/2023

ABSTRACT

This Case report describes the treatment of a completely edentulous, mentally retarded patient with epilepsy with an implant retained overdenture. The intractable epileptic condition of the patient with frequent grand mal seizures and complex partial seizures required a stable, well retained prosthesis, however the maxilla and the mandible were severely atrophied. The bone volume of the maxilla allowed the placement of only two implants at the region of the canines, compared with the generally required four. On long time recall, after one year, patient's chewing ability was satisfactory.

KEYWORDS: Dental implant, Edentulous, Epilepsy, Overdenture.

INTRODUCTION

Epilepsy is a common neurologic disorder affecting 50 million people worldwide. Its prevalence reaches 1% in developed countries.^[1,2] Epilepsy is characterized by various types of recurrent seizures, some of which are associated with loss of consciousness.^[3] In almost all aspects of oral health and dental status, patients with epilepsy showed a significantly worse condition, as compared to the non-epileptic, general population. The observed difference is due to a combined effect of neglected oral hygiene and dental care, and seizure related oral cavity injuries and increased exertion on the teeth.^[4] Furthermore, anti-epileptic drugs are associated with side-effects, which may include oral complications, such as gingival overgrowth, xerostomia, and fungal infections.^[5]

Overall, patients with epilepsy have an increased risk for losing teeth, which are less frequently replaced and become edentulous at a younger age than healthy controls.^[6] According to the data of Buck et al.,^[7] 24% of seizure related injuries involve the head and neck region with tooth injury and tooth loss. Fixed prostheses are thus preferred over removable partial dentures, depending on the type and frequency of seizures, because of the risk of foreign body ingestion or aspiration. If a removable denture is unavoidable, than a metal base is recommended to minimize the risk of fracture.^[8]

Dental implants may be indicated when the missing teeth need to be replaced, or a complete denture requires stabilization. Cune et al. examined patients with severe refractory epilepsy and additional motor and/or

intellectual disabilities over an observational period of 16 years. The probability of functional implant survival was estimated to be 97.6%, which can be considered as an excellent result.^[9]

Nevertheless, oral hygiene was inadequate in around 72% of implants. Presently, available evidence is insufficient to decide whether implant treatment in patients with epilepsy is feasible or contraindicated. However, some authors advocate the preference of conventional dentures or fixed partial dentures over endosseous dental implants. Edentulous patients with severe maxillary or mandibular atrophy experience problems with dentures, due to lack of stability and retention, which leads to the deterioration of chewing ability.^[10]

Endosseous implants, to which an overdenture can be attached, may solve this problem and represent a cost-effective treatment.^[11] In a comparative study, Kleis et al.^[12] found that the locator-attachment system with double retention showed a higher rate of prosthodontic maintenance than ball attachments. No significant difference in patients' oral health-related quality of life and biologic parameters was observed. The aim of treatment described in this case report was to provide a completely edentulous epileptic patient with two implant-retained maxillary and mandibular overdentures. Placement of more than two dental implants in the anterior maxillary region would have been possible only by a bone-splitting technique and augmentation, which was refused by the patient.

CASE REPORT

A 43-year-old woman with a history of refractory epilepsy presented to the Department of Prosthodontics with a completely edentulous dental status. She was mentally retarded due to perinatal asphyxia. Symptomatic epilepsy started in her teenage years, characterized by frequent seizures, including weekly simple and complex partial seizures, and grand mal seizures approximately every six months. The patient was on carbamazepine (600 mg tid daily) and

clonazepam (0.25 mg tid daily). She was also treated for hypertension with enalapril (5 mg bid daily), for cardiac arrhythmia with metoprolol tartarate (25 mg bid daily), and hypercholesterolemia with atorvastatin (10 mg qd daily).

The patient had no dental prosthesis previously. Due to the severe maxillary and mandibular atrophy, sufficient or at least an average retention and stability of a complete denture was not to be expected (Figure 1.).

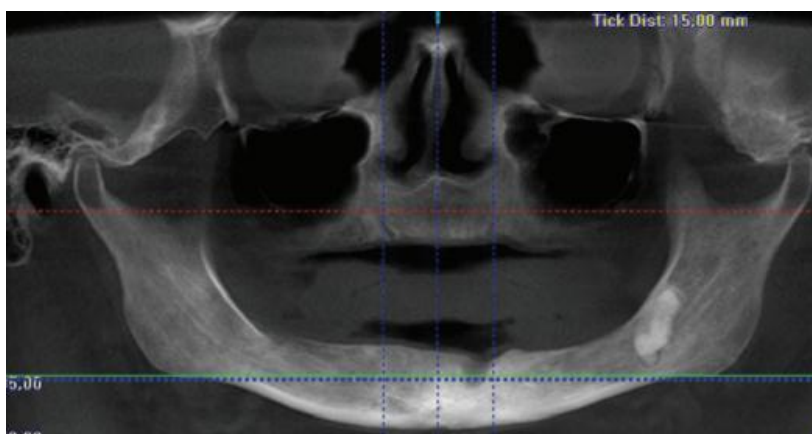


Figure 1: CBCT.

Because of her refractory epilepsy, retention was required and this was planned to be achieved by an implant-retained overdenture. However, the placement of more than two implants in the maxilla as generally at least four implants are required would have been possible only by bone-splitting technique and augmentation, which was refused by the patient.

Therefore, Two dental implants were placed in general anesthesia in the maxilla and mandible, each of them at the region of the canines (Figure 2.). The length of each implant was 13 mm, the platform had a diameter of 4.3 mm in the maxilla, and 3.5 mm in the mandible.

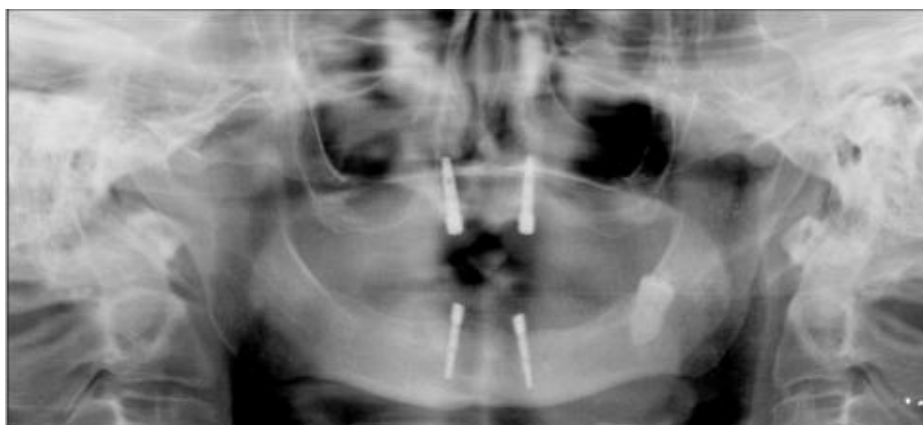

Figure 2: Panoramic radiograph of the endosseous dental implants in the maxilla and mandible.

The cavity of the implant screw was widened with a Nobel Ag osteotome (Nobel Biocare AG, Göteborg, Sweden), because of narrow and soft (D3, D4)^[13] bone quality. The oral cavity was disinfected by rinsing with 0.2% chlorhexidine digluconate (GlaxoSmithKline, Brentford, UK) 3-4 times a day. To avoid postoperative complications and pain, clindamycin (300 mg qid daily) was given for five days, and diclofenac (50 mg) as required.

Extraction of a retained left mandibular wisdom tooth was not planned taking into account the patient's age and lack of complaints. The left mandibular canine was extracted approximately six months earlier, its remineralized region is seen on the panoramic radiograph. After a 5.5 month-long osseointegration period, the four healing screws were inserted into the implants, forming and shaping the keratinized gingiva for two weeks. The depth of gingiva was 3 mm in the

maxillary and 4 mm in the mandibular implants. The appropriate size of the neck of the locator abutments was chosen. For the screwing in of the locator abutments, a torque wrench was used to achieve a maximum seating force of 30 Ncm and to prevent screw loosening.

The combination of interior and exterior retention provides a greater retention area than ball attachments, and ensures longest implant survival. Locator caps with black processing males were inserted into each locator abutment, and anatomical impressions were taken using hard silicon putty Zeta Plus (Zhermack SgA, Badia Polesina, Rovigo, Italy). The borders of clear acrylic special trays Meliodent (Heraeus Kulzer, Hanau, Germany) were outlined on the primary impressions. The locator caps were resealed into each locator abutment, and mucostatic secondary impressions were taken with soft silicone impression material Oranwash (Zhermack SgA, Badia Polesina, Rovigo, Italy).

It was casted with class IV stone Begostone Plus (Bego, Brema, Germany), and the borders of the metal baseplate were outlined on the cast. Due the refractory epilepsy and in order to avoid fractures, a metal base was deemed necessary. Wax rims were placed on the metal baseplates, and the horizontal and vertical dimensions of the centric occlusion were determined. With the help of a face-bow, the rims were fixed into a KaVo Protar 5.B. articulator (KaVo dental GmbH, Biberach, Germany), and a bilaterally balanced occlusion was established.

The definitive baseplate was reduced palatally because of an increased gag reflex sensitivity. The locator male was placed by the dentist directly in the patient's mouth, and fixed with a self-curing acrylic resin Meliodent (Heraeus Kulzer, Hanau, Germany) into the recess of the base. A white block-out spacer was first placed over the head of each locator abutment, to block out the immediate surrounding area. This allowed the full resilient function of the pivoting metal denture cap. The dentures in centric occlusion were maintained in passive condition, without pressing the soft tissues. After the acrylic resin was cured, a white colored replacement nylon male was placed into the maxillary denture, and a red colored replacement nylon male was placed into the mandibular denture to correct the divergence of implants, which was over 10° in the mandible in the present case. As a good oral hygiene is essential for implant success, the patient and her husband were taught how to clean the implants thoroughly by an end-tufted toothbrush, superfloss and water. The importance of a follow-up examination after three months was explained to the patient in order to detect early any tilting of the dentures and to prevent dislodgement of the implants. Patient compliance was good, as she appeared for regular follow-up.

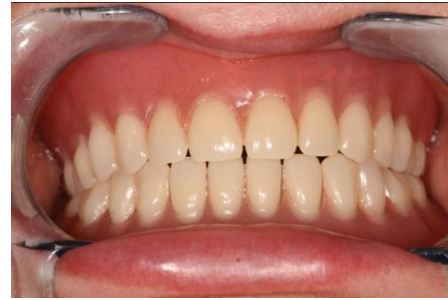

Figure 3: Definitive implant-supported prosthesis in function for over 12 months.

The cost of dental implants and prosthesis was covered by the patient. Summary Prosthodontic treatment of edentulous patients with epilepsy in some cases involve implant-retentive, which has a positive influence on the patient's quality of life. As a compromise, the number of maxillary implants had to be reduced. The importance of regular dental follow-up and adequate oral hygiene was emphasized.

CONCLUSION

Restoration of the edentulous mandible is a challenge. Among different treatment options, an implant-retained overdenture is a simple, cost effective solution in the rehabilitation of the edentulous maxilla and mandible. Despite widespread acceptance of this treatment, some controversies still exist with regard to the design of the overdenture, selection of the appropriate attachment system, and the most optimal techniques for the overdenture fabrication. Clinicians and dental technicians have to adhere to sound design principles such as simplicity in fabrication, ease of maintenance and repair and cost control.

REFERENCES

1. Hauser WA, Annegers JF. Epidemiology of epilepsy In: Laidlaw J, Richens A, Chadwick D (eds.). A textbook of epilepsy. Edinburgh: Livingstone, 1993; 23-45.
2. Annegers JF. The epidemiology of epilepsy In: Wyllie E (ed.). The treatment of epilepsy: Principles and practice. Baltimore: Williams & Wilkins, 1996; p. 165-72.
3. Aragon C.E, Burner JG. Understanding the patient with epilepsy and seizures in the dental practice. I Can Dent Assoc, 2007; 73: 71-6.
4. Károlyházy K, Kovács E, Kivovics P, Fejérdy P, Arányi Zs. Dental status and oral health of patients with epilepsy an epidemiological study. Epilepsia, 2003; 44: 1103-8.
5. Stoopler ET, Sollecito TP, Greenberg MS. Seizure disorders: Update of medical and dental considerations. Gen Dent, 2003; 51: 361-6.
6. Károlyházy K, Kivovics P, Fejérdy P, Arányi Zs. Prosthodontic status and recommended care of patients with epilepsy J Prosthet Dent, 2005; 93: 177-82.

7. Buck D, Baker GA, Jacoby A, Smith DF, Chadwick DW. Patients' experiences of injury as a result of epilepsy. *Epilepsia* 1997;38:439-44.
8. Sander BJ, Weddel JD, Dodge NN. Managing patients who have seizure disorders: Dental and medical issues. *J Am Dent Assoc*, 1995; 126: 1641-7.
9. Cune MS, Strooker H, Reijden WA, Putter C, Laine ML, Verhoeven JW. Dental implants in persons with severe epilepsy and multiple disabilities: a long-term retrospective study. *Quintessence*, 2009; 24: 534-40.
10. Sugerman PB, Barber MT. Patient selection for endosseous dental implants: oral and systemic considerations. *Int J Oral Maxillofacial Implants*, 2002; 17: 191-202.
11. Naert I, Alsaadi G, Quiryneen M. Prosthetic aspects and patient satisfaction with two-implant-retained mandibular overdentures: A 10-year randomized clinical study. *Int J Prosthodont*, 2004; 17: 401-10.
12. Kleis WK, Kämmerer PW, Hartmann S, Al-Nawa B, Wagner W. A comparison of three different attachment systems for mandibular two-implant overdentures: One year report. *Clin Impl Dentistry and Related Res*, 2010; 12: 209-18.
13. Misch CE, Judy KWM. Classification of partially edentulous arches for implant dentistry. *Int J Oral Implant*, 1987; 4: 7-13.