EUROPEAN JOURNAL OF BIOMEDICAL AND PHARMACEUTICAL SCIENCES
http://www.ejbps.com

ISSN 2349-8870
Volume: 10
Issue: 12
229-231.
Year: 2023

MANAGEMENT OF TUBAL BLOCK IN AYURVEDA WITH REFERENCE TO ARTAVAHA STROTO SANGHA – A CASE STUDY

Dr. Shravani P.*[1], Dr. Maheshwari Danappagoudara[2] and Dr. Savita S. Patil[3]

[1]3rd Year PG Scholar, [2]3rd Year PG Scholar, [3]Professor, Head of the Department,
Department of Prasuti Tantra & Stree Roga, Sri Sri College of Ayurvedic Science and Research, Bengaluru, Karnataka.

***Corresponding Author: Dr. Shravani P.**
3rd Year PG Scholar, Department of Prasuti Tantra & Stree Roga, Sri Sri College of Ayurvedic Science and Research, Bengaluru, Karnataka.

Article Received on 19/10/2023 **Article Revised on 09/11/2023** **Article Accepted on 29/11/2023**

ABSTRACT
In Ayurveda, fallopian tubes itself is not mentioned directly, but can be understood as *Artavaha srotas* and any blockage in the tubes as *Artavaha Srotosanga*. Any injury to *Artavavaha strotas* leads to *Vandhyatwa*. Infertility is defined as failure to conceive within one or more years of regular unprotected coitus. There are many factors responsible for conception, among which tubal factor plays an important role in conception. 30-40% of femal infertility is due to Tubal factors. Though Vandhyatwa due to Fallopian tubes are not mentioned directly in Ayurveda, , with the help of Principles said in our *Samhitas* and also with the investigation tools available today, it can be diagnosed and treated accordingly making a couple fit for the conception. **Case Study:** A female aged 30 years, approached OPD complaining of anxious to conceive since 2 years and with the history of 1 ectopic pregnancy. The case was managed with Shodhana and Sthanika chikitsa along with internal medication.

KEYWORDS: *Vandhyatwa, Infertility, Tubal block, Artavaha stroto sangha, Basti.*

INTRODUCTION
Infertility is defined as failure to conceive within one or more years of regular unprotected coitus.[1] There are many factors responsible for conception, among which tubal factor plays an important role in conception.[2] The patent tubes helps in picking up the oocyte from fimbriae end and any pathology in the tubes leads to infertility[3] and it accounts for 30-40% of female infertility.[4]

CONCEPTUAL VIEW
In Ayurveda, fallopian tubes itself is not mentioned directly, but can be understood as *Artavaha srotas*[5] and any blockage in the tubes as *Artavaha Srotosanga*. Any injury to *Artavavaha strotas* leads to *Vandhyatwa, Maithunasahishnuta, Arthava nasha*.[6] Definition of *Vandhyatwa "Yasya Garbhadharana margarupa bandhanam sampyathi sa Vandhya".*[7] The condition in which, there is hindrance in the normal process of conception, and thus women is unable to conceive even after unprotected intercourse which can also be understood as *Kshetra dosha.* Acharya Sushrutha while explaining the *Garbha Sambhava Samagri,* has explained about *Kshetra* in the conception.[8]

"ध्रुवं चतुर्णां सान्निध्याद्गर्भः स्याद्विधिपूर्वकम् ।
ऋतुक्षेत्राम्बुबीजानां सामग्र्यादङ्कुरो यथा"॥ (Su.Sha.2/33)

Kshetra can be understood as healthy and normal functioning female reproductive system (*Yoni*) i.e. includes ovary, **Fallopian tubes**, uterus, cervix, and vagina.

Hence Fallopian tubes can be understood as both *Aratavaha Stroto vikara* and *Kshetra Dosha.*

CASE REPORT
Patient details: A Female aged 30 years, from Bangalore, Occupation: House-wife, Religion: Hindu, Socio-economic status: Middle class, Marital status: Married. OPD Number: 216808.

Case history: Patient with the age of 30 years had a regular MC since menarche. She has a marital life of 2 years and is anxious to conceive since then. 1 year ago she had ectopic pregnancy and underwent left salpingectomy. Later underwent HSG and was diagnosed with Right tubal block, for which she was suggested operative line of management, hence patient approached our hospital for further management of same.

Past surgical history
- Left Salpingectomy – 1 year ago
- Appendectomy – 10 years back

Menstrual history

- Age of Menarche : 13 years of age
- LMP 1 : 06/10/2020
- LMP 2 : 10/09/2020
- Menstrual Cycle : 4-5days/ 25-28day (Regular)

Obstetric history

Marital life- 2 years

$P_0L_0A_1$

A1 – 1 and half month of gestation (ectopic pregnancy) – Left salpingectomy done.

COITAL HISTORY: 2-3 times in week

Deep Dyspareunia +

Examination

GENERAL EXAMINATION

- ❖ Temperature : 97.1° F
- ❖ Pulse : 74 bpm
- ❖ BP : 110/80 mmHg
- ❖ Weight : 62.5 kg
- ❖ Height : 158cm
- ❖ BMI : 25kg/m2

SYSTEMIC EXAMINATION

CNS- Well oriented to time, place & person.

CVS- S1, S2 heard, No murmurs.

RS- NVBS+, No added sound.

LOCAL EXAMINATION

BREAST EXAMINATION: B/L Symmetry, No tenderness, No palpable mass, No discharge from the nipple.

P/A EXAMINATION: Soft, non-tender. No organomegaly, Bowel sound – present.

P/S EXAMINATION: Cervix – Mild Hypertrophy of cervix.

P/V EXAMINATION: AV/ FF / NS/ Cervical motion tenderness (+)

Investigations

HSG (29-06-2021) –

Impression: S/O Right side fimbria end block.

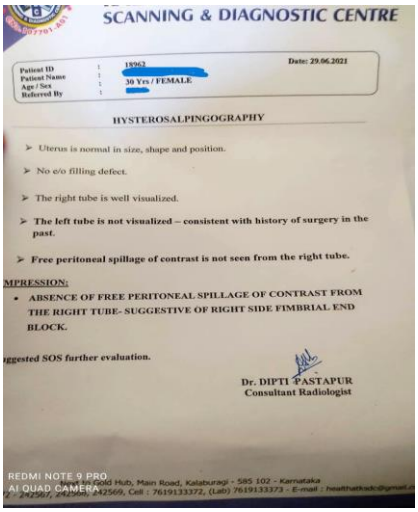
SCANNING & DIAGNOSTIC CENTRE

Date: 29.06.2021

18962

30 Yrs / FEMALE

HYSTEROSALPINGOGRAPHY

- Uterus is normal in size, shape and position.
- No e/o filling defect.
- The right tube is well visualized.
- The left tube is not visualized – consistent with history of surgery in the past.
- Free peritoneal spillage of contrast is not seen from the right tube.

IMPRESSION:

- ABSENCE OF FREE PERITONEAL SPILLAGE OF CONTRAST FROM THE RIGHT TUBE- SUGGESTIVE OF RIGHT SIDE FIMBRIAL END BLOCK.

ggested SOS further evaluation.

Dr. DIPTI PASTAPUR
Consultant Radiologist

NIDANA PANCHAKA

❖ NIDANA

Aharaj: Fast food, Junk food (Burger, Finger chips, Bajji)

Viharaj: Ratri Jagarana, Sedentary life, Stress

❖ ROOPA

Unable to conceive

❖ **SAMPRAPTI**

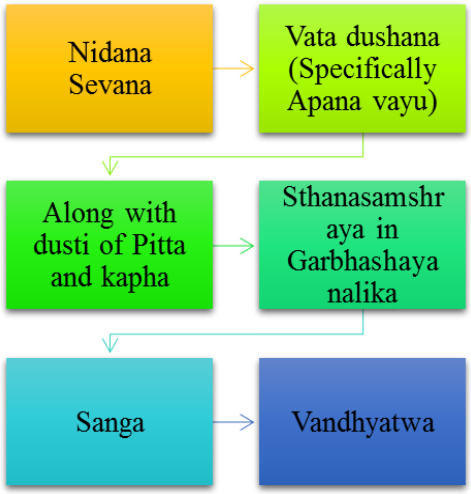

❖ **SAMPRAPTI GHATAK**

Dosha: Vata pradhana Tridosha

Dushya: Rasa, Rakta, Artava

Agni: Dhatvagni

Srotas: Arava- bijavaha

Sroto Dushti: Sanga

Udhabhava Sthana: Amapakvashaya

Vyaktasthana: Garbhashaya

Adhisthana: Garbhashaya nalika

Rogamarga: Abhyantara

VYADI VINISHCHAYA

KAKAVANDYA

(SECONDARY INFERTILITY)

TREATMENT

1) YOGA BASTI (Oct 2021)

- ❖ NIRUHA BASTI – DASHAMOOLA KASHAYA BASTI
- ❖ ANUVASANA BASTI – DANWANTHARAM TAILA (60ml)

2) UTTARA BASTI

- ❖ DHANWANTARAM TAILA for 1st cycle X 3 days (Oct 2021)
- ❖ KSHARA TAILA for 2nd & 3rd cycle X 3 days (Nov and Dec 2021)

INTERNAL MEDICATION

For 1st and 2nd month (Nov and Dec 2021)

- Cap Grab 2BD (A/F)
- Tab Dhanwantaram 2BD (B/F)
- Chirabilwadi Kashaya 15ml BD (A/F) with 30ml water.
- Kankayana Vati 2BD (A/F)
- Varunadi Ghrita 2tsp OD (E/S)

For 3rd month (Jan 2022)

- Gomutra Arka (E/S) 10ml with 20ml water
- Tab Shilajatu 1BD (A/F)
- Dashamoolarista 2tsp BD with equal water

FOLLOW UP – on March 2022 patient came with missed periods with LMP: 14-02-2022. Underwent UPT and was positive, suggestive of the tubal clearance.


KANAKAPURA ROAD

Name	Mrs.	Patient ID	PDJ29365
Age & Gender	30-Y/Female	Visit ID	22PK29418
Ref Doctor	DR. SAVITHA PATIL	Visit Date	13-05-2022 14:40:00

OBSTETRIC ULTRASONOGRAPHY

LMP: 14-02-2022 GA by LMP:12 weeks 4 days.

A single live intrauterine gestation with a crown rump length of 54.8 mm is seen corresponding to 12 weeks 1 day. EDD:24-11-2022

Embryonal cardiac activity is well seen and is regular (FHR - 165 bpm).
Placenta is at fundal wall with grade '0' maturity.

Nuchal transfucency : 1.2 mm
Nasal bone is seen.

No evidence of tricuspid regurgitation.
Ductus venosus shows normal waveform and velocities. No evidence of 'a' wave reversal.

Internal Os is closed. Cervical length: 3.4 cms.
Adnexa are free. No evidence of subchorionic bleed.

Screening of bilateral uterine artery doppler – Negative for PIH.

Impression:

- *A single live intrauterine gestation of 12 weeks 1 day.*

–Suggested anomaly scan between 20 - 22 weeks.

I, Dr. Amith R , declare that while conducting ultrasonography on Mrs. Priti kumari. I have neither detected nor disclosed the sex of her foetus to any body in any manner.

DR. ILT.GURURAJ RAO DR. L.S.PRAVEEN DR. AMITH R
CONSULTANT RADIOLOGISTS

BHIMA LIFESCIENCES LLP
LLPIN- AIG - 9559 www.primadiagnostics.com

DISCUSSION

Basti being one among the *Shodhana karma*, helps to eliminate the *doshas* at level of *Strotas* and thus helps to main the normal physiological function of the body. Similarly the obstruction caused in the *Artavaha strotas* can be managed with *Basti karma*.

Karmukhata of *Basti karma*[9]

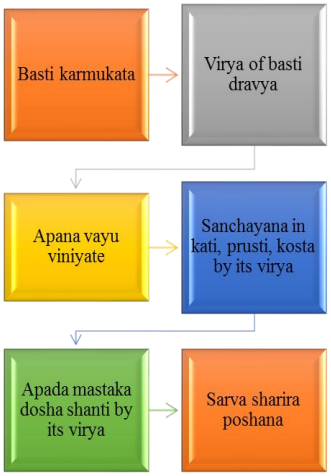

Uttarabasti being one among the *Basti* procedure, the mode of action locally depends on the drug administered and *Lekhana karma* in *Kshara taila* helps in relieving the *Sanga* in *Artavaha Stotra.*

CONCLUSION

Our *Acharyas* has mentioned that Love, Strength, Happiness, Fame, Pleasure are the attributes, which are acquired by children.[10]

Fallopian tube is the *Kshetra* of *Garbhadhana* and is quite near to *Artavavaha strotas.*

Although, *Vandhyatwa* due to Fallopian tube blockage is not mentioned directly in Ayurveda, but it can be understood by collecting all the disorders, where it can be assumed to be as an underlying cause.

Even though Infertility is the leading problem, with the help of Principles said in our *Samhitas* and also with the investigation tools available today, it can be diagnosed and treated accordingly making a couple fit for the conception.

ACKNOWLEDGEMENT

I would like to thank my parents and sister for their support and the faculty members of Dept. of PTSR, SSCASRH for valuable guidelines and support.

REFERENCES

1. Dutta D C. Textbook of Gynecology. Edition 7, New Delhi: Jaypee Brothers; 2019. p.470.
2. Dutta D C. Textbook of Gynecology. Edition 7, New Delhi: Jaypee Brothers; 2019. p.470.
3. Dutta D C. Textbook of Gynecology. Edition 7, New Delhi: Jaypee Brothers; 2019. p.474.
4. Dutta D C. Textbook of Gynecology. Edition 7, New Delhi: Jaypee Brothers; 2019. p.470.
5. Hemalatha Kapoorchand. Striroga. Varanasi: Chaukambha Vishvabharati; 2020. p.331.
6. Usha V N K. Streeroga Vignana. Delhi: Chaukambha Sanskrit pratishtana; 2016. p.201.
7. Usha V N K. Streeroga Vignana. Delhi: Chaukambha Sanskrit pratishtana; 2016. p.201.
8. Shastri KA. Sushruta samhitha, Shukra Shonita shuddhi, Dalhana, Edition 6. Varanasi: Chaukhambha Sanskrit Sansthan; 1985. p.15.
9. Govind Kumar Verma et al. An Ayurvedic approach on Basti: A Review. Int. J. Res. Ayurveda Pharm., 2020; 11(3): 128-142. http://dx.doi.org/10.7897/2277-4343.110375
10. Acharya J T. Agnivesha, Charaka Samhita of Acharya Charaka, Dridhabalakrit, Chikitsāsthāna, Vajikarana Adhyaya, Ver.21, Varanasi: Chowkhamba Sanskrit Series Office, 2018. p.391.