



## A CASE REPORT STUDY ON HOMEOPATHIC MANAGEMENT OF ATOPIC DERMATITIS

**Kajal Dineshbhai Purohit\*<sup>1</sup>, Dr. Chirag Desai and Dr. Kalindi Rameshchandra Solanki**

<sup>1</sup>Department of Pharmacology; ROFEL Shri G. M. Bilakhia College of Pharmacy, Vapi, India.

<sup>2</sup>Associate Professor of Pharmacology; ROFEL Shri G. M. Bilakhia College of Pharmacy, Vapi, India.

<sup>3</sup>Homeopathic Doctor at Kalindi Clinic, Valsad, India.



\*Corresponding Author: Kajal Dineshbhai Purohit

Department of Pharmacology; ROFEL Shri G. M. Bilakhia College of Pharmacy, Vapi, India.

Article Received on 22/08/2024

Article Revised on 12/09/2024

Article Accepted on 02/10/2024

### ABSTRACT

Atopic dermatitis (AD) is a chronic inflammatory skin disorder characterized by the interplay of immunological, environmental, and epithelial factors. So far, patients with poor results have expressed dissatisfaction and powerlessness with failed medications, concern about poor AD comprehension and awareness, and lack of new effective drugs to treat their disease. Homeopathic medicine is a complementary system of medicine that has been found useful in the management of skin-related problems. Studies comparing the efficacy of homeopathic medicine with conventional medicine are not undertaken in Bharat to assess the safety and efficacy of treatment. This case narrates homeopathic management in an illustrative case: A 39-year-old male suffering from itching eruptions and burning sensations. The patient presented with itching eruptions on various parts of his body, increased by hot weather and reduced by cold applications. He was prescribed homeopathic medications such as Fagopyrum, Graphites, Sulphur, Urtica urens, Histaminum, Rhus tox, and E.P., through assessment of his symptoms. With regular check-ups starting in September 2020, he showed a progressive improvement in his symptoms, followed by gradual resolution of the burning sensation and itching up to April 2021. The present study serve as an good example of how homeopathic medicines can be used to treat chronic dermatological disease like AD. The case also proves the concept that treatment must be individualized and based on symptomatology and response patterns. Further studies are thus indicated to confirm these results and clearly demarcate the full role of homeopathic medicine in dermatological care, particularly in conditions like AD.

**KEYWORDS:** Atopic dermatitis, homeopathy, itching eruptions, urticaurens.

### INTRODUCTION

Atopic dermatitis (AD), sometimes referred to as atopic eczema, is a persistent inflammatory skin disorder linked to immunological, environmental and epithelial factors. The term "atopy" refers to the hereditary propensity to produce immunoglobulin E (IgE) antibodies in response to trace levels of common environmental proteins, including pollen, dust mites, and food allergens.<sup>[1]</sup>

The Greek terms "derma" and "itis" mean "skin" and "inflammation," respectively.<sup>[2]</sup> Eczema is a type of superficial skin inflammation that is characterised by vesicles, crusting, scaling, redness, itching, and occasionally lichenification.<sup>[3]</sup> Dry skin is a genetically established skin barrier deficiency that can be the initial sign of AD pathogenesis in certain situations.<sup>[2]</sup> The disorder causes dry, scaly patches of skin to appear, especially on the forehead, flexor surfaces of the arms, chest, and cheeks. Individual with a history of severe pruritis, xerosis,

erosions, excoriations, and ill-defined erythematous regions during acute flare-ups may be diagnosed with AD.<sup>[4]</sup> Atopic dermatitis (AD) is a chronic inflammatory disease that affects 3% of adults and more than 20% of children worldwide.<sup>[5]</sup> Patients' and their families' quality of life is greatly diminished by the disease's chronic, relapsing nature, financial hardship, and the need for the entire family to participate in the treatment process. Compared to agriculture-based countries, developed countries see higher rates of AD.<sup>[2]</sup>

The principle of homeopathy is "like cures like." Clinical studies and meta-analyses demonstrated the distinct activities of homeopathy.<sup>[2]</sup> Suppressed eruptions usually result in deeper disorders, according to homeopathic principles; for this reason, homeopathic customized medicine should be used to treat such eruptions.<sup>[3]</sup> A distinct and traditional form of medicine is homeopathy.<sup>[6]</sup>

Atopic Dermatitis' Clinical Features:

- Itching and scratching
- Apath characterized by flare-ups and remissions
- Typical eczematous dermatitis lesions
- An individual or family's history of atopy (eczema, food allergies, allergic rhinitis, or asthma)
- Longer than six-week clinical course
- Skin lichenification
- The existence of dry skin<sup>[7]</sup>

Here, we describe a case of eczema that was managed with the therapeutically chosen homeopathic treatment.

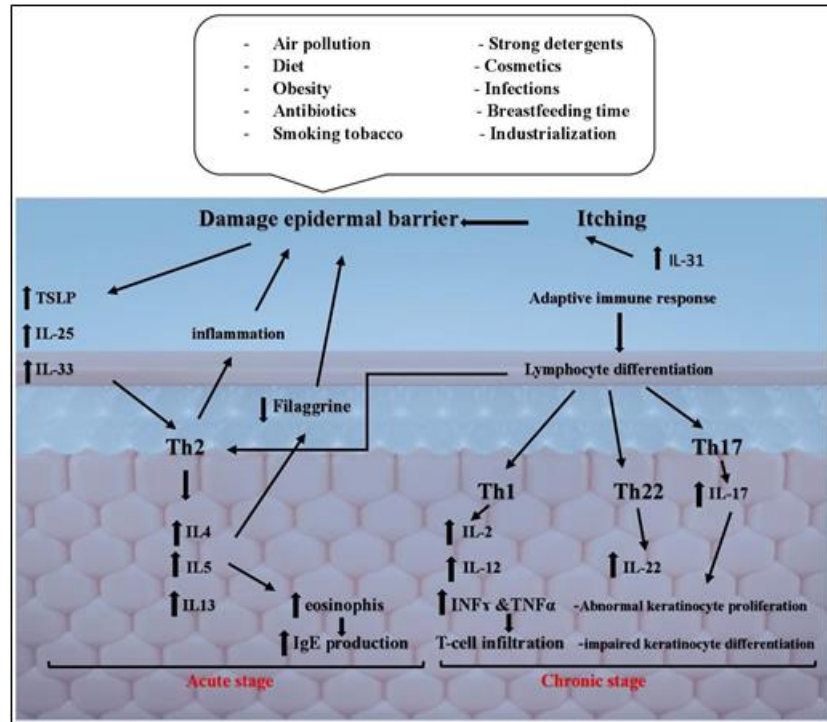


Fig. 1: Atopic dermatitis (AD) pathogenesis.

[IL25(Interleukin25),IL33(Interleukin33),TSLP(Thymicstromal lymphopoietin), Th2(T helper cell 2), IL4 (Interleukin 4), IL5 (Interleukin 5), IL13 (Interleukin 13), Th1 (Thelper cell 1), IL2 (Interleukin 2), IL12 (Interleukin 12), TNF $\alpha$  (Tumor necrosis factor alpha), INF $\gamma$  (Interferon gama), Th22 (T helper cell 22), IL22 (Interleukin 22) Th17 (Thelpercell 17), IL17 (Interleukin17)]

### CASE PROFILE

This is a clinical observation of homeopathic management of atopic dermatitis with complementary system of medicine at a Kalindi clinic Valsad, Gujarat. We first sought the patient's permission to use the data for future medical research before proceeding.

### Patient information

A 39-year-old man belonging to middle-class family residing in rural area reported at the Kalindi clinic on 21-September-2020. The patient presented himself with following complaints. Patient is having Itching eruption on face, upper eyebrow, head, behind ear and upper shoulder since 1 to 2 year. He has also complaint of burning sensation on every part of the body. The itching and burning sensation were aggravated in hot weather and improved in the evening and with cold

applications. The patient was found to be conscious and oriented, with normal reflexes, a soft and non-tender abdomen, and audible S1 and S2. The remainder of the general physical examination was found to be normal. There was no significant past medical history or family history of similar diseases. Particularly with regard to chronic illnesses, information regarding the long-term impacts is highly valuable. Therefore, the current study goal was to outline the long-term follow-up's effectiveness after 6 months.

### Assessment and Diagnosis

On the basis of examination, patient revealed that his itching eruption was localized on specific areas of his body, mainly his face, upper eyebrow, head, behind the ear and upper shoulder. The reports indicated widespread suffering due to the burning feeling occurring on different parts of his body. The patient was diagnosed with eczema, which is characterized by itching eruption and burning sensation, based on the aggravating circumstance and presenting symptoms.

### Totality of symptoms

- Itching eruption on face and upper eyebrow, head, behind ear and upper shoulder
- Burning on every part of the body

- Redness
- Hotflushes
- Irritation
- Aggravation of symptoms in hot weather
- Improvement of symptoms in the evening and with cold applications

#### Treatment Plan and Follow-up

Upon evaluation, the patient was prescribed Graphites 200 BD and Sulphur as a single dose for 15 days, with SL (sublingual) administration every 3 days. The follow-up visits and adjustments to the treatment plan are summarized as follows in table 1:

**Table 1: Follow up visit with symptomatic evaluation and treatment of patient of AD.**

Sr. No.	Date	Symptoms	Medicines
1.	02-10-2020	Redness as it is, Irritation mild decreased, Hot flushes as it is	Fagopyrum 200 BD Urticaurens HS Histaminum OD
2.	11-10-2020	Better burning, Redness as it is	Fagopyrum in afternoon Rhus tox in evening
3.	02-11-2020	Itching, redness on forehead and eye brow decreased, burning and redness on ear decreased	Fagopyrum 200 OD Urticaurens 200 HS
4.	02-12-2020	Itching and redness decreased, burning decreased	Fagopyrum 200 HS Urticaurens 200 OD
5.	08-01-2021	Mild redness, burning decreased	Fagopyrum 200 HS Urticaurens 200 OD Anti-dandruff shampoo
6.	01-02-2021	Itching decreased, little bit redness	Urticaurens 200 HS Graphites 200 OD
7.	24-03-2021	Eczeema on eyebrow + itching Burning on head as it is	Sulphur x 15 days Urticaurens 200 BD (morning & evening)
8.	06-04-2021	Itching, smaller eruption on eyebrow + burning decreased	Urticaurens 200 BD (morning & evening) Histaminum 200 (afternoon & night) Fagopyrum 200 (afternoon & night)
9.	27-04-2021	Redness No itching	Urticaurens 200 BD (morning & evening) Histaminum 200 (evening & night) E.

#### RESULT

The patient responded well on treatment, he showed significant improvement throughout the treatment course. Most symptoms such as redness, itching and burning progressively decreased and eventually resolved at the end of the treatment. It was particularly the individualized homeopathic medication according to patient specific symptoms and reaction, which reportedly decisively influenced reflecting success.

Homeopathic management focuses on a holistic healing approach, taking into account not only physical symptoms but also mental, emotional, and environmental factors affecting health. This case illustrates the effectiveness of homeopathic treatment in managing itching eruption and burning sensations, especially in a patient without significant past medical or family history of similar conditions. The success of the treatment was due to the individualized approach, regular follow-ups and adjustment based on the patient's progress.

#### DISCUSSION

The treatment in this case followed homeopathic principle, fastening on the individual holistically by considering the summation of symptoms, including physical, mental, and emotional aspects. The chosen

homeopathic drugs were based on the patient's unique symptoms and their response to the environmental factors. The homeopathic approach took into account not only the physical symptoms but also the patient's mental and emotional state, as well as environmental factors that might influence the condition.

Atopic dermatitis is not always allergen sensitized. This suggests that the disease manifests in a variety of ways and that each patient's genetic and phenotypic makeup should be taken into account when designing a treatment plan. New therapy approaches including the inhibition of these interleukins are being investigated in light of recent research that have demonstrated the significance of interleukins generated by mast cells in the development of itching in AD.<sup>[5]</sup>

#### Medications and Their Roles

##### • Sulphur

Sulphur was initially prescribed to address the patient's burning sensation and itching eruption. Sulphur is known for its effectiveness in treating burning sensation and symptoms aggravated in hot weather. Previously reported cases shown that sulphur and graphites, both well-known for their effects on the skin, can be effective in the eczema. When both medicines were administered

in the correct sequence, follow-ups showed significant improvement.

**Reason for use:** Sulphur is well-regarded for its strong affinity for skin condition characterized by itching, burning and redness. It is often recommended for cases with a history of suppressed skin eruptions and symptoms aggravated by warmth and hot weather.

**Symptom matching:** The patient's symptoms, including burning sensation and intense pruritis aggravated by hot weather, matched the symptoms profile of sulphur.

**Role in treatment:** Sulphur was used to manage the intense pruritis, itching and chronic nature of the eczema.

- **Graphites**

Graphites are initially prescribed based on the efficacy in treating condition with the patient's symptoms. Graphites are known for their effectiveness in management of eczema case, mainly the symptoms like itching eruption and redness on the face and behind the ears. Graphites was chosen to address the patient's major complaints of burning sensation and itching which is aggravated by hot weather.

Reason for use: Graphites is effective in the treatment of eczema, especially where there is redness, and itching eruption on the face and behind the ears.

Symptoms matching: Patient's major complaints of itching and burning sensation, particularly in hot weather, matched the symptom profile of Graphites.

Role in treatment: Because Graphites and sulphur are related, graphites were first prescribed to treat the burning sensation and itching eruption.<sup>[3]</sup>

- **Urtica urens**

As the patient's symptoms changed during the course of treatment, Urtica urens was prescribed.

Reason for use: Urtica urens was effective in reducing redness and itching, especially on the eyebrow and forehead. Urtica urens also have anxiolytic properties.

Symptoms matching: The patient's redness and itching, particularly on the eyebrows and forehead, matched the symptoms profile of Urtica urens.

Role in treatment: Urtica urens was used to reduce the itching and redness.<sup>[8]</sup>

- **Histaminum**

Reason for use: Histaminum is effective in symptoms like, burning sensation.

Symptoms matching: Patient's burning sensation on different parts of the body matched the indications for Histaminum.

Role in treatment: It was used to relief from burning sensations experienced by the patient.

- **Fagopyrum**

As the patient's symptoms changed during the treatment, Fagopyrum was prescribed.

Reason for use: Fagopyrum was effective in reducing the redness, irritation, and hot flushes.

Role in treatment: It was used to reduce the redness, irritation and hot flushes experienced by the patients.

- **Rhus tox**

Rhus tox was used in the treatment of eczema, especially in reducing burning sensation and redness, particularly in the evening. Rhus tox is mainly used in treating symptoms that worsen in the evening and with exposure to cold and damp weather.

Reason for use: Rhus tox is mainly known for treating symptoms that worsen in the evening and exposure to cold and damp weather.

Role in treatment: Rhus tox was used for reducing burning sensation and redness, particularly in the evening.<sup>[5]</sup>

- **Regular Follow-ups and Adjustments**

The treatment plan was dynamic, being regularly reviewed and adjusted according to the patient's response. This is a key aspect of homoeopathic practice, which involves continuous assessment and fine-tuning of the treatment regimen to ensure it remains aligned with the patient's changing symptoms and overall condition.

## CONCLUSION

This case study demonstrates the effectiveness of homoeopathic medicine in managing chronic dermatological condition characterized by itching eruption and burning sensation. The personalized approach to treatment, which considered individual symptoms and response patterns, contributed to the successful outcome for this patient. Although similar case reports have been performed and published but generating evidenced based practice in different geographical locations may definitely provide further benefits for development of newer treatment guidelines of options. By generating documented evidence and establish standard of care especially skin conditions where alternative system of medicine like homeopathic and ayurveda are effective with minimum untoward complications can replace existing over practiced steroids and immunomodulatory synthetic analogies to reduced health and economical burden on our country. Creating evidencebased practice for such skin and immune complications through traditional system of medicine may reduced irrational dermatological practice. Therefore, further research and clinical studies are warranted to explore the full potential of homoeopathic medicine in dermatological care.

## ACKNOWLEDGEMENT

Authors would like to express their sincere thanks to patient for providing valuable consent for the study and homeopathic clinic for providing necessary support. Authors also express their sincere thanks to the principal

of ROFEL Shri G M Bilakhia College of Pharmacy for providing necessary support.

#### REFERENCES

1. Dr. Navita Bagdi, Dr. Hanuman Ram. A case report for successful treatment of atopic dermatitis (AD) with a Constitutional homoeopathic medicine *Natrum muriaticum*. *Int J Hom Sci.*, 2020; 4(2): 46-51.
2. Dr. Tanmay Sarkar, Dr. Abhinandan Das. Atopic dermatitis successfully treatment by constitutional homoeopathic medicine graphites: A case report. *Int J Hom Sci.*, 2022; 6(4): 503-509.
3. Meena BS, Kumar A, Bagdi N. A case of eczema treated with homoeopathic medicine. *Journal of Integrated Standardized Homoeopathy*, 2020; 3(1): 20-23.
4. Mahesh S, Mallappa M, Habchi O, Konstanta V, Chise C, Sykiotou P, Vithoulkas G. Appearance of Acute Inflammatory State Indicates Improvement in Atopic Dermatitis Cases Under Classical Homeopathic Treatment: A Case Series. *Clin Med Insights Case Rep.*, Feb. 11, 2021; 14: 1179547621994103.
5. Rossi, E.G., Bartoli, P., Bianchi, A.R., & Da Frè, M. "Homeopathy in paediatric atopic diseases: long-term results in children with atopic dermatitis." *Homeopathy*, 2012; 101: 13 - 20.
6. Neeta Sharma, Yashasvi Shakdviya, Deeksha Agrhari, Vartika Garg, NipunSingh Dabi, Sandhya Goyal. Case report on atopic dermatitis treated with single dose of homoeopathy medicinegraphites. *International Journal of AYUSH*, 2022; 11(3).
7. Doukkali Z, Taghzouti K, Boudida EL, Nadjmouddine M, Cherrah Y, Alaoui K. Evaluation of anxiolytic activity of methanolic extract of *Urtica urens* in a mice model. *Behav Brain Funct*, Apr. 24, 2015; 11: 19.