



**AN AYURVEDIC MANAGEMENT OF SIRAJ GRANTHIKRUT VRANA W.S.R.  
VARICOSE ULCER-A CASE REPORT**

**Dr. Yash Kansara<sup>\*1</sup>, Dr Chintan Bhatt<sup>2</sup> and Prof. Dr. Kalapi Patel<sup>3</sup>**

<sup>1</sup>PG Scholar 3<sup>rd</sup> Year, PG Department of Panchkarma, J S Ayurveda Mahavidyalaya.

<sup>2</sup>Associate Professor, PG Department of Panchkarma, J S Ayurveda Mahavidyalaya.

<sup>3</sup>H.O.D., Principal and Superintendent, PG Department of Panchkarma, J S Ayurveda Mahavidyalaya and P D Patel Ayurveda Hospital, Nadiad.



**\*Corresponding Author: Dr. Yash Kansara**

PG Scholar 3<sup>rd</sup> Year, PG Department of Panchkarma, J S Ayurveda Mahavidyalaya.

Article Received on 12/12/2025

Article Revised on 02/01/2025

Article Accepted on 22/01/2025

**ABSTRACT**

**Background:** Varicose veins are dilated, tortuous, elongated veins in the leg. There is reversal of blood flow due to its malfunctioned valves of the lower limb. There are signs like twisted, dilated veins. It involves a genetic predisposition, incompetent valves, debilitated vascular walls, and increased intravenous pressure. Potential complications include infection, leg ulcers, stasis changes, and thrombosis. **Ayurvedic view:** In Ayurveda science, Sira is mentioned as the Upadhatu of Rakta dhatu and Acharya Shushrut mentioned Sira granthi which resembles to varicose veins. In this condition blood veins are enlarged, fibrosed, tortuous and twisted specifically in lower limbs. The prime treatment mentioned by Acharya Shushrut is Shodhan followed by Jalauka avacharan procedure for improvising Sira granthi clinical condition. **Clinical findings:** 41 year old male patient who is suffering from varicose vein since 10 year which was converted to varicose ulcer. **Diagnosis:** On performing Color Doppler study suggest dilated veins on medial aspect of proximal leg and lower thigh in both lower limbs which make the confirmed diagnosis about varicose vein. **Management:** The conventional medicine suggests surgery for varicose ulcer. Hence considering the alternate management patient came at P D Patel Ayurveda Hospital. He was admitted in P.D. Patel Ayurveda Hospital for 1 month and treated with Shodhan procedure followed by Jalauka avacharan and Shaman chikitsa.

**KEYWORDS:** Sira granthi, Varicose ulcer, Virechana, Jalauka avacharana.

**INTRODUCTION**

Varicose vein occurred due to valvular insufficiency of Saphenous vein causes permanently elongated, dilated veins with tortuous path causing pathological circulation. Risk factors are hereditary, female sex, occupation that demands prolonged standing, immobility, raised intra-abdominal pressure like in sports, tight clothing, pregnancy, raised progesterone level and altered estrogen-progesterone ratio, chronic constipation, high heels etc., it increases the venous pressure of lower limb and causes decreased venous return to heart which is responsible for Varicose vein.<sup>[1]</sup> It affects 22 million women and 11 million men between the ages of 40 to 80 years. They affect 10–20% of population in the Western world but in India, it is 5%. Prevalence rate increases to 80% men and 85% women.<sup>[2]</sup> There are 2 types of varicose vein 1. Primary varicose vein and 2. Secondary varicose vein.

Venous leg ulcers develop when persistently high blood pressure of the leg causes damage to the skin, which

eventually breaks down and form an ulcer. It occurs due to increased venous hydrostatic pressure. Generally, manifests on the medial side of lower one third of the leg due to long saphenous varicosity and on the lateral aspect of lower leg region which suggests short saphenous varicosity. It is generally shallow and superficial, edge is sloping. Never penetrates deep fascia, floor is covered by pale granulation. The adjacent area of the ulcer is hyper pigmented, indurated and tender.<sup>[3]</sup> Varicose vein can be treat using Conservative method, oral medications and surgery. Treatments like Elastic crepe bandage application, Diosmin therapy to improve venous tone, elevation of the limbs, sclerotherapy, surgeries like Trendelenburg operation (Crossectomy), Stripping of vein, Ligation of short saphenous vein.

In *Ayurveda* science varicose vein having the similar sign and symptoms as mentioned in *Sira-granthi vyadhi* mentioned by *Acharya Sushrut*.<sup>[4]</sup> *Sira* is *Upadhatu* of *Rakta Dhatu*. Considering *Pitta dosha* is having *Ashrayee Ashray Bhav* with *Raktaa dhatu*.<sup>[5]</sup> In

Ayurvedic classics the treatment of *Rakta Dhatu* and *Pitta Dosa* is *Shodhan, Shaman* and *Raktamokshana*. Specifically, *Jalauka Avacharan* is mentioned by *Acharya Sushruta* for vitiated *Pitta dosha*.<sup>[6]</sup>

*Sushruta* has advocated that *Rakta-mokshan* by application of *Jalauka* can be practiced treating *vrana* having *Shotha, Srava, Pakwa, Shula, Grudhasi, Vata-rakta*, Diabetic ulcers, varicose ulcers. It is considered most unique and most effective method of *Rakta-mokshan*. It can be tried in all mankind including females, children, old and patients having poor threshold to pain. It drains impure blood which is the causative factor behind *Pitta dushti, Raktaj vyadhi*, various *Twak vicar*.<sup>[7]</sup>

#### Brief Case History

Age: 41 year  
Gender: Male  
Religion: Hindu  
Occupation: Carpenter  
Diet: Vegetarian

Address: Ahmedabad, Gujarat.

#### Chief complaint with Duration

Patient having complained of elongated and tortuous vein at left lower extremities associated with severe pain since 10 year.

Wound along with discoloration of skin and serous discharge from the wound at the anterior aspect of left leg since 1 year.

He was suffering from the above symptoms since last 10 years and then he developed a wound since one year. He consulted conventional medicine and underwent with color Doppler venous study suggestive of varicose vein. He started the conventional medicine for the same but could not get relief.

#### General examination

All the vital parameters were within normal limits.

#### Treatment

Table – I.

Procedure	Medicine	Date	Dosage
<i>Snehapana</i>	<i>Panchtikta ghrita</i> <sup>[8]</sup>	29 <sup>th</sup> April 2022 To 2 <sup>nd</sup> May 2022	In increasing order from 40 ml to 85ml <i>ushnodak</i>
<i>Sarvang Abhyanga</i>	<i>Jatyadi taila</i> <sup>[9]</sup>	3 <sup>rd</sup> May to 5 <sup>th</sup> May 2022	<i>Abhyang</i> was perform in all the 7 position as describe for approx. 30 min.
<i>Sarvang Naadi Svedana</i>	Using plain water vapor	3 <sup>rd</sup> May to 5 <sup>th</sup> May 2022	<i>Swedana</i> was perform till the <i>Samyak sweda lakshan</i> i.e for approx. 10 minutes.
<i>Virechan karma</i>	i. <i>Eranda Sneha</i> + <i>Dindayal churna</i> with <i>Draksha kwath</i>	5 <sup>th</sup> May 2022	40 ml + 5 gm
<i>Samsarjan karma</i>		6 <sup>th</sup> May to 8 <sup>th</sup> May 2022	
<i>Sarvang Abhyanga</i>	<i>Jatyadi taila</i>	8 <sup>th</sup> May to 6 <sup>th</sup> June 2022	
<i>Sarvang Naadi Svedana</i>	Using plain water vapor	8 <sup>th</sup> May to 6 <sup>th</sup> June 2022	

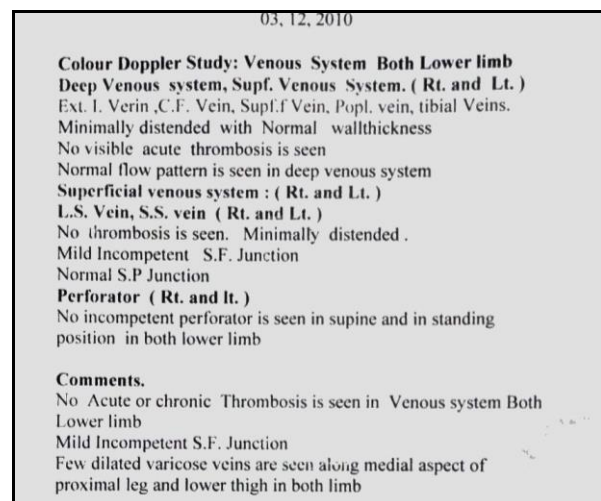
Investigation  
HB: 13.7 mill/mm<sup>3</sup>  
RBS: 92 mgm%  
S. creat: 0.9 mgm%  
HBsAG: negative

#### Local examination

Site of Ulcer: Anterior aspect of left foreleg.  
Smell: Foul  
Discharge: +2  
Hyperpigmentation: +3  
Epithelization: +2  
Lower limb Trendelenburg test<sup>1</sup>: Positive.

#### Color Doppler study: Venous system of both lower limbs.

On dated 3<sup>rd</sup> December 2010 in Color Doppler venous study few dilated veins were seen along medial aspect of proximal leg and lower thigh in both lower limbs.



(Image – I Color Doppler Study)

<i>Shaman chikitsa</i>	i. <i>Kaishor guggulu</i> <sup>[10]</sup>	9 <sup>th</sup> May to 6 <sup>th</sup> June 2022	2 tab 3 times with <i>ushnodaka</i>
	ii. <i>Manjisthadi kwath</i> <sup>[11]</sup>	9 <sup>th</sup> May to 6 <sup>th</sup> June 2022	40 ml twice a day
<i>Niruha Basti</i>	<i>Pathyadi</i>	9 <sup>th</sup> May to 6 <sup>th</sup> June 2022	320 ml
<i>Jalauka avacharan</i>	2 <i>jalauka</i> were used On anterior surface of left foreleg 1 <i>jalauka</i> over the varicose ulcer and another below varicose ulcer	9 <sup>th</sup> May 2022 17 May 2022 24 May 2022 31 May 2022	45 mins 45 mins 45 mins 45 mins

### **Jalauka-Avacharana**

#### **Purva Karma**

For the preparation of procedure *Jalauka-avacharana*, *Nirvisha Jalauka* were selected and kept in clean water in mud pot.



(Image II – *Jalauka Sambhar sangrah*)

Before starting the procedure, *Jalauka* were kept into turmeric water to remove *Klama-avastha*, active movement of *Jalauka* indicates they are ready for the application.



(Image III – Preparation of *Jalauka*)



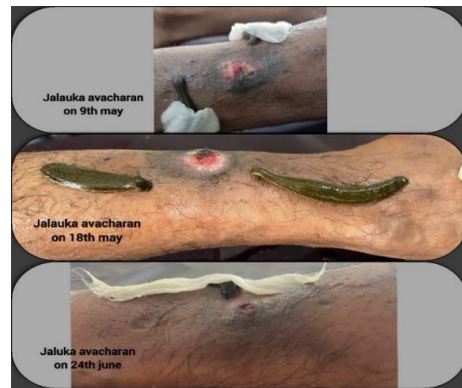(Image V *Vamana of Jalauka*)

Then further kept it in pure water in mud pot.

*Jalauka avacharan* was repeated weekly in 4 seating and then further carried out for 5 times more in OPD bases.

#### **Pradhana Karma**

After cleaning of application site, and after getting the proper *vigata klama* of *Jalauka*, it placed near the Ulcer.



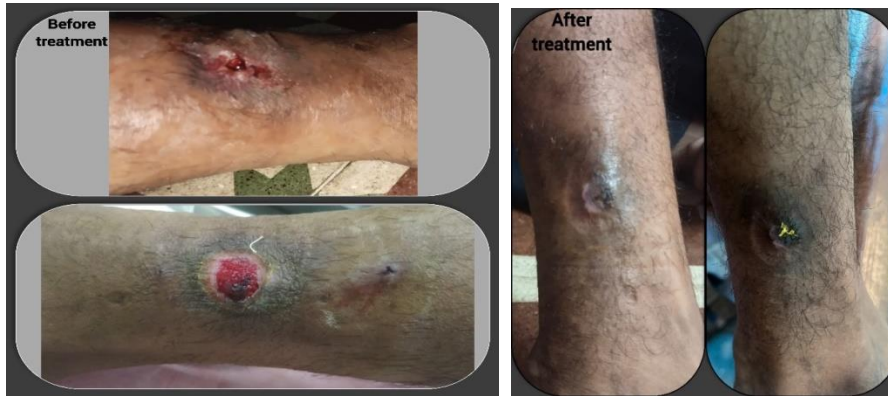(Image IV - *Jalauka application*)

#### **Paschat karma of Jalauka avacharan**

When *Jalauka* left the site by its own. Wound was cleaned and *Haridra* was sprinkled over the wound and wrapped using dressing material.

As it is detached, it kept for the *Vaman* and all impure material which was sucked would be expelled out from the *Jalauka*.

## RESULTS



(Image VI – Results at the end of treatment)

## DISCUSSION

In Ayurveda classics as per treatment principles of *Sira Granthi*: *Shodhan, Shaman and Jalauka Avacharan* are mentioned.<sup>[12]</sup> *Abhyantara Snehapana* was done as pre-operative procedure before *Virechana Karma*, which causes *Dosha Utklesha*. *Snehapana* will make *Dosha* to move from *Shakha* to *Kostha* and softens the vitiated *Dosha*. *Panchtikta ghruta* was used for the purpose of *Snehapana* which subsides *Rakta Vikara, Twaka Dosha, Pittaja Vyadhi etc.*<sup>[13]</sup> *Panchtikta ghruta* will perform *Rakta Prasadana* which enhances the *Twaka Prasadana* also, as *Twacha* is *Upadhatu of Rakta Dhatu*. *Samyaka Snehana Lakshanas* were observed like moistness of body skin specifically observed around wound, increased semi solid stool frequency.<sup>[14]</sup>

After attaining these *Lakshana*, *Abhyanga* was done using *Jatyadi Taila* as it is specifically indicated in *Vranadi Adhikara* by *Acharya Sharangdhar*. *Jatyadi Taila* is having its effects on *Dushta Vrana, Vrana Ropanakarma*.<sup>[15]</sup>

*Abhyanga* followed by *Mrudu Nadi Svedana Karma*. *Nadi Svedana* will liquefy vitiated *Dosha* that adheres to the micro channels and traverse them from *Shakha* to *Kostha*.<sup>[16]</sup>

*Virechana Karma* was performed using *Eranda taila* and *Dindayal Churna* along with *Anupana of Draksha Kwatha* for the elimination of *Pitta Dosha*. It does the proper evacuation of *Kaphadi dosha* which indicated lightness in umbilicus region, *Manas tusti* and *Vatanulomana*.<sup>[17]</sup> *Samsarjan karma* was followed for 5 *Anna kala* i.e for 3 days.

*Niruha Basti*<sup>[18]</sup>, a *Shodhana* treatment to eliminate vitiated *Dosha* and *Mala* from the body. Additionally, *Niruha Basti* possesses *Rasayana* action, which reduces degenerative process and nourishes the *Dhatu* and *Upadhatu* in the body. *Pathyadi Kwatha*<sup>[19]</sup> is having *Pitta Shamaka* and *Rakta Prasadak* property. *Niruha basti* given using *Pathyadi Kwatha* will nourish *Raktadi Dhatu* which also nourishes *Twacha* by the improvement of *Rakta Dhatu*.

*Kaishor guggulu*<sup>[20]</sup>: In *Sharangdhar samhita*, *kaishor guggulu* is indicated in *Kustha, Vatarakta, Nadi Vrana* etc. if *Kaishor guggulu* given along with the *Manjisthadi kwath* it helps specifically in *Kustha* and *vata Rakta* which directly suggest its mode of action over *Rakta dhatu, Pitta dosha* and *Vata dosha*.

*Manjisthadi kwatha*<sup>[21]</sup>: In *Sharangdhar samhita*, *Manjisthadi kashaya* is indicated in *Vata rakta*, and *kustha roga dhikar* which also suggest that it will work over *Pitta dosha* and *shodhan* of *Rakta dhatu*.

Probable mechanism of Leech therapy<sup>[22]</sup>

*Jalaukaavacharan* is type of *Raktamokshan* and it has been practiced for management of *Pittaja dushti* condition having *Grathita & Avagadh rakta* (clotted blood) as mentioned in *Sushruta Samhita*. *Jalauka Avacharana* corrects venous hypertension, reduces vascular congestion due to presence of Carboxy peptidase-A inhibitors, Histamine-like substances & Acetylcholine, which corrects venous valve dysfunction and extra vascular fluid perfusion and prevents leakage of proteins and isolation of extra cellular matrix molecule and growth factors, which helps to heal the ulcer. *Jalauka* application has peripheral vasodilator effects due to presence of vasodilator constituent in the saliva which improves blood circulation and corrects 'Ischemia' around the ulcer and promotes wound healing. *Jalauka* application has Anti-inflammatory action on nerves due to presence of substance like *Bdellins & Eglins* in the saliva which prevents leukocyte accumulation in the surrounding vessels and inhibits release of inflammatory factors that causes chronic wound formation. Hence *Jalauka avacharan* helps to increase the permeability of cell and improves the tissue regeneration and blood circulation.

## CONCLUSION

Here we can conclude that the non-healing varicose ulcer completely healed after two months of treatment. The moderately healed varicose ulcer showed improvement within 30 days, with the patient continuing *Shamana Aushandhi* on an OPD basis for one month, following four sittings of *Jalaukaavacharan*. *Ayurveda* has the

potential to offer a ray of hope in the treatment of varicose veins and ulcers. However, based on individual case studies, no definitive conclusion can be drawn. A comparative clinical trial, along with valvular studies, is needed to establish a standardized treatment protocol for *Siraj Granthikrut Vrana* (varicose veins and ulcers).

## REFERENCES

1. Sriram Bhat M MS (General Surgery), SRB'S manual of surgery, 4<sup>th</sup> edition, venous disease, pg no. 235.
2. Ahajournal.org, Hamdan A. Management of Varicose veins and venous insufficiency. Sriram Bhat M MS (General Surgery), SRB'S manual of surgery, 4<sup>th</sup> edition, venous disease, pg no. 28.
3. Richard H. Jones, MD, MSPH and Peter J. Carek, MD, MS.
4. Sushruta samhita, edited by Dr Ambikaduttshastri, published by Chaukhambha Sanskrit Sansthan, Part 1, Nidana sthana, chapter 11 / 8, 9, pg no. 351.
5. Vidyath R, editor. Aṣṭāṅga-hṛdyam: Original Sanskrit Text in Devanagari with English Translation, Additional Information, and Color Illustrations. Sutrasthana, Chapter 11, Verse 26. 1st ed. Varanasi: Chaukhambha Surbharati Prakashan, 2010; p. 192.
6. Sushruta. *Sushruta Samhita*, edited by Dr. Ambikadutt Shastri. Chikitsa Sthana, Chapter 18/8–10, p. 104. Varanasi: Chaukhambha Sanskrit Sansthan.
7. Dr Renita D'souza, <https://www.easyayurveda.com/2018/08/22/leech-therapy-procedure-benefits-side-effects-treatment/>
8. Govind Das Sen. Bhaishajya Ratnavali with Bhasha Tika and Hindi translation by Vaidya Shankar Lal. Mumbai: Khemraj; 1942. Visphotachikitsa Prakarana, 6. Pg no. 1117.
9. Pandit Sarngadharacarya. *Sarngadhara-Samhita*, containing *Anjananidana of Maharshi Agnivesa*, annotated with 'Dipika' Hindi commentary. Dr. Brahmanand Tripathi, editor. Madhyam Khanda 9/168–171. Varanasi: Chaukhambha Surbharati Prakashan.
10. Pandit Sarngadharacarya. *Sarngadhara-Samhita*, containing *Anjananidana of Maharshi Agnivesa*, annotated with 'Dipika' Hindi commentary. Dr. Brahmanand Tripathi, editor. Madhyam Khanda 7/70-81 p. 136. Varanasi: Chaukhambha Surbharati Prakashan;
11. Pandit Sarngadharacarya. *Sarngadhara-Samhita*, containing *Anjananidana of Maharshi Agnivesa*, annotated with 'Dipika' Hindi commentary. Dr. Brahmanand Tripathi, editor. Madhyam Khanda 2/137-142 p. 102. Varanasi: Chaukhambha Surbharati Prakashan
12. Shastri A, editor. Sushruta Samhita: Ayurveda Tatva Sandeepika. Chikitsasthana, Chapter 18, Verses 8-10. 1st ed. Varanasi: Chaukhambha Sanskrit Sansthan, 2010; p. 77.
13. Govind Das Sen. Bhaishajya Ratnavali with Bhasha Tika and Hindi translation by Vaidya Shankar Lal. Mumbai: Khemraj; 1942. Visphotachikitsa Prakarana, 6. Pg no. 1117.
14. Agnivesa, Charaka, Dridhbala. Charaka Samhita, with Ayurveda Dipika commentary by Chakrapanidatta, edited by Vaidya Yadavji Trikamji Acharya. Sutra Sthana 13/58, p. 85. Varanasi: Chaukhambha Publications.
15. Pandita Sarngadharacarya. *Sarngadhara-Samhita*, containing *Anjananidana of Maharshi Agnivesa*, annotated with 'Dipika' Hindi commentary. Dr. Brahmanand Tripathi, editor. Madhyam Khanda 9/168–171. Varanasi: Chaukhambha Surbharati Prakashan.
16. Sharma RK, Dash B, editors. Caraka Samhita: Text with English Translation & Critical Exposition Based on Cakrapani Datta's Ayurveda Dipika. Volume 4. Siddhisthana, Chapter 1, Verse 7. 1st ed. Varanasi: Chaukhambha Sanskrit Series Office, 2012; p. 142.
17. Shastri A, editor. Sushruta Samhita: Ayurveda Tatva Sandeepika. Chikitsasthana, Chapter 33, Verse 25. 1st ed. Varanasi: Chaukhambha Sanskrit Sansthan, 2010; p. 575.
18. Agnivesha. Charak Samhita, by Vaidya Yadavaji Trikamji Acharya, Varanasi, Chaukhambha Surabharati Prakashana; reprint, 2015; Siddhisthana 1/40-41, 684p.
19. Pandit Sarngadharacarya. *Sarngadhara-Samhita*, containing *Anjananidana of Maharshi Agnivesa*, annotated with 'Dipika' Hindi commentary. Dr. Brahmanand Tripathi, editor. Madhyam Khanda 2/143-145 p. 102. Varanasi: Chaukhambha Surbharati Prakashan.
20. Pandit Sarngadharacarya. *Sarngadhara-Samhita*, containing *Anjananidana of Maharshi Agnivesa*, annotated with 'Dipika' Hindi commentary. Dr. Brahmanand Tripathi, editor. Madhyam Khanda 7/70-81 p. 136. Varanasi: Chaukhambha Surbharati Prakashan.
21. Pandit Sarngadharacarya. *Sarngadhara-Samhita*, containing *Anjananidana of Maharshi Agnivesa*, annotated with 'Dipika' Hindi commentary. Dr. Brahmanand Tripathi, editor. Madhyam Khanda 2/137-142 p. 102. Varanasi: Chaukhambha Surbharati Prakashan
22. Samaranayake G.V.P., Pushpakumara A.A.J., Waliwita W.A.L.C.