



MANAGEMENT OF URETHRAL STRICTURE WITH KSHAR TAILA UTTARBASTI - A CASE REPORT

Dr. Bharat K. Oza¹, Dr. Brinda S. Patil^{2*}, Dr. Madhavi S. Banarase³, Dr. Sahil N. Rahate⁴

¹Associate Professor, Dept. of Shalya Tantra, PDEA's College of Ayurveda and Research Centre, Nigdi Pune, Maharashtra India.

²PG Scholar, Dept. of Shalya Tantra, PDEA's College of Ayurveda and Research Centre, Nigdi Pune, Maharashtra India.

³HOD and Professor, Dept. of Shalya Tantra, PDEA's College of Ayurveda and Research Centre, Nigdi Pune, Maharashtra India.

⁴PG Scholar, Dept. of Shalya Tantra, PDEA's College of Ayurveda and Research Centre, Nigdi Pune, Maharashtra India.



***Corresponding Author: Dr. Brinda S. Patil**

PG Scholar, Dept. of Shalya Tantra, PDEA's College of Ayurveda and Research Centre, Nigdi Pune, Maharashtra India. DOI: <https://doi.org/10.5281/zenodo.19279729>

How to cite this Article: Dr. Bharat K. Oza¹, Dr. Brinda S. Patil^{2*}, Dr. Madhavi S. Banarase³, Dr. Sahil N. Rahate⁴ (2026). Management Of Urethral Stricture With Kshar Taila Uttarbasti - A Case Report. European Journal of Biomedical and Pharmaceutical Sciences, 13(4), 129–132.

This work is licensed under Creative Commons Attribution 4.0 International license.



Article Received on 22/02/2026

Article Revised on 14/03/2026

Article Published on 01/04/2026

ABSTRACT

Urethral stricture is a narrowing of the urethra due to scar tissue or inflammation. It can block or restrict urine flow. The symptoms like Weak urine stream, Dribbling or spraying of urine, Frequent urination, dysuria and Incomplete bladder emptying. Major complications caused by this disease are obstructed urine flow, urine stasis leading to urinary tract infection, calculi formation, etc. This condition can be correlated with Mutramarga Sankocha in Ayurveda. Modern medical science suggests urethral dilatation, which may cause bleeding, false passage and fistula formation in few cases. In Ayurveda, urethral stricture can be correlated with mutramarga sankoch (urethral obstruction). It's often linked to Vata and Kapha dosha imbalance. Modern medical science suggests Urethral dilatation (stretching the urethra), Urethroplasty (surgery to repair or replace the urethra) and Medications for symptoms. Uttar basti, a para-surgical procedure is the most effective available treatment in Ayurveda for the diseases of Mutravaha Srotas.

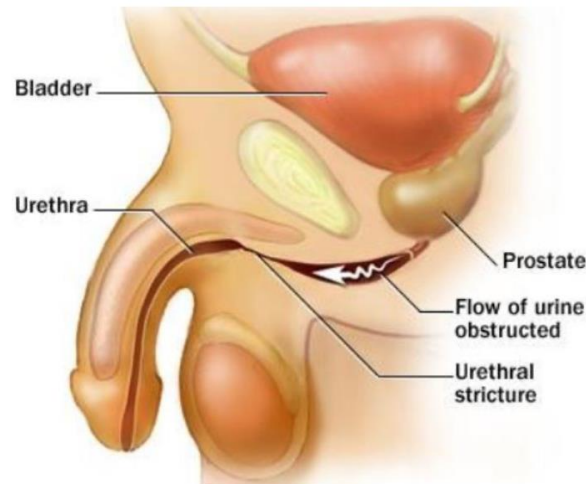
KEYWORDS: It's often linked to Vata and Kapha dosha imbalance.

INTRODUCTION

Uttarbasti an ancient Ayurvedic therapy, showcases the profound understanding of human anatomy and physiology our ancestors possessed. This specialized treatment involves infusing medicated oils or decoctions directly into the urinary bladder through the urethra, targeting issues like urethral stricture, urinary retention, and chronic infections. With its potent anti-inflammatory and rejuvenating properties, Uttarbasti provides effective and lasting relief, making it a go-to solution for many urological concerns. Loha Shalaka is used in Uttarbasti to gently dilate the urethra before administering the medicated oil or decoction. It's a preparatory step to ensure smooth insertion and effective treatment. Typically, the dilators are used in from small to large to

gradually widen the urethral passage. Mutravaha Srotas in Ayurveda refers to the channels or pathways responsible for urine production, storage, and elimination.

Mutramarga Sankocha can be correlated with stricture urethra. Pathologically it becomes narrowed by a fibrotic tissue, which hampers excretion. Imbalances in Mutravaha Srotas can lead to disorders like urinary retention, incontinence, or painful urination include Vrukka (kidney), Gavini (ureter), Mutrashaya (urinary bladder), and Mutramarga (urethra), according to Ayurvedic Sharira Rachana. Ashtanga Hridaya defines that urination is the function of Vata, and its vitiation settles in disturbed urinary functions.



PRESENT HISTORY

A 42 year old male patient with complaints of weak-stream of urine, dysuria and difficulty in micturition since 2-3 years. symptoms started worsening so patient came to OPD Department of shalyatantra for further management.

PAST HISTORY

Sx/H/O - Cystoscopic Urethral dilatation in 2018
Family History-No any relevant family history found

GENERAL EXAMINATION

PR-82/min
BP-130/80mmhg
SPO2-98%
TEMP-Afeb

PERSONAL HISTORY

Diet-mixed
Bowel- regular
Sleep- 7-8hr in 24 hr
Appetite- good
Addiction- No any

PHYSICAL EXAMINATION

Average built, no clubbing/cyanosis/icterus/No any lymphadenopathy observed

SYSTEMIC EXAMINATION

Respiratory System Bilateral air entry- Normal
Cardiovascular System S1, S2 – Normal
Central Nervous system -Conscious and well oriented

P/A - Soft, NT

INVESTIGATIONS

MICTURATING CYSTO-URETHROGRAPHY AND RETROGRADE UROGRAPHY

CLINICAL PROFILE:
H/o decreased micturition associated with straining since 5 months.
H/o nocturia and frequency present.
No H/O abdominal pain / lithuria / frequency / hematuria / pyuria / fever
H/o simialr complaints 3 years back- 7VIU done and as on self dilatation
No other co-morbidities
USG KUB : Non obstructive left renal calculus. Significant residual urine volume.

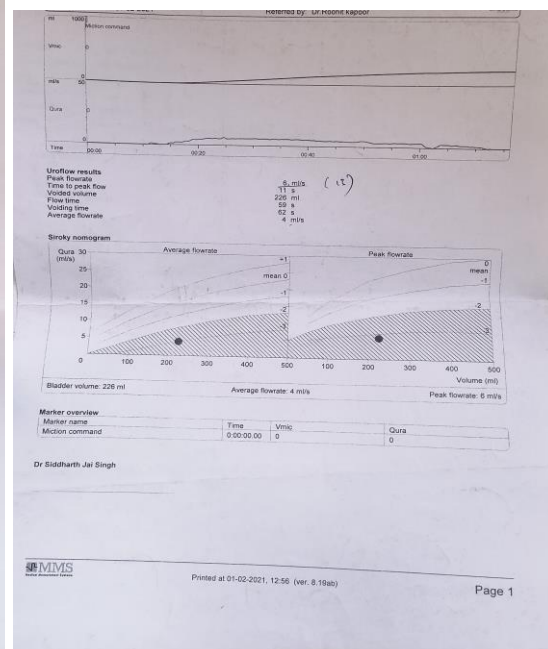
TECHNIQUE:
Under aseptic precaution procedure was carried out by cannulating the external urethral meatus and injecting 1:1 diluted and films are taken.
Under aseptic precaution procedure was carried out with infant feeding tube. This was followed by injecting 1:4 diluted 60% urovidee into the bladder. Then patient is made to micturate & serial films are taken during micturition.

FINDINGS
BLADDER
It appears normally distended with contrast.
No filling defect noted.
No evidence of vesicoureteric reflux, bilaterally.

URETHRA -
Free flow of contrast noted through the urethra
There is a short segment stricture at bulbous urethra with proximal dilatation of membranous and prostatic urethra seen.
No mucosal irregularity seen.

IMPRESSION -

- Stricture at bulbous urethra with proximal dilatation of membranous and prostatic urethra seen.
- No evidence of vesicoureteric reflux, bilaterally.



MATERIALS AND METHODS**MATERIALS USED**

- Sterile sheets
- Lox2% jelly
- Betadine solution
- Surgical gloves
- Hegar's dilators
- Autoclaved Kshar taila
- Kidney tray
- Feeding tube no 10
- Sterile gauze piece
- 50ml disposable syringe
- Sponge holder

METHOD

Uttarbasti is performed in following 3 phases as follow.

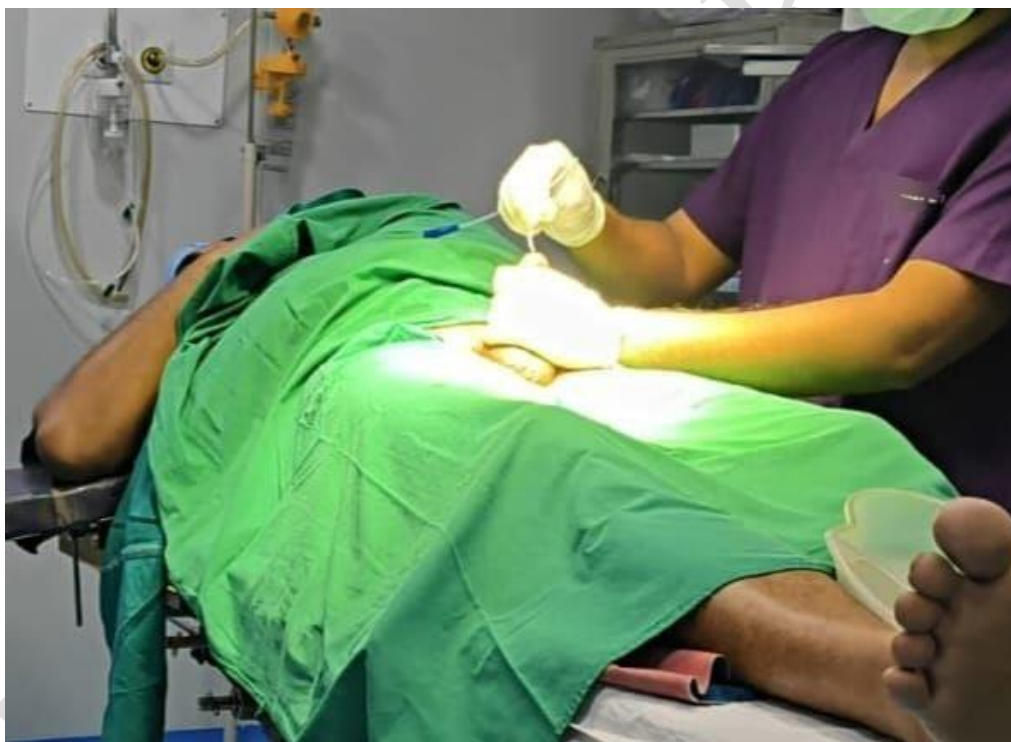1. PURVA KARMA

- All the necessary investigations are done and vitals are checked.

- Patient is asked to void urine and to be free from natural urges. Then asked to lie in supine position with cloth undone.
- Antiseptic care is given.

2. PRADHAN KARMA

- Painting and drapping done.
- Hegar's dilators used to dilate urethral opening small to large respectively.
- Fetal feeding tube no 10 is inserted and when it reaches bulbomembranous urethra patient is asked to take deep breathe. further tube is inserted till it reaches bladder.
- Post void urine drained out.
- Medicated Kshar Taila instilled into urethra by the help of syringe in one shot. scrotal massage given for 10 minutes.
- patient asked to remain in same position till 15 minutes.

**3. PASHCHAT KARMA**

- Patient asked avoid to micturate till 45-60 minutes after procedure.
- Post procedure vitals are taken and noted.
- Patient is called for follow up on regular interval.

The patient underwent Uttarbasti treatment with kshar taila for initial 3-days, followed by 18 sessions of Uttarbasti administered at intervals of 3, 8, 15, and 30 days. The treatment involved inserting a sterilized feeding tube into the urethra and infusing 20 ml of kshar taila.

OBSERVATION AND RESULTS

Symptoms	Before treatment	After treatment
Painful micturition	+++	+
Dribbling micturition	++	-
Weak urine flow	+++	+
Straining	++	-

DISCUSSION

Mutramarga Sankocha is a clinical entity where in vitiation of Vata Dosha specifically of Apana Vayu, sheltered in the Basti and Medhra occurs. Hetu-Sevana results in Vikruti of Apana Vayu in consequence to this, Chala, Ruksha, Khara Guna increases resulting into Sansaktata of Mutramarga and hence the Mutramarga Sankocha. There is a synergistic action of Kshara Taila and action of the Uttarabasti. Kshara Taila has the properties of the Lekhana and Ksharana. Therefore, it might be resulting into the Ksharana and Lekhana of Mutramarga gata sansaktata. The Ushna and Snigdha Guna of Tila Taila pacifies the increased Rukshatwa, Kharatwa and Chalatwa of Apana Vayu, restoring its normal function and thus brings about Stroto Shodhana and local Snehana actions. The study drug is directly instilled into the urethra, a known Sthana of Vayu, which gives direct access to the seat of Srotovaigunya and Dosha Dushya Sammurchhana. This directly acts on the Vikruta Vayu and breaks the Samprapti.

CONCLUSION

The study revealed that, Kshar Taila Uttar basti is as good as that of dilatation technique. As recurrence with Kshar Taila Uttar basti is significantly lesser, it is an ideal minimal invasive treatment in urethral stricture in an Indian setup and may be preferred in comparison to the dilatation methods. It is proposed that, continuing the treatment for a longer period with proper follow-up may avoid or postpone further complications.

ACKNOWLEDGEMENT

I'm grateful to the patient for their consent and cooperation, making this case report possible. Heartfelt thanks to my respected teachers for guidance, encouragement, and sharing invaluable knowledge. Thanks to colleagues for assistance, suggestions, and motivation, helping shape this article.

REFERENCE

1. Jaiswal S, Dhule M, Thakur K.A clinical case study of Uttarbasti in the management of stricture urethra. *Alochana Chakra Journal* [Internet], 2020 May; IX(V): 258-61. Available from: (ISSN NO: 2231-3990)
2. Kazi W, Sharma RK, Shah H, Sharma V, Panchal S. A Single Case Study - efficacy of Urethral dilatation with Uttarbasti in the management of Recurrent Urethral Stricture. *Asian J Pharm Res Dev* [Internet], 2023; 11(3): 125-8. ISSN: 2320-4850
3. Kapse PR, Jare S. Effective management of urethral stricture (Mutramarg Sankoch) with Uttarbasti – A case study. *World J Pharm Res*, 2021; 10(6): 1263-7.
4. Sushruta Samhita, Kaviraj Ambikadatta Shastri, Chaukhambha Sanskrit Sansthan, 2012, Uttar Tantra 58/15-16.
5. Sushruta Samhita, Kaviraj Ambikadatta Shastri, Chaukhambha Sanskrit Sansthan, 2012; Uttar Tantra 58/27.
6. Das S. Text book of surgery, 9th Edition, publisher; S Das, 13, Old Mayor's court, Kolkata, p-1300-1303.
7. Bhat SM SRB'S Manual of Surgery, 5th Edition, JAYPEE-The Health Sciences publisher, New Delhi/ London/Philadelphia/Panama.p-1054, 1055.
7. Rajput SA, Mata S, Dei LP, Donga SB, Shaikh N. Effect of Apamarga Kshara Taila Uttarbasti in the Management of Infertility w.s.r. Tubal-blockage. *Int J Ayurvedic Med* [Internet], 2015; 6(1): 51-8. ISSN: 0976-5921.