



**STHANIK CHIKITSA (REGIONAL REMEDY) - A CONVENTIONAL PROTOCOL TO
TREAT CHRONIC CERVICAL EROSION - A CASE ANALYSIS**

Dr. Pooja Ravindra Kadu^{1*} Dr. Prathamesh Pradeep Kashikar²

¹Assistant Professor, Prasuti Tantra and Stri Roga Department, PDEA's College of Ayurved & Research Centre, Nigdi, Pune.

²Assistant Professor, PhD Scholar, Shalyatantra Department, Bhimashankar Ayurved College, Manchar, Pune.



***Corresponding Author: Dr. Pooja Ravindra Kadu**

Assistant Professor, Prasuti Tantra and Stri Roga Department, PDEA's College of Ayurved & Research Centre, Nigdi, Pune. DOI: <https://doi.org/10.5281/zenodo.19730309>

How to cite this Article: Dr. Pooja Ravindra Kadu^{1*} Dr. Prathamesh Pradeep Kashikar². (2026). Sthanik Chikitsa (Regional Remedy) - A Conventional Protocol to Treat Chronic Cervical Erosion - A Case Analysis. European Journal of Biomedical and Pharmaceutical Sciences, 13(4), 549-553.

This work is licensed under Creative Commons Attribution 4.0 International license.



Article Received on 05/03/2026

Article Revised on 25/03/2026

Article Published on 01/04/2026

ABSTRACT

Tryavarta yoni and the illnesses associated with it are discussed in the classics of Ayurveda under the term Yoni vyapad. The study of Strisharir and Striroga is crucial for combating various gynecological illnesses that affect women. Many women seek the OPD with any of these concerns, including infertility, white discharge, vaginal itching, back pain, and pelvic discomfort. Cervicitis may be one of the key contributing factors. Patients present with the aforementioned concerns, and per speculum examination reveals cervical inflammation along with erosion and a white discharge. Allopathic science includes treatments like Antibiotics, Vaginal Pessary, Cauterization, Cryosurgery, Laser Therapy, and Conization. However, these treatments have a significant recurrence rate. According to Ayurveda, disease should be treated from its root cause. Sthanik chikitsa in Striroga is a boon for treating such disorders. Various types of Sthanik chikitsa like Yoni dhawan, pichu, varti, pindi, dhupan, kalkadharan, Uttarbasti, etc are explained for treating number of Yoni vyapads. A case study of mid age housewife complaining of white discharge, back pain and lower abdomen dull ache for 5 months was successfully treated by Yoni Dhawan, Apamarga kshar pratisaran, Yoni pichu and oral Ayurvedic medicines for 3 menstrual cycles. Significant effect was seen symptomatically and on pre and post per speculum examination.

KEYWORDS: Sthanik chikitsa, Yoni dhawan, Yoni pichu, Kshar pratisarn, Striroga, Cervical erosion.

INTRODUCTION

Ayurveda is an ancient science, originated in India where numerous diseases are treated by traditional drugs and treatment modalities. Woman is the only one who propagates human progeny. *Ayurveda* has given utmost importance to *Stri* and hence the anatomy concepts of *Strisharir* and physiological parameters of *Krutuchakra*, *Rajaswala paricharya*, *Garbhini paricharya* and *Sutika paricharya* are meticulously described in *Ayurveda*. That what disturbs this normalcy and produces any pathological condition is termed under the phrase *Yoni vyapad*. *Sthanik chikitsa* are the local therapies like *Yoni Dhawan*, *Dhupan*, *Pichu*, *Uttarbasti*, *Varti*, *Kalka dharan* etc used to treat variety of *Yoni vyapads*. Puberty, menarche, reproduction, and menopause are the phases of life that affect women. There are different disorders to deal with in each phase. Patients visit the OPD

complaining of dull abdomen pain, white discharge, vulvar itching, infertility, back pain, pelvic discomfort, painful intercourse, and other symptoms. The majority of the findings on Per Speculum, Per Vaginal examination includes white, purulent, or mucous discharge, tenderness, congestion, cervical erosion, and hypertrophy. These complaints resemble the symptoms like *shwet*, *picchil yoni strav*, *yonikandu*, *yonishool* of many different diseases, including *Kaphaj yonivyapad*^[1], *Archarna yonivyapad*^[2], *Upapluta yonivyapad*^[3], *Shwetpradar*^[4], and others. Here is a case presentation of white discharge with abdominal pain and back discomfort that was successfully treated by *Sthanik chikitsa*. A potential treatment protocol of *Yoni dhawan*, *Kshar pratisaran* and *Yoni pichu* is explained.

METHODOLOGY

Brief history: A 28 years old housewife visited the outpatient department complaining of per vaginal white discharge from 5 months, backache in the last 1 month and lower abdomen dull pain occasionally. She disclosed no specific history of intake of any medicines or chronic disease. Patient underwent LSCS surgery five years ago and there isn't any pertinent family history. Her menstrual history revealed menarche at age of 13 years, Regular cycle of 28-30days, 3-4 days duration, 2-3 pads/day moderate soaked, painless in nature. She was married 8 years ago and her obstetrical history enclosed P2 L2 A1, P1 – Female child 7 years FTND at hospital, P2 – Male child 5 years LSCS I/v/o Non progress of labor, A1 – MTP by pills (GA – 6 weeks) 3 years ago. Coital history once in 15 days.

Personal history

Diet – Mixed
Appetite – Normal
Micturition – Normal
Bowel – Normal
Allergy – None
Addiction – None

Physical Examination

Built – Moderate
Nutrition – Satisfactory
Pallor – Nil
Icterus - Nil

General Examination

General Condition – Fair
Temperature – Afebrile
Pulse – 82/min
Blood Pressure – 110/70 mm of Hg
Respiratory Rate – 18/min
SPO₂ – 98%

Systemic Examination

Respiratory System – Air entry bilateral equal, no abnormal lung sounds were heard.
Central Vascular System – S₁S₂ were heard.
Central Nervous System – She was in conscious state with very well orientation to present Place, Time, Date.

Per Abdomen Examination– Soft, mild tenderness at hypogastric region, Previous LSCS Scar noted.

Genitourinary Examination

External examination – Vulva was in normal state.

Treatment Protocol**Table 2: Treatment Protocol (Internal and Local Therapies).**

Sr. No.	Treatment module	Treatment Details	Dose / Duration
1.	Abhyantar Chikitsa (Internal Treatment)	Tab. Chandraprabhavati (250mg) ^[5]	2 tablets twice a day for 15 days
		Tab. Triphala guggul (250mg) ^[6]	2 tablets twice a day for 15 days

No excoriation, wart, lesion was noted.

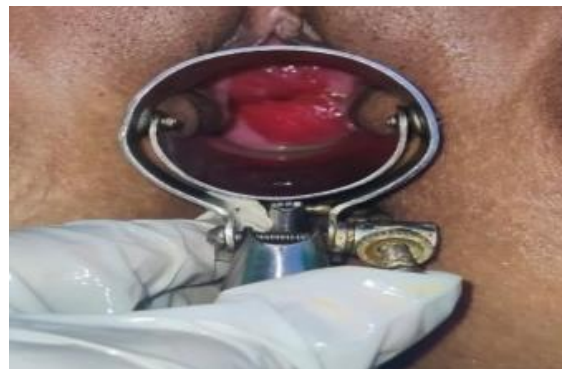Per Vaginal – Uterus AV – normal in size.

Mild tenderness in fornixes.

No adnexal mass was palpable.

Per speculum Examination**Table 1: Per Speculum examination findings.**

Sr. No.	Parameters	Findings
1.	White discharge	Present (+)
2.	OS – Cervical erosion	Present (++)
3.	Cervical hypertrophy	Present (++)
4.	Vaginal walls	Normal

**Figure 1: Per Speculum Examination determining cervical erosion.****Investigations****1. Ultrasonography (Abdomen & Pelvis)****Findings**

Uterus measures 7.9*3.7*4.1 cm, normal in size, shape and position.

Endometrial thickness – 7mm

Right ovary measures – 3.1* 3.1 cm

Left ovary measures – 2.5*1.7cm

No significant abnormality detected.

2. PAP Smear**Findings**

Inflammation ++

Negative for intraepithelial lesion, any growth and malignancy.

Inflammatory smear.

3. Complete Blood Count

Findings: Hb – 10.2gm %, WBC – 7700/cumm, Platelets – 2.90 lakhs/cumm.

Other parameters were within normal limits.

2.	Sthanik Chikitsa (Local Treatment)	<i>Yoni dhawan with Triphala kwath</i>	7 days (3 consecutive menstrual cycles)
		<i>Apamarga Kshar Pratisaran</i>	7 days (3 consecutive menstrual cycles)
		<i>Jatyadi tail Yoni pichu</i>	7 days (3 consecutive menstrual cycles)

[Note: Procedures were done from 6th day of menses for duration of 7 days and the same regime was conducted for 3 consecutive menstrual cycles.]

Sthanik Chikitsa (Local Procedure)^[7]

It is very important to note that all the local therapies were conducted under strict aseptic precautions in minor OT along with preparedness for emergency conditions.

Yoni dhawan

- 1) Before commencing the procedure, informed consent was obtained and appropriate aseptic precautions are taken.
- 2) A lithotomy position was given to the patient.
- 3) The rubber mackintosh was positioned beneath the patient's waist.
- 4) The vagina was cleaned out with sterile cotton swab.
- 5) An enema pot filled with lukewarm decoction was kept away and, on a height, (on an IV Stand).
- 6) Sterile rubber catheter was inserted in vaginal orifice and gently *yonidhawan* was given with *Triphala Kwath*.
- 7) Sterile cotton was used to dry the vulva following the procedure.
- 8) On the corresponding days, same process was repeated.

The above said procedure was carried out for 7 days (3 consecutive menstrual cycles)

Apamarga Kshar Pratisaran

1. Above procedure as mentioned in *yonidhawan* was carried out in the same manner up to point number 4.
out for 7 days (3 consecutive menstrual cycles)

2. Pre-lubricated Cusco's speculum was inserted and vagina was examined with areas of erosion on cervix.
3. Using sponge holding forceps, a sterile cotton swab dusted with fine powder of *Apamarga Kshar* was applied over external OS of cervix over the areas of erosion for 100 *matra* [approximately 1.5 minutes].
4. Later on area of *kshar pratisaran* was thoroughly washed with solution made from Inj.Vit.C and sterile water.
5. Area of cervix and vagina was dried using sterile swabs.

The above said procedure was carried out for 7 days (3 consecutive menstrual cycles)

Jatyadi tail Yoni pichu

1. After *Apamarga Kshar Pratisaran*, A sterile cotton ball / tampon tied with a long tread was soaked in lukewarm *Jatyadi* oil.
2. Soaked cotton ball/ tampon was then placed in vagina with proximal end of the thread lying outside the vagina.
3. After 2 hours, proximal part of the thread was gently pulled so that the cotton ball / tampon was evacuated.

The above said procedure was carried.




OBSERVATION AND RESULT

Assessment Parameters

Table 3: Assessment parameters (Before and After Treatment).

Sr. No.	Parameters	Findings (Before Treatment)	Findings (After Treatment)
1.	White discharge	Present (+)	Absent
2.	OS – Cervical erosion	Present (++)	Absent
3.	Cervical hypertrophy	Present (++)	Absent
4.	Vaginal walls	Normal state	Normal state
5.	Back pain	Present (+)	Absent
6.	Abdominal pain	Mild	Absent

Per speculum examination also revealed significant results for the same.

1 ST CYCLE	2 ND CYCLE	3 RD CYCLE
		
EROSION ++	EROSION +	EROSION ABSENT
HYPERTROPHY ++	HYPERTROPHY +	HYPERTROPHY ABSENT
WHITE DISCHARGE +	WHITE DISCHARGE MILD	NO WHITE DISCHARGE

DISCUSSION

1. Yoni Dhawan^[8]

“धावतीशुध्यति इति धावन् ॥” (सु. चि. २८/३९)

“योनी विशेषेण शोधनं नाम शुद्धीकरणम्।” (च.सु.१३/१५)

Yoni dhawan is a procedure for cleansing vagina, vaginal canal and cervical lips with medicated kwath. The medicated kwath consists of dravyas which works through the Rasa, Virya, Vipaka and Guna to counteract the sthanik dosha dushti.

Properties of Triphala^[9]

“त्रिफला कफपित्तघ्नी मेहकुष्ठहरा सरा ।
चक्षुष्या दीपनी रुच्या विषमज्वरनाशिनी ॥“
(भावप्रकाश हरीतक्यादि वर्ग)

Triphala has proven anti-inflammatory, antibacterial and antioxidant properties which improves circulation and reduces infection. According to Ayurveda, it has Krimighna, and Vronaropan (wound healing) properties. Thus, is helpful in treating the disease.

2. Kshar Pratisaran^[10]

“क्षारो दश गुणः शस्त्र तेजसोः अपि कर्म कृत् ।
आचूषन् इव संरम्भात् गात्रम् आपीडयन् इव ॥
सर्वतो अनुसरन् दोषान् उन्मूलयति मूलतः ॥
कर्म कृत्वा गत रुजः स्वयम् एव उपशाम्यति ॥“
(अ.ह.सू.३०/२४-२६)

Pratisaraniya kshar is described by Acharya Shushruta in the management of dushta vrana. Kshar karma is mentioned among one of the Shashtiupakrama.

Kshar is Agni and Vayu mahabhut Pradhan. Its nature is suitable for Chedana, Bhedana and Lekhana Karma. Kshar acts as a corrosive, eliminating the unhealthy slough and generates healthy base for healing.

Properties of Apamarga^[11]

Following are the properties of Apamarga as mentioned in classical texts.

Latin name – Achyranthes aspera, Rasa – Katu, Virya – Ushna, Vipaka – Katu, Doshagnata – Kapha vata shamak, Gana – Krimighna, Shiro-virechanopag. Application of Apamarga Kshar in case of cervical erosion is an effective form of herbal cauterization. Combined effect of Apamarga and Kshar leads to shodhan of dosha and enhancing its healing properties.

3. Yoni Pichu^[12]

A sterile medicated cotton swab/ tampon soaked in lukewarm medicated oil is kept inside the yoni (vagina) under all aseptic precautions for a time period of 2 hours or till urge of urination. Jatyadi tail is described in Bhaishasjya-Ratnawali under Vranashotha Chikitsa adhyaya. Its mode of action is explained as Vrana Sodhaniya (wound purifier) and Vrana Ropaniya (promotes wound healing).^[13] Jatyadi tail is a herbal oil frequently used to treat various wounds. It helps to reduce the incidence of infection and prevents its spread. It has Vata Sahamaka, anti-inflammatory and wound healing properties.

CONCLUSION

Sthanik Chikitsa are great alternatives as local therapies for treating numerous Yoni rogas. Triphala kwath yoni dhawan acts as a good cleaning and an anti-inflammatory property, Apamarga Kshar pratisaran due its lekhan, shodhan properties and Jatyadi tail yoni pichu with its Vrana Ropan properties treat this disease remarkably. Above mentioned treatment protocol is cost effective Ayurvedic management. Chronic cases of Cervicitis, Vaginitis and Cervical erosion are contributing factors for infertility, PID and are more affinitized towards HPV infection which may lead to cervical neoplasia. Such cases can be prevented and

treated with combined protocol of *Sthanik Chikitsa* of *Yoni Dhawan*, *Yoni Pichu* and *Apamarga Kshar Pratisaran*.

Various types of *sthanik chikitsa* are thoroughly explained in classical *Ayurvedic* texts, these techniques are effective must be introduced in modern era with advances to evolve efficient treatment protocols for curing diseases in Gynecology field.

Future Scope of Study

This study must be done on a larger number of subjects to prove its accuracy and note the possible adverse effects if observed. Local therapies must be promoted with modern advances to lower the risk of adverse effects of internal medications and antibiotic resistance that has been widely seen in present era.

REFERENCES

1. Charaka Samhita, Pandit Kashinath Shastri, Dr. Gorakhnath Chaturvedi, Choukhamba Publication, Chikitsasthan, 2012; 30: 13-14.
2. Charaka Samhita, Pandit Kashinath Shastri, Dr. Gorakhnath Chaturvedi, Choukhamba Publication, Chikitsasthan, 2012; 30: 18.
3. Charaka Samhita, Pandit Kashinath Shastri, Dr. Gorakhnath Chaturvedi, Choukhamba Publication, Chikitsasthan, 2012; 30: 21-22.
4. Vijay Lakshmi, Ramesh Kumar Gupta, Ayurvedic Concept of Leucorrhoea: Swetapradara. Int. J. Ayur. Pharma Research, 2014; 2(3): 119-123. ISSN.2322 0910, 119.
5. Sharangdhara Samhita, Shrikanth Murthy Editor, 2006, Varanasi Chaukhambha Sanskrit Samsthan. p.200 Pp.398.
6. Sarngadhara, Sarngadhara Samhita A Treatise on Ayurveda, Translated in English by Ayurveda Vidwan Prof. K. R. Srikantha Murthy, Reprint Edition, Chaukhamba Orientalia, 2012; 335: 109.
7. Dr. SushilaSharma and Dr. Varsha Singh's, Abhinava striroga vigyana, edition 1st, Ayurveda sanskrita hindi pustaka bhandara, Jaipur, 2016.
8. International Journal of Applied Ayurved Research ISSN: 2347- 6362 Effect of Triphala Kwatha Yoni Prakshalana and Hayamaradi Taila Yoni Pichu in Acharana Yoni Vyapad (W.S.R Pruritus Vulvae) – A Case Report 1 Shreenidhi. S. Hakki, 2 Shreyes. S, 3 Sarojini Byadagi, 4Yogitha Bali M.R
9. Parveen R, Shamsi TN, Singh G, Athar T, Fatima S. Phytochemical analysis and In-vitro Biochemical Characterization of aqueous and methanolic extract of Triphala, a conventional herbal remedy. Biotechnol Rep (Amst). 2018 Feb 8; 17: 126-136. doi: 10.1016/j.btre.2018.02.003. PMID: 29619331; PMCID: PMC5881245.
10. Dr. SushilaSharma and Dr. Varsha Singh's, Abhinava striroga vigyana, edition 1st, Ayurveda sanskrita hindi pustaka bhandara, Jaipur, 2016.
11. Jadav HR, Galib R, Prajapati PK. Pharmaceutical standardization of Apamarga kshara. J Ayurveda Integr Med., 2015 Oct-Dec; 6(4): 290-4. doi: 10.4103/0975-9476.172387. PMID: 26834430; PMCID: PMC4719491.
12. JaymalaShirke, edited Ayurvediya Striroga vigyan, 1st edition, Pune, Tathagat Prakashan, 2003.
13. Prasannan D, Shindhe PS, Jadar PG, Killedar RS, Priyanka K. Efficacy of Jatyadi, Madhughrita and honey tulle in wound management: a three-arm randomized controlled clinical trial. J Ayurveda Integr. Med., 2023 May-Jun; 14(3): 100719. doi: 10.1016/j.jaim.2023.100719. Epub 2023 Jun 2. PMID: 37271064; PMCID: PMC10242641.