EUROPEAN JOURNAL OF BIOMEDICAL AND PHARMACEUTICAL SCIENCES
http://www.ejbps.com

ISSN 2349-8870
Coden USA: EJBPBO
Volume: 13
Issue: 5
Year: 2026

PERFORATED APPENDICITIS ON THE SECOND DAY OF LIFE IN A NEONATE: A CASE REPORT

Ra'ad Al-Daboubi[1], Khaled Qattash*[1], Osama AL-Fanek[1], Adnan Bawaneh[1], Yazan Hanandeh[1], Heba Abbassy[2], Ayah Abu Seini[2]

*[1]Department of Pediatric Surgery Specialist, Queen Rania Hospital for Children, Royal Medical Services, Amman, Jordan.
[2]General Surgery Resident Royal Medical Services, Amman, Jordan.

***Corresponding Author: Khaled Qattash**

Department of Pediatric Surgery Specialist, Queen Rania Hospital for Children, Royal Medical Services, Amman, Jordan.

DOI: https://doi.org/10.5281/zenodo.19913164

How to cite this Article: Ra'ad Al-Daboubi[1], Khaled Qattash*[1], Osama AL-Fanek[1], Adnan Bawaneh[1], Yazan Hanandeh[1], Heba Abbassy[2], Ayah Abu Seini[2] (2026). Perforated Appendicitis On The Second Day Of Life In A Neonate: A Case Report. European Journal of Biomedical and Pharmaceutical Sciences, 13(5), 227–229.

This work is licensed under Creative Commons Attribution 4.0 International license.

Article Received on 05/04/2026 **Article Revised on 25/04/2026** **Article Published on 01/05/2026**

ABSTRACT

Neonatal appendicitis is a condition that is extremely rare and usually manifests with nonspecific signs of abdominal pathology that can easily mimic more common conditions in neonates such as necrotizing enterocolitis, resulting in delayed diagnosis and a high incidence of perforation and mortality. Unlike appendicitis in older children, neonatal appendicitis is usually associated with ischemic events, necrotizing enterocolitis of the appendix, or congenital and anatomical issues that can predispose to early perforation. Early diagnosis is difficult, and most cases reported in the literature are diagnosed after perforation has already occurred, making the need for high clinical suspicion and early surgical intervention even more important.

INTRODUCTION

Surgical condition of appendicitis occurring during the neonatal period is extremely rare and constitutes a small percentage of neonatal abdominal emergencies, only less than 100 such cases have been reported in literature so far.[1,4,7]

Due to its rarity and nonspecific clinical presentation without any specific signs of this condition, neonatal appendicitis (NA) is often missed resulting in delayed diagnosis and increased complications from this condition. The nonspecific clinical presentation of NA includes abdominal distension, feeding difficulties, vomiting, sepsis, and pneumoperitoneum, which are common presentations of many common neonatal conditions such as NEC, intestinal perforation, or neonatal sepsis.[1,5,8]

In contrast to appendicitis in older children, where appendiceal obstruction is the common underlying cause the pathophysiology of NA seems to be distinctly different. There is evidence to suggest that appendiceal perforation in neonates is more likely to be secondary to ischemia, immaturity of the vascular supply, infection, or NEC of the appendix rather than obstruction.[2,3] Anatomical differences in neonates, such as a funnel-shaped appendix with a wide lumen and a predominantly liquid diet, make the formation of fecaliths even less likely.[1,4]

Due to these considerations, perforation is often present at the time of diagnosis, as it has been reported in up to 70-85% of neonatal cases.[1,2,4] Although improvements in neonatal intensive care and early surgical treatment have led to a better prognosis in recent years, NA is still a difficult diagnosis to establish. Rare cases, such as appendicitis within an Amyand's hernia, make diagnosis even more difficult and illustrate the wide spectrum of this disease.[6]

Due to its rarity and difficulty in diagnosis, it is important to report further cases in order to increase awareness and promote earlier diagnosis and treatment in this high-risk population.

CASE REPORT

A two-day-old, 2.3 kg, full-term male neonate was admitted with neonatal jaundice, associated with

progressive abdominal distention and bilious vomiting. The baby had passed meconium spontaneously. Physical examination revealed abdominal distention and tenderness. Nasogastric aspiration showed bilious fluid mixed with milk, and the diaper was found to have loose stool with mucus and blood streaks, which was also present after anal stimulation.

Laboratory studies showed marked leukocytosis (WBC count of 31,000/µL). Abdominal X-ray showed the small bowel loops to be dilated without pneumoperitoneum.

An emergency exploratory laparotomy was done, which showed a perforation in the mid-appendix with localized fecal contamination. The small bowel was dilated but the colon was normal without any other areas of perforation or bowel gangrene. Appendectomy was done and intestinal biopsies were obtained, a diverting ileostomy with a mucous fistula was constructed about 15 cm proximal to the ileocecal valve.

Histopathological studies confirmed acute perforated appendicitis with serositis and all colonic and rectal biopsies showed the presence of ganglion cells. Ileostomy closure was done uneventfully after four months. At the last follow up, the patient was doing well, active, and meeting normal developmental milestones.



Figure 1: Plain abdominal radiograph demonstrating mildly dilated small bowel loops without evidence of pneumoperitoneum or free intraperitoneal air.

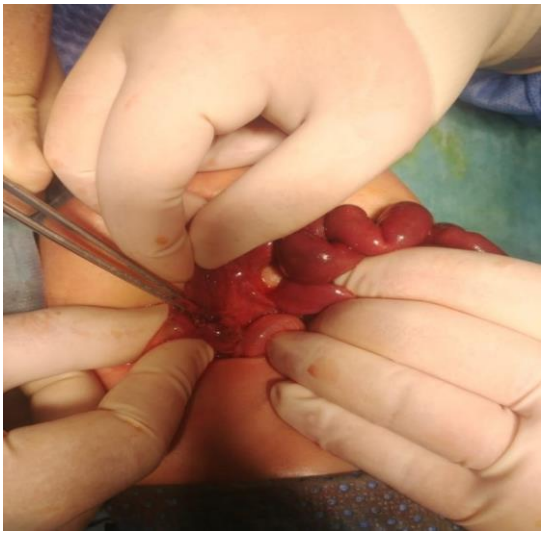

Figure 2: Intraoperative findings showing a perforated appendix with localized contamination and mildly dilated small bowel loops; the colon appeared normal without additional areas of perforation.

DISCUSSION

Neonatal appendicitis (NA) is a remarkably rare condition and still remains a challenge in terms of diagnosis due to its non-specific clinical presentation, which can easily be confused with that of necrotizing enterocolitis (NEC) and other emergencies of the neonatal abdomen.[1,4,5] Like in other reported cases, the patient also had abdominal distention, bilious vomiting, bloody stools, and significant leukocytosis, which have been described in the literature as common but

nonspecific symptoms of neonatal appendicitis.[1,7] These nonspecific symptoms often result in misdiagnosis of the condition, such as necrotizing enterocolitis or neonatal sepsis, which often results in delayed surgery and a high incidence of perforation at the time of presentation.[4,5] Unlike appendicitis in older children, in whom luminal obstruction is the main pathogenic factor, NA is postulated to occur largely due to ischemic or infectious events. The anatomical characteristics of the appendix in neonates, such as a large lumen and a liquid diet, render the formation of fecaliths unlikely, thus favoring a non-obstructive pathogenesis.[1,4]

Perforation at the time of diagnosis has been observed in 70-85% of cases of neonatal appendicitis.[1,2,4] The early perforation that was noticed in our patient at the age of only two days is in line with the previously documented rapid progression of inflammation in neonates due to ischemic injury, immature vascular supply, or localized necrotizing enterocolitis confined to the appendix rather than luminal obstruction.[2,3,7]

Ischemia has been postulated to be an important etiologic mechanism, possibly induced by hypoxia, sepsis, or microvascular thrombosis, resulting in rapid transmural necrosis and early perforation.[1,3] Tumen et al. also proposed that NA may be a localized form of NEC confined to the appendix, rather than a distinct disease process.[2] This hypothesis would explain the observed high rates of perforation in neonates, ranging from 70% to 85% at the time of diagnosis.[1,2,4]

Early surgical intervention continues to play a crucial role in achieving a good outcome. Appendectomy, peritoneal lavage, and antibiotics have greatly improved survival rates with advances in neonatal intensive care.[4,5] The successful outcome in our patient confirms the need for a low threshold for early exploratory laparotomy in neonates with unexplained peritonitis.

Recent case series have shown improved survival rates with early surgical exploration, appendectomy, and appropriate antibiotic treatment, especially with the advent of neonatal intensive care units.[4,5,7] The good postoperative outcome in our case, with uneventful progress and normal development, is in keeping with the literature and once again highlights the need to maintain a low threshold for exploratory laparotomy in neonates presenting with unexplained peritonitis.[7,8]

CONCLUSION

Appendicitis in neonates is a rare condition with a difficult diagnosis and a high mortality rate. However, it should not be ruled out in neonates with unexplained peritonitis, as early diagnosis and prompt surgical care can improve survival rates.

Declarations

ACKNOWLEDGEMENTS

None.

Consent for publication

All authors reviewed the results, approved the final version of the manuscript and agreed to publish it.

Data Availability

The experimental data used to support the findings of this study are available from the corresponding author upon request.

Conflicts of Interest

The authors declared that they have no conflicts of interest regarding this work.

Funding Statement

There is no specific funding to support this research.

REFERENCES

1. Raveenthiran V. Neonatal appendicitis: A review of 52 cases with abdominal manifestation. J Neonatal Surg. 2015. https://pmc.ncbi.nlm.nih.gov/articles/PMC4420402/
2. Tumen A, Chotai PN, Williams JM. Neonatal perforated appendicitis attributed to localized necrotizing enterocolitis of the appendix: a review. J Neonatal Surg. 2017. https://pmc.ncbi.nlm.nih.gov/articles/PMC5593479/
3. Van Veenendaal M, Plötz FB, Nikkels PGJ. Further evidence for an ischemic origin of perforation of the appendix in the neonatal period. J Pediatr Surg. 2004. https://www.sciencedirect.com/science/article/pii/S0022346804002969
4. Bence CM, Densmore JC. Neonatal and infant appendicitis. Clin Perinatol. 2020. https://www.perinatology.theclinics.com/article/S0095-5108(19)30124-1/abstract
5. Kayastha K. Neonatal perforated appendicitis. J Neonatal Surg. 2012. https://pmc.ncbi.nlm.nih.gov/articles/PMC4420304/
6. Ngom G, Amadou I, Ibrahima KA. Amyand's hernia with perforated appendix in a neonate. BMJ Case Rep., 2025. https://casereports.bmj.com/content/2010/bcr.03.2010.2847-0.abstract
7. Karaman A, Cavuşoğlu YH, Karaman I, et al. Neonatal appendicitis: A rare cause of abdominal distention in the newborn. *Pediatr Surg Int*. 2003.
8. Arliss J, Holgersen LO. Neonatal appendicitis. *J Pediatr Surg*. 1990.