



CEREBRAL DEVELOPMENTAL VENOUS ANOMALY; IMAGING FEATURES

Dr. Krishna Kumar*

Associate Professor & HOD of Radiology. Department of Radiology & Imaging. DM Wayanad Institute of Medical Sciences. Naseera Nagar, Meppadi P O, Wayanad. Kerala- 673577.

***Author for Correspondence: Dr. Krishna Kumar**

Associate Professor & HOD of Radiology. Department of Radiology & Imaging. DM Wayanad Institute of Medical Sciences. Naseera Nagar, Meppadi P O, Wayanad. Kerala- 673577.

Article Received on 24/09/2015

Article Revised on 13/10/2015

Article Accepted on 03/11/2015

ABSTRACT

Developmental venous anomalies (DVAs), formerly known as venous angiomas are presumably benign embryologic vascular variants that are usually incidentally discovered on enhanced CT or MRI of the brain. Most DVAs are asymptomatic or uncomplicated, and surgery is no longer considered necessary. We report two symptomatic patients with DVAs, one presenting with headache and another patient with seizures. Clinical symptoms, imaging features & management of DVAs are herewith discussed.

KEYWORDS: CT Angiogram, CT Venogram, Cavernous malformation, Developmental venous anomaly, MR Venogram, Venous angioma.

INTRODUCTION

Developmental venous anomalies (DVAs), which have been called venous angiomas, are extreme variations of the normal transmedullary veins that are necessary for the drainage of white and gray matter. Because no angioma or malformation is present with DVA, Lasjaunias et al proposed the name be changed from venous angioma to developmental venous anomalies.^[1]

DVAs serve as normal drainage routes of the brain tissue. Though most DVAs are discovered fortuitously and bear no clinical significance, their diagnosis often generates concern among physicians. Moreover, their management requires thorough understanding of the nature of DVAs, including their frequent coexistence with other types of vascular malformations and the existence of more complex but rare forms such as arterialized DVAs.^[2]

The aim of this article was to describe, radiological findings of DVAs. In addition, we analyzed magnetic

resonance imaging (MRI), computed tomography (CT) Angiography, CT venography (CTV) and magnetic resonance venography (MRV) findings of DVAs and reviewed the clinical significance of DVAs.

CASE REPORT

We evaluated the radiological findings in 2 cases of Supratentorial deep DVAs.

Case. 1

24 Years old female with persistent Head ache, not relieved by medicines was referred for Contrast CT of Brain. Her medical history was not significant. No neurologic deficits were present on physical examination.

Contrast Enhanced CT were obtained using a GE Light speed vCT 64 slice CT scanner after administration of 70mL of omnipaque 350 (Iohexol) via automated antecubital venous infusion.

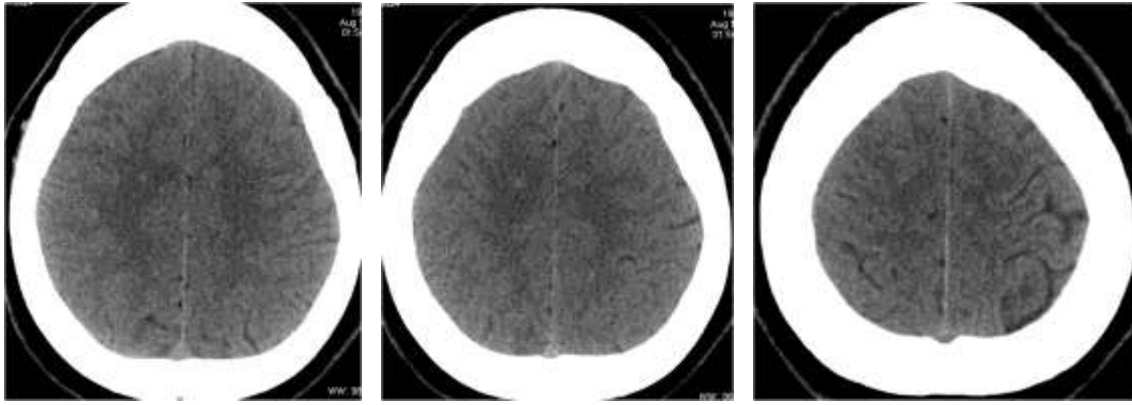


Fig.1a-c. Axial nonenhanced CT Brain revealed a tiny isodense dot in right centrum semiovale.

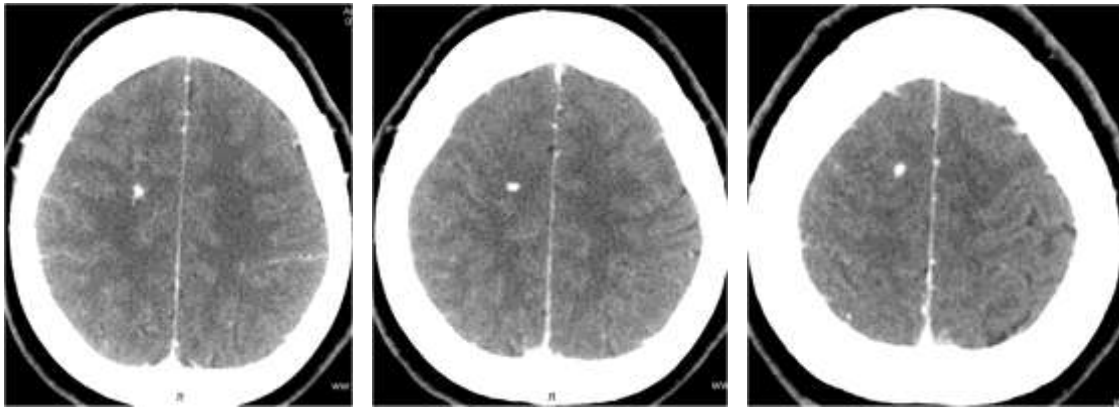


Fig.2a-c. Contrast enhanced axial CT revealed a tiny intensely enhancing dot in right centrum semiovale with few small draining veins into it.

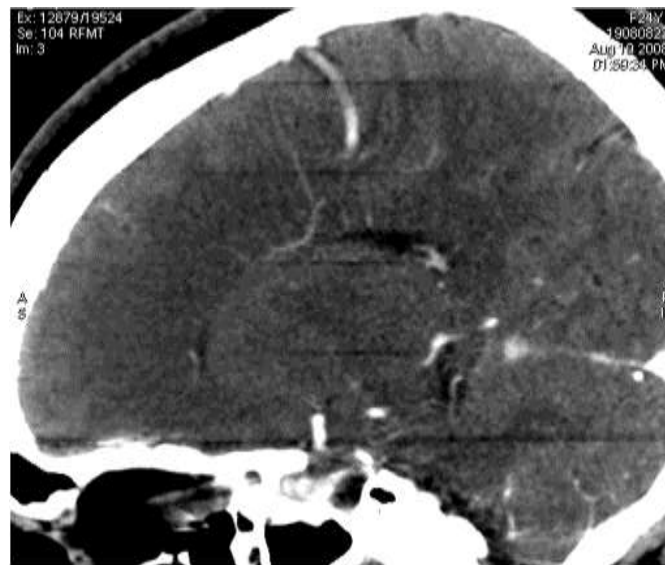


Fig. 2d. Sagittal reconstructed CT scan images revealed a linear supratentorial large transcerebral vein, draining into superficial cerebral convexity vein.

Provisional Diagnosis of Developmental Venous Anomaly (DVA) was made and patient was advised CT angiogram. Patient did not turn up for CT angiography and lost for follow up.

Case. 2.

7 years old male patient presenting with Head ache and Seizures was referred for contrast enhanced MRI Brain.

His blood pressure and pulse were within normal limits. No neurologic deficits were present on physical examination.

The MRIs were performed using 1.5 T magnets (Signa GE Medical Systems). Standard T1- and T2-weighted, Fluid attenuation inversion recovery (FLAIR), spin-echo pulse sequences were used.

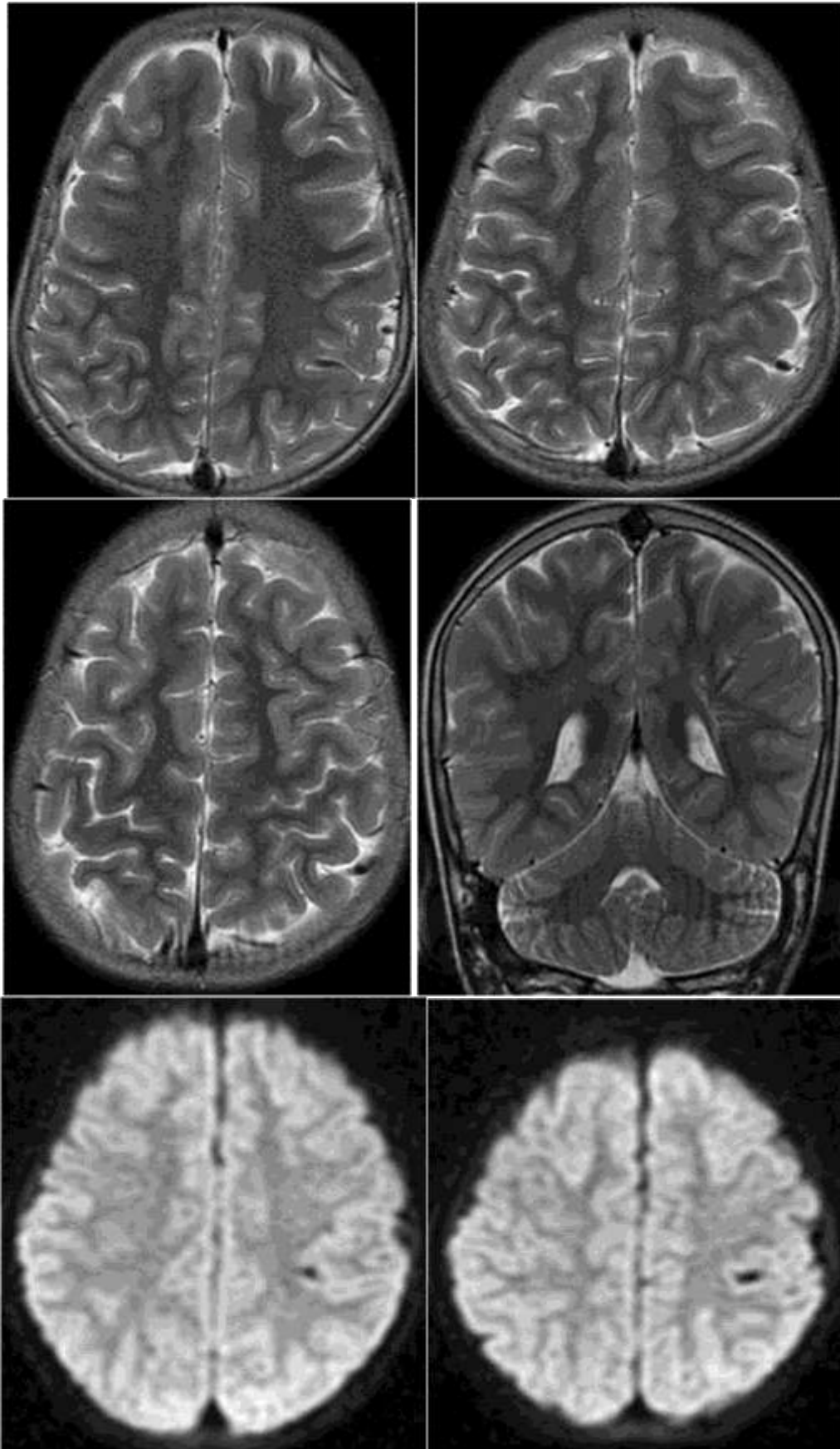


Fig.3a-d. T2-Weighted axial, coronal & ADC images (Fig.3e-f) shows a curvilinear flow void coursing from the left hemispheric deep parietal white matter and cortex to the convexity.

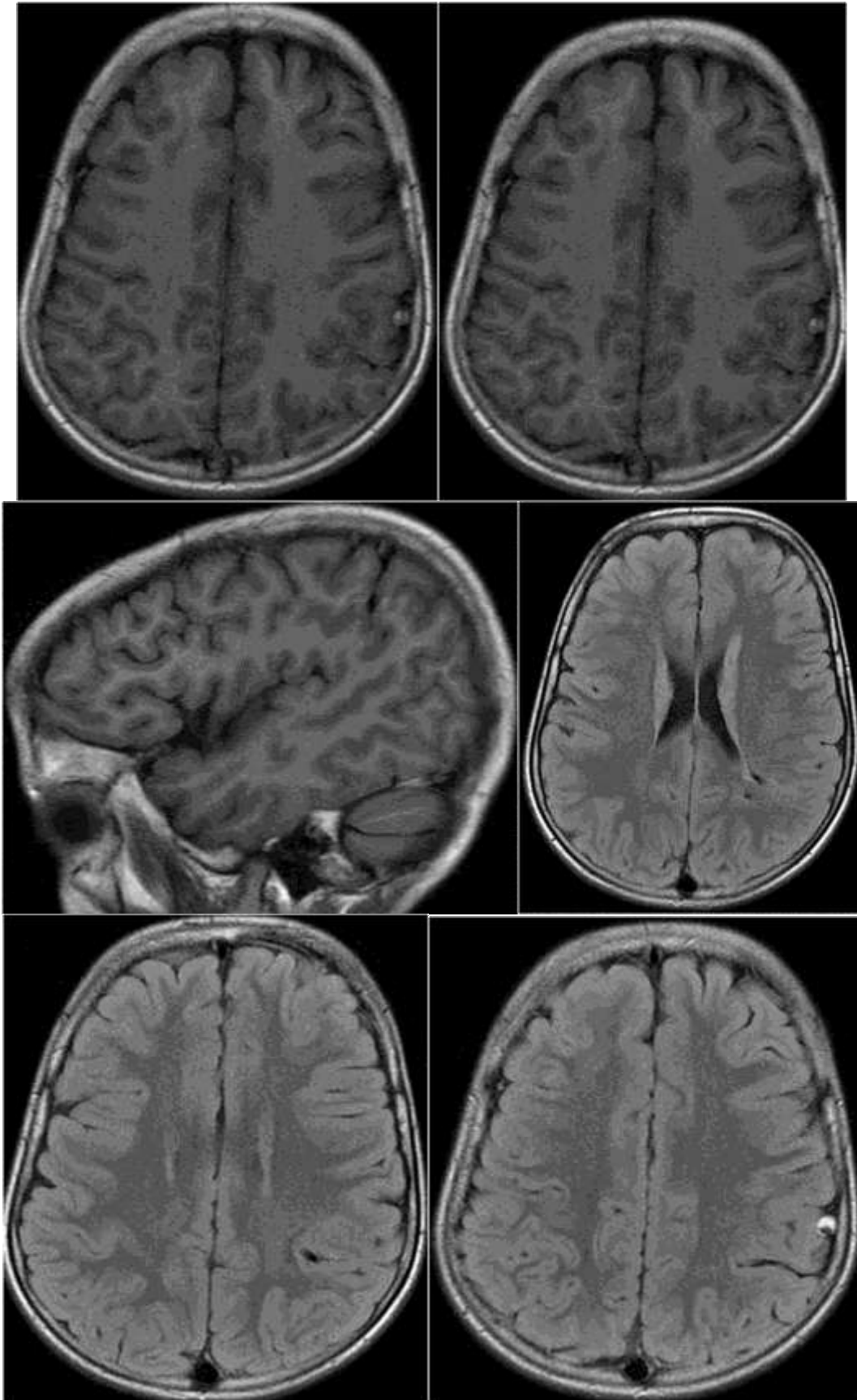
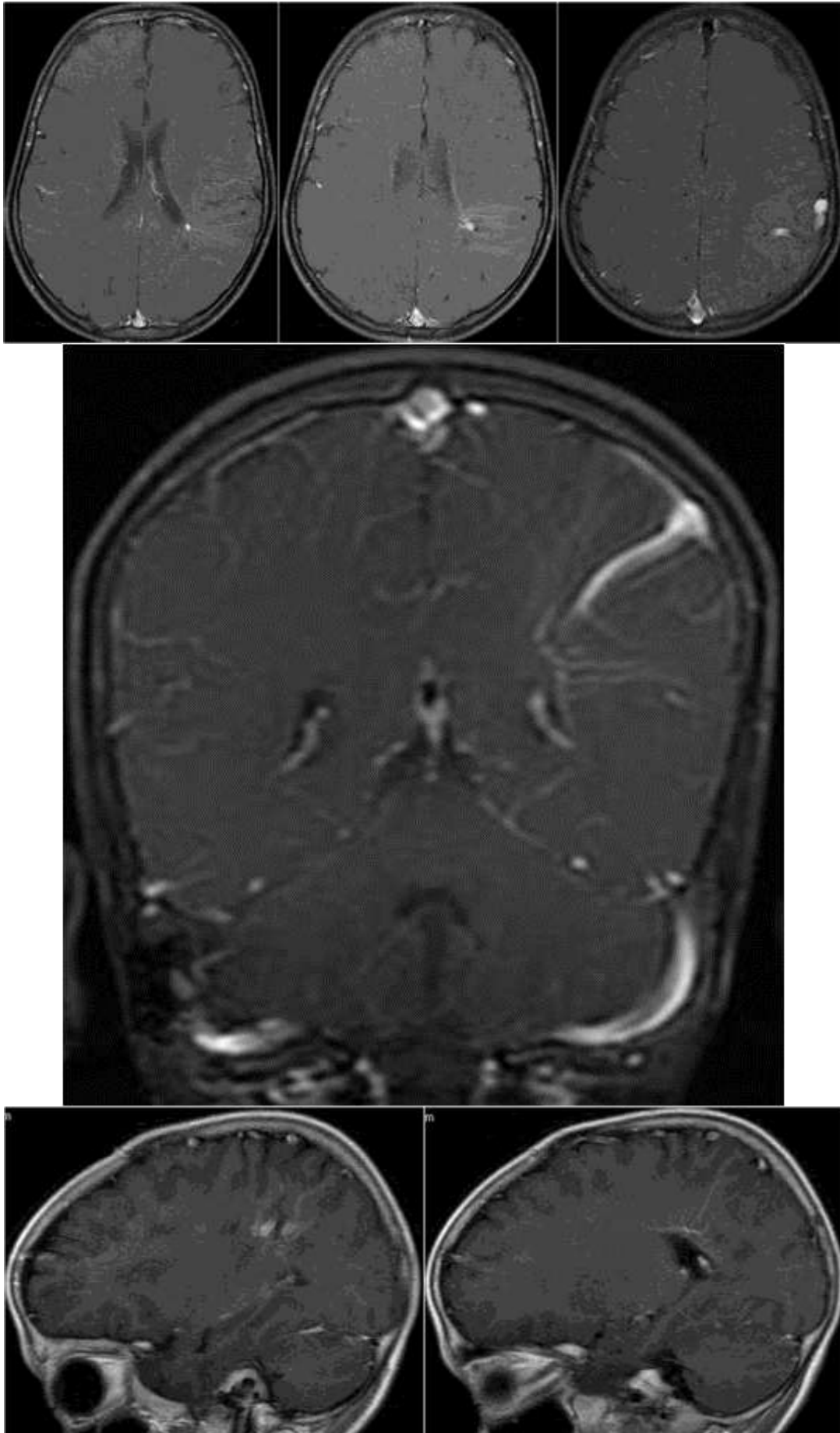

Fig.4a-c. T1-Weighted axial, sagittal and axial FLAIR images (Fig.4d-f) reveal a curvilinear flow void coursing from the left hemispheric deep parietal white matter and cortex to the convexity vein, which appear hyperintense due to slow sluggish blood flow.



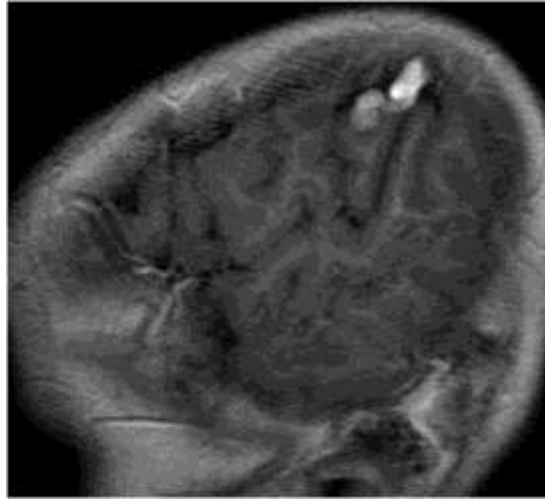
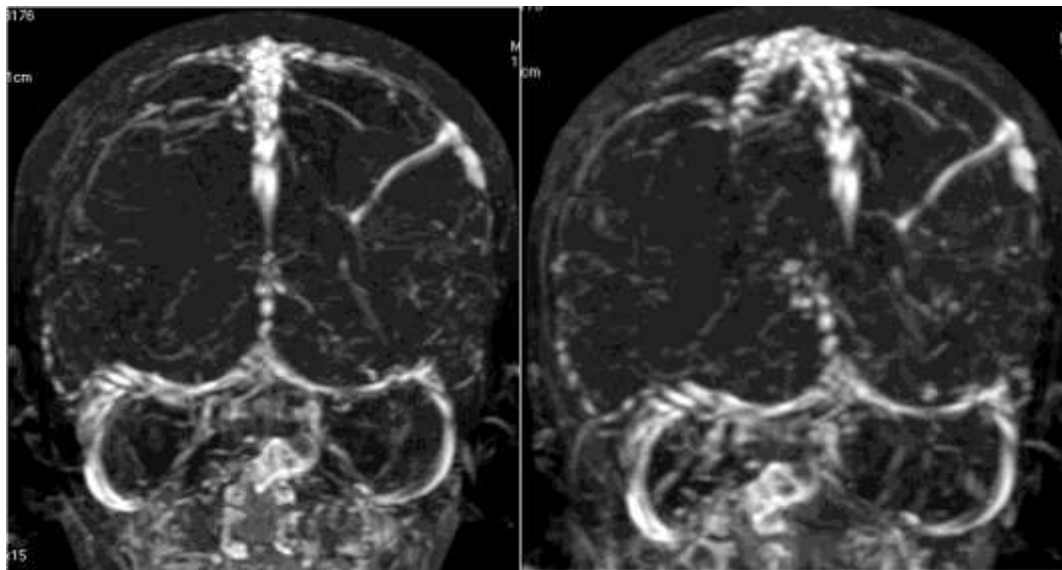


Fig.5a-c. T1-Weighted Contrast enhanced (0.1 mmol/kg gadopentetate dimeglumine) axial, coronal (Fig 5d) and sagittal (Fig.5e-g) MRI studies exhibited good resolution of DVAs. Radially oriented cluster of small veins seen joining a single larger vein, which drains into a superficial convexity vein.

For the Magnetic Resonance Venography (MRV) studies, a two-dimensional time-of flight (TOF) technique was used with a neurovascular phased array coil.



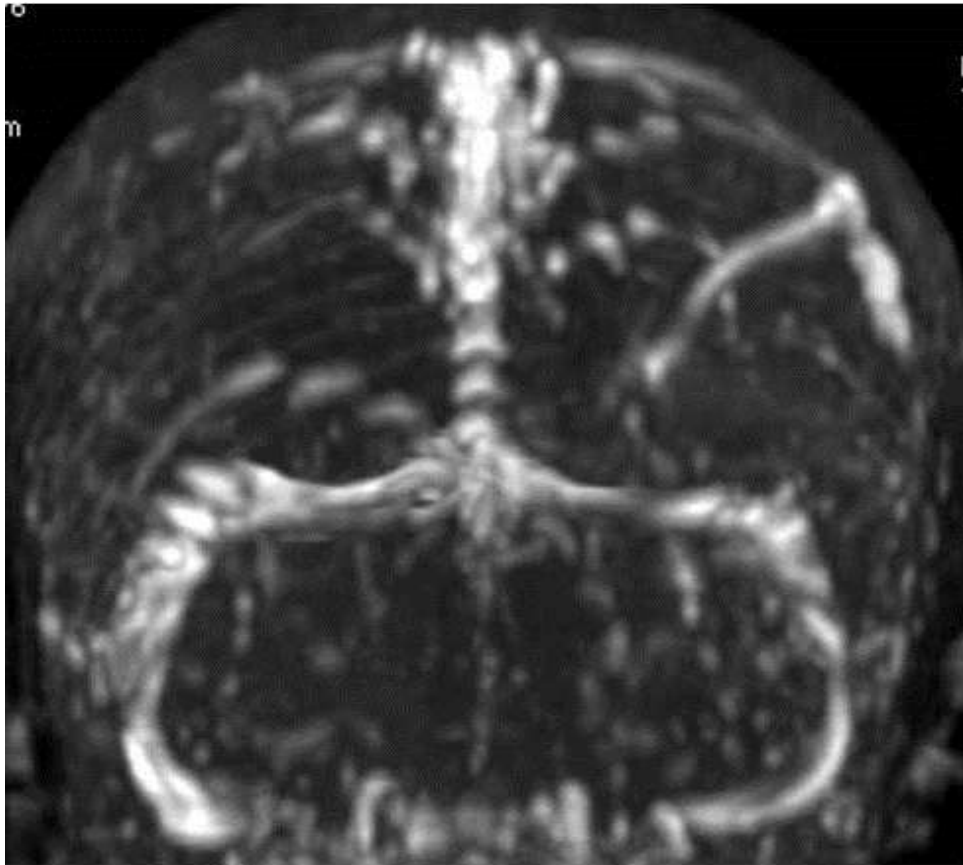
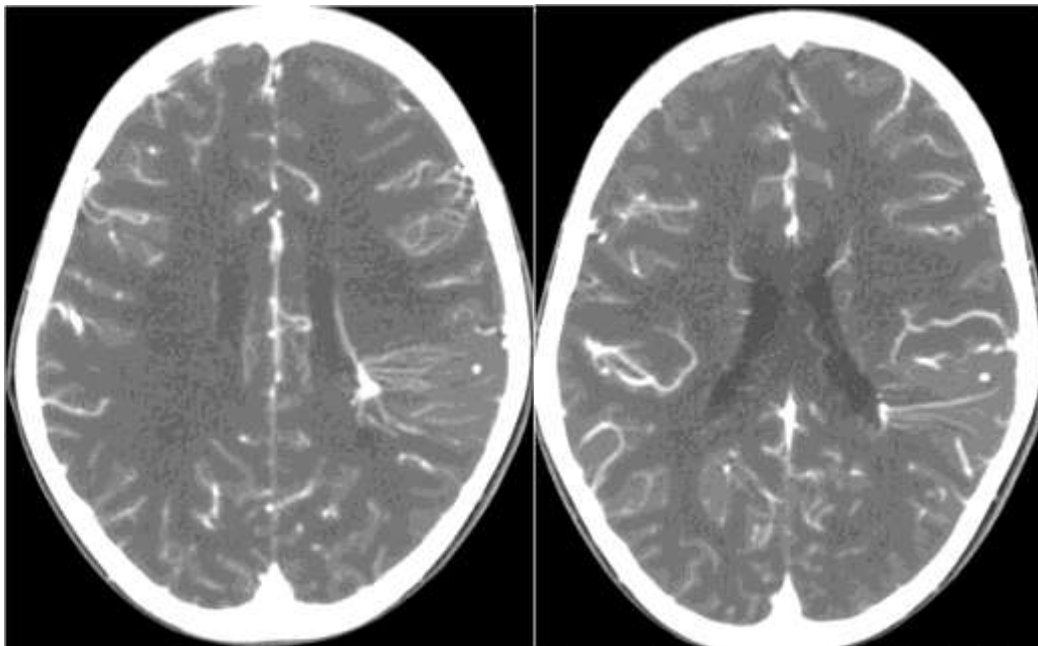
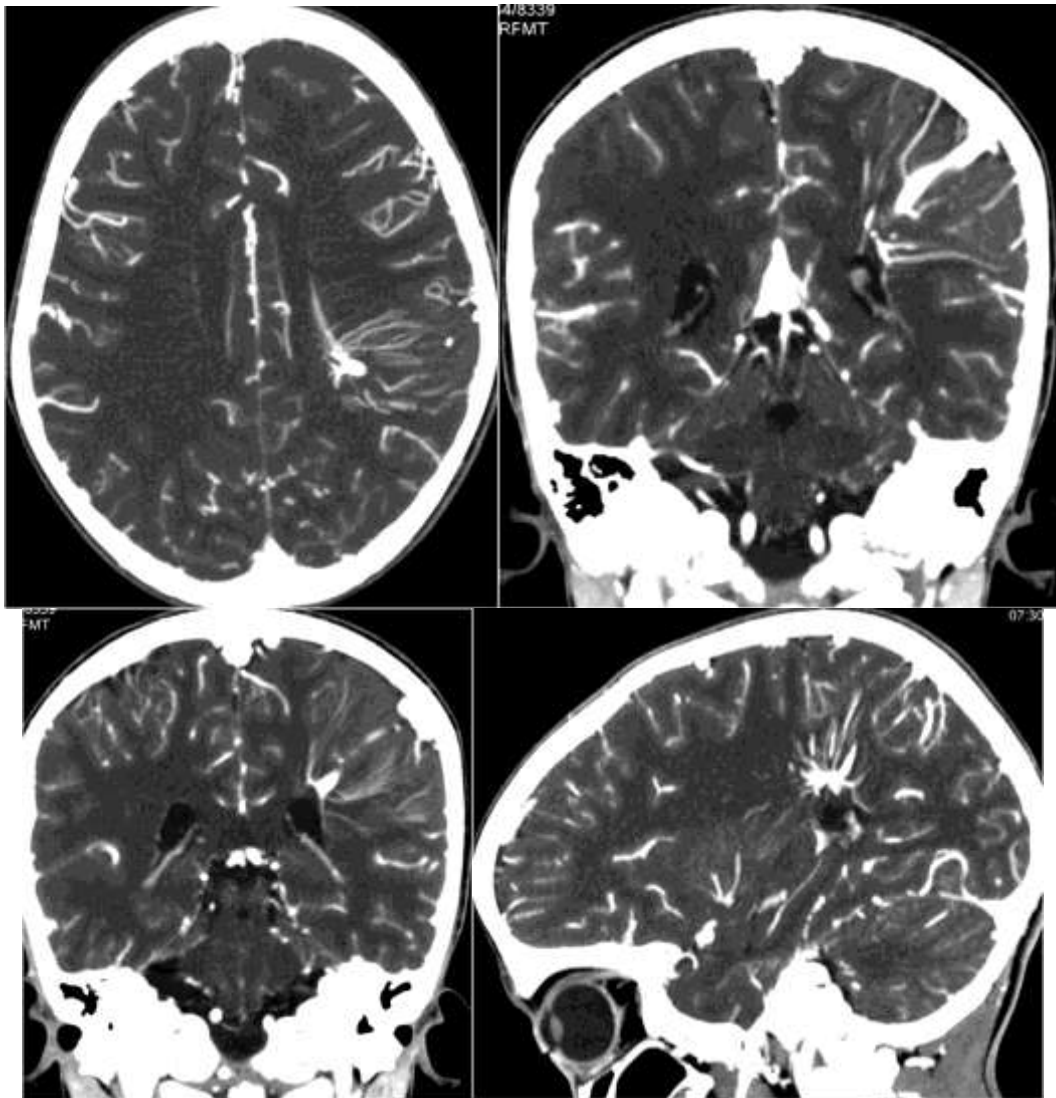


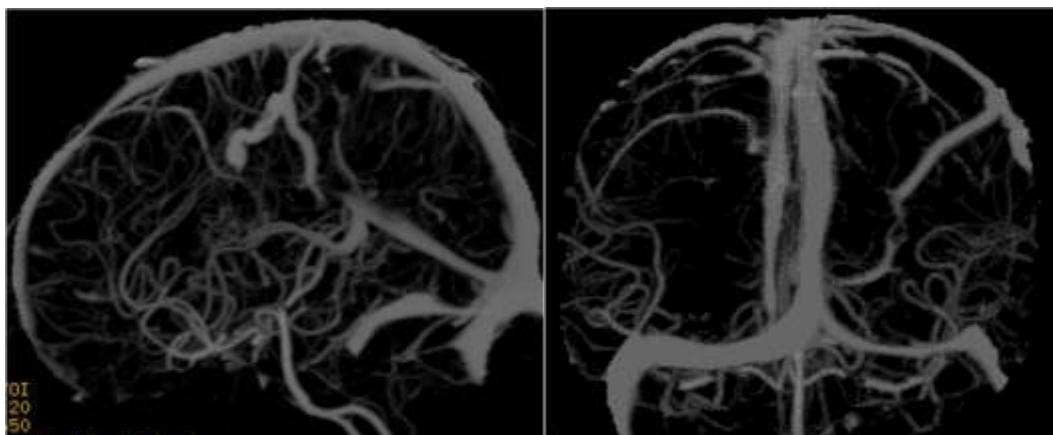
Fig. 6a-c.MRV shows Radially oriented cluster of medullary veins, draining into a larger collector vein, which joins the superficial cortical vein and drains into superior sagittal sinus.

CT angiography were obtained using a GE Light speed vCT 64 slice CT scanner after administration of 90mL of omnipaque 350 (Iohexol) via automated antecubital venous infusion.





Axial CT angiographic images (Fig.7a-c), reconstructed coronal (Fig7d-e) & sagittal images (Fig.7f) exhibited good resolution of DVA with supratentorial superficial venous drainage.



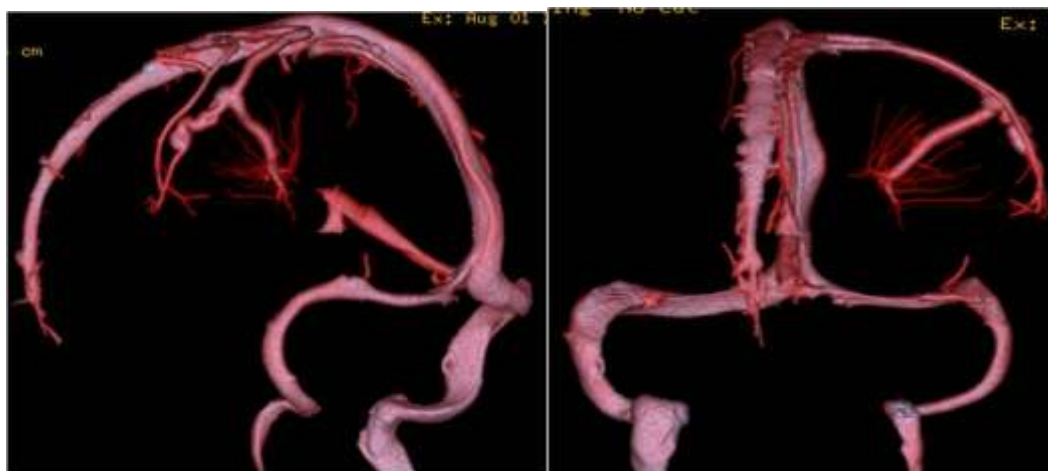


Fig. 8a-d. CT venogram clearly depicted the tuft of umbrella shaped medullary veins draining into a single enlarged dominant transcerebral vein (spoke wheel or medusa head configuration), which in turn drains into a superficial convexity vein and terminates in superior sagittal sinus.

The location of the DVAs was parietal in 2 cases. All DVAs had only one draining vein. The venous drainage system was a superficial supratentorial vein in 2 DVAs. Associated pathologies like cavernous malformation (CM), meningiomas and arterio-venous malformation were absent in our cases.

DISCUSSION

DVAs were defined as vascular lesions with multiple enlarged vessels converging on a single (sometimes multiple) dilated parenchymal vessel.

Developmental venous anomalies represent the most common vascular variant, accounting for 63% of intracranial vascular malformations in one large autopsy study, with an overall incidence of 2%–4%.^[5]

The DVAs were also classified by location as juxtacortical, subcortical, and deep, according to Valavanis et al.^[4] According to these authors, the juxtacortical DVAs drain superficially to cortical veins or sinuses; periventricular DVAs drain deep to the subependymal ventricular veins and ultimately into the vein of Galen; and subcortical DVAs may drain either way.

Juxtacortical (or superficial) was defined as within the gray matter or at the gray-white junction. Subcortical was defined as below the juxtacortical region but not adjacent to the ventricular wall.

Deep (or periventricular) was defined as adjacent to the lateral, third, or fourth ventricle or within the center of the structure, such as the pons. Supratentorial deep DVAs were defined as being adjacent to the frontal horn, the mid-body of the lateral ventricle, the temporal horn, the trigone, or the occipital horn.

Infratentorial deep DVAs were those adjacent to the fourth ventricle within the brachium pontis or dentate nucleus. The terminal or draining vein to which the

caput medusa joins was classified as either a deep or superficial draining vein.

In the supratentorial compartment, superficial draining veins were identified as those that joined either a cortical vein or the sagittal sinus. Deep draining veins were identified as those that joined the subependymal veins of the lateral ventricles and ultimately the vein of Galen.

In the infratentorial compartment, superficial draining veins were identified as those that joined the cerebellar hemispheric veins, superior and inferior vermian veins, transverse or sigmoid sinus and torcula.

Deep draining veins were those that joined the subependymal veins of the fourth ventricle and thus either the anterior or lateral transpontine veins, or laterally and inferiorly to the veins of the lateral recess of the fourth ventricle, or superiorly to the precentral cerebellar vein.^[5]

The series of Garner et al.^[6] of 100 patients with DVA is the largest, in which frontal (42%), parietal (24%), cerebellar (14%), basal or ventricular (11%), occipital (4%), brain stem (3%), and temporal (2%) locations were identified. DVAs are rarely identified on CT without contrast enhancement, unless they are associated with a Cavernous Malformation. On contrast-enhanced CT, the venous collector of the DVA is readily detectable as a linear or curvilinear focus of enhancement, typically coursing from the deep white matter to a cortical or a deep vein or to the dural sinus.^[7]

In our study, enhanced CTs presented good visualization of the draining vein but none of the enhanced CTs confirmed the diagnosis of DVA. CT angiography revealed the presence of DVAs including the draining vein (Fig. 2).

On MRI, DVAs typically have a transhemispheric flow void, on both T1- and T2-weighted images. Noncontrast T1- and T2-weighted MRI may demonstrate flow voids and phase-shift artifacts produced by the collecting vein of a DVA.^[7] The collector vein is detected as a linear or small, round, signal-void structure on all sequences and is shown most clearly on T2-weighted imaging. After the administration of gadolinium, significant enhancement of the medullary veins and venous collector is observed because of the slow flow.^[7]

On contrast enhanced MRI, the cluster of veins in DVAs has a spoke-wheel appearance; the veins are small at the periphery and gradually enlarge as they approach a central draining vein.^[8] This appearance has been referred to as caput medusae (**or the head of Medusa**). The classical angiographic appearance of caput medusae for transmedullary veins is visualized during the early to middle venous phase, draining into a large venous collector, which can extend either to the superficial or deep venous system depending on the type of DVA.^[7]

It is the orientation of the DVA and the imaging plane that determine whether the typical caput medusae appearance will be seen.

Direction of flow can be determined more definitively with angiography or phase-contrast MR angiography. MR venography and conventional angiography should be used if the size of the DVA and its draining vein needs to be known.^[5]

In most cases with DVA, angiographic studies illustrate the underdevelopment of the normal venous drainage pattern adjacent to a DVA.^[9] It is hypothesized that this results from a focal arrest of venous development and retention of primitive medullary veins that drain into a single, large draining vein.

The histologic examination of the vessel wall does not reveal any vessel abnormality. The anomaly in DVAs is the abnormal course of the draining vein.

Surgical excision of DVA has led to disastrous postoperative complications resulting from venous infarction and cerebral edema, because the brain was deprived of functionally normal venous drainage conduit.

Hemodynamically, DVAs represent low flow, low resistance lesions that are less likely to bleed. The reported high incidence of intracranial hemorrhage associated with DVAs in previous studies is currently attributed to the coexistence of a cavernous malformation.^[9]

The coincidence of cavernous malformation and DVA was 24% in patients referred for surgical removal of a cavernous malformation and more so significant in posterior fossa. The incidence of hemorrhage was 38% in patients with cavernoma alone and 62% in patients with cavernoma and DVA.^[10]

Some surgeons found an anatomical and physiological communication between cavernomas and associated DVAs. Therefore, it might indeed be possible that venous hypertension in association with DVA can predispose a cavernoma to bleed.^[11]

Perfusion MR imaging is capable of noninvasively characterizing the hemodynamic features of DVAs both at the site of these anomalies and in the surrounding tissues and thus may provide further insight into their physiological significance.^[12]

Beside the risk and discussion of hemorrhagic complications, DVAs have been associated with vague neurological symptoms, such as nonspecific headaches and dizziness, or with more specific symptoms and/or signs like seizures.^[13]

Conservative management of isolated DVAs is warranted. Neither neurosurgical intervention nor stereotactic radiosurgery is adequate for the treatment of isolated DVAs, because these practices can lead to unacceptable morbidity. Accurate surgical planning during dissection of coexisting lesions should focus on sparing the DVA. In the rare cases, in which isolated symptomatic DVAs cause hemorrhage or thrombosis, surgical treatment should target not DVA but resultant complication. Anticoagulation therapy may be an option in the uncommon event of DVA thrombosis and ischemic complications.^[9]

CONCLUSION

Developmental venous anomalies are benign vascular anomalies that are usually incidentally discovered on imaging studies performed for unrelated problems.

Enhanced CT identified only the collecting vein of DVAs in some cases. CT angiography, CT venogram, MRI with contrast enhancement and MR venogram yielded detailed findings of DVAs. Contrast enhanced MR images can clearly show the caput medusae and direction of the venous drainage.

DVAs were located mainly in the supratentorial space and the main venous drainage system of supratentorial DVAs was a superficial vein. Although infrequent, hemorrhagic transformation and, much less frequently, ischemic complications have been reported. Resection or radiosurgery remains contraindicated, because these DVAs drain normal brain parenchyma.

REFERENCES

1. Lasjaunias P, Burrows P, Planet C. Developmental venous anomalies (DVA): the so-called venous angioma. *Neurosurg Rev.*, 1986; 9(3): 233-42.
2. San MillánRuíz D, Gailloud P. Cerebral developmental venous anomalies. *Childs Nerv Syst.* 2010 Oct; 26(10): 1395- 406.
3. Sarwar M, McCormick WF Intracerebral venous angioma. Case report and review. *Arch Neurol*, 1978; 35: 323–325.
4. Valavanis A, Wellauer J, Yasargil MG. The radiological diagnosis of cerebral venous angioma: cerebral angiography and computed tomography. *Neuroradiology*, 1983; 24: 193–199.
5. Lee C, Pennington MA, Kenney CM 3rd. MR evaluation of developmental venous anomalies: medullary venous anatomy of venous angiomas. *AJNR Am J Neuroradiol*, 1996 Jan; 17(1): 61-70.
6. Garner TB, Curling OD, Kelly DL, Laster DW. The natural history of intracranial venous angiomas. *J Neurosurg*, 1991; 75: 715–722.
7. Pereira VM, Geibprasert S, Krings T, Aurboonyawat T, Ozanne A, Toulgoat F, et al. Patho-mechanisms of symptomatic developmental venous anomalies. *Stroke*, 2008 Dec; 39(12): 3201-15.
8. Augustyn GT, Scott J A, Olson E, Gilmor RL, Edwards MK. Cerebral venous angiomas: MR imaging. *Radiology*, 1985 Aug; 156(2): 391-5.
9. Rammos SK, Maina R, Lanzino G. Developmental venous anomalies: current concepts and implications for management. *Neurosurgery*, 2009 Jul; 65(1): 20-9; discussion 29-30.
10. Abdulrauf SI, Kaynar MY, Awad IA A comparison of the clinical profile of cavernous malformations with and without associated venous malformations. *Neurosurgery*, 1999; 44: 41–46, discussion 46–47.
11. Little JR, Awad IA, Jones SC, Ebrahim ZY Vascular pressures and cortical blood flow in cavernous angioma of the brain. *J Neurosurg*, 1990; 73: 555–559.
12. Daniel L. A. Camacho, J. Keith Smith, John D. Grimme, Harold F. Keyserling and Mauricio Castillo Atypical MR Imaging Perfusion in Developmental Venous Anomalies *AJNR Am J Neuroradiol*, October 2004; 25: 1549–1552.
13. McLaughlin MR, Kondziolka D, Flickinger JC, Lunsford S, Lunsford LD The prospective natural history of cerebral venous malformations. *Neurosurgery*, 1998; 43: 195–200, discussion 200–201.