



## HISTO-TOXIC EFFECTS OF THE DRUG POSTINOR®-2 ON THE LIVER OF FEMALE WISTAR RATS

<sup>1</sup>Adigun M. S., <sup>2</sup>Fasogbon S. A., <sup>3\*</sup>Ajileye A. B. and <sup>4</sup>Arije B. S.

<sup>1</sup>State General Hospital, Ogun State, Nigeria.

<sup>2</sup>Public Health In-vitro Diagnostic Control Laboratory, Medical Laboratory Science Council of Nigeria.

<sup>3</sup>Department of Medical Laboratory Science, College of Medicine and Health Sciences, Afe Babalola University, Ado Ekiti, Ekiti State.

<sup>4</sup>Medical Laboratory Services, University College Hospital, Ibadan, Oyo State.

**\*Corresponding Author: Dr. Ajileye A. B.**

Department of Medical Laboratory Science, College of Medicine and Health Sciences, Afe Babalola University, Ado Ekiti, Ekiti State.

Article Received on 16/10/2016

Article Revised on 06/11/2016

Article Accepted on 27/11/2016

### ABSTRACT

**Aim:** The purpose of carrying out this research work is to determine the histo-toxic effects of the drug Postinor®-2 on the liver of female wistar rats. **Materials and Methods:** A total number of twenty five (25) adult female wistar rats were acquired from the animal house of the college of medicine, Ambrose Alli University Ekpoma and were used for this research work. The female wistar rats were divided into five (5) groups of five (5) rats in each group. The female wistar rats in Groups I-V were orally treated with the dose of Postinor®-2 at different concentrations (1ml of 1.5mg/100ml; 2ml of 1.5mg/100ml; 3ml of 1.5mg/100ml; 4ml of 1.5mg/100ml) and group V which is the control group were only fed with their normal food and water. At the end of the experiment, the rats were sacrificed, the liver was harvested and histological processed, sectioned with a rotary microtome, stained with haematoxylin and eosin and were examined microscopically. **Results and Discussions:** Microscopic examination of the liver revealed vacuolation, necrosis of the hepatocytes. Inflammatory cells and presence of perinuclear hallow around the recorded hepatocyte. **Conclusion:** From these findings, it may be inferred that excess use of Postinor® is associated with cellular and tissue damage of the liver.

**KEYWORDS:** Postinor®-2, Vacuolation, Necrosis, Perinuclear, Hepatocyte.

### INTRODUCTION

Postinor® is a brand name of levonorgestrel, contraceptive tablet manufactured by a Hungarian firm (Adelaide, 2007). Postinor is marketed in Nigeria as a post-coital drug for the prevention of conception. It has not been shown to be safe or effective for the prevention of conception. It has been proposed that postinor® should be marketed as an emergency contraceptive, the only indication for which has been shown to be effective, but its uses may not change unless the reasons why women use it are addressed. Postinor® is manufactured as tablet, each containing 0.75mg of the progesterone levonorgestrel. Postinor® is currently sold in Nigeria in packet of 10 tablets (Bottomly, 1992). It appears to be available from larger pharmacies in urban centers in Nigeria. It contains one blister sheet containing one levonorgestrel and the following inactive ingredients: potato starch, maize, silica colloidal anhydrous magnesium stearate, talc, lactoc (Jolin and Rapkin, 2002). It is used as an emergency contraceptive to prevent unwanted pregnancy after unprotected sexual intercourse; or if a contraceptive method that has been used has failed Postinor®-2 is also used to control

menstrual disorders and treatment of endometriosis (Palter and Olive, 2002). Levonorgestrel postinor-2 (1.5mg) is the same progesterone used in regular contraceptive pills, but used in higher concentration (Bottomly, 1992). It is thought to work primarily by preventing ovulation and fertilization, if one had unprotected sex in the first two weeks of the month before ovulation has taken place, which is when likelihood of fertilization is the highest. It also helps to reduce the chances of implantation by preventing development and thickening of the endometrium (lining of the uterus) that is needed for implantation of the fertilized egg, so that the fertilized egg would not be able to implant and grow. If fertilization and implantation has already taken place, taking Postinor-2 will no longer be effective (Kalantaridou *et al.*, 2006). Postinor-2 is formulated to function in a manner similar to the female hormone progesterone allowing for the prevention of pregnancy if taken within a reasonable period of time. Generally, it is recommended that postinor-2 be taken no later than three (3) days of having unprotected sex. However it has proven to be more effective in cases

where the treatment was started closer to the time of the sexual encounter (Bottomly, 1992).

## MATERIALS AND METHODS

### Study Area

This research work was carried out at the Department of Medical Laboratory Science, College of Medicine, Faculty of Basic Medical Sciences, Ambrose Alli University, Ekpoma, Edo-State, Nigeria.

### Postinor®

The drug which is the brand name of levonorgestrel was obtained from a government approved pharmacy shop in Edo state. It was in a packet of 10 tablets.

### Drug Dilution (Postinor®-2)

The drug contains 0.75mg of progestrogen levonorgestrel. Two of the drugs (1.5mg) was dissolved in a 0.1litre (100mls) of distilled water then stored in the refrigerator at 4°C until required.

### Experimental Animals

Twenty-five female Wister rats were obtained from the animal house of the college of Medicine, Ambrose Alli University, Ekpoma, Edo- State. The animals were in healthy conditions and weighed 100g-160g. On transfer to the experimental location, the rats were properly fed and allowed to acclimatize for 2 weeks under favorable climatic conditions.

### Experimentation

Twenty-five female Wister rats were randomly divided into five groups of five rats and acclimatized. The female

Wister rats in group I- IV were orally treated with different concentrations of postinor-2 drug dilutions (1ml of 1.5mg/100ml; 2ml of 1.5mg/100ml; 3ml of 1.5mg/100ml; 4ml of 1.5mg/100ml) and group V which is the control group were only fed with their normal food and water for a period of one week.


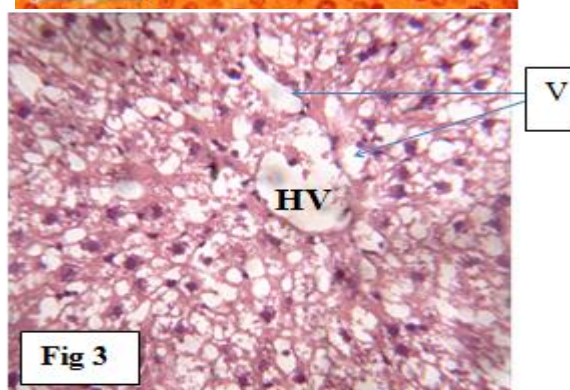
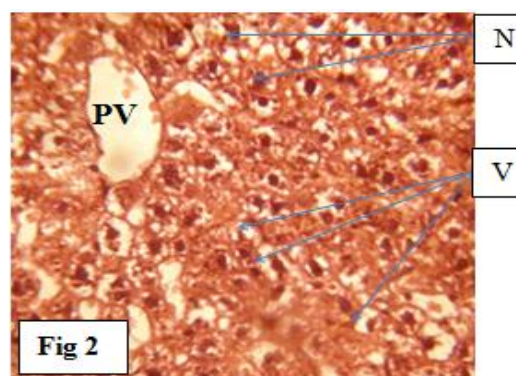
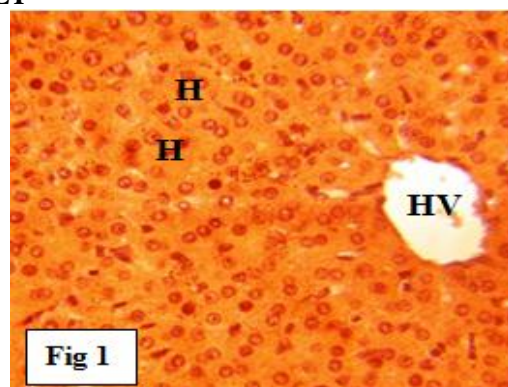
### Sample Collection and Preparation for Histology

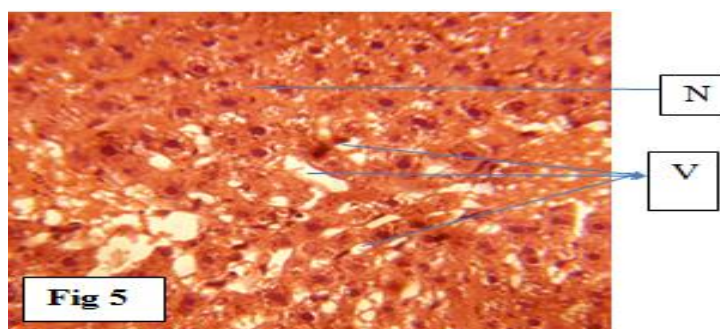
At the end of the experiment, the animals were fasted overnight then sacrificed by spinal dislocation. The liver was harvested and examined for gross morphological changes. The tissues were fixed in 10% formal saline and standard automatic tissue processing techniques were employed. Sections of about 3µm -5µm were cut with a SLEE Medical rotary microtome, stained with haematoxylin and eosin, viewed and captured on a Brunel light microscope, 20 mega pixels (Brunel SP35 Digital Trinocular).

### Observation during Drug Administration

The hairs of the rats were falling off from the third day of administration. The rats were very active before each administration but very calm immediately after administration. Well-formed hard dark stool were excreted throughout the experiment but pale yellow and deep yellow urine were excreted before and after administration.

## RESULT





**Fig 1:** Control tissue section of the liver from an albino female wistar rat showing a normal HV= Hepatic Venule, and H= Hepatocyte.

**Fig 2:** Tissue section of the liver from an albino female wistar rat treated with 1ml of 1.5mg/100ml of postinor for 7 days, showing evidence of V= Vacoulation, PH= Perinuclear Hallow, N= Necrotic cells.

**Fig 3:** Tissue section of the liver from an albino female wistar rat treated with 3ml of 1.5mg/100ml of postinor for 7 days showing HV= Hepatic Venule and numerous of V= Vacoulations.

**Fig 4:** Tissue section of the liver from an albino female wistar rat treated with 4ml of 1.5mg/100ml of postinor for 7 days showing the presence of PH= Perinuclear Hallow, V= Vacoulations and N= Necrotic cells.

**Fig 5:** Tissue section of the liver from an albino female wistar rat treated with 2ml of 1.5mg/100ml of postinor for 7 days showing numerous V= Vacuoles and N= Necrotic cells.

## DISCUSSION

Postinor-2, also known as the 'morning after pill', is used as an emergency contraceptive. It is a morning pill taken after unprotected intimate intercourse to prevent pregnancy. Postinor-2 contains one blister sheet containing two round white tablets. Each tablet contains 750 micrograms of levonorgestrel and the following inactive ingredients: potato starch, maize starch, silica colloidal anhydrous, magnesium stearate, talc and lactose monohydrate (Jolin and Rapkin, 2002). This research study was able to discover the histomorphological effects and histological alterations of postinor on the liver of wistar rats, as a result of different doses of postinor administered orally, which gave rise to important alteration in hepatic drug excretion and metabolism. When excess postinor-2 is being administered orally, some of the components such as silica colloidal anhydrous, give rise to deleterious effect on the liver which include inflammatory disorders and sarcoidosis (Newman *et al.*, 2004). The liver metabolises drugs that enters the blood stream and also governs drug activities throughout the body. Once drug enters the blood stream, the liver converts the drug into chemicals, these chemicals can attack and injure the liver. Drug-induced liver injury can resemble the symptoms of any acute or chronic liver disease. Rarely, long term use of a medicine can cause chronic liver damage (Soworbrick *et al.*, 1990). In this research work, Loss of weight and dullness was observed in all the groups treated with various doses of Postinor-2 drug. Also the microscopy shows vacoulation, necrosis of the hepatocytes, inflammation and presence of perinuclear hallow, were observed in the perivascular area of the liver tissue. From the foregoing, its is quite evident that the drug postinor-2 has a wide spread effect on the visceral organ, as seen in the liver of female wistar rats which conform with a research carried out which says; when excess postinor® is being administered orally, some of the components such as silica colloidal anhydrous, give rise to deleterious effect

on the liver which include inflammatory disorders and sarcoidosis (Newman *et al.*, 2004).

## CONCLUSION

One may infer from the result of this study that postinor-2 should be taken according to prescription or should be avoided, because its frequent consumption can result in tissue damage in human organs. Public awareness by health organisations should be put in place to educate people on deleterious effect of the abuse of postinor intake.

## REFERENCES

1. Adalaide, E. Australian medicines handbook. Pharmaceutical society of Australia Press. 2007; 130-300.
2. Bottomly, D.R. Article on postinor. *Acta Pharmaceuticals Hungry*, 1992; 60(2-3): 85-99.
3. Carlton, S.M. Text Book of Histochemical Techniques, 4th Edition, Oxford University Press, 1967; 48-137.
4. Jolin, O.L. and Rapkin, N.Y. Drug Interactions: Analysis and Management. *Klu publications, Westport*, 2002; 63-66.
5. Kalantaridou, T., Traub, A. and Resh, B. Premature ovarian failure, endothelial dysfunction and estrogen-progesterone replacement. *Trends endocrinology metabolism*, 2006; 30: 134-150.
6. Newman, L.S., Rose, C.S. and Bresnitz, E.A. A case control etiologic study of sarcoidosis: Environmental and occupational risk factors. *Journal of American Medical Association*, 2004; 170(6-7): 1324-1330.
7. Palter, R.I. and Olive, G.D. Monogenic disorders of puberty. *Journal of Clinical Endocrinol Metabolism*, 2002; 86: 724.
8. Soworbrick, J., James, C. and Boylan, T. *Encyclopedia of Pharmaceutical technology*, 1990; 38: 2274.