



## DIASTEMA CLOSURE WITH ALL CERAMIC RESTORATIONS: A CASE REPORT

**Dr. Yogesh Kumar<sup>1</sup>, Dr. Vikram Aggarwal\*<sup>2</sup>, Dr. Neetu Jindal<sup>3</sup>, Dr. Renu Aggarwal<sup>4</sup>, Dr. Kanika Aggarwal<sup>5</sup>**

<sup>1</sup>Professor, Director Principal and H.O.D, Department of Conservative Dentistry & Endodontics, Surendera Dental College and Research Institute, Sri Ganganagar. India

<sup>2</sup>Post Graduate Student, Department of Conservative Dentistry & Endodontics, Surendera Dental College and Research Institute, Sri Ganganagar. India

<sup>3</sup>Professor, Department of Conservative Dentistry & Endodontics, Surendera Dental College and Research Institute, Sri Ganganagar. India

<sup>4</sup>Reader, Department of Conservative Dentistry & Endodontics, Surendera Dental College and Research Institute, Sri Ganganagar. India

<sup>5</sup>Senior lecturer, Department of Conservative Dentistry & Endodontics, Surendera Dental College and Research Institute, Sri Ganganagar. India

**\*Author for Correspondence: Dr. Vikram Aggarwal**

Post Graduate Student, Department of Conservative Dentistry & Endodontics, Surendera Dental College and Research Institute, Sri Ganganagar. India.

Article Received on 20/01/2016

Article Revised on 11/02/2016

Article Accepted on 02/03/2016

### ABSTRACT

A confident smile is the most charming aspect of one's personality. With the advancements in the area of cosmetic dentistry, the dental professionals have got new opportunities in conservative and esthetic restorative procedures. Diastema, tooth size discrepancy, discolorations, staining, fractures in teeth, endodontic treatment, and smile designing are some of the reasons for which patient seek esthetic dental treatment. Multiple options are available to treat problems arising in the zone of high esthetic sensitivity. The use of all ceramic crowns to solve esthetic and/or functional problems has been shown to be a valid management option especially in the anterior esthetic zone. This case report highlights the treatment of midline diastema with all ceramic crowns.

**KEY WORDS:** Diastema, RED proportion, All ceramic crowns.

### INTRODUCTION

The maxillary midline diastema is, indisputably, one of the dentoalveolar disorders that cause special concern to parents and patients. Presence of maxillary midline diastema is a normal characteristic in the development of the stomatognathic system in the mixed dentition period but in adults, the prevalence of maxillary midline diastema ranges from 1.6% to 25.4%. These spaces usually distort a pleasing smile by concentrating the observer's attention not on the overall dental composition, but on the diastema.<sup>[1]</sup>

*Keene* describes Midline diastema as anterior midline spacing greater than 0.5 mm between the proximal surfaces of adjacent teeth.<sup>[2]</sup>

Many treatment modalities can be used for diastema closure. A careful diagnosis, which includes a determination of the causal elements, and advanced treatment planning, allows the most appropriate treatment to be selected for each case.<sup>[3]</sup>

Orthodontic correction often results in a sensible esthetic improvement and is well accepted by patients. However,

orthodontics alone often may not be able to correct the problems associated with all the cases of diastema. In many cases, restorative and periodontal procedures are also necessary.

The specific goals of treating diastema are: creating a tooth form in harmony with adjacent teeth, arch and facial form; maintaining an environment for excellent gingival health; and attainment of a stable and functional occlusion.<sup>[4]</sup>

Numerous factors contribute to proper tooth and arch interrelationships. These may include the relative height, width, orientation and the number of teeth as well as the size and shape of the dental arches. An imbalance in size and shape of the teeth and dental arches may limit the ability of the teeth to fit together properly. This may result in the formation of a single or multiple diastema. It is important to understand the origin of the problem. The significance of any single factor may vary among patients, thus each patient must be evaluated thoroughly before the initiation of any treatment.

Dentoalveolar discrepancies may be listed among the most common causes of anterior diastema in adults. It usually result from disharmonies between the size of the dental arch and the width of the teeth or from the presence of bone defects that cause diastema.<sup>[5]</sup>

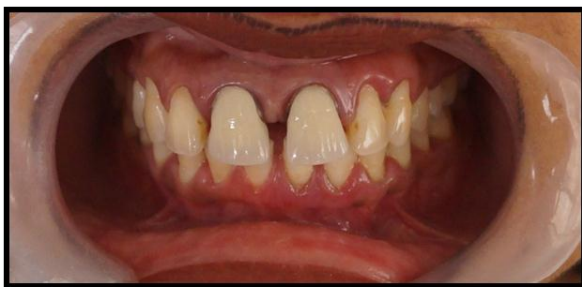Therefore, this case report highlights the rare etiology and management of midline diastema with all ceramic restorations.

### CASE REPORT

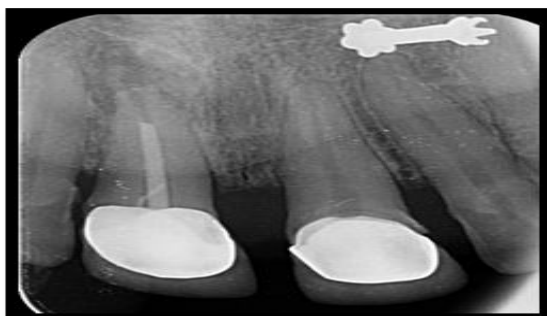A 34 year old female patient reported to the department of Conservative Dentistry and Endodontics with the chief complaint of unaesthetic tooth colored crowns and spacing between the upper front teeth region. Patient gave history of traumatic injury 6 years back and generalized spacing in the front teeth region. For that she had undergone root canal therapy and crowns by a general dentist.

Clinical examination revealed diastema in between maxillary anteriors with unaesthetic Porcelain fused to metal crowns irt 11 and 21 (Fig. 1). On vitality tests, the tooth number 11 and 21 gave negative response and 12 and 22 showed vital response. On radiographic examination, the tooth number 11 was poorly obturated, but there was no signs of periapical pathology irt all the four maxillary incisors. There was W- shaped intermaxillary suture instead of V shaped notch, which could be one of the reasons for this midline diastema (Fig. 2).

After thorough clinical and radiographic examination and patients expectations for esthetics, the All- ceramic crowns irt 11 and 21 and direct composite resin build-ups irt 12 and 22 were planned with her consent.

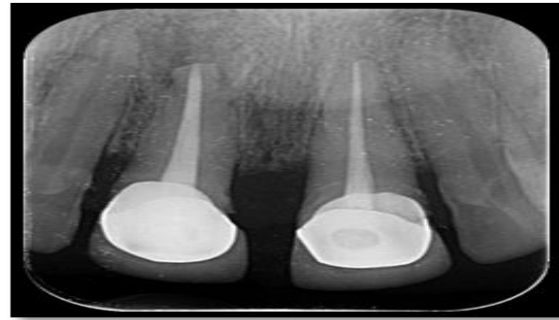


**Fig. 1 Pre- operative intraoral View**



**Fig.2 Pre- operative IOPA**

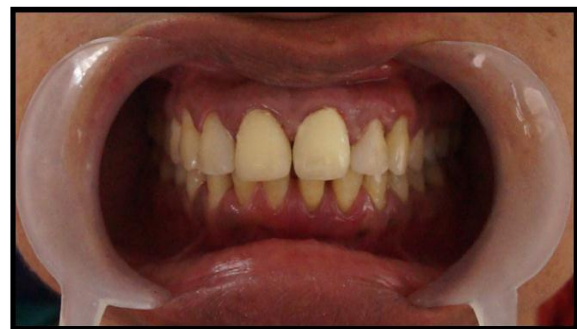The retreatment (RCT) irt 11 and root canal treatment irt 21 was done through the PFM crowns (Fig. 3).



**Fig. 3 Post-Obturation IOPA**

The upper and lower Alginate impressions were made after removal of PFM crowns. The maxillary and mandibular working casts were prepared. This was followed by complete smile analysis and calculation of tooth- arch discrepancy by using RED proportion.

The temporary crowns (as a part of indirect intra-oral mock-up) were made with the help of cold cure auto polymerizing resin irt 11 and 21 using A2 shade on the working casts. The temporary crowns were cemented with the help of zinc oxide temporary material. This was followed by direct composite resin build-up irt 21 and 22 (Fig. 4).



**Fig. 4 Intra-oral View after cementation of temporary crowns and composite build-ups**

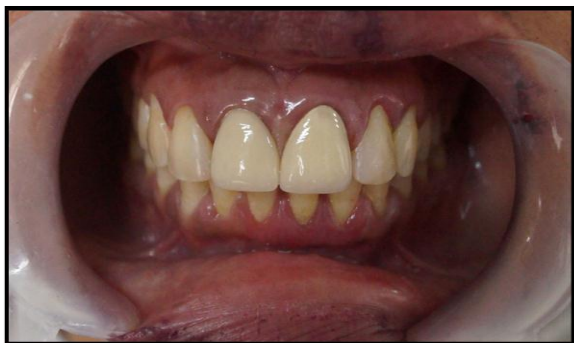After patient's complete satisfaction with intraoral mock-up, the provisional crowns were removed and tooth preparation for all ceramic crown was done irt 11 and 12. A circumferential 1 mm width of shoulder margin was prepared for all ceramic crowns. Furthermore, the preparation of finish lines was done 1 mm subgingivally to eliminate the occurrence of black triangles.

The shade selection was done using Vitapan 3D master shade guide and 2L-1.5 shade was selected.

The final impression with vinyl polysiloxane impression material (Aquasil, Dentsply/ Caulk, Milford, DE) was made using putty- wash 2 step technique. The final master casts were prepared and sent to lab for fabrication of pressable all-ceramic crowns irt 11 and 21. The tooth

number 11 and 12 were again temporized with new provisional crowns.

After 1 week the all-ceramic crowns were cemented using dual-cure resin cement (Luxacure, DMG America). The patient was completely satisfied with new smile (Fig. 5).



**Fig. 5 Final post-operative view**

## DISCUSSION

The arrangement and proportion of maxillary anterior teeth are the major determinants for a pleasing appearance. To evaluate and describe the ideal tooth-to-tooth proportion, Levine applied the golden proportion (proportion of 1.618:1.0) to relate the successive widths of the anterior teeth as viewed from the front. The golden proportion implies that the maxillary central incisor should be 62% wider than the lateral incisor, which is consistent between the widths of the maxillary lateral incisor and canines.<sup>[6]</sup> However, Preston reported that only 17% of the patients had the golden proportion in terms of the relationship between the maxillary central and lateral incisors. In addition, when using the golden proportion, the lateral incisors and canines appeared too narrow.<sup>[7]</sup> Therefore, Ward indicated that the recurring esthetic dental (RED) proportion was more appropriate to individually fit the face, gender, and body type of each patient. The average range of RED proportion from 62% to 80% was considered acceptable. In this case, the RED proportion was calculated prior to removal of PFM crowns to confirm the ideal space distribution and the tooth-to-tooth proportion. The calculated RED proportion was 70%.<sup>[8]</sup>

Metal ceramic restorations have been available for more than three decades. This type of restoration has gained popularity from its predictable performance and reasonable esthetics. Despite its success, the demand for improved esthetics and the concerns regarding the biocompatibility of the metal has led to the introduction of all-ceramic restorations.<sup>[9]</sup> Among all ceramic restorations few systems use single-layer glass-ceramic material (e.g., Dicor, Dentsply/Caulk; IPS Empress, Ivoclar/Vivadent), whereas others have a dual-layer design (In-Ceram, Vident; Procera, Nobel Biocare). Further improvements in high strength all ceramic technology have been achieved with the advent of CAD/CAM systems.

In this case, In-Ceram (Vita Zahnfabrik) system was used for the fabrication of all ceramic restorations.

The system has two-stage technique for fabricating the core for the crown. Firstly, a sintered porous alumina framework is cast onto a duplicate die and then the second stage involves infiltration with glass. Finally, the core is veneered with feldspathic porcelain for the final aesthetics. The sintering process creates a dense coping demonstrating excellent marginal fit and flexural and compressive values well above other all-ceramic systems. It has been reported that survival rates of all-ceramic restorations range from 88- 97% after 5-15 years. However, limitations aside, when selected and used correctly, all-ceramic restorations can have excellent aesthetic, biological and mechanical/physical properties. The end results can be both attractive to patient and rewarding to the clinician.<sup>[10]</sup>

## CONCLUSION

Diastema closure in clinical practice requires detailed case analysis. The successful treatment of diastema depends on etiological factors, size and extent of the diastema, and the patient's affordability in terms of treatment time and cost. All ceramic restoration is a viable approach for diastema closure and results achieved have been gratifying for the cosmetic dentist and the patient alike.

## REFERENCES

1. Esthetics in dentistry Ronald E Goldstein 2nd edition.
2. Keene HJ. Distribution of diastemas in the dentition of man. *Am J Phys Anthropol* 1963; 21: 437-41.
3. Modena KCS, Colombini-Ishikiriana BL, Ishikiriana SK, Scotti CK, Nahsan FPS. Multidisciplinary esthetic approach for multiple anterior diastema: 36-month clinical performance. *Braz Dent Sci* 2015; 18(4): 110-19.
4. Oquendo A, Brea L, David S. Diastema: Correction of excessive spaces in esthetic zone. *Dent Clin North Am* 2011; 55(2): 265-81.
5. Furuse AY, Herkrath FJ, Franco EJ, et al. Multidisciplinary management of anterior diastemata: clinical procedures. *Pract Proced Aesthet Dent* 2007; 19(3): 185-91.
6. Chang KJ, Chang TW, Feng SW. An Interdisciplinary Approach for Diastema Closure In the Anterior Maxilla: A Clinical Report. *J Prosthodont Implantol* 2013; 2(2): 22-5.
7. Preston JD. Golden proportion revisited. *J Esthet Dent* 1993; 5: 247-51.
8. Ward DH. Proportional smile design using the recurring esthetic dental (RED) proportion. *Dent Clin North Am* 2001; 45: 143-54.
9. Fischer H, Marx R. Fracture toughness of dental ceramics: comparison of bending and indentation method. *Dent Mater* 2002; 18(1): 12-9.
10. Rimmer S. Modern Dental Ceramics: An overview. *International Dent* 2006; 8(4): 32-40.