



## RELATIVE POSITION OF RIGHT AND LEFT HEMI DIAPHRAGMS ON NORMAL CHEST RADIOGRAPH AT BPKIHS, DHARAN, NEPAL

\*Mishra N., Shrestha A., Singh A. K. and Rai B.

Assistant Professor, BP Koirala Institute of Health Sciences, Dharan-18, Nepal.

\*Corresponding Author: Dr. Mishra N.

Assistant Professor, BP Koirala Institute of Health Sciences, Dharan-18, Nepal.

Article Received on 24/10/2017

Article Revised on 13/11/2017

Article Accepted on 03/12/2017

### ABSTRACT

**Background & objectives:** The positions of the domes or cupola of the diaphragm are extremely variable because they depend on body build and the phase of respiration. While interpreting chest radiographs, the position and shape of the diaphragm are routinely used to evaluate whether the lungs are underinflated, as with inadequate inspiration effort or restrictive lung disease, or overinflated, as in emphysema or other obstructive lung diseases and also for the interpretation of normal variant which can otherwise be misdiagnosed as elevated or depressed diaphragm. This study was carried out with objective to study the relative position difference of Right and Left Hemi diaphragms on normal chest radiograph at BPKIHS, Dharan, Nepal. **Methods:** The study was Cross Sectional which was carried out in the Department of Radiodiagnosis & Medical Imaging, B.P. Koirala Institute of Health Sciences over the period of 3 weeks. The study population consisted of normal individuals coming for chest radiograph in Department. All patients of any age group referred from various outpatient departments of BPKIHS for chest radiograph were included in the study. Patients who had radiographic evidence of chest abnormality were excluded. **Results:** Our study showed that the right hemi diaphragm was higher than the left in 98.6%, the left was higher in 1.4% and they were in the same height in 0% of the participants. The minimum position difference between the hemi diaphragms was 0.9 cm and maximum position difference was 2.2 cm. **Conclusion:** out of 72 patients in our study on normal chest radiograph, the right hemi diaphragm was higher than the left in 98.6%, the left was higher in 1.4%. Our data are helpful in understanding normal relative position and normal relative position difference of Right and Left Hemi diaphragms on normal chest radiograph in our population which is important in image interpretation.

**KEYWORDS:** Hemidiaphragm, normal chest radiograph, relative position difference.

### INTRODUCTION

The diaphragm is a curved musculo-fibrous sheet that separates the thorax from the abdominal cavity. It's convex upper surface faces the thorax and concave inferior surface is directed towards the abdomen. The positions of the domes or cupolae of the diaphragm are extremely variable because they depend on body build and the phase of respiration.<sup>[1]</sup> Thus the diaphragm will be higher in short, fat people than in tall, thin people<sup>[2]</sup>, and over inflation of the lung, as occurs for example in emphysema, causes marked depression of the diaphragm.<sup>[1,2]</sup>

Usually, after forced expiration the right cupola is level anteriorly with the fourth costal cartilage<sup>[3]</sup> and therefore the right nipple, whereas the left cupola lies approximately one rib lower. With maximal inspiration, the cupola will descend as much as 10 cm, and on a plain chest radiograph the right dome coincides with the tip of the sixth rib. In the supine position, the diaphragm will be higher than in the erect position, and when the body is

lying on one side, the dependent half of the diaphragm will be considerably higher than the uppermost one.<sup>[1, 3]</sup>

Although the use of Computerized Tomography has greatly increased over the past decades, chest radiography remains the most frequently performed imaging examination.<sup>[4]</sup>

A good understanding of normal anatomy and variations is essential for the interpretations of chest radiographs. While interpreting chest radiographs, the position and shape of the diaphragm are routinely used to evaluate whether the lungs are underinflated, as with inadequate inspiration effort or restrictive lung disease, or overinflated, as in emphysema or other obstructive lung diseases and also the interpretation of normal variant.<sup>[4,5,6]</sup> This study was carried with an aim and objective to study the relative position of Right and Left Hemi diaphragms on normal chest radiograph and to study the relative position difference of Right and Left

Hemi diaphragms on normal chest radiograph at BPKIHS, Dharan, Nepal.

### MATERIALS AND METHODS

The study was Cross Sectional which was carried out in the Department of Radiodiagnosis & Medical Imaging, B.P. Koirala Institute of Health Sciences (BPKIHS), over the period of 3 weeks. The study population consisted of normal individuals coming for chest radiograph in Department of Radiodiagnosis & Medical Imaging. All patients of any age group referred from various outpatient departments of BPKIHS for chest radiograph were included in our study. Patients who did not give consent and the patients who had radiographic evidence of chest abnormality were excluded.

After taking informed consent, demographic variables were collected. The procedure was explained to the patients. Chest radiograph was taken in both AP & PA view with proper centring and in full inspiration, using high peak kilovoltage (120 – 130 kVp) for adequate penetration. After ideal chest radiograph acquisition and processing, measurements were done. Straight line was drawn at the maximum height of each hemidiaphragm, parallel to each other. The lines were then measured using appropriate measuring device. Ethical clearance was obtained from Institutional Review Committee of BPKIHS. Purposive sampling was done. Data analysis was done after selecting the cases as per the selection criteria.

### RESULTS

Total number of 72 patients referred for chest radiograph was included in the study on the basis of inclusion criteria. Age of patients in our study ranged from 4-62 years. The mean age of the patients was 32.44 years. The maximum number of cases (n= 31) were in the age group of 21-40 years of age in our study.

Out of total 72 patients, 35(48.6 %) were Males and 37(51.4%) were Females. The Male to Female ratio was 1:1.06.

Among the male patients the mean position difference between the Right and Left Hemi diaphragms on normal chest radiograph was 0.95 cm and among the female patients was 1.02 cm as described on Table 1.

**Table 1: Mean position difference between the Right and Left Hemi diaphragms difference with sex.**

Sex	Frequency	Mean Difference in Hemi diaphragm (Mean ± S.D.)
Male	35	0.95± 0.52
Female	37	1.02±0.44

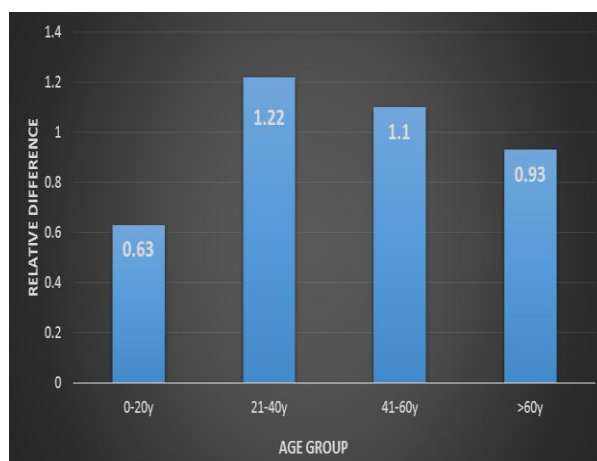
In our study we found the minimum position difference between the hemi diaphragms was 0.9 cm and maximum position difference was 2.2 cm. Among the male patients

range of positional difference was 0.9 to 2.0 cm and in female patients the range was 0.1 to 2.2 cm.

In our study the mean position difference between the left and right hemi diaphragm in age group 0-20 years was (0.63±0.47), 21-40 years was (1.12±0.47), 41-60 years was (1.1±0.37) and in age group >60years was (0.93±0.15) as illustrated in Table 2 and Fig 1.

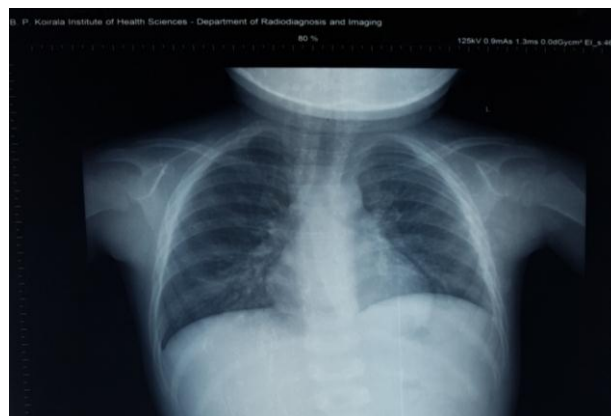
**Table 2: Mean difference in position between the Right and Left Hemi diaphragms according to age group.**

Age Group	Mean difference in the position of left and right hemidiaphragm (cms)
0-20	0.63±0.47
21-40	1.12±0.47
41-60	1.1±0.37
>60	0.93±0.15



**Table 3: Overall positions of the Right and Left Hemi diaphragms.**

Overall	Frequency	Percentage
Right diaphragm higher	71	98.6%
Left diaphragm higher	1	1.4%
Both diaphragm at same levels	-	0%



**Figure 3: Postero-anterior chest radiograph of 4 year Old Male patients, where left hemi diaphragm is higher than the right by 0.9 cm.**

## DISCUSSION

Lennon *et al.*<sup>[3]</sup> conducted a study on 500 patients on the height difference of the diaphragm in the chest radiograph of normal adults on the basis of standard postero-anterior radiographs. All the subjects were more than 21 years old and were assessed in three age groups, viz.: 21-40 years (370, 74 %), 41-60 (95, 19%), over 60 (35, 7 %) out of which 250 were male and 250 female (Male to female ratio 1:1). In terms of averages the diaphragm was slightly higher in females, in heavy persons and after the age of 40 years. Abiru *et al.*<sup>[7]</sup> conducted a nearly similar study on 1000 chest radiographs comprising 482 men and 518 women ranging in age from 20 years to 90 years. Male to female ratio was 1:1.7. In our study, age of patients ranged from 4-62 years and the maximum number of cases (n= 31) were in the age group of 21-40 which was comparable to the study done by Lennon *et al.*<sup>[3]</sup> Out of total 72 patients in our study, 35(48.6 %) were Males and 37(51.4%) were Females. The Male to Female ratio was 1:1.06 which was comparable to the study done by Abiru *et al.*<sup>[7]</sup>

According to the study done by Salih *et al.*<sup>[4]</sup> on "Height Difference between right and left hemi Diaphragm in Normal Sudanese Adults using Postero - Anterior Computed Chest Radiograph". The height difference of male hemi diaphragm ranged between 0.6-2.8 and female ranged from 0.5-2.9cm.

In our study, the height difference of male hemi diaphragm ranged between 0.9 to 2 cm and female hemi diaphragm ranged between 0.1 to 2.2 cm. The slight variation in the ranges from their study may be due to small sample sizes in our study as per time limitations.

In Salih *et al.*<sup>[4]</sup> study on 100 subjects, the result of their study showed that the right hemi diaphragm was higher than the left in 98%, the left was higher in 1%. In similar study of Suwanatpongched *et al.*<sup>[6]</sup> study, the right hemi diaphragm was higher than the left in 91% of all patients in their studies. In Abiru *et al.*<sup>[7]</sup> study on 1000 subjects, their study result showed that in 94.2%, the right hemi diaphragm was higher than the left.

Our study showed that the right hemi diaphragm was higher than the left in 98.6%, the left was higher in 1.4 % and there were no participants having both diaphragms at the same level, this may be due to small sample sizes. The results of our study are comparable to the study done by Salih *et al.*<sup>[4]</sup>, Suwanatpongched *et al.*<sup>[6]</sup> and Abiru *et al.*<sup>[7]</sup>

## CONCLUSION

While interpreting chest radiographs, the position and shape of the diaphragm are routinely used to evaluate whether the lungs are underinflated, as with inadequate inspiration. Our study showed that on normal chest radiograph, the right hemi diaphragm was higher than the left in 98.6%, the left was higher in 1.4 %. The minimum

position difference between the hemi diaphragms was 0.9 cm and maximum position difference was 2.2 cm. Among the male patients range of positional difference was 0.9 to 2.0 cm and in female patients the range was 0.1 to 2.2 cm. There were not statistically significant mean position difference between the between the Right and Left Hemi diaphragms on normal chest radiograph in both sex.

The result of our study was comparable with many previously published similar studies with minor variation in few data's as discussed, which may be due to small sample size due to limited duration in our study. Although the number of the radiographs we evaluated may not be large, we believe our data are helpful in understanding normal relative position and normal relative position difference of Right and Left Hemi diaphragms on normal chest radiograph in our population which is important in image interpretation which otherwise in the absence of proper reference population based data can be misdiagnosed as elevated or depressed diaphragm.

## REFERENCES

1. Standring S.Gray's Anatomy, Diaphragm, 40<sup>th</sup> Edition, Amsterdam: Elsevier; 2008.
2. Kanaka S, Nightingale SS, Kanaka SB, Pulipati AK, Gaikwad MR. Radiological study of range of Respiratory movements in Thin and Overweight individuals. International Journal of Biological and Medical Research. 2012; 3(3): 1988 -1991.
3. Lennon EA, Simon G. The Height of the Diaphragm in the Chest Radiograph of Normal Adults. British Journal of Radiology. 1965; 38: 937-943.
4. Salih HAA, Ayad CE, Abdalla EA, Hassan IA, Ahmed AS.Height Difference between right and left hemi Diaphragm in Normal Sudanese Adults using Postero-Anterior Computed Chest Radiography. Global Journal of Medical research Radiology, Diagnostic, Imaging and Instrumentation. 2013; 13(3): 09.
5. Ramachandran S, JayawardenaDLN, Warakaulle MB. Significance of elevation of the right dome of the diaphragm. Postgraduate Medical Journal, 1976; 52: 154-155.
6. Suwatanpongched T, Gierada DS, Slone RM, Pilgram TK, Tuteur PG.Variation in Diaphragm Position and Shape in Adults With Normal pulmonary Function. Chest. 2003; 123(6): 2019-2027.
7. Abiru H, Ashizawa K, Hashmi R, Hayashi K. Normal radiographic anatomy of thoracic structures: analysis of 1000 chest radiographs in Japanese population. The British Journal of Radiology.2005; 78: 398-404.