



**CRITICAL MITRAL STENOSIS ASSOCIATED WITH INDOLENT CARDITIS: A RARE PRESENTATION OF PEDIATRIC RHEUMATIC HEART DISEASE.**

**<sup>1</sup>\*Dr. Rajkumar M. Meshram (MD), <sup>2</sup>Dr. Swapnil Bhongade (MD), <sup>3</sup>Dr. Nikita Gupta and <sup>4</sup>Dr. Shweta Dhasal**

<sup>1</sup>Associate Professor Dept of Paediatrics Govt. Medical College and Hospital, Nagpur (M.S.).

<sup>2</sup>Assistant Professor Dept of Paediatrics Govt. Medical College and Hospital, Nagpur (M.S.).

<sup>3,4</sup>PG Student Dept of Paediatrics Govt. Medical College and Hospital, Nagpur (M.S.).

**\*Corresponding Author: Dr. Rajkumar M. Meshram (MD)**

Associate Professor Dept of Paediatrics Govt. Medical College and Hospital, Nagpur (M.S.).

Article Received on 18/01/2017

Article Revised on 08/02/2017

Article Accepted on 02/03/2017

**ABSTRACT**

Although the prevalence of rheumatic fever has declined in most developed countries, the disease continues to be quite common elsewhere. Isolated severe rheumatic mitral stenosis in children and young adults is frequently encountered in developing countries. A 9 years old school going female was presented with hemoptysis and chest pain without any history suggestive of rheumatic fever in past with cardiovascular examination showed finding of rheumatic mitral stenosis with severe pulmonary hypertension which was confirmed by echocardiography. She was successfully treated with diuretics, antibiotics, balloon mitral valvotomy and she was on long term penicillin prophylaxis. Though hemoptysis is one of commonest presentation of respiratory diseases, rheumatic mitral stenosis should be considered in children of developing countries.

**KEYWORDS:** Rheumatic fever, Rheumatic heart disease, Mitral stenosis, Indolent carditis.

**INTRODUCTION**

Though, rheumatic fever (RF) and rheumatic heart disease (RHD) has declined in developed world, it continues to be a significant cause of morbidity and mortality in developing countries including India. In India, the estimated prevalence to be about 1.5-2 per 1000 in all age group.<sup>[1]</sup> Mitral valve disease alone or in combination with other valvular lesion is almost exclusively because of RHD. The severity of rheumatic mitral valve disease in developing countries differs in many ways from that in the developed countries. Recurrent and sever episodes of RF can lead to early development of RHD in younger age. Juvenile mitral Stenosis of rheumatic origin associated with ventricular septal defect is reported as early as 3 years in literature.<sup>[2]</sup>

Progression of mitral stenosis is malignant and often interventions are necessary during teen age group in developing countries. Here, we report a school going girl with critical mitral stenosis that developed in patient with indolent carditis.

**Case Presentation**

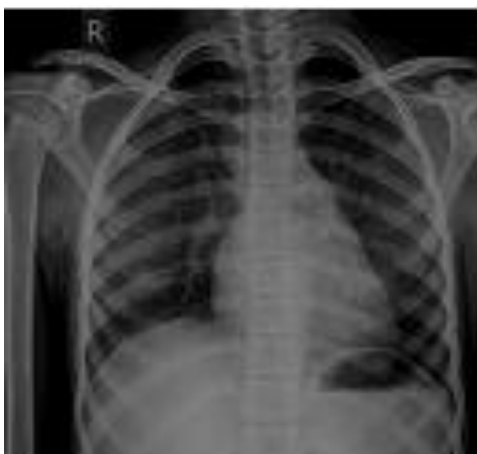A 9 years old female presented with bouts of cough with blood in expectoration for 7 days duration with mild fever and chest pain. Mother gave history of gradual onset exertional dyspnea for last 2 years which was non-seasonal and slowly affected outdoor activities to daily activities of the patient. On further inquiry, there

was history of not gaining weight, palpitation, repeated bouts of non productive cough followed by post-tussive vomiting, repeated episode of upper respiratory infection for which she received some oral medication on Out Patient Department basis. There was no history of joint pain, skin lesions, abnormal movement, nodular lesion, dysphagia or hoarseness of voice, no history suggestive of tuberculosis, collagen vascular diseases. No family member was suffering from rheumatic fever or rheumatic heart disease but there was history overcrowding and poor ventilation.

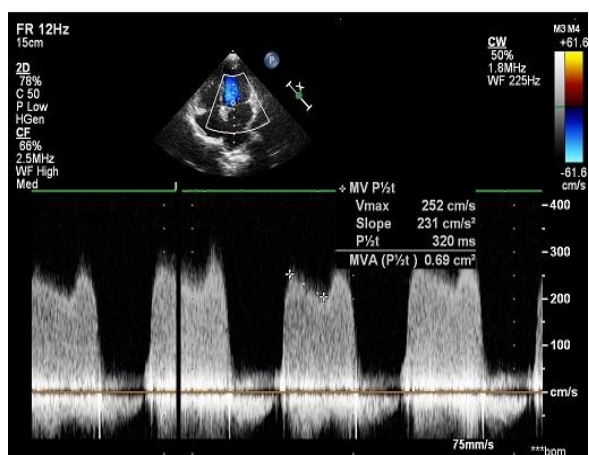
On anthropometric examination she was underweight. She was afebrile and comfortable in sitting posture but mild respiratory distress in lying down position. Pulse was 108/min, regular, low volume, thready with respiratory rate 30/min and SpO<sub>2</sub> 98% without O<sub>2</sub>. Blood pressure was 110/70 mmHg. There were no signs of congestive cardiac failure or infective endocarditis except pallor. Cardiovascular examination shows bulging of precordium with pulsation over apex, left parasternal area and pulmonary area. Apex was outward, ill sustained and of tapping character with palpable second heart sound and diastolic thrills at apex. On auscultation, first heart sound was sharp and loud. A low pitched mid diastolic murmur of grade IV was audible at apical region and conducted towards axilla, early systolic murmur at left lower parasternal area grade III. Apart

from this there was fine crepitation in basal chest without organomegaly.

Investigation showed normal total leukocyte and differential count, platelet count. Hb was 8.2gm%, ESR -30mm at end of first hour, ASO titer 466 IU/dl and CRP was negative. ECG showed sinus rhythm. Chest X ray shows straightening of left heart border. In echocardiography, anterior and posterior mitral leaflets were thickened, fixed with restricted mobility with critical mitral stenosis (<0.69sqcm) with pressure gradient 20/12 mmHg and severe pulmonary hypertension and mild tricuspid regurgitation without vegetation. She was treated with antibiotics, diuretics and referred to cardiologist for mitral valvotomy. Valvotomy was done successfully and put on penicillin prophylaxis and discharge after 3 weeks after surgery. She was in regular follow up and symptomatically better.



**Figure 1: Chest X ray PA view shows straightening of left heart border**



**Figure 2: Echocardiography shows critical mitral stenosis**

## DISCUSSION

Rheumatic fever and rheumatic heart disease are nonsuppurative complication of Group A Beta hemolytic streptococcal pharyngitis.<sup>[3]</sup> RHD is a late sequelae of rheumatic fever due to immune-mediated damage to the cardiac valves, and to the commonest affected is mitral

valve alone or in combination with other valve.<sup>[4,5]</sup> The age is one of the most important risk factor, as occurrence of rheumatic fever, below 5 years of age increases the risk of severe cardiac involvement and RHD because of increases severity of the valvulitis during each episode of rheumatic fever. Poverty, illiteracy, lack of awareness and poor health facilities are all hindrance in early diagnosis of rheumatic fever in developing countries. Mitral stenosis is not uncommon in RHD in developing countries like India. Severe rheumatic MS is rampant in younger children and around 25% of patients are younger than 20 years of age.<sup>[6]</sup> In juvenile MS, there is severe involvement of subvalvular apparatus with more critical stenosis of the mitral valve. Approximately 10-13% of the children with juvenile rheumatic MS present before 12 years of age and associated with rapid progression with severe symptoms.<sup>[7,8]</sup> Karmakar BC et al reported critical mitral stenosis in 8 years old boy which was rapidly progress within 2 years of RF.<sup>[9]</sup> Though rheumatic fever below 5 years of age is rare because of incomplete maturation of the immune system, rare cases occurring at as young as 2 years of age are reported in literature.<sup>[10]</sup> Surgical closed or open mitral commissurotomy is the traditional mode of treatment for MS. Mitral valve replacement in children in addition to its acute risk of surgical intervention, need of re-intervention later after 10-15 years carries another disadvantages. Percutaneous transluminal mitral commissurotomy in adult has similar result to open commissurotomy and has better result that of closed commissurotomy. Percutaneous transluminal mitral commissurotomy is an attractive alternative in children with MS with suitable mitral valve<sup>[11]</sup> Our patient was undergone to balloon mitral valvotomy and she had responded well and better in follow up.

## CONCLUSION

Though hemoptysis is one of commonest presentation of respiratory diseases, rheumatic mitral stenosis should be considered in children of developing countries. Percutaneous transluminal mitral commissurotomy is an attractive alternative in children with MS with pliable mitral valve.

## Source of Funding

None.

## Conflict of interest

None.

## REFERENCES

1. Kumar RK, Tandon R. Rheumatic fever & rheumatic heart disease: the last 50 years. *Indian J Med Res*, 2013; 137(4): 643-58.
2. Vijay SK, Tiwari B, Misra M, Vijaywargiya T. Juvenile rheumatic mitral stenosis in association with perimembranous ventricular septal defect in a 3 year old boy. *BMJ Case Rep* 2013. doi:10.1136/bcr-2013-200560.

3. Rheumatic fever & rheumatic heart disease. World Health Organ Tec Report Series, 2004; 923: 1-122. back cover.
4. Faheem M, Hafizullah M, Gul A, Jan H, Khan MA. Pattern of valvular lesions in rheumatic heart disease. *JPMI*, 2007; 21(2): 99-103.
5. Oesman IN, Gunardi H, Madiyono B, Sastroasmoro S, Putra ST. Profile and prediction of severity of rheumatic mitral stenosis in children. *Med J Indones*, 1996; 5(3): 152-157.
6. Shrivastav S, Tondon R. Severity of rheumatic mitral stenosis in children. *Int J Cardiol*, 1991; 130(2): 163-7.
7. EL-Aroussy W, EL-Hagracy N, Fawzy H, Zaher S, Taha N, Moustafa S. Prevalence of rheumatic valvular heart disease among Egyptian school children: an echocardiographic screening. *Med J Cairo Univ*, 2013; 81(1): 139-144.
8. Tadele H, Mekonnen W, Tefera E. Rheumatic mitral stenosis in children: more accelerated course in sub-Saharan patients. *BMC Cardiovascular Disorders*, 2013; 13(1): 95. Doi:10.1186/1471-2261-13-95.
9. Karmakar BC, Das AK, Guha D, Halder RC, Paria PP. Critical mitral stenosis: a rare presentation of pediatric rheumatic heart disease. *J of Evolution of Med and Dent Sci.*, 2015; 4(2): 282-284.
10. Kapoor A, Moorthy N, Kumar S. Inoue ballon mitral valvotomy in a 4 year old boy: to treat fulminant rheumatic mitral stenosis. *Tex Heart Inst J.*, 2012; 39(1): 108-11.
11. Shrestha M, Adhikari CM, Shakya U, Khanal A, Shrestha S, Rajbhandari R. Percutaneous transluminal mitral commissurotomy in Nepalese children with rheumatic mitral stenosis. *Nepalese Heart Journal*, 2013; 10(1): 23-26.