



CLINICOPATHOLOGICAL STUDY AND MANAGEMENT OF PRIMARY HEPATIC SPACE OCCUPYING LESIONS

¹Dr. Niranjan Jadhav, ^{*2}Dr. Harshal Ramteke and ³Dr. Dhirendra Wagh

¹Post Graduate in Department of General Surgery, AVBRH, Sawangi (Meghe), Wardha.

^{2,3}Professor in Department of General Surgery, AVBRH, Sawangi (Meghe), Wardha.

***Corresponding Author: Dr. Harshal Ramteke**

Professor in Department of General Surgery, AVBRH, Sawangi (Meghe), Wardha.

Article Received on 16/06/2018

Article Revised on 06/07/2018

Article Accepted on 27/07/2018

ABSTRACT

The liver is the largest organ in the abdomen, weighing about 1800 g in men and slightly less in women. A space occupying lesion by definition is a discrete abnormality arising within the liver. Space occupying lesions of the liver can be classified into developmental, neoplastic, inflammatory and miscellaneous. Although in some cases, it is difficult to distinguish these entities with imaging criteria alone, certain focal liver lesions have classic ultrasonic, computed tomographic (CT) and magnetic resonance (MR) imaging feature. The majority of these lesions are detected incidentally in asymptomatic patients.^{[2] [3]} An accurate history and physical examination are essential for the diagnosis and treatment of solid liver masses. For example, the use of oral contraceptives or anabolic steroids might be related to hepatic adenoma (HA), alcohol use and occupational exposure are associated with angiosarcoma and primary sclerosing cholangitis, liver fluke, Caroli's disease, and choledochal cysts are associated with cholangiocarcinoma.^[4] Physical examination should look for liver tenderness, stigmata of chronic liver disease, or general deterioration signs (fever, weight loss). High alkaline phosphatase, high lactate dehydrogenase (LDH), low albumin, high prothrombin time, and iron overload are non-specific but might suggest an underlying chronic hepatitis, cirrhosis or an infiltrative process.^[4] Hence, this study mainly intends to know the incidence, various modes of presentation, different modalities of diagnosis, treatment and prognosis in a rural setup, studied to identify factors which can help in better management of these cases thus helping to improve the prognosis and management care in primary hepatic space occupying lesions. **Aim:** To do the clinicopathological study and management of primary hepatic space occupying lesions. **Conclusion:** This study was carried out at Jawaharlal Nehru Medical College and Acharya Vinoba Bhave Rural Hospital, Sawangi(M), Wardha, Maharashtra, between July 2015 TO October 2017. → Out of 45 primary hepatic space occupying lesions in this study, most common lesion were liver abscess and hydatid cyst of liver and the most common neoplastic lesion was hepatocellular carcinoma. → USG was the imaging modality of choice and was highly effective in diagnosis with 100% sensitivity and specificity, although this is operator dependant. → Percutaneous drainage proved to be the best treatment modality in case of liver abscess with supportive therapy and was associated with less complications, which is suggestive that minimal invasive treatment is the need of the hour. → Partial cystectomy with omentoplasty was the treatment of choice in case of hydatid cyst of liver with better outcome. → Management in case of malignant lesions such as hepatocellular carcinoma and intrahepatic cholangiocarcinoma who presented in advanced stages was done by palliation and chemotherapy. → Cholangitis is the most common complication in our study, which is associated to the direct consequence of the disease or due to the iatrogenic causes such as instrumentation during surgery or any image guided procedure.

KEYWORDS: Liver, primary hepatic space occupying lesions, hydatid cyst, cholangiocarcinoma, liver abscess.

INTRODUCTION

The liver confounds the surgeon's dependence on anatomy. With its smooth, soft, shiny exterior the liver leaves a shadowy harmless first impression. Yet as those well acquainted with its ways could assure, it is one of the most difficult organ a surgeon can handle.^[1] Bismuth wrote in 1982, — The time when liver surgery was confined to atypical hepatectomies or wedge resections,

according to location or volume of a lesion, belongs to the past. At present, liver resections are based upon the precise knowledge of natural lines of division of the liver which define the anatomical surgery of the liver.^[1] Complete understanding of the surgical anatomy is essential for any practitioner who intervenes in the liver and biliary tract, which ever be the mode of intervention. The liver is the largest organ in the abdomen, weighing

about 1800 g in men and slightly less in women. A space occupying lesion by definition is a discrete abnormality arising within the liver. Space occupying lesions of the liver can be classified into developmental, neoplastic, inflammatory and miscellaneous. Although in some cases, it is difficult to distinguish these entities with imaging criteria alone, certain focal liver lesions have classic ultrasonic, computed tomographic (CT) and magnetic resonance (MR) imaging feature. The majority of these lesions are detected incidentally in asymptomatic patients.^[2,3] An accurate history and physical examination are essential for the diagnosis and treatment of solid liver masses. For example, the use of oral contraceptives or anabolic steroids might be related to hepatic adenoma (HA), alcohol use and occupational exposure are associated with angiosarcoma and primary sclerosing cholangitis, liver fluke, Caroli's disease, and choledochal cysts are associated with cholangiocarcinoma.^[4] Physical examination should look for liver tenderness, stigmata of chronic liver disease, or general deterioration signs (fever, weight loss). High alkaline phosphatase, high lactate dehydrogenase (LDH), low albumin, high prothrombin time, and iron overload are non-specific but might suggest an underlying chronic hepatitis, cirrhosis or an infiltrative process.^[4] Liver abscesses, both amebic and pyogenic, continue to be an important cause of morbidity and mortality in tropical countries. The primary mode of treatment of amebic liver abscess is medical; however, as many as 15% of amebic abscesses may be refractory to medical therapy. Also, secondary bacterial infection may complicate 20% of amebic liver abscesses. In recent years, imaging guided percutaneous drainage has been increasingly used to treat liver abscesses with reported success rates ranging from 70% to 100%.^[5] Cystic diseases of Liver constitute a large percentage of the liver space occupying lesion Hydatid disease of the liver is still endemic in certain parts of the world. The diagnosis of noncomplicated hydatid cyst of the liver depends on clinical suspicion. Ultrasonography and computed tomography, the most important diagnostic tools, are helpful for determining the complications and planning treatment. The modern treatment of hydatid cyst of the liver varies from surgical intervention to percutaneous drainage or medical therapy. Surgery is still the treatment of choice and can be performed by the conventional or laparoscopic approach. Percutaneous drainage and treatment of the cyst with hypertonic saline or alcohol seems to be a good alternative to surgery in selected cases. Currently, we treat types I and II by ultrasound-guided percutaneous drainage and types IV and V (excluding totally calcified cysts) surgically. Type III cysts can be managed either way depending on the presence of drainable content.^[6] Modern imaging techniques have led to the recognition of some incidental lesions that usually have no clinical relevance, e.g. simple liver cysts, liver capillary haemangiomas.. Simple hepatic cysts are a congenital abnormality that are usually asymptomatic, but, as with all lesions that may have either no clinical importance or may be part of a defined condition or syndrome (e.g.

polycystic kidneys, von HippelLindau disease), the prevalence and characteristics of these lesions within the population should be known.^[7] Hepatocellular carcinoma (HCC) is the most frequent primary liver malignancy and the third cause of cancer-related death in the Western Countries. The well-established causes of HCC are chronic liver infections such as hepatitis B virus or chronic hepatitis C virus, nonalcoholic fatty liver disease, consumption of aflatoxins and tobacco smoking. Clinical presentation varies widely; patients can be asymptomatic while symptomatology extends from right upper abdominal quadrant pain and weight loss to obstructive jaundice and lethargy. Imaging is the first key and one of the most important aspects at all stages of diagnosis, therapy and followup of patients with HCC. The Barcelona Clinic Liver Cancer Staging System remains the most widely classification system used for HCC management guidelines. Up until now, HCC remains a challenge to early diagnose, and treat effectively; treating management is focused on hepatic resection, orthotopic liver transplantation, ablative therapies, chemoembolization and systemic therapies with cytotoxic drugs, and targeted agents.^[8] Biliary tract cancer accounts for Cholangiocarcinoma (intrahepatic, hilar and distal) and gallbladder cancer, are distinguished with different pathogenesis and prognosis. The treatment is based on surgery, radiotherapy in selected cases, and chemotherapy. The standard cytotoxic treatment for advanced/metastatic disease is represented by the combination of gemcitabine and cisplatin, whereas fluoropyrimidines are generally administered in second line setting. At the present time, no biologic drug demonstrated a clear efficacy in this cancer, although the molecular characterisation could provide a promising basis for experimental treatments. A good supportive care and an early palliative care are warranted in most patients and should be delivered as a part of a global approach.^[9] Hence, this study mainly intends to know the incidence, various modes of presentation, different modalities of diagnosis, treatment and prognosis in a rural setup, studied to identify factors which can help in better management of these cases thus helping to improve the prognosis and management care in primary hepatic space occupying lesions.

AIM: To do the clinicopathological study and management of primary hepatic space occupying lesions.

OBJECTIVES

To study the clinical features and mode of presentation of different types of primary hepatic SOL in different age groups & sex.

To study different modalities of investigations available to diagnose various types of primary hepatic SOL.

To study various modes of management including complications, morbidity & mortality.

MATERIALS AND METHODS

This Present study was carried out at Acharya Vinoba Bhave Rural Hospital (AVBRH) of Jawaharlal Nehru Medical College between July 2015 to October 2017 in which total 45 cases of primary hepatic space occupying lesion which were studied prospectively. Type of Study: prospective study. Sample size : 45 cases. Sample Size Formula: $N = \frac{\chi^2 p(1-p)}{C^2(N-1) + p(1-p)}$ Where χ^2 is the chi-square value at 5% level of significance =3.84 N=Total no of cases of primary hepatic space occupying lesions in three years in AVBRH =108 C= Desired confidence interval =0.05 P=Proportion =0.50 $N = \frac{3.84*(0.5*0.5)}{+108*0.5*0.5} = 27.96$ In present study N =45 total patients Inclusion criteria: All patients more than 18 yrs having primary hepatic space occupying lesions. Exclusion criteria: Patients with suspected secondaries in liver Patient of bleeding diathesis. Patient on anticoagulant medication. Noncooperative patient who refuses to undergo the study.

Mode of study

After detailed history, complete general and systemic examinations, provisional diagnosis was done. Diagnosis was confirmed with the help of various diagnostic modalities like USG, CT scan & FNAC. USG was done in all cases but CT scan & FNAC were done in selected patients where the diagnosis was in doubt or more detailed information about the pathology was needed. Along with various diagnostic investigations, patients were subjected to routine investigations such as haemogram, liver function test, PTINR, kidney function test etc. to know the status of the disease, condition of the patient & feasibility for surgery/procedure. After

complete evaluation, mode of management was selected depending on extent of disease.

Statistical analysis

Statistical analysis was done by using descriptive and inferential statistics using chisquare test and software used in the analysis were SPSS 22.0 version and GraphPad Prism 6.0 version and p.

OBSERVATION AND RESULTS**Demographics**

In present study, it was observed that the youngest patient was 22 yrs who presented with amoebic liver abscess & the oldest was of 86 yrs diagnosed as pyogenic liver abscess & mean age of presenting PHSOL was 49.22 ± 15.69 yrs.

Liver abscess manifested most commonly in 7th Decade & mean age is 50.42 yrs. hydatid cyst of liver manifested most commonly in 4th decade & mean age is 45.85 yrs. hemangioma of liver manifested most commonly in 4th & 5th decade & mean age is 43.20 yrs. hepatocellular carcinoma manifested most commonly in 7th decade & mean age is 61.85 yrs. cholangiocarcinoma manifested most commonly in 3rd decade & mean age is 43.60 yrs. out of 45 cases, there were 33 males & 12 females showing male: female sex ratio of 2.75 :1.

In present study, liver abscess and hydatid cyst were more common in males.(92.86% & 71.43%). HCC was found in 5(71.43%) males & 2(28.57%) females. Intrahepatic cholangiocarcinoma was found in 3(60%) males & 2(40%) females. Hemangioma was found in 2(40%) males & 3 (60%) females.

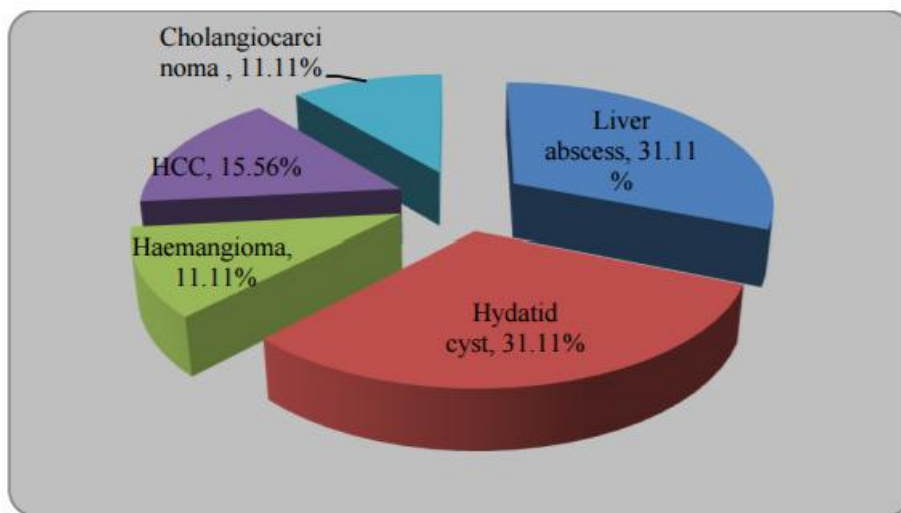
Symptoms of PHSOLs

| PHSOL | No. of cases | Pain in abdomen | Fever | Nausea / Vomiting | Loss of appetite | Abdominal lump |
|--------------------|---|-----------------|------------|-------------------|------------------|----------------|
| Liver abscess | 14 | 13(92.86%) | 12(85.71%) | 4(28.57%) | 7(50%) | 1(7.14%) |
| Hydatid cyst | 14 | 4(28.57%) | 2(14.29%) | 1(7.14%) | 4(28.57%) | 10(71.43%) |
| Hemangioma | 5 | 0(0%) | 0(0%) | 0(0%) | 0(0%) | 1(20%) |
| HCC | 7 | 5(71.43%) | 4(57.14%) | 2(28.57%) | 6(85.71%) | 3(42.86%) |
| Cholangiocarcinoma | 5 | 5(100%) | 3(60%) | 3(60%) | 4(80%) | 1(20%) |
| Total | 45 | 27(60%) | 21(46.67%) | 10(22.22%) | 21(46.67%) | 16(35.56%) |
| P value | 29.60, p-value=0.020, Significant, p<0.05 | | | | | |

Clinical Signs of PHSOLs

| PHSOL | No. of cases | Pallor | Icterus | Abdominal tenderness | Hepatomegaly | Abdominal lump |
|--------------------|----------------------------------|------------|-----------|----------------------|--------------|----------------|
| Liver abscess | 14 | 6(42.86%) | 2(14.29%) | 13(92.86%) | 12(85.71%) | 9(64.29%) |
| Hydatid cyst | 14 | 1(7.14%) | 0(0%) | 4(28.57%) | 13(92.86%) | 11(78.57%) |
| Haemangioma | 5 | 0(0%) | 0(0%) | 2(40%) | 1(20%) | 1(20%) |
| HCC | 7 | 3(42.86%) | 2(28.57%) | 6(85.71%) | 7(100%) | 4(57.14%) |
| Cholangiocarcinoma | 5 | 0(0%) | 5(100%) | 5(100%) | 1(20%) | 1(20%) |
| Total | 45 | 10(22.22%) | 9(20%) | 30(66.67%) | 34(75.56%) | 26(57.78%) |
| P value | 35.44,p-value=0.0035,Significant | | | | | |

USG finding of different PHSOLs



| PHSOL | No. of cases | Lesion size in (cm) | | | | P value = |
|--------------------|--------------|---------------------|------------|------------|-----------|---------------------|
| | | 1-5 cm | 6-10 cm | 11-15 cm | 16-20 cm | |
| Liver abscess | 14 | 0(0%) | 3(21.43%) | 10(71.43%) | 1(7.14%) | 31.22 P=0.0018,S |
| Hydatid cyst | 14 | 0(0%) | 9(64.29%) | 4(28.57%) | 1(7.14%) | |
| Haemangioma | 5 | 3(60%) | 1(20%) | 1(20%) | 0(0%) | |
| HCC | 7 | 0(0%) | 3(42.86%) | 3(42.86%) | 1(14.29%) | |
| Cholangiocarcinoma | 5 | 1(20%) | 4(80%) | 0(0%) | 0(0%) | |
| Total | 45 | 4(8.89%) | 20(44.44%) | 18(40%) | 3(6.67%) | |

Haematological investigations of different PHSOLS

| Blood investigation | Liver abscess(14) | Hydatid cyst(14) | Hemangioma(5) | HCC(7) | Cholangio Ca(5) |
|--------------------------|-------------------|------------------|---------------|-----------|-----------------|
| Hb (<10 gm/dl) | 7(50%) | 1(7.14%) | 0(0%) | 3(42.85%) | 2(40%) |
| TLC (> 11000 cell/dl) | 11(78.57%) | 2(14.29%) | 0(0%) | 2(28.57%) | 5(100%) |
| S albumin (<3g/dl) | 5(35.71%) | 0(0%) | 0(0%) | 1(14.29%) | 2(40%) |
| T bilirubin (>2.0 mg/dl) | 5(35.71%) | 1(7.14%) | 0(0%) | 1(14.29%) | 5(100%) |
| AST (>40 U/L) | 11(78.57%) | 10(71.43%) | 2(40%) | 6(85.71%) | 5(100%) |
| ALT (>40 U/L) | 10(71.43%) | 10(71.43%) | 2(40%) | 6(85.71%) | 5(100%) |
| ALP(>170 U/L) | 13(92.86%) | 12(85.71%) | 3(60%) | 7(100%) | 5(100%) |
| PT/INR (>18 sec/1.5) | 2(14.29%) | 0(0%) | 0(0%) | 0(0%) | 0(0%) |

Mode of management of PHSOLs

| PHSOL | Wait and watch | Medical | Embolisation | RFA | PCD | PAIR | Surgical |
|---------------------------|------------------------------------|-------------|--------------|------------|-------------|----------|-------------|
| Pyogenic liver abscess(2) | 0(0%) | 0(0%) | 0(0%) | 0(0%) | 2(100%) | 0(0%) | 0(0%) |
| Amebic liver abscess(12) | 0(0%) | 2(16.67%) | 0(0%) | 0(0%) | 10 (83.33%) | 0(0%) | 0(0%) |
| Hydatid (14) | 0(0%) | 3(21.43%) | 0(0%) | 0(0%) | 0(0%) | 1(7.14%) | 10 (71.43%) |
| Hemangioma(5) | 4(80%) | 0(0%) | 1(20%) | 0(0%) | 0(0%) | 0(0%) | 0(0%) |
| Hcc(7) | 0(0%) | 7(100%) | 0(0%) | 1 (14.29%) | 0(0%) | 0(0%) | 0(0%) |
| Cholangiocarcinoma (5) | 0(0%) | 5(100%) | 0(0%) | 1(20%) | 0(0%) | 0(0%) | 0(0%) |
| Total (45) | 4 (8.89%) | 17 (37.78%) | 1(2.22%) | 2 (4.44%) | 12 (26.67%) | 1(2.22%) | 10 (22.22%) |
| X2-value | 115.40,p-value=0.0001, Significant | | | | | | |

Post operative/ post procedure complications

| COMPLICATION/ LESION | Cystocutaneous Fistula | SSI | Cytsobilliary Fistula | Infection in Residual Cavity | Cholangitis | Pulmonary complications | Mortality |
|---|---------------------------|--------------|--------------------------|------------------------------------|----------------|----------------------------|---------------|
| PYOGENIC LIVER ABSCCESS(2) | 0(0%) | 0(0%) | 0(0%) | 0(0%) | 0(0%) | 1(50%) | 1(50%) |
| AMOEBIIC LIVER ABSCCESS(12) | 1(8.33%) | 0(0%) | 0(0%) | 2(16.67%) | 1(8.33%) | 2(16.67%) | 0(0%) |
| HYDATID(14) | 0(0%) | 1 (7.14%) | 1(7.14%) | 1(7.14%) | 2(14.29%) | 0(0%) | 0(0%) |
| HEMANGIOMA(5) | 0(0%) | 0(0%) | 0(0%) | 0(0%) | 0(0%) | 0(0%) | 0(0%) |
| HCC(7) | 0(0%) | 0(0%) | 0(0%) | 0(0%) | 2(28.57%) | 0(0%) | 3(42.86 %) |
| CHOLANGIOMACARCINOMA (5) | 0(0%) | 0(0%) | 0(0%) | 0(0%) | 5(100%) | 2(40%) | 2(40%) |
| Total (45) | 1 (2.22%) | 1 (2.22%) | 1 (2.22%) | 3 (6.67%) | 10 (22.22%) | 5 (11.11%) | 6 (13.33%) |
| X2-value 28.49,p- value=0.24, Not Significant | | | | | | | |

DISCUSSION**Demographic Features**

The present study was carried out in, Acharya Vinoba Bhawe Rural Hospital (AVBRH), Jawaharlal Nehru Medical College, Sawangi (Meghe), Wardha. Over the period from July 2015-October 2017, patients presenting with Primary Hepatic Space Occupying Lesions admitted in this hospital were taken in this study. Total 45 cases were studied prospectively. In our study maximum number of patients i.e. 14 were in the age group of 61-70 years, the youngest patient in our study was 22 years old while the eldest was 86 years with the mean age of 49.22±15.69. In studies conducted by Yeouda et al (1999),^[228] had maximum number of patients in the age group of 61-70 year. Also, studies conducted by Vishwanath et al (2013),^[229] and Hima bindu et al (2014),^[230] had maximum number of their patients in the age group of 41-50 year group. A study conducted by Parahjuli et al (2011),^[231] also had similar reports which were comparable to our study. In our present study of 45 patients, 33 patients were male and 12 patients were female giving the M: F ratio of 2.78: 1. Our finding was similar to Vishwanath et al (2013),^[229] and Roy sk et al (2015),^[232] However few studies such as Yeouda et al (1999),^[228] and Hima bindu et al (2014),^[230] have also shown equal predominance in males as well as females as compared to our study.

Signs and symptoms

In our study, the most common symptom was pain in abdomen 60% followed by loss of appetite and fever 46.67% each, with a significant p-value of 0.02. Similar

findings were seen in studies conducted by Yeouda et al (1999),^[228] Vishwanath et al (2013),^[229] & Hima bindu et al (2014),^[230] with most common sign as pain in abdomen followed by fever and weight loss, Although the percentage values were different because of the variation in the sample size due to inclusion of liver secondaries. In our present study, most common sign was hepatomegaly 75.56% followed by abdominal tenderness 66.67%. Our finding was similar to studies conducted by Yeouda et al (1999),^[228] Vishwanath et al (2013),^[229] & Hima bindu et al (2014),^[230] having hepatomegaly as the commonest sign followed by abdominal tenderness. In another study conducted by Basak NC et al (2017),^[233] showed similar outcome although the study included metastatic lesions.

USG findings

In our present study, solitary liver lesion was commonly found in 66.67% with most common lesion size range 6-10 cm 44%, followed by 11-15 cm 40%. The right lobe of liver was more commonly involved with incidence of 55.56%. A study conducted by Vishwanath et al (2013),^[229] had 62% of solitary lesions with 65% involvement of right lobe of liver. Also, in a study conducted by Hiral Hapani et al (2014),^[234] had 56% of solitary lesions with 56% involvement of right lobe of liver which was marginally less than the present study. However, in a study conducted by Richard Mspigeal et al (1978),^[235] significantly different results were observed in comparison to the present study as it includes only benign lesions.

Liver abscess

In our present study out of the 45 PHSOLs, 14 were found to be liver abscess with the mean age of 50.42 ± 17.65 years, most common incidence was in 7th decade & the M: F ratio was found to be 13:1. In the study conducted by Soumik et al (2014),^[236] had mean age of 41yrs with similar sex ratio of 13.3: 1. Also, studies conducted by A H Mohsen et al (2014),^[237] & Hyo Min et al (1993),^[238] had similar observations in view of mean age but were significantly different in sex ratio. A study conducted by Lodhi et al (2004),^[239] had similar observations and is comparable to our present study.

Signs and symptoms

Our present study, pain in abdomen 92.86% was the most common symptom followed by fever 85.71% & loss of appetite accounting for 50% of cases. In study conducted by Hyo min et al (1993)^[238] 85% cases had pain in abdomen & 71% cases had fever. Also studies conducted by A H Mohsen et al (2002),^[237] Lodhi et al, (2004),^[239] S singh et al,(2013),^[240] had similar observations as our present study. However, in a study conducted by Jonathan et al(2015),^[241] observed significantly different findings with 40% having pain in abdomen and 47% having fever. In our present study, abdominal tenderness 92.86% was the most common sign followed by hepatomegaly 85.71%. In studies conducted by Huang et al (1996)^[242] had 65% abdominal tenderness & 48% had hepatomegaly. However, study conducted by Lodhi et al (2004),^[239] had similar observations as our present study with 87% abdominal tenderness and 71% having hepatomegaly. Also, studies conducted by Mangukiya et al (2012),^[243] S singh et al (2013),^[82] had similar observation as our present study and were comparable.

Haeatological investigations

In our present study, Alakaline phophtase levels were elevated most commonly (92.86%) followed by leucocytosis in 78.57% of the patients. In studies conducted by Lok et al (2008) (44), low albumin levels were found in 92.8% of patients Leukocytosis (74.8%), increased alkaline phosphatase (72.1%), and elevated alanine aminotransferase levels (ALT; 58.6%). Also studies conducted by Hyo min et al(1993)(238), Haung et al(1996)(242), S. Singh et al(2013)(82) showed similar results and were comparable to our present study.

USG finding

In our study out of 14 cases of liver abscess, 78.57% cases involved the right lobe, 21.43% cases involved left lobe & none of the cases involved both the lobes. In the study conducted by S. Singh et al (2013), 80% cases of liver abscess involved the right lobe while 15% involved left lobe & 7% involved both the lobes. Also, the studies conducted by Hyo Min et al (1993),^[238] Lodhi et al (2004),^[239] Mangukiya et al (2012)^[243] had similar results and were comparable to our present study. A study conducted by Jonathan et al (2015)^[241] involved right

lobe in 59.5% cases, left lobe in 16.7% cases and both lobes in 23.8% cases which were found to be different as compared to our present study. The more common involvement of right lobe could be explained on the basis of a) There are blood channels divided into two halves and the major portion supplies the right lobe of the liver.

b) The bulk of right lobe is larger as compared to left lobe. In the present study, out of 14 liver abscess the maximum volume was found to be 900cc while the minimum was 160cc. In 3(21.43%) cases the volume was found to be between 100 -300 cc, in 4(28.57%) cases the volume was found to be between 301 -600 cc and in 7(50%) cases the volume was found to be between 601 -900 cc. In a study conducted by Singh et al (2013),^[82] observed that volume of abscess cavity was between 150 cc – 350 cc & only 2 cases were found to have volume between 600 – 900 cc.

Treatment

In our present study, 16.67% cases underwent only medical management & 85.71% cases underwent percutaneous drainage with supportive therapy. In a study conducted by A Mohsen et al (2002),^[237] 17.39% cases were treated by medical management alone, 18.9% underwent percutaneous drainage with supportive therapy & 14.5% underwent surgical management. Also studies conducted by Soumik et al (2014),^[236] showed comparable results to the current study. However, Hyo Min et al (1993)^[238] observed 21% surgical management and none of the patient underwent percutaneous drainage due to the lack of technique at that time. In our present study, the mean time of 50% reduction of abscess volume was 4 ± 1.6 days & most commonly the pigtail was removed between 6-9 days after insertion. The reduction in volume was checked by doing USG on 3rd day after pigtail insertion In a study conducted by S. Singh et al (2013)^[82] the mean time for reduction in volume was 4.9 ± 1.6 days & the pigtail was removed between 6 – 9 days after insertion. Rajak et al (1997)^[5] observed the mean time in reduction of abscess volume of 5 days and pigtail removal in a period of 7- 9 days. However, study conducted by Jonathan et al (2015)^[241] the pigtail was kept in situ for 14.4 ± 17.6 days which was different as compare to the present study.

Complications

In our present study out of 14 cases of liver abscess, 1(2.22%) developed cystocutaenous fistula, 2(16.67%) developed infected residual cavity, 1(8.33%) developed cholangitis, 3(21.42%) developed pulmonary complications & 1 (7.14%) died post operatively/ procedure. Complications such as hemorrhage, pleural effusion/ empyema, persistent bile drainage, catheter displacement, sepsis etc., have been reported with PCD 12% in the studies of Lambiase et al(1991).^[244] Baek et al (1993).^[245] described the much lower incidence of complications with PNA than with PCD as one of the major advantages of needle aspiration over catheter drainage. However, in our study and some studies like of

Rajak et al (1998),^[5] Yu et al,(2004),^[246] the procedures were found to be safe if performed properly with minimal complications. There was no mortality in either of the study groups.

Hydatid cyst of liver

Demographics

In our present study of the 45 PHSOLs, 14 were of hydatid cyst of liver and they manifested most commonly in 4th decade & mean age was 45.85 yrs, with M: F sex ratio of 2.5: 1.

On comparing the various studies with our present study, it was observed that the studies conducted by Palanivelu et al (2006),^[249] & Mergen et al (2007),^[251] had mean age similar & had male preponderance. On the contrary, the studies conducted by Ahmet et al (1999)^[247] Yorganci et al (2002),^[248] & Daradekh et al (2006)^[250] had similarities in mean age with our study but had female preponderance.

Signs and symptoms

In our study out of 14 cases of hydatid cyst, 71.43% had complaint of lump in abdomen & 28.57% had complaints of pain in abdomen. the commonest sign was observed as hepatomegaly in 85.71% cases. In studies conducted by Ahmet et al (1999),^[247] Yorganci et al (2002),^[248] Palanivelu et a(2006)^[249] Mergen et al (2007)^[251] had contrasting observations as compared to our present study in view of symptoms, as they had abdominal pain as their most common symptom, which is suggestive that the maximum patients in their study came in the infective stage Although hepatomegaly was seen as the most common sign in these studies which is similar to our present study. In a recent study conducted by Ankit kayal et al (2014),^[252] had similar results as our present study and lump in abdomen was the most common symptom, even if the percentage is different but the more amount of patients presented with lump in abdomen and commonest sign was hepatomegaly.

Imaging studies

In our present study out of 14 cases of hydatid cyst, 7(50%) had solitary lesion, 7(50%) had multiple lesions, 6(42.86%) cases involved the right lobe, 4(28.57%) cases involved left lobe & 4(28.57%) cases involved both the lobes. In studies conducted by Yorganci et al (2002),^[248] Yagci et al (2005)^[253] & Mergen et al (2007)^[251] in turkey, observed similar findings with right lobe of liver with 72.6%, 64.78%, 73.1% respectively predominantly involving right lobe, but differed in the percentage of lesions having more number of solitary lesion 71%, 68%, 69% respectively. Also studies conducted by El tahir et al (1992)^[132] & another study conducted by Palanivelu et al (2006)^[249] had similar observations which can be compared with our study.

Treatment

In our present study out of 14 cases of hydatid cyst, 21.43% underwent medical management, 71.43%

underwent surgical management & 7.14% patient underwent puncture aspiration injection and re-aspiration (PAIR). The management was decided by considering factors like patient's age, general condition, systemic disease, American Society of Anesthesiologists (ASA) values, viral hepatitis markers, radiological images, liver function tests. Medical management included, oral Albendazole 400mg BD over a period of 21 days followed by 7 days withholding time, followed by another cycle. It was given in patients with multiple cysts in two or more organs, or peritoneal cysts.^[128]

The facilities for radical liver surgeries were not available at our centre, hence the patients mainly underwent conservative surgery in the form of Partial Cyctectomy with Omentoplasty. Yagci et al (2005),^[253] observed similar outcome in his study, with 39.4% patients undergoing PAIR, 56.61% patients undergoing conservative surgery & only 4% underwent radical surgery. None of the patients in this study underwent solely medical treatment. Also Elzer et al (2004),^[255] & Yorganci, et al (2002)^[248] observed similar findings which have been compared in table above In a recent study, conducted by Sami et al (2010)^[256] it was observed that 69.5% patient underwent conservative surgery, while 30.5% underwent radical surgery.

Complications

In our present study out of 14 cases of hydatid cyst, 7.14% developed surgical site infection, 7.14% developed cystobiliary fistula, 7.14% developed infected residual cavity & 14.29% developed cholangitis. In a study conducted by Ahmet et al (1999),^[247] most common complication was infected residual cavity with 29.5% in PAIR patients & 4.5% in omentoplasty patients, 6.6% developed cholangitis, 8.9% developed cystobilliary fistula which resolved spontaneously. Daradekh et al (2006)^[250] observed most common complication as cystobilliary fistula 15.6%, infected residual cavity in 11% & pulmonary complications in 7% patients. The overall morbidity rate of this series was 53.8%, for which the author gave an explanation that 37.8% of these presented with pre-existing comorbidities.

Hemangioma

Demographics

In our present study, there were 5 patients of hemangioma. The mean age was 45 years and the male: female sex ratio was 1:1.5.

On comparison with the other three studies done by Gandolfi et al (1991)^[257] & Gedaly et al(1999)^[258] there was similarity in the mean age. Recent studies done by Arash et al (2011)^[259] showed similar demographic data & increased female preponderance.

Signs and Symptoms of hemangioma

In this study lump per abdomen was the most common symptom (25%). Most common signs were Hepatomegaly and Abdominal tenderness 20%.

Investigations

In the present study, 5 cases were diagnosed as hemangioma of liver in which hematological and liver function tests were within normal limits. In various studies chronic anemia is not uncommon in patients requiring surgical excision. 12 of 24 (severe in two cases) in the series of Belli *et al.*^[260] and 6 of 49 in the series of Trastek *et al.*^[261] The only study with a low incidence of anemia was in that of Kato *et al.*^[262] with 1 of 55 patients who had anemia. Imaging studies in 4 out of 5 patients, the hemangioma was an incidental finding, CECT abdomen was done in one of the patient presenting with giant hemangioma and clinically had abdominal lump along with tenderness and hepatomegaly. Anaemia was also present in this patient.

Treatment

In our study maximum patients were treated by wait and watch technique, only one patient underwent Transarterial embolisation as the size of the hemangioma was large and the patient was symptomatic. This procedure was done under interventional radiology, transarterial embolisation after which the patient was referred to higher centre for surgery as the facility for liver resection and haemostasis were not available in our hospital.

Hepatocellular carcinoma

Demographics

In our present study of the 45 PHSOLs, 7 were found to be hepatocellular carcinoma with the mean age of 61.85 years, most common incidence was in 7th decade & the M: F ratio was found to be 2.5:1. On comparison of our present study with studies conducted by Nelly *et al.* (2000),^[263] & Thomasset *et al.* (2015)^[268] had their demographic distribution similar with mean age being 56 yrs, 58yrs and sex ratio of 2.8:1, 3.5 :1 respectively. Also in the other studies conducted by Saini *et al.* (2006),^[264] R kumar *et al.* (2008)^[265] & yin *et al.* (2012)^[267] had similar observations as shown in table above, and mainly had more number of male cases which has been mainly linked with increased alcohol and HBV infection. In contrast with our present study, the observations made by Shashi bhalla *et al.* (2011),^[266] had lower mean age of incidence (45 years).

Signs and symptoms

In our present study, the commonest symptom was loss of appetite/weight 85.71% and the most common sign was hepatomegaly 100%.

Liver function

In our present study out of the 7 cases of HCC, 14.29% cases had S albumin 2.0 mg/dl, 85.71% cases had AST >40 U/L, 85.71% cases had ALT >40 U/L & 100% cases

had ALP >170 U/L. There was no significant derangement seen in the serum bilirubin & serum albumin level, although the sample size of our study is small and the results may vary on comparison. On comparing our current study with Llovet *et al.* (2008)^[269] who studied the effect of sorafenib in advanced HCC, observed similar findings with the mean serum albumin & serum bilirubin levels 3.9 g/dl & 0.7 g/dl respectively. The cases in this study mainly consisted of child pugh score A in view of liver function test.

USG finding

In our present study, USG assessment was done regarding size, site & no. of lesions. Out of the 7 cases of HCC, 3(42.86%) cases had lesion size 6-10 cm, 3(42.86%) cases had lesion size 10 -15 cm, 1(14.29%) cases had lesion size 16-20 cm, 5(71.43%) cases involved the right lobe, none involved left lobe, 2(28.57%) cases involved both the lobes, 4(57.14%) had solitary lesion & 3(42.86%) had multiple lesions. In studies conducted by Gellati *et al.* (2003),^[270] observed that 69% patients had multiple lesions & 55.1% patients had tumor size between 2-5 cm. Also studies conducted by R kumar *et al.* (2008),^[265] Shashi bhalla *et al.*, 2011^[266] Nelly *et al.* (2000)^[263] observed predominant involvement of right lobe of liver, similar tumor size ranging maximally from 1- 10 cm & more no. of solitary lesion. Dubbins *et al.* (1991)^[271] in his study over USG findings and diagnosis via USG of hepatocellular carcinoma observed similar results in terms of site of tumor as both the lobes of liver were involved in 63 % cases and 63% cases had multiple lesions which was contrasting to our present study.

Imaging studies & Cytopathological relations In our present study, USG was done in all the PHSOLs and CECT abdomen was done in all the malignancy patients which was then followed by FNAC/FNAB. Out of the 7 patients of HCC, the FNAC was positive in all the patients with a result of primary hepatocellular carcinoma.

Treatment

Out of 7 cases of HCC, 7(100%) underwent medical management in the form of chemotherapy, 1(14.29%) underwent radiofrequency ablation. On comparing the present study with the various studies in the above table, Nelly *et al.* (2000)^[263] Gellati *et al.* (2003)^[270] Saini *et al.* (2006)^[264] & Borie *et al.* (2008)^[273] had similar management with chemotherapy being the most common choice of treatment, only few underwent Radiofrequency ablation and curative surgery with R0 resection. However, in a recent study conducted by Takayoshi *et al.* (2016)^[272] at a centre in Osaka, Japan had most common line of treatment as major and minor hepatectomies (92.5%). This was possible because of early screening of the patients & early diagnosis followed by due follow up, yet out of the 30 patients 1 died and 6 survived for 8 years and the other 23 developed recurrence which were treated with chemotherapy and radiofrequency ablation.

In our present study, plenty of limitations are present in view of treatment modality of HCC. Patients usually presented in advanced stage of the disease & lack of facilities for liver surgeries and non availability of various newer advancement in management of HCC such as TACE etc.

Intrahepatic cholangiocarcinoma

Demographics

In our present study, 5 patients were of intrahepatic cholangiocarcinoma. Patients manifested most commonly in 3rd decade & mean age is 43.60 yrs. It was found in 3(60%) males & 2(40%) females.

On comparison of our present study, mean age in intrahepatic cholangiocarcinoma 44yrs and a M : F sex ratio of 1.5 :1 showing male preponderance with various studies mentioned in table above, it was observed that study by Weber et al(2001)(204), Gugliemi et al(2009)(275), Ahmad Ramzi et al(2012)(276) & Yan Ming Zhou et al(2014)(277) had equivocality with our study in terms of sex ratio but slightly differed in the mean age of the patients.

Signs and symptoms

In our present study, the most commonest symptom is pain in abdomen 100% followed by loss of appetite 80% while the most common sign seen in the patient was icterus 100%, although the sample size is small but these findings were found to be significant. The studies conducted by R T Schlinkert et al(1991),^[274] Roayaie et al(1998)^[198] & Endo et al(2008)^[199] have commonest symptom of presentation as pain in abdomen and sign as icterus, but they differ in the percentage with the present study which is mainly due to proper and early screening techniques in patients presenting in premalignant states and large amount of sample size.

Haematological study

In intrahepatic cholangiocarcinoma out of the 5 cases, 40% cases had Hb 11000 cell/dl, 40% cases had S albumin 2.0 mg/dl, 100% cases had AST >40 U/L, 100% cases had ALT >40 U/L & 100% cases had ALP >170 U/L. The raised bilirubin levels (70% & mean = 15.7) is further indicative of biliary obstruction and it is also an indicator for unresectability of the tumor, Roayaie and colleagues (1998)^[198] concluded that jaundice as a presenting symptom is predictive of unresectable disease because of significant involvement of inflow structures bilaterally or the presence of massive parenchymal replacement.

Treatment

In our present study, the patients mainly presented in advanced stage of the disease, so the main domain of treatment was by chemotherapy and palliation 100%. As most of our cases presented with jaundice and elevated serum bilirubin levels, they were first subjected to percutaneous transhepatic biliary drainage and internal stenting (PTBD) which was followed by systemic

chemotherapy in the form of Gemcitabine and Carboplatin, patients also presented with pre existing co-morbidities which were detrimental in the final outcome of the patient.

Complications

In our study, Out of 5 cases of intrahepatic cholangiocarcinoma, 5 (100%) developed cholangitis, 2(40%) developed pulmonary complications & 2 (40%) died. The late presentation of the patients with advanced stage of disease was very much responsible for the outcome. The complications found in our study were commonly found in various studies mentioned in table above, but there was marked difference in the percentage of patients involved. This difference was seen due to the difference in the sample size of various studies when compared to our present study. One of the commonest complications which were seen in all the studies with surgical dominance was recurrence which was then followed by cholangitis and mortality.

CONCLUSION

This study was carried out at Jawaharlal Nehru Medical College and Acharya Vinoba Bhave Rural Hospital, Sawangi(M), Wardha, Maharashtra, between July 2015 TO October 2017. → Out of 45 primary hepatic space occupying lesions in this study, most common lesion were liver abscess and hydatid cyst of liver and the most common neoplastic lesion was hepatocellular carcinoma. → USG was the imaging modality of choice and was highly effective in diagnosis with 100% sensitivity and specificity, although this is operator dependant. → Percutaneous drainage proved to be the best treatment modality in case of liver abscess with supportive therapy and was associated with less complications, which is suggestive that minimal invasive treatment is the need of the hour. → Partial cystectomy with omentoplasty was the treatment of choice in case of hydatid cyst of liver with better outcome. → Management in case of malignant lesions such as hepatocellular carcinoma and intrahepatic cholangiocarcinoma who presented in advanced stages was done by palliation and chemotherapy. → Cholangitis is the most common complication in our study, which is associated to the direct consequence of the disease or due to the iatrogenic causes such as instrumentation during surgery or any image guided procedure.

RECOMMENDATIONS

Detailed history, thorough clinical examination is very important to reach correct clinical diagnosis of primary hepatic space occupying lesions. → USG abdomen should be considered as first investigation of choice for diagnosing PHOLs. → In patients of liver abscess with size of abscess cavity.

REFERENCE

1. Martins AC de A, Martins C. History of liver anatomy: Mesopotamian liver clay models. *HPB.*, 2013; 15(4): 322–3.

2. Premashis kar et al – imaging of space occupying lesions of liver –medicine Update, 2011.
3. Cong W-M, Dong H, Tan L, Sun X-X, Wu M-C. Surgicopathological classification of hepatic space-occupying lesions: A single-center experience with literature review. *World J Gastroenterol WJG.*, 2011 May 21; 17(19): 2372–8.
4. Assy N, Nasser G, Djibre A, Beniashvili Z, Elias S, Zidan J. Characteristics of common solid liver lesions and recommendations for diagnostic workup. *World J Gastroenterol WJG.*, 2009 Jul 14; 15(26): 3217–27.
5. Rajak. Percutaneous treatment of liver abscesses: needle aspiration versus catheter drainage. : *American Journal of Roentgenology*: Vol. 170, No. 4 (AJR) [Internet]. [cited 2017 Oct 17]. Available from: <http://www.ajronline.org/doi/abs/10.2214/ajr.170.4.9530055>.
6. Sayek I, Onat D. Diagnosis and treatment of uncomplicated hydatid cyst of the liver. *World J Surg.*, 2001 Jan; 25(1): 21–7.
7. Gnarra M, Behr G, Kitajewski A, Wu JK, Anupindi SA, Shawber CJ, et al. History of the infantile hepatic hemangioma: From imaging to generating a differential diagnosis. *World J Clin Pediatr.*, 2016 Aug. 8; 5(3): 273–80.
8. Dimitroulis D, Damaskos C, Valsami S, Davakis S, Garmpis N, Spartalis E, et al. From diagnosis to treatment of hepatocellular carcinoma: An epidemic problem for both developed and developing world. *World J Gastroenterol.*, 2017 Aug. 7; 23(29): 5282–94.
9. Squadroni M, Tondulli L, Gatta G, Mosconi S, Beretta G, Labianca R. Cholangiocarcinoma. *Crit Rev Oncol Hematol*, 2017 Aug.; 116: 11–31.
10. Celsus AC, Spencer WG. *De medicina* [Internet]. Cambridge, Mass.: Harvard university press; London : W. Heinemann, ltd, 1935. [cited 2017 Oct 17].
11. Androulakis J, Colborn GL, Skandalakis PN, Skandalakis LJ, Skandalakis JE. EMBRYOLOGIC AND ANATOMIC BASIS OF DUODENAL SURGERY. *Surg Clin.*, 2000 Feb. 1; 80(1): 171–99.
12. Biliary tract disease since antiquity. [Internet]. [cited 2017 Oct 17]. Available from: <https://www.ncbi.nlm.nih.gov/pmc/articles/PMC1749880/>.
13. Chakrovorty RC, Wanebo HJ. Historic preamble: liver and biliary cancer. *Hepatic Biliary Cancer Marcel Dekker N Y.*, 1987; 13.
14. Fortner JG, Blumgart LH. A historic perspective of liver surgery for tumors at the end of the millennium. *J Am Coll Surg.*, 2001; 193(2): 210–222.
15. IV. Surgical Treatment of Tumor of the Liver, with the Report of a Case, [cited 2017 Oct 17].
16. Kousnetzoff M, Pensky J. Sur la resection partielle du foie. *Rev Chir.*, 1896; 16(501): 954.
17. Garrè C. On resection of the liver. *Surgical Publishing Company of Chicago*, 1906.
18. Pringle JH. V. Notes on the arrest of hepatic hemorrhage due to trauma. *Ann Surg.*, 1908; 48(4): 541.
19. Fong Y, Blumgart LH: Useful stapling techniques in liver surgery, *J Am Coll Surg*, 1997; 185: 93-100.
20. Jarnagin WR, Gonen M, Fong Y, DeMatteo RP, Ben-Porat L, Little S, et al. Improvement in perioperative outcome after hepatic resection: analysis of 1,803 consecutive cases over the past decade. *Ann Surg.*, 2002; 236(4): 397.
21. Pack GT, Islami AH, Hubbard JC, Brasfield RD. Regeneration of human liver after major hepatectomy. *Surgery.*, 1962; 52(4): 617–623.
22. Blumgart LH, Leach KG, Karran SJ. Observations on liver regeneration after right hepatic lobectomy. *Gut.*, 1971; 12(11): 922–928.
23. Quattlebaum JK. Massive resection of the liver. *Ann Surg.*, 1953; 137(6): 787.
24. Serrea P, Brunschwig A. Freezing of liver parenchyma with liquid nitrogen for hemostasis in excisional liver surgery: an experimental study. *Cancer*, 1955; 8: 1234–1238.
25. Fortner JG, Kim DK, Maclean BJ, Barrett MK, Iwatsuki S, Turnbull AD, et al. Major hepatic resection for neoplasia: personal experience in 108 patients. *Ann Surg.*, 1978; 188(3): 363.
26. Tabuse K. A new operative procedure of hepatic surgery using a microwave tissue coagulator, 1979.
27. Papachristou DN, Barters R. Resection of the liver with a water jet. *Br J Surg.*, 1982; 69(2): 93–94.
28. Hodgson WJ, DelGuercio LR. Preliminary experience in liver surgery using the ultrasonic scalpel. *Surgery*, 1984; 95(2): 230–234.
29. Hochwald SN, Blumgart LH. Giant hepatic hemangioma with Kasabach–Merritt syndrome: is the appropriate treatment enucleation or liver transplantation? *HPB Surg.*, 2000; 11(6): 413–419.
30. Cardinale V, Wang Y, Carpino G, Alvaro D, Reid L, Gaudio E. Multipotent stem cells in the biliary tree. *Ital J Anat Embryol*, 2010; 115(1/2): 85.
31. Claude Couinaud | Gastroenterology | JAMA Surgery | The JAMA Network [Internet]. [cited 2017 Oct 17].
32. Clinically Oriented Anatomy - Keith L. Moore, Arthur F. Dalley, A. M. R. Agur. [cited 2017 Oct 17].
33. Bismuth H. Surgical anatomy and anatomical surgery of the liver. *World J Surg.*, 1982; 6(1): 3–9.
34. Abdel-Misih SRZ, Bloomston M. Liver Anatomy. *Surg Clin North Am.*, 2010 Aug; 90(4): 643–53.
35. Jamieson GG. The anatomy of general surgical operations. Elsevier Health Sciences, 2006.
36. Kogure K, Ishizaki M, Nemoto M, Kuwano H, Yorifuji H, Ishikawa H, et al. Close relation between the inferior vena cava ligament and the caudate lobe in the human liver. *J Hepato-Biliary-Pancreat Sci.*, 2007; 14(3): 297–301.
37. Skandalakis JE, Skandalakis LJ, Skandalakis PN, Mirilas P. Hepatic surgical anatomy. *Surg Clin.*, 2004; 84(2): 413–435.

38. Blumgart LH. Surgery of the liver, biliary tract, and pancreas, 2007.
39. Ger R. Surgical anatomy of the liver. *Surg Clin North Am.*, 1989; 69(2): 179–192.
40. Van Gulik TM, de Graaf W, Dinant S, Busch OR, Gouma DJ. Vascular occlusion techniques during liver resection. *Dig Surg.*, 2007; 24(4): 274–281.
41. Fraser R, Dobbs BR, Rogers GW. Lipoproteins and the liver sieve: the role of the fenestrated sinusoidal endothelium in lipoprotein metabolism, atherosclerosis, and cirrhosis. *Hepatology*, 1995; 21(3): 863–874.
42. Chunyue Yin,¹ Kimberley J. Evason,² Kinji Asahina,³ and Didier Y.R. Stainier¹ Hepatic stellate cells in liver development, regeneration, and cancer *J Clin Invest.* 2013 May 1; 123(5): 1902–1910.
43. Meddings L, Myers RP, Hubbard J, Shaheen AA, Laupland KB, Dixon E, et al. A population-based study of pyogenic liver abscesses in the United States: incidence, mortality, and temporal trends. *Am J Gastroenterol.* 2010; 105(1): 117.
44. Lok K-H, Li K-F, Li K-K, Szeto M-L. Pyogenic liver abscess: clinical profile, microbiological characteristics, and management in a Hong Kong hospital. *J Microbiol Immunol Infect.* 2008; 41(6): 483–490.
45. Lai H-C, Lin C-C, Cheng K-S, Kao J-T, Chou J-W, Peng C-Y, et al. Increased incidence of gastrointestinal cancers among patients with pyogenic liver abscess: a populationbased cohort study. *Gastroenterology.* 2014; 146(1): 129–137.
46. Chou F-F, Sheen-Chen S-M, Chen Y-S, Chen M-C. Single and multiple pyogenic liver abscesses: clinical course, etiology, and results of treatment. *World J Surg.*, 1997; 21(4): 384–389.
47. Seeto RK, Rockey DC. Pyogenic liver abscess changes in etiology, management, and outcome. *Medicine (Baltimore).*, 1996; 75(2): 99–113.
48. Chang FY, Chou MY. Comparison of pyogenic liver abscesses caused by *Klebsiella pneumoniae* and non-*K. pneumoniae* pathogens. *J Formos Med Assoc Taiwan Yi Zhi.*, 1995; 94(5): 232–237.
49. Cosme A, Ojeda E, Zamarreño I, Bujanda L, Garmendia G, Echeverría MJ, et al. Pyogenic versus amoebic liver abscesses. A comparative clinical study in a series of 58 patients. *Rev Esp Enferm Dig.*, 2010; 102(2): 90.
50. Chen W, Tsai W, Chen C, Hsu W, Shih C. Outcome and Prognostic Factors of Patients with Pyogenic Liver Abscess Requiring Intensive Care. *Respirology.* 2006; 11: A209.
51. Yang DM, Kim HN, Kang JH, Seo TS, Park CH, Kim HS. Complications of pyogenic hepatic abscess: computed tomography and clinical features. *J Comput Assist Tomogr.*, 2004; 28(3): 311–317.
52. Jeffrey Jr RB, Tolentino CS, Chang FC, Federle MP. CT of small pyogenic hepatic abscesses: the cluster sign. *Am J Roentgenol.* 1988; 151(3): 487–489.
53. Ng FH, Wong WM, Wong BCY, Kng C, Wong SY, Lai KC, et al. Sequential intravenous/oral antibiotic vs. continuous intravenous antibiotic in the treatment of pyogenic liver abscess. *Aliment Pharmacol Ther.*, 2002; 16(6): 1083–1090.
54. Johannsen EC, Sifri CD, Madoff LC. Pyogenic liver abscesses. *Infect Dis Clin North Am.*, 2000; 14(3): 547–563.
55. Bowers ED, Robison DJ, Doberneck RC. Pyogenic liver abscess. *World J Surg.*, 1990; 14(1): 128–132.
56. Chung YF. Pyogenic liver abscess—predicting failure to improve outcome. *Neth J Med.*, 2008; 66(5): 183–184.
57. Mølle I, Thulstrup AM, Vilstrup H, Sørensen HT. Increased risk and case fatality rate of pyogenic liver abscess in patients with liver cirrhosis: a nationwide study in Denmark. *Gut.*, 2001; 48(2): 260–263.
58. Li E, Stanley SL. Protozoa. *Gastroenterol Clin.*, 1996; 25(3): 471–492.
59. Ximénez C, Morán P, Rojas L, Valadez A, Gómez A. Reassessment of the epidemiology of amebiasis: state of the art. *Infect Genet Evol.*, 2009; 9(6): 1023–1032.
60. Guerrant RL. The global problem of amebiasis: current status, research needs, and opportunities for progress. *Rev Infect Dis.*, 1986; 8: 218–227.
61. Tannich E, Horstmann RD, Knobloch J, Arnold HH. Genomic DNA differences between pathogenic and nonpathogenic *Entamoeba histolytica*. *Proc Natl Acad Sci.*, 1989; 86(13): 5118–5122.
62. Stanley SL. Vaccines for amoebiasis: barriers and opportunities. *Parasitology.* 2006; 133(S2): S81–S86.
63. Irusen EM, Jackson T, Simjee AE. Asymptomatic intestinal colonization by pathogenic *Entamoeba histolytica* in amebic liver abscess: prevalence, response to therapy, and pathogenic potential. *Clin Infect Dis.*, 1992; 14(4): 889–893.
64. Thomas PG, Ravindra KV. *Amoebiasis and biliary infection. Surg Liver Ad Biliary Tract 3rd Ed* N Y Saunders WB Impr-Elsevier Sci., 2000; 916–918.
65. Agarwal DK, Bajjal SS, Roy S, Mittal BR, Gupta R, Choudhuri G. Percutaneous catheter drainage of amebic liver abscesses with and without intrahepatic biliary communication: a comparative study. *Eur J Radiol.*, 1995; 20(1): 61–64.
66. Loulergue P, Mir O. Pleural empyema secondary to amebic liver abscess. *Int J Infect Dis.*, 2009; 13(3): e135–e136.
67. Kapoor OP, Joshi VR. Multiple amoebic liver abscesses. A study of 56 cases. *J Trop Med Hyg.*, 1972; 75(1): 4–6.
68. Baxt LA. Characterization of a rhomboid protease in *Entamoeba histolytica*. Stanford University, 2010.
69. DeBAKEY ME, Ochsner A. Hepatic amebiasis; a 20 year experience and analysis of 263 cases. *Surg Gynecol Obstet.*, 1951; 92(3): 209.
70. Martinez-Palomo A. In Martinez-Palomo A. ed:—*Amebiasis: Human Parasitic Diseases.* Elsevier Biomed. Div. Amsterdam, 1986.

71. Ralls PW, Colletti PM, Quinn MF, Halls J. Sonographic findings in hepatic amebic abscess. *Radiology*, 1982; 145(1): 123–126.
72. Sukov RJ, Cohen LJ, Sample WF. Sonography of hepatic amebic abscesses. *Am J Roentgenol*, 1980; 134(5): 911–915.
73. Kurland JE, Brann OS. Pyogenic and amebic liver abscesses. *Curr Gastroenterol Rep.*, 2004; 6(4): 273.
74. Malik AA, Bari SU, Rouf KA, Wani KA. Pyogenic liver abscess: Changing patterns in approach. *World J Gastrointest Surg.*, 2010; 2(12): 395.
75. Kimura K, Stoopen M, Reeder MM, Moncada R. Amebiasis: modern diagnostic imaging with pathological and clinical correlation. In: *Seminars in roentgenology*. Elsevier, 1997; 250–275.
76. Radin DR, Ralls PW, Colletti PM, Halls JM. CT of amebic liver abscess. *Am J Roentgenol*, 1988; 150(6): 1297–1301.
77. Restrepo MI, Restrepo Z, Villareal CLE, Aguirre A, Restrepo M. Diagnostic tests for amoebic liver abscess: comparison of enzyme-linked immunosorbent assay (ELISA) and counterimmunoelectrophoresis (CIE). *Rev Soc Bras Med Trop.*, 1996; 29(1): 27–32.
78. Hira PR, Iqbal J, Al-Ali F, Philip R, Grover S, D'Almeida E, et al. Invasive amebiasis: challenges in diagnosis in a non-endemic country (Kuwait). *Am J Trop Med Hyg.*, 2001; 65(4): 341–345.
79. Ormaechea TG, de Fuentes Corripio I. Amebiasis En España: Diagnóstico Molecular Y Estudio Epidemiológico De Una Parasitosis Emergente.
80. Chavez-Tapia NC, Hernandez-Calleros J, Tellez-Avila FI, Torre A, Uribe M. Imageguided percutaneous procedure plus metronidazole versus metronidazole alone for uncomplicated amoebic liver abscess. *Cochrane Libr.* 2009.
81. Khanna S, Chaudhary D, Kumar A, Vij JC. Experience with aspiration in cases of amebic liver abscess in an endemic area. *Eur J Clin Microbiol Infect Dis.*, 2005; 24(6): 428–430.
82. Singh O, Gupta S, Moses S, Jain DK. Comparative study of catheter drainage and needle aspiration in management of large liver abscesses. *Indian J Gastroenterol*, 2009; 28(3): 88–92.
83. Jain NK, Madan A, Sharma TN, Sharma DK, Mandhana RG. Hepatopulmonary amoebiasis. Efficacy of various treatment regimens containing dehydroemetine and/or metronidazole. *J Assoc Physicians India*, 1990; 38(4): 269–271.
84. Stanley SL. Amebiasis. *The Lancet.*, 2003; 361(9362): 1025–1034.
85. Thompson Jr JE, Forlenza S, Verma R. Amebic liver abscess: a therapeutic approach. *Rev Infect Dis.*, 1985; 7(2): 171–179.
86. Khan R, Hamid S, Abid S, Jafri W, Abbas Z, Islam M, et al. Predictive factors for early aspiration in liver abscess. *World J Gastroenterol WJG.*, 2008; 14(13): 2089.
87. Sharma MP, Dasarathy S, Verma N, Saksena S, Shukla DK. Prognostic markers in amebic liver abscess: a prospective study. *Am J Gastroenterol*, 1996; 91(12).
88. Wells, Christopher D., and Miguel Arguedas. "Amebic liver abscess." *Southern Medical Journal*, July 2004, p. 673+. Academic OneFile, Accessed 1 Nov, 2017.
89. Balasegaram M: Management of hepatic abscess, *Current Problems in Surgery*, May, 1981; 18(5): 281-340.
90. Brunetti E, Kern P, Vuitton DA. Expert consensus for the diagnosis and treatment of cystic and alveolar echinococcosis in humans. *Acta Trop.*, 2010; 114(1): 1–16.
91. Thompson RCA, Jenkins DJ. Echinococcus as a model system: biology and epidemiology. *Int J Parasitol*, 2014; 44(12): 865–877.
92. Larrieu EJ, Frider B. Human cystic echinococcosis: contributions to the natural history of the disease. *Ann Trop Med Parasitol*, 2001; 95(7): 679–687.
93. Romig T. Epidemiology of echinococcosis. *Langenbecks Arch Surg.*, 2003; 388(4): 209–217.
94. Derbel F, Mabrouk MB, Hamida MBH, Mazhoud J, Youssef S, Ali AB, et al. Hydatid Cysts of the Liver - Diagnosis, Complications and Treatment. 2012. [cited 2017 Oct 19].
95. Bourée P. Hydatidosis: dynamics of transmission. *World J Surg.*, 2001; 25(1): 4–9.
96. Krige JEJ, Beckingham IJ. Liver abscesses and hydatid disease. *BMJ.*, 2001; 322(7285): 537.
97. Krige JEJ, Beckingham IJ. ABC of diseases of liver, pancreas, and biliary system: liver abscesses and hydatid disease. *BMJ.*, 2001; 322(7285): 537.
98. Vuitton DA. Echinococcosis and allergy. *Clin Rev Allergy Immunol*, 2004; 26(2): 93–104.
99. Pitt HA, Korzellus J, Tompkins RK. Management of hepatic echinococcosis in Southern California. *Am J Surg.*, 1986; 152(1): 110–115.
100. Gharbi HA, Hassine W, Brauner MW, Dupuch K. Ultrasound examination of the hydatid liver. *Radiology.*, 1981; 139(2): 459–463.
101. Beggs I. The radiological appearances of hydatid disease of the liver. *Clin Radiol.*, 1983; 34(5): 555–563.
102. McCorkell SJ. Unintended percutaneous aspiration of pulmonary echinococcal cysts. *Am J Roentgenol*, 1984; 143(1): 123–126.
103. Rinaldi F, De Silvestri A, Tamarozzi F, Cattaneo F, Lissandrin R, Brunetti E. Medical treatment versus —Watch and Waitl in the clinical management of CE3b echinococcal cysts of the liver. *BMC Infect Dis.*, 2014; 14(1): 492.
104. Eckert J. Geographic distribution and prevalence Echinococcosis. *WHOIE Man Echinococcosis Hum Anim Public Health Probl Glob Concern.*, 2001; 100–142.
105. Şahin E, Enön S, Cangır AK, Kutlay H, Kavukçu Ş, Akay H, et al. Single-stage transthoracic approach for right lung and liver hydatid disease. *J Thorac Cardiovasc Surg.*, 2003; 126(3): 769–773.

106. Baskaran V, Patnaik PK. Feasibility and safety of laparoscopic management of hydatid disease of the liver. *JLS.*, 2004; 8(4): 359.
107. Bickel A, Eitan A. The use of a large, transparent cannula, with a beveled tip, for safe laparoscopic management of hydatid cysts of liver. *Surg Endosc.*, 1995; 9(12): 1304–1305.
108. Krige JEJ, Millar AJW, Rode H, Knobel D. Fatal hypernatraemia after hypertonic saline irrigation of hepatic hydatid cysts. *Pediatr Surg Int.*, 2002; 18(1): 64–65.
109. Belghiti J, Benhamou J-P, Houry S, Grenier P, Huguier M, Fékété F. Caustic sclerosing cholangitis: a complication of the surgical treatment of hydatid disease of the liver. *Arch Surg.*, 1986; 121(10): 1162–1165.
110. ÇOKER A. The optimal treatment of hydatid cyst of the liver: radical surgery with a significant reduced risk of recurrence. *Turk J Gastroenterol.*, 2008; 19(1): 33–39.
111. Abu ZM, El-Eibiedy G, Abu-El-Einien A, Gad E-HN, Abd E-WM, Azzat F. Surgical treatment of hepatic hydatid cysts. *Hepatogastroenterology*, 1998; 45(23): 1802–1806.
112. Özaslan E, Bayraktar Y. Endoscopic therapy in the management of hepatobiliary hydatid disease. *J Clin Gastroenterol*, 2002; 35(2): 160–174.
113. Sielaff TD, Taylor B, Langer B. Recurrence of hydatid disease. *World J Surg.*, 2001; 25(1): 83–86.
114. Akyıldız HY, Akcan A, Karahan İ, Kucuk C, Sözüer E, Esin H. Recurrent liver hydatid disease: when does it become symptomatic and how does one diagnose it? *Clin Imaging*, 2009; 33(1): 55–58.
115. Jerraya H, Khalfallah M, Osman SB, Nouira R, Dziri C. Predictive factors of recurrence after surgical treatment for liver hydatid cyst. *Surg Endosc.*, 2015; 29(1): 86–93.
116. Bedioui H, Ayari H, Bouslama K, Maghrebi H, Hsairi H, Jouini M, et al. Recurrence of hydatid cyst of liver: predictive factors: tunisian experience. *Bull Soc Pathol Exot.*, 1990, 2012; 105(4): 265–269.
117. El Malki HO, El Mejdoubi Y, Souadka A, Zakri B, Mohsine R, Ifrine L, et al. Does primary surgical management of liver hydatid cyst influence recurrence? *J Gastrointest Surg.*, 2010; 14(7): 1121–1127.
118. Moro P, Schantz PM. Echinococcosis: a review. *Int J Infect Dis.*, 2009; 13(2): 125–133.
119. Nari GA, Palacios RO, Russo N, López BS, Albiol M, Falgueras L, et al. Liver resections as radical surgery for hepatic hydatidosis: results in 50 patients. *Acta Gastroenterol Latinoam*, 2014; 44(1): 39–44.
120. Derveniz C, Delis S, Avgerinos C, Madariaga J, Milicevic M. Changing concepts in the management of liver hydatid disease. *J Gastrointest Surg.*, 2005; 9(6): 869–877.
121. Mueller PR, Dawson SL, Ferrucci Jr JT, Nardi GL. Hepatic echinococcal cyst: successful percutaneous drainage. *Radiology.*, 1985; 155(3): 627–628.
122. Akhan O, Özmen MN. Percutaneous treatment of liver hydatid cysts. *Eur J Radiol.*, 1999; 32(1): 76–85.
123. Ben AN, Gargouri M, Gharbi HA, Golvan YJ, Ayachi K, Khouck H. Trial therapy of inoperable abdominal hydatid cysts by puncture. *Ann Parasitol Hum Comp.*, 1986; 61(6): 689–692.
124. Khuroo MS, Dar MY, Yattoo GN, Zargar SA, Javaid G, Khan BA, et al. Percutaneous drainage versus albendazole therapy in hepatic hydatidosis: a prospective, randomized study. *Gastroenterology*, 1993; 104(5): 1452–1459.
125. Saremi F, McNamara TO. Hydatid cysts of the liver: long-term results of percutaneous treatment using a cutting instrument. *AJR Am J Roentgenol*, 1995; 165(5): 1163–1167.
126. Schipper HG, Lameris JS, Van Delden OM, Rauws EA, Kager PA. Percutaneous evacuation (PEVAC) of multivesicular echinococcal cysts with or without cystobiliary fistulas which contain non-drainable material: first results of a modified PAIR method. *Gut.*, 2002; 50(5): 718–723.
127. Doğru D, Kiper N, Özçelik U, Yalçın E, Göçmen A. Medical treatment of pulmonary hydatid disease: for which child? *Parasitol Int.*, 2005; 54(2): 135–138.
128. Arif SH, Wani NA, Zargar SA, Wani MA, Tabassum R, Hussain Z, et al. Albendazole as an adjuvant to the standard surgical management of hydatid cyst liver. *Int J Surg.*, 2008; 6(6): 448–451.
129. Bradley M, Horton J. Assessing the risk of benzimidazole therapy during pregnancy. *Trans R Soc Trop Med Hyg.*, 2001; 95(1): 72–73.
130. Saimot AG. Medical treatment of liver hydatidosis. *World J Surg.*, 2001; 25(1): 15–20.
131. Franchi C, Di Vico B, Teggi A. Long-term evaluation of patients with hydatidosis treated with benzimidazole carbamates. *Clin Infect Dis.*, 1999; 29(2): 304–309.
132. Keshmiri M, Baharvahdat H, Fattahi SH, Davachi B, Dabiri RH, Baradaran H, et al. Albendazole versus placebo in treatment of echinococcosis. *Trans R Soc Trop Med Hyg.*, 2001; 95(2): 190–194.
133. Hao W, Pei-Fan Z, Wen-Guang Y, Jian L, Yun-Hai W, Jing-Hui Z, et al. Albendazole chemotherapy for human cystic and alveolar echinococcosis in north-western China. *Trans R Soc Trop Med Hyg.*, 1994; 88(3): 340–343.
134. Choi BY, Nguyen MH. The diagnosis and management of benign hepatic tumors. *J Clin Gastroenterol*, 2005; 39(5): 401–412.
135. Toro A, Mahfouz A-E, Ardiri A, Malaguarnera M, Malaguarnera G, Loria F, et al. What is changing in indications and treatment of hepatic hemangiomas. A review. *Ann Hepatol off J Mex Assoc Hepatol*. 2014; 13(4).
136. Biecker E, Fischer HP, Strunk H, Sauerbruch T. Benign hepatic tumours. *Z Für Gastroenterol*, 2003; 41(02): 191–200.
137. Kim DY, Pantelic MV, Yoshida A, Jerius J, Abouljoud MS. Cavernous hemangioma presenting

- as Budd-Chiari syndrome. *J Am Coll Surg.*, 2005; 200(3): 470–471.
138. Cobey FC, Salem RR. A review of liver masses in pregnancy and a proposed algorithm for their diagnosis and management. *Am J Surg.*, 2004; 187(2): 181–191.
 139. Von Herbay A, Vogt C, Willers R, Häussinger D. Real-time Imaging With the Sonographic Contrast Agent SonoVue. *J Ultrasound Med.*, 2004; 23(12): 1557–1568.
 140. Perkins AB, Imam K, Smith WJ, Cronan JJ. Color and power Doppler sonography of liver hemangiomas: a dream unfulfilled? *J Clin Ultrasound*, 2000; 28(4): 159–165.
 141. Kim T, Federle MP, Baron RL, Peterson MS, Kawamori Y. Discrimination of small hepatic hemangiomas from hypervascular malignant tumors smaller than 3 cm with three-phase helical CT. *Radiology*, 2001; 219(3): 699–706.
 142. Semelka RC, Martin DR, Balci C, Lance T. Focal liver lesions: comparison of dualphase CT and multisequence multiplanar MR imaging including dynamic gadolinium enhancement. *J Magn Reson Imaging.*, 2001; 13(3): 397–401.
 143. Yamamoto T, Kawarada Y, Yano T, Noguchi T, Mizumoto R. Spontaneous rupture of hemangioma of the liver: treatment with transcatheter hepatic arterial embolization. *Am J Gastroenterol*, 1991; 86(11).
 144. Charny CK, Jarnagin WR, Schwartz LH, Frommeyer HS, DeMatteo RP, Fong Y, et al. Management of 155 patients with benign liver tumours. *Br J Surg.*, 2001; 88(6): 808–813.
 145. Wahab MA, Elghwalby N, Fathy O, Bisuony N, Wahab KA, El Sorogy M. Enucleation of a five-kilograms hemangioma of the caudate lobe of the liver: A case report. *Int J Case Rep Images IJCRI.*, 2013; 4(7): 358–362.
 146. Deutsch GS, Yeh KA, Bates III WB, Tannehill WB. Embolization for management of hepatic hemangiomas. *Am Surg.*, 2001; 67(2): 159.
 147. Gaspar L, Mascarenhas F, Costa MS, Dias JS, Afonso JG, Silvestre ME. Radiation therapy in the unresectable cavernous hemangioma of the liver. *Radiother Oncol.*, 1993; 29(1): 45–50.
 148. Ferlay J, Soerjomataram I, Dikshit R, Eser S, Mathers C, Rebelo M, et al. Cancer incidence and mortality worldwide: sources, methods and major patterns in GLOBOCAN 2012. *Int J Cancer.*, 2015; 136(5).
 149. Chang M-H, Chen C-J, Lai M-S, Hsu H-M, Wu T-C, Kong M-S, et al. Universal hepatitis B vaccination in Taiwan and the incidence of hepatocellular carcinoma in children. *N Engl J Med.*, 1997; 336(26): 1855–1859.
 150. El-Serag HB. Epidemiology of viral hepatitis and hepatocellular carcinoma. *Gastroenterology*, 2012; 142(6): 1264–1273.
 151. Morgan TR, Mandayam S, Jamal MM. Alcohol and hepatocellular carcinoma. *Gastroenterology*, 2004; 127(5): S87–S96.
 152. Kuper H, Tzonou A, Kaklamani E, Hsieh C-C, Lagiou P, Adami H-O, et al. Tobacco smoking, alcohol consumption and their interaction in the causation of hepatocellular carcinoma. *Int J Cancer.*, 2000; 85(4): 498–502.
 153. Arase Y, Kobayashi M, Suzuki F, Suzuki Y, Kawamura Y, Akuta N, et al. Effect of type 2 diabetes on risk for malignancies includes hepatocellular carcinoma in chronic hepatitis C. *Hepatology*, 2013; 57(3): 964–973.
 154. Hoshida Y, Toffanin S, Lachenmayer A, Villanueva A, Minguez B, Llovet JM. Molecular classification and novel targets in hepatocellular carcinoma: recent advancements. In: *Seminars in liver disease.* \copyright Thieme Medical Publishers, 2010; 035–051.
 155. Yachida S, Jones S, Bozic I, Antal T, Leary R, Fu B, et al. Distant metastasis occurs late during the genetic evolution of pancreatic cancer. *Nature.*, 2010; 467(7319): 1114.
 156. Yap TA, Gerlinger M, Futreal PA, Pusztai L, Swanton C. Intratumor heterogeneity: seeing the wood for the trees. *Sci Transl Med.*, 2012; 4(127): 127ps10–127ps10.
 157. Cornella H, Alsinet C, Villanueva A. Molecular pathogenesis of hepatocellular carcinoma. *Alcohol Clin Exp Res.*, 2011; 35(5): 821–825.
 158. Liaw Y-F, Sung JJ, Chow WC, Farrell G, Lee C-Z, Yuen H, et al. Lamivudine for patients with chronic hepatitis B and advanced liver disease. *N Engl J Med.*, 2004; 351(15): 1521–1531.
 159. Liver EAFTSOT. EASL–EORTC clinical practice guidelines: management of hepatocellular carcinoma. *J Hepatol*, 2012; 56(4): 908–943.
 160. Sangiovanni A, Del Ninno E, Fasani P, De Fazio C, Ronchi G, Romeo R, et al. Increased survival of cirrhotic patients with a hepatocellular carcinoma detected during surveillance. *Gastroenterology*, 2004; 126(4): 1005–1014.
 161. Bruix J, Sherman M. Management of hepatocellular carcinoma: an update. *Hepatology*, 2011; 53(3): 1020–1022.
 162. Chen L-D, xu h-x, xie x-y, xie x-h, xu z-f, liu g-j, et al. Intrahepatic cholangiocarcinoma and hepatocellular carcinoma: differential diagnosis with contrast-enhanced ultrasound. *Eur Radiol.*, 2010; 20(3): 743–753.
 163. Patel T. Cholangiocarcinoma—controversies and challenges. *Nat Rev Gastroenterol Hepatol.*, 2011; 8(4): 189–200.
 164. de Lope CR, Tremosini S, Forner A, Reig M, Bruix J. Management of HCC. *J Hepatol*, 2012; 56: S75–S87.
 165. Vauthey J-N, Lauwers GY, Esnaola NF, Do K-A, Belghiti J, Mirza N, et al. Simplified staging for hepatocellular carcinoma. *J Clin Oncol.*, 2002; 20(6): 1527–1536.

166. Pugh R, Murray-Lyon IM, Dawson JL, Pietroni MC, Williams R. Transection of the oesophagus for bleeding oesophageal varices. *Br J Surg.*, 1973; 60(8): 646–649.
167. Okuda K, Ohtsuki T, Obata H, Tomimatsu M, Okazaki N, Hasegawa H, et al. Natural history of hepatocellular carcinoma and prognosis in relation to treatment study of 850 patients. *Cancer.*, 1985; 56(4): 918–928.
168. Reig M, Darnell A, Forner A, Rimola J, Ayuso C, Bruix J. Systemic therapy for hepatocellular carcinoma: the issue of treatment stage migration and registration of progression using the BCLC-refined RECIST. In: *Seminars in liver disease.* Thieme Medical Publishers, 2014; 444–455.
169. Llovet JM, Bruix J. Systematic review of randomized trials for unresectable hepatocellular carcinoma: chemoembolization improves survival. *Hepatology*, 2003; 37(2): 429–442.
170. Burrell M, Reig M, Forner A, Barrufet M, de Lope CR, Tremosini S, et al. Survival of patients with hepatocellular carcinoma treated by transarterial chemoembolization (TACE) using Drug Eluting Beads. Implications for clinical practice and trial design. *J Hepatol.*, 2012; 56(6): 1330–1335.
171. Cheng A-L, Kang Y-K, Chen Z, Tsao C-J, Qin S, Kim JS, et al. Efficacy and safety of sorafenib in patients in the Asia-Pacific region with advanced hepatocellular carcinoma.
172. Llop E, Berzigotti A, Reig M, Erice E, Reverter E, Seijo S, et al. Assessment of portal hypertension by transient elastography in patients with compensated cirrhosis and potentially resectable liver tumors. *J Hepatol*, 2012; 56(1): 103–108.
173. Mazzaferro V, Regalia E, Doci R, Andreola S, Pulvirenti A, Bozzetti F, et al. Liver transplantation for the treatment of small hepatocellular carcinomas in patients with cirrhosis. *N Engl J Med.*, 1996; 334(11): 693–700.
174. Martin P, DiMartini A, Feng S, Brown R, Fallon M. Evaluation for liver transplantation in adults: 2013 practice guideline by the American Association for the Study of Liver Diseases and the American Society of Transplantation. *Hepatology*, 2014; 59(3): 1144–1165.
175. Olnes MJ, Erlich R. A review and update on cholangiocarcinoma. *Oncology*, 2004; 66(3): 167–179.
176. Lazaridis KN, Gores GJ. Cholangiocarcinoma. *Gastroenterology*, 2005; 128(6): 1655–1667.
177. Shaib Y, El-Serag HB. The epidemiology of cholangiocarcinoma. In: *Seminars in liver disease.* Copyright) copyright 2004 by Thieme Medical Publishers, Inc., 333 Seventh Avenue, New York, NY 10001, USA, 2004; 115–125.
178. Farrant JM, Hayllar KM, Wilkinson ML, Karani J, Portmann BC, Westaby D, et al. Natural history and prognostic variables in primary sclerosing cholangitis. *Gastroenterology*, 1991; 100(6): 1710–1717.
179. Pitt HA, Yeo CJ, Dooley WC, Cameron JL. Malignancies of the biliary tree. *Curr Probl Surg*, 1995; 32(1): 13–90.
180. Harewood GC. Endoscopic tissue diagnosis of cholangiocarcinoma. *Curr Opin Gastroenterol*, 2008; 24(5): 627–630.
181. Haswell-Elkins MR, Mairiang E, Mairiang P, Chaiyakum J, Chamadol N, Loapaiboon V, et al. Cross-sectional study of *Opisthorchis viverrini* infection and cholangiocarcinoma in communities within a high-risk area in northeast Thailand. *Int J Cancer*, 1994; 59(4): 505–509.
182. Sripa B, Kaewkes S, Sithithaworn P, Mairiang E, Laha T, Smout M, et al. Liver fluke induces cholangiocarcinoma. *PLoS Med*, 2007; 4(7): e201.
183. Chen, M.-F., Jan, Y.-Y., Wang, C.-S., Hwang, T.-L., Jeng, L.-B., Chen, S.-C. and Chen, T.-J. A reappraisal of cholangiocarcinoma in patient with hepatolithiasis. *Cancer*, 1993; 71: 2461–2465. doi:10.1002/1097-0142(19930415)
184. Liu Z-Y, Zhou Y-M, Shi L-H, Yin Z-F. Risk factors of intrahepatic cholangiocarcinoma in patients with hepatolithiasis: a case-control study. *Hepatobiliary Pancreat Dis Int.*, 2011; 10(6): 626–631.
185. Kim YT, Byun JS, Kim J, Jang YH, Lee WJ, Ryu JK, et al. Factors predicting concurrent cholangiocarcinomas associated with hepatolithiasis. *Hepatogastroenterology*, 2003; 50(49): 8–12.
186. Ohtsuka T, Inoue K, Ohuchida J, Nabae T, Takahata S, Niiyama H, et al. Carcinoma arising in choledochocoele. *Endoscopy*, 2001; 33(07): 614–619.
187. Goto N, Yasuda I, Uematsu T, Kanemura N, Takai S, Ando K, et al. Intrahepatic cholangiocarcinoma arising 10 years after the excision of congenital extrahepatic biliary dilation. *J Gastroenterol*, 2001; 36(12): 856–862.
188. Shaib YH, El-Serag HB, Davila JA, Morgan R, McGlynn KA. Risk factors of intrahepatic cholangiocarcinoma in the United States: a case-control study. *Gastroenterology*, 2005; 128(3): 620–626.
189. Buetow PC, Buck JL, Pantongrag-Brown L, Ros PR, Devaney K, Goodman ZD, et al. Biliary cystadenoma and cystadenocarcinoma: clinical-imaging-pathologic correlations with emphasis on the importance of ovarian stroma. *Radiology*, 1995; 196(3): 805–810.
190. Lipshutz GS, Brennan TV, Warren RS. Thorotrast-induced liver neoplasia: a collective review. *J Am Coll Surg*, 2002; 195(5): 713–718.
191. Wise C, Pihanthanond M, Perry BF, Alpini G, McNeal M, Glaser SS. Mechanisms of biliary carcinogenesis and growth. *World J Gastroenterol WJG.*, 2008; 14(19): 2986.
192. Sia D, Hoshida Y, Villanueva A, Roayaie S, Ferrer J, Tabak B, et al. Integrative molecular analysis of intrahepatic cholangiocarcinoma reveals 2 classes that have different outcomes. *Gastroenterology*, 2013; 144(4): 829–840.

193. Jaiswal M, LaRusso NF, Burgart LJ, Gores GJ. Inflammatory cytokines induce DNA damage and inhibit DNA repair in cholangiocarcinoma cells by a nitric oxide-dependent mechanism. *Cancer Res.*, 2000; 60(1): 184–190.
194. Schottenfeld D, Beebe-Dimmer J. Chronic inflammation: a common and important factor in the pathogenesis of neoplasia. *CA Cancer J Clin.*, 2006; 56(2): 69–83.
195. Berthiaume EP, Wands J. The molecular pathogenesis of cholangiocarcinoma. In: *Seminars in liver disease*. Copyright/copyright 2004 by Thieme Medical Publishers, Inc., 333 Seventh Avenue, New York, NY 10001, USA., 2004; 127–137.
196. De Oliveira ML et al: Cholangiocarcinoma: thirty-one-year experience with 564 patients at a single institution *Ann Surg*, 2007 May; 245(5): 755–762.
197. Weber SM, Jarnagin WR, Klimstra D, DeMatteo RP, Fong Y, Blumgart LH. Intrahepatic cholangiocarcinoma: resectability, recurrence pattern, and outcomes. *J Am Coll Surg*, 2001; 193(4): 384–391.
198. Roayaie S, Guarrera JV, Michele QY, Thung SN, Emre S, Fishbein TM, et al. Aggressive surgical treatment of intrahepatic cholangiocarcinoma: predictors of outcomes. *J Am Coll Surg*, 1998; 187(4): 365–372.
199. Endo I, Gonen M, Yopp AC, Dalal KM, Zhou Q, Klimstra D, et al. Intrahepatic cholangiocarcinoma: rising frequency, improved survival and determinants of outcome after resection. *Ann Surg*, 2008; 248(1): 84–96.
200. D'angelica M, Fong Y, Weber S, Gonen M, DeMatteo RP, Conlon K, et al. The role of staging laparoscopy in hepatobiliary malignancy: prospective analysis of 401 cases. *Ann Surg Oncol*, 2003; 10(2): 183–189.
201. Edge SB, Byrd DR, Compton CC, Fritz AG, Greene FL, Trotti A. American joint committee on cancer staging manual. 7. New York: Springer, 2009.
202. Nathan H, Aloia TA, Vauthey J-N, Abdalla EK, Zhu AX, Schulick RD, et al. A proposed staging system for intrahepatic cholangiocarcinoma. *Ann Surg Oncol*, 2009; 16(1): 14–22.
203. Edge SB, Byrd DR, Compton CC, Fritz AG, Greene FL, Trotti A. *AJCC cancer staging handbook*. 7. *Chic Am Jt Comm Cancer*, 2010.
204. Weber SM, Ribero D, O'reilly EM, Kokudo N, Miyazaki M, Pawlik TM. Intrahepatic cholangiocarcinoma: expert consensus statement. *HPB*, 2015; 17(8): 669–680.
205. Ebata T, Yokoyama Y, Igami T, Sugawara G, Takahashi Y, Nagino M. Portal vein embolization before extended hepatectomy for biliary cancer: current technique and review of 494 consecutive embolizations. *Dig Surg*, 2012; 29(1): 23–29.
206. Chu K-M, Fan S-T. Intrahepatic cholangiocarcinoma in Hong Kong. *J Hepato-Biliary Pancreat Sci.*, 1999; 6(2): 149–153.
207. Shirabe K, Shimada M, Harimoto N, Sugimachi K, Yamashita Y, Tsujita E, et al. Intrahepatic cholangiocarcinoma: its mode of spreading and therapeutic modalities. *Surgery*, 2002; 131(1): S159–S164.
208. Nozaki Y, Yamamoto M, Ikai I, Yamamoto Y, Ozaki N, Fujii H, et al. Reconsideration of the lymph node metastasis pattern (N factor) from intrahepatic cholangiocarcinoma using the International Union Against Cancer TNM staging system for primary liver carcinoma. *Cancer*, 1998; 83(9): 1923–1929.
209. Pichlmayr R, Lamesch P, Weimann A, Tusch G, Ringe B. Surgical treatment of cholangiocellular carcinoma. *World J Surg*, 1995; 19(1): 83–88.
210. Cherqui D, Tantawi B, Alon R, Piedbois P, Rahmouni A, Dhumeaux D, et al. Intrahepatic cholangiocarcinoma: results of aggressive surgical management. *Arch Surg*, 1995; 130(10): 1073–1078.
211. Fu B-S, Zhang T, Li H, Yi S-H, Wang G-S, Xu C, et al. The role of liver transplantation for intrahepatic cholangiocarcinoma: a single-center experience. *Eur Surg Res.*, 2011; 47(4): 218–221.
212. Schwartz JJ, Hutson WR, Gayowski TJ, Sorensen JB. Liver transplantation for cholangiocarcinoma. *Transplantation*, 2009; 88(3): 295–298.
213. Rai R, Manas D, Rose J. Radiofrequency ablation of recurrent cholangiocarcinoma after orthotopic liver transplantation—a case report. *World J Gastroenterol WJG.*, 2005; 11(4): 612.
214. Kim JH, Won HJ, Shin YM, Kim K-A, Kim PN. Radiofrequency ablation for the treatment of primary intrahepatic cholangiocarcinoma. *Am J Roentgenol*, 2011; 196(2): W205–W209.
215. Yu M-A, Liang P, Yu X-L, Cheng Z-G, Han Z-Y, Liu F-Y, et al. Sonography-guided percutaneous microwave ablation of intrahepatic primary cholangiocarcinoma. *Eur J Radiol*, 2011; 80(2): 548–552.
216. Burger I, Hong K, Schulick R, Georgiades C, Thuluvath P, Choti M, et al. Transcatheter arterial chemoembolization in unresectable cholangiocarcinoma: initial experience in a single institution. *J Vasc Interv Radiol*, 2005; 16(3): 353–361.
217. Vogl TJ, Naguib NN, Nour-Eldin N-EA, Bechstein WO, Zeuzem S, Trojan J, et al. Transarterial chemoembolization in the treatment of patients with unresectable cholangiocarcinoma: results and prognostic factors governing treatment success. *Int J Cancer*, 2012; 131(3): 733–740.
218. Aliberti C, Benea G, Tilli M, Fiorentini G. Chemoembolization (TACE) of unresectable intrahepatic cholangiocarcinoma with slow-release doxorubicin-eluting beads: preliminary results. *Cardiovasc Intervent Radiol*, 2008; 31(5): 883–888.
219. Kuhlmann JB, Euringer W, Spangenberg HC, Breidert M, Blum HE, Harder J, et al. Treatment of unresectable cholangiocarcinoma: conventional transarterial chemoembolization compared with drug

- eluting bead-transarterial chemoembolization and systemic chemotherapy. *Eur J Gastroenterol Hepatol*, 2012; 24(4): 437–443.
220. Glazer ES, Liu P, Abdalla EK, Vauthey J-N, Curley SA. Neither neoadjuvant nor adjuvant therapy increases survival after biliary tract cancer resection with wide negative margins. *J Gastrointest Surg*, 2012; 16(9): 1666–1671.
221. Valle J, Wasan H, Palmer DH, Cunningham D, Anthony A, Maraveyas A, et al. Cisplatin plus gemcitabine versus gemcitabine for biliary tract cancer. *N Engl J Med*, 2010; 362(14): 1273–1281.
222. Yamanaka K, Hatano E, Kanai M, Tanaka S, Yamamoto K, Narita M, et al. A single-center analysis of the survival benefits of adjuvant gemcitabine chemotherapy for biliary tract cancer. *Int J Clin Oncol*, 2014; 19(3): 485–489.
223. Miller SJ. The National Comprehensive Cancer Network (NCCN) guidelines of care for non-melanoma skin cancers. *Dermatol Surg*, 2000; 26(3): 289–292.
224. Yi SW, Kang DR, Kim KS, Park MS, Seong J, Park JY, et al. Efficacy of concurrent chemoradiotherapy with 5-fluorouracil or gemcitabine in locally advanced biliary tract cancer. *Cancer Chemother Pharmacol*, 2014; 73(1): 191–198.
225. Jarnagin WR, Schwartz LH, Gultekin DH, Gönen M, Haviland D, Shia J, et al. Regional chemotherapy for unresectable primary liver cancer: results of a phase II clinical trial and assessment of DCE-MRI as a biomarker of survival. *Ann Oncol*, 2009; 20(9): 1589–1595.
226. Stein DE, Heron DE, Rosato EL, Anné PR, Topham AK. Positive microscopic margins alter outcome in lymph node-negative cholangiocarcinoma when resection is combined with adjuvant radiotherapy. *Am J Clin Oncol*, 2005; 28(1): 21–23.
227. Ben-Josef E, Normolle D, Ensminger WD, Walker S, Tatro D, Ten Haken RK, et al. Phase II trial of high-dose conformal radiation therapy with concurrent hepatic artery floxuridine for unresectable intrahepatic malignancies. *J Clin Oncol*, 2005; 23(34): 8739–8747.
228. Non-imaging-guided fine-needle aspiration of liver lesions: a retrospective study of 279 patients [Internet]. [cited 2017 Oct 30]. Available from: <https://www.ncbi.nlm.nih.gov/pmc/articles/PMC4688542/>.
229. Thimmaiah VT. Evaluation of focal liver lesions by ultrasound as a prime imaging modality. *Sch J App Med Sci.*, 2013; 1(6): 1041–59.
230. Hima Bindu P, Shukla AK, Krishnappa N. Sonographic evaluation of focal and diffuse hepatic lesions.
231. Parahjuli S, Tuladhar A, Basnet RB. Ultrasound and computed tomography guided fine needle aspiration cytology in diagnosing intra-abdominal and intra-thoracic lesions. *J Pathol Nepal.*, 2011; 1(1): 17–21.
232. Roy SK, Sultana S, Mollah NU, Yasmin T, Sarker A, Jahan M uz. Role of ultrasonography in diagnosis of solid space occupying lesion in the liver correlation with FNAC. *Bangladesh Med Res Counc Bull.*, 2016 Oct 18; 41(2): 81–8.
233. Basak NC et al, A Study of 200 Cases of Space Occupying Lesion in Liver; Incidental Detection of Two Cases of Hepatic Tuberculosis with Uncommon Presentation [Dinajpur Med Col J, 2017 Jan; 10 (1): 66-69].
234. Hapani N, Kalola J, Trivedi A, Chawla A. Ultrasound evaluation of focal hepatic lesions. *J Dent Med Sci.*, 2014; 16(12): 40–45.
235. Spiegel RM, King DL, Green WM. Ultrasonography of primary cysts of the liver. *Am J Roentgenol*, 1978; 131(2): 235–238.
236. Ghosh S, Sharma S, Gadpayle AK, Gupta HK, Mahajan RK, Sahoo R, et al. Clinical, laboratory, and management profile in patients of liver abscess from northern India. *J Trop Med.*, 2014; 2014.
237. Mohsen AH, Green ST, Read RC, McKendrick MW. Liver abscess in adults: ten year's experience in a UK centre. *Qjm.*, 2002; 95(12): 797–802.
238. Yoo HM, Kim SKS, Chun WH, Kang JK, Park IS. The Changing Patterns of Liver Abscess. *Yonsei Med J.*, 1993; 34(4).
239. Lodhi S, Sarwari AR, Muzammil M, Salam A, Smego RA. Features distinguishing amoebic from pyogenic liver abscess: a review of 577 adult cases. *Trop Med Int Health.*, 2004; 9(6): 718–723.
240. Singh S, Chaudhary P, Saxena N, Khandelwal S, Poddar DD, Biswal UC. Treatment of liver abscess: prospective randomized comparison of catheter drainage and needle aspiration *Ann Gastroenterol Q Publ Hell Soc Gastroenterol.*, 2013; 26(4): 332.
241. Dulku G, Mohan G, Samuelson S, Ferguson J, Tibballs J. Percutaneous aspiration versus catheter drainage of liver abscess: A retrospective review. *Australas Med J.*, 2015; 8(1): 7.
242. Huang C-J, Pitt HA, Lipsett PA, Osterman Jr FA, Lillemo KD, Cameron JL, et al. Pyogenic hepatic abscess. Changing trends over 42 years. *Ann Surg.*, 1996; 223(5): 600.
243. Mangukiya DO, Darshan JR, Kanani VK, Gupta ST. A prospective series case study of pyogenic liver abscess: recent trends in etiology and management. *Indian J Surg.*, 2012; 74(5): 385–390.
244. Do H, Lambiase RE, Deyoe L, Cronan JJ, Dorfman GS. Percutaneous drainage of hepatic abscesses: comparison of results in abscesses with and without intrahepatic biliary communication. *AJR Am J Roentgenol.*, 1991; 157(6): 1209–1212.
245. Baek SY, Lee MG, Cho KS, Lee SC, Sung KB, Auh YH. Therapeutic percutaneous aspiration of hepatic abscesses: effectiveness in 25 patients. *AJR Am J Roentgenol.*, 1993; 160(4): 799–802.
246. Yu SC, Ho SS, Lau WY, Yeung DT, Yuen EH, Lee PS, et al. Treatment of pyogenic liver abscess: prospective randomized comparison of catheter drainage and needle aspiration. *Hepatology*, 2004; 39(4): 932–938.

247. Balik AA, Başoğlu M, Çelebi F, Ören D, Polat KY, Atamanalp SS, et al. Surgical treatment of hydatid disease of the liver: review of 304 cases. *Arch Surg.*, 1999; 134(2): 166–169.
248. Yorgancı K, Sayek I. Surgical treatment of hydatid cysts of the liver in the era of percutaneous treatment. *Am J Surg.*, 2002; 184(1): 63–69.
249. Palanivelu C, Senthilkumar R, Jani K, Rajan PS, Sendhilkumar K, Parthasarathi R, et al. Palanivelu hydatid system for safe and efficacious laparoscopic management of hepatic hydatid disease. *Surg Endosc Interv Tech.*, 2006; 20(12): 1909–1913.
250. Daradkeh S, Husam E-M, Farah G, Sroujeh AS, Abu-Khalaf M. Predictors of morbidity and mortality in the surgical management of hydatid cyst of the liver. *Langenbecks Arch Surg.*, 2007; 392(1): 35–39.
251. Mergen H, Genç H, Tavusbay C. Assessment of liver hydatid cyst cases-10 years' experience in Turkey. *Trop Doct.*, 2007; 37(1): 54–56.
252. Kayal A, Hussain A. A Comprehensive Prospective Clinical Study of Hydatid Disease. *ISRN Gastroenterol.*, 2014; 2014.
253. Yagci G, Ustunsoz B, Kaymakcioglu N, Bozlar U, Gorgulu S, Simsek A, et al. Results of surgical, laparoscopic, and percutaneous treatment for hydatid disease of the liver: 10 years experience with 355 patients. *World J Surg.*, 2005; 29(12): 1670–1679.
254. Cirenei A, Bertoldi I. Evolution of surgery for liver hydatidosis from 1950 to today: analysis of a personal experience. *World J Surg.*, 2001; 25(1): 87–92.
255. Ezer A, Zafer Nursal T, Moray G, Yildirim S, Karakayali F, Noyan T, et al. Surgical treatment of liver hydatid cysts. *HPB.*, 2006; 8(1): 38–42.
256. Akbulut S, Senol A, Sezgin A, Cakabay B, Dursun M, Satici O. Radical vs conservative surgery for hydatid liver cysts: experience from single center. *World J Gastroenterol WJG.*, 2010; 16(8): 953.
257. Gandolfi L, Leo P, Solmi L, Vitelli E, Verros G, Colecchia A. Natural history of hepatic haemangiomas: clinical and ultrasound study. *Gut.*, 1991; 32(6): 677–680.
258. Gedaly R, Pomposelli JJ, Pomfret EA, Lewis WD, Jenkins RL. Cavernous hemangioma of the liver: anatomic resection vs enucleation. *Arch Surg.*, 1999; 134(4): 407–411.
259. Arash Etemadi,, 1,2 Asieh Golozar,, 1,2 Akhgar Ghassabian,, 1,3 Mahsa Zarei, 1 Amir Pejman Hashemi Taheri,, 4,* Sanford M. Dawsey, 2 and Reza Malekzadeh,. Cavernous hemangioma of the liver: factors affecting disease progression in general hepatology practice *Eur J Gastroenterol Hepatol.* 2011 Apr; 23(4): 354–358.
260. Wesson RN, Cameron AM. Differential diagnosis of focal hepatic lesions. In: *Primary Liver Cancer.* Springer, 2012; 79–126.
261. Trastek VF, van Heerden JA, Sheedy PF, Adson MA. Cavernous hemangiomas of the liver: resect or observe? *Am J Surg.*, 1983; 145(1): 49–53.
262. Kato M, Sugawara I, Okada A, Kuwata K, Satani M, Okamoto E, et al. Hemangioma of the liver: diagnosis with combined use of laparoscopy and hepatic arteriography. *Am J Surg.*, 1975; 129(6): 698–704.
263. Mohmad NH, EL-ZAWAHRY HM, Mokhtar NM, Faisal SS, Gad El-Mawla N. Review of Epidemiologic and Clinico-pathologic features of 403 Hepatocellular Carcinoma (HCC) Patients. *J Egypt Nat Cancer Inst.* 2000; 12: 87–93.
264. Saini N, Bhagat A, Sharma S, Duseja A, Chawla Y. Evaluation of clinical and biochemical parameters in hepatocellular carcinoma: experience from an Indian center. *Clin Chim Acta.*, 2006; 371(1): 183–186.
265. Kumar R, Saraswat MK, Sharma BC, Sakhuja P, Sarin SK. Characteristics of hepatocellular carcinoma in India: a retrospective analysis of 191 cases. *QJM Int J Med.*, 2008; 101(6): 479–485.
266. Paul SB, Gamanagatti S, Sreenivas V, Chandrashekhara SH, Mukund A, Gulati MS, et al. Trans-arterial chemoembolization (TACE) in patients with unresectable Hepatocellular carcinoma: Experience from a tertiary care centre in India. *Indian J Radiol Imaging.* 2011; 21(2): 113.
267. Yin X, Zhang B-H, Qiu S-J, Ren Z-G, Zhou J, Chen X-H, et al. Combined hepatocellular carcinoma and cholangiocarcinoma: clinical features, treatment modalities, and prognosis. *Ann Surg Oncol.* 2012; 19(9): 2869–2876.
268. Thomasset SC, Dennison AR, Garcea G. Ablation for recurrent hepatocellular carcinoma: a systematic review of clinical efficacy and prognostic factors. *World J Surg.*, 2015; 39(5): 1150–1160.
269. Llovet JM, Ricci S, Mazzaferro V, Hilgard P, Gane E, Blanc J-F, et al. Sorafenib in advanced hepatocellular carcinoma. *N Engl J Med.*, 2008; 359(4): 378–390.
270. Gelatti U, Donato F, Tagger A, Fantoni C, Portolani N, Ribero ML, et al. Etiology of hepatocellular carcinoma influences clinical and pathologic features but not patient survival. *Am J Gastroenterol.* 2003; 98(4): 907–914.
271. Dubbins PA, O'Riordan D, Melia WM. Ultrasound in hepatoma—can specific diagnosis be made? *Br J Radiol.*, 1981; 54(640): 307–311.