



## ORTHOPAEDIC IMPLANT-RELATED SARCOMA: A STUDY OF TWELVE CASES

**Dr. Vignesh D.\*<sup>1</sup>, Dr. S. Santhosh<sup>2</sup>, Dr. Venkat Kiran P.<sup>3</sup>, Prof. V. Vijay Narasimman<sup>4</sup>**

<sup>1,2,3</sup>Final Year M.S (Ortho) PG, Dept. of Orthopaedics.

**\*Corresponding Author: Dr. Vignesh D.**

Final Year M.S (Ortho) PG, Dept. of Orthopaedics.

Article Received on 07/08/2018

Article Revised on 28/08/2018

Article Accepted on 18/09/2018

### ABSTRACT

Sarcoma developing in association with a metallic orthopaedic prosthesis or hardware is an uncommon, but well recognized complication. We review 12 cases of sarcomas arising in bone or soft tissue at the site of orthopaedic hardware or a prosthetic joint. Nine patients were male, and three were female. Their ages ranged from 18 to 85 (mean 55) years at the time of diagnosis of the malignancy. Five patients had undergone hip arthroplasty for degenerative joint disease, four had been treated with intramedullary nail placement for fracture, two had staples placed for fixation of osteotomy, and one had hardware placed for fracture fixation followed years later by a hip arthroplasty. The time interval between the placement of hardware and diagnosis of sarcoma was known in 11 cases and ranged from 2.5 to 33 (mean 11) years. The patients presented with pain, swelling, or loosening of hardware and were found to have a destructive bone or soft tissue mass on radiography. Two sarcomas were located primarily in the soft tissue and 10 in bone. Seven patients developed osteosarcoma, four malignant fibrous histiocytoma, and one a malignant peripheral nerve sheath tumor. All sarcomas were high grade. Three patients had metastatic disease at the time of diagnosis. Follow-up was available on eight patients: five patients died of disease 2 months to 8 years (mean 26 months) after diagnosis; two patients died without evidence of disease 7 and 30 months after diagnosis; and one patient is alive and free of disease 8 years after diagnosis. Sarcomas that occur adjacent to orthopaedic prostheses or hardware are of varied types, but are usually osteosarcoma or malignant fibrous histiocytoma. They behave aggressively and frequently metastasize. Clinically, they should be distinguished from non-neoplastic reactions associated with implants, such as infection and a reaction to prosthetic wear debris.

### INTRODUCTION

Metallic orthopaedic hardware and prosthetic joints have been used for decades to repair skeletal defects and replace poorly functioning or severely painful joints. Over 140,000 total hip arthroplasties, 103,000 revisions, and 30,000 partial hip replacements were performed in the United States in 1996 (0.7% of the U.S. population)<sup>[1]</sup> and metallic hardware is routinely used for fracture fixation as well as other orthopaedic procedures. The biomaterials used in these devices are generally considered to be nontoxic; however, some of the constituents have been shown to be potentially carcinogenic in laboratory animal studies<sup>[2, 3, 4, 5, 6, 7]</sup> and malignancies have been associated with orthopaedic implants in pets.<sup>[8]</sup> In humans the development of an orthopaedic implant associated malignancy is a rare, but well recognized complication. Thirty-one case reports of implant-related sarcoma<sup>[9, 10, 11, 12, 13, 14, 15, 16, 17, 18, 19, 20, 21, 22, 23, 24, 25, 26, 27, 28, 29, 30, 31, 32, 33, 34, 35, 36, 37]</sup> and two cases of implant-related lymphoma are present in the English language literature.<sup>[38, 39]</sup> The literature describing this phenomenon has stressed the clinical aspects of the cases or the metallic composition of the implants that have the

highest association with malignant transformation; however, none has focused on the pathology of orthopaedic implant-related sarcoma. Herein, we present the clinical aspects and review in detail the pathologic findings of 12 implant-associated sarcomas.

### MATERIALS AND METHODS

The patients were treated at the authors institutions or their slides were reviewed in consultation by some of the authors. Between 1 and 45 hematoxylin and eosin stained slides were available for review on each case. Electron microscopy was performed on Case 4, and immunohistochemistry was performed on Cases 4 and 6. Follow-up information was obtained from the patient charts or from the referring physicians. Five of the cases were previously reported.<sup>[20, 21, 23, 34]</sup>

### RESULTS

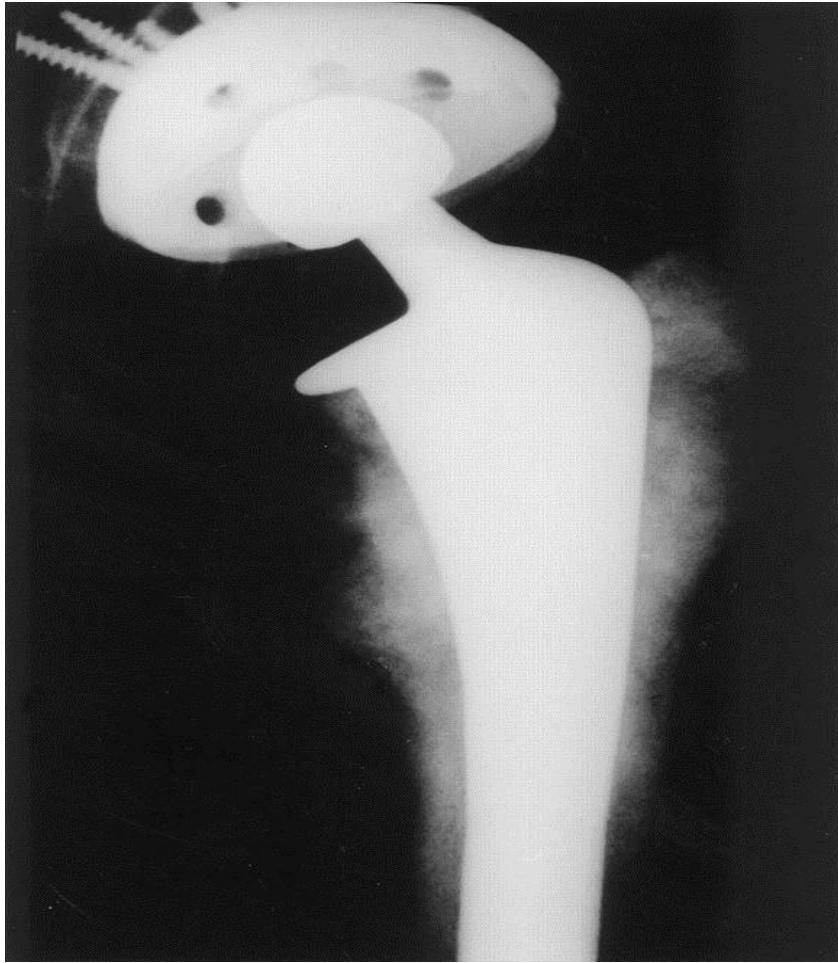
(Table 1.) The patient's ages ranged from 18 to 85 (mean 55) years at the time of diagnosis of the malignancy. Three patients were female, and nine were male. All tumors were associated with implants in the femur; eight in the proximal femur and four in the distal femur. Five patients had undergone total hip arthroplasty for

osteoarthritis, four had intramedullary nail placement for fracture fixation (three in the proximal femur and one mid-shaft), one had staples placed after osteotomy for a genu valgum deformity, one had staples placed for an unknown reason, and one had hardware placed for fracture fixation followed 33 years later by a total hip arthroplasty on the same femur. The time interval between hardware placement and sarcoma detection was

known in 11 cases and ranged from 2.5 to 33 (mean 11) years. The presenting symptoms were pain, stiffness and swelling. Ten sarcomas arose within the bone, and two in the adjacent soft tissue. Radiographically the tumors were located immediately adjacent to or surrounding the implant (Fig. 1) and demonstrated permeative destruction of the adjacent bone. Four sarcomas demonstrated obvious neoplastic matrix production.

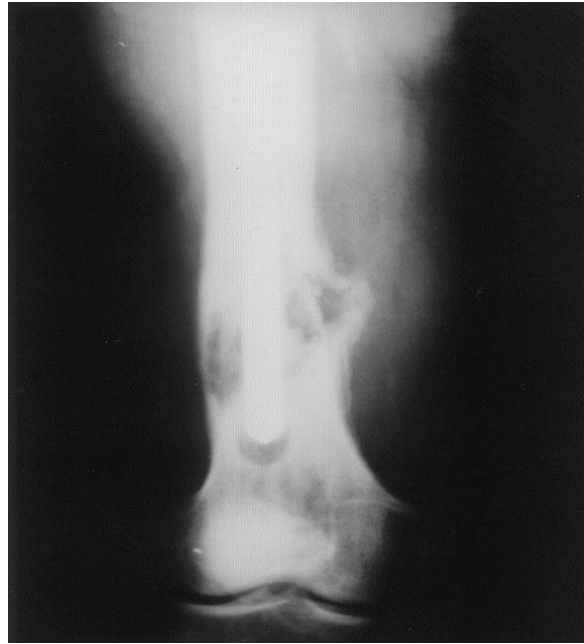NO.	Age/Sex	Procedure	Diagnosis	Time Interval	Symptoms and Radiographs
1	73/F	R THR for OA	Osteosarcoma	2.5 years	Pain
2	18/M	B femoral osteotomies, staples	Osteosarcoma	10 years	Pain, swelling, fall with pathologic fracture, osteolytic lesion with periosteal new bone formation
3	50/M	R femur fracture with fixation, R THR	MFH	2.5 year THR, 33 years fx fixation	Pain in thigh, diagnosed as infection on biopsy
4	85/M	L THR for OA	MPNST	7 years	Pain × 4 weeks
5	16/F	R femur staples	Osteosarcoma	Unavailable	Unknown
6	75/M	R THR for OA	MFH	5 years	Unknown
7	54/M	Intramedullary nail for fracture (stainless steel)	MFH	14 years	Pain, tenderness, destructive diaphyseal mass with cortical breakthrough and periosteal new bone formation
8	65/F	Smith Peterson nail L femur fracture (stainless steel)	Osteosarcoma	9 years	Pain, nail removed, continued pain, THR for “osteoarthritis”
9	38/M	Vesely-Street nail L femur fracture (stainless steel)	Osteosarcoma	20 years	Severe pain, permeative bone changes with calcification at nail tip
10	68/M	B THR for OA (titanium alloy)	Osteosarcoma	3 years	Pain, stiffness, swelling for 3 months, osteoblastic lesion
11	56/M	Sampson nail R femur fracture (stainless steel)	Osteosarcoma	15 years	Pain, lytic lesion distal to old fracture
12	61/M	L THR for OA (chromium and cobalt)	MFH	6.5 years	Unknown

THR, total hip replacement; OA, osteoarthritis; MFH, malignant fibrous histiocytoma; MPNST, malignant peripheral nerve sheath tumor.



Radiograph demonstrating the blastic component of an osteosarcoma that surrounds the implant in Case 10. In five patients the initial symptoms of the tumors were attributed to the pre-existing orthopaedic problem, which may have delayed the diagnosis (cases 2, 3, 8 to 10). In Case 2, an 18-year-old man who had a long history of Morquio's syndrome and related orthopaedic deformities recently developed pain but did not seek medical assistance for 2 months, at which time a large mass had become palpable. The patient in Case 3 sought medical advice because of pain and a biopsy was interpreted as infection. The biopsy was repeated one month later because of persistent pain and swelling, and the diagnosis of infection was again rendered. Four months later, when the mass was 25 cm in greatest diameter, the patient was rebiopsied and the diagnosis of inflammatory malignant fibrous histiocytoma was given. The patient in Case 8 had pain at the site of an intramedullary nail. An X-ray was interpreted as negative. After the pain persisted, the nail was removed, but the pain did not subside. A total hip replacement was performed several weeks later

because the pain was thought to be secondary to osteoarthritis. Sarcoma was noted at the time of surgery. The young man in Case 9 experienced pain in the leg, which contained an intramedullary nail. An X-ray disclosed calcifications at the nail tip, but was thought to be otherwise normal. A lumbar disk was implicated as the cause of continued pain, and the patient underwent laminectomy. Because of persistent pain, the nail was finally removed at a later date, which led to profuse bleeding because of an underlying telangiectatic osteosarcoma. In Case 10 the patient waited 3 months before seeking medical attention, at which time a large mass was noted on X-ray. After 4 weeks of pain, the patient in Case 4 sought medical attention at which time a large soft tissue mass was discovered. The remaining three patients in which clinical information is known sought medical assistance soon after the onset of pain. Radiographic studies in Cases 1, 7, and 11 obtained at that time of presentation demonstrated destructive bone lesions (Fig. 3).



**A destructive, lytic malignant fibrous histiocytoma surrounds the intramedullary nail in Case 7.**

### Pathology

(Table 2.) All sarcomas arose in close proximity to the implant (Fig. 3), 10 in bone and 2 in soft tissue, and all were high grade. Seven tumors were osteosarcoma, four malignant fibrous histiocytoma (MFH) and one a malignant peripheral nerve sheath tumor. The size of the tumors ranged from 5 to 25 (mean 11) cm in greatest dimension and they varied from tan-grey to tan-yellow, and usually had areas of hemorrhage and necrosis (Figs. 4 and 5). Seven tumors were centered within bone and demonstrated bone formation by malignant cells. Histopathologically, five of these were osteoblastic osteosarcomas (Fig. 6), displaying plump atypical cells with a high nuclear to cytoplasm ratio

and abundant mitotic activity. Prominent in one of these tumors were areas where the malignant cells were spindled and formed fascicles arranged in a storiform pattern (Fig. 7) (mixed osteoblastic and malignant fibrous histiocytoma-like osteosarcoma). Another osteosarcoma displayed large areas of high-grade malignant cartilage admixed with neoplastic bone (Fig. 8) (mixed osteoblastic and chondroblastic osteosarcoma). Lastly, one osteosarcoma was extensively cystic, with multiple blood-filled cavities (Fig. 9). The cyst walls contained malignant cells with hyperchromatic, enlarged nuclei, which produced osteoid (telangiectatic osteosarcoma).

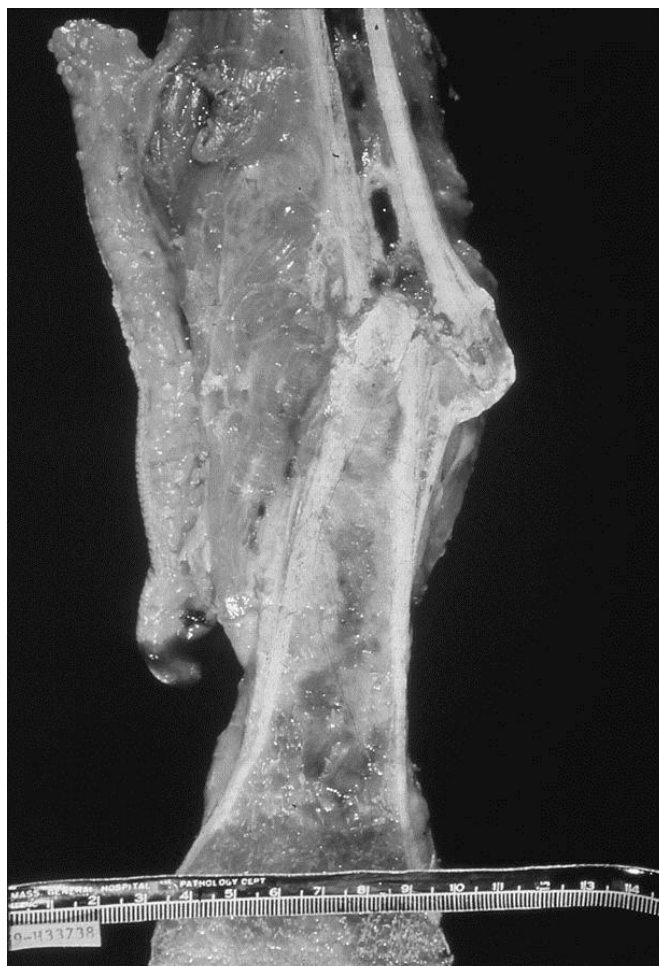
**Table 2: Pathologic Findings in Patients with Implant-Related Sarcoma.**

From: Orthopaedic Implant-Related Sarcoma: A Study of Twelve Cases

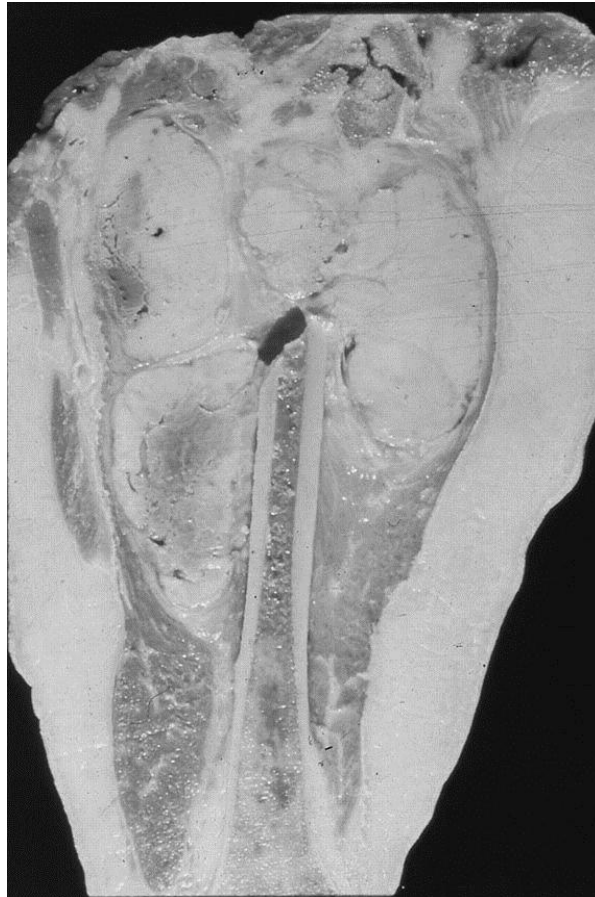Case	Location	Diagnosis	Gross Description	Follow-Up
1	R proximal femur	Osteosarcoma, osteoblastic and MFH-like types, grade 3/3	8 × 7 cm, tan-grey	Pulmonary mets, debulking, chemo, XRT, met to pubis, DOD 1 year
2	R distal femur	Osteosarcoma, osteoblastic type, grade 3/3	9 cm, tan, focally hemorrhagic, path fracture	h/o Morquio's syndrome, chemo, resection, LTF
3	R proximal thigh	MFH, inflammatory type, grade 2/3	25 × 25 × 15 cm, tan-green and yellow	External hemipelvectomy, LTF
4	L proximal thigh	MPNST, grade 3/3	10 cm, tan-yellow, focally hemorrhagic, firm	XRT, resection, DWOD 2.5 years
5	R distal femur	Osteosarcoma, chondroblastic type, grade 3/3	13 × 9 × 7 cm, pink and yellow, hard	Above the knee amputation, LTF
6	R proximal femur	MFH, grade 2–3/3	5.5 cm	XRT, resection. Died 7 mo
7	L distal	MFH, high grade	Unknown	LTF

Case	Location	Diagnosis	Gross Description	Follow-Up
	femur			
8	L proximal femur	Osteoblastic osteosarcoma, high-grade	5 cm tan, hemorrhagic, firm	XRT, chemo, resection, mets DOD 8 years
9	L proximal femur	Telangiectatic osteosarcoma, high-grade	10 cm	Pulmonary mets, XRT, embolization, DOD 2 months
10	L proximal femur	Osteosarcoma, high-grade	15 × 8 cm	Pulmonary mets, hemipelvectomy, DOD 6 months
11	R distal femur	Osteoblastic osteosarcoma, high-grade	7 cm	Hip disarticulation, alive 6 years
12	L proximal femur	MFH, grade 3/3	Unknown	Hip disarticulation, DOD 1 year

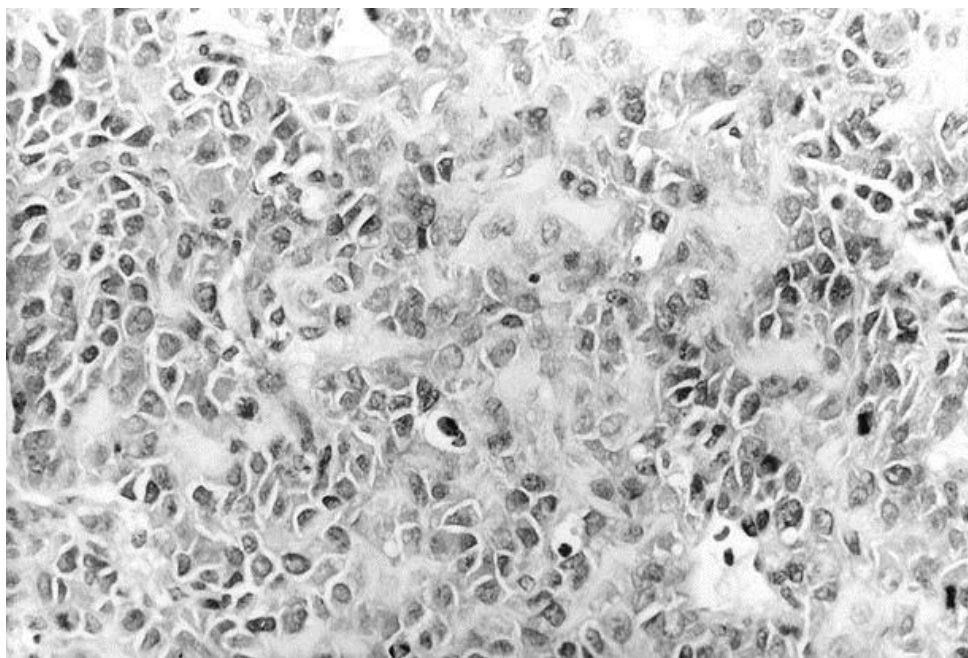
THR, total hip replacement; OA, osteoarthritis; MFH, malignant fibrous histiocytoma; MPNST, malignant peripheral nerve sheath tumor; DOD, dead of disease; DWOD, dead without disease; mets, metastases; LTF, lost to follow-up; XRT, radiation therapy.



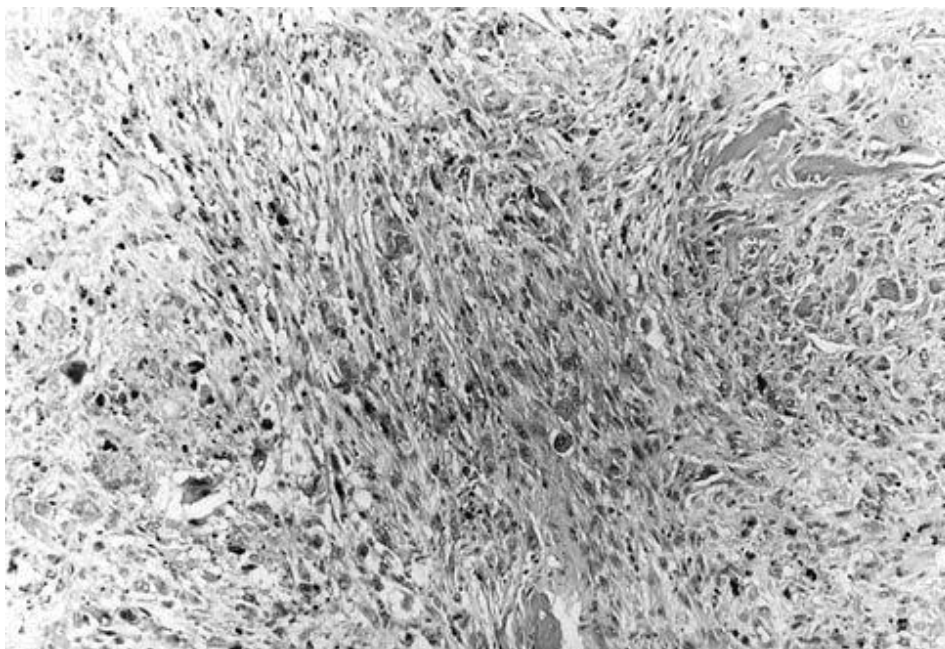
A pathologic fracture is present through the tan and red, focally cystic osteosarcoma in Case.



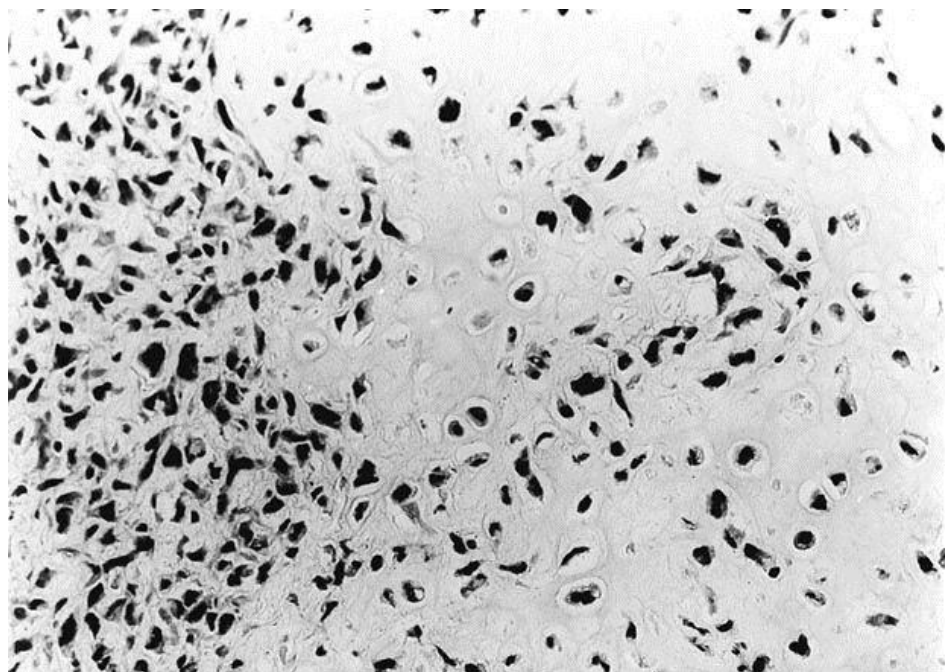
Areas of hemorrhage are present within the tan, fleshy malignant fibrous histiocytoma, which surrounds the femur in Case 3.



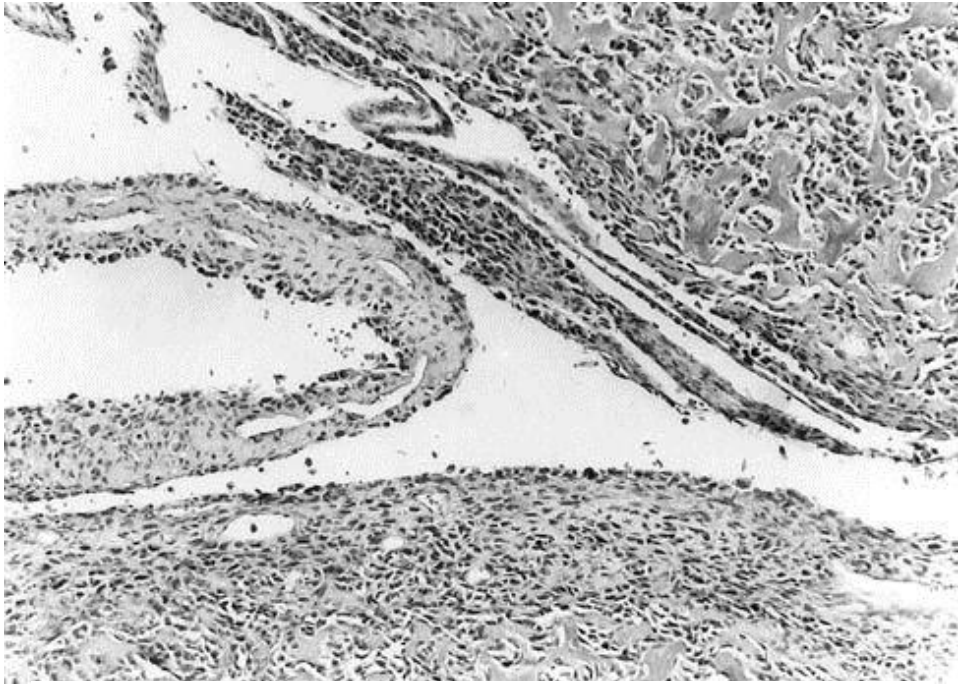
Plump tumor cells demonstrate osteoid production in Case 9.



Osteosarcoma, which has a focally fascicular growth pattern (Case 1).



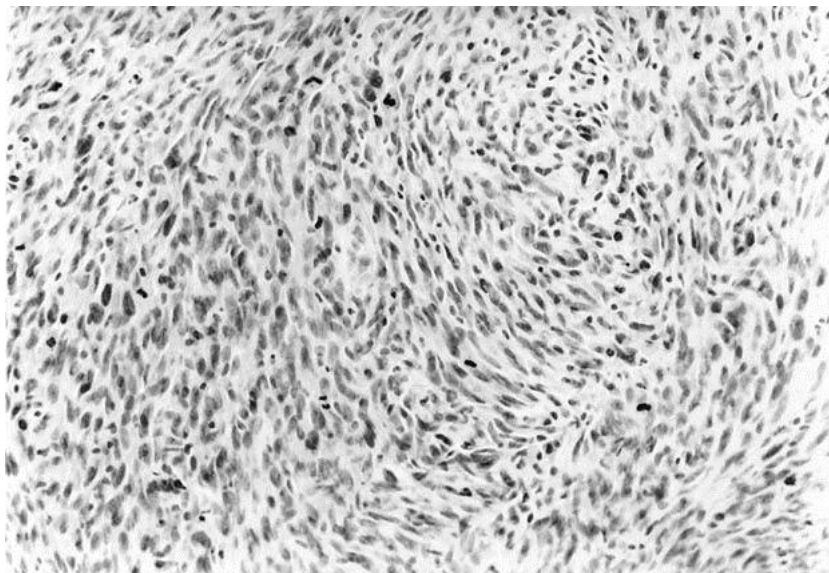
The osteosarcoma in Case 5 has areas of neoplastic cartilage formation.



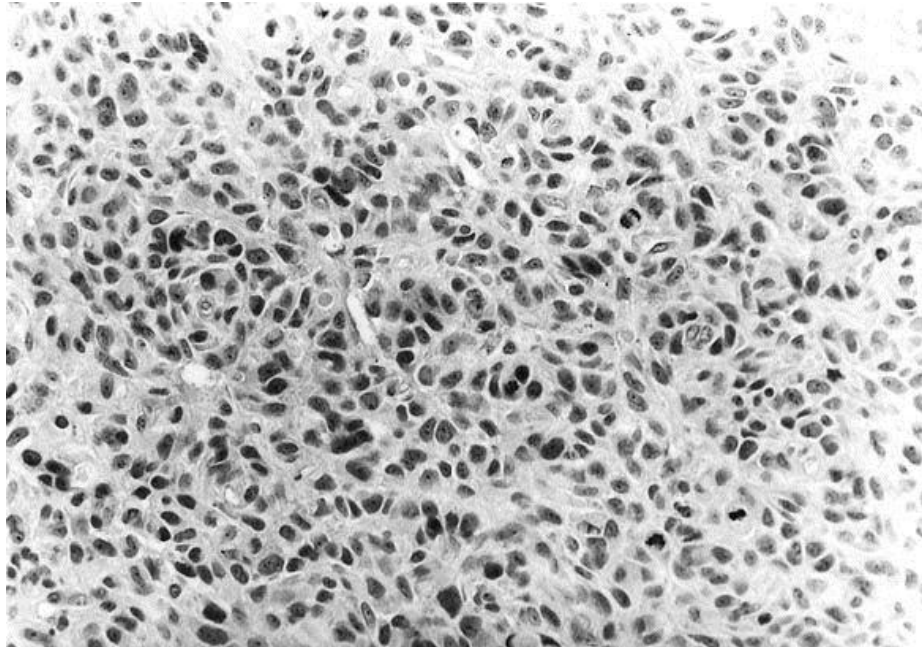
**Cystic, spaces are characteristic of the telangiectatic osteosarcoma in Case 2.**

Of the four cases of MFH, three were the storiform-pleomorphic type and were located within bone. They were composed of severely atypical and bizarre spindle cells that were arranged in a storiform pattern (Fig. 10). Mitoses were numerous. The remaining MFH (Case 3) originated within the soft tissue adjacent to a hip prosthesis and was composed of atypical epithelioid and spindle shaped cells that were infiltrated by numerous inflammatory cells including eosinophils, neutrophils and lymphocytes and was

considered to be an inflammatory MFH (Fig. 11). Immunohistochemistry performed on formalin-fixed paraffin-embedded tissue showed that the tumor cells in Case 6 expressed vimentin, actin, smooth muscle actin, alpha-1-antichymotrypsin, and alpha-1-antitrypsin. They did not express desmin or S-100 protein. This staining pattern supports the histologic impression of MFH with myofibroblastic features. Immunohistochemistry was not performed on the other cases of MFH.



**Acute and chronic inflammatory cells virtually obscure the malignant component of the inflammatory malignant fibrous histiocytoma (Case 3).**



**This malignant peripheral nerve sheath tumor is composed of epithelioid cells with a high mitotic rate (Case 4).**

The malignant peripheral nerve sheath tumor (MPNST) was composed of large, spindle and focally epithelioid cells that had eosinophilic cytoplasm (Fig. 12) and were arranged in small swirls around vessels or other tumor cells. Multinucleate tumor cells were scattered throughout the mass. Mitotic activity was high, with many atypical forms and there was focal necrosis. Immunohistochemistry performed on formalin-fixed, paraffin-embedded tissue showed that the tumor cells expressed vimentin, alpha-1-antitrypsin, alpha-1-antichymotrypsin, and were focally positive for keratin. The tumor cells did not stain for desmin, smooth muscle actin, leu-7, S-100, or KP-1. Ultrastructural analysis revealed long, intertwining cell processes, intracellular junctions, and basal lamina, diagnostic of Schwann cell differentiate.

#### **Treatment and Follow-Up**

Three patients had pulmonary metastases at the time of diagnosis. The surgical treatment is known for 11 patients. Nine patients underwent wide resection of their tumor, and usually received adjuvant chemotherapy and/or radiation therapy (see Table 2). One patient had surgical debulking combined with radiation therapy and chemotherapy, and the patient with the telangiectatic osteosarcoma refused surgery and had radiation therapy and embolization of the tumor. Follow-up information is available on eight patients. Five patients died of disease 2 months to 8 years (mean 26 months) after diagnosis. Two patients died without evidence of disease 7 and 30 months after diagnosis. One patient is alive without disease 6 years after diagnosis.

#### **DISCUSSION**

The use of orthopaedic hardware and prosthetic joints has greatly advanced the treatment of skeletal diseases.

Although the materials composing these implants are relatively biologically inert they may induce a variety of tissue responses.<sup>[40]</sup> By far the most serious complication of orthopaedic hardware and prosthetic material is malignancy. Animal studies analyzing the biological effects of the components of prosthetic joints revealed carcinogenic properties of beryllium, cadmium, chromium, cobalt, iron, lead, nickel, selenium, zinc, and titanium.<sup>[2, 3, 4, 7, 41]</sup> In humans, prostheses containing cobalt, chromium, stainless steel, nickel, iron, manganese and silicon have been implicated as being carcinogenic. Other authors state that the placement of an implant may induce osteonecrosis, which in itself is a risk factor for the development of a sarcoma.<sup>[37, 42]</sup> To date only 31 cases of implant-related sarcoma have been reported in the literature since the 1950s (Table 3).<sup>[9, 10, 11, 12, 13, 14, 15, 16, 17, 18, 19, 20, 21, 22, 23, 24, 25, 26, 27, 28, 29, 30, 31, 32, 33, 34, 35, 36, 37]</sup> This number is minuscule when compared with the 270,000 hip surgeries in addition to the hundreds of thousands of other hardware-related procedures performed in the U.S each year.<sup>[1]</sup> Furthermore, a Finnish study of 31,651 patients who received polyethylene and metal hip prosthesis reported no associated sarcomas.<sup>[43]</sup> However, the fact that malignancies have arisen in close proximity to metallic implants is strong evidence that there may be an important relationship. Chromosomal aberrations have been reported in the marrow adjacent to hip arthroplasties.<sup>[44]</sup> In other anatomic sites, such as the lung, metal foreign bodies have also been associated with the development of malignancy.<sup>[45]</sup>

**Table 3: Prior Reports of Implant-Related Sarcoma.**

Reference	Age/Sex	Diagnosis	Site	Time Interval	Hardware
Arden <i>et al.</i>	58/NA	FSA	Femur	3 years	THR
Bago-Granell <i>et al.</i>	79/F	MFH	Femur	2 years	THR
Brien <i>et al.</i>	69/F	OSA	Femur	8 years	THR
Cole <i>et al.</i>	63/F	MFH	Femur	2 years	THR
Delgado <i>et al.</i>	40/M	OSA	Tibia	3 years	Plate
Dube <i>et al.</i>	84/M	Angiosarcoma	Tibia	26 years	Plate
Haag <i>et al.</i>	78/F	MFH	Femur	9 years	THR
Harris <i>et al.</i>	70/F	CSA	Femur	3 years	THR
Himmer <i>et al.</i>	87/F	Angiosarcoma	Femur	1.7 years	TKR
Hughes <i>et al.</i>	42/M	MFH	Femur	30 years	Plate
Jacobs <i>et al.</i>	65/M	MFH	Femur	0.5 years	THR
Lamovec <i>et al.</i>	62/M	Synovial sarcoma	Femur	12 years	THR
Lamovec <i>et al.</i>	65/F	OSA	Acetabulum	10 years	THR
Lee <i>et al.</i>	58/M	MFH	Femur	14 years	Plate
Martin <i>et al.</i>	76/F	OSA	Femur	10 years	THR
McDougal <i>et al.</i>	42/M	Ewing's	Humerus	30 years	Plate
Nelson <i>et al.</i>	72/F	MFH	Femur	11 years	THR
Penman <i>et al.</i>	80/F	OSA	Femur	5 years	THR
Ryu <i>et al.</i>	52/M	Sarcoma	Acetabulum	1.25 years	THR
Swann <i>et al.</i>	67/M	MFH	Femur	4 years	THR
Tait <i>et al.</i>	56/F	MFH	Femur	11 years	THR
Tayton <i>et al.</i>	11/F	Ewing's	Femur	7.5 years	Plate
Troop <i>et al.</i>	54/M	MFH	Femur	10 years	THR
van der List <i>et al.</i>	84/F	Epithelioid hemangioendothelioma	Femur/acetabulum	12 years/0.5 years	THR
Vives <i>et al.</i>	70/M	MFH	Femur	1.75 years	THR
Weber <i>et al.</i>	81/F	Epithelioid sarcoma	Tibia	4.5 years	TKR

MFH, malignant fibrous histiocytoma; OSA, osteosarcoma; THR, total hip replacement; TKR, total knee replacement.

An animal model for the development of sarcomas in rats that have been implanted with various biomaterials has shown that up to 67% of implant sites developed either a sarcoma or a reaction that they termed "proliferative, probably preneoplastic".<sup>[5]</sup> There was no correlation between the morphology of the sarcoma and the type of biomaterial that was implanted. The materials most often associated with these histologic changes were

polymethylmethacrylate (67% of sites), polyethylene (59% of sites), silicone (56% of sites), and aliphatic polyurethane (52% of sites). Pure titanium, nickel chromium, cobalt-chromium alloy and aluminum oxide were less often associated with proliferative and malignant changes. Preneoplastic mesenchymal lesions have not been well defined or classified and its exact meaning in this study is unclear.

The majority of our cases of implant-related sarcomas were osteosarcoma, followed by MFH, and a single case of MPNST. Combined with the cases reported in the literature previously, 15 are MFH, 12 osteosarcoma, 2 angiosarcoma, 2 Ewing's sarcoma, 1 each of fibrosarcoma, MPNST, epithelioid sarcoma, synovial sarcoma, epithelioid hemangioendothelioma, chondrosarcoma in a patient with Maffucci's syndrome, and an unclassified sarcoma. The age range of all patients who developed implant-related sarcomas is 11 to 87 (mean 50) years, which is similar to the age range in our series. The time interval from the insertion of the implant to the development of malignancy has ranged from 6 months to 30 years (mean 9) years, which is also similar to our results. Thirty-one sarcomas occurred in the femur, three in the tibia, two in the acetabulum, one in the humerus, and one involved both the femur and acetabulum. The propensity of the sarcomas to arise in the femur is probably related to the fact that it is the most common bone to be treated with an orthopaedic implant.

### CONCLUSION

Large, high-grade sarcomas arising in bone or soft tissue have a poor prognosis. When coupled with a delay in the diagnosis of malignancy, prosthetic-related sarcomas have a high mortality. Follow-up information available on 14 of the 26 implant-related sarcomas reported in the literature demonstrates this point; one patient was free of disease 15 months after surgical therapy, 5 patients were dead 1 year after diagnosis, and 8 patients were dead less than 1 year after diagnosis. At least 8 of the 13 patients that died had metastatic disease at the time of death. The clinical outcome of our cases is similar. Of the eight patients with follow-up information, seven died of disease a mean of 26 months after diagnosis, and only one patient is alive and disease free. Clinically it may be difficult to detect an implant associated malignancy as implant-related symptoms caused by other processes are more common and radiographic imaging studies are compromised by the artifact induced by the metal component of the implant. Although the possibility of a sarcoma developing in association with an implant is extremely small, physicians should at least consider this possibility when pain or other new findings develop in relation to metallic orthopaedic hardware.

### REFERENCES

- Mushinski M. Average charges for hip replacement surgeries: United States, 1997. *Stat Bull Metrop Insur Co* 1999; 80: 32–40.
- Heath JC, Daniel MR. The production of malignant tumors by cadmium in the rat. *Br J Cancer* 1964; 18: 129.
- Heath JC, Freeman MAR, Swanson SAV. Carcinogenic properties of wear particles from prostheses made in cobalt-chromium alloy. *Lancet* 1971; 1: 564–566.
- Kirkpatrick CJ, Alves A, Kohler H, Kriegsmann J, Bittinger F, Otto M, *et al.* Biomaterial induced sarcoma. A novel model to study preneoplastic change. *Am J Pathol* 2000; 156: 1455–1467.
- Memoli VA, Urban RM, Alroy J, Galante JO. Malignant neoplasms associated with orthopedic implant materials in rats. *J Orthop Res* 1986; 4: 346–355
- Sunderman FW. Metal carcinogenesis in experimental animals. *Food Cosmet toxicol* 1971; 9: 105–120.
- Sinibaldi K, Rosen H, Liu S, De Angelis M. Tumors associated with metallic implants in animals. *Clin Orthop* 1976; 118: 257–266.
- Arden GP, Bywaters EGL. Tissue reaction. In: Arden GP, Ansell BM, editors. *Surgical management of juvenile chronic polyarthritis*. London: Academic Press; 1978: p. 269–270.
- Bago-Granel J, Aguirre-Canyadell M, Nardi J, Tallada N. Malignant fibrous histiocytoma of bone at the site of a total hip arthroplasty. *J Bone Joint Surg (Br)* 1984; 66-B: 38–40.
- Brien WW, Salvati EA, Healy JH, Bansal M, Ghelman B, Betts F. Osteogenic sarcoma arising in the area of a total hip replacement. *J Bone Joint Surg* 1990; 72-A: 1097–1099.
- Cole BJ, Schultz E, Smilari TF, Hajdu SI, Krauss ES. Malignant fibrous histiocytoma at the site of a total hip replacement: review of the literature and case report. *Skeletal Radiol* 1997; 26: 559–563.
- Delgado ER. Sarcoma following a surgically treated fractured tibia. *Clin Orthop* 1958; 12: 315–318.
- Dube VE, Fisher DE. Hemangioendothelioma of the leg following metallic fixation. *Cancer* 1972; 30: 1260–1266.
- Haag M, Adler CP. Malignant fibrous histiocytoma in association with hip replacement. *J Bone Joint Surg (Br)* 1989; 71-B: 701.
- Harris WR. Chondrosarcoma complicating total hip arthroplasty in Maffucci's syndrome. *Clin Orthop* 1990; 260: 212–214.
- Himmer O, Lootvoet L, Deprez P, *et al.* Angiosarcome apres prothese totale de genou. A propos d'un cas. *Rev Chir Orthop Reparatrice Appar Mot* 1991; 77: 125–128.
- Hughes AW, Cherokee DA, Hamblen DL, Reid R. Sarcoma at the site of a single hip screw. *J Bone Joint Surg* 1987; 69-B: 470–472.
- Jacobs JJ, Rosenbaum DH, Hay RM, Gitelis S, Black J. Early sarcomatous degeneration near a cementless hip replacement. *J Bone Joint Surg* 1992; 74B: 740–744.
- affe KA, Morris SG, Lemons JE, Robinson LH. Sarcomas around implants: three cases and a review of the literature. *Journal of the Southern Orthopaedic Association* 1994; 3: 127–134.
- Khurana JS, Rosenberg AE, Kattapuram SV, Fernandez OS, Ehara S. Malignancy supervening on an intramedullary nail. *Clin Orthop* 1991; 267: 251–254.

21. Lamovec J, Zidar A, Cucek-Plenicar M. Synovial sarcoma associated with total hip replacement. *J Bone Joint Surg* 1988; 70-A: 1558–1560.
22. Lane JM, Rosenberg AE. Case records of the Massachusetts General Hospital (Case 4-1991). *N Engl J Med* 1991; 324: 251–259.
23. Lee Y, Pho RW, Nather A. Malignant fibrous histiocytoma at site of metal implant. *Cancer* 1983; 54: 2286–2289.
24. Martin A, Bauer TW, Manley MT, Marks KE. Osteosarcoma at the site of total hip replacement. *J Bone Joint Surg* 1988; 70-A: 1561–1567.
25. McDougall A. Malignant tumor at the site of bone plating. *J Bone Joint Surg* 1957; 38B: 709–713.
26. Nelson JP, Phillips PH. Malignant fibrous histiocytoma associated with total hip replacement. *Orthopaedic Review* 1990; 19: 1078–1080.
27. Penman HG, Ring PA. Osteosarcoma in association with total hip replacement. *J Bone Joint Surg (Br)* 1984; 66-B: 632–634.
28. Ryu RKN, Bovill EG, Skinner HB, Murray WR. Soft tissue sarcoma associated with aluminum oxide ceramic total hip arthroplasty. *Clin Orthop* 1987; 216: 207–212.
29. Swann M. Malignant soft tissue tumor at the site of a total hip replacement. *J Bone Joint Surg* 1984; 66-B: 629–631.
30. Tait NP, Hacking PM, Malcolm AJ. Malignant fibrous histiocytoma occurring at the site of previous total hip replacement. *Br J Radiol* 1988; 61: 73–76.
31. Tayton KJJ. Ewing's sarcoma at the site of a metal plate. *Cancer* 1980; 45: 413–415.
32. Troop JK, Mallory TH, Fisher DA, Vaughn BK. Malignant fibrous histiocytoma after total hip arthroplasty. *Clin Orthop* 1990; 253: 297–300.
33. van der List JJJ, van Horn JR, Sloof TJJH, ten Cate LN. Malignant epithelioid hemangioendothelioma at the site of a hip prosthesis. *Acta Orthop Scand* 1988; 53: 328–330.
34. Vives P, Sevestre H, Grodet H, *et al.* Histiocytome fibreux malin du femur apres prothes totale de hanche, a propos d'un cas. *Rev Chir Orthop reparatrice Appar Mot* 1987; 73: 407–409.
35. Ward JJ, Thornbury DD, Lemons JE, Dunham WK. Metal-induced sarcoma. A case report and review of the literature. *Clin Orthop* 1990; 252: 299–306.
36. Weber PC. Epithelioid sarcoma in association with total knee replacement. *J Bone Joint Surg* 1986; 68: 824–826.
37. McDonald I. Malignant lymphoma associated with internal fixation of a fractured tibia. *Cancer* 1981; 48: 1009–1011.
38. Jacobs JJ, Skipor AK, Black J, Urban RM, Galante JO. Release and excretion of metal in patients who have a total hip-replacement component made of titanium-base alloy. *J Bone Joint Surg* 1991; 73-A: 1475–1486.
39. Pedley RB, Meachim G, Williams DF. Tumor induction by implant materials. In: Williams DF, editor. *Fundamental aspects of biocompatibility*. Vol. 2. Boca Raton, FL: CRC.
40. Hamblen DL. Sarcoma and joint replacement [editorial]. *J Bone Joint Surg* 1984; 66-B: 625–627.
41. Paavolainen P, Pukkala E, Pulkkinen P, Visuri T. Cancer incidence in Finnish hip replacement patients from 1980 to 1995: a nationwide cohort study involving 31,651 patients. *J Arthroplasty* 1999; 14: 272–280.
42. Case CP, Langkamen G, Howell RT, Webb J, Standen G, Palmer M, *et al.* Preliminary observations on possible premalignant changes in bone marrow adjacent to worn total hip arthroplasty implants. *Clin Orthop Relat Res* 1996; 329: S269–S279.
43. Siddons AHM, MacArthur AM. Carcinomata developing at the site of foreign bodies in the lung. *Br J Surg* 1952; 39: 542–545.