EUROPEAN JOURNAL OF BIOMEDICAL AND PHARMACEUTICAL SCIENCES
http://www.ejbps.com

ISSN 2349-8870
Volume: 9
Issue: 12
65-66
Year: 2022

ERYTHEMA NODUSUM IN PREGNANCY CONSEQUENCE OF CAMPYLOBACTER INFECTION–A CASE REPORT

***Mayigaiah S., Utekar T. and Cooley S.**

[1,2]Registrar Obstetrics, Rotunda Hospital.
[3]Consultant Obstetrician, Rotunda Hospital.

***Corresponding Author: Mayigaiah S.**
Registrar Obstetrics, Rotunda Hospital.

Article Received on 02/10/2022 **Article Revised on 23/10/2022** **Article Accepted on 13/11/2022**

INTRODUCTION

Erythema Nodusum following Campylobacter Gastroenteritis is a rare entity in pregnancy. We present one such case of a 35yr old P1 lady of 4+5 weeks of gestation, presented with 3 day history of watery diarrhoea and widespread itchy rash all over the body after consumption of sushi. She was adequately treated with I/v fluids and appropriate antibiotics. The patient had successful treatment with azithromycin and made complete recovery over 2 weeks.

CASE REPORT

A 35yr old P1 lady of 4+5 weeks of gestation presented with 3 day history of watery diarrhea and widespread, itchy rash all over the body. She had lower abdominal cramping pain mainly on the left side and occasional nausea. She had 8-10 episodes of greenish, watery, foul smelling diarrhoea. On presentation she was severely dehydrated with dry mucous membranes. Blood Pressure was 100/60 mm Hg, Heart rate of 92bpm and respiratory rate of 14. Abdomen was generally tender in and around the umbilicus region and Left iliac fossa. The rash was diffuse, ill defined, erythematous present all over the abdomen, back and both upper and lower limbs(Pic 1).

Her haemaglobin was 107g/L, white cell count - 16.4×109/L, C-reactive protein - 88 and a lactate of 1.23. Urine dipstick showed +3 ketones. LFT's were slightly deranged with ALT 45, AST 35IU. Transvaginal Ultrasound revealed thickened Endometrium, normal adnexa and ovaries. BHcg was 488. Blood and urine cultures were negative. Stool culture –campylobacter species was isolated, but was negative for clostridium, cryptosporidium, Giardia, salmonella, shigella, adeno & enterovirus. She received adequate fluid resuscitation and I/v antibiotics-Cefotaxime and Gentamycin. As the stool culture report was available, I/v antibiotics were stopped and Oral azithromycin was commenced as per advice from Microbiology team. Patient was thoroughly explained about the diagnosis, risks, treatment options re supportive treatment alone vs adding azithromycin and its side effects. Her Diarrhoea, abdominal pain and nausea resolved over the next 5 days following admission. The rash was slowly resolved with Piriton, topical emollient and completely resolved over 2 weeks. The pregnancy is ongoing and she is attending routine Antenatal care in our hospital with nil concerns until date.

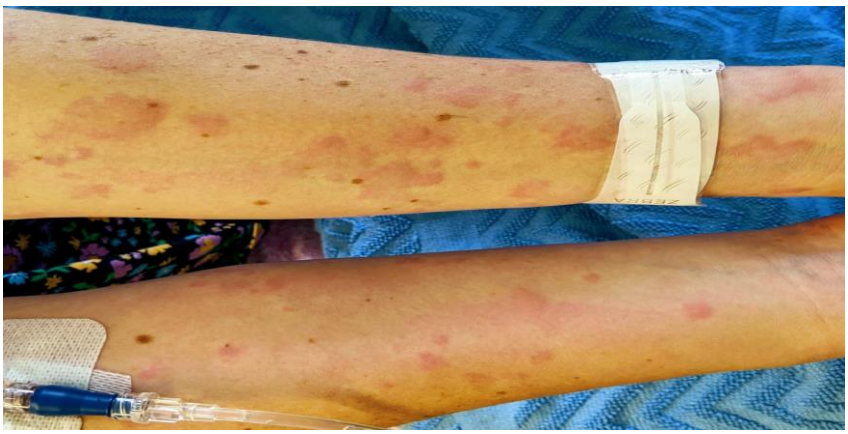

Pic 1: Erythematous rash all over the forearm.

DISCUSSION

This is a unique case in pregnancy and on review of literature(Pubmed with keyword search-Campylobacter assosciated erythema nodusum & pregnancy) no previous similar cases were found/described. Campylobacter is the leading cause of acute infectious diarrhea in most industrialized countries.[1] Campylobacter species are gram negative, motile bacilli. Most infections are acquired through improper handling/ undercooked chicken, ingestion of unpateurised milk/ milk products.[2] Campylobacter induced bacteremia during pregnancy is associated with increased risk of spontaneous abortion, intrauterine infection of the fetus, stillbirth, or early neonatal death. Infection of a newborn by the mother during the birth process or shortly after birth may lead to neonatal enteritis, bacteremia, and/or meningitis.[3] The two potentially devastating conditions- Guillain-Barre syndrome and Reiter's syndrome are reported as a sequelae of infection with Campylobacter.[3] It can present as a common presentation as fever or as a severe disseminated infection. Campylobacter should be suspected in pregnant women with enteritis and blood and stool cultures should be sent. The most important treatment is maintainence of proper hydration and electrolyte balance. Because of severe consequences and adverse outcome following campylobacter infection, treatment should be done with antibiotics. Macrolides are the antibiotics of choice, azithromycin & erythromycin are used commonly. Preventive measures are likely to have the greatest impact, Good kitchen hygiene when handling/preparing food of animal origin, good hygienic practices when in contact with dogs and cats will help prevent the infections and associated complication.

REFERENCES

1. Kapperud G. Campylobacterinfeksjon. Epidemiologi, risikofaktorer og forebyggende tiltak [Campylobacter infection. Epidemiology, risk factors and preventive measures]. Tidsskr Nor Laegeforen, 1994 Mar 10; 114(7): 795-9. Norwegian. PMID: 8009498.
2. Wagenaar JA, van Bergen MA, Blaser MJ, Tauxe RV, Newell DG, van Putten JP. Campylobacter fetus infections in humans: exposure and disease. Clin Infect Dis., 2014 Jun; 58(11): 1579-86. doi: 10.1093/cid/ciu085. Epub 2014 Feb 18. PMID: 24550377.
3. Smith JL. Campylobacter jejuni infection during pregnancy: long-term consequences of associated bacteremia, Guillain-Barré syndrome, and reactive arthritist. J Food Prot, 2002 Apr; 65(4): 696-708. doi: 10.4315/0362-028x-65.4.696. PMID: 11952223.