



**A CASE SERIES STUDY OF POST COVID ASSOCIATED SINONASAL  
MUCORMYCOSIS WITH HARD PALATE INVOLVEMENT ATTENDING GGH,  
KAKINADA**

**Dr. V.CH.V.Siva Kumar<sup>1</sup>, Dr. A.Janani<sup>2</sup>, Dr. Tadi Jyothsna Priya Bhavani<sup>3</sup>**

<sup>1</sup>Assistant Professor, (Designated Associate Professor), Department of ENT, Rangaraya Medical College, Kakinada, Andhra Pradesh.

<sup>2</sup>Junior Resident, Department of ENT, Rangaraya Medical College, Kakinada, Andhra Pradesh.

<sup>3</sup>Junior Resident, Department of ENT, Rangaraya Medical College, Kakinada, Andhra Pradesh.

**\*Corresponding Author: Dr. V.CH.V. Siva Kumar**

Assistant Professor, (Designated Associate Professor), Department of ENT, Rangaraya Medical College, Kakinada, Andhra Pradesh.

Article Received on 25/12/2021

Article Revised on 15/01/2022

Article Accepted on 05/02/2022

**ABSTRACT**

**Background:** Mucormycosis is an opportunistic, fulminating fungal infection caused by fungi of the order Mucorales of subphylum mucormycotina (formerly known as the class zygomycetes). Mucormycosis being a rare disease, it causes highly invasive and progressive diseases in immunocompromised patients. Early diagnosis and intervention play an important role in the outcome. Rhino cerebral mucormycosis is common while palatal involvement is a rare occurrence. Mucormycosis of the hard palate is an ominous sign due to POSTCOVID-19 association and other predisposing factors that made it AN EPIDEMIC WITHIN THIS PANDEMIC. **Materials and Methods:** In this study, A total of 25 patients who presented with hard palate involvement and had a history of covid infection in the past and who filled the inclusion criteria, were chosen for the study. For all the cases a detailed history was collected and necessary evaluations were done. **Results:** On observation in this study, males are more commonly affected (80%), more common in DE Novo diabetic patients (80%), with the average window period being 56.2 days. The most common sinus involvement associated with hard palate involvement is the maxillary sinus (100%) according to the MRI and CT scan. The most common symptoms are palatal swelling (100%) followed by numbness in the upper jaw and upper lip (80%). We have observed recurrence in 12% of patients and 20% of patients had post-operative squeals like fistula (20%) and post-operative numbness in 40%. Others 28% of patients recovered without any complications. **Conclusion:** With proper suspicion in post covid patients with hard palate swelling and associated symptoms along with early diagnosis and adequate resection of the tumor, the disease can be conquered.

**KEYWORDS:** MRI- Magnetic Resonance Imaging; CT- Computed Tomography; HARD PALATE; PALATAL MUCORMYCOSIS; POST COVID.

**I. INTRODUCTION**

Mucormycosis is an opportunistic, fulminating fungal infection caused by fungi of the order Mucorales of subphylum mucormycotina (formerly known as the class zygomycetes). It causes highly invasive and progressive diseases resulting in higher rates of morbidity and mortality. Early diagnosis and intervention play an important role in the outcome. Rhinocerebral mucormycosis is common while palatal involvement is a rare occurrence. Mucormycosis of the hard palate is an ominous sign. Mucormycosis is a rare disease.

COVID -19 infection and other predisposing factors leads to immunocompromised state, factors like diabetes mellitus either DE Novo or chronic uncontrolled diabetes, systemic steroidal therapy which reduce the

host immune response, prolonged oxygen supplementation during hospitalization for COVID-19 infection, ICU admission for critically ill COVID -19 patients played a major role in the rise in the rate of infection of mucormycosis in post COVID recovered patients, which eventually made it AN EPIDEMIC IN THIS PANDEMIC.

**II. AIMS AND OBJECTIVES**

To study their presenting clinical features, to assess treatment modalities, intra op findings, and outcomes of patients after surgical management.

### III. MATERIALS AND METHODS

#### Inclusion Criteria

In this study, 25 patients presented to the Otorhinolaryngology Department, Government General Hospital, Kakinada with symptoms and signs of Sinonasal mucormycosis with hard palate involvement with the previous history of covid infection for which they had undergone treatment in GGH, KAKINADA from May 2021 to November 2021 were evaluated, clinical data collected and analyzed.

#### Methods of collection of data

A total of 25 patients who presented with Sinonasal mucormycosis with hard palate involvement, who fulfilled the inclusion criteria, were chosen for the study. For all the cases a detailed history regarding any swelling, numbness, ulceration, any lesion or bone exposure in the roof of the oral cavity, loose tooth, decreased vision, purulent nasal discharge, headache,

facial pain, Proptosis, epistaxis, nasal obstruction, and history of covid infection or any previous surgery and history of bleeding diathesis, cardiac disorders, uncontrolled hypertension, diabetes was carefully noted. All the subjects underwent swabs for KOH mount and fungal culture and sensitivity, endoscopic examination, hematological studies, radiological evaluation, and Ophthalmological assessment.

### IV. RESULTS

In this study, 25 patients presented to the Otorhinolaryngology Department, Government General Hospital, Kakinada with symptoms and signs of Sinonasal mucormycosis with hard palate involvement with the previous history of covid infection for which they had undergone treatment from May 2021 to November 2021. The approach to mucormycosis treatment is multi-disciplinary.

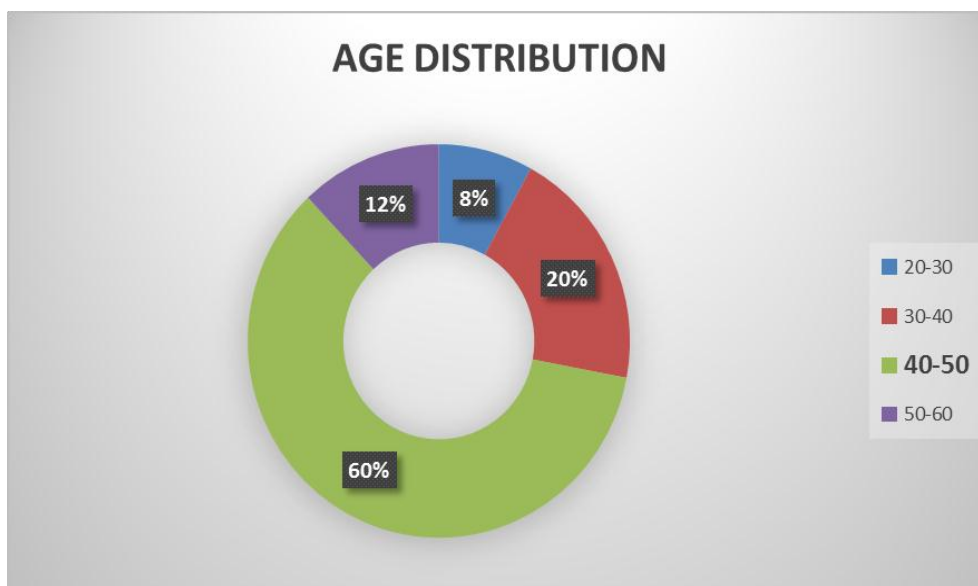
### AGE AND SEX DISTRIBUTION

**Table 1: Age and Sex distribution.**

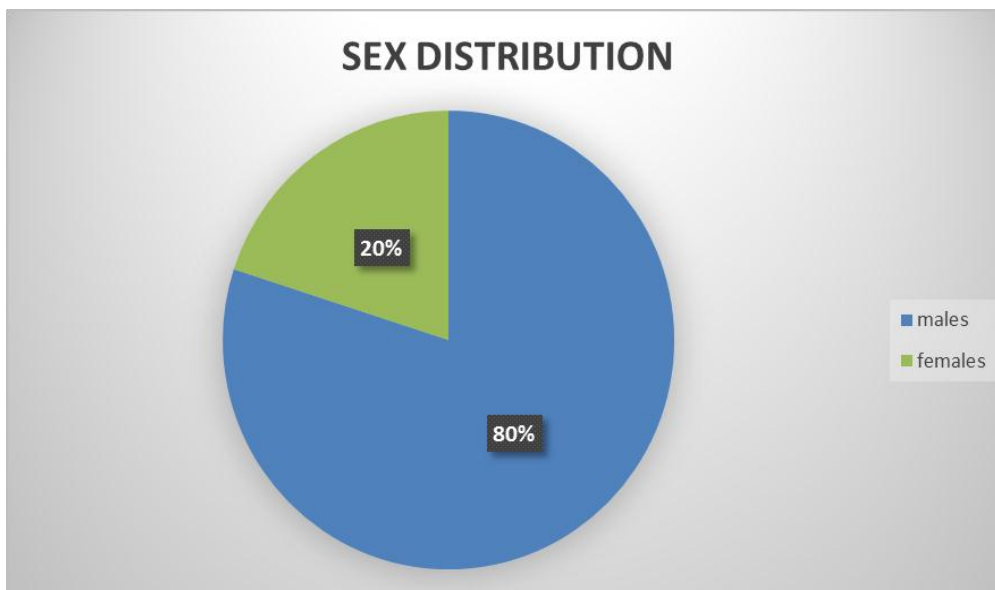
AGE GROUP	PATIENTS	MALES	FEMALES
20-30	2	2	0
30-40	5	3	2
40-50	15	12	3
50-60	3	3	0
<b>TOTAL</b>	<b>25</b>	<b>20(80%)</b>	<b>5(20%)</b>

In this study, the age group was from 20-60 years range, 40-50 years of age group people are more commonly involved 60% with the mean age being 42.72 years.

In this study, out of 25 patients, 20 were males which is about 80%, out of 20 males most of them belongs to the age group of 40-50 years (60%) and 5 were females which are 20%, out of 5 females also the most common age group being 40-50 years (60%).



**Graph 1: Age Distribution.**



Graph 2: Sex Distribution.

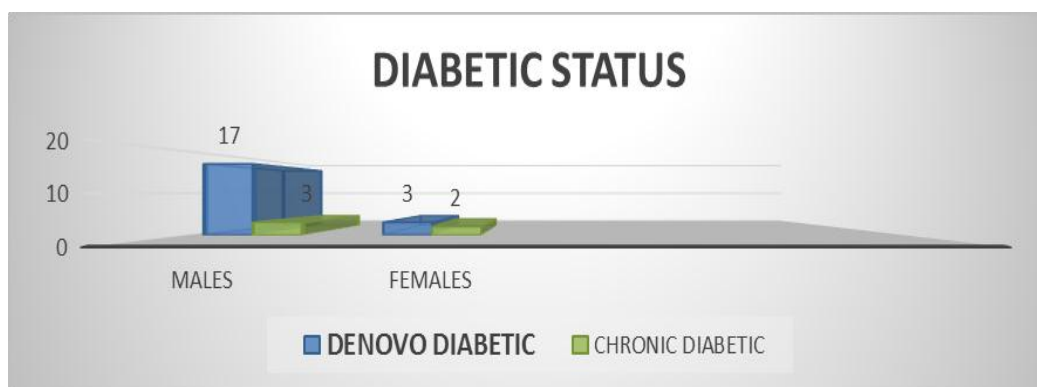
**DIABETIC STATUS**

Table 2: Diabetic status of patients.

SEX DISTRIBUTION	DENOVO DIABETIC	CHRONIC DIABETIC
MALES	17(85%)	3(60%)
FEMALES	3(15%)	2(40%)
TOTAL	20(100%)	5(100%)

In this study, 17 out of 20 were males with denovo diabetes which is about 85% and 3 out of 20 were females which is about 15%.3 out of 5 were males with

chronic diabetes which is about 60% 2 out of 5 were females which is about 40%.



Graph 3: Diabetic Status and Sex Distribution.

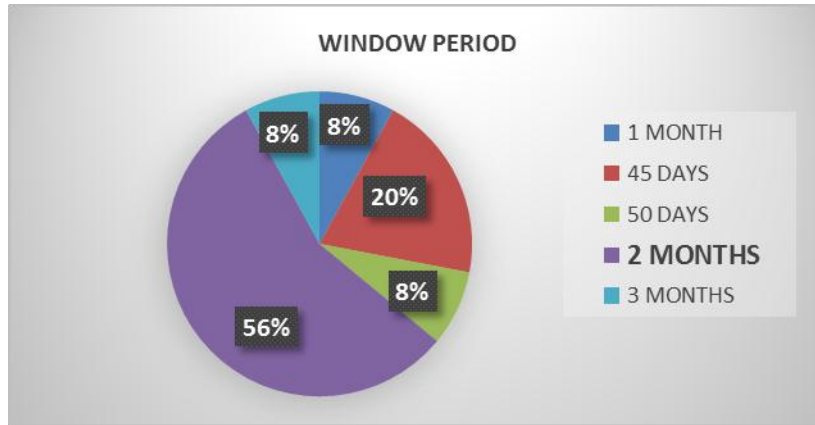
**WINDOW PERIOD OF PRESENTATION**

Table 3: Window Period.

WINDOW PERIOD	NO.OF PATIENTS
1 month	2
45 days	5
50 days	2
2 months	14
3 months	2
TOTAL	25

In this study, we have observed that the patient presented to us with symptoms of mucormycosis from about 1-month post covid status to a maximum of 3 months of

post covid period with the average being 56.2 days of post covid status.



Graph 4: Window period.

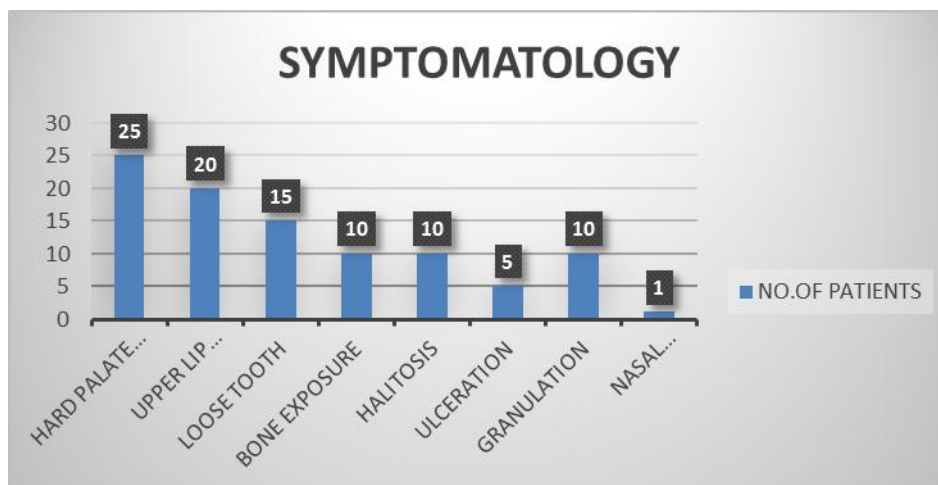
**SYMPTOMATOLOGY**

Table 4: Symptomatology.

SYMPTOMS	NO. OF PATIENTS
Hard palate swelling	25(100%)
Upper lip numbness	20(80%)
Loose tooth	15(75%)
Bone exposure	10(40%)
Halitosis	10(40%)
Ulceration	05(20%)
Granulation	10(40%)
Nasal regurgitation	1(4%)

In this study, we have observed that the most common symptom is hard palate swelling in all 25(100%) patients, followed by Upper lip numbness 20(80%)

patients, Loose tooth 15(75%), Bone exposure 10(40%), Halitosis 10(40%), Granulation 10(40%), Ulceration 5(20%), Nasal regurgitation 1(4%) in decreasing order.



Graph 5: Symptomatology.

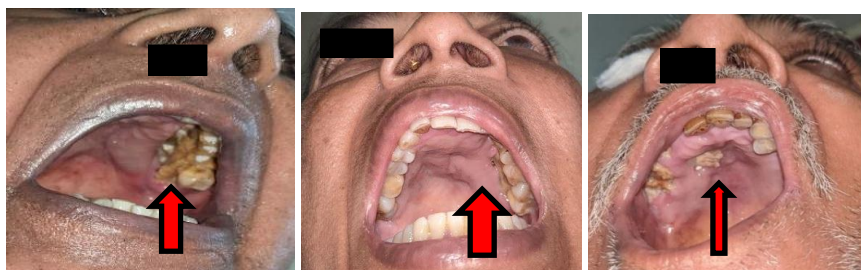


FIG 1

FIG 2

FIG 3

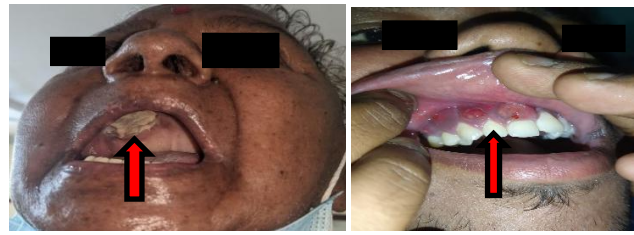

FIG 4

FIG 5

FIG 1,2,3,4,5: Shows Bone Exposure In Hard Palate, Roof of Oral Cavity Swelling, Bone Exposure With Fistula In Roof of Oral Cavity, Bone Exposure, Granulation In Upper Alveolus Respectively.

**FUNGAL CULTURE**

In this present study, we have observed that all the patients had mucoracea family rhizopus spp in 20

patients (80%) being the most common followed by mucor spp in 5 patients (20%)

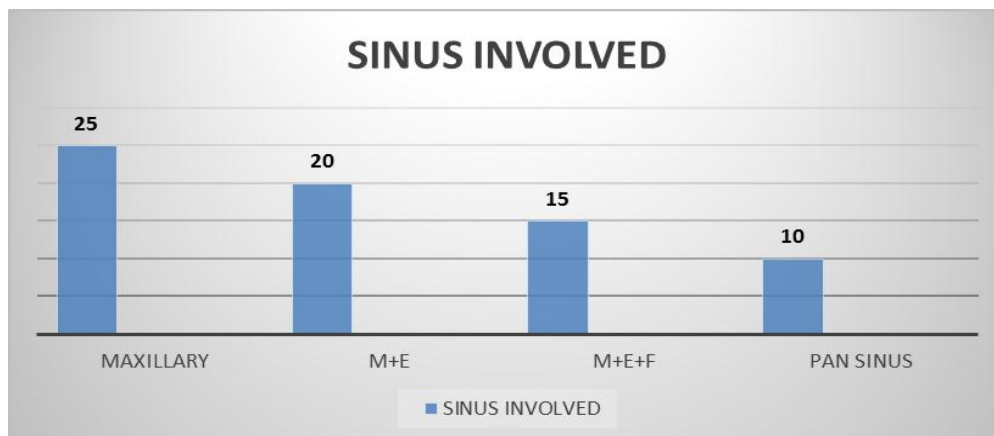
**PARANASAL SINUS INVOLVEMENT**

Table 5: Sinus Involvement.

SINUS INVOLVEMENT	NO. OF PATIENTS
MAXILLARY SINUS	25
MAXILLARY + ETHMOID SINUS	20
MAXILLARY + ETHMOIDS +FRONTAL SINUS	15
PAN SINUS INVOLVEMENT	10

In this study, we have observed that, maxillary sinus was involved in all the 25 patients followed by involvement of ethmoid along with maxillary 20 patients, maxillary,

ethmoid, and frontal involvement in 15 patients and pan sinus involvement in 10 patients as per MRI and CT findings.



Graph 6: Sinus Involvement.

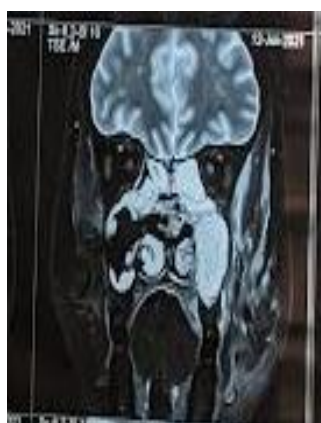

FIG: 6

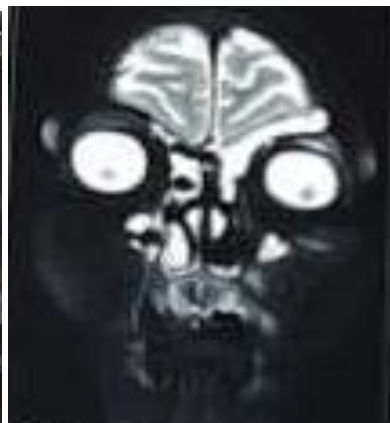

FIG:7

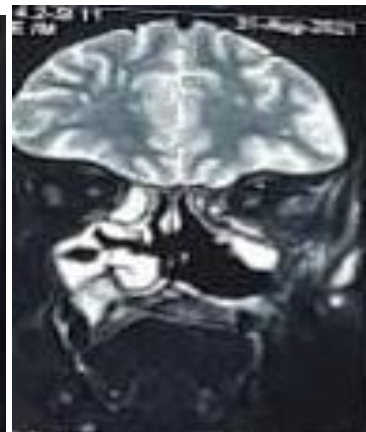


FIG: 8

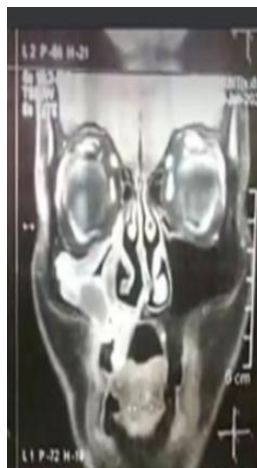

FIG: 9

FIG 6,7,8,9: MRI Paranasal Sinus Showing Involvement of Maxillary Sinus, Frontal Sinus, Ethmoid Sinus, CT shows lesion extending Into The Palatal Mucosa.

Following are the few images showing the comparison between the CT images and clinical pictures and the intraoperative images of the patients

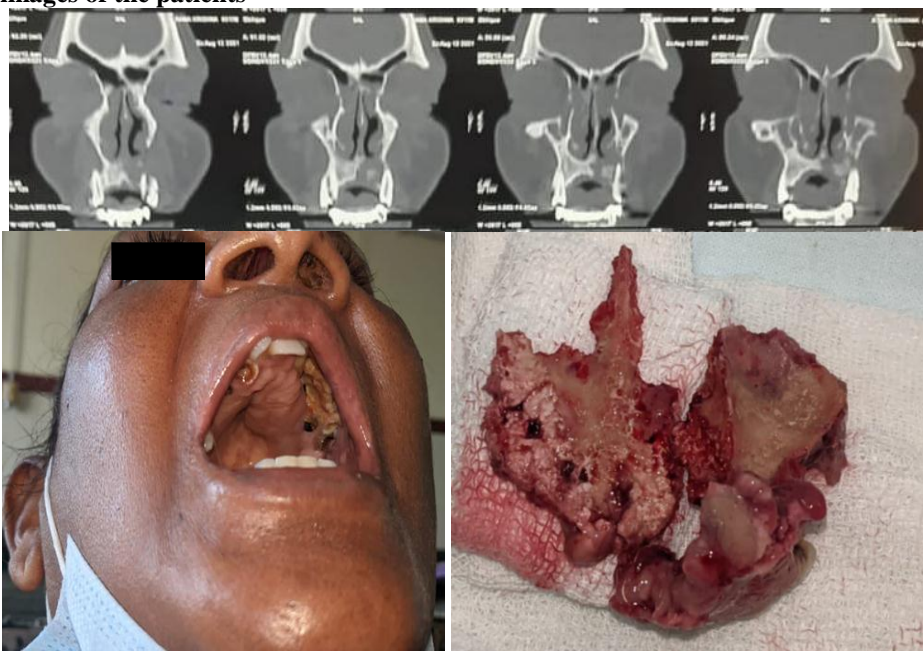
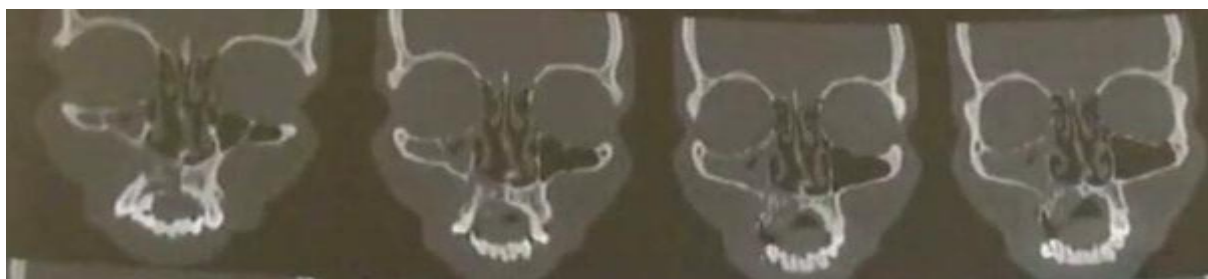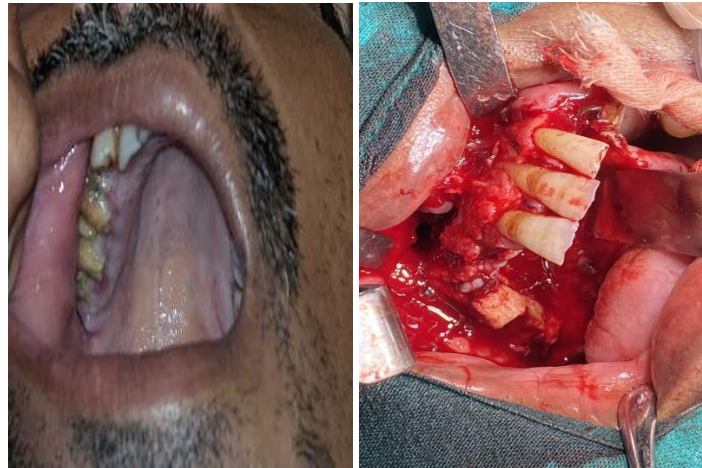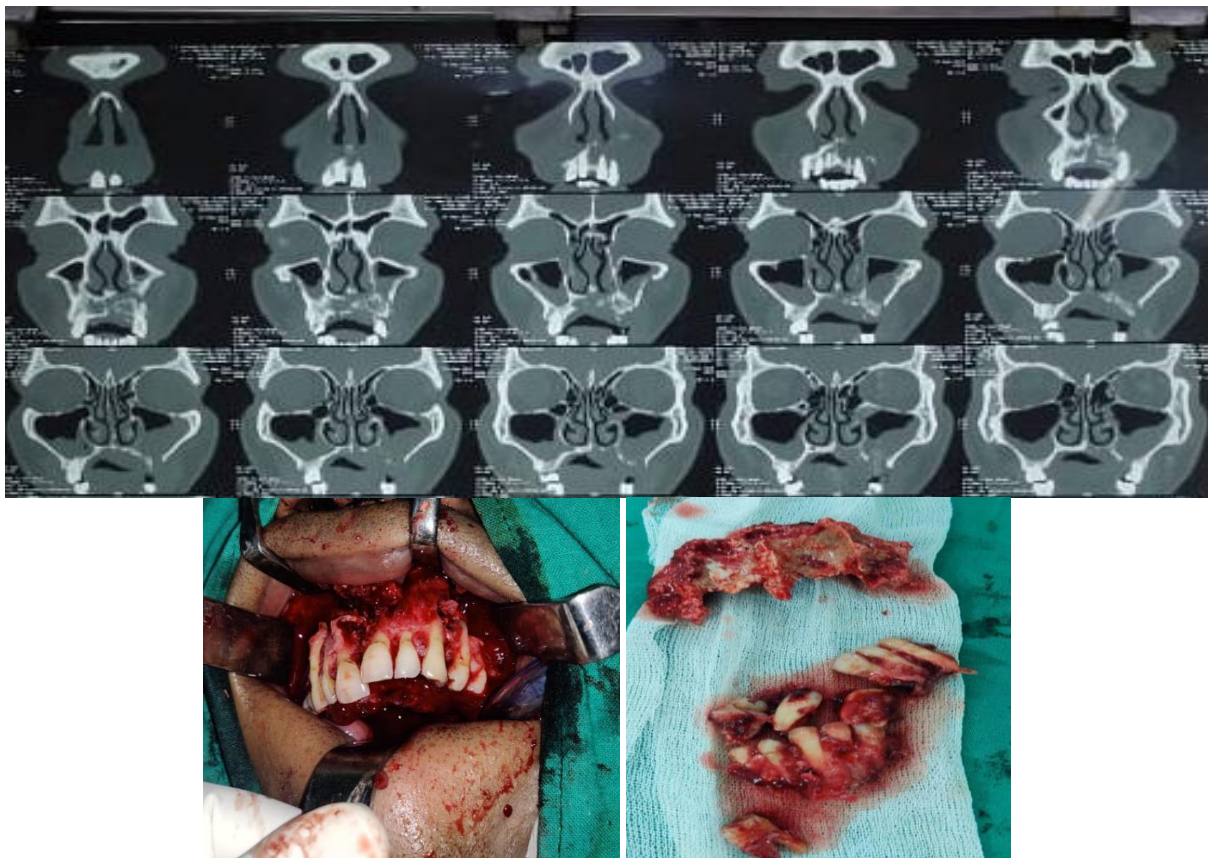


FIG 10: CT Scan Showing Left Cortical Erosion of The Hard Palate And Clinical Picture And Post-Op Bone Specimen During Partial Maxillectomy.

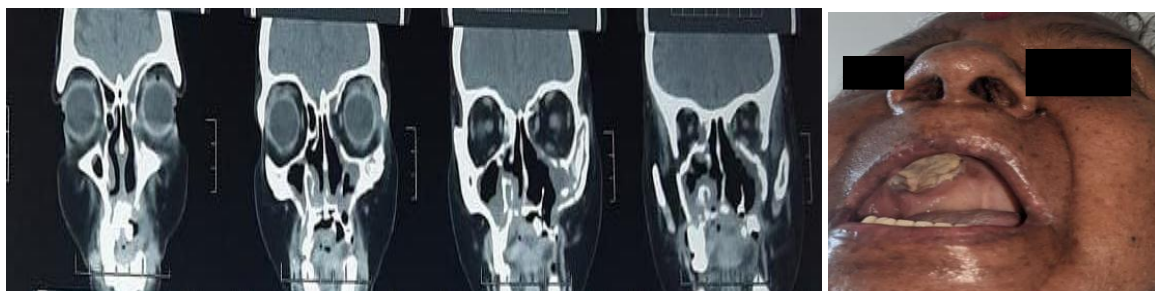


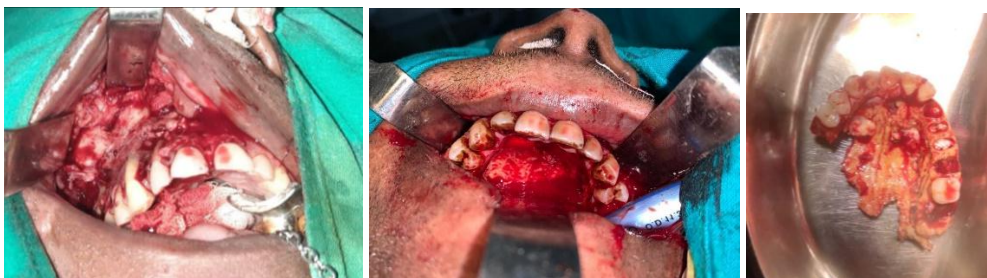

**FIG 11: CT Scan Showing Right Side Cortical Erosion of The Hard Palate Comparing With Clinical Picture and Intraop Findings Showing The Necrosis of The Right Hemi Palate.**



**FIG 12: CT Scan Showing Bilateral Palatal Erosion Compared With The Intraop Pictures Showing The Exposure of The Necrosed Palate Bilaterally and Necrosed Bone Removed Along With The Extracted Tooth.**





**FIG 13: CT Scan Showing Cortical Erosion of The Hard Palate Along With The Involvement of The Floor of The Maxillary Sinus Compared With Clinical And Intraop Photos.**

The most important factor during surgery is that proper exposure of the affected area and most probably the intraop finding will vary from the preop evaluation and radiological studies.

We observed in most cases that the patient presents with loosening of tooth alone and supporting radiological evidence for alveolar erosion but on examining the case intraoperatively there might be an extension to the hard palate also.

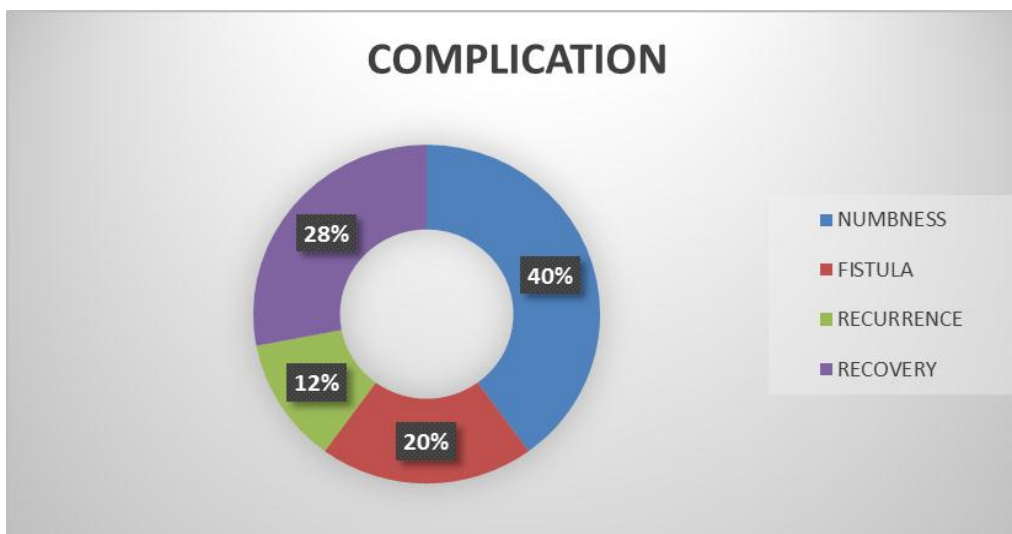
**POSTOPERATIVE COMPLICATION**

**Table 6: Postoperative Complication.**

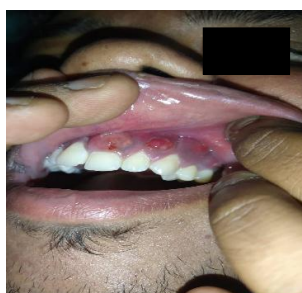POSTOPERATIVE COMPLICATION	NO. OF PATIENTS
FISTULA	5
NUMBNESS	10
RECURRENCE	3
RECOVERED	7

In this study, we have observed that out of 25 patients 5 (20%) presented with fistula formation, 3 (12%) presented with recurrence, 10 out of 25 (40%) patients

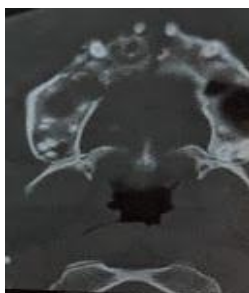
had postop numbness, and 7 (28%) out of 25 patients recovered with no complications.



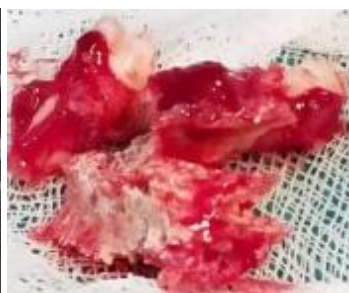**Graph 7: Postoperative Complication.**



**FIG 14**



**FIG 15**



**FIG 16**

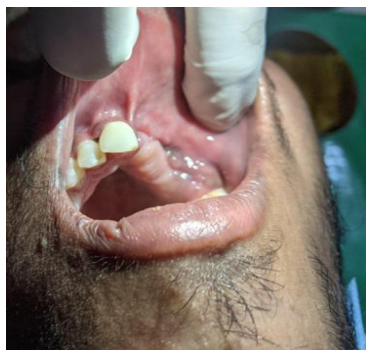

FIG 17

FIG 14, 15, 16, 17: Shows the granulation in the upper alveolus and CT showing erosion of alveolar process, the sample removed after alveolectomy and post-operative complete recovery without any complication respectively.

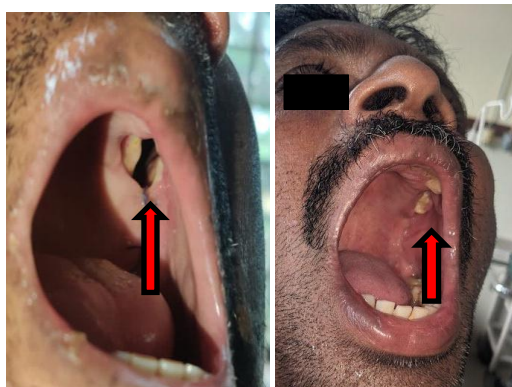

FIG 18

FIG 19

FIG 18, 19: Shows post-operative complication like fistula; recurrent in the post alveolectomy patient shows involving the remnant maxilla respectively.

## V. DISCUSSION

Mucormycosis is a medical as well as surgical emergency and requires rapid action. Empirical antifungal medication and surgical debridement should be considered early in the course of infection in potential cases of ROCM based on risk factors, clinical features and imaging findings. No guidelines are available for management of mucormycosis in COVID-19 patients; the guidelines for mucormycosis are usually adopted with individualized modifications according to the patient's requirement.

A tripartite approach is usually adopted consisting of reversal of the immunosuppressive state, administration of antifungal medication and extensive surgical debridement.<sup>[1]</sup>

In this study, 25 patients presenting to the Otorhinolaryngology Department, Government General Hospital, Kakinada with symptoms and signs of Sino nasal mucormycosis with hard palate involvement with previous history of covid infection for which they had undergone treatment in GGH, KAKINADA from May 2021 to November 2021 were evaluated, clinical data collected and analysed. Patients were observed over this study period for morbidity, mortality and improvement after the surgical debridement and timely intervention for the patient in this study population.

According to the observation made during the analysis of the data the involvement of the palate was observed due to either direct involvement of the palate due to erosion of the floor of the maxillary sinus or due to the involvement of the greater palatine artery due to the necrosis of the artery as observed in the cases.

The immuno compromised state due to uncontrolled diabetes and steroid therapy during and post recovery phase of covid to be addressed properly for proper recovery of the patient. And adequate antifungal cover with injection Liposomal Amphotericin B or Tablet or Injection Posaconazole should be given after evaluating the renal and liver function test both pre operatively and post operatively and on alternate days from the onset of treatment for observation of renal status since the drugs are nephrotoxic.

## AGE AND SEX DISTRIBUTION

In this study, the age group was from 20-60 years range, with mean age being 42.72 years.

In this study, out of 25 patients 20 were males which is about 80%, out of 20 males most of them belongs to the age group of 40-50 years (60%) and out of 5 females also the most common age group being 40-50 years (60%).

## DIABETIC STATUS

In this study, 17 out of 20 were males with DE novo diabetic which is about 85% and 3 out of 20 were females which is about 15%. 3 out of 5 were males with chronic diabetic which is about 60% 2 out of 5 were females which is about 40%.

## WINDOW PERIOD OF PRESENTATION

In this study, we have observed that the patient presented to us with symptom of mucormycosis from about 1 month post covid status to maximum of 3 months of post covid period with the average being 56.2 days of post covid status.

## SYMPTOMATOLOGY

In this study, we have observed that the most common symptom being hard palate swelling in all 25(100%) patients, followed by Upper lip numbness 20(80%) patients, Loose tooth 15(75%), Bone exposure 10(40%), Halitosis 10(40%), Granulation 10(40%), Ulceration 5(20%), Nasal regurgitation 1(4%) in decreasing order.

## FUNGAL CULTURE

In this present study, we have observed that all the patient had mucoracea family rhizopus spp in 20 patients

(80%) being the most common followed by mucor spp in 5 patients (20%).

## PARANASAL SINUS INVOLVEMENT

In this study we have observed that, maxillary sinus involved in all the 25 patients followed by involvement of ethmoid along with maxillary 20 patients, maxillary, ethmoid and frontal involvement in 15 patients and pan sinus involvement in 10 patients as per MRI and CT findings.

## POST OPERATIVE COMPLICATION

In this study we have observed that, out of 25 patients 5 (20%) presented with fistula formation and 3 (12%) presented with recurrence and 17 (68%) out of 25 patients recovered with no complications.

For fistula, secondary suturing done under local anaesthesia.

For recurrence patient was evaluated completely and reoperated for surgery under general anaesthesia.

## PROPOSED STAGING<sup>[4]</sup>

Proposed Staging of Rhino-Orbito-Cerebral Mucormycosis (ROCM)

Staging of Rhino-Orbito-Cerebral Mucormycosis	Symptoms	Signs	Primary Assessment	Confirmation of Diagnosis
<b>Stage 1: Involvement of the nasal mucosa</b> 1a: Limited to the middle turbinate 1b: Involvement of the inferior turbinate or ostium of the nasolacrimal duct 1c: Involvement of the nasal septum 1d: Bilateral nasal mucosal involvement	Nasal stuffiness, nasal discharge, foul smell, epistaxis	Foul-smelling sticky mucoid or black-tinged, or granular or haemorrhagic nasal discharge, nasal mucosal inflammation, erythema, violaceous or blue discoloration, pale ulcer, anaesthesia, ischemia, eschar	Diagnostic nasal endoscopy, Contrast-enhanced MRI (preferred) or CT-scan	Deep nasal swab or endoscopy-guided nasal swab or nasal mucosal biopsy for direct microscopy, culture and molecular diagnostics; nasal mucosal biopsy for rapid histopathology with special stains
<b>Stage 2: Involvement of paranasal sinuses</b> 2a: One sinus 2b: Two ipsilateral sinuses 2c: > Two ipsilateral sinuses and/or palate/oral cavity 2d: Bilateral paranasal sinus involvement or involvement of the zygoma or mandible	Symptoms in Stage 1 + facial pain, facial edema, dental pain, systemic symptoms (malaise, fever)	Signs in Stage 1 + unilateral or bilateral, localized or diffuse facial edema, edema localized over the sinuses, localized sinus tenderness	Diagnostic nasal endoscopy, Contrast-enhanced MRI (preferred) or CT-scan	Same as Stage 1 + sinus biopsy for direct microscopy, culture and molecular diagnostics and rapid histopathology
<b>Stage 3: Involvement of the orbit</b> 3a: Nasolacrimal duct, medial orbit, vision unaffected 3b: Diffuse orbital involvement (>1 quadrant or >2 structures), vision unaffected 3c: Central retinal artery or ophthalmic artery occlusion or superior ophthalmic vein thrombosis; involvement of the superior orbital fissure, inferior orbital fissure, orbital apex, loss of vision 3d: Bilateral orbital involvement	Symptoms in Stage 1 and 2 + pain in the eye, proptosis, ptosis, diplopia, loss of vision, infraorbital and facial V1 V2 nerve anesthesia	Signs in Stage 1 and 2 + conjunctival chemosis, isolated ocular motility restriction, ptosis, proptosis, infraorbital nerve anesthesia, central retinal artery occlusion, features of ophthalmic artery occlusion and superior ophthalmic vein thrombosis, V1 and V2 nerve palsy indicating orbital apex/superior orbital fissure involvement.	Diagnostic nasal endoscopy, Contrast-enhanced MRI (preferred) or CT-scan	Same as Stage 2 + orbital biopsy if indicated and if feasible (if the disease is predominantly orbital) for direct microscopy, culture and molecular diagnostics and rapid histopathology
<b>Stage 4: Involvement of the CNS</b> 4a: Focal or partial cavernous sinus involvement and/or involvement of the cribriform plate 4b: Diffuse cavernous sinus involvement and/or cavernous sinus thrombosis 4c: Involvement beyond the cavernous sinus, involvement of the skull base, internal carotid artery occlusion, brain infarction 4d: Multifocal or diffuse CNS disease	Symptoms in Stage 1 to 3 + bilateral proptosis, paralysis, altered consciousness, focal seizures	Signs in Stage 1-3 (some features overlap with Stage 3) + V1 and V2 nerve anesthesia, ptosis, and features of III, IV and VI nerve palsy indicate cavernous sinus involvement. Bilaterality of these signs with contralateral orbital edema with no clinico-radiological evidence of paranasal sinus or orbital involvement on the contralateral side indicate cavernous sinus thrombosis. Hemiparesis, altered consciousness and focal seizures indicate brain invasion and infarction.	Diagnostic endoscopy, Contrast-enhanced CT Scan, MRI (preferred)	Same as Stage 3

If the post covid infected patient presented with any above mentioned symptom, we should have a strong **SUSPICION** for the proper evaluation of the patient as early as possible.

With further evaluation and confirmation of the diagnosis, **INITIATION** of the treatment as soon as possible.

After complete surgical evaluation, **ADEQUATE SURGICAL DEBRIDEMENT** to be done, the tissue should be exposed and resection should be done up to the margin of normal perfusion.

Last but not the least **REHABILITATION**, since maxillectomy will cause facial disfigurement which may lead to social stigmata and decreased quality of life. So the patient should be rehabilitated with temporary prosthesis until the permanent prosthesis can be placed.

It is a Multi-disciplinary approach. We have to apply divide and conquering technique to defeat the disease completely.

## VI. CONCLUSION

In the present study,

1. There is male predominance.
2. The mean age group is 42.72 years.
3. Most of the people are DE novo diabetic than chronic diabetic.
4. The mean window period being 56.2 days.
5. The most common symptomatology is hard palate swelling followed by upper lip numbness.
6. In fungal culture, all patients underwent KOH mount in which mucoracea family with rhizopus being most common spp isolated.
7. All the patient had involvement of maxillary sinus followed by ethmoid sinus.
8. Most of them recovered without any complication.
9. Most encountered complication is fistula formation.
10. With early suspicion, timely initiation and adequate resection followed by rehabilitation patient might defeat the disease along with proper antifungal cover and strict diabetic management

## VII. REFERENCES

1. Rudrabhatla PK, Reghukumar A, Thomas SV. Mucormycosis in COVID-19 patients: predisposing factors, prevention and management. *Acta Neurol Belg*, 2021 Nov; 24: 1–8. doi: 10.1007/s13760-021-01840-w. Epub ahead of print. PMID: 34820787; PMCID: PMC8612391.
2. Jain, A., & Taneja, S. (2021). Post-COVID fungal infections of maxillofacial region: a systematic review. *Oral and maxillofacial surgery*, 1–7. Advance online publication. doi.org/10.1007/s10006-021-01010-5.
3. Gupta, Amod et al. "The emergence of post-COVID-19 mucormycosis in India: Can we prevent it?." *Indian journal of ophthalmology*, 2021; 69,7: 1645-1647. doi:10.4103/ijo.IJO\_1392\_21.
4. Honavar SG. Code Mucor: Guidelines for the Diagnosis, Staging and Management of Rhino-Orbito-Cerebral Mucormycosis in the Setting of COVID-19. *Indian J Ophthalmol*, 2021 Jun; 69(6): 1361-1365. doi: 10.4103/ijo.IJO\_1165\_21. PMID: 34011699; PMCID: PMC8302268.
5. Milind N. Naik & Suryasnata Rath (2021) The ROC Staging System for COVID-related Rhino-Orbital-Cerebral Mucormycosis, *Seminars in Ophthalmology*, DOI: 10.1080/08820538.2021.1946094.
6. Yadav T, Tiwari S, Gupta A, Garg PK, Khera PS, Rajagopal R, Goyal A, Soni K, Chugh A, Jain V, Sureka B, Elhence P, Misra S. Magnetic Resonance Imaging in Coronavirus Disease - 2019 Associated Rhino-Orbital-Cerebral Mucormycosis (CA-ROCM) - Imaging Analysis of 50 Consecutive Patients. *Curr Probl Diagn Radiol*, 2022 Jan-Feb; 51(1): 112-120. doi: 10.1067/j.cpradiol.2021.09.004. Epub 2021 Nov 3. PMID: 34802841; PMCID: PMC8564981.
7. Desai EJ, Pandya A, Upadhyay I, Patel T, Banerjee S, Jain V. Epidemiology, Clinical Features and Management of Rhino Orbital Mucormycosis in Post COVID 19 Patients. *Indian J Otolaryngol Head Neck Surg*, 2021 Aug; 15: 1-5. doi: 10.1007/s12070-021-02807-2. Epub ahead of print. PMID: 34414101; PMCID: PMC8364626.
8. Desai SM, Gujarathi-Saraf A, Agarwal EA. Imaging findings using a combined MRI/CT protocol to identify the "entire iceberg" in post-COVID-19 mucormycosis presenting clinically as only "the tip". *Clin Radiol*, 2021 Oct; 76(10): 784.e27-784.e33. doi: 10.1016/j.crad.2021.07.002. Epub 2021 Aug 2. PMID: 34353524.
9. Ahamed SK, Al Thobaiti Y. Mucormycosis: a challenge for diagnosis and treatment--2 case reports and review of literature. *Oral Health Dent Manag*, 2014 Sep; 13(3): 703-6. PMID: 25284541.
10. Madney Y, Khedr R, Ahmed N, El-Mahallawy H, Youssef A, Taha H, Hassanain O, Ahmed G, Hafez H. Overview and outcome of mucormycosis among children with cancer: Report from the Children's Cancer Hospital Egypt. *Mycoses*, 2019 Nov; 62(11): 984-989. doi: 10.1111/myc.12915. Epub 2019 Aug 26. PMID: 30983046.
11. Karadeniz Uğurlu Ş, Selim S, Kopar A, Songu M. Rhino-orbital Mucormycosis: Clinical Findings and Treatment Outcomes of Four Cases. *Turk J Ophthalmol*, 2015 Aug; 45(4): 169-174. doi: 10.4274/tjo.82474. Epub 2015 Aug 5. PMID: 27800226; PMCID: PMC5082276.
12. Samanta DR, Senapati SN, Sharma PK, Shruthi BS, Paty PB, Sarangi G. Hard palate perforation in acute lymphoblastic leukemia due to mucormycosis - a case report. *Indian J Hematol Blood Transfus*, 2009 Mar; 25(1): 36-9. doi: 10.1007/s12288-009-0009-3. Epub 2009 Apr 6. PMID: 23100971; PMCID: PMC3453487.

13. Rapidis AD. Orbitomaxillary mucormycosis (zygomycosis) and the surgical approach to treatment: perspectives from a maxillofacial surgeon. *Clin Microbiol Infect*, 2009 Oct; 15 Suppl 5: 98-102. doi: 10.1111/j.1469-0691.2009.02989.x. PMID: 19754767.
14. Barrak HA. Hard palate perforation due to mucormycosis: report of four cases. *J Laryngol Otol*, 2007 Nov; 121(11): 1099-102. doi: 10.1017/S0022215107006354. Epub 2007 Feb 26. PMID: 17319990.
15. Gamaletsou MN, Sipsas NV, Roilides E, Walsh TJ. Rhino-orbital-cerebral mucormycosis. *Curr Infect Dis Rep.*, 2012 Aug; 14(4): 423-34. doi: 10.1007/s11908-012-0272-6. PMID: 22684277.