



**MANAGEMENT OF BHAGANDARA (FISTULA IN ANO) WITH KSHARASUTRA: A
CASE STUDY**

Dr. Ganapathi Rao I.*¹, Dr. Chandrakanth Halli², Dr. Subodh Kamthikar³

¹Ph.D Scholar, ²Guide & HOD, Department of PG Studies in *ShalyaTantra*, N.K.Jabshetty Ayurvedic Medica College & PG Centre, Bidar, Karnataka.

³Associate Professor and Co-Guide, Department of Anaesthesiology, Bidar Rural Institute of Medical Sciences, Bidar, Karnataka.

***Corresponding Author: Dr. Ganapathi Rao I.**

Ph.D Scholar, Department of PG Studies in *ShalyaTantra*, N.K.Jabshetty Ayurvedic Medica College & PG Centre, Bidar, Karnataka.

Article Received on 21/07/2022

Article Revised on 10/08/2022

Article Accepted on 31/08/2022

ABSTRACT

A disease Fistula in Ano is a chronic inflammatory condition in which having a tubular structure with opening in the Anal canal or Anorectal canal at one end and surface of perineum or perianal skin on the other end. Any opening in perianal region or area with on and of pusdischarge indicates fistulous tract. Obesity, Unhygienic condition, prolong sitting, Repeated irritation due to hair, may increase the risk of occurrence of Fistula. In Ayurveda Fistula in ano is correlated with Bhagandara. Acharya Sushruta classified Bhagandara as five types. He had explained Shastra karma along with Kshara karma and Bheshaja chikitsa as treatment of Bhagandara. Here a case of fistula in Ano in a 42-year male patient was examined in Shalya OPD of SSAMCH and treated with Ksharasutra, considering it as an ideal procedure in treatment of Bhagandara as it cuts, healing properly and cures the unhealthy tissue which present inside the fistulous tract.

KEYWORDS: Fistula in ano, Bhagandara, Ksharasutra.

INTRODUCTION

In Ayurveda it is mentioned that certain clinical condition requires surgical intervention for better cure. Acharya Sushruta has discussed in the detail about various Shastra karmas along with Anushastra karmas which includes Agnikarma, Jalaukavcharana and Ksharakarma.

Kshara is considered as one of the most important parasurgical procedure as it can produce excision, incision, scrapping and can pacify all three Doshas.

Acharya Charaka mainly a Charaka samhita treatise also stated that the diseases like Gulma, Arsha, Bhagandar, Ashmari may require surgical intervention.

Kshara application in the form of Ksharasutra, in anorectal diseases has become more popular due to its easy approach and low rate of recurrence. Ksharasutra induces both mechanical and chemical cutting and healing. Direct reference of Ksharasutra is found in Sushruta for treatment of Nadivrana. Chakradatta has referred to a medicated thread coated with Snuhi and Haridra powder in treatment of Arshas and Bhagandara. But the modified ksharasutra available now a day is re-established by Dr PJ Deshpande sir, in the Dept. of

Shalya Tantra, Banaras Hindu University, Varanashi. The standard Ksharasutra is prepared by 11 coatings of Snuhi Ksheera then 7 coatings of Snuhi Ksheera and Apamarga Kshara and then again 3 coatings of Snuhi Ksheera and Haridra Churna. This Kshara Sutra is used in treatment of fistula in ano due to its cutting, curetting and healing effect as well as it controls the infection. In this study a case report of Fistula in Ano treated by Ksharasutra which was cured and no further complaints were found in the patient during follow up period.

Ayurvedic view of bhagandara and kshara sutra

Acharya Sushruta described Fistula in Ano under the heading Bhagandara along with its symptoms, types and its management. The disease which creates Darana (tear) like yoni in the area of pelvis, rectum & urinary bladder is called as Bhagandar and when these are not opened it's called as Bhagandara Pidaka. An abnormal passage between a hollow or tubular organ (bhaga, guda, or basti) and the body surface or between two hollow or tubular organs is called fistula.

Kshara destroys the vitiated tissue and make them fall off. It is the most important among Shastra and Anushastra because it does functions like excision, cutting and scrapping, also mitigates all the three doshas.

Acharya Sushruta described that Nadivrana (sinus) should be cut open by Kshara Sutra and also, he said the same procedure should be adopted for Bhagandara.

CASE REPORT

Patient Name- XXX, Age- 38 year Gender- Male Occupation-Tailor.

Date of admission- 22/5/2022, Date of recovery- 20/6/2022.

Chief complaints and duration

Patient complains of pus discharge with mild pain at the right side of perianal region in the past 5 months.

H/o present illness

Patient was apparently normal before 6 months. Then he had developed boil with intermittent discharge in perianal region since last 4 months. He also complained of mild pain and discomfort while sitting and continuous pus discharge in the past 3-4 months. He had taken analgesics and Antibiotics for it, but didn't get any relief. Therefore, for further treatment he came to OPD of Shalyatanra, SSAMCH, BIDAR.

Family history

No H/O TB, HTN, DM or any other major illness

General examination

G.C-moderate Afebrile

CVS- S1 S2 Normal,

Pulse- 78/min, BP- 120/80 mm Hg,

RS- Chest clears on both sides.

Digestive System- Appetite- normal, Bowel- constipated.

Uro-genital System- NAD

Local examination

In lithotomy position of patient, the findings observed were: patient had hairy perineal region with a small opening in right side of perianal region with seropurulent pus discharge through that opening, tenderness on touch with indurations was felt around external opening. Probing was done from external opening to access the internal opening but internally it was fibrosed. About 6 cm tract was found during probing.

On Proctoscopy examination no any anal pathology was seen. After complete examination the diagnosis was confirmed as Fistula in Ano i.e., Bhagandara.

In this patient perianal skin was normal with no dermatitis.

Ksharsutra application pre-operative preparation

Local part preparation i.e., shaving was not done as patient didn't allow due to some ritual believe. 5gm panchasakar churna with luke warm water was given to the patient at night before operation. Proctoglycerin enema was given at early morning on day of operation. After proper bowel passed, patient was taken to recovery room and injection T.T. 0.5ml IM was given and plain xylocaine 2% was given subcutaneously for sensitivity

test.

Operative procedure

Patient was taken in lithotomy position on operation theatre table.

After proper painting and drapping, local anaesthesia with 2% xylocaine was infiltrated nearby opening and around anal verge.

Reassessment of extension of tract was done by probing. Probe was removed through anal opening via internal opening after feeding of ksharasutra and ksharasutra ligated appropriately. Complete haemostasis was maintained and T bandaging was done.

Post-operative procedure

Broad spectrum antibiotics, analgesic along with ayurvedic medicine and sitz bath was given. Patient was admitted to the Hospital for 7 days till next ksharasutra was changed.

Oral medications

Amoxy Clav 625 Twice a day

Dolostat sp Twice a day

Triphala guggulu Trice a day

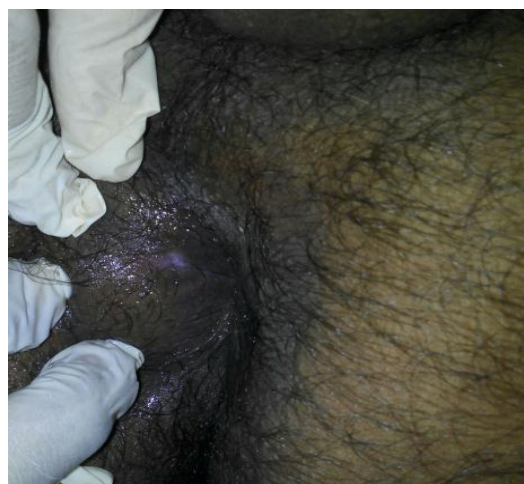
Gandhak rasayan Trice a day

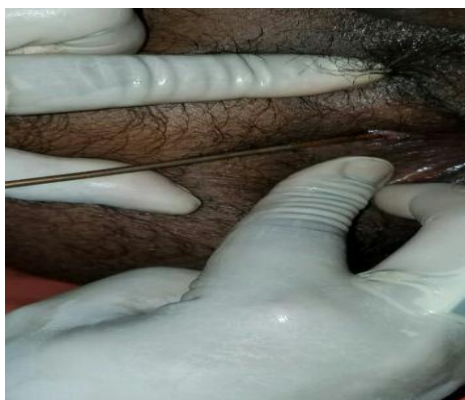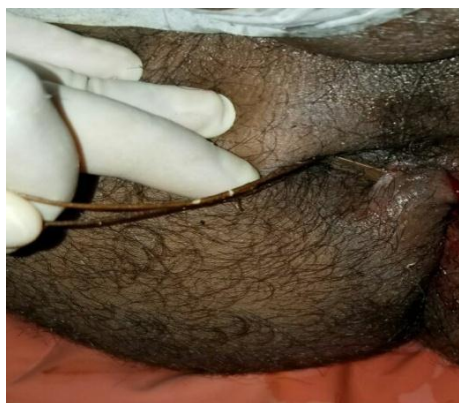Sitz bath with Triphala kwath Twice a day.

Patient was advised to take Khichdi and Daliya during hospital stay. He was also advised to resume his normal day to day activities.

Follow up

Patient was discharged from hospital after 1st ksharasutra change and then asked for changing ksharasutra every 7th day till cutting of the tract. Hot sitz bath and Yashtimadhu taila local application was done during this period. Patient was allowed to do his routine job after discharged from hospital. After 6 sitting the tract was totally cut and healing was achieved simultaneously. Yashtimadhu taila application on scar mark was advised.





mechanical pressure of ksharasutra knot. Haridra powder having antiseptic action helps in healing of the tract.

CONCLUSION

The incidence of fistula in ano is increasing now a day due to improper job style where a person sits for long time on hard surfaces. The management of anorectal diseases need a complete knowledge of anorectal anatomy and pathophysiology. Also, it needs to be diagnosed early so that appropriate treatment can be given without delay. Ksharasutra helps in removal of debris and also prevent from bacterial infections. Ksharasutra at a time provides both cutting and healing so we can use it in any type of fistula tract. So, we conclude that in fistula in ano ksharasutra treatment is a better option due minimum complication and patient can resume normal activities earlier.

REFERENCES

1. Sushruta Samhita, Nidan Sthan, Vaidya Yadavji Trikamji Acharya, Chaukhamba Publications.
2. Sushruta Samhita, Chikitsa Sthan, Vaidya Yadavji Trikamji Acharya, Chaukhamba Publications.
3. Sushruta Samhita, Nidan Sthan, Kaviraj Ambika Dutta Shastri, Chaukhamba Sanskrit Samsthan.
4. Sushruta Samhita, Chikitsa Sthan, Kaviraj Ambika Dutta Shastri, Chaukhamba Sanskrit Samsthan.
5. Deshpande P.J, Pathak S.N, The Treatment of Fistula in Ano with Kshara Sutra Treatment.

DISCUSSION

Sushruta described the treatment of fistula in ano as bhesaj, ksharakarma, agnikarma and Shashtra karma. In modern medicine treatment like fistulotomy, fistulectomy, seton ligation are indicated. These treatments have more recurrence rate and post operative complications like haemorrhage, pain, delayed healing etc. In comparison to Modern Treatment Ksharasutra ligation is better due to its minimal complications and less recurrence. Even fecal incontinence and anal stricture are not seen in this case.

The application of Ksharasutra is having anti-inflammatory and anti-microbial property and due to its alkaline property helps in cutting and healing. Cutting mainly occurs due to local action of kshara, snuhi and the