

SINGLE STEP APEXIFICATION WITH MTA – A CASE REPORT**Dr. Ifzah*¹, Dr. Zain Patel², Dr. Humaira Salroo³ and Dr Mohammad Shakeel⁴**¹Consulting Pedodontist, Maya Cleft Centre, Srinagar.²Consulting Orthodontist, Pune Dental Centre, Pune.³Registrar, Department of Oral and Maxillofacial Pathology, Government Dental College, Srinagar.⁴Head of Department of Maxillofacial Surgery, SKIMS Medical College, Srinagar.**Corresponding Author: Dr. Ifzah**

Consulting Pedodontist, Maya Cleft Centre, Srinagar.

Article Received on 01/06/2016

Article Revised on 22/06/2016

Article Accepted on 13/07/2016

ABSTRACT**Aim:** To create an apical barrier in non-vital immature permanent teeth with Mineral Trioxide Aggregate (MTA).**Summary:** A case report where in the patient reported with trauma to upper front teeth. Clinical and radiographic examination showed open apex in one tooth. Apical stop was created with mineral trioxide aggregate by apexification and the root canals were obturated with thermoplasticized gutta-percha followed by placement of post and core and metal ceramic crowns.**KEYWORDS:** MTA, Apexification, Post and Core, Trauma.**INTRODUCTION**

Traumatic injuries sustained before closure of the apex often results in immature pulpless teeth. In such situations, the absence of a natural constriction at the end of the root canal makes control of filling materials difficult. Due to the lack of an apical constriction, an alternative to standard root canal treatment, apexification or root end closure has been advocated.^[1]

Apexification is a procedure to promote the formation of an apical barrier to close the open apex of an immature tooth with a nonvital pulp such that the filling materials can be contained within the root canal space.^[2]

The aim is to seal a sizeable communication present between the root canal system and the periradicular tissue and provide a barrier against which obturation material can be compacted.^[3]

A case report is presented in which MTA was used for apexification in open apex case to develop an apical stop to facilitate obturation.

CASE REPORT

A 9 year old boy reported to the Maya Cleft Centre and Centre for Aesthetic Facial Surgery for the evaluation of traumatized upper front teeth. The trauma had occurred 1 year back but the patient had not undergone any treatment for the same.

Clinical examination showed that both teeth had Ellis class III fracture involving enamel, dentine and pulp (Figure 1). Intra Oral Periapical radiograph showed an

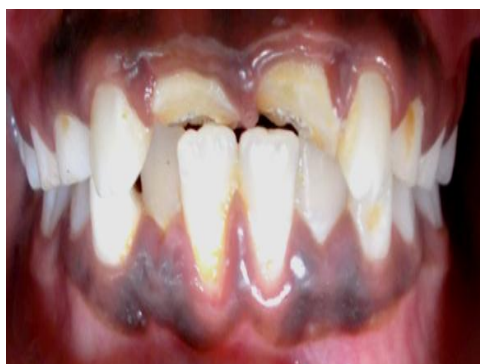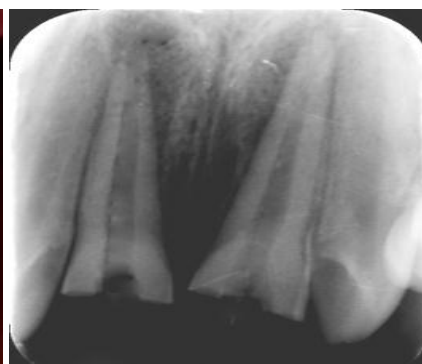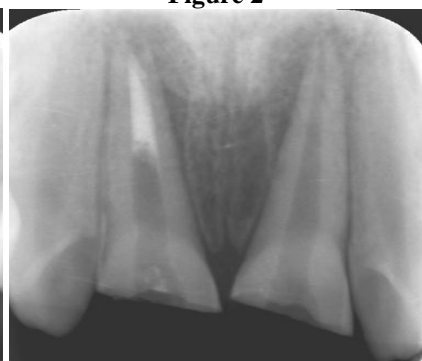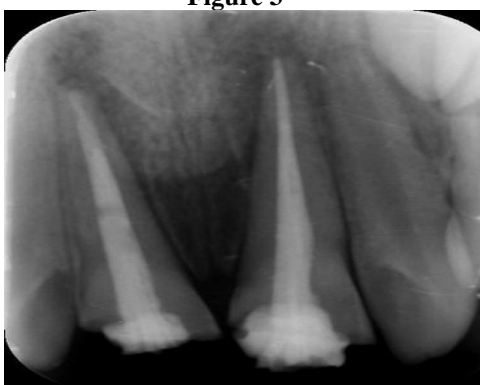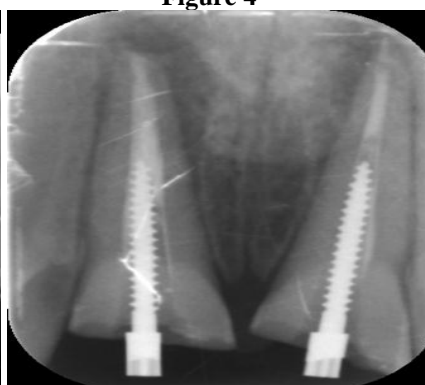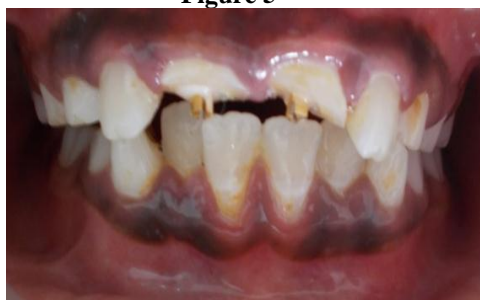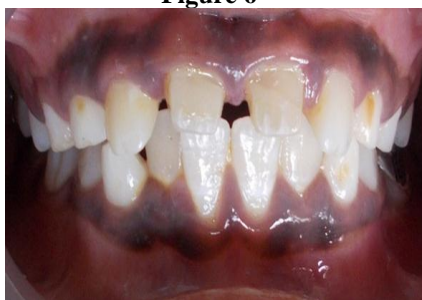open, incompletely formed apex surrounded by a diffuse radiolucent lesion in relation to 11 and loss of enamel, dentine with exposure of pulp in relation to 21 (Figure 2). On the basis of clinical signs and symptoms, vitality tests and radiographs, the teeth were diagnosed to be non-vital.

The treatment plan decided was to close the open apex in 11 with MTA apexification, conventional root canal treatment in 21 followed by placement of post and core and metal ceramic crown in 11 and 21. Access cavity was prepared and working length radiograph was taken (Figure 3). The cleaning and shaping of the canals was performed with hand K files (Dentsply Maillefer). Irrigation was done with 3% NaOCl and normal saline (0.9% w/v). Canals were dried with sterile absorbent paper points. Calcium hydroxide was given for one week to disinfect the canals.

At the second appointment, calcium hydroxide was flushed with 5% sodium hypochlorite and rinsed with saline. Before obturation, the canals were irrigated with 5.25% NaOCl to remove the smear layer. Final irrigation was done with 2% chlorhexidine and the canals were dried with paper points. MTA (Dentsply, Tulsa Dental, Johnson City, USA) was mixed according to the manufacturer's instructions and carried to the canal (tooth 11) with an amalgam carrier. Apical plug of 4mm of MTA was placed and confirmed radiographically (Figure 4). A sterile cotton pellet moistened with sterile water was placed over the canal orifice and the access cavity was sealed with Cavit (3M ESPE, Seefeld, Germany).

The next appointment was scheduled after 24 hours wherein the hard set of MTA was confirmed. Restoration of the teeth was planned to be done with prefabricated post and core. Root canal in 11 and 21 were obturated with thermoplasticized gutta-percha (Obtura II, Obtura Spartan, Fenton, Missouri, USA) using cold lateral condensation technique (Figure 5). Peeso reamer number three and four (DentsplyMaillefer, Ballaigues, Switzerland) were used to prepare post space and to remove any undercut that may be present on canal walls.

Perfectly fitting posts (Luminex; Dentatus AB, Stockholm, Sweden) were selected and verified for fitting inside the canals. The posts were cemented in the canal using dual cure Rely XU100 self-adhesive universal resin cement (3M ESPE, ST. Paul, Germany) (Figure 6 and 7). Thereafter, core buildup was done with composite (Figure 8) followed by tooth preparation for metal ceramic crown (Figure 9). Crown cementation was done with luting glass ionomer cement.

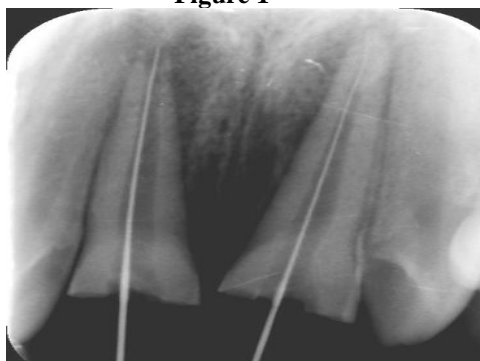
**Figure 1****Figure 2****Figure 3****Figure 4****Figure 5****Figure 6****Figure 7****Figure 8**

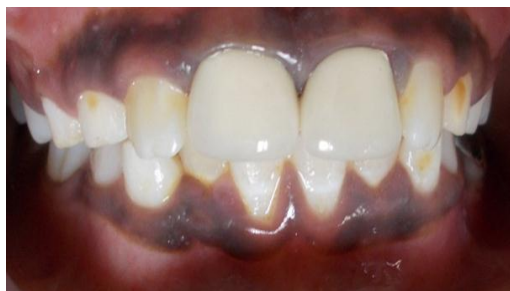

Figure 9

DISCUSSION

MTA has been developed by Torabinejad and coworkers in 1990 at Loma Linda University. Mineral Trioxide Aggregate is a powder consisting of fine hydrophilic particles of tricalcium silicate, tricalcium aluminate, tricalcium oxide and silicate oxide.

It also contains small amounts of other mineral oxides, which modify its chemical and physical properties. Hydration of the powder results in formation of colloidal gel that solidifies to form a strong impermeable hard solid barrier in approximately three to four hours.⁴ Bismuth oxide powder has been added to make the aggregate radio-opaque. Mineral trioxide aggregate has a pH of 12.5 after setting, similar to calcium hydroxide.^[5]

Calcium hydroxide has been the first choice of material for apexification with repeated changes over the course of 5-20 months to induce the formation of calcific barrier. However it presents with several disadvantages such as variability of treatment time (average 12.9 months), difficulty of the patients recall management, delay in the treatment and increase in the risk of tooth fracture after dressing with calcium hydroxide for extended periods.^[6,7,8]

For these reasons, single visit apexification has been suggested. Mineral trioxide aggregate (MTA) has been proposed as a material suitable for one visit apexification because of its biocompatibility, bacteriostatic activity, favourable sealing ability and as root end filling material.

The primary issue while restoring an immature tooth is the weakened radicular structure due to thin and fragile dentinal walls.^[9] Thus post endodontic treatment should reduce the risk of tooth fracture thus prefabricated post and core were used in this case.

CONCLUSION

MTA has numerous applications in endodontic therapy that range from apexification to pulpotomy. MTA provides with multiple advantages which include reduced number of appointments, development of proper apical seal and excellent biocompatibility.

REFERENCES

1. Seltzer S. Endodontology: Biologic considerations in Endodontic Procedures, 2nd edn. Philadelphia: Lea and Febiger, 1998.
2. American Association of Endodontists. Glossary of Endodontic Terms, 7th edn. Chicago: American Association of Endodontists, 2003.
3. Rafter M. Apexification: a review. Dent Traumatol, 2005; 21: 1-8.
4. Torabinejad M, Hong CU, McDonald F, Pitt Ford TR: Physical and chemical properties of a new root-end filling material. J Endod, 1995; 21(7): 349-353.
5. Torabinejad M, Hong CU, Pitt Ford TR, Kettering JD: Antibacterial effects of some root end filling materials. J Endod, 1995; 21(8): 403-406.
6. Bernabe PFE, Holland R, Morandi R, Souza V, Nery MJ, OtoboniFilho JA, Dezan Junior E, Gomes Filho JE. Comparative study of MTA and other materials in retro filling of pulpless dogs teeth. Braz Dent J, 2005; 16: 149-155.
7. Ghose LJ, Bhagdady VS, Hikmat BYM. Apexification of immature apices of pulpless permanent anterior teeth with calcium hydroxide. J Endod, 1987; 13: 285-290.
8. P Ghaziani, NAghasizadeh, M Sheikh-Nezami, Endodontic treatment with MTA apical plug: a case report. Journal of oral science, 2007; 49(4): 325-329.
9. Tait CM, Ricketts DN, Higgins AJ. Weakened anterior roots-intraradicular rehabilitation. Br Dent J, 2005; 198: 609-17.