

NASAL CHONDROMA OF CARTILAGINOUS SEPTUM: A RARE CASE REPORT

Dr. Saarthak Wadhwa*

Department of Otolaryngology, BPS GMC, KHANPUR Sonapat Haryana India.

Corresponding Author: Dr. Saarthak Wadhwa

Department of Otolaryngology, BPS GMC, KHANPUR Sonapat Haryana India.

Article Received on 04/12/2016

Article Revised on 25/12/2016

Article Accepted on 15/01/2017

ABSTRACT

Chondromas are benign neoplasms of cartilaginous origin. Most of these tumors are found in the long bones and pelvis. The incidence of nasal chondroma is very rare. Nasal septum and larynx have an intrinsic cartilaginous framework, predisposing to chondromas from these anatomical sites. Nasal bones and sphenoid sinuses are also site of chondroma origin. The diagnosis of nasal chondroma is based on a combination of clinical, radiologic and pathologic findings. Differential diagnoses include schwannoma, inverted papilloma and sinonasal tumors. Making a histological distinction between benign chondroma and malignant chondrosarcoma may be difficult. Wide surgical excision with negative margins is the treatment of choice. Radiotherapy has little role to play in histopathologically benign tumors but may be useful in treating primary and recurrent malignant cartilaginous tumors.

KEYWORDS: Nasal chondroma, cartilaginous septum, endoscopic excision.

INTRODUCTION

Chondromas are benign neoplasms of cartilaginous origin. They are the second most common neoplasms of bone. Most of these tumors are found in the long bones and pelvis. In head and neck region, chondromas have been reported in the ethmoids (50%). Other sites include maxilla, sphenoid sinuses, palate and nasopharynx. The incidence of nasal chondroma is very rare and so far in English literature only 150 cases have been reported since 1842.^[1] There is no sex predilection and about 60% occur in patients less than 50 years of age.^[2] Examination of specimen by histopathology is mandatory for diagnosis.^[3] Wide surgical excision with negative margins is the treatment of choice. We hereby report a case of a 68 year old woman with chondroma of nasal cavity originating from cartilaginous septum.

CASE REPORT

A 68 year old woman presented with nasal block since 4 months. It was initially right sided but slowly became bilateral. There was no history of nasal discharge or bleeding. On anterior rhinoscopy, a pale mass was seen occupying the entire right nasal cavity. It was firm, insensitive to touch and did not bleed on touch. In left nasal cavity, the mass was seen posteriorly abutting the left middle turbinate. (FIGURE 1)

On diagnostic nasal endoscopy, on right side a firm well encapsulated mass occupying the right anterior and posterior ethmoidal region was noticed impinging upon the middle turbinate and meatus. On left side, the mass was abutting the middle turbinate and meatus. There was

no intratumoral calcification or cervical lymphadenopathy. (FIGURE 2)

The unenhanced CT scan of paranasal sinuses showed mass to be involving right anterior ethmoidal region and occupying the whole of right nasal cavity arising from cartilaginous nasal septum. Bony septal destruction was seen with the mass projecting into left nasal cavity as well. Posteriorly, the mass was seen to extend till the sphenoid sinus. (FIGURES 3 & 4)

Endoscopic excision of nasal mass was done under general anesthesia. After the procedure anterior nasal pack was kept in the left nasal cavity, which was removed after 24 hours. Postoperative period was uneventful. The histopathological report showed chondroma with proliferating chondrocytes. The patient is under regular follow up since last 6 months and has no signs of recurrence.

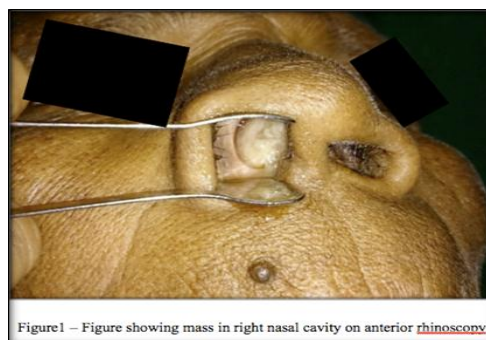

Figure1 – Figure showing mass in right nasal cavity on anterior rhinoscopy

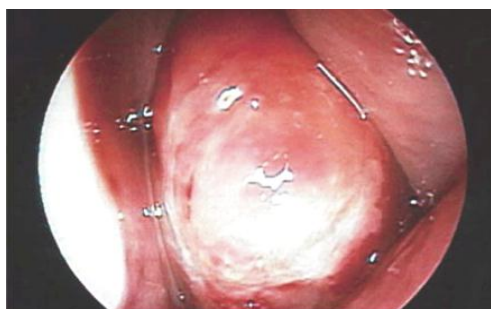

Figure 2 – DNE finding of mass in left nasal cavity

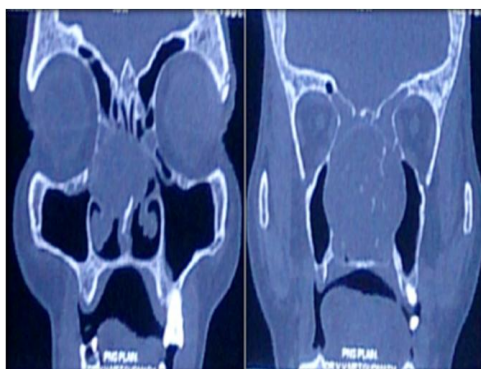


Figure 3 – CT-PNS scan view showing involvement of bilateral ethmoid sinuses

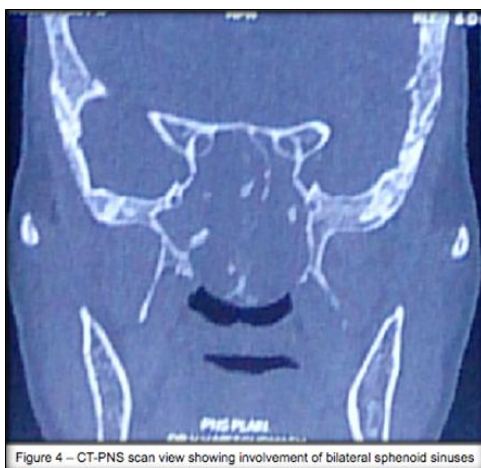


Figure 4 – CT-PNS scan view showing involvement of bilateral sphenoid sinuses

DISCUSSION

Nasal chondroma is usually seen as a rare, slow growing, firm to hard nasal mass but may even present with epistaxis.^[4] In a review of literature, it was found that 50% of nasal chondromas originate from ethmoids and only 17% from the nasal septum.^[3,5] Nasal septum and larynx have an intrinsic cartilaginous framework, predisposing to chondromas from these anatomical sites. Nasal bones and sphenoid are also site of chondroma origin. Macroscopically, benign chondromas are smooth, firm and lobulated tumors with a gritty “ripe pear feel”.^[4] Making a histological distinction between benign chondroma and malignant chondrosarcoma may be difficult.^[7] In 1943, Lichtenstein and Jaffe identified three histological criteria for diagnosis of malignant chondrosarcoma. (1) Presence of giant cartilage cells with large single or multiple nuclei or with clumps of chromatin (2) more than a few cells with two nuclei and

(3) presence of many cells with plump nuclei. Hence it can be deduced that chondroma shows duplication of normal cartilage despite increased cellularity, but chondrosarcoma shows enhanced irregularity in number and size of cells and in degree of hyperchromatism.^[8]

Chondromas usually are well circumscribed, and appear fairly homogenous on CT. They tend to be expansile lesions that remodel bone. They do not provoke sclerotic bone at their margins. Calcification of chondroid matrix occurs rarely. The diagnosis of nasal chondroma is based on a combination of clinical, radiologic and pathologic findings.^[3] Radiotherapy has little role to play in histopathologically benign tumors but may be useful in treating primary and recurrent malignant cartilaginous tumors.^[1]

REFERENCES

1. Sreedharan S, Kamath MP, Hedge MC, Sundar S, Lobo FD, Raju PK. Chondroma of nasal bone: a case report. *Ear Nose Throat J.* 2006 Jan; 85(1): 44-6.
2. M.I.Kater, Dr. S.A.Jaiswal, Dr. S.G. Chintle. Chondroma of nasal septum: A case report *Indian Journal of Basic & Applied Medical Research;* 2013; 8(2): 958-960.
3. Rivas Lacarte MP, Perello Scherdel E, Novell V. Solitary chondroma of nasal septum. *Anales Otorrinolaringologicos Iberoamericanos* 1996; 23(4): 431-4.
4. Tokimoto T, Miyazaki T, Yoshizaki T, Masuda (1987): A case of chondroma arising from nasal septum. *Auris Naris Larynx* 14(2): 93-6.
5. Kilby D, Ambegaokar AG. The nasal chondroma. 2 case reports and a survey of the literature. *J Laryngol Otol* 1977; 91(5): 415-26.
6. Swamy KVN, Gowda BVC. A clinical study of benign tumors of nose and paranasal sinuses. *Indian J Otolaryngol Head Neck Surg.* 2004; 56: 265-8.
7. Evans HL, Ayala AG, Romsdahl MM. Prognostic factors in chondrosarcoma of bone: a clinicopathological analysis with emphasis on histologic grading. *Cancer* 1977; 40: 818-31.
8. Lichtenstein L, Jaffe HL. Chondrosarcoma of bone. *Am J Pathol* 1943; 19: 553-74.