

LEVOSULPIRIDE INDUCED HUNTINGTON'S DISEASE: A CASE REPORT**B. Rajasekar^{1*}, Rona Sudhakar¹, Beya Baby¹, A. Moushmi¹, Priya Saji¹ and S. Hajasherief²**¹Pharm D., Nandha College of Pharmacy, Perundurai, Erode, Tamil Nadu, India.²Department of Pharmacy Practice, Nandha College of Pharmacy, Perundurai, Erode, Tamil Nadu, India.***Corresponding Author: Dr. B. Rajasekar**

Pharm D., Nandha College of Pharmacy, Perundurai, Erode, Tamil Nadu, India.

Article Received on 10/10/2019

Article Revised on 31/10/2019

Article Accepted on 20/11/2019

ABSTRACT

Huntington's disease is an inherited disease that causes progressive breakdown of nerve cells in the brain. It has an impact on person's functional abilities and usually results in movement, cognitive and psychiatric disorders. We report a case of 47 year old female patient with levosulpiride induced Huntington's disease.

KEYWORDS: Huntington's Disease, Levosulpiride, Chorea.**INTRODUCTION**

Huntington's disease (HD) is an autosomal dominant neurodegenerative disorder which is presented with cognitive, motor and also psychiatric clinical features. It is actually an inherited disease that causes progressive degeneration of brain nerve cells leading to brain deterioration which affects movement, behavior and cognition. HD is caused by a cytosine- adenine-guanine (CAG) trinucleotide repeat expansion in huntingtin protein located on chromosome 4p16.3. The mutant huntingtin accumulates within brain cells causing cell toxicity and dysfunction of neurons throughout the brain when the disease progresses.^[1]

Drugs and systemic illness have been linked to Huntington's disease without any brain lesions.^[2] However such instances are extremely uncommon. Most people with this disease develop their signs and symptoms in early 30s and 40s. When the disease develop before the age of 20, it is called Juvenile Huntington's disease.^[3,4,5]

Levosulpiride (LVS) is a highly selective dopamine D2 receptor antagonist that is widely used for treatment of schizophrenia, anxiety disorders and dysthymia, also been used for functional dyspepsia, GERD and irritable bowel syndrome.^[2]

CASE REPORT

A 47 year old female patient with a history of dyspepsia present at our hospital with the complaints of increasing involuntary movement of lips, hands and legs along with fever for past 1 week. The patient is not having any prior family history of involuntary movements. She had been visited the hospital previously with complaints of abdominal discomfort, burning sensation and bloating

which was later diagnosed as dyspepsia and was on multiple medications for past 6 months with mild improvement of symptoms. Her medications contained LVS 75 mg/day, ranitidine 150 mg/day and antacid. For past 6 months she has been taking LVS temporarily correlating with worsening of her neurological symptoms. She had no past or current history of any previous antipsychotic use. After complete withdrawal of her previous medications, the involuntary movements significantly subsided.

During hospital admission, her laboratory examinations shows a reduction in hemoglobin and all other parameters were found to be normal. Systemic examination shown an involuntary movement of lips, both legs and hands. Although her conditions were improving, she continued to complain of the involuntary movements, and clonazepam (0.5mg) was prescribed at night time. A Magnetic Resonance Imaging (MRI) was performed and it did not reveal any responsible abnormalities. To exclude other systemic causes, Computed Tomography (CT) scan were also performed which were normal. (Fig 1)

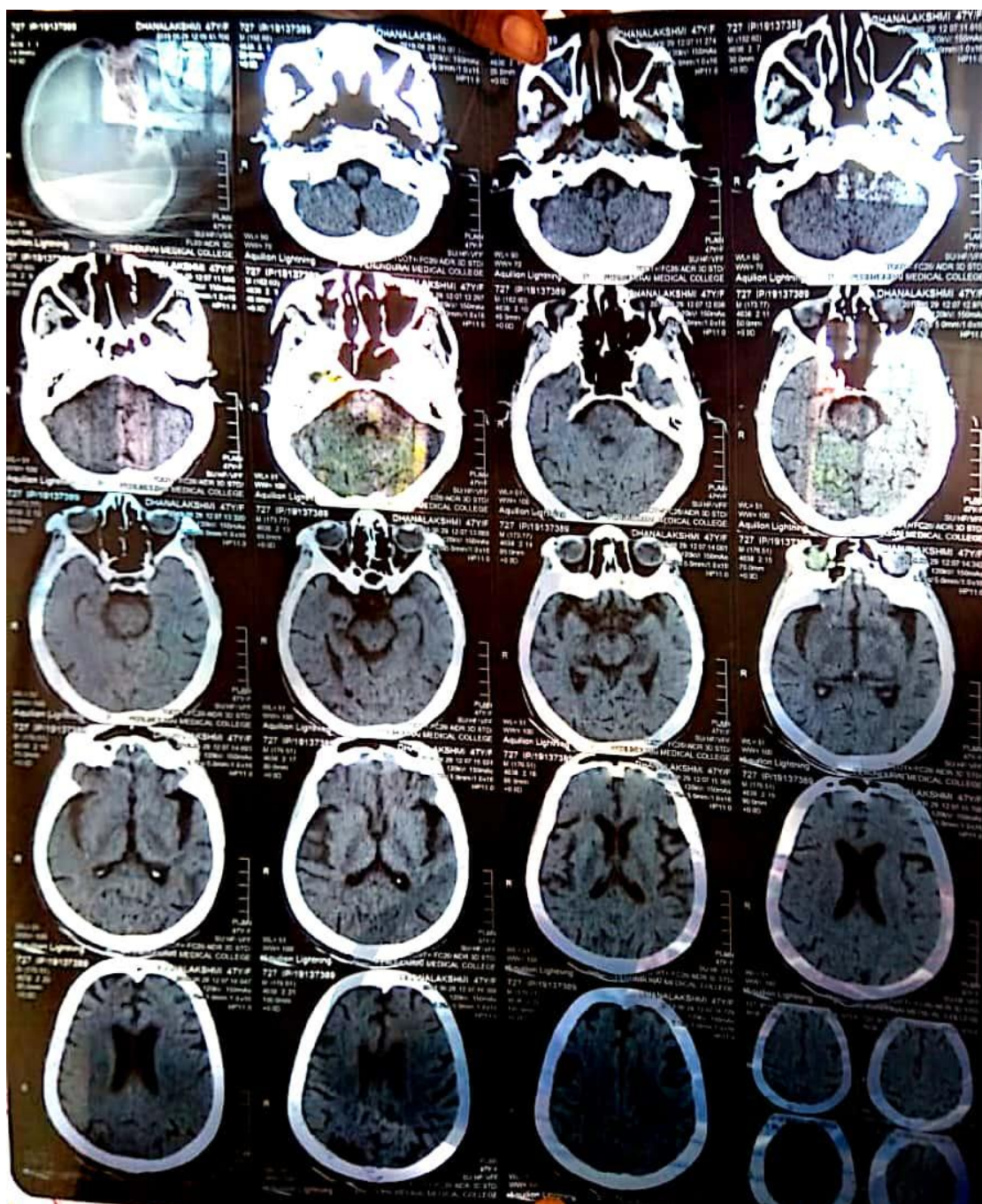


Fig 1: CT Brain Plain: Serial of axial section shows –CT Brain plain within normal limits. Mucosal thickening in right maxillary sinus.

Although, HD is not usually expected to occur in the absence of brain lesions, it is the most possible cause, considering the temporary relationship between LVS administration and HD. The rapid improvement after LVS withdrawal and normal laboratory and brain MRI findings pointed out the close correlation of onset of drug and chorea, provisional diagnosis of Levosulpiride induced Huntingtons disease (LIH) was made and the offending drug was stopped.

She was later treated with tetrabenazene (TBZ) 25mg-75 mg/ day and clonazepam (CLZ) 0.5-1.0 mg/day along

with tablet ferrous sulphate and paracetamol. At 1 month follow up there was 30-40% improvement in symptoms.

DISCUSSION

LVS is a newer prokinetic drug with increasing extensive use in India by general physicians. It selectively inhibits presynaptic dopamine D2 receptor with sodium dependent function, in gut and central nervous system. There has been an increase in the prescription of LVS in recent years and consequently an increase in the incidence of Levosulpiride induced Huntington's disease (LIH).^[6,7]

Huntington's disease also called as Huntington's chorea is an inherited condition in which nerve cells in the brain breakdown over time.^[8] It is a progressive brain disorder which causes emotional problems, uncontrolled movements, and loss of cognition. The main sign and symptoms includes:

Movement disorders

- Involuntary jerking or writhing movements (chorea)
- Muscle problems such as rigidity or muscle contraction (dystonia)
- Slow or abnormal eye movements

Cognitive disorders

- Difficulty in organising
- Lack of flexibility
- Lack of awareness of one's own behavior

Psychiatric disorders

- Insomnia
- Fatigue
- Suicidal thoughts
- Social withdrawal^[9]

In this case, the symptoms of the patient were subsided with the withdrawal of the offending drug. And later on 30-40% improvement were seen when treated with tetrabenazine along with clonazepam.

CONCLUSION

It is important to be aware about rare inherited disorders like Huntington's disease in patients with involuntary movements. We want to highlight the long latency in diagnosing LIH. This case report warrants the need for awareness about extrapyramidal side effects of LVS among physicians. A warning label about extrapyramidal side effects of LVS on drug envelope is highly recommended.

ACKNOWLEDGEMENT

We express our sincere gratitude to all our friends and our staffs who had guided and supported us throughout the period.

CONFLICT OF INTEREST: NIL.

REFERENCES

1. Coppen EM, Roos RA. Current pharmacological approaches to reduce chorea in Huntington's disease. *Drugs*, 2017 Jan 1; 77(1): 29-46.
2. Lee HC, Hwang SH, Kang SY. Levosulpiride-associated hemichorea. *Yonsei medical journal*, 2016 May 1; 57(3): 803-5.
3. Myers RH. Huntington's disease genetics. *NeuroRx*, 2004 Apr 1; 1(2): 255-62.
4. Patra KC, Shirolkar MS. Childhood-onset (Juvenile) Huntington's disease: A rare case report. *Journal of pediatric neurosciences*, 2015 Jul; 10(3): 276.

5. Roos RA. Huntington's disease: a clinical review. *Orphanet journal of rare diseases*, 2010 Dec 1; 5(1): 40.
6. Radhakrishnan DM, Goyal V. Levosulpiride-Induced Dystonia: 7 Cases. *Journal of The Association of Physicians of India*, 2018 Jun; 66: 95.
7. Choudhury S, Chatterjee K, Singh R, Shubham S, Trivedi S, Chatterjee S, Kumar H. Levosulpiride-induced movement disorders. *Journal of pharmacology & pharmacotherapeutics*, 2017 Oct; 8(4): 177.
8. <https://www.mayoclinic.org/symptoms-causes/syc-20356117>.