

PALATAL RUGAE REPLICATION IN MAXILLARY DENTURE: A CASE REPORTReeta Yadav^{*1} and G. Ajay Kumar²¹Post-Graduate Student, Department of Prosthodontics, Army College of Dental Sciences, Secunderabad, Telangana, India.²Head of department of Prosthodontics Department of Prosthodontics, Army College of Dental Sciences, Secunderabad, Telangana, India.***Corresponding Author: Dr. Reeta Yadav**

Post-Graduate Student, Department of Prosthodontics, Army College of Dental Sciences, Secunderabad, Telangana, India.

Article Received on 19/05/2020

Article Revised on 09/06/2020

Article Accepted on 29/06/2020

ABSTRACT

This case report presents duplication of patient's palatal rugae on complete denture during fabrication. The palatal rugae are important for better tongue adaptation, phonetics, taste perception and play role in forensic odontology. Therefore, duplication of rugae will make the denture mechanically functional, aesthetically pleasing and permit normal speech.

KEYWORDS: Rugae, tactile, phonetics, tongue, incisive papilla, putty index.**INTRODUCTION**

Palatal rugae also called plicae palatinae transversae and rugae palatina, present as ridges on the anterior part of the palatal mucosa, each side of the median palatal raphe and behind the incisive papilla.^[1,2] They are elevations of the mucous membrane and are very prominent in most of the animals where they help in gripping the food before tearing it with brute force.

Speech consists of respiration, phonation, resonance, articulation, neural integration, and audition.^[3] Some patients develop problems after the insertion of complete dentures because they experience a loss of "tactile location" skills. The speech changes to palatal contour of complete denture. The palatal contour of complete dentures may adversely affect the affricative and fricative sounds.^[4] Thus rugae play important role in phonetics.

Literature review suggested that artificial duplication can be done using corrugated metal plates, plastic palate forms, free hand wax carving of anatomical palate forms etc. If artificial rugae made too prominent they may interfere with speech.^[5]

Phonetics is one of the important factor and is neglected because of the adaptability of patients. It is true that most patients can learn to produce satisfactory speech in spite of an unsatisfactory denture. The problem in speech in most instances is not recognised until a patient complains of inability to produce certain sounds with the dentures.^[6]

The purpose of this article was to present a method of adding palatal rugae to complete removable dental prostheses by using putty index and clear acrylic resin.

CASE PRESENTATION

A 50 year old male patient presented to the department of prosthodontics with the chief complaint of missing teeth and difficulty in chewing. The past dental history revealed that loss of teeth was due to periodontal involvement and edentulous since 2 years.

Following a detailed complete examination and careful evaluation of the objective parameters of the patient i.e. age, aesthetic, profession (teacher), functional demands and affordability, conventional complete dentures were planned with rouge duplication for better speech.

Procedure

The Primary impression was made with impression compound and the primary cast was poured using dental plaster. Border moulding followed by secondary impression using zinc oxide eugenol paste was made and the master cast was poured using dental stone. (Fig 1, 2)

Rouge duplication

Putty is adapted over rugae area of maxillary cast to record prominent rugae on the palate. (Fig 3) Clear self cure acrylic resin was mixed and adapted over the putty impression slowly and carefully to record the imprints of rugae over the impression. (Fig 4)

Facebow record taken and mounted on semi adjustable Hanau articulator after assessing the vertical jaw relation. (Fig 5) Teeth setting done followed by try-in.

Prior to wax-up, Observe and outline the palatal rugae area on the master cast and Transfer the outlined area onto the intaglio surface of the maxillary trial denture by reseating on the master cast. The outlined area was trimmed from trial denture. (Fig 6)

Wax up done followed by clear acrylic stent with imprints of rugae was placed on maxillary trial denture base, adapted carefully on the palatal portion of the maxillary trial denture base. (Fig 7) After deflasking the prominent rugae were observed (Fig 8) followed by curing, finishing and polishing. (Fig 9).

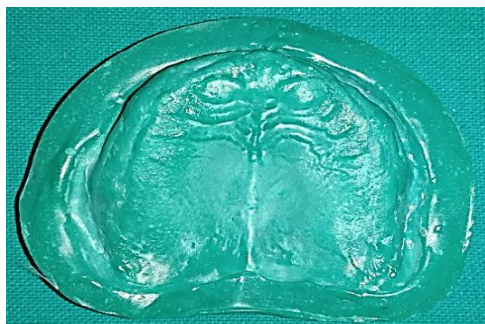

Fig 1 maxillary master cast

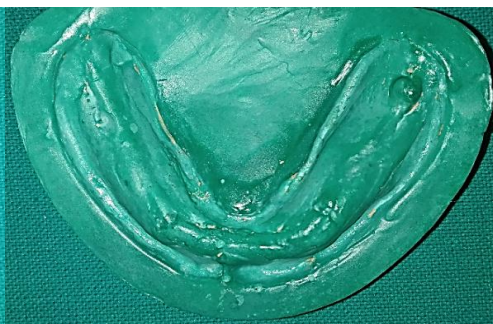


Fig 2 mandibular master cast

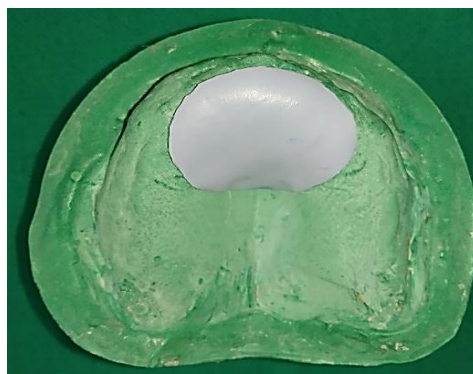

Fig. 3: Duplicating Rugae With Putty




Fig. 4: Acrylic Stent With Imprint Of Rugae.



Fig. 5: Jaw Relation And Mouting On Articulator.

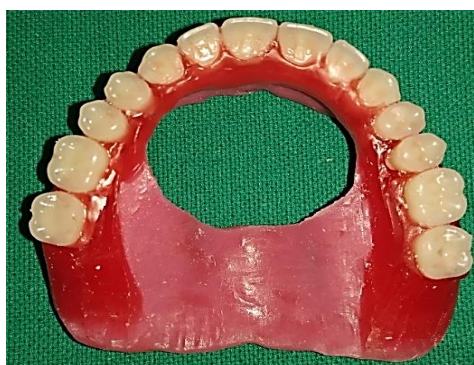

Fig 6 removal of rugae area

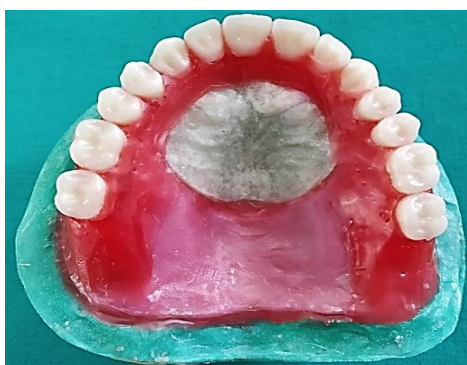

Fig 7 adapted acrylic stent

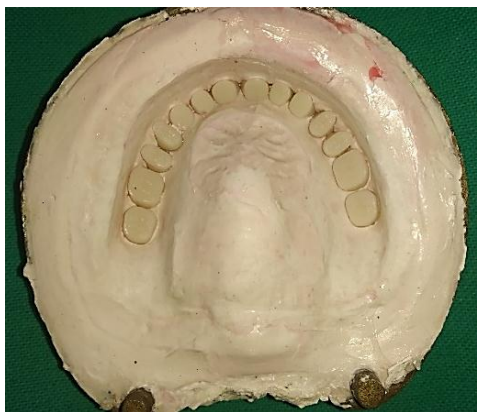

Fig. 8: Prominent Rugae Duplicated In Plaster Seen After Dewaxing.

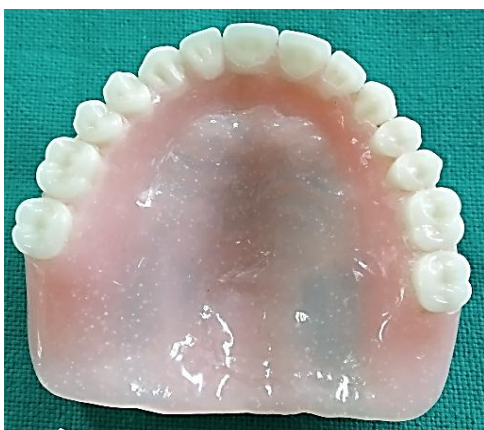

Fig. 9: Final Denture With Duplicated Rugae.

DISCUSSION

The tongue plays a major role in enunciation of speech as involved in articulation of consonant sounds that are produced by an effective contact among the tongue, teeth, and palatal vault. In order to produce articulate speech in complete denture patients, an effective tongue-to-palate contact is an important factor. In this case, the patient was satisfied and with follow up, no problem in speech was observed.

However, when natural teeth are lost and a maxillary denture is placed in the mouth, the tongue loses the tactile sensation and positional relationship with palatal structures. Immediately after insertion of denture, tongue usually has to function against a highly polished palatal surface of the denture, leading to an altered speech pattern.^[7] Therefore to reduce this problem, Palatal rugae duplication procedure should be followed in every denture. This slight bulging of the denture base palatal to the anterior teeth probably helps in improved pronunciation of /s/ and /sh/ sounds.^[8] Patient require a tactile sense to orient their tongue, and palatal rugae can help the tongue identify irregular and rough regions rather than slippery and smooth ones.^[9]

A method for duplicating the contour of the palatal vault of maxillary complete denture can be achieved at the trial stage of denture construction and incorporated within the

finished denture. The method described here for recording rouge with putty index and then duplicating imprint with clear acrylic can be done directly in patient mouth or on master cast if recorded properly.

Palatine rugae when duplicated on the denture improved patient's taste perception and identify flavors especially sour foods.^[10] Both response times as well as qualities of perception of sour taste improved with denture that was characterized with Palatine rugae.

CONCLUSION

One of the benefit of the method is that the ease with which it can be quickly and effortlessly be accomplished by the dentist or the laboratory technician and the minimal requirement of any extra material or equipment. Moreover, no special skills are required to achieve successful results, which may be exceptionally gratifying.

REFERENCES

1. Lysell L. Plicae palatinae transversae and papilla incisiva in man: A morphologic and genetic study. *Acta Odontol Scand.*, 1955; 13(18): 5-137.
2. Thomas CJ, Kotze TJ. The palatal rugae pattern: A new classification. *J Dent Assoc South Afr.*, 1983; 38: 153-7.
3. Haitas GP, Wolfaardt JF, Carr L. Speech defects in prosthetic dentistry, part I—the mechanism of speech production. *J Dent Assoc S Afr.*, July, 1985; 381-6.
4. Tanaka, H.: Speech patterns of edentulous patients and morphology of the palate in relation to phonetics. *J PROSTHET DENT*, 1973; 29: 16.
5. Palmer, J. M.: Structural changes for speech improvement in complete upper denture fabrication. *J PROSTHET DENT*, 1979; 41: 507.
6. Goyal BK, Greenstein P. Functional contouring of the palatal vault for improving speech with complete dentures. *The Journal of prosthetic dentistry*, Dec 1, 1982; 48(6): 640-6.
7. Dirksen LC, Campagna SJ. Mat surface and rugae reproduction for upper partial denture castings. *Journal of Prosthetic Dentistry*, Jan 1, 1954; 4(1): 67-72.
8. Allen, L. R.: Improved phonetics in denture construction. *J PROSTHET DENT*, 1958; 8: 753.
9. Gitto C, Esposito S, Draper J. A simple method of adding palatal rugae to a complete denture. *J Prosthet Dent*, 1999; 81: 237-9.
10. Sanjay VB, Priti S, Sadekh A. Reproducing functional palatal contours in complete dentures to improve speech—a case report. *J Indian Dent Assoc*, 2012; 6(2): 111-114.