

**HISTOPATHOLOGICAL STUDY OF PROSTATE LESIONS-AN INSTITUTIONAL
EXPERIENCE****Dr. Neha Mahajan^{1*}, Dr. Vaishali Nagose², Shirish Gondane³ and Dr. Vipin Todase⁴**¹Associate Professor, ²Associate Professor, ^{3,4}Assistant Professor

Department of Pathology, Dr. Ulhas Patil Medical College, Jalgaon, Maharashtra. India.

***Corresponding Author: Dr. Neha Mahajan**

Associate Professor, Department of Pathology, DrUlhas Patil Medical College, Jalgaon, Maharashtra. India.

Article Received on 28/09/2020

Article Revised on 19/10/2020

Article Accepted on 09/11/2020

ABSTRACT

Introduction: Prostate gland pathologies are an important cause of morbidity and mortality in male patients. Disease spectrum for prostate comprises of inflammatory conditions, benign hyperplasia, malignancies, etc. Prostatic biopsy is an important test which helps determine various benign conditions as well as cancers in patients with specific indications. Other diagnostic modalities like radiology, prostatic biomarkers have developed, however histopathological examination on tissue biopsy is the gold standard for final diagnosis. **Aims and objectives:** To study Histopathological features in transurethral resection of prostate (TURP) and needle biopsies and to classify tumours of prostate as per WHO recommendations with analysis of adenocarcinoma prostate according to Gleason's grading system. **Materials and methods:** This study is a prospective study which was conducted from January 2018 to December 2019. The biopsies were fixed in 10% neutral buffered formalin and routine paraffin processing followed by hematoxylin and eosin staining was done. All the specimens were analysed with reference to type of specimen, age of patient and histopathological diagnosis. **Results and conclusions:** Benign hyperthrophy of prostate (BHP) was the commonest encountered lesion 114 cases (85%) which was accompanied by prostatitis in many cases. Prostatic adenocarcinoma was found in 10 cases (7.4%). Gleason's score were predominantly of high values 7-9. The age range was 25 to 89 years and mean age was 57 years.

KEYWORDS: Prostate, Lesions, Histopathology, Gleason score.**INTRODUCTION**

Lesion of prostate have been increasing over the past few decades due to increase in life expectancy. Diseases of prostate cause significant morbidity and mortality in male patients. Prostate is affected by variety of diseases but frequently encountered are BHP, prostatitis and prostatic carcinoma. In males over 40 years of age, BHP is most common urological disorder. Clinical incidence of BHP is 8% in 4th decade but reaches 50% in 5th decade and 75% in 8th decade of life.^[1] Prostatic carcinoma is most common internal malignancy among men in U.S and is responsible for 10% of carcinoma deaths.^[2] In India, prostate cancers constitute about 5% of all cancers in Males.^[2,3] The aim of this study was to determine various Histopathological patterns of prostatic lesions, age distribution, scoring of prostatic adenocarcinoma according to Gleason system.

MATERIALS AND METHODS

The study was conducted in the Department of Pathology, DUPMC, a tertiary level hospital of Jalgaon. The present study was a prospective study carried out from Jan 2018 to Dec 2019. Specimen were received as TURP and needle biopsies in 10% neutral buffered

formalin. Routine paraffin processing was done followed by hematoxylin and eosin staining. The slides were examined under light microscope and various lesions of prostate were noted down. The morphologic types of BHP were described according to classification by Frank's.^[4] The tumors were classified according to WHO classification^[5] and histological grading of adenocarcinoma was done as per the Gleason's system. The data was analysed using tables, figures and percentages in MS excel.

RESULTS AND DISCUSSION

A total of 134 cases were studied over two year period from Jan 2018 to Dec 2019. All the specimens received were transurethral resection of prostate biopsies. The age range of our patients was 25 to 89 years with a mean of 57 years and peak age group of 60 to 70 years. Age distribution of cases is represented in the Chart 1.

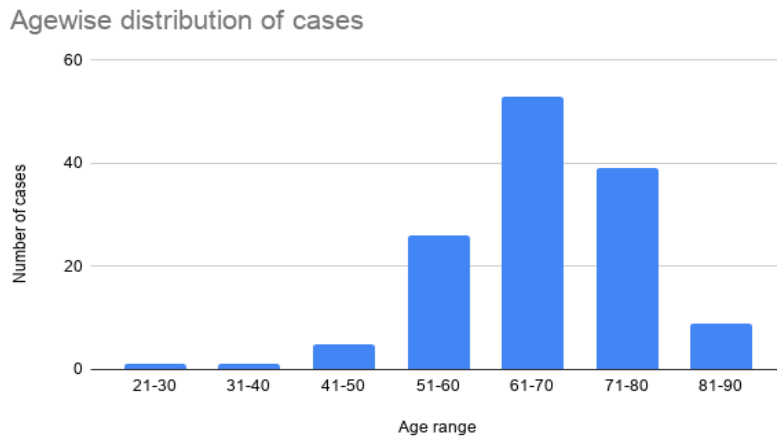


CHART 1: Agewise distribution of cases.

Of the 134 cases, 114 cases (85%) were of benign prostatic hyperplasia, 3 cases of lymphocytic prostatitis (2.2%) 2 cases each of granulomatous prostatitis, Low grade prostatic intraepithelial neoplasia (LGPIN) and High grade prostatic intraepithelial neoplasia (HGPIN). 10 cases (7.4%) cases of prostatic adenocarcinoma were encountered while one case of metastasis was observed

in the study. The spectrum of histopathological lesions is shown in Chart 2 and microscopy images in figure 1.

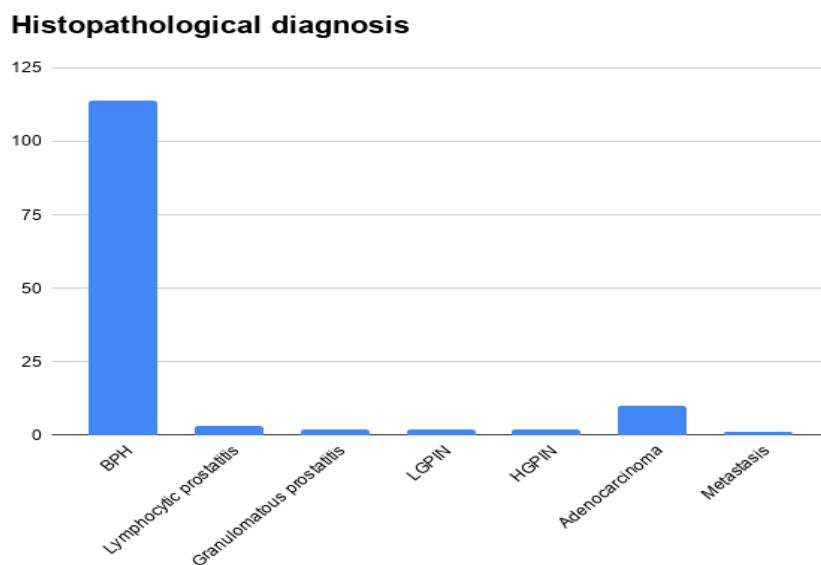
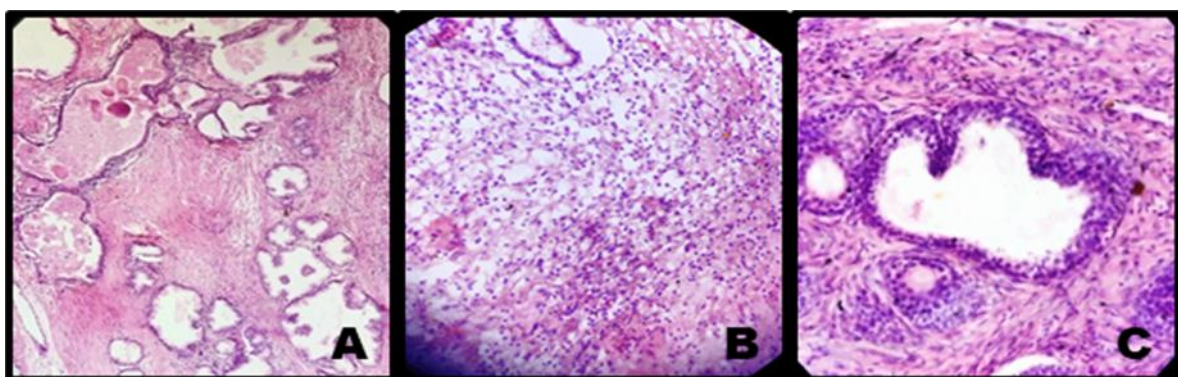


CHART 2: Spectrum of prostatic disease histopathologically.



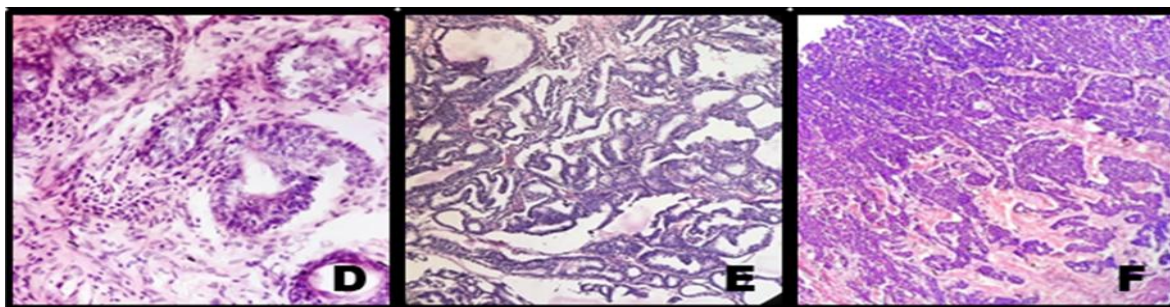


Fig1:A) Benign hypertrophy of prostate(10X), B) Xanthrogranulomatous prostatitis(40X), C) LGPIN (40X), D) HGPIN(40X) E) Adenocarcinoma(1+1) F) Adenocarcinoma (3+3) (40X)

Microscopically BHP shows glandular and stromal hyperplasia and the acini being lined by bilayer of cells. Corpora amylacea in acini, cystic changes, transitional cell metaplasia and calcification are among variably presented associated features. Histologically five types of BHP growth patterns are described i.e fibromyoadenomatous, fibroadenomatous, fibromuscular, muscular and stromal. We found 50.7 % cases of fibroadenomyomatous, 26.1% of fibroadenomatous, 7.4% of fibromuscular and 0.007% of stromal patterns of BHP. Youngest patient among 114 cases of BHP was of 25 years and oldest was 83 years old. We found 3 cases of BHP with squamous metaplasia and 2 cases associated with reserve cell hyperplasia.

Inflammatory changes affecting prostate were divided into acute, chronic and granulomatous on the basis of inflammatory cells present. Chronic prostatitis was observed in 28 cases (20.8%), acute prostatitis was seen in 7 cases (5.2%) and granulomatous prostatitis in 2 cases.

Out of 134 cases 10 cases of prostatic adenocarcinoma were found, of these youngest patient was of 55 years old and oldest was 89 years old. All the cases were graded according to Gleason's grading system. Gleason's grading system is based on the extent of glandular differentiation and growth pattern of the tumor as seen in lower magnification, under light microscope. Five

patterns are described by this system. Both the primary (Predominant) and secondary (second most prevalent) architectural patterns are identified and assigned a grade from 1 to 5, with 1 being the most differentiated and 5 being undifferentiated.^[6]

The combined Gleason grades (Gleason score) range from 2(1+1), which represents tumor uniformly composed of Gleason pattern 1 tumor, to 10(5+5=10), which represents totally undifferentiated tumors. In our study, prostatic adenocarcinoma with Gleason score 7 and 9 were the commonest and there was no tumor with Gleason score 2, 3, 4, 8 or 10. Table 1 represents the age range of the cases categorized as per Gleason score. Chart 3 shows distribution of prostatic adenocarcinoma according to Gleason score.

Table 1: Age range of cases according to Gleason score.

| Gleason score | Age range 41-50 | 51-60 | 61-70 | 71-80 | 81-90 |
|---------------|-----------------|-------|-------|-------|-------|
| 3 | - | - | - | 1 | - |
| 4 | - | - | - | - | - |
| 5 | - | - | - | - | - |
| 6 | - | - | - | - | - |
| 7 | - | 1 | 5 | - | - |
| 8 | - | - | - | - | - |
| 9 | - | - | 1 | 1 | 1 |

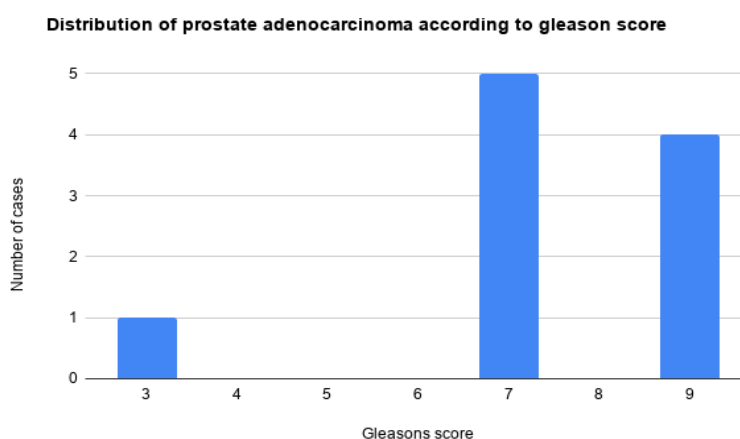


CHART 3: Distribution of prostatic adenocarcinoma according to Gleason's score.

Prostatic diseases are an important cause of significant morbidity and mortality in elderly males. Although screening tools like TRUS, PSA are used for prostatic cancer screen, biopsy still remains gold standard for final diagnosis. Common prostatic pathologies encountered are BHP, prostatitis and prostatic cancer. Hormones such as androgen and advanced age are like factors associated with prostatic lesions.^[7] In the present study mean age for benign and malignant lesions were 54 and 72 years respectively. Benign lesions were common in age group of 61 to 70 whereas malignant were common in age group of 71 to 80 years which is concordance to studies by Bhat *et al*^[8], Deshmukh *et al*^[9], Kasliwal *et al*^[10], Patel *et al*^[11] In the present study of 134 cases of prostate lesions, 114 (85%) were diagnosed as BHP and 10 cases (7.4%) cases were diagnosed as prostatic cancers, these findings were similar to studies done by Jehoram *et al*^[12], Bal *et al*^[13], Dawan *et al*^[14], Bhat *et al*^[8] whose studies found 93%, 87%, 86% and 92.4% cases of BHP in their studies respectively.

Most common histological pattern of BHP was found to be fibroadenomyomatous 50.7% followed by fibroadenomatous 26% which was similar to studies done by Deshmukh *et al*^[9] & Kimet *et al*^[15] Chronic prostatitis was seen in 28 cases, all these cases were seen associated with BHP. These are similar to findings of studies done by Anim *et al*^[16], Mohmad *et al*^[17], Bhat *et al*^[8] which also found chronic prostatitis as most common inflammatory lesion followed by acute and granulomatous prostatitis. Granulomatous prostatitis can be classified as Idiopathic (non specific), Infectious, Malakoplakia, Iatrogenic and associated with Systemic diseases.^[18] We noted 2 cases of Idiopathic (non specific) granulomatous prostatitis. It is thought to result from foreign body response to colloidal substance, bacterial products, refluxed urine or from an immunological response to extraductal prostatic secretions arising from ducts obstructed by hyperplasia Mohan H *et al*^[19]

All the prostate carcinomas were histologically adenocarcinoma in this study similar to other studies by Mohmad *et al*^[17] and Begum *et al*^[20] Adenocarcinoma were graded according to modified gleason system which was based on degree of glandular differentiation at low power examination. The gleasons grading correlates with tumour aggressiveness, tumour volume and prognosis.^[21] Tumours with gleason score 8 to 10 have advanced cancer with poor prognosis.^[7] Gleason score of 7 was seen in 6 out of 10 cases (60%) followed by gleason score of 9 which was seen in 3 out of 10 cases (30%) which was in concordance to study done by Brawn *et al*^[22]

Involvement of prostate by secondaries is rare. Occasionally urothelial carcinoma of bladder and colonic adenocarcinoma may secondarily involve seminal vesicles.^[5] Secondary neoplastic involvement of prostate occurs through direct extension by carcinoma of bladder and urethra, colorectum and anus and soft tissue tumor. Distant mets have been seen from lung, carcinoma,

melanoma, Renal cell carcinoma and other tumour types.^[1,6] We too encountered such a rare case of metastasis in prostate from carcinoma of bladder.

CONCLUSION

We found the pattern of prostatic diseases in this region were similar to other regions of India and world. BHP was the commonest lesion found and many cases were associated with prostatitis. Prostatic adenocarcinoma were seen in 7.4 % of cases. Histopathological examination of prostatic specimens play a crucial role in diagnosis and management of various prostatic lesions.

ACKNOWLEDGEMENT

None.

REFERENCES

1. Rosai Juan. Rosai and Ackerman's Surgical Pathology. 9 ed. Milan, Italy: Elsevier, 2005; 917 to 992.
2. Egevad L. consolidated report of population based cancer registries 2001-2004: Incidence and distribution of Cancer. Bangalore (IND): Coordinating Unit, National Cancer Registry Programme, Indian Council of Medical Research, 2006.
3. Garg M, Kaur G., Malhotra V, Garg R. Histopathological spectrum of 364 prostatic specimens including immunohistochemistry with special reference to grey zone lesions. Prostate Int, 2013; 4(4): 146-151.
4. Franks LM. Benign nodular hyperplasia of the prostate; a review. Ann R Coll Surg Engl, 1953; 14: 92-106.
5. Holger Moch, Peter A Humphrey, Thomas Ulbright, Victor E Reuter. WHO Classification of tumours of urinary system and male genital organs. IARC, Lyon 2016; 135-183.
6. Stephen S sternburg, Donald A.A, Daryl. Carter, Stacey. E, Oberman H.A. Diagnostic Surgical Pathology. 3rd ed. Newyork: Lippincott Williams & Wilkins, 1999.
7. Vinay Kumar, Abul.K Abbas, John C Aster. Robbins & Cotran Pathological Basis of Disease. 10th ed. Chicago, Illinois: Elsevier, 2020; 975 to 982.
8. Bhat S, Chaudhari S, Bhat P, Hatwal D. Histopathological study of prostatic diseases in Garhwal region. Int J sci Stud, 2015; 3: 136-140.
9. Bhakti D Deshmukh, Nayan A Ramteerthakar, Kalpana R. Sulhyan. Histopathological study of lesions of prostate – A five year study. IJHSR, January, 2014; 4: 1.
10. Kasliwal N. Pattern of prostatic disease-a Histopathological study with clinical correlation. EJPMPR, 2016; 3: 589-97.
11. Patel SK, Surti HB. analysis of prostatic biopsies in a tertiary care hospital in correlation with prostate-specific antigen levels: A clinicopathological study. Int J Med Sci Public health, 2017; 6: 842-846.

12. JehoramTA, Sitara AS, MohmadEB. Hyperplastic, premalignant and malignant lesions of the prostategland. *Hum Pathol*, 2005; 36: 480-5.
13. Bal MS, Kanwal S, Goyal AK, Singla N. Prostatic lesions in surgical biopsy specimens. *JK Pract.*, 2011; 16: 33-4.
14. Dawan D, RafindadiAH, Kalayi GD. Benign prostatic hyperplasia and prostate carcinoma in native Africans. *BJU Int.*, 2000; 85: 1074-7.
15. Kim KB, Kim KS.A Histopathological observationon 48 cases of benign prostatic hypertrophy. *Korean J Urol.*, 1982; 23(8): 30.
16. AnimJT, Ebrahim BH, SatharSA. Benign disorders of the prostate: A Histopathological study. *Ann Saudi Med.*, 1998; 23: 1127-31.
17. Mohmad AZ, Nwana EJ, anjorin AS. Histopathological pattern of prostatic diseases in Nigerians. *Afr J Urol*, 2005; 11: 33-8.
18. Young HR, srigley RJ, Anim Bm, ulbright MT, Cubilia LA. Tumour-like lesions of the prostate. In: *Tumours of the prostate gland, seminal vesicles, male urethra and penis: Atlas of Tumour pathology*. Washington DC:Armed Forces Institute of Pathology(AFIP-28), 1998; 289-345.
19. MohanH, Bal A, Punia RPS, Bawa AS. Granulomatous prostatitis-an infrequent diagnosis. *International Journal of Urology*, 2005; 474-78.
20. Begum Z, Attar AH, tengli MB, Ahmed MM.studies of various Histopathological patterns in TURP specimens and incidental detectionof carcinoma prostate.*Indian J Pathol and Oncol.*, 2015; 2: 303-308.
21. Josephine A.Clinicopathological study of prostatic biopsies.*J ClinDiagn res.*, 2014; 8: 4-6.
22. Brawn PN, Ayala AG, vonEschenbach AC, Hussey DH, Johnson DE. Histologic grading study of prostate adenocarcinoma. The development of new system and comparison with other methods-A preliminary study. *Cancer*, 1982; 49: 525-532.