

AYURVEDIC MANAGEMENT OF *SHWITRA*: A CASE STUDY¹*Dr. Mayur M. Morey and ²Dr. Vijaykumar U. Gawai¹PG Scholar, Government Ayurved College, Nanded.²Professor and HOD, Government Ayurvedic College, Nanded.

*Corresponding Author: Dr. Mayur M. Morey

PG Scholar, Government Ayurved College, Nanded.

Article Received on 23/05/2021

Article Revised on 13/06/2021

Article Accepted on 03/07/2021

ABSTRACT

Beauty of the person is assessed by the complexion and texture of the skin. Healthy skin is determined by its proper structure, natural color and clear appearance. Skin is considered as *Twak* in Ayurveda. *Twak vikara* or disorder are considered under *Kushta Roga* in Ayurveda. *Shwitra* is considered as one of the varieties of *Kushta* in Ayurvedic classics. Partial or complete loss of skin pigmentation giving rise to white patch on any part of the body is called as leukoderma or vitiligo. It has an unknown etiology even today but its an acquired condition in which circumscribed depigmented patches develops. This depigmentation results due to destruction of melanocytes, which may be unknown in origin or due to autoimmune endocrinopathies selective IgA deficiency. According to Ayurveda *Shwitra* is caused due to vitiation of *tridoshas* and *dhatu*s like *Rakta*, *Mamsa* and *Meda*. A female patient aged 12 yr has complaint of white patch behind right ear region since 2 year. Patient was treated with both *Shodhan* and *Shaman chikitsa* for period of 3 months with follow up every after 15 days. Patient got relief from the complaint and it is assessed by noting the changes in the size of patch was reduced. Present case study revealed that efficacy of Ayurvedic *Chikitsa* in *Shwitra* management.

KEYWORDS: *tridoshas* and *dhatu*s like *Rakta*, *Mamsa* and *Meda*.**INTRODUCTION**

Skin is the largest organ of body by surface area and weight. Total area is about 20 sq.feet. Skin protects us from microbes and the elements, helps regulate body temperature and permits the sensation of touch heat, cold. As skin is exposed to external environment it is more prone to various skin problem. Skin disorder are considered under *Kushta roga* in Ayurvedic classics. The word *Kushtha* is derived from the root '*Kush nishkarsh*' e i.e. to tear or to expel with suffix k. It means the disease which definitely despises and disfigures the skin or body is called *Kushta*.^[1]

Vitiligo is a skin disease with unknown etiology in which skin loses its color in blotches and develops in white patches. Partial or complete loss of skin pigmentation giving rise to white patch on any part of the body is called as leukoderma or vitiligo. The exact cause is unknown but may be due to autoimmune disorder which may destroy melanocytes in skin. Vitiligo can affect people of any age gender.

In Ayurveda vitiligo is correlated with *Shwitra*. In *Charak Samhita Sushruta Samhita Ashtang sangraha* we found the description of *Shwitra* as synonyms etiology types *sadhya asadhyatva* and *chikitsa*. In Ayurveda *Shwitra* is a disease explained in *Khshudrakushta*. It is called as *Kilas Daruna Shweta kushta*.^[2]

Ayurveda states that causes of *Shwitra* may be *chardivegadharana atisewan of amla-katu-ushna-lavan-madhur aharsewan, virudhhahar and atimatra bhojan* along with *navann sevan* and *dahi sevan*. In *Charak Samhita* while explaining the *Nidana* of *Shwitra* *Acharya Charak* has explained *Virudha aharvihar* (unbeneficial food) and *Paap karma* (bad deeds) are the main cause of *Shwitra*.^[3]

Above etiological factors produces the imbalance of *Doshas*(body humours) like *Vata*, *Pitta* *Kapha* specially *Bhrajak Pitta* which helps in the formation of and maintain the color of skin. These *Doshas* are vitiated along with *Rasa Rakta Mamsa and Meda Dhatus*.^[4] Satisfying treatment is not available in modern science. Various *Panchkarma* procedures and Ayurvedic drug have been proved useful for these manifestation.

A CASE STUDY**Case report**

A 12 year old female patient comes in an OPD with complaint of white coloured patch behind the right ear since 2 year. Patient underwent several for several allopathy treatment but got not that much satisfactory relief. Then patient come to the Balroga OPD of Government Ayurvedic college, Nanded. Then patient admitted on the same day for further Ayurvedic treatment.

History of present illness

Patient was normal before the 2 years she is not aware of the disease. She noticed that she was having a white patch behind right ear which gradually increase in size. She visited dermatologist for the same. She was advised some internal medicines along with topical steroids for that white patch. She took treatment for more than 2 years but not got satisfactory result so she approached for the Ayurveda consultancy for the same.

History of past illness

No history of DM, bronchial asthma.
No history of previous other skin disease
No any history of major illness

Family history

No any maternal or paternal history of vitiligo

General Examination

Nadi- 74/min
Mala- Baddhamalapravrutti
Mutra – Samyaka
Jivha – Sama

Treatment**First line of treatment- Deepan- Pachana**

Day	Medication	Anupana
1	Amlaki+Musta+Guduchi churna each 2 gram	Koshna jal(warm water)
2	Amlaki+Musta+Guduchi Churna each 2 gram	Koshna jal
3	Amlaki+Musta+Guduchi Churna each 2 gram	Koshna jal
4	Amlaki + Musta +Guduchi Churna each 2 gram	Koshna jal
5	Amlaki+Musta+Guduchi Churna each 2 gram	Koshna jal

Second line of treatment- Mrudu Rechan

Drug	Dose	Duration	Anupana
Erandbhrishta Haritaki churna ^[5] for Mrudu Rechan	5 Gram	5 days	Koshna jal

Third line treatment- Shaman Chikitsa

Sr.no	Drug	Dose	Duration	Anupana
1	Mahamanjishthadi Kwath ^[6]	10 ml BD	3 month	Koshna jal
2	Arogyavardhini vati	1 BD	3 month	Koshna jal
3	Vidangarishta	10 ml BD	3 month	Koshna jal
4	Mahatikta ghuruta	1 tsp BD	3 month	Koshna jal

Local Application

Bakuchi oil^[7] on the white patch in morning and sun exposure for ½ hour for 3 month.

Shabda- Spashta

Sparsh - Anushnasheet

Druk- Spashta

Akriti- Krush

Prakriti – Kaphapradhan pittanubandhi

Weight – 20 kg

Temperature – 97.2°F

Personal history

Aharaj – Nonveg diet weekly 3-4 times

Fast food like chips, pizza, burger, biscuits, toast more frequently

Viharaaj- Ratri jagran upto 1:00 or 2:00 AM

Manasik- Irritable


Samprapti Ghatak

Dosha- Tridoshaj (Pitta-vatapradhan)

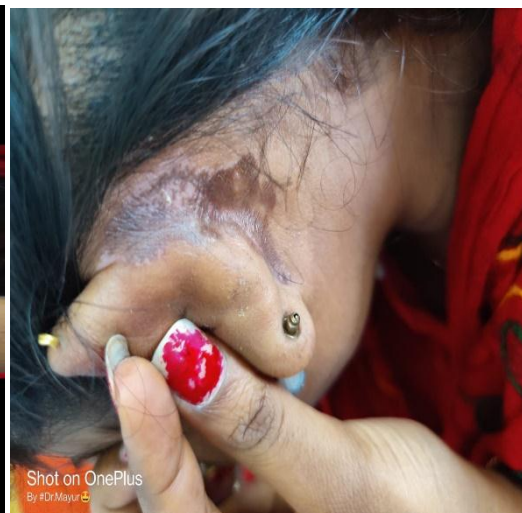
Dushya- Rasa, Rakta, Mamsa, Medas

Adhisthan- Twak

RESULTS



Before treatment white colored patch



After treatment of 3 month

DISCUSSION

Amlaki churna is given for *deepan pachan* because it has *Tridoshaghna* properties. *Musta* having *Tikta rasa* is good for *deepan* and *pachan*. *Guduchi* also has the *Tridoshahar* properties. That's why combination of above drug *churna* is given for the purpose of *Deepan* and *Pachana*. Both Castor Oil and *Haritaki churna* are appreciated as good laxative. Their unique combination is excellent in treating almost all *Apanavaat* disorder. Castor oil for deep invading and taking out the wide spread vitiated *Vata dosha* from various channels. The other ingredient *Haritaki* is proclaimed for its carminative and anti-flatulent effect. *Mhamanjisthadi kwath* having the *Rakta dhatu prasadak* properties which helps to remove impurities from blood. *Arogyavardhini vati* helps to remove *Ama* toxin from the body. It has antioxidant, antipruritic nature alleviates itching sensation. *Vidangarishta* possesses properties of *Krumighna* (anti helminth). *Mhatikta ghrita* is *tiktarasapradhan Kaphahara* and is indicated in *Kushta vikara*. *Bakuchi* oil contain psoralen isopsoralen, bakuchiol bavchinin and corylin which have antioxidant properties helps in stimulates melanocytes for melanin synthesis immuno-modulatory effect and inhibitory against antigen induced granulation.

CONCLUSION

Shwitra is a disease having high impact on the body and mind. Ayurvedic treatment for this skin disease have given a blissful life by improving the immune system as well as boosting the level of confidence in the individual. The lesion of white patch which was present behind right ear of 12 year old patient was fully recovered after 3 month of treatment. *Shodhan* therapy helps to remove the root cause of the disease and prevent the disease from its reoccurrence by eliminating aggravated *Doshas*. This case study on *Shwitra* conclude that better significant result can be achieved by *Shodhan* and *Shaman chikitsa* and also by external application of medicine. Patient

found significant result and thus treatment protocol can be used for management of *Shwitra*.

REFERENCES

1. Ankur Kumar Tanwar Dr. Sujata Rajan (2019) A Correlation between Man and Twak Vikar: A Conceptual review study. International Journal Of Indian Pscycology.
2. Shukla R Tripathi 2009 Agnivesha Charak Samhita Hindi translation. Choukhamba Sanskrit Pratishthan. Chititsa 7/16.
3. Shukla R Tripathi 2009 Agnivesha Charak Samhita Hindi translation. Choukhamba Sanskrit Pratishthan. Chititsa.7/174.
4. Shukla R Tripathi 2009 Agnivesha Charak Samhita Hindi translation. Choukhamba Sanskrit Pratishthan. Chititsa.7/3.
5. Brihat Nighantu ratnakara-sleepada chikitsa Bhavprakasha.
6. Sharangdhara Samhita Madhyamakhand Chukhamba Bharati academy 2/137-142.
7. Mahendra AA, Bandra GK, Rohini GA, Disha JC Studies on the composition and standardization of Bakuchi oil An Ayurvedic medicine oil prepared from psoralea corylifolia L used in the treatment of vitiligo, International Journal of research in Ayurveda and pharmacy, 2012; 3: 411-415.