

EFFICACY OF BUCCAL FAT PAD AS AN ADJUNCT IN PALATOPLASTY**¹Dr. Anand Mangalgi, ²Dr. Viqar Ahmed, ^{3*}Dr. Sowmya T., ⁴Nagesh Ingleshwar, ⁵Dr. Supriya Patil**¹Reader, Department of Oral and Maxillofacial Surgery, HKE's S Nijalingappa Institute of Dental Sciences And Research, Kalaburgi-585105.²Associate Professor, Department of Oral and Maxillofacial Surgery, K B N Medical College, Kalaburgi 585105.³MDS, Oral and Maxillofacial Surgery, HKE's S Nijalingappa Institute of Dental Sciences and Research, Kalaburgi-585105.⁴Reader, Department of Prosthodontics, HKE's S Nijalingappa Institute of Dental Sciences and Research, Kalaburgi-585105.⁵Reader, Department of Conservative and Endodontics, HKE's S Nijalingappa Institute of Dental Sciences and Research, Kalaburgi-585105.***Corresponding Author: Dr. Sowmya T.**

MDS, Oral and Maxillofacial Surgery, HKE's S Nijalingappa Institute of Dental Sciences and Research, Kalaburgi-585105.

Article Received on 30/06/2023

Article Revised on 21/07/2023

Article Accepted on 11/08/2023

ABSTRACT

Background: The use of a pedicled buccal fat pad graft to cover palatal osseous defects and to prevent or repair fistulas has gained popularity in recent years. Buccal pad fat graft is a useful, easy and uncomplicated alternative method for the reconstruction of small to medium-sized defects of the oral hard and soft tissue. The objective of this study was to test the feasibility and efficacy of pedicled buccal fat pad graft as an adjunct in cleft palate surgery. **Materials and methods:** In this study, 10 patients with primary and secondary cleft palate defects were selected. The patients underwent primary palatoplasty or redo palatoplasty for palatal fistula repair using pedicled buccal fat pad graft as an adjunct. All patients were followed up for minimum of 3 months at intervals of 3 days, 1 week, 1 month and 3 months, to evaluate the postoperative healing, infection, dehiscence, herniation of buccal fat pad, fistula and scar formation. **Results:** In all the patients, mild pain was present on the 3rd post-operative day which subsided by the end of 1 week post-operatively. Infection of the graft was observed in 1 patient one week post-operatively, which resolved on continuing antibiotics for 3 days and good oral hygiene maintenance. Dehiscence and herniation of buccal fat pad was not noted in any of the patients. 2 patients with bilateral cleft palate repair presented with fistula 1 month post-operatively. Scars were classified as discrete (thin incision line without fibrosis), fibrosed (visible discrete fibrosis on the incision line), hypertrophic. In 7 patients, healing was excellent with thin, discrete scar formation. 2 patients developed fibrosed scar and 1 patient developed hypertrophic scar 3 months post-operatively. **Conclusion:** Pedicled buccal fat pad graft as an adjunct in cleft palate surgeries is safe, and reliable alternative for tissue deficit repair in cleft palate surgery.

KEYWORDS: Cleft palate, pedicled buccal fat pad, palatoplasty.**INTRODUCTION**

Cleft lip and cleft palate together are the most common congenital deformities of the head and neck. The primary goal of cleft care is to optimize function and appearance while minimizing surgical interventions and complications. The ideal treatment objectives for a cleft repair are: normalized facial aesthetics, integrity of the primary and secondary palate, normal speech and hearing, airway patency, class I occlusion with normal masticatory function, good dental and periodontal health, and normal psychosocial development. Numerous surgical techniques^[1] for cleft palate repair may be chosen based on cleft classification, cleft width, surgeon's experience and preference. In order to reconstruct and maintain the levator palatine flap in its proper position, various flaps have been used to cover

the raw areas caused by the displacement of the oral mucosteal flap. Local flaps like anteriorly based tongue flap, buccal mucosal flap, oral muco-periosteal island flap and buccinator flap make up for the tissue shortage in the surgical treatment of cleft palate. The persistent palatal fistula following cleft lip surgery is of particular concern for both the patient and the surgeon. The challenges surgeons encounter during their treatment of these patients include the presence of scars, absence of local tissue and higher recurrence rates. In recent years, the use of pedicled buccal fat pad graft has become more popular for covering bone defects and preventing or treating fistulas. For reconstruction of minor to moderate oral hard and soft tissue defects, the buccal pad fat graft technique is a useful, easy and straightforward alternative method. The use of buccal pad fat to repair

primary cleft palate was first described in Chinese by Zhao et al. in 1998.

The pedicled buccal fat pad is an effective and reliable complement to cleft palate surgery due to its easy extraction and mobilisation of the graft, good blood supply and minimal complications at donor sites. Within 4 weeks the transferred buccal pad fat is fully epithelialised with healthy oral mucosa, irrespective of whether a graft has been covered in palatal mucosa or not. Using the buccal pad fat pad flap allows the surgeon to design a turn-down flap freely and to close the nasal layer without tension. Many studies confirm the excellent and predictable healing of buccal pad fat intra-orally with minimal donor morbidity. It is easy to use, safe and requires less surgical experience.

The aim of the present study is to assess the feasibility and efficacy of pedicled buccal fat pad graft as an adjunct in palatoplasty.

MATERIALS AND METHODS

10 patients were included in the study who had non-syndromic unilateral cleft palate patients, Non-

syndromic bilateral cleft palate patients, Palatal fistulas requiring surgeries. In case of primary cleft palates, the conventional Bardach's two flap technique or Von Langenbeck technique is followed to repair the cleft of the palate. Buccal fat pad as a pedicled graft is obtained through the existing incision or a separate incision in the buccal mucosa on either side. It is then transpositioned to the lateral raw surfaces and sutured.

In cases where nasal layer lengthening and augmentation is required, once the nasal layer closure is done, a transverse incision is placed in the midline to create a gap in the nasal layer. Bilateral pedicled buccal pad grafts harvested in the above described manner are transpositioned and sutured to nasal layer to close the gap and to lengthen the nasal layer. Any perforations in the nasal layer will also be covered with pedicled buccal fat pad. Palatal fistulas are also treated by transpositioning the pedicled buccal fat pad in three layer closure (figure 1). Post-operative follow up is done at 3 days, 1 week, 4 weeks and 3 months intervals. All patients were assessed with respect to healing, infection, dehiscence and recurrence in case of palatal fistula. (figure 2,3)

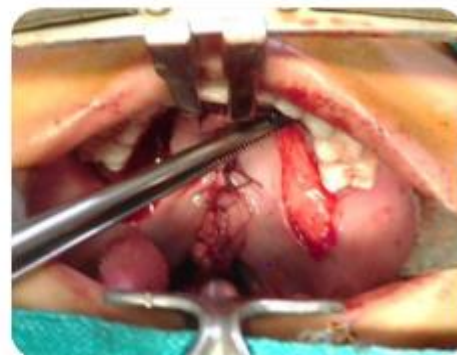
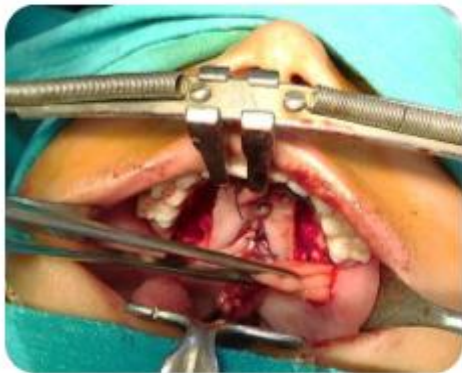

Figure 1: Harvesting pedicled Buccal fat pad graft.

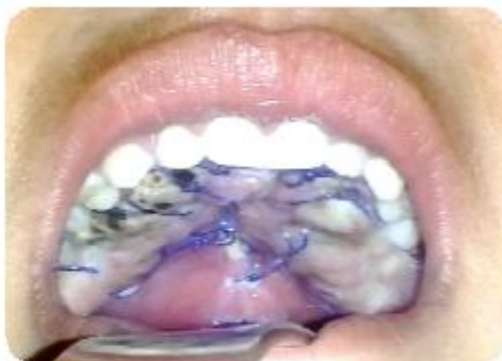

Figure 2: Post Operative 7th Day

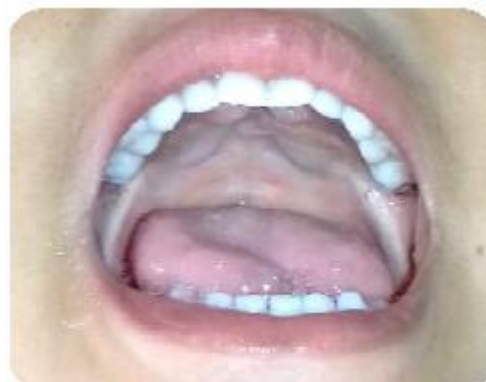

Figure 3: Postoperative 3 months.

RESULTS

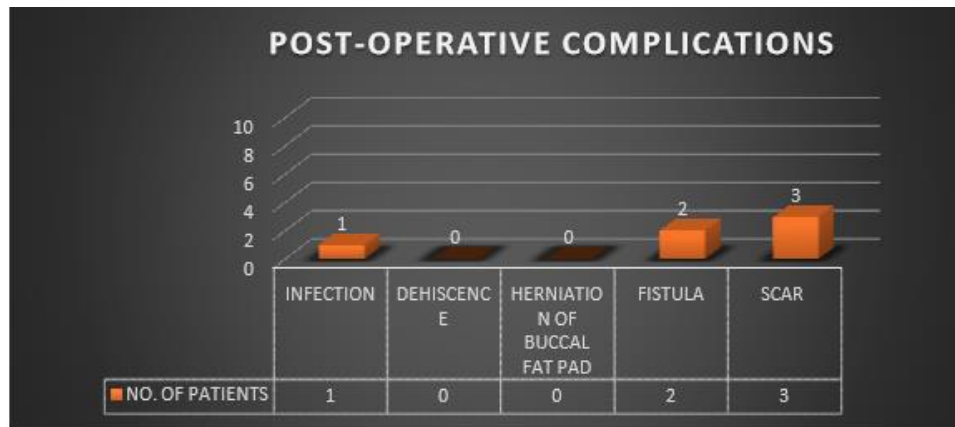
10 patients (4 males and 6 females) underwent primary palatoplasty and fistula repair with pedicled buccal fat pad as an adjunct. Out of 10 patients, 8 patients had cleft palate and 2 patients had palatal fistula.

In all the patients, mild pain was present on the 3rd post-operative day which subsided by the end of 1 week post-operatively. Infection of the graft was observed in 1 patient one week post-operatively, which resolved on continuing antibiotics for 3 days and good oral hygiene

maintenance. Dehiscence and herniation of buccal fat pad was not noted in any of the patients. 2 patients with bilateral cleft palate repair presented with fistula 1 month post-operatively.

Scars were classified as discrete (thin incision line without fibrosis), fibrosed (visible discrete fibrosis on the

incision line), hypertrophic. In 7 patients, healing was excellent with thin, discrete scar formation. 2 patients developed fibrosed scar and 1 patient developed hypertrophic scar 3 months post-operatively.(graph 1)(table 1).



Graph 1:Representation of incidence of post-operative complications.

Table 1: post operative follow up.

S. NO	PARAMETER	3 RD POST-OP DAY	1 WEEK POST-OP	1 MONTH POST-OP	3 MONTHS POST-OP
1	INFECTION	nil	1	nil	nil
2	DEHISCENCE	nil	nil	nil	nil
3	HERNIATION OF BUCCAL FAT PAD	nil	nil	nil	nil
4	FISTULA	nil	nil	2 patients	2 patients
5	SCAR	nil	nil	3 patients	3 patients

DISCUSSION

One of the most common congenital anomalies is cleft lips and palate, with a wide partial cleft lip and Palate one of the more severe types. Full closure of the mouth, velopharyngeal proficiency and normal maxillary growth have been identified as surgery objectives for Palate Repair.^[3]

A number of etiologies such as tension knots in wound closure, cleft width, infection and hematoma formation have been reported for the development of large defects following a cleft palate repair.^[4,5] However, it appears that the most frequent cause of this complication is necrosis of the mucoperiosteal flap. Palatal flap necrosis can be due to local causes (compression, tension, stretching, or section of the pedicle, vascular thrombosis,

bleeding and hematoma, and surgical damage during the intervention).

The present study was conducted to evaluate the efficacy of pedicled buccal fat pad as an adjunct in cleft palate surgery. In this study 10 patients were included with age range between 3 years to 18 years, out of which 6 patients were female and 4 patients were male. 6 patients had unilateral cleft palate and 2 patients had bilateral cleft palate and 2 patients had palatal fistulas. Patients remained un-operated for such a long period as they live in low socioeconomic conditions and far from efficient medical centers. 6 patients underwent Bardach's two flap palatoplasty and lateral gap augmentation with pedicled buccal fat pad, 2 patients underwent Von Langenbeck repair with lateral gap augmentation and 2 patients underwent Von Langenbeck repair with nasal layer

lengthening. All the patients were monitored regularly for 3 months post-operatively.

The post-operative development of maxillofacial deformities in cleft palate mainly involves alveolar crest collapse, severe underbite, midfacial retrusion and lower facial protrusion. Some studies have suggested scar tissue of the palate which is stiffer than normal tissue is an important factor in the restriction of maxillary growth.

An important step in successful wound healing is the coverage of soft tissue. Intra-operatively an adhesive periosteal suture in the midline bares the bone on both sides of the relaxing incision, and the use of iodoform gauze⁶ to stimulate the formation of scar tissue leads to pain, fever, and inconvenience during eating, infection and restriction of maxillary growth, resulting in the inward incline of tooth and alveolar structures and facial deformities.

Buccal fat pad flap (BFP) has been used for the reconstruction of maxillary defects induced after tumour resection since it was first reported in 1977 by Egyedi. Buccal fat pad was first mentioned by Heister⁷ in 1732. From then, many clinical applications of BFP have been introduced. The buccal fat pad appears 3 months in utero and continuously grows until birth.⁸ There is little change in the volume of buccal fat during aging, and it is approximately 10 ml. Therefore, it is a reliable flap for the reconstruction of oral defects. Most published studies have reported a high success rate among BFP procedures due to BFP's rich vascularity, proximity to the recipient site, low donor-site morbidity, and simple surgical procedure for grafting.

In bilateral complete cleft palate to decrease tissue tension for closure and lengthen the soft palate, a transverse incision was made on the nasal mucosal layer at the junction of the hard and soft palates and then a rhomboid nasal defect was left. There was no or very limited muscle tissue at this site. An incision to the upper buccal sulcum, approximately lateral to the mandibular tuberosities, has been carried out in order to harvest BFP. The BFP herniated spontaneously and was mobilized by blunt dissection with forceps, transferred into the defect and sutured to the margins. 2 patients in our study underwent Von Langenbeck repair and nasal layer lengthening with buccal fat pad augmentation as described above. Grobe et al (2011)⁹ conducted a study on the clinical use of pedicled buccal fat pad in cleft palate surgery. It was a retrospective evaluation of 24 patients who had BFP pedicled flaps used for the prevention and for the repair of Type III cleft palate fistulas. He proposed that BFP can be used for covering the raw bone surface after sealing the palatal flap.

The present study demonstrates a technical innovation in cleft palate repair utilizing pedicled buccal fat pad graft in conjunction with conventional palatoplasty techniques. We present 10 cases of cleft palate repair of

which 8 patients underwent palatoplasty and lateral raw gaps augmentation with buccal fat pad and 2 patients underwent nasal layer lengthening with pedicled buccal fat pad. All the patients demonstrated full epithelialization of the surgical defect and 2 patients with complete cleft palate showed persistent fistula formation during 3 months follow up period. We consider that this technique allows durable, autologous and vascularized coverage of denuded bony hard palate. Buccal fat pad also reinforces areas of high tension and decreases postoperative fistula formation. Thus buccal fat pad graft is a simple and safe alternative for the repair of tissue deficits in cleft palate repair.

CONCLUSION

Pedicled buccal fat pad graft as an adjunct in cleft palate surgeries is safe, and reliable alternative for tissue deficit repair in cleft palate surgery. Its dense vascular supply, close proximity to the surgical site, easy handling, resistance to infection and rejection owing to its rich blood supply make it an excellent choice over other grafts. The use of buccal fat pad graft avoids donor site morbidity and permits a good healing with no functional deficit as contracture or contour deformity.

REFERENCES

1. Leow AM, Lo LJ. Palatoplasty: evolution and controversies. *Chang Gung Med J.*, Jul, 2008; 31(4): 335-45.
2. Scammon RE. On the development and finer structure of the corpus adiposum buccae. *The Anatomical Record*, Jan 1, 1919; 15(6): 267-87.
3. Levi B, Kasten SJ, Buchman SR. Utilization of the buccal fat pad flap for congenital cleft palate repair. *Plast reconstruct surg.* Mar. 1, 2009; 123(3): 1018-21.
4. Rossell-Perry P. Flap necrosis after palatoplasty in patients with cleft palate. *BioMed research international.* Jul 26, 2015; 2015.
5. Bardach J, Kelly KM. Does interference with mucoperiosteum and palatal bone affect craniofacial growth? An experimental study in beagles. *Plast Reconstr Surg.* 1990; 86: 1093-100.
6. Gosain AK. Discussion: two-stage palate repair with delayed hard palate closure is related to favorable maxillary growth in unilateral cleft lip and palate. *Plastic and reconstructive surgery.* May 1, 2010; 125(5): 1511-3.
7. Marzano UG. Lorenz Heister's "molar gland". *Plastic and reconstructive surgery.* Apr 15, 2005; 115(5): 1389-93.
8. Arce K. Buccal fat pad in maxillary reconstruction. *Atlas of the oral and maxillofacial surgery clinics of North America.* Mar 1, 2007; 15(1): 23-32.
9. Grobe A, Eichhorn W, Hanken H, Precht C, Schmelzle R, Heiland M, et al. The use of buccal fat pad (BFP) as a pedicled graft in cleft palate surgery. *International journal of oral and maxillofacial surgery.* 2011; 40(7): 685-9.

10. Hudson. Use of pedicled buccal fat pad as an adjunct in the reconstruction of palatal cleft defects – oral surg oral med oral path oral radiol endod, 1995; 80: 24-7.
11. Boo-Chai K. An ancient Chinese text on a cleft lip. *Plast Reconstr Surg*, 1966; 38: 89-91.
12. Millard DR. Alveolar and palatal deformities. *Cleft craft: the evolution of its surgery*, Little, Brown and Company, 1980; 3.
13. Rogers BO. History of cleft lip and palate treatment. In: Grabb WC, ed. *Cleft Lip and Palate*. Boston: Little, Brown and Company, 1971; 142-69.
14. Langenbeck von B: Operation der angeborenen totalen Spaltung des harten Gaumens nach einer neuen Methode, *Dtsch Klinik*, 1861; 8: 231–232.
15. Veau V: Grundsätzliches zur Gaumenplastik Langenbeck-Axhausen, *Dsch Chir.*, 1936; 247: 300–316.