

**ORGANOPHOSPHATE COMPOUNDS INDUCED ACUTE NECROTIZING  
PANCREATITIS****Paramjot Kaur<sup>1</sup>, Sandeep Kanwar<sup>2</sup>, Amit Kumar<sup>3\*</sup>, Megha Chauhan<sup>4</sup>, Nihal Negi<sup>5</sup> and Sanjay Mahajan<sup>6</sup>**<sup>1,3,4</sup>Junior Residents, Department of Medicine, Indira Gandhi Medical College, Shimla (H.P.)<sup>2</sup>Junior Resident, Department of surgery, IGMCM Shimla (H.P.)<sup>5</sup>Senior Resident, Department of Medicine, Indira Gandhi Medical College, Shimla (H.P.) <sup>6</sup>Professor, Department of Medicine, Indira Gandhi Medical College, Shimla (H.P.)<sup>6</sup>Professor, Department of Medicine, Dr. Rajendra Prasad Government Medical College and Hospital, Tanda (H.P.)**\*Corresponding Author: Dr. Amit Kumar**

Junior Residents, Department of Medicine, Indira Gandhi Medical College, Shimla (H.P.).

Article Received on 21/10/2024

Article Revised on 11/11/2024

Article Accepted on 01/12/2024

**ABSTRACT**

Acute necrotizing pancreatitis is an uncommon yet significant complication arising from organophosphate poisoning, a prevalent form of self-poisoning due to its widespread availability and potency. This case report details the presentation and management of a 28 years old female who ingested Dichlorvos, an organophosphate compound, with typical presentation. While she started improving with injectables, she developed severe epigastric pain within hours, leading to a diagnosis of acute necrotizing pancreatitis. The discussion explores the pathophysiological basis of organophosphate-induced pancreatitis, attributing it to cholinergic overstimulation of pancreatic acinar cells and ductal hypertension. Reviewing pertinent literature underscores the rarity of this complication, emphasizing the importance of clinical vigilance in its recognition and timely intervention to mitigate potential morbidity and mortality. While routine pancreatic enzyme testing in all organophosphate poisoning cases is not recommended, awareness of this complication facilitates prompt diagnosis and targeted management, thereby optimizing patient outcomes. This case highlights the critical role of early intervention in managing uncommon but serious complications of organophosphate poisoning.

**INTRODUCTION**

Organophosphates and carbamates have reached epidemic proportions in self-poisoning due to their ease of access and high fatality. Occupational, suicidal, and homicidal exposure to organophosphates produce characteristic symptoms in humans, which are treatable, thus early recognition and action are of great importance to physicians for the well-being of their patients.

The initial symptoms and signs of organophosphate compound poisoning include salivation, lacrimation, bradycardia, emesis, miosis, excessive urination; these can be explained by irreversible bonding of these compounds with acetylcholinesterase enzyme, thus causing increased amounts of acetylcholine, resulting in excessive cholinergic stimulation of various organ systems.<sup>[1]</sup> Further symptoms and signs may involve muscular weakness, and can be both, early and late complications of organophosphorous poisoning. Intermediate syndrome occurs around 24-96 hours after poisoning, and Organophosphate Induced Distal Polyneuropathy is a delayed symptom, occurring between 2-3 weeks of ingestion.<sup>[2]</sup>

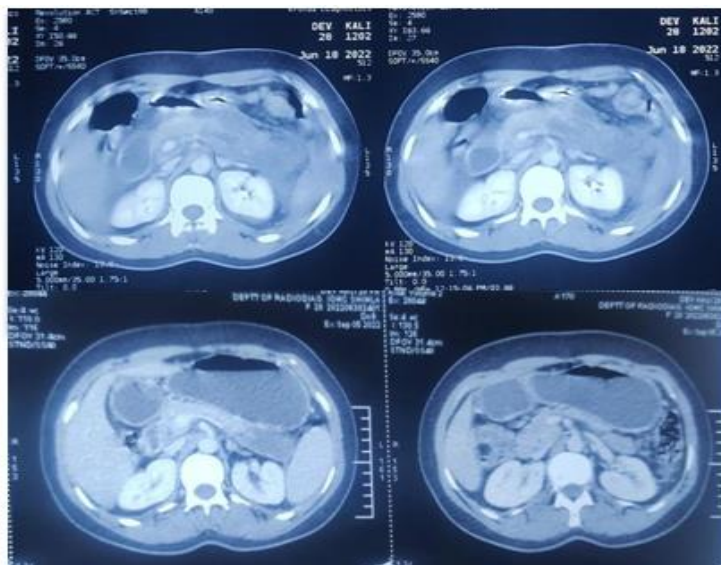
While the common presentations of organophosphate poisoning are the ones enlisted, acute pancreatitis has been encountered rarely, which requires urgent attention and early management for a better outcome.

**CASE REPORT**

A 28 years old female presented to the Emergency Department with alleged history of consumption of around 30 millilitres of Dichlorvos (dichlorovinyl dimethyl phosphate), one hour back. On examination, the patient was drowsy, responding to voice, not oriented, and GCS was 11/15, blood pressure was 120/78mmHg, pulse rate was 68/min, oxygen saturation was 80% on room air. The patient had miosis, salivation, vomiting, and had passed urine in her clothes. Chest examination revealed crackles in bilateral lower lung fields. She was managed with oxygen support, gastric lavage, injections atropine and pralidoxime. The crackles settled as the patient started to stabilize. About 2 hours later, thus 3 hours after the ingestion of the poison, she experienced severe epigastric pain, which was sudden in onset and reached to its peak in next 15-20 minutes. On abdominal examination, she had tenderness and guarding in the epigastric and umbilical regions. Her investigations

revealed haemoglobin 12.9g%, total leukocytes of  $8.6 \times 10^3/\mu\text{L}$ , normal renal, and liver functions. The pain in epigastrium was worsening and was non-responsive to routine analgesics. Thus serum amylase and lipase were done and ultrasound abdomen was done after two hours of admission. Amylase was 1561U/L and lipase was

1685 U/L, with ultrasound abdomen showing bulky distal body of pancreas. The CECT abdomen revealed acute necrotizing pancreatitis, with possible splenic vein thrombosis.



CECT abdomen of the patient showing necrotizing pancreatitis with acute necrotic collection with non-visualisation of splenic vein, with repeat CECT abdomen done eleven weeks later, showing walled off necrosis in the tail of the pancreas, with splenic vein thrombosis.

The patient was managed with intravenous fluid administration, with opioid analgesics, along with atropine, pralidoxime and oxygen inhalation. The patient improved symptomatically over next four days and was monitored with serial investigations. The serum amylase and lipase levels were 565U/L and 559U/L respectively on day 3. The patient was accepting orally on day 4. A repeat ultrasonogram abdomen with hepato-portal doppler showed no evidence of splenic vein thrombus, although, bulky head of pancreas was still visible. The patient had recovered fully on day 8 and was discharged after a detailed psychiatric evaluation.

A repeat CECT abdomen was done eleven weeks later, which showed peripherally enhancing collection in relation to the tail of pancreas, which was walled off necrosis with splenic vein thrombosis.

## DISCUSSION

Dichlorvos and other organophosphorus poisoning cause an irreversible acetylcholinesterase inhibition leading to cholinergic stimulation of organs. Acute pancreatitis is an unusual complication observed in about 12.7% of the patients.<sup>[3]</sup> The mechanism of pancreatitis by organophosphate poisoning has been attributed to cholinergic stimulation of pancreas, leading to a hypersecretion by the acinar cells, leading to ductular hypertension, thus further increasing the secretion<sup>[4]</sup> Additionally, some organophosphate compounds inhibit two cholinesterase isoenzymes further increase sensitivity of pancreas fragments to

acetylcholine.<sup>[5]</sup>

In the very first study reporting pancreatitis complicating organophosphate intoxication, the pancreatitis was mild and the effects of organophosphate on pancreas disappeared in 72 hours and complicated pancreatitis improved in 3-5 days. A canine experiment revealed that organophosphate anticholinesterase causes a functional ductal obstruction and stimulation of pancreatic exocrine secretion. Pancreatic interstitial edema, acinar cell vacuolization, hyperamylasemia and hyperlipasemia was observed. In the canine model, interstitial pancreatitis was transient, and frank pancreatic necrosis or haemorrhagic pancreatitis was not seen.<sup>[6]</sup>

In a prospective study, of the 79 patients with OP poisoning studied, serum amylase was found to be elevated ( $>200$  S.U) in 37 patients (46.95 %). Among them, 3 patients had amylase of 800 S.U. There was evidence of acute pancreatitis in one case, on ultrasonography and CT abdomen, while the other two were normal.<sup>[7]</sup>

In another report, a 23 years old man developed pain abdomen, sweating, and vomiting, 3 hours after ingestion of dichlorvos of unknown amount, with raised serum amylase and lipase levels. CT abdomen done six hours later revealed acute necrotizing pancreatitis, and then developed shock. The patient had to undergo a distal spleen and vessel preserving distal pancreatectomy. Early postoperative recovery was noticed and the patient was

discharged on postoperative day 12.<sup>[5]</sup> In almost all cases, the increased serum amylase level can probably attributed to salivary secretion of the enzyme.

## CONCLUSION

Acute pancreatitis is not an uncommon complication of organophosphate poisoning. This life threatening complication should be suspected when a patient with consumption of organophosphate poisoning presents with acute pain in abdomen, as the diagnosis and treatment can be life saving. This will help start early treatment and decrease morbidity and mortality of the patients.

## REFERENCES

1. Eddleston M. Novel clinical toxicology and pharmacology of organophosphorus insecticide selfpoisoning. *Annu Rev Pharmacol Toxicol*, 2019; 6, 59(1): 341-60.
2. Peter JV, Sudarsan TI, Moran JL. Clinical features of organophosphate poisoning: A review of different classification systems and approaches. *Indian journal of critical care medicine*, 2014; 18(11): 735.
3. Sahin IC, Onbasi K, Sahin H, Karakaya CE, Ustun YU, Noyan TE. The prevalence of pancreatitis in organophosphate poisonings. *Human & experimental toxicology*, 2002; 21(4): 175-7.
4. Kandalaft K, Liu S, Manivel C, Borner JW, Dressel TD, Sutherland DE, et.al., Organophosphate increases the sensitivity of human exocrine pancreas to acetylcholine. *Pancreas*, 1991; 1, 6(4): 398-403.
5. Roeyen G, Chapelle T, Jorens P, de Beeck BO, Ysebaert D. Necrotizing pancreatitis due to poisoning with organophosphate pesticides. *Acta gastro-enterologica Belgica*, 2008; 1, 71(1): 27-9.
6. Dressel TD, Goodale Jr RL, Arneson MA, Borner J. Pancreatitis as a complication of anticholinesterase insecticide intoxication. *Annals of surgery*, 1979; 189(2): 1991.
7. Singh S, Bhardwaj U, Verma SK, Bhalla A, Gill K. Hyperamylasemia and acute pancreatitis following anticholinesterase poisoning. *Human & experimental toxicology*, 2007; 26(6): 467-71.