

A CASE REPORT OF MULTIPLE VALVULAR HEART DISEASE IN ULCERATIVE COLITIS AT OLUWAROTIMI SPECIALIST AND DIAGNOSTIC CENTRE AKURE, ONDO STATE, NIGERIA

Folorunso Timothy Oluwarotimi^{*1}, Kenechukwu Okonkwo², Pelemo Olumuyiwa³, Tawose Olamide Oluwabukunmi⁴

¹Consultant Physician and Cardiologist, ²Consultant Gastroenterologist ³Consultant Pathologist, ⁴Nursing Officer.



*Corresponding Author: Folorunso Timothy Oluwarotimi

Consultant Physician and Cardiologist.

Article Received on 17/07/2025

Article Revised on 06/08/2025

Article Accepted on 26/08/2025

ABSTRACT

Background: High index of suspicion is key to accurate clinical diagnosis. **Case report:** A 65 years old man presented with recurrent history of fatigue, cough, palpitation and abdominal pain with associated passage of loose, mucoid and bloody stool. There is history of weight loss, anorexia, low grade fever and migratory myalgia and athralgia. He is not hypertensive, diabetic, asthma or peptic ulcer disease patient. He presented in shock with cold clammy extremities and sweaty with tachycardia 108/m regular and small volume, blood pressure of 80/50mmHg, elevated JVP and heart sound s1 s2 s3 with mitral, aortic and tricuspid regurgitant murmurs. There was bibasal rales and tender hepatomegaly. Echocardiography revealed preserved systolic function, bi ventricular diastolic dysfunction, left ventricular concentric hypertrophy and calcific degenerative changes involving both aortic and mitral valve with severe aortic, mitral and mild tricuspid regurgitation. Lower G I endoscopy revealed pan colitis and internal haemorrhoid. Histologic revealed mucosal infiltrations of inflammatory cells, focal areas of crypt abscess admixed with congested vessels. **Conclusion:** Inflammatory bowel disease; ulcerative colitis is a rare condition in our environment. No wonder the index case has been in and out of several health facility without respite.

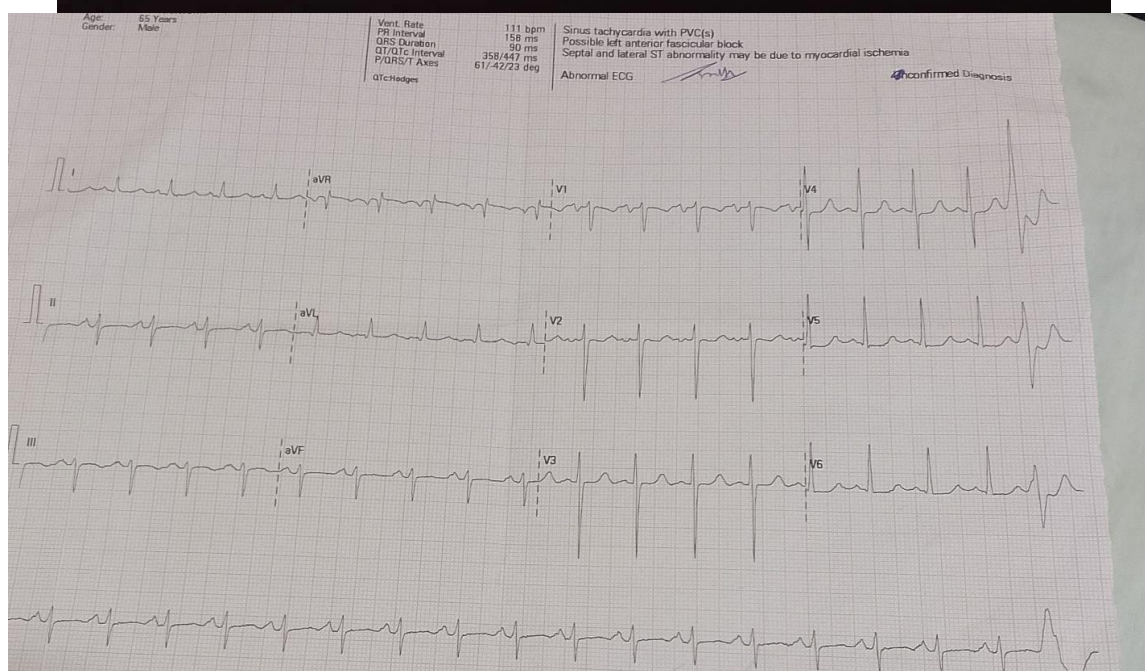
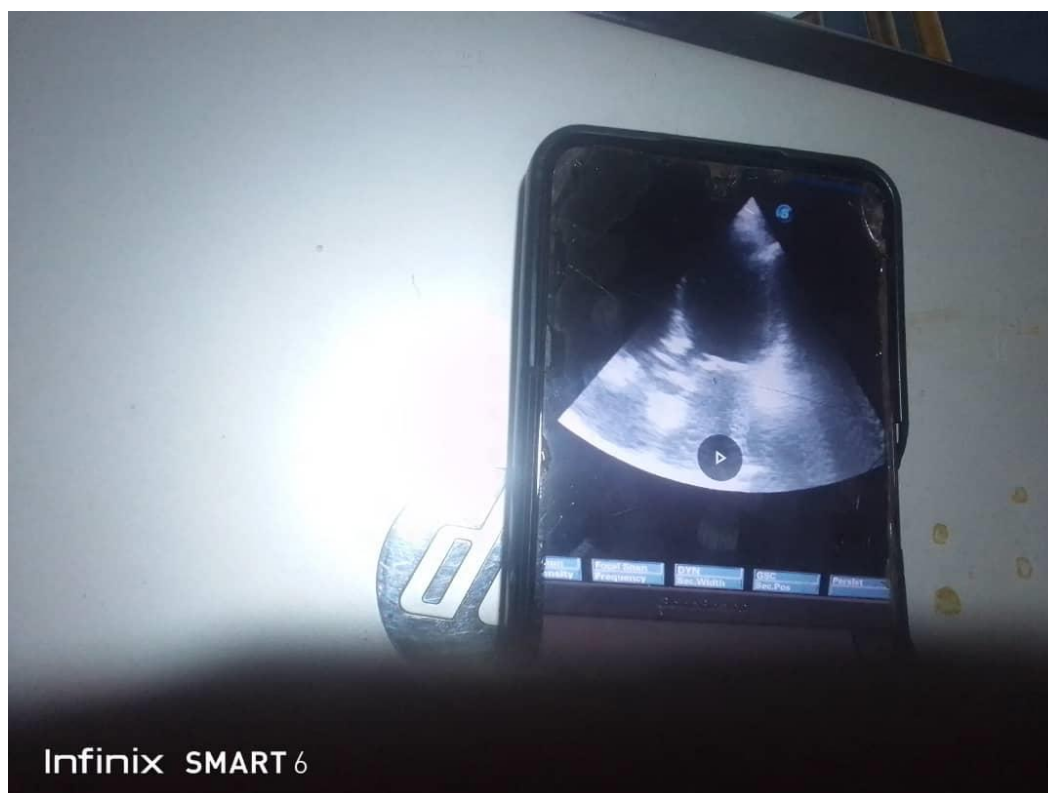INTRODUCTION

A 65 years old man referred as a case of heart failure to our facility with 5 months recurrent history of fatigue, cough, palpitation and abdominal pain, localized in the flanks. There is associated passage of loose mucoid and bloody stool. He equally admitted to history of low grade fever, anorexia and weight loss but no night sweat or contact with anyone with chronic cough. He had 2 pints of blood transfused before referral and had been treated for malaria and typhoid in several hospital without improvement. He is not a known hypertensive, diabetes, asthmatic or peptic disease patient. He neither smokes nor takes alcohol and no family history of hypertension, diabetes, asthmatic, peptic ulcer disease or similar illness. Examination revealed a chronically ill patient, conscious but sweaty and has cold clammy extremities. He was neither pale, afebrile, anicteric, cyanosed nor has pedal oedema. Cardiovascular examination revealed tachycardia heart rate 108/m regular and small volume. Blood pressure was 80/50mmHg both sitting and supine and Jugular venous pulse was elevated. Heart sounds were S1 S2 S3 with loud P2 and there is mitral, aortic and tricuspid regurgitant murmurs. There is bibasal rales, tender hepatomegaly and minimal ascites. Neurological examination was grossly normal. Patient was initially resuscitated by admitting him in cardiac position,

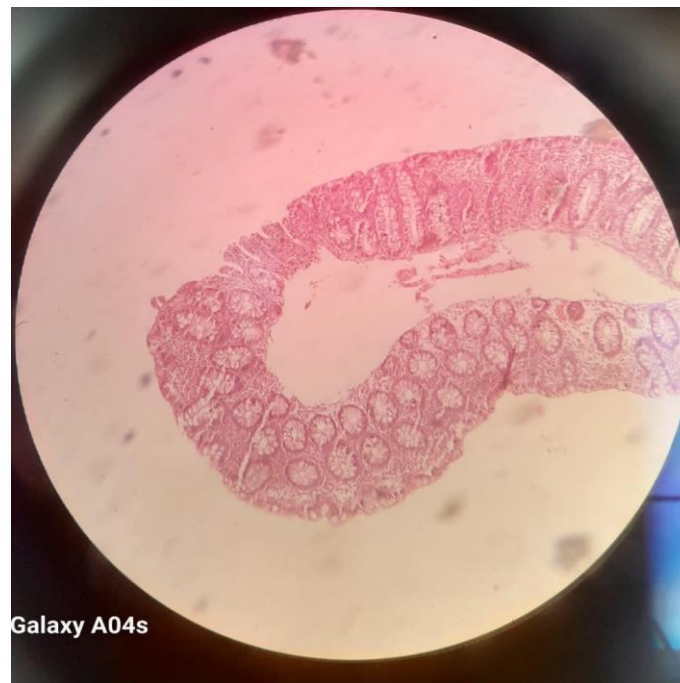intranasal oxygen given, dopamine infusion, intravenous ceftriaxone and metronidazole and intensive care monitoring of vital signs. Patient was out of cardiogenic shock after 48 hours with BP of 110/70mmHg and pulse rate of 74/m and was placed on ant failure regimen. However patient symptoms persisted with more frequent passage of watery mucoid and bloody stool, cough non-productive, nausea and vomiting. Subsequent review revealed similar recurrent history of passage of loose to watery mucoid bloody stool in the last 5 years with migratory myalgia, althralgia involving neck and both upper and lower limbs. Inflammatory bowel disease was suspected and lower GI endoscopy was requested. Available results of investigation done includes; Full blood count with packed cell volume 42%, ESR 25mm/hour, normal total WBC, differentials, platelet count. Serum and urinary chemistry, prostatic surface antigen, HbsAg and anti HCV were all normal. Chest X ray showed mild cardiomegaly but lungs fields were clear. Electrocardiography revealed sinus tachycardia HR 111/m with premature ventricular complex and left anterior fascicular block. Echocardiography showed preserved systolic function, bi ventricular diastolic dysfunction, left ventricular concentric hypertrophy, dilated left atrium, right ventricle and atrium and calcific degenerative changes involving both aortic valve leaflets

and posterior mitral valve leaflet with severe aortic, mitral and mild tricuspid regurgitation. Lower GI endoscopy revealed oedema of the entire colon and internal haemorrhoid with tiny bleeding points. Patient was commenced on intravenous hydrocortisone for 48 hours and oral prednisolone, omeprazole, ciprofloxacin, metronidazole and rivaroxaban, hematinics and antidiarrhoea as appropriate. Patient became symptoms free after 5 days and antifalure regime was discontinued with sustained clinical improvement. Patient was

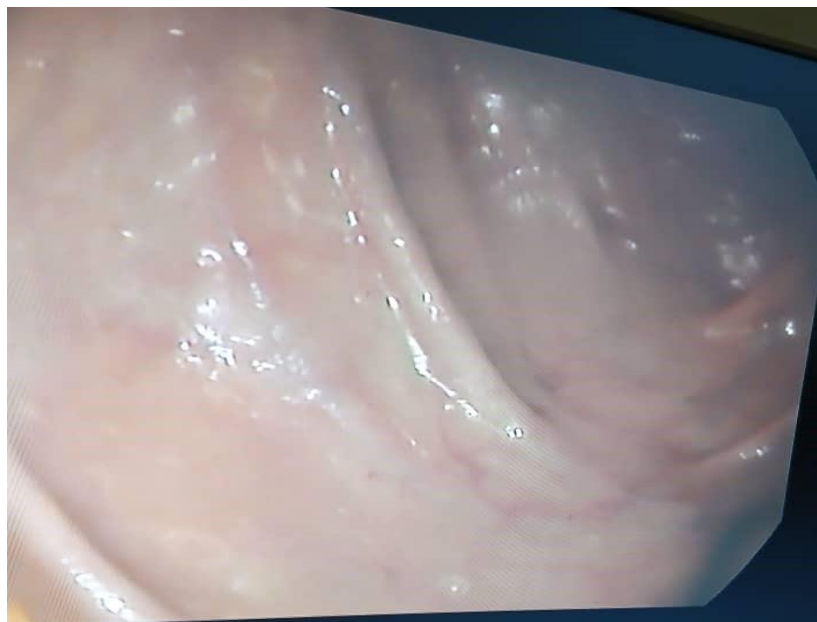discharged home on 10 days of admission. He was placed on following medications, rivaroxaban, omeprazole, ciprofloxacin, hematinics, cartinex and analgesia, to come back for follow up in 10 days with the result of endoscopy biopsy. Histologic slide revealed mucosal infiltration of inflammatory cells, focal areas of crypt abscess admixed with congested vessels. This is in keeping with features of inflammatory bowel diseases; ulcerative colitis.



Electrocardiographic record of reported case



Histologic slide revealed mucosal infiltration of inflammatory cells, focal areas of crypt abscess admixed with congested vessels.



Endoscopic image revealed pan colitis

DISCUSSION

Inflammatory bowel disease is rare and comprises of both ulcerative colitis and crohn's disease. Aetiopathogenesis of IBD is not fully known but involves an aberrant immune system, genetic factors, environmental factors and intestinal microbiome such as bacteria, viruses and fungi. Inflammatory response is mediated by immune cells; T helper 1 & 17 in Crohn's disease and T helper 2 in ulcerative colitis. Other inflammatory respnses includes cytokines such as; $\text{TNF}\alpha$, $\text{TNF}\beta$, IL-12, IL-17, IL-23, chemokines, reactive oxygen species, neuropeptide. There are other non-immune cells suchs as myeloid, epithelioid,

mesenchymal, lymphoid, neurogenic and endothelial cells. Chronic inflammation stimulates fibrosis, tissue remodelling, angiogenesis and tissue destructive processes. Inflammatory bowel disease present with systemic, gastrointestinal manifestations and extraintestinal manifestations. Intestinal manifestations includes abdominal pain, mucoid and bloody stool, tenesmus. Our patient presented with recurrent abdominal pain localised in both flanks with passage of watery, mucoid and bloody stool sometimes resolved without treatment or after treatment for malaria or typhoid in different health facility over the last 5 years. He also presented with systemic or constitutional

symptoms such as low grade fever, fatigue, anorexia and weight loss. Extraintestinal manifestations of inflammatory bowel disease includes; hepatobiliary, genitourinary, musculoskeletal, respiratory, ophthalmic, cutaneous and cardiovascular symptoms. Prominent presentation of our patient was cardiovascular symptoms; palpitation, hypotension, tachycardia and symptoms and signs of heart failure and cardiogenic shock. He was actually referred to us for echocardiography study and cardiologist review. Echocardiography revealed preserved systolic function, bi ventricular diastolic dysfunction, left ventricular concentric hypertrophy, dilated left atrium, right ventricle and atrium and calcific degenerative changes involving both aortic valve leaflets and posterior mitral valve leaflet with severe aortic, mitral and mild tricuspid regurgitation. Other prominent presentation in our patient was cough which was non-productive, migratory myalgia and arthralgia involving the neck and both upper and lower limbs. There are growing reports indicating increased risk of cardiovascular diseases in patient suffering from IBD. The prevalence of cardiac complication in IBD remain uncertain. Though this is low, it is higher than general population. Cardiovascular manifestation reported in IBD includes; pericarditis, myocarditis, venous and arterial thromboembolism, arrhythmias, atrioventricular block, heart failure, endocarditis and valvulopathies and takayasu arteritis. Valvular heart disease in IBD presents with calcific aortic valve, mitral valve prolapse and endocarditis resulting from the chronic inflammation underlying the disease. Our patient echocardiography revealed calcific aortic valve leaflets and calcific thickening of posterior mitral valve leaflet with severe mitral and aortic regurgitations and functional regurgitation of tricuspid valve. He actually presented to us in heart failure with tachycardia, premature ventricular complex and left anterior fascicular block.

REFERENCE

1. Zather A Extraintestinal Manifestations of Inflammatory Bowel Disease: Unraveling Valulopathy Connections, 2024 Apr. 10: 16(4): e57996. doi:PMID:38738160:PMCID: PMC11087212
2. Bunu D M, Timofte C E, Ciocoiu M, Floria M, Taniceriu C C, Balboi O B and Tanase D M. Cardiovascular Manifestations of IBD: Pathogenesis, Diagnosis and Preventive Strategies. *Gastroenterol Res Pract.*, 2019; 3012509. doi10.1153/2019:3012509.
3. Talia F. Malik, Danilo M, Aurelio Extraintestinal Manifestations of Inflammatory Bowel Disease. *StatPearls(Internet)* Last Update March 6, 2023.
4. Danese S, Semeraro S, Papa A, Roberto I, Scaldaferri F, Fedeli G, Gasbarrini G, Gasbarrini A, Extraintestinal Manifestation in Inflammatory Bowel Disease, *World J Gastroenterol* 2025; 11(46): 7227-7236. doi, org/10.3748/wig.v11.i46.7227