

## SUCCESSFUL LAPAROSCOPIC MANAGEMENT IN A CASE OF RUPTURED SECOND TRIMESTER RUDIMENTARY HORN PREGNANCY

<sup>1</sup>Dr. Namdev Bhure, <sup>\*2</sup>Dr. Snehal Shinde, <sup>3</sup>Dr. Shankar Chavan, <sup>4</sup>Dr. Pramod Junjare, <sup>5</sup>Dr. Shrihari Gutte<sup>1,\*2,3,5</sup>Ankur Super speciality Women's Hospital, Nanded, Maharashtra, India.<sup>4</sup>Trimurti Diagnostic Centre, Nanded, Maharashtra, India.**\*Corresponding Author: Dr. Snehal Shinde**

Ankur Super Speciality Women's Hospital, Nanded, Maharashtra, India.

DOI: <https://doi.org/10.5281/zenodo.19415563>**How to cite this Article:** <sup>1</sup>Dr. Namdev Bhure, <sup>\*2</sup>Dr. Snehal Shinde, <sup>3</sup>Dr. Shankar Chavan, <sup>4</sup>Dr. Pramod Junjare, <sup>5</sup>Dr. Shrihari Gutte. (2026). Successful Laparoscopic Management In A Case of Ruptured Second Trimester Rudimentary Horn Pregnancy. European Journal of Pharmaceutical and Medical Research, 13(4), 342-347.

This work is licensed under Creative Commons Attribution 4.0 International license.



Article Received on 05/03/2026

Article Revised on 25/03/2026

Article Published on 01/04/2026

**ABSTRACT**

**Background:** Pregnancy in rudimentary horn of unicornuate uterus is rare however if not diagnosed timely it can lead to devastating outcome. This case report shows how one such case of ruptured rudimentary horn pregnancy at 18 weeks gestation was managed successfully with laparoscopic approach. **Case Description:** We report a case of 20years, primigravida with 18 weeks gestation presenting with complaints of severe abdominal pain, giddiness with cold clammy extremities. On clinical examination patient was in a state of shock with severe pallor. Per abdominal examination revealed abdominal distension with tenderness in hypogastrium. With ongoing aggressive resuscitative measures bedside ultrasound was done which revealed gross fluid in abdomen with internal echoes, empty uterine cavity with intraabdominal ensac fetus with absent cardiac activity. Differential diagnosis made upon this were of rupture uterus or abdominal pregnancy with hemoperitoneum in shock. Patient was immediately taken for laparoscopic management. Intraoperative findings noted were gross hemoperitoneum with ensac expulsion of fetus with placenta from ruptured rudimentary horn on right side. Excision of ruptured rudimentary horn with right salpingectomy was then performed with bipolar shearer. Posterior colpotomy was done with bipolar shearer. Specimen retrieval was completed vaginally through colpotomy incision. Her postoperative span was uneventful and she was discharged on post operative day 5. Patient was thus successfully managed with minimal access surgical approach aided by vaginal retrieval of specimen. **Conclusion:** Pregnancy in rudimentary horn poses a diagnostic challenge. Laparoscopic management seems safe and feasible even in cases of ruptured rudimentary horn pregnancies provided the prerequisites of surgical expertise in advanced laparoscopy aided with multidisciplinary team approach are met.

**KEYWORDS:** Rudimentary Horn Pregnancy (RHP), Unicornuate uterus, Laparoscopic management, Ruptured rudimentary horn pregnancy.**INTRODUCTION**

Unicornuate uterus is a rare congenital uterine anomaly. It is classified as Class IV, specifically as Class IVa (the rudimentary horn with a cavity) or IVb (without a cavity) as per the ESGE CONUTA Classification.<sup>[1]</sup> Its most common type being noncommunicating rudimentary horn with a cavity. Pregnancies in rudimentary horn are rare and can lead to devastating consequences if not managed timely. The incidence of pregnancy in a rudimentary horn is 1/76,000.<sup>[2]</sup> Natural course of pregnancy in rudimentary horn is its rupture in first or second trimester. Early diagnosis and timely intervention

are of paramount importance and can be lifesaving in such cases.

**CASE DESCRIPTION**

We report a case of 20years old, primigravida with 18 weeks gestation by dates presenting to us with complaints of severe abdominal pain, giddiness with cold clammy extremities. On clinical examination patient was in a state of shock with severe pallor, tachycardia (low volume pulse with heart rate of 126/min), systolic BP of 70mmHg with diastolic BP non recordable. Per abdominal examination revealed abdominal distension

with tenderness in hypogastrium. Per speculum examination revealed normal vagina and cervix. Per vaginum examination revealed a closed os. With ongoing aggressive resuscitative measures bedside ultrasound was done which revealed gross fluid in abdomen with internal echoes, empty uterine cavity with intraabdominal ensac fetus with absent cardiac activity. Biometry of foetus roughly corresponded to 16 weeks gestation. Differential diagnosis made upon this were of rupture uterus or abdominal pregnancy with hemoperitoneum in shock. Hemogram revealed haemoglobin of 7gm%. Patient was immediately taken for laparoscopic management under GA with sos need of exploratory laparotomy explained. Surgery proceeded with one primary and 3 ancillary ports. Intraoperative findings noted were gross hemoperitoneum with organised blood clots (approximating 2.5lit), ensac expulsion of fetus with placenta from ruptured rudimentary horn on right side. Bilateral fallopian tubes and ovaries were normal. Hemoperitoneum was suctioned out. Anatomical course of right ureter was defined. Excision of ruptured rudimentary horn was then performed with its detachment from round ligament, fallopian tube and utero ovarian ligament with bipolar shearer. Ruptured horn was found to be non-communicating with the cavity of main horn of unicornuate uterus. Thin fibromuscular band connecting the two was incised with bipolar shearer. Right sided salpingectomy was done. Posterior colpotomy was then performed with bipolar shearer. Sterile urobag was then introduced through colpotomy incision which served the purpose of endobag. Fetus with placenta, excised ruptured rudimentary horn were inserted in urobag. Urobag was then inverted upside down with edges directed downwards through colpotomy incision. Edges of inverted urobag were retrieved vaginally and caught with allis forceps. Contents of urobag were retrieved vaginally and bag removed vaginally. Posterior colpotomy incision was then closed vaginally with Vicryl 2347. Thorough peritoneal wash was given with warm saline and haemostasis confirmed. Intraoperative drain was placed. Patient received 3 packed red cells and 4 fresh frozen plasma intraoperatively. Estimated blood loss was around 3liters. Patient was monitored in high dependency unit postoperatively for 3 days. Post operatively 2 more Packed red cell transfusions were given. Her postoperative span was uneventful and she was discharged on post operative day 6. Histopathology report was consistent with ruptured rudimentary horn of uterus. Patient was thus successfully managed with minimal access surgical approach aided by vaginal retrieval of specimen.

## DISCUSSION

### Clinical presentation and diagnosis of unicornuate uterus and RHPs

Clinical presentation in women with unicornuate uterus include infertility, menstrual problems like dysmenorrhea, chronic pelvic pain, endometriosis, recurrent miscarriages, rupture of rudimentary horn

pregnancies. Our patient lacked any of these classical symptoms and also did not have any pregnancy dating ultrasound done before. Hence her case remained undiagnosed till the time of her catastrophic presentation to us. Diagnosing unicornuate uterus involves a combination of medical history, clinical examination aided with 3D USG, MRI. A uterine anomaly should be suspected based on clinical examination during the first trimester of pregnancy with findings of a normal-sized uterus with latero-uterine mass palpable. According to a recent analysis of the literature, only 5% of reported RHPs had a pre-operative diagnosis.<sup>[3]</sup> Hence diagnosis of unicornuate uterus seems to be often missed and it requires a high index of suspicion to precisely diagnose it. Most RHPs rupture between 10 and 20 weeks of gestation because of the weak and underdeveloped myometrium.<sup>[4]</sup>

### Laparoscopic management of RHPs

Traditionally majority of the cases of ruptured RHPs have been managed with emergency laparotomies. However there has been rising evidence of these cases being managed successfully with laparoscopic approach. Very few cases of laparoscopically managed second trimester ruptured RHPs have been reported till date and ours being one of them. Standard surgical technique in laparoscopy involves defining the course of ureter to avoid any inadvertent injuries. This is followed by transection of round ligament, fallopian tube, utero ovarian ligament. Fibromuscular connection between the rudimentary horn and the main horn of unicornuate uterus also needs transection. If any dilated vascular pedicles are encountered at any step they can be suture ligated or secured with vessel sealer devices. Minas et al. in their study have collated 20 reported RHPs which have been managed laparoscopically.<sup>[5]</sup> This study revealed that bipolar forceps was the most commonly used hand instrument used for horn excision. There were different techniques employed for tissue or fetal extraction in different cases. Contained morcellation was used in 20% cases, extension of port incision to up to 3cm was used in 25% cases where as posterior colpotomy technique (as used in our case) was used in only 10% cases.<sup>[5]</sup> Also, all contents were retrieved vaginally through posterior colpotomy incision without any need for extension of any port incision. Entire horn excision was completed with bipolar shearer in our case. Retrieved fetus weighed 200grams.

### Role of preoperative feticide by medical methods followed by laparoscopic management in RHPs

There have been cases reported of preoperative feticide especially in advanced gestation followed by definitive laparoscopic surgery. As per a case reported by Lennox G et al. they used fetal intracardiac injection of potassium chloride followed by complete laparoscopic excision of rudimentary horn with 16 weeks pregnancy 48 hours later.<sup>[6]</sup> Whereas Ueda M et al. in their case did preoperative feticide with methotrexate injection in gestational sac under USG guidance followed 48 hours

later by laparoscopic excision of non-communicating RHP of 6 weeks.<sup>[7]</sup>

#### Future pregnancy outcomes after laparoscopic excision of RHPs

It is recommended that women diagnosed with unicornuate uterus with rudimentary horn who wish to become pregnant in the future get pre pregnancy excision of rudimentary horn.<sup>[8]</sup> There have been many cases reported of pregnancies with live birth following laparoscopic excision of rudimentary horn. One such case of successful vaginal term delivery after laparoscopic excision of non-communicating rudimentary horn has been reported by Kanno *et al.* in 2020.<sup>[9]</sup> Such pregnancies should be treated as high-risk ones and according to a study conducted by Pados G *et al.* most of such pregnancies had preterm delivery by caesarean section.<sup>[10]</sup>

List of abbreviations

RHPs-Rudimentary Horn Pregnancies

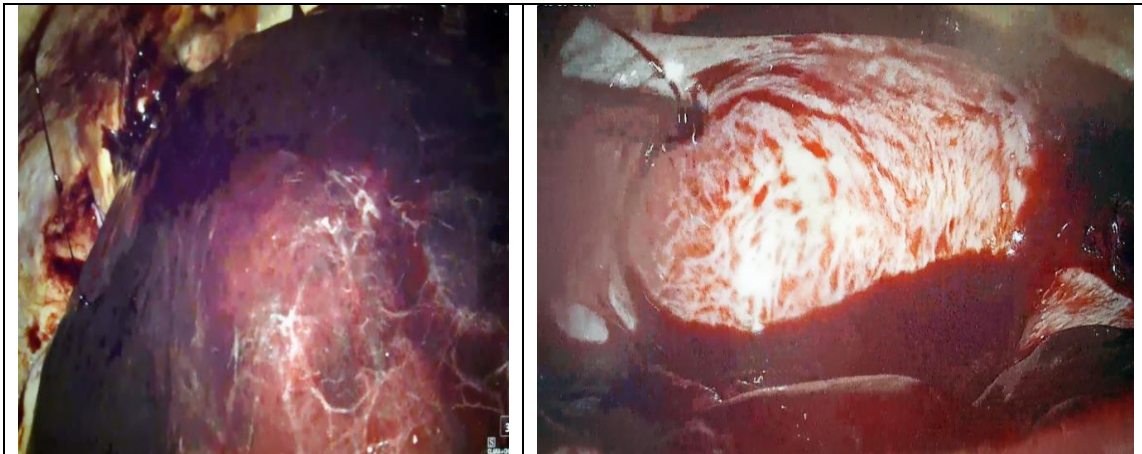
GA-General anaesthesia

USG-Ultrasonography

#### Role of laparoscopic management in hemodynamically unstable patients of ruptured RHPs

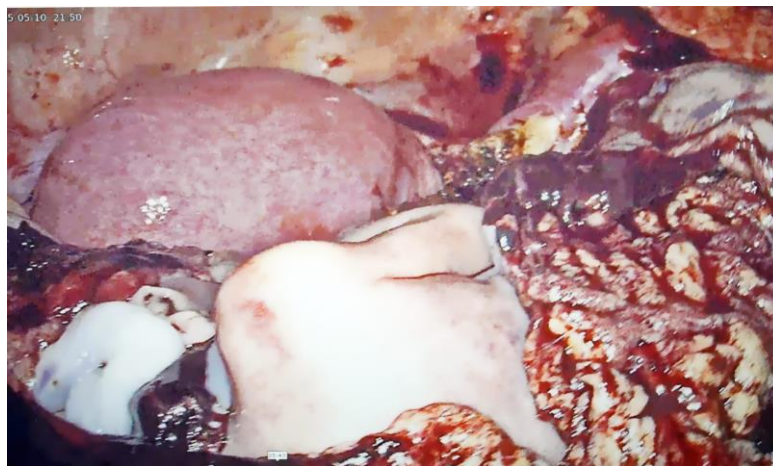
Majority of these cases are managed by laparotomy. However, there is rising evidence of successful laparoscopic management in such cases. Crucial factors for managing such cases by minimally invasive surgical approach include surgical expertise in advanced laparoscopy, multidisciplinary team support, advanced cardiovascular monitoring, easy availability of blood and blood products. Hence laparoscopy appears to be equally safe as laparotomy and potentially superior to laparotomy with added benefits of faster postoperative recovery, less postoperative adhesions, lesser morbidity in managing patients of ruptured RHPs.

#### FIGURES



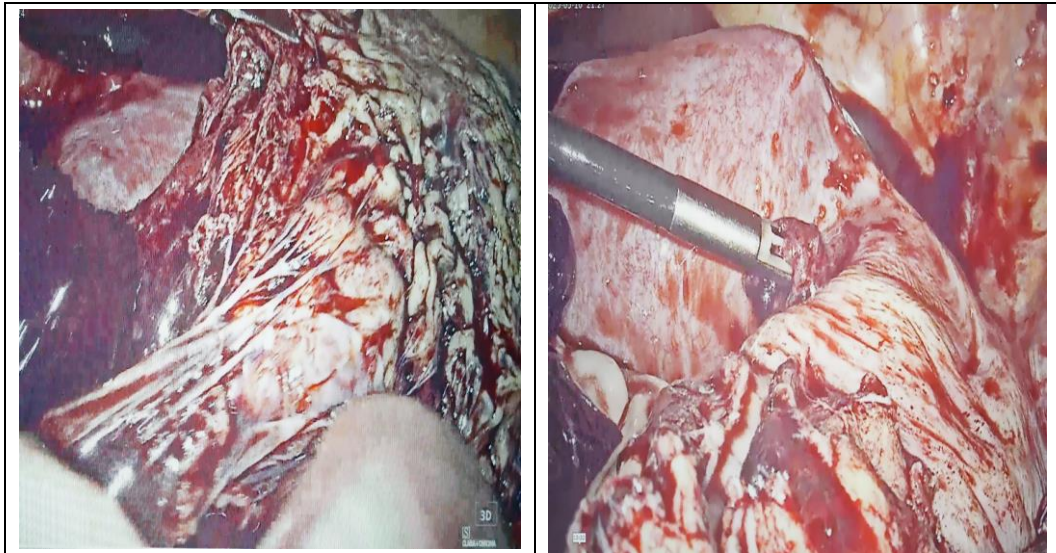
**Figure1.**

A-Intraoperative picture of organised blood clots with gross hemoperitoneum.



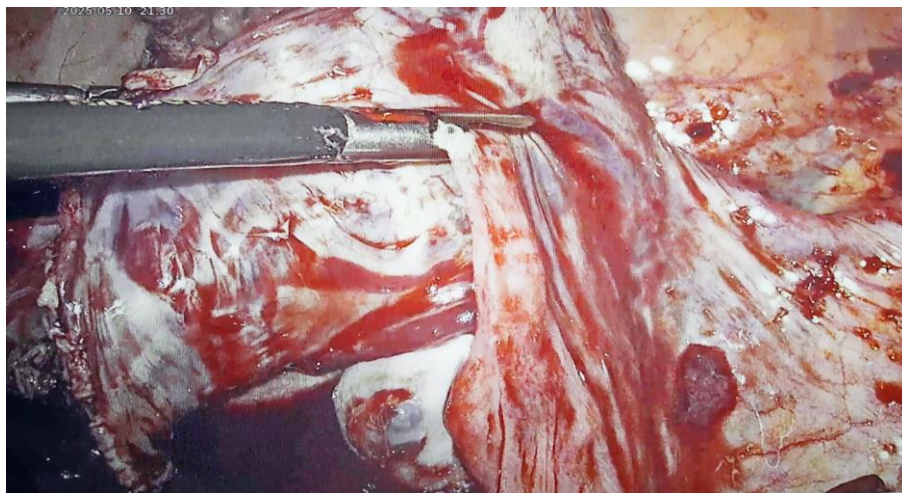
**Figure 2.**

Fetus with placenta expelled out from ruptured right rudimentary horn of uterus.



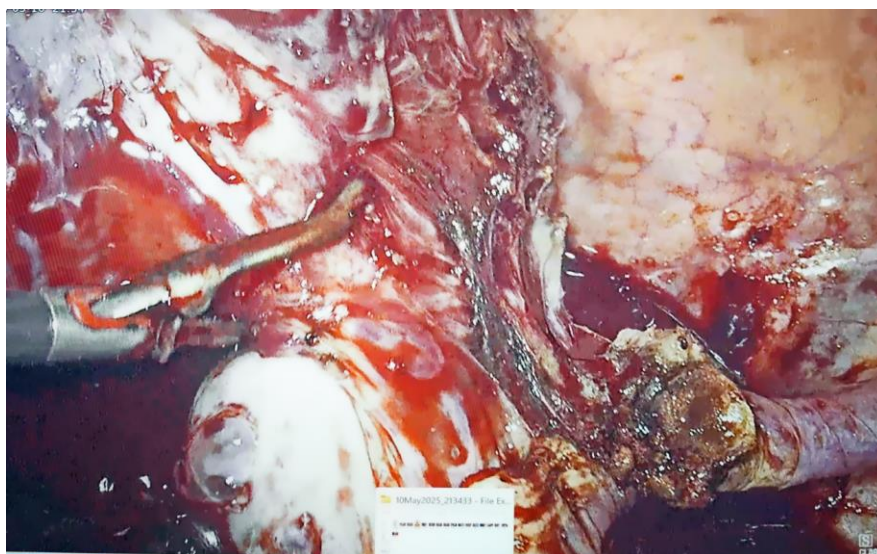
**Figure 3.**

Ruptured right rudimentary horn of uterus with its relation to main horn of unicornuate uterus



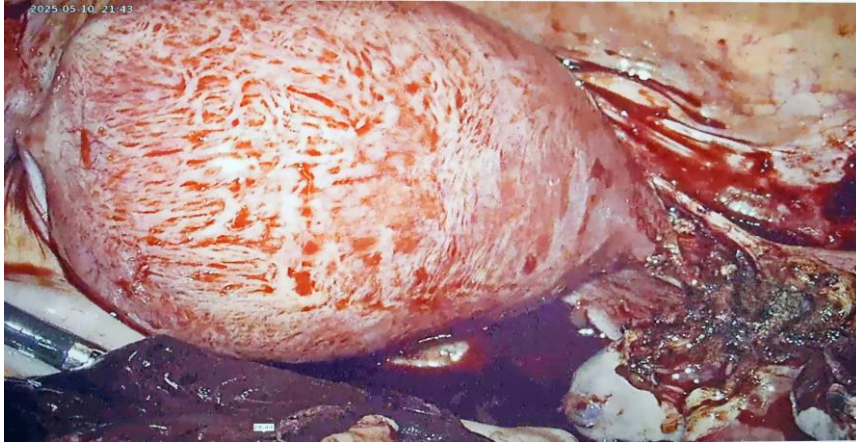**Figure 4.**

Excision of rudimentary horn with bipolar shearer with its detachment from right fallopian tube.

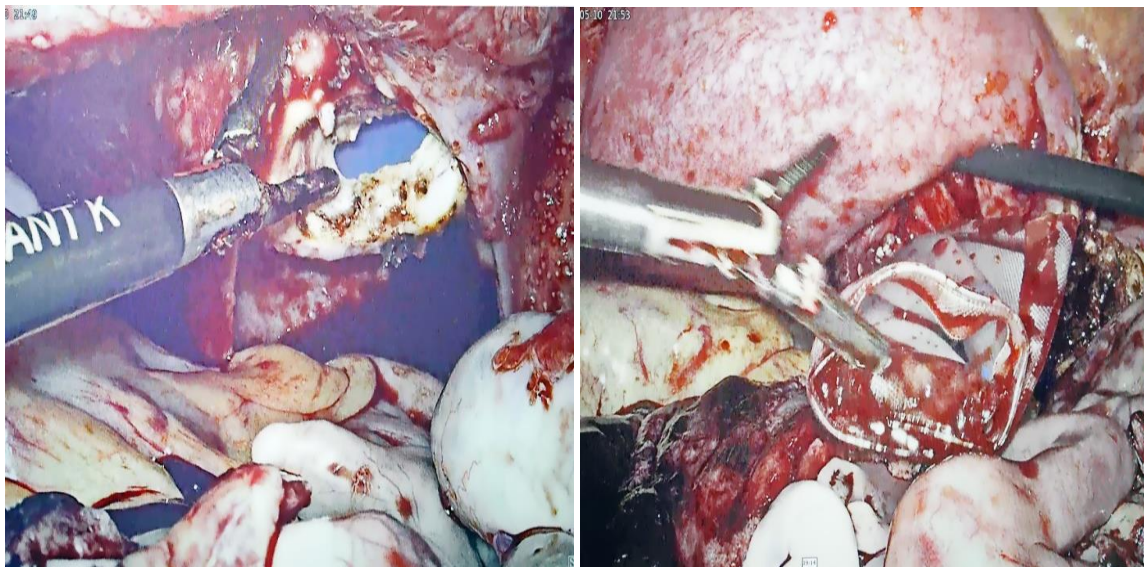


**Figure 5**

Excision of rudimentary horn with its detachment from utero ovarian ligament.



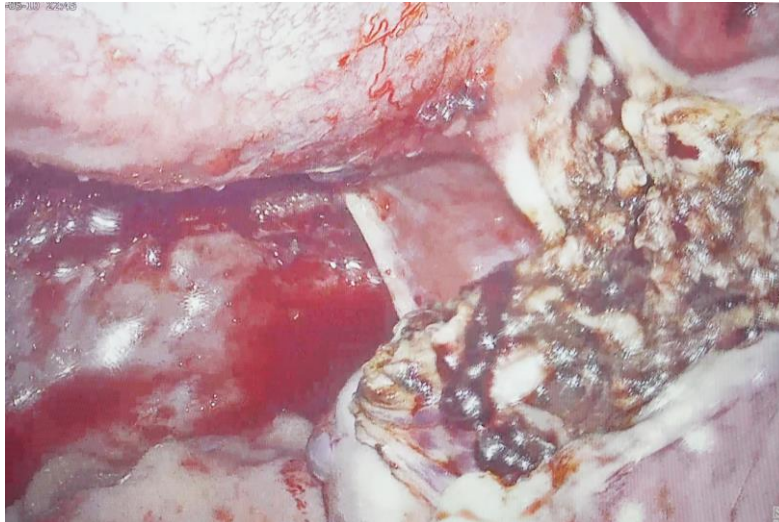
**Figure 6**  
Right Rudimentary horn excised completely.



**Figure 7**  
Posterior colpotomy done followed by introduction of urobag through colpotomy incision.



**Figure 8**  
Ruptured rudimentary horn with placenta and fetus being filled in urobag for specimen retrieval.

**Figure 9**

Completely excised rudimentary horn with right fallopian tube and right ovary preserved.

### CONCLUSION

Pregnancy in rudimentary horn poses a diagnostic challenge and require a very high index of suspicion. Timely diagnosis and surgical intervention can prevent catastrophic consequences and emerge as life saving measures. Laparoscopic management seems safe and feasible even in cases of ruptured RHPs provided the prerequisites of surgical expertise in advanced laparoscopy aided with multidisciplinary team approach are met.

### CLINICAL SIGNIFICANCE

Clinical examination aided with first trimester dating ultrasound thus is of paramount importance in diagnosing ectopic pregnancies and associated mullerian anomalies. Undiagnosed cases can land up in life threatening circumstances. Such cases can be managed successfully by laparoscopy in feasible setups with surgical expertise in advanced laparoscopy complemented with multidisciplinary team approach.

### REFERENCES

- Grimbizis GF, Gordts S, Di Spiezio Sardo A, Brucker S, De Angelis C, Gergolet M, Li TC, Tanos V, Brölmann H, Gianaroli L, Campo R. The ESHRE/ESGE consensus on the classification of female genital tract congenital anomalies. *Hum Reprod.* 2013 Aug; 28(8): 2032-44.
- Nahum GG. Rudimentary uterine horn pregnancy. The 20th-century worldwide experience of 588 cases. *J Reprod Med.*, 2002 Feb; 47(2): 151-63.
- Van Esch EM, Lashley EE, Berning B, de Kroon CD. The value of hysteroscopy in the diagnostic approach to a rudimentary horn pregnancy. *BMJ Case Rep.*, 2010 Dec 20; 2010: bcr0820103229.
- Chopra S, Keepanasseril A, Rohilla M, Bagga R, Kalra J, Jain V. Obstetric morbidity and the diagnostic dilemma in pregnancy in rudimentary horn: retrospective analysis. *Arch Gynecol Obstet.*, 2009 Dec; 280(6): 907-10.
- Minas, V., Shaw, E. & Aust, T. Laparoscopic management of an 11-week rudimentary uterine horn pregnancy using extracorporeal Roeder knot to secure the dilated vascular pedicle. *Gynecol Surg*, 2014; 11: 159–164.
- Lennox G, Pantazi S, Keunen J, Van Mieghem T, Allen L. Minimally invasive surgical management of a second trimester pregnancy in a rudimentary uterine horn. *J Obstet Gynaecol Can*, 2013 May; 35(5): 468-472.
- Ueda M, Ota K, Takahashi T, Suzuki S, Suzuki D, Kyojuka H, Jimbo M, Soeda S, Watanabe T, Fujimori K. Successful pregnancy and term delivery after treatment of unicornuate uterus with non-communicating rudimentary horn pregnancy with local methotrexate injection followed by laparoscopic resection: a case report and literature review. *BMC Pregnancy Childbirth*, 2021 Oct 26; 21(1): 715.
- Henriet E, Roman H, Zanati J, Lebreton B, Sabourin JC, Loic M. Pregnant noncommunicating rudimentary uterine horn with placenta percreta. *JLSLS*, 2008 Jan-Mar; 12(1): 101-3.
- Kanno Y, Suzuki T, Nakamura E, Goya K, Nishijima Y, Shinoda M, Hayashi M, Izumi S. Successful term delivery after laparoscopic resection of a non-communicating rudimentary horn in a patient with a unicornuate uterus: a case report. *Tokai J Exp Clin Med.*, 2014 Jul 20; 39(2): 59-63.
- Pados G, Tsolakidis D, Athanatos D, Almaloglou K, Nikolaidis N, Tarlatzis B. Reproductive and obstetric outcome after laparoscopic excision of functional, non-communicating broadly attached rudimentary horn: a case series. *Eur J Obstet Gynecol Reprod Biol.*, 2014 Nov; 182: 33-7.