

FENESTRATED MIDDLE CEREBRAL ARTERY, A RARE FINDING: A CASE REPORT

***Dr. Neeraj Salhotra, Dr. Ali Al Balushi, Dr. Mohammad Al Tamimi, Dr. Samit Biniwale, Dr. Livingston C., Dr. Ahmed Wadee, Dr. Faraz Qayyum Khan, Dr. Kauther Zakwani, Dr. Sameera H. Khalil, Dr. Hotchand Maheshwari**

Consultant Neurosurreon Khoula Hospital Muscat.



***Corresponding Author: Dr. Neeraj Salhotra**

Consultant Neurosurreon Khoula Hospital Muscat.

DOI: <https://doi.org/10.5281/zenodo.19415672>



How to cite this Article: **Dr. Neeraj Salhotra, Dr. Ali Al Balushi, Dr. Mohammad Al Tamimi, Dr. Samit Biniwale, Dr. Livingston C., Dr. Ahmed Wadee, Dr. Faraz Qayyum Khan, Dr. Kauther Zakwani, Dr. Sameera H. Khalil, Dr. Hotchand Maheshwari. (2026). Fenestrated Middle Cerebral Artery, A Rare Finding: A Case Report. European Journal of Pharmaceutical and Medical Research, 13(4), 364–365.

This work is licensed under Creative Commons Attribution 4.0 International license.

Article Received on 05/03/2026

Article Revised on 25/03/2026

Article Published on 04/04/2026

ABSTRACT

Middle cerebral artery (MCA) fenestration is a very rare anatomical variant of the middle cerebral artery, typically incidentally found during MR or CT angiography. It has an incidence of ~0.5% (range 0.2-1%) .We herewith report a case of middle cerebral artery fenestration in a case of middle cerebral artery aneurysm.

INTRODUCTION

Variations of the cerebral circulation are common findings on cross-sectional or angiographic imaging. Their detection and knowledge of their clinical implication is important, especially in the setting of cerebrovascular diseases such as acute stroke and subarachnoid hemorrhage. In addition, some anatomical variants, such as fenestrations, harbor potential risk of vascular abnormalities such as aneurysms, arteriovenous malformations, or ischemic and hemorrhagic complications.

CASE REPORT

Our patient was a 57 yr old lady old case of Ca breast treated, presented with sudden severe headache with drowsiness. GCS was 14/15 on arrival and neck stiffness was present. CT brain revealed subarachnoid haemorrhage mainly in right sylvian fissure with small temporal haematoma. Patient underwent CT angiogram which revealed right middle cerebral artery aneurysm. Patient underwent cerebral angiogram with possible coiling of aneurysm by intervention neurologist. Which revealed wide neck aneurysm in the middle cerebral artery bifurcation. The aneurysm was 3.3x2.8 in maximum diameter with neck size 2.8 mm. The aneurysm was pointing posteriorly and medially. It also had daughter sac. There was fenestration of proximal middle cerebral artery. Atherosclerotic changes were seen in vertebral

artery. Hence not injected. Aneurysm was found uncoilable.

Patient family was explained of all possible risks and benefits of surgical clipping and risks of vasospasm due to subarachnoid haemorrhage. Once family agreed patient GCS had dropped to 13/15. Patient underwent right pterional craniotomy and clipping of aneurysm. Fenestration of proximal MCA was seen. Post operatively patient was extubated GCS was 11/15. Postop scan revealed some ischemia in MCA territory. Milironin was added to nimodipine. However over coming 5 days GCS further deteriorated and CT revealed progression of MCA infarct with pressure effect hence required decompressive craniectomy. Patient required tracheostomy and presently is in ward with GCS of E3M3Vt on rehabilitation .

DISCUSSION

Mohammad Abdulkader et al in 2019 discussed thromboembolic and haemorrhagic complications of middle cerebral artery fenestration.^[1] Oliver M in 2018 discussed role of high resolution mri in studying vessel wall in middle cerebral artery dissection.^[2] Dimmick SJ in 2009 studied the normal variants of cerebral circulation by multi detectot CT.^[3] Sanders WP in 1993 studied the fenestration of cerebral vessels with special attention to associated aneurysms and other anomalies.^[4] Gailloud P in 2002

described 5 cases of middle cerebral artery fenestration.^[5]

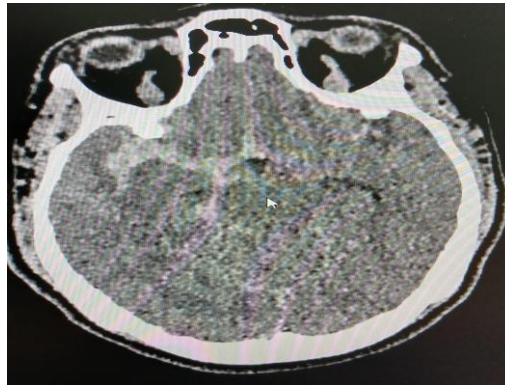


Fig. 1: CT scan revealing the subarachnoid haemorrhage.

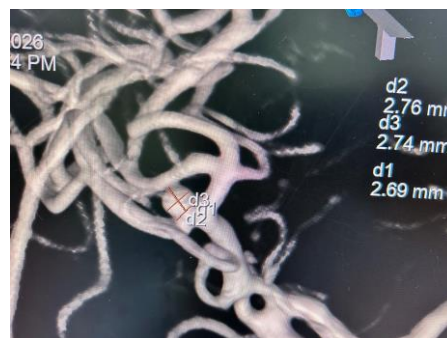


Fig. 2: DSA revealing fenestrated right MCA with bifurcation aneurysm.

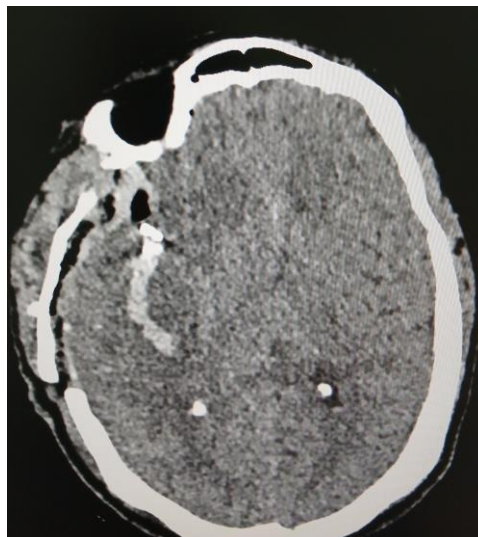


Fig 3 Postoperative status with clip in place.

CONCLUSION

Even though a causative link between arterial fenestration and vascular pathologies is not absolutely established, a fenestration detected in an artery relevant to the vascular symptoms should be carefully considered as an additional or causative factor for the clinical syndrome. Radiologists, interventionalists, and neurosurgeons should be familiar with cerebral vascular variants and the pathological associations in order to avoid potential complications or unnecessary treatment.

REFERENCES

1. Interv Neuroradiol. 2019 Jun 17; 25(6): 644–647. doi: 10.1177/1591019919857157 Middle cerebral artery fenestration: Thromboembolic and hemorrhagic complications Mohamad Abdalkader, Christian Raftopoulos, Patrice Finet, Thanh N Nguyen, Pierre Goffette.
2. Oliver M, Rai V, Mulderink T, et al. High resolution vessel wall MRI in diagnosis of MCA dissection: a case report and review of the literature (P6.220). Neurology 2018; 90.

3. Dimmick SJ, Faulder KC. Normal variants of the cerebral circulation at multidetector CT angiography. *Radiographics*, 2009; 29: 1027–1043
4. Sanders WP, Sorek PA, Mehta BA. Fenestration of intracranial arteries with special attention to associated aneurysms and other anomalies. *AJNR Am J Neuroradiol.*, 1993; 14: 675–680.
5. Gailloud P, Albayram S, Fasel JHD, et al. Angiographic and embryologic considerations in five cases of middle cerebral artery fenestration. *AJNR Am J Neuroradiol.*, 2002; 23: 585–587.