


Case Report

Ramsay Hunt Syndrome with cranial polyneuropathy and aseptic meningoencephalitis: A Case reportLumal Soysa^{1*}, Francisca Sivagnanam¹¹National Hospital of Sri Lanka, Colombo, Sri Lanka**Abstract**

Ramsay Hunt Syndrome is characterized by paroxysmal ear pain, and vesicular rash around the ear with ipsilateral facial nerve palsy. It is due to the reactivation of the Varicella Zoster Virus (VZV) in the facial nerve ganglion. It is considered the second most common cause of peripheral facial nerve palsy. A 14-year-old immunocompetent boy presented with fever associated with vertigo, facial asymmetry and difficulty in swallowing. He had a few crusted lesions in his left ear pinna and ear canal on examination. A cranial nerve examination revealed a left-sided facial and palatal palsy. Cerebrospinal fluid (CSF) analysis was suggestive of a viral meningoencephalitis.

This case highlights the importance of clinicians recognizing Ramsay Hunt syndrome amongst patients presenting with multiple cranial nerve involvement and amongst those with meningoencephalitis.

Keywords: Ramsay Hunt Syndrome, Cranial nerves, Acyclovir, Varicella Zoster, meningoencephalitis

Copyright: ©2023 Soysa L *et al.*  This is an open-access article distributed under the Creative Commons Attribution License, which permits unrestricted use, distribution, and reproduction in any medium, provided the original work is properly cited.

Funding: None**Competing interest:** None**Received:** 14.03.2023 **Accepted revised version:** 03.06.2023**Published:** 25.07.2023***Correspondence:** : lumalms@gmail.com <https://orcid.org/0009-0003-8377-692X>

Cite this article as: Soysa L *et al.*, Ramsay Hunt Syndrome with Cranial polyneuropathy and aseptic meningoencephalitis: A Case report. *Anuradhapura Medical Journal* 2023; 17 (2): 46-49, DOI: <http://doi.org/10.4038/amj.v17i2.7762>

Introduction

Ramsay Hunt syndrome (RHS) was first described by J. Ramsay Hunt in 1907. [1] It is the occurrence of unilateral peripheral facial nerve palsy with the reactivation of the Varicella Zoster Virus (VZV) [2]. Incidence is variable worldwide. A study in Denmark reported the incidence to be around 5 per 100,000 accounting for up to 12% of facial nerve palsies [3]. Although the facial nerve is most commonly involved other cranial nerve involvement is possible, which includes VII, VIII, IX, X, V and III/XI cranial nerves in descending frequency of involvement. The syndrome is postulated to occur due to the reactivation of VZV in

the geniculate ganglion of the facial nerve [4]. Multiple cranial nerve palsy could be due to the spread of infection to the adjacent ganglia due to contiguous anatomical contact [5].

This case is unique as this immunocompetent child had both cranial polyneuropathy as well as meningoencephalitis both being uncommon associations of RHS. Such complications usually occur amongst immunocompromised patients.

Case Report

A 14-year-old previously healthy boy was admitted with a complaint of a painful rash on his left ear which had settled spontaneously. It was followed by vertigo and fever for one week. He also complained of dysphagia and nasal regurgitation for one day and imbalance. He denied any weakness in his limbs. He had no headache, photophobia, phonophobia or neck stiffness. He had chicken pox when he was 7 years old which was uncomplicated.

On examination, he was thin-built and not in any respiratory distress. He had a left-sided lower motor neuron type facial nerve palsy (Figure 1A and B) and a left-sided palatal palsy (Figure 1C) The eighth nerve examination revealed normal hearing. He had an ataxic gait swaying to the left. Romberg's test was positive. The rest of the cranial nerve examination was normal.

He had no neck stiffness and Kernig's sign was negative. The rest of the neurological examination was normal. Ear examination revealed crusted lesions of the pinna and external auditory canal suggestive of a recent Herpes Zoster infection. (Figure 1D). Routine blood investigations, Pure Tone Audiometry and MRI brain were normal. Cerebrospinal Fluid (CSF) analysis results are shown in Table 1.

A clinical diagnosis of RHS with involvement of seventh, eighth and tenth cranial nerves and VZV meningoencephalitis was made. He was started on IV Acyclovir 10 mg/kg three times a day for 14 days along with prednisolone 1mg/kg/day for ten days which was then tapered off.

He was reviewed after one month and the facial and palatal weakness had completely resolved.

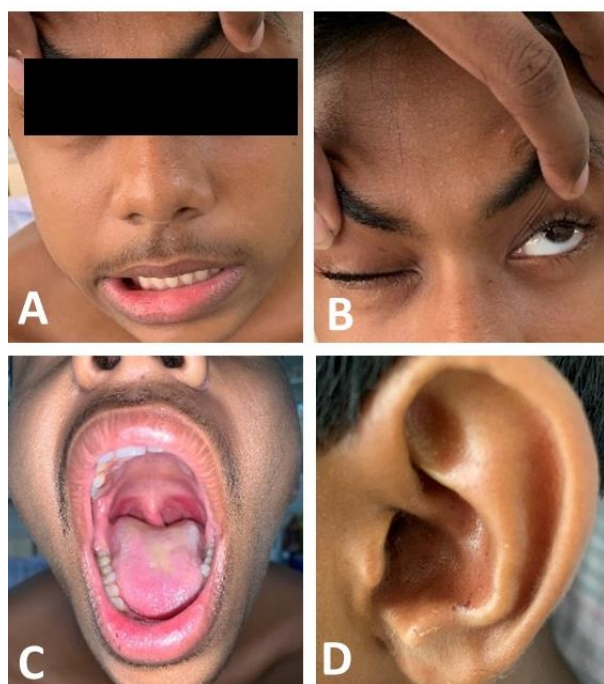


Figure 1: Left facial nerve paralysis: A, patient has been asked to smile showing a mouth deviation to right side and B, patient has been asked to close eyes against resistance and is unable to do so on left side; C, Left palatal palsy: the patient has been asked to open the mouth and say “aaah” and the palate on left side has sluggish movement with deviation of uvula to the right; D, crusted lesions in left pinna: scars from possible previous vesicular lesion

Table 1: Cerebrospinal fluid analysis results

	Value	Normal
Protein	73 mg/dl	15-45 mg/dl
Cell Count	86/mm ³	<3/mm ³
Neutrophils	1/mm ³	
Lymphocytes	85/mm ³	
CSF Sugar	68 mg/dl	
Random Blood Sugar	96 mg/dl	
CSF: serum sugar	0.7	>0.6
Varicella Zoster Virus PCR	Positive	Negative
Herpes Simplex Virus 1 and 2 PCR	Negative	Negative
Cytomegalovirus PCR	Negative	Negative
Tuberculosis Gene Xpert	Negative	Negative
CSF culture	Negative	Negative

Discussion

This patient is unique as the child had both cranial polyneuropathy as well as meningoencephalitis both being uncommon associations of RHS. Such complications usually occur amongst immunocompromised patients. But this case report highlights the need to consider the possibility of RHS amongst immunocompetent patients presenting with

multiple cranial nerve involvement and Reactivation of the VZV in the geniculate ganglion causing lower motor neuron facial palsy is a common presentation in clinical practice. However, involvement of other cranial nerves has been less commonly reported in the literature. In addition to the lower motor neuron facial nerve palsy, this patient had ipsilateral tenth cranial nerve palsy. Involvement of the eighth cranial nerve too was a likely cause for his vertigo and positive Romberg's test. Normal hearing suggested the involvement of only the vestibular component of the eight cranial nerves. Studies have shown vestibular nerve involvement up to three- to four-fold higher than that of cochlear nerve [6]. The patient also had CSF fluid analysis suggestive of meningoencephalitis with CSF being positive for VZV DNA. The patient's clinical presentation was possibly due to the spreading of reactivated VZV causing local meningoencephalitis and multiple cranial nerve involvement. This is a rare combination of symptoms with a few cases reported previously [7] Further literature review showed that such extensive spread of the virus was rarely seen in immunocompetent patients such as this patient [8]

Due to the widespread involvement of unilateral cranial nerves, the possibility of malignant infiltration or sarcoidosis was considered although unusual at his age. Screening for these entities was negative.

meningoencephalitis.

There is no clear evidence for the use of anti-viral drugs in RHS. This patient was started on early antiviral treatment as his CSF analysis was suggestive of viral meningoencephalitis. Treatment with acyclovir has been shown to reduce the duration of symptoms of certain viral meningoencephalitis [9].

Neuroimaging in RHS is likely to show abnormal enhancement of the canalicular segment of facial nerve or asymmetric enhancement of the geniculate ganglia. However, in this patient MRI was normal. Review of literature revealed that MRI and other neuroimaging being normal in such patients have been reported before [10].

Conclusion

Peripheral facial nerve palsy is a relatively common presentation in clinical practice and physicians should always consider the possibility of RHS amongst such patients. Involvement of multiple cranial nerves should not diverge the diagnosis from RHS but should rather be supportive of it. This case report also highlights the possibility of coexisting meningoencephalitis in such patients and the need for performing CSF analysis in patients with RHS.

References

- [1] Hunt JR. On herpetic inflammations of the geniculate ganglion. A new syndrome and its complications. The Journal of Nervous and Mental Disease. 1907; 34(2):73-96. DOI:10.1001/archneur.1968.00470350143016
- [2] Sweeney CJ, Gilden DH. Ramsay Hunt syndrome. J Neurol Neurosurg Psychiatry. 2001; 71:149–154. DOI: 10.1136/jnnp.71.2.149
- [3] Peitersen E. Bell's palsy: the spontaneous course of 2,500 peripheral facial nerve palsies of different etiologies. Acta Otolaryngol Suppl. 2002;4–30. DOI: <http://dx.doi.org/10.1080/000164802320401694>.
- [4] Van SV, Kuhweide R, Vlamincx S, Casselman J. Varicella zoster virus: beyond facial paralysis. Acta Otorhinolaryngol Belg. 2004; 58:61–66.
- [5] Hunt JR. The symptom-complex of the acute posterior poliomyelitis of the geniculate, auditory, glossopharyngeal and pneumogastric ganglia. Arch Intern Med. 1910; 5:631–675. DOI: 10.1001/archinte.1910.00050280097006
- [6]. Turner JE, Geunes PM, Schuman NJ. Cranial polyneuropathy-Ramsay Hunt's syndrome: case report and discussion. Oral Surg Oral Med Oral Pathol Oral Radiol Endod. 1997; 83:354–357. DOI: 10.1016/s1079-2104(97)90243-2.

- [7] Nagano K, Yoshimura K, Yamasaki M. A case of Ramsay Hunt syndrome associated with local meningitis, multiple cranial neuropathy, and the second cervical nerve involvement. *Rinsho Shinkeigaku*. 1999; 39(4):475-7.
- [8] Habib AA, Gilden D, Schmid DS, Safdieh JE. Varicella zoster virus meningitis with hypoglycorrhachia in the absence of rash in an immunocompetent woman. *J Neurovirol*. 2009; 15(2):206–208. DOI: 10.1080/13550280902725550
- [9] Gnann JW, Whitley RJ. Clinical practice. Herpes zoster. *N Engl J Med*. 2002; 347(5):340–346. DOI: 10.1056/NEJMc013211
- [10] Dyachenko PA, Dyachenko AG. A case of MRI negative herpes virus encephalitis presented by Ramsay Hunt syndrome. *Wiad Lek*. 2020; 73(11):2555-2556. DOI:10.36740/WLek202011139



Submit your next manuscript to
**Anuradhapura
Medical Journal**

Submit your manuscript at
<http://amj.sjoi.info/>