


Case reports

The wild boar *Sus scrofa cristatus* attacks in Sri Lanka: a case series and review of literature

Sujeewa Thalgaspitiya¹, Buddhika Wijerathne^{2*}, Mahesh Madusanka¹¹Department of Surgery, Faculty of Medicine and Allied Sciences, Rajarata University of Sri Lanka, Saliyapura 50008, Sri Lanka.²Dubbo Medical and Allied Health Group, Dubbo, NSW, 2830, Australia.**Abstract**

The wild boar, *Sus scrofa*, is a mammal found in Eurasia and North Africa. The incidence of attacks has slowly risen due to the dwindling forest cover, an increase in population, and intrusion into the wild boar's natural habitat. Injuries caused by wild boars include soft tissue injuries, fractures, internal organ damage, and, in some instances, death. Here, we describe three cases of wild boar attacks presented at Teaching Hospital Anuradhapura. Early intervention, stabilization, and transportation to the appropriate tertiary care are crucial.

Keywords: Wild boar, *Sus scrofa cristatus*, Injury, Attack, Sri Lanka**Copyright:** ©2023 Thalgaspitiya SPB *et al.*  This is an open-access article distributed under the Creative Commons Attribution License, which permits unrestricted use, distribution, and reproduction in any medium, provided the original work is properly cited.**Funding:** None**Competing interest:** None**Received:** 31. 08. 2023**Accepted revised version:** 01. 12. 2023**Published:** 31.12.2023***Correspondence:** buddhikatbw@gmail.com <https://orcid.org/0000-0002-5378-6065>

Cite this article as: Thalgaspitiya SPB *et al.*, The wild boar *Sus scrofa cristatus* attacks in Sri Lanka: a case series and review of literature. *Anuradhapura Medical Journal* 2023; 17 (3): 27-34, DOI: <http://doi.org/10.4038/amj.v17i3.7802>

Introduction

Wild boar, *Sus scrofa*, is a mammal found in Europe, North Africa, the Middle East, and Asia [1]. The subspecies, *Sus scrofa cristatus* (Wagner 1839) (Figure 1), is distributed from the highest hills to the coast of Sri Lanka [2,3]. Adult wild boars measure 155–170 cm in length, 83 cm in height at the shoulder, and weigh between 100 and 127 kg [3]. Both male and female wild boars possess long, sharp tusks capable of inflicting severe wounds [3].

Attacks by wild boars on humans are more frequent in rural and forested areas [4-18]. Wild boars can cause a wide range of injuries in humans, including lacerations,

wounds penetrating to the internal organs, fractures, tendon damage, knee joint infections, and, in some instances, death [5,7,12,18]. In this report, we will discuss the demographics, patterns of injuries, circumstances, and treatments of three patients brought to Teaching Hospital, Anuradhapura (THA) due to boar attacks. Additionally, we conducted a literature review on wild boar attacks to investigate injury mechanisms, various types of injuries, and treatment options."

Case Presentation

Case 1

A 55-year-old farmer was attacked in April 2016, of inter-monsoon season while he was gathering firewood in the forest in the late morning hours. The previously injured wild boar caused injuries to the front of his left thigh before the farmer could retreat. After the attack, the farmer walked home, and relatives took him to THA within two hours. On admission, he was hemodynamically stable. A large laceration was noted in the front of his left thigh, and the distal neurovascular bundle was intact. The patient was given intramuscular (IM) tetanus toxoid, 750 mg of intravenous (IV) cefuroxime, 500 mg of metronidazole, non-steroidal anti-inflammatory drugs (NSAIDs) three times daily, and proton pump inhibitors (PPI) twice daily. He was vaccinated against rabies, both actively and passively, with anti-rabies vaccine (ARV) and anti-rabies serum (ARS). Wound irrigation was done under regional anaesthesia in the theatre. There were no bony injuries. The laceration in the quadriceps femoris muscle was primarily sutured. He was kept in the ward for three days and discharged with oral antibiotics and analgesics for two weeks. On follow-up, no complications were observed, except for the presence of a scar (Figure 2A).

Case 2

In January, 2017 of the northeast monsoon season, a 45-year-old driver sustained injuries to his scrotum while trying to release a trapped wild boar in the early morning hours (Figure 2B). He was immediately taken to a peripheral hospital, where 750 mg of IV cefuroxime, 500 mg of metronidazole every eight hours, 500 mg of cloxacillin every six hours, tetanus toxoid, ARV, ARS, NSAIDs three times daily, and PPI two times daily were given. On admission to THA, he was hemodynamically stable. There was a five-centimetre laceration on the right hemiscrotum, and the right testis was exposed. Wound irrigation and primary suturing were done under spinal anaesthesia. The patient was discharged on the fourth postoperative day, and there were no complications at the two-week follow-up.

Case 3

In January, 2017 of the northeast monsoon season, a 53-year-old farmer was attacked by a wild boar while he was chasing parrots in the chena (swidden farming practised

in Asian countries) in the early morning hours. On admission to THA, he was hemodynamically stable. There were lacerations on the right leg (2 cm x 1 cm), on the medial aspect of the thigh below the knee (6 cm x 2 cm), and on the ankle (2 cm x 1 cm), respectively. There were three lacerations on the left leg (4 cm x 9 cm, 2 cm x 1 cm, and 0.5 cm x 1 cm) (Figure 2 C, D, E and F). In the operating theatre, the wounds were explored, and no nerve, vascular, muscle, or tendon damage was noted. Wound irrigation and primary suturing were done under local anaesthesia. The patient was given oral amoxicillin and clavulanate (625 mg) every eight hours, NSAIDs three times daily, and PPI twice daily. Tetanus toxoid, ARS, and ARV were given. He was kept in the ward for three days and discharged with the same oral antibiotics and analgesics for a week on the second postoperative day and reviewed after a week. On follow-up, there were no complications.

Methods of literature review

A literature search was performed to identify articles that reported wild boar attacks on humans. The studies published before January 1, 2023, were identified through systemic searches of electronic databases. Electronic databases were searched using the keywords (including MeSH terms) "wild boar," "Sus scrofa," and "wild boar attack." The following databases were used for the search: PubMed, Web of Science, ScienceDirect, and Trip. A grey literature search was done using the same keywords on Google and Google Scholar. Further, the reference lists of the selected studies were checked for relevant articles. Articles on domestic pig attacks and articles published in a non-English language were excluded. The country of report, mechanism of injury, type of injury, and management strategies are summarised in Table 1.

Discussion and literature review

We evaluated past literature and compared it to our cases to analyze patient demographics, damage mechanisms and types, treatment strategies, and methods of preventing future wild boar encounters described in different countries.

Attacks were commonly reported from India, where *Sus scrofa cristatus* is abundant. Most victims were male. The wild boar attacks were more frequent in the winter months, morning hours, and breeding and/or farrowing seasons. The majority of the attacks were unprovoked and occurred while the victims were working on the

farms, in the vicinity of the jungle, or during a visit to the jungle. In several cases, the wild boar attacked suddenly

from behind without giving the victims a chance to escape. [9,12-14,16-18].

Table 1: A summary of the demographics, incidents, pattern of injury and management of wild boar attacks on humans

Author Year Region/Country	Patient details Date or month and time	Activity	Injury	Management and outcomes
Gubler 1992 [4] Northern India (Jim Corbet Park, Himachal Pradesh)	24 Y, F, Swiss tourist, Date and time NR	She was attacked by a boar in a tiger reserve when she was sleeping by a campfire.	Her left leg and forearm were lacerated by the boar's tusks, while her right knee was bit.	Initially, in India, wounds were cleaned with hydrogen peroxide and suture up at a local hospital. The patient received oral antibiotics (amoxicillin 500 mg PO t.i.d and dicloxacillin 500 mg po tid) in addition to anti-rabies and anti-tetanus prophylaxis. Within seven days of arriving in Switzerland, she developed septic arthritis, which was effectively cured
Manipady 2006 [5] Karnataka State, India	50 Y, M, June, 7 AM	He was using the nearby agricultural field as his toilet when the event happened. There was a large, dense rainforest nearby.	Laceration on the head, neck, and thorax Penetrating wound on the abdomen (prolapsed intestine and mesentery) Hip (deep down to the bone) Thigh (deep down to the muscles) Shine (deep down to the bone)	Person died
Gunduz 2007 [6] Trabzon, Turkey	46 Y, F, January 2004, 10.30 AM	she was engaged in hazelnut harvesting. The largest boar among a group of eight to ten others attacked her.	Lacerations Dorsum of the right wrist (5cm) Left proximal thigh (7-8 cm length, 4- 5 cm deep)	Pulse lavage was used to irrigate the wounds. Tetanus toxoid and antibiotic prophylaxis were used. The wounds were sutured.
	47 Y, M, January 2004, 11 AM ,	While she was working in a hazelnut orchard. The attack was carried out by the biggest member of a herd comprising 8 to 10 individuals Same place above patient attacked	Subcutaneous tissue laceration Posterior surface of the left knee extending to the distal thigh (3cm) Laceration extending posteriorly from the left tibial tuberosity (5cm) Medial aspect of the left proximal upper arm (4cm long, 4-5 cm deep) Anterior of the thorax, near the xiphoid process, and extending to the left (6-7cm long and 1.5-2 cm deep).	
	35 Y, M, January 2006, 9AM	He was attacked by a boar in a forest while cutting down trees.	Subcutaneous tissue laceration Posterior aspect of the right distal thigh (10cm) Right proximal lower leg (4 cm)	
Shetty 2008 [7] Karnataka State, India	26 Y, M, Late evening	Walking through a tropical rain forest	His thighs' backs are covered with abrasions and puncture wounds. The victim's skull was punctured by tusks, which caused a fatal craniocerebral damage.	Person died
Attarde, 2010 [8] Maharashtra, India	65 Y, F, Date and time NR	attacked by a wild boar while she was working on the farm.	The right face, tongue, and neck all have lacerations. Low-level subcondylar fracture extending from the coronoid process to the posterior edge of the ramus, overriding right mandibular body fracture. fracture of the sixth cervical vertebra that is not dislocated	Lacerations on the mouth, chest, and cheeks were debrided, cleaned up, and sutured. reduction of an open fracture. Continued for 5 days was amoxicillin with clavulanic acid.
Kose 2011 [9] Antalya, Turkey	34 Y, M, February 2011, 10.30 AM,	The victim was moving through an area of thick vegetation. Wild boar made a rear attack.	2 subcutaneous lacerations in the posterior aspect of the left thigh, 1. 3 cm in length, not deep, 2. 8 cm in length, and 2 cm wide and deep	Wound irrigation and suturing Tetanus toxoid anti-rabies vaccine Human rabies immune globulin (HRIG) given Antibiotic IV co-amoxiclav (Augmentin 1.2 IU)
Moini 2011[10] Iran	NR	NR	This case presented with a chest laceration, pneumothorax, lung laceration, and fracture of the 5th to 7th ribs.	An injured lung was repaired following a thoracotomy, and a chest tube was kept for ten days.

Šprem 2014 [11] Glina, central Croatia,	27 Y, M, November 2012, 10:30 AM,	He was attacked by a boar while out hunting when he approached a young, injured male boar.	A 4 cm long laceration of the left knee's skin and underlying soft tissue (without damage to the muscle).	A situational clip was inserted after the wound was cleansed and examined. He recently got immunoglobulins for tetanus and rabies. For seven days, 875 mg of amoxicillin and 125 mg of clavulanic acid, divided into two doses of 1000 mg each, were administered.
Tumram NK 2015 [12] India	65 Y, M December 2013, 8.30 AM	When travelling through brushwood, a victim was attacked by a wild boar from behind.	In the middle third of the left thigh, two lacerations were observed. The medial laceration severed the femoral artery, severed the femoral nerve, and severed a portion of the femoral vein, in addition to causing muscle injury.	Patient died possibly due to haemorrhagic shock.
Akhade 2015 [13] India	42 Y, M, February 2014, 8 AM,	While he was at work at his farm, a wild boar attacked him from behind.	single penetrating lacerated wound on the poster medial aspect of the lower one third of the left thigh of size 6 cm*2 cm*4 cm, directed obliquely upwards and medially	The patient died from haemorrhagic shock
Bhingare 2016 [14] Village of Gadchiroli district, India	24 Y, M, Date and time NR	attacked from behind while collecting firewood	attacked the perineal area. The patient presented to the hospital days later and developed a recto-vesico-cutaneous fistula following a perineal injury. A 3x2 cm cruciate-shaped penetrating wound was seen in the perineum. erythema and tenderness in the perineal and scrotal regions, with some necrotic patches over the scrotum.	Surgical correction was done to the internal perforated lesion, and perineal and scrotal lesions were managed.
Nagasawa 2017 [15] Japan	74 Y, M, Winter 2017, Daytime,	Bites without provocation when he is in the farm	Boar bites on the left leg, foot, and right foot	5 L of sterile saline were used to irrigate the wounds. Under anaesthesia, wounds were sutured. A booster dose of tetanus toxoid and amoxicillin/clavulanate for prophylaxis against infection were administered.
Okano 2018 [16] Japan	83 Y, M, 2017	A wild boar that had been injured by a hunting trap turned on the farmer from behind and attacked.	several significant puncture wounds on his legs; a 3 cm long puncture at the sixth intercostal space in the right anterior chest wall that entered the intrathoracic space; Deep perineal wound connecting with anal canal and distal rectum; degloving injury to right posterior thigh and buttock; deep laceration with active bleeding to right posterior thigh.	The patient was treated for haemorrhagic shock and pneumothorax, and iliac fractures were treated conservatively. Damaged arteries were ligated and nerves repaired, and deep laceration was sutured. Faecal diversion with a temporary proximal colostomy was performed, and the patient was stabilized and admitted to the intensive care unit. Intravenous ampicillin/sulbactam was started prophylactically, and Tetanus toxoid and human tetanus immunoglobulin were administered. The patient had residual partial sciatic nerve palsy and a permanent colostomy.
Nagasawa 2018 [17] Japan	54 Y, M, Late winter	He was attacked by a wild boar that sprang out of a bush behind him, and as a result, he fell 10 metres from the cliff into the sea.	He was almost drowned to death, but his leg wounds were not reported.	Treatment was given for a nearly fatal drowning.
Govind 2022 [18] India	57 Y, M March 2010 6AM	A cyclist hit a boar that was crossing the road and fell on the road.	Wounds on head, upper limb and lower limb wounds due to tushes or teeth	Patient survived
	52 Y, M March 2010 5.30AM	A motorcyclist hit a boar that was crossing the road.	one laceration on calf of right leg wounds due to tushes or teeth	Patient survived

42 Y, M March 2010 4.30AM	A motorcyclist hit a boar that was crossing the road.	upper limb and lower limb wounds due to tushes or teeth	Patient died
42 Y F March 2011 1.30PM	While the victim was washing clothes, a boar charged from behind and slashed its tusks upward.	Lacerations were found on her left forearm and left leg calf.	Patient survived
55 Y F February 2012 2.30PM	The victim was watering crops near a well when a boar charged from behind and slashed its tusks upward.	one laceration on the right calf	Patient survived
24 Y F February 2012 11 AM	The victim was working in a plantation when a boar attacked him from behind, severing his tusks upwards.	one laceration on the left calf	Patient survived

Y: years, F: female, M: male, NR: not reported, PO: per os (by mouth), T.d.s : three times a day

Injuries caused by wild boars ranged from subcutaneous lacerations to serious injuries involving penetrating injuries to internal organs, bone fractures, tendon damage, knee joint infections, and, in some instances, death. Most of the injuries were from the waist down, including the pelvic region, thighs, and legs. Abdominal and chest injuries were reported among the victims who fell during the attacks. In our cases, all of the victims were males, and they were attacked while working in Chena, at the edge of the jungle, or within the jungle. Males visit the forest to gather cattle, gather non-timber forest products (NTFP), and hunt. Therefore, they are more likely to encounter wild boars. Most of the attacks occurred in the forest, the fringe of the forest, orchards, or farms [4-9, 11-18]. Two attacks occurred with one occurring in January and the other in April. One case was an unprovoked attack, but an injured boar was involved in the other two cases. Injured boars are aggressive and more prone to attack. The victims sustained injuries to their thighs, more in the posterior aspect similar to other reported cases [5,6]. The average height of a wild boar is around 80–90 cm, which is approximately the height of a human waist. Therefore, a wild boar attack causes more injuries in the perineal area, thighs, and legs of the victims [9,14].

The most important step in the initial management of an injury is first aid to reduce bleeding. The wounds should be thoroughly cleaned and irrigated with normal saline or povidone-iodine to minimise the inoculation of bacteria that dwell in wild boars' mouths. *Staphylococcus* spp., *Streptococcus* spp., *diphtheroids*, *Pasturella multocida*, other *Pasturella* spp

, *mycoplasma*, *Haemophilus influenzae*, *Actinobacillus suis*, *Flavobacterium-like* spp., *Bacteroides fragilis*, and anaerobic Gram-negative bacilli were commonly found in wounds inflicted by domestic pigs [9,19]. Thus, prompt treatment with antibiotics to cover Gram-negative and Gram-positive bacteria and anaerobes must be initiated. All the patients in these cases were treated with broad-spectrum antibiotics.

Sus scrofa bites may be deep and may harbour tetanus and rabies [20], so tetanus toxoid should be administered depending on the immunisation status of the patient. Injuries to tendons, nerves, vessels, and underlying soft tissues should be explored under appropriate anaesthesia, and any nonviable tissues should be excised to reduce infections. Primary suturing after a mammalian bite is a controversial issue, as some of the sutured mammalian bites are apt to get infected [19].

The primary limitation of this study is that it included only three cases of wild boar attacks, potentially introducing selection bias and limiting generalizability. However, this case series primarily serves to raise awareness among healthcare staff about potential management strategies. Furthermore, hunters, farmers, hikers, and individuals who visit the jungle to gather Non-Timber Forest Products (NTFP) are at risk of encountering wild boars and should, therefore, remain vigilant when venturing into the forest. In the event that a wild boar charges at you from a distance where you can safely do so, seek refuge by climbing a tree or finding an elevated object. If it's not possible to avoid the attack, be prepared to defend yourself [20].



Figure 1: *Sus scrofa cristatus* A. adults, B. curved canine, C. piglets (Photographed by BW while on safari in a Yala National Park, Sri Lanka).

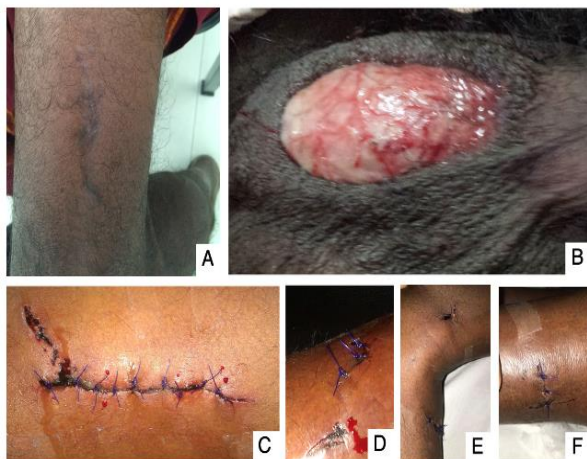

Figure 2: A. Healed laceration (An image taken at the time of the injury is not available), B. scrotal injury, C, D, E, F. Sutured laceration

Conclusions

In conclusion, wild boars are capable of inflicting fatal injuries on humans. Early resuscitation, stabilization, and transportation to appropriate tertiary care are vital, as almost all incidents occur inside forests, jungles, or rural and remote areas far from definitive care.

Consent

A written informed patient consent was obtained for publication of the report and any accompanying images.

Financial/Material Support: None.

Disclosures: None

References

- Keuling O, Leus K. 2019. (*Sus scrofa*. The IUCN Red List of Threatened). Accessed: 28/05/2023: <https://www.iucnredlist.org/species/41775/44141833> accessed 05 July 2023.
- Santiapillai C, Chambers MR: Aspects of the population dynamics of the wild pig (*Sus scrofa linnaeus*, 1758) in the ruhuna national park, Sri Lanka. Spixiana. 1980, 3:239-250.

3. Phillips WWA. Manual of the Mammals of Sri Lanka. 2nd ed. Colombo: Wildlife and Nature Protection Society of Sri Lanka, Colombo; 1980.
4. Gubler JGH. Septic arthritis of the knee induced by *Pasteurella multocida* and *Bacteroides fragilis* following an attack by a wild boar. *J Wilderness Med* 1992;3(3):288-291. DOI:10.1580/0953-9859-3.3.288.
5. Manipady S, Menezes RG, Bastia BK. Death by attack from a wild boar. *J Clin Forensic Med*. 2006;13(2):89-91.
6. Gunduz A, Turedi S, Nuhoglu I, Kalkan A, Turkmen S. Wild boar attacks. *Wilderness Environ Med*. 2007;18(2):117-119.
7. Shetty M, Menezes RG, Kanchan T, Shetty BSK, Chauhan A. Fatal craniocerebral injury from wild boar attack. *Wilderness Environ Med*. 2008;19(3):222-223.
8. Attarde H, Badjate S, Shenoi SR. Wild boar inflicted human injury. *J Maxillofac Oral Surg*. 2011;10(1):77-79
9. Kose O, Guler F, Baz AB, Akaln S, Turan A. Management of a wild boar wound: A case report. *Wilderness Environ Med*. 2011; 22(3):242-245.
10. Moini M, Peyvandi AA, Rasouli MR, Khajei A, Kakavand M, Eghbal P, et al. Pattern of animal-related injuries in Iran. *Acta Med Iran*. 2011;49(3):163-168.
11. Šprem N, Škavić P, Deždek D, Keros T. The wild boar attack – a case report of a wild boar inflicted injury and treatment. *Coll Antropol*. 2014;38(4):1211-1212.
12. Tumram NK, Dhawne SG, Ambade VN, Dixit PG. Fatal tusk injuries from a wild boar attack. *Med Leg J*. 2015; 83(1): 54-56.
13. Akhade SP, Rohi KR, Phad LG, Dixit PG: Fatal penetrating lacerated wound by tusk of Indian wild boar. *Journal of Indian Academy of Forensic Medicine*. 2015, 37:100.
14. Bhingare PD. A case of recto-vesico-cutaneous fistula following perineal injury by wild boar. *J Clin Diagnostic Res*. 2016; 10(5):PD03-4.
15. Nagasawa H, Omori K, Maeda H, Takeuchi I, Kato S, Iso T, et al. Bite wounds caused by a wild boar: a case report. *Wilderness Environ Med*. 2017;28(4):313-317.
16. Okano I, Midorikawa Y, Kushima N, Watanabe Y, Sugiyama T, Mitachi K, et al. Penetrating anorectal injury caused by a wild boar attack: a case report. *Wilderness Environ Med*. 2018; 29(3): 375-379.
17. Nagasawa H, Omori K, Takeuchi I, Fujiwara K, Uehara H, Jitsuiki K, et al. A case of near-fatal drowning caused by an attack from a wild boar. *Wilderness Environ Med*. 2018;29(4):549-551.
18. Govind SK, Jayson EA. : Attacks by wild boar, *Sus scrofa* on humans in central Kerala, India. *Journal of the Bombay Natural History Society*. 2022, 29:119.
19. Barnham M. Pig bite injuries and infection: report of seven human cases. *Epidemiol Infect*. 1988;101(3):641-645.

20. Brook I. Management of human and animal bite wounds: an overview. *Adv Skin Wound Care*. 2005;18(4):197-203.
21. Chen E, Hornig S, Shepherd SM, Hollander JE. Primary closure of mammalian bites. *Acad Emerg Med*. 2000;7(2):157-161.
22. John J. Mayer: Wild Pig Attacks on Humans. Armstrong JB, Gallagher GR (ed): Proceedings of the 15th Wildlife Damage Management Conference, 2013, 151



Submit your next manuscript to
**Anuradhapura
Medical Journal**

Submit your manuscript at
<http://amj.sjoi.info/>